A practical treatise on the diseases of the eye / by Haynes Walton.

Contributors

Walton, H. Haynes 1816-1889.
Norton, Arthur T. 1841-1912.
Allbutt, T. Clifford 1836-1925.

Publication/Creation

London : J. & A. Churchill, 1875.

Persistent URL

https://wellcomecollection.org/works/qmp6v2xb

License and attribution

This work has been identified as being free of known restrictions under copyright law, including all related and neighbouring rights and is being made available under the Creative Commons, Public Domain Mark.

You can copy, modify, distribute and perform the work, even for commercial purposes, without asking permission.

Wellcome Collection
183 Euston Road
London NW1 2BE UK
T +44 (0)20 7611 8722
E library@wellcomecollection.org
https://wellcomecollection.org


22101663892

sented to the Library
by

To Dr. B. Carpenter
with the Authors
regards

BRITISH MEDICAL
Library
ASSOCIATION

A PRACTICAL TREATISE

ON THE

DISEASES OF THE EYE

BRITISH MEDICAL ASSOCIATION
CANCELLED

A

PRACTICAL TREATISE

ON THE

DISEASES OF THE EYE

BY

HAYNES WALTON, F.R.C.S.

MEMBER OF THE COUNCIL OF THE ROYAL COLLEGE OF SURGEONS OF ENGLAND,
SURGEON TO ST. MARY'S HOSPITAL, PADDINGTON, SURGEON IN CHARGE OF THE OPHTHALMIC DEPARTMENT OF THE SAME, LECTURER ON OPHTHALMOLOGY,
LATE TEACHER OF ANATOMY, AND OF THE SURGICAL OPERATIONS ON THE DEAD BODY, IN ST. MARY'S HOSPITAL MEDICAL SCHOOL,
LATE SURGEON TO THE CENTRAL LONDON OPHTHALMIC HOSPITAL

THIRD EDITION



LONDON
J. & A. CHURCHILL, NEW BURLINGTON STREET
1875

CANCELLED

9704433

M20400

WELLCOME INSTITUTE LIBRARY
Coll. welMOmec
Call No. WW 100
1875
W23p

PARDON AND SON, PRINTERS, PATERNOSTER ROW, LONDON.

TISH MEDICAL
Library
ASSOCIATION

Dedication.

TO

MY DISTINGUISHED COLLEAGUES,

MEMBERS OF THE COUNCIL OF THE ROYAL COLLEGE OF SURGEONS OF ENGLAND.

PRESIDENT.

Frederick Le Gros Clark.

VICE-PRESIDENTS.

Sir James Paget, Bart. | Prescott Gardner Hewett.

John Hilton
Sir William Fergusson, Bart.
George Busk
Henry Hancock
Thomas Blizard Curling
Henry Spencer Smith
John Birkett
John Simon
George Murray Humphry
Luther Holden

John Gay
John Eric Erichsen
William James Erasmus Wilson
Henry Lee
Thomas Spencer Wells
George Critchett
Barnard Wight Holt
John Marshall
George Southam
Alfred Baker

I DEDICATE THIS WORK AS A TOKEN OF RESPECT.

H. W.

BRITISH MEDICAL
Library
ASSOCIATION

ABBREVIATIONS.

Art. C. R. Arteria Centralis Retinæ.

Ant. Ch. Anterior Chamber.

C. Cornea { 1. Conjunctival Layer. 2. Cornea proper. 3. Posterior elastic Lamina.

C. A. Ciliary Arteries, Anterior Long and Posterior.

C. M. Ciliary Muscle.

C. P. Ciliary Process.

Ch. Choroidea.

Conj. Conjunctiva.

Cl. of P. Canal of Petit.

Cl. of S. Canal of Schlemm.

I. Iris.

L. Lens.

O. N. Optic Nerve.

O. S. Ora Serrata.

Post. C. P. Posterior Ciliary Process.

Post. Ch. Posterior Chamber.

R. Retina.

Scl. Sclerotica.

S. L. Suspensory Ligament.

V. B. Vitreous Body.

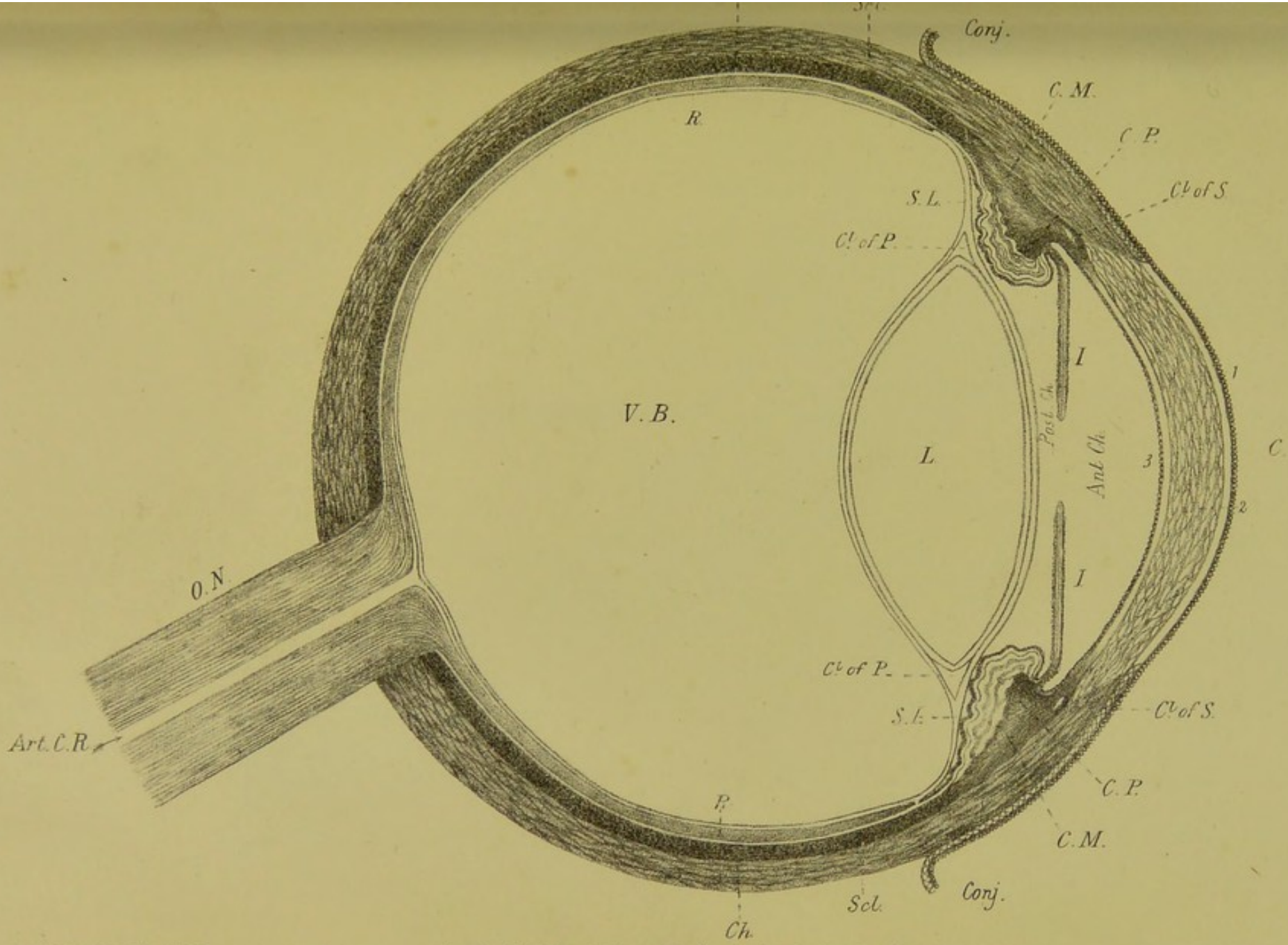

J.S. Coleman Del et Lith.

A vertical section of the eyeball from before backwards, showing a lateral view of the structures of which it is composed.

Harrison & Sons Lith.

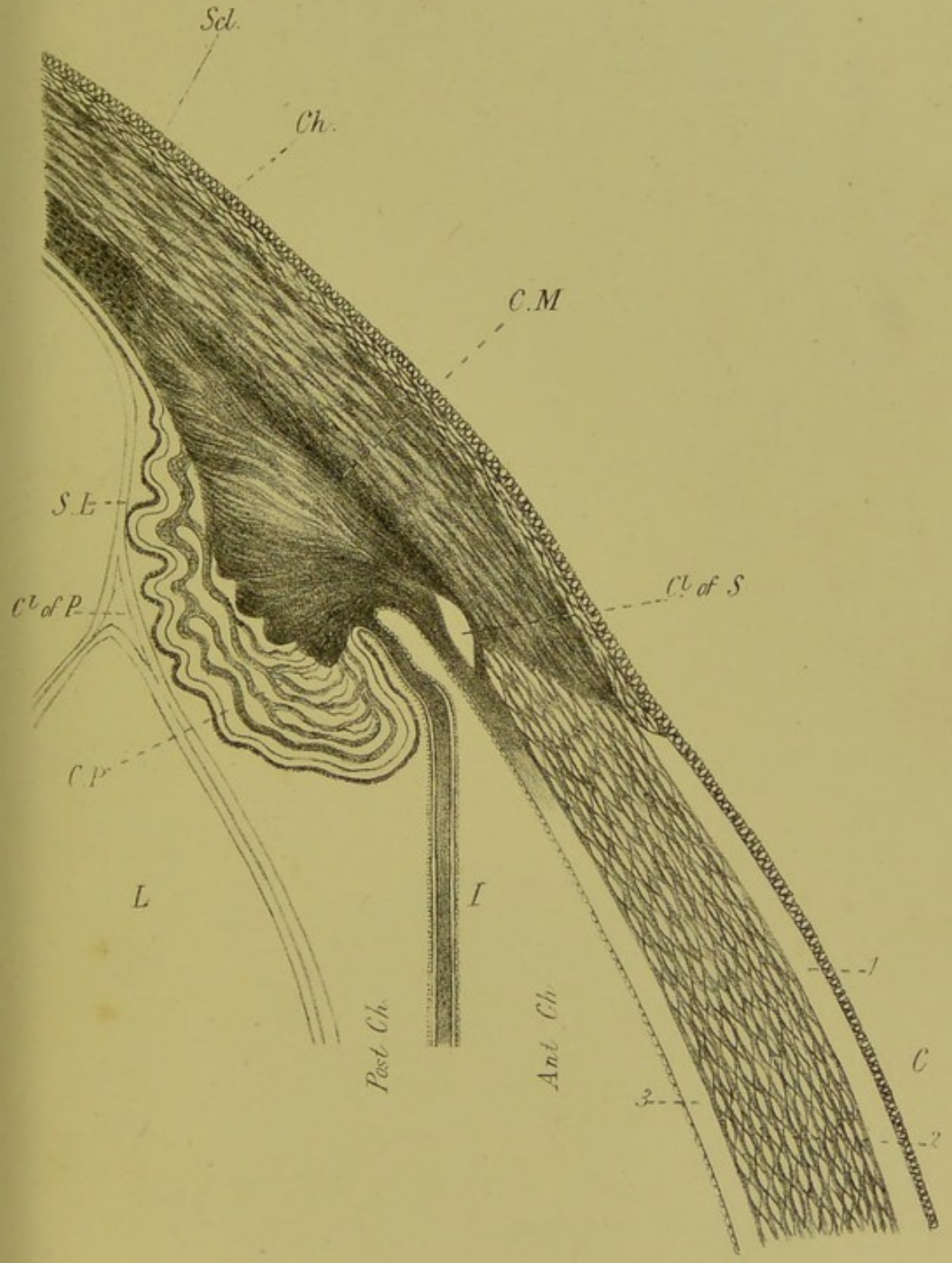

An antero posterior section showing the ciliary muscle and its attachments, the ciliary processes in a non erect condition, and the iris in the position which it occupies when arranged for distant vision.

J. Coleman Del. et Lith.

Harrison & Sons, Lith.

VASCULAR LAYER.

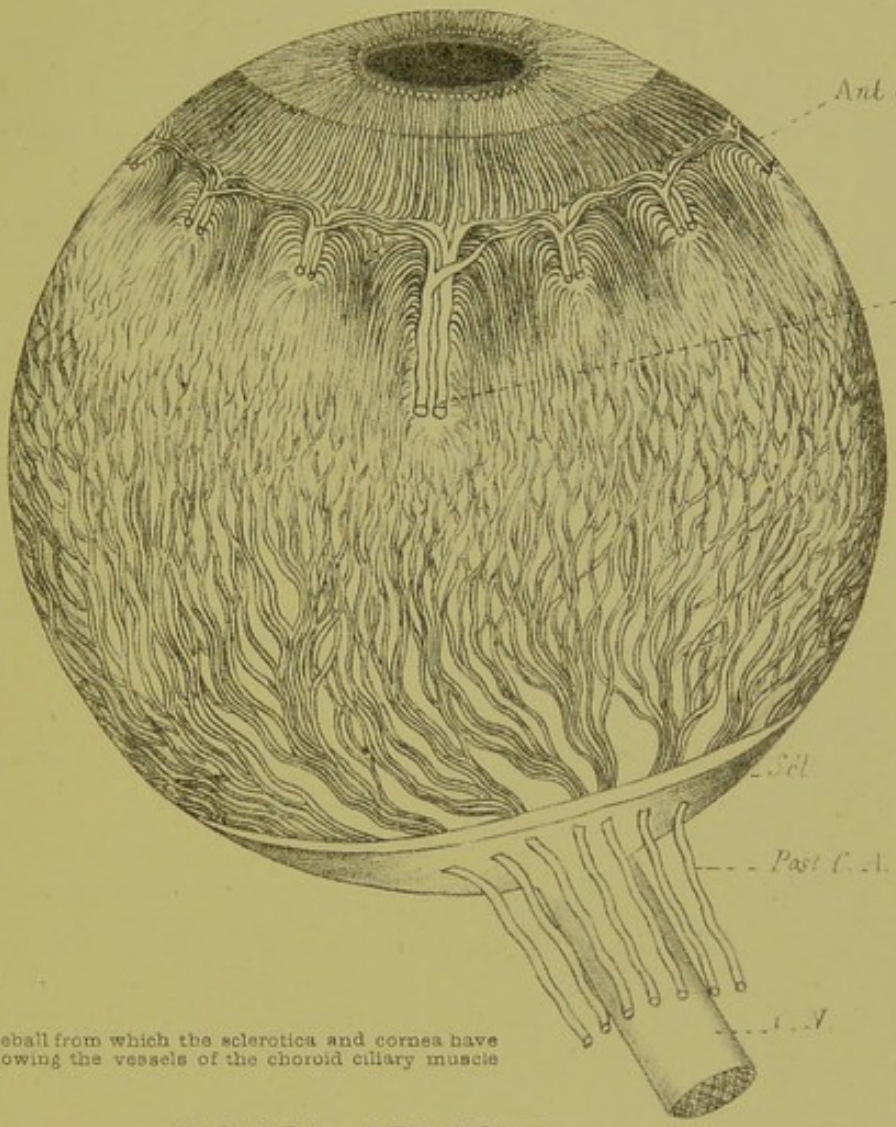

Fig. I.

A view of an eyeball from which the sclerotica and cornea have been removed, showing the vessels of the choroid ciliary muscle and iris.

CILIARY PROCESSES.

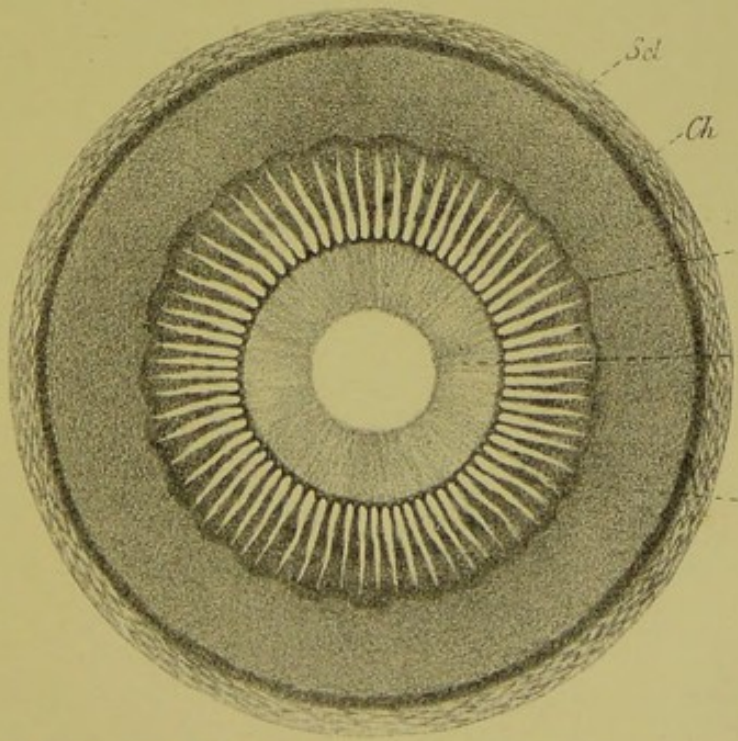

Fig. II.

A section through the eyeball, about ¼-inch behind the cornea, from which the lens and its suspensory ligament, together with the retina, have been removed.
It exhibits a posterior view of the circle of ciliary processes, the white radii, with the iris at their inner extremities, and the dark pigmentary line which corresponds to the ora serrata at their outer extremities.

Day et Lith.

POST^R CILIARY PROCESSES & LENS.

Fig. 1.

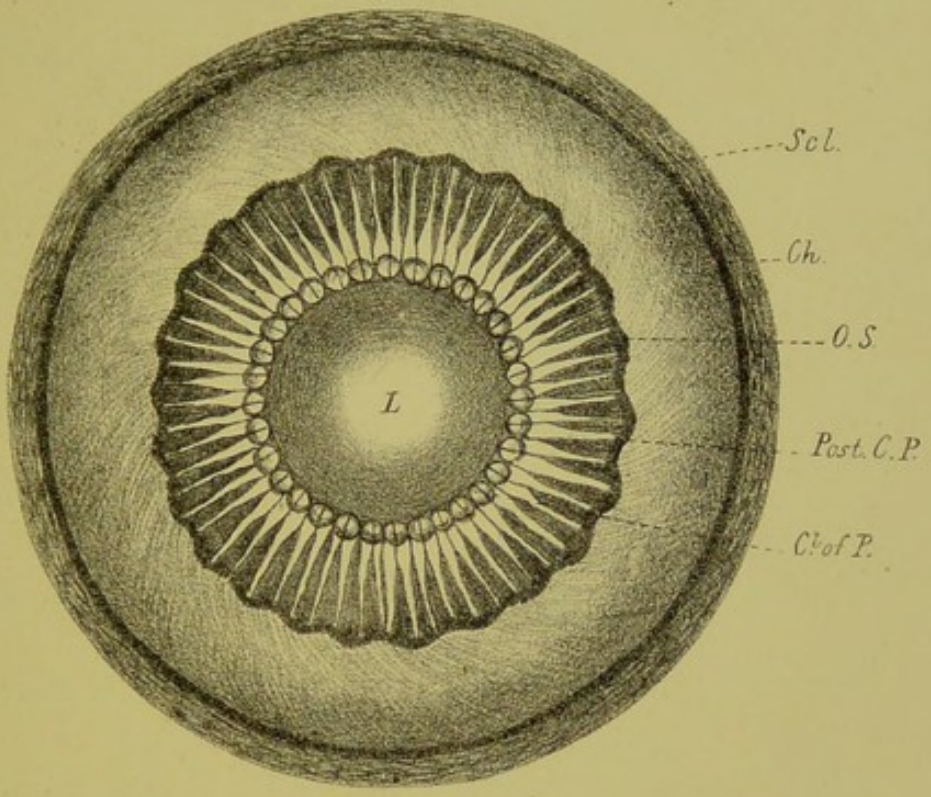

A section through the sclerotica and choroidea, about ¼-inch behind the cornea, showing an anterior view of the posterior or false ciliary processes, the black radii, surrounding the lens. The canal of Petit is filled with air and appears like a circle of beads.
This section corresponds to Fig. II, Plate III, which was removed from the same eyeball.

RETINA

Fig. II.

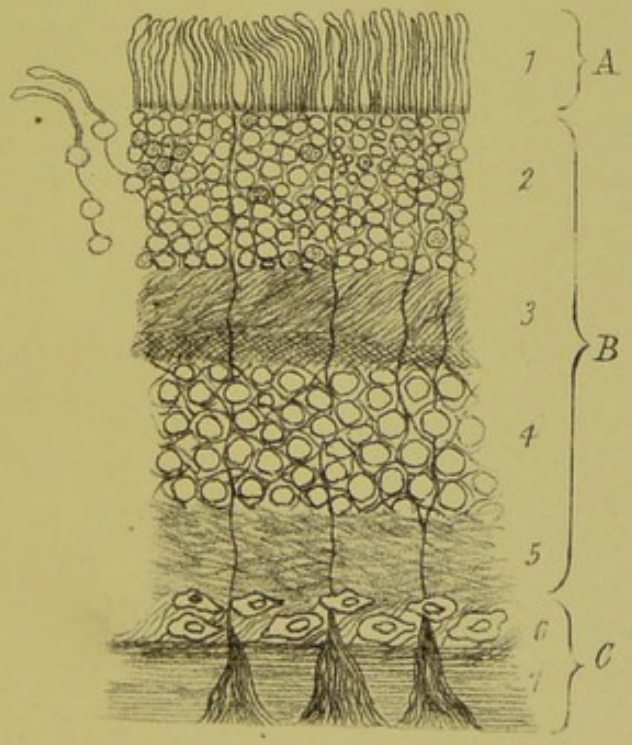

A section through the depths of the retina, near to the macula lutea, and in a line radiating from that spot.

Surface of Lens

Fig. I.

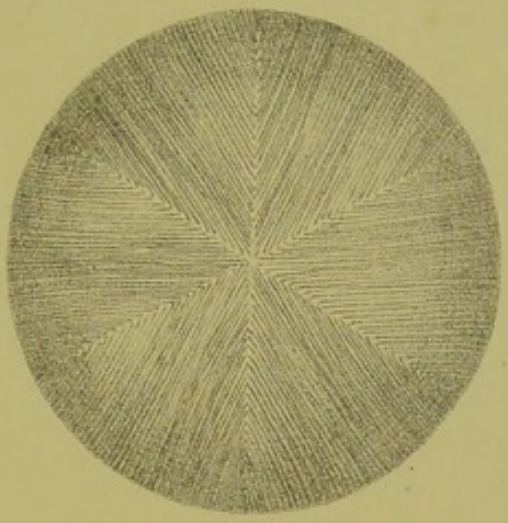

Fig. III.

Cells of Capsule.



Cells from between the lens and the anterior lens capsule.

Fig. IV.

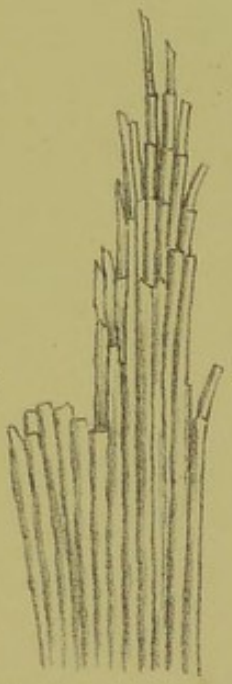

Fibres of Lens.

Fibres of lens separated after boiling.

Segments of Lens.

Fig. II.

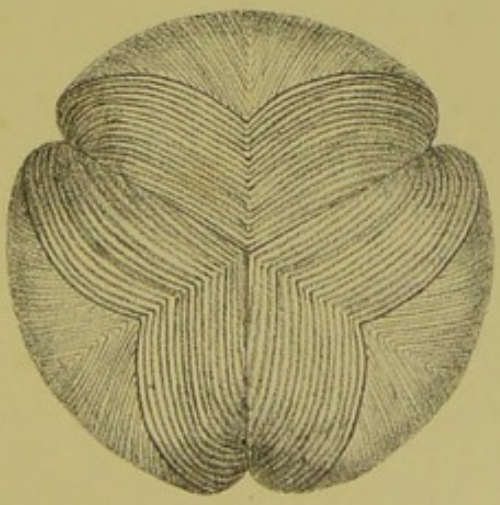

Drawing of a lens which accidentally fell and ruptured into six segments. Three are represented in the Diagram. The others were on the opposite surface, in alternation

PREFACE TO THE FIRST EDITION.

As an untried writer, I cannot be otherwise than anxious for the success of this work. I have spared no pains in my attempt to make it of practical value, and I have laid under contribution all the literature that has come within my reach, whether English or Foreign, on the subject of Ophthalmic Pathology and Surgery. I have given at length my own personal experience. It remains for me to particularize some of those to whom I feel myself especially indebted.

First of all I mention the venerable Dr. John Richard Farre, who, in conjunction with Mr. John Cunningham Saunders, established the first public Institution in this Kingdom for the treatment of Ophthalmic Diseases.

To this great Physician, full of years and of honour, I am indebted for the advice to study Ophthalmic Medicine and Surgery, and by him I was introduced as a pupil into this department of Science.

Having had the good fortune to be both pupil and, for a time, Acting House-Surgeon to the Royal London Ophthalmic Hospital, under the superintendence of Mr. Tyrrell, Mr. Scott, and Mr. Dalrymple, I must record my admiration of the zeal, the practical skill, and the advanced science which characterized the practice of those illustrious men, whose premature death is a loss as well to the Public as to the Medical Profession. To Mr. Lawrence, eminent alike as a scholar and as a surgeon, I am

under deep obligations for the knowledge which I gained on Ophthalmic subjects, while his Dresser and his House-Surgeon at St. Bartholomew's Hospital.

To Dr. Mackenzie, of Glasgow, I am much indebted, and have compared my own observations with his valuable experience, as detailed in his excellent work on the diseases of the eye.

No one who is at all acquainted with Ophthalmic Surgery is ignorant of the immense value of the profoundly scientific and eminently practical researches of Dr. Jacob, of Dublin: his writings I have studied with care.

To Mr. Wilde, of Dublin, I must also pay my tribute of thanks and admiration, and no less to my friend Mr. Browne, of Belfast, who have greatly assisted me by many important suggestions.

My colleague, Mr. Taylor, has rendered me most important assistance by working with me, and taking many of the sketches that adorn this volume.

I am under obligations to others whom I name not in detail, that I may escape the charge of parading the catalogue of my kind friends. To all and each, I tender my warm and respectful thanks.

The Illustrations, one hundred and sixty-nine in number, by the Messrs. Bagg, will doubtless fully sustain the high character which these Artists have acquired.

HAYNES WALTON.

69, Brook Street, Hanover Square.
December 31*st*, 1852.

PREFACE TO THE SECOND EDITION.

This is a New Edition in the fullest sense of the word.

The history of Ophthalmic Surgery, consisting of forty six pages, has been omitted.

Chapters II., VI., X., XXVI., XXVII., are entirely new.

Chapters I., XIV., XVI., XXII., have been re-written.

The remaining chapters have been either recast, or thoroughly revised in every page. I would allude particularly to the IV., V., XIII., XXIII., and XXV., as being those most changed.

Several new woodcuts have been introduced.

All of the many reviews of the last edition were most satisfactory to me. Some of them were by the highest Ophthalmic authorities in England, Scotland, and Ireland. That by the father of British Ophthalmology, Dr. Mackenzie, of Glasgow, in the "British and Foreign Medico-Chirurgical Review," and to which he appended his name, was the most elaborate, extended, and valuable. I have availed myself of many of the remarks and suggestions it contains.

There have been several reprints of the work.

From friends I have received numerous hints and more or less assistance; for all of which I am grateful. But I must particu-

larize among them, my colleagues Mr. R. Taylor and Mr. E. Hulme, the former of whom has besides overlooked the proof sheets with his characteristic kindness and carefulness.

Mr. G. H. Davis, a former pupil of St. Mary's Hospital, and a late House-Surgeon, has rendered me much help with the Index, which is very copious.

HAYNES WALTON.

69, Brook Street, Hanover Square, W.
July 1*st*, 1861.

PREFACE TO THE THIRD EDITION.

My former editions embraced only the surgical diseases of the eye. My present one, in its extended form, is in some sense, a new book.

In my earlier chapters clinical illustrations are freely used. As the volume progressed and threatened to be large I became more and more sparing in the use of such details, and in my later chapters scarcely any cases are narrated.

Several acknowledgments require to be courteously made.

To the literature of the age I am necessarily largely indebted. I have not made a bibliological display.

I have received assistance from many friends.

Mr. A. T. Norton, my colleague, has written the very concise anatomical introduction, and sketched with great care from recent specimens, the lithographic illustrations which accompany it. He has also helped me in looking over many of my proof sheets.

Mr. R. Taylor, my former colleague for many years at the Central London Ophthalmic Hospital, has also aided me largely with my proof sheets, and rendered other valuable service.

Dr. Clifford Allbutt, promptly and kindly, responded to my request, when I was very much pressed for time, and wrote Chapter XIV. on the Ophthalmoscope.

Several of my pupils have written a great deal to my dictation from notes, have looked up references, &c. I must particularize by name Mr. G. C. A. Moir, and my present House-Surgeon, Mr. Perkins.

To Mrs. Mackenzie, the widow of my late friend the great ophthalmologist of Glasgow, and to the publishers of his work, I am indebted for the use of several woodcuts, some of his modern ones, which adorn this book.

Dr. Maurice Davis kindly gave me the woodcuts, ophthalmoscopic and other ophthalmic drawings, which belonged to the late Mr. Zachariah Laurence, only a few of which I have been able to use, as my labour was nearly finished before I received them.

HAYNES WALTON.

1, Brook Street, Hanover Square.
January 1*st*, 1875.

CONTENTS.

PAGE

ANATOMICAL INTRODUCTION . . . . . xxi—xxxii

CHAPTER I.

OPHTHALMIC INSTRUMENTS IN GENERAL . . . . . 1—10

CHAPTER II.

ANÆSTHETICS.

The use of chloroform in ophthalmic surgery—Importance of preparatory measures—A proficient chloroformist often needed—Advantages of chloroform in early life—Operations on the adult eye in which chloroform is necessary—Question of using chloroform in the operation for the extraction of cataract—Cases in which chloroform may be dispensed with—Nitrous oxide—Bichloride of methylene . . . 11—15

CHAPTER III.

EYE-DOUCHES—EYE SYRINGES . . . . . 16—19

CHAPTER IV.

EYE SHADES . . . . . 20—23

CHAPTER V.

ENTOZOA.

Entozoa about the ocular appendages and within the eyeball—Cysticercus cellulosæ—Hydatid—Filaria medinensis—Filaria oculi humani—Distoma—Steatozoon folliculorum . . . . . 24—41

CHAPTER VI.

DISEASES OF THE ORBIT—INJURIES OF THE ORBIT WITHOUT AND WITHIN.

Orbital cellulitis—Periorbitis—Contusions and contused wounds on the orbital edge—Fractures of the orbit—Incised wounds of the orbit—Gun-shot wounds of the orbit—Foreign bodies within the orbit—Dislocation of the eyeball in connection with orbital injury—Caries of the orbit—Secondary necrosis—Chronic protrusion of the eyeball—Enlargement of the thyroid gland, and increased action of the heart, or Graves's disease—Rheumatic inflammation of the ocular tunic—Adhesion of the ocular tunic, with serous effusion—Effusion of blood in the orbital tissues—Intra-orbital abscess—Hypertrophy of the orbital cellular tissue—Hyperostosis of the orbital bones—Dilatation of the orbit from pressure within, together with absorption of a portion of the walls—Cysts in the orbital walls—Emphysema about the orbit . . . . . 42—117

CHAPTER VII.

Diseases of the Frontal Sinus.

PAGE

Anatomical consideration — Diseased conditions — Inflammation and abscess—Encysted tumours—Effusion of blood—Exostosis—Solid tumour—Fracture . . . . . 118—124

CHAPTER VIII.

Tumours.

Ocular tunic—Tumours of the eyelids; of the conjunctiva, and under it; of the sclerotica; of the cornea; of the orbit, without and within . . . . . 125—182

CHAPTER IX.

Protrusion of the Eyeball.

Protrusion considered in a diagnostic point of view—Acute and chronic protrusion, intra-orbital and extra-orbital—Causes—Position of the eyeball as a means of determining the cause of protrusion—Mobility, or immobility, as a diagnostic symptom—Amount of protrusion not invariably represented by the size of the protruding body—Protrusion not necessarily increased by the growing of a tumour—The effect of pressure on the protruded eyeball as assisting diagnosis—Diagnostic assistance from focal range—Condition of pupil—State of vision—Protrusion not admitting of diagnosis—Distinction between protrusion of the eyeball and enlargement . . . . 183—196

CHAPTER X.

Erectile or Vascular Tumours in Association with the Eye.

Capillary vascular tumour, or nævus maternus—Venous vascular, or cavernous tumour—Lymphatic cavernous vascular tumour—Arterial erectile tumour, or aneurism by anastomosis . . . . . 197—221

CHAPTER XI.

Aneurism in Connection with the Eye.

Aneurism in the orbit—Intra-cranial aneurism of the carotid artery—Vascular protrusion of the eyeball—Traumatic aneurism of the frontal branch of the ophthalmic artery—Aneurism of the central artery of the retina . . . . . 222—234

CHAPTER XII.

Geometrical Optics.

Light—Luminous bodies—A medium—A pencil—Refraction and reflection—Lenses and their properties—Cylindrical lenses—Orthoscopic lenses—Stenopæic spectacles . . . . . 235—256

CHAPTER XIII.

PAGE

Construction of Spectacles . . . . . 257—263

CHAPTER XIV.

The Ophthalmoscope.

Discovery of the ophthalmoscope—Conditions which conceal the eye from common observation—Erect and inverted image—Actual, or real image, as opposed to a virtual, or apparent one—Examination by the direct method; so as to see the erect virtual image—Examination by the indirect method; so as to see the real inverted image—A few words on ophthalmoscopes in general—Description of some of the ophthalmoscopes in use—Binocular ophthalmoscopes—Directions for using the ophthalmoscope—The normal aspect of the retina and of the optic disk—Anomalies of the fundus of the eye . . . . . 264—309

CHAPTER XV.

Examination of the Eye by Lateral or Oblique Illumination.

Examination by artificial light—Examination by daylight—Ophthalmo-microscope . . . . . 310—312

CHAPTER XVI.

Paralytic Affections of the Muscles of the Eye—Effects of Certain Agents, when Applied to the Eye, in Altering the Size of the Pupil.

Method of investigating the subject—Actions of the muscles that move the eyeball—Paralysis of the sympathetic nerve—Paralysis of the portio dura nerve—Paralysis of the third nerve—Paralysis of the fourth nerve—Paralysis of the sixth cranial nerve—Nystagmus—Luscitas—Ptosis—Myotics, or agents that contract the pupil—Mydriatics, or agents that dilate the pupil . . . . . 313—357

CHAPTER XVII.

Ptosis, or Falling of the Upper Eyelid.

Paralytic ptosis—Senile ptosis—Congenital ptosis—Ptosis from hypertrophy of the palpebral integument—Ptosis from falling of the eyebrow—Ptosis from erysipelas and inflammation of the conjunctiva—Ptosis from mechanical injury to the eyelid—Ptosis simulated—Supplementary operation . . . . . 358—364

CHAPTER XVIII.

Strabismus, or Squint.

Definition—Period at which it occurs—Internal squint: Causes—Morbid Anatomy—Varieties—State of vision—Treatment—Results—External squint: Pathology—Varieties—Causes—Treatment—Defects . 365—412

CHAPTER XIX.

Injuries from Mechanical Agents.

PAGE

Burns and scalds—Blows—Wounds . . . . . 413—461

CHAPTER XX.

Injuries to the Surface of the Eye from Chemical Agents.

Nature of accidents—Effects—Treatment . . . . . 462—467

CHAPTER XXI.

Wounds of the Eyelids, of the Surrounding Integuments, and of the Conjunctiva . . . . . 468—473

CHAPTER XXII.

Extirpation of the Eyeball.

Extirpation; including the entire contents of the orbit—Extirpation of the eyeball alone . . . . . 474—478

CHAPTER XXIII.

Artificial Eye.

Antiquity of the appliance—Manufacture—Conditions best suited for it—Advantages—Preparations—Mode of Application . . . . 479—484

CHAPTER XXIV.

Foreign Bodies on the Surface of the Eye—Larvæ of Insects under the Eyelids—Foreign Bodies within the Eyeball . . . . 485—511

CHAPTER XXV.

Anchyloblepharon—Symblepharon . . . . . 512—521

CHAPTER XXVI.

Diseases of the Excreting Lacrymal Apparatus.

Affections of the puncta lacrymalia and of the canaliculi—Displacement of the lower punctum—Displacement of the upper punctum—Affections of the lacrymal sac and duct . . . . . 522—561

CHAPTER XXVII.

Artificial Pupil.

Conditions under which an operation may be undertaken, and those which contra-indicate it—Relative advantages of the several positions for a pupil—Size of the pupil—Shape of the pupil—Classification of the principal morbid states of the eye requiring a pupil, with the appropriate operations—Concluding general remarks . . 562—598

CHAPTER XXVIII.

Anomalies of Accommodation and of Refraction of the Eye, etc.

PAGE

Accommodation—Paresis of the ciliary muscle—Spasm of accommodation—Mechanism of refraction—Acuteness of vision—Binocular vision—Presbyopia—Classification of these anomalies—Hypermetropia—Asthenopia—Myopia—Astigmatism . . . . . 599—667

CHAPTER XXIX.

Diseases of the Eyelids.

Restoration of the eyelids by plastic operations—Trichiasis—Entropium—Ectropium—Epicanthus—Inflammation of the eyelids and of the eyebrow—Œdema of the eyelids—Palpebral sweating—Congenital fissure of the eyelids—Abscess of Meibomian gland—Acne ciliaris—Herpes—Eczema palpebrarum—Xanthelasma palpebrarum . . 668—733

CHAPTER XXX.

Diseases and Injuries of the Crystalline Lens.

Cataract—Spontaneous dislocation of the crystalline lens . . . 734—844

CHAPTER XXXI.

Affections of the Conjunctiva, and of the Sub-Conjunctival Areolar Tissue.

Sketch of conjunctivitis—Simple catarrhal ophthalmia—Severe catarrhal or purulent ophthalmia—Purulent ophthalmia of infants—Granular conjunctivitis—Idiopathic erysipelatous conjunctivitis—Phlyctenular conjunctivitis—Diphtheritic, or fibrinous conjunctivitis—Cuticular conjunctivitis—Affections of the sub-conjunctival areolar tissue . . . . . 845—888

CHAPTER XXXII.

Diseases of the Cornea.

Inflammatory diseases—Corneitis—Phlyctenular corneitis—Diffuse corneitis—Punctiform corneitis—Neuroparalytic corneitis—Results of corneitis—Suppurative corneitis—Conical cornea . . . . . 889—933

CHAPTER XXXIII.

Diseases of the Iris.

Pupil-iritis—Syphilitic—Idiopathic—Rheumatic—Treatment . . . 934—954

CHAPTER XXXIV.

Ophthalmitis.

Ophthalmitis in general—Traumatic ophthalmitis—Pyæmic ophthalmitis 955—960

CHAPTER XXXV.

Sympathetic Ophthalmitis.

PAGE

Origin of the affection—Danger—Diagnosis—Time of appearance—Symptoms—Treatment . . . . . 961—966

CHAPTER XXXVI.

Diseases of the Sclerotica.

Colour of sclerotica—Hyperæmia of the sclerotica—Staphyloma of the sclerotica and choroidea—Total sclero-choroidal staphyloma—Partial sclero-choroidal staphyloma—Anterior annular choroidal staphyloma—Results of increasing sclero-choroidal staphyloma—Treatment—Ulceration of the sclerotica . . . . . 967—974

CHAPTER XXXVII.

Diseases of the Vitreous Body.

Inflammation of the vitreous body, or hyalitis . . . . . 975—979

CHAPTER XXXVIII.

Cancer and other Malignant Affections of the Eye, of the Ocular Appendages, and of the Orbit . . . . . 980—1000

CHAPTER XXXIX.

Benign Intra-Ocular Tumours . . . . . 1001—1007

CHAPTER XL.

Calcareous Concretions or Calculi; Tear-Stones, or Dacryoliths; Osseous and True Bony Deposits, about and in the Eye . . 1008—1012

CHAPTER XLI.

Fistula of the Eyeball . . . . . 1013—1014

CHAPTER XLII.

Diseases of the Secreting Lacrymal Organs.

Inflammation of the glandulæ congregatæ—Diseases of the lacrymal gland—Lacrymal fistula . . . . . 1015—1024

CHAPTER XLIII.

Entoptics.

Muscæ volitantes—Myodesopia sensitiva, or physiological muscæ . . 1025—1036

CHAPTER XLIV.

Syphilitic Diseases of the Eye.

PAGE

Orbit—Eyelids—Conjunctiva—Cranial nerves supplying the eye and its appendages—Congenital syphilis—Optic nerve—Retina—Choroidea . . . . . 1037—1044

CHAPTER XLV.

Painful Affections of the Tri-Facial, or Fifth Cranial Nerve affecting the Eyeball and its Appendages, apart from Pain arising out of Inflammation or its Consequences . . . 1045—1049

CHAPTER XLVI.

Insensibility of the Eye to Certain Colours, usually called in England Colour-Blindness . . . . . 1050—1053

CHAPTER XLVII.

Diseases of the Optic Nerve.

Retinal blood-vessels—Optic tract and optic nerve—Hyperæmia of the optic disk and the retina—General field of vision—Optic neuritis—Primary or white atrophy of the disk—Temporary partial interruption to sight—Amaurosis—Apoplexy of the optic nerve—Tumour of the optic nerve . . . . . 1054—1093

CHAPTER XLVIII.

Diseases of the Retina.

Neuro-retinitis—Retinitis albuminurica—Retinitis syphilitica—Retinitis leucæmica—Retinitis pigmentosa—Hyperæsthesia optica—Cystic or colloid disease of the retina—Embolism of the central artery of the retina—Detachment of the retina from the choroidea and from the vitreous body—Hemeralopia or day-blindness . . 1094—1134

CHAPTER XLIX.

Diseases of the Choroidea.

Physiological, anatomical, and ophthalmological remarks—Hyperæmia of the choroidea—Cyclitis—Choroiditis—Tubercle in the choroidea—Rupture of the choroidea—Detachment of the choroidea from the sclerotica—Colloid disease of the choroidea—Coloboma of the choroidea—Glaucoma . . . . . 1135—1174

ANATOMICAL INTRODUCTION.

THE EYEBALL CONSIDERED AS A WHOLE.

THE eyeball is nearly spherical, with a slight prominence in front. In a horizontal section one-sixth of the circumference is formed by the cornea, and the remaining five-sixths by the sclerotica. In its measurement, it is about one inch in the antero-posterior, and a little less, by one-sixteenth of an inch, in the lateral diameter.

PROTECTIVE PARTS OR TUNICS OF THE EYEBALL.

Cornea.

The Cornea is slightly overlapped by the sclerotica, and is continuous with it. *Structure.*—It has three distinct layers. An anterior, continuous with the surrounding conjunctiva. A middle, the true cornea, or cornea proper, constituting the principal thickness of the whole. A posterior, the posterior elastic lamina, or Descemet's membrane.

In a middle-aged adult it is about one-thirtieth of an inch in thickness. In youth, it is a little thicker. In old age, it is a little thinner.

The anterior or conjunctival layer, a continuation of a mucous membrane, is composed of epithelial cells lying upon a homogeneous sub-cellular layer. The cells are disposed in strata; the more anterior are flattened or tesselated. The more posterior are irregularly elongated, and vary in form between the columnar and the spheroidal type of epithelium.

The sub-cellular layer, known as the anterior elastic lamina of Bowman, is not always equally defined. It is homogeneous, and from $\frac{1}{1200}$ to $\frac{1}{2000}$ of an inch in thickness. Processes from it pass obliquely into the true cornea.

The middle layer or true cornea, is a dense fibrous tissue. A vertical section from a dried specimen, displays fibres arranged in strata, most of which are nearly parallel to each other, but some pass obliquely into the deeper layers. Their connection is so firm that they cannot be torn from each other. If such a specimen be soaked in glycerine coloured with carmine, the fibres swell and become less distinct, whilst elongated nuclei appear in their course.

The posterior elastic lamina resembles the anterior corneal layer, and consists

of a basement membrane, which is attached to the true cornea, and an epithelial surface which lines the front of the anterior chamber of the eye.

The first is transparent and homogeneous in its greatest extent; but its circumference is dark and fibrillating. From this fibrillation the posterior set of fibres pass in fasciculi, backwards to the iris, under the name of the anterior pillars of the iris, or ligamentum pectinatum iridis. The anterior fibres, comparatively few in number, pass in front of the canal of Schlimm to the sclerotica. The median fibres pass to the base of, and give origin to, the ciliary muscle.

The second is only a single layer of tesselated epithelial cells.

All that is transparent of this lamina is highly elastic, and when separated from the cornea, curls at its margin.

Blood-vessels are not traced into the substance of the cornea. From the quickness in which the circumference of the conjunctival layer may become vascular after an injury to the eye, especially of a chemical kind, it is probable that capillaries do pass over its margin, but are too small in their healthy state for the passage of blood corpuscles.

The nerves of the cornea. These are derived from the ciliary nerves, and are very numerous. Losing their outline, they divide freely beneath and in the substance of the conjunctival layer. Cohnheim states that their fibrillations terminate in the surface of the epithelium. Hulke has traced them through the middle tiers of these cells. It may however be questioned whether they end in, or even pass through, a tissue so changeable as epithelium. They more probably finish their course in the complete inosculating plexus which they form in the sub-epithelial layer.

The curvatures of the cornea are described in the chapter on the Anomalies of Accommodation, &c., p. 650.

Sclerotica.

Speaking of the general conformation of this coat, it is thickest behind where the optic nerve pierces it a little below and a little internal to the centre. It gets gradually thinner towards the front as far as a line immediately behind its junction with the cornea, where it again increases in thickness. Just at its junction its texture is traversed by a circle of small blood-vessels in a circular canal.

This canal, of Schlimm, is partly in the sclerotica, and partly in the cornea, that is between the anterior and the middle sets of fibres of the posterior elastic lamina of the cornea.

The contained fine vascular plexus communicates with the blood-vessels of the sclerotica, and through the ciliary muscle, also with those of the choroidea. The plexus is supposed to consist of veins. It is more likely composed of capillaries which supply the nutritive material for the cornea.

The outer surface of the sclerotica is bluish white. The centre is dense white. The inner surface is stained brown by the choroidal pigment.

Structurally, the sclerotica consists of fibrous tissue, in fasciculi which cross each other in a very compact areolar arrangement, running chiefly in a direction from behind forwards with a tendency to lamination. Reddish brown pigmentary matter is dispersed through it, particularly among the most internal layers.

From the inner surface fibres pass into the choroid coat.

To the outer surface, for about the distance of the third of an inch behind the cornea, the conjunctiva is attached.

Blood-vessels. These are branches from the posterior or short ciliary arteries and the anterior ciliary or muscular branches. In their passage through the tunic, they give off to it a few small twigs. The vascular choroidea within, and many surrounding vessels without, must be regarded as indirect nutritive supplies.

The nerves are few in number, and are derived from the ciliary nerves.

Choroidea.

Position. The choroid, or dark brown vascular coat, lies within and in contact with the sclerotica, and between it and the nerve layer or retina. Its proper structure terminates anteriorly on a level with the ora serrata of the retina, from which line it is continued forward to the iris by the ciliary body, a compound structure formed by the ciliary muscle, and the ciliary processes.

Structure. Although this thin coat is but $\frac{1}{200}$ of an inch in thickness, it is composed of five layers.

First, Externally Membrana Fusca, a fine areolar layer, containing brown pigment.

Second, Tunica Vasculosa, a layer of arterial and venous trunks, supported by areolar tissue. Into this layer enter the posterior, the long and the anterior, ciliary arteries, and as these vessels break from their point of entrance, converging or diverging rows of vessels make their appearance. It is probably this arrangement which gave rise to the name of vasa vorticosa.

Third, Capillary layer, or tunica Ruyschiana, composed of minute capillaries derived from the arterial and venous trunks of the second layer. This affords the pink colour when the eye is examined with the ophthalmoscope.

Fourth, Elastic lamina, or basement layer, of a homogeneous character.

Fifth, Epithelial layer, a single layer of large well-formed hexagonal cells, each containing a nucleus surrounded by pigmentary matter.

Within the structure of the choroidea, there is also found a quantity of pigment, some of which is red, and some black, destined for the purpose of absorbing the surplus rays of light which are not focussed upon the retina.

The last two, the elastic and the epithelial layers, are continuous with the same structure on the ciliary processes.

The Ciliary Body, composed of two parts, the Ciliary Muscle and the Ciliary Processes.

The ciliary muscle is a circle of involuntary muscular fibres, about $\frac{1}{11}$ of an inch in length, from before backwards, situated at the circumference of the iris. An antero-posterior section shows the muscle to be of a triangular form, with the base forwards. Externally, that is its superficial part, is in contact with the sclerotica; internally, it rests on the ciliary processes. Anteriorly, at its base, it is attached to the iris, and posteriorly at its apex, it is continuous with the choroid.

It arises from the median fasciculi of fibres from the posterior elastic lamina of

the cornea. The fibres pass backwards. The deeper strata about one-third the length of the superficial, curve round to insert into the base of the ciliary processes. The other strata pass with grades of obliquity backwards, to insert two-thirds into the connective tissue of the ciliary processes, and the remaining third, consisting of the most superficial and longest fibres, into the connective tissue of the choroid coat. Müller describes, in addition to the antero-posterior fibres, a belt of circular muscular fibres situated near the circumference of the iris, the existence of which is questionable.

Within the ciliary muscle are numerous blood-vessels and nerves, which together with connective tissue, come from the choroid coat. Through the ciliary muscle must pass all vessels as well as nerves, which go to the iris, and to the ciliary processes, so that, upon the contraction of the muscle must greatly depend the quantity of blood supplied to, or existing in those parts. Now since the ciliary processes consist chiefly of blood-vessels, it follows that they are capable of undergoing great variations in size, according to the quantity of blood they contain, and therefore of exerting a pressure upon the margin of the lens. A pressure upon the margin would render its poles more convex, and so regulate the accommodation of the eye.

The ciliary processes are a circle of radiating folds of vascular membrane, situated behind and within, and partly attached to the deeper surface of the ciliary muscle. They float within the posterior chamber of the eye, between the iris which is in front, and the lens with its suspensory ligament, which are behind. They are about seventy in number, and vary in length and size.

Each process is a delicate film of a pyriform shape, flattened laterally, and attached by its anterior margin to the ciliary muscle. Its posterior margin is free, and its base, also free, extends towards the pupil, and behind the iris, without being attached to the latter. Both the free margin and the base are festooned when the vessels are not dilated with blood. Each is surrounded by a thin elastic membrana limitans, of homogeneous character, supporting a great deal of dark pigmentary matter, and which is continuous with a similar structure lining, in the one direction, the inner surface of the choroid coat, and in the other, the posterior suface of the iris. Each is composed of loose connective tissue and reticulations of blood-vessels. An artery of comparatively large size, leaves the ciliary muscle, near to its apex, and having entered the process courses along its posterior margin. As it proceeds towards the base of the process, it gives off four or five branches from the concavity, all of which assuming a course somewhat similar to the parent vessel, enter the base in curves, and turn to loop with each other, and to be lost in a capillary plexus from which venous radicles commence. Numerous twigs are given off from the divisional branches which communicate freely with each other. A venous trunk returns beside the artery.

The posterior margins of the processes are impressed into the substance of the zonule of Zinn, both around, and also for some distance in front of the lens. By this means, alternating elevations and depressions are produced upon the zonule, and these being made more evident by the deposit of black pigment, have erroneously received the name of the posterior ciliary processes.

Source of supply of blood to the choroidea, and to the ciliary body.

The posterior or short ciliary arteries, ten or a dozen of them, perforate the sclerotica in the neighbourhood of the optic nerve, and each at once divides into

a lash of some six or eight branches which run for a distance between the sclerotica and the choroidea, and enter the tunica vasculosa of the choroid, where they end in smaller branches, and communicate with the posterior branches of the anterior ciliary arteries. They are subsequently distributed as capillaries in the capillary layer of the same.

The long ciliary arteries, four in number, pierce the sclerotica some distance in front of the former, and run between the sclerotica and the choroidea towards the ciliary muscle, where each divides into two.

The anterior ciliary branches are numerous twigs derived from the arteries supplying the recti muscle, and which perforate the sclerotica immediately behind the posterior margin of the ciliary muscle. Each trunk divides into a vortex of branches, some of which may be described as the posterior branches, and pass backwards to unite with the posterior or short ciliary arteries, and to be lost in the choroidea. Others may be termed the anterior branches, and pass forwards to unite with the long ciliary arteries, and with each other, and so form a chain round the margin of the ciliary muscle. From this chain, numerous twigs enter the ciliary muscle and communicate laterally. Through the muscle also, branches pass to the ciliary processes and to the iris.

The venous radicles are derived from the Ruyschian layer, and from the ciliary muscle, and through that muscle from the iris and the ciliary processes.

The venous trunks correspond to the arteries in position and in number, and after leaving the eyeball, finally fall into the ophthalmic vein.

The nerves, of the choroid coat, seem to be distributed to the blood-vessels. They come from the short ciliary branches which perforate the sclerotica close to the optic nerve, and ramify between the sclerotica and the choroid coat, before dipping into the latter.

PARTS SUBSIDIARY TO THE PERFECTION OF THE EYE, AS AN OPTICAL INSTRUMENT.

Iris.

General characters and attachment. The iris is a circular curtain which divides the anterior region of the eyeball into chambers. It has a nearly central circular aperture, the pupil, through which light reaches the retina, and by which the chambers communicate. Until the seventh month of fœtal life, there is no pupil, because the membrana pupillaris occupies its destined position.

The posterior surface is in contact partly with the ciliary processes, and partly with the crystalline lens. The intervening space, which varies very much in capacity, is the posterior chamber. In early life there is scarcely, if any, such space, therefore there is very little or no chamber. The anterior surface corresponds in extent to the cornea. The intervening space is the anterior chamber. The chambers are filled with the aqueous humour.

The circumference of the iris is much thinner than the rest of it, and is bent backwards over the bodies of the ciliary processes, to be attached to the ciliary muscle. By this arrangement, the main portion of the curtain falls in a plane about $\frac{1}{20}$ of an inch anterior to the line of its attachment, and when the pupil is contracted, and the iris thereby stretched, the ciliary processes are pushed backwards against the crystalline lens.

The chief portion of the circumference of the iris, its middle layer, is incorporated with the ciliary muscle, and is composed of areolar and elastic tissue, blood-vessels and nerves, but no muscular fibres. The anterior layer is continuous through the ligamentum pectinatum iridis, with the posterior lamina of the cornea, and is composed of membrana limitans supporting epithelial cells. The posterior layer, also composed of membrana limitans with epithelial cells, and thick dark brown pigmentary matter, is continuous with the corresponding structures of the ciliary processes.

On the anterior surface of the iris ridges radiate from the pupil. These are most apparent near the pupil. They are produced by puckering consequent on contraction of the sphincter muscle, and are less evident when the pupil is dilated.

Structure. The iris is mainly composed of involuntary muscular fibres, intermixed with elastic fibres.

Upon its anterior surface is a single layer of squamous epithelial cells, intermixed with some pigment, upon which the "colour of the eye" depends. Beneath the cells is a fine homogeneous layer with which the epithelium is connected. Upon its posterior surface are many layers of cells, nearly spherical, containing, and surrounded by, a large quantity of pigmentary granules. Beneath these also is a homogeneous layer. The anterior and posterior homogeneous layers, together with their covering of epithelium, is continuous, as has been explained, with corresponding tissues upon the cornea, and upon the ciliary processes.

The intermediate portion is composed of muscular and elastic fibres, of areolar tissue, and of vessels and nerves.

The muscular fibres are of the pale or involuntary class. They have a circular and a radiating form. The circular, in large bundles, are chiefly around the pupil, and constitute its sphincter. There are besides two or three small circular bands at intervals from the sphincter. The radiating fibres are arranged in fine fasciculi, intermingled with elastic fibres.

The elastic fibres also radiate, are numerous, very distinct, dark in outline, and wavy. The elasticity of the iris is due to them.

The blood-vessels supplying the iris, large and numerous, are derived from the circular chain at the posterior margin of the ciliary muscle. In their course they run through the ciliary muscle. They proceed towards the pupil without anastomosing. They divide, communicate laterally and form a circular anastomosis around the sphincter muscle.

The veins of the iris correspond to the arteries. They pass parallel with the arteries through the ciliary muscle, and are lost in the veins of the choroidea.

The nerves of the iris are derived from the ciliary nerves. Short ciliary branches from the lenticular ganglion, twelve in number, have already been described as perforating the sclerotica near to the optic nerve. Two long ciliary branches from the ophthalmic nerve, also perforate the sclerotica in front of the former. All pass towards the ciliary muscle, between the sclerotica and the choroidea. The short ciliary twigs give branches to the vessels of the choroid coat. Before arriving at the ciliary muscle, a division and an inosculation of all ensue. From this plexus branches pass into the cornea, and through the ciliary muscle into the iris, where they run towards the pupil, dividing and communicating with each other. As soon as they enter the iris, their outline becomes indistinct.

SPECIALLY SENSITIVE PARTS.

The Retina.

General disposition. The retina is the nervous layer situated between the choroidea and the vitreous body. It lies in adaptation to the former, without being incorporated. It has delicate connection with the latter, through prolongations or processes of its own homogeneous membrana limitans. It is freely attached to the optic nerve, with which it is in part continuous. It terminates at the marginal outline of the suspensory ligament of the lens, the posterior limit of the ciliary muscle, in a festooned border, the ora serrata. This border is marked upon the choroid coat, by a corresponding festoon of pigmentary matter.

Macula lutea. In the centre of the retina is a small elliptical spot about $\frac{1}{10}$ of an inch in size, called the macula lutea. Its centre is dark, appearing as if perforated, and is termed the fovea centralis.

Optic disk. Internal to, and somewhat below the macula lutea, is the optic disk, nearly spherical but with a slight tendency to a perpendicular ellipse. At this point, the optic nerve fibres perforate the sclerotica, to spread into the retina. In its centre appears the arteria centralis retinæ, and its accompanying vein.

Structure. The retina appears to be made up of at least three sets of tissues.

External layer. Rods and cones.

Intermediate layers. Nuclear and molecular matter.

Internal layers. Nerve tissues.

External layer. Rods and cones. This is termed bacillary layer, or membrana Jacobi. It is composed of a single layer of columnar bodies adapted laterally to each other, and supported by a homogeneous inter-substance. Some of the bodies are enlarged at their inner extremity, and are termed cones, whilst the rest, which are of equal size throughout, are termed rods. Ritter considers that both rods and cones consist of an envelope containing a medullary substance in which a nerve filament terminates. The inner extremities of the rods and cones are connected with an oval cell or nucleus, from which proceeds a fine filament through the retina to its innermost limiting membrane. These fibres which were first described by Müller, and which are called by his name, are connected with other cells in their passage through the retina, and at their attachment to the limiting membrane, they fibrillate in a pyramidal form.

It is separable from the rest of the retina as a distinct layer.

Its outer surface exhibits the rods and cones projecting, and not situated on an even plane. Their free extremities therefore appear clubbed or curved. A distinct line separates this layer from the next.

Intermediate layers, nuclear and molecular matter.

External granular layer. This is composed of spherical or elliptical particles, doubtless cells, completely occupied by a nucleus. Fibres may be seen connecting the particles to each other. The fibres of Müller pass nearly perpendicularly between them, and a very fine areolar tissue pervades the layer.

Intergranular or external molecular layer. Under a high microscopic power, this shows a composition of fibres, greater in number than the fibres of Müller,

which latter pass nearly perpendicularly. The fibres proper to this layer come from the particles of the outer granular layer, and many of them pass obliquely, some even transversely, and in the deepest portion of the layer, an anastomosis takes place.

Internal granular layer. This is made up of spherical or elliptical particles, nucleated, similar to those of the external granular layer, but they are contained within the spaces of a much more developed areolar tissue. The particles also are somewhat larger, and are not so closely packed.

Internal molecular layer. Under the $\frac{1}{4}$-of-an-inch objective lens, this appears to be finely dotted or molecular, but under one of the $\frac{1}{12}$-of-an-inch, it is seen to be a very fine and closely webbed areolar tissue. The fibres of Müller cross through it, and fibres of communication may be traced upwards to the areolar tissue of the internal granular layer, and downwards among the fibres of the optic nerve layer.

Internal layer. Nerve tissues.

The internal part of the retina may be looked upon as true nerve tissue. It consists of an innermost layer of nerve fibres, and external to this a layer of nerve cells.

The nerve fibres are derived from the optic nerve. As soon as these enter the retina, they lose their white substance, and continue only as a grey nerve or axis cylinder. From the optic disk they radiate outwards, dividing and inosculating with their smaller branches. Numerous filaments turn to communicate with the nerve cells of the outer layer, and probably terminate in them. They do not cross the macula lutea, but pass around its circumference.

The nerve cells are intermixed with the nerve fibres, but they are also congregated into a layer external to the fibres. They are nucleated, and correspond in form to ganglionic nerve cells. They are caudate, or multipolar, and from them proceed filaments which communicate with other cells and with the nerve fibres.

The arteries of the retina are derived from the arteria centralis retinæ, which makes its appearance in the centre of the optic disk. The artery divides, into from three to six branches, which radiate from the disk. From these vessels a complete capillary network is produced, which traverses the whole structure of the retina, with the exception of the membrana Jacobi.

The veins correspond to the larger radiating branches of the artery.

A fine membrana limitans bounds the retina internally, and separates it from the vitreous body. The structure of this membrane must be looked upon as homogeneous connective tissue. It is difficult to trace any fibrillation, but connective tissue corpuscles may be found in it. With it, the fibres of Müller are connected, spreading into a cone at their attachment.

From the membrana limitans, processes of similar structure may be distinctly traced into the substance of the vitreous body connecting the two together. These have been alluded to in speaking of the retinal attachments.

Macula lutea. At the macula lutea the retina is remarkably thin and appears perforated. The layers are here differently disposed. The nerve fibres do not cross over the spot, but on reaching it they diverge and pass around it. The granular and intergranular layers are absent, but the nerve cells occur in small quantity. Fibres of Müller are present. The colour of the macula lutea is considered to be due to pigment proper to the region, but no doubt

the pigment of the choroid is visible to an extent through the thinnest portion of the spot. Minute capillaries course up to the macula and form recurring and anastomosing loops, but none pass in front of it.

DIOPTRIC PARTS. REFRACTIVE MEDIA, OR LENSES.

The Vitreous Body.

The vitreous body is a highly refracting transparent glassy substance, occupying a large portion of the space within the coats of the eyeball. In form it is rather more than half a sphere, *convex* in every surface except anteriorly, where it is in part flattened by the suspensory ligament of the crystalline lens, and in part excavated or concave, for the reception of the posterior surface of the same.

Its convexity is adapted to the limiting membrane of the retina, to which it is somewhat firmly attached, by very numerous processes of homogeneous tissue.

Structure. It is surrounded by a capsule, termed the hyaloid membrane, and its substance is composed of processes of this membrane which extend inwards, and form an areolar network, the spaces of which contain a fluid holding in solution salts and a small quantity of albumen.

In fœtal life connective tissue nuclei and stellate cells are detected within it, but they are few in number, and at a later period are not to be found.

If the vitreous body be removed from the coats of the eye, the fluid rapidly drains away, and a small quantity of filmy membrane remains.

This hyaloid membrane is, without doubt, fibrous tissue. The fibres of the capsular portion do not cross each other to any great extent, but have a tendency to run parallel. Fasciculi pass from it through the substance of the vitreous body. These cross each other, and produce the areolar spaces above alluded to. They cannot be exhibited within the vitreous body unprepared, for they are swelled by infiltration, and are further rendered invisible by the density of the fluid. The fluid is therefore contained within the areolar spaces, and in the substance of the infiltrated fibres. The fibres become apparent after the vitreous body has been immersed for a time in a solution of chromic acid.

When the vitreous body is boiled, it becomes opaque by the coagulation of albumen, and a continuation of the boiling process causes it to contract to about one-fifth of the size of the crystalline lens, beyond which it will not decrease.

Blood-vessels are not supplied to the vitreous body. It must receive therefore its nourishment by imbibition. But in fœtal life, a branch from the arteria centralis retinæ is continued from the optic disk through it, and breaks up in a cone of small branches upon the posterior capsule of the crystalline lens.

Nerves are not found within it.

SUSPENSORY LIGAMENT OF THE CRYSTALLINE LENS.

The suspensory ligament of the lens may be said to commence where the retina terminates, that is, close to the posterior margin of the ciliary muscle. It has

no attachment whatever to the choroidea, or to the ciliary muscle, for the limiting membrane of the ciliary processes, together with the pigmentary layer, are continuous with the corresponding structures of the choroid coat, passing between the suspensory ligament and the ciliary muscle. There is no separation between the suspensory ligament and the anterior portion of the hyaloid membrane. In fact the ligament appears to be that structure increased in thickness and strength by elastic fibres and perhaps by the addition of fibres derived from the connective tissue of the retina.

The suspensory ligament is highly elastic, and though a large portion of it appears homogeneous, yet it contains fibres radiating from the centre towards the circumference. A few cross each other.

It lies in front of the crystalline lens, and is firmly attached to the anterior surface of its capsule, with the exception of a small portion around its circumference. By it, the anterior capsule is considerably increased in thickness, and by it also, the lens is flattened and compressed into the vitreous body.

Ciliary zone. The anterior surface of the suspensory ligament is deeply indented by the ciliary processes, and between the indentations it projects in folds or ridges. For this reason the term zonule was applied by Zinn, hence zonule of Zinn. The plaits or ridges have received, as before mentioned erroneously, the name of the posterior ciliary processes. When the true ciliary processes are removed, much of the black pigment remains adherent to the plaits, making them as distinct as ciliary processes.

Canal of Petit.

As the crystalline lens frequently alters its shape, increasing or decreasing in circumference, according as it decreases or increases in depth from before backwards, it follows that the vitreous body must give way at the equator of the lens, or that there must exist a cavity between the suspensory ligament and the vitreous body, in order to receive the circumference of the lens during its enlargement. There is then a channel, termed the canal of Petit, surrounding the lens. It is about $\frac{1}{12}$ of an inch in size. It has fibres crossing it, and in consequence of which, when it is filled with air by a blow-pipe, it has the appearance of a circular chain of beads.

CRYSTALLINE BODY, COMPRISING THE LENS AND ITS CAPSULE.

The capsule of the crystalline lens is a transparent, homogeneous, highly elastic envelope, which encloses the lens. It is arbitrarily described as anterior and posterior capsule. The posterior capsule rests within the excavation of the vitreous body, to which it is attached through the medium of the hyaloid membrane. The anterior capsule is much thicker than the posterior, being increased by the addition of the suspensory ligament of the lens, except at its margin, which is beyond the attachment of the ligament. Between the anterior capsule and the lens is a layer of nucleated cells of large size. They are chiefly polygonal in form, but towards the margin they become oval and imbricated. They are considered to influence the nutrition of the lens, and after death, by absorption to produce the fluid contained within the capsule, to which has been given the name of the liquor Morgani.

Neither blood-vessels nor nerves are distributed to the capsule except in fœtal life, when a branch from the arteria centralis retinæ, the capsular branch, passes through the vitreous body, and is expended on its posterior surface.

The crystalline lens is a nearly circular, bi-convex disk, contained within its capsule, which closely invests it.

The posterior surface is the more convex of the two, and lies within the lens fossa, or excavation in the vitreous body.

The anterior surface, the flatter, with the suspensory ligament intervening, lies in contact with the bulbous extremities of the ciliary processes, which overlap its equator, and with the iris, which, when accommodated for near vision, it slightly pushes forwards. Its pole corresponds to the centre of the pupil.

The lens is kept in position by the vitreous body, the posterior capsule being attached to the hyaloid membrane, and by the suspensory ligament, which is connected with the anterior capsule.

Structure. When a lens is boiled it becomes pearly-white and hard, from the coagulation of the albumen which enters into its composition, and it will now readily separate in concentric laminæ or in planes. An extension of the boiling will cause either the laminæ, or the planes, to separate into shreds which are the lens fibres.

If a lens be carefully examined both surfaces present three lines radiating from the centre or pole, to the circumference or equator, as though dividing the surfaces into three triangles. The lines of the one surface do not however correspond to those of the other surface, but lie in an intermediate position. These lines may be recognised, in a normal lens, during life, by oblique illumination.

The lens fibres are considered to be tubules of protein in early life, but afterwards to become solid. They have numerous nuclei connected with them, and their cut extremities are hexagonal. The fibres of each lamina are all about the same length. Some commence from the centre or pole. Others from the radiating lines. All pass over the equator to the opposite surface, but their terminations differ. Those which commenced at the pole, extend to a point but just over the equator, whilst those which commenced from the lines, extend in graduation, further and further over the equator, till the lowest approaches the opposite pole. It is owing to this arrangement that the radiating lines of the two surfaces do not correspond, but alternate in position.

The lens possesses no blood-vessels, but receives its nourishment through the fluids with which it comes in contact.

Nerves are not distributed to it.

Chambers of the Eye.

Between the crystalline lens, and the posterior surface of the cornea, there exists a cavity separated into two unequal parts by the iris. These are the anterior and posterior chambers of the eye. They communicate through the central aperture, the pupil. The anterior chamber is bounded in front by the cornea, and behind by the iris. The posterior chamber is bounded in front by the iris, and behind by the crystalline lens, with its suspensory ligament, on which are impressed the ciliary processes, so that the anterior chamber is far

the larger of the two. They cannot be called a serous cavity, for it is acknowledged by all observers that there are no epithelial particles covering that portion of the boundary which is formed by the lens.

The chambers are occupied by a watery fluid, termed the aqueous humour. It is composed of water containing a small quantity of the salts of the blood, and is probably secreted by the vessels of the ciliary processes, and also by the epithelial layer of the cornea and of the iris, for it is understood that, when the chambers are separated in fœtal life by the membrana pupillaris, each is then occupied by the fluid.

This anatomical description of the eyeball embodies new facts. Some of these bear on the mechanism of accommodation, a subject of sufficient physiological interest to entitle them to particular notice, especially as they support a theory different to the one generally accepted, and which is given in the chapter on the Anomalies of Accommodation and of Refraction of the Eye, &c.

It is a matter of anatomical deduction, that while the ciliary muscle is the motor power for the effect of accommodation, the ciliary processes are the agents through which the action is accomplished, and that the rapidity of the accommodation is due to the action of the iris.

The blood-vessels of the ciliary processes pass through the ciliary muscle near to its apex. Contraction of the muscle therefore produces an erectile condition of the processes, which in consequence, overlap and compress the equator of the crystalline lens. By such compression, the lens surfaces are rendered more convex, and the eye is focussed for near vision. Complete erection cannot be momentary, and to obtain rapidity of accommodation, the iris comes into play.

A reference to the plate will show that the plane of the iris is $\frac{1}{20}$ of an inch in advance of its attachment. Pupillary narrowing, as is well known, is associated with accommodation for near vision. When the sphincter pupillæ contracts and narrows the pupil, it draws upon the line of attachment of the iris, and throws the iris plane back upon the ciliary processes, which in turn are pressed against the crystalline lens. If it be said that the iris pressure would rather flatten the processes than compress the lens, the answer is, about two-thirds of the fibres of the ciliary muscle, as the delineation shows, are inserted into the connective tissue of the processes, so that when the muscle contracts, the processes are drawn towards it, and rendered tense upon their contained vessels.

No doubt, the arrangement of the fibres of the ciliary muscle would enable accommodation to be carried on without the aid of the iris, an explanation of the well-known statement of Graefe, to the effect that, in an individual instance in which the iris was absent, accommodation was not destroyed. That it was imperfect, cannot be questioned, for the rapidity of action, a characteristic of the healthy eye, must have been absent.

A PRACTICAL TREATISE ON THE DISEASES OF THE EYE.

CHAPTER I.

OPHTHALMIC INSTRUMENTS IN GENERAL.

It is easy to comprehend the extent of influence exerted over the success of a surgical operation by the perfection or imperfection of the instrument with which it is performed; and if this be the case in surgery at large, it is more particularly true in ophthalmic operations.

To lessen the defects of an instrument is tantamount to an improvement in the branch of surgery to which it belongs. Simplicity and due adaptation to the purpose intended are the qualities which a surgeon who operates on the eye should endeavour to acquire for his implements. The improvement of those in our day contrasts advantageously with the coarseness of form and inferiority of workmanship in times past. For these reasons alone I should deem it proper to notice the subject; but, further, I take this view of the matter, that in treating of any department of operative surgery, an opportunity for communicating practical instruction is lost when hints and observations on the instruments concerned are omitted.

The plan adopted is, to introduce the several instruments with the subjects requiring their use, and to describe them apart from the operations, as it possesses the advantage of securing a fuller attention for them than if they were spoken of digressively; while the descriptive details of the operations, being uninterrupted, will be the easier understood. Some few, of general use, will be given at the end of this chapter.

As each instrument will be illustrated by an engraving which will convey exact ideas of it, those parts only which deserve especial attention, or which the figure less prominently sets forth, will be dwelt on in the description. Those only are introduced that I am actually in

the habit of using, and which appear to me to be the most appropriate to each operation, and the most convenient for the several purposes which they are intended to fulfil.

With Ophthalmic Instruments, lightness is an element of the highest importance. The lighter they are, the greater is the delicacy with which they can be applied. With light instruments the resistance to be overcome is better appreciated, as well as the amount of force required for that purpose. The blades should be highly polished, and never of greater size than the use intended requires. Advantage is attained by exchanging the ivory handle so generally adopted, notwithstanding the nicer appearance, for one of light wood. The minimum of the dimensions compatible with the kind of instrument should be made the rule. In successive years, as I have required to renew my instruments, I have gradually had their size reduced; and the effect has been to adapt them better to the several operations. Besides remedying the clumsiness and awkwardness which attach to those of greater bulk, in several instances positive evils, arising from inordinate size, have been avoided.

To all small instruments, such as cataract knives, cataract needles, and the like, I prefer round handles; for, when of this form, they can be held with more ease and freedom, while stiffness and constraint are overcome, and a more individual independent control is thus given to the fingers. I am also of opinion that the handles should be smooth and not cross-cut. There can be no other reason why the handle of a surgical instrument should be roughened, and thereby rendered unpleasant to the touch, as well as less suitable for delicate use, than that surgeons, having been careless about the subject, have permitted the instrument-maker to indulge his fancy, merely to give an air of finish to his workmanship. I believe it to be true, and if so, it is a fact of much significance, that a mechanic never uses rough-handled instruments.

All instruments designed to puncture the cornea should have such a form, from the gradual increase of thickness from the point, as to act on the principle of a stopper in the aperture that is made. The effect of this is to retain the aqueous humour as long as possible, so that the natural prominence of the cornea is for a time preserved, and the subsequent steps of the operation are facilitated. The gradual augmentation of size sufficient for this purpose, while at the same time a proper stiffness of point is preserved, need not, in cataract needles, exceed at the largest part from 1-36th to 1-40th of an inch.

Sharpness of point, and keenness of edge, are of paramount importance; and these qualities of a perfect instrument should be carefully sought after, and ascertained by delicate processes. The little drum

is the best criterion I know of to test the point of an instrument. It is made of leather stripped from the softest kid skin, and stretched over a metallic cylinder, of which the annexed figure is a representation. A less perfect method is, to stretch the leather across the fingers. In either case, if the point be in order, little more than the weight of the instrument should cause it insensibly to penetrate the tissue. If, on the contrary, the point be dull, it requires to be forced through. If otherwise defective by being turned or broken, in addition to the force required to make it penetrate, a sharp cracking sound is emitted. A well-made needle, then, enters noiselessly, and when withdrawn raises the leather a little at first.

In consequence of the natural pores in the leather, several punctures should be made, to ensure the passage of the point of the instrument through an unbroken space.

Fig. 1.

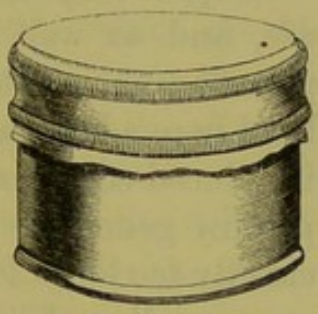

The edge should be tried on the palm of the hand where the cuticle is thinnest; for instance, on the ball of the thumb. With a slight drawing motion it should at once enter, or bite, as instrument-makers say.

Properly tempered instruments may always be secured by dealing at some highly respectable London shop, where each, from the largest to the smallest, is separately hardened, and individually tempered, and where the extent of sale is such as to enable the maker to maintain in constant employment a workman whose sole occupation it is to manufacture delicate instruments of this class. By such exclusive attention alone can the highest perfection be reached.

It is necessary, also, that scissors be inspected. Their efficiency depends not only on the blades being properly sharpened, but also on their being lightly made and securely riveted. The simplest, and, at the same time, the surest test, is to close the blades gently and without any lateral pressure, on a very thin piece of wetted paper; when, if properly made, they will readily divide it, if not they will close over it without cutting.

I cannot refrain from adding a remark on sponges. It would hardly be supposed that the success of an operation can, in any degree, be

dependent on the mere purity of sponges; yet the partial or even the entire failure of the process of adhesion may be caused by the transmission of particles of sand from them to the surfaces of wounds. The impossibility of buying a new sponge that is not loaded with earthy particles is well known. To remove these, time is requisite; washing, necessary as it is, cannot at once cleanse it. The very best method of ridding it of grit is, to employ the best sponge of the shops for common domestic purposes for several months, taking care that on frequent occasions, when dry, it is beaten for some time.

Fig. 2.



Fig. 3.



Fig. 4.



Scalpel.—An instrument in such general use, and so well known, would have been passed over in silence, were it not that the kind here advocated, my ophthalmic scalpel, is reduced considerably below the size of scalpels in general. The ordinary ones are decidedly too large for all dissecting operations on a small scale, especially on the eyelids, where very much precision and neatness are imperatively demanded; and also for the removal of tumours about the eye and its appendages, and those which encroach upon the orbit, or are within it. The point is placed centrally, and this position, while it allows of a requisite amount of curve, renders it better adapted for minute dissection than when it is in a line with the back of the blade; and in a central point there may be the union of the greatest fineness with the greatest strength. In nearly all operations with the scalpel, it is the point of the blade that is principally available, and to its properties the value of the knife is chiefly due. The breadth of the handle is of some consequence, for, if carried beyond a certain extent, it is not so readily used. I also recommend that the part to which the points of the fingers are applied should be round. The length may be what fancy suggests, unless, as is the case with myself, the instrument be held in a particular manner,

as a common table-knife is held, my fingers being placed near the blade, a method which demands shortness of handle. This mode of holding it I adopt for almost all purposes, finding that it combines the greatest freedom of motion with the greatest power, and the lightest touch.

Forceps.—The proper length for ordinary dissecting forceps is such as allows them to rest on the hand between the thumb and the finger, when held in the ordinary manner; any beyond this is useless, and increases weight. The blades should be slightly bowed, well-hardened, and of a substance, in thickness rather than in breadth, that will not allow them to slip on each other, or bend under any force of pressure that can be required during their use. Were their extremities to gape, which they surely would if the centres of the blades were weak, they must cease to be effectual. The spring should not be made stronger than sufficient to sustain their weight. Round points are, I think superior to any other form. The holding or interior surfaces of the extremities should be raised and obliquely cut for at least a quarter of an inch, the serratures being large, and exactly fitting. This roughness is quite compatible with an accuracy of edge adapted for minute purposes.

It is frequently required to use tenaculum forceps in operations about the ocular appendages, for the ordinary ones do not lay hold with sufficient firmness. The lesser figure, representing merely the points of such, shows the direction the teeth should have. When so placed, they seize more readily than when made to meet at a right angle, although they cannot retain their grasp quite so securely. In order to be effectual, their blades should be stout enough to enable sufficient pressure to be made at the points. When shut without an intervening substance, the teeth necessarily cross. A catch-spring, like that usually added to tenaculum forceps, and originally introduced for Amussat's treatment of bleeding arteries by torsion, is not only useless for dissection, but a decided impediment.

Delicate Forceps, straight and curved, some with ordinary points,

Fig. 5.



others with teeth, are needed for minute operations, and especially for operations on the eyeball, and particularly for artificial pupil.

Annexed are those I generally employ. One of them has a cross action, by which it can be opened when the points are within the eyeball.

Fig. 6.



Fig. 7.



Fig. 8.

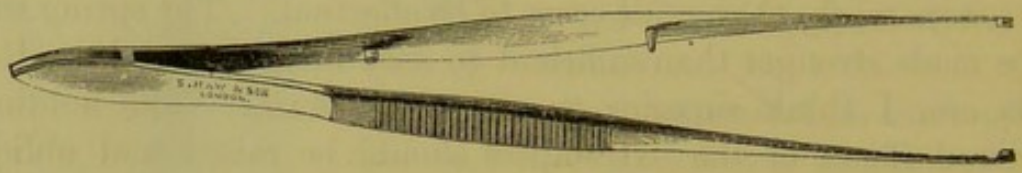

Fig. 9.



A broad and deeply serrated edge forceps, with lock-catch, is useful on some occasions for holding securely parts that are to be dissected away.

Fig. 10.



A pair of catch-spring forceps, very wide and smooth, are very convenient for holding the eyelid and everting it in post-palpebral operations.

Fig. 11.

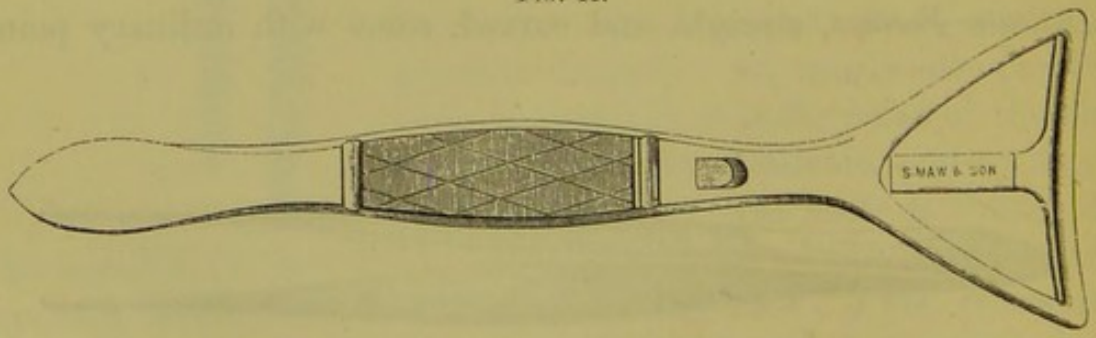

Eyelid-retractor.—Of the many single instruments in use for the purpose of retracting the eyelids, whether to procure an examination

of the eye or to facilitate the performance of operations, I give the preference to this, which is designed to be passed within the eyelid, and which is of full size for an adult. For infants and children a smaller one is necessary. Its length and lightness are such as to enable it to be applied with delicacy, and to be maintained in the desired position without the exercise of force. The bent portion deserves attention. It should not be longer or more obtuse than is sufficient to secure and confine the edge of the eyelid, otherwise its action might be detrimental; because if the sinus or sulcus of the eyelid were reached, a resistance would be immediately encountered, which would not only prevent the eyelid from being properly raised, but be a source of pain, owing to the dragging and violence then requisite to effect any degree of retraction.

Fig. 12.



Double Wire Eyelid-retractor.—This might be called the operator's assistant, as it quite supersedes the fingers of an assistant in nearly all the operations that need efficient retraction of the eyelids. It is more generally useful than any instrument in the ophthalmic case. It is rather less effective when used without chloroform, because the involuntary muscular action of the orbicularis palpebrarum overcomes much of the spring force. It is well to have two sizes: one as in Fig. 13, applicable for most purposes, and a smaller for children. The manner of application can hardly be mistaken. The spiral or spring part, the outer end, is to be on the temporal side of the eye, while the retracting portions, at the ends of the blades, are to be inserted under the eyelids. It is an improvement to have the outer end bent, so that it turns over on the cheek, and is more out of the way of the operator. I use this almost exclusively.

Fig. 13.

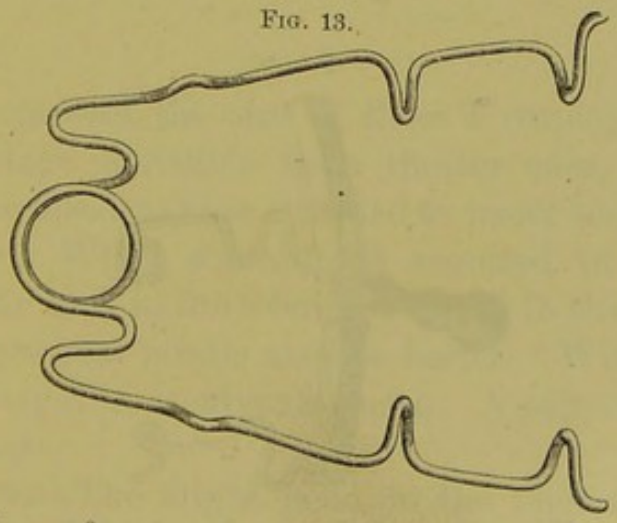

This description of retractor is also made with a cross-bar and

binding screw, so that it can be fixed to any degree of expansion, and accommodated to different eyes; so modified, it is more applicable to children, or to adults when not made insensible by an anæsthetic. Here is a sketch of the instrument.

Fig. 14.

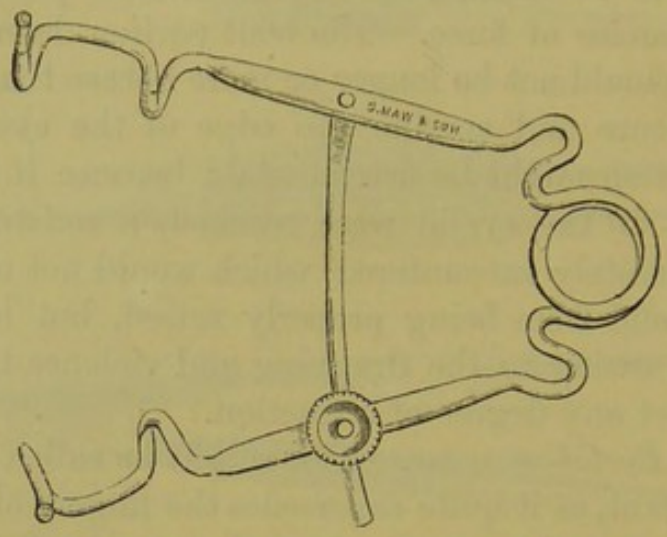

Another is constructed for the spring part to pass over the nose, so that the outside of the eye shall be left free for any necessary use of instruments.

Fig. 15.

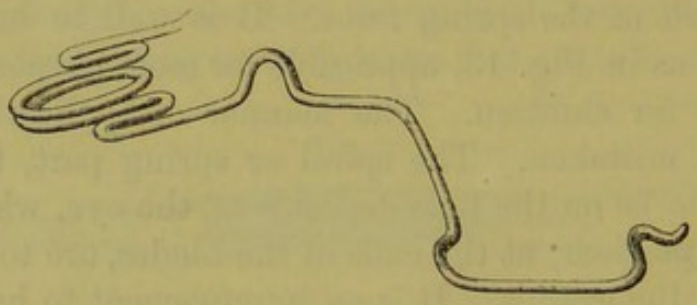

An American retractor has just appeared, as a new invention. It is very small, and acts with cogs.

Fig. 16.

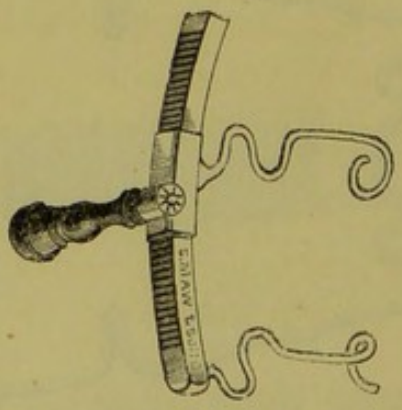

Suture Needles.—That the stitching of wounds is very often the most

painful part of an operation is a fact early impressed upon the student of surgery. Without doubt, much of the suffering is too frequently to be attributed to the imperfection of the needle. Good surgical needles are rarely to be met with, merely because their manufacture is in general neglected, and they are not rendered hard enough to bear proper sharpening. The point, or cutting part, should be large enough to make a channel though which the shaft can glide with ease, or at least pass without force sufficient to stretch or tear the skin. These requisites seem to be fully united in the well-formed glover's needle, which has three edges, of which Fig. 17 is an illustration. The stoutness should be proportionate to the thread which is required; by

Fig. 17.

which standard, indeed, the size of a needle should invariably be regulated. The length is a matter of convenience. Where circumstances admit of choice, I always prefer the straight form, because a straight needle enters more readily, and is more easily guided than a curved one.

A different body is desirable for a bent needle. The front, or concave part, should be quite flat from side to side, and the posterior, or convex side, oval across. If both are oval, the edges cannot be made thin enough consistently with smallness and strength. This pattern illustrates the description.

Fig. 18.

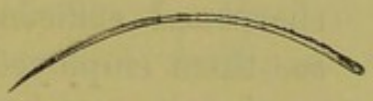

The figures represent the size of those I employ. Besides there being no advantage derivable from shorter ones, for ordinary use there is a positive disadvantage attached to lesser length, arising from difficulty in use. When stitching is required in the corner of a sunken eye, or far back in the sclerotic coat, as in the case of a wound, a smaller and more bent needle may be better. With such, a needle-holder, or porte-aiguille, is advantageous. A pair of common forceps is a good substitute.

Curved Scissors.—The slight bend in the blades of these scissors renders them very useful on many occasions, and the ophthalmic case

is scarcely perfect without them. The points should be of a certain width, and not too delicate, in order to ensure proper strength.

Fig. 19.

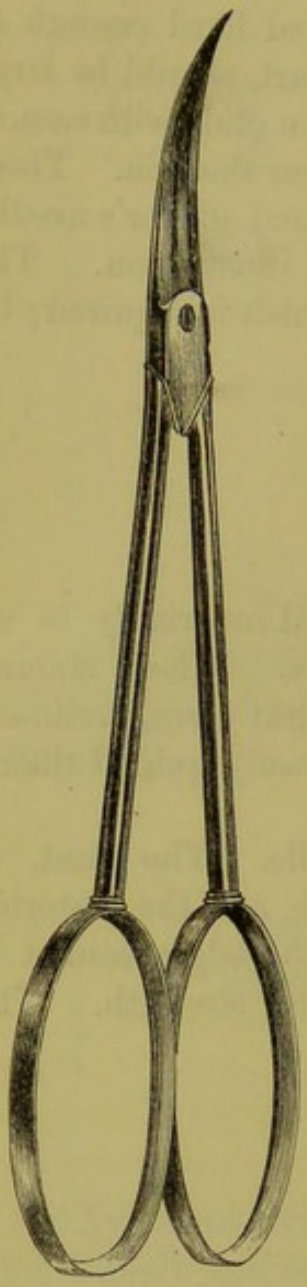

Messrs. Weiss have registered two kinds of joints for scissors, and other double-bladed instruments of the same class. The one is called the lever joint, the rivet being placed at the side in an angular projection; by which it is said that greater power is given, and the mode of cutting is rather improved, and a substance is less likely to slip from between the blades. The other, which I highly approve of, is a sort of lock-joint, a screw not being used, and the advantage of which is, that the blades do not become loose, but ever keep their degree of tightness, and the instrument can be the more readily used with either hand, and easily unlocked for the purpose of being cleaned.

I have seen scalpel edges recommended for scissors that are intended, like these, to be used for cutting the living tissues. Such are impracticable. At the same time, the blades should be made as thin as is consistent with efficient use, for there is a great difference in the practical effect between those of ordinary make and those so prepared.

I would suggest that scissors are not sharpened sufficiently often. I frequently see them employed when they are long past service.

CHAPTER II.

ANÆSTHETICS.

THE USE OF CHLOROFORM IN OPHTHALMIC SURGERY—ALLUSION TO NITROUS OXIDE AND BICHLORIDE OF METHYLENE, AND FREEZING THE SURFACE—IMPORTANCE OF PREPARATORY MEASURES—A PROFICIENT CHLOROFORMIST OFTEN NEEDED—ADVANTAGES OF CHLOROFORM IN EARLY LIFE—OPERATIONS ON THE ADULT EYE IN WHICH CHLOROFORM IS NECESSARY—QUESTION OF USING CHLOROFORM IN THE OPERATION FOR THE EXTRACTION OF CATARACT—CASES IN WHICH CHLOROFORM MAY BE DISPENSED WITH—DEGREES OF ANÆSTHESIA FROM CHLOROFORM—NITROUS OXIDE—BICHLORIDE OF METHYLENE.

Special application.—In the former editions of this work I went fully into the subject of chloroform, considering it in all its bearings. Now I shall merely give but a few general hints about it, and confine nearly all I shall say to its application in Ophthalmic Surgery.

Necessity for preparatory measures.—Much detrimental interruption from the vomiting of a patient during an operation, and after-discomfort, frequently arise from neglect in preparatory measures. I earnestly advise the operator to see that all the details connected with the administration of this valuable agent be thoroughly attended to, in order to avert suffering and danger, and also to secure its full benefit.

Insensibility imperative.—Many an operation is spoiled on account of a patient not being sufficiently insensible. In ophthalmic practice the last stage of insensibility is needed.

Obtain a proficient Chloroformist.—Whenever an operation is of such a nature as to demand the prolonged attention of the operator, the assistance of a proficient chloroformist ought to be secured, for I have found that if the administration be undertaken by a chance person,

or, as more frequently happens, by the general medical attendant of the patient, frequently it is so inefficient, that I have to be the chloroformist and the operator too, so little is the process generally understood, although attention to a few rules, with some opportunities of actual practice, will enable most men to officiate with safety. I say most men, because the physical incapabilities of some wholly unfit them to see with composure the convulsions and struggles that might arise, or to exercise the necessary judgment and perseverance not unfrequently required with those persons who are less easily affected.

Period of life at which chloroform is indispensable.—In infancy and in childhood chloroform does afford very great help in all operations on the eye, for without it resistance on the part of the little patient is certain. Besides, the very diminutiveness of the young eye, whereby there is much less room for the use of the fingers and for instruments, together with the greater delicacy of the parts, demand that when the eyeball is the subject of operation, there should be the utmost exposure of it together with the greatest steadiness. I declare it to be impossible, except under a degree of force or mechanical contrivance that would not be tolerated in these days, to operate in the best manner on such subjects without chloroform. It is curious to read of what was done in former times to procure stillness, but never with a full effect.

Children and young persons are the best subjects for chloroform. The younger the individual, the quicker is the effect produced, and the quicker is it recovered from with the least unpleasant effect. I have great trouble in convincing parents of this, because they suspect the very opposite. I often employ chloroform merely to examine the eye in children. It repeatedly happens when the little patient is brought to me, that the true state of the eye can be ascertained only under insensibility.

Conditions in adult life under which the use of chloroform is advisable.—I now pass to those operations on the adult eye in which considerable assistance may be received from insensibility. There should be a distinction between such cases as require chloroform merely because of lack of moral courage, and those in which it is of positive advantage under any condition; as in the one we may leave the choice to the patient, or we may object; in the other it is our duty to recommend it. The majority of operations for artificial pupil, especially where the proceeding is complicated, and requires the use of more than one instrument, or the re-introduction of the same, fall under the latter category. An eye, for the most part, that requires this aid, is much damaged in several of its tissues, and has, perhaps, been recently the subject of inflammatory attacks. Such an unfavourable

and delicate state is not suited to long-continued manual efforts. The vitreous humour, too, is frequently more or less disorganized. There is needed the greatest steadiness of the eyeball, with continuance of a given position, and an absence of much pressure. Now the movements of the eyeball may be quite involuntary, and the eyelids will twitch, in spite of the most resolute will. But not the least disadvantage of consciousness is the compression that the straight and oblique muscles can, and do, exercise in such operations. When acting violently, they exert considerable influence; and the effect of such an agency, at such a time, is always hazardous, in several ways. Again, the sooner the manipulation ends, and the instruments are out of the eye, the more certain is the result. These remarks may be said to apply, in the main, when the eyeball is to be opened for the extraction of any body, be it capsule, animalcule, or any particle driven into it from without, and decided difficulty in operating, or intricacy is apprehended. So then, with the fullest consent of a person, and with the greatest determination to be quiet, indeed, with a resolution that could endure a limb to be severed from the body without a groan or a cry, and with every desire to assist the operator, anæsthetic sleep may be advantageous.

Examination of the question whether chloroform is necessary in the extraction of cataract.—All that is to be said on this head is meant to apply to middle age and after, when cataract ought only to be extracted. There are physical peculiarities of the eye which impede the operation for extraction, and which may be surmounted by the aid of chloroform. They are mainly those that present impediments to exposing and steadying the eyeball sufficiently to enable the cornea to be divided in an ample manner, such as a sunken eye, a narrow palpebral aperture, unusual prominence of the orbital ridge. During stupor the eyelids can be more widely extended, and the eyeball fixed with a lightness of touch that would, on account of the peculiarities, be insufficient during sensibility. Beyond this chloroform does not assist us here. Nor is it essential when a patient has tolerable fortitude. At all events, whatever be his mental emotion, so long as he remains master of his will, and can direct his eye to the position desired, and there are no impediments to exposing his eyeball to the required extent, insensibility does not help in the execution of the operation. If this were all, it would be better to save an aged person from the formality and distress of an inhalation, and to see him rise and walk to his bed or couch rational and thankful, than to have him removed, perhaps half conscious, and nauseated, requiring attention for several hours, both on account of the constitutional effects of the chloroform and the injury

he might inflict on his eye. Although he might not vomit or even retch after the inhalation, he might remain some hours in a squeamish state, with little or no appetite for food; and this might be more injurious than a vomit, for it is of the greatest importance, especially late in life, that nutrition should be well maintained. Such unpleasant effects do not make the rule, but the exception. With a full knowledge and experience of all this, I believe that the balance is largely in favour of the chloroform.

During extraction, a patient's determination sometimes fails, and a worse thing cannot happen for him. Then certain unexpected but well-known drawbacks may be encountered, and impediments may arise, all of which can be better met and overcome under chloroform. I believe, therefore, that if chloroform were always given, when admissible, greater success would be secured. Practically, I have no objection to chloroform.

Damage to the eye from vomiting may be, according to my experience, always prevented by closing the eyelids with court plaster, and where there is much vomiting a compress also of cotton-wool. I never have had a bad result under such measures. Of this I shall say more in the chapter on "Cataract." At the same time, I advise the greatest caution in giving chloroform to the aged. I should object to it in the very old and enfeebled, in whom the heart is so often diseased by being degenerated. Fortunately, such persons usually stand the operation better than others. Their sensibility is very much lessened. A glass or two of wine adds to their good behaviour.

When chloroform is not necessary in adult life.—In operations about the eyelids in adults, in the removal of tumours from the eye and from the orbit, and in extirpation of the eyeball, it may be left to the patient to decide whether he will be chloroformed or not.

When chloroform may be always required.—The anæsthetic sleep may be necessary at all periods of life, to enable an irritable eye to be examined, or an extraneous substance to be removed. It may be very requisite, besides, for the examination of the eyes in young children and in infants, merely to learn with accuracy the nature of any affection, and its extent, when from the perverseness of the little patient, or from blepharospasm, an inspection cannot be obtained.

The degrees of the anæsthetic effect requisite for the several operations requires adaptation. This is not sufficiently recognised, and therefore the chloroform is often improperly used, and some of the unpleasant effects of its deepest influence induced unnecessarily. The lighter inhalation of it, the rapid recovery, and therefore the adapta-

tion to even slight operations, is always overlooked when it is compared with other anæsthetics.

I have said nothing heretofore about other anæsthetics in use—the nitrous oxide and the bichloride of methylene. The first I find not suited for ophthalmic operations, because of the shortness of its effects, and the rapidity of execution which is necessary, a quickness hardly consistent with efficiency and safety in many operations, and which renders it inapplicable for nearly all the operations on the eyeball.

The second admits of a wider application, and some surgeons say that they use nothing else. I have employed it; but for what may be called lengthy operations, I prefer the chloroform. Although sickness is far less frequent than with chloroform, it does occur under long administrations. Death has resulted from its use. I suspect that all the fatal cases have not been published.

Freezing the surface, for the purpose of rendering the part insensible to pain, is wholly inapplicable to ophthalmic surgery.

CHAPTER III.

EYE-DOUCHES.—EYE SYRINGES.

In the local application of water, hot or cold, in a continuous stream, as a remedial agent, by the douche, there is no novelty; yet such an appliance is seldom employed. Why so valuable a means of treating disease is not more commonly resorted to can be accounted for only, I imagine, on the supposition that there is general lack of knowledge on the subject. Among the men of reputation who have pointed out the advantages of the douche, Mr. James, of Exeter, stood prominent. Those who have had the advantage of attending his hospital practice could not fail to be struck with the benefit of it under his supervision.

An eye-douche is a valuable addition to our ophthalmic therapeutics. For many years I have been prescribing it, especially for those of my patients who are old enough to manage it.

It is most applicable where a slight effect of cold is required, or short temporary influence.

The continuous stream of a douche is better than the interrupted stream from a syringe.

Although the question of this local bathing of the eye is considered in many parts of this work, under the head of treatment, it may be mentioned here that in the inflammatory affections of the eye-ball, and particularly the chronic, the directly sensitive effects of the douche are soothing and sedative. Pain is frequently stopped, and a return of it sometimes prevented. Inflammatory affections of the eyelids are lessened by it.

It is not less valuable as a means of applying cold to the over-worked and fatigued eye.

It is a ready and efficient manner of soothing the eye after some operations.

It may be useful in washing away extraneous substances, and may assist in reducing the effects of chemical agents.

It is a ready and efficient method of cleansing the eye in purulent ophthalmia.

The Fig. 20 shows the one I recommend ordinarily, and the manner of using it.

Fig. 20.



It was made, at my suggestion, by Mr. W. Cooper, of 26, Oxford-street, who bestowed pains on its construction. It consists of a metal box, capable of holding about six pints of water, that can be suspended, or rested on a bracket. To this is attached an elastic tube, terminated by a pedestal stop-cock, with a rose or a jet, which will stand easily in a basin. As there are no valves, the apparatus is so much the less likely to get out of order.

The full quantity of the water may be taken at once. The frequency of the application must of course depend on the circumstances of individual cases and the effect. One need not be afraid of repetition, as it can hardly be abused.

Every ophthalmic institution should have several douches with a continuous supply of cold water, and so arranged that warm water may be used. For the poor man a douche may be extemporized with a pail or pan for the reservoir, a bit of small gas-tubing bent

as a syphon, and at the other end, which should be bent, a simple stop-cock with one jet, all of which can be got for a shilling or two.

There are several eye-douches before the public, worked by the hand. The most perfect is a continuous-action one made by S. Maw, Son, and Thompson, of 11, Aldersgate-street. The water is applied to the eye by a cup of glass or china, which just fits the eye, and there is a waste-pipe, so as to allow a stream to be passed

Fig. 21.

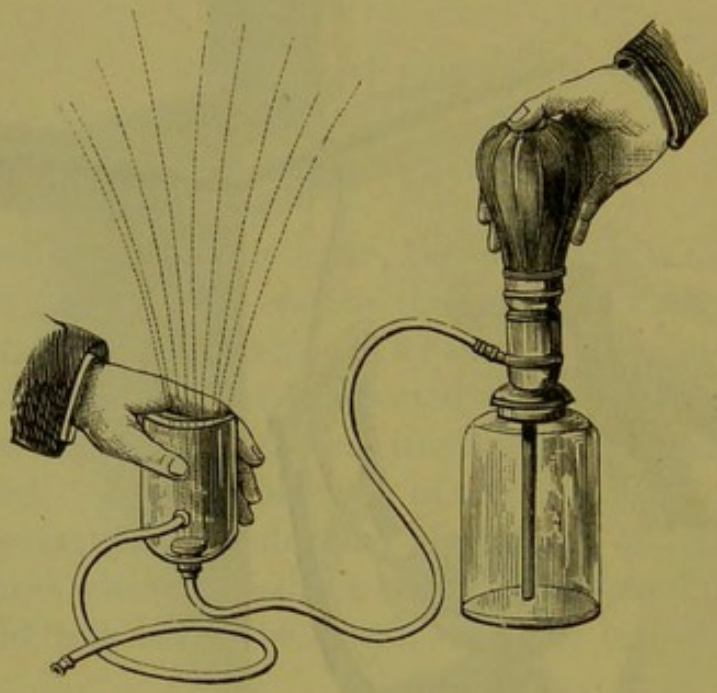

through the cup. The accompanying figure shows the instrument, and renders further description unnecessary.

Although there is not the same amount of refrigeration as with the open stream, and the parts around the eye—the orbital region, the cheek, the temple, and the forehead—are not acted on, and therefore there is not as much therapeutic effect as with the free and open shower, this one has merits. It is very portable, is always ready for use, and can be employed anywhere, and at any time. It affords an easy and effectual way of applying astringent lotions to the eye. I suspect that it would be valuable in purulent ophthalmia in cleansing the eye and in using drugs.

There are also spray-producing douches—ingenious and neat little toys; happy resources for fashionable and idle people. They are absurdly named water pulverizers. Scented tinctures are added to them. Possibly they may be of use for applying anodynes.

Syringes, of an ordinary kind, are required in ophthalmic surgery. A well-made one, capable of holding six ounces, with a blunted

extremity, should always be at hand, for cleansing the eye in disease and in accident.

When it is required for a person to syringe his own eye, the most convenient instrument is that here figured.

Fig. 22.

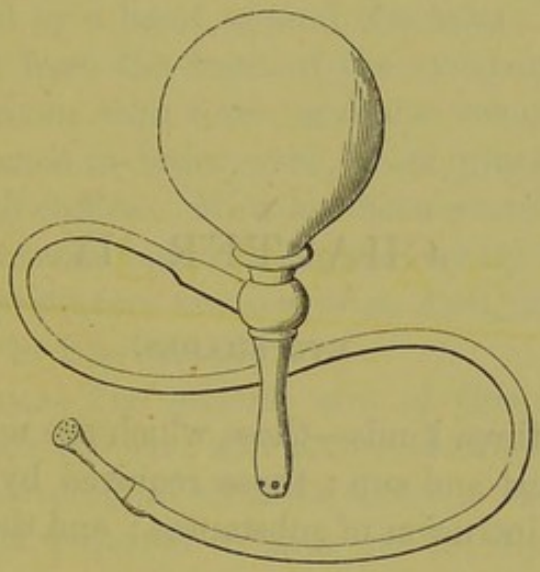

The only hint necessary to be given about its use is, that the same water be not employed again. The face should be held over a second vessel, so that the water which has touched the eye is carried away. Messrs. Maw make this also.

CHAPTER IV.

EYE SHADES.

These consist of three kinds—those which are needed to save the eye from wind and dust and sun ; those required by workmen to protect the eye from the intrusion of substances ; and those which are wanted to subdue light.

As a screen from atmosphere and intense light, Calkin's shade is the best of all that I have seen, being the most simple and the most effectual. It consists of a very light wire framework, nicely adapted

Fig. 23.

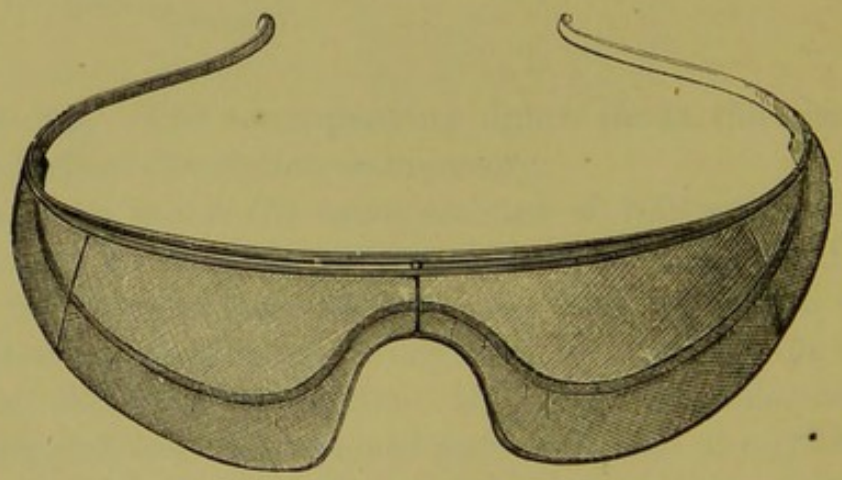

to the orbits, to the nose, and to the temples, which it embraces by elasticity, covered in front by an extremely fine fabric of gauze, fine enough to protect the eye. There is a little contrivance above for ventilation ; it is the coolest of all shades. It is made in three colours—brown, blue, and green, also in black. The black is to be preferred. Plain grey is better than the colours named. There are two sizes manufactured. It is extensively sold by S. Maw and Son. The preceding figure gives a good idea of it.

Veils used for the same purposes should be black or grey.

The artizan's shade should be of blue gauze wire, when it is necessary to protect the eye from the blows of large bodies. The eye should be sufficiently covered on all sides, for which a cup-like form is necessary. While sometimes this shade may be worn in a strong spectacle frame, at others it is more convenient and secure for it to be more firmly fixed by a band around the head. When a shade is required to keep off from the front of the eye particles that are not hard, or are not driven with force, and also when accurate light is needed, as for instance in lathe work, thick glass sufficiently wide, set as spectacles, will suffice. Mica has been recommended instead of glass because of lightness, but it is not sufficiently clear.

These forms of protectors are not often used, and many eyes are annually destroyed in England alone.

The patient's shade.—The general aim of this is to lessen bright light, in fact, to shade the eye; and such end cannot be accomplished without the eye is covered on all sides, and the entire field of vision darkened. It is not required to shut out all the light—a patient needing such exclusion had better be in a dark room—but to reduce it according to circumstances. This is to be accomplished by coloured glass, by which light is absorbed. The requisite tint is to be determined by the nature of the case. Too dark a hue may be nearly as prejudicial as too light. The patient's sensation is a good guide. That which prevents any discomfort when the light is faced is enough. The visual field may be too much darkened, and the retina rendered too sensitive to light. Again, with an unduly dark field, there is over-straining of the eye to see small things.

It is only in a bright light that the glasses should be used. To wear them in a room already darkened, or on a cloudy day, would be prejudicial.

When artificial light is used, and shading the candle or the lamp produces sufficient darkness for the patient, the glasses should be left off; the eye is better without them. As to the colour, grey, or neutral tint glass, as a mere darkener, is preferable to any for wear by daylight. After operations on the eyeball, and those for cataract may be particularly named, such a shade is indispensable.

When in association with any chronic inflammatory affection of the interior of the eyeball, a patient might be allowed to use his eye to some extent, but for the discomfort produced by the light, blue glass is preferable. This is because the orange rays offend. Blue of a light shade interferes but little with the function of seeing.

There is a popular error about green glasses being the best for weak eyes; this is due, no doubt, to the idea now exploded that the

red rays offend. They are decidedly prejudicial, because in a bright light there is transmitted a very dark green, approaching a yellow, which increases rather than diminishes any existing irritation of the eye. Blue glasses are preferable, because a less intense impression is made in the retina, but in very bright light even these produce some pain. When there is scarcely any depth of colour, little or no protection is afforded. Theoretically speaking, blue glasses ought to be what is desirable, because they neutralize or exclude the orange rays, those which are supposed most to irritate the retina, and because blue makes the less impression on the eye, from its position in the solar spectrum. However, practically, although the reason why may not be explainable, for a very irritable eye, the grey or neutral tint moderately darkened,

Fig. 24.



often called smoke grey, is to be preferred. It throws objects, as it were, in a twilight, and while it subdues their intensity, enables them to be seen in their natural colours, tolerably uniformly reduced, so that the retina receives the natural stimulus. When the eye wants still more protection, a deeper tint must be used.

Even light green is not a mild colour, and the light refracted on the eye through a light tinted green glass irritates. Reflected dark green, such as that which occurs from grass and from foliage, is pleasant to the eye. In selecting coloured glasses their shades will be best appreciated by placing them on white paper.

When patients have no defect of refraction, the glasses should be plain on both surfaces.

However large a flat glass may be, it will not shade the eye

enough. A semi-spherical form is needed, so as to arch over the eye, and to touch the circumference of the orbit. Another plan is to use flat glasses in front and flat side glasses. This is the old-fashioned shade, but it is not at all effectual. The best protection is the modern goggle with flat glass in front, and crape at the sides. It is not heavy, and when well fitted to the eye and to the nose, it is comfortable, and excludes all white light. As it contains a minimum of coloured glass it absorbs the least heat when worn in the sun. It is generally applicable as a shade for light, wind, and dust. It is what I employ for most cases of intolerance of light, and almost always after operations on the eyeball, when my patients begin to move about.

When it is necessary to have the eye as cool as it can be kept, and to screen it from the full flow of light, and at the same time to allow it to be used for most purposes, the pent-house shade, or slope, does best. Subjoined Fig. 24 is an excellent one of the kind. It is a very good shade for reading or writing by artificial light, since the eye is shaded from the luminous body, and perceives the light only reflected from the thing looked at. It can be adjusted to any angle by the small screw on each side. It is known as Müller's patent eye shade.

CHAPTER V.

ENTOZOA.

ENTOZOA ABOUT THE OCULAR APPENDAGES AND WITHIN THE EYEBALL —CYSTICERCUS CELLULOSÆ—HYDATID—FILARIA MEDINENSIS—FILARIA OCULI HUMANI—DISTOMA—STEATOZOON FOLLICULORUM.

The cysticercus (*telæ*) *cellulosæ*, the young or larval state of the tænia solium, or pork tape-worm, gains access to the human body by being swallowed in an earlier larval condition. To understand how this occurred was formerly one of the most difficult problems in natural history; but now, owing to the labours of experimental helminthologists, among whom Dr. Cobbold, F.R.S., is pre-eminent, the question of the mode of ingress is entirely set at rest. There can be no doubt that the cysticercus begins its development by escaping from the egg of the tape-worm in the form of a six-hooked embryo. This embryo bores its way through the intestinal walls, and gaining access to the circulation, is carried along until it reaches the eye, brain, or some other organ where it undergoes its final metamorphosis.

FIG. 25.

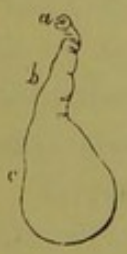

Many of the patients with the disease have had tape-worm, from which circumstance it has been inferred that the eggs of the full-grown worm must have gained access to the stomach, and thus have become cysticerci in the body generally.

It is the form well known as the measles in pigs. It may develop itself in almost any situation in the human body, but is most frequently found in the subcutaneous areolar, and intermuscular connective tissue; next most commonly in the brain and eye; and, lastly, in the substance of the heart and other viscera of the trunk. But its

presence in the eye is a rare event. The many cases on record are apt to induce a different conclusion. This is reconciled when it is told that in all probability every case recognised, has been published.

It may not be uninteresting to delineate the parasite.

The Fig. 25 shows a full-sized entozoon in its cyst: *a* indicates the head, *b* the neck or body, and *c* the dilated vesicular tail.

Its size varies from the bulk of a pea to that of a small marble. The head and neck may be so retracted as to give a globular form. Among muscles, or in a solid viscus, it has an external cyst, but in close cavities, as in the ventricles of the brain, or in the eye it floats free.

While it is confined to the eyelids, or to the external part of the eye, danger does not impend, but should it exist in the interior of the eyeball, the organ is in jeopardy, and, as far as records allow me to speak, would be sacrificed, unless it were removed.

The cysticercus about the ocular appendages.—The cysticercus has been found in the subcutaneous cellular tissue of the upper eyelid, as recorded by Sichel, in the "Revue Medico-Chirurgicale," April, 1847; as well as in the neighbourhood of the palpebræ. Also, in the same tissue of the temple.

It has perhaps been most commonly met with between the conjunctiva and the eyeball, in the connective tissue. When in this ocular region, it is generally at one of the angles close to the transverse diameter of the eye. It is round, of a pale rose colour, or yellowish, somewhat semi-transparent in the centre, where a circumscribed whitish or yellowish disc has been noticed. It does not adhere to the conjunctiva, and is slightly attached posteriorly to the sclerotica. It is painless, and affects neither the pupil nor the vision. The movements of the eyeball are uninfluenced. When the spot in the centre of the tumour is clearly made out, in contrast to the surrounding vascular or red margin, it is diagnostic of the parasite. It does not produce any inflammation of the eye.

The following case was nicely reported and illustrated:—A child two years and seven months old, whose vision was perfect, was brought to Mr. Canton at the Westminster Ophthalmic Hospital, with a small yellowish tumour of the consistence of soft jelly, near the inner canthus of the eye, lying between the conjunctiva and the sclerotica. A snip of the conjunctiva gave exit to serum and a cysticercus. At the end of two or three days the edges of the wound were united. The entozoon was about the size of a garden-pea, and presented at one part of its circumference a circular opaque body, projecting into the interior of the vesicle; the retracted head

and neck. I copy these illustrations of the animalcule deprived of its cyst, from Mr. Canton's publication in the *Lancet* for July, 1848.

The natural size is observed. In the first sketch, *a* shows the head, *b* the neck or body transversely lined, *c* the tail vesicle glistening white, and it should be rather conical, and containing fluid. In the second, the head and body are retracted within the tail vesicle.

Parallel instances have been given by Arlt and Graefe.

Fig. 26.

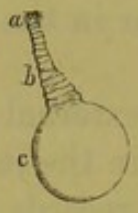

Fig. 27.



The cysticercus has also been met with between the palpebral conjunctiva and the eyelid. It causes irritation and inflammation of the adjacent tissue, with inflammatory depositions.

The cysticercus may implicate the proper tunics of the eyeball, and yet be extra-ocular. Mr. James, of Exeter, sent me a patient with a small growth on the inside of the eyeball, between it and the caruncle under the conjunctiva. It only disfigured. I could not tell what it was, but I proceeded to dissect it out. Only after the removal did I detect a cysticercus. A small depression was left in the sclerotica.

An analogous case occurred in the practice of M. Baum, of Dantzig, and is reported in the "Annales d'Oculistique," t. 11, p. 69. The patient, a female, was twenty-three years old; the tumour, which had been noticed for six months, was at the internal angle of the eye, in the sclerotica; the conjunctiva covering it was thickened. A depression remained in the sclerotica after its removal. Vision was unimpaired.

In the same journal is the record of another case by Hoering, in a girl seven years old; the cyst adhered to the sclerotica, towards the external angle of the eye. Sight was saved.

Mr. Estlin, of Bristol, published in vol. xxii. of the *London Medical Gazette*, a similar instance that happened in a girl six years old.

Cysticercus in the cornea.—A case of this nature is reported and figured in the "Archives d'Ophthalmologie," t. 1, p. 58.

Reports of many other cases of the cysticercus occurring about the front of the eye, are scattered in British and foreign periodicals. To quote them would be merely to repeat what has been said, without adding an idea.

The treatment is strictly operative; it is to remove the parasite wherever it may be found. Although I have spoken of a certain diagnostic mark, that distinction does not always exist, and I much question whether it would be recognised by most surgeons. The little tumour is like other cysts, and even like some solid growths. A happy guess may be made as to its presence, but nothing more. All that need be said is to enjoin care during the removal of such small tumours from the eyeball, and not to wound the sclerotica.

The diagnosis can only be perfectly sure after operating. The hooks and the suckers of the little animalcule, seen under a lens, will be sufficiently characteristic.

It is probable that many cysticerci have been removed but not detected, being supposed to be small tumours of a cystic nature.

The cysticercus within the anterior part of the eyeball.—Irritation is always excited by a cysticercus within the eyeball.

Great interest attaches to the internal implication of the eye, from the opportunities of examining the parasite and the attendant risk to

Fig. 28.

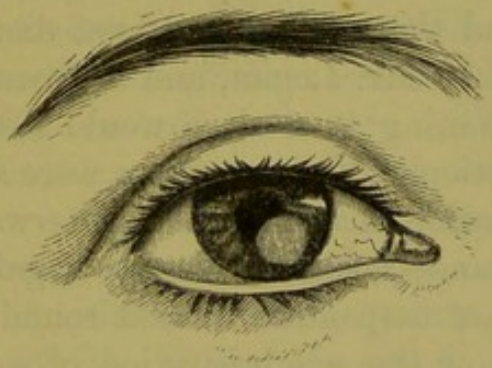

the eye. A man, forty-five years old, applied to me at the Ophthalmic Hospital in consequence of frequent pain that had existed in his right eye for six weeks. The sight had been quite lost a year previously, from a sudden attack of inflammation. The conjunctiva was much inflamed, the cornea vascular and semi-opaque. At his next attendance I saw in the anterior chamber what I took for an opaque capsule, which slipped into the posterior chamber when I commenced to examine the eye, and could not be got to its former place by any change of position or shaking of the head. The man, who was quite aware of this shifting, which he said occurred many times in the day, was directed to apply when the body was visible. He did attend, when the foregoing sketch was taken. The cornea is supposed to be semi-opaque. In the original the pupil was not by any means so visible.

To relieve the pain the body was extracted, and it proved to be a cysticercus. The cornea healed readily, and cleared very considerably; the pain was removed, but vision was not restored. The crystalline lens must have been absorbed, or the cysticercus could not have passed so readily through the pupil.

The opacity of the cornea obscured the only means of diagnosis—the alteration in the form of the vesicle, by the descent and retraction of the tail.

Mr. Logan's remarkable case, originally published by him in a pamphlet, and afterwards recorded by Dr. Mackenzie, possesses many points of value. A girl seven years old was the subject of it. From August to January there had been several inflammatory attacks in the left eye, producing slight opacity of the lower part of the cornea. Then a semi-transparent body, from which hung a slender process, with a slightly bulbous extremity like the proboscis of the common house-fly, sometimes retracted, sometimes protruded, was seen loose in the anterior chamber. A cysticercus was diagnosed. When floating, the vesicle is uppermost. Objects placed above the level of the eye could be distinctly seen, but not when placed below, or directly in front, showing that in the latter positions, the rays of light were merely obstructed, and that the eye was not damaged. Increase of size was not observed by Mr. Logan, and he trusted that its natural period of existence coming to a close would free the eye from the danger of disorganization. Various means were suggested for killing the parasite in its situation, that it might be afterwards removed or left, according to circumstances; such as electric or galvanic shocks passed through the eye, oil of turpentine rubbed round the orbital region, and given internally, or the administration of some vegetable bitter known to be inimical to the life of parasitical animals. The sequel is given in Dr. Mackenzie's work. Several weeks afterwards, extraction was attempted by Dr. Robertson, of Edinburgh. The child struggled so much that the cornea was opened, the lens was forced out, and the hydatid ruptured. After a long interval she was induced to open the eye, and the cysticercus was brought away in shreds. A portion of the iris remained in the wound, but nothing would induce her to allow Dr. Robertson to attempt to return it. The eye healed, and the cornea remained clear, except at the cicatrix: there it was only semi-transparent. The pupil was elliptical in consequence of adhesion of the iris to the cicatrix, and was occupied by opaque capsule. The power of recognising the presence of light remained.

Any entozoon within the eye that can be readily got at should be extracted on the earliest recognition of its existence. The smaller it is, the easier can it be removed. The cornea should be opened to an

extent equal to the size of the mass which is to be removed. Directly the knife is withdrawn, the blunt canula forceps, the cross-spring, or any other appropriate ones, should be used. In other respects the proceeding is to be conducted as for the extraction of a cataract. In Mr. Logan's operation, the unfortunate issue arose from the perversity of the patient. Chloroform should always be given.

In Dr. W. Sœmmerring's case, which has been often quoted by writers, from having been one of the earliest, if not the first ever recorded, the parasite was extracted alive; it moved about in luke-warm water for half an hour, and then gradually turned opaque, and white. In the original, given in the "Isis Von Oken" for 1830, the result of the operation is not mentioned. The record seems more with a view of illustrating a point in natural history than for the advancement of medicine. As in Mr. Logan's case, the cysticercus was observed after active inflammation, which subsequently subsided, and it scarcely produced inconvenience, except when moving about. In seven months it had doubled its volume, and when extracted was as big as a pea. The subject was a girl aged eighteen.

In a case which Rosas quotes of a lad fourteen years old, who was under Neumann, the eye was otherwise healthy, and dilatation of the pupil caused the cysticercus to quit the anterior chamber and lie across that aperture, from which the further use of belladonna could not free it. The new position caused much pain. The animalcule was depressed and the pain was comparatively removed, but suppuration of the eyeball ensued.

The most satisfactory case of extraction of a cysticercus from within the eye on record, is to be found in a communication to the Medico-Chirurgical Society by Dr. Mackenzie, and is published in vol. xxxii. of the "Transactions." The girl, sixteen years old, applied at the Glasgow Eye Infirmary. Inflammation of the eye was the first symptom. Vision would have been perfect but for the partial obstruction to the rays of light by the cysticercus. Eighteen days after recognition of the animalcule, the cornea was opened to the extent of three-twentieths of an inch, and it was removed, and received into a teaspoonful of warm blood-serum; but its movements were not so lively as when transferred to tepid water. Next day the patient felt quite well, the eye appeared natural, and she said she saw as well with it as with the other. No reaction followed. The author thinks that the attack of ophthalmia immediately preceding the appearance of the hydatid, was owing to the development of its ovum in one of the blood-vessels of the iris or choroid; and that the inflammation ceased suddenly as soon as it dropped into the anterior chamber, where it lived at its ease, amply furnished with sustenance from the

aqueous humour, and unrestrained by any external cyst. The truth of this theory would seem to be confirmed by the presence of inflammation in the majority of the other cases prior to the full development of the insect; and it might have existed in each instance for any proof that we have to the contrary.

After a cysticercus cellulosæ has spoiled the eye, the mischief arising from it is not certainly over, not even though its extraction has been accomplished, as the morbid action excited by its presence may continue. Mr. Canton watched one for several months previous to its removal; the symptoms were gradual diminution of vision, consequent upon an increasing nebulous state of the cornea, with slight inflammation of the conjunctiva and the sclerotica. By degrees the central part of the cornea became more opaque than the circumference. Almost constant darting pain in and around the eye was unrelieved by the various modes of treatment that were resorted to. An opening was made by Mr. Guthrie, through the most prominent part of the cornea, and a cysticercus in a perfect state escaped. Relief ensued. The circumstances of the case, six or seven months after, appearing to require a similar procedure, the cornea was again opened and what was supposed to be a cysticercus removed, but this most likely was the crystalline lens, a close examination of the boy not having been made. Three years afterwards there was constant pain about the eye, and such symptoms as induced Mr. Guthrie to suspect the presence of another cysticercus. The cornea was again divided, and vitreous humour alone escaped. The operation removed the pain.

The following case, narrated by Dr. Mende, is copied into the *Medical Times and Gazette* for March 23rd, 1861, from Graefe's "Archiv für Ophthalmologie," vol. vii. p. 122. It is here given in abstract.

The wife of a shoemaker, twenty-five years of age, of healthy appearance, and far gone with her first child, applied to the author on account of an obscurity of vision. A cysticercus was perceived with the utmost distinctness in the anterior chamber of the right eye. The vesicle was so transparent that the brownish iris could be seen through it. It was motionless, and movements were not induced when the patient moved her head, or when a strong light was directed upon the eye. It was very interesting to observe through a lens how it thrust its head here and there, just as a leech, before it fixed on a spot to commence sucking from. When it attached to the anterior surface of the iris, a quivering movement, like that seen in a sucking leech, was imparted to the tube-like process of the body while the bladder remained motionless. The woman was confined on

the third day after being seen, and continued under observation for about three weeks before an operation was performed. The parasite frequently changed its position, attaching itself to the various surrounding parts, without seeming to inflict any injury on them by its sucking process. It was removed, and the eye regained its perfect powers.

There can be little doubt that in this part of the eye, the iris furnishes the entozoon, and a case has been published by Mr. Teale, in the "Royal London Ophthalmic Hospital Reports," in which the animalcule adhered to this tissue. Inflammatory symptoms preceded the recognition and accompanied the development.

The cysticercus has been found within the crystalline lens.—It is said in "Deutsche Klinik," 1865, p. 115, that when Von Graefe was performing an operation for cataract, a cysticercus slipped out of the opaque lens.

The cysticercus within the posterior part of the eyeball.—The cysticercus is found in all parts of the vitreous humour, in the retina, and behind the retina. In these situations it appears to occur more frequently on the Continent than in England. In Northern Germany it is common, in Southern uncommon.

There is every probability that here the original seat is the retina.

The subjective symptom is at first a loss of a part of the field of vision, with irritation, there being a round spot in which nothing is seen, and ultimately total impairment of retinal function.

I have never been fortunate enough to meet with a case. According to the published descriptions, the parasite has been discovered in its earliest states behind the retina, and in its texture. Its tendency is to perforate the retina and come forward. When it has made such an advance, it appears as a roundish tumour of a blue or green hue, or greyish-white, the colour being due to the reflected light from the fundus, passing through its semi-opaque structure. It is enveloped by a turbid membrane traversed by vessels, and which appears to be a portion of the retina split off into a pouch-like cavity. Sometimes the membrane has a more prolonged form, the posterior end of which is connected with the retina on the optic nerve, and the anterior extends forwards and is free, or seems attached to the crystalline capsule. When this sheath is much attached the parasite moves but little. The head is recognised as a small appendix, more opaque than the rest, varying its position. If the sheath ruptures, the head and neck protrude, and are clearly seen; the expansion and retraction being very evident. The vessels that were apparent now disappear, or seem as delicate lines. The breach in the sheath enlarges, the

parasite becomes more exposed, and all that may remain in the sheath are opaque shreds. The several parts of the little intruder, including the hooklets, have been at times clearly made out.

The membranous envelope is seldom absent. It is said to have been wanting when the cysticercus was moving about in the vitreous humour.

The characteristic mark of a cysticercus behind the retina is the sharp outline of the vesicle, many times larger than the optic disc. The contiguous choroid is greyish or yellowish.

Liebreich, in his "Atlas der Ophthalmoscopie," figures two cysticerci. The first was primarily developed behind the retina, which it perforated, and entered the vitreous humour, where its movements, including the undulations of the vesicle, could be seen. A minute account is given of its head and hooks. Its transparency allowed a distinct view of the parts in the eye before and behind it. The neck and its attachment to the vesicle were more opaque and dotted with white points, "calcareous deposits." He says, in alluding to this illustration: "The small grey and circular spots which surround in part the vesicle are partial opacities of the vitreous body; they are pathognomonic of the presence of the cysticercus, and are produced by the suction which constitutes the mode of nutrition of the animals."

The second figure shows a cysticercus behind the retina, which is raised in a kind of pouch in front, containing retinal vessels ramifying on it. The head and the neck are embedded in the vesicle. So long as a cysticercus is behind the retina it cannot be accurately diagnosed, but merely guessed at, as no part could be clearly recognised.

He besides alludes to a cysticercus which he removed from the vitreous humour with success, and describes the operation by saying that he thrust through the sclerotica a pair of capsule forceps, and watched the movements of the parasite by means of an ophthalmoscope fixed to his head, and which illuminated the eye. No mention is made of the kind of vision the patient retained. I suppose it must be assumed that the sclerotica was incised before the forceps were introduced. Wecker, in commenting on the cases which are delineated, remarks, that it is very rare to see the cysticercus so distinctly; that generally the vitreous humour is full of opacities, which become thicker and thicker, and in the course of one or two years irido-choroiditis sets in and spoils the eye, which ultimately shrinks. In some cases, then, it remained behind the retina, but attached to it, the choroid being little affected; in others, while in this position, it became encysted. In some, again, the head pene-

trated the retina, and was ultimately withdrawn, a scar remaining. When it did enter the vitreous humour it generally retained a retinal attachment.

The treatment of a cysticercus, when in this region of the eye, has been generally expressed in the cases which have been narrated. To extract a living parasite from the vitreous humour is a great achievement in ophthalmic surgery, and such practice must now be considered established, and is therefore a rule to be followed.

As the cysticercus invariably spoils the eye, and produces subsequent damage, the operation should be done as early as the animalcule can be fairly seized. It may be prudent, therefore, to wait for a time and watch its progress. Whether it should be removed through the sclerotica, or through the cornea, after the lens has been extracted, must depend on certain matters of detail respecting its position, but more especially perhaps on the state of the eye. If sight have been destroyed, there can be no objection to adopting the easier method, and incising the sclerotica. As the neck is the toughest and strongest part, the forceps should be applied to it. The sclerotic wound should be united by suture, directions for which are given in the section on "Wounds of the Sclerotica," in the chapter on "Injuries from Mechanical Agents."

I can give an example of extraction through the cornea. In the "Archiv für Ophthalmologie," band iv. abt. 2, are the details of a case in which Professor Graefe removed a cysticercus from the vitreous humour. He first performed iridectomy. At a subsequent period he extracted the lens, which was clear and transparent; and, finally, he succeeded in removing the cysticercus; the patient recovering from the three operations with a fair amount of vision. It is impossible to conjecture what really was the state of sight. The expression is too vague to be worth much.

When the vitreous humour is too hazy to forbid the extraction, the eyeball should be extirpated. Several cases are published of subretinal cysticerci, causing destruction of the eyeball. In one, a disorganized eye had been removed, cancer being suspected, and a cysticercus was found.

It is likely that cysticerci make their way to this region of the eye, cause destruction to sight, afterwards produce disorganization of the eyeball, and yet escape detection. Such an oversight is not supposed to occur to anyone who is conversant with eye diseases.

The cysticercus within the orbit.—A cysticercus has been removed from the orbit, between the inferior rectus muscle and the floor. In this situation, it would always have a dense cellular envelope. There

are no physical characters by which it can be diagnosed from any other cystic tumour.

The preventive treatment of the cysticercus is to avoid drinking water which contains the eggs of the pork tapeworm.

Hydatids.—Some confusion prevails among surgical writers, both at home and abroad, as to the nature of these larval forms of cystic entozoa. Hydatids, acephalocysts, and echinococci are described as distinct species of entozoa, and the separate accounts given of them are inaccurate. It is necessary to be correct, for the better understanding of the subject.

Acephalocyst and echinococci are hydatids, and therefore animal parasites in the form of cysts. Both are of the same species; both come from one of the tapeworms that infect the dog. The latter constitute a more advanced state of the parasite, arising from the development of echinococcus heads, in daughter cysts, and granddaughter vesicles.

The medical student need not trouble himself, so far as the mere surgery of the matter is concerned, beyond knowing that acephalocysts and echinococci inhabit the same situations, give rise to the same symptoms, and require the same treatment.

Sir William Lawrence was the first to discover and describe an orbital hydatid. He met with an instance in a man forty-two years old. The eyeball was protruded, and the discovery of a small, firm protuberance under the superciliary ridge, which seemed to be part of a deeply-situated swelling, induced him to recommend ocular extirpation as the only chance of relief. This was refused; the disease increased, the eyeball was turned completely out of the orbit, and sight was destroyed. A puncture was made in the protuberance, clear fluid escaped; two days after, a soft opaque white substance, which protruded, was extracted, and proved to be an hydatid; others were discharged, and ultimately, by enlarging the aperture and injecting water into the sac, half a teacupful was removed. The cyst suppurated. The opening closed in a month, the eye returned to its natural position, and all uneasiness ceased. A little motion of the iris, and slight perception of light, returned. The particulars of the case are in the "Medico-Chirurgical Transactions," vol. xvii.

Another example was met with by Mr. Bowman. A man was admitted under Mr. Bowman's care at the Royal London Ophthalmic Hospital with a tumour in the left orbit, which had produced considerable protrusion of the eyeball, and disorganization. At one spot there was an obscure sense of fluctuation. It was supposed that soft cancer was present. The disease began three years before. It had caused for a long time frontal headaches. The tumour was

punctured and a quantity of perfectly pellucid water escaped; the incision was enlarged, and Mr. Bowman introduced his finger into a cavity which extended to the apex of the orbit. The optic nerve and some of the recti muscles could be felt, as it were, dissected by the encroachment of the cyst in their interspaces. Search was expressly made for hydatids with the finger, and a scoop was pressed down, but without bringing any into view; it was then concluded that the cyst was a simple aqueous one, surrounded by tissues altered from its pressure. With the view of producing obliteration a piece of lint was inserted, the end of which projected from the orifice, and the patient was sent to bed with a poultice over the whole. Considerable swelling followed, and at the end of about a week, suppuration being established, three hydatids appeared in the discharges, two of them being as big as large marbles, and the third half that size. They were nearly globular, and their walls composed of a thin semi-pellucid membrane.

The swelling of the orbital tissues now gradually subsided, and they resumed nearly their natural dimensions, the remains of the eyeball having sunk down to a level with the margin of the orbit.

Within a few nights after the emptying of the cyst, the man began to sleep well, the intense headache from which he previously suffered so much having been quite removed.

Here is a third example in which the echinococci were found. A man, about thirty years of age, was brought to Mr. Jones at University College Hospital with an eye protruded and disorganized. Mr. Jones at once removed it from the ocular tunic, and while examining the orbit, he detected a fluctuating tumour adhering to the upper and outer part of that cavity and extending towards the apex. He proceeded to remove the tumour, but finding the dissection difficult to accomplish, he incised a portion; serum escaped, and a smaller cyst was discovered lying free, which proved to be an echinococcus vesicle with its contained fluid and colony of echinococci.

The wall of the orbit where the cyst had been attached was beset with exostotic spiculæ.

The walls of the echinococcus cyst were composed of an external coat, laminated, extremely tough, and of a yellowish colour, and an internal coat, rough and easily lacerated. In the clear fluid filling the cyst were suspended an immense number of echinococci, round cells, and detached hooklets. The echinococci, which were just visible to the naked eye, varied a good deal in length and outline, some from having the head retracted, some from having it protruded, some from being in different stages of development.

Other cases could be quoted were it necessary.

The ill effects of these parasites arise mostly in consequence of the pressure that they exert on the eyeball and its appendages. When they are situated in the subcutaneous cellular tissue of other parts of the body, they scarcely produce serious consequences, and they are for the most part discharged after a slow and painless suppurative stage. In the bony box of the orbit, their very growth is injurious, and natural expulsion by suppuration would perhaps always be destructive to the eye. In the records of the cases that I have examined, there are but few instances in which the hydatid has interfered with the movements of the eyeball.

Treatment.—The presence of an hydatid in the orbit has never been diagnosed in an early period of its existence, nor in any case has its nature been suspected. Some other kind of tumour was always supposed to be present. Besides, as this parasite has never been recognised, except when there have been daughter-cysts or echinococci, what can be more probable than that, in the first stage of development, it has frequently passed unnoticed as such, and supposed to be an ordinary sero-cyst?

In every case, therefore, in which serous fluid escapes, or limpid fluid, when a cystic tumour is punctured, the presence of an hydatid should be suspected, and exploration made for daughter-cysts, by freely opening the outer or cellular sheath. When these are not found, the cysts should be treated according to the principles laid down in the chapter on tumours, for dealing with simple cysts. When they are discovered, warm water should be freely injected, so as to wash them out. If their escape cannot be accomplished in this way, nor readily by dissection, suppuration should be induced by the introduction of a piece of lint; but this should be done with circumspection and care.

The advantage of such practice has been confirmed in treating hydatids in the liver. In one case, recorded in Dr. H. Bennet's "Principles and Practice of Medicine," after the parent cyst had been opened with some difficulty, and using the scoop at the end of a director, about one ounce of a viscid substance was drawn out, consisting of broken hydatid sacs and serum. The sacs varied in size from a large grape to a pea; some of the smaller were unruptured. There was no retraction of the tumour from the parietes, no bleeding, no purulent discharge. The opening was dilated, and kept open by means of lint. From four to eight ounces of bloody viscous matter, crowded with hydatid cysts, were discharged daily. Recovery ensued.

Attempts have been made to destroy hydatids in other parts of the

body, by injecting into the cyst substances supposed to be inimical to them, but success has not ensued, and such a plan of treatment is not trustworthy.

An hydatid has been removed from the wall of the orbit. Such a case is narrated by Mr. Keate in the "Medico-chirurgical Transactions." The tumour occupied the frontal base, but was mostly over the left orbit. It is said to have been of the size and shape of three-fourths of a large orange. An operation was performed, and from first to last twenty-eight daughter-hydatids came away. The patient continued well.

An instance of hydatids lying in the brain, between the orbital cavity and the brain, and in the orbit, is given in the chapter on "Protrusion of the Eyeball."

An echinococcus has been discovered between the choroid and the retina. "Notes sur les Helminthes des Yeux, dans les Archives de Médecine comparée," par P. Rayer: Paris, 1843, p. 67-154.

The Filaria medinensis, Dracunculus, or Guinea worm, infests the eye. This worm was known at a very early period. It was spoken of by Agatharchides, four or five hundred years before Christ. But there is still greater antiquity for it, if it be true that Moses was its first historian; for it is more than probable, according to Dr. Cobbold and others, that the fiery serpents which afflicted the children of Israel during their stay in the neighbourhood of the Red Sea, were neither more nor less than specimens of our Dracunculus medinensis. It is found in tropical regions of the globe, but especially in districts in Asia and Africa. Unlike many of the other entozoa, it does not enter the human body by the mouth or the stomach, but the larvæ are conveyed by water to the surface of the body, and gain access by penetrating the ducts of the skin. There is no evidence of any other source of infection.

In man it usually resides in the cellular tissue, and is only known in the mature female condition. In this state it always contains an enormous quantity of young filariæ, each of them measuring the 1-25th of an inch long. The adult resembles a piece of uniformly thick white whip-cord, and attains an average length of about twenty-five inches.

As a rule, a person is unconscious of its presence till it is fully matured. In the majority of cases only one is present. It wanders from the one part of the body to another, and generally gets under the skin and moves in a downward direction. During the first period of its existence in the human body it is latent, residing at a considerable depth from the surface. The second period is marked by characteristic symptoms, and comprehends its maturation. It

produces pricking, itching heat, and then a vesicle, after which the anterior end protrudes; but a week or two may pass before it appears.

All records agree in assigning to this parasite an annual recurrence, annual periods of increase and subsidence, and a fixed latent period. It never makes itself manifest before the second season of residence in the place where it is endemic. It is only when it dies that great mischief happens to the part which it occupies. Then and there it acts as a foreign body.

The filaria about the ocular appendages.—It has been detected in the caruncle.

Many examples of this worm about the eye have been collected by M. Guyon, and given in "Les Annales d'Oculistique," tome 52, p. 241. They occurred in South America, and in Africa. It is stated that there the filaria has always been found between the sclerotica and the conjunctiva, through the latter of which its movements can be seen. It may disappear, and re-appear again and again. The author brought before the Academy a very marvellous case of two filariæ existing in the same subject, one in the right eye, and the other in the left, both of which were occasionally found in the same eye. The transit was made with the greatest rapidity under the skin at the root of the nose. They were separate when the extraction of one was effected; and when the second was looked for in the other eye, it was found to have slipped into the eye from which the first had just been taken, whence it was removed by a new incision.

The rapid movement of the worm has been verified by another observer, who records two cases, in each of which it travelled round and round the cornea beneath the conjunctiva, and caused no inconvenience beyond the sensation of something moving about the eye, and a little itching. Both were extracted through the conjunctiva, which was snipped. Neither worm was more than two inches long.

In one of the cases the worm was lodged in the orbit; it was seen only occasionally between the conjunctiva and the sclerotica.

One worm, the largest, it is said, ever extracted, measured fifteen centimetres. It would be useless to quote more cases.

It would seem that the best method of removing the worm, when it can be got at, as under the conjunctiva, is to attack it by incision. The worm is very apt to jump away when it is touched, therefore the plan of proceeding is to raise the conjunctiva with a pair of forceps and to snip it through, or to snip out a piece, then with the same forceps to keep the aperture open, and with another pair to make the extraction.

Should the filaria protrude its head while the body is hidden in

the orbit, this should be secured by a strong thread, and the process of extraction commenced by coiling the thread round some small substance, such as a piece of bougie, and by gentle turns daily, to wind until the whole worm is removed. When each turn is made, the bougie should be fixed with a piece of plaster.

Through the kindness of Sir Wm. Fergusson, I saw a case of filaria at King's College Hospital, in the leg of a lad who had just returned from the Coast of Africa. It was in the course of being extracted by the winding process.

The Filaria lentis, called also Filaria oculi-humani, and Filaria oculi.—The best account of this is by Cobbold, in his work on "Entozoa." It is suggested that this worm may possibly prove to be identical with the Filaria lacrymalis, a viviparous species infecting the eye of the horse. It was first discovered by Nordmann, in 1831, in a case of lenticular cataract under the care of Graefe, and subsequently by Jüngken, under similar circumstances. The filaria has been met with in the anterior chamber of the eye. A case was shown *in situ* at a meeting of the Ophthalmological Congress, held at Brussels, by Quadri.

Another case was observed by Gescheidt, in which Von Ammon operated for cataract. In this instance there were three filariæ, two of which measured about one-sixth of an inch each, while the third was only one-fifteenth of an inch. Dr. Cobbold says that the two former were regarded as females, but it is very doubtful if any of them were sexually mature, and the same might be said of all the others hitherto mentioned; and if so, it becomes impossible to tell how many distinct species of entozoa these several examples of so-called filariæ may represent. To his mind, all of them are embryonic nematodes, which have, accidentally or otherwise, entered the body as their intermediary 'host,' or bearer.

A living filaria in the vitreous humour is recorded by M. Fano, in the "Ann. d'Oculist:"—F. C., æt. 12 years, discovered impaired vision of the right eye. He could only read type such as Jaeger, No. 17. After the pupil was dilated with atropine, the eye was examined with the ophthalmoscope singly. A black filament was seen at first lying perpendicularly across the pupil, it then moved posteriorly and disappeared. In a few moments it again re-appeared, and as quickly disappeared. The refractive media were perfectly transparent, and nothing was seen in the vitreous humour save this filament.

The eye was then examined with the ophthalmoscope and the lens. The optic disk was pale. The vessels of the retina seemed very numerous, and the choroidal pigment was scanty. The supposed worm appeared as a greyish-black filament close to the optic disk, and a part

of it was in motion. Its length was estimated at seven millimetres; its thickness less than that of a fine hair. Nothing is said about any treatment.

Dracunculus Loa is a distinct worm from the Filaria oculi, according to Dr. Cobbold and Diesing. It is identical with that described by Guyot, as dwelling beneath the conjunctiva of negroes at Congo, and in the Gaboon district generally.

It is, according to Dr. Cobbold, rather more than an inch in length. It is said by the natives that, after a period of several years, the worm quits the eye, and thus the disease becomes naturally cured. It enjoys a wide geographical distribution, as it has been observed by Clot-Bey in a negress who had come from the town of Moupox, situated on the banks of the river Magdalena; by Figand, who saw one in the eye of a negress in Brazil; by Blot, at Martinique, who saw two in a negress originally from Guinea; by Beyon, who met with one in a little negro girl who had come from Guadaloupe; by Mougin, who found one in a negress who had been living on the island of San Domingo; and by Lestrille, who removed one from beneath the conjunctiva of a negro who came from Gaboon.

Duraine's treatise contains all the above-mentioned cases more or less fully reported, together with several important extracts from the writings of the eminent surgeon, Guyot, who made several voyages to the coast of Angola, and paid special attention to the eye-diseases produced by the parasite.

Distoma, or fluke.—This has been discovered in the opaque lens. In speaking of the animalcule, I prefer following Dr. Cobbold, who, under the title of "Distoma Ophthalmobium," combines the two so-called species of human-eye trematodes. He says, without, however, for a moment supposing that we have either in the Distoma ophthalmobium of Diesing, or in the Monostoma lentis of Nordmann, a genuine sexual immature fluke, he thinks it highly probable that both forms may be the young of one distoma, and quite possible that they may both of them be referable to the species "Distoma lanceolatum."

He adds that, in the case of the so-called Distoma ophthalmobium, Gescheidt found four specimens in the eye of a child five months old, born with lenticular cataract. No one of the examples exceeded half a line in length. They were between the lens and capsule. He believes that Von Nordmann's Monostoma lentis is identical with this worm. A great deal of difficulty surrounds the investigation of these internal parasites of man. My object is merely to draw attention to the fact that, as in this case, a particular part of the eye may be invaded by them. Whether there is always cataract when they are

present, I cannot learn, but I suspect that there is degeneration of the lens.

Trichina spiralis, the spiral threadworm. The Trichina epidemics, lately in Germany, have attracted much attention to this worm. It is a minute microscopic parasite, which, for a term of its existence, lives in muscular tissue. As yet, no cases of it in the living human subject have been observed in England, although it has been detected in post-mortem examinations about thirty times. It is mentioned here, merely because the ocular muscles, along with most of the other muscles of the body, have been infected by it.

The Steatozoon folliculorum of Mr. Erasmus Wilson is sometimes found about the eyelids. It is an animalcule that forms in the oil-tubes in any part of the body whenever there exists any disposition to the unnatural accumulation of their contents. It is very minute, being the forty-fifth of an inch in length. In form and shape, in the perfect state, it is like a caterpillar, having a distinct head with feelers, a chest with four pairs of legs, and a long tail. In Mr. Wilson's work on "Healthy Skin," all relating to the history of this little insect is narrated. It appears that Dr. Simon discovered it; but his descriptions and figures were imperfect; several points of entomological importance were overlooked, and Mr. Wilson has completed our knowledge of the subject, and changed the name of the insect to that it now bears.

Entozoa would seem to be more common in the eyes of the lower animals than of man. The filaria is often met with in the horse in India. They have been found in horned cattle, pigs, sheep, birds, frogs, lizards, and fishes. In the last, they have been discovered in the vitreous humour, in the crystalline lens, between the lens and its capsule, between the laminæ of the cornea, in the iris, in the retina, and in the aqueous humour. In the crystalline lenses of some fishes, they are so numerous as to produce opacity, and to impair sight.

CHAPTER VI.

DISEASES OF THE ORBIT—INJURIES OF THE ORBIT WITHOUT AND WITHIN.

ORBITAL CELLULITIS — PERIORBITIS — CONTUSIONS AND CONTUSED WOUNDS ON THE ORBITAL EDGE—FRACTURES OF THE ORBIT—INCISED WOUNDS OF THE ORBIT—GUN-SHOT WOUNDS OF THE ORBIT — FOREIGN BODIES WITHIN THE ORBIT — DISLOCATION OF THE EYEBALL IN CONNECTION WITH ORBITAL INJURY—CARIES OF THE ORBIT—SECONDARY NECROSIS, OR CHRONIC—PROTRUSION OF THE EYEBALL—ENLARGEMENT OF THE THYROID GLAND, AND INCREASED ACTION OF THE HEART, OR GRAVES'S DISEASE—RHEUMATIC INFLAMMATION OF THE OCULAR TUNIC—ADHESION OF THE OCULAR TUNIC, WITH SEROUS EFFUSION—EFFUSION OF BLOOD IN THE ORBITAL TISSUES—INTRA-ORBITAL ABSCESS—HYPERTROPHY OF THE ORBITAL CELLULAR TISSUE—HYPEROSTOSIS OF THE ORBITAL BONES—DILATATION OF THE ORBIT FROM PRESSURE WITHIN, TOGETHER WITH ABSORPTION OF A PORTION OF THE WALLS—CYSTS ON THE ORBITAL WALLS —EMPHYSEMA ABOUT THE ORBIT.

ORBITAL CELLULITIS.

The anatomical relations of the orbit should be remembered, for the better understanding of the effects of inflammation on the parts it encircles, as well as the general symptoms of the disease. Every portion of the orbit is invested by periosteum, which passes through the numerous foramina of the cranium, and becomes continuous with the dura mater. The layer of dura mater which surrounds the optic nerve divides into two laminæ on entering the orbit, the outer of which is continuous with the orbital periosteum; the inner forms a dense whitish sheath for the nerve fibres, and accompanies them to

the sclerotica, with which it becomes continuous. It is between these that the ophthalmic artery is transmitted. At the base of the orbit the periosteum joins that of the bones of the face; here it is connected with the palpebral fascia, or fibrous layer of the eyelids.

While the internal surface of the orbital bones thus gets its nourishment from the periosteum, the roof above is supplied by the dura mater, the floor below by the mucous membrane of the antrum, the inner wall on its mesial surface by the mucous membrane of the nose, and the outer wall or its outer surface, by the periosteum of the temporal fossa. The structural connection with the surrounding parts is still more intimate and extended through the medium of the blood-vessels which unite throughout the whole region, and communicate also with the soft parts of the orbit.

All the interspaces of the orbit, between the vessels, nerves, muscles, eyeball, &c., are filled up with cellular tissue and fatty tissue. The cellular is thickest immediately around the several constituent parts, and, as it were, it forms sheaths of support for them, and septa, which retain them in position, and become continuous with the periosteum.

All this shows that when there is inflammation in the orbit, its influence must pass far beyond the mere limit of the bony cavity. It also shows the impossibility of isolating the inflammation to the bone, to the periosteum, or to the orbital contents; so that there can scarcely be any such isolated affections as ostitis, periostitis, or orbital cellulitis. The latter term is allowable only when the morbid action is intensified in the soft parts of the orbit. Inflammation beginning in any part may easily extend to the rest. These anatomical considerations must convince us that all descriptions of inflammatory disease about the orbit, characterized by divisions and subdivisions, are arbitrary and artificial, although practical convenience and the use of language oblige such arrangements.

Orbital cellulitis is one of the three varieties of erysipelas, the others being the cutaneous and the cellulo-cutaneous. It is often called by modern pathologists, diffuse inflammation of the cellular tissue. It is especially an acute disease of rapid development. In a typical case, the cellular tissue or areolar is primarily affected, the skin secondarily, the disease travelling from within outwards. There is an unpleasant sensation in the orbit, a feeling of heaviness, then pain, deep-seated, with a sense of tension, sometimes intermittent. The pain may extend over the head, the temple, and cheek. The eyelids become œdematous and red, the cheek is also œdematous. The conjunctiva is swollen, with a vascular chemosis that surrounds the cornea, and overlaps it to a greater or less degree. The eyeball is a little prominent. The ocular movements are restrained or lost.

The slightest touch on the eyeball is attended with sharp pain. In conjunction with the local symptoms, there is inflammatory fever of an asthenic form; the pulse is quick, and the tongue is furred. Vomiting may ensue, and, perhaps, delirium at night.

As the disease proceeds, all the symptoms are aggravated to a pitch which is almost intolerable. The eyeball is thrust further out, often beyond the palpebræ, and appears large. The pain intermits a little; throbbing and rigors are felt, suppuration takes place, and an abscess is formed, without, however, any material relief to the patient, since the bony parietes of the orbit cannot yield. Ultimately, the matter makes its way to the surface, presenting either at some part of the orbital margin or under the eyelid, usually the lower, pushing forwards the fold of conjunctiva passing from the eyelid to the eyeball.

The eyeball may get involved by implication in the surrounding orbital disease, its tissues spoiled, and vision destroyed; the symptoms being those of inflammation of the interior chiefly, by which the greatest changes are shown in the iris, and by closure of the pupil. As a rare event, suppuration may ensue in some part, generally the cornea, and perforation follows. But the commoner effect is destruction of sight from lesion of the optic nerve, not from pressure, but because the nerve fibres participate in the inflammation and become engorged, the ultimate effect of which is atrophy, as revealed by the ophthalmoscope, in which case the eyeball may not show externally any implication of disease. The ciliary nerves suffer likewise, reflex action between the retina and the iris is lost, and the pupil is immovable. More is said on this, in the chapter on "Injuries from Mechanical Agents."

Cerebral inflammatory symptoms may ensue, and death be induced by primary acute symptoms of the brain, or by the internal planes of the cellular tissue being involved—erysipelatous arachnitis; or, secondarily, from the extension backwards of the disease; or from the effects or products of inflammation, as pyæmia.

In a child, two years old, who died quickly from the affection, I made the post-mortem examination. The orbit was quite a pus sop. The ophthalmic vein and the cavernous sinus were filled with pus. The anterior lobe of the brain on the same side had suppurated, and there was a great deal of pus in the membranes at the base of the brain. Parallel cases are recorded.

It is uncertain when the suppuration occurs. As the pus is deposited in a diffuse form, rather than in a circumscribed abscess, it is apt to be overlooked, especially when by the side of the eyeball within the eyelids. This is a process which always escapes the notice of those who are unacquainted with the nature of the disease. It is common

for the conjunctiva to slough at a small spot, and to form an aperture for the escape of the ill-formed pus and the decomposed shreddy tissue. If the pus be deposited more towards the margin of the orbit, it is not discharged so readily by a natural process through the skin; greater suffering is occasioned, and secondary implication of the brain is more likely.

Variations and departures from the typical symptoms selected for description will be met with, and differences seen in the degree of vascular action, the pain, the nature of the suppuration, and the extent, the duration of the affection, especially of its several stages, and the spoiling effects on the eye. Pus may not be formed, for an attack may be so slight as to pass off without any disadvantage, ending in "resolution." It would be tiresome and useless to go into detail.

About the chemosis a special remark may be made, as there is much variation in the extent of it. It may only just bulge around the cornea, or it may cover it, or protrude so as to conceal the eyeball, and be more marked at one portion of the circumference of the eyeball than another. The following sketch of this state is taken from a child of two years old.

Fig. 29.

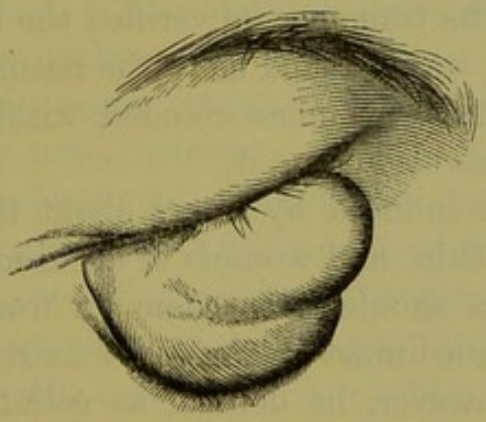

It gives, at a first glance, the idea of chemosis of both eyelids, a state that I thought existed, till a careful examination proved that the projection was from the upper part of the orbit. The groove in the swelling answers to the spot of reflection of the conjunctiva from the eyeball to the upper tarsal cartilage. The poor child being most rebellious, chloroform was administered in order to examine the disease carefully, and to adopt any surgical measure that might be deemed requisite. The eyeball was slightly prominent, and the lower eyelid only a little inflamed.

Cellular inflammation here is just the same as cellular inflammation in other parts of the body. It is best seen and observed in the limbs. There is no modification in the disease as such, on account of the anatomy of the part in which it occurs. The greater pain, the

protrusion of the swelling in one direction, the course of the abscess, are all physical symptoms arising out of the construction of the orbit.

The secretions from the surface of the eye vary. When the disease arises from a wound implicating the conjunctiva, there is generally a free purulent discharge. When it comes from a blow on the orbit, there may be scarcely any flow.

Causes.—I scarcely know of any except those of a traumatic origin. I have seen it produced by the following operations:—That for the extraction of cataract, and that for the solution with the needle; that for squint, in one case the eyeball suppurated; that for exploring the lacrymal duct, the eyeball suppurating; those for the removal of orbital tumours. In one instance, a small exostosis was violently removed by chisel and mallet. I saw the patient ten days after, when the brown and blackened tunics of the collapsed eyeball rested on a peduncle of thickened protruded orbital tissues, an inch and a half forwards. There was scarcely any secretion from the surface of this strange-looking mass, the sides of which were covered apparently by granular conjunctiva, riddled with small sloughed-formed apertures. I suspected that there was malignant disease, and so did several surgeons who were present. It was only when I had watched the gradual decrease of the tumour, and verified the lad's statement about the operation, that I was satisfied as to the nature of the disease. It was two months before the mass receded within the orbit. Penetrating orbital wounds also cause it.

Cellulitis is besides induced by blows about the orbital circumference, without and within, and wounds of all kinds.

If orbital cellulitis should ever come on from causes other than traumatic, the occurrence must be rare. Its existence as an idiopathic disease must not, however, be denied, as cellulitis does occur in a limb, without its being possible to trace a local cause. Such a case is now in one of my wards at St. Mary's Hospital, and a more definite one was never seen. All the stages, to the last of tegumentary sloughing, were passed through in ninety-six hours.

It is certain that cellular erysipelas is often confounded with abscesses occurring in scrofulous subjects, and in those who are debilitated from disease; also with cutaneous erysipelas. Of course, whenever there is suppuration in the orbit, some inflammation of the cellular tissue must have preceded; but the acute form, with its peculiar symptoms that I have been describing, is a distinct affection.

Treatment of a well-marked case.—This must be undertaken always with the conviction that the disease is of a depressing nature, and

that whatever tends in a general sense to reduce vital force is hurtful. The excitement of the circulation, the restlessness, and the feverishness of the early stage must not mislead. Depression is sure to come. Suppuration and gangrene are likely. The asthenic type of fever generally follows, and is most marked in this variety of erysipelas. Recovery is, therefore, always slow.

In all cases, the patient should be put to bed with his head and shoulders raised.

The room should be well ventilated, and not made artificially hot above sixty degrees of Fahrenheit.

In the advantage of giving a mild laxative at first, and once only, if there be no contra-indication, I fully believe.

Local blood-letting is serviceable. It should be done effectually, once for all. It will prevent depression if it stops the disease, and blood lost in this way can never have the lowering effects that might follow general bleeding. When leeches are used, their number should be according to the age of the patient, one or two for a child; six, eight, or more for an adult. After the leeches fall off, a hot linseed poultice should be applied for an hour, to encourage the bleeding, when such further effect seems desirable. Cupping is more mechanically applicable for an adult; but even in them, I think that leeching produces the better effect. The natural leech is better than the artificial. It inflicts less violence.

Scarification of the chemosed conjunctiva may be requisite. The palpebral skin also may need incisions.

Cold is another valuable agent, without the bleeding, or after it, according to circumstances. It influences local nutrition by lessening the temperature of the inflamed tissue, causes contractions of the vessels, decreases the amount of blood supplied to the inflamed part, and very materially lessens its sensibility as well as its exalted functional power. Its continuance should very much depend on the sensations of the patient. If it give pain and uneasiness rather than comfort, it can no longer be beneficial. Short of this, it will never be injurious while the surface of the affected part is hotter than the physiological temperature, no matter what may be the duration of its application.

When I desire to get only the least degree of cold, I use thin rag laid over the part and wetted sufficiently often to prevent it from getting dry; or I irrigate. When more cold is wanted, I employ iced water with the rag, or water with sp. etheris, and sp. vin. rect., or ice in a bag. Circumstances sometimes determine the choice of the one over the other. It is only when the skin is actually frozen, or nearly so, that injurious reaction is likely to be set up; and such a

degree of cold is never accidentally developed, and would require for its creation other means.

Opium in its various preparations is a valuable resource later in the attack, not only in subduing pain, but through such influence, removing one of the causes of impairment of circulation and nutrition. As regards its internal administration, it is only necessary to warn the student not to give it so as to cause depression, but merely to calm and soothe, to avoid its worst ill effects, and to remember that some persons bear it badly, and are apt to vomit. Many of its disadvantages, especially those arising from disturbance to digestion, may be overcome by giving it in the rectum, where a larger dose is necessary. This local application of it I employ more and more. For quick action, the hypodermic method is the best. The skin on the temple, or elsewhere, is pinched up, the point of the screw syringe introduced, the skin released, and the piston turned till the desired quantity is thrown into the areolar tissue. The process is almost painless, when it is done neatly. From the quarter of a grain of morphia to the half may be so used. The action may be manifest in half a minute. There is generally more primary excitement if the dose be large than when the drug is given internally. If nausea and vomiting occur, they soon pass away. No ill comes from the extravasation of the fluid into the areolar tissue. In a very few cases burning sensation over the skin, acrid taste, redness of the face, tinnitus aurium, rapid action of the heart, and even convulsions have rapidly come on. These symptoms are attributed to the injection having entered a vein, and passed quickly to the heart. I know of an instance in which death ensued. The safeguard is, at first, to use a small dose, not more than the sixth of a grain, to inject very slowly, and to watch the effects while injecting. A patient who is very intolerant to opium should not be treated by this method.

Surface applications of the opium, although not very potent, are worth something ; a strong solution of the watery extract is the best. Opium may also be used in ointment.

Chloroform and belladonna in liniments, according to the British Pharmacopœial preparations, are useful as adjuvants in removing pain.

Counter-irritation, as blisters and setons in the vicinity of the eye, are worse than useless. I am sure that they do harm by increasing the excitement of the part. I cannot understand how a surgeon can ever apply such measures to a part which is acutely inflamed. In their effect at a distance I have no faith.

The diet should be light and easy of digestion. If the appetite be bad, milk should be the chief aliment.

Many cases of orbital cellulitis I have stamped out by such remedies as I recommend. When a cure has not been effected by resolution, no doubt the after-stages have been less severe, and the convalescence sooner obtained. If the disease should progress, and pass to the secondary phenomena of inflammation, or the tertiary, more or less destruction of parts ensues; and the system is much affected. The areolar tissue suffers most. Every texture in the orbit, according to its physical and vital properties, may show the spoiling effects of the inflammation. The eyeball itself may have its several parts disorganized, and even suppurate and collapse. More will be said of this in connection with cellulitis following certain injuries. Here the surgeon's duty in assisting the process of repair is more marked. He is to soothe and give comfort, and help to remove the products of the disease that nature cannot sufficiently throw off, and assist to heal the breaches that have been made, while he supports the general strength. Warm applications are now wanted. All growth needs warmth and moisture. The opiate fomentations, the hot flannels, the bran poultices, are requisitions, and must be used where there has been suppuration, ulceration, or mortification, till cicatrization has set in.

Constitutional measures must be adopted according to the state of the vascular system, and the digestion. Should the heart's action become feeble, I prefer to give, during the activity of the disease, diffusible stimulants, rather than alcohol. The fever is apt to be increased, and the little appetite spoiled by the bad alcohol with which patients are often dosed. Such would make a sound man ill. This remark applies to the usual description of port wine and sherry, less, however, to French wines and Rhenish. If a surgeon should make a mistake, and err in giving a stimulant, he does the greater harm with the alcohol; and the worse the spirit, the greater the evil.

The occurrence of suppuration should be always expected, and the presence of pus sought for by touch, within the eyelids and without, near to the orbital margin. With the least suspicion of the purulent fluid as indicated by rigors, and even when it cannot be yet detected by touch, suitable exploring incisions should be made. Although the pus does not point, as in an ordinary abscess, fluctuation in some degree can generally be felt. The position of the eyeball may help in the search. When the centre of the intensity of the disease is lateral, there will be ocular displacement to the opposite side of the orbit.

Should it appear that pus is deposited in the eyeball, the sooner it is evacuated the better for the patient, as regards relief from pain, and the shortening of his illness. The suppuration, as far as I have seen, is always partial, and never but a small amount of

pus has flowed when I have used the knife; but with the pus disorganized vitreous humour and serum have escaped.

Chemosed and exposed conjunctiva, must be protected from the air by greasy applications.

Relapses are apt to occur, and must be guarded against, chiefly by not allowing the patient to move about too soon.

Fistulæ of the orbit, unconnected with diseased bone, are not uncommon, when there has been much suppuration with sloughing. They heal quickly if they be not irritated by drugs. Cleanliness alone is wanted.

Secondary abscesses are to be feared. They may be attended with as bad results as the primary suppuration, and be accompanied by pyæmia. They should be opened as early as possible.

Effects of this cellulitis.—Even when the eyeball escapes injury, and the sight is not damaged, changes may arise among the soft tissues, such as infiltrations, whereby the eyeball may be, in some degree, permanently protruded, or its movements interfered with, by adhesions, or by the loss of muscular power from damage to the muscular tissue. The nature and effects of such changes are best seen and studied in a limb. Caries and necrosis have resulted from it, in consequence of acute inflammation of the bone. These effects are generally preceded by the stripping of the periosteum.

PERIORBITIS.

This is meant to include inflammation of the orbital bones, and of their investing periosteum.

It is more correct, clinically and pathologically, to consider the two structures, the bone and its investing membrane, as involved at the same time, when there is any marked degree of inflammation of the orbital walls, than to speak of periostitis or ostitis. The periosteum, highly organized, envelopes the bone in all parts, and the same system of vessels intimately pervade the two in a closely-set network. Greater changes may occur in the one tissue than in the other, according to which of the two is primarily affected, or in which there is greatest intensity of action, but there is no peculiarity in this. It would be impossible, then, to describe well-marked periostitis, without speaking of changes participated in by the bone; or to tell of ostitis, without saying that the periosteum participated in the morbid action, and became highly vascular, swollen, and tender, and that the medullary membrane also was involved. This generalization of disease applies with particular force here, where there was no great difference, in most parts of the orbit, between the thickness of the two tissues.

It must be pointed out that the periosteum may be separated without the bones being necrosed; bare bone is not necessarily dead bone. The bone may ulcerate, and undergo other changes for a long time, without the periosteum being detached.

The affection, in its essence as a disease, is best studied in a more exposed part of the body, especially on the surface of one of the long bones, where it is generally called periostitis. About the orbit symptoms are added to it, mostly ocular, solely on account of the anatomical relations of the region. From the same cause certain modifications may exist. Thus it may partake somewhat of the symptoms of orbital cellulitis. I have sought in vain, in the early stages of the two diseases, for physical signs of distinction between them, that could always be depended on. A careful analysis of cases shows that no reliance can be placed on the line of direction of the protruded eyeball. In either it may be directly forward, or oblique. More is to be gathered from the history of the disease, the first being nearly always constitutional, the second traumatic. It may be followed by the cellulitis, or supervene on it. It is not, therefore, possible always in a given case to say what was the starting-point of the disease, what the consequence.

In a typical case these outward symptoms may be expected.—An œdematous swelling of the eyelids, occasionally with ptosis. Slight protrusions of the eyeball, directly forwards, or with displacement. If it be thrown out of axis, there will be double vision. At first there is much lacrymation. At a later period usually none. This must be due to the suspension of the secreting power of the lacrymal gland, and not, as is generally supposed, to mere pressure on its ducts. There is serous chemosis. Constitutional symptoms are always present; depression, and even prostration, prevail.

The subjective signs are also plain. Deep-seated pain in the orbit, and sometimes also over the head, aggravated at night, are rarely absent. Tenderness under touch, or actual pain when the orbital margin is pressed on, or the interior of the orbit, is very characteristic. This tenderness exists so long as the severity lasts, and distinguishes the affection from supra-orbital neuralgia, in which there is sometimes pain under pressure, and sometimes not. The intolerance to touch may be participated in by the cheek, forehead, and root of the nose. The movements of the eyeball are painful. I have known the eyeball itself to be tender. The several symptoms are rapidly developed.

There is generally a focus of diseased action, or intensity, at a spot, most commonly at the inner part of the orbital roof; and sometimes a circumscribed swelling may be felt.

Some of the orbital muscles, or all, may be paralyzed, and even the ophthalmic division of the fifth nerve may lose its sensation. This, of course, arises from pressure on the nerves at their entrance to the orbit.

There is more or less acuteness in these symptoms, and the variations are occasionally so great, that cases may be classed as acute, sub-acute, and chronic. In the first two the effects are more immediate. Some of the orbital tissues may slough. An abscess may form, cerebral symptoms may ensue, and death occur. In the latter the effects follow much later; hence nodes, chronic abscesses, exostosis, caries, death at a remote period from secondary implication of the brain.

The destructive terminations of the disease are, damage to the orbital soft tissues, thickening of the periosteum and the bone, slight permanent protrusions of the eyeball, permanent partial paralysis of some of the ocular muscles, exostosis, caries, death. Some of the chronic effects may linger for years.

The disease may recur, and attack the same eye, or its fellow.

Exceptions are to be met with, in the nature of the symptoms. At this moment I have under my care a male adult, in whom all the features of an acute attack, such as I have recounted, including the paralysis, were present, except those of pain in the orbit, pain when the eyeball was moved, and pain when it was pressed backwards. The only pain that ever existed, was that of headache. The case was a puzzle to all who saw it.

Causes.—A rheumatic derivation is well understood. The affection may occur with general rheumatism, or after it; or may be developed in a person of a slightly rheumatic habit. It may appear as the first attack of that disease; but, I suspect, never in this way, except in persons who have been recently depressed or debilitated, and then exposed to trying atmospheric influence. I never saw a more severe example than occurred in a noble lord, naturally robust, and very strong, but who, after excessive fatigue in the hunting-field, and with yeomanry, and the exhausting influence of card-playing till very late hours for many nights, was exposed for some hours to a severe east wind. He was so low and excitable on the night on which I was called to him that a cinder which fell from the grate to the fender caused an hysterical fit. Syphilis is an undoubted cause. Struma likewise has its influence. A traumatic origin might be claimed; but I am inclined to reject the latter, except as an exciting cause in those who have the constitutional conditions that have been named.

It may creep to the orbit from like disease in the frontal sinus, the maxillary antrum, or from the interior of the cranium.

Treatment.—In acute cases, with much pain, and marked vascular

excitement, leeches to the temple, followed by a large linseed poultice to encourage the bleeding are useful. Cupping is of great service. Cold should be applied after the manner directed in the foregoing directions for orbital cellulitis. It is indicated when there is a marked increase in the local temperature, and so long as it gives comfort to the patient, no matter what may be the origin of the disease. This is my conclusion after much clinical experience.

When there is a marked rheumatic diathesis, such constitutional disturbance and indications should be well looked after, and treated according to the prominent symptoms. The same must be said of syphilitic taint.

As there may be an absence of any palpable co-existing rheumatic or syphilitic origin, it is essential always to go into the history of the case, to ascertain if there have been any primary indications of these disorders; and this is particularly necessary with reference to the latter, because the syphilitic poison, in a secondary form, may crop out for years, at long intervals, sometimes in one organ and sometimes in another, as it were, in an isolated form. With the possibility, therefore, of the presence of this subtle virus, the suitable treatment should be adopted.

I have belief in the advantage of mercury both in the rheumatic and syphilitic cases. I give it in the form of Hydr. cum cretâ, with the Ext. hyoscyami; care being taken to prevent purging, or any degree of salivation.

I combine opium, if there be much pain, or want of rest. Such a remedy should be proportioned to the patient's strength. When there is any general depression of the vital powers, I give some form of cinchona, or of iron as well. I stop the mercury where syphilis does not exist, as soon as the acute symptoms are subdued. Where there is any strong contra-indication to mercury, and in the less acute cases, the Potassii iodidum should be given.

The eye should be kept at rest, and the patient made to lie down and keep quiet.

A periosteal swelling that causes pain and interrupts rest may be incised with advantage.

An abscess should be evacuated without delay. But periosteal abscesses are not always apparent, that is, within reach; nor is the sense of fluctuation always definite, even in those that can be touched; so that exploration may be necessary at any time. When the symptoms warrant deep exploration, a narrow-bladed knife, sharp at the point only, should be pushed along the wall of the orbit to the suspected position. The pus is tolerably sure to be on the side from which the eyeball is turned; therefore, such deviation should always

be looked for. If the pus should escape while the knife is yet in the orbit, the incision in the walls of the abscess should be enlarged. When pus does not escape after the use of the knife, a sharp-pointed silver probe should be introduced into the wound, and pushed still further, for a more extended exploration. It can be employed with less danger. Oftentimes I have seen the abscess missed with the knife, but opened with the probe. Secondary explorations at intervals of a few days may be necessary. Before exploring, the anatomical bearing of the important parts within the orbit should be called to mind.

In subacute cases, less active measures are needed, and with shorter application of them.

In chronic cases, there is less to be done locally in arresting the disease. Here the treatment must be chiefly directed to the removal of the effects of the inflammation, the well-known secondary and tertiary results, which have been already spoken of.

Relapse in all stages is likely, and should be guarded against.

The result of treatment is very satisfactory in the acute cases; so much so, indeed, that I always approach them with confidence. In the chronic, when abscesses occur, recovery is tedious, and the result uncertain.

CONTUSIONS AND CONTUSED WOUNDS ON THE ORBITAL EDGE.

These should be regarded as more serious than a similar amount of injury to any other part of the surface of the body, because, in addition to the ordinary risk, the proximity of the eyeball and its appendages, and of the brain, and the effects that may be produced on these, heighten the danger. Damage here from falls, blows, or injuries of any kind should never, therefore, be regarded as trivial accidents, because they may be productive of much local disease, damage to the eye, or destruction of it, and even death from cerebral implication. Such results may follow quickly, or appear late, so late as to induce a doubt as to the causes.

Periorbitis is a common sequence when the blow is inflicted on unhealthy children, and suppuration generally follows. It is then a fortunate occurrence if the bone does not become involved, and the patient escapes without caries.

Orbital cellulitis is always imminent.

Occasionally a severe injury is quite unattended with any bad effects.

Head affections may supervene from orbital blows, especially when the upper edge of the orbit has been struck, that is, the frontal bone. Concussion of the brain is the most common of these. I have seen this complication many times.

In all probability there is always some brain lesion in concussion, however slight. Some abnormal state is, I believe, always found when death follows such a symptom.

A worse effect of the injury, and usually when there is in association much damage to the soft parts and to the cranial bone, is inflammation of the internal table of the bone, involving the membranes of the brain. The patient may be progressing well to all appearance, when the wound may get unhealthy; fever ensues; the periosteum is separated. A similar change takes place in the dura mater: it separates, and pus is deposited between it and the bone, and, perhaps, too, internal to the dura mater. It is soon apparent that the brain is suffering. If the patient live over this complication, the arachnoid membrane, the pia mater, and the brain substance may get involved, and if this be so, rigors, drowsiness, and coma close the scene.

Of this secondary complication I have lately had two cases. The last occurred at St. Mary's Hospital, during the year 1867. The wound sloughed, and the bone was exposed. Suppuration spread around, between the occipito-frontalis muscle and the skull. The symptoms of general depression and vomiting showed that the cerebral mass was implicated. I told my class the danger there was at hand. The man died, and my diagnosis of internal inflammation of the brain and suppuration was verified.

In another case admitted into St. Mary's Hospital, with a contused wound on the outer orbital edge, the patient died from a large abscess in the cerebellum.

Traumatic inflammation of the brain is likely to end in deposit of pus in the meninges, or in the brain substance, and such inflammation is liable to occur after any injury of the head.

The liability to internal inflammation of the head depends much on the nature of the action in the external wound. When a healthy process of repair is established at the seat of injury, and continues, nothing is to be feared; but in proportion to the absence of this, and particularly when sloughing sets in, dire consequences are at hand.

A very insignificant external injury as to extent, may be associated with the severe condition of separation of some of the facial bones at the transverse suture. Some, or all of these bones, may be disconnected by a blow on the face, or a fall on the same. I have seen instances of the former; and South, in his translation of Chelius, gives one of the latter.

An example, attended with inter-arachnoid hæmorrhage, and death, is recorded by Mr. St. John Edwards, in the *Medical Times and Gazette* for June 10th, 1854.

The particulars are given here in abstract:—

A girl, æt. 25, a street prostitute, was in perfect health up to the night of the 8th of October, when she went out to pursue her usual degraded avocation. She received a blow on the left eye, which was blackened in consequence; and she returned home drunk. She complained repeatedly of her head. On the night of the 18th, she became uproarious and unmanageable; so much so that her friends locked her up towards evening in her own room, in order to get rid of her for a time. She had the full use of all her limbs, and undressed herself. She was seen in bed at half-past 7 p.m., and again at 11 p.m., and on the latter occasion was spoken to. She appeared sensible, but returned no answer. At noon next day, the 19th, she was alive, breathing heavily, and asleep; at 1 p.m. she was dead.

Post-mortem appearances.—Body well formed, and in excellent condition. No remains of bruise on the left eye. The dura mater covering the left hemisphere was observed to be much darker than that of the right side. The cause of this was obvious. All that portion of the left arachnoid cavity, which lay above a horizontal line, drawn level with the top of the ear, was filled with blood, partly fluid, partly coagulated; the coagulated portion being of the colour and consistence of black currant jelly, and containing in the middle a fibrinous clot. Fluid blood was found to extend downwards to the base of the brain, where it occupied the anterior portion of the middle fossa, the sella turcica, and the parts around. The optic nerves were bathed in it. There must have been between four and five ounces in all. On the convex surface of the hemisphere, midway from front to back, the clot had formed an oval depression in the convolutions, the longest diameter being fully an inch and a half. The membranes were all deeply stained, so also was the substance of the convolutions, in some places to the depth of a quarter of an inch. The brain itself was throughout quite healthy. Searching the base of the skull for the cause of the hæmorrhage, it was discovered that the small wing of the sphenoid bone on the left side was disarticulated from the adjoining portion of the frontal bone, and displaced backwards and upwards. The dura mater was not pierced, or otherwise injured. The displaced portion of bone was exactly in a position to wound the middle cerebral artery in the fissure of Sylvius. Unfortunately, there was not time enough to make an examination, to ascertain whether such had been effected. There were no evidences of inflammation of the dura mater, around the seat of the injury.

Treatment.—In every recent accident, a careful search should be made for extraneous substances. If the surface be broken, and the wound too narrow for the finger to be used, the probe must be

employed. When the injury is slight, producing no shock, and only swelling and ecchymosis of the integuments, the case is not likely to be serious. Little is required externally, and all that is necessary is given in the chapter on "Injuries from Mechanical Agents." But no matter how small the outer damage, if periorbitis set in, or cellulitis, there is an important affair that calls for most judicious treatment. If there be stunning, that is, true concussion, or any mental aberration, there is still greater danger. The treatment of such affections of the head, however, does not come within the scope of this work.

Whenever the integument is cut through, and there is the possibility of the wound uniting by adhesion, sutures should be used, and the edges most carefully adjusted. Plaster will assist the process.

Sometimes the wounds are as clean and straight as if inflicted by a surgical instrument, and it is these that give the quickest and best result of repair.

Wounds with irregular or jagged edges may quickly unite if properly brought together by sutures. So long as healthy integument can be readily adapted, it should be treated with the object of getting primary union, no matter what may be the form of the tear, or even the extent. If the edges do not unite, other parts may. More is said in detail on this point in the chapter on "Wounds of the Eyelids, and of the Surrounding Integuments."

There is no danger in the use of sutures. The supposed disadvantage of them about the head is one of the popular errors in surgery; and it is on this account, that I take so much pains to insist on their use by my house-surgeons, as well as to point out their utility to those who attend my hospital practice. So long as there is no better means of accurately adapting wounds, they are indispensable. They should not be allowed to remain long enough to act as setons, but be removed sufficiently early, when, in fact, it is ascertained that union is effected, and at once, when the existence of suppuration proves their failure.

When sutures are inapplicable from loss of parts, judicious dressing can effect a great deal. By carefully adapting surfaces, and maintaining apposition by a thin layer of cotton wool and a bandage, some adhesion may generally be got. I have seen the advantage of this in wounds about the eye, even of an irregular or ragged form.

It should ever be remembered that all parts of a wound which do not unite by adhesion, can heal only by the slow and disadvantageous suppurative stage.

A strip of integument which could scarcely unite at any part may be saved, and made ultimately available, through supporting its

vitality, by maintaining it in the natural position by plaster and by bandage. In this way I obtained success in the case of a lad, from whose upper orbital edge a wedge-shaped piece of integument, together with periosteum, containing nearly all the hairy eyebrow, was stripped by a blow from a cart wheel. A narrow bandage was applied, and the separated parts were kept in situation during the many weeks while the bone was granulating, and the under part of the strip was adhering. In the end, the two granulating surfaces so united that the integument nearly recovered its wonted place, and all the time the patient escaped even discomfort.

When the wound must necessarily be closed by cicatrization, those measures must be adopted that favour growth in all living organisms. Heat, and moisture, and room for expansion effect this. At first a poultice, and afterwards, when the desired action is well in force, water-dressing, with wet lint and oil-silk. When the granulations are fully formed, I think that the cotton wool and bandage dressing facilitate the cure. Of the advantage of the cotton, and the mode of applying it, an account is given in the treatment of burns and scalds of the eyelids.

The œdema and ecchymosis that usually follow these injuries are always alarming to patients.

Erysipelatous inflammation, both of the skin and of the subjacent tissue, is apt to ensue in these accidents. It is unnecessary to speak of the treatment of this disease. All that I shall say is to advise the evacuation of pus as soon as it is detected, in order to prevent sloughing and deformity.

FRACTURES OF THE ORBIT.

Fractures of the orbital edge, or extending into and involving the walls of the orbit, whether simple or compound, are always dangerous to the integrity of the eye, from direct injury to the optic nerve, or to the eyeball; or indirect injury to the nerve and to the eye, through inflammation of the orbital contents; or to the optic nerve, through lesion of the brain; or to the muscles of the eye, from direct injury to them, or indirect by paralysis. They are likely also to affect the brain secondarily. Besides partaking of the general nature of like osseous injuries, there are, moreover, some peculiarities in these cases that arise out of the region, that should be mentioned.

Fractures about the circumference of the orbit are generally the result of great violence, and are, for the most part, associated with an external wound. When the fracture runs across the frontal sinus, the maxillary sinus, or the ethmoidal cells, air from the nostrils may pass into the areolar tissue of the eyelids and the surrounding

parts. The appearance of emphysema is the same as that of ordinary œdema. To the touch, it imparts the feeling of crepitation. Mention is made of an accident of this nature in the *Ophthalmic Review*. A man was struck with the fist on the temporal side of the orbit. Three days afterwards, while blowing his nose, his eye was quite driven out of his head from emphysema. He partially replaced the eyeball, and the prominence lessened after that. On the fifth day the upper eyelid was much swollen, and crepitated distinctly under the finger. The vision was natural, and the mobility of the eye was but slightly interfered with. There was evidently fracture by counter-stroke of the inner wall of the orbit, by which there was a communication between the frontal sinus, or the nares and the orbit.

The anterior wall of the frontal sinus is sometimes alone broken, causing effusion of blood. It is only when the posterior is fractured that there is much severity, and that damage is likely to accrue to the brain. In a case in which inspissated secretion escaped from a fractured frontal sinus, it was for a time supposed that cerebral matter was oozing out.

The orbit is involved in fracture, running across the base of the skull, when the crack extends through the anterior fossa. With such an occurrence, there will most probably be extravasation of blood into the orbit, or into the cellular tissue of the eyelids. It is by such fracture that intercranial aneurism of the carotid may be produced.

Fractures of the upper wall of the orbit, running far back, or in association with other cranial fracture, may be complicated with injury to the dura mater, and to the anterior lobe of the brain. The symptoms of effusion of blood, and, probably, disturbance of brain function, would point to the nature of the injury.

Fractures by counter-stroke have been seen in the orbital walls, from blows on the forehead and on the head.

Mr. P. Hewett states that, in the year 1869, a patient was admitted into St. George's Hospital, whose orbital plate of the frontal bone was fractured from a blow on the perpendicular portion, without any injury whatsoever being perceptible in the intervening osseous tissue. He speaks of a similar case, as recorded by Boyer.

The upper wall of the orbit may be fractured by a blow on the orbital margin, apparently of an insignificant nature. I am aware of three deaths from such accidents. This is the most recent :—A carman was kicked on the upper edge of the left orbit by a horse, November 9th, 1868, and was brought to St. Mary's Hospital. He walked into the ward. My house-surgeon stitched up the cut in the integuments, over the centre of the upper orbital edge. I saw the patient the next day. He was sensible, and not in pain. There seemed to be a mere

tegumentary wound. I remarked casually to the students that such a case was never devoid of danger, and alluded to the occasional occurrence of fracture, never suspecting that it was present. Twenty-four hours later, cerebral symptoms set in, and death ensued in two days. At the post-mortem examination, the following conditions were found:—Clots of blood beneath the integuments around the wound. A fracture, commencing at the upper and inner angle of the orbit, passed through the orbital plate of the frontal bone, the cribriform plate, and the lesser wing of the sphenoid. A second fracture across the roof of the orbit met this at a right angle. The portion of the orbital wall thus partially isolated was driven up, and lacerated the anterior lobe of the left hemisphere of the brain, and the front part of the middle lobe.

When the frontal sinuses are fairly developed, a blow over one of them may fracture the bone, and drive it inwards; and although there may be considerable depression at the spot, cerebral symptoms may not occur directly from the fracture, because it is the outer table of the frontal bone that is damaged and driven in, the inner table, the true skull cap in this instance, remaining intact. The case is altogether different when fracture occurs before the sinuses are developed.

Treatment.—Adaptation of parts, soft and hard, and the maintenance of adjustment, is practicable in some cases, particularly when the margin only of the orbit is involved. The effects of nice manipulation, with sutures, plaster, compresses, and bandages, were well shown in a private patient of mine, with comminuted compound fracture of the nasal bones, the ethmoid, and the centre of the frontal, produced by a violent blow, maliciously given, with a large and heavy stick.

After I had pressed up the nasal bones, and adjusted the portion of frontal, by lint pushed up within the nostrils, I attended to the external dressing, with sutures, plaster, compresses, and bandages. There is, of course, disfigurement, but to the least degree; and the eyes preserve their perfect integrity. Although life was nearly lost from brain symptoms, and depositions were taken as from a man supposed likely to die, death did not ensue; and all, I believe, through judicious surgery at first.

In instances of compound comminuted fracture, an isolated piece of bone should not be removed so long as it retains periosteal attachment. If it be ascertained that any fragments of bone are impacted, or any driven into the brain, they should, if possible, be removed.

If it were tolerably certain from symptoms that the brain were compressed by any part of the upper orbital wall, and the displaced

bone could not be got at except by exploring the orbit, I would explore, and, with sufficient encouragement, I would remove the eye, to enable the bone to be replaced.

The emphysema, with the accompanying protrusion of the eyeball, which may ensue when the inner wall of the orbit is fractured, and which always causes so much alarm, is a most harmless thing. No active treatment is needed, and for the most part it may be left alone, for it will soon subside. Should it increase, the eyelids must be closed with court-plaster, and slight pressure made with cotton wool and a bandage for a few days. The patient should abstain from blowing his nose, or breathing violently. As soon as repair sets in, the aperture by which the air can escape is closed.

All extraneous substances should be removed. If their presence be even suspected, they should be sought after.

Abscesses should be opened directly that they are detected, and exploration made, if it be probable that one has formed. The advantage of this judicious seeking is told by Mr. J. Hilton, in his book on "The Influence of Mechanical and Physiological Rest." This surgeon had under his care, in Guy's Hospital, a patient, with fracture at the base of the skull, extending across the posterior part of the orbit. After a little time, the soft parts of the orbit swelled, and the eyeball protruded. Vision became extinct, and there was much pain in the orbit, and constitutional disturbance. In the expectation of finding blood or pus deep in the orbit, he divided the upper eyelid with a lancet, and then passed a grooved probe towards the apex of the orbit. As a little pus was visible in the groove, he introduced, by the guide of the probe, the blades of a small pair of dressing forceps, and opened an abscess by expanding the forceps. There was a free discharge of pus; the patient was relieved of his distress; the amaurosis disappeared; and recovery ensued without further aid.

Acute necrosis may occur in any case of fracture. The appearances of the part are unmistakeable by those who are accustomed to treat compound fractures of the limbs. Much swelling, with diffused redness, great pain, constitutional disturbance, and, if the fracture be compound, unhealthy edges and dark-coloured and unhealthy pus, more like yeast than pus, will declare its existence. The sooner the dead bone is removed the better. Incisions may be necessary.

Remarkable recoveries have followed orbital fractures. Sometimes cerebral matter has escaped; sometimes large portions of the orbit have exfoliated, including the greater part of the orbital wall.

Paralysis of some of the orbital muscles may ensue, according as there is damage directly to the muscle, or to its motor nerve.

A piece of bone may be severed, and hang in the partially detached

integument. Even then, the approximation of parts is to be carried out. This principle has been fully established by many of the modern operations in general surgery, of which that of Pirogoff is the best illustration. But the propriety of so doing dates much further back, in a valuable exemplification of the practice, as quoted by Dr. Mackenzie, from the memoirs of a French Society. A wound was received from a cutting instrument, and extended obliquely, from the upper part of the left temporal fossa across the root of the nose, to the right canine fossa. The divided skin, muscles, nerves, and arteries hung over the cheek, in which were also present a portion of the orbital arch of the frontal bone, together with the external angular process, so that the cavity of the cranium was laid open, as well as that of the orbit, whereby the brain and the globe of the eye were exposed to view. The brain was unhurt and so was the eye, and all of its parts, except the levator palpebræ. An injudicious surgeon put linen with cerate between the wound; M. Ribes, who soon afterwards saw the patient, removed the linen, and brought the edges of the wound accurately together. In six weeks the patient was cured, without fever or suppuration. Vision was destroyed, and the eye subsequently shrank.

Injuries to the nerves connected with the eye, from orbital and cranial fractures.—Damage to the orbital nerves from fracture of the bone, has been alluded to, yet something special remains to be said.

The optic nerve may be completely torn across in an orbital fracture, when blindness would be instantaneous. It may also be pressed on by a fragment of bone at some distance from the optic foramen. A patient admitted into St. George's Hospital, with fracture and depression of the parietal bone, was blinded by the accident. At a post-mortem examination, it was discovered that the optic nerves were pressed upon by a fractured portion of the sphenoid bone.

Mr. Prescott Hewett says that he has several times seen in severe injuries of the head, and especially about the orbits, the neurilemma of the optic nerve distended with blood, the nerve fibrils being neither torn nor injured.

Although the third pair of nerves is less liable to injury from fractures, it may suffer from the pressure of clots of blood produced by such accidents. Paralysis has been induced by a clot lying in the space between the crura cerebri.

A case of ptosis of the left upper eyelid, connected with pressure on the inferior surface of the left hemisphere of the cerebrum, has been recorded by Sir B. Brodie, the pressure being, as he says, so situated as to affect the nerve of the third pair, immediately behind the cavernus sinus. The partial paralysis, as exemplified in a case

such as the above, is particularly alluded to in the chapter on "The Paralytic Affections of the Eye."

Paralysis of the ophthalmic division of the fifth nerve, has been noticed several times in orbital injuries, and in injuries of the head alone, and also in connection with injury to other cerebral nerves. It would seem as if the nerve suffers sometimes from pressure of a clot, sometimes from pressure of the fractured bone, and sometimes from injury to the nerve substance. So it is that the paralysis manifested in loss of sensation may disappear in a few weeks, or may never be recovered from. The influence that the paralysis may have on the cornea is spoken of in the chapter above alluded to.

The sixth nerve, from its filament-like form, and its position, in a groove on the superior border of the petrous portion of the frontal bone, is very liable to be torn across in a fracture of the bone. The symptom would be internal squint.

INCISED WOUNDS OF THE ORBIT.

These are very rare. I have seen only one example. A gentleman was cut obliquely across the upper edge of the orbit with a sword, the bone being cleft. The eyeball was uninjured. This was one of many cuts about his face in a murderous attack on him. The orbit has been completely laid open by a sabre cut, so that its contents were exposed to view. The frontal bone and the brain have been divided down to the eyes.

Treatment.—The correct practice is to bring all the divided parts together, and to maintain them in apposition by suture and by bandage, and thereby to endeavour to secure union. So far as the bone is concerned, it is in no worse a condition than in an ordinary compound fracture.

GUNSHOT INJURIES OF THE ORBIT.

These comprise injuries from shot and shell, from splinters, and damage from any kind of firearms.

Wounds received in this way, and for the most part in war, are remarkable for their greater irregularity, extent, and depth, and still more for their injurious effects.

Almost every conceivable kind of accident has been produced and chronicled. A portion of the eyeball has been shot away without any damage to the eyelids, or to the surounding parts. The eyeball has been torn from its socket, with more or less injury to the orbital appendages. It has been drilled by a bullet. It has been reduced to mere shreds. One, and both optic nerves have been cut across by bullets traversing both orbits at the same time.

The bullet may strike the eyeball directly and lodge in the brain.

The whole of the contents of the orbit, with the outer wall, may be swept away.

In a patient of mine at St. Mary's Hospital, the eyeball, the outer wall of the orbit, and the lower, were removed in as clean a manner as if by a surgical operation. In another, at the same institution, both orbits, with the nose, and the entire upper jaw, were completely shot away by a fowling piece.

It is the circumference of the orbit that is most frequently damaged, and the upper and outer angle more than any other part.

The position in which a person shot is standing determines the direction that the projectile takes; a knowledge of this is, therefore, important.

The bullet that enters the orbit obliquely, although it generally destroys the eye, is not likely to enter the brain.

The bullet that passes in a transverse direction through one or both of the orbits, and damages the cribriform plate of the ethmoid, generally causes death from the shock, or subsequently from inflammation of the brain.

Bullets have often been lodged in the frontal sinus, when the inner table of the skull has generally been fractured.

The course that bullets take is generally irregular, devious, as Henner, the greatest of all our writers on military surgery, calls it, to such an extent, indeed, as to cause astonishment. A surgeon should ever bear this in mind. It is mentioned in the *Edinburgh Medical Journal* that during the late Indian war, a private was struck in the right eye by a bullet, which was subsequently removed from the back, between the edge of the right scapula and the vertebral column. This man lived some weeks after. Dissection of his body showed that the ball had traversed the inferior part of the orbit and the base of the skull, then passed out of the skull in front of the foramem magnum, entered the neck, and rested in the back.

The bullet has entered the eye, and come out in front of the corresponding ear. In another case, it entered the right eye, and passed out of the left ear. Pages might be filled with these astonishing effects. The bullet may enter the face, and lodge in the eye, or in the orbit.

The course of a bullet that has entered the eye cannot always be determined. This is in accordance with the rule of irregular transit, which has been spoken of.

Hæmorrhage is not common in these gunshot wounds, unless produced by grape-shot or fragments of shells. Dr. Browne, of Belfast, met with an example to the contrary during the Belfast riots. A girl was shot in the eye, and brought to the hospital in a state of great prostra-

tion from loss of blood. Besides this, she vomited an astonishing amount of coagulated blood. The ball could not be found. As the bleeding seemed to come chiefly from the posterior nares, it was supposed that the ball might have lodged in that direction.

There is seldom immediate pain from gunshot wounds.—This is a well-known fact. I have noticed it in many cases in general surgery that I have had both in public and private practice. I arrived in Belfast just after one of the violent religious riots, and saw many men with bullet wounds in various parts of their body, and they all declared they scarcely knew that they had been struck. A man who had a bullet lodged in the lower part of his tibia, said that he felt only a little stinging sensation when the injury was received, and did not know that he was shot until he saw the blood running.

Those who desire more information on this subject should consult the works on military surgery which have appeared in this country and abroad. An amazing amount of information has been gathered and published.

It would be a waste of time to give in detail the symptoms that ensue on these injuries. The nature of the accident is clear, and the local and the general effects are just what would follow a like mechanical injury elsewhere, with the addition of high inflammatory symptoms, great swelling, and much pain. The liability to cerebral complication is the special point worthy of notice, for after all, the great danger arises either from lesion of the brain, or disturbance of it and its membranes. This may be primary, or secondary; if primary, from extravasation of blood, or from a part of the orbit, or a splinter of the bone, having been driven inwards, and compressing the brain, or from the missile entering the brain; if secondary, from cerebral inflammation. The mere fracture of bone seems of trifling consequence. Wounds about the region of the face, not implicating the brain, are not often fatal, nor can they even be considered to be highly dangerous. Among the privates in the Crimean war there were 751 examples of this injury, only eighteen of which terminated fatally. One was from tetanus, two from inflammation of membranes of the brain where the eye had been destroyed, and two from the same cause where the eye had not been touched.

The tendency to necrosis when any of the orbital bones have been injured is imminent.

It could answer no useful purpose to quote any of the curious circumstances, not directly of a practical surgical nature, attaching to this class of accident, such as the tooth of a soldier being found in his comrade's eye, and so forth. These are more fitted for the amusement of the general reader in popular writing.

Treatment.—To go into this comprehensively, and to give constitutional measures is out of the question, on account of the extent of the subject. Besides, it does not fall within the domain of this book. It is sufficient to speak of topical treatment.

Extraneous substances should be sought for and removed. An earnest endeavour should be made to discover the bullet or the fragment of shell, or any body which may be present, by careful exploration.

The presence of something from without may be suspected if the eyeball should protrude, and inflammation and suppuration of the wound supervene. If the eye be not destroyed for visual purposes, a most unlikely occurrence, an attempt should be made to remove whatever may be there, and to preserve vision. But if it be spoiled, extirpation should at once be performed, to facilitate the search.

Fortunate extraction does not always rid the patient from bad symptoms, because there may ensue all the troubles of acute inflammation in which the eyeball participates. Inflammation of the brain may supervene. Sudden death even has followed these acts of surgery.

Any lacerated and hanging portion of the eyeball should be at once excised. If in consequence of the extent to which the tunics have been torn, there be no chance of saving a stump, on which an artificial eye can rest, the operation of extirpation should be performed.

Bullets that have been left in the orbit from oversight, or because their exact positions were not known, or because their removal would be attended with immediate risk to life, generally set up irritation, produce necrosis of the bones, and escape in different situations. Some pass through the maxillary antrum into the fauces, and others through the spheno-maxillary fissure. Troublesome sinuses almost invariably follow this natural expulsion..

If the presence of a ball be suspected in the frontal sinus, the trephine should be applied. It may be necessary also to trephine the inner table of the sinus, an operation which may be performed with most safety by using the smallest trephining instrument. It would seem that fistula does not ensue from the application of the trephine in this region.

What has been said in the last section against the hasty removal of comminuted bone, applies equally here. Shattered bones of the face frequently unite by virtue of their great vascularity.

There are peculiar secondary dangers attaching to gunshot wounds, dangers arising from secondary hæmorrhage and constitutional disease, when sloughs begin to separate. It is at this time that the wound should be carefully and daily inspected, to ascertain if there

be any exfoliated bone or extraneous material which cannot escape and is keeping up irritation. There should be no hesitation in making free incisions for removing anything that offends.

In the case of Moss, the baker, who was shot by Cooper, the last highwayman who was hanged at Newgate, there was very little suffering of any kind till about the eighth day, when the violent local disturbance and general fever seemed certain to destroy life. While syringing out the wound, I detected a blade of grass. I immediately made an incision in the direction from which it was drawn, and removed a bunch of grass blades, which proved to be the wadding that the murderer had rammed over the bullet. Recovery commenced from that moment and proceeded uninterruptedly.

Pus will in all probability form as an abscess in the tissues around the wound, and should be evacuated as soon as detected. This is, in practice, an essential point which is too commonly neglected.

It is now, too, that a secondary search should be made for bone that may be depressed, and for pieces that may be quite detached. That which is driven in should be raised, that which is completely separated should be removed.

The most careful surgical dressing is required when the process of repair sets in, consisting chiefly of cleanliness and approximation of parts, by plaster and by bandage, so as to facilitate healing, and to lessen deformity. The after-condition of a part is favourably influenced in a high degree by such judicious manipulation.

Recovery often takes place under apparently most discouraging circumstances. It has ensued after a considerable portion of the face has been lost along with the floor of the orbit. Even when it has been necessary to remove the roof of the orbit, death has not followed. The loss of a portion of the bones of the orbit, or even the whole of them, does not necessarily destroy life. There is an instance reported, in the treatment of malignant affections of the eye, of complete exfoliation of the orbit, without any bad results. I believe that not to be the only case of the kind on record.

When the ball is lodged in the brain, immediate death generally ensues, yet occasionally a long time may elapse before there is any head symptom. It is supposed that in one or two cases no ill effects arose.

Recovery has many times followed, even when the orbital wound has been attended with loss of cerebral substance. This is no more than is sometimes seen in head injuries, of which full notice is taken in works on general surgery.

Wounds received during sport being generally produced by small shot, and inflicted at a long range, are the least severe. So far as the eyeball proper is concerned, the subject is treated of elsewhere, in the

chapter on "Injuries from Mechanical Agents." All that is said here, applies to the orbit.

Shots imbedded in the orbit may cause neuralgia for any length of time. The pain may be the only evidence of their presence.

Shots that have been encysted for years may at last be a source of disturbance, and demand removal. It has fallen to my lot to extract many under these circumstances.

Displacement laterally, of the eyeball, with more or less of loss of motion, may ensue, in consequence of damage to the motor apparatus, directly to the muscles, or indirectly to the nerves.

Treatment.—Small shot more frequently stick in the skin than pass beyond it. When they can be felt, their removal should at once be undertaken. If a patient be seen directly after the injury is received, and they cannot be detected by a superficial examination, the shot holes should be explored, and if the probing be successful the shots should be removed, no matter how deep they may seem to lie.

When shots cannot be detected in the soft parts by the finger, nor with the probe, there should not be any further attempt made to find them. If, however, it be at all likely that they are imbedded in the bone, a search should be made for them, as if there, in all likelihood they will cause necrosis, or exostosis.

PENETRATING WOUNDS WITHIN THE MARGIN OF THE ORBIT.

The effect of these may be very slight, or of the most serious nature, according, for the most part, to the nature of the injuring body, and the course it takes. When there is doubt respecting the damage that has been done, the patient should be kept very quiet and watched, till past that period at which it is unlikely that any untoward circumstances will occur.

A mere puncture generally matters nothing, even although it be deep, so long as its course is confined to interspaces of important parts. The surgeon often makes cautious exploring punctures with full impunity. The cause of danger consists in injury to the eyeball or to its appendages, and therefore bears some ratio to the depth of the wound and to its obliquity. Orbital cellulitis may, it is true, arise from the slightest injury of this nature, and therefore it can never be said that danger is altogether absent.

Hæmorrhage and extravasation of blood in the orbital tissues may ensue, and protrude the eye, sometimes considerably.

The eyeball itself seldom gets wounded laterally, because it is hard, and suspended in such a nicely-balanced manner in the midst of yielding materials, that it is quickly thrown sufficiently aside when

touched. Its rotatory motion serves too for its protection. But it is sometimes hurt, the sclerotica being ruptured or merely pierced. The effect of the one or the other is soon manifested.

Damage to a muscle, or to a nerve supplying it, may be attended by loss of motion in that muscle, as, for instance, the levator palpebræ; or loss of motion in the eyeball, as when one of the recti, or one of the oblique muscles is hurt; and the nature of the injury would always be apparent. Examples are common enough. This explains the squinting inwards, or the squinting outwards that not unfrequently follows a punctured wound received by accident.

Yet it must be pointed out that loss of action does not invariably happen. Perfect recovery does sometimes occur after a muscle has been nearly torn through. At first there is deficiency of power, and the defect gradually disappears.

Damage to the ciliary nerves, and to the optic nerves, is always shown in the state of the pupil, and in that of vision. Lesion of the former would produce impairment of sight, with dilatation of the pupil; lesion of the latter would affect the sight alone. Ophthalmoscopic symptoms would be added if the optic nerve should suffer.

Fracture and displacement of the orbital walls, are the worst complications of this accident; and the magnitude of the evil depends on which of the walls is penetrated.

The outer wall generally escapes these states, because of its hardness.

The lower wall generally gets free, because of its position; very few thrusts being received from above.

The inner wall is readily broken; but immediate bad effects would scarcely arise from fracture or puncture of the ethmoid bone about its body. The cribriform plate would be readily pierced by an oblique wound, and the brain entered.

The upper wall can seldom be broken without severe effects following either at once, or remotely, on account of the brain resting on it, and participating in the injury. Very slight force will effect fracture, and even penetration, especially if the intruding body be sharp-pointed, because of the thinness of the bone, which, in parts, does not exceed that of ordinary writing-paper.

Of course, the brain may be reached through the sphenoidal fissure, without any part of the orbital wall having been touched. I have collected several cases of such accidents; in all of them, death has been instantaneous.

If there be no symptoms after the receipt of the injury, it cannot be told that an orbital wall has been fractured; but there may be strong suspicion, suggested by a knowledge of the direction

of the wound, and other circumstances connected with the injury, such as the state of the instrument which has penetrated, the force employed, &c.

When the upper wall has been fractured, and the bone driven up, the symptoms may be immediate, such as fainting, vomiting, coma, or paralysis; or convulsions from extravasation of blood; or instantaneous death.

But although death may be sudden, and without any premonitory symptoms, it is not always immediate. This has long been known, and many examples published. The most remarkable is that quoted by Mackenzie. A man who was wounded by a sword in the orbit, feeling no inconvenience, thought that he was not much hurt; he covered the aperture with plaster, walked two leagues, and ate and drank heartily with his companions. Next morning he was found dead. An examination showed that the sword had penetrated to his cerebellum.

A case of death in a child, from the penetration of the upper orbital wall by a blacklead pencil, is published by Mr. P. Hewett, in the "Pathological Transactions." At first, brain symptoms were absent. Much force was required to extract the pencil. On the sixth day, she started often, kicked the bed-clothes, and screamed when moved. Then followed trismus, difficult breathing, and convulsive movements. Death ensued on the seventh day. Beneath the arachnoid membrane, on the surface of the hemisphere, was an extensive effusion of greenish-yellow lymph and serum, with other morbid changes. Over the orbit, the brain had suppurated. The roof of the orbit was much fractured. When the eyeball was pressed, pus flowed from the orbit to the cranium.

Or the symptoms may be secondary, from cerebral irritation; or there may be fever and delirium, from inflammation of the brain and its membranes; rigors, and coma, from abscess of the brain. Caries of the bone, and exfoliation may ensue.

Even in death from secondary effects, it is often not known that the brain has been injured, till the post-mortem reveals the fact. In some of these, the symptoms have not set in for days. Many examples of this kind are on record. What stronger evidence can there be of the danger of these accidents, the uncertainty of the prognosis, and the necessity for surgical watchfulness in the care of them?

The first accident that came under my notice in connection with the eye was a penetrating orbital wound, attended with immediate death. Two boys were playing; one locked the other in the bed-room. While the incarcerated one was peeping through the key-hole, the boy

outside thrust a large packing-needle at him through it; the needle penetrating his orbit, entered the brain, and caused immediate death.

Treatment.—The first and natural thing to be done is to remove the object that has penetrated; and this is what any intelligent bystander would do, whether professional or not. But this may not always be an easy matter to accomplish. In the celebrated case of the Duke of Guise, the lance entered above the eye, passed out between the ear and the nape of the neck, fracturing the orbit, and tearing the soft parts; and it stuck so fast that it was necessary to procure a farrier's pincers to pull out the broken piece.

The same care should be taken of the patient in every case which seems at all serious, as if he had received an external fracture of his skull, without acute symptoms. He should be put to bed, and every symptom most carefully watched, so that the earliest indication of danger may be noticed and attended to. In order to secure perfect rest of the eye, and to limit its movements, it, as well as its fellow, had better be closed for a few days with strips of court-plaster.

Respecting the propriety of attempting to elevate depressed bone, or to remove any bit of it that is injuriously acting on the brain, there would, perhaps, be a difference of opinion among surgeons. My feeling is not to condemn interference. What I said at the end of a foregoing section, about the treatment of fractures at the circumference of the orbit, applies here also.

For the general treatment, it is unnecessary to give directions, as it differs in no wise from that required for an ordinary fracture of the skull.

FOREIGN BODIES WITHIN THE ORBIT.

This classification is meant to apply to bodies that are so much within the orbit as to be concealed from view. It necessarily includes two states, the impaction of a part of the body in the bone, and its position among the soft parts only. But no one can tell where a thing actually lies or how far it has gone. Brain symptoms would induce the suspicion of the roof of the orbit being penetrated.

It is sometimes in the first instance difficult to decide, sometimes impossible, from the external condition of the eye, as to whether any foreign body has really entered the orbit or not, even although the person be seen very soon after the accident. A punctured wound in the skin is always small in relation to the body that has penetrated, on account of the cuticular elasticity. The swelling which may quickly ensue would always render the aperture less distinct. In the absence then of any marked external evidence, and of symptoms of any kind to assist in the diagnosis, a body which has been driven in may be

temporarily overlooked, even indeed when it must have transfixed the one or the other of the orbital walls, and lie partly in the orbit, and partly in some surrounding region, usually called cavity. The two following and most remarkable cases illustrate this, and they settle it as a fact for ever.

An old man, turned seventy-three years of age, being drunk, fell downstairs some time in the last few days of May. He injured the nasal side of the right eye, and bled very freely from the wound; but he did not seek medical aid till the 1st of June, when he went to Mr. A. Clarke, of Gloucester, who found a ragged conjunctival wound, and much swelling of the eyelids. The patient presented himself at intervals until the 6th of June, when Mr. Clarke discovered the presence of a piece of iron in the wound, which he seized with forceps and commenced to withdraw. By using considerable force, and after much time, he removed the entire shaft of a cast-iron hat-peg, measuring three inches and three-tenths in length, and weighing twenty-five scruples (Fig. 30). On further inquiry, Mr.

Fig. 30.



Clarke found that this hat-peg had been one of a row screwed to the wall near the bottom of the staircase; so that the man must have fallen upon the end of the peg and broken it by his momentum after it had become completely buried in his orbit. The base of the hat-peg was still in its place in the row, and presented a recently fractured surface fitting accurately to that of the portion removed from the patient.

When the question arose with regard to the exact period of impaction, no one could answer it. There were the seven days during which the patient had been under medical observation; but he could not remember on what day of the week he fell down, and could only say that it was four or five days before he went to the doctor; but it may be presumed that the actual period of impaction was between ten and twenty days. Recovery ensued without a single unfavourable symptom. Vision and the movements of the eye were unimpaired, and the lacrymal apparatus was perfect.

Mr. Carter, who examined the man on the 12th of November, says: "The hat-peg appears to have lacerated the conjunctiva of the globe a little to the inner side of the cornea, and to have passed between the ocular muscles and the lacrymal apparatus without injury to either."—*Ophthalmic Review*, for January, 1865.

The second case of the same class, but more remarkable in some respects, is also given by Mr. Carter in the same journal, as a quotation from a German work.

A man, twenty-six years old, applied at Nélaton's hospital on account of a lacrymal fistula. Three years previously he had received a blow in the inner angle of his left eye, from the ivory handle of an umbrella. He was taken to Desmarres' hospital with a bleeding wound, which was examined with a probe. It was believed that a splinter from the superior maxillary bone had been driven between the eye and the inner wall of the orbit. Various fruitless endeavours were made to remove this supposed splinter, and some small white particles were brought away by the forceps. The eyeball was unhurt, but its movements towards the nose were impeded, and mydriasis was produced. The suppuration gradually diminished, and the skin contracted, leaving only a fistulous channel leading to the supposed splinter. He was discharged. On presenting himself to Nélaton, he exhibited slight exophthalmus on the left side, with strabismus divergens; the sclerotica yellowish, or slightly coloured, as if from ecchymosis; the refracting media normal. Below the inner angle of the eye was a sinus, one centimetre in depth, having an external opening precisely like that of a lacrymal fistula, but the lacrymal sac was healthy, and the tears passed into the nose without impediment. A probe, introduced with some difficulty, struck upon a very hard, smooth, and immovable substance. Notwithstanding the certainty of the patient that there was no foreign body, and that the umbrella had not been broken by the blow, Nélaton determined to remove the hard substance, whatever it might be. He made an incision, two centimetres in length, over the inferior margin of the orbit, and seized the substance with strong forceps. To the astonishment of everybody, an ivory handle was withdrawn, cylindrical in shape, four centimetres, one inch and five-eighths in length, and a centimetre and a half in thickness. The end that had been turned outwards showed where it had been broken from the wood of the umbrella-handle, and presented indentations produced by the attempts at extraction made by Desmarres three years before. There followed some bleeding from the right nostril. The pains disappeared, and the eye regained its movements inwards. After a few days the patient left the hospital with his vision improved, and with the fistula nearly healed.

This case too, is worth giving :—A girl, seven years old, fell while knitting, and perforated the right eyeball with one of the needles. It was supposed that the needle was taken out whole. Sight was destroyed. A fixed convergent squint was produced, and the eyeball atrophied. From time to time there were sub-acute attacks of

inflammation in the eye. Some years later an attempt to operate for the strabismus failed. Womanhood had now arrived, and at twenty-four years of age sympathetic ophthalmitis invaded the left eye, and she sought advice at Weisbaden. It was considered necessary to remove the collapsed right eyeball. It was found impossible to abduct the stump so as to admit of the internal rectus muscle and the superior oblique, being divided.

In the dissection which ensued, a piece of metal was met with which pinned the sclerotica to the orbital wall. The metal was not removed. Distressing headaches and vomitings followed, and foul discharge issued from the orbit. A second operation was undertaken to remove the foreign body, and a fragment of a rusted knitting-needle was withdrawn. Slight hæmorrhage and cerebral symptoms came on. After three weeks the patient improved and left the hospital. In a few weeks she returned with cerebral symptoms and died in a month. A post-mortem examination disclosed a purulent deposit extending from the left side of the medulla oblongata into the substance of the brain. A similar deposit was on the pons Varolii, between the pia mater and the arachnoid.—From Wecker's "Maladies des Yeux."

At any time, however remote, after any injury from which there is the least likelihood of a foreign body having been driven into the orbit, protrusion of the eyeball, pain, especially of a neuralgic nature, and impairment of sight, may be taken as the strongest presumptive evidence of the presence of such body.

Treatment.—The direct effects incidental to the accident by which the body is wedged, such as injury to the several contents of the orbit, and to the bony walls, are the same as those from penetrating wounds, and need not be repeated.

All the danger which usually attaches to the impaction of extraneous substances about the limbs, or about the trunk, are very considerably increased when a cavity is invaded, and still more when that cavity is the orbit. Cellular erysipelas ensues. Vision is often destroyed from inflammation of the optic nerve, or of the eyeball; or from suppuration of the latter. The most dangerous effect, however, is extension of the inflammatory action to the membranes of the brain, or abscess within the brain, without any apparent continuity of inflammation, by which death is caused.

It is a strange fact that the cases which have ended worst, either in destruction of the eye, or in loss of life, are those in which the impacted body has been rather small, and in most of these, the orbital walls have escaped primary injury.

In a recent accident, with the slightest suspicion of anything being

lodged in the orbit, careful examination with a probe should be made for it, and it might be prudent to enlarge the aperture to facilitate the probing. The encouragement to do this will be the greater, according to the nature of the thing imbedded, or suspected to be imbedded. The larger it is likely to be, the more determined should be the search. I have, in a former section, spoken of small shots in the orbit, and those remarks apply equally to portions of metal, or any other hard substance of the same size. Here I am referring to larger bodies.

More must be said about exploring. Much will be gained by seeking for a hidden body in the direction in which it has entered, an observation that applies to the limited cavity of the orbit, as well as to any other region of the body. If it be supposed that a substance in the orbit can be found the more easily, because it must necessarily be in a more limited space, it must be borne in mind that the search is restricted, on account of the many close-lying and important parts, and the danger of hunting for it.

If the line of entry be between the eyelids, the exploration should be made there. To accomplish this effectually, the outer commissure should be divided, and the one or the other of the eyelids turned upwards or downwards, as the case may require. The oculo-palpebral fold of the conjunctiva should be also cut through at the required spot, and the exploration made. To effect all this in the best manner is easier to be described than to be done. Directly that incisions are made, and the blood begins to flow, the landmarks seem to fail, and difficulties arise. Anatomical knowledge, and much surgical tact are now needed.

If the line of entry be outside the eyelids, but yet near to the eyeball, I should proceed as above described. If it be near to the margin of the orbit, I should explore from without. If at the upper part of the orbit, I should endeavour so to place my incision as to avoid cutting across the levator palpebræ. Any slight likelihood of ptosis, or ectropium, must be risked to accomplish the desired end.

If it be possible to feel the body from without, the incision should be made over the prominence wherever it may be.

If the body be ever touched during the exploration, it must be removed, no matter how intricate may be the required dissection, or how strong the pull to disengage it from the bone.

It might be required to sacrifice the eyeball. The actual necessity for so doing has been met with. On one occasion it was required to incise the eyeball, to evacuate the humours, and to cause collapse of the tunics, to obtain space. This is an alternative dreadful for the patient, but one that does not arise from any defect in the art of

surgery. A surgeon is relieved from all responsibility by putting the circumstance before the patient, or his friends, from whom must be the yes, or no; to lose the eye and save life, or the alternative. It is a question that is of daily occurrence as regards the loss of other parts of the body for the saving of life.

When the eyeball is evidently destroyed, the extirpation of it may greatly facilitate the removal of a foreign body. It will prevent useless damage being done in the orbit, and secure greater safety for the patient.

Considerable force has been sometimes found necessary for extracting the body, if it have entered one of the orbital walls; and hence we read of hand-vices, screw-pliers, and strong forceps having been required.

If, during the extraction, it should appear that any orbital muscle is being dragged, or torn, it should be divided close to the eyeball as in the operation for squint.

The careful adaptation of the divided parts should be enforced according to the directions given for treating wounds about the eyelids and the orbital appendages. It is only necessary to add, that the patient should be kept in a state of repose, till every trace of inflammatory action shall have passed away, because of the dangers of these operations, and of which special mention is made in the section on gunshot wounds of the orbit, p. 66.

If osseous disease have set in as the result of chronic periostitis, or from original fracture, the fact is generally declared by the formation of a sinus.

The greatest encouragement for the saving of the eye exists in the timely extraction of the body, if the eyeball itself, or the optic nerve have been uninjured by the accident.

The removal of small bodies from the orbit has generally restored health to the part. But it has happened that inflammation has lingered about the orbit, and the eyeball participating, has either suppurated or atrophied.

The success, which has attended the withdrawal of large bodies, has been so quick, and so complete, even as regards sight and ocular movements, as to create astonishment, and to be regarded as not the least of the remarkable incidents of these several cases. But this has not been invariable; secondary symptoms have set in, and produced much suffering. Sometimes loss of vision, or death even has followed from tetanus or other causes.

The orbit is often tolerant of the presence of small things, and sometimes of large ones, when the bones are not touched; they become encysted, and may lie harmless for months, or years, or

during the natural term of life. But sometimes, active irritation is set up after long repose, and except judicious measures be adopted, disastrous consequences may ensue. I ask those who are less experienced in these matters, not to delay the application of practical surgery from any dread of its severity.

The general result, however, when a substance is not at once extracted is a natural effort at expulsion by orbital inflammation, abscess, and ulceration, and it may be thrown out at the surface; or after a slow and tedious process of disease of the orbital wall, escape in the fauces, or in any other direction, as I have pointed out in the section on gunshot injuries of the orbit. Rather more commonly the eye inflames, and is early spoiled as an optical instrument, or suppurates, a condition that may be associated with like pathological changes in the orbit. Or the brain participating, the fatal symptoms of delirium, rigors, and convulsions usher in death.

Treatment of an accident seen at a later period.—Much may be done at a later period, even if general orbital inflammation have set in, the eyelids being red, swelled, and perhaps closed, the eyeball protruding, or even if there be throbbing in the orbit, with great pain, and constitutional symptoms be well established. Then it will be necessary to explore in the direction in which the body has entered, or is supposed to have entered, or over any hard circumscribed inflammatory swelling which would probably be the commencement of an abscess around the body. In all the cases of this kind of which I have any knowledge personally, or by report, the patient has recovered when the body has been removed, and in several the eye has been saved.

I can give a good example of the removal of a body at a late date. A stone ink-bottle filled with gunpowder, exploded close to the face of a drummer boy. A piece of the bottle was driven into the left eye, which was destroyed. The first effects of the accident were recovered from. Six months afterwards, the boy was admitted into the Portsmouth Hospital, because of eversion of the upper eyelid, and orbital irritation. As there was a suspicion of a foreign body being in the orbit, Mr. Norman made a search, and he removed with a pair of forceps, after very considerable force, a portion of the stone bottle, which had been imbedded in the roof of the orbit, in the situation of the lacrymal gland. The fragment was an inch and a half in length, three quarters of an inch in breadth, and a quarter of an inch in thickness. Recovery ensued.

An abscess that forms and bursts, or is opened artificially after it is supposed that a body has entered, or might have entered, should be carefully probed to ascertain whether anything be present.

It is a good precaution to keep the aperture open for several days with a bit of lint, and to syringe it out daily. I have known bodies thrown out in that way, after they have escaped detection with the probe.

A sinus that follows any kind of wound from an injury should be carefully explored, and for the most part should be enlarged to facilitate the search, for in all probability there is something retained that irritates.

Extraneous bodies have been driven into the cranial cavity through the sphenoidal fissure, and produced death.

The skin, or the conjunctiva, may heal quickly over a body that has penetrated either the one or the other, and for a long time no disturbance may ensue. Healing may fail, and a fistula form.

If after a sufficiently careful exploration the body be not found the attempt should cease, for unnecessary damage must be avoided.

When there is neither wound nor sinus, and all acute symptoms are absent, but the protrusion of the eye and other conditions, particularly pain and disturbance of vision, induce the belief that something extraneous is in the orbit, exploration should be made.

Only once have I seen irritation set up when a foreign body has been at rest for several years. A gentleman met with an accident, and it was supposed that a bit of metal had entered the orbit at the inner side. Fifteen years afterwards, symptoms of disturbance, in pain and inflammation in the orbit, brought to mind the accident. At the consultation I proposed exploration. Happily at once, along the inner orbital wall, I detected a piece of lead, and removed it. The wound healed rapidly and all was soon well.

DISLOCATION OF THE EYEBALL IN CONNECTION WITH ORBITAL INJURY.

The eyeball may slip out of the orbit, and lie external to the eyelids, more easily than would be thought. There is a natural conformation that might predispose to it, that of large eyes and shallow orbits. In such instances of peculiar though natural formation, the posterior part of the eyeball may be seen by a little manipulation. If, during such examination, the eyelids were forcibly tucked in, they would grip the eyeball and force it from the orbit.

I may mention incidentally, that some years ago I was extracting an osseous cataract from a prominent and disorganized eye; the upper section was made, and the cataract had been just got out with the curette, when, before the eyelids were released, the eyeball was forced out, actually dislocated; and as it appeared to me, by the action of

the orbicularis muscle. The protrusion was evidently increasing, I, therefore, quickly put the spoon of the curette under the edge of the upper eyelid, and lifted it forwards, while I pressed the eyeball back and restored it to its place. The whole occurrence could not have occupied twenty seconds. Vitreous humour did not escape. I have read of a similar occurrence during the examination of an eye that was much protruded by an orbital tumour. The reduction was accomplished with difficulty. It is not, then, difficult to understand how it is that the eyeball is dislocated by anything thrust into the orbit, or that so acts around the orbit as to compress its walls.

The optic nerve and the muscles may be only stretched in this accident, or partially torn. The conjunctiva suffers the least.

Some of these dislocations have occurred with but little wounding of soft parts.

Sight is always lost while the optic nerve is on the stretch.

At a meeting of the Surgical Society of Ireland, Dr. Jameson detailed a case of dislocation of the eyeball that had lately come under his notice. A powerful man, thirty years old, while staggering about in his room, drunk, struck his right eye against a small iron hook, or nail, which entered at the outer angle of the upper eyelid, and protruded the eyeball, rendering it firmly fixed, staring, and devoid of vision. When examined two hours and a half afterwards, the cornea was dry, cloudy, and rather opaque; the pupil moderately contracted, was uninfluenced by the light of a candle. Blood was not extravasated, nor was there any unnatural vascularity of the conjunctiva, although its upper sinus was partially torn through.

To reduce the dislocation, the margin of the upper eyelid, which was invisible, was sought and elevated, and the eyeball pressed back to its place, which it entered with a distinct snap. It was supposed that the snap indicated the integrity of the muscles. A similar case is mentioned by B. Bell, in his "System of Surgery." Pains in the head and in the eye ensued, for which he was cupped and purged. Six days after the accident, all symptoms had disappeared, and vision was quite restored.

Treatment.—Remove any extraneous substance that may be lodged in the orbit. It is plain that as the upper eyelid is most concerned in maintaining the dislocation, before an attempt be made to get the eyeball back, a probe or a wire retractor must be inserted under the tarsal edge, the elevation of it effected, and the eyeball gently passed into position. The under eyelid can have but little effect, actively, or passively, but should it seem to bind, it also must be elevated.

It might not be possible to reduce the dislocated eye, as the following case shows:—A patient was admitted under Mr. Hutchinson's care at the London Hospital, with his left eye completely ejected from its socket. It was literally lying on his cheek, tightly strangulated by the everted eyelid. Some one had thrust a stick into his orbit, and caused the accident. All efforts at reduction failed. Mr. Hutchinson removed the eyeball. The optic nerve had been torn across. A portion of the orbit at its apex was denuded of periosteum. The patient got well without a single bad symptom.

Instances are recorded of the eyeball having been dislocated from accident for many days, or even for weeks, and ultimately reduced with the restoration of vision, slight protrusion being the only remaining symptom.

The eyeball has been completely severed from the orbit.—A fisherman, who was drunk, fell against the handle of a door-key, which was in the lock. The upper eyelid was divided vertically, and the eyeball was completely enucleated, and fell upon the floor. The debauched man was so intoxicated that he went to bed and fell asleep. In the morning the astonished wife saw the eye on the floor. The physician, who was sent for, found his patient in bed, covered with blood, and his orbit filled with clots, and some portion of the ocular muscles hanging out between the eyelids. The man was taken to the hospital and quickly recovered. The case is reported in the "Annales d'Oculistique." A drawing is given of the key, which is bent at an obtuse angle, and of the eyeball, with more or less of the ragged muscles adhering to it. In all probability this unfortunate man did not get his eye gouged out by a single stroke, but that his orbit became fixed on the key, and in struggling he tore the eyeball away.

Dislocation from effused blood.—In this case, related in the "Annales d'Oculistique," there can be little doubt that effused blood caused the dislocation. A lad fell from a great height on board ship, and struck the left side of his head. He was insensible, and blood flowed from his ears, nose, and mouth. The eye was dislocated to the tip of the nose. Three months after, the protrusion remained and vision was gone. In five months there was not any protrusion, but the blindness remained.

CARIES OF THE ORBIT, AND SECONDARY OR CHRONIC NECROSIS.

By the term Caries, I understand increased vascularity of a bone with interstitial absorption; or softening, followed by ulceration and suppuration. The organized portion of the bone is broken down, and the earthy materials are thrown off in molecules in the pus which accompanies the diseased action. Caries chiefly affects the cancellous structures.

Necrosis, signifies death of the bony tissue in a mass, and is analogous to the sloughing of the soft tissues. As a chronic affection, such as it would occur in the orbit, not traumatic as from a fracture, but idiopathic and secondary, it is generally confined to the compact texture of the bone.

Caries and necrosis frequently co-exist about the orbit; the latter coming on at a later period of the osteous disease; but generally occurring in a very limited degree. Perhaps there is no such thing as caries without some degree of necrosis, if we include as necrosis, the separation of any recognisable bit of bone.

The disease is ushered in by inflammation of the eyelids, and of the conjunctiva. An abscess forms and bursts. Accordingly as there is acuteness, or sub-acuteness, in this, the first stage, will there be constitutional symptoms with fever, or not. There is, therefore, a great difference in this respect in cases. In the same way, there may be much pain or none. So it happens too, at first, that no one may be able to say whether there is merely a simple abscess, or suppuration the forerunner of caries. As the disease progresses the skin becomes depressed, pale, or bluish, granulations spring up around the aperture, and a fistula is established.

Probing detects bare bone.

The early pus is ill-formed and coloured, and often offensive to smell. It tarnishes the silver probe. It gets healthier only when the diseased action is reduced.

Causes. Of the predisposing causes, struma is the most frequent; indeed, if syphilis and the abuse of mercury be put aside, there are comparatively few cases that cannot be traced to its influence. My own observation induces me to think that syphilitic caries very rarely affects the orbit in the adult. It is difficult to say how far inherited syphilis may produce caries in children, which we call strumous caries. Of course, from the history of a case only can the diagnosis be made. The state of the ulcerated surface affords no indication. The afflicted individuals are chiefly children who have been scrofulous, or are at the same time affected with some scrofulous disease of the osseous system. A blow is a common exciting cause.

Caries and necrosis may occur in any portion of the orbit, but every part is not equally liable to suffer from it.

The circumference, especially the outer inferior angle, is most commonly involved, and more frequently in children. Cases so circumstanced are the most favourable, because the disease is external. They are more easily treated, and the damage to the parts around is not generally so marked.

External effects. These are according to the destruction of the soft

parts and of the bone, and as respects deformity, according to the part of the orbit involved.

First, of the disease at the margin of the orbit, in front of the orbito-palpebral fascia.

Distortion of the palpebræ and retraction, arising out of adhesion of the skin and implicating the periosteum, thereby constituting cicatrices, which are formed during the continuance of the disease, but are more marked when it ceases, are the common consequences. The eyeball may be permanently exposed, and suffer from chronic inflammation and nebula of the cornea; or from deposit of pus between the layers of the cornea, with ulceration, which may end in prolapse of the iris, or collapse. The exposed conjunctiva may become granular. The greater portion of the eyelid may be lost by suppuration and ulceration.

Fig. 31.

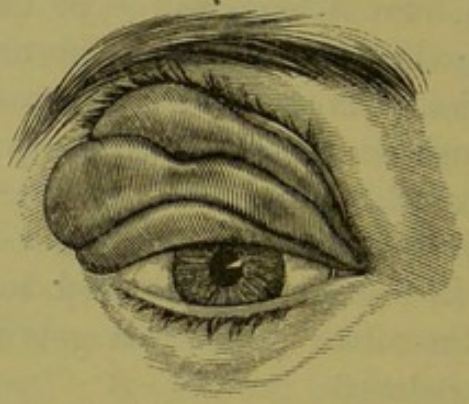

Fig. 31, taken from a patient with caries of the upper edge of the orbit, shows to what degree the eyelid may be influenced when the disease has proceeded unchecked for years, as it did in this young

Fig. 32.

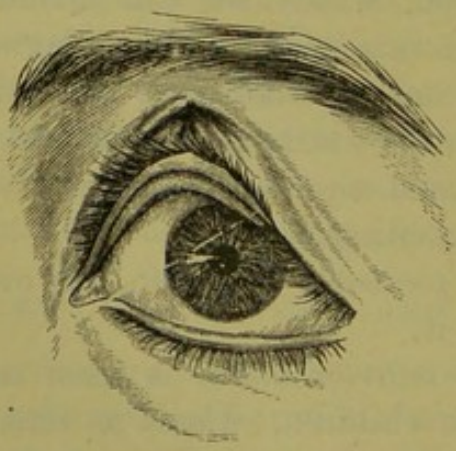

Fig. 33.

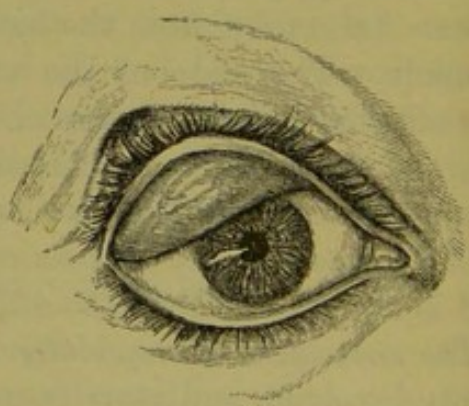

man. The tarsal edge is drawn up to the eyebrow, and the conjunctiva very much thickened from chronic inflammation, stands out in prominent folds with deep furrows. It is the most marked example of

ectropium of the upper eyelid from this cause that I have ever met with.

The worst effect, then, is damage to external parts. There is very rarely that internal cerebral implication by which life is lost.

The other sketches show the more common degrees of the same kind of deformity. Fig. 32, taken from an old man, shows elevation of the eyelid and retraction, with little eversion of the tarsal border.

Fig. 33 gives the eyelid quite everted, without damage to its border.

The next sketch is a very faithful delineation of damage to the lower eyelid, with displacement.

Fig. 34.

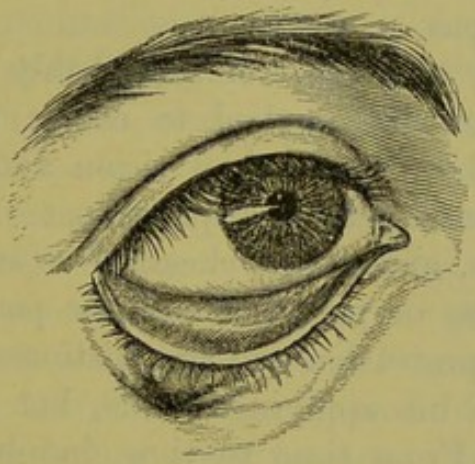

Disease within the orbit. The more internal the disease lies, that is, when it is behind the orbito-palpebral fascia, the more severe will be the effects, the greater will be the danger to the eyeball, and more also, the risk to life.

Deep-seated caries may ensue from inflammation and suppuration of the orbital areolar tissue, between the roof of the orbit and the levator palpebræ superioris, or between the floor and the rectus inferior oculi; if the pus be not evacuated, or do not escape externally. The periosteum gets involved and inflames, and then the bones ulcerate. But the pus may escape into the nose by the lacrymal passage, or into the zygomatic fossa by the spheno-maxillary fissure. It may reach the frontal sinus, or the cranium, or the maxillary antrum by causing absorption of the contiguous bones.

With so much complication, mistakes in diagnosis are not to be wondered at.

Deep orbital caries. Death. Henry Bird, aged eleven, was admitted into King's College Hospital, suffering from severe cerebral symptoms, which supervened on caries of the orbit. Three years previously an abscess formed over the orbital edge, and from time to time

there were exfoliations of bone, till the lower and outer borders of the orbit were completely destroyed, and a deep suppurating fissure formed. The lower jaw was rigidly closed, the lower eyelid everted, and the cheek much swollen. He died of symptoms of pneumonia, with inflammation and compression of the brain. The following state was revealed by a post-mortem examination, at which I was present. A large portion of the malar bone was destroyed by exfoliation. The orbital and cerebral surfaces of the greater wing of the sphenoid bone were carious, and the periosteum, and the dura mater, were soft and pulpy, and separated by pus. In that part of the middle lobe of the left hemisphere of the brain, lying on the diseased bone, was a circumscribed abscess, about the size of a large nut, which had opened into the sac of the arachnoid. In the left lateral sinus was about a drachm of pus.

A second case may be given. A remarkably robust and powerful carter, forty-two years old, applied to me at the Central London Ophthalmic Hospital, with impaired vision and slight protrusion of the left eyeball, without lateral displacement. The integuments of the external canthus, and of the cheek, were swollen and indurated without either redness or pain. The other portions of the eyelids were healthy. The protrusion and the mistiness of sight commenced three years prior to his applying to me, but the swelling was of recent occurrence. From time to time hundreds of leeches had been applied, partly by the direction of a surgeon, and partly by his own desire. I lost sight of him for seven months, when paroxysms of pain induced him to return. The eyeball was now more prominent, its movements were restricted, vision decidedly worse, the tumefaction greater, and the parts inflamed. He was emaciated and very weak. Even now I could not be certain that suppuration existed, but I made a puncture over the outer and lower edge of the orbit, apparently the most favourable spot, and deepened the cut through the brawny tissue to the bone before the pus flowed, about a dessert-spoonful escaping. Much temporary relief ensued. He became very debilitated, left me, and went into King's College Hospital. After much nervous excitement, delirium, and fits of an epileptic character, coma supervened, and he died. I attended the post-mortem examination, which was performed in the presence of Dr. Todd and Sir W. Fergusson. No trace of disease could be found within the cranium. There was caries of the whole of the interior of the malar bone and of its outer aspect. A small sinus, not involving the bone, had burrowed through the spheno-maxillary fissure into the zygomatic fossa. An abscess completely encircled this bone. There can be no doubt that the disease commenced in

the interior of the orbit, and in all probability at the most posterior part of the malar bone, and subsequently passed to the exterior.

Caries may exist at the back of the orbit, and run through its stages, and produce death by inflammatory changes in the membranes of the brain, or in the brain substance, without any external abscess, the only symptoms being protrusion of the eyeball, with more or less immobility, both of which might be produced by an orbital tumour. Therefore a wrong diagnosis might be made. Indeed, in such a case, it could scarcely be guessed what is the disease. Only an examination after death could verify the presence of caries.

Here the function of sight may be lost, from implication of the optic nerve in disease, when the portion of the sphenoid bone, including the optic foramen, is carious. The optic disk would give evidence of such complication.

In rare instances several portions of the orbit may, at the same time, be affected with caries, and several distinct sinuses may exist, some opening on the eyelids, some around the orbit. I have not myself met with such. These sinuses are said to be caused by severe orbital cellulitis. When the inner wall of the orbit is carious or necrosed, and the bone penetrated, the pus passes into the nostril.

When the affection is left to itself it lingers for many years, it may be, during the entire growing period of the individual, and inflicts much damage before arrest ensues. Medicine and surgery can be depended upon, as a rule, for staying its progress in any of its stages.

Treatment. As the earliest local indication of the disease is inflammatory action tending to abscess, the treatment in a case seen sufficiently early should be to stop the suppurative action by leeching, by the application of cold, by rest, and that which tends to improve the health. Success is more likely to ensue if the diseased action should commence in the soft parts rather than in the periosteum or in the bone. Should these endeavours fail to prevent an abscess, they may notwithstanding, have the effect of limiting its volume and of preventing much damage.

When an abscess has formed, the pus should be evacuated without delay. There is no exception to this. Thereby much is done in preventing caries, especially if the periosteum be the primary seat of the abscess, or of limiting it, if its origin be in the bone. The incision should be ample, and the periosteum should be always thoroughly cut through when pus is behind it.

The opening should be directly over the fluid, and not made indirectly through the conjunctiva, by the side of the eyeball.

The probe should at once be used, and necrosed bone sought for,

because such may exist, and a sequestrum may lie ready to be removed. Necrosis alone may be present.

The incision always has a tendency to contract, therefore, if necessary, it should be daily dilated with lint. An occasional enlargement with the knife may be requisite. The formation of a sinus is always prejudicial. If the secretion be what is known as unhealthy, the abscess cavity should be stimulated with astringent injections.

The abscess should never be opened with escharotics, and above all, not with caustic potash, for this is a clumsy and painful way of applying practical surgery. As regards the potash, its action always extends beyond the spot touched, and more sloughing is often produced than is expected or wished for. I never use it about the neck or face for any purpose.

Warm applications are now most required. At what time the poultice, which is the chief of these, should be discontinued, must be left to the judgment of the surgeon.

If the diseased action should progress, and caries be established, everything must be done to arrest it, and if necrosis should be associated, the formation of the sequestrum must be assisted indirectly by withholding anything which irritates, and by such local and general measures as will prevent attacks of inflammation.

Sometimes necrosis is a happy combination with caries, in causing a natural step towards cure, by the separation of the dead bone taking place at a spot where there is capability of healing.

Mere exposure of bone from an abscess must not be mistaken for caries or necrosis. The child of a noble family had several abscesses about the body, together with one at the lower and outer edge of the orbit, which was opened by a small puncture. Little relief followed; and as the eyelids remained swollen, the eye inflamed, and bare bone was felt by the probe, it was supposed that caries existed. I made a free incision through the swollen and boggy tissues, giving a proper exit to the pus, and for a few days maintained an opening by introducing a strip of lint. The improvement was most marked, and in less than three weeks the child left town with the abscess nearly cicatrized. In another week it was well. Caries was never present. Acrid, thin, and fœtid purulent discharges with unhealthy granulations, are pretty sure signs of the bone being diseased, and the probe will generally confirm these indications.

Chemistry and the microscope assist us to diagnose disease of bone. An appreciable quantity of phosphate of lime in an ounce of pus, taken from a lumbar abscess or psoas, is an indication of a carious condition of the vertebræ. This test will serve when the

abscess is small. If the necrotic pus be placed under the microscope, an amorphous deposit will be seen, which will disappear on the addition of dilute acetic acid. Or if the pus be burnt away in a platinum spoon, the phosphate of lime will be left in the form of a greyish powder, which may be dissolved in muriatic acid without effervescence, and then precipitated by an excess of ammonia.

The chief local point in the treatment of caries, is the maintenance of a sufficient opening, whereby there shall be a free exit for all secretions. It is astonishing how much of inspissated pus and cheesy material collects in these cases. Mere washing is often insufficient to dislodge it, and scraping it out from time to time will alone suffice.

Modern surgery teaches us that the process of cure may be much facilitated at times by removing the carious bone, which is incapable of repair, and is rarely cast off except by a very tedious process. The necessity of cutting beyond the diseased part into the new bone, which is thrown out by nature for the purpose of repairing the lesion, is well known; yet surgeons seem loth to carry out the practice in caries of the orbit, and disease, that might be cut short in a few months or weeks, is allowed to continue for years. The gouge is the instrument that must be used, but with the greatest care about those parts of the skull that are contiguous to the brain. This should not be undertaken till there is actual necessity for it, till local and general measures have been fairly tried, and have failed, and till sinuses, if they exist, have been efficiently dilated. If this caution be observed, the injurious practice of operating when the soft parts are in a state of acute inflammation is obviated, and the best period for this the last attempt is secured, viz., when the natural powers have made an effort at repair in the surrounding bone.

It is chiefly about the circumference of the orbit, where this form of practical surgery is applicable. The upper orbital wall could not be so treated. It may be necessary to use the gouge more than once, at one spot.

Dilute nitric and phosphoric acids may be employed with advantage in those cases in which the gouge cannot be used. The late Mr. Bransby Cooper recommended phosphoric acid diluted with an equal weight of water, as being useful in facilitating the removal of sequestra, by converting the phosphate of lime into a bi-phosphate, which is more soluble and more readily acted on by the pus. This lotion is too strong to be used freely about the neighbourhood of the eye, for its accidental contact with the conjunctiva would be very painful, if not otherwise injurious; but it may be applied

accurately and in small quantities with a brush, or by means of a bit of lint. Less care is needed if a much weaker solution, say one part to seven of water, is employed, but of course the efficacy would be much less.

A sequestrum must be removed as soon as it is detected. It may be felt for the first time only when the gouge is being used. Here, as in other parts of the bony frame, it may be so locked in that mechanical relief is demanded.

A patient of mine at St. Mary's Hospital, a lad eleven years of age, of a scrofulous diathesis, had caries of the upper edge of the orbit, and the surrounding soft parts being in that quiescent state that warranted interference with the bone, I scraped away the carious portion from the outer side. While applying the gouge for a similar purpose to the inner, I discovered a necrosed piece as big as a pea, which was easily released from the enclosing cavity by a few touches with the gouge.

I subjoin a sketch, taken after cicatrization, to show how little deformity remains.

Fig. 35.

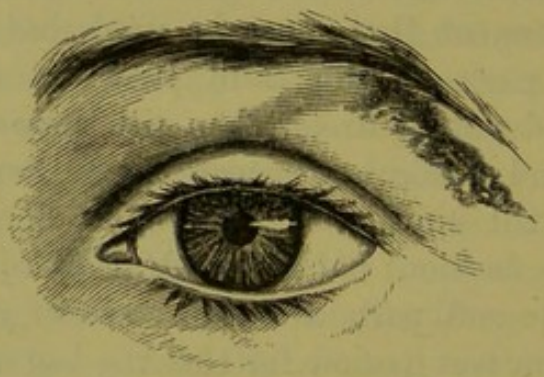

Had there been neglect in this case, a distressing ectropium must have been inevitable.

A good deal of deception is sometimes occasioned, during the treatment of these cases, by the contraction of the outer aperture of the skin, and attempts are made by strapping and other means to close the wound, when all the time, the caries is as bad as ever, or a sequestrum is yet to be removed. This error must be prevented by carefully examining the bottom of the wound from time to time. So long as a bony surface can be touched, so long also must it be considered that disease of the bone is present, and that treatment for it is necessary. As soon as it is certain that granulations only are touched, and not bone, the process of cicatrization should be helped by the approximation of surfaces, and so forth.

The breach which is made by the loss of bone about the orbit,

is not filled up otherwise than by a cicatrix. Sometimes a kind of osseous repair is seen, but it is not the reproduction of new bone, in the manner so beautifully and fully effected in the long bones. It is a kind of imitative process, occasioned by the growing out of irregular processes of bone from the healthy periosteum around the injured part. I have seen a patient with ectropium of the lower eyelid in whom a sharp, tooth-like process was thrown out from the edge of the orbit, which wonderfully ameliorated the original depression of the tarsal edge. I have seen also the same compensation in two of my own patients. In one of them, the new bone was at the orbital margin, just external to the supra-orbital foramen.

Constitutional treatment is no less essential than local. If caries or necrosis should arise in a healthy individual as the result of an injury, of course the prognosis is very favourable, and in the attention to the general health, less is required than in those cases in which the local affection is of constitutional origin, the result of mal-nutrition occurring after debilitating diseases, or especially arising out of struma or syphilis. A very careful investigation of each case is needed, in order that the appropriate remedies be selected. All that need be said in addition may be expressed in the narrow compass of a few words. Besides any so-called specific course, improvement of health must be sought in clothing, food, ventilation of apartments, climate, exercise, and medicine.

The mal-position of the eyelid arising out of the caries is the last thing to be noticed. Much need not be said here, as ectropium in

Fig. 36.

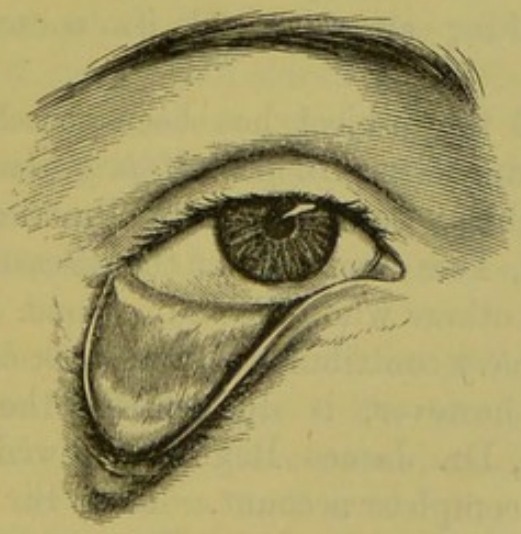

all its forms is fully treated of elsewhere. The following case is given, to show the existence of caries and necrosis very much within the orbital edge, and because it was attended with the most remarkable depression of the eyelid I have ever witnessed from such a

cause. L. P., aged fourteen years. At the age of three years she had caries and necrosis of the right thumb, and afterwards, in succession, of the left foot, right lower jaw, right malar bone, and, to a small extent, of the outer edge of the left orbit, from each of which places, small pieces of bone came at intervals. In consequence of the ulceration and subsequent cicatrization attendant on the disease of the right orbit, the lower eyelid was completely destroyed, with the exception of its ciliary margin, which was drawn down and firmly fixed at the bottom of a deep depression half an inch below the margin of the orbit. The eye had been in this state for six years, when the girl applied to Mr. Taylor at the Central London Ophthalmic Hospital. The sketch of the deformity is critically correct.

Transplantation of skin was done with success, and the eyelid restored. The eye, as it appeared after the operation, is delineated among the illustrations of ectropium.

PROTRUSION OF THE EYEBALLS—ENLARGEMENT OF THE THYROID GLAND—INCREASED ACTION OF THE HEART.

The names this affection has received from different men, at home and abroad, are very numerous. The most familiar among us are these: Anæmic exophthalmos; anæmic protrusion of the eyeballs; affection of the heart and thyroid gland; exophthalmic goître; vascular bronchocele and exophthalmos; cardiagmus strumosus; struma exophthalmica; anæmia and its consequences; Graves's disease.

The literature of the subject has been searched most fully by Dr. Fletcher, of Manchester, *British Medical Journal*, vol. i., 1863, and Dr. James Begbie, "Contributions to Practical Medicine," 1862. They show that St. Ives wrote about the disease in 1722, and give the names of many others who followed. Some of our countrymen in years long past have contributed to the stock of knowledge.

To Dr. Graves, however, is due chiefly the merit of modern research. In 1835, Dr. James Begbie followed. Then Basedow, who gave the most complete account. Then Sir H. Marsh. Then Dr. Stokes, of Dublin; Romberg and Henoch, Virchow and Oppoltzer, and Graefe, in Germany; James Begbie, James Warburton Begbie, Dr. Laycock, of Edinburgh; Dr. Fletcher, of Manchester; Dr. Reith, of Aberdeen; and Drs. Aran and Trousseau, of Paris.

The disease occurs in the greater number of cases in females, as

recorded by Romberg and Henoch, and Mr. R. Taylor, and Withuisen, and others.

The period of life at which it appears is almost in every case during reproductive activity, although it may arise at any age.

The males that have been affected have always been of a markedly nervous temperament, and nearly always at a more advanced period of life than the females. As an exception, Mackenzie relates an example at sixteen.

Symptoms. The approach of the disease is generally marked by extreme nervousness, irritable and capricious temper, palpitation of the heart, and throbbing of the vessels, headaches, flushing, and fulness of the head, face, and neck, with slight enlargement of the thyroid gland, and a feeling of pressure on the throat, sleeplessness, and a lustrous appearance of the eyes. There may be also a peculiar pigmentation of the whole eyelids. Menstruation is sooner or later affected, and the patient is, as a rule, pale and anæmic; and there are generally present the so-called anæmic murmurs over the heart and great vessels.

It is of the commonest occurrence for persons to present themselves with such symptoms in the out-patient rooms of an hospital. They complain generally of some irregularity of the catamenia, and get well after the usual remedies.

Graefe speaks of cases not very rare, where rapid action of the heart and defective movement of the eyelids are alone present. He also points out that the superior eyelid, which in health should follow the eyeball in looking upwards or downwards, moves little or not at all in exophthalmos, and besides, leaves the eyeball too much uncovered, a symptom which he considers as pathognomonic in early and slightly marked cases. He shows that this state of the lid is independent of the exophthalmos, that it may come on during the progress of the disease, and disappear without the exophthalmos getting less. Voluntary closure of the eyelid is free and unimpaired, unless the degree of the protrusion mechanically interferes, as it may.

As the disease advances, the palpitations of the heart and vessels become more and more distressing. The thyroid gland enlarges, the eyeballs gradually become more prominent, and assume a wild appearance. The nervousness and irritability increase, and the least emotion greatly intensifies the symptoms.

Vertigo, beatings in the ears, throbbing of the temples, a feeling of fulness in the chest, and increased heat of the body, annoy the patient.

The sensation of heat is not imaginary, but real, for both Basedow

and Tiessier have noted an increase of temperature in the body to the extent, according to the latter, of two or three degrees. Warburton Begbie says this feeling is not localized, but is general, and is often great in the feet.

Professor Trousseau also mentions the presence of the "tache cérébrale," produced almost immediately by the slightest irritation on the skin.

Sleepless nights, emaciation and weakness, with frequent vomiting, come on, as well as loathing of animal food and craving for vegetables. This last symptom is not, however, invariable; some persons refuse food of all sorts. Begbie has found many suffering from lienteria, the food being only partially digested.

Not infrequent epistaxis and other hæmorrhages take place, rendering the patient still more prostrate.

Dyspnœa of a severe and occasionally paroxysmal character, is sometimes present, threatening suffocation. This is happily, however, not of frequent occurrence.

Kuth mentions a case of a female whose hair began to get partially grey and to fall out, at the age of twenty-nine, when first attacked by the disease.

The order of the symptoms should be studied, and each examined in detail.

The first symptom generally complained of is palpitation. Stokes, and most authorities, seem to believe that the heart is the first organ to become affected, and the goître generally, but not always, to precede the exophthalmos. Trousseau, however, says, "that all phenomena which are due to the same cause, appear simultaneously and have the same period of invasion," and that any succession is more apparent than real, and depends upon the patient or physician finding it out. In the *Gazette des Hôpitaux*, 1863, p. 389, is mention of a female, in whom all this took place from grief in a single night. In one case observed by myself, all the symptoms were simultaneous. But certainly, if these symptoms commence generally at once, there is irregularity in their development.

The palpitation is often sudden, vehement, rapid, and sometimes uncountable. The heart occasionally beats with extreme irregularity, although no organic disease be present. Sometimes, distinct *frémissement* is heard over the whole præcordial region.

There is much discrepancy of opinion regarding the presence or absence of cardiac hypertrophy. Several men believe that, more or less, hypertrophy does generally exist. Trousseau doubts the frequency of it, as the radial pulse is generally normal; but believes that the hypertrophy is apparent only and due to the thinness of the

patient's chest-walls. The numerous post-mortem examinations point to the frequent occurrence, in cases of long standing, of dilatation and valvular disease, especially on the right side, with hypertrophy or without.

In other cases, again, of some duration of the exophthalmos, the heart is reported as having been perfectly healthy. It is to be feared, however, that it rarely escapes without more or less implication.

Traube examined, during life, eight cases reported by Graefe, and found distinct increase of the cardiac volume with other signs of valvular disease. Oppoltzer reports one case in which the heart was hypertrophied in all directions.

Bellingham, in his valuable book on diseases of the heart, says that this disease commences always in functional derangement of the heart; after persisting as such for an indefinite period, it either subsides under treatment, or it passes into organic disease of the organ. Virchow states that there is in nearly all, dilatation of the heart, but that hypertrophy is an advanced stage of the disease; the left ventricle then suffers most.

In a well-marked and recent case, the heart-sounds are generally much accentuated; there is occasionally pericardial friction sound, and a soft systolic bellows murmur, heard at the base. A loud systolic blowing murmur is frequently present in the carotids and large vessels, sometimes very loud in the abdominal aorta; and according to J. Warburton Begbie, it may sometimes be heard in the vessels of the extremities.

In a case seen by Mr. Brickwell, of Sawbridgeworth, the action of the heart was so excessive that the sound could be heard at a distance of some feet. The patient died some time afterwards with general dropsy; the valves of the heart were, however, normal, but the left ventricle was thinned and dilated.

Sir Henry Marsh also details a similar case.

A *bruit de diable* is commonly present over the jugulars. The veins of the neck are enlarged and prominent, and in many cases a purring thrill is communicated to the hand.

The excessive pulsation of the superficial arteries is almost invariably present, and is one of the most peculiar features of the disease. The carotids are perhaps the most affected. The greatest pulsation is sometimes in the abdominal aorta.

Dr. John Murray informed me that in a patient whom he had watched, and who died lately under the care of Dr. Goodfellow, in the Middlesex Hospital, the marked features on admission were emaciation, constipation, urgent vomiting with extreme irregularity, and frequency of the heart's action, the pulse being too frequent to

be counted; excessive pulsation of the abdominal aorta, so much so indeed that it presented all the appearance of a large aneurism. At this time the cervical pulsation was not greatly marked, and there was little prominence of the thyroid or of the eyes. Latterly, the small radial pulse contrasted greatly with the carotid, which throbbed in an excessive manner.

It is commonly found after death that more or less disease of the vascular system is present. There is dilatation chiefly of the jugular veins, thyroid and vena cava inferior, with enlargement and disease of the arteries. The inferior thyroids are those chiefly affected; and in a case of Newman's the ophthalmic artery was found to have undergone atheroma. The arterial disease was very general, the aortic and mitral valves being considerably affected.

The enlargement of the thyroid gland generally precedes any marked protrusion of the eyeballs. The increased size of the gland has at least been noticed before any peculiarity of the eyeballs. In a few cases the affection of the thyroid has remained totally absent, while the other symptoms have been present.

At first the gland usually presents a slight graceful swelling in front of the neck. It gradually enlarges, and although it rarely advances to the size of endemic goître, it reaches occasionally considerable dimensions, and has been known to threaten suffocation. It has been so large as to require support. It has even projected before the margin of the lower jaw.

In males, the enlargement of the gland makes its appearance at a later period, and does not usually reach the same dimensions as in females.

Although the augmentation is, as a rule, gradual in development, still it may be rapid and marked in a few hours, and gradual enlargement may become suddenly increased.

The right lobe is chiefly affected, but in many cases the two are pretty equally enlarged.

The isthmus may become involved.

The size of the gland is variable, as emotion or physical exertion of any sort produces temporarily a marked and instantaneous effect.

The nature of the bronchocele depends chiefly on the length of time it has been present. If recent, the surface of the tumour presents a uniform smooth, soft, and elastic character, and is at this time a simple vascular bronchocele. The superficial veins are unduly prominent. In such cases the tumefaction often disappears. If the disease is not relieved and the swelling does not subside, there is great tendency to structural change, the gland undergoing cirrhosis or fibrous induration, nodular or not, and occasionally partial cystic

degeneration, which may again undergo various metamorphoses. It may be stated as a rule, the more chronic the affection, the greater the likelihood of structural change, with cystic or gelatinous formation. There is, however, no one characteristic pathological condition. The arteries and veins may become enlarged and diseased, rupture of some of them ensue, and extravasation occur into the parenchyma.

In the recent stage of enlargement, before structural disease has taken place, there is first the arterial pulsation, secondly the diastolic throbbing of the gland, and lastly a peculiar thrill, sometimes only over a portion, similar to that of the aneurismal varix. The seat of this thrill is uncertain.

If the gland becomes structurally diseased, the thrill and blowing sound have been often known to disappear entirely, although there may exist a murmur in the veins of the neck.

The enlargement is different from ordinary bronchocele, in remaining stationary just at that period of its development when the growth of the latter usually begins to be accelerated. Its liability to production is not connected with the influence of soil or climate. Trousseau says that endemic goître is an hypertrophy of all the elements of the gland, whereas in exophthalmic goître there is glandular hypertrophy proper, hypertrophy of the acini, and great development of the blood-vessels.

The exophthalmos or protrusion of the eyeball is the last symptom to be considered. It is generally the latest in its full appearance, or that complained of by the patient. In a well-marked example of the disease, it is by far the most striking characteristic.

The eyeballs are seldom protruded directly forwards, generally a little downwards or inwards. Their movements are always more or less restricted. The sclerotica, usually brilliant, is much exposed, and a wild and savage expression is produced. The pupils are generally dilated. Not unfrequently the prominence is so great as to prevent closure of the eyelids. Trousseau refers to a case related by Dr. Pain, where the eyeballs were pushed forwards so much that one of them actually came out of the orbit, was dislocated, and required to be put back with the fingers.

It is by no means necessary that there should be both the protrusion and the stare. The eyelids only may be retracted so as to show the white of the eye preternaturally, and thus give a fallacious appearance of protrusion.

Exposure of the eyeball is rarely if ever followed by ophthalmitis, as in paralysis of the fifth nerve. Stokes refers to a case in which for upwards of a year the eye was never closed, and yet no ophthalmia of any kind occurred. This is explained most ingeniously

by Professor Laycock, to the effect that, in paralysis of the fifth, although there is increased vascularity of the conjunctiva, there is decrease of temperature, which, if the patient is in bad health, predisposes to ophthalmia; whereas in Graves' disease, the paralysis which is of spinal or sympathetic origin, the temperature of the parts is increased, and thus the eye is enabled better to resist external influences. Although I have seen a great many cases, recent and chronic, I have never met with any alteration in the sensation of the eyeball, or its nutrition, but other surgeons have. There is described diminished sensibility of the cornea, and of a portion of the conjunctiva, with dryness and increased thickness of the epithelium, so that the excito-motory union between the sensory nerves and the front of the eyeball, and the motor nerve of the orbicularis muscle, is diminished or lost. Ulceration of the cornea is also mentioned, and penetration with collapse of the eye has been met with. This latter has occurred at the same time in both eyes. Such conditions are due to the exposure of the eye, and its loss of moisture from imperfect winking.

The tears are well secreted, but their removal is interfered with, and they readily overflow.

Both eyeballs generally become equally prominent, whether suddenly or gradually, and in a simultaneous manner. This is, however, not invariable. Cases are recorded where one was at first more affected than the other; and Prael, of Brunswick, has given three cases in which the affection was confined to the right side. Reith, of Aberdeen, gives another, where there was an interval of many years between the appearance of exophthalmos on the two sides. The eyes are most prominent under the influence of mental emotion and at the menstrual periods.

Nearly always, if the eyeballs be pressed on by the palms of the hand, they will retract a little, but they protrude again when the pressure is remitted.

There is generally little or no discomfort from this state of the eye. Sometimes there is pain in the eyelids, and a fulness and feeling of distension experienced, as if the eyes were going to drop out, a sensation which is increased more or less by excitement of circulation.

Vision has been unimpaired in every case that I have examined. I am unaware of any marked defect having been detected by any one familiar with ophthalmic medicine. Schoch reports a case with amblyopia and double vision.

That the eyeball is merely protruded and not enlarged, I am quite sure. The difference in general between these states is given in the chapter "Protrusion of the Eyeball."

As to the immediate or physical cause of the exophthalmos. Dalrymple taught that there is an absence of the proper tonicity of the muscles by which the eye is retained in its natural position in the orbit, and some amount of venous congestion of the tissues forming the cushion behind the globe. R. Taylor, spasms of the muscles of the neck impeding the return of blood from the head and producing dilatation of the orbital veins. Basedow, Hastenger, Kœben, and Neumann, hypertrophy of the post-ocular cellular tissue. Hensinger, Desmarres, and Middlemore, an extraordinary accumulation of fat in the cellular tissue behind the eyes. Mackenzie, a varicose state of the ophthalmic veins. J. Warburton Begbie, congestion and vascular dilatation of the ophthalmic vessels, with effusion of serum into the post-ocular cellular tissue. Laycock, partly, at least, to change in the motor mechanism of the eyelids and eyeballs, which view, he thinks, is the more likely if the periosteal muscle of the eye, described by Professor Turner, be confirmed. Aran, irritation of the sympathetic affecting the orbital muscles. Dr. C. J. B. Williams, enlarged orbital and cerebral circulation. Trousseau speaks obscurely and undecidedly. Reith, partly congestion, partly nervous influence. Fletcher, distension of the orbital vessels, pressing the eyeball forwards. Virchow, in his magnificent work on tumours, says that the essential change lies in the fatty tissue of the orbit, which may be hypertrophied, but mostly expanded by a hyperæmic swelling capable of being overcome by pressure during life, and readily disappearing after death. He appears to believe also that the fatty degeneration of the muscles of the eyeball, pointed out by Recklinghaussen, would increase the protrusion.

Ophthalmoscopic appearances. Withuisen describes a case in which the fundus oculi was found to be congested, and on each side of the optic papillæ semilunar masses of pigment, almost black in hue, were deposited. The point of entry of the optic disk presented a yellowish-red tint. The anterior chamber was flattened. An examination was also made during convalescence, when the hyperæmia was found much decreased, the pigment as before. There was varicose dilatation of the vessels of the conjunctiva about the insertions of the recti muscles. Both eyes were alike.

Graefe has also found increased vascularity of the choroid.

Congestion of the retinal vessels has been noticed by several writers.

Dr. Begbie gives, in his work on "Clinical Medicine," the result of an examination by Dr. A. Robertson. There was in the left eye general deficiency of the choroidal pigment at the margin of the optic disk.

As a rule, the tissues of the eyeball are unaffected, and exceptional cases, units in hundreds, must be looked on as accidental, and not as arising from the disease.

The post-mortem appearances have always produced disappointment, as regards the condition both of the orbit, and of the parts around. The want of constancy in any particular morbid state, has also created astonishment. I will give the statements of several observers.

Hensinger, a case with increased quantity of cellular tissue, and a case without. Hirsch, a case in which there was not much fat in the orbital cavity. Neumann, orbital fat increased, aqueous humour thick with crystals of cholesterine, capsule of the lens opaque, coats of the eye more or less injected. Roche, œdema of the cellular tissue of the orbit. Trousseau, a large quantity of cellular and adipose tissue in the posterior part of the orbit. Reith, congestion of the orbital veins, with effusion of blood. Begbie draws attention to the dark fluid state of the blood in several instances which came under his observation; this is, however, not always the case, although mention is frequently made of it in accounts of autopsies. The abdominal viscera are usually more or less congested, and if the protrusion of the eyeball be of long standing, some disease of the kidneys or liver may be present. Nutmeg congestion of the liver is frequently noticed, and also enlargement of the spleen, generally simple, but in one or two recorded cases, structural disease has been observed. The brain has been found congested and softened, and, in two instances, it contained apoplectic clots. Hirsch describes a case in which he found, besides congestion of the brain, blood in the arachnoid cavity.

There is, however, one morbid appearance which has been witnessed in several cases within the last few years, and which is of the greatest importance, as there is good reason to believe that it points to a solution of the difficulty regarding the real pathology of the disease. It is change in the cervical sympathetic nerves and ganglia. Since 1859, when M. Kœben attributed the affection to a lesion of the sympathetic, there have been, so far as I can discover, five autopsies on examples of the disease, in which the sympathetic has been examined. The first case mentioned is by Trousseau, in his "Clinical Medicine," that of a female sixty years old, to whom reference has been made, and who, seven years before, became affected with the disease suddenly in one night, from a shock caused by the death of her father. She died in the Hôtel Dieu of apoplexy. At the post-mortem examination were found hypertrophy of the heart, atheroma of the aorta, slight cirrhosis of the liver, and a somewhat

similar condition of the thyroid gland, which was very slightly enlarged. The thyroid arteries were small, but neither calcareous nor flexuous. The spleen was large. Some appearances of nephritis were present. A mass of cellular and adipose tissue thrust out the eyeball, which was redder than usual. The inferior cervical ganglia of the sympathetic, were greatly increased in size and unnaturally red. Numerous vessels ramified over and within them. By microscopic examinations many vessels were seen in their interior, with thick admixture of connective tissue, and in the midst of their fibres nuclei and fusiform cells.

A second case is mentioned in the *Deutsche Klinik* for 1863, p. 286. The sympathetic nerve and ganglion were extremely thin. The pneumogastric was natural. The heart was hypertrophied. The valves were normal. There was an unusual quantity of adipose tissue in the orbit. The orbital muscles were almost yellow from fatty degeneration. The muscles of the trunk had undergone fatty degeneration.

A third was in the case mentioned to me by Dr. John Murray, in which Dr. Cayley discovered no lesion of the sympathetic or pneumogastric. There was double pneumonia of both bases of the lungs, nutmeg congestion of the liver, and dilatation of the heart; but not any valvular disease.

A case has been published recently in *L'Union Médicale*, 23rd January, 1868, by Dr. Fournier and Dr. Ollivier, in which the extremities became gangrenous, but, although the sympathetic was examined carefully by the microscope, there was not discovered either any increase or decrease in volume, nor was there any modification in consistence or colour in any part whatever.

The last case to be mentioned occurred under the care of Dr. Reith, who has published it in full in the *Medical Times and Gazette* for November 11th, 1865. A male, æt. twenty-four. Left eye first protruded, some years afterwards the right followed to nearly the same extent, and sufficiently to prevent him from closing the eyelids. Vision unimpaired. Conjunctivæ chemosed, and much congested. He had fallen down in fits some weeks before, and he had been sleepless, and suffered great headache. Some days previously to his death his memory was affected. He had œdema of the back of the neck and of the ankles. The carotids and radials pulsated normally. He died two days after admission into the hospital.

A minute description of every viscus of the body is given. Thyroid gland half as large again as usual, without passing either backwards or outwards so as to interfere with the vessels. Scalp, brain, and whole cranial cavity much congested. Veins of the

right orbit were in a similar condition, and there was a small quantity of grumous blood effused at the forepart of the orbit above the eyeball. Left orbit healthy. Organs of circulation otherwise normal. Spleen large, congested and pliable. Liver, large and congested. Cervical sympathetic, the nerves of both sides, especially of the left, enlarged. Middle and lower ganglia on both sides, but especially on the left, much enlarged, very firm and hard. They were loaded with granular matter. Connecting cords correspondingly enlarged, obscuring greatly the nerve tubes and cells, resembling a sympathetic gland in the early stage of tubercular deposit. Cellular tissue surrounding the ganglia thickened and hard. Dorsal, lumbar, and semilunar ganglia, of nearly the natural size. The other organs, except being perhaps congested, were healthy.

Cases are mentioned by Fletcher in which the blood was examined. One was a male aged twenty-eight, and the second a female of forty-seven. It coagulated slowly and imperfectly, and there seemed to be a deficiency of red corpuscles. In the one, there was an excess of white cells, and in the other cholesterine was detected. Dr. Laycock examined it in one case, but he found no change. A fatal case mentioned in the *Deutsche Klinik*, exhibited no changes.

The ultimate cause of the disease must be now discussed. Modern investigation throws light on it. The importance of the records of some of the above cases will now be apparent.

Dr. Begbie argues with great skill, "to prove that the essence of the disease consists of a vitiated or impoverished condition of the blood, a true anæmia, and that the disease is always preceded by some cause such as menorrhagia or hæmorrhoids producing the anæmia; that this abnormal condition, this attenuated quality of the blood, acting directly on the cardiac nerves, excites the heart and vessels to over action, which again is followed by the other symptoms characteristic of the disease."

Dr. Stokes believes that there are strong reasons for holding that the disease is originally a neurosis of the heart, and perhaps also of the cervical vessels themselves.

Withuisen holds a somewhat similar view, that it is a nervous disease of the heart, which may indeed give rise to organic cardiac disease, but not necessarily so.

Dr. Kœben, in 1859, attributed the affection to lesion of the sympathetic, which view was concurred in by Aran and Trousseau. The brilliant experiments of Brown-Séquard, Claude Bernard, Walker, Schiff, Budge, Valentin, and many others, seem to countenance the view of Dr. Kœben. Claude Bernard found that section of the cervical sympathetic causing paralysis, produced contraction

of the pupil, a narrowing of the opening of the eyelids, retraction of the eyeball, and increased flow of blood to the side operated on; that the small arteries pulsated with increased force, and the temperature was considerably raised in the cranium externally and internally. When the upper divided end was galvanized, causing irritation, the opposite effects were produced: dilatation of the pupil, widening of the eyelids, with exophthalmos, &c.

Although in the disease, the exophthalmos and dilatation of the pupil be present, there is dilatation of vessels and increased temperature, a symptom of paralysis. This has not been satisfactorily explained, but it is probable that the vessels become dilated from the reaction consequent on the irritation.

Following this, Dr. Laycock, *Edinburgh Medical Journal* for February and July, 1856, founded a theory based on experiments of Bernard, Waller, and others, that there is a definite tract of the spinal cord extending from the first cervical vertebra to the second dorsal, which he called the oculo-spinal, or cilio-spinal, which acts through the cervical sympathetic; that the exophthalmos, palpitations, and pulsations, with the accompanying nervous affections, and the vascular bronchocele, are due to the disturbance of the function of this region, and of the more extended cerebro-spinal centre, of which it forms part. He states that the connection of diseases of the thyroid with the reproductive function, points both to a group of vaso-motor centres in the oculo-spinal region as the seat of the neurosis, and to a common source of morbid irritation of that spinal centre generally. He acknowledges that anæmia, or a morbid condition of the blood, is a very common coincidence or predisposing cause. Anæmia would not explain the disease. Both Oppoltzer's and Virchow's views with regard to the anæmic theory, appear to coincide with Dr. Laycock's more or less.

Dr. C. J. B. Williams says that the disease depends on diminution, and not increase, of nervous power, producing a kind of aneurismal varix of the thyroid, and enlargement of the whole cerebral circulation, and he believes that this enlargement accounts for the exophthalmos.

Reith adheres to the same opinion as Trousseau and other French authorities. He thinks that the connection of the sympathetic with the heart and thyroid gland are satisfactorily demonstrated; and as excitement of the female sexual organs influences by reflex action through the ganglionic system, both the heart and thyroid, there is ample room for assuming that a lesion of that system would operate directly on the organs connected with it. Also as regards the exact pathological lesion of the cervical sympathetic, that as syphilitic

deposit may take place in the nerves and other tissues of the body, of an albumino-fibroid description, a tubercular deposit may in like manner occur; and considering that the case of his, an extract of which I have given, presented well-marked local appearances of this diathesis, he believes he is warranted in assuming that the ganglia of the sympathetic were involved in a like manner.

Dr. J. Warburton Begbie states his belief that the true pathology lies both in the blood and in the nervous system, but that the primum mobile is in the former; that an altered state of the blood, for a time stopping short of what is generally known as anæmia, but in many cases amounting to a well-marked anæmia, acts directly on the nerves of the blood-vessels, and on the nerves of the heart, which is followed by consequences constituting the ordinary features of the disease.

Dr. H. Jones, my learned and practical colleague, in his most valuable work on "Functional Nervous Disorders," recognises the influence of diseased action of the sympathetic nerve, and in alluding to cases in which no pathological changes have been detected, says it is quite possible that the mere disorder may be functional in some cases, organic in others. He thinks that there is good ground for attributing the arterial relaxation to vaso-motor nerve paresis. He continues, that the cerebral arteries are affected in the same way as the thyroidal, may be inferred from the mental excitement and anxiety, the insomnia, the occasional occurrence of a maniacal condition, and of actual extravasation in the brain. Also, the diarrhœa which so often wastes the patient, may reasonably be referred to relative increase of intra-vascular pressure, as well as to decrease of relative power in the smaller vessels.

Prognosis. In the majority of cases, suitable treatment early applied sooner or later produces a cure. If neglected, however, organic disease to a greater or less extent takes place. The thyroid becomes permanently enlarged, dilatation and structural disease of the heart and blood-vessels, with their consequences, ensue, the liver and kidneys becoming secondarily affected. Ultimately the result is fatal. Trousseau states that there is in some cases considerable danger of a fatal result from choking. This is certainly not of frequent occurrence.

The cases on record afford scarcely sufficient data to enable one to speak with much authority on the subject of a fatal termination; but asthenia from sleeplessness, great anæmia and urgent sickness, diarrhœa, apoplexy, pneumonia, bronchitis, disease of the liver and of the heart, with their consequences, appear to bring about a fatal issue.

The treatment which is recommended varies considerably. This is

not to be wondered at, as there are as yet scarcely any rational indications. The remedies, however, which have been used of late years are singularly few in number. When the disease was first recognised last century, the means employed were, according to the fashion of the day, chiefly bleeding, and local applications to the thyroid, particularly iodine. The effect of iodine seems to have been almost invariably bad; it increased the enlargement. The same may be said of bleeding, which was followed in nearly all the recorded cases by the direst results.

Dr. Begbie, following up his anæmic theory, employed chalybeates largely, and with great success, although he used at the same time some sedative. He points out the importance of first ascertaining the exciting cause, such as uterine derangement, piles, &c., and administering chalybeates, unless contra-indicated, for a prolonged period, with good diet, ale or porter, passive exercise and change of air. He says of his usual treatment, "It is the combination of iron with calmatives and sedatives that have been most useful, especially the tincture of the muriate of iron with the tincture of henbane."

Graefe, on the other hand, says iron should not be given when there is considerable vascular excitement, and the pulse more than one hundred, to one hundred and ten.

Trousseau believes that iron does harm as a rule, and that the successful cases were due to digitalis, or some sedative given with it. He accordingly recommends digitalis, and speaks highly of hydropathy, and of ice to the thyroid gland, and to the præcordia.

There can be no doubt, according to my idea and practice, that iron is most valuable, and markedly so in combination with a sedative, thus fulfilling what would seem two important indications of treatment, the improving of the state of the blood, and the calming of the excited circulation and nervous system generally. It is not yet clear which sedative is to be preferred; but theoretically belladonna deserves the largest amount of confidence, as being a powerful excitant of blood-vessels, causing contractions, and thereby overcoming congestions. Dr. J. Warburton Begbie speaks most highly of the results he has obtained from this drug, and says that in internal doses of a sixth, or a quarter of a grain of the extract, or one-sixtieth of a grain of atropia, or externally applied on a plaster over the enlarged thyroid gland, he has found it produce speedy effect on the eye, causing its retirement and removing the stare; it also induces speedy diminution in the bulk of the thyroid, and modifies and controls the excited action of the heart and blood-vessels.

Reith recommends belladonna among other remedies, and Bellingham speaks of the good effects produced by belladonna applied to the præcordial region.

Laycock has considerable confidence in digitalis, and uses cold applications to relieve the activity of the heart and vessels.

Fletcher has found great benefit resulting from the use of morphia to produce sleep, and digitalis to quiet the circulation, combining iron at the same time to improve the state of the blood. A considerable number of authorities, as Handfield Jones, Reith, Williams, and others, recommend among other things strychnia, which has been found successful in not a few instances.

In this age of extended practical ophthalmic surgery, it was not likely that the exophthalmos would escape an operation, and true to expectation Graefe practised two. He adopted, as a last experiment, tenotomy of the levator palpebræ in a partial manner, so as to produce a kind of incomplete ptosis, to neutralise any retraction of the eyelid.

INFLAMMATION OF THE OCULAR TUNIC, WITH SEROUS EFFUSION.

Dr. O'Ferrall has pointed out that under the orbicularis muscle is a distinct layer of fascia, and that this is the first element of the eyelid that enters the orbit; that there is another layer of fascia beneath the levator palpebræ, which also enters it, and by uniting with that above, forms a sheath for the accommodation and support of the muscle; and he points out the attachment of the ocular tunic to the orbital margin of the tarsal cartilages. This anatomical arrangement he then traces on the outer surface of the eyelid in the two portions separated by the natural fold of the skin, the upper portion constituting about one-third of the surface of the lid, the lower the remaining two-thirds. From these he makes the pathological deduction, that certain forms of disease within the orbit that are seated internal to the muscles, the motor apparatus of the eyeball, that is, in the substance of, or within the cavity of the ocular tunic, such as inflammation, and the effusion of fluid, extend their effects to the lower portion of the eyelid with which they are continuous, and that certain other affections situated external to the motor apparatus, which is that part of the orbit containing the fat, will show themselves by inflammation or other changes in the upper division of the same. But he shows that this difference can be recognisable only in the early stages of disease, when there is isolation. Later, when inflammatory action spreads, as it is wont to do,

all distinction is lost. The following practical comments are made by him :

Protrusion of the eyeball appears a very simple and inevitable result of inflammation of the tunica vaginalis oculi. There are here no soft parts to receive and divide the pressure or protect the globe of the eye. Inflammation of this capsule must then be immediately followed by pressure; and when we recollect its conical form, and that effusion at once takes place into the cellular tissue connecting it to the ball of the eye, we perceive there is nothing to prevent the dislocation of the eye.

This effusion into the cellular tissue will make itself evident in another way. The conjunctival reflection from the eyelid to the eyeball, covers the tunica vaginalis in front. At this point it will not only receive the pressure of the effused serum, but will become separated from its connection with the sclerotic coat, by the extension of the infiltration; hence the amber-coloured chemosis without vascularity. Chemosis originating in conjunctivitis, always presents, in addition to serous infiltration beneath, one or other of the forms of hyperæmia.

The concluding remarks possess much value. In distinguishing these cases, " I would not be supposed to mean that inflammation of this tunic is never combined with a similar condition of the periosteum or cellular tissue on the one hand, or with inflammation of the eyeball itself on the other. I am aware they may exist together, for I have seen such cases. All I mean to assert is, that inflammation of the tunic described may be the primary affection, and that the tunic may be the point from which the diseased action may spread to the other fibrous layers in the orbit, and finally reach the periosteum; that the attack may even be limited to the tunica vaginalis oculi; that it may here produce a train of symptoms of the most dangerous kind, symptoms which have been hitherto supposed to reside in the periosteum, because the existence of other fibrous membranes in the cavity was not suspected. Presuming that there were no other tissues in the orbit to which to attribute the disease, practitioners would naturally refer the majority of cases to one or other of those with which they were acquainted. The solution of such cases would be less difficult if our clinical researches were based upon a more correct knowledge of the structures actually existing in the orbit."

Two of his cases are worth quoting.

A man, thirty-two years old, had violent inflammation, and considerable protrusion of the right eye: the cornea and the iris seemed healthy, but vision was confused; the conjunctiva was chemosed,

but not vascular; the eyelids were swollen and red, the upper one dusky with distended veins; the lower part of it so much tumefied that the cilia appeared to grow at an unusual distance from each other, and its transverse diameter was considerably increased. From the superciliary ridge to the inflamed portion of the eyelid, there was an interval about half an inch deep along the whole breadth of the lid, where there was neither redness nor swelling. There was agonizing pain in the eyeball, and while a little moderate pressure of the palm of the hand against the whole tumour gave some relief, the patient could not bear pressure by the finger of another person, except when made gently on that portion of the palpebræ which has been described as being free from redness, and then slowly and not suddenly, so as to cause a shock, and provided it was in a direction upwards towards the roof of the orbit. The report then shows that there had been a severe attack of rheumatism. Loss of blood from the temporal artery, with calomel and opium, cured the ocular and general disease.

In a second case, both eyes were consecutively affected. The right eye, the first attacked, protruded three-quarters of an inch, and looked bright in the midst of an amber-coloured chemosis, without vascularity. The upper eyelid was of the dusky colour and tawny appearance of that in the above case; and as in it, the orbital portion did not participate in the change, but was separated by a very abrupt line of demarcation. Pressure upon the upper division was not followed by pain. The second eye was invaded in precisely the same manner. Both were cured by the iodide of potassium.

Of course the ocular tunic never escapes, when there is orbital cellulitis, or periorbitis.

This research and reasoning render lucid many of the heretofore anomalous cases of protrusion given by authors, and several that have occurred to myself; some appearing after fever, measles, erysipelas, or other constitutional disturbance, in which the ocular tunic alone was diseased. O'Ferrall had not recognised such. His attention had been arrested only by examples of rheumatic disease; hence he wrote always of rheumatic inflammation of the part, and described severe symptoms.

The following cases seem to be those of the simplest forms of inflammation of the tunic.

An interesting girl of thirteen was brought to me with slight protrusion of one eye, with the single accompanying symptom of slight chemosis of the conjunctiva, which had a dirty white metallic-like aspect, without a trace of vascularity. I watched the case for

months, scarcely adopting any treatment, for no particular plan was indicated. That there was effusion in the ocular sheath can scarcely be doubted. In another instance with protrusion, the lower half of the conjunctiva was chemosed without vascularity. In a third the globe of the eye projected, with a sudden elevation of the conjunctiva, by serum, on the outer side of the cornea.

These views have been questioned, but certainly not overthrown. Wecker thinks that O'Ferrall's cases were merely those of inflammation of the fatty tissue of the orbit, or of the periosteum, but not of the ocular tunic. He adds, that true capsulitis never goes on to suppuration except when it accompanies phlegmonous inflammation of the globe of the eye. Dr. Mackenzie met with prominence and a fixed state of the eyeball, which were due to mere effusion within the ocular tunic, as was proved by evacuating the fluid, when the prominence disappeared and the movements returned. He remarks, in connection with this, that when the eyeball is protruded, and its motions free, the cause of pressure is certainly without the ocular capsule.

Treatment. This must depend on the supposed cause of the inflammation by which the capsule is attacked. If rheumatic, or syphilitic, the indication is clear. When there is no apparent constitutional cause, a local one probably exists. But there may be nothing to account for the effusion. Rest to the eye, and rest to the body, are called for in every case.

Adhesion of the ocular tunic. Union between this sheath and the eyeball is described by Dr. O'Ferrall. The cause is said to be inflammation, and the effect prominence with immobility. Protrusion and violent inflammation of a motionless eyeball, with distracting pain; immoveable and dilated, but regular pupil; imperfect vision; a tumid and slightly œdematous upper eyelid, are the symptoms. The immobility remains after the other states have nearly passed away. He imagines that the real cause of such symptoms is adhesion of the sheath, as well as the consolidation of the several fibrous layers which envelope it and form the thecæ of the muscles. Moreover, he considers that the adhesion may be accompanied by union of the tendons of the muscles to the edges of the openings through which they pass, the ocular movements being thereby impeded in proportion as the usual gliding motion of the parts is destroyed. Immobility may be the effect of the ocular adhesion, but it may be produced from other causes.

M. Demarquay has collected some cases of this kind. The following occurred to M. Carou du Villards. An orphan girl, seventeen years of age, had considerable protrusion of the eyeball, accompanied

by very acute pain when she stooped, or when pressure was applied over the eye. The eyeball seemed encased in a uniformly hard swelling. The cornea and the conjunctiva were unaltered. Vision was lost. The operation for removing the eyeball was commenced. When making the cut through the optic nerve, by which the ocular tunic was opened, a yellowish fluid escaped, and the supposed tumour disappeared.

In two other cases it was noticed that protrusion of the eyeball was increased when the head was bent forwards.

EFFUSION OF BLOOD IN THE ORBITAL CELLULAR TISSUE.

The diagnosis of this can be made only by swelling of the eyelids, and the discoloration of the ecchymosis, or by the same effects on the conjunctiva. The other symptoms, the protrusion of the eyeball, the double vision, the partial or complete loss of the ocular movements, differ in no wise from those produced by many other causes, except in their rapidity of occurrence; but, of course, this is a material difference.

The cause of orbital hæmorrhage is nearly always traumatic, and when the damage is external, the case is clear. But it may occur from fractures of some parts of the orbit concealed from our view, associated with fracture of the skull or not. The accident ward of a general hospital is the place to witness such accidents.

Fracture of the roof of the orbit, implicating the frontal bone and the sphenoid, may rupture the neighbouring veins, or even the ophthalmic artery.

For a great many years surgeons have been trying to discover some point of diagnosis in the position and extent of the effusion, by which they could tell what part of the orbit had been fractured, and limited observation caused some men to propagate error. When the extravasation in the eyelids is not accompanied with subconjunctival effusion, it is probable that the fracture is confined to the orbital margin. Many exceptions have been seen. On the other hand, an absence of eyelid ecchymosis, with much subconjunctival extravasation, and some evidence of hurt to the cranial bones, would seem to indicate fracture far back. Beyond this, indefinite as it is, nothing worthy has been made out. Sometimes one eyelid only is ecchymosed, and nothing is to be learned from the one or the other being affected. The difficulties in the way arise from the fact that a fracture at the base of the skull is often attended with effusion of blood in the orbit; that blood which

is thrown out at any part of the orbit, may rapidly diffuse itself over the whole of the cavity; that blood may enter through the optic foramen, and through the sphenoidal fissure, without the occurrence of fracture; and that bleeding from accidents, falls for instance, may originate in the soft parts of the orbit.

Fracture may occur in any part of the orbital walls without orbital hæmorrhage. For the blood to become extravasated here, there must of necessity be a rupture of the orbital periosteum, as well as of the bone, and the bleeding, too, must be considerable. This extract from Mr. Hewett's article on "Injuries to the Head," in Holmes's "System of Surgery," is to the point: "Out of twenty-three cases of fractured base, involving more or less extensively the orbital plates of the frontal, all of which occurred at St. George's Hospital within the space of ten years, it was found in eight cases, that there were no traces of extravasated blood to be seen, either in the eyelids or under the ocular conjunctiva; and in five cases, that the effusion of blood occupied the eyelids only; so that in these thirteen cases there could have been no suspicion whatever as to the existence of a fracture. But, on the other hand, the nature of the injury was made manifest in the ten remaining cases by the blood effused under the ocular conjunctiva and in the lids."

"Blood may, however, be effused into the lids and under the ocular conjunctiva, in fractures of the malar, or superior maxillary bones; and this may give rise to an error of diagnosis. But such cases are of rare occurrence."

The formation of traumatic aneurism in the orbit, is considered in the chapter on "Aneurism in the Orbit, &c."

The eye has been thrust out of the orbit of an infant, from extravasated blood, the effect of damage from obstetric forceps. M. Demarquay has quoted such a case. The conjunctiva was everted, and very much injected with blood. The cornea suppurated, and the eye was lost.

Respecting spontaneous orbital hæmorrhage, I have never met with an example, but there are well-authenticated cases. Some have occurred during violent muscular exertion, some during typhus fever.

The reason why blood extravasated in the orbit does not find its way under the skin of the eyelid, is because it is circumscribed by the orbito-tarsal layer of fascia.

Treatment. It must be a rare circumstance which could induce a surgeon to do more than to keep his patient quiet, and apply soothing remedies. Nature must be trusted to, and art kept in

abeyance; absorption will seldom fail to do the work when the tissues are merely permeated. It is different when clots form. These, when large, are apt to break down, when they become softened, and suppurate. The sooner the fluid products are evacuated, the better.

If there be reason to believe from the increasing protrusion of the eyeball and other symptoms, that the bleeding in the orbit is continuing, compression must be tried, in whichever way may seem most advisable; but, of course, this must have its limit on account of the damage which might accrue to the eyeball from any excess of it. Pressure on the carotid artery should be tried. Should that fail, the only alternative in a severe case would be to ligature the common carotid artery. There is recorded in the "Medico-Chirurgical Transactions," a valuable case of tying the artery by the late Mr. Scott. A boy fell, got contusion and swelling of the right side of his head, concussion of his brain, and protrusion of the right eyeball. He recovered from the concussion, but the eyeball protruded more. The eye was propelled forward at each stroke of the heart. Pressure on the eyeball was applied for two days, but was abandoned on account of the pain it caused. The carotid artery was tied, and all the eye symptoms passed away.

INTRA-ORBITAL ABSCESS, THAT IS, ABSCESS WITHIN THE ORBITO-PALPEBRAL LIGAMENT.

This deserves a special consideration. It has been frequently alluded to, but the mention has only been in association with other pathological states.

The most common cause is traumatic lesion, injuries without the orbit from a blow or a wound, and injuries within from all causes, including the impactment of foreign bodies. To these must be added surgical operation about the orbit and the ocular appendages, operations on the eyeball, abscission, and extirpation. Cellulitis is induced and abscess follows. All that concerns cellulitis has been described, and repetition is unnecessary.

The next most frequent cause is extension of surface inflammation from a neighbouring part to the orbit. Erysipelas of the head and of the face gives the most numerous examples. There may be several erysipelatous abscesses, each small, yet distinct.

Disease in the frontal sinus will produce the abscess, and so also will affections of the nasal fossæ. The irritation of decayed teeth, whereby disease of the antrum is set up, is the most frequent of these.

In the majority of cases there has evidently been but mere extension of the inflammatory action around, yet its very early appearance in the orbit in some, would tend to give the idea that it is simultaneous with that around, and not secondary.

The extraction of decayed teeth has induced antrum disease, followed by abscess in the orbit.

Periorbitis and caries must next be mentioned. All concerning them and the accompanying abscesses have been already considered.

Phlegmonous abscess. This is sufficiently common for me to have met with several cases in the course of my practice. I have seen the affection with the swelling of the palpebra, chiefly on the side where there is the intensity of the action, the throbbing pulsatile pain, the shining skin, and the purple red spot where the surface is being approached by the pus. The chronic phlegmonous abscess is, perhaps, the most common. It forms almost without any local disturbance, without any constitutional symptoms, and it exists in its full development for a long time without coming to the surface. It may have years of duration.

Secondary abscesses from pyæmia, and abscesses from typhus fever, if they occur in the orbit, must be very rare. This statement may be misunderstood, unless I point out that the ophthalmitis, with the intraocular suppuration which is seen as the consequence of such affections, is often spoken of as orbital abscess.

On the diagnosis, and on the correct treatment of intraocular abscess, will often depend the fate of the eye, and the life of the patient. It is not possible to lay down correct and uuerring rules of guidance for discovering the disease. The most experienced men will find themselves baffled in many cases, because there are so many symptoms in common between abscess and other orbital diseases, especially tumours. Yet there is something to be said for the help of those who are altogether ignorant of the subject.

With all abscesses, the common symptom is displacement of the eyeball forward, and nearly always laterally as well.

An exception may occur. Dr. O'Ferrall gives a case of sub-acute orbital abscess, with depression of the globe of the eye, without any appreciable protrusion, which he deems dependent upon the limitation of the abscess posteriorly by adhesive inflammation. *Dublin Hospital Gazette*, vol. i.

In what may be called the traumatic abscess, the recognition is easy. The febrile symptoms, the pain, the tension in the orbit, the hardness in the affected part, and later, the fluctuation, establish the fact.

The abscess from caries could hardly be mistaken. The inflam-

matory symptoms that precede are an indication of the deposit of pus. With acute vascular action, the eyelids are always œdematous and red, and the conjunctiva chemosed.

Abscess arising from the extension of pus from a neighbouring part is always obscure. It is difficult to say whether the eyeball is protruded from such a cause, or from mere inflammation of the soft parts, without suppuration.

The acute phlegmonous abscess is, perhaps, to surgeons in general, the most easy of all to tell; but it may be simulated in the rapid protrusion of the eye, the infiltration of the orbit, the swelling of the eyelids, and the chemosed conjunctiva, attendant on intercranial aneurism of the carotid artery, and disease of the cavernous sinus. Some of our best surgeons have been unable to tell which of these diseases was present, and explored for abscess, when cranial disease existed. Mr. Tyrrell has narrated a case of an abscess of this nature, although he does not name it as such, attended with a marked degree of vascular disturbance. Symptoms of acute inflammation, with great protrusion of the palpebræ and the globe of the eye, induced preparation to be made for the evacuation of pus, when it was discovered that so strong a pulsation pervaded the whole swelling, even moving the eyeball, that the presence of an aneurism was suspected. Reviewing the history of the case, a different opinion prevailed, and it was decided that a small puncture should be made between the eyeball and lower eyelid, which was done by Mr. Scott, and the result was an immediate escape of blood, of an arterial character, in jets corresponding to the pulsatory movement of the swelling, which was synchronous with the pulse. Pressure stopped this, and when the compress was removed a day or two after from the pain it occasioned, there was a free discharge of matter, and all the symptoms were greatly mitigated. A free incision would no doubt have at once evacuated the pent-up pus.

The chronic indolent abscess is often a puzzle; it cannot be told at any time from a cystic tumour, and sometimes when fluctuation is obscure, from a solid tumour. Cancerous tumours, of course those of soft cancer are meant, occasion the greatest difficulty. The history of the case will considerably help to clear the obscurity, but exploration alone may elucidate the true condition of things; and this should be resorted to in all instances of doubt. This question of diagnosis is spoken of at length in the chapter on "Tumours."

When an abscess is produced by disease creeping from the zygomatic fossa, the temporal, the nasal, or the frontal sinus, it will probably be difficult to say what is the nature of the orbital

affection. A very careful scrutiny will be needed, and yet nothing may be ascertained without exploration.

There may be an infiltration of pus from the cranium to the orbit. The fluid may pass from the brain-substance through the optic foramen, or take another route. Mr. H. Lee, in his work on "Phlebitis," tells us that in consequence of a scalp wound, pus that was formed between the dura mater and the brain, extended to the base of the skull and through the sphenoidal fissure into the orbit.

It is supposed that the position of the eyeball will afford a criterion as to the existence of an abscess, because abscesses more commonly form on the inner side of the orbit than elsewhere; but the exceptions to this rule quite spoil its value.

Treatment. It seems to me to be necessary here, only to recognise the presence of an abscess; the preceding stages having been sufficiently noticed in connection with the several affections that produce suppuration, phlegmonous abscess only excepted. With regard to the treatment of the first stages of the phlegmon, the choice of remedies should rest very much on the patient's feelings. With much pain, leeches should be applied to the temple, and cold to the whole orbital region, continuously by evaporating lotions, or interruptedly by ice in a water-proof bag. With any marked vascular chemosis, the swollen part should be scarified, and bleeding for a short time encouraged by fomentation. The local use of opium should not be neglected. With less acute symptoms, especially when there is very little pain, bleeding is less necessary. Directly the cold ceases to give comfort, it should be abandoned, and warm applications tried. Rest is very essential. Any defective constitutional conditions should be looked after.

With reference to abscess in general when pus is formed, and its presence can be detected, it should be evacuated immediately. The extent of the incision should depend on the kind of suppuration. The more circumscribed the abscess, the narrower it need be. A free incision may prevent osseous disease. The knife should be used at the most central part of the abscess. The proper spot is generally indicated by bulging of some orbital portion of the lid. Hints about the caution to be observed in doing this have been given in a foregoing section. The amount of pus that may escape is sometimes surprising.

When the pus is not apparent, exploration must, under certain conditions, be made for it. With protrusion of the eyeball, with pain, with or without loss of ocular movements, redness of the eyelids, and puffiness and throbbing, together with constitutional symp-

toms of fever, search should be made for this product of inflammation. Pus may follow some days after an incision is made.

The advantage of exploratory puncture is still more apparent in the chronic abscesses, which are sometimes so long in getting to the surface, and which show so few external symptoms. A trocar may be used sometimes with better advantage than a knife.

An abscess may form within the ocular tunic, when the symptoms would be protrusion of the eyeball, and pouting or swelling externally between it and the eyelid. With suspicion of such an abcess, the line of incision should be within the eyelids, by the side of the eyeball. A lady had protrusion, with intense suffering and general symptoms of the formation of matter: several medical men were consulted, and more than once a puncture was made deep into the orbit, but ineffectually. The lancet seemed to have been directed away from the globe of the eye to avoid injury to it, or to the parts around. Her almost insupportable state, and the loss of sight, induced the medical advisers to talk of extirpation; but another surgeon, who was now consulted, directed that a lancet should be passed through the distended conjunctiva by the side of the globe. A large quantity of pus flowed out, and in a few weeks the eye was perfectly restored.

A case of precisely the same nature was brought to me by Dr. Sawyer, of Guilford-street. The eyeball projected three-quarters of an inch. The child was well a week after I evacuated the matter.

A passing remark is required for those cases in which decayed teeth have been the cause of orbital abscess. In addition to attention to such abscesses, the remains of the carious teeth should be extracted, and the antrum perforated from a tooth's socket to admit of the discharge of any accumulation of pus. The same treatment is needed if the orbital disease should supervene on antrum abscess after the extraction of teeth.

The after-treatment of orbital abscess is quickly told. In the absence of caries, the less that is done the better; mere cleanliness is nearly always sufficient. To effect this, it is sometimes necessary to syringe out the cavity with warm water. If it should seem that the aperture has a tendency to close prematurely, it should be dilated from time to time by the introduction of a piece of lint, or enlarged by incision. Drainage tubes, and like contrivances for the supposed better escaping of the pus, have, according to my observation, been injurious. They have irritated.

There are certain special dangers associated with orbital abscess. The greatest of these is risk of life from implication of the brain

and its membranes, and inflammatory action of the cavernous sinus, through extension of inflammation from the orbital veins. The traumatic abscess is attended with the most danger. The symptoms of the cerebral implication are always manifest, readily to be recognised by any well-educated surgeon, and do not need description. A patient does not necessarily sink when such symptoms arise: I have seen recovery after undoubted meningitis.

Abscess, associated with caries, places the patient's life in jeopardy.

The phlegmonous abscess may affect the brain and cause death. I have had four examples of this in my own practice.

Another danger applies to vision. The eyeball may be involved in the surrounding inflammation, and may be destroyed from suppuration of the cornea, or it may participate in slight inflammatory disease, by which vision is impaired. Besides this, the optic nerve may be spoiled at an early period from inflammation of the nerve substance, and atrophy may follow. This state is revealed by the ophthalmoscope. This kind of damage is always imminent so long as inflammation lingers about the orbit.

Certain other pathological conditions may ensue, such as paralysis of the muscles, or permanent protrusion of the eyeball from infiltration of the orbital tissues, or partial ptosis.

HYPERTROPHY OF THE ORBITAL CELLULAR TISSUE.

This is a rare orbital affection. I have no doubt that I have met with it several times, and as I believe, the change which occurs is precisely the same as that seen in elephantiasis on the surface of the body. The eyeball is more or less thrust out of its socket. I recognised my first case in a remarkably powerful man in the meridian of life. The eyeballs were prominent, but yet unhindered in motion. The conjunctivæ were highly injected, of a coarser structure than natural, and bolstered out around their ocular attachments, by the posterior swellings, which were dense and doughy. Vision was perfect; there was much pain; I saw my patient but a few times, and never learned his fate.

Infiltrations of the orbital cellular tissue. This can scarcely be spoken of as a distinct disease, but rather as a mechanical effect, due to several causes interfering with the circulation.

It may occur in newly-born children who have been long squeezed during parturition. It happens in persons who have the circulation impeded by pressure on the throat. It has occurred in the straining of child-bearing. It is sometimes seen in the players of wind instruments. Asthmatic people may get it.

The pathological change is the effusion of serum, and engorgement of the blood-vessels.

It is temporary or permanent, according to the cessation or the persistence of the cause.

HYPEROSTOSIS OF THE ORBITAL BONES.

This is hypertrophy from an excess of bony matter. It is probably due to periorbitis. It is the rarest of orbital diseases. It may occur strictly as an orbital affection, and be partial, or implicate the entire orbit, and exist in connection with similar disease of the cranial and facial bones. It may progress until the orbital walls are in contact.

I have not seen the disease in life, nor do I know of any clinical description of it. The several published accounts are of dry bones. In the skull of a Peruvian exhibited in the Museum of the Royal College of Surgeons, all the bones of the face are enlarged and thickened in a remarkable manner, and the orbits are nearly closed.

DILATATION OF THE ORBIT FROM PRESSURE WITHIN, TOGETHER WITH ABSORPTION OF A PORTION OF THE WALLS.

The orbit, like other bony cavities and recesses of the body, including even the skull, enlarges from the pressure of abscesses, and tumours of any kind. It is by means of this enlarging process that an incredibly large amount of soft cancer may be contained in the orbit, when there has been but slight protrusion of the eyeball.

CYSTS IN THE ORBITAL WALLS.

The bones of the orbit, as a part of the osseous frame, are liable to cystic tumours, just as other bones of the body, yet I have not met with any. The only disease on record placed under this head, is that of hydatid, of which a case has been given in the chapter on "Entozoa."

EMPHYSEMA ABOUT THE ORBIT.

The most common cause of this is rupture of the lacrymal sac. Cases are described in the chapter on "Injuries from Mechanical Agents." An orbital fracture may tear the sac. Fractures which open the frontal sinus, the upper chamber of the nose through damage to the ethmoid cells, or the maxillary sinus, may all produce emphysema.

The inflation may be limited to the orbit, and may protrude the eyeball, or not, according to its extent, or it may involve also the eyelids and the surrounding parts.

There may be ocular emphysema, as a part of general entrance of air from a fractured rib. Such a case has lately occurred to me at St. Mary's; the upper half of the body was enormously inflated, and the eyelids were nearly closed over the protruded eyeballs.

There is no treatment proper for emphysema. When it is possible, pressure on the spot where the air enters the orbit, as over the lacrymal sac, is all that can be done. But this is really unnecessary, because here, as elsewhere, as soon as repair sets in, the pneumatic channel gets closed.

CHAPTER VII.

DISEASES OF THE FRONTAL SINUS.

ANATOMICAL CONSIDERATION—DISEASED CONDITIONS—INFLAMMATION AND ABSCESS—ENCYSTED TUMOURS—EFFUSION OF BLOOD—EXOSTOSIS—SOLID TUMOUR—FRACTURE.

ANATOMICAL CONSIDERATION.

The sinuses vary in their capacity in different individuals, being scarcely found in some, while the large cavities in others push forward the lower margin of the forehead to such an extent as to give a prominent feature to the countenance. They are developed later in life than would be supposed, any traces of them being hardly discoverable before fifteen years of age, from which period to the twenty-third year, and even much later, they steadily increase in size.

They may be described as spaces existing between the external and internal tables of the vertical portion of the frontal bone, and having for a floor the orbital plate of the same bone. They are really accessory portions of the nose, with the middle meatus of which they communicate by the infundibulum.

Should any abnormal strain be brought to bear upon the interior of these sinuses, we should expect the thinner orbital and cerebral walls to yield before the anterior thick one; and this actually occurs. The floor gives way the most readily, and by bulging into the cavity of the orbit may cause serious injury to the structures contained therein. It is in this manner that disease of the sinuses becomes an object of interest from an ophthalmological point of view.

DISEASED CONDITIONS.

The diseased conditions may be classed under the following heads: Inflammation and abscess, encysted tumours, effusion of blood, exostosis, solid tumours, as polypi, fracture.

INFLAMMATION AND ABSCESS.

Inflammation of the mucous membrane lining the sinus with the secretion of pus, may be apparently spontaneous, or due to some very obscure cause; or it may be occasioned by caries or necrosis of the bone; or by direct violence; or caused by some diathetic condition of the patient, as syphilis. The general symptoms of the disease are, sharp and fixed pain in the brow, tenderness, headache, with a purulent discharge from the corresponding nostril.

If, however, the pus be pent up from the communication with the nose being cut off, serious consequences ensue. A constant and severe pain in the region is present, the sinus is dilated by the increasing quantity of pus, and the nasal eminence of that side is made much more prominent. As the space enlarges the roof of the orbit yields, and bulges downwards; the eyeball is thus displaced in the same direction, but as the tumour has a tendency inwards the eye is forced outwards as well. The upper eyelid cannot be completely raised. The upward movement of the eye is hindered, and there is double vision in the upper half of the visual field. Should this enlargement still go on, disorganization of the contents of the orbit would be imminent, and the brain might suffer from pressure. But generally the inner part of the anterior wall of the sinus gives way, and a tumour slightly fluctuating makes its appearance at the inner angle of the eye, in fact, just above the inner canthus. The early symptoms being those of a firm swelling at the inner part of the orbit, might lead to an error in diagnosis. The bony wall having been absorbed, the skin next gives way, either at the inner canthus through the upper eyelid, its most common position, or sometimes just beneath the middle of the supra-orbital arch.

Treatment. In an uncomplicated case of primary inflammation, leeching on the tender part, hot applications and rest, are the essential agents. A cure generally ensues, although there might be relapses. In secondary or symptomatic inflammation, which is almost necessarily chronic, there is required, in addition, special attention to the exciting cause, be this local or general.

In the second stage of the disease, the formation of the abscess, there can be no doubt that the proper course is to make a sufficient incision in the skin over the tumour, and to open the sinus with a knife or a small trocar, or a very small trephine, and to evacuate its contents. Death may ensue unless this be done. The sinus should be washed out daily. Astringents should be used with the view of removing any unhealthy condition of the mucous membrane. The state of the system in general must be attended to. In the only two cases of this kind in which I have been concerned, the apertures never healed. I will mention the particulars of one of them.

An elderly lady consulted me with symptoms of an abscess in her frontal sinus, which had existed for many months. The pain, the displacement of the eyeball, and the headache, at last constant, induced her to come to me. She had consulted other London surgeons. I evacuated the pus under the orbital ridge. For a few weeks after this, the daily washings of the cavity with water by a syringe, ran through the nose. After a time there was no nasal escape. In spite of all treatment by injections and otherwise, there still issued a purulent discharge from the opening I had made. Mr. Paget, and other surgeons, were called by my patient in consultation, in the hope of their suggesting some remedial measure. I had exhausted all resources, so that they could suggest nothing more likely to be effectual. All was in vain. Now, after the lapse of four years the sinus is still there, and the good old lady covers it with plaster, which she finds necessary to change three or four times a day, because after a few hours the secretion trickles over the brow.

A man, twenty-six years of age, consulted Mr. Bowman on account of an almost constant pain which he had suffered over the left brow for six years, during the last two of which a tumour was forming below the brow, which caused the eyeball to project, and its upper movements to be limited. An abscess was felt at the roof of the orbit and could be emptied by pressure, the pus escaping by the nose. General treatment was unavailing, and as giddiness came on, together with other urgent symptoms, an incision an inch and a quarter long was made into the tumour just under the supra-orbital ridge, and fœtid pus let out. It proved that the frontal sinus was opened, the dimensions of which were so enlarged that in the horizontal direction it measured two inches, and in the vertical one and a half. The anterior wall of the sinus was healthy. The posterior wall was absorbed. The mucous membrane felt velvety. A copious purulent discharge continued for several months. A permanent sinus remained. The case is detailed at great length in the "R. L. O. H. Reports."

In one instance related by Beer, in which the patient would not submit to an operation, the outer wall of the sinus gave way. A fortnight later the eye was lost, most of the orbit and nose were destroyed by caries, and the vision of the other eye destroyed.

Although the inferior wall of the sinus bulges most frequently and to the greatest extent, yet the cerebral wall sometimes expands upwards to the brain, causing greater or less cerebral symptoms, and it may become perforated. Richter records such a case. Cerebral symptoms evidently attendant on pressure of the brain, set in after acute inflammation and much swelling of the left eyelid. This was followed by ulceration in the middle of the eyelid, and the discharge of an enormous quantity of pus. The man died with apoplectic symptoms. Post-mortem examination. The skin over the forehead and eyelid was dissected off. At the upper margin of the orbit, quite close to the supra-orbital foramen, a hole was discovered. On the opposite side was another hole, which entered the cranial cavity. An aperture was found passing into the right frontal sinus. Both the sinuses were much enlarged and filled with pus. Further examination of the head was not allowed. The friends who were present gave the following history of the disease: Two years before, the deceased was trying to break a bit of iron with a big hammer. A piece flew off with violence, and struck him on the orbit close to the spot where the external hole was discovered. Since then he had often complained of an aching pain in his forehead, and a few drops of pus escaped from his nose. He had never been obliged to leave off work.

For the special treatment of caries and necrosis, the reader is referred to the preceding chapter.

ENCYSTED TUMOURS.

Encysted tumours of the frontal sinus may be a real dropsy of the cavity, or merely a collection of mucus or hydatids. The last must be very rare. Professor Langenbeck has given two cases. In both there was considerable displacement of the contents of the orbit. In the one, the tumour seemed to be due to striking the right temple in a fall against a table. In the other, a blow with a racket bat on the side of the nose was the apparent cause. Whilst operating on them he found in the former a white shining cyst filling the whole of the sinus, enclosing a clear ropy fluid; in the latter a shut sac in the same position filled with a greyish-white tenacious mass. The diseased structure was removed in each case. Probably they were nothing but collections of mucus and thick matter.

The diagnosis of these diseases will rest on the position and character of the tumour. These are the same as in abscess. But the constant pain which occurs in abscess is absent here. Distinction, however, between these two is of little importance, as the treatment is the same. The cavity should be opened and the morbid products removed; the parts will then, in many cases, return to their original condition.

Expansion of the sinus by an accumulation of mucus. Maria M——, æt. twenty, came to Carey-street Dispensary with a small tumour at the upper and nasal side of the right orbit, which protruded the eyelids, and displaced the eyeball downwards and outwards. She complained of a slight aching pain and tenderness on pressure. A puncture, which was at this time made with a grooved needle through the eyelid, gave exit to blood only, and a week afterwards the tumour was diminished. Mr. Wood made an incision through the upper eyelid, parallel with the upper border of the orbit. A free puncture into the tumour gave vent to some inspissated mucus, and it became apparent that the case was one of dilatation of the frontal sinus, the bony wall of which, where it contributes to form the orbital roof, had been absorbed so that the lining membrane of the sinus, distended with thick jelly-like sticky mucus, protruded. About a table-spoonful of this inspissated mucus, partly yellowish and opaque, partly transparent, escaped through the puncture with some impulse. A probe could not be passed into the nose. Moderate inflammation followed the operation. A small drainage-tube was used to favour the escape of pus, and the cavity was syringed out. The wound contracted, leaving a small orifice the eighth of an inch in diameter, which for a long time discharged a small quantity of muco-pus.—"R. L. O. H. Reports."

EFFUSION OF BLOOD.

Should the walls of the frontal sinus be fractured, blood must of course be poured into the cavity, but there would be no special symptoms. But if the fracture extends to the inner table of the skull, or to the roof of the orbit, blood might be effused into the cranial or orbital cavities, when the symptoms characteristic of each injury would appear.

EXOSTOSIS.

Exostosis of the frontal sinus is very rare. Still the disease has been known to occur, and a few specimens of it are preserved.

There are two very large ones, one in the Hunterian Museum at the College of Surgeons, and one in the Cambridge University Museum, but from their size it is impossible to determine the original seat of their growth. There is a smaller one in the Museum of St. Bartholomew's Hospital, and Mackenzie said that he had two undoubted, but small preparations of the disease. They are not of much interest surgically, for if they were small, their diagnosis would be impossible, while if large, it would not be practicable to remove them, as they would be too hard, and wedged in among the cranial and facial bones.

SOLID TUMOURS.

Solid tumours or polypi. It is rare to find polypi in the frontal sinus without their occurring at the same time in the nose; still they do occasionally grow there even when the nose is quite free from them. In their increase, which is slow, they carry before them the walls of the sinus just as an abscess does. The same injurious effects on the contents of the orbit will be observed. They have been known to fill and dilate the sinus, even when they took their origin at some distance, as in the maxillary sinus. It would be very difficult to diagnose them from abscess and encysted tumours, in fact, impossible; a matter, however, not of much importance.

In the treatment the sinus ought to be opened and the growth, which generally has a narrow pedicle, entirely removed. The following is a typical case. A boy, aged ten, was put under Dr. Wuth's care, on account of a disease of the left eye, which had troubled him nine years. The eye was so entirely pushed out of the orbit, that it lay on a level with the nose. Its lateral displacement projected it so much over the cheek bone that, viewed in front, it hid the neighbouring side of the face. Its displacement downwards brought it into a line with the front of the nose. For the last three years the eyelids had closed less and less completely, and now covered it so imperfectly that the cornea, with a circumference of sclerotica four lines broad, remained constantly exposed. A large, deep ulcer of the cornea threatened a speedy disorganization of the eyeball. The regions of the frontal and nasal bones were greatly protruded. From the stretching of the skin, the left eyebrow was separated widely from the right, and dragged downwards. The skin itself was thickened and doughy to the touch, while at the outer-under part of the eyebrow was a small opening, from which, on pressing the surrounding region, a whitish mucus welled out. Dr. Wuth made a vertical incision two inches long

from the root of the nose upwards through the soft parts, and then a horizontal one, also two inches long, close above the eyebrow. He next dissected back the triangular flap thus formed, so far as to permit the frontal sinus to be trepanned. In the middle of the superciliary arch was a small hole in the bone, opening into the sinus, and explaining the source of the fluid already mentioned. In consequence of the great dilatation of the sinus, it was necessary to make two openings into it with a small trephine, whereupon an immense quantity of polypi protruded, and were removed. The healing of the parts occupied twelve months, the frontal sinus being by that time considerably lessened in all directions, and the eye having partially retreated into the orbit. The ulcer of the cornea soon cicatrized. From the first night after the operation the patient enjoyed sleep, such as he had not had for years, and he speedily improved in health.

FRACTURE.

This has been treated of in the preceding chapter.

CHAPTER VIII.

TUMOURS.

OCULAR TUNIC — TUMOURS OF THE EYELIDS; OF THE CONJUNCTIVA, AND UNDER IT; OF THE SCLEROTICA; OF THE CORNEA; OF THE ORBIT, WITHOUT AND WITHIN.

OCULAR TUNIC, OR TUNICA VAGINALIS OCULI.

The ocular tunic was demonstrated in 1804, by Tenon, who called it "the tunic of the eye." Since then other anatomists, among whom are Dr. O'Ferrall, Bonnet, and Dalrymple, have described it; but to Dr. O'Ferrall is due the merit of a surgical and a pathological application. His memoir on the subject is in vol. xix. of the *Dublin Journal of Medical Science*.

Anatomical relations. It is a white fibro-cellular tunic, completely surrounding the eyeball, and separating it from the orbital muscles. Tracing it from behind, it commences around the optic foramen, encircles the optic nerve loosely, and expands to enclose the eyeball, on the front of which it divides, one portion becoming lost on the sclerotica, a little posterior to the cornea, the other passing to the orbital edges of the tarsal cartilages. Externally, it blends with the orbital areolar tissue. Internally, it has a very slight cellular attachment to the sclerotica, but is yet so smooth that the eyeball moves freely in it. In front it is pierced by the tendons of the oblique muscles, with which it is incorporated, and still more anteriorly, the recti muscles pass through it obliquely to their insertions, and are more or less connected with it. It protects the eyeball, and serves to keep it in position. By the muscles passing through it, they get their force properly directed, securing ocular

rotation, and opposing retraction, which would otherwise predominate. Students always cut it away, when they dissect the orbit.

The readiest way of exposing the tunic is to cut through the palpebræ vertically, to turn back the separated parts, and to divide the conjunctiva at its angles of reflection, from the surfaces of the

Fig. 37.

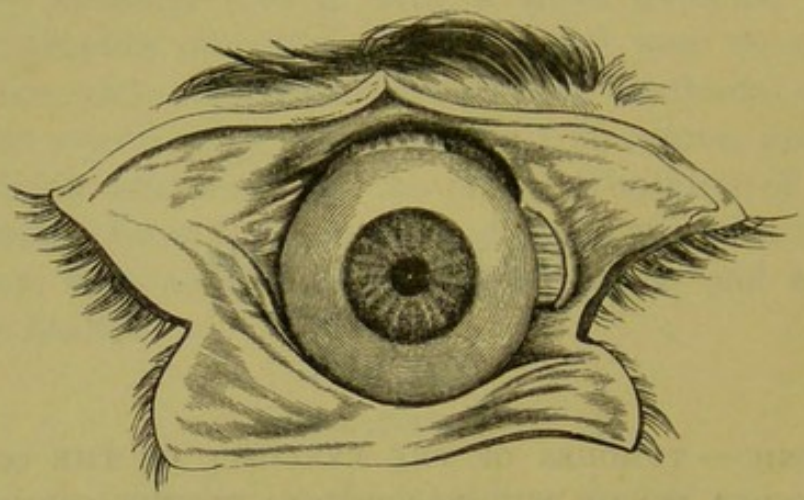

eyelids to the eyeball. The preceding drawing is taken from a dissection I made in this manner. Two only of the recti muscles are visible, for the eye was in this instance very deep in the orbit, and the insertion of the other muscles could not be seen. To exhibit them it would have been necessary to cut away a portion of the orbit, and then the connection of the tunic with the eyelids must have been destroyed.

TUMOURS OF THE EYELIDS.

To prevent bleeding during the removal of small tumours from the eyelids, and at the same time to give more command in operat-

Fig. 38.

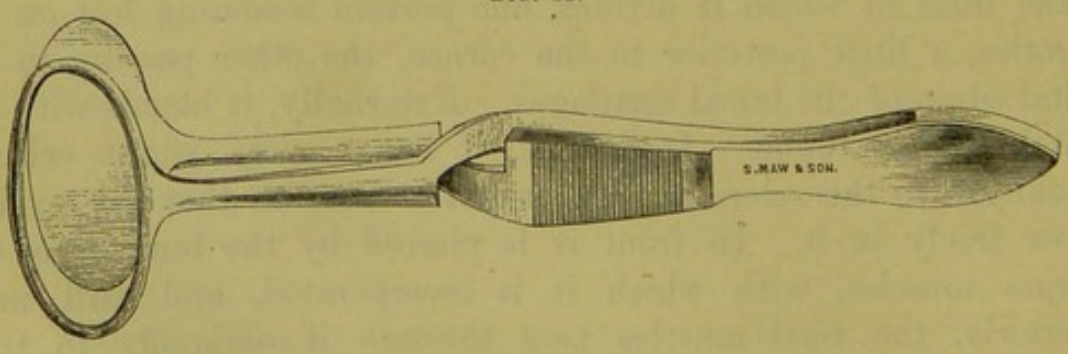

ing, by holding the part, forceps are made with rings at their extremities, between which the eyelid is placed. Fig. 38 shows the instrument, which closes by a cross-action spring.

A better form of the same appliance is illustrated by the next figures, and it would be further improved by cross-action. Spring catches for closing surgical instruments should be abandoned.

I must be candid enough to say that I never have used any of these forceps, because I have never felt the want of them. Some surgeons recommend them, and foreigners think them indispensable.

Tumours of the sebaceous system of the skin of the eyelid. These arise from detention of the sebaceous substance. They are directly

FIG. 39.

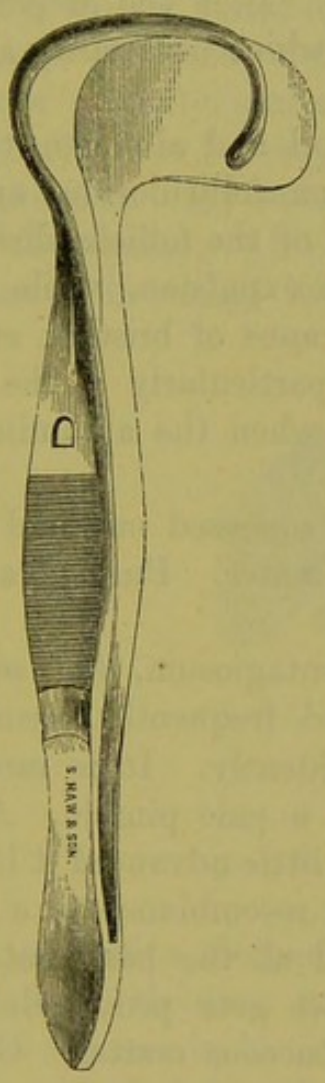

FIG. 40.

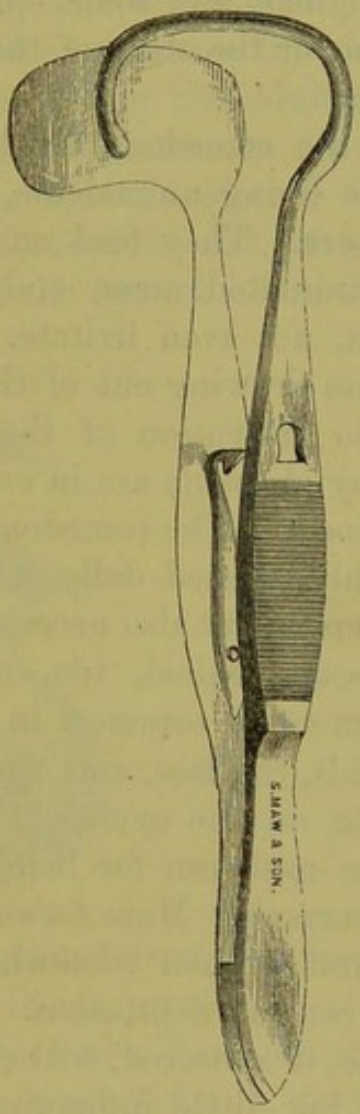

due to deficiency of expulsory power in the follicles and ducts of the sebaceous glands, or to condensation of the secretion, by which the expulsory power is destroyed, or to the obliteration or absence of the excretory opening of the follicle, or to the accumulation externally of the sebaceous secretion in a hard and compact mass.

Comedon. This is the simplest of all cutaneous tumours, and is merely an accumulation of sebaceous matter in the follicles of those persons whose skin is torpid in action. The accumulation appears as a black point occupying the aperture of a follicle. It constitutes what is popularly known as worms, or grubs, of the skin. It is

readily squeezed out, and appears white and cylindrical, not unlike a maggot with a black head. These accumulations are not confined to the face, they are found in every part of the skin that is supplied with follicles, being more abundant and larger in some parts than in others.

The excreted matter of the follicles of the skin is composed of four principal elements, water, oil, albumen, and cholesterine. In the sebum, or sebaceous substance, the water, oil, and albumen, form a kind of emulsion, inspissated with the denser materials of the cells of the follicle, and some epidermic scales. It is the preponderance of the one or the other of these elements which necessarily alters the secretion.

It is the comedon, which is rich in oil and albumen, that contains the living animalcule, the steatozoon folliculorum, and often in numbers. They feed on the contents of the follicle, disintegrate the accumulated mass, and facilitate its expulsion, while they do no harm, not even irritate. The appearance of bristles, or spines, sometimes growing out of the skin, and particularly of the eyelids, is due to protrusion of the comedones, when the albuminous and the horny elements are in excess.

Treatment. The comedones should be squeezed out, and the skin thoroughly washed daily with soap and water. Pure air and sufficient exercise are also necessary.

Molluscum, called, too, molluscum contagiosum, seu sebaceum. This tumour is common in children, and frequently occurs about the eyelids, the face, and the neck, coincidently. It is rarely solitary even on the eyelids. It begins as a pale pimple. A group might be mistaken for lichen. When a little advanced it looks like a little currant. More forward, it bears a resemblance to a salivary gland, and is then somewhat constricted at the base, flat topped, with a central depression. It sometimes gets pedunculated. A large one, if squeezed, will emit white sebaceous matter. Generally there is but little inflammation around the base, but occasionally such action is developed. Sloughing may ensue, and all the morbid material is then likely to be thrown off. It is seen in different stages of growth in the same person. It may suppurate in the centre, protrude and become covered with incrustation, which makes it look like a warty growth, or even a horn. It may grow as big as a cherry, or very large. One on the upper eyelid was large enough to hang down and completely cover the palpebral aperture.

The morbid anatomy consists in distension, by sebaceous matter, of the ducts of the sebaceous gland, from their primary branches to the ultimate outlet, by which the gland is forced up above the

level of the skin. The appearances are accounted for by the pathological changes. The summit becomes indented, where the sebaceous substance appears in the aperture of the distended duct. The sides are lobulated, in conformity with the arrangements of the lobules of the gland. The semi-transparency is from distension of the super-imposed stratum of the derma.

It has received several adjective denominations, according to its aspects at different times, but of these one only need be mentioned, that relating to its contagiousness. Respecting this, there is disagreement among surgeons. Those who accept contagion, advance in its favour the occurrence of the disease at the same time in all the children of a family, and sometimes even among the adults. Those who reject it, refer the implication of several persons to an endemic, or an epidemic. My own opinion is for the contagion in the early stage of the disease. Dr. Mackenzie witnessed the fact of a gentleman's hands becoming inoculated from the face of his child. Mr.

Fig. 41.

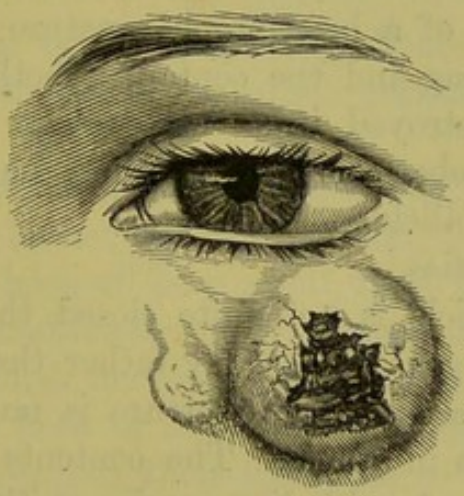

Hutchinson saw a mother's breast inoculated from the face of her sucking child, eighteen months old. Other proofs are published. The virus appears to be conveyed by the white fluid which exudes from the orifice of the tumour. The subjoined figure, from a girl seven years old, represents two of these tumours on the lower eyelid. The larger was partly covered with black incrustation, from beneath which a little pus escaped. This patient had no more of them; but her sister's face was covered, and a third member of the family, the mother, had also a few.

The treatment consists in cutting the tumour completely across by a free incision, and squeezing it out with the thumb-nails. If the cyst do not separate at the same time, the forceps must be used for its extraction.

Milium, called also sebaceous tubercle and miliary tubercle. This

is a yellowish-white, pearl-like looking tumour, about the size of a pin's head, as dense as fibro-cartilage. It takes its name from the likeness to a millet seed. It is commonly met with in clusters on the faces of young persons, and most frequently on the eyelids, especially on their margins.

It is due to an affection of the sebiparous system, although not a gland affection like the sebaceous tumour, but an accumulation of the epithelial portion of the sebaceous secretion in the upper layer of corium, and possibly in one of the ramifications of the gland, without there being any opening communicating with the surface. It is probable that it has its origin in an abortive follicle. Occasionally, calcareous matter, such as phosphate and carbonate of lime, is deposited in the epithelial cells.

Treatment. Break through the surrounding epithelium with a sharp-pointed instrument, and squeeze out the accumulated material.

Sebaceous tumour. This belongs to the class of cutaneous proliferous cysts. It consists of an accumulation of sebaceous secretion, together with disease of a hypertrophic nature in the coats of the follicle. The containing and the contained both grow. The gland is supposed to be destroyed in an early stage by pressure, and if this be the case, the sebaceous material must be the product of the dilated and diseased follicle.

There are two varieties.

In the first the follicle is not quite closed, there being a gigantic comedon. This enlarges horizontally rather than vertically, so that it is better felt than seen. The aperture is much more contracted in some examples than in others. The contents are solid and laminated, and made up of epithelium scales, with occasionally cholesterine. Should it soften and escape, a crust forms, or even a little horn.

The following sketch is of one that was growing just over the lacrymal sac, in a lady seventy-five years old. It was like a miniature bladder of lard, and retained for a while any form into which it was pressed.

Treatment. In a recent case, not congenital, a free incision with thorough squeezing out of the contents, is followed by inflammatory action, and a cure ensues. When the cyst walls have become thickened, they must be destroyed by some chemical agents, after the contents are evacuated, otherwise they will not perish or granulate. In a congenital example, occurring in a young lady who was sent to me by Mr. W. Adams, of Henrietta-street, the opening was very large, and the secretion could be readily and entirely evacuated by

pressure. This process of emptying had been frequently done with a curative intention. I passed a minute piece of potassa caustica to the bottom of the cyst. A little slough ensued, and healthy granulation followed. In general, nitrate of silver is sufficiently caustic for such a purpose.

The second variety constitutes the true cystic sebaceous tumour, with the closed cyst. It is very rare about the eyelids. I have

Fig. 42.

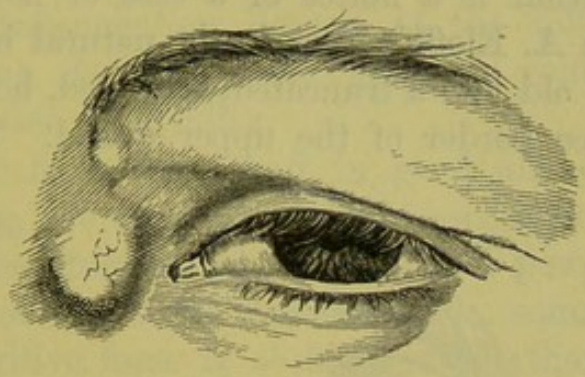

never seen one, but it occurs frequently about the eyebrow, when it is called an orbital tumour, under which classification it will be fully noticed.

Horns. I have met with a few specimens of the deposit of inspissated sebaceous matter on the eyelids, constituting what are called horns. They have all been small, time being wanting to give the more marked characteristic horny appearance to which they owe their name, and of which the scalp furnishes the best examples.

It is uncalled for here to say more of their structure than that these dense appendages owe their existence to the drying and hardening, as fast as it escapes, of the contents of the first form of the sebaceous tumour just described. To those who desire extended information on the pathology of the subject, I recommend the perusal of a very excellent paper by Mr. Erasmus Wilson, published in vol. xxvi. of the "Medico-Chirurgical Transactions," descriptive of a horn developed from the human body, with observations on the pathology of certain disorders of the sebaceous glands.

The following case of cutaneous horn of the lower eyelid is reported in the *Boston Medical and Surgical Journal* for February 11th, 1869:—A small pimple appeared on the lower eyelid of an Irish labourer, sixty-five years of age. There soon followed a fine, hair-like, hard growth. As it continued to grow, it assumed the appearance of a horn, and when it was an inch and a half in length, and about the same measure in circumference at the base, being now of six years' duration, it dropped off. In a few days a second horn

sprouted; in nine months it was as large as the first, and caused eversion of the eyelid with displacement of the punctum lacrymale, and overflowing of the tears. Its length was an inch and three quarters. Its circumference at the base, an inch and seven-eighths. Amputation was done by making a circular incision in the skin around the base. The tarsal cartilage and the hair bulbs were not damaged. This sketch is reduced to half proportions from a life-size portrait.

In the same journal is a notice of a case of horn of the upper eyelid, published in A. Eloffe's work in the natural history of horns. A child five years old had a truncated, wrinkled, horny appendage, growing on the free border of the upper eyelid. The length was

Fig. 43.

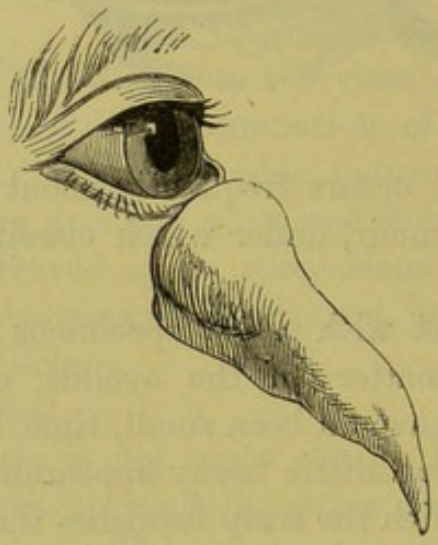

rather more than a centimetre. The thickness about that of the stem of a tobacco-pipe. It was easily pulled off. Nitrate of silver was applied. A year after, the child was attended for two similar growths on the upper eyelid of the other eye.

Treatment. A single stroke of the knife will be sufficient to remove a horn from the eyelid. The excrescence being pulled forwards, the separation should be made through the integuments, that the cyst from which it grows may be entirely taken away, or a return of the disease is risked. Sutures should be used, if from the nature of the wound primary union might ensue. Otherwise, water dressing is necessary.

An excess of epidermis often occurs when there is slight inflammation of the papillæ with growth, and forms little bent or twisted horns.

Acne. This may be as well-marked on the eyelid as on the face. When it is severe, it is accompanied by much redness and œdema

of the integument because of the thinness and looseness of the textures. The conjunctiva may participate in the inflammation.

The affection is produced by the detention of sebaceous matter in the follicle, by which irritation is set up. Congestion and inflammation follow. This at least is the mechanical explanation. There must be originally something wrong in the system generally, and in the cutaneous system especially. It is not necessary here to speak particularly of the many stages of acne, the punctiform, the pustular, the tubercular, and the indurated; it is enough to show that it is an inflammatory disease of the follicles of a chronic nature, occurring for the most part in youth, and that it is mainly attributable to debility.

The treatment is to be found in good air, exercise, food, and judicious feeding, the removal of depressing agency, and the resuscitating of the flagging energies of the vital power. The medicines most suitable are sometimes mineral acids, sometimes chalybeates. Where the nutritive force is at fault rather than the assimilative, arsenical preparations suit best.

For a local application, perhaps the best is the perchloride of mercury, one, two, or three grains to an ounce of water, or water and spirits of wine, or emulsion of bitter almonds. After the surface has been washed with soap and water and well dried, and rubbed with a towel, the lotion should be applied. This should be done twice or thrice a day.

Serous cyst. This well-known simple, or barren cyst, belonging

Fig. 44.

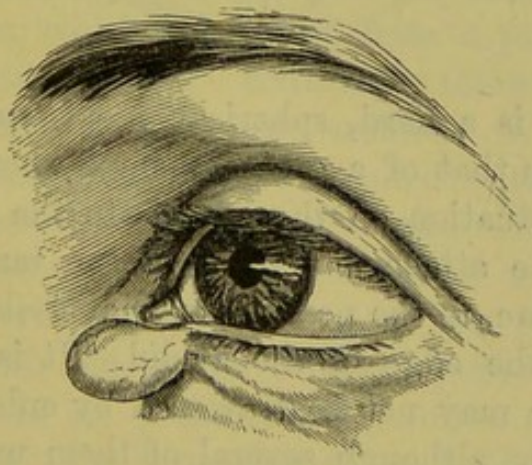

to the class Hygromata, frequently grows on the eyelid, and generally on the margin. It may be single, or several may be present. It may stand out from the surface well defined, although yet small, with very thin cyst walls, or be so much covered by the skin as scarcely to project. Its contents may be serous, or glairy, or honey-

like, clear or coloured. Figure 44 shows one of a peculiar form, that had existed for five years, and which was filled with clear serum. I have seen one at the outer corner of the eye overlapping the edges of the eyelids, and interfering with sight. The old gentleman, who had carried it for a quarter of a century, could never make up his mind to have it removed. It has its origin in the gland apparatus of the skin.

Treatment. Where the tumour is small, a free incision, by which the contents are evacuated, will suffice. A little suppuration ensues, and the cyst is destroyed; or it dries, and is exfoliated. The cyst wall, which is areolar tissue, with a few elastic fibres, is too thin and too much connected with the parts around to admit of being pulled away. Where it is large and projects, all of it that can be reached should be cut off. When the cyst is thick, the application of an escharotic may be required in addition to the incision.

Tumours produced by disease of the Meibomian apparatus.

Meibomian cyst. This is better known by the incorrect name of

Fig. 45.

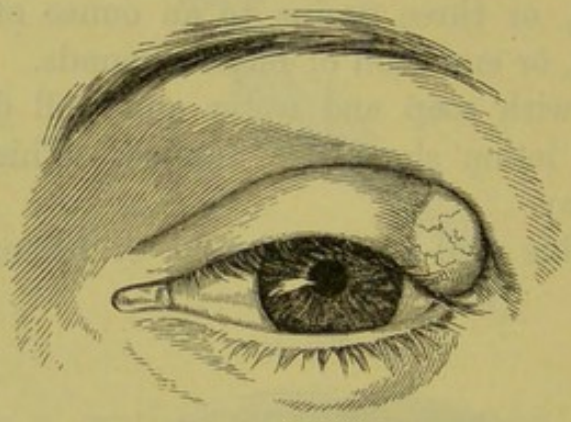

tarsal tumour. It is a hard, spherical, fixed, well-defined tumour, varying in size from that of a grain of small shot to that of a pea, and limited in a situation on the eyelids to the space between the cilia bulbs, and the attached margin of the tarsal cartilages. It corresponds, therefore, to the position of the Meibomian glands, and does not grow at the edge of the eyelid. It is inadherent to the skin, which may or may not be traversed by enlarged blood-vessels. It is usually solitary, although several of them may be present, and for the most part occurs on the upper eyelid; yet it acquires the largest dimensions on the under one, where the skin generally retains its natural state, and does not inflame. Not unfrequently the internal surface of the eyelid, just behind the cyst, is preternaturally vascular, and at a late period looks dark in the centre, from the thinning of the tarsal cartilage and the conjunctiva, the result of

pressure. Its position differs, therefore, from that of a stye, from which it is totally distinct, in being above the edge of the tarsus, and clear of the cilia. Figure 46 represents a cyst in the lower eyelid.

Fig. 46.

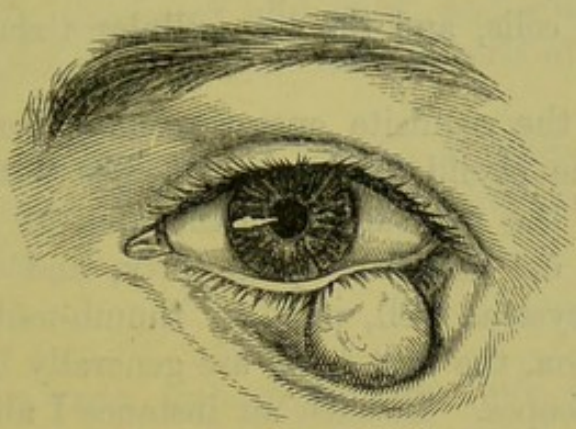

The cyst increases very slowly, and years may pass away before one acquires the size of the smaller of the two which are figured. The largest tumour of the kind on record is preserved as a specimen in the Museum of the Royal College of Surgeons. It is three quarters of an inch in diameter.

Debility of constitution seems to be a predisposing cause of the disease. Acne of the face frequently precedes it.

The morbid anatomy is clear. The tumour takes its origin in one of the æcini of a gland, in consequence of distension and blocking up by sebaceous matter. The glands, with their ducts, lie in the substance of the tarsal fibro-cartilage. I will give the result of the dissection of a very large cyst, which I removed from a patient with the view of making such an inspection. Externally there was a dense fibrous envelope connected with the tissue around. Within this, a cellular layer, soft, pink, abundantly supplied with vessels from the fibrous cyst, composed of fibro-plastic cells, with a little intercellular fibrillary matter. Within this again, a thin pellucid cyst containing a puriform liquid, made up of pus globules, epithelium cells loaded with oil, and in the centre a perfectly round pellet of sebaceous matter. In all probability the following was the order of development. First, the formation in a Meibomian follicle of a pellet of a hard sebaceous matter. Secondly, the secretion of epithelium and fluid matter around. Thirdly, the growth of fibro-plastic cells outside the obstructed gland follicle, distending the loculus of fibrous membrane into a cyst.

Pathological variations occur in the contents of the cyst, and in the cyst walls. On this point, supposing the immediate cause of the

tumour to be always one and the same, I venture to suggest that some of these characters depend on the changes effected in the fibro-plastic growth that is formed. For instance, with the onward development of this plastic growth, white or yellow fibrous tissue is produced, as in the tumour commonly called polypus, hence, the more solid tumour; but, if it degenerate, the cells are converted into pus, or pyoid cells, and the intercellular tissue into a creamy fluid.

Treatment. As the requisite operation may for the most part be done within the eyelid, it is advisable for it to be so effected. Where, therefore, the tumour is small, and its position is well marked within, I cut it across posteriorly, and squeeze out the contents, and the cyst as well, with my thumb-nails. Where there is fluid degeneration, the cyst walls are generally broken down, and merely the fluid escapes. In such an instance I abstain from unnecessary after-squeezing. Enough has been done at first. Success ensues.

The patient should be warned not to expect an immediate cure; for, from the swelling that ensues, it may seem that the tumour is as large as, or larger, than before. It is only after a few days that reduction is apparent, and generally not till after a few weeks that all trace of enlargement is lost.

A little fungus may spring from the wound as a very rare occurrence. If it be small, a touch of nitrate of silver will suffice to destroy it. If it be large, it should be snipped off.

When the tumour is large, and stands out well in relief in front, I divide it anteriorly, by transfixing it, and cut from within to without in a free manner, and squeeze it, as I have already described.

There need not be any fear respecting the formation of a scar, for if the incision be made horizontally, and the edges be brought together by a strip of plaster, no trace of the operation is left.

A Meibomian cyst is never too small to be treated; but if it be not enough developed to admit of such, after the manner described, it must be punctured in whichever position seems to be the most favourable, and the interior broken up with a sharp-pointed probe.

Meibomian duct tumour. An accumulation of the natural secretions may stop up a duct, and cause the appearance of a short white streak just within the edge of the eyelid. A further state of this, in which there is enlargement, constitutes a tumour. A hard concretion may form not unlike a calculus. In two instances when I thought I had taken away calculi, minute examination proved the dense particles to be made up of inspissated epithelium. Cal-

careous material may be deposited with the epithelium. A tumour of this kind, on the upper eyelid, caused absorption of the cartilage and ulceration of the conjunctiva, and then the friction produced pain, inflammation of the conjunctiva scleroticæ, and opacity of the upper part of the cornea. It was composed of concentric layers of hard earthy material. The microscope disclosed epithelium scales, closely agglutinated, thickened and hard, and containing granular earthy molecules, phosphate of lime with a trace of the carbonate of the same earth.

The treatment is to remove the deposit at once. All should be taken away. Some is apt to be left, being hidden by the bleeding which occurs quickly.

TUMOURS ARISING FROM DISEASE OF THE TRUE SKIN OR DERMA.

Stye, or hordeolum. This is a miniature boil or furunculus, which occurs upon the edge of the eyelid among the cilia, some of which it displaces. A cilium is always in the centre of it. The commencement is œdematous swelling of the palpebra. A little hard tumour of a deep red colour then appears, and soon gets excessively tender and painful, but slowly passes to maturity, and suppurates only imperfectly on the summit. Ultimately there forms a little slough or core of mortified cutaneous tissue, a portion of the substance of the derma. It diminishes tardily, and sometimes leaves chronic redness, which may last for several months. The amount of pus which is formed is always very insignificant, although the suppuration has for its object the separation and expulsion of the core.

A stye is commonly single, but two or more may exist on the same eyelid.

Authors are still disputing whether a stye begins in a hair follicle or in a Meibomian duct. It seems to me that the derma is the part affected; hence my classification. Both follicle and duct must be involved in the inflammatory action. Like all the family of the furunculi, it is a disease of debility, sometimes of nervous origin, sometimes of nutritive, but more frequently of assimilative, therefore it is common in strumous subjects or in any class of individuals whose health is broken down. With the predisposition of impaired health, it is very prone to appear if there be long-continued employment of the eyes by artificial light.

Treatment. Rest of the eyes, and, in the early stage, frequent applications of cold lotions to the exterior of the eyelid, to subdue heat and inflammation. Plucking out the cilia that are most

affected is advantageous. If the inflammation increase, and sloughing and suppuration are inevitable, fomentations and poultices are required. It is only when the stye has nearly arrived at its climax that an incision is useful. At this period, the slow separation of the little slough may thereby be facilitated. Now, too, stimulants, such as the Unguentum Hydrargyri Nitratis, diluted, seem serviceable. Constitutional treatment should be attended to, with the view of removing any existing error.

Tegumentary mole. This is a congenital tumour, often spoken of as nævus. It is merely enlargement of a portion of the skin, with an occasional irregular increase of some of its tissues without any decided pathological change. The hypertrophy may embrace all the cutaneous structures. There may be an increase in the quantity of the natural pigment, whereby the tumour is tawny yellow, or brown, or black. Sometimes hair, more or less coarse, grows from it or around it. It is not characterized by vascularity. About half a dozen patients with moles have applied to me, but I have not thought it necessary to adopt treatment. The circumstances which should induce interference would be disturbance to the eye in some way, by which its functions are interfered with, or decided evidence of increase in the tumour, with likelihood of the occurrence of such disturbance.

Warts. Under this denomination of skin affections occurring about the eyelids, are two very distinct growths, such as the pedunculate and the sessile tumours.

The pedunculate is a prominence of the skin produced by simple tegumentary growth, and which differs in no wise from the surrounding skin, except that it is pedunculated. It has the appearance of a small pendulous bag of integument. It is not congenital, but forms about the middle period of life, and may grow to the size of a small pea, or to that of a pigeon's egg, or even larger. The largest I have ever seen grew from the centre of the upper eyelid of a woman. It closed the eye, and hung down to the lower margin of the orbit. My patient would not allow me to remove it.

Treatment. Excision with a knife or a pair of scissors is the proper measure.

The sessile, a true cutaneous papillary growth, is the hard tumour resulting from hypertrophy of the papillæ of the skin, that is, increase of the dermal and epidermal structures. In a large one, the papillæ are separated, and each is covered with a distinct sheath of epidermis. The occasional filiform appearance of this wart is due to the hypertrophy of a few papillæ, or of one.

I have seen the entire surface of both eyelids of one eye occupied

by warts. There were few interspaces. Heister alludes to a wart that was big enough to restrict the motions of the upper eyelid. Dr. Jacob removed a tumour from the lower eyelid, supposing it to be of malignant growth, but which, after having been thoroughly cleansed, proved to be a gigantic wart. The surface was covered with a cream-coloured structure, made up of coarse fibres which stood out fully the eighth of an inch perpendicularly from the surface, and which he considered as a cuticular growth. The patient, who was eighty years of age, died after its removal, from erysipelas of the face.

Treatment. An escharotic will suffice to remove all small warts. Several applications of it may be necessary. Large warts should be shaved off, and then the escharotic used. It may be best sometimes to resort to the severe measure of removing the skin along with the wart.

TUMOURS SITUATED BENEATH THE SKIN OF THE EYELID.

Very few tumours of any kind occur in this position. *A fibro-plastic one* is recorded by a French surgeon, and quoted by Dr. Mackenzie. An enormous nodulated growth on the upper eyelid, of several years' standing, hung so low that the cilia were carried down to a level with the chin. It rose in relief above the prominence of the nose. It measured six inches in its vertical diameter, and five in its transverse. The upper part passed into the orbit and adhered to the eyeball, which was partially atrophied. It was removed, and a new eyelid was made at the same time. In two months the eyelid could be raised and depressed. Its dimensions nearly corresponded with that of the opposite lid. The tumour was imbedded in a fibrous envelope several lines in thickness. Little serous cysts were in its centre.

Painful subcutaneous tumour. This small fibrous or fibro-cellular tumour, which is nearly hard and elastic, and grows in the subcutaneous areolar and adipose tissue, is well known about the trunk and the extremities, but is very rarely met with in the eyelids. It seldom grows bigger than a pea, is not round, but oval or cylindriform, and is surrounded with a loose capsule. It grows very slowly, and may be painful from the beginning, or not till it has nearly reached its full growth. The pain is paroxysmal or periodic. It differs in no wise in its physical characters from an ordinary fibrous or fibro-cellular tumour. The skin over it is generally red. Why it should be painful is a mystery to us, for it is unlike a neuromatous tumour, which is a fibrous tumour imbedded in the sheath of a nerve;

and nerves have not been traced to it but occasionally, and then only after the manner in which a few nerve fibres are distributed to ordinary innocent tumours that are painless. Only a single instance has come under my notice. The tumour grew just under the hairy brow. Mr. Middlemore has met with several examples.

Treatment. Extirpation is the remedy.

TUMOURS OF THE CONJUNCTIVA.

Growths and excrescences of all kinds springing from the conjunctiva are decidedly rare, but they have been seen on all parts, especially the caruncle and the semilunar fold.

Polypus is the most common. It looks like a vascular prolongation of the conjunctiva with a long but delicate peduncle, sometimes so slight that it breaks during an examination. It is of a rose colour rather than red. The surface is irregular. It is, in fact, a fibro-cellular tumour, in which the gelatinous or serous element prevails, covered with epithelium. I removed one lately from a member of our profession. Its chief structural characteristic was its extreme vascularity. It sprang from the palpebral conjunctiva of the lower eyelid, and lay half within the lid, half above it, and protruded like a vascular fringe.

One has been described as large as a hazel-nut.

Sir W. Lawrence had seen several small polypi in the same person, growing from the palpebral conjunctiva and the sinus, or fornix.

Warts may grow from any portion of the palpebral conjunctiva, singly or in clusters. They generally produce inflammation of the conjunctiva, with muco-purulent discharge. Dr. Mackenzie removed a small one from the external surface of the lower eyelid. A crop then grew on the conjunctiva of the eyeball. They disappeared spontaneously, but left partial symblepharon of both upper and lower eyelid. In another case, he saw a wart growing by a narrow neck from the conjunctiva scleroticæ, not involving the sclerotica, and so large as to cover the eyeball. By pressing the tumour aside, the sound cornea was brought into view. These warts could not have had papillæ as their starting-points of growth. The palpebral conjunctiva contains papillæ. The sclerotic portion is devoid of them.

A youth of eighteen, a patient of mine, had two strange-looking tumours arising from the conjunctiva; the one, of a red colour, having a mulberry wart-like look, was on the inner surface of the upper eyelid, and overlapped and destroyed the punctum; the other,

also red, possessed more of a fungoid appearance, and overlapped and obscured a part of the cornea. It was sufficiently wide to appear connected with the caruncle, but the base was attached to the sinus,

Fig. 47.

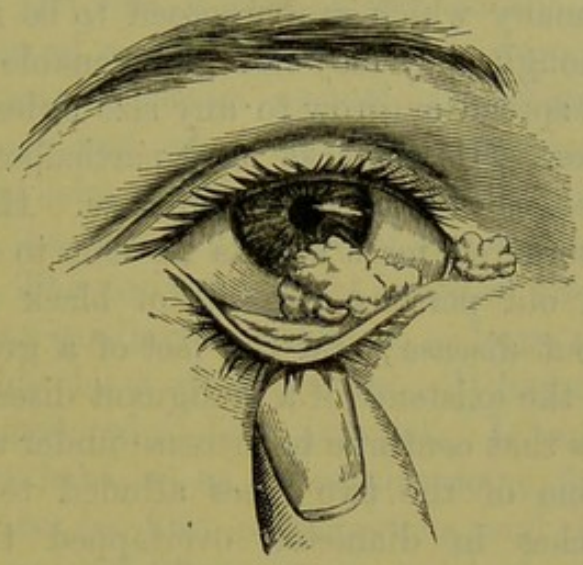

and received a remarkably large supply of blood-vessels from the sclerotica. Figure 47 shows the relations of both of them.

A slight purulent discharge from the conjunctiva was all the inconvenience that ensued. I removed both with the scissors. They proved to be warts.

A circumscribed black mass, about the size of an almond, growing lengthwise in the interior of the left lower eyelid, which it partially everted, was observed by myself in a man, aged sixty-four, in attendance at the C. L. O. Hospital. The attachment seemed slight; indeed, the peculiarly well-defined base induced the idea that the mass might be readily pulled away. The conjunctiva around and on the lower part of the eyeball was of a dirty brown colour. Vision was perfect. Two years prior, the disease was discovered as a little black pimple. There had been no pain, but merely inconvenience from the restriction to the movements of the eyelids.

I did not again see him for three years, when he reapplied at the Hospital. The growth had increased so as to cover the globe of the eye; while a piece, about the size of a nutmeg, protruded from between the eyelids, and was with some difficulty pulled aside to expose the cornea, which was hazy. I wished to admit him into the house, and then carefully to examine the eye while he was under the influence of chloroform; and he went home with the avowed intention of procuring some personal articles, but never returned. He left a wrong address, and I could not find him. The suspicion of melanosis crossed my mind; but the duration of the affection without

the surrounding glands being implicated, and the absence of pain, may be taken as some evidence against the likelihood of malignancy. The case bears upon the writings of Dr. Jacob, of Dublin, in the *Dublin Medical Press*, in which he urges surgeons to investigate more fully the nature of tumours of the eye and the orbit, it being his opinion that many which are supposed to be malignant are not so in reality, although they may not be amenable to medical treatment, and would spread or grow to any size unless removed by the knife or escharotics. His remarks have particular reference to what we are accustomed to call melanotic tumours. He argues that the blackness of a disordered mass affords no clue to its true character. He had seen, in old persons, deposits of black matter under the conjunctiva without disease; and the fact of a growth not healing, in no way proves the existence of a malignant disease, as he instances in sores and warts that continue to increase under any kind of topical treatment. In one of the two cases alluded to, a black spongy tumour, two inches in diameter, overlapped the eyelids in all directions, so as nearly to close the whole opening of the orbit. The surface was lobulated, and appeared to have been compressed by the bandage with which it had been covered, and bled slightly when the adherent dressing was removed. It appeared to be attached to the eyeball by a cylindrical stalk, which was slightly enclosed by the eyelids. Being prepared to remove the contents of the orbit, if necessary, Dr. Jacob drew his knife across the stalk, as a preliminary step of the operation, and found that he had incised a healthy eyeball, the disease being confined to the conjunctiva of the cornea, and of the sclerotica. It was, in fact, a tegumentary growth from the front of the eye. The divided eyeball healed kindly. Sufficient time had not elapsed to enable him to pronounce as to the true nature of the disease, whether it was to be considered malignant or not. Its black colour, spongy texture, and slightly lobulated appearance, did not convince him that it was a fungoid growth of a fatal nature; although it might have produced death by growing to a mass which could not be arrested or reduced by remedies.

This was probably a wart.

Treatment. Extirpation with a pair of scissors is the ready mode of dealing with small warts, care being taken that the incision is carried through sound conjunctiva. Large warts require to be carefully dissected off, and whether or not an escharotic should be employed in addition, must quite depend on the circumstances of the case.

It is well known that any kind of morbid growth, especially on a mucous membrane, that keeps up chronic irritation, may induce epithelial cancer. All tumours, therefore, about the conjunctiva,

should be removed early, and the risk of still more dreadful disease prevented.

Cartilaginous tumour of the conjunctiva. I removed a small one, apparently composed of true cartilage, developed in the conjunctiva, close to the caruncle. Sir W. Lawrence met with several cartilaginous bodies, about the size of pins' heads, in the substance of the sclerotica conjunctiva of a young lady. They were imbedded in the membrane, which was otherwise normal, projecting on the surface sufficiently to be seen and felt. As uneasiness was experienced in the eye, which the lady referred to this peculiar condition of the mucous membrane, he removed a few of the bodies, using a small hook and scissors. The patient was not heard of after.

He also describes a cartilaginous tumour, as large as a pea, attached to the upper palpebra by a slender stalk. It had a smooth mucous surface, and was considered to be a polypus. In snipping it off he found the peduncle hard, so as to require some force for its separation. It proved to be fibro-cartilaginous and thoroughly hard internally. It had existed fifteen years, and had caused trichiasis of one quarter of the eyelid. No doubt the same diversity of structure that is met with in tumours of this class, in the body generally, exists in those that occur on the eye.

The treatment is to remove the tumour along with the piece of conjunctiva from which it grows.

Fungus of the conjunctiva. Under this head, Dr. Mackenzie describes two distinct diseases.

In the first kind, of which he had met with an example, the fungus was of a deep red colour, and adhered chiefly to the conjunctiva covering the sclerotica. It was elevated in regular soft smooth masses.

It may arise from the inside of the eyelids, but never from the surface of the cornea. It may be pushed forward by the eyelids, so as to hide the cornea. It is unattended by pain. When exposed to the air it becomes encrusted, gets tender, and is apt to bleed when touched. Portions of it may slough away. The eyeball suffers from the pressure, inflames and bursts; or ulceration spreads from the fungus to the sclerotica, and so destroys the eye. The subjects of it are of a decidedly scrofulous habit. It has been described and delineated by Beer.

In the second kind, of which he had no personal knowledge, the conjunctiva is almost of a gelatinous consistence, and of a light yellow or brownish colour. It is met with chiefly on the inside of the eyelids, and especially of the upper one, and in the sinus. It sometimes attains a very considerable size, and although soft and destitute of blood-vessels, it is apt to prove destructive by the pres-

sure it exercises on the eyeball. The exuberant growth and loose textures of the fungous mass, distinguish it from epithelial cancer of the conjunctiva.

Treatment. Remove the fungus with knife or scissors. If necessary, cut through the eyelids at their temporal commissure, to allow the whole of the diseased conjunctiva to be exposed. Should the eyeball be damaged and vision lost, extirpate it at the same time.

Vascular excrescences may be thrown out by the membrane in consequence of irritation. They are red, soft, fissured, or granulated, sometimes pedunculated, and sometimes growing by a broad basis. They may acquire such size as to irritate the eyeball and the eyelids, or to overlap the cornea inconveniently.

The caruncle, and the semilunar fold, may become enlarged and form a tumour. I have been applied to by a patient to have both of these structures removed, in consequence of enlargement brought on by a long and severe attack of conjunctival inflammation. There was a diminution of the tumour, on leaving off the escharotics that had been injudiciously applied for its reduction, but there remained a hard growth about the size of a horse-bean. I lost sight of the man.

The caruncle may enlarge and form a tumour, from structural changes and proliferation due to chronic inflammation consequent on residence in the tropics. It may thus granulate, and throw out many growths. In a case met with by myself, it displaced the lower eyelid together with the punctum, and produced epiphora. The entire conjunctiva was much inflamed.

A tumour made up of areolar tissue, and occupying a part of the caruncle has been described by Graefe. It was removed with success.

Extirpation is the proper treatment in all such tumours. Merely acute swelling, from inflammatory enlargement of the parts, must not be mistaken for tumours strictly so called.

Tumours of uncertain nature. Very large tumours of the conjunctiva are described by numerous writers on ophthalmic surgery, of the nature of which there is no definite pathological account. In all probability some were of a malignant nature, but the sequel of others induces me to suppose that they were benign.

Pterygium. This generally grows as a flat triangularly-shaped tumour on the ocular conjunctiva, at the inner corner of the eye; the base being within, the apex without. At first it is always on the conjunctiva, as it has its origin there; later, it invades the cornea. It gets its name from the supposed likeness to an insect's wing. It is laboriously described by some authors, who treat of four varieties, the cellular, the vascular, the fatty, and the fleshy. But pathology

does not warrant such an arrangement, and description does not need it. At different periods of its growth, different appearances may exist: one that is thin may become thick, and a pale one may become red; and in like manner, several changes may occur. One-half of the growth may be transparent and delicate, while the other is like a piece of muscle.

Certain variations in form, position, number, and size, must be mentioned. The edges may be unequal and undefined. The base may be at the cornea, while the apex is within. Either end may be bifurcated. Two, three, or four may exist at once, in which case they do not crowd on each other, but lie in the direction of the recti muscles, their apices being generally towards the cornea. A single one may occupy the greater portion of the conjunctiva, in the region where it occurs, and at the same time almost envelope the cornea. Both eyes are generally symmetrically affected.

The following sketch of the disease, taken from a gentleman of colour, from the island of St. Kitts, exhibits a very marked specimen.

Fig. 48.

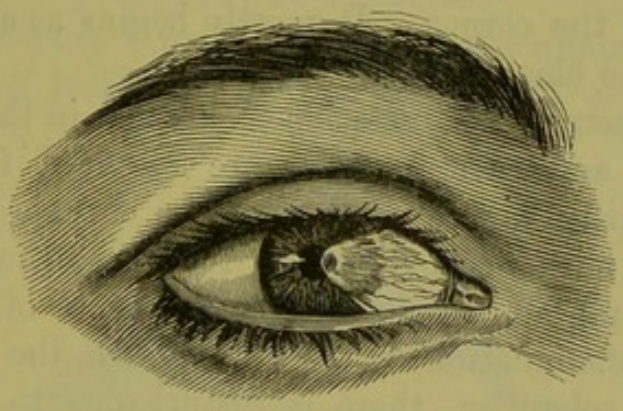

The position is the ordinary one, at the inner corner of the eye, with the base connected with the semilunar fold, from which it would seem to grow. The form also is that which is most usual.

Etiology. The conjunctival portion consists essentially of hypertrophied conjunctiva, and thickened sub-conjunctival tissue, with a growth of blood-vessels. I have seen a little fat in some old ones. The corneal portion is thick and tendinous, being made up of cellular tissue, blood-vessels, and thickened epithelium. It may be but loosely attached to the anterior elastic membrane, or incorporated with the true corneal tissue.

The origin of this adventitious production is chronic congestion, or chronic inflammation, of the conjunctiva. It is always preceded by increased vascularity of the spot of the conjunctiva in which

it appears. Tropical influence is almost invariably the excitant. Nearly every case I have seen has originated in a hot climate. But it is now and then exceptionally met with in temperate latitudes, where workmen are long exposed to much heat, glare, and dust. I have seen it in labourers at gas-works, and at lime-kilns, and in stokers. As marked an example as I ever saw was in a girl who received a small particle of quick-lime in her eye. It was a genuine pterygium, and not a symblepharon. The residue of a grain of exploded gunpowder, which had long been harmless, has at last caused one. It is ascribed, too, to corneal herpes. I have never seen such an origin.

It is usually after the adult period that pterygium appears; yet it has been seen immediately after birth by Mr. Wardrop, when, doubtless, it must have been congenital. It is seldom, in these latitudes at least, that we have an opportunity of observing its commencement and progress. Mr. Wardrop, in his work on the Eye, gives a drawing of one that he saw from a very early period, and watched for upwards of eight years. Its first appearance was that of a small globule near the junction of the cornea and the sclerotica; it then became larger, so that its base adhered to the semilunar fold, and its apex passed over the edge of the cornea. It mostly begins as a pale globule or vesicle, among the blood-vessels.

Prognosis. There is but little inconvenience in the earlier periods of the growth, and several years are required for any decided increase. The disturbances arise from the chronic inflammation of the conjunctiva, most marked in the region of the pterygium, the eclipse of the pupil, and the loss of the acuteness of vision. Where there is much inflammation of the conjunctiva, the sub-conjunctival tissue, and the sclerotica, there is disturbance to sight from the interior of the eye becoming congested. With a change of residence from a hot climate to a cold one, a pterygium may not increase.

Treatment. All local applications are worse than useless, because they irritate, and cause the pterygium to grow. Excision alone can be depended on. A mere division, by cutting across the growth, is insufficient. Indeed, scarifications may irritate, and so induce rapid augmentation.

When there is only a conjunctival pterygium, the whole should be removed. When there is a conjunctivo-corneal one, and the corneal bit is very small, it should be left while the conjunctival portion is excised, because it will shrink, and the cornea is saved all the risk of an operation. When the corneal portion is large enough to admit of being held with a pair of forceps, all that can be raised should be cut off.

The excision is best accomplished with a pair of scissors. The eyelids must be well retracted, and for a young operator, the eyeball had better be steadied with a pair of forceps. I dissect only the growth away, and take care not to remove any healthy conjunctiva. The semilunar fold should be left as intact as possible. If the pterygium be adherent to the sclerotica, it must be removed at the expense of denuding this coat of the eye.

Sutures may be used with advantage. I dissect up the conjunctiva slightly on each side, so as to transpose it a little, put in one or two stitches at the extreme margin, and bring the edges together. If the space left be too large to allow of accurate adaptation, but yet permit of a tolerable approximation, I still adopt the practice, and partially adapt the parts, as healing is thereby expedited. If the threads do not fall out in four or five days, in which case, in all probability, some of the sub-conjunctival tissue is included, I remove them. Of the use of sutures in wounds of the conjunctiva, I have spoken especially elsewhere.

Other operations are recommended by different surgeons, but as they are for the most part ineffectual, and sometimes make the pterygium grow, they need not be described.

Fig. 49 is a sketch I took from a naval captain, who had been long in the West Indies. The pterygium had existed for several

Fig. 49.

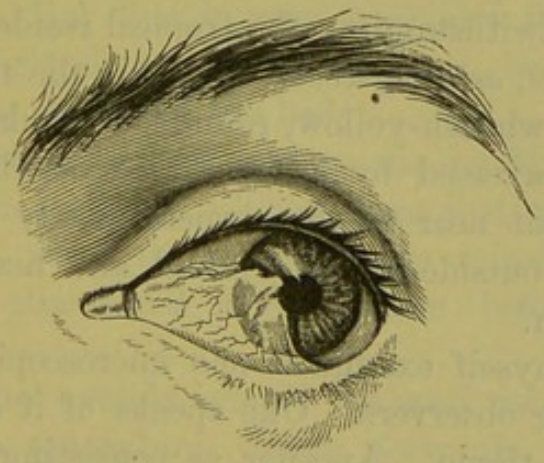

years, and was gradually increasing. It was very irregular in outline. The corneal portion was remarkably thin. I dissected off nearly the whole of that which grew on the conjunctiva.

There always remains opacity of the cornea, to the extent to which the pterygium had occupied it

A naval officer, æt. twenty-seven, consulted me with double internal pterygia. That on the left eye had just reached the cornea. The

conjunctivæ, palpebral and ocular, were much injected. There was constant discomfort in the eyes, and prolonged use of them gave pain. Distant objects were not seen so well as formerly. I operated on both. My patient has just returned, after two years' absence. The right eye bears no trace of the disease. On the left, a mark on the cornea is all that is to be seen. The conjunctivæ are natural. There is no inconvenience in using the eyes, and distant vision is restored.

In old, large, and adherent pterygia, when the sclerotica is necessarily much bared in their removal, the natural appearance is not regained. The part is always a little red.

As marked instances of pterygia as ever I met with occurred in a mulatto, Mrs. Seacole, of Crimean notoriety. This heroine was brought to me, about ten years ago, by Mr. Ambler, formerly one of my pupils at St. Mary's Hospital. There was a large pterygium on the inner corner of one eye that had passed over the cornea and travelled to the margin of the pupil; it was very much raised from the surface, and as red as a piece of muscular fibre, from the numerous vessels which traversed it. There was a pterygium on the other eye, similar in kind, but not so advanced. I operated on the larger one. Mrs. Seacole has been travelling about since then, and has been a long time in the tropics. She has just come to me with the second pterygium as much developed as the former. I have operated on this also. It is satisfactory to find that the first operation has been quite successful, and that there has been no further growth, notwithstanding the tropical residence.

Pterygium Pingue, or Pinguecula. This is the term applied to an opaque, moveable, whitish-yellow, roundish, lobulated little tumour, surrounded and traversed by a few blood-vessels, that is situated on the sclerotic coat near to the cornea, mostly on the inside, but sometimes on the outside of the eyeball, and nearly always at the horizontal meridian.

I have never myself examined one microscopically. There is a discrepancy among observers. One speaks of it as made up of ill-developed cellular tissue. Another as consisting of pavement epithelium of the conjunctiva exclusively, rather hypertrophied, and destitute of vessels. A third dwells on its vascularity. Like pterygium, it is very common in tropical countries, yet it is not very uncommon in temperate latitudes. I meet with examples of it yearly, yet I know of but one instance in which it encroached on the cornea, and then it passed merely to the margin. It grows to the size of No. 4 shot, and remains stationary. So inoffensive and

the persons possessing it, than for the surgeon, to decide about its removal. There is involved merely the question of taking away a little blemish or deformity. When it grows large, as it may according to some writers, although I have never seen a big one, an operation is demanded.

The operation is simple enough. The tumour and the conjunctiva are to be seized with the tenaculum forceps, drawn forwards, and cut off with the curved scissors.

Hair has been met with on the caruncle, and on the conjunctiva.

SUB-CONJUNCTIVAL TUMOURS.

All sub-conjunctival growths are classed by some surgeons as orbital.

Dacryops, is a simple or barren cystic tumour, associated with the lacrymal gland. It consists of a little bluish-white, semi-transparent bag, just under the reflection of the conjunctiva. It may be discovered when small by the irritation which it produces; or it may not be noticed until large, when it causes projection of the eyelid. It does not seem to grow larger than a pigeon's egg.

The origin, in general, is no doubt dilatation, with more or less obstruction of a duct of the lacrymal gland. The proofs consist in increase of the tumour while crying, and pressure producing the escape of some of its contents on the conjunctiva, through a gland duct. This is after the manner of growth of cystic tumour of the mammary gland. But that it may arise also from enlargement of the acini of the gland, cannot be doubted, because of analogous formations in other glands of the body.

A gentleman, æt. sixty, was sent to me by Mr. William Coulson, with a dacryops in each eye. They were just apparent externally, and very marked when the eyelids were raised with the fingers. They had been discovered a few years before, and grew but slowly.

Treatment. The eyelids should be well retracted, the tumour transfixed with a tenaculum, drawn forwards, and cut off. The whole should be removed if possible. To operate from without, is to run the risk of damaging the lacrymal gland, as well as the formation of a fistula.

Small cystic semi-transparent tumours, which are described as forming between the conjunctiva and the eyeball, are doubtless cysticerci.

Fatty tumours, which lie in the front of the eye, and bulge the

Solid sub-conjunctival tumour. It has fallen to the lot of few men to meet with any disease of this class. Graefe observed a tumour within the edge of the orbit. He everted the upper eyelid, and there sprang forward from the palpebral sinus a circumscribed tumour of an oval form, as large as half a hazel nut, and covered with conjunctiva. He drew it forward and excised it. Externally, it was composed of very dense cellular tissue, and internally, of a nucleus of true bone, somewhat resembling in shape an incisor tooth.

TUMOURS OF THE SCLEROTICA.

Dermoid tumour. This is a small, yellowish-white congenital growth. It generally has its origin close to the cornea, and afterwards invades it. It is covered by the conjunctiva, the epithelium of which is very thick. Fig. 50 shows two of them in the same eye,

Fig. 50.

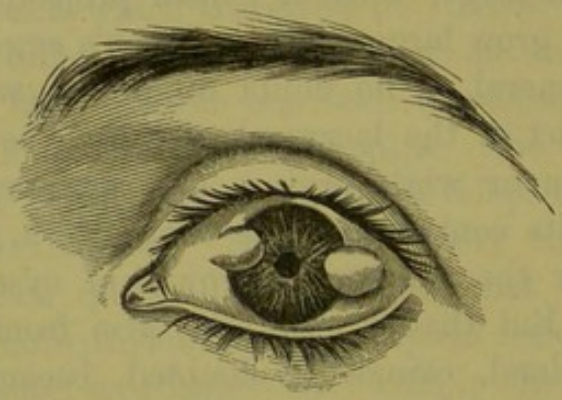

an unusual occurrence. In this instance, the cornea was not reached till puberty. The patient was thirty when I took the sketch. Small hairs may grow on it.

The tissues that have been found under dissection in different specimens, and at various stages of growth, are cellular and elastic tissue, fat, blood-vessels, nerve fibre, hair follicles, sebaceous glands, and sweat glands.

Its tendency is to increase, but yet slowly. In a case on record there was one on each eye at birth. At fifteen, they encroached on the cornea, and one of them had passed beyond the margin of the pupil.

I have met with a variety. A man, æt. thirty, came to me with a circular one in each eye. The entire corneæ were surrounded, and both pupils were partially covered, the one so much that vision was

conjunctivæ. The tumours had gradually increased since boyhood. I could not learn how they commenced. My proposal to operate was declined.

Treatment. The sooner the tumour is removed the better. The operation is readily effected by shaving off all that projects, to a level with the surface of the eyeball. No bad consequences have ever followed any of my operations conducted in such a manner. A careless operator managed on one occasion to cut through the sclerotica. A large amount of the vitreous humour escaped, and the eye was lost.

A semi-transparent firm oval swelling about the size of a pea, on the sclerotica, close to the margin of the cornea, of some years' duration, is mentioned by Sir W. Lawrence. Evacuation of the contents had been tried, but without effect. Then the cyst was punctured, and the prominent part cut away with curved scissors. The excised bit was thin but tough, the sides being firm enough to retain the figure of the tumour. The interior of that which was left was smooth, and a round aperture was observed in the middle, apparently passing through the sclerotica. The wound quickly healed.

A cyst on the sclerotica, as large as an almond, producing irritation when the eye was moved, is described by the same author. An operation was performed as in the last case. The patient was not seen again.

Scrofulous tubercles, growing from the sclerotica, and elevating the conjunctiva, have been described. They are whitish or yellowish, appear as if about to suppurate, but continue firm, increase slowly to perhaps the size of a hazel-nut, and burst, but do not suppurate. If left to themselves they are apt to induce disorganization and atrophy of the eyeball. If extirpation be undertaken, the diseased mass is found to be soft and easily torn.

TUMOURS OF THE CORNEA.

A small dermoid tumour, in all respects like that which I have described as growing from the sclerotica, and sometimes occupying as well a part of the cornea, may be entirely seated on the cornea. It is always supplied with blood-vessels. Hairs may grow from it.

Warty tumours grow on the cornea. Two tumours of this class, covering the front of the eyeball, were beautifully delineated by the late Mr. Wardrop, in two plates, in his work on the Eye. One is called tumour of the corneal conjunctiva; and here the growth

it, no regular form, and a fine granulated texture. The other consists of a warty excrescence, occupying two-thirds of the cornea, with an uneven surface of a peculiar dark brown colour. Other instances are recorded by authors, in one of which the tumour involved the whole cornea, and had attained the size of a hen's egg. In the Museum of the Royal College of Surgeons, is the anterior half of an eye from Sir A. Cooper's collection, with a large and broad wart-like growth covering the superficies of the cornea and a small portion of the sclerotica around, and standing out in relief for about half an inch.

Fleshy, fatty, and albuminous tumours, are described. Nothing of their real nature can be gathered from the vague accounts given of them. Some have grown to a great size. Bouttatz's celebrated case, mentioned by Abernethy in his "Surgical Observations on Tumours," was seven inches long and three and a half in circumference, and weighed two pounds and a half.

Growths which were originally corneal may spread to the sclerotica, and become identified with it.

Treatment. A strong reason for the early removal of all tumours, is to be found in the slighter attachment of a recent growth. At first, in the true surface tumours, the epithelium, and the anterior elastic lamina of the cornea, are alone involved. In time, the proper corneal tissue is reached. The testimony of British and Continental surgeons establish the fact that it is possible for the cornea to regain its transparency after the removal of a growth. But it may be relied on that this can occur only where the tumour is small, and the corneal laminæ have not been interfered with.

To remove by dissection, with knife or scissors, the whole of the tumour, is the rule. Where the connection with the cornea is such as to render this impracticable without cutting through it, and there yet remains unspoiled a portion that can transmit light to the retina, a part of the growth must be excised, all that is superficial. If this should not suffice to arrest the disease, an escharotic must be resorted to. When vision is lost in consequence of the pupil being covered, complete extirpation must be made, that is, the cornea must be cut off, the operation for abscission being adopted. When the tumour has reached to the sclerotica as well, in which case the growth will possess much activity, extirpation of the eyeball, within the ocular tunic, is the proper course.

A few words of caution about the use of escharotics may be acceptable. Caustic potash, and the mineral acids, are unsafe agents about the eyeball, for unless great care be exercised, they are apt to run

the potash applied to a little tumour of the sclerotica near the margin of the cornea, and although as a precaution, the cornea was oiled, yet the caustic spread to it, and produced opacity. Again, strong escharotics may produce a deeper slough than is required; and however unimportant going a little beyond bounds might be in other parts of the body, here precision must be secured. The potassa cum calce, is more manageable and safer, and should be used in preference. But the milder caustics, such as nitrate of silver, sulphate of copper, and dilute acids, should be tried first, and always, when practicable, with the precaution of covering the transparent part of the cornea with such substances, in themselves harmless, as have the power of protecting it, or of neutralizing the agent, should it pass beyond bounds. During this process the eyelids should be held open, and before they are set free, any superfluous portion of the escharotic must be wiped off. It is well to grease the surfaces that have been cauterized, lest they affect the parts with which they naturally come into contact.

Warty growths on each cornea existed in a chimney-sweeper, aged thirty. In the right eye the pupil was entirely obscured, and the greater part of the cornea was covered. I left this eye alone. In the left, the lower portion of the cornea only was involved, and but half of the pupil eclipsed. I scraped off the excrescences completely. There was a little bleeding. As they were reproduced, I repeated the process three times in two years. The effect in completely stopping the spreading of the warts was beyond doubt. Scrotal cancer now appeared, and the poor sufferer soon died from hæmorrhage consequent on cancerous ulceration in the groin.

Another instance of warty opacity of the cornea relieved by operation, is published by Mr. Bowman. The growth is spoken of as an old standing prominent opacity of the right cornea, with a rough surface like that of a soft corn, and having the iris adherent to it. It fretted the eyelids, and kept up inflammation, was of four years' standing, and had followed a severe ophthalmia. Astringents were of no avail. It was sliced off to the level of the cornea. The excised bit contained a great abundance of papillæ, covered with thick epithelium. The report concludes with saying that the part is much flatter and the sight has improved.

TUMOURS WITHOUT THE ORBIT.

The circumference of the orbit is a frequent site of tumours. There is seldom here any difficulty in diagnosis.

cutaneous proliferous, because there grows on its internal surface a structure with the productive properties of the skin, by which certain cutaneous secretions are produced, such as epithelium and sebaceous matter. It is not necessarily connected with the skin. Indeed, it is subcutaneous, it is rarely seen in man, except in this situation. It is generally seated at the upper margin of the orbit, and constitutes the common tumour of this region. It is soft, and not attached to the integument. The cyst is usually thin, and often contains hair, either loose, imperfectly formed, and mixed with the fatty contents, or growing from the cyst-wall, with bulbs of nearly natural size. Lebert has detected in it the minute structures of skin. But it may be dense and even semi-cartilaginous; hence it is then that the tumour, from its hardness, might be mistaken for a fibrous one. But the contents vary very much. They may be

Fig. 51.

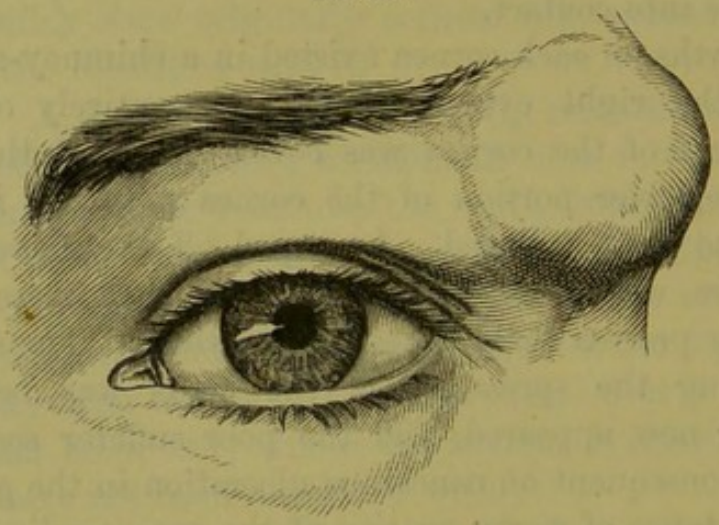

chiefly epithelium scales with cholesterine, &c. The accompanying sketch conveys a good idea of the form and usual position of the tumour. The locality, however, may vary; some of these tumours are at the internal angle, some just within the orbital ridge, some quite under it. All are congenital, and beneath the orbicular muscle, and are partially adherent to the periosteum.

On one occasion, when removing what seemed to be the ordinary sebaceous tumour, I discovered that the cyst contained, to all appearance, pure oil.

Treatment. Extirpation. If an attempt be made to remove the cyst entire, the edge of the knife must be kept rather away from the surface after the superficial dissection has been completed, which is contrary to the general rule for the extirpation of solid tumours, or in all probability the cyst will be cut into. This is very likely to

happen even in the first incision except to a practised hand, if the integuments be not pinched up and divided from within outwards.

I never undertake to dissect out such a tumour unbroken, for it is most difficult to effect, unless a very large preliminary incision be made; even then the tumour is frequently cut into at the base. Instead, therefore, I tighten the integuments, transfix the tumour to the bottom, cut outwards, then squeeze out the contents, and afterwards dissect away the cyst with the tenaculum forceps and scalpel. The integuments should be brought together by sutures. It is distressing to see the wound stuffed with lint or charpie, a practice of some surgeons. The operation performed in the way described is more certainly and expeditiously executed. More than this, primary union is almost certain, and should it not occur, the smallest possible scar only is left. I have seen very tedious suppuration after prolonged dissections in the ordinary way.

If a portion of the cyst be left, and is not destroyed by suppuration or ulceration, it will not heal over, and a fistula ensues; or there will be a reproduction of the tumour, this last depending on the amount of the cyst that remains.

I operated on the largest specimen of this disease that I have seen. It was situated partly over the eye, and partly on the temple, and of eighteen years' growth. A few years before, there had been an ineffectual attempt at its removal, the reproduction soon following the operation. I proceeded as I have advised, cutting through it from within outwards. The incision passed through the old cicatrix. Without any difficulty I then removed the cyst, which was as usual in contact with the periosteum. The temporal artery passed over the tumour and was of course divided. Some ligatures were applied.

The bone is often indented. I removed a cyst from a boy, æt. nine, brought to me by Dr. Randall. After the contents, which were so thin as almost to escape observation, had been removed, the cyst came away with the gentlest application of the forceps, The bone was indented so deeply that it readily received the tip of the little finger, and it was quite bare, so that the cyst had been in contact with it and acted as periosteum.

I have not met with a single bad result from the extirpation of a cystic tumour external to the orbit, although I have removed over sixty. In one instance erysipelas ensued, but the patient soon got well. I find that Mr. Tyrrell mentions two cases, and alludes to others, where exfoliation of bone followed.

Fatty tumour. This is uncommon here. I will give one example.

Anne B., aged twenty-five, applied at St. Mary's Hospital on

account of a tumour about the size of a walnut, which overlay the upper border of the right orbit, elevating the eyebrow, and depressing the eyelid. It extended a little into the orbit, and very slightly protruded the eyeball. It had firm attachments; felt dense and solid. The skin covering it could be pinched up, excepting in some parts, where, in the lines of cicatrices of former treatment, it was adherent. There were several large tortuous veins over it. The disease had existed from birth, but had increased very slowly. Till she was about the age of fourteen it was in the forehead, and then seemed to drop. This is not altogether an imaginary thing, for there can be no doubt that fatty tumours may shift their positions. It was quite painless, and annoyed her only by the deformity. Pressure seemed a little to reduce its volume. When the jugulars were compressed, it appeared to swell. She said that, when she was excited, it generally filled out more than usual. She had been under the care of a surgeon a few months ago, who told her it was a nævus, and treated it with setons. I made a free incision over the long axis, and soon found that the doubtful tumour consisted of an encapsuled mass of very dense fat. That part which lay over the frontal bone had contracted very firm adhesions, and required to be dissected away; but the lobule which extended into the orbit was not adherent, and came out by mere traction. Very active hæmorrhage took place, and several vessels required ligature. Recovery was rapid. I saw my patient three years afterwards; she was well, and happy in having been operated on.

The obscurity in the diagnosis arose from the cellular tissue in the tumour prevailing over the fatty.

Tuberculous matter deposited around the circumference of the orbit, and constituting a tumour. A pale and most miserable-looking child, eight months old, was brought to the Central London Ophthalmic Hospital, with a hard swelling of the eyelids, something resembling that attendant upon infantile purulent ophthalmia, but having a wider circumference. The scalp, the trunk, and the limbs displayed several swellings of similar physical characters. The lobes of the ears were enlarged, and very hard. The testicles were four or five times their natural size, and of stony hardness; and the foreskin was about as large as a pigeon's egg. A few weeks later the orbital tumours increased and became livid, at which period the following sketch was taken.

There was an increase of all the deposits. The eyes were closed so tightly by the distended palpebræ, that a sight of the eyeballs could not be obtained. The head and face being swollen to more than twice their natural size, there was the most hideous deformity.

The entire frame was distressingly misshapen. The child died seven weeks after I saw him. The swellings were all formed by infiltrations of tuberculous matter. The heart was exhibited by myself at the Pathological Society of London, as a rare specimen of tuberculous deposit in that organ. Except the lungs, which were healthy, every

FIG. 52.



other internal organ gave manifestation of this remarkable example of malnutrition. The child was perfectly healthy until five months old, when the eyes began to be affected, and then the disease appeared in other parts of the body.

Symmetrical tumours of doubtful character. I was requested by Mr. Francis A. Bulley, of Reading, to meet him in consultation on a patient who seemed in danger of having his eyes closed by a series of small tumours around the edge of each orbit, to consider the propriety of a surgical operation for his relief. The palpebræ of each eye, but particularly of the left, were so pushed together, and the eyeball so covered, that vision was interfered with. The tumours were irregular in form, very moveable, of a stony hardness, varying in size; the largest was about the size of a marble, and appeared to arise just within the edge of the orbit. The symmetry of the disease was very striking. The orbital affection, however, was but a local manifestation of a disease existing in many parts of the body,

including the absorbent glands. I did not operate. The man died soon after. A full history of the case, as supplied by Mr. Bulley, is in the last edition of this work.

Special directions about the removal of solid tumours about the orbit are not necessary. I will only say that when the tumour is small and cannot be readily got at, I often bring it nearer to the surface, and secure it by pushing a strong steel pin under it. The process is simple. I introduce the pin vertically, carry it under the tumour, turn it up sharply, and bring the point to the surface. But the plan may be applicable to any free tumour.

INTRA-ORBITAL TUMOURS.

Remarks respecting the position of these tumours, their diagnosis, and their physical effects.

A tumour may lie in one of many positions around the eyeball. It may be within the ocular tunic, at the apex, or any part within the circumference of the orbit. It may be merely attached to the areolar tissue, or adherent to the periosteum, or to any of the orbital textures, or to most of them. It may lie partly within the orbit, and partly without, passing out through the one or the other of the orbital foramina. One has been found within the very substance of the inferior rectus muscle, the muscular fibres expanding over the cyst.

Tumours are far more frequently seated between the muscles and the walls of the orbit, than between the eyeball and the muscles, or the optic nerve and the muscles.

According to M. Berand, when the tumour lies between the levator palpebræ muscle and the eyeball, it will, as it grows, thrust the muscle upwards, and leave the eyeball almost uncovered; and if the finger be placed on it, and the patient told to raise the eyelid, the effort which is made by the muscle to contract is felt. When, on the contrary, it lies between the muscle and the orbit, the eyelid can still be naturally lowered, and when it is raised, the finger feels no muscular contraction.

The mere projection of the palpebræ will not always suggest the exact locality of a tumour. An eyelid may be thrown forward in such a manner as to cause the supposition that the morbid growth is nearer to the orbit than to the globe of the eye, and very little covered by soft parts, while it is in actual contact with the eyeball, and deeply situated.

It may be remarked incidentally, that orbital tumours are to be distinguished from inflammatory swellings and exudations, by the absence of any acute symptoms, and by duration.

A knowledge of the nature of a tumour, whether it be cystic or solid, malignant or benign, is the key to prognosis and to treatment. On it rests the question of operating or not.

The differential points of diagnosis are to be learned chiefly by touch. Only the surgically educated finger can avail much.

A tumour may be marked by œdema of the conjunctiva and of the eyelids, yet if a bit of it can be fairly touched, its form, size, and character, can generally be told.

A cystic tumour mostly gives the sense of fluctuation, and seems capable of being temporarily pushed back. The thicker the cyst, the less is fluctuation apparent, and the harder will the mass seem. The cystic are the most common, and the largest, and grow the fastest.

A solid tumour has a feeling of elasticity, except the bony, which may always be recognised by its hardness.

Between hard and soft cancer, and tumours not of this nature, there is not in reality any absolute line of demarcation. All tumours are constitutional, and most are liable to return after removal; but for our object sufficient distinction exists.

Innocent tumours do not adhere to the skin; they progress slowly; have an uncertain period of increase, and may remain stationary for an indefinite time; are definite in outline and moveable, or at least are not firmly fixed as though incorporated with the bone; are unattended with surface vascularity; are painless.

Malignant tumours possess opposite characters: pain is a great characteristic, and they may be painful from the first. Pain and fixedness, and rapid growth, should be regarded with the greatest suspicion as evidence of the presence of the horrible and destructive disease. It may be added, that in a late stage they may feel dense part, and soft in another. Nothing can be gathered diagnostic of malignancy, from the state of the patient's health in the early stage of the disease, although later, the malignant cachexia may be well marked. For more directions on these points, the reader is referred to the chapter on "Malignant Affections."

The so-called semi-malignant, or intermediate class of tumours, spoken of often as cancroid, those which in their structures are identical with normal tissues, or very closely resemble them, but recur after extirpation, and involve contiguous parts and the system in general, such as the malignant fibrous, the fibro-plastic or the recurrent fibroid, have not, while growing as primitive tumours, any marks by which they can be distinguished from solid innocent tumours. The enchondroma or cartilaginous tumour belongs to this class. But I am unaware of any example having been met

with about the orbit, unless we receive in confirmation of such, a statement of the late Mr. Travers, that he removed a tumour of the hardness of cartilage and of great extent from the outer side of the orbit, by scraping it away from the bone. The patient was lost sight of.

The effects of intra-orbital tumours are serious. The following account includes the worst of them.

Ocular protrusion. All tumours have a tendency to come forwards, that is to the surface, and in their transit to protrude the eyeball, generally to turn it aside as well, and to bulge the eyelids. Eversion of the tarsal borders occasionally happens. The eyeball may be pushed quite out of the orbit. In proportion to the protrusion are the ocular movements generally restricted. When the tumour is above, ptosis is often produced.

The effect on the eyeball may be complete destruction by bursting; or when the protrusion is very great, a collapse from ulceration of the cornea and suppuration. I think that the latter is not due altogether to the mere protrusion, but also to local conditions that injuriously influence the nutrition. Atrophy may supervene without bursting, or suppuration.

The return of blood from the interior of the eye by the retinal veins may be retarded, and secondary mischief to the eye thereby occasioned.

Alteration in the orbital circulation. Any arrest to the return of blood from the orbit, through compression of the ophthalmic vein, causes tumefaction of the eyelids, and preternatural vascularity of the conjunctiva, with œdema of the orbital structures.

Disturbance of sight. Double vision may be the first recognised effect of an orbital tumour. This is due to the parallelism of the eyes being lost. The least deflection may cause it, yet it might be absent when the divergence is very marked; and why there should be that uncertainty I know not.

There is very often deterioration of vision from pressure on the eyeball, or pressure on the optic nerve, or elongation of it. There may also be changes in the focal range, and the eye seem to become myopic or presbyopic; but this is not the true nature of the change, as concave or convex glasses give no help.

The solid orbital walls may suffer in several ways, from the pressure of agrowing tumour. Periostitis may be set up, inducing abscess, and ultimately caries.

Expansion of the greater part, or the whole, of the orbital cavity may ensue, and to such a degree as to alter the form of the forehead, the nose, and the upper jaw.

One or more of the orbital walls may be absorbed.

The brain may be damaged from alterations in the upper orbital wall: death even may ensue.

Injury to the orbital tissues. The lacrymal gland may become atrophied from pressure.

The motor nerves may be injured, and the ocular muscles may be thereby paralyzed.

The fifth nerve may suffer from pressure.

Pain is not generally present, but it might be, and with extreme severity. It is nearly always of a neuralgic character, and is most felt in the eyebrow and the head, in the direction of the supra-orbital nerve.

Watering of the eye. Epiphora exists when the lower punctum is thrown out of place, from eversion of that portion of the eyelid on which it lies.

Progress. There is no regularity in the order of the appearance of the several effects or symptoms, nor in their development. Thus it is that the eye may be blinded before it is displaced, or sight may be perfect when the protrusion is very considerable, and pain which was excessive at first, may decline with the increase of the tumour. These seeming irregularities (pathology is never wrong) depend on the nature of the tumour, and its form and attachment. Some growths exist for years without any subjective local symptoms, which may ultimately come on most markedly.

In the chapter on "Protrusion of the Eyeball," there are mentioned some other points in connection with the symptoms of orbital tumours, which are better placed there, as they relate to obscure tumours, of which the position is doubtful.

General surgical observations. Tumours in the orbit capable of being eradicated, should be treated early, because it might be easy to remove one while it is small, but difficult or even impossible when it has grown large; to say nothing of the injurious influence from augmentation to the motor apparatus of the eye, as well as to the eyeball itself, and to the parts around. Spontaneous cure is never to be expected.

The sacrifice of the eyeball must not be regarded should its removal be requisite to ensure extirpation of a tumour, undertaken chiefly on account of cerebral symptoms arising from pressure on the brain.

It would be bad surgery to remove a comparatively insignificant tumour, one that may protrude the eyeball a little, but does not threaten any damage to the parts around, where injury to sight, or loss of sight, might be the consequence.

Much valuable time is frequently lost in attempts to disperse tumours by local applications and medicines; indeed, great faith in drugs is necessary to suppose that they can remove cystic, fatty, and osseous growths.

In the operations for extirpation, the size, figure, and position of the tumour to be removed, must determine the direction, the form, the number, and the extent of the incisions. Although no special rule can be laid down on this head, yet it may be stated generally that the preliminary cuts through the skin should be sufficiently extensive to facilitate the intended dissection; that the most direct route is generally the best; that the most prominent part of a tumour should be that first reached, over which therefore the centre of the dissection should fall; that when much room for operating is needed, and some part of the eyelid must be cut through, it is better to make the division at the external commissure, than vertically, through the tarsal cartilage, while the latter method is preferable to division at the internal commissure. Further, the eyelids should be left intact whenever a tumour can be removed by dissecting within them. It may also be observed that all external cuts should be made with reference to the least after-disfiguration; and this may be effected for the most part by horizontal incisions, a little curved, to correspond with the wrinkles about the eye. Such cuts have the advantage of being in the direction of the fibres of the orbicularis muscle, and not across them.

Healthy integument scarcely ever requires to be removed. A bit that adheres to the tumour should be excised. The loss of a piece of healthy skin is always a disadvantage, except in pendulous tumours.

A disagreeable sense of numbness and coldness, and partial insensibility to touch, affect the integument of the forehead and the side of the head, after the division of the supra-orbital and the supra-trochlear nerves. Such division should therefore be avoided if possible. A gentleman in whom this state existed could not at first feel a comb or a brush when used to the head. He nearly recovered the natural sensations at the end of a year.

The position of the levator palpebræ must be remembered, for an operation should not be commenced beneath it, for the removal of a tumour which lies above; nor the contrary, for ptosis will follow the division of the muscle. It is also advisable that the scalp should not be cut, on account of its great liability to erysipelas; but the superior palpebra may be so attenuated that an incision might risk its vitality; in which case it would certainly be much better that there be a division of the cranial integuments.

An extensive dissection about the upper eyelid, followed by sup-

puration, is apt to cause ptosis, which may remain or not, the cause being apparently infiltration and condensation of the skin and subjacent tissue, and perhaps, too, of the levator muscle, rather than loss of nerve-force. There seem to be two ways of avoiding this: to be scrupulously careful not to involve the eyelid in any operation, more than is absolutely necessary; and to use all means to secure primary adhesion. When the wound is large, and there is a tendency to oozing of blood, the surfaces should not be brought together until all bleeding has ceased, to insure which it may be better in some cases to wait some hours till they are glazed. No more sutures should be used than are actually required. Erysipelatous attacks should meet with prompt treatment. Surely all this inculcates the necessity for removing tumours while they are small.

Whenever it is possible to remove a tumour without cutting through the palpebral ligament, and so opening the cavity of the orbit, it should be done, because if the true orbital tissues be troubled, orbital cellulitis is risked.

The scalpel which is figured at page 4 is from its size and shape particularly adapted for operations about the orbit; and small as the blade is, I have found it safer, when dissecting deeply, to blunt the greater part, and to use the point alone, so as to pick and scratch rather than to cut.

A syringe may be very useful, for a jet of water, by washing away the blood and clots, will often expose parts when a sponge cannot well reach them.

Small, bent, metal spatulas are necessary to pull aside the eyeball, and also at times to protect it from injury, as well as to guard other parts.

A pair of tenaculum forceps, with points of the size and shape that are figured at page 4, together with curved scissors, complete the instruments necessary for the removal of any tumour about the eye.

Careful adaptation of divided parts, with the adoption of all the measures that are calculated to promote primary union, are among the chief essentials after operating.

Cystic orbital tumours. These may consist of the simple or barren, and the proliferous cysts, just as we have seen occur about the eyelids.

The serous cyst. Its origin here is not from a secreting gland, but by the enlargement and consolidation of a natural space in the areolar, or other tissue which secretes fluid; or by the independent development of nucleate cells which become exaggerated into a cyst, and even perhaps by other changes which need not be described. It is the commonest of all orbital tumours. It is

met with no larger than a pea, or as big as a turkey's egg. Its contents have been already described.

The proliferous cyst has been spoken of. The cutaneous form, which I have described as occurring at the circumference of the orbit, is frequently intra-orbital, and is the most common variety of that class met with here. It is the atheromatous and the steatomatous tumour of the old authors. Even a liquid like pure oil may be secreted. I have met with an example. Another on record is copied into the Catalogue of the Museum of the Royal College of Surgeons, from a manuscript volume of cases in Medicine and Surgery by Sir E. Home, originally collected by John Hunter. A young gentleman had a small tumour in the upper part of the orbit, at first no larger than a pea, but which increased and extended towards the nose, and pressed down the upper eyelid, keeping the eye half shut. It was unattended with pain. Reading by candle-light induced uneasiness of the eye, with throbbing. It was not firmly attached to the orbit, and evidently contained fluid. By puncture it poured forth pure oil perfectly clear and sweet, that burned with a very clear light, did not mix with water, and when exposed to cold became as solid as human fat.

It often contains large and complicated cysts, having many cells, holding dissimilar materials. It may be partly cystic and partly solid. Indeed, in the orbit there occur nearly all the proliferations that have been met with in this cyst in other parts of the body.

Cystic tumours are generally below the eyeball, and extend somewhat behind. Seldom do they originate on the temporal or nasal side. They accommodate themselves to the parts among which they grow. At first they adhere slightly, and get firmer connexion with age.

Treatment. A cystic tumour should be explored by a probe with care and delicacy, and in an efficient manner, through an opening made with a scalpel, or a trocar. By this procedure, the class to which it belongs can generally be ascertained, and certain mistakes are avoided. There is no external physical sign by which a cyst can be distinguished from a chronic abscess, and it is no very uncommon thing for it to suppurate in consequence of a blow, or even without any injury.

When exploration has proved the existence of a cyst the rule is to remove it. A small superficial one admits of ready removal. Without complete extirpation there must be always uncertainty as to the result. Under some conditions it may be better to leave a cyst after evacuating its contents. These conditions are, the nature and size of the cyst and its attachments. This half measure of operating might be quite effectual in causing the cyst to heal, especially if it

be a serous one, or to suppurate and be destroyed; or to discharge pus for a few weeks and then to be exfoliated. Of the three processes I have had several examples. When, then, I meet with a simple cyst which cannot be removed in consequence of its extent, I merely open it freely and wait for the result. When I find a large proliferous cyst with any internal growth, say a sero-cystic sarcoma, I dissect it away at any cost, because short of this no treatment can be depended on. When I find one of the same class to be "cutaneous" and of large dimensions, or of intricate attachments, I remove all of it that can be readily reached and see what happens. In such a case the dissection should be carried as far as possible before the partial amputation is made, because premature collapse might spoil the proceeding and mar the operation. I have known operations partly done, and abandoned in despair, when a little more patience and confidence on the part of the operator would have enabled him to complete them.

Whether in any instance the eyeball should be taken away with a morbid growth, must depend on the nature of the tumour, and other circumstances of the case. With all the advantages of superior appliances, and better knowledge of the anatomy of the ocular appendages, the relations of a tumour may render its detachment impossible, without some of the contents of the orbit being also taken away. The probability of so dire a contingency should, as far as possible, be considered before operating. But this applies more especially to solid tumours; since the nature of the case must be peculiar which would necessitate extirpation of the eye before trying the effect of the partial removal of the cyst, or other means for its destruction.

When the free incising, or partial excision systems fail, and the cyst continues to discharge for weeks or months, a cure must be attempted by injecting an astringent fluid, or by placing some solid material in the wound, as a piece of lint, to excite destructive or adhesive inflammation. I am quite familiar with this practice. I will give two of my cases.

A man applied to me with his eyeball thrust forwards and outwards. I detected a fluctuating tumour, opened it, and evacuated serum. After a short time the aperture healed, and the eye partially returned to its place. In a few months the symptoms returned with greater severity, and vision was nearly lost. The cyst was now opened by Mr. John Gay. Two months afterwards I was called to see the patient in consultation with Mr. Gay. The eyeball had receded but little, although the discharge, which was creamy, had lessened. The aperture was just above the upper eyelid, and near to the inner canthus. A probe could be passed to the apex of the orbit, and when bent with an elbow of half an inch, could be turned

completely round, which showed the extent of the cavity. I recommended an injection of sulphate of zinc, two grains to the ounce of water, to be used twice daily. In a week the discharge ceased. A month later the eye was very much less protruded, and vision was returning.

I treated successfully also in private a case like the above. The cyst passed to the apex of the orbit, and opened by a fine orifice, just under the eyebrow. There had been spontaneous evacuation of the contents several months before, and the thin purulent discharge had existed ever since. I enlarged the aperture, and directed a weak zinc injection to be used daily. Healing was soon effected.

Many drugs may be used for injecting with equal effect. Surgeons mostly give the preference to this or to that agent, according to the practice that they have seen. French surgeons nearly always employ iodine.

Should the process of injecting the cyst, or of stuffing it, fail, it might be necessary from threatening symptoms to resort to extirpation. Such a measure is but seldom called for as a last resource. The difficulty of dissecting out a collapsed cyst can only be appreciated by one who has done it.

Sero-cystic sarcoma within the orbit. My patient was a female aged forty-two. The figure shows correctly the form and proportion of the parts between the eyeball and the orbit. The

Fig. 53.

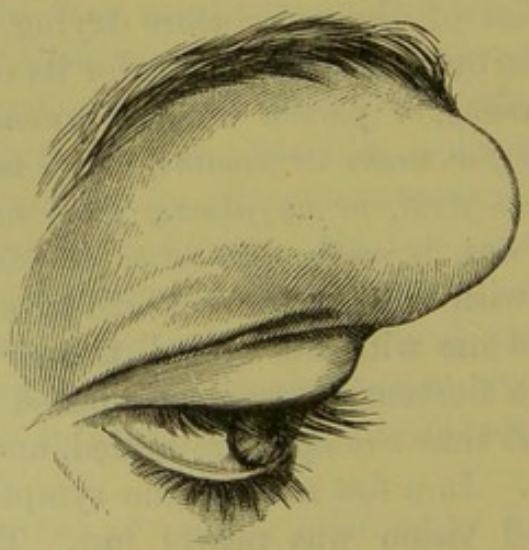

ocular movements were not interfered with till pressure thrust the eyeball downwards and outwards, when they were nearly altogether arrested. The tumour was hard and immovable, projected far beyond the eyebrow, which was raised, while its orbital limit passed out of the reach of the finger. There had been an unsuccessful

attempt at its removal ten years before, by a surgeon who was unaccustomed to operate, and the patient now sought relief only because the sight was nearly extinct, from pressure on the globe of the eye.

As there was no doubt about the nature of the case, extirpation was undertaken. I divided the skin crucially, and removed the mass entire. The orbital portion was flattened, reached to the centre of the orbit, and adhered to the periosteum. The bleeding was very free, and difficult to suppress.

Recovery was slow, the wound being six weeks in healing; but before that time the position of the eye was quite restored, and the impairment of the vision consequent on pressure was nearly removed. Three years after, I had the gratification of learning that the result, up to that period, was satisfactory.

Hydatids. The acephalocyst, and echinococci, have been fully described in the chapter on "Entozoa," but must be alluded to here. They are the sero-hydatid tumours of most authors. I have said that the presence of an hydatid has never been diagnosed in an early period of its existence; I must now add that, according to what I have seen and read, whenever the presence of one has been suspected, it has turned out that some other tumour was present. Still, whenever an operator opens a serous cyst, he must bear in mind that he may have before him an hydatid, and therefore it is wise to examine for such, not only at once, but on other occasions when he is dressing the wound or carrying out his plan of treatment.

Recognition may be accomplished by seeing the daughter cyst or cysts protrude, or come away; and by detecting echinococcus hooks in the fluid that escapes. In every case of serous tumour, the fluid should be examined by the microscope, with an object-glass of a quarter of an inch focal power. The hooks are very minute, and require to be carefully looked for. Again, the cyst wall is extraordinarily elastic, and does not collapse entirely. Nor when dead does it lie at the bottom of the fibrous envelope, but adheres to particular spots by a kind of plastic exudation.

I shall quote a few cases of cystic tumours which are of great surgical value. The first, as far as mere operating goes, is a splendid record of what may be accomplished in the small orbital cavity. The result was singularly fortunate. The practice is rather bolder than that which I advocate. The late Mr. Barnes, of Exeter, was the operator, and he has recorded the operation in full in the "Medico-Chirurgical Transactions." I shall give them much condensed.

A tumour occupied a considerable portion of the orbit, and pushed

the eyeball upwards, in a lad æt. seventeen. It extended far backwards, and projected beyond the orbit. A superficial groove, running obliquely across the projecting surface, formed a slight line of division between the more prominent and moveable part, and that more immediately under. This front portion could be moulded into different shapes by the fingers; the posterior was more elastic. It adhered firmly to the outer angle, and part of the lower edge of the orbit. It was painless, and the eyeball was sound.

The hidden or deep-orbital part of this very remarkable growth was revealed at the operation. It extended to the bottom of the orbit, and occupied more of the cavity than the eyeball itself. As it was impracticable to proceed far in the dissection, without greatly endangering the eyeball, the contents of the cyst were partially evacuated, to obtain room, and the sac was separated from its deeper attachments. Towards the posterior point on the inner side, and more than an inch from the edge of the orbit, the sac felt as if it embraced a sharp bony process, projecting outwards nearly in a perpendicular direction, and apparently attached to the periosteum. This proved to be a tooth, in form and size like one of the supernumerary teeth sometimes found in the palate. The crown was within the sac; the root, with its dental vessels, was attached to the orbit. There were two cysts. The front one had a chalky matter on some parts of it, and contained a compact lardaceous yellow substance; the other, which in the interior was smooth, excepting a part near the tooth, contained a whey-coloured fluid, and a yellow curdy substance. The patient did well; he could not move the eye downwards, or freely in any direction, but vision was perfect.

The two next are taken from Sir W. Lawrence's work.

Langenbeck removed from the orbit of a woman, forty years of age, a steatomatous tumour which was connected with the eyeball and its muscles. It was situated behind the lower eyelid, reached from the inner to the outer angle, and extended to the upper margin of the orbit. The eyeball was pushed upwards and inwards. It was natural in appearance. Vision was lost. The eyelids were separated at the external commissure, and the tumour was then dissected away by cutting through the conjunctiva. The eyeball gradually returned to its proper position, the deformity caused by its displacement was completely removed, and the patient was able to see the smallest objects before she left the hospital.

Another case of a much slighter nature in which Langenbeck operated, the patient during the next day showed symptoms of cerebral inflammation, and died quickly.

The removal of the right eyeball, and a large encysted tumour,

is recorded by Dr. Bushe in the *Lancet*. The child was seven years of age. A tumour at the upper part of the orbit pushed the eyeball downwards and forwards. It was supposed by some, from the situation of the swelling, its rapid growth, and the accompaniment of cerebral symptoms, that a fungus was growing from the anterior lobe of the brain. Dr. Bushe correctly argued that as the brain was not primarily damaged, the symptoms, the coma, the paralysis of the left side of the face, body, and of the upper extremity, the dilated and fixed pupil, arose from pressure of the tumour on the brain, and under this idea he proceeded to operate. He divided the commissures of the eyelids, and discovered in the dissection that the tumour and the eyeball were so connected that to remove the one the other must be sacrificed. He continues to say, "I therefore drew the contents of the orbit downwards and forwards, by inserting a curved needle armed with a strong ligature through the edge of the tumour, and globe of the eye; I now cautiously proceeded to detach the tumour at its posterior part; but before I had proceeded far I was not a little surprised to find that what I had anticipated was correct, viz., that the tumour pressed on the anterior lobe of the brain, the posterior and superior part of the roof of the orbit being absorbed; however, I cautiously pursued the separation of parts to the foramen opticum, and finally divided the optic nerve and recti muscles with a curved scissors. Slight hæmorrhage followed the operation, but was easily restrained by a portion of sponge." In ten days the wound had nearly healed, and the little patient was walking about without any inconvenience.

Cystic tumours may even pass beyond the orbit. Thus, in the *London Medical Gazette*, Dr. Hall has given an abstract of a case that occurred to Delpech, where a tumour passed through the optic foramen, into the cavity of the skull, and was imbedded in the left anterior lobe of the brain. The foramen was dilated sufficiently to admit the finger, the optic nerve having disappeared. Death ensued from the puncture of the cyst, which had formed a large projection between the eyelids.

In another instance that occurred to Delpech, a cyst which followed the ocular movements, and seemed to belong to the globe of the eye, had also intimate connections within the orbit.

Enough has been said incidentally to show that danger attaches to the treatment of orbital tumours by any surgical proceeding. Such should always be remembered, and when intense inflammation arises, it must be treated in a prompt manner.

Solid orbital tumours. These are not so common as the cystic. They consist chiefly of the fibrous, the fatty, and the bony classes.

Any part of the orbit may be occupied by a solid tumour, and the contents more or less involved by it. A large one has been found, completely encircling the optic nerve, and resting on the posterior surface of the eyeball. Such connexions were inseparable; and when, in the course of operating, this difficulty appeared, the eyeball was extirpated with the tumour.

Another, intimately connected with the orbital contents, is exhibited as a preparation in the Museum of St. Bartholomew's Hospital, and is much more marked and peculiar in its relations than any I have seen. It is firm, compact, and lobulated, and adheres to the back part and sides of the sclerotica. The optic nerve, which is elongated, passes through it. The recti muscles, quite unaltered, adhere to it externally. The humours of the eye escaped through an ulcerated opening in the cornea. The retina and the choroid are collapsed, and occupy the axis of the eye between the entrance of the optic nerve and the iris; and the space thus left between the choroid and the sclerotica, contains a clot of blood.

A fibrous tumour, preserved by the late Mr. Liston, and now the property of the Royal College of Surgeons, filled the orbit, surrounded the optic nerve and the eyeball, and extended forwards as far as the conjunctiva.

More examples are unnecessary.

The fibrous tumour is the rarest of orbital solid tumours. It is for the most part attached to the periosteum, of which it seems to be an expansion. It increases tardily, does not grow very large, is somewhat lobulated, and indolent as regards pain or tenderness, when touched.

The following case was under the care of Mr. Critchett. It is reported in the *Medical Times and Gazette* for 1852.

In the lower half of the right orbit was a large solid tumour which protruded the eyeball and turned it upwards and outwards. The upper eyelid was distended and tense, the lower was everted. There was very little pain.

The operation was executed in this manner. The conjunctiva was dissected off the tumour, parts of which were removed, till the mass was found to extend very deeply into the orbit. In consequence of considerable hæmorrhage, and the unmanageableness of the patient, the operation was abandoned.

A large slough came out of the orbit.

The tumour increased to nearly its former size, and was removed just a year after by the same surgeon. It had a fibrous capsule, was as big as a walnut, and consisted of white fibrous tissue with many elongated cells, numerous particles of bone, and a few very small

smooth-walled cysts. There were no ecchymosed spots, nor any tumour juice.

Acute suppuration of the cellular tissue of the orbit ensued. A month afterwards the parts had healed, the eye being a little sunken. Vision was perfect. The eyeball was directed a little upwards. It could be moved with ease, except in a downward direction. The reporter of the case remarks that the tumour belonged to the loose-textured cyst containing variety of the fibrous class, and had, as is not unusual, undergone interstitial calcification. Many examples are recorded by De Marquay, Lawrence, and others. Some have been found much lobulated, with attachments to several parts of the periosteum of the orbit.

Fibrous tumour within the ocular tunic. Such a case is given by Dr. O'Ferrall, in vol. xix. of the *Dublin Journal*. A woman, twenty-eight years old, had the right eyeball displaced upwards, inwards, and forwards. The lower eyelid was thrown forward. A firm tumour could be felt through the eyelid, and through the conjunctiva, when the eyelid was depressed. A free incision was carried along the inferior palpebral sinus, the tumour exposed, hooked, drawn forwards, and detached by a few slight touches of the scalpel. A process remained, which passed backwards in close contact with the eyeball. By drawing downwards and forwards the ocular sheath, it was brought more fully into view, and readily separated with the sharp end of a probe. The wound healed in a few days, and vision, which had been nearly lost, was soon regained. The tumour was lobulated, and encapsuled.

Treatment. Exploration is often called for to establish the diagnosis of a solid tumour. Where extreme caution is required, it might be prudent even partially to dissect and expose the tumour before deciding what should be done ultimately.

Where it is possible, the tumour should be removed within the eyelids, by cutting through the conjunctiva. If it be attached to the conjunctiva, the adhering portion of this membrane must also be excised.

An operation done much within the orbit is always difficult and dangerous, because the space is very limited, and important parts lie in the way of dissection. After a tumour has been exposed, its separation should be affected as much as possible by drawing it well forwards and cutting on it. If it be encapsuled, the process is all the easier accomplished. If it do not actually surround the optic nerve, nor is particularly adherent to the orbit, it may be pulled out to an extent almost incredible.

Fatty tumour. I shall speak first of the true tumour, the cir-

cumscribed fat with a capsule of fibro-cellular tissue, sometimes called the discontinuous tumour. It is probably frequently congenital. I have met with several of small size just under the ocular conjunctiva, in the space between the external and inferior recti. They were oblong and bulged between the eyeball and the orbital margin.

It may be seated in any position. It is often mistaken for a cystic tumour. The most skilful surgeon might not at times be able to tell whether he has under his fingers the one or the other. When it can be pinched up, that is, when it is just under the skin, lobules are sometimes apparent, standing out like little dimples, and this would at once declare the nature of the disease; but such a test is not often available in the orbit.

It may differ much as to firmness. In some the capsule is very thin, the septa delicate, and the loculi very large, containing pure fatty material. In others, the ultimate lobules are minutely subdivided, forming granular fat, and the proportion of fibro-cellular tissue to fat, very considerable; the capsule is very dense. The latter kind are often difficult to distinguish from other tumours, since they possess none of the softness and pseudo-fluctuation of fat.

A young girl applied to Mr. Simon, of St. Thomas's Hospital, with symptoms of an orbital tumour. The eyelid was pushed out, but the eyeball, excepting having been turned a little down, was not much displaced. Mr. Simon made a free incision beneath the eyebrow, and exposed a large mass of clear white fat. The edges of the wound being held widely asunder, the deep attachments were carefully divided, and the whole mass, about the size of a walnut, was removed. The wound healed kindly, and no ill effects remained.

Symmetrical fatty tumours in both orbits. These came under Mr. Bowman's notice. The swelling was nearly limited to the outer half of each eyelid, and extended from the brow to within a quarter of an inch of the tarsal border, where it ceased by a groove, over which hung the relaxed and distended integument. These tumours were quite soft, as if from œdema of the parts subjacent to the skin, and pressure did not meet with any resistance, nor did indentation ensue. In one a seton was passed to produce consolidation of the parts, under the conviction of there being œdema only, and afterwards medicines and low diet were enjoined. Subsequently an operation was undertaken to remove a piece of the supposed infiltrated tissues; the skin, orbicularis muscle, and fascia were divided, and there fell forward a mass of fat as large as an almond, in pellets or lobes, resembling the fat in the orbit. The second eye was operated upon. Success ensued.

Fatty tumour mistaken for hydatid. A case is given by a foreign author, of a tumour as big as an egg, protruding above the eyeball and pushing it outwards and downwards. The cornea became opaque. Hydatid was suspected, but exploration gave no result. The eyeball and the contents of the orbit were extirpated. The disease was a fatty tumour, somewhat altered in parts, as if from inflammatory deposits.

Diffuse fatty tumour, called also, fatty outgrowth, and continuous fatty tumour. This has not any capsule, and is less soft and elastic than the true tumour. It cannot therefore be said where the natural fat ends, and the morbid deposit, if it can be called such, begins. It has been described as occurring in the orbit. Such a state is merely increase of the orbital fat. I think that I have met with such a case. It is described in the chapter on "Protrusion of the Eyeball." There are not any diagnostic points that can be relied on.

Treatment. A small fatty tumour at the front of the orbit may be removed, by sufficiently dividing the conjunctiva, drawing it forwards, and cutting the attachments with a scalpel or scissors. Any adhering portion of the conjunctiva should be removed with it. Where it is deep, it must be treated according to the general rules I have given for the removal of a tumour in such a situation.

As to whether an operation should be undertaken for the removal of some of the fat, in a case of suspected diffuse fatty tumour, it is difficult to give a general opinion. I should not interfere, except under the most pressing urgency from protrusion of the eyeball, and after exploration had declared the presence of fat. I have operated for such a tumour in the neck, and reported the particulars in the *Medical Times and Gazette*.

Bony tumour. Exostosis. Even within the orbit there has grown a bony tumour among the soft tissues, after the manner more commonly seen in other parts of the body. Surgically speaking, it possesses no special interest. It is the tumour that is attached to some part of the orbital walls that I intend to write about: the exostosis.

It is questioned by some whether an exostosis is not a continuous outgrowth of bone, rather than a tumour, according to modern definition. I shall consider it in a surgical sense, as a tumour. It is necessary practically to make a distinction between an exostosis, which I recognise as a tumour having a defined base, and an accumulation of new bony matter, the result of inflammation of periosteum, or of bone.

An exostosis is really true bone. In some examples, there are

differences in the arrangements of the blood-vessels, and in the size and development of the bone corpuscles and their canals.

There are two varieties of this tumour, the compact or ivory, and the cancellous or spongy.

The compact variety is intensely hard. This is due to mechanical difference in the manner in which the material is compacted, and not to chemical dissimilarity from ordinary bone. It is the exostosis almost proper to the orbit, is generally attached to the frontal bone, and probably has its origin by ossification in the periosteum, or congenitally in the fibrous membrane, from which the bone to which it is attached is formed. The cranial bones are developed from the ossification of fibrous tissue.

It is uniform or simple, when the base is generally small; or lobulated, with a large base, from which it may project only on one side, like, as Mr. Paget says, a bi-convex lens resting with one convex surface on the skull; or a nut bisected, the flat surface being in contact with the skull. It may be dense throughout, or consist of a dense exterior, and a cancellous interior, continuous respectively with the outer table and the diploe.

The cancellous variety is very much less dense than the other, and is rarely found about the orbit. It is round, with lobules smooth or rough. Sometimes they are angular or pointed. Most likely it is formed about the orbit from ossification of outgrowth of cartilage, as occurs on the ends of the long bones, and phalanges of the fingers and toes, where it is not uncommon. A case is published by Mr. Heath in the "Pathological Transactions," of a large cartilaginous tumour of the face, implicating the orbit, undergoing ossification. Another of the same kind occurred in the practice of Sir William Fergusson, of which I shall presently say more. Like the compact variety when it is fully formed, its compact and cancellous portions correspond with those of the bones to which it is attached.

An exostosis may grow from any part of the orbit, but it is mostly developed at the upper and outer sides.

When an exostosis can be touched, its nature is readily determined. When it is hidden, for instance when it lies behind the eyeball, or at the side of the orbit out of reach, there is not any objective symptom by which it can be distinguished from any other tumour. The slowness of growth is the only circumstance that might cause a suspicion of its nature. It may be attended with pain or not, but being itself devoid of subjective symptoms, any distress arising from it would be due to its pressing on a nerve. It is the only kind of tumour which grows in the orbit, that is never detrimental except from pressing upon other parts. Death has ensued from one of

them pressing upon the brain, before the orbital contents were injured.

Of the constitutional origin of exostosis, we are ignorant. It has been fairly traced to outward injuries. Among these may be mentioned a butt from a cow; a blow from a stick; fracture of the orbit; in each of which it has grown where the force was received.

Treatment. As the density of an exostosis, and its mode of attachment to the bone of which it is in fact a part, render it very difficult of removal, and the operation somewhat dangerous, as a rule, only those which are outside the orbit, or about its edge, should be submitted to operations, whether the orbital appendages be affected or not. If the tumour be in the orbit, and cannot be readily reached, and the eyeball is merely protruded, it had better be left alone and watched, because it may cease to grow at any time. But if there be much pain, and especially if the integrity of vision be threatened, there should be no delay; its removal is called for. If it spring from the upper wall of the orbit, it is better not to interfere except under the most urgent circumstances, because of the proximity to the brain, and the thinness of the bone to which it is attached. With the strongest call for surgical relief, if the base be not small it would be better that the eye be sacrificed than an operation undertaken, as life would be risked by it.

Excision is unquestionably the proper surgical treatment. It might be necessary to make a preliminary exploratory dissection, to ascertain the extent and attachments of the tumour before actually proceeding to remove it. I know of some cases in which such examination would have saved the surgeons and the patients from much disappointment.

Instruments of a coarse nature are required, such as strong, straight, and curved bone forceps, with short blades and long handles; very strong narrow saws, and a chain saw; gouges of different sizes; trephines and centre-bit. Indeed there should be provided all the modern instruments that are used for operations on diseased bones.

The periosteum should be dissected off the tumour, and the excision effected at its base. Fortunately, the adjacent portion of bone is generally thickened, and forms a kind of safeguard from damage by instruments to surrounding parts.

When the whole of the tumour cannot be got away, either on account of its density, or from extensive attachments, it might be advisable to apply certain chemical agents to the remainder, with the object of producing necrosis and exfoliation. Sir B. Brodie and

Mr. Keate used in this manner, each in one case, caustics at intervals for some years, and obtained exfoliation. Necrosis and separation have ensued after abandoned operations, without the application of escharotics. Indeed, some surgeons have from the commencement intended only to remove parts of the growths, in the hope that death of the rest, as the effect of the partial operation, would rid their patients from the disease.

Exostosis of both varieties have been known to become necrosed without any treatment. A very large one which was situated between the nostril and the orbit, was exfoliated naturally. It weighed fourteen ounces. The particulars are published by Mr. Hilton, in the "Guy's Hospital Reports."

Where there is left exposed a surface of ivory exostosis, and exfoliation has ensued, granulations do not spring from it, but there it remains for years. Although this is of little matter outside the orbit, because the remainder gets, as it were, bound round by dry and hard skin, it is of consequence within, on account of the fistula which will form, and the morbid action thereby set up in the orbit.

When the eyeball has been destroyed by an exostosis, it is better to extirpate whatever remains of it before commencing the specific operation on the tumour.

It is necessary to advise young operators to use the formidable instruments which are required in these operations with care and management, and to avoid violence and shock. Some of the rudest operating I have ever seen has been for the removal of an orbital exostosis with the objectionable chisel and mallet. The proximity of the brain was forgotten, and disastrous results ensued from cerebral inflammation.

The soft parts are generally and unavoidably so much lacerated by the instruments, that primary union is seldom accomplished.

It has been proposed always to treat exostosis, solely by applying an escharotic to its surfaces, after removing the periosteum, in the hope of producing necrosis and exfoliation. Without altogether condemning the measure, I would say that it should never be the rule. It would be admissible only in very exceptional cases.

Ivory exostosis of the orbital edge. A carter, forty years of age, was admitted under my care at St. Mary's Hospital with an exostosis on the upper edge of the orbit, growing with a very broad base. The greatest point of projection was two inches. The upper part was covered by the eyebrow, which was considerably thrown up. The under dipped into the orbit, touched the globe of the eye, and thrust it downwards and outwards, protruding it about half an inch, thereby nearly destroying vision. The inner and the

outer boundaries were less marked. The surface was tuberculated, and hard as stone. The skin was moveable, shining, and traversed by a few blood-vessels. The following figure gives some idea of its appearance.

Fig. 54.

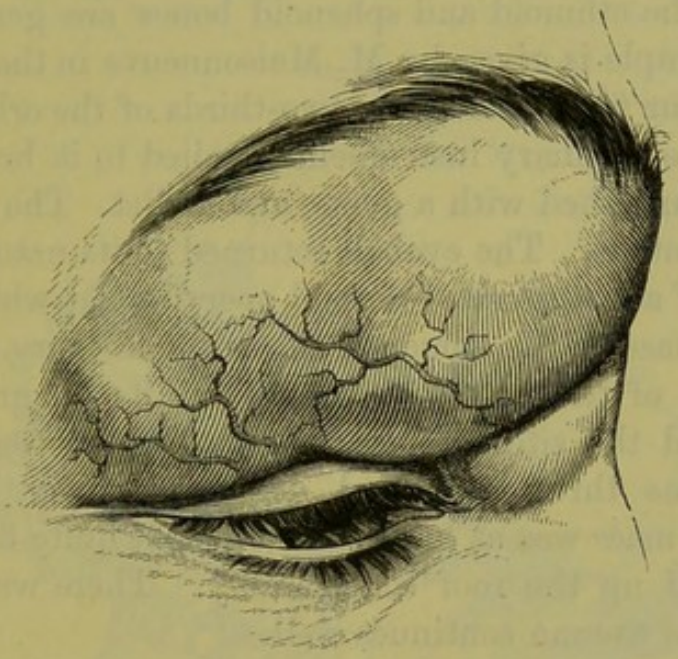

When only a lad he had fallen down-stairs, and pitched on the front of his head. Two months afterwards a little swelling appeared on the orbital ridge, which gradually increased in size. There was no doubt as to the nature of the disease. Hardness, immobility, slow growth, continuity with the bone, and absence of pain and inflammation, sufficiently marked its character.

Chloroform having been administered, I made an incision in the line of the eyebrow, which had been previously shaved, along the entire superior edge of the tumour, a second one from the inner extremity of that cut to the root of the nose, and a third from the outer extremity to a little below the level of the outer corner of the eyelid. I then dissected the flap downwards till the base of the tumour was reached, when I passed a narrow saw between it and the eyeball, and sawed through it circularly, from below upwards, endeavouring to follow the natural line of the brow. The texture was as dense as ivory, and two saws were dulled in the operation. The integuments were brought together by sutures; a course to be adopted only when an exostosis is superficial. Union by the first intention followed throughout the lines of incision, except at a central spot of the transverse cut, through which healthy pus discharged for eight weeks. After a year the eyeball was restored to its place, the sight had returned, and very little indication existed of what had been

done. The eyebrow, which concealed much of the scar, descended to its proper level, and the eyelid could be raised nearly as much as its fellow.

I have met with an exostosis on the orbital edge of the lower maxilla.

The internal wall of the orbit is seldom the site of an exostosis. When it is so, the ethmoid and sphenoid bones are generally implicated. An example is given by M. Maisonneuve in the *Gazette Hebdom.* The tumour filled more than two-thirds of the orbit. It was so hard that all the ordinary instruments applied to it broke. The removal was accomplished with a gouge and mallet. The wound healed by the first intention. The eyeball returned to its natural position.

Recurrence of an exostosis. Second operation, at which I was present. Mr. Borlase Childs removed an enormous ivory exostosis from the upper edge of the orbit. Seven years after, a growth of bone appeared around the site, and grew within and without the orbit. The eyeball was thrust out and destroyed. Mr. Childs again operated. The mass was as hard as before. It quite filled the orbit, and had pressed up the roof considerably. There were no cerebral symptoms. The woman continues well.

I never saw a more remarkable case of exostosis than one which I was asked to examine by Sir W. Fergusson. The patient, a male, was twenty-one years of age. The cheek, the inner and the lower parts of the orbit, were occupied by a large prominent tumour of stony hardness. The eyeball was considerably protruded, and thrust upwards and outwards, above the external angle of the orbit. The orbital muscles retained much of their action, and monocular vision was very little impaired. Sir William operated, but unfortunately the man died. The principal deep attachments of the tumour were to the body of the sphenoid bone. Prolongations were discovered in the anterior and middle fossæ of the brain. The portion which was removed during life, weighed after drying 387 grains. The optic nerve was surrounded on all sides. The case is given in detail in the "Transactions of the Pathological Society of London."

A very characteristic specimen of the cancellous variety of exostosis in association with the orbit, is in the Museum of the Royal College of Surgeons. It shows how a growth from a neighbouring part may be of an equally serious nature with one originating in the orbit itself. Fig. 55 is a most accurate representation of the appearance and the proportions. It has its origin in the antrum. It was five years in progress, and had destroyed all the right orbit except its roof, and more or less the right malar, superior maxillary, and frontal bones. The dried portion, which has

been submitted to maceration, consists of an oval mass of light cancellous bone, about five inches in diameter and four in length. It might have been removed even in its latest stage with ease, and at an early period, with every prospect of success. The irregularities which are depicted in the cranial and the orbital sutures, exist in the original.

Fig. 55.

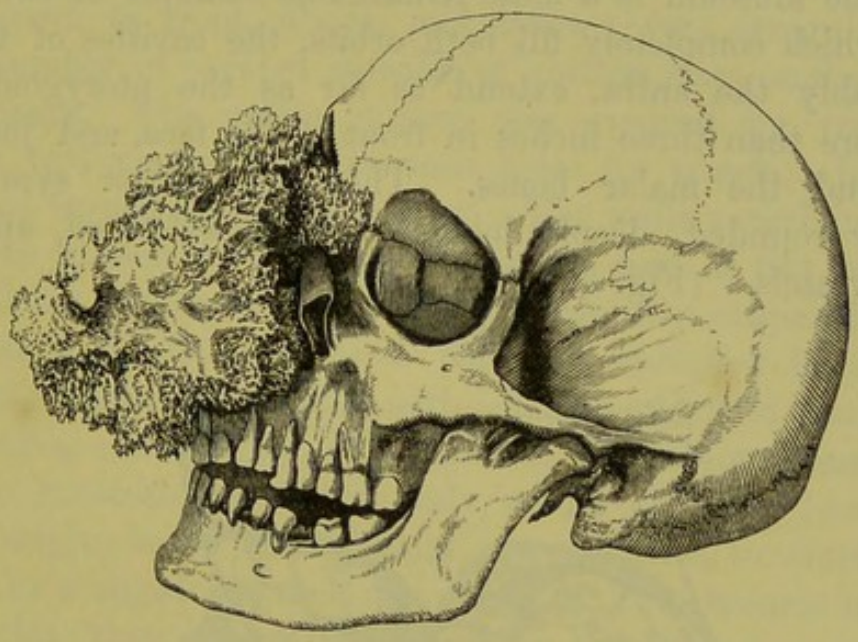

A rare form of osseous tumour, the description of which I have reserved till now, generally grows between the tables of the skull, or in the frontal sinus, and becomes large and nodulated, and destructive to the eye, and to life. All the specimens which I have seen have arisen from the orbital portion of the frontal bone. It spreads as much within the orbit as without. An example is in the Museum at St. Bartholomew's Hospital. The subject of it was a female, twenty years old, who was admitted into the hospital with protrusion of the eyeball, the result of a tumour, which was readily ascertained to be osseous. It had been growing for three years, and was still augmenting. An attempt was made to remove it, but only a part could be taken away. She died from suppuration of the anterior portion of the brain. A more remarkable specimen is in the Museum of the University of Cambridge. The posterior part of the tumour extends for a long way into the cranium. A case is mentioned by Dr. Baillie, in his "Illustrations of Morbid Anatomy," in which the tumour filled the left orbit, dilated it very much, passed across into the other orbit, and backwards into the cavity of the cranium. It was nodulated, and intensely hard. It is astonishing

how life is supported with such pressure on the brain as these tumours must cause. By their development the brain is adapted to their form.

The orbital cavities may be greatly reduced and almost closed, from hypertrophy of their bones in common with hypertrophy of the facial and the cranial bones. In the skull of a Peruvian, in the Museum of the Royal College of Surgeons, all the bones of the face are enlarged and thickened, and the orbits are nearly closed. In the same museum is a most remarkable example of two osseous growths which completely fill both orbits, the cavities of the nose, and probably the antra, extend as far as the pterygoid plates, project more than three inches in front of the face, and jut out an inch beyond the malar bones. They are almost symmetrical, irregularly rounded, deeply lobulated, and perforated, apparently for blood-vessels. (Fig. 56.)

FIG. 56.

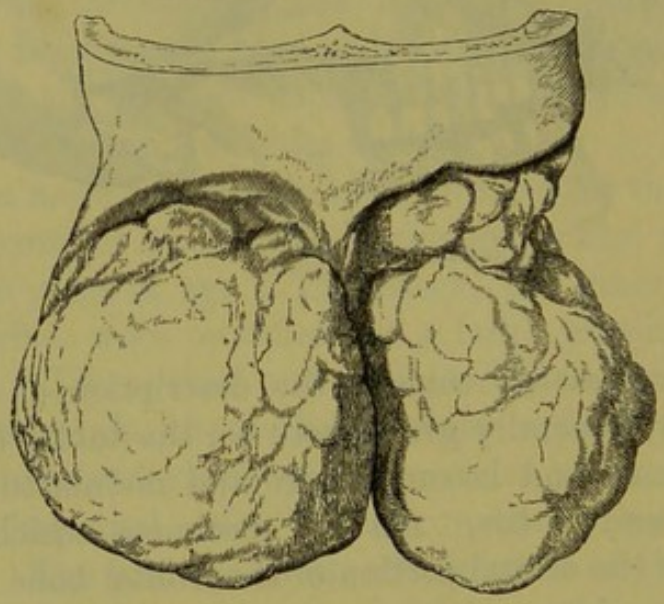

During their growth the patient suffered much pain in the orbit, face, and head. The eyeballs, of course, projected. The right collapsed after inflammation and sloughing of the cornea; the left eye was accidentally burst by a blow, while it was in a state of inflammation. During the last two years of this man's life, he occasionally showed symptoms of insanity; he died suddenly of apoplexy. The cranial bones were very thick and hard, and all the sutures were obliterated. The periosteal covering of the tumours was thick and dense. The preparation was taken from a man sixty years old. The disease began eighteen years before his death, in consequence, it was supposed, of severe blows received on his face in prize-fighting.

A very curious orbital exostosis, with a skull, is in Dupuytren's Museum. The subject was a woman thirty-six years of age. She

was attacked with the disease when four years old. At the outer angle of the right orbit, exactly at the junction of the external orbital process of the frontal with the malar bone, appeared an osseous tumour, as large as a lentil. It increased so much as to compress the upper and inner walls of the orbit, and to dislocate the eyeball entirely. In the course of thirty-two years it grew as large as the patient's head. It invaded the left orbit a little and diminished it. Externally, it seemed to be formed of compact osseous tissue, very hard, smooth in front, above, and below; very irregular behind, with a number of pointed spiculæ of various sizes, and grouped in various ways. The entire surface was grooved by vascular impressions, and pierced by numerous holes for vessels. It was sawn across, and turned out to be hollow. The walls varied in thickness from a line to nearly an inch. The upper part of this bony cavity was filled by a polypus-like growth, apparently originating in the frontal sinus, whilst the lower part was occupied by a mass of cretaceous substance, saturated with ichorous and fetid matter.

Osteophites, so called by M. Rognetta, are tumours analagous to the ivory exostosis, and differ only, so far as I can learn, in the mode of origin, being developed in bony cavities, to which they are attached by a slight peduncle; or lying in little fissures or recesses. In the orbit, they have always been in the line of a suture, and chiefly in the situation of the foramen lacerum, and have generally varied in size from that of a pea to that of a marble.

It is only after death that the nature of an osteophite can be told. M. Carron du Villards took a sketch of one that filled the orbit, and projected outwards, being about the size of the head of the femur. It was perforated by apertures for nutritive blood-vessels. It was firmly attached to the orbit, and imbedded in a cavity made for itself. This tumour occurred in the head of an old woman who had always been healthy, and whose eye, without any apparent cause at first, had protruded. She lived with it for ten years without pain, and died of a typhoid affection. Similar cases, it is said, have been met with.

The after-treatment of operations about and in the orbit. The simplest measures are the best, because the safest. Water dressing is the most applicable so long as there is not acute inflammation, in which case hot applications are called for. Whatever be the system of dressing adopted, the materials should be sufficiently changed, to prevent the accumulation of morbid products. This is very seldom properly carried out. It is positively injurious to apply stimulating lotions. A watery preparation of opium is admissible to relieve pain.

The anti-putrescent, or antiseptic method of treatment with carbolic acid, is as applicable here as in any other part of the body.

Whenever a tumour has been removed from within the orbit, and especially an exostosis, there will be some degree of orbital cellulitis, and whether this be mild or severe, will often depend on the immediate treatment of the wound. Except for the purpose of stopping uncontrollable hæmorrhage, the wound should not be stuffed with lint or charpie, or anything else, as the introduction of an extraneous substance will increase the intensity of the inevitable vascular action.

To guard against unsuccessful results, the utmost vigilance must be bestowed on the preparatory and after-treatment of the patients. An essential part of the latter is perfect rest of the body, and of the eye, for many days, or weeks. The slightest appearance of erysipelas should be carefully attended to, and any collections of matter early and freely evacuated.

The recovery from operations in the orbit for the removal of tumours is much more favourable than might be anticipated from their peculiar locality and close proximity to the brain. The operations do not seem to be more dangerous than those in general about the head and upper part of the face, which are never devoid of risk. Death has followed simple puncture, partial removal, and complete extirpation of tumours, both encysted and solid. The excision of exostoses is, perhaps, attended with the most danger.

The return of the eyeball to its position after it has been more or less dislocated by an orbital tumour, and the recovery of vision after it has been impaired from pressure on the eyeball, or stretching of the optic nerve, may be complete when the disturbing causes are removed. But both have their bounds, beyond which a favourable result is impossible. With regard to the latter, so long as the structural integrity of the eyeball remains, the transparent media being unaffected, there may be hope of entire return of vision.

When a dislocated eyeball cannot, unaided, recover its position, the use of a compress in the direction of the axis of its protrusion may be perfectly successful.

In one of the cases of orbital tumours related and figured by Dr. O'Ferrall, in the *Dublin Hospital Gazette*, all of which are very valuable records, the eyeball lay naked on the cheek an inch below the tarsal margin of the eyelid, was in constant movement, and occasioned much pain. The elongation and tension of the muscles and nerves seemed to be the chief cause of the patient's great suffering. Extirpation was performed, and relief followed.

CHAPTER IX.

PROTRUSION OF THE EYEBALL.

PROTRUSION CONSIDERED IN A DIAGNOSTIC POINT OF VIEW—ACUTE AND CHRONIC PROTRUSION, INTRA-ORBITAL AND EXTRA-ORBITAL—CAUSES—POSITION OF THE EYEBALL AS A MEANS OF DETERMINING THE CAUSE OF PROTRUSION—MOBILITY, OR IMMOBILITY, AS A DIAGNOSTIC SYMPTOM — AMOUNT OF PROTRUSION NOT INVARIABLY REPRESENTED BY THE SIZE OF THE PROTRUDING BODY—PROTRUSION NOT NECESSARILY INCREASED BY THE GROWING OF A TUMOUR—THE EFFECT OF PRESSURE ON THE PROTRUDED EYEBALL AS ASSISTING DIAGNOSIS—DIAGNOSTIC ASSISTANCE FROM FOCAL RANGE—CONDITION OF PUPIL—STATE OF VISION—PROTRUSION NOT ADMITTING OF DIAGNOSIS—DISTINCTION BETWEEN PROTRUSION OF THE EYEBALL AND ENLARGEMENT.

PROTRUSION CONSIDERED IN A DIAGNOSTIC POINT OF VIEW.

Protrusion of the eyeball needs to be separately considered. Prominence is a symptom in many and very dissimilar ophthalmic diseases. It is one which frequently says that there is displacement of the eyeball and nothing more. It cannot, therefore, be used alone as a means of diagnosing disease, if it expresses nothing beyond mechanical disturbance. It is merely an effect, the source of which requires to be sought for; and although for the most part this can be discovered, sometimes it is doubtful, and sometimes it cannot be at all understood. But protrusion is often the first indication of disease. It is always a cause of alarm to a patient, and it should be a source of interest to the surgeon. It is the starting-point for investigation.

This chapter, then, is devoted to the diagnosis alone of ocular protrusion as a means of discovering encroachment on the eyeball in any direction, and the nature of the disturbance, but does not include ocular dislocation from direct mechanical injury of any kind. It is so arranged as to allow of a rapid survey of all the known disturbing causes, not, however, in full detail, because most of the diseases producing the disturbance are fully treated of in the several places, according to the general classification of this work. It is done, too, to prevent repetition in many places, and to save further subdivision of many subjects.

For convenience, the protrusion may be called acute and chronic.

In the acute, the causes are generally palpable, and are nearly always intra-orbital. The following classification may be made.

Inflammation of the orbital tissues, idiopathic and traumatic.

The *first, or idiopathic*, is most common in the later stages of the exanthemata, and may occur during rheumatism and puerperal fever. In all the cases I have seen there has been more of serous infiltration than of vascular excitement. It occurs, too, from the participation of the orbital tissues in surrounding inflammatory action, whether on the surface, such as erysipelas, carbuncle, abscess, &c., or within the brain. As an illustration of the latter, the rarer condition, may be mentioned a case recorded by Mr. Hamilton in the *Dublin Journal of Medical Science*. A man had severe pains in the orbit, temple, and side of the head, for four or five days, with fever. There were no head symptoms. A few days after, the orbital tissues and appendages became inflamed, and the eyeball was pushed downwards and outwards. Vision was uninfluenced. The orbit was explored twice and to great depths with a scalpel, in the hope of finding pus, but with no effect. In four days the man died. His vision was unaffected, and his intellect was clear, to within a few hours of his dissolution. An examination showed the disease to be a circumscribed abscess in the anterior lobe of the brain, and the orbit to be merely implicated in inflammatory action, with considerable serous effusion, as an effect.

Pus may be deposited in the orbital cavity, within or without the ocular sheath.

Whether acute, subacute, or chronic suppuration be established, the physical characters will be the same. The rapid symptoms of protrusion, the accompanying external inflammation, and the bulging of the orbital portion of the eyelid, that part of it corresponding to the seat of the inflammation, reveal most unmistakably the nature of the case.

In phlegmonic inflammation, pulsation has been felt, as from an aneurism.

Adhesion of the ocular tunic is spoken of at page 107. Immobility of the eyeball, along with protrusion, is not always an effect, as Dr. O'Ferrall supposed. Dr. Mackenzie met with prominence and a fixed state of the eyeball, which were due to mere effusion within the ocular tunic, as was proved by evacuating the fluid, when the prominence disappeared and the movements returned. He remarks in connection with this, that when the eyeball is protruded, and its motions free, the cause of pressure is certainly without the ocular capsule.

Periorbitis. The protrusion here is slight, but the cause is not obscure; a little investigation will disclose it. The pain occasioned by pressure, and the nightly exacerbation of suffering, assist in the diagnosis.

Paralysis of the orbital muscles. The falling forwards of the eyeball from this cause, ophthalmoplegia, is very rare, because it requires not only that the muscles supplied by the third pair of nerves should be paralyzed, but that all the recti should lose their power, the fourth and the sixth nerves also being affected. The diagnosis of the protrusion, which is not very marked, is at once obvious. The eyeball may be temporarily replaced by pressure.

The second, or traumatic, in some form or other, is common. It is produced by hæmorrhage in the orbit; by inflammation of the orbital contents, but particularly the areolar tissue; by external injuries to the orbit of all kinds; by inflammatory action, the result of operations about the orbit; by operations on the eyeball which are attended with suppuration; by the impaction of foreign bodies in the orbit; by penetrating wounds.

The diagnosis is generally easy, as the inflammatory action is marked.

Orbital diffuse aneurism may be specially noticed. The slowness of the protrusion of the eyeball at first, followed by rapid increase, together with the symptoms of vascular disturbance, or on the other hand, very rapid protrusion from the first with such symptoms, will be sufficiently diagnostic. This is treated of in the chapter on "Diseases of the Orbit."

Emphysema, from fracture of the orbital wall. This produces excessive protrusion, which lasts for several days. The subject of the escape of air from the lacrymal apparatus is further considered in several places of this work, the references to which will be found in the index.

In this class one eye only is affected, except when the protrusion is from erysipelas of the face.

In the chronic, the causes are not always manifest; they are more numerous, and more dissimilar. While many are intra-orbital, many are extra-orbital.

Intra-orbital causes. Tumours. Under this origin of protrusion are included tumours of all kinds, belonging to the classes cystic and solid, benign and malignant; also enlargement of the lacrymal gland from several forms of disease. Any one of these may thrust out the eyeball to a marked degree, especially if its seat be deep in the orbit, before its existence as a tumour can be determined. It is only when it has acquired a very large size, except it be in front, that it can be detected. The nearer it is to the margin of the orbit, the sooner can it be recognised. An enlarged lacrymal gland is not as readily diagnosed, as might be supposed, from its proximity to the edge of the orbit.

Disease of the optic nerve. Böhm, of Berlin, observed in the body of a young man who died of phthisis, a tumour in the nerve, just a little behind the sclerotica, of the size and shape of an olive, and consisting principally of thickened neurilemma. It displaced the eyeball upwards and outwards, and had nearly destroyed vision.

The symptom that would point to implication of the optic nerve is disturbance of sight. Changes in the optic papilla would soon be visible with the ophthalmoscope.

Excess of orbital fat sometimes co-exists with an excess of fat in the body, and protrudes the eyes. Both eyes are then always affected. I have seen some very marked examples. I believe that it may exist in the form of increase of fat, apart from general obesity, as a diffuse fatty tumour. The fat in the orbit is subject to variations in quantity, like that in other parts. A man who is emaciated always has sunken eyes.

Remarks. It is the size of the tumour which first causes physical disturbance. The intra-orbital organs are compressed. The optic nerve may withstand the effects of pressure for a long time, and its function remain unaffected. When it escapes from this, stretching may damage it. But it will stand, with impunity, much elongation. Pressure on the fifth nerve causes pain. Pressure on the motor nerves affects the actions of the orbital muscles, and influences in the same way the pupillary movements. Pressure of the veins causes congestion of the eyelids, and of the conjunctiva, and œdema of the orbital areolar tissue.

The adaptation of the orbital contents is so exact, and the several parts so little compressible, that any addition in the form of a growth must cause ocular displacement in the one direction or the other. The eyeball being the least capable of resisting the pressure, on account of its mobility, quits its socket.

Protrusion of the eyeball is seldom directly forwards, except in dropsy of the ocular tunic. In lateral displacement, the deviation is always towards the side opposite to the tumour. Sometimes as the result of pressure there is distortion of the orbital walls, or removal of a part of them, by caries, or by progressive absorption, in which case new symptoms will arise. If the growth should enter any of the cavities around, the same effects may ensue as if it originated there.

If the eyeball continue to protrude, there arrives a time when the eyelids can no longer afford the proper protection to it, and then follow the symptoms of epiphora, intolerance to light, ulceration of the cornea, inflammation, or perhaps collapse, from loss of some of the contents.

Extra-orbital causes. Protrusion arising from pressure external to the orbit is apt to be overlooked, unless the sources from whence the pressure may arise be known. The position of the orbit exposes it to encroachment on all sides. Diseases of each of the cavities and sinuses around may reduce its capacity, and displace the eyeball.

I shall speak of the surrounding regions separately.

The most common of the diseases which produce the disturbance is cancer. Next in the order of frequency are cystic tumours, solid tumours, including exostosis, abscess.

Morbid changes within the cranium. The most common example from a cerebral origin is to be found in chronic hydrocephalus: the roof of the orbit is pressed down by the enlarged brain, and the depth of the cavity much lessened. The cause is at once palpable.

Cerebral tumours may protrude the eyeball.

Intercranial aneurism of the carotid artery is a well-recognised cause.

Any cerebral disease that implicates the cavernous sinus, so as to interfere with the flow of the venous blood from the orbit, will cause protrusion.

Other changes in the cranium may displace the eyeball, as the following examples show.

A thief, jumping out of a window to escape detection, fractured his skull just above the left orbit; probably damaging the frontal sinus. A portion of the frontal bone which was loose, was removed; suppuration ensued, and there was a discharge of pus for a year. The eye protruded to about three-quarters of an inch beyond its fellow, and was in that state when I saw the man, six years after the accident. Vision was unaffected.

A young nobleman was thrown from his pony. Concussion of the brain was produced, and was followed by long-continued cerebral symptoms, which nearly destroyed life. He recovered completely,

except that the right eyeball protruded slightly, and has remained so for thirty years. Vision is unaffected.

Where the physical cerebral cause is not objective, headache, loss of memory, fits, partial paralysis, or other indication of lesion in the great nervous mass, with the previous history of the case, will generally determine its existence. Some subjective symptom is rarely absent where there is sufficient mechanical change in the brain or its membranes to displace the eyeball. Very large tumours may exist in the head without affecting the eye.

Frontal sinus. Distension of this sinus from any cause, does not necessarily displace the eyeball. For such an effect the floor, or upper orbital wall, must be more or less pushed downwards.

Maxillary sinus. This is the seat of the most frequent external cause of displacement, for it is often diseased. A tumour of any magnitude here can scarcely fail to throw up the orbital floor sufficiently to affect the eyeball, and such could rarely be mistaken. Distension in some other direction, and some collateral symptom, would coexist and determine the form of the disturbance. It matters not what may be the kind of the tumour, whether aneurism by anastomosis, polypus, or other soft growths of a mild nature, cancer, fibrous tumour, simple exostosis, or malignant affection of the bones. All of these have been met with. Deposits of pus, or of serum or mucus, might have the same effect, if the collections were large. Suppuration, however, may greatly enlarge the sinus, which in the natural state is very small, without throwing up the orbital boundary. I have met with some examples of this, and the most remarkable was in a patient in private, submitted to me for an opinion by Mr. William Coulson. The orbital, palatine, and nasal sides did not bulge, the expansion being externally, anteriorly, and posteriorly. An aperture was made through the distended bone in front, and when the pus escaped, so great was the cavity, that my forefinger could but just reach the back wall.

Perhaps the most fertile of all sources of disease in this position, by which the eyeball is affected, arises from disease of the tooth follicle during dentition, and of the tooth cavity in after-life.

Disease of the sinus may proceed so far as to destroy the floor of the orbit, before influencing the position of the eyeball.

Diseases of the walls of the sinus may affect the eyeball, just as those of the antrum itself.

Nasal fossa. Nasal tumours, and I allude especially to polypi, and suppuration in the ethmoid cells, could not advance and injure the orbit without detection. A careful examination of the nose would always render the cause apparent. Obstruction of the nasal

duct too, would surely precede such intrusion. In treating of obstruction of this conduit, I shall give an example of both nostrils being blocked up by polypi, and each duct temporarily destroyed.

A polypus commenced to grow in the middle meatus of the nose. It penetrated the os planum, entered the orbit, and ultimately passed to the outer orbital edge and protruded the eyeball considerably, causing destruction of it. Somewhat analogous cases are published.

Several instances of supposed polypi have proved to be but parts of tumours, having their origin elsewhere.

Sphenoidal sinus. Notwithstanding that I cannot advance any instance of protrusion of the eyeball from distention of this sinus by fluid, the possibility of the occurrence should be remembered; for the anatomical arrangement of the parts would seem readily to admit of it.

A fibrous tumour, originating here and in the roof of the nostril, besides spreading in other directions, passed under the temporal muscle, and entered the orbit through the spheno-maxillary fissure, and protruded the eyeball. The upper maxillary bone was removed under the false impression of the disease originating there. The case is published in the "Medico-Chirurgical Transactions."

Virchow records an instance of enlargement of half of the sphenoid bone protruding the eyeball.

Temporal and zygomatic fossæ. An exostosis has been known to grow from the temporal bone, to disarticulate the malar and the superior maxillary bones from the frontal, and to project into the orbit, dividing it into two compartments.

An encysted tumour that had its origin in the temporal and zygomatic fossæ, pressed on the outer wall of the orbit, and displaced the eyeball. It was supposed that the maxillary sinus was diseased. Exploration of the sinus proved the mistake.

Pharynx. Even from this region the orbit has been affected, by pressure from the growth of polypi, and from a fibrous tumour.

Tumours arising in the frontal and maxillary sinuses, and in the nasal fossæ, can generally be early recognised by physical changes in the natural outlines of the external parts, as well as by associated alterations in the physiological conditions of breathing and speaking. Vitiation of the nasal discharge will most probably occur. Such assistance in diagnosis cannot be got when the other parts around the orbits are involved.

Exostoses have been met with in all the regions around the eye, and by which the orbit has been affected.

Fibrous tumour on the fifth nerve. A man had protrusion of the

eyeball, produced, it was supposed, by a nasal polypus. An ineffectual attempt to remove the polypus caused inflammation of the brain, and death. A fibrous tumour sprang from the neurilemma of the second division of the fifth nerve, just after it had left the skull. It had five lobes, one of which passed into the orbit through the spheno-maxillary fissure. The supposed polypus was a part of the tumour. ("Archives Gén. de Méd.")

Position of the eyeball a means of determining the nature and the situation of the cause of protrusion. Theoretically speaking, and in the absence of any peculiarity, the tumour should be on the opposite side to that in which the eyeball is protruded. Thus a tumour at the lower wall of the orbit would be expected to throw the eyeball upwards, and an enlarged lacrymal gland to direct it downwards and inwards.

In estimating the value of physical signs, the dissimilar axes of the eyeball, and of the orbit, demand attention. In the large majority of cases the protrusion has a lateral inclination outwards.

The manner in which the eyeball is tied by the oblique muscles, and the anatomical relations of the optic nerve, will influence the direction of its protrusion when the pressure is posterior.

Displacement inwards is more readily effected than in other directions.

When from the commencement the displacement is lateral to the axis of the eyeball, it is reasonable to presume that the protruding force is also lateral.

Direct protrusion will, in general, prove the most embarrassing; for with bony and other growths at the side of the orbit, within certain limits of size, and situated posteriorly, the eyeball may be pushed forwards without any lateral displacement. This, I presume, must be attributed to the mechanical properties of the fat in the orbit. Yet if the only symptom be direct protrusion, until further evidence is obtained, the cause must be considered to be seated at the back of the orbit. I will not say the apex, for that is a very rare position for any tumour to occupy.

The state of the muscular movements of the eyeball may help to elucidate the subject.

As a rule, in proportion as the eyeball protrudes, is its mobility reduced.

When there is restricted movement in a given direction, it is natural to infer from mechanical principles, that there is an obstacle at such a spot; but as in the animal economy motion is developed through nerve force, the probability of the loss of it through paralysis in any case before us, lessens the value of such indication. Yet something may be gathered from the ocular movements. They

may be almost perfect or quite lost. Freedom of action shows that there is no adhesion of the eyeball to the ocular tunic, that its muscles are healthy, and that there is no pressure on any of the nerves, and therefore no dense tumour at the apex of the orbit, and probably no solid tumour present.

The amount of protrusion is not invariably represented by the size of the protruding body. There is no definite relation between them. This is a difficult question, and has connected with it something beyond the mere mechanical pushing of a tumour. See how the eyeball protrudes in exophthalmic goître, even when there is no change in the orbital tissues. In a case of medullary cancer of the orbit, the eyeball protruded but little, although it was not involved in the disease. Yet I was amazed at the mass of cancer that I took away. It seemed enough to fill the orbit by itself.

The growth of a tumour does not necessarily increase the protrusion. It surely will if the tumour be seated behind the eyeball; but if it be in front of it, an increase may only press forwards the ocular appendages, push aside the eyeball, and impair its movements.

It is probable that after the protrusion has reached a certain degree, variable according to the form of the eye of the individual, the action of the orbicularis may tend to produce further displacement.

The effect of pressure on the eyeball, in reducing the protrusion, indicates its cause somewhat negatively. If the eyeball return to the protruded state in a marked manner, after having been pushed back, there can be no tumour. Disease of the local vascular system may be strongly suspected, if in a case of this nature the protrusion be affected by position of the head, such as stooping, or lying, and above all, if the protrusion lessen when the circulation of the carotid artery of the same side is stopped by pressure.

Certain alterations in the accommodation of the protruded eye have been said to possess valuable indications. The theory is that the sight will be made long or short, according as the eye is affected in its antero-posterior or lateral diameter, and as the one or the other of these prevails, it is to be assumed that the tumour presses at the side of the eyeball, or behind it. This is fallacious. An effect on sight is never of this nature. It is that of impairment, loss of acuteness.

With the greatest protrusion the pupil may be natural; but in any case it may be dilated and moveable, dilated and fixed, or of its natural size and motionless. I am not aware that any practical indication can be gathered from any acquired forms.

The state of vision is seldom interfered with in direct protrusion, even when one eye only is affected, but with the least loss of parallelism,

in any direction, it may be double. To determine the position of the second image, is often to discover the site of the pressure. Rules for doing this are given in the chapter on "Paralytic Affections of the Eye."

Impairment of sight, with flashes, stars, and coruscations, is very common in protruded eyes, as the effect of pressure on the eyeball and on the optic nerve. Ophthalmoscopic evidence of such, has its value in diagnosis.

It is evident that attention, care, and perception are required in forming an accurate diagnosis respecting the disturbance of the beautiful balance of the eye in the orbit. There is enough to test the knowledge of a well-educated surgeon. Nothing in the way of concurring circumstances should be omitted in the investigation. The history may be important. It is of consequence whether the protrusion have been quick or slow. The condition of the circulation, the healthiness of the orbital tissues, the presence or absence of any of the evidences of inflammation, are all to be taken into account. The protrusion may be the result of inflammatory change, an effect of some diseased action without the orbit, and so far secondary or indirect. The examination should be extended beyond the mere orbital region.

Several cases are recorded of obscure protrusion of the eyeball, in which the nature of the affection was referred to a definite cause, merely because the protrusion was lost when certain drugs were used or certain applications employed. Diagnosis made in such a manner is literally worth nothing. Except there be some demonstrable evidence of the nature of a disease, the result of no case should be used to illustrate a pathological fact.

There are states of protrusion that cannot be diagnosed. In spite of all examination, and of all assistance rendered by optical appliances, including the ophthalmoscope, and optical tests, and the help that the ear gets from the stethoscope, our diagnosis may fail. Many skilful surgeons saw a patient whose history I shall give, and could make out nothing of her affection.

A healthy girl, twelve years old, applied at the C. L. O. Hospital, with her eyeball almost out of its orbit. In the sketch, Fig. 57, the eyelids are a little retracted, to give a more adequate idea of the distance between the cornea and the orbit.

The movements were in concert with those of its fellow, which was natural, and rather retracted than prominent. Great pains were taken to test the power of vision, which proved to be perfect. The most careful examination failed in detecting any other symptom than the prominence, which had commenced a year before, and

gradually progressed. Mercury was tried, but in vain, and no success attended the use of iron and other tonics. Slight pressure was adopted, and at first seemed beneficial, but ultimately proved inefficient; for in a day or two after remitting it, the protrusion became as marked as before.

If there be a state justifying the suspicion of considerable increase of the orbital fat, unattended with changes in the vascular, nervous, or motor apparatus of the eye, surely it is illustrated here. Any dense substance at the apex of the orbit, large enough to protrude the eyeball in such a manner, would, I presume, derange some of those structures that are so close to each other in that situation, and produce corresponding effects. I regarded the disease as a diffuse fatty tumour.

Fig. 57.

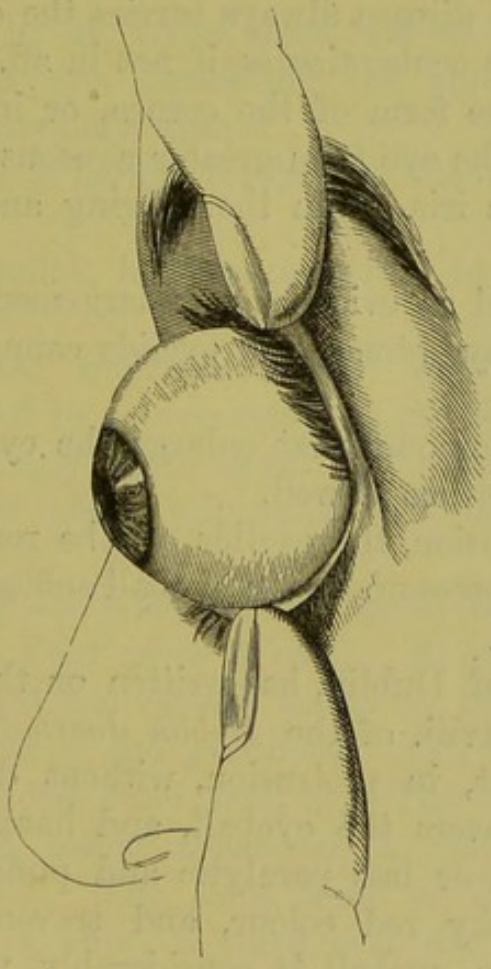

Another remarkable, and perhaps unique, case of protrusion, is related by Dr. Mackenzie. A man discovered that when he stooped forwards, if only for a few minutes, he had a sensation as if something were pressing above his right eye, which immediately began to protrude, and when the head was raised the protrusion was very striking, and he then saw indistinctly. The eye soon began to

retire, and in a few minutes righted itself. There was not any loss of muscular power when it had regained the natural position, even when it was displaced it could be moved. The iris acted naturally. He complained of considerable pain in the orbit, which was removed by bleeding and purging. The peculiarity had existed for five years, and commenced after carrying a heavy load on the back. M. Demarquay cites this case as one of dropsy of the ocular tunic.

Distinction between protrusion of the eyeball and enlargement of the same. A protruded eyeball is frequently mistaken for an enlarged one, an error very excusable in the inexperienced.

Congenital enlargement has been met with, although very rarely. I have seen only two instances, in which, while the proportions of all the structures remained the same, the absolute enlargement of the organ was apparent.

Enlargement from disease always carries the evidence of diseased action in some of the ocular tissues, if not in all. Physical changes are perceptible in the form of the cornea, or in the increased size of the chambers of the eye from greater aqueous secretion, or in the altered plane of the iris, or in the bulging and bluish tint of the sclerotica.

It may be received as evidence of enlargement, if, in addition to any of the above symptoms, the eyelids cannot be readily closed with the fingers.

All intra-ocular tumours that enlarge the eyeball, will give the appearance of prominence as well.

With slight protrusion, the eyelids can be readily closed with the fingers, and gentle pressure on the eyeball suffices to return it temporarily to the orbit.

Dr. J. O'Beirne, of Dublin, has written on the diagnosis of these two states in vol. xviii. of the *Dublin Journal*, and the conclusion he arrives at is that, in protrusion, without distinction of causes, the upper eyelid covers the eyeball, and hangs down lower than usual, and is more or less paralytic and puffed, with its surface generally of a dusky red colour, and traversed by large veins. In enlargement, the eyeball is considerably uncovered, and presents a staring appearance, while the upper eyelid is pushed forward and retained in that position, but is in other respects unchanged.

Shortening of the eyelids, and especially of the upper, from any cause, the contraction after an abscess is the most common, sometimes makes the eyeball appear to protrude at the inner canthus.

Tumours passing from the cranial cavity to the orbit. The progress of a tumour from the interior of the skull to the orbit is not remarkable. It is, as regards the pathological process, whether the tumour is malignant or not, just the same as when it passes from the orbit to the skull. But for the brain and its membranes to enter the orbit and form a hernia cerebri, is a very remarkable occurrence. Such cases have been collected by Demarquay.

A child, five years old, was shown at the *séance* of the Société de Chirurgie, in 1858, by M. Guersant, with a tumour at the inner canthus, of the size of a cobnut, in which it was easy to recognise pulsations synchronous with those of the arteries. It was the opinion of the exhibitor, and of those present, that it was formed by the membranes of the brain protruding through the fronto-ethmoidal suture. Some of the members thought, besides, that brain substance also was present.

In a case related by M. Lyon, there was an encephalocele at the inner angle of each eye, presenting the appearance as if each lacrymal sac was extremely dilated.

Richoux has seen a hernia cerebri at the outer angle of the right eye.

M. Breslau, of Munich, has seen a hernia at the inner angle of the left eye.

That such a tumour sometimes passes through the sphenoidal fissure, is demonstrated by a preparation in the Museum of Bonn.

In the absence of any pathological particulars of these cases, I conclude that all of them originated in congenital malformations.

Hydatid invasion of the orbit from the skull, deserves to be mentioned. Jean-Louis Petit gives a case. A tumour at the inner orbital angle protruded the eyeball nearly an inch. The subjective symptoms were headache and giddiness. The tumour was opened by caustic, and a reddish fluid escaped. The eye returned to its position. When the eschar separated, a cyst bulged, and was opened with a lancet. The same kind of discharge as before came out. Two days after, a third cyst was observed, and was punctured. The eye became everted, and again projected. Head symptoms and fever set in. The patient became comatose and died. An examination was made. Three hydatids were found, each as large as a walnut. One was in the orbit; a second was half in the orbit and half in the skull; a third was lying between the dura mater and the brain.

Another case may be quoted. It is from an old German journal.

There was a hydatid in the skull between the dura mater and the bone. It extended through the substance of the brain and entered the orbit by the sphenoidal fissure. It was about the width of a finger.

It does not appear that vascular tumours, those strictly so-called, erectile tumours, or aneurisms of any form, have penetrated the orbit from any neighbouring cavity.

CHAPTER X.

ERECTILE OR VASCULAR TUMOURS IN ASSOCIATION WITH THE EYE.

CAPILLARY VASCULAR TUMOUR, OR NÆVUS MATERNUS — VENOUS VASCULAR, OR CAVERNOUS TUMOUR — LYMPHATIC CAVERNOUS VASCULAR TUMOUR—ARTERIAL ERECTILE TUMOUR, OR ANEURISM BY ANASTOMOSIS.

NÆVUS MATERNUS.

All these tumours possess the property of becoming more or less erectile. They are essentially made up, either of extra-developed natural blood-vessels of the spot where they occur, or of new vessels, tied together by a little intermediate areolar tissue.

Surgically considered, nævi may be artificially divided into two classes, the cutaneous, and the subcutaneous.

The cutaneous is a tumour, either not rising above the skin, or standing out in relief. It has a conglomerate form, or is irregular in outline, and may be even stellate or spider-like, that is, with a small centre, and vessels branching off in many directions, and decreasing in size till they are lost. It may vary temporarily in size, accordingly as it is distended with blood or not; in a passive state being somewhat flaccid; in an active, being plump and shining. In other words, it occasionally gets erectile. These internal changes are best seen in a child when it cries, and for a short time afterwards. It varies in colour, and is spoken of as being arterial or venous. The predominance of the one or of the other set of vessels would have much to do with the colour. The position in the skin, too, will generally have its influence; the more superficial it is, the brighter. The state of the

circulation also would have an effect; the greater the activity, the greater the brightness.

The structure is made up of a network of dilated, tortuous, and convoluted blood-vessels of the cutaneous papillæ. A healthy papilla has but a single convoluted vessel.

The subcutaneous is a tumour with less surface definition than the other. It is lobulated and round, or oval, or disk-shaped, of a light blue tint, or colourless, according to its depth. Its structure is so like erectile tissue, that it is almost impossible to tell it from the corpus cavernosum penis, being made up of dilated blood-vessels with fibrous septa. The vessels in which the disease originates, are the deep ones of the derma; those of the sebaceous cysts, of the hair follicles, and of the subcutaneous fat globules. In my last edition I spoke more in detail on this matter, and recorded some valuable dissections made by Mr. Birkett and others. Additional dissections are given in Mr. Paget's valuable "Lectures on Surgical Pathology," edited by Turner. It is there stated that the arteries appear to pass into the vascular mass from the under surface of the skin, and that veins radiate from it of larger size and more numerous than they, but scarcely exceeding the proportions of the normal cutaneous veins and arteries. It is important in a surgical point of view to know, that if there be dilatation of the arteries, or of the veins, around the well-defined examples of the tumour, it is only just before the former enter the tumour, and only directly after the latter leave it. I shall allude to this again further on. Where there is no clearly defined tumour, the mass being diffuse, any dilatation is gradually lost.

It may be incorporated with the skin in different degrees, or have no connection with it, being entirely beneath. The latter state is not common about the eye.

When very deep, it seems to be in all external respects like a common fatty tumour, and then its true nature may be so obscure as to be overlooked. Some of our best surgeons have been deceived, and have recorded their mistakes.

When pressure is applied, the tumour is more or less emptied, and when the pressure is remitted, it refils.

The two classes are often united, a fact which points out their similarity in nature. A surgical recognition of this will be noticed under the head of treatment. Indeed in a pathological sense, the simple dilatation of the cutaneous blood-vessels without swelling, which form a kind of port-wine spot or coloured stain, and the nævi of both classes, are the same kind of disease, with a little difference in character, from further morbid alterations, together

with certain degenerations, incidental to duration and position. But development is a subject I must not consider.

Most nævi are congenital. Sometimes they appear after birth, even as late as manhood.

Nævi do not pulsate. For arterial thrill to be present, there must coexist arterial disease.

Treatment of the cutaneous class. This form of nævus has a tendency to decline, especially when it is seated on the neck, or on the trunk. The supply of blood that is requisite for its maintenance is apt to diminish, the nævus tissue contracts, the disease is cured, and only a cicatrix remains. Some surgeons rely very much upon this natural course, and recommend no treatment; but it should be remembered that increase is apt to take place when the tumour is seated upon mucous membrane, or contiguous to it; or, when near to arterial

FIG. 58.

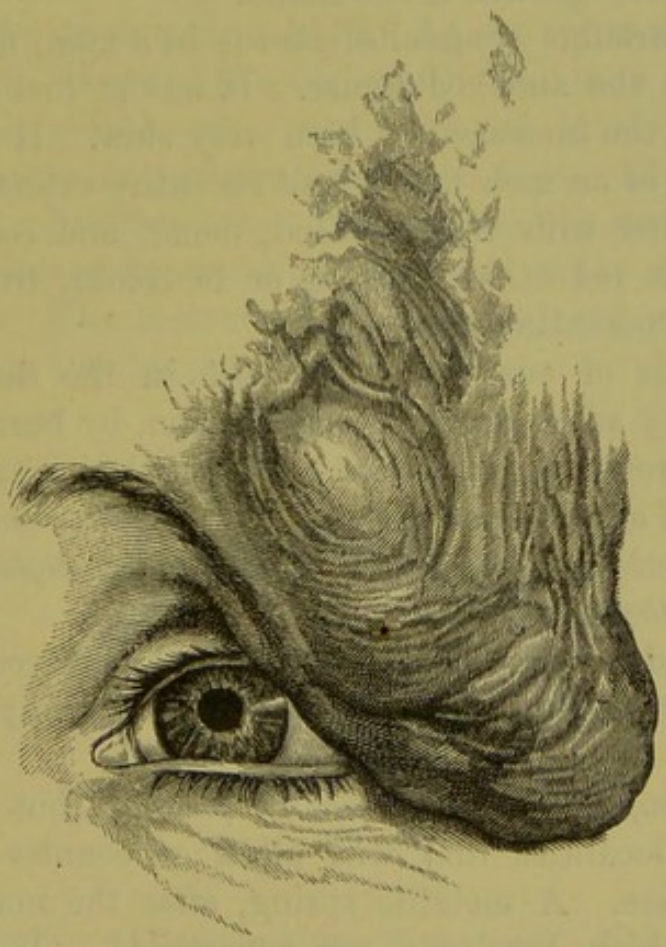

branches. Also, that there is always some danger of bleeding from accidental wounding. A nævus, too, is apt to inflame from injury or disease, whereby ulceration may ensue, which rarely heals in a sound manner. My own course of proceeding is unhesitatingly to adopt treatment where the nævus, however small, shows any signs of

increase; and this, knowing that the enlargement may be only temporary. Activity and increase may set in many years after a nævus has been stationary. If at any time surgical proceedings be delayed in a case for the sake of watching, the slightest perceptible augmentation should be the signal for acting. But when time is thus allowed, there may be deep spreading, without external evidence of the extension of the disease. Nævi about the eye, and its immediate vicinity, in consequence of the mechanical derangement they may cause to the eye, independently of ordinary evils, require a strictness of attention scarcely demanded in any other part of the body.

This argument may be advanced about an early operation. In an infant a nævus is at its least size, and is then easier to get rid of. There is less to do, the operation is less severe, and the result is the more perfect. All this is important to be recognised, as nævus tissue is the most difficult of all tissues to destroy, and the period of its most active growth is childhood.

A very remarkable congenital nævus in a man, forty years old, is represented in the annexed figure. It was at first a mere dot upon the brow, and the increase had been very slow. It was raised about three-quarters of an inch throughout its entire extent, was dark blue, apparently filled with venous blood, dense, and cold. It did not admit of much reduction in bulk, or in colour, from pressure. It was subject to periodic pains.

The methods of cure by art consist in the destruction of the nævus tissue by adhesion and consolidation, by burning, by extirpation, by escharotics, by injection, by strangulation and sloughing.

There should always be an endeavour to effect the removal of the disease with the least subsequent deformity, and with the slightest disturbance or destruction of the surrounding parts.

It is an advantage to possess several resources of treatment, for the better adaptation of means to the many conditions met with.

The most simple measure is that of pressure, but its use must be restricted to localities that will allow of counter-pressure, by an opposing surface. A metallic spring, after the manner of a truss, is best, by which bandages are superseded. But pressure may irritate, and eventually augment the growth, instead of effecting a cure; moreover, it can never be thoroughly relied upon in well-marked instances. It always requires long perseverance, is troublesome in application, and irksome and annoying to the patient. Its trial is admissible only in a small nævus of the stellate form, when the slightest scar is objected to. Combined with the breaking up

of the interior of the tumour with a needle, through one place of puncture, it may be more effectual.

The seton is followed by less scarring than any other surgical measure by which the surface is broken. It is, however, uncertain, but its failure is unattended with any disadvantage, save disappointment, while it does not render the nævus at all less fit for other treatment. Threads of various materials and size, are passed by a needle in several directions, and at different depths. They may be charged with irritant fluids, such as a solution of lunar caustic, or of caustic potash, or the tincture of the perchloride of iron, or croton oil, or the tincture of cantharides. As a precaution against hæmorrhage, the seton should fill the wound made for it. I should not resort to it except for a small tumour. Should it be applied to a large one, the threads must be so passed in all directions, as to leave but very small interspaces.

I subjoin an example of the practice in the infant daughter of a physician. The child was born with a nævus at the inner angle of the eye, not larger than a pin's head. In six weeks it had acquired the size of a bean. Twisted threads, which had been moistened in a solution of caustic potash, were passed into it, in several directions, with a curved needle, and retained for three days. Slight inflammation was excited, a healthy eschar formed, and the nævus was cured. Neither contraction of surrounding skin, nor of the cartilage of the eyelid, followed. The lacrymal sac was uninjured, and the scar is just perceptible, as the figure indicates.

Fig. 59.

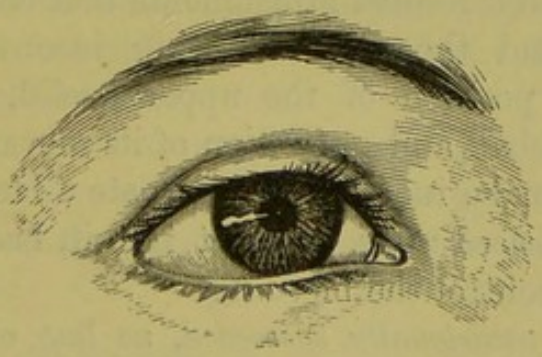

Very slight degree of contraction of the soft parts at the internal angle of the eye would have drawn the puncta lacrymalia away from the eyeball, and might, if considerable, have been injurious to the lacrymal sac.

Intense cold is an agent that has of late been much spoken of and advocated. I have given the method a full trial, and cannot recommend it. With much care I have persisted with it in individual

instances of growing nævi; I have applied it as often as twenty times, on each occasion the surface being frozen, and never have I been able to arrest the increase.

A plan of cutting and searing nævi by means of a piece of platinum wire made red-hot by a galvanic current, has been applied by Mr. Marshall. The application of heat, produced by ordinary means, has long been practised. M. Carron du Villards passed long pins through the greatest diameter of the tumour, bent them till their extremities met, united them by a metallic knot, and then applied the flame of a candle to the pins till they were of a white heat, moistening the tumour during the while with oil; a practice together with the actual cautery of M. Cloquet, not likely to be generally followed in England. Puncture with red-hot needles is, however, recommended and practised by some English and American surgeons. Troublesome suppuration and contraction often ensue.

Removal by extirpation is of old date; it is somewhat dangerous, from hæmorrhage, and not lightly to be undertaken. It should not be practised in small nævi, on account of the unnecessary sacrifice of healthy tissue, to say nothing of the hæmorrhage. Allan Burns, in his "Surgical Anatomy of the Head and Neck," gives an instance of a cutaneous nævus that he extirpated from the eye, temple, and side of the face, in a middle-aged man. A part of the upper eyelid, and the outer part of the eyeball, including the conjunctiva and the sclerotica, were involved. The operation was undertaken because of the growth increasing, especially in its ocular portion, and threatening to obscure the eye, and also the patient's anxious desire to be relieved of it. A very tedious and intricate dissection was required; the tumour dipped in and formed attachments that could not be foretold. Success ensued, and the only resulting inconvenience was some alteration in the position of the upper eyelid, in consequence of adhesion to the eyeball and restriction of its movement.

Should a surgeon be induced to extirpate a large nævus, he must cut beyond the diseased mass, and not into it, because of then being able the better to control the bleeding.

Vaccination has occasionally succeeded, as has every other irritant treatment that has been tried; but I have seen it cause very rapid increase in several cases. It would seem to be most applicable where a single pustule would circumscribe the nævus. The late Dr. Gregory, of the Small-pox Hospital, who tried it most extensively, told me that from the frequent failures he had ceased to employ it.

Escharotics form a very powerful and efficient class of remedies, and are frequently used. Potassa caustica and nitric acid are to be preferred. The surrounding parts should be protected by plaster, or

substances that will neutralize these chemical agents. I never use the potash on the face or any exposed part, on account of the liability of sloughing beyond the extent of surface touched. I have already alluded to this drug in the treatment of caries of the orbit, and the remarks apply here also. The "Potassa c. calce" is not open to this objection; it is far more manageable, and does not deliquesce so quickly; indeed, it might be called a safe application. I have not myself employed it in these cases.

During the several years of my pupilage to Sir W. Lawrence, he employed nitric acid in the treatment of all cases of cutaneous nævi, applying it by means of a little mop of lint, tied on a stick, a plan generally adopted at St. Bartholomew's Hospital during the time of my connection there. In this way I destroyed the largest cutaneous nævus I ever saw. The late Mr. Hey, and myself, were summoned to a gentleman's seat, in Yorkshire, to treat a nævus on the leg of a child three months old. It seemed cutaneous, was mottled red and purple, raised about half an inch from the surface, and occupied rather more than the central third of the leg, very nearly encircling it, a thin strip of integument at the back being sound. At birth, it was the size of a five-shilling piece, and till the child was a month old, it was nearly level with the skin, and had not spread. A single application of the acid sufficed. The whole of the eschar did not separate till the expiration of three months. I have by this method treated very many small nævi on the eyelids, and with the best result. I usually, however, apply the acid with a glass rod, more or less pointed. The nævus should be touched with the acid till it is charred. After the eschar separates, any parts which have not been destroyed, should be re-touched. It is generally about the edge of the nævus that the re-application is required. The strongest acid which is made should be used.

The acid in combination with mercury is a better agent, as it penetrates more readily, and is more manageable. Mr. Startin, to whom I am indebted for many practical hints in surgery, gave me this formula for it:

Hydrargyrum, ʒj.
Acidum Nitricum, sp. gr. 1·40, ʒij.

The acid treatment is the most certain and least irritating, and the least disfiguring of any that involves removal of surface. It is admirably adapted for the very superficial nævi, and for those that are very irregular in outline.

The injecting of irritant fluids. This was introduced by the late Mr. Lloyd. His method was to puncture the integument at some

distance from the tumour, introduce the nozzle of a syringe, and inject the fluid. Some of the objections, such as the risk of extravasation of the fluid, and the liability to extensive and violent inflammation and sloughing, which would be especially dangerous in the vicinity of the eye, have been in a considerable degree obviated by the employment of more delicate instruments, one of which is a screw syringe, an appliance that secures the utmost precision as to the quantity of the agent used, and the direction in which it is thrown, and by the employment of fluids such as solutions of perchloride of iron, and of tannic acid, which are not merely irritants, but at once coagulate the blood. Thus modified, this treatment has of late years been extensively tried.

Fig. 60.

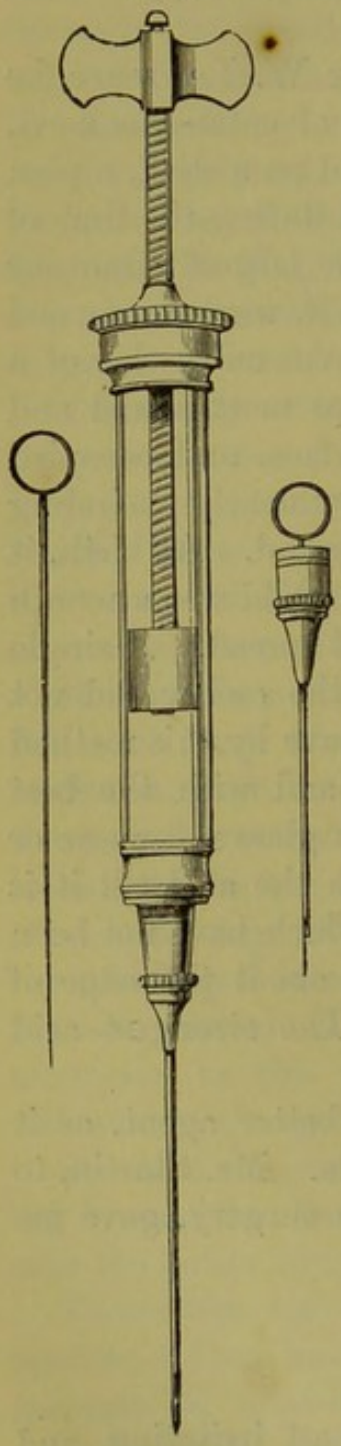

Fig. 60, shows the instrument. On the one side is a stilette for cleaning the tube in the syringe. On the other, a spare tube with a stilette in it. But this practice is almost inapplicable for this form of nævus. I have never resorted to it, although it is very valuable for the sub-cutaneous class.

The twisted suture, called also harelip suture, is resorted to by some surgeons. A pin is passed through the tumour, and a thread carried over it, in a figure of 8. If the object be to cut off the supply of blood, several pins are generally used, and made to circumscribe the base of the nævus. The suture should not be used merely as a means of exciting inflammation, since it is less effectual for this purpose than the seton, and is sure to be attended by a well-marked scar, should the pin be allowed to ulcerate its way out.

The ligature in various forms, to cause strangulation of the nævus, is in common use, and is to be relied upon, and is the more suitable in proportion as the nævus loses its superficial character. The most simple manner of applying it is to transfix the base of the tumour with pins of soft steel, to tie it with a strong string below them, and to conclude by cutting off the pin points.

Sometimes, when the tumour is small, only one pin is required, but two are generally needed, and when they are, they should be placed at right angles to each other. The ligature should be allowed

to remain till the nævus surface is blackened over, and the superficies evinces a loss of vitality, by which time the entire nævus is generally destroyed. As tying the skin gives great pain, and will in children sometimes produce constitutional disturbance, it should be spared as much as possible.

A single ligature will suffice only when the nævus is narrow; if it be broad, the centre cannot be constricted, except more than one noose be used, and a double ligature should then be applied with a needle, set in a handle. The tumour is transfixed, and each half tied separately. Sometimes, from the form of the nævus, many ligatures

Fig. 61.

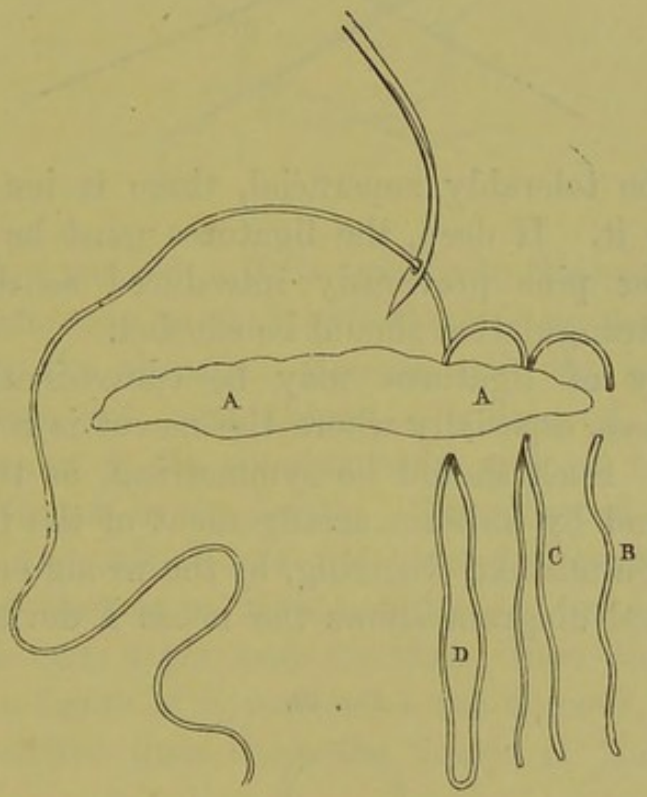

A, A, Projecting nævus to be tied.
B, Single ligature, passed beyond the limits of the growth.
C, Cut extremity of the first loop, to form a knot with B.
D, Third loop, uncut.

are required, in which case the needle must be passed across at short intervals, so that the entire growth may be traversed, and every part included within the circles of the thread, as above represented.

Mr. Luke's method may be adopted when several ligatures are necessary. He threads several straight or curved needles, apart from each other about twelve inches, with one long thread, the length of which corresponds with the size of the tumour to be treated. The needles are passed in a row under the tumour, as represented in

Fig. 62. They are then removed by cutting the ligature near to the eye of each; and a succession of loops is tightened by tying *a* with *a*, *b* with *b*, *c* with *c*, and so on to the end.

Fig. 62.

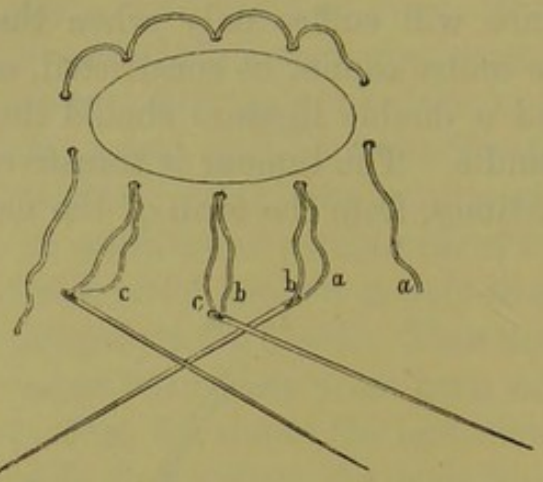

If a nævus be tolerably superficial, there is not any difficulty in thus treating it. If deep, the ligatures must be kept down by being tied under pins previously introduced as deeply as it is necessary, that strangulation should be effected.

A multiplicity of ligatures may be conveniently replaced in particular instances, especially where the nævus is round, by certain forms of noose. Such should be symmetrical, as ties work better when so made, and by uniform arrangement of the threads, there is less likelihood of a mistake occurring, by the wrong ends being taken up. The annexed diagram shows the noose I devised, and which

Fig. 63.

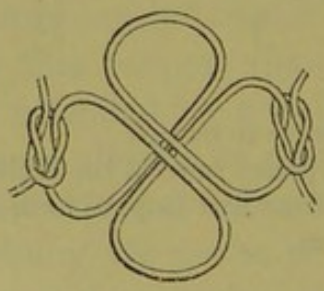

is tied in the following manner. A nævus needle, with an eye sufficiently large to be readily threaded, armed with a double thread, is passed obliquely from left to right across and under the tumour. The bow of the thread is divided, the thread disengaged, and the needle withdrawn. The needle is again threaded with the upper end of the thread on the right side, brought round on the right, entered midway between the two punctures, and carried directly across; the thread is disengaged, the needle not yet withdrawn, but

first threaded with the lower end of the thread, on the left side of the first puncture, and then drawn back. If these directions have been correctly followed, the tie will have the form of Fig. 64.

Fig. 64.

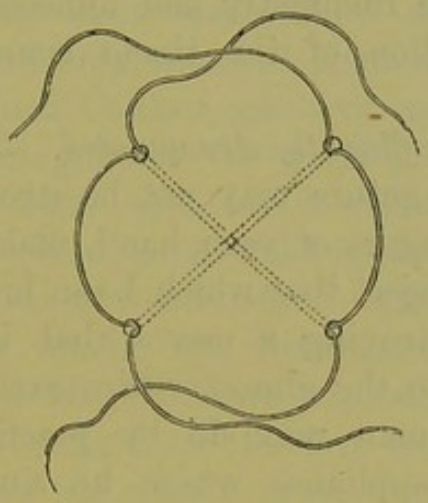

In the following method, a little inferior to the symmetrical noose, the common needle may be used, and there is no liability to make a mistake in tying the threads. Blacken half the length of a long white thread with ink, and thread a wide-eyed needle with it. Transfix the tumour in the common way, and cut the bow so as to keep the black thread in the needle. Then thread the needle also with the white end, which has not passed through the tumour, and transfix the tumour at right angles to the former direction. Draw the white ends tight and tie them, then the black. Each thread includes a figure of 8 portion of the tumour, as is shown in Fig. 65. The dotted lines show the course of threads under the tumour.

Fig. 65.

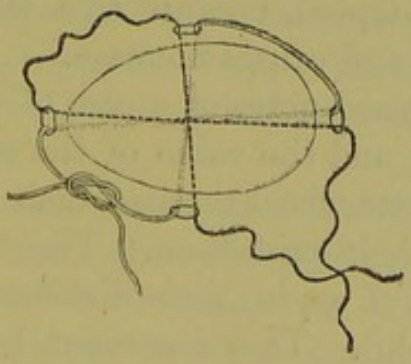

It may be sometimes advisable to cut the skin, and so make a channel for the threads. Should any part of the tumour seem likely

to slip from the grasp of the ligature, a pin should be temporarily pushed into it to keep the ligature down.

I remove the ligatures, as a rule, as soon as it is evident that the tied parts have lost their vitality, and then apply the suitable dressing, to facilitate the separation of the dead materials. To allow them systematically to be cast off by sloughing, except in instances of very small nævi, would be frequently and unnecessarily to cause undue severity and destruction of the tissue beneath, and to prolong recovery.

A nævus should be sufficiently strangulated. This caution I know to be necessary. The ligature may not be strong enough. I always wrap it round the fingers of each hand, make a steady pull, and so test its strength. I reject that which I can break without a jerk.

Any plan for destroying a nævus that is tolerably successful, might be employed to the almost entire exclusion of others. It is astonishing what a man may do by practice, perseverance, and ingenuity, with an appliance which he singles out, and uses in general in surgical treatment, even although it is inferior of its sort. He may surpass most men with less tact, who have the advantage of superior measures. Such an one would laud his system above all others, and give it, for a time at least, undue prominence. This applies to the treatment of nævi. There is, however, a choice to be made, and an adaptation of means to cases and to individual peculiarities.

When a nævus passes through the entire thickness of the skin, and becomes as well, partly subcutaneous, there is more difficulty in destroying it, and the treatment must be modified. Strangulation is now called for. Half measures will not suffice. I have seen failures from want of boldness, and from dread of doing too much. According to its size, form, and activity of growth, it might be requisite to employ several measures consecutively, or even simultaneously. Directly that one system is observed to fail, another must be immediately adopted, because that which does not cure, for the most part irritates, and causes increase.

The following condensed notes of a case of this kind show how all treatment was baffled; and the value of the example is enhanced by the fact that the surgeons who exercised their skill had attained the highest eminence in their profession. Two distinct red spots, not larger than the point of a pin, were discovered fourteen days after birth, on the lower eyelid. They increased, but were not treated till the child was nine weeks old. Mr. Aston Key applied caustic potash without decided effect, a very small portion only having been used, through fear of the escharotic entering the eye. The potash

was again applied, and repeated five times. It was now considered necessary to use nitrate of silver from time to time. The family left town for another residence, and as the nævus still increased, Mr. Key was written to. He ordered local application of the tincture of iodine. Two months later when he saw the child, he was greatly surprised to find how much the nævus had augmented. Before the time appointed for the next consultation had arrived, this able surgeon was almost suddenly removed from his extensive sphere of usefulness. Mr. William Coulson was now consulted; he employed the ligature, and strangulated the greater part of the growth. He afterwards used nitric acid, which excited a severe purulent ophthalmia, followed by an abscess of the upper eyelid. Sir Benjamin Brodie and Mr. Coulson now attended. The baronet's method of puncturing and using caustic was four times adopted. Still the disease crept on, and at Mr. Coulson's request, I was now consulted, at a period of eleven months from the first treatment. I found the cheek much scarred, and the cutaneous portion of the nævus nearly destroyed, but the subcutaneous part was in full activity. The space from the external angle of the eye to the angle of the mouth, and to the side of the nose, was occupied by it. The bridge of the nose was also traversed, and a narrow portion was stealing under the other eyelid. It was no easy matter to decide on what should be done, on account of the very great extent, the peculiarly irregular outline, the position of the disease, and the probability of eversion of the eyelid, should sloughing ensue. There was a slight amount of eversion after the use of the ligature, but this had passed away. I decided on passing some fifteen or twenty threads in many directions, as a first trial. The day was arranged for this, but afterwards postponed, as the child had an attack of measles. I never heard more of my patient.

I was called by Dr. Maurice Davis, to meet several surgeons in consultation on a case like the above, but differing only in being smaller. Several attempts had been made in vain to cure it. I was out-voted in what I proposed. I was afterwards told that many different plans were tried, and at last my suggestion was adopted, and the disease arrested.

Tying the common carotid artery, on the side corresponding to a nævus, has been practised, when the position of the disease about the head or face, or other circumstances, forbade the adoption of any of the foregoing means; or when local measures have proved unavailing; the object being to promote coagulation in the affected vessels, and the propriety of which cannot be questioned. I was informed by the late Mr. Wardrop that, of six instances in which he

tied this artery, three were for nævi. One of these was that of an infant five months old. The disease covered one-half of the root of the nose, the eyebrow, and the upper eyelid, and penetrated the orbit deeply. The colour was pale-blue, and numerous tortuous veins were in the integument. It did not pulsate, was doughy and inelastic, and capable of great diminution by pressure. Complete success ensued.

A case by Dr. Arenat, communicated to the Medico-Chirurgical Society by Mr. Wardrop, illustrated the necessity of tying the carotid artery, as a preparatory measure to other treatment. A man who had from birth several nævi in different parts of his body, received a blow on one of them, situated on the right temple. It increased rapidly in size, acquiring a prodigious bulk in the space of two hours after the injury. The carotid artery was ligatured. The tumour burst during the operation, and the loss of blood was calculated at not less than eight pounds. On the next day the tumour was entirely empty of blood, a considerable portion of skin was cut away, and about twelve small arteries tied. Success followed.

The severity of some cases has necessitated the tying of both carotids. Möller practised it on a child four years old with success. In a child three years of age, Mott obtaining only imperfect results from tying one common carotid artery, subsequently tied that on the other side. It would be useless to multiply examples, for enough has been advanced to prove the legitimacy of these proceedings, which have been frequently successful. Sometimes when the disease has not been removed, it has been checked, and reduced to a harmless state; yet in some few cases, cutting off the direct supply of blood, with the addition of local measures, have failed.

Treatment of the subcutaneous class. The subcutaneous nævus has not a tendency to decrease like the other, therefore, it should be treated as soon as it is discovered.

Fewer methods of treatment are available, and more accuracy and practical skill are needed for obtaining a good result.

Caustic combined with subcutaneous puncture, introduced by Mr. Wardrop, was extensively employed by Sir B. Brodie, and some other surgeons. Sir Benjamin punctured the tumour in several places with a narrow flat-bladed knife, broke up the tissue, introduced a flat probe coated with nitrate of silver, and moved it about in the torn mass. He repeated this at intervals, according to the effect. It has the demerits of being very tedious in action, and requiring repetition.

Injection is a valuable resource on account of its efficacy, and of

the slight after-evidence of treatment in the shape of deformity. There must be restriction in the use of agents.

The Tinctura Ferri Perchloridi is unfitted unless only a drop or two be injected. The French preparation for the same is less liable to set up intense inflammation. Yet as I have seen abscess follow the employment of both, I do not venture to use either about the eye. To overcome this, it has been proposed to use a neutral tincture of the iron, such as is prepared by Mr. Squire, of Oxford-street; but then, the acid being removed, the coagulating property of the liquid is lost.

I have often employed with perfect success, tannic acid, one drachm of the acid, with an ounce of water; not a saturated solution, as an ounce of water takes up readily two drachms. I generally use the screw syringe. I insert the point at the most prominent part of the nævus, and then gently inject a few drops or more of the fluid. When this is sufficiently done, the tumour becomes hard, through coagulation of the blood. Sometimes I break up the structure of the nævus before injecting. I have done this only in those nævi that were dense. Should an ordinary syringe be employed, much force must not be used, or extravasation into healthy textures may ensue. Sloughing would follow such an occurrence. There is an intimate connection subsisting between the reticular texture of the lobes of nævi and the veins. A few days after the operation a dark-coloured discharge may issue from the point of puncture, but the coagulated blood is generally absorbed without this.

I have resorted to injection more often than to any other method, and I still give it the preference in the greater number of cases. It is most sure, and does not disfigure. If it fail, it is only in part, and then the repetition is easy. It causes no suffering, and seldom any constitutional irritation, unless the nævus be large.

A remarkable case treated by me, in which the nævus involved the eyelid, and passed deep into the orbit, is published in detail in the "Medico-Chirurgical Transactions" for 1857–58. I give here but an abstract.

A young lady was sent to me by Mr. Square, of Plymouth, under whose care she had been. The tumour was on the left side. The eyeball was a little everted, much restricted in motion, and incapable of rotation inwards. The lower eyelid was prominent, of a bluish tint, traversed by large veins, and just above the edge of it, and in connection with the conjunctiva, appeared a part of a vascular tumour, around which there were many contorted veins, some of them as large as a crow-quill. By depressing the eyelid more of the tumour was brought into view, and a very cursory examination now

showed that the diseased mass certainly extended far into the orbit, and probably elsewhere. Vision was very much impaired. There was frequently pain in the part, as well as in the forehead and face, and especially at the menstrual period. There had been inability to lie flat in bed for many months, and this, as well as general distress, made the lady very anxious for relief. Some years before, she had consulted Sir B. Brodie, Messrs. Lawrence, Tyrrell, Dalrymple, Sir William Fergusson, and Bowman, all of whom advised delay. An attempt was subsequently made to arrest the growth by some surgical treatment, but ineffectually. Fig. 66 illustrates the tumour.

Fig. 66.

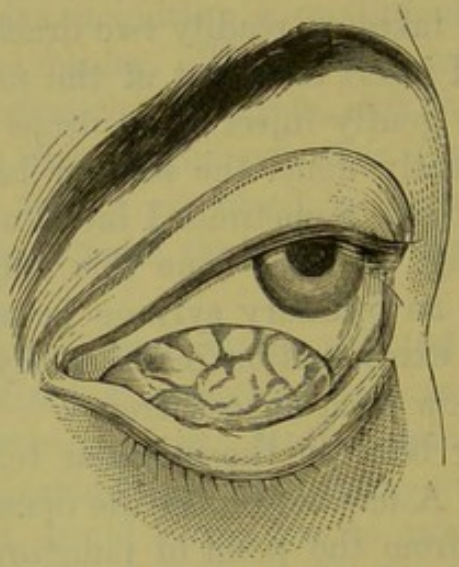

I determined to inject with tannic acid. In the presence of Mr. Square, and some other surgeons, I made a small opening, introduced the coarse nozzle of an Anel's syringe, and injected a syringeful of a solution of tannic acid. Hæmorrhage, which was for a few seconds copious, soon ceased, and the tumour became solid. I suspected that much blood would escape, and that a good deal of injection would be required, and therefore I used this syringe.

Severe inflammatory action, abscess, with discharge of the solidified blood, and great constitutional fever, followed the operation. In three months the abscess had healed, the eyeball had sunk to its natural level, the tumour was destroyed, and all the distress occasioned by it had passed away. At this date, Sept. 23, 1870, the cure is still complete. The ocular movements are restricted, and there is no vision, but the eyeball looks quite natural. My patient is well satisfied with the result.

The circumstances that induced me to resort to tannic acid, together with my experiments with it, and with preparations of iron, are given in the volume above referred to.

Extirpation is sometimes resorted to by surgeons. The skin is reflected, and the dissection completed. It has always appeared to me to be the most severe mode of effecting a cure, and it is one which is nearly always followed by much disfigurement. As soon as any large vein is cut, the nævus generally collapses, and the dissection becomes difficult. Where the nævus is thoroughly subcutaneous, it is generally encapsuled, and this is most perfect in those with predominance of the venous element. In consequence of the usual varicose state of the vessels immediately outside the tumour, a condition to which I have drawn attention, the dissection should be made sufficiently far to escape it.

The tying process is a good one, but its application must be subcutaneous. The oldest method is to divide the surrounding skin by a crucial incision, to reflect it, to pass a pin or two across the base of the tumour, and then to tie it; or to tie it without the pins. The intention is to get at the diseased mass, and to destroy it without

FIG. 67.

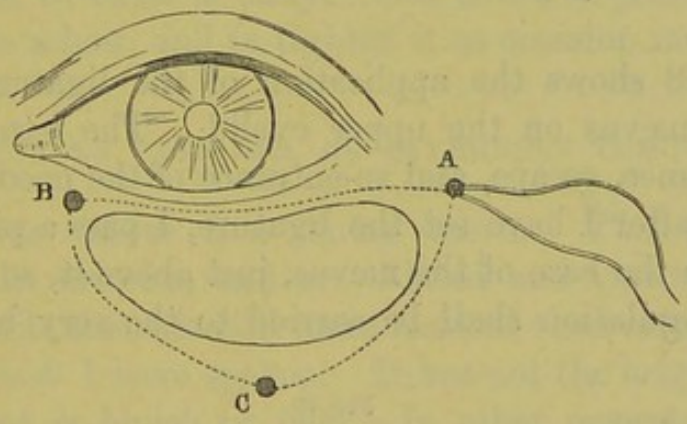

A, Point at which the ligature was introduced.
B, Point at which the ligature was brought out and again inserted.
C, Second point of exit and third of insertion.
The dotted line marks the course of the ligature subcutaneously.

spoiling a corresponding amount of skin. This is, however, too severe for the region of the eye, and fortunately it is never needed, as a nævus there can always be tied subcutaneously, and without breaking the skin, except at the puncture where the ligature is introduced. I believe that Mr. Curling, late of the London Hospital, was the first to do this. The above diagram is from a sketch of his, and is intended to show a nævus of the lower lid so treated. Setons had been used by him and failed, and another surgeon had applied escharotics several times in vain. Of the manner of operating: he took a slightly curved needle armed with a strong silk ligature, and inserted it at the outer margin of the eyelid, passed it close beneath

the skin transversely across near the margin of the palpebra, and brought it out at the inner side of the swelling. He then re-inserted it at the point of exit, carried it in like manner close underneath the skin downward, and brought it out below the lowest part of the nævus. The needle was again introduced at the point of exit, and carried upwards beneath the skin to the point at which it was first inserted. By this there was subcutaneous encircling of the whole of the morbid growth. The ligature ends were then drawn tight and tied. The nævus was entirely obliterated.

Fig. 68.

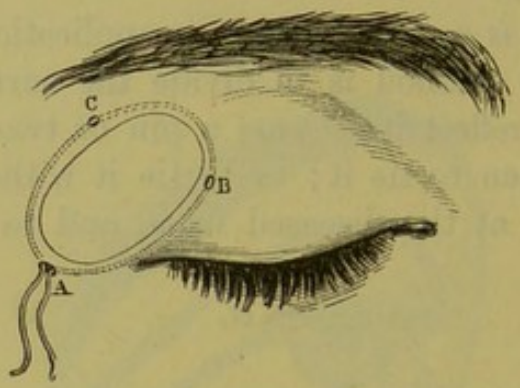

The Fig. 68 shows the application of the ligature in the same manner to a nævus on the upper eyelid. The letters indicate the points of entrance, escape, and re-entrance of the needle.

Sometimes after I have set the ligature, I pass a pin, or several of them, through the base of the nævus, just above it, so that when it is tied, the strangulation shall be carried to the very bottom. I have

Fig. 69.

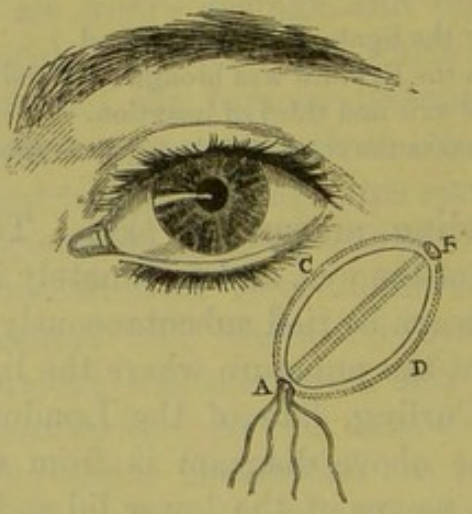

on the same principle drawn the nævus up with a tenaculum before drawing the noose. Such assistance is chiefly required when the nævus is not prominent, and the parts to be tied are deep.

The subcutaneous tie may be made multiple, when a tumour needs to be strangulated in portions. It may be effected in this manner. The armed needle is passed transversely under the nævus, from the one side of its base to the other, as in the Fig. 69, from A to B. The loop is then cut and the needle set free. The needle is again armed with an end at D, and carried round one side of the base of the nævus, in the course of the dotted line B C A; then another needle is armed with the other end, and carried round the other side, in the course of the dotted line B D A. Each ligature is to be drawn tight and tied at A.

I have applied my symmetrical noose, Fig. 63, subcutaneously. My patient was a child a few months old, brought to me by Dr. Druitt, with a large nævus between the side of the nose and the eyelid. Several kinds of treatment had been ineffectually tried, and the disease was progressing. I carried the ligature down to the periosteum. The nævus was destroyed.

The ligature must be allowed to come away uncut. The process is slowly effected, if unassisted, therefore it is better after suppuration has set in to twist it daily. But a better plan is, in the first instance, to tie a bow, and to tighten it as occasion may require.

VENOUS VASCULAR, OR CAVERNOUS TUMOUR.

The cavernous tumour is a venous nævus. The veins are much larger than the arteries, and are dilated and varicose. Its resemblance to erectile tissue is still more marked than any of the vascular tumours of which I have spoken. It has not the bright red colour of the nævus, but is bluish or pale. In other respects, namely, as to origin, position, increase, and erectile property, it is like a nævus.

Wecker devotes much space to the description and delineation of this tumour. I suspect that some of the cases which he quotes are in reality those of the true nævus or capillary vascular tumour.

Dr. Payne, the teacher of morbid anatomy at St. Mary's Hospital School, has recently met with several of these tumours in a patient's liver. He kindly demonstrated their structure to me.

The treatment is the same as that which is necessary for nævi.

LYMPHATIC CAVERNOUS VASCULAR TUMOUR.

Of this tumour, I have no practical knowledge, either in connection with the eyelid or elsewhere. The account I shall give of it is borrowed from Mr. Paget's "Lectures on Surgical Pathology," edited by Turner. I quote all that is said on the subject.

"Cases in which one or more of the lymphatic vessels of a part have been dilated, and in which the dilatation either was or was not associated with expansion of the lymph-spaces within the lymphatic glands, have occasionally been described. But other, though rarely seen, cases have been observed, in which not merely had a dilatation of the normal lymph-vessels of a region taken place, but an actual new formation of such vessels had apparently occurred. A tumour had been in this manner produced, which, in its structure, was similar to the venous cavernous tumour, except that the spaces did not contain blood, but a fluid which closely resembled lymph. Tumours of this kind have been named cavernous lymph-angeioma, or lymph-vascular tumours. Like the cavernous blood-vascular tumours, they possess the property of erectility. These growths seem more especially to affect the tongue, occasioning one of the forms of makro-glossie, the lips, the cheeks, and the eyelids. They are usually congenital. Billroth has described an illustrative case, in the lower lip, where a semi-globular tumour was composed of a cavernous tissue, the bars of which consisted of connective tissue, which contained many elastic fibres and blood-vessels. The spaces were lined by an epithelium. They contained a clot with a serous fluid, in which small corpuscles like those of lymph were found."

ARTERIAL ERECTILE TUMOUR OR ANEURISM BY ANASTOMOSIS.

This aneurism in its most marked form, consists of the natural vessels of some portion of tissue, usually the subcutaneous or submucous, enlarged and closely packed, so as to form a tumour, in the substance of which, and round about, are larger, dilated, and thin-walled arteries, twisted into pulsating masses. The arteries in the immediate vicinity are enlarged, and even the large trunks from which they spring may be increased in size.

The veins are smaller than the arteries, by which there is a kind of obstruction to the return of the blood. All the large vessels are sometimes much degenerated, and the areolar tissue connecting them often gets coarse and cellulo-fibrous.

The tumour pulsates perceptibly, giving also to the hand placed on it, a thrilling sensation; while by means of the stethoscope, a whizzing or buzzing bruit is heard.

It is nearly always congenital, but it may be perhaps acquired, yet it rarely begins except in young people.

The more it is fed by large vessels, the quicker does it grow.

However small the disease might be in the beginning, it always grows.

Treatment. If the tumour be superficial and small, it can be got rid of by excision or strangulation. By the first method there is some danger from hæmorrhage. Able assistants should be engaged, and the operation executed very rapidly.

When the disease is about the appendages of the eye, the ligature is I believe always preferable, and the manner of tying to produce strangulation is in all respects the same as for nævus. I have successfully tied one on the lip, one on the lower eyelid, one on the cheek, and another on the back, of four individual children.

Sometimes, and especially when the tumour is large, surgical resources are taxed to the utmost. The most energetic attempts at strangulating, or even ligaturing the arteries passing into it, may fail to effect a cure. Examples of the latter are to be found in cases recorded by Messrs. Lawrence, Bell, Brodie, and Warren. Even the bolder procedure of tying the main artery supplying the region of the body in which the growth is situated, is sometimes ineffectual, especially when the tumour is about the head or face.

Dr. Massey, of America, tied both common carotid arteries, within an interval of twelve days, for a large congenital nævus upon the head of a man, and was obliged ultimately to dissect the diseased structure away.

Mr. Collis relates the case of a young man, in the "Dublin Hospital Gazette," for 1858, who had almost all his life been under treatment for a large nævus over the right parietal bone. Pressure, ligature of the posterior auricular artery, and subsequently of the carotid, had been tried without effect. Six large arteries which could be felt leading to it were obliterated by the twisted suture; this failing, the entire growth was surrounded with a circle of fourteen pins and twisted sutures, and these were allowed to cut their way out, a process which required six weeks. This was only partially successful, and setons were tried; at first simple, then of woollen thread charged with a solution of sulphate of copper. By this means inflammation was set up, and an abscess formed; but it was still found necessary to apply caustic freely before a cure could be effected.

Aneurism by anastomosis in the orbit, is an exceedingly rare affection, very few cases having been met with. Many which have been published as such, were but examples of inter-cranial disease of the carotid artery. I allude especially to those narrated by Travers, Dalrymple, Guthrie, and Scott. The late Mr. Nunneley pointed this out long ago, in an elaborate paper published in the "Medico-Chirurgical Transactions." He showed that aneurism

by anastomosis does not appear suddenly, that its increase is always slow and gradual, that it is not caused by direct violence, and that its circulation and pulsation are not necessarily checked by tying the main artery of supply. He alludes in contrast to the following existing conditions. Nearly all the patients were adults. No mention is made of congenital development of the disease. The tumours often appeared suddenly, and had traumatic origins. Tying the carotid artery, stopped the pulsation, the thrill, and the tumefaction.

The following example of unmistakable aneurism by anastomosis occurred to myself.

A remarkably fine girl, two months old, was brought to me at the Central London Ophthalmic Hospital, in 1851, with a slight prominence of the right eyeball, which had been discovered within a

FIG. 70.



month after birth. The cause of protrusion was not apparent, and after a few visits, the infant was not again brought till she was four months old. Now the eyeball was prominent, the eyelids swollen, the cheek puffy, and the conjunctiva thickly set with large bright-red vessels. Pressure on the eyeball lessened the protrusion for a few seconds, while crying increased it and rendered its surface more vascular. In a fortnight there was an increase of all the symptoms;

pulsation was felt, and the stethoscope applied over the eyeball detected an arterial *souffle*, an indication not heard at the other orbit. Those of my colleagues who examined the case, agreed with me that there was an aneurism by anastomosis. It was not considered prudent to apply pressure, on account of the pain which it seemed to produce. The Fig. 70 conveys a good idea of the child's appearance.

On the 5th of June, when the child was four months and three weeks old, with the assistance of Mr. Coulson, Dr. Browne, of Belfast, and Mr. R. Taylor, and with the use of chloroform, I proceeded to tie the common carotid artery. The incision was made an inch and three quarters long, over the course of the artery. The undeveloped state of the muscles of the neck, rendered the use of the knife necessary for their separation. Only a very small portion of the internal jugular vein was seen. The ligature was passed, but not tied till the effect of the chloroform had subsided, as a precautionary measure, but there was not the slightest perceptible effect on the brain when the circulation was checked. Only a few drops of blood were lost.

As soon as the child had become insensible from the chloroform, the protrusion of the eyeball was greatly lessened.

June 6th.—The protrusion remains the same.

7th.—The wound seems to have healed by the first intention. The protrusion is sensibly diminished; the surrounding integuments have a less swollen appearance.

June 10th.—The protrusion is gradually decreasing, and the child can now easily close the eyelids when asleep, which she could not do prior to the operation.

The sutures were removed on the fourth day, and, except where the ligature lay, there was perfect union.

Pressure was now applied on the eyeball by means of pads, retained by an elastic bandage around the head.

The last time I saw the child was three years later. I then took it to St. Mary's Hospital, to show it to my colleagues, and to the pupils. She was well grown and intelligent. She had never evinced the least symptom of cerebral disturbance or disordered intellect. Vision was perfect. The eyeball was yet a little prominent, but not so much as to constitute a deformity, and was not thrown out of its axis. The ocular movements were natural. The pupil was of the same size as that of the other eye, and the iris moved readily. A few tortuous vessels, deeply placed in the conjunctival sinuses, marked the site of the disease; but to get a view of them, the eyelids required to be everted. The vascular supply to the two sides

of the face appeared to be alike. The scar of the incision in the neck was still apparent, but was very small.

An objection to my procedure was taken by some surgeons, who thought the rapidity of the establishment of the collateral circulation at that early period of life, would render the operation useless, and that the disease would progress uninterruptedly. The result fortunately disproved the apprehension.

Mr. G. Southam has recorded a case of this disease in the "Medico-Chirurgical Transactions." It is valuable in showing how it spread, the danger of it, the difficulty of treatment, and the necessity of having several therapeutic resources. The aneurism was at first of limited extent, implicating only the vessels over the upper portion of the parietal bone, but it gradually spread towards the temporal fossa, behind the ear, and in the direction of the occiput. Then the parts over the frontal bone, and the palpebra of the right eye became affected. The patient was now twenty-eight years old. The disease was discovered when she was ten. She came to Mr. Southam on account of hæmorrhage from an ulcer that had formed over the parietal portion. There had been several bleedings, and this, the last, was the most severe. On removing the dressing used to prevent the loss of blood, there was a renewal of hæmorrhage to such an extent that neither local pressure nor styptics could control it, and the common carotid artery was tied above the omo-hyoid muscle, with the desired effect. Three days after, the bandages and the compresses were removed from the head. The ulcerated surfaces were dry, with the exception of the wetting from a few drops of arterial blood which exuded where the lint had adhered. No pulsation was perceptible in the vessels of the temple or any part of the scalp. The wound in the neck was healthy. Six days later, arterial blood flowed from the edge of the ulcer when the part was dressed. Four setons about four inches long were passed in different directions through the tumour. Some after-pulsation near the sore induced Mr. Southam to pass three more setons into the largest vessels, and this stopped the pulsation in an hour. The carotid ligature came away favourably, and the setons promoted free suppuration. Pulsation being seen more than a month after, over a small spot, a seton was inserted along the length of the artery. Seven months subsequent, the report says, "Scalp carefully examined, but not the slightest trace of the disease could be discovered." This is of course a very condensed abstract; nor is notice taken of some sloughing over the eyelid, on the scalp, and other things of secondary moment.

In making some concluding remarks, I begin by advising no delay of treatment when it is well ascertained that an aneurism by

anastomosis is present. I strongly advise the avoiding of any timid half-measures, when any severe case is to be treated. There should be careful deliberation, a plan maturely arranged, and promptly and fully carried into effect. I give emphatic warning against such meddlings as are likely only to irritate and to augment the tumour, to whip it into furious activity, and to render the cure more difficult.

In a very severe case, and the greater the superficies the more severe, local treatment alone, or the tying of the main vessel supplying the region of the body in which the tumour is situated, alone may fail. The first may be ineffectual because all the diseased arteries are not reached and acted on; the second because consolidation is not generally induced by a clot, or by the deposit of fibrinous layers in the vessels, as the nature of the disease does not readily admit of it, there being no central and single sac, and without clot or deposit, a complete arrest of the circulation through the distended arteries cannot take place. It must be remembered that not only the arteries, but the veins also are enlarged, and the capillaries too. I should be disposed at once to commence the double treatment, to tie the main vessel, in order to depress the circulation in the tumour, and to adopt local measures; selecting, as a rule, the seton before anything, and using coarse worsted threads, with the idea of plugging the apertures that the needle makes. I think that Mr. Southam's practice of passing the threads into the vessels themselves to be good.

By tying the main artery the circulation is weakened in the tumour, not arrested; and coagulation may perhaps partly occur, causing obliteration to a limited extent. All the vessels of the tumour are, too, comparatively emptied, and must remain so until the collateral circulation is fully established. This is the best time then for the local attack.

CHAPTER XI.

ANEURISM IN CONNECTION WITH THE EYE.

ANEURISM IN THE ORBIT—INTRA-CRANIAL ANEURISM OF THE CAROTID ARTERY—VASCULAR PROTRUSION OF THE EYEBALL—TRAUMATIC ANEURISM OF THE FRONTAL BRANCH OF THE OPHTHALMIC ARTERY—ANEURISM OF THE CENTRAL ARTERY OF THE RETINA.

ANEURISM IN THE ORBIT. INTRA-CRANIAL ANEURISM OF THE CAROTID ARTERY.

According to the present state of knowledge, true or diffuse aneurism in the orbit, that is aneurism of the ophthalmic artery, must be regarded as a very rare affection. Indeed it is almost unknown if unequivocal evidence of its existence be demanded. It is very unlikely to occur in consequence of the small size of the vessel. It has been simulated by aneurismal disease, and by inflammation of accessory parts of the vascular system in relation to the orbit, such as the cavernous sinus, and also by disease having only an accidental presence near the eye, and arising from a new product, such as cancer. This is at variance to what was taught up to a few years ago, and it illustrates on what uncertain basis does the diagnosis of many physical changes rest, when unconfirmed by sight, or touch. My meaning will be more apparent as I proceed.

It fell to the lot of the late Mr. T. Nunneley to be the man in his generation to put us right in this matter of aneurism. In the forty-eighth volume of the "Medico-Chirurgical Transactions," is a paper by him on "Vascular Protrusion of the Eyeball," which may be considered a continuation of his communication in the forty-second volume of the same Transactions, on "Aneurism by Anastomosis in the Orbit," particularly noticed in my preceding chapter. In it he

says that, although he is not prepared to assert that true aneurism can never occur to any of the intra-orbital arteries, or that possibly some of the reported cases were not of this nature, he fully believes that in several of them there has not existed any aneurism at all, and in the great majority, where there was aneurism, this disease was within the cranium. Further, he states that the prominent symptoms described in these cases would not essentially depend upon an aneurism, either true, or false, whether in the orbit, or in the cranium, as a primary or necessary cause, though they might be secondary. More than this, they might arise from other and varied causes, which produce post-ocular pressure upon the ophthalmic veins. For this reason he has ventured to suggest the name of "Vascular Protrusion of the Eyeball," as more in accordance with the pathology of the affection than the name of aneurism of the eye, or orbit, which may or may not exist, while he believes that direct or indirect pressure upon the ophthalmic vein will always be found. He narrates four additional cases of his own, and adduces others from which he forms his opinion.

Case 1. *Traumatic vascular protrusion of the eyeball.* A publican, while drunk, was thrown from his horse, and continued insensible for four days, with all the symptoms of fracture at the base of the skull. Some days after, symptoms of what seemed to be acute conjunctivitis with pain came on, and for this, a month after the accident, Mr. Nunneley was consulted. The eyelids were now swollen and dark; they could not be closed over the eyeball. The conjunctiva was greatly chemosed and purple, with large congested blood-vessels. The eyeball protruded considerably, and was much congested. The pupil was dilated and inactive, and the lens dusky. Vision was greatly impaired. There was pain in the eyeball, in which pulsation also was perceptible to sight and to touch. A bruit was heard by the stethoscope. The patient's intellect was confused, and he was troubled with noises in his head, and pulsation in his left ear, the function of which was much impaired. All these symptoms were materially checked by pressure on the left carotid artery. Local and general treatment was tried with no effect. Matters being worse at the end of the week, the left carotid artery was tied. There was a sudden reduction in all the symptoms. The eyeball returned to its proper position. Sight was so far recovered that he could read moderate-sized print with ease. The noise in the head ceased and the hearing was restored. Twelve months after the operation the eye looked so healthy, that no one could tell anything had been amiss, except by careful examination.

Case 2. *Protrusion of spontaneous origin, treatment declined.* A

robust short woman applied to Mr. Nunneley, in May, 1864. The eyeball was protruded and congested, the conjunctiva red and tumid, the pupil dilated and sluggish. There was a throbbing pain in the orbit, and the eyeball pulsated synchronously with the pulse. There was dulness of hearing, and noise in the ear of the same side, with giddiness. Pressure on the carotid artery lessened all the symptoms. Five months before, while getting out of bed, she was seized with a "giddy fainting fit, and something queer in the head," immediately after which the eye began to be affected, and had gradually got worse. She declined to have anything done. Her symptoms became worse from time to time.

Case 3. *Cancer in the orbit and cavernous sinus; deligation of carotid artery; cure of protrusion of eyeball; subsequent death; examination.* This case was watched for two years and a half. Neither Mr. Nunneley nor any of the many medical men who saw it were sure of its pathology. A stout, thick, broad-set man, aged forty-three, applied with considerable protrusion of the right eyeball, of four months' duration. There was vascularity of the surface of the eye, indistinct pulsation, and dimness of vision. He had giddiness and confusion in the head. He had a very large bronchocele and a large sternal tumour. The eyeball continued to project, until it protruded altogether beyond the orbit. It was more congested than formerly. The orbit was filled with a soft pulsating mass. In association with this were some soft, pulsating, compressible tumours without the orbit. It was certain that the protrusion of the eyeball was due to posterior if not inter-cranial pressure, which was distinctly relieved by closure of the carotid artery. His vision was lost; sloughing of the eyeball was impending, and the head symptoms were getting more distressing. The carotid artery was tied. On tightening the ligature, all noise and confusion in the head instantly ceased, the eyeball became less prominent, and the two external tumours lessened in size and ceased to pulsate. Erysipelas followed, and the man became hemiplegic. The report goes on to say, the orbital mass gradually lessened, and there was no pulsation in it or the cranial tumours. After various illnesses, the man sank a year after from exhausting diarrhœa. "On opening the skull the surface of the brain was found covered with serum; its structure was soft, but otherwise normal. By the side of the sella turcica, passing through an opening into the apex of the right orbit, was a continuation of the diseased orbital mass, which had obliterated the right cavernous sinus. The mass was more solid than those on the head. The ophthalmic vein had been pressed on until it was lost in the mass, thus, in my judgment, proving that the ocular protrusion was

essentially of the same nature in this as in the other cases I have reported, different as the material causing the pressure might be. The vessels constituting the circle of Willis were alike on both sides." The carotid artery had been securely tied. Below the ligature it was much dilated. The left carotid in its whole course was also dilated. Both vessels would just admit the tip of the little finger.

Case 4. This gives the post-mortem examination of a case related in the first paper in the "Medico-Chirurgical Transactions." The facts during life were these. The disease began instantaneously. The carotid artery was tied three weeks afterwards. The woman recovered, although some time elapsed before the eyeball returned to its natural position, and the swelling and congestion of the eyelids had passed away. Opacity of the lens, and a little dulness of the sclerotica, were all that remained. Four years and a half afterwards she died of serous apoplexy. On the right side of the sella turcica was found a circumscribed aneurism of the ophthalmic artery, just at its origin, as large as a hazel-nut, which was filled with a dense solid red clot, so loosely attached to the arterial walls, that when these were cut into the clot at once fell out. The ophthalmic artery and its branches were small.

Discussion of the subject. In commenting on the foregoing case, and the others of supposed orbital aneurism, Mr. Nunneley points out the true direction of the seat of the disease, and thus discusses the pathology:

"In fact, in the great majority of such cases of protrusion of the eyeball there is no disease whatever in the orbit; the seat of it is most commonly intra-cranial. The protrusion of the eyeball is passive, and the other distressing symptoms are secondary, depending upon obstruction to the return of the blood through the ophthalmic vein, just as happens in those cases of popliteal and axillary aneurisms where the limb swells below the tumour, because this presses upon the accompanying vein. That this pressure, in the great majority of acute spontaneous cases, is caused by an aneurism of the carotid as it passes into the cranium, or of the ophthalmic artery near to its origin, is, I think, now certainly proved. In cases of traumatic origin, supervening soon after severe injury to the head, the cause is most probably effused blood near to, or within the cavernous sinus; while in those cases where the protrusion does not come on until some time after the receipt of the injury, or where the violence has not been so considerable, it may be serum or fibrine, or even pus, the result of suppuration in the sinus. This latter was most probably the true cause of the protrusion of the orbital contents in the woman who died after the deligation of the carotid, in the

Moorfields Ophthalmic Hospital, where the protrusion had not supervened until some time after the receipt of a violent blow with the fist upon the temple, and where, as only pus was found after death in the cavernous sinus, some doubt appears to have been entertained as to the correctness of the diagnosis and the propriety of the operation." Mr. Nunneley here alludes, I presume, to a case published in the Royal London Ophthalmic Hospital Reports, in which Mr. Bowman supposed that there was orbital aneurism, on account of protrusion of the eyeball and pulsation, and tied the carotid artery with the effect of diminishing these symptoms at first, but in about thirteen days after the operation the eye again became prominent and congested. There was, however, no return of the pulsation. Death took place on the nineteenth day, and the only disease that could be detected to account for the symptoms was inflammation of the dura mater about the cavernous and other sinuses at the base of the skull, with coagula in their canals. The carotid was of natural size, the ophthalmic artery was not dilated, nor were its branches more numerous, or larger than usual, but the ophthalmic vein was much enlarged, and had the appearance of a varix.

Mr. Nunneley then considers the question with reference to anatomical conditions. He continues:

"That the aneurism of the ophthalmic artery, or effused fluid, whatever its character, or even a tumour, may be seated within the orbit rather than in the cranium, is quite possible; but, inasmuch as those conditions which would make a small amount of pressure felt considerably do not exist in the orbit, but do exist to a very considerable degree immediately behind its apex in the cavernous sinus, it will, I apprehend, be in reality found that in this situation the actual cause does not exist in the great majority of cases. In the orbit there is a large quantity of soft, yielding material, which would require a body of considerable size to cause sufficient pressure to produce the urgent symptoms witnessed in a sudden and acute case of protruded eyeball, whether of spontaneous or traumatic origin; whereas, bound closely together as the artery, veins, nerves, and absorbents are in the dense, unyielding fibres forming the walls of the cavernous sinus, a very small cause will necessarily produce a very great effect. Further, it must not be forgotten, that it is very rare to meet with aneurism in any of the arteries of a size such as are found in the orbit. When an aneurism does spontaneously form, it is almost invariably found in connection with a vessel of some considerable size, the coats of which are far more obnoxious to that loss of elasticity which predisposes the inner one to give way, than are those of the size of the orbital branches. The ophthalmic artery

is much larger at its origin and in the cavernous sinus than it is soon after entering the orbit."

Afterwards he alludes to the frequency of vascular protrusion of the eyeball in a lesser degree:

"I would further remark that, though this vascular protrusion of the eyeball in its most acute form is evidently one of the rarer diseases, or more frequent instances of it would have been recorded (for I cannot suppose that the fact of so many as seven cases having been treated by myself within the space of twelve years, is more than one of those curious fortuitous circumstances for which it is impossible on any rational ground to account), I believe in a less intense degree, and more chronic condition, protrusion of the eyeball resulting from posterior venous congestion is by no means uncommon. Whatever obstructs the return of blood, may indirectly, if not directly, induce fulness of the eyeball. Tumours of every kind in the orbit, cranium, or neck, may all be causes."

There is a great deal of force in all that Mr. Nunneley has written. His physiological reasoning and accurate clinical observation on the many cases that he has seen, and his pathological records, go far to confirm what he has advanced. It is, too, as he shows, an incontrovertible fact that, in the only four cases in which post-mortem examinations have been made, no tumour, aneurismal or otherwise, had existed within the orbit.

There is a case recorded by M. Demarquay in his "Tumeurs de l'Orbite" which is worth quoting. A very thin woman, thirty-two years old, with disease of the heart and the cerebellum, was seized with acute pain in her eye. The next day the eye was protruded and vision was extinct. The eyelids became red and swollen, and the eyeball fixed. In the orbit there was pulsation and a bruit. It was supposed that orbital aneurism was present. The patient died. The intra-orbital veins were gorged with blood. In the cavernous sinus was a blood-clot that surrounded the carotid artery and the ophthalmic artery. The orbital arteries were for the most part obliterated. There was no extravasation of blood in the orbital cellular tissue.

I am enabled to give a case from another source that strengthens the above views. It is recorded by the late Mr. Z. Laurence, in the *Ophthalmic Review* for October, 1867. A drunkard, æt. forty-one, fell on the back of his head on the kerbstone. He was taken home. He fell again, and after lying where he had fallen for about three hours, he complained of aching pain on the left side of his forehead. His eye was then noticed to be slightly protruded. Afterwards he had a fit, was insensible, convulsed, and breathed

stertorously. When Mr. Laurence saw him, on January 25th, these were the symptoms. The eyeball was considerably thrust forwards and apparently enlarged. In order to expose it to view, it was necessary to raise the upper eyelid, which was expanded over it, and was livid, congested, and more or less œdematous. There was considerable conjunctivitis and chemosis. The eyeball pulsated forwards and synchronously with the pulse at the wrist; the pulsation was completely stopped by firm pressure on the carotid artery. A distinct blowing murmur could be heard over the eye synchronously with the pulse. At a later period of the case, the region of the murmur was more completely defined. It extended from the eyeball over the left temporal and parietal, the frontal and right parietal regions; it was loudest at a spot about two inches behind the left external canthus. The man complained of a blowing sound like that of a pair of bellows at the left temple, which ceased at once when the left carotid was compressed. At the same time it was found that the bruit ceased in all the parts where it had before been remarked. The details of the fundus oculi presented no special characters. There was scarcely perception of light. During the progress of the case some further symptoms were observed; such as loss of smell with both nostrils, and nearly every day slight bleeding from the nose.

Compression of the carotid artery was fairly tried with Skey's tourniquet almost constantly, for twelve days. It was not altogether continuous, in consequence of the interference with respiration. Yet it was effectually tried. Ice was applied locally, and digitalis and opium were given to no effect; on the contrary, the symptoms got worse. The carotid artery was tied.

On the 23rd of April, 1867, the following notes were taken:

The eyelid is no longer tense, but presents simply the appearance of a case of extreme ptosis. The eyeball is no longer congested, and all its movements are present to a moderate degree. There is only a single line of chemosis below the cornea. The right iris is hazel-coloured, the left dull grey. The left pupil is irregular and fixed. The cornea is misty, the fundus is illuminable, but no details can be seen. There is no pulsation or bruit in the orbit or any part of the head.

When the patient was last seen, June 26th, 1867, the eyeball had completely retreated into the orbit, the ptosis had all but disappeared; the ocular movements were nearly perfect. The eye itself presented much the same appearance as at the last examination. All vision was lost. No pulsation was felt in the carotid above the point

Mr. Laurence, in the first instance, regarded this case as one of orbital aneurism. After the operation, he came to the conclusion that he was wrong, and believed that he had an example of rupture of the ophthalmic artery, at or near its origin, from the internal carotid artery, leading to the effusion of blood without the orbit, and produced by some fracture of the base of the skull in the neighbourhood of the foramen opticum. The epileptic seizure was supposed to proceed from the fracture.

Other observers have verified the deceptive effect of extravasations in the cavernous sinus around the carotid artery.

Nélaton's case of aneurismal varix in the sinus, from a wound of the artery by a splinter of bone from fracture of the carotid canal, is a remarkable one, and to the purpose.

M. Demarquay, to whom I have referred, describes what was said to be a case of orbital aneurism. It was nothing of the kind. It was aneurism of the internal carotid, involving the origin of the ophthalmic artery. He mentions, besides, that M. Carron du Villards accidentally met with an aneurism of the artery in the dissecting-room, of the size of a little hazel-nut. No particulars are given, but a reference is made to the original, which I cannot obtain. Dr. Parrish reported a so-called case of aneurism in the orbit, nearly thirty years ago, in the *New York Medical Journal*. The clinical report is very meagre, and the remarks indefinite. My own impression is that the disease was a nævus. After an ineffectual local tying, the patient was dismissed from the hospital.

Some observers in England and abroad speak of having seen aneurism at the origin of the ophthalmic artery. In the absence of any minute details, it might, I think, be inferred that the carotid alone was involved.

Several instances in which the eyeball has been observed to be influenced by forced respiratory movements, or by a bent position of the body, and regarded as examples of orbital disease, might perhaps be more correctly referred to morbid changes in the cranium.

VASCULAR PROTRUSION OF THE EYEBALL.

Till our diagnosis is more sure, I am disposed to employ this term according to the sense in which Mr. Nunneley introduced it. For it must be apparent, from what I have written, that all which has been published about aneurism of the ophthalmic artery is worth nothing as a true record of such disease, although it is not without

We are better prepared now to understand protrusion of the eyeball associated with pulsation, and orbital tumours communicating systolic action of the heart; and we are far less likely to blunder in the direction of supposing that there is true aneurism of the ophthalmic artery when there is nothing of the kind.

It will be an interesting subject for investigation, to ascertain the signs by which intra-cranial and orbital aneurisms may be distinguished from each other, and from obstruction to the return of blood by the ophthalmic vein from any cause within the cranium.

When vascular protrusion has a traumatic origin from blows on the head, it is more likely to be the carotid artery that is injured, where it is in close relation with the bone in the cavernous sinus, than the ophthalmic, lodged in the soft tissues of the orbit. It is probable that in the cases of disease which most closely simulate aneurism by anastomosis, those, for instance, in which the pulsation seems to spread beyond the margin of the orbit, or reappears after ligature of the carotid, the cause will be found to be due to venous obstructions, either from pressure on the ophthalmic vein, or from disease in the cavernous sinus.

The treatment of vascular protrusion of the eyeball, that which is produced by intra-cranial aneurism of the internal carotid artery, or aneurism of the ophthalmic artery, true or false, is involved in the principle of interrupting the supply of blood, by obstructing the circulation through the common carotid artery. It must be resorted to when a patient is seen with more or less protrusion of the eyeball, and surface congestion, or not, associated with pulsation, or conveying to the ear an arterial *souffle*, which pulsation or *souffle* is stopped by pressure on the common carotid artery of the same side. Still more surely is it applicable when the disease is increasing. It is unnecessary to mention other and secondary symptoms, most of which have been given in the cases quoted.

It is unnecessary here to say anything but in mere allusion to those exceptional conditions noticed above, which have baffled diagnosis, since we are not in possession of any sure distinctive marks by which they can be distinguished from aneurismal disease.

Doubtful diagnosis must not prevent a surgeon from endeavouring to relieve his patient, if there be unequivocal symptoms, which seem likely to be relieved by art; nor should he suffer remorse if he find that he has been unable to discover recondite disease, after having done his best to understand it.

It must be borne in mind, that obstruction to the return of blood through the ophthalmic vein, from any cause, is sufficient, not only

which is communicated by the ophthalmic artery. But this should not cause any delay, when the treatment which is being discussed seems called for. In the case No. 2 of Mr. Nunneley, the woman would not have her carotid tied. She refused the only course that seemed advisable, although it could not be said, with certainty, what the disease was. At the end of three years, Mr. Nunneley informed me by letter that he had just examined her, at her own house, as she was unable to travel. She complained of a constant noise and confusion in her head, with incessant pulsation, which was so much worse in the recumbent position, and so increased by stooping, or the least exertion, that she was unable to do any work. She slept but little, on account of the noise and frightful dreams. The hearing on the affected side was not so good as on the other side. The eyeball, although still prominent, had somewhat receded, and was not so congested. There was very little motion in the pupil, and only just the power of perceiving daylight remained. By applying the ear, or stethoscope, to the eyeball, a very strong, hard, whizzing burr was heard, synchronous with the systole of the heart; but this was lost on pressure being made on the carotid, on the same side, and the noise in the head was then arrested. He concluded by saying, though this was with one exception (case the second), the least acute and intense of any of those reported by him, her present condition contrasted unfavourably with all in which the carotid artery was tied, and in a manner seemed to prove the propriety of these operations.

The common carotid artery must be tied, or compression resorted to.

The application of the ligature is the more sure process, and perhaps that which, in the present state of surgery, will always be necessary.

Compression, as a rule, in the treatment of aneurism, is a work of time, whether it be done with an instrument or with the fingers, and in the neck the process is very uncertain. The relations of the artery render it unfit for such treatment. The slightest pressure on the trachea interferes with respiration. The pneumogastric and the sympathetic nerves, and the internal jugular vein, cannot long be pressed on with impunity. The pain, too, that is produced, is intolerable. Digital pressure has been fairly tried in this country twice, without advantage, and several times abroad without any result. Still, should a case seem to admit of the practice, it may be applied. It should be ceased as soon as its inefficiency is apparent or even suspected. About the detail of it I must be silent.

I cannot attach any value to the recommendation of applying

the collateral circulation, and so to prevent that disorder to the brain which has sometimes followed the sudden stoppage of the blood by the ligature. I do not believe in the advantage of such a measure, and I should not adopt the process.

TRAUMATIC ANEURISM OF THE FRONTAL BRANCH OF THE OPHTHALMIC ARTERY.

The following case is published in the *Lancet* for March 15, 1862, by Mr. Hart:

A boy, eleven years old, received a blow from the end of an iron rib of a parasol, at the inner angle of the left upper eyelid. Rapid swelling of the eyelid followed from considerable effusion of blood.

The boy returned to school, and went on as usual. He complained afterwards of headache and singing in the ears; but it was not until the end of 1860, four years after the accident, that the attention of his mother was drawn to a swelling in the site of the original wound of the eyelid, which beat with a perceptible pulsation. This gradually increased in size, the eyelid became protuberant, and the eyeball projected, and was unduly vascular.

There was, in fact, an aneurismal swelling at the inner angle of the orbit, just below the margin of the bone. A thrill, and a very loud-whizzing bruit, could be heard over all the left side of the head and temple. As the bruit was continuous through both systole and diastole, but louder during diastole, it was inferred that there was a communication between the artery and vein, and that there was present an arterio-venous aneurism, resulting from the transfixion of the frontal branch of the ophthalmic artery and its satellite vein by the forked end of the umbrella. There was no scar perceptible where the external wound had been. The eyelid was swelled. The general health of the lad was good. He complained of a whizzing noise in the head, like that of a steam-engine at work, and he suffered from headache.

By passing the finger between the eyeball and the roof of the orbit, it could be felt that the projection at the angle was due to an enlarged and tortuous coil of artery, and that the artery was tortuous and dilated along the roof of the orbit.

"Here, then," says the writer, "was a case of arterio-venous aneurism, with the cissoid dilatation of the artery, and probably also of the vein, which commonly accompanies that disease."

Digital pressure was made on the carotid during three weeks, by a staff of three persons, who maintained intermittent but complete

At the end of three weeks there was much the same state of things as before. The carotid artery was now tied. Perfect success ensued. All trace of the tumour was lost. The noises in the head were no longer heard.

In the paper, allusion is made to two cases of aneurism in the orbit, cured by digital compression. I question whether they were true aneurisms of the orbital arteries, from the symptoms. The rapidity of the cure is another cause for suspicion, although of course not a strong one.

In the one, treated by Professor Gioppi, of Padua, "the cure was effected by compression for a few hours in four days." The other was treated at Verona, "by intermittent compression occupying seven hours and twenty minutes in the course of eighteen days."

Mr. Nunneley's opinion of the compressive treatment is unfavourable. He writes: "I would only venture to say that in the most acute attack, whether spontaneous or traumatic, I believe tying the common carotid of the same side will be found the best. Indeed, the symptoms are so urgent as to necessitate the promptest measures, or the eyeball and lids will slough. Of the six cases in which I have adopted this plan, five were cured, and in the one which died, the affection of the eye was arrested, death resulting from exceptional causes; while in the one case which is still under observation, although by no means so acute as most of the others, where only an expectant plan has been hitherto adopted, the disease appears to be steadily advancing, and in one of those where ligature of the carotid speedily cured the patient, rest and other means had previously been perseveringly but unsuccessfully tried for upwards of seven months."

The statistics respecting mortality from tying the carotid artery in vascular protrusion of the eyeball, and also the effect on the disease, are most favourable when all things are considered. In twenty-three instances of published and unpublished cases that I have been able to collect, there have been only three deaths from the operation; none from secondary causes. Seventeen are said to have been successful, the rest not influenced, or but partially successful. Considerable latitude must be allowed for the term successful, as unless details be entered into, it must be made to include many degrees of variation. Perhaps the strongest point shown, is the small mortality of the proceeding.

In the last edition of this work will be found many references to cases in which the operation has been done.

Vision is, for the most part, as far as I can ascertain, very much impaired or quite lost. This, however, will very much depend upon

eyeball, before the carotid has been tied, and the pressure upon it taken away; but if the changes in the retina are not too great, this tissue may recover itself sufficiently after the operation to allow of good vision. Thus, in two cases reported by Mr. Nunneley, the sight at once became as good as that of the other eye. In a third, that of the acute traumatic case of the publican, though vision at the time of the operation, and subsequently, was very much impaired, after the lapse of eighteen months it was in great degree restored, so that ordinary letter-press could be read.

Aneurism of the central artery of the retina. About three cases have been described in ophthalmic literature. All examples of the disease have been in women. In one case the disease was on both sides. This is the celebrated one of a princess of Baden. The aneurism compressed the optic nerves and caused blindness. In another, the artery was distended to the diameter of a stalk of grass. The retinal veins were varicose. The third is a case given by Dr. G. Sous in the "Annales d'Oculistique." It was recognised with the ophthalmoscope. The patient was sixty-four years of age. She had had palpitation for seven years, for three years noises in the ears, and for five months a slight impairment of vision. There were not any external objective symptoms. By the ophthalmoscope was seen, on the lower part of the optic disk, an ovoid red tumour, large above, then contracting, passing a little beyond the disk, and becoming lost in a retinal artery. It pulsated. The other arteries were thread-like, and the veins large. Perhaps this was rather disease of a branch of the central artery of the retina.

CHAPTER XII.

GEOMETRICAL OPTICS.

LIGHT—LUMINOUS BODIES—A MEDIUM—A PENCIL—REFRACTION AND REFLECTION — LENSES AND THEIR PROPERTIES — CYLINDRICAL LENSES—ORTHOSCOPIC LENSES—STENOPÆIC SPECTACLES.

I HOPE that students will be glad to find a chapter on pure optics, short and concisely written. It is meant to assist them to understand the optical construction of the eye, to materially help them to master the descriptions of its optical defects, to teach them the nature of the appliances which art supplies to remedy such, as well as to counteract the natural changes in the eye interfering with vision, but which cannot be called disease, and to show them how to appreciate many things which are spoken of in the chapter on "The Ophthalmoscope," and in other chapters.

LIGHT.

This is the agent which enables us by the eye to become sensible of the existence of a material body, and of its form and position. Geometrical optics examines the circumstances of the propagation of light, and is founded on certain laws which have been established by experiment.

LUMINOUS BODIES.

This includes those bodies which are themselves sources of light,

sun, the fixed stars, a red-hot poker, a burning lamp. But most known bodies are not of this nature, and can only be seen by means of light originating in some foreign source; for example, when a light is brought into a dark room, objects which were before unseen become visible, and as we know, the moon shines only by light which originates in the sun.

Luminous bodies radiate lines of light in all direction as divergent rays.

A MEDIUM.

This is any substance through which light can pass, as glass, air, water, &c. The term is also applied to a vacuum.

In a medium of uniform density, light is propagated in a straight line.

A PENCIL.

This is an assemblage of rays proceeding to a fixed point, or from it, which is called the focus. There are several kinds of pencils.

FIG. 71.

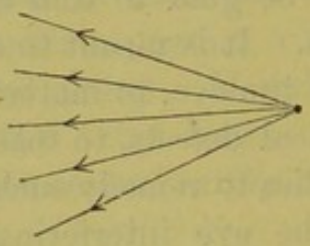

A divergent pencil, Fig. 71, is one in which the light proceeds from the focus, so that the rays separate further and further from each other, as an example of which may be given the rays from a near body, such as those from a candle, or a lamp.

FIG. 72.



A parallel pencil, Fig. 72, is one in which the focus is at so great a distance that the rays do not perceptibly diverge, but may be regarded as parallel lines, such as those proceeding from a lamp which is distant the length of the street. In such cases as this,

practically speaking, they are parallel, and as such they may be regarded for the purpose of my optical illustrations, when, for instance, such rays fall on a small object, as the eye, or on a lens. But in correct language there are no parallel rays in nature.

A convergent pencil, Fig. 73, is one in which the light, in its onward course, tends to a focus, and the rays therefore approach closer and closer to one another, until they meet in a point; but such a pencil does not naturally exist, and is produced only by an optical instrument such as a convex lens.

The form of a pencil of light is, therefore, in geometrical language, either a cone or a cylinder; and a luminous point in general becomes visible by means of a conical pencil whose vertex is the luminous point itself, and whose base is the pupil of the eye. It is important to observe that the diameter of the base of this cone is small compared with its height, from which property the pencil may be termed small.

FIG. 73.

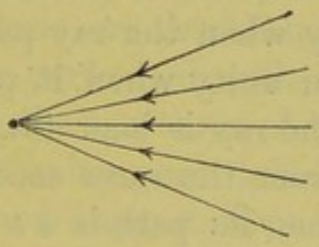

It must be borne in mind that many of the properties of lenses and prisms, which will be announced as facts in the course of this chapter, are only sensibly true for small pencils, and that an increase in the size of the pencils would cause changes in the results, for an account of which I refer the reader to a treatise on optics.

REFRACTION AND REFLECTION.

When a ray of light passes from one medium to another, it is partly reflected, partly refracted, and partly scattered. The angle which the ray makes with the normal, or line perpendicular to the common surface of the media at the point of incidence, is called the angle of incidence. The ray which is reflected, or apparently rebounds from the surface without entering the second medium, makes an angle with the normal, which is called the angle of reflection. The ray which enters the medium whose surface it strikes, and is refracted, makes an angle with the normal, which is called the angle of refraction. The direction of the reflected ray

The direction of the refracted ray is such that the ratio of the sines of the angles of incidence and refraction, is constant for the same media. The scattered rays proceed from the point of incidence as from a self-luminous point.

Light is reflected in the greatest quantity when it strikes the polished surface of an opaque body. The surface is itself rendered visible by the scattered light; but as it is with refracted light that we are concerned, another and more simple explanation of the law of refraction will now be given.

Let P A, Fig. 74, be the direction of a ray, incident at the point A on the surface C A B, of a medium, and let A Q be its direction after entering the medium. With A as centre, and any radius, describe a circle meeting the incident and refracted rays in P and Q. Draw the straight line D A E perpendicular to C B, which is called the normal, and also P M, and Q N perpendicular to D E. Then the law of refraction is this. The ratio P M : Q N, is constant for all directions of the incident ray, provided the two media, and the colour of the light, remain the same. This ratio is called the index of refraction, and is greater than unity when the ray passes from a rarer medium to a denser, but less than unity when it passes from a denser to a rarêr. In other words, the ray is bent towards the normal when its path is P A Q, Fig. 75, from the rarer medium to the denser, but is bent from the normal when its path is Q A P, from the denser to the rarer. The index of refraction from air to water is $\frac{4}{3}$; from air to glass $\frac{3}{2}$.

Fig. 74.

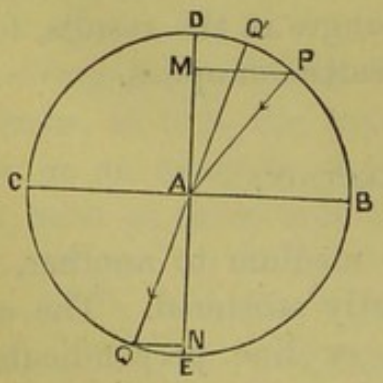

Fig. 75.

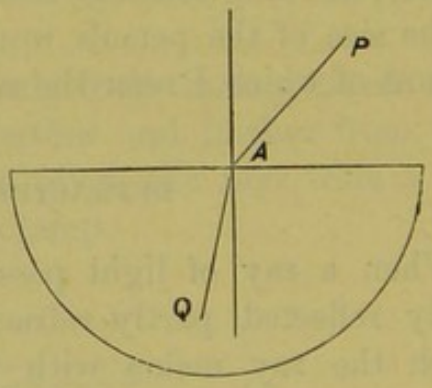

In Fig. 74, C A B, the bounding surface of the medium has been drawn plane; if, however, the bounding surface is spherical, we must draw D E in the direction of the centre of the sphere.

If Q A be produced through A to Q', then the angle Q A Q' is the change which the direction of the ray has undergone, and is called the deviation. The angles P A D and Q A E, are respectively the

The law of refraction shows that if the angle of incidence be zero, that is, if D A is the direction of the incident ray, then A E is the direction of the refracted ray, or the ray in this case enters the medium without changing its direction; so that both the angle of refraction, and the deviation, are equal to zero. The law further shows that as the angle of incidence increases, the angle of refraction also increases, but not at so great a rate; thus the difference between these two angles increases as they increase, or in other words, the angle of incidence, the angle of refraction, and the deviation, increase and decrease together.

If the direction of a ray be at any time reversed, it will retrace the whole of its former path. Thus, if Q A be the direction of a ray in the denser medium, C E B, incident on the surface at A, it will be refracted, so as in the rarer medium to take up the direction A P. It follows from this property, that the value of the index of refraction is the reciprocal of its former value; thus the index of refraction from water to air is $\frac{3}{4}$, from glass to air, $\frac{2}{3}$.

It may be well to add a few words in explanation of what is meant when it is said that these laws are established by experiment. Of course, no experiment can be performed with an accuracy so perfect as of itself alone to justify the exactness of the language in which these physical laws, or any other, are laid down. Experiments merely point to the laws, and suggest them: their truth is finally established by the fact that the results of calculation, deduced theoretically from these laws alone, agree in every respect with the results of experiment.

The case of a small pencil of rays incident upon the plane surface of a medium, may be now considered.

FIG. 76.

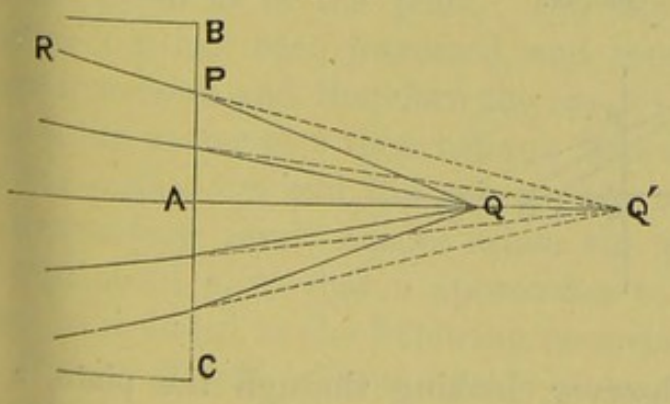

FIG. 77.

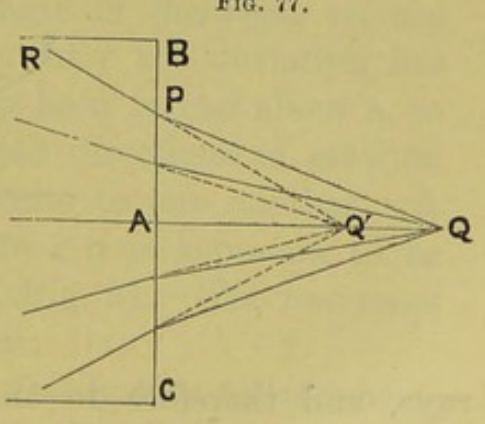

Let Q, Figs. 76 and 77, be the focus of the pencil, and Q A the ray which is incident perpendicularly on B C, the surface of the medium, and which, therefore, enters the medium without deviation. Suppose a

a point Q′ so that Q′ A $= \mu \times$ Q A, the rays on entering the medium will be deflected, and will proceed as if they had originated in Q′ as focus. Thus to find the path of any ray Q P, after entering the medium, join Q′ P and produce it to R, then P R will be the path required. It is evident from the above, that, to any eye situate in the medium, the luminous point Q will appear to be at Q′; that is, it will appear to be further from the observer, Fig. 76, or nearer to him, Fig. 77, according as μ is greater or less than unity. To take a familiar example, a clear lake appears to a person in a boat to be less deep than it really is; for, since the index of refraction from water to air is $\frac{3}{4}$, the apparent distance of any point in the bottom, will be only $\frac{3}{4}$ of its real distance.

If the rays pass through a plate, that is a medium bounded by a pair of parallel planes, the two refractions take place independently, and may be examined separately.

As before, Fig. 78, let Q be the focus of the incident pencil, and Q A B the ray which is incident perpendicularly on both surfaces, and which, therefore, passes directly through the medium. Let Q′ be the point from which the rays diverge whilst within the medium, so that Q′ A $= \mu$. Q A. Then the path P R of any ray whilst within the medium will be directed from Q′; but on emergence at R the ray will be again refracted, so that its direction R S will be parallel to its original direction Q P. The reason of this is evident, for reverse the ray Q P R, then the angle of deviation, or the angle R P makes with P Q, is the same as the angle that P R makes with R S; but the deviations are in opposite directions, therefore they counteract one another, and the direction of the ray is unaltered. If the direction of R S produced meets Q A in q, then q is the focus of the emergent

Fig. 78.

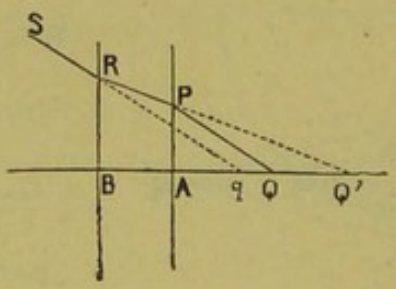

rays, and therefore to an observer, looking through the plate, a luminous point at Q will appear to be at q.

If the plate be denser than the surrounding medium, the apparent position of the object will be nearer to the observer than its real distance, by a definite fraction of the thickness of the plate; for

change of position will be too small to be perceptible, and the object will therefore be seen unchanged in position.

An object viewed through a plate-glass window furnishes a familiar example of this theory.

An optical prism is a portion of a medium bounded by two plane surfaces, inclined to one another.

The effect of a prism on the direction of a ray of light which passes through it, can easily be inferred from the effect of a plate.

Suppose A B, C D, in Fig. 79, to be the bounding surfaces of a plate, and P Q a ray incident upon A B at Q; let Q R be the direction of this ray within the plate after one refraction, and R S its direction on emergence; then we know that R S is parallel to P Q.

Fig. 79.

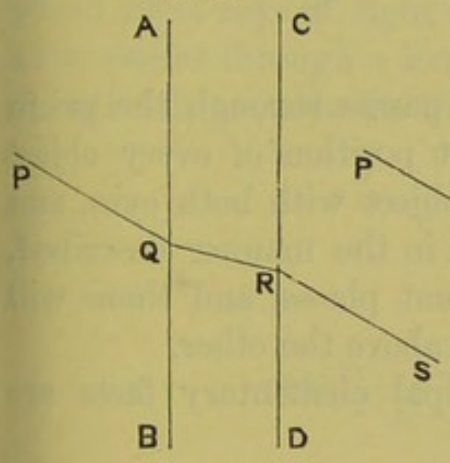

Fig. 80.

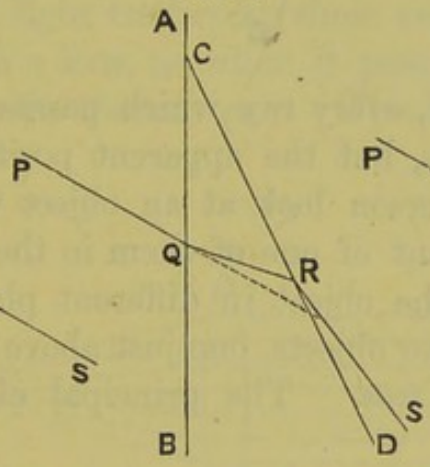

Fig. 81.

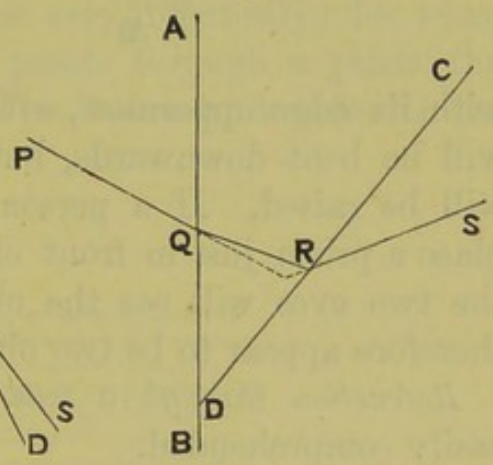

If we imagine the surface C D to be turned about the point R, which itself remains fixed, so that C approaches A, the plate is converted into the prism B A D, as in Fig. 80. This change in the position of the surface C D has of course no effect upon the refraction at the surface A B; therefore the path of the ray is, as far as the point R, the same in the prism as in the plate. But the angle of incidence on the surface C D has been increased, and consequently the deviation has been increased, and therefore the ray R S has been turned about R, so that S lies nearer to B than before; that is, the directions of rotation of the surface C D and the ray R S are opposite to one another. A corresponding result ensues when the plate C D is supposed to be turned about R, so that D approaches to B, Fig. 81. The two cases may be included in the following enunciation:

If a ray of light traverse a prism of greater density than the surrounding medium, the total deviation is always towards the thicker part of the prism.

This property of the deviation of a single ray leads us at once to a knowledge of the apparent change in position of a luminous point when viewed through

emitting rays which traverse the prism B A C; then since each ray in its passage is bent toward the thicker part B C, the point q from which they apparently diverge on emergence will be nearer than Q to the edge A: this is shown in Fig. 82, where two rays are drawn.

It appears from the above that if a prism be placed before an eye

Fig. 82.

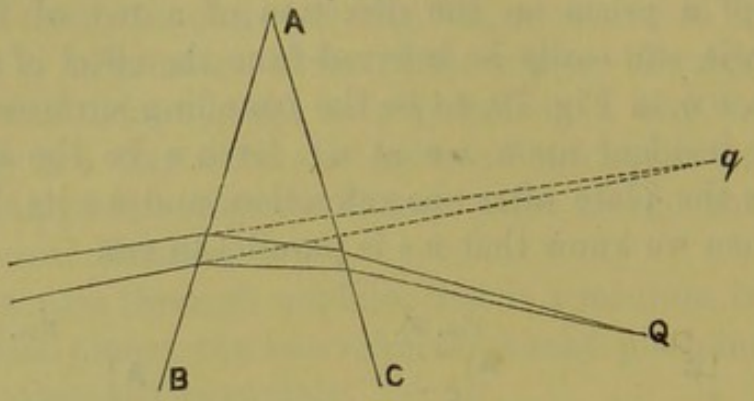

with its edge uppermost, every ray which passes through the prism will be bent downwards, but the apparent position of every object will be raised. If a person look at an object with both eyes, and place a prism just in front of one of them in the manner described, the two eyes will see the object in different places, and there will therefore appear to be two objects, one just above the other.

Refraction through a lens. The principal elementary facts are easily comprehended.

A spherical lens, usually called a lens, is a portion of a refracting medium, bounded by two spherical surfaces, or by two surfaces one of which is spherical and one plane.

The axis of a lens is the line joining the centres of the two surfaces, if both are spherical, or the line drawn through the centre of one surface, and perpendicular to the plane surface, when only one is spherical.

Fig. 83.

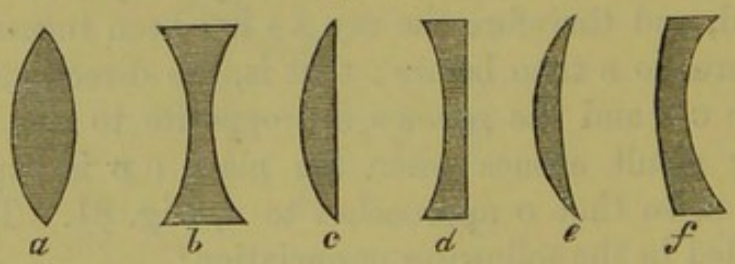

Lenses are of six different forms, as represented in Figure 83, and their names depend upon the nature of their bounding surfaces.

a, is a double convex or positive lens.

b, a double concave or negative lens.

c, a plano-convex lens.

d, a plano-concave lens.

e, and *f*, are convexo-concave, or concavo-convex, according as the light passes through the convex surface first, or the concave.

c, and *d*, are also respectively known as concavo-plane, and convexo-plane lenses, when the light passes through the curved surfaces first.

e, in which the curvature of the convex surface is greater than that of the concave, is commonly known as a meniscus.

A concavo-convex, the convex surface being of greater curvature, is spoken of as a positive meniscus. A convexo-concave, the concave surface being of greater curvature, as a negative meniscus.

The preceding figures show at once that lenses are of two kinds, those which are thickest in the middle, and those which are thinnest. *a*, *c*, and *e*, are of the first kind; *b*, *d*, and *f* of the second. This distinction is of importance: it divides all lenses into two well-marked classes, which affect rays of light traversing them very differently; for when a ray passes through a lens, as when it passes through a prism, the deviation is towards the thicker part. The reason is obvious, for the

FIG. 84.

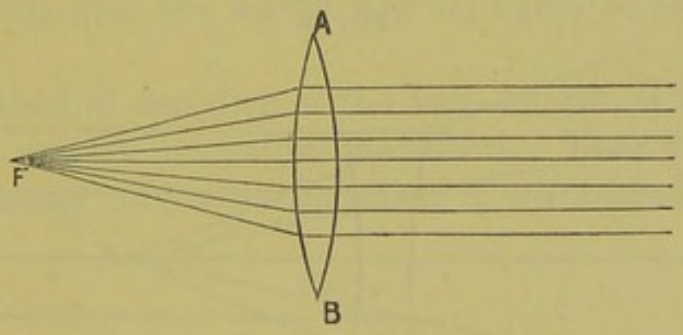

lens will produce the same effect on a ray, as the prism formed by the planes touching the two surfaces at the points where the ray cuts them.

It is necessary to explain that I adopt the foreign nomenclature of lenses, because it is mostly used in the literature of ophthalmology. In the treatises on optics in this country, a convex lens is called a negative lens, and a concave a positive one.

Let a pencil of light fall upon a double convex lens, or any other which is thickest in the middle, and let the rays of the pencil be all parallel to the axis of the lens. Upon emergence every ray will be bent towards the thicker part of the lens, and therefore towards the axis; but, further than this, the rays will all meet the axis at the same point, F, Fig. 84, so that the light will emerge from the lens as a convergent pencil of which F is the focus. F is also called the focus of the lens; its distance from the lens measured along the axis is called the focal length, and is the same whichever surface is presented to the incident light.

The focal length depends upon the curvature of the surfaces, and varies inversely with the sum or difference of the curvatures of the two surfaces, according as the faces of the lenses are both convex, or concave, or are, one convex, and one concave. If one surface is plane, the focal length varies inversely as the curvature of the spherical surface.

Since, if the direction of the light is reversed, it will retrace its former path, it is clear that if a luminous point is placed at the focus F, the light after traversing the lens will emerge as a parallel pencil. This is a principle sometimes made use of in lighthouses; the light is placed in the focus of a convex lens, and thus the rays issue from the lighthouse in the form of a parallel pencil.

Now suppose a pencil of light to fall upon a double concave lens, or any other which is thinnest in the middle, and let the rays of the pencil be all parallel to the axis of the lens. Upon emergence the rays will all be bent from the axis; they will together constitute a divergent pencil, and proceed as if they had originated in a focus F, as in Fig. 85.

FIG. 85.

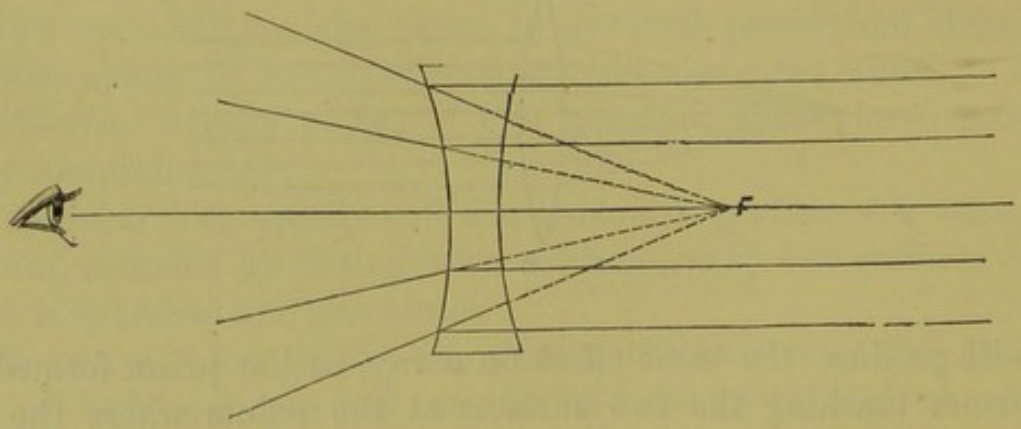

This focus, through which the rays do not actually pass, but only apparently, is called a virtual focus. It must be carefully distinguished from a real focus, one through which every ray passes, as in Fig. 84.

By reversing the path of the rays, it is seen that if light is incident on a lens, which is thinnest in the middle, in the form of a pencil converging to the focus on the opposite side, it will on emergence assume the form of a parallel pencil.

A parallel pencil is therefore made convergent by a lens which is thickest in the middle, but divergent by one which is thinnest in the middle. On account of these properties, the lenses are commonly distinguished as convergent and divergent, as well as convex and concave, as above expressed. Double convex and double concave lenses, whose surfaces have equal radii, are said to be equi-convex

and equi-concave. The focal length of such a lens, when made of glass, is equal to the radius of either surface.

A knowledge of the focal length of any lens is very important, and so it is necessary to have practical methods by which such length may be easily determined. In the case of a convex lens we have only to let fall upon it the sun's rays, or light from some object sufficiently distant, say across the street, and receive the image or optical reproduction, formed by the rays on their emergence, upon a screen, or a sheet of paper. When the image is most distinct, the distance between the screen and the lens will be the focal length.

The focal length of a concave lens is not quite so easily determined, but the following method may be used for the test: Cover completely the surface which is to be presented to the incident light, with the exception of two pin-holes equi-distant from the axis. Let light now fall upon the lens from some distant object, as the sun, or a distant lamp, and receive the two rays which are allowed to pass through the pin-holes upon a screen. When the luminous spots on the screen are twice as far apart as the pin-holes on the cover, the distance between the lens and the screen will be equal to the focal length required.

Another method of arriving at the focal length, is to find the convex lens which exactly neutralizes its effects. The two lenses should be placed in contact, and with their axes in correspondence, and close

Fig. 86.

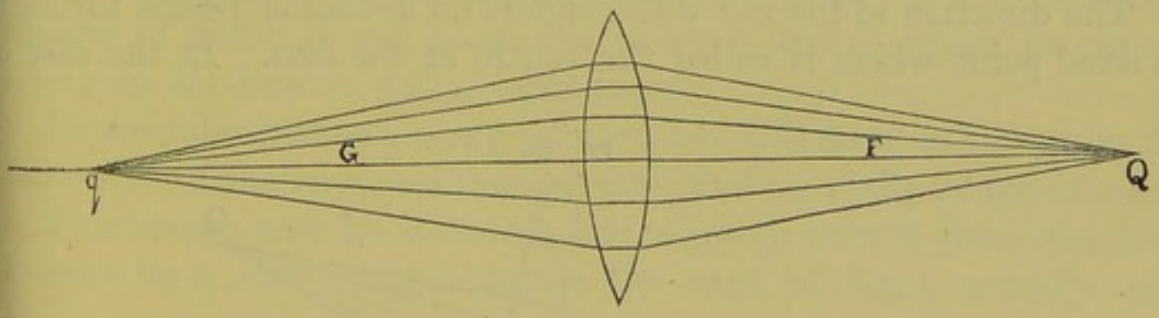

to the eye. If the neutralization be complete, objects will be seen naturally. If otherwise, they will be magnified or diminished, according as the power of the positive lens, or the negative, prevails.

To return to the consideration of refraction through a convex lens. Suppose a divergent pencil of light to be incident upon a lens, the focus being in the axis at a distance from the lens greater than the focal length. Let F and G, Fig. 86, be the foci of the lens, one on each side of it. The convergent power of the lens is not capable of bringing the rays in this case to a focus at G; but after traversing the lens they will all meet the axis at a point q beyond G, and the nearer Q is to F the further will q be from G.

But if Q, Fig. 87, the focus of the incident pencil, be nearer to the lens than F, then the divergency of the pencil is so great, that the lens is not able to make the rays converge to any point, but on emergence they will still diverge as if from a focus q in the axis beyond F. The nearer Q is to F, the further off is q from F.

FIG. 87.

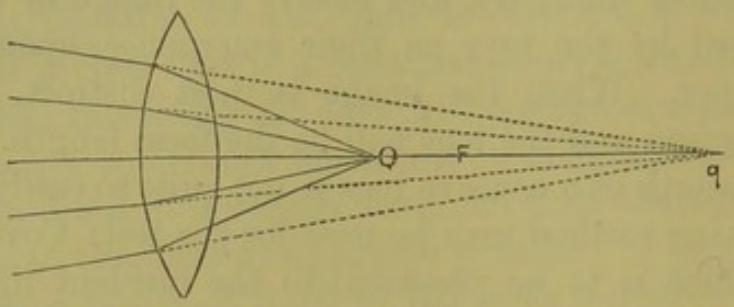

Oblique pencils. I have hitherto considered direct pencils where the light diverges from a point on the axis of the lens, and in this case the focus of the emergent rays is also on the axis. But when the focus of incident light is not on the axis, or the case of oblique pencils, there can still be found one ray which passes through the lens without deviation; that is, a ray, the directions of which before entering the lens, and after leaving, are parallel. It is upon the line, which represents this ray, that the focus of the emergent light will be found, and through which the refracted pencil approximately passes. The nearer the object is to the axis, or the more direct the pencil is, the nearer this approximation approaches the truth.

The direction of the ray which suffers no deviation, passes through a fixed point which is called the centre of the lens. In the case of

FIG. 88.

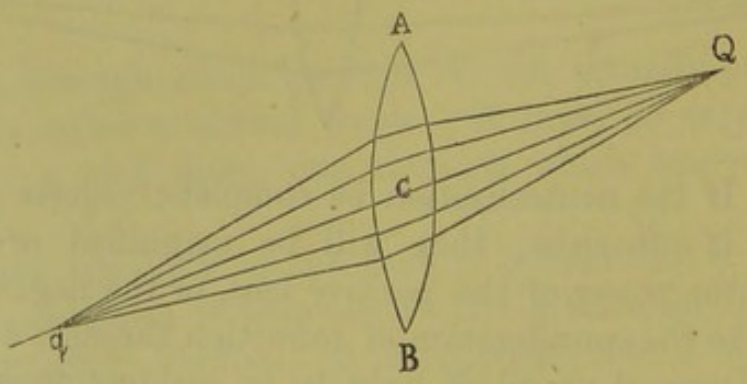

an equi-convex or equi-concave lens, the centre lies on the axis midway between the surfaces. If, then, there is given an incident pencil of light, diverging from a point not on the axis of the lens, it is only necessary to join this point with the centre of the lens, to find a line on which the focus of the emergent pencil will be formed. This is illustrated in Fig. 88, where C is the centre of the lens

A B, and Q q, the foci of the incident and the emergent pencils, lie upon a straight line passing through C.

There has been considered, up to this point, only the case of a single pencil of light incident upon a lens. When a luminous object is placed before a lens, every point on the surface is the focus of an incident pencil, and gives rise to an emergent pencil, and a focus of emergent light. The image of the object is the assemblage of these foci of emergent rays, and as far as it can be examined by the eye, bears a resemblance to the object itself.

To understand the nature of an image formed by a convex lens. Suppose an arrow, as drawn in the figure, to be placed before it, so as to be perpendicular to the axis, and at a distance from it greater than the focal length.

FIG. 89.

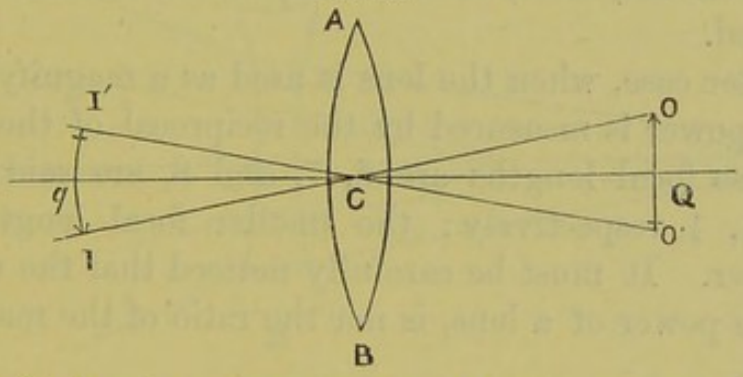

Let Q, Fig. 89, be the point in which the arrow cuts the axis, and O, O′, its extreme points; then the image of Q will be at q on the axis. Let C be the centre of the lens, and draw the lines O C, O′ C; then the images of O and O′ will be at the points I and I′, which lie respectively on the line O C and O′ C produced.

In a similar manner, every point in O O′ will have an image on the other side of the lens, and thus we shall find I q I′ the image of O Q O′.

This image will be inverted, and slightly curved from the lens. It will be a real image, because the rays of light actually pass

FIG. 90.

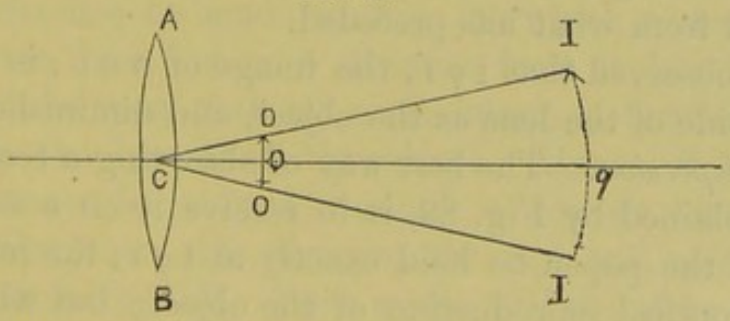

through it. The best method of observing it is to receive it on a screen, but it may be seen as an aërial image if bright enough.

If the object be nearer to the lens than the focus, an image of quite

The rays from any point o, Fig. 90, of the image o q o′, after traversing the lens, will proceed as if from a focus i on the same side of the lens as o, but further off. The point i will be on the line drawn from c, the centre of the lens through o, and will be a virtual focus. Thus there will be formed an image i q i′ of the object o q o′: this image will be virtual, erect, and magnified.

These two methods of forming an image by means of a convex lens, are very distinct, and the distinctions, which are important, can be thus recapitulated.

When the distance of the object from the lens is greater than the focal distance, the image is real, inverted, on the opposite side of the lens as the object, and may be either magnified or diminished. When the distance of the object from the lens is less than the focal distance, the image is virtual, erect, on the same side of the lens as the object, and magnified.

In the latter case, when the lens is used as a magnifying glass, the magnifying power is measured by the reciprocal of the focal length. Lenses whose focal lengths are 6, 7, and 8, are said to be of the powers $\frac{1}{6}$, $\frac{1}{7}$, $\frac{1}{8}$ respectively; the smaller focal length giving the greater power. It must be carefully noticed that the number which expresses the power of a lens, is not the ratio of the magnified image to the object.

An important fact must be mentioned. If a series of thin lenses be placed in contact, so as to have a common axis, the power of the combination is equal to the sum of the powers of the separate lenses. By this we are enabled to calculate the focal length of the combination. For example, if three lenses be placed in contact, whose focal lengths are 10, 15, and 20 inches respectively, then the power of the combination is $\frac{1}{10} + \frac{1}{15} + \frac{1}{20}$, or $\frac{13}{60}$, and, therefore, the focal length of the combination is $\frac{60}{13}$, or $4\frac{8}{13}$ inches.

The effect of a concave lens on a single pencil of light, and its method of forming an image, are illustrated in Figs. 91 and 92, which will be understood from what has preceded.

It is to be observed that i q i′, the image of o q o′, is virtual, erect, on the same side of the lens as the object, and diminished.

Circles of dispersion. The best way of observing a real aërial image such as is explained by Fig. 89, is to receive it on a screen or sheet of paper. If the paper be held exactly at i q i′, the image will be a very distinct optical reproduction of the object; but when the screen is moved nearer to the lens, or further from it, the image becomes blurred, though it is still to some extent an optical reproduction of the object. The reason of this is at once rendered evident by an

nous point Q converges to a point q: hence if a screen be passed exactly through q, there will be seen on it a single bright point; but if the screen be moved either nearer to the lens, or further from it, the pencil of light will illuminate not merely a single point, but a circular patch. Turn again to Fig. 89, and consider the object O Q O′ to be made up of a collection of luminous points: then it is clear that, if the screen be not held exactly at I q I′, but only near it, the image will be made up of a collection of bright circles, which by their overlapping give the blurred appearance to the image which has been mentioned. Circular bright patches formed in this manner, are called "circles of dispersion." These will be frequently alluded to in the chapter on the "Optical Defects of the Eye."

FIG. 91.

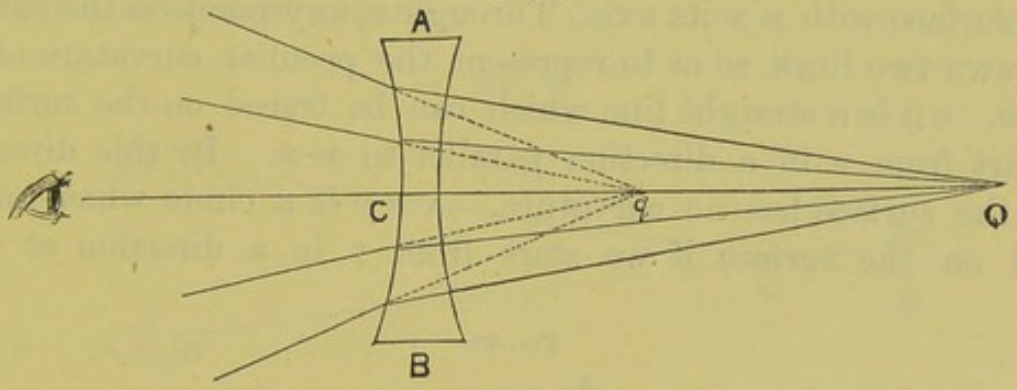

FIG. 92.

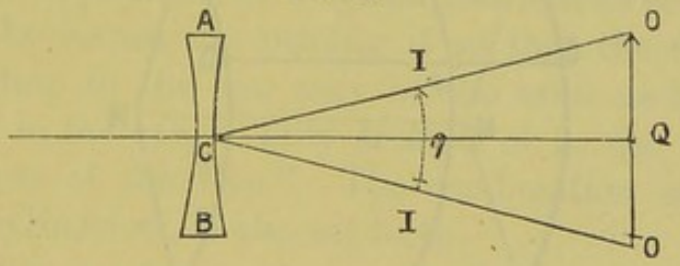

Explanation of the use of lens in spectacles. The explanation of the simpler properties of lenses which has been given is sufficient to enable the theory of ordinary spectacles, and their use, to be understood. If reference be made to Fig. 90, which represents an object before a convex lens, but at a distance from it less than the focal length, it will be seen that an erect image is formed at a greater distance from the lens than the object. Hence, if an object at a moderate distance be viewed through a convex lens, whose focal length is greater than this distance, the rays will enter the eye as if the object were further off. Such a lens will therefore enable a long-sighted person, or presbyopic, to see an object which is not within the field of his unaided eye.

Again, if reference be made to Fig. 92, which represents an object

a smaller distance from the lens than the object. Hence, if an object be viewed through a concave lens, the rays will enter the eye as if the object were less distant: such a lens will therefore enable a short-sighted person to see an object which is beyond the distance of distinct vision of his unaided eye.

Cylindrical lens. A cylindrical surface is one which in untechnical language would be best described as the surface of a straight tube, and may be considered as formed by a number of circular rings placed side by side. The axis of a cylinder is a straight line drawn through the middle of it, so as to be equidistant from all parts of the surface: it passes through the centre of each of the imaginary component circular rings.

The accompanying figure, Fig. 93, represents a portion of a cylindrical surface with M N its axis. Through P, any point on the surface, are drawn two lines, so as to represent the peculiar curvature of this surface. C D is a straight line which can be traced on the surface if we start from P in a direction parallel to M N. In this direction, then, the surface has no curvature. A B P is a circle which can be traced on the surface if we start from P in a direction at right

FIG. 93.

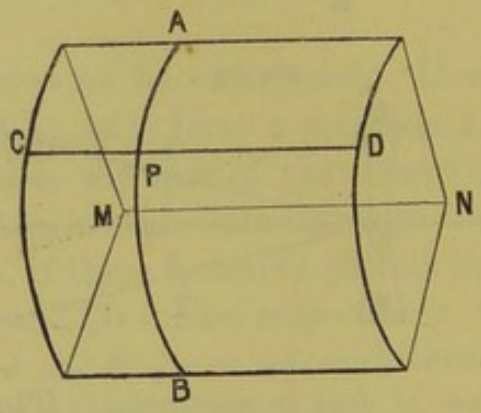

angles to C D or M N: it is one of the component circles of the surface, and in this direction the surface has its greatest curvature. In intermediate directions are to be found all degrees of curvature between these two extremes.

A cylindrical lens is one which has either of its surfaces, or both, cylindrical. Such a surface may be externally either convex or concave; and thus it is at once clear that there may be a variety of cylindrical lenses corresponding to the different spherical lenses illustrated in Fig. 93. The number can, however, be increased by altering the relative directions of the axes of the two surfaces, and cylindrical lenses have been divided into two classes.

Simple cylindrical lenses, those whose surfaces are cylinders, whose

Bi-cylindrical lenses, those whose surfaces are cylinders, whose axes are at right angles to one another.

Spherico-cylindrical lenses have one surface cylindrical, and one spherical.

A cylindrical surface is astigmatic in its effect upon a pencil of light: that is, after refraction the pencil does not even approximately converge to a single point or focus, or diverge from it. The focal length of a cylindrical lens is the focal length for those rays which are most refracted, or which are in the plane of greatest curvature.

Two cylindrical surfaces may be made to counteract one another's astigmatism. If one is convex, and one concave, these axes must be parallel for this purpose: if both are convex or both concave, their axes must be at right angles.

FIG. 94.

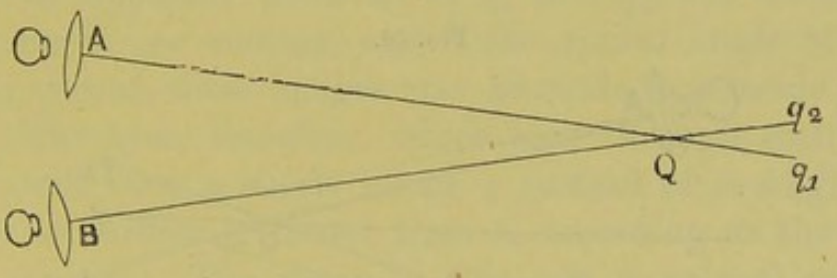

The practical application of a cylindrical lens to certain defects in the curve of the cornea, by placing it so that the direction of the greatest refraction in the lens may be the same as the direction of least refraction in the eye, is fully treated of in the chapter on the "Optical Defects of the Eye." The combination of the spherical lens with the cylindrical, is also set forth.

It is generally speaking unnecessary to have both surfaces of a lens cylindrical.

FIG. 95.

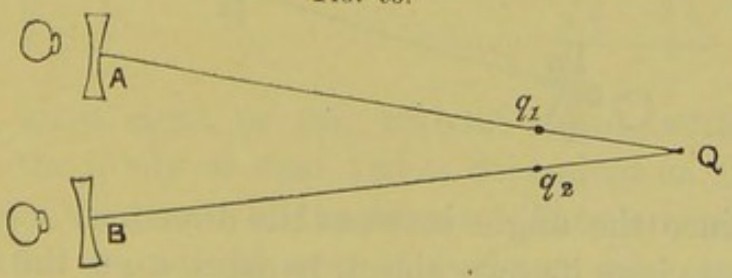

Orthoscopic lenses. All that has been said about lenses, so far as it applies to their use in assisting vision, is with reference to their application to one eye, and thus far nothing more is to be desired. Ordinary spectacles which are so made that each glass is a symmetrical convex lens, or concave, are theoretically defective, because

use of the two eyes for the production of binocular vision. This I proceed to show. The subject was first very beautifully demonstrated by Dr. Giraud-Teulon, of Paris. It has been more fully worked out by Scheffler, in his "Optical Defects," and to the translation of which by Mr. Carter I am indebted for much information and for some diagrams.

A and B, in Fig. 94 or 95, are a pair of equal lenses, and an object Q, is viewed through them. Each lens will form an image: q_1, that formed by the lens A, will lie on A Q; q_2, that formed by the lens B, will lie on B Q. These images will be further from the eyes than Q, if the lenses are convex, Fig. 94, but nearer if they are concave, Fig. 95. The light, then, enters the eyes as if proceeding from objects at q_1 and q_2; the eyes act, therefore, as if they were regarding separate objects, and not a single object as in unassisted vision; yet the objects are not presented to the eyes so as to give rise to double

FIG. 96.

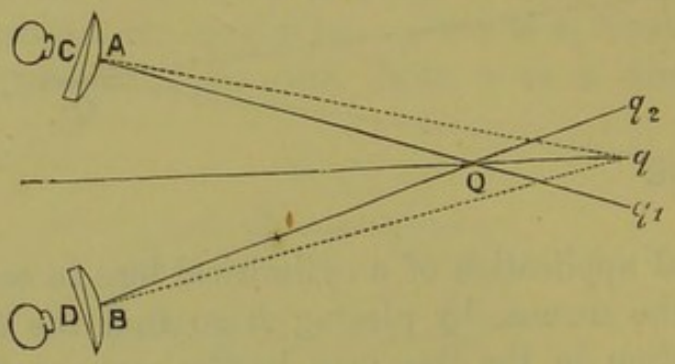

FIG. 97.

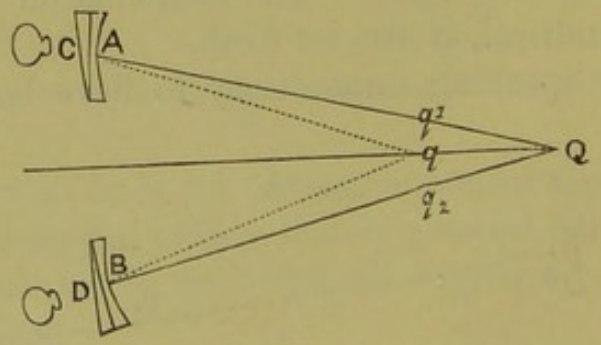

vision; but since the angle between the directions A q_1, and B q_2, in which each eye views its own object, remains A Q B, the same as if the lenses were removed, and yet the distances A Q and B Q are altered to A q_1 and B q_2, it is clear that the natural relation between these distances and the angle between them is destroyed, and that in consequence, a common pair of lenses, as set in spectacles, must produce an undesirable visual strain: the eyes are convergent for one point

between convergence and focusing is broken. This difficulty has been overcome, and spectacles known as "orthoscopic" or "decentered," have been constructed, by which the convergence of the optic axis and the changes in accommodation coincide. Each glass is a combination of a lens and a prism, as shown in the accompanying figures.

A and B are a pair of equal lenses, either plano-convex, Fig. 96, or plano-concave, Fig. 97, and through these lenses an object Q, is viewed. Then, as before, images q_1 and q_2 will be formed, one by each lens. Now, let prisms C and D be placed one against the plane face of each lens, and so that the thin ends of the prisms are turned in opposite directions, pointing both outwards if the lenses are convex, but both inwards if they are concave.

It has been shown that the interposition of a prism changes the apparent position of a luminous point, making it seem nearer to the edge. The effect of the prisms C and D, then, will be in each case as follows. The apparent positions of q_1 and q_2 will be altered and thrown nearer to one another, and if the optical angle of the prism be properly chosen, these images may be made to coincide in a single image q. The eyes, therefore, which look through such a pair of spectacles, will view a single image q instead of a single object Q, which will be further or nearer than Q, according as the lenses are convex or concave. The vision in this case is natural and without strain.

Orthoscopic spectacles, whether convex or concave, whether of short foci or long, are peculiar, in that they may be used by persons of

FIG. 98.



FIG. 99.



normal sight, short sight, or far, without strain, with clearness of vision, within the limits of clear vision dependent on the eyes themselves, and upon the power of the lenses. They are said to be peculiarly suited for the normal eyes of workmen who are engaged in watch-making, engraving, and such minute work. It must be observed that they are orthoscopic in one position only, that neither lens will bear any rotation about the visual line, but that they act together as a pair, and not independently, as do the lenses of common spectacles.

as they have been drawn and described for the sake of simplifying the explanation. The prism may be inserted between two convex lenses, or two concave, so as to give the shapes as in Figs. 98 and 99, or between one convex lens and one concave, in which case the convergent or divergent nature of the combination, or meniscus, will depend upon the relative curvatures of the two surfaces.

The relation between the angle of the prism and the power of the lens, or combination of lenses, which with it forms an orthoscopic combination, depends upon geometrical and physical principles only; that is, if the power of a pair of ordinary spectacles be given, together with the distance between the eyes for which they are to be used, then the prisms which will render the combination orthoscopic are determined at once, without reference to any defect in the sight.

Another definition of orthoscopic lenses may be given, which not only leads to a more simple theory of their effect, but also to an easy method of fabrication. Imagine a lens placed before the face in a vertical position, with its centre midway between the eyes, and suppose the lens so large as to reach beyond the eyes on each side. Also, suppose that light from an object Q, Fig. 100,

FIG. 100.

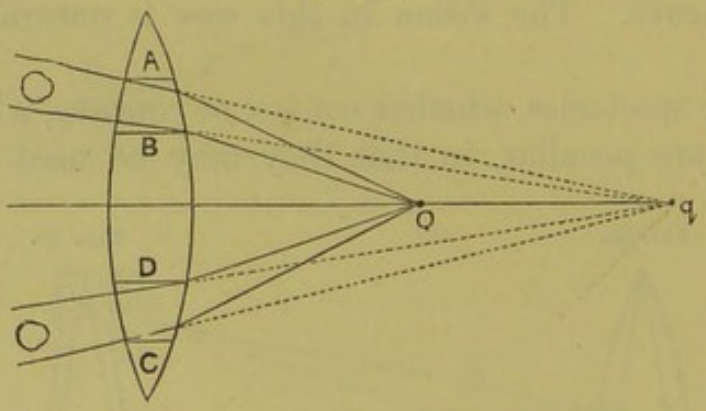

after traversing the lens, emerges from it as if it came from q; then q will be the apparent position of Q to the observer behind the lens. Now let the surface of the lens be entirely covered except the parts A B and C D immediately before the eyes, then the light traversing these parts has not been interfered with, and may still be said to emerge as if leaving the image q, if we neglect the error due to the obliquity of incidence. If the parts A B and C D be now cut out from the larger lens, and fixed in spectacle frames at the same distance apart and in the same relative positions, they will constitute a pair of orthoscopic spectacles: hence orthoscopic glasses may be considered as prismatic lenses cut excentrically out of a larger lens. From this, of course, arise the names "excentric" and "decentered"

To write with greater accuracy it should be mentioned that the distance between the glasses A B and C D, when formed into spectacles, should not be exactly the same as it was before they were cut out of the lens; for by slightly altering this distance the error just mentioned, which is due to the obliquity of the incidence, is corrected.

Several pairs of orthoscopic lenses can be cut out of one large lens, as is shown in Fig. 101.

This considerably reduces the cost of manufacture.

Fig. 101.

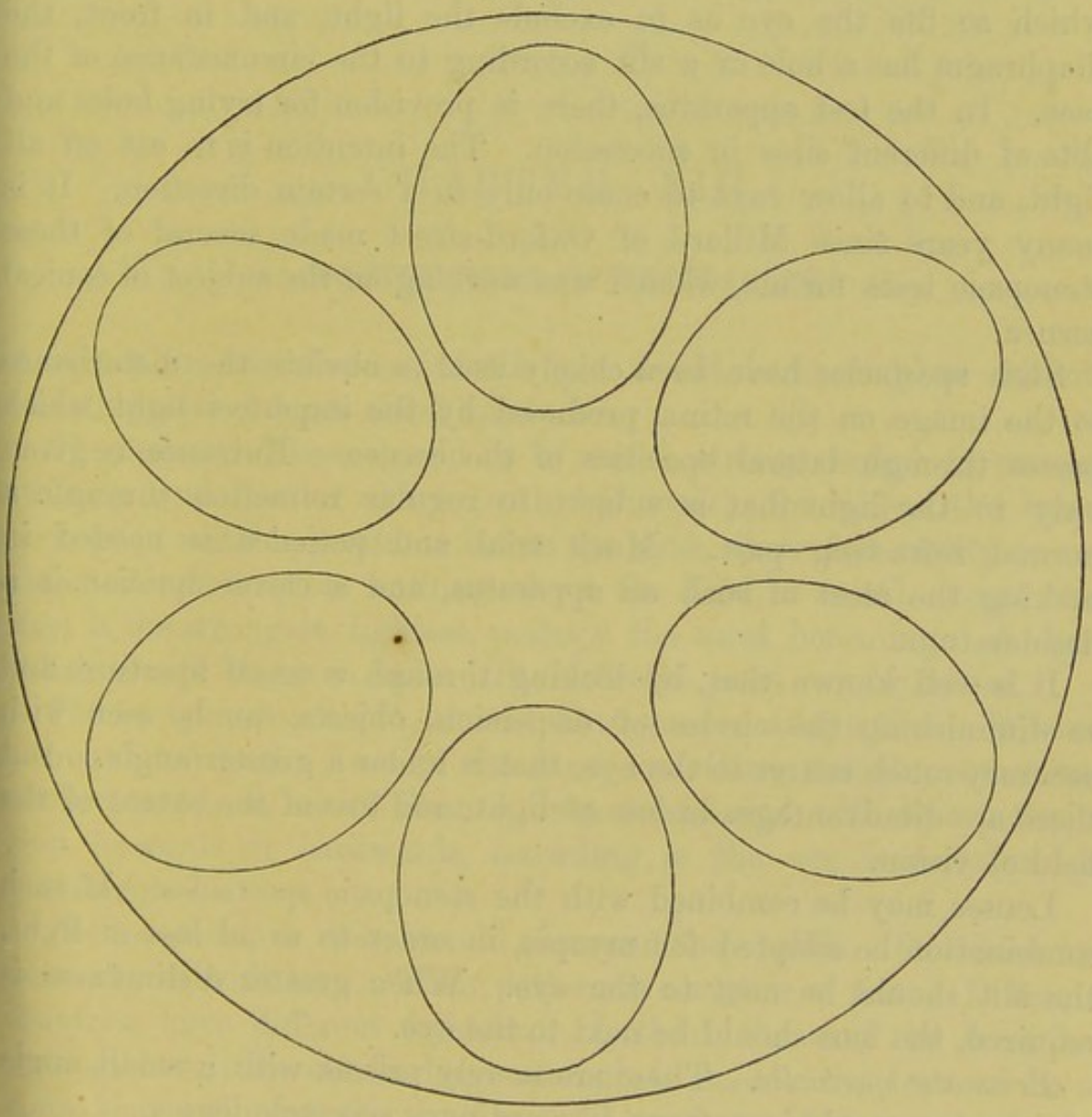

For further details I refer the reader to Scheffler's very elaborate work.

Orthoscopic spectacles are not yet articles of commerce. They are not made in England, nor imported, except to demonstrate their scientific worth. They are necessarily very expensive. Unless the lenses are of a very low power, they are most unsightly, because one part of the margin is thin, the other very thick, and the spectacle

have been supplied, and who have been thoroughly acquainted with their principles, have refused to wear them on account of their ugliness.

Stenopæic spectacles, literally, peep-hole spectacles, are better known in science than in practice, because they do not afford all the benefit that their theory holds out, but they have some practical advantage, and besides, afford assistance in examining the optical defects of the eye.

Speaking of the appliance, as for one eye, it consists of a goggle, which so fits the eye as to exclude the light, and in front, the diaphragm has a hole or a slit according to the circumstance of the case. In the test apparatus, there is provision for trying holes and slits of different sizes in succession. The intention is to cut off all light, and to allow rays to enter only in a certain direction. It is many years since Millard of Oxford-street made several of these stenopæic tests for me, when I was working on the subject of conical cornea.

Such spectacles have been chiefly used to obviate the disturbance to the image on the retina, produced by the imperfect light which passes through lateral opacities of the cornea. Entrance is given only to the light that is subject to regular refraction through a normal refracting part. Much trial and patience is needed in making the most of such an apparatus, and a clever optician is a desideratum.

It is well known that, by looking through a small aperture, and so diminishing the circles of dispersion, objects can be seen with accuracy much nearer to the eye, that is under a greater angle. But there are disadvantages in loss of light, and loss of the extent of the field of vision.

Lenses may be combined with the stenopæic spectacles. If such combination be adopted for myopia, in order to avoid loss of light, the slit should be next to the eye. When greater distinctness is required, the lens should be next to the eye.

Prismatic spectacles. These are merely prisms with a small angle of refraction made in pattern, like ordinary spectacle lenses.

CHAPTER XIII.

CONSTRUCTION OF SPECTACLES.

A WORK on the diseases of the eye would be incomplete without certain practical hints about spectacles.

The frames.—These should be of metal, strong enough to prevent twisting and loss of shape, with fair wear; for unless the lenses be kept in suitable positions before the eyes, their full utility is not obtained. It matters nothing about the kind of metal, except that steel is the strongest, lightest, perhaps the most becoming. A dead polish should be given to it. The different parts require notice.

The nose-piece, or saddle, should have proper adaptation. It must be regulated to the form of the nose, sometimes straight, sometimes much curved, so as to form a deep recess, and with this perhaps, bent forwards or backwards, according as the eye is more or less prominent.

The eye-pieces, or rims, should surround the eyelids. Opticians are generally at fault here. Their pattern is a matter of taste. Different countries have different fashions. I think the oval the most becoming, but it should be large enough to enable the lens to be of a size that will cover the pupil in full lateral use of the eye.

The lenses should be so placed that the centres of them correspond with the visual lines as near as is practicable, when the eyes are in a straight position. Different plans have been invented for accomplishing this adaptation. The simplest and most accurate is to direct the patient to look at an object, while the distance between the centre of each pupil is measured with a rule, on which are traversing indices. Another method is to make a mark on the under eyelids, just

the measure. They should be always on the same level. Any difference in height will cause much confusion in sight.

As spectacles in actual use are always shifting, or being shifted, especially in the vertical direction, with every movement of the eyes, the relationship between the visual lines and their centres is frequently changed. Again, they are not always used for the same distance, so that in the alteration of the visual lines, in the acts of accommodation, and convergence of the eyeballs, variations must ensue. But this form of deviation will be in the slightest degree if the lenses are placed according to the rule I have given, and thus, practically it does not matter much.

The disadvantages of inadaptation are well understood. When the axis of the lens is parallel with, but seated laterally to the visual line, the object is also displaced laterally. With a convex lens it is thrown in an opposite direction. With a concave it is thrown in the same. With, therefore, concave lenses which are set too close together, the objects will be seen outwards, and when set too far apart, they will be seen inwards. With convex lenses the reverse takes place. But this defect is only palpable when the deviation is in excess, particularly in spectacles that are needed for out of doors, or for seeing at long ranges. It has long been pointed out, that the more or less ocular convergence, which must be frequently employed with all spectacles, is of no consequence, and that if any inconvenience is felt for short ranges, an involuntary regulation is made of the distance between the eye and the object.

The axis of the lenses and the visual lines necessarily vary much when objects are placed much below the eye. The objects are apparently changed in position, and are seen less accurately, particularly when lenses of short focal lengths are employed.

From all these circumstances, the following rules have been deduced.

When spectacles are required only for long distance, the axes of the lenses should be parallel, and should correspond to the visual lines when the eyes are directed to a very far point, and the lenses should be placed in a vertical position.

When they are required for short distance, the axes should converge in correspondence to the visual lines, because the eyes always converge for the near point, or near vision. The setting of the eyes in different individuals, the width of them, must be taken into account, for there is accordingly a difference in the angle of convergence, or the binocular parallax. Besides this, the lenses must be turned backwards below a little from the perpendicular. By this,

made according to this principle have long been sold by Messrs. Horne and Thornthwaite, under the name of pantoscopic, and they answer the purpose admirably. They have an additional advantage for presbyopic persons, who require assistance for near vision only, and need no optical help for seeing at a distance, because when the eyes are raised from a book or a desk, they are as readily directed above the lenses to things around. The following figure shows the spectacles in use.

Fig. 102.



In monocular vision, when, for instance, only one eye is available, and the pupil is lateral from any cause, it may be necessary to make the axis of the lens correspond to that of the pupil. The same application may be brought into requisition for the two eyes, and binocular vision obtained.

The figure of the lens is of importance. The double convex and the double concave, are most used. The plano-convex, and the plano-concave, are the least fitted for the purpose of spectacles, because with equal degrees of power, they have the greatest spherical aberration.

The meniscus is the best, because the image is less distorted when objects are looked at obliquely, and therefore a greater range of vision is obtained without moving the head. The term periscopic is applied to it. The highest benefit is manifest when a lens of a short focal length is used. There are theoretical objections about greater weight, and the liability, under some circumstances, of disturbance to sight by reflection from the concave surface. All lenses at times puzzle with reflection. The difficulty of making the meniscus well, and the higher cost of production, are the reasons

The centering of the lenses is of the utmost importance. This is accomplished when the vertical points of both surfaces are directly opposite to each other, and are everywhere at an equal distance from the margin of the lens. It is obtained with most difficulty in lenses of an oval form. Any defect is most marked in lenses of high power, the result of which is a prismatic effect. Cheap spectacles are always defective in this respect.

The sides of the spectacles require regulation, not only as regards comfort in wearing, but for the proper position of the lenses to the eyes. They should not press on the temples, but take their hold beyond, on the head. A single side is enough where the spectacles are temporarily worn, but when they are to be always on the face, there should be a folding joint, long enough to form a gentle spring, which lightly presses on the back of the head; or else bent in the form of a hook, to encompass the ear. They should be fitted according to the length of the head, and the kind of lens to be used.

Concave lenses should be brought as close to the eye as the eyelashes or the eyelids will admit. If not, they will reduce the image on the retina, as well as cause indistinctness, because the peripheral rays will be lost. The higher the focus of the lens, the greater will be the disadvantage of distance. Practically, it matters nothing to place a low lens at three-quarters of an inch from the eye. This will be better understood by referring to the Figs. 85 and 91.

Convex lenses should also be placed close to the eye, although not so many peripheral rays are lost when they are in a more forward position, as in the case of concave ones. Fig. 87 explains this.

It is altogether different, when a convex lens is used as a reading glass. Fig. 86 will explain what is meant. In this case, the emergent light is convergent, and therefore there is a definite point at some distance from the lens, at which the eye receives the greatest quantity of light. The distance between the object and the glass must be greater than the focal distance of the glass. The field of vision is reduced, the further the eye is held from the glass.

The materials of which lenses are made demand a short notice. Crystal, or Brazilian quartz, has advantages over glass in being harder, and therefore less likely to scratch, and not so liable to break, in bearing a higher polish, and in being more refractive, requiring less curvature in working, and therefore less thickness as a lens. The disadvantages are, the difficulty of procuring a thoroughly

colourless piece, without specks and impurities, the usual mass of it in the market being defective and coloured.

It may be mentioned that crystal should be cut in its optical axis, that direction in which only single refraction is given. To economise the material, unworthy opticians work it in other directions, and therefore supply an improper article. A polarising apparatus at once detects the imposition.

Glass is often supplied by rogues for crystal. Any one can ascertain whether he has before him the one or the other by applying a file to the edge of the material. The density of the crystal is at once apparent. Glass is readily cut. The ground edge of crystal is always clearer than the ground edge of glass.

The dispersive power of crystal is sometimes spoken of as being disadvantageous. This has nothing to do with the question of spectacles, although it may interfere with lenses for telescopes and microscopes.

Crown glass is the material of which lenses for spectacles should be made. Although it scratches easily, its commercial value is low, and when the frequent necessity for changing spectacles is taken into consideration, it has an advantage in a monetary point of view. An inferior glass not well polished, is often supplied to save expense, and as very few persons who are not practical opticians can tell anything about the quality, the buyer must ensure a good article by dealing with a trustworthy optician. A great many of my patients have been well served, and reasonably, by Mr. Millard, of 334, Oxford-street. I must also speak well of what has been done, according to my orders, at the establishment of Messrs. Horne and Thornthwaite, of Newgate-street.

Hypermetropic persons who require spectacles for reading, as well as for seeing distant objects, may have the lenses ground in two curves, a lower with the greater curve, an upper with the lesser. I think it better to have the two lenses cut into semi-circles, and put edgeways on each other, because there is less disturbance of sight when the eye crosses the break of the foci, and the change is more definite. The wearer must take care that his spectacle-frame is so placed that the lenses fall well into their required positions. These spectacles are sold under the names of Franklin's glasses, and glasses *à double foyer*.

Spectacles which are made in a nose clip require a strong spring, else they wabble, and get displaced. Unless the lenses be very large, they are never sufficiently in proper position when used. Sometimes extra metal or shell is added to the insides of the eye-pieces to throw

the lenses further out. Other devices are adopted for the same purpose.

Tinting or colouring. This can be combined only with lenses made of glass. Tinted lenses are in fact worked out of coloured glass. With lenses of low power there is not much disadvantage in colouring. With those of high power, colouring is objectionable, in consequence of the intensity of the colour in the thicker parts. The convex lens will be darkest in the centre, and the concave at the circumference. The effect of colour can, however, be obtained with any focal power, however high, without disadvantage, by selecting that which is required in a plano-convex, or a plano-concave form, and attaching to the plain surface a strip of coloured glass with Canada balsam.

Besides what I have said in the chapter on "Eye Shades" about screening the eye with colour, I make the following remarks because of the present rage for tinting lenses under the idea of preserving the eyes. To the healthy eye coloured spectacles are objectionable, because they remove the natural stimulus of white lights, and render the retina unduly sensitive. Colour used in this way is more likely to induce disease than to prevent it.

Cataract spectacles. This means lenses that are required after cataract has been removed, or after the crystalline lens has been lost in any way. The lenses are necessarily of very high power.

The crystalline lenses being absent, all power of accommodation is lost. The lenses that are used as a substitute can give distinct images only at definite distances. Two sets practically suffice, the one for near vision, the other for far.

The required foci must be determined by actual experiment. Their values will much depend on the formation of the eye, whether it be emmetropic, hypermetropic, or myopic. For most patients who have been emmetropic, lenses of two inches and a half foci are required for the near point, and four inches foci for the far. The myopic eye requires lower powers. Patients sometimes try to make one pair of spectacles answer for all purposes, by pushing them close to the eyes to see far things, and away from the eyes to see small objects. It is impossible by such a plan to get a proper visual range.

Theoretically, there are grave optical disadvantages in placing lenses outside the eye, to supply the removal of the natural lenses. Practically, they are not recognised.

As the lenses are necessarily heavy, the spectacle frames should be as light as is consistent with strength.

Rims of tortoiseshell between the frames and the lenses are useless. They possess no advantage, are disfiguring to the wearer, and publish to the world that he has had cataract.

The lenses for near vision should be set obliquely in the frame, after the pantoscopic form. Those for far seeing should be placed according to the rules above given for long range spectacles.

Eccentric pupils, from prolapse of the iris, or otherwise, require the lens to be placed accordingly.

In lateral opacities of the cornea, advantage may be derived by partially covering a part of the glass with black, after the stenopæic method of spectacles.

CHAPTER XIV.

THE OPHTHALMOSCOPE.

DISCOVERY OF THE OPHTHALMOSCOPE—CONDITIONS WHICH CONCEAL THE EYE FROM COMMON OBSERVATION—ERECT AND INVERTED IMAGE—ACTUAL, OR REAL IMAGE, AS OPPOSED TO A VIRTUAL, OR APPARENT ONE—EXAMINATION BY THE DIRECT METHOD; SO AS TO SEE THE ERECT VIRTUAL IMAGE—EXAMINATION BY THE INDIRECT METHOD; SO AS TO SEE THE REAL INVERTED IMAGE—A FEW WORDS ON OPHTHALMOSCOPES IN GENERAL—DESCRIPTION OF SOME OF THE OPHTHALMOSCOPES IN USE—BINOCULAR OPHTHALMOSCOPES—DIRECTIONS FOR USING THE OPHTHALMOSCOPE—THE NORMAL ASPECT OF THE RETINA AND OF THE OPTIC DISK—ANOMALIES OF THE FUNDUS OF THE EYE.

The ophthalmoscope is now so familiar to us, and its use so well known, that it is no longer necessary, in a treatise like the present, to be eloquent in its praise; nor is this the place to enter at any length upon the history of the discovery of the instrument. Foreshadowed by Cumming, Brücke, and Babbage, five and twenty years ago, and perfected by Helmholtz five years later, it is one more example of the important truth, that great discoveries are not made by lucky hits, or by the sudden insights of clever men, but are the slowly-won produce of laborious and earnest search, the harvest of long-sown seed and patient husbandry.

An account of the conditions which conceal the back of the eye from common observation must first be explained, in order that we may learn so to adapt our means of observation as to bring it into view.

How is it, when we look into the eye through the little round

As it is, so far from seeing a chamber with bright and variously-coloured walls, we are met by an absolute darkness. To understand this remarkable exception to the ordinary results of vision, we must examine a little more closely into the conditions of vision.

An object, in order to be visible, must project rays of light in the direction of the observer's eye; which light may be its own, or may be borrowed light, as has been fully shown in the chapter on "Geometrical Optics." Any object, therefore, which does not project rays of light in the direction of the observer's eye, is invisible, and, so far as that observer is concerned, darkness occupies its place. Many objects absorb the light which falls upon them, and in the degree in which they do this they are called dark or black objects. Few objects or none, however, absorb every ray of incident light, and few or no objects, therefore, are absolutely black. Still less is the inner eye a black object; on the contrary, when we do succeed in seeing it, we find it bright and beautifully coloured. The reason why the inner eye seems dark to an observer is not that it is really black or absorbs all incident light, for it reflects a good deal of light, but that it reflects such light in a direction other than that of the observer's eye. Light projected away from our own eye is to us as useless as light wholly absorbed. If, then, we can get the inner surfaces of the eye to project light in the direction of our own eye, or if we can get our own eye into the path of the light which they project, we shall then see that these surfaces are highly luminous.

This is one part of the problem, namely, how to perceive mere light from the inner eye. But we want to see more than mere light, we want to see a picture of details. We do not wish to see the inner eye luminous as an opal, but to see its structure in all the variety of its parts. We wish to turn a dark chamber into a luminous one, and the luminous into a pictured chamber.

It appears, then, that we have here two distinct problems: first, to make the inner eye luminous instead of dark to us; secondly, to advance from mere luminosity to the distinction of details. I shall now proceed to explain accordingly, first, why it is that the inner surfaces of the eye project their reflections away from the eye which looks towards them; and secondly, how it is, when we do succeed in intercepting these reflections, that they give us the impression of mere illumination, and not of a picture. The cause of both these difficulties lies in the dioptric media of the eye, the cornea, the lens, and the humours, which impress a peculiar direction upon the rays of incident and issuing light which traverse them in entrance and exit. The action of these media is first to return the rays of light

cannot be our own pupil, for both pupils, the observing and the observed, are in a like difficulty of darkness. Secondly, they are not dispersing but condensing media, and they therefore send forth the rays reflected from the back of the eye in a pencil of convergence. Now, converging rays falling upon our own normal eye cannot give details, for they will meet too soon, and form their picture anterior to the retina, the retina receiving only a sense of confused light. In the normal eye those rays only can be united upon its retina which are parallel or divergent, parallel rays uniting upon it without effort, and divergent rays being compelled to unite there by means of the apparatus of accommodation.

Fig. 103.

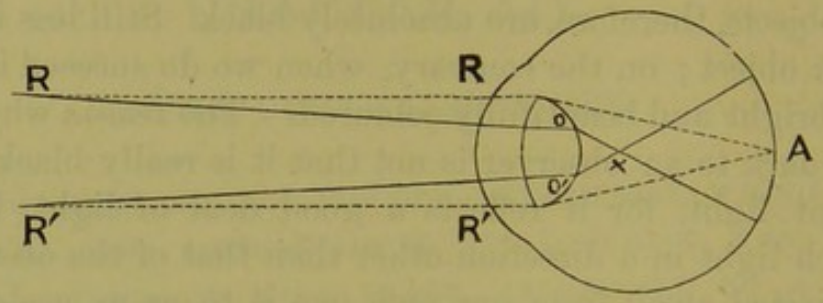

In Fig. 103, we see the normal eye at rest, so that the parallel rays R R, R′ R′, meet upon its retina at A. It is clear, then, that the convergent rays, as R O, R′ O′, would meet at a point *x*, anterior to the retina, and cross over to form a circle of dispersed light upon it.

Let us take another view of the matter, and let A, Fig. 104, be any point on the surface of the thing seen, and A X, A Y a pencil of divergent rays of light reflected therefrom. These rays, as they strike the cornea and lens, leave the air, and traverse these denser

Fig. 104.

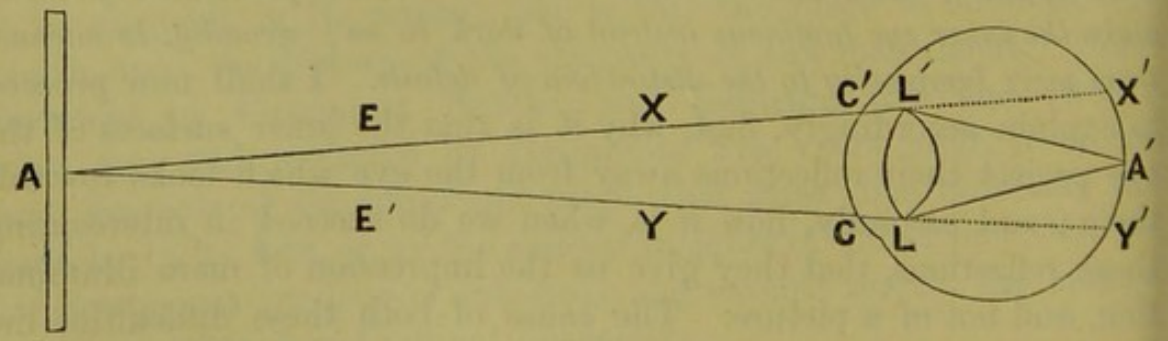

media, which refract them, and bring them again to a point. Let us, however, put this aside for the moment, and suppose, as in Fig. 103, the rays from the many opposite points of the object to pass through the cornea and lens simply as through the air, and

to suffer no change of direction. These rays would then fall upon the retina, still diverging, and would disperse themselves upon the retina in a circle, which circle or field of vision would be determined in size by the pupillary aperture.

In Fig. 104, the dotted lines represent the course which the rays, from the one point A in the object, would take were it not for the lens and other refracting media. Now, as that which is true of the point A is likewise true of each one of the infinite number of points which make up the visible surface of the object, it is evident that in this case each point of the visible surface of the object would be represented not at one, but at every opposite point of the retina. But if we are to have the details of an object reproduced in their clearness and order, we must have some definition in place of this confusion. We must have, that is, each point of its surface represented, not on all the opposite points of the retina at once, but only on one certain point, for a picture cannot be formed unless each point of the visible surface of the object has its own proper place upon the corresponding surface of the retina; otherwise, as I have said, we should receive with the eye not a picture of the object, built up point by point, but a blended and formless light, coming at once from every point of the object to each point of the retina. In order to reproduce each point of the visible surface upon one proper point in the retina, we must so condense these pencils of diverging rays as to bring them each to its own place again upon the retina. A picture will thus be formed upon it which will be a counterpart of the surface seen. This is done by the refracting media, of which the lens is the chief, and by it the diverging or parallel rays, with which we have chiefly to do, are brought to a focus. At their focus, in the normal eye, is spread out the perceptive surface, the retina.

Now, it is clear that what is true for rays entering the eye must also be true for rays which leave it, for whether they traverse the refracting media from before, backwards, or from behind, forwards, makes but little difference. As the rays from the object, then, are so arranged by the lens through which they pass as to form a picture of the object at its inner focus, the retina; so the rays which are reflected from the retina will diverge and traverse the lens again in the outward direction, and will be conveyed by it as before, so as to form a picture of the retina in its turn at the opposite focus on the hither side. In this case the retina becomes itself the object. Now, this outer focus is of course at the object for which the eye is accommodated, the retina and the object being at what are called the "conjugate foci" of the lens, a term which is farther explained in the chapter on "Simple Lenses."

picture of the retina is formed upon the object for which that eye is accommodated, it is clear that this picture cannot be formed also upon the retina of the observer, unless the retina of the observer be itself the object. Here, however, we are met by the other difficulty to which I have alluded. If the observer's retina be the object for which the observed eye is accommodated, this latter eye is accommodated for an object from which it receives no light, for an object, that is, which does not illumine it; whereas, as we have seen, all objects which are visible are visible only by means of the rays of light which they emit or reflect towards the observer. The retina cannot, it is clear, give off a picture of itself if there are no rays of light incident upon it which it can reflect in order to form such a picture.

But we are not yet at the root of the question, how it is that no light is reflected from the back of the observed eye to the retina of the observer; how it is, in a word, that the pupil is black? It cannot be, as I have said, that no light is reflected from the back of the eye, for no objects absorb all the light which falls upon them, still less an object like the inner surface of the eye, which in one place is nearly white, and is nowhere black, even in our common sense of the word. It must be then, as we supposed, that light is reflected from the inner eye, and that it passes through its own pupil, but is so directed that it does not pass through the observer's pupil. Helmholtz has given a parallel instance to this in the eye-piece of a microscope. He says, let the ocular glass of the eye-piece of a microscope be replaced by a piece of white drawing paper. If, now, the objective lens correspond in focal length with the length of the tube, as it generally does, then this lens must form pictures of surrounding objects upon the drawing paper, as our lens does upon our retina. But if we look through the objective the drawing paper will appear to us quite dark; like the pupil, it shows us nothing but darkness. It is necessary for the success of this experiment that the tube of the eye-piece be well blackened within, or we have not only reflections from the drawing paper, but also irregular reflections from the sides of the tube, which will render the drawing paper visible, as in the case of albinos, where we have irregular illuminations, by means of an unpigmented iris, and in whom, therefore, the back of the eye is not invisible.

How is it, that in the eye-piece of the microscope, in a camera obscura, and in the human eye, we have this invisibility of the light reflecting parts which are opposite to the lens? After what I have said, the explanation is almost unnecessary. I have shown that the lens of the eye has two foci, conjugate as they are called, and that the rays, if accurately reflected, which is the case or nearly so, must play between these two foci and only between them. There should

be no vagabond rays detached on either hand. To refer again to our figure, the rays from any point A′, in the retina, form the pencil of divergent rays A L, A L′; they then strike the lens L L′, and, being refracted, form the corresponding and opposite cone L A L′, the apex of which is at the object from which the light is originally reflected. Here A, the picture of A′, is formed. But although the picture of A′ is at A only, yet there is reflected light proceeding from A′ at any point within the cone L A L′; and an eye placed anywhere within that cone would therefore perceive such luminosity, while an eye placed anywhere without its bounds, as at E or E′, would not receive any of the reflected rays, and the point A would be to such an observer a dark point, because the rays from it pass him by. The eye, then, which is to receive light from A′, must be placed within the cone L A L′. But here lies the difficulty: the eye of the observer cannot be placed within the cone L A L′, to receive the pencil of emergent rays, without at the same time, and by the same movement, intercepting the incident pencil, which is, of course, exactly co-incident and commensurate with it; without intercepting, that is, the very light which is to illumine the back of the eye and make it visible. Thus, by the interposition of heads, we darken our neighbour's eye, and our own eye is darkened to him. The ophthalmoscope, therefore, which reveals to us the back of the eye, must do so by eluding these difficulties. It is clear that, as the main difficulty lies in this, that our own eye is not a source of light to our neighbour's eye, if we can make our own eye a source of light, we shall then get over the difficulty. And we can do so by means of a pierced reflector. By looking through a small hole in a polished plate, which plate reflects the light of a lamp on to the eye examined, we get exactly in the line of the rays playing between the plate and the eye which looks at it, without, as in ordinary circumstances, intercepting the incident rays. In this way we may receive light from the back of the eye in front of us.

By the ophthalmoscope alone, then, can we arrive at any clear vision of the fundus of the eye. Such, at least, is the abstract reasoning of the matter. At the same time, although light is reflected from the inner eye with almost perfect regularity, yet there are some rays so irregular that by a little management they can be received by the observer, and the retina just seen by means of them. If the reflection were absolutely true, no luminosity from A′ could be seen outside the emergent cone L A L′, yet, as a matter of practice, it is not absolutely true, and the eye, if cleverly placed just at the borders of this cone, may catch a few truant rays. To do this, let the reader place a candle opposite to an eye, and then so place

a screen between his own eye and the candle, that the candle is just obscured, and only just; the reflected light from the observed eye ought now all to return to the candle, but, in fact, some few rays are reflected irregularly, and these may be caught by the observer's eye if he peers closely past the edge of the screen and candle into the object eye. The screen is necessary, as the light from the candle would otherwise dazzle the experimenter, and render the few irregular rays invisible by contrast.

Another experiment will illustrate the state of things still farther. The reason we see no luminosity from our neighbour's eye is because the rays reflected from the back of it are all made up into a cone by the lens, and returned to the point, and only to the point whence they came; and none do come from within our own eye. Suppose, however, we could neutralize this action of the lens, and prevent its returning all the rays to the outer focus exclusively, the observer might then receive a number of them, and the back of the eye would appear luminous. This is easily done by placing a dispersing medium in front of the eye to neutralize the converging action of the lens.

Fig. 105.

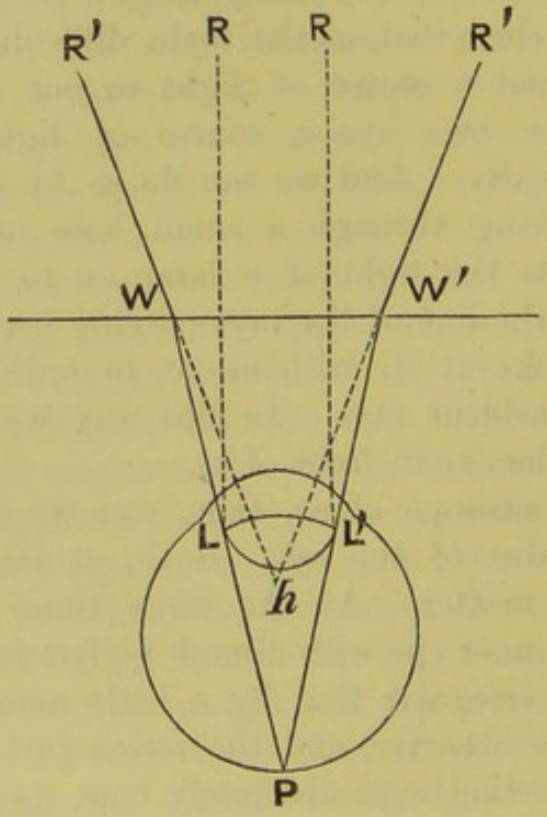

Such an observation was made by Méry in 1704, who happened, for some ends of amusement or philosophy, to be holding a cat under water. The cat's retina became luminous at once; the reason

being, that the emergent pencils of rays, when they leave the lens and cornea, pass through water, which, unlike the air, being of equal refractive power to the aqueous humour, or nearly equal, does not deflect them. On leaving the plane surface of the water, however, they enter the air, and the air being of a lower refractive power, disperses them, and gives an *erect virtual diminished image* of the fundus anterior to the retina.

In Fig. 105, let W W′ be the water level, L L′ lens, L R, L′ R, rays issuing from a point P at the back of the eye P. These rays, passing into the air from a normal eye at rest, would be parallel, as I shall soon explain. But let L W, L′ W′, be such rays issuing under water, and therefore not changed in direction, and let W R′, W′ R′, be the lines of their divergence on leaving water for air, which meet in *h*, they will thus appear not to come from P, but from *h*, and the picture will seem to be formed at *h*, and will evidently be a diminished image of P.

Two words have been used in qualification of the image of P which must be fully explained, as they will frequently re-appear, and they are very important. These are "erect" and "virtual."

The adjective erect, and the opposite adjective inverted, are not difficult to understand, for they are used in their ordinary senses.

An erect image is shown at Fig. 90, page 247; an inverted image at Fig. 89, page 247. In each of these figures, I *q* I′ is the image of an object O Q O′. The formation of these images is explained by Figs. 86 and 87, and the corresponding letter-press.

If, on the other hand, instead of using a condensing or convex lens, we use a concave or dispersing one, we shall see that the rays passing through the lens are no longer so directed as to tend to an inverted image.

A virtual or apparent erect image, as opposed to an actual or real inverted one, is next to be distinguished. The difference between them is very important.

An image seen by the eye may be actually situated in the plane where it seems to be, or it may be really formed elsewhere, and only appear to be in the plane attributed to it by the observer.

In Fig. 106, let L M be the surface of some water in a basin, L N M. Let A B C be a pole meeting L M in B. If D be any point in the part B C, which is beneath the surface, then it has been shown by Fig. 77, page 239, that the apparent position of D will be at D′, which is directly above it. Similarly, every point in B C will have its apparent position directly above it. These apparent points will give B C the position B C′. Thus the pole will appear to be bent at B, but the image seen within the water will not really be formed

it appears to be, the deflection of the rays from D not actually taking place until they reach the surface L B M.

Fig. 106.

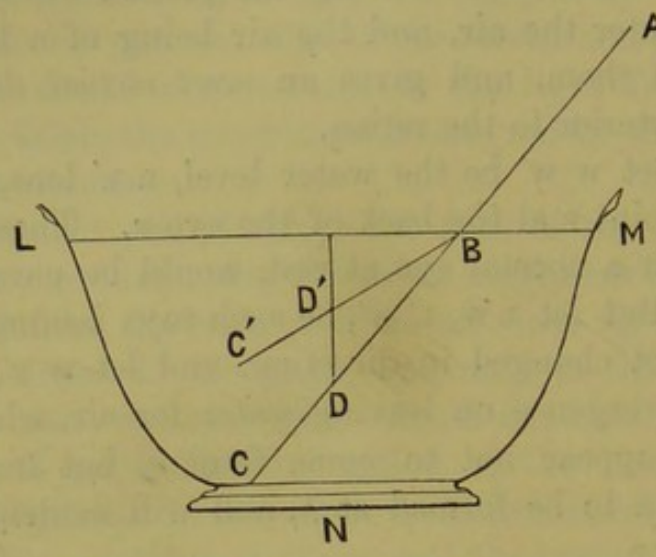

By a virtual image, therefore, we mean that, although at a certain place no image is really or actually formed, nevertheless it is as good as formed there, so far as the effect upon the observer is concerned.

The formation of a virtual image is also shown in Figs. 90 and 92, pages 247 and 249.

Fig. 107.

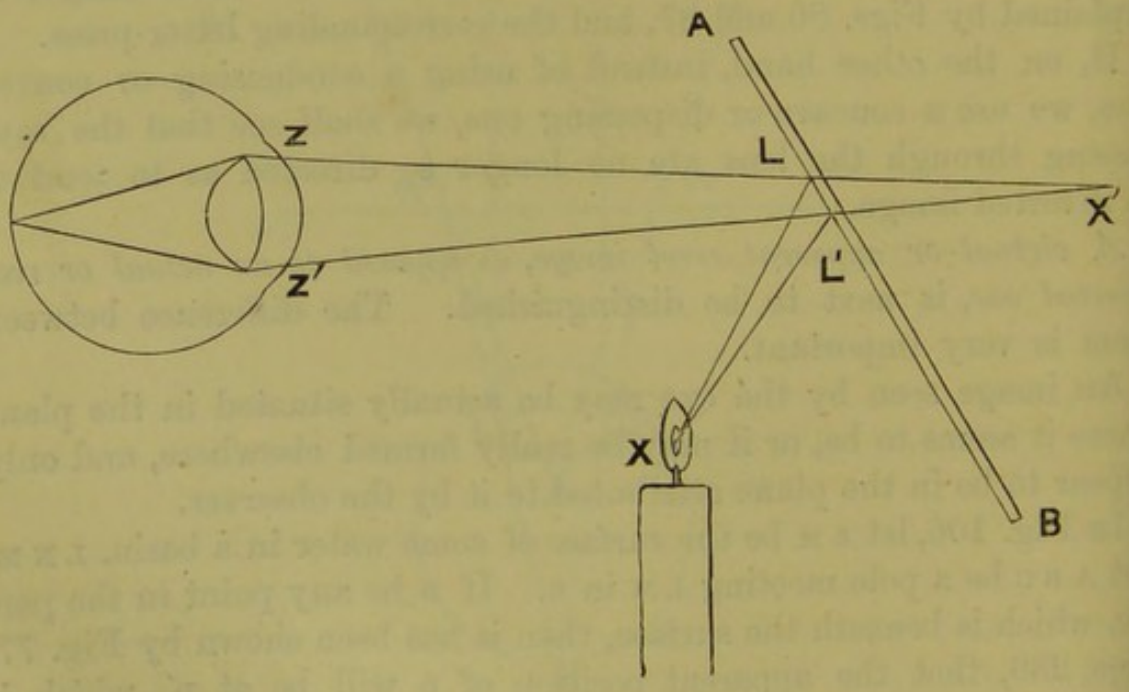

I have considered a very simple instance, but one which will make Fig. 105, referring to the cat's eye under water, still more clearly intelligible. Let me now take another instance. In Fig. 107,

the candle or light point, x, is placed in front of the toilette mirror A B, and its rays are thence reflected to the observer's eye. The image of the candle, as common experience tells us, now seems to be formed behind the mirror, and as far behind as x is really in front of it. It is simply the supposition made by the eye, which has learned to judge of distance by the degree of divergence of the incident rays, that the rays L Z, L′ Z′, are continued till they meet in x′, and the eye assumes that the continuation is directly onward, and not diverted, as is actually the case. The eye, in fact, naturally assumes the triangle x L L′ to be in the position of x′ L L′. The image, then, although not really formed at x′, is as good as formed there, so far as regards its effect upon the observer. When the image is in this way virtually seen behind, or as good as behind, the mirror, it is said to be in negative position; when, on the contrary, it is seen before it, it is said to be in positive position. The image of the candle in this looking-glass, then, is an erect, virtual, negative image.

Once more, the course of the rays issuing from objects at an infinite distance from us has been fully demonstrated in the chapter on "Geometrical Optics." Such rays may be regarded as parallel, and they act as if they were parallel. Now, a healthy eye is an eye whose parts are so adjusted that such rays fall, without effort of accommodation, exactly upon its retina, thus:

FIG. 108.

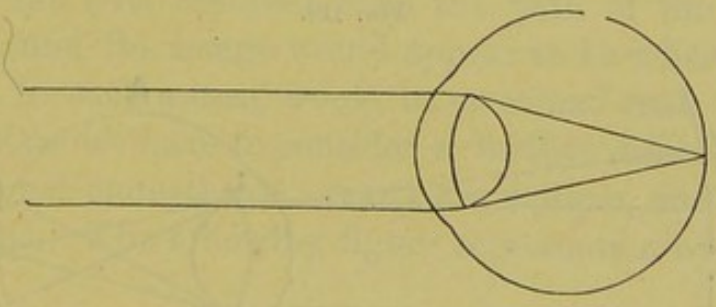

As objects, however, approach the eye, the angle of emergence becomes sensible, and the rays become more and more divergent as the object approaches nearer and nearer. In order, therefore, to keep up their convergence exactly upon the retina, we have to alter, and we do insensibly alter, the dimensions of our crystalline lens, so as to increase its converging power. In Fig. 109, the convergence is so much strengthened by a supposed exercise of accommodation for a near point, x, that parallel rays are now united at a point before the retina, as at A. They then cross and form a circle of dispersion upon the retina, so that the objects from which they are reflected are very indistinctly seen, or seen only as formless

sources of light, while the near point, x, is seen clearly. By these changes in its accommodation, the eye insensibly learns to judge of distance; and this faculty may be cultivated in a remarkable way by riflemen, surveyors, and others. When, therefore, the rays which issue from any point are divergent, that point is said to be at a finite distance from the eye ; if parallel, the point is said to be placed

Fig. 109.

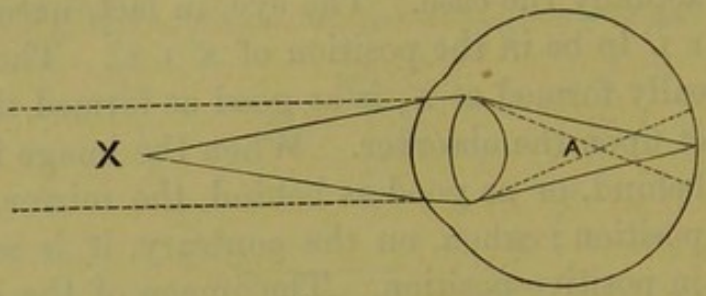

at an infinite or indeterminate distance, infinite, that is, in relation to the confines of vision. Thus it is for the normal or so-called emmetropic eye. In such an eye, when no effort of accommodation is made, or as we say less accurately, when it is accommodated for infinity, parallel rays come to a focus upon the retina, and of course in the reverse sense, it follows that rays reflected from any point in that retina issue parallel from the eye. In Fig. 108 we supposed the eye to be normal, and in such an attitude.

Fig. 110.

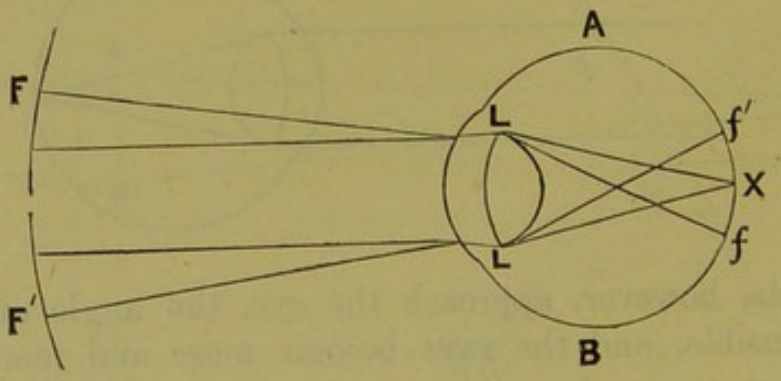

Again, in Fig. 110, let A B be an emmetropic eye, and let its accommodation be set at rest, either by cutting off its vision of near objects, or by paralyzing its accommodation with atropine. Next let us throw the light of a flame into it from a converging mirror, then F L, F′ L, will represent such rays of reflected light, which, on traversing the dioptric apparatus, the cornea, lens, and humours, will be united before the retina, and will cross as L *f*, L *f*′, making a circle of dispersed light upon the retina. A district of the retina

corresponding to the pupillary aperture is now illuminated, and reflects light back again through the same media. Let us take any point, x, in this district, the rays from x traversing the media will now issue from the eye parallel as I have explained, and will be received as parallel by an observer's eye, which is supposed to be placed behind a small hole in the centre of the mirror. Now, if the observer's eye be likewise emmetropic, and without accommodation, these parallel rays from x and other illuminated points will fall exactly upon his retina, and there form an image of the illuminated retina. In practice, the rays which issue from the normal eye, A B, are not quite parallel, nor can every observer so command his eye as completely to suspend its accommodation. The rays, therefore, tend really to meet at a point a little anterior to the observer's retina, and the image is not formed exactly at the retina, but a little in front of it. To overcome this difficulty, we place a concave lens of low value, as a correcting lens, between the two eyes behind the mirror. This separates the rays still more by counteracting their convergence, and these now fall divergent upon the observer's cornea, and are reduced insensibly, by his own accommodation, to a focus upon his retina. The image thus found is erect and virtual: erect, because the rays have not crossed; virtual, because the dioptric media of the eye, A B, like the water above the pole immersed in it, interfere with the path of the rays issuing from its retina, and so make the place of the retina appear other than it is. Were the eye, A B, empty, and the cornea and the lens removed, then the path of the rays would not be deflected, and the image would appear to be where it actually is. The image, in such a case, would be erect and real.

In the next place we have to consider a further difficulty, namely, that all eyes are not emmetropic; many are myopic, and many more are hypermetropic. The following figure represents a hypermetropic

Fig. 111.

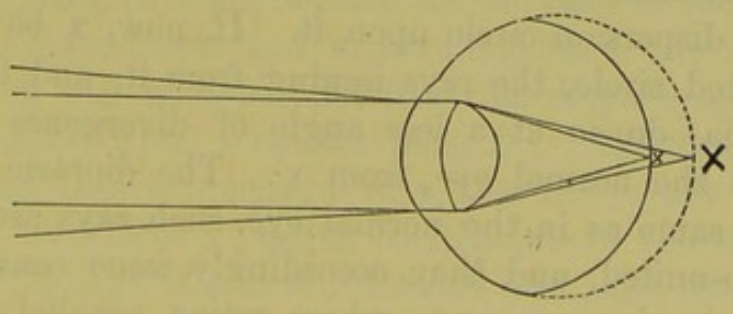

eye. Such eyes are too short in their antero-posterior diameter, and the retina, therefore, is interposed between the dioptric media and the point at which these media would unite parallel rays in such

a normal eye as is represented by the dotted line. In a hypermetropic eye, therefore, the lens being of normal focus, but the distance of the retina too short, when accommodation is at rest, parallel rays do not come to a focus upon its retina, but form a circle of dispersion there. If, now, x′ be any point in this illuminated circle, the rays from it will not issue parallel as they would do from x, which is further off, but with a divergence proportioned to the degree of the abnormal nearness. Now, divergent rays can easily be brought to a focus by the accommodation of an emmetropic observer, so that hypermetropic eyes are easy to observe, and often need no concave lens at all.

With myopic eyes, the course of things is different again. Let A B, Fig. 112, be a myopic eye, the dotted semicircle representing

Fig. 112.

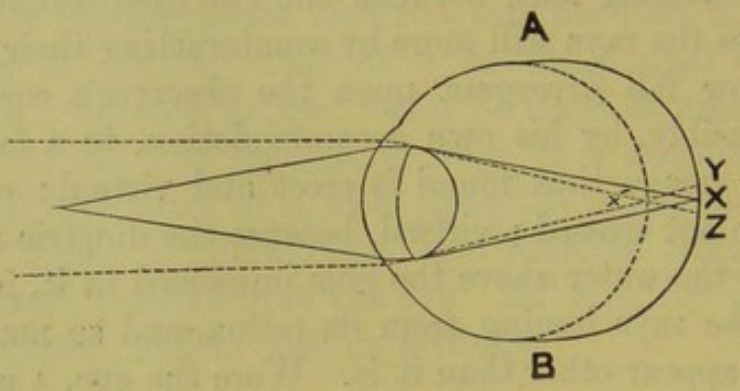

a normal outline. In these eyes, when accommodation is at rest, parallel rays would meet at x′, which is the focus of the dioptric media, and the situation of the retina in an emmetropic eye. But in the myopic eye, whose globe is lengthened, the rays will cross at x′, re-diverge, and form a circle of dispersion upon the too distant retina. It is clear, if parallel rays thus cross at a point anterior to the myopic retina, that converging rays concentrated upon such an eye from a mirror must also cross before it, and cross still sooner, forming a still larger dispersion circle upon it. If, now, x be any point in this illuminated circle, the rays issuing from it, and traversing the dioptric media, do so at a less angle of divergence than if they sprang, as in the normal eye, from x′. The dioptric power being, however, the same as in the normal eye, such rays are sooner overcome and re-united, and they accordingly issue convergent. But the emmetropic observer, upon whose retina parallel rays come to a natural focus, and in whom accommodation acts only by reduction of divergent rays, has no contrary accommodation by which he can open out converging rays. So the rays returning from a myopic

eye must come to a focus at some point anterior to his observing retina, and will then cross and form a mere dispersion circle upon it. This point will be nearer or farther from his retina, and the resulting dispersion circle smaller or larger, according to the degree of the myopia. If the myopia be slight, its returning rays will meet, if not upon the observer's retina, at any rate but little in front of it, and the dispersion circle will be very small. In such a case the picture, although not upon the retina, is nevertheless very near it, and we should see a sort of blurred image of the retina of the myopic eye. As the myopia is increased, however, the focus of the issuing rays is formed farther and farther in front of the observer's retina, the dispersion circle gets larger and larger, and the image is dislimned. The retina of an eye, therefore, which is more than slightly myopic, cannot be seen as an erect image without the interposition of a correcting, concave, or dispersing lens, to counteract the convergence of the rays, which always issue from it convergent, even when its accommodation is absolutely at rest. Thus we conclude that a hypermetropic eye may always, and easily, be seen in this way without a concave lens, because the rays which issue from it during suspended accommodation are divergent. An emmetropic eye, from which, in such a case, the issuing rays are parallel, should, strictly speaking, also be well seen without a concave lens, though such a lens is of some advantage. A myopic eye, again, if but slightly abnormal, may be seen indistinctly, by a skilful observer, without a concave lens; but if decidedly abnormal, it cannot be seen at all, as an erect image, without one, because the rays which issue from it are always convergent, whether its accommodation be at rest or in activity. Such are the principles of the examination by the direct method, which mode is indispensable to all accurate observers.

An actual or real inverted image is now to be examined. Let x, Fig. 113, be any point in the retina of an emmetropic eye A, illuminated by rays from a pierced mirror M M, in front of the observer's eye, B. These illuminating rays are omitted for the sake of simplicity. Then if A's eye be emmetropic and unaccommodated, the rays x y, x z, issuing from x, will issue parallel from the dioptric apparatus. Let them fall parallel upon a convex lens, L L′; this lens will then so strengthen the dioptric apparatus of A, that the rays x y and x z will be converged at a focus x′, which corresponds to the strength of the lens L L′. An image of x is thus formed at x′, and this image might be thrown upon a screen, were a screen so placed at this point as not to cut off the illumination. Now, what is true of x, is of course true of all other points in the illuminated part of A's retina; and these points being all reunited in the plane of x′, will build up

a picture of that part of A's retina. An observer placed in front of the screen would therefore see this image of A's retina upon it. Such a method of demonstration is obtained by means of Laurence's ophthalmoscope. But suppose that no such screen be present, the image would still be formed as an aërial one, and B's eye would receive from it divergent rays x′ y′, x′ z′, as from any other visible object at a finite distance. They pass through the opening in the

Fig. 113.

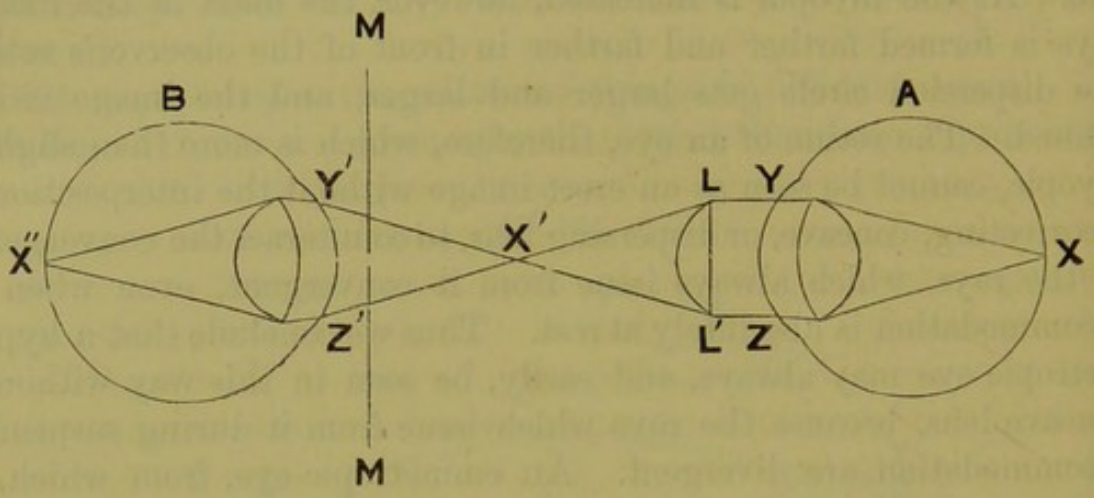

mirror, fall upon B's dioptric apparatus, and are converged by a corresponding effort of his accommodation upon his retina. Here, then, x is once more reproduced at x″, and so for other points, so that the aërial image, at the focus of the lens L L′, is reproduced upon B's retina, and accurately represents the original object at x, which is thus seen indirectly. The image of x at x′ is real, for it is not only apparently, but actually formed at x′; it is also inverted by the inverting action of the convex lens L L′, which we know would form in the plane of x′ an inverted image of an object in the plane of x.

We now know, I think, what is meant by the direct virtual image of the illuminated *fundus oculi*, and the indirect real inverted aërial image. Before going on to point out the way in which the methods of seeing these images may be best utilized for purposes of investigation, before comparing the value of the direct and indirect examinations respectively, I shall describe, in the next place, a few of the chief ophthalmoscopes in use.

SHORT REVIEW OF OPHTHALMOSCOPES.

The number of instruments which have been devised is very great, and it would be wearisome to the reader were I to describe them all, or any great number of them. When the principal varieties are

known, the details of other instruments will be readily understood without help.

A few words on ophthalmoscopes in general must precede a description of the specific differences and various advantages of certain instruments in particular.

An ophthalmoscope consists essentially in an illuminating apparatus, together with a series of spherical lenses of various kinds. To this must be added some source of light. A gas-lamp is now generally used in England, as it is easily kept in order, readily adapted to changes of position, and can be regulated to any degree of illumination. A bracket with parallel arms, and having a universal movement, is often employed. I prefer a gas-lamp which is much used in the watch-making district of Clerkenwell. It is a small Argand burner, with certain arrangements to make the flame steady, that is readily moved up and down on a rod with a firm base, and as readily turned from side to side. A piece of metal is attached at one side to screen the flame from the patient's eye. The gas is conveyed to the burner by an elastic tube, with a spiral wire. The yellow light must be corrected by means of a pale blue cylindrical chimney. Such a glass is very important in estimating the delicate tints of the disk, as seen by the direct method.

Some patients are more sensitive to light than others, but most of them will bear a moderately strong light without discomfort and without injury. In amaurotic states, patients show great insensibility, even to very strong illumination. The more the light, however, the narrower is the pupil, and this, as it narrows the field of observation, is so serious a drawback to examination, that we endeavour to work with as little light as possible. Moreover, under strong illumination, the corneal reflections become brighter, and interfere much with observation. Indeed, in cases of abnormally narrow pupils, such as we see in hypermetropia, in cerebro-spinal disease, or in old people, the gleaming cornea cuts off all chance of seeing the parts beyond it. This is due to the fact, that the cornea, which is a convex surface, forms virtual diminished erect images of all light objects in front of it, and of the mirror in particular. The brighter the light, then, the more obtrusive are the corneal reflections, and the narrower is the pupil. After a little practice, the observer will find that a comparatively feeble light will enable him to obtain a very good picture of the back of the eye, and he will only use a stronger light for occasional purposes. In pupils that naturally enlarge and contract in a marked manner, sufficient dilatation may be obtained by making the patient look at a distant object with the eye under examination, while the other is closed or covered.

Atropine, when instilled into the eye, is a great assistance. It paralyzes the accommodation and enlarges the pupil. Weak solutions are slow in their action, but the eye soon recovers. It is an object to obtain the greatest dilatation with the least effort on the apparatus of accommodation. Strong solutions, consisting of two grains or more to the ounce of water, act quicker in producing the desired effect in from fifteen to twenty minutes, but the action is more persistent. I have known it endure for ten or fourteen days, and such a persistent disturbance of vision is very annoying while it lasts. It may even cause the patient to accuse the surgeon of tampering with his sight; and should the patient be afflicted with rapidly advancing disease, he might attribute that deterioration to the atropine which is really due to the farther lapse of time. While, therefore, we cannot do without atropine, it must be used rarely and cautiously, of a minimum strength, and must be reserved for cases in which a large field is absolutely necessary. It is a wise precaution to tell the patient that he will have an uneasy sensation of dazzling when he looks at a bright light, and that his near point of distinct vision will recede from the eye, so that he is presbyopic. Also, that in all probability, distant objects will become very indistinct. At the same time, he should be assured that these unpleasant acquired effects will pass completely away. In the chapter on "Cataract," further remarks are made about this drug, to which, perhaps, the reader will refer.

The direct method needs less light than the indirect, and it is therefore in many cases to be preferred for the above reasons, as well as for many others.

The modes of reflecting light into the eye are manifold. It is done by unsilvered and by silvered reflectors; by reflectors alone, and by reflectors in combination with lenses; by prisms also, and by lenses which are themselves silvered. The first reflector of Helmholtz was a plain unsilvered glass plate. Other mirrors are concave; others again are plane, or convex, with a convex lens attached. Of these, the silvered mirrors are the strongest illuminators; but mirrors may likewise and with advantage be made of polished metal. These metal mirrors are less easy to make, and are less easy to keep in order than the silvered glass mirrors, but they possess certain advantages which are pointed out in another part of this chapter, p. 286.

The illumination by means of a plane mirror is from a virtual image of the flame, apparently behind the mirror, and the rays falling upon it from the flame, and thence diverted to the object eye, seem to come from a point not really in existence, but corresponding

to a point as far behind the mirror as the flame is in front of it. I have already explained how this comes to be.

The flame is usually more than one focal length, and less than twice the focal length from the mirror, so that the light thrown into the eye arises from a real enlarged inverted image of the flame lying in front of the mirror. If the flame were at or within the focus, the illumination would spring from an enlarged virtual image of the flame lying apparently behind the mirror. A little consideration will explain this on the principles I have already laid down. If we interpose a convex lens between the mirror and the eye, of course we shorten its focal length. The first concave mirror was made by Ruete, and concave mirrors have since been made in endless variety.

If the mirror, instead of being concave, were plane, we could concentrate rays upon it by means of a condensing lens placed between it and the flame. The rays condensed by the lens are directed into the eye by means of the mirror, behind which the observer's eye is placed. If the flame be placed at or within the focus of the lens, we have the same illuminating source as we had when the flame was at or within the focus of a concave mirror alone, namely, an enlarged virtual image of the flame. Such is the principle of the Helmholtz-Follin ophthalmoscope, and of the autophthalmoscope of Coccius when used with a collecting lens. Commonly, however, as in the useful ophthalmoscope of Coccius, the flame is beyond the focal length of the collecting lens, and in this case convergent rays fall upon the mirror, and are thence reflected to form in front of it a real inverted image of a flame whose apparent position is negative, that is to say, behind the mirror. This image is the direct means of illumination, as it was in the case of a flame placed beyond the focus of a concave mirror. When I describe Coccius' instrument, I shall explain that an advantage is gained by illuminating the eye by means of an image which is nearer the eye than the mirror itself, for which latter the eye is accommodated. If the convex lens have a focal length of ten inches, and the mirror be two inches from the lens, the rays from a flame placed at an infinite distance would form an inverted image ten inches behind the lens, and, therefore, eight inches behind the mirror in apparent position, and eight inches in front of it in actual position. This corresponds of course to a concave mirror of eight inches focus. But the arrangement has the advantage over a concave mirror, that the convergence of the rays may be easily increased or diminished by changing the lens. Convex mirrors are not used alone, as they form diminished images of the flame, and their illumination is poor. A convex mirror has, however, been used for this very reason by MacDonald, of New

York, in order so to temper the sun's rays that they may be used as a source of light. This exception apart, a convex lens is always used with convex mirrors. Zehender's ophthalmoscope is of this kind. The flame is placed beyond the focus of the lens, and converging rays, therefore, fall upon the mirror. If these have such a convergence that they will meet behind the mirror at its supposed focus, then they will be reflected parallel; if they have such a convergence that they would meet beyond that focus, they would be reflected divergent from the mirror, and the illuminating image of the flame in either case would be virtual and erect; if, however, the rays tend to converge at a point between the supposed focus at the back of the mirror and the mirror itself, then the reflected rays will be convergent, and will form a real image in front of the mirror, which will serve as the medium of illumination.

The variety of arrangement which can be obtained by moving the lens makes this ophthalmoscope a useful one; for the same variety can only be obtained with the concave mirror by constantly changing the lenses.

It is undoubtedly the best form of instrument for the examination of the erect image.

Description of some of the ophthalmoscopes in use, and, first of all, those of Babbage and Helmholtz.

Cumming, our countryman, whose distinction it is to have been the first who mastered the principles of ophthalmoscopy, did not make an instrument. The first ophthalmoscope, however, was constructed in England, although unfortunately it did not meet with a proper welcome. In 1847, Mr. Babbage had made an instrument on the right principle, which must have sufficed to demonstrate the interior of the eye in a great number of cases. It consisted of a tube, blackened within, and carrying at the proximate end a mirror set at such an angle that the light which fell upon it through an opening in the side of the tube was directed into the object eye. The mirror was made of silvered glass, the silvering being removed in two or three places near the centre. The distal end was to rest on the patient's orbit. This instrument could only be used in this form for emmetropic eyes, or hypermetropic: for the observation of myopic eyes a concave lens would have been needed. Such an addition, however, could easily have been made, had the new invention fallen into the hands of anyone who knew how to appreciate its value. As it happened, Babbage had no knowledge of the want of the surgeon, and his beautiful little instrument for him was but a scientific toy.

Four years later, Helmholtz made his ophthalmoscope, and utilized

it, therefore he is considered justly the practical inventor; for he first put forth an efficient and complete instrument, and pointed out the importance of its application. I shall describe his instrument, not only because it was the first of ophthalmoscopes, but because it has an excellence of its own.

The principles on which Helmholtz' ophthalmoscope is constructed. It has a plain unsilvered mirror, consisting of one or more plates of glass, Fig. 114.

Let M M be such a mirror consisting of one sheet of glass only, and let A be the eye of the observer, and B that of the observed; the two eyes being opposite to one another, and upon the horizontal line *a b*, now let M M be placed at such an angle that the rays *x y*, coming from a lamp at *x*, strike the mirror at an angle of 45°. Then in accordance with the laws of refraction, a portion of the rays will traverse the mirror, and the remainder will be refracted in the direction of *y b*. Of these remainder rays which enter the pupil of

FIG. 114.

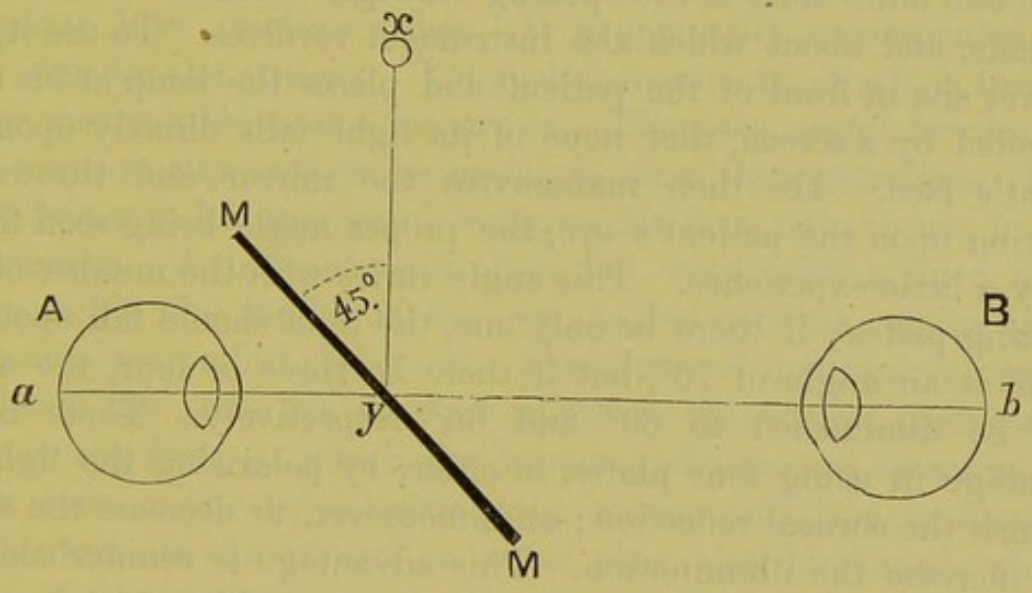

B, another portion is lost by absorption in the choroid, but the chief part is reflected, and again falls upon the mirror, to pass through it in part, and to be reflected in part as before. This time, however, it is the reflected part which is lost, for it is returned to the lamp, while the rays which pass through, enter the observer's eye at A, and A sees B illuminated. The degree of this reflection depends upon the part of B illuminated.

The two opposite points of the eyes, *a* and *b*, are supposed to be the macula centralis of each. From this portion the reflection is weakest, as the macula has the least reflecting power and the greatest perceptive power. From the optic disk, on the other hand, the perceptive power of which is least, and the reflecting power

greatest, we see a stronger illumination. In the case now under consideration, the light source seems to be from a point as far behind the mirror as the lamp is in front of it, and the rays returning from *b* to *a* are of course convergent, so that no picture, but only an illumination of B is seen, as the reader will understand from what has been said. The reader will probably likewise foresee that by the introduction of a concave or dispersing lens, between the observer's eye and the mirror, this returning pencil of converging rays may be made divergent, and in this state can be united by the accommodation of the observer's eye to form a picture upon his retina. It was here that Helmholtz stepped in. Von Erlach had succeeded in illuminating the retina, but he had not succeeded in rendering it pictorially visible. The figure of the instrument is represented in Zander's work, translated by Mr. Carter. It consists of a triangular box, one angle of which is a right angle; one side is formed of reflecting glass plates, and the others are lined with black velvet to prevent disturbing reflections from them. In the smaller of the two outer sides is the opening through which the observations are made, and about which the instrument revolves. To use it, the observer sits in front of the patient and places the lamp at his side, so shaded by a screen, that none of its light falls directly upon the patient's face. He then manœuvres the mirror and throws its reflection upon the patient's eye, the proper angle being soon found out by a little experience. This angle varies with the number of the reflecting plates; if there be only one, the light should fall upon the mirror at an angle of 70°, but if there be three or four, the angle must be diminished to 60° and 56° respectively. There is an advantage in using four plates, in order, by polarizing the light, to diminish the corneal reflection; and, moreover, to decrease the angle is to increase the illumination. This advantage is counterbalanced by the difficulty of getting plates so even as to fit accurately; and, again, the difficulty of getting the glass mirror perfectly homogeneous is rendered greater according to the number of plates required. Badly fitting, or striated plates, will give dim or distorted images. The dispersing lenses are interposed by means of the well-known revolving disks, which contain a number of lenses. The observer brings each lens in turn into the axis of vision, till he finds that which he requires. Each of these disks contains five openings, so that ten lenses are at hand, eight of which are concaves of various values. By bringing forward that concave which best suits his eye, he can now turn the illuminated into a pictorial background. This ophthalmoscope is a good one for the direct examination of the erect image, and, if necessary, it may be

borne by the patient for hours. Hence it is useful in physiological observations. Its illuminating power, however, is feeble, and for common purposes an instrument of another kind is required. Indeed, for ordinary use, we want one which is not only of more illuminating power, but which by magnifying lenses gives a larger field of observation. It is true that such illumination has been increased by the addition of a convex or condensing lens near the lamp, the two being fixed upon a horizontal arm. This instrument has been used both by Helmholtz and Follin, but it has many drawbacks in actual practice; it is alluded to under the head of light images.

The second to be noticed is that which consists of a perforated concave mirror. This form was first introduced by Ruete, and it may be used either for the inverted image with a convex lens, or for the upright image with a concave. It is made either as a standard instrument or in a portable shape. Of this kind, the standard one designed by Liebreich is the best. It is fixed to a table or stand, and all the parts, the mirror, the lenses, and the shade, are mounted on moveable bars, or draw tubes. It is generally accompanied by a chin rest for the patient. Yet such instruments, of which there are many, are cumbrous and expensive. They are useful for drawing, and they are supposed to be useful in class demonstrations; but it is far better to let each pupil learn, as his first task, to use his own instrument. A beginner will often fail, even with a fixed instrument, to see the fundus of the eye, as few patients can be trusted to maintain a perfect steadiness. One form of instrument, however, in which the parts are fixed, is useful to the clinical observer, and that is the form in which the mirror and lens are mounted in a draw tube. The tube bearing the mirror and lens is blackened inside, and travels within an outer tube, also blackened, which is fitted to the patient's eye. By means of this a patient can be examined in the daylight; a very important gain in the case of patients lying in the wards of a hospital, or in large, well-lighted bedrooms. The best of these instruments was designed in 1862 by Galezowski, but many others have been made which differ only in unessential details.

All mounted instruments lack the advantage to be gained by the free movement of the mirror or lens in any direction. For ordinary purposes, therefore, we use the separate mirror and lenses in a portable form known as the ophthalmoscope of Anagnostakis, or the "small Liebreich." It consists of a concave mirror in a case, with four or six concave lenses and two convex lenses.

The best mirrors, I have said, are made of metal, because a metal

one can be pierced and thinned down at the back around the perforation. If the perforation be made through the full thickness of the metal, it is not a simple sight-hole, but a tunnel from the sides of which irregular and teasing reflections arise. If the mirror be made of glass from which the silvering only is removed at the centre, then, again, we have another source of interfering reflections ; some rays are reflected by the anterior surface of the glass and some by its posterior; moreover, the rays which pass through are refracted, and probably distorted also, unless the glass be very good.

The necessity for a convex lens to complete the appliance of the ophthalmoscope for making the indirect examination of the eye has been explained at page 278, and such a lens should of course be in the ophthalmoscope case. Where there is only one lens, it should be of two-and-a-half inches focal value. I prefer to have two lenses, the one of two-and-a-half inches, the other of three-and-a-half inches value.

A concave lens also is requisite, as I have shown at page 277, for examining a myopic eye by the direct method. A further consideration of this lens will come under the head of correcting or ocular lenses.

Fig. 115.

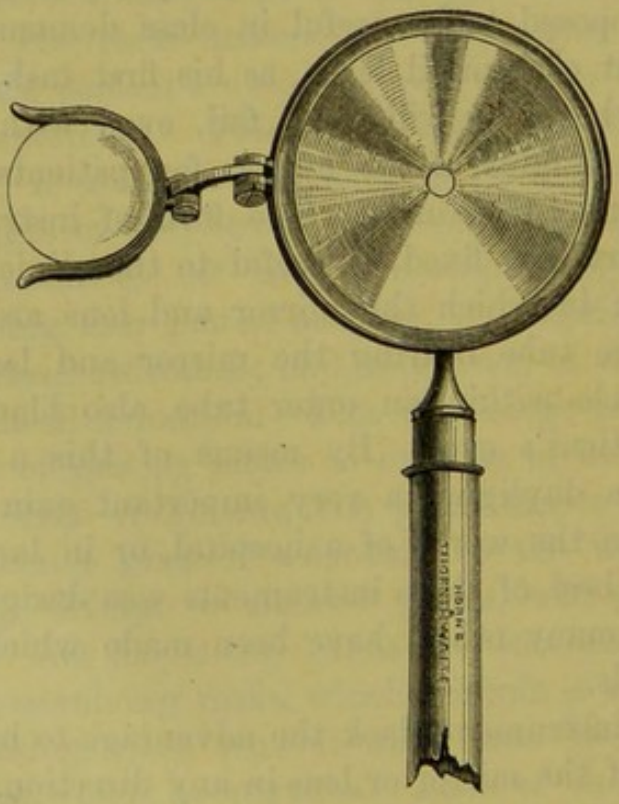

The ophthalmoscope with a concave mirror is so convenient that it will probably always be the favourite for ordinary purposes. Such an one, the copy of that which I use, is represented in Fig. 115, with the spring clip for the correcting lenses.

Correcting or ocular lenses. The mirror and object-lens are the essential parts of an ophthalmoscope, but in addition to these, certain small eye-pieces, or convex and concave lenses, are needed, which aid materially in obtaining accurate pictures of various eyes, both in examining the upright and the inverted images. They are usually made much smaller than the object-lens, and are placed in a spring clip at the back of the mirror. The convex lenses are of course required for the indirect method, or the inverted image, in case a magnified image is required, and the concave for the direct method, or the upright image under the existence of myopia, as above explained. These correcting lenses are also of very high importance in estimating anomalies of refraction, and the diameters of the eye. Theoretically, of course, they should be very numerous, and of all focal values, but in practice we find that four bi-concave lenses of the values, say of six, eight, and twelve inches, and one or two bi-convex lenses, say of the values of ten and twelve inches, are amply sufficient. They are necessary, too, for observers who are myopic, or presbyopic, or hypermetropic. They are sometimes set in a revolving disk, which enables the observer to change them quickly and easily.

Coccius' instrument, which I shall next describe, is the best ophthalmoscope for all purposes. In this instrument the rays of the lamp flame do not fall directly upon the mirror, but fall first upon a convex lens, which is placed at more than twice its focal distance from the flame, and within its focal distance from the mirror, so that they arrive in a convergent state upon the mirror, which is plane. In this ophthalmoscope, therefore, a different flame image is formed to that formed in the Helmholtz-Follin's instrument, in which the flame is placed within the focus of the lens.

Suppose, in Fig. 114, *a* to be any point in the dispersion circle formed of the over-crossing of the convergent rays within the eye B, then the rays returning from that point will, as the reader may remember, be all returned to the conjugate foci of the dioptric apparatus, namely, to the point for which the eye is accommodated.

Now, the eye may be accommodated for the perforation in the mirror, or for the flame image in the mirror. If it be accommodated for the perforation, the eye examined will return a dark image of the perforation, that is, of the observer's pupil, and in practice will seem very faintly luminous, or even black if the pupil be small. If, however, it be accommodated for the lamp image in the mirror, it is accommodated, as the reader will also remember, not for the plane of the mirror itself, but for the plane of the virtual image of the lamp, which is as far behind the mirror as the lamp is in front of it.

The rays from the illuminated point will therefore be returned to a conjugate focus considerably behind the eye of the observer, who will therefore find himself placed within the cone of returning rays, and will see a fully illumined fundus. The image of the perforation will now be formed behind the retina illuminated, and the retina itself being occupied with an image of the flame, it is obvious that the perforation in the mirror must be made as small as is compatible with clear way of sight. It should never exceed two lines in any case. The accompanying illustration, Fig. 116, shows the instrument.

In the examination of the inverted image, a convex object-lens is of course also needed. Zander, Carter's edition, gives the following simple directions for the use of this ophthalmoscope: "In use the collecting-lens is turned towards the flame, which should be at least some inches further from it than twice its focal length, and on the same level as the eye to be examined. By loosening the screw, the mirror is set obliquely to the lens and to the eye of the patient; and

Fig. 116.

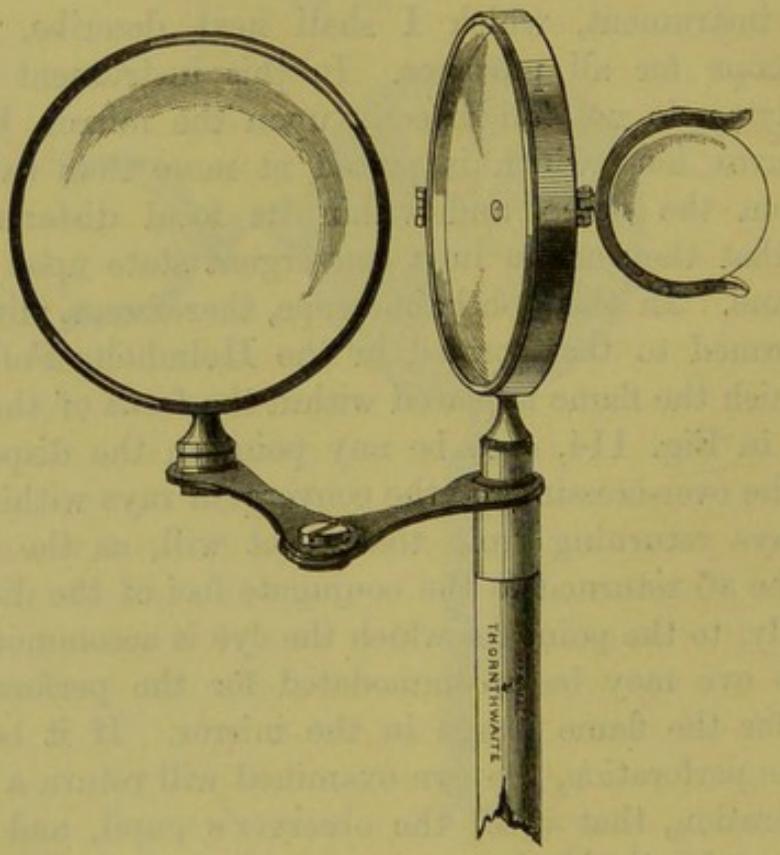

when it is rightly directed, we see, by casting the enlarged image of the flame upon the patient's cheek, a luminous circle with a dark central spot, corresponding to the hole in the mirror. The patient must now look fixedly at an object behind the observer and on

the side opposite to that of the eye under examination, and the dark spot must then be thrown upon the centre of the pupil, while the observer, with his eye as close as possible behind the mirror, looks into the eye of the patient. Dilatation of the pupil by atropine is not necessary. For examination of the inverted image, a convex lens of two-and-a-half inches or less, often of half an inch, is used, and is held either between the thumb and forefinger of the free hand, in front of the eye examined, or upon a handle six inches long with a spring clip at the top ; while in examination of the short-sighted, concave glasses are used of the values of $\frac{1}{12}$, $\frac{1}{8}$, $\frac{1}{6}$, $\frac{1}{4}$, $\frac{1}{3}$, $\frac{1}{2}$." The great advantages of this instrument are, that the observer's eye is within the cone of light falling upon the patient's eye, which advantage is lost in the concave mirror, where the observer's eye is beyond its base, that by moving the lateral lens the focal length of the mirror and the degree of the illumination can be altered, and that there is very little irregular reflection, a matter of much importance when the pupil is small.

Zehender's instrument is the last of this kind that I shall describe. It consists of a combination of a convex lens with a convex mirror. It resembles that of Coccius, except in the form of the mirror. It is a very good ophthalmoscope, and, among its other advantages, there is not any loss of light from its central perforation, and corneal reflections are much diminished. The illumination on the retina indeed is not single but multiple ; the strong curvature of the collecting lens being sufficient to produce considerable spherical aberration, so that the image of the flame reflected from the mirror is not formed in a single plane, but in several, on which account, in the illuminated portion of the retina, there is a bright nucleus surrounded by a comparatively dim margin.

In describing the various kinds of mirror image, I pointed out that the image of this instrument depends upon the degree of convergence of the rays falling upon the convex mirror ; this ground need not be gone over again.

In this ophthalmoscope the light is placed beyond the focus of the collecting lens, so that converging rays fall upon the mirror. Then, as I have explained, if the convergence is such that the rays would meet at a point between the mirror and its imaginary focus behind it, then these rays are reflected convergent, and form a real image of the flame before it ; this being formed, the farther from the mirror the farther the point of convergence is from the mirror backwards, and the nearer it is to the imaginary focus. When this point of convergence recedes so far as to coincide with the focus of the mirror, the reflected rays will of course be parallel. I recall

these details in order to show another great advantage which the

FIG. 117.

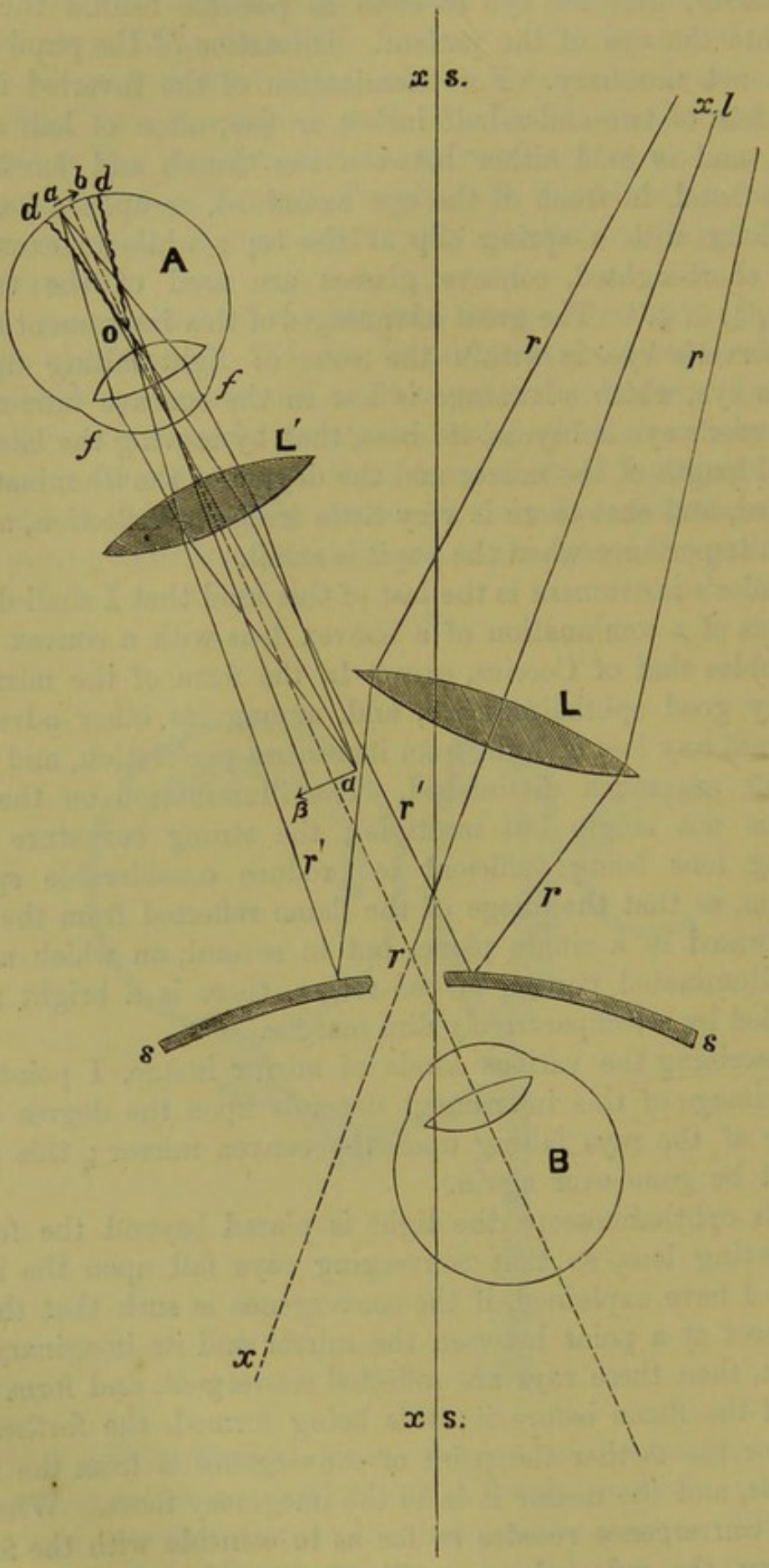

instrument has over those of Coccius and Liebreich. To obtain reflections of various degrees of convergence, we have in Liebreich's instrument to change the mirror for one of another focal length; we attain this end more easily in Coccius' instrument by changing the collecting-lens, but here the end is attained more easily still by moving the lens to or from the mirror along a line equal to the focal length of the latter. Thus, without lessening the quantity of light, we continue to send the strongly-condensed rays of the collecting-lens into the eye at a degree of convergence so much less that the rays do not unite until they approach the retina. As Zander neatly expresses it, we thus collect the same quantity of light into a narrower section, and on an equal base, make the light cone smaller, but neither shorter nor less luminous. The curvature of the mirror is six inches, the focal length of the collecting-lens being one inch or two. The ocular lenses may be fixed in a clip upon a jointed arm turning behind the mirror.

It must be apparent that the instrument is a modification of that of Coccius. It is very like it in the manner of mounting.

The annexed diagram, Fig. 117, borrowed from Mr. Hulke, illustrates the indirect method of examination with this ophthalmoscope. *r r*, are rays collected by the lens L, falling convergent on the speculum *s s*, which reflects them still converging towards A, the observed eye. While, however, they are on their way, they are intercepted by the double convex lens L′, which so increases their convergence that they meet at o, then cross and diverge, and form a circle of dispersion, *d d*, on the retina. The pencil of rays coming from *a b*, points in this circle, would meet at some point in the prolongations of *a a*, *b β*, the lines of direction which cut the optical centre of A, but passing through L′, they are brought to an earlier focus at *a β*, where they form an inverted image of *a b*.

In the direct method, Fig. 118, the rays reflected from *a b*, would meet at *a′ b′*, but by passing through the concave correcting lens L′, they acquire the direction *a″ b″*, which they would have, if they reached the observer's eye from *a β*, where the geometrical image of *a b* seems to lie. The situation of this image is determined by the focal length of the patient's eye, and that of the correcting lens. It will be remembered that a concave correcting lens is necessary only when the eye to be observed, or that of the observer, is myopic.

Farther remarks on Mirrors. Before leaving the mirror as a means of illumination, I shall now describe the silvered glass lenses, which are used as ophthalmoscopes. Of spherical lenses we have the bi-concave and the bi-convex: we have also the varieties of meniscus, the so-called periscopic lenses; the convex-concave, in which

the convex is the stronger curve, and the effect therefore condensing,

Fig. 118.

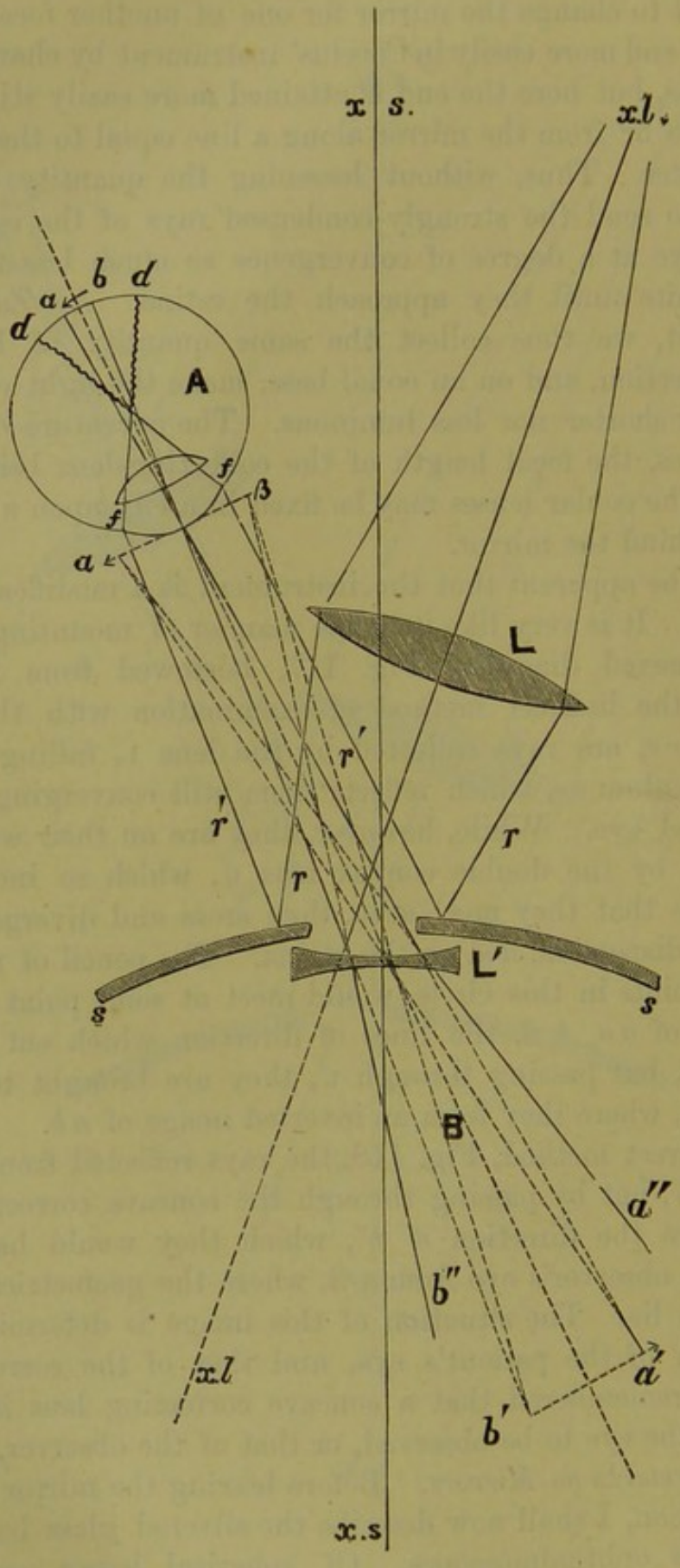

and the concave-convex, in which the concave surface is the stronger curve, and the effect therefore dispersing. This is more fully given

in the chapter on "Geometrical Optics," together with the terms which are applied to such lenses, such as negative and positive.

If we take a bi-concave lens, and silver one surface, we shall obtain the effect of an intensified convex mirror. I have said a convex mirror without a convex lens is the worst possible illuminator, and only used for reflecting such intense light into the eye as that of the sun. We gain little, therefore, by the use of a silvered bi-concave lens, unless we wish to throw sunlight into the eye. If, on the other hand, we silver one surface of a bi-convex lens, we have the combination of a concave mirror with a condensing lens; that is, with a radius of curvature in the silvered surface of, say, eighteen inches, we should have an instrument with a focal length of six inches. It is clear that such an ophthalmoscope can only be used for the inverted image. A negative meniscus is more useful for silvering. Such a lens is represented in Fig. 83 and described. The curvature of the concave surface is the stronger, that is, its radius is shorter than the radius of the convex surface. The convex surface, when silvered, makes a concave mirror, and the lens still acts as a concave lens. Such a combination of a powerful mirror with a negative lens is very useful in examining the upright image; it cannot be used for the inverted image, except in cases where the patient is extremely myopic. Three or four of such lenses, however, are as useful and portable and cheap an apparatus for the upright image as can be had, and I am surprised that these menisci are not more commonly used. A positive meniscus is next to be considered. (See Fig. 83.) Here the silvered convex surface still acts as a concave mirror, but the radius of its curvature is shorter, and the curve therefore stronger than that of the concave surface. This and the bi-convex silvered lens are available for the inverted image chiefly, though they may be used for the upright image in hypermetropia as the negative meniscus may be used in myopia.

The relations of the degrees of surface curvature in these silvered lenses, and the distance of the flame, are closely calculated in Zander, pp. 50, 51, and it is needless for us to pursue this question into any farther detail. I will only add that Mr. Laurence used an unsilvered meniscus as a reflector, so that by lessening the illumination, he might increase the field of vision. His "meniscus ophthalmoscope" has a concave surface of twelve centimetres radius, and a convex surface of four centimetres radius.

Prisms also are used in place of mirrors as illuminating media.

Ulrich of Göttingen was the first to make this application of the prism, and to construct the neat little instrument known as Ulrich's prisms. A full account of it will be found in Carter's Zander.

Prisms will never come into general use as ophthalmoscopes. Their refraction is perfect, but they are very difficult to manage, and they are also expensive. Moreover, they do no more than direct the course of the incident rays; they have no focusing action like that of the concave mirror, or mirror with collecting-lenses. In one form of ophthalmoscope, however, they are indispensable, namely, the binocular instrument.

Fig. 119.

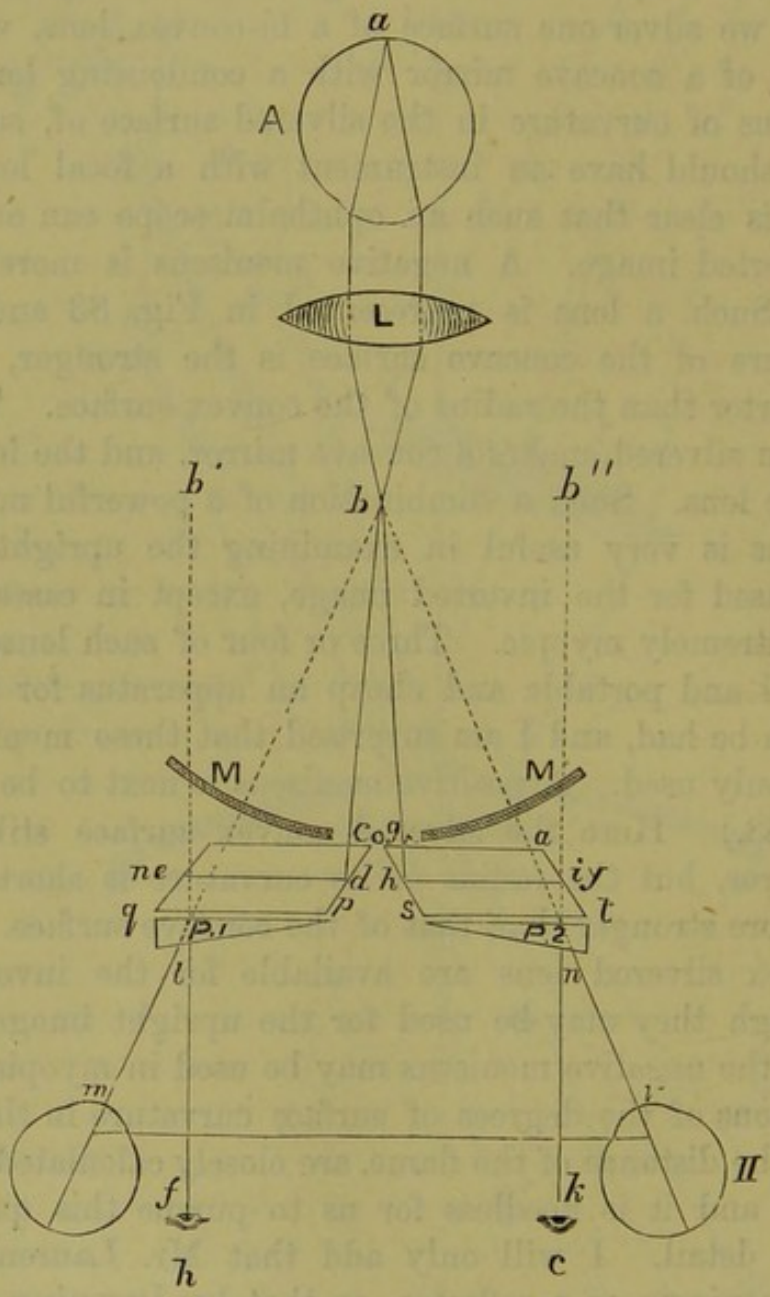

Binocular ophthalmoscopes. All the ophthalmoscopes I have so far considered are adapted for one eye only, and consequently do not give the results of binocular vision. By an ingenious adaptation of the prism, an instrument has been constructed for binocular sight, by means of which the parts at the back of the eye can be seen in due relief or "stereoscopically." Under ordinary circumstances it is impossible to get a view of the inverted image with both eyes,

because we are too near it. In order that the returning rays may become sufficiently divergent to be received with both eyes, we must retire to a distance which is beyond all convenient limits. Dr. Girard Teulon met this difficulty by causing an artificial increase in the divergence of the returning pencils, an increase great enough to include both the pupils of the observer.

A glance at the accompanying diagram, taken from Mauthner's Lehrbuch, explains Dr. Teulon's method. An inverted image of the point *a*, is formed at *b*, and the rays *b c*, *b g*, are intercepted by two rhomboidal prisms at *c* and *g*. These rays strike the sides of the prisms at *d* and *h*, whence they are refracted in the direction of *d e* and *h i*; these thus strike the opposite sides of the prisms at *e* and *i*, and are deflected in the directions *f* and *k*. An eye placed at *f*, now sees *b*, not at *b*, but at *b'*. In like manner, an eye placed at *k*, sees *b* at *b''*. The rays *f l*, and *k n*, being now parallel, will not give distinct vision to an emmetropic eye, for to such parallel rays mean infinite distance in the object. To meet this, two supplementary prisms, P_1 and P_2, of known value are interposed, which divert the rays *l f* and *k n* in the direction *l m* and *n v*. These new lines prolonged would meet at *b*, and thus the two eyes, I and II, of the observer, receive a single binocular or stereoscopic image of *b*. The instrument must be adjusted for each observer.

An improved adjusting binocular ophthalmoscope has been invented and made by Mr. Laurence Heirch, allowing inclination of the mirror in all directions, and also allowing the distance between the angles, *t* and *q*, of the prisms to be varied readily, by means of a transverse screw. By this means the prisms may be exactly adapted to the distance between the pupils of any observer. Other differences are made in the form and arrangement of the prisms, but the principle remains unchanged. The advantages of the instrument may be thus summed up. Perfect adjustment for differences of the distance between the pupils of different observers. Facility for producing union of the two images at any required distance from the eyes of the observer by a tilting of the prisms, and avoidance of any fatigue to the eyes, as there is no forced convergence of the eyeballs.

The binocular ophthalmoscope is not adapted for the inverted image. For the direct image it has been suggested that one of Coccius' or Zehender's heterocentric reflectors may be fitted to Laurence's instrument. It is very valuable in giving the relation of parts in depth. It gives a greater amount of light, a more extended field of vision, and a greater accuracy of definition and perception of relief. There is all the difference that exists between seeing a thing

with one eye or seeing it with two. The binocular microscope is a parallel to it. It shows the optic disk as it really is, whether it projects, is excavated, or level. It shows the real thickness of the retina, and any changes from the natural standard. It detects the slightest detachment of the retina. The exact position of extravasations of blood, or of morbid deposits in the vitreous humour, or in the retina, or in the choroid, or between these, can be accurately ascertained. It is very valuable, therefore, for drawing, and every observer should be familiar with the stereoscopic appearance of the eye, though, when he has gained this familiarity, he may find a monocular ophthalmoscope thenceforth sufficient. Every student should look with a binocular instrument at some time or other, and the sooner the better, in order that he may form true conceptions.

The prism is also ingeniously applied by Dr. Heymann to autophthalmoscopic purposes, or the revelation of one's own retina to one's self. Dr. Heymann's instrument affords to one eye an inverted picture of the other. The instrument is pretty and ingenious, but of little practical value; its chief or only use is to ascertain the limits and degrees of sensibility in the retina. Autophthalmoscopy was first practised by Coccius with his own plane mirror. Diagrams, with descriptions of the use of his instrument, and of the autophthalmoscopes of Dr. Heymann, Girard Teulon, and Zehender, are to be found in Carter's edition of Zander, to which work the reader is referred for further detail.

DIRECTIONS FOR USING THE OPHTHALMOSCOPE.

The student of diseases of the eye, as of other parts, must in the first place learn the appearance of the eye in health. This simple precept, which seems almost too evident to need repetition, is nevertheless almost wholly disregarded in practice. Nothing is more common in ophthalmic classes than to set men to examine diseased eyes who have no sort of familiarity with the normal conditions. It is difficult to say how much of the loose way of reporting ophthalmoscopic appearances, and how much of the indiscriminate enumeration of relevant with irrelevant details, which is too often manifest even in the writings of teachers themselves, are due to this deficiency in their early education. A pupil who has first of all been made thoroughly familiar with the healthy standard, and with its variations within the limits of health, will thus learn the true significance of the various details which he has before him, and will learn to record cases with point and discrimination. Without such a standard he loses himself in the multiplicity of the details, records

those which are inessential, and omits to record those by which the nature of the affection is betrayed.

Several years ago, Dr. Mackenzie, our great ophthalmologist, made this remark to me in a letter: "I have made very little of the ophthalmoscope. It requires much time and pains to make it profitable. The differences in the appearances of the retina, even in healthy eyes, must render its application to pathological inquiries still more difficult and uncertain."

The appearance of the normal eye is shown in a plate at the end of this work. Nothing, however, can take the place of direct observation, and I strongly advise the student to do as I did when I began ophthalmoscopy, to examine the eyes of his friends as often as they will allow him to do so, and to examine the eyes of dogs and cats, which present beautiful images.

The manner of conducting an examination by the indirect method, so as to obtain a real inverted enlarged aërial image. It is called the indirect method because, instead of receiving into our eye the rays of light

FIG. 120.

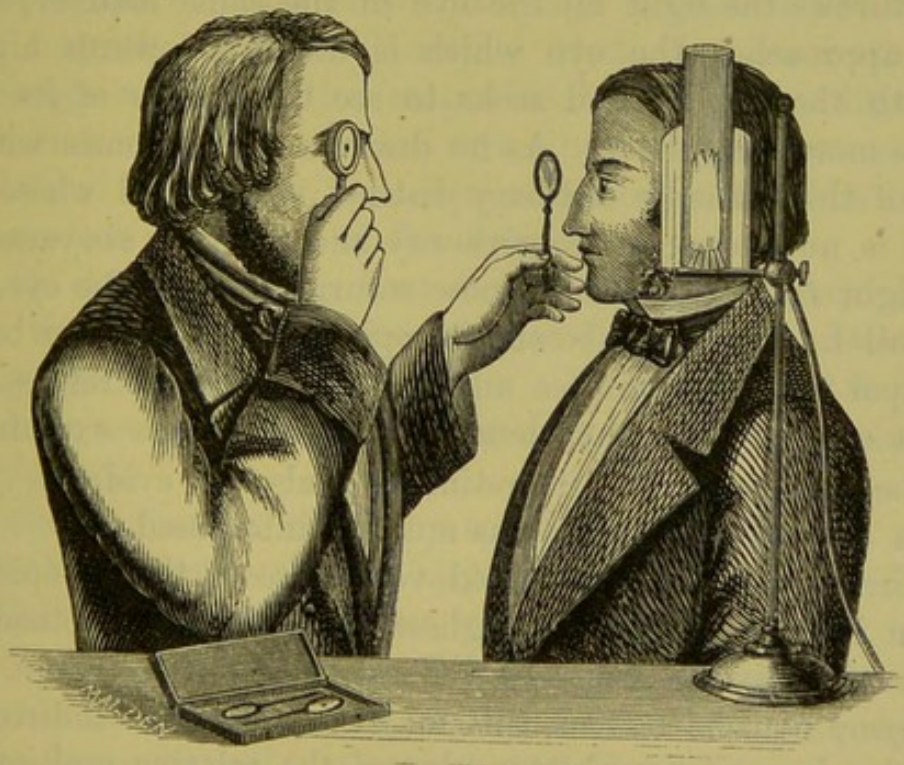

which came direct from the retina of the observed eye, we get them as they come indirectly from it, and directly from an aërial image of it. The patient sits by the side of a convenient table. The lamp is placed close by the side of his head and a little behind the temple; the flame put on a level with the eye, from which it is screened by a little metal plate fixed to the burner. The observer takes his position directly in front, and sits slightly elevated, holding the ophthalmoscope close to his own eye, in an oblique position, to

receive the light from the lamp, and at about eighteen or twenty inches from the patient's eye, on which he throws the reflection. Looking through the central aperture, he moves the instrument forwards, and endeavours to get the focus. A diffused reddish glare shows that the interior of the eye is illuminated. With a little adjusting, the retinal vessels, or the optic disk may be seen. The exact focus is now obtained. He then holds the object-lens vertically before the eye, at the distance of its focal range from the retina, two-and-a-half inches, to condense the returning rays in front of his own eye, and to obtain the inverted aërial image which is formed by re-convergence of such rays in a plane two-and-a-half inches on its hither side. For this point we must accommodate our eye, and not for the illuminated retina itself, and here lies a difficulty which many beginners experience.

Fig. 120 is intended to illustrate these directions.

The manner of conducting an examination by the indirect method, so as to obtain an erect virtual image. Let it be supposed that the patient and the lamp are placed as for the above examination, that the observer throws the light on the eye in the same manner, but that now he approaches the eye which is directed towards him much closer with the mirror, and seeks to see the details of its interior, which are more magnified. As he draws near, he comes within the distance of the patient's ordinary distinct vision, and whose accommodation is now supposed to give way and fall into abeyance. The rays of light from the mirror, now returning from the eye, should issue parallel. If the eye be emmetropic, and the observer be within its principal focus, he will see an erect image of the retina, with or without a correcting concave lens, in the way I have explained. If the eye be hypermetropic, its retina will also be evident. If it be myopic, a concave correcting lens must be interposed.

The mirror must be approached very close to the myopic eye, to within an inch or two in the highest degree of that optical defect. Under such conditions it is very difficult to obtain an image.

To compare the two methods, this may be said. The indirect, while it magnifies less, gives a better idea of the relative position of the parts, and a larger field. The direct gives a larger image, and a better scrutiny of fine objects, such as the pulsation in the vessels, and changes in the optic nerve. By it, the form and position of morbid growths are better made out. The position and extent of detachments of the retina can be well ascertained. By it, points which are doubtful under the indirect method may be cleared up.

For very exact inquiry, the two methods should be applied.

The student will facilitate his learning by examining eyes with

dilated pupils. When he is tolerably proficient, he should spare his patient the annoyance that atropine produces, and resort to it only when it is requisite to examine a larger field of the fundus than the size of the natural pupil will admit of, especially for scanning the peripheral portions.

It is not necessary to shift the position of the lamp according to the eye to be examined, as the eye which is away from it can be inspected as well as that which corresponds to it. As a matter of habit I place it on the left side of the patient, as the sketch shows, and the metal screen to the flame is adapted for this. Some observers place the lamp more behind the head, and disregard the horizontal flame, not caring whether it be high or low. Others place it above the patient's head. This position is absolutely necessary for the binocular ophthalmoscope.

A few words about the object-lens are necessary. To increase the focal length of the lens is to magnify the image still more. There is an advantage in accustoming one's self to use the same lens, and to employ another only exceptionally. Hence it is, as a rule, I use that of the value of two inches and a half focus, and when I desire an extra magnifying effect I employ that of three inches value. But the image may be further magnified by using in addition to the two-and-a-half inch object-lens, a correcting or ocular convex lens, in the clip behind the mirror, the required value of which will depend on the condition of the eye of the observer.

About the use of correcting lenses it is unnecessary to say more than to advise the student to try the effect of them over and over again till he is familiar with their effects. No amount of writing can supplant this, and I believe that I have said enough to direct him in his investigation.

When the student has a healthy eye before him, let him not look at it in that purposeless way which teaches nothing, but with a clear idea of what he is seeking. Let him first learn to find the optic disk by the indirect method, and to keep his eye upon it. This is good practice, as in this way he forms the habit of moving in opposition to the movements of the patient, and of tilting and turning his mirror and lens so as to avoid disturbing reflections. When he has learnt to keep the disk before him in this way, let him watch the vessels, distinguishing the arteries from the veins. Let him also notice exactly the tint of the disk, comparing one eye with the other; and if there be any white or black edging to the disk, let him observe it minutely and learn not to write it down carelessly as disease. The yellow spot will be the next object of his regard; its central point and its tint must be minutely examined, and the course of the

vessels around, and not through it, must be noted. When he is thoroughly familiar with these two central parts, and with the distribution of the retinal vessels, he must then endeavour to survey the field of the retina without losing himself; this will be learnt by constantly recording within himself at what part he is looking, and how the position can be expressed in relation to the disk and the yellow spot. In the inverted image, of course the apparent position will be the contrary of the actual position of the parts, but he learns to make allowance for this in the eye, as instinctively as he does in the microscope. When he has become thoroughly familiar with the brilliant and extensive field of the inverted image, he must then go through the same course of training for the direct method. He will find now that he has to encounter a new set of difficulties

Fig. 121.

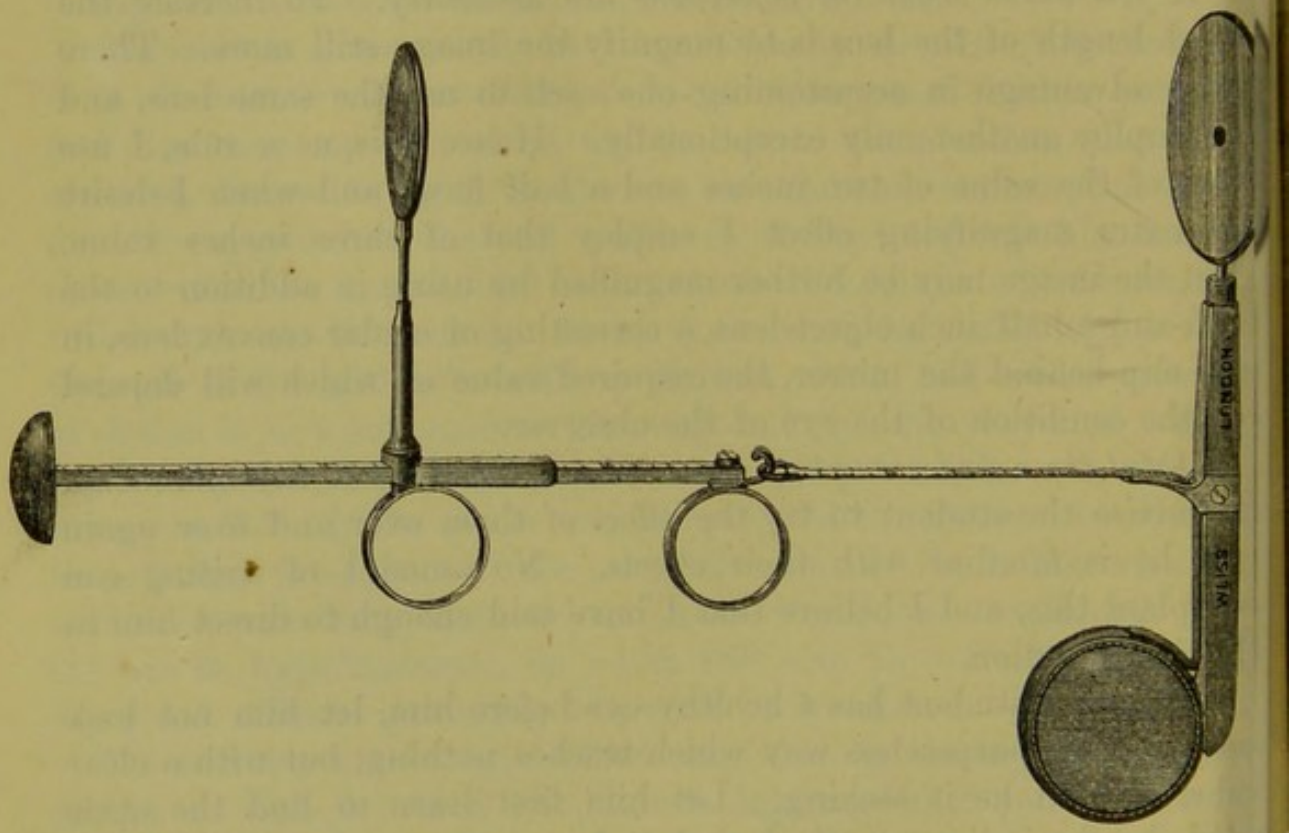

arising from the higher magnifying effect, which means, of course, a lower illumination and a smaller field. But he will also discover new advantages, and learn many new details.

All beginners find difficulty in focusing the ophthalmoscope, and in adjusting the object-glass, as well as in maintaining the proper distances when they are found. Mr. H. Greenway, whose practical ingenuity in surgical appliances is well known, has afforded help here. He has given many of the advantages of a fixed instrument without any of the disadvantages. His improved ophthalmoscope (*see* "British Medical Journal," Nov. 28, 1868) consists of two parts.

a bi-convex lens mounted on a stem, which slides on a graduated brass bar, at one end of which is a knob which rests against the patient's face, the other end terminating in a hook, and a concave mirror, supported on a handle, from the centre of which runs a spring measuring-tape.

In Fig. 121, only a small portion of the tape is seen, as the mirror and the lens are necessarily represented nearer together than they should be in practice. The remainder of this self-winding tape is contained in a box at the lower end of the mirror-handle. Since the drawing was made, a hinged clip has been placed at the back of the mirror, as in Liebreich's small ophthalmoscope.

Rules for use. To prepare the ophthalmoscope for the indirect examination of the eye, draw out the tape to the focal length of the mirror, about eighteen inches, connect the tape with the graduated bar, and set the lens on the slide at its focal length, about two-and-a-quarter inches. This done, and the patient being seated in the usual manner a little in advance of the lamp, the instrument is used thus: Place the thumb of the one hand in a ring, fixed underneath the hook at the near extremity of the graduated bar, and the middle finger in a ring attached to the under surface of the slide, and the forefinger on its upper surface; then lay hold of the mirror-handle with the other hand in such a manner that the tape may pass between the fore and middle fingers in front, the thumb being placed behind. The knob at the extreme end of the brass bar should now be applied against the patient's face, and in such a position that the mounted lens shall be in a line with the spectator's eye, and that about to be examined. By gently pressing the bar towards the patient with the thumb of the lens-hand, and by keeping the tape slightly on the stretch with the mirror-hand, the speculum being held in position, the whole instrument will have the steadiness of a solid construction. As a further aid, the surgeon may sit sideways on a high chair, and make its back serve as a rest for his elbow. Any slight adjustment of the lens can be made, if required, during examination, by gently sliding it on the bar. A rotatory movement of the lens can be gained by turning its tubular support with the forefinger, which lies close to it. A slight to or fro motion of the finger across this tubular shaft will cause it, and consequently the lens, to rotate. The use of thus slightly altering the direction of the lens is to throw aside any reflected images of the speculum.

For the direct method of examining the eye, the presence of the tape-box will not prevent the mirror being used in the ordinary manner.

The student will do well by practising the use of the mirror on

some small object placed in a proper position. A pill-box, with the interior coloured red, about an inch deep, and of the same width, with a hole punched in the centre of the cover, on which an iris is sketched to serve as a pupil, will answer the purpose.

THE NORMAL ASPECT OF THE RETINA, OF THE OPTIC DISK, AND OF THE CHOROID.

I shall now proceed to describe the appearances of the fundus in the healthy eye, and I shall take first the optic disk and its neighbourhood.

I shall presume that the inverted image is used, and that the pupil is dilated. Now, if the eyes of the patient and of the observer are upon the same axis, the observer will see an illuminated red background, and somewhere in the field he will soon detect a blood-vessel. Let him fix this vessel, and then move himself in the direction opposite to its apparent convergence, he will thus arrive at the place where the retinal vessels meet, and at which point is the optic disk.

The optic disk, or blind spot, is not, then, in the centre of the fundus, as our daily experience tells us; it is at a spot lying a little to the inner side of the visual axis, and the diverging optic nerve, if prolonged, would traverse the cornea about its outer third. The observer is, therefore, now looking obliquely as regards the patient, or he may more conveniently stand opposite and direct the patient to turn the eye under examination inwards and slightly upwards. The optic disk will then come into view, and it is retained in place by directing the patient to fix his eye on some convenient point. This should be a distant point, in order to dilate the pupil, unless, as at present, we have used atropine. Otherwise, I tell him to look at the tip of my ear. When, therefore, I examine his left eye, he looks at my left ear, and he looks at my right ear when I look at his right eye, all the time keeping his head straight.

The disk itself is seen, in the inverted image, as a round, or more frequently a slightly oval spot, appearing, with a convex lens of two inches, to be about three lines in diameter. At a point near its centre the vessels meet and penetrate it, and their sheath of connecting tissue, being bloodless, appears as a small white depression, *porus opticus*. The disk is circumscribed by another portion of connective tissue which forms the inner sheath of the optic nerve, and which appears to the eye as a white ring. This ring is always evident in the erect image, but is generally invisible as such in the inverted image. When the sheath is abnormally prolonged, it is very evident, even in the inverted image, as a stout ring or crescent,

which must not be mistaken for the edge of a cup, or recorded as the evidence of any disease. The cylinder of nerve-bundles which is traversed by the white sheath of the vessels, and the vessels themselves, has to the eye a somewhat convex appearance, and is therefore called the "papilla." This appearance is, however, deceptive, and the binocular instrument shows that the disk is in reality very slightly concave, and has a marked central depression at the entrance point of the vessels. Its colour is a compound of the white of the fine neurilemmatous canals which subdivide it, of the delicate grey of the nerve-fibres themselves, which here leave the canals, and of the crimson of its fine capillary network. The tint which results from the delicate blending of these colours is difficult to describe; moreover, it varies a little in different persons and at different ages. It appears to vary when there is actual variation in the colour of the fundus which stands in contrast with it; different degrees of illumination and accommodation, and different modes of observation also influence its appearance, and finally the colour of the inner half is actually a little different to that of the outer half. The nerve-bundles turn over more thickly on the inner half of the disk, so that the white of the lamina cribrosa formed by the ends of the neurilemmatous canals is less evident, and the inner seems also to be a little more vascular than the outer half. The tint may, however, be called a rosy cream white, which under some circumstances becomes really or apparently redder, but this is seldom uniform. Sometimes it has a bluish or greenish tint upon it, generally noticed rather in the erect image. Sometimes it seems rather to be a white closely stippled with red, and this in some cases is suggestive of past congestions; or it may be marked with grey dots and streaks, especially on the outer edge. These dots or streaks, which are best seen in the erect image, depend upon a normal anatomical arrangement, and are the visible terminations of the nerve-canals. As these canals cease on the expansion of the nerve-bundles, the translucent grey fibres allow us to look down more or less obliquely into the canals, and we see a dot or a streak of grey, according to the obliquity. These dots or streaks are not to be seen, or at any rate are much less visible at the inner side, where the bundles are thicker, and the details better concealed. They are not mere curiosities, but are very important guides to us in determining the presence or the degrees of atrophy which advances at the expense of the grey neurine, and at the gain of the white connective tissue.

The disk is sometimes partially surrounded by a crescent of black pigment, and in rare cases this crescent may be completed into a ring. If so, however, it is never uniform, but is always thicker

at some places than at others. Very commonly, on the other hand, we see a dotting of pigment about the edge of the disk which does not amount to a crescent. We must remember that in point of fact the disk has no edge, and that its so-called edge is really the edge of the choroidal opening through which it passes. Any accumulation of pigment in its neighbourhood is therefore choroidal, and the peculiarity described is unimportant. Black pigment is sometimes seen upon the disk itself, but very seldom, and in small quantities.

The vessels are the next objects to which our attention must be especially directed. They penetrate the disk, as I have said, a little excentrically, and thence spread themselves over the retina. The arteria centralis retinæ generally issues from the disk by a single stem, or at any rate its bifurcation is nearly always delayed until it has approached the surface sufficiently nearly to be visible through the transparent nerve-fibres. The two branches into which it generally divides pass, the one upwards and the other downwards, upon the retina. The vein nearly always divides before it comes into view, so that two or more veins appear upon the disk; we generally, indeed, see a pair of veins passing upwards and another pair downwards. We find no constancy of arrangement, however, in the vessels, and we rarely see two eyes exactly alike in these particulars. It is easy to distinguish the veins from the arteries; the larger branches present marked differences of appearance, and the smaller branches are easily referred to the larger. On comparing a venous with an arterial stem, we notice that an artery is less in diameter than a vein, and pursues a straighter course; it is also of a brighter red, and being rounder, refracts incident light in such a way as to give the impression of a double outline. Mauthner states that by the direct method, and in some peculiar states, white streaks or boundaries may be seen along the sides of both arteries and veins, which are the walls of the vessels. Of this I have no experience. On leaving the disk the arteries and veins begin to divide dichotomously, and spread over the retina, avoiding only the yellow spot. They are seen better in fair people than in dark, in whom the choroid absorbs so much of the light which in fair people is reflected.

Under certain circumstances, a pulsation of the blood can be seen both in the arteries and the veins, though but rarely in the former. I say but rarely, because an arterial pulse is described by some authors, and although I have never been able to detect it, yet I cannot, therefore, wholly deny its existence. A venous pulse, generally confined to the disk, may, however, be seen almost at will, by compressing the eyeball with the finger. It is seen best at the bend

of a large vein. In some eyes it is constantly present. The venous pulse is of little or no practical importance, and depends only upon the change in the tension of the contents of the eyeball, which is caused by the arterial diastole. The pressure of the arteries at the heart-stroke is transferred by means of the vitreous humour to the veins, in accordance with a well-known hydrostatic law. The veins are thereby partially emptied, and refill again as the arterial systole relieves them. We call forth the venous pulse where it does not exist, by slightly increasing the intra-ocular pressure with the finger, and thus increasing the tension of the vitreous. The venous pulse passes, of course, from the centre in contraction, and towards the centre in dilatation. The contraction is sudden, like the arterial diastole, and may lessen the vessel to one-third of its size; the dilatation is much slower, and depends on the gradual filling of the vessel from behind. The pulsation, however, varies very much; sometimes it varies in an eye during the time of examination, so that it evidently depends on many conditions of the circulation.

The retina itself is a highly translucent, rather than a transparent, membrane, and it is therefore not distinctly visible, though no doubt it modifies the brightness of the underlying choroid. It has a pearly-grey tint, and this may be detected with the mirror alone in dark eyes. In light eyes, and with a strong light, it may also be detected around the disk where the retina is thickest. The retina is thinnest, on the contrary, at the so-called yellow spot or macula lutea, for here the fibrous layer, to which its slight opacity is almost wholly due, ceases altogether. Here, too, the choroid is most thickly pigmented. In this region, then, we get more absorption and less reflection, and the region of the macula presents a duller and somewhat darker appearance than elsewhere. This we should expect, for the yellow spot is the point of best vision, as the highly reflecting disk is a point of blindness.

To see the yellow spot in the inverted image it is not well to make the patient turn his eye directly upon the mirror, as, unless atropine be used, the pupil will promptly contract to its smallest dimensions. Keep his eye rather in the oblique position, and seek the spot by turning the mirror and lens a little aside in the required direction, and pursue the investigation patiently and diligently. The description of this region is a difficult matter, and authors give very different accounts of it. This discrepancy is readily accounted for by my own experience, for I have found the visible marks of it to differ much in different persons, and under differences of illumination. It is best studied in the inverted image. Little is to be seen of it in the erect image, but Mauthner states that in the

latter its central depression, *fovea centralis*, is to be made out as a bright white depressed point. The descriptions of Helmholtz, Coccius, and Liebreich, are usually quoted in treatises on the eye, but these descriptions are incongruous, and that of Liebreich, which seems the most careful, certainly will not serve for all cases. It is not difficult, however, in the first instance, to find a dull region of the retina lying about two diameters of the disk from that part, and circumscribed by vessels which do not pass into it. This region has, no doubt, in a great number of cases, a yellowish tint, the cause of which is unknown, but which is, perhaps, some illusion colour. It is generally rather larger than the papilla, and at its centre is a bright point called the fovea centralis, which Donders says is the point of clearest vision. This point, which has been likened to all sorts of incongruous objects, is surrounded by a halo which partakes more of the deep choroidal colour, and is more rusty in tint than the yellower district in which it lies. The halo varies in size, and Liebreich calculates that in some eyes it covers a third of the whole yellow spot.

The choroid coat. It is evident from what has gone before, that although in examining the fundus of the eye we commonly speak of the disk and retina as one object, yet it is, indeed, the choroid rather than the retina, which we see; and the choroid, like the disk and retina, is liable to many changes in disease. Absent only at the entrance of the optic nerve, it spreads from that point all over the back of the eye up to the ciliary processes. Indeed, we may call the iris and choroid one vascular membrane lining almost the whole of the inner eye. It has two layers, the inner one consisting of an elastic structureless lamina, which supports an epithelial pavement of polygonal cells. This epithelium in the tapetum lucidum of animals is without pigment, but in man the pigment is very abundant, and of a dark sepia colour. The outer layer is formed almost entirely of a minute network of large and small blood-vessels, with much scattered pigment, some stellate pigment cells, and some fibrous elements. It is attached by a tissue called the lamina fusca to the sclerotic, and adheres closely to the sclerotica in the neighbourhood of the optic nerve entrance.

The radiate convergence of the veins, or vasa vorticosa, on the hinder surface of the vascular layer is well known. This portion is by some writers considered as a separate layer from the capillary layer in front of it, but the separation is an imaginary one, and of little practical value. It is easy to see that when the pigment cells are evenly loaded but little light can penetrate it, and the vascular layer behind can have but little effect upon the details of the fundus. In the

negro, for example, the fundus of the eye is almost black. The amount of light which may penetrate the epithelial layer depends, however, not upon the pigment only, but also upon the kind and degree of illumination, so that the colour of the fundus varies remarkably in different modes of examination. In the erect, and highly magnified image, the epithelial cells themselves may even be seen, so that the field has a granular appearance, and Liebreich justly points out that these cells should be carefully examined in cases of suspected disease. In the brightly-illuminated eyes of persons whose pigment is scanty, as for instance in blondes, a good deal of light passes through the epithelial layer, not only giving the fundus a lighter colour of red or pink, but allowing the larger vessels to be clearly visible. In them we see distinctly the vasa vorticosa, collecting into larger trunks, and meeting at a vanishing point in the equatorial plane, where they end in a single trunk, which passes backwards. In darker persons the vasa vorticosa may be followed, if less thoroughly, yet often more easily, at least, to a certain extent, as the inter-vascular meshes are filled up with dark colour. It is unnecessary to detain the reader any longer in describing the appearances of the choroid in various persons, and under various conditions. More he is not likely to learn by reading. I advise him to make himself familiar with all varieties of the human eye, by personal examination, without which he can never understand the subject.

ANOMALIES OF THE FUNDUS OF THE EYE.

I shall now proceed to enumerate the principal peculiarities to which the normal eye is liable, and thus warn the student against the inference of disease from appearances which have really no ill meaning.

The innocent varieties of the optic disk and retina.

1. *Extension of the neurilemma.* There are certain white patches which are sometimes seen upon the edge of the disk and invading the retina. They are not, I think, very uncommon; they may occur in one eye or in both, and they may be single, or two or more may be present. They are based upon a segment of the circumference of the disk, and may extend upwards, downwards, or inwards; they seldom extend towards the yellow spot, for reasons which will be evident when we have explained their anatomy. They shine with a pearly-white or greenish lustre, or have, as Von Recklinghausen says, an "asbestos-like" appearance, especially in those cases in which they present a striated character. This striated character may

indeed always be made out by the direct examination, and is an important point in their diagnosis. Their borders are jagged or irregular, and they generally shade off a little into the neighbouring retina, which by contrast appears very red. They do not interfere with vision, they are always congenital, and in some animals are a part of the normal state. In these cases streaks may sometimes be seen also along the borders of the vessels, and such streaks taken together with the patches might lead an unwary observer to suppose the presence of albuminuria, though the appearance of alb. retinitis is really very different. The vessels which traverse the white patch stand out, of course, with great distinctness when they pass over its surface; when, however, they pass through the thickness of the patch, they are more or less concealed, or they may pass along at various depths in its substance, when they appear thicker or thinner, according to the depth at which they are embedded. This striking abnormity depends upon an intrusion of the sheath of the nerve beyond the cribriform plate, the patch being in fact made up of non-transparent insulated nerves. The normal transparency of the retina, as we know, depends upon the arrest of the nerve-sheaths at the optic disk: if the sheaths, therefore, be accidentally continued beyond this point, we have an opaque white patch corresponding to the number of fibres so sheathed. At the borders of the patch the neurilemma thins off, leaving the axis to pass on in the usual way.

2. *The excavation of the optic disk*, beyond the normal, which sometimes appears as an individual peculiarity, may well be mistaken for commencing disease, such as atrophy or glaucoma. In the normal eye there is always a slight depression near the centre of the disk, at the point where the vessels issue from it, and in some cases this depression may be so exaggerated as to become an actual cup. It is best seen, of course, with the binocular instrument. This excavation fortunately never proceeds, though it certainly often presents steep walls. It seldom sinks deeper than the thickness of the retina and choroid, and never transgresses the lamina cribrosa; nor, again, does it ever involve the whole disk, but preserves its original character as an exaggeration of the central pore. The excavation is in some cases accompanied by other inequalities, a part of the disk being hollowed and another part elevated, or we may see a sloping wall on the side of the yellow spot, and a steep wall on the opposite side; or, again, the excavation, instead of being circular, may be irregular or angular. The change of colour of the disk in these cases is more striking than its change of form, and the full redness of the disk around the cup, contrasting with the white or grey of the cup itself, may give a strong impression that disease is present. I have never seen the

vessels bend under the edge of the cup so as to be lost to observation, as we see them in glaucomatous excavation, nor have I noticed any difference in the vessels themselves except the slight difference in colour, which of course takes place in consequence of the changed reflections. These physiological excavations should be borne well in mind, for I believe they are by no means uncommon.

3. *Senile changes take place in the eye as elsewhere.* Tissues lose their transparency, and undergo some farther changes of a degenerative kind; and the more delicate the part, of course the more obvious will such changes be. As the skin loses its brightness and delicate vascularity, so the optic disk and retina lose their transparency and the tints of their complexion. The dioptric media become a little coloured, and this is particularly marked in the lens, so that the back of the eye is less distinct, and the tracery of the disk and retina loses the sharpness and delicacy of its earlier and fresher life. Changes, therefore, which in youth would lead us to recognise an atrophic or even a sub-inflammatory process, in age would cease to have any such meaning. Practice alone can teach us to estimate these little variations at their true value. The frequent occurrence of a white or black edging upon the margin of the disk, or upon a part of it, I have described and explained, and have said that dots of black pigment have sometimes, but rarely, been seen upon the disk itself.

In the choroid likewise we see individual peculiarities, to which indeed the pigment about the disk is to be ascribed. Patches of pigment, often of some size, may not uncommonly be seen likewise upon other parts of the choroid, and taken alone they mean nothing, and are probably congenital. The senile changes occur in the epithelial layer and in the stroma. The cells of the epithelium tend to burst, so that the colour runs, and light-coloured or whitish spots are seen with accumulation of dark pigment about their edges; inequalities of colour may also be noticed in many other parts of the field. This change seems to originate, as H. Müller thinks, in a thickening of the lamella, with development of "colloid" bodies, either from it or from the nuclei of the pigment epithelium. Atheromatous and like degenerative changes occur in the chorio-capillaris, and are only visible to the mirror in so far as they disturb the overlying epithelium.

CHAPTER XV.

EXAMINATION OF THE EYE BY LATERAL OR OBLIQUE ILLUMINATION.

EXAMINATION BY ARTIFICIAL LIGHT—EXAMINATION BY DAYLIGHT—OPHTHALMO-MICROSCOPE.

This method is effected by incident light. It is particularly suitable for examining the anterior part of the eyeball, both without and within. By brilliant illumination many things which might be overlooked by the diffused daylight, are clearly discerned, and diagnosis is helped. The cornea, the iris, the pupillary margin, the capsule of the lens, the ciliary processes, and even the front of the vitreous humour, can be thus inspected. Corneal nebulæ and plastic deposits on the capsule of the lens are rendered very apparent by it. The nature of a cataract is more easily determined by this than by any other mode of examination. The consistence of the cortex of the diseased lens, and the colour of the nucleus, and the density, can be well told by it. Opacities of the vitreous humour, which are solid and always appear black when examined with the ophthalmoscope, can be seen, when sufficiently anterior and small, in their natural colours and in their proper positions, and the inequalities of their surfaces, and other peculiarities, can be estimated.

Examination by artificial light. A darkened room is better for a beginner; one that is partially illuminated will suffice for an observer who is experienced in the method.

The patient is placed, sitting or standing, with his head at the side, on a level, and a little behind the bright flame of a lamp. The observer takes his position in front of the patient and holds a bi-convex lens, of three, two-and-a-half, or two inches focal value, in such a

manner as to receive the lamp rays and to condense them on the region of the eye to be examined.

The fullest amount of illumination is got by placing the patient close to the lamp and using a very high lens.

Any special point to be examined must be placed under the focus of the lens.

For examining the crystalline lens, the degree of obliquity of the cone of rays must be less as the equatorial portion is inspected, and greater as the pole is looked at.

In examining the vitreous humour, the rays must be thrown in the greatest obliquity. The observer must be prepared to find the interior of the eye no longer black, but purple or smoky.

The object examined may be magnified by the observer using a convex lens, the selection of which should depend on his own state of sight.

The Fig. 122 shows the eye under the double examination.

Fig. 122.

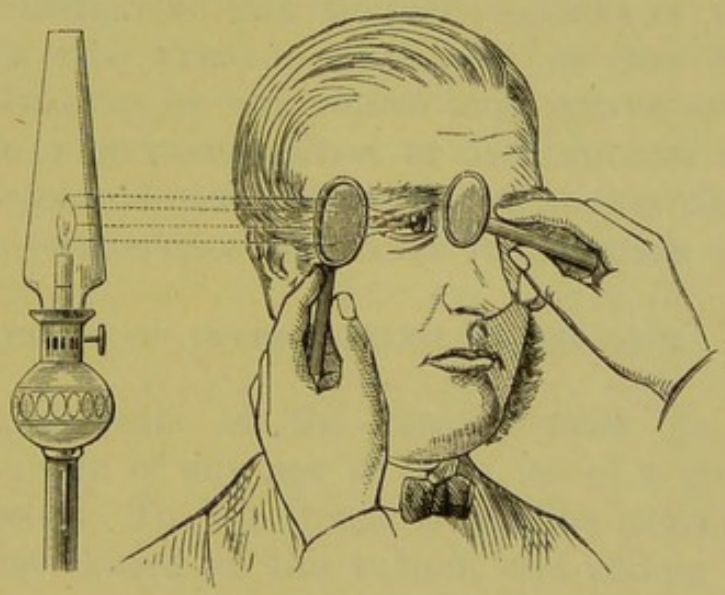

Examination by daylight. The lateral illumination by natural light is not new. I saw it in use when I was a student. After the above description it is unnecessary to say how this is to be done. It is enough to remind the reader that the patient should be placed near a window, and in as strong a diffused light as can be got.

Dr. Heddaeus has strongly advocated the use of this form of examination. He uses a pencil of rays admitted through a central perforator, from one to two inches in diameter, in a screen sufficiently large to shield the head of the patient from diffused light. The pencil is concentrated by a lens in the usual way. The doctor claims for it the advantages of showing objects in more natural colour, of

easy application, and an absence of discomfort to patient and observer. He avoids sunshine, and finds the diffused light even of a cloudy day sufficient for all purposes.

Ophthalmo-microscope. This is merely a compound microscope with which an examination of the object is made by reflected light. It is for the most part employed with lateral illumination of the eye.

The chief use of the instrument is for minute pathological research in the living eye; for the better seeing of corneal deposits, minute vessels in the cornea, minute changes in the iris, and in the lens. For practical purposes it possesses no advantages over the simple microscope or lens.

Dr. Liebreich brought out the first ophthalmo-microscope sixteen years ago, and he constructed his instrument to be used as a fixture, that is, to be screwed to a table for the purpose of steadiness. Some modifications, but not improvements, have been made by other men. That which is most known has arrangements by which it rests on the patient's face. Such an one is delineated in Wecker's "Études Ophthalmologiques."

CHAPTER XVI.

PARALYTIC AFFECTIONS OF THE MUSCLES OF THE EYE.—EFFECTS OF CERTAIN AGENTS, WHEN APPLIED TO THE EYE, IN ALTERING THE SIZE OF THE PUPIL.

METHOD OF INVESTIGATING THE SUBJECT—ACTIONS OF THE MUSCLES THAT MOVE THE EYEBALL—PARALYSIS OF THE SYMPATHETIC NERVE—PARALYSIS OF THE PORTIO DURA NERVE—PARALYSIS OF THE THIRD NERVE—PARALYSIS OF THE FOURTH NERVE—NYSTAGMUS—LUSCITAS—PTOSIS—MYOTICS OR AGENTS THAT CONTRACT THE PUPIL—MYDRIATICS OR AGENTS THAT DILATE THE PUPIL.

METHOD OF INVESTIGATING THE SUBJECT.

The physiological state of the muscles must be understood before the deficiency of any one of them, or of a group, can be sufficiently detected. To Von Graefe is due the merit of removing many errors that existed on this subject, and adding considerable information.

The action of individual muscles must be examined, and that of certain muscles collectively. The binocular actions must be included in this investigation. The binocular actions are of two kinds: those of association, in which the eyeballs move from side to side, in parallelism as we say, when taking a general range of distant things, in which case the visual lines are parallel; and those of focusing, in which the eyes are converged to examine a near object, when the visual lines meet at an angle which necessarily varies according to the distance of the thing looked at.

The paralysis of an ocular muscle may be approximately determined by its inability to turn the eye in a given direction. The test is not

absolute, inasmuch as the muscle may not act, or cannot, because its antagonist is contracted. This is illustrated in the subject of squint. For the present, and to prevent much writing, let it be supposed that it is with paralysis that I am dealing.

The paralysis may be too slight to be detected by a second person, and yet enough to interfere with the balance of the muscles, to destroy the relation of the optic axes, and disturb sight by causing double vision. Strange to tell, however, the double sight is not always produced, either in slight or great deviations. But in nearly every case of individual loss of muscular power, the deviation of the eye from its axis will be apparent, or double vision will be present. The disturbance to binocular vision may be but slight. The second image may seem but as a halo around the other, or just overlap it; or it may be far from it. It is always seen at a point opposite to that which it occupies on the retina. As the double vision can be certainly depended on to prove the presence of deformity, its characteristics must be described.

When there is paralysis of the external rectus muscle and the eye turns inwards, and objects are doubled, the distorted image is always on the side of the deviating eye. If the right external rectus be deficient, the distortion will be on the right side; if the left external fail, the distortion will be on the left. When the internal rectus is paralyzed and the eye turns outwards, the distortion is seen on the opposite side. So long as the lateral recti only are affected, there will be merely lateral deviation of the images. When the superior rectus is paralyzed, or the inferior, the distorted images will be above or below, according to the side of the paralysis. The same is to be said with regard to the oblique muscles. The details shall be given as I proceed.

It will assist the investigation at times to use a piece of glass coloured red, and to hold it before the eye which is being examined, while the flame of a candle, a few feet off, is looked at. In paralysis of the right external rectus there will appear a red flame on the right side, and an uncoloured one on the left. The reverse will be the case in paralysis of the internal rectus. The methods for investigating the vertical deviations of the eye are just the same. During the experiments the candle should be placed at different distances, and should also be moved from side to side, upwards and downwards, and in other directions, while the patient keeps his eye directed forwards. By these changes the images will be more or less separated. When the candle is carried very much away from the paralyzed side, the double vision may altogether disappear.

Most of the effect of the diseased state of double vision, or diplopia

as it is technically called, can be imitated by pressing the eyeball with the finger, inwards, or outwards, or upwards.

ACTIONS OF THE MUSCLES THAT MOVE THE EYEBALL.

The eyeball is acted upon by six muscles, four recti and two oblique. All its movements are due to the action of these muscles, either singly or in combination. Most of the movements are merely rotations round a fixed axis.

Origins and insertions of the orbital muscles briefly considered.

The recti muscles arise by a common tendinous origin round the border of the optic foramen, but the rectus externus is also attached to the margin of the sphenoidal fissure. Passing forward in an irregular curve over the eyeball, they are all inserted into the sclerotic coat at different distances behind the cornea. The muscles separate from each other in their passage outwards, and so run that they form an oblique rather than an equilateral pyramid. The rectus internus is the strongest, and is attached nearest to the cornea; the superior is the weakest; the external is the broadest and longest; it is inserted about half a line farther from the cornea than any other muscle.

The superior oblique muscle is the most superficial in the orbit, and arises from the upper margin of the optic foramen. Passing along the inner side of the orbit between the rectus superior and internus, it ends in a round tendon which runs through the trochlea, or ring of fibrous tissue attached to the frontal bone; it then turns backwards, and outwards, and downwards, expanding much, and running under the rectus superior, it passes through the ocular tunic to be inserted into the upper and outer part of the sclerotica, between the rectus superior and externus, about three lines above the position of the yellow spot of the retina. It may be called the suspensory muscle of the eyeball.

The inferior oblique arises from the superior maxillary bone, behind the lacrymal groove, and passing along the lower part of the orbit, in a direction outwards and backwards between the eyeball and the inferior rectus, it comes upwards and backwards around the eyeball, to the inner side of the external rectus, and above the level of this muscle. It penetrates the ocular tunic and is inserted into the sclerotica, just over the position of the yellow spot, close to the attachment of the superior oblique.

Method of examining the actions of the muscles. A line drawn through the middle of the insertion and the origin of each muscle will show in what direction the muscle will act. The term muscle-

plane is given to an imaginary plane passing along this line. A line drawn at right angles to each of these planes in the muscles is called the axis of evolution. In studying the action of any muscle it is not enough to know what movement it can impress upon any one point of the sphere; there must also be noted the position of two points, or a point and a meridian. The centre of the cornea is taken as the point, and the longitudinal vertical plane of the eye as the meridian. In watching the movements of the eye, it is then necessary to notice in what direction the central point moves, and the extent of inclination which the vertical meridian undergoes. In paralysis of the muscles of the eye it is important to ascertain these points. Some muscles act chiefly in altering the height of the cornea, others in causing an inclination of the longitudinal vertical meridian. It is evident that whenever the muscle-plane coincides with the vertical meridian, the effect on the height of the cornea is at its greatest, while that on the vertical plane is at its least; conversely, the action on the vertical meridian will be the more marked in proportion as the two planes diverge from one another.

Arrangement of the muscular action. The muscles may be placed under three divisions: 1st, the external and internal recti; 2nd, the superior and inferior recti; 3rd, the superior and inferior oblique.

1st. Of these groups the action of the first is the easiest to understand.

FIG. 123.

FIRST DIVISION.

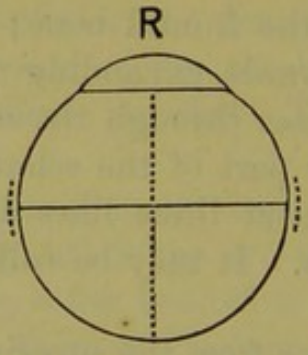

HORIZONTAL SECTION OF EYEBALL. SHORT DOTTED LINES, INSERTIONS OF THE EXTERNAL AND INTERNAL RECTI MUSCLES; LONG DOTTED LINE, VERTICAL MERIDIAN; TRANSVERSE LINE, AXIS OF EVOLUTION.

The muscle-plane of this group, Fig. 123, corresponds to the horizontal meridian, and the axis of evolution to the vertical meridian of the eye. The action of each muscle is to move the eye directly inwards or outwards. There is here no change in the height of the centre of the cornea, nor in the inclination of the meridian, which still remains vertical. This is the only group the muscle-plane of which corresponds to a major segment of a sphere; all the rest cut a smaller segment of a sphere.

2nd. The superior rectus is inserted into the sclerotica about three lines from the cornea, and obliquely, so that the inner margin of the tendon is nearer to the cornea than the outer. The centre of the attachment does not coincide with the vertical meridian of the cornea, but is a little to the inner side of it. Fig. 124.

FIG. 124.
SECOND DIVISION.

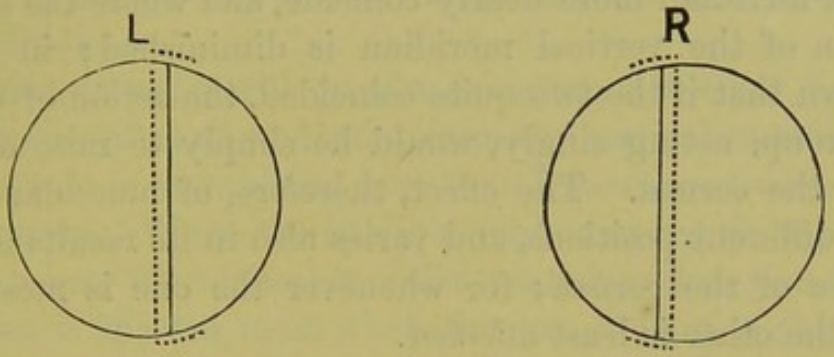

TRANSVERSE VERTICAL SECTIONS. SHORT DOTTED LINES, INSERTIONS OF SUPERIOR AND INFERIOR RECTI MUSCLES; LONG DOTTED LINES, VERTICAL MERIDIANS; LINES TO THE RIGHT AND LEFT, MUSCLE-PLANES.

The inferior rectus is inserted in a like manner into the sclerotica, about three lines from the cornea; the central point of its insertion is not in the same straight line with the centre of the cornea, but about half a line to the inner side of the vertical meridian. Both of these muscles traverse the orbit obliquely.

It is evident, that if the muscle-plane of this group coincided with the vertical meridian of the eye in the same way as the muscle-plane of the first group coincides with the horizontal meridian, the result of their combined action would be to raise or lower the position of the central point of the cornea, while the meridian would still remain vertical. This, however, is not the case, for in consequence of the insertion of these muscles to the inner side of the vertical meridian, it follows that the muscle-plane will correspond to a smaller segment of a sphere than the vertical meridian.

The result of the contraction of these two muscles is to draw the eye a little inwards; acting singly, the superior rectus raises the centre of the cornea, and draws the upper end of the vertical meridian inwards; the inferior rectus, contracting by itself, lowers the centre of the cornea, and inclines the upper end of the vertical meridian outwards. This is true, when the eye is considered to be looking directly forwards, but different results are obtained if it be looking in other directions. When it is turned outwards, the muscle-plane of this group more nearly coincides with the vertical meridian, and therefore the latter is but slightly inclined. It is obvious that if the muscle-plane exactly coincided with the vertical meridian, the latter

would still keep vertical when this group of muscles contracted; hence it follows that by moving the eye in such a position as to approximate the plane and the meridian, the effect on the latter will be much slighter than when by turning the eye in an opposite direction the two are more directly opposed to each other. It is clear also that when the inclination of the meridian is most affected, the position of the cornea is less altered than in those cases where the muscle-plane and meridian more nearly coincide, and where the effect on the inclination of the vertical meridian is diminished; in fact, it has been shown that if the two quite coincided, the action of each muscle of this group, acting singly, would be simply to raise or lower the centre of the cornea. The effect, therefore, of muscular contraction varies in different positions, and varies also in its results on the plane and centre of the cornea; for whenever the one is most altered in position, the other is least affected.

Any point, therefore, within the range of movement, will cause a different result when the muscles contract; when the eyeball is turned outwards the position of the cornea is affected most, and the vertical meridian least; when inwards, the position of the central point is not much altered, while the angle of inclination undergoes more deviation.

3rd. It has been mentioned that the insertions of the two oblique muscles are in the posterior and outer quadrant of the eyeball; their muscle-plane is vertical, but at an angle with the vertical meridian; the plane passes diagonally from below upwards, and from without inwards.

FIG. 125.
THIRD DIVISION.

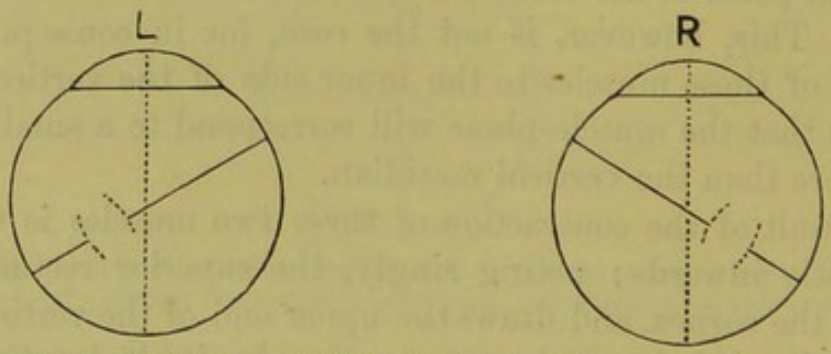

HORIZONTAL SECTIONS OF EYEBALLS. SHORT DOTTED LINES, INSERTIONS OF OBLIQUE MUSCLES; LONG DOTTED LINES, VERTICAL MERIDIANS; OBLIQUE LINES, MUSCLE-PLANES, WHICH, ALTHOUGH VERTICAL, FORM A LARGE ANGLE WITH THE VERTICAL MERIDIAN.

It follows, from an examination of the diagram, that the superior oblique will roll the cornea downwards and outwards, while the inferior oblique will roll it upwards and outwards: acting together, they will only move the cornea outwards. When the superior oblique acts, the upper end of the vertical meridian will be drawn inwards;

when the inferior oblique acts, the upper end of the vertical meridian is drawn outwards.

In the first group I have shown that neither the height of the centre of the cornea, nor the vertical meridian, is altered; but there is merely simple lateral movement.

In the second group, that where the muscle-plane does not exactly correspond to the vertical meridian, the height of the centre of the cornea, and of the position of the meridian, are both altered under certain conditions.

In the third group, a still greater deviation is noticed, because the muscle-plane is still farther distant from the vertical meridian.

The same rule is exemplified here that I mentioned when speaking of the last group. When the eye is moved inwards, the muscle-plane approaches nearer the vertical meridian, and it is then that the height of the cornea is affected most when the two obliqui contract. Conversely, when the eye is turned outwards, the muscle-plane forms a still greater angle with the meridian-plane, and the axis of evolution approaches nearer the optic axis; hence the obliqui will act most upon the inclination of the vertical meridian when the eye is directed outwards.

Thus it may be laid down as a general law, that whenever a muscle-plane exactly coincides with a meridian, it cannot affect its inclination; conversely, when they are as far opposed as possible, the action on the inclination will be most marked. Between these points the action will be more or less, according as the muscle-plane is farther or nearer the meridian. The action on the position of the centre of the cornea is greatest when the meridian-plane is acted on least, and *vice versâ*.

The following table shows the action of each muscle:

1st group	Internal rectus	Inwards
	External „	Outwards
2nd group	Superior rectus	Upwards and a little inwards
	Inferior „	Downwards „ „
3rd group	Superior oblique	Downwards and outwards
	Inferior „	Upwards „ „

These movements take place when the eye is looking directly forwards; in other positions the action of the muscles is modified, as has before been pointed out.

All the recti muscles acting together draw the eye within the orbit; the opposite effect is produced by the contraction of the obliqui.

Although a lateral movement may be performed by a single muscle, a vertical movement must be the result of the action of two

muscles; thus, the rectus superior will not be enough to move the eye upwards, but will require the help of another muscle to counteract the movement inwards; and so the inferior oblique is associated with it; both move the cornea upwards, and the inward tendency of the one is checked by the outward movement of the other.

In like manner, the superior oblique is associated with the inferior rectus in producing a direct downward movement.

In the movement upwards and inwards, the superior rectus and inferior oblique are aided by the internal rectus.

In moving the eye upwards and outwards, the external rectus is associated with the above-named two muscles, in the place of the internal rectus.

The movement downwards and inwards is caused by the inferior rectus and superior oblique acting with the internal rectus.

When the eye moves downwards and outwards, the inferior rectus and superior oblique are associated with the external rectus in the movement.

It appears to me to be an advantageous arrangement for the sake of pathological investigation to pursue the subject in the following manner.

PARALYSIS OF THE OPHTHALMIC PORTIONS OF THE SYMPATHETIC NERVE, AND THE EFFECT ON THE IRIS, AS SHOWN BY THE CHANGES IN THE PUPIL.

The researches of the last few years have thrown much light on the influence which the sympathetic nerve exerts over the iris, but much yet remains to be worked out.

The reader may be reminded that the iris is structurally composed chiefly of non-striated muscular fibres, arranged in a circular and in a radiating direction; the former, being supplied by the third nerve, act as a sphincter pupillæ, and tend to diminish the size of the pupil; the latter, supplied by the sympathetic nerve, increase the aperture when stimulated to contract.

Discrepancies exist in descriptions of the results of experiments upon this nerve by observers, on different animals; this may, in some measure, depend upon the variation in the vascularity in species. In this respect the man differs from many of the lower animals.

When the sympathetic is divided in the neck, the blood-vessels become dilated on that side; there is increased heat of the surface, the pupil contracts, and the eyeball falls forward. A similar result ensues also when the lower portion of the cervical region of the

spinal cord is cut, or the upper part of the dorsal, and this is due to the fact that the fibres which pass to the iris from the sympathetic, are intimately connected with this part of the spinal cord. Some observers think that the fibres which supply the radiating fibrils of the iris are really of spinal origin.

Irritation of the sympathetic nerve produces a perfectly opposite condition; in this case the pupil is dilated, and the eyeball drawn a little within the orbit.

Pathological observation has verified much of what has been found out by physiologists, and numerous cases are recorded in which tumours in the neck, or aneurisms, or injuries, have produced a marked effect on the pupil.

Mydriasis, or dilatation of the pupil, is caused by paralysis of the third nerve, as well as by irritation of the sympathetic, and myosis, or contraction, may result, not only from paralysis of the sympathetic, but by irritation of the third. There are, therefore, four conditions under which the pupil may be enlarged or diminished.

Paralysis of the sympathetic or Irritation of the third	Causes contraction of the pupil.
Paralysis of the third or Irritation of the sympathetic	Causes dilatation of the pupil.

It is important to recognise this, and, if possible, to diagnose each of these conditions.

If the ciliary fibres of the third nerve were the seat of the injury or disease, it is most probable that the other branches of the nerve would be affected, and the patient would most likely squint externally, or be unable to raise the eyelid. The cause must be cranial or extra-cranial.

When the sympathetic is affected, the phenomena of dilated vessels and increased flow of blood may be met with, and there will probably be evidence of disease in the neck, or else in the spinal cord.

In a case of recent implication of the pupil, it would be easier to find out the cause, probably, than in more chronic ones, as the symptoms of vascularity, or of squint, as the case might be, would be more marked.

Von Graefe has published a case in which a partially dilated pupil on the right side was caused by a tumour at the base of the brain, involving the corresponding third, fourth, fifth, and sixth nerves. After a time the left third nerve became paralyzed, and there was complete dilatation of the left pupil. This was assumed by him to

depend upon coexistent irritation of the sympathetic nerves at the base of the skull. Dr. Robertson, in commenting on this case, thinks it is more likely that the paralysis was due to the implication of the ciliary branches of the third.

Dr. Fleming, in the "Edin. Med. Journal," for March, 1863, thinks that the size of the pupil depends on the state of its vessels. When a solution of atropia is applied to the web of a frog's foot, contraction of the small arteries results; arguing from this, he believes that the arteries of the iris contract in a similar way; the membrane is relaxed, and the radiating fibres contract and cause dilatation of the pupil. Against this view it may be urged that atropine does not cause contraction of the vessels of the iris. Schneller believes that by the use of atropia the ciliary muscle is paralyzed, and in consequence there is increased intra-ocular pressure, and so the vessels of the iris are distended, and not contracted.

Dr. Robertson gives a case of glaucoma, in which the pupil was much dilated, and the vessels of the iris at the same time were distended. A still greater objection to this view is to be found in the fact, that for a short time after death the iris will dilate on applying atropia.

Any tumour in the neck, or any morbid condition involving the cervical sympathetic, may have an effect on the state of the pupil; many cases are recorded in which an aneurism of the aorta has involved this nerve, and caused dilatation or contraction of the pupil, according to the extent of the lesion. It sometimes happens that although at first dilatation is noticed, yet afterwards contraction occurs; this is due to the fact that a lesion may, at its commencement, merely irritate the nerve, but finally become so extensive as to destroy it at that spot, and then the effects of paralysis are met with. In such a case there would be an absence, probably, of any cranial disturbance, while, if it were an aneurism, there would be evidence of a thoracic tumour, such as dulness over the tumour, increased pulsation, and other pressure signs, as œdema of face and neck from the obstruction to the venous circulation, or a diminution of the amount of air entering one or other lung according as one of the bronchi was pressed upon.

A peculiar ringing cough is also often met with in these cases, and this is due to a spasmodic action of those muscles of the larynx which are supplied by the recurrent laryngeal nerve.

Cancerous tumours, injuries, deep abscesses in the neck, may also cause paralysis or irritation of the cervical sympathetic nerve.

Dr. W. Ogle, in a paper recently read before the Royal Medica

arising from disease of this nerve in the neck. He found that the pupil was dilated, and the face colder on the affected side than on the other. It was singular that after exertion, the patient perspired more freely, and the face was hotter on the affected side than on the other.

A similar perspiration confined to one side of the face has been noticed in cases of typhoid fever, where the sympathetic nerve seems to be considerably involved, as shown by the flushed cheek and dilated pupil.

Injuries or lesions in the upper portion of the spinal cord will cause similar results, inasmuch as the fibres which proceed to the iris communicate with this portion of the cord.

The pupil may thus be functionally or organically affected; an ephemeral mydriasis has by some been noticed. Von Graefe has shown that this is sometimes a premonitory symptom of insanity.

One difference between the mydriasis caused by paralysis of the third nerve, and that brought about by irritation of the sympathetic nerve, is that, in the former, the ciliary muscle is often paralyzed, I may say, almost always, and so the power of accommodation is more or less lost; thus, also, symptoms are put down as a result of mydriasis which may really arise from the accommodation being affected.

Treatment. Neither my clinical experience, nor my reading, allow me to say much on this head. All that can be done therapeutically is to remove any tumour, capable of being removed, that irritates.

PARALYSIS OF THE PORTIO DURA NERVE. DISEASE OF THE ORBICULARIS PALPEBRARUM.

The portio dura arises from the same nucleus as the sixth, in the fasciculus teres, near the middle line in the floor of the fourth ventricle. It issues from the lateral tract of the medulla oblongata closer to the pons Varolii, and internal to the auditory nerve; it enters the internal auditory meatus, and passes through the aqueduct of Fallopius, and is then conducted through the stylo-mastoid foramen to the face. A lesion anywhere from the nucleus to its peripheral termination will cause paralysis of one, or more muscles, which will be affected on the same side as the lesion. A lesion above the nucleus of the nerve, as in the crus, corpus striatum, or thalamus, may give rise to a certain degree of paralysis of the facial muscles, but in this case the paralysis is always partial, and usually temporary, and on the opposite side to the lesion.

one side of the face, including the orbicularis palpebrarum, the only ocular muscle involved, and therefore the only one with which we are directly concerned.

In describing the different diseases to which the nerve is liable, it will be convenient for the purpose of diagnosis to trace the causes from within outwards. A tumour, or an abscess, or softening of the brain, may all produce paralysis of a cranial nerve, and when we are excluded from examining the affected parts, and the seat of the disease only can be made out, other symptoms must be sought for to elucidate the nature of the lesion.

When the disease affects the nucleus, the sixth nerve is also liable to suffer.

In such a case, in addition to the inability to close the eyelid, there would be internal squint of the eye on the same side, as the external rectus muscle would be paralyzed. Dr. Hughlings-Jackson, in Vol. I. of the "London Hospital Reports," narrates a case in which there was paralysis of both sixth nerves, and of the portio dura on the right side. The patient could not shut her right eye, nor wrinkle her forehead on that side, as the corrugator supercilii was paralyzed. The mouth was drawn a little to the left; the pupils were equal and normal, and there was slight weakness of the limbs. After death a tumour, as large as a walnut, was found in the pons Varolii, but more on the right side than on the left.

When disease of the pons Varolii gives rise to paralysis of the facial muscles, it is seldom that the portio dura only is affected; usually there is hemiplegia or paraplegia with it, or some affection of another nerve.

The paralysis of the limbs is on the opposite side to the facial paralysis, and the reason of this is apparent, when the anatomy of the parts is considered. If the injury be confined to the right side, and the sixth and seventh nerves are affected, it is clear, as already told, that the paralysis of the face and external rectus will be on the right side also; but with the limbs the reverse is the case, as the spinal nerves have already crossed, and pass close to these cranial nerves on their way to the corpus striatum and optic thalamus; hence a lesion here will produce the same effect on the spinal nerves as it would higher up, and so, when the disease is on the right side of the pons, the limbs on the left side of the body will be affected.

Disease of the pons is a very rare condition, and it is still more uncommon for it to be so localized as to cause the nerves of only one side to be affected.

poisoning; the pupils are generally contracted, and the spinal nerves on both sides are often affected so that the patient is unable to move. As these cases prove fatal so rapidly, they are of interest rather to the physiologist than to the practical surgeon.

A slowly growing tumour, in this situation, may cause symptoms which are of great importance in diagnosis. It is well to remember that if there be paralysis of one of the facial nerves, with hemiplegia of the opposite side of the body, the disease, unless there are two lesions, must be far back, and affecting the medulla oblongata or pons Varolii, for here alone do the spinal nerves come close to the portio dura.

If the disease be not confined to one side, there will be more or less weakness of both sets of extremities, but generally more on one side than the other. The paralysis of the portio dura will be complete or partial, according to its implication in the diseased region. If the sixth nerve on the same side be paralyzed, then the nucleus, which is common to both, will be the seat of the disease. If there be no internal squint on that side, then the lesion will be between the nucleus and the emergence of the facial nerve from behind the pons. Sometimes there is total deafness as well, as the auditory portion of the seventh nerve may be implicated.

Dr. H. Jackson has published a case in which there was paralysis of the facial nerve on the right side, together with left hemiplegia; there was also sudden and total deafness on the right side; here the lesion must have been in the right side of the pons, and involving the nerve before it emerged from the brain.

If an artery supplying this part of the brain be plugged, as in cases of embolism, arising from disease of the left side of the heart, the nerve tissue beyond the obstruction will be deprived of its nutrition, and white or atrophic softening will result. A similar change may also take place if the vessels of the part have undergone atheromatous or calcareous degeneration; in each case nutritive changes are interfered with, and softening follows as a consequence.

Syphilitic nodes or other tumours arising from the dura mater at the base of the skull, or an aneurism, may involve the portio dura before its entrance into the temporal bone, and cause facial palsy and inability to close the eyelid; here, however, it is probable that there would be deafness on the same side, and, if the disease were extensive, other nerves would be involved, and show that the seat of the disease was cranial.

Paralysis of the nerve may [illegible]

probable occurrence of deafness on the same side will lead to a right diagnosis.

Sometimes hæmorrhage, as Dr. Moxon has recently pointed out, may take place in the canal in which the nerve lies, and cause either complete or partial palsy; after a time, the blood becomes absorbed, and the paralysis may disappear if the nerve be not too much injured.

Inflammation of the lining membrane of the canal, may cause paralysis by pressure on the nerve.

Where the nerve emerges from the stylo-mastoid foramen it is liable to external injuries, as wounds or blows.

Pressure from enlargement of the parotid gland, as in cases of mumps, may produce paralysis. Here the local affection and the evident implication of only one nerve will point out the cause.

Any tumour in the parotid region, arising from disease of the glands, or aneurism of the vessels around, may cause a similar result.

Local injuries to the branches which supply the orbicularis palpebrarum, may be caused by a stab or blow, or by a surgical operation, and then only those muscles would be paralyzed which were deprived of their nerve-supply. It has happened several times, that branches of the nerve have been cut through in the removal of tumours in front of the ear, and inability to close the eye has ensued.

The above is a brief account of the pathological changes which may bring about facial palsy when the lesion is on the same side as the paralysis. When the disease has its seat in the pons, then other important symptoms are met with; it is, however, rare to find injuries so localized in the pons or medulla as to affect merely one-half. When it is in the temporal bone, paralysis of no other nerve but the seventh will be found; when external to the temporal bone, the local nature of the disease is generally sufficiently clear.

I now pass to the consideration of those cases where the facial palsy is on the same side as the hemiplegia. It has been above stated that it is partial, and, as a rule, often passes away if the patient lives a few days or weeks. It has been shown that whenever the disease is in the pons, the paralysis of the face and the hemiplegia must be on opposite sides; this, however, does not exclude those cases in which the lesion is so extensive as to cause more or less paralysis on both sides of the body. Besides these, it is not uncommon to find a person suddenly seized with a paralytic attack; supposing the hæmorrhage, or the softening of the brain producing such, to be on the right side of that organ; the hemiplegia must necessarily be on the left side of the body, but, in addition, he may be unable to close

The palsy is only partial, and is most marked when an attempt is made to whistle or to close the eyes forcibly, as in these attempts the deficiency in the action of the muscles is most evident. The injury to the brain-substance in such a case would be found either in, or close to, the corpus striatum, or thalamus on the right side; if anterior or external to this, there is seldom much facial palsy. The occurrence of paralysis on the left side of the face, in the case supposed, is explained by the decussation of the fibres connecting the nerve-nucleus with the higher centres, which takes place in the cranial nerves, as well as in the spinal. The palsy is partial, because, as has been shown by my colleague, Dr. Broadbent, the action of the facial muscles is for the most part bilateral, and when the corresponding muscles of the two sides of the body act only in concert, the nuclei of their nerves are associated by commissural fibres, so as almost to become one nucleus. The paralysis being thus proportionate to the unilateral independence of the muscles, is never very marked in the orbicularis palpebrarum, even when distinct in the face, and usually becomes manifest only when the eyes are forcibly closed. The reflex act of winking is not interfered with, as it is when the trunk or nucleus of the nerve is the seat of the lesion, a difference which should be borne in mind.

The palsy is partial, inasmuch as an injury from which a man may recover can seldom be so extensive as to involve all the radiating fibres.

As only some of the fibres are implicated, this form of paralysis is, as a rule, only temporary, and in some cases it disappears after the first few days from the attack.

In many cases of recent hemiplegia this form of facial paralysis has been noted.

It may, therefore, be an useful rule to recollect:

1. That when the facial palsy is on the same side as the hemiplegia, the paralysis will be partial, and the lesion is either in the optic thalamus or in corpus striatum on the opposite side.

2. That when the facial palsy is on the opposite side to the hemiplegia, the paralysis may be complete or partial, and the lesion will be in the medulla, or pons Varolii, and on the same side as the facial paralysis.

This applies to those cases in which there is only one seat of disease; in other cases very different results might ensue.

Other causes may produce facial paralysis which cannot be included under the foregoing heads.

Exposure to

an open window, is a very common cause of the palsy. In other cases it seems to be brought about by an affection of peripheral extremities of the nerves. This form often frightens a patient from the suddenness of the attack.

Dr. Marshall Hall has shown that sometimes when the paralysis is disappearing, spasmodic action of the muscles takes place.

There are also emotional causes of this affection, and numerous cases have been recorded in which sudden fright, the announcement of bad news, or a violent fit of anger, have induced facial palsy.

The clinical history of this disease may be briefly stated in the following clauses :

In cases where the palsy is complete, the face is drawn to the opposite side, while the cheek on the affected side flaps during forced expiration. The patient is unable to close the eye, the habitual winking movements cease, the lower eyelid falls away from the eyeball, and is besides everted, and the eyeball often seems to protrude. The corrugator supercilii or occipito frontalis are also unable to act, so that he cannot frown or wrinkle the forehead. Sometimes the eyelids are puffy.

During sleep, when the levator palpebrarum is relaxed, and the eyeball turned up, the upper eyelid partially covers the eyeball, but the lower one remains depressed.

There is, generally, a slight movement in the upper eyelid, according as the levator palpebræ is in action or relaxed ; in the latter case, the eyelid may droop a little when the patient looks down.

The eyeball is liable to be injured from the intrusion of extraneous substances. The conjunctiva always becomes inflamed, and the cornea may get ulcerated. The eyeball may be destroyed, exactly after the manner described, when speaking of its exposure from ectropium.

Where the palsy is but partial, the eyelids may meet, but cannot be firmly closed, as on the healthy side.

The tears run down the cheeks in some cases, as when the lower lid is depressed and everted.

Other facial muscles are also generally affected at the same time ; thus the act of whistling is difficult, and the amount of paralysis is then well seen ; when the patient grins, the angle of the mouth on the affected side is not drawn up. Food often remains between the gums and the palsied cheek, and so has to be removed.

If the palsy has lasted long, the muscles on that side begin to waste, and give a flat or sunken appearance to the cheek.

Pain is a symptom which varies with the cause ; in disease of the temporal bone it may be very severe ; in the causes which have an

filaments of sensitive nerves being implicated; the portio dura being purely a motor nerve.

In cases of cerebral disease, the patient may suffer from headache, giddiness, loss of memory, and paralysis of other nerves. Absolute deafness would show that the portio mollis was implicated; mere dulness of hearing is not infrequent, and need not necessarily show that the auditory nerve is affected; thus disease in the temporal bone may cause a change in the tympanum or Eustachian tube, as in cases of scarlet fever.

The uvula is sometimes drawn to the unaffected side, and this occurs when the lesion is above the spot where the greater superficial petrosal nerve is given off; this nerve communicates with Meckel's ganglion, and sends a motor twig to the palate.

More rarely both facial nerves are paralyzed. Dr. Mackenzie relates a case of this kind in which a man was maltreated and kicked on the occiput.

There may be dysphagia and difficulty in speaking clearly, if the soft palate be affected. In such cases both cheeks will hang down and be flabby, and all movements of expression will be lost. Sensation of the face is not affected unless sensitive nerves are simultaneously involved.

Treatment. I consider that this has been more than half expressed in the various symptoms of this disease, which have been described. As a correct diagnosis is so important, a great deal of space has been devoted to the subject. The chief difficulty which a practitioner meets with is to discover the cause of the affection. Supposing this to be sufficiently done, it is rather easy to determine whether a given case will be remediable, or not.

It is of moment, to distinguish whether the origin of the disease is within the cranium or without, central or peripheral. If, in the former case, there be evidence of much tissue lesion, little benefit can be hoped for; but, if there be not much structural damage, something may be effected by a natural process of repair, and by remedies. When the affection is peripheral, cure will be the rule, not the exception.

To decide, in a head lesion, whether a patient should have blood taken from his temples, or dry cupped, ice applied to his head, and purging resorted to, or, instead, a tonic and stimulating plan of treatment, for each is necessary at times, demands an extensive acquaintance with the practice of medicine, and will tax the judgment of a well-educated surgeon, and on his judgment and knowledge all must rest. He must remember that nearly all the diseases

when this is the cause, the indication is to restore strength, to supply nutrition.

When a case is chronic, with an origin from inflammation, counter-irritation is valuable. Here, too, galvanism is often beneficial. Galvano-puncture has effected a cure.

The cases of syphilitic origin can generally be diagnosed. The history of a case, or the coexistence of syphilitic marks on the surface of the body, or other concomitant facts, will prevent a mistake. Here, mercury, in some form or other, judiciously used, with iodide of potassium, or the latter, alone, will be indicated; prognosis is favourable.

Disease of the temporal bone must be treated according as there is necrosis, or caries present. In either of these, as primary affections of the bone, the dura mater and the brain are apt to be secondarily affected, and death brought about. Scrofulous children are liable to that. The membrana tympani is always more or less destroyed. In all probability, the osseous disease will be associated with a marked scrofulous diathesis. Inflammation of the canal traversed by the nerve, and of the bone itself, must be combated by active local depletion, and the application of warmth.

An enlarged parotid gland, arising out of inflammation, requires active treatment. Any tumour on the gland should be removed. Among my earliest operations in surgery, was that of dissecting out a small fibrous tumour from the surface of the gland, by which the nerve-disease was checked.

Division of the nerve from cuts or fracture of the bone, generally produces permanent paralysis, although the severity of it may very much pass away. In a case which I have been watching for years, there was at first complete paralysis on one side of the face, from injury received by a cart-wheel going over the head. Now, after ten years, so slight traces of the muscular inability exist, that no one would observe it, when the face is quiet. In winking, or in attempting to whistle, some remains of the paralysis is apparent.

Exposure to cold, or to a current of cold air, is the most frequent extra-cranial cause. This is often spoken of as rheumatic inflammation of the nerve. But there is seldom any strict evidence of a rheumatic implication. In all probability there is inflammation of the nerve-trunk, and sometimes, also, inflammation of the periosteum lining the aqueduct of Fallopius, and reduction of its calibre, whereby the nerve is pressed. Leeching, and the application of warmth, with rest, and some preparation of cinchona, are the remedies. While cold and heat are the best measures we have for alleviating pain, we have no certain guides, when the surface of the body is

not wounded, by which to determine the choice of means. Experiment is the only test to be relied on; if one fails, try the other.

In every case treated by myself, of which I have any record, the attack has been preceded by acquired feebleness of the body, and, for the most part, by mental depression. Some of the patients have been overworked, some have had intense anxiety in business.

As the eyeball is apt to suffer from exposure to the atmosphere, and from particles of dust, and other extraneous things, collecting on the conjunctiva, it should be frequently washed with warm water, and the eyelid moved over it. During sleep, the eyelid should be kept down by a compress and roller.

When recovery does not ensue, the ectropium may be removed by operation, an example of which is given in the chapter on "Affections of the Eyelids," under the head of "Ectropium." In the same class of cases, in order to obviate the tucking up of the upper eyelid, the levator palpebræ has been divided subcutaneously.

The orbicularis palpebrarum muscle is affected by clonic spasm, morbid winking, twitching of the eyelids; and tonic spasm, blepharospasm, reflex diseases of the portio dura nerve.

Morbid Winking. In this clonic spasm, individual branches of the muscular fibres may be influenced, causing a peculiar tremulousness. In the more common form, the upper portion of the muscle is affected, or the lower, seldom the whole, and there is established morbid winking. The closing of the eyelids is done rapidly, while the opening of them is effected more slowly. The upper eyelid may, therefore, be principally affected, or the lower; or both equally. Generally both eyes are involved, but only one may suffer.

The cause is sometimes severe conjunctival irritation, such as an inverted eyelash, or chronic conjunctivitis, or chronic ophthalmia tarsi; but it is sometimes of constitutional origin. Whenever I have seen it in children there has coexisted marked debility. I have witnessed it many times in weak schoolboys, who have been overworked. I have seen an aggravated case in an undergraduate at Cambridge, who broke down from mental work. Sometimes the cause is not traceable, and then the act is attributed to trick.

Treatment. If the cause be apparent, the remedy may readily be found. The pathological information must therefore be sought for.

Twitching of the Eyelids, or Quivering. This is known also as life-blood, spasmodic, or muscular tic. There is a twitch or quiver of that portion of the orbicularis palpebrarum over the tarsal cartilages, either so slight as not to be visible, although plainly felt, or very apparent. The one lid may be affected, or the two. It is

unattended generally with pain, and is only annoying; but, exceptionally, pain has been felt resembling that of tic-douloureux.

There can be no doubt that this state is closely allied to morbid winking.

The cause is generally derangement of the digestion, especially from the use of alcoholic drinks. Feebleness from overwork, when associated with anxiety, will produce it.

Blepharospasm, by which the eyelids are violently and persistently closed. This is a common affection, and comes under the notice of all practitioners. Nearly always it is associated with intolerance of light, and frequently with discharge of tears as well.

Causes. It is remarkable that these should originate in so many different sources. They may arise in the eye itself, or in other organs, and transmit their influence to the brain at the origin of the portio dura, through the fifth nerve, the optic, the vagus, the sympathetic, or directly from cerebral disturbance.

The fifth is functionally most closely in relation with the portio dura, and the nuclei of the two nerves lie in close proximity in the floor of the fourth ventricle: that of the portio dura near the median raphé in the fasciculus teres, that of the trigeminus nearer the side. This nerve is consequently most frequently the channel of the morbid influence. The superior division only of the fifth is normally concerned in the reflex act of winking, but irritation of other branches, reaching a certain degree of intensity, may be propagated to that part of the seventh which supplies the orbicularis, or to the nucleus of the entire nerve. Functional relations also exist, demanding association of their nuclei, between the vagus and the portio dura, as we see in the respiratory movements of the alæ nasi, and the lower end of the nucleus of the seventh is very near the nucleus of the vagus. These, which are the simpler relations, functional and anatomical, of the portio dura, exemplify and illustrate the more intricate connections of this nerve with different parts of the nervous system, and help to explain the variety of causes which may give rise to blepharospasm.

Extraneous matters in the eye, or trichiasis, will produce it. Generally, only one eye is affected. Strumous conjunctivitis, especially when there is any corneitis, gives the most frequent examples, and both eyes are generally affected. Here it may persist for weeks and months, with some slight interruption in the evening. There may be but the least redness of the conjunctiva, or much. The spasm is rationally supposed to be due to the intolerance of light, but this is not the whole truth, for when the light is absolutely shut out for days, the eyelids are as firmly

clenched as ever. Long persistence of the action when the conjunctiva is swelled may cause the tarsal margin, especially that of the lower lid, to be everted.

In operations that involve the opening of the eyeball, particularly that for the extraction of hard cataract, if there be any inflammation of the lower eyelid, the spasm may ensue and produce entropium.

In all the above instances, the irritation is conveyed through the first division of the fifth nerve. Disease in the other ramifications of this nerve has caused the spasm, and by the removal of the sensory irritation, the extraction of the carious tooth, or the tooth with periosteal abscess, a cure has been effected. Supra-orbital neuralgia is to be included in this catalogue of nerve-cause.

Retinitis from overwork of the eyes, especially when the nature of the employment is injurious, such as working by bright lights, is the commonest cause in adults.

There is always, in the first instance, much intolerance of light.

The persistence of spasm sometimes is remarkable I have seen it continuous, with but intervals of only a few days, for thirteen years. In this, the case referred to, it still persists, although the gentleman has lost the intolerance to light, and his vision is perfect. He yet keeps to a dark room when at home, and when he drives out he wears dark goggles and a black veil.

Dr. Mackenzie says that sometimes spasm of the orbicularis palpebrarum of one side is brought on in consequence of a blow on the head, or other injury, the effects of which have been communicated to the brain or its membranes. The spasm continues long, for weeks, perhaps, or months, and is apt to be mistaken for palsy of the levator of the upper lid. A restless state of the edge of the upper lid, and the difficulty experienced in raising it, even with the finger, will serve to distinguish this state from palsy. Also that cerebral congestion, from liver and other causes, apoplexy, and various other disorders of the brain, are productive of blepharospasm. In such cases, both sides are generally affected, the intolerance of light is excessive, and exposure to strong sunlight is apt to produce violent and universal muscular spasms. Besides this, he mentions that the organic nerves of the digestive system are sometimes the medium by which an irritation is transmitted to the nervous centre, whence it is reflected to the facial nerve, and the muscles which it serves to excite, as it often is to other nerves and other organs.

Blepharospasm is also of hysterical origin. Here the occasional entire remission of symptoms for days, the absence of any other ocular disturbance, and the general condition of the person, will

enable the diagnosis to be made. It is apt to be mistaken for ptosis.

It happens sometimes that no origin direct or remote from any diseased centre can be discovered. An intelligent artizan, thirty years old, came to me on account of the occasional but complete attack of double blepharospasm, which generally lasted two hours. The cause of the affection was not apparent. Any sudden loud noise, or anything producing agitation, such as anyone striking him on the shoulder, brought on the attack. While on his way to me, and about to cross the street, a carter snapped his whip loudly; he was startled, and the eyes at once closed; a stranger in the street led him home. Everything failed to benefit him. There was neither intolerance to light nor lacrymation.

Blepharospasm may be associated with spasm of the facial muscles.

Treatment. The source of irritation should be sought for in each case, and the treatment which seems most appropriate applied to it. To remove the cause, therefore, if possible, is the right line of treatment. Very frequently does it admit of speedy and effectual removal, especially when of a mechanical nature.

Whether the spasm can be directly affected, and more or less reduced by any local therapeutic measure, is well worth experiment. I do not think that anything has been made out about the value of topical applications. Different men speak with equal praise of the most dissimilar agents, and there is recommended irritants, vesicants, setons, leeching, dry cupping, narcotics, stimulants, hot applications, cold applications, acids, alkalies, prussic acid, iodine, hypodermic injections.

A patient discovered that pressure with the finger on the portio dura, in front of the ear, caused the spasm to subside and the eyelid to open. This lasted as long as the pressure was kept up. Sir C. Bell, who reports the case, found that when he put the point of his thumb under the angle of the jaw, and pressed the carotid artery against the vertebræ, the same effect was produced. On pressing down the cartilages over the left hypochondriac region, so as to affect the cardiac portion of the stomach, the eyes opened, and remained open, while the pressure continued. This led to the further discovery that pressure on other parts will temporarily stop the spasm. To my disappointment, I have not met with any cases that could be so affected.

Treatment by practical surgery has not been neglected. Dieffenbach, who was foremost in the division of tissues for the cure of disease, made subcutaneous division of the offending muscular fibres, with the view of cutting the branches of the portio dura. To cut the

trunk of the nerve would be to produce facial paralysis. Later, in Germany, the supra-orbital nerve has been divided, and, it is said, with much benefit, in those cases in which pressure on this nerve caused cessation of the spasm. I cannot give any personal experience. In all the cases, according to my personal knowledge, where this nerve, or the infra-orbital, have been divided for tic-douloureux, the pain has returned. Even when a piece of the nerve-trunk has been cut away relapse has ensued.

PARALYSIS OF THE THIRD CRANIAL NERVE.

The third nerve supplies most of the muscles of the eyeball, and hence has received the name of motor oculi. It is more liable to palsy than the other cerebral nerves. Its superficial origin is on the inner side of the cerebral peduncle, in front of the pons Varolii, and close to the locus perforatus. Its filaments have been traced deeply to a nucleus in the upper part of the floor of the fourth ventricle. It passes along the wall of the cavernous sinus, enters the orbit through the sphenoidal fissure, and there divides into two parts. The upper, and smaller, supplies the levator palpebræ and superior rectus muscles. The under, and larger, sends offsets to the internal and inferior rectui, and to the inferior oblique. In addition, the nerve sends filaments to the iris, and to the ciliary muscle. All of these muscles may be paralyzed by lesions involving the nucleus of the nerve, on that part of the crus cerebri through which the nerve-filaments pass to the superficial origin; or by disease, or injury, implicating the trunk of the nerve, in its passage along the base of the cranium to the sphenoidal fissure, or affecting one or more of its branches within the orbit.

The crus cerebri may be affected by the various morbid conditions which have been mentioned in the section on paralysis of the portio dura, as occurring in the pons Varolii, and need not again be enumerated; and the third nerve may be implicated, giving rise to impaired movements of the eyeball. This, however, can scarcely be the case, without injury, also, to some of the fibres ascending in the crus, from the medulla, to the great ganglia at the base of the brain, and a degree of hemiplegia will thus be produced proportionate to the number of fibres destroyed. The hemiplegia and the paralysis of the third nerve, will be on opposite sides, for the reason already given in explaining the cross paralysis of the face and limbs, in disease of the pons, and this affords a ready means of diagnosis in the somewhat rare cases in which the ocular muscles are paralysed from lesion in the crus.

Hæmorrhage into the thalamus, corpus striatum, or cerebral hemi-

spheres or other disease affecting these parts does not give rise to paralysis of one of the third nerves, either on the same or opposite side, but a curious condition is sometimes observed in some cases of apoplectic effusion, a lateral deviation of both eyes, which are persistently turned towards the sound side, but cannot be made to look towards the paralyzed side.

The morbid conditions which are likely to affect the nerve in its course along the base of the brain, are aneurism of the cerebral arteries in its vicinity, or tumours arising from the dura mater. Perhaps the commonest cause is syphilis, generally in the tertiary stage, giving rise either to gummy tumour in the pia mater, or to node of the dura mater.

If the disease be within the skull, the trunk of the nerve will be affected, and so all the muscles which receive their nerve-supply from this source, may be more or less paralyzed.

If the disease be within the orbit, although most of the muscles may be completely paralyzed, some may escape. All may be partially paralyzed, or only some of them. Some may be quite paralyzed, and others only partially. A single muscle may be affected. The iris alone may be implicated, even without the ciliary muscle; more will be said of this presently. In the two eyes, the corresponding muscles may be paralyzed, or different ones.

Ptosis, or drooping of the eyelid, external squint, and dilated pupil, are the signs by which complete paralysis of this nerve is recognised. As the orbicularis palpebræ now preserves its power, it keeps the eyelid constantly closed, so that the eye cannot be used, except the eyelid be raised by the finger. The loss of the inward movement of the eyeball is generally most marked; but there is failure, also, to act properly in an upward or downward direction, as will be obvious when the action of the paralyzed muscles is taken into consideration. Nevertheless, it can still move a little downwards by the aid of the superior oblique, which is supplied by the fourth nerve. The external movement is made by the external rectus, and as there is no muscle to counteract its action, divergent squint results; and this is more apparent after a time, when secondary contraction of the external rectus ensues. The position of objects seems changed. They may seem to move when an attempt is made to move the eyeball, and vertigo is complained of.

The drooping of the eyelid is a most obvious sign. Sometimes, when the paralysis is only partial, it can be slightly raised, but more often it hangs down over the eyeball; it is therefore generally necessary to raise the eyelid with the finger, and move an object before the eye, and direct the patient to follow it, so as to see what ocular movements are impaired.

The dilatation of the pupil is due to paralysis of the sphincter pupillæ. The ciliary muscle also is paralyzed, and the power of accommodation is lost. If the eyelid be lifted up while the other eye is open, there will be double vision. If the diseased eye only be opened, the quality of the sight will depend on the state of the refracting media, minus the accommodation.

It is important to remember, that inability to use the levator palpebræ may be due to other causes than affections of the third nerve. It may be caused by mere œdema, or a tumour, or elephantiasis of the eyelid. A man had an aneurism in the thorax, which, by obstructing the venous circulation, caused serum to be effused in the subcutaneous areolar tissue; here the cause was very evident.

A woman was suffering from renal disease, and always lay on one side, and so the dependent eyelid became œdematous. It is common enough to see both eyelids puffy from heart or kidney disease.

Individual paralysis of the several muscles.

Paralysis of the Internal Rectus of the Right Eye. In looking to the left, the internal rectus of the right eye and the external rectus of the left eye act together, and so in palsy of the third nerve the patient is unable to perform this movement properly; the left eye will act naturally, but the right will not pass the median line; a divergent squint is the consequence, and objects are seen double.

In the section on the action of the different muscles, it was shown that only a horizontal movement is made when either the internal or external rectus contracts. Hence, there is no alteration in the height or straightness of the second image, as the vertical meridian still remains unaffected, and the centre of the cornea is neither raised nor depressed.

In the diagonal movements a different result is met with. If the healthy eyes look upwards and to the left, the following muscles are brought into action to produce the movement of the right eye inwards and upwards, namely, the superior rectus, internal, and inferior oblique; to move the left upwards and outwards, the superior rectus, external rectus, and inferior oblique. These act at the same time, and so the planes of both eyes remain parallel.

In a case, however, where the right internal rectus is paralyzed, the vertical meridian remains almost straight, and a merely upward movement is made with the right eye, while the vertical meridian of the left eye is turned outwards, and so the planes, instead of being parallel, converge below and diverge above. Double vision necessarily ensues.

Therefore, in diagonal movements, in consequence of the non-

parallelism of the vertical meridian of each eye, a difference in the height of the images will result.

It will be noticed, that while the internal rectus, acting singly, has no effect on the inclination of the vertical meridian, yet it has when associated with other muscles in a diagonal movement.

The patient can sometimes move the eye slightly inwards, but this action is due to the combined contraction of the superior and inferior recti. The movement is but very slight.

The divergence of the two eyes is greater when the eyes are cast upwards than when they are directed downwards. Diplopia, or double vision, will not exist when the patient looks to the right, nor always when he looks straight forward. The line which separates the field of single and double vision is not vertical, but is directed from right to left.

So long as the associated movements are unaffected, in any given position, there is single vision. But when they are broken, double vision at once appears.

After a time a patient either disregards the image thrown on the squinting eye, or moves his head in such a manner that the images are thrown on the field of single vision. See chapter on "Squint." It is rare to meet with cases in which single muscles only are paralyzed; in the majority of cases nearly all supplied by this nerve are more or less affected at the same time.

As an exceptional case, the internal rectus becomes just sufficiently paralyzed to interfere with the convergence of the eye with its fellow for near vision; or, in a still less degree of implication, the eyes converge for a time, under strong volition, but are not able to maintain the action. Thus a person sees double when commencing to read, or to do close work; or at first is able to see, but after a short time the action of the muscle fails, the eye turns a little outwards, and double vision ensues. The disease is first noticed from the double vision. I have met with this a few times in young persons who have been exhausted by excessive mental labour, or privations with insufficiency of food, or debauchery. The squint may be so slight as to be detected with difficulty, and to determine the defective eye, it may be necessary to examine the position of the second image.

Paralysis of the Superior Rectus of the Right Eye. Since the action of this muscle is to direct the eyeball upwards, and a little inwards, it is easy to understand how these movements will be affected in a case of paralysis.

It is evident that diplopia will only exist when the patient is looking upwards, and not when the eye is moved below the horizontal diameter. It has been shown that this muscle alters not merely the

height of the cornea, but in consequence of its oblique insertion, it influences the position of the vertical meridian, and therefore, in all movements in which it fails to act, whether single or associated, the vertical meridians of the two eyes will cease to be parallel, and a squint will ensue. And this will be more evident in that position of the eye in which the action of the muscle upon the vertical meridian is most marked. In this case, therefore, when the eye is turned inwards, the inferior oblique muscle is unopposed, and the vertical meridian is drawn out, being more inclined than if the eye were turned to the right, for in that position the muscle affects the height of the cornea chiefly, and to a less degree the vertical plane. Hence, in the attempted position upwards and inwards the two vertical meridians will be more diverging than in any other; for in looking in such position, the right eye will fail to move inwards and upwards, and the left healthy eye will be directed at the same time upwards and outwards. The consequence is, that the two planes will diverge at the top, and double images will be formed. These will cross, the distorted one being to the left.

The two images vary in height according to the position of the eye, the difference being most marked when the eye is directed outwards, and least so when turned in the opposite direction.

In those movements of the eye in which this muscle is not called into action, the patient will be able to see well, supposing no other muscle is affected. He often throws the object into the lower half of the field of vision, by putting his head back, so as to counteract the paralysis as far as possible.

Paralysis of the Inferior Rectus of the Right Eye. This muscle moves the eye downwards and a little inwards; when associated with the external rectus and superior oblique, it moves the eye downwards and outwards. Like the superior rectus muscle, it never moves the eye when acting singly in a vertical plane; in the ordinary downward movement it is assisted by the superior oblique, so as to counteract the inward tendency.

The influence of this muscle upon the vertical meridian is most felt when the eye is turned inwards. Now, when in paralysis the eyes are directed downwards and to the left, it follows that the planes will not be parallel; a double image will form and be cross.

After what has been said in considering palsy of the superior rectus, it will be enough to state that in the movement of the eyeball downwards and outwards, the position of the height of the cornea is most affected, and therefore, in this position of the eye, the difference in the height of the double images is most marked. Diplopia will only occur when the eye is directed downwards; when

objects are held above the horizontal meridian line, the patient can see distinctly.

Paralysis of the inferior oblique of the right eye. The action of the inferior oblique is complicated. It rolls the eye upwards and outwards, and inclines the vertial meridian outwards. Associated with the superior rectus, it produces an upward movement, as it counteracts the inward tendency of the latter muscle. It assists in the diagonal upward movements of the eye. The effects of paralysis can be made out by considering these movements. As they are precisely the opposite of those which occur in paralysis of the superior oblique, the student will easily make out what should be the symptoms. This muscle is very rarely the only one paralyzed.

The fifth nerve and the portio dura, are generally unaffected when the third is paralyzed.

Whether the disease be central or peripheral, is the important point to find out. When central, probably all the ocular muscles are more or less paralyzed, and notably the levator palpebræ, the iris, and the internal rectus; so that the symptoms met with will be external squint, ptosis, and a dilated pupil.

If a tumour or an aneurism at the base of the brain be the cause of the disease, certain changes will also be probably found in the retina. The reason of this being that such lesions are liable to press on the venous sinuses at the base of the brain, and so obstruct the passage of the blood. As a consequence, there is passive congestion of the vessels of the retina, followed by effusion of serum, and sometimes this congestion may go on to inflammation, and set up changes which totally destroy the sight.

The general symptoms pointing to cerebral disease, would be headache, giddiness, loss of memory, pain, and perhaps convulsions. Should hemiplegia come on, it would affect the opposite side, and it would point to white softening or hæmorrhage in the crus cerebri.

Exostoses, tubercular deposits, cysts or tumours in the brain, and effusion of blood, act as causes.

Central disease sometimes arises from syphilis, in consequence of nodes on the dura mater at the base of the skull.

Peripheral disease from syphilis is more common, and there is generally orbital periostitis as well.

Rheumatism is often an exciting cause, producing inflammation of the sheath of the nerve. This generally comes on after exposure to cold, and is accompanied by severe pains in the head and eye.

The paralysis is always more rapid in causes associated with inflammatory action, than with mere physical disturbances producing pressure.

In locomotor ataxy, it is not uncommon to find some of the muscles supplied by this pair of nerves, more or less paralyzed. In this disease, granular degeneration of the posterior columns of the spinal cord is met with, and it is doubtful whether the eye-muscles are paralyzed by reflex action, or by an extension of the disease to the cerebrum. There is, perhaps, a reflex origin, as now and then the ocular paralysis passes off after a time, even though the spinal disease increases. The peculiar staggering walk, especially when the eyes are shut, the inability to stand erect without looking at the ground, and absence of any actual loss of power in the lower extremities, are the chief signs of this disease.

Lead poisoning and hysteria are also causes of paralysis; in such cases the history would lead to a correct diagnosis.

A lesion in the orbit might involve all the branches of this nerve, but then there would be distinct evidence of local disease. Injuries to one or other branch from external violence, or by wounds, might cause a single muscle to be affected. The levator palpebræ is thus sometimes paralyzed without any other muscle being affected.

Dr. Brown-Séquard quotes several cases in which palsy of the third nerve has been caused by reflex action. "Physiology and Pathology of the Nervous Centres," p. 165. In four cases neuralgia of the fifth pair, produced such effect. In two others, palsy of the levator palpebræ occurred from the same cause.

Neuralgia of the supra-orbital branch of the fifth nerve, also produced palsy of the third and sixth pairs of nerves, and the paralysis ceased quickly after the cure of the neuralgia.

Blood-poisoning may affect this nerve, so may poisoning from lead.

Long and exhausting fevers have affected some of the branches of the nerve.

In chronic paralysis of the muscles supplied by the third nerve, the external rectus has become paralyzed, whereby the eyeball has assumed a central position, the cause being implication of the sixth nerve in the disease primarily affecting the third.

When the eyeball is motionless it is likely to project. Sir Charles Bell records a case of this, with anæsthesia of the parts supplied by the fifth nerve.

Treatment. All that has been said about the treatment of paralysis of the portio dura applies here.

Some few things required to be added. Cerebral origin of the disease can scarcely be overlooked. In this variety the attack may be sudden or slow; the first may partake of an apoplectic character, or may arise from violent exertion, mental emotion, fatigue of brain, sunstroke, injuries to the head, or intemperance. The second advances with the

progress of cerebral disease. In the early state of either of the forms the symptoms may remit and recur.

In the first class of cases there may be perfect recovery. Within a short time I had six examples, affected in various degrees, and all have completely recovered. One was in a clever schoolboy, thoroughly overworked. Two were in medical men, one thirty years old, the other sixty-two, both exhausted from professional labour. Another was in a gentleman who took too much wine and tobacco. The fifth occurred in a young man during a fit of intoxication. The last was in an old labouring man, from mental emotion, on hearing of the death of his daughter.

In the second class, those of slow development, there is little scope for treatment.

Orbital origin is generally associated with some displacement of the eyeball, or some palpable disease of the bones, or of the soft parts, whereby discrimination is easy.

Idiopathic, extra-cranial affections of this nerve are, with few exceptions, brought on from exposure to cold air, or to draught, when persons are out of health, or temporarily depressed in body or mind. It has occurred on both sides of the face in a man who wore his hat after it had been wetted from falling in the water. There may be pain in the face, or in the orbit, or not any. Here tonics are clearly indicated, with the additional treatment of removal of any depressing agency, and doing all that is likely to bring the patient to his highest state of health. I prescribe iron and quinine, in large doses, combined or separate; and direct the face to be kept warm. The result is nearly always satisfactory, and rapid. Some of the most marked cases, in which complete paralysis existed in some or all of the muscles, got well in three, four, or six weeks. Some were longer. It is most interesting to watch them, as the paralysis passes off from the one muscle or the other, till all are well. Paralysis, associated with rheumatic symptoms, or occurring in a rheumatic person, is more persistent, and therefore more difficult to treat.

Sometimes during the treatment, when the upper eyelid begins to be raised, double vision may annoy the patient. The eye should then be closed with a piece of plaster, or covered with a shade.

Some men have suggested the use of prismatic glasses, for the benefit of the chronic cases of paralysis of this nerve, especially of the branches supplying the lateral recti, but, as often happens, the therapeutic influence does not come up to the scientific expectation. The action of these glasses has been explained, and need not be repeated. If a prism be found serviceable in removing the annoyance of double vision in a case that is palpably beyond cure or relief, except by an

operation, and a patient will not submit to such, there can be no objection to its use, let it be applied. But as a remedial measure, in setting the eye straight, it is useless, and a mere scientific toy. If it fuse the images it becomes a hindrance to the recovery of the affected muscle rather than otherwise; hence it is recommended that they be only approximated, so that the patient may be induced to use, unconsciously, of course, that amount of volition which will fuse them, and so improve the action of the paralyzed muscle. To this, I say, that as the disease has been enough to allow the eye to deviate, and to fall away from the axis of vision when the power of volition to overcome such deflection was at its height, namely, when the deviation was at its least degree, and at *first*, *too*, when as yet the antagonist had not contracted, certainly at a later period, volition is valueless. There is a loss of generation of nerve-power, and which cannot be generated by the will. Besides, there are no physiological grounds for reasoning that the application of a prism will cure a paralytic squint. It may be answered, that as an adjunct it is useful. Practically, it is inapplicable, for a nicety is needed in the adaptation that is scarcely to be obtained, and a patient will seldom be troubled with the trial, nor will he persevere under any condition. He soon sees the inutility of the thing. This is a subject which has been largely written on.

Galvanism has been spoken of in laudatory terms by many surgeons. I have prescribed it several times for my patients, and applied it myself a few times, and, so far as I could judge of it in combination with other treatment, I was satisfied; but my data are not sufficient to draw accurate conclusions from. Speaking of the advantages of the treatment from analogy, that is, its usefulness in other parts of the body, it should be received as valuable. Dr. Moritz Benedikt has contributed a very long paper to the "Archiv. f. Ophthalmologie," on the subject, of which a translation, twenty pages, appears in the "Ophthalmic Review," entitled "Electro-therapeutical and Physiological Researches on Paralysis of the Ocular Muscles." There are a few points which are well worthy of notice. He found that the production of contractions of the paralyzed muscles was not necessary to a cure, and was not often possible. Also, that the cure was dependent, generally speaking, upon reflex excitation through the fifth pair of nerves, and not upon direct excitation of the nerves supplying the muscles themselves. In most cases a curative action was only produced when the excitement was relatively weak, and when no trace of muscular contraction was produced by the electricity. The proper measure for the strength of the current is always furnished by the sensitiveness of the fifth

pair; yet the intensity of it must be such as to produce slight sensation in the parts excited. An important principle is, that the excitation should only continue about half a minute at each sitting. The frequency of the sitting is not given. He had only used the galvanic current, and he thinks that the operators who use faradization, have in general been unsuccessful. It is stated that it may happen that the normal mobility of the eye is restored, but that the field of double vision continues at least comparatively large. This is at variance with all that is recognised and taught and acted on, about double vision depending on displacement of the eye; and an attempt is made to account for it by an elaborate and speculative physiological argument.

These rules are given for the practical working. "Paralysis of the abducens is best treated by placing the copper pole upon the forehead, and moving the zinc pole over the neighbourhood of the cheek-bone. In mydriasis, the copper pole should be placed on the closed eyelid, and the zinc pole applied as before. In ptosis, the copper pole may be either upon the forehead, or may be applied by means of a short catheter-like rheophore, to the mucous membrane of the cheek, while the zinc pole is drawn over the lid. For all the other branches of the third nerve, the copper pole is applied as above. Then, in order to act upon the rectus internus, or inferior oblique, the zinc pole must be drawn over the skin of the side of the nose, near the inner angle of the eye, and in order to act upon the rectus inferior, over the lower margin of the orbit. In paralysis of the superior oblique, I have succeeded best by placing the copper pole on the forehead, and by drawing the zinc pole on the inside of the nose, near the internal angle of the eye."

Paralysis of the ciliary muscle, that is, paralysis of accommodation, is often met with alone. Paralysis of the motor muscles of the eyeball supplied by the third nerve seldom exists without paralysis of accommodation.

Uncomplicated paralysis of the ciliary muscle has but one objective symptom, dilatation of the pupil, with immobility. The dilatation is very seldom excessive, and admits of being increased by the use of atropine. In complete paralysis not a trace of accommodation, or of reflex movement, is seen. But the connection between paralysis of the pupil and paralysis of the ciliary muscles cannot be called absolute, for Donders found satisfactory accommodation still coexisting with absolute immobility of the pupil. In one instance, too, paralysis of accommodation disappeared without a return of the mobility of the pupil. On the other hand, with perfect or almost perfect loss of accommodation, the pupil may be but little disturbed.

Under paralysis of accommodation, the state of the interior of the eye, and the integrity of the retina, may be judged of by the condition of the refracting media.

Near-sighted persons, myopics, whose farthest point is not more than fourteen inches from the eye, find no difficulty in reading at this distance, or less. Objects at a greater distance appear more diffuse than usual on account of the larger pupil. Again, within the distance of their combined nearest and farthest point, they cease to see accurately. These disadvantages are but slight when the paralysis is incomplete. Persons with healthy eyes, or emmetropes, can no longer read or write, and a certain dimness is forthwith observed. If distant vision be good, and with either a concave or a convex glass becomes diffuse, while for near objects the convex glass is necessary, the disturbance to sight is merely that arising from loss of accommodation.

In hypermetropes vision is considerably imperfect, and more so than usual, for distant objects as well as for near, and any involuntary accommodation which they possessed for partially overcoming their defect is lost; considerable disease of the interior of the eye is therefore suspected. Testing the eye with lenses for near and for far vision will reveal the true nature of the case.

With slight paralysis of accommodation, paresis as it is often called, the near-sighted persons often have no inconvenience. The emmetropes complain of fatigue only in using the eye for near objects. The hypermetropes have a little more difficulty in seeing at all ranges. Under this state, asthenopia quickly occurs.

The treatment here is included in what has been said above.

Paralysis of the Ciliary Muscle, the result of Diphtheria. A great many years ago, Dr. Mackenzie described the loss of the power to adjust the eyes in adults and in children after febrile diseases, influenza, and inflammation of the tonsils, with febrile excitement, and clearly distinguished this from presbyopia and asthenopia. He attributed it correctly to the result of "disturbance of the nervous power upon which the adjusting apparatus of the eye depends." Then diphtheria had not been described as a distinct disease, nor was the mechanical adjustment of the eye clearly understood. Of late years, the paralysis has been frequently noticed in diphtheria, not only in association with paralysis of the muscles of the palate, but of slight general paralysis.

Here, so far as I know, the pupil is not affected. The paralysis is generally slight, hence it is usually called paresis; sometimes, also, loss of tone of the ciliary muscle.

There is not any special treatment for this. In all the cases I

have seen, recovery has ensued. I can say the same of the paralysis of the muscles of the palate. Only general tonics were employed. The use of the Calabar bean is unavailing. This subject is spoken of besides in the chapter on the optical defects.

Mydriasis from Paralysis of the Sphincter Pupillæ. This is characterized by dilatation of the pupil, with fixedness. Generally only one pupil is affected, except the cause be cerebral. The subject has been somewhat anticipated above. The dilatation is seldom very great, and hence it is that it may generally be increased artificially by the use of atropine. The pupil form may be natural, or irregular, being oval in the one direction or the other, or some portions may be more dilated than others. The blackness of the aperture is lost, and this is in proportion to the dilatation.

Generally there is not any, or but the very slightest, pupillary action under the presence of light, or during convergence of the optic axes, or during the exertion of accommodation. The ciliary muscle is mostly paralyzed as well, to a greater or a lesser degree, but it may escape implication. The disturbance to vision is, of course, greater when the accommodation also is paralyzed. It is but slight when the iris alone suffers; indeed, if the dilatation be small, only the least visual defect may ensue.

Circles of dispersion are formed on the retina, and are caused by the dilatation of the pupil, and the asymmetric curvature of the cornea, and of the lens, whereby there is produced a slight amount of blurring, yet this may be so trifling as not to be detected except by a comparison with the other eye. I will cite an example. A lad, æt. 15, was affected with mydriasis from a blow on the eye. At first he could not read one-and-a-half of Snellen's test-types, and his distant vision was a little impaired. When some of the dilatation passed away he could read one-and-a-half, and his distant vision, as he thought, was perfect. It was only by a careful comparison with the other eye, that vision both at his near and his far points was found to be a little defective.

In uncomplicated mydriasis, looking through a small aperture in a card, will generally remove the disturbance to sight.

An ephemeral mydriasis is described as occasionally coming on at different periods of the day.

Causes. Besides peripheral origin, such as cold, &c., described above among the causes affecting the trunk of the third nerve, may be named effusion into the ventricles of the brain, concussion of the brain, basilar meningitis, certain narcotics, blows or falls on the head, and incised wounds and lacerations about the temple and brow. Diseases of the cerebellum, and apoplectic effusions

at the base of the brain, and glaucoma, also, must be named. Sometimes there is not any perceptible origin. Even in perfectly healthy subjects, under adult age and beyond, the sphincter pupillæ may be dilated, the rest of the eye being healthy, and the dilatation having been accidentally discovered. Such is the history of several cases that have come under my notice.

Treatment. We should endeavour to discover the nature of the original diseases, and direct our efforts to combat it. After what has been said on this subject respecting the treatment of paralysis in general of the third nerve, nothing need be added. Whether we possess any therapeutic measure by which we can excite contraction of the sphincter as an adjunct to general treatment, is the only point to be considered. More than fifty years ago it was discovered that acrid liquids applied to the conjunctiva caused contraction of the pupil, even where the mydriasis was excessive, but the effect was temporary. In recent times the Calabar bean has been declared to be valuable, because it produced contraction, but its influence is as transient as all other agents that have been tried. It is said that electricity is beneficial.

The conjunctiva has been irritated with many drugs, under the hope of producing reflex action to the sphincter, through the fifth pair of nerves.

Strong efforts to accommodate the eye are recommended. Counter-irritation in every variety about the temples and forehead has been found useless.

Mydriasis from disease of the sympathetic nerve has been considered among the affections of the ophthalmic portion of that nerve.

Myosis. This is persistent regular contraction of the pupil far below the medium size, with immobility, or with but the slightest movements under light, or under the use of atropine, and without change of structure in the iris, or in the eye.

It has always been classed under the two forms of paralytic and spasmodic. Of the first, which ought not, strictly speaking, to be placed under my definition, sufficient notice has been taken in the section on paralysis of the sympathetic nerve. Contraction of the pupil, which occurs when the third nerve is irritated, in brain diseases, in apoplectic effusions, in opium poisoning, or in photophobia, is not paralytic.

Of the pathology of the second, or true mydriasis, nothing is known, and we can only reasonably suppose that there must be some nerve change in the nerves supplying the iris. The aperture may be of the size of a pin's head, or even the point of a pin. It is very black. The visual field is contracted. The brilliancy of retinal

images is decreased, and high illumination is necessary for clear vision. With excessive contraction there is almost blindness. Both pupils are generally affected. In some cases the person only sees during some hours of the day. Headaches are often associated. The most frequent subjects of it are those of a debilitated constitution and cachectic, and those who are exceedingly nervous and irritable.

It is supposed that the use of the eye on minute objects, such as watch-making, engraving, and the like, is an exciting cause. If such occupations are thus injurious, it is because of the constant use of the high positive lenses which are employed therewith. I have met with myosis most frequently as a complaint in persons who have not required to labour for their living. I have never seen it under adult age.

There is not any special treatment. Nothing that has been tried has proved of any avail.

Tremulous Iris. This is loss of motion of the iris, inaction, with shaking, or tremulousness, when the eyeball is moved quickly. The movement may be very marked and apparent, as if the iris were loose, or but so slight as not to be seen except it is carefully looked for, when the eyeball is sharply twitched about. It is often called paralysis of the iris. It seems to me that the term is inapplicable.

The iris is unchanged in structure. The pupil is round, a little reduced in size, not contracting or expanding under the usual influences of nature, instances to the contrary being very exceptional. It acts, however, freely under atropine.

The affection is frequently seen after the removal of the lens by all of the operations for cataract, but particularly that for displacement. It is invariably marked after extraction, where vitreous humour has been lost. I never saw it, in any degree, in connection with prolapse of the iris after the operation for extraction. It often results from a blow on the eye when any internal damage is produced, particularly when the retina suffers. It may follow a wound that involves the sclerotica and the choroid. It is seen in cases of capsulo-lenticular cataract, not of traumatic origin. It is a complication not uncommon in congenital cataract. I saw it once slightly in a girl, whose eye was otherwise healthy, and whose vision was perfect.

Of the true nature of the lesion we are ignorant. There are several theories about it. One attributes it to loss of support of the iris, by the removal of the lens. This cannot apply to all cases. Another to fluidity of the vitreous humour. It is not an objection to that to say that bodies are seen moving in the humour, when the iris does not shake. The breaking down of the humour may be partial and central. It may be that for the trembling there must be reduction

of volume as well as fluidity. A capsulo-lenticular cataract of full volume often shakes with the iris. The increased size of the posterior chamber in association with the affection, has been noticed by many surgeons. There is not any scope for treatment.

PARALYSIS OF THE FOURTH CRANIAL NERVE.

The fourth nerve, or trochlear, is the smallest of the cranial nerves, and arises from two nuclei: the anterior one is close to the aqueduct of Sylvius, and the posterior one is in the upper part of the fourth ventricle; the superficial origin is from the valve of Vieussens. It passes between the cerebrum and cerebellum, on the side of the crus cerebri, and enters the tentorium cerebelli near the posterior clinoid process. It then passes forward into the orbit, and supplies the superior oblique muscle.

The action of the superior oblique muscle is to roll the cornea downwards aud outwards, and to incline the vertical meridian inwards. The muscle assists the inferior rectus in producing a direct downward movement, and is further associated with other muscles in producing diagonal movements.

In paralysis of this nerve, objects will be seen properly in the upper half of the field of vision, but not in the lower, where diplopia will exist. In such a case, also, the inferior oblique will be unopposed in its action, and hence, the eye has a tendency to be rolled upwards and outwards. In the attempt to move the eye downwards and outwards, the left eye, if normal, looks downwards and inwards.

The superior oblique exerts the most influence on the position of the vertical meridian when the eye is moved downwards and outwards, and conversely, most on the height of the cornea, when the eye is moved in the opposite direction. Thus, when it is paralyzed, the difference in the height of the double image will be most marked when the object is moved to the left, as then the eyes look downwards and inwards, and the loss of power over the position of the centre of the cornea is most felt; and in this movement the inclination of the double images is least marked. On the other hand, when the eye looks in the opposite direction, the inclination of the double image is greater, because the vertical meridians of the two eyes are then most divergent, and then, also, the difference in height of the two images is not so great. The distorted image, which looks nearer, is homonymous, or on the same side, when an object is looked at below the horizontal meridian. It is crossed when an object is looked at above that line.

Paralysis of this nerve is rare. The causes are nearly always due to pressure, from tumours, &c.

The treatment is implied in what has been said under this head with respect to the other nerves, with the exception of an operation.

PARALYSIS OF THE SIXTH CRANIAL NERVE.

This nerve supplies the external rectus only, and hence, when paralyzed, the eyeball of that side cannot move outwards, and internal squint results.

Since the muscle, when acting singly, only moves the eye in the horizontal meridian, the centre of the cornea is neither raised nor lowered, nor is the vertical meridian inclined. When an object is held before the eye, all movements which do not involve the action of this muscle are made perfectly; thus the patient can direct the eye upwards, downwards, and inwards properly, but not outwards. Yet with very strong volition, a slight outward movement is possible, because the superior and inferior oblique muscles each move the eye externally.

In a similar manner the eye moves inwards a little, when the internal rectus muscle is paralyzed, owing to the action of the superior and inferior recti muscles.

It has been shown that when the lesion is at the nucleus of this nerve, there may be associated with it facial palsy of the same side.

In describing palsy of the internal rectus, I have mentioned that in diagonal movements involving that muscle the position of the centre of the cornea and the inclination of the vertical meridian with that of the sound eye were altered, and so double images were formed varying in inclination, and in height.

Precisely similar remarks apply to the diagonal movements, in which the external rectus muscle takes part. It is, then, unnecessary to say anything further on this subject, as the student can easily make it out himself, by remembering that the movements are in just the opposite direction to those mentioned when treating of the third nerve.

The causes are most frequently cranial. I have seen the paralysis several times as the result of general depression from exhausting influences.

Treatment. What has been said respecting the fourth nerve applies here.

The subject of paralysis of the muscles of the eye is a very difficult one to learn. To gain any knowledge of it which can be made

practically available, requires a very careful investigation of a sufficient number of cases, in which variety is met with. Complication of an insurmountable character is produced, when with the paralysis the eyeball is displaced in any direction, from causes whether in the cranium, without it, or in the orbit.

M. Desmarres, jun., suggests a method which he thinks facilitates the detection of the paralyzed muscle. Two lines, the one vertical, and the other horizontal, are chalked on a black board, which is so placed that the first one corresponds to the centre of the patient's body, while the other is on a level with his eyes. The eyes are alternately covered with a piece of coloured glass, and the flame of a candle is moved across the field of vision till two images are seen. One of the images will be farther from the vertical line than the other, and the eye with which this deviation is perceived is the paralyzed one. The rule given above, about the image being homonymous, or crossed, holds good here in proving convergent or divergent squint.

General Results. Many cases of paralysis, doubtless, will get well. Some will be only improved by treatment, although the degree of improvement will remain. Some will not be benefited by any of the measures that have been described, and these will, in all probability, become worse through the contraction of the muscle antagonistic to that which is paralyzed; and this holds good with the recti muscles, as well as with the oblique.

In the cases of paralysis of one or of the other of the lateral recti, as soon as permanent squint is established, an operation should be resorted to.

TREMBLING OF THE EYEBALLS, SOMETIMES CALLED NYSTAGMUS.

The symptoms consist of an involuntary tremulousness of the eyes, almost rhythmical, without impairment of the muscular movements. The balancing action, or controlling of the muscles, is weakened. The one eye may be affected, when the other is lost. The shaking is generally from side to side; sometimes it is rather in an oblique direction, sometimes the motion is rotary, and varies from a scarcely perceptible degree to, perhaps, nearly a quadrant. Sometimes other movements are met with difficult to be defined; hence the trembling has been described as oscillatory, rotary, and mixed.

They are nearly always permanent, continuing without interruption during the waking hours, and are beyond control. They vary in intensity. Periods of rest are sometimes noticed, when objects are intently looked at in a given direction. Under special

circumstances they are greatly increased if the person be excited, and sometimes, too, when the muscles of accommodation and convergence are much tried, or if small objects cannot readily be recognised in a weak light. They do not interfere with the simultaneous action of the two eyes. They are sometimes associated with internal squint.

Effects. The patient himself is not aware of the oscillation. Objects may be seen as they are in motion or at rest. But some persons complain of apparent unsteadiness, or tremor, of whatever is looked at. The movements were very marked in a case observed by Dr. Mackenzie, when the eyes were directed towards any object; but when the upper eyelid of the one eye was held up, and the patient told to shut the other, the oscillation ceased. To this individual all objects appeared tremulous. In another patient the oscillation ceased when she looked downwards, but became very great when she looked upwards. Convergence of the eyes, as in reading, seemed in this case to remove the oscillation. When both eyes were open, the oscillation was striking; but if one eye were closed, the other became perfectly steady. In a case recorded by Sir C. Bell, the patient read with perfect ease, and yet there was no cessation of the motion of the eyes. She threaded her needle without any apparent difficulty, and then showed how she could sew, which was with the usual nimbleness. All objects seemed to be in their natural state of rest or of motion.

Cause. The disease nearly always arises in infancy, and is produced most frequently by congenital cataract, which is sufficiently advanced to destroy vision, or to impair it very much. Any cause which brings on blindness in both eyes of an infant may develope it; therefore it is seen when the corneæ have been spoiled by purulent ophthalmia. I have known it to come on when a child has been long deprived of sight by corneal opacities, which afterwards cleared away. I have seen it in arrest of development of the eyes, and also in congenital defects of the optic nerve and the retina. It may occur from infantile purulent ophthalmia. It is said to come on sometimes at the commencement of school life, when from impairment of sight, sharp or moderately clear perceptions are difficult, and the object is brought close to the eyes. It is rather common to the albino, when there is an absence of the pigmentum nigrum. I do not believe in its being congenital.

The true nature of the affection is unknown. We ascribe it to morbid conditions of innervation. It is not, one would suppose, a spasmodic affection. The power of voluntary movement of the eyes in a certain direction is evidence against such, as also other

conditions which disassociate it with trembling of the limbs, for instance, its different cause, its exclusive occurrence at the early period of childhood, the regularity and constancy of the symptoms, the complete similarity in the movements of the eyes, and the persistency of the symptoms. A case is recorded by Dr. Mackenzie in which there was oscillation of both eyes attendant on apoplexy, along with palsy of the left side of the body, diminished power of the right abductor oculi, and a degree of impaired vision.

It has been observed in many cases of degeneration of the white substance of the posterior columns of the spinal marrow. Dr. Waters has recorded, in the Med. Chir. Trans., a case arising from injury to the medulla oblongata.

Treatment. Nothing can be done directly for the affection. The early removal of its cause when practicable, the impaired vision, has been known to mitigate it considerably. But it may remain unchanged after the cataract has been absorbed, or any other excitant has passed away.

It is useless to attempt as a remedy any ocular tenotomy; all the trials of it have been useless, or have made the eye worse in other respects. Any coexisting strabismus should be treated. It is said, but I question the assertion, that when the disease interferes with sight, as in reading, relief may be got by holding the book in some irregular position.

The cases of spinal origin, are of course beyond relief.

LUSCITAS, OR A FIXED STATE OF THE EYEBALL, FOR THE MOST PART WITH DISTORTION, HENCE OFTEN CALLED IMMOVEABLE DISTORTION.

The power of ocular movement is extremely limited, or entirely lost, so that the globe of the eye is rigid and can be moved neither by will nor by the fingers. The stability of the angle of distortion, when there is deviation from the orbital axis, by which the eyeball cannot in any degree follow the movements of the other eye, distinguishes this disease from squint.

Luscitas is but a symptom of many and dissimilar morbid states. Paralysis of the third nerve, in consequence of which the eyeball is turned outwards by the abductor muscle, is the commonest cause of the fixture. Paralysis of the abductor will cause internal luscitas. It is in this way, by affecting the motor nerves of the eyeball, that injuries to the brain, and diseases of the same, among which chronic hydrocephalus is prominent, bring on the affection.

Direct injury to the muscles of the orbit, and to their nerves, as from wounds, or the matting together of the muscles from plastic effusions in orbital cellulitis, are also causes. Besides these, must be mentioned the mechanical influences of tumours within the orbit, and without, growths on the eyeball, and even staphylomatous enlargement of the sclerotica, by which the immovability is produced in the one direction or the other, upwards or downwards, as well as inwards or outwards, or centrally.

Treatment. Nothing is of use when the luscitas is traumatic, nor where the eyeball is fixed by inflammatory changes in the orbit. When of a direct mechanical origin, as in the case of tumours which act as wedges, the removal of them may effect a cure. When of paralytic origin, there is hope for amelioration, or cure, according to the nature of the loss of the nerve force.

MYOTICS, OR AGENTS THAT CONTRACT THE PUPIL.

The Calabar bean has been lately found to be a very powerful myotic. It is the seed of a leguminous plant, the *Physostigma venenosum*, and the active principle is contained in the kernel. The preparation used in experimenting upon the eye, is a solution of the alcoholic extract, of the British Pharmacopœia, in glycerine, one minim of which is equal in strength to four grains of the bean.

The effects of the application of a drop of the solution to the eye are, contraction of the pupil and spasm of accommodation. The immediate effects are slight irritation, and soon after, spasm of the lower eyelid. The contraction of the pupil and spasm of accommodation commence almost simultaneously after, from four to ten minutes. The contraction of the pupil is at its maximum after forty minutes. This diminishes slowly after three hours, and disappears entirely in two days.

Dr. Fraser has observed a slight dilatation first, and then a contraction, and in some experiments he noticed that the pupil oscillated between dilatation and contraction. Perfect immobility of the pupil, however, has never been attained, for by employing the entoptic method of exciting consensual action by opening and closing the other eye, the narcotized pupil will be observed to move slightly, though slowly, even when most strongly contracted.

With regard to the effects upon the accommodation, it is found that when a drop of the standard solution has been instilled into the healthy eye, after ten minutes distant objects appear dim, indistinct, and larger than natural. Such disturbance gradually increases, till

the greatest effect is produced, which is reached in about one hour. Then the farthest point of distinct vision from the eye will be found to be only five or six inches, and the near point only three, or three and a half inches. The eye, in fact, has become intensely myopic. This has nothing to do with the contraction of the pupil, for Von Graefe obtained precisely the same result in a person who had complete deficiency of the iris. Thus it is certain that it is the ciliary muscle which is affected, and that it is placed in a state of complete spasm; the fatigue which is felt in the eye is an evidence of the fact. When we remember that the third nerve supplies the sphincter pupillæ, which is now strongly contracted, and recollect also that the same nerve supplies the ciliary muscle, it cannot be doubted that the real effect of the bean is to stimulate this nerve, and possibly, in addition, to paralyze the sympathetic. In regard to its action on the sympathetic, it may be stated, that when administered internally it prolongs the diastole of the ventricles of the heart, and finally stops the heart's action altogether.

Calabar bean, therefore, is a direct antagonist to the effects of atropia on the eye.

If Calabar be dropped into an eye under the influence of atropia, some contraction of the pupil follows, and a certain amount of accommodation returns. The effect, however, soon passes off, and the atropia once more resumes its sway.

MYDRIATICS, OR AGENTS THAT DILATE THE PUPIL.

It is among the solanaceæ that the most useful mydriatics are found, and of these belladonna, stramonium and hyoscyamus are the best. In practice, however, atropia is universally used, a solution of the sulphate producing the required dilatation, usually without any bad symptoms.

I will give the effects on the healthy eye of a drop of a strong solution of atropine, four grains to the ounce of water.

Gradual dilatation of the pupil, followed by complete insensibility of the same.

Diminution of accommodation, followed by total loss of it.

The dilatation commences in man within fifteen minutes, and is complete in twenty or twenty-five. The pupil does not regain its normal state till twelve days afterwards.

The loss of accommodation is not much marked till after twenty-six minutes, but then proceeds rapidly up to sixty minutes, and is complete in a hundred and three minutes after the instillation. Some

amount of accommodation has returned after forty-two hours; more on the fourth day, but it is not until the eleventh day that full power is restored.

Mode of Action. The experiments of Donders and Von Graefe have established beyond a doubt, that atropia passes directly through the cornea into the aqueous humour. They performed the following experiment with identical results: A solution of atropia was repeatedly instilled into the eye of a rabbit, and then the eye was thoroughly washed with a stream of water. The aqueous humour was then discharged and introduced into the eye of a dog, and kept long in contact with it. Considerable dilatation of the pupil ensued. A solution containing one part of atropia in one hundred and twenty thousand parts of water, kept equally long in contact with the cornea, acted more powerfully, so that a very minute trace of the substance will produce the characteristic effects on the pupil.

Where only temporary dilatation of the pupil is required, weak solutions of atropia are preferable to strong ones. The practical advantage is spoken of in the chapter on cataract.

Atropia undoubtedly acts upon the nerves distributed to the eye. It cannot act directly upon the muscular fibres, as is proved by the sphincter of the pupil being paralyzed, while the dilator is stimulated to contraction after its absorption.

We have the following facts to reason from. The sphincter muscle becomes paralyzed. Reflex movements and accommodation are lost. Paralysis of the ciliary muscle, with loss of accommodation, ensues; this muscle being more deeply seated is affected last. Now all these effects occur in paralysis of the third, or oculo-motor nerve. Therefore, we may conclude that atropia has a paralyzing action upon this nerve, or on its fibres at their distribution. The dilator becomes strongly contracted.

That real contraction occurs is shown by the known fact, that in oculo-motor paralysis, the size of the pupil is still further increased by atropia. Stimulation of the sympathetic nerve has been found to produce dilatation of the pupil. Some physiologists argue from this, that the atropine has an action on the ganglionic cells of the sympathetic nerve.

Dr. Argyll Robertson has, in a pamphlet on "Eye Symptoms in Spinal Disease," very ably discussed this point, in the following manner:

Those who believe that atropia excites the radiating fibres to contract, rest their opinion mainly on the fact that, when the pupil is dilated from complete paralysis of the third nerve, it will still further dilate on the application of atropia, and further, that when the

sympathetic is divided, no contraction ensues in a pupil fully dilated by atropia. But, he continues, experiments on animals have negatived these views in a great measure. There yet remains, however, the singular fact, that division of the sympathetic nerve will cause the pupil to return to a medium size in cases where it has been previously fully dilated by division of the third nerve, but it will fail to do so if the dilatation is due to the action of atropia.

Again, it has been shown by Bridge, that belladonna acted on the pupil thirteen months after the sympathetic had been divided on that side, and where after death galvanism did not induce dilatation, as it did in the other eye.

Dr. Robertson thinks that these facts warrant us in believing that the dilatation is due to paralysis of the third nerve. In cases of paralysis where additional dilatation follows the application of atropia, it may be that the nerve was not completely paralyzed previously, and it must be remembered that there are nervous ganglia in the iris, which act as secondary centres of nervous force, and the local application of belladonna may induce paralysis of these, which before were not affected.

Without further discussing the results of experimenters on both sides of the question, I am inclined to think that the balance of evidence is much in favour of those who believe that atropia paralyzes the circular fibres of the iris.

CHAPTER XVII.

PTOSIS, OR FALLING OF THE UPPER EYELID.

PARALYTIC PTOSIS—SENILE PTOSIS—CONGENITAL PTOSIS—PTOSIS FROM HYPERTROPHY OF THE PALPEBRAL INTEGUMENT—PTOSIS FROM FALLING OF THE EYEBROW—PTOSIS FROM ERYSIPELAS AND INFLAMMATION OF THE CONJUNCTIVA—PTOSIS FROM MECHANICAL INJURY TO THE EYELID—PTOSIS SIMULATED—SUPPLEMENTARY OPERATION.

PARALYTIC PTOSIS.

Descent of the upper eyelid may arise from various causes, and there are degrees in the falling of it, from the slightest lowering, just enough to be detected, to that dropping by which its edge is below the margin of the under eyelid, and every wrinkle or marking on the surface is removed. This form of the loss of the functions of the eyelid, is due to paralysis of the levator palpebræ muscle. Paralytic ptosis is the most common. It may occur along with paralysis of some of the other muscles supplied by the third nerve, or exist alone. But as all the conditions under which paralysis of the levator may ensue, have been given in detail in the chapter on "Paralytic Affections of the Muscles of the Eye," under subdivision, paralysis of the third cerebral nerve, mention of them here is unnecessary.

The most marked form of ptosis is the fullest degree of the paralytic variety.

Treatment. It is only necessary here to speak of the treatment by operative surgery, because general therapeutic measures have been already discussed. When, then, the possibility of a cure by general treatment can be no longer entertained, an operation may be resorted

to. The cases best adapted for this, are those in which the levator is the only ocular muscle paralyzed. Where there is paralysis of some of the other muscles supplied by the third nerve, and the eyeball is displaced, and double vision, or confusion of sight, exists when the eyelid is raised, an operation is inadmissible, unless the patient will submit to the removal of the squint as well as the ptosis.

An early effect of ptosis from any cause, is elevation of the eyebrow, which is produced by the frequent efforts of the occipito-frontalis to raise the eyelid. It is by taking advantage of such compensating muscular movement, that the defect is remedied. The eyelid is shortened, and thereby brought under the influence of this muscle of the head.

The necessary operation is merely one of excision, and consists in the taking away of an elliptical portion of the palpebral skin of the width of the eyelid, and the depth of which should be determined according to the degree of the ptosis. When there is partial loss of power, the removal of a small piece to tuck the eyelid up slightly is sufficient. Where the levator palpebræ is motionless, or nearly so, the eyelid must be more shortened. Besides this difference in cases, respecting the amount of skin requisite to be removed, the condition of the skin itself must be taken into account, whether it be unhealthy, unnaturally thickened, or loose and baggy. Of kindred importance also is the state of the eyebrow, whether lax or tense. The usual action of the occipito-frontalis of the patient must be inspected, for in some persons it is nearly motionless, and then it would be almost useless to operate, while in others its contractions are remarkable.

The orbicularis palpebrarum should be left uninjured, for it is called on to exercise exaggerated power to compensate in some manner for the shortening of the eyelid. But yet the closure of the eye after the operation is principally effected by the lower eyelid being raised above the ordinary level. Without this the eye would be more or less open, and the eyeball exposed to injurious influences.

To do the operation well an assistant is necessary. He should make the integuments tense by raising the eyebrow and pulling the eyelid down.

The piece of skin to be removed should be taken by dissection with a scalpel, from the highest part. The upper incision should be as near to the edge of the orbit as circumstances will permit, or else the edge rather than the body of the eyelid will be influenced. Sutures are necessary.

It is generally recommended, in order to be exact, that the integument should be first pinched up, and, as it were, measured with a

pair of forceps constructed for the purpose; but for any information that may be so gained, the use of the finger and thumb will suffice.

Sometimes the skin is raised with an instrument, and cut off with a scalpel or a pair of scissors. Independently of the inaccuracy and insufficiency of this proceeding, a disfiguring scar is the inevitable result, a great contrast to my method, by which there is scarcely ever any trace of the operation.

If there be any doubt about the extent of skin to be removed, the amount should be fixed at the supposed minimum, for a fault on the other side would be serious. In the earlier operations of most surgeons, generally too little is removed; and it is only after considerable practice that a proper estimate of the requisite breadth can be made. When it is necessary to dissect away an unusually large piece, the outer portions of the incisions must not pass beyond the external angle of the eyelids, or the angle will be drawn unduly upwards.

SENILE PTOSIS.

In this form, both eyes are affected, and the dropping of the eyelids is very gradual. It arises from loss of muscular power in the levator, consequent on age. In slight cases of the affection the eyelids can be much raised for a short time by the will of the individual. In this respect it differs materially from paralytic ptosis.

A woman, aged sixty-four, came under my care at the Central London Ophthalmic Hospital, with complete double ptosis. With a strong effort, which she could not long maintain, the two eyes could be opened sufficiently for her to recognise any one before her, but for her to move about or to engage in anything, she was obliged to keep one of the eyelids raised with her finger.

Treatment. An operation after the manner directed for the removal of paralytic ptosis. In the above case I operated on both eyes with success.

CONGENITAL PTOSIS.

Congenital deficiency of the levator palpabræ, may occur. This is recognised in the thin and wasted look of the drooping eyelid. In all probability the muscle is sometimes quite absent, yet the eyelid even then seldom drops down as in the paralytic form. Subjoined are notes of two cases of this affection.

Ptosis of one eye. W. B., Esq., aged twenty-two. When the eyes were opened to their utmost, and directed to an object on their

level, the cornea of the left was not half uncovered, but about two-thirds of it were concealed, as is shown in the sketch.

Fig. 126.

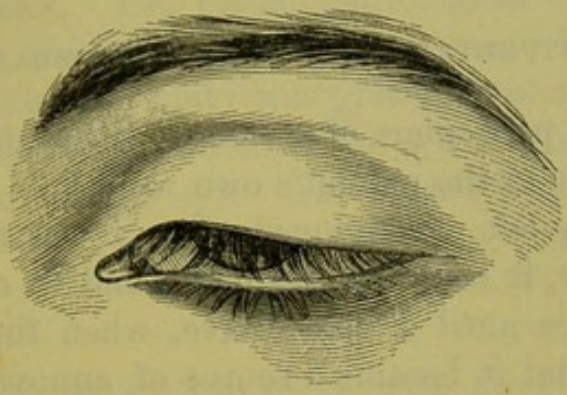

When the two eyes were shut, they differed in no respect from each other. The eyebrows were in a line, and the skin of both eyelids was wrinkled alike.

The eyeballs were parallel, the recti muscles perfect in action, and vision was unimpaired. When Mr. B. was depressed in spirits or fatigued, the eyelid always drooped more. I operated. The skin which was removed was of the following size and shape.

Fig. 127.



Four sutures were applied, but as circumstances obliged my patient to return home next day, I withdrew them just before his departure, so that they were in only twenty-seven hours. Three weeks after, I received a note saying that there was great improvement in the usefulness and in the appearance of the eye; that although the eyelid was not quite as high as the other, the abstraction of any more skin would have prevented the eye from closing.

A woman, aged twenty-four, applied to the Central London Ophthalmic Hospital with ptosis of the left eye. The unwrinkled and elongated eyelid peculiar to complete dropping was well displayed. With great effort, she could expose a small part of the eyeball. The recti muscles were sound. I dissected off a large semi-lunar piece of skin. On the third day the sutures were removed. I did not see my patient for a year, and the success of the operation was very great. There was but a faint mark of the wound.

The eyelid could be raised to the same height as its fellow, and brought down nearly to the same extent. The eye could be easily and completely closed, this being effected by the lower eyelid rising a little to meet the upper.

PTOSIS FROM HYPERTROPHY OF THE PALPEBRAL INTEGUMENT.

I shall give the particulars of a case to illustrate this variety, the history of which is in the patient's own words.

"The lid of my left eye drooped when I was two years old, and as years passed by, it continued to droop and to enlarge; but I felt little inconvenience until I was twelve, when the swelling had so much increased that it became a source of annoyance from the constant inquiries of persons. Then, although I could yet see downwards, I wore a shade till twenty. I was now operated on. The hæmorrhage was considerable, and produced feebleness, that lasted for many weeks. I was afterwards introduced to Mr. Smee."

In consultation with Mr. A. Smee, we determined to reduce the

FIG. 128.

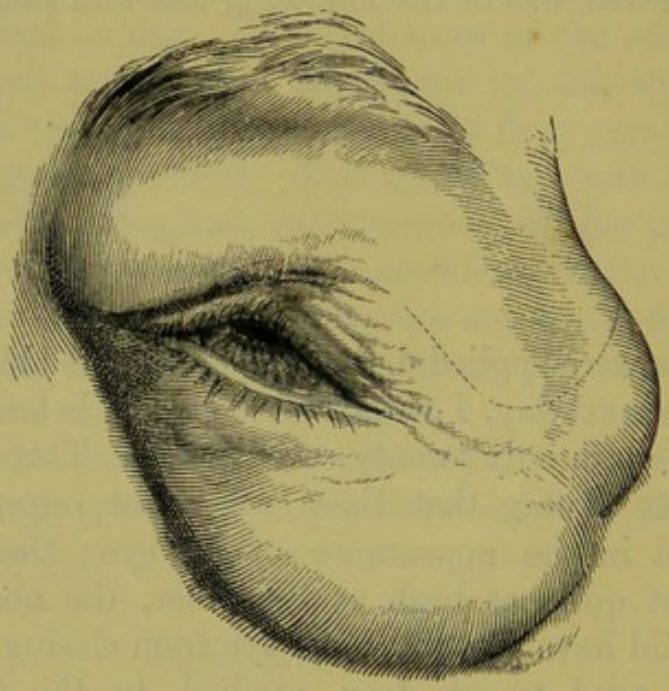

mass, to lessen the deformity, and thereby to endeavour to render the eye useful. At this time the whole of the palpebral skin, the outer part of that of the brow, and a part of that of the temple was swollen into a mass that hung over the eyeball, and nearly concealed it, the weight closing the eyelid, and prevented its being elevated by natural efforts. All that was pendulous was circum-

scribed by transverse elliptical incisions by Mr. Smee, and removed. Very active bleeding ensued, and several ligatures were required.

The appearance of the excised portion was like the thickening and enlargement of the skin in elephantiasis of the scrotum which takes place in hot climates. The actual pathological change was hypertrophy of the skin and subjacent cellular tissue. The result was not unsatisfactory, for the deformity was greatly lessened, and the eyelid could be sufficiently raised to render the eye available. Figure 128, shows the after state of the eye. The dotted line marks the course of the cicatrix.

PTOSIS FROM FALLING OF THE EYEBROW.

During my house-surgeoncy at St. Bartholomew's Hospital, there was in attendance as an out-patient, a man thirty years old, whose left eye was nearly closed from falling of the eyebrow. The skin was not unhealthy, nor could I observe any other change than paralysis of the occipito-frontalis muscle on that side. He told me that he was born in that state. The levator palpebræ was sound, for when the eyebrow was held up the eyelid could be raised. The other side of the face was unaffected. Fig. 129, is an accurate sketch

Fig. 129.



of the appearance of the eye. At the time of the sketch the patient was sitting and looking directly at the draughtsman, who was on the same level.

I doubt not, but that this man might have been relieved by removing some of the integuments of the forehead.

Some foreign surgeons regard mere looseness or relaxation of the skin as a cause of ptosis; but it is not easy to see how that can have any influence, unless increased weight be added to relaxation. Undue ponderance in any of the tissues of the eyelid will affect its movements.

PTOSIS FROM ERYSIPELAS AND INFLAMMATION OF THE CONJUNCTIVA.

Ptosis, in a slight degree, may ensue, after the eyelid has been severely inflamed from erysipelas, or from chronic inflammation of the conjunctiva, in the so-called chronic ophthalmia with granular eyelid. It has never occurred to me, to see the affection sufficiently marked, to induce me to recommend an operation.

PTOSIS FROM MECHANICAL INJURY TO THE EYELID.

This scarcely comes under consideration here, but should rather be classed with wounds and injuries to the eyelids. A case in point is there given.

SIMULATED PTOSIS.

Ptosis is simulated when the eyeball is a little less in size than its fellow from congenital defect, or from atrophy consequent on disease, so that the eyelid droops. An operation will materially improve the personal appearance in such cases, by raising the eyelid and exposing more of the globe of the eye. A young patient of mine availed herself of this. The eyeball was congenitally small, and the narrow aperture of the eyelids gave the usual disagreeable appearance.

SUPPLEMENTARY OPERATIONS.

In a few cases of ptosis, I have found it necessary to add a supplemental operation to that above described; for, although I had removed sufficient skin to affect the greater part of the eyelid, the inner angle yet drooped. The removal of more integument in an oblique direction over the drooping spot, has been effectual.

Two other operations have been suggested for ptosis, and practised, but, as I believe, without benefit. The one is to dissect up the palpebral end of the levator palpebræ, and attach it to a spot in advance. The other is to divide the skin of the eyelid along the entire width, close to the tarsal margin, to separate the edges of the wound, to remove a considerable portion of the fibres of the orbicularis, and to close the wound by sutures.

CHAPTER XVIII.

STRABISMUS, OR SQUINT.

DEFINITION—PERIOD AT WHICH IT OCCURS—INTERNAL SQUINT—CAUSES—MORBID ANATOMY—VARIETIES—STATE OF VISION—TREATMENT—RESULTS—EXTERNAL SQUINT—PATHOLOGY VARIETIES—CAUSES—TREATMENT—DEFECTS.

Fig. 130.

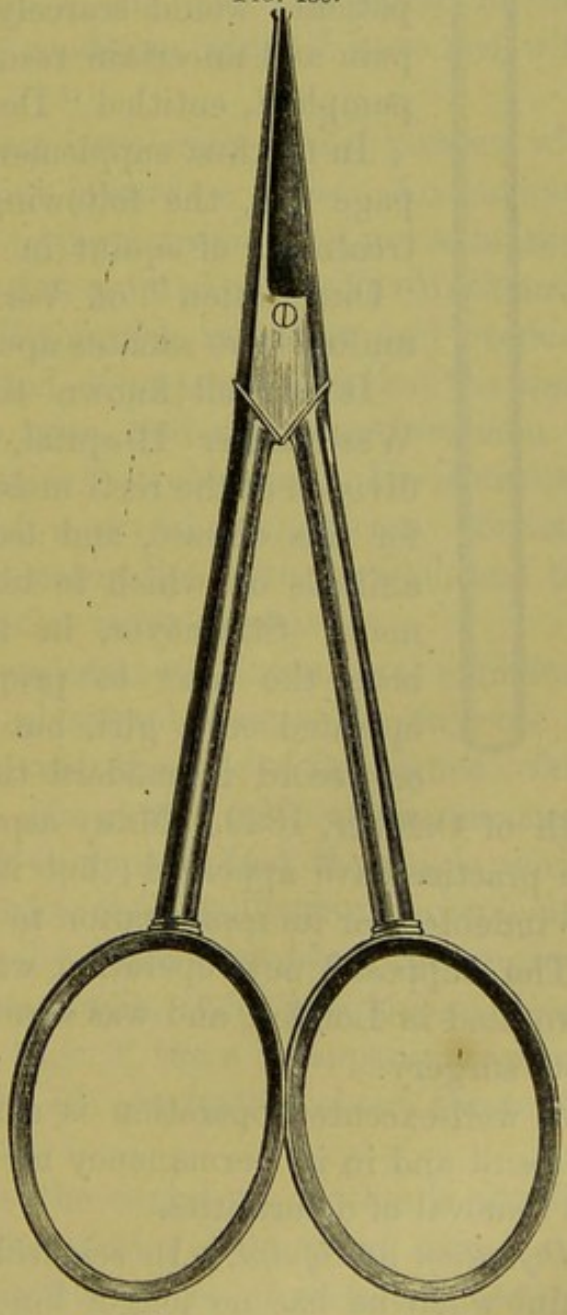

Scissors. The obtuseness of the points of the scissors here figured effectually prevents injury being done to the eyeball, while it does not interfere in any degree with their cutting powers.

Large bows facilitate the use of the instrument, by allowing it to be held easily, and in a line with the fingers; and short handles ensure greater steadiness in directing it.

All kinds of curved scissors are unsuited to the operation.

Blunt Hook. Fig. 131. The curvature ought not to be greater than will allow of the ready passage of the instrument under the muscle, while it should be sufficient to enable it to be used as a hook. The point should be round and smooth. A bulbous end is objectionable.

It is more than a hundred years ago since our countryman Taylor, an itinerant oculist, operated for squint. In the

Mercury of France for June 1737, there is the following announcement:—"Dr. Taylor, oculist to the King of Great Britain, has just arrived at Paris, at the London Hotel, rue Dauphiné, where he proposes remaining till the beginning of July, after which he will leave for Spain. He requests us to publish the discoveries he has made, of straightening squinting eyes by slight and almost painless operation, and without fear of accident."

Fig. 131.



It was suspected that he operated only on the inferior oblique muscle; but, being a charlatan, he kept his secret, miracle as it was called, to himself, and it is most probable that the lateral recti were divided. Heurmann, who wrote at Leipsic, in 1756, on the newest surgical operations, criticises Taylor's practice, declaring that it was attended with only temporary benefit, and that patients would scarcely submit to it, on account of the pain and uncertain results. In 1738, Taylor published a pamphlet, entitled "De Verâ Causâ Strabismi."

In the first supplement of the "Annales d'Oculistique," page 258, the following sentence occurs relative to the treatment of squint in England by an operation, in the "Dissertation" of Verkeyden, 1767: "Strabones, permultos ferro sanatos apud Anglicos vidi."

It is well known that Mr. Anthony White, of the Westminster Hospital, suggested, forty years ago, the division of the recti muscles, as an eligible surgical process for this disease, and looked out diligently for squinting animals on which to test his theory, before operating on man. Stromeyer, in the year 1838, appears to have been the next to propose it; and Pauli, of Landau, operated on a girl, but failed. The first successful case on record in modern times was by Dieffenbach, on the 26th of October, 1839. Many aspirants for the honour of reviving the practice have appeared; but it is universally conceded that we are indebted for its resuscitation to Dieffenbach.

The supposed new operation was quickly adopted and zealously advocated in London, and was soon recognised as belonging to legitimate surgery.

A well-executed operation is singularly successful, surpassing in its result and in its permanency most of those which are practised for the removal of deformities.

Definition of Squint. In scientific terms, a person may be said to squint when he has no longer binocular vision, that is, when from

lateral malposition of one or both eyeballs his visual lines, or axes, do not meet at a fixed point; and when, therefore, the yellow spots of the retinæ receive the images of different objects. The visual axes may be described as imaginary lines passing from the yellow spots through the optical centres of the eyeballs. There is over-balancing, exercised temporarily or permanently, of one of the muscles of the eye in the associated movements of the eyeballs, in consequence of which, the axes are not directed at the same time to any one point in the visual field, but deviate in a certain direction, and according to the loss of such balance, in a uniform angle. It is, therefore, a moveable distortion of the eyeball or eyeballs.

To reduce it to simpler and shorter language, one may say that there is squint, where the two eyes cannot be simultaneously directed to an object.

But this definition is not absolutely comprehensive, as it does not include a squint when there is only one eye, the other having collapsed from injury or disease, a condition which I have met with as internal squint several times.

Apparent Squint. Every one must have noticed that persons who are very near-sighted seem to squint inwards a little. An outward deviation is sometimes met with in hypermetropic eyes, not so marked in its kind as the other. This was first pointed out by Dr. Mackenzie, who showed that we require to distinguish inversion and eversion from mutual convergence and mutual divergence, and that the want of parallelism in the axes of the eyes, and not mere inversion or eversion, is the essential characteristic of strabismus. He illustrates this by a case which was submitted to a careful examination. Strictly speaking, however, the eyes are not naturally quite parallel, and the anatomical arrangement of the muscles is for divergence.

The conditions on which these appearances depend, are explained by Donders as being caused by an abnormal increase or decrease in the angle formed by the visual axis with the axis of the cornea, while the axes of both eyes correspond. He gives a table of the measurements in a normal eye, from which it appears that the angle varies from 3°, 5 to 7°; also a table of calculated results from myopic and hypermetropic subjects. It seems by these that when the angle is beyond 7°, as it often is in hypermetropia, there is apparent divergent squint, and when much less than 3° there is apparent convergent squint. It is necessary to give his conclusions about the centre of motion, with his diagrams:

1st. That in the emmetropic eye the centre of motion is situated at a considerable distance behind the middle of the visual axis.

2nd. That in myopic individuals the centre of motion is situated

more deeply in the eye, but also farther from the posterior surface, and indeed so that in the eyes of such persons the relation between the parts of the visual axis situated before and behind the centre of motion is nearly the same as in the emmetropic eye.

3rd. That in hypermetropic eyes the centre of motion is situated not so deeply, but relatively very much closer to the posterior surface of the eye.

The subjoined figures, Fig. 132 representing an emmetropic eye, Fig. 133 a myopic, and Fig. 134 a hypermetropic eye, are intended to illustrate the meaning of that angle, and at the same time the position of the centre of motion *d*. All are seen in horizontal sections carried through the optic nerve *n*. I is therefore the innermost, E the outer-

Fig. 132.

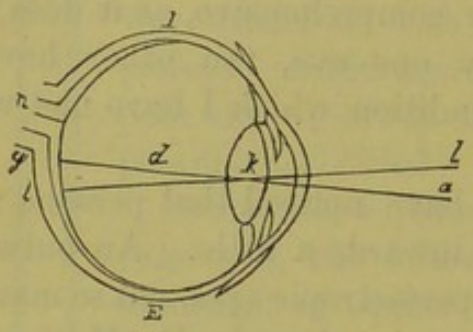

Fig. 133.

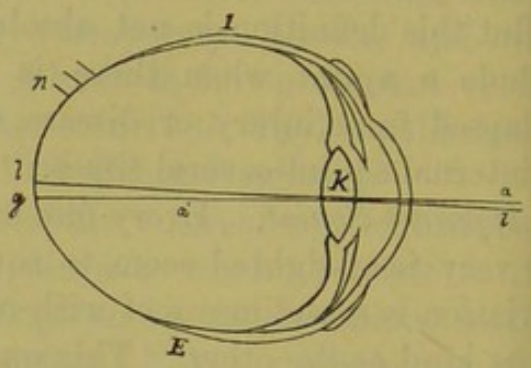

Fig. 134.

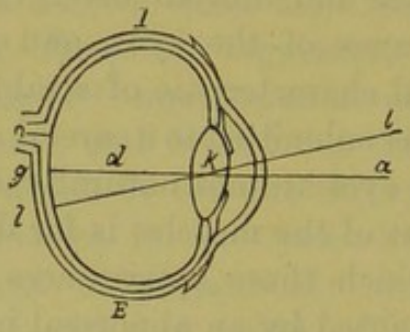

most part of the eye. The axis of the cornea, *g a*, cuts the cornea in the middle; to this, in fact, the apex of the ellipsoid of the cornea corresponds. Now this axis is by no means directed to the object looked at, which, as such, has its image in the fovea centralis of the yellow spot *l*. A line drawn from the retinal image of the fovea centralis towards the object is the visual line *l l*, and this may be considered to cut the axis of the cornea in the united nodal point K. The angle, *l* K *a*, is therefore the angle between the axis of the cornea and the visual line in the horizontal plane. In the vertical plane this is usually much less, and has no special bearing on our present subject. Now, it appears that in the emmetropic eye the visual line cuts the cornea to the inside of its axis. Hence, it follows, Donders concludes, that in

looking at distant objects while the visual lines are parallel, the axes of the cornea in emmetropic individuals diverge about 10° more in those who are hypermetropic, but less in myopic persons, in which last they may even converge. This gives, considering the position of the eye in emmetropic subjects to be normal, in hypermetropics apparent strabismus divergens, in myopics apparent strabismus convergens.

There is an apparent squint of another kind, in persons who have one eyeball much larger than the other, so that the palpebral aperture is much wider on the one side, and the one cornea therefore much farther from the middle line, than the other.

True squint is, then, a deviation of the visual axes. The axis of the one eye being directed to the object desired to be seen, while that of the other is turned too much inwards, internal squint, or outwards, external squint.

Degree of Squint. This varies very much, from a slight deviation of the natural position of the eyeball, to the most marked inversion or eversion. There is no direct practical advantage to be obtained from a knowledge of the degree of the squint, although this is asserted by some, because the operation for the removal of the squint is not regulated by the amount of the deformity. Several methods have been devised for taking the measurement. A very handy one is by the strabisometer of the late Mr. Z. Laurence. The instrument is a little gauge, made in ivory, and curved like the lower eyelid, having a graduated border with lines and half lines. To use it, the centre is placed at the margin of the lower eyelid, exactly where the centre of the cornea should be, this being judged of by the healthy eye while looking at a distant object, and the measurements of the inversion of the eyeball or the eversion are then taken. There is an instrument by Meyer, which is still more accurate, but it is complicated.

The simplest and readiest manner of effecting the measurement without an instrument is done in this way. The patient looks at an object twenty inches distant. A dot is then made at the margin of the lower eyelid of the squinting eye, just under the centre of the pupil. The healthy eye is then covered, while the squinting eye is used. A second dot is now made on the same eyelid, just under the pupil, in its altered position. The distance between the two dots indicates the degree of strabismus, which is spoken of accordingly as two, three, four, or six lines, &c. It is also called the primary angle of deviation. The term secondary angle is applied to the deviation which takes place in the second eye, which is supposed to be sound, when the distorted eye is directed forwards.

Methods have been devised for taking the measurement by angles, but it is unnecessary to describe them, as they are merely ingenious and difficult scientific refinements, more for the amusement of the inventors than for use in practice.

But the measuring of a squint is open to fallacy, because the angle of deviation may occur voluntarily, just as a person may squint with normal eyes, and a squinting person often makes use of such power. This applies to internal as well as external squint.

The period of life at which squint occurs. From early infancy the eyes may lose their parallelism and turn inwards. As all new-born babies have a somewhat squinting appearance, it is not always easy to say whether squint really does or does not exist till the infant gets sufficient intelligence to clutch at objects. I am myself quite satisfied that squint has existed in several children who have been brought to me within the month, and therefore it is not unreasonable to suppose that the statements of the mothers, to the effect that the squints were observed a few days after birth, were correct. There is no reason at all why squint should not be congenital, since there is congenital club foot, and other congenital muscular contractions. The age, however, at which the deformity generally appears is between the fifth and ninth years. It rarely occurs as late as the eighteenth year.

Paralytic squint forms an exception, and generally comes on after childhood, and not infrequently in adult age.

Ophthalmoscopic changes observed in squinting eyes. Congenital anomalies are found in one or both eyes; but there is no constant and invariable appearance, which may be taken as pathognomonic. The margin of the optic disk is sometimes ill-defined, and more highly vascular on the inner side, so that in this direction the disk appears shaded off into the rest of the fundus. Sometimes there is an irregularity in the outline of the disk, with a morbid deposit of pigment at one spot. Perhaps the most common appearance is hyperæmia of the whole fundus of the eyeball, or of a part of the optic disk. This may be due to a very chronic choroiditis. When hypermetropia exists, the well-known refraction of this state of the eye is at once apparent.

INTERNAL SQUINT.

This is the more common form of the two recognised varieties.

Causes. First, remote or indirect, or exciting causes. In most of these vision is interfered with.

Hypermetropia. In many cases this optical defect exists. The very frequent association of abnormal sight with squint had been recognised long ago by many surgeons. Within the last few years this connection has been put forth prominently by Donders, whose opinions I shall freely give. In general, says this observer, it is not the highest degree of hypermetropia with which strabismus is combined. Often, at least in young persons, the hypermetropia is completely latent. It is involuntarily neutralized by tension of the power of accommodation, and is first recognised on artificial paralysis of the accommodation, by the use of atropia.

Two of Donders's colleagues examined sixty-two cases of convergent concomitant squint, and found hypermetropia in twenty-nine. Donders readily accepted this result, because he considered that they had detected only manifest, not latent hypermetropia. He himself had not been able directly to establish manifest hypermetropia in much more than fifty per cent. of his cases. He goes on to remark, the hypermetropic individual, to see distinctly, must accommodate comparatively strongly. This holds good for all distances. Even in looking at remote objects, he must endeavour to overcome his hypermetropia by tension of accommodation, and in proportion as the object draws near, he must still add as much accommodation as the normal eye would need. The vision of near objects, therefore, especially requires extraordinary tension. There exists a certain connection between accommodation and convergence of the visual lines. The more strong the convergence, the more powerfully is the faculty of accommodation brought into action. A certain tendency to increased convergence, so soon as a person wishes to put his power of accommodation upon the stretch, is therefore unavoidable. This tendency exists in every hypermetropic person. An emmetropic person also may convince himself of this by holding negative glasses before his eyes, and thus bringing the eyes temporarily into a condition of hypermetropia. He will distinctly remark that on endeavouring to see accurately, double images every time threaten to appear as the result of increased convergence, and that he soon has a choice only between indistinct vision and squint. Probably this conflict exists unconsciously in all hypermetropic persons.

As hypermetropia is a very common defect, even more so in some races of men than myopia, and many thousand cases exist for each one of squint, the idea at once occurs how is it if the two stand so much in the relation of cause and effect, that squinting bears so small a proportion to the faulty refraction? Donders offers an

In general the necessity of seeing an object single with both eyes together is deeply felt. The direction of the visual lines is thereby forcibly determined. If a weak prismatic lens, with the refracting edge turned inwards, be brought before one of the eyes, the object looked at is directly seen double, but increased convergence is immediately involuntarily produced, which makes the double images coalesce, and if in a few moments the lens is turned, double images immediately reappear, which, however, rapidly disappear in consequence of lessening the convergence. This abhorrence of double images, or rather the instinctive adherence to binocular vision, preserves most hypermetropic individuals from strabismus. They sacrifice the advantages of seeing accurately, rather than that objects should form their images on the two yellow spots. In this, therefore, is found the reason why most hypermetropic persons do not squint. If one eye be covered with the hand, while it, as well as the other, is open, the visual line will, in most hypermetropics, rapidly deviate inwards. The same thing takes place when an emmetropic person holds a negative lens before the uncovered eye.

Donders next reviews the circumstances which must co-operate to give rise to squint in hypermetropic persons, and concludes that they are those which diminish the value of binocular vision, and those which render the convergence easier.

To the first, as the chief cause, he assigns congenital deficiency in the accuracy of vision, or in the refractive condition of the eyes, and to the latter of which he considers due, in part, to astigmatism, in part to a still unknown imperfection of the retina, and supplies this theory: If the diminished accuracy of vision affects only one eye, then, on too great convergence, the image of this eye will not so much disturb vision. The same is the case when the degree of hypermetropia in the deviating eye is greater, and the image in this eye is, therefore, less accurate. In either case, consequently, strabismus will more easily arise. But the tendency doubly increases when both circumstances, a higher degree of hypermetropia and diminished accuracy of vision, as is often the case, occur combined in the same eye. If the eye has long deviated, there arises a secondary diminution of the accuracy of vision, as a result of strabismus.

As an accessory cause, he ascribes spots on the cornea. He does not admit that these in themselves can be capable of exciting strabismus, because although the image of the affected eye is less perfect, experience shows that even then the preference is given to binocular vision. He says it is quite a different question whether, where hypermetropia exists, specks on the cornea and other obscurities

might not increase the tendency to strabismus, or whether the less accurate image in the visual axis might not make the image less disturbing, and diminish the abhorrence of an accessory second image. I am quite sure that squint may follow any defect which mechanically interferes with accurate sight even in emmetropic eyes.

To the second cause, those which render convergence easier, and, as such, would promote the squint, he assigns:

First, peculiar structure or innervation of the muscles, easy mobility of the eyeball inwards. All that follows in support of this appears to me to be purely hypothetical.

Secondly, relation between the visual line and the axis of the cornea. The arguments here may be thus summed up: That as hypermetropic persons in general are obliged to make more than ordinary divergence of the visual axes, to give a parallel direction to the visual lines, it is natural to assume, that when for single vision more than ordinary divergence of the corneal or visual axes is required, the divergence may easily be insufficient, and that, accordingly, as a matter of course, for seeing at a shorter distance there may readily be too great convergence.

It certainly seems to me that although Donders in his writings, at first, gives such a prominent place to hypermetropia as the cause of squint, the qualifications which are subsequently introduced tend much to reduce its validity. The following paragraph bears this out: "Everything seems to indicate that the hypermetropic eye must be considered as an incompletely developed organ, and this not only from its structure, but also from the very imperfect manner in which it performs its functions. It appears to me from my examination of cases, as well as from the history, that when the distortion arises from any peculiarity of vision the spoiling of the sight is due more to some defect in the retina, or in the optic tract, congenital or acquired, than to mere hypermetropia."

One of his early remarks about squint is that it is merely a symptom, depending on very different conditions, and, as such, connected with different phenomena; but he writes besides, in another place, since in strabismus convergens hypermetropia in general exists, no other connection is conceivable than that hypermetropia is the cause of the deviation." "Hypermetropia," he adds, "is, indeed, the primary anomaly; strabismus is a secondary condition, which does not arise until some years after birth."

Might it not be said, as an answer to this, that the defective sight which he admits to be common, and to arise from congenital causes or otherwise, frequently exists before the strabismus, and when so exist-

In vain have I been looking for squint with hypermetropia only, that form of faulty refraction with good power of accommodation, in which the application of lenses will enable the squinter to see minute and distant bodies.

I find, as a rule, that where hypermetropia is present with squint, loss of acuteness of vision is more frequently associated with it than not. I am, therefore, disposed to attribute the deformity more to the impairment of sight than to the hypermetropia. I suspect that hypermetropia is seldom absent when there is any other visual congenital defect.

Where, in periodic squint, with hypermetropia, some loss of acuteness of vision occurs, a convex lens enables the eye to right itself. I consider that such a result is as much due to increase of the visual angle and enlargement of the object, as to the hypermetropia being neutralized.

Anything which interferes with binocular vision may produce squint, and the more likely is the deformity to occur, the greater the disturbance. On the other hand, any kind of defective sight may exist in the one eye, with hypermetropia, without squint ensuing.

A few more words will conclude this part of the subject. Donders, in continuing his investigation of the hypermetropic influence in producing squint, reiterates the statement that in the highest degree of hypermetropia squint is rarely observed, and he accounts for it by saying that in such cases the power of accommodation is, even under abnormally increased convergence, not sufficient to produce accurate images, and such hypermetropics are thus led rather to the practice of forming correct ideas from imperfect retinal images than, by a maximum of tension, of improving the retinal images as much as possible. I cannot, myself, accept this as satisfactory.

It is difficult to understand, too, notwithstanding the following explanation, how it is that the hypermetropia, which is so often completely latent, can exercise the evil influence attributed to it. That in the main degrees of the defect, the facultative and relative, the eye can adapt itself for parallel, and even for diverging rays, and can, moreover, maintain this accommodation for some time, yet often only with convergence of the visual lines to a point, situated closer to the eye than the point whence the rays proceed. That the minimum of hypermetropia, at which strabismus occurs, depends undoubtedly on the angle between the visual line and the axis of the cornea, and on the range of accommodation; the less the latter, and the greater the angle is, the less degree of hypermetropia will be sufficient for the production of the squint. Diminished energy, or paresis of accommo-

connected with the increase of years, are said to be little liable to produce the deformity.

In order to avoid any injustice to the great observer of Utrecht, who has done so much in the way of increasing our knowledge of the optical defects, I beg to refer those who wish to go more minutely into the hypermetropic question, to his own writings.

Inflammatory Affections. Ophthalmia, that is surface inflammation, which produces no corneal opacity, has been the cause of as many as fourteen cases of squinting, out of two hundred examples of the disease taken promiscuously. This kind of inflammatory origin of squint, with or without any lasting damage to the eyeball, has been much overlooked. It is likely here, that the squint occurs in two ways. First, from disuse of the eye in consequence of vision being temporarily interfered with, and secondly, in consequence of inflammatory action of the subconjunctival tissue, and of the internal rectus muscle. The latter state finds a parallel in other parts of the body. The inflammatory action of a surface abscess, or of the skin from wounds and injuries, often involves the subcutaneous tissue and the muscles, and produces muscular contraction. It is common when operating, to find the conjunctival and sub-conjunctival tissue, and the edge of the ocular tunic, thickened and contracted, and preternaturally attached to the eyeball.

Derangement of the visual apparatus, comprising opacities of the cornea, opacity of the lens, opacities in the vitreous humour, as well as any disease of the eye within, of an idiopathic nature, or of traumatic origin, or without, by which vision is impaired or destroyed, will cause squint. That such distortion is not very infrequent after opacity of the centre of the cornea from strumous corneitis, or from opacity following a mechanical injury, the prick of a thorn, the wound from a needle, the burning from metals, is a fact which is too common to escape notice, and that it occurs without any hypermetropia I have fully satisfied myself.

The occurrence of cataract, from any cause, is very apt, during childhood, to produce internal squint.

Closure of the pupil, in consequence of prolapse of the axis through a corneal ulcer, or through a wound, by which vision is nearly or completely destroyed, is a common cause.

Damage to the interior of the eye, from idiopathic inflammation, or from changes consequent on traumatic injury, whereby vision is more or less injured, may cause the inversion.

Paralysis of the Abductor Muscle. This is a more common cause than would be supposed.

the appendages, which render the natural movements of the eyeball painful. Dr. Mackenzie was consulted by the friends of a little boy, who became affected with squint immediately after squirting the oily juice of a piece of orange skin into his eye.

A man admitted into St. Mary's Hospital, under my care, who had been shot in the neck and face and head by small shot, and was struck on the eyeball by a shot, which did not penetrate. Much surface inflammation ensued, with pain. Internal squint was established in four days.

Causes not interfering with vision. It is supposed by some that squint may arise from imitation. This seems to me to be most unlikely. I could never discover, from inquiry, that any child or adult ever systematically or even repeatedly practised squinting in the way of imitation. Merely looking at a distorted eye does not cause the beholder to turn his eye inwards or outwards. My own belief is against such a cause. I am also inclined to reject the statements that looking at a scar on the nose, or on the cheek, or looking sideways, can have anything to do with squint. This opinion I have expressed years ago. Donders comes to the same conclusion, so far as the normal eye is concerned, but he thinks that in the hypermetropic eye such influences might operate, for under these circumstances the fixed point can be seen only by one eye, since the field of vision of the other is limited by the nose, and if only the one eye sees the object, the second eye wants the guide which directs its movements, and there is nothing to prevent too strong convergence for the sake of distinct vision, and in this manner the internal muscles of the eye might acquire a preponderance, which would promote the development of strabismus.

Lesion of the brain, or of the ocular nerves. Many children have squinted after a violent fit of passion. A child has squinted for months after a violent fit of crying. A little boy awoke in the night on board a steamboat, and was greatly alarmed; a squint was quickly developed. In another boy the affection appeared in consequence of bathing him in the sea, notwithstanding violent screams and other expressions of terror.

The irritation arising from intestinal worms, and from teething, has unquestionably produced squinting.

I may add that the muscles of the orbit are liable to be palsied by any of the causes which in general produce paralysis, having their origin in the brain.

Besides any primary disease in the trunk of a nerve, whereby paralysis is induced, a nerve may have its function spoiled by the invasion of disease from a neighbouring part, especially the bones.

The several diseases of the brain to which squinting has been indisputably traced are: Inflammation, ramollissement, apoplexy, epilepsy, hydroceplalus, and scrofulous tubercles.

Squinting is not uncommon in that diseased condition of the brain generally having its origin in infantile diseases, from which there is a marked want of co-ordination of the actions of the muscles. It coexists generally with deformities of the extremities. It frequently exists with talipes, congenital and acquired.

Diseases within or without the orbit, which damage the function of the external rectus muscle directly or indirectly, by hurting the motor nerve. Tumours, inflammations, traumatic or specific, abscess, neuralgia, all these are capable of doing the damage.

Causes continued. Secondly, direct, essential, proximate, or immediate causes. In non-paralytic squint, these are due to faulty muscular action, excessive action of the internal rectus muscle, and sometimes, perhaps, of some of the other ocular muscles.

That in general the squint depends on no structural change of the internal rectus in the first instance, is evident by the motions which the squinting eye performs with its fellow, and the free and natural movements of which it is often capable under full volition, when the other eye is closed. This shows also that there is not, necessarily, any paralytic state of the external rectus muscle. Congenital deficiency in the development of this muscle may sometimes occur, but this is a separate cause, and has nothing to do with the question.

But there must, of necessity, be some functional change, some shortening, at first dynamically, afterwards, at a varying period, organic shortening, with or without hypertrophy, according to the age of the squint. These changes, which are, of course, not visible in life, are well understood by analogous alterations in muscles in other parts of the body, of which it would be useless to give instances.

It is during the operation for squint that the chief opportunities are met with for observing the state of the affected muscle.

So often do I meet with changes in length and volume that I always expect it, except in very recent squint. The last case on which I operated, the muscle was so short that there was difficulty in passing the hook under it. The tendon was so thick, and so firmly attached to the sclerotica, that some nicety was required to divide it without damaging this coat of the eye. It was unnaturally vascular, and a central blood-vessel bled freely. This high vascularity is an unusual event. Many operators, whose opinions are thoroughly trustworthy, have recorded alterations in the bulk of the muscle.

Morbid Anatomy. From what has been made out by actual dissection, and during operations, it appears that several changes may take place in the recti muscles. I will mention some of them.

In paralytic cases, passive contraction of the healthy muscle, in consequence of paralysis of its antagonist, and after a time hypertrophy. At a still later period there may follow structural shortening and thickening of the contracted muscle, with degeneration of its tissue. Even complete atrophy and shortening may be grafted in this last change.

In the non-paralytic cases there may be simple hypertrophy, the antagonist being healthy.

It may be fairly assumed that in all cases of non-paralytic permanent strabismus of long standing there is some shortening of the muscle in the direction towards which the eye is drawn. Before the internal rectus is divided, the eye can seldom be everted to the natural degree, although it can be properly turned out afterwards. It would be useless to give other evidence respecting the contraction. The fact of an operation on the internal rectus setting the eye straight, and restoring the harmonious action between the eyes, is full evidence that the phenomenon of internal squinting is due to muscular shortening, and not to any defect in the co-ordinating functions of the brain.

In some dissections not the least morbid alterations in the muscular tissue have been discovered with the naked eye.

Enough has been said, without treating the subject statistically, to draw the attention of the student sufficiently to the pathology of the affection, to the prominent facts, and to teach him to investigate for himself. It remains only to be mentioned that while certain conditions, which are here called causes, for the most part objective, are followed by squint, deformity is not a necessary consequence of them, as they may exist for years without such association. Also, that squint may arise in an eye that seems healthy in all other respects, there being no apparent cause.

Varieties. The forms under which internal squint occurs, including the degrees of distortion, and the restriction of motion, and the implication of one eye, or of both. It is of the first importance in learning the characteristics of squint, to be able to recognise the difference between the distortion, and the varying mobility of the eyeball. The result from treatment depends on these states. The distortion is as nothing if the movements be free, for the prospect of remedy is good. With slight distortion, with much impairment of mobility, a case is scarcely remediable. Loss of mobility is generally due to paralysis.

Whether the one eye be affected, or both, is another important thing to be ascertained.

Classification. In the following division five varieties are recognised. Such arrangement affords an easy analysis, and facilitates description. But it must be borne in mind that it is only an artificial division, and, like all arbitrary tabling of disease, is necessarily imperfect, as only the more marked examples, among even which there are exceptions, can be classified, and that the gradations must be left out. Besides, the classification, excepting that of paralytic squint, is founded more on differences in degree than on differences of pathological origin.

The first form is the paralytic or fixed squint, arising from more or less paralysis of the external rectus, generally of the one eye, exceptionally of the two. There are degrees of this fixedness. I mean there is more or less power of straightening the eye under strong volition. There may be almost total absence of outward movement, while the inversion is excessive, the greater part of the cornea being hidden; or the lateral movement may be but partially restricted.

Except in rare instances, where an orbital tumour interferes, or the squint is manifestly due to direct mechanical injury or lesion of the external rectus muscle, paralysis of the sixth nerve in some degree is the cause. Paralytic seizures, and marked cerebral derangements, are sometimes associated.

A correct diagnosis of paralytic squint is very essential, because it is the only form of squint in which recovery may be expected from general treatment, and it is that in which, in marked cases, the least improvement is to be got by operating. It rarely occurs till after youth is passed.

The history of the case should be carefully ascertained, and other paralytic conditions sought for, cerebral functions examined, any disturbance in this quarter, even that of headache, noted, and the general health inquired into. I have met with it in cranial affections, and in association with paralysis of several of the cerebral nerves. A syphilitic origin is not uncommon. In the absence of any collateral general symptoms to verify diagnosis, the movements of the squinting eye must be carefully scrutinised. The loss of abducting power is the chief guide. If the patient can evert the eye to the fullest extent there is no paralysis. A student should learn how far a healthy eyeball can be abducted.

An examination should be conducted in this manner. While the patient stands with his head straight and steady, the examiner takes up his position six or eight feet off in the same line, holds up his

finger to the level of his head, and tells the patient to look at it, and then to follow it with his eyes, while he moves it from side to side through a long range. The examination is made more complete by testing the abducting power of the eyes at a close range. By this method, the state of the disassociated movements is at once ascertained, and if the squint be single, the faulty eye is quickly detected. The patient is then directed to cover the sound eye with the hand of the same side, and to look at the examiner's finger, which is moved outwards, to ascertain the power of the lateral movements of the eyeball. The other eye should be tested in the same way for comparison.

In all the examinations made to detect the squinting eye the patient's head should be quite straight, because squinting patients sometimes acquire the knack of twisting the head a little to overcome any optical defects, and this brings the eyes into a somewhat more correct position, and may be the means of a slight squint being overlooked.

In complete paralysis of the external rectus the eyeball cannot be moved outwards to any extent. In partial paralysis there is an amount of abduction, which is in proportion to the remaining power of the muscle. When the paralysis is very marked, but yet incomplete, abduction is never effected in a strictly horizontal direction, but oscillates a little up and down, which movements are, no doubt, produced by the alternating actions of the oblique muscles.

In very slight paralysis, abduction may be but slightly interfered with.

Now, as experience in operations show that the power of eversion is sometimes partially lost through contraction of the internal rectus, it may be, and often is, impossible to tell in some cases whether we have before us or not paralytic squint. It has been supposed that the primary angle of the squint is always less than the secondary. This is not peculiar to the paralytic state. These difficulties show the value attaching to the history of a case. But in complete paralysis a mistake cannot occur, as no mere contraction of the internal rectus ever fixes the eyeball in motionless inversion.

Paralytic squint may be double as well as single.

The second form is that of intermittent single squint. The distortion may be only occasional and transient, and more marked on some days than others. Sometimes the squint exists only when a near object is looked at. The ocular movements are perfect in every direction, and under strong will the eye can be placed parallel with its fellow.

This is the so-called periodic squint, and some surgeons speak of it

as simple strabismus, because it is always the same eye that deviates. As it almost invariably ends in permanent squint, it must be regarded as one of the modes in which ordinary squint begins. We are seldom consulted in this early stage of it, but rather when there is more determinate deformity.

In the third form, the squint is readily detected as ordinarily settled in the one eye, but when from strong will or any other circumstances, that eye is straightened, then the other eye turns in. In a strict sense both eyes squint, and the squint is functionally double, while it may be said to be structurally single: one internal rectus only being contracted. The question, then, is to discover which is the truly faulty eye. As a rule, the state of the vision will materially assist in the diagnosis, for nearly always, more or less, defective sight exists in the squinting eye. Whenever there is unusual visual form, the better-seeing one is always used in preference to the other. But there are exceptions; besides, there may be such very slight difference in vision in an early squint, that a mistake may occur if the sight be solely relied on, particularly in children; therefore, I never neglect a test which I have employed and relied on for many years. In the "Medical Times and Gazette" for October, 1856, I published the particulars of a case on which I had operated, with remarks, showing that the squinting eye may be the better seeing of the two. Since then, and as my attention has been directed to the point, I have met with many examples, several of which I have pointed out to my colleagues and to my pupils. This is my test. I place the patient in front of me, at the distance of four or five yards, or farther; tell him to cover one eye, say the left, to look at me with the other, and to keep his head straight. The right eye will then be in the centre of the orbit. I direct him to uncover the left. Now, if the right, which has been open, be normal, or only functionally affected, it will keep its central position, while the left is turned inwards; but if it be deformed it will turn in, while the left will become straight. The experiment should be reversed. In the case of a child, I place an adult behind, and make him cover and uncover the eyes as required.

When there is any doubt, the patient's attention should be diverted from a fixed gaze, and volition be interrupted, by causing him to wink a few times. He should also be made to close the eyes for a few seconds, then to open them, and quickly to look at an object. Cases are met with in which the greatest nicety is required to detect the faulty eye. Some are even scarcely embraced in the test. Here the primary and secondary angles of deviation are alike.

I venture this explanation of the matter. The eye which may be called sound, in which there is no individual loss of antagonistic force among its muscles, is actually affected, as I believe, through the influence of the associated movements of the lateral recti, and partakes of the greater amount of volition which is required for the play of the muscles of the deformed eye. For, instance, the right eye squints. To look to the right with this eye, much greater volition is needed, and more muscular power is called into action, than if it did not squint; and such extra-exercise of power is, by the associated movements of the eyes, transferred or directed to the associate muscles of the left eye, and especially to its internal rectus, thereby overmatching the antagonising muscles, and turning it unduly inwards. To avoid intricacy and minute detail, the actions of the lateral recti alone are taken into consideration, although the other orbital muscles are more or less involved.

It might with sufficient plausibility be assumed that the exaggerated associated action of the internal rectus of the sound eye, or that functionally affected only, will in time pass into a new and independent sphere of contraction, whereby it is rendered an undue antagonist for the external muscle, causing in fact a confirmed squint. Indeed, I am sure this often happens; and that one squint thus produces another. But I am also aware that exceptions are met with. I have operated on patients who have squinted in one eye for years, in whose squinting eyes were those conditions favourable for the implication of the other eye; namely, full abducting power under strong volition and good sight in them, enabling them to be used sometimes somewhat freely, and consequently the internal recti of the other eye to be unduly acted on, and yet the second eye has escaped confirmed deformity.

The fourth form is the most common of all, one eye being always inverted, yet not always the same eye. The squint seems to pass from the one to the other, alternating rapidly, so that either might, for a time, be regarded as that only affected. The alternative too, takes place spontaneously, and as it were accidentally; hence this form has been called alternating squint. It is described by some authors as double or concurrent squint, by others as single. The position of the eye is regulated by the object looked at, and is subservient to its exercise of vision; the position of the other is regulated by the associated movements between the eyes, and depends no more on vision than does the position of a blind eye, in a person whose eyes are parallel.

It may happen that one eye always squints when a near object is looked at, and the other always when a distant one is regarded.

Again, when an object is looked at within a certain range, one and the same eye only may squint.

A very careful examination shows that the primary and secondary angles do not generally quite correspond, although to a casual observer there seems to be no difference. When my test is applied, it is often discovered that the one eye differs in its movements from the other, being more adducted, and having a greater tendency to remain distorted. Vision may be unaffected, or there may be but very little disparity. The exceptions are infrequent. Although I am convinced that this form is only often an advanced stage of the variety last described, I am also sure that it is frequently an original condition.

The fifth and last variety is double squint, both eyes are always more or less mutually inverted, and although there is a disparity in the distortion, the inequality is not persistent; sometimes the adduction is greater on this side, sometimes on that, so there is, even here, a tendency, though a limited one, to alternate. Neither eye is ever perfectly straight when the patient looks at an object directly in front of him. It is very seldom, therefore, that either eye can be fully everted. An attempt to produce eversion of either, is attended by remarkable inversion of the other.

This form is, for the most part, the squint of the adult, and of the aged. It is merely a more advanced stage of the ordinary double squint of early life, that treated of in the last variety. I think it is confirmed double squint.

The above descriptions, imperfect as they may be, will help the student to understand the deformity as it may appear before him, and, at least, they will teach him how to proceed, so as to understand the bearings of a case.

That squint may appear as a single affection, being limited to one eye, and as a double deformity, implicating both eyes, there can be no doubt. Definite and well-marked examples of the two, are distinct and indisputable, if any value rests here in objective symptoms. Besides, the fullest confirmation of this, is to be found in the facts that one operation, that is an operation on one eye, will restore parallelism in some cases, while in others, two are required.

From the nature of the affection, however, and from the manner in which the distorting influence passes from the one eye to the other, it is impossible always to draw the line of demarcation between the two, and to say, from an examination, whether a squint be single, or whether it be double. The difference between single and double squint, as ordinarily understood, is but one of degree. If the mutual convergence be slight, and apparent only during musing, while at

other times there be merely inversion of one eye, single squint is supposed to be present. If, on the contrary, the mutual convergence be very marked and always exist, double squint is supposed to be present.

I will revert, for a moment, to the subject of measuring the angle of a squint. I agree with Stellwag, who tells us that the probable size of the angle of the squint may be measured from the movements which the eye makes in the several experiments which have been described. He shows that the relative position of the vertices of the corneæ affords no trustworthy means of measurement, unless the position of the optic centres, that is, the angle which the visual lines make with the long corneal axis, has been accurately determined. Also, that the neglect of this has induced many mistakes, among which, the acceptation of the existence of an incongruity of the retinæ is prominent.

State of the vision in convergent squint. This subject has been partly considered when discussing the views of Donders respecting the common occurrence of hypermetropia. But it is with sight as affected by squint, with which we are now concerned.

Double vision of squint, or diplopia. This, seeing of two objects instead of one, is a consequence of squint; and it is produced by the image of the object in the distorted eye falling on an eccentric portion of the retina. This second image is always indistinct. It is still more imperfect when there is any defect in the refracting power of the eye, or any retinal disease. I seldom find it absent in recent squint, although it may soon be lost. It is usually persistent when the sight of the two eyes is equally good, or there is but little disparity between them. It is most common and annoying when the squint is slight. Its position is lateral, or horizontal, and it is placed on the side of the squinting eye; that is, if the right eye squint, it is to the right of the object looked at. This is called homonymous. Sometimes it is a little vertical as well, this depending on the position in which the eyeball has been placed by the implication of other muscles. Sometimes it is a little diagonal.

Double squint in the slightest form is not very definite, as the second image overlaps that of the other, so that a kind of halo appears around the object looked at. The greater the angle of deviation, the more will the double images be separated.

A person troubled with double vision in single squint, generally soon learns to neglect the distorted eye, and to employ the other, in order to obtain single vision. At first, this is accomplished chiefly by the position of the head; afterwards by the position of the eyes.

In double squint, when there is no disparity of sight, an individual

is a long time in learning to use the one eye. Whenever this is accomplished, the disused eye gets more convergent, and then the sight of it deteriorates. Several times I have met with squinting patients who have acquired such power over the position of their eyes, that they could at once, according to desire, produce double or single vision. Sometimes, under any condition, the double image does not altogether disappear, but becomes so faint or so wide from the image of the sound eye, that it is practically disregarded. With an extreme angle of deviation, the distorted image is far away from the field of vision of the other eye, and it is dimly seen, because it is projected on the fundus of the eye, away from the least sensitive portion of the retina.

Binocular vision is lost in squint.

The squinting eye is of service in adding to the visual field by lateral quantitative perceptions, provided that the retina be not spoiled.

Strabismic Vision. Apart from the optical effect of double vision, as the result of the eyes being displaced, certain other impairments of sight are produced by the ocular distortion. This has nothing to do with diminished sensibility of the retina from disuse, as has been supposed by some surgeons, because the improvement in sight after the operation for squint is always immediate. It may be mentioned in parenthesis that the retina does not become insensible from disuse. This matter is spoken of more particularly in my chapter on "Cataract."

The strabismic vision is a loss of some of the acuteness of sight, and much of the power of adjusting. It almost invariably attends an old squint, even if the sight have been perfect when the deformity was acquired, and it is always superadded to any existing imperfection of sight, congenital or otherwise. Its exact nature is not understood. It is difficult to investigate it, especially in children. It does not arise from the optic nerve being bent on itself, or because objects are projected on the retina away from the yellow spot, for it is observed as well when the eye is distorted, as when it is straightened by the will of the squinter. The state of vision before an operation cannot be properly tested, except the eye be brought to the centre of the orbit, or nearly so.

Strabismic vision is in all probability due to some interference with the delicate apparatus of adjustment, by an effort to overcome the disturbance of binocular vision, caused by the loss of the balance of antagonism between the recti muscles. Perhaps it is due to pressure.

Such secondary implication of sight very much masks any defect

that may have existed before the eye became disturbed. It invariably gets worse. The field of vision becomes contracted. Hence it is, most probably, more from this than from any previous unhealthiness of the eye, that vision is generally so bad in chronic squint. The long distorted eye is almost always very considerably inferior in sentient power to its fellow.

When both eyes have been inverted for years, vision is frequently very imperfect, and often useless for minute purposes. It may, too, be said in general that the degree of the distortion, and the inferiority of the vision, are proportionate. Not the least peculiarity of this strabismic influence is the fact that, in those cases of single squint in which the squint at times alternates, the vision of the now distorted eye, that in which there is only functional derangement, may become impaired. If there be no visual implication beyond this, the imperfection will disappear when the ocular parallelism is restored by operation. This subject will be concluded when the effects of the operation for squint are discussed.

It is chiefly with reference to the probable condition of the eye after an operation that the impaired sight of squinting concerns us. For our own credit as surgeons, the patient or his friends should be made aware of any degree of imperfection that might exist when we are consulted. The more imperfect the sight when the eye is distorted, the more imperfect will it be when it is straightened. The retina may be so insensible as to be destroyed for useful vision. This is a point which is not difficult to be ascertained. All that is necessary is to close the better eye, and to try the other. The retina may lose its power in part, that is, in spots. The internal portion of it first declines, and next the outer. This fact had been practically ascertained long ago, by carefully noting the condition of the eye during the distorted state, and afterwards when it was righted. Latterly, the information has been often sought by the use of a prism, with its base turned outwards, so as to produce diplopia. It is said that with it can be detected which part of the retina has lost its power. The presence of diplopia would prove that the retina is sensitive; the absence of it that it has lost its power of binocular vision, a very serious loss, because there must be ever an imperfection that cannot be removed, and such eyes, although they may be made straight, are very apt in time to become everted, because volition has no control over them.

This is a subject which admits of much scientific investigation. Among other things for examination are the following:—The state of refraction of the two eyes, the extent of accommodation, the degree of acuteness of vision, the angle of deviation, the field of vision, the

presence, or otherwise, of binocular vision. I cannot myself find that any such knowledge is directly beneficial, beyond giving some indication of what will be the nature and degree of the sight after an operation. So it is, that an examination with the ophthalmoscope is of advantage in a diagnostic point of view. If there be hypermetropia, an approximative idea of its degree can be obtained, and the two eyes can be compared. This is particularly valuable in children, whose vision can rarely be well tested. Then opacities in the vitreous humour, and retinal defects, may thus be discovered.

Many peculiarities that are met with as visual subjective symptoms are yet a mystery. There is disagreement among the best of modern observers respecting them. Some of their theories are supported by supposed congenital mal-position, or unequal development of portions of the retina, or of the optic disk, and reasoned with plausibility.

TREATMENT.

Traumatic Squint. Under this head, I include those cases in which there is direct injury to the one or the other of the lateral recti muscles, or to its motor nerve, and those which are produced in any mechanical manner, as by pressure from tumours, and otherwise. As no short practical classification can be made of these, it cannot be said how far in general they are remediable. Nothing, however, can be done except by operative surgery, and a little familiarity with the theoretical details of squint, will enable a student to tell when such should be applied. As a rule, relief cannot be obtained unless the motor apparatus of the eye can be used.

Paralytic Squint. This is the only form of decidedly confirmed internal squint in which I have seen spontaneous recovery, and the only one in which any benefit can be expected from general treatment, although, of course, a great many cases do not admit of any remedy. To know when to look for a result, and when not to expect it, demands a knowledge of general surgery and medicine by which the causes of the squint can be estimated. The selection of the kind of treatment must be based on the diagnosis of the original brain or nerve lesion.

Paralytic affections of the orbital muscles require a separate consideration in a distinct chapter. It must be understood here, if only for the sake of easy systematic arrangement, that the paralytic squints are confirmed and irremediable, except by an operation. These remarks apply to external squint as well.

A squint, attended with any degree of impaired vision, that is, retinal defect, whether as a cause of the affection, or as an effect

of it, and not being produced by paralysis, is never removed except by practical surgery. I have never met with an exceptional authentic case. Even without any defect in sight, after the persistence of the distortion for a few months, recovery is an exceedingly rare event, an unit in thousands. Squint is the most enduring of all deformities produced by muscular action.

Squint arising out of infantile diseases, is said to be sometimes removed when the diseases are subdued. I cannot speak on this point from experience. The distortion of the eye during the acute stage of convulsions can hardly be classed here, any more than that which accompanies drunkenness, or concussion or compression of the brain.

Local treatment consists in exercising the muscles of the eye by forced lateral movements, and by stereoscopic exercises, with the intention to suppress the second image, to strengthen the antagonist muscle, and to stimulate the tendency to binocular vision. This is very ingenious, but, according to my knowledge, quite useless.

Other methods for exercising the eye in single squint, consist in using atropine to the sound one, so as to impair its vision, and in wearing a darkened glass to dim the image. These are valueless. The attempts to cure by goggles, side glasses, side reading, by binding up the one eye, by patches of black sticking-plaster on the outer edge of the orbit, and by prismatic spectacles, are unavailing and worse than useless if they cause delay of the proper, only certainly effectual, and perfectly safe remedy, which is an operation.

It sometimes happens that the hypermetropic squinting eye, especially in the periodic squint, does become straight with the use of a sufficiently convex glass, and remains so while it is worn. A little patient of mine always squinted when he looked at near objects, unless he used his glass. Yet the glass improved his sight but little. The strabismic vision was not benefited. Even in those cases where the sight is much deteriorated, an operation is to be recommended, because the strabismic vision may be removed. Where hypermetropia alone is present, being yet the only visual defect, the use of a convex glass may cure the squint. I have not myself been fortunate enough to get such an effect, but Donders says that he has.

Tenotomy. The object of this operation is to diminish the action of the muscle by dividing it, and to cause it to connect itself to the eyeball, posterior to its natural attachment.

Application of the operation. As only one eye may squint, so only one operation may be required; but with the least structural implication of the second eye, two operations are wanted. There are many cases in which single distortion can be readily enough

made out; but it is not always possible to say till the one eye is treated, whether the second really squints. I assure my reader that after many years of practical acquaintance with the subject, and many hundred examinations, I cannot invariably be certain. Many times when it has seemed at first that only one operation was needed, I have found it necessary to operate on both eyes.

The two eyes should never be operated on as a matter of course. Putting aside the argument against an unnecessary operation, eversion, or external squint, is often caused by operating on an eye in which there is no permanent contraction of its internal rectus; and the more certainly will this occur when there is any very marked defect in the vision of the eye that squinted. Such caution necessarily requires, when chloroform is given, that the patient should sufficiently recover to be able to use the eyes, so that they may be examined. All the necessary information may be got even before consciousness is completely restored. A single glance of the eyes, as they roll from side to side, is enough for the purpose. No certain information can be obtained so long as the patient is in the anæsthetic sleep.

Where there is any doubt whether the affection be single or double, that eye should be first treated which is any way the inferior to its fellow as an optical instrument, or in movements. This should be a well-recognised rule.

If there be decidedly good abducting power, and after the one eye have been operated on, parallelism be not restored, the other should be subjected to operation, although the squint would seem to be still confined to the eye first treated. Where there is no disparity in vision, nor in the muscular movements of the eyes, both appearing to be equally implicated, that is, both squinting, the two will need operations. Next to the ineffectual division of the contracted muscle, nothing has so tended to bring the surgical treatment of squint into contempt, as not operating on the second eye when an operation is requisite; and not to do so is certain failure on the part of the surgeon. An operator is often deterred from finishing his work, because he thinks the remaining deformity is slight, and that it may get better without interference, a great delusion; or because he has not courage to demand that it shall be done against the objections of the patient, or his ignorant friends.

After having spoken about the primary and secondary angles of squint, and having told how to take the deviations from the correct positions by measurement, it will not perhaps seem strange to my reader, considering the disparagement that I rather threw on measurement, that nothing of this kind has been practically in-

corporated here. I can only say to him that really a case cannot be treated any the better for the most accurate information arising out of the application of a gauge. It is easy to determine when a squint is fit for an operation. Where there is sufficient distortion to produce deformity that is readily recognised, such distortion should be treated. But there may be distortion enough to produce double vision, without such being apparent as a squint. Here, also, an operation may be necessary. This question is treated of in the chapter on "Paralysis of the Ocular Muscles."

It would be useless to operate in complete paralytic squint. In the partially paralytic case, an operation will remove some of the deformity, and if the paralysis be slight, parallelism may be nearly restored. I have said before that partial paralytic squint cannot always be diagnosed, therefore on many occasions the prognosis of an operation must be doubtful. Several of the disappointments, and so-called failures from operations, in the hands of good operators, have been due to the existence of paralysis, of which they were ignorant.

TREATMENT BY OPERATION.

There are certain local conditions which positively contra-indicate an operation. I will name them. Inflammation of the eyeball, or of its appendages; partial opacity of the cornea, producing the squint, by which means the person is enabled to see, the other eye being lost; tumours; cicatrices from wounds; contraction after an abscess; or indeed any accidental mechanical means that pushes, or draws the eyeball from its axis.

When I am satisfied that a squint has settled into a permanent deformity in a child or an adult, there not being apparent any general symptoms of the disease to which it seemed due, or which at least accompanied its development; when general treatment has been tried, as for paralysis, and proved unavailing; when, on first seeing my patient, I learn that the squint has existed for years, or even many months, or when it is congenital, I advise an operation.

There are many disadvantages in delaying this treatment. Vision gets worse. Strabismic vision comes on. The contracted muscle undergoes morbid changes, and we have evidence, too, of its antagonist becoming abnormal. The other recti, in all probability, acquire a different sphere of action. During the growing of the body, the distorted position of the eyeball favours the irregular development of all the displaced parts, so that success must be imperfect in proportion to the postponement. An operation

in manhood for a squint acquired in childhood, is very seldom beneficial.

A late surgeon in England did much harm by strongly advising that a squint, occurring in infancy, or in childhood, should not be submitted to an operation till after the period of puberty. In consequence of his extensive ophthalmic practice, this opinion was disseminated in public, as well as among the profession. It would be as reasonable to delay the treatment of congenital club-foot till the sufferer was fourteen or fifteen years old, or of any deformity or defect in infancy, till the same period of life. Much, therefore, is to be gained by the early treatment; and double squint may frequently be prevented by timely removal of the single affection. I cannot mention a single fact in favour of the delay, while half-a-dozen may be given against it. I have operated as early as the seventh month on a double congenital squint, with success.

The operations with which I have any personal acquaintance, or which have seen performed, may be classed into those executed with the curved knife and director, or knife alone, and those with the hook and scissors.

The first is objectionable on account of the extent of the wound inflicted, such as that practised by the late Messrs. Guthrie; and the second, on account of the uncertainty of dividing the muscle, as in the sub-conjunctival plan of Guérin. There is great danger to the eyeball when the knife is the only instrument used, which must be sharp-pointed in order to penetrate the conjunctiva, to say nothing of the general inapplicability of the proceeding.

The third comprises the hook and scissors method; and includes the sub-conjunctival plan executed with these instruments, and the better method of cutting through the conjunctiva at the spot over where the muscle is to be divided.

I advocate and practise the latter, with modifications of my own, adopting the application of sutures, because I find it the most sure, the easiest in execution, the least likely to be detrimental, the most generally applicable, and, as I fully believe, that which gives the best result, and leaves the smallest trace of performance.

Operations for internal squint. The eyelids should be opened with the spring wire retractor. The internal rectus muscle should be divided close to its attachment, and therefore internal to the ocular tunic. A probe passed vertically under the muscle of an adult, and pressed against its attachment to the sclerotica, will reach to nearly within three-eighths of an inch of the cornea.

I commence the operation by taking up a fold of the conjunctiva horizontally with the forceps, opposite the lower edge of the muscle,

which generally corresponds to the inferior edge of the pupil, and only far enough from the cornea to leave room for the sutures, and cut it through vertically, to the extent of a couple of lines. I then incise the sub-conjunctival tissue and the ocular tunic to the same extent, introduce the hook, secure the muscle, and make it prominent. If the upper part of the muscle be covered with the conjunctiva, as in all probability it will be, I push the membrane aside with the forceps, while I make the hook-point more prominent, and, keeping the muscle very tense, I divide its tendinous expansion, together with the sub-conjunctival tissue and the opposite edge of the opening in the ocular tunic, between the hook and the eyeball, with the blunt-pointed scissors. I would rather advise a beginner to incise the conjunctiva more freely, as he will thereby take up the muscle the more readily, and there can be no particular objection against the extended incision, beyond the rule of cutting as little as possible. I often make it larger than I have suggested when I expect any little difficulty. At any rate, scarcely more need be cut through than actually covers the muscle. A skilful surgeon can operate efficiently with a very small conjunctival aperture. The hook should always be passed a second time, to ascertain whether the operation has been completed. Besides muscular tissue, portions of condensed areolar tissue might escape division in the first instance.

It is a very common error to attempt to secure the muscle before cutting through the sub-conjunctival tissue and the ocular tunic. The first is thin naturally; but generally in squint of some standing, and always where there has been chronic inflammation of the conjunctiva, it is changed and thickened. I conclude by applying one or two sutures, using such a needle as that depicted in the chapter on "Instruments," but one stitch carefully adapted generally suffices. This is very readily done by raising the corneal portion of the membrane with the forceps, transfixing *it close to the margin*, and dealing with the other edge in the same manner. It is necessary to be particular about the exact position of the suture, lest there be any tension of the conjunctiva, and because the thread should be thrown off in three or four days by ulceration. Not the least irritation ensues from the stitch, and the patient is rarely ever aware that he has such in his eye.

Primary union quickly follows this operation. It is the rare, the very rare exception, not to have it. I cannot therefore conceive a more efficient and perfect manner of operating. The little ecchymosis, the slight redness, and the rapid removal of such effects of the operation, point to this. There is no fungus growth from the edges of the wound, a likely occurrence whenever the conjunctiva

does not heal at once, and no irritation, which is common with the process of granulation.

No particular direct course of after-treatment is ordinarily required. Nothing more is demanded than the general attention necessary for a wound of the ocular appendages. I prefer that the eye be not bandaged up, as I suspect that it is better for the muscles to be used, if only, as in the case of a weak abductor, to prevent the divided tendon from uniting too much anteriorly.

Whatever be, then, the degree of the squint, the muscle is to be thoroughly divided, in every case, and on every occasion, where there is single squint and where there is double. To attempt less is to incur failure.

There is very little disturbance to the surrounding parts by dividing the muscle close to its attachment, and on the integrity of such parts does the after position of the eye very much depend. A free dissection is inevitably attended with prominence of the eyeball. Then it is of the utmost importance that the muscle should be re-attached very close to its natural position. The operation is intended to weaken muscular force, and not to destroy it. If the ocular tunic be too much interfered with, the muscle will be thrown back too much, and then it gets attached to the tunic. Under such circumstances, the eyeball is sure to become everted, and secondary squint produced.

When the operation was first practised the muscle was cut through far back, and the proximal end pushed far behind ; hence the dreadful deformities that usually ensued.

In the so-called sub-conjunctival operation, the conjunctiva is divided horizontally at the lower part of the eyeball, and the hook and the scissors are used under the membrane. It is a very fumbling proceeding, and a much larger aperture is required, for the passage and the use of the instruments, than is necessary in the other and superior method. It is most readily done in prominent eyes. There is much uncertainty of thoroughly dividing the muscle where the eye is sunken, where there is fixed inversion of the eyeball, where the muscle is shortened, in the small eyes of children and infants, where the conjunctiva is thickened and thrown into folds, and especially where the sub-tissue is likewise altered. Then, as regards the peculiar consequences, the parts are very much disturbed, the conjunctiva is very freely separated, the ocular tunic much cut, and much blood is extravasated. It is a common practice to make a counter-puncture to attempt to let the blood out ; but, in fact, little can be got away in this manner because of the coagulation. I have seen very extensive chemosis and ecchymosis thus produced even in the hands of the best operators. I have read of the effusion of blood being so

considerable that the eyelids closed with difficulty. With this manner of operating in the dark, the uncertainty of dividing any condensed tissue about the muscle that should be severed, or of any posterior adhesions, must be self-evident, and need not be dwelt on.

The following quotation from the writing of Mr. Critchett, advocating the operation, will show that I have not made over-statements. In his "Practical Remarks on Strabismus, with some Novel Suggestions respecting the Operation," he says: "But it may be asked if there are any objections to this operation, and any cases in which the old operation is preferable. It must be admitted that it is rather more difficult to perform, that there is a greater liability to leave some portion undivided, and sometimes some inversion remains, in consequence of the attachment of the muscle to the fascia after it is divided from the sclerotic. This will often rectify itself afterwards, and where this is not the case it is better either to operate on the other eye, or, if the cast is slight, be content to leave the case in that state, rather than risk eversion by further interference. It is only in cases of long standing, and where the strabismus is very extreme, and where the eye is small and deep set, and where the sub-conjunctival operation produces but very little effect, that the old operation is justifiable."

Guérin's object was to obviate the vacancy produced at the inner corner of the eye, by the interference with the caruncle and plica semilunaris, which was inseparable from the dissections that were practised in the early operations, when it was thought necessary to cut through the body of the muscle far back. That it was an improvement on such free dissections there can be no doubt; but that neither it, nor any other method, always completely obviates all trace of an operation, I shall show.

The use of the suture must set at rest objections against dividing the conjunctiva in any direction.

A comparative trial between the sub-conjunctival method and that which I adopt, was made on a patient by a gentleman who practises exclusively the sub-conjunctival plan with the scissors and hook, and by myself. In my patient's eye the thread was cast off on the fourth day, the conjunctiva being quite healed; and on the eighth there was scarcely any trace of surgical interference. In his, at the end of two weeks, there was so much conjunctival inflammation that treatment for it was considered necessary, and the conjunctival wound was yet open. So much inflammatory action was, no doubt, exceptional.

Failure depends on more or less paralysis of the antagonist muscle. Adhesions. Variety in, or abnormal position of the muscles. Before

I consider any of these, I venture to say that a long and familiar acquaintance with the subject has convinced me that to the operator is to be attributed the want of success in most of the unsuccessful cases occurring in early life. Over and over I have seen patients dismissed under the supposition that it was impossible to put their eyes right, when I have been certain that the muscle had not been divided. That there is a great liability to take up only a portion, any one may convince himself by operating on the dead subject, when he will find that, unless there be great precision, this will occur. A partial separation will frequently lessen the squint; but for its entire removal every portion must be cut across, and to this there is no exception. After the muscle has been divided, the patient has not the power to adduct the eye in concert with the other.

It is often erroneously supposed after the operation, in consequence of an imperfect examination, that the eyes are parallel. The inability, or often the unwillingness of the patient to open the eyes, prevents a satisfactory inspection. These obstacles must be overcome by gently raising both eyelids at the same time, and comparing the positions of the eyeballs.

Respecting paralysis, enough has been said above.

My own experience of the existence of adhesions preventing the eye from assuming a central position is limited to what I have supposed to be condensation of areolar tissue, around and about the muscle. In order to divide any such adventitious connections, it has generally been necessary to make the conjunctival incision rather longer than ordinary.

I know nothing personally of the attachments said to exist between the body of the muscle and the sclerotica; nor can I quite comprehend how they exist, as the "ocular tunic" intervenes. This sheath, I suspect, is often mistaken for adhesions. Mr. Duffin, who was ignorant of its existence, remarks, in his papers on squint in the "London Medical Gazette," that bands of fibro-cellular connection, passing between the sclerotica and the under surface of the muscle and its sheath, frequently retain the eye in an abnormal position after the tendon has been divided, and render many cases only partially successful; that he has met with them very far back, even beyond the greatest diameter of the globe of the eye; and that in two cases they were almost cartilaginous, and so unyielding, that the patients were wholly unable to move the pupil out of the inner canthus.

Another surgeon records finding in two cases a strong fibrous band, closely united to the sclerotica, beyond the vertical axis of the eye; and in a third, numerous short, strong bands, situated like-

wise posteriorly, retaining the organ in the inverted position after the muscle and the conjunctiva had been freely divided. I can well understand that the "ocular tunic" might adhere to the eyeball, and the possible occurrence should be remembered when the eye is not righted after the muscle has been severed. The pathological changes that often take place in the muscle, and in the tissue surrounding its insertion, may give the idea of the muscle being abnormally adherent. In this condition of parts, the operator is apt to transfix the muscle with the hook, and to leave a part undivided.

The following quotation from Sir W. Wilde's ophthalmic report, in vol. xxvii. of the "Dublin Journal of Medical Science," expresses nearly all that is known of the irregularity in the muscles: "Since the adoption of the operation for strabismus, much attention has been paid to the pathological condition of the muscles in the orbit; but few of the abnormal appearances described by authors appear to have been original and not acquired defects after birth. And those attachments of one to another, or the blending of two muscles with one, as the levator palpebræ with the superior rectus, the trochlea with the internal rectus, and the trochlea itself with the trochlea, &c., appear to be also acquired pathological conditions, Morgagni and Wrisberg; but instances have recently been recorded, by good authorities, of decided false insertion, and also bifurcation of the internal rectus at its sclerotic extremity, Dieffenbach; of the external rectus being double, Zagorsky; and also the superior oblique, Albinus; while Caldani saw, more than once, an additional muscle, which, from its insertion and use, he has denominated m. detractor palpebræ inferioris; and both recti and both obliques have been found wanting, in cases of monstrosities, by Sieler and Colomb."

I may add that Ammon has seen bundles of fibres inserted behind the tendon of the muscle.

It is supposed by some that thickening of the conjunctiva, and the subjacent tissue, may retain the eye inverted. It would seem that for this effect, there must be more or less contraction of these tissues.

The practical lesson to be gathered from the foregoing considerations is, that an operator should be careful to divide the muscle, to be certain of which he should always ascertain, by the re-application of the hook, that no muscular fibres have escaped; that, after the efficient performance of this part of the operation, should the eye be still adducted, he must seek for adhesions, and separate any that may be found.

Several accessory operations have been practised when the division

of the internal rectus has not been followed by the removal of the squint.

The internal edges of the upper and of the lower recti muscles, have been divided simultaneously. I have no personal knowledge of the proceeding.

In the Ophthalmic Hospital Reports for October, 1858, the following occurs: "In a case of congenital extreme internal strabismus, aged fourteen, with congenital cataracts, both internal recti and the neighbouring fasciæ were divided; but the eyes being still turned in, Mr. Poland passed the hook beneath the superior and inferior rectus, encircling that edge of the muscles nearest the internal rectus. This was done sub-conjunctivally through the same opening by which the internal rectus had been divided. Both eyes now remain straight." A little doubt crosses my mind about the accuracy of this report. It is difficult to understand how the *edges* of the upper and under recti are to be cut through when the muscles are not seen.

The following operation, applicable to both kinds of squint, appears, from all I can learn, to have originated with Dieffenbach. Sir W. Wilde applied it first in divergent squint. I take my description of the method from his "Monograph on Entropium and Trichiasis," to which is appended the description of "a case of severe trichiasis and convergent squint of both eyes successfully treated by operation, and the application of ligatures on the recti muscles." The patient, a female, was thirty years old. The right eye was first operated upon, and a primary difficulty was to bring any portion of the sclerotica internal to the cornea into view. Having satisfied himself that every fibre of the muscle was fairly divided, but that considerable convergence still remained, he laid hold of the sclerotic extremity of the muscle with a pair of forceps, and passed a fine curved sewing needle, armed with a single silk ligature, through it in two places. Having obtained a direct purchase, he drew the eyeball towards the external angle, till the cornea was rather inclined outwards, and secured the ends of the ligature over the malar bone by adhesive plaster. This was done on the fourth of the month. On the morning of the seventh, the thread had cut its way through the end of the tendon, but the eye retained its straight position. Nine days after, the other eye was similarly treated. On the evening of the second day the ligature was withdrawn, and both eyes were now in a natural position. There was temporary double vision. The woman was last seen after an interval of nine months, and her favourable state continued.

Other instances of the adoption of this method in double convergent and in divergent squint are alluded to by Sir William Wilde, who

states that he has employed these means with perfect success in seventeen cases of divergent squint, and thirteen of convergent; and in nine of the latter the ligature had been applied in both eyes. The length of time the ligature is allowed to remain varies according to circumstances; but, as a rule, it should never be removed till the eye has righted itself. Luscitas, or fixture of the eye, in the straight position, has followed, especially in cases of divergence, where he had reason to believe that paralysis and atrophy of the internal recti had previously existed. This has lately been described as a new operation.

The antagonist muscle has been divided and brought forward after the principle of treating excessive divergence from an operation on convergent squint, in a manner to be presently described, but the attempts have been barren.

It requires no measurements, no special tests, to tell to what degree the operation is successful. It is only to make the patient look at you, and the thing is determined. Any one can see this as well as a professor of ophthalmology. The after movements of the eye rarely undergo more than the slightest variations from those assumed directly that the operation is over. The eye can be used well in all directions in the associated movements with its fellow. There is generally some loss of adduction when the two eyes are forcibly converged. Now and then a little oscillation of the eyeball exists, and this is more marked if adduction be not perfect.

Improvement in vision is not so marked after the operation as the removal of the deformity, and this is, of course, because the squint is so frequently due to impairment of sight, or to some defect previous to its existence. It is therefore to the removal of what I have called the strabismic defective vision that we must here look; and this will be the more manifest in proportion to the healthiness of the vision before the squint. The improvement is apparent in the greater acuteness of vision. In the most marked degree the type of an ordinary book may be read, when before not a word could be deciphered. Besides this, the focal range being lengthened, objects are not held quite so close to the eyes, and therefore the field of vision is enlarged. Distant sight is likewise improved.

Secondary treatment. This is meant to express nothing but the painstaking adaptation of glasses to any existing optical defect, whereby the eye may be made more available, for near and distant objects. Perfection is not to be got, but any visual benefit is a gain to the patient, and in single squint, in proportion to the degree in which the eye can be used with its fellow, will be the permanency of the cure. I am sure that relapses and eversion are often due to

disuse of the eye. They are more common when an almost sightless eye is operated on.

The use of the stereoscope is recommended, that binocular vision may be exercised.

Result. There are few cases of squint in early life that may not be considerably improved by the operation, or completely remedied.

Binocular vision is restored to nearly half of the cases in which the deformity is removed. A lesser number have it with a limited range of the field of vision.

It is the paralytic form in which, as a rule, there is only partial recovery, and here there are degrees of improvement, bordering in its highest effect almost to success.

After puberty, in any case, the chances of righting the eye decreases with the age of the individual, the paralytics giving the least result.

Supposing, then, paralysis to be absent, and vision to be tolerably good, a well-executed operation in childhood is immediately followed by success. The results may be said to be almost always immediate, for it is seldom indeed that there is any after benefit. There may be as rare exceptions, intervals of hours, or even of a day or two, before an eye takes its destined position. Cases in illustration are given in the last edition of this work. Improvement in vision is always immediate.

EXTERNAL SQUINT.

Apparent divergent squint is generally due to a condition commonly associated with hypermetropia, the centre of the cornea being a little external in position to the visual axis.

True divergent squint. This form of the distortion is very much less frequent than the other. It is analogous to it, and differs only in the reversed position of the eyeball. It seldom appears before puberty, except in connection with a diseased brain, and occurs most frequently in adults.

PATHOLOGY.

Remote or existing cause. These seem to bear the same relation to the eyeball as in internal squint.

Shortsightedness, or rather the conditions incidental to it, is the commonest of these. This was recognised by the ancients, as is shown by a passage in Pliny. The association has been noticed by modern writers, but no one has attempted to explain it so scientifically as Donders. He makes a distinction between well-known degrees of the squint, into relative and absolute.

In the relative, the visual lines are properly directed at great distances. At close work the squint occurs, and only one eye is

used, because there is a formation of different images on the two yellow spots of the retinæ. It exists as soon as the proximity required for accurate sight excludes binocular vision.

In the absolute, there is divergence of the visual lines in distant vision. For close vision, the divergence sometimes remains unaltered, sometimes not.

According, also, to this author, the chief cause of the deviation outwards depends on the distention and change of form of the globe of the eye. When, he says, myopia depends exceptionally on a flattening of the cornea, strabismus is not to be looked for. All the diameters of the eyeball are increased in myopia, but especially that which corresponds to the optic axis; it follows, therefore, that the eyeball has a tendency to take the form of an ellipsoid, of which the major axis is the optic axis. These large diameters may diminish the mobility of the eyeball in general; and movement is especially affected by the ellipsoidal form, which opposes a much greater resistance to rotation on its minor axis in the interior of a cavity of the same shape. The centre of motion is not only at a distance from the anterior, but also from the posterior pole of the eye. The elongation of the axis affects the movements inwards as well as outwards. We take it for granted that there is an insufficiency of motion inwards, where the lines of vision cannot be brought to intersect at a distance of 2″·5, at which they cut one another at an angle of about 51°. In high degrees of myopia this insufficiency pretty nearly always exists. Donders proceeds to state that relative diverging squint may arise from insufficiency or weakness of the internal recti muscles, and that in cases of high degrees of myopia, it may arise without any such insufficiency of muscle, but that it occurs in its most important forms when myopia and insufficiency of the muscles are both present in a moderate degree; also that the small angle which the visual line forms with the optic axis, increases the tendency to squint. He mentions besides that in high myopia, when objects are brought close to the eyeballs, double convergence can scarcely be maintained, the tendency being for one of them to diverge.

To those persons who desire to learn Donders's details, his measurements, and his arguments, I recommend his monograph on the "Pathogeny of Squint."

All that I have said refers in general to irregularity of ocular movements, so slight as scarcely to be detected, that which may be called the least degree of the absolute form of squint. I cannot myself receive the whole of the causes as they are given by Donders. I do not believe that the form of the myopic eye interferes with its movements. The alterations in it are too slight for any such effect.

to say nothing of the natural configuration and adaptation of the parts around within the orbit, in the process of development. The diagrams of the myopic and of the hypermetropic eyes, are, as I have already said, greatly exaggerated. But I do not find that very palpable enlargement of the eyeball, from disorganization and distention of its coats, or from the internal development of a tumour, interferes with its movements.

I admit, in a general acceptation, the statement about the insufficiency of the recti muscles, but it must be remembered that the word insufficiency is merely another term for paralysis of those muscles, unless congenital arrest of development be admitted. It is supposed by some men that with increasing myopia, it is necessary that the internal recti should acquire preternatural power in order to prevent eversion. Paralytic squint in a slight degree, comprises a large portion of this disease, and it often exists where there is no myopia. Respecting the marked and indisputable squint, Donders admits that a certain number of cases must be referred to primary disturbance of the muscles arising in paralysis, inflammation, contraction, and complicated congenital anomalies. He writes besides, "It has appeared to me as if there was another origin, in addition to myopia, for the higher degrees of strabismus."

I have, I believe, without an exception, traced the cause of that definite form of squint for which a surgeon is generally consulted, to my own satisfaction, to be due to some form of impairment of vision affecting both of the eyes, or only one of them; or to difference in the refraction of the two eyes, or some disparity between them in the function of sight. The one or the other of these states is commonly associated with myopia. The truth of this seems to be borne out by the fact that the so-called relative squint does not pass into the absolute or marked form, the definite affection, in any pathological sequence or association. The rare occurrence of relative squint, makes it difficult for me to recognise as its cause, those conditions which are present in a more or less degree in nearly all cases of myopia.

Impairment of sight in any form of eye, that is, in eyes with normal refraction or otherwise, from any disease without or within the eyeball, by which sight is materially deteriorated or destroyed in manhood, is another cause of external squint. It is a fact difficult to be explained, that the circumstances which at one time of life determine an internal squint, shall at another be followed by the outward deviation of the eyeball. The age of the individual seems to exert influence. A child seldom acquires an outward squint; an adult seldom acquires an internal one. I never met with internal

squint in the aged as the result of cataract, although a slight deflection outwards is not uncommon. Internal squint, from cataract produced by any cause in early life, especially when one eye is affected, is not unusual. Not any satisfactory explanation has been found for this.

Direct cause. Putting aside any excessive action of the external rectus muscle from cerebral influence analogous to that of the internal muscle in inward squint, the direct causes are the same in the two affections. The eye is influenced in the same way by effusions in the orbit, tumours, and all mechanical lesions of its muscles.

Paralysis of the motor oculi nerve. To this alone are due nearly all the cases of the disease. It occurs, as I have already mentioned, in different degrees.

The forms under which external squint occurs. Three varieties include them, and these are readily recognised.

First form. This is associated with paralysis in some degree of the internal rectus, and some of the other muscles supplied by the third nerve. There is often more or less ptosis. The term paralytic squint is here applied. According to the extent of the paralysis of the internal rectus is there inability to turn the eyeball inwards.

There is impairment of the power of adjustment when the ciliary muscle is paralyzed. A much dilated pupil, arising out of paralysis of the sphincter pupillæ, has, too, its effect on the sight. But there may besides be confusion of vision, arising solely from the malposition, or loss of parallelism of the eyeball; in other words, double vision. Strabismic vision also occurs. The deformity is usually confined to the one eye, but both may be affected.

The second form is single squint, and it is very similar to the second form of the internal affection, although it is more common in its kind. There is eversion in the one eye, no material divergence. The eyeball can be brought to the centre of the orbit by strong will, and kept there without causing eversion of the other eyeball. It may become parallel with its fellow when a near object is looked at. Sometimes it can be inverted, and both eyes can be made to converge mutually.

This squint, in its least degree, has been particularly spoken of in the foregoing chapter, at the end of the section on paralysis of the third nerve. The eversion is first recognised from the double vision that is produced, when convergence of the optic axes is attempted for near vision. There is not any loss of acuteness of sight.

The third form, the commonest, is double squint, that is, mutual divergence. According to my observation, except it be produced

by paralysis, it rarely commences double. In this it differs from internal squint, in which the double affection from the first is common. In the very marked cases the mutual divergence is very striking, and the diagnosis is unmistakeable. In the lesser degree there is rather a deceptive appearance, the deformity seeming to alternate. But implication of the two eyes can generally be made out, although there is nearly always a difference in the degree of the eversion; not so apparent by individual examination as when scrutinizing them together. Taken separately, either sometimes may be brought to the centre of the orbit, and even more or less inverted. But they cannot be made to converge, nor even to become parallel.

The influence of the associated movements of the recti muscles is, no doubt, exerted also in this kind of squint, and causes the better eye to be turned unduly outwards, when an attempt is made to bring the more squinting eye to the centre of the orbit.

TREATMENT.

Mere local treatment of any kind is useless.

All that has been said about the general treatment for paralytic internal squint applies here. It is only necessary to add that better results will be obtained in this variety than in the other.

The local conditions which have been pointed out as contra-indicating an operation for internal squint, contra-indicate that also for external squint. The general remarks, too, which immediately follow, have a like application in the two varieties.

Operation for external squint. There is no difference in the details between the operations for internal and external squint, except that as the attachment of the external rectus muscle is a little more posterior than the internal, the conjunctiva should be divided a little farther from the cornea, and more freely. The hook should be passed just below the muscle, and close to its attachment to the sclerotica, or the inferior oblique muscle is liable to be taken up. The operator must be prepared to find the conjunctiva and the subjacent tissue, looser and thicker on this side of the eyeball, and that the tendon of the muscle, in consequence of its greater breadth, does not admit of being so indefinitely raised and exposed as in the internal operation: it appears more like fascia than tendon. This operation may, therefore, be said to be the less easy of the two; and there can be no doubt that it is far more likely to be ineffectually performed. I always apply sutures, for, although less important here, still they are very serviceable.

I understand that some of the warmest advocates for the sub-conjunctival operation, do not apply it to external squint. I have not seen it adopted.

The rules that have been given in the first section on internal squint, as to whether the single or the double operation should be performed, apply here. All besides that has been said, respecting care in dividing the muscle and seeking for adhesions, must be understood with reference to this operation; and so too as regards after-treatment.

In general both eyes require to be operated on.

Results. As convergent squint is so essentially a paralytic affection, success will mainly depend on the degree of paralysis under which the internal rectus muscle labours. Where it is slight, the eye will be righted; where it is considerable, there will be only improvement in the eversion.

The full benefit of the operation is not usually manifest at once, but is developed gradually.

DEFECTS OF THE OPERATION FOR SQUINT.

Defects are inevitable, for nothing could be more unlikely in practical surgery than that an operation of the above nature could be done on a part of the body with such configuration and mechanism, and endowed with such peculiar action in a limited sphere, for the removal of disease in the motor apparatus, without the remains of some trace of the hand of art. The slightest alteration of the natural lines in the corner of the eye can be discerned. It is so freely open to scrutiny, and the fellow-eye is close by for comparison. Only exceptionally is it, even in the most satisfactory instances of the removal of an internal squint, that there does not remain a blemish, however slight it may be. While some of the cases defy detection of the treatment, others palpably exhibit what has been done. As the manner of operating will often determine the degree of the imperfection, whether it shall be slight or otherwise, a systematic review of the subject is necessary.

Movements of the eyeballs. After the internal rectus muscle has been divided, there is often a little loss of internal movement of the eyeball. This is attributable to the acquired attachment of the muscle being posterior to the natural one, but such a cause does not always operate, since sometimes all the consentaneous or associated muscular movements are restored. The action may be considered satisfactory if the ocular parallelism is maintained when an object is viewed at a distance either of twelve feet or of six inches. Parallelism

of the visual lines for very near points of convergence, and for the viewing of very distant objects, is rarely attained.

Marked eversion, is the inevitable consequence of bad operating, and this, together with the almost invariable accompaniment of considerable prominence, were the chief causes that brought the operation into the disrepute from which it has scarcely yet recovered. All operators at first were at fault, but in different degrees. They had not yet learned how to operate. A great surgeon from the North, who did more in his short time to improve the practice of surgery than any of his contemporaries, turned out the worst examples. His very free dissection, by which he exposed the greater part of the inner side of the eyeball, and his manner of cutting through the body of the muscle, were the causes of it. Besides this, he in common with others, thought it well to thrust back the cut muscle with a probe, and particular directions for doing this, were given in the rules for operating. The amount of distortion that might be thus produced is almost incredible. No one earlier than myself, as my writings will show, endeavoured to remedy this by a more limited operation, and although at the time the rationale was not apparent, it has since been revealed by actual dissection. We now know that the divided muscle either acquires an attachment to the sclerotica, directly, or by cellular connection, or through the intervention of the conjunctiva. Or it adheres to the ocular tunic; or the ends unite with more or less intervening new material, or lie far apart between the sclerotica and the conjunctiva; or become joined to the conjunctiva alone. Now, in exact proportion as the influence of the muscle is lost by being dissected away and completely displaced, or by a piece being cut out as I have seen done many times, will there be eversion, when the abductor is healthy. The aim and object, therefore, should be to provide for the re-adhesion of the ends of the muscle with as little displacement as possible. Some time is requisite to weaken the muscle, as I have said, but the less the better. If the tendon only be cut through, as I advise and practise, there is secured the minimum of displacement. It is supposed that the reader will remember what stress has been laid on not unnecessarily disturbing the ocular tunic.

The use of the suture tends to prevent displacement of the muscle, and the effect of it is greater when the operation is done on a more extended scale than that adopted by myself. It will, therefore, be of more advantage in the operations of beginners, who are not likely to operate with accuracy and neatness. Some surgeons speak of regulating the tension of the stitch, by taking up more or less of the

conjunctiva, according to the effect that may seem necessary on the position of the eyeball; and on the same principle, it is recommended that the stitch be sometimes withheld. I have not found such instructions necessary to be carried out.

It should be understood, however, that slight eversion may at once, or in a day or two, follow the best-executed operation. But I say positively and undeniably, that when the operation is well done, according to the rules which I have laid down, it will be a very rare occurrence.

Eversion, which may be called secondary, might ensue some months after the operation. This is because the eye is not brought into use, perhaps from the want of sight. I shall speak more of this presently.

The treatment of eversion has not been overlooked. The first plan was that of dividing the antagonist muscle. It was done to a great extent at one time in London. In several of the persons who came under my notice, considerable prominence of the eyeball ensued, although the defect was more or less remedied. In one instance, it was so excessive that the eyelids could not be closed without great effort. But there need be no fear of any such bad result, if the muscle be divided in the careful and limited manner that I advocate. On the contrary, the effect will be beneficial in righting the eyeball, provided there be not marked prominence with the eversion.

For eversion with much prominence, two operations are required. The external rectus is to be cut through. The internal is to be re-cut and so placed as to ensure a more forward attachment. The eyelids should be retracted as in the ordinary operation for squint. A dissection is to be commenced at the inner corner of the eye, about two lines from the margin of the cornea, and carried upwards and downwards; and a flap of conjunctiva, sub-conjunctival fascia, cicatrix and muscle, with all the condensed tissue around it, so raised as to expose the inner third of the surface of the eyeball. The external rectus muscle should next be divided. A small semi-circular needle, threaded with fine silk, should be passed through the flap, which has been raised at the inner corner, as far back as possible. Two, three, or four sutures must be passed in the same way at regular intervals, according to the size of the flap. Each needle must then be carried through the piece of conjunctiva by the side of the cornea, in proper correspondence. The anterior portion of the flap, that in front of the sutures, should then be cut off, and the operation completed by tying each suture so as to make a stitch, by which the conjunctiva and the cut edge of the flap shall be approximated.

By this, inversion should be established; that is necessary, as there is always a little outward yielding afterwards. To Mr. Critchett is due the merit of the plan. The sutures must be allowed to drop out. It is not to be wondered at, that the mobility of the eye is much impaired by the operation, and that sometimes an almost fixed central position is acquired. Partial relapse occasionally ensues.

Another method has been practised by Dr. Agnew, "New York Medical Journal." The conjunctiva with sub-tissue is to be divided horizontally opposite the internal rectus muscle, from within a line of the cornea to the semilunar fold. The tendon of the muscle is to be secured and pulled forwards, by a squint hook armed with a thread, and tied close to its attachment. The external rectus muscle is then to be divided. The internal rectus is next to be cut away from the sclerotica. The operator should now estimate the amount of adduction which may be necessary to cure the divergence. This he can do by catching with forceps the sclerotic edge of the cut tendon of the external rectus and drawing the cornea towards the inner canthus, while he holds up upon the stretch the muscle to be advanced. The retentive sutures can now be placed. For this purpose two delicate, short, and sharply-curved needles are to be armed with fine, well-waxed silk, and adapted to a needle-holder. The sutures are to be passed through the muscle and its sheath, as far back as may be necessary, yet always enough to leave a longer bit between them and the ligature on its end, than the distance of the divergence, the angle of the squint. Such bit is to be cut off.

The next step is to carry the sutures beneath the conjunctiva above and below the cornea. It is better to place the upper suture first. The point aimed at in carrying the needle along the sclerotic, beneath the conjunctiva, should be about a line above the cornea and over the centre of the line of implantation of the superior rectus muscle, and there the suture should emerge. Before tying the upper, the lower suture should be brought out at a corresponding point over the inferior rectus insertion. While the operator is cautiously tying the sutures his assistant should, catching hold of the insertion of the external rectus, carry the cornea towards the internal canthus as much as possible, and thus effect what may be considered the real intention of the operator, namely, to adduct the eye strongly, and thus place the end of the shortened internal rectus in coaptation with the sclerotic at the natural line of the sclerotic implantation. The exercise of a little care will cause the muscle to spread out and be hidden behind the horizontal pillars of the wound, through which the retentive sutures have been carried.

A certain degree of dropping of the caruncle is seldom absent, and arises out of the unavoidable disturbance of the parts at the corner of the eye. As it is due to the displacement of parts behind the conjunctiva, the inevitable consequence of change in the position of the attachment of the muscle, and on the contraction attendant on cicatrization, it takes place when the operation has been performed in the most limited and perfect manner. But it is increased by free dissection, and it is always very much marked where there has been previous contraction of the tissues at the inner corner of the eye, as the result of inflammation. It is always more apparent in prominent eyeballs than in those which are deep set. No method of operating heretofore devised, is free from it. Apart from the mere disfigurement, it may interfere with the removal of the tears by the puncta.

After very badly executed operations the caruncle may altogether disappear, and then a chink or crevice is left at the corner of the eye.

The only way to limit this defect to the least possible degree, according to the individual condition of each eye, is to operate in the careful manner which I have advised, and to stitch the conjunctiva.

Liebreich has been making dissections in order to ascertain if he can remedy this, as well as to lessen the necessity, as he says, for operating on the same eye twice, thrice, or four times. His anatomical details are described in the "British Medical Journal" for December 15, 1866, a reprint of which the author has just kindly sent me. He gives a new description of the "ocular tunic," capsule of Tenon, as he calls it, of its relations with the muscles of the eye, the sub-conjunctival tissue, and the conjunctiva. The following quotations will suffice: "The capsule of Tenon, which encloses the whole eyeball with the exception of the cornea, consists of two very different portions. The posterior half, with its smooth, firm, inner surface, forms a cup, in which the eyeball moves freely, as the head of a joint in the socket. This cup is pierced by the four recti muscles, and forms at the point of perforation, a sharply-defined ring, which enters into so close a connection with the muscles, as to render any displacement between the two impossible. This close adhesion between the muscles and the posterior half of the capsule is, moreover, increased by sheath-like processes which run backward from the outer surface of the capsule towards the orbit, and which are, for a certain distance, firmly connected with the muscles. But towards the eyeball no sheath-like processes extend from the posterior capsule; the latter terminates abruptly in the form of a ring, which encloses the spot where the muscles penetrate, and whence, for a very short

distance, the muscles are quite free from any adhesion. But before the tendon is inserted into the sclerotic, it penetrates between the sclerotic and the anterior half of the capsule, and becomes united with the latter.

"This anterior half of the capsule, which may be considered as standing towards the posterior portion in the relations of a semicircular lid to a semicircular cup, is much thinner than it, and is difficult to dissect, more especially on the dead body; for like the conjunctiva it rapidly diminishes in thickness and firmness after death.

"Within a zone which is bounded on one side by the opening on the margin of the cornea, and on the other by the line uniting the insertions of the four recti muscles, the conjunctiva, the capsule of Tenon, and the sclerotic, are firmly and immoveably connected together. At the periphery of the zone, this condition becomes, however, changed. The connection between the capsule and the sclerotic is interrupted by the passage of the muscles."

He thus sums up: "1. The connection of the muscle with the capsule of Tenon is twofold. On the one hand, there is the annular connection of the posterior capsule and its sheath-like processes, which are reflected towards the orbit, with the belly of the muscle; on the other, the firm adhesion of the anterior half of the capsule to the surface of the end of the muscle, which penetrates into the capsule.

"2. The conjunctiva is firmly connected with the outer surface of the capsule of Tenon from the edge of the cornea to an irregularly circular, sharply defined, marginal line; and consequently, it stands in a very important relation to the muscles of the eye.

"3. The caruncle, together with the semilunar flap, rests upon a band-like ligament, which passes from the capsule of Tenon towards the edge of the orbit. Now, when the internal rectus is contracted, and the eye rolled inwards, this band is rendered tense; and the caruncle, which is fixed to it, is subsequently drawn into the inner end of the orbit. But the outer edge of the caruncle, together with the semilunar fold and an adjoining portion of conjunctiva, are drawn backwards into a furrow. This is partly due to the fact that, during the movements of the eye, the conjunctiva lies, up to a certain point, in close apposition to the eyeball; and partly also to the fact that, on contraction, when the muscle, on account of its connection with the anterior half of the capsule, must draw the latter backwards, when it will be followed by the conjunctiva, which is likewise connected with the capsule, the semilunar fold, and the caruncle."

I will now describe his operation: "If the internal rectus is to be divided, I raise with a pair of forceps a fold of conjunctiva at the lower edge of the insertion of the muscle; and, incising this with scissors, enter the points of the latter at the opening between the conjunctiva and the capsule of Tenon; then carefully separate these two tissues from each other as far as the semilunar fold, also separating the latter, as well as the caruncle, from the parts lying behind. When the portion of the capsule which is of such importance in the tenotomy has been completely separated from the conjunctiva, I divide the insertion of the tendon from the sclerotic in the usual manner, and extend the vertical cut, which is made simultaneously with the tenotomy, upwards and downwards, the more so if any considerable effect is desired. The wound in the conjunctiva is then closed with a suture.

"The same mode of operating is pursued in dividing the external rectus; and the separation of the conjunctiva is to be continued as far as that portion of the external angle which is drawn sharply back when the eye is turned outwards."

I can say nothing about the anatomical account, because I have made no dissection to verify it, but respecting the manner of operating, this conviction is forced on me that, it is only now that Liebreich has learnt to sever the muscle efficiently. He now understands how to do this thoroughly, and he sees the importance of dividing a portion of the ocular tunic as well. He completes the process by the very important act of applying a suture, the necessity for which, as a safeguard against the dropping of the caruncle, I have inculcated for many years. I attribute the virtue of the operation, not to the method of the dissection, ingenious as it seems, but to the use of the suture, and the primary union of the conjunctiva. I fully believe that the best result will be got with the least amount of tissue-cutting. I must here state that I do not believe in the necessity, at any time, for the repetition of the operation for squint, except there be a relapse. I can receive the statement only on this qualification, that on each repetition, the preceding operation was never thoroughly done.

Protrusion of the eyeball, in some degree is common, perhaps never absent, but oftentimes so slight, that very close inspection is required to discover it. Theoretically speaking, the balance of the recti muscles cannot be disturbed by dividing one of them without the eye starting somewhat forward. Naturally prominent eyes will display it more than those which are deeper set. In eyes that are popularly called small, it seldom constitutes a deformity. It is always less noticeable when both eyes have been operated on.

Like the dropping of the caruncle, it is unavoidable in a slight degree, but an exaggerated amount can never occur with judicious operating. It is often combined with eversion. Indeed, it cannot be very marked without it. There is no recognised method of removing it. Reducing the palpebral aperture, by an operation at the outer commissure, has been recommended.

Double vision is another unpleasant result occasionally met with. It may appear at once, or in a few days after the operation, whether the one eye have been operated on or the two. As it results from loss of correspondence in the visual axes, it is absent in proportion as parallelism is restored. It is, therefore, most common where there is eversion, although it is not a necessary concomitant with it. Like the double sight, the effect of a recent squint, it generally soon passes away. I only know of a single instance of its permanency among my own patients. I operated on a young man, slight eversion ensued, and very troublesome double vision with crossed images followed. For years he continued to call on me, ever telling the same distressing tale, and always refusing to allow the external rectus muscle to be divided.

Occurrence of accidents. The operation for squint is but little liable to accident, and to bad results, the consequence of inflammation. Well performed, it is the surest and safest operation I know of. The ill-effects have been almost always due to bad operating, or to after imprudence on the part of patients.

The sclerotica has been cut through several times, chiefly in children, in whom it is very thin. In the cases which I have been able to watch, the eyeball has collapsed, even when the vitreous humour did not escape when the wound was inflicted.

The orbital fat has protruded during the operation.

Dangerous hæmorrhage has ensued, and life has been saved by transfusion of blood.

Orbital cellulitis ending in abscess, has occurred several times after prolonged operations.

Acute inflammation of the eyeball ending in suppuration has come under my notice once.

Death from pyæmia, consequent on an orbital abscess, has been recorded.

Relapses occur, but their rarity may be correctly inferred when I state that I have met with only four cases in my private practice. All belong to the internal variety of squint, and all occurred within six months of the operations. Two were in medical students, aged respectively twenty-one and twenty-two; one of these was a single squint, the other a double, one eye of which relapsed. In both,

second operations were successful. The third was in a male, thirty years of age, and, like the others, was ultimately set right. The fourth occurred in a young lady of eighteen. I have kept no account of relapses that may have followed any of my public operations. I do not remember any. There can be little doubt, that in many of the supposed cases of the recurrence, the operation has never been completely done. I have verified this when operating on them. M. Malgaine has noticed relapse a year after the eye has been straight.

In repeating the operation, far more nicety is needed than in the first instance, as conjunctival cicatrix must be cut through, and the muscle is not so readily found, nor so easily divided, and the caruncle drops in an excessive manner.

CHAPTER XIX.

INJURIES FROM MECHANICAL AGENTS.

BURNS AND SCALDS.—BLOWS.—WOUNDS.

BURNS AND SCALDS.

The surface of the eye is liable to be injured by heated liquids, by explosions of gas, of gunpowder, and all other inflammable compounds, and by glowing or molten metal. Yet it enjoys wonderful immunity from ordinary burns and scalds, which more or less overspread or involve the face and head, by virtue of the involuntary closing of the eyelids, and the instinctive tendency to maintain them shut. It would be a waste of time to attempt to describe the several conditions that are met with from these accidents, varying, as they do, from simple redness, to charring or calcination. The conjunctiva often suffers when other parts escape. There can be no mistake about the nature of these injuries.

The treatment, is comprehended in a few simple rules. Tepid bathing with the eye-douche or the syringe is the first general measure, to remove any extraneous material, and to soothe. After this, diligent search should be made, to ascertain if anything has intruded.

When the cornea or the conjunctiva has been abraded, comfort is given by the application of olive oil, which may be used several times a day. If the cornea be very much hurt, the eyelids should be closed with a strip of court plaster. By so doing, the air is excluded, moisture and warmth are ensured, and the parts are maintained in quietude. Evaporating lotions, hot or cold, or water dressing and anodyne applications, according to the circumstances of the case, and a strict attention to cleanliness, include all which is necessary.

When the eyelids are involved, the discharges should be carefully removed from time to time, and this may be facilitated by cutting off the cilia and keeping their edges greased. Farther topical treatment

is seldom available. Stimulating and astringent ointments and lotions of all kinds, in an early stage, are injurious by increasing irritation.

Bodily rest and attention to constitutional symptoms are imperative. Neglect of them might bring the penalty of prolonged suppuration, or inflammatory action of the entire eyeball.

If the vitality of any part have been destroyed, or a wound inflicted, such treatment must be adopted as would be used to a similar injury in any other part of the body.

That which is to be most feared, next to the loss of sight, when the accident is severe and destroys tissue, is contraction, and subsequent adhesion of the eyelids to each other, or to the eyeball; inevitable conditions, accordingly as the angles of the eyelids are injured, or the conjunctiva is destroyed. Cicatrization cannot be fully effected without such contraction; but the quicker it is brought about the less will be the defect. The prudent course, therefore, is to endeavour to reduce the healing process to the shortest limit, and afterwards to attend to the adhesions. In proportion to the duration of suppuration, is the amount of contraction.

Accidents from gunpowder affect the eye in several ways. The scorching effects are most common, and these are met with from mere reddening of the conjunctiva to positive charring of it, and of the cornea and the surrounding parts, by which the eye is quite destroyed. Some examples of the latter have been among the worst spectacles of eye accidents which I have seen.

Treatment. For the slighter damage, this is the same as for burns and scalds. For the greater, I keep the burnt parts thoroughly oiled, apply cold applications to lessen pain, and to subdue vascular action. When suppuration sets in, I use warmth, chiefly through the agency of poultices. In most cases some preparation of opium is required to procure sleep. Recovery is necessarily very tedious.

When the eyeball is much damaged, sight being destroyed, it may lessen the severity of symptoms, and abridge the process of cure, to extirpate it, or what remains of it. As soon as such an operation is necessary, it is a great pity to delay it.

The impacting of grains of gunpowder, or the charcoal residue of the powder, in the cornea, in the conjunctiva, and in the skin of the eyelids, frequently occurs. It has been strongly recommended by some surgeons that such particles should be picked out. I think the question of picking or not, should be determined by circumstances. I should leave the skin alone, because only a portion of any individual particle forced into the true skin, can actually be removed from it without taking away some of the texture in which it is

embedded. The same remark applies to the conjunctiva. I have seen a recommendation from a French source, to apply violently stimulating lotions to the surface directly after the accident, strong solutions of corrosive sublimate, for instance, for days together, to produce a violent eczema, by which epidermic scabs are raised, and the gunpowder also, more or less, with them. Which of the two, the remedy or the disease, is the worse, is a question that must occur to the mind of the reader! Very differently, however, would I act if the cornea were affected. I would chloroform my patient, and try to remove all that was central, and at all likely to interfere with the transmission of light; and leave any which might be at the circumference. But only the superficial deposits can be extracted, those which are scarcely in the true corneal tissue, without inflicting very much permanent damage to this delicate tissue, through subsequent opacity.

Sometimes the particles are driven through the conjunctiva into the sclerotica, and through the cornea into the chambers of the eye. The capsule of the crystalline lens, and the lens also, have been penetrated, when opacity of these parts ensued; and cases on record show that the powder may pass through the substance of the iris, and then enter the lens. These conditions are irremediable except by the removal of the cataract, which is induced.

Severer effects still, are produced on the internal parts of the eye by concussion, arising out of the expansive force of the gunpowder. The lens with its capsule may be displaced; the iris also, more or less detached, and thereby blood effused in the chambers of the eye.

Still worse is rupture of the eyeball. A poor boy in one of our West India islands suffered in this way. A gentleman who heard of the accident, all honour to his memory for the generous deed, went to see him, and being encouraged in the hope of getting sight restored, because light could be discerned from darkness with the one eye, and also because a medical man thought something might be done, brought him to London to me. What indigent boy was ever before conveyed thousands of miles for surgical treatment? I found one eye completely collapsed, only a mere button of tunics remaining. The other had been ruptured across the cornea. It was partially collapsed to about half its original size. Now, at the time of my inspection, a few months after the explosion, which originated in a boyish trick with a large quantity of gunpowder, the blindness was complete. Every portion of the face was blue with the powder grains and charcoal residue.

Burns produced by melted metals, offer no peculiarities whatever: The most frequent accidents of this kind are from lead, and the slightness

of the effect is frequently a matter of marvel. Pages might be filled with the wonderful escapes that are recorded, the greater number of which relate to the entrance of lead that had moulded itself to the surfaces of the eyeball and to the eyelids, thereby showing that it had entered the eye in a fluid state. The theory suggested to account for this is, the protection afforded by the evaporation of the fluid on the eye, by which a stratum of steam is quickly formed.

In the last occurrence of the kind that I saw, many of the cilia of both the eyelids were tied together with a lump of solder, and the eye could not be opened till they were cut off. The edges of the eyelids were severely singed.

The following remarkable accident from molten iron is recorded in the "Ophthalmic Hospital Reports." Some molten iron at a white heat was spirted into the left eye of a workman. It struck the eyeball over the lower edge of the cornea and the adjacent part of the sclerotic coat. A fellow-labourer removed the metal with some difficulty after it had solidified on account of its adhering firmly to the charred tissues. It had in cooling, been accurately moulded to the surface of the eyeball and to the edge of the lower eyelid. The affected parts of the cornea and sclerotica, which included the greater part of the thickness of each, sloughed off, as also did some of the palpebral mucous membrane. The eyeball itself, however, did not inflame. In the healing of the scar, the pupil was drawn downwards by puckering of the iris at its attached margin, but union was retained. Some adhesions between the eyeball and the lower eyelid resulted, but they did not constitute any material deformity, nor occasion much inconvenience.

Treatment. Burns and scalds of the eyelids are generally followed by very distressing contraction, from the mobility of them and the thinness and looseness of the skin, and the mobility of the tarsi. Paramount attention is therefore required, to prevent the suppurative stage, or to lessen it when established.

Of all local applications that I have myself tried and seen used, none are equal to nicely-dressed cotton-wool; it is soft, light, and cleanly. It should not be applied in a lump, but put on in minute bits, and pressed with a probe so as to make it smooth and uniform. Where there is merely an abraded surface, from loss of cuticle, it excludes the air, and soaks up any superfluous secretion. If suppuration should exist, it absorbs the superabundant fluid, while enough is left for the purpose of sufficient moisture; and under its influence the sore does not grow flabby and indolent, requiring stimulants, as so frequently happens with water-dressing, and the granulations are kept in a condition that precludes the necessity for escharotics. I

I have frequently seen ordinary ulcers that had resisted other applications heal under this, the simplest of all means. The changing of the material is readily effected. Any portion adhering to the sound skin must be wetted to facilitate removal; that over the raw surface will always readily separate when surcharged with moisture. Should a mild astringent ointment seem requisite subsequently, the Pharmacopœia supplies many to choose from.

No method of primary treatment that is known will prevent subsequent contraction, if the true skin, the cutis vera, be much damaged or destroyed; all that can then be done, when there is such damage, towards lessening the deformity, is to endeavour to shorten the period of suppuration, or, in other words, to promote healing as quickly as possible.

Where the edges of the eyelids are ulcerated, the special indication is to prevent them from uniting, and this may generally be done by careful daily dressing. The use of goldbeater's skin, the retraction of the palpebræ, or any other device that ingenuity can supply, should be resorted to if it seem likely to be beneficial. But when the angles, that is the corners of the eyelids, have become raw, the greatest care is needed to check the attachment. More or less contraction during cicatrization is certain, and cannot be stopped.

It must at once be apparent that I speak partially of the effects and of the treatment of burns and scalds, and refer only to those cases where there is some ophthalmic bearing, something peculiar to the eye and its appendages. The general details of such accidents with the degrees of severity, the several stages of repair, and the appropriate treatments for each, may be found in any good book on surgery, and are unnecessary here.

ECCHYMOSIS.

The ready production of ecchymosis or extravasation of blood into the cellular tissue about the eyelids is, of course, owing to the superficial position of the bones of the orbit, and the contusion that the skin therefore receives even from a slight tap; while the accompanying considerable tumefaction which is so common after any blow, is due to another peculiarity of the orbital region, the looseness of the skin.

Treatment. In slight ecchymosis I question whether any means, except general friction, can hasten the natural process of absorption. Briony root, or Solomon's seal, scraped and made with bread into a poultice; and infusions of rosemary and arnica, are often recommended. The tincture of arnica and water is the present popular local remedy for all bruises; and a patient would scarcely be satisfied

unless he receive a prescription in which it be included. Dr. Garrod made a series of experiments with arnica, with reference to its power in producing absorption. He selected patients in whom dry-cupping had been performed sufficiently to produce ecchymosis. He tried the action of arnica spirit lotion, spirit lotion, and spirit. His conclusion was that the application of spirit to a bruise is decidedly of advantage, but that the addition of arnica is not attended with any increase of the benefit.

It is not, I suspect, a fact as supposed, that prize-fighters possess means by which they can disperse these results of their savage encounters. I believe they last in them as long as in other people: but as their accustomed personal exhibitions after fights are at night, and by gas-light, most of the blood colour, especially the lighter hues, are invisible, and hence the popular assumption of the potency of their remedies. If it be true that in them the extravasation is quickly dispelled, it is more probably owing to their youth, and to the perfection of the nutrient and absorbent processes, which exist in their high bodily condition.

There does not appear to be satisfactory evidence that depressing the temperature of the surface by frigorific mixtures hastens absorption; and, theoretically speaking, I should rather expect it to retard nature in her operation.

Large extravasations of blood may demand special treatment. The extravasation may be increasing. The supra-orbital, or infra-orbital vessels, or other arterial twigs, may continue to ooze, and resource must then be had to pressure, or to cold, or the heart's action must be reduced, if necessary, by general loss of blood, or by a smart purge, and above all, by perfect rest.

Where the extravasation is considerable, the probability of suppuration is to be borne in mind, and the state of the system must be looked after, and all febrile threatenings attended to. Neither incisions nor punctures should be made, with the intention of turning out coagula; for suppuration may follow. The knife should be withheld, unless there be suppuration or erysipelatous inflammation, or sloughing is impending, or has commenced. Leeches on the injured part are worse than useless; they do not imbibe coagulated blood, while they add to the local injury. The feelings of the patient must sometimes guide us in the choice of local applications. There may be pain, which possibly can be relieved only by warm anodyne lotions.

Several times, after large extravasations of blood about the trunk and limbs, I have made small punctures to ascertain the changes that were taking place in the clot. It would seem from such observations, that the surface breaks down into a very dark fluid, which is composed

chiefly of blood-corpuscles in various degrees of disintegration. This is removed, to be replaced by further melting of the clot, till all is reduced to fluid. During the process, fluctuation is always perceptible.

Ecchymosis of the conjunctiva, as every one knows, is produced by very slight causes, such as the most trivial blow, a cough, or a sneeze, or retching in sea-sickness. Indeed, it is not uncommon without the slightest trace of its origin. It is distinguished from inflammation of the conjunctiva by the entire absence of distended vessels, of pain, and other inflammatory symptoms; and by the uniform dark reddish-brown tint of the discoloration which continues to the edge of the cornea, and there terminates abruptly. It is very persistent, but need not excite the smallest anxiety. Even with tumefaction from extravasated blood beneath the membrane, it is not hurtful. I have seen every variety of this swelling from accidents, and after operations; and I never have deemed it prudent in the worst examples to make incisions, nor have I ever regretted non-interference. I have, on the contrary, seen the disadvantages of incisions. What good can they do? The blood is no longer fluid, and therefore it cannot escape.

All that I have said relates to ecchymosis alone in its several degrees, without any complication with contusions or wounds.

My rule then, as to treatment, is to trust to the natural process of repair, and to do nothing unless there be pain, or heat, or any discomfort, or other untoward conditions, when I treat the existing symptoms according to the general rules of practical surgery; and therapeutically, using cold, or warmth, or opiates, as may seem necessary.

BLOWS AND THEIR RESULTS.

A blow on the eyeball from a small body, such as a shot, or a cork, or the lash of a whip, may injure the sight, or even destroy it. A violent blow will more certainly inflict damage.

Immediate and noticeable effects are, bleeding in the eye, cataract, dislocation of the lens, dilatation of the pupil, change of colour in the iris, tremulousness of the iris, detachment of the retina, laceration of the retina, laceration of the choroid, and softness of the eyeball from damage to the vitreous humour. Any of these states may exist alone, or most of them may be present at the same time.

When there is no outward mark, in association with the impaired sight after a blow, we shall find sufficient internal injury to account for the loss of function. These consist of internal hæmorrhages in various parts associated with other lesions, dislocation of the lens backwards, inflammation of the interior of the eyeball, with or without degenera-

tion of tissues, atrophy of the optic disk. I believe that there is always some palpable lesion which the opthalmoscope will detect. I say this after carefully investigating every case of this form of accident which has come under my notice. I cannot understand how any one with physiological knowledge, and who has studied pathological changes in detail, can entertain a belief that the function of any organ can be spoiled without preceding structural deterioration. Sometimes the morbid anatomy can be easily detected, sometimes it is too subtle to be understood by the unaided senses, but that it exists there can be little doubt. I will illustrate what I say by a case from general surgery. A patient of mine in St. Mary's Hospital, received a blow on the lower and back part of his neck; there was no mark, and no pain after the first day, nor was the part ever painful under pressure. He was admitted five days after the accident in consequence of partial paralysis of his legs. He died of general paralysis. I removed his spinal cord for examination. A well-known physician who was present, and who has written on pathology, said, in looking at a section of it, "How firm and natural it seems! there is no appearance of disease." Dr. Bastian, our curator, examined the nervous structure carefully. He discovered extensive secondary degeneration in its whole length. So remarkable, and so new to science were the morbid changes, that he embodied them in a paper which he read before the Royal Medico-Chirurgical Society, under the title of "Concussion-lesion of the Spinal Cord."

I believe that surgeons are often deceived, by patients with perfect eyes pretending to have their sight damaged from blows or alleged blows. I am justified in this opinion, as I have been myself deceived for a while in five instances. The last of them was the most deceptive. A young mercantile man sent for me several days after he had been in a railway train which met with an accident. He declared that he had been struck on his left eye, and that his sight was materially impaired. There was no outward mark of injury. His wife supported him in his detail of symptoms, and his usual medical attendants said that his statements could not be doubted, as his position in society and his character put fraud out of the question. As he described his state so well, and without apparent exaggeration, having no doubt informed himself in the matter of impaired vision, I thought that I had met with an exception to the general rule. He declared that he was getting worse daily. He received a large compensation without going to trial; not, as it happened, through any support obtained from me. I heard that he was again at his office, and I obtained an interview with him. He had the audacity to tell me that his sight returned suddenly, a few days after he was paid, while he was walking

in the street, and finding himself quite well he went to his usual employment.

There is so much fraud and exaggeration put forth in claims for compensation, that it is dangerous to attempt to gather pathological facts from the statement of claimants.

Formerly there were many theories to account for the loss of sight from a wound or a blow on the eye, or in the vicinity of the eye, and the most generally received among them was that, injury to the branches of the fifth nerve ramifying externally, communicated irritation to the nervous centres, and by a reflex action, influenced and diseased the optic nerve. But if the optic nerve were in such manner involved in inflammatory action, or degeneration, there must, I imagine, be structural changes, which the ophthalmoscope would detect.

The spoiling effects of a blow on the eye farther considered.

Hæmorrhage. Anterior intra-ocular. It is in the chambers of the eyeball, the space in front of the lens, that bleeding most commonly occurs, and it is oftener seen in the anterior than in the two chambers. When the bleeding is confined to the chambers, it must proceed from the iris, or the ciliary processes, although the source of it, the precise spot whence it issues, is generally not apparent. But a rent in the iris, or the partial separation of the iris from the ciliary attachment, occasionally proclaims the source. The quantity may vary from an amount only to be easily seen, to that which fills the chambers. The blood does not mix with the aqueous fluid, but sinks. It may remain fluid, when it is apt to change its position according to that of the head. It may coagulate or not, or partially coagulate.

Though hæmorrhage as a traumatic effect is always immediate, if the blood which is thrown out be the chief mischief, the rest of the eye being unhurt, recovery is sure. The following case well represents many of the more extreme instances of hæmorrhage which I have met with. A man, fifty-two years old, walking in the street on a Saturday night, was struck on his eye by a stone, and lost his sight, and on Sunday he was brought to me. The chambers of the eye were occupied with blood, and neither the iris nor pupil was visible. Cold lotion and a cathartic were ordered, and alcoholic drinks proscribed. On Tuesday evening the pupil was visible, the aqueous fluid still turbid, and a clot of blood was at the bottom of the anterior chamber. Sight was returning. On Thursday, at noon, the chambers were clear, and a very minute light-coloured clot was noticed lying across the capsule of the lens. The iris was thrown forward nearly in contact with the

cornea, a state which was attributed to effusion of blood posteriorly. Just a fortnight later the anterior chamber was restored, vision had returned, and the eye had completely recovered from the injury.

The removal of the blood may or may not be rapid; in twenty-four hours a small quantity has disappeared, yet weeks may be required for the accomplishment of the same process, if coagulation ensue. There is very marked difference in the time required for the absorption, when the blood is effused into chambers occupied by serum, the consequence of pre-existing disease. A clot has remained during six months under these circumstances, before it lost its shape or characteristic hue, and it was undergoing very slow absorption at the end of twelve months.

In a female, in whom both of the chambers of the eye had been filled with blood, the discoloured remains of a large clot floated about for weeks. I lost sight of the case.

Hæmorrhage continued. Posterior intra-ocular. Hæmorrhage into the vitreous humour is not common, but it is always of a serious nature, because it is caused by great violence to the eye, and it inflicts considerable damage to the hyaloid membrane, and to the vitreous fluid. When effused in large quantities, which is rather uncommon, it is nearly always at once destructive to the eye by disintegrating the vitreous humour; or almost certainly ultimately, by secondary changes in itself and in the vitreous humour, in the retina, and in the choroid. Suppuration in it may ensue.

In small quantities, hæmorrhage may spoil sight by the remains of the clot acting as a veil, or even by secondary changes.

The changes that take place in the blood clot depend on its position and size. When well in front, it may retain its colour for months. Further back, it shrinks, and becomes discoloured, and if large, may break up into smaller portions. The contracted fibrine may be absorbed, and the vitreous humour become clear. But months and years may be required for this accomplishment. I have watched a case through its entire process. At first there was blindness, and at last perfect sight was restored.

More commonly the contracted fibrine is not absorbed, but remains to be seen as a black object, moving about, in a round mass, or in shreds, and if the eye be otherwise sound, vision will be interfered with according to the size and position of such deposits, and the shadows that they throw on the retina. I saw a patient who had been shot five years before. A single shot struck the eye, and remained between the sclerotica and the conjunctiva. Severe inflammation

ensued, by which vision was very considerably impaired. Afterwards the shot was removed. The man now applied at the hospital, because his sight was getting gradually worse. An examination of the interior of the eye, with the ophthalmoscope, showed merely some shreds floating in the vitreous humour. Oblique illumination discovered a red blood clot on the lower and anterior part of the retina. It was visible only when the eye was turned downwards. It is remarkable that the colour of the blood should have lasted so long. The optic disk was healthy. The vitreous humour a little hazy.

The usual position of the effusion corresponds to the ciliary region, and the source of it must, therefore, be near. It is likely that the bleeding here, is really from the anterior part of the choroid, where the coat is the most vascular, and perforates the retina which is thinnest at this situation. But it also occurs in the posterior part of the humour.

The secondary changes by which the eye is spoiled, are just the same as when destruction ensues from the entrance of an extraneous body into the eye, and there is a parallel farther in that the extraneous body may, or may not directly, produce the spoiling action. The eyeball shrinks, the vitreous humour becomes fluid and discolored, or, more or less disappears, while the retina is separated from the choroid by serous fluid; sometimes retaining its attachment only at the optic nerve and the ciliary processes. Sometimes there is plastic effusion over the optic disk. All this seems to be brought about by mal-nutrition, rather than by inflammatory action.

Hæmorrhage farther back in the eye, that is, in the retina, or between the retina and the choroid, or in the choroid, or between it and the sclerotica, is still more rare.

These hæmorrhages are necessarily caused from rupture of the several coats, in whole, or in part. The tearing may be extensive, or involve but a few vessels.

Bleeding behind the retina, and originating in the retina, is generally easily diagnosed if the effusion be small, and such hæmorrhages are generally small. The retina is more or less detached and torn, according to the amount of blood effused. Two men were shot at the same time about the face and neck, by a cockney trap-pigeon shooter. The pigeon which was fired at escaped, but two human creatures were crippled, and they were brought to St. Mary's Hospital. In one of the men, a shot perforated the under eyelid, and struck the sclerotica on the outer part. In addition to external chemosis, the greater portion of the outer side of the retina was detached by blood. In the other, a shot perforated the upper eyelid, and

struck the sclerotica nearly at the same spot. In this eye, a small clot was deposited in the front of the retina.

It is rather singular that while I was writing the last sentence, a gentleman came to my house with this rare form of extravasated blood from an accident, having been sent by Mr. Coulson, of the Old Jewry. He was fifty-one years of age. While visiting a warehouse, a bale of cork weighing a hundredweight, fell on his head, crushed his hat, and knocked him down. There was not any scalp wound. Headaches with loss of memory, and impediment of speech followed. For four days after the accident he could not see to read. Some days later, he discovered that one eye was defective. As soon as Mr. Coulson, who was attending him, heard this, he told him to consult me. I quickly recognised a small clot in the vicinity of the macula lutea, bulging the retina. Vision was affected in the following manner: The centre of the field was lost, while the circumference remained, but not in perfection, as only very large type, No. 12, could be read. I watched this patient for five weeks, the clot was nearly absorbed, and vision was almost normal. After his last visit to me he was suddenly taken ill with cerebral symptoms, and died in a few days.

With reference to bleeding from the choroid, small isolated vessels may be ruptured, but much more generally there is a large tear, the effusion of blood is extensive, and a clot may be observed occupying a considerable and important extent of the field of vision. Usually the retina is neither torn nor raised. But it may be ruptured, and the blood may project through it into the vitreous humour. Palpable rents in the retina, with blood clots in them, have been seen. Sometimes the retinal rupture is revealed only by time; the cicatrices left after the absorption of the blood showing the nature of the injury. It often happens that it is only at a late period that the source of the hæmorrhage can be told.

In connection with this subject, there is, among some beautifully illustrated ophthalmoscopic reports, published in Dr. Beale's "Archives of Medicine," by my late colleagues, Messrs. Taylor and Hulme, a case from which I take the following abstract:

"Mary Jones, a drunken, dissipated woman, received a blow on the right eyeball one evening in a quarrel. Next morning on awakening she found the eye so damaged that she could only distinguish the outlines of large objects. A few days afterwards she applied at the hospital. The fundus of the eyeball was of a much brighter red than usual, from choroidal congestion. The optic disk was of a rosy red hue, owing to which, and to the heightened colour of the choroid, its circumference was not so sharply

marked as in the healthy eye. There was no change in the retinal vessels. A little to the inner side of the disk, and nearer its margin, lay a clot of blood of a somewhat crescentic form, deep red, almost approaching to black in the centre, and gradually shaded off to bright carmine at the edges.

"The blood was gradually absorbing, and in proportion as this took place vision returned. As the clot diminished in size, it assumed more and more the circular form, suggesting the idea that this might possibly be the process of formation of certain peculiar spots, which have been occasionally observed at this hospital, and probably also elsewhere, also very dark brown, almost black, shaped somewhat like a quoit, being circular in form, with a bright, nearly colourless spot in the centre. An opportunity was not afforded of ascertaining the correctness of this idea, as the patient discontinued her attendance when the sight was almost perfectly restored, but before the change in the clot had ceased."

Professor Esmarch, of Kiel, "Archiv. für Ophthalmologie," Band IV., Abth. 1, s. 350, 1858, gives an interesting case of perforation of the retina by choroidal hæmorrhage, which he had the opportunity of watching for some time. The case is illustrated diagrammatically, showing the progressive absorption of the clot. The Professor states his opinion, to the effect that small perforations of the retina may cicatrize without a mark; but extensive openings generally leave a visible scar, with proportionate defect in vision.

It is only about recent bleeding from the retina and the choroid, the immediate effect of traumatic injury, that I am writing. The several changes which take place in the course of repair in these parts, and the appearances presented, are spoken of at sufficient length, in the chapter on "Diseases of the Choroid," and to which I beg to refer my reader.

The subjective symptoms are just what would be expected, the spoiling of the field of vision to the extent of the amount of the retina raised. But there may be blood enough effused to separate the whole of the retina from the choroid, and therefore at once to destroy sight. In such a case there would be no more reflex from the fundus with the ophthalmoscope, than when the vitreous humour is traversed in its entire vertical plane by blood.

Sometimes coincident with a limited effusion in this situation, there is blood in front also of the retina, and there may be or not extravasation into the vitreous humour. In the latter position it is, I presume, always let in by a rent in the retina, produced by the original accident.

The connection between the retina and choroid is so slight, being

scarcely more than mere apposition, that blood passes between them readily from one spot to another, without structural impediment, where the retina is not rent, and separates them.

Where the choroid is diseased, and there is generally some external evidence of such degeneration, very slight external causes, such as light blows, slight pressure, or vomiting, may cause hæmorrhage. I often call such an eye, a hæmorrhagic one.

Extravasation of blood between the choroid and the sclerotica, I have not met with as the result of an accident, without rupture of the eyeball.

The diagnosis of posterior intra-ocular hæmorrhage is seldom definitely made out at once. When a patient is seen, after an accident occasioning the hæmorrhage, there are generally many circumstances practically interfering with an examination of the interior of the eyeball. The question of interruption to vision, from such a cause, must, therefore, often for a while be undeterminable, although a tolerably approximative opinion might be formed. Tension of the eyeball and bulging of the iris would go far towards confirming its existence. The ophthalmoscope must be used to determine the fact. Even then, the evidence may only be negative, although sufficient, for if there be much blood present, nothing can be seen, for there is no illumination, no reflex from the fundus of the eye. Oblique illumination will sometimes reveal the deposit, by giving a red reflex. Partial hæmorrhage is readily recognised.

The prognosis of hæmorrhage among these parts of the eyeball is favourable when the bleeding is small, so far as absorption is concerned, and it is said that the functions of the retina may be quite restored where it has been raised, or ruptured, or both. I have never seen this; in three cases which I have watched, there have been cicatrices in the retina, with, and without, displacement of this membrane at the spot of injury, and generally some alteration in the retinal vessels around. Only partial recovery has ensued. Very much, however, depends on the site of the extravasation. Effusion that might be almost harmless at the side of the retina will be fatal in the centre, that is, at or about the macula lutea, the integrity of which is so essential for accurate vision.

In giving the treatment of intra-ocular hæmorrhage, I shall direct my remarks first, to blood in the chambers of the eye. It would be unwise to perform an operation with the intention of evacuating the blood. Such is unnecessary. Measures should be directed to prevent, or to subdue inflammatory action, and thereby to serve the double purpose of saving the eye from further damage, and

promoting absorption. In proportion as the aqueous humour is kept free from any admixture of serum, and serum is caused by inflammation, so will be the rapidity of the removal of the blood. Rest and the occasional application of cold water, or iced water in summer, with a thin rag, may be relied on, if there be no excessive vascular action. If there be inflammation, I cup at the temple, or apply leeches, and perhaps give a gentle purgative.

Opportunities of noticing the interesting phenomena of the absorption of the blood, are often afforded when an artificial pupil is made, or when the iris is wounded after any operation, or when during the operation for extraction, blood from the wounded conjunctiva gets under the cornea. The removal is then as rapid as when there has been no opening of the eyeball, and therefore no escape of the aqueous humour.

Hæmorrhage into the posterior part of the eye, produces little or no primary irritation, and is generally not immediately discovered. It is with the view of alleviating pain, if any supervene, and to prevent secondary changes, that the treatment should be undertaken. Nothing of a specific nature can be done. We possess no means of producing blood absorption directly, we can only in a measure prevent any interruption to the natural process of repair, by preventing inflammatory action, and the destructive processes which may accrue from it, or materially lessen it. A longer period of rest of the eye and of the body is necessary, than for hæmorrhage in the chambers, because of the longer time naturally required for recovery. More watching is therefore necessary.

Opacity of the lens, or cataract, may be caused at any period of life by a blow on the eyeball. Probably the effect is often from compression of the sclerotica in one direction, and its extension or expansion in an opposite, and thereby damage to the lens. The capsule of the lens may be broken by the accident, and palpably so, when lenticular matter sometimes escapes into the chambers.

Sometimes there remains after the accident a dense linear opacity in the capsule, with or without general opacity, which would seem to be the mark of a rent. Then, when the capsule is unbroken, it generally becomes opaque if the lens lose its transparency. But the capsule is often broken, and escapes general notice, because the breach is at the circumference, where the thick anterior and the posterior portions join. I have seen the very centre of the anterior capsule ruptured. After a careful scrutiny I have sometimes detected very slight, partial moving of the cataract. The opacity of the lens has no doubt been the result of this separation, because of interference with the nutrition of the lens.

The lenticular and the capsular opacities may ensue in a few hours. I have seen them in eight hours after the injury. They may not be developed for weeks or for months. I will give one example of this lesion. A marker at a shooting ground was standing at a target more than eighty yards from a shooter, in a London pigeon match. A No. 6 shot struck the outer part of the sclerotica of his left eye. He felt no pain, merely a slight tap, and but a small spot of redness of the conjunctiva marked the site of the blow. Opacity of the lens soon set in, and in a few weeks there was a full-formed capsulo-lenticular cataract. The capsule was not ruptured.

The capsule may become partially opaque from external injury to the eyeball, while the rest of it permanently retains its transparency. An explosive compound destroyed the left eye of an experimenter. The appendages of the other eye were damaged. A square central opacity of the capsule of the lens was all the internal hurt that the eyeball sustained. I saw the man fifteen years after the accident. The rest of the capsule was transparent, and so was the lens. Without dilatation of his pupil, he was nearly blind; with dilatation, he could read a newspaper.

But few remarks respecting treatment are necessary here. If the case be simply one of cataract, an operation will be required, for which full instructions are given elsewhere. The plan to be pursued where there is an escape of lenticular matter into the anterior chamber, at the time of the accident, is described under the head of wounds of the eyeball.

Dislocation of the crystalline lens is another effect of a blow on the eyeball.

Dislocation may be said to exist when the antero-posterior axis of the lens is thrown out of the axis of the eye, or the centre quits its position. The displacement is effected with very little force, because the lens is but slightly held in its place.

The lens is nearly always in its capsule, because the capsule easily breaks away from the slighter resistance of the zonula.

The lens may get fixed in the pupil, but rarely for long, as it falls behind the iris, or in front of it.

Dislocation forwards, that is, into the anterior chamber, is the most usual accident. Blood is generally effused into this chamber, and probably also into the posterior one. When the blood is gone, diagnosis is easy, as the lens is readily seen resting on its circumference on the bottom of the chamber, more or less opaque, the iris being pushed back, and the pupil fixed and partially dilated. But the lens may not become opaque when the capsule is whole for some weeks or months, although it may soon get a faint tinge of yellow.

One author speaks of the transparency remaining after twenty years, and another, after thirty-six. As a rule, opacity quickly ensues on the dislocation.

When opacity does not ensue in the lens or its capsule, the lens shows itself in the anterior chamber like a drop of water, of different specific gravity from the rest of the aqueous humour, and its margin seems surrounded by a narrow gilt ring of a splendid yellow colour. In this state the lens has been extracted before it and the capsule have exhibited the least opacity, although they had been dislocated for weeks. If any doubt should occur respecting the dislocation, oblique illumination or the ophthalmoscope will clear it up.

Vision is of course impaired, accommodation being lost.

The history of an unfavourable case is this: There is pain, chiefly of a neuralgic character, in the eye, and about the orbit and the head. Neuralgic pain is a common occurrence when a lens is out of its position. Acute inflammation of the eye supervenes, and if nothing be done, vision is lost. The eyeball may become atrophied.

After an inflammatory attack, the lens and capsule may adhere to the iris, or to the cornea; the adhesion to the latter, has been followed by ulceration and penetration. I have, in a few cases, seen low inflammatory action, with little or no pain, equally fatal to the eye.

But the lens alone, out of its capsule, may lie in the anterior chamber without any untoward symptoms, and be gradually absorbed. More than this, the lens and capsule might not irritate. The late Sir W. Lawrence, in his treatise on the eye, mentions the particulars of a patient who occasionally visited him, with the lens surrounded by its capsule in the anterior chamber, where it had been for twenty-eight years. The general state of the eye is not given. But this is, of course, a very exceptional case.

It is recorded that osseous deposits have occurred on the capsule of a dislocated lens, while the lens itself remained transparent.

In laying down rules for treatment, I give those I act on, and which I have gathered chiefly from my own experience. In children and in young adults, when the naked lens is dislocated, and no irritation is set up, I leave it to be absorbed. Indeed, even with slight local disturbance, without much pain, in a person under thirty-five years of age, I should not interfere, but wait to see what happened. There is no disadvantage in waiting if a case be seen sufficiently often, so that irritation is not allowed to go too far. So frequently have I, by this method, got perfect results, as far as absorption was concerned, that I am always inclined to afford the absorbing process every chance. I have seen untoward results from operating, and I have had to regret not leaving some cases alone. I should adopt the

watching course if I saw the patient soon after the accident, or after the lapse of a few days, and there were not any bad symptoms. After the age of thirty-five or forty, when the lens fibres are more dense, and the nucleus more firm, and therefore absorption cannot so quickly ensue, I make the earliest well-marked symptoms of irritation the signal for extraction. I extract through as small an aperture as possible, and scoop it out rather than press or squeeze it out, as in the ordinary extraction operation; my chief reason for this being to prevent loss of vitreous humour, because the hyaloid membrane having been broken, the humour will readily escape through a large corneal section. More is said about this subject in the chapter on "Cataract."

The necessity for prompt extraction of a dislocated lens, increases with the age of the patient, because of the increased density of the lens tissue. The older the individual, the less is there of the soft cortical portion of the lens, and the more of the dense nuclear part, and it is the nucleus which so obstinately resists absorption.

The adult eye is by far more liable to become irritated than the young eye, and this susceptibility increases with age. Very frequently the blow which produces the dislocation of the lens, at the same time so injures the eyeball, as, at once, to cause inflammatory action, and thereby to produce complication.

A dislocated lens surrounded by its capsule, should be extracted as soon as there is assurance of the capsule being there, for months and years may pass away before absorption occurs; and even were it to be effected before the eye has been destroyed, the capsule, which remains, might prove a source of much irritation, and, perhaps, become the seat of calcareous deposit.

Mr. H. Howard has related an instance of dislocation of lens and capsule into the anterior chamber of the eye, being productive of cerebral derangement. A female, aged thirty, suffered from pain and inflammation in her left eye for nearly seven months, during the latter three of which, headaches, attended with vomiting, were so severe as to deprive her of her senses. Mr. Howard found the whole eyeball inflamed, and the lens, with a small quantity of lymph, lying in the anterior chamber. Extraction was performed. From that time the vomiting ceased, and the head symptoms gradually subsided, and were quite lost after forty-eight hours.

Dislocation partially forwards, that is, into the posterior chamber. The lens does not need much displacement for this accident to occur. The least slipping suffices. It may rest a little on the iris, in which position, a part of the iris will bulge, while a part will fall back from loss of support, and will probably become tremulous. It may fall

altogether against the iris, and bulge it considerably in its whole extent. Should the lens retain its transparency, when a patient is seen, the nature of the accident would be apt to be overlooked.

Lateral displacement is the rarest form of dislocation. The lens is driven sideways towards the ciliary processes. It may be so much displaced that but little of it is visible in the pupil. It has been wedged in, it is said, between the ciliary processes and the sclerotica.

In all these dislocations the lens is almost invariably in its capsule.

The treatment is to extract the lens.

Dislocation of the crystalline lens into the vitreous humour. This is a severe accident, because it inflicts immediate damage to the surrounding parts, is serious in its ultimate result, and the most difficult to treat. It is generally caused by a violent blow. As blood is, probably, always effused into the chambers of the eye, at the same time, and often, too, into the vitreous humour, the nature of the accident cannot at once be made out. When the chambers are free of blood, the pupil will probably be found dilated and clear, the iris tremulous and curved backwards. Vision is always very much impaired, and if any part of the lens be in the line of the pupil and at all twisted, there will be anomalies of refraction, very puzzling to the patient and perhaps to his surgeon. In every case of dislocation which I have examined among my own patients, and in those of my colleagues, and in all which I have met with in reading, the lens seems to have been enclosed in an unbroken capsule. This explains why the transparency of it remains for weeks or months, and why ophthalmoscopic examinations are necessary to detect the dislocation. I have never seen the lens and capsule quite detached, but always partially, some portions of the circumference being adherent, and occasionally moving in a swinging manner. In one of the cases, a patient of my late colleague, Mr. Taylor, the lens and capsule were turned nearly round in the vitreous humour, so that a part of the fundus of the eye could be seen through them, and a part by the side of it. I watched this eye from time to time for several months. It was only towards the end that the lens was getting opaque. The patient would have nothing done.

Even when the lens has fallen into the vitreous humour, its position can be made out, although the whole of it can seldom be seen. It may be requisite to make the patient turn his eye downwards, while the ophthalmoscope is used obliquely, and from above.

When the lens gets opaque, its presence is more readily determined.

Although the eye does not so quickly resent the injury by pain and inflammation, as when the lens and its capsule are thrown into

the one or the other of the chambers, the destructive action is ultimately developed. But as yet we have not learned much about this accident. The cases that have been recognised have been too few for our instruction. There is this difference between the old operation for "depression" and the injury to which I am now referring, namely, that in the operation the lens is denuded of capsule, or ought to be. But as compared to the spontaneous dislocation of the lens and capsule in a cataractous state, when they swing about in the vitreous humour, which is partially or entirely fluid, there can be little mechanical difference, yet this form of dislocated cataract does not always irritate.

Treatment. If there be no disturbance, beyond the hypermetropic sight, I should not interfere. With the least irritation, the correct practice is to remove the dislocated lens. I have never operated. I learn from Mr. Lawson's work on "Injuries to the Eye, Orbit, and Eyelids," the particulars of two cases so treated. In the first by himself, he made an incision in the cornea-sclerotic junction, passed a cataract spoon into the vitreous humour, and lifted out the lens and capsule. The pupil was widely dilated. Vitreous humour escaped as soon as the eyelid was opened. This patient, forty-six years old, had been in pain from the time of the accident, three months before, and his sight was almost useless. Improved vision ensued, but it did not last. The eye became atrophied and blind.

The second case was under the care of Mr. Bowman, also a male, forty-one years old. The lens was taken out in an entire capsule after seven weeks of dislocation. Vitreous humour was lost. All pain ceased, and vision was improved. "With a convex glass he was able to count fingers and to guide himself about a room."

It may be a surer proceeding, in the first instance, to transfix the lens with a needle passed through the sclerotica, and to push it into the anterior chamber, to hold it against the cornea, and then to extract it.

Where in an eye, the function of which is destroyed, the dislocated lens is causing sympathetic irritation, the operation of "abscission" of the eyeball, or "extirpation" should be done. In such a state, the eye in which the dislocation has occurred, will be spoiled, so that there is no sacrifice of sight, and moreover it will be much inflamed. I should prefer the former operation if it seemed probable that when the cornea was away, the lens could be readily hooked out. If the eyeball were much disorganized, I should prefer the latter. Mr. J. Dixon extirpated a disorganized eyeball, on account of the lens having been in the vitreous humour. It had been there for thirteen years. With the ophthalmoscope it was seen as

whitish well-defined substance lying at the lower part of the eye. Dissection showed that the vitreous humour was perfectly fluid, and that the lens and capsule were converted into a hard and heavy cretaceous mass.

Excessive dilatation of the pupil is often met with from a blow on the eyeball. Blows from corks, especially from soda-water bottles, are fertile sources of this condition. It may be unassociated with any other damage to the eye, being due solely to paralysis of the sphincter pupillæ, and whether this be the case or not, can be readily ascertained by using the ophthalmoscope, and by testing the state of the vision through a pin-hole. If there be good sight through a minute aperture, the prognosis is favourable, and recovery will most probably ensue. As long as the dilatation lasts, vision will be impaired. The dilatation, although lessening, might not pass away for months. In one case under my notice, it had disappeared only at the end of a year. The dilatation may be associated with paralysis of the ciliary muscle.

The pathology of the affection is obscure.

Discoloration of the iris, apart from any inflammatory state, is an effect of a blow on the eyeball. It is an ecchymosis. It may exist alone, but most commonly it is seen in association with conjunctival ecchymosis. It is not of any consequence, and soon passes away.

Tremulousness of the iris is a serious result of an accident. It denotes lesion to the nerves of the iris. The pupil ceases to act, and is motionless. The tremulousness is seen only when the eye is moved. The iris then shakes like a loose diaphragm. It seems to reflect more light than in the healthy state. If the softness of the eyeball be taken as evidence of fluidity of the vitreous humour, fluidity and the paralysis often coexist. Impairment of vision is an accompaniment. The state is irremediable.

Detachment of the iris. The iris is often torn away from its attachment at the circumference. The separation may be very slight, so as to be overlooked by the casual observer; or it may be large, and so form a second pupil. When there is doubt about the detachment, the student should examine the eye with the ophthalmoscope. It may be torn away at corresponding parts of the circumference, leaving only a central strip without any trace of the original pupil, as in Fig. 135. In every variety of this accident the pupil is irregular. The detached parts never unite.

As this detachment, or coredialysis, produces a second and false pupil, the effect of it, as a rule, is to interfere with sight, to produce confusion. It may even cause confused double sight in the one eye.

It is one of the few conditions in which double sight can exist in one eye. These effects, of course, mainly depend on the extent of the separation. When the detachment is slight, there is practically no

Fig. 135.

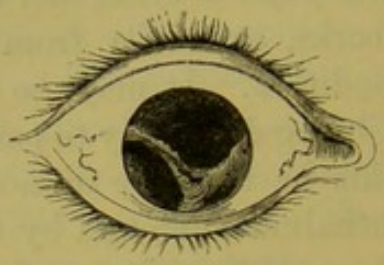

effect. In a case in which the fundus of the eye could be seen through the pupil, and through the false aperture, the patient perceived no second image, although there was a want of acuteness of sight. This is exceptional. The following case is more remarkable still: In a well-authenticated example of this injury, the iris was detached in three places, while the deformed pupil remained in the centre; notwithstanding this, the patient saw objects in their proper position, there being no multiplication of images, and no imperfection of sight.

Detachment of the iris, with laceration. Sometimes a blow detaches the iris, and tears it across at the same time. Fig. 136 is illustrative of this.

I am indebted to Dr. Browne, of the Belfast Ophthalmic Hospital, for the following remarkable illustration. A sharp chip of metal

Fig. 136.

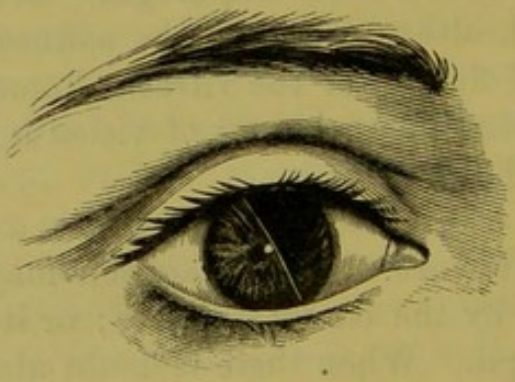

wounded the cornea and the iris, and produced extravasation of blood in the chambers of the eye; and when absorption had cleared the aqueous fluid, the eye exhibited nearly half of the muscular fibres of the iris torn away from the uvea, and rolled up, as the above sketch shows.

These peculiar effects of violence to the iris, unattended as they may be with destruction of sight, and sometimes without damage to

any other part of the eyeball, not excepting even the crystalline lens, are very remarkable. They remind us of other instances of most delicate results produced by violence. It would be useless to multiply examples. Enough has been cited to give the general characters of these accidents, all of which are attended with effusion of blood into the chambers of the eye, and unfortunately, so far as the mere mechanical lesion is concerned, do not come within the scope of treatment. The edges of a rent will retract, and a partially detached iris will remain separated.

The apparent loss of a part of the iris, or the whole of it, after a blow. This form of injury has only lately been properly accounted for. Where the iris has been entirely absent, it has been supposed that it might have escaped through any existing rupture of the eyeball, or wound, a very unlikely thing where the breach is small, and an impossibility where the cornea and sclerotica have remained entire. Mr. Solomon has given a short and interesting communication on the subject, to the "British Medical Journal," 14th April, 1860.

He alludes to several conditions which must have been noticed by men engaged in ophthalmic practice; first, that if the iris be lacerated in its transverse diameter in two or three places, the whole of the segment included in the injury will, in the course of a few days, atrophy and cease to be apparent, although the aqueous humour shall be pellucid; and secondly, that if the ciliary nerves be divided by wounds, so much of the iris as the nerves supply will collapse, and the pupil extend to the rim of the cornea. And again if in the extraction of a cataract, the vitreous body become forced out through the wound, and be allowed to remain there without interference, "that part of the iris which is in proximity with the corneal section atrophies, disappears, and, in time, loses its characteristic structure, being converted into a fibrous band." Moreover, dissection has proved that the greater part of the iris may escape an external examination, and yet be found within the eyeball. Then follows this valuable notice in connection with the above, from the "Archiv für Ophthalmologie," vol. i., part ii., page 119, by Von Ammon, who gives the details of an examination after death, of an eye in which the major part of the iris was rendered invisible by the concussion from a musket, which was loaded with water instead of lead, and discharged into the mouth, by a young soldier who had determined on committing suicide. The only visible portion of iris in the right eye was a crescentic fragment towards the external side. The point where this portion disappeared was neither torn nor abruptly folded inwards, but disappeared without its being possible to discern what had become of it; dissection showed that

the upper, inner, and lower borders of it were pushed back. The lens, with its capsule, were partly dislocated. The vitreous humour was more or less ruptured, and forced forwards by the edge of the twisted lens. It was now therefore, so to speak, partially dislocated. The lens and vitreous body had displaced the iris. When the lens and vitreous body were removed under water, the iris slowly returned to its position. Ammon's report is very long. It gives a most elaborate and tiresome description of the inspection of the two shattered eyeballs.

In examining such cases with the ophthalmoscope, the ciliary processes cannot be seen, and this should cause the nature of the case to be suspected.

Laceration of the retina. This does not occur except in association with hæmorrhage; and enough has been said respecting this, when speaking of hæmorrhage.

Laceration of the choroid may be caused by blows on the eye, and may be the sole damage noticeable. The edges of the rent may be widely separated if the laceration be transverse. The white sclerotica is seen to shine through the gap. The circumference of the wound is generally marked by pigment spots.

Softening of the eyeball from fluidity of the vitreous humour. This may be the immediate effect of a blow. I have seen it within two hours after the eye has been struck. In every case the iris has been tremulous. In all, inflammation of the interior of the eye has followed.

Inflammation of the interior of the eyeball. I wish to limit my remarks to those cases in which the diseased action occurs in the interior of the eyeball, in a limited or isolated form, damaging or spoiling the internal structures palpably, while it is scarcely, or not at all, accompanied by any external evidence of its existence. The inflammation may steal on most insidiously. A lady who was sent to me by my colleague, Dr. Markham, was struck by the lash of a carriage whip on her eyeball while sitting by the side of her husband, who was driving. The merest temporary pain ensued, and all was forgotten till the accidentally-discovered imperfection of sight months after, brought the blow to mind. I found the vitreous humour hazy. The fundus of the eye could not be clearly made out.

A lad applied to me because he saw imperfectly with his right eye. He could only count his fingers. He had visited several ophthalmic institutions, and had been submitted to divers kinds of treatment. Sixteen months before he was struck on the eyeball with a dead pigeon, and vision was soon lost. I examined him, to determine whether there was any external sign of injury.

Not the slightest defect could be observed. Atropine was then used, and with the ophthalmoscope minute black specks on the surface of the capsule of the lens showed that the posterior part of the iris had been in contact with it, but the patient declared that he was quite unconscious of there having been any inflammatory action. But a greater change was yet to be observed. In the turbid vitreous humour hung shreds, or threads, of an inflammatory origin. The optic disk could not be seen. The choroid coat had undergone much pathological change. Except so far as the loss of sight as a subjective symptom, there was nothing to arouse suspicion of the great mischief going on in the eyeball.

A boy was struck on the eye with a stick, and brought to me a week afterwards, having in the meantime been bled and blistered because of the pain that ensued. The surface of the eyeball was a little injected, but the pupil dilated under atropine, no slight evidence of the absence of inflammatory action in it. The lens was clear. The vitreous humour was turbid, and the state of the retina could not be made out satisfactorily in consequence. The choroid seemed spotted, as if from the removal of the choroidal pigment. There was scarcely any vision. The eye was perfect before the accident. The several changes were all effected in a very short space of time, and with but little, if any, external evidence of what was passing within.

I conclude my examples with a case that I saw among Mr. Hulme's patients, the particulars of which are reported in the volume of Dr. Beale's "Archives of Medicine" already referred to. A very beautiful ophthalmoscopic chromo-lithograph is appended. Besides amplifying what has been said, it shows the very rare occurrence of sympathetic implication of the other eye.

"Mrs. A., æt. sixty-one, received a smart blow on the right eyeball from the handle of a saucepan five years ago. Pain, which was very acute at first, subsided in the course of the day, but from that time the sight began to fail, and has become gradually worse. She has not had any medical treatment, and only applied now because the vision of the left eye has, within the last few months, become seriously impaired. In neither eye has there been any pain during the progress of the declining sight. In the left eye she has frequent faint flashes, and the eye is slightly intolerant to light. There is no external appearance of disease in either. In the right eye there was no useful sight. In certain positions a face could be seen, but not the features. With the left, nothing less than No. 14 of Jaeger's test type could be used, but only for a few seconds, as the letters seemed to run into each other, and got confused.

"*Ophthalmoscopic examination.* Right eye: The superficial choroidal pigment has been almost entirely removed, exposing the network of orange-coloured vessels as distinctly and sharply marked as a well-injected specimen of intestinal capillaries, which they much resemble. A broad band of brilliant white, extremely irregular in form, crosses the fundus of the eye transversely, surrounding the optic disk. In this space the choroid is completely atrophied, and the white is due to the sclerotic, shining through the diaphanous membrane. Masses of pigment, irregular in form, and jet-black in colour, are dotted over the fundus of the eye. The optic disk is of dark-grey colour, deeply shaded towards the margin. For about two-thirds of its circumference, it is surrounded by a line of jet-black pigment. The retinal vessels are distended, and the arteries cannot be distinguished from the veins by their colour. At a little distance beneath the optic disk are two small spots of a greyish colour, woolly or flocculent; probably small masses of effused lymph. One of these is situated in the course of an arterial branch, which passes beneath it, and is concealed during its transit.

"The appearances of the interior of the left eye are of the same general character as those in the right, but in a much less advanced stage."

The treatment is the same as that which should be adopted in internal traumatic ophthalmitis, associated with a surface wound.

A blow on the eyebrow, or on the face in the vicinity of the eye, or on the head, may produce the same physical changes in the eyeball, the same effects on vision, as when the eyeball itself is struck. I have met with many examples, some of which I shall give.

Effects of blows on the forehead. A workman, of middle age, was struck severely on his forehead, just over the left eyebrow, and soon lost all useful sight. When the swelling of the eyebrow and the ecchymosis had passed away, the eye was found to be useless. After applying to two hospitals he came to me. There were no external objective symptoms. I discovered that the greater portion of the retina was detached by serous effusion.

A gentleman while playing at single-stick, received a smart stroke just above the upper margin of the orbit. Cataract in the corresponding eye followed in a few weeks.

A cabman slipped, during a snowstorm, while alighting from his box, and struck his forehead against the cab-shaft. He quickly discovered that he had damaged his sight. Four days after I saw him, no mark of outward injury was visible; his left crystalline lens was dislocated into the anterior chamber.

A child, four years old, fell violently while running, from

tripping over a stool in the drawing room. One of his lenses was dislocated across the pupil.

Effect of blows on the face. R. T., æt. nineteen, was jolted off the tail of a van, which was too sharply driven round a corner, and thrown on the left side, the left cheek coming to the ground. Ecchymosis of the skin around the left eye was all the apparent damage. Three weeks after he found the sight of the left eye to be imperfect, being misty. Soon he saw that his pupil was milky, *i.e.*, cataract was forming, and in two months it was white. When he applied to the Central London Ophthalmic Hospital, there was a fully-formed bluish-white cataract, dislocated into the posterior chamber, and resting against the iris, which was bulging. The pupil was not altered. A very delicate pink zone in the conjunctiva, and in the sclerotica just around the cornea, and a few large veins in the conjunctiva, were all the visible vascular disturbance.

An engineer was striking a bar of iron with a sledge-hammer, a piece of the metal broke off, was projected against his face, and fractured his nasal bones, the eyebrow never having been touched. I saw him three days after the accident. The conjunctiva of the left eye was slightly ecchymosed, and the pupil greatly dilated, and vision was extinct. The interior of the eye was not examined.

A woman endeavoured to catch a little boy who was tumbling downstairs, and was struck violently on the nose. The vision of the right eye became impaired, and was lost. There was only the slightest accompanying redness of the eyeball. Many months after she applied to me, for the first time, to ask some questions about the other eye. In the right I found white atrophy of the disk, and degeneration of the choroid, the pigment of which was removed in large patches. That these changes were the effect of inflammatory action from the blow, I cannot doubt.

Effects of blows on the head. I have given above, under the head of posterior intra-ocular hæmorrhage, the particulars of a case of damage to the interior of the eyeball, from a blow on the top of the head, to which I need only refer.

A lady fell backwards to the ground, out of her waggonette, pitching on the back of her head. She felt no damage at the time. A few days after, one of her eyes became painful, and now there was developed and well-marked internal ophthalmitis, associated with outward vascularity. Vision was nearly lost. I saw this patient but twice, on both occasions she was brought to me from the country, and I am ignorant of the end of the case.

The treatment has been described when treating of direct injury to the eyeball.

Blows about the orbit that induce inflammation in the orbital tissues may be the cause of destroying sight, in consequence of the optic nerve, or the eyeball, becoming implicated in the inflammatory action. The ophthalmoscope revealed this to me. It is several years since I mentioned publicly that a severe blow on the temple, or on the margin of the orbit, producing protrusion of the eyeball from orbital cellulitis, was generally attended with damage to vision. I showed that it had been so in all the cases of which I had taken notes, and four had been seen by me in one year. In some, vision was impaired, in others it was lost. There were, too, common states in all; namely, more or less loss of motion in the orbital muscles, and absence of any external change in the eyeball, except where the pupil was inactive.

The same conditions were noticed after severe inflammation of the orbital contents, consequent on the injecting of an orbital nævus, the particulars of which will be found in the chapter on "Nævus." It is only within the last few years that I have examined such cases ophthalmoscopically.

First, as regards damage to the optic nerve. A military officer, while drunk, was thrown out of his dog-cart, and struck on his right temple. When I saw him, about a week afterwards, there was very acute orbital cellulitis, with the accustomed protrusion of the eyeball, and impaired vision. The orbital symptoms subsiding, the eyeball gradually returned in the orbit, but the ocular movements were impaired in an upward direction, the rectus superior being paralyzed. Vision, however, became worse and worse. In order to get this man out of debauchery in London, he was sent for a voyage to New Zealand. After the lapse of nine months, I examined him. The exterior of the eyeball seemed healthy. The loss of power of the rectus superior was as marked as before. There was total blindness. Ophthalmoscopic investigation revealed bluish-white atrophy of the optic nerve, with a jagged choroidal rim, and the usual accompanying contracted state of the central artery of the retina.

An artisan with an obstructed lacrymal duct, applied to a surgeon. An ineffectual attempt was made to pass a style. Acute inflammation supervened, considerable protrusion of the eyeball followed at once, and vision was soon lost. There were no cerebral symptoms of any kind. I examined the interior of the eye four months after. There was the evidence of past optic neuritis, the details of which need not be given.

It appears to me that the paralysis of the orbital muscles may be explained in the same way, *i.e.*, by the implications of their nerve-trunks in the inflammatory action.

Secondly, as regards damage to the eyeball. A publican's wife was thrown out of her gig on to the pier of a bridge, and received a violent blow on the temple. The orbital tissues became inflamed, the eyeball was protruded, and the conjunctiva was chemosed. I saw her nine weeks after the accident. There was a scar on the external angular process of the frontal bone, with thickening of the bone, complete ptosis, with an everted and motionless eyeball, and a fixed pupil elongated outwards. All this denoted paralysis of the third pair of nerves. Vision was nearly lost.

The vitreous humour was too hazy to enable the fundus of the eyeball to be seen. I lost sight of this patient.

The treatment is to endeavour to prevent the occurrence of inflammation in the orbit, when such damage has been received as may produce it, by rest, by the application of cold, and perhaps local blood-letting. Or if it should have come on when a patient is first seen, and be still acute, to try by the same measures to subdue it, or, at least, to lessen the intensity of it.

Blows on the eyeball, attended with rupture of the external coats, and disturbance of the contained parts. Blows on the globe of the eye may cause rupture of its coats, or the separation, or dislocation, of some of its internal parts. Bursting is no uncommon occurrence.

When the sclerotica is ruptured it is certain that very severe violence, and for the most part direct, has been received. There is inevitable participation of rupture of the immediately adjoining internal tunics. Some surgeons think that resistance is requisite to cause the rupture; as for instance, the eyeball being struck upwards while the head is bowed. The rent is generally about the eighth of an inch long, and is almost always in the same region, at the upper part of the eyeball between the cornea and a line concentric to the attachment of one of the recti muscles; less frequently it is at the inner side. Still less at the outer, and of this I have seen but one example. Very rarely indeed it is at the under. But the rupture has been met with far back behind the conjunctiva, at the upper part. Such a case occurred in the practice of Mr. Bowman. The nature of the accident was not discovered till the eyeball was extirpated. The cause was a blow on the eye from the corner of a carriage door.

It has been suggested, in explanation, that the sclerotica tears at a point nearly opposite to that which is struck; the blows which reach the eyeball being, for the most part, on its lower or its outer side, the upper edge of the orbit and the nose protecting it in these positions.

Rupture rarely happens till after the thirtieth year, when the sclerotica has lost some of its elasticity.

But no theory that has been offered, and there have been several, sufficiently accounts for it. Although the front of the sclerotica is much thinner than the back part, yet it is not the thinnest portion, that which is just behind the attachment of the recti muscles, which commonly gives way. As the question has not the slightest practical bearing, I shall say no more.

I am in the habit of calling this accident a disorganizing one, because it affects so many parts, and inflicts such terrible injury. Indeed, in the worst cases, all the internal parts of the eye are implicated in injury, and the eye is destroyed. The iris is more or less detached at its circumference, and prolapse ensues. Fig. 137 illustrates the appearance. The crystalline lens is generally forced

Fig. 137.

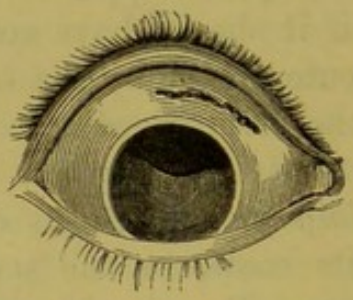

out and lost. Vitreous humour escapes freely. There is always hæmorrhage from the ciliary processes and the choroid; and when it is severe from the latter, the retina is displaced, and may even be prolapsed. The chambers are always filled with blood.

In a lesser form of injury where the rupture is unassociated with the dislocation of parts, as the choroid coat or the ciliary apparatus is damaged, the pupil undergoes a change which must be referred to damage of the ciliary nerves, causing partial paralysis of the iris. It is dislocated to the utmost to the injured side. Sometimes the iris disappears, after the manner explained above.

External dislocation of crystalline lens. Sometimes a blow produces a rent in the sclerotica, while the conjunctiva remains intact, or but slightly torn, and the crystalline lens is forced out of the eye, and rests between these in close proximity to the cornea, constituting what is called external dislocation of the lens. The conjunctiva stretches, and by that the lens is retained. With this the choroid coat is torn, and the iris is more or less paralyzed or torn, and a portion is always carried out with the lens. Fig. 138 exemplifies this. Much blood is effused within the eyeball, but when the effusion is confined to the chambers, or occurs in them, and to a limited degree in the vitreous humour, vision may not be lost; but when it is effused between the coats at the fundus, the eye is spoiled.

Diagnosis is generally easy. The conjunctiva is raised in a round semi-transparent swelling at the part of the eyeball where rupture

Fig. 138.

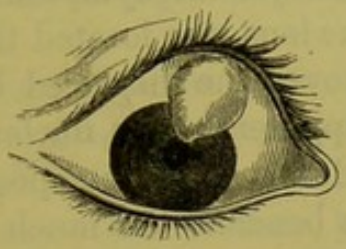

usually takes place, and the prolapsed iris displaces the pupil in that direction.

The treatment is to raise the conjunctiva, snip it, and remove the lens. The aperture should be ample that all may be removed with ease. The fear of vitreous humour escaping is groundless. The capsule may be unbroken, or broken with some extravasation of lens matter.

It has been recommended not to interfere till a fortnight after the accident, that an opportunity may be afforded for the healing of the sclerotica, and a simple rupture thereby be not converted into a compound one. In two cases I tried the method, but I conferred no benefit on my patients. In one, a young adult female, at the end of a fortnight the lens had become decomposed, and then was revealed the cause of the undue irritation, which before was unaccountable. In the other, there was continuous pain.

The following case, while showing other changes which the crystalline lens may undergo when allowed to remain dislocated, illustrates my subject farther: An elderly man presented himself with a violent contusion of the right eye, that had been received some days before. So great was the degree of swelling and ecchymosis of the palpebræ and of the ocular conjunctiva, that I could not discover the actual state of things. I feared, however, that the eyeball was ruptured, because it was evident that the chambers of the eye contained blood. There was considerable pain, but no constitutional disturbance.

At my next visit to the hospital I was enabled, by the reduction of the tumefaction, to discover that there was a rupture at the inner part of the eyeball, at about the junction of the cornea and the sclerotica. Blood still filled the chambers. There was nothing, however, so far remarkable, nothing but the ordinary course of events when the eye receives a certain amount of violence.

I did not discover for some days later, till the chemosis had greatly abated and the redness of the eye had much reduced, the presence of the crystalline lens on the inside of the eyeball,

just posterior to the rupture, between the sclerotica and the conjunctiva. I could not, of course, see the lens; but discerning the tumour in that position, in connection with the pupil drawn to the side, and regarding other objective symptoms, I naturally concluded that, in all probability, the lens was located there. At once I snipped the conjunctiva and removed the displaced body; but not entire, for only a small part of it, apparently the nucleus, remained unchanged, the rest had broken down by decomposition into a gruel-like material. The sclerotica beneath was much indented, puckered, and of an unhealthy aspect. This was just fourteen days from the accident.

A hard amber-coloured lens may remain for days unchanged.

A case is recorded in which the lens was not sensibly changed at the end of thirteen days.

The lens may be partially dislocated through the rupture in the eyeball, and lie half within the eye, and half without. This is an extremely rare occurrence.

The cornea is rarely ruptured, because of its greater strength, and when it is, the effect to the eye is by no means generally so severe as when the sclerotica is burst.

An instance is given by Dr. Mackenzie of a rupture occurring in a gentleman who accidentally struck his eye with his thumb. There must have been a diseased state of the tissues, for in the uninjured eye there was a distinct arcus senilis, a little way within the verge of the cornea, while between the arcus and the sclerotica, the cornea seemed thin and transparent. It was in this transparent position, in the other eye that the rupture occurred.

Treatment of rupture of the eyeball. While I recognise the great power of natural reparative action, and the danger of interfering with it, I am no less sure that much is either lost or gained according as there is no treatment, or as judicious means are used.

No extent of injury short of actual collapse should destroy hope of being able to restore an eye to some degree of usefulness. Many a golden opportunity is lost simply because in the first instance a case has been thought hopeless.

Physical repair and degrees of functional restoration, are now and then beyond expectation, and surprise even those practically well versed in surgical diseases of the eye. In the earlier years of my practice I published several of these wonderful recoveries in the weekly medical periodicals.

It must not be expected that there can be perfect recovery of vision after much mechanical lesion, including the loss of the lens; but I need not stop to show that an eye with even imperfect sight still possesses relative and absolute value.

If the direct inflammatory effects of an injury are quickly got over, the chances of the other eye ever suffering from irritation are immensely lessened. If inflammation lingers, many of the tunics are involved, pathological changes ensue, and the other eye is threatened.

Adaptation, in an accurate manner, of divided parts, slight sustaining pressure, local and general rest, are the things indicated, and the objects to be accomplished. When I see a patient sufficiently soon, I make no farther examination than is needed to ascertain the nature of the injury, to be assured of the line of action required, and to be able to form a tolerable prognosis. Taking care to remove, by washing or otherwise, all extraneous substances, I close the eyelids, and keep them shut by one or two strips of court-plaster, which fulfils the first two indications, adaptation and slight sustaining pressure with the great addition of excluding the atmosphere; I do not like packing with cotton-wool. When the accident is severe, I enjoin rest of body and disuse of the other eye. The quicker the union of the wound, the more certainly is the desired object gained, the more perfect the result, and the less the suffering.

It is positively hurtful to apply stimulating lotions; soothing, and not irritation, is needed. Swelling of the conjunctiva, chemosis, as it is called, is the inevitable result of the injury, and readily passes away. Sometimes it may be well to incise it. The frequent use of cold water by irrigation, or a cold lotion applied with a rag sufficiently thin to allow of evaporation, is most advantageous; and if much pain exist, the addition of some preparations of opium will generally afford relief.

The internal administration of opium may be necessary. Cases are met with in which nothing but the local abstraction of blood will give ease.

I learned, in the operations for the extraction of cataract and for artificial pupil, how much is to be gained by not opening the eye for at least a week after it has been incised. That knowledge has been applied here, and I have found it advantageous to keep the eye closed even longer. No object is to be gained by an early internal inspection, or one from day to day. If matters are doing well, it is not needed; and if any untoward events supervene, their existence is always manifested in appearances of the upper eyelid and the cheek; and then it is, more than at any other period, that opening the eye is likely to be hurtful.

But what is to be done when the iris is more or less prolapsed through the cornea, or perhaps through the sclerotica? The latter state is the more common. Most assuredly, as a rule, the

less interference the better. But very seldom indeed can it be necessary to act. I have thought it prudent a few times, from the amount of the prolapse, from the large bit that was hanging out, to reduce the flap with a pair of scissors, and so to lessen or prevent irritation; but in general nothing of the kind is needed. By a natural and a safe process, whatever is superfluous and not wanted in the process of plugging and cicatrization is removed. The application of nitrate of silver cannot be beneficial; it destroys primary cicatrization, and, besides, increases inflammatory action by irritating the eye; so that it is doubly hurtful.

Constitutional treatment must not be neglected, and all measures likely to prevent or reduce acute inflammatory action must be attended to.

When it is clearly ascertained, however early, that a wounded eye is decidedly lost, and that suppurative inflammation has set in, with the accompanying pain and constitutional disturbance; or, when such should supervene at any stage of treatment, operative surgery should be resorted to, and the eyeball removed. Possessing such means for safe and instantaneous relief, and by which, besides, the greatest protection is afforded to the other eye from sympathetic ophthalmitis, we ought not to allow a continuation of suffering and prostration which no other treatment will check, and which ceases only after certain consecutive morbid changes in the lost organ.

Actual dislocation of the eyeball may occur from a blow. Such an instance is quoted by Mackenzie: "A man was struck with a racket ball; dislocation occurred. It was so complete, that Covillard, the surgeon, found one of the patient's friends with scissors in hand ready to cut it away. Reduction was effected, and vision was restored."

WOUNDS OF THE EYEBALL, INCLUDING THE SLIGHTEST AND THE MOST SEVERE.

Abrasion of the corneal surface. In this which is, mechanically speaking, the slightest of corneal wounds, the epithelium is scraped off. Generally speaking, the accident is of little import, but it might produce destruction of the eyeball. The symptoms are, pain, intolerance to light, lacrymation, the sensation of something in the eye. But as these results are common to other injuries, correct diagnosis can be made only by an inspection of the ocular surface. Therefore, whenever an injury is received and the eyelids are closed, an involuntary act common to all injuries, no one can tell what has actually happened.

The repair is so simple and so rapid, that surgical aid is rarely

necessary. The epithelium being a tissue formed by nutritive repetition, it is completely restored. Even when much of it is lost, the reparation of it may be quick, and the closing of the eye for a few hours will be sufficient to overcome or to prevent discomfort.

The most manifest stages in the process of repair are haziness of the part, the filling up of the depression, and then the restoration of transparency. But very grave symptoms might ensue. Corneitis might be developed, and the worst form of it, traumatic corneitis, with its distressing effects. An insignificant scratch from the soft and undeveloped nail of an infant's finger, a scratch from the beard of barley while reaping, the stroke of a hair from the switching tail of a horse, a tap from a rebounding twig in a hedge, or a penetrating wound from a thorn, might alike develop it.

For all that relates to the symptoms of traumatic corneitis, and the treatment, I must refer my reader to the chapter on the "Diseases of the Cornea."

Wounds of the cornea involving the true corneal tissue. If the wound do not go through the cornea, but divide merely the epithelium, the anterior elastic membrane, and a part of the true corneal tissue, and the eyeball be not opened, it differs in no respect from the above, except in being more severe. The edges of it swell and gape. When there is any interruption to repair, besides the ordinary contingency of corneitis, there is the risk of ulceration and perforation.

Diplopia, or double vision of the affected eye, is for a time, according to Dr. Mackenzie, produced by this accident. This has escaped my observation.

An accidental wound of the true corneal tissue always leaves a mark or scar, in proportion to the damage.

The reparative process, after a wound in a healthy cornea, is sometimes rapid and remarkable, being quickly effected without suppuration or sloughing. It is the adhesive process in the simplest form, being in a tissue naturally without blood-vessels. Regarding it in a physiological point of view, Mr. Bowman well remarks, to the effect, if it be borne in mind that all tissues have a proper life of their own, of which their several properties and actions are the necessary manifestations, and that blood-vessels are but ministerial to the proper life of the tissues they supply, by serving as the medium through which the materials essential to life are brought within their reach, and what is rejected by them is carried away, it is readily understood how it is that a tissue, which, like the cornea, originally grew, and has its ordinary life sustained without the presence of interstitial vessels, may be repaired and renewed without them within

certain limits. He adds the following remarks on the stages of repair. That if the cornea be punctured or incised, the first effect is a change in the natural actions of nutrition then existing in the wounded part, a mechanical interruption to those actions which has been called a stimulus, from the resultant train of phenomena, which is speedily followed by an increased quantity of blood in the vessels of the conjunctiva and sclerotica; and thus the materials whence the breach is to be made good are brought in great abundance to the part. There cannot be a doubt that as these vessels, comparatively so remote, are thus affected, so the part of the corneal tissue intervening between them and the seat of injury, is pervaded by a corresponding change, that it is one of exalted nutritive vigour; the play of forces and the interchange of materials, which mark the nutritive function, being more energetic and more rapid than before. In a short time, even in a few hours, as he had ascertained in the case of the lower animals, the vicinity of the injured part begins to contain in abundance those minute particles, nuclei, or cytoblasts, as they are called, which exist naturally, though sparingly, in the corneal lamellæ, and the relative quantity of which may be regarded in most cases as an index of the intensity of the nutritive function. These particles hastily and imperfectly formed, are speedily found choking the interstices of the tissues in the lips of the wound, and covering its surface, so as to occupy whatever space was left between its opposite sides, and bringing them into temporary union. From the presence of these embryo materials of new tissue, is derived that slight milky opacity which envelops and marks the seat of wounds, and which, if the injury be extensive, may engage a considerable extent of the cornea in the direction of the neighbouring blood-vessels. The breach being filled, the new material is gradually transformed into products resembling those tissues from which it has been formed, the blood-vessels resume their normal size and length, and in the most favourable instances all vestige of the wonderful process which has taken place vanishes away.

Such is the progress which usually ensues when the cornea is punctured by the needle in the operation for cataract. In wounds with loss of substance or attended with extensive division of parts, the demands on a tissue so feebly nourished must exceed its limited power. The result will be oftentimes the failure of the adhesive process, with the establishment of a temporary ulcer or open breach, and often with actual sloughing of the lips of the wound. The reparative action then is slower and by granulations.

These are valuable observations, the understanding of which will be the surest safeguard against the officious meddling of hurtful

treatment, during the necessary stages of corneal repair. They explain too, how it is that a simple puncture with a cataract needle, or even a larger clean-made wound, may leave no mark. But for this there must be no loss of substance of the true cornea. When any portion of the lamellæ is lost either mechanically, or by any of the destructive processes of inflammation, a material of a lower organization supplies the place. It is the same in most of the structures of the body, perfect restoration, or new tissues, being the exception. The repair is usually made up of an imitation tissue. Here the new element, although not inferior in strength, is fibrous and opaque, not like the old, lamellated and transparent. This topic is more fully dwelt on in the chapter on "Diseases of the Cornea."

A wound of the cornea may produce enlargement of the eyeball, evidently the effect of chronic disorganization. The cornea is lost, and the iris covered by a plastic material, as in staphyloma; it is enlarged, sometimes gets conical, and of a dark blue colour. The enlarged sclerotica does not generally yield in any one spot, but is uniformly distended in every part, with more or less loss of its whiteness, being dark blue or brown, or coloured in spots. The state answers to what is called dropsy of the globe or hydrophthalmia, and although such is supposed to be an idiopathic affection, it may result from unhealthy action consequent on wounds. It is more generally denominated "sclerotico-choroiditis." The fact is, that there is general inflammation of the whole eyeball, not one of its parts escaping, and each exhibiting changes which arise out of its peculiar organization.

The cornea generally suffers the least, its circumference alone may

Fig. 139.

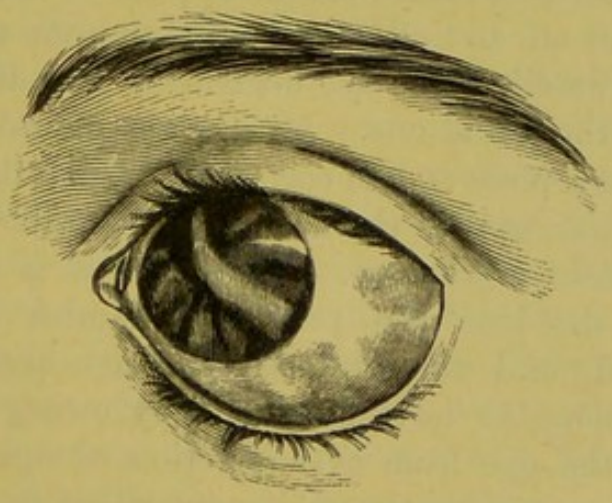

be opaque. Perhaps the whole may be opaque, or both opaque and enlarged. Or a part only may be thus changed, so that its implica-

tion is only a matter of degree. The demand for surgical aid may arise, as in true staphyloma of the cornea or sclerotica, from the great increase in the volume of the eyeball, and the consequent symptoms of irritation and sympathetic affection of the other eye. Or what is more likely, from the mere pain, which is insupportable, and which seems to arise solely from distention : a result almost inevitable when the eyeball is much stretched. This enlargement is illustrated by an example of the disease (Fig. 139) sketched from one of my patients.

At three years of age, an accidental blow was received on the eye from a beef-bone thrown by the girl's father, and sight was immediately lost. From the position and extent of the cicatrix on the cornea I conceive that it was burst. At fourteen years of age the eyeball began to enlarge. It then became painful, and continued to increase and to ache for two years, since which it has been stationary and nearly devoid of uneasiness. The cornea was enlarged and blue, except at the cicatrix, and the sclerotica generally enlarged, with irregular dark blue protrusions. The other eye was becoming sympathetically affected. The long interval in this case, between the receipt of injury and the enlargement, is remarkable.

In the first volume of the "Lancet" for 1850, Mr. Dixon has recorded some examples of this affection, occurring from wounds. I will give two of them. A delicate boy, five years old, received a wound on the cornea; the iris prolapsed, and the lens and capsule became opaque. A little more than two years afterwards the whole globe was enlarged, and its forepart changed into a half-opaque, conical protuberance, of a dark bluish colour. Five years later the eye was considerably larger, the cornea more nearly hemispherical, and its surface uneven from hypertrophy and vesication of the epithelium. The sclerotica was thinned and bluish in several places, and unsightly; besides, there was much pain. The central third of the cornea was cut off, and after various symptoms and consequences, that need not be detailed, the eye ultimately dwindled to a little less than the bulk of the sound one. Mr. Dixon remarks that the morbid changes which took place in the cornea itself, and in the chambers of the aqueous humour, appear the more unaccountable as the lens had undergone complete absorption. I presume it is inferred, that by the removal of the lens the posterior chamber would be more or less destroyed, and the aqueous secretion arrested. He adds that the pain seems to have been entirely owing to distention of the forepart of the eye from over-secretion of aqueous humour, the vitreous body being apparently unchanged either in bulk or quality.

Another case is remarkable as showing the period over which the diseased action extended. An extensive wound of the cornea was

followed by gradual enlargement and pain, occurring twenty-seven years later.

A female, thirty-seven years old, came under my care at the hospital, with inflammation of the whole eyeball of five months' standing. The eyeball was enlarged, and the opaque lens was thrust against the hazy cornea which was just expanding at its circumference, where there was an ash-coloured ring. Three months later the cornea was more expanded, and stood out almost square and greatly enlarged. The sclerotica was now distended to a prodigious size, and uniformly discoloured.

This state of enlargement is in marked contrast to shrinking of the eyeball, which is so common an effect of continued inflammatory action from traumatic irritation, especially when a substance is lodged in the eyeball.

The treatment required is to lessen deformity, to check or to prevent suffering, and to prevent or arrest sympathetic inflammation. Among the many methods that have been practised and recommended is that of puncturing the eyeball frequently through the cornea, and applying a compress and a bandage. Although some good result has followed this method, and so correct a writer as Dr. Mackenzie speaks confidently of curing a case, I must say that it is uncertain in reducing the enlargement, or in stopping the increase, although for a time it might assuage pain. I must also speak of it as being injudicious, because it often increases the diseased action, and sometimes it occasions suppuration.

I recommend "abscission," or "extirpation." The first is most applicable in the early stage of the disease, while the posterior part of the eyeball is healthy, because to give the result proper to the operation, the cicatrizing over of the vitreous humour, this humour must retain some of its density, and there must be no bleeding between the sclerotica and the choroid.

When there is reason to believe, from the size of the eyeball, the intensity of action, or any other symptom, that the vitreous humour is disorganized, excision only is to be recommended.

In the case I have illustrated, the tapping and bandaging were fairly tried, and for a time was supposed to have been beneficial; but after the bandage had been left off for a few days, and the vessels of the orbit had re-filled, it was evident that there was no reduction. Another surgeon, to whom the patient went, tried pressure without tapping, for several weeks, without any benefit. Ultimately I performed "abscission." A large portion of the degenerate vitreous humour escaped, but there was not complete collapse, and, strange to say, no bleeding. A tolerable stump remained, to

which an artificial eye was fitted, and I never saw a nicer adaptation of this appliance.

Wounds of the cornea with prolapse of the iris. By the term prolapse, is always meant partial protrusion. An accidental penetrating wound of the cornea, whether by puncture, incision, or rupture, is almost invariably followed by prolapse of the iris; and this is still more sure if the wound be near the margin of the cornea. The iris is carried out by a gush of aqueous humour which escapes with varying force, according to the nature of the accident, and becomes wedged in the gap. By the elasticity of the cornea the prolapsed piece is tightly embraced.

Fig. 140.

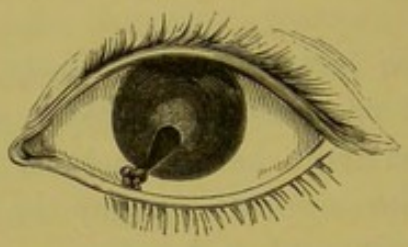

The effect on the pupil is always marked, there is distortion with diminution, the aperture being pulled to the spot where the iris has escaped (Fig. 140). The pupillary movements are therefore interfered with. It is seldom with a lateral prolapse that any part of the pupillary edge is involved; although as a very rare occurrence I have seen the greater part of the iris thrust out in this position, carrying with it the entire pupil, and stretching the rest of the iris across the chambers. With a central wound of the cornea, a very slight prolapse may destroy the pupil. The worst of this class of cases is that in which there is a considerable rent there, as in Fig. 141, the anterior chamber being destroyed, and the iris in contact with the cornea.

Fig. 141.

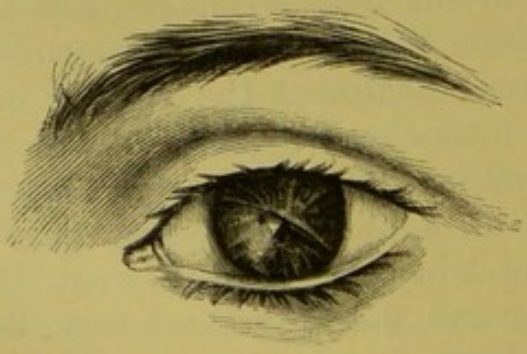

These accidents are remarkably common; the commonest of all the [illegible] occur for the most part among children during play

with sharp-pointed instruments, with stones, bits of slate, &c. I meet with several cases every year in private and in hospital practice.

Treatment. The thing indicated is to return the iris within the eye. This reduction is often talked about, and rules are given for effecting it; but since I have not met with a man who has seen it carried out, and as I have not been able to effect it, the accomplishment of such must indeed be rare. But credit must be given to published reports, in which complete and partial success is announced. The cases are too well authenticated to admit of doubt. It is often said that if a bit of iris which is intentionally prolapsed in the making of an artificial pupil, sometimes annoyingly slips back, regains its position, and spoils the desired object, why may not an accidental prolapse be pushed back? There is a physical difference in the several states. In the former there is no wedging, no forcing of the iris into a wound as far as it can be driven. It is gently drawn into a smoothed-edged aperture much larger than itself: hence the all-significant difference in the two between the relative proportions of the aperture and the contained mass, therefore the occasional slipping back.

If the reduction of any ordinary case of prolapse be possible, it can only be within a few hours after it has occurred, for very quickly does the process of repair set in. A trustworthy observer, Roser, examined portions of prolapsed irides at periods, varying from two days to five after the accident, and found in all a coating of lymph easily separable. This is formed in the course of the natural cure. The new membrane incorporates itself with the divided edges of the cornea, just as happens in the case of disease, when a part of the cornea is lost by ulceration or sloughing, and the iris protrudes, and a staphyloma is formed. It would be useless and hurtful to attempt any reduction after such action is set up.

I will name what is recommended to be done in cases of recent prolapse.

As to drugs, the use of Calabar bean when the circumference of the iris protrudes; and atropine when the pupillary margin escapes.

Now, while I have no faith in the beneficial actions of either of these in decided prolapse and strangulation, I admit their usefulness, and I speak particularly of the latter when the iris is not actually protruding and incarcerated, but just in the wound. I saw a lad, H. W., in less than a quarter of an hour after he had wounded the outer part of one of his corneæ with a scalpel. A portion of the iris was just embraced by the lips of the wound, to which the pupil was pulled, but did not protrude. A drop or two of a strong solution of atropine was at once used, and in three-quarters of an hour the pupil

was well dilated and perfectly round, showing that the iris was quite extricated. The dilatation was kept up for several days. A small scar on the cornea is the only trace of the accident.

As to manipulative measures, rubbing the cornea gently through the medium of the upper eyelid for a few seconds, so as to push back the iris, and then suddenly exposing the eye to a bright light; repeating this several times in succession, taking care that the sound eye is shaded while the friction is employed, and simultaneously exposed to the light with the injured one.

Where a little bag of iris protrudes, using atropine, chloroforming the patient, puncturing the bag to empty it, and pressing back the collapsed bit.

A small or moderate-sized prolapse generally passes through its destined stages of repair, without any ulterior result, provided ordinary care be observed during the period. The care consists in doing everything to soothe the eye, and in closing it with court-plaster. In addition, the patient should be kept tranquil. These measures should be continued till the lacrymation and intolerance to light have ceased, at which time the repair is well established, a condition that will be manifest by the loss of the undue vascularity in the eyeball, except just where the protrusion is, the vessels there being the last to disappear. But if the wound involve a portion of the sclerotica as well as the cornea, and involve the sensitive ciliary region; or if the prolapse be very large; or if it be accompanied with any other damage to the eye, any of the other effects of a blow; there is greater seriousness in the accident, and longer treatment is needed.

Some notice must be taken of the piece of displaced iris, that without the eyeball. In primary prolapse the less that is done the better. I have tried all the recommendations, and carefully watched the different kinds of treatment employed by other surgeons, and I come to the conclusion that those patients did best in which there was no irritation produced by the nitrate of silver, or any other drug; they made the best recoveries.

Nitrate of silver is apt to destroy the adhesions to the cornea, and thereby produce a greater prolapse.

I never snip away any portion of the iris; it is unnecessary, because the soft and delicate bit never irritates, and the act of cutting it away is itself an injury, which has to be repaired. Whatever is not needed in the formation of a proper cicatrix is sure to be efficiently and neatly removed by a natural process, and with a better and quicker result than if interfered with by art.

Secondary prolapse, occasioned by ulceration of the corneal wound,

may be assisted in healing by surgical aid. What I recommend will be found in the chapter on Cataract under the head of prolapse after the operations for extraction.

There is a tendency among surgeons to cease attention to these accidents too soon, and the consequence often is a recurrence of inflammation with the attendant events.

The effect of a prolapse on vision is according to the displacement and diminution of the pupil. Sometimes, therefore, vision is not damaged. The more the pupil is pulled to the edge of the cornea the more is sight interfered with. The cause of this is explained in the chapter on Artificial Pupil. All that I have said above respecting the treatment of prolapse from rupture of the cornea, applies here as well.

Cataract often ensues when the eyeball is wounded. This is a serious complication. That the lenticular opacity is often acquired without the lens being directly wounded, and in consequence of the capsule being partially detached from its ciliary connections, is certain. In such cases, it is probable that the disconnection has interfered with the nutrition of the part, and hence the opacity. But I have also ascertained that the cataract does form without any separation, having been produced by other mechanical influence. The rapidity of the occurrence sometimes is astonishing. There is no difference between the production of cataract from a blow on the eyeball and from a wound, so long as in the latter the lens is not wounded. What, therefore, has been said above about the blow applies also to the wound.

Cataract is most usually the result of direct injury to the capsule of the lens, and to the lens.

The capsule of the lens does not invariably became opaque in its entire extent when wounded. Dr. Mackenzie mentions an instance in which a sharp body pushed through the cornea, merely scratched the capsule, and did not penetrate the lens. A permanent whitish mark was all that resulted.

The lens does not always become uniformly opaque when wounded. It is the impression among those most engaged in ophthalmic practice that a wound penetrating the lens is invariably followed by cataract. Opacity does ensue generally, but not universally, although the exception is extremely rare.

A gentleman wounded his eye with a thorn while hunting. The thorn was extracted. Twelve months afterwards I saw him. The cornea and the iris had been transfixed, and the lens penetrated laterally, nearly to its centre. A small bit of the circumference of the iris was adherent to the cornea. Atropine gave full dilatation

of the pupil, except where there was adhesion. A small pointed opacity with an irregular dot-like outline in the lens, corresponding to the iris injury, was evidently the course the thorn took. The rest of the lens was transparent. There was no mistake about my observation. The novelty of the case induced me to examine it thoroughly.

Mr. Power in his "Illustrations of some of the Principal Diseases of the Eye," gives the case of a delicate girl, who wounded her eye with a pair of scissors, just at the corneo-sclerotic junction, penetrating the iris and the lens. Dilatation of the pupil showed a large white patch, with numerous striæ emanating from it, apparent with the naked eye and the ophthalmoscope. A year after the patient was examined, and the opacity was stationary.

Partial repair of lens opacity. Mr. Power gives also an instance of the actual lessening of a partial traumatic lens opacity. A boy was wounded in the eye with a steel pen propelled from a catapult. The sclerotica was transfixed just behind the attachment of the iris. The lens was penetrated and marked with a black stain, which might have been ink with which the pen was charged, but more probably it was a portion of the pigment of the ciliary processes. After a short time three striæ radiated through the inner segment of the lens, and were plainly visible under the ophthalmoscope. Three months after the accident, there was scarcely a trace of the original injury.

Another accident which tends to illustrate this subject, is recorded by M. Desmarres, "Maladies des Yeux," vol. iii. p. 22-25. An engineer received a small piece of steel in his eye, it transfixed the cornea and the iris, and penetrated the lens. Much inflammation ensued. With the ophthalmoscope a dark body, the size of a pin's head, was seen near the external border of the lens, just opposite the wounds in the cornea and in the iris. It was surrounded by a nebulous opacity. The inflammation lasted for four weeks. The opacity then diminished, but there remained a dark spot, with reduced opacity, about twice its size. Sight remained good. At the end of three months things were in the same state.

The morbid changes occurring in the lens and its capsule, from wounds by which cataract is formed, are given in a summary by Stellwag. These are extracts from it:

"Partial traumatic cataract. Very fine punctures, which do not penetrate deeply, heal, in some rare cases, without leaving the least trace. Usually, shortly after the injury, superficial cloudiness occurs around the wound and subsequently disappears. More frequently, however, the opacity becomes permanent, and at the spot

of the capsular wound a cicatricial, fatty, chalky material. The lens substance surrounding the puncture swells up, disintegrates, and enters the wound in the capsule, or projects beyond its edges. A part is absorbed. A part is likely to become calcareous when any severe inflammation arises, thus a sort of plug is formed which closes the capsular wound like a cicatrix, but often penetrates the lens substance, and is usually covered with a neoplastic hyaline layer, a continuation of the capsule walls. Exceptionally, extensive opacities of the lens, even such as have been caused by severe wounds, such as the entrance of an arrow, clear up with very slight remains, and leave only a proportionately slight disturbance of vision.

"Complete traumatic cataract. This begins with very decided swelling of the lens substance. As a result of this, the capsule not unfrequently tears from the edge of the wound. A portion of the cataractous mass protrudes and is absorbed, while the edges of the capsule retract, and are fastened together by the calcifying remains of the cataract. The result is an opaque capsule with a reduced lens. Where, however, the capsule is not further torn, the wound in it is soon closed by the secondary metamorphosis. The ultimate state much depends on the density of the lens at the time of the accident. Where there has been a distinct nucleus, as in adults, there will remain a nuclear cataract, with a fatty chalky base. Where the lens is soft, as in youth, the whole of it will be absorbed, and a disk-like capsular cataract remain. The larger the wound in the capsule, the more certainly does total cataract occur, because more lens substance is exposed to the action of the aqueous humour."

Certain inflammatory results which may be called secondary, may arise when the eyeball inflames after injury to the lens and capsule. These are, more or less adhesion of the iris to the capsule, adhesion of the iris and the capsule to the cornea by tendinous bands, atrophy of the eyeball. With the increase of age, there is greater chance of these secondary implications.

During several successive generations, surgeons and physiologists have made experiments on the lower animals, with the view of elucidating the causes of the changes in the crystalline lens, from slight wounds. But the marked power of repair possessed by brutes being so much greater than that of man, has been the chief difficulty in the inquiry. It is nearly half a century since Dr. Dieterich's investigations were made. An account of his prize experiments on dogs, on this subject, published in an inaugural dissertation in 1824, is alluded to by Sir William Lawrence in his work on the eye.

He wounded the anterior portion of the crystalline capsule with a

cataract needle, in various manners thirty-six times. Opacity of the lens followed in one case only, probably from its having been unintentionally wounded. The capsule retained its complete transparency, and the wounds in it healed without leaving a cicatrix, even when it had been divided transversely. He punctured the posterior portion of the capsule seven times. Lenticular cataract ensued in one instance only. He incised the capsule twelve times, and on eleven occasions the lens became opaque. Wounds of the posterior capsule were not followed by opacity. In seventeen experiments the anterior portion of the lens was punctured; no visible change occurred in the eye in twelve of these. In three lenticular cataract occurred, and in two violent internal ophthalmia. Of nine instances in which incision was made into the interior part of the lens, four were not followed by any morbid change, while in the five others, where the wounds were deeper, cataract ensued.

Superficial injuries of the lens, on its posterior surface, were not followed by cataract. Such wounds, whether of the anterior or posterior part, when not accompanied with displacement, produced no change in the eye. In a few days they were completely healed. Wounds extending to the centre of the lens were constantly followed by cataract, iritis, and inflammation of the globe. Of eleven experiments, in which the lens was displaced, three were not followed by cataract, while in the others opacity of the crystalline and violent internal ophthalmia ensued. Parallel results on a much smaller scale have been obtained by other Continental surgeons.

Supposed reproduction of the crystalline lens in man. In a publication of the late Mr. Guthrie's, in 1834, on the certainty and safety with which the operation of extraction of cataract from the human eye may be performed, &c., p. 43, an instance is given of what the author considers to be regeneration of the lens. "Anne Wholly, aged twenty-three, came under my care nine years ago, when fourteen years old, having congenital cataracts of both eyes, on which I operated with success. Some circumstances induced her mother to go out of town suddenly, before the eyes were quite clear, and I did not see her again until the 11th of March last, when a small portion of capsule appeared to impede vision at the lower part of the pupil of the right eye, the left being quite free. Supposing that the removal of this portion of capsule would improve her sight, I proposed it to her, and on doing it, I found to my great surprise that the lens had been reproduced, and was quite transparent. It became, of course, opaque, and is now dissolving in the usual manner."

The partial reproduction of the lens, after its removal from the frog and some of the other lower animals, is well known.

Cataract may ensue in consequence of central perforation of the cornea. If the perforation be very small, and the capsule get attached to a mere point, the adhesion will most likely give way when the aqueous humour is again fully secreted. A small central spot in the capsule would then mark the injury. When the wound exceeds half a line, the capsule remains attached by the cicatricial plug to the cornea, and cataract is very likely to ensue. The iris, too, frequently becomes attached to the cornea. Several times I have seen a thin cord of adhesion between the corneal wound and secondary cataract; opaque capsule only, in the posterior chamber. In very large corneal wounds, if the capsule be pressed in the aperture, it may burst, and a part or whole of the lens may escape. Any lens tissue that remains in the capsule always becomes opaque.

Sclerotic wounds are necessarily more serious than corneal wounds, because they involve the choroid, the retina, and the vitreous humour; and besides frequently produce posterior intra-ocular hæmorrhage, which may spoil the eye by the blood accumulating between the ocular coats, or passing in large quantities into the vitreous humour. The chief danger consists in their magnitude. In a large one, the eye is at once spoiled from the escape of the vitreous humour.

Only a few years ago sclerotic wounds were thought to be fatal to the eye, and Sir W. Lawrence in speaking of them, says that they do not unite. Perhaps this is meant to apply to accidental wounds, for the sclerotica has been punctured in the posterior operation for cataract for ages. The practice of some modern surgeons in cutting through this tunic close to the cornea in certain operations for cataract, &c., shows that even large incised wounds may readily unite.

Several times I have tapped the eyeball, very far back in the vitreous region with my small iris knife, and evacuated the fluid behind a detached retina, and sometimes made several punctures. There has been ready union. The healing process may fail, as it does anywhere else. I saw the sclerotica wounded in the operation for squint, about a line behind the attachment of the internal rectus muscle. Large sharp-pointed scissors were used in the operation. A gaping wound was made. There was no escape of vitreous humour, nor prolapse of tunics. A week after there was no marked change in the wound, but the eye was fading by a slow disorganizing process. The iris had lost colour, and the pupil was much contracted. Vision was impaired. A week later the wound was sloughy, and the eyeball was slightly inflamed. Collapse followed, and in a few months,

when my next observation was made, there remained only a button of contracted tunics.

I have, on some occasions, seen a small globular prolapse of the retina and choroid, through a sclerotic wound. It looked like a pupil in the sclerotica. I have never been able to watch such to the end, as there has invariably been some interruption, by which the patient was lost sight of.

Lacerated sclerotic wounds sometimes unite, and sometimes suppurate.

The treatment consists in closing the breach. When the edges are in apposition, nothing more is wanted than to shut the eye and to keep it closed by plaster. All is then plain and easy. But nothing that can be done in the way of compressing or bandaging, can bring together the lips of a gaping wound. For such Mr. Bowman has suggested and practised, the easy and simple expedient of a suture. We are told, on the authority of Mr. Lawson, that he adopted it in two cases. In the first, an adult male, the wound had remained patulous five days, after an injury from a piece of metal that had been stuck in the sclerotica, and was pulled out. In the second, a child, no attempt at union had taken place, one week after an accidental wound from a piece of china. In both cases immediate adhesion followed the application of the stitch. The man's case was complicated with other damage to the eye, but sight was so far saved that No. 10 Jaeger test type could be read. The girl's eye got quite well. The suture in each instance was a fine silk thread, to both ends of which were attached needles, for the purpose of transfixing each lip of the wound from within outwards. This is a great addition to the treatment of these accidents, and should be practised in all gaping wounds whenever it is applicable. The suture should be removed before it becomes a source of irritation. The needles must be short and very much curved.

I cannot say, from practical experience, what is best to be done when there is a prolapse through the sclerotica. I suspect, however, that the less there is of interference the better. The effort of nature is likely to do more than the hand of art.

Gunshot injuries to the eyeball by small shot. Such accidents are usually very severe, from the velocity with which the shot is projected. The eye is nearly always destroyed at once. There are exceptions in the instances of spent shot. Two cases are recorded, in each of which a small shot penetrated the cornea, fell into the anterior chamber, and was extracted without detriment to the eye. When an eyeball is shot within a short range, even very small shot may be driven entirely through it, and lodged in the orbit.

When shot strikes the sclerotica, accompanying ecchymosis often prevents it from being ascertained whether this tunic be penetrated. If the vision be retained, the probability is against penetration. From the presence or absence of pain at first, nothing can be gathered.

Where there is a prolapse of the iris through the cornea, the probability is that a shot is in the eye, but in the absence of other signs or symptoms there is no certainty about it.

Blood in the chamber of the eye shows damage of some internal part or parts of the eye, but it may be of the iris only.

Where the lens is torn, the lenticular substance quickly gets opaque. The displacement of lenticular substance, will be according to the extent to which the capsule is torn. The anterior chamber is always occupied by any portion of the lens that may be detached.

The eyeball as rarely suppurates from internal injury from gun-shot, as it does from any other description of accident.

Secondary destruction of the eyeball from the internal lodgment of a shot or shots, is generally by slow disorganization, resembling mal-nutrition. This effect is most common when shot is in the vitreous humour.

It is generally more difficult to discover the locality of a shot impacted in the eyeball, than any other hard extraneous substance.

The practical surgical treatment, differs in no wise in principle, from that which has been given for the fore-mentioned accidents of a like nature to the eyeball. An eyeball which is destroyed and much torn should be removed.

It is well to save any part of the eyeball, when this may be done, with reference to the after adaptation of an artificial eye. It may therefore be prudent sometimes to perform "abscission," rather than to extirpate.

Slight wounds, or slight lacerations should be treated with the utmost simplicity, according to the rules already given.

An eyeball which has suppurated, whether from external injury, or from the lodgment of a shot in it, or behind it, should be freely opened by incision, or extirpated. I should select the latter if there were much suffering, locally or constitutionally.

CHAPTER XX.

INJURIES TO THE SURFACE OF THE EYE FROM CHEMICAL AGENTS.

NATURE OF ACCIDENTS—EFFECTS—TREATMENT.

STRONG chemical agents applied to the eye very rapidly exert their influence, and therefore quickly spoil the tissues which they touch.

It is not necessary to describe the several effects of these accidents as symptoms. All that need be done is to speak of the immediate therapeutic measures according to the nature of the damaging substance, and then of the remedy for the after or secondary effect, of the same.

TREATMENT.

All reasonable effort should be made to limit the action of the chemical agent, by removing any part of it, as far as possible, that might not have exhausted its power, by washing, and by neutralization.

The free use of water should be first resorted to.

After the washing, science must supply re-agents.

Where a strong alkali has been applied, acetic acid is best for our purpose.

A drachm of the acidum aceticum of the British Pharmacopœia, to seven drachms of water, is the proper formula. A less proportion of the acid cannot be depended on, and a greater quantity would render it too pungent to be borne. Vinegar may be used when at hand.

For injury with an acid, an alkaline solution should be employed, and the bicarbonate of soda, or the bicarbonate of potash, answers

well. From five to ten grains of either, to an ounce of water, will suffice. Magnesia and water may be used. Even soap and water is beneficial. These re-agents should be applied in each instance, once and neatly, with a large camel-hair brush, to the required spot. It is useless and hurtful to continue with them, for repeated use irritates the eye and the skin around.

When lime or mortar enters the eye, after diligent washing, the entire conjunctiva should be searched to discover any adherent bits, and any such should be picked off. The sinuses of the eyelids should be well inspected, and, in deep-set eyes, where this is not so readily effected, a camel-hair, or better still, a sable brush moistened with gum, should be swept along them; but minute particles may yet adhere.

Water is but a poor solvent for lime, and cold takes up more than hot water. A pint at 32° dissolves 13·25 grains; at 60°, 11·6; and at 212°, 6·7; and because of this, it has been imagined that there is great scope for the exercise of practical chemistry, and the specious recommendations that are published, are a sufficient excuse for the student supposing that the eye may be held harmless from any such injuries.

The true state of the case is that this alkaline earth spoils the epithelium very quickly, always too quickly for us to stop certain effects; yet perhaps, supposing that the person were seen immediately after the accident, and everything at hand, there would be more opportunity to lessen the degree or intensity of action, than with most other escharotics. An acid lotion, as above recommended, should be tried. A more effectual way would be to employ a solution of sugar, and to apply the acid afterwards. Dissolve one part of sugar in one part of hot water, dilute with an equal bulk of cold water, so as to have a solution lukewarm, and apply it freely to the eye. With the lime as lime, the sugar will in great part unite to form saccharate of lime; but with carbonate of lime, some of which is sure to be present, and will be quickly increased by exposure to air and moisture, no combination will be formed. It is therefore better to wash the eye subsequently with dilute acetic acid, which will dissolve out the carbonate of lime in form of acetate of lime. A few drops of castor oil afterwards, as a local application, will afford comfort, and acts as a protecting medium against the action of the air. It may be re-applied three or four times a day.

This is, so far as I know, the sum of all that can be done in these distressing injuries. I am aware that other re-agents have been recommended, some on such purely hypothetical grounds, and others so obviously inapplicable, that I shall not speak of them.

I think it unnecessary to continue further with the subject.

Enough has been said, I hope, to establish the value of washing the eye at once, thoroughly, and not to waste any time in seeking for remedies that can rarely ever be serviceable. If, for instance, particles of nitrate of silver were the offending material, it would be far more prudent instantaneously to resort to the water nearest at hand than to delay succour till salt and water could be procured. First wash in every instance, and then seek for chemical aid if there be a probability of assistance from it.

A few words about the washing. When a syringe is not at hand, the patient should be laid on his back, the eyelids held well open, and water from a tea kettle, or anything with a spout or nozzle, poured into the eye. Should nothing of this kind be available, water should be taken into the mouth and spirted by a fine jet into the eye. This method cannot lay claim to novelty, and it is that which might suggest itself to anyone.

Distilled water is always better than ordinary water. In all establishments in which these accidents are liable, there should be ready at hand a supply of distilled water, with a douche, to which the workmen can readily resort. I have induced several masters to attend to this.

After treatment. Having done all that mechanical and chemical skill places within our reach, the after treatment must next occupy our attention. We should exercise great watchfulness to assist the reparative efforts of nature. Total rest of the eye, with hot or cold narcotic lotions, opium ointment to the temple, sedatives internally, in short, anything that gives relief, is indicated. The use of very cold, or iced water, for a limited period, I have found to be very grateful, though occasionally objected to from mere prejudice.

The secondary effects of chemical injuries demand notice. We are most familiar with those which arise from lime in some form or combination. Weak mortar, although freely applied to the surface of the eye, may produce no worse effect than slightly whitening the conjunctiva, and giving a thin cloudiness to the cornea, from which there may be complete recovery. A stronger compound will have a greater influence, with more or less permanent result on the cornea; yet an opacity that seemed indelible and dense enough to render the eye almost useless, may be cleared enough to afford useful vision. When very strong mortar, lime, or worst of all, unslacked lime, enters the eye, the conjunctiva in its whole thickness is entirely and rapidly acted on, and so is the epithelium on the cornea, as also the true corneal tissue, and the worst effects ensue.

There is an insidiousness about the course of these cases that deceives. An inexperienced observer cannot be aware that the

slighter damages, which would merely indicate that the cornea has not escaped scathless, may seriously impair its transparency, or even affect its vitality. Nor can he have any idea of the distressing results that are to ensue when the conjunctiva alone has been severely acted on. The whitening and the swelling, which occur with absence of pain, are not threatening symptoms, and even the separation of the decomposed part gives little or no indication of what must follow.

It is only when the part which has been injured by lime has separated, and cicatrization is rather far advanced, that the inevitable contraction becomes apparent. Inevitable I say; for wherever there is destruction of the conjunctiva from this cause, or indeed by any escharotic, there must follow a corresponding amount of contraction, and of adhesion of the eyelids to each other, or to the eyeball.

The corneal opacity is indelible. Experiments have been made in vain on the eyes of man and of the lower animals, to remove or to reduce it, by chromic, hydrochloric, and acetic acids.

Dr. H. de Gouvéa, of Heidelberg, has been applying lime to the eyes of some of the lower animals, for the purpose of studying pathological changes which ensue; especially the ultimate alteration of the tissues, as revealed by the microscope. His conclusions may be thus concisely summed up.

Cornea. The first effect is the destruction of the epithelium, the remains of which mixed with lime form a detritus.

If the lime have remained for some time in contact with the cornea, it causes more or less deep destruction by the rapid withdrawal of its fluid, and penetrates in variable quantities in small dust-like particles.

A large portion of the cauterised tissue is cast off during the inflammatory process, and replaced by cicatricial tissue containing lime. This tissue is very cellular, and the cells very freely anastomose with one another. It contains nerves, the arrangement and termination of which are similar to the normal corneal nerves.

If the detritus be not immediately removed, it often happens that, besides the above changes, true petrifaction of the substance of the cornea ensues.

If the cauterised portion of the cornea be removed, the white, characteristic opacity does not ensue as the wound heals, but is replaced by transparent tissue. I may remark, that in consequence of this effect, which has been long known, it has been proposed, in accidents which affect only a part of the cornea, at once to scrape off the cauterised piece. The practice might be valuable when the injury is over the pupil.

Conjunctiva. When the conjunctiva is cauterised, the lime quickly enters the sub-conjunctival tissue in different-sized globules, and ultimately forms encrustations on the sclerotica and the adjoining muscles.

In the severer injuries, when the destroyed parts have been cast off, deep ulcers have formed, and granulations appear and contractions begin to show themselves, the common practice is to endeavour to destroy this surface with caustics and escharotics. Even the probe is brought into requisition, and any coalescing edges are rudely torn asunder. I have seen this treatment carried out most diligently, and I am sure that it is highly injurious. It irritates, inflames, prolongs the healing, augments the damage, increases suppuration, and therefore produces greater contractions. I suspect that this error is perpetuated because surgeons lose sight of their cases at too early a date. There is never a greater production of granulations than is required for cicatrization, for the mass disappears in time, in the process of contraction. I am sure that actual adhesion of the granulating surfaces is rare, more so than is imagined, and that the contractions are mistaken for it. The occurrence of adhesion I consider far more favourable for after-treatment by operation, and, if this be true, it should be encouraged. I say, then, use all means to ensure speedy healing; support and approximate the parts by plaster or bandage.

The less the wound is irritated, the shorter will be the suppurative stage, the quicker will be the repair, the less the contraction, and, necessarily, the fewer the bands and the bridles, and therefore greater chance will be afforded for rectifying any deformity by practical surgery. The only exception to this rule is that rare condition in which the opposite sides of the palpebral and ocular conjunctiva have been damaged, while an intermediate portion of the membrane, the sinus, or fornix, as it is called, remains intact, and adhesion is likely to ensue in an isthmus-like form. Then persevering attempts must be made by daily dressing and guarding the surfaces with goldbeaters' skin and ointment, keeping the eyelid retracted, or by any ingenious plan to ensure the individual healing of each. If the glass guard, in shape like an artificial eye, with a hole in the centre, which has been so much recommended of late to be worn to prevent contractions, be at all admissible, it is here, although I think that the object may be obtained in a less objectionable way; for several persons who have used it for other purposes, have complained of much pain and distress; but when one appliance fails, another must be tried.

While wishing to be most emphatic on abuse of treatment, I am

not unaware of the timely advantage of a mild stimulant, or astringent, carefully and neatly applied to an indolent or unhealthy ulcer; and the only drugs contra-indicated are lead and nitrate of silver. When the cornea is ulcerated, or excoriated, lead lotions are inadmissible, on account of the deposit of insoluble sulphate and chloride. The most careful preparation with distilled water does not free it from this objection, because the saline matter in the tears will produce a precipitate. I have picked off the deposit many times.

Respecting nitrate of silver. I thoroughly believe that more harm has been inflicted by it in ophthalmic injuries than benefit conferred. Thousands and thousands of eyes have been destroyed by its injudicious use, by its caustic and irritating effects. It is the cause of a large number of men being invalided from the public services, and it produces a class of miserables, who spend their days in seeking relief from place to place. This salt, when resorted to as an astringent, should be employed of a less strength than produces pain. If one grain to the ounce of water be too strong, less should be used. But I must leave this, and speak about the staining effect, which ought to be noticed here.

In proportion to the strength of nitrate of silver lotion, is there danger of the conjunctiva becoming stained, and the length of time it is used has its influence in the development of this unpleasant effect; yet a weak lotion, not long applied, may discolour. Staining has happened in a fortnight, with only one daily application. During the repair of lesions about the conjunctiva, there is greater likelihood of the nitrate being changed to the insoluble chloride, and ultimately to the oxide, and, probably also, to the metallic state. Where the conjunctiva is unbroken there is less likelihood of discoloration. At all events, let caution be observed. Enough has been said to induce the point to be regarded.

I am not aware that a very decided stain can be removed by chemical action, but I know that it may be reduced by the application of hyposulphite of soda, as strong as the eye can bear it, beginning with eight or ten grains to an ounce of water. It should be applied with an eye-glass. I have never attempted to act on a slight stain.

Acute inflammation of the eyeball may ensue after any of these injuries, and at any stage of repair.

CHAPTER XXI.

WOUNDS OF THE EYELIDS, OF THE SURROUNDING INTEGUMENTS, AND OF THE CONJUNCTIVA.

WOUNDS OF THE EYELIDS, ETC.

It is not too artificial to make the distinction here between incised, punctured, and lacerated wounds.

Of incised wounds, much depends on their direction. Those which are horizontal, and implicate merely the skin, or a portion of the orbicularis muscle, and do not extend to the tarsal cartilage, are generally of little importance, and scarcely disfigure. When they are large, their effects are likely to be more felt in the upper eyelid, because if the levator palpebræ muscle be cut through, ptosis will follow. Again, the suspensory ligament of the eyelid might be divided. Vertical wounds disfigure more than the horizontal. Where the tarsal margin is cut through, it is difficult to prevent deformity.

When these wounds are severe, and are left untreated, or when badly managed, they are frequently detrimental by causing malposition of parts, and producing trichiasis, entropium, or ectropium. With the last, there is more or less exposure of the eyeball, and displacement of the punctum lacrymale. They might, besides, be complicated with damage to the eyeball, or penetration of the orbit. In the one case, sight might be implicated; in the other, orbital cellulitis is risked, with all its evil consequences. Where the palpebral and ocular conjunctiva are cut through, these are apt to unite and produce symblepharon.

Punctured wounds are not, as a rule, troublesome. They heal readily, unless any extraneous substance be present. There are two direct points of danger connected with them. The one is that the orbital plate might be penetrated, and the brain wounded; the other, that the substance which inflicts the injury might get broken and impacted. These contingencies should be kept in mind, and looked for.

Lacerated wounds are the worst of all, as they are injurious, whether small or large. Sloughing, which is imminent at all times, is a very evil consequence.

The rules for treatment are few and simple. Care should be taken that extraneous bodies are removed. Particles of grit will be best extricated by a stream of water from a strong syringe.

Whether the wounds involve the skin only, or pass through all the palpebral tissues, there should be the most careful adaptation of their edges, as primary union is of the first importance. Adhesion of their edges will often depend on the manner in which the bleeding is managed. Many a time it is prevented by the attempts made to stop the hæmorrhage with astringents, and by stuffing the wound with lint, &c. So long as there be not a divided artery that requires a ligature, the hæmorrhage will always cease where it is only between the skin and the subjacent tissue, or skin and muscle, by simple pressure, effected by whatever surgical measure is required for the adaptation of the parts, and a bandage.

Plaster alone is not sufficient, except for the most superficial wounds.

Sutures are nearly always required, and always with deep or extensive divisions of parts. They should be removed early, and never allowed to remain long enough to act as setons. When many are applied, one or more should be removed in about twenty-four hours, and then one or two each day. After this, plaster comes in well. I enter thus into detail, because I see so much inaccuracy and carelessness in the treatment of these accidents. The wonder then is, that primary union ever takes place. A divided tarsal cartilage is to be stitched through its entire thickness, just as well as integuments. The finest thread is the proper material for the purpose. Wire of any kind is abominable. Thread accommodates itself to the tender tissues; whereas the tissues have to accommodate themselves to the wire. The first is applied with ease and accuracy, and is readily removed. The second is not easily introduced, and is removed with difficulty and pain, and disturbance of tissue, disadvantages which should cause it to be banished from ophthalmic surgery. If it should happen, when the cartilage of the eyelid is cut through or torn, that the natural form cannot be maintained by the suture alone, the pin and ligature may be effectually resorted to, as a hare-lip suture. Several may be required. I have always found that the pin is well supplemented with suture. When, from the nature of the wound, sutures cannot be used, and water-dressing or a poultice is necessary, the process of cicatrization is materially assisted by drawing together and supporting the contiguous surfaces

by plaster, or bandage and compress. I have often thereby effected much, in lessening deformity and shortening the period of cure.

Whether it be advisable to pare or remove any torn or jagged edges, for the purpose of adapting the parts, must depend on the circumstances of the case, and the period at which the patient is seen. If more than a few hours have elapsed, and the suppuration stage have commenced, adhesion is impossible, and any interference of this kind will make matters worse. All operative proceedings must then be of a secondary nature, and delayed till every trace of inflammatory action has ended.

A young brewer tore the upper eyelid, close to the orbit, very severely, against a gas-burner; the integuments hung about in a manner which left me little hope of preventing deformity, and ptosis seemed tolerably sure. With the exercise of some ingenuity in trimming and adapting the edges, I got a very satisfactory position of parts. The sequel was gratifying; for when all inflammatory action had passed away, the eyelid could be raised a little. A few months afterwards complete power of elevation returned, and there was little mark of what had happened.

It may be necessary, when parts heal irregularly, to remove the edges of the irregular surfaces, and so to endeavour to restore the natural form.

A cook fell on the brass arm that suspended a bottle-jack over the fire-place, and tore the lower eyelid away from the corner of the eye, without injuring the canaliculus. She did not apply at the hospital till the wound was healed, when the annexed sketch was taken. I

Fig. 142.

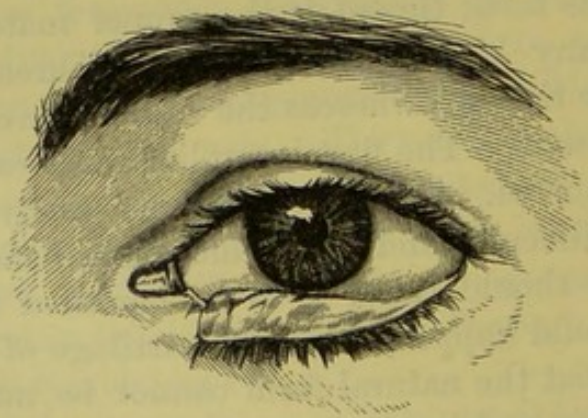

pared the edges, brought them together by suture, and kept the eyelid rather pulled up by semicircular strips of plaster passed from the root of the nose to the temple for eight days. Perfect

I have treated several like instances of injury to the inner part of the upper eyelid, which it would be useless to particularize, each of course requiring little individual matters of attention that would be tedious to detail.

A naval officer, in a drunken brawl, by which he lost his eye and his commission, was pelted by a messmate with a broken decanter. The eyeball and the lower eyelid were cut across. Six months after the accident the outer portion of the eyelid was considerably everted, while the inner was adherent to the eyeball. The deformity induced him to wear a green patch to conceal the eye. By a rather free dissection, I brought the displaced bit in contact with that which was adherent to the eyeball. After the eyelashes, which I had cut off previous to my operation, had grown, so little trace was there of any injury, that it was scarcely noticeable to a casual observer.

The division of a canaliculus in connection with wounds about the inner portion of the palpebræ is an unfortunate complication. When this delicate tube is cut across, adaptation might be effected as a matter of chance, by the introduction of wire or a bristle. As a rule, the eyelid should be adjusted as accurately as possible, regardless of the canaliculus, which must be attended to at a future period if necessary. Nothing is gained by slitting up the proximal end at once, but just the reverse. It is only after contraction from the healing of the eyelid has ceased, that the ultimate and relative position of the several parts concerned can be known.

More will be found on this subject in the chapter on "The Affections of the Puncta, the Canaliculi, and the Lacrymal Duct."

Opening of the lacrymal sac, followed by emphysema, is one of the accidents incidental to wounds in this region. Charles Porter, a young man, received a slight scratch on the inner corner of one eye in a scuffle; he thought no more of it till the evening, when he blew his nose, and felt a puff of air in the corner of the eyelids. Rather amused by the novel sensation, he continued to inflate his nostrils, till he found that his eyes were nearly closed, and his face much swollen. When he came to Mr. Taylor, at the hospital, two days after the accident, his eyelids were almost closed by emphysema, and the swelling had extended down to the cheek as far as the under edge of the jaw. The air could easily be pressed in different directions, conveying a fine crepitating sensation to the finger. He soon got well without any treatment.

Another example of rupture, of which I took notes, was caused by a slight blow from the branch of a tree on the face. This, like the

Seven other cases of emphysema from this cause have applied at the hospital in the course of six years. Although some of the patients were very much puffed up about the face, in all did the effused air get quite absorbed in a few hours or days, without any inconvenience except the trifling deformity, and without treatment.

If the supply of air to the cellular tissue do not soon cease, pressure should be applied over the site of injury, for the cure consists in the healing of the breach through which the air has passed.

Chemosis, or swelling of the conjunctiva, and of the sub-conjunctival cellular tissue from serous effusion, is a common sequence of injury to any of the ocular appendages, and is very likely to excite alarm, but is innocuous so long as unattended with a copious purulent discharge, which would indicate purulent ophthalmia. The extent need never create alarm; the brightness of the cornea, and the integrity of sight, may be taken as certain assurances of the absence of any danger. I have seen the cornea nearly covered by it, from a blow on the eyebrow, and the swelling entirely disappeared in a few days without treatment. Different forms may be assumed by the chemosis, according to the extent or position of the swelling, but these need not be particularized, for they are of no particular importance. I have observed very extensive chemosis, with protrusion from between the eyelids, and yet neither eyelid was everted, but the lower was so tightly pressed against the eyeball that I could not depress it. This peculiarity was evidently from the conjunctiva of the lower palpebral sinus alone being affected. A blow on the eye had produced the mischief.

The treatment is involved in that which is required for the primary injury. All that I have found necessary in addition has been the application of a cold lotion.

Farther or after-treatment, by rest, and the application of water-dressing, is wanted in most cases in which an injury is severe.

It may be mentioned as a concluding remark, that punctured and lacerated wounds, superficial as they may seem, are not devoid of risk of damage to the brain from inflammation. Symptoms which arise in that direction need early recognition.

In the performance of surgical operations about the eyelids in connection with wounds and injuries, allowance must frequently be made for after improvement by plastic surgery. The likelihood also of ptosis from injury to the levator palpebræ, during any dissection, should be remembered.

It may be stated here, that although the usual causes of permanent traumatic ptosis are either laceration and damage to the

intense inflammatory action on the eyelid, consequent on a suppurating wound in it, or in a neighbouring part.

Wounds of the surrounding integuments, that is, about the orbital edge, partake of the character of incised wounds, and should be treated as such. I have written fully on this subject among orbital injuries.

Wounds of the conjunctiva are of little consequence regarding ultimate result, and need cause no apprehension. The last generation of surgeons thought differently, and taught differently.

There is no organized part of the human body that can be cut, wounded, and lacerated with such impunity. In several hundred operations for squint, of which I preserved notes, there was not a single instance of any of the secondary or after-destructive processes of inflammation. There was always an uniform progress of repair from the time it was incised. My continued observation up to this period confirms the same. Prior to the introduction of the operation, when this structure was accidentally wounded, it was thought imperative that the person be submitted to the rigour of strict antiphlogistic measures, and long confinement to a darkened room.

Sutures are of much avail here. The conjunctiva unites more readily than skin. When the wound gapes, or when it is much or irregularly torn, sutures are wanted. Even when any portion is partially detached, they are more especially applicable, for then much that would perish may be saved; always, therefore, is the healing process materially facilitated, and deformity often removed.

The sutures should be applied at the very margin of the wound, and allowed to come away of themselves, a process generally accomplished in three or four days. I have used no smaller needle than that which is figured among the instruments, but it might sometimes be more convenient to employ one more bent and shorter.

Local applications of all kinds are injurious, because they irritate. All in addition that may be requisite is to close the eye.

CHAPTER XXII.

EXTIRPATION OF THE EYEBALL.

EXTIRPATION; INCLUDING THE ENTIRE CONTENTS OF THE ORBIT—EXTIRPATION OF THE EYEBALL ALONE.

Where the eyeball is to be removed on account of being affected with malignant disease, the whole of the contents of the orbit should be taken away. Unless this be done, the important rule, always to endeavour to eradicate every part of the diseased structure by cutting beyond it, or by removing along with it some of the healthy tissues, could not be carried out. As this topic is particularly dwelt on in the chapter on "Malignant Affections of the Eye," more need not be said.

Should the extirpation be required from disorganization arising out of a scrofulous affection, in which exhausting pain or profuse discharge are the urgent symptoms, the parts around may be so diseased, that their removal would be advisable. It is very seldom, however, that such a case is met with.

EXTIRPATION; INCLUDING THE ENTIRE CONTENTS OF THE ORBIT.

The patient should lie on his side, to allow of the escape of the blood, whereby the operator sees what he is about, and is enabled to proceed with his operations safely and quickly.

Ordinarily, there need be no external incisions, but if room be wanted on account of an enlarged eyeball, or otherwise, the external commissure of the eyelids, including the conjunctiva, should be divided to the extent of half an inch, or more; and it may even be required to dissect up the divided integuments for more space.

The eyelids should be retracted in whichever way may seem best, by the fingers of an assistant, by the spring-wire retractor, or by bent

When the eyeball cannot be laid hold of with the fingers, it should be seized with a pair of tenaculum forceps.

With a small scalpel, the reflections of the conjunctiva should be cut through. The levator palpebræ should be divided as close to the tarsal cartilage as possible. The inferior oblique muscle should be severed close to its bony attachment. The trochlea of the superior oblique should be cut from the bone. The eyeball should be turned from side to side, while the knife is swept around the orbital walls to divide the cellular connections and the small vessels and nerves. The muscles, the optic, and other nerves, and the ophthalmic vessels, should now be divided at the apex of the orbit; to effect which, the eyeball should be pulled forwards and inwards, and the scalpel used on the outer side. The slant of the outer wall of the orbit affords more room for the instrument. Lastly, the lacrymal gland should be dissected away, together with whatever of fat and areolar tissue that might have been left. Scissors may be used instead of a scalpel.

Besides the necessary sponging, syringing the orbit may be advantageous in cleaning away the blood to expose the cavity.

In cases of melanosis, the orbital tissues are sometimes so altered from condensation, that a tedious dissection may be required for their complete clearance.

The bleeding from the ophthalmic and other arteries, although very smart at first, readily ceases. Should it continue rather long, or after the application of cold water, a compress must be used. Oozing of blood from the orbital cavity may be checked by applying cotton wool or lint, wetted with a saturated solution of alum. Some surgeons invariably fill the orbit with lint. This is objectionable, on account of the irritation which is produced.

A divided commissure should be united by suture.

A patient requires much attention and careful watching after the operation. Several deaths have ensued from it.

EXTIRPATION OF THE EYEBALL ALONE.

The removal of the eyeball alone, by detaching it from the ocular tunic, sometimes called "enucleation," was proposed almost simultaneously by Dr. O'Ferrall and M. Bonnet, in 1841.

When this limited operation may be done, it is certainly no small advantage over the above, for hæmorrhage of any consequence is avoided, because only the smaller branches of the arteries are cut; all the orbital muscles, with the adipose and areolar tissues are left, and the parietes of the orbit not being stripped, there is scarcely any

non-malignant affections; whenever, indeed, it becomes necessary to get rid of the eyeball, and it alone.

The operation is so simple, that convalescence is generally established in a few days.

Method of performing the operation. The eyelids should be retracted by the spring-wire retractor. The conjunctiva, the fascia beneath, and the ocular tunic, should be cut in a circle, with forceps and scissors, close to their attachments round the cornea. The recti muscles should be severally taken up with the squint hook, and cut across close to the sclerotica, with the exception of the internal muscle, which should not be cut so close, in order that a piece of sufficient length be left for the purpose of being held with the forceps. The ocular tunic should be detached, that is, pushed off, from the eyeball with the closed scissors, or with the hook, and the eyeball made to protrude by pressing backwards the eyelids. The ocular portion of the tendon of the internal rectus should now be laid hold of with the forceps, and the eyeball drawn inwards, while the optic nerve is divided with the scissors. Unless the scissors be kept in contact with the sclerotica till the position of the nerve be reached, when they should be opened and used, some difficulty will ensue. Many operators endeavour to feel the nerve before they open the scissors, knowing how likely it is to miss the exact point. But this is not easily effected, and if the scissors be only passed far enough backwards in the orbit, it is unnecessary. When it is suspected that the retina is involved in any recurring disease, the nerve should be divided as far back as possible. When the nerve is severed, the eyeball starts forwards. The eyeball being then very much liberated, should be held with the fingers, and drawn forwards and inwards, to enable the oblique muscles to be divided close to their sclerctic attachments, as well as any cellular or other connections which may require separation.

If there be any active hæmorrhage, the eyelids should be kept open till it has ceased, in order to prevent the extravasation of blood in the areolar tissue in the parts in front of the divided conjunctiva, and cold water should be applied. Usually there is so little bleeding from the central artery of the retina, that attention to it is not needed; but I have seen very acute hæmorrhage, on a few occasions, requiring well-adjusted and long-continued pressure to control it. Unless, then, a compress and a bandage be at once applied, a patient ought not to be left alone, but watched. The compress should be put on over the closed eyelids. I use cotton-wool, and over that a bandage.

It is a material point that as much conjunctiva be left as possible, the reasons for which are given in the chapter on "Artificial Eye."

Some surgeons approximate the edges of this membrane, or adapt them when they admit of it, by one or two sutures. This is unattended with any advantage. The parts always unite as well and as quickly as when sutures are used. Sutures are often objectionable, by retaining clotted blood, causing irritation, and at times by preventing the escape of inflammatory products. Their removal is always annoying to the patient.

When there has been any pathological change in the orbital contents, by which the sclerotica is adherent to a contiguous part, it may be requisite for separating such adhesion to make a careful dissection with the scissors or a scalpel.

Any alteration in the shape of the eyeball, from a staphyloma or a tumour, may complicate the operation. Especial care is then required that the eyeball be not cut into and opened, for it would at once collapse, and be very difficult to be removed.

With a thin staphyloma of the cornea, or even ulceration, pressure on the eyeball must be avoided during the excision, lest it be burst.

A shrunken or collapsed eyeball is troublesome to remove, because the conjunctiva is not so easily dissected, the ocular tunic is generally more or less adherent, and the ocular muscles, being atrophied, are not readily hooked up. A painstaking dissection may be necessary. More than usual care is required to cut the optic nerve.

Treatment. The patient should be kept at rest, and water-dressing applied. Generally, the recovery is rapid, and nothing is required to be done of a special nature. Sometimes the eyelids and cheek swell, and there is ecchymosis, and discharge from the orbit. With this, some constitutional disturbance is set up. Water-dressing should still be used, and renewed as often as every two hours, and the patient should lie down. Syringing the orbit with warm water might be requisite. In such a case, the position of the eyelids need attention, for inversion is apt to ensue from the swelling, and if so, the cilia will irritate. If the inversion be not overcome by righting the eyelids each time that they are dressed, court plaster must be used for the purpose. If the skin around should get excoriated, it must be protected with pure lard, or mutton suet recently melted. It is unnecessary to speak about the general treatment.

Acute and dangerous symptoms may arise, for this operation is not devoid of risk. No surgical operation is devoid of risk. Loss of life has ensued from it. Von Graefe has recorded two instances in which death ensued in consequence of inflammation of the orbital tissues and cerebral implication. A parallel case occurred in one of our provincial towns. A man had incipient cataract in one eye

A surgeon persuaded him to have the cataract removed, and as a preliminary measure punctured the capsule "to ripen" it. Suppuration of the eyeball ensued. Enucleation was now done. After much constitutional disease, cerebral meningitis ensued, and death followed.

There is often some discharge of a purulent character after the operation, which may continue for weeks, and require the use of some astringent lotion. Granulations may spring up, and require removal.

CHAPTER XXIII.

ARTIFICIAL EYE.

ANTIQUITY OF THE APPLIANCE—MANUFACTURE—CONDITIONS BEST SUITED FOR IT—ADVANTAGES—PREPARATIONS—MODE OF APPLICATION.

In remote ages, mankind sought to remedy the horrid deformity arising out of a shrunken eyeball, and the rudest substitutes were worn, sometimes without the eyelids, being supported by bands, sometimes within them. It is said that such imitation of the feature has been discovered among the mummies of ancient Egypt. It is represented in antique statues.

The first surgical writer who gave an account of an artificial eye, with a delineation, was Ambrose Paré.

The eye has been made of various materials, at different ages, such as gold, copper, glass, porcelain. It was not until the beginning of the eighteenth century that enamel was used, and the French have the credit of the introduction.

The improvements which have of late been effected by the principal artists of London and of Paris in this manufacture, and especially in the method of colouring, render the imitation so perfect that not only may the casual observer be deceived, but even the professional man who is conversant with ophthalmic practice may not detect the counterfeit readily.

A modern artificial eye is but a very light shell, a section of the

FIG. 143.

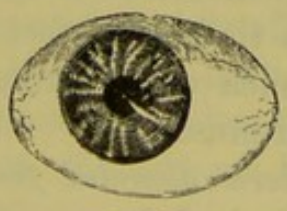

surface of a sphere of soft enamel and glass, with an iris and a cornea, made to represent the front of the living feature. [The

adaptation and correspondence demand much more nicety than is necessary merely to match the colour.

The convexity of the shell must be increased with the age of the patient. It is required to be largest in adults. The size of the whole must vary according to that of the stump to which it is to be fitted. It may, therefore, be almost hemispherical, or when the eyeball is removed, quite hemispherical.

The back must be hollow.

To secure the necessary lightness, the sclerotic part should scarcely exceed a quarter of a line, and the corneal, half a line in thickness. While on the one hand it should not be made too thick on account of weight, it should not be made too thin on account of brittleness.

French makers generally turn the edges under a little, in order that they may not irritate.

Sometimes a most singular outline is required to ensure adaptation to deformities of the orbit, or to contractions of the soft parts, arising out of disease or injury. It is better to grind the eye to fit an adhesion, than to cut the adhesion.

The entire surface, including the edges, should be enamelled, but it is a common practice among agents for sale who are not makers, to grind the shell to the required size, without afterwards restoring the desired smoothness, for which the action of fire is necessary.

There are not more than three or four houses in Europe that have attained high proficiency in this branch of manufacture.

All, however, does not rest with the mechanic. The best mechanism will fail in fullest effect, unless the shrunken globe of the eye retain sufficient form to be moved by the muscles, and so to act in concert with its fellow. For such accomplishment the back of the false eye must be well supported, that is, rest on something, and the front must be fixed by the eyelids. Those, then, in whom the eye remains, and is below the natural size, with the cornea flattened and the conjunctiva natural, are best supplied with an artificial eye. An enlarged eye must, therefore, be reduced by operation, and staphylomatous projections must be excised; the operations for which are given elsewhere. With very little more than a mere button of collapsed tissues, I have seen artificial eyes that few persons would have detected, except from their imperfect movement. Some degree of motion is obtained in such cases through the conjunctival reflections, acted on by the recti muscles.

When the eyeball has been dissected from its cellular sheath, the artificial eye may get a limited degree of motion for a few months after the operation, by the conjunctiva and the pad that remain, through the influence of the recti muscles; the amount of which

has been very much exaggerated. The eyelids themselves impart some vertical action. But when the swelling and infiltration have passed away, and especially when the natural wasting of the fatty tissues ensues, even this movement is greatly reduced and often lost. A larger eye is then required, as it must, most disadvantageously, rest on the orbit. In the best of these cases, the eyelids fall in, and leave a hollow around. Yet, an artificial eye that is motionless, is certainly very much less objectionable than the distressing vacancy of an empty orbit, or the disfiguring patch that is often worn as a screen.

When the entire contents of the orbit are taken away, we have the worst condition for the adaptation.

With collapse of the eye before adult age, the orbit seldom attains full growth and the eyelids are similarly influenced. The earlier in life that the accident has occurred, the less will be the development of this part of the face, and the case will be proportionally less adapted for the assistance of art. This points to the advantage of preventing collapse from the bursting of staphyloma of the cornea by the timely reduction of the enlargement, so readily effected by abscission, and it is one of the many reasons against indiscriminate extirpation of blind eyes.

In some cases the adaptation of the false eye is at once, and most easily done, in the fullest perfection as to size and movement. In others, to get a satisfactory result, many eyes must be tried, many made purposely, and many alterations effected in form, size, and outline.

When there is a sufficient stump that moves well in all directions, and the ocular appendages are healthy, I am never satisfied till the artificial member matches the other.

Many are the advantages of an artificial eye. In childhood and during growth it prevents contraction of the eyelids, and in some measure that of the orbit. At all times it may be of essential service in keeping the eyelids in their natural position, and preventing the cilia from turning in on the conjunctiva and producing irritation. It places the puncta in a more natural position for conveying away the tears, and so prevents an accumulation of this secretion in the orbit. It acts as a defence against intruding bodies, which are apt to be retained, and thereby to produce irritation. It enables persons to obtain a livelihood, by removing deformity. To my own knowledge, many a servant wears one without his employer being aware of the fact.

Before the false eye can be inserted, some preliminary surgical measures may be necessary, such as the removal of bands and bridles, produced

by cicatrization, or of ectropium. I have prepared a squinting stump by setting it straight. But extensive adhesion between the eyelids, or between the eyelids and the eyeball, may render the application inadmissible.

By the bursting of a gun a man lost the right eyeball, a part of the outer wall of the orbit, and some skin of the cheek. The cicatrization in the face produced a well-marked ectropium of the outer portion of the lower eyelid, and, besides, pulled the upper eyelid considerably downwards, and threw its cilia on the conjunctiva lining the floor of the orbit. The deformity was necessarily very great. I was applied to for relief from the annoyance occasioned by the constant discharge of tears over the cheek, and the irritation produced by the cilia. An artificial eye was placed as well as could be, so as to give an indication of the kind of operation required to restore the eyelids to their proper places, and to allow the full benefits that such an eye, well fitted, might afford. This having been ascertained, I left it to my patient to decide whether that description of operation should be done which would enable him to wear the false eye, by which his appearance would be improved, and most probably, the lacrymal secretion would be carried away through the natural channel; this, of course depending on the degree of accuracy with which the edges of the lids could be brought to bear on the surface of the enamel, or whether the lacrymation alone should be attended to, by the removal of the lacrymal gland. He was also given to understand that in case the first operation failed to arrest the discharge over the cheek, the lacrymal gland might then be extirpated. The first proposition was preferred. I removed a wedge-shaped piece, including skin, muscle, cartilage, and conjunctiva, from the most everted portion of the lower eyelid, and dissected the skin of the cheek from its attachment sufficiently to admit of its being drawn up. I applied sutures, raised and supported the cheek with strips of plaster. By this the ectropium was entirely removed, and the edge of the tarsal cartilage brought nearly to a straight line. The upper eyelid being released, the levator palpebræ acted, and the cilia were righted. In a few days the sutures and the plasters were taken away. Three weeks later the false eye was applied, and my expectations were realized, for the tears passed by the natural conduits; and although the stump of the eyeball was small, and the movement of the artificial eye necessarily limited, my patient and his friends were agreed as to the improvement effected in personal appearance.

An artificial eye is nearly always used too soon. It is inapplicable for two or three months, because the parts on which it is to be put

have not reached their destined size through shrinking; and besides, not being yet in a quiescent state, they are apt to be very much irritated, and become inflamed, and throw out an annoying muco-purulent discharge. Ulceration, too, is likely to ensue, with its inevitable consequence, contraction, the disadvantages of which have been pointed out. It is inadmissible, therefore, so long as there remains any inflammation or irritability of the conjunctiva or of the stump. These objections apply with still greater force when there has been "sympathetic ophthalmitis." It should not then be used for a still longer period, and when employed the effect should always be watched, in order that any irritation may be detected sufficiently early.

The wearing of the eye may be delayed too long; for the eyelids may contract, and the conjunctiva atrophy, and even the orbit may shrink.

Method of introducing the artificial eye. Hold the eye between the forefinger and the thumb; wet it by dipping it in water. Push the broad outer end under the upper eyelid, and slide it upwards towards its destined position as far as it will readily go; retain it there with the forefinger of the one hand, with the finger of the other hand draw down the lower eyelid till the lower edge slips in.

Method of removing the artificial eye. Depress the lower eyelid with the finger; pass the finger-nail, a tooth-pick, the head of a hair-pin, a little hook, or any blunt little instrument (a neat little spatula is made for the purpose) under the edge of the eye, lift it forward, and let it slip out. Receive it in the hand, or on a handkerchief, or on a bed, as a fall on the ground would fracture it.

A person soon learns to perform these two acts for himself, after a few lessons gently, slowly, and encouragingly given. Children acquire the knack quickly.

In most instances, but especially when the parts in the orbit are tender, it is requisite to begin to wear a smaller eye than that which is required to match the other. It may be necessary to use several gradations of size. The small one had better at first be left in position for two or three days. When the full-sized one is introduced, it ought to be allowed to remain in only for a few hours at a time, till the second or third time of wearing.

Nightly removal is necessary. Cessation of use prevents ulceration of those parts on which it rests. If it be kept in longer than a day from any special cause, the under eyelid should be depressed, and its lower edge lifted a little forwards, to allow of the escape of any tears that might collect behind.

If discomfort should arise after wearing the eye a week or more,

there is something wrong which needs attention. Very probably the eye is too large, and the eyelids cannot be closed over it. But irritation may arise at any period of the wearing; rest, and the temporary use of a smaller eye, will generally remove it.

Where the eyeball is merely atrophied, in which case some of the true corneal tissue yet remains, irritation is apt to occur, unless there be a sufficient hollow in the false eye to prevent the cornea from being touched. In any instance where the proper provision for escaping pressure on the cornea cannot be made, the cornea should be excised.

An artificial eye requires great cleanliness, and should be removed every night. After removal, it should be dipped in tepid water, wiped with clean lint or soft rag, and put in a box on cotton. It is improper to place it in cold water, because such water is apt to produce fine cracks on the surface, and the presence of any acid or salts will roughen the enamel.

To dissolve the grease which sometimes forms on it, the surface should be wiped with lint wetted with alcohol.

If the eyeball be much sunken, the interior of the eyelids should, if possible, be syringed with tepid water every morning and night.

Should there be an habitual natural conjunctival secretion, or should such be excited by the pressure of the eye, a weak astringent lotion, used night and morning, may remove or lessen it.

Sometimes fibrinous growths are thrown out on the conjunctiva as the consequence of irritation, unaccompanied by any discharge. They are readily removed. I have seen too, a plastic exudation, like diphtheritic membrane, growing over the palpebral conjunctiva. Several applications of the nitrate of silver were required to destroy it, and to prevent reproduction.

From ignorance respecting the manner of putting in the eye and taking it out, and sometimes from laziness, persons will wear it for months. Some have not removed it for years, not even when all polish has been lost. It is seldom that such persistence in use can be tolerated.

A new eye is needed after the gloss is lost and the surface roughened; for if the damaged one be still used, irritation of the eyelids is set up. The average period of wear is about twelve months.

Sometimes minute granules of earthy materials from the tears and the conjunctival secretion are deposited on the back of the artificial eye, and produce irritation. They cannot be seen when the surface of the enamel is wet. They are best removed by gentle rubbing with very fine pumice stone or rouge.

CHAPTER XXIV.

FOREIGN BODIES ON THE SURFACE OF THE EYE — LARVÆ OF INSECTS UNDER THE EYELIDS—FOREIGN BODIES WITHIN THE EYEBALL.

INSTRUMENTS FOR REMOVING FOREIGN BODIES FROM THE SURFACE OF THE CORNEA.

Fig. 144.



The miniature gouge (Fig. 144) is the twentieth part of an inch broad. It is hollowed or scooped, round, bevelled, and sharp. Maw and Son make a little instrument for the pocket-case with a gouge at one end and a spud at the other; each covered with a screw-top.

FOREIGN BODIES ON THE SURFACE OF THE EYE.

The intrusion of bodies in the eye is of very common occurrence, and the effects vary according to their size, their shape, and the manner in which they impinge.

An almost microscopic particle of matter may adhere, slightly irritate the eye, be readily dislodged by the movements of the eyelids and washed away by the tears; or, perhaps, removed by the fingers from the corner of the eye. Or a body may be projected with great violence on the eye, become impacted and destroy it either at once, or ultimately, from secondary causes.

It is wholly unnecessary to describe minutely the symptoms of a patient thus injured. The sensation or pain, the irritability of the eye, with the flow of tears, and the almost impossibility of opening the eyelids, and the redness of the eyeball, all point to the reception of an injury, the actual nature of which can only be known by a careful examination.

In every instance, therefore, in which it is likely that anything has fallen on the eye, the surface of the eyeball

should be examined. If nothing be recognised, the inner surfaces of the eyelids should be surveyed, and sometimes also the entire conjunctival surface. It is necessary to mention that immediate relief does not always follow the removal of the intruding body. For hours a patient may declare that he is unrelieved. He may be assured that the deceptive impression will pass away.

If a body be driven through the conjunctiva, for instance, a grain of shot, it may sometimes be more readily felt with the tip of the finger than seen.

The excretory lacrymal channels must frequently convey away minute substances; for whatever is below the diameter of a punctum may be so carried away, if its length do not interfere. Hence the popular impression that blowing the nose will remove such things. A particle enters, irritates, and causes a flow of tears. If it be loose, it is washed to the inner corner of the eye, and is either carried through a canaliculus, and so to the nose, or rests on the caruncle, where it is usually wiped away with the finger or the handkerchief, or escapes externally. It may stick in a punctum.

One of my late colleagues at the St. Pancras Royal General Dispensary suffered from an irritation of his eye that was to him inexplicable. Three days before he applied to me, while sitting in his drawing-room, he felt a very sharp pricking in the eye; but neither could he discern the cause, nor could another surgeon succeed in discovering it. I found the semilunar fold of the conjunctiva swollen and very red, and the entire conjunctiva inflamed. A hair, protruding just sufficiently to allow of being laid hold of with a pair of forceps, was visible from the upper punctum. It was easily drawn out, and proved to be a portion of hair that had remained about him after a recent process of hair-cutting. It measured half an inch in length. The cilia often get into the puncta and protrude.

A brass-finisher complained for several days of pain and great irritability of one eye. A small yellow point projected from the upper punctum. It was withdrawn, and proved to be a piece of fine spiral turning which had been projected from his lathe.

The cornea is that part of the eye on which extraneous bodies usually rest. It is there that the greatest irritation is produced. A substance is for the most part impacted, being rubbed into the anterior elastic membrane by the rubbing of the eyelids, which is so forcibly and involuntarily done by most persons when anything enters the eye.

The position of the little body is generally at once detected. Yet the minuteness of it may cause it to be overlooked, especially

when over the pupil, although this is generally much contracted from the irritation. Often it cannot be discerned, except in a particular light, and by the loss of polish of that portion of the cornea upon which it rests. When it consists of white metal, or of glass, detection is often impossible, unless the surface of the eye be illuminated by the concentrated light of a high convex glass, or by oblique illumination. When an ordinary examination of the cornea and of the conjunctival surface has been fruitless, and the patient is yet unrelieved, illumination should be resorted to.

It is a rule, without any exception, that all things of a dense and hard nature that have been thrown on or into the cornea are to be taken away, for although there may be no unpleasant symptoms for days, there will be bad consequences. In the natural process of separation, which is by infiltration of inflammatory products around, and by ulceration or sloughing, there is risk to the integrity of the eye from opacity of the cornea, or from partial staphyloma, and still greater danger from suppuration in the cornea, or perhaps of the eyeball. Even the remarkably rare occurrence of a body being encysted is not without its perils, for I have known the accompanying vascular action prove fatal to the retina, and destroy sight. I have seen ulceration of the cornea and prolapse of the iris occasioned by the presence of a particle of iron that had entered a week before, but which was so diminutive that a surgeon did not detect it.

When substances merely adhere, they are easily removed, the chief requirement being the fixing of the eyeball, and which should be done as if an operation for cataract were about to be performed. When, from want of practice, or any other cause, the fingers are not efficient, the eyelids should be opened and fixed with a retractor. In most instances there is more than mere adhesion. When there is impactment in the anterior elastic lamina, or in the true cornea, some perseverance is required to extricate. A small scoop, such as I have figured, is superior for the purpose to everything else that I have tried. The body is sooner withdrawn with it, and remaining on the end of the instrument, is readily removed; and very much less injury is inflicted on the eye than in the usual attempts with spatulas, needles, cataract-knives, or any angularly pointed blades. It may be used when the body is on the surface, and when it is impacted. Manipulation is safer with it than anything else. A speck may be taken off more lightly, and certainly more readily than with a blunt instrument. But it may not be all-sufficient. I have found it necessary to employ a minute pair of forceps to extract a wood splinter. Even more than this, I have been obliged to cut the cornea a little before I could extract with the forceps a bit of

brass from a lathe that had entered obliquely. The outer end being beyond the surface of the cornea, it could not be taken hold of without preparation for so doing. This is a very nice proceeding. During these extractions all care must be taken not to push the body into the anterior chamber. Carelessness might add such a terrible complication to the accident. For difficult cases of this nature, Mr. Lawson's suggestion is good. It is, to push the end of a broad needle between the laminæ of the cornea, just posterior to the extraneous material, as a support, while the process of picking, or extracting, is being done. Another method of his is, to introduce the point of a broad needle into the anterior chamber, press it against the inner surface of the cornea by the side of the body, carefully hold it in that position, and with another needle to scrape through the corneal layers until the body is reached.

A body may be so driven into the cornea, that the outer end is covered by corneal tissue, while the inner projects into the anterior chamber. The removal may be effected in three ways. The first is by incising the cornea, using forceps, and extracting it. The second is by incising the cornea, pushing it partly back with the forceps in the direction contrary to which it entered, and extracting it in front. The third is by inserting the point of a broad needle into the anterior chamber, pushing it partly out, and extracting it in front. By modifying these methods, or combining them, resources may be found for extracting any impacted bodies. Satisfactory healing usually attends this rude kind of surgery.

No opacity follows when the conjunctiva and the anterior elastic lamina only have been involved, and none that is practically recognisable where the gouge is carried deeper. A small speck of opacity is all that remains when the wound has passed through the cornea.

The following case, occurring in the practice of Dr. Browne, of Belfast, shows how much may be required to be done in these accidents, and how great may be the repair. The entire surface of the cornea, and the greater portion of the conjunctiva scleroticæ, were literally paved by fine particles of iron. A man was drilling a hole in the cylinder-case of a steam-engine. He stooped down to observe his progress, and holding a lighted candle, there was an explosion of some gas that had collected between the cylinder and the case. The eye was scorched, and the particles from the drilling driven on its surface. The particles were removed from the cornea to an extent that saved the eye, and rendered it useful. Deformity, however, remained, from the stains on the cornea and the presence of some of the iron in the surrounding conjunctiva, from which but a

small quantity was extracted. Some of the metal was even under the conjunctiva.

The only exception, I imagine, likely to be found against interfering with any extraneous substance in the cornea is in that rare condition where it has been imbedded for many days or months without any ill effects arising, the surrounding portion of the cornea not being hazy, and pain, vascularity, and lacrymation being absent; and where there has been a complete cessation of all acute symptoms. Several times I have been consulted about such cases. In each it was a bit of a percussion cap that had entered. The copper did not produce any irritation. It was not projecting beyond the surface. I decided not to interfere, because, in each case, to extricate it would, in all probability, have been a difficult job, and one likely to cause destruction of the eye. Besides, there was time enough to operate if irritation ensued.

The late Mr. Parrott, of Clapham Common, brought his niece to me, a girl æt. five. Four months previously she struck a copper cap between two pieces of iron, and a portion of the copper entered her right eye. The cornea was divided nearly perpendicularly; the iris had prolapsed, and the pupil was lost. Considerable irritation and inflammation followed the injury, but now the eye had recovered from the acute symptoms, and was, as is usually the case after these accidents, a little shrunken and flaccid. About the centre of the cicatrix was a minute piece of the copper, and a question was raised about its removal. The girl's mother was opposed to this, and I did not press interference, as it was not producing any irritation.

I saw a carpenter who had carried a bit of iron in his cornea for two years. It had never produced irritation.

These are examples of great rarity. I suppose in all of them that the process of encysting, of which I shall now speak, had taken place.

Mr. Wardrop, in his "Pathology of the Human Eye," correctly observes, that it sometimes happens, after a body is imbedded in the cornea, a layer of new substance is produced over it, so that it does not excite inflammation, but remains through life in a kind of sac. He quotes a curious case, in which the hard elytra of a beetle traversed in two years from the upper part of the eyeball to the centre of the cornea, immediately opposite the pupil, finally lodging there. In the case of a patient at the C. L. O. Hospital, a bit of wire was impacted at the lower part of the cornea. There was on it a dark-brown deposit, in the centre of which appeared a darker spot. The injury had been received sixteen years before, but as it did

not occasion the least inconvenience, I did not interfere. Such phenomena, I repeat, are rare.

But the form of a body and the peculiarity of its impaction may, as Dr. Mackenzie observes, prevent its either escaping or becoming encysted; and a case of Dr. Wardrop's, reported in the "Lancet," is adduced as an example. A bit of gold wire had entered the cornea, and a small part protruded, while the larger portion was impacted within, where it had remained fourteen weeks before it was removed with a pair of forceps; but in the meantime the eye was nearly lost, and the iris was adherent to the cornea when the patient applied to Mr. Wardrop. The portion of wire was fully three lines in length; one extremity had entered the anterior chamber. The aqueous humour escaped at the extraction.

After a metallic fragment, especially of iron, has been removed, some rust-mark, or stain, may remain. This is of no consequence, and should not be picked at, nor be attacked with chemical re-agents; for it is soon cast off. Very little practice enables a surgeon to ascertain when the particle has been removed. Carbonized and other substances leave such traces; without a knowledge of this, unnecessary injury may be inflicted. I have known vegetable matter produce stain.

In the "Medical Times and Gazette" of April 24th, 1852, Dr. H. Jeanneret very ingeniously proposes to dissolve particles of iron in the cornea by the chemical action of a solution of sulphate of copper, of the strength of from one to three grains to the ounce of water. This method should not give place to that of mechanical removal, but it might be of value when a surgeon is not at hand, and relief cannot otherwise be obtained. An eyeglass filled with the solution and held to the eye would be the proper mode of using this agent.

The employment of magnets has repeatedly been suggested as an easy and effectual means of extracting particles of iron and steel, and various shapes have been given to them, some pointed, some crescentic, and so on; but they are mere playthings, and not of any practical value.

When a substance is lodged about the conjunctiva, the patient may be able to define its exact seat, a matter of some moment; but when he cannot, and a survey of all the exposed parts of the eye fails to detect it, the eyelids should be retracted, and a greater surface of the globe of the eye exposed, the entire cornea rendered visible, and some of the sclerotica beyond it. Should that not suffice to reveal it, the interior of the eyelids must be searched; the under, by depressing it and pulling it from the eyeball, which should be

directed upwards; the upper, by reversing it, that is, turning it inside out, which may be easily done by holding some of the central cilia and the edge of the corresponding portion of the tarsal cartilage, drawing the eyelid down and away from the eyeball, resting a probe or any other small instrument above the cartilage, and then folding the tarsus upwards. The retroversion may be adroitly effected with the finger and thumb. Nineteen times in twenty, the object sought will be found about midway on the tarsus, and rather near the edge. The removal may be always readily effected with the finger. This part of the eye is next in sensitiveness to the cornea. Even when the eyelid is everted, a small extraneous substance may still remain concealed, as the recess of the upper eyelid has not yet been exposed; and to unfold or open it to view, an eyelid retractor, a narrow spatula, or paper-knife, or something of this kind, is required. When the object is perceived, its detachment is generally easy. But minute particles, impalpable substances, may still escape observation in this situation, especially by artificial light; for the length of this recess in a deep-set eye may prevent perfect and satisfactory exposure. A jet of tepid water thrown up from a syringe with a bent pipe, projected with sufficient force, should be employed whenever, in such a case, there is reason to suppose that anything remains. Some surgeons use, as an instrument of search, a camel-hair brush; or, what is better, as it is stiffer, one of sable, that has been gummed or oiled.

There are occasions when, from the multitude of the particles, the syringe cannot be dispensed with. A lad had both eyes filled with cement-powder. It was necessary to use the syringe for a long while, the eyelids being all the time held apart, before the material could be removed.

The less sensitiveness of the sinus or the oculo-palpebral fold of conjunctiva of the upper eyelid, as it is more frequently called, is the reason why the presence of a body there may not be felt, or suspected, till suppuration or inflammation ensues, or a fungus sprouts out; or why it may produce so little annoyance, or even cause symptoms that may be referred to other causes. I examined the eye of a private patient, as I thought, carefully, but without discovering the cause of the slight annoyance which she felt. I saw her several days afterwards, and was requested to take another survey, as she was tolerably certain that something was present. A more thorough search discovered a fragment of window glass there, so large as to make it a wonder that its presence had not been most intolerable. Sir W. Lawrence removed a bit of a twig, from the bough of a tree, that had been under the eyelid for several weeks,

without the patient being aware of its having entered the eye. He gives another example of a gentleman who consulted him on account of uneasiness in his eyes, into one of which a small insect had flown a few weeks before, although the patient was not disposed to attribute all his sufferings to that circumstance. Within the under eyelid was found one of the elytra, the wing cover, of a minute species of beetle, and within the upper the corresponding one.

A gentleman consulted Dr. Jacob on account of a fungus growth resembling a polypus projecting from beneath the upper eyelid. The Doctor seized it with a pair of forceps, to extirpate it, and found it firm and resisting. He examined farther, and discovered a bit of a rush, three-quarters of an inch long, within it. The gentleman then recollected that, about a year before, he had a fall from his horse while hunting, and for several days felt as if something had got into his eye, but as the sensation went off, he thought no more of it.

The first time I saw a fungus proceeding from this cause I was deceived for a time, because I had no knowledge on the subject, and I was unassisted in my diagnosis by any information from my patient, the morbid growth alone having attracted his attention.

In the Ophthalmic Hospital Reports, vol. i., p. 35, is recorded a case in which a husk remained under the eyelid for two months, and produced, by its irritation, a warty-looking growth, and besides, a fibrinous exudation that had become moulded by the movements of the eyelid. Ptosis was produced.

A young girl had a soft red fungus growing out of her eye, as large as a filbert. It was of some weeks' standing, and was attributed to a hurt inflicted by a straw striking the eye. It was ascertained without doubt that it took its rise in the oculo-palpebral fold. It was cut away, but in three weeks it was as large as ever. It was again removed; a bit of straw, half an inch in length, was observed and extracted; the cure was complete in a few days.

A man consulted Dr. Monteath on account of an inflamed state of his eye, induced by a fall, five months before, among some bushes, in descending a steep mountain. He felt at the moment that some part of the eye was wounded, and from that period the eye remained in a tender state. On everting the upper eyelid, a fungous state of the conjunctiva was discovered very high up, and a probe gave assurance that something was there. It was seized with a pair of forceps, and, when extracted, proved to be a portion of a twig from a bush, three-fourths of an inch in length, and nearly as thick as a crow-quill. This substance had remained in the oculo-palpebral

fold of the conjunctiva for five months, and had got into that situation without wounding the eyeball.

The usual effect of substances long lying under the upper eyelid is inflammation of the conjunctiva, more or less chronic. The conjunctival papillæ enlarge, there is muco-purulent or purulent discharge, and the entire eyelid loses its natural appearance, becomes swollen, and sometimes inflamed. I have known cases that have been supposed to be ordinary purulent ophthalmia due to the intrusion of substances. With the slightest suspicion, therefore, of anything having entered the eye, in conjunction with any of these symptoms, a thorough examination ought to be made. It may be necessary to use chloroform to do this, from the irritability and tenderness that exist.

The patient's sensations are not an infallible proof of the presence of a body within the eyelids. With a full persuasion that something yet lingers in the eye, he may be mistaken. Again, he may be entirely deceived, not any substance having entered the eye, the whole source of discomfort arising from a few enlarged conjunctival vessels about the outer ocular angle. One of the symptoms of inflammation of the conjunctiva is the sensation of sand, or grit, as it is usually expressed, in the eye. On the other hand, it is not unusual that the error is on the side of the surgeon, who, imagining the substance to have been removed, directs his treatment against the supposed consecutive inflammation, while the true cause, the irritating body, is still extant. A gentleman perceiving that something had entered his eye, and having in vain tried to remove it, applied to his usual medical attendant. Nothing was found. His suffering continued. On the following day inflammation and pain rendered him unable to attend to his duties. He was cupped, confined to a dark room, and salivated. Six weeks of misery were passed in implicit obedience to the rules of his adviser, who now became not only very anxious, but actually alarmed, and requested a consultation with some one more conversant with eye diseases. This was granted. I everted the upper eyelid and removed a portion of cigar ash from about the centre of the tarsus. Relief was instantaneous, the symptoms declined rapidly, and the cloudy cornea recovered its transparency.

No advantage would accrue from my enumerating the various substances in the mineral, vegetable, and animal kingdom, that may enter the eye. Lists have been published of such, and the altered forms that some of them undergo have been carefully recorded.

Metallic particles are frequently imbedded in the conjunctiva, and the usual result is irritation for a few days, and no more trouble. I saw

an old mechanic, who worked at metal lathe turning, with both conjunctivæ paved with iron chips. His cornea had many opacities. When a particle entered the cornea, or got under the upper eyelid, he went to the eye infirmary of the town and had it removed. Sometimes he did the same when the conjunctiva was invaded, but not always, only when irritation was unusually severe. As far as sensation went, he was unaware of the state of his eyes.

The conjunctiva may be penetrated, and a particle of matter remain between it and the sclerotica. Encysting is very likely to follow several examples of which I have seen. The patients have either applied to me on account of something else, or I have met with them accidentally. Mr. Wardrop tells us that he has found a bit of whinstone inclosed in a sac of cellular membrane, lying close to the sclerotic coat. It had remained for ten years prior to the person's death, without occasioning the least uneasiness or even suspicion of its presence. Iron has remained encysted for years.

The sclerotica itself is often penetrated and retains bodies without much inconvenience. I have several times removed particles of iron, when they seemed to irritate, by snipping through the conjunctiva, and then accomplishing the desired end, with forceps or gouge.

I have seen many accidents from the percussion cap, never among sportsmen, but from improper use of it, from playing with it, such as exploding it with a hammer, or a stone. I have seen five eyes destroyed in one year. This cap accident is common at fairs, where people snap them on popguns for nuts. The cap of the nut-seller's toy is highly dangerous, being peculiarly constructed. The copper is not cleft, as in the ordinary cap, but entire, to concentrate the force of the ignition. Thus it splits with violence and flies about, not merely to the injury of those who use them, but to others.

Occasionally an exfoliative effort is seen on the surface of the eye. Bodies that have been lying quiet in the cornea or the sclerotica, may, after the lapse of months or years, obey the well-known law and begin to work out. This is more common when the eye has been destroyed, and is more or less shrunken. A young man received a portion of a percussion cap in the sclerotica, just outside the cornea, and after a week of inconvenience he returned to his work. He was unaware of any defect. Nine months after, he came to me, complaining of an occasional pricking in the eyelid, of a few days' standing. In the centre of a granulation at the site of the old injury, I saw an angle of the piece of copper, and extracted it. The broken cap was being cast out.

After-treatment is seldom required. The symptoms usually disappear as readily as they were manifested. Where inflammation has been

severe, and there is pain, with heat and intolerance of light, a fold of thin rag, large enough to cover the eyelids, dipped out of cold water, applied, and renewed every few minutes, will soon give relief. The addition of some narcotic to the water may be useful. This, with rest to the eye, quiet of body, moderate abstinence, and perhaps slight purgation, amply suffice for every case.

LARVÆ OF INSECTS UNDER THE EYELIDS.

The larvæ of insects are sometimes deposited beneath the eyelids. In the "Annales d'Oculistique," it is told by M. Armand Bouilhet, that a young woman, while cutting rye, felt something impinge on the eye, and immediately suffered pain. M. Bouilhet thought he had to deal with some foreign body. After opening the eyelids he perceived a whitish point, put it on a pin to show it to the patient, and to his astonishment saw that it moved. He examined it attentively, and discovered a little worm. Remembering that some flies deposit their larvæ in different parts of animals, he thought this little insect might not be the only one. He poured a few drops of olive oil upon the globe of the eye, and withdrew, successively, ten worms.

A child, of ten to eleven years of age, who since the preceding evening had experienced great uneasiness in the eye, was brought to M. Bouilhet. The symptoms had come on immediately after a fly had flown into the eye, though it scarcely remained a moment. M. Bouilhet examined it attentively, and discovered little worms in the sinus of the upper eyelid. Oil was used, and six worms were drawn out. As the case was spoken of as something extraordinary, a physician went to see the child, and detected other worms. He immediately sent him back to M. Bouilhet, who took away two more.

A unique case is related by Cloquet, in his "Pathologie Chirurgicale." A man, fifty years of age, who was drunk, fell asleep in the fields; flies, *musca carnaria*, deposited their ova at the orifice of the nostrils and ears, between the eyelids, and on the prepuce. The larvæ made their way into the body in these several situations; the eyes were completely destroyed, for on removing the larvæ, the lenses escaped through the perforations they had effected in the corneæ. Under the cranial integuments they formed large deposits, from which they could be pressed in thousands through ulcerated openings. The miserable mortal survived for about a month in a state of imbecility. The bones of the skull were partly necrosed, and the corresponding parts of the dura mater and arachnoid membrane were in a state of inflammation.

FOREIGN BODIES WITHIN THE EYEBALL.

Every accident of this nature impairs the eye. The direct danger is in proportion to the size of the impacted body. The eye may be hopelessly destroyed at once, from laceration of the many textures, and the impossibility of repair, or the destructive inflammation that at once sets in. The secondary risk of destruction is according to the locality in which the body is planted, there being the least peril when the anterior chamber is occupied, the greatest when the vitreous region is the site. Besides, there is secondary severity according to the textures involved. The iris is the most tolerant. The ciliary processes, the choroid, and the retina show resistance in the order mentioned. The deleterious effects arise primarily from acute inflammation, on which suppuration may follow, although it is rare; or, secondary and chronic inflammatory action, that spoils every tissue.

There is generally produced a great deal of pain, and there is a tract of suffering in the course of the ramifications of the fifth nerve over that side of the head. It has a neuralgic character. I have never seen greater suffering than I have witnessed in some of these attacks.

Respecting treatment. The interest of a patient is best secured by the prompt removal of extraneous bodies. It is our duty, as a rule, to try to remove whatever is driven into the eye. Whenever this is practicable, an endeavour should be made to extract anything, unless it has passed out of sight, and cannot be felt with a probe, or when its position cannot be ascertained, in which cases the eye must, for a time, be left to take its chance. So, likewise, when it is so small that it is scarcely possible to be seized; or when it is of a nature that is likely to be absorbed; or is a soft substance which, though insoluble, cannot be removed, and unlikely to be injurious, as gunpowder, or its residue.

It is no easy matter to execute this operation with the least possible injury, and effectively. Attempt upon attempt is often made in vain. A well-tutored hand only can be expected to be successful. It is an undertaking, above all others, that needs self-possession, knowledge of operations on the eyeball, and cleverness in manipulation. Chloroform is often indispensable. The details must be regulated by the individual peculiarities of the case. The retracting of the eyelids, the steadying of the eyeball, and the opening of the cornea, must all be attended to as in extracting a cataract. In addition, the eyeball may be kept motionless by forceps or hooks. The cornea should be sufficiently incised with knife or keratome. The aqueous humour should be allowed to escape before the cutting instrument is

withdrawn, in order to prevent prolapse of the iris, for that would spoil the intended course.

The position, or the mode of attachment of the body, is to be the guide in selecting the spot for the incision. The nearer to the margin the opening is made, the less will be the danger of protrusion of the iris. Whether forceps, hook, probe, or curette be used, its extremity should be blunted, to avoid injuring the textures it may come in contact with, especially the capsule of the lens; for, if that be torn or scratched, opacity will ensue. The spoon of the curette will be found very serviceable. Loose bodies are more readily removed than adherent ones. It cannot always be determined beforehand what shall be the actual procedure. I have commenced an operation with a determination to adopt a particular course, and circumstances have arisen that required a different method. Emergencies will arise, and should be expected and provided for.

It is worthy of note, that while the most trivial injury to the cornea is likely to be followed by abscess, and the suppurative action may involve all the ocular tissues, injury to the interior of the eyeball from the presence of substances is rarely the cause of suppuration. On the contrary, attacks of inflammation, sometimes slight, sometimes severe, may supervene and more or less damage several structures and spoil the sight, and the inflammatory action may recur again and again over several years, the eye never perhaps, being free from morbid action; and yet suppuration may not be induced. Atrophy is the common result.

It is impossible to express forcibly and definitely, in a general statement, all that is necessary to be done in those accidents. The subject must be discussed and practical remarks appended according to the varying conditions that may exist, especially the several positions of the foreign bodies.

Foreign bodies in the anterior chamber of the eye. When a body is lodged here, and lies loose, it generally produces destructive irritation. The eyeball inflames, and the early apparent changes are dullness of the cornea, inflammation of the iris, and surface redness of the eye, objective symptoms of general ophthalmitis. But sight may too be lost when there is scarcely any such recognisable feature of disease; the disorganization proceeding without what we are accustomed to call inflammation. Or acute symptoms may at first appear and lapse into morbid chronic action. Or these may alternate.

Exceptionally, examples have been met with in which there has been tolerance to the presence of intruded bodies for days, weeks, and years. In one instance, a bit of stone was fourteen

years in the anterior chamber before it set up irritation. It was originally driven into the lens, and when this became absorbed, it fell into the chamber, still having an attachment to the lens capsule. It was successfully taken out. In a still more particular instance, one remained for sixteen years. But as a rule the end is disastrous. Except the very unlikely process of encysting should ensue, the eye will perish without treatment. Here is a case in point.

A gentleman was engaged, in February, 1858, in making oxygen gas for a lecture, and employed a wrought-iron bottle, with a tube about two feet long. An explosion ensued, and he was stunned, but not blinded, as he found his way to a water-butt. After this he could not open his eyes for three weeks. The right eye got well; the other remained inflamed. In five months he had recovered sufficient strength to get about, but the left eye was not available for nine or ten months, when all seemed well. In July of the year 1867, he was introduced to me as a patient by Mr. Joseph Skelding, in consequence of irritation of both eyes, particularly of the left; but very slightly of the right. He had been all along aware that a few particles from the explosion had been lodged in the cornea of the left, but only lately had he known that some were floating in the anterior chamber. I regarded the inflammation as due to rheumatism, especially as both eyes were involved; and the good effects of treatment seemed to confirm this. He returned to me in August with well-marked ophthalmitis in the left eye, apparently due to the irritation of the particles in the anterior chamber. There was general inflammation of the eyeball, haziness of the cornea, ocular tension, pain, and very imperfect vision. The other eye was not affected. I determined to remove the particles, and was prepared to wash out the chamber of the eye with water, if necessary. He was chloroformed. I made a small lower section of the cornea at the very margin, and fortunately the particles escaped with the aqueous humour. A great deal of acute inflammatory action ensued, and a prolapse of the iris followed. In a month the corneal section had quite healed, and the iris was so far retracted, that the pupil, still round, was displaced but very little downwards, being just out of the centre. I attributed the good result to my perseverance in keeping the eye closed with plaster, until all external evidence of inflammatory action had ceased. Vision is quite restored.

This illustrates four points: very severe and long-continued inflammation, kept up by the bodies in the anterior chamber; complete temporary cessation of all symptoms; return of

symptoms, for there can be little doubt, as the sequel proved, that when I first saw him, it was traumatic irritation, and not rheumatic inflammation which was present; cessation of symptoms when the particles were removed from the chamber.

Certain exceptions must be named against immediate interference, if no irritation be set up. We have sufficient evidence, through Sir W. Lawrence and others, and I have personal knowledge of an instance, that a portion of steel, such as the point of a cataract-knife, or of a cataract-needle, provided that it be but a mere fragment, will become oxidized and absorbed in the anterior chamber, leaving the eye uninjured. So long, then, as an oxidizable bit of metal sufficiently small does not produce symptoms, it is prudent to wait and see the issue. But this does not hold good with copper or brass. These resist the saline action of the aqueous fluid, and should be taken away, and the sooner the better.

The length of time that may have elapsed since a foreign body has entered should be no reason against endeavouring to extract it when its presence becomes injurious. In the "Dublin Medical Press" for December, 1846, Dr. Jacob tells of a bit of stone, the fourth of an inch long, and a sixth in diameter, and very sharp, that had remained loose in the anterior chamber for nearly four years, before much irritation was set up. He operated, with the hope of saving the eye from complete destruction.

If a first attempt at removal should fail, a second may succeed. In Ammon's "Zeitschrift," vol. iii., p. 103, we are told that a small glass ball, which had been filled with spirits of wine, and as a so-called joke put into the fire, burst and threw into the left eye of a female a fragment which became fixed in the middle of the cornea. Next day a surgeon was called, who, in attempting extraction, unfortunately drove it into the anterior chamber. For a whole year the woman suffered the severest pain. The cornea continued transparent for about six months, and during that time the glass splinter was visible, freely floating in the anterior chamber; subsequently the cornea became opaque, and acquired a pannus-like condition. The patient went to Vienna, where she applied to many surgeons, none of whom, however, believed in the existence of any foreign substance, as it was no longer visible. By degrees the cornea became clear, and vision returned; but the severe pain, extending from the eye towards the head, remained unmitigated. At the end of five years of suffering, she again repaired to Vienna, and saw Dr. Carl Jäger, who made an incision in the cornea with a common cataract-knife, and with various forceps, probes, and other instruments, endeavoured, but in vain,

to extract the body, which, in consequence of bleeding from the iris, was now hidden. The eye was soon in the same condition as before the operation, although less painful. In a few months, however, her sufferings returned, and again she applied to Dr. Carl Jäger, who now succeeded in detecting the piece of glass, which was of a triangular shape, measuring in its greatest diameter about five lines, covered with a light-brown coloured exudation, and extracted it with a pair of forceps. No injurious consequences followed, and vision was scarcely impaired. Many other cases are on record.

Experience, and much inquiry, have convinced me that after symptoms of irritation have set in, it is a fallacy fraught with danger to wait till they subside for an opportunity to operate. The subsidence, for the most part, never arrives, let the general treatment be what it may, till the eye is destroyed, and the most threatening symptoms will rapidly end when the irritant has been removed. There should be no delay.

The long continuation of symptoms, no matter how severe they may have been, should not extinguish hope of saving some sight, if the eye be not disorganized. I know of an instance in which useful vision was regained after the removal of a body that had been in the anterior chamber for six years, and had irritated the eye all the while. It was supposed that the internal parts of the eye were spoiled.

At no period, even in any disorganized stage of the eye, should we abstain from removing a body to subdue pain.

The process of encysting is always rare, and the fortunate occurrence bears but a small proportion to the usual result. Mr. Tyrrell speaks of a small particle of granite, and, in two instances, of minute portions of copper caps, thus fortunately encased.

Except for very cogent reasons, I should be disposed to leave an encysted body alone. I should not interfere so long as vision was not interrupted, or likely to be damaged by this conservative effort. I should interfere if the least irritation were set up. But a substance so tied down, is not altogether, and for ever, out of reach of harm. Effusion of lymph, or a capsule around it, does not absolutely secure immunity from future disturbance. The cyst may open spontaneously, or be broken by violence, or become injurious in itself. We learn, in Mr. Middlemore's "Treatise on the Diseases of the Eye," that a man came to him with a bit of metal at the bottom of the anterior chamber. There was acute inflammation of the eyeball; this was reduced. Encysting took place in a few weeks. Two years afterwards the eye was struck, the

cyst burst, and the particle set loose in the chamber. Suppuration of the eyeball threatened, but was checked by the timely extraction of the particle.

A foreign body may be impacted in the iris. Anything so placed ought to be extracted, because observation shows that an exception to its being troublesome can scarcely be expected. If it project, and can be readily seized, an attempt at extraction should be made; but if much impacted, or very minute, or covered by exudation, the piece of iris involved should be withdrawn and encised, as in the operation for the formation of an artificial pupil by "excision." Besides the damage that may accrue to the iris, and to the capsule of the lens, in trying to extricate an encased body, such bleeding is likely to occur as would prevent the completion of the operation. Unless it project, and can readily be seized, the difficulty of extraction is very great, and the operation is likely to be injurious, therefore it is better to excise the bit of the iris, than attempt what has proved a tedious and fruitless process, that of picking out the fragment, particularly when more or less covered by exudation.

The curative effect of encysting is most common on the iris, yet, even here, this effect does not preclude mischief, as the encysted body may become loosened, detached, and produce very ill effects. In the "Dublin Quarterly Journal," an instance is recorded of a very minute scale of copper cap in the iris becoming encysted, and remaining so for eight years, during which time it produced repeated attacks of inflammation of the eyeball, and, ultimately, it exfoliated through the cornea.

Irritation may be set up, and for the first time, while the body is in the cyst. I have known this to occur, and without any apparent cause. The eye was threatened with destruction. I do not know the end of the case.

The cyst itself may prove injurious. The late Mr. Scott deemed it imperative to remove an enclosing cyst, because of its growth. A bit of iron entered the iris of a blacksmith's apprentice, and after several weeks of active inflammation, good vision was recovered, notwithstanding a disfigured pupil. Some months subsequently, a small cyst formed in connection with the injured part, and grew, with a white and tendinous-like structure, to the size of a pea, when it was thought fit to operate.

An eye may be destroyed while the encysting is going on. The case I give to illustrate this process, is full of pathological facts in association with these accidents.

Impactment of a foreign body in the iris, of two-and-a-half years' standing. Formation of a cyst around it. Recurrent

attacks of inflammation. Loss of the eye. Sympathetic weakness of the other eye and myopia. Removal of the front of the diseased eye, and the foreign body along with it. A stout, healthy man, twenty-two years of age, was struck on the left eye by a percussion cracker, containing fragments of flint and detonating powder, which was thrown at him from a window twenty feet high. It exploded as it struck him. The eyeball was not painful until night. Next day it was better. For a fortnight there was not any discomfort. The eyeball then inflamed, and continued in that state for six weeks, when vision was so impaired that it was useless for practical purposes. It recovered for a time, and again inflamed for several weeks. Vision was now quite lost. The man then became a patient at the C. L. O. Hospital. The following was his condition when admitted :

Left eye. Surface vascular. Anterior chamber much contracted. Cornea a little hazy. Iris discoloured, and on its surface, nasal side, was a fibrous-looking node, about the size of half a hemp-seed. A sharp pucker at this spot deformed and displaced the pupil, and drew it inwards. The lens was obscured by lymph, to which the pupil was adherent. The eyeball was tender when touched. The most careful examination failed to discover any evidence of injury to the cornea, the sclerotica, or any part of the exterior of the eye, so that there was no direct evidence of anything having entered the eye ; but the presumptive evidence was in favour of the eye having been penetrated by a body which was lodged in the iris and had become encysted.

Right eye. All external appearances were normal. The sight was perfectly healthy before the accident. Six months after, near-sightedness commenced. A concave lens assisted vision. With the near-sightedness dates also irritability of the eye, and incapacity to read for more than three hours, on account of pain in the eye and dimness of vision. Sympathetic ophthalmitis became very marked.

The front of the left eye, including the iris, was removed. The crystalline lens was absent, having been absorbed. No vitreous humour was lost at the operation. In the centre of the nodule on the iris was a minute angular piece of flint.

Besides the conservative process of a foreign body in the eyeball becoming encysted, occasionally an accompanying effort is made at exfoliation. In the many instances recorded of this nature, the eye had generally been lost before the foreign body was thrown out. In one, however, I find that the eye was saved by such a course.

A man came under the care of Mr. Dixon, with an inflamed eye,

and a little mass about the size of a mustard-seed at the lower and inner part of the iris, which seemed to be a foreign body thinly covered with fibrine. Eight years previously his eye was injured, while he was standing a few yards from a man who was shooting sparrows. Two attacks of inflammation followed, for which he was treated. Three or four years after, during a third, a thin flat scale of a percussion cap, half denuded of its fibrous covering, was clearly seen.

The eye never seemed in a condition to admit of an operation, and continued in an unsatisfactory state. A little white elevation, with a dark spot in the centre, was observed in the middle of a fibrinous patch in the cornea. A few days later, a fine black point, that protruded, was extracted by Mr. Dixon, and proved to be a scale of metal. The lower half of the pupil was clouded by an opacity, the iris acted well, good vision was restored. ("Dublin Quarterly Review" for 1848.) A rare event like this should be regarded rather in the light of a curiosity, and never reckoned on or trusted to.

When a foreign body has entered the posterior chamber of the eye, it should be extracted, if possible. Dilatation of the pupil will often facilitate the operation. As a rule, it will be useless to attempt the extraction unless the body can be seen. I shall append two cases in illustration. The first is recorded by Mr. Critchett, in the "Lancet" of April 1, 1854.

An engineer was struck with considerable violence on the left eye by a piece of metal from a lathe. He suffered very much from pain in the eyeball and dimness of vision, and on the following day applied to Mr. Critchett, who found an irregular corneal wound, which was so far closed as to retain the aqueous humour. At the pupillary margin above, there was a dark-looking mark, which appeared like a foreign body. The lens was becoming milky. Judging, both from the history and the appearances, that a foreign body had entered the eye, Mr. Critchett proceeded to attempt its removal. He first introduced a small probe through the wound in the cornea, towards the dark spot on the pupillary margin, and ascertained that this appearance depended upon a slit in the pupil, caused by penetration. As traumatic cataract was forming, he proceeded to remove it, and to seek for what had entered. The opening in the cornea was slightly enlarged, and the scoop of a curette introduced, with which the greater part of the lens was gradually spooned away. When the lens was thus nearly removed, a dark, oblong piece of metal suddenly came into view, lying behind and across the pupil, and resting upon the hyaloid membrane, which was evidently not

wounded. A pair of delicate forceps were now introduced, for the purpose of seizing and drawing it out; but although there was no difficulty in holding it, the blades slipped off whenever the least traction was made, owing to the smooth polished surface of the metal, and to its prismatic form. It was subsequently lifted out with the scoop of a curette, but, in doing so, the hyaloid membrane was wounded, and a small amount of vitreous humour escaped. The eyelids were closed, and the man was put to bed. Some slight swelling ensued, together with pain, but these symptoms gradually passed away. The state of the eye, ten weeks after, was as follows: a faint mark of the wound in the cornea; pupil small and filled with a thin layer of lymph; above, slight adhesion of the iris to the cornea; a good anterior chamber; some perception of objects; the eyeball firm, and free from pain and inflammation ever since the first week after the accident.

The second is taken from the "Ophthalmic Hospital Reports" for January, 1859. A healthy young mill-stone maker applied at the Royal London Ophthalmic Hospital, February 15th, 1858, his left eye having been struck with a splinter while he was at work on the preceding evening. The conjunctiva was red and slightly chemosed; the iris was bright and active. At the outer border of the pupil was a small but conspicuous greyish object, which projected very slightly into its area, and extended outwards, behind the iris, for about one-sixteenth of an inch. A faint linear scar about the centre of the cornea was only detected by close examination. The sight was but slightly affected. He was quite free from pain, except when out of doors. Mr. Bowman, supposing that the object was a splinter of stone, determined to remove it. An attempt was made to seize it with the canula-forceps, introduced through a small incision at the inner edge of the cornea. A small thread of lymph came away in the grasp of the instrument, and exposed to view a minute scale of metal which it had enveloped. The scale was easily withdrawn with the scoop of a curette. It was a portion of the chisel with which the man was working.

He presented himself again on the 23rd; the eye was not inflamed, the pupil was active and circular, the lens was clear, and his sight uninjured.

Bodies get impacted in the crystalline lens. The lens should be extracted as soon as the eye is fit for the operation. It must be done at once, or delayed for a few days or week, if the eye be inflamed. An inflamed cornea will not unite. In the only accident of this kind that I have had, treatment was not allowed. But some good examples are recorded.

While a young farmer was at work with tools, a chip of iron struck his right eye, which became a little inflamed, but got well in a week. The sight got misty, and rapidly became worse. Mr. Bowman detected a minute cicatrix near the outer edge of the cornea, and observed a small black spot on the outer part of the iris. The nature of this spot was doubtful; it might be a minute ecchymosis, or a small dot of uvea, or a hole in the iris. The ophthalmoscope proved the last supposition to be the correct one. The pupil was dilated with atropine. The lens was semi-opaque in all its superficial parts, and near its posterior surface, below the nucleus, a small fragment of iron was very plainly visible. It could also now be discerned with the naked eye by reflected light. Mr. Bowman recommended its immediate removal. The patient was chloroformed, and a needle was passed through the cornea backwards into the lens, the point being directed obliquely behind the bit of iron, which was then brought forward to the front of the lens, whence its removal was easily accomplished with a curette, introduced through a small incision in the border of the cornea, as in Gibson's operation. The soft lenticular matter was removed through the same opening, and a clear, black, circular pupil obtained. No inflammation followed the operation, and the patient went home in a few days with good sight.

A quotation from Dr. Jacob's paper in the "Dublin Quarterly Journal" for December 9th, 1846, shows what has been observed when a piece of metal is allowed to remain in the lens. A bit of a gun-cap was projected into the lens of a boy. It did not lose its brilliancy, nor did it cause any sensible effect for two or three years beyond producing cataract, which was absorbed, and the copper lay entangled in the opaque crystalline capsule. A year after the boy came to Dr. Jacob. The copper had disappeared, the pupil was dilated, the chambers filled with blood, and the organ in fact spoiled. The cap was nowhere visible, and had probably fallen to the bottom of the eye. The doctor thought it advisable to do nothing.

The cataract which is caused by such injury is sure to be absorbed in children and in young adults, and if the foreign particle gets loose, the eye will be irritated. Even when it is enclosed in the capsule it might be injurious. Again, with such an accident in elderly and old people, the eye may be destroyed by inflammation, during the slow and uncertain process of the absorption of the cataract. It is therefore easier to operate in the first instance, and thereby a patient is better served.

The lodgment of a body in the vitreous humour is attended with the greatest danger to the eye. The violence that accompanies the

accident usually so damages the choroid and the retina, and is productive of so much bleeding, particularly when the penetration is through the sclerotica, that the eye scarcely escapes immediate destruction. There are several cases recorded of small bodies remaining for weeks embedded in the vitreous humour, and producing no great harm, and of two for two years, the length of time that the several patients were under observation, although there had been acute inflammation at first, in some of them, of the eyeball and its appendages, and even some limited choroidal changes. But there is ever the contingency of any substance gravitating to the retina, in consequence of morbid changes it may produce in the vitreous humour, whereby it becomes fluid, spoiling the eye.

The desideratum is to extract the object, just as when any other part of the eye is invaded, but the means of execution is only just within the range of possibility. The principle of treatment here is, therefore, reversed; the rule being to do nothing in the way of extraction, the exception being to extract. To warrant any interference, the body must be visible, and advantageously placed for removal. As an example of what may be achieved, I quote a case from the first volume of the "Ophthalmic Hospital Reports."

A young cooper came under the care of Mr. Dixon, half an hour after having received an injury of the left eye from a chip of metal. A small vertical wound, a little above the margin of the left upper eyelid, marked the spot where the iron had entered the skin. A corresponding wound of the palpebral conjunctiva was observed. In the sclerotica, nearly on a level with the upper border of the cornea, and about a line from its inner edge, was a small gaping wound, a line long, surrounded by sub-conjunctival ecchymosis, through which a vesicle of vitreous humour protruded. The pupil was active, and the patient could read large type, but saw all objects as through a slight mist.

Ophthalmoscopic examination discovered a clot of blood at the upper and inner part of the pupil, behind the lens, hanging down from the wound, and slightly waving to and fro. Just below the optic nerve, a small round body was noticed, looking almost like a minute air-bubble, and it appeared as if it were a portion of clear lymph effused round a foreign body, which was assumed to have entered the eye; but as there was no vascularity surrounding it, this hypothesis was doubtful. The little wound in the sclerotica was closing. There was no pain, and not much redness of the conjunctiva. Sight was less dim than on the patient's first visit, and good-sized type was pretty easily read. Sight continued to improve, and by the 30th all redness of the conjunctiva had disappeared; the little

wound in the sclerotica presented a hardly traceable grey line; there was no intolerance of light.

Again examining with the ophthalmoscope, the little globular body could not be detected. At a sudden turn of the eyeball there started from behind the inner portion of the iris an oblong, black body, which was instantly recognised as a chip of metal. It was entangled in a few thread-like remains of clot, which kept it suspended in the vitreous humour, and allowed it to move freely backwards and forwards. Mr. Dixon decided to open the eyeball from below, and to endeavour to extract it. This he preferred to following the route it had taken in entering, lest he should break through the suspending threads, when it would fall down out of reach. As it sank backwards and disappeared whenever the recumbent position was assumed, chloroform was not used. Standing behind the patient, who was seated in a chair close by the window, the eyelids being separated with a spring retractor, he fixed the globe of the eye by nipping up a fold of conjunctiva just above the cornea. A Jäger's lance-knife was then thrust in a little distance from the margin of the cornea, and the point directed backwards, to avoid wounding the lens. The knife was now withdrawn, and Assalini's iris-forceps introduced, with which, after one or two unsuccessful attempts, the body was grasped and extracted. It proved to be a part of the edge of a chisel, about 1-10th of an inch long, and weighed a quarter of a grain. The eyelids were immediately closed with plaster, and cold rags applied. The pupil was circular and clear. The patient could read the large type on his bed-ticket. The edges of the wound had drawn together. There was a small quantity of blood extravasated beneath the conjunctiva, and but very little increased vascularity of this membrane. A week later, and the pupil was round and contractile; there was no intolerance of light, and the patient could read a pica type. A few threads of clot, quite unattached, were floating in the vitreous humour. The lens was perfectly clear, and the only appearance which could be called morbid was a slight reddening of the retina and the optic nerve, the effect probably of a slight traumatic inflammation from the operation. Later still, the sight was steadily improving. Unless the humour be fluid, nothing can move within it.

In some concluding remarks the operator says, that the instruments he employed were not the best he could imagine for the purpose, but that they were the best at hand, and the delay of a day might have caused the body to fall on the retina; that he could obtain but a dim view of the object, as it was not brilliant, and only now and then gleamed indistinctly as the light fell on it; also, that

in such cases there is a certain lucky chance, without which the most skilful manipulations may fail.

Such a fortunate result can fall to the lot of but few operators, nor is a parallel case likely to occur. Still, in allied accidents, the circumstances should be studied with a view to similar treatment.

Instances will occur in which the object may be seen, but extraction is impossible. The surgeon may be tantalized and disappointed, but he must do nothing till disorganizing symptoms set in, not act in anticipation, and then not with the view of saving the eye, but with the intention of saving the other. He must either freely incise the eyeball and evacuate the vitreous humour, and so let out the foreign body, or resort to "extirpation." But such desperate expedients should be left to the last extremity.

The encysting of a body sometimes, though rarely, takes place in the vitreous humour. In some of the cases the process has been but partial, the attempt having failed, and the body has fallen on the retina. The best example of the completion of it, is mentioned by A. Von Graefe, "Archiv. für Ophth.," 1865, who says that he has seen a piece of steel which had lodged in the vitreous body become surrounded by a kind of exudation, and remain in the eye for five years without causing any disorder. It was in the lower part of the vitreous humour, but sufficiently far from the bottom to enable it to be seen with the ophthalmoscope. Vision was not interfered with.

When the presence of a body in the eye cannot be ascertained by sight or by touch, although there may be strong presumptive evidence of its entrance by an external wound, and there are not marked symptoms of irritation, no operation should be undertaken. The conditions under which this question will arise, occur, perhaps, most frequently in accidents from small shot. When it is supposed that a shot has been driven into the eye, and is hidden, whether it have entered through the cornea or otherwise, it is impossible to tell in the first instance if it be still in the eyeball, or has lodged somewhere in the orbit. In all such cases, I say, do not interfere, except to relieve some symptom. The formation of cataract, the closure of the pupil, with discoloration of the iris, and a serous state of the aqueous humour, with or without atrophy of the globe of the eye, are no evidences that there is anything within or even about the ocular tissues. Nay, even severe ocular pain does not confirm it, for there are authenticated cases in which the eyeball has been extirpated, and nothing has been discovered.

A farmer with one eye only available, was unfortunate enough to be shot by a boy, a few yards in front of him. The greater part of the charge went through his hat, but several shots lodged in his scalp, his

forehead, and in the eyebrow of the sound eye, and he was blinded. The anterior chamber of this eye was occupied by blood. The eyeball was hard and tender to touch. There was no evidence of shot having entered it, yet its state could not otherwise be accounted for. Vision was quite destroyed. I was consulted, by the recommendation of Mr. Marriott, of Kibworth, for the intense pain in the brow, frequently associated with pain in the orbit, and in the eye. Other surgeons had been resorted to, and the conclusions arrived at were different to my own, which was to leave the eye alone; not to extirpate it, but to remove the shot. I attributed the pain to the shot in the scalp and about the eye. I extracted all that I could get at, that is, all that I could feel. Some were imbedded in the bone. My patient being a very large and a remarkably fat man, they were the more concealed. Every wound healed by the first intention. Considerable relief followed; but pain, at longer intervals, still tormented him, and some months later, when the position of a few more shots could be traced, I removed them with advantage. Once again he came to me, as two that yet annoyed him could be felt, and they were the last, for twelve years have passed away without pain in the scalp, or in the eye.

It is a great satisfaction to me that I avoided extirpation, which would have been ineffectual, and must have further spoiled a fine and benevolent countenance; for notwithstanding the front of the eye is not quite natural, the pupil being closed and the iris discoloured, there is no marked disfigurement.

Another case will illustrate farther what is meant. A gentleman, while partridge-shooting, was shot by a friend who was about seventy yards away. A single shot reached him, and that entered the upper eyelid and blinded him. I was consulted a few days after. There was so much swelling and pain that I used chloroform in my examination. I obtained leave to do whatever I might deem necessary. The upper eyelid was perforated. The cornea was semi-opaque and wounded close up to the margin, at a point corresponding to the hole in the eyelid, and there was slight prolapse of the iris. There was blood in the anterior chamber. I decided to abstain from any operation, but to wait for the symptoms. A cold lotion was applied, and rest enjoined. In three days all pain had left. Twelve days later the ophthalmoscope could be applied. The crystalline lens was clear, but there was an effusion of blood in the vitreous humour that prevented illumination of the interior of the eye. There was no vision. Two months later, the eye had so far recovered that the only external evidence of the injury were a scar on the eyelid, a prolapse of the iris, and an irregular pupil. The

remains of blood clots were in the vitreous humour. There was absolute blindness. Now, at the end of six years, the eye is yet quiet. Although the probability is against the shot being in the eye, it cannot be positively asserted that it is not. That the patient is a gainer by retaining his eye, sightless as it is, there can be no doubt.

When disorganising action is set up in an eye, in consequence of a foreign substance having been driven into it, that cannot be extracted; or when there is suspicion of such action being due to such a cause, in association with an accident, the eyeball should be extirpated. The organ is already damaged beyond recovery, and the saving of the other, by warding off sympathetic inflammation, is the duty to be fulfilled. Substances have often been detected in eyeballs removed in doubt respecting their presence. The following case is a happy instance in point, and it shows the symptoms to be expected when an eye resents the presence of a foreign body. A gentleman received a few shots about his temple and brow from a fowling-piece, and it was supposed that all of them had been removed. Four years afterwards, the eye on the same side began to fail. Impairment of sight was followed by periodic pain. The eyeball was tender, but not inflamed. The iris lost colour, the pupil acted feebly, and the vitreous humour became hazy. Atrophy set in, and vision became extinct. The pain continued much the same. The other eye began to fail from sympathetic disturbance. Under the impression that a shot had entered the eye when the temple was injured, I recommended extirpation of the eye, but this was refused. After several months, when the sympathetic inflammation had become much worse, the operation was readily allowed. A shot, partly encysted, was discovered in the lower part of the vitreous humour, just posterior to the lens. The other eye recovered completely. It is well to note the fact that the irritation from the shot continued while the eyeball was shrinking. It would have lasted, if there had been collapse of the tunics to a mere button. This has been witnessed several times.

A most remarkable case of the impaction of a duck-shot in the optic nerve, where it lodged for six years and six months, is recorded in detail in the "London Medical Gazette" for 1834, vol. xiii. The shot entered the eye at the inner side of its surface, near the cornea. Occasional and intense pain for four years and a half, and the serious disturbance of the functions of the other eye, induced the patient, contrary to medical advice, to have the body sought for. The lens, which is described as partly bony, partly calcareous, was removed with the hope of affording relief, but without benefit; pain continued, and as that most distressing complication, sympathetic ophthalmitis, which is ever to be dreaded in such cases, had

evidently set in, an attempt to find the shot was made, but unsuccessfully. The sufferer now determined to have the eye extirpated, and the shot was found impacted, as the report says, in that part of the optic nerve which expands and forms the retina. The right eye was daily regaining health when the last communication was sent to Dr. Butter, the operator.

All the preceding remarks have been made with reference to foreign bodies actually about or in the eyeball. It remains for me to speak of those occasions in which, with injury in the absence of a wound, there is doubt as to whether anything is present when it cannot be seen.

Before any decision is come to, the eye should be most carefully surveyed. Dilatation of the pupil will assist in examining the posterior chamber, and the lens, as well as the posterior part of the eyeball. The ophthalmoscope will also help in looking into the lens, and by it alone can the vitreous region be searched. Oblique illumination will assist in the survey.

When symptoms arise which would seem to be caused by the presence of a body in the eyeball, such as general inflammation, or the iris changing its colour, the pupil getting motionless or contracted; or the sclerotica becoming dingy; or much pain, the treatment should at first be directed to subdue the pain, the irritation, or the inflammation, because any or all of these may be produced by external injury alone. It is only after local and general treatment is unavailing that diagnosis is more sure. But all attempts should be made to save the eye till disorganisation has set in, because of the absence still of unequivocal evidence of any foreign body within, and the possibility of anything there becoming encysted. When disorganisation is established, no time should be lost. Extirpation should be the rule to arrest suffering, and to save the other eye from sympathetic ophthalmitis. There is no form of destructive inflammation so much within our control as that arising from sympathetic implication. There is no serious disease of the eye so much disregarded. It is a result to be feared in all traumatic injuries to the eyeball, attended with decided diseased action.

CHAPTER XXV.

ANCHYLOBLEPHARON—SYMBLEPHARON.

ANCHYLOBLEPHARON, OR ADHESION OF THE EDGES OF THE EYELID.

Causes.—This rare affection is seen as a congenital defect, and as the result of injury and disease of the eyelids.

Of the congenital state an interesting example is given by M. Rognetta, in his "Cours d'Ophthalmologie," in which the eyelids were united by means of the palpebral conjunctiva, so as to form a sort of moveable veil over the cornea of about three lines in breadth, the tears flowing through a little aperture at the external angle. Mr. Travers alludes briefly to a remarkable example in a well-grown boy, whose eye was found perfect after the division, though he had been thus blind from infancy. From his remarks it seems to have been similar to the co-adhesion of the nymphæ or of the labia pudendæ in infants. Mr. Middlemore, who refers to the experience of many authors in the congenital deformity, has himself seen three cases. In one the defect occurred in both eyes. The eyelashes were not formed, and in the situation of the edges of the eyelid there was a narrow sulcus, lined by a delicate vascular portion of skin, which admitted of extension, but not absolute separation. In another the eyeball appeared imperfectly developed, and seemed adherent to the eyelids.

The late Dr. Hocken, in his Ophthalmic papers in the "Lancet," alludes to a child who was brought to the Exeter Eye Infirmary, with a small filamentary portion of the integuments causing adhesion of the left eyelid. The band occupied the site of the junction of the outer with the middle third of the eyelid, was of the size of a common sewing thread, round, and consisted of integument. In all other respects the eye was healthy.

It would be out of place here to consider the physiological bearings of this arrest of development. To those interested in the matter,

I would recommend Sir W. Wilde's writings in vol. xxvii. of the "Dublin Journal of Medical Science."

Anchyloblepharon, as an acquired state, may be produced by mechanical and chemical accidents, by any of the causes which occasion adhesion of the eyelids to the eyeball, and by ulceration of the tarsal margins and angles.

It may be partial or complete.

In the complete, there is nearly always an aperture, however small, through which the lacrymal secretions pass. I have seen an exception. A man was sent to me with entire adhesion of the left eyelids, and in which not the least aperture existed. The accidental explosion of gunpowder had destroyed the globe of the eye, and in a few weeks the eyelids had united. There was not any accumulation of tears. Probably, the conjunctiva was destroyed, and the lacrymal gland more or less damaged. Anchyloblepharon may exist with symblepharon, the same accident producing the two.

Of the partial form, a youth exhibiting a tolerably well-marked instance, applied to Mr. Taylor, who took the following sketch. He had long suffered from strumous ophthalmia, combined with severe ophthalmia tarsi.

Fig. 145.

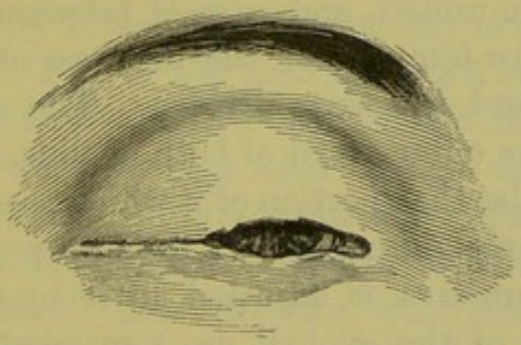

Those parts of the eyelids not in contact were quite raw. The union was recent.

Treatment. In the partial form, separation is to be done with a director and a scalpel. There is great difficulty in the prevention of fresh adhesion; and it is towards the corners of the eyelids that re-connection usually occurs. The protective means ordinarily prescribed are stimulating ointments, escharotics, and desiccative powders. Some surgeons have thought it advisable that sleep should be prohibited for twenty or more hours; or if the patient be allowed to go to bed, that he be awoke at intervals, and the dressing, whatever it may be, re-applied.

The application of goldbeaters' skin, or touching the surfaces with

collodion, after they have been well dried, is, I think, superior to any other method. The depression of the lower eyelid by strips of plaster, and the elevation of the upper, is a valuable adjunct; care being taken to protect the eye from dust. It may be requisite to moisten the cornea with oil.

I have very much mitigated several cases of most intimate union of the outer portions of the tarsi, produced by adhesion and contraction of the ulcerated surfaces from disease. In one instance, a very decided deformity was so reduced as no longer to be remarkable. I shall allude again to the subject in connection with "entropium."

If a suitable opportunity were to offer, I should try a plan which has been, as I understand, successfully adopted in webbed fingers; that of establishing an aperture at the most remote part of the adhesion, and then dividing the remainder. The rationale is obvious.

Stœber has very ingeniously proposed, that after the disunion of the eyelids, a portion of conjunctiva should be raised, drawn forward to the lip of the wound, and fastened by sutures.

The idea has been further developed by M. Hamer, "Annales d'Oculistique," vol. liii. p. 177, who has applied it to instances of marked adhesion at the outer canthus. His method, as I understand it, is this: One limb of a sharp-pointed pair of scissors is entered where the eyelids are united, and carried between the skin and conjunctiva, towards the temple, for the distance of a quarter or two-fifths of an inch, and the skin divided. The conjunctiva is then dissected off from the outer third of both eyelids, commencing at the ciliary border, and also that portion of it which passes inwards towards the eyeball. The original incision is then deepened with a scalpel, and the flap of conjunctiva is adjusted in it by sutures. It is said that the movements of the eyeball are somewhat restored, the form of the eyelids improved, and the chances of relapse are less than when there is simple division of the eyelids.

Dr. Mackenzie makes a distinction between close and intimate adhesion by the inosculation of ulcerated surfaces, and a bond of connection by the intervention of coagulable lymph; and he directs, in operating on the latter, that the first incision should be made close to the edge of the under eyelid, leaving the whole of the pseudo-membrane attached to the upper, from which it is to be dissected with a pair of scissors.

In the complete form, the rules for operating are just the same as those which have been described for the partial. When, however, there is not any aperture, however small, one must be cautiously made at the inner angle, and the probe alone used for breaking

through the connection, or the scalpel and director, according to circumstances, and the secondary treatment carefully carried out.

The contra-indications to operating are, opacity of the cornea, and the co-existence of adhesion of the eyelids to the eyeball. This question of complication by adhesion is ascertained by pinching up the united eyelids while the patient endeavours to move the eyeball from side to side, and upwards and downwards. Any marked restriction in the ocular action is proof of the presence of symblepharon. To make matters still more sure, a probe may be passed through an exploring puncture, and a search made. Besides these, it would be useless to operate if the eyeball were destroyed; a point easily determined by the want of natural prominence, and the absence of all power of sight; or even if sight were gone, without collapse of the eyeball.

The capability of discerning light must be made the test, imperfect as it may be, for the integrity of the eyeball. Where the one eye is sound it should be closed, and a comparison of the light-detecting power of the two may decide the question.

Some writers have described, in connection with this disease, a state which they call blepharophymosis, and intend to express by the term a lessening of the palpebral fissure by contractions of the outer canthus, with shrinking of the conjunctiva and the tarsal cartilages, the result of inflammatory action, apart from any actual adhesion of the edges of the eyelids. I have not seen any such result in which there has not been ulceration of the free edge of the tarsal margin. In a careful scrutiny of such cases, I have always detected such lesion, associated, it is true, with chronic tarsal inflammation. It is common in the severer cases of entropium, and of trichiasis, and should be considered as a part of those diseases, particularly of the former, in connection with which it is considered farther on.

SYMBLEPHARON, OR COMPLETE OR PARTIAL ADHESION OF THE EYELIDS TO THE EYEBALL.

When the conjunctiva is burned or scalded, or severely acted upon by escharotics, or receives a lesion that is followed directly by loss of substance, or subsequently by sloughing, or ulceration, contraction ensues from the resulting cicatrices. According to the extent of the implication, the eyelid is more or less united to the globe of the eye, which is restricted in its movements, or rendered motionless.

The one eyeball, or both, may be affected from the same cause.

Causes. Any operations that involve the removal of much of the

conjunctiva, particularly above or below the horizontal axis of the eyeball, may produce it; although it must be remarked that the contraction which follows from this cause is very different in character and in extent from that which follows chemical injury.

Severe purulent ophthalmia may be a cause of one form of the affection. A patient of mine, at St. Mary's Hospital, a man æt. thirty, afflicted with such ophthalmia, had the entire surfaces of both eyelids intimately adherent to the eyeball, the conjunctiva oculi being dry or cuticular.

The treatment of inflammation of the conjunctiva by escharotics plays no unimportant part in producing these adhesions in a limited degree. The nitrate of silver is often used in substance, and in very strong ointments, in a most lavish manner, a practice which sometimes produces sloughing. M. Desmarres, who is fully alive to this abuse of the caustic, says he has been informed by Dr. Furnari that, "during his stay in Africa, he had seen and operated on so large a number of symblepharons from that cause, that he was quite tired of them."

Congenital symblepharon has been met with. Mr. Wardrop has recorded a case in which it seemed owing to a cuticular condition of the conjunctiva. ("Dublin Journal of Medical Science," vol. xxviii.)

By the kindness of Sir W. Fergusson, I saw a child four months old, in whom there was almost entire deficiency of the lower eyelid, and the defective portion was tied to the eyeball by cuticular-like conjunctiva, that reached just half-way up the cornea. There existed also a double harelip.

Two forms of adhesion only need be recognised: the common one, in which there is continuous union between the eyelid and the eyeball, uninterrupted symblepharon; and the rare one, in which there is a bridle or isthmus-like tie between these parts, interrupted symblepharon.

The connection may be membranous, that is, of conjunctival tissue, or fibro-cellular, when the conjunctiva is destroyed, being then made up of thickened sub-conjunctival tissue. The latter is the more serious condition. It may be both membranous and fibro-cellular.

The adhesion may be partial or complete, slight or severe. In the latter, the ocular tunic is generally involved.

With few exceptions, all the examples of symblepharon which have come under my notice have been occasioned by the action of quicklime, or mortar. From such a cause, the accretion always takes place slowly, is extensive in proportion to the original injury, may occur even when not expected, and is not necessarily attended with the process of sloughing of the entire texture of the conjunctiva, and is

most detrimental at the lower part of the eye. Several times I have watched the effects of quicklime from the commencement, and I have totally failed in stopping this accustomed after-effect. In each case the injury was partial, and confined to the lower part of the eyeball. The entire conjunctiva became intensely red, except where the lime had rested; that was white or whitish, from the chemical action that had taken place; this spot soon swelled, its epithelium separated in shreds, and contraction commenced.

In the following very aggravated example, resulting from a burn, the lower eyelid was not only universally and closely adherent to the motionless eyeball, but was also drawn much over the cornea, which

FIG. 146.

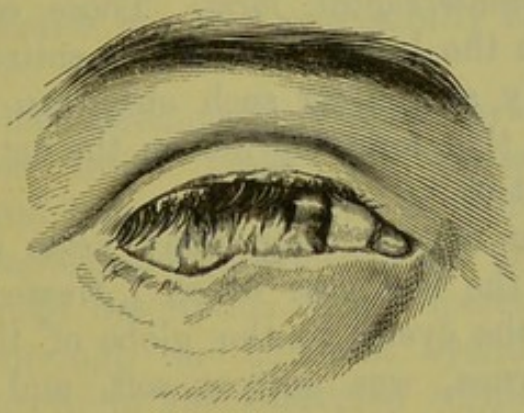

had been injured in the greater part. The tarsal edge above, although scarred, was free.

The upper eyelid might be adherent to a considerable extent without any inconvenience to the eye. The under is restricted in its movements by a slight connection, especially if its margin be involved.

Treatment. It is necessary to understand when treatment should be undertaken, for some cases do not require it, and others are beyond it.

Where the sinus of the eyelid has been damaged, and the adhesion is partial and slight, passing but a short way on the eyeball, the motions of which are not interfered with, treatment is not wanted. Such a symblepharon is probably hidden.

Where the cornea has become opaque, the question of operating should not be entertained, except to relieve pain and a feeling of dragging consequent on the use of the eyes, which restrains in some measure the motions even of the sound eye.

It is unavailing to attempt to do anything where there is complete or universal adhesion.

In the uninterrupted form of the affection it is useless to interfere, unless an operation of a plastic nature can be done. Merely to

sever the adhering parts is worse than useless. The failure or the return of the agglutination is not, according to my observation, due to the adhesion of the opposed surfaces, which I believe to be a very exceptional occurrence. The divided parts come together by means of the contraction of the granulations through which they are healed, just as happens generally in other parts of the body in cicatrization from burns. Several times, and in spite of very great care, and under what appeared to be most favourable circumstances, I have removed the cicatrices, and carefully dissected off the bands; but the contractions have returned to the same, or even greater extent. The mechanical contrivances used to prevent the relapse, such as plates of metal, glass shields, &c., are unavailing. The same may be said of everting the eyelid by ligature.

Respecting the uninterrupted form. Those cases are the most favourable in which the lesion is chiefly or entirely of the conjunctiva, and necessarily small; for such only can there be complete success. The issue, therefore, depends on the nature of the adhesion as well as the extent of it.

I adopted a plan of operating many years ago which gives a lasting result. In the first case which I treated, the band which tied the centre of the eyelid to the globe of the eye, encroached a little on the cornea, was narrow, soft, and loose; I divided it twice, and each time it returned to its former state. I then removed a small central portion of what appeared to be cicatrix, and brought the edges of the divided conjunctiva, those on the eyelid, and those on the eyeball, severally together by sutures, and the result was very gratifying. The last time I saw the patient, several months after the operation, there was but a slight contraction at the lower part of the interior of the eyelid, a spot where there would, I suppose, be a certain amount of puckering, in all cases of equal amount of injury, under any plan of treatment. The globe of the eye was no longer unnaturally covered by the eyelid, and the feelings of restraint to its movements were lost.

In the second, I was more fortunate, on account of a still more favourable condition; for perfect success ensued. The patient, who was twenty-six years old, had, when a lad, accidentally received some quicklime in his eye; and the usual process of adhesion followed cicatrization of the conjunctival slough. The annexed sketch (Fig. 147) accurately expresses the state of the eye before the operation. The connecting medium, which seemed to consist entirely of conjunctiva, was long and nearly isolated. Putting the eyelid on the stretch, I divided the band vertically through its entire thickness, carried the incision into the tissue below, and brought the edges of

each side severally together by three sutures. In four days the stitches were removed.

Fig. 147.

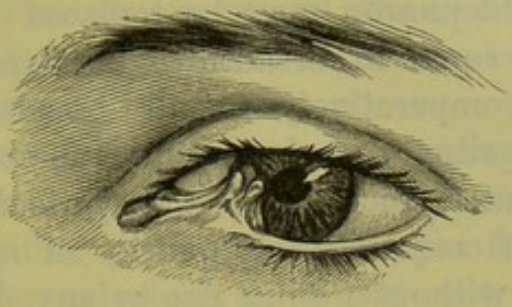

In others, I have had more or less success, according to the state of the case. My practice has been successfully followed by some of my colleagues.

Mr. T. B. Teale has ingeniously operated by transplanting conjunctiva in the more severe cases. He writes about it in the "Ophthalmic Hospital Reports." A case is delineated in which the symblepharon encroached on the cornea to the margin of the pupil. I will give a condensed description of his operation. Having first made an incision through the adherent eyelid, in a line corresponding to the margin of the concealed cornea, he dissected the eyelid from the eyeball, until the latter moved as freely as if there had been no unnatural adhesions. By this, the apex of the symblepharon, a part of the skin of the eyelid, was left adherent to the cornea.

In the next place, two nearly vertical flaps of conjunctiva alone were formed, on either side of the cornea, one from that portion of the eyeball near the inner extremity of the raw surface, the other from that near its outer extremity, each nearly a quarter of an inch in breadth, and two-thirds of an inch in length. They were then carefully dissected from the eyeball, until they were so far at liberty as to stretch across the chasm without great tension, care being taken to leave a sufficient thickness of tissue near the base of each. They were then adjusted to their new situation. The inner flap was made to stretch across the raw surface of the eyelid, being fixed at its apex to the healthy conjunctiva at the outer edge of the wound by sutures. The outer flap was fixed across the raw surface of the eyeball, its apex being stitched to the conjunctiva, near the base of the inner flap, and the edges connected by sutures. Thus they were dovetailed into the wound. Their vitality was further provided for by incising the conjunctiva near their base, in those directions in which there seemed to be undue tension, and by

stitching together the margins of the gap whence the transplanted conjunctiva had been taken.

After many operations, he draws these conclusions: That conjunctiva may be transplanted without losing its vitality or properties; that a symblepharon may be replaced by loose moveable conjunctiva, at least equal in breadth to the flaps originally transplanted; that a comparatively small breadth of conjunctiva introduced into the situation of a symblepharon, is sufficient to afford greatly increased motion, if not perfect freedom, to the eyeball; that flaps of conjunctiva, a quarter of an inch in breadth, may be taken away without giving rise to any deterioration of the parts whence they have been taken; that in separating the adherent eyelid from the globe, it is not necessary to dissect off from the cornea any portion of skin that may be adherent to it, but that it is better to commence the separation of the eyelid at the margin of the cornea, leaving the opaque apex of the symblepharon adherent to it.

In the yet more extended adhesions, where the ocular conjunctiva is much damaged, M. Blandin's operation will afford relief. I will quote a case illustrating it.

A man was burned by a drop of melted metal. The cartilage of the lower eyelid was destroyed, and adhesions united the contiguous parts. The lower half of the cornea was covered by a semi-elliptical, bluish-white cicatrix, while the upper remained clear. The eyeball had lost its mobility, in a great measure, and a feeling of constraint was very fatiguing. M. Blandin dissected the cicatrix from above downwards, turned the dense bluish-white structure inwards, in the form of a hem, so as to form a substitute for the palpebral mucous membrane, and retained it in position by the glover's suture. The two extremities of the thread were carried horizontally to the right and left, and fixed with a certain amount of tension to the corresponding temples, so as to keep the border of the eyelid free of the cornea. The sutures were removed on the fourth day. The patient was dismissed from the hospital about three weeks after the operation. The eyeball had quite recovered its mobility, and could be directed at will towards any object. The part of the cornea which was formerly overspread by the cicatrix, was now covered only by a delicate film of cellular tissue, which did not granulate, but daily decreased in thickness and opacity. The new eyelid had a rounded border; it was rather short, but could be approached without difficulty to its fellow, and effectually defended the eye from the light.

On the same principle, Mr. Taylor applied this operation in all its

detail, successfully, at the C. L. O. Hospital. I assisted at it. The band of adhesion was evidently chiefly of conjunctiva. The patient, a lad of fifteen, had both eyes severely injured by lime. The right eyeball was united to nearly the entire length of the lower eyelid by a broad band, which overspread the cornea, so as almost to conceal the pupil; the little chink which was left being obscured by a faint bluish opacity. Its movements were limited, and accompanied by a disagreeable sensation of dragging and stiffness. The result of the operation was very satisfactory, and as the patient was seen by Mr. Taylor four years afterwards, the fact of its permanence is established. The palpebral sinus was restored, and the ocular movement, in every direction, decidedly free. The pupil was clear except at the lower part, where there existed the opacity alluded to, and vision was excellent.

Respecting the interrupted form or bridle variety. I have had but a single example. It is only requisite to divide the band, and to keep the cut surfaces apart by interposing some substance, and success must ensue.

During an attack of erysipelas in a patient who was attended by Dr. Mackenzie, the upper and the lower eyelid suppurated; union took place between the upper lid and the lower edge of the cornea. The probe could be passed readily around the point of union. The adhesion was divided, and the eyelid restored to its natural motion. The centre of the cornea was clear.

CHAPTER XXVI.

DISEASES OF THE EXCRETING LACRYMAL APPARATUS.

AFFECTIONS OF THE PUNCTA LACRYMALIA AND OF THE CANALICULI—DISPLACEMENT OF THE LOWER PUNCTUM—DISPLACEMENT OF THE UPPER PUNCTUM—AFFECTIONS OF THE LACRYMAL SAC AND DUCT.

PROBE.

A SILVER, or a gilt steel instrument, of the shape Fig. 148, is more manageable, and can be used with greater precision and effect than a thin, flexible piece of wire.

FIG. 148.



The one extremity is larger than the other, and more conical.
It is necessary to have a second probe of larger dimensions.

DISSECTION SHOWING THE PUNCTA, THE CANALICULI, AND THE LACRYMAL SAC.

I dissected away all the parts covering the corner of the eye, so as to expose the course of the canaliculi, the lacrymal sac and duct.
A part of the tendo oculi is left attached to the bone.

FIG. 149.

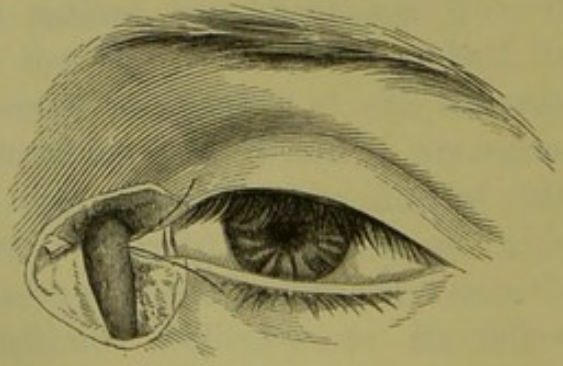

The canaliculi opened in this instance, as is usual, into the sac

separately, about the level of the palpebral ligament. Sometimes they are close. Sometimes far apart. Sometimes they communicate by a common aperture. Their irregular course is altered by the bristles that were inserted, and they are made to assume a straight line; whereas, to reach the surface of the eyelid, each bends almost at a right angle, forming an elbow, and then turns a little inwards, a beautiful provision, whereby the puncta are the more certainly adapted for their office. This bend should be remembered while using the probe, and the little impediment thereby overcome, by drawing the eyelid out, and straightening the canal; or, merely everting the tarsal edge a little, and passing the probe vertically for about half a line, and then inwards.

FIG. 150.



The length of each is about the third of an inch, the diameter the twentieth of the same. They are formed of fine, pale, smooth mucous membrane, with a few mucous glands, and pavement epithelium. They are surrounded by a highly vascular connective tissue. They have not valves at their opening in the lacrymal sac.

CANALICULUS DIRECTOR.

This instrument is more readily used when attached to a handle. The stem is fine-pointed, not actually sharp, but nearly so, for ready entrance, and grooved in its entire length, so that the knife may run out without impediment. On the handle, corresponding to the groove, is a dot which may be useful to indicate the side that is channelled. I have many times seen the want of this little index when blood was about the instrument. The artist has not depicted it.

OBSTRUCTION OF THE PUNCTA.

These parts are very seldom the primary seats of disease.

A patulous state is said to interrupt the passage of the secretions. I am not familiar with such a pathological change. Now and then large puncta are met with, but I have not seen any defective action associated therewith. The watery eye of the aged is commonly assigned to such enlargement. It would be more correct to attribute it to failure in those mechanical movements of the eyelids that are so necessary to bring the puncta into proper play; and also to the more or less displacement of other parts, from those alterations incidental to age. Senile lacrymation is often due

severally to an unhealthy condition of the lacrymal gland, and of the conjunctiva.

Contraction simply of the puncta, and thereby obstruction to the passage of the excretions without injury, or any disease around, is unknown to me, and must therefore be very uncommon, if it exist at all.

Contraction of them, as the result of ulceration of the eyelids, of chronic inflammation of the conjunctiva, of ophthalmia tarsi, of wounds, burns, and chemical injury, is common. Complete closure may ensue from any one of these causes. They may be covered over with dry epithelium.

The puncta may be destroyed by accident. I know an instance of this, in which, in consequence of the annoyance that the overflowing of the tears produced, the lacrymal gland was removed.

The puncta may be congenitally absent, as many writers testify. In vol. xxvii. of the "Dublin Journal of Medical Science," Sir W. Wilde alludes to a case mentioned by Morgagni, in his "Epistolæ," in which all four were closed; and gives an example lately seen by himself, of a young girl without a punctum on the left upper eyelid, or the papilla, on which this little aperture is usually situated.

Two puncta have been seen on the same eyelid. Other deviations are recorded.

Treatment is far more satisfactory than might be supposed. When a punctum is merely narrowed, the patency is readily restored by careful use of the probe. When it is closed, provided there be no distortion of the parts around, the canaliculus may possibly be reached by a cross or oblique cut, or by a dissection, then opened, and the channel re-established to the nose. If no orifice can be found after the transverse section, the lacrymal sac should be opened below the tendo oculi, and the canal slit up near the obstruction, or a probe run into it from the opening in the sac. The internal orifices of the canaliculi are so large that a skilful surgeon can readily accomplish this.

If the upper canaliculus be slit up, a probe may be passed through it into the lower canaliculus on to the position of the punctum, where an aperture may be made by cutting on the probe. It is possible to pass a curved probe without slitting the upper canaliculus.

OBSTRUCTION OF THE CANALICULI.

Obstruction of a canaliculus is more common than contraction of a punctum, and is due to malformation, to the intrusion of extraneous substances, to accident, and to structural disease.

I have met with congenital deficiency. In one instance the lower canal was not developed in the inner half, while the remainder was remarkably fine, and the punctum so minute as scarcely to be recognised. This was discovered while making a dissection on a young man who had died of consumption. I ascertained that the defect produced no inconvenience, and was unknown to him. The upper canal, with the punctum, were unusually developed.

In another case there was congenital deficiency of the inner part of both canaliculi in one eye. The patient, a girl, was fourteen years old. In early childhood an unnatural flow of the tears was noticed. The persistence of this annoyance prevented her from entering on any employment.

In another instance, in an infant, the entire canaliculus was dilated, and looked like a cyst, without any external opening.

The intrusion of an extraneous substance is not very rare. Sometimes a canaliculus gets blocked by it. A neighbouring cilium may enter, or a detached cilium. I have removed varieties of particles from them, such as small bits of hair, of thread, of feather, and even metallic chips. Epithelium may choke it up. This is more common in old persons.

Calculi are met with. Sometimes the calcareous matter is wedged in, like the calculi of the salivary ducts. Sometimes it is more in the form of a distinct round calculus, a little distance within. The punctum is red, and patulous, and tumefied, and exudes a little pus.

The treatment, in the case of an inverted cilium, is to withdraw it, and pluck it from its root. Loose bodies should be removed with a pair of forceps. Epithelium is readily picked out with the probe.

A calculus must be extracted. This is readily done after the canaliculus is slit up.

Mr. Carr Jackson brought me a private patient who had been troubled with a watery eye, and afterwards a purulent discharge from the lower punctum. I found swelling of the integuments over the lacrymal sac, and a tumour in the course of the everted canaliculus. My suspicion of a calculus was at once expressed. I made an incision over the swelling; first a chalky-like material, which proved to be epithelium, was removed, and then a phosphate of lime calculus, just the size of a No. 4 shot. Perfect recovery ensued.

The lower canaliculus is more prone to concretions than the higher.

The canaliculus may be divided or torn by an accident, or quite

destroyed. This is treated of in the chapter on "Wounds of the Eyelids, &c." It remains only to be said, that when both canaliculi are destroyed, there being no trace of them left, it is better to extirpate the lacrymal gland than to attempt to establish an opening into the lacrymal sac, because success is seldom attained. The effect of removing this gland is given in a section of this chapter.

Chemical injury could scarcely be inflicted on a canaliculus, without some portion of the eyelid participating in the accident. The treatment would be the same as for a closed canaliculus from any other cause.

Contraction and disease arising out of structural changes, is the commonest defect of these minute parts, and such constitutes what may be termed ordinary stricture of the canaliculus. The origin is an inflammatory state, which is for the most part an extension of the same disease which exists in the eyelid, and perhaps along the mucous tract through the lacrymal sac and duct to the nose. Or it may be from the conjunctiva alone, as in the case of granular ophthalmia. It is supposed that, in the latter case, the stricture arises from contraction, consequent on the cicatrization of the granular disease within the tube. Such stricture is spoken of as made up of callosities.

The ordinary effect of the stricture is a watery eye, called stillicidium lacrymarum. The stricture may be incomplete or permanent. In the first, the probe may be passed through the canaliculus, and the inner wall of the sac touched, but with some amount of difficulty. In the second, there is no entrance, and the stoppage is easily detected, because when the probe is pushed on, the canaliculus, with the skin over it, moves towards the nose, and an elastic resistance is felt.

Another mode of discovering permanent stricture in association with disease of the sac, is to press the lacrymal sac. If there be no regurgitation of tears, nor any other fluid, the canaliculus, which does not admit of such discharge, is obstructed. In perfect health of the eye nothing will escape by the canaliculi, no matter how firm the pressure may be. It is only when there is disease of the sac that the test will apply.

Occasionally, minute abscesses form in the eyelid, in the immediate vicinity of the obstructed canaliculus, or around it.

These descriptions apply to obstruction, or stricture, solely, that is unaccompanied with any change of position of the angle of the eyelid. It will be shown that mere displacement of the eyelid will produce overflow of the tears.

Whatever may have been the degree of inflammation of the conjunctiva preceding the stricture, it is invariably made worse by obstruction to the escape of the excretions.

It is the lower canaliculus that is generally strictured. Any obstruction here, except as a congenital effect, is always attended with symptoms. I have met with but a single exception. The canaliculus was cut across and destroyed, and yet no inconvenience resulted. Sir William Lawrence saw a like case, in which the canaliculus had been removed in a surgical operation. In these instances, the higher conduit did the required work. Very probably the higher might be strictured, or thrown out of action, without detriment.

Treatment. Mechanical measures alone will do but for a small number of cases; only those in which the affection is not of constitutional origin. In proportion as the mucous membrane around the stricture is diseased, and the constitution enfeebled, so must there be added general treatment, attention to health. All that is said in the section on "Disease of the Lacrymal Sac and Duct" on this head, applies here. A strictured canaliculus differs from a strictured lacrymal duct only in the effect of disease being manifested in a different portion of the excretory mucous tract.

For the incomplete stricture, the passage of the probe is the remedy. At first the smaller one should be used, and then in a few days the larger one, and the operation repeated. As the punctum is of less size than any part of the canal, it may be necessary to slit it to carry that out. Most careful manipulation is required not to make false passages, or to tear the canal.

For permanent stricture, that is, when there is such obstruction as to cause resistance to the probe, and all attempts at dilatation have failed, a passage must be made and established, and this can only be done by perforation and after-treatment. My own plan of proceeding, and that which seems best, is to push the lacrymal director into the sac in the line of the canaliculus, and to divide the parts along the whole length, from the punctum to the sac, with the ophthalmic scalpel, including the division of a portion of the sac as well. This is facilitated by drawing the eyelid outwards, and making it tense after the director is passed. It is unnecessary to give a long description of the details, such as the manner of holding of the eyelids, &c. An expert surgeon can do all himself. An inexperienced one wants an assistant. Some operators use a pair of scissors for doing this, others employ a peculiar kind of knife.

An elegant little instrument, which is used by some of the French

surgeons, is here shown. It is said to be more applicable for the upper canaliculus.

The point is to be carried to the desired spot, and the blade, which is kept in position by a spring, pushed down by pressure on the handle.

Fig. 151.



Of course there is adhesion of the cut surfaces in a few hours, therefore it is necessary to re-open the entire channel the next day, with a director or probe, and to repeat the process each day, until there is no longer any adhesion. Even after this the larger probe should be occasionally passed for some weeks, to prevent the adhesion of granulations at the acquired aperture.

To save the necessity for this troublesome after-manipulation, I tried the application of mild escharotics, under the hope that they would irritate the raw edges and prevent adhesion, but too much severity ensued. Even the hydrargyri oxidum rubrum set up far more action than was desirable. For this reason I have given up any such measure. The simple process only, therefore, that of using the probe, is admissible.

The ultimate success of these operations on the puncta and on the canaliculi, will very much depend on the state of the surrounding parts. Where the disease is confined to this portion of the excretory channel, or there is associated but slight surrounding chronic inflammatory action, a good result may be expected. Where, on the contrary, the conduits are involved in general disease of the palpebral conjunctiva, and of the lacrymal sac and duct, the result is uncertain, as the acquired aperture is very apt to close by contraction, from a kind of cicatricial shrinking. Earnest attention should be therefore given to the treatment of any complication, by local and by general measures. As a final resource in relapse, the operation must be repeated, the sac laid open, and the aperture maintained, as well as can be, by dilatation with probes from time to time.

Growths within the canaliculus, may be considered as a continuation of contraction and disease, arising out of structural changes.

Little polypi, just like conjunctival polypi, which are described in the chapter on "Tumours," may grow within the canaliculus. Several authors make mention of their existence.

Fibroid growths, so loosely attached as readily to escape under pressure from the dilated canaliculus, and numbering several in the same case, are authentically recorded.

Treatment. The scissors or the knife should invariably be used for all abnormal growths. Escharotics are inadmissible from the damage that might accrue to the neighbouring parts.

DISPLACEMENT OF THE LOWER PUNCTUM.

Considerable disturbance of the functions of the lacrymal apparatus, comes from a displaced and everted lower punctum. Dislocation occurs under a variety of causes. These may be classed as follows:

External or extra-ocular, for the most part of a simple nature, and very limited, although palpable, such as superficial ulceration of the integument to a very slight extent, or in a more marked degree, arising from a severer cause. Both of these may be produced by idiopathic disease, or by accident. The punctum is quite healthy in all such recent displacements.

Internal, or intra-ocular, produced by some disease of the ocular appendages, such as swelling of the conjunctiva, and of the caruncle, and granular disease of the palpebral conjunctiva. With this is associated alteration of form in the punctum itself, arising out of chronic inflammation. The prominence on which the punctum is placed may disappear. The orifice is then on a flattened, rounded, cutaneous surface, at a little distance from the mucous lining of the eyelid; much reduced in size, and not wetted by the tears, but dry, the mucous papilla, on which it opens naturally, being destroyed.

It is necessary, for a punctum to act, that it be submerged in the lacrymal secretion.

In every instance of watery eye, therefore, the lower punctum should be carefully surveyed, and its integrity scrutinized. But any deviation from its position, or any slight morbid change, cannot be appreciated except by one who has studied the part in health. The beautiful manner in which it is brought into play by muscular action in winking, and applied against the eyeball, should be inspected in several individuals.

Even in health, variety exists in the movements of the punctum. In some persons, during winking, it is shot inwards like the sting of a wasp. In others, it moves slowly and lazily, seeming scarcely to touch the eyeball.

Excessive inversion of the punctum is spoken of as a defect arising from retraction of the eyeball, or from age, and as a cause of overflow of tears. I have never seen it. In the entropium of the aged, such a condition is absent.

Treatment. For the simple turning out of the punctum, the removal of the limited ectropion will generally suffice, and bring the canaliculus into play. It has been all-sufficient in the many cases I have treated. So far as I know, the operation originated with myself

My plan is to dissect off the palpebral conjunctiva from a spot just posterior to the canaliculus, and to regulate the amount to be removed by the degree of the eversion; for as it is by the ensuing contraction that the eyelid is braced to its place, a certain proportion is required. For the most part, I have not applied sutures, but my present impression is in their favour.

This operation is far more generally applicable than I suspected when I first applied it.

Where, however, the corner of the eyelid is so much everted, from the loss of external tissue, that replacement is impossible, I advise that the upper canaliculus be opened according to the foregoing directions, and a portion of the sac also divided, and an endeavour made to keep the sac as well as the canaliculus open, by passing a probe daily for some weeks.

Where, with displacement of the punctum, the tarsal edge has been damaged in the manner which I have shown, or so changed by chronic inflammation that perfect readaptation of the parts, so far as to restore function, is impossible, the tears may be directed in their proper course by operating for the ectropium and slitting up the canaliculus as well.

Fig. 152.



I suspect that in the intra-ocular causes of displaced punctum, it is always necessary to combine the two operations, that for the ectropium and that for making an open canal for the canaliculus.

The higher punctum does not get displaced except in ectropium of the upper eyelid from extra-ocular causes. This is treated of in the chapter on "Diseases of the Eyelids."

The remarks which are made at the end of the description of the treatment for strictured canaliculus, with reference to success and the necessity for combating with coexisting inflammatory affections, apply here also.

DISEASE OF THE LACRYMAL SAC AND DUCT.

Knife for the Lacrymal Duct. The requisites here, Fig. 152, are sufficient narrowness, length, and strength of blade. It is better for the trustworthiness of so slight an instrument that it be without a shoulder, a spot at which delicate knives frequently break. The upper part of the blade is quite round, the next oval, and the point nearly flat.

It certainly would seem that the ordinary affections of this part of the lacrymal apparatus, obstruction of which

rarely exists before the seventh year of age, can be traced to a common local primary cause, namely, asthenic inflammation; and that the several effects are due to the degrees of stricture of the duct that may arise from such, modified by many circumstances; as, for instance, the health of the patient, constitutional diseases, surrounding circumstances of life, age, sex. Also, that the proximal origin is an enfeebled constitution of body, hereditary or acquired. The local manifestations of struma are very often co-existent. The common occurrence of symmetrical development of the disease likewise points to this truth.

In young people, the severer exanthemata and typhoid fevers are occasionally precursors.

According to this doctrine, the pathology is clear, and the indications for treatment are palpable.

I believe that the lacrymal tube in its entire length is always affected, although it may be more so in some parts than others. This difference is due to the natural constrictions in the passage. The encasement of the greater portion by bone precludes the exhibition of those results that are manifested in its upper and free end, the lacrymal sac; hence the idea that the sac alone is generally diseased.

Very slight narrowing of the duct would, I imagine, be attended with interruption to the functions, as the means of escape is not much greater than is required. In the healthy condition, any augmentation of the secretions produces an overflow, and with the slightest stricture, the ordinary amount must be too much for the transit.

Stricture of the canaliculi, especially of the lower, is frequently associated with that of the duct.

The palpebral conjunctiva is often at the same time involved in inflammation. The Schneiderian membrane does not always escape; so that the entire surrounding continuous mucous surfaces may be unhealthy. This is regarded by me merely as a greater condition or extension of the same disease: more superficies affected. It matters nothing in any way, except that of intensity, at which point the inflammation commences. It is possible that it may begin at any part of the oculo-nasal tract, and ultimately invade the whole.

That there is a specific form of inflammation seems sure. The affection never follows catarrhal inflammation of the conjunctiva, nor that produced by extraneous bodies, nor purulent ophthalmia from infection; nor is it ever the result of traumatic inflammation which may follow wounds of the parts. It is evident, therefore, that I do not accept the supposition that the disease is often a mere continua-

sometimes co-exist. So, too, is there sometimes found at the same time, in scrofulous subjects, chronic inflammation of the tonsils, and of the external auditory passages. There is merely the common connection of a blood disease.

It is a drawback in the description of diseases that artificial distinctions are requisite, and that lines of demarcation must be made; but for brevity and for teaching, this is unavoidable. Perhaps the least objectionable and easiest way of dividing this subject is to speak of chronic inflammation of the sac and duct, the usual form of disease that is met with; afterwards of acute, and ultimately to consider the condition of fistula lacrymalis.

There are natural or physiological variations in the size of the lacrymal sac, and the lacrymal duct, as well as in the bony parietes which surround this excretory tract, all of which depend on the natural conformation of the face, and more particularly of the skeleton. In all probability, they depend entirely on osseous development. But this has nothing to do with the performance of the function of the part, as has been supposed. It does not produce disease, nor does it involve any different principles of treatment. It matters not, therefore, whether a man's nose be flat and broad, or prominent and narrow.

The external wall of the sac may have a superficial recess, which will mark the division between the sac and the duct. When this is absent there is no boundary. There may, therefore, be a decided contraction, or merely a plain surface. The contraction, when it exists, seems to be caused by thickening of the periosteum at the point of entrance to the bony canal, or of the aponeurosis of the lacrymal sac. The course of the bony lacrymal canal, which encloses the lacrymal duct, is curved downwards, outwards, and backwards, but the convexity differs in different persons. This would, perhaps, be due to the height of the upper jaw, to the width of the nasal cavity, and to the variable position of the internal turbinated bone. Another influence is that of the duct varying in the spot at which it opens in the nose, being higher or lower, sometimes very posterior.

CHRONIC INFLAMMATION OF THE LACRYMAL SAC AND DUCT.

The obstruction from this cause usually begins imperceptibly, and increases insensibly, till a watery eye, with temporary cloudiness of vision, and distention of the sac by tears and by mucous secretion, disclose its existence. The common history, then, of these cases is,

sometimes particularly troublesome. The handkerchief is frequently used, and the sufferers may sometimes empty the sac by pressing on it, the contents, tears and mucus loaded with epithelium, escaping through the duct into the nose, or partially through the puncta between the eyelids. This stage may last for months or years, and with very little inconvenience if the conjunctiva be not markedly diseased, because in the absence of such complication there is not any surplus excretion to be carried off. But the retained excretions act as an irritant.

It is usually painless.

The experienced practitioner can at a glance tell what is at fault with such an eye by the fulness of the inner corner, the swelling and redness of the integuments, and the wetted caruncle.

Increase of the disease is shown by exaggeration of the symptoms. Slight attacks of inflammation, with pain, occur in the sac, which is now distended with a higher inflammatory product, more epithelium, and perhaps fibrinous exudation, and even pus cells, and this will escape by pressure through the puncta, and not into the nose; or sometimes regurgitate without pressure, because the duct is stopped.

The eyelashes get sopped.

The amount of the morbid secretion varies. It may be incredibly large. The quality, too, is uncertain; sometimes there being a predominance of mucus, sometimes of pus. Occasionally there are white streaks in it, the effect of the fibrinous exudation.

There is fluctuation in these conditions, according to the season of the year and the state of the weather. In winter the disease is at its worst. In summer it may almost cease, when there is but little inconvenience, except in damp or cold days.

Although these stages are usually spread over months, sometimes even years, there may be such rapid succession of them as to induce the belief that the attack is due to acute primary inflammation in the duct, an occurrence of great rarity.

In different individuals there is much variety in symptoms, and it is in the vascular implication. It is in the absence or presence of inflammation, that the greatest difference appears. In some cases there will be scarcely redness. It is in these, the more chronic, that the sac gets loaded with mucus and tears only. These variations have been described by authors as a separate disease, under the name of mucocele of the sac, catarrh, and relaxation; but this is incorrect, tends to no practical end, and only misleads, mystifies, and puzzles. There is too much subdivision. Sometimes the inflammatory attack will seem to be the chief evil.

The more pus there is in the secretion, the more is the interior of the sac affected. Pus may be produced from ulceration. I suspect that with ulceration there is occasional bleeding. The dark-coloured discharge sometimes seen is produced from an admixture of blood.

It would be tiresome to describe all the changes that may take place as the result of inflammation. Enough has been said for the purposes of diagnosis and of treatment.

When the vascular action is mild, or when it is absent, the disease lingers on for years. When active and paroxysmal, an abscess is the ordinary occurrence, and when this bursts considerable relief follows. A fistula, that is, a fistulous ulcer, at the inner angle of the eye, communicating with the lacrymal sac or duct, is now formed, and in the course of time its edges cicatrize. There will be discharged tears, or pus and tears, or mucus and tears, according to the more or less diseased state of the mucous membrane. The position of the opening is determined by accidental circumstances. The common situation is over the sac, just below the tendo oculi, as portrayed in the following sketch; but it may be at some distance

Fig. 153.

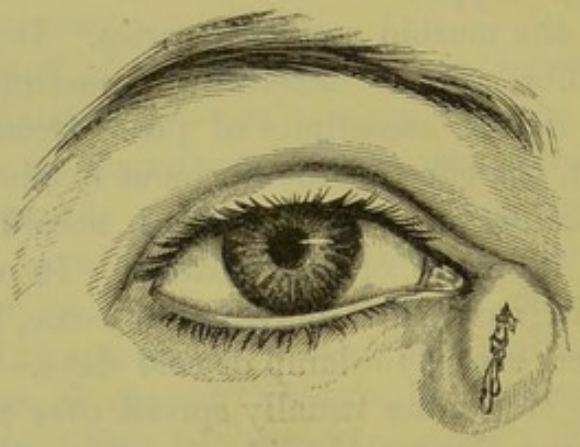

even on the cheek, or on the nose, or within the nose, or within the palpebræ. There may be several external openings, with as many sinuses, while there is but one sinus communicating with the sac, from which all branch off.

The abscess is always attended with much local suffering, and constitutional excitement, and after-depression.

It has been observed by Hosner, that partial ulceration, and subsequent cicatricial contraction of the lacrymal duct, may occur with the formation of an abscess. Also that after phlegmonous inflammation of the sac, the nasal duct may be changed, through the greater part of its extent, to solid tendinous cord.

A fistula, therefore, is but a natural process of cure; it is an outlet by which the excretions shall escape.

The fistula may heal, and the disease may be cured, or it may seem for a time to have ceased, but if the patient remain untreated, the same stages may recur again and again; or it may remain and become less troublesome as it is chronic, especially if a sinus does not form.

Except for the severer paroxysms which disclose the severity of the affection, a person does not generally seek advice, unless, perhaps, the conjunctiva be inflamed and the Meibomian secretion vitiated, and these derangements, so frequently associated, are often considered to be the cause of the obstruction.

Treatment. It is easy to relieve these cases; it is difficult to cure them. Yet a great many do admit of cure, however obstinate for a time they may be. Of course there are degrees of the disease in which restoration cannot be expected; where, for instance, natural structure is in part destroyed. But such are not beyond relief. It is well, therefore, to understand what can be accomplished, and what cannot. A quick result can never be obtained in any instance. At best, success will follow only a well-directed and long-continued course of surgery and medicine. It must be remembered that not only is the mucous part of the canal diseased, but the surrounding tissues are involved, and sometimes to a great extent. Ulceration and contraction are the usual defects.

The measures needed are, therefore, from what has been shown, twofold: constitutional, to conquer the cause of the disease; local, to overcome the inflammatory state, including mechanical aid, to dilate the narrowed channel, or to open it when entirely closed. Of these, the first is the most important, as it goes to the origin of the evil, and in the earlier states it alone may suffice. If either were to be used to the exclusion of the other, in the majority of cases, the patients would have the best chance under the constitutional. It is needed at all periods, and everything else may be said to be but auxiliary to it. It can never be dispensed with. At once, therefore, general derangements should be sought out, and every endeavour made to improve them medically and dietetically.

Among the poor, undoubtedly, sufficient clothing, especially flannel to the skin of the delicate, proper and sufficient food, and ventilation to dwellings, are the things that are mostly needed. Without improving mal-nutrition, we shall attend to the ophthalmic symptoms in vain.

In cases where the indication is apparent, especially in the

scrofulous, the change of residence from this country to a warmer, or to a tropical climate, produces wonderful benefit. By this alone, I have seen complete recovery from advanced stages of the disease. By my recommendation, patients have found voyages to Australia and to India very curative.

To impress the importance of the influence of constitution over the local disorder, I may mention a very marked case of recovery effected by a change of climate alone. A scrofulous youth was brought to me, with symptoms that left no doubt of the complete obstruction of the duct, but abscess had not supervened. The lower eyelid was partially everted, and a constant discharge of secretions from the conjunctiva and the sac had excoriated the cheek. A great many applications in the form of blisters, ointments, and stimulating lotions had been used. A refusal was given to the treatment I proposed. I then suggested that the young man should be allowed to join his mother, who was in the West Indies. Eighteen months in the warm climate re-established his health, and with the disappearance of glandular swellings about the neck, the eye was restored.

It would be unwise to particularize any forms of medicine, as there is no specific, and each case will have its own indications for this or that drug. In the scrofulous stricture, there is wanted just the same general or constitutional remedies as if there existed enlarged lymphatic glands, or chronic synovial disease of a joint, or caries of a bone, without the association of any eye disease. In the debilitated, the functions most at fault, whether of digestion, assimilation, or sanguinification, must be carefully attended to. Here is it, as on many other occasions in practice, a surgeon must be a physician, and something more.

That the local disease is originally and essentially inflammatory, and that the obstruction is kept up by inflammation, should never be lost sight of.

The degree of inflammation should be regarded. The morbid secretion proceeds from an inflamed mucous membrane, the tumefaction of which is the first agency by which the duct is closed. No advance can be made till such is subdued. Leeching over the sac, one leech or two, is valuable. The quantity of the blood to be taken should be regulated by the redness or tenderness under touch, and the repetition or not by the result.

The fullest effect of the leeching can be got only in the earlier stages of the disease, where there is yet some perviousness of the duct. Where there are accessions of inflammation from reacting irritation, arising out of the duct being closed, blood-letting is

contra-indicated. Closure exists when the contents of the sac cannot be passed into the nose.

After the leeching, a cold application is called for, such as cold water with a rag, or iced water, or a spirit lotion, or ice poultice, that is, ice pounded and applied in an india-rubber bag.

The sac should be pressed, and emptied of its contents, three times a day, an act that the patient can be taught to effect. By this the injurious effect of the distention, which helps to keep up the inflammation, is removed. The evacuation will be greatly facilitated by slitting up the upper canaliculus, and converting it into a canal, after the manner above described. Indeed, this should be done early.

An application of an astringent to the interior of the sac and duct is beneficial at some stages of treatment, and particularly after the more active symptoms have been reduced. An injection is the more easily done through a divided canaliculus. As some of the injected fluid enters the throat, only harmless drugs should be used. I employ tannic acid. It is well to wash out the passages first with warm water. Very few patients have ever allowed me to do this sufficiently often, that is, daily.

An india-rubber bottle, with a fine tube, is better for this purpose than any syringe. A part of the injection will escape by the nose, and a basin should be held to receive it.

Most persons will submit to any annoyance from disease, rather than syringing. A great deal that is written and recommended about probing and syringing is never really carried out. It is mere description to make the plan of treatment appear perfect. Some authors speak of injecting the sac and duct through a hollow probe. My usual practice is to apply, to the corner of the eye, a drop of the lotion after each emptying of the sac, and to repeat the application. Some of the lotion must enter the sac, and all that goes there must pass through the duct, so long as it is pervious.

If a patient will carry out this general and topical treatment, he will obtain a good result. The cure will be the rule, the failure the exception.

But the disease may not cease under any measures without dilatation, because the duct is too much narrowed. There has not been mere swelling of the soft tissues, but structural change of them, and permanent thickening. The stricture keeps up the irritation.

When the dilatation should be undertaken is a nice matter to decide, both while a patient is being treated, and the first time he is seen.

As the narrowing of the duct proceeds very gradually, the exact

time when the channel is closed cannot be told, and therefore the proper time for the dilatation can be judged of only long after the necessity for it has arrived. I will mention the conditions by which I am guided.

After a sufficiently long course of general and topical treatment, however much improvement there may be, if the sac still continues to fill, dilatation is wanted.

When I first see a patient, I ascertain the state of the canaliculi, and the condition of the parts about the lacrymal sac, as conveyed to the touch. When one of the canaliculi is choked at the inner end, especially the lower one, there is, as far as I have observed, almost invariably stricture of some part of the lacrymal duct as well. Where there is decided thickening of the parts over and about the lacrymal sac, so that the edges of the bones cannot be felt as in health, there is that condition far advanced which needs dilatation. The thickening is chiefly periosteal. Perhaps the bones lose their sharpness of outline. These rules have fewer exceptions than any that I know of. A profuse discharge, even of purulent matter, through the puncta, although frequently associated with stricture, is not in itself, as I have frequently ascertained by actual exploration, an unerring sign of permanent duct obstruction. Again, all degrees of narrowing of the duct, and even complete occlusion, may exist, without the escape, under pressure, of pus, and but little of any secretion, by the puncta.

The age of a patient gives no guidance, and I fear that surgeons often postpone mechanical treatment on account of tender years. I have often been obliged to resort to it in children, and once in an infant three months old, who was brought to me with a lacrymal fistula. Nine days after the birth, an abscess over the duct was opened, and a fistula ensued. It cannot be doubted that the disease commenced *in utero*.

Being satisfied that dilatation is necessary, we must proceed to effect it by the natural channel; this is done by getting at the duct through a canaliculus; I prefer the lower. The first thing, therefore, is to slit it up, and to maintain it open. How to do this has already been pointed out. In France and Germany, the higher canaliculus is usually selected.

After the channel through the canaliculus has been established, the next stage of treatment should commence. Mr. Bowman, to whom we are indebted for this, is, so far as I can gather, an advocate for gradual dilatation of the duct, with probes of different sizes, passed at intervals of a few days. The process I consider tedious; and is so disagreeable that but few persons, in public or in private,

will submit to it sufficiently long. Many patients have left other surgeons and come to me, solely because they would not submit to it; and I know that some have left me on the same account. It is inapplicable to children.

Several sorts of probes are sold for the purpose. That which is shown (Fig. 154) seems to be most used; not, however, by myself.

Fig. 154.



My practice used to be to dilate for a short time only, using in the first instance a small, straight probe, and afterwards a larger one; and then to introduce a style. Now, I generally explore the duct in the first instance, with my second-sized probe. If the channel be not very much narrowed, I insert a style. If it be so affected, but is evidently yet penetrable, I introduce a small silver wire, about the thickness of a hair-pin, and long enough to be readily used, and allow it to remain, but cut off the upper part, and turn the end down over the eyelid, which is effected with two pairs of pliers, one to hold the wire, the other with round points, to bend it in the form of a little hook. This is a sketch of such an appliance that has been used. In a few days I remove this, and use a style.

Fig. 155.



It would be mere waste of time to give anatomical directions for the passing of the probe, or the wire. A man must learn to do it as he would learn to pass a catheter. One trial will serve him more than the most elaborate description. It is only the metallic instrument that can be depended on to press the duct at the seat of stricture, and cause the thickened part to atrophy.

The stricture may prove to be very tight, so dense indeed that it cannot be readily penetrated by the probe or the wire. It damages the duct too much to drive the probe through the stricture with violence. It must then be divided by the style knife, till the resistance is overcome, and, if needs be, to the end of the duct. Many times I have met with a degree of obstruction, and sometimes, too, when not expected, that required an incredible amount of pressure to be overcome; an amount indeed that a beginner would not have courage to exert. After a few days the channel is enlarged, and

a style can be introduced. The secretions readily pass by this little cylinder.

Styles of different calibre and of standard silver should be kept. It may be advisable at first to use but a small one. That shown (Fig. 156) is of full thickness. As a pointed end facilitates the

Fig. 156.



Fig. 157.



introduction, I seldom now use any other (Fig. 157). The form was given by Mr. Taylor, when, many years ago, he effected dilatation through the sac inside the eyelids, and with marked success. It was a more perfect plan than had yet been adopted. The little tail prevents the instrument from getting out of sight, and should be worn just outside the lower eyelid. A style may be too large. Sufficient space should be left, that the duct walls be not destroyed by pressure. Some styles that are sold would almost fill up the bony canal in the skeleton.

Different lengths in styles are needed, for in every application of this instrument, the foot should reach the palatine process of the superior maxillary bone, the floor of the nose. There is then no risk of the style slipping down, nor of the upper end producing irritation or ulceration by pressure. It is well in each case to ascertain the required length with a probe, and to select a style accordingly.

An operator should be certain that he has really made a proper channel into the duct, and is working within it, and not outside, on the face, or through the lacrymal bone; and the only sure test is to feel the floor of the nose with the probe.

The success of the entire proceedings of the treatment rests on the accurate passage of the style. Liability to failure consists in the tendency there is to penetrate the lacrymal bone, rather than in the line of the strictured duct. I know of no more common mistake in ophthalmic surgery than for a false passage to be made.

I can give no rules for guidance beyond those of acquiring anatomical knowledge of the part, which a single dissection will afford, and practising many times on the dead body; of exercising great care; and of never being satisfied that the operation is completed till the probe touches the floor of the nose.

For descriptive anatomy of the part, a work on anatomy should be consulted.

Few men do this operation well, still fewer readily and correctly at the first attempt.

From time to time the style should be removed and cleaned, and if it should ever become uncomfortable or irritating, the cessation of wear for a day or two generally enables it to be tolerated. Some patients wear it at night only.

As to the duration of its application, I continue it until inflammatory action has been subdued, which is indicated by an absence of all purulent or other secretion of an unhealthy nature from the style aperture when the sac is pressed on. This is the best indication that can be got.

Among the several advantages of dilating an obstructed duct through the natural passages is this, that there is no after trace of treatment, no marks on the face, no metallic stains, no fistula to heal up, no sinuses to destroy. Besides, this method has a more extended application than any yet devised. There is hardly a complication beyond its reach. Although I have refrained from giving many cases, I shall briefly allude to an instance in which a great deal was effected in association with other operations.

A boy was kicked on the face by a horse, and the inner corner of the eye, together with the nasal bones, much injured. When I saw him, four years after the accident, the internal commissure was drawn inwards by a cicatrix on the nose, the inner portion of the lower eyelid inverted, and the lacrymal sac distended with thick mucus, which was always overflowing through the upper punctum, and producing much distress. It was a long time before I could discover the lower punctum; it was out of the usual position, no doubt, from having been injured, and hidden by the folded lid. When found and penetrated with the probe, I learned that the inner portion of the canaliculus was imperfect, and the sac could not be reached. I first established an opening to the sac by pushing the director through the occluded canaliculus, dividing the canal in the entire length, and using the probe each day till the edges no longer united. Then I operated for the entropium with success. After that I proceeded to dilate the duct; and, as it was almost impervious, I introduced the style at once, preparing the way with the style-knife, and allowed it to remain till no longer needed. There yet lacked a little practical surgery. The caruncle was enlarged to a degree that interfered with the working of the lacrymal apparatus, and I removed it. With these four operations, the channel from the eye to the nose was efficiently established, the misery of an obstructed duct abolished, and the boy's personal appearance materially improved.

But a few years ago such an example of disease could only have been half treated. Although the duct might have been made pervious, inflammation would have yet lingered in the sac, because of stricture in the lower punctum.

Practically speaking, I recognise stricture as existing alone in the lacrymal duct, that portion of the tube inclosed in the bony canal, the nasal duct. Personally, I do not know of strictures of the sac arising out of idiopathic disease, but it is said to exist, and I must not doubt that it has been met with. I have not myself felt any obstacle, arising out of such stricture, to the passage of a probe or of a style, after I have divided a canaliculus and a part of the sac; but some surgeons say they have, and recommend as a means of overcoming such, the cutting subcutaneously of the internal palpebral ligament, by a cutting instrument introduced by the route of the divided canaliculus into the sac. It may be done as a canaliculus would be divided, and with the same implements. This seems to me as if the stricture were caused by constriction of the ligament, which is only fascia covering the sac.

The latest new suggestion for mechanical treatment is by Stilling, who advises that the canaliculus be slit up, a grooved director passed into the duct, carried through, or down to the stricture, and the mucous membrane divided in three or four different directions. This is all. No dilatation is to follow. Such a measure must be inefficient for cases of actual stricture of the duct. Where there is not actual stricture, mechanical treatment is not necessary.

The use of the style does not supersede general treatment, or such other general measures as I have described as usually necessary in the earlier form of the disease. A great deal may yet be required of the constitution, as this case shows. A young member of our profession in delicate health, in whom I introduced a style, made little real progress. The lacrymal sac still remained unhealthy. I advised him to take a trip as a ship surgeon to Australia. He did so, and improved in health, and the lacrymal disease benefited. He went again, and returned a healthy, stout, and powerful man, and the eye was well.

After the style has been withdrawn, and when the opportunity offers, I use the probe once a week, or at longer intervals, for a few times, and allow it to remain in for some hours.

The result of the style treatment has been in many cases a thorough restoration of the excreting channel; in others, the removal of severe symptoms, and of continued discomfort; and only exceptionally, in severe weather, or during ill-health, is there any remains of the past trouble. In some cases the natural structures have been so much

damaged that a relapse ensued, and re-application of the style was necessary. I occasionally see a few old patients who have worn the silver for ten or fifteen years, and who, as a rule, rather continue with it than risk a relapse by taking it out.

What may be the true nature of the pathological change that takes place in an impermeable duct I am unable to say, never having examined a specimen.

Many complications may exist with this form of the disease, arising out of unhealthy states of the conjunctiva, and of the eyelids, including entropium and ectropium. As these need distinct treatment, just as if the excreting apparatus were healthy, and as all are fully considered in their respective places, it is enough merely to allude to them here.

ACUTE INFLAMMATION OF THE LACRYMAL SAC AND DUCT.

Acute sudden idiopathic disease of these parts without any previously existing irritation is unknown to me.

The acute attacks are undoubtedly the consequences of pre-existing disease of a chronic nature, excited by circumstances which are sometimes recognisable, sometimes not.

In a slight case the sac chiefly is affected.

In a severe case the entire excretory duct participates. The sac is hard, and swollen, and prominent, and filled with an excess of morbid secretion of mucus. There is considerable pain, which extends to the nose, and the slightest touch is intolerable. The tears overflow, because the channels are all closed by swelling. The inflammation extends to the integuments around, and even the cheek participates. Phlegmonous inflammation is established. The sac, now greatly distended with mucus and pus, stands out more than ever, even in relief, if there be not much surrounding inflammation. Headache and fever come on, and there may be delirium.

Writers who make unwarrantable distinctions between the several phases of disease of the sac and the duct, would speak of this as phlegmon, in distinction to the mucocele of the chronic inflammation.

The over-full sac bulges in front, just where it is uninclosed by bone, and where only such distention can occur. The contents cannot pass downwards, because the lacrymal duct is closed by the swelling of its own lining membrane, nor outwards through the canaliculi, because they are closed by swelling.

The last stage of acute inflammation appears over the sac. The skin

becomes darker and shining. Progressive absorption of the soft parts is going on within, by which the pus travels to the surface. These conditions having reached their limit, a slough forms at a minute spot, separates, and gives exit to the pent-up secretion; or a yellowish vesicle crops up and bursts; and as in abscesses in general that open naturally by either of these processes, the thinner parts of the secretions at first escape. Relief is at once afforded.

As the intensity of the inflammation subsides, the pus lessens, and clear mucus oozes, and the presence of tears may be detected, if the upper part of the sac be pressed on, a proof that the canaliculi are again patent.

What has been said respecting the physical conditions of the bursting of the abscess in chronic inflammation of the sac applies here, and need not be repeated.

An abscess may form external to the sac, and not communicate with it, as sometimes happens in stricture of the urethra, when pus is deposited in the perineum, external to the urinary canal, although this is not so common.

Distention of the sac from accumulation of mucus alone may produce that degree of inflammatory action that would end in sloughing of the integuments. I have used the bistoury in such a case under the suspicion of an abscess being present, and given vent to glairy fluid merely.

A great deal of relief ensues when the fistula forms, and pus, mucus, and tears are discharged, afterwards mucus and tears only. The canaliculi are again free, so that, if the sac be pressed on, the secretions flow through them. The fistula may heal of itself, and if the duct remain impervious, the patient generally resorts to the expedient of pressing the secretions through the canaliculi two or three times a day.

A more favourable termination of acute inflammation is a kind of resolution, by which the symptoms decline before they reach the last stages, and the secretions in the sac, whatever be their nature, flow first through the puncta, and afterwards through the duct.

A severe acute attack may damage the lacrymal channel in some parts of its course, by ulceration or sloughing, from the puncta to the termination of the duct, or may obliterate the whole of it; but the chief damage is generally inflicted on the duct, by which it is rendered impervious.

Treatment. With any evidence of acute inflammation of the sac, I order a few leeches to be applied, prescribe a cold lotion, keep my patient quiet, and attend carefully to any apparent disorder of the digestive functions.

Slight inflammatory attacks of the sac readily yield to such a course.

The severer examples, in which the sac and the duct are involved, are not so readily terminated, and especially because there has pre-existed, as I have shown, chronic disease of the parts. But I think that an abscess may nearly always be prevented. Patients, however, very rarely apply in the early stage of the disease.

When suppuration has set in, it is unwise to wait until the abscess bursts, as that would prolong the patient's suffering, and risk a fistulous aperture. The matter should be evacuated when it points, the sac opened at the same time, and the duct also. Even when the knife is used, the pus may not escape till the duct is penetrated. The following directions may be useful in this procedure, for the usual rule that is given to find the position of the sac by pulling the eyelids outwards, and making tense the tendo oculi, is not applicable when disease exists. Indeed, with very much swelling and induration, there is not any landmark absolutely trustworthy; but so long as the lower and internal angle of the orbit can be felt, it may form an unerring guide. The correct place for the puncture corresponds externally to a spot a little below, and internal to the inferior punctum. With the forefinger of the left hand placed on that part of the edge of the orbit that stands in front of the bony canal, to get the level, and to give an idea of the distance of the sac from the surface, the knife, with the edge outwards, should

Fig. 158.

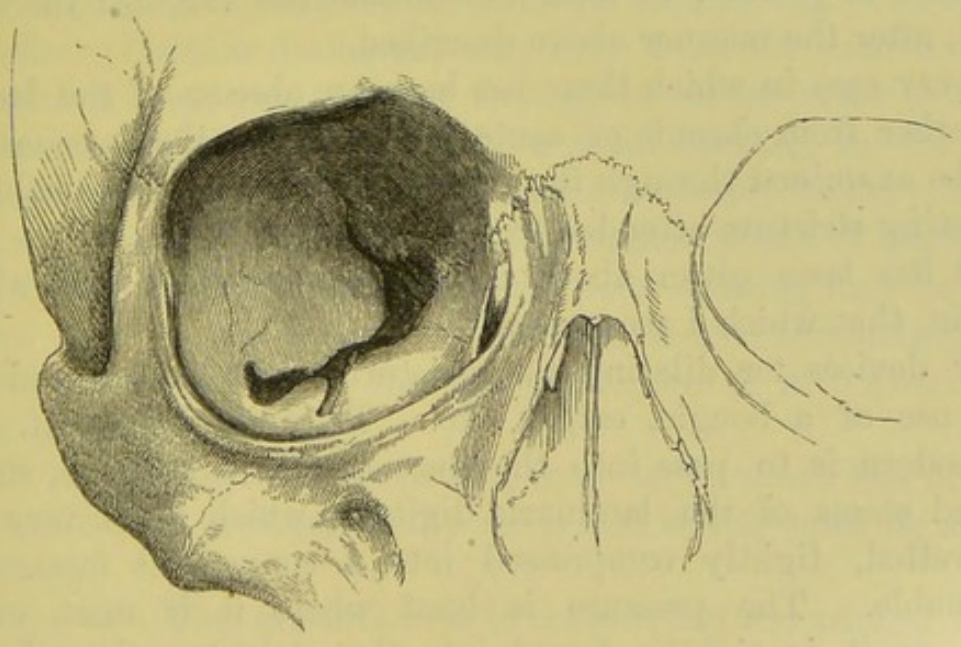

be entered below and internal to the punctum, carried a little inwards behind the ridge of bone, and then downwards, inclining slightly outwards and backwards, to the required extent. A reference to the

the relations of the bony canal, the ductus ad nasum, may be useful.

It is needless to attempt to pass the knife while the point is in contact with bone, for the right course has been missed. When the instrument is adroitly used, a bony surface is not touched.

The inclination of the facial angle influencing the direction of the nasal duct should be remembered. In the Ethiopian variety of our race it inclines very much backwards; in our own, or the Caucasian, it inclines forwards.

Even now, after the abscess stage, judicious treatment may effect a cure, although such a happy event is by no means certain, the result of course mainly depending on the condition of the duct prior to the acute symptoms. Warm applications are indispensable. Whenever there is suppuration, cold is intolerable. A small, warm linseed poultice, often repeated, gives the greatest comfort. The sac and the duct should be washed out with the lacrymal syringe daily, through the aperture which has been made, and the duct dilated from time to time with as large a probe as can be introduced. As soon as the health of the duct seems sufficiently restored, the external aperture should be encouraged to close, by being covered up with strips of plaster and a compress. If the duct should be found to be impervious, or tightly strictured, it would be useless to attempt dilatation in this way.

The most practical proceeding then is to endeavour to heal the fistula, and to proceed to treat the obstruction through the natural channel, after the manner above described.

In every case in which there has been an abscess of the lacrymal sac, whether from chronic or acute inflammation, the lacrymal duct should be examined through the previously prepared canaliculus, and any existing stricture attended to.

What has been given above is my own practice; that which I believe in, that which I recommend.

Many devices for dilating the strictured duct are advised; such as the use of a bougie, catgut, &c. They are inefficient. The most modern is to pass into the duct certain substances, such as the dried stems of the laminaria digitata, which swell very much when wetted, tightly compressed into a convenient form. It is objectionable. The pressure is least where it is most wanted, because, as it is tightly forced into the stricture, there is little moisture to be had there for the expansion, till it be got by diffusion from above and below the stricture. If the substance be left till this occur, the lower end will swell so much that it cannot be taken out without tearing the duct, and some of it may be left behind.

The suggestion of overcoming this drawback by coating the end with copal varnish is not practical, as exact measurements must be had for the extent of the varnish.

Elastic catheters are likewise to be condemned, and all appliances which need that the sac and the tissue around be more or less cut or torn for their introduction. I believe that many of the devices recommended are never really practised as they are described. It would be impossible to carry out all the surgical details.

FISTULA OF THE LACRYMAL SAC.

An established opening into the lacrymal sac is the excessive effect of an abscess. It is associated nearly always with stricture of the duct, and often with stricture of one canaliculus, or of both. It is the termination of the worst form of extensive inflammatory disease of these parts, and must be set down to total neglect of treatment, or to the insufficient administration of it.

The preceding inflammatory action often damages the texture of the surrounding portion of the sac, and even the contiguous structures at the corner of the eye, especially the edge of the eyelid and the conjunctiva. The canaliculi may suffer. Sometimes contraction follows, and there may be ectropium. It is the nature of severe erysipelatous inflammation to do this. The entire excreting region without may be involved; the integuments around, and even the nose, may suffer. Copious discharges may issue from the nostrils.

The fistula may, for practical dealing, be classed under two heads: the state in which there is merely a small opening in the sac, the canaliculi being pervious, and the eyelid tolerably healthy, and that in which the aperture is large, with much destruction of parts.

With the first, or limited fistula, the outer opening may be directly over the sac; or at a distance, when there is a corresponding length of sinus under the skin, or through the texture of it. There may be several external apertures.

With the second, or large fistula, there is too much loss of integument to admit of a sinus, for the sac is laid widely open by slough or ulceration.

Treatment. The indication is to remove the stricture of the duct, to slit up a canaliculus, or even both of them, and to attend to any external complication. A style is imperative; there is nothing equal to it; but the manner of using it should depend on the condition of the disease to be encountered, according as it may belong to the one or the other of the following classifications.

If, as in the first state, the soft parts will admit of it, the dilatation should be conducted through the natural channels, as if there were no fistula.

Any sinus, or sinuses, should be divided, and water-dressing applied. Nothing is gained by using escharotics, or any violent applications, or even so-called astringents. If the stricture be removed, so that the conducting power of the duct be maintained, and regurgitation from the sac be made easy through a divided canaliculus, and the fistula be kept clean, nothing more is wanted; Nature does the rest. The exceptions are very rare. In an obstinate case, unattended with any decided loss of integument, the edge of the aperture may be made sore by nitrate of silver or an acid, as a means of inducing healing by granulation. Caustic potash is inadmissible.

If, as too frequently happens in the second state, the natural passages are not available, the style must be passed in another direction. A selection must be made between passing it into the sac from within the eyelids, or from without, according to the practice of former years, through the skin of the face. I prefer the former whenever it is practicable. When the latter is inevitable, it is of the utmost practical importance that the entrance for it be made in unbroken integuments, and not through the fistula, and as high as possible, because the entire extent of the stricture may be traversed, and the fistula may be allowed to heal. The rules for doing this are the same as those I have given for opening the sac to evacuate an abscess. The less the fistulous aperture is used as the channel for dilating the duct, by style or probe, the better.

The following figure shows the form of the style that is usually employed by me. The bend causes it to sit better, and

Fig. 159.



prevents the head, which should be thick, with obtuse edges, from resting on the skin and irritating it. Styles are sometimes fluted or perforated in a part of their extent, under the supposition that the tears will pass more readily; but that form of construction, a modification of the metallic tube of Wathen, which used to be placed within the palpebral aperture, is decidedly objectionable.

The length of this style, too, must be regulated, like that of the other above spoken of, by the length of the patient's duct. The

thickness required for an adult is about the thirteenth of an inch. Sometimes I use slightly larger ones. In severe cases of fistula, especially where the bone also is diseased, a globular headed one is preferable, as not being likely to irritate the healing surfaces. Even with the round head, the stem should rest on the floor of the nose, so that the weight of the instrument be taken off the soft parts. On three or four occasions, patients have had toothache in some of the incisor teeth, from the style irritating the branches of the fifth nerve. This has been removed by shortening the style.

The silver style may become tarnished, and corrode during the ulcerative stage of the soft parts or the bones. It may be affected by deposits from the decomposition of the tears, of which I met with an unusually marked example in a youth from whom it had not been withdrawn and cleaned. After the lapse of two years, it could hardly be pulled out, from the mass of accumulation, especially on the end, consisting of incrustation, to a considerable depth, of sulphuret of silver, which rendered it exceedingly brittle. The sulphuret was doubtless formed from the sulphur compounds contained in the lacrymal secretions acting gradually on the metal. This is a sketch of it, after the deposit had been burned off.

Fig. 160.



It will be seen that the neck was nearly corroded through.

Where expense is not a consideration, a silver-gilt style, or one of solid gold, or of platinum, should be preferred.

Fungous granulations are not uncommon with fistulæ, and may be readily removed by a mild escharotic, or a stimulant, such as the powder of the red oxide of mercury (hydrargyri oxidum rubrum).

Syringing the lacrymal sac and duct with warm water through the style-hole may be useful, indeed requisite, if there have been copious suppuration. Some astringent, or other medicinal preparation, may be added. I subjoin a sketch of the syringe that I use, reduced a

Fig. 161.

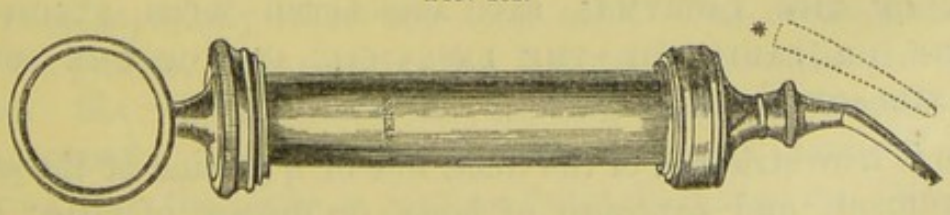

gives the real size of the nozzle, and it is well to have several of these of various sizes and lengths, for different cases.

The treatment of a closed canaliculus should be consentaneous with that of the fistula.

Where there is ectropium, whether it should be attended to at once or subsequently, must be decided according to the circumstances of the case.

The principles of constitutional or general treatment which have been sketched will apply to all the varieties of these diseases. It is only necessary to add that the strumous diathesis is generally seen here in its greatest development.

Varieties in fistulæ will occur, which may require particular modifications of the one or other plan, and these must be met by the experience and the skill of the surgeon; and nowhere else in practical ophthalmic surgery is there a greater demand for such qualities. The permanent wearing of the style is more likely to be required here than where there has not been a fistula.

Patients, being naturally desirous of disguising all blemishes, ask how the head of the style may be best concealed. White metal is certainly conspicuous, and a bit of black or coloured wax, melted smoothly on the surface, previously roughened, tends to render it less apparent. Instrument makers usually put on paint or enamel, but neither wears well; and, as any one can apply the wax, a clean unbroken surface can always be commanded. Gold is less conspicuous; and if the head of a gold style be reduced, as it may with safety after a few weeks' wearing, nearly to the diameter of the body, very little unsightliness remains.

The success, even when all has been done that can be accomplished in the best manner, must mainly depend on the degree of integrity of the parts that existed when the treatment was undertaken, and the non-success on the amount of damage that had been inflicted. Many a case that, in the strictest sense of the word, could not be called successful, is so far improved, that all trouble is removed, except when an inordinate flow of tears is called forth. In some cases, the persistence of comfort can be maintained only by introducing the probe at the interval of a few weeks, and keeping it in for an hour, or wearing the style for a day or two occasionally.

FISTULA OF THE LACRYMAL SAC ASSOCIATED WITH EXPOSURE OF BONE, OR CARIES OF THE LACRYMAL, AND OF THE SUPERIOR MAXILLARY BONES.

There is here stricture of the duct, loss of a portion of the sac, and of integument, and exposure of bone, or disease of bone; combinations of the destructive processes of diseased action.

The bone may be exposed simply from the loss of the soft parts over it, and not diseased. But it may be affected with caries and necrosis.

While there can be no doubt about the osseous disease being at times a mere extension of contiguous morbid action, it must be admitted, from analogy of disease in other parts of the body, that in all probability the bone may be primarily involved, and the duct and the sac secondarily, and the inflammation and the erysipelas of the face, caused by the dead bone, mistaken for original disease of the soft parts. I say admitted, because the true condition of things can be hardly observed in this region. It is well known that there may be caries and necrosis of the neighbouring bones, especially of the interior of the nose, without the sac being damaged by the extension of the inflammation. But it is likely to be involved, if not in ulceration, in contraction, consequent on the cicatrization after the removal of the osseous disease.

A recognition of these two pathological states should impress the importance of evacuating pus immediately that its presence is detected, as a means of checking the extension of disease; for when the bone is exposed or diseased, there exists the worst of all the conditions of damage to these parts, and the most difficult for amelioration.

Treatment. When there is fistula with bone merely bared, there is nothing required, so far as concerns the stoppage of the duct, beyond what has been described in the last section, for stricture with fistula. The style is the remedy, and its application is the more or less advantageous as the fistula is low or high; according, in fact, as there is integument above through which it can be passed, or none, when it must be inserted through the fistula.

The question might arise out of the local condition, as to whether the style should be used at once, or after some previous treatment. The following case illustrates this:

A female, forty years old, an Ophthalmic Hospital patient, applied with the palpebræ of the right eye closed from swelling, and a copious sanious discharge issuing from a fistula lacrymalis. She was greatly depressed. The circulation was feeble, and the tongue thickly furred. Five years previously, the eye began to water, and gave more or less annoyance, especially when she took cold. Pus occasionally flowed from the puncta, and during the last twelve months it constantly escaped. Six weeks before she applied, abscesses formed and the fistula ensued. The bone around the sac was denuded. While exploring with the probe, a copious fœtid discharge ran into the nose and issued also from the fistula. A tonic course of treatment was

adopted. In a week, sloughs separated from the fistula, and more bone was exposed lower down. A healthy action ensued, granulation set in, and in a month no bony surface could be felt. I introduced a style externally, passing it through a bit of integument high up that was healthy. The fistula healed, and in three months she persisted in her determination of suspending all treatment, local and general, as she thought herself well. This case establishes the difference between caries and the mere exposure of bone by the loss of soft parts, while there is not disease of it, from which state it quickly recovers. The information that the probe affords is not sufficient for a diagnosis; the symptoms and the history must also be guides.

Where, with denuded bone, the greater portion of the sac has been lost, together with the subjacent integuments, the style must be passed through the fistula. Bad as such a case may be, there is yet an opportunity for relief, if the canaliculi are intact. The formative action, in imitation of the healthy organization, is so carried out during the repair by cicatrization, that an acquired canal may be established, a duct of cicatricial tissue, one, perhaps, not equal to convey away an excess of tears, but sufficient for ordinary use. The style should be kept in no longer than it is absolutely required, not after cicatrization has been fully accomplished, and pus is no longer secreted.

When caries is present, associated as it may be with necrosis, special attention is required for it. The maxillary bone is generally affected. The gouge should be used at the proper time, and the unhealthy surface cut away. Necrosed bone should not be allowed to remain. For further information on this subject, I beg to refer to the chapter on "Caries of the Orbit."

The lacrymal fistula in these uncommonly bad cases may remain pervious in spite of all treatment; sometimes large, but reduced, it may be, to a size that causes no annoyance when a style is in the duct, and but only occasional inconvenience when it is out, being often but a mere capillary aperture, and allowing passage to a tear-drop only when the sac is pressed.

I have ceased to try any plastic operation for these cases with the view of curing the fistula, because I have never got success, but only been able to ameliorate. It is a common recommendation to pare the edges of the fistula, and bring them together with a stitch or two, but union must be a rare event. I have not seen it.

Constitutional treatment is required no less here than in the other states of the disease.

CERTAIN DEFECTS CONNECTED WITH THE STYLE WHEN APPLIED EXTERNALLY, AND OTHER INCIDENTAL CIRCUMSTANCES ASSOCIATED WITH ITS USE.

The occasional defects of the style must be named. After the removal of this useful appliance, a slight depression, with sometimes a bluish tint, due to a deposit from the tarnished silver, may mark the spot where it has been inserted. I have never seen the stain, however, except in hospital patients who would not remove the style and wipe it occasionally during its wear.

The style aperture generally heals readily; indeed, I have seen but few cases in which it has remained patent. When repair fails, the hole contracts to a minute point, through which a tear-drop exudes when the sac is pressed. In two cases which occurred in my private practice, the patients deemed it unnecessary to have anything done for it.

If the style be improperly passed through the lacrymal bone, disease of bone is set up, and the aperture rarely heals. In the case of a gentleman, previously operated on before coming under my care, not only was the point of entrance through the skin badly chosen, but the lacrymal bone was penetrated. As the annoyances of the obstructed duct remained, I withdrew the style and entered it correctly, little doubting that the first aperture would heal; but in this, as well as every other attempt to effect its closure, I was disappointed. The edges were pared, raised, brought together, and retained by sutures, the muscles of the face kept quiet, and the use of the handkerchief for a few days laid aside, that air might not be blown up into the duct. All necessary precautions were taken, but to no purpose. Escharotics also were unavailing. Transplantation alone was left untried, and that would have been done had my patient not suddenly left me and placed himself under the care of another surgeon, whose endeavours were equally fruitless.

In a private patient, within an hour after the style was passed, profuse hæmorrhage from the nose took place, which could only be arrested by plugging the anterior and posterior nares.

On a few occasions the style has seemed to produce irritation, when I have withdrawn it. In a week or two I have replaced it, without the least appearance of its being injurious.

A style that escapes accidentally from blowing the nose, or that falls out, should be replaced at once.

NOTICE OF OTHER METHODS OF TREATMENT.

Several methods have been adopted for the treatment of inveterate disease of the lacrymal duct, of which no mention has yet been made. Some of these are so obsolete that they need not be named. Each in its turn has had its advocates.

The metallic tube of Joubert and Dupuytren, which was thrust through the sac into the nasal duct, was, at the time, thought a great discovery, but a fair trial, by unprejudiced surgeons, proved its uselessness and frequent injuriousness.

Woodhouse's suggestion of perforating the lacrymal bone was tried and abandoned.

Nannoni's method of obliterating or destroying the lacrymal sac, has been adopted by many modern Continental surgeons, and spoken favourably of, especially by M. Desmanes. It has been followed in England. The practice is fast falling into disrepute. It is essentially bad.

Various are the methods which have been adopted for this purpose, including escharotics, used in many ways, and the actual cautery. The elaborate descriptions which have been given of the practical application of these, together with all the minutiæ of detail, would fill a small volume.

The principle is wrong. So long as there is a lacrymal gland to secrete tears, and there is not a conduit to carry the tears away, there must be an overflow.

Opening the sac and cauterising it has been much practised, perhaps more than anything else, and this can claim great antiquity.

Nasal probing of the lacrymal duct has many times been revived and abandoned. The difficulty of the proceeding from the anatomical intricacies of the part, the necessary tortuosity of the instrument, and the injury to the duct that is inseparable from the operation, are more than sufficient to banish it from practice.

It must not be supposed that, because a sound can be forced into the passage in the dead body, a similar proceeding can with impunity be done in the living.

I introduce this notice of the practice to condemn it as a means of treatment, rather than to recommend it. Indeed, I should have dismissed the subject with but a few words, but for the possibility of the probe being of use in affording some information as a sound, relative to the degree and position of a stricture, in connection with morbid growths that encroach on the duct.

PROBE OR SOUND FOR THE LACRYMAL DUCT.

Fig. 162 is about the average size for an adult; and the form is that I find to be the best, after many trials on the dead body. Each nostril requires one for itself, and this belongs to the left. The metal should be soft or virgin silver, admitting of easy adaptation by the fingers, or a pair of pliers, to any figure, for the individual peculiarities of a patient. The round and delicate handle almost ensures gentle usage, and is an improvement on a broad, flat one, which affords considerable leverage, and is besides awkward.

Fig. 162.



The lesser figure is a front view of the end, or bent portion.

These are the directions for using the instrument. The point should be introduced into the nose horizontally, and carried along its floor to a distance that will ensure the position of the duct being reached, when it should be turned upwards and outwards under the turbinated bone, against the wall of the antrum, and moved about till it is engaged in the aperture. The usual cause of failure in its entrance consists in not carrying the instrument sufficiently low to ensure its being in the proper chamber of the nose, and in attempting to find the orifice before it has been carried enough back. It is to be feared that the membranous wall of the duct is more often entered than its orifice. When it is properly inserted, the end may be felt at the angle of the orbit in the sac. The entire proceeding, the introduction and the withdrawal, requires much delicacy of touch. I have introduced it a few times in the living body. There has always been much bleeding, and an expression, as well there might be, on the part of the patient, of considerable dissatisfaction, and of a strong determination not to submit to it again.

The subjoined sketch of a dissection of the nasal duct from an adult female, may prove useful.

In many examinations that I have made of the nasal opening of the duct, the aperture has not been discoverable, as might be imagined, after the inferior turbinated bone had been cut away; it

has been necessary to search for it with a probe. It is, in fact, but a minute slit. Indeed, to make it apparent for the sketch, it was a little ruptured and opened. I have never seen any exception to this,

Fig. 163.

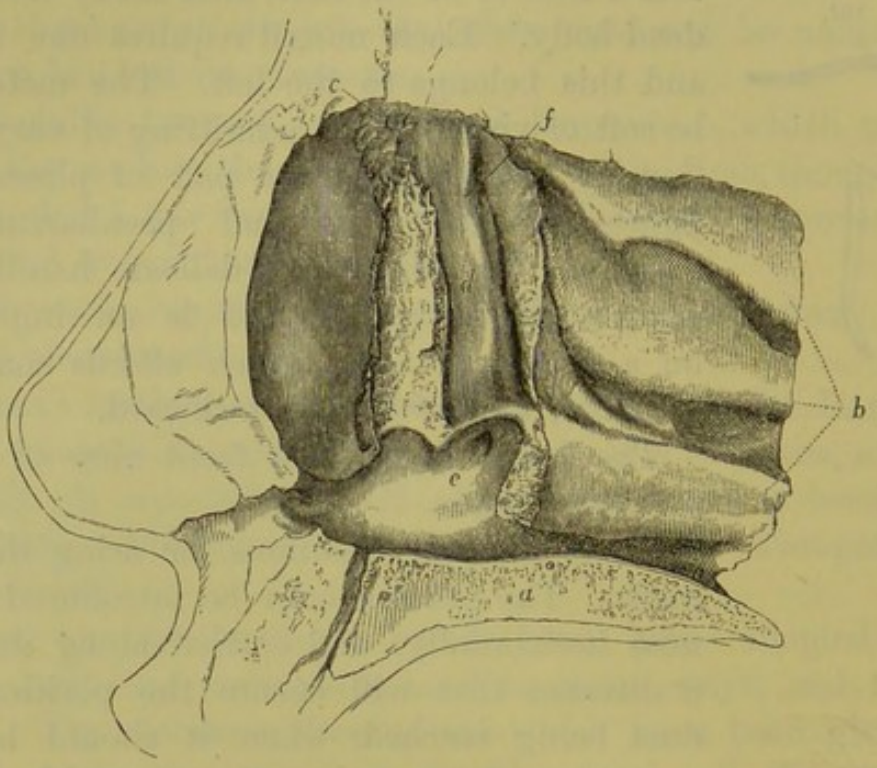

a, The palatine process of the superior maxillary bone.

b, The turbinated bones: the anterior half of the lowest one has been cut away to show the opening of the tube (*e*) in the lowest chamber of the nose.

c, The surface left after a part of the nasal process of the superior maxillary bone has been cut away to exhibit more clearly the duct (*d*), the entire surface of which is bared of its bony parietes.

f, The point at which two bristles, that were passed through the puncta, met.

and have not, therefore, met with round patulous apertures, oval ones, &c., described by authors; but it must be stated that my examinations have not exceeded twenty. There is, as I have mentioned above, variation in its position, in different subjects, perpendicularly and horizontally. Sometimes, too, it is on a depression in the wall of the antrum, sometimes on a projection.

Extirpation of the lacrymal gland was done by Dr. Paul Bernard, about a quarter of a century ago, who seized on the only thing that seems to be left undone in the way of surgical treatment. It was a great idea.

To Mr. Z. Lawrence is due the merit of reviving the operation in England, and practising it systematically. He has given the result of nine operations, with remarks, in the number of the "Ophthalmic Review" for October, 1866, in a paper entitled "On the Removal of the Lacrymal Gland, as a Radical Cure for Ophthalmic Disease."

The results were as follows: the disappearance of the watering of the eye, immediately and permanently, so far as his observations extended; and this ensued, whether the gland was completely or partially removed.

Heretofore, he says, it has been considered imperative, to prevent lacrymation, that the whole of the gland should be taken away.

In one case, that of an infant, not included among the nine cases reported, he could not succeed in removing the gland; but, curiously enough, although the eye had previously watered since birth, within eleven days after his aborted operation all lacrymal symptoms had ceased, and forty-nine days subsequently, when the child was last seen, the cure remained permanent. He remarks that these facts suggest the idea, whether a simple division of the ducts might not be sufficient for the cure of these cases; and adds, that some such idea occurred also to Sezokalski, when he proposed to ligature the ducts of the gland to induce atrophy.

The eye continues moist after the operation. This agrees with the experience of Mackenzie and O'Beirne, who have removed the lacrymal gland on account of disease of it, and with my own experience also.

The abscess of the sac, and discharge of pus through the puncta, gradually cease.

The sac being no longer irritated by over-distention by the tears, which doubtless acquire acrid properties from undue retention, the lacrymal cystitis ceases.

In most of his operations which have been performed by the external incision, a slight degree of ptosis has followed. This, which was due to a partial division of the levator palpebræ and œdema of the upper eyelid, gradually disappeared.

With one exception, all the wounds healed by the first intention.

He considers that removal of the lacrymal gland is applicable to those cases of inveterate fistula, in which other methods, after a fair trial, fail to cure, the operation offering the best prospect of a radical and permanent cure.

He candidly says that some of the cases might have been cured by other means; but his object was to re-open a field of experimental inquiry to solve this question, "Will removal of the lacrymal gland cure lacrymal abscess?"

He gives further experience on the removal of the gland in the following number of the "Ophthalmic Review," and tabulates twenty cases, all that he can collect, in which the operation has been performed for this disease. The only parts, however, that I need notice, relate to matters which he had before touched on. He

corroborates the statement that the partial removal of the gland suffices for the purpose, as well as the complete, and adds that several explanations of this fact, each, however, more or less open to objection, suggest themselves. These are, that in the operation the excretory ducts are severed; that a part of the gland left behind atrophies; that a removal of a portion of the gland decreases the flow of tears sufficiently to prevent the epiphora.

In referring to the effect of the removal of the gland on the abscess of the lacrymal sac, he advises, when the secretion of pus does not readily cease, to promote its cessation by slitting up the lower canaliculus, in order the more efficiently to apply local remedies to the mucous membrane, either in the form of collyria or injections. He adds that the extirpation does not necessarily quickly cure the lacrymal abscess, as purulent fluid may exude from the puncta on firm pressure over the sac, for months or years. The loss of the gland takes away the primary cause of the abscess, but it neither removes the inflammation of the mucous membrane, nor its disposition to secrete pus; but the curative influence is greatly promoted by the subsidence of the continuous irritation of the membrane by the pent-up tears.

He concludes by saying that it is incumbent on him to state certain unwished-for results, which may follow the operation, and mentions slight conjunctivitis as being common in most cases, while in one instance it ran on to inflammation of the deeper structures, without, however, inflicting any permanent injury to the eye. Also, that by far the most serious result that followed was ptosis of the upper eyelid. This was, in almost every instance, of purely inflammatory origin, and gradually subsided spontaneously. In a few, it was apparently due to a partial division of the levator palpebræ. In one case he thought it was owing to a too free use of the knife; for the ptosis was at first complete, although it subsequently became less. Besides this, the lateral movements of the eyeball were so paralyzed as to give rise to considerable binocular diplopia. After this case, he was particularly careful not to prolong the incision either too far inwards, or too deeply backwards.

My personal experience is limited, as I have operated but once. An adult female was sent to me with fistula lacrymalis and partial ectropium on the inner side of the lower eyelid. She had suffered for years, and had been treated by several surgeons, and was still in a miserable state. The eye had been poulticed for two years unremittingly. Her lacrymal bone was perforated, no doubt from the passage of a style or the use of a probe, for these instruments had been resorted to many times. I righted the everted eyelid,

and slit up the lower canaliculus, and afterwards introduced a style. Nothing could prevent some discharge of tears and mucus through the fistula on the cheek, even when the style was in, yet the state of the patient was better, as there was less annoyance from the ocular secretions and excretions; and as the eyelids could be opened, but not to the full extent, because the palpebral aperture had been contracted at the outer commissure from long-continued tarsal inflammation, the eye could be used. As the fistula remained in spite of all treatment, I removed the lacrymal gland, and did it with the least possible injury to the parts around. The method of operating is given elsewhere. Nothing was left to be desired, so far as the effect on the lacrymal sac and duct was concerned, for there was an end of all trouble, and the fistula healed. The inflammation that lingered about the eyelids, and the integuments at the inner corner of the eye and about the cheek, disappeared. The surface of the eye did not suffer from lack of moisture. The drawback was ptosis. Six weeks after, the eyelid had nearly fallen to the level of the under one, and there seemed to be atrophy of the levator palpebræ.

Henceforth, I shall not remove the gland except in an extreme case of fistula, in which the use of the style does not afford sufficient comfort; or where there is ectropium of the lower eyelid, of a nature which does not admit of remedy, and the tears and the conjunctival secretions fall on the cheek.

Long-continued pressure on the lacrymal duct, by compress and bandage, and by a metallic truss, has had its advocates, and many successful cases have been published.

DISEASE OF THE EXCRETING LACRYMAL APPARATUS FROM MECHANICAL CAUSES, WITHOUT AND WITHIN.

The functions of the lacrymal sac or duct may be arrested, and the several effects of stricture produced, by pressure from tumours, malignant and others, in any of the neighbouring cavities, the orbit, the antrum, and especially those in the nose.

A girl, eighteen years old, came to the Ophthalmic Hospital, with a large lacrymal fistula on each side, of several months' duration. Till there were these free apertures she had frequent abscesses, attended with much discharge of pus through the puncta. The bridge of the nose was enlarged, and the integuments very red. Both nostrils contained polypi, and from the right, part of one protruded. The treatment was very apparent, to remove the obstructions, wait the result, and in case the fistulæ did not heal, to pass styles. Strangely enough, she indignantly refused to have

the nose touched, but was not the least unwilling for the fistulæ to be treated. I do not know what became of her.

A rare kind of tumour, in connection with the lacrymal sac, is given by Sichel, "Annales d'Oculistique," vol. xxx., p. 82. It was just over the sac, bluish red and elastic. It was opened. A yellowish red fluid escaped. Fibrinous vegetations were within. It is said that the mucous membrane seemed transformed into serous.

A polypus has been removed from the duct itself several times.

Actual bony deposit may occlude a part of the nasal duct, and several instances have been met with. Mr. Travers says, in his "Synopsis of the Diseases of the Eye," that he had often found the canal completely obliterated by ossific inflammation at its upper orifice in skulls, and he knew of cases of enlargement of the ossa nasi, and of periosteal inflammation and thickening, marked by habitual overflowing of the tears, and occasionally by erysipelatous inflammation of the surface, in which the canal was evidently destroyed.

A young man applied to me with the tertiary form of syphilis, having large nodes on several places. There was a deposit of bone on the orbital ridge that quite obstructed the duct. I adopted that course which should always be followed if practicable, whatever be the cause of the deposit, whether specific, as in this instance, or arising from simple exostosis, of carrying the style through the obstruction, a practice which is preferable to perforating the lacrymal bone; an expedient that should be resorted to only in cases of the greatest emergency. A small hydrocele trocar was used, and after a short penetration, the duct was reached. He was able to dispense with the style.

On two other occasions, I have re-established the channel through bone, but I have lost sight of the patients.

Foreign bodies. Calculi have been met with in several parts of the sac and duct. A description of such will be found in the chapter on "Calcareous, Osseous, and True Bony Deposits about the Ocular Appendages, &c."

Fracture of the facial bones may more or less occlude the sac or the duct. This may, or may not, cause chronic disease, associated with morbid secretions. It is probable that the difference is sometimes due to the absence or the presence of diseased bone, but more particularly at the spot at which the canal is damaged. In the only case witnessed by myself, the sac was destroyed, but no trouble was experienced in that quarter. Overflow of the tears was the only annoyance.

The sac may be closed by the cicatrix from a wound. In a single case of this that came under my notice, the epiphora only, troubled.

CONGENITAL DEFECTS OF THE SAC AND DUCT.

An instance of supposed congenital fistula lacrymalis is mentioned by Sir W. Lawrence. It occurred in a boy at school, in whom it seemed to be a natural peculiarity, as no inflammation or any other affection of the part had been noticed. A small drop of clear fluid appeared frequently on the surface of the skin, just below the tendon of the orbicularis.

Mr. Middlemore appears to have seen this defect several times, for he speaks of it as the most frequent congenital deficiency of the lacrymal apparatus he has witnessed. In all the cases both ducts were affected, and the tears flowed over the cheeks.

I have met with one example.

The question of treatment must depend on the inconvenience that is produced. It would be well in all instances to examine the duct from the nose.

A more remarkable defect is that of absence of the nasal duct. A man, twenty-one years of age, was admitted into the Hospital Necker, on account of congenital fistula lacrymalis, which discharged a limpid transparent fluid. There was constant epiphora. When the angle of the eye was pressed in the morning, a muco-purulent fluid flowed from the fistulous orifice and the puncta. An artificial nasal duct was made by piercing the os unguis after the manner of Woodhouse. A silver canula, half an inch long, and enlarged at both its extremities, was introduced. Three days after the operation the small wound had cicatrized. In two months, the patient having neglected the directions of the surgeons, what they were is not stated, returned with epiphora; the canula was changed, and the case is said to have done well.

The treatment for malformation and congenital defects will depend so much upon individual peculiarities that it is impossible to lay down any precise rules. In the case of my own alluded to above, I operated, and accomplished all that was necessary in two weeks.

CHAPTER XXVII.

ARTIFICIAL PUPIL.

CONDITIONS UNDER WHICH AN OPERATION MAY BE UNDERTAKEN, AND THOSE WHICH CONTRA-INDICATE IT—RELATIVE ADVANTAGES OF THE SEVERAL POSITIONS FOR A PUPIL—SIZE OF THE PUPIL—SHAPE OF THE PUPIL—CLASSIFICATION OF THE PRINCIPAL MORBID STATES OF THE EYE REQUIRING A PUPIL, WITH THE APPROPRIATE OPERATIONS—CONCLUDING GENERAL REMARKS.

GENERAL CONSIDERATIONS.

An artificial pupil may be defined to be the formation of a new aperture in the iris, or the enlarging of the natural pupil or the changing of its position by operation, for the admission of rays of light to the retina, when disease or accident has rendered the natural pupil inefficient.

The operation is justifiable when there is complete closure of the pupil by lymph, by the adhesion of its margin to an opaque capsule, or by prolapse of the iris through the cornea; or when the pupil is so eclipsed by an opacity of the cornea as not to admit of relief by artificial dilatation. There cannot, then, be any doubt, abstractly, of the propriety of operating. Artificial dilatation will often restore a greater degree of sight than any operation. Practical hints for the use of atropine to dilate the pupil are given elsewhere.

When, however, the pupil is only partially interfered with, it must frequently be a very nice practical question to decide whether an operation should be undertaken, and the answer must be based on the degree of sight that exists, whether sufficient or not; and if defective, the applicability of means to improve it.

The morbid states of the eyeball that forbid an operation are generally very palpable, and are especially declared in altered states of the cornea, the iris, and the retina.

When the true tissue of the cornea has been lost, and its place is supplied by a cicatrix, an operation is contra-indicated, for the iris

is necessarily incorporated with the new material, although there may be a part of the cicatrix nearly or quite transparent. If the student be at a loss to detect the cicatrix, let him touch the part with the point of an instrument, and the palpable thinness will decide the presence of the abnormal material.

An operation is also contra-indicated when the iris is adherent to the corneal tissue, as an aperture could not be made in the portion so adhering, for it is an indispensable condition that these parts be distinct, however closely they may lie; although actual apposition renders operating very difficult. It is not, therefore, essential, as I shall show, that an "anterior chamber" should exist.

An iris that has lost its characteristic fibrous appearance and lustre, and bulges in consequence of disease, whereby its tissue is spoiled, affords but a doubtful prospect of success, from the tendency there is for the breach that is made in it to close by adhesive inflammation; and, moreover, the eye in general is, for the most part, so disorganized as to render the application of an operation questionable. Still, no structural change in the iris, taken alone, imperatively forbids a trial at a false pupil.

To determine whether the retina has entirely lost its function is certainly not difficult. A moderate light may be intercepted by closure of the pupil, combined with capsulo-lenticular cataract; but bright rays would always reach the fundus of the eye, for the sclerotic and choroid coats are not impenetrable to light. Besides the experiments with light and shade, by natural and artificial light, lenses should be employed to focus the rays on the eye. The ophthalmoscope, too, may be useful in the trials.

The power of discerning colour has often deceived me. Several times, when the shades of the same colour could be made out, the retina has proved too unhealthy to afford any available sight. This is curious. So also does it happen sometimes that even when a small flame can be discerned, no useful vision is obtained, although a good pupil be made. When therefore the retina is feeble, and it frequently is in the class of cases under consideration, the propriety of operating cannot always be readily decided, for although yet sensitive, it may be practically spoiled; but the rule of affording every chance for restoring some vision, assists us out of the difficulty, justifying an attempt under discouraging conditions. With a disorganized retina, and a fluid vitreous humour, the external appearances of the eye may be most encouraging. It must, therefore, occasionally happen, that a well-made pupil proves unavailing.

There are certain conditions, local and general, that are essential to ensure the success of the operation.

The local conditions are numerous. The cornea should be sufficiently transparent. Yet it is not necessary that it be absolutely clear, but tolerably so. Slight haziness is often overlooked till after a pupil has been made. In many cases it may be found, by oblique illumination, that a cornea, which appears at first sight uniformly clouded, is really much more transparent at some spots than at others.

There should be freedom of the eyeball from active or chronic inflammation. A long interval should be allowed to elapse after the cessation of the disease or injury which has occasioned the loss of the pupil.

In certain traumatic cases, closure of the pupil is the only trace of the mischief which the eye has sustained.

When inflammation of the entire eyeball has caused the occlusion, the disappearance of preternatural surface vascularity proves the cessation of the more active state. The absence of the subjective symptoms of flashes, coruscations, and intolerance of light, and the decrease in the size, the number, or the blackness of muscæ, are the criteria of the more chronic condition having subsided. But when such influence has been of long duration, the eyeball rarely becomes freed from an unnatural vascularity, or varicosity, which, in most cases, must be regarded as an irrecoverable state of the blood-vessels, rather than as evidence of the persistence of the morbid condition. If the original disease have long passed away, and a fair trial have been given to means calculated to subdue inflammation, if the health be good, and the eye be free from irritability, and not tender under touch, and if there be much encouragement from the soundness of the retina, I consider such varicose condition of no importance, and do not hesitate to operate.

It often happens that an eye which at one time seemed too much damaged to be restored, may improve sufficiently to admit of this surgical treatment. This case may impress the fact. A man suffered from the explosion of gunpowder; one eye was burst, and the other very much damaged. Some months after the accident he was sent to me by Mr. J. Skelding, of Euston Square, to ascertain if anything could be done. I thought the blindness irremediable. A year later he returned because he could distinguish light from darkness. I made an artificial pupil, and good sight was recovered. With proper glasses he could see as well as anyone who has been successfully operated on for cataract.

The general condition that is requisite, is the absence, in an

active form, of any virus or taint that may have induced the ophthalmic affection. When syphilis, gout, rheumatism, or struma, are yet predominant, it is dangerous to operate, owing to the great probability of re-establishing severe local disease. It has been said that when loss of the pupil in childhood has arisen from any scrofulous affection, an operation should not be performed before puberty. I really think that this should be discretional, as the disadvantages of keeping a child blind are most assuredly very great.

An eye that has seemed to be in an almost hopeless condition directly after the subsidence of the disease that has rendered its pupil useless, may, on the restoration of the general health, improve considerably, and be brought into a proper state for a successful operation. Thus it is that an iris which has been for several months apparently permanently spoiled, will lose much of its dulness, and even recover some of its colour; and a cornea that has been in part densely opaque, will clear to an extent incredible to those unaccustomed to observe eye diseases: indeed, so great may be its restoration, especially in children, that an operation for an artificial pupil should never be attempted on account of such opacity, until all suitable means have been tried for its removal, and a considerable time allowed for their operation, as well as for that of the restorative power of Nature. The importunity of patients to be relieved from blindness, and the anxiety of surgeons lest they should appear to be negligent, are not unfrequent causes of premature operations.

There are several morbid states of the ocular appendages more or less obnoxious, and which should be, as far as possible, removed or reduced, prior to operating. As these apply still more forcibly to the operations for cataract, they are given in the chapter on "Diseases of the Crystalline Lens."

There is a choice in the position for an artificial pupil. A central place is superior to a lateral one. This is confirmed by the natural arrangement of the eye, the configuration of the cornea, the lens, the vitreous body, and even the retina, the most sensitive part of which is opposite the pupil. The imperfections of a lateral aperture, arising from the indistinctness of the image formed by the irregular refraction through the circumference of the lens and the cornea, and the disadvantage of its falling on a part of the retina not the most sensitive, are facts which the elements of physiology teach us, and the details of practice confirm. As a natural effort to obviate these defects, when the pupil is external, the eye generally squints inwards. It has often been a matter of surprise to me to see how slightly vision has been interfered with by central opacities of the cornea, so long as the pupil was natural, and its margin extended

a little beyond the opaque part; and also, how little the visual disturbance, where there has been general, although slight, loss of corneal transparency. As a rule, therefore, I prefer forming a pupil centrally, even though it should be by the side of a dense opacity of the cornea, or be even entirely shaded, to choosing the circumference of the iris, though there the cornea may be transparent.

There is much diversity of opinion regarding the most advantageous spot to be selected, when a pupil cannot be made centrally, supposing all parts of the iris circumference to be available. This discrepancy arises from the real difficulty that invests the subject, inasmuch as we are almost without the assistance of practical deductions; for it is seldom that the results of lateral pupils can be compared with each other, owing to the very different states of the eye, and the variation in the sizes and in the shapes of the pupils in different individuals.

My own opinion is in favour of an aperture at the inferior margin of the iris in a sufficiently prominent eye, as next best to the centre, because I think that position possesses the greatest advantages, and it is that which I should adopt whenever it can be executed. The visual line cuts the cornea just a little internal to the centre. If, however, the eye were deeply set, and the lower eyelid likely to cover the pupil, I should operate on the inner side.

The late Mr. Guthrie, who paid much attention to the subject, and operated much, preferred the positions in the following order: 1st, The inferior part of the iris inclining inwards; 2nd, The internal, a little below the transverse diameter of the eye; 3rd, The inferior and external.

He said that the lower and inferior parts of the iris are to be preferred, for the following reasons: because the line of vision being through that part, the eye is less removed from its natural axis, and consequently less squinting is occasioned than when vision is acquired in any other direction; and if both eyes are operated upon, the axes of vision are made more nearly parallel. A decided preference of a position not higher than the centre of the iris, is founded upon the natural position of by far the greater number of objects of vision, which it is essential for a person to see, being viewed forwards or downwards.

The nasal side on the level of the natural pupil was thought best by Sir W. Lawrence, because the normal aperture is nearer to the nasal than to the temporal edge of the cornea. The next position he chose was the temporal, and after that the lower. Each of these several situations has had its advocates for superiority among both English and foreign surgeons.

The upper or frontal position is the worst of all. A pupil there is seldom of much use.

It would be well to have some principle by which we may regulate the size of an artificial pupil, when the physical peculiarities of the case do not limit its dimensions. The multiplicity of the conditions to be taken into account, especially when the crystalline lens has been lost, renders it difficult to solve the problem on purely theoretical grounds, and experience must be our guide.

If the aperture be clear and well defined, a small one, a line in width, is better than a large one. In the middle of the iris, however, size seems of less importance than when the aperture is lateral; for then, except it be of a certain capacity, a line and a half to two lines in diameter, sufficient light will not enter, and if very large, too much will be admitted, and confusion of vision must ensue.

With a very large pupil a strong light always dazzles. There is another disadvantage, when the lens is absent, the loss of accommodation causes circles of dispersion, whereby the retinal images are imperfectly formed.

Except it cannot be helped, a pupil should not be made at the very margin of the iris, for the ciliary processes interrupt the passage of light, and the retinal image must be imperfect in proportion to the nearness of the aperture to the edge.

The simple slit, or still better, the pear-shape, with the apex outwards, is to be preferred for a lateral pupil.

The condition of the cornea, also, must be taken into consideration in selecting a position. The more natural the cornea, the better is the spot for the pupil to correspond to; the more unnatural or irregular, the less is it fitted.

The form of the new pupil matters somewhat, but it is seldom entirely under our control, especially in making a central aperture. When circumstances will admit of it, enough marginal strip of iris should be left to intercept entrance to peripheral rays of light. In general, an operator should not be dissatisfied if he can effect an aperture of any figure at the spot he desires, provided it be ample.

The corneal incision must be made correctly. It should be executed slowly, especially the last part, the withdrawal of the knife, in order to save as much aqueous humour as possible, for the after part of the operation. Besides this, slow movement may prevent intra-ocular hæmorrhage. Rapid removal of the natural pressure from diseased vessels of the choroid and the retina is apt to cause bleeding.

The incision must be large enough. If it prove too small, it must be enlarged with the secondary knife. It must be made directly through the corneal layers, and not in an oblique manner, as that

would interfere with the use of instruments, as well as with the withdrawal of the bit of the iris, in the operation for "excision."

When the iris is to be strangulated or excised, the incision should be sufficiently on the side, so that enough can be withdrawn or removed to leave an available pupil. It must necessarily be very lateral.

It may be requisite to open the anterior chamber through the sclerotica, and then the knife must be entered about half a line from the cornea, and pushed through obliquely, and made to appear within, in front of the very margin of the iris.

Should an artificial pupil be made in the one eye while the other is yet sound? My own opinion is against operating, as a rule, so long as the one eye is efficient, unless the pupil can be made in the centre of the iris of the disabled or blind eye, the lens being present or absent; or upwards or downwards, the lens being present: for if the pupils do not have this correspondence, there will most probably be confusion of sight, double vision, or squint. A dissimilarity in the positions of the pupils is generally, but not always, followed by the one or the other of these consequences: why only occasionally I am unable to say; I only know the fact that, under apparently the same circumstances, when the pupils disagree, sometimes there will be the derangement, and sometimes not. I recommend the operation, even although sight should not be altogether restored, but only a moderate amount of it acquired; because there is much gain, especially in the lateral use of the eye. The visual field is increased.

I beg to refer the reader for a fuller consideration of this subject to that part in the chapter on "Cataract," in which is discussed the propriety of operating for cataract on the one eye, while the other is unaffected. All the arguments and facts apply equally here.

It can happen but as a rare opportunity that an artificial pupil may be made in the centre of the iris, while the crystalline lens is present, and transparent. Where this can be effected, the highest attainable perfection is necessarily gained. All the functions of the eyes are restored. Nearly always, however, the lens is absent when a pupil may be made centrally, and minute sight must depend on the use of a lens of a high power, commonly called a cataract glass. But there are practical objections to the use of such. It is better to use the eye unaided, and to allow the disparity to remain between the two; for, according to my experience, confusion of vision does not follow the restoration of the pupil when there is perfect vision in the other eye.

When two artificial pupils are made, the crystalline lenses being absent, both must be central, or that confusion of sight will ensue which will oblige one of the eyes to be closed.

INSTRUMENTS FOR MAKING THE ARTIFICIAL PUPIL.

IRIS SCISSORS.

In the scissors represented at Fig. 164, one blade is probe-pointed, and longer and broader than its fellow, which is sharp. When the two are closed, the lesser blade is completely shielded by the

FIG. 164. FIG. 165.

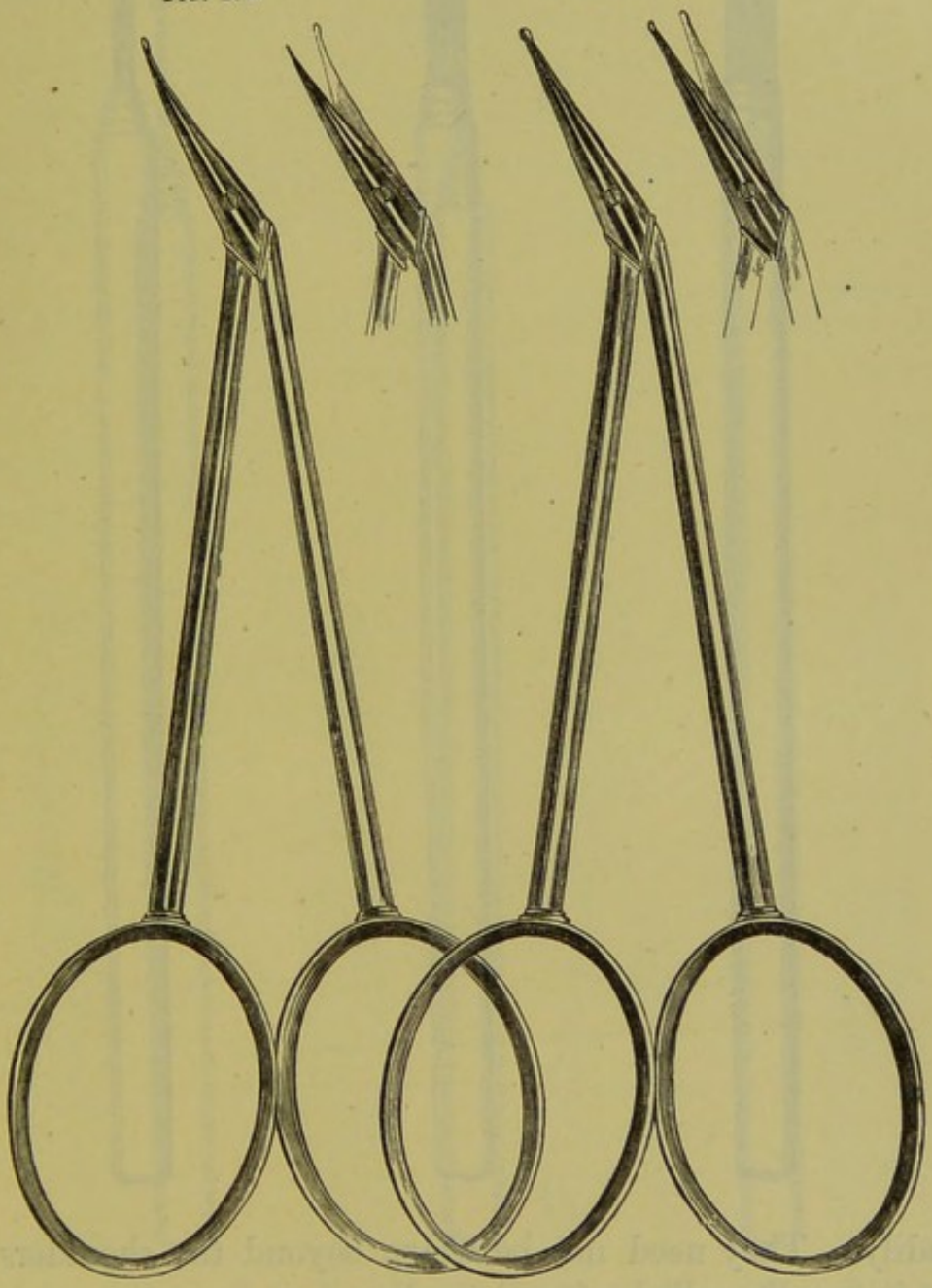

greater, the instrument being then blunt, as is shown in the larger wood-cut. Great nicety of workmanship is required for the sharp limb to be fine enough to penetrate the iris readily, and to have also a cutting edge to the very extremity.

The scissors, Fig. 165, are merely blunt-pointed.

The joints should be accurate and very firm, in order that the blade-points may meet well, and not cross, when the instrument is shut.

IRIS KNIVES.

These should be sufficiently thin to penetrate the cornea and the

Fig. 166. Fig. 167. Fig. 168.

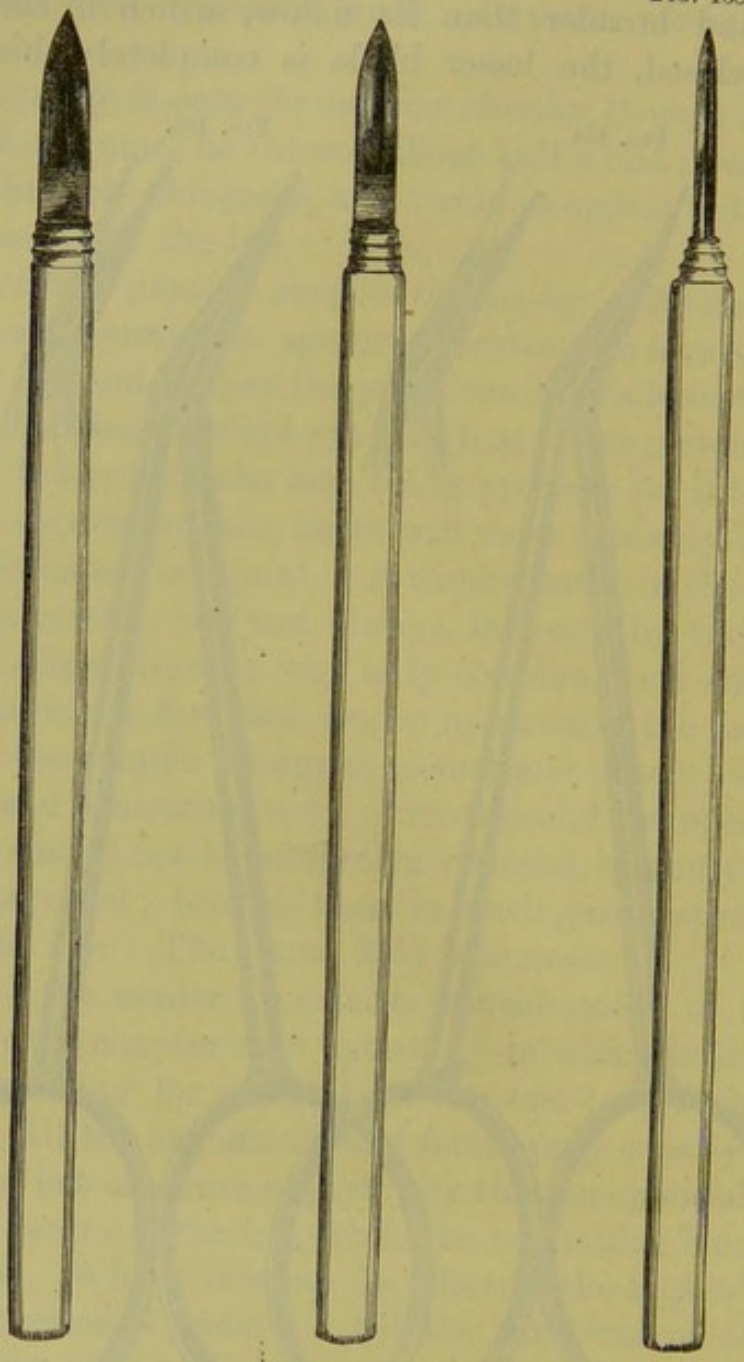

iris readily. They need not be sharp beyond the shoulders. The smallest is usually called a broad needle.

ANGULAR CORNEA KNIFE, OR KERATOME.

For convenience in operating, it is well to have a second knife bent on the flat.

Fig. 169.

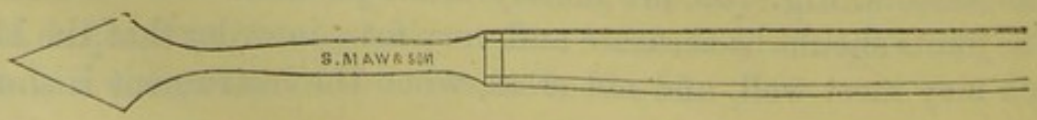

IRIS HOOKS.

The first, Fig. 170, known as Tyrrell's, owes its efficiency to its long and narrow recess, within which the iris can be securely retained. As a precaution against the capsule of the lens being injured, the point

Fig. 170. Fig. 171. Fig. 172.

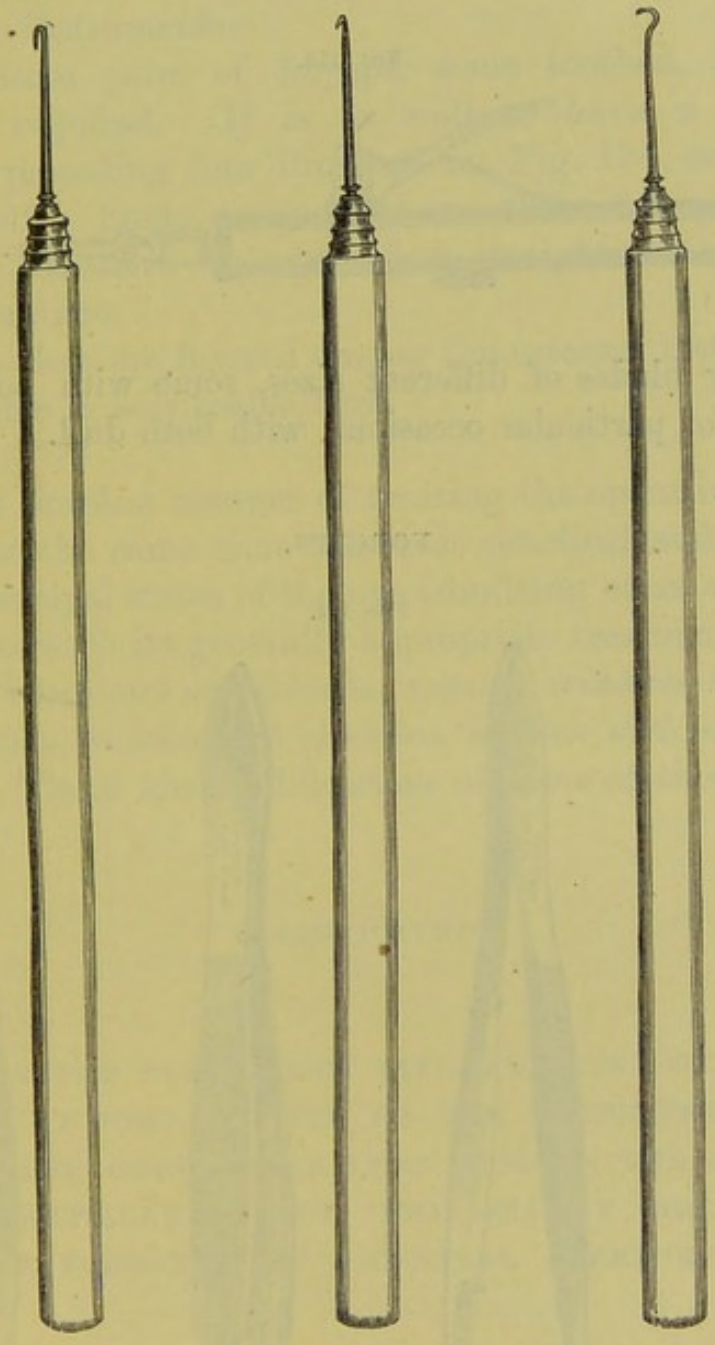

is blunt, smooth, and inclined a little inwards. One with a shorter bend and more interspace is better adapted to draw out a smaller bit of the iris.

Fig. 171 is like a lady's crochet needle, but has a blunter and more prominent barb. I have found it useful on certain occasions when it has been necessary to disengage the instrument readily from the iris. Fig. 172 illustrates a hook that I have often used, and to which allusion will be made.

A hook, like Fig. 170, bent at an angle to the shaft, should be in the ophthalmic case.

IRIS CANULA SCISSORS.

The lesser figure, representing the instrument partly open, shows the form of the blades, one of which is blunt. There should be

Fig. 173.

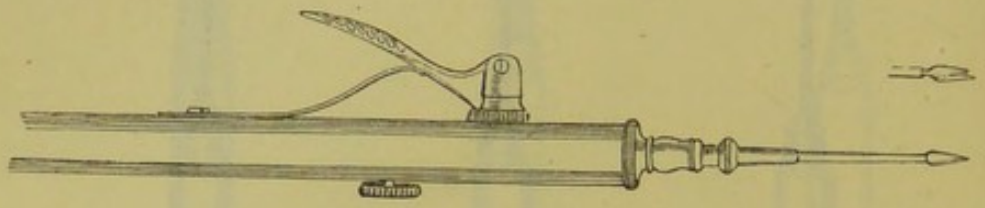

supplementary blades of different sizes, some with both extremities sharp, others for particular occasions, with both dull.

FORCEPS.

Fig. 174.

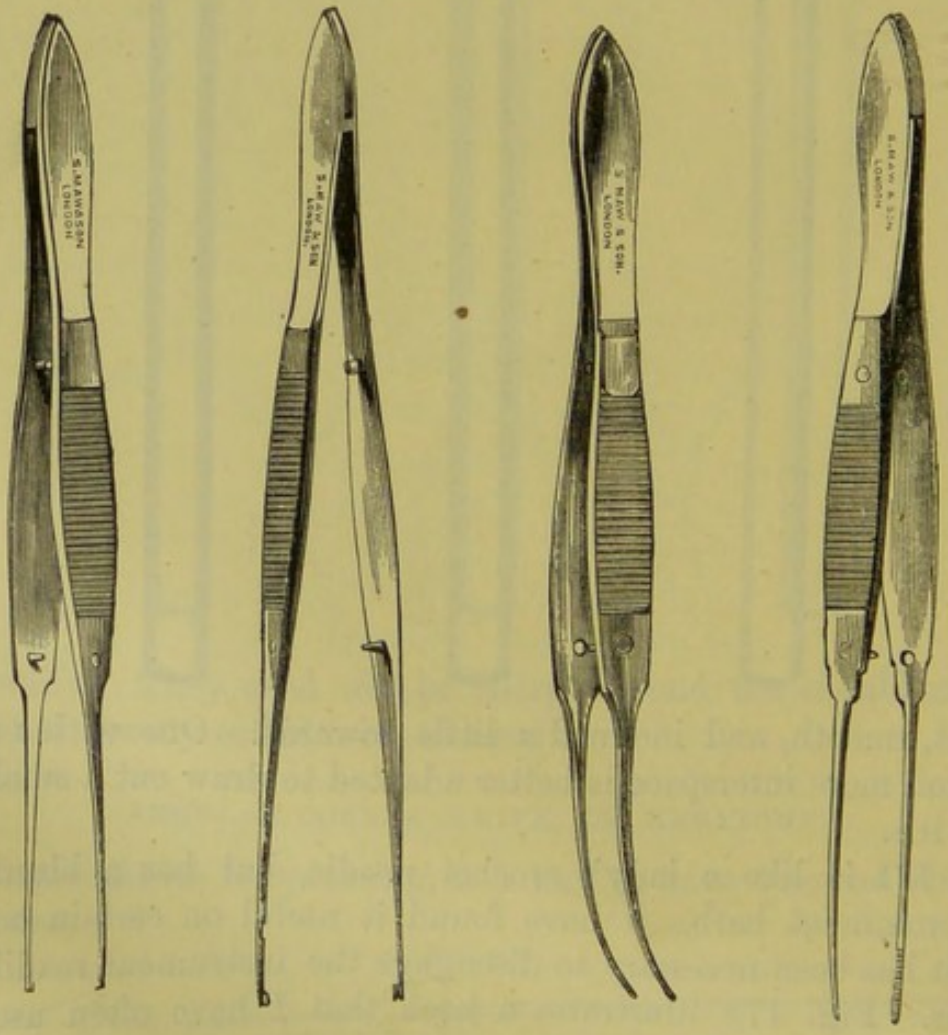

The supposed value of these scissors is that they can be used

without previously incising the cornea, which allows the aqueous humour to escape; but unless the blades be thin enough, and so wrought that they may penetrate readily, they will not only be ineffectual, but are very likely to inflict severe injury on the cornea and the iris. I do not use them.

To Sir W. Wilde, of Dublin, is due the credit of this addition to our ophthalmic instruments.

Several delicate pairs of forceps, some toothed, some merely serrated, are required. It is as well to have a pair a little curved. The preceding four illustrations, Fig. 174, represent those used by myself. Some surgeons have their forceps very much curved. Such excessive departure from straightness appears to me to be a disadvantage.

The forceps that are figured among the cataract instruments with cross action come in serviceable here.

Perhaps the simplest manner of treating the operative part of this subject, and at the same time the most practical and concise, is to classify the principal states of the eye admitting of an artificial pupil, and to annex to each its generally appropriate treatment.

The several operations are, incision, excision, iriddesis, tearing, separation, strangulation, incision with extension, incision with excision, tearing with excision. There are modifications of some of these.

CLASSIFICATION.

1. CLOSURE OF THE PUPIL FROM INFLAMMATION; OR, PROLAPSE OF THE IRIS AT SOME PORTION OF THE CIRCUMFERENCE OF THE CORNEA; THE CRYSTALLINE LENS ABSENT; THE CORNEA CLEAR, OR, IF PARTIALLY OPAQUE, THE OPACITY NOT INTERFERING WITH THE FORMATION OF A CENTRAL APERTURE.

Incision. Incision with extension, incision with excision. When, after the loss of the crystalline lens, inflammation has destroyed the pupil, the iris does not necessarily alter its position. It does not bulge from want of communication between the chambers of the eye, provided its tonicity is preserved, and then the size of the anterior chamber is not only undiminished, a matter of importance in operating, but may be actually increased by the falling back of the iris in consequence of there not being any lens. There may be but a

mere trace of the pupil; or the aperture, very much contracted, may be closed by lymph, or by opaque capsule.

When prolapse of the iris through the cornea has shut up the pupil, there must always be a reduction in the size of the anterior chamber, the diminution depending on the position at which the iris has escaped.

The two states, closure of the pupil from inflammation, and prolapse of the iris, may co-exist.

The operation of "incision" with the knife, is the most appropriate in any case when the iris retains enough of its physical properties to gape on being divided, and the less it has suffered from the effects of inflammation the more certain will be the result. In every case in which the substance of the iris is not greatly altered by inflammation, we may expect a successful issue to the operation by incision, in whatever direction, or in whatever part of the iris the incision be made. This holds good whether the cut be above or below, or in the line of the natural pupil, and whether it is a mere pin-hole, or extends to two-thirds of the diameter of the iris.

Independently of the superiority of a central pupil, it must certainly be an advantage, as tending to produce a more perfectly formed aperture, to divide the iris in its centre, that the circumferential or dilating portion may act equally on the divided part. Perhaps, too, there may be some practical advantage in cutting through those fibres by the interlacing of which a sort of sphincter muscle is provided; besides, it is in these pupillary fibres that there is generally the greatest agglutination from inflammation.

I invariably operate through the cornea. The following methods of steadying the eye are applicable to all these operations. An assistant draws down the lower eyelid, resting his finger on the malar bone. I raise the upper eyelid with my forefinger, and with the tip of it, and that of the middle finger steady the eyeball, after the manner indicated by the following diagram, which represents an operation on the left eye. If in any case the steadying of the eyeball, by the assistant holding the conjunctiva with a pair of forceps, seem likely to be serviceable, it should be adopted.

Sometimes I retract the eyelids with one or the other of the spring wire retractors, while the assistant steadies the eyeball with the forceps. This is more advantageous when it is important to prevent early escape of the aqueous humour.

With the first or second-sized iris knife, according to the circumstances of the case, I divide the cornea as near to the circumference as practicable, and penetrate the iris as centrally as possible, thrusting the blade up to the shoulder. In the figure, the second-sized knife

s introduced, but for most cases the largest is required. Unless the

Fig. 175.

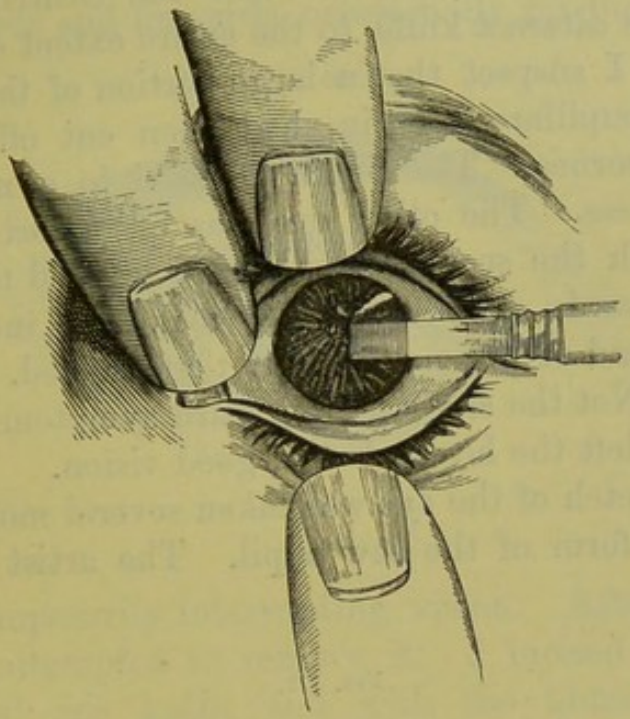

knife be sharp and well used, the iris may be dragged on and torn from its ciliary attachment.

The aperture thus made is about the third of the diameter of the iris, elliptical and vertical.

A great deal of stress is usually laid on the special fitness of "incision" in cases where the iris is on the stretch from prolapsus. The advantage is much over-rated. The choice of the operation, so far as the state of the iris can be taken as a guide, should be made to depend on its actual structural condition; because any advantage that the mere stretching could afford, might be lost by slight interstitial change, and inflammation of the eyeball is often a cause of the prolapse.

Fig. 176.

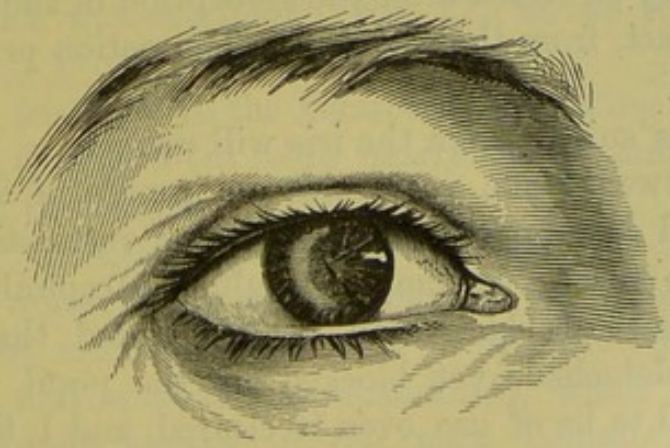

The annexed sketch of a pupil closed by prolapse of the iris is

from a man seventy years of age, who applied to me after having undergone the operation for extraction. The broad white line on the outer side of the cornea indicates the cicatrix of the faulty incision with the cataract knife, to the entire extent of which the iris was adherent. I suspect that a large portion of the iris, including a part of the pupillary margin, had been cut off in making the section of the cornea. The pupil, reduced to a minute aperture, was nearly useless. The other eye was quite lost in the attempt to extract. With the second-sized knife I divided the iris obliquely upwards and inwards, endeavouring to make the incision divaricate from the upper end of the narrow slit that existed. My object was accomplished. Not the slightest untoward symptom ensued, and in a week the man left the hospital with good vision.

This second sketch of the eye was taken several months afterwards and exhibits the form of the new pupil. The artist has shown the

Fig. 177.

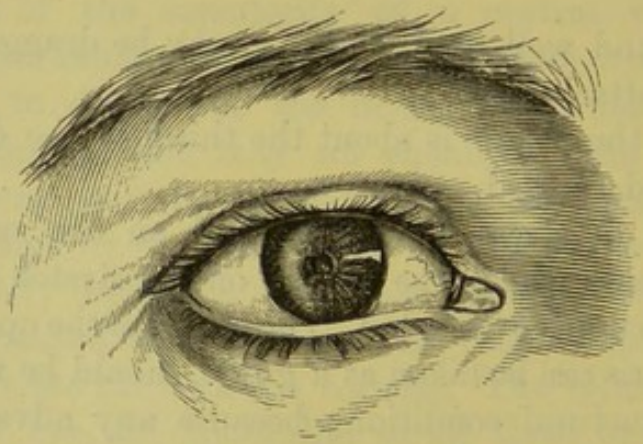

reduction in the opacity of the cornea, the consequence of the natural process of repair.

The pupil may be closed after the absorption of the lens in capsulo-lenticular cataract, from the result of inflammation prior to an operation, or after it.

"Incision" is suited when the iris will retract.

J. Browne, twenty-one years old, an inmate of the St. Pancras Workhouse, had been operated on at some institution in London. When he came to me, at the Ophthalmic Hospital, I found that the lenticular cataract had been absorbed, and that the capsule, though partly detached, yet blocked up the pupil, which was too much contracted to be of use even if cleared, and I therefore determined to make an artificial one. The Figure 178 represents the state

The operation of "incision" with the knife was performed, and an ample pupil resulted. The capsule separated from the iris during the operation, but retained a part of its natural attachment, and, moving backwards and forwards, occasionally produced much incon-

FIG. 178.

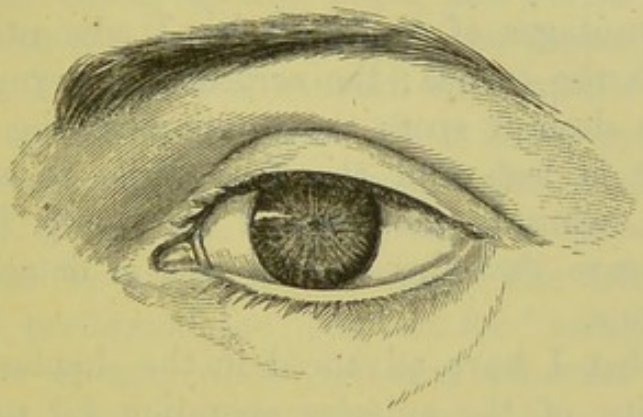

venience by temporarily interrupting vision. After the lapse of a few months I attempted to remove it. I incised the cornea with the second-sized iris knife, and with the blunt canula capsule forceps withdrew the greater part. The portion that remained,

FIG. 179.

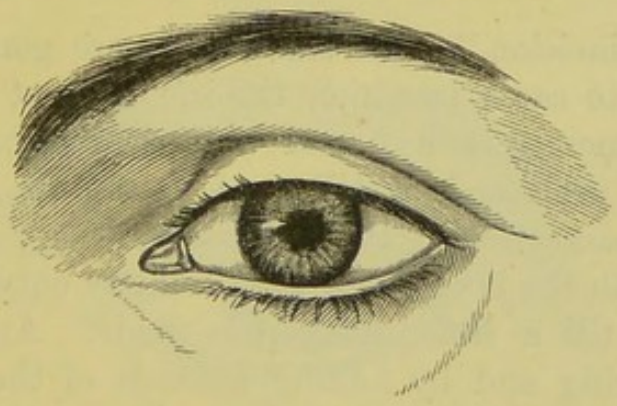

being behind the iris at the inner side of the eye, did not interfere with vision, which was excellent. Fig. 179 shows the after state of the pupil.

I prefer the iris knife to the keratome for making incisions in the cornea, because it gives a cut more nearly of the same size through both surfaces of the cornea.

It was by "incision" performed through the sclerotica that Cheselden, our countryman, and surgeon to St. Thomas's Hospital, the originator of artificial pupil, used to operate. His method fell into disrepute and was almost abandoned, when Sir W. Adams revived it. Adams speaks in the most laudatory terms of his operation, as he was wont to call it, but [illegible]

the difficulty of making a sufficient aperture, and the risk in the attempt, of detaching the iris at its circumference; the cause of both of which, namely, operating through the sclerotica, seems to have escaped his notice. Irrespective of these objections, however, is the very serious one of the great violence necessarily inflicted on the eye by operating posteriorly.

The great advantages of the operation I advocate, are its being executed through the cornea; the certainty of being able to make the pupil at the desired spot; the division of the iris before the aqueous humour is lost, and therefore while it is tense, by an incision, which, owing to the form of the knife, is effected with such slight pressure that there is no risk of detachment from its natural connections.

The reasons that I have advanced in the chapter on "Cataract" for the superiority of the anterior operation for solution over the posterior, as respects injuring fewer textures of the eye, apply here also, and with greater force, because of the larger wound inflicted. More than this, in Cheselden's method, there is generally much bleeding within the eye, and the blood may proceed from many sources, whereas in the anterior, the iris is the only part from which it can issue, and very frequently it does not bleed when cut.

To render "incision" with the knife more generally applicable by adapting it to cases in which the iris has not sufficient tone to contract when merely incised, and when it is more or less tied or fixed, by being prolapsed, or adherent to capsule, I proposed, some years ago, a modification of the above operation; namely, to divide the iris, and with the hook (Fig. 172) to draw outwards the outer lip of the wound, till a sufficient gap is made. An aperture is thus effected by tearing and by folding inwards of the flap. This may be denominated "incision with extension."

Fig. 180.

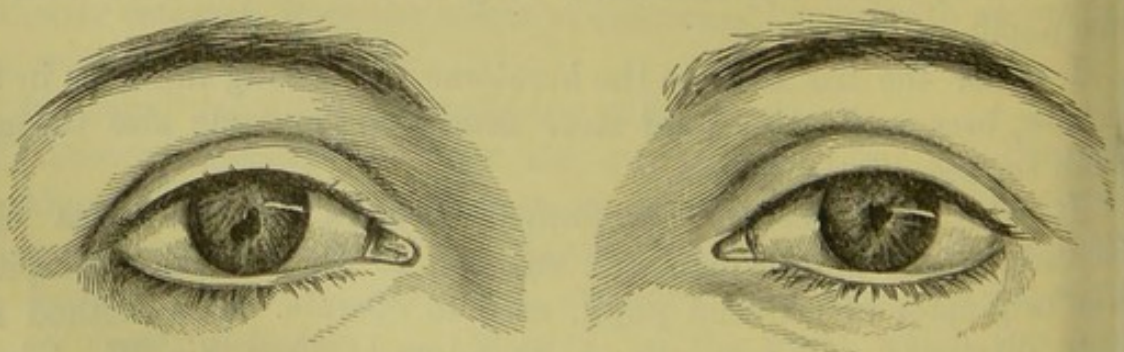

The above sketch shows two pupils I made after this method

The man had been operated on for cataract, by "extraction." The remains of the natural pupils, displaced by prolapse of the iris, and closed by lymph, are represented above the artificial ones.

I have done this operation very often.

It not unfrequently happens that a dense layer of lymph or thickened capsule blocks up the pupil, and forms an impediment to "incision" with the knife, at least to the formation of a central aperture by it. Perhaps, too, without any capsule the iris is not healthy enough to retract when cut. With, however, the combination of another mode of operating, "excision," the details of which are given in Class 2, a pupil can be made towards the centre, and of a better shape than by any other means. The following case will explain this. I performed the operation for "solution" on a youth of eighteen years of age, whose iris was adherent to the capsulo-lenticular cataract, but I could not, by any endeavour, make a patent opening in the dense capsule and the lymph on it, nor detach the mass from the pupil. Having divided the iris close to the capsule, with the largest iris knife, I seized the outer portion with an iris hook, drew it without the cornea, and cut off a piece. Fig. 181 represents the eye after the operation. A portion of the capsule is

Fig. 181.

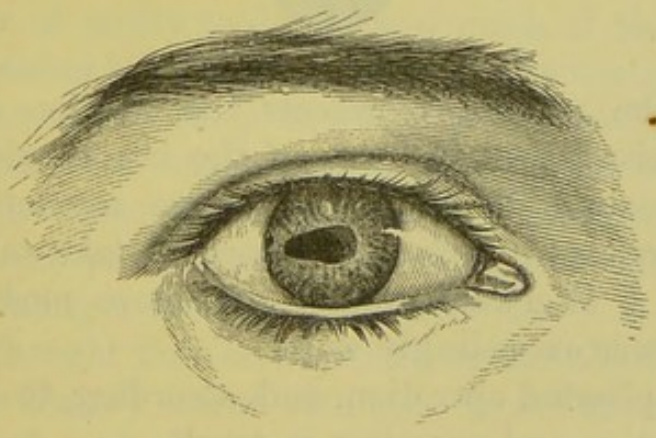

seen at the inner side of the pupil; the remainder of it lay rolled up behind. The two black dots at the margin of the cornea indicate two very minute portions of the iris that prolapsed. This patient recovered sufficient vision to enable him to get his living as an errand lad. The other eye was quite disorganized. By making the incision a little internal to the centre of the iris, when practicable, the pupil will be still more central.

When a large piece of capsule alone blocks up the pupil, the process of tearing it through with two needles, as given in connection

have not myself, however, found it as well adapted here, as when applied to capsule that is merely in the field of vision and not adhering to the iris, or at least is but partially adherent, so that there is pupillary movement.

In connection with these cases it may be mentioned that Janin's operation improved by Maunoir, is usually recommended when the unhealthy condition of the iris renders "incision" alone inapplicable. The principle of it is, to form a flap of a portion of the iris, by the shrivelling of which an aperture may result.

The cornea is divided towards its margin to about a fourth of its circumference, and the scissors introduced sideways till they reach the desired spot, then turned, opened, the iris pierced with the sharp limb, and the instrument carried on till sufficiently advanced, as indicated by the blunt limb that traverses the anterior chamber, when the cutting is to be effected. A second incision is then to be made at an acute angle with the first. The two should be as nearly as possible in correspondence with the diverging lines in the following diagram.

FIG. 182.



The line at the margin represents the incision of the cornea. Mr. Tyrrell advised that the flap of the iris should be depressed towards the vitreous body by the scissors, on account of its liability to unite. He writes: "I formerly used to take take out a piece of the iris, but I afterwards found the above modification of the operation to answer exceedingly well."

This is a complicated operation, and according to my experience, difficult in execution and uncertain in result.

2. PARTIAL OPACITY OF THE CORNEA, OBSCURING THE PUPIL; THE IRIS UNADHERENT; THE LENS AND ITS CAPSULE TRANSPARENT.

Excision. Strangulation. Iriddesis. "Excision," which is of very old date, is the operation adapted for this condition, and that which I have generally executed.

The cornea should be incised to about a fourth of its circumference, close to its margin, and in that direction which may seem most desirable for a lateral pupil. In proportion to the diminished size of the anterior chamber is the greater care needed in the use of the

knife or keratome. I prefer the cataract knife when there is little space to work in. Should the iris prolapse as soon as the cornea is cut, an occurrence not unusual, it is seized with a pair of forceps, drawn out sufficiently, and the required portion, including the pupil-edge, cut off with the scissors. It may be advisable to make the incision through the sclerotica if the cornea be opaque near to the margin. As there is danger of making the pupil too large, the operator must be cautious.

When the iris does not prolapse, it should be drawn out with a pair of forceps; a short Tyrrell's hook may be employed, the ordinary one being apt to seize too much in these cases; the pupillary margin should be caught, and the retraction made. There may be some embarrassment in withdrawing the hook, on account of its catching the edge of the cornea, to avoid which it should be half rotated when it arrives at that part. The capsule of the lens may be touched with impunity by a blunt and smooth instrument.

The opacity of the cornea may so obscure the pupil that the hook cannot be readily applied to its margin; in such a case the iris must be withdrawn with a pair of forceps. I object to an attempt to cause its protrusion by pressing on the eye, from the attendant danger of dislocating the lens.

It is a matter of nicety to decide how much of the iris should be excised; and nothing but actual practice can ever teach this. However, I may state that too much is likely to be removed, rather than too little. The nearer the scissors are applied to the hook, the smaller will be the pupil. The operation is finished by endeavouring to return within the eye any part of the iris that yet protrudes. When it is returned, the healing is more quickly effected.

Mr. Tyrrell thought that he improved on the above by incising the cornea to a very limited extent with the "broad needle," seizing the iris with his hook, and retaining it in the wound, strangulating it, as the process is generally called. A channel so made is pear-shaped, the apex at the margin of the cornea, and this is a good form for a lateral pupil. But the process of strangulation is so extremely uncertain, from the spontaneous extrication of the iris from the wound, an occurrence of great likelihood when it is healthy and has not any adhesions, that I do not always trust to it, but, as a rule, perform the older operation. Some operators invariably operate through the sclerotica, and make an oblique incision through it to the anterior chamber, commencing half a line or three-quarters from the cornea.

A method of operating in this condition of the eye has been

"Iriddesis," as he calls it, is given in the first volume of the "Ophthalmic Hospital Reports," p. 220. It is here particularly applicable. The name has undergone several changes. I use the original. This is the simplest class of case to which it is suitable; namely, a central defined opacity of the cornea, in which it is only required that the natural pupil should be slightly moved to one side, and brought opposite to a transparent part. I will describe the operation.

The wire retractor is inserted, and the eye is fixed by seizing a small fold of conjunctiva with a pair of forceps. A small opening is then made with a broad needle into the anterior chamber; it should be close to the sclerotic, and just large enough to admit the canula forceps, with which the iris is caught near, but not close to, its ciliary attachment, and drawn out until the pupil is sufficiently displaced. The small piece so held without the eyeball is secured and strangulated in a loop of floss silk, previously slipped over the canula forceps, and, at the proper time, brought down and drawn tight, by holding each end in a pair of ordinary forceps. The ends of the silk are then cut off, and the operation is completed. If the incision in the cornea be unnecessarily large, the iris may return into the eye. I have heard it advised, if such an accident be expected, that one end of the ligature should be left long enough to be readily seized if required, for again drawing out the iris. The prolapsed iris soon shrinks, and the ligature may generally be removed on the second day, or allowed to drop off.

The advantages are, that the size, form, and direction of the pupil can be exactly regulated according to the exigencies of the case. That its margin is uninjured, and that the natural motory power is in some measure retained. The disadvantages are, that a corneal fistula is apt to be made, and that iritis is likely to be induced.

I have at times deviated from the above manner of operating, as regards the details, such as not holding the eyeball with the forceps, and the manner of applying the noose. Some operators make a loop of the silk, and lay it over the corneal incision before the forceps are applied, in preparation for the tying. Like all the other operations for artificial pupil, it must be adapted to the fitting cases. It does not supersede "excision;" indeed, it is not so good when the pupillary margin needs to be removed.

3. Complete closure of the pupil by lymph, the lens and its capsule transparent, or opaque.

Tearing away a bit of the iris; excision; operation for solution; laceration of capsule; incision; excision; operation for extraction;

division of iris adhesions. As it cannot always be told with certainty whether the pupil is completely adherent, it may be at times prudent to examine the eye under the influence of atropine, because if there be a part of the iris unattached it will retract, and produce the appearance of a dark spot at the pupillary edge.

Until within a very recent period it was generally supposed that the lens and capsule necessarily become entirely opaque when a deposit of lymph completely closes the pupil, a condition in which the iris is necessarily adherent to the capsule of the lens. It is now known that, while the centre of the capsule just under the lymph may be opaque, the rest of it, and the whole lens, may be transparent. With this knowledge we now avoid the destruction of the lens, and proceed to make a pupil in a manner that shall not injure it or the capsule. Of course it cannot be determined beforehand, with certainty, whether they are transparent. The history of the case, and the perception of light which the patient may possess, will afford us some guide; but we ought, whenever there is a probability of the absence of opacity of these parts, to proceed on the assumption of their integrity.

The condition of the lens will depend much on the amount of plastic material deposited on the capsule. A deposit within the area of the pupil, or a little beyond it, certainly does not seem to have any influence. With a more extended exudation, reaching for instance to the equator of the lens, by which the iris is universally adherent, the lens nutrition is interfered with. According to what has been observed, it would seem that the hexagonal lens cells, and the subjacent lens fibres, become opaque, either through atrophy, fatty degeneration, or other changes. In time the whole lens gets opaque. When inflammation has been intense, and has spread to the anterior part of the choroid, thick exudations are deposited over the whole anterior capsule, in the zonule of Zinn, and the hyaloid fossa, so that the iris, the capsule of the lens, and the plastic deposits form a thick partition between the anterior part of the eye and the posterior.

When the lens and its capsule are transparent, there seem to be only two appropriate operations; for in those in which the iris is transfixed, or cut, they can hardly escape injury.

One of the operations is very simple. The cornea is punctured, the blunt canula forceps introduced, a portion of the iris beyond the point of adhesion is seized, and a piece gradually torn away, drawn out, and cut off. A reapplication of the forceps may be needed. If the iris, being atrophied, be too rotten to admit of being so detached with the canula forceps, the cornea should be opened to a greater

extent, and a larger pair of forceps used, so that a large bit can be at once grasped. It would be well, with sufficient suspicion of such rottenness, to do this at first. Repeated trials are apt to induce much inflammation. Moreover, after the first tear, blood is apt to be effused and to obscure any farther proceeding.

The pupillary margin is always left, as an adherent piece. There cannot be a double pupil, because the natural pupil is quite closed.

It would be imprudent to separate the iris at the spot of its attachment to the lens, because not only in the centre of the lens is there opaque material deposited, but for half a line or more around, pigmental exudations unite the iris to the capsule of the lens.

The other applicable operation is "excision," one form of which has been described in Class 2. Here a modification is required, because different circumstances exist. The pupil is adherent; there is, therefore, greater difficulty in removing a piece of the iris. The cornea should be incised, as in the other operation; but to a greater extent, because here forceps are required, instead of a blunt hook. The forceps must now be applied, the iris laid hold of, withdrawn, and excised.

Of course there can be no prolapse of the iris through the wound thus made, when the pupil is adherent, but it may bulge, more or less; and this will depend on the extent to which it is attached to the capsule of the lens; the less adherent to, the easier and more certain the operation.

I have adopted the first method often, and with the best result. In every instance the pupil has been closed from rheumatic inflammation. In all I have suspected the lens to be clear, from the history of the case, and the degree of perception of light, and I have not been disappointed.

The second I have no personal knowledge of. It has by some been deemed impracticable, unless the pupil be in part free, so as to admit of a portion of the iris being readily drawn out. The following case shows the fallacy of such an opinion.

A young woman, twenty-one years old, applied at the Central London Ophthalmic Hospital, with trichiasis. An artificial pupil in that eye quickly attracted my notice, for it was the most efficient I had ever seen at the side of the iris; for, with the naked eye, the smallest print could be read. The lens was present. The accompanying figure (183) is a representation of the eye after the trichiasis was removed.

The iris had lost its fibrous appearance, and the remains of the

pupil in its centre, closed by lymph, was just perceptible. The girl could not tell who was the operator; she knew only from her mother's account, that when a child, she was taken to a gentleman

FIG. 183.

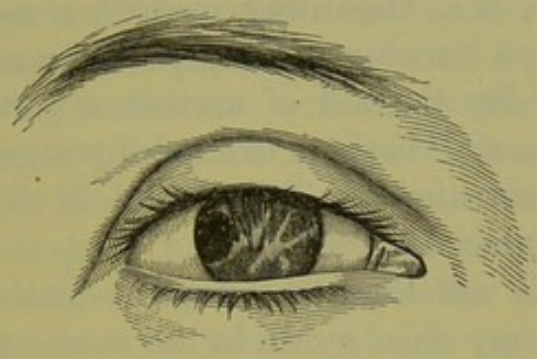

in London, who operated, and restored sight, which had been lost in infancy, from a severe attack of inflammation.

When a portion of the circumference of the iris cannot be withdrawn, excision is inapplicable, and a piece must be torn away.

A recent writer, Mr. Bader, has described a method of clearing the pupil in this class of cases. He does not say whether he has done the operation. It is one from which I should not expect success. In order that he may not be misunderstood, I quote his own words:

"*By Corepalinanoixis*, that is, by reopening the natural pupil by removing any opaque membrane from its area, that may have remained there, *e.g.*, after iritis.

"Excellent results have been obtained by this operation, which, if the crystalline lens is not wounded, and the opaque membrane is but loosely attached to its capsule, admits of restoring, as regards position, the original pupil. The opening into the anterior chamber is made with the smallest lancet-shaped knife through the sclerotic near the cornea. The point of the knife, if the entire margin of the pupil is adherent, is thrust through the iris, behind that portion of its margin which lies farthest from the incision of the sclerotic.

"Having thus made an opening to allow of the iris hook being carried behind the iris, the knife is quickly withdrawn, so as to lose but little aqueous humour. The hook is then introduced, and its short bent portion carried through the artificially made, or through an already existing, opening behind the margin of the pupil. The short portion of the hook, being turned towards the crystalline lens, is made to glide behind the opaque membrane, which, on withdrawing the hook gently, may be seen following in its wake. The

membrane, which is generally elastic, need not be drawn out of the anterior chamber, but may be detached from the greater part of the margin, and from the area of the pupil, and left to itself. We should select another mode of operating, if after one or two attempts we do not succeed in passing the hook behind the membrane."

Some years since, Mr. Greenway devised a method whereby, in cases of closed pupil, a circular opening could be made in the iris in the axis of vision. By the aid of suction a portion of the iris is drawn into a canula, and is there excised by a guillotine blade. A description of the instrument will be found in the "Medical Times and Gazette," December 15, 1860.

When the pupil is adherent to a capsulo-lenticular cataract, the age of the patient is my chief guide to the course to be adopted. In early life, and before the fortieth year, I should first operate on the lenticular cataract for "solution;" and after a full and sufficient time had been allowed for absorption, and I beg to refer to some special remarks on this class of case in the chapter on "Cataract," I should make the pupil, either by tearing through the capsule, by "incision," or otherwise, as may seem most necessary. I would adopt the same plan in old age, if I had any proof, or strong suspicion of the breaking down of the cataract, the nucleus becoming soft, from fatty and calcareous deposits; no uncommon change in this state of the eye at all ages. It is possible at times to ascertain the nature of the cataract, from its appearance through the veil of lymph over it. When the eye has been long and intensely inflamed, the cataract gets broken down.

These pathological remarks of mine, founded on actual observation, have been met by a statement to the effect that the adhesion of the iris causes the cortical layers of the cataract to be firm and gelatinous, and the nucleus to be harder than what is natural at the time of life.

When, however, there is the hard cataract of age, my usual plan is to extract the cataract, and to make the pupil at the same time. This was first practised and made public by the late Mr. Travers. He cut the cornea as for "extraction," raised the centre of the iris with a pair of forceps, cut off a piece, and then removed the cataract. When there has been too small an anterior chamber to allow the corneal section to be made in the ordinary way, I have made an incision and then used the "secondary" knife, as described in the cataract operation, for enlarging the aperture. I have besides, with excellent success, extracted the cataract, partly by tearing through the capsule and the exudation on it, and partly by snipping the iris with the scissors. On one occasion, with the curette alone, I

separated the pupillary adhesions enough to admit of the escape of the cataract, and with the best results.

Here, at the end of this class, is the best place to speak in detail of the fact above alluded to, that the iris adheres to the capsule of the lens in varying degrees. Founded on this is the distinction by V. Graefe, of "Annular Synechia," in which merely the pupillary margin is adherent; and "synechia posterior totalis," in which the whole of the back of the iris is adherent, and the posterior chamber lost. It is said by Mr. Windsor, in quoting from V. Graefe's memoirs, that in the synechia totalis, the place of the chamber is sometimes occupied by a tough, whitish-grey membrane, even containing calcareous or bony deposits, closely adhering to both the capsule and the iris. Also, that there are cases in which the iris can be only imperfectly separated from the newly-formed membrane by hooks and forceps, and that in the most successful attempts at a clearance, no light can enter such an eye till the exudation is removed, an act difficult in itself, and pretty sure to rupture the capsule of the lens, so that there can be no success without the removal of the pseudo-membrane and the lens also. That besides, the tissue of the iris seems tightly stretched, and its fibrillation is indistinct, its colour changed, through red vessels in it, and cloudiness of the aqueous humour. The whole of the surface is pressed forward, by which the anterior chamber is diminished. This state is to be distinguished from "annular synechia" by the whole of the iris being uniformly affected, and by the absence of any depression in the region of the pupil.

A worse condition of the eye for the formation of an artificial pupil than that in which such changes described are met with, can scarcely be imagined. Success is not to be expected, for the eye is spoiled. The retina can seldom be sentient.

4. Partial closure of the pupil by lymph, the lens and its capsule transparent.

Excision. Iriddesis. This state differs from the last described merely in the pupil not being entirely lost. "Excision" is chiefly applicable. The cornea should be punctured at or near the margin with the smallest iris knife, the most suitable hook introduced, the point carefully inserted into the opening of the pupil, which would necessarily be very small, and an endeavour made to tear out a piece of the iris. Sometimes a thin strip is brought away, which may or may not be snipped off, according to the length of the piece. Sometimes only a fissure is made, and therefore an inadequate aperture because of the condition of the iris, from its altered structure, the

hook readily tears out. It may, therefore, be necessary, at a future period, to enlarge the fissure. Of course this should not be attempted till it has been well ascertained that the pupil so made is insufficient; for a linear pupil, apparently too narrow, may afford good sight. After it has been determined in which direction the enlargement shall be made, the cornea is punctured on the corresponding side, the hook introduced, the margin of the fissure seized, withdrawn, and cut off or strangulated, according to circumstances. A triangular-shaped opening will be made.

The hook is more in contact with the capsule of the lens in this, than in any other operation for artificial pupil; yet if properly made, and carefully used, it will not inflict any injury.

It matters not, as far as the performance of the operation is concerned, at which side of the eye the free portion of the pupil be situated, for the stem of the hook can be so bent as to allow the instrument to be used in any direction; but it is better, when the iris is unadherent in a direction not the best suited for a pupil, to disregard any advantage, so far as mere manipulation is concerned, arising out of there being a free edge to deal with, and with the canula forceps to tear an aperture in the most advantageous situation.

To obviate the inconvenience arising from the loss of the aqueous humour in the preliminary incision with the knife, and which consists chiefly in the alterations that take place in the relative position of the iris and the lens, several surgeons have suggested the use of a sharp hook, as here shown, that may be pushed through the cornea, and applied to the iris while the anterior chamber is yet filled.

Fig. 184.



I have given the instrument a fair trial; the difficulty, however, in withdrawing it is a fatal objection. Besides, the liability of wounding the lens, and the impossibility of reapplication on the same occasion, are strong objections against any general employment of it, and must narrow its applicability.

With particular care, prevent the escape of the aqueous humour, by not pressing on the eyeball, but steadying it by having the conjunctiva held with forceps, employing also the spring-wire eyelid retractor. Make the incision in the cornea slowly, and withdraw the knife gently, and exactly as it was introduced, without twisting, that the wound may not gape. By these rules so little of this fluid will ooze out, that the loss may be practically unimportant.

The operation "Iriddesis," described in Class 2, is also applicable here, if not by one tying, by two, at a few lines apart, whereby a triangular aperture is made. It must be mentioned that the iris may be too rotten to be tied.

5. DIMINUTION OR CLOSURE OF THE PUPIL FROM PROLAPSE OF THE IRIS THROUGH THE CORNEA, OR ADHESION OF IT TO THE CORNEA IN CONSEQUENCE OF A WOUND, A PENETRATING ULCER, A SLOUGH, OR SUPPURATION OF THE CORNEA; THE CORNEA ITSELF MORE OR LESS OPAQUE IN THE CENTRE, THE LENS AND ITS CAPSULE TRANSPARENT, OR OPAQUE, OR THE LENS LOST.

Cutting, or tearing through the adhesions. Excision. Incision. Iriddesis. Separation. Under this head occur the greater number of cases requiring an artificial pupil; and of these the majority arise from ulceration of the cornea and prolapse of a part of the iris; but as, in a surgical point of view, it is the same whether the pupil be lost by prolapse, or by mere adhesion of the iris to the cornea, I shall not practically recognise any difference.

When a small part of the margin of the pupil is prolapsed, the pupillary aperture being merely diminished, and the opacity of the cornea is limited, or if extensive, not so dense as to obstruct light, the practice should be to detach the iris from the cornea, without injuring the capsule of the lens. A slight tag of the iris may be readily divided with the smallest iris knife, and the operation is simple. The cornea should be punctured at the spot where the adhesion can be most readily reached, subject only to the rule of avoiding that part under which the pupil will fall; the blade of the knife should be directed between the iris and the cornea with great care, as the anterior chamber is necessarily small. If the knife be carried too far, and then withdrawn, the aqueous humour will escape, and the operation probably fail. I have torn away such connection with a blunt hook.

When the larger portion of the pupil is involved, in which case a considerable part of the body of the iris is generally tied to the cornea, it is scarcely possible to operate in the above manner; for in attempting to divide the iris the aqueous humour escapes, and then the operation must be abandoned, or the capsule of the lens will be wounded, and rendered opaque. I have witnessed many marked failures of this kind. I have incised the cornea, and divided some of the connections with the blunt iris scissors, and established useful pupils. In a few instances I have used the scissors to the utmost, and torn the remainder through with one

or other of the blunt hooks; but I do not recommend it, on account of the tediousness of the proceeding, and the violence it inflicts.

"Excision" is often well adapted. I have made some excellent pupils by it.

It is supposed that the canula scissors are well suited to this class of cases, but I find that they are not generally applicable; and when they may be used with freedom the iris knife may also be employed, and with greater safety. There is not generally space enough for them to be worked in, without their inflicting injury to the back of the cornea, or to the capsule of the lens. The chief objection to them is the lacerated wound they inflict when pushed through the cornea, especially in an unhealthy cornea. Their withdrawal is not easy. That they may be used when the pupil is much deranged there can be no doubt, and I have applied them myself, although not lately. The following example of their employment in Mr. Bowman's practice, I take from the "Medical Times." The case, too, serves to illustrate very extensive adhesion of the iris.

A dense leucoma occupied the greater part of the cornea, nearly concealing the lower portion of the iris, and obscuring the pupil. When the eye was shaded the pupil rose a little above the leucoma, and his sight was considerably improved. The cornea was slightly hazy above the leucoma, to nearly its upper margin. The lens appeared to be clear. The lower edge of the pupil adhered to the leucoma.

The scissors were introduced at the outer side of the cornea, at a nebulous spot, and pushed on as far as the existing pupil, where it was almost obscured by the leucoma. Atropine had been applied. The shorter, blunt-pointed blade was then passed behind the upper border of the pupil, and the long sharp-pointed one in front of the iris, and the upper margin of the pupil cut to the extent of about 1-16th of an inch. Vision was improved. The man returned for inspection. He saw more distinctly when the eye was shaded; and the pupil then enlarged slightly upwards. The operation was repeated, and the iris incised at the same point, but to a greater extent. A minute strip of iris remained between the two cuts.

Fig. 185.



The capsule of the lens did not become opaque, although it was, as report says, "evidently touched with the scissors, and that, too, not slightly." This was, therefore, a very fortunate escape.

The first diagram shows the size of the pupil before operation. The oblique line indicates the course of incision by the scissors. The line at the margin points out the position at which the cornea was divided. The second diagram represents the pupil after the first operation.

My own practice in such cases has been to make a linear pupil with the hook after the manner given in Class 3, as in cases of that nature, a better general result will be got by it.

"Iriddesis" also is applicable.

When the pupil is quite closed, the choice of the operation must depend chiefly on the extent of the corneal opacity, and the state of the lens, whether transparent or opaque; or whether present or absent.

In the following instance, in which the lens was absent, I adopted double "incision." A girl, nine years old, whose right eye had been quite destroyed by an attack of purulent ophthalmia in infancy, was placed under my care by Mr. Harding, of Percy Street, for the purpose of having an artificial pupil made in the left eye. The central lower part of the cornea was occupied by a dense cicatrix (Fig. 186), to the entire extent of which the iris was adherent, the pupil being of course lost; and the rest of the cornea was more or less opaque. Acting on the supposition that the lens had escaped, or having become opaque was absorbed, my opinion being founded on what I had observed in parallel cases, I incised the iris at the outer and upper part with the second-sized

Fig. 186.

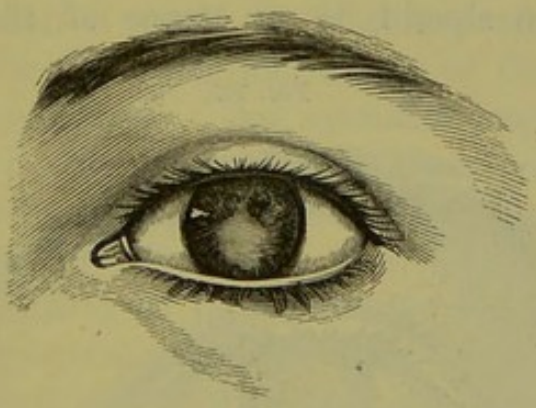

iris knife, according to the manner described in Class 1, but its texture was too much damaged for a gap to ensue. However, the incision did not close, and a few weeks afterwards I divided the cornea on the outer side, near its margin, and with the iris scissors (Fig. 165) cut the iris transversely at each extremity of the incision and a good-sized, well-shaped, and well-placed pupil resulted, as the sketch shows.

The lens was absent. Scarcely any inflammation followed either operation. Very little benefit ensued, for the retina was, it appeared, too much damaged to admit of useful sight. This loss of power is a very common effect of purulent ophthalmia. The general damage of the eye is always more than would be suspected, except by those who have experience in the matter.

In parallel cases it must be left to the judgment of the operator whether "incision," combined with "extension" or with "excision," described in Class 1, be done.

The following case, combining morbid alterations in many of the ocular tissues, may be given advantageously here. The patient was sent to me by the late Mr. E. A. Lloyd, of St. Bartholomew's Hospital. He had been injured by an explosion of gunpowder. The right eye was quite lost. The cornea of the other was densely opaque in the central portion, and some black dots showed where grains of the powder had entered. The pupil, so far as could be made out, was adherent to an opaque capsule, from which bands of adhesion, apparently of lymph, passed to the opaque part of the cornea. The iris was discoloured, but not bulging. I suspected that the lens was absent; that, as some years had elapsed since the accident, it had been removed by absorption. I cut through the cornea at the lower and outer edge of the cicatrix, and "incised" the iris, but an attack of inflammation frustrated my operation. Some months afterwards I divided the cornea near the circumference, again "incised" the iris, and attempted to draw out the external portion with a blunt hook; but as this was not readily effected I desisted, lest there should be an escape of the vitreous humour,

Fig. 187.

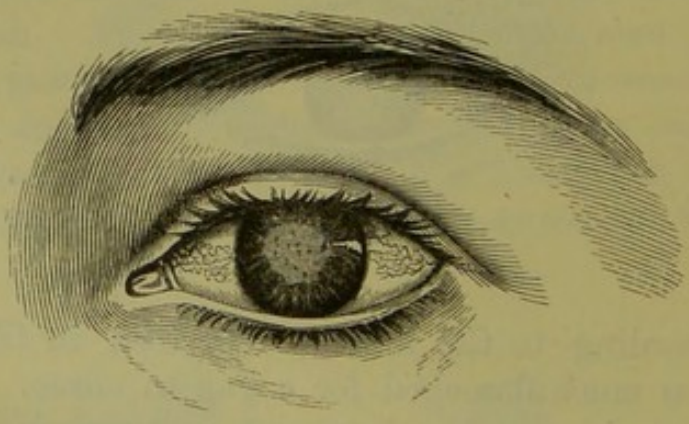

which was supposed to be degenerated. When the eye was opened a week after, a small and irregular, but useful pupil was discovered, and in a few days the man was able to walk alone in the streets. Mr. R. Taylor took the above sketch of the eye.

The pupil will be observed at the outer and lower part of the corneal opacity; the vessels at each corner of the eye were the remains of the very active inflammation that had existed; such probably will be always present. The lens was absorbed, and the capsule had contracted towards the centre, and was quite away from the position of the pupil; very likely the iris knife had torn it from its external attachments.

When a pupil, diminished from proplase of the iris through a more or less opaque cornea, is associated with capsulo-lenticular cataract, a troublesome complication exists. A careful survey of all the circumstances must be taken before it can be well decided whether it be proper and advisable to treat the cataract first, as for "solution;" or to make the pupil first, and to treat the cataract after; or, to form the pupil, and to "extract" the cataract at the same time, as described in Class 3.

When the lens is present, and supposed not to be opaque, the question is, whether a portion of the iris should be torn away with the capsule-forceps, as described in Class 3, or Mr. Tyrrell's operation adopted, namely, that of incising the iris close to the cornea, with the smallest iris knife, and with the blunt hook withdrawing a portion of it, as in the operation for enlarging a pupil. The latter is the more hazardous of the two, to the capsule of the lens.

When the pupil is closed from extensive adhesion, and only just the circumference of the cornea is transparent, "separation," or the tearing away of the iris from its natural attachment, is the chief or only resource; for then it would be most imprudent to incise that part of the cornea for the execution of any of the other operations, lest opacity of it should ensue. An operation may be done through the sclerotica, but it is risky, through the chance of failure in union, and opacity of the adjacent cornea ensuing. When the transparent portion is at the upper or the inner side, even although it be not so very limited, "separation" may be required, from the impediments to the performance of other operations in such situations. But it should be a very restricted operation, as it inflicts much injury, and, according to my own experience, is less successful than any of the methods of making a false pupil that have been described. Besides this, it may be stated in general, that eyes requiring it are most unfavourable for an operation, as they are usually the wrecks of disease, and fall only just within the compass of operative surgery. The cornea, besides having dense opacities from slough or penetrating ulceration, is frequently staphylomatous; and adhesions of the iris to it diminish, or even destroy the anterior chamber, whereby the operation is

rendered very difficult. It need not be done as a rule, except there be the absolute necessity of incising the cornea through an opaque spot.

To execute "separation," the cornea should be divided obliquely with the second-sized iris knife, opposite, or as nearly as possible opposite, the portion of the iris to be detached, and so far only from its margin that, when enough of the iris is torn away, it shall readily reach the incision, so as to allow of a part of it being withdrawn and cut off, or strangulated. If the incision be very far, too much will be separated. The next step is the important one of extracting the piece of iris. The canula-forceps are very applicable; I have used them with perfect satisfaction, and should now always employ them. They are far preferable to a hook, because they more certainly retain the tissue of a diseased iris, and are less likely to injure the capsule of the lens, and are more readily withdrawn. The only hook that I have employed is the ordinary "lens hook" figured among the cataract instruments. Dr. Mackenzie, in his review of the last edition of this work, in the "British and Foreign Medico-Chirurgical Review," vol. ix., in speaking of this, says, that from its liability to let the iris loose after the separation has begun, and to tear through the iris when the membrane is unbound, it is inferior to Schlagintweit's hook, or even the hook forceps of Reisinger. Also, that the withdrawal of the simple hook, with the portion of separated iris, is more difficult than that of the guarded hook of Schlagintweit. Whichever be the instrument selected, it should be carried in front of the iris to its margin, where it is implanted and separation effected. The circumference of the iris being a little behind the sclerotica, the

Fig. 188.

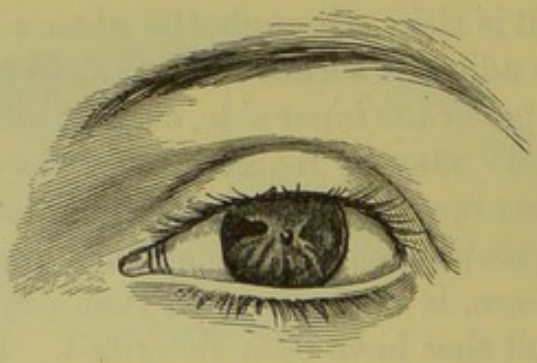

extremity must pass out of sight to seize it. It must be kept close to the cornea while being withdrawn, lest the capsule of the lens be injured. When the hook is used the withdrawal through the cornea requires adroitness, and unless the aperture be ample, the iris will probably be shaken off; the size should therefore bear some relation

to that of the hook, being, of course, always much larger. When the manipulation is successful, the form of pupil that usually results resembles that shown in the preceding sketch, which was taken from a person I met with, on whom I did not operate; and I may observe that here this operation of "separation" had been badly chosen, and the pupil badly placed, and that vision was very defective.

There is, I believe, greater uncertainty in the execution of "separation" than any of the foregoing operations; it is, moreover, attended with great pain. Instead of a portion of iris of the required size separating, a mere strip of it may give way, or, what is more common in a diseased state, the instrument may tear out without effecting any separation. Sometimes, directly that the detachment is commenced, blood is poured out, and the subsequent steps of the operation are obscured.

A male, twenty-two years of age, applied to me at the Central London Ophthalmic Hospital, to know if his right eye could be submitted to an operation similar to one which had been performed on his left by Sir W. Wilde, of Dublin, namely, "separation." I have never seen an instance to which this form of operation was more adapted or a better example of its execution. Fig. 189 is a sketch

Fig. 189.

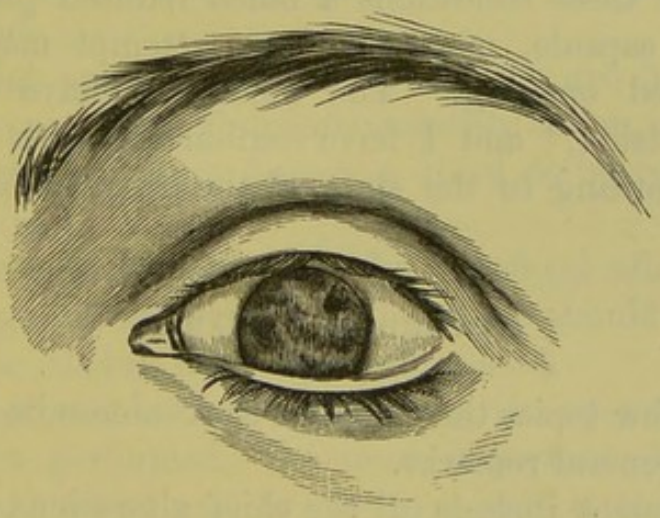

of the eye. A severe attack of purulent ophthalmia, which had completely destroyed the right eye, had also rendered opaque the cornea of the left, with the exception of a strip at the outer and upper edge, which was hazy.

The iris had entirely lost its fibrous appearance, and was, as far as I could judge, in actual contact with the cornea. The remainder of it was adherent to the leucoma. There was sufficient sight to read

very large print, such as the titles of books, without glasses; to do which, however, the eyelids were almost closed, to diminish the aperture and reduce the rays of light. I did not ascertain whether the lens was present. In an answer from Sir William, to whom I wrote about this person, I learn that in the majority of cases in Ireland requiring artificial pupil, purulent ophthalmia has so damaged the eye that "separation" is the operation most suitable, and that for the most part he strangulates the iris in the wound in the cornea, though he sometimes cuts it off, and then the pupil is less triangular. In this instance he thinks that the latter must have been practised.

I shall consider in this class that displacement, and generally too at the same time that diminution of the pupil, which may occur after the operation for "extraction," and which is nearly always produced by prolapse of the iris. When the aperture is very small, and the iris therefore tense, I have enlarged it by simple "incision" with the knife. When, although perhaps large enough, it has been too much displaced to be of full benefit, that is, by being concealed under the upper eyelid, and needs to be enlarged towards the centre, "incision" with the knife is not generally applicable, but a cut may be done with the scissors. I divide the cornea to the required extent with the cataract knife, and with the scissors I make a snip in the centre of the free edge. "Iriddesis" may be applied.

When under these conditions a much reduced pupil is associated with adherent capsule, more than one attempt may be needed to get the required opening. The method I have most generally adopted is "incision," and I have combined it with "extension" or "excision," according to the state of the iris, whether more or less healthy.

CONCLUDING REMARKS.

There are a few topics that may for convenience be introduced here as concluding general remarks.

The above classes include all the chief alterations in the eye that give rise to the necessity of an operation, having for its principle the formation of a permanent aperture in the iris, opposite to a sufficiently transparent portion of the cornea.

The classification has been solely for the sake of perspicuity and brevity, and I hope it has been made sufficiently clear, that the choice of any operation must be based on a careful examination and analysis of all the particulars of the case.

The operations described, embrace those which are practised in

this department by modern surgeons. To describe those which have been superseded and are now obsolete, would not be compatible with the character of this work.

I profess to give only general principles. It is practically impossible to supply minute details, for the full guidance of a beginner, in any class of operations.

When the size of a pupil is a matter of consideration, it should be remembered that "excision" invariably gives the largest aperture, and that the smallest is mostly got when a piece is torn out of an adhering iris.

The bleeding which may ensue at the commencement of an operation is sometimes a hindrance to the subsequent steps. An iris not much altered by disease seldom bleeds. The more unhealthy it is, the more the hæmorrhage. If the bleeding be slight, the corneal incision should be opened with a blunt probe, and pressure made on its posterior lip, when probably the blood will escape. A little pressure on the front of the cornea may be of service.

If the hæmorrhage continue, the operation should be suspended till another day, and pressure applied on the eye by cotton wool and a bandage. If blood be poured out into the chambers of the eye after an operation, supposing it to be confined there, and to have ceased to flow, there need not be any apprehension. I am not aware that it is attended with any disadvantage; it is soon absorbed, sooner in some cases than others, and does not require any special treatment.

If an artificial pupil should close, and the eye be not too much damaged by the accompanying inflammatory action, a second attempt may be successful. I have known a third to be required, before a result was obtained.

It is possible that atropine may be beneficial after operating, by keeping the edges of the pupil more apart; it should always be used, except when the iris has been left strangulated.

The after-treatment is the same as when the operation for "extraction" has been performed; the most important points being rest to the patient, perfect rest to the eye, and if there be pain, the application of cold and opiates.

Where the crystalline lens has been lost, "Cataract Glasses" are required, directions for which will be found elsewhere.

Certain mechanical contrivances may be of advantage when the pupil is too large, such as a diaphragm in a spectacle frame, with a hole or a slit to look through. I have found that several patients with lateral pupils have seen better when the side light has been shut out, by a sort of goggle.

CHAPTER XXVIII.

ANOMALIES OF ACCOMMODATION AND OF REFRACTION OF THE EYE, ETC.

ACCOMMODATION—PARESIS OF THE CILIARY MUSCLE—SPASM OF ACCOMMODATION—MECHANISM OF REFRACTION—ACUTENESS OF VISION—BINOCULAR VISION—PRESBYOPIA—CLASSIFICATION OF THESE ANOMALIES—HYPERMETROPIA—ASTHENOPIA—MYOPIA—ASTIGMATISM.

ACCOMMODATION.

To understand this is to be able to interpret most of that which concerns these optical defects; yet so difficult has it been to discover the key, that master minds have laboured in vain for several generations. At last, and through a long period, and only after the one philosopher has suggested a little and the other a little, each basing his views on the established facts of progressive science, has its simple mechanism been appreciated.

It is impossible to see a near and a distant object simultaneously and distinctly. If, for example, I hold up a walking-stick about a foot from my face, and at the same time look at a distant steeple, I find that when the outline of the one is clear and well defined, that of the other is blurred and indistinct. I cannot see them both accurately at once. To explain this it is necessary to repeat something of what has been said about light.

Those rays of light only which reach our eye from infinite distance are parallel; but for practical purposes rays from objects at or beyond a distance of eighteen or twenty feet, may be considered as parallel, their divergence being so slight as to be inappreciable in ordinary calculations. See the chapter on "Geometrical Optics." Such rays falling on the healthy normal eye, are refracted and brought to a focus upon the retina, and the image thus formed is clear and well

defined. On the other hand, rays proceeding from near objects are not parallel but divergent, and if the eye were to remain unaltered, they would be arrested by the retina before they had come to a focus. The apex of the cone of rays would be as it were cut off, forming what are termed circles of dispersion (see page 249), and the resulting image would be blurred and indistinct. In order to obtain a clear retinal image, it is necessary that the refractive power of the eye should be increased in proportion to the proximity of the object regarded; in other words, that the eye, taken as a whole, should become a stronger lens. The eye possesses this faculty within itself. It can bring to an accurate focus upon the retina, both parallel rays, and rays in various degrees of divergency. It can see clearly and distinctly at different distances, adapting itself for the position of the object looked at; and this it is which is called the power of accommodation; more shortly, accommodation, or adaptation.

The Theory of Accommodation. There have been a great many opinions as to the nature of the change which takes place in the eye when it is accommodated for near vision. It would be quite a waste of time to discuss all these speculations. I shall only allude to a few of those which have attracted most attention.

According to one theory, the axis of the eyeball is elongated in near vision by the pressure of the straight and oblique muscles, and the retina is removed farther from the crystalline lens, and to the exact focus of the converging rays. A sufficient answer to this is that accommodation has been observed by Von Graefe to be perfectly undisturbed in a case in which all the external muscles of the eyeball were paralyzed.

The theory that the iris is the agent in accommodation is also disposed of by Von Graefe, who relates a case in which the entire iris was accidentally removed, and yet accommodation remained unimpaired.

Increased convexity of the cornea is a theory which, though satisfactorily disproved years ago, has again been advanced quite recently. The very careful observations of Helmholtz with his ophthalmometer have shown, beyond the possibility of doubt, that no change of shape whatever occurs in it.

That accommodation is effected by alteration in form of the crystalline lens, through its elasticity, so long as the capsule is uninjured, is a doctrine which was taught many years ago by Dr. Young; but his views met with but little acceptance from his contemporaries, partly, it may have been, because he attributed muscularity to the fibres of the lens itself, and asserted that by their contraction the change is brought about. The truth, after having laid dormant for

many years, was revived by Helmholtz; and to him, and to Donders, and more especially to Cramer, we are indebted for observations and experiments which would seem to set the question definitely at rest.

Cramer's experiments consisted of careful measurements, by means of an ingenious instrument which he contrived for the purpose, of the reflected images of a flame, known as Purkinje's images, on the anterior and posterior surfaces of the lens, when the eye was adjusted for distant and for near vision. The size of the reflection from the anterior surface was carefully measured, when the eye was in a state of rest, in other words, adjusted for distant vision. When the eye was now accommodated for near vision, the size was considerably smaller, thereby showing that the anterior surface of the lens had increased in convexity. The exact changes which have been ascertained to take place are, increase of curvature of the anterior surface of the lens, and nearer approach to the cornea, with slight increase of convexity of the posterior surface. Besides the changes here described, says Donders, none others occur in the dioptric system in accommodation. Dr. Knapp, also, has proved that the alterations occurring in the crystalline lens, are in general sufficient to account for the ranges of accommodation; and he has satisfied himself that where the crystalline lens is absent, even in young people, not the slightest trace of accommodating power remains.

The lens is then the passive agent in accommodation. Strictly speaking, the eye in health is always set for accommodation, even when it is in a state of rest, or when looking at distant bodies, and receiving parallel rays, for the tonicity of the ciliary muscle keeps up its action on the lens. This action is destroyed by those agents which paralyze the muscle, atropine being the most powerful, and then the refraction of the eye is decreased.

The means by which the change of form in the lens is effected. We may at once dismiss all idea of the agency of the external ocular muscles; for, as I have already mentioned, accommodation has been found to be unimpaired where all have been paralyzed. A celebrated case is on record, in which the iris was absent without disturbance of accommodation. We are thus limited, by exclusion, to the ciliary muscle, to which alone, as an active agent, the curvings of the lens in accommodation, as rigidly defined, are due. Independently of pathological evidence, we have proof that this is the case by the action of atropine, which, by paralyzing the ciliary muscle, destroys accommodation; and this point, I may observe, was carefully inquired into by Professor Graefe in the case in which the iris had been accidentally removed. He found that atropine produced precisely the same effect upon accommodation as it does when the iris

is present and healthy. Farther evidence, were it necessary, might be adduced from the action of the Calabar bean, which has been shown by Dr. Argyll Robertson to possess the property of exciting the contractile power of the ciliary muscle, thus producing spasm of accommodation. But I shall not dwell longer on this point, as the evidence appears to me to be overwhelming, that this muscle is the active agent in accommodation.

The accommodation for near and for far bodies, is associated with pupillary movements. For near seeing there is contraction, and for viewing distant objects there is dilatation. Thus there is a functional connection, between the ciliary muscle and the sphincter pupillæ, clearly accounted for by the nerve distribution.

With the contraction of the pupil for near adjustment the lateral rays of light are cut off and the image on the retina is rendered more sharp and clear, but this must be considered as merely auxiliary to distinct vision.

The recti muscles undergo associated and relative changes, coincident with the act of accommodation. In accommodating for near binocular vision, the eyeballs are turned inwards, that is, adducted, and for viewing distant objects they are placed parallel. The extent of the connection, which is not absolute, but relative, bears a proportion to the refractive power of the eye, and to the extent or range of the accommodation ; to its seeing power in fact. This applies to the eye at the different times of life, as well as to individuals. Besides what may be called the natural relative ranges of accommodation and convergence, a person can, by will, induce a certain cultivation of muscular activity, and use it for near work.

To say more on this subject, would oblige me to enter into detail, which would occupy many pages without any profit to my reader. What I have written, embodies the chief facts connected with accommodation. There are some minor points relating to the mechanism or movements of the parts actually concerned in accommodation, about which we have not exact knowledge, but these are very immaterial, and concern the physiologist, rather than the practical surgeon.

MECHANISM OF REFRACTION ILLUSTRATED.

Fig. 190 is a diagram of an emmetropic eye, looking at a distance, the accommodation of which is therefore passive. The parallel rays fall on the pupil, and are focused on the retina.

When objects are sufficiently far off to transmit parallel rays of

light to the eye, they are frequently spoken of as being at an infinite or indeterminate distance. When they are sufficiently near the eye

Fig. 190.

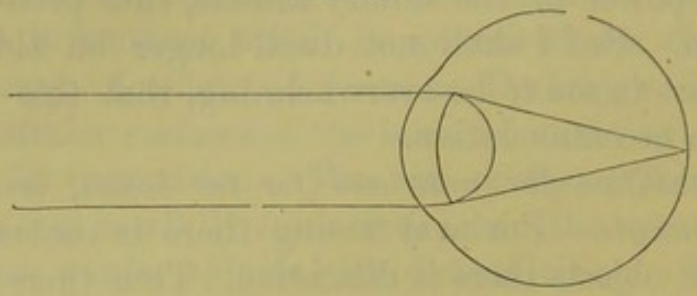

to emit divergent rays, they are said to be at a finite distance. Without this explanation the use of the terms might cause confusion.

Fig. 191 is the diagram of an eye which is supposed to be looking at a near or finite object X. As the rays reach the pupil in an angle of emergence or as divergent rays, they must be very much converged before they can be focused on the retina, and this is actually done through the crystalline lens being rendered more convex, by the contraction of the ciliary muscle.

Fig. 191.

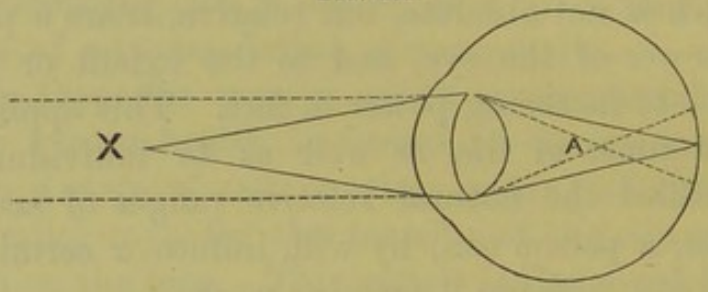

The dotted lines are meant to show what would be the effect on parallel rays of light from an object at an infinite distance entering an eye so accommodated. Being very much converged, they would meet at A, their point of focus, then cross, diverge, and form circles of dispersion on the retina. This is precisely what takes place in an eye when an endeavour is made to look at a near and a far object at the same time. The effect may be easily understood by holding the end of a pencil-case six or eight inches from the eye, accommodating the eye for it, and at the same time trying to see some moderately small object several yards off.

PARESIS OF THE CILIARY MUSCLE.

Paralysis of all the muscles which are supplied by the third cerebral or oculo-motor nerve, has been already treated of, and therefore the ciliary muscle has been included.

The term paresis, is meant to express suspension of function of the muscle; that is, temporary loss of action, interfering with the process of accommodation; rather than confirmed paralysis. Besides this, I restrict the term to affection of this muscle alone, not complicated with mydriasis, and not of cerebral origin, but due to disease of the short root of the ciliary ganglion, the source of the oculo-motor nerve supply. Paresis is sometimes spoken of synonymously with asthenopia, but I regard it as a distinct condition, because it does not arise out of, nor is in any way connected with, defective refraction.

Symptoms. Removal of the near point a long way from the cornea, and therefore inability to direct the focus of the eye to anything near. Focusing might be effected for a second or two under great effort, when the paresis is but slight, but it quickly fails, and the quicker, the nearer the object is held to the eyes. An analogous state is found in the muscles of the body in general. Under strong volition, a partially paralytic muscle is made to act as it were spasmodically, but the effort soon exhausts that which remains of the muscle force.

Distant vision, the range of which will of course vary with the natural refractive state of the eye, is unaffected in the normal or emmetropic eye, and persistent without any tension of accommodation; therefore without fatigue, and consequently is not assisted by a convex lens. Herein lies the distinction between paresis and hypermetropia. In the former a convex lens will establish a near focus, and a trial with it will prove the nature of the affection, and dispel any idea about amblyopia, or loss of the power of the retina.

The effect on vision in general, according to the refractive condition of the affected eye. The myopic eye suffers the least, especially when the far point is at no great distance from the cornea, or in other words, sufficiently close to enable a small object to be tolerably distinctly seen. The hypermetropic eye suffers the most, because both near and distant vision is impaired, and the eye is placed under the same state as when the ciliary muscle is paralyzed by atropine.

According as the paresis is partial or complete, is the adjustment of the eye partially or wholly lost.

Paresis is nearly always a double affection. There is not any objective symptom.

Cause. Paresis is always seen in association with illness, exhausting disease, or some sudden condition which has exhausted the nervous power. I have met with it after typhus fever, after hæmorrhage, especially in association with parturition, after exhaustive lactation; after diphtheria, particularly in association with paresis of the muscles of speech.

In most instances, there is a proportionate condition of debility of the whole muscular system. After diphtheria, there may be, exceptionally, want of this proportion. The muscles of locomotion may be unaffected, while the ciliary muscle is more or less paralyzed. To save repetition, I beg to refer my reader to the sixth paragraph on page 345, for further remarks. I will take this opportunity to say, that the word, uncomplicated, in the fourth paragraph on the previous page, should be written complicated. I meant to infer complication with paralysis of the sphincter pupillæ.

Paresis in a slight degree is common, and when a personal discovery of it is made after illness, it is very rationally associated by the sufferer with the preceding malady, and expected to disappear when strength is restored, and therefore, special advice is not sought. It is only when severe, or associated with paralysis of the constrictor pupillæ, that the ophthalmic surgeon is seen.

Treatment. This consists in the adoption of those general measures which will restore health.

I have not found that local measures have been of service, and I allude particularly to the use of preparations of the Calabar bean, for the purpose of causing spasmodic action of the muscle, and blistering. As soon as the action of the bean had passed away, the paresis was just the same.

In all the cases in which I have been personally concerned, the paresis has ceased when the general health has been restored. It is disadvantageous to allow convex lenses to be worn by those whose eyes were emmetropic before the attack. I always forbid the use of spectacles to any patient, be the state of his refraction what it may, till his health is restored.

SPASM OF ACCOMMODATION; THAT IS, SPASM OF THE CILIARY MUSCLE.

By the term spasm, is meant a state of the ciliary muscle analogous to that which is produced by the application of the Calabar bean to the eye. This subject is at present an obscure one. Few cases have been recorded, and the accuracy of some of them is doubtful; facts are required. I have no practical acquaintance with the affection, although I have been looking for it among a large number of ophthalmic patients. The pith of what has been published about it may be readily given.

The spasm is attributed to two kinds of causes.

First, to reflex action, arising from irritation of the ciliary nerves, in consequence of inflammation, accompanied by hyperæsthesia of the retina, and perhaps spasm of the pupil, and of the orbicularis

palpebrarum. Also to hyperæsthesia of the retina and of the optic disk.

In persons with low or medium grades of myopia, the following phenomena of the spasm occur. When an object under examination is removed beyond the far point of the individual, it does not become gradually indistinct, but suddenly imperfect, and with the sensation of an altered accommodation. The person under the attack sees things sharply, at one or two feet distant, but at three or five feet they appear to him more indistinct than they would to others of an equal or higher degree of short-sightedness. Examination shows that the sudden indistinctness is caused by a strain of accommodation, associated with increased convergence of the eyeballs.

In another class of cases the spasm occurs when near objects are looked at, whereby accommodation is called into action. The ciliary muscle now contracts too much, more than is required, and the convergence of the optic axes increases disproportionately, and one of the eyeballs turns in. In other instances, as soon as an object is brought to a certain point, the maximum of accommodation and convergence is excited, and remains unchanged even if the object be moved far away. Such cases might be mistaken for high degrees of myopia; but that myopia does not exist, is shown by the power of vision for long ranges under ordinary circumstances.

Secondly, the spasm is excited sympathetically, from the morbid action of the internal recti muscles. When an object is brought to within a certain distance of the eyes, a strong contraction of the internal recti and of the ciliary muscle ensues, so that even while the far point may be great, the person can only read or write at the distance of three or four inches.

Treatment. The indications are to prevent the spasm, by avoiding employments which require near vision. Where this cannot be accomplished or proves inefficient, the long-continued use of atropia is indicated. It is said that in the second form of the affection the adaptation of prismatic glasses, of two or three degrees, has removed the spasm.

In the cases of spasm, or supposed spasm, which have been published, only local treatment has been used. In true spasm general measures ought not to be neglected.

ACUTENESS OF VISION.

Near and far points of vision, or ranges of accommodation. The nearest distance to the eye at which a small object can be seen distinctly by the maximum of accommodation, that is, by the

greatest effort to see, is termed "the near point." The farthest distance at which anything can be clearly discerned with critical distinctness is termed "the far point." The interval between the near and the far point is termed the range or territory of accommodation.

Vision tests. Some standard or test is necessary, by which the quality of sight may be tried. States of disease frequently demand knowledge in the matter. The tests embrace the conditions of requiring the recognition of definite things at definite distances. Print is the object that is generally used. We are sure that it must be seen with tolerable distinctness to be read.

The distance at which any print can be recognised, depends of course upon its size and the facility with which a person reads. Some will recognise the letters from their shadows, while they are but dimly seen. The normal standard distance for recognition by an adult, pointed out by experiment, is about that at which a letter subtends an angle of 5′ at the eye, which is very nearly equivalent to saying that the distance should be 689 times the height of the letter.

Perfectly accurate results cannot be got here, because 5′ is too great a visual angle for persons under adult age; therefore for such, the angle must be decreased. More than this, two persons of the same age scarcely ever have the same focal range and visual acuteness. Then the manner in which the print on the visual field is illuminated, or on the contrary shaded, will have a decided influence on the result of the examination. Hence the same eye may see differently under different methods of testing it. Farther still, when different prints are used, the values obtained for the acuteness of vision will not be all equal. Therefore, it is necessary not only to record the value of the acuteness, but also the size of the print used.

It is very difficult to test the sight of one who cannot read. For him we must resort to figures, whose form can be promptly stated, such as dots, chequered patterns, vertical and horizontal lines.

Acuteness of vision decreases with age, because the refracting media lose some of their transparency, and the retinal image is consequently less distinct; and because of the lessened perception of the retina and the optic nerve. Again, the size of the pupil affects sight very materially. When an object is feebly illuminated, it will be the better seen in proportion to the largeness of this aperture. Where there is confusion of vision, arising from circles of dispersion on the retina, or owing to defective adjustment, or to irregular refraction, a small pupil improves it.

I must here speak of three scales of test print that are in use in England, namely, Snellen's, Jaeger's, and that which I employ. In Snellen's, the letters, which were formerly Roman, but are now square, have limbs equal to one-fifth of their height. Over each gradation of print is placed the number, in Parisian feet, at which the letters can be seen at an angle of 5′. It must be borne in mind when using this print, that an English foot is only ·92 of a Paris foot, so that one of the latter measures a trifle more than thirteen English inches.

As an example of application, suppose it is found impossible for an eye to recognise the print marked 3, when it is distant more than twenty-four inches; then, since the standard distance for this is three Paris feet, or about thirty-nine inches, the acuteness of vision is measured by $\frac{24}{39}$ or $\frac{8}{13}$.

Jaeger's scale, which is the better of the two, commences with a smaller print. It is farther graduated, and reaches to much larger print.

Test type was first introduced by my former colleague, Mr. A. Smee, twenty years ago, and his tablet was used by us at the Central London Ophthalmic Hospital. He employed the print of the English press, which I subjoin at the end of this work. It is well to throw a little gibberish into the text, so that unexpected words occur. A few mis-spellings also may be adopted.

It should be an invariable rule to try the sight of each eye separately.

According as there is a departure from the standard for the acuteness of the eye, is there more or less of defect or disease present.

M. Burchard is dissatisfied with print as a test, and suggests displacing such by that of a system of dots, and which he wishes to call an international test. He attacks Snellen's print particularly, with the condemnation of not supplying the advantages of form which the author claims for it.

His objections are these: Print can be used only for those who can read. All letters are not equally visible at the same visual angle. Letters of different languages, although they may be printed according to Snellen's model, are not all seen with the same facility. Letters are not applicable for astigmatic persons, on account of the disparity in their lengths and breadths.

He selects the globular figure because it is the best for grouping. Each group should contain from four to six dots. A larger number make the test too difficult, a smaller too easy.

He has published tables of dots, with the distances at which they ought to be read.

Theoretically speaking, the dots are best, for they will give more accurate results than print. With them can be ascertained, with a closer approach to accuracy, the acuteness of vision of any one, and his focal range, than with print. But the difference is marvellously little, and I do not ever require such precision. The novelty of the scheme will ensure for it fashion. Where adaptation of lenses for the near print is the question, print is far beyond dots in value, simply because the eyes are tried in that very object for which they specially require help. Dots or lines must be used for those who cannot read, and such have been employed for years in all countries.

BINOCULAR VISION.

This is a very complex subject, of much interest, the principles of which are well understood. In a physiological sense I have nothing to do with it. I have to speak of the bare and simple mechanical method of ascertaining whether such vision be present or absent in any particular individual.

Vision in everyone must be monocular; that is the result of seeing with the one eye; or binocular, when the two eyes are brought to bear at once on the same object. As the eyes are made to act together, being organised for such a purpose, the use of only the one cannot give full sight.

The monocular sight fails in the main, in the estimation of distance, and in determining the solidity of things. A one-eyed man misses that which he tries to touch, and he is deceived about form, mistaking round objects for flat ones. These defects can be in some measure overcome by study and practice. A certain correction too may be made by moving the head or the trunk, so that an object can be seen from different positions, and a parallax obtained. As convergence is lost, accommodation is impaired.

A peculiar negative property of monocular vision is a kind of stereoscopic effect, which is obtained when light and shade in proper contrast, such as in a well-executed painting, produce a negative form of binocular vision; but true binocular vision shows that the painting is on the same plane, that is, flat. With the one eye the flatness cannot be recognised with certainty, so that the effect of relief is obtained by a defect in visual perception.

Binocular sight can do more than the monocular. In visual examinations at short ranges solidity is so much better estimated, because the two eyes see different sides of the object, and the deception of any artificial arrangement is more quickly detected. A larger visual field is obtained. More is said about this in the chapter on "Cataract," with reference to operating on the one eye, while the other is

sound. The rate of motion of anything approaching or receding from the eyes is better understood. The same holds good when the head is moved forwards or backwards. From the loss of this property, monocular people often strike their eyes against things. The inner side of each retina receives impressions not reciprocated by the other.

Conditions determining the existence of binocular vision in the same individual. There is acuteness of vision, without any disparity in refraction between the eyes, the smallest print being readily read at the same distance with either eye alternately.

If a prism, from 15° to 17°, be held before the one eye with the base outwards, while some small object, at ten or twelve feet distant on a level with the eyes, be looked at, such as the tassel of a window blind, or a candle flame, it will be doubled, and the two images will appear side by side, and equally distinct. Eyes so constituted are binocular for near and distant vision, and are adapted for all kinds of binocular instruments.

If a low prism be used in the experiment, the eye which is applied to it is apt to squint inwards by an involuntary effort to overcome the double vision, and for the most part the squint is visible to a bystander. As soon as the prism is removed the eye rights itself.

Binocular vision is developed according to the shortness of the distance at which the eyes are used. When a very distant object is looked at, the axes of the eyeballs are practically parallel, and nearly the same view is obtained with the one eye as with both. But when the eyes are employed for close inspection of things the axes converge at an angle proportionate to the proximity, and so form a binocular parallax.

DIFFERENCE OF REFRACTION IN THE TWO EYES.

The eyes are for the most part alike in all physical configurations and proportions, and their refractive conditions correspond. Exceptionally they differ in structure, and a difference of refraction is the consequence. The disparity may be congenital or acquired.

Conditions under which difference of refraction occurs. While the one eye is emmetropic, the other may be either myopic or hypermetropic.

Hypermetropia, or myopia, may exist in different degrees in the two eyes.

The one eye may be myopic and the other hypermetropic.

With dissimilar refraction, the radii of the two corneæ usually differ as much as the radii of corneæ of different individuals.

The use of the two eyes with difference of refraction. The combination may be arranged under the following heads:

Simultaneous vision. Generally speaking, there is simultaneous vision with normal eyes. Yet it is not at all uncommon for such perfect binocular vision to be occasionally disregarded, and the one eye only to be used. The preference is generally given to the right eye. For instance, when a distant object is looked at with both eyes, it is found, if the left eye be closed, that the right has been chiefly employed. Again with both eyes open, if an object a few yards away be covered by an upheld finger, it will be perceived by closing the eyes alternately, that the covering is made for the right eye. The result, as regards the prevailing eye, will be somewhat influenced by the finger held up, whether it be of the right or of the left hand. But still it will be found that most persons have a prevailing eye, and that such eye is the right. It is probable that the usual right-handedness explains this, the use of the right eye being combined or associated with the accurate manual movements of the right limb.

Where there is difference of refraction, that eye is used, as a rule, with which the vision at the required distance is most acute and easy. Notwithstanding this, for the ordinary or more superficial observation of objects, there may be binocular vision, within the limits of easy and full convergence, and with considerable difference in the refracting media. In spite of the unequal magnitude of the retinal images, and their unequal acuteness, they assist each other, not only in ascertaining more correctly the solidity and the distance of things, but in adding to the acuteness of vision. This is the more easy to be understood, if it be remembered that even in normal eyes there are not any absolutely identical or corresponding points, for the feeble tints of the diffuse image in the imperfect or the more imperfect eye disappear, when the action of the round or the better eye is combined with it.

In slight external squint, where there is only a little difference of refraction between the eyes, there may be binocular sight, according to the amount of the field of vision which is common to the two eyes.

In further illustration of this may be mentioned the unequal magnitude and acuteness of the two retinal images, which are formed in normal eyes, from a near object viewed laterally. The one eye does not disturb the other unless it has a corneal or lenticular opacity, through which much difference of light reaches the retina. And that this disturbance is not the rule is proved by the rarity of squinting in eyes so affected, and the possibility of cataract being developed in the one eye in total ignorance of its existence.

With the difference of refraction, if the acuteness of the vision be sufficient in the two eyes, the ranges of accommodation are usually alike. It is easy to ascertain the near and the far points of each eye

separately. If there be greater difference in the accommodation than in the refraction, the nearest point of the least refracting or longest-sighted eye, lies at a less distance than the farthest point of the most refracting or nearest-sighted eye.

Even where the difference of refraction is too great for any degree of binocular vision, the unavailable eye does not interfere with the other. After a time it generally squints outwards.

Alternate use of the eyes. Where a low degree of external squint is acquired, but sufficient to prevent binocular vision, the eyes are generally used alternately, the one for near and the other for distant vision. If it should so happen that there be emmetropia in the one eye and myopia in the other, there will appear to be a very great range of accommodation, far greater than could occur in an individual eye.

Treatment. Difference of refraction does not necessarily demand any optical help. Under the middle period of life, where the one eye is emmetropic, defective refraction of the other, whether from hypermetropia, or slight myopia, does not interfere with binocular vision, and persons with such eyes see near and distant things sufficiently well. It is only when presbyopia has arrived and convex spectacles are necessary, or there exists some optical defect in the better-seeing eye, and which requires to be corrected, that the special adaptation of lenses need be entertained. The indication under such circumstances is to render the existing binocular vision more available. To approximate the near point, or to lengthen it, or to lengthen the far point, is all that can be done. And then arises the important question, whether there should be similar or dissimilar lenses for the two eyes. The answer must be determined by actual experiment. Only by it can we ascertain what is really suitable; because the existing differences of the eyes having become habitual, certain influences are exercised in the corresponding points on the retinæ, and fixed rules are impossible.

In the first place, I ascertain, accurately, the state of refraction of each eye, and then proceed to make my trials with the lenses.

Where there is presbyopia with hypermetropia, or hypermetropia only, if the better-seeing eye, that which needs the least refractive lens, be properly suited, the same lens power will in all probability do for the other eye.

To endeavour to bring the ranges of accommodation more in accordance, by dissimilar lenses for the eyes, will most likely be attended by disappointment.

Sometimes when binocular vision is easy at any distance, and when there is no great disparity in the refraction, dissimilar lenses may be beneficial.

An exception to the above rule, respecting the disparity, is to be found after the operation for internal squint, when the eye which has been straightened deviates outwards or inwards in consequence of its very imperfect refraction. Then a properly applied lens throws such an image on the retina of that eye as will enable the eye to be used, whereby it is brought under the will, and no longer deviates. This is effected even when there is not acuteness of vision.

Dissimilar lenses are often required in myopia, but benefit can rarely be got with a greater disparity than within from $\frac{1}{40}$ to $\frac{1}{30}$.

PRESBYOPIA, OR OLD SIGHT.

I shall speak first of the natural changes in the accommodation of the normal eye, and in the refraction of the same, which are inevitably produced by age.

The accommodation begins to alter, the near point getting farther from the cornea very early in life. Indeed, in childhood, this elongation sets in, and at the fourteenth year, a palpable alteration can be recognised. All children seem to be myopic, because they carry things close to their eyes. A youth holds print at about from six to eight inches from his eyes, and examines small objects at the same range. Onward goes the focal change to the end of the longest life.

In childhood, and till manhood, there is a geat deal of accommodation to spare. The young and healthy eye can read the smallest type, with forced accommodation, at the distance of three-and-a-half or four inches, but such near vision is never wanted. As years roll on, the spare accommodation gets less.

The hypermetropic eye is likewise affected, and so is the healthy myopic eye of a low grade.

This decline of power, for such it really is, arises from the crystalline lens getting denser, and therefore becoming less capable of being acted on by the ciliary muscle in the process of accommodating.

The refraction diminishes after the power of accommodation has very sensibly declined. These bear a relation to each other. With most emmetropic persons at thirty-five years of age, fine print, which used to be agreeable at the eighteenth or twentieth year, is discarded for that which is larger. Later on, still larger print is preferred. The absolute, or farthest, point of distinct vision declines, and the focal range is thereby lessened. This may not occur in an emmetropic eye till the sixtieth, sixty-fifth, or seventieth year. Sometimes it is very marked. With the loss of range, there may be loss of acuteness of vision, arising from retinal obtuseness.

The size of the pupil will have some corrective influence here. Its volume lessens with increasing years, and the smaller the aperture becomes, the better influence will it have on the quality of the sight because of the reduction of the circles of dispersion. Except there be hypermetropia, lenses will not afford any help to distant vision.

The reduced refraction is due to the lens getting flatter, and to its layers degenerating into a more uniform density. This latter is effected by the cortical portion becoming firmer.

No changes in the human body come so surely and regularly as these. Exceptions are rare. When they seem to occur, they are almost invariably due to the presence of a low degree of myopia.

Presbyopia then may be defined as diminution of accommodation, for near objects, with diminution of refraction, consequent on age. It may be said to be established when the near point of distinct vision for small print has receded to nine or ten inches. Practically, it is not recognised till small type is no longer easily read by artificial light; soon after which, by daylight, small objects must be held at twelve inches or more, from the eye, to be well seen. A bright light is sought, because the object is better illuminated, and the pupil contracts. It is fully developed, when reading a newspaper is attended with difficulty, in spite of the best light, and straining efforts to see. Now, at this stage, the letters which are like each other are not easily distinguished; single strokes appear double, and one dot seems to be two. Figures are more indistinct than letters.

In myopia, only the eye with a low grade of the defect can ever become presbyopic, so far as regards the removal of the near point to nine inches or farther, and the presbyopia is generally ten years later in arriving than it is in the emmetropic eye.

The time at which presbyopia in general arrives, varies. It may appear at forty, forty-five, or fifty years of age. It may come on slowly, or so quickly as to appear sudden. At the period when it may be said to be due, a month, or even a week, will sometimes make all the difference in the condition of the eye. A patient who came to me distressed on this matter, found that in two days the change of focus was very apparent. Debility of body arising at this time from any cause will hasten its coming. Patients frequently tell me that their sight was good, until some illness or accident, when they could no longer read as before, and attribute the change to bodily ailment.

I may mention in parenthesis, that this accelerated arrival of presbyopia is often made the basis for laying claims, in cases of accident, to which liability is attached; the plea being damaged sight. I know of several instances in which heavy compensation has

been received. I am aware also, that persons who had received no damage whatever, but who had an opportunity for making a claim, being presbyopic, but never having used glasses, have resorted to them, and attributed their necessity to personal injury, and have thus fraudulently claimed hundreds of pounds compensation, and have received it from the hands of credulous jurymen. I speak from personal knowledge.

Diagnosis. Amblyopia is the only condition with which presbyopia is likely to be confounded.

In pure presbyopia the lowest convex lenses will not assist far vision, except at the distance of a few yards. In amblyopia there is impairment of vision which cannot be removed by the use of lenses.

Treatment. This consists in wearing convex lenses sufficiently strong at first, rather to increase the sharpness of the retinal range, and afterwards to supply the deficient accommodation without neutralizing or superseding whatever natural amount of that power may remain. They should be worn so soon as they are wanted for the particular employment of the individual, and they should be sufficient. The majority of persons will not resort to them early enough. Some delay from vanity; especially foolish people, who will suffer much privation rather than receive the necessary help. Some persons again, postpone them from the fear that if they take to them, thay must always use them. Some, the minority, because they are not aware that spectacles are necessary. To delay their adoption, and to endeavour to see small things without them, is to subject the eye to undue strain of accommodation, without obtaining a good result.

The required power of the lenses must be ascertained by actual experiment; that is, by trial with lenses. Formulæ are used for calculating what may be needed, but I shall not give them, as they are useless, on account of individual exceptions; they might serve, if there were fixed data from which the calculations could be made. No two persons have exactly the same power of accommodation, or degree of refraction; or length of focal range; and very little difference in either of these, from any received standard, spoils the calculation. I never knew a patient to be satisfactorily fitted by such methods. What plan can be so ready, or so short, or so sure, as that by which the eyes are tried with the very things they are in want of? The plan does not admit of an error. Those lenses should be selected by which small print can be readily read, at from nine to ten inches from the eyes. Such an adaptation will enable the eyes to be ordinarily used for reading, &c., comfortably, at about the distance of

fourteen inches. A higher power would tax the accommodation. This shows that the power of vision must be brought up to the point at which it was, before the presbyopia was established. After the sixty-fifth or seventieth year, another arrangement is required, because of the reduced sensibility of the retina. The visual angle must therefore be increased by bringing the objects nearer. As the rays proceeding from such objects necessarily converge more, the nearer the objects are to the eye, the higher must be the value of the lens to reduce them to a focus on the retina. Accommodation being nearly or quite lost, that power of lens should be chosen which will enable ordinary reading to be easily exercised, or any accustomed work to be done at seven, eight, or ten inches from the eye.

Night-work demands higher lenses than day-work. When the night spectacles must be changed from their insufficiency, they may be draughted for day use. This system of rotation should be always observed.

Few presbyopics change their spectacles sufficiently often for near work, and those who are ill suited, are seen by night, holding the candle or lamp close to the object, and by daylight, screwing up the eyelids, seeking for a bright light, and carrying the object far from the eyes.

The following tables from Donders' work have been formed approximative of the powers of the lenses which are usually wanted for presbyopia occurring in the originally emmetropic eye, as years roll on.

SPECTACLES SCALE.

Age.	Power of lens. In inches.	Nearest point of distinct vision. In inches.	Distance which is most pleasant for reading and working. In inches.	Furthest range of vision. In inches.
48	$\frac{1}{60}$	10	14	60
50	$\frac{1}{40}$	12	14	40
55	$\frac{1}{30}$	12	14	30
58	$\frac{1}{22}$	12	13	22
60	$\frac{1}{18}$	12	13	18
62	$\frac{1}{14}$	12	13	14
65	$\frac{1}{13}$	11	12	13
70	$\frac{1}{10}$	10	10	10
75	$\frac{1}{9}$	9	9	9
78	$\frac{1}{8}$	8	8	8
80	$\frac{1}{7}$	7	7	7

With the least disease of the ciliary muscle, or in the fundus of the eyeball, or with the coexistence of hypermetropia, the deductions which are made from normal conditions are inapplicable.

Such a table might be resorted to by a surgeon for his patients, when he has not a set of trial lenses, and an optician is not at hand.

The following rules might be applied, under the same circumstances, instead of the table. When the near point has not receded very far, let the distance at which small print can be most distinctly seen, say eighteen inches, be multiplied by the distance for easy reading, say twelve inches, and divide the product, 216, by the difference between the two numbers. The quotient, 36, will be about the focal length of the required lenses.

When the near point has receded considerably, the required focal length of the lenses will be equal to the distance at which it is desirable to see objects most distinctly.

When, however, the acuteness of vision has declined in a very marked degree from retinal changes, it would add damage to the eyes by fatiguing them, to use lenses sufficiently high to magnify small objects, so as to enable them to be seen. No such attempt must be made to compensate for loss of the normal power. Minute work of all kinds and small print must be discarded. Some old people instinctively take to very large print. The grandmother, with her book printed in letters which look ridiculously large to the younger members of the family, knows that she is doing the best thing for her poor old eyes.

A "reading-glass" may be at times advantageously resorted to, although there can only be monocular vision with it. It is a double convex lens, of six, eight, or ten inches focal value, from three to five inches in diameter, set in a frame with a handle. An intelligent person will soon learn to hold it to the best advantage; that is, closer to the object than the focal distance, so that the rays may converge on his retina. The position of his eye from the glass will not matter much. The nearer it is, the less will be the magnifying power, but the more extended will be the visual field.

When a presbyopic person requires, from his peculiar employment, to make his reading distance at eighteen inches or two or more feet from his eyes, there is not any disadvantage in his using lenses sufficiently low for the purpose.

Respecting the disadvantage arising from loss of association between the convergence of the eyes, and accommodation, resulting from the use of spherical lenses, especially those of high value, I beg to refer the reader to my remarks on orthoscopic spectacles.

Before presbyopia has arrived, it would be positively injurious to the eyes to wear convex glasses for minute work. Some persons are guilty of the folly, in the hope that the presbyopia may be prevented. It would be as sensible to endeavour to arrest the coming of any senile change.

When the nature of an artizan's employment requires that he should see very minute objects distinctly, within a few inches of his eye, he must resort to a high lens, long before he is presbyopic. Practice seems to have established the use of monocular vision in such instances; hence the well-known watchmaker's glass; and perhaps the workman is the gainer thereby.

CLASSIFICATION OF THESE ANOMALIES.

Emmetropia. This signifies sight within due measure. It is applied to an eye of perfectly normal refractive power, which brings parallel rays to a focus on the retina. Critical inquiry, however, shows that it is the exception to find eyes, during rest of accommodation, to be perfectly emmetropic, so that the natural focus is exactly on the bacillar layer of the retina. But in the mass, the deviation of the focus, whether before or behind the retina, is so slight, and the circles of dispersion are so small, that the sharpness of the image suffers but very little. Donders has introduced the word emmetropia, because it expresses with accuracy and precision what is meant, as regards the refraction of the eye. The term normal is not so appropriate, as it does not carry a like special signification. It is generally used in relation to healthiness of structure.

The eye may deviate from emmetropia under the two following conditions. Such deviation is sometimes called ametropia. I shall not use the term, because it is likely to confuse.

Hypermetropia. This signifies above the measure. In this state the rays of light from distant objects form a focus behind the retina in an eye passively accommodated, and the divergent rays from near objects cannot be focused on it, except under very forced accommodation, or until they have been rendered convergent by artificial means.

Myopia. This term, which has been long used, is retained in modern ophthalmology, instead of introducing that of brachymetropia, which signifies in front of the measure, or short of it, although more in accordance with the above definition.

In myopia, parallel, or even insufficiently divergent rays, are brought to a focus in front of the retina.

The following table after Laurence may be useful:

THE EYE IN A STATE OF REST. THE CRYSTALLINE LENS AT ITS MINIMUM CURVATURE. THE OPTIC AXES PARALLEL.

Eye.	Parallel rays are focused	Far-point.	Eye in a state of rest, adapted for	Effect of lenses for distant objects.
I. Emmetropic.	On the retina.	At an infinite distance.	Parallel rays.	Convexes and concaves deteriorate vision.
II. Myopic.	In front of the retina.	At a definite distance and positive.	Divergent rays.	Concaves improve vision.
III. Hypermetropic.	Behind the retina.	At a definite distance and negative.	Convergent rays.	Convexes improve vision.

HYPERMETROPIA.

In this affection, which is the opposite condition to myopia, parallel rays of light entering the pupil do not unite and form a focus on the retina; on the contrary, the focusing point is behind it, and were the sclerotica removed posteriorly, they would converge to a point behind its boundary. Therefore, it is still farther impossible for divergent rays to be properly refracted for the function of sight. Only rays that have been artificially rendered convergent by a convex lens are properly focused within the eyeball.

It is strange that this defect of vision, of such very frequent occurrence, and one which is the most common of all the causes of that extremely troublesome disease, asthenopia, should not have been worked out till lately. Janin, in his work on the eye, published in 1772, gives a very clear account of a case of the affection, in which the patient commenced to use convex glasses at the age of twelve, and at thirty he was wearing spectacles suitable for a man of seventy or eighty. He attributes the defective refraction to undue flatness of the lens, and speaks of its not unfrequent occurrence. Again, hypermetropia is pointed out and clearly defined by Dr. Mackenzie in his "Physiology of Vision." Still it failed to attract general attention until it was taken up by Donders, to whose laborious investigations we are indebted for the greater part of what is known on the subject.

Form of the hypermetropic eye. The eyeball is smaller than in the emmetropic eye, being generally imperfectly developed. Around the cornea the sclerotica is rather flattened. A section of the eyeball through the visual axis has the form of an ellipse, of which the

visual axis is the shorter. A section perpendicular to the visual axis, carried through the equator, is almost a circle.

Fig. 192 is a diagram of a vertical section of a hypermetropic eye. The dotted line is meant to show the outline of a normal eye. As the lens is of a normal focus, the retina is too near, and consequently the rays of light are not properly focused on it, because their apex should be at X, whereas the retina is at x. The diverging lines represent the manner in which rays of light are returned from a hypermetropic eye. The parallel lines are meant to express the manner in which the rays would be returned from an emmetropic eye.

Fig. 192.

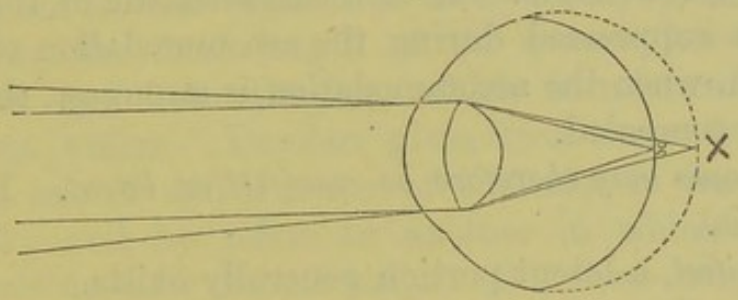

If the dimensions of all the axes are less than in the emmetropic eye, the expansion of the retina is also less, and the optic nerve is not so fully developed. The asymmetry in the several meridians is also greater.

The diminished depth of the anterior chamber makes the cornea look rather flat. The diminution is due to a more anterior position of the crystalline lens and of the iris, peculiarities of this eye.

The ocular movements are influenced by the arrest of development. The centre of motion is relatively more posterior, and the range is more extended, although in such there is less displacement of the optic nerve.

The visual line requires to be noticed. The cornea is cut to the inside of its axis without exception by this line. The angle is on an average not less than 7°55. The usual maximum is 9°. It has been met with as high as 11°3. The minimum is 6°. In the emmetropic eye it amounts on an average to only 5°82, and in the myopic, where it may even lie to the outside of the axis of the cornea, and thus become negative, it is generally somewhat less than 2°. How intimately this angle is connected with hypermetropia and myopia appears especially from the fact that the maximum in myopia is exceeded by the minimum in hypermetropia. I must ask my reader to refer to the chapter on "Strabismus" for a more ample

examination of this part of the subject, and to commence to read at page 367, from *Apparent squint.*

It is considered that, between the angle of the axes of the cornea with parallel visual lines, in the most extreme case of hypermetropia and myopia, a difference of 25° may exist.

The cause of hypermetropia is therefore a peculiar formation of the eye, designated hypermetropic structure.

The defect is congenital, and often hereditary.

There is a kind of acquired hypermetropia, arising out of paralysis of the ciliary muscle, out of corneal flattening, from synechia anterior, and from loss of the crystalline lens; but in each instance it is very different from the congenital defect in question, and ought not to be mistaken for it.

Forms of hypermetropia. It is a characteristic of the defect that a part of it is suppressed during the accommodation of the eye, and that in youth, when the accommodation is strongest, the whole of it is frequently concealed.

Hypermetropia may therefore be manifest or latent. I must enlarge a little on this.

When manifest, a latent portion generally exists.

When it is all manifest there is deficiency of the power of accommodation from paralysis of the ciliary muscle, or from degeneration of the same, or from senile changes in the crystalline lens, whereby it cannot be influenced by the ciliary muscle.

The latent form decreases with age, while the manifest becomes more apparent. This is due, of course, to the changes in the eye effected by time.

Latent hypermetropia in a child may become partially manifest at from twenty-five to forty years of age, and wholly manifest at seventy.

Manifestation of hypermetropia. The absolute, the relative, and the facultative, must be recognised. They have accurate boundaries.

The absolute exists when with the strongest convergence of the visual lines accommodation cannot be obtained for converging rays, or even for parallel ones. It is scarcely ever found with strong accommodating power. Vision is never acute.

The relative is usually seen between twenty-five and forty years of age. It exists in relation to the convergence. For instance, in order to see accurately at a distance of sixteen inches, there must be convergence of the eyes for a distance of twelve inches, but as this is not done, the vision is imperfect except through convex spectacles. Early in life it might not be observed. Late, it gives place to the absolute form.

The facultative is present when objects can be accurately seen at any distance, with and without convex glasses. A person under thirty years old may be able to see accurately at a distance, as well with lenses of $\frac{1}{20}$ as with $\frac{1}{30}$. His relative range of accommodation with parallel visual lines therefore amounts to $\frac{1}{20} + \frac{1}{30} = \frac{1}{12}$. At the distance of 10·5 he can see binocularly for a short time. It is generally recognised by the asthenopia which accompanies it. To this will probably succeed relative hypermetropia before the thirty-eighth, and absolute hypermetropia before the forty-fifth year. During long fatigue, weakness of body, and with the increase of years, this gradation is always very apparent.

The degree of hypermetropia varies greatly, just as does that of myopia, and it may be spoken of as low, medium, and high, although the grades are not so well marked as those in myopia. Its amount is expressed by the focal length of the convex lenses minus the distance of the eye from the lens which is required to procure distinct distant vision. Donders gives two cases from his own experience, in one of which lenses of 2·97 and in the other of 3·5 were required; and he refers to another in which those of the value of $1\frac{7}{8}$ were used for distant vision. But these are most extreme instances of defective refraction. It will much more commonly be found to range from $\frac{1}{8}$ or $\frac{1}{10}$ to $\frac{1}{24}$ or $\frac{1}{30}$; which means that such glasses will be required to correct the deficiency in the refracting power of the eye.

So long as any power of accommodation can be brought to bear, the actual amount of hypermetropia cannot be told except by paralyzing the ciliary muscle with a few drops of a strong solution of atropine applied to the conjunctiva. Four grains of the sulphate to an ounce of water will suffice. An hour is required for the complete paralysis. I will show how this applies. Suppose a convex lens of $\frac{1}{30}$ is required in a young person to clear up distant vision, when the ciliary muscle is not paralyzed. The amount of the affection as so declared is termed the manifest hypermetropia. But we are sure that some degree of the defect is suppressed or modified by the involuntary contraction of the ciliary muscle, increasing the refractive power of the crystalline lens by rendering its surface more convex. If, however, the muscle be artificially paralyzed, a more powerful lens, it may be one of $\frac{1}{10}$ or $\frac{1}{8}$ inches, is necessary to render distant objects clear. This lens then expresses the total hypermetropia, and the difference between it and the manifest, represents the latent hypermetropia, or the amount of accommodation which has been unconsciously exerted by the eye.

Diagnosis. There are objective symptoms, often more or less

apparent, such as the flat anterior portion of the sclerotica, the strong curve in the region of the equator of the eyeball, the flat anterior chamber, the relatively small pupil, and sometimes the convergent squint. But it is on the subjective symptoms that reliance must be placed. The state of the vision alone can be received as evidence of the existence of the defect.

Perhaps this part of the subject may be the better taught by explaining the manner in which the symptoms come on, and pointing out the states under which relief is sought. Let it be supposed that the patients are under the adult period; and that the hypermetropia is of a low or a medium grade.

Complaint is made of inability to work long, or to read for a length of time without pain in the eyes or sight becoming fatigued, and the objects looked at growing indistinct. These symptoms are, strictly speaking, those of asthenopia, the effect of hypermetropia, of which I shall speak in the next section. The two affections are so associated that it is impossible to treat of the one altogether separate and apart from the other.

Whether the hypermetropia, supposing it to be low, shall cause disturbance of vision, will depend on the use to which the eyes are put. So long as close work is not done, it will never be recognised, but with near ocular employment discomfort will be felt. To see minute things, intense accommodation must be exercised, and great strain is felt.

Defect of distant vision is very seldom complained of, and if it be, it is spoken of in some transient manner, as about a little fatigue when looking at pictures, or something of the kind which requires much scrutiny.

The symptoms may be very gradually developed, but occasionally they appear suddenly; sometimes a week will comprise the time between a school-boy being able to do his work and his inability to see, in consequence of the fatigue of his eyes.

To speak in the abstract, hypermetropia may be said to exist when convex glasses of a low value, say from $\frac{1}{70}$ to $\frac{1}{48}$ inches value, assist distant vision.

In proceeding to test the condition of the refraction, care must be taken to eliminate a common source of error. Our patient may unwittingly deceive us. If his accommodation be normal, he is apt, unconsciously, to suppress his manifest hypermetropia and make it latent. Indeed, it might even happen that trying him in a cursory manner with concave lenses does not materially help in the investigation, because he may not lose much definition by it. He may lose less than a myopic person would gain by them: more than this, he

will sometimes astonish us with the power of seeing with them. Testing his sight quickly with low convex lenses at a distance, may give a negative result, because he has been so long accustomed to accommodate for a distance, an act not required in the emmetropic eye, that he cannot immediately relax that effort, which the convex lenses are intended to supplant.

A mistake is the more likely to be made when the vision is acute, and small type is easily read. The investigation should therefore be conducted slowly, and in a subdued light. Sometimes patients wilfully deceive us, from the dread of being obliged to wear spectacles.

In some cases of doubt as to the existence of hypermetropia, it might be necessary to use atropine, and paralyze the ciliary muscle so as to suspend all accommodation, and then to proceed with the examination. The emmetropic eye under such a condition, cannot see near things without a convex lens, while it can see distant ones. Whereas the hypermetropic eye must have a lens to see the near and distant things as well; yet I do not by any means recommend the indiscriminate use of this method, as it is very distressing to the patient, and the information which is gained by it is only exceptionally useful.

The ophthalmoscope may be called to our aid in the diagnosis of the medium and of the high degrees of this affection. The direct method of examination should be employed. While the eye is being examined, its accommodation is more relaxed than ordinarily. The fundus, with its details, can be seen at a distance of fourteen, fifteen, or twenty inches, the space required for the definition increasing in proportion to the intensity of the hypermetropia. This is called the hypermetropic refraction. The image is, of course, erect. If the ophthalmoscope be moved from side to side, the image appears to move in the same direction. If the eye be examined by the indirect method, the emerging rays being divergent, the image is formed farther off than the focal distance of the object lens, and is therefore larger than it would be in emmetropia. Again, in this method of examination the disk diminishes in size, in proportion as the object lens is removed from the eye.

The unequal refrangibility of the different coloured rays of the solar spectrum has been brought to bear as a test for hypermetropia. Dark violet or cobalt-blue stained glasses, only permit the blue and red rays of light, the highest and least refrangible rays of the spectrum, to pass through them. The flame of a candle or of gas looked at through such a piece of glass by a hypermetropic person, would appear reddish-blue, surrounded by a red margin.

To a myopic eye so treated, the red rays will be nearly focused

on the retina, still the blue ones form large circles of dispersion. Therefore the flame will appear violet-red, surrounded by a blue margin.

In the high degree of hypermetropia the acuteness of vision is seldom unimpaired. Complaints are made of the want of sight. With this additional defect the diagnosis is easy. It is only necessary to resort to the test print to establish the fact of the deficiency of vision, and to employ suitable convex lenses to restore the power of seeing near and distant objects by increasing the visual angle, unless the hypermetropia be unusally high, when no augmentation of lens power may be able to bring the sight to a normal standard, in consequence of coexisting amblyopia. With very high error in refraction the one eye is generally more defective than the other, and vision is proportionately deteriorated. The worse eye is little used, and with the exclusion, there is a psychical suppression of the retinal images, and the fullest hypermetropic amblyopia ensues. The retinal sensitiveness fails most in the region of the yellow spot. This monocular deterioration is particularly well seen when internal squint is developed.

An abnormally distant position of the near point, may be taken as very conclusive evidence of the presence of hypermetropia. It is an unerring guide under the period of manhood. The deviation may be slight, but it is to be detected.

After manhood, the detection of hypermetropia is easy. Only the very lowest grades can then be at all masked. Many a person with low hypermetropia gets through life till he is an adult, doing much eye-work without any optical assistance, although feeling inconvenience, without clearly knowing what is the matter with him. In manhood, however, the changes in his crystalline lenses, which would not be regarded in a normal eye, so affect him, as to oblige him to seek optical assistance.

The marked removal of the near point, the loss of acuteness of vision, the very decided assistance afforded to far vision by a convex lens, and generally the high value of the lens needed for seeing small type, are sufficiently confirmatory.

The hypermetropic eye is affected by senile changes very much earlier than the emmetropic eye.

Hypermetropic vision. Loss of the acuteness of sight frequently exists, but it does not so much characterise hypermetropia as the existence of the error in refraction, which requires another use of the power of accommodation.

The hypermetropic person begins his accommodation with a deficiency. The emmetropic person relaxes the accommodation as much as possible, when he wishes to see accurately at an infinite

distance. He converges his eyes for near seeing, and accommodates for such convergence. In early youth his near point is six, five, or four inches from the cornea. It may be less.

The hypermetropic person on the contrary, in order to see at a distance, must bring his power of accommodation into action to supply his deficiency of refraction. Commencing with this, he has still for each convergence, to add as much range of accommodation as the emmetropic person. Such an eye unaided by optical help is never at rest.

In a youth with facultative hypermetropia, the eyes may fulfil their daily requirements without discomfort, because accommodation adapts itself to the refractive condition, and a person so young, learns by necessity, with relatively little convergence, to bring a relatively great part of his accommodation into action. He cannot omit the increased tension, but at each convergence he finds himself still nearer to the maximum of possible tension, and both his absolute and his binocular nearest points lie farther from the eye than they do in the emmetropic subject. But, with increase of age, the absolute range of accommodation diminishes; the relative, for a definite distance falls too short, and pain or fatigue now rapidly ensues. Therefore, in the slightest degree of hypermetropia, premature presbyopia occurs, which has more the character of asthenopia, the higher the degree of the facultative hypermetropia is, and the earlier the age at which difficulty in working at near objects sets in.

In relative hypermetropia, the case is worse. As I have explained, there may be accommodation for parallel, and even for diverging rays, but only on condition that the eyes converge to a point nearer than that from which the rays proceed. Binocular vision and acute vision thereby exclude each other: with one eye, under excessive convergence, there might be acute vision; but generally speaking, if one eye be used, periodic squinting follows in the other, and is succeeded by permanent squinting.

Vision in relative hypermetropia, strictly speaking, is never acute, either for distant or near objects, and all attempts at definition are quickly followed by fatigue. An endeavour is ever being made to discover the distance at which small things can be seen relatively well. A bright light is sought for, because it contracts the pupil and affords help, by reducing the circles of dispersion; and for the same purpose an attempt is made to cover the pupil partially, by more or less approximating the eyelids. With all this the maximum of accommodation is brought to bear, and the distance of the posterior converging point is lessened. When the illumination is weak, and the pupil is large, adjustment is very difficult: hence hypermetropics see badly in dim twilight or in darkened rooms.

The defective vision in the higher degrees of relative hypermetropia, and in the absolute, is liable to be mistaken for myopia complicated with amblyopia. Small print cannot be read, hence the appearance of impaired vision, and larger print can be read only when it is held close to the eyes: hence the resemblance to myopia. But there are the following differences: Objects at a distance can be discerned as well as those that are near, and print placed at the distance of several feet can be seen better with low convex lenses than without them.

The reason that print is seen better when it is held nearer to the eye than at ordinary reading distance, is because with the approach of the object the retinal image is enlarged. Besides, with the approximation of it to the eye, the greatest amount of accommodation is exercised with the strongest convergence. The pupil contracts and the eyelids are partially closed, so that the circles of dispersion are as much overcome as possible. By practice also, the true form of objects is deduced from imperfect retinal images. There is more of this than credit is given for: the remark applies to myopia as well.

Treatment. To neutralise the optical defects by proper convex lenses, and to prevent the ciliary muscle from being unduly taxed, is to effect all that can be accomplished; but this must be well done, or the eye will suffer as much from the deficiency of the assistance, or the surplusage, as if it were used unaided. The effects likely to accrue to the eye without help are, deterioration of vision, asthenopia, congestion of the fundus, and squint.

The defect should be remedied as early as it is detected, be that in youth or in childhood. Such lenses should be adapted as will, so far as it is possible, enable the wearer to see objects as well as they can be seen by the normal eye, with the same amount of accommodation. Yet it must be remembered that under no condition can the hypermetropic eye equal a normal one in full power, because of loss of acuteness of sight, or deterioration of adjustment, or the slight unavoidable defects attaching to the use of lenses.

Theoretical rules for selecting the value of the required lenses are worse than useless. There are too many disturbing circumstances, optically and vitally, and too much variation in the quality of the sight of persons, to admit of the application of scales and tables. Actual trial must be made after such a manner as I have shown for assisting the myopic eye.

In low hypermetropia, where as yet the near point is within the normal range, and the acuteness of vision is maintained by forced adjustment, and fatigue ensues only when reading, and exceptionally when looking long at more distant objects, with little or no alteration

in the range of accommodation, I should experimentally supply lenses of the value of $\frac{1}{24}$ inches. A sufficient trial can be made only by the patient at his own house, and on several long occasions. According to his report, whether these lenses be sufficient or not, am I guided in what should be done. If the fatigue be removed the lens will do, or even a lower power may suffice; if not, one of a higher power is required. Here one set of lenses will generally suffice. Although a very low power, say $\frac{1}{80}$ or $\frac{1}{70}$, would assist the eyes for prolonged use in distant sight, unless such use be demanded, the hypermetropic person will get on sufficiently well, and be quite satisfied without the assistance. A late patient of mine, æt. 32, whose near and far points were normal, and whose acuteness of sight was unimpaired, but who suffered very much pain from forced adjustment for reading, and even for looking at pictures, or any distant things intently, happily found that after she had taken to lenses of $\frac{1}{24}$ for reading, the eyes were not fatigued as formerly by attending picture galleries, &c.

In medium and high hypermetropia only the manifest hypermetropia should at first be neutralised. If the latent also is neutralised, or, in other words, the total hypermetropia, the effect on the patient will be painful and insupportable. Lenses of lower powers should therefore first be used, and afterwards higher ones. The latent hypermetropia will, in all probability, become manifest when the strain is taken off. The habit of forced accommodation cannot be laid aside abruptly, and by using such lenses at once as might ultimately be required, we confer on the patient an excess of refractive power, and practically render him myopic. The habit of instinctive accommodation is overcome much more rapidly by some persons than others, but several changes are generally necessary, and some time must elapse before the lens which neutralises the total hypermetropia can be worn with comfort. Here, most persons will require two lenses, the one for near vision, the other for far, if clear distant sight be a necessity.

Where the hypermetropia is of the highest type the near point will have receded, the range of accommodation will have been reduced, and in an adult some loss of the acuteness of vision will have taken place. Two sets of lenses are now wanted, the one for reading and close work, the other for distant sight. The selection ofttimes is an easy matter. The first, the high power, must be chosen by trial with a test print. I select that which will enable the smallest print, or the second, or the third, to be read at the distance that a normal eye at the same age could see it, at a distance that would be called an easy reading one, eleven or twelve inches from the eye. According therefore to the

age of the patient and the requirements of his eyes should the lenses be chosen. The second I choose also by large test print placed at fifteen or sixteen feet, or farther away, from the eye. The size of the print for this must depend on many things, the patient's age, range of accommodation, acuteness of vision, for which no written rules can be given: how to do it must be learnt practically. As each power of a lens can confer only a definite assistance to the patient, that lens must be selected which will meet the demands of the eye. We may adjust for seeing certain print at the length of a room, but our patient may need it for seeing at a hundred yards off. It so happens that we must learn what our patient wants.

When the hypermetropia increases, as is commonly the case in old age, lenses of higher and higher values must be employed .Sometimes a strong reading hand-glass must be resorted to.

When there is a disparity in the powers of the hypermetropic eyes, but the two are yet used for binocular vision, the lenses should be chosen according to that eye which has the greatest range of accommodation, which sees best near and far.

ASTHENOPIA.

This may be defined to be inability to maintain the adjustment of the eye for short distances, for a sufficient period without fatigue.

There are not any objective signs. The eyeballs look healthy. Their associated movements are natural, and their converging power is unimpaired.

Subjective symptoms. Fatigue of sight from rapid exhaustion of the muscle of accommodation during close use of the eyes, that is, when the smallness of objects demands close approximation of the eyes, as, for instance, in reading, or doing needlework, or perhaps in writing, especially by insufficient light, or by artificial light. The fatigued muscle relaxes, and the convexity of the crystalline lens decreases, and objects being seen in increasing circles of dispersion, vision is indistinct and confused, and a feeling of fatigue of the eyes with tension follows. Close vision cannot be maintained. The sufferer soon learns that he can recover his sight by closing his eyes and rubbing them, but he is unaware that it is by the pause and rest to the ciliary muscle, however short, that he obtains the relief. The eyes can be used by repeated pauses, and the longer they rest the longer also is the time of their uninterrupted employment. After a while, ranging from weeks to months, the retina, which has been called on for extra work and definition on account of the defective refraction, gets fatigued, and objects seem to swim before the eyes whenever near work is done. At last symptoms of vascular and

nervous irritation appear, which increase during a straining effort to see. The first makes itself felt as pressure and fulness in the eye; the second as tension and pain in the forehead. Sometimes the pupils become contracted and the conjunctiva reddened. These symptoms are quite compatible with temporary acuteness of vision.

Asthenopic eyes seldom tire when employed on objects beyond a range of twenty or twenty-four inches, unless the asthenopia be in an extreme degree, when vision even at an infinite distance cannot be long exercised without fatigue. Where the hypermetropia is well marked the asthenopia would be always apparent, if an attempt were made to accommodate the eye accurately for objects at a long distance and for a long time.

The chief cause of asthenopia is a hypermetropic formation of the eye. There is, therefore, a close relationship between the two affections. In the pure forms of asthenopia I believe that hypermetropia is never absent. Most persons with severe asthenopia, of whom I make inquiry, tell me that some defect of vision evidently existed in childhood during their earliest educational period, which prevented their reading small print quickly, and that the deficiency was attributed to inattention or dullness. At such time it was probably the hypermetropia that most troubled them.

Asthenopia then arises from want of sufficient refraction in the eyeball. Fatigue of the ciliary muscle is produced in the attempt to keep up the required focus, and such fatigue is but a symptom of the affection, and not the affection itself. I will explain this more fully.

Condition under which asthenopia occurs. In the emmetropic eye, the accommodation for different distances which is affected by the muscular system of accommodation does not produce fatigue. The asthenopic eye, being originally defective in refraction, exerts extraordinary tension of accommodation for all close work, and at first overcomes the hypermetropia. With an increase of age the accommodation diminishes, and the fatigue is first felt when there is insufficient light, or by artificial light. The symptoms mostly appear from the twentieth to the twenty-fifth year of age. The fatigue is that of the muscle of accommodation.

The period of the development of asthenopia depends chiefly on the degree of the existing hypermetropia: the higher that degree the earlier is the asthenopia noticed. This accounts for the occasional development of asthenopia at the early age of ten.

Occupation, too, has its influence. In those employments where there is long-continued application of the eyes, with, of course, tension of accommodation, especially by insufficient light, the affection appears the earlier.

Asthenopia must not be confounded with presbyopia. In asthenopia acute vision is effected only by special effort of the power of accommodation, whether the object be at ten or twenty inches. In the commencement of presbyopia in an emmetropic eye, although acute vision at eight or ten inches is impossible, at twelve or sixteen inches it can be exercised without any special exertion, and at a great distance, a convex lens of the lowest power blurrs the object. The hypermetropic eye, therefore, is not benefited by removing the object a little farther, while the presbyopic by such an act is greatly benefited. The former is soon obliged to cease working, while the latter can work provided the visual angle at the distance of sixteen inches be not too small. Far advanced presbyopia in the aged is more like hypermetropia, because convex glasses are required for seeing objects around distinctly. But there is still the difference that in it, however much the eyes may be exercised with their imperfect vision, they do not fatigue when lenses are not used.

There is some chance of confounding asthenopia with the inconvenience felt on continued exertion of the eyes, in consequence of irritation of the internal ocular tunics, as in the congestion of myopia and in some affections of the retina and of the choroid, especially when patients do not describe their symptoms accurately.

I am always on my guard to prevent a mistake. Here there is no asthenopic fatigue in reading, and the print does not become dim, but after a time so much discomfort or pain sets in that the eyes must be rested. I find that the quickest way of making a diagnosis is to describe both affections slowly and clearly to the patient, and to let him say which of them he suffers from.

Asthenopia and hyperæmia of the optic disc, and of the retina, are often combined.

Treatment. This consists in the use of suitable convex lenses as spectacles, and the proper value of these can be learned only by experiment in each individual instance. Where the hypermetropia is slight, the accommodation good, and the acuteness of vision normal, conditions met with only in youth, I order lenses of a low value, say $\frac{1}{40}$, $\frac{1}{36}$, or $\frac{1}{30}$ inches, in spectacles. I direct them to be worn always for close work, but not for a longer period than an hour without resting the eyes, and request my patient to make a visit to me in a week. At first the lenses are apt to produce a sense of discomfort, and the patient declares that they will never suit him. Apart from any misapplication of the necessary lens power, this arises from the eyes still keeping up the undue effort of accommodation. Rest to the eyes from all close work for several days is then necessary.

Where there is high hypermetropia there will be in all probability

the loss of acuteness of vision, with much receding of the near point. I select, therefore, such lenses as will enable the smallest point on my test-page to be read as close to the eye as nine or ten inches, and order them to be worn for a week under the conditions above expressed.

If the selected lenses be of sufficient power the asthenopia will be removed, and the fatigue on using the eyes will not return. But an asthenopic eye cannot be worked, like an emmetropic one, without feeling distressed. No matter however well the defective refraction be compensated for, the eyes can never be brought up to a natural standard. An emmetropic eye will grow weary after prolonged use. An asthenopic one is not fit for more work than half of what a healthy one is good for.

If the lenses be insufficient, the asthenopic symptom of fatigue will most certainly return, although it may be not so soon as formerly. Most probably it will now be found that the near point of binocular vision for reading or working, as defined by the lenses, is too far from the eyes. The insufficiency must be met by farther experiments with higher lenses, till the proper power is selected.

But the lenses may be too high, and this is declared in the necessity for holding the object to be looked at too near to the eye, whereby a sense of discomfort is occasioned, which is called muscular asthenopia. The remedy is to resort to much weaker lenses, just sufficient to reduce the asthenopia.

As soon as the senile changes of the eyes appear, the power of the lenses must be increased. It is a groundless fear, often expressed by patients, that the demand for higher lenses will be greater than can be supplied. I am frequently obliged to give assurance of this, and to reiterate it. Again and again patients come to me merely to be reassured. Those who are troubled with muscæ, generally have the greatest dread of blindness. Nothing that may be said can subdue the dreadful apprehension of some people.

I am well aware that asthenopia is classed by some surgeons under two forms, the accommodative and the muscular. The first is that which I have treated of. The second is named the muscular form, attributed to relative or absolute deficiency of power in the internal recti muscles, whereby they cannot maintain proper convergence for near sight. I do not recognise this as asthenopia, and I have considered the so-called insufficiency of the recti muscles, but which I believe to be partial paralysis, in the chapter on "Paralysis of the Muscles of the Eye," and in that on "Squint."

MYOPIA, OR SHORT-SIGHTEDNESS.

In myopia, distant or parallel rays of light are brought to a focus before they reach the retina, and the image which is formed on the retina is blurred and indistinct. Only divergent rays, that is, rays coming from near objects, are accurately focused on the retina. A B, Fig. 193, is a diagram of a myopic eye.

FIG. 193.

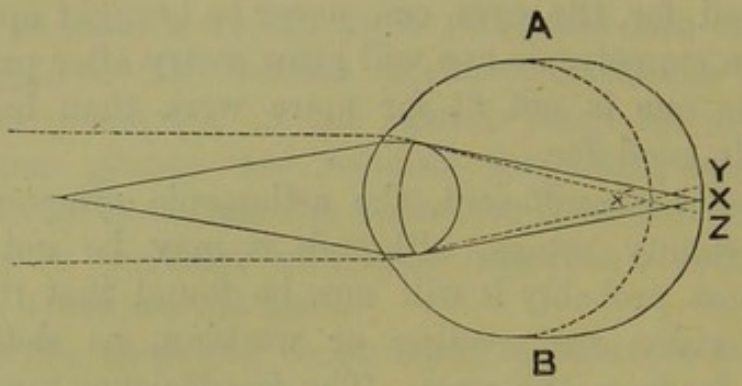

The dotted semicircle represents the outline of a normal eye. Parallel rays are meant to be shown by the parallel and dotted lines. These meet at x′ the focus of the refracting or dioptric media, and which is the position of the retina of an emmetropic eye. In the elongated myopic eye the rays cross and re-diverge after they are focused, and therefore form a circle of dispersion, Y, X, Z on the myopic retina.

The diverging lines are intended to show the manner in which rays are returned from the myopic retina. Being reflected out of the eye from a given point, say at X, they proceed at a smaller angle of divergence than in a normal eye; and as the dioptric media are normal, they are the quicker brought together, and they issue forth in sharp convergence.

While, therefore, the myopic eye can see near objects, it cannot see distant ones well without optical assistance.

The myopic far-point is always at a definite distance. In exceptionally high cases it may be within a few inches of the cornea. The near point bears a proportion to the far. The lower the grade of the myopia, the farther will be the former, and the farther also the latter. When the far point is very close to the eye, there is little difference in the distance between it and the near point. In such instances there is scarcely any power of accommodation, or not any.

A person with normal eyes will understand the state of vision in shortsightedness by looking at a landscape through convex lenses. The experiment may be made more interesting by his holding before

such lenses concave ones of equal value. The artificial myopia will then be removed, and the eyes will see as usual.

A necessity at once arises, for the sake of description, for artificially classifying myopia according to the position of the far point. Three grades will suffice. The low, is recognised where the far point is at twenty inches; the medium, where it is at ten inches; the high, where it is at five inches, and upwards; usually expressed by the values of the respective reducing lenses, as myopia of $\frac{1}{20}$, $\frac{1}{10}$, and $\frac{1}{5}$.

General state of vision. In low myopia remote vision may be so little affected that the presence of the defect may not be felt. Near things are seen as distinctly as by persons with normal vision, with much less strain, and therefore less fatigue. And low myopics have a range of accommodation equal to that of emmetropics. Even with myopia of $\frac{1}{18}$, most kinds of work can be done with the naked eye.

In high myopia there may be simple increase or intensity in the defect of sight, the far point shortening, without any disturbance or derangement of vision, but only discomfort; but usually the acuteness of vision suffers, because there is so commonly associated some pathological change in the fundus of the eye-ball, by which minute objects cannot be seen. Then the range of accommodation is very limited, or nearly lost. Besides, when the eyes are used for binocular vision there must be great convergence, an act which causes strain of accommodation.

The diagnosis of myopia is generally easy. The myopic person sees near things distinctly, but distant objects appear indistinct, unless they are looked at through a suitable concave lens.

To determine the question of the existence of the defect, test print should be employed. If numbers one, two, three, or four can be read, and if print of double the size cannot be read at double the distance at which the first was discernible, myopia must be suspected. The distance at which a person with medium or high myopia usually reads a book in small type nearly expresses his far point of clear vision.

The next step of inquiry in a case is to apply a convex lens. The print should be held just beyond the range of the patient's vision, and if this be six, eight, ten, or twenty inches, a convex lens of $\frac{1}{6}$, or $\frac{1}{8}$, or $\frac{1}{10}$, or $\frac{1}{20}$ inches power should be tried, and if vision be improved myopia is certainly present.

The degree of myopia may now be found. If there be disparity between the eyes, that eye should be tried which is generally used. If there be none, the two should be tested together. Without a change of position the print should be looked at with lenses of lower and higher powers, to ascertain what is required to give the most distinct vision. Young persons possess a maximum accommodation,

and are apt to select lenses which are too high. During the examination the eyelids must not be partially closed, as is the habit with myopic persons when looking at a distance, for the purpose of somewhat covering the pupil, to cut off some of the lateral rays of light, and thus diminish the circles of dispersion which are formed on the retina. The less the degree of the myopia the farther must the print be placed from the eyes, and therefore the larger must it be.

We must guard, however, against hastily concluding that a person is short-sighted simply because he brings objects close to his eyes, for this is done in many cases of amblyopia from various causes.

The accommodation of the myopic eye is the same as that of the normal eye at corresponding periods of life, excepting in high degrees, when it is less, or even nearly absent.

Myopia can also farther be diagnosed by means of the ophthalmoscope. For this purpose the direct method ought first to be employed, by which is meant that the mirror alone is to be used, without the convex or object lens. High myopia is at once detected. The image is formed a few inches in front of the cornea, and is apparent to the examiner a few inches farther off. The peculiarity consists in the close proximity of the eyes of the observer and the observed, and it is called the myopic refraction. It is in marked contrast to hypermetropic refraction, in which the eyes are very far apart. A clear and enlarged view of the fundus is thus obtained. The optic disc is particularly well seen.

The indirect method of examination has its advantages. With it the image is reversed; it is inverted and virtual. This is fully explained in the chapter on the Ophthalmoscope. If we fix our eye on one of the retinal vessels, and then move our head slightly from side to side, they will seem to move in an opposite direction. After the fundus has been focused, the degree or intensity of the myopia may be judged of by the quickness with which the focus is got, as the opthalmoscope is carried towards the eye. This is a useful test in cases of simulated myopia, which sometimes occur in the practice of military surgeons. The absence of such effects proves the absence of myopia.

The myopic refraction, as seen by the direct method, will be the better understood if it be contrasted with the indirect, by which the parts will appear smaller.

In medium and low grades of myopia the ophthalmoscopic test is less applicable. The image is formed farther off, and is not so bright. The examiner must be farther; the fundus is less illuminated. Besides, if the pupil is small, but a portion only of the retina may be seen.

Causes. It is a most uncommon occurrence for myopia to appear after the fifteenth year of age, and it is never acquired after the twentieth in eyes that are normal. In the supposed exceptions the primitive errors in refraction have been overlooked, and the effects have not been detected till the defect was progressing.

The hypermetropic eye never becomes myopic.

The predisposition to myopia is almost invariably congenital and hereditary. Having once occurred it is liable to be transmitted to progeny, and under fresh exciting causes it is more and more developed, and more surely hereditary. Children of highly myopic parents can hardly escape the defect.

Whether myopia ever exists, without hereditary influence or exciting causes, as an error in development, is a question which forces itself on attention. Whilst no one can undertake to say that it never has such an origin, all observation tends to throw doubt on it, and to induce the belief of an acquired origin, the result of eye straining during education. As so arising, it must be introduced before adult age. Yet the acquirement is rare, while the transmission is common.

There is no longer any doubt about the nature of this optical defect. The old idea of the refractive power of the eye being in excess is quite exploded. Now, the doctrine of the too great length of the antero-posterior axis of the eyeball, is that which is received, and is unquestionably the correct one. How this comes about is thus explained by Donders, whose theory stands almost unquestioned. He ascribes it to tension of the eye, which is inseparable from looking at near objects. The close approach of the object to the eyes, necessary in close sight, requires the constant and strong action of the internal recti muscles to produce that convergence of the optic axes which is requisite to bring corresponding portions of the retinæ into use. The muscular pressure thus exerted, and the stooping position which is generally an accompaniment, combine to cause congestion and accumulation of blood in the internal ocular tissues, which, from the tension thereby induced, gradually yield, especially in the direction in which muscular support is deficient; that is to say, directly backwards. The eyeball thus assumes a more or less oval form; the choroid and the sclerotica become thinned and atrophied, and in advanced cases may bulge so as to form a posterior staphyloma. In some individuals, when the orbits are shallow, and the myopia considerable, this alteration can be distinctly recognised, if the eyeball be strongly directed inwards or downwards. In connection with this ascribed cause the injurious effect of eye work, by insufficient light, must be mentioned, because

weak illumination renders it imperative that objects should be closer to the eyes, and hence the stronger convergence. So it is that the same causes which produce the myopia are very favourable to its farther development. It seems that the worst effect is noticed in boarding schools, where the pupils read in the evening by weak light, and write with pale ink. But there is a predisposing congenital disposition of the parts at the back of the eye, hereditary, no doubt, which will be noticed under the head of the pathological states of the myopic eye. The reason given why watchmakers and others, who look all day through a magnifying glass, and stoop so as to approximate the eye and the object, do not get myopia, is because they only use one eye, and therefore they converge but little, or not at all.

Myopia is therefore an accompaniment of civilization, being, it is said, unknown among barbarous nations. It is so far, in one sense, respectable to be myopic. It prevails chiefly among the cultivated classes, who, in childhood and in youth, have to spend many continuous hours in close study. It is rare among the poorer classes, and of these the inhabitants of towns, as might be expected, from the nature of the occupations in which many of them are engaged, are more liable to it than the inhabitants of the country.

There is no truth in the constantly repeated assertion that the cornea is unduly convex in myopia. This is a convenient theory, but it fails to stand the test of careful examination. From a number of accurate observations made by Donders, with the ophthalmometer, he arrived at the unexpected conclusion that the cornea in such cases is, on the average, actually flatter than in emmetropic eyes; and, farther, that in the most myopic persons the cornea is the flattest. Similar investigations have led Professor Helmholtz to form the same opinion.

Development and progress. In congenital myopia the symptoms may be sufficiently marked to attract attention in childhood. I have seen the high form of the affection in a child five and a half years old. This boy was well suited with the power of his father's spectacles, which were of very high value. Usually there is no internal evidence of anything abnormal till perhaps the tenth or the fourteenth year of age.

Any decided decrease in the far-point is due to the addition of staphyloma posticum, and the point may lessen until it is only three or two inches from the nose. In high myopia, there is always a tendency to such implication, and it occurs generally in youth, very rarely in manhood. Under these conditions, the power of accommodation, whatever it may have been, is nearly lost.

But there is not necessarily an onward aggravation of the

symptoms. They may stop at any time. Nor is the progress regular. It is often irregular. There may be an arrest of the morbid course, and then an increase. Sure prognosis is therefore impossible, and all that can be said is, that the worst is to be feared if the staphyloma be large and progressive, the edge of the crescent losing its definition, being blended in diffuse atrophy, or if it be of recent formation, and if there be, as well, inflammation of the fundus. Such inflammation is very threatening. It declares itself in cloudiness of sight, with other deterioration of the visual power, in intolerance to light, in tenderness of the eyeball when pressed, all of which are produced by degeneration of the internal ocular tissues, the several morbid states of which are readily seen with the ophthalmoscope.

In the advanced examples of progressive myopia, in which binocular vision is yet available, there is much forced convergence of the eyeballs; because the axis of vision cuts the long axis of the cornea at an acute angle, or cuts the cornea at a point external to the centre of its curve; and this may be to such a degree as to make the eyes appear to squint. The tax is often too much for the internal recti muscles, and by a sort of curative influence only one eye is used, and the other involuntarily turns outwards, thereby producing external squint. But relief is given to the eye which is straightened, in the increase of the far point. Very near-sighted old people seldom use but one eye for near vision, and almost always the same eye. The neglect of the one eye more readily happens when there is disparity in the focal ranges.

Low degrees of myopia may not increase, indeed they generally remain as they existed at adult age, where the occupation does not necessitate use of the eyes for close work, and the eyes are otherwise healthy.

Myopia undergoes modifications from age. This has not escaped the notice of all classes of society, and some of the effects have given rise to the erroneous popular idea that nearsightedness is the best kind of sight, that it is strong sight. What a fallacy, to suppose that a diseased eye is better than a sound one! The alterations are merely those caused by senile changes in the lens and in the ciliary muscle. They are most developed in low, but slight in medium, and not at all in high myopia. Some loss of accommodation is first noticed. The near point has receded. It may so happen that low convex lenses are required for seeing near objects. This explains the common puzzle that the same eyes sometimes want both convex and concave lenses. In time the far point recedes.

Myopic eyes may be dissimilar in their refraction, the one being more

nearsighted than the other. While this is rare in low, it is very common in high myopia.

One eye may be myopic, and its fellow normal, or presbyopic, or hypermetropic.

Binocular vision is often lost in high myopia. This is owing mostly to the unequal vision of the eyes, the disparity above spoken of, in consequence of which one eye only is used. But it may be lost without any visual disparity, and through paralysis of one of the internal recti muscles, or both of them, by which squinting is produced.

Pathological states of the myopic eye. There are certain morbid conditions of several of the ocular tissues which are most marked in high myopia; less in the medium degree; least, and sometimes not at all, in the low form.

In the choroid coat the most palpable changes ensue. The membrane is practically atrophied at the fundus of the eye, especially in the vicinity of the optic nerve, and for the most part on its outer edge, constituting the so-called myopic crescent. A circumscribed form of the affection is frequently in association with thinning of the corresponding portion of the sclerotica, a state which is designated staphyloma posticum. Hence it is that the terms myopia and staphyloma posticum are often used synonymously. I must speak of the atrophy in detail.

Myopic crescent. This is a cresentic, strongly reflecting surface, mostly existing between the outside of the nerve and the boundary of the pigment of the choroid. Fig. 194 is a good illustration.

FIG. 194.

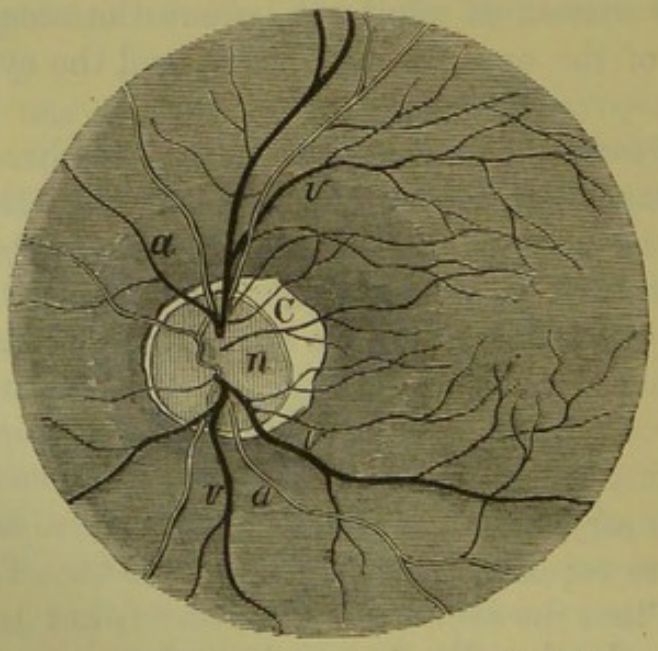

c, myopic crescent. *n*, termination of optic nerve. *a*, the disk. *a*, *a*, retinal arteries. *v*, *v*, retinal veins.

In its development it acquires a paler shade than the rest of the choroid, and at first the larger choroidal vessels, extending across it, in a horizontal or radiating direction, are frequently seen with unnatural clearness. They seem more numerous than natural, because the smallest of them are seen against the white ground. Between the straightened vessels, the remaining pigment in the stroma appears as small oblong brownish-grey spots, and the choroid capillaries seem no longer to carry blood. The atrophied place now looks grey or marbled, and at last white, reflecting with greater power than the nerve surface itself, although the latter has also become whiter. Sometimes, especially near the margin, some darker pigment spots, pigmented epithelium, resembling those in the adjoining red tissue, remain in the atrophied place. Occasionally it is much excavated; this is apparent by the curve in the retinal vessels on its outer margin. The crescent is therefore caused by the sclerotica going through the atrophied choroid. The stroma pigment in the intervascular spaces is diminished, and the epithelium of the pigment cells is reduced.

So far the term crescent applies, but there are varieties in this form of the atrophy. The degeneration may pass in a diffuse manner, and without boundary, into the normal tissue. It may be so slight, whether diffuse or defined, as to be only just noticeable. It may be semi-annular, and the longer it is, the broader it also is. It may be annular, completely encircling the disk, in which case it is always broader on the outer than on the inner side, where it is often narrower than above and below. It may be bounded very irregularly, being ramified. Or it may stand as an isolated spot, a little separated from the disk. Where it is large enough to be called extensive, other parts of the choroid are generally diseased.

Low myopia may exist in young persons without the atrophy, although it is rarely absent at the fortieth year. The higher the myopia, the more surely and earlier is the atrophy present.

It will be more convenient to show how the crescent is formed when I am describing staphyloma posticum.

The disk. In high degrees of myopia, this undergoes a partly apparent, and a partly true, change of form. Respecting the first, the horizontal diameter often seems comparatively smaller. Respecting the second, where the choroidal atrophy is external, the greatest diameter is in a direction perpendicular to the axis of such atrophy.

In young myopic persons the disk is particularly red, constituting capillary hyperæmia. In other respects it is not altered. Later in life, in high degrees, the defect is, on the contrary, in general, strongly reflecting. Frequently, it is partially superficially excavated,

with a clearer appearance of the more superficially situated lamina cribrosa. This partial implication, when shelving into the staphyloma, makes the disk look more oval than it is, because it is seen foreshortened, hence the apparent, or deceptive change to which I have alluded. Or, somewhat excavated over the whole surface, apparently atrophic, and sometimes passing into the strongly reflecting atrophy, without any marked boundaries.

It is difficult to form an estimate of the exact size of the disc, on account of the very complicated influences exercised by the myopic refraction on the magnitude of the inverted image.

The retina. For the most part, this coat accommodates itself to the posterior enlargement of the eyeball, and no disturbance to function ensues. But a large and rapidly-forming crescent may so influence it as to impair sight. I will speak of some of the morbid changes which may ensue.

Circumscribed changes in the yellow spot, and in the fovea centralis. These interfere with direct vision. They consist exceptionally of an extension of atrophy from the myopic crescent, or of independent spots of atrophy, appearing as scattered irregular granular pigment, sometimes lying on oval or angular bright red spots, or sometimes without such spots, surrounded by diffuse pigment. Or, as dark groups of pigment either on a white ground, or alternating with white spots. Or, as a single sharp-defined bluish and elevated spot, which has probably its origin in extravasation of blood.

The retinal vessels are seen with great clearness in high myopia, and particularly over the crescent. Their straight course is very characteristic, and is due to the stretching of the retina in its adaptation to the sclerotica. The calibre of the vessels is scarcely altered.

Other changes, not essentially connected with myopia, but appearing for the most part when it is high, consist of choroiditis disseminata, of extravasated blood in the retina, in one or more spots, of detachment of the retina either by blood, or more often by serous exudation. Another state, which I have not seen, is described as a deposit of a grey, moveable, slender, and long flake, passing from the disc into the vitreous humour.

In the vitreous humour, when it becomes fluid, moveable flakes are formed.

The lens may lose its transparency, whereby cataract ensues, and this is more common where there is detachment of the retina, with, or without, secondary iritis.

Staphyloma Posticum. Much laborious microscopic investigation has been bestowed on this difficult and intricate subject, by several most trustworthy and scientific labourers; and there is attached to it a

degree of pathological and practical interest which is not inferior to that appertaining to any of the abnormal states of the eye, in association with the defects in question.

A preliminary partial anatomical survey of the region of the eyeball which receives the optic nerve, is requisite for the proper explaining of the morbid structural changes which ensue. A figure also, after Donders, will afford material assistance. To Ed. Jaeger especially the honour is due for working out this subject in a series of dissections.

Fig. 195.

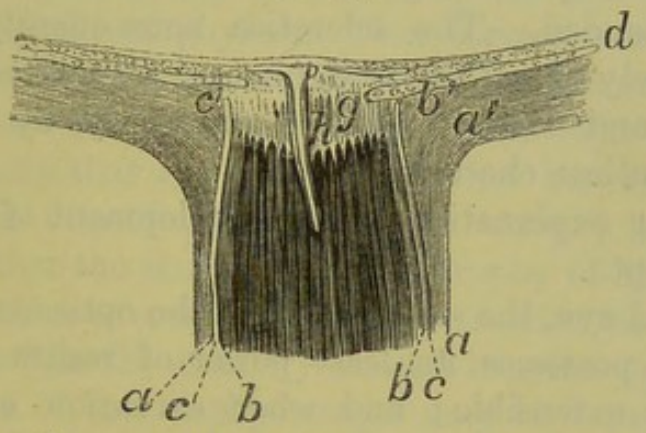

The optic nerve has a double fibrous sheath, an outer and thicker one, *a*, which becomes identified at *a'* with the sclerotica, and an internal and thinner one, *b*, which accompanies the nerve as far as the choroid *d*, and externally joins it, throwing also some fibres into the sclerotica *b'*; while, internally, it blends with the lamina cribrosa *g*. Between the two fibrous sheaths, *a* and *b*, is the connective tissue-sheath *c*, consisting of loose connective tissue, which passes close to the lamina cribrosa *c'*.

Fig. 196.

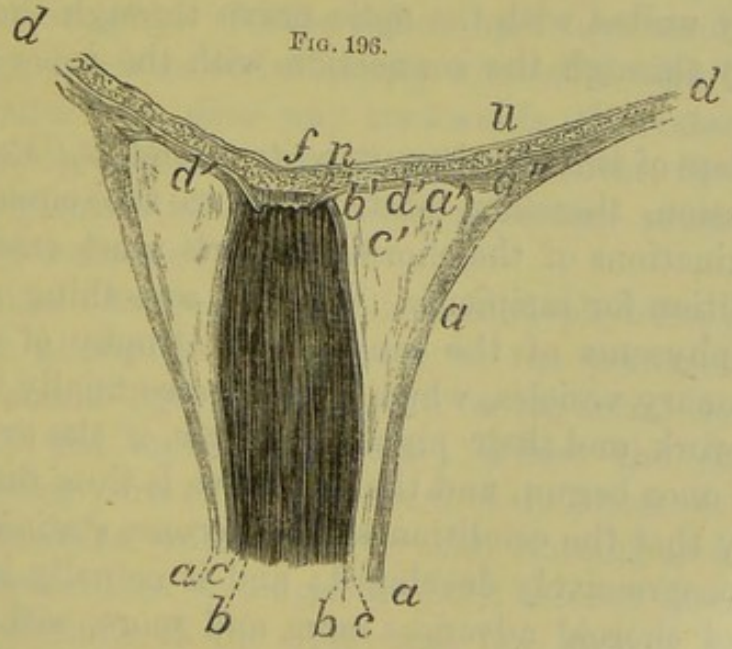

The morbid anatomy will now be more readily understood. Fig. 196, also from Donders, represents a section of the region with which

we are concerned, of an eyeball with circular staphyloma posticum. The following explanation is given.

The external sheath *a*, escapes near the sclerotica, from the nerve. A small part *a'*, here turns inwards, but the greatest part *a''*, inclines outwards towards the sclerotica. The inner sheath *b*, continues closely to surround the nerve, near the nerve-surface *f*, forms the lamina cribrosa, and now passes at *b'* outwards into the sclerotica, running to meet the fasciculus *a'*, of the outer sheath turning inwards. This thin fasciculus, *a' b*, bounds the loose-connected tissue *c*, which at *c'*, has acquired a great breadth, and is therefore evidently very much extended. The sclerotica consequently here consists almost exclusively of a thin fasciculus, *a' b'*, derived from the two nerve-sheaths, and this is covered anteriorly by the completely atrophic pigmentless choroid *d'*.

The following explanation of the development of the staphyloma posticum I accept.

In the normal eye, the sclerotica near the optic nerve, especially on the outer side, possesses its least power of resistance, or, in other words, is most extensible; and when extension occurs, the outer sheath of the nerve is removed from the nerve-substance, while the connective-tissue-sheath is extended as at *c'*. *b'* represents the attenuated sclerotica in front of the sheath, and with it, the stretched choroid *d'*, and a part of the lamina cribrosa. With such changes, the retina must rest on the unsupported sclerotica and choroid. It is only in a more outward direction, that the external sheath of the optic nerve *a*, strengthens the sclerotica. With this extension the origin of the myopic crescent seems to be connected. The choroid *d'*, is immediately united with the optic nerve through the nerve-fibres, and mediately through the connection with the inner sheath of the nerve.

At the borders of this attachment, writes Donders, "its vessels cease; on any extension, therefore, obstruction to the circulation in the extreme terminations of the chorio-capillaris must easily arrive, and thus the condition for incipient. We find something similar in the origin of emphysema of the lungs from atrophy of the most distended pulmonary vesicles, which thereby also finally lose both their capillary network and their pigment. Now, if the excessive extension has here once begun, and the resistance is thus diminished, it is more unlikely that the condition should become stationary, than that it should be progressively developed; and it actually is the rule that the atrophy of choroid advances more and more, without the visual axis, in slight degrees of staphyloma, necessarily becoming persistently longer and longer. The extension at the margin of the optic nerve

takes place often only at one side, and indeed principally at the outside, with which the atrophic crescent keeps pace at the same side. The number of my observations is not sufficiently great to enable me to form a positive opinion, but it appears to me very likely that, if the apex of the staphyloma falls nearly in the optic nerve, the outer sheath has given at all sides of the nerve, and that to this the annular and circular atrophy of the choroid also correspond. If, as is usually the case, the apex of the staphyloma is situated at the outside of the optic nerve, atrophy of the choroid is also found especially at this side; and even the fact, that the yellow spot, to which the apex of the staphyloma often corresponds, is situated at the outside of and a little beneath the nerve surface, and that the axis of the atrophic crescent usually extends in this same direction, indicates most distinctly that there is a connection between the apex in question and the direction in which the atrophy of the choroid advances. Whether the sharply-defined atrophy of the choroid does not reach farther than over the extended connective tissue *b'*, I cannot decide." Again, "In the ordinary cases, when the optic nerve does not lie in the apex of the staphyloma, it may be a question, whether the extension does not commence rather in the region of the yellow spot, and only secondarily become communicated to the outside of the optic nerve. This view is the more admissible, not only because by it the position of the optic nerve at the inside of the ellipsoid would be explained, but also because in very young persons, with comparatively high degrees of myopia, the crescentic atrophy of the choroid is still often absent, or at least is very slight. We can also very easily imagine how extension in the region of the yellow spot gives rise to the atrophy. In the yellow spot the choroid, which here abounds in pigment, is more intimately connected with the sclerotica. If the membranes here give way backwards, the extension will be equal on all sides, and the choroid will, moreover, the more easily maintain its connection with the sclerotica because precisely here it is more intimately connected with it."

The anatomical changes which ensue in staphyloma posticum, are attended by an alteration in the form of the posterior part of the eyeball. The actual figure will depend on the form, the extent, and the position of the myopic crescent. Where the staphyloma is extensive, the polar portion of the sclerotica is flattened. Sometimes the sclerotica becomes pointed, the eyeball running to a point at the optic nerve. Sometimes it bulges on both sides of the optic nerve. The relative positions of the optic and the corneal axes therefore vary much. This stretching of the sclerotica produces the bluish ap-

The development of the staphyloma always increases the length of the antero-posterior diameter of the eyeball.

I cannot but attribute the origin of staphyloma posticum to a congenital condition, a state of congenital weakness of the parts around the optic nerve, but especially on its outer side, by which they are incapable of the resistance required to preserve the integrity of the eyeball under certain trying conditions. That it arises out of an arrest of development is most probable, from what is known about the formation of the back of the fœtal eye, the separate growth of the sides, and the ultimate closure. The congenital defect of coloboma of the choroid, strengthens this theory. As the last point in evidence may be mentioned, the occasional existence of the staphyloma in infants.

That staphyloma posticum arises, and that it may progress, without any inflammation of the interior of the eyeball, is certain. When it is in slight degree, it is sometimes accompanied by symptoms of irritation which may be unimportant. When it is in high degree, inflammation is often present, especially at a late period.

State of sight arising out of pathological changes in the myopic eye.

In low myopia we hear of no complaints. It is in the medium and the high, that there is disturbance of sight, superadded to the defect of refraction.

It is often a matter of astonishment to surgeons to find marked anatomical changes in the fundus oculi, with slight subjective symptoms, or none. This is explained by the alterations being chiefly in the choroid, and of slow growth, and by which gradual development the retina is but little influenced. There is not any very marked effect till there are changes in the region of the yellow spot. Even with a few atrophic patches of white and yellow, there may be tolerable central vision, but diffuse atrophy may here spoil the sight. Rapid development of staphyloma posticum is always attended by marked deterioration of visual power.

Muscæ volitantes, small or large, black or grey, and photopsia, are early effects, that cause much distress. They produce much mental depression from their supposed association with blindness. The pathological muscæ may be floating or fixed. They are due respectively to proliferation of the hyaloid cells, and to partial detachment of the choroid and retina, spots of atrophy chiefly in the lower half of the eyeball, from serous exudation or extravasation of blood, or retinal hæmorrhage.

The enlargement of the blind spot is a common occurrence. At first, the outer part of the object looked at, is misty, then a black

spot is formed, and this always appears in the visual field, and causes partial interruption to vision.

Fatigue of the eye, consequent on close use of it, and pain, follow in the next stage, and are accompanied with hyperæmia within and without the eyeball. The disturbance is greater when the existing ocular tension and extension of the retina give rise to general irritation of the latter. Now amblyopia may ensue, so that print and writing look dim, and there is imperfect definition of everything. Straight edges seem irregular or broken, or curved lines are distorted and interrupted.

Contraction of the field of vision, or limitation, as it is more commonly called, declares the loss of retinal impressions.

Without limitation of the visual field, or scotomata, and even when the ophthalmoscope does not reveal a morbid fundus oculi, direct vision may be much diminished in the region of the yellow spot.

The vitreous humour is morbidly influenced when the fundus oculi is unusually diseased, and floating exudations may trouble the patient, and even interfere with vision. Fluidity of the humour often ensues.

Opacity of the lens, cataract, is a likely complication, after the above changes have occurred.

Treatment. Practical surgery is inapplicable.

The defect in any degree, is incurable. Only relief can be afforded, and this by the means of concave lenses.

It is for medium and high myopia, that treatment is chiefly required.

First, as to concave lenses wherewith to overcome the errors of refraction. These give upright virtual diminished images of objects at the person's far point, or a little beyond, and make them clear and perceptible, with the exercise of a little more effort of accommodation, and at a greater visual angle, than the normal eye would require for seeing the same distinctly. Such lenses also make the objects appear at a greater distance than they really are. This effect has been thus explained. The myopic eyes with their appropriate lenses, really see the virtual images of distant objects, at the negative focal length of the lenses, but mentally refer them to their true planes of situation. Mr. Laurence, from whom I quote, gives an experiment in illustration. He writes: "View the object with either eye in such a way as to see it simultaneously both through and not through a lens; we then at once perceive the object at its real distance from the eye, its image at a distance from the lens exactly equal to its focal length."

Certain rules must be attended to in the selection of lenses. Too strong ones make myopic eyes hypermetropic, and thus produce a constant strain upon whatever amount of accommodation that exists,

and thereby develop bad consequences in the over-distended eyeballs. The degree of the myopia must be first determined, and for this the test print should be employed. Ascertain carefully the distance at which the paragraph number three, or four, or even five, can be distinctly read. That is, ascertain the far point. If it be legible at, say eight inches, lenses of seven inches and a half value will be theoretically required to neutralize the myopia. Half an inch is allowed for the distance from the eyeballs to the lenses. When the far point exceeds twelve inches, the distance from the eyeballs to the lenses may be disregarded. In practice, however, it will generally be found that lenses so chosen are too strong. I will explain this. In reading at a distance of eight inches, there is necessarily considerable convergence of the optic axes, and associated with this, there is tension of the ciliary muscles, so that the eyes are accommodated for near vision; but when the lenses are put on, and distant objects are looked at, the eyeballs become parallel, the ciliary muscles are relaxed, the crystalline lenses become less convex, and the refractive power of the eyes being thus considerably reduced, they do not require so much optical help. Such a test, then, is merely an approximative one. The required accuracy is readily obtained by supplementing another. Let the same lenses be used for looking at the twentieth paragraph of the test print, at the distance of twenty feet. Then hold before them a pair of convex lenses of a very low value, say $\frac{1}{72}$, or $\frac{1}{80}$. If these act as correctors, and improve the vision, it shows that the concave lenses are too strong. Should they deteriorate the vision, remove them, and supply their place with a pair of concaves of very low value, to make sure that the originals are strong enough. If the vision be improved, it is evident that they are not sufficiently strong. By applying these rules with care, and in detail, sufficient accuracy can be got. As an invariable rule, concave lenses reduce in a degree the acuteness of vision of the myopic person.

Whether spectacles, as I shall now say instead of lenses, ought to be used for reading and close work, and if so, whether the same should be employed for near and for distant vision, is next to be considered.

When the myopia is low, in which case there is generally a fair amount of accommodation, spectacles are not necessary for what is called close use of the eyes. A person with refraction so little defective, holds his book nearly as far as he whose eyes are normal. He ought not to use spectacles to look at anything within the limit of clear vision, because if he do, he will unduly tax his accommodation.

When the myopia is medium, and the accommodation is good, spectacles will be most likely required for reading, because the book

ought not to be held nearer to the eyes than eleven or twelve inches, and the same will generally suit also for far vision.

When the myopia is high, for instance $\frac{1}{6}$ or higher, spectacles must be always used. Type cannot be read unless it be held close to the eyes, and with the inevitable forced convergence, the recti muscles press the eyeball, and thereby increase any existing staphyloma, in a manner already explained. I have mentioned too that often to relieve the discomfort which ensues, one eye only is used. The loss of binocular or stereoscopic vision, is more than compensated for by the acquired comfort. For reading and writing, and seeing all near objects, spectacles are indispensable. But it must be remembered that, if the very slight accommodation which exists be quite neutralized, an unpleasant effect will be produced, because the images are so very much reduced. It is enough if a book in ordinary type can be read at a distance of fourteen inches. Higher spectacles will be needed for seeing distant objects, and it is better even here not to neutralize the myopia altogether if spectacles be always worn. The neutralization is admissible only if hand-glasses be occasionally resorted to. But the far sight in very high myopia is seldom satisfactory, and the loss of accommodation limits the extent of visual range.

It is a good practical rule, to adapt the spectacles to the actual visual necessities of the individual. Ascertain what is required of his eyes, learn what is the minimum demand, for by this, comparatively low powers, according to the degree of the myopia, may suffice, a matter of no small advantage, as I shall show.

The myopic eye can never be made equal to the emmetropic eye, especially with respect to the relative degree of accommodation, for each convergence. The difference is in proportion to the high degree of the myopia. When spectacles of high value are used, the retinal images are much reduced, and objects that lie very wide of the visual line are distorted, on account of the great deviation of the lateral rays. These disadvantages are intensified as their value increases. And they are so much the more apparent if there be amblyopia. In consequence of this, I generally encourage the use of lower spectacles than would be ordinarily selected for seeing at long ranges. Stenopæic spectacles may now be of use, by reducing the circles of dispersion.

In high myopia, even with the most artistically adjusted spectacles, vision is very often imperfect, from the incidental pathological conditions of the choroid, and of the retina, already described, and besides, from the elongation of the eyeball, and the consequent stretching of the retina also mentioned, whereby its perceptive power is diminished. With such defect and disease, the less minute work that is done, the better for the eyes.

The recognition and treatment of intra-ocular irritation and inflammation, no uncommon effects of high myopia.

All ocular congestion tends to increase any existing staphyloma posticum.

Capillary hyperæmia of the retina and of the disk is a common state, but it seldom becomes intense and passes into definite disease, unless the eyes are overworked. Then there arise fatigue and pain, and muscæ, with sometimes intolerance to light. Spasm of accommodation may be brought on. Irritation even of a high degree may arise in youth. An examination with the ophthalmoscope makes the diagnosis sure.

A decided inflammatory attack of the internal tunics could not be mistaken. Besides the subjective symptoms, there would be objective ones within the eyeball, as I have said, and very often also without it. Such disturbance involves the retina and the choroid. The vitreous humour frequently participates in the inflammatory action.

These several morbid conditions are produced by other causes, as well as by myopia. The treatment is on this account systematically given in the chapter where the diseases of the choroid and the retina are considered. But I must speak here of the deleterious effects of wearing improper spectacles, and say what is called for remedially in this respect.

Unduly high spectacles may produce an attack of inflammation. All myopics have a tendency to get improper ones. The spectacle-makers encourage them in the error. When the eyes are affected from this cause, they should be rested. They should not be used by artificial light, nor used at all, for close vision. After the attack seems to have passed, the cessation from work will besides rest the accommodation, and then there can be ascertained the minimum power of the spectacles that will be sufficient for the ordinary demand that is made on them, and such only should be used. At first, they ought not to be subjected to any prolonged work, but rested for a few minutes, at intervals, which should be regulated according to the circumstances of individual cases.

While reading, the book should be raised to the head, to avoid any tendency to ocular congestion, which a stooping position may occasion. Writing should be done at a high and sloping desk.

During an attack of intense irritation or inflammation, in elderly and old persons, there might be marked decline in the acuteness of vision in the course of a few weeks or months. Yet if there be no palpable morbid internal changes, there is hope not only of preventing any such, but also of improvement in the subjective symptoms, by which reading and writing may be affected. But there can be little

scope for the restoration of direct vision, if the visual field be obscured by a defined scotoma, and still less, if the cause of such be ophthalmoscopically visible. In such a case complete blindness is likely to follow, although it is not inevitable. There is always a tendency to the recurrence of an inflammatory attack, and where it has done structural damage, each additional one is apt to spoil the eye more.

At all times, the use of very high spectacles dazzles, and the inconvenience is so great that often they are put away, and others are resorted to which are too weak to sufficiently neutralize the myopia. The evil, which is often a very serious one, may be remedied by the very simple expedient of tinting the lenses, instructions for effecting which are given in the chapter on the Construction of Spectacles.

Precautionary and, in a manner, preventive measures, applicable in early life. This applies to the emmetropic, as well as to the myopic eye.

A child who is very fond of reading, and is always over a book, should be made to interrupt the habit, so as to avoid the prolonged use of his eyes for hours, and the consequent fatigue. There should be a break and a rest. Two hours' reading or writing at a time is enough. Minute print, especially from bad type, should be avoided. The smaller the print the closer must it be held to the eyes, and the greater must be the convergence of the eyeballs, with all the accruing disadvantages already spoken of. That print only should be used which can be read at least ten inches from the eyes. It should be raised to the eyes so that stooping is avoided. There should be always sufficient light for reading, whether by day or artificial light.

The myopic child demands all the above rules, even with stricter application, and more especially if the atrophy of the choroid around the optic disk be diffuse rather than circumscribed. He is sure to carry his eye nearer to objects than his myopia requires. As soon as it is discovered that his myopia is medium or high, he should be supplied with spectacles. There can be no greater mistake than to withhold them. His employment should not be that which requires laborious use of the eyes on minute work. If he receive sufficient optical help, and if due attention be paid to every general therapeutic rule relating to his defect, and if he avoid over-working his eyes, he will most possibly escape the actual diseases incidental to his myopia, and even irritation and the discomfort which arises out of it.

Boys seldom receive attention on account of near-sightedness. I am frequently consulted about myopic girls, because of their not being able to see music without poking their heads over the keys of the piano. The music learning is nearly always the starting point for attention to their

Adaptation of spectacles when the eyes have different foci. To furnish each eye with a lens according to its individual want, is admissible so long as the difference in the refraction is less than one-thirtieth. With greater disparity, the eye which is usually employed for distant vision, namely the least near-sighted of the two, should be supplied with a lens, while the other is left alone, because a lens adapted to it as well would cause confusion of vision.

Senile changes in the myopic eye require changes of spectacles. The value of which must be decreased as the far point recedes.

ASTIGMATISM. CYLINDRICAL EYE.

The term astigmatism is used to express a state of sight resulting from want of symmetry in the anterior portion of the eyeball. The rays of light do not unite by convergence, and form in a regular manner in one point or focus on the retina, but reach it partially or irregularly, some of them coming to a focus in front of it, or not forming any focus, whereby circles of dispersion or diffusive images fall on the retina, and indistinctness of vision is produced.

We owe the recognition of astigmatism to our countrymen: Dr. Thomas Young, who showed that it exists nearly in all eyes. Astronomer-royal Airy pointed out when it passes into a condition of disease. Professor Whewell invented the name. Until within a few years, the subject was treated of only in English literature.

Normal astigmatism. The cornea is not of a uniform curvature, but has different radii in its several meridians. It is not a segment of a sphere; that is, a surface of revolution in which the curvature of all its sections through the axes is equal. It is a segment of an ellipsoid, and the axes are unequal, and therefore it refracts unequally in its meridians. The most marked deviations from symmetry are called for the purposes of teaching the chief or principal meridians, more correctly, astigmatic meridians; and these are usually found in the vertical and the horizontal directions. Such directions are seldom strictly vertical or horizontal, indeed, they vary considerably; therefore when they are spoken of as being in the one or the other of these, it must be understood that the term includes variations. The curvature of the vertical meridian is generally the greater of the two. There are exceptions, so that the maximum of curvature may be horizontal, and the minimum, vertical.

In consequence of this almost universally prevailing corneal arrangement, and of there being only one fixed and definite power of accommodation, very few persons can see all parts of objects

equally well. Vertical and horizontal rays of light have somewhat different foci. It is found that fine vertical and horizontal lines which are on the same plane, for instance, drawn on the same piece of paper, are not successively seen at the farthest point of distinct vision with the like definition, but that as a rule, the vertical are better made out farther than the horizontal. In the same kind of experiment, two threads made to cross each other at right angles, and at the same plane, are not discerned with the same acuteness. To get equal sharpness, the one must be brought nearer to the eye than the other. This is the explanation: In order to see the vertical line acutely, the rays which diverge from it in a horizontal direction must be brought to a focus on the retina. It is not necessary that those diverging in a vertical direction should also converge into one point, as the diffusion-images still existing in a vertical direction cover one another on the vertical line. On the other hand, in order to see a horizontal line acutely, it is necessary only that the rays of light diverging in a vertical plane should unite in one point upon the retina. Horizontal lines are generally acutely seen at a shorter distance than vertical ones; consequently, rays situated in a vertical plane, which are refracted in the vertical meridian of the eye, are more speedily brought to a focus than those of equal divergence situated in a horizontal plane; and the vertical meridian, therefore, has a shorter focal distance than the horizontal.

So long as the astigmatism keeps within a certain limit, it is practically unimportant. Thousands of astigmatic persons are not aware of their natural defect, and this shows that the asymmetry is seldom sufficiently marked to interfere with ordinary occupation. While then it does not spoil the acuteness of vision and needs no appliance for correction, it is called normal; but when it is so substantial an optical deviation as to require to be neutralised, it is called abnormal. The distinction is of course an arbitrary one, because there is no natural boundary, and any degree of the defect is capable of being detected. Again, a person's occupation will have a determining influence. A degree that would be unnoticed when the eyes are employed in seeing large objects, may be at once distressing when minute work has to be done.

REGULAR ABNORMAL ASTIGMATISM.

The existence of this is mainly due to asymmetry of the cornea. In a high degree there is sometimes a complication arising out of

predominates. For the present, however, I postpone the consideration of the lens' influence. In this sub-division the term astigmatism alone will be used ; and by it, abnormal astigmatism will be meant.

Astigmatism is often hereditary, and for the most part both eyes are similarly affected, but the one may escape ; or the one may be implicated in a different degree and manner to the other.

The astigmatic disturbance, whatever its degree may be, is less appreciable when the power of accommodation, that is adjustment, is in fullest activity. A given amount which in early life is unfelt, will cause disturbance at adult age. Late in life, the contraction of the pupil, incidental to advanced age, has a correcting tendency. High astigmatism is manifest in childhood.

Subjective symptoms. Astigmatism is likely to be mistaken for high degrees of hypermetropia, or of myopia, on account of the more or less loss of acuteness of vision which attends them. The insufficiency of spherical lenses to remedy the defect should always arouse the suspicion of astigmatism.

As myopia may be acquired in astigmatism, if the eye be much taxed with forced accommodation, a knowledge of the likelihood of its presence might prevent it from being mistaken for the original affection.

An astigmatic person generally holds objects close to his eyes in order to enlarge them, and so in a measure compensates for any loss of the acuteness of vision.

While there may be tolerable recognition of the size and figure of most bodies that are near, there is a want of definition for certain objects, particularly those made up of lines disposed in different directions, in the same plane. When they are apart, they are looked at alternately, and the accommodation corrects any aberration. When they are close, the diffusion images of the one direction fall over the defined images of the other for which the object is accommodated, and confusion ensues. The lines of adjoining letters seem to cover each other. In capital Roman letters this soon occurs.

Things at a distance are sometimes seen double. There is a blurring effect, and the edges of the lines seem to be drawn out in a horizontal or in a vertical direction, according to the form of the astigmatism.

Lines of equal length in two opposite directions do not appear equally long, and there arises an incorrect estimation of the images which are formed by them. A square figure will have the appearance of an oblong.

But no statement which a patient may give, can be taken as

corroborative of the presence of astigmatism, however strong a suspicion it might arouse of its existence. A special examination is requisite. Indeed, this must be done in every case, even with the most determining preliminary information.

Examination to ascertain the presence of astigmatism. The examiner must be prepared to find that the astigmatic sight differs from that due to loss of the sensibility of the retina, amblyopia, in which everything looked at is ill circumscribed, and recognised with uncertainty. And from that caused by opacity of the vitreous humour, or of the crystalline lens, in which the diffuse light falling on the retina causes mistiness of vision, and destroys the contrast between the light and shade of objects.

The examination should be commenced by finding the principal astigmatic meridians of the cornea, the maximum and the minimum of curvature.

The light-test is a valuable one. It consists in looking at a small round point of light, at a distance of from ten to fifteen feet, the exact distance being chosen according to the patient's range of accommodation. The less the range, the nearer should he be to the light. The examination may be arranged for bright day-light through a hole in the window shutter, or in a screen placed against the light, but I prefer artificial light, and use a darkened lamp with a rotating disk opposite the flame, in which there are small round apertures, varying in sizes from the diameter of half a line to two lines. The aperture selected, and I generally use the smallest, should be covered with a thin piece of ground glass, so that no direct rays of light from the flames shall pass through the apertures. A small hole in a metallic cylinder placed around the flame of a lamp answers nearly as well.

To the astigmatic eye the light hole will give a diffusive image, that is, will appear elongated in opposite directions; the longer limb corresponding to the direction of the minimum, the shorter to the direction of the maximum of corneal curvature. The extremes of refraction are found in meridian planes which are perpendicular to each other.

The rays of light from a luminous point, like rays proceeding from any object, as before explained, consist of two sets, vertical and horizontal. If the one set be focused accurately, the others form a linear image, by a series of circles of diffusion linearly disposed on the retina.

Here accommodation comes in to play, and its effect must be recognised, as the diffusion image of the point of light alters through such, both in size and form. Only when the centre of the focal space corresponds to the

nearly round. In every other state of accommodation, supposing such to be perfect and the astigmatism to be low, will it be vertically or horizontally extended according as the patient is focusing for vertical or horizontal rays. The same effect is produced by varying the distance of the light-point; but some distance may always be found, in which the luminous point appears drawn out to a stripe, in the direction of the chief astigmatic meridian. It may happen, that to obtain a strictly accurate result, it is necessary, artificially, to paralyze the accommodation. The enlarged pupil is advantageous as it proportionately increases the diameter of the circles of diffusion, and renders the symptoms of the astigmatism more marked.

But the myopia or the hypermetropia, one of which must be present, may be of such a nature as to prevent the person under examination from bringing either the vertical or the horizontal rays definitely to a focus. To such an one the circles of diffusion being the same, the luminous hole will appear as a diffused light, or as an ellipse with its major axis vertical, or horizontal, according as the circles of diffusion arising from the vertical or horizontal rays are larger in area. Then it is imperative to supplement the light experiment with spherical convex or concave lenses, so as to unite in the retina, the less or the more refracted of the two sets of rays. The direction of the linear image observed by aid of the convex lens, gives the astigmatic meridian of the maximum curvature, and that observed by the concave lens, the meridian of minimum curvature. Some ophthalmologists systematically resort to these lenses.

During the examination the patient's head should be kept perpendicular, or mistakes will occur respecting the meridians. Some astigmatics discover the influence of such change, and while reading, place the book in that direction which helps them most.

In high grades of astigmatism there is chromatic aberration. Luminous objects sometimes appear surrounded by variously coloured borders, the arrangement of which differs according to the distance of the object, and the natural refraction of the eye. It is capable of modification within certain limits, by spherical negative or positive lenses. These phenomena are made more apparent during the examination by passing sunlight through dark violet, or lamplight through dark cobalt glasses. Some interesting experiments have been instituted with regard to this, but they scarcely have any practical bearing.

All the above physical facts have been artificially illustrated by observing the forms of the images thrown on a screen which represents the retina, from a distant luminous point by a refractive combination of a $\frac{1}{6}$-inch ordinary spherical convex lens, next to which is placed

a $\frac{1}{30}$-inch convex cylindrical lens, with its axis vertical. When the screen is five inches from this compound lens, the horizontal rays will be accurately united to a focus, having been refracted by the $\frac{1}{6}$-inch spherical, and by the $\frac{1}{30}$-inch cylindrical lens ($\frac{1}{6} + \frac{1}{30} = \frac{1}{5}$). The vertical rays are in progress of union to a focus, but are not yet united, and will consequently, by their circles of diffusion, produce a vertical line on the screen. When the screen is six inches from the compound lens, the vertical rays are united to a point, whilst the horizontal ones, having been already united at five inches, have diverged again, and form a horizontal line on the screen. In an intermediate position, between five and six inches, the image is that of a circle, whilst in front of this circle it is an ellipse, with its major axis vertical; behind it, one with its major axis horizontal. If the screen be fixed, as the retina is, say in some position intermediate between the positions necessary to exhibit the one or the other of the two linear images, the entire system of images may be thrown forwards or backwards, by means of an appropriate convex or concave lens, in such a way as successively to bring the horizontal or vertical linear images on to the screen. Or the screen may be fixed altogether in front of or altogether behind the limits of the two lines, the focal interval. In the first position, one of inequality of hypermetropia in the two meridians, an appropriate convex lens will produce a vertical line, a still stronger one a horizontal line on the screen. In the second position, one of inequality of myopia in the two meridians, a concave lens will produce a horizontal line on the screen, and a still stronger one, a vertical line.

Most of the phenomena of astigmatism may be observed by anyone, if he will make his eye asymmetrical with a cylindrical lens. If the lens be positive, its axis should be placed horizontally, and vertically if it be negative: then will be obtained the shortest focal distance in the vertical meridian, as is generally the case in astigmatics.

So far, the examination is supposed to prove the presence of astigmatism. Another step is to be taken.

Systematic examination as to whether the rays of light which pass through the principal astigmatic meridians form more accurate images than those from the whole refracting surface of the cornea. For this, a stenopæic apparatus is wanted. Such an appliance is merely a thin circular metal plate, about the width of a penny, with a slit of an indefinite length, but not wider than from a third to a half line, or a little more. If the aperture be too narrow, it will rather obstruct the light. If it be too wide, it will not sufficiently correct the astigmatism. It is required for different cases to have several plates, with slits of different

sizes; or else, some mechanism by which one slit can be narrowed or widened.

In conducting the experiment, the eye which is not under examination should be covered.

The stenopæic plate should be placed close to the eye, and the slit successively turned in the directions of the chief astigmatic meridians, to ascertain if the acuteness of vision be thereby improved. If no result is obtained, spherical concave and convex lenses of different values should be individually held before the slit. If there be no improvement of vision, with either the one or the other mode of examination, astigmatism is not the cause which affects the acuteness of sight. If, on the contrary, vision be improved by the slit alone, or with the addition of a lens, it shows that astigmatism exists, enough to be detrimental to sight. A note should now be made of the correcting angle or angles of the slit, and of the kind and value of the required spherical lens or lenses.

The examiner must exercise caution and precision, and be aware that when the slit is not quite coincident with one of the chief meridians, the light-point may still be somewhat drawn out, partly because the circles of diffusion are elongated in the direction of the slit, and partly because all the normals of a meridian laid through only one axis, do not lie in one plane, and therefore all the refracted rays do not continue in the same plane. Mr. Millard, of 334, Oxford Street, has made for me a rotating plate, with an index, set to a spectacle frame, and which is slowly worked by a perpetual screw, the advantage of which is, that a patient can himself make the experiment.

The character of the astigmatism, whether myopic or hypermetropic, having been now made out, as well as the directions of the astigmatic meridian or meridians, we proceed to correct the faulty vision.

The grade of the astigmatism is ascertained by learning the value of the lowest lens of its kind which gives the most acute vision, and by such lens is the difference in the refraction between the two chief meridians declared. For instance, as a limited example, if the vision be most improved by a spherical convex lens of $\frac{1}{24}$ in one of the two chief meridians, and no lens gives improvement in the other meridian, there is hypermetropic astigmatism equal to $\frac{1}{24}$ and so on. All grades above $\frac{1}{40}$ are considered abnormal. All above $\frac{1}{30}$ high. The highest which has been recorded is $\frac{1}{4}$.

Sharp-seeing eyes rarely have more than from $\frac{1}{140}$ to $\frac{1}{60}$.

The optical disturbance is always in proportion to the grade of the

In all suspected cases of astigmatism, the following questions must therefore be determined:

Its existence.

The directions of the principal astigmatic meridians, that is, those of the maximum and minimum of refraction.

The refractive state of the eye in each of the principal astigmatic meridians.

Direct method of examination. This is very inferior to the systematic. It affords less definite results, occupies a great deal of time, and can scarcely be used by those who are learning the subject. It embraces two kinds of observations.

Ophthalmoscopic investigation by the direct method. This gives decided evidence in hypermetropic astigmatism. In a normal eye, when the retinal vessels are looked at by an emmetropic observer, they are seen radiating from the optic disk in all directions, with an equal amount of accommodation. In an astigmatic eye, the observer must, to see all parts well, alter his accommodation during his observation. To view the horizontal vessels, he must relax that power. To discern the vertical ones, he must exercise considerable tension of it.

If the object lens be employed, the difference between the normal and the astigmatic eye is less marked. The object lens may even correct slight astigmatic effects.

The form of the optic disc appears to be altered from the normal type. It seems to be oval in the one direction or the other, according to the form of the astigmatism. The disk is more magnified in the direction of the greater, and less in that of the lesser meridian.

Trial with cylindrical lenses. After the vision has been brought up to the highest definition by spherical convex or concave lenses, a cylindrical positive or negative lens, the value of which should correspond with the spherical lens which most improved the sight, should be held before the eye, and turned to ascertain if there be any position in which vision is further improved. If it be improved there is another proof of the presence of astigmatism.

There are objective symptoms of astigmatism. The hypermetropic formation of the eyeball above spoken of is generally apparent.

The form of the cornea may be so marked as palpably to declare the existence of astigmatism. Its vertical meridian may be perceptibly shorter; or perceptibly longer, so that the corneal and sclerotic sections are not in the same plane.

Fig. 197.

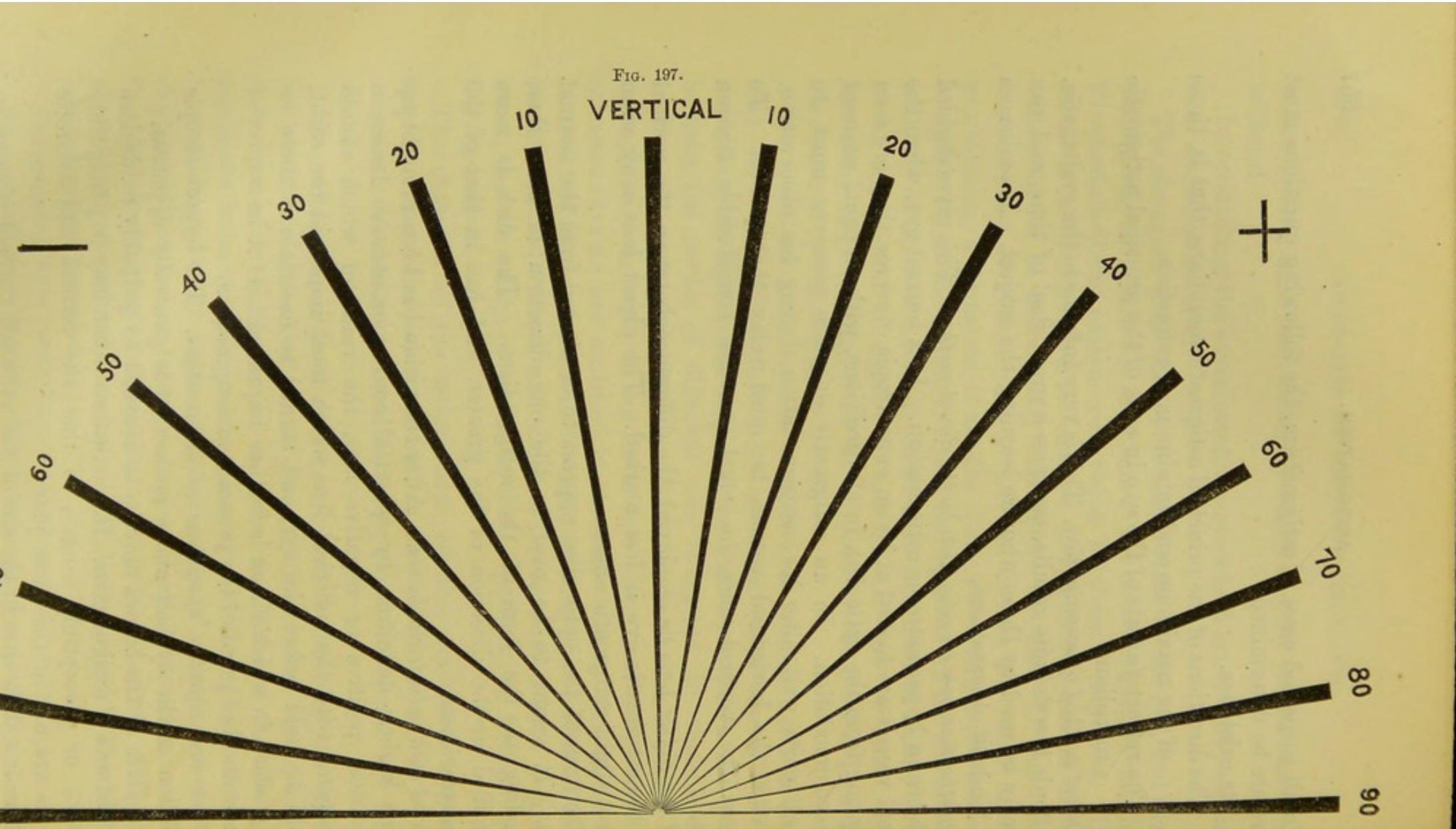

The numbers are given to indicate the astigmatic meridians. The mark of minus indicates the left, and that of plus the right.

curve being more magnified. This is apparent also by lateral illumination.

Instead of the light-test, Snellen's test-circle, or Dr. Pray's striped

FIG. 198.



PRAY'S STRIPED LETTERS REDUCED.

letters may be employed in the primary investigation. Sometimes they are more ready and convenient.

and accommodation, and the examination commenced. If all parts of either can be seen distinctly, astigmatism does not exist. If there be astigmatism enough to interfere with acuteness of sight, some lines of the circle, or some of the letters, will be correctly seen, and appear black, while others will be indistinct and pale.

The letters, as shown here, are reduced from the original, in which they are two inches and two lines in length and a line and a half wide. The reduced form does well for myopic astigmatism.

The stenopæic plate should next be used, with the spherical lenses, as with the light-test.

Pray's form of test table is the best which has been published. Twelve letters are chosen, so as to give lines for every fifteen degrees, numbering the degrees from left to right, through the half-circle. The letters with stripes at right angles to each other, are placed in pairs, so that the attention of the patient can be readily directed from the one letter to the other. During the examination of an astigmatic eye, three or four letters will appear darker than the rest, but a careful scrutiny will show that in one of them, the black lines and the white space are more distinct than in the other. If there be difficulty in deciding between three letters in a line, the middle one should be taken for special experiment, and afterwards, a comparison made with the others. By this, the amount of astigmatism is ascertained. This table has been imitated by lines set at different angles, and arranged in small disks, for testing the near point of vision.

So far, the examination has been conducted for the far point of vision.

The time has now arrived for me to classify astigmatism.

Forms of Abnormal Astigmatism.

Myopic astigmatism signifies myopia in only one meridian of the cornea. In strict definition, such a condition is extremely rare. Few instances are met with in which there is total absence of myopic astigmatism, however low the degree may be in the opposite meridian. It is not taken into account, as it is normal and does not disturb.

As a rule, according to what has been explained, vertical lines are seen at a greater distance than horizontal ones.

Simple myopic astigmatism. Let it be understood that the myopia, which is tolerably sure to be vertical, is twelve inches.

Vertical astigmatic meridian, myopia $= \frac{1}{12}$.
Horizontal astigmatic meridian, normal $= \frac{1}{\infty}$.

Then, there is simple myopic astigmatism. $\text{M A} = \frac{1}{12} - \frac{1}{\infty} = \frac{1}{12}$.

Compound myopic astigmatism. This, which is closely allied to

the simple, consists of myopia in different degrees, in the chief astigmatic meridians. It is rare, and it is difficult to be diagnosed. It has such a resemblance to ordinary myopia with amblyopia, that it is often mistaken for the combination of the two affections. Near objects are rather better seen than distant ones. Persons under adult age find that their vision is much improved by spherical concave lenses.

Let it be understood, that the myopia in the vertical astigmatic meridian is fifteen inches. In the horizontal astigmatic meridian, thirty inches.

Vertical astigmatic meridian, myopia $= \frac{1}{15}$.
Horizontal do. do. myopia $= \frac{1}{30}$.
Then there is myopic astigmatism $= \frac{1}{15} - \frac{1}{30} = \frac{1}{30}$.

Expressed, or written as, myopia. M $= \frac{1}{30}$ + myopic astigmatism. M A $\frac{1}{30}$.

Hypermetropic astigmatism. Under this head, fall most cases of abnormal astigmatism. The hypermetropic eye is particularly prone to astigmatism. In it, normal astigmatism always ranges higher than in emmetropic and myopic eyes. It is in this eye too, that the highest astigmatism is to be found. The loss of acuteness of vision, so common with high degrees of hypermetropia, is more frequently than not, in association with astigmatism. There are two forms of hypermetropic astigmatism.

Simple hypermetropic astigmatism. The hypermetropia is generally very marked in the horizontal meridian, and it varies in grades, from $\frac{1}{40}$ to $\frac{1}{8}$, or $\frac{1}{6}$. In the vertical meridian there may be emmetropia, or the lowest grades of myopia, or very low hypermetropia, but not enough to be taken into account. It is rare, and is scarcely ever discovered in young persons, unless the power of accommodation is artificially paralyzed.

Let it be understood, that the hypermetropia in the horizontal meridian is sixteen inches.

Vertical astigmatic meridian, normal $= \frac{1}{\infty}$.
Horizontal astigmatic meridian hypermetropia $= \frac{1}{16}$.
Then, there is simple hypermetropic astigmatism.
H A $= \frac{1}{16} - \frac{1}{8} = \frac{1}{16}$.

Compound hypermetropic astigmatism. There is abnormal hypermetropic astigmatism of the whole cornea. That is, a high grade of hypermetropia in the horizontal astigmatic meridian, and a low grade in the vertical.

In both forms, the simple and the compound, particularly in the latter, distant vision is improved by spherical convex lenses. In both

too, horizontal stripes are better discerned at a distance than vertical ones.

Let it be understood that the hypermetropia in the horizontal astigmatic meridian, is twelve inches. In the vertical astigmatic meridian, eighteen inches.

Horizontal astigmatic meridian, hypermetropia $= \frac{1}{12}$.
Vertical astigmatic meridian, hypermetropia $= \frac{1}{18}$.

Then, there is hypermetropic astigmatism, H A $= \frac{1}{12} - \frac{1}{18} = \frac{1}{36}$.

Expressed, or written as, hypermetropia. H $\frac{1}{18}$ + hypermetropic astigmatism. H A $\frac{1}{36}$.

Mixed astigmatism. This is a very exceptional condition. There is hypermetropia in the one chief meridian, and myopia in the other; or, the contrary state prevails.

Myopia, predominant, understood to be in the vertical astigmatic meridian, twenty-four inches.

Hypermetropia, in the horizontal astigmatic meridian, forty-eight inches.

Vertical astigmatic meridian, myopia. M $= \frac{1}{24}$.
Horizontal astigmatic meridian, hypermetropia. H $= \frac{1}{48}$.
Then there is myopic and hypermetropic astigmatism.
M H A $=$ M $\frac{1}{24}$ and H $\frac{1}{48} = \frac{1}{16}$.

Hypermetropia, predominant, understood to be, in the horizontal astigmatic meridian, twenty-four inches.

Myopia, in the vertical astigmatic meridian, forty-eight inches.
Horizontal astigmatic meridian, hypermetropia. H $= \frac{1}{24}$.
Vertical astigmatic meridian, myopia. M $= \frac{1}{48}$.
Then there is hypermetropic and myopic astigmatism.
H M A $=$ H $\frac{1}{24}$ & M $\frac{1}{48} = \frac{1}{16}$.

The lenses, and the stenopæic plates, which may be required for conducting the necessary examinations and experiments, are generally used as detached pieces, but they may be more efficiently and readily employed by being fixed in a frame and made to fit the face after the manner of spectacles. It increases the value of such an appliance by attaching to it a scale marked with degrees, by which the directions of the chief astigmatic meridians may be noted.

Treatment. The action of one cylindrical lens destroys that of another of the same power. I have explained this together with the physical characters of cylindrical lenses in the chapter on Geometrical Optics. Hence the astigmatic or cylindrical eye may be corrected by a cylindrical or astigmatic lens. These facts are made more intelligible, more impressive and very interesting, by experimenting with cylindrical lenses on one's own eye.

Simple myopic astigmatism. Having found the myopia to be twelve inches, $\frac{1}{12}$, in the vertical meridian, a concave cylindrical lens, of $\frac{1}{12}$ inch value, should be placed before the eye with its axis horizontal, by which is meant in the direction exactly opposite to that of the astigmatic meridian. This may, or may not be, as I have said, strictly vertical. It will therefore be in the line of least refraction. Such adaptation is according to the principles given in the chapter on geometrical optics. The light which passes through the axis of the lens, undergoes no refraction. That which passes in the plane vertical to its axis, that is through the cylindrical surface, is rendered astigmatic in its refraction, and so counteracts the existing ocular astigmatism.

The examination for the near point of vision, or in other words, the acuteness of vision, should next be tried with the cylindrical lenses.

We now resort to test-print, to judge of the practical result of our labour. It is in reading, that astigmatism is most felt. It may be proved that lenses slightly higher, or lower, than those originally selected, are required. Myopic astigmatics, as they must approach the print nearer than the hypermetropics, should be tried with a size proportioned to their myopia.

Compound myopic astigmatism. The myopia in the vertical meridian being fifteen inches, $\frac{1}{15}$, and in the horizontal meridian thirty inches, $\frac{1}{30}$, a concave-spherico-cylindrical lens is required. A concave spherical lens of the value of $\frac{1}{30}$ inch, should be placed before the eye, and a cylindrical concave of the same value, with the axis turned horizontally, and the acuteness of vision tested as before.

When the values of such lenses are found, the spherico-cylindrical one combining the two values is to be prescribed. Such a lens is a combination of a plano-concave spherical, with a concave cylindrical lens. This is obtained by cutting a spherico-cylindrical lens in a plane perpendicular to the axis of the spherical surface.

The astigmatism is therefore corrected by $-\frac{1}{30}$ spherical $\frac{1}{30}$ ⌓ cylindrical.

Simple hypermetropic astigmatism. The hypermetropia in the horizontal meridian being sixteen inches, $\frac{1}{16}$, a convex cylindrical lens of $\frac{1}{16}$ inch value, should be placed before the eye with its axis in the vertical meridian, and the acuteness of vision examined.

Compound hypermetropic astigmatism. The hypermetropia in the horizontal meridian being twelve inches, $\frac{1}{12}$, and in the vertical, eighteen inches, $\frac{1}{18}$, a convex spherico-cylindrical lens is needed. A convex lens of $\frac{1}{18}$ inch value should be placed before the eye, and before such lens, a positive cylindrical lens of $\frac{1}{30}$ inch value and

vision tested. The positive spherico-cylindrical lens must combine the above values. The direction of the axis is to be vertical. The astigmatism is therefore corrected by $\frac{1}{18}$ spherical, $\frac{1}{36}$ ⌓ cylindrical.

Mixed astigmatism. Bi-cylindrical lenses are required. In such lenses, the surfaces of curvature are concave on the one side, and convex on the other. Their axes are at right angles to each other, therefore parallel incident rays of light after refraction, converge in the plane of the one axis, and diverge in that of the other.

Myopia predominant. Myopia in the vertical astigmatic meridian, being twenty-four inches, M $\frac{1}{24}$,

Hypermetropia in the horizontal astigmatic meridian, being forty-eight inches, H $\frac{1}{48}$,

A convexo-concave cylindrical lens is needed. The concave surface should be of $\frac{1}{24}$ inch negative focal value. The convex surface should be of $\frac{1}{48}$ inch value. The axis of the concave surface should be placed in the direction of the hypermetropic meridian; and that of the convex surface in the direction of the myopic meridian.

The double astigmatism is therefore corrected by $\frac{1}{48}$ convex cylindrical, and $\frac{1}{24}$ concave cylindrical.

Hypermetropia predominant. Hypermetropia in the horizontal astigmatic meridian, being twenty-four inches, H $\frac{1}{24}$, myopia in the vertical astigmatic, meridian, being forty-eight inches, M $\frac{1}{48}$,

Then there is need of a concavo-convex lens. The concave surface should be of $\frac{1}{48}$ inch value. The convex should be of $\frac{1}{24}$ inch value.

The axis of the convex surface should be placed in the direction of the myopic meridian; and that of the concave surface in the direction of the hypermetropic meridian. Each will therefore be perpendicular to the other.

The double astigmatism is therefore corrected by $\frac{1}{48}$ concave cylindrical, and $\frac{1}{24}$ convex cylindrical.

When treating of myopia, I pointed out conditions in which it is not always expedient to neutralize the whole of the defect. Similar remarks were made in reference to hypermetropia. It is supposed that the same end can be attained in astigmatism, by deducting the desired degree of myopia or hypermetropia, from the ascertained refraction of the two principal meridians. This complicated method, though capable of being expressed in formulæ, is scarcely applicable in practice.

The effect of the crystalline lens in regular abnormal astigmatism. After the most laborious investigations by many labourers in this most difficult field, very little has been discovered. It is certain that the deep position of the crystalline lens, must diminish the effect of any asymmetry in it. It is tolerably certain that with high corneal

astigmatism, asymmetry of the crystalline lens also exists, but such asymmetry modifies rather than increases the regular or corneal astigmatism, in virtue of the form of its surfaces, or from slight obliquity. The crystalline lens acts therefore in such a direction, that the astigmatism for the whole eye is nearly always less than that proceeding from the cornea.

Actual dislocation of the crystalline lens causes symptoms allied to astigmatism. Of these I shall speak when treating of lens diseases.

Setting of the cylindrical lenses in the spectacle frame. The closer these lenses are carried to the eyes the better, in order to reduce the inevitable displacement of the nodal points.

When spherico-cylindrical lenses are used, if both be convex, or both concave, the surface of least curvature in each instance, should correspond to the eye. When they are concavo-convex, or convexo-concave, the same rule should be observed.

The axes of the surfaces of curvature should correspond to the principal meridians of the refractive system of the eye. This will necessitate the lenses being set for reading, or for distant sight, as the patient may require.

The optician must be duly instructed in all these matters. At all times most explicit and careful instructions should be conveyed to him, respecting the position in which the cylindrical lens should be placed in each individual case.

Results. It is to be regretted that the treatment does not accomplish all that can be desired of it, for the cylindrical lens does not completely counteract the astigmatism. The causes are well known.

Absolute coincidence of the nodal points in the different meridians cannot be obtained. The consequence is, that the form of bodies is elongated in the direction opposite to that in which the astigmatism appeared, before it was corrected. Some of this imperfection, and most of it in many cases, may be prevented by attending to the rules which I have given for getting correct lenses.

In the movements of the eyeballs, the directions of the axes of the cylinders lose perfect coincidence with the principal corneal meridians, and the correction of the astigmatism is accordingly imperfect.

The accommodation changes in the accommodating apparatus in the astigmatic eye, and particularly after the correction of the astigmatism, does not produce corresponding effects of accommodation, in both principal meridians.

I know from my own experience, that several patients who have been supplied by others and by myself with cylindrical lenses, have thrown them aside and resorted to spherical convex or concave lenses. Some have preferred using the stenopæic plate set in a

spectacle frame, in association with a convex or a concave spherical lens.

Besides the asymmetry of the cornea, it has been made out that the eye, taken as a whole, is not symmetrical. That the refracting media, considered as one mass, shows a difference of radius of curvature in its several meridians. That the regular astigmatism of the entire system does not correspond exactly in direction, nor in degree, to that of the cornea. That the maximum of curvature lies closer to the vertical, than to the horizontal meridian.

Acquired abnormal regular astigmatism. When the pupil is decentred from accident or disease, or in consequence of an operation, the eyeball is rendered asymmetrical, and the symptoms of astigmatism occur.

After the operation for the extraction of cataract, the form of the cornea is often altered, on account of the slightly irregular manner in which the corneal flap heals. Astigmatism is thereby produced.

Inflammation of the cornea, which causes any irregularity in the corneal curves, will make the eye astigmatic.

More or less dislocation of the crystalline lens, from accident or disease, will produce symptoms allied to those of astigmatism. I will speak of this particularly in the chapter on Diseases of the Crystalline Lens.

The essential difference between this and congenital astigmatism is too apparent to need being enlarged on.

Irregular astigmatism. This depends on the faulty refraction of rays of light in the one and the same meridian, that is through the crystalline lens. It differs, therefore, from regular astigmatism, in which, as I have shown, the faulty refraction depends on the difference in the focal lengths of the corneal meridians.

There is normal and abnormal irregular astigmatism.

Normal irregular astigmatism is scarcely absent from any healthy eyes. It is less apparent in youth than in adult age, because of the better power of accommodation. Its chief characteristic is multiplied vision under certain conditions with the one eye, known as polyopia monocularis. It may be recognised by many experiments. The mention of one of them will suffice. Make a minute black spot, •, on white paper, and approach it closer to the eye than the distance of clear vision, and it will appear like a circle of greyish points. Slowly remove the spot from the eye, the polyopia will gradually decline, and the spot is again seen single and black. During the experiment, in order that the pupil be kept as large as possible, it is desirable to avoid tension of accommodation. This necessitates that the eye be kept accommodated for the far point.

The spot may be easily carried beyond the point of distinct vision,

to an emmetropic eye, by rendering the eye myopic with a $\frac{1}{10}$ or $\frac{1}{12}$ inch focal value concave lens. To continue with the experiment in this manner the spot should be made a little larger. In this case several spots appear, but now there is a central darker one, around which paler ones are more or less regularly grouped.

It has been clearly proved that the polyopia monocularis, as well as the radiant appearance of a light at a distance, or a star, for which the eye is not accommodated, have their origin in the crystalline lens.

It has been unequivocally ascertained that the cornea is not concerned in these effects.

It has not been ascertained with certainty, the manner in which the lens acts in irregular astigmatism, but it is supposed that the cause can be traced to its peculiar organization, and that each of its sectors forms a separate image. Besides this, that each is astigmatic. With such arrangement, even with accommodation, there is imperfect coincidence of the rays of light on the retina.

From this form of astigmatism the acuteness of vision is scarcely disturbed, and it is less when the eyes are of equal refraction, and both of them are used at the same time. The astigmatism is never exactly equal in each eye, and therefore the retinal images are not quite alike. But they coalesce in our idea, and hence it is, considering the astigmatism only, that the form of a small object is more correctly estimated by binocular vision.

Abnormal irregular astigmatism. The cornea comes here into play when it assumes a conical form, constituting "conical cornea." I prefer to delay a consideration of this till I speak of conical cornea in the chapter on Corneal Affections. I say the same about spots on the cornea, irregularities in form from inflammation, transparent ulcers, which also cause irregular astigmatism.

Crystalline lens influence. There may be an effect through some physical alteration in the lens tissue. It may occur while the lens is transparent, but it is more common when lenticular cataract is forming. A patient with incipient cataract, is almost certain to tell you that with the cataractous eye luminous bodies are multiplied. The moon is generally mentioned.

Treatment. Fortunately irregular astigmatism by itself, rarely interferes with acute vision. That it sometimes co-exists with regular astigmatism, and complicates it in a manner which prevents relief from cylindrical glasses, is well known.

High irregular astigmatism is irremediable.

The polyopia of low astigmatism generally disappears when the loss of accommodation is compensated for by proper spectacles.

CHAPTER XXIX.

DISEASES OF THE EYELIDS.

RESTORATION OF THE EYELIDS BY PLASTIC OPERATIONS—TRICHIASIS—ENTROPIUM — ECTROPIUM—EPICANTHUS—INFLAMMATION OF THE EYELIDS AND OF THE EYEBROW—ŒDEMA OF THE EYELIDS—PALPEBRAL SWEATING—CONGENITAL FISSURE OF THE EYELIDS—ABSCESS OF MEIBOMIAN GLAND—ACNE CILIARIS—HERPES—ECZEMA PALPEBRARUM—XANTHELASMA PALPEBRARUM.

Several diseases which are met with about the eyelids are described among different classes of affections according to the plan of this work. For instance, tumours, malignant affections, injuries both mechanical and chemical, and wounds, are given in chapters devoted to these subjects. In this chapter are described only those affections which are proper to the eyelids.

RESTORATION OF THE EYELIDS BY PLASTIC OPERATIONS.

Restoration of an eyelid which has been lost, in the strict sense of the term, is impossible. How can a transplanted piece of skin represent the beautiful and complex palpebra, with its glandular apparatus, muscular and mucous tissues? At the very best, and when the most is done that a plastic operation can effect, the result is very miserable, and is to be deplored rather than admired. The amount of benefit in any direction is but small; yet some little advantage may be derived from the application of this form of surgery.

Restoration is generally applicable when a part of the eyelid or the whole of it has been lost through its entire thickness from disease, an accident, or an operation. Yet this is not without exceptions, for it is well known that the upper eyelid will to a great extent supply the

loss of the under, and the under that of the upper. Even when a large portion of both eyelids has been removed, contraction may follow sufficient to prevent the necessity of any operation for compensation.

Indeed, when the under eyelid is lost, the deformity and inconvenience arising from its want, is so trifling that an operation is nearly always, according to my own experience, unnecessary. The contraction of the cicatrix, for the most part, brings the skin of the cheek to the level of the orbit. The palpebral opening is reduced transversely, and from above downwards, in consequence of the descent of the upper eyelid.

The loss of the upper eyelid is more injurious.

Yet it is only when the eyeball is permanently exposed, the cornea incipiently affected, and the loss of sight endangered, that an operation is specially indicated and justifiable.

Sometimes the eye may be sufficiently protected by the act of winking by day, but yet be injuriously exposed during sleep.

A man had phlegmonous erysipelas of the face, and such was the damage done to the skin from the scarring and contraction that both eyelids of each eye were everted. In this state he came to me. Each tarsus was turned sharply backwards. By very strong winking efforts the eyeballs were just covered by the exposed and villous palpebral conjunctiva. During sleep they were fully exposed. The cornea suffered. The one became cuticular, the other ulcerated and opaque. This poor sufferer declined all surgical relief.

It may be necessary to remove part of the eyelid, or the whole of it for cancer, and other diseases about the eye.

It may be necessary to do the same operation after bites from rabid animals. Such bites on any uncovered part of the body are the more serious from the free contact of the dangerous saliva; and with this greater chance of the morbid inoculation, no well-assured method of treatment should be neglected.

A lad, eight years old, was brought to St. Bartholomew's Hospital, when I was house-surgeon, by an elder sister, in consequence of injuries received from having been knocked down by a strange dog, while at play with his schoolfellows. On the upper eyelid of the right eye was an abrasion about three-quarters of an inch long, and half an inch broad. All the information that could be collected was, that the dog leaped at him and knocked him down. As one of his knees bore the evidence of a fall, and the face was covered with mud, the eyelid was supposed to have suffered from the same cause. Dressing was applied, and I sent directions to his mother to make inquiries about the dog. Just two months after, the poor lad re-

appeared at the hospital with hydrophobia, and died the next day. At the inquest a hubbub was made, and a question raised as to the neglect of removing the eyelid; but I was able to prove that the probability of danger was pointed out to the sister, and that I had done my duty. It appeared that the mother had learned a day or two after this that the dog was killed as rabid, but was persuaded by a neighbour not to let me know. To have resorted to such a severe measure as the removal of an eyelid without any evidence that the part had been bitten, would have been as culpable as to neglect it, had I been in the possession of all the facts.

Treatment. All that is written farther on, in ectropium, about plastic operations, applies here. Indeed so much is given which is common to this subject as well, that little is left to be pointed out.

Any portion which remains of the edge of the damaged eyelid should be saved. The conjunctiva also should be saved, for no part of it ought to be removed, whether thickened or otherwise; nor of the skin, whether hardened or contracted; nor of the cellular tissue.

The incisions to prepare the bed for the flap should be so made through integument, or even cicatrix, that some part of the old tissue shall form the free edge of the lid. In this there is the double advantage of having an outline that is not likely to contract, and a better supported flap with its vascular supply insured.

As this operation is more extensive than the plastic one for most cases of ectropium, it is the more important that the state of the integuments whence the flap is taken should be quite healthy.

It is sufficient if the eyeball can be so far protected, especially above, as to save it from being destroyed. Any operation beyond this is superfluous, and may probably fail, from its magnitude. The more limited an operation of this kind the more readily is repair effected.

I append two cases of restoration of the lower eyelid. One was done by Dr. Baumgarten, in a child six months old, labouring under aneurism by anastomosis on the right lower eyelid. The rapid increase of the growth, encroachment on the cheek, great size, and the imminent danger of rupture induced its extirpation. The flap was borrowed from the temple, and slipped laterally into the required place; the upper edge was fixed to the tarsus by means of four points of suture, the inner by six, the outer remaining free. Union by the first intention followed, and on the fourth day the last suture was removed. In a week the loss of substance in the temple was repaired, and the eyelid presented a good appearance.

The other was performed by Dr. Ammon. The lower eyelid was

involved in the excision of a suspicious-looking tumour. The flap, in this instance, also was taken from the temple. Primary adhesion was not effected, yet the flap survived, and in five weeks adhered, by granulations.

The late Dr. Richard Mackenzie, of Edinburgh, was successful in a large facial operation, including the restoration of the lower eyelid and other parts. The case was one of unusual destruction of features. Nearly the entire cheek, with the lower eyelid, the side of the nose, and the half of the upper lip, were destroyed by mortification after scarlet fever. Necrosis followed, and the nasal bones were lost, with the greater part of the superior maxillary bone.

The child, now seven years old, was in good health, and the parts in the neighbourhood of the extensive cicatrix in a perfectly sound condition. The absence of the lower eyelid had given rise to a vascular condition of the conjunctiva of the right eye, and the part of the cornea which was exposed was dull, and slightly nebulous.

Dr. Mackenzie attempted to restore the lost parts, by bringing up a large flap, consisting of the lower lip, and of the integuments over the base of the jaw, so as to fill up the whole gap at once. The contracted flap was retained as much as possible in the situation of the upper lip, and his object so far attained as to bring the parts into a condition nearly similar to that of simple harelip.

About six weeks later, by the harelip operation, the edges of the cleft were brought into apposition; perfect union was established, and the natural appearance of the upper lip was thus nearly restored.

The deformity of the face, although much diminished, was still very great, from the absence of the nose, eyelid, and greater part of the cheek. A third operation was performed, three months after, and the gap was filled by a large flap of skin brought from over the ramus of the jaw, the base being situated over the upper part of the malar prominence, and its extremity corresponding to the angle of the jaw. In addition to the improved appearance of the features, articulation was rendered much more distinct.

The child, nothing daunted by what she had undergone, was now anxious to have her appearance still further improved by the formation of a nose. This proposal was negatived, as the operation is applicable only in adults.

The true Italian, or Taliacotian method, of transplanting a flap of skin, has been executed by Mr. W. Jones. The details are in his "Ophthalmic Manual." The integument was taken from the hand.

TRICHIASIS. CILIA FORCEPS.

The first, Fig. 199, have, on their rounded points, a broad fine cross-cut, or file-like surface, for taking secure hold. The edges are so much rounded that they cannot cut. The blades are strong enough to admit of proper pressure being exerted at their extremities during use. This is my usual instrument.

Fig. 199.



The second, Fig. 200, have round ends, with perforations in them.

Fig. 200.



Trichiasis signifies a misdirection of the cilia, or eyelashes, towards the globe of the eye, upon which they more or less rest. Practically, the term is not applicable until the maldirection has arrived at a state that occasions some inconvenience or injury to the cornea. It is frequently associated with entropium.

Trichiasis, although among the most common affections of the eye that call for surgical relief, demands as serious attention as any in the Ophthalmic catalogue; for, notwithstanding it does not rapidly destroy the eye, yet, if allowed to proceed unchecked, or if merely partially relieved, it becomes, sooner or later, from the constant irritation and subsequent changes which it causes in the eyeball, one of the most destructive diseases.

The effects vary, according to the extent of the displacement of the hairs, and the part of the eyeball that is touched. When the conjunctiva is fretted, inflammation of that part ensues, and it may be circumscribed. When the cornea receives the contact of the cilia, the worst symptoms ensue. Corneitis is a common effect, with ulceration and prolapse of the iris. With these there is generally pain, with the sensation of a foreign body in the eye. Also epiphora, intolerance to light, and blepharospasm. The eyeball may be involved in inflammation, which may become chronic, and produce atrophy.

Trichiasis varies in degree, from a slight deflection of some of the cilia, just sufficient to touch the eyeball, to the inveterate implication of all except the smaller ones at the corners, which are usually exempt. But

the greater portion are seldom inverted, unless there be entropium as well.

The figure was taken from a good specimen of the affection. A

Fig. 201.

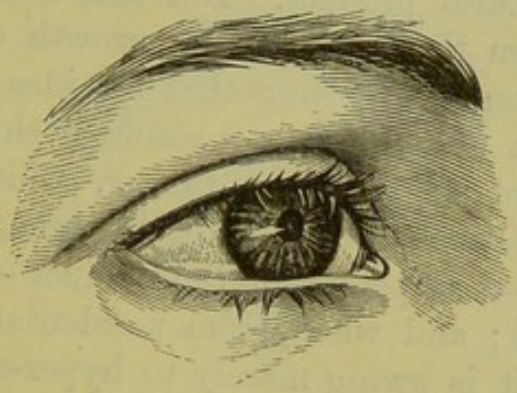

few of the cilia just touched the cornea, and a small bunch rested on the sclerotica. The edge of the eyelid was natural, and not in the least turned in. There then was trichiasis only.

The manner in which the more internal of the cilia may turn inwards either in a limited number in one or more places, or along the greater length of the eyelid, has induced some surgeons to suppose that there is actually a new production of an inner set of hairs, from follicles produced after birth, a supplemental development from a more internal part of the eyelid. The name of distichiasis has been given to this ideal state. Fig. 202 well illustrates the appearance.

Fig. 202.

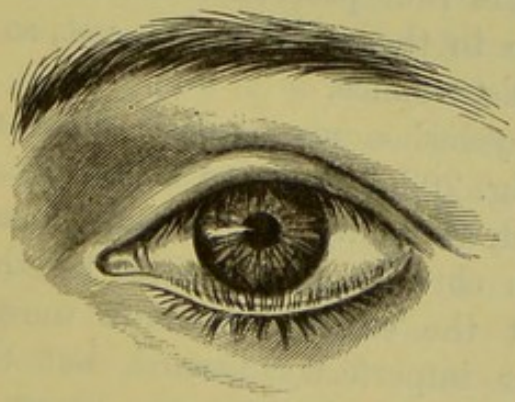

It has been a question much discussed whether this is, or is not the case; whether new cilia spring forth, or old ones deviate. I have not myself been able to gather any facts that support the creative theory. All the evidence that I can collect is adverse to it. The supposed new row is a mere deception.

The chief argument against the growth of supplemental hairs is, that they do not exist congenitally, and there is no such thing as a secondary formation of hair in any part of the surface of the body, the hair-follicles being all of primary development. It is well known that hair is occasionally found in the ovaries, and other situations where it is not a natural product. But this is no argument for its abnormal position on the eyelids. Its growth on parts that have been repeatedly blistered, has suggested the idea that it might likewise be generated in the eyelids as a result of chronic inflammation. Experience does not support the theory, which is advanced in ignorance of the fact that the surface of the human body at the time of birth equals, if not surpasses, in the number of hair-follicles, that of any other animal; and when, from accidental causes in after life hair springs forth, it is owing merely to hyper-nutrition of original germs.

The utmost that can be urged is, that in the eyelid an animating influence might be exerted on dormant bulbs; but the arrangement of the parts renders most doubtful the existence of such an occult capability.

I do not, therefore, recognise any such separate disease as distichiasis.

Some surgeons, who are not disposed to believe in the creation of new hairs, assert that the displaced cilia are growths from old follicles, which pierce the eyelid in the wrong place. But this is both anatomically and pathologically incorrect; for the internal cilia are close against the cartilage, and issue by the side of the edge, as near to it as it is possible.

The very fine hairs that proceed from the skin at the margin of the eyelid, and close to the eyelashes, do not, so far as I know, ever grow and produce disturbance.

Sometimes the eyelashes are twisted in many directions. The next illustration, Fig. 203, is from an unusually severe case.

The upper eyelid, the only one affected, had been involved in its inner surface in chronic inflammation for three years, and was much thickened at the edge. The cilia were healthy. None of them were lost, or imperfectly formed, but they were scattered. There were two well-marked rows, the upper of which, from its unnaturally high position, had as much the appearance of a new row as the under, from its inner position, had of a supernumerary growth. Not the least interesting fact is, that a year after the sketch was taken, when the inflammatory symptoms had declined, and the edge of the eyelid was nearly reduced to its natural thinness, the cilia had in a great measure regained their lost relations,

and the duplex arrangement was no longer recognisable, mere bushiness remaining.

Cause. Excluding chemical and traumatic injuries to the eyelids,

Fig. 203.

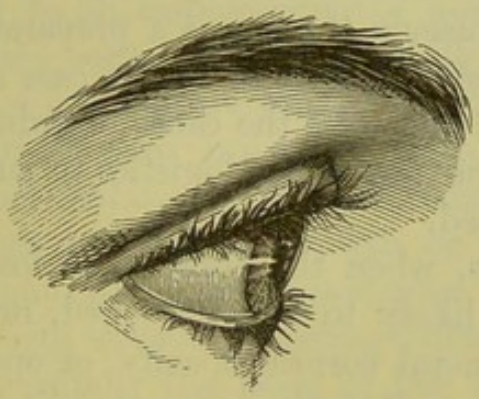

most of the causes, direct and remote, that produce trichiasis, are palpable.

The inversion may be a permanent state of distortion of the cilia by some traumatic means, without any other diseased condition. Or it may be an idiopathic affection, due to a pathological change in the edges of the eyelid itself, from strumous inflammation of the conjunctiva, by which the posterior edge is lost, and cicatricial tissue is formed, producing contraction, and involving the cilia follicles. This is not always, it is true, apparent when the trichiasis is partial, but it is generally sufficiently well marked to be easily recognised when it is extensive.

The displaced cilia may be healthy, or abortive and pale, from original disease of the hair follicles, or defective growth from frequent plucking. Pulling them out is a cause of their sickliness.

The cilia that fret the eye, may be so minute as to escape the observation of those unaccustomed to look for them. Even with a knowledge of their presence, their exact position may not readily be detected, and minuteness does not diminish their powers of mischief. Therefore, with the sensation of something in the eye, attended by continued inflammation of the conjunctiva, or of the cornea, or superficial ulceration of the cornea with or without opacity, and with any of these states, intolerance of light, the existence of trichiasis may be suspected, and disarranged lashes should be searched for.

It is no uncommon circumstance for the individual who suffers from the effects of trichiasis to be ignorant of the nature of his malady. Eyes are lost under such a condition.

A young woman had an inverted cilium in each upper eyelid that touched the cornea and produced ulceration, which ended in penetra-

tion and prolapse of the iris. After this, as the cicatrix on each eye was insensible, there was no more irritation. The appearance of the two eyes was remarkably symmetrical. The poor creature was nearly blind. She told me that all the treatment she received had been directed to the inflamed state of the eyeballs.

In Mr. Liston's museum there was a preparation exhibiting four or five delicate eyelashes, which, as in the case above, not only cost the patient her sight, but were the cause of ruin to her constitution, through the use of fruitless antiphlogistics to subdue the inflammation that they produced.

In the later stages, when the cornea has lost its sensibility, the disease is still more likely to be overlooked, or mistaken. This is never till there is general corneal opacity, or opacity of that portion touched by the hairs. But the general irritation of the eyeball, with the accompanying spoiling effects, may be going on.

The treatment of trichiasis is palliative and temporary, or radical and permanent.

Of the palliative, that alone is worthy of notice which is so naturally resorted to, the pulling out of the cilia by forceps. Of a method so generally adopted, and apparently so universally applicable, it is well to ascertain in what species of implication it is advisable to be practised, and, besides this, how long in any instance it may be persevered in.

The condition of the cilia that irritate, and the state of the eyelid on which they are seated, should be taken into consideration.

Where the irritation is occasioned by a few well-formed, but inverted hairs proceeding from an eyelid that does not seem otherwise unhealthy, there cannot be a doubt about the propriety of using the cilia-forceps, because there may not be a return of the inversion; and even if the hairs so treated show on their reproduction a tendency to become distorted to a like degree, their injurious effect can be anticipated, and the process of extraction repeated. It thus becomes a mere matter of consideration to the patient whether he shall submit to the periodic repetition of the process, or to a rather more severe and effectual plan, resulting in a cure.

When the extraction is followed by an increase in the number of inverted cilia, and abortive ones may spring from one follicle, the application of the cilia-forceps has reached its limit, and, as a rule, should be discontinued. There cannot be a doubt that the continued removal of any of them by force is very frequently hurtful to the follicles, renders the direction of them more perverse, causes abortive productions, tends to involve the contiguous follicles,

also, where the eyelid is unhealthy, and the offending cilia, although few in number, are abortive, and grow directly inwards, extraction is contra-indicated. Some effectual treatment then only is admissible, some radical cure; for in the majority of such cases, with all the vigilance of both patient and surgeon, and extraction weekly practised, there will be an impossibility of keeping the globe of the eye exempt from their contact. The majority of such fine cilia are not in reality plucked out, but are broken off, and with any accession of growth, again exert their injurious effect, long before the eye recovers from the last irritation. Actual extraction can scarcely be done till the lash has attained its growth, or nearly so. It is said that one takes five months to get to maturity, and then falls. The follicle is supplied with several secreting bulbs, and there is always ready a new lash to supply the place of the old. The succession may be so quick, that the future protrudes by the present one. Notwithstanding the gradual deterioration of the state of the eye under this palliative treatment, patients will still desire a continuance of it. Careful periodic plucking will greatly delay the arrival of the worst effects, while neglect or careless manipulation will hasten it.

The proper way of using the forceps, is to press on the upper or the under part of the tarsus, according to the eyelid affected, evert its edge, apply the points close to the cilium as it emerges, and pull it out in the direction of its growth.

The radical cure consists in the adoption of two operative measures. By the one, skin is removed, and the maldirection of the cilia is influenced. By the other, the cilia are dissected away, or amputated with a part of the eyelid.

The first of these, the excision of a portion of the palpebral skin, in depth and extent proportionate to the required effect, to give a slight outward position to the edge of the tarsus, is a very valuable resource, applicable frequently to the upper eyelid, and nearly always practicable in the lower. It is suited in general to those cases in which the cilia retain their proper size, are merely slightly misdirected, and just touch the globe of the eye, and exceptionally, to abortive cilia that do not grow much towards the eyeball; and, it may be, its greatest extent of application is to be found when the central cilia are affected. Its adaptation to any given case is readily decided by rendering the skin of the eyelid tense, and observing the effect. It is difficult to point out what degree of inversion may be so treated; that must be left to the judgment of the surgeon. This may be said that, whenever the eyeball can be just cleared by the greatest admissible amount of eversion, the principle is yet available

effect of the operation, when the irritation of the eye, and consequent swelling of the eyelid, have ceased.

Where it is desirable to act on the entire length of the tarsus, that is, in the worst cases, I operate in this way. An assistant stands behind the patient, makes the eyelid tense by drawing its external angle outwards and raising the eyebrow. With a scalpel, I cut through the skin in the direction of the lines on the eyelid in the following diagram, making the under incision the first, and with the aid of the forceps, dissect off the flap, commencing at the inner angle, and endeavour not to interfere with the subjacent muscle. The sponge, if required, should be used by a third person when he can be commanded. I apply three or four sutures.

As regards after-treatment, water-dressing, or greased lint, may be used. I employ nothing unless the eyelid be unhealthy, when one or the other is chosen; the latter when it is likely that trouble will not be taken to renew the wet lint sufficiently often, and to apply it neatly and properly.

The upper incision is not so readily accomplished as the under. I recommend those who are not in the constant habit of operating, after the first incision has been made, to lay hold of the centre of the upper portion of the skin with the forceps, and draw it downwards, and thus secure it for the second cut.

In operating on the right eye, as a matter of convenience the dissection should be made from the inner to the outer corner of the flap.

The operation on the under eyelid in nowise differs in principle

Fig. 204.

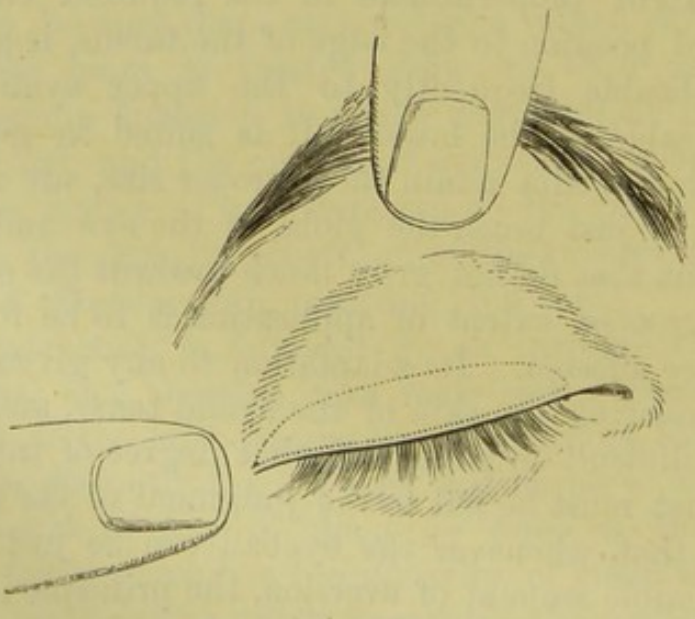

of the assistant, and the advantage of making the under incision first, include the dissimilar points.

The partial operation is to be done in like manner, but it cannot be generally depended on, unless a strip of skin not less long than half the breadth of the eyelid be removed.

After many years' experience in this operation, I am unaware of a single drawback. It does not interfere with the proper escape of the lacrymal secretions, as the positions of the puncta are not altered.

A young woman, who was obliged to leave her situation from the effects of trichiasis, was sent to me. The central cilia of the upper eyelid, and the outer ones of the lower, were inverted, and rested on the cornea. The cilia-forceps had been repeatedly used. I operated on each eye. The very accurate sketch below shows the state of the eyelids seven months after the operation, and it exemplifies the peculiar adaptation of the principle to the lower eyelid, where the cilia that were completely reversed were made to clear the eyeball.

Fig. 205.

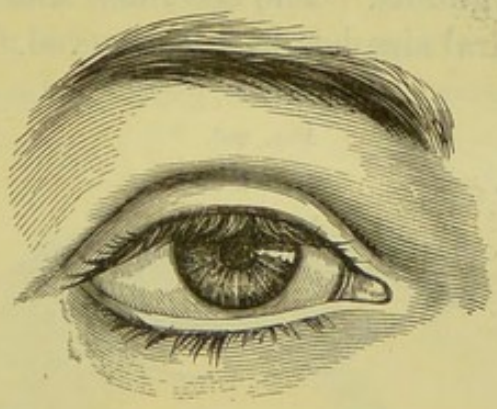

It must be apparent that only with a knife can the skin be incised with that accuracy and closeness along the edge of the tarsus which are necessary; but even if the scissors could be equally efficacious, the conspicuous scar that is inseparable from their use, is more than enough to proscribe them.

The excision of the cilia, the second radical operation, may be partial or entire. It is an effectual remedy in all stages of their inversion, but the operation produces deformity, and disfiguration about the face is secondary in importance only to disease. Besides, the direct injury that is inflicted on the Meibomian glands, and the effects from cicatrization, whereby their outlets get closed, and the tarsal cartilage atrophied, should induce us to reserve

viciously turned in, and cannot be righted by the removal of skin, as in the above operation. It is a very common impression that with care the glands may be avoided. No dissection in the living subject, that shall remove the cilia in an effectual manner, can fail also to bring away a portion of the cartilage, and, therefore, to a greater or lesser extent, injure and destroy some, at least, of the Meibomian glands, because some parts of their follicles always adhere to the cartilage. The objection applies chiefly to complete amputation. Partial excision is much less severe, and may often be advantageously resorted to when it is expedient to get rid of a cluster of very much inverted eyelashes.

The following display of the cilia, by the removal of the integuments and muscle, may be a useful reminder of their position on the cartilages. The eyelids are supposed to be laid flat, and the lower cilia are turned up to afford the best view. The irregular manner in which they are planted in the dense fibro-cellular and fatty tissue, admits the entire extent of only the most superficial to be exposed. Their bases are a little more than a line from the edge of the lid. Within each follicle, and near the mouth, are the ducts of several sebaceous glands. The specimen was taken from an adult female, and the natural size has been preserved.

Fig. 206.



The second diagram shows the edge of the eyelids in profile, and exhibits the relations of the several parts.

Fig. 207.



For the partial excision, the eyelid should be secured, as in the foregoing diagram, for the removal of the skin. An incision is made on either side of the bunch to be taken away, long enough to reach beyond their follicles and through the skin and orbicularis muscle, and a third transversely, at the very edge of the eyelid,

falling in with the two vertical ones, as in Fig. 208. The little flap is then raised and entrusted to the care of an assistant, who keeps it

Fig. 208.



turned up with an instrument or his finger, and attends to the bleeding and checks it. The mass of follicles, with the investing tissue, are carefully hooked with the tenaculum forceps, and dissected out. The small scalpel should be used. The flap is then to be restored and retained by three sutures, one on each edge. Sometimes a strip of court plaster will suffice. Unless the skin be raised to a greater extent than will merely uncover the cilia, there would be a deficiency of space for operating efficiently, and the base of the flap, which I generally make broader than the apex, would not be sufficiently wide to ensure its vitality. The destruction of healthy cilia is inevitable; no one who has dissected the edge of the eyelid, and made himself conversant with the parts, will believe in any method of operating by which it is proposed to remove a given number of irregular lashes, without injuring contiguous ones.

Fig. 209.

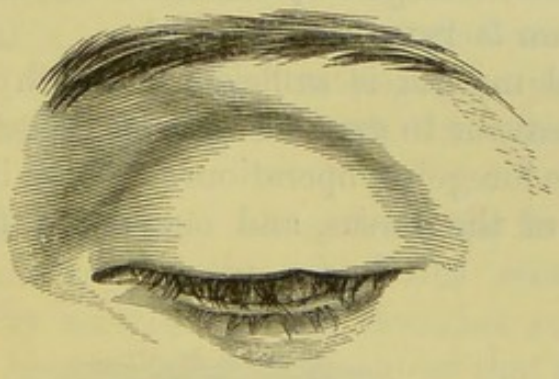

The above illustration of partial removal from the upper eyelid, was taken four months after the operation.

The patient, a female forty years of age, had been long tormented by ten or twelve cilia that rested on the globe of the eye; they were very minute and white, and grew directly inwards. She had given a long trial to the cilia-forceps.

The partial operation may be executed on a more extended scale than the diagram shows, and may be applied at the commissure, as well as at the horizontal edge. It may be done in two places on the

Another method of the partial operation is to dissect out the integuments, muscle, and cilia by a triangular flap, the base of which is at the tarsal edge, and then to raise the integuments on either side by a little dissecting, and to approximate their edges, as nearly as may be, by plaster. This facilitates healing, some of which must be by granulation.

Some operators do a modified operation, separating the cilia, or rather trying to do so, from the tarsal cartilage, by passing a knife between them at the edge of the eyelid, splitting, as it were, the edge, and then remove them along with the integuments and the muscle. This is a most uncertain proceeding, because the cilia are so apt to be cut across.

To remove a portion of the entire thickness of the eyelid with the cilia, is an operation of old date, and is objectionable. It occasions much deformity. Mr. Tyrrell, who had much experience, after advising the measure where several cilia are inverted together, says: "Such a plan is not, however, advisable when there are many cilia remaining, as the contraction of the new cicatrix is very likely to produce inversion of some of the neighbouring hairs. The patient must therefore be contented with having them extracted with forceps whenever their growth occasions the slightest irritation."

The entire excision is called for where there is very decided inversion of the hairs in several places. The indications are to remove the cilia with as little damage as possible to the tarsal cartilage, and to leave the punctum lacrymale untouched.

When the tarsal margin is sufficiently healthy to admit of the plan, I always endeavour to save the skin by reflecting it. The eyelid is fixed as in the foregoing operations. Three incisions are made, one at each corner of the tarsus, and one along the margin. The

Fig. 210.

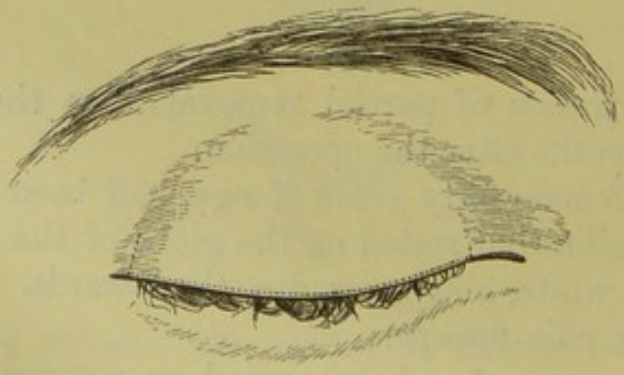

skin and muscle are then raised and held back, the cilia dissected off, and the parts adopted by sutures. It requires great caution not to allow some of the cilia bulbs to escape; and unless the tenaculum forceps

be used, and the sponge be nicely employed by the assistant, so that the operator may clearly see the several steps of his course, a few are likely to be left behind. More care is required than might be supposed.

The diagram 210 shows the lines the knife should take.

Where unhealthiness of the eyelid will not allow of excision of the cilia alone, there must be more of an amputation, and the skin removed with the eyelashes. An incision is made through the skin and the muscle, at about the eighth of an inch above the tarsal margin, from the outer angle nearly to the punctum, or from within to without, according

Fig. 211.

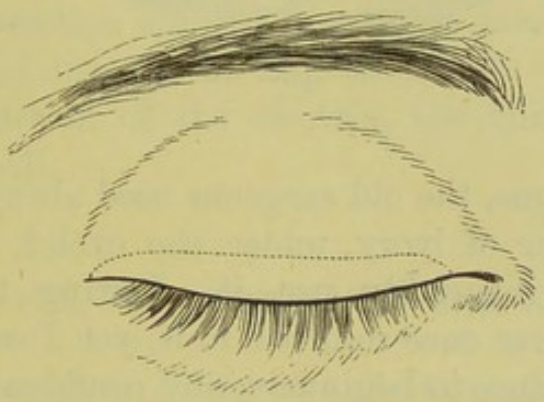

to the eye to be treated, as in the diagram, Fig. 211. The dotted line shows the direction to be taken; one end seized with the forceps, made tense, and skin, muscle, and cilia all dissected off in a mass by vertical cuts. Some of the cartilage is necessarily removed. This is far preferable to cutting through the entire thickness of the eyelid.

The execution is necessarily slow, from the frequent demand for the sponge. Should any of the cilia-bulbs escape detachment, a point ascertained by scrutinising the denuded surface, or the part excised, they must be removed. It is seldom that a few fine hairs at the inner corner are not left; indeed such must happen when they grow over and beyond the punctum; but it matters little, as they are very rarely inverted, and may be eradicated if they cause any inconvenience. The edge of the cartilage and that of the skin, may be brought together with accuracy by a few sutures.

Here is an example of the several operations for the radical cure. The lower eyelid was operated on by a surgeon, long since deceased. The intention was not quite fulfilled, for the greater number of the cilia escaped the knife, the central ones only having been removed; and when there was a fresh growth of those that had been merely cut

the tarsal margin, and rectified the evil. I also performed the entire excision on the upper eyelid. It was considered by the artist that a sketch, with the eyelids approximated, would give the best representation. (Fig. 212.)

Fig. 212.

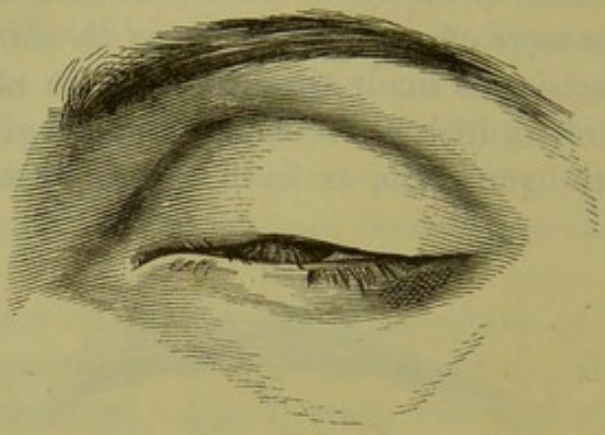

In these operations, the old surgeons used always to place a curved spatula, of wood or of ivory, under the eyelid, and I believe that foreign operators invariably use it. During the whole of my practice I have never once resorted to it, yet I can well understand it may give assistance to beginners, and confidence to those who do not operate frequently.

Other methods of treatment have, during centuries, accumulated into a long catalogue. They consist for the most part in different kinds of cauterization of the eyelid, or of the cilia-bulbs, with the actual cautery, or escharotics; and in attempts to destroy the hair-bulbs by suppuration by means of a seton, introduced between them and the skin. But the greater part of them are obsolete, and need not be farther mentioned. Others are, in my judgment, far inferior to the surgical measures I have advanced. Sir W. Wilde's ingenious plan I have not tried. In a paper on Entropium and Trichiasis in the "Dublin Journal of Medical Science" for 1844, he says, a single lash, or one or two lashes, will sometimes turn in upon the eye and produce the greatest annoyance. The patient gets tired of plucking them out, and applies for surgical relief. In such cases, placing the horn-spatula within the eyelid, he makes an incision with a small knife down to the root of the inverted lash, and, having waited until the hæmorrhage has ceased, applies a point of nitrate of silver by means of a small port-caustic, down to the bottom of the wound, and then removes the lash. This seldom fails, but frequently it destroys two or three of the neighbouring cilia. He adds, partial distichiasis also, or more extended trichiasis, may likewise be successfully treated by the same means.

Transplantation of the cilia, combined with the removal of a portion of the palpebral skin, is a late suggestion.

An inter-marginal incision is made along the eyelid between the tarsal cartilage and the cilia-bulbs. The skin and the cilia are thus dissected from the cartilage along the length of the lid, while a strip is raised at each corner. Then a piece of skin is dissected from off the eyelid. The first incision is to be made about two lines from the tarsal edge; the second, about three lines higher, and joining the other at each end. This semi-elliptical piece is to be taken away. The flap which has been raised with the cilia, is to be stitched to the edge of the skin above. In other words, the edges of the wound which have been left by the removal of the skin, are to be united. The objections to the operation are, the damage it does to the Meibomian glands, and the liability of the flap to slough. More than these, through the contraction of the cicatrix, the cilia are often again thrown on the eyeball.

ENTROPIUM, OR INVERSION OF THE EYELID.

Entropium, or turning in of the edge of either of the eyelids, may be a traumatic, or an idiopathic disease. The first is classed with injuries to the eye in another chapter. It is with the second that we are now concerned.

Idiopathic entropium is met with in three states. In a spasmodic form, for the most part occurring in old people, and almost always confined to the lower eyelid, the tarsal margin being healthy and the eyelid capable of being readily righted or returned to its place. In a chronic form, which may affect both eyelids, but generally exists in the upper, for the most part associated with more or less inflammation of the tarsal edge, whereby the cilia are mal-directed or influenced, and the pliancy of the parts lost. In an acute or inflammatory form, when the eyelid is inflamed.

Effects. Inversion of the upper eyelid produces graver symptoms than that of the under; because of the constant contact of the cilia with the globe of the eye in all the stages of the affection; the cilia here are longer, larger, stronger and more numerous; and in certain cases from increased irritation due to thickening and induration of the tarsal edge.

General course of the affection. A feeling of something in the eye followed by ulceration and opacity of the cornea, and either partial destruction of the eye for visual purposes, or loss of vision from opacity of the cornea, or from changes in its internal parts, resulting from

general inflammation, followed by atrophy. Sometimes the cornea long resists the irritation; the opacity is not usually that which attends corneal ulceration. It creeps up slowly from the cornea margin, beneath the epithelium, in a new creation of round formative cells, and grows over the cornea as a connective tissue. This condition may for a while be stationary. Then the ordinary inflammatory changes of interstitial deformity ensue. A common termination is, after months, or it may be years, of suffering, for the conjunctiva to become thickened and insensible. But the severity depends on the degree of the entropium, the condition of the cilia, the state of the edge of the eyelid, and the constitution on which the local irritation acts.

Entropium of the under eyelid is not, generally speaking, a very serious affection. The cilia are finer, shorter, and less numerous than those of the upper, grow slower, and from their mode of insertion, and the lowness of the lid, they rarely come in contact with the cornea. When they do encroach on it, opacity is seldom produced, and their presence on the conjunctiva of the sclerotica is less irritating. In well-marked cases there may be no more inconvenience than conjunctival inflammation, with slight lacrymation, and gumming together of the eyelids at night. Even with complete inversion, the eyeball does not suffer, because the cilia do not recline upon it; the tarsal cartilage being folded inwards, they are put out of the way, and lie at the bottom of the eye in the sinus of the conjunctiva. But before this state of perfect inversion arrives, the eyeball has generally become more or less tolerant to the contact of the cilia; because very slight structural change in the conjunctiva, which is soon set up, is sufficient to defend it from their irritation. It is more common in this lid because the cartilage does not resist its formation.

The ultimate cause of entropium is contraction of a part of the orbicularis palpebrarum muscle. I have taught this for many years, and in former editions of this work I have given anatomical descriptions of the muscle, with delineations, in illustration of my views. There is sufficient power in the ciliary portion of the muscle to produce the inversion. When I was first investigating the subject, one of my ophthalmic colleagues showed me that he could, by his will, bring this so-called ciliary muscle into spasmodic action, and invert the edges of both his lower eyelids, produce the most complete entropium, and conceal his long and numerous cilia. Lately I have met with a patient who could do the same thing.

There are other theories respecting the cause of the disease which I am forced to notice, because they are still believed.

One attributes it to relaxation of the skin of the eyelid. To say that looseness of the skin allows of the inversion, would be to affirm that in a healthy eye the skin is antagonistic to some power acting on the eyelids; a statement unphysiological and erroneous. The skin is never tense, but always loose, as a natural provision for unrestrained palpebral movements.

Another ascribes it to thickening of the palpebral conjunctiva. In incipient entropium the conjunctiva is frequently quite healthy. After a time, when the entire conjunctiva is involved in that general inflammation of the surface of the eye, as an effect of the entropium, which is sure to ensue in the progress of the affection, the palpebral portion, from its peculiar structure, will show the greatest morbid changes. At the same time, the posterior edge of the margin of the eyelid has generally disappeared, and the tarsal fibro-cartilage is thickened and hardened. Again, cicatrices, the result of conjunctiva disease, are frequently met with on the palpebral conjunctiva without the co-existence of entropium.

A third supposition is that a primary change occurs in the tarsal cartilages, whereby they become curved. To examine into its correctness, cases of the affection should be chosen for the investigation, in which the tarsal cartilages have not suffered from disease.

It will simplefy the inquiry even more to look principally to an inverted lower eyelid, because it offers a greater facility for observation, as the natural direction of its border is outwards, and away from the globe of the eye; and any change in its direction can be better appreciated than in the upper, where the margin inclines somewhat inwards. Besides, there is a very marked difference in the size of the two cartilages, and this may throw additional light on the inquiry, the upper being considerably broader and more compact than the under, as the outline of them below shows. These so-called cartilages are thickened areolar tissue, largely interspersed with elliptical nuclei, and are continuous with the tarso-orbital fascia.

Fig. 213.

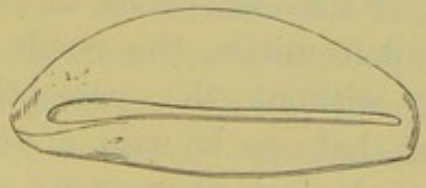

In the most marked or aggravated stage of entropium, then in the under eyelid, the narrow cartilage does not rest against the eyeball, as though it bound it, because it is contracted; but it is so com-

pletely turned on itself, and rolled upon the eyelid, that its position is completely reversed, and the cilia are hidden. It is dislocated in a manner which I attempt to explain by the next diagram.

It is evident, from the narrowness of the cartilage, that no curve of it, nor any kind of contraction, could produce these changes. But more than this, I have never been able to satisfy myself that the cartilage is ever altered or modified in form; and if not, it cannot have any degree of influence in producing the inversion.

FIG. 214.



g, The eyeball. *c*, The cilium. *t*, The tarsal cartilage.

In entropium of the upper eyelid, the inverted cartilage rests against the eyeball, and the convexities of the cilia are then on the cornea, while their extremities are directed outwards, a position that their ends assume from the handkerchief being used in that direction during the frequent calls for its application. In some aggravated cases they lie spread out on the globe of the eye.

Now, this difference in the direction of the edges of the eyelids ought not, I think, to be attributed to dissimilar causes, but to the same cause acting on the dissimilar physical construction of the eyelids themselves. Thus the upper cartilage is merely curved because its breadth does not allow it to be rolled up, like the under.

The existing or disposing cause is not always to be discerned. Although I am now satisfied as to the pathology of entropium, it is as difficult to decide what are the circumstances that bring about such unequal and prejudicial action of the orbicularis, as to account for most cases of squinting, or other deformities, the result of perverted muscular action. These occur without the perceptible influence of any excitant; and the most that can be said of them is, that sometimes they follow other pathological phenomena of common occurrence which are then regarded as excitants.

In the spasmodic form in the aged, there is really no apparent cause, for all the ocular appendages may have their textures natural although late in the disease they are morbidly influenced.

In the chronic kind, there is generally associated more or less inflammation of the tarsus with the accompanying roughened conjunctiva, and it may be, too, contracted palpebral aperture. I am induced to use the term "chronic," simply because chronic disease of an inflammatory nature, and the entropium, usually coexist; but strictly speaking, the expression may be inaccurate, and the same may be said of the word "spasmodic;" but this is immaterial, so long as I make known what I wish to express, the phases of the disease. Here the entropium is secondary, and the consequence of the preceding disease.

In the acute state, inflammation of the integuments in which the tarsus participates, is the direct cause. In any operation or accident to the eyeball, especially in the aged, which produces inflammation of the palpebræ, entropium of one or both eyelids may follow, although such an effect is happily rare. The same may be said of corneitis in children when the palpebræ are inflamed.

Treatment. In the acute or inflammatory form, if the eyelid be returned to its natural position and there maintained by a strip of court plaster for a few days, or till the vascular excitement has entirely subsided, the entropium will disappear. Collodion may be used.

In the early stage of the spasmodic form in the under eyelid, the above treatment by plaster, carried out for a few weeks, or even for a shorter time, may suffice.

In the chronic form, with its permanent inversion, or with persisting inversion without the presence of inflammation of the parts, a definite surgical measure is needed, which must be modified according to certain physical complications. This will be explained and illustrated as I proceed.

The fundamental operation I adopt is founded on what appears to me to be the pathological interpretation of the affection, and the objects of which are, to overcome the means of the inversion by dissecting away the marginal thick portion of the orbicularis, and to remove as much of the skin of the eyelid as may be necessary to produce such tension as shall overcome the deformity which other tissues of the eyelid may have acquired, from the irregular position into which they have been thrown by the muscle. In a few instances of short duration of the entropium, I have dissected out the muscular tissue only. I doubt not that this limited operation would suffice in most cases if done very early, but usually patients do not apply till there are mechanical changes in most parts of the eyelid, and then the skin must be removed as well.

In permanent spasmodic entropium this operation is all-sufficient;

in chronic entropium, generally nothing more is needed. When, however, the tarsal edge is very much thickened and hardened, or when there coexists severe trichiasis, it is insufficient alone: the cilia must also be excised, or perhaps even the edge of the tarsus, including the cilia follicles, cut off.

This is the way to operate. An assistant stands behind the patient, and having made the eyelid tense, by drawing it outwards and raising the brow, as is shown in the operation for trichiasis, the operator makes two incisions through the skin and the muscular fibres, in the course indicated by the lines in the following diagram

Fig. 215.

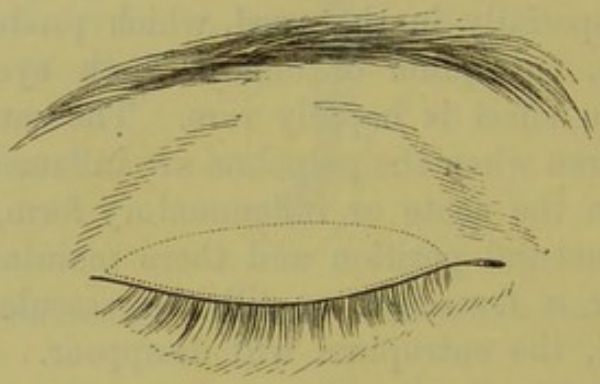

(Fig. 215). This will include what I shall call the ciliary portion of the muscle. The ancient anatomists called it the ciliary muscle.

The flap thus outlined is drawn forwards, and slowly dissected by vertical strokes of the knife, from the one corner of the eyelid to the other, and not taken away by horizontal cuts, or else the muscular portion will not be effectually removed. The wound should be very carefully sponged during the operation. Any arterial jet must be checked by sufficient pressure with the finger. I have never found a ligature to be necessary. The exposed surface must be inspected; and if any muscular fibres have escaped, the forceps and knife must be re-applied. The assistant should continue the proper retraction of the skin till the knife has been laid aside, as essential to steady and effectual dissection. Three or four sutures should be used. Union is always effected by first intention.

The operator and his assistant must take their positions according to the eye to be operated on.

The cilia might appear to be in danger of being dissected off, but in reality they are not. A part only of the dissection is over them; and the muscle is readily raised, in consequence of its looseness, from the dense fibro-cellular tissue in which they lie.

Water dressing should be applied, and the patient kept quiet for a few days. The sutures should be removed on the third day.

Double entropium of upper eyelids. F. B., a pale, thin girl, aged twenty, suffered from entropium of both upper eyelids. The right was the more turned in of the two, and the cilia of each, except a few fine ones at the corner, rested on the globes of the eyes. The eyelids were not in the least thickened, nor was trichiasis present; so that when their edges were turned out, the lashes were nearly in their natural position, being necessarily a little disarranged. The upper parts of both corneæ were hazy, the left being the less affected.

The illustration (Fig. 216) is an accurate representation of the right eye in profile, taken the day before I operated. I removed

Fig. 216.



rather more skin along with the muscle from this eye than from the left, which was treated at the same time. On the third day the sutures were removed, and the patient left the hospital for home.

Three months after, she called to show herself. Faint scars merely indicated the operations. The lacrymation and intolerance of light,

Fig. 217.

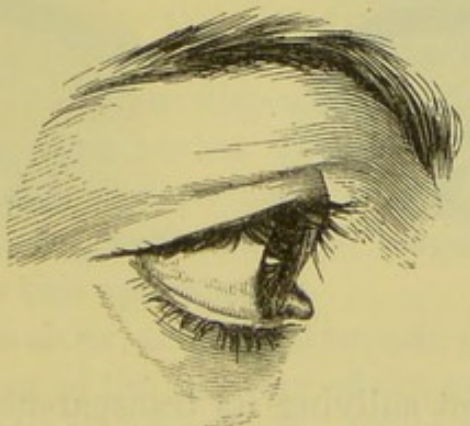

and the conjunctival inflammation, had passed away. The right cornea had much improved in

natural, there being only a little loss of lustre. I now discovered that she was near-sighted. The sketch (Fig. 217), taken at the latter period, shows the eyelid righted, and the cilia raised.

Double entropium of upper eyelids, one eye having been previously operated on. E. H., a female, aged thirty. The upper tarsal cartilage of the left eye was inverted, and nearly all the cilia were resting on the globe of the eye, causing considerable irritation. The cornea was ulcerated and hazy. The eyelid bore on its upper part near the orbit, a large and peculiarly disfiguring scar, the result of the removal of a portion of the skin with scissors in an attempt by some surgeon to remedy the deformity. The right eyelid had been operated on by another surgeon. He had removed skin, used nitric acid, and slit the tarsus. I operated on the left eye after the manner I have advocated, and with success, as shown in Fig. 218.

Fig. 218.

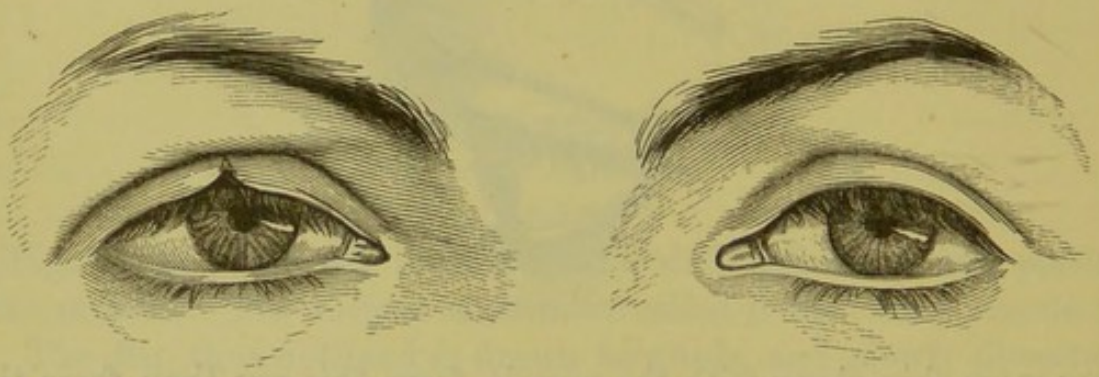

Entropium of the lower eyelids; the right completely turned in, and the left only tilted or half-inverted, with the cilia on the globe of the eye (Fig. 219). M. H., aged sixty-seven. In the left eye the cilia were thrown against the globe of the eye; some of them rested

Fig. 219.

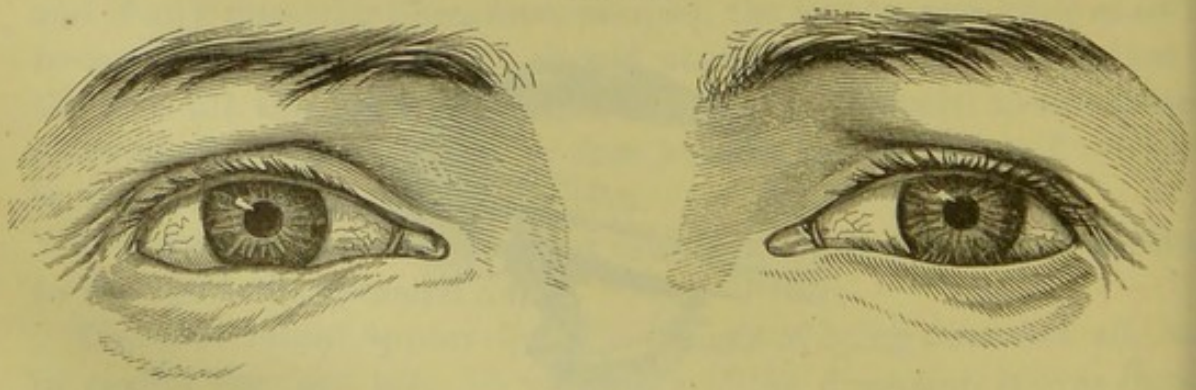

on the cornea without sullying its transparency. The integument just under the tarsal cartilage bulged in a singular manner. In the right eye the lid edge was completely inverted. Each affection had existed a year and a half.

The Fig. 220 was taken three months after operation on both eyes.

Usually, it is not requisite to dissect out more of the skin than will admit of the easy removal of the ciliary portion of the muscle. But where the edge of the eyelid is a little thickened and indurated,

Fig. 220.

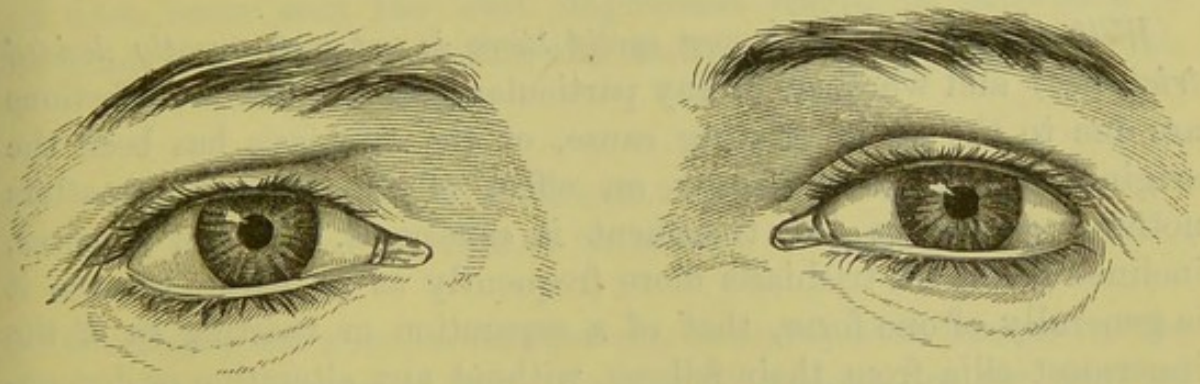

and not quite so easily acted upon, and in the entropium of the aged, where, from the reduction in the volume of the eye, and from its retraction, and the natural tendency to tegumentary folding, a larger amount must be excised, but not more than is necessary to reduce the edge of the eyelid to its correct position. Eversion, or depression of the tarsus, must not be produced. The cause of the deformity being taken away, there cannot be a return of the dislocation.

After-treatment, beyond water dressing, is seldom required. This seems to point to the fact, that the pathological changes in the conjunctiva are for the most part the consequence of the entropium, and not independent conditions.

Results. It is seldom that any trace of the operation is seen after the interval of a few months, sometimes weeks, provided that the edges of the skin have been brought neatly together, and the sutures taken out on the second or third day, and not allowed to be thrown off by ulceration.

The only indication of the former existence of disease that the eyelids exhibit, is the irregular disposition and staring arrangement which the cilia acquire from having been in contact with the globe of the eye, and subjected to its movements. The greater their length, the more abundant their growth, and the longer the duration of the inversion, the more is this apparent.

It is by observation alone, that an adequate idea can be formed of the rapidity and extent of the recovery of the eye, and especially the cornea, from the effects of entropium. From the moment that the cilia cease to irritate, all the distressing symptoms begin to yield; and so quickly is repair exhibited, that on the third day, the period

when I remove the sutures, cases have not been directly recognised by those who have assisted me with the operation; the conjunctiva having lost its vascularity, and lacrymation being subdued.

ENTROPIUM, WITH TRICHIASIS.

With inversion of the upper eyelid there is not unfrequently decided trichiasis; and whether, in any particular instance, the two affections are due to the same exciting cause, or the trichiasis has been the original affection, or merely an effect of the inversion, matters nothing so far as the treatment is concerned. I am, however, inclined to regard trichiasis more frequently as an effect, because it is generally of one form, that of a separation or twisting in of the innermost cilia from their fellows, without any alteration or degeneration in the individual hairs; and because, for the most part, the removal of the entropium is generally sufficient to take it altogether away.

It is prudent, before operating in any case of entropium, to ascertain whether trichiasis exists, and if so, to learn, if possible, whether the restoration of the eyelid to its natural position will, or will not, counteract the mal-direction of the hairs. Should it not, then more skin must be taken away, with muscle, than would otherwise have been necessary, and a slight degree of eversion of the centre of the tarsal margin produced. The amount is easily determined. When it is apparent that such moderate eversion will not suffice, the treatment must depend on the extent of the trichiasis; for if it be general, the entropium and the trichiasis must be attacked by one operation, and the cilia excised at the same time, after the rules given under the head of Trichiasis.

When the trichiasis is partial, as it usually is, the skin and muscle should first be dissected away, and then the irregular cilia sought for and excised. When there is a doubt about the necessity of removing them, the entropium should be alone attended to, and the result observed; because it is not always possible, before the operation has been performed and the eyelid restored, as well as recovered from the inflammation and swelling induced by the inversion, to ascertain with exactness to what extent the trichiasis may be benefited. If afterwards, a bunch of hairs should turn in, it must be dissected out with care and accuracy, after the manner already described.

With many of the cilia broken, and some just reproduced after having been plucked out, it cannot be known what direction they

may assume when grown, and such a case should be watched for several weeks.

It must be very seldom that the removal of entropium from the lower eyelid does not at the same time separate any irregular cilia from contact with the globe of the eye, for a single exception only has occurred to me.

I have never seen the least unpleasant result, or drawback of any kind, from slightly everting the centre of the edge of the eyelid.

ENTROPIUM, WITH CONSIDERABLE THICKENING OF THE TARSAL MARGIN.

The ordinary operation for entropium is unsuited, when inversion of the upper eyelid is associated with considerable changes in the physical character of the tarsal edge, from long-continued inflammation, by which it has been rendered thick and very hard; a state in which disease of the fibro-cellular tissue around the cilia-follicles plays no unimportant part. The point can always be readily determined, by trying how far the eyelid can be everted by the fingers. Generally, little or no impression can be made on the entropium, however much the eyelid be lifted. The tarsal edge is so hard that it feels like a bit of wire under the skin. There is not necessarily trichiasis. In some of the worst cases that I have had to treat, the eyelashes have been neither irregular nor abortive, but still they act injuriously on the eyeballs. I have seen the cornea with all the appearance of ligamentous structure.

My practice here is to excise the cilia and the diseased tarsal margin, with scalpel and forceps, and bring the edges together with a few sutures. There need be no apprehension about passing the threads through the cartilage.

Entropium, with trichiasis, thickening of the tarsal margin, and contraction of the palpebral aperture. There are here all the complications that can occur in this affection. An eye thus involved is in a deplorable state, for with all this outward deformity, there is much internal disease. The conjunctiva is thickened and granular, and parts of it are in that state which is known by the term cicatricial. It is supposed that the tarsal cartilage becomes partially atrophied. I doubt this. The cornea is more or less opaque, and often otherwise affected. These combinations are rarely seen, except among the most destitute individuals of the community, and arise from neglect of early treatment.

The narrowing of the aperture is due to contraction at the outer

commissure, the effect of chronic inflammation, attended for the most part with superficial ulceration of that part of the tarsal edges.

The cilia and the tarsal margin must be excised, after the manner described in the last section. But more is generally needed, for the remainder of the tarsus, by the physical changes that have been described, may yet bind the eyeball. The best result is got by cutting through the eyelid vertically in the centre. A more permanent effect ensues if the skin and the under surface of each side of the wound are brought severally together by a couple of sutures, because there is then quick healing. If this be not done, suppuration may ensue, and subsequent contraction will then almost close the incision.

After the irritation from the entropium has been removed, the chronic inflammation ceases, and there is no more palpebral contraction. Much suffering is checked, and an opaque cornea may recover sufficiently to afford useful sight.

It is not enough to divide the tarsus without the other operations.

I do not recommend the operation for dividing the eyelids at the outer commissure, because there is generally so much chronic inflammation around this part of the aperture that it is almost impossible to get the cut edges to heal separately, a condition necessary to ensure an extension of tarsal edge. If the two edges do not unite, they heal by granulation, and contraction ensues, whereby the effect of the division is lost, and even greater narrowing is caused.

CONCLUDING REMARKS.

Besides describing my own practice, some notice should be taken of that of others.

The most common operation is the removal of a transverse portion of the skin, by pinching it up with the finger, or by the entropium forceps, an instrument invented for the purpose, and cutting it off with a pair of scissors.

That some improvement occasionally follows such contraction of skin, and that more frequently in the under than in the upper lid, I am perfectly aware ; but it is apparent in incipient cases only, and then it is for the most part temporary. In all well-marked instances of inversion, such methods scarcely improve them in the least. It is true that excision of the skin from the lower eyelid, to a considerable extent, may always be effectual in removing an entropium from it,

owing to the configuration of its cartilage, as pointed out. But then to bring about this alteration by removal of the skin alone, the eyelid must actually be depressed and everted; and thus one evil would be exchanged for another.

The next most frequent method is the destruction of the skin of the eyelid by the actual cautery, or some escharotic, so as to produce a cicatrix, the contraction of which is expected to remove the inversion, and it is thought to be better if the cartilage be involved in the scar. I declare it to be inefficient, and a clumsy, painful, and disfiguring proceeding. Besides, the contraction often curves the eyelid laterally.

There is the division of the outer commissure, and the vertical incision of the cartilage at the centre. The removal of a central portion of cartilage. Also the vertical cut at each angle, the horizontal incision of the conjunctiva, and the elevation of the eyelid during the healing process, by an instrument called the suspensorium palpebrarum, a sort of elevator. Then the still severer method of dividing the tarsal cartilage of the upper eyelid longitudinally as well as vertically, of the under eyelid vertically only, taking away a fold of the skin besides, and fastening the eyelid to the brow, or to the cheek, by means of several fine ligatures passed through its edge, and secured by strips of plaster, for the space of eight or ten days, followed up by frequently touching the incision with sulphate of copper to ensure healing by granulation. All these are uncertain in confirmed entropium; for with the cicatrization the power of the muscle is wont to be renewed, and the entropium returns, and the eye is disfigured by each of them.

It would take several pages to speak even briefly of the many other operations. Some are thoroughly impracticable; others are evidently mere suggestions, originating in dead-house dissections, and capable of demonstration on a normal eye, but useless in a diseased living eye. My duty as an author is to spare the student the puzzle and confusion that the description of such is apt to occasion.

ECTROPIUM, OR TURNING OUT OF THE EYELID.

There are variations of ectropium, from the slightest eversion of a part of the tarsal edge, to the most marked turning out of the whole of it, by which the inner surface of the eyelid is freely exposed.

Ectropium is common in the under, and very uncommon in the upper eyelid.

Effects, when the under eyelid is involved. Epiphora, or overflow of the tears. This symptom is always most marked when the lacrymal papilla, in which the punctures open, is displaced. Therefore, with but the least ectropium of the inner side of the edge of the lid, the puncture is out of place, and the tears overflow.

In the exposed conjunctiva, marked changes occur. At first, there is slight congestion. It then becomes hypertrophied, and lastly granular.

I have remarked that although for a while it is very sensitive, a period arrives when it loses much of its sensibility, and gets actually tolerant to exposure, and even in a measure to the presence of extraneous substances.

The tarsal margin soon loses its sharp outline, and gets rounded, and the inflammatory changes by which this is effected in a measure spoil the Meibomian apparatus.

The cornea suffers whenever the eyelids cannot be closed. The continual exposure, and the inability to wipe off or brush aside intruding particles, produces inflammation, opacities, and infiltrations, and it may be, even ulcers and loss of sight. Dry, or cuticular cornea may ensue.

The impairment of sight is often hastened by acute attacks of inflammation of the eyeball, whereby the internal tissues are spoiled.

The effects, when the upper eyelid is involved, are those of irritation and inflammation of the eyeball from exposure.

The causes of ectropium are lesions externally, that is, without the eyelids. I shall detail them under four heads.

The first includes abscesses about the orbit, usually at the circumference; burns; scalds; chemical injuries; ulcerations, either simple or specific, as from syphilis, lupus, suppuration, and sloughing after erysipelas; wounds; contusions; and surgical operations. Of these, the effect of the cicatrization of abscesses about the circumference of the orbit is by far the most frequent. The usual seat of suppuration is the lower and outer part of the edge. The next in frequency is the upper and outer. Taking all these causes into consideration, both eyelids are alike liable to suffer.

The second is the consequence of disease of the eyelid itself. The under eyelid is the more generally affected.

The third arises from the enfeebling effects of age.

The fourth is due to palsy of the portio dura, hemiplegia facialis, by which the orbicularis palpebrarum muscle, among those that are palsied, no longer acts, and the power of closing the eye is lost. The upper eyelid cannot be depressed, while the under falls down and turns outwards, becoming more everted in process of time.

Details must be given.

The eversion from the first class is the most severe. It is associated with damage of the parts around the eye, and calls for the exercise of more surgical skill than any other. Some of the cases are beyond benefit, others can be relieved, and some cured.

Ectropium of the under eyelid.

In Fig. 221 is shown a well-marked instance, from a child four years old. The scar on the side of the nose points out the remains

FIG. 221.

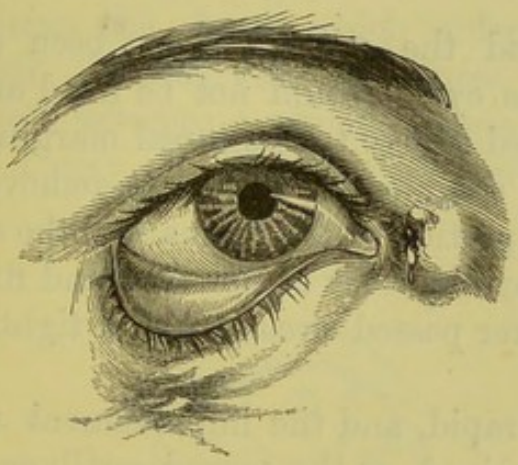

of an abscess coeval with that on the cheek. Both were scrofulous, and unconnected with disease of the bone.

For the remedial measure, in a case of this nature, the objects are to procure a supply of healthy tissue to replace what has been lost, and without which there can be no permanent improvement, so that when the eyelid is liberated and put in position, there shall be a continuity of healthy structure, and to excise the granular conjunctiva. The second part of the operation has for its ends the removal of a diseased tissue, and the making of a breach, by the contraction of which the swinging tarsus is readily acted on and drawn up to the eyeball. The lower tarsal cartilage, as I have shown in a diagram in the section on Entropium, is very narrow, and very unlike the higher.

The actual loss of skin from the abscess in such cases is, in fact, very slight. It is mainly the cellular tissue that is destroyed by suppuration, the contraction from the loss of which pulls aside the skin, and ties or binds it down. Merely to release the eyelid from its adhesion by any plan of dissection, and to leave the wound to be filled up, and to heal by granulation, would be perfectly useless; nay, the attempt might aggravate the ectropium and add to the scar.

The operation in this patient was thus performed. The cicatrix was sparingly removed

wound two straight incisions were made, after the plan in the following diagram; the surrounding skin was then separated from its attachments to a considerable extent, especially on the cheek, by which it admitted of transposition or gliding, so as to serve the place of that which had been damaged and removed.

Fig. 222.



So extensively had the cellular tissue been destroyed by long suppuration, that the eyelid could not be freed and replaced till the dissection had reached nearly to the tarsal margin.

A portion of the conjunctiva was next removed from the sinus, opposite the everted portion of the tarsus, and the operation concluded by drawing up the eyelid as far as possible, and fixing it by means of narrow slips of plaster passed circularly and tightly from the nose to the temple.

Cicatrization was rapid, and the improvement so far satisfactory. Some deformity remained, as the curved cartilage could not be made to accommodate itself to the eyeball; and a few weeks later, I removed that part of the eyelid yet distorted, with the tenaculum forceps and the scalpel, and applied two sutures.

By any one not aware of the nature of the operation, I am sure that the former condition of the eye could never have been imagined.

Fig. 223.

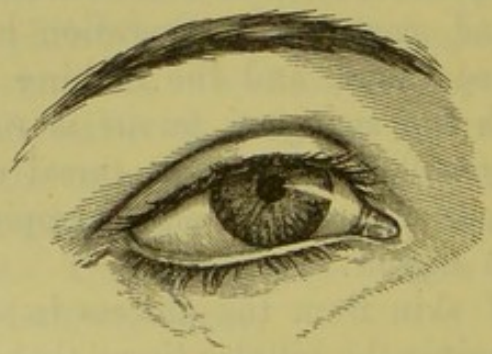

The preceding sketch shows a correct likeness of the alteration that was effected.

It is not often necessary to shorten the tarsus, nor always, perhaps, to excise any conjunctiva; but when either process is required, it is, I think, generally better to execute it simultaneously with the transposition of the skin. I suspect that the tarsus with its coverings is never

in reality much stretched. I doubt not that it yields somewhat, but the depression must be due principally to displacement; for when it is much pulled down, and apparently lengthened, the upper eyelid is lowered. The surrounding skin stretches.

Cartilage should therefore not be removed except on special occasions, for if the tarsus be not elongated any loss will tend to depress the eyelid. Yet for the removal of a piece of cartilage to be really effectual, it must be large enough to shorten the eyelid to the natural dimensions. The following diagram gives the size of the portion that was taken in the case under consideration, marks its position, and shows the shape, which differs from the V-form, usually recommended. The curved sides come easily together, and make the edge level; whereas a retiring angle is produced by the straight incisions. I may add that the portion was taken from a

FIG. 224.

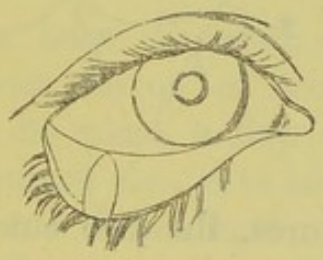

part where the tarsus had become bent and irregular, and had acquired a form not to be overcome by means that would ever bring the rest of the border to the correct line.

The removal of cartilage from the outer angle, by which a portion of each eyelid is included, might be executed when there is not a necessity for taking it from a given spot, and any subsequent scar is somewhat hidden by the natural folds of the skin.

But with stretching of the tarsus at a given point, the operation that is illustrated is to be preferred. The corner operation has many disadvantages. It interferes with the action of the upper eyelid. It contracts the palpebral aperture, and produces deformity. It is an indirect manner of affecting the eversion, and it can never take a curve out of the cartilage. It can never be proper, except when a very limited operation will suffice, therefore in some very slight case.

Removing a central bit of the cartilage has no disadvantage whatever. There is not any cicatrix to irritate the eyeball as some have asserted, nor any injurious effect, arising out of tightness.

Other methods embodying the same principle of dealing with the

of the cuts, have been proposed and practised; but mine is superior on account of its limit, the smallness of the subsequent scar, from the absence of angular flaps, and the greater certainty of healing by the first intention.

The peculiarity of a cicatrix, the size, the position, and the presence of more than one, will require modifications in the direction, number, and extent of the incisions. This will be illustrated farther, when I speak of ectropium of the upper eyelid.

An operator must not restrict himself to any form of flap, although he must remember that acute angles are the more likely to slough.

Dieffenbach operated in this way. A triangular flap, including the cicatrix, being raised, the sections *a a* are extended freely on either side, to allow of the ready approximation of the two sides, *b b*; these

Fig. 225.

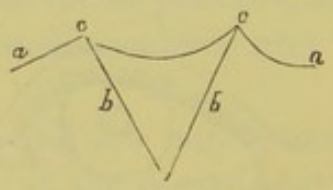

being then fixed by sutures, the two cut margins *a c* and *c a* are connected with the corresponding margins of the eyelid included between *c c*.

Most examples of this class, especially those of ectropium from abscess, may be treated on this plan.

When, however, from much loss of skin, the eversion is excessive, transposition will seldom suffice, and skin must be borrowed by a plastic operation, from a spot where its loss cannot ultimately be detrimental. But even this may be impracticable, for healthy skin may be out of reach, and unless a healthy piece can be raised, the operation had better not be undertaken. For instance, a lad of eleven years of age was scalded in infancy, the right cheek was covered with cicatrices, and the alteration of the features actually defied immediate recognition of the exact nature of the change. The upper tarsus was dragged down below the level of the under one, and beneath it was a plane surface about an inch square, at first supposed to be an ulcer, but which was the conjunctiva, and below that and the distorted side of the mouth, a short and irregularly disposed row of cilia marked the inferior tarsus. His condition was irremediable.

Such plastic operations demand considerable nicety, and require for

The skin to be borrowed must be healthy. There are two means of operating. In the one, skin is raised from an adjacent part and twisted round to the required spot, so that the axis may be horizontal, vertical, or oblique. In the other, with the maintenance of a connecting slip, the skin is slided laterally from a contiguous site, and without a twist. The adoption of either must be regulated by circumstances, the situation of the part at which the skin is required, the extent of the demand, and the position from which the skin may be taken. The first is most used, because more generally applicable, and it is executed in the following manner.

FIG. 226.



After the cicatrix has been dissected out as symmetrically as possible, with the greatest saving of sound skin, and the eyelid liberated and carried to its place, a flap of skin, cellular and even adipose tissue of the required size, is to be raised and twisted to the place made to receive it, as is shown in the preceding diagram.

The new bit is to be taken from a place in a line with the spot for which it is destined. There must be a sufficient bridge or isthmus left uncut. It is to be borrowed from the nearest point, so as to limit the twist; because the shorter it is the less is the circulation interfered with, and therefore the greater security to the preservation of vitality, while it moreover facilitates coaptation. Yet there should not be any stretching or straining of the skin, for that would spoil the chance of union.

When the skin is healthy, it is very extensible, and can be twisted round in an almost incredible manner. It is advisable not to wait till bleeding has ceased, but at once to adapt the parts and apply the sutures, as that will stop all hæmorrhage, and diminish the risk of failure from the exposure and chilling of the surfaces, and the exsanguine state of the flap is avoided. In all operations about the eyelids, I approximate the surfaces that are to come together as quickly as possible, irrespective of bleeding; and numerous instances of uninterrupted success confirm the propriety of so doing. Perhaps the rule will hold good in all cutaneous operations. Of course union could not ensue if clots interposed; but

The gap that is left should be diminished, in whatever manner may seem most expedient. The nearer the edges can be brought together, and thus maintained, so much the better; and the quicker the surface heals the less will be the scar.

Fig. 227.

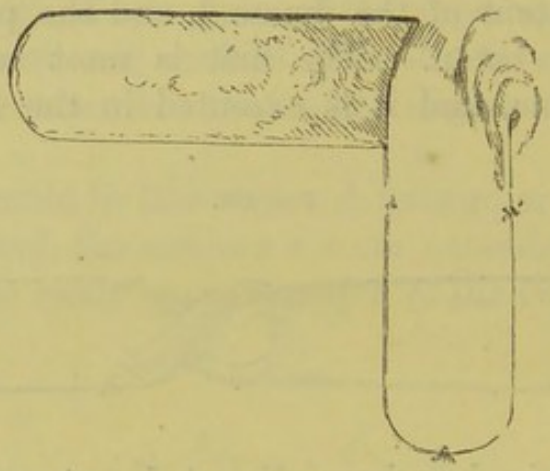

It would be still preferable when possible, to avoid the isthmus of skin by an arrangement of the following kind, the flap being taken from below or above, as occasion may require.

With all that has been recommended failure will ensue, unless the after-treatment is well done. The parts should be thoroughly supported by plaster and a bandage, and kept warm with cotton wool, and the patient placed at perfect rest. Such should be the nature of the dressing, that all movements of the eyelids should be prevented. It is seldom that this may not be accomplished by plaster, compress, and bandage. In any exceptional case, if it could not be accomplished otherwise, I should not hesitate to stitch the eyelids together for a few days. The sutures should be moved gradually, and not all at once. If inflammation exceed the limits of health, and pass into the phlegmonous form, cold applications may be required, and even leeching. But more is to be feared from sloughing or congestion, arising either from want of a sufficient supply of blood, or from some obstruction to the conveying away of the blood by the venous channel.

When the skin has been turned completely round, or nearly so, the attachment may subsequently require to be divided, and made flat by a little dissection.

There should be jealous watching against making the flap too small. Allowance should always be given for contraction,

gap to be filled, especially in fat persons. It is supposed to contract about a sixth. A pretty just idea of what will in general be required, with the necessary twisting, may be obtained by practising on the recently dead subject; indeed, without such preparation, mistakes are certain to be made on the living. With a little practice, however, rules of proportions will readily suggest themselves. In the case from which the first diagram was made, the place to be filled was an inch long, but the length of the flap was two inches; less would not have been enough for the twist, and to ensure sufficient vascular supply. In the second, where there was only half a twist, the

Fig. 228.

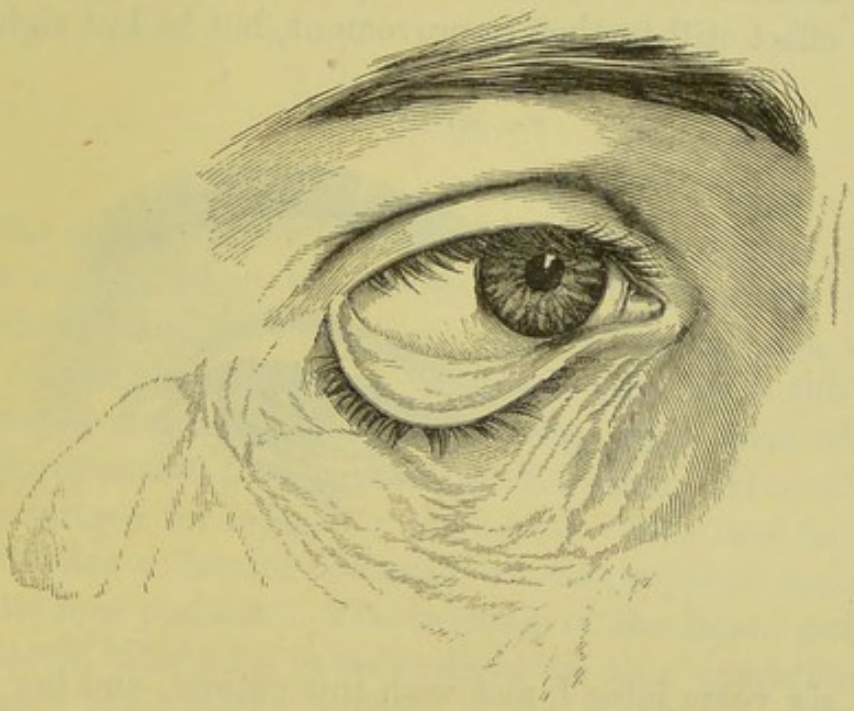

proportions were different; the flap to fill the same sized wound as the first, was an inch and three-quarters. It may assist the operator to trace out with tincture of iodine the size of the flap to be raised.

The beautiful and accurate illustration of the operation on the lower eyelid, Fig. 228, shows the usual result of insufficiency of flap, both in length and in breadth; in other respects the operation was well executed.

The patient had, in childhood, fallen into the fire. The scars about the cheek indicate the extent of injury. The outline of the flap, and the spot from which it was taken, are just visible. The transplantation was made at a hospital in London, when the man was thirty years old; and, according to his statement, half the

I assisted Mr. Taylor in operating in the very inveterate case of ectropium which is given in the chapter on Diseases of the Orbit, p. 89, and to which the reader is requested to refer. The edge of the tarsus and the conjunctiva were carefully dissected up, and the flap, which, in consequence of scars on the cheek, was taken from a spot directly opposite, placed in the desired position. The proportions which I have given in my diagrams were observed, and they answered well. At a later period a part of the conjunctiva was removed. The only untoward circumstance was sloughing of a small part of the end of the flap, but that was immaterial, as the very correct likeness, Fig. 229, shows. The twist at the base adjusted itself so nicely that any treatment of it was unnecessary. Mr. Taylor ultimately proposed to effect still further improvement, but he lost sight of the

Fig. 229.

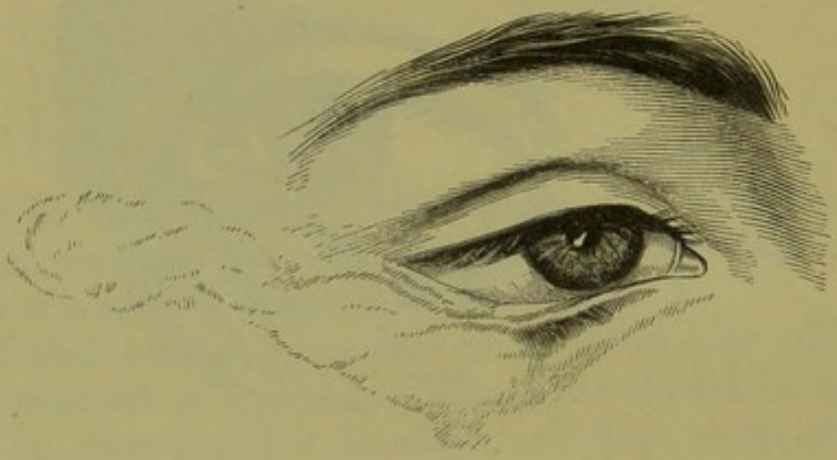

girl. Just six years later I met with this patient, and her condition was still better than when I last saw her. The removal of a bit more of the conjunctiva would have been advantageous.

The method of Dieffenbach I have no practical acquaintance with. I have borrowed the diagram, Fig. 230, from Ammon's "Zeitschrift," vol. iv., where it originally appeared. The account of the plan was first published in Casper's "Wochenschrift" for 1835; and Ammon was the first to adapt it to the lower eyelid.

The operation is commenced by two incisions, one extending from each commissure of the tarsus; and when the lower eyelid is the subject of restoration, the incisions are so inclined towards each other as to meet at an acute angle on the cheek; or above the eyebrow, when the upper eyelid is defective. This triangular flap is then dissected up, and completely removed, care being taken to spare as much as possible the neighbouring nervous filaments. The space *a* thus left is that intended to be occupied by the transplanted flap *b*.

The next step, whether for the upper or the lower eyelid, is to

carry a horizontal incision from the external canthus over the zygoma, and in a straight line towards the external auditory meatus; this incision must, in any case, exceed in length the breadth of the

Fig. 230.

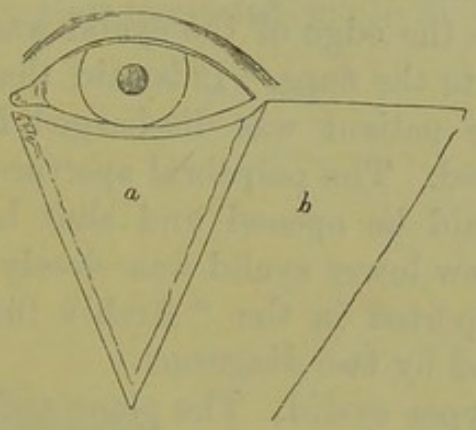

defect in the eyelid. From the extreme outer point of this incision another is carried, when the lower eyelid is required, downwards upon the cheek; and for the upper eyelid, upwards upon the temple. In either case the incision must be nearly parallel to the outer line of the removed flap; its termination being on a level with, though slightly approximated to the point of the same. Here then, everything is arranged for replacing the eyelid. The new flap is gently raised, and after a careful cleansing of the prepared space it is removed to its new position. The twisting of the broad pedicle which is thus placed inferiorly, is very slight in this operation; for that which formed the superior margin of the flap becomes the edge of the lower eyelid, the converse being the case in the upper operation. The same course, as regards sutures, is pursued in this as in the other operation. The importance of saving the ciliary margin, in the preliminary dissection, is self-evident. When that is out of the question, or when it has been originally lost, a great effort must be made to procure a conjunctival lining for the edge of the flap, and some dissection of that membrane towards the eyeball may render more of it available. The conjunctiva and the skin must be adapted by sutures.

The plan of transposing the skin, by raising it on either side and drawing it together, has been done on a large scale for the restoration of the lower eyelid, by my friend H. Knapp, late of Heidelberg. The patient had a hard, irregular, and, as it is called, cancer mass, which took up the inner two-thirds of the under eyelid, and extended beyond the corner to a slight extent on the skin of the nose. It penetrated deep into the orbit. The operation was performed by

making two straight horizontal incisions above and below the diseased tissues, and vertical ones at each extremity. After the removal of the mass the horizontal cuts were prolonged towards the nose, and a flap raised, and then towards the cheek, in two curves, with their convexities opposite, and a flap there raised also, with a broad base. The two flaps were then drawn together, and united by suture. As the edge of the eyelid was removed, the conjunctiva was stitched to the flaps. It is said that the wound united rapidly, and that the patient was discharged fourteen days afterwards, completely cured. The palpebral aperture was diminished in length. The eye could be opened and shut by the action of the upper eyelid. The new lower eyelid was closely applied to the eyeball. The case is reported in the "Archiv für Ophthalmologie," 1867, and is illustrated by two diagrams.

Ectropium of the upper eyelid. The plans and details of operating that have been described as necessary for the affection in the lower eyelid, are required here. But the dissimilar anatomical arrangements of this lid, and the usual considerable depth of the abscesses that cause the ectropium, and through which the contraction is so much greater, render it less favourable for amelioration. Besides, it is in the upper eyelid that traumatic ectropium is generally met with; and such cases demand more surgical ingenuity, care, and patience in treating them. Then I have found failure after operating from imperfect union, whether of flap or edges, more likely to occur; and this is the more unfortunate, as any retraction above, that is of the upper eyelid, exposes the eyeball more than when occurring below.

With ectropium of this class there may be some lesion of the tarsus. It may be torn or cut through. Whether this complication be attended to at the same time as the ectropium, or subsequently, must depend on many circumstances, and this the surgeon will decide according to his knowledge.

A boy, twelve years old, was wounded in the upper eyelid. The cut was near the inner angle, and passed from the eyebrow to the margin of the eyelid, completely dividing the tarsal cartilage. The contraction, the eversion, and the deformity were great; but as there had been no loss, though considerable puckering of the skin, and as the distortion was evidently due to neglect of the recent injury, I recommended treatment, and promised much success. After dissecting away the cicatrix, and paring the edges of the cleft portion through its entire thickness, I transposed very freely, united the parts with sutures and soft steel pins, and strapped the eyelids together. Subsequently I removed portions of the conjunctiva, all,

indeed, that had been exposed, and had undergone change in structure. The effect was beyond my expectation. The deformity was almost removed; the eyeball was no longer exposed, and the eyelid, which could now be closed and brought to meet its fellow, merely showed a small notch in the margin.

Ectropium of the upper eyelid, caused by an accident from strong sulphuric acid. Mr. Gay requested me to meet him in consultation

Fig. 231.

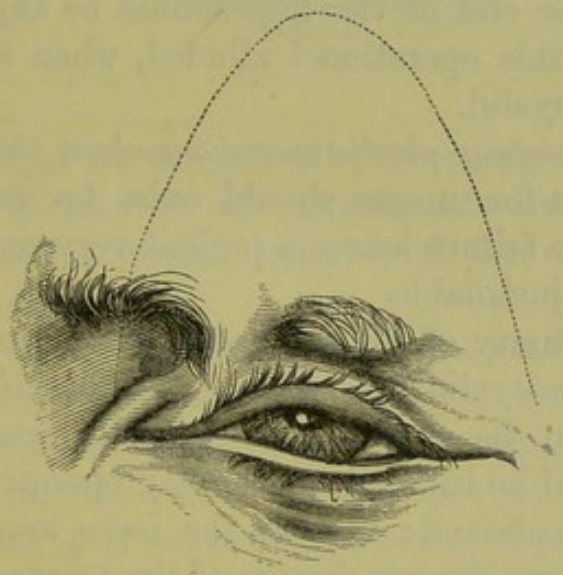

on a case of this kind. Fig. 231 shows the eye closed to the utmost that could be effected, and gives some idea of the effects of the injury.

In the ordinary state there was a stare, the eyelid was everted, and the inside of the cartilage shown. At my recommendation Mr. Gay shaved the irregular hairs of the eyebrow, made an incision corresponding to the curved line, and dissected off the flap, which

Fig. 232.

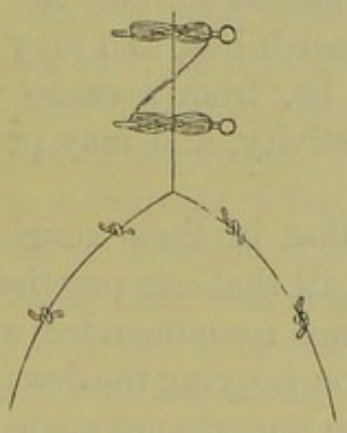

allowed the eyelid to descend. Then freely separating the edges of the skin on either side, he brought them together over the exposed surface, retaining them by sutures, somewhat after the manner

shown in the diagram, Fig. 232. Ultimately he dissected away a piece of conjunctiva along the edge of the tarsus. The result was more satisfactory than I had anticipated, and after four months the patient could nearly close the eye, the ectropium being removed, and the corneitis consequent on the exposure of the eyeball having disappeared.

Unless the flap to be raised be dissected down to the tarsus, success will not ensue. Any attempt to pull down undetached integument, and retain it by force, must end in failure of the desired end. As a rule, the end of the flap should be angular, rather than round. It was to this operation I alluded, when speaking of ectropium of the lower eyelid.

Further hints respecting plastic operations about the eyelids. All the necessary conditions for success should exist for an operation to be undertaken, because failure leaves a patient very much worse. Mere experiments are unjustifiable.

Not until all activity of the disease that has produced ectropium has ceased, and the eyelid has reached its maximum of eversion, should an operation be undertaken. At the same time, I must observe that it would be injudicious to delay operative measures when the proper time has arrived; because the issue would be less sure or perfect, from the more chronic disease of the tarsus.

Whenever dissections are to be made over the supra or infra-orbital foramina, care should be taken to avoid the vessels and the nerves which they transmit.

There may be a loss of sensibility in the borrowed flap. This has occurred in all cases of plastic operations that I have seen, but it has been temporary. In a few weeks, or months, sensation has returned. Should it have been restored prior to the division of the twisted portion, this little operation will again suspend it.

A certain degree of puffiness follows the best executed of these operations; this becomes much less, and may quite disappear.

The hair-follicles may be, from a cause which it is difficult to explain, stimulated into activity, and may produce hair of considerable length.

It is to be regretted that in these surgical measures, the most difficult and uncertain of all that are practised on the human body, many plans of operating are recommended which are impracticable. The diagrams usually accompanying the descriptions are the offspring of the imagination. These remarks are made after trying most of the recommendations on the dead body.

Cicatrices on the temple may produce more or less partial eversion of the corners of the eyelids; or they may merely pull them away

from the globe of the eye. The defect must be reduced b removing a triangular bit after the manner here shown, althoug a very much greater portion must be taken away than the sketc

Fig. 233.

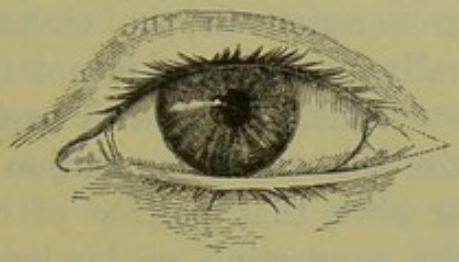

indicates, and larger on the one side, according to which eyelid is th more affected. It may be also necessary to transpose the skin, an perhaps to remove a certain amount of the conjunctiva, after th method already detailed.

I have repaired cases of this kind that seemed at first sight to b irremediable. In an instance that occurred at St. Mary's Hospita produced by scrofulous caries of the outer edge of the orbit, nearl half of each eyelid was almost entirely everted, and the commissu was pulled half an inch outwards. I removed the cicatrix sparingly thoroughly transposed the integument, and applied pins and suture A few weeks after, I excised a considerable piece of conjunctiva fro each eyelid. The improvement was so great, that the defect was n longer noticed.

Second head. Ectropium from morbid changes in the eyelids. Her the affection is the consequence or termination of palpebral diseas and generally of the conjunctiva. It is supposed that the eversio is mostly owing to the contraction of the skin of the eyelid from th excoriating influence of the tears. Ulcerations that penetrate th skin sufficiently to produce a scar, and extensive contraction, woul doubtless be followed by such an effect, be the cause of that ulcera ration what it may; but ectropium is not usually associated wit ulceration of the exterior of the eyelid. Roughness and even exc riation of the skin, is a frequent effect of eversion, and both ar common in lippitudo, where eversion is absent. The direction of th tarsus somewhat indicates, also, that it is not entirely influenced b tension of the skin, for it is not so much pulled down or away fro the globe of the eye as turned outwards.

Causes. I believe the ectropium to be due to inflammation, an almost always of a strumous kind, existing in three forms. In the one the conjunctiva is first inflamed, lacrymation follows, with more o less intolerance of light. Afterwards the Meibomian glands ar

involved, and the entire edge of the eyelid being implicated, the cilia drop out, or become stunted; that state called lippitudo generally occurs, and the eversion follows. There seems to be not only actual loss of substance of the eyelid in the rounding of its edge, but a shrinking of the cartilage and the tarsal ligament. This appears to me to receive corroboration in the circumstance that, in the lippitudo which generally precedes, it is not uncommon to observe inability to close the eyelids, except with great effort. Perhaps I may venture to surmise that the inflammation which lingers about the eyelid may so far alter that portion of the orbicularis on its edge, as to impair the supporting or binding influence. In the second, there are changes in the palpebral portion of the conjunctiva producing thickness, which everts the edge of the eyelid, the cilia and the glands remaining entire. In the third, eczema palpebrarum pre-exists.

After the tarsus is everted, and the edge turned downwards, the action of the orbicularis is to perpetuate the displacement.

Fig. 234 is a representation of ectropium of the first kind, that with considerable disease of the eyelid. It was taken from a young man of nineteen, a patient at the C. L. Ophthalmic Hospital. Both eyes were similarly diseased. Having been the most marked case that had been at the hospital for some months, it was chosen for representation before treatment by operation, with the intention of

Fig 234.

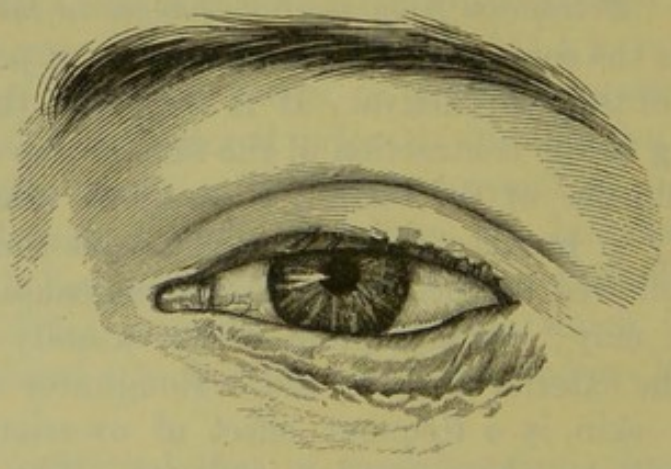

contrasting it with the after improvement; but the patient subsequently declined my assistance. A better illustration of an aggravated case could not be desired. All the conjunctiva on the everted eyelid was thickened, and the edge of the tarsus ragged, from former ulceration. In the upper eyelid also, there was slight eversion, and most of the cilia were lost.

Treatment. In the first and third forms, improvement may be effected in acute cases that are slight, in which the eversion is very limited, by general and local treatment, by restoring the health, and the use of mild astringents, and keeping the eyelid raised by plaster; but, in general, and always when the exposed conjunctiva is decidedly altered in structure, an operation is required, the conjunctiva must be removed according to the principle given in the description of the treatment under the first head.

Escharotics strong enough to produce slough have been recommended to supersede the knife, but they are inferior in effect, and objectionable also on the score of danger; it being difficult, or even impossible, sufficiently to limit their action.

I practise here, excision of a portion of the conjunctiva.

The eyelid having been well pulled down, two incisions are to be made, an internal one circumscribing the inward limit of the diseased conjunctiva, and an outward one along the tarsal margin; the isolated piece is then seized with the tenaculum forceps, and dissected away. The outer incision should be carried to the edge of the tarsus, along the entire length of the eversion, or the operation is imperfectly done. Frequent sponging is required. I generally use sutures.

It must be recollected that eversion may be changed to inversion, by removing too much, and that the tarsus may be contracted from side to side.

The sketch, Fig. 235, was taken from a girl fifteen years old, with partial ectropium of both lower eyelids, from long existing strumous ophthalmia, which had also destroyed all the cilia.

Fig. 235.

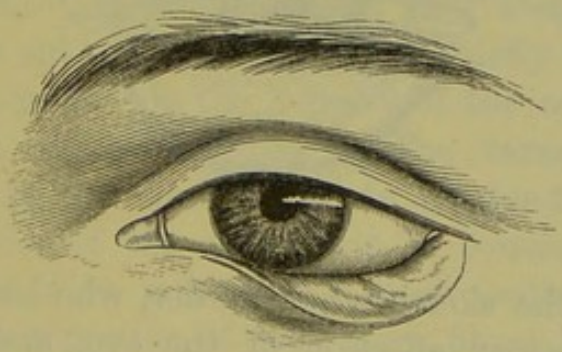

The greater part of the exposed membrane was dissected away, and with such an effect that, four months after, the eye was in that state which the second sketch accurately represents.

For so perfect a result the eyelid must have escaped ulceration, and the tarsal cartilage been but little damaged. The only

trace of the operation is a bridle of conjunctiva, which unites the eyelid to the globe of the eye, but does not interfere with the ocular movements.

Fig. 236.

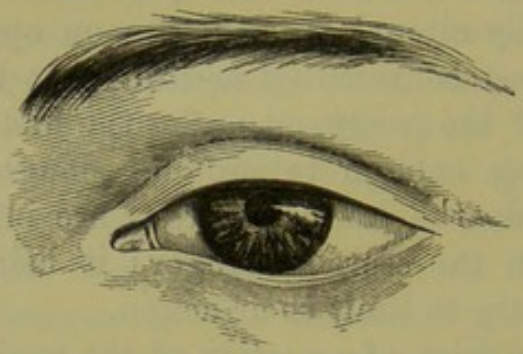

In the second form, that of eversion from thickening of the conjunctiva without tarsal disease, of which the next figure is an example, a double operation is generally required, the removal of the conjunctiva, and of a bit of the tarsus. It is better to do this operation about the centre of the eyelid. The contraction consequent on the loss of the conjunctiva is not sufficient, except in slight cases. In an instance like the following, there is always a pucker that demands the loss of a portion of the whole eyelid.

Fig. 237.

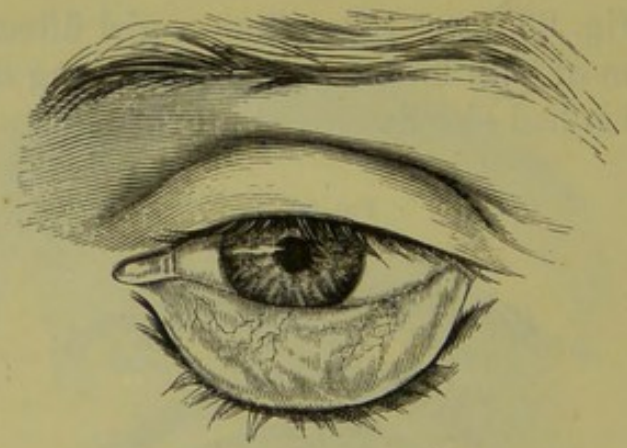

The subject of the sketch was a soldier, who had been discharged for some inflammatory affection of the eye, and who assures me that the ectropium came on a few months after the application of sulphate of copper three times a week, for nine months, when he could no longer submit to it. I removed a large portion of the membrane; and six weeks later a bit of the tarsus, and united the edges by suture. So great was the improvement that the eye was not recognised by several medical men who had seen it prior to the

first operation. The following sketch was taken ten days after the second.

Fig. 238.

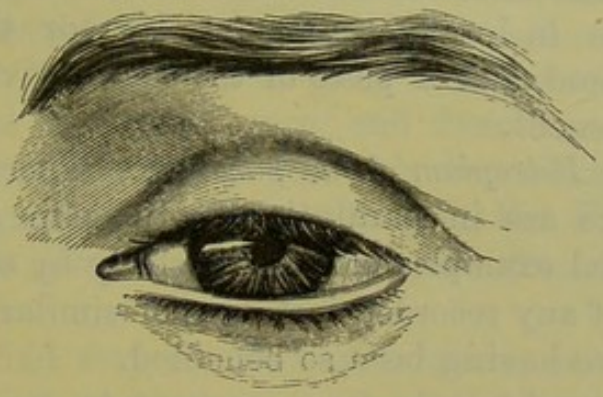

I find it better, except under special circumstances, not to do the double operation at once, but to wait awhile after the first for several times, contrary to my expectation, the removal of the conjunctiva alone has sufficed.

In some of my cases I have effected still farther improvement by adjusting the outer angle of the eyelids by operation, and when the punctum is displaced, by removing a bit of the conjunctiva just behind, and sometimes, in addition, slitting it up. This treatment of this lacrymal conduit, when out of position, is fully given elsewhere.

It will give an adequate idea of the applicability of the treatment to this form of ectropium when I state that I have required no other since I learned how to apply it, and that embraces a period of eighteen years of hospital and private practice.

Third Head. Ectropium from senile atrophy. This is seen only in the very aged. The under eyelid falls away from the eyeball rather than turns out. The defect seems chiefly to depend upon the loss of sustaining power, or the support of the orbicularis muscle to the tarsus, and relaxation also of the tarsal connections. M. Desmarres supposes this senile defect to be due to actual change in the relative position of the orbicularis, in consequence of relaxation of the skin; that there is besides a transposition of a part of the muscle, the greater portion of the ciliary fibres being carried to the lower, or adherent border of the tarsus by the cutaneous folds; and that the tarsus so circumstanced swings about during their contraction. He says he has proved this pathological change in a great number of cases, by actual dissection.

Treatment is not generally adopted in this country, but this is a pity, as considerable relief from the accompanying symptoms,

especially the overflow of the tears, may be got. The plan of operating is to remove two, three, or four pieces of skin, according to the severity of the affection, at equal distances, vertically, from the eyelid. Each dissection should reach to the tarsal margin, and involve about an inch of integument, two or three lines wide. Sutures are required, and a piece of the conjunctiva may sometimes be excised with benefit.

Fourth Head. Ectropium from paralysis. There are degrees of this, just as there are in paralytic affections in general. I have treated two marked examples most successfully by operative surgery. I am not aware of any recorded instances of similar practice; nor do I know of any case having been so benefited.

A gentleman, aged twenty-four, was sent to me, on account of a distressing and increasing ectropium of the left lower eyelid from facial paralysis on that side, which occurred in childhood. It is unnecessary to speak of the condition of the face. The ectropium produced much deformity, as the margin of the eyelid was very much depressed, and the conjunctiva was thickened and projecting, and very vascular. But a more annoying result was the constant flow of tears and mucous secretion over the cheek, roughness of the skin, and some excoriation. Chloroform having been given, I removed a strip of the diseased conjunctiva along the entire length of the eversion. The lengthening of the tarsus, and the total loss of muscular support to it, required something more to be done. The undue rising of the upper eyelid was another obstacle to meet. To overcome these complications, I shortened both tarsi, by removing a portion of each at the outer canthus, taking away conjunctiva as well, and then brought the wound together by stitches. The repair was rapid, and as effectual as it was possible. The stare of the eyeball and the exposure were almost overcome. So little indeed remained of either as not to be noticed by a casual observer. The punctum lacrymale in each eyelid having been returned to its proper position, the tears were thoroughly conveyed away through the proper channels. Withal, there was no trace nor mark of the use of the scalpel.

EPICANTHUS, OR ENCROACHMENT OF THE SKIN ON THE CORNER OF THE EYE.

This is a congenital malformation, due to flatness of the nose, with excess of integuments, and sometimes associated with increased width between the orbits. The inner canthi are covered by a crescentic fold of skin passing from the nose over the caruncles and

often the puncta. Although a slight degree of this deformity is not very uncommon, an aggravated state is rare among Europeans. There are, however, varieties of our race in whom a kind of epicanthus is very frequent. In an article on the malformations and congenital diseases of the organs of sight, in vol. xxvii. of the "Dublin Journal," Sir W. Wilde gives it as his opinion, from what he has seen of the Mongolian race, and from the examination of a great number of their crania, that this disposition of parts which we regard as a congenital malformation in the European and the Caucasian races, is allied to the natural condition of the Chinese and the Calmuc.

The abnormal fold may interfere with vision, or cause trichiasis in the upper eyelid. A marked example of the latter I have seen in an infant.

The accompanying representation of the affection (Fig. 239) is from a child nine months old.

The fold may be reduced or pulled aside, by forcibly pinching up the intervening integuments of the nose.

The defect may exist in one eye.

Epicanthus may be acquired, that is, may result from the cicatrix of a wound displacing the eyelids, and pulling the skin over the corner of the eye.

Epicanthus does not disappear, or even get less, with the growth of the person.

Treatment. It would not be judicious to interfere with a slight degree of this deformity. Only when the disfigurement is great, or some evil effect arises out of the disease, is any surgical treatment justifiable; and even then it should be ascertained with sufficient assurance, that benefit will follow.

There is but one operation applicable; that of removing skin from between the eyes.

Fig. 239.

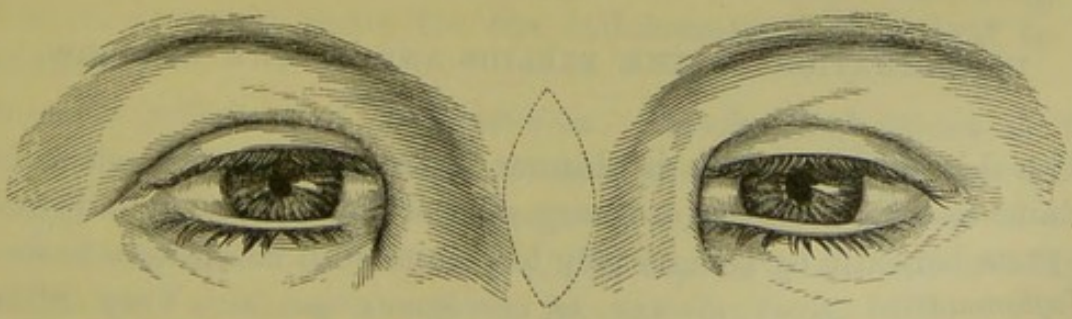

The required size of the piece to be removed is tolerably ascertainable by the amount that must be pinched up to clear the eyelids.

The lines on the nose in the above sketch mark the direction of the incisions, and the size of the piece of skin that I removed in the patient whom it represents. Another case on which I operated is reported in the "Medical Times," for August 27, 1853.

Latterly I have made the angle of the ellipse less obtuse, by lengthening the incisions, because there is more certainty of primary union.

After the piece is taken out, and the operation requires accuracy in making the incisions, which should be through the entire skin and somewhat bevelled inwards, the edges of the wound must be raised, that is, dissected up all round, to allow of their easy approximation; or else, from the natural tightness of the skin in this part, there will be a strain which may endanger union by the first intention, and such union is essential to success. The hare-lip suture must be used, and the pins entered the eighth of an inch from the edge, carried entirely through the skin, and brought out at a corresponding distance on the opposite side. Two will generally suffice. One or two sutures may be required. Instead of the ordinary coarse, clumsy, and expensive silver pin, I use sharp ones, of soft steel, that are easily cut with the pliers. Common toilet pins would answer as well, and might be used, were it not for the popular objection to them, on the score of their festering properties, not groundless, perhaps, when the plating is lost. At least five days should elapse before the pins are withdrawn, or else separation is risked; but they should not remain longer, or suppuration might ensue around them, and marked scars would follow.

When epicanthus is on one side, and an operation is required, the above proceeding must be a little modified. One incision must be straight, the other in the form of a curve towards the affected side.

I have seen a deficient palpebral fissure mistaken for epicanthus, and operated on for such. Eversion of the inner part of each eyelid ensued.

INFLAMMATION OF THE EYELIDS AND OF THE EYEBROW.

The skin of the eyelids is thinner, more delicate, less elastic, and contains less fat than the ordinary skin of the body. It is bound to the parts beneath by remarkably loose and thin connective tissue.

Inflammation from disease of contiguous parts. Very little is required to be said about the œdema of the eyelids, in consequence of inflammation, which has its origin in any part of the surrounding orbital or facial region. The nature of such disease

can scarcely be mistaken. This secondary inflammation, as it is sometimes called, is most intense in traumatic inflammation of the eyeball, especially when the cornea suppurates.

The symptoms are, swelling and redness of the eyelids, and incapability of opening them. The upper eyelid is always the more affected. The inflammatory action quickly disappears when the central cause is subdued, and, generally speaking, the eyelids are restored to health. But should they be frequently inflamed from repetition of the cause, or should the cause become chronic, hypertrophy of the skin and of the areolar tissue is apt to ensue.

Phlegmonous inflammation. This differs in no wise from phlegmonous inflammation which occurs in any other parts of the surface of the body.

Both eyelids may be equally affected, but the attack is generally confined to the upper. Children are more prone to the disease than adults. The inflammation begins with swelling and redness of the integuments at the edge of the lid. Then the whole lid becomes swollen, very red, shining, not very painful, throbbing, and motionless. It is circumscribed by the orbital edge. When the under eyelid escapes the acuteness of the attack, it gets œdematous. The cheek and the temple are usually a little inflamed. Active fever is rarely absent. The inflammation intensifies, the surface gets of a purple red colour, and pus forms. It is very seldom that suppuration does not ensue. Prominence or pointing, at a spot on the skin, declares the centre of a circumscribed abscess. The escape of the matter by ulceration, or by sloughing, relieves the active state. The abscess may point behind the eyelid, and burst on the conjunctival surface.

Perfect recovery, with the exception of a cicatrix, may ensue, but fistulæ may remain. Or there may be loss of tissue, by which the eyelid is shortened and tied to the edge of the orbit. With this may be combined severe ectropium.

The abscess is generally seated centrally in the eyelid, but it may be at the one or the other of its corners. So long as there is no apparent cause for the inflammation, it is said to be idiopathic.

Traumatic phlegmonous inflammation. Mechanical injury to the eyelid, even of the most trivial nature, such as a slight abrasion, may induce phlegmonous inflammation. In all the cases of this form of disease which have come under my care, the inflammatory action has been very acute, and the general symptoms high.

Treatment. The indications are to cut short the inflammatory attack, if possible, or to limit it, and thereby to prevent or reduce the secondary or destructive inflammatory processes. It is unneces-

sary to give in detail an account of the applicable local and constitutional measures, because they are comprised in general surgery, and are much dwelt on in all surgical works. I will speak only on two points. Rest of the body is specially indicated with reference to preventing head symptoms. Pus should be evacuated by a low horizontal cut, immediately that its presence is detected, with the view to prevent destruction of tissue, and the distressing effects therefrom which have been mentioned. This practice is most important when the inflammation is rather sub-acute, and the abscess is more likely to spread than to burst.

Erysipelatous inflammation. This attacks the eyelids very often, in all its several forms, singly or combined. It may commence without any apparent cause. Or it may spread to them from inflammation which is elsewhere about the face, or in the scalp. Or it may be excited from mechanical or chemical injury, including the sting of an insect.

The one eyelid only may be affected; the upper is that which is generally singly involved; but nearly always both get affected. The one may be first attacked, or the two may suffer simultaneously, and with equal severity.

The eyelids are always swollen, and if the inflammation be at all severe they are invariably closed, and cannot be opened by natural effort. There is much variation in other local symptoms. The redness, the stinging and burning sensation, the puffiness, or the hardness, and the tenderness under touch, differ according to the tissues involved; that is, whether there is present the cutaneous, the cellular, or the cellulo-cutaneous inflammation. Much too in this direction will depend on the rapidity or the slowness with which the symptoms follow each other in any given case.

Constitutional symptoms are never absent, and the preceding rigors, the irritative fever, the derangement of the digestive organs, and the headache are in greater severity than is usual, with the same or a greater amount of erysipelas elsewhere.

Other effects of the inflammation on the special parts of the eyelids, and some parts around them, occur.

The conjunctival secretion is augmented and altered. It may become purulent. The Meibomian glands suffer, and their secretion becomes vitiated.

The lacrymal sac and duct frequently inflame. The swelling blocks up the canaliculi and the nasal aperture of the duct. It increases the natural secretion, and adds inflammatory products. The sac may become very much distended, and an abscess may form within it.

Cerebral implication is no uncommon complication, and death sometimes ensues from inflammation of the brain and its membranes.

Treatment. The cutaneous erysipelas is rarely severe, and seldom requires any other measures than rest, slight purgation, and local application of cold in the first instance, and afterwards, when desquamation is taking place, some unctuous application, to guard the surface from the action of the atmosphere.

The treatment of the cellular inflammation having been already given, under the head of Orbital Cellulitis, at page 46, need not be repeated; but I beg my reader to look to the reference, and see what is said.

The treatment for the cellulo-cutaneous inflammation is precisely the same as that for the cellular, with the addition of earlier and freer local bleeding. Of late years I have leeched less, and resorted more to pricking the skin with a fine scalpel, in ten or twelve places, with a view of bleeding the part. I think that this is as efficient as leeching, while it is more readily applied, and is devoid of the extravasation of blood, and the œdema, which are so likely to follow leeching about the eyelids. The bleeding may be encouraged by a hot poultice.

I will venture to reiterate the importance of making incisions through the skin sufficiently early to allow of the escape of pus, as well as any portion of the areolar tissue which may have lost its vitality, whereby sloughing of the skin and extension of the inflammation may be saved. There is no pointing of an abscess, such as I have described, in phlegmonous inflammation, and the sense of fluctuation is seldom definite, and often very obscure. The diffuse nature of the suppuration, the facility for its spreading, from the large meshes of the long fibred, areolar tissue of the lid, and the proneness of this tissue to slough, ought to be remembered.

The cellular and the cellulo-cutaneous inflammations are apt to inflict damage in the delicate tegumentary and areolar tissues of the eyelids, and to spoil their natural mobility and pliancy. Such result is certain, if the skin be allowed to slough.

The patentcy of the canaliculi and of the lacrymal duct are frequently more or less damaged.

The erysipelas may spread from the eyelids to the orbit.

ŒDEMA OF THE EYELIDS.

The eyelids readily become œdematous, from the peculiarity of their structure, and the tumefaction may be slight, or astonishingly

large; so large indeed as to interfere with or prevent palpebral movements, and to cause complete closing of the eye.

The pale, puffy, soft, and smooth swelling, indicative of serous effusion in the skin, and in the subjacent areolar tissue, cannot be mistaken. To these, in severe cases, is added œdema of the conjunctiva, constituting chemosis.

The upper eyelid is usually more affected than the under. Irrespective of the cause, the upper is more swollen towards the edge, and the under towards the orbit.

Œdema from general causes. Feeble adults are prone to slight œdema, which is usually most marked on rising in the morning. The swelling often disappears towards the end of the day.

Œdema often appears after exhausting illnesses.

In these instances the conjunctiva is not affected.

Œdema from local causes. This is either the consequence of direct injury, such as the bite or the sting of an insect; or of exposure to cold; or it is incidental to other affections.

Respecting the direct injury, when the cause is mechanical, only one eye is affected, and the mark of the injury may always be found, around which there is generally redness. When the cause is atmospheric, both eyes are affected.

Respecting the incidental origin, near and remote implication must be recognised.

Among the first are included inflammation of the eye-ball from any cause, inflammation of the conjunctiva, inflammatory affections of the skin of the face, and orbital diseases, especially periostitis, necrosis, and tumours of all kinds. Also tumours in the nasal sinuses, particularly polypi.

Among the latter are renal, cardiac, and hepatic diseases.

Œdema is not a condition which is in itself hurtful; therefore its presence need never create alarm.

Treatment. When the disease is the result of direct injury to the eyelid, it will disappear as soon as the severity of the damage is over, and the treatment must be directed to the seat of the swelling. In other cases we can hope to relieve only by a more indirect manner; but in these also the cause of the effusion must be sought out, and, if possible, removed. Constitutional or local means may be called for.

EMPHYSEMA OF THE EYELIDS.

This, as a traumatic affection, has been treated of in the chapter

on Diseases of the Orbit, as well as in that on Wounds of the Eyelids, &c., and its nature and treatment have been fully discussed. I notice the subject again only to point out that the escape of air from the nose to the eyelids may ensue from rupture of the lacrymal sac in the simple act of blowing the nose.

HYPERTROPHY OF THE INTEGUMENTS OF THE EYELIDS.

I have met with three cases of this disease. All have been congenital, and in all, the upper lid has been very much more affected than the under. There seemed to be hypertrophy, and nothing more. One of them is spoken of at page 362, in the chapter on Ptosis. The second existed in a young lady whom I watched for fifteen years. When I first saw her the integuments of the brow were but little enlarged. Ultimately they grew much, hung down with the enlarged eyelid, and closed the eye. The following illustration is from the third case. The subject of it was a girl eighteen years old.

Fig. 240.

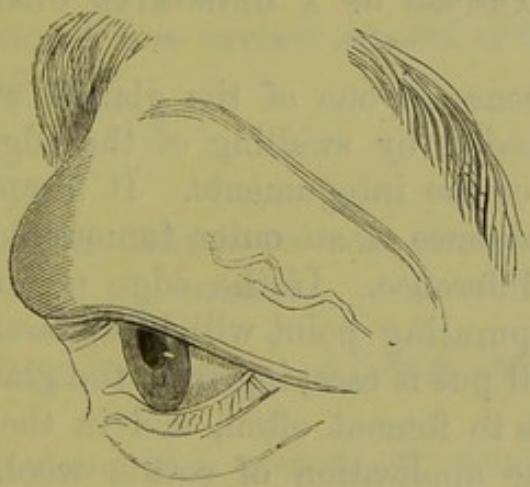

Both eyes were similarly affected. The surrounding integuments were scarcely implicated.

The treatment can only be purely mechanical. A certain amount of integument must be removed. It is a question whether the operation should be undertaken early, or only when the eyelid begins to cover the pupil. I should not operate till the latter period.

PALPEBRAL SWEATING. EPHIDROSIS.

This is meant to signify sweating of the upper eyelid, for the

undue secretion has not been observed in the under one. At all times, whether the body be at rest, or undergoing exertion, sweat is poured out, and accumulates on the surface of the lid, usually most on the inner side, and evaporates, rather than runs down, but yet so slowly that there is always sweat there, unless it be removed by the handkerchief.

There is no known remedy for this annoyance.

CONGENITAL FISSURE OF THE EYELIDS. COLOBOMA.

This is the rarest of congenital malformations. Both eyelids of the same eye, or only the one lid, or one in each eye, may be fissured vertically. The defect is an arrest of development in the histological transformation of the tissues. It is always complicated with congenital malformation of the surface of the eyeball, in association with the development of portions of skin, or of small dermoid or other tumours on the eyeball.

ABSCESS OF A MEIBOMIAN GLAND.

Suppuration occurs in one of the glands, without any apparent cause. It is preceded by swelling of the edge of the eyelid, and then of a portion of the integuments. It is apt to be mistaken for a stye, but the absence of an outer tumour and the acute pain at once mark the difference. If the edge of the eyelid be a little inverted, the suppurating point will be apparent. Patients seldom apply for relief till pus is escaping from the gland duct.

The treatment is to foment often, and in the interval to keep the eye warm, by the application of cotton wool. If the pus do not escape, but become pent up, and bulge on the inner surface of the lid, it should be evacuated by a small incision.

ACNE CILIARIS, OR SOLITARY PUSTULE OF THE EYELID.

This constitutes disease of a sebaceous follicle at the margin of the eyelid, and appears in a fully developed state as a roundish, red, ill-defined ciliary tumour, varying in size from that of a hemp-seed to that of a pea. It is seated in the subcutaneous tissue, blends with the skin, and pushes forward and separates the cilia. It is

generally solitary, but if there be several, they are nearly or quite isolated.

It appears in an acute form as a little red swelling, covered with exfoliated epithelium, or thin crusts of sebaceous matter. Usually there is but little surrounding inflammation, unless the tumour forms quickly, when the whole of the lid is apt to become inflamed, swollen, and very tender.

Persons who are suffering from acne of the face, or comedons, are prone to have acne ciliaris.

Course of the affection. Exceptionally does it form quickly and soon terminate; almost always the progress is by slow stages. It may decline at any period without the occurrence of suppuration; but suppuration is the most advanced condition. The formation of pus is always limited, and very slight for the size of the tumour. The escape of it may be by the gland duct, or through the skin close to a cilium. Induration and callosity, or hypertrophy of the subcutaneous tissue, may be the permanent remains of it.

The worst, and fortunately the rarest termination, is ulceration, because the ensuing radiating cicatrices cause contraction of the edge of the lid, and displace the cilia; or the cilia follicles may be involved, and the cilia destroyed.

It is easy to understand how several attacks of the acne may more or less damage the lid.

HERPES FRONTALIS, OR HERPES OF THE SKIN OF THE ORBITAL REGION.

This is a local form of herpes, of which herpes zoster is the type.

In its visible symptoms it is recognised, when fully developed, as an acute inflammation of the skin of the forehead, occurring in bright red, slightly swollen, oblong patches, of various sizes, on which are seated a crop of semi-globular semi-transparent vesicles, sometimes separate, sometimes confluent, in groups varying in number from three or four to twenty or more. In its sensitive symptoms it is known as a very painful affection, chiefly of a neuralgic character.

Diagnosis. It is likely to be confounded with only one other disease, that of cutaneous erysipelas. But there are marked differences. Herpes is always unilateral. Erysipelas is seldom confined to one side of the face, but overpasses the median line. Herpes is attended with less swelling, less surrounding œdema, with a very great deal more local pain, with less constitutional disturb-

ance, but with far more discomfort, and the vesicles are not so large, are better defined, and more numerous.

Mode of attack and development. Herpes is, according to our present knowledge, a peripheral disease, commencing in the territory of a branch of a sensory nerve, and following its distribution. From this circumstance we speak of herpes of this or that nerve. In this variety of the affection it is almost exclusively developed in the first division of the fifth nerve, very seldom at the same time appearing in any branches of the second or the third division of the same.

The attack is ushered in by hemicrania, or general headache, or by neuralgic pain in the course of the frontal nerve and its ramifications, or continuous circumscribed pain in the brow. The hemicrania, or the general headache, and the fixed or the neuralgic pain, may coexist. Then follows inflammation of the skin, and two days afterwards vesicles appear which are at first transparent, but become yellowish or purplish and wrinkled two or three days later. From the further decline of these, yellowish scabs are formed, which are very hard, and about the sixth or seventh day fall, and leave purpleish pits in the skin. The thicker the portion of skin attacked, the deeper the pits. In this way the skin affection runs a regular course from about twelve to fourteen days.

The variations are few. Local pain may not be felt till the vesicles appear; or, having existed in the first instance, may decline with the shrinking of the vesicles. Or it may continue more or less mitigated, after all inflammatory action has passed away, for weeks, or months, or years.

Loss of sensibility, or numbness of the part which has been inflamed, and sometimes of parts even beyond it, is a common sequel. The herpetic pits are not sensitive. The general indisposition and feebleness, which is always present, lasts long after the intensity of the local action has left, so that a severe attack of the complaint may incapacitate a patient for several weeks.

Extent of the herpes. The upper region of the forehead, of the scalp, and the temple, as far as the frontal nerve-distribution goes, may be diseased. The morbid action may travel, too, in the course of the descending nerve branches, whereby the upper eyelid and the side of the nose, the root, or the middle and the tip, may be implicated in like manner. I may mention that the nose gets its nerve twigs from the frontal, supra, and infra-trochlear branches.

The under eyelid escapes, and partakes only of the general surrounding œdema. The looseness of its tissues causes it to swell very much; and this, together with inflammatory swelling of the

upper lid, may cause sufficient tumefaction to prevent the eye from being opened.

Implication of the eye. The conjunctiva rarely escapes palpable congestion and œdema; in any severe instances of the disease, and when the eyelid is affected, it is always implicated. It may be much chemosed, and pour forth a copious muco-purulent discharge. This is merely an extension of the local inflammation. Partial and temporary ptosis ensues when the eyelid has been very much inflamed.

Disease of the eyeball proper, apart from the slight implication consequent on conjunctivitis, may occur. I am disposed to regard it as an effect of, and not a continuation or extension of, the eruptive complaint.

Corneal affections are the most common; and general inflammation, with varying degrees of opacity, is seen, rather than ulceration or softening, which are more generally marginal than central.

General inflammation of the eyeball, of which the most prominent symptom is iritis, is not uncommon, and may impair or destroy sight, and even produce atrophy of the ocular tissues and shrinking of the globe.

The cornea participates in the accustomed partial loss of sensibility, from which it may not recover.

Implication of the motor nerve of the eye, the third cerebral nerve, has been observed by Mr. Hutchinson. He records dilatation of the pupil in several cases, with and without ocular inflammation, as well as dilatation with ptosis, and dilatation with external squint, both with and without ocular inflammation. In each instance the paralysis had been temporary. He remarks that these occurrences of motor paralysis, together with the herpetic eruption, seem to favour the belief that the starting point of irritation is central, rather than in the nerve trunks, and points to some observations of Dr. Broadbent, on herpes, to the same effect.

The eyeball is very liable to inflammation, when the entire side of the nose suffers. This may be due to the greater extent of the herpes, and with the nasal invasion, the eyelid is nearly always involved. Mr. Hutchinson takes another view, and suggests a nerve connection, nutritive theory, and influence. He alludes especially to the anatomical arrangement of the oculo-nasal nerve. This nerve, soon after leaving the main trunk, gives off the long root of the ciliary ganglion, from which ganglion ciliary nerves pass to the iris. Its root gives off the long ciliary branches, which run directly to the ciliary muscle and to the iris. Subsequently it divides into two branches, which supply the middle and the side of the tip of the

nose with sensation, under the names of the infra-trochlear and naso-lobular branches.

Treatment. The burning, the tingling, the heat, and the pain are symptoms urgently calling for relief. I wish I could name any local application which would certainly mitigate suffering. Morphia, aconite, belladonna, and chloroform may be unavailing; yet sometimes the one or the other of them is beneficial. Neither can I say that any internal remedy can be resorted to with the certainty of affording relief. Perhaps from quinine has the most benefit been derived; and there can be no doubt that the general debility which usually attends the complaint, and needs treatment, is more quickly removed by some of the preparations of cinchona.

The frontal nerve has been divided subcutaneously several times, with varying degrees of success. In all the cases it afforded mitigation of suffering for a time.

When there is not much pain or irritation, it is sufficient to keep the parts clean, and to apply benzoated zinc ointment.

The conjunctival and ocular inflammation must be treated according to the rules laid down elsewhere for such affections.

ECZEMA PALPEBRARUM.

This is the most common affection of the eye. It is usually, but incorrectly, called tinea tarsi, and ophthalmia tarsi.

The disease is chiefly developed on the free portion of the palpebra, the margin; but the greater part of it may be involved.

The characteristics are the same as those of eczema of the trunk or of the limbs, a little modified by position, to which are added certain effects arising out of the conformation of the part.

The skin is the texture most palpably implicated. It is inflamed, and there are marked changes in its structure, as well as derangement in its functions. Its sensibility is augmented. It is thickened by serous infiltration, and, as a consequence, is œdematous and sometimes fissured. It exudes at times a serous lymph. Sometimes papules, sometimes vesicles, sometimes pustules form on it. Most or all of these may coexist. The commonness of the last entitles the disease to be placed under the pustular form. There is nothing peculiar in this from an ophthalmic point of view, because the pustules prevail in hairy situations. Cuticle thus raised may be entirely thrown off and replaced by a soft, lardaceous-looking material, which is merely unhealthy cuticle, attended by muco-purulent secretion, or later by a thick crust formed by the drying of the morbid secretions

which are poured out from the skin itself, the Meibomian glands, the cilia follicles, and the conjunctiva.

The usual appearance of the disease when we are consulted is that of crusts on a part or the entire edge of the eyelid, by which the cilia are glued together in groups. In children there is usually associated an overflow of tears, and the cheek is excoriated or roughened.

The subjective symptoms are itching or tingling, but neither of these is well marked and the patient escapes much torment; or soreness; or stiffness of the eyelid; or a sensation of roughness on the eyeball; or of grit in the eye, which necessitates the eye being kept partially closed; nearly always agglutination of the eyelids during sleep, and intolerance to light.

The usual variations in eczema are met with here. The inflammation, or the papules, or the pimples, or the pustules, or the exudation, or the infiltration, may predominate. This includes mildness or severity of such symptoms. Thus, there may be present but the least redness, or swelling, or scurf between the cilia; or most of the eczematous features in the fullest intensity.

The upper eyelid suffers more than the under.

Both eyelids are usually diseased, and in both the eyes.

Effects of Eczema. Beneath the incrustations which adhere to the cuticle there is always excoriation, from which serum and thin pus exude. The ulceration may be sufficiently deep to destroy the skin, and even some of the tarsal cartilage.

The cilia follicles seldom escape damage, from which the cilia grow abortively and irregularly, or they are lost from suppuration in their follicles.

The fibro-cellular tissue of this situation becomes thickened and dense. This is the chief source of the thickening of the ciliary region.

The tarsal cartilage becomes thickened and hardened, and contracted from side to side.

The Meibomian glands inflame and become altered in function, pour forth a viscid secretion, the cause of the agglutination of the eyelids, are ultimately destroyed, and their outlets closed by cicatrization. Some of them may suppurate.

The conjunctiva undergoes the morbid changes usually produced in it by inflammation.

Entropium may ensue.

Slight ectropium is more common. This is associated with damage to the punctum lacrymale, together with displacement of it.

Loss of the inner, and part of the outer edge of the eyelid, with cuticular degeneration of the surface, ensue, by which a glazed red margin is left, constituting what is called lippitudo.

The whole of the palpebral and most of the ocular conjunctiva may inflame.

Eczema is essentially, in the eyelid, a chronic affection, without any specific course, although there are stages or periods of irregularity of the several morbid phenomena. It may last for years, and even for life, with intermission to the more prominent symptoms, all the while spoiling the eyelid more and more. It generally lessens in severity, and may even cease, when the cilia follicles and the Meibomian glands are destroyed.

Cause. Struma, or poor nutrition, so frequently precedes the eczema, that it must be regarded as the remote or predisposing cause. There is great frequency of the disease among the children of very poor people. In nearly every case there are evidences of an inherited, or of an acquired scrofulous constitution. There are enlarged lymphatic glands, or a swollen upper lip, or sore ears, or a tumid belly, or derangement of digestion, or strumous conjunctivitis, or paleness, with looseness of the skin.

There are immediate or exciting causes, such as small-pox, measles, scarlet fever, smoke and filth in bad dwellings, impure air.

General Treatment. I regard the constitutional remedies as the most essential. If the eczematous diathesis be subdued, that is, if the poor nutrition, or the debility from whatever origin, which is the predisposing cause of the affection be removed, the local manifestation of the disease will soon vanish; yet sooner, if assisted by local measures.

The secret of the cure consists then essentially, in discovering the nature of the debility, whether it be assimilative, nutritive, or nervous, and subduing it. This includes attention to the disordered function of any internal organ. I have known of several severe examples of the affection which have been completely cured by change of residence, and nothing else, from this to a warmer country.

Local Treatment. In every instance the cilia should be closely cut. Any of them that are irregular or abortive should be plucked from their follicles. For the eczema itself, the remedy must be shaped according to the condition of the eyelid when the patient is seen, subject to the principles of reducing the inflammation, stimulating to a more healthy action the exuding surface, removing accumulated secretions or crusts, and healing excoriations or ulcerations.

When the inflammation is acute rather than chronic, the use of an evaporating lotion to reduce any unnatural heat is advantageous. When it is chronic, warm applications, as fomentations, are prefer-

able. With the reduction of inflammation the case is materially better.

When the disease is in an early stage, and the surface-accumulation is scanty and of the lighter form, chiefly from serum, and the inflammation is subdued, or when it is so slight as not to be a prominent symptom, stimulation is called for.

But the necessary agents are not so suitable in lotions, on account of their liability to irritate the conjunctiva and the cornea. Ointments answer better, and they serve the double purpose of enabling them to be definitely and persistently applied, while they prevent the eyelids from adhering. The substances selected are demanded of varying strengths, according as irritability or sluggishness of the skin prevails; the stronger being for the latter state. They should be applied twice or thrice daily, with a sable brush, after the part has been cleaned with warm water and Castile soap, and any secretion washed off. The merest smearing of the surface will suffice. After trying various substances, I have settled down to the use of the hydrargyri oxidum rubrum. My weakest formula is one grain of this to a drachm of the unguentum cetacei; my strongest, two grains to the same.

The greater the strength of the ointment, the more sparingly and neatly must it be used, lest it should get within the eyelids, and inflame the eye. If any seem to irritate, it should be used less strong or less often.

When the disease is of old standing, and the incrustations are dense and adherent, being made up of dried pus, epithelium scales, sebaceous matter, carbon and dust from the atmosphere, beneath which there is sure to be excoriation and ulceration, other treatment is needed. The incrustations must be removed without damaging the eyelid. My plan is to keep them oiled with almond oil for a couple of days, and then to sop them for a long time with hot water and a rag, until they are sufficiently softened to be wiped off or picked off; then to oil the lids, and on the following day wash and dry them thoroughly, and touch all the excoriated or ulcerated parts with nitrate of silver. For years I used strong solutions of this drug, but now I apply it solid, scraping the stick to a point, and touching the parts lightly and definitely, taking the greatest care not to let any of it enter the eye. I keep a piece of blotting-paper at hand to soak up any moisture which may be about the edge of the lid. Should any of the caustic accidentally enter the eye in spite of all caution, the eye should be very freely washed at once in a basin of tepid water, to relieve the burning. This plan may require to be repeated several times. An interval of a week at least should be allowed,

during which the eyelids should be washed and oiled twice or thrice daily. From time to time the cilia should be re-cut or re-plucked.

Or, again, the application of the nitrate of silver is required when there are pustules on the lid, with, as yet, little or no incrustation.

Any excoriation or roughness of the cheek should be attended to.

Eczema palpebrarum will readily yield to the methods which I practise and recommend. Certain damage which has been inflicted on the cilia follicles is capable of much repair, and tolerably healthy cilia may grow in the place of abortive ones, or of many which have dropped. But many, or all of the follicles may be destroyed. The Meibomian glands are always more or less destroyed in all prolonged or severe cases of the affection. When treatment is undertaken before the glandular apparatus of the eyelid suffers, every trace of the disease may be removed.

The injury which the disease inflicts, and which is so apparent, must not be mistaken for the disease itself, and treatment continued when it is unnecessary, or undertaken when the eczema is cured.

The trichiasis, the entropium, or the ectropium which may be induced, demands special treatment.

XANTHELASMA PALPEBRARUM.

This is a form of a disease common to all parts of the surface of the body, and generically named by Mr. E. Wilson, Xantholma, because it sometimes occurs, and always begins, in small tuberculous masses. Its old name is Vitiligoidea plana.

When well developed, it is an irregular patch of yellowish, or ochre-coloured, or chamois leather-like deposit, in a curved form, sometimes smooth, sometimes granular, around the eyelids, and at some distance from their edges. It may spread to the side of the nose and the cheek.

There are varieties in its appearance. Occasionally plugs of sebaceous matter protrude from the outlets or follicles, surrounded by the yellowish deposit. The follicular derangement may be the most marked symptom.

The epithelium, the glandular structures of the skin, the rete-mucosum, and the corium, are all affected. It is unnecessary to give minute histological characters; it is enough to describe the affection sufficiently to enable it to be recognised.

Xanthelasma begins at the inner canthus and passes outwards, curving around the eyelids to a third or a half of their extent, or

even more, but rarely encircling them. It varies in breadth, and is usually broader on the upper eyelid. It begins symmetrically, but should it fail in this it ends symmetrically. It does not decrease or decline.

Treatment. In the early and limited state it may be advantageously removed by an escharotic, after the manner of treating a cutaneous nævus.

CHAPTER XXX.

DISEASES AND INJURIES OF THE CRYSTALLINE LENS.

CATARACT—SPONTANEOUS DISLOCATION OF THE CRYSTALLINE LENS.

CATARACT.

Some of the physiological conditions of the crystalline lens and its capsule require to be told, to enable me to explain sufficiently the formation and the diagnosis of cataract.

Crystalline lens. At birth the lens fibres are in their most delicate state. The protein element, crystallin, is at its least quantity. This increases, density is added, and that chiefly centrally. Soon after puberty a nucleus is apparent, although it is yet soft. It becomes denser from year to year. Then comes coloration. There is no longer perfect colourlessness, the nucleus having acquired a light yellow tint. At the adult period the colour is deeper, and pervades the whole lens.

There is no absolutely definite time to a year or so for these developing changes to be fully marked. There is much variation in their coming on. Perhaps it is about the thirty-fifth year that they may be fully recognised. Those persons who get grey early, and soon show shrinking of the skin textures, have their ocular changes proportionately early.

There are senile changes in the lens, consisting of greater density, especially in the nucleus, more coloration, and loss of convexity. These get more marked as life is prolonged. The lens of a very old man is coloured like amber, and is nearly twice as heavy as that of a child. It is said that a boundary line may be seen sometimes between the nucleus and the cortex with a simple microscope, and that occasionally it is more apparent from a cloudy stratum between them, due to certain demonstrable structural alterations in the lens fibres.

Capsule. Alteration in the capsule from age consists, according to a few observers, of a deposit of hyaline, or transparent material, on the posterior part of the anterior capsule, which gives a thickened and uneven look.

While the capsule resists the touch of any blunt instrument, such as those used for the extraction of any extraneous bodies from the chambers of the eye, or for the formation of an artificial pupil, and does not easily break under pressure, it is very readily wounded by sharp ones, and then, owing to its elasticity, quickly tears, and has a tendency to split beyond the limit of the wound. The torn edges of the anterior capsule in life, always roll inwards. It may be farther mentioned that it never breaks into scales under injury, but into shreds, and the edges of which are mostly clean and not jagged.

After birth the lens and its capsule get their nourishment directly from the aqueous and the vitreous humours, and indirectly from the vascular parts around. It is supposed that the ciliary processes contribute much to their nutrition. The health of the lens must therefore depend upon the state of the blood in general, as well as on the local circulation. This physiological point has been much elucidated by the philosophical experiments of Dr. Bence Jones, "on the rate of passage of crystalloids into the vascular and non-vascular textures of the body and out." Dr. Jones's paper is in the *Proceedings of the Royal Society* for June 15, 1865. I strongly advise the perusal of it. In one instance, six hours after two grains of chloride of lithium were given to a Guinea pig, its presence was detected very distinctly in the smallest part of the lens.

When the lens is opaque, all its physiological functions are not quite lost; for in several experiments which Dr. Jones made the lithium was detected in cataracts from patients who had recently taken carbonate of lithia in water. The subject is further pursued in papers read before the Royal Institution of Great Britain.

Senile changes in the lens and its capsule are apparent in the living eye, and are most striking in the state of the pupil. In elderly people the pupil loses the blackness, and gets cloudy or of a light amber tint or brownish-yellow, and the colour seems to penetrate deeply. This is so often the source of mistakes, it being supposed that disease is present, that I never lose an opportunity of speaking about it. An elderly person never has a black pupil so long as his lens is present. When the changes are far advanced, they frequently give the appearance of cataract.

The coloration is most marked in dark races of men, and sometimes in them to such a degree, that it may not be possible, at first

sight, to determine whether cataract does exist or not. I have seen it so apparent in mulattoes, and I am told it is still more marked in negroes, that an experienced surgeon might have been deceived when looking at the pupil with his naked eye, and pronounced cataract to be present, if any one of these persons had complained of defective sight. In the case of a woman of colour, an operation for supposed cataract was proposed by one to whom, both as an author and as a practitioner, ophthalmic surgery in this country owes much of its advancement. The coloration was so intense as to deceive him, the defective sight being due merely to presbyopia and vitiated secretion from the Meibomian glands in consequence of conjunctival disease.

Examination of the pupil by oblique illumination, and with the ophthalmoscope, will show the true nature of the change in a definite manner.

Cataract is loss of transparency of a part, or of the whole of the crystalline lens. Or of a part, or of the whole of the capsule. Or of a part, or of the whole of the lens and the capsule. There are, therefore, lenticular cataract, capsular cataract, and capsulo-lenticular cataract; three forms of the disease.

LENTICULAR CATARACT.

There are different kinds of lenticular cataract, and a classification is requisite. My plan is to arrange them as hard and soft, making two divisions. It is the least objectionable, and by far the easiest for the student to learn, and it is sufficient.

Hard Cataract is merely greyness or opacity appearing in an already discoloured and dense lens, one which has undergone what I have designated as senile changes. Hence it cannot occur before that time of life at which the lens has increased in density, and acquired a definite and hard nucleus, and much colour.

Soft cataract is opacity invading a lens that has not become dense by age, and is not much amber-coloured, and therefore exists in children and young persons, and young adults.

As the natural changes in the crystalline lens are gradual, the density increasing by slow degrees, it cannot always be definitely determined when a cataract should be classed as hard or soft, especially as there is very great variation in different individuals in the arrival of those several changes of structure incidental to age. Hard cataract does not occur under the forty-fifth year, if we require

as the proof of hardness, a well-marked amber, or amber-grey colour.

Spurious cataract is spoken of by all authors, meaning various deposits on or within the capsule of the lens. Hence we have a variety of such cataracts, described as the fibrinous, the pigmentous, the purulent, the sanguineous, and a great many others. Such conditions can exist only in eyes that have been inflamed, and literally bear no pathological connexion whatever with cataract as a disease of the crystalline lens, or of the capsule. The term should be abandoned.

Morbid anatomy. This has been thoroughly worked out. It is a subject easy to investigate, and specimens for examination are numerous. There are primary and secondary changes.

Primary changes. The morbid phenomenon may be described as loss of nutrition, producing atrophy, and sometimes combined with proliferation, or cell growth.

The atrophy is conversion of the lens fibres into different solid and fluid materials. This action much depends in degree, on the consistence of the lens.

In the dense lens of hard cataract, there is in the commencement, very little alteration of tissue, and, with marked atrophy, much light is yet transmitted. This explains how it is that persons with this form of cataract far advanced, the capsule being yet clear, can still see so much. A long description would be necessary to tell minutely what has been observed about this metamorphosis as seen with the microscope. The coarser morbid anatomy only avails us surgically, in pointing out rules for treatment.

The commonest changes may be thus expressed. Softness of the cortex of the cataract, and specially the very surface. Many of the hexagonal cells lose their walls, and their nuclei get opaque. Sometimes these cells quite disappear. The cortex may be softening to the state of a semi-fluid pulp, with the remains of opaque fibres, molecular substance, and fatty tissue. There is the most variation in this part, in the degrees of atrophy, and the depth to which it extends. Increased hardness and dryness of the centre. The nucleus becomes hard and dry to a degree far exceeding what is ever seen in the healthy lens. To break through it requires as much pressure as a modern cataract-needle will bear. The fractured surface has the same appearance as a bit of broken yellow wax. These lens fibres are hard, atrophied, and brittle, and are rendered more or less opaque by fine molecular deposits, as well as by little cracks and fissures, and sometimes fat globules. There are also seen transparent particles, called myeline.

In a given number of cataracts that may be extracted, there will be found much difference in the relative proportions between the amount of lens fibres in the cortex that have undergone softening, and the amount of the nucleus which has become hardened. Hence it is that we find sometimes a large nucleus, sometimes a small one. In some exceptional cases, not often met with, there is softening nearly throughout the lens, and in some still rarer, very little softening, the whole lens being dense and adherent to the capsule. The latter is always associated with much darkening of the cataract.

In the lens of soft cataract, the atrophy more resembles that which takes place on the circumference of a hard lens. There is a breaking up of the lens tissue into a paste-like material, or a more fluid degeneration of a thin milk-like colour with granular flocculi, corpuscles, and fatty material.

It is said that there are pathological changes allied to atrophy which are produced by inflammation, a sort of lentitis. But inflammation of the lens and its capsule occurring alone may be said to be unknown. The inflammation occurs only as an extension of disease from other parts of the eyeball.

Secondary changes. These vary very much in the time that they appear, and this would seem to depend on the healthy or the unhealthy state of the rest of the eye, the latter facilitating them. Although there is sufficient regularity in the order of the degeneration, to admit of a division into primary and secondary for the sake of more easy teaching, exceptionally, some of the later destructive forms set in early. The final degeneration may be very rapid.

In hard cataract, the already hardened nucleus undergoes very little further change; it merely becomes harder, dryer, and darker. The darkness of the entire cataract is occasionally so great as to cause astonishment. Some years ago I made some remarks before the Medico-Chirurgical Society of London on a case of this description in a patient, which I denominated black cataract. It was certainly more black than brown; indeed, so black that it could not be detected by any one till the eye was examined by the ophthalmoscope, or by the concentrated oblique light of a powerful lens. Since then I have had two like examples, the one sent me by Mr. Philbrick, of Colchester, the other by Mr. Lacey, of Poole.

Some cases of black cataract have been published by Mr. Solomon in the *Reports of the Pathological Society of London*. One was from a disorganized eye. It was of a jet-black colour by reflected, and of a deep red colour by transmitted light. Its equatorial margin for half a line was whitish. Another was also from a disorganized eye. In a report made on these specimens, it is stated that the colour

proceeded from brown tinging of the lens fibres, and not from the presence of fine granular pigment.

Mr. Dixon mentions a case of a cataract entirely black, which was extracted by one of his colleagues. There were several fine whitish lines radiating on its anterior surface, produced by white deposits.

A perfectly black nucleus, with a greyish-white and soft cortex, has been described.

I have seen a lens quite black, escape from a disorganized eye, after the removal of a large staphyloma corneæ.

Nearly always the intense darkness or blackness is associated with disorganization of the eyeball.

The superficies of the cataract degenerates markedly, in losing its watery elements, becoming denser and reduced in bulk, so that flattening is produced. A still further change may ensue. There may be conversion into fatty materials, either disseminated, or in masses of granules, or globules. Cholesterine scales may form early, and may be recognised by oblique illumination, as a few bright dots here and there. In other cases, where there is much of this degeneration, the scales are seen in great numbers, and form a pretty object even to the naked eye. There may be long crystals of fatty acid, or free oil in globules.

The absorption of the cortical layers may be so great, as to leave only the hardened nucleus covered by a thin veil, studded with earthy spots and groups of cholesterine. Carbonate, and sometimes phosphate of lime, are found in minute molecular deposits, mixed with organic materials, forming a sandy pulp, in separate or diffused masses, giving a dead white, chalky appearance. The latter are seldom seen except in cataract, the result of traumatic inflammation of the eyeball. This white degeneration may interfere with diagnosis.

If there has been much scondary change, the deposit is mortar-like, and contains fatty matter, with cholesterine and margarine. There may be an outer shell of chalk, or the whole cataract may be converted into a solid piece of the same, which will ring when struck with a steel probe. In this state, the form of the lens is not lost, although reduced. Sometimes true bone is formed. More is said of this stony and osseous change, in the chapter on Calcareous, Osseous, and True Bone Deposits about the Ocular Tissues. Myeline substance also is found.

Exceptionally the nucleus, instead of increasing in hardness, becomes pulpy around, with a loss of cohesion centrally, by which it is readily broken into pieces.

If the destruction of the lens tissue should cause the cortical layers to degenerate to fluidity while they are whitish, the fluid is white, and, if while they are dark, the fluid will be dark, either brown, chocolate-coloured, or even sepia.

The nucleus also may pass into fluid degeneration, but this is an exceedingly rare event.

A very marked difference in the atrophy may occur in the opaque lenses of the same individual. I performed double extraction in a female sixty-nine years old. The one lens had a hard amber-coloured nucleus, surrounded by soft whitish brown matter. The other did not exhibit the slightest amber tint, but was grey throughout, and softer. With the former the posterior chamber was natural. With the latter it was lost by the iris being pressed forwards.

It sometimes happens that, after the greatest destruction of the cortical portion, even to fluidity, the nucleus is yet but in the primary change, and still yellow.

In *soft cataract*, the lense loses much of its bulk, and gets flat. It may lessen at the margin, and break away more or less from its zonular attachment, and become irregular in form. The lens tissue is changed into fatty material, perhaps with cholesterine and lime, causing elevations. Or the degeneration may take another course, and pass into a dry brown substance, which breaks up on the least pressure.

But the organic base may become fluid, and the entire cataract break down into a lime-water-like material, with earthy granules and fatty matter floating, or deposited on the capsule walls. This fluid or emulsive metamorphosis is almost always connected with soft cataract, and is the result of a chronic inflammatory process. The fluid does not remain long, but, becoming absorbed, leaves generally crystallized fatty matter. When the capsule remains tolerably clear and the eye is at rest, denser parts of the degenerated lens are sometimes seen to gravitate in accordance with the position in which the head is held. In consequence of this the lower portion seems almost opaque, while the higher is whey-like, bluish-white, and less opaque. I have seen the line of separation very marked. The general colour is restored by moving the eye about, or pressing on it.

All the primary, and even some of the secondary changes, may occur in the lens without the capsule becoming generally or even partially opaque.

It is impossible to describe all the appearances in the living eye, that hard and soft cataract may present in the several stages of primary and secondary changes. Their physical characters are easily

learned from actual observation. But it is necessary for me to caution the student not to mistake hard cataract that has passed into secondary degeneration with its whitened surface, for soft cataract, that which can exist only in children and young persons. A hard cataract in which the secondary change has affected the greater part, is, strictly speaking, more soft than hard, and is entirely soft if the nucleus also be secondarily degenerated; but it is at once apparent that any rare or pathological condition of this nature, is a very different thing from what has been described as soft cataract. The practical importance of the matter is that there may be a dense nucleus within the whitened and semi-fluid or fluid cortex, as above described, and therefore a different operation will be required from that which should be applied to a soft cataract.

Traumatic cataract. This term is used merely to express the manner in which the cataract originates. Nearly always it is produced by a wound that cleaves the capsule and the lens or the capsule alone, enough to admit aqueous humour to the lens tissue, and less frequently by a blow on the eye, or on the face, or the head, by which the capsule is torn. Still more rarely it is brought on by a blow on the eye or the head, or the face, without any tearing of the capsule, at least without such being apparent.

The cataract will be hard or soft, according to the period of life at which the accident happens. In childhood and in youth, it will not materially differ in density from idiopathic cataracts occurring at those times. In the elderly and old, it is dissimilar from the ordinary senile cataract in never being so dense. There are not the slow pathological deposits in the nucleus, by which it is made more dense, nor the absorption of the more fluid portions of the cortex. The surface is never brown, but always whitish. This influences treatment. It may be said to be opacity of the lens, without the other alterations of cataract.

Traumatic cataract, according to my observation, is always capsulo-lenticular. It is said that exceptions have been seen.

The aspect of traumatic cataract is generally cloudy, and in proportion as the capsule is thickened, so will it be whiter. There can be no error in diagnosis, as the history of a case is a safeguard against this.

The cause of the cataract, the blow or the wound, is often the cause also of other injury to the eye; hence we may have coexisting detachment of the retina, blood effused into the vitreous humour, tearing of the choroid, &c.

CAPSULAR CATARACT.

It used to be thought that the capsule loses its transparency, until Stellwag examined about fifty cataracts with altered capsules, obtained at post-mortem examinations in the General Hospital at Vienna, and confirmed what had been stated by Müller, to the effect that the opacity is generally due to deposits from the diseased lens, looking like fibro-granular-mesh work, or cloudy membrane, and that it is capable of removal by mechanical or chemical means. With this alteration the natural elasticity is lost, and brittleness acquired. It is so far made out that the true capsular tissue or hyaline membrane is not altered in itself that it maintains its integrity. This great observer has detected opaque spots in the capsule, enclosed in thickened portions of it, but not, he says, as transformation of itself.

But I retain the terms of capsular cataract and opaque capsule as they are generally employed. Surgically speaking, they are unobjectionable.

Anterior capsule. Deposits may form on the outer part of the anterior capsule as a rare occurrence, when, for instance, the lens enclosed in its capsule is dislocated into the anterior chamber. Here the material is from the aqueous fluid.

Fibrous deposits on the front of the capsule are common results of inflammation of the eyeball, in which the iris participates. Those which form under the iris are more or less mixed with the uveal pigment, hence their blackness. Those within the area of the pupil are not coloured.

A very small central spot is sometimes seen in front after severe purulent ophthalmia in infants, when there may be a corresponding dot on the back of the cornea. This is more frequent in one eye than in both. There can be no doubt that the cause is contact between the inflamed cornea and the capsule of the lens. The baby's lens is very convex, and is nearly on a level with the pupil. It may even, I believe, stand out a little beyond it. Besides, the anterior chamber at this time of life is remarkably small. It is easy, therefore, to understand how the swollen cornea may touch the lens, especially as in all probability, the lens is pushed forwards by congestion of the eyeball. The dot may be the result of the effusion of lymph. Probably the lymph is always deposited on the cornea as well, but sometimes it gets absorbed. I have seen a delicate film passing between the cornea and the capsule. For more minute details the reader is referred to the writings of Stellwag, and to extensive researches in

the French edition of Dr. Mackenzie's work on the eye, by MM. Testelin and Warlomont.

In ordinary cataractous capsular opacity, that is, in the absence of any appreciable inflammation, the opaque deposits are on the interior of the capsule. They are thin, and consist of the nucleated cells, which line the capsule in a thickened, dark, and granular condition, and of condensed cataractous substances of a granular basis, or chalky, or fatty material, with a certain amount of pigment in which are scattered in conglomerated groups lime-salts, and cholestrine crystals, and plates of muriate of lime, and still more rarely black crystals. There may be, too, a thickened layer of disintegrated lens tissue.

If there be complication with inflammatory affection of the interior of the eye, more or less cell proliferation takes place.

The conclusion is inevitable that the capsule spoiling is intimately connected with degeneration of the lens surface.

When there is much capsular change in the density and in the thickness of the deposits there is a departure from the usual course of the lens atrophy, in more morbid action, and generally some other ocular disease.

Very marked capsular changes are in all probability the result of inflammatory action. There is a thick stratum between the capsule and the secondarily metamorphosed cataractous mass, in which the disintegrated remains of the lens tissue mingle with well-formed elements that have originated from cell proliferation.

The capsule may get very dense, when there is marked secondary lens degeneration, and the lens tissue nearly metamorphosed, especially in soft cataract, by the formation of a layer of very firm connective tissue on the internal wall. This is most common in congenital cataract. Sometimes chalky deposits predominate, and increase the thickness; hence the chalky capsule. The capsule may become ossified.

The opacity of the capsule, together with the fullest pathological alterations, are most marked in soft cataract, and particularly in the complete congenital form. As it is not uncommon to find an otherwise unhealthy condition of the child's eye, in consequence of which full success in operating is often not obtained, I am induced to suppose that some inflammatory action of the eye in the womb, produces the cataract.

The most marked forms of capsular cataract, occurring after birth, exist when there is fluid degeneration of the lens, in part or in whole. A fluid cataract in an adult is never uncomplicated.

The posterior capsule, differing from the anterior, in being so much thinner, and not resting on nucleated cells, has not the same ten-

dency to become opaque, although it may be so affected, in dots or patches, or entirely. It may be affected alone, or along with the anterior.

Partial capsular cataract may exist in the anterior or the posterior capsule without the whole of the lens being opaque. The commonest condition of the partial state is met with accompanying partial lenticular opacity. In any partial form some lens change is always the cause of the opacity. Such change, however, must at times be very slight indeed, and probably limited to the superficies, for, to judge occasionally from what is discernible in the living eye, the united opacities would seem no thicker than opacity of the capsule alone, and these remarks apply even more forcibly to partial cataract of the posterior capsule.

Complete capsular cataract arising after birth, I believe always to depend on entire lenticular cataract, and to be associated with complications arising out of inflammation.

The capsule is affected by the secondary changes of loss of bulk in the lenticular cataract, accommodating itself to the lessened contents; it contracts and wrinkles, and, to a corresponding degree, loses connexion with the hyaloid membrane and zonular attachments. This explains the occasional detachment of the lens and the capsule during operations, and it accounts also for the spontaneous separation of a cataract when the vitreous humour is not fluid.

Whether the capsule may altogether and absolutely escape opacity when the lens is opaque, I am unable to say. It may keep clear so long as the nucleus of the lens only is opaque, and there remains a layer of clear lens material next to it. If it be always more or less affected in complete idiopathic lenticular cataract, the opacity is generally so slight in the uncomplicated hard cataract, as not to be practically recognised during primary changes. Very slight opacity is probably very often overlooked.

It is not unlikely, I suppose, that a complete slight capsular cataract may form, without the whole lens also at once becoming opaque.

The many changes in appearance that the capsule undergoes, have induced surgeons to give distinct names to the cataracts. This confuses rather than enlightens.

Capsular cataracts after the removal of the lens by operation, or by accident. There is, I believe, always capsular cataract after the loss of the lens. Investigation by the various means at my disposal, including the ophthalmoscope and oblique illumination, has always detected it, when the naked eye has altogether failed to do so. Only when the pupil is occupied in part, or in whole, does its presence become of practical importance. It may be so highly opaque as

not to interfere much with the reading of large type, although the smallest cannot be seen. It is always, as I understand, actual opacity that thus intercepts the light.

Mr. Bowman, in writing on capsular obstructions in the "Ophthalmic Hospital Reports," says that there may be obstruction to sight not by the capsule being rendered opaque, but from being simply wrinkled and folded in such a way as to refract the light unequally in its passage, and consequently to confuse the image, and that the ophthalmoscope detects this state. Neither a sharp image of the fundus of the eye nor of the optic disk can be seen. That the situation of the disk is detected by its whiteness, and perhaps, according to the degree of the capsular folding, its general shape, or even its vessels may be observed, but they appear distorted as though seen through very finely wavy glass.

Capsular cataract, in a marked degree, is sometimes the effect of some portion of the atrophied lens being incarcerated in the contracted capsule, especially cretaceous degenerations of it; or from the atrophy of transparent lens tissue which has been left. Probably the capsule always retains portions of the one or the other of such tissue. Most likely the hexagonal cells, when existing, are always retained. According to Dr. Schweigger, they may still be adherent to the capsule after it has been freely broken up and exposed to the action of the aqueous humour. It is stated by him that they may be the seat of an imperfect process of growth. Mr. Bowman, in commenting on this, says, that the retention is apt to occur where the torn capsule rolls up; also where the anterior and posterior capsule have fallen together with or without adherent lens substance, and that it may be the source of new lens growth of very appreciable thickness, usually opaque. Occasionally he thinks he has seen in some degree and for some time, the transparency of natural lens substance. The growth, which is very limited, adds very considerable toughness to the capsule.

Capsular cataract always remains in the area of the pupil, and gives much trouble when operations have been performed on immature cataracts, those in which there have yet been portions of transparent lens.

The commonest cause of secondary cataract obscuring the pupil is inflammation. No matter how transparent the anterior capsule may have been at the time of an operation of any kind, if inflammation of the eye ensue, dense capsule will appear in the pupil. The capsule participates in the general inflammation. Acquired density is always an early effect of the inflammation. If however the vascular action be long continued, in the end the capsule may degenerate and get as

it were rotten, so that it is most readily torn. This late effect is most apparent when there are on the capsule external deposits with adhesion of the pupil. It is now, too, that calcareous deposits are common.

These capsule changes should be understood, because it matters materially whether a natural thin, delicate, and elastic tissue is to be cut, or torn, or removed; or a membrane that has acquired the opposite qualities.

The soft superficies of lenticular cataract may remain a long time enclosed in opaque capsule, after an operation either for extraction, or for solution. I suspect that in all such instances the capsule has contracted completely around it, or perhaps uniting, has sealed it in. I have observed it after the most successful cases of extraction. Three and a half months after I had extracted a cataract from a man fifty years of age, the pupil was very much obscured by what seemed to be merely capsule. In using the needle to clear a sufficient space, there fell from the capsule into the anterior chamber, an amount of lenticular matter that quite surprised me. No inflammation, contrary to my expectation, followed. The chamber was cleared of it by absorption in ten days.

CAPSULO-LENTICULAR CATARACT.

This is used merely as a convenient term, to express coexisting opacity of the capsule and of the lens.

There may be a deposit on the outside of the capsule without any lens atrophy, but any capsular opacity arising from a deposit within, must, as I have shown, be associated in correspondence with some lens change, however slight. There may be but a mere dot of capsule opacity, over a large spot of lenticular. If this be a universal truth, there is never capsular cataract, be it ever so limited, alone. It is always capsulo-lenticular. However, the term is scarcely used unless the whole of the anterior capsule is opaque.

Capsulo-lenticular cataract is almost confined to the early years of life, those under manhood, and, therefore, it is generically soft cataract.

It has been pointed out, that capsule changes are intimately associated with inflammatory diseases of the eyeball. Those remarks apply here. It is common for a characteristic capsulo-lenticular cataract, at all periods of life, to co-exist with other ocular disease,

especially with a congested state of the eyeball. Sometimes the iris is altered in colour.

Some authors use the term inflammatory capsular cataract, rather than capsulo-lenticular.

There are often deposits on the outside of the capsule sufficiently dense to influence the effect of operations on it, a matter of practical moment. These may be rendered more apparent by oblique illumination.

CONGENITAL ANOMALIES OF THE CRYSTALLINE LENS.

Absence of the lens. It is doubtful whether this condition has ever been met with except in monstrosities. The same may be said about two lenses existing in the same eye.

Malposition of the lens has been recognised many times; more will be said on this point under the head of spontaneous dislocation of the lens.

Irregularity in the equator of the lens has been met with in hypermetropic eyes, and with the otherwise congenital defective condition of coloboma iridis.

Grooves in the lens and depressions have been discovered.

Those who are interested in the malformations of the organs of sight, and in the congenital diseases of the same, should consult the very able pages in the *Dublin Quarterly Journal*, by Sir William Wilde. They extend over many years.

PROGRESS OF CATARACT.

The less complicated the cataract with other disease of the eyeball, the slower does it proceed. Inflammatory complications cause the quickest development.

When the entire lens tissue is invaded by opacity, there is always a continuation of atrophy, however slow.

When the opacity commences in the nucleus, several years frequently elapse before the whole lens becomes opaque.

Opacity of the cortex of the lens, primary or secondary to that of the nucleus, is quickly followed by full-formed cataract. Small striæ of opacity, although very numerous, precede slow formation of cataract. Broad striæ precede the quicker development.

Soft cataract quickly gets matured. In a few months, or at most a year or two, is the entire lens opaque. The secondary changes follow

in proportion. Inflammatory complications seem to have a more rapid effect here than in the hard.

Hard cataract is the slower in passing through its stages.

There are exceptions to the progressive development of the cataract in both varieties which cannot be accounted for, and which render it impossible for a surgeon to give any decided prognosis respecting progress, and oblige him to speak generally and to talk of probabilities. Instances occur in which the cataract appears to be stationary for years. Most cataracts increase irregularly. There may be a marked difference in the development of cataract in the separate eyes of the same person.

Partial cataract occurring at birth generally remains stationary. An exception is rare, but that it does occur I am fully aware from actual observation.

Partial cataract occurring in childhood may not increase for years, but it is likely to become general. When it has remained long unchanged, it is apt to take on activity about the period of puberty.

Primary and secondary degenerations do not proceed in the partial cataracts as in the complete. The secondary do not follow so quickly or so certainly. When degeneration does proceed and some absorption occurs, there may be shrinking of the cataractous portion, and of the corresponding part of the capsule. As transparent lens tissue remains, the lens is changed in shape accordingly. The capsule is involved in partial opacity in these cases and gets wrinkled, and sometimes otherwise altered from various deposits.

Traumatic cataract is always rapid in its formation. A few days or even hours may suffice for dense opacity of the entire lens and its capsule. Examples, with remarks, are given in the chapter on Mechanical Injuries to the Eyeball.

Single and double cataract. When cataract is produced in the one eye by any palpable intra-ocular cause, which is limited to that eye, or when it is traumatic, the other eye does not become implicated. When it proceeds without any palpable cause in an eye of a young or of an old person, both eyes are tolerably sure to be affected. In the double affection the one eye is generally in advance of the other.

In hard cataract the right eye is nearly always the first affected.

DIAGNOSIS OF CATARACT.

We no longer seek for cataract by subjective symptoms. As the disease is visible in all stages, it must be looked for. The search

is facilitated by dilating the pupil, and employing oblique illumination and the ophthalmoscope.

Visible symptoms. Opacities produced by the primary and the secondary changes that the lens fibres undergo, and by the deposits on the capsule, are clearly reflected. These physical signs are striæ or stripes, as radiating opacities, dots or spots, large or punctiform patches, fringes, flocculent opacities, and general cloudiness when the entire surface of the lens is affected. So long as mere striæ exist, only the primary changes have occurred in the lens fibres. Patches denote secondary alterations.

The distinction between well-marked senile colorations and cataract is easy. Coloration is well seen by oblique illumination. It nearly disappears when the ophthalmoscope is used, and the fundus of the eye is seen, yet not with the clearness and brightness to be observed in youth.

The state of the sight will help in the investigation. If the person examined can see distant things well, and if he can besides read small type without glasses, or the smallest even with them, he cannot have cataract.

Besides making out that cataract is present, it is possible to say in the partial state of some cataracts which part of the lens is affected.

Hard cataract. The cataract of adults, elderly and old people. It is almost always cortical in the early stage, and shows itself as opaque streaks, or radii of different lengths, on the anterior and the posterior surfaces of the lens, branching as they extend towards the equator of the lens, and getting more curved. This is due to the disposition of the lens fibres, which are arranged in radii, converging from the outer part of the lens to the centre in curves, which curves decrease as they approach the centre. The striæ may be short, and thickly set, at the very equator. Sometimes there are more patches of opacity than striæ, especially near the equator.

Striæ in front are at once detected, and look white. Those deep-seated, especially at the back of the lens, are yellowish, because they are seen through the coloured nucleus.

The striæ increase and blend into patches, the lens in general gets hazy, and less light enters the eye. At last all striæ are lost, and only the opaque anterior lens surface can be seen.

When the cataract is ushered in by nuclear opacity, there is a diffuse brownish or yellowish grey cloudiness, which is more or less curved from the shape of the nucleus, less dense at the margin, through which the light passes to the fundus of the eye. There is then apparent a transparent space, from the opacity to the pupil, in thickness according to that of the cortical stratum of lens fibres that

is not involved. In a well-marked case, by weak ophthalmoscopic illumination, there appears a roundish cloudlike opacity in the centre of the pupil. By high illumination, the fundus of the eye is seen as through a mist, very cloudy in the centre, but clearer at the sides, where the several parts may be made out more or less. Oblique illumination shows better the colour of the nucleus, the form, and the outline. This cataract is always very slow in forming. Striæ may appear in the cortical portion, but the completion is generally effected by the whole lens being occupied by extension of the opacity.

The rarest form of developing cataract is that in which the entire lens is pervaded from the first by generally diffused opacity. If there be distinct markings they are more like convolutions of fine threads, than the ordinary regular striæ of most cataracts.

The cortical and nuclear changes may proceed together. This is the quickest forming cataract.

The appearance in the fully formed ordinary cataract of primary change, is a mixture of dark grey and amber, more deeply shaded in the centre, or mottling of grey and amber, or amber only.

When the secondary atrophic changes take place, the cataract surface generally gets more opaque and white, and more patchy, from the addition of earthy and fatty matter, and molecular deposits, and cholesterine.

I am not aware that there are any diagnostic distinctions in mere aspect between a hard lens so secondarily altered, and full-formed cataract occurring in early life, except that the former is of a more uniformly whitish colour and devoid of cloudiness, never exhibiting radiating or other streaks, and that the capsule is rarely, if ever, opaque, and excepting such symptoms as alterations in the chambers of the eye may indicate. In hard cataract there is nearly always a posterior chamber in correspondence in size with the age of the person, and this increases as the cataract gets smaller, as it is apt to do. In soft cataract the posterior chamber is very frequently reduced, and may be lost, the iris being pushed forwards, its movements impaired, and even the anterior chamber reduced. The cataract may even protrude through the pupil. But the age of the individual is a leading point.

Besides the size of the posterior chamber in giving a correct idea of the volume of the cataract, the shade cast by the iris in the form of a dark crescent on the cataract surface, shows the distance of the cataract from the iris, and therefore indicates lenticular diminution. There is no shade when the cataract is large and close to the iris. The shadow is the more marked as the cataract is light coloured.

Slight tremulousness of the iris from the loss of peripheral support is another proof of the reduction of a cataract.

It is not possible to tell before operating whether the secondary changes on the surface of a cataract have produced partial fluidity. On one occasion, during extraction, when I proceeded to rupture the capsule, a dark fluid unexpectedly escaped, and for a time interrupted my progress by obscuring the iris. Another patient, a lady seventy-seven years old, with double cataracts, consulted all the present men of ophthalmic eminence in London, and, without an exception, extraction was recommended. I saw her, took the same view, and was selected as the operator. The capsule did not contain a particle of lens, but was filled with material like coffee-grounds. I operated only on one eye; sight was restored. There is always an absence of all striæ or markings that can exist only so long as the lens fibres remain, however atrophied.

Soft cataract. This varies more in appearance than the hard kind during the stages of formation, and when fully formed, and during the secondary metamorphoses.

It must be considered under two heads. First, as opacity invading a lens that has not become amber-coloured and denser by age, as exists in children and young persons.

Secondly, as occurring in a lens a little denser, in which the coloration is slight, as in young adults.

There are such dissimilarities between the states of the disease mentioned under the first head, as to warrant separate consideration of them, as they appear from birth to puberty, and from puberty to manhood.

Of the cataracts met with from birth to puberty, the greater part are congenital; indeed, I am inclined to suppose that nearly all have this origin. When they are discerned a few years after birth, they are but the extension of previously existing opacities. A slight partial cataract is very commonly overlooked altogether in early childhood. In a child the power of accommodation is great, and the dioptric media in general so clear that he requires very little illumination of an object to see it; he is therefore less affected by a partial opacity than an adult. Till a child can read, and is old enough to understand questions about his sight, and to investigate it somewhat a little himself, any slight visual defect is almost certain to be attributed by his parents and friends to a little nearsightedness.

Congenital cataract. A child may be born with a cataract fully or partially developed. The latter state prevails. It will save time to arrange this form in the following manner.

First, in the more common state, it is a spot of chalky whiteness,

sometimes a mere dot in the very centre of the anterior part of the lens, being degeneration of the lens tissue to that extent. The capsule may be affected to the same degree, or even less, but it may not be implicated. In many instances the cataract is not discovered till years after birth; sometimes not until adult life. The opacity is always well-marked in the clear black pupil.

Second, as a more extended form of the above. Besides the primary and secondary lens degeneration, there is an addition of calcareous or earthy matter, which projects, and carries the opaque capsule in front. A white opaque excrescence stands out more or less pyramidally, with a base that may be as large as the natural pupil, though generally much smaller. This is the pyramidal cataract of the old authors. An examination of such a pyramid that became detached, showed a thickened portion of capsule, over parallel plates of neoplastic cloudy substance. It seemed as if the pyramid had grown from the lens substance. In some cases there is opacity at the back of the lens as well, or striæ in several parts of it. The first case I ever saw was pointed out to me by Sir W. Lawrence, when I was his house-surgeon. The subject was a boy of twelve years old, whose sight was so imperfect from partial opacity of the lens, that the operation for solution was undertaken. The base of the little excrescence occupied the entire area of the undilated pupil. The apex nearly touched the cornea. The entire piece dropped off in the course of absorption of the lens, and remained harmless in the anterior chamber.

Third, the commonest form. There is central lenticular opacity with or without greyish-white striæ passing from it to the equator of the lens. This partial atrophy may occupy the entire thickness of the lens, or the anterior or posterior cortical portions, or lie between the centre of the lens and the surface. As yet there is no nucleus to the lens.

It matters nothing, however, as far as the disease is concerned, where the opacity is seated, nor is there any practical value attaching to the accurate diagnosis of the position of such.

Dilatation of the pupil shows the nature of the affection more fully. The unaffected portion of the lens looks quite black, and the more so if there be no lateral striæ.

Formerly a pathological mistake was made about partial cataract which involved nearly the whole lens, but left a marginal strip clear. It was supposed that the lens was smaller than natural, and opaque. I pointed out the fallacy of this, before the ophthalmoscope was used.

Fourth, fully formed cataract, which may be in the primary or secondary stage of lens degeneration.

I have heard it said that cataract may be acquired in childhood, not being congenital. The proof adduced is that the children had seen well up to their seventh or eighth year. I question the accuracy of the diagnosis. It cannot be proved that there had been accurate sight in anyone in whom cataract is detected so early in life, while the probability is strongly in favour of congenital disease, slight at first, and discovered from the increase.

Bluish white is the aspect of fully-formed cataract of this kind.

Both eyes are generally similarly affected.

Opacity of the capsule is a very common occurrence in congenital cataract. It would be omitting a feature in this infantile affection were there not mentioned the marked changes that the capsule may undergo in regard to thickness and opacity. The greatest alterations that I have observed in these respects have been here.

The cataract occurring from puberty to manhood, that is, up to the period at which the lens is yet soft, being without a distinct nucleus, next occupies attention. If the opacity should begin in the cortical portion of the lens, a bluish-white, slightly glistening zone, sometimes interrupted, appears near the equator. Glistening striæ on the anterior and on the posterior surfaces next appear, converge towards the poles, and are seen in the pupil. The interspaces may be clear or a little cloudy. Then the whole lens-tissue loses its transparency. While the lens centre remains clear, the cataract is, of course, less dense there. The extreme equatorial parts may long remain clear. Again, on the anterior or on the posterior cortical portion, or both, spots and striæ may form, which increasing, unite at the poles and at the equator.

The opacity may commence centrally, in a star-like form, and as it progresses make the lens look as if it were divided into sections.

When the entire lens is opaque, the opacity is densest in the centre of the cataract.

Glistening radii are more commonly seen here than in hard cataract, and are brighter. When they are very numerous, and there is besides, interstitial opacity, the cataract looks like a piece of fractured spermaceti.

The cataract generally retains some transparency till the secondary metamorphosis sets in, and, by reflected illumination, radiating striæ may be seen till a late period.

Light grey colour, or greyish-white, is the appearance of this cataract when fully formed, and in proportion as the cataract occurs earlier in life is the grey more apparent. Sometimes there is a bluish whiteness, resembling milk-and-water. The colour is generally

deeper in the centre, but the contrast is not so marked as in the hard variety.

It is supposed that soft cataracts may increase in size beyond that of the healthy lens, indication of which is afforded in smallness of the posterior chamber. This is really no proof, as changes in the posterior part of the eye, especially preternatural vascularity of the ciliary apparatus, may throw the cataract, and even the iris, forward, and more or less destroy, too, the anterior chamber. Besides, such enlargement could not take place, unless the capsule also enlarges, a very unlikely occurrence. According to my experience, this kind of displacement is always present, when cataract is complicated with marked inflammation of the eyeball.

When cataract is the product of severe inflammation of the eye, that part of it which is visible, not being covered by an adherent pupil nor by inflammatory deposits on the capsule, appears of a chalky whiteness, or of a mother-of-pearl lustre. There is mostly much calcareous degeneration.

The marked characteristics of fluid cataract prevent it from being mistaken. They are a milk-like whiteness, or a cloudy grey aspect, without striæ or lines or any markings, such as occur among lenticular fibres. There may be minute dots on the posterior part of the anterior capsule. Gravitation of the more solid particles, before spoken of, so that the lower part of the cataract is the denser, is the most marked physical sign.

Inflammatory complications modify the appearance of cataract, but only the capsulo-lenticular variety, by causing the deposit of inflammatory materials on the front of the anterior capsule. The case is this: the iris inflames and becomes adherent to the capsule of the lens, and then lymph is effused. The appearance is that of a dead white with a dull lustre. There may be chalky deposits, also cholesterine, when there is glistening. Such conditions, especially the latter, are rarely seen, except in disorganised eyes which are past treatment.

DIAGNOSIS OF CAPSULAR CATARACT.

Partial capsular cataract of the anterior capsule has a chalky white or cretaceous look. It may have a definite outline, or be surrounded by a bluish halo. It is generally central, and can be recognised by its anterior position.

Its appearances are rendered more manifest by raising the upper eyelid, desiring the patient to look to the ground, and making the inspection sideways.

When partial opacity of the capsule occurs, in conjunction with partial or complete opacity of the lens, the colour of the two may so resemble each other that, without looking into the pupil obliquely in the manner I have described, an inexperienced observer will be deceived. The definite outline of the capsule is well contrasted with the posterior, hazy, and diffused lenticular opacity.

Opacity of the posterior capsule can be seen well only with the ophthalmoscope. It appears as a dull concave, deeply-seated opacity.

Complete capsular cataract has chiefly a bluish white aspect, the blue or the white prevailing according to the absence of the lenticular matter, or the presence of an opaque lens. Any deposits on the inner surface of the capsule, chalky concretions, cholesterine, and fibrous materials, are more or less visible.

The capsule is rarely so densely opaque throughout as to conceal the cataractous state of the lens, unless the opacity be caused by injury, or be congenital. Some little spots less altered than the rest generally afford the information. The age of the individual does not seem to influence its changes, as in lenticular cataract, for precisely the same conditions may be observed at any period of life.

Whether complete capsular cataract encloses a lens or not is judged of chiefly by its volume. When the lens is absent, the symptoms are, flatness of the capsule, greater size of the posterior chamber, with more or less retraction of the iris with perhaps tremulousness.

Sometimes there are densely opaque patches, sometimes thick cretaceous deposits, on capsulo-lenticular cataract which exists at birth. The last stage of secondary lenticular metamorphosis or fluid degeneration is often met with in conjunction with this dense capsule change. It would seem that absorption of the degenerated lens material is always greater, as the capsule is thicker. This is the cause, I suspect, why capsule only is met with in children, when the disease, originally capsulo-lenticular, is not operated on early. I am unaware whether there is ever any arrest of lenticular development in such cases of the congenital disease, but I suspect that there often is, because there are frequently associated congenital ocular defects.

An empty capsule is mostly less opaque. It generally extends in part to the ciliary processes. There is frequently more opacity at the circumference, because whatever remains of degenerated lens, as fatty and chalky deposits, are collected in that position, and this arrangement may produce the appearance of a circular cushion or wreath.

Ordinary capsular cataracts do not interfere with operations on the lens.

THE EFFECT OF CATARACT ON SIGHT.

One or two opaque dots in the lens, or small striæ, may not interfere in any appreciable manner with vision. I have proved this by careful tests again and again. Early points of opacity may be detected with the ophthalmoscope in the one eye, the other being either cataractous or sound, without the person so afflicted being aware that the eye is diseased.

When the opacity is sufficient to produce visual influence, the earliest effect is indistinctness of sight, that is, mistiness. Distant things are worse seen. Objects look as though they were viewed through a mist or fog, or a bit of glass that had been breathed on. This arises from absorption of the light in consequence of alterations in the lens tissue. Added to this is impairment of the adjusting power, arising out of loss of lens elasticity. As the disease progresses, vision declines in proportion, and near objects are indistinct. Diffuse light is now avoided. Twilight, or a dull or subdued light, is very much preferred, because with the pupil expanded more rays pass through the lens. A patient shades his eye with his hand, and receives benefit from neutral-tinted glasses, with dark sides attached, such as goggles. Sometimes there is besides such an intolerance to light that associated disease might be justly inferred. Having watched many cases with reference to this, I can say that it has not arisen from any co-existing inflammatory state of the interior of the eye. After the cataract has been removed, and sight restored, this symptom has been lost. Of the nature of the complication, therefore, I am unaware. It may exist alike in the early or in the fully formed cataract. I have seen an infant eighteen months old, with congenital cataract in the one eye, who always closed that eye to exclude bright light.

Objects may be doubled or farther multiplied, and seen in fantastic forms. The moon is often mentioned, as showing such changes well. This arises from several parts of the lens yet remaining transparent, or nearly so. The refraction, as to where the image will fall, whether to a focus on the retina, or behind it, will depend on the density of that portion of the lens yet transparent. Out of this may arise irregular astigmatism. With such marked lens changes, and alteration in curve, there may be phenomena, so complex and so confused, as at first to be with difficulty interpreted. A late patient of mine, who had fully-formed hard cataract in one eye and incipient in the other, was in the habit, when in London, of going out to be

amused with the multiplication and refraction of the street lights; the pyrotechnic effect was beautiful. Looking at the long train of lamps in Piccadilly was the greatest treat. A perfectly successful operation on each eye proved that this peculiarity was due to the cataract alone.

Later in the disease, as the opacity proceeds, the flame of a candle is so obscured that its position only is discernible.

Almost every cataract patient complains of muscæ; some have them very large and in showers. They matter nothing. Flashes, stars, fiery circles, bright metallic light, bright spectra like silver, have nothing to do with the cataract, but are caused by other disease, and which generally spoils the eye, rendering it unfit for any operation.

Every surgeon must at times be astonished at the slight disturbance there is to vision with cataract far advanced, when the eye is shaded, and the object looked at is well illuminated, particularly when the morbid changes are chiefly confined to the nucleus of the lens in elderly people.

In congenital cataract occupying nearly the greater portion of the area of the pupil, there may yet be vision enough to enable some occupations in life to be followed, and education may be little interfered with.

It remains only for me to speak of what is usually described as acquired near-sightedness in cataract. This is not in reality myopia, in the true sense of the term. The exact state is quickly told. The patient loses the power of seeing distant objects, and is unable to define anything, however large, a few yards from him; but to his surprise he finds, if he have been presbyopic or hypermetropic, that he no longer requires his convex glasses, because he can read large type a few inches from his eyes. With this return of his near visual point, there is always a want of acuteness of vision; minute objects cannot be seen. This is a great puzzle. I saw a gentleman, aged fifty-five, with nuclear opacity of one eye. He had been slightly hypermetropic. I saw him seven years later; the whole of the lens was opaque, the centre being the denser. There was, too, slight general capsular opacity. When I examined his eye with the ophthalmoscope no reflex could be obtained from the fundus, and there seemed to be fully formed cataract. I remarked that there was very little vision now remaining. He said I was mistaken, and asked me to give him a book. I covered the sound eye, and at the distance of eight inches he read No. 3 of Snelling's test-type; the eye quickly fatigued, however. I have met with three such cases.

The effect of cholesterine crystals is mentioned among the complications of cataract.

Cataractous patients scarcely ever derive any benefit from convex glasses.

CAUSE OF CATARACT.

Although lenticular cataract may form at any period of life, no age being exempt, from that of the child in the womb to that of the utmost limit of man's existence, it appears to belong, as an idiopatic affection, more properly to infancy, when it is mostly capsulo-lenticular; and to advanced years, when it is usually lenticular. Of the exact nature of the change that produces the opacity, and the processes that regulate it, we know nothing, and our ignorance is generally told in the expression, that it is due to defective nutrition.

Experience, however, teaches that cataract may follow certain states or circumstances which may be regarded as causes. Thus a wound of the capsule alone may in a few hours cause both lens and capsule to be opaque. This is fully treated of in the chapter on Injury to the Eye from Mechanical Agents. Inflammation of the interior of the eye, especially of the anterior portion of the choroid, in which the ciliary region is much involved, may produce the same effect.

That cataract is common in young adults who have diabetes, and that it appears late in the affection, is fully proved. There is not any peculiarity about such cataracts; except that they are always pushed forward by some changes in the eye posteriorly, and bulge the iris, an occurrence erroneously attributed to increase in the volume of the cataract; and also that the cortex is whiter than in the slower forming cataract of adult life.

I have seen cataract appear quickly after fever, in a young man who was much emaciated.

Lenticular cataract, which is seen after the forty-fifth year of age, cannot generally be accounted for. It appears without any palpable cause. Pathology and physiology do not yet afford any elucidation, and all the theories which have been advanced concerning it, some of which are very ingenious, are untenable. It must be remarked that we meet with it often in a complicated state, co-existing with other diseases in the eye, either of an active or of a low type.

It is likely that complications often exist and escape notice, because we are not able to detect them. Perhaps all idiopathic cataracts are the result of complicated disturbance in the ocular circulation.

The healthier the eye, the slower does the cataract form.

Some surgeons say that the difference between the senile changes in the lens and hard cataract is merely one of degree, and that therefore it cannot be said where such cataract actually begins. It is impossible to subscribe to this. Age merely never causes cataract, and the pathological cataractous atrophy of soft cataract, where there is no senile change, is the same as that which occurs in hard cataract.

Lenticular cataract occurring before adult age, that is, soft cataract, is equally obscure in origin, but it is more frequently complicated than the hard. In the congenital form, it is not uncommon to have some other congenital defect of the eye. It is met with, too, in disease of the brain and its membranes, and most frequently in hydrocephalus.

Cause of opacity of the capsule, also, often cannot be accounted for; yet it would seem, more commonly than that of the lens, to be owing to contiguous inflammation, from the changes in thickness and density that it frequently undergoes. In traumatic cataract, the capsule is nearly always opaque; and the anterior and the posterior portions are affected. Except in congenital cataract, the capsule is rarely found opaque without there being evidence of some degree of inflammation in the eyeball, and the capsular changes are generally in proportion to the severity of the accompanying vascular action. Moreover, it is seldom altered in the uncomplicated cataract of the aged; or if changed, but slightly, and then only the anterior capsule is affected.

Hereditary influence has long been recognised. The surest evidence of this is the development of double cataract at birth, when one of the parents has been so affected. Several children in the same family have been cataractous.

I lately operated on twins with the hereditary disease. One of the boys had both eyes affected, the other only one.

TREATMENT.

This involves the consideration of the curing, the arrest, and the removal of the cataract.

First as to the curing. It is supposed rather than proved, that the superficial portion of the lens and the capsule, may become cloudy in some forms of inflammation of the eyeball, and recover their clearness. Such repair may not be impossible.

In true cataract, or lens-element atrophy, I disbelieve in any cure

by restoration. Assertions to the contrary have been made, but there is no reliable evidence as to their truth. A kind of amelioration is described as occurring in partial cataracts, by the absorption or removal of damaged lens fibres. Such rare exceptions could have been seen but by very few men. The absorption is said to be the most likely in cataract of the superficial layers, especially in striated opacity of the middle portion of the posterior cortical stratum, and it is stated to occur most readily in young persons, and that the diminution of the opaque region is attended with corresponding change of form in the lens; and that it is in this way vision which has been much impaired, or even lost, may be improved to a considerable extent, or partially restored, and remain stationary, if the rest of the lens does not become cataractous.

Some observers speak of the disseminated opacities, which occur in irido-choroiditis, being removed. They attribute their locality to the hexagonal cells. Others state that slight lens haze, in connection with diabetic cataract, may disappear if the diabetes is arrested.

Next as to the arresting. Cataract may stop at any period of its development, or proceed so very slowly that a credulous patient may readily believe in an arrest.

Some surgeons believe that they have caused a check by general treatment, others by local applications, others by frequently tapping the cornea, and letting out the aqueous fluid. I am among a multitude of men engaged in ophthalmic practice, who doubt whether we possess any means of checking the progress of an uncomplicated lenticular cataract; at the same time, I must confess my belief in the possibility of staying the disease when it is yet incipient, if it be complicated, such as cataract the result of chronic inflammatory affection of the posterior part of the eyeball. I am myself satisfied of having obtained such results. Acting under this belief, I invariably seek for inflammatory complications in every patient who consults me with incipient cataract, and finding such, treat them according to existing indications. In all cases too, where I suspect any complication, I endeavour to induce the patient to avoid action, so far as the eye is concerned, that may call into activity any latent disease; to abstain from exercising acute vision at short distances, and especially by insufficient light, so that the strain of supporting high adjustment shall never occur. When there is no trace of complication in a slowly developing cataract, I do not forbid the patient to use his eyes in any way which is not generally injurious to eyesight. I should not prevent him from reading and writing in moderation, even by artificial light, nor from following any of the

usual habits of life, which do not impair health, nor tend to irritate the eyes.

Constitutional implication may have an effect in quickly developing cataract, especially those states of system arising from malnutrition. Acting on this supposition, I should expect to retard the cataract, if I could restore the patient to better health, and most certainly I would try.

Indirect relief by effecting the expansion of the pupil naturally and artificially. Assistance to sight can be obtained in central partial cataract, whether cortical or nuclear, by expansion of the pupil. This exposes the transparent part of the lens at the circumference, by which more light enters the eye, and the retinal image is brightened.

For the natural expansion of the pupil, different kinds of eyeshades may be used, and out of doors, broad-brimmed hats. When it is desired to produce the greatest effect, dark glasses in goggles must be employed, by which bright and diffused light shading is reduced.

The eye thus shaded has the additional advantages of the illumination of the spectrum from the opaque portion of the lens being lessened.

For the artificial expansion of the pupil, atropine must be used, or an artificial pupil made.

The advantages of dilating by atropine are very great, being, when most marked, as from blindness to sight; but it is impossible to tell till the trial is made, how far the measure may serve, in consequence of the arrangement of the cataract, and its extent. Sometimes the dilatation confuses. In order to prevent the adjustment of the eye from being much interfered with by complete paralysis of the ciliary muscle, the solution of atropine should be used in the lowest available degree of dilution, and therefore of not greater strength than is sufficient to dilate the pupil a little. As different persons are dissimilarly affected by this drug, the desired strength can be got only by trial. A single grain of the sulphate of atropia in ten or twelve ounces of water may suffice. Dr. Garrod has tried several experiments on man. He tells me that in one instance, one-third-millionth of a grain caused sensible dilatation. In several instances, half a millionth of a grain produced an effect; one hundred thousandth of a grain often causes free dilatation.

The action of belladonna is further commented on in the chapter on Paralytic Affections of the Recti-muscles of the Eye, &c.

With the same view of not influencing adjustment more than cannot be avoided, the atropine solution should not be applied unnecessarily

often, and as some individuals are more tolerant to it than others, this also must be made a matter of experiment. Most persons are sufficiently affected by an application of a single drop of the solution to the conjunctiva every third day. These remarks apply, of course, only to the cases in which there is but very slight partial cataract, because with much lens atrophy adjustment is lost.

The effects of the atropine do not wear out as some imagine, the same quantity always producing the same result, at any interval, however prolonged. I saw a housemaid, eighteen years old, with partial capsulo-lenticular cataracts that almost blinded her when the pupils were in the natural state; but when dilated by a very weak solution, applied three times a week, she executed her work so efficiently that her employer was unaware of her defect. Dilatation had been resorted to since childhood.

I might mention other cases, in which, under the same assistance, the most minute work, as engraving and watch finishing, has been most efficiently executed.

Generally under these conditions, for minute sight, the objects must be brought very close to the eye.

Sometimes in complete cataract, when the opacity is not at the densest, dilatation of the pupil will afford some benefit. Here strong solutions of atropine should be used, to get the greatest expansion.

Indirect relief by an operation. Some surgeons have preferred, in congenital cataract, to make an artificial pupil, to draw the pupil aside, rather than to use the atropine. It is beyond doubt that this is the wrong practice in all cases, because it is less effectual than the relief afforded by the atropine, because it is exposing the eye to the risk of injury during the operation, namely that of wounding the capsule of the lens, and afterwards to the risk inseparable from any surgical operation on the eyeball. Besides, if the entire lens should become opaque, an event always probable, the eye is in a worse state mechanically, for the removal of the cataract, by the most safe operation, that for solution; and if the cataract were well got rid of, there could never be the best attainable state of vision, on account of the absence of a well-formed central pupil.

Complications of cataract, with intra-ocular diseases, which interfere with treatment. It is necessary to repeat that opacity of the lens, and of the lens and its capsule, is often associated with disease of the eye-ball, and is sometimes the consequence of it, and too is not unfrequently co-existent with disease of the optic nerve, so that it is a subject of surgical importance to know how to detect the complication. Several of the diseases are apparent externally; others, such as retinitis,

detachment of the retina, optic neuritis, and exudative choroiditis may exist without outward symptoms. When the cataract is the undoubted consequence of inflammation, by which the nutrition of the lens is interfered with, there may be external signs of the inflammation, or not.

All available modes of testing the general state of the eye should be known, and should be practised as occasion may seem to require, and all signs indicative of disease should be looked for.

In the early cataractous state, when the disease is partial, or the general opacity is but slight, if the pupil be dilated, the ophthalmoscope may be most advantageously used. Opacities in the vitreous humour, retinal extravasations, and alterations in the optic disk, may be detected through the yet transparent portions of the lens, or some parts of it only slightly opaque. The periphery of the choroid can also be scanned.

In all cases of cataract, I invariably scrutinise the fundus of the eye.

When the lens is too opaque to allow of intra-ocular inspection, objective and subjective symptoms, the surface of the eyeball, must be called to our aid.

Choroidal complications can generally be made out by the state of the iris. When they are present the iris loses colour and lustre, and ceases to be a freely acting diaphragm. It may become quite atrophied. A dark-coloured iris may undergo changes of structure that are not readily visible, certainly not as readily to be detected as in one of a light colour.

Modification of the pupillary functions are undoubtedly produced by the cataract itself, for it acts as a veil to the retina, rendering it less sensitive to light.

It is possible for a capsulo-lenticular cataract, especially if the capsule be very much thickened, or the lens much degenerated, to efface external impressions sufficiently to render the pupil nearly motionless under variations of light and shade; but such instances are rather uncommon. If, after covering the eye and then exposing it to a moderately bright light, the pupil be motionless, suspicion is justly entertained of unsoundness of the retina. The eye not experimented on should, of course, be covered all the while.

As a rule, in the absence of any adhesions of the iris, there should be contraction and dilatation according to the opacity of a cataract, whether capsulo-lenticular, or lenticular only; for except the cataract, while incipient, press on the iris, and so impair its movements, there should be a marked action of the iris, differing little from that of a healthy eye. In certain forms of complete amaurosis the pupil may act freely, but this complication cannot lead to error, as the total loss of the perception of any degree of

light which can never occur from cataract, would alone declare the disease.

The ordinary habitual size of the pupil in different individuals must not be lost sight of in these examinations. There is a relation, I do not say invariable, but sufficiently constant to be recognised, between its accustomed dimensions and certain temperaments, a fact too often overlooked; hence our guide should rather be the relative, or proportionate changes under different degrees of light, than the actual alteration; generally, the smaller the natural size, the more limited will be its movements. The various degrees of activity of the iris in different persons must be remembered, as well as the influence of age. The more lively in the young. I examined the eyes of a lady, eighty-one years of age, with full-formed lenticular cataracts, at the window, on an autumnal day, when the pupils were contracted to a degree that at first induced suspicion of some co-existent ocular affection; but farther examination with different degrees of light, showed a variation in them that removed all doubt. She herself was well aware of the activity of her irides, and the disadvantage accruing from the pupillary contraction had induced her, since the commencement of the cataracts, to wear a large shade to shut out bright light.

When only one eye has cataract, unless some other disease exist in it, or the other eye be defective, there is not any disparity in the pupils.

Variation in the pupillary apertures may arise from imperfect development of the iris, but this will be readily recognised as a congenital defect.

A dilated and motionless pupil is a pretty sure indication of deep-seated ocular disease; and if with the dilatation there be irregularity, all doubt is removed. The opposite condition, contraction, may proceed from a like cause, but it is very rare.

I believe that the use of belladonna may be made subservient to diagnosis, and the very slow, as well as imperfect dilatation, taken as an index of unhealthiness. Moreover, it might discover adhesions, and so show the true nature of the case, which may otherwise, perhaps, be overlooked.

The size of the anterior chamber may help in the investigation. If the cataract bulge, press the iris forwards, and reduce the anterior chamber, there is almost sufficient evidence of intra-ocular disease. There can be no doubt, if to it be added tension of the eyeball, or fulness of the vessels in the ciliary region.

If near-sightedness have existed and progressed, and if also there have been a rapid decrease of sight, accompanied with dull pain in the

eye, or slight ciliary pains, there is present choroiditis. With this the nutrition of the eye is so damaged that there can scarcely be success from an operation. Slight opacity of the lens is so common in choroidal degenerations, that when it is seen in adults before the age at which senile cataract occurs, suspicion of such complication should be aroused.

Disease of the optic nerve and of the retina must be tested subjectively.

Cataract alone never shuts out the light. An amount of retinal discernment, varying according to the density of the cataract, exists in all uncomplicated cataractous eyes during the most advanced states of the disease.

It is not always possible to say with certainty whether, in a particular case, any undue faintness of the perception of light is owing to the opacity of the cataract, or to a diseased retina. But it can generally be made out. Something, such as a penknife, or the finger, should be passed between the patient's eye and the light, as a test of sight; if he perceive the shadow, the retina may be considered sound. Unhealthiness may be suspected in proportion as only larger bodies can be discerned. An operation undertaken when the retina evinces decided feebleness must ever be attended with doubtful results. With total loss of power, any surgical proceeding is inadmissible.

The lamp-test is used by some surgeons, and, although not generally required, it is not without value. A small lamp, that is, a lamp with a small flame, is placed in a dark room, and, according to the distance at which the flame can be seen by the patient, is the integrity of the retina judged of. A gas flame will answer well enough, and it possesses the advantage of admitting of being increased or reduced. Incomplete cataract will allow a longer range-view than total, and soft total cataract, than hard. With complete soft cataract, a healthy eye should see the light at fifteen feet or more. Many ways of varying the examination will suggest themselves. With complete hard cataract, it can be observed from ten to fifteen feet. With disease of the retina the distance is decreased, and in proportion to such disease is the space shortened.

The volume of the cataract should be taken into account in this quantitative trial, as with absorption of the cortex the light is less veiled.

Capsulo-lenticular cataract darkens the eye more than the lenticular.

An opaque capsule, with fluid lens degeneration, darkens the eye the most.

It is said that loss of perception of a portion of the retina, arising

especially from detachment, may be judged of by moving about a lighted candle or taper near the eye, in different directions, and noting that position in which it is the best seen. The least perceptive part declares the diseased spot.

The arrest of development of some of the internal ocular tissues, sometimes present with congenital cataract, may much interfere with the sensitiveness to light. So often is there an imperfection of some other part of the eye, that such deviation from health should be sought for.

The chief complications that have been met with are these: Division of the iris, or cleft. Imperfect development of all of the tissues of the eyeball. Absence of the iris. Conical cornea. The lens not fully formed, and irregular in outline. In one case of supposed deep-seated opacity of the lens, an opaque substance was found from which passed backwards a fibrous cord through the vitreous body to the retina, and was there attached. It enclosed blood-vessels. The preparation is in the Moorfields Museum. High near-sightedness. Adhesion of the iris to the surface of the cataract. Atrophic changes in the choroid and the retina. Partial persistence of the pupillary membrane. Corneal opacities.

The perception of colour is a deceptive test. A cataractous person may see bright colours, and shades even of them, when his retina is so diseased that there is not any useful sight after his cataract is removed. I have noticed this many times.

Certain conditions of the globe of the eye, indicative of pathological changes in the posterior parts, go so far towards rendering operations abortive, that their detection is very essential. These are softness or flaccidity, and the opposite state, unnatural hardness. The first is due to deficient quantity of the vitreous humour, with which there is associated a diseased retina, and commonly detachment. The second arises from an increase of the humour, with a dissolved state of the hyaloid membrane.

Tremulousness of the iris is frequently seen in connection with an unhealthy condition of the vitreous humour, and it is sure to exist in a marked degree if the humour be fluid and deficient. But it may be owing to another cause, as I have already mentioned, that of reduced volume of the cataract, by which the iris loses support. In such a case the shaking is but slight.

Unusual vascularity of the sclerotica, with discoloration, especially if the vessels that emerge from it near the cornea in the ciliary region are large and tortuous, is a very unfavourable complication, because it indicates a diseased circulation of the choroid, and a glaucomatous tendency.

Tenderness of the eyeball, especially in the ciliary region, in connection with vascularity, will confirm the presence of internal disease.

As cataract is often the result, the common and last of the changes in the ocular tissues of chronic glaucoma, the connection of the two must be noticed. Only the most inexperienced men can blunder here. In glaucoma, with all the usual symptoms well marked, the eyeball is hard, and not elastic, as in health. The sclerotic coat is discoloured, with, perhaps, the addition of dark patches, and large tortuous dark-coloured veins emerge from the ciliary region, that is, to within a short distance of the cornea. The enlargement of these veins denotes disturbance of the intra-ocular circulation. The cornea loses its lustre, and always, more or less, its transparency; looks uneven or rough, of a ground-glass-like appearance. The iris is in part or entirely discoloured, being dark and convex, apparently in contact with the cornea. The motionless pupil is dilated, perhaps to a degree that shows only a mere ring of iris, and it may be round, or irregular, frequently it is transversely oval. In the opaque lens striæ may be seen, but there are never present the characteristics of uncomplicated hard cataract; nor those of soft, except where there is a breaking-down of the superficies, or actual fluid degeneration. It rather presents hues peculiar to this general invasion of disease. A sea-green state of pupil, which, in fact, means a green lens, is so commonly described as the chief feature in glaucoma, that surgeons are apt to disregard all other evidence of the disorganization, if this be wanting. Any actual shade of green is really very rare. The common appearances, which cannot be well expressed in words, are best represented by the expressions dirty-white, dirty-yellow, copper-brown, greenish-drab. They often resemble the darker shades that are seen during the decline of a cutaneous ecchymosis.

If it were possible for anything more to be wanting to confirm the existence of glaucoma, it may be gathered from the subjective symptoms; flashes, coruscations, and bright colours arise. Intense pain and loss of sight complete the catalogue. Added to these, the history of a case must afford the fullest conclusion; for whether acute, and with such intensity of action that blindness ensues in a few days, or chronic, that weeks, or months, or years are required to extinguish sight, opacity of the lens is the last result.

There are inflammatory complications of the retina, and of the optic nerve, that may not be detected except by certain subjective symptoms, as flashes, sparks, shining appearances, as reflections from bright metals, bright rings, and spectra of various kinds. I always inquire about these, and if it be said that there is anything peculiar in this way which has attracted attention, I know that there is disease

in the deep parts of the eye, sufficient in all probability to spoil the organ.

A caution must be given here to prevent mistakes. Crystals of cholesterin in the cataract may cause somewhat similar effects to those of morbid sensations of stars and bright specks.

Muscæ alone matter nothing. All cataractous patients have them, and complain much. The subject has been already noticed. This has long induced me to suspect that there is no such thing as purely uncomplicated cataract; no such thing as atrophy of the lens alone, while the rest of the eye is perfect. This is the more impressed on me, as the muscæ are always so large and so numerous.

The history of a case should be carefully inquired into, and relied on when tests are insufficient to give assurance of the state of the eye.

Without proceeding further in detail respecting symptoms, it may be stated that any deviation whatever from what would be considered a state of health in any of the textures composing the globe of the eye, except the lens, is a complication, according to its kind and degree, rendering an eye more or less unfit for any operation.

These considerations of complications would be imperfect, if the alterations in the nutrition of the tissues consequent on old age were forgotten. The eye decays, like all other organs and parts, and shrinks. The eye of a very old man is less likely to resist the effects of an operation, and meet the repair, than that of a young one. The difference in loss of force is seen in many diseases, and still more in the healing of wounds. Senile degeneration and its disadvantages must be remembered.

It would be imprudent to operate on an eye that had been recently inflamed from any cause. A very long interval should be allowed to pass after the last trace of such disturbance.

Complications of cataract with extra-ocular disease which interfere with treatment.

Success will seldom be obtained from extraction, when there is chronic inflammation of the surrounding parts, or chronic eczema palpebrarum, or chronic conjunctivitis, or chronic inflammation of the lacrymal sac. Perhaps it is that these interfere with the nutrition of the lens.

The truth of this was forced on me at an early period of my career, from the results of my own practice and from watching that of others. With such complications I suspect that the operation for depression is better suited. These may interfere somewhat, too, with the operation for solution.

Mechanical changes in the eyelids from accident or disease, that in

any way interfere with their proper motions, or produce irritation of the cornea, may be a bar to successful operating, especially when extraction is applied. Entropium, ectropium, and trichiasis mostly offend. Many of these may be altogether removed by preliminary measures.

Decided emaciation of the body, with a dry and harsh skin, is a condition very unfavourable for the operation of extraction. The corneal wound is unlikely to heal. Such patients lose much of the orbital fat.

THE REMOVAL OF CATARACT. GENERAL CONSIDERATIONS.

It is a cardinal point in ophthalmic surgery not to operate on an eye for the removal of cataract, so long as it may be rendered available for ordinary purposes, by optical appliances, or otherwise.

An operation ought never to be undertaken in anticipation of blindness, because the cataract may not increase, and the hard variety is often very slow in formation. Years may pass away with but little progress.

The several conditions of lenticular cataract require different operations, and the choice of any one should rest solely on the circumstances of the disease.

The hard cataract should be extracted, that is, removed from the eye, or it should be displaced by being pressed into the vitreous humour. So long, therefore, as the opaque lens is yet hard, and not reduced in density, by the secondary changes of atrophy, it would be imprudent to attempt to make it disappear by absorption, because such action would be very slow, and during the tedious process, the eye is particularly liable to inflame, and so be thereby damaged. Besides, particles of the cataract which might fall into either the anterior or the posterior chamber, would most likely set up an attack of inflammation and endanger the eye. The failing nutrition of the eye of an old person renders it most unfitted to bear irritation from such a source, for while it causes high susceptibility, it destroys power of resistance.

Some years ago I tried with the utmost care to effect absorption in patients beyond the age to which this method is generally restricted by most surgeons, and although I did get some good effects, the general result fell far below that from extraction. Now, I always extract when there is any visible amber change in the cataract, and also when the lens has a whitish surface, the result of the secondary change, if the age of the patient renders it likely that there is a hard nucleus.

Soft cataract should, as a rule, be allowed to remain in place. It should be lacerated, so as to admit of the process of absorption or solution, to which its softer texture readily yields; for with this simple operation, the natural powers are quite capable of causing its complete dissipation.

Capsular cataract must be removed from the eye, or be cut or torn through to enable it to contract.

Preparation of a patient. Operations implicating the globe of the eye demand for their success, so far as the body of the individual is concerned, that state of health in which a wound can be inflicted on a delicate and sensitive organ with the greatest impunity. In the operation for extraction, unless union of the cornea be quickly effected by adhesion, success must always be more or less imperfect, and destruction of the organ will frequently ensue. Although we have no means by which to test this bodily state, because there may be power enough where its presence is doubted, and it may be lacking in those who are apparently in good health, yet certain bodily conditions can be pronounced as being in the main unfavourable. Those persons who have long undergone want of sufficient food give the worst results. My success with hospital patients never equals that in private life.

A debilitated constitution requires to be improved to the highest standard that the idiosyncrasy of the person will allow.

Plethora should always be avoided. An accustomed eye soon detects the habit of body that is popularly called "rude health," and a person exhibiting it in a marked degree should be reduced by regulation of diet, exercise, and gentle purgation if necessary, till any excess disappears, and the circulation is rendered more natural.

So long as we are unable to say where health ends, and disease begins, and to make a distinction between the failing of the living machine from decay and from actual disease, a patient should be left alone unless he exhibit some decided abnormal constitutional symptoms, in the treatment of which we can be tolerably sure of beneficial effect. I do nothing for the great majority of my patients.

Dr. Jacob, in his *brochure* on the operation for cataract with the fine needle, makes excellent remarks, which are not less practical than original. The sense of them is this: the value of preparatory and after-treatment, as part of the surgeon's care in cataract operations, has been fully appreciated, and, in practice, amply made available; but the value of a respectful consideration of all the functions of the animal economy upon which health depends has not been so well understood. It is assumed, he continues, that a patient should be prepared for an

operation by taking physic and abstaining from food; yet a rational man, acquainted with the consecutive operation of each apparatus provided for the growth, repair, and preservation of the living being, may well doubt the correctness of such a view. The universal faith reposed in the practice of giving and taking physic has led practitioners not only to place too much reliance on that resource, but to resort to it sometimes to the injury of the patient. In preparing a patient for an operation, he does not act on the belief that empty bowels are essential to health, or that what are called *fæces* should not be found in the intestinal canal; on the contrary, he proceeds on a conviction totally different. If a patient be in good health, notwithstanding an habitual retention of the contents of the bowels beyond the usual periods, he does not risk an interruption of health by disturbing the natural functions of the stomach and bowels, and therefore refrains from giving physic. But if not in good health, he endeavours to bring him into that condition by every means, and resolutely resists every attempt to induce him to operate until he has accomplished that object. Above all things, he thinks that the state of the digestive organs should be fully studied, and when found defective, if possible repaired. He believes that nothing seems to require more attention than the condition of the tongue as indicative of the state of the stomach and bowels. If it be coated with discoloured adhesive mucus, the functions of assimilation and nutrition are probably imperfectly performed, and a resulting tendency to destructive inflammation from local injury is engendered. He adds in conclusion, it is usual in preparing for this and other operations to make great alterations in diet, substituting liquid for solid, and vegetable for animal aliments. This, however, must be done with caution, leading as it inevitably does to disturbance of the digestive function and interruption of the assimilating and nutritive processes, if suddenly or exclusively adopted. Without digestible nutritious food, good chyle and blood cannot be produced, and without good blood, local injuries are liable to suffer from destructive inflammation. I endorse all this.

The whitish and rather coated tongue of the aged should not be mistaken for a symptom of unhealthiness. In them this organ is not so ready an index of the state of health as in early years; attention should therefore be paid to the urine, the deposition of uric acid, or of the urate of ammonia, being a sure indication of dyspepsia, or excess of nitrogenized food, or of fever; and that of phosphate of lime or the triple phosphate, of the opposite states of prostration and nervous depression. Yet an operation should not be undertaken with a decidedly loaded tongue. The abdominal evacu-

ation should, with the least apparent necessity, be examined for evidence of the hepatic state, and for information respecting the digestion of food, particularly in those past the meridian of life, because it is then that these functions are mostly at fault, and all kinds of operations less successful. In the majority of persons far advanced in years, who have passed through operations under my hands, it has been necessary to give tonics and extra stimulants. Towards the limit of the natural term of life we should not, without ample necessity, cut off the accustomed amount of daily nourishment or the usual alcoholic drinks. These remarks apply more particularly to hospital patients.

My immediate preparation of a patient is never more than the administration of some mild laxative the day before operating, solely that the necessary quiet after the operation may not be disturbed for a day or two, by the natural action of the bowels, and that any likelihood of straining at stool may be avoided.

Some general conditions contra-indicate operating. The presence of active specific inflammation, as the strumous, gouty, syphilitic, or rheumatic, in any part of the body, would contra-indicate an operation. So also may be said of pregnancy. Some surgeons avoid the period of menstruation.

Organic disease in the chest is not necessarily an impediment to operating. I saw extraction done on the eye of a female fifty-seven years old, who had valvular disease of the heart, ascites, and anasarca. The operation was quite successful, and the patient returned home on the eleventh day after its performance. Her heart had been diseased for five years. I have operated several times successfully when the heart has been diseased, and in the early stage of phthisis.

Kidney disease renders a person most unfavourable for an operation.

Atheromatous arteries interfere with primary union of the cornea after extraction.

While unquestionably the result of an operation of any kind will much turn on the state of the patient's health, that for solution may be undertaken and success secured, when that for extraction is scarcely admissible, and unfortunately the latter is most required when the complications are most likely to exist, namely, in old age. Chronic bronchitis and asthma interfere, I believe, more from their general effect than from any mechanical disturbance to the eye from the cough, although, if this be violent, it will prevent the healing in the right way.

As we cannot select or reject our patients according to the absence or the presence of complications, we should never operate under dis-

advantageous circumstances, without making the drawbacks known to them or to their friends.

Advanced age is not in itself an objection to operating if nothing else forbid. The best attainable results have followed extraction after ninety, in the hands of Sir W. Lawrence. The late Mr. Scott did the same operation on a female between ninety and a hundred. I have several times performed it to my complete satisfaction after the eightieth year, and once as late as the eighty-sixth. Two cases of success are recorded after the patients have turned 100 years each. Of course after the seventieth year a person is less favourable for the ordeal of extraction, from a variety of circumstances, and from contingencies inseparable from long life.

When only one eye is blind from cataract, whether an operation should be performed on that eye, is a question about which there is difference of opinion.

A person with one eye labours of course under disadvantages, the greatest of which is the narrowing of the field of vision laterally; he is blind on one side.

The removal of the cataract is not demanded on the score of the retina losing its function, because it is veiled. The retina never becomes diseased from the eclipse. This has been proved.

The age of the individual assists much in determining the course to be pursued.

In early life the appearance of cataract in one eye may materially affect a person's prospects. It is at this time, too, that a cataract is more visible from its nature, being soft. Now also the operation which is applicable, that for solution, is almost sure to succeed.

Late in life the prospects of an individual, social and otherwise, are quite altered, and personal appearance is not then of so much value, and the suitable operation, that of extraction, is not so certain. On many points, therefore, an operation is more admissible in a young person.

The advantages at any period of life, notwithstanding the imperfect image on the retina of the lensless eye from the circles of dispersion, are enlargement of the visual field, and as the eyes act together in binocular vision, increase in the intensity of optical impressions and better appreciation of the dimensions of bodies and of distance. I beg to refer my reader to what I have said on binocular and monocular vision.

Neither practically nor theoretically is there any disadvantage in operating. In every instance in which I have removed the cataract, both in young persons and in those of middle life, I have received the distinct assurance that much advantage was obtained, and all were pleased at having submitted to the treatment.

Several times I have endeavoured to unite the foci of the eyes, for distant and for near vision, so as to give a common distinct perception, by means of convex glasses, but I have been unable to affect it satisfactorily, on account of the inequality of the images, and the loss of accommodation in the one eye.

The rule therefore which I follow is this: in early life I advise an operation, and in late life I state the particulars to my patient, and ask him to decide.

When one eye is blind with cataract, and the other so far affected with cataract as materially to impair sight, there can be no question in the abstract, about the propriety of operating on that which is fully cataractous. There is no solid reason why a person should be allowed to become quite blind in both eyes before sight is restored to the one. Much inconvenience is prevented by operating on the one eye before the other is quite obscured.

When both eyes are equally affected with blindness from cataract, only one at a time should be operated on for extraction, and the first should be allowed to recover before the other is touched. There is thereby less shock to the system. Besides, if at a first operation there should appear any constitutional peculiarity of bad tendency, it might be removed, or in some measure reduced, before a second is undertaken.

When the double operation is done, inflammatory effects on the system from one eye unfortunately going wrong, might be the means of spoiling the healing process in the other.

Both eyes may be operated on at the same time for solution.

The operation for extraction should be done at a certain stage of the cataract. It is possible to perform it too early, or too late.

When the lens is not entirely pervaded by atrophy, and the circumference has not undergone such change, it will not quit the capsule readily, and an easy escape is an important element in the success of the operation. Besides, while there remains any surface lens tissue unaltered, much of it, or all of it, is tolerably sure to be left in the capsule, and some may remain in the chambers of the eye; in either case irritation is produced, and there may be some inflammation. Therefore, a cataract should be matured before an attempt is made to extract it.

Some surgeons have adopted the process of what they call anticipating the cataract by pricking it with a needle, so as to render it fully opaque. This is to be condemned; injurious inflammation is risked, and the eye is always rendered less fitted for the extraction, as it always inflames a little in old people. Healthy lens tissue resists a wound more than that which has atrophied. Again, if this be done

with the view of getting the cataract to quit the capsule easier, it is useless, for there is not that softening at the surface which is so characteristic of the natural atrophy.

When the lens has undergone the secondary change or late atrophy, in which calcareous deposits have formed on the surface and on the inside of the capsule, and so have thickened it, the case is less favourable for extraction, because not only does the capsule not tear well when it is scratched with the curette, and allow of the easy escape of the cataract, but the calcareous deposits are more or less retained, and accordingly obscure the pupil.

The operation for solution should not be undertaken until the cataract is thoroughly mature, because any healthy lens tissue that is rendered opaque by the operation, and exposed to the aqueous humour, invariably swells very much more than that which is cataractous, and thrusts the capsule against the iris, producing adhesions between the two, and may besides cause injurious effects to the eye from the pressure. At the same time the operation should not be delayed till secondary degeneration is far advanced, because then the capsule is likely to be much affected in the manner above described, and therefore trouble may arise from thickened capsule being in the pupil.

A surgeon should be cautious, even under the most favourable circumstances, never to overrate the chances of success of any operation for cataract, nor to allow it to be thought that any is infallible. Above all, when there is the slighest indication which might render the result questionable or imperfect, owing to individual peculiarity or constitutional taint, hereditary or acquired, it is right, as regards the patient, and a safe provision for himself, that all the particulars for and against operating should be clearly and intelligibly told without the least dissimulation.

The season of the year most fitted for operating has occupied attention. With reference to needle operations, I suspect it matters not; nor, perhaps, is any operation in our climate influenced by the mere degree of temperature, which is rarely in either extreme. In extracting in cold weather the room to which the patient is confined should be kept at a uniform temperature, not lower than 60° Fahrenheit for the first few days. Many very excellent surgeons never extract in winter, and Mr. Tyrrell thought the best time for that operation to be between March and October. Where a choice is permitted, I should, as a rule, prefer that period, because regular exercise prior to the operation, is less likely to be interfered with, from the greater certainty of settled weather, while, after the operation, the apartment can be better ventilated, and the patient will be able

sooner to take out-door exercise, and recover his lost strength and spirits, the consequence of anxiety and confinement. At this time, therefore, convalescence is less likely to be protracted. Again, when the state of the eye is such as to render the success of the operation somewhat doubtful, I should prefer summer weather.

OPERATIONS FOR EXTRACTION.

Cataract knife. Beer's triangular knife, more or less modified, has obtained general approbation. The form Fig. 241 I employed for several years, but I found the breadth too great. I altered it to ten-twelfths of an inch by seven-twentieths, and I yet use this for a sunken eye, or where the eyeball cannot be well exposed. But I prefer the original Beer's, Fig. 242, whenever it is applicable. If the angle of the blade be much increased, the cornea is less easily punctured, the aqueous humour is apt to escape prematurely, and the iris to fall on the knife edge.

Fig. 241. Fig. 242.

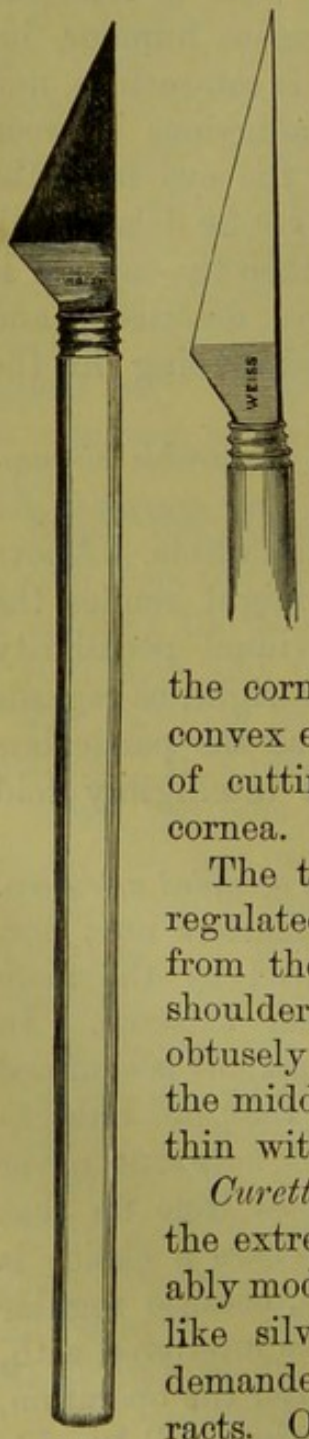

The edges of these knife-blades are straight. It is demonstrable that a perfectly regularly formed section of the cornea is easier accomplished by a slightly convex edge. The advantage rests on the facility of cutting out the last tag or portion of the cornea.

The thickness of the knife should be nicely regulated. There ought to be a slight increase from the point, which should be stiff, to the shoulder. The back should neither be square nor obtusely rounded, but rolled off gradually from the middle of the blade to an edge sufficiently thin without being sharp.

Fig. 243.



Curette and curved needle, Fig. 243. Both of the extremities of this instrument are considerably modified from the usual forms. The spoon-like silver end peculiarly suits the purposes demanded of it, to remove fragments of cataracts. Other forms of the spoon are made; one

of them, known as Schuft's, is more applicable for extricating a dislocated cataract. It is generally made as a separate instrument, without the needle end. The needle is curved only as much as is actually required, for the less the deviation from a straight line the greater is the facility in using it, and the less risk is there of injurious contact with the iris or the cornea. A side view cannot, of course, convey an idea of the breadth, which is nearly that of the stem within a short distance of the point. The very extremity only is sharp. It is better to have a needle point than a scarificator,

Fig. 244.



Fig. 245.

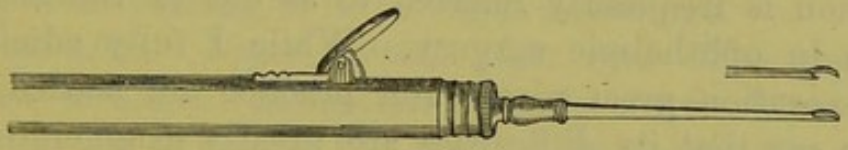

Fig. 246.



flat and set at a right angle, because the former acts in whichever direction it may be applied, whereas the latter can be used only in one direction.

Guarded curette, Fig. 245. I had this made many years ago. The point is concealed by a little guard, so that it can be carried with ease and safety to the acquired spot, and bared by pressure on the trigger in the handle. By remission of the pressure the guard returns to its place.

The larger figure shows the instrument shut; the lesser, a little open. It is suited for beginners.

Secondary knife. I give the preference to one of the form Fig. 244. The point is rounded and blunt. A straight blade requires less force in using than a convex or concave one; moreover, it is capable of receiving a keener edge, and these are advantages of higher importance here, because the occasion which calls for the secondary knife offers peculiar difficulties, owing to the flaccidity of the eye, the impracticabilty under the circumstances of applying enough pressure to keep it quite steady, and the necessity of cutting in a certain direction under unusually limited restrictions.

Sharp hook. This, Fig. 246, is commonly called a lens hook. The point is sharp, yet the hook itself ought not to be very fine, for a very delicate extremity would not be sufficiently

retained by the displaced cataract, and would be more apt to become entangled in the parts over which it passes, or with which it comes in contact, and to scratch or otherwise injure them. It is an instrument very seldom needed, especially by a good operator.

Operation for extraction by a crescentic corneal cut. This is the operation which is the most suited for the removal of a hard cataract. By it alone can the best results be obtained, and, as I believe, the highest average of success. It is preferable to all methods of extraction, whether in the hands of the inexperienced, or in those of the most skilful.

Extraction is frequently referred to as one of the most difficult operations in ophthalmic surgery. While I fully admit that for accurate execution great nicety and practice are needed, I do not hesitate to say that its difficulties are greatly exaggerated. Every step of the operation requires to be well done, or failure ensues. All must be exact.

The pupil should be always dilated, because more room is then given for the laceration of the capsule. Some of the dilatation is lost when the aqueous humour escapes, but some remains. The dilatation may have some effect in keeping the iris out of the way of the knife. It, too, will always discover the existence of any adhesion between the iris and the capsule of the opaque lens, and disclose that state of the iris, apart from adhesion and inflammatory disease, whereby the pupil will not expand much, and which is an obstacle to the escape of the cataract.

A patient should always lie down at full length on his back, with his head alone a little raised. He can be steady only in this position. It matters not whether the operator sits or stands, so long as he has sufficient command over his work.

The importance of a properly regulated light is evident. An operator will, of course, choose that which, according to the arrangement of the room, suits best. In private practice, he should ascertain this by trial with his assistant.

All the principal articles of clothing should be taken off, the patient prepared to go to bed, and a morning gown put on, to prevent the inconvenience of undressing afterwards.

I divide the cornea in the upper part, preferring that section, as it possesses many advantages over the lower, such as the greater certainty in making it effectually, and the less likelihood of the flap being interfered with by the eyelid. Should the iris prolapse, it will be less irritated in this situation, and an upward position is always the best acquired marginal one for a pupil. Any cicatrix is also better hidden.

It is better to stand behind the patient in every instance, as it gives much greater command over the globe of the eye. But when the left eye is to be treated, if want of practice or deficiency of confidence disqualify the left hand, the operator must stand in front of him, and submit to the great disadvantage of resigning to another, his assistant, what he ought to do himself, two most important acts, the retracting of the upper eyelid, and the steadying of the eyeball, while he uses the knife in the direction he prefers, upwards or downwards.

I always grease my knife with olive oil, because it prevents the corneal flap from sticking to it, no slight advantage.

Actual operation. Upper section, right eye. The preliminaries having been arranged, an assistant gently draws down the lower eyelid, resting his finger on the malar bone, so that the eyeball be not pressed.

The operator stands behind the patient's head, which is, of course, at a convenient height, places his left hand on the forehead, with his forefinger elevates the upper eyelid, locks it under the edge of

FIG. 247.

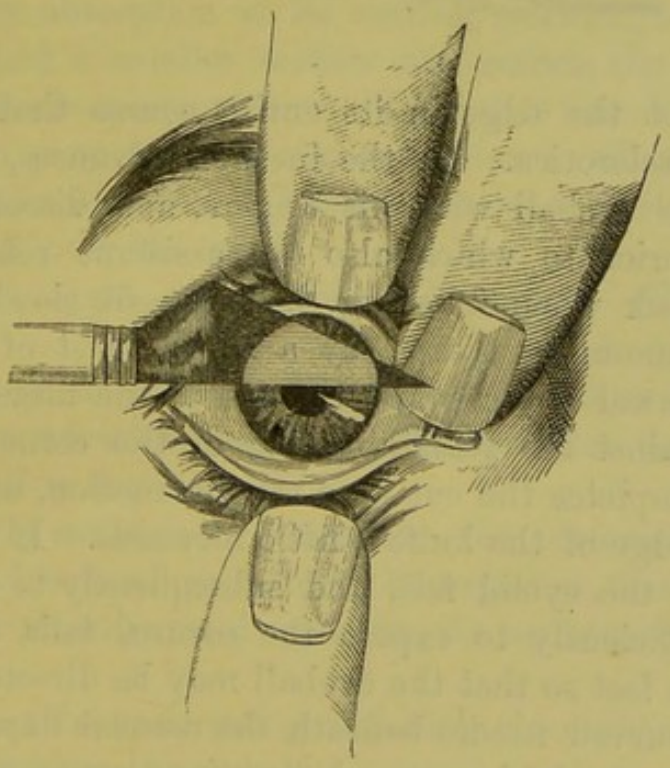

the orbit, and with the tip of it presses gently against the eyeball to prevent any upward motion, and with his middle finger presses on the inner side of the eyeball, to counteract any movements in an inward direction, as in Fig. 247.

Neither finger should encroach on the cornea, but be kept away

as far as possible. Undue pressure may thrust the iris forwards. He rests his other hand against the side of the face, holds the knife lightly and unrestrained, enters it on the equator of the cornea about the twentieth of an inch anterior to the sclerotica, passes it rapidly through the anterior chamber parallel to the edge of the sclerotica, and carries the point out on the inner side at a spot as nearly as possible opposite to that of entrance. He thrusts the knife slowly along with the same continued movement, and takes

FIG. 248.

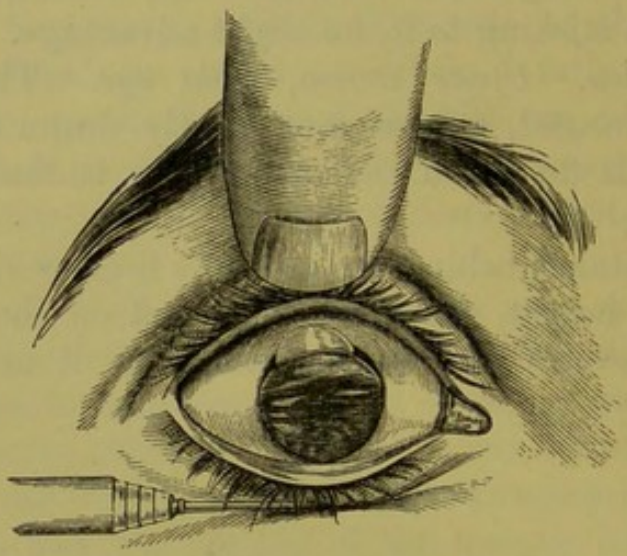

care so to direct the edge in its entire course that it shall pass parallel to the sclerotica. As the incision advances, he remits the pressure on the eyeball with his fingers, and discontinues before it is finished, prior to which also the assistant relaxes his hold. To prevent a jerk when finishing, he proceeds slowly, and allows the aqueous humour to escape by a slight twist of the knife, or the least withdrawal of it; places the end of the finger, or the back of the nail, against the remaining tag of the cornea as a rest or support, and completes the cut by a sawing motion, and at the same time turns the edge of the knife a little forwards. If the patient be sensible, he lets the eyelid fall, and subsequently to a brief repose he raises it sufficiently to expose the cornea, tells the patient to look towards his feet so that the eyeball may be directed downwards, introduces the curved needle beneath the corneal flap, and lacerates the capsule very freely in several directions across the entire area of the pupil. If the patient be insensible, he proceeds with the operation as is most convenient on the occasion. He now starts the cataract by pressing on the eyeball above, through the medium of the eyelid a little raised, with the finger, used as a wedge between it and the orbit, and below with the curette, through

the medium of the lower eyelid, increases the pressure, and alternates it at these points till opening of the lips of the cornea by the bulging of the iris indicates that the cataract has left its position, as in Fig. 248, steadily continues till it has passed the pupil, and has fairly protruded externally, when the elasticity of the cornea will suffice for the expulsion. If the cataract should stop at such a position, and not readily pass out, it should be picked out with the needle.

The pressure may be made above on the eyeball, with the finger between the eyeball and the eyelid, and below in the corresponding position with the curette.

Any soft portion of the cataract which may be left between the edges of the cornea should be moved with the curette. Any remaining in the pupil should be left, because any attempt at clearance will risk the bursting of the hyaloid membrane. The operation is now over.

The Fig. 249 shows the course the knife should take. If the cut be nearer to the sclerotica, there is not enough support left for the iris, and it is apt to prolapse. If it be more anterior, there will scarcely be room enough for a full-sized cataract to escape. When a small cataract, one reduced by absorption of its cortical portion, is to be extracted, and a smaller section will suffice, the cut may then be made more anterior. I am sure that better results will be obtained in proportion as the extraction is effected at a greater distance from the sclerotica. There must be a limit to this, lest the scar should fall over the pupil.

Fig. 249.



The patient's sight ought not to be tested. The act may be detrimental.

When the patient is insensible, the eyelids may be retracted by the double wire retractor, and the entire operation done continuously with the eyeball so exposed.

In a perfectly satisfactory extraction, the posterior capsule, which now bulges, and is in all probability transparent, forms the boundary of the posterior chamber, and separates the aqueous from the vitreous humour.

If the cataract be undergoing softening throughout, it may fall in pieces while passing through the corneal section, and some of the fragments may remain in the anterior chamber. The curette should be used to withdraw any of these that may interfere with the adaptation of the corneal flap, and perhaps some which may lie between the iris and the cornea; but any that occupy the pupil may safely be left alone to the process of absorption.

If the circumference or soft part merely of a cataract remain behind, it should be left untouched, unless any portion occupy the incision of the cornea, for it is rapidly absorbed.

Sometimes the capsule of the lens occupies the pupil, or in some other way intrudes itself on our notice. It is dangerous to meddle with it, lest the hyaloid membrane be ruptured, and vitreous humour flow out. Unless a portion of it should be in the corneal wound, there should be no attempt at removal.

The iris does not always recover itself and contract after the escape of the cataract, but may prolapse and be unmanageable. If after gently touching the eyeball a few times, or rubbing it through the closed eyelids, waiting a little, and again repeating the rubbing, the prolapsed portion do not return, the guarded curette, or any appropriate appliance, must be called to our aid to replace it. But this demands the most gentle manipulation, without which the hyaloid membrane will be ruptured. One attempt only should be made. There is always a chance of spontaneous return after all efforts have failed. But the complication is a serious one, and I think that the protruded piece had better be excised, whereby the adaptation of the edges of the cornea is ensured.

Adjustment of the flap of the cornea is the last particular of the operation requiring attention. In every instance it should be ascertained that there is adaptation and no eversion. With a prominent eye the eyelid may displace it, turning it down. Should it be turned down, instead of attempting replacement with the curette, which is always troublesome and not devoid of risk, the eye should be opened, the cilia taken hold of, and the eyelid raised, perhaps sometimes with the forceps, and lifted over.

Inversion of the flap, which, it is said, may occur, would certainly require the curette, or some blunt instrument, to restore it.

The cutting of the cornea should not be commenced till the eyeball is straight. When chloroform is used, it may be necessary for the assistant to pull the eyeball into the proper position with a pair of broad-bladed forceps. As the conjunctiva of an old person is rotten and tears readily, the sub-conjunctival tissue as well should be pinched up. The eyeball should not be pressed on during this act.

When the patient is not under chloroform, the eyeball cannot always be kept motionless without an injurious amount of pressure, but may roll a little during the introduction of the knife, and its passage through the chamber. Great nicety is required to adapt the hand to such movement, and without it a proper counter-puncture cannot be made. After the cornea is transfixed, the

eyeball is under the operator's control, and may then be correctly placed if it have deviated out of the proper position. Some surgeons have the eyeball held with forceps from the commencement.

It matters not if the point of the knife be entered higher or lower than the median line of the cornea, provided that the counter-puncture correspond to it in a semicircle.

It is a very common error for the operator to hold his knife in such a position that the cutting edge, instead of the back, is in a line with the transverse diameter of the cornea, and which causes the instrument to take a wrong course, not including a sufficient portion of the cornea.

Some surgeons enter the knife in a vertical direction, and then change the position. This is wrong, as the twist of the lips of the wound, which must ensue, is apt to cause the aqueous fluid to escape.

Considerations of the several acts of extraction in detail, together with contingencies.

A complication may arise by the iris falling in the way of the knife. This may be produced by the premature escape of the aqueous humour, from undue pressure on the eyeball, from not making a continuous onward movement with the knife, by which it is kept adapted to the incision, or from what, in fact, amounts to the same thing, twisting it or using it in some improper manner, and causing the edges of the wound to gape.

If the aqueous humour escape prior to the counter-puncture, the knife should be withdrawn, and the operation delayed. If when the cornea be nearly divided a considerable portion of the iris be in the way, the instrument should be taken out, and the section completed with the secondary knife, the blade of which must be introduced under the remaining uncut part of the cornea, and used in the most convenient direction. The only exception may perhaps be in the case of a beginner, for when a man is quite untutored in extracting, the eye will probably suffer less violence from a wounded iris than from the use of the secondary knife. Therefore, in inexperienced hands, the incision had better be completed, regardless of the amount of iris that may be cut off. If only a small bit of the pupillary margin should get on the knife, it should be disregarded and shaved off.

When the iris is wounded, it almost always adheres to the cornea in a manner which interferes with the healing of the corneal wound, and the pupil is enlarged and necessarily displaced. A shallow anterior chamber, and a contracted pupil, render this accidental wounding liable to occur.

If a second pupil be made by cutting out a circular bit of the iris, and it be large, the isthmus should, if possible, at once be divided with the blunt-pointed iris scissors, for the cataract may become fixed in the acquired aperture. Besides, a second pupil may cause confusion of sight.

It is recommended by some, always to attempt to free an entangled iris by pressing it between the cornea and the knife; but I have seen many such efforts made without a single successful issue.

The iris may bleed or not, when wounded. The chief disadvantage of the bleeding is that it may prevent the operation being completed, or much obscure the subsequent steps. If slight pressure on the cornea with the handle of any instrument do not discharge enough of the blood for the purpose of enabling the parts to be seen, the operation should cease. The blood in itself matters nothing, as it is soon absorbed. These remarks apply also to blood which may enter the eyeball, from the eyelid being wounded with the cataract knife.

A young operator seldom allows time enough for tearing the capsule with the curved needle, and therefore fails to do it effectually. One scratch is not enough. I think cross-cuts the best. The capsule should be left untouched at the equator, to avoid the risk of opening the hyaloid membrane. Evidence of insufficient laceration is given by the cataract not quitting its place. Should the capsule seem too dense to admit of being properly torn, the cataract had better be at once hooked out. Rough use of the needle may displace the cataract. In such an accident the cataract must be hooked out.

But the cataract may slip away, in consequence of disease of the tissues around, before there has been enough pressure for the proper laceration of the capsule, just, in fact, as the needle is applied. The cataract must be hooked out if possible.

After the hyaloid membrane has been broken, no attempt should ever be made to press out the cataract, under any circumstance.

A faulty section of the cornea, one that is too small to allow the cataract to pass, is very frequently made. This may arise from entering the knife too much above the transverse axis of the part, or too far from the sclerotica, or from running the point for some distance between the corneal laminæ, or from making the counter-puncture in the wrong place. Again, the cornea may be admirably transfixed; but the edge of the knife has been brought out too far from the sclerotica. All these mistakes are equally bad.

The corneal section should be inspected as soon as it is made, and if found to be too small, should be enlarged. Any fault will be readily recognised by the cataract having partly passed through the

pupil, and yet not escaping. The use of the secondary knife is the correct expedient, for any attempt at expulsion by squeezing would be fruitless, and likely to be fatal to the eye from the vitreous humour rushing out. Some surgeons recommend scissors for the same purpose. I have not used them.

If a faulty counter-puncture be discovered before the section be completed, it is the best plan to cut on till a mere tag of the cornea remains, to withdraw the cataract knife, to lengthen the cut on one side with the secondary knife, and to cut through the tag afterwards with the same. This has the merit of keeping the eyeball in form, while the section is being enlarged.

Should the counter-puncture be made too near to the sclerotica, or in it, the knife should be withdrawn and the operation postponed. I have seen the mistake occur several times, and the attempts made to correct it by withdrawing the knife and re-entering it, and other manœuvring, have been the cause of destruction of the eyes.

Pressing out the cataract is about the last thing a man learns to do well. It should be a slow process. Sudden escape of it may in part or entirely paralyze the iris, and produce an irregular pupil. Or it may expel the cataract in its capsule with force, and along with it vitreous humour. The pressure at first should be made backwards towards the centre of the eyeball. If it be made forwards, probably the cataract will not start. When the cataract is well on the move, pressure in any direction will suffice. The cataract can escape well, only by first turning on its transverse axis, and presenting with the upper edge forwards. When so far dislodged, the slightest pressure is enough to thrust it out. A cataract with a soft exterior comes out more readily than one in which there is not this degeneration, and therefore less pressure is needed.

When the cataract will not be started by the pressure, notwithstanding that the capsule is sufficiently lacerated, the cause of it will be due, ninety-nine times in a hundred, to a faulty corneal section. The resource is to enlarge the section. The danger of continuing to press while there is not enough room for the escape, is sinking of the cataract and escape of the vitreous humour. Should this happen, the cornea must be further incised and the cataract hooked out with the lens hook. Some surgeons advise the removal of a part of the iris, as in the operation for artificial pupil, by excision, to facilitate this step.

The cataract may not quit its place after the admissible degree of pressure, independently of any fault of the section of the cornea, or of imperfect laceration of the capsule. There may be that excep-

tional condition of very little softening of the cortex, by which it adheres to the capsule so that it does not readily move and cannot quit. Or its capsule may be thick and dense. Then it must be hooked out. The lens hook must be entered like the needle, passed through the pupil and implanted in it. Unless in the hands of a most expert manipulator, this is certain to be attended with loss of the vitreous humour, from pressure in attempts to steady the eyeball. If the capsule be hooked out as well, there is the greatest risk of vitreous humour escaping.

A rigid pupil, a rare event, may prevent the cataract from escaping. The operator ought to be aware of the rigidity, because atropine should always be used prior to the operation, for reasons given, as well as to discover whether the pupil will or will not admit of dilatation. The pupillary margin should be cut with a pair of scissors.

A small tag of adhesion between the iris and the capsule of the cataract, may interfere but little with the escape of the cataract. But should it be determined on beforehand to cut through the adhesion, the position of it must be well ascertained, or else it may not be readily made out when the eye is flaccid. Probe-pointed scissors should be employed. I have preferred to slit the iris across the pupil to obtain room, as the easier of the two.

Extensive adhesion may require the removal of that portion of the iris corresponding to the pupillary attachment, as in the making of an artificial pupil by excision. This is preferable to bruising the iris by detaching it at the points of adhesion.

Loss of a portion of the vitreous humour, is perhaps the commonest untoward event in extraction. The humour may escape by the side of the cataract, while it remains in the eye, in consequence of a faulty corneal incision; or too much pressure in starting the cataract; or dislocation of the cataract with the needle; or it may escape when the cataract is expelled, on account of undue pressure on the eyeball, or because it is fluid from degeneration, in part or in whole, when no operative skill may retain it.

In the first instance, the section should be carefully enlarged, and the lens hook should be brought into use, and applied, if possible, to the back of the cataract, and the extraction completed.

Should the cataract sink out of sight, it ought to be abandoned.

When the humour gushes out, along with the cataract, the eyelids should be at once closed. After a rest the upper eyelid should be raised by laying hold of the cilia with the fingers, or with forceps applied to the margin of it, in order to avoid all pressure on the eyeball, and the corneal flap looked at. If reversed, it must, if

possible, be replaced. If it be not turned back, although gaping, because of vitreous humour lying in the aperture, the eyelids should be again closed. Any attempt under such circumstances to close the wound will be attended with further evacuation of the humour. Should iris be in the wound, it must be left alone. Under the conditions, it will be safer for the eye not to excise any portion of it. When the humour is of normal consistence, and hangs out like jelly, it may be requisite to cut it off from the cornea with scissors.

The loss of any amount of the humour is a serious accident which imperils the eye, and adds largely to the catalogue of failures. This statement is not invalidated, because occasionally good sight is preserved after more or less escape of it. The eye may suffer in several ways. I have noticed prolapse of the iris. Prolonged healing of the cornea, and the attendant risks of the delay, with displacement of the pupil to the side. Diminution of the pupil. Intra-ocular posterior hæmorrhage; severe pain comes at once in the eye, and blood quickly trickles from between the eyelids, or the bleeding may not ensue till the patient has been in bed for some hours, or even days; the eye is always destroyed. Detachment of the retina. Intra-ocular inflammation. Morbid changes in the humour that is left, by which it gets hazy or opaque. Shrinking of the eyeball without any apparent inflammation.

Certain physical states of the eye render extraction particularly difficult, and require some modification of the ordinary operation.

Smallness of the anterior chamber is a common difficulty. The dimensions may be so reduced that the corneal incision cannot be made without considerable injury to the iris. A healthy iris is not a perfect plane, but a little convex in front at the centre.

When the chamber is only a little reduced, much may be done to spare the iris, by carefulness and lightness of touch, and tact in the use of the knife, so as not to press it backwards against the eyeball, but after the counter-puncture is made, rather to draw it forwards during the remainder of the cut.

In any instance in which there is a possibility of making a satisfactory counter-puncture, an operator need seldom fail in finishing the section as desired. When I have found it impossible to avoid wounding the iris if the triangular knife were used, I have operated almost entirely and successfully with the secondary knife. I have made an aperture with the triangular one, only just enough to admit the blunt extremity of the other, with which I effected an ample corneal flap.

Smallness of the palpebral aperture offers an obstacle to steadying

the eyeball with the fingers, without undue pressure, from actual want of space. Some mechanical means must then be employed, and the use of the forceps is particularly indicated.

Encroachment of the eyelids on the cornea, so that there is hardly room for the knife, is another disadvantage arising out of the same condition. The only thing I can recommend for this, is to use a smaller knife. I have seen a surgeon widen the commissure by an incision at the outer angle. The proceeding was unnecessary.

Extraction may be required under the less favourable condition of dislocation of the cataract, from certain changes in the eye already alluded to, by which the vitreous humour is degenerated, and the suspensory ligament is ruptured. The opaque lens falls into the anterior chamber, or rests on the iris, or tumbles backward, and produces a degree of irritation that demands removal.

If the cataract be in the posterior chamber, I recommend that an attempt be made to bring it forwards through the pupil with a needle, and then for it to be extracted. The kind of needle with which this should be done, whether straight or curved, as well as the place of its introduction, whether through the cornea or the sclerotica, must in a great measure depend on the circumstances of the case, and be left to the judgment of the operator. The anterior operation should be preferred when practicable. It may be necessary to keep the cataract fixed with the needle while the corneal section is being made.

If the cataract be in the anterior chamber, the opening in the cornea for its removal should, if possible, be made at a spot opposite to the site it occupies. In all cases the corneal opening should be large, the peculiar circumstances demanding a very easy exit for the cataract.

Extraction may also be required for the removal of the nucleus of a lens, or of portions of lens, and as this most certainly requires the employment of a hook or some similar instrument, an aperture in the cornea larger than would be supposed is needed. Here, as in the ordinary extraction of a cataract, success depends mainly on the facility with which the body is removed. If the nucleus have been displaced by violence, the hyaloid membrane will probably be ruptured. The readiness therefore with which the vitreous humour may escape should be remembered.

Immediate after-treatment. The eyelids should be closed with two or three straps of court plaster, about an inch and a half long, and a quarter of an inch broad, applied vertically. This secures adaptation of the wound, supports the corneal flap, excludes the atmo-

sphere, and ensures rest to the eye. It is the simplest appliance by which the eye can be kept closed. It accomplishes all that can be done for the wound without disadvantage. The tears readily escape, because there is enough of the eyelids left uncovered. There is no other method by which the continuous closure of the eye can be ensured. Bandages and compresses of all kinds are inferior to it; they are hurtful in proportion to their extent and pressure. All pressure beyond that which is produced from closing the eyelids must tend to be prejudicial, and at all times be positively damaging. Whatever keeps the eye hot must be bad; whatever soaks up the secretions is objectionable. A patient is often injuriously disturbed at night by the annoyance caused from the tears drying and sticking a bandage to the eyelids, or to the cheek.

The other eye should be plastered in the same manner.

The patient should at once go to bed.

Whenever it seems requisite to protect the patient's eye from the contact of his hands, to provide against accidents, a shade of some kind should be provided. Calkin's acts well.

Darkness of the patient's room is a necessary condition well recognised, but it is too common to combine imperfect ventilation with it; the bed-curtains are drawn, every window is shut, the door is kept closed, and a foul atmosphere is generated. Absolute darkness is unnecessary; there may be a degree of light not injurious, that will enable an attendant to move readily about the room. Ventilation should always be secured.

Special instructions should be given to the patient to endeavour to keep the eyeball quiet, not to roll it about, and to repress any inclination to sneeze or cough. He should be apprised that there will be for a day or two an occasional gush of fluid from between the eyelids, aqueous humour combined with tears, or the unexpected occurrence will excite alarm.

The patient should have his usual diet. Slops must not be given under the idea that chewing is hurtful to the eye. In man the action of the muscles of mastication cannot in any way influence the eyeball. The more I practise, the more am I confirmed in the propriety of allowing the usual diet from the first at the usual times, and letting the patient satisfy his appetite. An old person who is confined and fed on slops, is almost certain to have his digestive organs deranged, and if so, will most assuredly suffer from injurious prostration of strength, which may more or less interfere with the success of the operation. Starvation here is no safeguard against inflammation, while it seems frequently to retard the needed reparation, or to prevent it. Wholesome food, given in a state

of system capable of assimilating it, will not produce diseased action.

Accustomed stimuli should not be absolutely prohibited. In some cases they may be requisite at the beginning. Aged persons may have a degree of prostration directly after the operation that demands alcoholic and other stimulants.

From day to day the cheek should be carefully cleansed with warm water. Unless the edges of the eyelids and the corner of the eye absolutely require cleansing, there is no advantage in washing them, and the quiet of the eye will be better secured by leaving them untouched. Should the plaster get hard, and so produce discomfort, it should be thoroughly sopped, removed, and fresh pieces applied. The action of the bowels must be looked after, and if the third or fourth day arrive without an evacuation, and the patient seem to be restless or feverish from such a cause, a mild laxative should be given, such as the compound rhubarb pill, a dose of castor oil, or the sulphur electuary, or any particular medicine known to agree, or an enema should be administered.

The patient should be in bed for the greater part, or the whole of the first week, not necessarily between the sheets. Should he find the bed very irksome, he may be allowed to sit in an arm-chair after the third or fourth day.

When seven clear days have been passed without unfavourable symptoms, success is pretty certain, and the plaster may be removed. After the edges of the eyelids have been thoroughly cleaned with warm water, the sight may be tried by putting the patient's back to the light, and guarding the eye while he looks at something held before him on which the light falls, the observer's face or hand. For the same purpose a candle may be held behind his head. The examination should be short. However well the case may have progressed, there will be irritability of the eye, and redness of the conjunctiva and of the sclerotica, with some haze about the corneal cut. The surgeon should endeavour to see the front of the eye, so as to ascertain if the cornea be healed. If the chambers be filled with aqueous fluid, the cornea must have healed. It will then be convex, and there will be a space between it and the iris. For the inspection a candle should be used, before which is held a sheet of note paper to reduce the brightness of the light.

The cornea may have healed satisfactorily, and the eye quite free from inflammation, when at the same time the patient cannot see, simply because there is some cortical portion of cataract in the pupil, or some capsule.

When the examination has been satisfactory, the plasters need not be re-applied, but if otherwise, they are required.

The pernicious practice of opening the eye at an early period cannot be too strongly deprecated. An examination of this kind must be useless, and involuntary resistance follows, attended by spasmodic action of the orbital muscles. Several times I have observed inflammation of the eyeball to arise immediately after this unhappy mistake of interfering. If nothing worse ensue, pain is sure to follow, which may last for hours or days. Should the cornea not be healed, prolapse of the iris, with a forcible gush of aqueous humour, will probably occur, and if there be already any degree of prolapse, more of the iris will be forced out.

These remarks apply to an eye that is doing well. When unfavourable symptoms exist, the examination is certain to aggravate any evil, and in no instance can it disclose symptoms for guidance more certain and more valuable than those of the patient's sensations, and the state of the eyelids, particularly of the upper one.

Restoration to sight after extraction is very often effected without any inconvenience beyond the necessary confinement. Pain rarely attends a successful case.

When all goes well the eye is not disfigured, the pupil is central, or very nearly so, and an ordinary observer would not detect that anything had been done.

The occasional rapidity with which the cornea may heal is astonishing. A hospital patient, aged sixty-five, who was submitted to operation on the 22nd of the month, told me on the 25th that he had taken off the plaster, had tried his eye, and found that he could see. The corneal incision was united, and the chambers were filled with aqueous fluid. On the 27th, contrary to my order, he left the house. A second patient, a female aged eighty-two, finding by a like experiment on the third day that she could see well, was with difficulty kept in the hospital a day longer. An old gentleman, a patient of mine, difficult to control, shaved himself before the glass on the fourth day. But these are very exceptional instances. It had been asserted that adhesion may occur in a few hours. For the safety of the patient the surgeon should remember that, however quick the union, there must always be that delicacy of attachment of the wound within a week which demands great care to prevent separation, and that the longer the union is delayed the less firm it is when it does unite, and therefore the necessity for keeping the eye longer at rest.

When success is attained, the admission of light to the eye must be gradual, and a large shade should be worn for some weeks.

Exercise should be taken directly that circumstances will admit of it.

Unfavourable conditions which retard the recovery, damage the eye, or quite destroy sight, together with later after-treatment.

Hæmorrhage may come on soon after extraction, irrespective of any loss of the vitreous humour. It is always destructive to sight. It never occurs, of course, except in eyes in which the choroid is diseased; and in all cases that I have seen there has pre-existed undue vascularity of the surface of the eyeball, or duskiness of the sclerotic coat.

Non-union of the cornea, in part or in whole, with prolapse of the iris. Nearly the sum of the troubles which appear after extraction have their origin partially or entirely in defective union of the cornea. I advise my readers to turn to some remarks on corneal wounds at page 447.

It may happen that on the seventh day, when the eye is open, the cornea has not healed, but is not in any way altered, and the eyeball, with the addition of a little redness, looks as it did just after the extraction. Or there may be a little prolapse of the iris, of which there has been pre-indication from a sensation of something being under the eyelid, like a bit of grit, or an eyelash, or a small fly, and the escape of fluid from between the eyelids, consisting of tears and mucus.

I am disposed to consider this form of prolapse as a condition arising out of failure of corneal adhesion, or suspension of repair, quite distinct from non-union of the cornea, the result of inflammation of the eyeball, although in the later stages of each there is a strong resemblance.

Perhaps the iris does not prolapse until some swelling within the eyeball forces it out. The cornea is at fault and not the iris. I believe that the prolapse is often a beneficial state in saving the eye, for by it there is quicker secondary healing. The process of repair that follows is precisely the same as that which ensues when the iris bulges in a corneal wound which has been accidentally inflicted. The corneal edges become cicatrized to the iris, and the latter is soon covered by cicatricial material.

We cannot tell why the cornea sometimes does not unite when there is no mechanical obstruction. It may not adhere in those who seem to be in the best health even in middle life. Failure from a little excess of inflammatory action is likewise a puzzle. We are accustomed to talk of deficiencies of nutritive power, and want of vital force, as injuriously influencing an operation, and some valuable general facts have been established; but we cannot say of any individual, whose eyeball is unhealthy only so far as there is cataract, that his cornea is more likely to inflame than that of another. No

one can point out to me a man in whom the functions of life are well performed, and say that his nutritive power unfits him for the healing of a small wound. A patient who is old and feeble, with organic disease about him, has his cataract extracted under a kind of protest against his fitness for an operation, and complete success rapidly ensues. Another man apparently in the best health is operated on, the wound does not heal, and general symptoms arise characterized by depression, to explain which we suppose the pre-existence of some constitutional defect. Without ignoring the baneful power of subtle constitutional influences, I am rather disposed to regard the wound as the starting-point in most cases, and as the cause of the general disturbance. I have seen a patient operated on, and get well in a few days. Three months later the other eye was operated on by the same surgeon with equal skill, but the cornea would not heal, and the eye was lost. In another case an operation on the first eye failed, and that on the second eye, executed a few weeks after, turned out in the best manner. Three healthy men between fifty and sixty years of age had both eyes operated on by the same skilful operator at different periods of the year. All the operations were equally well done. In each patient one eye succeeded beautifully, while the other was lost from non-union of the cornea, in such a manner that would induce some men to suppose that it arose from want of constitutional vigour.

When the anterior chamber is more or less destroyed by prolapse of the iris, and the iris and the cornea are touching each other, the healing of the corneal section must be judged of by the appearance of the wound and that of the eyeball. Vascularity decreases with the process of cicatrization.

Non-union of the cornea may occur in consequence of slight inflammation of the eyeball. There has been the sensation of something being under the eyelid, certain discomfort about the eye generally, rather a free secretion of mucus and tears, perhaps a little redness about the margin of the eyelids, and pain of the eyeball when it is touched. The cornea is whitish and swollen at its edges; slight opacity may extend a little beyond this; or the entire cornea may be hazy, or semi-opaque. With these corneal changes there is always vascular chemosis with redness of the eyeball, and pain of a neuralgic character; also general symptoms, headache, restlessness, and almost always depression.

It is very questionable whether any beneficial treatment can be found for the eyeball beyond keeping the parts quiet by closing the eyelids. The interruption in the case has already occurred when the symptoms are recognised. If complaint be made about decided pain,

I would apply other treatment as well. The general disturbance must be treated.

Primary union may be prevented, in consequence of prolapse of the iris occurring at the time of the operation, with loss of the vitreous humour. The most that can be done in the first instance is to keep the eyelids closed for a longer period with plaster than if the accident had not occurred. They should be retained shut for fourteen instead of seven days. The eye may show symptoms of irritation or inflammation from the time of the operation, but fortunately bad symptoms do not always occur, and there is merely delay in the healing, which is always by a secondary process.

Non-union may be produced in consequence of the iris having been forced through the corneal wound a day or two after the operation, from rough handling of the eye, or opening it to inspect it, straining efforts, pressure with a bandage, or from accidental circumstances. Or a recently healed cornea may be burst through from the same causes.

There are marked degrees in the extent to which the iris protrudes, and in the effect on the pupil in any of the above states. There may be slight bulging of the iris, with a little disturbance of the pupil, or the entire corneal flap may be free, with a very large portion of the iris without the wound, and considerable displacement of the pupil, and alteration in its form, by which it is enlarged, or contracted, or quite closed. All this, as far as the pupil is concerned, is a purely mechanical act, apart from any inflammatory exudation by which it is closed.

When the cornea has not healed without prolapse of the iris, or with it, the eyelids should be again closed with plaster, in the same manner as after the operation. In all probability there will be better results if this be carried out during the entire period of irritation, or of inflammation, than if they be left free. Sometimes the healing of the wound is not sufficiently firm for six or eight weeks. Care, too, should be taken that there be not any muscular effort, or any imprudent act, by which more of the iris is likely to be pushed out.

Any acute inflammation must be treated by cold applications, and perhaps, according to the severity, by leeches to the temple. Febrile symptoms should be attended to.

Where constitutional feebleness, especially with depression, is coincident with want of corneal adhesion, there must be general treatment to meet it, not in mere routine, but with most careful adaptation to the requirements of each patient.

The adhesion of the cornea may give way, and prolapse of the iris come long after such an event seemed impossible. I have known it occur so late as the seventh week.

Tedious recovery of the eye and the persistence of unfavourable symptoms, is a sure consequence in cases of all kinds of prolapse of the iris. The time occupied will depend chiefly on the form in which the iris prolapses, and thereby the degree to which the edges of the cornea are separated. The greater the gaping, the more severe will be the local symptoms. Some cases go from bad to worse, chronic inflammation of the eyeball ensues, the pupil closes, and after some months atrophy is established.

The eye may be made worse by meddling surgery. After having very carefully watched many cases of this nature, after accidents and after extractions, in which different treatment has been adopted by myself and by others, I feel certain that those in which there has been no additional irritation, produced by the use of nitrate of silver in substance or in solution, or by any other agent, made the best recoveries. Therefore I have left off all local applications that can in any way

FIG. 250.

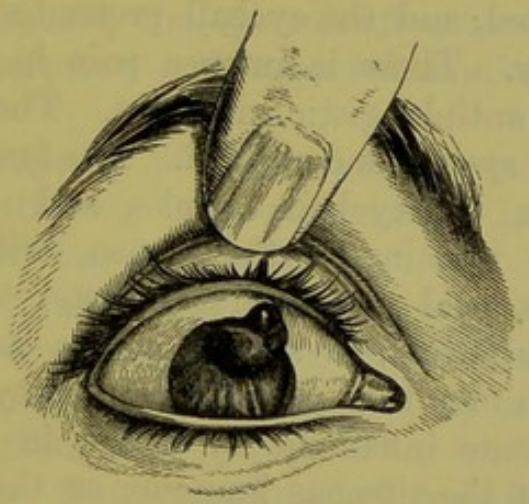

irritate the eye. This subject has been already spoken of in the chapter on Injuries from Mechanical Agents.

The only occasion on which I venture to assist Nature is, when the iris bulges considerably by the pressure of the aqueous fluid, and forms what is called staphyloma iridis; then pricking the tumour occasionally, and giving vent to the fluid, seems advantageous in promoting contraction.

The repair may be considerable, even in aggravated cases accompanied by extensive projection of the flap of the cornea; indeed, so effectual may it be in a few months, that all trace of the tumour may disappear.

Good vision may exist with the pupil much displaced, and it is not incompatible with considerable prolapse of the iris.

The above figure, which shows very remarkable displacement of

the pupil, with much separation of the edges of the cornea, illustrates my statement. The lady whom it was taken from, sees to read and write, notwithstanding that the greater part of the pupil is covered when the upper eyelid is free. The protruded iris, which is coated by a delicate white cicatrix, forms a boundary of the anterior chamber.

The cornea is always more or less damaged by opacity around the prolapsed iris, which frequently overshadows the pupil.

Accordingly as sight is interfered with, by alterations in the position of the pupil, or in its size, or by corneal opacity, will there be the necessity for an artificial pupil to be made.

Acute inflammation of the eyeball as a direct consequence of the operation, is a cause of failure, but by no means so commonly as might be supposed. It usually appears early, within the first twenty-four hours. In a severe case, almost suddenly pain is felt in the eyeball, then in and around the orbit, the eyelids swell, are inflamed, and become bright red. Purulent discharge follows. The tissues of the orbit also are involved, and the eyeball protrudes. The temple and the cheek get puffy. There is intense pain in the orbit, scarcely interrupted by any antiphlogistic measures. The power of sleeping is lost. The whole system is deranged. Pus forms in the cornea as diffuse suppuration, the eyeball shrinks, and in the front is the diminished opaque remains of the cornea, with more or less of cicatrix. Or the corneal flap ulcerates away, or sloughs, and the eyeball shrinks to a button; or shrinks and a staphyloma forms in front. Suppuration may take place within the eyeball, as a further extension of the acute inflammatory action in the ciliary region, involving a part of the vitreous humour, or the whole of it. The suppurative action may extend to the retina and to the choroid. In proportion to the extent of the suppuration is the local and general suffering, and the degree to which the eyeball collapses.

Less severe attacks sometimes occur, and the cornea inflames, but is not destroyed. The iris may prolapse, and the pupillary margin become adherent to the capsule of the lens, and the cornea rendered more or less useless from opacity.

The later the acute attack, the less severe it is. The milder invasion, which may come on four or five days after the operation, and which generally terminates in closure of the pupil as its worst effect, is called iritis, but it is in fact inflammation of the whole of the ocular tissues.

Acute inflammation may supervene, as a rare event, without any indications to be gathered from the outward state of the eye; not even is there sensitiveness of the eyeball to touch in some cases; yet

not without headache and loss of appetite, or some other general symptoms. In such an eye, at the end of a week or a little later, the cornea may be healed, the aqueous humour turbid, the iris dark, and the pupil irregular, and occupied by opaque material, or quite contracted. It is strange that this often happens without the iris prolapsing, even when the healing of the cornea is delayed. This, then, would seem to be an exception to the remark above, that any irregularity in the progress of a case may be told in the state of the eyelids, and therefore it is unnecessary to open the eyelids from day to day to inspect the eye. It is, I repeat, a rare exception, and does not lessen the value of the rule to leave the eye alone. But other indications are given of the disease, and sufficiently early opportunities for inspecting the eye occur.

In all particulars these forms of inflammatory attacks resemble those of inflammation of the eyeball consequent on accidental injury. They are, in fact, traumatic inflammations.

However impossible it may be to check the inflammation altogether in any part of its course, the eye can often be saved from complete destruction by treatment, and rendered available for a secondary operation.

A very marked amount of depression always follows these cases, from which the patient is long recovering. It is still worse when depressing treatment has been used.

A great deal of relief may be effected by incising the cornea, when it contains pus; also by giving free exit to pus and the other products of suppuration within the eye, by a free cut across the corneo-sclerotic region.

Extirpation of the disorganized eyeball is a sure method of putting a stop to the patient's suffering, and of quickly promoting his convalescence.

Sub-acute inflammation is more common than the acute, and is frequently mistaken for it. The attack comes on some days after the operation. The swollen eyelids have scarcely a flush of red, being rather of a darkish hue, and infiltrated with serum, the upper one showing this the most. The cornea is generally hazy, the wound has not healed, and its edges are thickened and creamy. The ocular secretion is thin, and the conjunctiva, although chemosed, is scarcely vascular. The external characters will generally offer sufficient guidance for treatment, and render it unnecessary for an experienced surgeon to open the eye to see what are the changes within. The state of the system is the reverse of that in the acute attack. The circulation is feeble and languid, and the extremities are often devoid of their natural warmth.

The course of general treatment is well indicated. It is to support the patient, and to stimulate him.

The well-marked symptoms of the acute and sub-acute forms of inflammation do not, of course, always exist, and the line of treatment to be pursued is not always clear. Pain is severe in both conditions, but here in the sub-acute, blood-letting and purgatives to subdue it may seal the fate of the eye. In all cases of doubt, the rule should be to stimulate, rather than to attempt to depress.

The feelings of the patient after taking food may, in some measure, furnish evidence of the condition of the system. If the pain be lessened after nourishment is taken, additional support is needed.

Cinchona is a valuable medicine, when a restorative is wanted, and the *extractum cinchonæ flavæ liquidum* of the British Pharmacopœia is an excellent preparation. It should be given in sufficiently large doses, that is, from thirty to fifty minims, in water. Carbonate of ammonia may be used. The *spiritus ætheris* resuscitates very old people in a remarkable manner. I give it freely. Wine or spirits may be necessary.

The sub-acute inflammation is more manageable than the acute, and very marked relief often follows these measures. The patient soon says that he feels better; he sleeps, and wakes refreshed. The state of the eyelids improves, and the cornea shows evidence of secondary healing, through the medium of the prolapsed iris. But success, that is, the actual saving of the eye, is by no means certain. It may perish with less intensity of symptoms than those produced by the acute inflammation.

A corneal abscess may form, and that very insidiously. It may appear with the least possible external evidence of any departure from healthy action, that is, with only rather more discharge from the eyelids than usual, the conjunctival secretion being in excess. The eye is thereby quite spoiled, and usually atrophies. I have seen this over and over, when there has not been the least swelling or redness of the eyelid, and pain has not been complained of. It is most common in this form in old persons who are emaciated. Severe symptoms, however, soon come on, and purulent discharge, with swelling of the eyelids, chemosis, and pain supervene. This is an analogous state to deposition of pus in the cornea after injuries, only here treatment is unavailable. The large corneal wound complicates the case.

Inversion of the lower eyelid, entropium, is apt to happen late after extraction, if there have been any inflammation about the eye, and the eyelids are œdematous. It irritates the eye very much, and may

be the means of the corneal adhesion giving way. If the eyelid cannot be kept in the right position by plaster applied to the cheek, the sooner the operation for entropium is done, the better.

Irregularity of the pupil sometimes occurs without prolapse of the iris, or adhesion of it to the cornea, in consequence of the injury sustained from stretching, during the escape of the cataract. The paralyzed spot generally corresponds to the portion of the iris over which the cataract has passed, just, in fact, where the greatest stretching has occurred, and is therefore in the direction of the incision of the cornea.

An attack of conjunctival inflammation is not very uncommon when persons begin to move about after the operation, to quit their rooms, and to get out, especially if they are weak, and the eye irritable; or if they expose themselves imprudently to noxious influences, such as sudden atmospheric changes, damp, the heat of the fire, fatigue, excitement, and undue indulgence in drinking. Unless the symptoms be threatening, cold applications and the recumbent posture for a day or two may be relied on to reduce them. These slight attacks are often misunderstood, supposed to be the commencement of a violent inflammation of the eyeball, and the patient is treated accordingly; but so long as pain is not the leading symptom, or the vision does not get dim, there need not be any apprehension; the eyeball is not affected.

Inflammation of the entire eyeball may supervene long after such an occurrence is least expected. In one of my patients several weeks had passed, and up to the attack there had not been the least interruption to success. The inflammation was of a low type; pus was effused in the chambers of the eye, and the iris so affected that the pupil closed without any acute pain coming on, or much intolerance to light, or much surface vascularity. Such occurrences point to the necessity of prudence and care on the part of patients, and watchfulness on the part of the surgeon.

A small vesicle sometimes rises from between the lips of the corneal wound. It seems like a thin semi-transparent membrane, distended by the aqueous humour. It may come on in a few weeks, or even months after the operation. It seems to have its origin in distention of cicatricial material between the edges of the cornea, and must arise from failure of primary union.

The treatment is to snip it off, and keep the eye closed for several days. Simple puncturing is generally insufficient.

Nearly all the after-dangers of extraction arise from the large corneal wound. When an operator has sufficient experience to enable him to diagnose the reduced volume in a cataract, and to proportion

his incision to its size, he will greatly increase his success in this method of removing cataract.

EXTRACTION OF HARD CATARACT THROUGH A SMALL SECTION OF THE CORNEA.

A great many years ago, Mr. Travers, Sir William Adams, and others, tried to effect this. The pupil having been dilated by belladonna, the steps of the operation are, to slit open the anterior capsule with a small bent needle introduced through the sclerotica, to tilt the cataract forward through the pupil, to keep it fixed by means of the needle which is now committed to the charge of the assistant, to open the circumference of the cornea to one-third of its extent, to withdraw the needle, to introduce a hook, to lay hold of the cataract and to pull it out.

The opening in the capsule will require to extend to its whole diameter, else the starting of the cataract will not be easily accomplished; and this latter act is usually effected by pressing with the needle on the cataract near the lower or the upper edge, so that the opposite edge from that which is pressed upon is tilted forwards through the pupil. It is desirable that the cataract should revolve, so that its posterior surface comes to be applied against the cornea. If the operator be satisfied that the capsule is sufficiently opened, and yet fails in bringing the cataract forwards, by pressing back one or the other of its edges, he may withdraw the needle from the posterior chamber, by carrying it under and hence behind the cataract, which he must then push forwards through the pupil. Retaining the needle in contact with the cataract till the section is finished, or even keeping it in the eye till the cataract is extracted, is no doubt of use, as it prevents the accident of the cataract falling back into its former situation, an occurrence which is likely, if the vitreous humour be fluid. At the same time, unless the patient be very still, the needle is apt to lacerate the iris and cause bleeding. Some operators, therefore, withdraw the needle immediately after the lens is dislocated.

The incision of the cornea is to be executed exactly as the semicircular incision; namely, by carrying the knife across the anterior chamber, unless there is reason to think that the vitreous humour is dissolved; in which case it is better to make a free puncture at the temporal margin of the cornea, and then to enlarge it upwards and downwards with the secondary knife. If this plan be not followed, but the extraction knife carried across the anterior chamber, the

cataract is very apt to be forced back through the pupil into the vitreous humour, where it sinks to the bottom.

The incision being made, the hook is to be introduced, flat, between the lens and the iris, as far as the centre of the pupil; the point of the instrument is then to be turned forwards, and the cataract laid hold of by the surface which happens to be towards the vitreous humour.

The extraction may then be accomplished without any pressure on the eye, which constitutes the great recommendation of this mode of operating in cases in which there is reason to suspect the hyaloid membrane to be unsound.

Of the comparative merits of a large wound of the cornea, or a small one for the extraction of hard cataract, this may be said: A well-performed semicircular incision disturbs the internal parts of the eye less than any other operation, while the after-dangers to the eye are very great.

A small section disturbs the parts within the eye more at the time of the operation, but there is certainly less risk after it from inflammation of the cornea. It requires as much care as the other, but less dexterity. The chief drawbacks to it arise from the tendency there is for portions of the cataract to be left in the eye, bruising of the iris, and stretching of the corneal wound. These expose the eye to more risks than a large corneal incision.

MODIFIED LINEAR EXTRACTION.

This is a bad term, as it is meant to express two distinct things, and it needs a long explanation. It is also incorrect, as used to signify what is done. It has grown out of the German name, "linear extraction," a method first applied by Gibson. The modification consists in removing hard cataract through a large wound in the sclerotica, and at the same time mutilating the iris, by cutting off a large part of it. The two operations, Gibson's and this, have nothing in common. Von Graefe, with a praiseworthy effort and much ingenuity, tried to reduce the risks to be encountered in the ordinary method of extraction, by introducing this, his well-known operation, which has many admirers, especially among his personal friends.

The special instruments required are a long and narrow knife, a peculiar curette, and a hook, all of which are kept by most of the London surgical instrument makers.

As the operation is remarkably painful and very lengthy, and as

the eye is very apt to be lost, from the nature of the manipulations, if the patient be not very steady, an anæsthetic to produce insensibility is necessary.

Method of operating. The eyelids may be retracted with the fingers, and the eyeball fixed, as in preparation for the operation of extraction, but it is better that a spring wire retractor be employed for the purpose. Whether the forceps be employed to hold the eyeball or not, must depend on the desire of the operator.

The blade of the knife, with the edge upwards, is passed obliquely from above downwards into the outer part of the sclerotica, about half a line or a little less from the anterior margin of the cornea, and a line below the highest point of the same, and directed towards the middle of the anterior chamber. It will appear close to the margin of the iris. It is pushed on in this direction about three lines, so as to ensure the effectual incising of the minor part of the sclerotica, then directed horizontally, and the counter-puncture made at a corresponding part of the sclerotica on the opposite side, the edge turned sharply forwards and the blade carried onwards to the hilt, and the section completed by a sawing motion. The conjunctiva becomes raised, and is divided most readily and with the smallest flap by cutting it forwards.

The wire retractor is absolutely required now in this the second stage. The flap of conjunctiva is turned forwards on the cornea, and the protruding iris seized with a pair of fine forceps, and drawn out sufficiently to enable a piece to be excised.

Graefe says that whatever of iris presents itself at the incision should be incised at the level of the external wound. If there remain any iris in the corners of the same, he pulls it out, and excises it.

The capsule is lacerated with the needle, from the lower part of the pupillary margin upwards along the inner side to the equator of the cataract, in a similar way, and along the outer to the same extent, and also above at the equator.

The cataract is now to be started. Here is a copy of Graefe's directions, taken from the third volume of the "Ophthalmic Review." The translation was revised by Graefe: "The mode of evacuating the lens varies according to the amount of soft surface matter. When there is plenty of it, the delivery is as a rule effected without the introduction of any instrument, merely by external pressure. The back of a broad and moderately arched spoon is, close to the centre of the incision, gently pressed against the sclera, so that the wound is made to gape. Thus, cortical masses are caused to escape, and the vertex of the nucleus presents itself. In order to promote as much as possible the thorough exit of the latter, the back of the

spoon is made to glide along the sclera, first with an equable degree of pressure laterally towards the corners of the wound, and thereupon withdrawing it from the wound, upwards with a continuous increase of pressure. If during these movements the diameter of the nucleus present itself, the pressure is more and more abated, and the delivery may be completed by applying the end of the spoon to the projecting edge of the nucleus. If there be but a thin stratum of soft cortex, the recommended "slide manœuvre" may likewise be tried, but ought to be abandoned as soon as we observe that during the lateral movements no presentation ensues; in this event the hook must be resorted to, which in the case of hard cataract is required *ab initio*. The blunt hook which I am in the habit of employing has its stem bent in such a manner as to enable it to be readily pushed under the nucleus. It is first laid flat on the opening made in the capsule, thereupon drawn back over the near edge of the nucleus, when, by a suitable elevation of the handle, it is brought in the direction of the posterior cortex, along which it is then pushed forward on the flat until it has passed the posterior pole of the nucleus. The instrument is now between the fingers, rotated round its axis, so that the plane of the curved extremity of the hook exchanges its horizontal for the vertical position; or, should resistance be felt, an oblique one, and the nucleus, or, as the case may be, the whole lens, is by a gentle traction carried towards the incision."

Nearly every operator who professes to do this operation, has some new scheme of his own for the execution of it. Some use spoons instead of hooks, and there is a difference in the form of those of different men.

If the vitreous humour should escape before the iris has been excised, it is better to make the excision, and to endeavour to remove the lens and its capsule with a scoop passed behind, into the vitreous humour, by lifting them out. This will necessarily occasion the loss of still more humour.

Any portion of the lens, or any fragments or bits of capsule, that remain in the wound, are to be removed.

All that has been noticed in the consideration of the several acts of extraction, by the crescentic corneal flap, applies here also.

The after-treatment is the same as that for extraction, by a crescentic flap.

It is incorrect to call the incision of this operation linear, for it is crescentic. As it is in the sclerotica, the necessary length of the wound is shortened by the height of the curve of this part of the eyeball, but crescentic it most undoubtedly is.

According to the strict rules for operating laid down by Von

Graefe, there is not room enough for a full-sized cataract to escape out of the eye; and hence it is that most operators, in consequence of having had failures, make more of a flap in the sclerotica; and hence it is also, that authors who advocate the operation never omit to say that, when the cataract is large, the puncture and the counter-puncture of the sclerotica must be made nearer to the horizontal meridian of the eye.

For a hard cataract to escape with safety, by which is meant, that the angles of the wound be not bruised and stretched, nor the cataract pressed into pieces, the incision must at least equal in length the diameter of the cataract, and gape in correspondence to its thickness. This cannot be got over by any ingenuity.

The wound in the sclerotica very much endangers the escape of the vitreous humour, one of the most serious of all the accidents incidental to extraction, and one that is here very frequently incurred. To avoid this, some operators depart from such a line of incision, and make their cut at the junction of the cornea and the sclerotica.

The iridectomy is for the purpose of getting as much space as possible. It is stated, besides, that it facilitates the removal of any fragments of cataract that may remain. It should be remembered that this operation has a great tendency to break the cataract, so that the iridectomy is an evil which is devised to remove other evils of a previous creation. As to being a prophylactic, as it is asserted to be, that is sheer nonsense.

Reputed advantages of the so-called modified linear extraction.

The easier removal of a cataract whose cortical portion is quite adherent. This means, I suppose, when there is not much soft material about the cataract. But cataracts of this nature escape easily enough, if the corneal section be properly made. Besides, no one can tell of this state beforehand.

Peculiar applicability when general or local conditions render suppuration of the cornea probable. This is just what cannot be told. There are not any signs by which it can be said, apart from chronic inflammation of the eyeball, or of its appendages, that suppuration is likely to follow a corneal section, and such states would probably cause suppuration from any form of extraction.

A valuable resource when the condition of a patient renders a less strict regimen advisable, or particularly a shortening of his time in bed. If convalescence be really longer in coming about in corneal extraction, and I am not prepared to deny it, two, three, or more days are nothing in comparison to the greater advantages of a given operation, whether to a rich or to a poor person.

That, as the wound cannot gape much, it must heal quicker than a corneal incision.

That the operation needs less after-treatment. The old operation, when successful, needs no treatment; all that is wanted is to keep the eyelids closed and the light away. Any operation for cataract that goes badly, puts the patient in a state that needs careful attention.

Less risk of the flap suffering from partial or diffuse suppuration. If this be true, it is a great advantage, but suppuration does occur. Stellwag von Carion, of Vienna, in pointing out what has been said in praise of this, writes thus: "It would be too much to hope by this operation entirely to escape shrinking of the eyeball, and to avoid fatal inflammation of the interior of the eye. The proceeding does not guarantee success, nor will it do so even with farther improvements of the method of operating."

The absence of prolapse of the iris as a complication. That certainly cannot prolapse which has been cut away, but the iris does prolapse at the edges of the wound, and nearly always it will prolapse, or become adherent to the wound. I beg my reader to call to mind what I have said about the probable advantage in some instances of the prolapse of the iris.

Special adaptation for removing a partially formed cataract, as all the lens tissue not atrophied can be the better got away with a scoop. A better eye can be obtained, if time be given for all the lens to atrophy, and then the ordinary extraction performed. The patient wants sight, not time.

Disadvantages. The impossibility of ever getting an eye to the highest attainable degree of usefulness. It is mutilated, its pupil displaced and spoiled, by which there is disturbance or confusion of vision inseparable from the iridectomy. With strong illumination, the enlarged pupil causes painful dazzling, and in proportion to its size increases the circle of dispersion on the retina, which is doubly felt from the entire absence of accommodation. The clearness of eccentric vision, and the capacity of the patient for seeing around him when he wears spectacles, are much impaired, for the deviation of marginal rays become very evident on account of the deficient arrest of the rays by the iris. The position of the upper eyelid does not obviate the disadvantages. The iridectomy is therefore a very serious objection, and to submit to its disadvantages there should be most unequivocal substantial advantages, readily recognisable and easily demonstrable.

I am told that although there is never the best success, there is less seldom the greatest failure, and therefore a better average. It is here that reliable evidence is so much wanted. Conjecture has been

used in its stead. Some are advocating this operation who have never attained to excellence of execution in the old one, giving to it a mere casual consideration, and foretelling its probable extinction. Some have never operated by any other method.

It was but lately that the scoop extraction of Waldau was extolled in this country as the most successful of any. This was substantiated by inaccurate statistics. If the modified linear be supported only by such evidence, it is not too much to expect that it will be abandoned in time.

The operation is most difficult of execution. This alone is an objection. It is not enough to teach that operation which only a very few, the very small minority, can do accurately. The mass of patients would be badly treated.

It is beset with dangers. Too small a wound, intra-ocular hæmorrhage, by which is obscured the latter part of the operation, difficulty of escape of the lens, loss of the vitreous humour, protrusion of the vitreous humour into the wound, are all more likely to be encountered than in the ordinary operation. But the largest risk is that of the vitreous humour escaping. The liability to the accident increases with the patient's age, because the humour generally loses its consistence as old age increases. Cystoid cicatrix, caused by the edges of the wound not uniting firmly, but by imperfect cicatricial material, which ultimately distends like a staphyloma, is common. In proportion as Graefe's original operation is departed from, and the old corneal one imitated, so are these risks lessened. There are men who, while they profess to adopt the modified linear method, never cut the sclerotica, and remove but a small bit of the iris.

As an imminent after-risk, must be mentioned that of inflammation of the eyeball, and which is usually called iritis.

Several other methods for extracting cataract have been practised of late, and, according to their respective authors, with a success hitherto unknown, and with quality of sight which leaves nothing to be desired. By some of the accounts we are also assured that only a few days' confinement of the patient is necessary. That these are descriptions of enthusiasts, I fully believe. For this reason, and because the operations are only some modifications of those above-mentioned, I shall not notice them.

OPERATIONS FOR DISPLACEMENT OR DEPRESSION.

Needle for displacement.

A curved needle is better adapted to displace the opaque lens into

the vitreous humour than a straight one. That which is represented at Fig. 251 I believe to be of the most approved form. The point only should be sharp.

There are three ways of effecting displacement.

Fig. 251.



The oldest, and now almost exploded method of "depression," is to press the cataract downwards till it disappears, as is meant to be shown in Fig. 252.

Fig. 252.

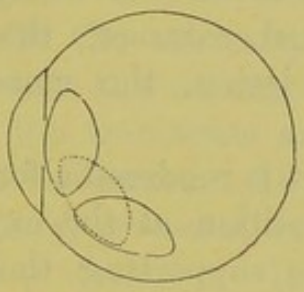

The second, "reclination," disposes of the cataract by tilting it backwards, and carrying the upper edge downwards, after the manner illustrated in the second sketch.

Fig. 253.

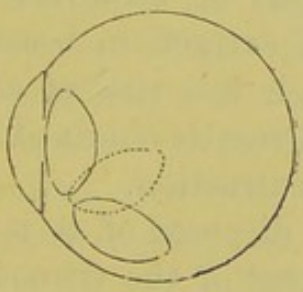

In the third (Egerton's plan) the cataract is pierced and carried down in an oblique position, as represented in the following figure.

Fig. 254.

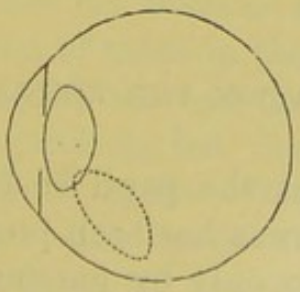

The diagrams must be regarded as demonstrating merely the

theory of the several processes, for in reality the cataract does not pass through the many positions that are figured, so as ultimately to rest just at the desired situation. There is the greatest uncertainty where it may actually go, especially in depression, an operation that I shall not describe, since, owing to the difficulty of pushing the cataract below the pupil, and getting it sufficiently covered by the vitreous humour without forcing it against the retina and the ciliary processes, or between the choroid and retina, or even through these membranes, it is now superseded.

Although the retina is very much less likely to be touched by a reclined than by a depressed cataract, the hyaloid membrane certainly suffers much more lesion, the more especially if it be healthy.

By displacement the cataract is rendered a foreign body within the eye, and placed in a new position at the expense of the vitreous humour, an organized tissue, supporting those parts of the eye which are of the highest importance to vision, and intimately connected with them, and which also are most intolerant to injury. The displaced cataract may also come into contact with the ciliary processes, and excite inflammation, or press on the retina, and thereby destroy sight.

Although displacement is a very inferior operation to extraction, it should not be condemned and made obsolete. More success may be obtained from it in the hands of unskilful and inexperienced operators than from any form of extraction, because it is an easier operation, and there is very much less risk of accidents during its performance. I have seen good results obtained by men who would probably never get success from extraction.

When the cataract is properly disposed of, it is pressed backwards and downwards into the lower part of the vitreous humour, opposite to the interval between the external and the inferior recti, and lies with the anterior surface upwards, and the superior edge backwards. It may be imbedded in the vitreous humour without being in contact with any other part of the eye, and so impacted that it will not be very likely to reascend.

OPERATION FOR RECLINATION.

It is indispensable that the pupil be fully dilated. An anterior operation through the cornea has been proposed and adopted, but is most inappropriate. It is only by passing the instrument through

the sclerotica that sufficient command can be obtained for proper displacement. The position of the patient, that of the operator, and the manner of securing the eyelids, and fixing the eye, are precisely the same as for extraction.

Manner of reclining the cataract. The conjunctiva, the sclerotica, the choroid, and the vitreous humour, must be wounded. But the ciliary processes, the retina, and the long ciliary artery, as well as the cataract, need not be wounded; and the choroidal vessels must be spared as much as possible, because hæmorrhage within the eyeball is likely to spoil the eye.

The needle, held with the convexity upwards, and the handle a little depressed, to render the entrance of the point more easy, is introduced exactly in the transverse axis of the eyeball, about the sixth of an inch behind the cornea. In that position injury will not be inflicted on the ciliary processes, retina, or long ciliary arteries, which vessels bifurcate posteriorly. It is directed forwards and inwards, to the extent of about seven-twentieths of an inch to the back of the cataract. In order to be precise, some operators have the needle gilded at the distance from which it should be within the eye to the handle, and a very good plan it is. It is now raised to the upper part of the posterior capsule, which is to be ruptured by repeated vertical movements. It had better also be carried a little way downwards through the vitreous humour. It is then brought very slowly over the upper edge of the cataract into the anterior chamber, where it will be apparent. This step needs much care, as in the natural state, the circumference of the lens is in contact with the iris. The anterior capsule is now torn in the same manner as the posterior. The needle is then raised above the transverse diameter of the cataract, its concave surface resting on the cataract, which is pressed downwards and backwards and a little outwards, and kept down for about a minute. It is then freed from the cataract, by rotation between the fingers, and very slowly raised. If the cataract should re-ascend, the reclination must be repeated. The ascension is certainly most often owing to the great elasticity of the vitreous humour, which must be in a healthy state to possess this property. The cataract should be made to assume a position as nearly as possible resembling the lowest of those in the diagram, Fig. 253.

When the needle has entered the eye the whole instrument must never be moved in any one position, but the point is to traverse in the one direction and the handle in the other, so as to form a lever of the first kind, the sclerotica being the fulcrum; and on this fulcrum there should be the least degree of pressure possible, without any

dragging of the eye. The diagram, Fig. 255, shows the third step of the operation.

If the anterior part of the capsule be opaque, and have not been sufficiently torn in the first instance to allow of a clear pupil, the needle must be applied to it before being withdrawn. When of normal consistence, it is almost always ruptured in the first instance.

The capsule may, if thickened, accompany the cataract, in spite of all endeavours to the contrary.

Should the cataract be accidentally projected into the anterior chamber during the operation, it must be extracted. If the needle

Fig. 255.

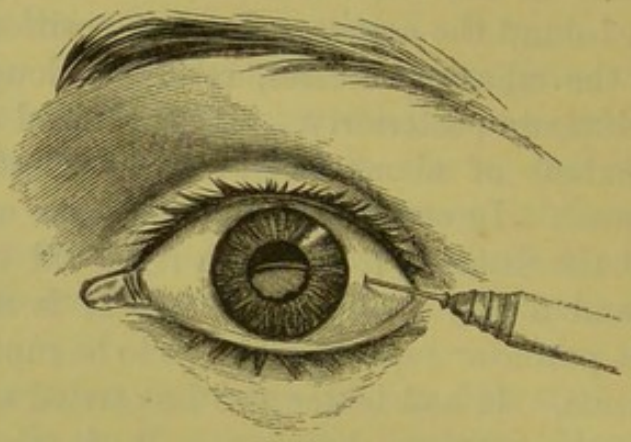

should enter the cataract in the first step of the proceedings, it must be withdrawn, and the operation commenced afresh, or failure will ensue.

Another manner of reclining the cataract is to introduce the needle as in the other operation, but instead of lacerating the posterior capsule, to bring it at once forwards to the front of the cataract, and make the reclination. This is a quicker and easier plan, but the objection to it is that the resistance offered by the capsule and by the firm adhesion of the suspensory ligament of the lens, will be impediments to the displacement.

Egerton's manner of piercing the cataract, and carrying it downwards in an oblique position. A straight needle is required, such an one as that figured as a straight solution needle. It is introduced through the sclerotica as for reclination; but instead of being carried to the centre of the vitreous humour for the purpose of avoiding the cataract, it is intentionally passed by a rotatory motion into it, the lower part of which is then turned backwards, and in that oblique position the cataract is carried downwards till the whole is just below the edge of the pupil, when the needle is most carefully withdrawn. Whilst

I attended the practice of the late Mr. Scott, of the Royal London Ophthalmic Hospital, he used to adopt this method, a little modified and improved, and allusion is made to it in his pamphlet on Cataract. He thought it better not to transfix the cataract, on account of the danger of accidental dislocation, and the greater difficulty in subsequently detaching the needle; and recommended instead, that it should be pierced only to such a depth as will enable it to be carried backwards. According to him, if the needle can be introduced into two-thirds of the cataract, sufficient command will then be obtained for the displacement.

The reputed advantages of Egerton's plan are, the less amount of injury to the hyaloid membrane, the greater facility with which the cataract can be placed in any position, the less probability of its rising, owing to the upper surface being covered by an unbroken part of the vitreous humour, and the less chance of injury to the retina from any accidental mal-position of the cataract. It is better to lacerate the anterior part of the capsule on an after-occasion through the cornea; for otherwise there is risk of the cataract being touched and returned to its place.

Accidents likely to occur during the operation, although they are not common.

A thrombus may form under the conjunctiva, if a large conjunctival vessel be wounded. Such a vessel, therefore, should be avoided. The thrombus will soon be absorbed.

A small fungus excrescence springs up from the external wound, and may require to be touched with an escharotic.

Hæmorrhage is the most imminent accident. Fortunately, even when the ciliary artery is wounded, or the ciliary processes punctured, the blood passes externally. Sometimes the blood is effused into the anterior chamber, and prevents the operation being completed. It may be poured out into both the chambers of the eye after the reclination. It is generally absorbed without producing pain or any other inconvenience.

The iris may be detached from its circumference, by a careless operator, when he is passing the needle into the posterior chamber. This will produce a very great deal of hæmorrhage. Should such an occurrence happen, the needle must be withdrawn, and the operation postponed. A false pupil will be a permanent defect.

The cataract may be accidentally pushed into the anterior chamber. It should be extracted. This will be best done by keeping the cataract securely in the chamber with the needle, making the corneal section as in the ordinary operation, and hooking out the cataract. As the hyaloid membrane is broken, vitreous humour will be most

likely to escape, therefore pressure must not be made on the eyeball.

Contingencies which may arise during the operation. The cataract may be friable, and fall to pieces as soon as the needle touches it; or so disintegrated that the needle passes through it. In either case it should be freely broken up, and a large central aperture made in the anterior capsule. The greater portion will then fall into the anterior chamber, where it will be absorbed. If, however, the fragments set up a great deal of irritation, the cornea must be opened, and the more prominent ones taken out with the scoop. If during the division of the cataract a hard nucleus is met with, it should, if possible, be reclined, or brought forward into the anterior chamber, and submitted to absorption. I should always myself rather try the latter process. If irritation be set up, extraction must be resorted to.

If a partially fluid cataract be encountered, possessing a dense nucleus, the nucleus must be reclined or extracted, or brought forward into the anterior chamber and submitted to absorption, or be extracted if irritation should arise.

If there have been entire fluid degeneration of the cataract, the coloured fluid will escape into the chambers of the eye, and should be evacuated along with the aqueous humour by a puncture in the cornea. Vomiting and pain and much irritation will thereby be prevented.

The cataract may re-ascend as frequently as the needle is raised in order to disengage from it. Supposing that all the steps of the operation have been properly performed, this may be ascribed to a greater degree of adhesion than is natural between the cataract and its capsule, or between the capsule and the hyaloid membrane. The best plan is to allow the cataract to re-ascend, and then to carry the needle over the upper edge and down behind the posterior capsule, move it upwards and downwards, and so destroy the adhesion of the capsule to the hyaloid, then to bring it from underneath into the posterior chamber, and repeat the dislocation in a slow manner.

Complete pupillary adhesion renders displacement inapplicable, for, independently of the pupil being so small that it would be impossible to see that the instrument is in its proper course, the iris must be considerably damaged before the needle could be made to appear in front of the cataract; and if the capsule were opaque and thickened, as in all probability it would be, it is more likely that the iris would separate from its ciliary attachments, than that the pupillary adhesions or the thickened capsule would give way under

the pressure. Such a state of eye is fully considered in the chapter on Artificial Pupil.

One or two or even more slight adhesions do not contra-indicate reclination, if the capsule be not much thickened. Some surgeons recommend that such adhesions should be broken down with the needle at the time of operating. I have not myself treated a case of such complication. Effusion of blood would most likely follow such separation, but that would not be of much consequence.

After-treatment. This differs in no respect from that which has been described as necessary after the operation for extraction, except in the necessity for keeping the pupil dilated, so that there may be no adhesions between the iris and the capsule, and that any cataract fragments may readily find their way into the anterior chamber. The eye requires to be kept at rest quite as long, and it is as necessary for the patient to be quiet. It is during the first week that the cataract is liable to ascend.

A longer period, however, should be allowed to pass before the eye is brought into use of any kind; and when it is employed everything should be avoided that gives pain, or causes lacrymation, or produces redness of the surface.

Severe pain of a neuralgic character and vomiting are not unfrequent recurrences after reclination. For the pain, our chief reliance must be opiates. Relief is not afforded by antiphlogistic remedies. The vomiting must be treated chiefly according to the temperament of the patient. In all cases effervescing draughts, and bits of ice swallowed at intervals, give relief. If the eyeball should inflame, local bleeding must be resorted to.

Causes which interfere with success. Acute inflammation. This often happens after the operation, especially when the manipulations have been unskilfully executed, and the suspensory ligament of the lens torn from its connection, or the needle kept unduly long in the eye. Besides these causes, the operation itself, however well performed, may be a source of acute inflammation. In addition to the usual symptoms of severe pain in the eye and around the orbit, the iris changes its colour, the pupil contracts, lymph is effused, the remnants of the capsule coalesce, become opaque, and adhere to the edge of the pupil. Vision is almost annihilated, and if the symptoms continue, pus is effused into the anterior chamber and between the layers of the cornea, and the eye is quite destroyed.

Chronic inflammation of the interior of the eye is still more likely. It comes on at a later period, and is equally destructive as the acute. Sight may have been restored to a considerable degree for some weeks after the operation, when the symptoms

creep on slowly, and in a few months all vision is extinguished. This may arise from pressure of the cataract on the iris, ciliary processes, or retina; from violence done to the structure of the vitreous humour; or from irritation occasioned by the unnatural position of the displaced body, in which latter case there will be all the symptoms which would occur if a foreign body were driven into the eye.

Really, there is no scope for successful treatment. The late Dr. Mackenzie, who saw a great many operations for reclination, gives the following advice. If the practitioner who has performed depression or reclination sees reason to suspect that the very means which he has adopted for restoring vision, threaten to destroy it, he ought not to hesitate about withdrawing the displaced cataract from the eye entirely. It is to be raised into its former situation by a needle introduced through the sclerotica, then pressed forwards through the pupil into the anterior chamber, and kept in contact with the cornea, and then extracted.

Ultimate state of the cataract. A great many eyes have been dissected, after reclination and depression have been performed, at periods from a few months to several years.

When the cataract has been stripped of its capsule, it may be absorbed entirely, or in part only, or it may be scarcely acted on for years; the result very much depending on the state of the lens atrophy.

A cataract displaced in its capsule is not absorbed.

Re-ascension of the cataract after several months. This is not common, but it may occur without any apparent cause, or from falls, or blows on the head. The cataract may re-ascend to its natural position, or pass into the anterior chamber. Some operators repeat the operation at once, after each re-ascension. Neither repetition of the displacement, nor extraction, should in my opinion be hastily done. There is always a possibility of the cataract becoming absorbed. But should irritation at once ensue, or should there be no appearance of dissolution after some weeks, the cataract should be extracted.

The nucleus of the cataract may slip into the anterior chamber. This should be treated as the above.

Success has attended the extraction of re-ascended cataract, and of nuclei, when the eyeball has been inflamed.

Mr. Solomon, in a communication to the R. L. O. H. Reports, suggests that two needles should be used for the operation of reclination.

He says that the desired object would be attained by pressing back

the outer and lower side of the cataract from the iris with a fine needle passed through the nasal side of the cornea, thus making a free space for the other needle to pass to the front of it. This is meant to overcome the difficulty which is experienced in getting the needle over the rim of the cataract, to the centre of the pupil, it being apt to transfix the lens or the ciliary body, or to get caught under the capsule, or in the iris. He thinks that some other advantages also are likely to occur, namely, an increased facility in the removal of the soft lens matter previous to the reclination of the more solid portion, protection of the iris from contusion, and prevention of dislocation of the cataract into the anterior chamber.

SPONTANEOUS DISLOCATION OF HARD CATARACT.

This may occur at any period of the lens atrophy, but it is most likely when the secondary change is far advanced. There are two conditions that generally precede the occurrence. The one is the separation of the cataract from the zonular connection to some slight degree. The other is more or less fluidity of the vitreous humour. When these states co-exist, the cataract is prone to be started by a blow on the eye, or about the orbit, on the head, or even from forcible contraction of the orbital muscles. It may occur without any obvious existing physical cause. So long as the cataract is detached only to a small extent, it will move in the direction of such separation, and a part of the pupil will be rendered clear when it falls backwards, and again eclipsed when it returns to its place. The discovery by the patient that some amount of sight is restored, and again destroyed, in quick succession, or in slow alternation, is nearly always the first indication of any form of dislocation. There is generally some slight tremulousness of the cataract at first, when the dislocation is not the effect of direct violence, but such slight disturbance is seldom recognised. In proportion as the separation proceeds, so does the cataract swing, till at last it falls backwards into the vitreous humour, retaining only the most slender attachment to the suspensory ligament as a hinge, or becoming quite freed. It may fall into the anterior chamber. It may pass backwards and forwards, between the vitreous humour and the anterior chamber.

The usual effect of a swinging cataract is chronic inflammation of the interior of the eyeball, usually called irido-choroiditis, by which the eye is spoiled, and sympathetic ophthalmitis rendered imminent. When the cataract sinks out of sight in the vitreous humour, it may

move about and bring on destructive inflammatory action. In some fortunate cases it may remain in this position without any ulterior consequences, because either the vitreous humour is fluid only in part, or the cataract has become attached by some inflammatory adhesion where it lies. Several examples of this quiet state have been seen by me, in which the sight has been as completely restored as after the most successful operation for extraction. This disposal of the cataract, partly by disease, and partly by accident, explains the wonder of the natural cure in old people popularly talked of, and even narrated by some writers.

Cases are alluded to by authors in which the partially detached cataracts have become attached in their natural position, by exudations thrown out during the inflammation consequent on their movement, and rendered harmless.

The rule is to remove the loose cataract. With any irritation, the operation should be promptly done. Whether the cataract be in the posterior chamber, pressing on the iris, or in the anterior, irritation is sure to be induced, and the eye will most certainly be destroyed, if nothing be done.

Extraction only is admissible. The manner of doing this will be the same as in ordinary cases of extraction, as regards the opening of the cornea; but the position of the section, whether upwards, downwards, or lateral, should be that which seems most likely to facilitate the subsequent steps of the operation.

It may be necessary to fix it in the anterior chamber with a needle, or to push it there as a preliminary measure, and whether the needle be used through the cornea, or through the sclerotica, must depend on the circumstances of the case. After the cornea is opened, all pressure on the eyeball must cease. The cataract must be taken from the eye, that is, removed with a scoop, or a spoon, or a hook. No attempt whatever must be made to press it out, for with pressure the vitreous humour will flow out.

The cataract is beyond removal with the saving of sight, when it lies in the vitreous humour.

OPERATIONS FOR SOLUTION, COMMONLY CALLED NEEDLE OPERATIONS.

Straight needle. Solution needles cannot be too fine, provided they are strong enough to be guided with precision.

The needle shown at Fig. 256 is a sketch of that which is used by myself. It is about the fortieth of an inch in thickness, with an angular and sharp point. The length, five-eighths of an inch,

is ample, as may be seen by reference to diagram, Fig. 257, which is intended to show the size and position of the crystalline lens, and the distance necessary to be traversed by a needle, to reach the centre of that body.

Fig. 256.



It is supposed that a cataract needle may be made with cutting surfaces above its shoulders. Such an instrument would, however, be without advantage. But it is impossible to put a keen knife-edge on the sides of a small needle.

Curved needle. A curved needle, although neither so readily introduced, nor used with such precision

Fig. 257.

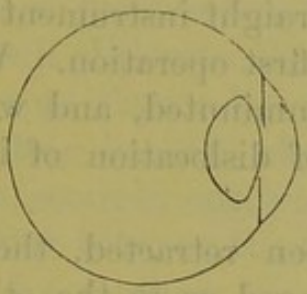

as a straight one, is sometimes required, and should differ from the above only in shape, and in the absence of shoulders, as in Fig. 258. It is scarcely practicable, so say the instrument-makers, to make it with a point like the straight one.

Fig. 258.



Application of operation. A cataract exhibiting the characteristics of softness, may be effectually removed through absorption, by opening its capsule, and admitting the aqueous humour to it. By the macerating action of the humour, the opaque and degenerated lens disappears. The freer the contact of the humour, the quicker is the absorption. But this is not the only consideration. The process needs regulation; for on such does success depend.

It should be a principle in "solution" to procure absorption of the cataract in its natural position. The less that the lenticular matter is displaced, the less subject is the eye to irritation. The less, too, the capsule is torn in the early stage of the treatment, the less likely is it to contract adhesions to the iris, and therefore the more easy is it to be disposed of afterwards, if it should block up the pupil.

There are two methods of operating: one of them is executed

through the cornea, the other through the sclerotica. These are respectively designated anterior and posterior operations. The anterior is more definite and simple, is less painful, inflicts less injury on the eye, and produces less irritation, for only one of its coats is punctured, it can be done as effectually as the other, and quicker, the instrument never being out of view. It is, moreover, the easiest, the safest, and the most successful of all operations for the treatment of cataract. I shall speak of it first.

Anterior operation.—The pupil should always be well dilated, not only to expose the cataract, but to place the iris out of the way of the needle.

Whether the one or the other kind of needle shall be employed, may be generally determined by the fancy of the operator. That either may do, is proved by the fact that each is exclusively used by different surgeons. The straight instrument is much easier to use, and is better suited for a first operation. With the curved one, a cataract can be more comminuted, and with less tearing of the capsule, and less chance of dislocation of its nucleus should there be one.

The eyelids having been retracted, the eyeball steadied, and all the preliminaries arranged as in the other operations for cataract already given, the straight needle is introduced through the outer part of the cornea at the horizontal meridian, and half

Fig. 259.

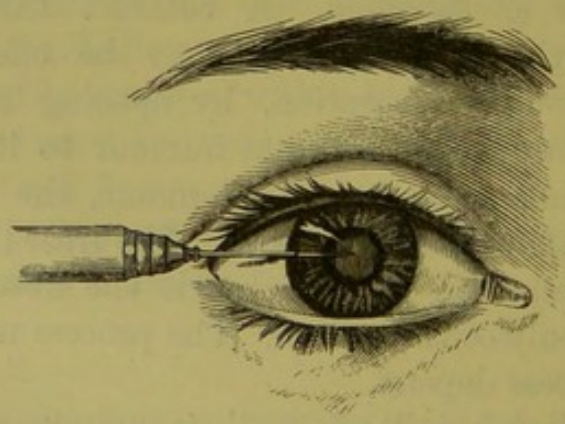

a line from the sclerotica, the point carried to the centre of the cataract, and used according to the circumstances of the case, as in Fig. 259.

The curved needle is inserted with the concavity upwards, that the stem may pass parallel to the iris, so as to avoid injuring it,

and when the pupil is reached, by a slight turn of the handle, the point is brought on the cataract.

If the needle be kept well adapted to the wound in the cornea, the aqueous humour will not escape till the withdrawal of it is commenced. Should the humour come away prematurely, the needle must be removed, and the operation delayed. Again, if the iris be wounded, and blood obscure the cataract, the operation must be deferred.

The cataract may be easier broken by piercing the cornea over the margin of the pupil, but the drawback is, the disadvantage arising out of any opacity which might ensue if the wound should inflame.

At a first operation on an ordinary soft lens, all that is desirable is to break the centre of the capsule, and to penetrate the cataract sufficiently to admit the aqueous humour to its texture. This should be done gently, because rough usage will dislocate the cataract. A straight cut in the capsule a little more than a line in length will suffice. The lens substance immediately beneath should be a little broken, and the needle, if it be the straight one, pushed into the cataract for a couple of lines, and rotated between the fingers. Too much disturbance would be created by rotating the curved needle, but as the cataract surface is the more readily broken with it, the penetration and rotation are unnecessary.

Dislocation of the cataract is to be avoided. Displacement is very readily effected, and is almost sure to occur at once, or subsequently unless certain precautions be observed. The most important of these is to make but a small straight aperture in the capsule, for so long as it retains its elasticity, a large incision, or cross ones, will be apt to be increased by rupture from the mere swelling of the cataract, and the dislocation is risked.

When the capsule is markedly opaque, and consequently has lost much or all of its elasticity and liability to rupture, a large aperture will have the advantage of giving freer entrance to the aqueous humour, and I may say is necessary to obviate the tendency of a wound in a capsule so altered to unite.

Not to carry the needle too deeply, nor to move it about too freely on the cataract, are farther precautions against dislocation.

The less leverage that is employed with the needle the better; the very reverse action is required to that which I have described as being necessary for the operation for "displacement."

The operator may be assured that the cataract will fall into the anterior or the posterior chamber, if he see it move in the least degree while operating.

The cataract in its capsule is most readily detached, if the capsule have partially lost its connection, a condition rarely met with in soft cataract, unless the capsule be much thickened and the cataract partly absorbed.

Another reason against using the needle freely at first and exposing a large surface of the cataract, is that any lens tissue that may have not become opaque, will swell considerably if much broken, and so will the cataract to some extent, if it be only in the primary change. Lens tissue in the secondary change swells but little or not at all. By the swelling the capsule is pushed on the iris, and adhesion is inevitable; and these parts always adhere, when in contact during the process of absorption. This is due, I suppose, to the capsule invariably becoming inflamed. The iris suffers from mechanical irritation arising out of the pressure, and the liability to this increases with the age of the patient. The mechanical irritation is greater and more dangerous, the greater the density of the cataract. In children, considerable swelling of the lens is often borne without any inflammation supervening. After puberty a small piece of projecting lens will often suffice to excite injurious inflammation. Besides, the eye of the child is less injuriously affected by any inflammatory action, than that of an older person.

Dilatation of the pupil is to be kept up, till the capsule recedes from reduction in the bulk of the cataract. Atropine should be applied to the eye daily, so that the fullest dilatation may be obtained. By this means, adhesions between the capsule and the iris may be prevented and pressure on the iris avoided.

After-treatment. Very slight irritation follows a well-executed operation in an eye in which the cataract is not complicated with some other disease, and there is not the necessity for that strict observance of rest so essential in the operations for extraction and displacement. However, the patient should remain in the house for a few days, during which time the other eye should not be used. Bright light should be excluded.

Should acute inflammatory action arise, it must be regarded as traumatic inflammation, and treated as such.

The eyeball invariably gets harder if the slightest inflammation supervenes. I know of no exception to this. Such a symptom need not create the slightest alarm.

The pain which always follows the operation, but is generally very slight, must not be mistaken for the commencement of an attack of acute inflammation. So long as the objective symptoms of active inflammation are absent, the administration of narcotics, and the application of cold lotions, need only be employed.

Vomiting sometimes ensues, when there is escape of some of the cataract from the capsule, and sometimes when there is not any. It is soon checked by taking ice in little lumps.

The first operation will most likely cause opacity of the capsule, if it be not already opaque, and render the cataract still more cloudy.

Portions of the cataract in the chambers of the eye. When the cataract is very soft in its superficies, some of the matter frequently falls into the chambers of the eye, especially the anterior, and becoming flocculent, is soon absorbed.

It might be absorbed without any disturbance. Should a little redness of the eyeball ensue, it must be disregarded, if there be no pain. Should pain come on and endure, the displaced material must be evacuated, by an incision through the cornea, assisted by the curette; or better still, by the grooved knife, which is described farther on.

When there is fluid degeneration of the cataract, the part so altered inevitably escapes, on the capsule being punctured, and renders the aqueous fluid more or less turbid. Vomiting, attended by great pain in the eye, and sometimes around the orbit, very frequently ensues, if the fluid be retained. The vomiting may be severe, and last even for days. The treatment is at once to evacuate the fluid along with the aqueous humour. I puncture the cornea at the lowest part with an iris knife, and twist the knife so as to make the wound gape, when out gushes the fluid. This knife inflicts less injury than the grooved knife.

If the entire cataract should fall into the anterior chamber, or the nucleus of it should follow the soft superficies, extraction is the rule; yet I should be inclined to wait for symptoms, because absorption may ensue without any untoward event. The most agonizing pain of a neuralgic character, in the eye, forehead, and head, is the usual accompaniment of the accident.

When the posterior chamber is much occupied by portions of the cataract, the greatest disturbance ensues from pressure on the iris. A cataract or its nucleus, when so situated, and producing irritation likely to destroy the eye, must, if possible, be depressed, or brought into the anterior chamber by a needle, and extracted; alternatives, I am happy to say, that have never been forced on me.

If the nucleus of the cataract should drop into the anterior chamber, an occurrence not likely to happen till late in the treatment, and when the greater portion of the superficies has been absorbed, it should be undisturbed, unless irritation ensue. I have watched large nuclei so situated, during the several weeks that were required for

their dissipation, with scarcely any appreciable disturbance. The eye gets more tolerant to the displacement of portions of cataract at a later period.

The most formidable impediment to success is inflammation, which may follow the operation. If the fragments of the lens be displaced, they may act, as I have said, as a foreign body in the eye. Nothing therefore can be more injudicious than an operation which is planned to fill the chamber with the fragments of the cataract. Even in infancy, when there is so much less danger from the effects of inflammation from the lenticular substance being so soft, as well as the less likelihood of inflammation consequent on the operation itself, it is better to obtain absorption *in situ*.

The time required for absorption depends on circumstances connected with the nature of the cataract, upon age, and upon individual peculiarities. Under apparently the same conditions, a cataract will resist the process of absorption longer in some persons than in others. The presence of inflammation is said to suspend absorption. This is in a measure correct, but not altogether. It is only during intense inflammation that the absorption seems at a standstill, and not always even then.

A single operation may suffice in many instances, especially in children; and it certainly will, when the cataract has degenerated to fluidity. A repetition is generally made on the grounds that absorption has ceased, or is deviating in its rate, which is more frequently assumed than indicated; indeed, there is no positive proof that it ever ceases altogether; and evidence rather goes to show that when once begun, it does not quite stop, even though the breach in the capsule may heal up. However, it can be hastened, and this by keeping the cataract more or less exposed to the aqueous humour. So long as lenticular matter yet projects from the capsule, interference is unnecessary. When this no longer exists, or when the wound in the capsule closes, the operation should be repeated.

In all subsequent operations the cataract tissue should be more broken up; but still the rules which I have given about endeavouring to prevent dislocation of its fragments should be attended to. At the last operation the anterior capsule should be freely torn across, if it eclipse the pupil. The posterior capsule should be spared. The operation should never be repeated when inflammation is present.

If a sufficient interval be allowed, there are few cases that will not yield to two or three operations; and the fewer they are, the better will be the result. The most successful examples are those in which the pupil is normal, and without any adhesions to the capsule. For this

there must have been great care in operating, and an absence of any inflammatory attack.

Posterior operation. This is performed precisely like that for "displacement," except that when the needle is brought in front of the cataract, it is used for laceration instead of reclination. This method is generally advocated solely on the score of affording greater facility for breaking up the cataract; hence it is recommended for infants, and some surgeons always practise it upon them.

I give a very decided preference to the anterior operation, for the reasons already stated. I may add, that it enables the lens to be broken to any extent that is necessary. Mr. Saunders, who introduced the operation for solution in children, preferred it. The only reason why he ever performed the posterior was from the supposed greater facility with which the lens could be comminuted. But we are informed by Dr. Farre, who edited his work, "Saunders on the Eye," that "he finally attempted to diminish inflammation by performing his anterior instead of his posterior operation." There is no surgeon living who has paid so much attention to needle operations as the late Dr. Jacob, of Dublin. He says, in his little book on the treatment of cataract with a fine sewing needle: "No anatomist aware of the nature and number of the structures injured in the posterior operation, can for a moment assume that such injury does not cause more risk of destructive inflammation than the injury inflicted on the cornea in the anterior one; and no surgeon who has compared the effects and consequences of the two operations can for a moment maintain that the results of the puncture through the sclerotica are not more injurious than those following the puncture of the cornea. No man who knows what the penetrated structures are could venture to maintain that the conjunctiva, sclerotic, ciliary ligament and ciliary processes, could be traversed by an instrument with the same or less injury than is inflicted in traversing the cornea; and no man who has compared the dimensions and relations of the anterior and posterior chambers of the aqueous humour, could venture to maintain that the narrow space behind the iris affords a more accessible passage for the needle than the comparatively capacious chamber anterior to it. Neither can any man who has witnessed the sufferings caused by this posterior operation, or the destructive consequences of the inflammation which it produces, venture to assert that such mischief follows the anterior one."

I understand that many Continental surgeons abstain from the anterior operation, from the supposed liability of the cornea to inflammation, a dread participated in by many of our countrymen. This is most unfounded. Any irritation therefrom is a very rare

event. On this question the further testimony of Dr. Jacob is very valuable. He says, with respect to the objection made to this operation, on the score of its endangering the cornea, and causing opacity of that structure, he can with safety state that there is nothing in it. He never yet saw vision impaired by any opacity caused by the wound of the needle, and very seldom indeed had he seen any opacity at all remain. In fact, in the course of a long practice, he had met but one case in which suppurative inflammation took place in the puncture, and in that case the suppuration and subsequent ulceration were confined to a circle not an eighth of an inch in diameter, and left behind an opacity not larger than the head of a pin, at a distance from the pupil, and consequently not impairing sight. He had also met with cases, but very rarely indeed, in which the whole cornea suppurated, and the entire eye participated in the destructive inflammation, as sometimes happens from any operation for cataract. This, however, he had never considered a consequence of the peculiar nature of the puncture in this peculiar structure, but the result of constitutional derangement operating on local inflammation following injury. He looked upon it as of the same nature as the abscess of the cornea which follows very slight injury, or irritable ulcer, and which takes place not from the mere injury or ulcer, but from that state of the animal economy, whatever it may be, which is attended by these local destructive processes. In my own practice, corneal inflammation has occurred a few times, and suppuration once, in several hundred operations.

The pupil may be, and very often is, sufficiently cleared, by the mere contraction of the capsule, and its greater or lesser separation from the suspensory ligament, or by retraction of its divided parts. Should it be blocked up, a special operation must be resorted to, and which is described under the head of capsular cataract.

Congenital cataract should be operated on before the eyeball oscillates; and, as a rule, a child may be safely submitted to operation after the first month of life.

The operation for solution is certainly the safest of all for the removal of cataract, as regards any immediate danger to the eye, and from none is better sight to be got. It is one of the most scientific and beautiful operations in surgery. Not any damages so little. It can be sufficiently well done by anyone with the least aptitude for operating. It is the appropriate one for soft cataract, beyond the possibility of a doubt. If the method of curing cataract without a surgical operation be ever discovered, absorption will be the process. If it were a modern operation, its merits would be advanced, to the exclusion of any other.

This old English operation is at this period apt to be neglected, because not sufficiently taught, in consequence of the love of novelty, the force of fashion, and enthusiastic admiration of some inferior foreign methods.

I have operated for solution on patients much older than those for whom I now recommend it. I have operated several times between fifty and sixty years of age, and a few times between sixty and seventy, observing in the most scrupulous manner the rules which I have laid down to procure success. Only a few times have I failed to obtain absorption *in situ*, and only once did I find it necessary to supplement the operation by extraction. In some of the cases complete success was accomplished. But the many months required for the absorption, and the inflammation which readily arises, and the pain, render it inapplicable to elderly persons.

Complication of capsulo-lenticular cataract with entire pupillary adhesion, combined with a deposit of lymph on the capsule or not. This state is preceded by inflammatory action of an acute or chronic character. As it is for the most part a condition of early life, the lenticular cataract would necessarily be of the soft kind. Observation of these cases shows that the lens quickly passes into destructive changes that reduce its consistence; so that if the affection originate in adult age, or rather in the middle period of life, the lens will not remain of the density proper to those periods of life.

The operation for solution is that most applicable. Even if the cataract be of the hard variety, there is no chance of mischief arising from its dislocation, or, at a later period, of fragments escaping into the chambers, because of the capsular thickness.

The operator must establish a sufficient aperture in the capsule to insure the entrance of the aqueous humour; and as the wound has a great tendency to unite quickly, this must be repeated, if necessary, at subsequent operations. As an unhealthy eye is being treated, the same cautious manipulating that has been pointed out, as being necessary in all needle operations, must be observed.

The pupillary adhesions so far modify the case, that the progress of absorption is not easily watched, nor can it readily be said when the cataract is quite absorbed. The only positive proof of an empty capsule is concavity of the iris, and consequently increased size of the anterior chamber; but this is not always present, as the iris may be too much damaged to admit of it, and changes in the posterior part of the eye may certainly cause it to bulge. It may be only therefore, by two, three, or more operations, done at sufficient intervals, that there can be the required assurance of the cataract having been removed.

The operations for the cataract alone will not suffice to restore sight. An artificial pupil will be needed. This condition of eye is therefore treated of in the chapter on Artificial Pupil.

EXTRACTION OF SOFT CATARACT.

The late Mr. Gibson, so long ago as 1811, "Practical Observations on an Artificial Pupil, with remarks on the Extraction of Soft Cataracts," &c., being rather dissatisfied with the operation for solution, as then performed, devised a plan for removing soft cataracts, through a small corneal wound. Having freely broken up the cataract with a needle, some weeks later, when, as he says, after inflammation had subsided, he opened the cornea, and removed the cataract piecemeal, with the curette. Gibson's plan was tried by several surgeons, as the late Sir William Lawrence informed me, and from the bad results which ensued, was given up.

In 1814, Mr. Travers also advocated extraction. He changed his method of performing the operation more than once. He has recorded his opinions concerning his practice in vol. v. of the Med.-Chir. Trans. But he changed his views and entirely abandoned extraction after he learned what could be effected by the needle operation, properly conducted.

Extraction was revived by Von Graefe in 1851, and called by him "linear extraction." His adaptation of it was more judicious, for he recommended it in early life in cases of fluid cataract, and those in which the lens had undergone secondary change and was pulpy; and especially after the operation for solution, or after an injury to the eye, from which the lens is very much swollen and is likely to damage the eye. He considered it unsuited to a lens of the natural consistence, or to cataract with a hardish nucleus. His method of operating consisted in making an incision in the cornea from two lines to two and a half in extent, and at about a line from the sclerotica, then lacerating the capsule and the cataract freely, and effecting the escape of the latter, by pressing the curette against the edge of the cornea, so as to make the wound open, and pressing also at the same time on the opposite side of the eyeball with the finger. Any portion of the cataract which remained and could be removed with the curette, was so treated. He then applied the operation to adults, making a larger incision. Finding that a hard nucleus could rarely be got out, even with the help of the scoop, without producing contusion of the iris, an occurrence that produced inflammation and damage to the eye, he added to the operation

iridectomy, and scooped out the cataract, passing the scoop between the posterior cortical substance, and the nucleus. Still, however, he did not adapt it to the hard cataract of old age.

Linear extraction, after this, was applied in this country to the cataract of children and young persons, irrespective of the state of the cataract. The following general direction is given for its performance.

The anterior capsule of the lens is to be broken up freely with a needle, and afterwards the whole of the cataract comminuted with the same instrument, so that all of it may be brought into contact with the aqueous humour. The posterior capsule is to be left intact. The patient is to be kept in a dark room, and atropine applied to the eye. The greater portion of the cataract falls into the chambers of the eye.

At a period ranging from three to six days, an opening is to be made in the cornea, about a couple of lines from its margin. The needle is to be withdrawn, and a thin narrow curette introduced; the eye is to be held with a pair of forceps, while the curette is moved from side to side, and so pressed on one of the edges of the wound as to allow the aqueous humour, with the comminuted cataract, to flow down its groove. Pieces of the cataract that have not come out with the first flow, are encouraged to escape by placing the curette under them. Atropine is to be applied as before. Some operators have broken up the cataract and extracted it at one operation. Some have performed iridectomy as well; some have applied the suction curette.

That it is possible for soft cataract to be got rid of in this way, exceptionally more quickly than by absorption, and with success, has been proved, but the method, as applied to soft cataract in general, gives an inferior result. It is a dangerous one, and always imperils the eye. It is a very difficult thing actually to remove soft lenticular cataracts by extraction. The majority of them cannot be expelled in this way, even with a large corneal section. With a small section a considerable portion of the cataract must be left behind.

There are great disadvantages inseparable from linear extraction. With the risk which attaches to the extraction, absorption must be relied on, under disadvantageous circumstances, to remove what remains. Several difficulties and dangers attend the operation, such as contraction of the pupil as soon as the aqueous humour escapes, by which the division of the capsule is prevented, as well as the escape of the cataract; prolapse of the iris during the operation; incomplete evacuation of the cataract; prolapse of the vitreous humour from the bursting of the hyaloid membrane, during the operation.

Knowing what I do of the operation practically, I cannot recommend

it as a system for general application. It inculcates the very reverse of all that I have laid down as rules for treating this form of cataract.

The eye is frequently destroyed or damaged from acute inflammation. When it escapes this, it is prone to be attacked by chronic inflammation, two or three weeks afterwards, which never occurs without producing serious injury.

Fig. 260.

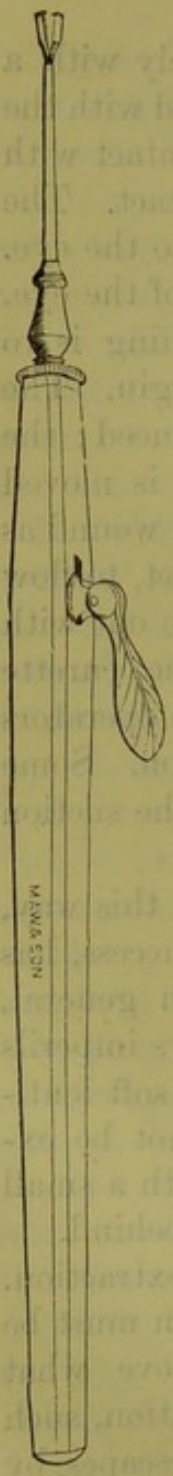

CAPSULAR CATARACT.

Blunt canula capsule forceps, Fig. 260. The blades are brought into play by a canula, which encloses them, shutting when the canula is pushed forwards, and opening when it is drawn backwards. Their expansion may be graduated by allowing more or less length for the canula to work over. The action is effected by a spring trigger. Figs. 262 and 263, are instruments with modified blades.

Sharp canula forceps. Fig. 261 portrays the forceps

Fig. 261.



open and shut. The larger and sharp blade is perforated about the centre, to receive the hooked end of the lesser, and the surfaces where the two come into contact are cross-cut like common forceps.

The sharp blade should be sufficiently keen to enter the cornea readily, and the lesser should have its edges so bevelled that there shall not be any projecting angles, or any obtuseness to impede penetration. The canula is worked by the finger. It is with this form of instrument that all of my sharp canula forceps work has been done, and I prefer it to one with a spring trigger.

When larger forceps are required, those with a cross-spring answer the purpose best. Here is introduced an effectual pair with an excellent arrangement, Fig. 264, made according to my design. One blade passes through the other, as a security against any lateral movement, and this adjustment enables a check to be placed against too great a separation of them. The extremities remain parallel at

any degree of opening. The points are toothed. The lesser figure shows these magnified. Fig. 265 represents a coarser and less expensive instrument, on the cross-spring principle, but one better adapted for seizing a large body, and for penetrating deeper than the others. The smaller cut shows the actual size of the teeth.

Fig. 262.



Fig. 263.

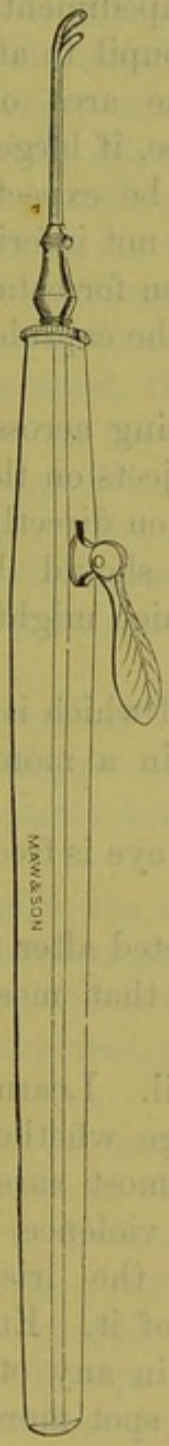

Fig. 264.

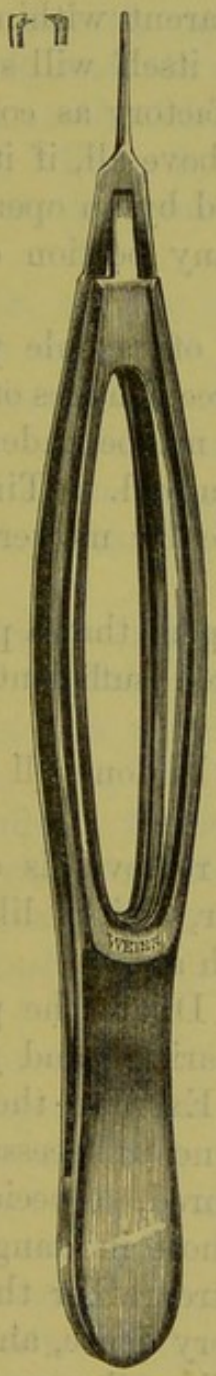

Fig. 265.

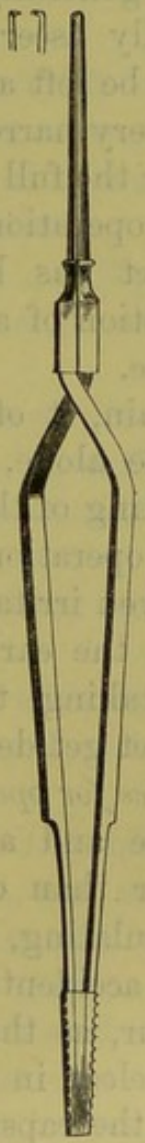

Operations for capsular cataract. After the lens has been removed by extraction, or solution, or displacement, the capsule may not roll up or contract sufficiently to leave the pupil clear, or at least available, but occupy it so as to obstruct the entrance of the light.

This may be in consequence of thickening or density, or from not having been sufficiently torn, or from being more or less adherent to the iris.

Capsule is never absorbed. The bulk of it is diminished by shrinking, or rolling up. Its tendency is always to roll up whenever it is torn, and that in a direction from without to within.

An operation should not be undertaken for the removal of capsule, except from necessity, arising out of impediment which it may cause to vision. There may be a sufficient pupil to afford excellent sight, while capsule is apparent within the area of the pupil. An aperture in the capsule itself will suffice, if large enough. If, therefore, vision be as satisfactory as could be expected from the general state of the eye, and, above all, if it be not inferior in amount to the vision generally restored by an operation for cataract, a matter which is easily ascertained, any portion of the capsule that is visible had better be left alone.

A very narrow strip of capsule passing across the pupil may not hinder the full and correct images of objects on the retina.

An operation should not be undertaken directly after the lenticular cataract has been removed. Time should be allowed for the absorption of any lenticular matter which might be adherent to the capsule.

Again, it often happens that a pupil which is obscured at first by capsule alone, is cleared sufficiently in a month or two, by the shrinking of the same.

No operation should be done till the eye is free from inflammation, and even irritation.

Yet the earlier the removal is effected after the eye is fit for the undertaking, the better, as it is likely that most forms of capsular cataract get denser with age.

Rules for operating. Dilate the pupil. Learn the position of the capsule and all its bearings, and judge whether some portions be thicker than others. Exercise the utmost care and gentleness in manipulating, so that no unnecessary violence be inflicted, and no parts accidentally injured, especially the iris and the vitreous humour, as they are most in danger of it. Endeavour to get the pupil clear in the centre rather than in any other position, except when the capsule is very dense, and a spot more favourable for the clearance be near. When the capsule must be torn through, make the first penetration in the thinnest part, and enlarge from that. A smaller aperture than is generally supposed suffices, and if a sufficient hole can be made in the capsule itself, enough has been done. It would be imprudent to proceed farther. Avoid setting portions of

the capsule free. Observe the same rules already propounded, in the descriptions of the cataract operations, for the preliminary preparation of the patient, the steadying of the eyeball, and so forth. Do not puncture the cornea in a transparent part when there is any opaque spot through which it may be done. Attempt to remove the capsule, or to tear it, or to cut it, but not to press it into the vitreous humour. Place the patient under an anæsthetic when capsule is to be extracted, and whenever sufficient steadiness on his part cannot be relied on.

The common conditions under which the capsule may be disposed in the pupil and partially obscure it, and the methods for its removal. The capsule may be unadherent to the iris, or it may be adherent and therefore complicate the case. There is a still greater complication when plastic depositions on it, the result of acute inflammation, are associated with adhesion.

Entire capsular cataract, that is, opacity of the anterior and the posterior capsule, is an unusual state. It is seldom seen except associated with congenital, or traumatic cataract the result of penetrating wounds of the lens. It is nearly always contracted, and therefore partially separated at the circumference. All parts of it are usually very thick, and there may be cretaceous and other deposits within it.

The capsule may be closed, forming a sac, or the anterior half may be torn, its edges being retracted. In the latter state the differences in thickness and opacity between the anterior and posterior halves are apparent.

With entire opacity, the capsule is frequently more or less separated from its ligamentous and hyaloid attachments.

Treatment. *Extraction* is the best mode of dealing with the capsule when it is conveniently detached, and lies somewhat isolated opposite the pupil.

An incision should be made through the cornea with an iris knife proportionate to the size of the capsule to be removed, and at a line from the sclerotica, to obviate the tendency there is in such extractions for the iris to be drawn out. It is an object that as much aqueous humour as possible be retained. The capsule should be seized with a pair of forceps and withdrawn. A twist or a turn or two of the forceps facilitates the exit, and may prevent it from being torn in two. Sometimes I have pushed the capsule into the anterior chamber, with a needle passed through the sclerotica, as a preliminary measure.

If the capsule be merely opaque, with no appreciable thickening, it may roll up in a piece sufficiently small to allow of

removal with the sharp canula forceps. The instrument, held with the short limb anterior, is pushed through the cornea near its circumference, into the pupil. When it has arrived at the edge of the capsule, it is opened, the sharp blade passed behind it, the short one in front, the seizure made, all pressure on the globe of the eye remitted, and the withdrawal commenced. A slightly twisting movement will facilitate detachment, and make the capsule clear the cornea more readily. It is essential that the aqueous humour be retained till the forceps are closed, hence the necessity of the patient lying down. Should it have escaped prematurely, the forceps must be withdrawn, and the operation delayed.

Slight adhesion to the iris does not prevent extraction. The capsule should be withdrawn to a sufficient extent and a portion of it cut off, the remainder being allowed to stop in the corneal wound. Or the whole may be drawn out till a bit of the iris appears externally, when the two should be disconnected by a snip of the scissors, the iris being spared as much as possible.

Partial separation is better suited when the capsule is much detached at one part of the circumference, and the free edge of which lies across the pupil. The operation should be done with a needle. Some portion of the capsular attachment must be retained. If the operation do not succeed, extraction ought to be resorted to.

The capsule is of less specific gravity than the aqueous humour, even when it is opaque, and always has a tendency to float into the pupil; therefore it is better, when practicable, to detach it below rather than above, so that it should float towards the upper part of the eyeball, and out of the field of vision.

If the capsule should become quite detached during the attempt at partial separation, it must be extracted.

But the capsule may be so disposed that it is better not to attempt separation at a part of the circumference, but rather to tear through its centre.

Obstruction by anterior capsule after the several operations for lenticular cataract.

Treatment. Laceration is then the most appropriate plan. This may be done with one needle. The instrument should be introduced about a line and a half from the sclerotica, carried across the pupil to the opposite side, pushed through the capsule, and the stem depressed so as to effect a rent. A second attempt at the laceration, or even a third, may be required to effect the aperture, this depending on the density of the capsule. The method is most applicable when the capsule is least thickened.

The vitreous humour may be spared injury by passing the needle

vertically rather than backwards; but if the posterior direction be absolutely necessary, it must be adopted.

When the capsule is dense one needle will not suffice, and two must be employed, and the rent made by their simultaneous action. They are to be passed a little obliquely through different parts of the cornea near the margin, and made to enter the capsule at the same point, or as near as possible, and the operation completed by the separation of their points. By this, there is no drag on the vascular parts, and the only tissues which are touched the cornea and the capsule itself. One of the needles may be made to furnish a fixed point of resistance, from which the other can be used with advantage. It must be obvious that by this measure various manipulations may be exercised, according as circumstances may demand. A band or bar may be twisted once or twice round the needles and broken through. It is material that the aqueous humour be retained during the operation. Besides the greater facility thereby ensured for the manipulation, the vitreous humour does not burst through the pupil, and stretching of the iris is avoided, and inflammation less apt to ensue.

The vitreous humour should not be punctured unnecessarily deep, nor unnecessarily broken up when the capsule is attached posteriorly.

Mr. Bowman, who introduced the method, insists that the needles "should be cutting for a twentieth of an inch at the spear point." He means that they should be sharp.

More than once it has occurred to me that the capsule has separated in a mass at the first endeavour to form a central aperture. Extraction should follow such an occurrence.

It is always safer for the eye to make the aperture in the capsule than to tear the capsule away from its connections, as this tears the ciliary processes, and may produce hæmorrhage into the vitreous humour.

Laceration is applicable when the capsule is more or less adherent to the iris.

The capsule may be disposed in a ring with an aperture, but an insufficient one. In such a case, laceration with the two needles may suit best.

A bar of capsule across the pupil is a troublesome disposition, because it is always associated with capsule at the circumference, which is generally dense and very adherent. It is rarely, indeed, that a cross piece, however slight, can be torn through by pressure with a needle, even though it be attacked through the sclerotica. The two needles might be used; or division effected

with an iris knife, especially if there be adhesion of the circumferential portion to the iris.

I have extracted such bars on several occasions with the sharp capsule forceps. The following case is in point:

A soft cataract had been removed by solution. Several attempts had been made to cut through two bars, without success, for under pressure they sank into the vitreous humour, from which they sprang unaltered to their former place; and the eye, unfortunately the only available one, remained with this impediment to vision. As they were very thin, and the capsule around very dense, and the iris free, I used the sharp canula forceps, and succeeded in twisting them off. Fig. 266 illustrates the eye before the operation.

Fig. 266.

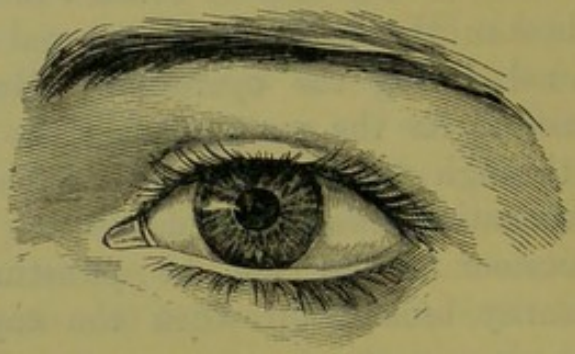

The second representation is from the eye of an adult who had undergone the operation for solution under the hands of a late distinguished surgeon. When the iris was in a natural state, the eye was nearly useless from the obscurity of the pupil.

It was a question whether the sharp forceps were applicable; however, they were used, and successfully: the broad but thin central piece of capsule came away, and the ring that remained was quite out of the way, when the pupil was undilated.

Fig. 267.

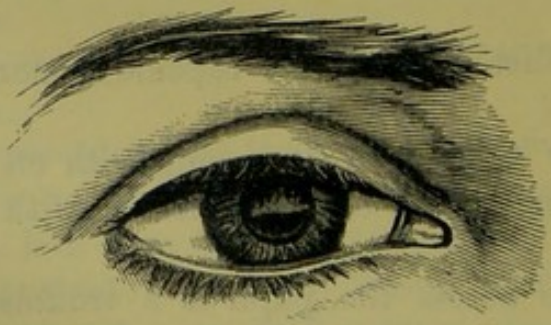

If the capsule be not much thickened, a central aperture may be made with the second-sized iris knife. If much thickened, it will sink before the point of the sharpest knife; and if attached to the iris, probably tear it from the choroid.

A pupil which is quite closed by capsule, falls under the classification of treatment by artificial pupil.

Obstruction by posterior capsule, which is unbroken, or disposed in threads.

A sufficient aperture may be made in the first instance by tearing the capsule across, with the needle passed through the sclerotica, so as to afford more leverage. If it be contracted, extraction may be applicable.

In the second instance I have always succeeded in clearing an aperture with one needle. If hæmorrhage within the eye should arise before the operation is finished, further proceedings must be delayed.

In many cases in which capsule needs removal, the operator must rely on his judgment and knowledge to select and to apply that operation, or the combination of such operations, as may seem most desirable to effect his object.

When the pupil has been so reduced that, even if tolerably cleared, there will scarcely be enough space for the passage of the light, the case is a proper one for an artificial pupil.

Capsule partially detached, or torn through, may not readily roll up. I have seen instances in which it remained unchanged for two months, and even more, but then contracted.

After an operation the pupil should be kept dilated till all chance of adhesion has passed away.

Inflammation often follows these operations, and when the capsulo has been cut or torn it may, by uniting the divided edges, render abortive all that has been done. It may do more than this by damaging the eye.

As a final remark I may say that extraction of capsule, except with the sharp canula forceps, is always attended with risk to the eye, and should not be undertaken when the capsule may be treated by some of the other measures which I have given.

REMOVAL OF SOFT CATARACT BY SUCTION.

The sucking out of an opaque lens is among the oldest of the operations for cataract on record, for we learn that it was practised by the Arabians in the fourth century. It has fallen into disuse and has been revived many times. M. Blanchet practised it during the present century. He cut the cornea with a large cataract needle, and introduced a sharp-pointed tube, with which he punctured the capsule of the lens. He then attached an Anel's syringe to the tube, and pumped out the opaque material.

To Mr. T. Pridgen Teale is due the merit of again introducing the operation. The instrument which he advocates for the purpose, and calls a "suction curette," is in principle precisely similar to one which had been previously invented by Mr. Greenway, of Plymouth, and described by him in the "Medical Times and Gazette," 1860, for the purpose of making an artificial pupil.

The impression which I received respecting the operation from cases which came under my notice was unfavourable. As it was possible that the failures were due to inefficient operating, I wrote to Mr. Teale, and asked him to be kind enough to give me some facts connected with his instrument, and the method of using it, together with any circumstances which bear on the subject. He promptly sent me a communication, which I append a little condensed, together with the accompanying woodcut.

Suitable cases. All full-bodied complete cataracts in persons under the age of forty. Herein are included cataracts spontaneously formed; diabetic cataracts, a most favourable class; traumatic cataracts, in which, from the rent in the capsule being of moderate extent, the eye remains quiescent until the cataract is entirely developed; in complete cataracts, which have been rendered complete by the careful puncturing of the anterior capsule.

Unsuitable cases. Incomplete or immature cataracts, in which portions are transparent and glutinous, and would require great suction force to draw them into the curette; traumatic cataracts in which the eye is in a state of excitement, or involved in iritis, or where there has been rupture of the posterior capsule, or in which from lapse of time the bulk of the cataract has been so far reduced that the anterior and posterior capsules are almost in contact. Cataracts which are congenital, or have formed in early life, or are of traumatic origin, and have undergone wasting and calcareous degeneration.

Instrument. The glass stem, five inches in length, allows the operator to watch the progress of the suction. The india rubber tube, eleven inches in length, and furnished with a mouth-piece, allows the operator to apply the suction either with considerable force, or with the most exquisite gentleness, and to use his tongue as a piston under the most perfect control.

The tubular curette is the most critical portion of the instrument, and the one in which deviations from a correct form are most liable to lead to disappointment. My original idea was taken from the old-fashioned curette used in flap extractions. This was roofed in so as to form a tube with a small opening near its extremity. In size and curve, the original was all that could be desired, but it has been improved by being shortened to five-eighths of an inch, and by being

slightly convex on its upper surface, instead of being flat, the whole calibre occupying an opening in the cornea no larger than would be required for the common curette. The point should be as round and blunt as possible, and the opening in the upper surface should be in size equal to the section of the tube, and as near to the extremity as the required bluntness will permit. In the larger figure *A* represents

Fig. 268.

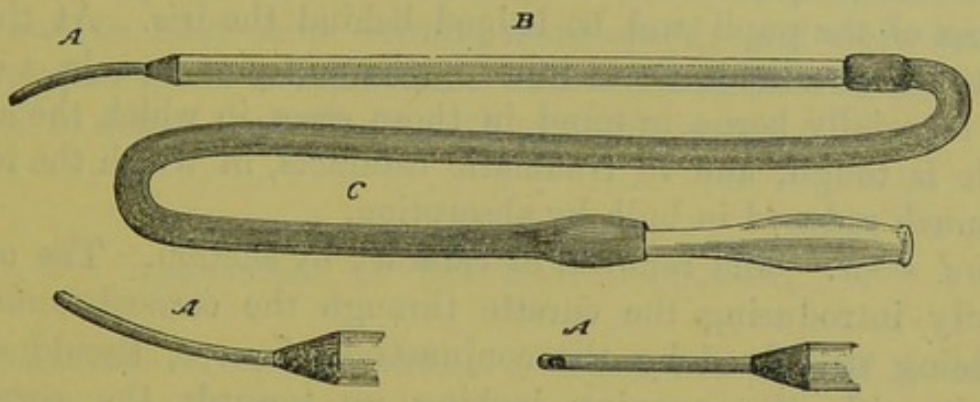

the curette, *B* the glass tube, *C* the india-rubber tube. In the smaller figures *A A* represent the curette in full size, in profile, and in front. A modification has been introduced into several instruments which has proved to be a serious defect. In order to facilitate the access of the lenticular matter to the opening in the curette, side notches were made in the margin of the aperture, thus defeating the cardinal point of safety, *that the cornea should act as a stop-valve*, when drawn down upon the flat margin of the orifice, and defend the iris and eye from the dangerous effects of prolonged suction. For a short period I used such an instrment, and was annoyed by the difficulty of avoiding injury to the iris.

Details of the operation. First stage. The pupil having been well dilated by atropine, and the eyelids fixed by the wire retractor, the eyeball should be steadied by conjunctival forceps in the left hand of the operator, whilst the opening in the cornea is made by a needle of sufficient width held in his right hand. The needle should enter the cornea at a point opposite the margin of the fully dilated iris, and passing obliquely through the substance of the cornea, should enter the anterior chamber at a point opposite to the margin of the pupil when of medium size. Such a valvular opening will provide that there is no scar in front of the pupil; that the wound is not so near to the attached margin of the iris, as to favour prolapse of the iris or adhesion of it to the corneal wound, and that the curette may not, when introduced, rest on or bruise the iris.

Second stage. Efficient rupture of the anterior capsule. This is perhaps, the most difficult and important part of the operation.

Sometimes Mr. Teale tears the capsule by two needles before making the opening in the cornea. On the whole, however, he thinks the best method is to effect a free opening with Graefe's cystotome passed through the opening made by the broad needle, care being taken to carry the instrument to the opposite edge of the pupil before making any breach in the capsule, for the simple reason that the object of this step is not merely to liberate the cataract, but also to ensure such a tearing up of the anterior capsule that it may curl back from the area of the pupil and be lodged behind the iris. At the same time he endeavours to avoid injuring the posterior capsule, a caution to be especially borne in mind in those cases in which the anterior capsule is tough, and in traumatic cataracts, in which the lens has been much reduced in bulk by absorption.

Third stage. The removal of cataract by suction. The operator carefully introducing the curette through the corneal wound, the eye being still fixed by the conjunctival forceps, should steadily hold it with the opening looking up towards the cornea, in the area of the pupil, and gently bury it in the opaque material, by pressing the convex surface, not the point, backwards towards the posterior capsule. The suction power should then be carefully applied, and continued gently as long as opaque matter comes forward into the pupil. When all is clear, the curette may be withdrawn, and the eye gently rubbed through the upper eyelid, which will bring into the pupil any remains of cataract that may have been lodged behind the iris. The curette must on no account be swept either in front or behind the iris in search of portions of cataract. If the suction be continued after the cataract has been removed, the cornea is drawn down upon the opening in the curette, blocks it up, and thereby arrests the suction before the iris can be drawn into the tube and so injured. In the more tenacious forms of cataract, considerable suction power must be exerted.

General conclusions. "If the operation have been efficiently performed, it will be found that the cataract has been completely withdrawn from the eye through an opening no larger than would be required by the common curette, without rupture of the posterior capsule, and with such complete division of the anterior capsule that it has disappeared completely behind the iris. It will also be found in such cases that recovery is most speedy, that the operation is followed by little or no irritation of the eye, that the patient in a week or less can read No. 1 Jaeger, and that the conditions which usually produce opacity of capsule, and demand secondary operations, have been guarded against. In one of my cases, the patient could read

No. 1 Jaeger immediately after the operation. Several others have been so well on the third or fourth day that they could return home into the country. Very few cases have required secondary operation for opaque capsule. I have rarely seen the operation followed by destructive inflammation; never as far as I can remember where the cataract, on the posterior capsule, has been in good condition.

"I am firmly convinced that within certain limits extraction by suction can be made more certain, more speedy and more brilliant than any other mode of removal of cataract, and that we are now in a position to define those limits with tolerable accuracy."

TREATMENT OF TRAUMATIC CATARACT.

This demands a separate notice. When the lens of a child is wounded, or that of a young adult, and aqueous humour is freely admitted to the lens tissue, and the newly-formed cataract is not dislocated, absorption will, in all probability, proceed satisfactorily. The more the capsule has been torn, the quicker will be the absorption. Also the younger the patient, the more rapidly will the pupil be cleared, and the less the irritation from the swollen cataract.

Every means should be adopted that will tend to reduce any existing inflammatory action, and thereby favour absorption.

When some of the lens tissue is in the anterior chamber of the eye, or blocks the pupil, it would be unwise to interfere as a matter of routine, and in the absence of symptoms.

Cessation of pain in the eye, or the reduction of vascularity, is sufficient evidence that the eye is recovering from the injury; and as the vascular symptoms decline, so is the organ rendered more and more safe from any disturbance, arising out of any irritation from the cataract.

When an eye has been much damaged, and there is displacement of the lens tissue, it can scarcely ever be told in the first instance whether any existing suffering, or inflammation, arises from such tissue being in the chamber or not. Now, as much danger to the eye would be incurred by operating when traumatic inflammation is present, the prudent plan is to watch the case, and to be guided by its course.

If from the amount of broken lens in the chamber, or from the swelling of the lens, pain should come on, particularly of a neuralgic character, either in the eye, or in the head, the broken lens tissue, or

the opaque lens, must be removed. The necessity for thus operating, will increase after puberty with the age of the patient, because the lens gets firmer in all its parts, and the denser centre of it will act more injuriously, if it gets dislocated.

To extract soft lens tissue the grooved needle recommended by the late Mr. Walker, is very effectual.

The following sketch shows the instrument, delineating the groove through which the broken lens escapes; but it is a little smaller than the original. I keep a second instrument which is much larger.

Fig. 269.



To execute the extraction. The pupil should be fully dilated, and the needle passed through the cornea and well behind any dislocated soft matter, which will readily gush out, or enough of it to give relief, through the groove, along with the aqueous fluid. A soft cataract in position, which has been more or less macerated by the action of the aqueous humour, may, if it seem to irritate, be sufficiently reduced by this instrument. In such a case it will be necessary to pass the point through it, and a little into the vitreous humour.

When the nucleus of a lens is dislocated and produces irritation, it should be extracted.

If the nucleus were so situated in the posterior chamber, that the removal of a bit of the iris by excision, would facilitate its extraction, a portion must be sacrificed.

When the lens becomes opaque from an injury without the eyeball having been wounded, or when the wound which causes it to be opaque, may be very slight, scarcely more than penetrating the capsule, which heals quickly, the case must be treated as one of ordinary cataract.

In addition to the arguments which have been used in favour of operating when only one eye is affected, must be added, that this cataract is particularly prone to set up that irritation which engenders sympathetic ophthalmitis.

Secondary, or capsular cataract, which may ensue, offers no peculiarity for treatment. It is more likely to occur as the patient is older.

The frequent complications of traumatic cataract with other lesion

of the eye, to which I have before alluded, is always to be expected and looked for.

Spectacles are required after the removal of cataract. At p. 262, under the head of Cataract Spectacles, will be found instructions for their selection. Only one remark is necessary. After the operation for extraction, the form of the cornea is nearly always altered. It is irregular, an effect of the healing of the wound.

Acquired abnormal regular astigmatism is produced in a greater or lesser degree, and accordingly interferes with the acuteness of vision. The remedy is the use of a spherico-cylindrical lens. Rules for discerning the astigmatism, and selecting the lens, will be found in the chapter on the Anomalies of Accommodation, &c. That the disturbance is not usually of any practical moment, I conclude from the sufficiently perfect sight my patients obtain with spherical lenses alone, for I have met with no difficulty in the matter, and I must confess never to have employed any others.

SPONTANEOUS DISLOCATION OF THE CRYSTALLINE LENS.

The lens is found more or less moved from its position in children and young persons, without any apparent co-existing disease of the eyeball, except occasionally, tremulousness of the iris, which is, no doubt, an effect of the troubled lens.

The condition must be referred to a congenital origin. All the evidence points in that direction. There is the discovery of it in childhood; its symmetrical existence; arrest of the development of the lens; myopic formation of the eyeball; hereditary influence, as recorded by Mr. J. Dixon, a mother and her three sons having been so affected. But what is the precise nature of the cause we have not discovered. If it occur in fœtal life, as I suppose, it must be late, because the lens does not seem less in size than that of a child of full growth. Of course the lens does not grow after its connections are more or less destroyed. Should it cease to grow with the rest of the eye, there must be stretch and strain on the zonula, together with some separation, and the adhesion between the posterior capsule and the hyaloid membrane, must be likewise interrupted. Some unknown circumstance would determine the direction in which the separation would occur. Arrest of development, or of growth, would account then for the dislocation.

Symptoms. The deformity is generally recognised in childhood, in consequence of some degree of defective sight. The degree and the nature of the defect will depend on the amount of the dislocation.

The subjective phenonema might be passed over, except that they

should determine the treatment to be adopted. Accommodation is lost, because the lens cannot be acted on by the ciliary muscle. Objects may appear confused, or broken, on account of some of the rays of light reaching the retina through the lens, and some by the side of it. Sometimes the prismatic effect of the lens causes them to appear double, or farther multiplied. When the pupil is contracted, and the free edge of the lens is covered by the iris, vision may appear to be myopic, but that it is not so, is proved by concave glasses not giving any benefit. It may seem also to be astigmatic. If the pupil be dilated and the edge of the lens is uncovered, so that light reaches the retina without passing through the lens, vision will be hypermetropic.

The objective phenonema are unmistakable. The lens is usually displaced upwards, and inwards; it, however, may be twisted in any direction, or quite turned. This includes slight displacement within the ciliary processes, with the maintenance of much natural attachment, and removal from the optic axis, with complete separation of all natural attachment.

When the lens is transparent, the edge which is forwards, appears as a dark curved line, or crescentic shadow, after the manner shown in this sketch.

Fig. 270.



The lens may be partially opaque, of which the usual manifestation at first is in marginal striæ.

It is clearly ascertained that transparency may remain for some years, during partial attachment. Opacity comes at last, but proceeds very slowly, and ultimately capsulo-lenticular cataract is formed.

A few more words about the ophthalmoscopic appearance. Behind the lens will be a red field, which is the fundus of the eye not in focus, because the lens is the object looked at.

If there be sufficient dislocation, and the pupil be dilated, the optic disk will be seen in two ways, the one through the lens distinctly, the other by the side of it, indistinctly and larger.

Treatment. Three things are to be considered: The expectancy of the case; the state of vision; the general condition of the eye.

By expectancy is meant, the fate of the eye if left alone; what may happen if nothing is done. The abortive misplaced lens may

remain transparent for years, if the displacement be simply eccentric, slight, and not more than the mere physical defect produced by the growing of the rest of the eye. Of course there is always the contingency of increased luxation by any force acting on the eyeball. Displacement, therefore, alone, would not in itself be a good ground for interfering. I am justified in saying, "the abortive lens," because such has been proved. A lens extracted by Mr. Bowman from a man twenty-two years of age, proved to be "too small and too convex, very like the lens of a young child." Of another patient eighteen years old, he writes, "the lenses are seen in about the upper two-thirds of the pupils, being displaced upwards, as well as too small and false in shape. For the lower margins, instead of being regularly curved, present several sinuosities."

Slight imperfection of sight would not justify any treatment, except that to be derived from optical appliances. The near and the far point should be ascertained, the field of vision tested, and lenses tried, while the pupil is natural and dilated. If a patient can see sufficiently well to enable him to be fairly educated, or to follow any occupation by which he can get his livelihood, without the use of a lens of any kind, or with it, I am quite sure that nothing should be done. This advice has been twice acted on by the parents of two children, about whom I have been consulted. But if from the nature of the displacement, or from the lens becoming more or less opaque, useful sight is lost, treatment for removal of the lens is imperative.

Again, if there be evidence in the general condition of the eye of inflammatory disturbance, arising out of irritation from the displaced lens, not a moment should be lost in ridding the eye of it, because destruction of sight would most assuredly follow. An overgrown girl of thirteen was brought to me with staphyloma of the sclerotic coat completely around and close to the cornea, enlargement of the cornea, with semi-opacity, much pain, extinction of vision, and general redness of the left eyeball. Her sight had been defective from childhood. While endeavouring to ascertain the cause of all this, an opaque capsule enclosing the lens passed forward into the anterior chamber. I now learnt that for some months this opaque body had been observed to pass from one chamber of the eye to the other. It was at once apparent that all the morbid action was produced by the irritation of the dislocated part. As the other eye was suffering from supposed sympathetic implication, I examined it carefully, and its lens and capsule, quite opaque, were seen reclining backwards in the vitreous humour, but yet retaining a slight attachment to the lower portion of the suspensory ligament. The necessary operation on the right eye, that of extraction of the lens, was followed

by a cessation of all irritation. The smallness of the lens was a matter of general remark by those who were present. The parents of the girl would not allow the other eye to be touched. Here were evidently the effects of a lens which had become quite loose after congenital partial dislocation.

It has been suggested as palliative treatment for the defective sight, to perform the operation of iriddesis on the side of the eye from which the lens has slipped, so that a pupil may be formed under the margin of the cornea, where there is no lens. According to the theory of this, the patient would see, as one who has lost his lens, and would require cataract glasses for near and for distant objects. I have not any practical knowledge of the operation, and I very much question whether the practice would be as good as the theory, whether there would not be disturbing optical causes, arising out of the presence of the lens which would too much interfere with vision to render it useful. Besides this, if the lens were to get farther displaced, and to set up irritation in the eye, its removal could not be accomplished without such complexity in operating as would render success very questionable.

For the removal of the lens, whether opaque or not, the operations for solution and extraction are applicable, but the latter is the more generally demanded. As a rule, the former should be chosen, only when the lens, whether clear or semi-opaque, or quite cataractous, yet retains much of its attachment, so that the absorption may be conducted *in situ*. But with all care in operating, complete dislocation is apt to occur, and if that be escaped, the empty capsule may separate and need extraction. The only case in which I so operated, success ensued. I beg my reader to see what I have said relating to this matter under the head of Dislocation of the Crystalline Lens, in the chapter on Injuries from Mechanical Agents, p. 428.

The manner of performing the operation for solution, and for extraction, under the unusual circumstances, is given in the chapter on Cataract.

CHAPTER XXXI.

AFFECTIONS OF THE CONJUNCTIVA, AND OF THE SUB-CONJUNCTIVAL AREOLAR TISSUE.

SKETCH OF CONJUNCTIVITIS—SIMPLE CATARRHAL OPHTHALMIA—SEVERE CATARRHAL OR PURULENT OPHTHALMIA—PURULENT OPHTHALMIA OF INFANTS—GRANULAR CONJUNCTIVITIS—IDIOPATHIC ERYSIPELATOUS CONJUNCTIVITIS — PHLYCTENULAR CONJUNCTIVITIS — DIPHTHERITIC OR FIBRINOUS CONJUNCTIVITIS — CUTICULAR CONJUNCTIVITIS—AFFECTIONS OF THE SUB-CONJUNCTIVAL AREOLAR TISSUE.

KNIFE FOR DIVIDING CHEMOSIS.

(Fig. 271.)

Some of the affections which, in a strictly technical sense, should be included in this chapter, are described elsewhere with other affections, being grouped generically with them, or classed with accidents.

ANATOMICAL SKETCH OF THE CONJUNCTIVA.

The conjunctiva, sometimes called conjunctival sac, is a muco-cutaneous membrane.

The palpebral portion, that which covers the tarsal cartilages, consists of thick connective tissue layers from the skin, very intimately attached by areolar tissue to the tarsal cartilages. It is opaque and light rose coloured. It has small cylindrical papillæ to within half a line of the anterior edge of the eyelid. The epithelium is of the pavement kind. The surface is perforated by the fine openings of the simple glands in its texture.

The oculo-palpebral portion, called also the retro-tarsal fold, and the fornix, that which extends from the tarsal cartilage to the eyeball, is thicker than the palpebral, and but loosely attached to the parts behind by a rough net-work of areolar tissue. It possesses, therefore, much mobility. It has few papillæ, and is covered with pavement epithelium. The simple glands are large. There are apertures on it, leading from the racemose glands which lie in the sub-conjunctival tissue. These, from their resemblance in structure to the lacrymal gland, have been described as accessory lacrymal glands. Trachoma glands are occasionally found, sometimes solitary, sometimes in groups.

Fig. 271.



The ocular or sclerotic portion is thinner than the palpebral. It contains elastic tissue, and is loosely attached, except immediately around the cornea, by areolar tissue containing a little fat. It has neither papillæ nor glands. It is covered with a great deal of pavement epithelium, and which is continued uninterruptedly over the cornea, where it is remarkably delicate and smooth, and so adapted as to give a brilliant reflection.

Prolongations of the conjunctiva pass into the canaliculi and join the membrane of the lacrymal sac. The ducts of the Meibomian glands, and those of the lacrymal gland, are also entered by it.

The whole of the conjunctiva is very vascular, particularly the ocular and palpebral portions. The vessels are in two layers. The superficial arteries are from the vulva-orbital, temporal, facial and lacrymal branches. The deep are from the muscular arteries of the recti and oblique muscles, and the anterior ciliary branches of the ophthalmic artery. All these anastomose freely, especially around the cornea, and communicate with the sclerotic vessels. While the arteries are very small, the veins are large. The blood is returned by the ophthalmic vein to the cavernous sinus.

The sub-conjunctival arteries are derived chiefly from the ophthalmic artery, and anastomose freely with the conjunctive arteries.

During health and full nutrition of the conjunctiva, its blood vessels are scarcely apparent. In disease, they are always very marked.

The nerve supply is from the fifth cerebral nerve, and it is large. The palpebral portion receives the most twigs, hence its greatest sensibility, while the oculo-palpebral portion gets the fewest.

The conjunctiva undergoes much change from age. In youth it is very tough, nearly colourless, and shows but few blood vessels. Then it gets thinner and weaker. In old age it is very vascular, and so attenuated that it readily breaks when it is held by a pair of forceps.

SKETCH OF CONJUNCTIVITIS IN GENERAL.

Without some knowledge of the natural history of primary inflammation of the conjunctiva, its effects cannot be sufficiently understood, and treatment must be conducted under disadvantages.

The phenomena of increased redness, pain, augmented heat, the effect of hyperæmia, and swelling, due to effusion of serum the result of congestion rather than of enlargement of the blood vessels, are evidences of true inflammation, any one of which may be in excess of the other, or any the least marked. They are but the outset of the affection, the developing of it from some injurious stimulation of the tissues attacked. This is not necessarily in itself a spoiling or destructive process, for even when it has reached a high state, it may decline under treatment, or without it, and not leave a trace of any mischief.

Inflammation of the conjunctiva, in common with that of all mucous membranes, is attended by morbid secretions. This is indeed the most marked phenomenon. When it is mild, mere mucus or epithelial element is secreted. This scarcely mingles with the tears, but lies, as it were, rolled up, and may be drawn out in shreds. It is thicker and more transparent, the slower the inflammation proceeds. With mere vascular action, especially when quickly developed, the corpuscular element is greater. The mucous base is more turbid, and streaked by mucus and pus cells. Next follows in development a greenish-white or yellow discharge, from the preponderance of pus cells. The several products in the discharge are the same as those from other inflamed mucous membranes. At this stage of the disease there is interstitial exudation, serum is poured out, and liquor sanguinis with its albumen and fibrine, increasing with the intensity of the inflammation. Swelling must ensue. Hæmorrhage into the parenchymatous connective tissue is common, from rupture of the capillary loops. The nutritive activity of the cellular elements is increased by the addition of abnormal cell structures, the product of the inflamed tissues, as well as by that of the leucocytes. The swelling of all the inflamed parts increases till the inflammation has reached its height. The palpebral conjunctiva swells least, because it is closely bound down. The effect of tumefaction on the oculo-palpebral and ocular portions is very marked.

The colour of the hyperæmia varies according to its variety, that is, whether it is active and arterial, or mechanical and venous. And again, whether the conjunctiva alone be hyperæmic, or with it the sub-conjunctival tissue and the sclerotic coat. It is further modified by the condition of the epithelium, by which are produced tints of rose, or lilac, or yellow, or brown.

In a favourable termination the inflammation lessens, the conjunctiva becomes pale, wrinkled and soft, although the blood vessels remain enlarged. Afterwards, the interstitial inflammatory growths, the result of proliferation, disappear. The blood vessels contract, and the surface tissue, which had been morbidly affected by the inflammation, is either atrophied or thrown off, and normal epithelium is restored.

A reduction in the quantity of abnormal secretions is simultaneous with the reduction of the inflammation. The pus element declines, the mucous basis gets thinner and more transparent, until at last the normal conjunctival mucus is restored, and all parts look healthy.

Unfavourable terminations are not uncommon. Complete or incomplete degeneration of the conjunctiva, chronic catarrh, or hyperplastic conditions may ensue. Slightly marked, however, in the ocular, more marked in the oculo-palpebral, and still more apparent in the palpebral portion.

The several primary and secondary conditions must be examined in detail: for this purpose, on account of the range of symptoms, and also the treatment, grouping under heads is requisite.

SIMPLE CATARRHAL, OR EPITHELIAL OPHTHALMIA.

THE MUCOUS VARIETY.

This is the mildest and commonest form of conjunctival inflammation, and although it is generally seen in those persons who have disordered health, it may appear in any one, and at any period of life, from the earliest existence, to very advanced age. But it is most common in early life, and new-born infants often have it. It just reaches its height without inflicting damage on any of the ocular tissues or appendages, and when there is abnormal secretion, which is the rule, it is scanty, and consists of mucus, or of pus added to it in a small proportion. It involves the conjunctiva and its ramifications in the Meibomian ducts, the canaliculi, and the ducts of the lacrymal gland.

Symptoms, in their order of development. Itching. A sensation of sand, or dust, or grit in the eyes. The deception is produced by the sensitive palpebral conjunctiva rubbing against the enlarged and

projecting blood-vessels of the sclerotic portion of the same. Adhesion of the edges of the eyelids in the night. Redness of the palpebral, and reticular redness of the rest of the conjunctiva. The undue colour is not vivid, but like brickdust, or bluish, or it has a tint of lilac or violet. This is because the hyperæmia is conjunctival. The vascular network, which consists chiefly of veins, moves with the conjunctiva when it is raised or drawn from the eyeball. There are often many spots or blotches of extravasated blood deposited in the meshes of it, varying in size from a pin's head to the breadth of the cornea. Hæmorrhage is a common result of this form of hyperæmia. It may occur from the passage of the red corpuscles of the blood through the capillaries, or from rupture of them.

While the degree of the hyperæmia of the ocular and the oculo-palpebral portions of the conjunctiva is unmistakable, that of the palpebral portion is not so apparent. It must be judged of indirectly or inversely, by the extent to which the Meibomian glands are obscured.

The arrangement of the blood-vessels on the ocular conjunctiva is reticular or areolar. Fig. 272. But it might be obscured by chemosis, or rendered less definite by the co-existence of hyperæmia of the sclerotica.

Fig. 272.

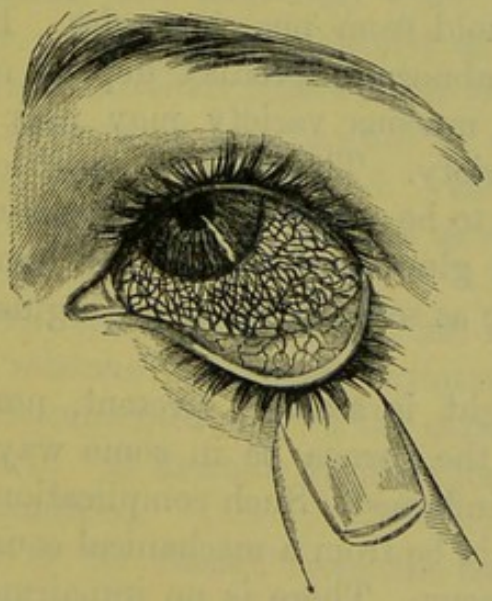

While thus speaking of this conjunctival inflammation in individual description, it must not be supposed that there is a definite line to the diseased action. Anastomosis of the blood-vessels renders this impossible. The vessels of the sub-conjunctival tissue particularly, and those of the sclerotica, are in some degree affected. When they are more than usually influenced, they may be readily discerned as being

deeper, darker, and lying in different directions to those of the conjunctiva. The student should learn to recognise them.

The conjunctiva swells. The palpebral portion is villous and irregular. This is due to the villi being engorged and turgid, and the glands being enlarged and prominent, from their increased activity. The oculo-palpebral and ocular portions of the same are thickened. This state must not be mistaken for the chronic condition of granular conjunctivitis. Irregularity of surface is a common effect of swollen mucous membrane. This is well seen in the pharynx, slight inflammation causing it to look very uneven.

Chemosis is very rare. It appears only when the inflammation is highest, is never very marked, and is always of the serous form. The conjunctiva never adheres to the cornea.

The ordinary lacrymal moisture is increased in the first instance. Then it stops, and its place is supplied by mucus from the inflamed membrane, and which has some corpuscular elements. The recent pus cells are partly emigrant white blood-corpuscles, and partly productions from within the epithelial cells, by endogenous multiplication. With the increased proliferation, some of the proper tissues of the part are destroyed, and are discharged with the mucus. The mucus glands give a freer secretion. The discharge gets thicker, and is whitish or yellowish. Later it may take on more of a purulent character from the greater number of the corpuscular elements. Most of these cannot be told from pus corpuscles. But the quantity and the quality of the abnormal product depend on the extent of the inflammation. The mucous variety may pass its bounds, and go into the purulent variety. There may be a little mucus lying on the eyeball, just enough to be recognised, or it may collect in quantity about the cilia, and glue them together in bundles, or it may be so purulent and profuse as scarcely to be distinguished from mild purulent ophthalmia.

Intolerance of light is scarcely present, nor is there increased lacrymation unless the cornea be in some way diseased or injured, or the sclerotica be inflamed. Such complications are extremely rare, unless the ophthalmia be from a mechanical cause.

Pain does not occur. There is no impairment of vision beyond what is caused by the secretions passing over the cornea, and forming a semi-opaque medium or cloud which obscures the sight; or some peculiarity of refraction, such as prismatic colours, or distortion of objects, which are due to alterations in the corneal epithelium.

The active pupil and the acuteness of vision declare the eyeball to be sound. So long as the visual power is unimpaired, we are sure that the redness is surface action, and chiefly conjunctival.

There are scarcely any constitutional symptoms, unless the mucous membrane of the nose and that of the frontal sinuses participate, when there is generally catarrhal fever, with headache, heat, chills, a foul tongue, impaired appetite, and perhaps sickness.

Both eyes are usually attacked, not always at the same time; and if separately, the second is involved just as the other is getting well.

Whatever may be the degree of the symptoms, they are usually more marked in the evening, but decline when the patient retires to rest. Sleep is not interfered with.

In very severe cases, the eyelids participate in the inflammation. It is then only that an appreciable elevated local temperature occurs, but it is of short duration.

Mild catarrhal ophthalmia. In this, which is usually described as slight inflammation of the conjunctiva, the symptoms of ophthalmia are not fully developed. There is slight hyperæmia and a sensation of grit in the eye, with itching, stiffness, and heaviness of the eyelids, as if they cannot be kept open, with or without adhesion of their edges at night. But only the palpebral, and the oculo-palpebral portions of the conjunctiva, together with that over the caruncle and the semilunar fold, are slightly swollen. There is no appearance of mucus, or there may be exceptionally, but a shred or two lying in the lower conjunctival sinus, and seen only when the eyelid is pulled from the eyeball, or a little of it collected at the inner canthus, in a fresh state, or dried into little yellowish or brownish crusts. The symptoms are much aggravated by exposure to wind, especially cold wind, and then lacrymation is produced. It is usually chronic, attacks persons in ill health, and is difficult to cure. Extravasation of blood may occur.

Diagnosis of catarrhal ophthalmia. Only one observation is necessary. It is, not to mistake the direct irritation produced by the presence of some extraneous substance in the cornea, or on some part of the conjunctiva, for it. If there be grounds for any doubt, the eye should be carefully examined.

The usual duration of the disease, from the commencement to the end, under treatment or without, is from three or four to ten days, and in severe cases from a fortnight to three weeks. When untreated, or when the exciting causes are not removed, it may last as a chronic affection for many weeks, or even months. Then the discharge becomes more purulent, perhaps altogether purulent, the conjunctiva thickened and granular, and the cornea inflamed. Febrile symptoms may appear.

Eczema palpebrarum may be a sequel.

The disease is apt to recur.

The causes are primary and secondary.

The primary are the more common. They include the intrusion of an extraneous substance. The inversion of eyelashes. Surgical operations on the eyeball. Anything which irritates the conjunctiva or the cornea. So far they are mechanical.

Foul air, with excrementitial exhalations. Smoke. Fumes from chemical works. Crowded rooms, with dusty occupations. Keen winds. Draughts of cold air. Wet clothes. Wet feet. Permanent exposure of the conjunctiva, from disease of the eyelids, or protrusion of the eyeball.

As organic influences, straining the eye by long employment on minute objects, especially by artificial light, and more especially if there be unrelieved presbyopia or hypermetropia.

To these must be added, in the case of new-born children, the irritation of the conjunctiva by various substances with which they are sometimes washed just after birth, such as soft soap, spirits, etc.

The secondary, arise out of the anatomical union between the conjunctiva and the surrounding parts, whereby inflammation of the mucous membranes of the lacrymal and the nasal regions, reaches the conjunctiva by continuity. The inflammation of the facial integuments from erysipelas, impetigo, eczema, and other cutaneous affections, including measles, scarlet fever, and small-pox, is thus conveyed. Also extension of inflammation from any of the tissues of the eyeball.

Catarrhal ophthalmia is occasionally epidemic, attacking numbers of persons, and, it may be, a large proportion of the inhabitants of towns or of rural districts. I have seen several epidemics of it in London during the spring months, and a very marked outbreak occurred in the summer in London a few years ago.

That it is infectious, is certain. I use the term "infectious" as including that of contagious. When one member of a family is affected the rest usually suffer, and very often other persons of the household. The infection of the one after the other, from the importation of the disease by a visit from one who has it, when there is no epidemic, proves the truth of its being conveyed from individual to individual. It is in this manner that the disease continues for years in public institutions.

In the year 1861 I was asked by the guardians of the Central London Union to visit the Central London Schools, at Cuckoo Farm, near Hanwell, where the disease had existed for several years, I think over eight, and to suggest means for its suppression. I made a careful

report. The new comers were nearly always attacked. I examined over two hundred children, who were in different stages of the disease. The inflammation was of the usual form, and was in no way intensified by its long propagation, nor was it complicated. Without an exception, the morbid action was confined to the conjunctiva. In several instances there co-existed other ophthalmic diseases, as corneitis, etc.; but I ascertained, without doubt, that they were antecedent affections.

Treatment. If the exciting cause be removed, the inflammation will nearly always decline under the influence of local cleanliness, and still quicker with the advantage of lessening suffering, under very simple treatment. This treatment consists in frequent fomentations, the use of astringents, rest to the eye, confinement to the house in cold weather, and if there be a marked mixture of pus with the mucus, when there are usually febrile symptoms, then confinement to the house regardless of the weather. Attention to any disordered constitutional states, be they those of depression or otherwise. The state of the general health may render a person liable to repeated attacks.

As the physiological temperature is not increased in any ordinarily recognisable degree, and as the period of inflammatory irritation is very short, and has generally passed away when we are consulted, antiphlogistic measures are not wanted. It is with the condition of relaxation of the mucous membrane that we have to contend.

It is difficult to point out the superiority of any one drug, as an astringent, over the many which are available in the organic and inorganic preparations of our Pharmacopœia. Whichever be selected, it should be diluted till it does not give pain, nor even decided smarting, or else harm rather than good will be produced. Detrimental practice in this direction is most likely to occur when the nitrate of silver is used. I believe alum to be as efficacious as any. I prescribe two or three grains of it to an ounce of distilled water, and direct a drop or two to be applied to the conjunctiva after each fomentation with hot water alone, which should be made thrice, four times or oftener during the day, according to the urgency of the symptoms. Besides the beneficial effect of the heat, the fomentation cleans the conjunctiva, and prepares it for the astringent. My detailed instructions are, to saturate a camel or sable hair brush with the lotion, and to discharge it at the outer corner of the eye, by depressing the under eyelid and drawing the brush across the tarsal edge. Afterwards, with the brush again charged, to wet the tarsal edges and the inner corner of the eye. There should be a change of drug, if that first employed do not produce a sufficiently quick result. The treatment should not be

continued too long. When the inflammation begins to decline the lotion ought to be used less frequently, and stopped as soon as the patient feels that the severity of the attack is over.

It may be necessary to grease the eyelids at night to prevent the discomfort of their sticking together. I employ warm mutton suet.

A case attended with very active symptoms should be treated as one of mild purulent ophthalmia.

When the inflammation is spreading by contagion, the diseased subjects should be isolated until the inflammation and its effects have passed away.

If the disease should attack an eye which has another complaint, other measures may be required, according to the symptoms arising out of such complication.

If in the mild chronic cases of the disease the above treatment be unavailing, there is probably some unhealthiness of the body which needs to be removed, before the ophthalmic symptoms will decline.

SEVERE CATARRHAL, OR PURULENT OPHTHALMIA. THE PURULENT VARIETY, AS IT OCCURS IN ADULTS. OR PURULENT OPHTHALMIA OF ADULTS.

This is a more severe or intensified form of the disease than the epithelial variety, being more of an exudative inflammation, and apt to damage the eye, or even to destroy it.

It is common and most severe in hot climates. When it occurs in temperate latitudes, it is more acute in the army, in the navy, in workhouses, in prisons, and in pauper schools, than in private life.

Development of symptoms. There is at first, itching and dryness about the eye, particularly in the inner corner. Suddenly, there may be a sensation of dust or sand being in the eye. The tarsal edges are stuck together in the morning, the eyelids are a little puffy, and a thin secretion is seen on the surface of the eye. The palpebral and oculo-palpebral portions of the conjunctiva, the caruncle, and the semilunar fold, are swollen and inflamed. Any of these readily bleed. The ocular conjunctiva is reddened. This, the purely inflammatory stage, may last only twelve hours, and it rarely exceeds thirty. It may be so mild and short as to be disregarded. Considerable mucous secretion, yet thin but viscid, and becoming semi-opaque, soon follows. It accumulates at the inner corner of the eye. It may be coloured with blood. Till now there is scarcely more than inflammatory mucus, which curdles. Pus forms in more

or less abundance, so that the secretion is suppurative, and the mucus and the pus are dissolved in the tears. These secretions overflow and pass down the cheek, which is soon irritated and reddened. The palpebral conjunctiva swells more, and looks sarcomatous and velvety. The ocular conjunctiva is now decidedly inflamed. It is dark red, and the individual trunks of vessels are no longer seen. The eyelids are more swollen, and their edges are a little everted. The temperature of the conjunctiva, and of all the ocular appendages, is much increased, and continues high until the period of relaxation occurs. There is pain also, hot and scalding, like that of cutaneous inflammation, which lasts while the inflammation is sthenic. It may extend to the temple and the forehead, when it is more of a neuralgic nature. There is a copious incrustation about the margin of the eyelids, and the cilia are matted together.

The intensity of the inflammation may decline, while the purulent discharge continues for weeks or months, and produces but little suffering, although much discomfort.

Both eyes may be attacked at once, or the one after the other. When one is affected it is generally the right.

A worse state of things may ensue, by the ocular conjunctiva getting more inflamed, with the addition of spots of extravasated blood in it, and raised by chemosis, which more or less overlaps the cornea; it may almost conceal it, and even protrude beyond the eyelids, standing out to the extent of three-quarters of an inch. Now, this chemosis arises from two causes, inflammatory infiltration of the conjunctiva itself, and inflammatory infiltration of the sub-conjunctival tissue by pure inflammatory effusion, liquor sanguinis, the amount of which varies with the intensity of the inflammation. I speak of it as hard chemosis, to distinguish it from the soft chemosis of the mucous variety of the disease, the result of serous effusion. It is most marked at the lateral sides of the eyeball, where it is scarcely pressed on by the eyelids. Hard chemosis, therefore, is indicative of a very high degree of inflammation of this part of the conjunctiva, and which inflammation generally spreads to the areolar tissue of the orbit, together with the tunica vaginalis oculi, so that the eyeball is a little protruded. The secretion is more decidedly purulent, and very profuse. The eyelids swell more, and the upper is so enlarged as to overlap the under one. It is very prominent, very red, and shines. Such tegumentary effect may not be developed for days, or it may rise up within a few hours. The disease is now at its height.

Protruding conjunctiva always everts the under eyelid, but it may evert both; and the everting effect is still more decided when the tumefaction of the eyelids subsides a little. Its villous appearance

is never so marked as now. Whilst the tumefaction remains, the protruded part has its volume increased by serous and sanguineous effusion, through the partial strangulation produced by the eyelids.

So far the eyeball may escape being diseased. The purulent discharge may continue with little change for several days, till the chemosis declines, when it gets less purulent and thin. The chemosis may quite disappear, while the caruncle, the semilunar fold, and the palpebral conjunctiva remain vascular. The palpebral papillæ may have undergone morbid changes, called granulation, to be afterwards considered, which mechanically irritate the cornea, affecting its transparency and rendering it vascular.

Still more unfavourable effects may follow through the eyeball becoming secondarily affected by extension of the primary inflammation. This seldom occurs, without the pain extending to the head, together with intolerance to light, and blepharospasm. Such extension is the chief source of danger in the complaint, whereby the organ is much damaged or altogether spoiled for the entrance of light, mainly through morbid alterations in the cornea, a contingency never to be forgotten.

The cornea may, then, suffer by the direct action of many pathological forces, singly or combined. It may be rendered opaque, in part or entirely, by interstitial changes. It may be destroyed by softening and ulceration, incorrectly called sloughing, partially or entirely. A sub-acute abscess may form in any part of it, preceded or not by superficial opacity and much disorganization of the epithelium. Such an abscess usually bursts, by which the chambers of the eye are opened. But the corneal tissue over it may throw out herpetic efflorescence, followed by one ulcer or more. Or such ulcers may end in penetration in one or more spots, by which the chambers are opened. Its lower half may be opaque, while the upper is clear. Large transparent ulcers may form.

The cornea may be affected besides, I suspect, in consequence of its nutrition being impaired by the abnormal condition of the circulation, the condition of stasis. That the long contact of pent-up pus is most injurious to it, and causes superficial ulceration, cannot be doubted. Pus corpuscles seem to have the property of more or less absorbing the tissues with which they come into contact, or at least of causing softening and disintegration.

That it is influenced by the pressure of the swollen palpebral conjunctiva is very likely.

The tumefaction of the palpebræ, with the swelling of the integuments of the temple and of the cheek, by which the eyelids are closed, may prevent all attempts to inspect the eye.

Acute abscess is imminent. Pulsatory paroxysmal pain in the eye, more severe at night, or intense continuous pain, aggravated by pressure, extending as well around the orbit, and involving, too, the temple and the cheek, tends to show that the cornea has suppurated. Ulceration of it at the centre of suppuration, by which it is penetrated, and the chambers of the eye opened, is now certain, and this may occur according to the rapidity of the acute symptoms, from the third to the eighth day. Such an event is seldom longer delayed. That rupture has occurred is known by the patient feeling that something has happened, with the accompaniment of a discharge of hot fluid, aqueous humour. Immediate relief invariably follows, and the acute inflammation subsides.

Farther symptoms of this ophthalmia. If the breach which is made in the cornea from the abscess be large, the lens and its capsule may be seen, both quite clear. So much sight may be temporarily restored that the patient thinks he is getting better. The lens may be expelled by the natural pressure on the eyeball; and whether this happens or not, the iris always prolapses, swells into a reddish fungus-like tumour, and a total corneal staphyloma is formed.

There is a form of ulceration more imminent and dangerous than that which I have mentioned, not arising out of any inflammatory condition of the eyeball, for it occurs while the cornea is yet bright and vision is unimpaired, while the inflammatory symptoms are not high, and the purulent discharge not in excess, while pain has scarcely been felt, and constitutional symptoms have not appeared. It is a circular grooving ulcer, sometimes clear, sometimes with opaque edges and bottom, which forms at the margin of the cornea, from a fourth to a third, or even to half of its circumference, and nearly always penetrates, and damages or destroys the eye. It is, I believe, produced by hard chemosis, which invariably adheres to the cornea. Pus cannot, therefore, collect between the two, as is supposed. All of the ulcer may be hidden by the chemosis, and concealed till it is declining. Or a part may be covered, while a part extends a little beyond. When penetration ensues, the cornea flattens in about twenty-four hours, and the acuteness of the local symptoms subsides; but in a few days pus is deposited between its layers, and a farther protrusion of the iris takes place, before or after which occurrence the lens may escape. In any of the terminations of the disease in which the lens is lost, the vitreous humour may flow out sufficiently to cause immediate collapse of the eyeball.

Modifications in the degree, and in the severity of the developing symptoms, occur in different individuals, who may be suffering simultaneously

at the same place, from the same source of infection. This would seem to depend on the state of health of each when attacked, the sex, and the age.

The disease is more severe in those who are scrofulous, and as the age is nearer to that of puberty on either side. Females suffer more than males.

Cessation of objective symptoms. The swelling of the eyelids first declines, then the chemosis, and afterwards the ocular conjunctiva clears from behind to before, in patches, so that red and white spaces alternate.

The caruncle and the semilunar fold, the oculo-palpebral and the palpebral conjunctiva, remain long swollen and vascular, and unless well managed, may never completely recover.

The eyelids return to their normal state, or they may be damaged. The under one falling away a little from the eyeball, the effect of the inflammation on its fibro-cartilage, and relaxation of the orbicularis muscle. The upper one dropping from the weight of its infiltrated tissues, and the impaired action of the levator palpebræ, or altogether mechanically pushed down by the swollen oculo-palpebral fold. This is ptosis.

Relapse is a serious complication. The infiltration of the sub-epithelial connective tissue, with corpuscular elements, must be removed before the conjunctiva can return to its normal state. While some degenerate into fatty material, some are absorbed. Till this is effected, the membrane is readily affected by fresh sources of irritation, since the irritability of any part is in proportion to the elements it contains, which are prone to irritation. A very practical lesson respecting treatment is inculcated here. This explains the return of the discharge on slight provocation, such as exposure to inclement atmosphere, imprudence in diet, etc. Relapse is generally more obstinate than the primary attack, and lasts longer. Each succession adds to the infiltration. The epithelium and the glandular apparatus become thickened, and persistence of these conditions is chronic catarrh.

The destructive influence of the ocular inflammation may extend to other ocular tissues before penetration of the cornea ensues. The iris may inflame, and if through the swelling of parts it touches the cornea, it will adhere. The vitreous body, the retina, and the choroid may be partially or quite spoiled. The sclerotica may become softened, and, yielding to internal pressure, admit of enlargement of the eyeball. When the crystalline lens is present in association with these pathological changes, it becomes quite yellow.

The inflammation from the beginning, to its destructive effects on the eyeball, may have a course of from a few days to three weeks.

Constitutional symptoms do not generally appear till the local action becomes severe, so that they are never primarily developed. When they intensify there may be much irritative fever. If the cornea have been penetrated by either of the above-mentioned processes, a very debilitated condition of the system always ensues. There may be even alarming prostration.

Diagnosis. It is only necessary to point out that catarrhal ophthalmia is the sole affection with which purulent ophthalmia is likely to be confounded. In the former the inflammation appears simultaneously over the whole of the conjunctiva. In the latter it begins in the palpebral conjunctiva, and is for a time confined to it. Then the latter is of long standing, is subject to relapses, is attended by chemotic and palpebral swelling, with intense conjunctival inflammation, and a profuse purulent discharge, and the eye frequently perishes through affections of the cornea. However it must be admitted, if the mere attack of the two diseases be regarded irrespective of the whole history, that they differ more in degree than in kind, and that while a mild catarrhal and an acute purulent ophthalmia have very distinct features, a mild purulent and a severe catarrhal ophthalmia are not so easily distinguishable. In consequence of this it has been suggested to use the term blennorrhœa to the inflammation when the mucous element seems to prevail, and pyorrhœa when the pus element seems to predominate. We cannot make a practical difference. Fortunately one is not needed. Catarrhal ophthalmia does not run into purulent ophthalmia. I have never seen such progressive development.

Prognosis. This is one of the most dangerous of all the inflammatory affections to which the eye is liable.

While the cornea is yet clear, and the chemosis not very hard, and grooving ulceration is not present, there is hope of recovery.

A rapidly developing chemosis is the beginning of a very intense and wide-spread inflammation, and therefore foretells great peril to the eye. Early implication of the eyeball declares the same. Under such conditions complete recovery is most uncertain.

The healing of ulcers, and damage done by interstitial suppuration, leave opacities varying from the thinnest film to the densest leucoma.

Every form of prolapse of the iris must affect the integrity of the pupil by altering its size or position, or by closing it, and the scope for surgical relief turns on the possibility of making an available artificial pupil, and on the integrity of the retina.

Causes of purulent ophthalmia. The disease may occur from atmospheric causes, and be sporadic or epidemic. It would seem to have an intimate etiological relation with other miasmatic disorders.

It may be, and is usually, spread by infection. It may therefore arise without the application of morbific matter to the eye, but, when once established, it can be transmitted from person to person, under circumstances which cannot be distinguished from infectious propagation.

It may be produced also from mechanical causes, such as the irritation of the conjunctiva by foreign bodies, or from a wound of the conjunctiva rudely inflicted, as from the thrust of a stick.

It is not always that the application of the purulent discharge to a healthy eye, by design or by accident, will be followed by inoculation. The infection is most marked under such local circumstances as atmosphere vitiated by human effluvia, crowded and ill-ventilated dwellings, and absence of domestic comforts. The escape of some persons under the most probable favourable conditions for its development, is common to purulent ophthalmia, as well as all infectious diseases; none of which act uniformly and invariably on all who come within their range. The presence of the source of the infection is only one of the many conditions necessary for the production of the morbid phenomena. The health, and the state of the eye in the exposed person, and the surrounding influences, are no doubt equally important for the effects, although not well understood.

It appears, then, that the disease is chiefly endemic; that it is mostly chronic; very intractable; is irregular in its course; has a tendency to return; leaves indelible marks. In these respects it bears a strong contrast to catarrhal ophthalmia, which is mostly acute; is easily contracted; does not return without renewal of the exciting cause; and leaves no trace of injury.

Gonorrhœal infection. I mean by this, the development of purulent ophthalmia by infection from urethral pus. I recognise no other origin. Here intense symptoms quickly occur, whether the matter is derived from another individual, or from the person himself. The eye is exposed to far more danger than it is in ordinary purulent ophthalmia. The entire conjunctiva at once inflames. Chemosis quickly rises up, and is very hard. The eyelids soon inflame. The tissues of the eyeball are early affected. The cornea may suffer after the manner I have described above. It is particularly liable to the grooving ulceration. It may slough superficially, or through its entire thickness in this manner. Serous infiltration occurs. Coloration of a part or of the whole ensues, and its transparency is lost, while it yet shines. The vitality is destroyed, the polish is lost, and a yellowish or brownish piece separates by ulceration.

The rarity of the infection has always been to me a matter of marvel, considering the frequency of the chance of such.

Gonorrhœal ophthalmia is not to be readily distinguished from the purulent discharges of the conjunctiva excited by other means, especially at a late period of the disease, there being no very determinable pathological difference. It is one and the same kind of inflammation, only intensified. The diagnosis must rest on the history of the case. There may be strong suspicions of the gonorrhœal origin, but unless the patient has a urethral or vaginal discharge, or can give assurance of the probability of having received infection from some one, a decided diagnosis ought not to be pronounced. If a correct recognition can be made it is valuable, for we are then better prepared to treat this destructive malady. It is too, important to be able to tell the friends of a patient when his disease is such as to excite serious apprehensions. For these reasons, whenever a severe case of purulent ophthalmia is met with, inquiries ought to be made respecting its origin.

Treatment. The object is to check the inflammation, and so prevent any of its effects extending to the eyeball. If this be accomplished, there will be stopped also the usual damage to the conjunctiva, inseparable from the disease in full development, as well as the prostration of the vital powers.

Certain general and also hygienic measures are necessary. These are to keep the patient lying down, for the most part in bed, in order to obtain all the advantages of rest of body, such as the avoidance of excitement, quickness of circulation, and to secure the easier return of the blood from the eyeball and the orbit. To endeavour to procure pure air. To ventilate the apartments, but not to overheat them. To exclude bright light. To keep the patient's mind generally tranquil, and especially free from apprehension as to the fate of his eye.

For the more direct treatment, let it be supposed that the patient is seen at the commencement of well-marked sthenic attack. The indication is to reduce the sthenic action, which is chiefly manifested in hyperæmia, swelling, increased heat, and pain. The eye should be washed with tepid water, the eyelashes closely cut off, and the edges and both corners of the eyelids thoroughly greased with warm beef or mutton suet, or with any greasy application if these cannot be obtained, and the greasing repeated at least three times in the twenty-four hours. When a brush is not at hand, the end of a stiff feather will suffice. Blood should be taken freely from the temple by cupping or by leeching, and, if the latter, the bleeding encouraged by a hot poultice. A brisk purge is very salutary. A light nutritive diet, without alcoholic stimulants, is best suited. Wet cold should be applied over the eye, the temple, and the cheek, to diminish the afflux of blood and to reduce the exalted temperature, by means of a

single layer of old linen, wetted with iced or very cold water. When the water has evaporated, there should be a reapplication with a fresh piece of rag. On each of these occasions of renewal the eyelids should be opened, and the conjunctiva cleansed with tepid water. The nurse should be instructed to turn the patient a little on his side, to open his eyelids as far as she can, and to wash away the discharge with a syringe or an elastic bottle with a fine pipe, slowly, so as not to spatter, and to wash also under the upper eyelid. The tumefaction of the eyelids may require a retractor to be used in order not to expose the conjunctiva at all. A nurse could hardly be expected to do this. Cleansing may be done, less effectually, however, by moving the eyelids backwards and forwards, so as to press out the discharge, and then wiping the surface of the eye with a piece of rag.

Hard chemosis which is overlapping the cornea should be freely incised. I have very great faith in the measure. The operation may be readily performed by standing behind the patient, who should be seated on a low chair, raising the upper eyelid with a retractor, while an assistant depresses the under, introducing the point of the knife (Fig. 271) at the spot of reflection of the chemosed conjunctiva on the cornea, and carrying it along the sclerotica to the sinus of the eyelid; then depressing the handle of it, and including within the curve of the blade the swollen conjunctiva. I generally endeavour to make four incisions at equal intervals. The incising of the upper parts of the chemosis is not so readily effected as that of the under, since the knife cannot be carried so far on the eyelid; but it may be done by applying the retractor first on one side of the lid, to make room for the knife, and then shifting it to the other. The discharge should be wiped off, and the place for the entrance of the knife made apparent. With common care the sclerotica will be uninjured. It is so imperative to make these incisions thoroughly, that, unless there be a certainty of the patient being submissive, chloroform should be administered. Scarifications do not produce any after damage. When the chemosed conjunctiva protrudes between the eyelids, the exposed surface should be kept well greased.

At this stage, some surgeons recommend slitting through the eyelids near the outer canthus, from the tarsal edge to the margin of the orbit, to relieve the eyeball from pressure.

To protect the other eye from infection is as essential as to treat that which is diseased. The readiest method is to strap the eyelids together with court plaster, pack the surface with cotton, and apply a bandage. If the patient will not submit to the discomfort arising from loss of

use of the eye, the less certain protection of covering it carefully with cotton or a handkerchief, must be resorted to whenever the diseased one is to be dressed or attended to, during which time infection is certainly more imminent.

The constitutional measure of giving the perchloride of iron in large and repeated doses, and well diluted, does yield a marked result. These rules should be persevered with till the intensity of the inflammation is subdued.

I rarely give an opiate; I trust rather to reduce any local pains by local bleeding and cold. To subdue pain by these measures is to check the inflammation and to save the eye. A patient may be sufficiently narcotised not to feel the pain while the inflammation is progressing, to say nothing of the directly injurious effects of the opium.

An astringent to the conjunctiva is called for as soon as the acute inflammatory stage is reduced, and that of relaxation has set in. It is hurtful to apply it before.

Of late years I have employed pure astringents, not escharotics, and chiefly alum or tannic acid. The former I use of the strength of five grains to an ounce of distilled water, the latter of strengths varying from eight to fifteen grains to the ounce of water, with half a drachm of glycerine. The eye should be cleansed after the manner I have described, and the lotion applied with a large camel or sable-hair brush, according to the instruction at page 853, for catarrhal ophthalmia. If the eyelids be now closed, and the eyeball gently rubbed with the finger a few times, the lotion will traverse all parts of the conjunctiva. As the brush must touch the eyelid to discharge the lotion, it ought to be washed after each using. The towel which catches the washings of the eye should be changed two or three times a day. The objects, therefore, which are to be obtained are, to prevent the eyelids from sticking together and retaining the discharge, to wash away the discharge so that it shall not become stale and irritate the conjunctiva and macerate the cornea, and to apply an astringent which shall act on the weakened and distended blood-vessels. These therapeutic measures should be repeated every two hours, till an effect be seen, unless the patient is asleep. As the cornea is more or less irritated by the lotion, the sooner the frequency of its application may be reduced, indicated by reduction of the symptoms, the better.

Much harm is done by the use of violent applications. They add to the already existing irritation, prolong the disease, and damage the structure of the conjunctiva and of the cornea. In spite of the strongest evidence to the contrary, many surgeons believe that the disease can be at once arrested by escharotics, and that the more acute

the symptoms the stronger should they be applied. Those who have attended my practice have renounced them.

If the temperature of the eyelids should at any time rise above that of the rest of the body, the cold application must be again resorted to.

When the disease begins to decline, the patient may be allowed to leave his room, and as soon after as possible to take gentle out-door exercise.

Antiphlogistic measures are uncalled for when the secondary and destructive effects of inflammation, such as ulceration of the cornea or sloughing, with or without penetration, have been produced. Warm, soothing, and anodyne local applications only are admissible so far as the eyeball is concerned; and if it should seem prudent to continue with the astringent lotion on account of the conjunctival discharge, the strength of it should be reduced by half, while four applications a day will suffice.

An ulcer of the cornea and prolapse of the iris should not be touched with nitrate of silver, because repair is effected better without it. It imperils the eye to puncture the ulcers. Should the posterior elastic lamina, with some of the corneal tissues, protrude as a vesicle through an aperture of cornea, caused by ulceration or otherwise, it should be punctured and allowed to collapse. For further information on these subjects see the chapter on Diseases of the Cornea. For the treatment also of abscess I beg to refer to the same.

The corneal repair is well established when vascularity appears.

Let it be supposed, on the other hand, that the patient is seen early in a sub-acute attack, a condition manifested by less swelling of the eyelids, less vivid redness, less discharge with a less consistence, and perhaps no pain. The principles of the treatment are the same, shaped in detail to meet the lower inflammatory action. Less local bleeding and a shorter application of cold will suffice. The astringent is earlier applicable. Already there will be feebleness of body, so that a purgative would be injurious. Whatever may be the condition of the tongue, the iron should at once be given, together with a diet as full and nutritive, as the appetite and the digestive powers will allow. The period of confinement to the house need not be so long.

I forbid sponges to be used in this complaint, because it is impossible to wash them clean from pus once imbibed. A piece of soft old rag answers every purpose for the process of cleansing.

Prevention. A great deal may be done to prevent the spreading of the disease by instantly sending away the infected person from those with whom he is in daily communication. This also applies

when relapses occur. Where separation to a sufficient distance cannot be accomplished, in consequence of the community in which the patient may be, he should be isolated as far as possible, and the remainder of the individuals placed under healthy sanitary arrangements, so that there shall be avoided those unhealthy conditions above mentioned under the head of causes, which tend to promote the contagious power and the spread of the disease.

Those persons who are exposed to the disease should be forewarned of its infectiousness and its danger. The use of an infected towel is a very common source of inoculation.

The same persons ought not to attend those who are diseased and those who are well.

No article of clothing which has been worn by a diseased individual ought to be used by a healthy one. This includes bedclothes.

PURULENT OPHTHALMIA OF INFANTS.

This is essentially the same disease as purulent ophthalmia in the adult, merely modified by the undeveloped tissues of the babe, and the activity of the growing processes, the infant organism, but it is generally more severe.

Symptoms. About three or four days after birth, the eyelids have a tendency to stick together, their edges are a little swollen and redder than natural, and, in the daytime, the light is distressing and the eyes are kept closed. After this a little muco-purulent secretion is found, then follows palpebral inflammation with the formation of purulent secretion. The palpebral tumefaction is greater in proportion than in the adult, so that the palpebræ stand out like tumours, and the upper is often pushed down over the under one. Such swelling necessarily presses them tightly together. Under this mechanical state, and as the discharge is not very copious, it is scarcely noticeable, and its character is not readily discerned. Its colour varies, being sometimes yellowish, sometimes greenish, and sometimes red from the admixture of blood. In a jaundiced child it is very decidedly yellow.

It is seldom that the disease at once assumes intensity. In consequence of this it is often erroneously supposed to have a later origin, that of two or three weeks after birth. The overlooking of it at an early period is unfortunately frequent in all classes of society. The child cannot complain and express its sensations. Even when the early inflammatory symptoms are noticed, too commonly they are attributed to a cold in the eye, and expected soon to pass away. The

consequence is that before treatment is applied, irreparable damage occurs.

The conjunctiva swells more than in the adult, and there is farther dissimilarity, in its being very much raised and actually loosened in all its regions by effusion of serum, in the sub-conjunctival areolar tissue. In consequence of this a prolapse of it is always impending, and occurs at any attempt to examine the eye, whereby the under or both eyelids may be everted. The retrotarsal fold may prolapse of itself, like a circular red roll, and evert the tarsal margins. The action of the orbicularis muscle increases any ectropium from this cause.

In from eight to twelve days from the early symptoms, when the ocular chemosis is greatest, the cornea gets hazy in spots or generally, and red at its edge, then semi-opaque and infiltrated with pus to a small extent, or through the entire breadth, followed by penetrating ulceration. Or without an abscess forming it may ulcerate in part, or entirely, and be penetrated through a portion of it. Just preceding either of these processes the eyelids swell yet more, especially the upper one, which is also very red and shining, and the secretions are more purulent and more copious. The child is restless through pain. There is considerable photophobia, the tongue is white, and the body wasted.

The ulceration, or the slough, or the abscess, is usually central, unless there be a multiple of the one or the other.

The lens is more prone to escape through the corneal breach in infants than in adults. With much loss of the cornea its expulsion is the rule.

As chemosis does not become hard and adhere to the cornea, there is, so far as I have observed, an absence of the grooving marginal ulcer.

With mere penetration of the cornea, or considerable or entire destruction of it, the acute symptoms decline, the bright red swollen upper eyelid becomes flaccid and dark red, and the discharge lessens and is less purulent. With penetration, the iris prolapses, and may effectually plug up the aperture, or, closing it imperfectly, a staphyloma is formed. With the destruction of the cornea, if the lens and the whole or a part of the vitreous humour have escaped, the eyeball shrinks to a mere button. If the humour be retained, whether the lens be lost or not, it shrinks with a flattened front, partly covered by shrunken cornea, and partly by transparent cicatrix, or entirely by the latter.

Relapses do not occur, and the conjunctiva does not become affected by the process of proliferation ending in granulation, as in the adult.

Milder cases are met with in which the inflammatory symptoms are very much less, but the difference as to sthenic and asthenic action is never so marked as in manhood.

Course. The disease generally begins in one eye, but not infrequently in both. When only one is primarily affected, the other is sure to be inoculated from it, unless precaution be observed.

When very sthenic, it is never subdued under ten or fourteen days, and weeks elapse before the conjunctiva is again healthy.

The eyeball is more likely to be involved from the extension of the inflammation than in the adult.

When the cornea becomes turbid at several points, or throughout, the danger has reached its height.

Diagnosis. Simple catarrhal ophthalmia is often mistaken for purulent ophthalmia. This accounts for the cures which we hear of from slight agency, such as excluding the light, applying a small blister to the temple, and so forth. It accounts also for reported epidemics of purulent ophthalmia among infants in this or that place, and said to be mild, and not inflicting damage to the eyes.

Hereditary syphilitic inflammation of the eyeball, with the symptoms of hazy cornea, and hyperæmia of the conjunctiva and of the edges of the eyelids, may be mistaken for purulent ophthalmia. The absence of any purulent discharge ought to be enough to prevent any blunder being made.

When the purulent disease is developed, the merest inspection of the conjunctiva will cause some of the discharge to flow out.

But more information is necessary than a mere knowledge of the existence of the disease. It ought to be ascertained if any and what damage has been done to the eyeball, and a systematic inspection must be adopted. This can only be done effectually by retracting the eyelids with two retractors, for the swollen conjunctiva prevents the cornea from being exposed by any ordinary method. If these instruments be not at hand, a pair may be extemporized out of bits of wire, or hair-pins. Besides, an eye capable of being saved may be destroyed by the bursting of a damaged cornea from rough handling.

Causes. Were I to give the result of my own observation from cases in which I have made careful investigation, and these amount to hundreds, I should attribute the origin of the ophthalmia to vaginal discharge of the mother, which has been transmitted to the eyes of the child during parturition, such discharge being for the most part leucorrhœal, sometimes gonorrhœal.

Surgeons speak of cases occurring in the children of perfectly healthy mothers, at least, of such as deny the existence of any kind

of vaginal discharge whatever, when they are questioned. If the investigation be not carried farther, the non-vaginal source in such instances must remain doubtful.

The same kind of agencies which produce purulent inflammation in the adult, may of course excite the disease in children, but this applies rather to a later age than I am considering.

The infection is supposed to be occasionally due to inoculation with the lochia, from the hands of the mother or those of the nurse.

That it is sometimes communicated from infant to infant, in nurseries and lying-in institutions, is certain. It is equally clear that it arises in such places where puerperal diseases prevail.

Whatever be the origin of the disease, the most frequent subjects of it are weakly children, who are exposed to the debilitating causes of bad air, cold, insufficient clothing, insufficient food, in fact, among the poor. Also premature infants. But are not the mothers of these children very prone to leucorrhœa?

Prognosis. The effects of the inflammation are more severe when there has been gonorrhœal inoculation. Then the destructive end quickly follows the first symptoms. The eyelids and the conjunctiva always swell and inflame more, the discharge is thicker and more copious, and the child suffers much pain. They are also more marked in damp and cold, than in dry and warm weather, and among the children of the poor, than among those of the rich. They are the cause of the blindness in the greater portion of the blind poor.

The longer the disease has been allowed to remain untreated, the more tedious will it be to cure.

While the cornea is yet clear the eye may be saved from any damage. If it be hazy, some destruction of it will probably follow. If there be superficial ulceration without interstitial suppuration, probably only a slight speck of opacity may remain, which would be of no consequence provided that it be not over the pupil. If the ulceration be deep, there will be a large opacity. Haziness in association with ulceration may be thick enough to hide the iris, and yet clear sufficiently to enable the eye to be used. When slight it may entirely pass away, except just around the ulcer, or the spot of penetration, proceeding from such, where it is always densest and always remains in some degree.

With prolapse of the iris through any corneal breach, the effects on the pupil will be the same as those which I have given under the head of purulent ophthalmia of adults.

If there be slight interstitial suppuration it may be absorbed. If it be considerable, in all probability the eye will be destroyed.

Sloughing of the cornea through its entire thickness, to any extent, is generally fatal to the eye.

Small partial central capsular cataract, like a white dot, sometimes very minute, and very rarely half as large as the pupil, may occur. Its nature has been explained under the head of Capsular Cataract. I disassociate it from any connection with ulceration of the cornea. The opacity proceeding from an ulcer and it, seldom correspond in position. It remains indelible. It interferes with the function of sight according to its size, apparently more by disarranging the adjustment than in any other way.

The acuteness of sight is very often impaired in consequence of injury to the choroidal and retinal coats. This may occur when the cornea has not been much damaged.

Nystagmus and strabismus are sometimes sequelæ.

Ectropium and partial ptosis may occur, as in the adult.

Treatment. The principles are precisely the same as those which I have given for the adult disease. Sthenic action must be reduced. A leech to the upper eyelid, or a leech to both lids, will produce sufficient bleeding. Children are quickly affected by the loss of blood, and the leech-bites should not be allowed to go on oozing. The application of cold is also called for, and its effects must be watched, so that there may be no undue chilling of the surface. The astringent should be resorted to rather earlier than in the adult, because it irritates less, and a quicker result is obtained. It may be applied after the manner I have described for the adult, or in this way: Two persons are required for the work. The head is held. The eyelids are opened gently, and the discharge which gushes out is wiped away with a piece of soft, wet rag. The lower, and then the upper lid, are everted and wiped with another piece of wet rag. The lotion is then introduced with a brush.

The repetition should be as frequent as in the adult. One or other of the eyelids may become everted during this operation, especially if the child cry. It is overcome by pushing the swollen conjunctiva back and bringing the edges of the lids together. I have never incised the conjunctiva. I have never resorted to any internal treatment.

Other details for general and local treatment should be the same as those given above for the adult, regulated to meet the tender age of the patient. If the mother cannot supply the natural food, a wet nurse is requisite. Artificial feeding under the best system is defective, and its insufficiency is more marked in a diseased infant.

When the inflammation of the palpebræ is but slight, and the increased temperature is not marked, the leeching and the cold should be dispensed with, and the astringent at once applied.

The effect of treatment is marked. In two or three days the child begins to open the eyes, and in a week the symptoms of active inflammation disappear. The general health improves quickly.

Prevention. In this destructive malady, the stopping of infection is all-important. For many years I have pointed out that washing the eyes of the new-born babe might be a preventive measure, and insisted on the method when the presence of leucorrhœa or gonorrhœa has been detected.

How far it is admissible to wash out from the vagina of the infectious mother the mucus secreted for the lubrication of the parts, is a question for the accoucheur to determine. I have spoken to several about it. Some mothers with leucorrhœa, infect all their children.

MORBILLOUS AND SCARLATINOUS OPHTHALMIA.

A certain amount of conjunctivitis always attends measles and scarlet fever. When it originates in the former affection, it scarcely proceeds beyond the simple catarrhal form, but it might pass into the purulent. When it springs from the latter, it is usually more severe, and is more likely to lapse into the purulent form.

Respecting the treatment, I have nothing to add to what has been recommended for conjunctivitis in general, beyond giving a warning to recognise the usually debilitated state of the patient.

VARIOLOUS OPHTHALMIA.

In most severe cases of small-pox, the outside of the eyelids and their margins rarely escape the development of pustules, by which they are much swollen and closed. Besides this, they are glued together by the vitiated Meibomian secretion, and discharge from the pustules.

Conjunctivitis is always excited, but for the most part it is mild, catarrhal, and unimportant, and we may be assured of this if the eye feels easy. Evidence of acute and dangerous inflammation, is afforded by pain in the eyeball, stiffness, a sensation of grit in the eye, increased uneasiness if the eye be moved, or an attempt be made to expose it to the light for a partial inspection, and a frequent discharge of hot tears. Purulent ophthalmia is then imminent.

Relief may be afforded to the palpebral symptoms, by pricking the pustules when they are matured, with a cataract needle so as to evacuate the pus, and anticipate the bursting of them. Also, by

diligent removal of the discharges by emollient applications, and bathing the surface frequently with warm milk and water.

The conjunctival symptoms must be met as far as may be, by the measures already advised for conjunctivitis.

GRANULAR CONJUNCTIVITIS.

The conjunctiva might not return to health after an attack of conjunctivitis, but undergo certain changes. These consist of proliferation of the papillæ, proliferation of the trachoma glands, and neoplastic growths. The sub-conjunctival areolar tissue also is involved in proliferation. The general effect is hypertrophy of the parts.

Conjunctival objective symptoms. Together with swelling and hyperæmia of the palpebral and oculo-palpebral portions of the conjunctiva and hyper-secretion, there are excrescences with physical characters according to their locality. Those in the former portion being abundant, chiefly like normal papillæ exaggerated. Those in the latter being scanty, pale, chiefly isolated, in the form of granules in rows crossed by furrows. There are degrees in their development, requiring artificial classification.

1. *The purely granular.* This is the mildest. The granules are found in various stages. As whitish specks or granules, just visible, requiring for the most part to be looked for, or more raised, at the base of the palpebral, and in the oculo-palpebral portions of the conjunctiva. When well advanced, they appear in general like boiled sago-grains, traversed by a coarse vascular network. The most prominent may stand out almost free of attachment. So long as they have undergone no metamorphosis, and are only enlarged, they are identical with the lymph or trachoma glands of the conjunctiva, which resemble the solitary glands of the intestines. They may be solitary or close-set. That they are really trachoma glands I doubt not, as an examination of them shows that they are succulent, consist of closed follicles, with an investing membrane of dense areolar tissue continuous with the surrounding same tissue. That within is areolar tissue less condensed, containing lymphatic cells, a few capillaries, and some moisture. They are so far solid that nothing escapes when punctured. Some surgeons still maintain that they arise from proliferation of the sub-mucous connective-tissue corpuscles, and allege, in confirmation of it, that they may appear on parts of the conjunctiva, where trachoma glands do not exist. They may pass through their vesicular and succulent form, as pointed out by Marston in Dr. Beale's "Archives of Medicine," and become part and parcel of that granular state

common to all the textures of the conjunctiva at a late period of granular conjunctivitis. Then, farther changes cannot be traced, because they cannot be distinguished from the outgrowths of the papillæ, and the generally hypertrophied condition of the conjunctiva.

2. *The pure papillary variety.* This is a low development. It consists of the normal palpebral papillæ, enlarged by proliferation. At a later period the red colour changes to a greyish-brown tint. This arises from an aplastic collection of opaque cells between them. These cover alike the palpebral and oculo-palpebral conjunctiva, and sometimes pass to the ocular also. It is said that they may occupy the cornea as well.

3. *The mixed variety.* This is the most usual form. It is a combination of the granular and the papillary, and constitutes what is best known under the term of granular eyelid. The palpebral conjunctiva is much swollen and relaxed, and the excrescences seem to exceed in number those of the papillary variety, and tend to run into the diffuse variety. The oculo-palpebral conjunctiva presses forwards with swelling, and displays the close-set granules in rows, red, rather than transparent, but among which a few genuine sago-like granules stand out.

4. *Diffuse variety.* This arises from a higher grade of development: more proliferation, more neoplastic formations. The palpebral conjunctiva is very much swollen, relaxed, and spongy, and there rise up from the deep parts of it irregular velvety or villous diffuse granulations, sometimes like condylomata, and intersected by fissures. Sometimes they are very like the large granulations of a suppurative wound. Sometimes they are pedunculated, when they may be large enough to make irregular bulgings of the integuments of the eyelid. The oculo-palpebral conjunctiva is flattened and studded with mixed granulations. The inflammatory product is always more marked in the superficial than in the deep parts of the conjunctiva.

In all severe cases, and therefore generally in the last two varieties, the sub-conjunctival tissue proliferates freely, and is much swollen from a gelatinous effusion, which infiltrates the conjunctiva and gives the well-known gelatinous appearance.

The caruncle and the semi-lunar fold are swollen and hyperæmic, and the latter is sprinkled with granulations of the mixed and diffused variety.

A microscopic examination of a piece of palpebral granular conjunctiva shows, on the free surface, a layer of recent cells in luxuriant proliferation, covering all elevations and depressions. Beneath this, that is, in the vascular tissue, a thicker layer of newly-formed cells with neoplastic blood vessels.

The ocular conjunctiva is not definitely affected in pure granular and pure papillary conjunctivitis. In the activity of the mixed and the diffused forms, it is hyperæmic and swollen. But these symptoms decline if the inflammation of the rest of the conjunctiva be reduced, and at most only a little hypertrophy of it remains.

An inordinate quantity of muco-purulent fluid is generally secreted in the more recent granular conjunctivitis. The tears also flow unnaturally under any local irritation, especially that of cold, or under any irritation of the system, especially from alcoholic drinks. The discharge quickly becomes purulent. This explains exacerbations. In cases of long standing, at intervals, there may be little or no discharge. In still more chronic and quiescent cases, there may be neither inordinate discharge of tears nor of mucus.

Palpebral symptoms. In the severer varieties, the eyelids are reddened and swollen, and the upper lid drops a little. The swollen oculo-palpebral portion of the conjunctiva interferes with the action of the levator palpebræ muscle. The tarsal cartilages swell, enlarging laterally, and no longer fit the eyeball. Through this the upper eyelid hangs loosely, and the under one is pushed away by the swollen conjunctiva.

The Meibomian gland-ducts swell and become granular.

Some degree of ectropium, by which the punctum lacrymale is displaced outwards, is apt to occur whenever the conjunctiva is much swollen. Overflowing of the tears is the result.

Eyeball objective symptoms. The cornea may become hazy, rough, or semi-opaque, and vascular, in advanced stages of granular conjunctivitis. Such opacity with vascularity is called pannus. This condition is described among the effects of corneitis. It may be induced through trichiasis, the result of induced tarsal disease, whereby the cilia are thrown against the cornea. Through entropium, excited by the same, whereby the granulations of the palpebral conjunctiva are applied to the cornea. But the greater effect is always from contact of the edge of the eyelid.

Eyeball subjective symptoms. Irritability, intolerance to bright light, high sensitiveness to cold air, dust, smoke, and wind. Pain from use of the eyes in reading or writing, and during minute work, especially if it be done by artificial light, attended in each instance by increased redness. Mistiness of sight, arising from the excretions passing over the cornea. Rainbow colours around luminous bodies from the same cause. Still more misty sight when the cornea loses its transparency. When the cornea has suffered long and intensely, the interior of the eyeball participates in the inflammation, whereby the function of the retina is much damaged.

Constitutional symptoms. Persons with well-marked granular conjunctivitis, in this country at least, always look unhealthy. Some evidence of hectic fever, with paleness and emaciation, is rarely absent in chronic cases.

Causes. All the above-described phenomena do not constitute any specific or independent disease. They are only sequences, the occasional modes of termination, therefore later stages, chiefly chronic effects, of conjunctivitis. They are developed far more frequently from mild than from severe inflammation, and they are common to all degrees of the catarrhal and the purulent varieties of ophthalmia. Sometimes they appear as a relapse, or exacerbation of an attack of catarrhal or purulent inflammation, with renewed activity of symptoms. The conditions which bring them about are not understood, for their appearance is uncertain. Influences which produce impairment of nutrition probably play an influential part. We only know that the perpetuation of the irritation by which the original inflammation was induced, the prolonging of it, seems specially to tend to their development. We find that what appears to be a slight catarrhal inflammation, often appearing and disappearing, either spontaneously or by treatment, or mild purulent ophthalmia with exacerbations, may leave after each attack a few granules or granulations, till at last there is the full-formed granular state. Such recurring inflammation has its seat as much in the organized products of former inflammations, as in normal tissue. And granular conjunctivitis might be developed so insidiously and from such mild preceding inflammatory action, as to bear the semblance of being an independent and acute disease. The early existence of the inflammation is apt to be overlooked or disregarded, occurrences more likely in warm climates. Slight conjunctivitis is very common in high temperatures, and pterygium may be induced by it, without, apparently, any discomfort. From this has arisen the error that the granular excrescences, the sago grains, which often arise from very slight conjunctival irritation, and may long exist unheeded, constitute the primary lesion which produces the granular eyelid with all its distressing details.

It is very common for the granular variety to remain for years, or altogether, without any other part of the conjunctiva becoming affected. I have watched such instances in this country. I have also learned that it does not necessarily precede other varieties of granulation.

Granular conjunctivitis among the poor of Ireland is notorious. It is the most common cause of blindness in that country, and sticks to the Irish when they emigrate, and is transmitted to their children. It is generally supposed to be due to their habits of crowding together

under conditions contrary to sanitary laws. But, allowing this to have its weight as a means of spreading contagion, their damp, cold climate has, I believe, much influence in originating the primary conjunctivitis.

Its perpetuation in communities is not due to any secretion proper to the hypertrophied parts, but to infection arising from the pus in the secretions.

Sir W. Wilde has published many valuable papers on this subject. The most comprehensive is his medical report of the epidemic of ophthalmia which prevailed in the workhouses and schools of the Tipperary and Athlone Unions.

The disease is rarely seen except among very poor people, and those who live in organized masses, such as in schools, in the public services, in pauper establishments, and in places of punishment. And the commonest of all existing causes, is the use of nitrate of silver in substance for the primary inflammation, or in lotions or salves, of such strength as to be highly irritating.

It is often masked. The severity of its subjective and objective symptoms declines. A renewal of inflammation from some excitement, is followed by remissions. These are repeated, but there is scarcely any discomfort till some variety in the recurrence, or some impulse given by new irritation, developes the granulation in a severe and permanent form.

Course. All varieties in children may get well spontaneously, and the repair may be quick. Granulation is, however, seldom seen so early in life, nor is it severe. Nor is it a condition of old persons. Slight attacks of any variety in adults may get well with or without treatment. Severe mixed and diffused varieties very seldom get quite well under any circumstances, by which I mean that the conjunctiva is restored. Yet if such be left untreated, the eyelids and the cornea become much damaged. The conjunctiva swells more, till its nutrition seems interfered with; then it is somewhat bloodless, and shrinking, it is converted partially or entirely into a kind of cicatricial tissue, which assumes several forms, such as spots, or streaks, or radii, among which may be interspersed reddish or yellowish-grey tissue. In some places there is no longer conjunctival tissue where such changes have been effected. The secreting power of the membrane is destroyed, and dryness of the eye is felt. Similar changes might occur in the granular variety. If the palpebral and the oculo-palpebral fold of the conjunctiva have undergone much partial or general cicatricial change, the conjunctival sac is shrunken and shortened, an effect which is very apparent when either of the eyelids is everted. Then too, the so-called posterior symblepharon is

apparent as vertical bands. The shrinking may be also seen in the restricted movements of the eyeball. With all this the caruncle and the semi-lunar fold shrink and almost disappear. The cornea passes into complete pannus or xeroma. The eyelids suffer in shrinking of the tarsal cartilages, destruction of the Meibomian glands, and trichiasis. Sometimes the cilia follicles are destroyed. Entropium may be induced.

Treatment. To remove any source or exciting cause of the inflammation, or any influence which may increase or maintain it, is to place a patient under the most favourable state for his recovery. Then, the vesicular and papillary varieties of the granulations may be subdued, and the conjunctiva restored to health. The mild-mixed and the diffuse varieties may be reduced so as no longer to cause discomfort, and severe examples of them may be much improved. In all of these cases, any thin corneal opacity may disappear. But in no instance can these desirable ends be accomplished quickly. The fullest improvement may not be arrived at for months, or even for some years.

The sthenic cases must be distinguished from the asthenic, and treated differently. Active inflammatory conjunctival symptoms must be subdued by appropriate antiphlogistics, such as leeching, cold, and the other measures, according to the rules given for the same state arising out of catarrhal or purulent inflammation. The cold should be persevered with so long as there is any morbid heat, and resorted to from time to time if such should return. No decided amendment will ensue while any objective evidence of developing inflammation is present. The swollen conjunctiva should be scarified longitudinally in several places, and the bleeding encouraged by moving the eyelids about with the fingers.

If the inflammation be chronic and associated with general debility, as in all probability it will, antiphlogistics, excepting the scarification, are contra-indicated. Fomentations with plain hot water, or with anodynes if there be pain, will be beneficial.

Besides the local measures, we must look to the careful management of the system, and do everything to restore the general health. When tonics are admissible, some preparation of iron will be most generally suitable, and in large doses.

In all cases the eyes should be shaded from bright light. It is necessary to avoid tainted air, including that vitiated with tobacco smoke. Minute eye work should be sparingly or not at all done.

A judicious change of residence often produces much effect. A sea voyage works wonders. It is well known that soldiers who are discharged from the army in hot climates with granular conjunctiva,

often get well during their voyage home, or after they have joined their friends, from hygienic influence only. Where such advantages cannot be obtained, isolation from others who may be similarly diseased is desirable.

Local applications to the conjunctiva are serviceable, but they should be used with the utmost caution, and astringents alone are admissible. Even they must be diluted enough not to irritate. I have settled down to the employment of alum or tannic acid in lotions neatly applied to the conjunctiva with a brush, three or four times a day.

The pure granular variety progresses better without any local application, and the same may be said of the low forms of the pure papillary.

When the excretions lessen, and especially when the mucous element preponderates over the purulent, the astringent is not required so frequently. It had better be discontinued altogether as soon as there is decided improvement in any of the prominent symptoms.

When the inflammation has done a certain amount of damage, only a certain amount of recovery can ensue. I cannot express these degrees in writing, but I can recognise them. They can be learned by observation and practice. It is important to know when remedies can do no more.

When there is no longer active hyperæmia, I believe in further advantage from the stimulating effect of blistering the integuments of the eyelids from time to time. I employ a blistering fluid, Bullen's, and while the patient lies down I put it on with a brush, I do not cut the blister, and a sore does not form. The British Pharmacopœia contains a liquor epispasticus.

Under these principles of treatment there is the best opportunity afforded for the removal of the inflammation, the casting-off, the absorption, and the shrinking of the morbid products.

Escharotics, by which I mean nitrate of silver in substance or in strong solutions, caustic potash, or sulphate of copper, augment and prolong the inflammation. I never saw a conjunctiva restored to health, or to comfort, where they have been industriously applied.

Patients present themselves with the mixed and the diffuse varieties so advanced that the conjunctiva is damaged beyond all hope of recovery, being thoroughly altered in structure, and the cornea is fast becoming spoiled, the effect of severe cauterization. My practice is to destroy the granulations, and this I do with the least damage to the tarsal cartilages and to the cornea, by applying the pure liquor potassæ. I evert the eyelid, dab on the liquid, wait for thirty

seconds, wash with tepid water and a bit of rag, dry the surface, and apply a little castor oil. The intense pain which is produced is not worse, and is shorter in duration, than that which follows the use of the nitrate of silver. I allow an interval of a week before making another application. The process has reached its applicability when the granulations are sufficiently reduced. The bad condition of the cornea improves.

Any very decided pedunculated papillæ or, more correctly, neoplastic growths should be snipped off.

It is not my plan to tell of the very many applications which are and have been resorted to by other surgeons, most of which I have tried. There has been nothing new here in the last quarter of a century. It would be difficult to introduce variety. The finely powdered diacetate of lead dusted on the granulations, rubbed in, and the washing afterwards to remove loose portions, and the rubbing in of quinine, both now extolled, are old suggestions.

The removal as far as possible of the granular conjunctiva from the palpebræ by the scissors, the knife, or by actual cautery is now seldom practised. While a student, I frequently used the curved scissors under the direction of my teachers, and then rubbed the cut surface with the sulphate of copper. Furious inflammation always ensued, and the vascular cornea got worse. For the treatment of pannus, I beg to refer to the chapter on the Diseases of the Cornea.

IDIOPATHIC ERYSIPELATOUS CONJUNCTIVITIS.

This must be a very rare disease, because I have either not seen it, or unnoticed it.

Symptoms. It commences with a feeling of slight tension in the eye and the parts immediately surrounding it. The conjunctiva becomes of a pale red colour and rises around the cornea in soft yellowish-red vesicles, which alter their form from every motion of the eyelids. Sometimes they are large, colourless, project from between the eyelids, and resemble drops of tears. No other diseased appearances are observed in the eye itself, and the eyelids may be entirely free from redness and swelling.

As the disease continues the conjunctiva increases in redness, and gets spotted with bright red spots, which are produced from extravasation of blood into the areolar tissue between it and the sclerotica. The vesicles become larger and more prominent. Their interspaces are covered with a thin white mucus. The lacrymation increases, and pain is added. At night, the eyelids are stuck together. In

the morning the cornea seems to be dim, this is merely the effect of mucus which collects on the surface. These symptoms gradually decline, and the raised conjunctiva becomes reattached to the sclerotica. Extravasated blood spots are the last symptoms to disappear, for a long time the conjunctiva remains detached from the sclerotica, and falls into wrinkles whenever the eyeball is moved.

Causes. These seem to be sudden changes of atmosphere, slight blows, the sting of insects, and various other causes.

Treatment. Rest, local antiphlogistic measures, according to the degree of the inflammatory symptoms, and puncturing the vesicles are necessary.

PEMPHIGUS OF THE CONJUNCTIVA.

This vesicular eruption has been seen on the eye in association with the same on other parts of the body.

The bullæ form on the ocular and palpebral conjunctiva, and are filled with serum. There may be sharp conjunctivitis, with purulent discharge.

Treatment. More is required constitutionally than locally because the disease in general is always associated with a most unhealthy and enfeebled condition of the body. An arsenical preparation seems to suit best, and the liquor arsenicalis should be given under the well-known condition. The bullæ should not be punctured, but allowed to decline, for the excoriated surface which is sure to ensue when the cuticle separates, will be more aggravated if the serum be discharged prematurely, and will be made still worse if with puncturing any escharotic be used. Fomentations give relief. The mildest astringents applied to the conjunctiva irritate it.

PHLYCTENULAR CONJUNCTIVITIS.

This is the commonest of the conjunctival diseases, from the eighth year of life to manhood, the period of its prevalence. Sometimes only one eye is affected, sometimes both are affected at the same time, in which case the one is generally worse than the other. Not unfrequently the eyes are attacked in alternation.

Objective symptoms. The phlyctenula or aptha is seated on the ocular conjunctiva, usually at the horizontal meridian of the eyeball, at its outer or inner side. It may be entirely on the conjunctiva, or partly on it and partly on the cornea. Exceptionally, it occurs on the oculo-palpebral or palpebral conjunctiva. Its size varies from that

of a fig-seed to that of a hemp-seed. But there may be many phlyctenulæ, either scattered or in groups, and sometimes disposed in a circular manner, partially surrounding the cornea.

At the spot of development, speaking of a single one, it commences by a minute vascular patch, in the centre of which in a day or two a roundish little nodule of lymph appears, as an exudation or efflorescence. At the summit, the epithelium is raised by serum into a vesicle. At this time the tears are secreted in superabundance. Then the conjunctiva swells, the vascular patch increases, the secretions of catarrhal ophthalmia are produced, and the nodule ruptures. To this succeeds a well-defined whitish and round ulcerous excavation, surrounded by shreds of epithelium. The distended blood vessels assume a reticular rather than a radiating form, and if the excited vascular action spread much, small extravasations of blood, ecchymoses, may occur in the meshes. The little ulcer secretes an opaque greyish substance by which healing is accomplished, or such secretion may break down, by which there is retrograde ulceration before repair is effected. Meanwhile the conjunctival swelling and vascularity decrease, the excretions are reduced, and the ordinary secretion is restored. This gives the outline of a typical course, which is run through in from about six to twelve days. There is more local disturbance when there are several phlyctenulæ than when only one exists, and also when the cornea is partially involved than when it is not.

A phlyctenula may form during an attack of catarrhal ophthalmia. It is more common with the chronic form of the inflammation.

Subjective symptoms. At first there is a little stinging, then itching, seldom actual pain. Intolerance to light is but slight, and there is no blepharospasm. These intensify when the phlyctenula is partly on the cornea, when it is multiplied, and when the sub-conjunctival tissue inflames.

The aspect of the eye varies considerably with the degrees of conjunctival vascularity, and through which errors in diagnosis may occur. Ordinarily, the redness is only on one side of the eyeball, and just about the spot of eruption. Sometimes the whole of the ocular conjunctiva is intensely red, and that even from the first. Of course in such a case, the entire conjunctiva would be preternaturally vascular, and the sub-conjunctival tissue would scarcely escape inflammatory implication.

This affection is very frequently confounded with an allied one of the cornea, which is often attended with very severe objective and subjective symptoms, and is usually protracted. It may exist with such.

Remote causes. Phlyctenular conjunctivitis sometimes appears without any manifest evidence of ill health, but it is more fre-

quently seen where there is debility. Besides hereditary weakness, impure air, insufficient diet, want of exercise, and insufficient clothing, must be placed under this head, conditions which produce impaired nutrition.

Exciting causes. These are cold and wet, and exposure to cold; hence the prevalence of the affection in these latitudes, and its extreme rarity in warm countries.

Results. Phlyctenular pannus is a sequel which arises out of frequent repetition of phlyctenular efflorescence, by which the conjunctival and sub-conjunctival tissue, and it may be a superficial portion of the sclerotica, is hypertrophied and raised with a definite border, and freely supplied on the orbital side by large blood-vessels. Along with some ulceration there are cicatricial elements.

Treatment. Constitutional measures should be prescribed according to any existing indication for them, and the same may be said of hygienic measures.

Unless these be sufficiently attended to, the disease will recur again and again, and such effect is to be overcome rather than the reduction of a single crop of the eruption.

Confinement to the house is unnecessary, unless the weather be inclement.

As to local measures, the eye should be shaded from bright light. Frequent fomentation is desirable. If there be marked symptoms of catarrhal ophthalmia, they should be treated according to the rules given for the same.

I have not been able to convince myself that any advantage is got from applying drugs to the efflorescence in any of its stages. Many surgeons speak of local specifics for cutting an attack short, and among them are nitrate of silver, sulphate of copper, calomel, ointment of the red, as well as of the yellow oxide of mercury. A contrary conviction is forced on me from actual observation, and I believe that all of these irritate the eye, and not one of them abridges any of the stages of the complaint.

With regard to the conjunctival pannus, the best recoveries will be made under constitutional and general treatment, and without the direct application of any agent to the diseased part.

DIPHTHERITIC CONJUNCTIVITIS.

This is the result of acute inflammation of the conjunctiva, and of the sub-conjunctival areolar tissue, produced by specific action, and is analogous to diphtheritic inflammation of the pharynx.

General symptoms. Inflammation of the entire conjunctiva. In-

flammation and swelling of the eyelids, hardness of them, and much tenderness. Elevation of local temperature. Pain in the eye and in the forehead. Sometimes fever. A discharge, at first thin, consisting chiefly of tears, then like whey, with greyish shreds and flocculi, and ultimately like the secretion of purulent ophthalmia, with the addition of largish flakes.

The internal parts of the eyeball may become inflamed, as in severe purulent ophthalmia, but such is always secondary, and depends on the primary conjunctival inflammation.

When the surface of the eye is examined, there appears a felted flocculent membranous-like substance, thin semi-transparent and greyish; or thick and opaque and generally yellowish, lying in raised patches on the palpebral conjunctiva, and on the oculo-palpebral fold. Or, one patch of it covers both these portions of the conjunctiva, and ends in a sharp edge at the tarsal margin, or blends with it, or partially unites the eyelids.

The morbid looking surface was supposed to be fibrinous exudation, but it is neither fibrine nor exudation, but conjunctiva itself, tumefied and deprived of blood by excessive corpuscular infiltration of newly-formed cells into the sub-epithelial connective tissue, so abundant as to compress the blood-vessels and arrest the circulation and nutrition. It is but a quantitative increase of the morbid proliferation which occurs in every catarrhal inflammation.

The surface secretions decline with the amount of the infiltration.

Mild diphtheritic conjunctivitis. In this, a line of demarcation is more apparent between the living and the dead tissue, so that a separation can be made, by tearing through the adhering medium of connective tissue fibres, elastic fibres, blood-vessels and nerves, a raw surface being left.

Severe diphtheritic conjunctivitis. Here the inflammatory process is in greatest severity, and the dead part of the conjunctiva cannot be completely separated from the living. An attempt at removal is but very partially successful, and causes surface and parenchymatous hæmorrhage.

In both varieties, the inflammation generally reaches its highest point quickly. When the active symptoms decline, the exudation is shed in a mass, or thrown off in fragments, the discharge returns, and granular conjunctivitis may ensue.

We see very little of diphtheritic conjunctivitis in this country, and never as an epidemic.

Causes. Some German authors tell us that an ordinary case of acute catarrhal or purulent ophthalmia, may be converted into diphtheritic conjunctivitis by the improper use of escharotics.

Inflammation of the eyeball, of the contents of the orbit, and the conjunctiva, occasionally produces the mild form, and so may mechanical irritation of the conjunctiva, of which I have spoken in the chapter on Artificial Eye.

Idiopathic diphtheritic conjunctivitis has a constitutional origin, as is shown from its occurring in persons with diphtheritic affections, with scarlet and puerperal fevers, and even with measles. In all probability there is an element of putridity within the organism, which predisposes the individual to become affected with this form of inflammation, or which disposes any inflammation otherwise excited, to take on a diphtheritic character. Many cases illustrating the scarlet fever connection, are most instructively recorded by Mr. Pritchard, in the "British Medical Journal," for 1852. There are scattered in the English medical literature of the last four years three other cases in association with scarlet fever. Foreign experimentalists have found that the purulent secretion of diphtheritic conjunctivitis placed on a sound conjunctiva generally excites the diphtheritic disease, but sometimes merely purulent ophthalmia; and that the pus of such may in turn excite diphtheritic conjunctivitis. By this unjustifiable inoculation we learn how the disease may be propagated.

Course. In the milder cases the diphtheritic infiltration may remain for days or weeks, and be ultimately thrown off. The conjunctiva loses its hardness, becomes very red and spongy, and covered by a purulent secretion. To this granular conjunctivitis may succeed. In the severer cases, the surface deposit is desquamated, and leaves depressions or pits, which are apt to bleed. The infiltration seems to deliquesce, is added to the purulent secretion, and the conjunctiva gets more relaxed and succulent, and diffused granular conjunctivitis is apt to follow.

In no instance can the morbid material undergo any changes but those of putrefaction and decomposition.

The ultimate effects of the inflammation on the conjunctiva may be symblepharon posterior and anterior, or anchyloblepharon, or xeroma. Or with much destruction of tissue, cicatricial shrinking.

The eyeball is apt to suffer secondarily, especially in adults, the cornea becoming inflamed, whereby an abscess may form, or penetrating ulceration ensue, or sloughing occur; in the same manner, and with the same result as in purulent ophthalmia, although here such processes are more severe, and by them the eye is more generally destroyed.

Treatment. This must be constitutional and local.

As the inflammation is always decidedly sthenic, the same principles of local treatment which I have advised for sthenic action in

acute purulent ophthalmia are applicable modified, of course, according to any variations in the intensity of such symptoms. These include local bleeding, the application of cold, and the free incising of any existing chemosis; and in addition, incising the diphtheritic spot in several places. By this we must tend to reduce the inflammation, to improve the local circulation, to restore the nutrition of the inflamed parts, and hasten the casting off of the dead parts. I doubt whether any application of astringent or escharotic to the conjunctiva is advantageous. Judging from my own experience I should say that the interest of the patient will be best served in dispensing with them, and only keeping the conjunctival surface as clean as possible by washing with warm water, removing any detached shreds of diphtheritic membrane which may be loose, and greasing the edges of the tarsi, so that they shall not stick and confine the discharges.

I deprecate the use of the nitrate of silver, for it has never proved beneficial in England, in the hands of any surgeon, that is, so far as I know, and so far as I can gather from reports of cases. Sometimes it has seemed to intensify the symptoms, whereby the eyeballs have perished. It could never be more fully tried than in the case of a child three years of age, who was treated by my late colleague, Mr. Hulme, at the Central London Ophthalmic Hospital, and watched by myself. Under chloroform a portion of the dead tissue was readily peeled off in one piece from the lower eyelid of each eye, but none could be removed from the upper except in shreds. When the bleeding was subdued Mr. Hulme cauterized the surfaces very freely. Three days afterwards, the proliferation was as profuse and as much as ever. Again was it dealt with as before, and the caustic resorted to. Altogether the caustic was applied four times to the right eye, and three times to the left, at intervals of from three to seven days. Mr. Hulme writes, in his details of the case in the "Medical Times and Gazette," that no benefit ensued from this treatment, the conjunctiva remained in the same condition as before. His microscopic examination of a piece of the dead tissue discovered "faintly marked longitudinal striæ, with numerous interspersed cells, large exudation cells in which nuclei appeared on the addition of acetic acid." Rindfleisch says that the morbid material is composed of cells, and nothing but cells, which have undergone a peculiar degeneration of their protoplasm, and an equally peculiar fusion with one another.

Mr. Hulme reports along with the above, two other cases, in which a very rigorous caustic treatment was inoperative for any good.

From constitutional treatment, much advantage may be obtained.

Such treatment includes attention to any existing general disorder, out of which the ophthalmic symptoms may arise, and the removal of any blood-contaminating influence, producing mal-assimilation, or mal-nutrition. My experience of the internal use of drugs has brought me to trust in large doses of the tinct. ferri perchloridi. Mercury in any form is highly detrimental, through reducing the patient's power, which is sure to be small.

It is almost impossible that any person, and especially any infant or child with this affection, can be sufficiently treated at a poor dwelling. Out-patients rarely do well.

CUTICULAR CONJUNCTIVITIS OR XEROPHTHALMIA.

The conjunctiva undergoes degeneration, whereby its structure is spoiled. The several secretions in association with it cease. Even epithelium is no longer formed. Its power of absorption is lost.

Symptoms. The white of the eye is without lustre, being dry, resembling parchment. The cornea is slightly vascular and turbid. Thus the front of the eye looks as if it were undergoing decomposition from death.

Course. The conjunctiva is dark red, dry looking, and rugous. The ocular portion becomes dry and shrivelled. Its hardness and loss of elasticity cause it to form wrinkles or plaits around the margin of the cornea, in a direction corresponding to the movement of the eyeball. The palpebral sinuses are reduced in depth, but they still secrete some mucus, so that the motions of the eyelids are tolerably well performed.

The cornea is now very perceptibly dry and semi-opaque, traversed by a few blood vessels, obscures a view of the pupil and of the iris, and is generally partially covered with particles of dust, swept into a line by the action of the eyelids. Vision is lost in proportion to such opacity.

Trichiasis or entropium may occur. Both may co-exist.

The conjunctival shrinking continues, and the oculo-palpebral folds forming the upper and under sinuses are pulled out, whereby the eyelids are drawn around the eyeball up to the cornea, which is partially covered by the upper one. By this tying and fixing of parts, the eyelids cannot be closed, and a portion of the cornea is permanently exposed, whereby the epithelium becomes so thick and opaque as to render the pupil invisible. Patients complain of the sensation of restraint which this condition imposes.

Corneal and conjunctival sensibility is lost, and the application of

irritants to them, such as ammonia, pepper, or snuff, produces no effect, or but the slightest reaction.

Pannus may appear on the cornea at this stage, accompanied by penetrating ulceration, with its usual effects.

A still farther stage is loss of demarcation between the cornea and the sclerotica.

The caruncle and the semilunar fold shrink and become dry, and scarcely a trace of them is left.

The puncta close at an early period.

The Meibomian glands and the cilia follicles are much impaired, or quite destroyed.

The tarsal cartilages shrink.

The ducts of the lacrymal gland close, and, I believe, early. The state of the gland itself as influenced by the disease, as well as by the closure of its ducts, has not been ascertained by actual observation. It is generally supposed to undergo slow atrophy, for when one eye has remained sound, and there has been weeping, the diseased one has become prominent and bloodshot, and pain has been felt in the gland, evidences, we may conclude, of some activity yet remaining in it.

Cuticular conjunctivitis may occur at any period of life, and affect one eye, or both symmetrically. Cases have been recorded at the ages of nine months, five and ten years. I have seen it only in adults. The case of supposed congenital origin published by Mr. Wardrop is not a reliable one. He saw the patient when she was twenty years of age, and supposed, from what he could learn about the appearance of her eyes in infancy, that the conjunctivæ were somewhat affected at that time. There might have been purulent ophthalmia.

Causes. There is no truth in the supposition that disease of the lacrymal gland, whereby its function ceases, produces dryness of the conjunctiva, because the moisture of the eye depends on the conjunctival secretions, and not on the tears. The conjunctiva remains moist and healthy after the lacrymal gland has been extirpated.

We invariably find that the cuticular change has been preceded by a long-continued or often-repeated inflammation, which in some instances has been altogether disregarded, and sometimes increased by the existence of entropium or trichiasis, or more generally by the injudicious use of powerful escharotics or stimulants. Why this peculiar disease is so rare among thousands of cases of acute and chronic inflammation of the conjunctiva, and hundreds of cases of granular conjunctivitis even when escharotics have been employed, and what is its exciting cause, is a question no one can answer.

I am unaware of any morbid anatomy examinations of the diseased conjunctiva, whereby the several structural changes have been detected. Respecting the pathology, it may be conjectured that inflammatory exudations in the membrane destroy the secretory apparatus in connection with it, and that the ultimate contracting of such, produces the shrinking which is so marked.

The corneal changes are probably mechanical, and the result of the conjunctival disease. For the cornea to remain transparent and lustrous it should be moistened, and the desquamation of the effete epithelium should be assisted by the friction of the eyelids. When at first the moisture fails, the dimness is caused by the drying of the epithelium, and a certain amount of transparency may be restored by wetting the surface of the eye with water, or saliva, after the manner of some patients. While the eyelids retain tolerable motion, and assist to remove the dead epithelium, the dimness is not considerable. Whether interstitial corneal deposits ever occur I have not been able to ascertain.

Treatment. A cure is beyond the reach of surgery. A mucous membrane which has lost its structure cannot be repaired. But something can be done to relieve suffering, and in some cases to restore an amount of useful sight.

Any existing trichiasis or entropium should be removed.

The eye should be protected from dust and other foreign particles, by a well-fitting goggle, mounted with plane glass.

As a substitute for the natural secretion, and for the purpose of softening and relaxing the hardened conjunctiva, and moistening the dry epithelium of the cornea, glycerine was introduced by Mr. R. Taylor twenty-one years ago. He sought for something which would not irritate, and possessed the power of retaining its moisture. He published three cases showing its good effects, with some excellent remarks about the disease, in the "Edinburgh Med. and Surg. Journal." I saw the patients with him many times.

The glycerine should be applied often, because, from the contraction of the conjunctiva, only a very small quantity can be laid on. The patient should take it about with him, and use it from time to time as required, with his finger, or a brush.

AFFECTIONS OF THE SUB-CONJUNCTIVAL AREOLAR TISSUE.

ŒDEMA.

The sub-conjunctival areolar tissue suffers from mechanical dropsy, when the return of the blood from it and the conjunctiva is interrupted from pressure on the ophthalmic vein, or on some of its branches.

Objective symptoms. The oculo-palpebral and ocular conjunctiva is slightly swollen, and raised up in a yellowish jelly-looking like fold, and the cornea is overlapped. Sometimes the upper part of the ocular portion is scarcely raised.

In such development it is but one of the signs of many diseases in and around the orbit, within the cranium, and of the eyeball, and is noticed along with those affections.

Another form of ocular œdema, but more diffused, occurs in old and feeble persons. It is unimportant unless it project beyond the eyelids. In some cases which have proved troublesome in this way, I have reduced the swelling by puncturing it a few times rather freely.

Œdema has been recorded in association with severe hemicrania and circumorbital neuralgia.

SUB-CONJUNCTIVAL PHLEGMON.

This is spoken of as circumscribed inflammation of the areolar tissue. The affected part of the conjunctiva is inflamed and much thickened. In a few days there forms a swelling about the size of a split pea, which rarely suppurates. Fomentations afford relief.

CHAPTER XXXII.

DISEASES OF THE CORNEA.

INFLAMMATORY DISEASES—CORNEITIS—PHLYCTENULAR CORNEITIS—DIFFUSE CORNEITIS—PUNCTIFORM CORNEITIS—NEUROPARALYTIC CORNEITIS—RESULTS OF CORNEITIS—SUPPURATIVE CORNEITIS—CONICAL CORNEA.

INFLAMMATORY DISEASES.

Although the fully developed and healthy cornea has not blood-vessels, it suffers more frequently from inflammation, and is quicker damaged by it, and recovers whether partially, or entirely, more slowly than any other component part of the eyeball. As it is naturally absolutely transparent, and its polish is perfect, any departure from these states must be regarded as conditions of disease.

The conjunctival layer, the anterior elastic lamina, the middle layer or true cornea, the posterior elastic lamina, undergo many inflammatory changes, whereby merely their transparency is affected, or they are disorganized. These morbid states are classed as exudation, ulceration, suppuration, and gangrene.

In no other tissue of the eyeball is the co-existence and succession of progressive and retrograde processes so marked.

Corneitis is always attended by some degree of inflammation of more or less of the surrounding conjunctiva, and still more of the sclerotica, and which does not necessarily, but may, spread to the other parts of the eyeball, when it is, so to speak, secondary. An explanation of the first condition is to be found in the structural or anatomical connections of the cornea, including its blood-vessels and nerves. It is in this way that some forms of corneitis are really

inflammation of the anterior part of the eyeball. There is a converse state. The cornea participates in all severe inflammatory diseases of the conjunctiva, and is apt to suffer in severe attacks of inflammation of the eyeball. In the latter case, it is more likely to be injured in organization in prolonged and relapsing inflammations. But when so secondarily affected, the changes are different to those which it undergoes in the more isolated forms of primary inflammations.

The pathology of an inflamed cornea, like that indeed of any tissue of the body, is a key to the understanding of its symptoms, and a wide step towards learning how to treat them. The facts which have been gathered respecting it have been, for the most part, from trials carefully made by several experimenters on the lower animals.

The first morbid change is generally ushered in by the conjunctival layer, the epithelium becoming visible through molecular cloudiness of the cell contents, and afterwards proliferation of the cells themselves, and the appearing among them of leucocytes, which are supposed to have emigrated from the hyperæmic vessels of the conjunctiva.

Then quickly follow implication of the true cornea and proliferation of the corneal corpuscles. These become dilated, and their contents opaque and granular, whilst at the same time, the nuclear elements increase in number by division. It is probable that they now rupture, for beyond this period nucleated cells resembling pus corpuscles, together with free nuclei, make their appearance in the surrounding tissue. Just where the inflammation is at its height, the cells are most numerous and closely packed, so that the fibrous structure of the laminæ cannot be well recognised. But as it declines, or as the distance from the centre of it increases, the proliferating process with the neoplastic elements decrease, and there are found only the swollen corpuscles, which soon recover their parallelism to the corneal surface. The cornea swells, and sometimes irregularly. The anterior elastic lamina resists inflammatory action for a long time.

The superficial corneal layers are more frequently and more severely inflamed than the deeper ones. This may be due to the greater number of corpuscles anteriorly.

The products of the inflammation vary with its intensity. When the inflammation is most severe, small bright nuclei are found, in which fatty degeneration soon occurs, and which are surrounded by fatty detritus, containing pus cells. From the anterior portion of the cornea such products are soon thrown off, because the anterior elastic

lamina is quickly destroyed by the contact of pus. From this process a more or less extensive ulcer is found. Within the cornea pus is long retained. The laminæ become opaque, and break down into fatty degeneration, and the pus collects in a cavity, constituting an abscess.

When the inflammation is less severe, there is less development of new products, but portions of them grow more, and acquire higher development, from which it is said that blood-vessels are formed. But in the present state of our knowledge, it is safer to infer that all corneal blood-vessels are but morbid offshoots from the natural vessels around. In a process of repair, they retrograde and are absorbed, or shrivel up. Their remains, with fatty detritus, may be found after years. It is supposed that they are capable of being rekindled into activity.

The posterior elastic lamina seems to be affected by inflammation in its epithelial surface, and not in its basement membrane. It may inflame generally, and cause opacity at the back of the cornea; but the characteristic effect is that of opaque spotting, in single points, or in groups. These products vary, according to the character of the inflammation; but they usually correspond to those of proliferation of epithelial cells elsewhere. The exudation from them may be large in amount.

The entire cornea is rarely at once the seat of uniform inflammatory changes. The vascular action may occupy the whole thickness, but it generally occurs only in parts.

CORNEITIS.

SIMPLE CORNEITIS, FOR THE MOST PART TRAUMATIC.

Symptoms. Hyperæmia, or congestion of the blood-vessels of the conjunctiva and the sclerotica immediately around the cornea, so that their anastomotic arrangement appears like a wreath, which seems to cover a small portion of the corneal periphery. The conjunctiva may be a little raised. This condition is frequently spoken of as ciliary irritation.

When the sclerotic vascularity prevails, and it does so in proportion as the corneitis becomes chronic, there is not the bright redness so remarkable in iritis or general inflammation of the eyeball, or so distinguished by the separate trunks of converging blood-vessels, but a purplish uniformly-diffused redness, and often disposed more in patches than in a circle around the cornea.

Roughness of the corneal conjunctiva and loss of polish. This is never absent in true corneitis, although sometimes it is less conspicuous because it is not accompanied by milkiness or opacity.

General dulness or greyish opacity on the anterior portion of the true cornea. This usually begins at the circumference, and spreads to the centre. But it may commence centrally, and pass outwards.

In acute inflammation of rapid development, and particularly in the younger subjects, the opacity is uniformly diffused. It varies from slight muddiness, which obscures the view of the iris, to an amount that hides the pupil, or renders the cornea white. In less acute cases of slower progress, it is more irregular, in patches, or spots, with transparent intervals. Whatever may be the form of the opacity, it becomes more dense and permanent as the disease lingers, and is chronic. This applies to all kinds of corneitis.

Blood-vessels, in fine net-work superficially arranged, follow the opacity from the circumference, being formed in the exuded material, whereby the cornea is reddened. They do not appear in any marked degree, nor proceed far, till the inflammation is protracted, or by relapses becomes chronic. They communicate with the blood-vessels of the conjunctiva. Exudations which begin in the centre of the cornea are rarely vascular till they reach the margin. It was taught by the late Dr. Jacob that the new vessels are composed of veins.

The true corneal tissue, or, at least, the posterior part of it, is only exceptionally affected, either by exudation or opacity, or by vascularity. When it is injected the blood-vessels may not be visible to the naked eye.

There are varieties in vascularity and opacity in corneal inflammation, which cannot be embraced in any description, however detailed.

Lacrymation, photophobia, and blepharospasm are never absent. Pain is generally present. Its duration and intensity depend on the extent to which the corneal nerves are exposed, by loss of epithelium, or of the anterior elastic lamina. If any of the true cornea be destroyed, whereby there is marked excoriation, the subjective symptoms are very severe, and deep corneal injection ensues.

Vision is interfered with according to the amount of the opacity over the pupil; and this aperture is easily eclipsed, because it is persistently contracted.

Causes. External injuries, or mechanical damages of all kinds, acting chiefly on the surface of the cornea. Chemical irritants, among which are strong eye lotions. Permanent exposure of the

eyeball from a paralytic condition of the eyelids. Phlyctenular corneitis, as well as granular conjunctivitis.

The course of the disease depends chiefly on the persistence, or the removal of the cause, modified by constitutional agencies. The inflammation may quickly or only slowly reach its height, and be ephemeral and leave no trace; or be long enduring, and ultimately leave opacity, or pass into pannus, or parenchymatous corneitis, followed by abscess and penetrating ulcers, whereby the eyeball is destroyed.

The reduction of the vascularity of the eyeball shows that the disease is declining. The corneal vessels are removed by a process of shrinking or absorption as already explained.

So long as superficial or deep opacity is the product of proliferation, is recent, and in no wise depends on cicatrization, it may clear away, no matter how dense or extensive. The younger the subject, the more quickly and certain is this to occur. After the body ceases to grow, such repair is slow and limited, and seldom complete.

Treatment. Scan the eye carefully to see if there be any extraneous body impacted in, or lying on, the cornea. See whether trichiasis or entropium offends. The removal of any of these will probably cure the inflammation, provided the eye and the patient be placed under the conditions which favour recovery; such as rest to the eye and rest to the body, in order to ensure tranquillity to the circulation. The same may be said with regard to any persisting chemical irritations, or, indeed, any cause which is capable of removal. The method of dealing with recent abrasions and wounds of all kinds, is given in the chapter on Injuries from Mechanical Agents.

Persistence or increase of the inflammatory action, supposing the cause to be removed, must be met with local and general measures commensurate with such symptoms. Among them pain must be regarded as the highest indication for action, for it cannot be intense and last long without considerable damage occurring to the eye. If it be not subdued by the application of cold to the eye and to the surrounding region, leeching or cupping the temple of the affected side will be required. Increase in temperature stands next in pathological importance. It should be subdued by cold applications.

Much photophobia, lacrymation, and blepharospasm may be caused by very slight local lesion, and do not necessarily call for active treatment.

The applicable remedies, when the exciting causes are phlyctenular corneitis, and chronic and granular conjunctivitis, have been

discussed along with these affections. Abscess and ulceration are treated of separately.

Constitutional remedies will be needed chiefly in the direction of febrile excitement.

PHLYCTENULAR CORNEITIS.

This is generally called strumous ophthalmia.

The symptoms usually begin with congestion of the conjunctiva on the side corresponding to the spot of the coming phlyctenulæ, and a lash of blood-vessels passes from the oculo-palpebral conjunctiva to the corneal edge. A small cloudy nodule appears on the cornea, at periods varying from a few days to weeks, and is partly embedded and partly raised above the surface. If it be at the very edge of the cornea, circumferential, the blood-vessels pass to it. If it be away from the edge, tending centrally, they do not reach it. The illustration, Fig. 273, shows the latter state. After that, a vesicle forms

Fig. 273.

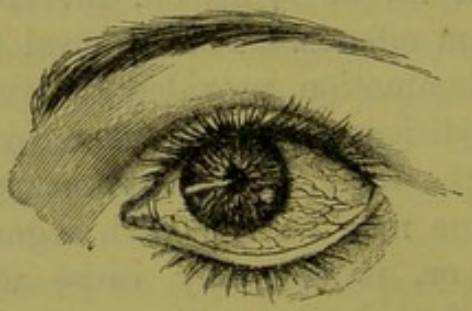

on the nodule, bursts and leaves an ulcer with sharp edges, covered by whitish, probably purulent, material. But a vesicle may not form; in which case the epithelium is shed, and an ulcer is developed.

When the nodule tends centrally, the intervening clear part of the cornea between it and the sclerotica, sometimes called phlyctenular bridge, is apt to inflame, constituting limited superficial corneitis, then the blood-vessels become continuous with the recently-developed ones in the conjunctiva. The inflammation may cease, and the vascular slip recover its clearness. Or corneal inflammation may not occur. In either case, the ulcer stands in clear cornea, looking smooth and transparent, as if formed by a piece of the cornea being chipped out. It is the clearest of all corneal ulcers. It seems as if lined by epithelium. According, then, as blood-vessels pass to the ulcer or not, do we speak of a vascular or a transparent ulcer.

A phlyctenula may be, and not unfrequently is, preceded or followed by corneitis, which would modify its ordinary symptoms.

The ocular conjunctiva, or the entire conjunctiva may inflame. There is seldom more than mild chronic catarrhal conjunctivitis, but this re-acts on the corneal disease.

The sub-conjunctival tissue becomes disproportionately inflamed, hence the tendency to eversion of the upper eyelid.

There is a modification of phlyctenular corneitis described as "herpes zoster corneæ," which commences with a collection of clean vesicles in the form of a wreath upon the cornea. Rupture of these leaves the appearance of a scratch. General corneal opacity soon follows with insensibility. The tension of the eyeball is generally reduced, and there is retinal venous hyperæmia. Herpes of the lip and cheek may appear at the same time. Some constitutional disorder mostly precedes the ophthalmic attack. The disease is chiefly monocular. The posterior part of the eye does not become complicated. There is no recurrence.

Accompanying the formation of the nodule and its final development, is intolerance to light, or photophobia, with blepharospasm, lacrymation, and impairment of vision, mildly or in great density.

The photophobia is the leading feature, yet its intensity is not in corresponding relation to the degree of the conjunctival inflammation, or of the corneal disease. It may be most severe while they are least marked. When children are suffering much from it they cannot allow the eye to be examined, and resist with all their power any attempt to inspect it. During the day, they systematically screen their faces from the light; and, if they are allowed, they will always lie on their faces. This may prevail for weeks or months. At night, the symptom abates; they get up, open their eyes a little, and even employ their vision.

Inspection of the eyeball is necessary, and should be made with eyelid retractors, or during anæsthetic sleep. I must mention in caution, that a small phlyctenula, or an ulcer, is apt to be overlooked; and if neither have yet formed, and the conjunctival vascularity be but slight, the nature of the disease might be altogether mistaken.

Epiphora, or lacrymation, is very marked. During the day, the least movement of the eyelids is attended by a flow of tears: or if the eye be opened voluntarily, or by another person, the water gushes out freely. The act reddens the conjunctiva and the eyelids. The cheek may be excoriated by continuous discharge.

Vision is generally interfered with by any vascularity of the cornea, and is always eclipsed if the nodule form over the pupil.

Absolute or inflammatory pain is not complained of in the day,

but it occasionally occurs in children at night during sleep, for they wake crying and complaining of it.

The mucous membrane of the nose is often inflamed, and the lips excoriated by the nasal secretion.

Sneezing, and even violent fits of it, and itching of the nose are common, especially when the patient tries to look up. The nervous association between the ciliary nerves which receive the primary irritation, and the Schneiderian membrane, accounts for these.

This ophthalmia occurs at all ages, but is most common in children.

Remote causes. A congenital scrofulous constitution is the most prominent among these. In such constitution I recognise two rather distinct external conditions. In the one there is the pale countenance, the swelled upper lip, the thickened septum of the nose, the inflamed joints, the tumid belly, the languid circulation, the pale and rough skin, the cold extremities, the flabby muscle, the torpor in bodily and mental functions, the enlarged lymphatic glands under the jaw. In the other the rapid circulation and the nervous irritable system, the quickness of mind, and the activity of bodily functions, the thin skin and marked ramification of the cutaneous veins, with the unnatural colour in the cheeks. Next to this is the condition allied to the former of the two, acquired by those who have been formerly healthy, or by the progeny of such, in consequence of the combined influences of insufficient and unwholesome food, deficient clothing, want of domestic comforts in general; sedentary occupations; impure atmosphere of crowded dwellings, especially in the confined parts of large cities. Or by those who have been improperly fed during infancy or after weaning. Debility from previous diseases.

Hereditary taint of scrofula, or of consumption, can be generally traced when the complaint appears in those who seem otherwise to be healthy.

The eye symptoms often alternate with the active development of some external scrofulous symptoms.

The connection of the affection with the desquamative stage of scarlatina, measles, and smallpox, which rouse into activity the scrofulous diathesis, has been long recognised. The same may be said in associations of eczema, and impetigo of the face and nasal mucous membrane, and herpes frontalis. So commonly is the nose diseased, that some suppose the eye symptoms to be caused and perpetuated by such disorders.

The liability to corneal affections, in those who have had smallpox, is notorious.

The most frequent exciting causes, are exposure to wet and cold, and a draught of cold air, by which a chill is brought about. Our

variable climate exerts its bad effect. The influence of cold and damp, or dry and warm days, in aggravating, or ameliorating the symptoms, forces itself on attention. North-easterly winds are very detrimental.

Perpetuation of the disease, is due to the development of crops of nodules.

Persistence of the disease renders the health still worse, and if paleness, or flabbiness of the muscles, enlargement of the lymphatic glands, be only somewhat marked, such are apt to be erroneously supposed to be altogether the effects of the ocular lesion.

Results. In slight and superficial phlyctenulæ, not perpetuated, there may be perfect recovery. The irritation and inflammation recede, the corneal excoriations or ulcerations fill up by clear tissue, and are covered by epithelium which is at first opaque but clears.

Deeper seated phlyctenulæ leave some traces. The true cornea may be well repaired, while the epithelium remains long, or permanently opaque. Or the ulcer fills up with opaque material, and is covered by opaque epithelium, both of which remain opaque. It is here that the ulcer remains long vascular, and the blood-vessels with the thickened epithelium, project beyond the surface.

In the transparent ulcer the healing is remarkably slow, extending over months or years, and the loss of substance is always filled up by more or less opaque matter, and is covered by opaque epithelium.

Although the subjective symptoms are greatly reduced while the process of healing is going on, the eye is yet very irritable.

Perforation of the cornea is not unusual. It may occur as a primary effect in a few hours, in a few days from breaking down of the nodule, or secondarily from inflammation and ulceration of the cornea, around the disintegrating nodule. These occurrences are more probable when the phlyctenulæ are confluent. With perforation the iris prolapses, and the protruding bit looks like the head of a fly, and is called myocephalon. The ulcer contracts, opacity appears around its margin, the prolapsed iris sloughs off, the pupil is displaced towards the perforation, and a dense white cicatrix, called leucoma, marks the breach, as is shown in Fig. 274.

Or some of the iris may appear in the leucoma, as a black dot.

Now and then all the true corneal layers are ulcerated through, the posterior elastic lamina remaining, and which bulges as a small transparent vesicle, hernia corneæ. In a few days it bursts, the aqueous humour escapes, and carries with it some of the iris. Then ensue the changes above described.

A leucoma may be unable to sustain the pressure of the aqueous

humour, and being thrust forwards, forms a partial corneal staphyloma.

Fig. 274.

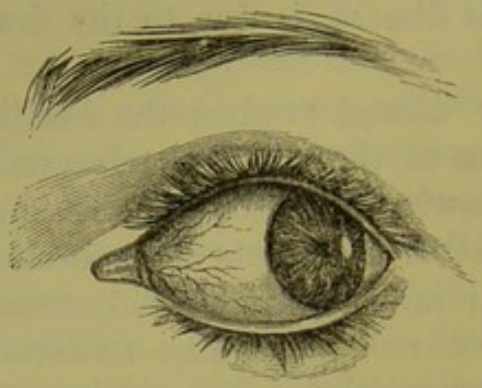

Pus may be deposited at the lower part of the cornea, constituting onyx.

Retrogressive action may ensue in the phlyctenular nodule, by which cartilaginous, or chalky material, is deposited.

Accompanying corneitis may leave opacity according to its extent, and its degree. The phlyctenular bridge is affected most.

Frequent relapses produce phlyctenular corneal pannus.

Strabismus is no uncommon effect.

Treatment. Local measures. The eyes should be well shaded, as long as the light is intolerant to them, but not covered with bandages, by which they are kept hot. See the chapter on Eye-shades.

In a recent and acute attack, with local elevation of temperature, the inflammation and irritability will be best subdued by the application of cold to the eye, by means of cold water, or spirit lotion, applied with a bit of rag, so as to produce evaporation, and long enough to produce an effect; yet not to cause detrimental reaction.

In a chronic case, especially a severe one, fomentation three or four times a day is called for. This may be done with a sponge or a flannel rag dipped out of hot water, or by holding the eyes over a vapour of hot water. Many drugs are recommended as adjuncts to this, the chief of which are belladonna, opium, hyoscyamus, camphor, and hydrochlorate of ammonia. But the moisture and the heat do more than the drugs.

The advantageous use of atropine as a mydriatic, or pupil dilator, is believed in when, with penetrating ulceration of the cornea at or about the centre, the iris is in contact with the small breech, the theory being that the dilatation pulls away the iris and prevents adhesion. Iris which is actually prolapsed cannot be pulled back by any means of artificial dilatation.

I do not apply any stimulants or astringents to the surface of the eye, so long as the cornea is in the least inflamed, because then they do harm by irritating, and the more so according to the acuteness of inflammatory excitement. I disbelieve in the local sedative effect attributed to them. This opinion is shared by all those who have seen my practice.

That the transparent or bloodless ulcer is roused into curative activity by an astringent, I admit. For this I use the exsiccated alum, and apply it neatly with a brush merely to the ulcer, and repeat the application once or twice a week, according to the absence of effect, till vascularity or opacity indicates that healing has set in.

I have in the last chapter alluded to the indelible olive hue which the nitrate of silver in solution may impart to the conjunctiva; a strong objection to its use. A black cicatrix of the cornea is an occasional occurrence when the nitrate of silver in solution or in stick, is applied to a corneal ulcer. A lotion of the acetate of lead employed under the same condition of ulceration, is apt to leave deposits of lead in the cornea, and which in time becomes encysted. They rise above the cornea and irritate the palpebral conjunctiva.

Scarification of the conjunctiva, even when it is inflamed, is unnecessary.

Division of the lash of blood-vessels passing from the conjunctiva to a chronic vascular ulcer, and executed by snipping out a conjunctival piece of them, is decidedly beneficial. The effect is seen on a larger scale in the perishing of the corneal portion of a pterygium, after the conjunctival part has been more or less removed.

Any co-existing cutaneous affection of the head or of the face, or any such of the latter excited by the lacrymal or nasal secretion, should receive the proper local attention from the first.

Local bleeding is quite uncalled for, unless under some conditions when the inflammation passes into diffuse corneitis, or extends to the eyeball in general, a complication which is rather rare if it be not excited by injudicious applications to the eye.

I must express my disbelief in the so-called counter-irritation to produce metastasis by means of blisters, issues, and setons applied behind the ears and on the temples. It is a barbarous mockery of treatment. My dispensing with them altogether, shows at least that my patients may get well without them, and as to the matter of saving suffering, especially among the poor, those who escape such, are no doubt great gainers.

A strong solution of sulphate of atropia, often applied to the conjunctiva, is the present fashionable application, under the idea that

it diminishes intra-ocular pressure, a false supposition, and that it acts as a local anæsthetic to the corneal and the ciliary nerves and relieves irritation, a statement not confirmed by my observation. I have discovered only the disadvantages of this alkaloid. Many persons are very obnoxious to its poisonous property, and show the effects in headache, burning sensation in the throat, sleepiness, restlessness, and rapid action of the heart. In other persons it produces immediate and intolerable irritation of the conjunctiva, and erysipelas of the eyelids and of the cheek. In others again, it is borne well for a time, but afterwards excites irritation of the conjunctiva and of the skin. The dilated pupil renders the eye still more sensitive to the light. A reference to the index will show that I have made other remarks about this agent.

Constitutional measures. The necessity for these is generally obvious enough, and the tendency of the phlyctenula to recur, establishes its universality. We must increase the nutrition of the body and so invigorate the system. The first step in that direction is to remove the patient from the influence of the cause which has brought about the unhealthy body. Pure air, ventilation of apartments, sufficient clothing, rich children are as often too naked about the legs as poor ones, wholesome nutritive diet, cleanliness of the skin, are indispensable; for without them, or any of them, a cure will not be effected. The disease may wear out, but the eye will be damaged or lost. Alone they may suffice. All else as treatment is secondary to them. This is the reason why the disease is so persistent when patients are merely dosed.

Exercise is requisite when the weather is not inclement, and the wind is not in the east in the winter and spring months; for chilling the surface is very detrimental.

Washing in tepid rather than in cold water is to be preferred. A hot foot-bath at night has a good effect.

Patients must not lie in bed in the daytime, and children must not be allowed to lie on their faces.

It is better than otherwise, that the eyes should be accustomed to a little light, if they can possibly bear it, rather than placed in absolute darkness, and that they be moderately used on large objects. While taking exercise, bright light must be excluded so long as it is painful.

Chalybeates and preparations of cinchona are drugs which can be relied on for facilitating recovery. The choice of either must be based on the defective bodily indications for it. It may be quite right before resorting to them, and under certain conditions of defective abdominal secretions to give a mild purgative, and even to repeat it once a week after the tonic has been commenced. The

treatment in general should be pursued after all the eye symptoms have been subdued, in order to restore health, and reduce the chance of a relapse. To attain the same end may be added a change of residence from a less salubrious district to a better one in a warm, dry, inland situation. The seaside is not to be generally recommended as long as the eye remains inflamed.

DIFFUSE OR PARENCHYMATOUS CORNEITIS.

In this the active inflammatory symptoms are less marked than in the above. The chronic character prevails, and which is by far the more usual condition of corneal inflammations, and the spoiling effects are greater.

Symptoms. In a well-developed typical form, the cornea has lost its natural polish, and resembles a piece of glass that has been breathed on. Or it may have a more stippled aspect, with greater roughness, whereby there is more haziness. With this there is a deeper-seated streaked or speckled whiteness or yellowishness, arising from interstitial deposits of materials in the true cornea.

There is morbid vascularity in varying degrees, of the surrounding conjunctiva, of its sub-tissue, and of the sclerotica. The more superficial the action, the redder will the eye appear. The deeper it is, the paler will it be; hence the lighter colour of purplish hue, above alluded to, and the arrangement of the blood-vessels in scattered radii, when the sclerotica is mainly implicated. There may be, in addition to the general and diffused enlargement of the blood-vessels, a vascular bright red crescentic ring around the upper part of the cornea, and perhaps overlapping it, looking rather like an extravasation of blood than an inflammatory patch, which it really is.

The opacity of the true cornea begins at the circumference, and creeps on till the whole is slightly misty, and then the more cloudy spots or streaks of various sizes and shapes appear. These may clear up in some directions and increase in others, or so augment as to produce general dense opacity. There may be a single central deep spot of any shape.

The true corneal tissue is not long pervaded by opacity in any form, before such opacity commences to be injected with blood-vessels. They may be few and isolated, and cross each other as they pass through the different layers, or numerous and close, looking like a red patch, in which no individual branches can be seen with the naked eye. As a rule, the dense opacities receive the most vessels.

Pigmentation is described by Dr. Hirschler as occurring in small spots, midway between the front and the back of the cornea, and apparent only when the corneitis is declining. They are supposed to be altered hæmatin from blood extravasation.

In the greater or lesser vascularity is to be found the widest variation in any outward character of the disease. The action around the cornea may be the most marked symptom, or so slight as readily to escape being noticed. On the cornea the variation may be as great. There may be not any, or but the least surface vascularity, or as much as in any case of corneitis.

Pain, photophobia, and blepharospasm seldom exist except in the beginning of the disease, and they usually decline when the corneal exudation occurs. An exception may occur when the cornea is very vascular. Again there may be remissions and exacerbations till the disease is conquered.

The palpebral and oculo-palpebral portions of the conjunctiva, are hyperæmic and œdematous.

The eyelids seldom escape some degree of vascular excitement.

The circulation is quickened, and the patient is restless. The skin is harsh and dry, and the extremities are cold.

The complications are alterations in the form of the cornea. The surface becomes more spherical and globular, hence the name of globular cornea, or an irregular spheroid, projecting on one side. This is by a process of morbid growth or perverted nutrition. It does not arise from pressure of the aqueous humour, because of an augmented quantity of the fluid. Pressure so exercised would spoil the retina. Such spoiling does not occur. Nearsightedness is produced, together with impaired vision, according to any existing opacity of the cornea. Cyclitis, and its effects on the form of the cornea and of the sclerotica. Irido-choroiditis. Ophthalmitis.

The effect on vision will depend upon the metamorphosing changes of the inflammation, whereby there is more or less corneal opacity; more or less loss of transparency in the dioptric system, or damage to the retina.

Only one eye may be affected, but both are generally implicated simultaneously, or the one after the other.

The time of life at which the disease usually occurs is from childhood to the eighteenth year. The most severe cases are met with from weaning to puberty, the period when nutrition and growth are proceeding most actively; and, too, when they are most readily disturbed by external influences. But it may appear at any age.

Prognosis. Diffuse corneitis in its mildest form is always tedious; and its effects are often disastrous to sight, through the spoiling of

the cornea or posterior damage to the eye. A severe case may last, in a chronic stage, for many years. It may be a question whether complete transparency ever returns to any part of the cornea which has been very opaque. It is said that even when repair seemed as perfect as it is possible, the microscope will detect the remains of inflammatory action in layers of cells and fatty molecular matter. Inflammatory injury to the post-corneal tissues, is always likely to happen, and frequently occurs.

However, recoveries are not infrequent, and children make the best of them. In childhood, an eye may be restored to health, when such success seemed most unlikely.

In the decline of the disease, vascularity in general decreases, and the opacity of the cornea gets thinner in spots, and so declines. The grey and more superficial cloudiness is more likely to disappear than that which is deeper and more opaque. The longer any exudation has existed, the less likely is it to be removed. After puberty, perfect recovery is unusual. After adult age it is extremely rare.

The disease is apt to recur when it has seemed almost cured, or, at least, when the inflammatory symptoms have nearly come to an end.

Recovery is generally quickest when the inflammation does not extend far beyond the cornea. The more the eyeball in general is implicated, the longer will the cornea suffer.

Neither ulceration, nor suppuration of the cornea, is incidental to this affection.

The spoiling effects on the eye may be thus summed up. Alteration in the refraction, through the changes in the curves of the cornea; and perhaps, too, in the form of the eyeball. Hence the myopia and the astigmatism. Limitation of vision, or partial or total eclipse of it, from the position or the density of corneal opacities. Adhesion of the iris to the cornea. Changes in the iris and in the crystalline lens apparatus, whereby the pupil is contracted, and its area more or less obscured by inflammatory deposits on the capsule of the lens, slight opacity of the capsule, and even of the lens. Deeper and inflammatory changes in the ciliary body, and in the choroidea. Also in the vitreous body and the retina. Atrophy, or collapse of the eyeball from ophthalmitis.

Causes. External injuries to the cornea. Constitutional states, the same as those which have been described as producing phlyctenular corneitis. I have said that phlyctenular inflammation may usher in diffuse corneitis. Sometimes there is no recognisable predisposing or direct influence.

Treatment. Respecting local measures, all that I have pointed out under this head as applicable for phlyctenular ophthalmia, is suitable

here: and, I must add, the more frequent necessity for a few leeches to the temple, arising out of marked inflammatory pain. Opiates, whether used by the mouth or subcutaneously, cannot supply the place of them. Local bleeding is often the only measure which will relieve the pain, and enduring pain is more a post-corneal than a corneal symptom. When there is a necessity for it, the earlier it is resorted to the more beneficial will it be.

Stimulating and astringent lotions to the eye are hurtful, by increasing the existing irritation. We must soothe, and not excite. Reducing vascular action, and removing nervous irritation, most favour retrogressive metamorphosis of the newly-formed elements.

Evacuation of the aqueous humour, or tapping the cornea, affords marked relief to the subjective symptoms when the eyeball is abnormally tense, or the cornea is becoming distended, a condition preceding what is called hydrophthalmia. I resort to it daily, or less often, according to the seeming demand for it.

During the declining stage of the corneitis, the last generation of surgeons believed in the stimulating effect of the vapour of prussic acid, applied to the eye occasionally.

The necessary general measures are identical with those also for the constitutional state in phlyctenular ophthalmia, and require to be longer persevered in, because the constitutional deficiency is generally more marked.

PUNCTIFORM CORNEITIS.

I regard this as but a variety or modification of diffuse corneitis, and not a permanent species. Sometimes a line of demarcation cannot be drawn between them, and it cannot be said in a particular instance under which of the two heads the affection should be classed.

Symptoms. Unusual fulness and apparently slight prominence of the eyeball. Loss of lustre of the surface of the cornea, with perhaps roughness. Diffused muddiness of a part or the whole of the true cornea; most marked, however, in the lower half, together with spots, which are produced by minute white circumscribed dots in the corneal laminæ, but chiefly in the posterior ones, and also in the posterior elastic lamina, accompanied by vascularity in the cornea and around it, and very frequently by inflammation of the eyeball.

The muddiness is most extensive in the posterior elastic lamina; and when it is general there, all parts behind necessarily look dull. The iris lustre is lost, and it is impossible, by looking at it, to say whether it is merely eclipsed or actually diseased. The aqueous

humour may become thickened and opaque by exudation. When these two causes operate, the pupil may be quite obscured.

The corneal changes may be quickly developed, and ushered in by marked surrounding inflammation and by corneal redness, or begin as a faint central deep-seated opacity, recognised only with a positive lens, as formed by the accumulation of whitish dots, in corneal tissue otherwise clear or but little cloudy, while there is but a narrow line of redness in the anterior zone of the sclerotica.

Vision is always affected, and generally more than the corneal opacity would seem to account for.

Photophobia and pain may be present, but they are as often absent. They depend chiefly on the disease spreading beyond the cornea.

The internal tissues of the eyeball posterior to the cornea are apt to become inflamed. This may occur simultaneously with the corneal disease, but more usually it is secondary. So often does the association exist, that some surgeons consider the punctiform state to be but a symptom of irido-choroiditis which is the common form of the general implication of the eyeball. It is on this account, too, that the name of aquo-capsulitis, one which is still used, was long ago given by Mr. Wardrop to the disease, and the cases adduced in illustration were those in which the inflammation of the eyeball, especially the iritis, was more apparent and striking than that of the cornea. But the symptoms were wrongly referred to inflammation of an aqueous membrane which was supposed to contain and secrete the aqueous humour, and cover the surface of the chamber of the eye.

The evidence of the irido-choroiditis, is, increased intolerance to light, and further loss of sight. Tenderness of the eyeball. A dull aching pain generally in the forehead and the side of the head, and a sensation of distension of the eyeball. Contraction of the pupil. Increased vascularity of the surface of the eye. Added to which is febrile excitement.

Punctiform corneitis occurs from childhood to early adult life. It is usually seen in a later age than diffuse corneitis, and is more chronic. It is nearly always a double affection and symmetrical. The eyes may be attacked simultaneously, or the one after the other.

When the objective symptoms are at their height, the surface of the cornea looks like a piece of ground glass and roughened, and the entire cornea is almost white, and vascular. A little later the vascularity produces a salmon or pinkish colour, at which time the conjunctiva around gets vascular in fringe-like patches.

Prognosis. This is in general unfavourable as regards quick or complete recovery. When there is no complication, the cornea may ultimately clear. Unfortunately the disease is very apt to linger for

months or years; getting better and worse alternately, without decided improvement, and to recur after it had seemed nearly to have passed away, till the opacity, especially the punctiform patches, are too dense to clear away altogether. But a still more unfavourable prognosis arises out of the complication of post-corneal inflammation. The distinctive effects on the eye, depend in a large measure on such complication, which acts directly on the tissues in which it occurs, and indirectly through its reaction, on the cornea. The health of the cornea depends on that of the eyeball in general. Hence it is that when the cornea is the centre of the inflammation, recovery is the rule, but the exception, when the inflammation extends much beyond it.

The recognisable damage done to the eye after the acuteness of an unsubdued complicated attack is over, consists of alterations in the form of the cornea, with more or less of surface and interstitial deposits. Change of colour in the iris, and adhesion of the pupillary margin to the cornea, or to the capsule of the lens.

Some loss of transparency of the lens, with dotted opacity on its surface. Muddiness of the vitreous humour, with floating shreds. Sometimes atrophy of the eyeball.

The causes. A scrofulous constitution is a foremost one, and general debility is rarely absent. Mr. Hutchinson, who regards the affection as "chronic interstitial keratitis," and thereby describes a part of it rather than the whole, attributes it to inherited syphilis, and for these reasons:—

"1. That in certain instances patients whom I knew beforehand to be the subject of inherited disease have, whilst under my observation, been attacked by it.

"2. That in a large number of other cases I obtained from the parents of the patient a free confession as regards themselves and a distinct history of specific symptoms in the child during infancy.

"3. That in almost all cases the subjects of it present a *very peculiar physiognomy*, of which a coarse flabby skin, pits and scars on the face and forehead, cicatrices of old fissures at the angles of the mouth, a sunken bridge to the nose, and a set of permanent teeth peculiar for their smallness, bad colour, and vertically notched edges, are the most striking.

"4. That in many cases one or more of the following suspicious forms of disease have either been coincident with it, or have occurred previously:—Ulcerative lupus, nodes on the bones, psoriasis on the face, otorrhœa, chronic enlargement and subsequent atrophy of the tonsils, ulcers in the throat, a thickened condition of the parts under the tongue, and chronic engorgements of the lymphatic glands.

"5. That the effect of specific treatment in mitigating the severity of these inflammations, and in shortening their duration, is often very marked, whilst mere tonic and dietetic plans are of no avail.

"6. That it is often either accompanied or preceded by iritis."

I must bear witness to the frequent presence and coexistence of the third class of general symptoms. My own opinion is this, that while I believe syphilitic influence to be pushed too far, I admit that anything which enfeebles a child may act as a remote cause, and as such I should regard inherited syphilis when it exists. But I do not consider it as a settled question that No. 3 symptoms are syphilitic. Thus, I have seen such symptoms without the punctiform corneitis, and the corneitis without them. Now, although they might as syphilitic states prevail apart from any eye symptoms, if the latter be dependent on the state of the system arising from syphilis which also produces the former, they would scarcely appear without them. I have seen the corneitis in its most characteristic form, very often in young women of ages from sixteen to twenty-five, whose teeth were perfect, and who were free from syphilitic taint.

As exciting causes I believe in excessive use of the eyes on minute objects, and sudden transitions from high to low temperatures.

Treatment. What I have recommended for the preceding forms of corneitis, with reference to the state of the system, and the predisposing causes, applies here, in the punctiform variety. The generous diet, the pure air, and the warm clothing, will do more than the medicine. The two combined will give the best result. I say the same as regards local measures. Some surgeons rely much on the almost constant application of warmth, by hot compresses. To this must be added treatment for inflammation of the interior of the eyeball, irido-choroiditis, &c. So far as the cornea is concerned, the use of mercury is uncalled for.

It is not necessary that the patient be kept in the dark, nor that all use of the eyes be forbidden.

NEUROPARALYTIC CORNEITIS.

This is anæsthesia and perverted nutrition of the optic apparatus, from complete interruption of conduction of the fifth cerebral nerve.

The causes are lesion of the central parts of the nerve, through implication of its root or trunk in tumours of any kind, in an apoplectic clot, in meningitis, in ramollissement of a part of the brain, in induration ramollissement or atrophy of the Gasserian ganglion.

Symptoms. These are nearly identical with those which ensue when the trunk of the nerve is divided in experiments on the lower animals, of which copious details are well given by Majendie and others.

In man the skin of the eyelids, the conjunctiva, the Schneiderian membrane, and other parts supplied with common sensibility by the nerve on the one side, become anæsthetic, and there is lateral loss of taste in the tongue, and the lacrymal secretion ceases. The muscles of mastication supplied by the motor division of the nerve suffer. Then conjunctivitis ensues. The cornea becomes rough, covered with tenacious mucus, and infiltrated, afterwards milkish white, swollen, still more opaque or actually yellow, ulcerates centrally, or circumferentially, and bursts, and shows changes not unlike those which appear in ordinary interstitial suppurative corneitis. The post-corneal ocular tissues participate in the inflammatory proliferation. The aqueous humour is cloudy, hypopion occurs, the iris adheres to the capsule of the lens, and vision is damaged or lost. Withal, the eyeball loses some of its natural tension, and is softer. Experimenters on the lower animals say that in them the crystalline lens and the vitreous body remain clear.

So great is the ocular insensibility from the first, that the surface of the eye may be freely handled, or pricked, or touched with pungent things, without conveying any impressions.

Severe neuralgia may precede or accompany the anæsthesia.

The voluntary power over the eyelids remains, and so does that over the ocular muscles, unless the portio dura nerve, or the sixth, or the third cranial nerve, or both, are involved in disease common to each, or to them all, and the fifth, when of course it would be lost.

Partial interruption of conduction of the nerve is attended by modified symptoms. There may be loss of sensibility of the eye to light, with insensibility of the eyelids and of the conjunctiva to common stimuli, with very little hyperæmia, while the tunics of the eyeball keep healthy, or the cornea may become only infiltrated, and afterwards improve. Or it may inflame in patches, which action takes a chronic course, then improves, then relapses, and ultimately ends in ulceration. There may be more neuralgia than anæsthesia. Such variations may obscure the nature of the malady.

The reason why the eye suffers in this special inflammatory manner, involves the large physiological question of nerves exercising a direct influence upon the nutrition of the tissues. I cannot doubt that in the higher vertebrata, nerve force is exercised in a general manner, in the nutrition of all the parts into which, and near which the nerves pass. Some persons believe that there are special nerve fibres

which regulate the nutritive process, and preside as trophic nerves, not through any influence on the blood-vessels, but by direct action on the parenchyma of the proper textures of the part. To this I cannot yet subscribe.

Snellen ignored the nerve nutrition influence, and suggested that from the anæsthesia and the absence of the tears, by which extraneous bodies on the eye were disregarded and never naturally removed, the irritation and inflammation were set up, and he tried to prove that if the conjunctiva and the cornea were sufficiently protected, in the eyes of rabbits in which the fifth nerve had been divided, that such irritation and inflammation would not ensue, and that the proper textures of the eyeball would not suffer.

I have shown elsewhere, that in paralysis of the portio dura, exposure of the conjunctiva to dust, and other sources of irritation will cause inflammation of it, and I believe that a little anæsthesia always accompanies an exposed eyeball, whether it be the persistent opening of the eyelids, from palpebral paralysis, or ocular protrusion. Protective influence will thus prevent inflammation, but such a case is not a parallel to that which I am describing.

Schiff repeated Snellen's experiments, and obtained different results. When he divided the nerve, and protected the eye, morbid changes set in, the cornea and the post-corneal tissues inflamed, although with less severity. Afterwards he showed that it was enough to divide the ophthalmic division of the nerve to get hyperæmia and anæsthesia. Meissner afterwards discovered that if the nerve trunk were divided, save the inner fibres of the medium branch, full anæsthesia was produced, and inflammation neither of the conjunctiva nor the eyeball ensued, although no protective influence was used for the eye. Also that if he reversed the experiment, and divided only the inner fibres, inflammation ensued, but no anæsthesia. He concluded that the outer portion of the nerve presided over sensibility; and that the inner presided over nutrition, and is trophic. However, later experimenters find that section of the sympathetic nerve in the neck interferes with the action of the ophthalmic branch of the fifth, and so far spoils Schiff's theory, and leaves the question of special trophic nerves in the eye unsettled.

Treatment. As the nerve disease and its effects are only secondary, the exciting causes, must, if possible, be discovered and met by any appropriate remedies, although I may say that such causes are not generally of such a nature as to admit of removal.

Local measures should be those which are indicated under like inflammatory conditions of the eyeball and of the conjunctiva from other causes.

Results of corneitis. Opacity of the cornea. The terms nebula, albugo, and leucoma, are frequently applied to corneal opacities, according to their degrees of density. The first is used to express slight opacity, the second and third white opacity.

All opacities of the cornea proceeding from inflammatory causes, are either abnormal deposits, the last effort of inflammatory change of normal tissue, or imperfect reproduction, imitation of lost tissue. They may be classed as interstitial or deep, and superficial opacities.

Interstitial and deep opacity. This may occupy the whole of the cornea, as a uniform, thin, semi-opaque cloud, or as closely set dots over the same extent, or as still smaller markings like millet seeds, in well separated groups, and which are chiefly seated over the posterior elastic lamina.

The corneal surface generally retains its lustre.

The whole class is composed of shrivelled nuclei in fat cells, together with partial fatty degeneration of the inter-laminar substance.

The cause is mostly interstitial corneitis.

Surface opacity. There are several forms of this.

The epithelial form. There is haze with roughness over the cornea generally, or it is limited, with varying degrees of density, and with distinct edges. Or hard, very opaque and raised partial opacity, with indefinite edges, from semi-opacity of the surrounding epithelium, and a little vascular when close to the conjunctiva.

In the former state, it is composed of deposits of thickened and irregularly laid epithelium, with traces of neoplastic material rendered opaque by fatty and molecular matter. In the latter, along with the altered epithelium, there is more neoplastic matter. Some interstitial opacity may coexist with this. *The cause* is simple and phlyctenular corneitis, or corneal ulceration from any cause.

The connective tissue form. This looks like conjunctiva traversed by tendinous laminæ. It consists of loose connective like tissue layers in folds, freely traversed by blood-vessels. It bleeds readily. When speaking of the granular ulcer out of which it arises, I mentioned that at the corneal margin it resembles a pterygium. It is called a pseudo-pterygium.

The mixed form. The connective tissue is covered by epithelium, in grades of disintegration, with fat, cholesterine, chalky material, and blood-corpuscles. Cretaceous and osseous changes may ensue.

It proceeds from the granulating ulcer unassociated with prolapse of the iris.

Course. Opacity is as a rule, perpetuated by the same process of assimilation which maintains the healthy tissue. Yet fortunately there is always until adult age, a very strong tendency for the

abnormal structure to return to a healthy state. By this the opacity is lessened or disappears. It is not that the abnormal deposits revert to normal tissue. They are removed, or reduced, or become transparent.

Treatment of opacity. My own belief is that nothing can be accomplished for its removal by topical applications, and that all improvement is effected by a natural process of repair. Many surgeons assert that advantage may be got from galvanism, irritating the cornea with drugs diluted with spirit, water, or grease, or with fumes from the same. From calomel and sulphate of soda, dusted on the cornea. From injecting salt and water under the conjunctiva, and so on.

When the pupil is obscured by an opacity, the question of making an artificial pupil arises.

This method of hiding indelible opacities dates in record from the time of Galen. It has fallen into oblivion and been reproduced several times.

The operation is best done with my gouge, p. 485, ground to a fine point, and the bottom filled with a concentrated solution of Indian ink. The eyelids having been retracted, and the eyeball steadied, close set punctures should be made in the opacity, beneath the epithelium. In a few days, when the slight irritation has passed, the interstices which have escaped tattooing, should be attacked, and so on till all is covered, which may occupy from four to eight sittings. The softer the opacity, or cicatrix, the more applicable is the operation. When the opacity is large, it facilitates the operation to have two gouges ready charged.

There can be no doubt that considerable cosmetic effect is produced by the operation, of which I have had some marked examples in my practice, especially at St. Mary's Hospital.

Tattooing may be employed for an optical purpose, as in semi-transparent central opacity of the cornea, which renders a lateral artificial pupil necessary. By blackening the haze, so as to prevent the diffusion of light from it on the retina, the visual power is increased.

Subjective Symptoms of Corneal Opacity.

Every opacity which in the least eclipses the pupil, disturbs the vision of that eye by the absorption, the reflection, or the dispersion of the light.

There may be distortion, and even multiplication of the images

of objects, from roughness of the epithelium of an opacity, with roughness of the surrounding clear epithelium.

Circles of dispersion on the retina, and astigmatism, produced by abnormal curvature of the cornea.

More or less loss of accommodation from synechia anterior.

Astigmatism from change in the position of the lens, in association with synechia anterior.

Injurious Physical Effects of Corneal Opacity.

Myopia, through straining one or both of the eyes from endeavouring to improve the sight by holding objects close to the eyes, so as to increase the visual angle.

Internal squint, arising out of forced accommodation, and forced convergence of the eyeballs. Also from excluding from binocular vision the eye which is defective, or if both be damaged, the more defective of the two.

PANNUS, OR VASCULO-NEBULOUS CORNEA.

This may be defined as the morbid product of preceding inflammation, to the maintenance or increase of which the nutritive process is confined. It is therefore a chronic affection.

It may be artificially classed as pannus tenuis, and pannus crassus.

Pannus tenuis. Symptoms. Greyish cloudiness, or more decided opacity, with vascularity and roughness of a part or of the whole of the conjunctival layer of the cornea with surrounding vascularity. The corneal blood-vessels are chiefly from the sclerotica. This gives to the eye a very dull and inexpressive appearance.

The causes are repetitions of the various forms of corneitis, in which the phlyctenular is prominent, and especially granular conjunctivitis. Besides the trachomatous growths on the cornea, from extension of the conjunctivitis, the palpebral granulations mechanically irritate, and the greater development of pannus crassus on its upper part, is because the upper eyelid, from its closer contact, irritates more than the under.

Pannus crassus. Symptoms. Vascular granulations of the cornea, like those in a healthy wound, more apparent in the upper half, because the upper eyelid, from its closer contact, irritates more than the under. In a later stage, a tendinous-looking layer on the

cornea, over which grows loose vascular connective tissue, continuous with the conjunctiva. The vascularity increases, and the cornea is ultimately surrounded by a thick tumefied network of varicose vessels, interspersed with numerous reddish-brown granulations. The corneal blood-vessels are chiefly from the conjunctiva.

Neither the iris nor the pupil may be visible, and the corneo-sclerotic junction concealed.

The causes are purely mechanical or traumatic, arising out of direct and long-continued mechanical irritation acting immediately on the cornea. Among these are cicatrices on the eyelids, the contact of the cilia in trichiasis and entropium, foreign bodies in the conjunctiva, chemical injuries.

Traumatic pannus is more often limited to a part of the cornea than occupying the whole. The partial implication enables the deep neoplastic changes to be seen.

Both varieties may be partial and sharply defined, or cover the entire cornea.

Morbid anatomy. This has been pursued with great diligence. Dissections have revealed the deposit of neoplastic elements. In pannus tenuis, thickening of the conjunctiva layer, and beneath it neoplastic cells. Integrity of the anterior elastic lamina, but beneath it thickly set neoplastic cells with blood-vessels. In pannus crassus, beneath the thickened epithelium, a layer of morbid connective tissue, abounding with blood-vessels. Disappearance of the anterior elastic lamina, and a deep deposit of modified connective tissue, uniting with that above, and vascular, some of the vessels passing into the true cornea laminæ. It is important to know that even in the inveterate cases the posterior laminæ of the cornea and the posterior elastic lamina are clear.

Pannus, however chronic, is capable of inflammatory exacerbations.

Course. Pannus tenuis remains without much change for years, unless there be a continuance of its exciting cause, when it may pass into pannus crassus.

Pannus crassus gets worse when it arises out of granular conjunctivitis, and then penetrating ulceration of the cornea, with collapse of the eyeball, or interstitial abscess, with similar effect, may follow, unless it pass into tendinous degeneration.

Treatment. To remove the cause is to do the most that a surgeon can accomplish, for nearly all the improvement which follows is the effect of Nature. Under such favourable conditions, the thinner and the less opaque the pannus, the greater will be the recovery. An

almost sightless eye may be nearly restored, and one blurred by haze may quite recover. Deep traumatic opacity is never but slightly reduced.

For pannus tenuis, local applications as irritants are worse than useless, for they augment the existing form of inflammatory action and its effects. The same may be said of all applications which produce decided reaction.

For pannus crassus, inoculation of the conjunctiva with pus from an eye suffering under an attack of acute purulent ophthalmia, whereby sharp purulent inflammation is produced, has afforded much benefit.

It is more than sixty years since Dr. Walker, an army surgeon, then stationed at Glasgow, introduced the practice and published his views. Pininger, of Gratz, and Jäger, of Vienna, adopted the method very largely, and wrote about it.

The principle for our guidance in the matter has been thoroughly worked out half a century ago. The inoculation is alike applicable to all varieties of complete pannus, accompanied or not with inflammation of the conjunctiva. It is inapplicable if any portion of the cornea be not vascular, because that which is not so affected is as much damaged as the vascular portion is benefited, or if ulcerated, or if there be xeroma, or any marked dyscrasia, such as struma, gout, rheumatism, syphilis, and such like. Therefore, besides local requirements, if the general health be not tolerably good and above par, the effects can scarcely be satisfactory.

The inoculating fluid should be fresh, and taken with a small brush from a patient with a mild rather than severe purulent ophthalmia, and applied to the inside of the eyelid. Infantile purulent ophthalmia furnishes the best source. The child should be of healthy parents. Scrofula and syphilis should be guarded against. Gonorrhœal matter has been used, but it produces rather too severe an inflammation. Besides the objection which most persons would have to such practice, there is always the chance of transmitting syphilitic virus through a chancre in the urethra.

If the first application should fail, either in not taking effect at all or in producing only partial results, the inoculation may be repeated several times. The usually severe inflammatory effects on the eyeball of purulent ophthalmia are modified by the vascularity of the cornea, whereby it probably resists both ulceration and sloughing; but these results have ensued, and so also staphyloma. Such danger renders the experiment admissible only when the eye is practically useless. Very active symptoms arise. We cannot regulate the degree of the vascular action. The cornea looks as if it were about

to slough, while chemosis overlaps it considerably, and the eyelids are very much swollen. The rule is not to adopt any antiphlogistic treatment, as it is better that the symptoms be prolonged. The good effects of the measure may be very apparent in fourteen days, or not till six weeks.

So satisfactorily has the cornea cleared by the almost wasting of the blood-vessels or the absorption of the neoplastic elements, in pannus complicated with cataract, as well as with closing of the pupil, that operations to remedy these states have been successfully performed. Both eyes should not be inoculated at the same time. When the one cornea is sound, or nearly so, it should be guarded while the other is being treated.

Syndectomy, or the removal of a zone of the conjunctiva and the sub-conjunctival tissue from the cornea, in a space extending from the corneal margin, to within the eighth of an inch of the line where the conjunctiva is reflected from the eyelid to the eyeball, is the operation recommended by M. Furnari. The sclerotica is to be thoroughly bared. The vascular cornea is then to be freely scarified, and as a finish, the cornea and the denuded sclerotica are to be touched with a camel-hair brush, which has been moistened and rubbed on a stick of nitrate of silver. I have seen eyeballs destroyed by it. Some surgeons say that without the caustic benefit is obtained.

SUPPURATIVE CORNEITIS.

I recognise in this, interstitial abscess, or suppuration between the layers of the corneal laminæ; and surface abscess, or suppuration with ulceration on the corneal surface, usually called ulceration of the cornea.

Interstitial Abscess of the Cornea.

Symptoms. They appear in two forms. As a yellowish pus spot, with whitish circumference, sharply bounded, or diffused, of variable shape and of uncertain position, in any part of the cornea, but usually below, standing in nearly clear cornea, or surrounded by more or less opacity, with or without corneal vascularity. Or as a deposit of pus throughout the cornea, so that the whole looks yellow, with or without roughness, and slight opacity of the corneal surface. But greater distinctions exist, according as the abscess is primary or secondary.

Post-corneal implication of the eye, slightly or severely, is inevitable.

The purulent material is neither puriform nor fluid at first, but consists of several inflammatory products between the corneal laminæ. Afterwards and at uncertain periods, according to the degree of the accompanying inflammatory action, the corneal laminæ break down into fatty granules, or they slough; the pus, now more fully developed, is in a single cavity and fluid.

The character of the pus varies. It may be pure pus, when it remains long without exercising any effects on the tissues around. Or it may be thin and very fluid, from fatty elements being in excess, when it spreads quickly, and has more of solvent power.

The spreading often is due also to proliferation, and to the pressure of the pus on the surrounding infiltrated and inflamed tissue.

There are some mechanical effects arising out of this suppuration. The cornea may bulge in correspondence with the extent of the abscess from pressure of the pus.

When the abscess is high and limited, some or all of the pus may gravitate through inflamed cornea, nearly to the lower margin of the cornea, in the form of a short, narrow, curved line. When it is large, the pus may gravitate more or less in a mass, which resembles the white mark at the root of the nail, hence the name of onyx.

Hypopion, that is, essentially a mucous and not a fibrous exudation in the anterior chamber, in which sometimes mucus, and sometimes pus corpuscles, predominate, lying between the cornea and the iris, in any degree, from a mere recognisable quantity to an amount that may rise up to the pupil, or altogether occupy both chambers of the eye, is often associated with the abscess. Flaky coagula may exist in the hypopion. The colour is usually creamy, but it may be streaked red with blood, or altogether red from the same. It is produced chiefly by inflammatory proliferation of the epithelium of the posterior elastic membrane of the cornea. The iris contributes to it, and so does the ciliary muscle. The ligamentum pectinatum iridis admits the passage of the morbid product in the latter case.

Hypopion is distinguished from onyx by its bulk, this being ascertained by looking at it from above, when its thickness is seen to be equal to that of the portion of the chamber which it occupies. Also from shifting its position in the chamber in a few minutes, according to change in the direction of the head from the perpendicular.

Interstitial abscess of the cornea may be primary, and the most prominent symptom of the morbid action present, or secondary, the effect of preceding corneal disease.

Primary abscess. At first there is no proper or invariable characteristic outward symptom. There may be a little cloudiness of the part of the cornea where the pus is to be deposited, and scarcely any accompanying redness of the conjunctiva, or of the sclerotica. It is not uncommon for patients to receive the first intelligence of their malady from the significant subjective symptom of defective sight. On the other hand, severe corneitis may at once set in, along with acute conjunctivitis, with intolerance to light, lacrymation, severe pain in the eye and in the head, and constitutional irritation, and usher in the abscess. *Hypopion* is not usually present.

The passive forming abscess may become as extensive and as distructive to the eye as that which is preceded by the most active symptoms.

The post-corneal ocular tissues always inflame, sooner or later, whereby there is ophthalmitis, sometimes slight, sometimes severe, and vision suffers accordingly.

Cause of primary abscess. Chemical and mechanical injuries of all kinds to the cornea, especially incised, lacerated, and contused wounds; the intrusion of foreign particles into the cornea, blows on the cornea.

Course. Even the very smallest abscess should be regarded with unfavourable prognosis, for the spread of it is certain, and the whole cornea may become involved.

The abscess may burst outwardly, by sloughing or by ulceration; or into the anterior chamber by ulceration. In either case, complete corneal perforation follows, succeeded by adhesion of the iris to the cornea or prolapse of it, with or without staphyloma, and often by atrophy of the eyeball. These secondary results are identical with those from surface suppuration or ulceration, and which I shall speak of in detail. In no case, however favourable the termination, does the pupil escape displacement and reduction; and, in nearly all, it is quite closed. It is extremely rare, under any condition, that useful sight is saved.

Treatment. The abscess should be opened as soon as it is recognised. To evacuate pus from a part possessing but the feeblest vitality, and incapable of quick repair, so constructed and so limited, that an abscess readily spreads over the whole of it, in which the natural process for the escape of the pus is destructive to the eye, is but to carry out a first principle of surgical treatment. Besides, the easy evacuation of pus, even where only a small drop of it is set free, stops the intensity of inflammatory action, and prevents damaging changes posterior to the cornea.

A free puncture should be made in the abscess, with the second or

third-sized iris knife, at a spot nearest to the margin of the cornea. When the abscess is large, it should be transfixed, and the incision made obliquely, that is, the edge of the knife should enter the lower edge of it, and pass across the upper edge, as a safeguard against considerable protrusion of the iris. The escape of aqueous humour facilitates the discharge of the pus. It is only by this measure that considerable destruction to the cornea and disorganization of the retina may be prevented, whereby an artificial pupil might be made available.

The pus will flow at once, or some now and some subsequently, according as it is all fluid or not. Any of it which may fall into the anterior chamber is soon absorbed.

If there be small hypopion, distinctly and separately from the corneal abscess, it should be disregarded, as it is soon wasted. If it be large and nearly or quite fills the chambers of the eye, and so causes distention of the cornea, it should be evacuated by a separate corneal aperture.

As after treatment, warm applications to the eye are beneficial.

The general treatment should consist of rest and such measures as will control the usual accompanying depression.

In surgical operations on the eye performed through the cornea, and in all special operations on the cornea itself, there is some risk of interstitial abscess; a contingency lessened, however, by the nature and size of the wound. A small penetrating wound which is made with a fine and sharp needle, as in the operation for the solution of cataract, is well borne. Liability to suppuration increases with the size of the wound. An incision which passes directly through the corneal laminæ is less injurious than one which penetrates obliquely.

Secondary abscess. This is the consequence of previous corneal disease, by augmentation of the proliferating process. It proceeds also from extension of general inflammation of the eyelids. It occurs, too, in the course of any intense inflammation of the conjunctiva. Under this form it is still more difficult to ascribe to it any invariable attending objective symptom. It is enough, however, to know when it may be expected; and I have pointed out the occasions, when speaking of the several corneal diseases, and how to recognise it.

The course is usually more chronic than the primary abscess. Onyx and hypopion often co-exist with it.

A small abscess in a child may be absorbed, and leave a dense leucoma, partly of new tissue, partly of metamorphosed remains of pus, and sometimes of chalky material. Contraction of the entire cornea may ensue if the abscess has been large. Absorption is very

rare in an adult. The abscess may burst, after the manner of the primary variety.

Treatment. The abscess should be evacuated, and the accompanying and existing disease attended to according to its requirements.

Surface Abscess, or Suppuration with Ulceration on the Corneal Surface, usually called Ulceration of the Cornea.

An ulcer, I shall use this term all through, may be superficial and involve only the conjunctiva, and the anterior elastic laminæ, or deep and involve most or all of the corneal laminæ, and even pass through the posterior elastic lamina. It may be of any shape, minute or extensive, ragged or smooth.

Primary ulcer. A part of the corneal surface becomes hazy and rough, and is cast off or exfoliated, and the breach constitutes an ulcer, which is covered by a fatty, purulent, or fibrinous product, unless the ulcer be small, the secretion very scanty and removed as quickly as formed, when it appears as an indentation with transparent walls.

A narrow semi-opaque ring, the effect of proliferation, bounds it. The surrounding cornea usually becomes very vascular, and a few of the blood-vessels may pass over the ulcerated spot.

If the ulcer be large or deep, the posterior wall may project from the pressure of the aqueous humour, in the form of a vesicle. If it be at the margin of the cornea, and partly involve the conjunctiva, or if it have penetrated through the cornea, and slight prolapse of the iris have followed, very vascular granulations may spring from its floor and project. The vesicle is always composed of some of the true corneal laminæ and the posterior elastic lamina. The latter is not strong enough in itself to resist the pressure of the aqueous humour.

The fully developed objective symptoms are these, damage to a part of the cornea which is excavated, and covered with a pus-like material, or which is transparent, or which projects, or which throws out projecting minute globular vascular granulations, attended by varying surrounding vascularity of the cornea itself, of the conjunctiva, and of the sclerotica, sometimes associated with onyx, sometimes with hypopion.

The subjective symptoms are those of interstitial corneitis, to which occasionally great pain is added.

In rheumatic, gouty, and syphilitic persons there is usually periodic uneasiness about the eyeball, severe brow pain of a nightly

periodic character, whereby sleep is disturbed. Fever is generally present. It is said that such ulcers are generally elongated and marginal, but they partake of all forms.

Causes. These include all which have been assigned to interstitial abscess, also injury causing mortification of a portion of the cornea, the suppuration being then the means of casting off the dead part, and producing cure.

Variolous origin. This demands a separate notice. The ulceration is secondary, or post-variolous, not a part of the primary disorder, does not belong to the exanthematous stage, for it is not produced from a pustule forming on the cornea. It appears about the tenth or twelfth day of the eruption when the pustules are declining, or not till the scales have fallen off. Or still later, at the end of five or six weeks, when there is convalescence, but much weakness.

There is no peculiarity in the formation of the ulcer, but there is strong tendency to onyx.

Interstitial abscess, instead of ulceration, may appear, attended by hypopium.

Iritis is no uncommon complication.

Recovery is always tedious.

Treatment. To prevent, and to limit the ulceration, is the chief indication. How to do this has been in a degree incidentally expressed in the therapeutic measures recommended in the different forms of corneitis out of which the ulceration springs. But more must be said.

Primary vascular and nervous irritation of the cornea, and of the neighbouring parts, must be met by antiphlogistic regimen, the local application of cold, and sometimes by local blood-letting.

Tapping the anterior chamber through a part of the cornea not ulcerated, gives relief to pain and other inflammatory symptoms. With very much pain and marked post-corneal inflammation, Hancock's operation a little modified, effects the tapping and does more, by the withdrawal of a little blood from the ciliary region and the canal of Schlemm, and sometimes a little of the vitreous body. It is done by pushing the point of the second-sized iris knife or a cataract knife to the depth of the sixth of an inch obliquely backwards at the lower part of the corneo-sclerotic junction, in a manner just to open the anterior chamber in its passage. The crystalline lens will not be injured unless the knife be thrust too deeply. After suppuration has occurred, warm dry or moist applications are suitable, the heat of which should be regulated by the patient's feelings. When there is much irritability of the eye

and fomentations are used, the addition of a solution of the extract of belladonna is effectual as an anodyne.

For ulceration arising out of a debilitated constitution, a very common condition, supporting and tonic measures are called for. Healing will not ensue till the vital power is recruited.

Applications to the ulcers are seldom needed and should not be made indiscriminately.

The chronic ulcers with little or no accompanying vascularity, for the most part transparent, and which resist general treatment and spread, must be stimulated. One or more neat applications of a minute portion of tannic acid, powdered alum, or red oxide of mercury, may suffice for this. I do not use the nitrate of silver, either pure or mitigated, because the least touch of it causes that kind of irritation by which the ulceration is increased. The reaction is too severe. Such ulcers may heal without blood-vessels being apparent to the naked eye in the cornea, but usually they are stationary till blood-vessels are palpably developed.

Vascularity in corneal ulceration is a process of repair. Mischievous local applications are mainly used on account of its existence. A greyish half-transparent tract forms between the ulcer and the nearest neighbouring blood-vessels. In this, vessels are soon developed, carrying the blood in a circuit through and about the spot of reparative action. This causes dulness of the cornea for a time, but it is necessary, according to the natural laws of growth and repair. When the healing is advanced, and less blood is needed, the new blood-vessels reduce, then disappear, and transparency is restored.

There are special reasons why lotions containing acetate of lead, nitrate of silver, and sulphate of copper, should not be used when ulceration is present. Such salts are decomposed by the tears and the mucus of the conjunctiva, and their bases are precipitated in insoluble states, and remaining there are cicatrized over.

When the ulcer is unusually irritable, and when the eye is intolerant to light, relief to suffering, and avoidance of mechanical irritation from the edge of the upper eyelid, is obtained by closing the eyelids with a strip of court-plaster. This does not interfere with other local measures, as the plaster may be often renewed.

All pressure on the eyeball, from so-called protective bandages acts injuriously. To press on the eyeball from without is also to increase intra-ocular pressure.

For inflammatory implication of the eyeball, the treatment is the same as that which I have recommended for a similar condition in corneitis.

The use of a solution of atropine to dilate the pupil, and of Calabar bean to contract it, in ulceration of the cornea, is theoretically recommended by most writers. The former, when an ulcer near the centre of the cornea threatens perforation, in order that the margin of the pupil may neither prolapse nor adhere, or to prevent adhesion of a large portion of it. The latter when an ulcer near the margin is likely to penetrate, in order to prevent prolapse, or adhesion of the body of the iris. In actual practice such desirable results are not obtained. When the aqueous humour escapes because of ulceration of the cornea, the iris invariably prolapses or adheres. The most that the atropine can do, is to assist to break asunder or to lengthen any slight adhesion between the iris and the cornea. The Calabar bean is useless.

Much has been said of late of the "ulcus corneæ serpens" on which Sämisch has written a treatise, and advised as a means of cure that it be cut through, the incision carried into healthy cornea, and once or twice a day, for a period from a few days to three weeks, the aqueous humour being pressed out, if necessary, by opening the wound with a probe. I know of several eyes having been lost by the process.

Results of ulceration of the cornea, or surface abscess. An ulcer, however superficial or small, may leave an indelible opacity. Rapid healing neither prevents nor mitigates opacity.

In infancy, and in childhood, extensive ulcers may heal without leaving any marks but slight ones, and as it is supposed, by true corneal tissue, or which lessen in the course of a few months or years. The tendency to perfect transparent repair declines as the individual grows older until adult age, when such an occurrence is we believe unknown. There is some transparent material with the opaque, in all imperfect repair.

Opacity, with raised cicatrix. Granulating ulcers fill up with a cicatrix of epithelium, or connective tissue in addition. Such cicatrices in marginal ulcers become continuous with the conjunctiva, and may produce a raised cicatrix, bearing a resemblance to a pterygium. This is most seen in ulceration from the effects of quicklime.

Opaque flat cicatrix, or prolapse of the iris. The projecting vesical ulcer always ends in penetration. The perforation may close and the vesicle form again, to be strengthened in its walls by cicatritial tissue, which contracts and terminates in an opaque flat cicatrix. Or the iris may prolapse as soon as the aqueous humour escapes.

Ulcerative corneal staphyloma. An extensive and superficial ulcer, a modification of the above, may end in spherical or conical protru-

sion of the remaining posterior portion of corneal tissue, and of the posterior elastic lamina. It is greyish and covered with purulent secretion, and called ulcerative corneal staphyloma. Perforation may ensue.

Cicatritial corneal staphyloma. But repair may set in, by which the protruding ulcerative corneal staphyloma is covered by a neoplastic corneal substance, and cloudy epithelium. Farther improvement may ensue in the contraction of the new material, and the reduction of the protrusion. This is cicatritial corneal staphyloma, or the bulging of a cicatrized ulcer. The most prominent part is the thinnest. The surrounding cornea is often curved in several directions, and affected with superficial and interstitial opacity. The staphyloma may burst.

Irregularity of the neighbouring healthy cornea, or flattening. Large deep ulcers attended by protrusion, when healed, produce irregularity of a part of the cornea around, or flattening, through contraction of the cicatrix, whereby the corneal refraction is disturbed.

Loss of a portion of the cornea from ulceration; its effects, according to the amount and the position of the loss. The deeper the ulcer, the more likely is penetration to occur, and it always ensues, if the posterior elastic lamina is exposed. Perforation is the chief danger of ulceration.

If the perforation be small central and the effect of bursting through an ulcer which yet has a floor of some thickness, only the aqueous humour escapes. If it be marginal, the iris will probably prolapse.

In the case of slowly healing central perforations of small size, the iris will probably adhere to the cornea, and so may the capsule of the lens. The aperture is plugged, and the reduced chambers are filled. The capsule may break away, or elongate the plug and fall backwards. I have seen such stretching enough to enable it to recover its normal position. A capsule which has adhered, and broken away, is always marked, either by a portion of the plug, or by chalky degeneration of it.

It may be said in general terms that, when the aperture of perforation does not exceed the size of a millet seed, the iris adheres to the cornea rather than prolapses, and that prolapse is more imminent in marginal ulceration, where the breadth of the iris falls over the opening, than in central. Also that, a central prolapse interferes more with vision than a lateral one, because in the former, the margin of the pupil, in part or entirely, is adherent, and the corneal opacity interferes with whatever pupillary space is left, whereas in the latter the pupil is generally free, although altered in

shape, and the corneal opacity does not interfere with it. From the prolapsed iris may be formed a vesicle, consisting entirely of iris, or partly of iris, and partly of neoplastic material.

Partial cicatritial iris staphyloma. If the cornea be penetrated by an opening the size of a pea, no matter where situated, the pupillary margin prolapses along with a large part of the iris, and which prolapsed bit proliferates, and soon adheres to the edges of the opening. The closed pupil has its margin glued together by exudation, which generally adheres to the capsule of the lens. The outer surface of the iris proliferates, cicatrizes, and the cicatrix is incorporated at the base with the cornea. If the cicatrized vesicle thereby formed enlarges, a partial cicatritial staphyloma is formed.

It is unnecessary to speak of the physical forms the staphyloma may take, for it matters not whether it be globular or conical, or of any other shape. Nor is its colour of any consequence.

The tumour is a cicatrized iris staphyloma, replacing a portion of the cornea. The posterior surface is formed of iris, and is irregularly pitted. The anterior surface is covered by thickish epithelium, more like the cuticle in the form of its cells than conjunctiva. The intermediate portion, or cicatritial material, is dense and irregularly interwoven white and yellow fibrous tissue, with imperfectly developed nuclei intermingled.

This staphyloma may be extremely attenuated at the apex, but it has a tendency to become thick in all parts, even far thicker than the cornea. It often grows large, and to an extent to interfere with the action of the eyelids.

Fig. 275.

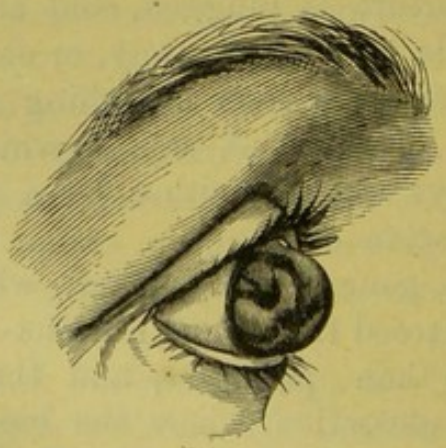

The period at which the bulging begins, varies from that of months to years, but once started, the growth continues tolerably regular. To be stationary is exceptional. Ulceration and bursting, with hæmorrhage, suppuration, and collapse of the eyeball, or bursting and

collapse without suppuration, are the usual terminations of the growing state.

Recurring attacks of intra-ocular inflammation are not unusual, and through the accruing disorganization of the intra-ocular tissues, the other eye is exposed to sympathetic ophthalmitis. Cretaceous degeneration of the crystalline lens is one of the prejudicial changes.

There is a traumatic variety of that staphyloma, arising out of corneal wounds.

In the preceding figure, the physical characteristics of a large staphyloma of this form, are well displayed.

The patient came to me six months after her cornea had been wounded. The projection was but small. The cornea was opaque, and rather shrunken. A year after I took the sketch.

The greater opacity of some parts of the projection is well shown, and the ring around the base of the tumour represents a portion of the true cornea, which had been gradually pushed aside by the new growth.

Dense flattened cicatrix. The crystalline lens, and some of the vitreous humour, may escape through a large perforation of the cornea, either immediately or afterwards. Inflammation of the eyeball may be excited, followed by internal hæmorrhage and suppuration. Or the front of the collapsed ocular tissue may fall together, iris intervening, by which the pupil is closed. The iris adheres posteriorly, becomes covered with cicatrix, which may thicken, contract, and form a dense flat front to a more or less atrophied eyeball. If the whole of the cornea be destroyed, the lens and some of the vitreous humour readily escape, and the eyeball usually shrinks. But the lens may remain, and the contracted pupil quickly closes by neoplastic exudation, which ties the iris to the capsule of the lens. The iris proliferates, and a dense flattened cicatrix ensues, by which the sclerotic zone is drawn in, and the eyeball atrophies more or less.

Total iris staphyloma. When a dense flattened cicatrix results from loss of the entire cornea, the cicatrized iris may project, in part or entirely, beyond the sclerotica. If it be entire and permanent, the adhesion between the pupil and the capsule of the lens does not stretch. The centre of the staphyloma will be depressed.

Staphyloma iridis racemosum. This is but a modification of total iris staphyloma. A cluster of projections, produced by the iris, being adherent to the capsule of the lens in several places, and the adhesions tethering the parts so that the cicatrized iris cannot expand equally. The cicatritial tissue being denser in some parts than in others, produces the same effect by resisting the general expansion.

Effects of the escape of the aqueous humour. While the blood-vessels of the interior of the eyeball are healthy, loss of the natural intra-ocular pressure does not affect them, because the mechanical resistance and muscular contractility of their walls oppose the lateral blood pressure, and at most merely passive hyperæmia of the retina and the choroid occur. While they are unhealthy, they remain intact only so long as the intra-ocular pressure is maintained. When it is lost, retinal or choroidal hæmorrhage, or both, ensue. Death has resulted from such bleeding.

Again, if the choroidal blood-vessels be unhealthy, and the vitreous body falls quickly forward on account of a very sudden escape of the aqueous humour, the defective vessels bleed, and the choroid may be separated from the sclerotica, and blood which remains within the eyeball becomes disorganized or suppurates.

TREATMENT OF THE EFFECTS OF ULCERATION OF THE CORNEA.

Opacity with raised cicatrix. This is seldom sufficiently raised to be irritated by the eyelids. In a few instances I have shaved it off.

Prolapse of the iris, in association with a flat opaque cicatrix, may in some measure be prevented by closing the eyes with court-plaster till the cicatrix is sufficiently firm. The eyeball is at rest, and not subjected to undue pressure arising from forced or sudden action of its motor muscles. A slight prolapse may be limited by the same measure.

Ulcerative corneal staphyloma and cicatritial corneal staphyloma may be benefited in the way of preventing increase by no other measure than the temporary closing of the eyelids.

In partial cicatritial staphyloma certain contraction may be brought about, by which much sight is saved, or the eye fitted for an artificial pupil. The late Mr. Tyrrell effected this in the following manner, and published cases of success. He applied nitrate of silver, or caustic potash, to the base of the projection. He says, a small slough separated, and the effect was, thickening of the parts touched. Afterwards he applied the caustic to a fresh spot, and so on, "until considerable or perfect reduction of the staphyloma had been accomplished."

It may be necessary to excise the staphyloma.

In partial iris staphyloma there is seldom any scope for saving or improving vision. The usual indication is to remove the tumour by surgical operation, that is, excision, whereby recurring attacks of inflammation are prevented, any strain on the iris is removed, for as

the staphyloma grows, the iris is pulled on till it may be torn from its marginal attachments, and the form of the eyeball saved.

The whole of the staphylomatous piece must be cut off, because any cicatritial tissue which is left is apt to grow. The eyelids having been retracted, I transfix the staphyloma with a sharp hook, and cut it off with a long narrow scalpel, close to the cornea. I remove the lens, whether it be clear or opaque. I place a roll of cotton wool, or a pledget of lint, quickly on the closed eyelids to prevent or to check bleeding, and maintain it with a bandage for two or three days. Then I remove it, and apply strips of plaster for a week. Healing is effected by the edges of the wound becoming glued to the vitreous body, and the interspace granulating. It is not unusual to find the parts sealed up when the plaster is removed.

When bleeding is from a vessel which has been cut through, it can be easily restrained. When it is internal, it can, for the most part, be stopped by the compress.

The operation once well performed, suffices. Some exuberant granulations may arise, but they are of no consequence; for if they do not decline of themselves, the use of an astringent lotion, or the application of the red oxide of mercury, will reduce them.

Sir W. Wilde recommends in small conical staphyloma, that one or two threads should be passed through the base of the cone, in order that after the excision, the lips of the wound should be brought together, to prevent escape of the vitreous. I have not found it to be necessary.

The smaller the staphyloma, the better will be the result; and when small, a stump is left very little less in size than the natural eyeball.

But excision only answers when there is little or no post-corneal disease, and the vitreous humour is sufficiently healthy for all of it, or the greater part, to be retained. When the humour has become fluid, in which case the retina and the choroid are unhealthy, the greater portion of it will escape. Active choroidal hæmorrhage follows, and requires well-adapted pressure for its restraint. Suppuration within the collapsed tunics generally ensues. When excision is inapplicable, the eyeball should be extirpated.

It has been suggested when the staphyloma is small and thin, to cut it through, split it, make the edges overlap, so as to unite in that position, and bandage over the eyelids.

Total iris staphyloma, and staphyloma racemosum. Excision or extirpation of the eyeball is the remedy. The excision should be made in front of, and not through the sclerotica. Just like excision for

partial iris staphyloma, because there will be less bleeding, and less likelihood of complete collapse of the eyeball.

The sketch below was taken from a patient after the operation, and shows the eyeball just a little reduced, and well adapted for the application of an artificial eye.

Fig. 276.

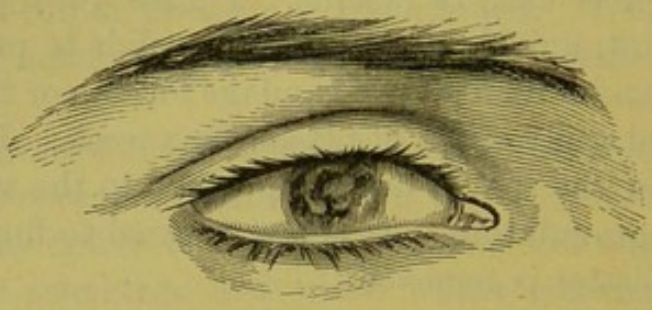

Abscission, or amputation of the front of the eyeball, with the use of sutures, after Sir W. Wilde's method, is practised, and said to give good reduced stumps. Four or five sutures are passed through the sclerotica, the amputation made, and the edges of the wound tied together for several days.

Opacity of the cornea from the deposit of lead may sometimes be removed, or be reduced sufficiently to clear the pupil by using chloroform, and carefully picking off any organic covering, and then the metallic deposit. I have been surprised at the clearances I have made. As much irritation is apt to ensue, the eyelids should be closed with plaster for several days.

ARCUS, AND ANNULUS ADIPOSUS.

This is a milk-white arch, or ring, more or less broad, which skirts the circumference of the cornea at a small distance from its margin. It usually begins as an arch on the upper edge. Sometimes there is in addition an outer and greyish-white arch or ring, which looks like an encroachment of the sclerotica on the cornea. A strip of clear cornea always intervenes.

The annulus sometimes extends towards the centre of the cornea. In a few instances I have seen it overshadow a large pupil.

It is seldom that the arcus or the annulus is seen before the fortieth year. The appearance of the one or the other is usually about the fiftieth year, but I have witnessed the arcus at thirty, and in three brothers under twenty, one of them being only fourteen.

Few persons after sixty-five are without an arcus, and few after seventy without the annulus; hence the more usual name of arcus senilis.

The function of the eye is not interfered with by this arch or circle, unless the pupil be shaded. Nor does either have any unfavourable influence in the repair of a wound in the cornea passing through it for the extraction of cataract.

Mr. E. Canton has demonstrated that this marking is fatty degeneration, or the deposit of innumerable oil globules between the layers of the cornea, the anterior and posterior elastic laminæ being unaffected. So far as his researches go, full development of this adipose condition is always attended by fatty degeneration of the ocular muscles and the heart.

From my own observation, I can say that many persons who die from fatty heart have not fatty cornea, and many who have fatty cornea early in life give no evidence of heart degeneration. I know several medical men who, having the arcus for more than thirty years, have led laborious professional lives, without the slightest indication of heart weakness. I suspect that most of Mr. Canton's post-mortem examinations, in association with this research, were on very old workhouse inmates, those in whom some fatty degeneration of most tissues is tolerably sure to be found.

The statements of Dr. Ammon, that the adipose cornea is likely to be associated with a corresponding white line on the margin of the crystalline lens, and of Dr. Schön, that the posterior capsule is affected in like manner, more often than the lens, is not verified by Mr. Canton.

CONICAL CORNEA.

General well marked objective characters. The cornea loses the spherical form, becomes conoidal, not truly conical, irregular on the surface, brilliant and sparkling, as if a tear-drop were on its front, and all the while is transparent.

The cone varies in size, prominence, and acuteness. It is sometimes irregular, by which the apex is a little lateral. The summit is seldom smooth, but more or less undulating, and generally becomes opaque, or dotted with opacities, or ulcerated, or covered with pannus. It is very apparent when the eye is looked at in profile. Fig. 277 is a sketch which I took from a very marked example of the disease.

The anterior chamber always looks large. The iris may be tremulous.

The subjective symptom has the character of myopia with astigmatism. While the person finds himself near-sighted, luminous objects lying in the long axis of the cone, seem smaller than natural and

distorted. A remarkable refraction of the rays of light is produced, the flame of a candle has a halo around it, or is broken up in several flames. Bodies are multiplied and distorted. In time, useful sight

FIG. 277.

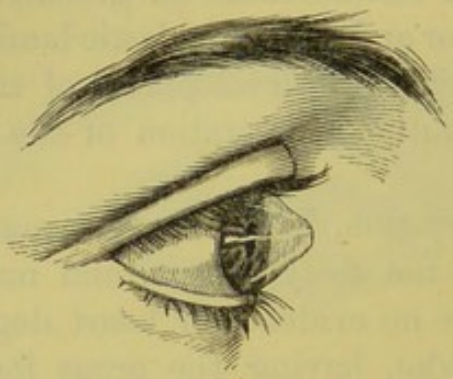

may be lost, things in front of the eye not being seen, and those at the side but very imperfectly discerned in rough outline.

In the earliest beginning of the cone vision is interfered with, and as an ordinary inspection of the eye reveals nothing, an error in diagnosis is imminent. But the ophthalmoscope comes to our aid, and discloses the secret. When the reflection from the mirror plays about the cone, at different angles, a dark line appears on the sides not in focus. The disk is never seen acutely in its integrity, but seems drawn out in various directions. It shortens or lengthens, according as the observer moves his head, or the object glass, from side to side.

Conical cornea may exist at birth, and occur hereditarily, but it usually appears about the fourteenth year, rarely in adults, and still more rarely after fifty years of age.

The slowness of its progress is striking. Bursting from ulceration sometimes occurs. I have seen it three times.

Both eyes are nearly always implicated, seldom symmetrically, but first the one, and after the abnormal change is well developed, the other, so that generally a long period intervenes.

A ratio of increase is uncertain. There may be sudden rapid growth, or an arrest of growth, at any stage.

We are in ignorance of any predisposing cause. It cannot be said that general debility has any effect, for the disease appears in the strong and robust. I have scarcely seen it except in persons in good general health. Respecting the direct cause, nothing has been proved. True conical cornea must not be mistaken for any of those changes in form associated with some loss of transparency of the cornea, arising out of corneitis, of which I have spoken.

Morbid anatomy. In all the recorded dissections the apex of the cone, whether transparent, or more or less opaque, has been thinner than any other part. In a case dissected by Mr. Bowman, the cornea began to thin at the base of the cone, and got thinner and thinner towards the nebulous apex, which was thinnest of all. The anterior elastic lamina was thinner upon the cone than elsewhere, and wrinkled. It was underlaid by a stratum of crowded, elongated, club-like nuclei, and beneath these the normal lamellar tissue was replaced by a web of caudate and nuclear fibres, amongst the meshes of which clusters of large oval and fusiform cells were packed. The peripheral region was perfectly normal, and there was a gradual transition from the diseased to the healthy tissue, the inter-lamellar corpuscles becoming more plentiful, branched and drawn out into fibres, which in many instances coalesced with those from neighbouring corpuscles. The posterior elastic lamina was unchanged, and so was the epithelium, both on the front and on the back of the cornea, so that the alterations were confined to the laminated tissue of the cornea and to the anterior elastic lamina. The substitution of a web of nuclear fibres and cells for the regular lamination of the cornea, explained, it is said, the nebulosity of the cone, and the liability to bulge.

Treatment. Very deep concave lenses sometimes afford relief in the incipient stage. As, however, the cone increases, so do such lenses become useless. Even then sight may be improved by wearing a goggle frame with a black diaphragm, perforated with a pin-hole, and stenopæic spectacles, to which a concave lens may be added. For the details of this I beg to refer to what I have said in the chapter on the Anomalies of Accommodation, etc., p. 656; also p. 256.

Very patient experiment is required to ascertain what relief may be afforded thereby, and whether the hole in the diaphragm or the slit is the better. Some assistance in the latter experiment may be got by ascertaining with the ophthalmoscope the direction in which the optic disk and the retinal vessels can be best seen. In such a position should the slit be turned.

I have not found benefit from cylindrical lenses.

There is sometimes even a resource when the above appliance fails. It is Tyrrell's operation of displacing the pupil to the side of the cornea, improved by Bowman, in giving it a slit shape, or cat's eye form, by double iriddesis.

The theory of the operation is to reduce the volume of the natural pupil, while an aperture is opened for the passage of the light through a part of the cornea where the spherical form is least departed from.

A robust farmer's daughter, twenty-four years old, was brought to me by Dr. Forester, with conical cornea in both eyes. In the left the disease was less advanced, and she could yet read and use her needle. The cone in the right was very prominent, the apex was slightly opaque, and all useful vision was extinct. She could not count my fingers. I made a linear pupil directly downwards by "iriddesis," using the canula forceps. A fortnight later I operated upwards in the same manner to my satisfaction. I tested the vision directly that the irritability of the eye had passed away, and had the pleasure to find that some sight had been restored. But a greater effect was got when a deep concave glass was used. She could then read the large words in title pages. I took this sketch of the altered pupil.

Fig. 278.

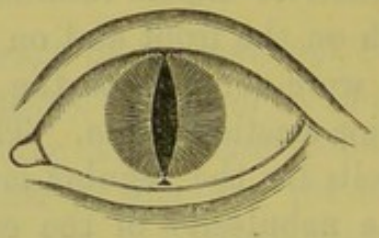

This was my first case. I have performed the operation many times since, and never without some benefit.

In a female aged twenty-four, who had suffered for eight years, and was at last unable to recognise her most intimate friends, or to get about alone in a strange house, I did the operation in both eyes. Two months after, at her last visit, the pupils acted a little under the stimulus of light, my patient could read large type, thread a needle and mend stockings, do the coarse needlework of the house, and recognise her friends across the street. She was so much pleased with the operation on the one eye, that she asked to have the other treated likewise.

The best position for the pupil should be sought for, as far as possible, with the ophthalmoscope and the stenopæic spectacles. The ophthalmometer is recommended for the same purpose.

The second operation on the iris should never be performed earlier than ten days after the first.

The incisions should be a little in the sclerotica, in order that the iris may not be pulled forwards out of its plane.

The first iriddesis always gives more benefit than the second.

Von Graefe has proposed a method of producing ulceration of the cone, founded on the fact of cicatrizing ulcers causing flattening of the surrounding corneal curve. He raised a little flap in the central

turbid portion of the cone with a thin cataract knife, without opening the eyeball, and then snipped it off at the base with the scissors. Two days later he touched the surface of the wound with diluted or mitigated nitrate of silver, and this cauterization was repeated at intervals of two or three days. The resulting ulcer was perforated in the fourth week with a stilet, and during the next week the closed fistula was reopened every day, or every second day. After this it was allowed to heal. The curvature of the cornea was already considerably improved, and also the vision with regard to a general survey of the room. The patient was discharged in the following condition: In the centre of the cornea a dense white opacity, half a line in diameter, surrounded by a slight grey halo, which made the diameter of the whole turbid part slightly exceed a line. At the most cursory glance, but especially by examining its reflections, the improvement in the corneal outline was very visible. The central opaque portion had fallen back almost to a natural position, and the whole membrane departed but little from its proper curvature. He read No. 9 fluently at an inch and a-half. The distant vision was $\frac{1}{30}$, but was raised to $\frac{1}{12}$ by a concave cylindrical glass. The clearness of the ophthalmoscopic image was so much increased as to render it probable that vision would have been still better but for the co-existence of a certain degree of amblyopia. Afterwards he modified the operation by touching the shaved piece of the cone on the second day with mitigated nitrate of silver, immediately neutralizing the action with salt and water, and repeated the process from three to six days, till a faintish yellow infiltration was produced. Sight is said to improve when the infiltration begins to contract. This may not be for several weeks.

I have said nothing respecting the use of local applications, simply because nothing has been of use. There has been no lack of experiments with every description of local astringent and stimulant. General treatment, too, has been unavailing.

CHAPTER XXXIII.

DISEASES OF THE IRIS.

PUPIL IRITIS—SYPHILITIC—IDIOPATHIC—RHEUMATIC—TREATMENT.

PUPIL.

The pupil, or aperture of the iris, is not placed exactly central, its axis being a little internal to that of the cornea.

Aspect of the pupil, or pupil area. This is black in the fair races of men until about the fiftieth or fifty-fifth year, when the amber change begins in the crystalline lens. Then it looks greyish, and the coloration increases with age until, in some instances, it may be mistaken for cataract, under which topic the subject is fully discussed.

In very fair persons, and in Albinos with dilated pupils, the red reflection of the eye is sometimes apparent in certain lights.

With the above exceptions, coloration in the pupil indicates disease of the eye posteriorly, and depends on deep-seated tumours, or cataract, or morbid deposits on the capsule of the lens. Lateral illumination and ophthalmoscopic investigation are needed to determine the nature of such diseases.

Pupillary movements. It would be more correct, but less convenient, to say iris movements.

There are two kinds of pupillary motions. The independent or direct, produced by the direct influence of light on the retina in its various degrees of intensity. The associated or sympathetic, which takes place in one eye when not exposed to change, in harmony to the movements produced in the other iris under alterations in the quality of light. So far does this go, that a blind eye receives the associated action from its sound fellow. In testing, then, pupillary movements, each eye must be examined by itself, and alternately exposed to light, and shaded.

When an eye is blind from disease of the retina, or of the optic nerve, or tract, there is no direct or independent action of the pupil. But there is such action under the influence of light if the retina and the nerve, and the optic tract be intact, and blindness is caused by brain lesion posterior to the corpora quadrigemina.

The degree of motion in the pupil, and the consequent amount of change in its dimensions, varies in different individuals. In some persons, although the ocular textures are unimpaired, and vision is not affected, the mobility is very slight.

Alternate contraction and dilatation of the pupil may occur in hyperæsthesia of the retina, and in hydrocephalus.

Sluggishness or inactivity of the pupil from intra- or extra-ocular disease is that with which we are often concerned, needs to be studied, and the cause sought out.

I do not include in these remarks affections of the pupil from disease of the brain or its membranes, nor of the spinal cord, nor from narcotic poisoning.

There are abnormal dimensions of the pupil.

Persistent contraction of the pupil, below the medium size, or myosis, is noticed in Chapter XVI., among the paralytic affections of the eye.

Respecting paralytic myosis, I would merely add, in amplification of what I said at page 322, of any morbid condition involving the cervical sympathetic, causing contraction of the pupil, that I include injuries of all kinds inflicting lesion on the so-called cilio-spinal region; see my remarks at the upper part of page 321, corresponding to the anterior roots of the two lowest cervical, and the six upper dorsal nerves, or, according to Brown-Séquard, even to the ninth or tenth.

Among such injuries are extravasation of blood in the spinal cord, and softening of the cord from injury.

All my remarks refer to uncomplicated cases, where the pupillary contraction is the only effect of nerve damage. Complications exist in which some of the oculo-cranial nerves are involved as well, and if the third, the characteristic contraction may be modified.

It has been because of difficulty in seeing near and distant objects well by weak illumination, that patients have come to me with this monocular affection. I have not observed retina lesion. The pupil has not been very small, but immoveable under light or shade. To see the contrasted effect between the eyes they should be examined by a feeble light.

Myosis occurs in progressive locomotor ataxy. Sometimes it is attended with slight conjunctivitis. The contraction, which is always

greater than in any other form, may reduce the pupil to the smallest possible size, and so powerfully, that it resists the influence of belladonna. During a paroxysm of pain, the myosis may relax a good deal. Dr. Radcliffe has published two cases in which the pupils opened when the pain reached a certain degree of severity, and had continued for a certain time. The vision is usually unaffected.

Atropine dilates the pupil to only about medium size, and its action is very transient.

Calabar bean will contract the pupil still farther, and sometimes to a greater degree than it produces in a healthy iris.

Persistent dilatation, or mydriasis, is also noticed in Chapter XVI.

The activity of the pupil decreases with age, and so does the size of the pupil, and this is in a measure compensative for the slight loss of retinal sentient power, as the refraction of the eye is increased, since only the centre of the lens is chiefly employed. This is assigned as a reason why some old people who required spectacles for close work are able to dispense with them.

CONGENITAL DEFECTS OF THE IRIS.

Congenital absence of the iris. Irideremia. The iris is wholly absent. The space behind the cornea is uniformly red, or of an orange tint, the effect of reflection from the fundus of the eye. With the ophthalmoscope, the margin of the lens and the ciliary processes are clearly discernible.

Partial absence of the iris. A narrow rim only of the iris, or a narrow segment of a portion of it, may be all that exists. The circular or the radiating fibres alone may be absent. Or all parts may be wanting except the uvea.

With these irregularities, there is generally associated some other defect or defects about the eyeball, such as small and hazy corneæ, stellated opacities of the crystalline lenses, deficiency of the ciliary processes. Mystagmus is seldom absent.

Although I have never seen an instance of this affection in which there was not impairment of vision, or a high grade of hypermetropia, or marked intolerance to light, many are recorded with the possession of acute vision, and the absence of any subjective disturbance. Stenopæic spectacles with spherical lenses are beneficial in some instances.

Persistence of the membrana pupillaris. Whatever may remain of the membrane is attached to the front of the iris near the pupil, as a raised piece with a nodulated border.

The entire pupil may be covered with the membrane containing many perforations, or partially veiled. Tags may float in it.

The only two cases which I have recognised, were of the partial form. In one, the strip of membrane had an attachment to the capsule of the lens, and it became tense or relaxed, as the pupil was dilated or contracted.

Adhesion of the iris to the capsule of the lens, the result of iritis, is often mistaken for this defect.

Cleft iris, or coloboma. This is an arrest of development, by which the fœtal fissure of the eye is incompletely closed, and the halves of the iris do not coalesce. The pupil is not round, but passes downwards to the margin of the cornea, and is pear-shaped, or triangular. But the fissure may be inclined to one side or the other, and even be horizontal or upwards.

There is a partial coloboma, in which the fibres of the iris alone are defective, the uvea being intact, and another, in which the iris is merely notched at the pupil.

Coloboma is generally a double affection, although not then necessarily a symmetrical one. Two colobomas may exist in one eye.

Coloboma of the choroidea is often present with that of the iris.

A small coloboma of the iris may not perceptibly interfere with vision. But when associated with choroidal fissure, or with congenital defects of the cornea, or with the capsule of the lens, the sight is always imperfect.

Eccentric pupils have been met with, combined with malposition of the crystalline lens.

Tremulous iris. This state is fully noticed at p. 348.

IRITIS.

Inflammation neither begins in the iris, nor is ever chiefly confined to it. So if the term "iritis" be used to convey the idea of the iris being the primary inflammatory seat, or ultimately the focus of it, the part in which the greatest pathological changes occur, it is incorrect. But unfortunately it is so used. The error crept in because the iris is fully exposed to inspection, and when inflamed, in consequence of its high organization and colour, undergoes many marked morbid alterations, while the tissues associated in disease are hidden, and their symptoms were misunderstood.

The iris has wide anatomical relations, for a description of which I must refer my reader to the anatomical introduction. I will merely say here that, while it is partially connected with the cornea, it is

really a continuation of the ciliary body and the choroidea, the so-called uveal tract, in which direction there is always disease when there is iritis. The retina and the vitreous body participate in inflammation of the uveal tract, and the sclerotica, as I have shown in the chapter on diseases of that tunic, reddens when the coats within it are preternaturally vascular. All these conditions taken together constitute inflammation of the eyeball, and it will be found that my description of iritis is in fact an account of developing inflammation of all the ocular tissues in a particular order, with a particular course, more conspicuous at first in the iris and its immediate region. Then as a consequence, the so-called complications of iritis, the corneo-iritis, the irido-cyclitis, the irido-choroiditis, and the irido-retinitis, names given according as the one or the other tissue shows the most marked implication, are but extensions of the same attack of ocular disease, and are never absent in some degree. With this explanation and understanding, I adopt the above classification.

Symptoms in full, of iritis in general, in or about their usual order of development. A sensation of discomfort in the eyeball. Hyperæmia of the anterior sclerotic zone. A little loss of the acuteness of vision. Muscæ. Tenderness or soreness of the eyeball under pressure. Alteration in the colour of the iris. Sluggishness, or limit of the pupillary movements. Pain. Intolerance to light, and lacrymation. General and intense hyperæmia of the sclerotica, with serous effusion in the ciliary region of the same; and of the conjunctiva. Iris exudation, with contraction of the pupil, and pupillary adhesions; the so-called parenchymatous changes. Corneitis. Febrile symptoms. Considerable impairment of sight. Still later, intensity of most of these conditions, with purulent deposits about the iris. Swelling of the eyelids, particularly of the upper, with redness of its edge. Disorganization of the eyeball, with softness, to which atrophy generally supervenes.

But no single case shows all these signs. Then iritis is not a uniform affection, always pursuing a certain course. Variations occur, sometimes in the order of the phenomena, sometimes in their intensity, and it may be in the very existence of some of them. On account of this the signs of the disease must be a little discussed.

Hyperæmia of the sclerotic zone. This is never absent in some degree, and it shows, as I have said above, that there is undue vascularity of the ciliary body and the choroidea. It appears as a pale pink red band round the cornea, deeper coloured, and abruptly terminated in front, gradually shaded off behind, the equator and posterior part of the eyeball being comparatively clear. It increases as the iritis increases.

The conjunctival blood-vessels soon become enlarged towards the anterior part of the eyeball as the iritis progresses, and uniting with those of the sclerotica, contribute to the sclerotic zone. The larger ones are readily discernible by their areolar arrangement and scarlet colour, from those of the sclerotica.

The hyperæmic zone may be partial rather than complete, which is due to the internal vascular excitement of the eyeball being more intense in one direction than in another.

Dimness of sight occurs in the commencement of iritis. I never saw any inflammation of the eyeball which could be called iritis, without the acuteness of sight being lost. Not as is generally supposed from the adjusting apparatus being out of gear, nor either from any changes in the iris itself, but from decline of the sentient power of the retina, or from alterations in the fundus. The deterioration is very easily ascertained by trying the patient with test types.

Full directions are given in appropriate places for ascertaining degrees of imperfection of sight.

It sometimes happens that the sclerotic zone is marked, while the objective iris symptoms are hardly enough to establish the presence of iritis. One has only to try the sight to determine the question. If the vision be misty, and there is loss of definition in association with the least recent iris change, including the slightest sluggishness of the pupil, iritis exists. On the contrary, no matter how red the surface of the eyeball may be, if vision remains acute, there is no iritis. Redness under such condition is in all probability due to hyperæmia or inflammation of the conjunctiva.

Tenderness of the eyeball under pressure can arise only from intra-ocular disease. Tension is not usually present, but it may exist in a slight degree. I shall refer to this again.

Alteration in the colour of the iris. This is the most striking outward characteristic sign of iritis. It arises at first from hyperæmia of the iris, rather than from proliferation of tissue, when only the lustre of the iris is lost and the muscular or pupillary movements are scarcely influenced. Farther alteration in colour from proliferation depends more on the degree of that morbid process than on the natural colour of the iris. The student should remember this, and not expect any definite tint, according to the aspect of healthy irides, farther than that the brighter the colour of the iris, the more marked will be the acquired hue. With the loss of the brilliancy, the beautiful fibrous arrangement is confused or disappears.

Coloration then of the iris is a valuable guide respecting the presence and the degree of disease, when the inflamed eye can be compared with its fellow which is sound. Error is liable if such

comparison cannot be made, or if the irides are naturally dissimilar in colour.

I should say something about anomalies in colour.

One iris may be brown, or rust-coloured, while the other is grey, bluish-grey, or blue.

An iris may be parti-coloured, half brown, and the rest grey or blue. Or the colour may be in different proportions.

The radiating fibres often differ in colour from the circular ones.

Dead white, generally concentric lines, occur near the margin of the iris.

A spotted iris is the commonest anomaly. The spots, or pigmentations, seldom exceed the size of a pin's head. One, or several, may exist. According to Ruete, these spottings would seem to be mere freaks in pigmentation. He says that in infants just born, the uveal pigment of the iris is developed, while that destined for the stroma is not, hence all babies have blue eyes. If the pigment fail, the iris will remain blue, and only get lighter as the iris tissues lose their transparency. If it be scattered and scanty, the eye is of a light grey-brown. If it be abundant, the eye will be nut-brown, and finally deep dark-brown. The parti-colouring then is merely irregular pigmentation. Aristotle mentions the fact of the infantile blueness, and the subsequent change to the proper hue.

The adult colour of the iris generally corresponds to the complexion of the individual and the colour of the hair. In fair complexions and light hair, the iris is blue or grey, or of some light tint. In persons of dark complexion and hair, it has a deeper shade, dark-grey, brown in various shades, of which the deepest is called black. In the negro, this is characteristic, the iris being so very dark, that it requires close inspection to distinguish between it and the pupil.

Sluggishness or loss of pupillary movements, the muscular action of the iris being impaired or destroyed. The pupil moves sluggishly at first from hyperæmia. When effusion has taken place, its movements are entirely suspended. The method for testing the movements are too well known to require description.

Pain is a variable symptom, and does not occur in proportion to the degree, or to the destructive effects of the inflammation. It is often found inconsiderable in severe cases, and where organic changes of the most injurious nature occur, while sometimes it is most distressing in less acute forms of disease, and in which alterations injurious to the integrity of the organ do not at first attract so much attention. It is not necessarily a prominent symptom of inflammation of the eyeball. In many cases it can scarcely be said to exist.

at all. In character, it is the throbbing, intense, dull pain of inflammatory tumefaction, sometimes caused by cough and sneezing, or any other effort which influences circulation through the respiratory organs. It differs from the pain of an inflamed conjunctiva, which is hot and scalding, like that of cutaneous inflammation.

Intolerance to light and lacrymation. There is generally some, and often considerable, intolerance in the beginning of inflammation, and in its early progress, together with increased lacrymation, the tears flowing freely on exposure of the eye to light.

General and intense hyperæmia of the sclerotica; with serous effusion in the ciliary region of the same; and of the conjunctiva. This shows a greater degree of inflammation of the interior of the eyeball, and especially of the uveal tract. When the surface redness is at its height all the external vessels of the eyeball, including those of the conjunctiva, participate in the irritation, and give to its visible surface a uniform fiery redness. Now all parts of the conjunctiva inflame.

Iris exudation with contraction of the pupil and pupillary adhesion. At this stage, quantities of neoplastic elements are thrown out, most of which is visible to the naked eye. They may be thus classed:

Pupillary excrescences or fibrinous exudations. These are for the most part scattered about the pupillary region of the iris, as exudations in the proper stroma of the iris, and perforating, come in contact with the capsule of the lens, to which they adhere, constituting synechia posterior. But they may be deposited about the body or the marginal portion as well.

The well-known tendency of the exudation to be particularly marked at a part only of the iris has induced some surgeons to suppose that the iris may partially inflame. All of it inflames, while the pathological changes are more seen in patches.

Exudation, as I have said, is incompatible with pupillary action or movements. As there cannot be developed iritis without exudation, there can be no natural pupillary action where there is iritis.

Pupillary contraction is due to swelling from the hyperæmia, the serous effusion, and the proliferation, and increases with the progress of the affection. It changes the figure of the opening, rendering it angular, or otherwise irregular, and sometimes eccentric.

The synechia may be partial or complete. The ties or exudation bands causing the synechia may be very slight and few, of a greyish colour, and difficult to be seen, requiring oblique illumination for their demonstration; or large, pigmented, and very apparent.

The terms partial and complete closure of the pupil are used synonymously with partial and complete synechia. With the latter, the

pupillary space, for the term is still applicable, is generally nearly or quite filled by a thin pseudo-membrane more or less continuous with the excrescences or exudations, and attached to the capsule of the lens, which destroys its clear black colour, and gives it a dull cloudy appearance; or one so thick that it stands up like a plug.

A word more about synechia, which means continuity or keeping together, and is applied to adhesion of the iris to the capsule of the lens, or to the cornea. In the former, it is distinguished as synechia posterior, and is said to be circular, partial or complete, when only the pupillary edge is tied down, in part or in whole, and total, when the back of the iris is glued to the capsule of the lens as well. In the latter as synechia anterior. Now this anterior is usually produced by the iris prolapsing through a breach in the cornea, or adhering to such or to cicatritial material. When produced by iritis, the circumference only of the iris adheres to the inflamed cornea.

When complete synechia posterior has occurred, the iris is necessarily much disorganized, and its natural striated appearance is for ever lost, and it is slate coloured. It bulges in a circle, or in pouches, and may even touch the cornea, from the pressure of the aqueous humour posteriorly, for, be it remembered, the chambers no longer communicate.

Granulations, or fibrinous infiltrations. These swell the iris and make it spongy and prominent. They are neoplastic nuclei and cells pervading the entire iris. They are mostly apparent on the anterior surface, and are rarely raised in relief. On the posterior surface they are very rare.

Gummy tumours. Nodules, identical with the syphilitic gummy tumours, as described by Virchow, in other parts of the body, by which the organic iris muscular fibres are destroyed. They are chiefly near the pupillary margin, and are elevated, single or many, partially or quite surrounding the pupil, separate or confluent. They are very vascular, and the vessels which are readily seen give each nodule a reddish, or yellowish grey, or cinnamon, or tan colour. Hæmorrhage may proceed from them.

When the iris undergoes any of these changes, its natural blood-vessels enlarge. The veins can often be seen.

Corneitis. This scarcely appears in the early stage of iritis, but comes on later, and in the form of diffuse or parenchymatous corneitis with the effects on the posterior elastic lamina well marked.

Febrile symptoms. There is great dissimilitude in the degree of constitutional disturbance. The most acute form of iritis is attended with severe pyrexia, high temperature, headache, restlessness, and want of sleep, pulse full and strong, tongue white, thirst, loss of

appetite, costiveness. Often, however, such symptoms exist only in a slight degree, or are entirely wanting.

The considerable impairment of sight, of the increased disease, is a fact which never escapes even the patient's attention. The physical conditions which induce it are, retinal inflammation, haziness of the vitreous humour, deposits on the capsule of the crystalline lens, corneitis. The presence of the first two may always be inferred, when either or both of the last two are absent. Or in other words, if the pupil be clear enough for sight, and there is no sight, the fault is posterior.

Pus, or corpuscular lymph, in connection with the inflamed iris, may exist as a thin surface formation, which is quickly thrown off, and gravitating in the anterior chamber constitutes, along with other inflammatory products of the aqueous chamber, hypopion. The amount of this may be, from only the least, enough just to be recognised, to that sufficient to fill both the chambers of the eye. It may be thrown into the posterior chamber from the posterior part of the iris, rise through the pupil, and enter the anterior chamber. Or it may appear like infiltration in the iris, or in patches, and in either case streaked with pigment or extravasated blood. These forms of deposits may occur on the capsule of the lens.

Swelling of the upper eyelid never occurs except in the most severe cases of iritis. It therefore unequivocally indicates the severity of the intra-ocular inflammation.

Some forms of iritis are more rapid in their progress and more active in their operation than others. In the rapidity or slowness of the developing inflammation, if extremes be taken, there is difference in time as to days, weeks, or even months. It is of clinical importance to know when the activity has ceased, and decline has commenced.

Capsulo-lenticular cataract is no uncommon association with iritis, attended by exudation on the capsule of the lens.

After this general account I must speak of varieties.

Acute and sub-acute iritis. Cases differ very much in the severity of the symptoms, the rapidity of their progress, and their entire duration. Serious mischief may occur in a few days, or weeks may elapse without permanent change of structure or injury of sight; and although there are numerous gradations, to which we cannot give names, there is enough to mark the difference of character between acute and sub-acute inflammation. In the former there is the bright external redness of the eyeball, with great distention of the blood-vessels, and perhaps chemosis, rapid and general change of iris colour, contraction of the pupil, effusion into its aperture, dulness of

the cornea, loss of sight, agonizing pain in the eye, severe headache, considerable fever, want of sleep, and restlessness. In the latter the disease arises slowly, there is but the faintest, scarcely to be detected sclerotic zone, without hyperæmia of the conjunctiva, the plastic effusions occur with slight vascular disturbance, with scarcely any pain, and vision becomes impaired, or even lost, before the existence of the malady is discovered. Perhaps it is recognised by accident.

Acute and chronic iritis. So long as the inflammatory symptoms increase, I speak of acute disease. When these abate, and I have before me chiefly the effects of them, I then speak of chronic disease.

Long persistence of some amount of redness of the sclerotica and conjunctiva is not unusual. Months may pass before the blood-vessels assume their natural calibre.

Chronic iritis, even of the most typical form, carries this significance, that while it endures, if the patient be exposed to causes usually inducing inflammation of the eyeball, there is likely to be reproduction of pain and other symptoms, and a relapse to the acute form.

IDIOPATHIC IRITIS.

I apply this name to a very rare form of iritis, because there is not connected with it any recognisable pre-existing or co-existing constitutional disorder, except that of debility. Yet I am not satisfied with it, because it carries merely the significance of ignorance, nor am I with that of serous iritis, which is sometimes applied.

The symptoms are much hyperæmia of the sclerotica and of the conjunctiva, with marked loss of acuteness of sight, which is accounted for by the condition of the retina, and slight loss of colour of the iris. The entire cornea inflames, and its surface loses its polish and gets steamy. At this stage the case is apt to be a puzzle, for the eyeball is certainly tenser than natural, which condition, with the steamy cornea, looks like sub-acute glaucoma. Then, too, there is but little proliferation in the iris, and the pupil, although inactive, contracts but very little, or may even dilate somewhat, and no pupillary excrescences tie it down. Iris adhesions do occur, but they are between the posterior part of the pupillary margin, the uvea, and the capsule, yet only partially, and so slightly that they readily break away, and leave their marks as pigment dots on the capsule.

On the other hand, as opposed to glaucoma, the pathological changes in the posterior elastic corneal lamina are well marked.

The chambers are enlarged through augmented aqueous humour, which fluid becomes turbid through exudation. Then pain is not a prominent symptom.

The corneitis is generally the most persistent symptom. The second eye is very apt to be attacked. Relapses occur. The cornea mostly bears some indelible damage, in the form of opacity, chiefly interstitial.

The disease attacks young persons, and lasts for months.

SYPHILITIC IRITIS IN THE ADULT.

This is a consequence of syphilitic infection of the system from syphilitic inoculation, appearing generally in the constitutional state of the disorder. It may however occur before the primary sore has healed, and may be the only after effect. But it is usually accompanied by some or many of the sequelæ, such as the papular, the scaly, the tubercular, and the pustular forms of skin eruption, or ulceration of the mouth and throat, or pains in the limbs, and periosteal inflammation, or swelling of the lymphatic glands about the neck, axilla, or inguinal region.

Diagnosis of the acute form, as gathered from the eye symptoms. It usually appears with the tertiary sequelæ. Very early there is much loss of acuteness of sight. The sclerotic zone is but faintly marked, and the iris is merely hyperæmic. Vision gets worse faster than the surface of the eyeball reddens.

The iris soon shows more inflammatory activity, more plastic effusion, by which the pupil is contracted, is more tied to the capsule of the lens, is more irregular and more displaced, than in any other form of iritis. Here only is that excess of exudation by which the chambers may be nearly filled, or that deposit of it on the circumference of the iris, anteriorly or posteriorly, so as to bulge the cornea, or to bulge the sclerotica and form a tumour under the conjunctiva. Here only do we get the gummy tumours round about the pupil, which are found only in syphilis.

Hypopion, either primary or secondary from abscess of the iris, rarely occurs except in persons who are much debilitated.

The cornea may keep clear in some of the worst cases. When corneitis does appear it is of the punctiform kind, and opacity of the posterior elastic lamina is very marked.

The aqueous humour, which is rarely free from exudation, soon becomes yellow and albuminous, like the fluid of hydrocele, and misleads one as to the true colour of the iris. The supposed green

iris is the effect produced by this fluid on an iris which retains any blueness.

The vitreous humour very soon gets cloudy, and filaments and shreds float freely about in it as the effect of inflammation.

The retina shows specific inflammatory changes which are spoken of elsewhere.

Pain is chiefly in the eyeball. It rarely occurs in the day, but comes on in the evening, or soon after going to bed, intensifies, prevents rest, and lessens towards morning. Where it is constantly present, there is marked exacerbation at night.

In the subacute form, which usually appears during the papular and scaly eruptions, there is marked modification in the developing inflammation, and in its results. The plastic tendency is slight, the exudation very meagre, and the gummy tumours are wanting. The sclerotic zone may be a mere narrow pink blush.

The mildness of the symptoms might induce a doubt respecting the specific nature of the affection. The constitutional history of syphilis, if clearly made out, will disperse the doubt. A difficulty might arise in proving syphilitic inoculation, because females have primary sores without knowing it, and a man may be inoculated in his urethra, and attribute his syphilitic symptoms to gonorrhœa.

Syphilitic iritis seldom relapses. A single attack is apt to damage the sight. One eye frequently escapes. Both may be attacked at once, or the one after the other.

RHEUMATIC IRITIS.

This is the most frequent form of iritis I meet with in private practice. There is the history of previous general rheumatism, or the existence of such. Or the rheumatic diathesis prevails, indicated by transient shifting pains, brief febrile paroxysms, and impaired gastric and renal functions. When the exception occurs, general rheumatism follows the iritis in a few days.

The eye symptoms. Subacute rather than acute vascular action. Much intolerance to light, with marked redness of the eyeball. The surface is dull red; this arises from the conjunctival vascularity, which is very prominent, rather obscuring the sclerotic zone. Added to which, as the disease is nearly always in adults, or elderly persons, the sclerotic zone would be less vivid than in those under adult age. Yet there is nothing sufficiently distinctive in such vascularity as to make it alone a true criterion of rheumatic iritis. Early but not extensive implication of the intra-ocular tissues, the retina especially escaping, so that the imperfection of vision is at first slight.

The iris is dull. The surface change is not very apparent beyond the loss of colour and swelling, and an untutored observer may fail to detect any alteration. There is loss of sharpness of outline of the pupil, which is contracted. A small amount of exudation occurs at the pupillary margin, and synechiæ posterior ensues.

The vitreous humour soon becomes hazy, and shuts out a view of the fundus of the eye.

Hypopion is very rare.

The nature of the pain and its extension to secondary parts is peculiar to this affection. Generally at the commencement it is in the head, although it sometimes also affects the eyeball itself. It is usually most severe in the temple of the affected side. It often involves the eyebrow, the cheek-bone, the teeth, or the lower jaw. Sometimes it is precisely confined to one-half of the head, and sometimes it attacks the interior of the nose, or of the ear. Wherever these pains occur, they are more of a dull, agonizing kind, than acute. They may be unceasing, but in most cases they remit, the paroxysms coming on at four, six, or eight o'clock in the evening, continuing most severely during the night, and abating towards morning.

In chronic cases, in addition to the ocular surface redness of iritis, there are large tortuous blood-vessels, derived from the vessels belonging to the recti muscles, which in a physiological state are visible in healthy eyes, producing the morbid varicose arrangement depicted in Fig. 279.

Fig. 279.

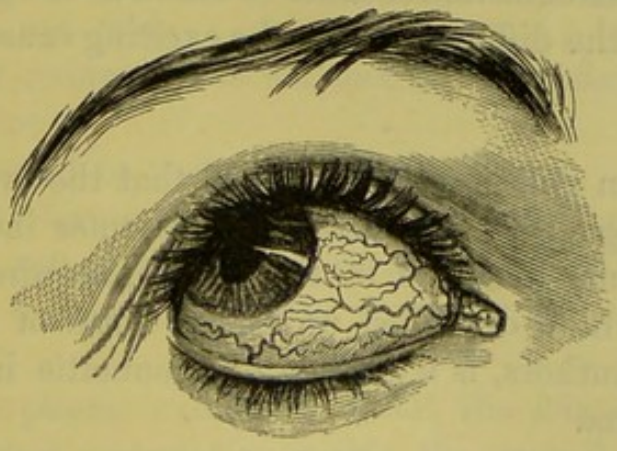

The cornea is always affected. It loses its polish, is pervaded by a muddy haziness which soon obscures the iris. These pathological changes are superficial rather than interstitial.

White froth collects on the edges of the eyelids and at their corners.

There is a tradition about the presence of a grey or ash-coloured

ring, partial or complete, immediately around the cornea. The ring may appear in any form of iritis, and depends on an anatomical variety in the eye. Where the corneal tissue passes obliquely into that of the sclerotica and overlaps it, the blood-vessels of the sclerotic zone do not advance close to the iris, and the intervening strip of cornea appears as a ring. Where the junction is short and sharp, the zone passes right up to the iris, and there is no ring.

Both eyes are usually attacked sooner or later.

The tendency for rheumatic iritis to return after it has quite passed away, is the worst feature of the complaint. Again and again does it relapse, even through a long life, so that a patient might tell of his tenth, fortieth, or fiftieth attack.

The acuteness of vision may be restored after each attack of the iritis, although the visual field gets progressively limited on account of the pupil area being reduced by circular exudation spreading from the pupil, till at last the aperture is closed. It is astonishing what mere pinholes of pupils suffice for vision, particularly if the lateral light is shut out. It comes then that the rheumatic eyes are spoiled by the closing of the pupil, rather than by disease of the tissues posterior to the iris.

There is no form of inflammation of the eye which has been so much unnecessarily classified as iritis. Even my division of it, expresses merely modifications of the same disease, for the nature and the effects of the disturbance in each class, are nearly the same. On this account, the local appearances do not always enable us readily to say under which variety a case should be placed, and the history and concomitant circumstances must be taken as the guide. Whereby it turns out that the difference is in the exciting cause, and not in the malady.

I have not been able to satisfy myself that the eyeball is ever the primary seat of gouty inflammation, or becomes inflamed in consequence of the gouty diathesis in the system, acquired or hereditary. That which has been described under the head of gouty inflammation by the old authors, is a jumble of rheumatic inflammation and subacute glaucoma.

From my own observation I am not aware that the interior of the eyeball ever inflames as an effect of gonorrhœa. In looking over reports of alleged cases, I am inclined to class them under two heads: first, diffuse or parenchymatous, and punctiform corneitis with some implication of the post-corneal tissues; secondly, rheumatic iritis.

Traumatic iritis is described as the inflammation which arises from the impaction of foreign bodies in the eyeball, from the presence of a cysticercus in the same, or from a surgical wound, as in the removal of cataract, etc. In an acute case every tissue of the eyeball is inflamed to the utmost, according to its organization, and suppuration of the cornea, or within the eyeball, occurs, a termination unknown in the conditions which I speak of as iritis.

Unusual development of the conjunctival inflammation in association with rheumatic iritis, has induced some surgeons to suppose that the addition constitutes enough difference to require the admission or recognition of another genus of the disease, under the name of catarrho-rheumatic ophthalmia. I cannot recognise any such nosological arrangement.

Principles for the treatment of iritis. Where the inflammation is full and acute, local blood-letting by leeching or cupping is valuable. The pain, the surface redness, the throbbing in the temple are removed by it, or very much reduced. The subjective symptoms also are benefited. Doubt may arise as to the admissibility of it, in cases of lesser degrees of the inflammation. The existence of pain should determine its adoption.

The exalted temperature of the eye and the surrounding parts, caused by the accumulation of heat in the blood, an injurious state, should be met by surface application of cold, the degree of which must be left for clinical experience to determine, but this may be said, that the cold is useful so long as it gives comfort, and prejudicial when it irritates or causes aching or shivering, and that dry is better borne than wet cold.

Such agents by reducing the violence of the inflammation, reduce also the products of it.

Bright light should be excluded from both eyes.

In the less acute forms of inflammation, shorter measures of these local therapeutics suffice, or the first of them may be omitted.

As to general measures. Bodily, mental, and ocular rest, are essential.

When there is plastic exudation about the iris, which is always accompanied by plastic exudation within the eyeball, mercury should be given, of the efficacy of which in facilitating recovery I am most fully assured, after experimenting very much with and without it, under most painstaking clinical observation. On it we must chiefly rely, not however to the exclusion of auxiliaries to meet outlying conditions.

Some cases of subacute iritis may get well of themselves without

any treatment, or with antiphlogistics short of mercury, so that the eye is restored without any appreciable damage to the sight, although marks of the iritis may remain. But when acute cases are left alone, or are treated without mercury, they usually end in conditions injurious to the vision, such as contraction and adhesion of the pupil, obstruction of the pupil area by adventitious membrane, damage to the retina, and loss of sight.

It is my experience, then, that acute iritis in general, and the syphilitic form in particular, may be most advantageously treated by the combined or successive employment of antiphlogistic measures and mercury, or by mercury alone. And that while such a plan will give the quickest relief, it will more effectually arrest the inflammation than any other known means, and afford the greatest security against the return of the disease. I never accept any case which is shown to me as evidence of the high value of the non-mercurial plan, if I detect the least damage to the eye, objectively or subjectively.

Our ignorance of the essential nature of syphilis, as also of the *modus operandi* of mercury, ought not to be enough to induce us to exclude mercurial treatment, when we have clinical and rational proof of its therapeutic value. Yet we should err if we make an abstraction of the disease syphilis, consider mercury to be the antidote, and ignore other curative measures.

The usual formula which I prescribe is this:

℞ Hyd. c. creta, gr. ij.
Ext. hyoscy., gr. iijss.

to be taken in a pill once, twice, or thrice a day, according to the severity of the inflammation. I avoid purgation, or depression, by lessening the frequency of the taking, or altering the proportions, of the pill. This plan, while it has the advantage of tentative administration, is less likely to disturb the appetite, or depress, or produce local irritation, than any which is practised. Therefore, as a rule, it can be employed with less regard to, but not to the ignoring of, individual peculiarities, diversity of constitution, and state of bodily power. It is, too, in public practice the best suited for out-patients, who are always less advantageously treated as such, and cannot be closely watched.

There is no proof that the hydrargyri perchloridum, or the hydrargyri iodidum rubrum, is more applicable than the hydr. c. creta.

It is most probable that so long as the mercury is absorbed into the blood, no matter how it gets there, its action is the same.

Inunctions and fumigations of mercury have each advantages, on the score of not irritating, but the difficulty of regulating the mercurial action of both, and of applying the second, render them

less applicable for practice. Either may be used when mercury cannot be borne by the stomach.

I continue to give the mercurial pill till I see reduction in the symptoms. That is till the redness of the eye diminishes, and the exudation, of whatever form it may have been effused, is removed. Till vision is nearly or quite restored. Till the iris is acted upon by atropine, and its colour has returned.

In most cases of iritis which I see, the period for beneficial blood-letting has passed away, and also nearly that for the use of cold, the opportunity for the mercury alone remaining.

The use of atropine does not in my opinion possess more than mechanical advantages. If the pupil could be kept dilated during iritis, adhesion of the iris to the capsule of the lens might often be prevented, but, unfortunately, in the very form of inflammation in which dilatation would be so beneficial, the iris is too much infiltrated to act. The application of atropine from the very commencement of the inflammation will not stay the inflammatory action in the iris, a part only be it remembered of the disease of iritis. Yet I employ it as soon as I see my patient, because it affords me correct information of the iris returning to health, in dilatation of the pupil, or whatever portion of it may be free. The pupil is not always tied closely to a deposit of lymph which fills its area. Only a few adhesions may pass between them, in which case irregular pupillary dilatation to some extent is possible, and a sufficiently clear space may be so got for useful vision.

There can be no inflammation of the iris if the pupil can be artificially dilated. A surgeon who has doubt about the presence of iritis may safely use this test.

It is interesting to see how the pupil expands irregularly, even where there is no adhesion, as this or that section of the iris successively gets healthy, till at last the dilatation is quite round. During this mode of return to health, the infiltrated, and as yet not acting iris fibres, are apt to be mistaken for points of adhesion, which ultimately are detached.

I employ the atropine also to break through or lengthen any pupillary or uveal attachments, which are capable of being so influenced.

Continental surgeons propound the theory that atropine is a most valuable therapeutic agent, and enumerate among its advantages, sedative effects, rest to the iris by suspending its movements, as if an inflamed iris ever moved. The lessening of intra-ocular pressure, by which the circulation of the eye is relieved, and an antiphlogistic effect produced. They prescribe it three or four times stronger than

ever I employ it; I find two grains to an ounce of water sufficient, and direct it to be employed from ten to twenty times a day. I have watched this practice, and could not fail to notice how frequently it has produced marked symptoms of poisoning, as well as those of catarrhal inflammation of the conjunctiva, and severe cutaneous erysipelas of the face. Still this practice is becoming extremely popularized in England as a fashion. For scattered hints respecting atropine, I beg to refer to the index.

Treatment of the varieties of iritis. For the idiopathic form of iritis, I give the least mercury and resort very early to preparations of iron, in doses according to the existing debility. When the corneal symptoms become very prominent, as they are prone to do, they should receive appropriate attention according to what I have recommended. Relapses are likely to occur, and must be guarded against by avoiding the conditions which seem to induce them.

In the syphilitic form, in young adults otherwise healthy, a full antiphlogistic course is required, and the mercury is needed in frequent doses. The more acute the inflammation, the more marked is the effect of the mercury. Here it is, in allusion to this medicine, perhaps more than in the whole range of surgical practice, that we have an example of the remedial influence of a medicinal agent on disease. In a few days it will arrest plastic exudation and the force of inflammation, which otherwise will most probably proceed unchecked to the damage or destruction of the eye.

Rheumatic iritis. In this, more than in any other form, is there derangement of the functions of important organs, as well as in the processes of absorption, nutrition, and secretion. I begin my treatment with purgation on the elimination principle, and then employ the mercury according to the degree of the inflammation. As soon as ever the vascular activity is reduced, I usually resort to iodide of potassium and cinchona.

Cold applications do not suit after any exalted temperature is reduced by them, then hot ones are grateful, especially sedative fomentations. An anti-rheumatic regimen should be strictly observed.

Iridectomy is often practised in acute, subacute, and chronic iritis. The practice is wholly unjustifiable; besides being a useless operation it is apt to produce opacity of the lens and abscess of the cornea. One of the excuses for adopting it is alleged relapse of the iritis because of total synechia posterior, it being argued that there is some disadvantage because the communication between the chambers of the eye is cut off. Also that the tension of the iris in consequence of the adhesion is injurious. If the latter were true, iridectomy

would be useless unless it rendered the pupil quite free. Synechia anterior from ulceration of the cornea often causes great tension of the iris from stretching; yet I never saw it set up inflammation.

Pathological effects of iritis on the iris. The alterations depend on the intensity of the inflammation to which the iris is subjected. The higher it is, the greater the development of neoplastic elements. The greater these elements the more surely does atrophy occur, and it may proceed so as to render the iris nearly transparent.

Atrophy causes the iris to bulge, and to such an extent that it may touch the cornea, although the pupil is contracted, and tied to the capsule of the lens.

Pupillary adhesion, synechia posterior, is scarcely escaped from in some degree in any case of iritis. So long as the adhesions are on one side, it practically matters nothing even if a quarter of the pupil be tied. But as synechia occurs only when the pupil is contracted, if it be total, or if partial, yet so disposed as entirely to prevent pupillary movements, vision is interfered with, as regards the formation of retinal images, and accommodation, supposing the retina to have escaped spoiling. They are very persistent, not being readily torn through by the resisting muscular power of the iris, although they may lengthen. The pigmentary spots which are often seen on the capsule of the lens after iritis, and said to be the remains of synechia posterior, are not such, but are the remains of adhering granulations which had formed in the uvea, and which readily give way.

Synechia anterior, or adhesion of the circumference of the iris to that of the cornea, the effect of the coalescence of two inflamed surfaces, remains.

Exudations on the capsule of the lens, which nearly or altogether close the pupil, and remain after the inflammation is declining, are permanent. The gummy tumours may be entirely absorbed, or suppurate and leave cicatrices, or pigmented nodules.

The hypopion, when quite fluid, or even containing flaky coagula, produced by the disintegration of morbid products on the surface of the iris, or on the posterior elastic membrane of the cornea, is soon absorbed. It may disappear and recur several times in the course of one attack of iritis. I have never evacuated it in this disease.

Prognosis as regards recovery of sight. A case may be said to be hopeless when there is much iris proliferation and considerable contraction of the pupil, with exudation in its area, intense external redness of the eyeball, and great and deep-seated pain. Nor is vision recovered from when a large effusion has taken place behind the iris, particularly if it should have caused bulging of the sclerotica,

or made its way through that tunic. Marked contraction of the pupil, and total synechia posterior, and a puckered and protruded state of the iris are very unfavourable circumstances.

The longer the inflammation lasts, the more likely is the retina to be damaged.

Iritis may be completely arrested, and vision quite restored, a fortnight or three weeks after the inflammation has set in. The same may be said when the inflammation is not very severe, at the end of a month, or even six weeks. And after longer periods useful vision may be recovered.

CHAPTER XXXIV.

OPHTHALMITIS.

OPHTHALMITIS IN GENERAL—TRAUMATIC OPHTHALMITIS—PYÆMIC OPHTHALMITIS.

The term ophthalmitis, which is meant to express inflammation of the entire eyeball with suppuration, is in contra-distinction to the term ophthalmia, which is generally used to express inflammation of the conjunctiva. Panophthalmitis and suppurative choroiditis are also names employed synonymously with it.

OPHTHALMITIS IN GENERAL.

Local symptoms. In a very acute case the whole eyeball seems involved at once in inflammation. Severe pain soon sets in. Then the surface of the eyelids reddens. The conjunctiva becomes œdematous very early, soon inflames, and develops into full chemosis, whereby the cornea is nearly covered, and so far the case looks like one of severe purulent ophthalmia, but there is scarcely any, or no purulent discharge. Haziness of the vitreous humour, almost from the beginning, prevents the fundus of the eye from being seen. There is intolerance to light, and the additional subjective symptoms of shining spectra and corruscations.

The corneitis and the discoloured iris give the semblance of severe iritis, but the crystalline lens is pushed forward, and behind the generally dilated and fixed pupil, there is a diffuse and rapidly increasing opacity, conditions which do not occur in iritis.

As the disease advances, the pain in the eye which existed at first is exchanged for pains at the back of the eye and in the orbit of a pulsatory nature, shooting to the forehead and the temple. Burning heat and tension as well are felt in the orbit.

The eyelids are now fully inflamed and very tender. The upper one drops, while the under one is somewhat everted. The cornea is semi-opaque, and may suppurate.

The eyeball is protruded by effusion into the ocular tunic, and into the orbital tissues, and this, with the swelling of the eyelids, causes it to appear much enlarged. That it does enlarge a little I fully believe. It is always very tense. It soon gets absolutely fixed in the orbit, so that it cannot even be pushed from side to side. This is due to inflammatory alteration in its muscles, and in the orbital tissues.

The conjunctiva, which is still more swelled, is covered by exudative coatings, especially on the lower palpebral portion, and which accumulation is reproduced as soon as it is removed.

There is now intra-ocular suppuration. The eyeball may burst through sloughing of the cornea, in consequence of the pus having made its way into the chambers of the eye, or in consequence of interstitial abscess, after which the intra-ocular pus finds a vent in that direction, or through ulceration of the sclerotica, for the most part where it is thinnest, just under the attachment of one of the recti muscles. In the latter case, the pus usually enters the ocular tunic before it finds the surface. But the suppuration may be very limited, and there may be no escape of the pus from the eyeball.

The constitutional symptoms vary, and chiefly according to the nature of the ophthalmitis.

In a sub-acute case, one tissue of the eyeball after another seems to be involved in inflammation, rather than many of them at once; and some of them may altogether escape. The symptoms are less severe, and the orbital contents are but little, or not sensibly, affected. From this, obscurity may arise. But notwithstanding such variety and mildness suppuration may be copious.

Ophthalmitis is modified by its cause. I recognise only two forms of it, the traumatic and the phlebitic.

TRAUMATIC OPHTHALMITIS.

This includes as its origin traumatic and chemical injuries to the eyeball of all kinds from without, with or unaccompanied by any breach of surface. The various operations for cataract, and, indeed, all operations on the eyeball, particularly those by which it is opened. Ulcerative perforations of the cornea with loss of the crystalline lens. Also injuries within the eyeball, as dislocation of the crystalline lens, particularly backwards, or the entrance of a cysticercus.

The course of the traumatic form is the more rapid of the two, and the symptoms, objective and subjective, the more severe.

Penetrating wounds usually produce the highest degree of inflammatory action, the sthenic or hypersthenic effect. The intrusion of extraneous bodies generally causes low inflammation, the asthenic effect, which may remit and recur. The same characters attend the ophthalmitis of ulcerative perforations.

In ophthalmitis associated with suppuration of the cornea from wounds, the pus is developed from before backwards, the iris and the ciliary body suppurate first, and the posterior parts afterwards.

The ophthalmitis usually quickly follows the injury. Exceptionally months, or even a year or two, may pass away between its development and the primary injury. This late appearance occurs even where the eye seems to have recovered from the symptoms of the original inflammation, however much or little of its effects may remain, and without any noticeable reason, or in consequence of a blow on the eyeball.

The constitutional effects follow the local ones.

The ophthalmitis is confined to the injured eye.

Atrophy of the eyeball is the consequence of partial suppurative ophthalmitis, and means simple diminution.

Collapse is the result of general suppuration, whereby the coats of the eye collapse and shrink to a small size, the cornea being scarcely, if at all distinguishable. The small tubercle which remains is subdivided into four parts by four superficial impressions, corresponding to the situation of the four recti muscles, and meeting together in the centre.

PYÆMIC OPHTHALMITIS.

This secondary inflammation is the effect of phlebitis in its various forms, and we see it often in association with puerperal diseases, under which influence it may appear from the third to the thirtieth day after parturition. Next in frequency it is due to febrile diseases, exanthematous fevers, among which erysipelas is prominent. At p. 44 I show that it is induced by orbital cellulitis.

It arises, too, from any deleterious and infectious materials entering the blood. The source of the affection is very commonly overlooked.

The ophthalmitis may be developed with symptoms very acute, or so little pronounced as regards pain and inflammation of the conjunctiva and the eyelids, that it would seem as if ready formed pus had entered the eye.

Both eyes are usually attacked, and when one suffers, the selection

seems to be determined by any previous weakness from inflammation. The general symptoms precede the local ones, and are of a typhoid nature, such as longer or shorter paroxysms of shivering, or frequent rigors, increased temperature, rapid pulse, thirst, prostration of strength, headache, a parched and brown tongue, restlessness from want of sleep.

The termination, as regards the eye, is loss of sight, and the effect on the eyeball is the same as in traumatic ophthalmitis.

As the tendency of pyæmia is to form multiple abscesses in various parts of the body, such occasionally exist with ophthalmitis, or occur after it.

Death often ensues from the same causes which destroy life in pyæmic poisoning in general, as well as from the direct propagation of the ocular inflammation to the brain and its membranes. The prognosis, therefore, as regards recovery of that patient is always most uncertain.

Morbid Anatomy.

Careful experiments, followed by microscopic investigations, have been made on lower animals, to discover the tissue of the eyeball in which the vascular action is set up, and to ascertain its progress. The starting-point is traced to the connective tissue among the choroid capillaries. When the choroidea is fully inflamed, fibrinous exudation proceeds from it, and pervades all the intra-ocular tissues, and suppuration occurs on its inner surface, and may then affect the entire tunic, and the ciliary body. Pus, serum and coagulable lymph are commonly deposited between the choroidea and the retina. When the amount is large, the latter is pushed inwards and "coarcted," that is, while it retains its anterior attachment, and its posterior connection to the optic nerve, it appears of a funnel shape. If its posterior attachment should give way, it is pushed in a heap against the crystalline lens. All this necessitates the more or less absorption of the vitreous body. But the deposit may be very small, and in isolated portions, so that these membranes are separated only at such points.

The retina is usually partially or entirely involved in the purulent action. It is questioned whether there is merely purulent infiltration, or actual primary suppuration.

Dr. Ritter, one of the several experimenters in this field, says that it cannot suppurate of itself, since it has no anatomical elements out of which pus can be formed. This is an anatomical point most diffi-

cult to be ascertained. That it gets infiltrated with pus, and broken down, is a fact.

Pus occurs in the vitreous body, either as a limited deposit, or a general pervasion, and, it may be, while the retina almost retains its choroideal attachment. I have never seen it in the human eye, without partial or entire suppuration of the hyaloid membrane, a fibrous tissue from which fasciculi pass into the vitreous body. Ritter holds the same view here of non-suppurating property as he does of the retina, and regards the pus found in it as derived from the choroidea. The vitreous has cellular elements enough in it for suppuration, but it lacks vascularity. However, he found the first appearance of pus in it to be just within the hyaloid membrane, whence it travelled toward the centre of the body. But this is a disputed point, as equally good observers hold different opinions.

This brief and scanty sketch is taken from traumatic ophthalmitis, some allowance must be made for the difference of the effects of inflammation between the eyes of men and rabbits, and it is like what has been observed in human post-mortem examinations.

It is only necessary to add that the ophthalmitis itself is produced by the altered condition of the blood in the blood-vessels of the choroidea causing thrombosis, and not directly by phlebitis. Not till the healthy nutrition is affected, and inflammation is set up, do the coats of the blood-vessels participate in the morbid action.

Treatment.

There is more scope for this in traumatic ophthalmitis, in limiting the production of pus, and lessening disorganization of the eyeball, by which there may be shrinking and not collapse, than in the phlebitic. Saving an eye in either is out of the question.

In the former variety, the removal of intruded extraneous substances, or of things within the eyeball, which offend, is very effectual. In both varieties, whether the inflammatory symptoms be acute or subacute, the local treatment should be the same as that which I prescribed for iritis, with these additions: The chemosis should be incised after the manner I advise for severe purulent ophthalmia. The evacuation of the products of the inflammation within the eyeball should not be neglected. While it reduces the local vascular action, it may save life.

The earliest call is to open a filled ocular tunic. An indistinct fluctuation around the prominent and tense eyeball, declares the presence of fluid there. The conjunctiva having been cut through

at an under position, close to the cornea, between the internal and inferior recti muscles, the point of a small scalpel should be passed close to the eyeball, and carried on within the ocular tunic till the serous fluid containing pus, or pus alone, escapes. After the evacuation the eyeball falls back and loses its tension.

Paracentesis of the cornea is beneficial whenever aqueous fluid, however reduced, is turbid. It may be repeated with advantage. Incision of the cornea should quickly follow interstitial corneal abscess.

Puncturing the sclerotica and at the same time, the choroidea, the retina, and the vitreous humour, at the lower part of the eyeball, or wherever the pus may point, should be adopted as soon as, with loss of sight, there is reasonable suspicion of choroideal suppuration, after which continuous hot applications are called for.

The constitutional or general treatment advised for iritis applies here also, and to which I beg my reader to refer. I will only add that in phlebitic ophthalmitis, the tendency to rapid sinking should be remembered and guarded against.

CHAPTER XXXV.

SYMPATHETIC OPHTHALMITIS.

ORIGIN OF THE AFFECTION—DANGER—DIAGNOSIS—TIME OF APPEARANCE—SYMPTOMS—TREATMENT.

HERE, one eyeball suffers from the effects of inflammation and disorganization in the other, in consequence, for the most part, of the impaction of foreign bodies, and injuries that penetrate or lacerate it, or from mechanical injury without any breach of surface; also from chemical injury; from acute inflammation, however induced; from the development of cretaceous materials in lost eyes, among the intra-ocular tissues; from intra-ocular tumours; from surgical operations; from the wearing of an artificial eye.

Thus sympathetic ophthalmitis seems to be due to a law of relative dependences between the eyes, in certain forms of inflammation, but not in all kinds, for suppurative ophthalmitis does not seem to produce it.

Sympathetic ophthalmia is a very dangerous malady, and the destructive effects are manifested by inflammatory changes of a low or sub-acute form, influenced perhaps by a low state of the general health; for the inflammatory effusion which ensues is quickly organized. If left to itself it invariably ends in blindness. It commences insidiously, and may spoil an eye, when occurring in childhood, almost before it is perceived. The effects are most rapid under adult age, and especially in children.

The sympathetic action can be diagnosed only by studying at the same time the cause as well as the effect, that is, by examining the two eyes; for its subjective and objective symptoms resemble those of some other inflammatory maladies. Again, as the eyes may be affected consecutively from several constitutional disorders, such might be mistaken for sympathetic action.

The traumatic cases are the easiest to discriminate.

The exciting eye, that originally diseased, is blind. If vision have not been lost at once by an accident, it is always destroyed by intra-ocular tissue changes, separately and distinctly from any physical incapacity, arising out of opacity of the cornea, or closure of the pupil, or cataract, before the sympathetic action is set up. Besides this loss of function, there are other symptoms which are more or less marked, according to the extent of the disorganization, that is, whether it be chiefly in the anterior part of the eyeball, or general. The chief of these are, undue vascularity of the front of the eyeball, a sense of discomfort, or actual paroxysms of pain; and always, it may be the only symptoms, soreness of the eyeball, whether it be partially atrophied, or enlarged, when it is touched or pressed in any part, and not the ciliary region only, or gently squeezed between the fingers. When every one of these symptoms of irritation are absent, the means of producing sympathetic disease are undeveloped.

The sympathizing eye has its symptoms well marked. They may be said to be those of plastic inflammation, nearly identical with those which belong to iritis, hence the affection is classed by some as iritis.

Subjective signs. Intolerance of light, for the most part with slight lacrymation, is usually the first result. Some form of impaired sight is the next bad omen, and this is shown in incapability of sustaining vision on minute objects. Loss of definition, and a feeling of discomfort or distress, which ensues when the eye is used. This simulates asthenopia. Muscæ, spectra, flashes, stars, and coruscations follow. I have twice met with complete loss of sight, occasionally for a few seconds.

The outward objective symptoms are like those of subacute rheumatic iritis, in addition to which there is corneitis, usually of the punctiform kind. The changes in the iris are always the most prominent among them, and at last, all which are possible in plastic inflammation, are passed through. By this the pupil is contracted, universally adherent to the capsule of the lens, and its area filled with lymph, and the body of the iris thinned and projecting. Ultimately the eyeball atrophies.

Ophthalmoscopic symptoms. Internal examination of the eyes sympathetically affected, gives no assistance in diagnosis, because internal organic changes are not visible till late in the disease. In many of the cases examined by me at the commencement, I have detected nothing abnormal. Even after there has been much intolerance of light, muscæ, spectra, and flashes, no change was perceptible. Later in the disease the choroid and the retina are congested, then inflamed, and there is haziness of the vitreous humour,

by which the fundus is obscured. It has been said that excavation of the optic disk is a characteristic mark.

Such is the group of symptoms as they generally appear; but variation is met with in the order of their appearance, as well as in the slowness or quickness in which they may follow one another. In one case the pain will be the leading feature; in another it may not exist. In some the inflammatory changes in the iris, and about the ciliary region, most attract attention; in others, choroidal changes. Then the failing vision alone may, for a long time, point to the existence of the disease. It might therefore seem, from a superficial observation, that there are different kinds of sympathetic action. But there are not. We must not make the prominence of any symptoms a basis for recognising species of this disease. A general and comprehensive view must be taken, and the several symptoms regarded as the many features, with modifications, of the same disease. In former years I thought plurality probable. Then too it seemed to me that there was sympathetic irritation which was not of consequence, distinct and apart from the graver and more advanced disease, which is characterized by neoplastic formations in all the internal tissues, except the lens, and which produces those changes which end in atrophy. I am aware now that any early symptoms, or anything which may be called irritation, inasmuch as there yet lacks true inflammatory characteristics, does in the end, if left alone, pass into destructive changes, and that the same consummation follows any variation in the order of symptoms, in their duration, or in their intensity.

A certain suspicious condition is often met with in an eye just after its fellow has been wounded and sight has been destroyed; and the same may be seen after an unsuccessful operation. There is fatigue from reading, and a sense of weakness of sight. This is not true sympathetic ophthalmia, for it soon passes away, after getting better day by day, but merely fatigue of adjustment arising out of general weakness and feebleness of brain perception from the same cause.

The exciting action may set in at any time after the exciting eye is partially or entirely disorganized, while it shows active inflammatory symptoms, or after they have subsided. It may ensue in a few weeks, or months, or not for years.

The ordinary history of most cases is that the eye has suffered several attacks of slight inflammation, with intervals of complete, or nearly complete, repose, but at last, during one of the paroxysms, the other eye began to be affected. So it is chiefly, at least in adults, that the morbid sympathy is propagated when the eye is in a

state of what may be called chronic inflammation. If the disease has been produced by the presence of a foreign body in the eye, the sympathy does not appear in the other till very late.

The sympathy is always imminent when an eye has been blinded by a wound, because chronic inflammation is so frequently induced and perpetuated. It is then, too, that calcareous degeneration of tissue is so apt to be produced. Such degeneration of the crystalline lens and of its capsule are no infrequent causes of the irritation, particularly when the lens loses its adhesions and becomes loose. Calcareous deposit may form simultaneously in several portions of the eye, including the corneal cicatrix. Osseous deposits for the most part occur in eyes which have atrophied from idiopathic diseases.

Fortunately the disease is very rare.

Cause of the sympathetic ophthalmia. This is really unknown. Nor is the ignorance to be wondered at, when we have not the power to interpret many natural double ophthalmic phenomena. Who can explain the coinciding effect of impressions on the two retinæ, or the simultaneous and equal effort of accommodatión in each eye, or say why irritation which produces lacrymation in the one eye, should cause the flow of tears in the other also, or why the reflex action producing contraction of the pupil in the one eye when exposed to light is followed by simultaneous contraction of the other, which is screened from the light. No doubt the morbid sympathy has its origin in the same anatomical mechanism which gives the physiological sympathy.

But I must notice the theories which have been advanced. One is that the blood-vessels on the side of the injured eye being inflamed, communicate to those on the opposite side with which they have connection within the cranium, a disposition to the same inflammatory action; another that the ciliary nerves of the injured eye convey to the third and fifth nerves an irritation which is reflected from the brain to the fellow nerves on the opposite side; another that the chief medium of the sympathy is exercised by the optic nerves; another that the disease is simply sympathetic ciliary neuralgia; another that the vaso-motor nerves that reach the eye with the blood-vessels themselves, have much to do with the influence.

Pathologists have been seeking for changes in the nerves themselves, whereby they may unravel the difficulty, but nothing satisfactory has been made out. The atrophy and other morbid changes are alike to be found in disorganized eyes, which have not caused any sympathetic disease. The frequent atrophy of the ciliary nerves is an answer to these not being the channels by which the irritation is conveyed. Neither has anything been learned from dissections of

the eyes secondarily affected. They give the sum of the morbid degenerations and other changes of tissues which are met with under conditions apart from this disease.

From my own observation, the exciting cause cannot be traced to injury of any particular region of the eyeball. In the remarkable case of gun-shot accident, treated by Dr. Butter, of Plymouth, in which sympathetic disease was set up, after the wounded eyeball was extirpated, the duck-shot was found firmly impacted in the optic nerve near to the retina.

Experiments which have been made on the lower animals by Donders and others, to solve the pathological problems, have given but negative results.

Treatment. No general measures, no local applications, no dietary system is of any avail in checking unequivocal sympathetic ophthalmia. The affection can be stopped only by treatment applied to the eye originally hurt. The source of irritation must be removed, or the disorganized tissues taken away. To Mr. Barton, of Manchester, are we indebted for this discovery. His practice was first directed to cases of traumatic ophthalmia. According to a report by Mr. Compton, in several instances a portion of copper had settled in the anterior chamber. Inflammation and disorganization of the eyeballs were soon followed by failure of the functions of the other eyes, together with structural changes. Mr. Barton excised the cornea in each, and applied a poultice in the hope that the copper cap would escape. This did happen, and produced great relief; but it had a more valuable effect, for it saved the sight of the other eye in all, although some of them seemed past hope.

It was at an early period of my connection with ophthalmic medicine, that my attention was arrested by sympathetic ophthalmia, and I lost no opportunity of examining the subject. I was joined in the work by Mr. Taylor. We both published many of our observations, with cases, in the medical journals during the years 1852, 1853, and 1854. It is satisfactory to find that our facts remain as such still, and that nothing then advanced as deductions has been rendered obsolete by the investigations of others.

Any extraneous body within the eye that irritates should, if possible, be extracted.

When, as in the case of a wound, or any other condition, the centre of the irritation is limited to the front of the eye, the front only should be removed by abscission.

When there is complete internal disorganization of the eyeball, or general enlargement, or atrophy, extirpation is necessary. Each operation, properly selected, will confer benefit equally lasting.

Abscission possesses many advantages, and is as reliable in its way as extirpation. I cannot question its permanent effects, since I have never been applied to by any patient on whom I have performed it, in consequence of its insufficiency, and I have seen some of them after periods of five, ten, and fifteen years. Mr. Taylor, who has operated as frequently as myself, tells me that his experience entirely coincides with mine.

Now, as to the effect on the ophthalmitis from such treatment. It is really marvellous. I speak from my own experience. In all cases in which there has not been appreciable structural change, complete recovery has ensued, and many times it has been as rapid as perfect.

When disorganization has been going on, it has been arrested, and useful, though somewhat imperfect sight, has been saved. So thoroughly and completely has the inflammatory action been stopped on some occasions, that even when the disorganization has proceeded far enough to spoil the eye for practical purposes, I have restored sight by establishing an artificial pupil, or removing a cataract which had formed from loss of nutrition of the crystalline lens.

Direct treatment, that is, measures applied to the sympathizing eye, has an effect. Even when no objective symptom is present, recovery will be all the sooner, from rest for some weeks or months, and for protection, if requisite, from daylight and artificial light.

When inflammatory symptoms prevail, I treat them generally and locally.

An attempt has been made to break the nervous chain necessary to the completion of the changes which constitute reflex action, and by which all reaction, all sympathy between the eyes, shall cease. Under this hope, and in the belief that the sympathetic irritation is conveyed by the ciliary nerves, these nerves have been divided, it is said, by Dr. Meyer, whose method of operating, together with his reputed success, is published with cases in the "Annales d'Oculistique" for 1867.

CHAPTER XXXVI.

DISEASES OF THE SCLEROTICA.

COLOUR OF SCLEROTICA—HYPERÆMIA OF THE SCLEROTICA—STAPHYLOMA OF THE SCLEROTICA AND CHOROIDEA—TOTAL SCLERO-CHOROIDAL STAPHYLOMA—PARTIAL SCLERO-CHOROIDAL STAPHYLOMA—ANTERIOR ANNULAR CHOROIDAL STAPHYLOMA—RESULTS OF INCREASING SCLERO-CHOROIDAL STAPHYLOMA—TREATMENT—ULCERATION OF THE SCLEROTICA.

Tumours of the sclerotica and mechanical injuries are described in their places, according to the plan of this book.

COLOUR OF THE SCLEROTICA.

The aspect of the sclerotica shows marked variation within the range of health, and the extremes are seen in fair and in dark persons. In the former, as looked at through the conjunctiva, it is brilliantly white. In brunettes it is less white. In the dark races of men it is dusky, occasionally with pigment spots in the ciliary region. Age exercises its influence here. In infants and young children it is frequently bluish, a condition due probably to its thinness. The blueness may be in spots rather than general.

HYPERÆMIA OF THE SCLEROTICA.

This is met with as vascular excitement of the sclerotica, in participation with hyperæmia, or inflammation of the choroidea. It is a sure symptom of preternatural vascularity within the eyeball, and the decline is no less instructive in telling

vessels are well seen in the whiteness and semi-transparency of the tunic, and are considered as evidence of inflammation, which is supposed for the most part to commence there.

Characteristics of Sclerotic Hyperæmia.

The enlarged blood-vessels, chiefly branches of the anterior ciliary arteries, converging according to their natural arrangement towards

Fig. 280.

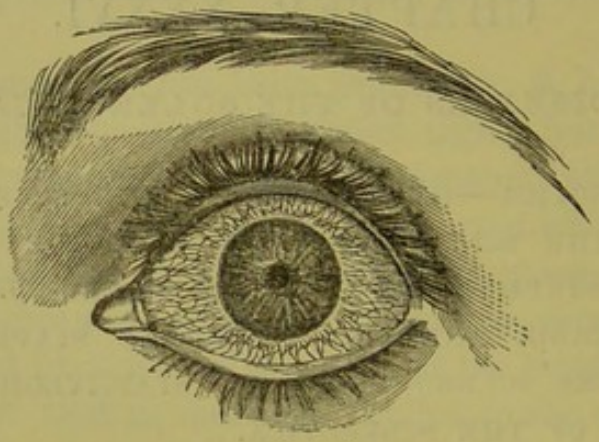

the cornea, and getting smaller till they are invisible to the naked eye as distinct twigs, present around the cornea the appearance of a vascular circle or zone.

Fig. 280, a sketch from an eye affected with syphilitic inflammation, gives some idea of the arrangement.

The colour of this augmented vascularity is of the bright pink or tint of arterial blood. It is brightest in young persons, in whom the sclerotica is whitest.

The difference in the larger trunks of these blood-vessels, in the arrangement and the colour, between those of inflamed ocular conjunctiva, which have an areolar arrrangement, and are dark red, is well marked.

The degree of the hyperæmia and its kind, whether acute or subacute, depends on the intra-ocular vascular disturbance.

Let it be understood that this character of arrangement of blood-vessels must prevail in all inflammations of the eyeball; and when not apparent in such inflammation, is masked by conjunctival vascularity. Conjunctival inflammation always, more or less, masks sclerotic hyperæmia. It may quite conceal it.

There is a passive form of hyperæmia, in which large veins irregu-

Partial Sclerotic Hyperæmia Occurs.

It is situated close to the cornea, and may be very limited and well defined, or surround the cornea. It may be associated with partial hyperæmia of the conjunctiva, in which case, one of the recto-muscular arteries enlarges, and running forwards ends in a broad lash of fine ramifications, which are distributed to the conjunctiva and the sclerotica.

The cause of this is most generally hyperæmia or inflammation of the ciliary body, because of the free anastomosis between its blood-vessels and those on the outer anterior zone of the sclerotica.

True inflammation, the sclerotica is not liable to. Its fibrous nature and small vascular nervous supplies, give it this immunity. Yet minute pathological dissection teaches that changes may be found; proliferation, for instance, which can only proceed from inflammation. But that is by implication, and not from disease arising in the tissue.

The so-called rheumatic and gouty inflammation of the sclerotica is inflammation of the interior of the eyeball, in which the sclerotica participates in vascular disorder. The defective sight and the palpable morbid condition of the interior of the eyeball declare the intra-ocular state.

STAPHYLOMA OF THE SCLEROTICA AND CHOROIDEA.

After protracted hyperæmia of the sclerotica or repeated attacks, or relapses of it, always in association with choroiditis, this tunic becomes thin and blue, and then bulges in whole or in part. As the nutrition of the sclerotica is mainly derived from the choroidea, and the two coats are intimately organically connected, it is easy to understand that it must suffer when the choroid vascular supply is vitiated by inflammation. It is not then a primary disease, or a consequence of any primary disease in the sclerotica itself, but always a secondary one.

The resistance of the sclerotica is lessened by the disturbance in its nutrition, and then it yields from the inward pressure of vascularity or inflammatory effusion.

We must not, then, speak of staphyloma of the sclerotica merely; we must include also disease of the choroidea, and say sclero-choroidal staphyloma.

The staphyloma is usually of very slow

The increase may be continuous; or spasmodic if there be exacerbations in chronic choroiditis; or quick with pain coruscations and photophobia, if the optic nerve should inflame; or very slow, so as to be perceptible only in years, and without subjective symptoms.

The direct cause of this disease is weakening of the tissue of the sclerotica and increase of the intra-ocular pressure, the results of the accompanying vascular action, and which, as I have said, is chiefly that of choroiditis.

TOTAL SCLERO-CHOROIDAL STAPHYLOMA.

There is here more or less increase in the size of the entire eyeball, and now and then some alterations in the form, by which it becomes roundish or cylindrical, or very irregular; and as corneal lesion, particularly from wounds, is generally the cause of the intra-ocular

Fig. 281.

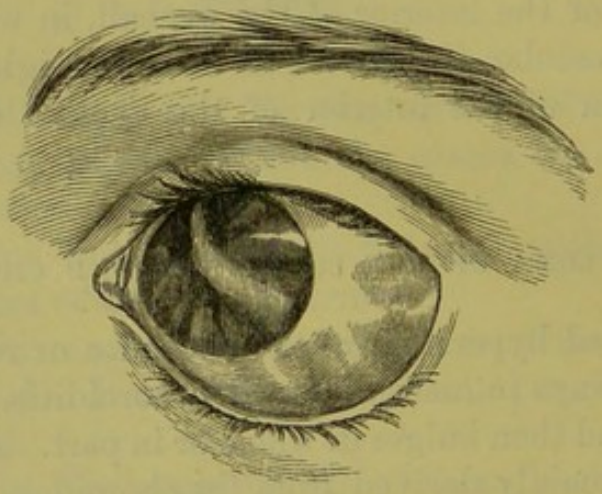

disease, the cornea participates in the enlargement under some form of corneal staphyloma. The natural whiteness is lost, being displaced by a darkish blue colour. Fig. 281.

There is ocular protrusion according to the size of the staphyloma, and the closure of the eyelids is impeded.

As the corneo-sclerotic junction is enlarged, there is stretching of the iris, of the ciliary body, and of the zonula. Over the ciliary region enlarged veins ramify.

Vision is nearly or quite destroyed, from the extensive disorganization of the internal tissues of the eyeball.

PARTIAL SCLERO-CHOROIDAL STAPHYLOMA.

Here there is bluish, partial projection of the much-thinned sclerotica, or several projections, separated by furrows. Any of the zones of the sclerotica, the anterior, lateral, or posterior, may be so affected, but the anterior one usually suffers. Fig. 282, in which the eyeball is directed downwards, and the eyelid elevated, to give the

FIG. 282.

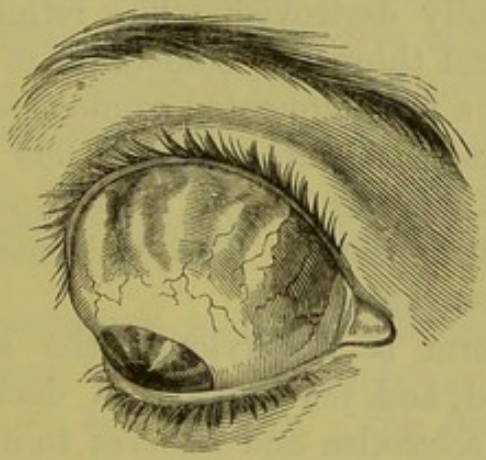

more extended view, shows many lateral staphylomata standing out like dark blue vesicles separated by furrows, and passing half around the eyeball in the equatorial zone. In this case, as usual, there was not any vision. The crystalline lens was absorbed, and its capsule floated in the posterior chamber. The iris was not thrown forward. The history of the case is that when the lady was a child, a scratch on the cornea from the finger of an infant excited intense inflammation, on which the staphyloma supervened.

ANTERIOR ANNULAR SCLERO-CHOROIDAL STAPHYLOMA.

This is a variety of the above class, with certain modifications. It may be partial, or total and circular. In its most usual development it appears as bluish, or blackish, elongated protuberances, separated by tendinous whitish bands, surrounding a part or the whole of the circumference of the cornea. Less commonly it stands out with more protrusion, tumour-like, resembling a grape, and encroaching on the cornea influences its anterior layers by stretching them, and widens the corneo-sclerotic boundary.

Although vision is usually destroyed, there are exceptions in the partial form, where there is only limitation to the visual field, because the damage to the interior of the eyeball is confined to its

MORBID ANATOMY.

It is enough to mention, very concisely, a few facts more intimately connected with the staphylomatous changes.

In the total form of the staphyloma, the sclerotica is thinned, atrophied, softened, and pigmented. The choroidea is, as a rule, far advanced in atrophy, and very adherent to the sclerotica. Sometimes it is shrunken to thin layers of stiff, dry hyaline. The ciliary nerves are partially or wholly destroyed. The retina is usually cloudy, anæmic, atrophied and thinned. Sometimes it is detached. Sometimes there are only a few pigmented connective tissue remains of it firmly attached to the choroidea, or ragged bits attached to the optic nerve entrance, and floating in the fluid vitreous humour. Sometimes it has quite disappeared. The optic nerve is atrophied, pigmented, and often excavated.

In the partial form of staphyloma, the staphylomatous walls are thinned, softened, and pigmented. A dark pigmented delicate membrane lines the sclerotica and adheres to it, and is attached also to the atrophied choroid, which is always in large extent, and often altogether disorganized. The cavity of the staphyloma is filled with serum, and but rarely with any solid material, and is generally behind the retina. A large portion or the whole of the retina is atrophied, and the optic nerve is usually excavated.

In the anterior annular form, the affected sclerotica may yield by the inner wall of Schlemm's canal breaking down, and the outer wall dilating; or the protrusion may ensue from the distension of the entire thickness of the sclerotica. The blood-vessels and nerves in the diseased sclerotica are ruptured, or atrophied, or quite destroyed. The ciliary muscle is ruptured. The ciliary body is occasionally torn through. When this does not happen, a rent is made in the anterior part of the choroidea.

RESULTS OF INCREASING SCLERO-CHOROIDAL STAPHYLOMA.

Suppuration within the eyeball, and collapse during very active inflammatory exacerbation. Spontaneous bursting of the eyeball, at the thinnest part of the sclerotica, especially in the partial form, evacuation of the greater part of the contents and hæmorrhage, and afterwards active intra-ocular inflammation, sometimes suppuration, and always atrophy.

TREATMENT.

This is meant to apply only to the physical condition of the developing staphyloma, and not to the suppression of the exciting causes, because they are better treated of respectively in the chapters devoted to the inflammatory diseases of the several tissues of the interior of the eyeball.

Total staphyloma. Removal or reduction of the staphyloma. This is called for whenever the staphyloma is painful from distension or so large or so circumstanced as to interfere with the closure of the eyelids, or to produce irritation of them. Under any of these conditions sympathetic ophthalmitis is apt to be excited. Extirpation of the eyeball is the proper remedy when it is probable that the vitreous humour is reduced to fluidity, and such degeneration is the prevailing condition.

Another surgical measure is to reduce the eyeball by letting out some of its contents, and this has an advantage in leaving a stump for the adaptation of an artificial eye. The disadvantages are, the probability of intra-ocular hæmorrhage and suppuration. The operation may be done in several ways: by removing the cornea; by mere incision; or by laying hold of a portion of the distended tunic, and after having made the eyeball flaccid by letting out some of the contained fluid, cutting it off.

Puncturing the staphyloma with a fine needle in several places, giving exit to the serous effusion, and applying pressure to prevent hæmorrhage, and repeating the process, has been thoroughly tried by myself, but it has not permanently reduced the size of the eyeball.

Atrophy of the eyeball may be brought about by the seton method, which is the introducing of a thread through the ciliary body, and removing it after twenty-four hours.

Partial staphyloma. Extirpation of the eyeball, or reduction of it after the above method, is called for. Some surgeons say that they have been successful in shaving off small staphylomata, as the breach was filled up by granulation. Others that good results have followed splitting the staphylomata, whereby the flaps overlapped each other and became adherent. Frequent tapping the anterior chamber, with or without iridectomy, is said by Continental surgeons to be advantageous.

Partial staphyloma occurring with acute choroiditis may subside without a surgical operation. The "Medical Times and Gazette" for May, 1855, contains a clinical lecture of mine on such a case. A small fly got under the upper eyelid. Some surgeons would have

eyeball with solid nitrate of silver to subdue the irritation which ensued. Considerable inflammation of the eyeball followed, and the sclerotica bulged in a distinct staphyloma, at the upper part, just posterior to the cornea. After long soothing treatment, complete recovery ensued, and vision was unimpaired. The only remains of the staphyloma were a few small stains of a sepia colour where it occurred.

ULCERATION OF THE SCLEROTICA.

Idiopathic ulceration of the sclerotica is so rare that I do not remember to have seen it. I find one case recorded in which, without apparent cause, symmetrical ulceration in each eye ended in perforation and collapse of both. Also a few cases of ulceration from syphilitic deposits, and two from what is called tubercle.

CHAPTER XXXVII.

DISEASES OF THE VITREOUS BODY.

INFLAMMATION OF THE VITREOUS BODY, OR HYALITIS.

Hyalitis, the chief morbid condition of this body, is an effect, and a very common accompaniment, of inflammatory processes in the surrounding vascular textures of the retina, and of the retina and the choroidea combined.

I do not recognise the existence of primary hyalitis. Many experiments have been made on the lower animals to determine this question, but they have never proved the existence of hyalitis by itself. The suppuration produced by the presence of a foreign substance cannot be taken as any affirmative evidence, since the substance may have passed through vascular parts to reach the body. The same may, I think, be said with regard to the process of encysting of foreign substances, of which mention has been made at p. 508, or of depressed cataract, etc.

Hyalitis is not excited by wounds, however much the vitreous tissue is broken or stirred about. Even a cysticercus hanging from the retina and floating in the body is innocuous. The rule would seem to be that, so long as anything encysted does not touch the retina or the choroidea, mischief does not ensue; but should it touch, ophthalmitis is set up, and hyalitis is induced.

Dr. Bagenstecher, of Wiesbaden, has performed twenty-two experiments, with surprising ingenuity and marvellous dexterity and minuteness, in the hope of settling this question of inflammation, together with other difficult abstract pathological ones, and comes to these conclusions, in an essay on the pathology of the vitreous body, which is a masterpiece of the kind: That in the vitreous body, the gelatinous material, as well as the elements contained in it, be they of

causes sufficient to produce it elsewhere, nor of forming lymphoid corpuscles by morphological changes. From which it follows that inflammatory products there found must immigrate from the surrounding tissues. That the body remains apparently quite passive, even under very strong irritation, and does not produce an accumulation of lymphoid corpuscles at the point of such irritation, a phenomenon which in a short time follows similar irritation in organs susceptible of inflammation. That therefore the vitreous cannot be said to be susceptible of inflammation in the same sense in which we use that phrase of other organs, but that every so-called inflammation of it is to be considered as a secondary state depending on the changes in surrounding tissues.

An irritation in the vitreous will therefore only lead to phenomena of inflammation, when it exerts an inflammatory influence upon the vascular tissues surrounding that body, and brings these into a state of actual inflammation. The products, or exudations, which are developed in consequence of such process, are those which traverse the vitreous, without regard to the nature of the irritation, and are capable of a further development, *i.e.*, the formation of new tissue resembling ordinary connective tissue. Under different circumstances they deposit themselves as purulent accumulations, or are the subject of a retrograde metamorphosis.

He points out, too, that cloudiness of the vitreous body developed around foreign bodies without any connection with the tunics around are not inflammatory products, but coagulations of the vitreous tissue.

The essential condition of hyalitis is exudation and proliferation, the product of an inflammatory process in the surrounding membranes, whereby opacity is produced. The pathological development appears as groups of cells, "incubation foci," visible only under the microscope. Nuclear bodies of the character of connective tissue corpuscles, throwing off short fibres, from which are formed neoplastic connective tissue, in which, as a rare event, blood vessels are formed. Such elements most abound in those parts of the body which are nearest to the highest inflammation of the surrounding tissues, and which is generally about the optic nerve entrance and the ciliary body.

Subjective symptoms. Haziness of vision, pathological muscæ, or the floating of small objects in the field of vision, and which change their form and size with alterations of the exudations. They differ besides this from physiological muscæ in being larger, seldom having a regular course of movement in the complete or partially fluid body, and being demonstrable with the ophthalmoscope.

Objective symptoms. Although hyalitis may be detected by oblique

illumination of the eye, the use of the ophthalmoscope is needed to recognise all its characters. It is necessary at times to employ the highest magnifying power, and also for the observer to accommodate his own eye for different depths of the body. Besides this, the patient should move his eye about so as to shake up any deposits, usually called opacities, which may have fallen out of the field of observation.

In slight hyalitis, producing diffuse or punctiform opacity, which is made up chiefly of exudation cells, the vitreous body looks like a mist behind the pupil. The retina, the optic disk, and all the parts at the fundus of the eye appear blurred. The eye is better seen if the ophthalmoscope be used at certain angles. With such variation of the mirror, greater density of some parts of the body, as well as striæ, may then be made out.

This form of opacity dims the sight more than large, but circumscribed opacities, with clear vitreous body around.

In more advanced hyalitis, with or without increase of the diffuse opacity, large floating exudations are thrown out, and appear as globules or shreds in bundles, with or without pigmentation or fibres, scattered or interlaced. They are spoken of as filamentous membranous, or flocculent opacities. As a rare condition, a few larger exudations may occur without the diffuse opacity. All these dart about with the least movements of the eye, and unless the pupil be dilated, come into the field of observation, and as quickly get out of it.

The colour of most opacities is greyish-blue. Blackness seldom prevails. Sometimes there is a blood tinge from rust-yellow to a dark red-brown.

Prognosis. The more sudden the hyalitis, in association with remediable inflammation of the eyeball, the more surely does it pass away. Its removal depends on the cessation of the cause, that is, the inflammation of the surrounding nodular parts. We see it disappearing and re-appearing when such inflammation remits and recurs. Syphilitic iritis gives one of the best examples of this. In the acute form, the body may be so opaque as to shut out the slightest glimmer of the fundus, to admit only the denser exudations moving about in it, to be seen, and yet under proper treatment all exudation may entirely pass away.

In quickly relapsing inflammation of the eyeball, and in long continued inflammation of the retina, or of the choroid, the hyalitis continues. Then the connective tissue formations are usual.

A permanent condition of hyalitis, with which I am not personally acquainted, is a deposit on the posterior capsule of the lens, and called polar, or posterior cataract, as it respectively covers a part or

the whole of the posterior capsule. A more advanced condition of this is a deposit over the whole of the front of the vitreous body.

Regarding then the ultimate results where atrophy of the eyeball does not come from ophthalmitis.

Slight hyalitis may pass away, not leaving a trace of the opacity. The more advanced hyalitis generally leaves some imperfection. The following changes in the several products have been observed :— Some shrink; some retrograde, and are absorbed. Some of the groups of nuclei may get fatty and augmented by other products into a solid body. Some degenerate into scales of cholesterine, which look, when numerous, like a silvery shower. This effect is called sparkling synchysis.

There is no treatment for hyalitis apart from that which is required for the inflammation of the parts of the eye which may produce it.

LIQUEFACTION OF THE VITREOUS BODY OR SYNCHYSIS.

Senile liquefaction. This is best known as one of the quasi-physiological changes in the eye which come on in old age; too often does the inevitable escape of some of the fluid body during the extraction of cataract spoil the eye. Without a direct symptom of any kind, not even tremulousness of the iris, it may be as fluid as water. This senile condition is said by one microscopist to be due to fatty degeneration of its septa, or membranous portion.

The tension of the eyeball whether above or below the normal, affords no criterion of the occurrence of liquefaction, since it is regulated by the fulness of the ocular tunics.

Pathological liquefaction. This is caused by hyalitis, and evidence of it is directly afforded by the presence of opacities.

In a perfectly normal vitreous body, an opacity would show some trembling when the eyeball moves. In proportion to the departure from the normal state towards liquefaction, do opacities move about.

This form of liquefaction may be limited to any parts, such as the surface or the centre of the body. Partial implication is usually associated with circumscribed atrophy, or inflammation of the retina or choroidea.

Partial like the general liquefaction, cannot be diagnosed with certainty unless opacities are seen moving in it, and they are seldom absent.

CONNECTIVE TISSUE DEGENERATION OF THE VITREOUS BODY.

There is a form of this met with in disorganized eyeballs, with more or less atrophy, from wounds, or ulceration of the cornea, with

loss of the crystalline lens. Without going into the surrounding pathological changes in the eyeball, for to do so would be useless, I will merely say that as the new neoplastic tissue is developed, the vitreous body is absorbed, that is, the fluid portion, which quickly disappears from intra-ocular pressure occasioned by any growths, or from pressure on the eyeball from intra-orbital causes. Ultimately the adventitious material contracts, becomes tendinous, and pulls the retina up. As the retina retains its ciliary and optic nerve connection, it assumes a funnel-shape. Serum supplies the space between it and the choroidea.

HÆMORRHAGE INTO THE VITREOUS BODY.

Traumatic hæmorrhage is described at page 422.

Idiopathic hæmorrhage, which is not very rare, may proceed from great bodily exertion, or from diseased states of the retina or choroidea.

The subjective symptoms are sudden impairment of sight by a dark spot, a cloud, or a mist, in the field of vision, or nearly total loss of sight. When dissolution changes commence in the clot, tints of red or green are seen by the patient, with mobility of any spectrum which may exist.

The ophthalmoscope quickly detects the cause of the subjective symptoms, as a dark mass, generally accompanying the lower portion of the vitreous body, and concealing all parts of the fundus of the eye which are behind it. The eclipsed region again becomes visible by degrees, through the absorption or breaking up of the clot.

Retinitis and hyalitis may ensue.

Prognosis. The blood is more slowly removed than blood effused into the aqueous humour.

Vision may be restored, but it is as frequently impaired or lost. Shreds of the coagula are apt to remain, and float about according to the amount of fluidity of the body.

Modern pathological researches clearly prove that the absorption of the blood takes place by means of the red corpuscles being gradually enclosed in contractile cells, which are furnished from the surrounding vascular tunics. Also that such cells may be converted into connective tissue cells.

The treatment is the same as that for traumatic hæmorrhage.

SUPPURATION OF THE VITREOUS BODY.

All that need be said on this point is expressed in the chapter on "Ophthalmitis."

CHAPTER XXXVIII.

CANCER AND OTHER MALIGNANT AFFECTIONS OF THE EYE, OF THE OCULAR APPENDAGES, AND OF THE ORBIT.

There are anatomical and clinical differences between the carcinomata or cancers, and the other malignant affections which attack the eye. The former consist of aggregations of cells of an epithelial type, without intercellular substance, held together by a fibrous stroma. In developing they spread by infiltrating the surrounding tissues indiscriminately. They affect the neighbouring lymphatic glands with growths like themselves; after which they cause cancerous tumours in the internal parts of the body. The latter, well known as the fibro-plastic, recurrent-fibroid, fibro-nucleated, myeloid, and gliomatous tumours, now included as varieties under the head of sarcoma, consist of embryonic connective tissue, with cells of varying size and configuration, interspersed within an intercellular substance, increase not only by the multiplication of their own cells' central growth, but by further development of their connective tissue matrix, peripheral growth, according to their variety, infiltrate tissues to different extent, usually spread quicker than cancer, are more prone to early return after extirpation, seldom affect the lymphatic glands, and are liable to appear as well within the trunk.

Origin. Cancer. The starting point of this is not absolutely determined. While the greater portion of the pathological evidence is in favour of epithelial derivation, we are forced to accept also a connective tissue beginning.

Sarcomata take their rise from connective tissue.

Mr. T. Nunn has pointed out (Pathological Society Transactions) that the cells of certain sarcomata have a definitely marked maturity and a persistent vitality, the inflammatory phenomena being dependent on extrinsic irritation; while in carcinomata, the cell elements are characterized by irregular development, and at an early stage betray a tendency to intrinsic degeneration.

CANCER AND OTHER MALIGNANT AFFECTIONS OF THE EXTERIOR OF THE EYEBALL.

Scirrhus. As a primary affection this is extremely rare. I have seen but one example confined to the eyeball. It occurred in an elderly man. The lower part of the cornea, and the adjacent portion of the sclerotica, were occupied by an irregular, firm, and very vascular tumour, having a granular or warty surface. The eyeball was extirpated. All its posterior parts were sound. Two years after, the patient died of medullary cancers in the heart and various other internal organs. The orbit remained sound.

Mr. Butcher, of Dublin, relates a case in which a "red fleshy pimple" appeared on the cornea, after middle life, and grew as large as the section of a walnut, being mammillated not vascular, and as hard as cartilage. The subjective symptoms were those proper to scirrhus. Microscopic examination proved the cancer structure. The cornea alone was occupied by the new growth, and the rest of the ocular tissues were healthy.

I have seen a few instances in which the cancer, having nearly destroyed the eyeball, spread to the ocular appendages and the orbit. In one case of six years' duration, the eyeball had disappeared, and the entire surface of the orbit was cancerous.

The other three varieties of cancer, the encephaloid, the epithelioma, and the colloid, probably never begin in the eyeball. The last has not, I believe, been met with in association with the eye or its surroundings.

Sarcoma occurs on the surface of the eyeball. Nearly always it is melanotic sarcoma. I have seen two examples. In both a part of the sclerotica and the conjunctiva were involved. Cases are related by Lawrence, Travers, Hibbert, Taylor, Curling, Magni, and others, in which the cornea, as well as the sclerotica and the conjunctiva, have been the primary seats of the tumour.

It is well known that melanotic or pigmented tumours, which are not sarcomata, occur on the surface of the eye. In general, all melanotic growths are sarcomatous.

INTRA-OCULAR MALIGNANT AFFECTIONS.

Till very lately it was thought that medullary cancer was the most common intra-ocular tumour. We now recognise instead of that some of the forms of sarcomata.

Virchow, from whom the greater portion of this improved knowledge comes, remarks that tumours of the retina are of two forms, gliomata and sarcomata, and adds that the characters of these two so frequently occur in the same tumour, that he proposes for such mixed forms the name of glio-sarcoma.

I think with the majority of pathologists, that glioma is but a variety of sarcoma.

I believe that all malignant intra-ocular tumours, and indeed nearly all tumours within the eyeball, are sarcomata. Glioma has a selection for the retina, and other forms of sarcoma for the choroidea, the ciliary body, and the iris.

Glioma. This begins in the neuroglia, the nerve connective tissue, in the filamentary layer of the nerve stratum of the retina. Perhaps it never commences in the optic nerve when intra-ocular.

Structure. Glioma somewhat resembles brain substances, being soft and grey-red. The colour, due to its rich supply of blood-vessels, is often increased by stains from effusion of blood, or the formation of apoplectic clots.

It is composed of granules, or rather of small round cells enclosing a nucleus, a little inferior in size to the cell itself. Between the cells is an albuminous material which becomes reticulated or fibrillated when immersed for a time in a preservative fluid.

There is a great resemblance between glioma and the nuclear layers of the retina, but it differs from them in the irregularity of its cell arrangement. As it increases, it pushes forward the anterior layer of the retina, which is usually visible on its surface, and may be dissected off with care, being thickened, semi-opaque, and indurated. It soon takes possession of all the retinal elements, and advancing into the vitreous body, occupies the interior of the eyeball; or it may affect the choroidea, where pigment may be developed, and it may then acquire another form of sarcoma, hence the complicated character of a glio-sarcoma.

Course. If now the tumour grow, the following objective symptoms may be expected.

First stage. The earliest appearance that generally attracts attention is a shining, yellowish, and deep-seated reflection at the bottom of the eye, as if from a piece of metal; best seen in particular lights, especially by oblique illumination, and when the pupil is dilated, and somewhat resembling the appearance of a cat's eye in a darkened room. At the same time, the iris will be found to have changed in colour, being rather darker than that of the other eye. The pupil is dilated and sluggish, and vision, even now, is nearly or altogether lost. Slight external inflammation, lacrymation, and intolerance of

light occur in some instances; but these are by no means necessarily, or even frequently, present. As the disease advances, the cause of the metallic reflection becomes evident. It is now seen to be owing to a tumour springing from some part of the fundus of the eye, of an irregularly rounded form, generally divided superficially into two or three lobes, and traversed by one or two small blood-vessels, which ramify on its surface. In colour it varies from a deep orange hue to nearly white, the most usual being, perhaps, a bright canary yellow. The growth gradually increases in size, approaches the front of the eye, causing absorption of the vitreous humour, and affecting the lens, which becomes opaque, and in most instances is ultimately absorbed; previous to which it is pressed on the iris, which loses whatever brilliancy it may have retained, changes to a greyish brown colour, and is thrust forwards against the cornea; both the anterior and posterior chambers of the eye being completely obliterated. Towards the conclusion of this stage, there is considerable tension from internal pressure; the eyeball feels hard, its motions are limited, there are attacks of inflammation with epiphora.

Second stage. The external parts of the eye now undergo a change. The cornea expands and becomes opaque. The sclerotica, thinned by absorption, allows the choroid to appear through it, is irregular in outline, rising into small dark-coloured knobs where the pressure has been most severe, or the absorption most rapid. In many instances it is so densely covered with large varicose vessels, that no alteration in colour is perceptible. The eyelids now become œdematous, and the eyeball prominent, from the swelling of the orbital tissues; and, apparently, greatly enlarged in size. I say apparently, for though I admit that enlargement takes place to a certain extent, I cannot conceive the possibility of the dense fibrous structure of the sclerotica expanding to two or three times its normal dimensions, as some authors have asserted. Rupture of the eyeball next ensues; and this may take place either in front or laterally. In the former case, the cornea becomes more and more attenuated, pus is effused into its structure, and ulceration or sloughing ensues. These changes are not witnessed in the sclerotica, the fibres of which, previously thinned and opened up by long-continued distention, finally give way in a small rent, through which the morbid mass, still covered by the conjunctiva, protrudes. During the latter part of this stage the sufferings of the patient are acute, the pain extending over the whole side of the head, and even down the neck, and are accompanied with the usual symptoms of febrile excitement. Great relief is experienced when the fungus escapes and the distention is removed.

Third stage. The tumour, now released from pressure, rapidly

increases in bulk, so as in a short time to distend the orbit and eyelids, and efface all appearance of the eye. When it has escaped through the sclerotica, at some little distance from the cornea, it is at first covered by the conjunctiva, but this is quickly and finally destroyed by ulceration and sloughing. In other cases of less frequent occurrence, the sclerotica gives way at the back part of the eyeball, so that the fungus escapes directly into the orbit. Under such circumstances the eyeball will be displaced in various directions, according to the position of the protruded mass, until finally this latter has acquired sufficient bulk to extend beyond the margin of the orbit, when it overlaps and conceals any remains of the eyeball that may have been visible.

The fungus, on its first escape, is soft, and generally of a light red or yellowish colour. This appearance, however, is rapidly changed as it increases in bulk. The surface becomes irregular and covered with ulcerations, which discharge profusely. Large, livid, and fungoid granulations form, which bleed freely on the slightest touch. Interstitial hæmorrhage takes place, forming clots. Large masses are detached from the surface by sloughing, giving rise to fresh bleeding, in some instances so profuse as to prove the immediate cause of death. No diminution in the size of the tumour ensues from the separation of the sloughs; on the contrary, there is augmentation with increased vigour, limited only by the length of time that the patient survives. The skin of the distended eyelids, and of the adjoining parts of the face, assumes a dark livid hue, and is traversed by large varicose veins. The glands in the neck and under the lower jaw enlarge, and, in exceptional cases, proceed to ulceration. But the disease may rather spread posteriorly, through the optic nerve to the brain. Death finally ensues, from constitutional irritation, and the exhausting effects of pain, hæmorrhage, and discharge, or, when the brain is implicated, by symptoms indicative of tumour of the cerebrum, irritability, convulsions, coma.

A *post-mortem* examination discloses that the contents of the orbit have undergone great changes. In cases of long standing, all means of distinction between the various textures are lost by their disorganization. The bony structures are softened and expanded, and frequently partially removed by absorption, so that the diseased mass is in direct contact with the brain. In many instances, I believe in most, the optic nerve will be found to be involved in the disease; thickened, except where it is constricted by the foramen opticum during its passage to the brain, and frequently again expanded so as to form a tumour immediately on its entrance within the skull. This change may take place at the earliest as well as at the most advanced

stages of the disease, a pathological fact of much importance, or the disease may pass to the chiasma and then involve the brain, in which case blindness of both eyes will ensue.

There may be exceptions to the above termination; such as fatty degeneration, with bony or calcareous deposits, the development of cysts, and the formation of apoplectic clots by the rupture of its blood-vessels.

It may cease to grow at any period, or even retrograde by degeneration, though such exceptions are extremely rare when it has extended beyond the eyeball. It may terminate in a slough, or in atrophy of the eyeball. It may lie dormant for a period, and again pursue its ravages.

Glioma probably occurs only in childhood. It has been seen in several children of the same family, and in both eyes of a child at the same time.

Cause. We are ignorant of the cause of glioma, whether remote or exciting. We know that it may be congenital.

Ophthalmoscopic symptoms in the earliest stage. A small protrusion from the retina, passing into the vitreous body, accompanied or not by enlargement of the neighbouring retinal blood-vessels, effusion follows, and often a sac of serum separates the tumour from the choroidea. Opacity of the vitreous body soon sets in. More will be said when I speak of its differential diagnosis.

Subjective symptoms. Loss of a portion of central or direct vision, and ultimately blindness.

For a long time there may be no pain, and the general health may seem perfect; or from the first pain might ensue. In the latter stages it is never absent.

Diagnosis of glioma of the retina from other tumours in the eyeball and other morbid changes. Glioma so far as is known at present is a disease of childhood, and it seems to be the only tumour which ever appears in the retina. It might be mistaken for unpigmented sarcoma of the choroidea, since it also very exceptionally occurs in childhood, the sarcoma of adults being invariably pigmented. But there is the following difference, shown in the direct ophthalmoscopic examination. Glioma in its early stages is of a vivid, often metallic and golden lustre, while white sarcoma of the choroidea appears dull white, or feebly yellowish in colour. In recent glioma the characteristic ramifications of the retinal blood-vessels can be recognised on the surface, while in white sarcoma of the choroidea an irregular branching of the blood-vessels, new formations, and numerous extravasations alone appear. Glioma commences as an extended surface degeneration, or as a formation of numerous small clusters, which

coalesce and spread from the optic nerve entrance to the ora serrata; while the white sarcoma of the choroidea appears from the first as a round or oval intumescence of considerable size, which long remains circumscribed.

Detachment of the retina can scarcely be taken for glioma, since its moveableness and dull greyish blue colour distinguish it from the diffuse yellow shining, dense, and nodular gliomatous degeneration of the retina. Again, detachment of the retina from diseases of the fundus of the eyeball does not occur in children.

In cysticercus of the retina, which resembles glioma, the retinal blood-vessels disappear, while in glioma they are preserved. The progress of either case will afford a more positive diagnosis.

Respecting the difference between glioma and inflammatory processes in the interior of the eyeball, we are guarded from mistakes by the history of the case, by the results of the inflammation, such as the adhesion of the iris, the diminution of the eyeball, its diminished tension, &c.

Sarcomata. These arise chiefly in the choroidea, as frequently in the anterior as the posterior section, and very exceptionally in the ciliary body. Being always associated with pigmented tissues, they frequently assume a form called melano-sarcoma, formerly known as melanosis or black cancer of the eyeball. It is the shape which most of the sarcomata of the eye take.

Structure of the sarcomata. The main feature is a preponderance of cells, acknowledged to be a form of connective tissue cells, without the power to develope into true connective tissue. These are massed together within a consistent inter-cellular substance, continuous with neighbouring connective tissue, and this substance, small in quantity when compared with the cells, may appear structureless, or granular, or finely fibrillated. These cells may be spindle-shaped, the fibro-plastic variety; or they may be small, round, and fully occupied by a nucleus resembling the cells found in glioma, hence Virchow's glio-sarcoma, or the white medullary variety; or they may occur as large spherical or irregular multinuclear cells, the giant celled or myeloid variety.

Pigment cells, and stellate pigment cells, and pigmentary granular matter, may be freely interspersed with any variety, but such pigmentation most commonly occurs in excess in that sarcoma in which the fusiform cells predominate.

Whichever form of cell exists, or whether one or more of the several varieties be present, the tumour differs from the class carcinomata, in that the cells are not grouped together in nests, but lie separately in the inter-cellular substance.

The nature of a sarcoma is influenced by the quality of the mother tissue. When the tumour arises in the outer, denser, more pigmented, and less vascular layers of the choroidea, they are harder, less vascular, and less pigmented. When it springs from the chorio-capillaries it is softer, more vascular, and unpigmented. From this arises the names of black, white, and vascular sarcomata.

The behaviour of sarcomata depends on their structure. The spindle-celled, the commonest of all, usually called the fibro-plastic or recurrent fibroid, is hard, and has some of the clinical characters of the fibromata, while the round-celled variety is soft, and has characters like medullary cancer.

If the sarcoma be undergoing degeneration, there are free fat granules, or even oil globules, within the cells, and fat granules throughout the inter-cellular substance.

This new growth is usually well supplied with blood-vessels, which, by reason of their imperfect walls, are liable to rupture and so to produce scattered apoplectic clots.

Course. A button-shaped tumour arises in the choroidea, covered by the hyaloid membrane and pigmented epithelium; or by the chorio-capillaries, according to its seat of origin. Neighbouring clusters may arise, and reaching the iris through the ciliary body, appear in the anterior chamber. The choroidea is perforated. The retina still covers the tumour, while beyond it is detached by serum or bloody fluid. The tumour advances into the vitreous body in a mushroom form, adheres to the sclerotica, bulges it and presses through it in dark masses like staphylomata, and perforating implicates the orbital fat. The eyeball is pushed aside and thrust under the eyelids. It is swelled and traversed by bluish tortuous blood-vessels, and its movements are mechanically interfered with. The conjunctiva is ruptured, and a fungus protrudes. Or the tumour may advance through the cornea and sprout as a fungus, like the usual course of gliomata. The optic nerve is soon infiltrated with the sarcoma, and lastly, all the orbital tissues and the orbital bones, and even the face become involved. But there is not generally such local destruction as in the carcinomata, because death ensues sooner from the sarcoma entering the brain, or appearing in the internal organs of the trunk. The liver is generally most severely affected.

Diagnosis of choroidal sarcomata. It is told from carcinomata and sarcomata arising in the orbit, inasmuch as the sight is lost. Long after the appearance of a mere extra-ocular tumour, the sight is unaffected.

While a sarcoma is intra-ocular, and is no longer small and

recognisable by the ophthalmoscope, it might be confounded with glaucoma, there being in both affections diminution of corneal sensibility, with or without corneal opacity, diffuse opacity of the aqueous humour, hyperæmia of the sclerotica, and pushing of the iris and the lens against the cornea. Indeed, any intra-ocular tumour may show the same symptoms. The history of a case must be relied on for evidence. On such doubtful occasions, incising the eyeball may be resorted to.

When the pupil is clear enough, and the vitreous body too, to admit the fundus of the eye to be tolerably well seen, detachment of the retina, with increased intra-ocular pressure, and ciliary neurosis will declare the existence of a tumour.

In the earliest stage it is difficult to diagnose sarcoma from detachment of the retina, arising out of simple, serous, or hæmorrhagic effusion, retinal tumours, detachment of the choroidea from the sclerotic, and detachment of the hyaloid membrane from the retina. The only sure guide is the recognition in the slightly opaque retina of the retinal vessels, and the tumour beneath it with its blood-vessels; then, with such an opportunity of observation, we may see whether a sarcoma be white, black, vascular, or spotted.

Two cases of white sarcoma of the iris have been seen and verified by dissections.

I have neither seen nor heard of a veritable case of intra-ocular carcinoma.

A collapsed eyeball may be attacked without or within by any malignant affection which may occur in the healthy eyeball.

Sarcoma carcinomatosum is a name given by Virchow to a case of tumour partially within, partially without the eyeball, while, in truth, the characters of a sarcoma were mixed with those of carcinoma, the latter prevailing externally. Virchow remarks it cannot be said that a sarcoma has become carcinomatous, since it is impossible to be clearly demonstrated that the carcinomatous proliferation commenced in the connective tissues without the intervention of an intermediate sarcomatous stage between the original condition of the connective tissue, and the ensuing cancerous state.

MALIGNANT AFFECTIONS OF THE EYELIDS.

Encephaloid cancer and sarcomata occasionally have their primary seat in the eyelids.

The sarcoma is usually of the pigmented form, melano-sarcoma.

When on the conjunctiva it has a raised and sharp outline, and the surrounding conjunctiva is often blackened in patches.

Scirrhus and epithelial cancer are the affections to which these parts are especially liable, and in the majority of cases, the under eyelid is the one that is attacked; a fact of which no satisfactory explanation has hitherto been given. They present, in many respects, a close resemblance to each other; so close, indeed, that it is to their history and mode of progress, rather than to their external appearance, that we must look for marks by which to distinguish the one from the other. They are unknown in childhood. They occasionally attack young adults, but are much more common in those somewhat advanced in years.

In scirrhus, the attention of the patient is generally first attracted by a feeling of stiffness in the eyelid, by which its free motion is impeded; and on farther examination, this is found to be due to an undefined thickening and hardening of the subcutaneous areolar tissue. As the disease advances, adhesions are contracted with the bone, and the eyelid may appear as if somewhat retracted within the orbit. The skin gradually becomes involved, and assumes a dusky, livid hue, from the presence of numerous small veins which ramify upon its surface. In some instances, severe lancinating pain is an early and prominent symptom; in others, there is merely a sense of uneasiness or itching, which induces the patient to rub or scratch the part, and this, by breaking the skin, leads to the commencement of ulceration. This process having once begun, follows the same destructive course as in other parts of the body, and produces the most frightful deformity. The bones as well as the soft parts are destroyed by ulceration, and the nose, mouth, and orbit may be thrown into one large cavity. As is the case with fibrous structures generally, the sclerotica long resists the attacks of the disease; and though all the other contents of the orbit should be destroyed, the eyeball may be seen lying there, almost as completely detached as if it had been dissected. In other cases, the irritation to which the eyeball is exposed leads to inflammation and sloughing of the cornea, the humours escape, and collapse ensues. Death takes place from the contamination of the system, and the formation of secondary deposits, or from the exhausting influence of pain and constitutional irritation.

Epithelioma, or epithelial cancer. This is seen only in manhood or old age. It may make its appearance in any crack or pimple, or any wart or mole, on the skin of the eyelid; or on the margin of the same, where it usually occurs at a corner. It is ushered in by the formation of small, hard, whitish elevations or

tubercles. It is hard, and appears to be situated in the texture of the part.

It slowly enlarges and has the appearance that would be caused by introducing a knotted thread, or a minute white bead, or a series of them, beneath the skin. In process of time these tubercles coalesce into a mass; itching or uneasiness is felt; the surface is irritated or scratched, and yellowish scabs form. It may heal, and then break out again, and so continue for years without any material augmentation. It proceeds gradually but regularly; at one part of its circumference it may be enlarging and secreting a thin, purulent fluid, while in another part it may be cicatrizing. So that there is a striking peculiarity in the tendency to partial reparation of one part of the sore, while ulceration is in active progress in another. Smooth, shining cicatrices, of a pale bluish colour are formed, but are seldom of long duration; they are again involved in ulceration, while the same process is repeated in another part.

It progresses with solid edges, and by scabbed excoriation, continuing in one uniform mass, and not by the development of isolated deposits.

Years may pass before the subcutaneous tissues are involved. When the eyelids are destroyed in part the areolar and fatty tissues of the orbit get involved, and then the eyeball, which last inflames, and atrophies, or may be opened by ulceration, and so collapse.

The disease continues in activity by eating deeper, and at length the walls of the orbit suffer, and at last half of the face, or even more, may be lost, the cavities of the mouth, nose, and orbit being thrown into one. No treatment arrests its ravages, but all tissues are regularly destroyed in its progress. The destruction, therefore, of parts, may equal that which is seen in scirrhus.

This is the same affection that is described by some men as the rodent cancer.

If the general health of the patient be unimpaired, and the local affection shielded from irritation, six or seven years may elapse before ulceration supervenes. Progress after the commencement of ulceration may be equally slow; ten, fifteen, or even twenty years may elapse, without any advance having been made. In other instances, however, and especially when by any means the general health of the patient is depressed, or the sore is injudiciously treated by irritating applications, the disease may advance with the most destructive rapidity.

Epithelioma may occur primarily on the conjunctiva of the cornea.

In those in whom the constitutional conditions necessary for the development of cancer are present, the spot at which the epithelial growth makes its appearance is frequently determined by local irritation; in the neighbourhood of the eye, for instance, it may be induced by the repeated friction of optical instruments.

It is a characteristic of the affection not to implicate the neighbouring lymphatic glands, exceptions to which are very rare, except in the last stages.

It seldom commences before the middle period of life. It is always more virulent when it appears late. Pain is not a prominent symptom of epithelial cancer; in some cases, even where the disease has committed the most extensive ravages, it may be almost entirely absent. At other times it is acute, but this seems to be owing rather to incidental complications, such as the exposure of the nerves by ulceration, &c., than to be an essential feature of the disease.

The distinction between scirrhus and epithelial cancer is to be drawn rather from their history than from their appearance. In the early stage, when alone the diagnosis is of any practical importance, it will be found that in scirrhus the skin is movable over the indurated mass, whereas the epithelial growth appears to be deposited in its texture. The tubercles of scirrhus are less prominent, more quickly become adherent to the subjacent textures, are of a more decided colour, and are more frequently attended with pain, than those which usher in epithelial cancer. The progress of the former, too, is in general more rapid; the constitutional cachexia is more speedily and decidedly developed, and the lymphatic glands are in general implicated; a complication which is rarely seen in epithelial cancer. In many cases, however, the differences are so slightly marked as to be scarcely perceptible, and the diagnosis becomes exceedingly difficult.

CANCER AND OTHER MALIGNANT AFFECTIONS OF THE ORBIT.

Tumours of this nature, originating deeply in the orbit, produce no physical changes in the surrounding parts, by which they may be readily distinguished from non-malignant tumours. But there are some symptoms, arising out of the malignant tumour itself, which help in diagnosis.

Rapid increase of a solid growth should excite suspicion of malignancy. Restraint, or pressure, will exert influence on growth. While a malignant tumour is behind the eyeball its progress is somewhat stayed, and even while it remains posterior to the oculo-palpebral

fascia, it is bound. Irregular development is explained by the effect of irregular restraint.

Loss of ocular movements disproportionate to the size of a tumour, the size is judged of chiefly by the ocular protrusion, is very suspicious on the side of malignancy, as an effect of infiltration of the recti muscles. At a late period of cancer, or sarcoma, all ocular movements are lost.

Fixedness, or consolidation of the tumour in the greater portion of its extent, is rarely met with apart from malignancy.

Unnatural vascularity of the surrounding integuments, especially by the enlargement of veins, is a malignant characteristic.

Of the four varieties of cancer, scirrhus, encephaloid, and epithelioma, have been found to originate in the orbit.

Scirrhus is the rarest of the three. It has been met with, infiltrating the areolar tissue both behind and above the eyeball in one mass, and as small hard circumscribed tumours in different parts of the orbital tissues. Its appearance seems generally to have been determined by some previous injury, or attack of inflammation. It is slow in growth, and not attended with much pain, so that for a long time it is especially difficult to distinguish it from a simple tumour. In an instance of it which followed an injury to the outer part of the orbit, there was so much hardness and adhesion to the orbit, as to cause it to be mistaken for an exostosis.

Encephaloid cancer. The objective symptoms run thus. The discovery of an orbital tumour, for the most part apparent at the inner side of the orbit, by which the eyeball is irregularly protruded and the eyelids bulged. The conjunctiva looks healthy, and there is no unnatural surface vascularity beyond some enlarged veins in the one or the other of the eyelids. The tumour imparts to the touch the sensation of fluctuation, and it might be to such an extent as to suggest the idea of the presence of a cystic formation. The excretory lacrymal apparatus at the inner corner of the eye is seldom interfered with. The growth is accelerated with the age of the tumour; that is, it grows faster at later periods. In a few months the cancer reaches the surface, the integuments become discoloured and ulcerate; and with much discharge, and accompanied by constitutional symptoms of debility, a fungus sprouts forth, and if the patient lives long enough, may grow to half the size of his head, all the while implicating parts around, and destroying the eyeball. Death may ensue from the local irritation, and the exhaustion consequent on the discharge, but it comes about from pressure on the brain, in consequence of absorption of the roof of the orbit, or from extension of the tumour to the brain, or secondary development of it there, or in other internal

organs. The secondary changes in these tumours, the fatty degenerations, and the hæmorrhages need not be described; to do so would be to go unnecessarily into general pathology.

For a long time subjective symptoms are wanting. Pain appears late. As regards the sight, it is unaffected, unless the eyeball be pressed on or invaded by the tumour.

Sarcomata. The objective symptoms will vary according to the kind of the sarcoma, and the remarks which I have made about the behaviour of sarcomata in the eyeball apply here. Owing to this, at one time it might be supposed that a fibrous tumour is present, and at another soft cancer. In the later stages of any of the sarcomata, the description which I have given of the later period of medullary cancer, is applicable.

When the sarcoma has a superficial integument origin, it is tolerably sure to be pigmented.

Glioma. Some cases of this have been published. According to what is accepted about the origin of this form of sarcoma, they must have sprung from the post-ocular portion of the optic nerve. The following case, reported by Von Gräfe, is rendered still more interesting from having been also investigated by the great pathologist Virchow. The patient was a girl six years old. The symptoms were protrusion of the eyeball by a firm, small, orbital tumour. The ocular movements were very much interfered with. Vision was almost annihilated. The eye was examined by the ophthalmoscope, and neuro-retinitis discovered. There were no head symptoms, and as the vision of the other was perfect together with all its movements, it was thought that the tumour did not extend to the brain. The eyeball was removed, and then the extirpation of the tumour was readily executed. It is said that there were no adhesions. On the tenth day the patient died of meningitis. A tumour as large as a walnut was found at the base of the brain, immediately behind the crista galli, and communicating with another very much larger before the left corpus striatum. Virchow called this a neuro-glioma.

Myeloid tumour has not been met with in the orbit, except in extension from other parts.

Epithelial cancer occurs as a sub-cutaneous, or sub-conjunctival tumour, and may be very well marked before it ulcerates and shows indication of malignancy. The following case is a typical one.

A man, sixty years of age, applied to my colleague, Mr. Taylor, on account of a tumour at the upper and inner angle of the orbit, observed some months before, which was gradually increasing and displacing the eye downwards and outwards. It was about the size

of a nutmeg, smooth and regular on the surface, firm, elastic, immovable, but apparently not attached to the skin. Fig. 283 delineates it.

Fig. 283.

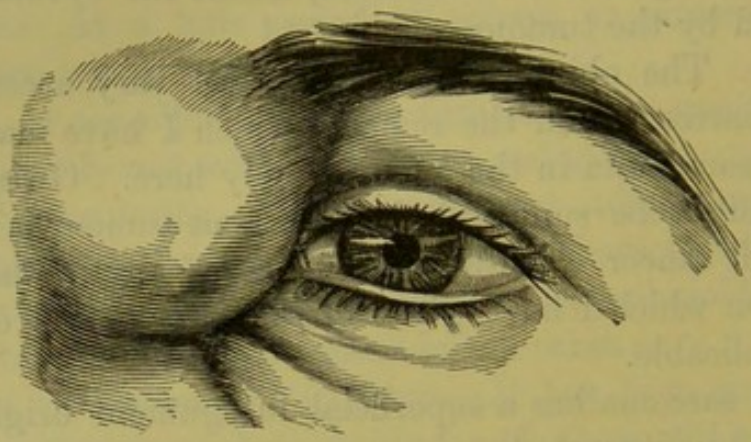

There was occasional slight pain in the situation of the frontal nerve, which was pressed upon by the growth. Vision was not impaired, though the eyeball was considerably displaced. Mr. Taylor operated, and I assisted him.

The tumour, which was adherent at one point to the bone, was removed, apparently entirely, partly by evulsion, and partly by dissection, and the exposed bone was scraped. The wound healed by the first intention, but the eyeball only partially recovered its proper position. A few weeks afterwards, the tumour returned, and the eyeball was more displaced than ever. A second operation was undertaken at which difficulties were encountered, for the morbid mass extended deep into the orbit, adhered firmly to the bone and the upper tarsal cartilage, and was thoroughly matted between the muscles and other surrounding textures. Every portion of tissue that presented a suspicious appearance was dissected out.

The disease soon reappeared; in six months the eyeball was nearly pushed out of the orbit, and much compressed by a purple growth as big as a hen's egg, which involved the skin, was studded with small tubercles, and gave out a slight discharge. The patient's health was fast declining.

Myxomata. This is usually considered a benign class of tumours, and any return of them, or internal secondary development, is supposed to be due to admixture of sarcoma. Stellwag says respecting them, it seems as if certain growths described as colloid cancer which have affected the entire eyeball, and the surrounding orbital tissues, should be regarded as myxoma. My reader must be told that the chief constituent of this is mucous tissue, normally represented by

the vitreous humour, the jelly of the umbilical cord, and the neuroglia of the nervous system. It is intimately related to fatty tissue, the one being directly convertible into the other by increase or decrease of fat. It is very soft, often fluctuating like a cyst.

From the cut surface exudes a filamentous fluid, which exactly resembles mucus. There is also found a filamentary basis, with elements much resembling connective tissue fibrillæ, but very loose, and filled with mucilaginous fluid. The intercellular substance contains cellular elements in variable amount, and of different forms. It has been observed in the optic nerve, where it forms tumours more or less extensive, which are encapsulated by the sheath of the optic nerve, push the eye regularly forward, and limit, without entirely arresting its motions, rapidly cause blindness, and run their course without pain. In one such case the humours of the eye were already evacuated, as a result of ulceration of the cornea. In another, the eyeball still retained its shape, and by the ophthalmoscope the pressure of the tumour on the papilla or disk could be made out, from the bulging forward and cloudiness of the latter, as well as from the congestion of the retinal vessels. In a third case, the myxoma in the papilla had developed, in company with a number of analogous small tumours in the fatty tissue of the orbit.

Examples are numerous of the invasion of the orbit by malignant affections which have had an intra-ocular origin. The ocular attachment may be extensive or slight, so slender, indeed, as to induce the idea of the eyeball having been secondarily involved. A diagnosis by means of the ophthalmoscope, can be generally made, certainly before the eyeball inflames, which it usually does, whereby the fundus is obscured.

Cancer and other malignant affections which originate in the immediate neighbourhood of the eye, such as the frontal or ethmoid cells, the antrum of Highmore, &c., frequently burst forth in the orbit. In the following sketch the tumour originated in the ethmoid cells, caused stoppage of the nasal duct, and then appeared at the inner angle of the eye. Removal of it was undertaken. Reproduction ensued, and both nostrils and both orbits were filled with it.

The orbital roofs were absorbed, the brain was pressed on, and death ensued.

TREATMENT.

Question as to the propriety of operating in cancer, and other malignant affections of the eye. There is, probably, not any subject in the whole range of surgery upon which more discordant opinions have

been expressed than upon the question as to the propriety of extirpating malignant growths. This is attributable to various causes, one of the chief of which I believe to be the careless and indiscriminate way in which the term cancer is applied.

Fig. 284.



There can be no doubt that non-malignant and malignant growths are constantly confounded, and, next to the mamma, this mistake occurs more frequently in the eye than in any other organ.

Another, and very common source of fallacy in examining this important question, is the prevalent and increasing custom of reporting cases as cured within a very short period after the operation, for the most part when the patient leaves the hospital. Were recovery from the immediate consequences of the operation to be considered as a true test of success, we might certainly look upon malignant growths as equally amenable to surgical treatment with almost any other form of disease. To do so, however, would be to overlook one of their most distinctive and deadly characteristics, the liability to return as well in the original seat as in the form of secondary deposits in the internal organs.

Fortunately in some forms of cancer, and of sarcoma, in certain situations, since the whole organ in which it occurs can be taken away, the removal of the malignant growth by extirpation and otherwise, is justifiable, because success ensues in the growth not returning, and also on the less satisfactory grounds of mitigating suffering, and sometimes prolonging life.

Importance of efficient operating. This applies with equal force to every case in which the removal of cancer or sarcoma is attempted. Every sensibly diseased particle must be eradicated, to ensure which, the incisions must be made in healthy textures. Without this can be done, an operation should on no account be entertained. Every stroke of the knife through the diseased part opens up channels by which the cancerous germs are conveyed directly into the circulation, and the condition of the patient, from whom the disease has been only in part extirpated, is thus rendered infinitely worse than if nothing had been attempted.

For small superficial malignant tumours, it matters little whether the knife or an escharotic be used. Where the tumour is larger than half-a-crown the former is supposed by some surgeons not to be so applicable as the latter. Speaking in a general way, it may be said that the instances are rare indeed in which the knife is not to be preferred, as at once more rapid and effectual, and much less painful. Escharotics frequently require to be several times repeated; their use is attended with intense pain, and in the event of their not succeeding, the irritation which they produce cannot fail to be followed by the most injurious effects.

Where the disease has affected the periosteum, or it and the bone, either the bone must be excised, or exfoliation of it produced by an escharotic. About the orbit I prefer the latter. The greater portion of the orbit has been thrown off in pieces, and even the entire orbital walls have exfoliated after the escharotic practice for different kinds of cancer. The museum of the Middlesex Hospital contains such specimens, and the museum catalogue tells how the patients were relieved, and lived in peace for years after.

The several caustics which may be resorted to, are potassa caustica, Vienna paste, acid nitrate of mercury, and chloride of zinc in a paste. As regards the ultimate result, I do not think there is much to choose between them. I have used the Vienna paste most frequently. The late Mr. Moore, of the Middlesex Hospital, who had great experience in these cases, employed the zinc very commonly. He showed me some of the worst cases of epithelial cancer, in which he had resorted to it with good results.

The following formulæ may be acceptable.

Vienna Paste.	Potassa caustica	ʒv.
	Calcis hydras	ʒvj.
Zinc Paste.	Zinci chloridum	ʒjss.
	Liquor opii sed. vel.	
	Aqua	ʒjss.
	Farina tritici	ʒj.

In applying either of these destructive agents the eyeball should be protected mechanically, and if possible chemically too, and the patient's head so placed as to prevent the caustic from falling on it. Whichever preparation be selected, it may be applied to the diseased part by itself, or on a piece of lint, till the eschar drops off. If there be very much suffering, an opiate should be given by the mouth or by the subcutaneous method.

It might be requisite to use the knife and the caustic more than once, but there is frequently more necessity to reapply the latter than the former. If the paste have not acted sufficiently deep, it should be reapplied when the eschar falls off, or the eschar cut through in several places, and the application then made, after the manner of Dr. Fell, the American, who made a great noise here some years ago as a cancer curer.

The zinc paste must be used with great care to the upper wall of the orbit, because in every instance in which it has been applied to the cranium, or to a diseased surface of the dura mater, an epileptic fit has ensued within two or three days, and unconsciousness has remained for many hours.

Scirrhus and sarcomata without the eyeball. Gliomata, and sarcomata, within the eyeball.

Removal of the eyeball alone, should be reserved for only the early stages of these affections, when they have advanced but little and are circumscribed.

In the extra-ocular forms, with the least evidence of quick growth, the orbit should be cleared of its contents.

In glioma, if the optic nerve be not yet infiltrated with the disease, and provided that there be no cerebral co-development of glioma in the brain, I am sure that success will follow the operation of extirpation of the eyeball. When the nerve is implicated, which may happen at any time, and can be told only when it is cut through, and which unfortunately is the rule, so surely will the distal end sprout forth in a vigorous glioma, and will in time affect the parts around, and cause death from irritation of the system, unless the patient sink from secondary gliomata in the brain. In vain is it to pull the distal end of the nerve forwards in order to cut off

still more of it; or in vain to apply escharotics to it. Death from the growth of gliomata in the organs of the trunk must be very rare, as I find only one record of such occurrence.

In the other intra-ocular sarcomata, less success only can be got, for besides the frequent implication of the optic nerve, the orbital tissues get secondarily affected, and internal development of the disease is common. I have seen every thoracic and abdominal organ studded with it. This is always described as secondary deposit. Surely the extent of such growths, and the quickness with which they may kill after the discovery of the eye symptoms, justify the belief of their co-temporaneous formations! We cannot be sure that the eye is not sometimes secondarily affected, in point of time, to that of the trunk organs. But I am watching two cases on which I operated eight years ago, and as yet, the patients are healthy. A gentleman has just died six years after an operation. The orbit kept clear. Death was sudden. I heard no more. Melano-sarcoma was the disease in all. May we not suppose that, in these exemption cases, the disease was but in low manifestation?

When these intra-ocular tumours nearly fill the eyeball, the only chance of doing good is to remove the contents of the orbit. If the optic nerve be affected, even that will be of course useless.

When the tumour has burst through the eyeball, in front or at the side, only very temporary relief from suffering can be got by operating. If anything be done, the orbit should be cleaned out.

When a collapsed eyeball is attacked by any of these affections, the treatment should be the same as if the eyeball were unreduced.

It is improper to operate, if there be symptoms of implication of the brain.

Malignant affections of the eyelids. Scirrhus. While this is tolerably limited, it may be removed. I know from my experience of the treatment of this cancer in other parts of the body, that in operating I shall remove local suffering, and in all probability add to the life of the individual. Implication of neighbouring lymphatic glands would not deter me, if it were recent and not extensive, and if the glands also could be removed. Moreover, under some conditions, I would remove glands which became affected after an eyelid has been extirpated.

Sarcomata. Operations, whether by knife or caustics, give very unfavourable results, in the return of the tumour.

Epithelial cancer. In this form of cancer, the development of cancer-growth appears to be at its minimum, and there is always encouragement for operating. If every part of the diseased structure be removed, in many instances there will be a cure, in some there

will be relief from present suffering, and life will be prolonged. The sooner the cancer is removed, the better for the patient.

Cancers and sarcomata in the orbit. In all of the many cases in which I have operated, or been present during the performance of operations, it has either been impossible to clear the orbit without scraping the bones, or a portion of the cancer has passed out of reach through some of the orbital apertures.

In all of these patients whom I watched, or of whom I could learn anything, there was a local return of the disease, and in all, death ensued from the local effect of the spreading tumour, or internal development of malignant growths. To apply an escharotic, after the manner before mentioned, to the bone when it is implicated, in order to cause exfoliation, is to do all within our power, and such a course should be carried out, or the bone removed. When the tumour passes out of sight, it cannot be followed, and the patient is in a worse state than if he had not been touched. These are then deplorable cases to deal with, and little can be expected, and little got, from treatment. Operations are unjustifiable as a rule.

Under certain circumstances, however, in any case of malignant disease of the eye, an operation may be not only permissible, but necessary. When, for instance, either from their original position, or from the direction of their growth, such tumours are in close contact with the roof of the orbit, they are liable, as they increase in size, to cause absorption of the bone, and death from pressure on the brain. Or when excessive or incessant pain induces relief to be sought at all hazard. In such cases, after having made the patient fully aware of the danger of his position, and having explained that interference is not with the hope of affecting a permanent cure, but merely with the view of averting impending death, or giving ease, it will be proper to deviate from the principle of not interfering, and to excise the tumour, removing at the same time the whole of the contents of the orbit.

To operate for recurring malignant affection, is to do that which can be justifiable only under such circumstances as I have alluded to in the last paragraph.

The question of constitutional treatment I shall not entertain, as it belongs more to general surgery.

CHAPTER XXXIX.

BENIGN INTRA-OCULAR TUMOURS.

Tubercular deposit, in the retina and the choroidea, is spoken of in the chapters on the diseases of those tissues.

Erectile, or vascular tumour, nævus maternus, has been met with several times in the iris.

CYSTIC TUMOURS IN THE ANTERIOR AND POSTERIOR CHAMBERS OF THE EYEBALL.

A cystic tumour in connection with the iris, when not congenital, or a cystic tumour in connection with the ciliary body, generally has a traumatic origin, being produced by a penetrating wound, an operation, or a blow on the front of the eyeball.

These tumours are liable to be mistaken for a dislocated crystalline lens, or a cysticercus cellulosæ, both of which it very much resembles. The chief characteristic distinction is attachment of the tumour, and when the tumour is large, displacement of the pupil. Therefore, should there be slight opacity of the cornea, it might not be possible to distinguish between them, except from the history of the case.

These cystic growths are of several kinds. The most common, and of which I shall first speak, consist of transparent tumours with fluid contents, or slightly opaque ones, with glutinous contents. I have had two samples of the former and one of the latter. They are for the most part of an oval form and flattened, and sometimes so transparent that both walls can be seen through. Occasionally some of the delicate fibres of the muscular layer of the iris are visible in front. They seem as if wedged in between the cornea and the iris, the latter of which is pushed back. They are generally entirely incorporated

with the iris, but may have only a pedunculated attachment. Fig. 285 represents one with semi-transparent walls.

Fig. 285.

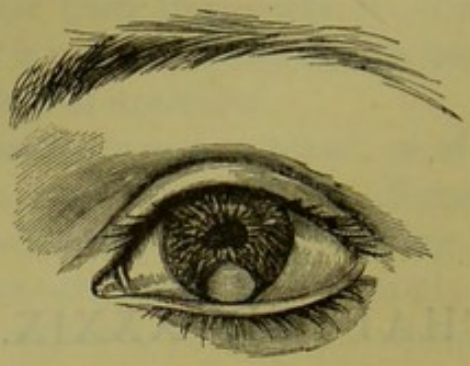

A girl, six years of age, wounded the right eyeball with a pair of scissors, and destroyed vision for all practical purposes. At eighteen years of age she became one of my hospital patients. The eyeball was a little shrunken and inflamed. A cicatrix on the upper part of the cornea, passing from the inner margin nearly to the opposite side, indicated the position of the injury. The iris had not prolapsed. The upper half of the anterior chamber, to the very circumference, was occupied by a semi-opaque cyst, which seemed to be connected with the cicatrix in the cornea, and certainly had an attachment to the margin of the pupil, which was much contracted and partly covered. The cornea was not pressed forward, but the increased space required for the morbid growth was obtained at the expense of the iris, which was thrown back, and the portion of which corresponding to the centre and greatest convexity of the cyst was rendered very concave, and attenuated. It could not be ascertained if the crystalline lens were present. Pain about the eye and orbit had induced relief to be sought.

Respecting the minute anatomy there is great difference of opinion; some maintaining that there is no new growth, but merely a formation of transparent fluid between the iris and the uvea, an idea first propagated in this country; but more careful examinations with better opportunities show the existence of a distinct cyst wall. This seems to have been first recognised by Gräfe, who describes the cyst as made up of connective tissue and lined internally with epithelium. These details have been confirmed by Mr. Hulke, who examined a transparent one, the particulars of which with microscopic drawings are in vol. vi., part i., of the Ophthalmic Hospital Reports. This cyst was covered in front by delicate fibres of the muscular stratum of the iris, and posteriorly by the uveal stratum. The cyst wall was a delicate homogeneous membrane, the inner surface of which was

lined by a pavement epithelium, the cells varying in size in different parts.

It is also established from what has been recorded by several men, that the cyst may have its origin in the ciliary body, and be therefore entirely behind the iris, which is pushed forward and attenuated.

The rarer forms of these cysts are the dermoid, and others, of which as yet there is not any exact knowledge of the structure, are of a denser nature. The walls are thicker. One is spoken of by Mr. W. Cooper as being dense like cartilage. There is also variation in colour; some being white and glistening like tendon, brown or lustrous; and irridescent like mother-of-pearl; sometimes besides parti-coloured, as that described by Mr. Turner in the "Monthly Journal of Medical Science," vol. i., the upper two-thirds of which was bluish-white, the lower third yellow. The contents, too, differ; in Mr. Turner's case it seemed to be a muddy liquid with a yellow sediment. In another the whole seemed made up of epithelium cells, so closely agglutinated that maceration was necessary to separate them.

Treatment. As the tendency of these cysts is to increase, to produce internal inflammation of the eyeball, ophthalmitis, to excite sympathetic ophthalmia, and to cause absorption of the lens, the rule should be to get rid of them as soon as they are detected, because the smaller they are, the less is there to be done, the more certain the removal, and the better in general will be the result. Moreover, an eye not as yet irritated by them, is more fitted for an operation than one which is.

The cyst must be punctured in front, incised, or extracted, but neither measure is quite free from risk to the integrity of the eye.

For the first and common kind of cysts, those with transparent, or slightly opaque walls, with fluid or gelatinous contents, the method of treatment by puncture is the best. The incision should be as free as possible in order that the cyst contents may be evacuated, to afford the fullest contact of the aqueous fluid with the cyst walls. I have always used the smallest iris knife. A second incision has been successful when the first has failed. Even a third has been required. This practice, therefore, should be fairly tried, and not prematurely abandoned. The cure is affected by the cyst contracting without any apparent action in it, or by palpable inflammatory stages. The cyst shreds may shrink and disappear, and the eye become perfect.

The following very instructive case is recorded in the "Mirror" of the "Lancet" for June 12th, 1852. A child, five years old, thrust the point of a fork into his eye, from which accident he speedily

recovered. About a year and a half after, uneasiness and inflammation induced the parents to apply for advice. There was now in the anterior chamber a large transparent body, at first supposed to be a dislocated lens, but ultimately recognised as a very delicate, watery cyst protruding from the posterior chamber into the anterior; the lower part of the iris having been detached from its ciliary connection, and pressed upwards. The cyst was punctured; a considerable quantity of fluid escaped, and it collapsed. The pupil lost much of its irregularity, and the interval formed by the separation of the iris became less. Soon afterwards the cyst refilled, and in two months it was repunctured through the cornea by Mr. Jones, who had not seen the case before. After a few days inflammation followed, and according to the report, "There was at the bottom of the collapsed cyst, a small quantity of yellow matter or lymph, with a minute vascular ramification upon its anterior wall." The eye became worse, from some indiscretion on the part of the child's mother. Leeches were applied, and calomel and Dover's powder were given. Some of "the matter of the cyst worked its way outwards at the junction of the cornea and sclerotica by a narrow passage." The mercury was discontinued after all the matter was absorbed. The cyst shrank in a manner that left little trace of it, and sight was quite restored.

A somewhat similar one is recorded by Dr. Mackenzie. A lady was affected with considerable pain in one of her eyes, which presented the appearance of a small vesicle pushing into the anterior chamber from under the ciliary margin of the iris, behind the lower edge of the cornea. The vesicle gradually increased, separating the iris more and more from the choroid, and as it caused severe pain he punctured it through the cornea, with an iris knife. A minute quantity of fluid was discharged, and it immediately contracted so much that it was no longer visible, and the pain was removed. It refilled and appeared in its former situation, but was larger than before. He punctured it a second and a third time, at the respective intervals of six and eight weeks. After this it did not fill again, the iris returned to its natural place, and vision was preserved.

Mr. Dalrymple gives the following particulars of one in a girl twenty-five years old. A semi-transparent cyst attached to the iris and to the posterior surface of the cornea, partly hid the pupil. It was punctured and evacuated of its pellucid fluid, without the aqueous humour being lost. In a few days it refilled, was again punctured, and now collapsed completely. Its walls were very thin, and through them could be seen an apparent aperture in the iris.

Puncturing may fail altogether. In a cyst treated by Mr. Dixon, it

did not answer notwithstanding he tore it open with two needles and let the contents into the anterior chamber. It filled again. But the operation is far safer for the eye, beyond comparison, than any other. Not in any of the cases recorded has the eye been lost through it.

Excision is demanded when the cyst is very large, or in the second kind of cysts, those which are very dense, or when puncturing has failed.

It is the only chance of saving the eye, but the operation is fraught with danger to vision, directly and remotely. Except the base of the tumour be very small and attached near the pupil, separation of the iris from the ciliary connection is apt to ensue. At all times opacity of the lens and its capsule is likely to be produced.

When the cyst originates posterior to the iris it cannot be detached without much damage to the eye.

The cornea should be sufficiently opened, and, if possible, the cyst completely detached. It may be prudent to leave a part, rather than to separate much of the iris. If simple traction will not suffice, such dissection must be made as may seem desirable, including the removal of a bit of the iris. The easiest operation is that in which the cyst can be drawn out and cut away, along with a bit of iris.

Mr. Tyrrell gives an example of a cyst growing in the anterior chamber, in consequence of injury from the beard of an ear of corn, that well illustrates the danger of inflammation from extraction.

The patient was a girl: the cyst was about the size of a pea, glistening, and attached near the margin of the pupil, with the motions of which it somewhat interfered, but vision was good. As it increased and excited inflammation, Mr. Tyrrell was induced to operate. The cornea was opened, the cyst drawn out, and the portion of iris to which it was attached cut off. The wound in the cornea healed readily. Active inflammation of the eyeball ensued, in consequence, it is said, of imprudent exposure; the other eye sympathized, and was similarly affected, but to a slighter degree, "exhibiting inflammation of the iris and aqueous membrane." After many weeks passed in treatment, the pupil became very much contracted, and the iris adhered to the capsule of the lens; however, large bodies could be discerned. The eye sympathetically affected recovered perfectly. (Tyrrell on "The Eye," vol. i. p. 368.)

I saw an eye lost by suppuration in an attempt to remove a cyst, which in all probability might have been destroyed by puncturing.

In the case of my own, above mentioned, I punctured the cyst through the cornea with the iris knife, and fluid escaped, it was supposed from the cyst alone. A decided reduction followed this treatment, but the effect was temporary. Repetitions of it on two

other occasions, at intervals of about a month, were not more effectual; indeed, they seemed to have been rather prejudicial in exciting the growth of the part, for it increased in all its dimensions, and the pupil was covered. The eyeball became very vascular, there was constant pain in the eye, and occasionally headache. I recommended excision, but this was not assented to till the symptoms were worse. The earliest state of sympathetic ophthalmitis soon set in, involving the sight, the symptoms being intolerance of light to a slight degree, and then excessive irritability of the retina which prevented the eye from being used at all, with paroxysmal pain. I feared that partial removal of the tumour would not be sufficient, and I determined to take away every part of it. The extents of the attachments could not be clearly ascertained, and it was probable that to effect my object, such damage might be inflicted as would risk suppuration of the eyeball. Rather than do this, therefore, I resolved to remove the front of the eye, if any difficulty should supervene. I made the upper section of the cornea, as for extracting cataract, passing the knife through the body of the cyst. Along with the aqueous humour, which was small in quantity, there escaped a transparent jelly-like substance, that was evidently the cyst contents. The flap of the cornea was held down by an assistant, and the cyst seized with a pair of tenaculum forceps, and after a little trial drawn away without any difficulty. The iris tore where it was rendered thin by distention. No vitreous humour was lost. The crystalline lens was supposed to be absent. The cut surfaces of the cornea were adjusted, and the eyelids retained together by adhesive plaster.

The cyst wall was composed of delicate fibrous tissue. It seemed to spring from a minute whitish cicatrix on the iris.

The corneal wound healed in a week. Already had the woman received benefit, for she could use the left eye without discomfort, and the third day after the operation she had not any pain in the right, only a sense of soreness.

Simple benign pigmented tumour of the iris, melanoma. This is liable to be confounded with melano-sarcoma. It is allied to the ordinary iris pigment spots, and very rare. According to Knapp, it consists of a circumscribed development of the stroma cells of the iris, with numerous branches which anastomose freely without well-defined boundary line, the greater portion being pigmented.

INTRA-OCULAR ENCHONDROMA.

For a description of a unique case of this kind, I am indebted to Dr. J. J. Chisholm, of the University of Maryland.

The patient was a male aged twenty-five. From the age of three, the eyeball commenced to enlarge, and continued enlarging, with occasional pain. From the orbit protruded a mass as big as a man's fist, which moved a little in concert with the other eye. The edge of the outer wall of the orbit was absorbed, and the nose was displaced. There was no trace of any ocular tissue, but some obscure remains of the cornea. The whole growth was removed after the usual manner of extirpating an eyeball, and quitted the orbit readily. On the fourth night from the operation, there was hæmorrhage to the extent of a few ounces. On the fifth night there was a recurrence of bleeding without the source of the hæmorrhage being discovered. On the evening of the ninth day, severe hæmorrhage took place, and the common carotid artery was tied. Death ended the scene four days after this was done.

The tumour was smooth, regularly ovoid, about three and a-half inches in its longest diameter, and two inches and a-half in its vertical and transverse diameters. Its outer surface was the expanded and thickened sclerotic coat, which had not been broken through at any point. This was filled with solid contents, mottled in appearance, and of varied consistence, among which were conspicuous white nodules of different sizes. These proved upon section to be cartilage, which character was confirmed by microscopic examination.

The specimen was sent to Dr. H. Knapp for minute examination, and that careful investigator has published a very lengthy and exhaustive report of it, which embraces pathological, histological, and clinical points, in his archives of ophthalmology.

CHAPTER XL.

CALCAREOUS CONCRETIONS OR CALCULI; TEAR-STONES, OR DACRYOLITHS; OSSEOUS AND TRUE BONY DEPOSITS, ABOUT AND IN THE EYE.

EXTRA-OCULAR DEPOSITS.

Calculi in the Meibomian apparatus. These are formed by the deposit of calcareous salts in the inspissated secretion of the glands. They are white and opaque, do not project at the edge of the eyelid, but on its inner surface; may be like grains of sand, or as big as a pin's head, or much larger. They act injuriously by inflaming contiguous parts, or partially ulcerating through the eyelid, and by irritating the eyeball. Several often exist on the same eyelid. One rather larger than a pea, formed in the upper eyelid of a middle-aged man. It was composed of concentric layers of hard earthy material. Its pressure had caused absorption of the cartilage and ulceration of the conjunctiva, and the friction produced pain, inflammation of the conjunctiva scleroticæ, and opacity of the upper part of the cornea.

All calculi should be removed as soon as they are detected. I have always accomplished the extraction with the point of my ophthalmic scalpel.

Calculi in the glands of the caruncle. I have met with but a solitary example of this. It had kept up chronic inflammation of the eye for many months, and had been overlooked by several surgeons conversant with eye diseases. A large granulation was thrown out, and while examining it I detached the solid calculus and removed it.

Dacryoliths deposited from the tears. These have been found in the excretory or tear ducts of the lacrymal gland. Stone formations in connection with the lacrymal apparatus, altogether of very rare occurrence, occur relatively most frequently, in the ducts of this gland. Twenty-three stones have, from time to time, been removed from the same patient.

One of the ducts becomes dilated with the deposit, and its walls thickened. Its mouth or outlet on the conjunctiva might not be closed, in which case fluid may be squeezed from it. When the tumour is small it is seen only by turning up the eyelid, when large it projects the eyelid.

Dacryoliths have been met with in the lower canaliculus. In a case of my own the concretion augmented considerably and produced irritation of the lacrymal sac and inflammation of the soft parts around. Its removal reduced all symptoms. It was as hard as a stone. An analysis of it gave carbonate of lime, phosphate of lime, magnesia, and chloride of sodium. Cases are described of collections of leptothric fungi in the canaliculi, enclosing concretions of chalk.

The rule of treatment should be always to remove the dacryolith.

Conjunctival dacryoliths have been described. It may be doubted whether any are formed on the free surface of the membrane.

All calcareous concretions found between the eyelids have probably descended from the lacrymal gland; such appears to be the explanation of a case by Mr. R. H. Meade, in vol. xv. of the "London Medical Gazette." A girl of nineteen, who had been in bad health, and suffered severe headache and pain over the left eye, was bled and leeched without relief. Inflammation suddenly appeared in that eye with lancinating pain in the upper and outer part of the orbit, and tenderness in the situation of the lacrymal gland, accompanied with sudden and profuse discharge of tears. Something which resembled a fragment of mortar was removed from the conjunctiva. The pain ceased, but returned in an hour after, and another similar bit came away. During the four following days there were several paroxysms of pain and inflammation, and as many as twenty-three similar pieces were discharged, after which the pain and inflammation abated. Neither abrasion nor ulceration of the conjunctiva was observed. The calculi were small, rough, very hard, and of a dirty-white colour, the largest being about a line in diameter. Through a microscope they looked like rough pieces of chalk studded with small portions of silex. They consisted principally of phosphate of lime, with a small quantity of carbonate of lime, and traces of animal matter.

A very remarkable case of the double affection is related by Walther, in Gräfe and Walther's "Journal," 1820. The rapidity of the formation of the calculi which were in the lower sinus was wonderful. In one eye, the first affected, they were removed twice, and even three times a day. Some years after this condition returned. The upper sinus of one eye was the seat of the deposit.

M. Desmarres has written very extensively on this subject in vols. vii., viii., and ix. of "Les Annales d'Oculistique."

Rhinoliths, or nasal calculi, which have always a foreign body for their origin, may involve the lacrymal duct. Of seven cases recorded in foreign literature, one is said to have been situated at the termination of the duct, and acted injuriously.

The treatment is to remove the calculus as soon as it is detected, for augmentation is certain.

Intra-ocular deposits. Calcareous deposits have been met with in all the structures of the eyeball, and true bone in some.

These deposits occur only in disorganized eyes, and the subject would be passed over, except that there is a practical point respecting them. It is well known that the transformation of any tissue of the eyeball into earthy material, or the deposit of such material in any part of the eye, may set up irritation and inflammation, liable to be transmitted as sympathetic ophthalmitis to the other eye. A short notice is therefore needed.

The new deposit, which is never thrown off by a natural process, may be hurtful when it is yet attached or firm, or when it is loose or free. Particles of calcareous materials may fall from a calcareous lens, into the anterior or posterior chamber of the eye, and set up irritation.

Traumatic inflammation, producing ophthalmitis, is for the most part the cause of destruction to the eyeballs, in which these changes are set up.

Cretaceous and ossific changes in the cornea. This implication is rare, and when it occurs the bony deposit is the most common, appearing as small thin scales in tendinous cicatrices. Yet it may appear in other forms. A girl, aged fourteen, was brought to Mr. Bowman, with acute inflammation of a disorganized and rather shrunken eye, in which there was no perception of light. There was much pain and irritation with every movement of the eyelids. A bony spiculum was partly embedded in a densely opaque cornea, and partly projecting. It was readily removed with a pair of forceps. Complete relief followed.

We learn, from the rich stores of Mr. Wardrop's "Morbid Anatomy of the Eye," that he found it necessary to remove a bit of bone, which he considered to have been a partial ossification of the posterior lamina of the cornea, from the anterior chamber. He had several times also observed thin laminæ of bone discharged from the anterior chamber through ulcers in the cornea. The same author gives cases of corneal ossification of more advanced degree.

Entire ossification of the cornea is recorded by another author.

Cretaceous deposits in the cornea. These are hard and solid, made up of earthy salts with organic matter; one has been met with as

big as a lentil; or a chalk pulp consisting of earthy salts, cholesterine, and oil cells, with other organic remains. They may appear in leucomata or cicatrices of long standing, or as deposits between the laminæ. They are attended always by surrounding corneal opacity.

Bony deposits on the iris. Mr. Wardrop met with a long shell of bone on the iris. According to the pathology of the day, it was described as ossification of the capsule of the aqueous humour.

Both irides have been affected, in each there was a cone of ossific material, three lines long, connected by its apex to the capsule of the lens.

Cretaceous and bony deposits in the crystalline lens and its capsule. It is here that the most frequent changes of these natures are to be met with. Both the lens and its capsule may be affected together, or either affected singly. The anterior hemisphere of the lens is more frequently so changed than the posterior. Sometimes the capsule is transformed into a thin shell, and encloses an opaque lens. In other instances, the lens is more or less absorbed, or completely removed, so that the capsule having shrivelled before the degeneration, has a less perfect form.

A dislocated lens is very likely to become cretaceous, and this, whether it fall into the vitreous humour, or into the anterior chamber. It has been remarked when a lens enclosed in a ruptured capsule falls into the anterior chamber, and the lenticular matter has disappeared by absorption, its place seems always to become partially occupied by calcareous deposit, or by a layer of such within the capsule.

Several lenses have been extracted, which had become cretaceous in the vitreous humour, and subsequently slipped forward through the pupil.

The late Mr. Queckett, of the Royal College of Surgeons of England, examined an ossified lens for me, in which he detected the structure of true bone.

Cretaceous degeneration of the lens and its capsule is by far more common than ossification. Among the specimens which I have removed, there have been chalky materials and some remains of degenerated lens fibres, or chalky materials alone.

There is no difficulty in the diagnosis. The altered lens looks like a piece of chalk, or a bit of frosted silver.

Ossification of the ciliary body. The whole of this has been found ossified in an eye that had been atrophied from the pressure of a cancerous tumour.

Ossification of the hyaloid membrane. This has been many times observed in connection with ossification of the crystalline lens and its

capsule. Thin scales of bony matter have been seen dispersed in an irregular manner through this body.

Ossification of the vitreous humour. In Virchow's "Archiv." for 1853, p. 580, Dr. Von Wittich has published the dissection of the disorganized and shrunken eye of a man aged sixty, in which the posterior part of the vitreous body was converted into bone. The choroid was thrown into shrivelled folds, the capsule of the lens opaque, and the lens itself the subject of earthy deposition. Traces of the retina were found lying behind and surrounding the bony mass which occupied the posterior part of the vitreous humour.

Retina. This is seldom affected by the changes in question. A good specimen is in the museum of the Royal College of Surgeons of England. Large plates are formed in the inner surface. A more complete specimen is in the museum of St. Bartholomew's Hospital.

Ossific deposit between the choroidea and the retina is common. Here true bone is often found. Specimens have been exhibited at the Pathological Society of London, and many are to be seen in anatomical museums. In a case which I examined there was a cup-shaped shell of bone passing to the ciliary body, and perforated behind for the optic nerve. The lens was calcareous. The change occurs in the capillary layer of the choroidea, or as a transformation of inflammatory products derived therefrom.

Speaking in a strict histological sense, and disregarding mere external characteristics, in no other part of the eyeball, except the crystalline lens and the choroidea, has true bone been found. The so-called bone means only calcifications.

Ossification of the sclerotica is mentioned by Mr. Middlemore. Both eyes were affected.

Concretions in the optic nerve. M. Demarquay has collected some examples of this. Walther found in the left optic nerve of a maniac, just as it had passed through the optic foramen, an oval concretion two lines in diameter. Mongagni found a stone in the very centre of the nerve, of the size of a pea.

The diagnosis of all intra-ocular calcareous or ossific deposits, posterior to the lens, must rest on hardness of the eyeball.

CHAPTER XLI.

FISTULA OF THE EYEBALL.

A fistulous aperture may ensue in the front of the eye from an accidental wound, from a surgical operation, or from ulceration.

It may occur under three forms, as corneal, as sclerotic, or either of these, with prolapse of iris.

In the first the cornea alone is involved, and the fistula passes directly through this tissue and opens into the anterior chamber. I have not seen it except after the operation for extraction of cataract, and in one instance it occurred in both eyes, and lasted for some weeks, during which time the patient had clear and bright eyes. The chambers remained filled, but as soon as the eyelids were raised, and the eyeballs directed to the ground, the aqueous humour spirted out.

The usual symptoms are. oozing of the aqueous humour, and an aperture in a depression of the cornea, redness and irritability of the eye, flatness of the cornea, and partial emptiness of the anterior chamber. Escape of the aqueous humour is facilitated by examining the eye.

Treatment. Irritating the fistula. In every case which I have had to treat, touching the aperture with a fine point of nitrate of silver, has effected a cure.

The second in which the sclerotica participates. This also, like the first, I have seen only after the operation for the extraction of cataract. It occurs when the incision has been improperly carried partly through the sclerotica. The conjunctival wound heals, but there is failure in union of a part of the sclerotica, and the conjunctiva is swelled up in a little bladder with the aqueous fluid, or more extensively raised, even entirely around the cornea.

Treatment. When the natural process of repair seems to be hopeless, from the cessation of the acquired vascularity, incise the

conjunctiva, press out the fluid, cauterize the fistula, and strap up the eyelids with court plaster.

In the third form there is a fistula of the cornea, or of the sclerotica, complicated with prolapse of the iris. It is the least noticed or suspected of the fistulæ because the aqueous humour oozes out so very slowly. The escape of the iris does not make the fistula, on the contrary, the iris prolapses because the corneal wound has not healed, and very often the iris plugs the aperture sufficiently well to close it altogether. This is the rule whereby many eyes are saved from being lost through corneal opacity, or disorganizing chronic inflammation. Without the prolapse fistulæ would indeed be common. Exception occurs because the edges of the wound are too unhealthy to admit of mere mechanical plugging or cicatrization with the iris.

Treatment. The eyelids should be kept closed with plaster, so that the parts be placed in repose. The state of the system should be attended to, as deficiency of reparative power is the cause of the fistula. If these means should fail the leaking aperture should be touched with nitrate of silver. The application should be made carefully and neatly. The eyelids having been retracted by the spring wire retractor, the aqueous humour should be gently pressed out, the fistula surface wiped, and the caustic applied in a point. When a more delicate touch is needed, a probe coated with the caustic is better. The eye should then be closed with a strap of court plaster. The idea of puncturing the cornea at a spot well away from the fistulæ, so that the aqueous humour should drain out and thereby admit of a few hours repose to the fistula, has occurred to several surgeons.

This subject is necessarily touched on in the chapters on Cataract and Injuries from Mechanical Agents.

CHAPTER XLII.

DISEASES OF THE SECRETING LACRYMAL ORGANS.

INFLAMMATION OF THE GLANDULÆ CONGREGATÆ—DISEASES OF THE LACRYMAL GLAND—LACRYMAL FISTULA.

ACUTE INFLAMMATION OF THE GLANDULÆ CONGREGATÆ.

The glands are small, variable in number, and lie scattered in the sub-conjunctival tissue, about the upper margin of the superior tarsal cartilage, and the outer commissure of the eyelids.

Symptoms. The external commissure of the eyelids is much swollen, red, and very tender, and both eyelids are involved in the inflammatory action. The conjunctiva inflames, and its secretions are altered according to the severity of the inflammation. The attack is sudden, and constitutional effects appear at an early period. If now the upper eyelid be raised and partially everted, some of the acini of the glands may be seen enlarged. In from three to five days pus is formed in one or the other eyelid, close to the commissure. The affection is frequently mistaken for that of hordeolum or stye.

Treatment. It is probable that antiphlogistic local measures applied at the commencement of the attack, might cause resolution of the inflammation, but patients do not seek aid until suppuration is at hand; then, moist warm applications are required. When pus has formed, it should be evacuated by a puncture within the eyelid. This not only relieves pain, but hastens convalescence by some days.

Hypertrophy of the glandulæ congregatæ occurs. It may happen to one eye, or to both.

The symptoms are, drooping of the outer portion of the upper eyelid and protrusion of the integuments.

The treatment which I have adopted has been to remove the enlarged glands, operating within the eyelid.

DISEASES OF THE LACRYMAL GLAND.

Any affection is extremely rare, and the gland falls within the domain of practical surgery less frequently than any other ocular appendage.

A healthy lacrymal gland cannot be felt with the finger.

Acute inflammation of the gland. I have seen several cases of this. In the majority only one eye, that is one gland, has been affected; both have been diseased in the lesser number. The palpebral portion of the gland bulges the conjunctival sinus.

Symptoms. I will narrate a typical case. A well-grown and healthy lad was brought to me, three days after he had discovered something wrong, with considerable swelling and inflammation of the upper eyelid, and slight swelling and redness of the under one. There was pain in the upper and outer part of the orbit, almost constant, but not severe. A hard swelling, painful when touched, was detected in the position of the lacrymal gland. Eversion of the eyelid, so far as the swelling of it permitted, discovered depression of the sinus of the conjunctiva or retro-tarsal fold, which was thickened and of a yellowish tint, yet not very vascular, by a moveable tumour. There was slight fever, with a foul tongue.

There was nothing peculiar about the tears, no copious flow of them, as it is said always occurs. I have noticed that an inflammatory state of the gland is never first recognised in consequence of disordered gland function, but from pain which is spontaneous, or excited by touch.

There is variation in the severity of an attack. The conjunctiva may be much inflamed, and the cheek œdematous. There may be orbital cellulitis, and the eyeball may be displaced and lose its movements, according to the amount of it, and the size which the gland acquires.

The treatment consists in applying leeches and cold locally, and attending to the febrile symptoms, rest being, of course, enjoined. All the cases that have come under my notice have ended in resolution. But suppuration, it is said, sometimes occurs, in which case the pus should be evacuated. A fistula, it is also said, is more apt to form when the abscess is allowed to burst.

Sub-acute inflammation of the gland. A man forty years old came with the outer portion of each eyebrow projecting, puffy, and a little

inflamed. The finger applied to these parts detected tumours which were irregular and loose. They were, however, hard. The examination caused pain; but except when making it there was an absence of uneasiness. There was no recognisable derangement of the secreting powers of the glands. Tumefaction, the symptom by which the disease was recognised by the man himself, was observed just six weeks prior to his application at the hospital, where he sought advice, not on account of any disordered feeling, but as to the propriety of the removal of the tumours.

The treatment must be allied to that for the acute state, yet less active. In the above case, I thought it prudent to give small doses of chalk and mercury with hyoscyamus twice a day (see my usual formula with directions, p. 950), from the suspicion of syphilitic origin. In four days the mouth was a little sore, and one pill was ordered on alternate days. The man did not return for three weeks. He had taken eight pills. The puffiness of the eyebrows was gone, and the glands could be only just felt. The pill was continued on alternate days. A fortnight later there was not any trace of disease. Just before this patient came to me, I had a case in private practice, almost parallel, differing only in being more chronic.

As to the cause of the affection, it is not known that any one thing in particular induces it. At the same time when it is symmetrical, the origin must be constitutional.

Suppuration is often spoken of as a termination of the inflammation, whether acute or otherwise. I have never seen it, nor do I know of a well-authenticated case. Without denying the possibility of the occurrence, I suspect that suppuration in the eyelid over the region of the gland, from local injury, has been described as such.

Chronic enlargement of the lacrymal gland. This is usually called hypertrophy.

Symptoms. A tumour in the situation of the gland, protruding the eye, and thrusting it into a position according to the form and degree of its enlargement. Yet it is evident that this is not unequivocal, for any other tumour may show the same signs, and the removal of several has been undertaken under the erroneous idea of an enlarged lacrymal gland being the existing disease.

There may, or may not, be subjective symptoms. Pain or inconvenience of some kind is usually present; yet these may be produced by a tumour contiguous to, or developed in the gland. Preternatural lacrymation, an early attendant on a tumour in the situation of the gland, together with a lobulated surface of the tumour, seems to be the most probable diagnostic; but both may be absent, and lobulation is not uncommon to adventitious growths.

The pressure of the enlarged gland on the levator palpebræ superioris muscle, may cause early loss of power of contraction, so that the eyelid hangs as it were paralyzed over the protruded eyeball. Besides this, when the eyeball is much protruded, the eyelid is œdematous and traversed by enlarged blood-vessels.

The affection generally occurs in young adults.

In one of my cases there was no subjective symptom. The objective symptoms were, protrusion of the eyeball, inability to turn it fully outwards, and a small hard, distinctly lobulated tumour in the position of the gland, partly exposed to touch, and partly hidden under the orbital edge.

Sir William Lawrence attended a gentleman twenty-seven years old, whose gland had enlarged five years previously. With the increasing displacement of the eyeball, vision became impaired. Sir William removed the gland; it was as big as a walnut, slightly tuberculated on the surface, of a light yellowish brown colour, which indeed is the natural colour of the gland, and firm. It was connected loosely by areolar tissue to the parts around, a circumstance indicative of the absence of malignity. The wound united by the first intention, and vision returned. The eye was not deficient in moisture.

Report of a tumour in the orbit, in connection with the lacrymal gland, is given by Mr. Savory, in "The Medical Times and Gazette" for February 21, 1857.

The subject was a man seventy-eight years of age. It was just two years and a half from the first symptoms, inflammation of the conjunctiva with chemosis, till the tumour protruded from the orbit as a mass of the size of an egg, and concealed the eyeball, except a small portion of the cornea, which was opaque. Death ensued. There was a strong suspicion of malignity.

Post-mortem examination. The brain and all the structures in the immediate vicinity of the orbit were healthy. The eyelids and the conjunctiva, which was thickened, were easily dissected off the point of the tumour. Nearly in the centre of the mass, the shrunken and flaccid eyeball was imbedded. It and the optic nerve were easily separated; the latter was considerably elongated. The muscles could be traced. No portion of the lacrymal gland could be distinguished. The tumour was of an uniform structure throughout; soft, somewhat elastic, easily torn with the needle, and the separated portions readily broke up and mingled with water. When the cut surface was scraped, a thick, white, opaque fluid appeared. It was composed entirely of gland cells and nuclei. Several portions of it were examined, and exhibited little else than clusters of gland cells, which were broken up at once by the gentlest manipulation. They

were remarkably uniform in size and shape. It was very difficult to distinguish anything like a lobular arrangement, and scarcely a trace of connective tissue could be discerned. It measured three inches in length, and two inches in breadth and depth.

Cause. We are somewhat ignorant on this point. From an analysis of the cases which I have collected, it seems that blows and injuries inflicted in the neighbourhood of the gland, usually bear the blame.

An instance of congenital hypertrophy has been met with.

As a point connected with diagnosis, it may be mentioned that a healthy lacrymal gland which is pushed forward along with the eyeball because of an intra-orbital growth, is soft, without definite outline, and does not feel lobulated, indeed it is scarcely to be recognised if the eyelid be swollen. Again, as I have said, it is possible for a tumour in the situation of the gland, to be mistaken for a diseased gland.

Double vision may trouble a patient at an early period, or may never exist.

Dimness of sight may occur early, but, notwithstanding all the stretching of the optic nerve, and the pressure on the eyeball, sight is usually retained, unless it be destroyed by ophthalmitis arising from constant exposure of the cornea, or corneal ulceration and penetration from the same.

The morbid changes in the gland have not been correctly described. In the collected specimens the external characteristics only are given. Of the two preparations at St. Batholomew's Hospital, both having been removed in life, one is oval, an inch long, and over an inch broad. It retains its lobular form and glandular appearance. The enlargement had been going on for several years.

In a case by Mr. Pemberton, in the "Dublin Journal" for 1847, the eyeball was quite concealed by an enlarged gland of ten years' standing, but not protruded. The gland was removed; it was as big as "an orange."

In Mr. Travers' work a case is mentioned in which the gland is said to have been greatly enlarged, and in a scirrhous state. The patient from whom it was removed continued well after the interval of some years.

In one of Mr. Todd's cases in the "Dublin Hospital Reports," the gland, almost as firm as cartilage but more elastic, had lobes with deep fissures between them, and contained cartilaginous cysts filled with glairy fluid, the interspaces containing a firm fatty substance, traversed by a few membranous bands. In Dr. O'Beirne's case, in the same Reports, the gland surface was granular, of a pink colour,

and the interior of the gland presented a cartilaginous centre, from which septa passed to the circumference.

Particulars of many other cases are published, but the majority of them are recorded in such a manner as to render them useless so far as pathology is concerned.

Cancer of the lacrymal gland. According to some writers, scirrhus of the lacrymal gland is not unfrequent. I have never seen a case of it. There cannot be a doubt that the term scirrhus as used in a cancerous sense, has been too indiscriminately applied to mere enlargement of the gland, and this is in keeping with the heretofore general latitude of expression, and looseness of description, concerning the supposed cancerous deposits in other parts of the body. The large size to which the gland attains, the absence of ulceration, of adhesion to the surrounding parts, of disease of the neighbouring lymphatics, and of constitutional cachexia, and, finally, the invariable success which attends its extirpation, are characters which are unknown in connection with scirrhus in any other situation, but which are universally recognised as features in the chronic inflammatory induration and hypertrophy of other glandular organs. I by no means intend to assert that scirrhus never occurs, or that there is anything in the structure of the lacrymal gland which should exempt it from liability to scirrhous infiltration. We have the authority of Dr. Mackenzie, Mr. Dalrymple, and other competent observers, for believing in its existence; and their descriptions lead us to suppose that the stage of induration is, as in other situations, succeeded by softening and ulceration, which involve the surrounding textures.

The symptoms of scirrhus are represented as being the same as those which indicate enlargement of the gland of a non-malignant nature; but the pain is said to be much more severe, and of a lancinating character. I am not aware of any means by which the cancerous nature could be ascertained, previous to the occurrence of softening and ulceration.

For cysts of the lacrymal gland, dacryops, see the chapter on Tumours, p. 149.

Treatment. Extirpation of the hypertrophied gland is the remedy when the enlargement is in any way detrimental. I have never seen constitutional treatment avail anything.

The method of operating is to make an incision parallel to the edge of the orbit directly over the gland, and to cut through the integuments and the fibrous layer of the upper eyelid. The gland having been well exposed, should be insulated as much as possible with the scalpel. It might be better sometimes, especially when the

gland is very large, to tear through the alveolar connections with a pointed instrument, such as a strong probe, and the finger, rather than to cut them, so as to avoid damaging the surrounding parts. It is a necessary precaution to proceed slowly and to endeavour carefully to ascertain the limit of the tumour, and to confine the dissection to it; for if an adventitious growth only be present, and it touch or be attached to the gland, the latter may be saved; otherwise, through carelessness, it might be injured or actually removed. I have seen the gland sacrificed more than once, and Mr. Tyrrell mentions having witnessed the removal of the healthy gland together with a steatomatous tumour. The rules laid down respecting the removal of orbital tumours in general, in the chapter on Tumours, apply here also, and need not be repeated. As a last step the gland should be drawn well forwards either by the fingers or a pair of forceps, and the remaining adhesions divided. The bleeding should be stopped by pressure, and the wound brought together by sutures, and the parts supported by compress.

It may be necessary to make the incision from the root of the nose to the temple, and to supplement it by another carried obliquely outwards across the forehead. Even a third may be required in another direction. When it is possible that one incision will suffice, only one ought to be made, but there should be no hesitation in making several in any direction, when the size of the gland may seem to demand such to facilitate the operation. If the eyeball be destroyed, its remains had better be extirpated. The same after-treatment which is necessary subsequent to the removal of tumours from the orbit is requisite here.

The eyeball retracts more or less into the orbit immediately after, and if the levator palpebræ be sound the patient may be able to open and shut the eye. The wound may unite at once. Orbital cellulitis, more or less severe, may come on and cause the eyeball to be again protruded, and a considerable quantity of pus may escape from the wound.

Weeks or months may pass away before vision, which has been lost from pressure on the eyeball, is restored, or the ocular protrusion is quite lost.

EXTIRPATION OF THE LACRYMAL GLAND.

Extirpation of a healthy lacrymal gland may be required when the natural channels that convey away the tears are no longer available.

Operation. An incision made in the eyelid, corresponding to the margin of the orbit and opposite the centre of the orbital ridge,

sufficiently external to avoid the frontal nerve, and ending a little below the superior external orbital angle, will afford ample room for the operation. The fibres of the orbicularis muscle, and the fascia beneath it being divided, a portion of the gland comes into view. It will be remembered that the gland possesses two lobes. The one, which may be called orbital, is nearly three-quarters of an inch long, is in relation above to the lacrymal fossa of the frontal bone, and below to the upper and outer part of the eyeball, and the superior and external recti muscles, and receives its vessels and nerves behind; the other, a palpebral portion, is smaller, seated on the eyelid, reaches as far as the tarsal cartilage, and has a sort of capsule. If after the dissection be made the orbital portion be drawn forwards with the tenaculum forceps, the removal of it is as easily effected as that of the smaller division, which is in front.

The annexed diagram of the eye, Fig. 286, with the position of the gland traced in a dotted line, may be useful.

Fig. 286.

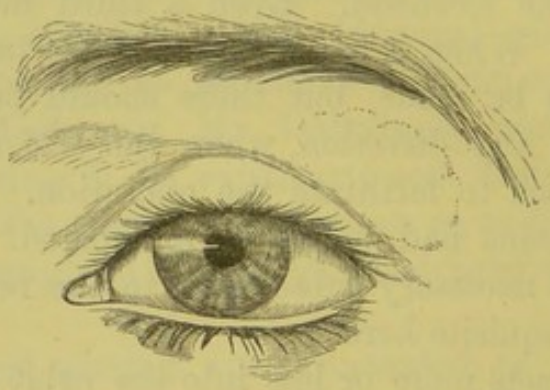

The lesser or palpebral portion of the gland may be overlooked and left behind during the operation.

The condition of the eye after the loss of the gland has been briefly noticed at p. 557. Although there can be no secretion of tears, the conjunctiva retains its usual brilliancy and moisture, proving that it secretes its own proper fluid, and that the humidity of the eye is not, as some have supposed, alone dependent on the secretion of the lacrymal gland.

Dr. Halpin, desirous, as he informs us in the "Dublin Journal of Medical Science," of ascertaining whether tears could flow from an eye deprived of its lacrymal gland, dipped the blunt end of a probe into tincture of opium, and touched the conjunctiva with it. Immediately the right eye, the sound one, became suffused with tears, which flowed over the cheek. In thirty seconds the probe

was re-applied. After sixty seconds a drop of fluid fell from the left eye. In thirty seconds more, another drop.

Weeping must certainly be taken as the most conclusive proof that a lacrymal gland yet remains; but increased conjunctival secretion must not be mistaken for tears.

Lacrymal fistula. This consists of an external opening communicating with the lacrymal gland, or with one of its ducts.

The symptoms are these: An aperture, usually very fine, in the outer portion of the upper eyelid, and through which there sometimes flow tears, or tears with pus. A minute probe can be passed for a short distance in the direction of the lacrymal gland. It does not come into contact with bone, which would be the case if the fistula were in association with necrosis.

The causes of the fistula, given in their order of frequency, are, abscess of the eyelid, especially when there has been sloughing of the integuments. Suppuration of the gland ducts. Wounds involving the lacrymal gland, or its ducts, accidentally inflicted, or during operations for the removal of tumours, and the removal of cystic tumours in supposed connection with the gland ducts.

Treatment. Fistulæ connected with glands of this class are often difficult to cure, and may resist all attempts at removal. Success has followed cauterizing with nitrate of silver through the medium of a probe coated with it; also cauterization with hot wire; also dissecting off the edges of the fistula and closing the wound by sutures. A result is more likely to be obtained if provision be made for escape of the tears internally. A case in which this was done by Mr. Bowman has many features of interest in connection with the present question. A woman, aged twenty-seven, went to him at the hospital on account of a troublesome trickling of tears from a small hole in the skin of the upper eyelid. Her mother had taken her there when she was nine years old with a swelling in the eyelid that was lanced, and from which was removed a hard body, resembling in form a plum stone. A fistula ensued. "A single thread of silk was armed with a needle at each end, and one of the needles was introduced into the fistulous orifice in the skin on the outer surface of the eyelid, and carried for a short distance upwards; it was then made to pierce the fibro-cartilage of the lid and the conjunctiva, and the thread was drawn out at the inner surface of the lid. A similar manœuvre was repeated with the other needle, and the thread was drawn out at the inner surface of the lid at the distance of a quarter of an inch from the first, and a little nearer the attached border of the lid. In this way this cyst was pierced at two points by the thread which encircled in a loop the small intervening portion of tissue. The two ends of

the thread were then brought out at the inner commissure, and secured upon the temple with a piece of sticking plaster." Tears continued to flow from the orifice in the skin, but less abundantly.

Ten days afterwards the thread was replaced by a thicker one, which produced more irritation. The aperture in the skin was cut out with a pair of scissors, and the wound brought together with two *serres fines*, which were replaced in the evening by strips of plaster; in four days the wound had quite healed, and the fistula was removed. The thread was now withdrawn, and a small bridge of tissue, which had been encircled by the loop, cut out. The opening thereby made continued patent. "Royal London Ophthalmic Hospital Reports."

MORBID TEARS.

It is well known that tears are an irritating secretion. The conjunctiva is always reddened by them, and instantaneously; they often cause excoriation of the skin of the cheek, especially in scrofulous children who are suffering from corneal or conjunctival diseases.

The very marked effect which is sometimes produced on the skin, has been the cause of supposed acquired chemical properties of the tears by which they have become unusually acid, but this has not been proved. In a case which produced some excitement at Glasgow, it was discovered that the deep lines of excoriation which ran down the cheeks of the child, were not the result of the tears but of a criminal application of sulphuric acid by the mother.

Bloody lacrymation, or hæmorrhage of the lacrymal gland. According to Dr. Mackenzie, several authors have recorded cases in which blood flowed from the eyes like tears, or was discharged from the lacrymal gland, even in such quantity as proved dangerous to life. Also that Professor Rosas witnessed a disease of this sort in a child of nine years of age, of scrofulous diathesis, and in whom it yielded to anti-scrofulous treatment. The learned doctor remarks that in all these cases, however, it is doubtful how far the discharge of blood was really from the lacrymal gland, and not from the conjunctiva.

Yellow tears have been met with, it is written, in persons severely affected with jaundice.

CHAPTER XLIII.

ENTOPTICS.

MUSCÆ VOLITANTES—MYODESOPIA SENSITIVA, OR PHYSIOLOGICAL MUSCÆ.

Symptoms. The perception at a short distance from the eyes of numerous shadows like dark specks, or like little flies or irregular-shaped filaments, which float in different planes over the field of vision. Muscæ volitantes.

There is the invariable characteristic of mobility in these perceptions, for by no effort of will can they be kept fixed in a position opposite to any object, and in this lies the chief subjective difference between them and blind spots of the retina or scotomata, which can be fixed. It must be remembered that, in making these experiments, in directing the eyeball to the top of any high object, there is a natural and very strong tendency for it to drop, in which act a blind spot would drop also. Any movement of the eye sends them at once in various directions. They may shoot across the general field of vision, or stop short in the centre of it; the range of direct vision; and if the eye now be kept still, some of them will sink and disappear, while others are yet perceptible. Although in different individuals they pursue different courses, when the eyes are moved, in each there is a fixed transit.

The farther a musca volitans is away from the centre of the visual field, the less can it be steadied for inspection.

Their colour varies. Even in different parts of the same perception, the colour may differ.

They are noticed, chiefly temporarily, by most persons, especially when such persons are subject to circumstances favourable to their production. But they prevail usually after the meridian of life.

Myopic and hypermetropic eyes are most prone to them, and in frequency and severity, according to the degrees of these anomalies of refraction.

Cause. They are due to the abnormal perception of objects on or within the eye, and the presence of which can be established only by entoptical methods of investigation. They must not be nosologically confounded with pathological muscæ, that form of visual impressions of a like nature which are due to pathological changes in the vitreous body, chiefly of a hemorrhagic or inflammatory exudative character, and admitting of detection with the ophthalmoscope. Those will be spoken of afterwards.

The terms myodesopia sensitiva, and insensitiva, have been introduced to represent respectively physiological muscæ and scotomata. In ordinary speaking, I say muscæ merely, when I mean the former.

For a thorough entoptic investigation of this optical phenomenon we are indebted to our countryman, Dr. Jago, of Truro. His skilful, philosophic, most laborious, and accurate researches have given us an approximative solution of a very difficult problem, and prove, beyond those of any other man, that muscæ are due to bodies on and within the eyeball. His work on entoptics stands alone and unrivalled. It is a masterpiece of original scientific literature, to which those must resort who wish to embrace this subject in all its bearings. But the names of Mackenzie and Sir D. Brewster, as others among our own people—successful workers in this field—must not be omitted. To the former we owe much respecting original research in the clinical part of the subject. Indeed, to his clinical facts little has been added. I shall avail myself largely of them.

An analysis of muscæ shows that they comprise sensations which arise—

1st. From the layers of mucus and tears on the surface of the cornea, &c.

2nd. Corpuscles, or bodies of some kind, between the external surface of the cornea and the focal centre of the eye.

3rd. Corpuscles, &c., between the focal centre of the eye and the sensitive layer of the retina.

1st. *Muco-lacrymal muscæ.*

These are apparitions produced by mucus, or tears, or fat globules and bubbles of air moving over the cornea.

According to Dr. Mackenzie's experiments, if a normal or a presbyopic eye look through a two-and-a-half inch focus, concave or negative lens, toward the flame of a candle placed at the distance of about twenty feet, a circular luminous figure appears, dotted all over

with minute round spots, and bounded by a finely-indented edge. The edge is that of the pupil greatly magnified; and the spots are images of the candle multiplied by the layer of fluid lying on the surface of the cornea, which consists of globules. The spectrum is inverted in this way of viewing it. The globules at the upper end of the cornea are seen below, and *vice versâ*. They are seen to run together occasionally, so as to form larger spots; and then to separate as we wink, into smaller ones. On closing the eye, the upper eyelid, with its cilia, is seen as if rising from the lower part of the field of view; and the globules, after each act of winking, appear as if they floated down over the cornea. The fluid which gives rise to this appearance is a mixture of tears with the mucous secretion of the conjunctiva, lying on the surface of the cornea in the form of minute drops, and exercising the function of preserving that surface in a moist and transparent state, fit for the easy transmission of the rays of light. Invisible, in general, to the naked eye, it is, in this simple experiment, rendered visible, by directing through it a small pencil of divergent light, each globule acting on the light which falls upon it, along with the refraction of the transparent media of the eye, so as to converge it sufficiently to bring it to a focus on the retina.

This is farther explained by the following passage from Dr. Jago. Since greater refractions occur at the eye surface than within it, slight inequalities there might be expected to betray themselves to our observation; yet the lubricating fluids are frequently so equally diffused over the conjunctiva that our pencils almost fail to disclose them; but, with fitting examples present, we may see with divergent rays both illuminated and opaque pictures of drops of fluid, a contrariety announcing a difference in form, both drops being transparent, with the effect that the former are elevated and the latter depressed in the middle. Thus the convex tier, the more frequent kind, brightens its image and gives shade to its areola, by abstracting from the divergency of the rays that penetrate it; whilst in the other case the areola is brightened at the expense of the image. When these drops are immersed in a convergent pencil of light the illuminated image becomes dark, and the darkened image bright; the convex tier, by increasing the convergency of the rays that pass through it, causes them to diverge sooner than the mass of rays; whilst in the other case they do not meet so early. These muscæ are seldom troublesome, unless in eyes in which the cornea is unusually and habitually covered with mucous globules, and then they appear as small round spots on the surface of the eye, surrounded by a little halo. Some are separate, some run together in spots and then dis-

appear, and a wink always takes them away or changes their positions. They appear most by artificial light. Sometimes they affect observers with the microscope, and particularly the telescope, to such an extent as almost to impede vision, or to prove a source of annoyance. These symptoms are quite different from those of the following variety.

Apparitions caused by eyelashes, and the edges of the eyelids, are not sources of complaint by patients.

2nd. *Muscæ depending upon corpuscles between the external surface and the focal centre of the eye.*

There are no trustworthy observations on record of impressions depending upon corpuscles, &c., floating in the aqueous humour.

Depositions in the cornea, or in the crystalline lens, are readily perceived by the individual himself, if he look through a hole made with the point of a needle in a blackened card. They may also be seen by the same means which enable us to see the muco-lacrymal muscæ. They are recognised from them by being in a plane posterior in the field of vision; by the double images formed of them, when exposing the eye to two divergent beams of light, being less separated from one another than the double images of the muco-lacrymal spectrum; and by their not moving in the act of winking. From corpuscles in the vitreous humour they are distinguished by their occupying an anterior plane in the field of vision; by their double images being more widely separated; and by the possibility of readily inverting their spectrum by the same means by which we invert that of the globules on the cornea.

All objects anterior to the focal centre of the eye are seen inverted through a double concave lens. To see them in their natural position it is sufficient to view a candle at twenty feet distance, through a double convex lens of one-and-a-half inch focus placed close to the eye. If we carry such a lens forward from the eye, so that the cornea is no longer within the focal distance of the lens, all objects on or in the cornea, in the aqueous humour or in the crystalline, are instantly inverted. But such depositions never produce the sensation of muscæ, but merely indistinctness of vision, as when a pin is placed close in front of the cornea. But it must be remarked that small and few depositions anterior to the focal centre of the eye, which is generally regarded as close behind the crystalline lens, will not be visible to the person in whose eye they exist, and will have little effect on the distinctness of vision, because of the slight mistiness or shadow which is thrown over the retina.

They may be visible to an eye affected with a high degree o

myopia. They may be very troublesome to observers using scientific instruments.

Dr. Jago has discovered in the crystalline lenses of his own eyes certain corpuscles. In the left eye they are scattered through the surface of the lens. The right lens is freer from them, but it has several larger objects near its posterior surface. Also in both lenses a few disks of a higher refracting power than the general surface of the lenses.

Donders says, for observing the spectrum of the crystalline lens, homocentric light and a very small opening are necessary. We find here in the visual field these objects. *Pearl spots*, tolerably round disks with accurately circumscribed darker margins, but brighter internally, nearly universally occurring in either eye. Some are situated close to the surface of the lens, eccentrically placed, and therefore appearing only when the pupil is artificially dilated. They are microscopically visible as large globules among the superficial fibres of the lens. These increase with age. *Black, or rather opaque, spots*, less common than the first. Microscopically they are superficial, white, granular, opaque corpuscles, almost always in the boundaries of the sectors of the lens. *A radiated figure*, more or less regular, with ramifications proceeding from about the centre. This is connected with the composition of the lens of the so-called sectors, which can be seen with lateral focal illumination, and a convex lens in the living eye, and of which I have spoken in the chapter on Cataract. All these irregularities of the lens increase with the time of life, and partly explain the diminished acuteness of vision in age.

3rd. *Muscæ volitantes depending on spectra between the focal centre of the eye and the sensitive layer of the retina, or entohyaloid muscæ. Called also spectrum of the vitreous body.* Dr. Mackenzie, who suffered much from muscæ (and it is only those who are so troubled that are fitted to speak with descriptive authority on the matter), gives this account. It tolerably agrees with the observations of other men.

Four different kinds of entohyaloid spectra, with fixed relative positions, produce these muscæ. If any one looks at the flame of a candle two or three feet from his eye, or at the sky, through a hole made in a blackened card with the point of a fine needle, or through a convex lens of a short focus, four sets of spectra may be observed, independent of the muco-lacrymal spectrum. The pearly spectrum, the most remarkable, appears nearest to the eye, and consists of twisted strings of minute pearly globules hung across the field of vision. The watery spectrum, the second in point of remarkableness, and the farthest of the four from the eye, consists of watery-like

threads, destitute of any globular appearance, and hanging chiefly from the upper part of the field of vision. Insulo-globular spectra, float between the above in two sets, not being aggregated into threads but insulated. The individual globules of the set farthest from the eye, hazy and ill-defined, are like small grains of boiled sago. The individual globules of the set nearest to the eye, are clear in their centre, outside which there is a sharp black ring, and beyond this a clear circumference.

The sensation produced by these spectra under ordinary conditions, when the eye is not examined entoptically, constitutes muscæ, the details of which I must next discuss, after the remark that some slight variations in form will be seen between some of the spectra and their muscæ, just as these may be noticed in the muscæ when they are examined in various ways and in different lights.

A. *Pearly muscæ.* These are the commonest. A minute dark body or bodies may dangle in the air, causing the idea of a bit or bits of soot, being adherent to the eyelashes, or the hat, until an attempt to remove it or them dispels the doubt. Or there may be instead a thin cloud like the wing of a fly. Or even semi-transparent threads like a spider's web. An examination of any of these against a clear sky gives rather the appearance of globules, minute rings, or a tortuous tube bounded by two wavy lines while the centre is occupied by spots or globules, some quite filling it, while others do not, some being nucleated, like the withered substance within the cavity of a quill. Sometimes a few globules of the insulo-globular muscæ seem to be attached to the outside of the tube. The tubes may seem to end in bulbous extremities formed of globules. These muscæ, while they ascend or descend, are seldom in the axis of vision, but eccentric to it, outwards or inwards, upwards or downwards, and a patient finds difficulty in seeing them according to their peripheral position, because they flit away, there being added to their own motion the movements of the eyeball. They have some degree of lateral motion, and undergo changes in the relative positions of their several parts. The end of one musca will sometimes bend in one direction, sometimes in another. One day a dotted tube will be straight, and on another curled. This originated the name muscæ volitantes.

The pearly muscæ are most observed when a clear sky, a thin light cloud, a snow field, a white wall, or water are looked at. They are seldom seen when the interior of the eyeball is feebly illuminated, hence they do not appear by weak artificial light, in weak daylight, or when a black object is in the field of vision. Their spectrum may always be detected by entoptic examination.

B. *Watery muscæ.* These are not observed until they are much exaggerated. They are described as a zigzag figure resembling threads of spun glass, without globules, laid across each other, or a fine lock of wool, above the centre of the field of vision, being rarely observed at the lower part of it. Forcible winking causes them to disappear for a time. This is hard to be explained, since winking does not affect their spectrum.

C. *Insulo-globular muscæ.* These are in two plains. The most anterior are ill-defined globules, lying immediately behind the watery muscæ. They rarely produce the sensation of muscæ. The posterior layer consists of globules sharply defined with black edges. They usually appear as simple black points, or black rings, are readily brought into the field of vision, and often disappear quickly when steadily looked at.

These distinct varieties may all exist at the same time, and be equally well marked. When only one set is visible, or preponderates, it is invariably the pearly variety.

What are the entoptic bodies which produce the muscæ, and how are their motions to be accounted for? Dr. Jago has helped us more to answer these questions than any other man. He appeals to the structure of the vitreous body for the answers. He gives a sketch of the anatomy of it, laying stress on the arrangement of the hyaloid membrane, and its partitioning of the body, and concludes by saying these compartments are filled with fluids of graduated density in such order, that the densest lie next the capsule of the lens, and the rarest next the retina; so that the vitreous body is, in all probability, a compound optical instrument, whose anterior constituents excel the posterior in refractive power.

First, as to the motions of the muscæ. He shows that when the eyeball rotates, the fluid within it will relatively rotate. No matter about what axis the rotation ensues, whether about one through the eyeball's centre by turning in its orbit, or about any other by the movement of the head, or of the body, the vitreous fluid will strive to abide absolutely at rest; or, translation of the orbit apart, to rotate within its cavity, through the same angle. But in consequence of the obstructions from the web, if not from some friction between the fluid and the parietes of the cavity, the latter must ultimately concur in the rotation. And as to the objects visible in the fluid, their connections must exercise control over their movements. Thus we have a modified result, or, upon the whole, the objects in the vitreous will travel in the direction of the rotation, but will start from their places at later respective instants than the beginning of that act; and will then go equally with the rate of rotation. And

when the ocular rotation is arrested, they will continue theirs a while longer, through the inertia of the now rotating fluid, until the fluid ceases to move, or until they reach the ends of their tethers; when, after a momentary pause, they tend to regain their original sites, as if by retraction, or the web's elasticity. Independently of these connections, rotation of the fluid in its vessel would cause the objects nearest the wall to journey through the greatest linear spaces, and the others gradually through less, until at the centre of the entire chamber they would remain at rest.

He adds, though these principles are found on trial to be generally agreeable with the movements of the bodies visible in the vitreous, yet we discover that their operation is disturbed by the influence of a force causing movements solely in the vertical direction *at the instant*, whatever part of the eye's circumference happens to be then uppermost; and which must, therefore, proceed from a difference in specific gravity of some of the contents of the vessel.

He further shows that the entoptic bodies must be immediately or mediately tied to the parietes of the cavity.

The seeming falling of the muscæ is shown to be no effect of gravitation of globules in liquefied cells of the vitreous body, but the result of the recovery of that body to its original form, after having undergone rotation, and which recovery is brought about through the connections of the hyaloid membrane, the tissue which furnishes the spectra for the muscæ, each spectrum having a home in the body, to which, after each disturbance, it finally retires. There is nothing, then, like free motion in the body. A musca has little or no motion till it is set in action by the movements of the eyeball, and when started it moves quicker than when returning to rest.

Just a word as to the relation of the movements between the spectra and the muscæ. Where the spectra are anterior to the focal centre of the eye, the real motion of them corresponds to the apparent motion of the muscæ, that is, when they descend in rotation, the muscæ seem to descend. If they be situated behind the focal centre, and perhaps all entohyaloid spectra are there, while they descend, the muscæ appear to ascend.

He next examines the size of the spectra which produce the muscæ, shows their approximation in breadth, the measurements being from $\frac{1}{840}$ to $\frac{1}{1060}$ of an inch, and continues with these remarks:—If we now single out, with a divergent pencil, one of the smallest images, or a bead nearest the sentient points of the retina, and move the eye about gently, we can note that it accompanies the movement, while others nearer it, with broader shadows, pass over it and swim about. If the eye rotate through a very small angle, it does the

same, though the others remain at rest, not *yet* having been set in motion. When the eyeball rotates sufficiently to cause the mass of globules less near the retina to appear to move, they will proceed, that is continue in motion, even after the eyeball has ceased to move, and regain their places by apparent retraction; whereas the object which we are especially watching moves, if not exactly, all but exactly, with the eyeball, and stops with it. Again, if we turn in succession to objects at different depths in the vitreous body, we observe that their several excursions from positions of rest, consequent upon ocular movement, are in accordance with what we should expect from objects tied together, as imagined, under the dynamical influences actually in play. In so far that, although we might never be able to divine how the seemingly solitary globules are retained in their relative places, we might be sure that they are parts of a system.

Secondly, as to the nature of the entoptic bodies producing the muscæ, Dr. Jago shows, I think, conclusively, that they are but fringes or processes of the areolar network of the fibrous hyaloid membrane, the sensations being an accident of the essential structure of all human eyes. He points to the manner in which the filaments and heads, and broken ranks of sundered black patches are produced, and concludes in these words:—

"But it may be better to speak directly of what I find in my own eyes. I have, then, quite familiarized myself with the webs, having a systematic but no other similarity to each other in my two eyes. I can at once locate in the tissue any thread that comes into view, and any globule that tumbles into sight I can restore to its place among the meshes of the web with facility. Again and again I have succeeded in stretching a host of seemingly disseminated beads into a tuft of neat fibres. And a number of them scattered separately among the meshes I have been able to distinctly assign to one or more crumpled fibres twined in among the rest. And if I have been occasionally unable to get a continuous inspection of certain fibres confined by others I have dotted out their course satisfactorily by the line which the projected beads indicate. Whenever I have been able to cast a swarm of plain circular images tolerably free from coincident projections, I have not failed to discover that they are constituents of fibres. In all the examples of the anterior portion of the vitreous that fall within the reach of our convergent pencil, it is quite obvious that there is not a stray bead, and that all the fibres are series of beads. There is an instance in which I have been a little puzzled to resolve fibres into beads; it is that of two parallel vertical nearly contiguous ones in my right eye lying

view by turning the head to the left, parallel lines, as if the image of a cylindrical refracting body, appear. By a strong rotation of the eye, however, both fibres exhibit themselves, twisting gently round each other like the threads of a rope which is broken up into equal fragments by the vanishing of all coils having a certain direction. The beads then reveal themselves. They can also be discerned, without this device, by a lucky placing of the source of a divergent pencil. Besides, these threads are only two among a number which form a sheet of net-work thereabouts, which lies in the path of the incident rays of light and dispenses them.

"Nevertheless, as in the immense multitude of beads, I do fall in with some so involved among fibres, or so widely away from the axis of vision, as scarcely to afford an opportunity for the establishment of their being items in a series, and a small group of beads, the nearest to the most sensible portion of the retina, where no contiguous ones are apparent, but which may be presumed to be merely displaying unusually strong images in a position where ordinary ones are not discernible; and these are plainly held in their relative places in the fluid by some means or other. So that, from all these observations, I feel all but absolutely certain that every bead forms a link in a fibre, and certain that there are no *loose* threads in the vitreous."

For the several methods of illuminating the eyeball with divergent pencils of light, to make careful and detailed entoptic investigations, I must refer my readers to Drs. Mackenzie's and Jago's works.

Prevalence of muscæ. These sensations rarely affect a normal eye. But they are often present in association with myopia and hypermetropia, their amount being in proportion to the degrees of these anomalies of refraction. They may remain stationary for many years, or increase but very slowly, or even decrease.

Exciting causes which occasion muscæ to be noticed, and make them often slight impediments to sight. Any long-continued and repeated fatigue of accommodation from use of the eyes, whether on minute, or other work, with or without optical appliances, especially by artificial light, may bring them into notice in any eye, and the quicker in abnormal eyes.

Whenever the brain is debilitated or exhausted from mental emotion or labour, or so affected by bodily ailments or diseases, muscæ are apt to be complained of. If muscæ have existed prior to such debility or exhaustion, either of these states will render them more intense, temporarily or permanently.

A patient will tell me that his muscæ may always be seen if he seeks for them against a clear sky, or through a pin-hole in a card,

but they do not as a rule intrude themselves on his notice, unless he has over-worked his eyes or his body, or has been guilty of some excess, when they sail before him slowly, no longer as usual flitting away when the eyes move, and sometimes obscure any small object which he may look at, especially print. Another will tell me that he judges of his general health by the prevalence, or otherwise, of his muscæ. When they are absent, he is well. When they are abundant, he knows he is not fit for anything.

Association of muscæ with ocular diseases. Muscæ are usually present in every diseased condition of the retina and choroidea, from simple hyperæmia, to more or less disorganization.

They are never absent in any form of ophthalmitis. Cataract seldom forms without their accompaniment, and a usual complaint after cataract is removed, embodies remarks about their existence, size, number, and blackness.

According to my observation the sudden development of muscæ, or the marked increase of muscæ of long standing, sufficient to be troublesome, is an indication of the eyeball being affected in its sentient, or vascular system.

It is a point yet to be determined, how it is that the physiological condition of the vitreous humour is made a source of such morbid subjective phenomena, as muscæ.

Treatment. When a patient applies to me with muscæ, I shape my course in this wise. If he see only occasionally a few muco-lacrymal muscæ, I tell him the nature of them and my inability to remove them. If he see them in excess, I shall in all probability find preternatural conjunctival secretion, the mitigation of which I undertake. If the entohyaloid muscæ be the subject of his complaint, and I ascertain that they are few, such as might be occasionally seen by any one, or are usually present in eyes affected with errors of refraction, that the vision is acute, or good for the time of life, or has not undergone recent deterioration, that the fundus of the eye is normal, I try to subdue his fear, assuring him of nothing being wrong, and promising that he is not likely to have an increase of the muscæ, although those which exist may never leave him. If, however, his muscæ be unnaturally present, I know that there must be an exciting cause, directly in the eye, or indirectly somewhere in the body, and affecting the eye secondarily. My attention is then directed to subdue such cause.

Muscæ of delirium tremens and fevers, like dreams, the result of efforts by a suffering brain, to realize impressions, made

Pathological muscæ, the effects of hæmorrhages, and of exudation in the aqueous humour and the vitreous body, and recognisable with the ophthalmoscope, are always associated with visible injury to the eyeball, or inflammatory states of it. They do not follow certain types of it like the entohyaloid muscæ, nor fall into definite positions. The inflammatory exudations in the vitreous body are best seen when the body has cleared, or nearly cleared, after any partial or general opacity, and liquefaction of it has occurred. A movement of the eyeball sends little objects flying in all directions. I suspect that much of the so-called exudation consists of opaque and broken-up hyaloid membrane.

CHAPTER XLIV.

SYPHILITIC DISEASES OF THE EYE.

ORBIT—EYELIDS—CONJUNCTIVA—CRANIAL NERVES SUPPLYING THE EYE AND ITS APPENDAGES—CONGENITAL SYPHILIS—OPTIC NERVE—RETINA—CHOROIDEA.

ORBIT.

Periorbitis, from syphilitic nodes. For a notice of periorbitis, I beg to refer my reader to the chapter on Diseases of the Orbit, p. 50.

I have there spoken of a syphilitic origin.

My own experience in this direction is small. From a practical point of view we must consider syphilitic periorbitis and gummy tumours as one affection.

The rarity of this condition in the orbit, considering the frequency of its occurrence on other facial bones, must be noted. Ricord has described several instances, and so have other authors, including Cullerier, Lanceraux, and Berkeley Hill.

Orbital caries. This, as caries, is sufficiently noticed among orbital affections, p. 81. I need only add that the nature of the complaint is generally revealed by its history, and the presence of other syphilitic symptoms. The prognosis is unfavourable as regards the eyeball, because it is often much damaged, or destroyed, by the exposure to which it is subjected from the eversion of the eyelids.

Caries of the bones around the lacrymal sac, and of those forming the nasal duct. That which is written in connection with caries in the chapter on Diseases of the Excreting Lacrymal Apparatus, p. 551, so far applies here as to render it unnecessary for me to say much more.

Syphilitic periostitis, commencing usually at the tertiary periods of the infection, may be the starting point of the orbital

of disease in the soft portion of this lacrymal apparatus is more slowly developed than when they are first attacked. Thus it is that after obscure tumefaction with considerable pain has been noticed in the neighbourhood of the os unguis, the apparatus is able to perform its duty. On the other hand, when the mucous membrane is first implicated, the discharge of the tears is early interfered with.

As the disease advances the mucous membrane becomes inflamed, and those symptoms of stricture follow which are common to inflammation from any cause. At a later period the posterior part of the sac becomes ulcerated, and with the development of the caries the ulceration of the soft parts increases, the integuments are destroyed, and a fistulous aperture is formed which leads to the diseased bone.

The starting point may also be in the conjunctiva or the mucous membrane of the sac, in either of which cases the symptoms appear early in the constitutional affection.

Treatment. An antisyphilitic treatment is imperative. The necessary mechanical measures are fully described in the chapter above alluded to.

EYELIDS.

These ocular appendages often suffer from syphilis, which affection is not generally recognised, the local disturbance being mistaken for some other affection.

Primary syphilitic sores, chancres, have occurred about the eye, and long since M. Ricord described a chancre appearing on the lower eyelid, and affecting the pre-auricular and submaxillary glands. It was supposed that the finger conveyed the virus. This is probably the case of the midwife, related also by Desmarres, "Maladies des Yeux."

Other unequivocal cases have been published by Cullerier, Mackenzie, Hill, Lawrence, and several others. I have never myself met with an example.

As it is no longer a matter of doubt that chancroid or soft chancre may appear on the face, the eyelids may be inoculated with this sore.

Secondary syphilis. This is the form in which we may expect syphilis about the eyelids, and the more we look for it the more cases we shall discover.

Hill says that a papule situated in the margin of the eyelid may develop into a mucous tubercle.

Secondary syphilitic sores here are with difficulty distinguished from epithelial cancer. In syphilis the skin is darker, and the edges

softer and less elevated, and the surrounding skin is not so glued down to the parts beneath, as in cancer.

All the chief lesions of constitutional syphilis which affect the skin and mucous membrane of the body in general occur on the eyelid, and on the conjunctiva. It is unnecessary to speak of them systematically.

The occasional damage of an eyelid, or the entire loss of it, through ulceration, requires to be specially noticed. From my observation, it occurs most often in association with general tubercular eruption of the body, and it is a sequel of the same eruption on the eyelid. The ulcer begins on the palpebral edge, and extends more on the skin than on the conjunctiva. Its damaging power is very much influenced by the degree of the accompanying inflammatory action, so that we may have a slowly acting, or a rapidly destructive, phagedenic sore. In a patient recently placed under my care, the upper lip, one ala of the nose, and the centre of one under eyelid, were alike attacked with what I denominated tubercular syphilitic ulceration, and these parts were damaged in varying extent, the nose suffering the most. In all of them there is the same loss of substance by notching through the entire thickness of the part. In a late patient the greater part of the lower eyelid was lost by rapid ulceration. Any part along the margin of the eyelid may be the seat of the ulceration, the selection depending upon the position of the preceding eruption.

I have met with ulcers away from the margin of the eyelid, close to the eyebrow, and two of the largest ulcers of this nature which I have seen partly involved the eyebrow, and partly the upper portion of the eyelid.

The conjunctiva may be inoculated with a chancre. Dr. Mackenzie gives a case. The sore was external to the cornea, and associated with syphilitic ulceration of the eyelid.

This membrane seems to enjoy greater immunity from secondary syphilitic attacks than other mucous membranes, but it does not escape. Although the whole or any part of it may be affected, the palpebral portion in general suffers, and the lesion is usually associated with the later stage of the secondary or the tertiary symptoms of syphilis.

A well-marked crop of papulæ over the trunk, limbs, face, and skin of the eyelids in a hospital patient of mine was associated with the same eruptions on the entire conjunctiva of each eye, modified by the moisture of the part.

What we most commonly find is ulceration of the palpebral conjunctiva in one place, or in several. It is this ulceration which is so

apt to be overlooked, especially where the tarsal edge is not involved, because the tarsus must be everted for it to be seen. There may be very little irritation about the eye, or a great deal. The conjunctiva may be only a little red, or highly inflamed, in association with palpebral hyperæmia.

In 1865 I was pleased to find that Mr. J. Windsor read a paper in Manchester on Ulceration of the Palpebral Conjunctiva, as the result of secondary syphilis, and gave the details of seven cases.

Diagnosis. The primary sore might, perhaps, be the most puzzling to discover, because it might appear in any one, at any age, since its inoculation must come from another person, and, apart from induration or inflammation of neighbouring glands, how is it to be identified? A rule often quoted is to the effect that, when we see an adult affected with an ulcer on one eyelid only, which has existed for months, and has resisted ordinary treatment, and rather increased, syphilis may be suspected.

The secondary affection, whether of the internal or the external surface of the eyelid, and whether eruptive or ulcerative, is so commonly connected with other secondary affections, especially of the skin and of the throat, that it can hardly be mistaken. There are exceptions. In one of my patients a gummy tumour of the tongue was the only other syphilitic symptom. In another, syphilitic ulcers of the throat completed the catalogue. I am sure that I have seen ulceration of the conjunctiva as the sole secondary disorder then present, and, as I believe, the result as sub-conjunctival gummata. In such a case the diagnosis is necessarily obscure, unless primarily syphilis be admitted. It must not be forgotten how difficult it often is to get the history of infection, not only because the inoculation may have passed unnoticed, but because patients will lie so dreadfully, and stick to it in order to escape censure.

Some of the affections for which secondary syphilis of the eyelids may be mistaken, are, eczema palpebrarum, epithelial cancer, and chronic conjunctivitis.

Treatment. The chief measure is the administration of constitutional remedies for syphilis, regulated to suit the patient's general condition, the nature of the eruption, and its degree. Respecting local applications, cleanliness of the part is indispensable, together with warmth and moisture. Whether an antiseptic lotion or ointment only should be used, or a stimulant, must depend upon the nature and state of the sore.

For conjunctival ulceration, if any lotions be used, only those are admissible which are sufficiently weak not to irritate the eye. If decided stimulation be needed, it had better be done once for all,

with the solid nitrate of silver, with as little damage to the surrounding conjunctiva as possible, and according to the method described for using this drug in eczema palpebrarum.

SYPHILITIC INFLAMMATION OF THE LACRYMAL SAC.

This is the most common form of syphilitic inflammation about the eye of an adult. It begins like periosteal inflammation at the inner corner of the orbit. Whether there be ulceration of the interior of the sac from the commencement, I cannot say; but I have seen the sac ulcerate, and the ulceration spread to the conjunctiva. Stricture of the lacrymal duct soon follows.

Besides antisyphilitic remedies, the local treatment for stricture is required.

SYPHILITIC AFFECTIONS OF THE CRANIAL MOTOR NERVES, WHICH SUPPLY THE EYEBALL AND ITS APPENDAGES.

In the chapter on the Paralytic Affections of the Muscles of the Eye, a syphilitic origin of such disturbance has been pointed out, and scarcely anything remains to be noticed. It may be mentioned that the secondary and tertiary effects of the syphilitic lesion, are nearly always manifested in chronic inflammatory processes. These may be briefly summed up as inflammation of the membrane at the base of the brain, of the orbital periosteum, fibroid indurations within the nerve trunks or in the tissues around, and gummata round about the nerves.

The third nerve, oculomotorius, is, as I have said, more often affected by paralysis than any other cranial nerve, and the cause is frequently syphilis.

The fourth nerve, nervus trochlearis, is very rarely affected from any cause, and therefore exceedingly rarely from syphilis.

The sixth nerve, nervus abducens, seldom shows any loss of power, and, when it does, inter-cranial effects of syphilis exist.

SYPHILITIC OPHTHALMATIS IN ADULTS.

This the so-called syphilitic iritis, is discussed in the chapter on Diseases of the Iris.

CONGENITAL OR ACQUIRED SYPHILIS.

The history of this form of constitutional syphilis is often neces-

sarily sought for when certain recognised physical conditions, indicative of secondary syphilis in an infant, a child, or a young person, are not well marked. It should, therefore, be known that the fœtus in utero and its membranes are very often affected with syphilis; that a father or mother with a primary sore, or with constitutional syphilis, may beget a child and transmit syphilis to it; that after impregnation from a healthy male, the woman may receive syphilis by inoculation from a primary sore, and give it to the child in her womb; that, in all probability, the father may beget a syphilized child without inoculating the mother directly, although she may be secondarily affected by absorbing the secretions from the syphilized fœtus.

Syphilitic ophthalmitis in infants. I must repeat that this is generally spoken of as iritis. To my former teacher, Sir W. Lawrence, is the world indebted for the discovery of this manifestation of syphilis. He published his observations, nearly fifty years ago, in his well-known work on the syphilitic diseases of the eye. The first cases of the complaint that I saw were pointed out to me by him, when I was his house-surgeon at St. Bartholomew's Hospital.

Symptoms. These differ in no essential points from those of syphilitic ophthalmitis in adults, except in being less severe and less complicated, and in the usual absence of intense intra-ocular inflammation. The surface of the eyeball, the sclerotica, and the conjunctiva are seldom very red. The as yet undeveloped eyeball may account for this.

In a typical case, an infant is attacked with copper-coloured eruptions, "snuffles," aphthæ of the mouth, and mucous tubercles about the genitals, or anus. The eyelashes are exfoliated, and the nails may be unhealthy. There are not found on the margin of the pupil the gummata, characteristic of the adult affection, but there is plastic exudation, which more or less fills the pupil, and may in addition be sufficient to fall into the anterior chamber, and even nearly to fill it.

No systematic account of acquired syphilis would be complete, dissociated from the name and labours of Mr. J. Hutchinson, who is the greatest and most successful of modern investigators in this field of pathology. At page 906, where I treat of punctiform corneitis, I have spoken of the general symptoms of acquired syphilis, as observed and recorded by Mr. Hutchinson. Clause 3 is that on which much stress is laid, and I know that it is generally accepted by the profession in this country.

From the smallness of a child's eye, and the natural tendency

during the disease to keep the eyelids closed, the ophthalmitis is very apt to be passed over by the medical attendant.

The following valuable abstract of symptoms, collateral states of body, and other circumstances in connection with the subject, is from a summary of twenty-three cases, some of which were observed and some collected by Mr. J. Hutchinson, in his work on the syphilitic diseases of the eye and ear.

Age. The youngest patient was six weeks old, the oldest sixteen months.

Sex. Five were males, and sixteen females. In the others, the sex was not specified.

Eye attacked. In twelve cases only one eye was attacked. In eleven, both suffered.

Phenomena of the attack. In only two instances was sclerotic hyperæmia well marked; although in ten others it was present. In fifteen cases, the plastic exudation was copious. In four, it was moderate. In three, the iris was merely tumid and discoloured. In one, the condition is not specified. The cornea escaped inflammatory complication in fifteen cases; in the others, it became more or less affected.

Result to the organ. In seven cases, ten eyes, the cure may be said to have been complete, every trace of lymph having been removed. In two or three other cases slender adhesions of the iris to the capsule of the lens remained. In three cases, four eyes, the result is not known. In twelve cases, one pupil was permanently occluded by organized false membrane. In nearly the whole of the last cases, in which the effusion was never absorbed, the patients came under observation only at a late period of the disease, after the effusion had become organized, and when very little chance of its removal remained.

Other symptoms of syphilis present at the time of the ophthalmitis. In several of the cases any account of co-existent symptoms is either wholly wanting or very imperfect. The specific cachexia is said to have been present in twelve instances; in five there was no trace of it. Psoriasis of the body was present in ten instances, a papular rash in two, psoriasis palmaris in one, erythema marginatum in two, and peeling of the skin in one. "Snuffles" existed as a marked symptom in eleven cases. In four, there were aphthæ or other sores in the mouth. In five, soft condylomata around the anus, and in one, vaginal discharge. In two cases there was nothing beyond the ophthalmitis.

Notwithstanding the great stir which has been made of late years about inherited syphilis, syphilitic ophthalmitis in infants is extremely

rare, and the rarest of all the symptoms of inherited syphilis. But a small percentage of the cases which are frequently reported as such are really suitable instances of the disease. I find that different stages of catarrhal inflammation of the conjunctiva are often mistaken for the ophthalmitis.

I occasionally meet among hospital out-patients some bearing undoubted marks or remains of infantile syphilitic ophthalmitis, in more or less damage to the iris. The majority had some, or all, of the symptoms above alluded to, as expressed at Clause 3, p. 306. The notched teeth most usually prevailed.

Treatment. The principles should be the same as those which I have recommended for syphilitic ophthalmitis in the adult, adapted to the early age of the patient. The mercury should be used by the inunction method, and rubbed into the soles of the feet, the axillæ, the groins, and the calves of the legs, from a scruple to half a drachm being employed daily. This agency should be continued according to the effect on the exudation. The general health of the infant will require the most careful attention, and a wet nurse should be employed during the ordinary suckling period. When one cannot be procured, milk diet, that is, cow's milk, with the proper dilution and sweetening, according to the age of the child, together with cream, and in sufficient quantities, should be solely given for nine months. For several months after that, milk should be the chief constituent of diet.

Acquired syphilitic corneitis is considered in the chapter on the Diseases of the Cornea, under the head of punctiform corneitis.

Syphilitic diseases of the optic nerve, the retina, and the choroidea are treated of along with the other affections of those parts.

CHAPTER XLV.

PAINFUL AFFECTIONS OF THE TRI-FACIAL, OR FIFTH CRANIAL NERVE AFFECTING THE EYEBALL AND ITS APPENDAGES, APART FROM PAIN ARISING OUT OF INFLAMMATION OR ITS CONSEQUENCES.

The ophthalmic or first division, and the superior maxillary or second division, of the fifth cranial nerve which supplies the eyeball, the ocular appendages, and the circum-orbital region, are very often the seat of neuralgia. The reasons, it seems, to be assigned for this are, the superficial positions of these nerve branches, whereby they are exposed to the influence of cold and mechanical injuries, and the passage of some of them through narrow bony canals, whereby they are pressed upon, in certain diseases in and about such foramina, especially periostitis. The almost unknown occurrence of neuralgia of the nerve branch which passes through the large spheno-palatine foramen to the nose, is probably due to the escape from pressure, even when the foramen is diseased, and the protection it has from the effect of atmosphere and from accidents.

A partial glance at the nerve distribution shows this arrangement. The ocular branches are the ciliary, from the nasal trunk, supplying the interior of the eyeball with sensibility. The branches radiating from the orbit to the surface are, the supra-trochlear and supra-orbital, from the frontal trunk, supplying the muscles and integuments of the forehead and upper eyelid. The lacrymal trunk, supplying the lacrymal gland, the conjunctiva, and the upper eyelid. The infra-trochlear, from the nasal trunk, supplying the orbicularis palpebrarum muscle, the caruncle, the conjunctiva, the lacrymal sac, the integuments of the eyelids and the side of the nose. The temporal and malar branches, from the orbital trunk of the superior

maxillary division, supplying respectively the integuments of the temple and those of the prominence of the cheek. Infra-orbital branches form the same, supplying the orbicularis palpebrarum muscle and the lower eyelid in its entire breadth. To speak of the general distribution of the whole nerve, it may be said that it perforates and supplies every muscle of the face, prior to ramifying in the integuments.

The commonest variety of neuralgia affecting the eye attacks the nerve branches from the frontal trunk and the lacrymal nerve. It is usually an acute affection. A chronic course may supervene.

In the commencement the pain occurs only momentarily and not oftener than once or twice in the day. The upper eyelid, the middle of the eyebrow, the nasal extremity of the superciliary arch, the inner canthus, or the temple, is its most frequent seat. The paroxysms often partake of a quotidian type. The suffering is most severe between morning and evening, and severest at noon. At night there is much mitigation. The conjunctiva becomes hyperæmic, and tears are freely secreted.

The involving of other nerve branches will introduce other symptoms, so that the eyeball gets implicated, and the nose too, when there is discharged a watery secretion. In association with neuralgia in the eyeball, the frontal and lacrymal branches are those the most frequently affected.

As the disease proceeds and gets chronic, the pain becomes more violent, but still continues only for an instant. Gradually its attacks are more frequent and last longer, though rarely for more than half a minute. Inflammatory conditions may appear in the form of swelling of integuments, and serous effusion.

In the very chronic cases, the eyebrows are knit, the lids firmly closed, the angle of the mouth is drawn towards the ear, the jaws are pressed together, and respiration as much as possible, repressed.

In some cases the malady is almost continuous. Most commonly it is remittent, and sometimes completely intermittent. Again, uneasiness may long continue, although the agonizing pain is gone. The painful parts may be very sensitive to the touch, whether they are broken or not.

This neuralgia may alternate with nervous pains in other parts of the body. *The cause* is frequently obscure, but we may sometimes discover it by examining, so to speak, the anatomy of the neuralgia. The larger the branch of the nerve that is affected, the more severe is the pain, because the nerve fibres are the more numerous, and the increase in size and in fibres augments towards the brain. Therefore, with severe and deep-seated pain, the cause is deep-seated. When

the pain is superficial and circumscribed, it is tolerably sure to have a peripheral origin, and such is usually traced to cold.

Malarious influence has long been recognised, the symptoms being attendant or alternating pyrexia, and generally periodically of attack.

By deep-seated origin is meant that which is intra-orbital, or intra-cranial. Among the disturbing influences in these positions may be named, thickening of the dura mater, orbital and cranial exostoses, aneurisms, tumours.

Neuralgia of the eyeball and side of the face in the direction of the supra- and infra-orbital nerves may arise out of the effects of the fangs of carious upper back teeth, from their relations to the orbit. From the same cause, partial paralysis of the third nerve has ensued.

Unequivocal brain or central origin of facial neuralgia has never been demonstrated. But most of these deep causes would affect other nerves as well, and probably terminate in such alterations of tissue, as would cause anæsthesia in the parts first attacked by the neuralgia, or even deformity of the skull. Exceptionally, a deep cause may only produce peripheral pain, not however circumscribed.

If the neuralgia be produced by pressure on the main trunk of the nerve, we may certainly expect pain in all parts supplied by its sensory fibres, such as the front surface of the ear, the skin of the forehead, temple and face, the orbit, nose, palate, tongue, floor of mouth and teeth. The whole of the tri-facial is then affected, when full "Tic douloureux" is said to be present. This "tic" may have a malarious origin. It is only the first and second branches of the nerve, with which we are chiefly concerned in an ophthalmic sense.

I have met with intra-ocular neuralgia almost unassociated with neuralgia of any of the nerves radiating from the orbit, and the paroxysms of pain have been as severe as in any other cases. One of the patients who had nearly monthly attacks, vomited during the height of the pain.

I will narrate the particulars of one case of this kind. The patient, æt. thirty-three, a very temperate and athletic man, was seized in August, 1873, with depression of spirits, which he could not shake off, and in a few days he felt severe pain at the root of the nose, and soon severe pulsatory pain in the left eyeball. The nose pain passed off.

September 9th, I saw him. The conjunctiva was hyperæmic, the pupil contracted, the eyeball a little prominent from serous effusion in the tunica vaginalis oculi, and very tender under touch, even the

movements of the eyelids on it were distressing. Vision was a little misty. The retina and the optic disk were hyperæmic. The contraction of the pupil, and the hyperæmia, were greatest when the paroxysms of pain were most severe. The pain only intermitted, was greatest in the evening, and prevented sleep at night for more than an hour at a time. Noise of any kind was most distressing. The right eyeball was attacked with neuralgia only for about a week, no objective symptoms appearing.

For three months was treatment tried in vain. Leeching and the administration of iron, cinchona, in various preparations, and many other drugs were inoperative. Nor did the local applications of belladonna, opium, and other things, applied hot and cold, have any marked effect. Counter irritation was useless.

My patient got tired of me. The feeling was mutual. He sought other advice, and followed it, but on went the neuralgia for three months unchecked. Not till four months had passed could he read without pain recurring in the left eye. The general health became much impaired. Now, Feb. 17th, 1874, the pupil and the retina and the disk are all healthy. Vision is perfect. Occasionally there is a little pain in the eyeball. The former bodily strength, notwithstanding that change of air has been tried, and other attempts have been made to recruit it, has not returned.

Traumatic variety. Neuralgia may occur in a cicatrix on any of the frontal branches, in the orbital region, the usual position of cicatrices, in consequence of a neuroma forming on the proximal extremity of the divided nerve. It is necessarily extremely rare, not only on account of the cause, accidents, but the infrequency of such new growths of nerve fibres, of which growths neuromata are composed. I have seen but one example.

The cicatrix contains a small nodule which is painful under touch at all times. It is said that a cord may sometimes be traced from the cicatrix, in the distal and proximal directions.

The cause or duration of the neuralgia depends on its origin. Where it seems to arise from cold, or originating in malaria, it has a short existence. Where springing from intra-orbital, or intra-cranial causes, it is long-persistent, and may remain for life.

Treatment. Neuralgia produced by cold or malaria will be benefited, if not cured, by large doses of quinine. Arsenic may do good when quinine fails.

When there is marked anæmia with neuralgia, preparations of iron are indicated. The internal administration of opium, conium, aconite, and stramonium, have all had their advocates. Subcutaneous injections of morphia may relieve. Sometimes hot, sometimes cold local

applications have effect. The continuous electric current is recommended by many, as well as what is called flying blisters. The removal of a painful cicatrix is nearly always curative. Iodide of potassium should be prescribed where there is any periosteal inflammation, or suspected nodes or gummy tumours. Putting aside those cases which it is obviously useless to treat, in consequence of existing exostoses and tumours which cannot be removed, there are many cases of obscure origin which admit of no cure. Division of the affected nerve branch, or excision of a portion of it, in chronic cases which have resisted treatment, invariably gives relief, and sometimes cures the neuralgia. I have seen only the supra and infra-orbital branches so dealt with. It would be useless to operate unless the neuralgia were limited and peripheral.

The common carotid artery has been tied in some cases to no purpose, and the removal of the upper jaw has been as useless. Hundreds of carious and as many sound teeth have been extracted without a particle of benefit, where it was suspected that they caused irritation.

CHAPTER XLVI.

INSENSIBILITY OF THE EYE TO CERTAIN COLOURS, USUALLY CALLED IN ENGLAND COLOUR-BLINDNESS.

This is a varied disturbance, a physiological defect or idiosyncrasy. Although it occurs in myopic and hypermetropic eyes, it has no special relation to such optical conditions, being mostly present where they do not exist.

Dr. Young, our countryman, in the beginning of the present century, propounded this his well-known theory. Light is composed of three base colours, producing three primary sensations of colour to the eye; determined as much by the constitution of the sense of sight as any thing without the eye; red, green, and violet, and which by their combination in various proportions produce the sensations of colour in all their varieties. This seems to be resuscitated and adopted by some modern philosophers of great repute.

It must be remembered that the colours here spoken of are the prismatic colours from light, and not those from artists' pigments; the respective combinations of which, as is well known, produce dissimilar effects.

The only data which we have for determining primary colours are derived from the comparison of colour equations by those who are colour-blind, and by normal eyes. The colour-blind equations differ from the others by the non-existence of one of the elements of colour, the relation of which to known colours can be ascertained.

The symptoms are subjective. They are the insensibility of the eye to the colours of red, green, or violet, or limited perception of some or all of them.

Red blindness is the common form of colour-blindness. The elementary sensation which is wanting is a red approaching to ver-

milion, lying both beyond vermilion and carmine. It is often called dichromic vision. The red looks dark, and is confounded with green, and pink with violet. Violet may be imperfectly distinguished from red, and is often mistaken for blue. Orange, purple, and brown, may be judged of with difficulty and imperfectly. Yellow and blue are always best recognised, especially light yellows and dark blues. The first seems to be always recognisable, the second nearly always.

Green blindness is the next common to red blindness, and, I believe, is always associated with it, green appearing as a shade of drab.

Three kinds of colour confusions, according to Dr. Wilson, a well-known writer, are, red with green, brown with green, blue with green. Wilson wrote in the "Monthly Journal of Medical Science," Edinburgh, 1854, and originated the term colour-blindness. Before that, Daltonism was generally used, in this country at least, because Dalton, the chemist, published an account of his colour-blindness in 1798. This distinguished man could not discern pink from blue by day. In the solar spectrum the red was scarcely to be seen, the rest being apparently made up of yellow and blue.

It is extremely rare for a person to have no perception of colour, a chromatic vision while the eye is otherwise healthy. With such deficiency only light and shade are attached to all objects.

Mixed hues, made up of any of the colours to which a person is insensible, will be to him proportionately darker.

Artificial light, especially gaslight, may enable red and green to be distinguished, where this is impossible by daylight.

There is no difficulty to the colour-blind in the perception of light, the retinal images apparently not losing the faintest grades of brightness. On this account the colour-blind can sort out all the shades of that colour of which he is deficient, and his placing among such, as one shade, that of another colour, green among the red, shows his colour deficiency.

Colour-blindness does not interfere with the proper eye functions, of communicating ideas of the form and size of bodies from a cognisance of light and shade, and does not incapacitate persons from being draughtsmen.

No two colour-blind persons see a pair of colours, which agree in intensity and tone, to be equal.

No objective symptoms, however trivial, are sufficiently constant to be relied on.

Both eyes, so far as I know, are always affected alike.

As a kind of advantage which arises out of the deficiency of colour-perception, it is recorded that an engraver could see a picture only as white and black, as light and shade, and want of colour-harmony

was always apparent in corresponding discord in the arrangement of its light and shade. This enabled him to translate with certainty colour which many of his brother engravers were in doubt about.

Consanguinity favours the appearance of this defect. It is frequently hereditary.

A congenital origin is the rule, and the defect remains the same through life. Only once have I known an exception of acquirement, without any other eye defect or known lesion. An engine-driver on one of our railways confessed, after an accident through his not distinguishing the red signal, that he had gradually lost his colour-power, which had been perfect; and so sensible was he of his loss that before the accident, he had determined to give up his situation as driver. The manager of the company who told me of the circumstance assured me that the man had been examined before his admission, only a few years back, and passed as possessing perfect sight. I have long suspected that railway accidents sometimes arise out of colour-blind servants, as well as imperfectly painted signals.

Long before the discovery of the ophthalmoscope, it was known and recorded that brain lesion, traumatic and otherwise, may produce temporary, intermittent, or permanent colour-blindness. Optic nerve atrophy, I have already spoken of, is, as shown by Leber, almost always attended by colour perception deficiency. Optic neurotic and inflammatory affections of the interior of the eye, according to ophthalmological records, might occasionally show the colour loss. The more the colour disturbance is looked for, the more often will it be found.

In a practical point of view, colour-blindness comes before the ophthalmologist under two considerations, how to detect it and how to treat it. The first may be easily disposed of, by having the prismatic colours as test objects, singly and grouped, or artists' pigments similarly arranged in primitive colours and in combinations, with which to conduct the examination. The examiner must bear in mind that the quickness or slowness with which colour recognition is made will depend on the illumination of the colour, the kind of colour, the size of it, and the distance from the eye, points on which I cannot dwell, and he must make a distinction between distinguishing a colour and its shades, or the colour only. Any colour long gazed at, fades more or less. The examination should be by day, and by artificial light. Coloured letters are often used. Every colour, except purple, is similar to some colour of the spectrum.

The following is, I believe, Woinow's test: A disk is carefully painted, circularly, in the centre, half black and half white. Without

that is a ring of paint, half red and half green; without that another ring, half red and half violet; without that, again, a ring half green and half violet. This embraces the three primary colours. When the disk is rapidly revolved, the centre is grey, the next portion yellowish, the next rosy, and the next greenish. To a colour-blind person, the ring which contains the colour not perceptible to his eye, appears greyish, like the centre. Several persons may be examined at the same time.

For the manner of conducting a scientific examination, I beg to refer to J. C. Maxwell's elaborate paper in the "Philosophical Transactions" for the year 1860, entitled Theory of Compound Colours, &c., in which colour-blindness is incidentally touched on. I would refer also to a paper by Dr. E. Rose, translated into English in the "London, Edinburgh, and Dublin Philosophical Magazine," 1866, entitled a Sketch of the Doctrine of Colour Disease. Artificial colour disease is considered, including that caused by taking santonic acid.

The cause of colour-blindness is unknown. In all probability the fault lies in the brain, and not in the eye.

There is no cure, and hardly any palliative remedy. The reputed advantage obtained from looking through coloured glass is thus noticed by Dr. Mackenzie: "On applying to Dr. Wilson, I was informed by him that he had found red and green glasses give no help to the colour-blind, in distinguishing between the red and green objects which, with unassisted vision they were likely to confound. It was otherwise with yellow glasses, which Dr. Wilson found markedly to assist a certain class of colour-blind persons. As artificial light differs from daylight, mainly, as is believed, by an excess of yellow rays, it struck him that if parties who were able to distinguish red and green by yellow candle or gaslight, were to use yellow glasses in daylight, they might thereby reduce the light of the sun to the quality of candlelight, and see by the former, as they did by the latter. Accordingly, Dr. Wilson distributed among his more accessible colour-blind friends, yellow or rather pale orange glasses. Several got no good from them, and all complained of the loss of light; but the parties found themselves able to make the same distinction between red and green by daylight, as, without such glasses, they made by gas or candlelight." It is probable that the yellow glass proves of use, not because yellow light, as has been supposed, has the power of exciting the retina to increased sensitiveness, but because it reduces the quality of daylight to that of artificial light, and communicates to objects those tints to which colour-blind eyes respond the best.

CHAPTER XLVII.

DISEASES OF THE OPTIC NERVE.

RETINAL BLOOD-VESSELS—OPTIC TRACT AND OPTIC NERVE—HYPERÆMIA OF THE OPTIC DISK AND THE RETINA—GENERAL FIELD OF VISION—OPTIC NEURITIS—PRIMARY OR WHITE ATROPHY OF THE DISK—TEMPORARY PARTIAL INTERRUPTION TO SIGHT—AMAUROSIS—APOPLEXY OF THE OPTIC NERVE—TUMOUR OF THE OPTIC NERVE.

THE RETINAL BLOOD-VESSELS.

These vessels are described in chief, at p. 302. I will add some details. The central artery of the retina is surrounded by its special sheath, whence proceed filaments which branch into the neurilemma. The vein has its sheath distinct from that of the artery. There is a misprint at p. 302, sheath for sheaths.

Among the variations in the branching of the central artery of the retina, this one occurs. Small twigs may proceed from the primary vessels while they are yet in the disk, and pass in many directions to the retina.

The vein leaves the optic nerve in the orbit, close to the posterior wall of the sclerotica, at a distance varying from one-eighth to three-eighths of an inch.

Remains of the hyaloid artery, and even its connection with the central artery of the retina at the porus opticus, have been met with. These varieties, among others, have been described. Short offshoots passing into the vitreous body. A thin thread going to the posterior capsule of the lens. A thin tube traversing the vitreous body and containing blood.

OPTIC TRACT AND OPTIC NERVE.

The optic tract commences at the corpora quadrigemina, arising primarily from within the nates and the testes. Passing onwards beneath the optic thalamus, it receives fibres from the grey matter of it and the corpora geniculata. Thus formed, it crosses as a flattened band beneath the crus cerebri, forwards and inwards around the tuber cinerium and immediately under the corner of the lamina cinerea, with all of which it is attached by some filaments. Finally it unites with its fellow of the opposite side, and the two form the commissure or chiasma.

The optic nerve commences from the chiasma. It leaves the skull, passing through the optic foramen into the orbit, where situated in the midst of the recti muscles, and surrounded by the short ciliary nerves and blood-vessels, it continues obliquely, forwards and outwards for about three-quarters of an inch, enters the eyeball and expands into the nerve fibre layer of the retina.

Structure of the optic nerve. The orbital portion has a firm sheath, made up of areolar tissue and a small proportion of elastic tissue. So highly is the areolar tissue developed, that it is often regarded as fibrous tissue, and as such have I described it at p. 641, where a diagram of the nerve is given. There is, therefore, an analogy in structure between it and the sclerotica. This sheath is separable into two layers. An outer one, readily removable, thick and continuous in the one direction with the posterior portion of the sclerotica, and in the other with the dura-mater. An inner one, the neurilemma, thin and not separable, continuous in front with the anterior layer of the sclerotica; there, therefore, intra-ocular and forming an edge, the connective tissue ring spoken of in the latter part of p. 302, in association with the optic disk, and behind with the neurilemma of the chiasma. The density is well marked. It gives off tubes which surround the bundles of nerve fibres. From the chiasma to the corpora geniculata, the neurilemma is very soft and thin. This explains the difference in density between the optic nerve and the tract, and enables us to understand how in neuritis, the optic nerve fibres and the blood-vessels suffer from pressure under swelling, because the dense neurilemma can yield but little.

The neurilemma portion of the sheath gives off tubes or fasciculi which surround bundles of the nerve fibres, and tubes for individual fibres of the bundles. On the walls of the tubes the nutrient blood-vessels ramify.

As the tubes approach the sclerotica they become more numerous;

the nerve trunk is lessened in calibre from reduction in the connective tissue element, and is smallest in the choroidal aperture; and when they reach the level of its internal edge, they receive strength from the envelopes of areolar tissue which surround the retinal artery and vein, as well as tendinous fibres from the sclerotica. Such additions constitute a perforated plate, the lamina cribrosa, holding in position the tubes which lie open, and as they cease there, they allow the disk boundaries to be seen through the clear expansion of the nerve fibres in their onward course from the tubes, as they pass from the axis of the nerve to the retina. The neurilemma being peculiarly abundant there is a rich supply of material for inflammatory proliferation.

Between the nerve sheaths is contained a thin layer of areolar tissue, many elastic fibres and fat cells, and according to Donders, a "vitreous" material containing large oval nuclei, finely granulated. This also is continuous with the sclerotica.

The optic tract and nerve in their course are freely supplied with nutrient blood-vessels.

The former, the tract, at its origin receives twigs from among the arteries which are distributed to the corpora quadrigemina, and whilst under cover of the optic thalamus, it approaches the choroid plexus, and by it is also fed. In the rest of its extent, including the chiasma, it is covered by pia-mater, from which farther vascular branches are derived.

The latter, the nerve, carries with it a large portion of the tract arterial supply, and gets, in addition, branches from the posterior or short ciliary arteries.

The arteria centralis retinæ, which is derived from the trunk of the ophthalmic artery, or from a ciliary or a muscular branch of the same, enters the optic nerve about three-eighths of an inch from the sclerotica, not, however, for the nerve supply, but to be distributed to the retina, although it does communicate with the nutrient vessels of the nerve.

It is therefore evident that the blood-vessels of the optic nerve and of the retina are distinct, since they are derived from different quarters, although they have a slight anastomosis.

THE NORMAL ASPECT OF THE OPTIC DISK.

Such appearance is given at p. 302, and the following remarks may be supplemented. Besides the white or connective tissue ring, the neurilemma boundary of the optic nerve and the margin of the disk, which not only varies in width in different eyes but in different parts

of the same eye, and may appear only as a crescent on the outer side, there are: the sclerotic ring, not usually well-defined except in morbid states of the disk; and the dark grey or choroidal line, called the boundary of the disk, and always well marked, but most so in dark persons.

The size of the disk varies with age. It is smallest in children, largest in adults, and reduced in old age. With senile reduction, the disk becomes darker, and approaches to grey. But in judging of the disk in a pathological survey, we must take its size from the nerve tissue, the part within the white or connective tissue ring, and which ring is, as I have said, the nerve boundary. Deviations in the size of the disk, so regarded, are very significant. Deviations in the choroidal boundary are unimportant, and often accidental variations.

The normal form of the disk is usually round or nearly so, but it may approach to an ellipse, or an oval. A slight deviation from the circle is no unusual senile alteration.

Elongation of the disk laterally has been described as a very rare physiological state; that it is really congenital is yet to be confirmed.

The disk may look very large and very irregular while it is round. Atrophy of the choroidea, as in staphyloma posticum, in association with myopia (see p. 639), and ordinary atrophy of the choroidea in patches around the disk, or the narrow circle of retinal and choroideal atrophy, which is so common in disk atrophy, will produce such deceptive appearance. Whenever the sclerotica is exposed and shines, the disk margin seems to be irregular. At p. 639, line 16, the word going should be showing. The correction is made by carefully examining the fundus where the nerve boundary is detected. So also will deception appear, where the retina and the choroidea immediately around the disk are obscured by a narrow ring of exudative material.

Sparkling points, supposed to be cholesterine scales, have been seen in the disks of old persons.

The physiological excavation of the optic disk, the natural cupping, has been spoken of at p. 308; only where it is in the exaggerated state alluded to does it concern us as medical practitioners, and then its recognition, as a normal condition, is of great practical importance. Being congenital, it is recognisable in infancy. It generally remains for life without any material change. It usually exists in both eyes, although there may be a want of correspondence in size.

I alluded at p. 309 to the altered colour of the blood-vessels in the excavation. They become darkened. This is due, not as there stated, to the effect of reflection, but to the oblique position of the vessels,

whereby the blood is seen, more or less, in the long axis of the vessels, and necessarily looks darker. Such darkness must increase with the depth of the cupping, that is, the steepness of ascent which the vessels encounter to reach the margin of the disk. A word more respecting the diagnosis. So long as there is no degeneration of the optic nerve, the physiological cupping may be always distinguished from the pathological cupping, a condition common in the diseases called glaucoma, which will be spoken of in association with that affection. But with deep physiological cupping, nerve atrophy and loss of disk boundary, the distinction from the pathological state cannot always be told by the use of the ophthalmoscope; and then the clinical history and the subjective ocular symptoms will form the better guides.

The position of the disk may be defective, that is, it may be a little out of the normal situation. Such deviation does not affect the vision. It is more common than supposed and is detected only by ophthalmoscopic examination.

In a solitary case, the nerve fibres have been seen to pass in two bundles upwards and downwards, the retinal vessels taking the same course.

Extension of the neurilemma of the optic nerve fibres.

I beg my reader to refer to what I have said on this point at p. 307, and the white retinal patches which it causes. To the caution which I have given about diagnosis, I wish to add that the normal conditions of other parts of the fundus, in association with the white patches, will prevent them from being mistaken from any opacity arising out of an inflammatory or other morbid condition. If, in neuritis, whitish ganglionic swelling of the nerve fibres be perceived, the rest of the disk will be semi-opaque and unhealthy; and inflammatory exudations in any part of the retina are associated with surrounding retinal charges, however limited and shaded they may be.

There is much variation in the size and position of this peculiar state. Nearly the whole of the disk may be involved, and a considerable portion of the retina, or small patches, may appear on each side of the disk.

Very exceptionally is a patch placed peripherally, clear fibres being between it and the disk.

The normal state of sight, more than all, declares the physiological condition. It is said that with a very extensive patch, the area of the "blind spot" is enlarged.

The optic disk blood-vessels. The disk being the extremity of the optic nerve, its vascular supply is mainly from the nerve and but very slightly from the retinal artery. These disk arteries anastomose

around the choroidal aperture with the chorio-capillaries. Only by this intercourse do the retinal and the choroidal arteries communicate.

Much variety is found in the capillary system of the disk, as to paucity and redundancy. In the latter case, the vascularity may

FIG. 287.



assume the form of a thick gauze, covering the greater portion of the disk and often more or less concealing the central blood-vessels of the retina.

A nosological lesson is to be gathered from this scant anatomical description of the blood-vessels, in explanation of differences in vascular conditions which are sometimes met with in the retina and in the disk, and the occasional independence of retinal and diskal hyperæmia and anæmia.

Vascular changes in the disk may be but a part of a similar condition in the cerebral blood-vessel, or arise out of influences working within the orbit. Abnormal vascular conditions in the retinal vessels may be local, or depend on disturbance to the central artery of the retina while in the orbit.

DEMONSTRATING OPHTHALMOSCOPE.

Since my chapter on the ophthalmoscope was written, Mr. C. F. Jeaffreson, of Newcastle-on-Tyne, has considerably improved the demonstrating ophthalmoscope of that period, and I am induced to notice this, his instrument.

The chief characteristic is rapidity of application in different cases.

There is a table 2 feet 9 inches long, 1 foot 8½ inches broad, 2 feet 4½ inches high, so constructed with rack and pinion work that certain parts of it, on which the ophthalmoscope is placed, are readily made to move vertically and laterally. Through such device, the height of a patient is provided for, the whole apparatus for examination is quickly adapted for either of his eyes, without altering individually the adjustment of the lens, the mirror, or the lamp. A material optical advantage added by Mr. Jeaffreson, is the substitution of a plain mirror, for the concave one of the older instruments, by which the field of vision is materially increased, the illumination made brighter, and the examination less disturbed by slight movements of the patient's eye.

HYPERÆMIA OF THE OPTIC DISK AND THE RETINA.

These are usually combined.

Hyperæmia within the eyeball has the same pathological bearing as hyperæmia in other parts of the body. It is simply blood congestion, in the more or less dilated intra-ocular vessels. It is not easy to determine the presence of ocular hyperæmia, since we require to recognise but a little departure from the healthy condition of the blood-vessels, without any alteration in structure. To this difficulty is added another, which arises out of the complexion of the individual, or the degree of the pigmentation of the pigment tissues in general,

to which the choroidea belongs. Choroideal variation in this respect, considerably modifies the vascular appearance of the fundus of the eye. A fair fundus has generally a hyperæmic look, while in a dark one, advanced hyperæmia might pass undetected.

The disk itself is much affected in appearance by contrast with the colour of the fundus, the less vascular the aspect of the parts around, the more vascular will it appear.

Then age exerts an influence in ocular vascularity. A young eye always looks more vascular than an old one. It deceptively appears that a child's eye possesses more retinal vessels than an adult's. Perhaps the smaller fundus of the former contributes to the deception. It is desirable, therefore, in an examination to take these several circumstances into consideration, to compare the eyes where this is practicable, and if possible to watch a case in which there is doubt about an abnormal state.

It is clear then, that there may be considerable differences in the vascular aspect of the eye within the limits of perfect health.

The colour of the artificial light which is used with the ophthalmoscope, has an effect on that of the disk. A blue-tinted object lens, or a similarly tinted chimney glass, whitens or purifies impure light, especially when gas-light is employed, and with such purified light, the fundus of the eye is the better examined.

We speak of active or arterial, and venous or mechanical hyperæmia. But really these forms are not always distinct, so that perhaps we are more justified in accepting an etiological than a symptomatological difference.

The active form, active hyperæmia, is an excess of blood in the arteries, with generally an acceleration of the flow.

Causes. Diminished arterial resistance through paralysis of the vasomotor nerve, from nerve lesion. Irritation of the sensory nerve of the eye, the fifth, either mechanically, such as arises in damage to the conjunctiva, or from exposure of the eye to very bright light; or functionally, as strained adjustment of the eye, for lack of sufficient assistance from spectacles. Inflammation of other parts of the eyeball, especially the choroidea.

Symptoms. When well developed, the whole fundus of the eye is reddened, the blood-vessels being seemingly increased in number. The arteries may be readily distinguished from the veins. The reddening may be more marked in tracts or patches.

The change in the optic disk is very marked through the turgescence, and the outline is obscured, but the outer edge is seldom lost to view.

The outward objective symptom is a rather contracted pupil.

The subjective symptoms are, a sensation of fulness in the eye, perhaps throbbing. Function may or may not be interfered with. This adds another difficulty to the diagnosis. Where it is disturbed, it takes the direction of exalted sensibility, so that the eye cannot be used long without uneasiness, unless in a very subdued light. Spectra.

Intolerance to light is not a proper symptom. Its existence must be ascribed to ciliary irritation, whereby implication of the fifth nerve is added to the hyperæmia.

Hypermetropic eyes suffer from hyperæmia, especially when asthenopia is combined. Highly myopic eyes too, are prone to it.

The passive, venous, or mechanical form, arises from excess of blood, principally in the veins, with general stagnation.

Causes. Albuminuria. Obstacles which directly impede the return of blood from the retina. These include tumours, and inflammatory exudations of all kinds, which may act within the orbit by compressing the ophthalmic vein, or extend their evil influence while the vein is in the sphenoidal fissure, or be prejudicial within the cranium by compressing the cavernous or lateral sinus. Within the skull there may be too, as obstacles to the venous circulation, conditions which increase the cerebral mass; such as meningeal inflammation and its consequences. Fracture of the skull with compression of the bone. Thrombus of the cavernous or lateral sinus. Contraction of the mitral orifice of the heart. Diminished cardiac action. Sometimes exophthalmic goitre.

Whether the hyperæmia be confined to one eye, or affect both, might afford some assistance in discerning the course of it.

Symptoms. Turgescence in the whole system of the retinal veins and capillaries. The arteries, on the contrary, so far as can be made out, for it is difficult to distinguish them, are normal, or rather contracted and pale; with tendency to tortuosity and to be forced into different planes. They, the veins, are not varicose, unless the obstruction is very decided.

Later on, dimming of all the blood-vessels, especially the larger ones in the vicinity of the disk, through œdema of the retina. Loss of disk boundary. Blood extravasations, with sharp outlines. In the latest stage the retina is more œdematous and more opaque, with remains of hæmorrhage in brown or white spots, and it may become atrophied.

Venous pulsation is not uncommon. When absent it is very readily produced by pressing on the eyeball.

The choroidea is necessarily involved in the hyperæmia, and often loses some of its pigment.

The outward objective symptoms are, dilatation of the pupil, and sometimes slight hyperæmia of sclerotica.

The subjective symptoms are, loss of acuteness of sight, and contraction of the field of vision.

I have desired to speak of hyperæmia in the abstract, and not as a symptom of retinal or optic nerve disease.

Treatment. Removal of the cause is the grand indication to be fulfilled. But even where this can be done, rest to the eye and other measures may be needed to prevent the development of inflammation.

ANÆMIA OF THE OPTIC DISK AND THE RETINA.

These, like hyperæmia, generally go together.

Objective symptoms. Feeble ophthalmoscopic illumination of the interior of the eye. Feebler still, if the choroidea be anæmic also. The partial filling of the retinal blood-vessels is apparent. The retina does not lose its transparency. Distinctive marks between the arteries and veins are seldom lost. The thinness of the arteries and the brighter colour of the blood in them is a condition of ready observation.

There is neither contraction of the blood-vessels, nor reduction in their number, as in disk atrophy.

The nerve fibre layer of the retina may be recognised by the striated and slightly hazy appearance where the fibres pass over the disk edge.

Excess or paucity of the choroidal pigment, as above explained when speaking of hyperæmia, operates even more strongly here, and, therefore, a highly pigmented eye hardly illuminates at all.

Causes. This loss of the normal vascular aspect of the retina and the disk, depends on the amount of stoppage of the arterial supply of blood, so that it may be partial from pressure on the central artery of the retina, or complete from embolism.

Subjective symptoms. Weak sight, requiring high illumination. Amblyopia in different degrees, where the arterial supply is nearly or entirely cut off.

It is said that the feeble vision met with after exhaustive fevers and prolonged lactation, is due to anæmia, but although with general reduction in the amount of the blood in the body, the fundus of the eye is pale, as is the skin or any mucous membrane, I am disposed to recognise feeble perception of the brain and paresis of accommodation, as the direct causes. The functions of all the special senses as well become impaired.

Muscæ, flashes, sudden and temporary loss of sight, especially in the morning, which are met with in anæmia, are due to the cerebral affections with which the anæmia may be associated, and not to the anæmia itself, although some physicians have endeavoured to find their solution in epilepsy of the retina.

Anæmia must not be confounded with the whiteness of optic disk atrophy, in which the retinal arteries are not readily distinguished from the veins, although both sets of blood-vessels stand out in clear recognition in the well-defined disk, till the latest stage of atrophy. Moreover, in the atrophy, if the choroidea be unaffected, the eye lights up well.

In anæmia of the disk, the disk margin is not as sharp as in the beginning of simple atrophy, and it is not difficult to distinguish the normal nerve structure, a recognition not so easy in atrophy. Then both eyes are usually equally affected, while the nerve disease scarcely progresses symmetrically, and the disk suffers, at first partially.

I cannot regard pure hyperæmia or anæmia, as a reciprocal relation of similar cerebral states. Were there such correlation, marked cerebral symptoms must, I imagine, appear.

GENERAL FIELD OF VISION.

This comprehends the extent of surface which is visible to an eye steadily directed towards any one given point, while the fellow eye is closed.

The form or outline of the field in each individual is influenced by the prominence or retraction of the eyeball, the formation of the eyebrow, the cheek and the nose. I need not give measurements which have been made by physiologists.

The following diagram, Fig. 288, represents a map of monocular vision, a monocular field.

A binocular field is formed by the monocular field of each eye overlapping the other.

The extent of overlapping is in a measure regulated by the setting of the eyes, whether they be near or far apart.

DIRECT AND INDIRECT VISION.

In all investigations respecting the quality of sight each eye should be examined separately.

All parts of the general visual field have not the same distinctness. In a small portion only of the field is there perfect vision. In the greater part there is imperfect vision.

Fig. 288.



MONOCULAR MAP, LEFT EYE.

M is the point corresponding to the macula lutea.

The sentient, or seeing power, of the retina decreases from the macula lutea, the centre, towards the circumference, but in a greater ratio in the vertical direction.

Direct central, or perfect vision. An object is seen in full clearness only when it is in the visual axis, that is, opposite to, or in a line with, the macula lutea, the most sensitive spot of the retina.

The visual axis and the optic axis, or axis of the cornea, are not identical. The dissimilarity is explained with the assistance of diagrams, at p. 368, in the chapter on Squint, and should be understood.

The extent of the visual axis, or point of fixation, like that of the visual field in general, is in relation to the distance of the object viewed. That is to say, at a given distance a word of one inch long may be read without the slightest movement of the head or eye, and a word half an inch long, at half that distance. The farther we look, the more we can see.

Indirect peripheral, or imperfect vision. Objects are seen indefinitely when not in the visual axis, not opposite to the macula lutea, because their images are formed on the less sensitive and eccentric parts of the retina, for, as already told, the retinal impressions decrease from the centre to the circumference.

The above physiological facts have their importance as tests or standards, with which we can compare impaired functions of the retina and the optic nerve.

The impaired functions are shown

First, in diminution, so-called contractions or limitations, of the visual field, that is, in a regular or an irregular deficiency at the circumference, or periphery of the field, extending more or less towards the visual centre.

Secondly, in interruptions, that is, partial or complete loss of vision, misty spots, irregularly-formed dark clouds, or sharply-defined black or blind spots, scotomata, fully within the monocular field. Temporary appearances of these subjective symptoms are met with in ordinary vision.

The interruptions are best seen in monocular vision.

Contractions generally begin laterally and not vertically to the visual axis.

I must call to remembrance the partial decussation of the optic nerve fibre in the chiasma, and the continuance of some of the fibres laterally, from the tract to the disk.

In a monocular field, all of the range internal to the point of fixation, which, of course, represents that part of the retina to the outer side of the macula lutea, is supplied by the lateral fasciculus of the same side; and that external to the point of fixation, which represents the retina to the inner side of the macula lutea, is supplied by the nerve of the opposite side.

Equilateral or homonymous hemiopia. Blindness, or loss of retinal functions, of the two right sides, or the two left sides of the eyes at the same time, occur according as the left or the right optic nerve is singly effected, and bears the above title.

Double temporal hemiopia. Blindness in the opposite sides of each retina, occurs when the optic nerve fibres are disturbed in the chiasma, at the point where the nerve fasciculi cross each other, and is named accordingly.

As an instance of application, I may mention that in forms of optic nerve disease, afterwards to be detailed, central vision may be acute, while peripheral vision is much reduced. That it might be impossible to say by an ophthalmoscopic examination only, whether there be present anæmia of the optic nerve, or the first stage of

atrophy of the same, while taking the visual field, will establish the diagnosis. This is fully set forth in the section on disease of the optic nerve. In their respective places, the occasions for the use of this visual field measuring will be found.

Method of applying the test for peripheral, or indirect, or imperfect vision. The simplest and readiest way of resorting to this means of diagnosis, is to place the patient in a good side-light in front of one's self, at about the distance of two feet, and to test his eye by our own. Both persons should look steadily at each other. The patient closes the eye not under inspection, or covers it with his hand. The examiner should now pass his finger or hand midway between the patient's eye and his own, move it about in his own line of peripheral, or indistinct vision, and in proportion as the patient loses the sight of it, or of different fingers while the examiner sees it on them, by so much is the patient's retina defective. The visual deficiencies discovered in this way, are always in a direction opposite to that in which the finger is moved.

The patient's bad eye may be compared with the visual field of his other, if that be available, and not of the examiner's.

I may say at once, that for practical purposes, an approximation to the true extent of the contraction of the field will suffice. We merely want to know that the field is affected, it hardly matters in which direction, for we do not base our diagnosis, nor our treatment, on mere degrees of the contraction. It is altogether different when scientific and physiological inquiries are undertaken in this department. Then, accuracy of investigation is all-important.

I will give some methods of more precise investigation.

Mapping system. The patient sits or stands at the distance of twelve inches before a black board, or a slate, or a sheet of black or dark purple paper, from two to three or more feet square. The examiner takes a piece of white chalk attached to a long black handle, and on the centre of the board, &c., makes a **X**, on which the patient steadily fixes his eye. He moves the chalk from the circumference of the board towards the **X** at the centre, stops short, and marks with a dot the point at which the patient first sees the chalk, perhaps but indistinctly. He then moves the chalk still further inwards, until it reaches a second point where it is quite distinctly seen, and then makes a second dot. Similar and sufficient trials are conducted from different sides of the board. A line is drawn, connecting the inner series of dots. A second line is drawn, connecting the outer series of the same. The space included in the former line represents the special field of distinct or qualitative vision. That between the lines marks the special field of indistinct

or quantitative vision. It may be found that only one of these fields, more or less distinct, is traceable.

The maps thus obtained exhibit the most varied forms. The subjoined diagram represents one of them.

Fig. 289.



The point of fixation is not necessarily in the centre of the map, but may be anywhere, even at the margin. The distance from the eye at which the map is taken may be made a matter of convenience or fancy. The nearer it is the smaller the map, and the sooner it is sketched.

To keep records of a case, so as to ascertain whether there be improvement or not, certain plans have been proposed; for instance, a light frame across which white threads are attached in both directions at every three inches, is placed over the black board, &c., and of which a miniature register is ruled upon paper, corresponding in reduction to one-twelfth, the squares of which are therefore one-quarter of an inch. On this reduced scale is copied the defective field of vision. The light frame may be dispensed with, if the board, &c., be ruled with rather faint lines. Almost every examiner who uses this method makes some personal modification.

Method of applying the test for direct, central, or perfect vision. This scarcely requires mechanical assistance, as there are few patients, those unable to read, who are not immediately aware of any diminution in the quality of central sight, and able to describe it. But the following instrument, an optometer (Fig. 290), may be put into requisition; and it is also useful in examining other conditions of vision, included under the heading "Acuteness of Vision," p. 606.

This optometer is a shoemaker's rule, or sliding scale, shortened for the page, the fixed upright of which is cut down and notched out

for the reception of the patient's eye. To the sliding upright are affixed three small springs, capable of retaining in position an ordinary address card, on which the smallest test-type is pasted.

Fig. 290.

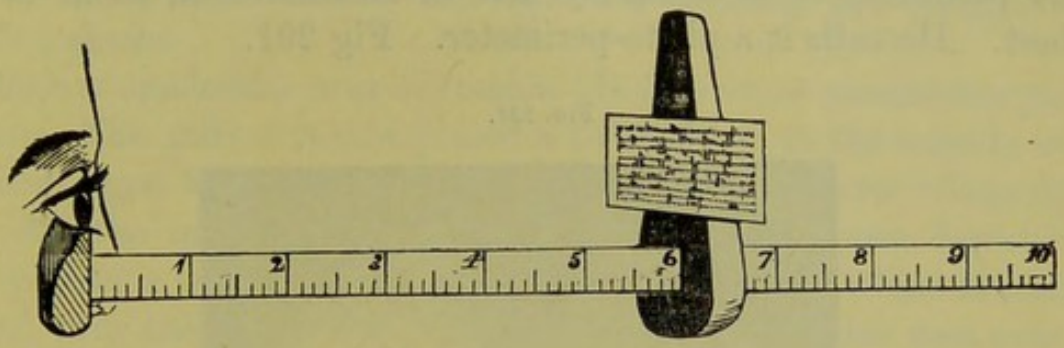

By slowly sliding along the moveable upright, we not only ascertain the quality of the patient's vision, but his near point. In medium and high degrees of myopia, the near, and approximatively the far point, may thus be learnt. A grooved ring might be added to the fixed upright for the reception of lenses. With a ten-inch convex lens, the far point may be ascertained in all cases. If for an eye, with suspended accommodation, to read the test-type distinctly, the sliding upright must be at ten inches, the eye is emmetropic. If the upright must be nearer, it is myopic. If the upright must be farther off, it is hypermetropic.

Types of any size may be used according to the requirements of the diseased eye.

Ackland's optometer, sold by Horne and Thornthwaite, displays more invention. It is fitted with a series of rotating lenses, and the stem is graduated according to their values. The sliding part is a rotating disk, on which different sized letters are painted. Disparity between the eyes, whether in accommodation or visual power, may be accurately ascertained with it.

Respecting scotomata or *blind spots*, if they lie within the field of direct vision, they are well recognised and understood by the patient long before he consults us, and we are spared tedious investigation. If they lie about the field of indirect vision, they seldom escape his notice, although he may not be able to define them.

Contraction of the visual field, unless very marked, can be told only by comparing the field of the affected eye with that of the other, if it be normal, or with some standard monocular map, which would necessarily be less perfect, since it has been taken from another person, or from an average of measurements from many individuals.

Perimeter. Ingenuity in these investigations has gone a step farther, and costly instruments, called perimeters, have appeared. However diversified these appliances may be, it is essential in their construction that there be a moving point, while the eye is fixed.

The perimeter brought out by Mr. C. E. Jeaffreson, seems to be the best. He calls it a photo-perimeter. Fig 291.

Fig. 291.

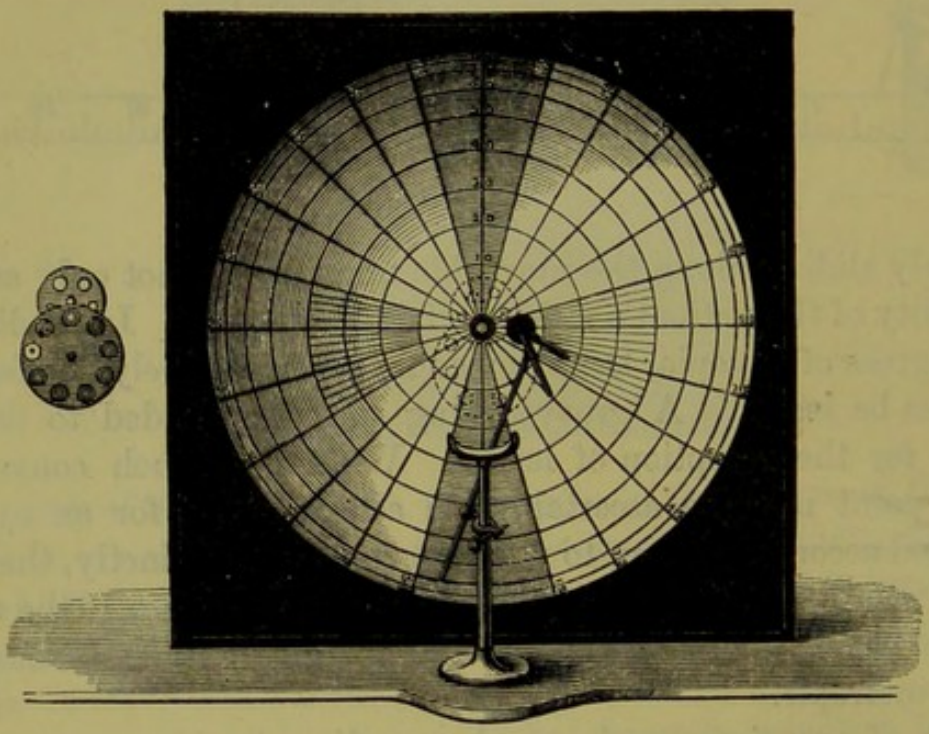

The advantages claimed for it are rapid and accurate application as a perimeter; also an instrument by which the eye may be tested for the appreciation of colour, and for certain defects of refraction.

Description of the instrument. It is a light hemisphere of zinc or copper, with a diameter of twenty-four inches. The convexity is painted dead white, and divided by fine black lines into degrees of latitude and longitude. The meridians of longitude commence at the pole, or centre, and extend towards the margin, or the equator. They have between them a space of 15°. The parallels of latitude encircle the pole, the first being placed at 10° from it, and each succeeding one at an interval of 10°. The pole is perforated by a circular hole, three-quarters of an inch in diameter.

Moveable point. An Argand burner is placed behind the hole, and so adjusted upon an upright moveable stand that, rays from it pass through the hole, and are made to fall on a small mirror attached by a rod to the chin-rest. As the mirror is ground to rather less than twelve inches focus, it will at twelve inches from the

pole reflect a clear light. To enable this defined disk of light to be thrown in any required direction, the mirror is fitted with a suitable apparatus.

Fixation point. The patient puts his chin on the chin-rest, at such a height that the eye to be examined shall be opposite the aperture at the pole, which should be looked at, the other eye being covered with a shade.

Mode of application so as to examine the indirect, or quantitative field of vision. The mirror is now placed a little below, to the outside of the patient's eye, and the light of the gas-burner thrown obliquely on it. All the markings of the instrument are of course depicted on the patient's retina in a reversed position. Light which is made to travel over the instrument from the mirror, will also pass over the

FIG. 292.

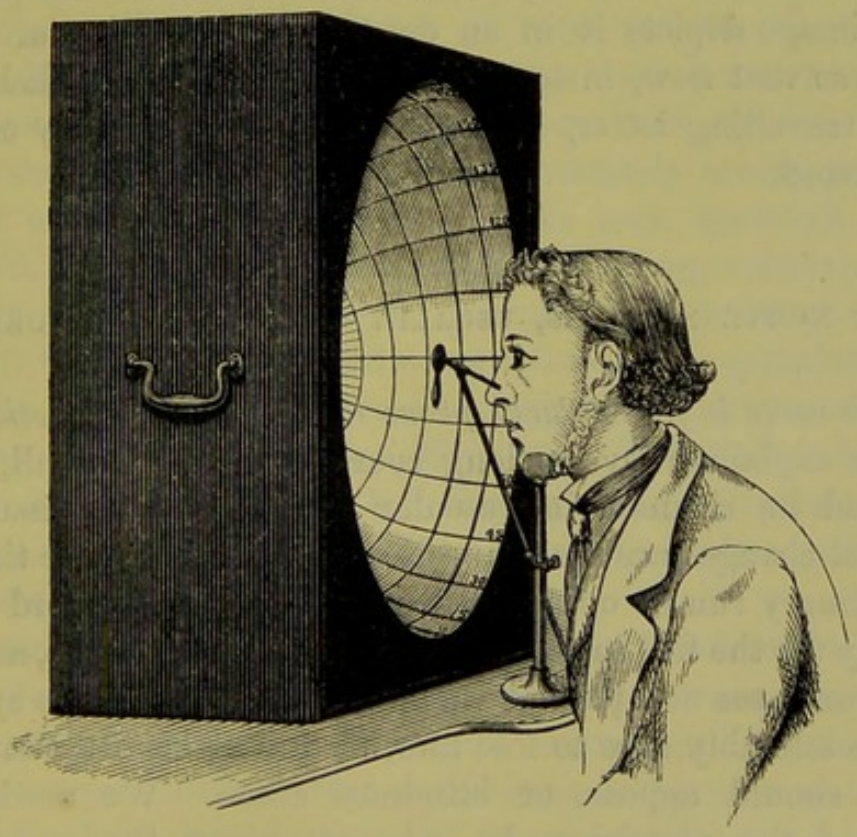

retina in a reversed position, and when it is not seen, a portion of the retina is defective.

The limits of the visual field are ascertained by making the disk travel along the various meridians of longitude, and noting the locality in which it is lost sight of.

The position of the optic nerve entrance, or blind spot, is readily detected, if it be sought for slightly to the nasal side of the yellow spot. To enable accurate measurement to be made of it, the corresponding portion of the instrument is divided into spaces of one degree.

Charts are prepared in different scales for taking the register of the results of examination.

Supplementary parts. There are two diaphragms represented by the side of Fig. 291. One of these diaphragms contains appliances by which the size of the central hole at the pole may be regulated. The more impaired the sensibility of the retina is, the larger must be the disk of light used for the examination. The blind spot is best examined with a small disk of light. These conditions will explain the necessity for regulating the hole. The smaller figure contains disks of coloured glasses, representing the prismatic colours, which are used for testing the sensibility of the eye to colour. Also a disk with a slit for astigmatic purposes, Fig. 292, represents the instrument in use.

For examining the direct, or qualitative field of vision, a stencil letter is inserted in an inverted position in the hole at the pole. The reflecting image depicts it in an erect position on the surface of the perimeter, so that now, instead of having a travelling disk of light, there is a travelling letter, and by this means the acuity of indirect vision is tested.

OPTIC NERVE NEURITIS, USUALLY CALLED OPTIC NEURITIS.

The optic nerve is particularly prone to symptomatic affections. The liability is explained by its long course within the skull, its wide centres, and its richness in vascular and connective tissues. The pathological changes are always well marked in the latter tissue.

The ordinary run of ophthalmic practice does not afford sufficient opportunity for the full investigation of this subject. We, as ophthalmologists, only see our patient when he has marked eye symptoms, and we are tolerably sure to lose him, if, during his attendance, head symptoms should appear, or blindness ensue. We need the co-operation of the physician, he, who attending the epileptic, the paralytic, the hydrocephalic, and those with cerebral disorders in general, being a scientific, practical, and accurate investigator of the abstract problems of disease, through the paths of clinical and pathological study, uses the ophthalmoscope as one of his instruments of research. In this country, Dr. H. Jackson stands forth as an early, original, and successful worker. His labours, partly recorded in the Royal London Ophthalmic Hospital Reports, the medical journals, and elsewhere, are well known. Dr. C. Allbutt, a later inquirer and very able physician, in his beautifully-written work on "The Use of the Ophthalmoscope in Diseases of the Nervous System, &c.," has more

encompassed and popularized the subject, and epitomized the literature of it. His appendix of 123 cases, chiefly compiled from much research, is very valuable. To such men our profession is much indebted, and I acknowledge that I use a great deal of the information which I get from them. I must mostly restrict what I have to say to an ophthalmological point of view.

Although there may be extensive brain lesions, including degenerative changes, without optic neuritis, provided neither the optic tract nor the chiasma be involved (as is verified by sudden deaths from such diseases, and the examinations of the bodies of persons who silently having such, died from other causes), optic neuritis may occur with any of them, which may be characterized as severe diseases, associated with "coarse" structural brain change. Functional brain diseases, if there be such without alteration of tissue, although very marked, seldom affect the eyes.

As general bodily accompaniments of optic neuritis, there may be some one, or several of the following deviations from health. Paralysis of cranial nerves, motor, sensory, and special. General, frontal, or occipital headache, slight, or intensely severe, even to the destroying of consciousness; noises in the ears, hiccough, sickness, loss of voice, difficulty of speaking and swallowing, ophthalmitis, loss of memory, hemiplegia, epilepsy, lateral movements of head and body. But these must be regarded as independent symptoms, which do not arise out of the neuritis, although they may or may not be due to the same cause as it. They may precede or follow the neuritis, as well as accompany it. Such variation depends, so far as the brain is concerned, on the part of it which is damaged, and the isolation or extension of the diseased action.

Still, neuritis may spring forth and be fully developed without the least symptom, other than that of impaired or lost sight, there being no accompanying head or spine disorder. Notwithstanding this, my own conviction is that neuritis is never a mere local optic nerve-change, but always arises out of encephalic causes which are occasionally hidden. I will again allude to this.

Ophthalmoscopic or objective symptoms of neuritis. These are precisely the physical changes which occur in inflammation of any large nerve, but they can be seen during life only in the eye; and the optic disk, as the optic nerve-end, is particularly favourable for their display. They are the cardinal signs of inflammation in general serous effusion, vascular turgescence, opaque swelling, proliferation.

The disk is reddish grey. It is prominent, particularly on the inner side, where the nerve fibres turn over more thickly, see p. 303. The

degree of the prominence may be tolerably judged of by the degree of arching of the central artery and vein. In a typical case so much does this affect the refraction of the eye, that, in high myopia, an inspection is readily made by the direct method of ophthalmoscopic examination, without a concave lens. Yet the inequality of the disk is best seen by the indirect method, with play of light from the mirror, and movement of the object lens.

The disk transparency is certainly more or less lost, because of the haziness of the nerve fibres, the acquired redness, and the inflammatory products; and its boundary is eclipsed. There are many degrees of obscurity, from the slightest departure from the healthy hue, even to complete opacity. Where the change is least apparent, and there is a reasonable doubt about a pathological condition, we may obtain confirmation of disease from the co-existence of subjective symptoms of neuritis, and the disordered state of the central vessels of the retina.

From the direct manner in which the light of the ophthalmoscope strikes the fundus, the angle not being favourable for sufficient diffusion, slight opacity, when regarded by itself, may be overlooked.

Very marked opacity always indicates far advanced neuritis.

The acquired vascularity is due to development of capillaries.

The central blood-vessels of the retina are affected, the arteries being more or less reduced in size, while the veins are dilated in their chief branches. If these vessels be traced from the circumference of the retina to the centre of the disk, it will be found that they are veiled at the disk border, that they then appear but in part, disappearing before they reach the lamina cribrosa. More than that, they may be scarcely visible at the border, and quite hidden in the disk.

Apoplexies occur, but they are often supposed to be present when they are not. Fine red spots, the windings of the newly-formed blood-vessels, are often mistaken for them.

Certain fancied resemblances of these morbid disks, have procured for them the adjective titles of mossy, woolly, striated, granular, etc. The physical effect from which the names are derived, is due to enlargement of the nerve fibres, striation, speckling, hypertrophy, and proliferation of the disk-connective tissue.

The retina may be unaffected beyond the condition of its central blood-vessels, or opacity of a small belt of it around the disk. But a considerable portion of it may inflame. When it becomes markedly, or entirely involved, we say that neuro-retinitis is present. I defer to speak of this advanced state in detail, till I treat of retinal diseases.

A part only of the disk may, for a short time, or altogether, show the inflammatory changes.

The choroidea generally escapes implication, but a ring of it around the disk may be thick with exudation, while the retina goes free.

Engorged disk. Difference in degree of optic neuritis induced Gräfe to describe a variety of this nerve-change under the above term. He thought that he had made out a special form of disease, and that he had found a cause for it. I regard the engorged disk as but the beginning of neuritis, or a slight form of it in the ocular end of the nerve, *i.e.*, a stage of the one process of neuritis. There is, no doubt, a different aspect between it and marked neuritis. I will try to show this, necessarily recapitulating a little, but it must all along be remembered that the distinction, like that of the many appearances of optic neuritis, rests, as has been well shown, on the differences in the amount and colour of the disk opacity; in the degree and kind of the disk swelling; in the extent of the vascular turgidity; in the predominance of some of these phenomena, and the super addition of what may be termed accidental occurrences, as blood extravasations; and appearances expressive of retrogressive metamorphosis of these and inflammatory products, and the manner in which these marks are combined and grouped.

In the engorged disk the redness is intense, the capillaries being very marked. The disk is defined and swollen, the one side being very much raised, while the other is scarcely elevated. This irregularity has been called horseshoe swelling. The central blood-vessels of the retina are in the least degree concealed. The arteries are seldom reduced in size, while the veins are very dilated and black. They may be varicose, and are very tortuous and prone to hæmorrhage. This is liable to be confounded with prominence of the disk, frequently seen in high hypermetropia, especially in children, where the retinal vessels are curved, and more so at the upper and lower portions of the disk. The retina resists implication. It is said by a few men who have made autopsies that the inflammation is sometimes confined to the disk, and limited by the lamina cribrosa.

It is a well-established fact, I repeat, arising out of anatomical states above shown, that the nerve may be inflamed without the retina suffering in like manner. Besides this, when a neuritis runs into a retinitis, or a retinitis into a neuritis, the morbid features of the part first attacked usually prevail.

In the full-developed neuritis the disk is not so vivid in colour. There is an admixture of grey, with marked cloudiness, and the disk boundaries are exceeded and hidden, and the natural shadings of the disk are no longer seen. The arteries are contracted, the veins

are not very tortuous, but are very much concealed, even circumferentially.

In neuro-retinitis the position of the disk may be lost, through the general vascularity. Wherever the central blood-vessels can be seen converging, there is the disk situated.

The disk swelling is not in excess, and therefore the steepness of one side not usually very marked. There is implication of the retina round the disk, and this may extend partially and irregularly over the fundus of the eye, particularly in the region of the macula lutea.

Anæmia of the choroidea may be apparent.

The characters of engorged disk and neuritis may so run into each other that no differential distinction can be made. Again and again may the engorged disk be seen to pass into the fullest neuritis. Practical men will know that a mixed form of disk appearance is more common than either an engorged disk or the full neuritis characters. Several times has it been proved by post-mortem examinations that, what was supposed to be merely an engorged disk, was but a part of neuritis extending up the optic nerve trunk, or in association with superficial neuritis in the entire trunk, the neurilemma being chiefly involved. To the latter state the term peri-neuritis has been applied. In a narration of cases of optic neuritis, by Mr. Hulke, in the Royal London Ophthalmic Hospital Reports, is the dissection of one, pointing out the association of engorged disk with "an indubitable coarse neuritis optica behind the eyeball, within the orbit and in the cranium." It is remarked, "perhaps, had the patient lived a little longer we should have seen the congested swelling, the engorged disk, replaced by that considered typical of neuritis descendens."

I will anticipate a little by remarking that the same subjective symptoms may attend the engorged disk and neuritis.

There is usually no external objective symptom so long as the acuteness of sight is not impaired. When this suffers the pupil might be, but is not necessarily, a little dilated, or sluggish, or immovable. Redness of the sclerotica does not occur unless ophthalmitis be grafted on the neuritis, and before the arrival of which there must be neuro-retinitis.

In advanced neuritis the vitreous body is apt to become more or less opaque.

It is said by Mr. Hutchinson that in the neuritis of children, "although there are rarely any indications of general neuritis, yet at the yellow spot itself there is sometimes seen a group of highly refractive globules, resembling, at first glance, a cluster of spider's eggs. These groups are almost symmetrical, and are very definite."

Subjective symptoms of optic neuritis. Any grade of optic neuritis,

like any grade of retinitis, might occur without such symptoms as intolerance to light. These might not be necessary, it is said, so far as neuritis is concerned, the negative subjective symptoms of impaired sight for weeks, or even months, although, if the objective symptoms do not pass away, impaired vision usually follows. In my own practice I do not meet with this puzzling state, because patients with neuritis do not come to me without some trouble in sight, but those who seek for such exceptional cases among individuals with epilepsy, paralysis, and head symptoms of all kinds, say that they find them. The only explanation is this: the neuritis being essentially, at first, disease of the connective tissue, rather than of the nerve fibres themselves, the changes in such tissue are well shown before the morbid products have choked or damaged the nerve fibres, by pressure or otherwise. If the sight be exceptionally preserved, never becoming impaired, of course the conducting nerve power has been unaffected. As ophthalmologists, we need not entertain the question in any other point of view. Many cases of so-called neuritis are but hyperæmia of the disk, neither the nerve nor the optic tract being affected.

It is well known that central vision may long remain unaffected, while peripheral vision is reduced. I strongly suspect that the peripheral defect is generally not detected in the cases of supposed perfect sight, with the marked objective symptoms of neuritis. On the other hand, very advanced subjective symptoms of defective sight occur in neuritis, from but small objective ones. This must be set down rather to central damage, which has not yet had time to show the effect in disk changes, than injury to the optic nerve fibres without objective symptoms.

Certain subjective symptoms are to be expected. Some of them are no doubt due to the nerve inflammation, and some are due to the implication of other parts of the eye, in which the fifth cranial nerve plays a large part. I will give those which I have seen, and in the usual order of their development. A few only will be found in any individual case. Sensitiveness to light. This is probably due to the fifth nerve. Slight pain in the eyeball. This may be due to the fifth nerve, or to the optic nerve. Subjective appearances of light, so-called sparks, or flashes, or photopsia. Subjective play of colours, coloured spectra or chromotopsy. The two last may occur when there is absolute blindness, and even the eyeball has been extirpated. Muscæ volitantes. Loss of acuteness of vision in any of the zones of the visual field. The most distinct point of vision may, exceptionally, be eccentric. When central vision is not acute, a patient brings his book close to his eyes, to increase the visual angle, and looks like a

myopic person. General or partial, and usually irregular contraction of the visual field. Such contraction is necessarily a serious symptom, always denoting, I believe, nerve atrophy. Blind spots in the visual field, or scotomata. Diminution in the quality of whatever remains of peripheral vision. Total loss of peripheral vision. Reduction of central vision, the acuteness of which is sure to be impaired, to a spot perhaps no bigger than a shilling. Total blindness. The loss of seeing does not occur unless nerve fibre is in some manner destroyed. This order of symptoms may be so far modified or reversed that decline of sight to complete blindness may occupy but from a few hours to as many days. There are added, when the retina is decidedly involved, the subjective symptoms of retinitis, such as haziness of sight, grey fog, thick smoke, of which more will be said in speaking of retinal diseases.

But in one class of cases, those with slight neuritis, engorged disk, and marked objective symptoms, and occurring generally in children and young persons; and in another with fully developed neuritis and still more marked impairment of vision, there is not a trace of any subjective disorder, save that of defective sight.

Some subjective head symptoms may accompany optic neuritis. They are the effect of the physical changes in the orbit, or in the head, which produce the nerve inflammation, and not neuritis signs. Among them are headache, loss of memory, vertigo, epilepsy, hemiplegia, and others already spoken of.

Morbid anatomy of optic neuritis. The optic disk is swelled from exudation, and contains cell and nuclear proliferation, especially about the course of the central vessels and the lamina cribrosa. The central blood-vessels are tortuous and thickened. The thickening being by virtue of the condensation and thickening of their sheaths. New blood-vessels are developed. Occasionally there is ganglionic-like swelling of nerve fibre.

The meningeal covering of the tract, and the sheaths of the optic nerve, particularly the inner one and their inter-connective tissue, display the earliest inflammatory tissue change in redness, and pervasion by soft inflammatory products. The sheaths of the nerve bundles are likewise involved. The quantity and the quality of the products in any part of the optic apparatus, including the disk, depend on the degree of inflammation.

The question of the disk being even alone inflamed, crops up in a more definite form here than heretofore. What has been said indirectly in the matter might be considered by my reader to be sufficient. I have long ceased to believe in isolation of inflammation in the disk end of the nerve, and my view grows stronger and

stronger. Some of those who take an opposite view, say that dissections prove their opinion; so they may, if only the disk end of the nerve be examined, while the rest, to the naked eye, appears healthy. A careful inspection with the microscope, when there are no coarse symptoms, of the nerve origin, tract, chiasma, and nerve trunk, is needed to furnish the answer, and so far as I can ascertain, when adopted, it has declared against the individuality of inflamed disk.

At a later stage, the proliferating nuclei and newly-formed cells become changed into groups of granules and colloid masses.

The nerve fibres long resist implication, but they become thickened and varicose, break up into fatty granules, and are quite destroyed. Any part of the tract or nerve may be more inflamed than the rest, but whatever may be the intensity of the inflammation, it is seldom that it does not pass through the entire thickness of the tract or nerve.

Symptoms of grey atrophy of the optic nerve consequent on neuritis, together with the morbid anatomy alterations. The atrophy will be best seen under feeble illumination by the direct method of examination. See Helmholtz's Ophthalmoscope, p. 284.

Blueish paleness of the disk without atrophic excavation. The paleness is due to the disk capillaries being lost, or more or less covered or masked by the proliferated connective tissue. But it depends chiefly on the former state, being more of an anæmia effect. The whiteness, or paleness, or blueish whiteness of a disk at any time, is not a symptom of tissue morbidly changed, as each one is the natural aspect of disk-connective tissue, more or less deprived of blood. It does not express an actual atrophic state of the nerve fibres, because, except the slight metamorphosis which they undergo, their removal constitutes their atrophy. The absence of excavation depends on the pressure of proliferated tissue. Loss of transparency of the disk prevents the central blood-vessels from being traced so deeply as in health. These vessels, reduced in number, seem laid on the disk, rather than coming out of it, and they do not shrink till an advanced degree of atrophy has arrived.

As the newly-formed connective tissue comes up to the surface of the disk, the lamina cribrosa, the nerve boundary, the choroidal and sclerotic boundaries, are more or less veiled, the disk outline is not well defined, being ragged or blurred, as if surrounded by a halo, and not readily distinguishable from the retina which is generally slightly clouded immediately around.

Such description expresses recent atrophy, the first destructive effect. In a few years when the proliferated connective tissue con-

tracts, the disk reduces in volume, gets more regular in outline and white, and the blood-vessels, especially the veins, contract, but the lamina cribrosa is always concealed.

The alteration in the nerve trunk is but a more advanced stage of the morbid alterations of neuritis. As the disintegrating processes proceed, the atrophy, the final destruction, converts all into a grey, shrunken filamentary mass. The nerve elements disappear, their place being filled by fatty degeneration, amyloid bodies, &c. Much of the areolar tissue disappears also, especially in the neighbourhood of the blood-vessels. The chromo-lithograph expresses this.

The fundus of the eye may now show one of several aspects. For instance, a greyish white disk, surrounded by a retina but little or not at all altered, through which the choroidea shines. Or where neuro-retinitis has prevailed with marked implication of the retina, the greyish white disk lies in a chronically congested retina, which reddens the entire fundus, and blots out the blood-vessels of the choroidea, or obscures or renders quite invisible the central blood-vessels of the retina, except where they are close to the disk, or a large branch of them takes rather a straight course. Or, a whitened disk, scarcely distinguishable from atrophied retina and choroidea.

Causes from intra-cranial influence.

Meningitis. The general prevailing occurrence of meningitis, the symptoms of which I shall not describe, at the anterior and inferior parts of the brain, in the latter case called basilar meningitis, from intra-cranial causes, is sufficiently known. We meet with it in association with tubercular and syphilitic deposits, gummata in the cranium, in fever, especially in children, and in erysipelas of the head and face. Meningitis from external causes, which are usually traumatic, chiefly affects the upper cerebral surface.

It is the position of the meningitis, and its continuity to the optic apparatus, the tract, the chiasma, and the optic nerve proper rather than the kind of it, which is important, although the syphilitic form concerns us more than any from its frequency, the tendency of the optic nerve to become attacked, and the active proliferation which attends it.

Extensive basilar meningitis would necessarily involve several nerves at the base of the brain, some in paralysis, and some in irritation, which is almost surely manifested in spasmodic contractions.

Hydrocephalus. This is a common cause of neuritis and blindness, whether it be simple and primary, or secondary and mechanical, the result of pressure on the veins of galen, the lateral sinuses, &c.

Intra-cranial tumours. These include exostoses, cysts, aneurisms,

tubercles, abscesses, blood-clots, hydatids, sarcomas, carcinomas, as well as the enlargement or thickening of any part which thereby encroaches on the intra-cranial space.

Intra-cranial tumours are certainly not common, but there is reason to believe that when they are present, they seldom fail, at some period of their existence, to affect the optic nerves.

If we endeavour to explain how or why the neuritis is developed in association with tumours, we soon get out of our depth and show our ignorance. In the hope of getting some facts in this direction to reason from, Dr. Allbutt has, with much labour, learning, originality, and ingenuity, divided the intra-cranial cavity into certain arbitrary regions, seventeen of them, and traced as far as he could, the ophthalmoscopic and other symptoms, objective and subjective, of disease found there. Unfortunately he is obliged to say, "Such are the facts concerning the ophthalmic signs of intra-cranial tumours, so far as we know them. No one admits more readily than I do how few these facts are, and how difficult it is to build up any thing upon them. Taking the chapter as a whole, the reader has seen that the occurrence of optic signs is so uncertain that the ophthalmoscope will give no encouragement to the practitioner who takes to it in the hope of making careful thought and quick sense unnecessary. On the other hand, its revelations in many cases are of the greatest value and importance, and in some may even determine a diagnosis. If the subject is to be successfully followed up, it must be by the addition of large numbers of carefully-observed autopsies." This industry is not lost, for in it many workers in the same field will find many close approximations to truth, and assistance for farther discovery.

We cannot tell during life with certainty, whether any stage of neuritis means the presence of a tumour strictly so called, or any other morbid state in the head. Still less can we tell the diseased cephalic region, the whereabouts in the cranium, whether it be in cerebrum, cerebellum, or at the base of the brain. We can only infer that there is an adventitious product somewhere. The position can be determined only by evidence other than the neuritis, which no more localizes it than any accompanying headache or vomiting, the most common of accompanying symptoms. Occasionally one might make a happy guess, after a thorough scrutiny of all the symptoms, and the history of a case. It is on account of this uncertainty that the mere clinical side of any instance of neuritis, can never form a valuable and full record, nor be safely used to base a theory on. A post-mortem examination is always needed as a corrector, and so it is that "our very interesting cases" date from

the post-mortem room. We must then, as Dr. Allbutt says, avoid the "misleading of cases not controlled by autopsy."

The difficulty of these investigations is increased, in consequence of the neuritis ensuing as an effect of tumours, &c., in parts of the brain which have no direct communication with the optic tracts; such as the pons and cerebellum; the cerebral irritation not being in the course of their fibres.

I think we must conclude that many causes come into operation. Prejudicial effects of indirect and direct pressure must operate largely. Mechanical interference to the blood-supply of the tract, or indirect interruption to the same, from loss of nutrition in the blood-vessels, through damage to their nerves at their origin, or in their passage, have been suggested. Inflammatory action in extension from other parts is proved. Benedikt's theory of vaso-motor disturbance arising out of morbid innervation of the sympathetic nerves, a symptom of manifold cerebral morbid processes, and causing the neuritis, is supposed by many to be applicable to the majority of cases. The narrowing and degeneration of arteries, and the direct effect of irritation of nerve nuclei, cells, and fibres, have their advocates.

To the two classes of cases alluded to, under the subdivison of subjective symptoms, without any other than impaired sight, no cause can be assigned. We rarely get autopsies of such. To refer them to states of disturbed cerebral circulation, and cerebral congestion, is the most we can venture to do.

Some of the theories respecting the cause of slight neuritis, the engorged disk, must be noticed. The supposition that mechanical impediment in the skull, presses on the cavernous sinus, interrupts the flow of blood through it, and indirectly that in the ophthalmic vein, whereby the circulation in the disk becomes strangulated, and the disk engorged, is untenable. The same may be said about any intra-cranial cause supposed to produce pressure and compress the cavernous sinus. A more powerful objection to the above than the anastomosis in the orbit between the ophthalmic and other orbital veins, through which the central vein of the retina does not altogether empty itself into cavernous sinus, and farther the anastomosis of the orbital veins with veins external to the orbit, especially the facial, whereby disk stasis is prevented, is, that, any symptoms really arising from the stoppage of blood in the cavernous sinus, would be resented by more marked intra-ocular changes, especially in the retina, and such orbital ones as I have described in Chapter XI. An erroneous conclusion which the advocates of the above views arrive at is, that engorged disk and intra-cranial tumour go together,

while advanced neuritis, and intra-cranial inflammatory action are associated as effect and cause. The frequent exceptions spoil any such rule. In Mr. Hulke's valuable and well-reported cases of neuritis optica, &c., in the Royal London Ophthalmic Hospital Reports, thirty-nine post-mortem examinations were made. In one of them with ophthalmoscopic signs of "neuritis descendens," the cavernous sinus was implicated in a sarcoma growing from the base of the skull. In the second, an engorged papilla was associated with a growing tumour in the middle fossa of the skull and orbit. The third I have already quoted, to show the existence of engorged disk with post-ocular neuritis. In it the cause was meningitis and node at the base of the skull.

Another theory is set forth, based on the alleged anatomical fact, for which we are indebted to the investigations of Schwalbe, continued by H. Schmidt, Manz, and others, that the arachnoid space is continuous with a canal which passes between the sheaths of the optic nerve into the lamina cribrosa. It is said that if there be dropsy of this canal from serous effusion, the effect of inflammation, or tumour-pressure, that is exaggeration of intra-cranial pressure, by which any naturally existing serous effusion in the arachnoid is pressed into it, not only will the lamina cribrosa be pushed forward and the disk made prominent, but the lateral pressure on the nerves will reduce the volume of the central artery of the retina, and also by compressing the accompanying vein, check the return of blood and so engorge the disk.

That there does occur effusion between the optic sheaths is certain. It is a point yet to be worked out in the post-mortem room, what are the relations between such and optic neuritis, and other conditions of the brain and its membranes, in which no disk-changes have ensued; in other words, what is the value of optic nerve sheath dropsy? Dr. Broadbent met with a fever patient in whom the optic disk though not prominent, was well-defined, pink, striated by vessels, the central veins being large, the arteries small. After death meningitis was detected with considerable effusion of *arachnoid* fluid, especially at the base of the brains. Along with inflammation of the tract and optic nerve, there was marked nerve sheath dropsy. Some writers tell us that the nerve dropsy is the rule in neuro-retinitis. Galezowski says that he has made more than fifteen autopsies in such cases, where cerebral tumours have existed there cerebral meningitis had occurred, and not once has he seen the nerve dropsy.

Neuritis from the presence of a poison introduced from without.

Alcoholic poisoning. I fully recognise a slight form of impairment of the acuteness of sight, amblyopia, without reduction of the visual

field or ophthalmoscopic signs, in hard-drinking men, and drunkards. I attribute it to the effect of exhaustion from innutrition.

I am not familiar with the presence of neuritis in persons with symptoms of alcoholic poisoning, but such association has been described in drunkards' delirium. It is easy to understand that the optic nerve may inflame when the arachnoid and pia mater membranes are so affected.

Tobacco-neuritis. This has no existence according to my observation. Without discussing the question, I will merely state that after much clinical investigation, and an examination of the literature on the subject, I conclude that tobacco has no special effect on the optic nerve. Where in cases of excessive smoking, the brain, "nervous centres," are affected, along with tremor, &c., the optic nerve may suffer in its function, just as the olfactory and the auditory nerves do, and impairment of sight ensue. Such instances are rare, but I have met with several, and never could I find a trustworthy ophthalmoscopic sign. In all of them, alcohol had been abused as much as tobacco.

Optic neuritis from lead poisoning. Through the kindness of Mr. S. W. Rayne and Dr. Hulme, medical officers to extensive white lead works at Newcastle-on-Tyne, I have, during professional visits to that town, examined many persons with saturnine neuritis. All were women. In every instance, there was the complication of one or several of the following symptoms. Blue lead mark in the gums around the teeth, lead colic, wrist drop, loss of hair, pain in the back and head, and occasionally vomiting; rheumatic pains, so-called, but perhaps neuralgic ones; facial paralysis.

At first I thought I had before me primary atrophy, but a farther examination showed slight exudation in and even about the disk, in association with decline in the disk vascularity. I suspect that disk anæmia sets in before the exudation occurs.

The remarkable contractions of the retinal blood-vessels, along with the disk blanching, and the integrity of the choroidea, are the objective characteristics.

The consecutive atrophy was blueish white rather than white.

The long persistence of sight, with so much disk change, as well as the retention of the acuteness of central vision, and undisturbed range of accommodation, very much astonished me. Peripheral vision was defective, but I had no means of testing the defect accurately.

A question naturally occurs, and which I cannot answer, Is the neuritis merely symptomatic of some brain change, or a primary effect of the lead influence?

I found that all the precautions provided to protect the artisans from the effect of the lead, were totally disregarded.

I did not see any instances of paralysis of the ciliary muscle, nor of saturnine retinitis. Both are said to be lead poisoning symptoms.

Neuritis from menstrual disorder. Existence of such is very questionable.

Neuritis from syphilis. This occurs in the secondary form of syphilis. It would seem that the chief difference between it and the neuritis from intra-cranial syphilis is the greater tendency for the one eye to be attacked, there being neuro-retinitis rather than pure neuritis, and the trunk of the nerve being affected in an ascending direction, ascending neuritis.

PRIMARY OR WHITE ATROPHY OF THE NERVE FROM INTRA-CRANIAL INFLUENCES.

This is so called from the whiteness of the disk, in association with the shrivelling of the nerve, and the supposed development of the change, without a preceding inflammatory stage. The prevailing modern pathological opinion is, that a state of inflammation or at least of hyperæmia, precedes the atrophy, neither of which need necessarily appear at the disk, the nerve end. It is probable that both often appear and are never detected. I do not believe in development of white disk atrophy apart from an abnormal state of the optic nerve or tract.

Although there is a wide distinction in a morbid anatomy point of view, between optic neuritis and white atrophy, the conditions which always determine the one or the other, are not indisputably settled. It seems at times, as if either might arise from the same cause. I find described grey atrophy from optic neuritis, on one side of each disk, and white atrophy on the other. When I have proposed to draw pathological conclusions respecting the optic nerve, from the conditions of neuritis and atrophy in other nerves, I am met by the statement that the optic nerve is perhaps an exception as one of special sense, and might be much influenced in its nutrition by the retina as atrophic centre.

The generally assigned origin of the atrophy is nearly always mechanical; such as interruption to the nerve nutrition from causes operating at the base of the brain, tumours, &c., dividing or crushing the tract at its origin or in its direct course, or so influencing the chiasma, and in a manner less marked, hydrocephalus, or ventricular

dropsy. To adopt this explanation will suit some cases of atrophy but not all.

White atrophy is said to be determined by sclerosis in the tract, or in the optic nerve, in association with the same in the brain, or in the spinal cord.

The association of atrophied disks, chronic myelitis, and locomotor ataxy, is well known.

Paralytic affection of the ocular muscles may appear early in locomotor ataxy, and the pupil may contract early, but as a rule the optic nerve is not affected in it, or in chronic myelitis, till the general effects of the spinal degeneration are well marked.

In general paralysis too, the optic nerve atrophies. Dr. Allbutt has published the following statistics, Med. Chi. Trans.: In fifty-three cases of the paralysis, the eyes showed no changes in five. Of the remaining forty-eight, the disk was atrophied in various stages in forty-one. In seven, any change was doubtful.

Ophthalmoscopic symptoms. Whiteness of the disks, for both are affected. Slight cupping, atrophic excavation. Reduction in the number and size of the central blood-vessels.

All atrophic changes are at first best seen towards the outer part of the disk, where the capillaries are fewest. In the latest stage, when the lamina cribrosa is much exposed from the destruction of the nerve fibres, the aspect as received by the indirect method, is tendinous and stippled, rather than white, and tints of grey or blue may be produced, by varying the light on the disk. But by the direct method, the white character is seen. To the atrophy of the disk-capillaries, is the whiteness due.

The disk is always sharply defined, although the outline may be irregular. In advanced stages it is frequently oval. These changes imply shrinking, which may be considerable, but the round and normal size may be long preserved with the fullest blanching.

The reduction in the calibre of the retinal blood-vessels commences in the arteries and, as a rule, progresses with the nerve-shrinking. The distinction between the arteries and the veins is soon apt to be lost. These vessels cannot be traced far into the retina, and some of them may nearly or quite disappear, or be accompanied by white threads like lines, due to alterations in their walls.

As exceptions, the blood-vessels may seem unchanged, or the arteries only altered, or if the veins be abnormal, they may be distended.

The atrophic morbid excavation or cupping of the disk must be well understood, in contradistinction to the physiological cupping. It means loss of disk nerve-fibre, with or without loss of connective

tissue, and thereby the production of an anæmic cavity, which affects the normal course of the central blood-vessels, by which altered course is demonstrated the existence of a cavity.

The back of the cavity is the lamina cribrosa. The margin is formed by that of the retina and the choroidea, or the latter singly. The side is either the sclerotica and nerve-fibre, or connective tissue, according to the degree of the atrophy, and any attendant tissue proliferation.

The excavation or cupping is shallow, deepest in the centre, although it may be very wide. It is shallow because the lamina cribrosa is not pushed back as in glaucoma, where the excavation is deep. It differs besides from glaucomatous excavation, inasmuch as, when well-marked by much loss of nerve-fibre and exposure of the lamina cribrosa, the sclerotic ring stands well out, particularly on the inner side. In glaucoma, this ring is pushed back, along with the lamina cribrosa. As the central blood-vessels have not to climb steep walls, on account of the form of the excavation, the margin not being abrupt, but walls which are gradual and sloping, they do not show much displacement at the edge of the disk, but pass over it with a more or less feeble curve, or scarcely any appreciable curve. Engorgement of the veins, so common at the edge of the excavation in glaucoma, is not apparent. The reduced blood-vessels may generally be traced from their entrance through the lamina cribrosa to the retina, no part of them being lost to view, as in glaucoma.

The fullest appreciation of the atrophic state can be received only when an opportunity occurs in the same person, of comparing the diseased eye with the sound one.

In the beginning of the atrophy, an oblique oval whiteness is seen in the disk, remarkable for its brightness. This surrounds the prus opticus on its temporal side. The brightness extends and becomes circular, but never goes beyond the connective tissue ring, or nerve boundary of the disk. Ultimately the disk becomes of a pale white, then of a dull cold aspect, like satin or mother-of-pearl.

The subjective symptoms differ in scarcely any particular from those of optic neuritis, so that what has been said respecting them applies here also.

The prognosis is still less favourable than that of optic neuritis, as blindness is more common, and complete recovery never ensues. Nor can I say that improvement is even met with, but the progress of the atrophy is often arrested.

The treatment is less clearly indicated than in neuritis. I believe

that the iodide of potassium, as a routine medicine, will afford the best chance of checking the disease.

I am often told, and even read, about the advantages of subcutaneous injection of strychnia, from one-fortieth or one-fiftieth of a grain, injected into the temple or arm daily, or on alternate days, or at intervals of a day or two, till there is benefit, or unless dizziness, itching, headache, or limb twitching ensues. Dr. Nagel has extolled the method in various degrees of optic nerve blindness. I have never seen the slightest benefit result from such treatment, where there has been any organic change visible in the optic nerve or in the retina. Where it is supposed to have been of benefit, as in cases of loss of acuteness of vision arising out of depression of the system from hæmorrhage, &c., such as those of which I have spoken at the end of the section on optic neuritis, we know that recovery may come about with hygienic measures without the use of drugs, although certain astringents and tonics add to the rapidity of the recovery. I have no room for the various other methods of treatment which are recommended. The continuous galvanic current is now fashionable, and therefore highly extolled. In no stage of this atrophic process do we find the retina inflamed, as we may see in that of neuro-retinitis. We do not, therefore, get the white disk in the red fundus.

THERE ARE SOME POINTS IN COMMON TO GREY CONSECUTIVE ATROPHY AND WHITE ATROPHY WHICH I HAVE PREFERRED TO PLACE UNDER A SEPARATE HEADING.

Extra-ocular causes. Disease of the optic nerve apparatus, or its coverings, of the brain, and of the spinal cord.

Intra-ocular causes. Retinitis, glaucoma, embolism of the central artery of the retina.

Disk atrophy, irrespective of cause, may pass through its stages and be developed in one eye without a single subjective symptom having been noticed, till blindness is discerned only by accident. I have met with such examples many times, and even in association with the most advanced state of the atrophy, by which was shown the long existence of the nerve disease.

The retina is always involved in both forms of atrophy from extra-ocular causes.

In the white, the internal layers, or nerve-tissues, suffer chiefly, becoming anæmic and wasted. The choroidea, too, becomes atrophic in patches near to the disk. The vitreous body liquefies.

The aspect of the atrophic disc does not, at any stage, afford indication by which it can be told that the atrophy is progressing or not.

In the grey or consecutive disc atrophy, all the layers of the retina are, more or less, generally implicated in atrophy, and retinal detachment may ensue.

Where from intra-ocular causes the retina is the starting-point of the nerve disease, it and the choroidea are early and completely disorganized.

Pathological pigmentation of the disc occurs (see Natural Pigmentation, p. 303) most commonly in atrophy consequent on traumatic ophthalmitis. It is due to the escape of the colouring matter of the blood, hæmoglobin, or to the blood itself, passing through the walls of the blood-vessels under conditions of congestion. Or, direct sanguineous extravasation from rupture of the blood-vessels. The hæmoglobin is chemically converted into reddish-brown or black pigment granules and crystals, hæmatoidin. Pigmentation occurs too in the retina around the disc, as irregular clumps, or offshoots, or bodies like true corpuscles, or patches.

The chief atrophic mark, I wish to lay stress on this, is the reduction in the number and size of the central blood-vessels. Only a single artery may remain, and pursue its course without a branch, or all may be removed from sight, and only a few small veins remain. I have seen a white disc from lead poisoning without a single blood-vessel of any size.

Colour-blindness in optic nerve atrophy. Lebert has given much attention to this subject, and shown that with the atrophy colour-appreciation is defective. He finds that while the defect is mainly like ordinary colour-blindness where there is no nerve atrophy, and that in neuritis without atrophy the appreciation of colour is not interfered with, the loss of the perception of red is about the first evidence of colour impairment. This is strange, as red is the most exciting and positive of all colours. Blue, the coldest and most retiring, is about the last which is perceived. Small coloured spots, or small pieces of coloured paper, are better to employ the test with than masses of colour.

Some cerebral pathological facts in association with neuritis, and with atrophy of the optic nerve, must be given.

Paraplegia existing with neuritis, signifies brain lesion in and beyond a hemisphere, which is the commonest seat of the causes of neuritis. Perhaps the corpus striatum is involved.

Disease of a hemisphere alone does not paralyze any cranial nerve.

Intra-cranial causes of neuritis and white atrophy almost invariably affect both optic nerves, even where the affection out of which it arises is limited to one hemisphere.

One eye often suffers more than the other with neuritis or atrophy, and even where only one hemisphere is diseased, there is no regular correspondence between it and the worse eye.

Neither neuritis nor white atrophy has ever been found with disease limited to the pons, the optic thalamus, or medulla oblongata.

Marked pathological changes in the disc are not infrequently associated with unilateral spasm and unilateral paralysis, but not unilateral irregular movements.

Intra-cranial disease, producing neuritis and white atrophy, is almost always what is called "coarse."

Neither neuritis nor white atrophy appears at the disc as an immediate effect of brain lesion, the lapse of days at least being required for either to be seen with the ophthalmoscope.

Recent cerebral hæmorrhages, although large, provided they do not destroy the visual centres, induce no ophthalmoscopic signs, certainly not during the state of insensibility which occurs from them. The presence of a clot, like all other foreign bodies, within the brain, may in time induce neuritis or atrophy. Yet the association is rare. A clot resting on the optic nerves may affect them directly by compression.

Brain softening, even when large, unless it interfere with the optic centres or tracts, does not spoil the optic nerve.

Intra-cranial abscess is a common cause of optic neuritis and atrophy.

The occurrence of neuritis in brothers and sisters, without any apparent head symptom, has been noticed by several surgeons. In my own practice, three brothers out of seven children were attacked, two at the age of fourteen, and one at the age of eleven. In all of them the affection progressed till peripheral sight was destroyed, and central vision was very much reduced and imperfect.

Intra-cranial aneurism rarely sets up neuritis or atrophy. If it be strictly at the base of the brain, it may produce symptoms like those of a cerebral tumour, except in not affecting any of the special senses.

In association with optic neuritis, Dr. Jackson describes epileptiform amaurosis, a mere temporary loss of sight, or temporary development of colours, sparks, &c.

Such ocular seizure may occur alone or be followed by a convulsion, or by loss of consciousness, or convulsive seizures. If there be with either variety of transient affection of sight, or with permanent

affection of sight from optic neuritis, an epileptiform seizure beginning in the hand, or cheek, or foot, we may conclude that there is disease of convolutions of the cerebral hemisphere, opposite the side of the body on which the convulsion begins, and that the part of the faulty hemisphere is near to the corpus striatum.

Temporary defect of sight occasionally becomes permanent, usually through the sequence of optic neuritis.

Often, in cerebral cases, epilepsy for example, there are found changes about the discs, such as silvery streaks along the blood-vessels, or specks on the vessels, or slight obscurity of the vessels just beyond the discs, or a sudden bending of the veins just beyond the discs. The interpretation of these appearances is doubtful, especially as to the probability of there being only physiological peculiarities.

While neuritis is so common a result of intra-cranial tumour, deafness scarcely ever, perhaps never, ensues, unless the tumour producing the neuritis compress the auditory nerve.

TEMPORARY PARTIAL INTERRUPTION TO SIGHT.

I meet with this as a part of the general debility which arises during fevers, or subsequently to them, or any exhausting illness, or hæmorrhage at parturition, or menorrhagia, or during pregnancy. This is distinct from the loss of accommodation, which is usually an accompaniment of the defective sight, but may exist alone and without any optic nerve impairment, and of which notice is elsewhere taken. There are no ocular objective signs. The pupil acts well, and the interior of the eye is not abnormal.

There is another form of temporary loss of sight, that without any apparent cause, and which pathologists say may be due to retinal or cerebral fault. We know that it may recur occasionally for a year without any bad symptom following. Its importance must be judged of chiefly by the existence of any objective symptoms, such as numbness of the limbs, unilateral spasm, &c. With such association, blindness may be expected.

Temporary coloured vision is met with, unassociated with any other defect. The remarks which I have made about the second form of temporary partial interruption to sight, apply here also.

AMAUROSIS, *ἀμαυρόω, to render obscure.* AMBLYOPIA, *ἀμβλύς, dull; ὤψ, the eye.*

These were in olden times the terms used respectively to signify blindness and impaired vision, when there was no discernible cause. It is a pity, now that the ophthalmoscope and other means reveal so much about blindness and the nature of defective sight, and too, when we are accustomed to speak of abnormal conditions of the eye definitely, that such expressions be retained, for they tend to confusion. Science and teaching will be benefited by their exclusion. Some writers wish to retain the term amaurosis, and to apply it to destruction of eye function from disease in the optic nerve apparatus, but even this cannot be done apart from confusion. It is far better where an eye is sightless to say that there is blindness, which will carry all the causes of loss of sight, and where there is impaired vision, to say, if we can, what the defect is, be it detached retina, grey atrophy of the optic nerve, retinitis, or loss of accommodation, displacement of the crystalline lens, &c., than amblyopia, which really expresses nothing. Systematic writers of eye books who devote a chapter to amaurosis and amblyopia, are forced to repeat what has been said before, respecting the several conditions of the eye in association with abnormal sight.

APOPLEXIES OF THE OPTIC NERVE.

Disc apoplexy has been described. Apoplexy of the optic nerve in the orbit, and commissural apoplexy, have been conjecturally diagnosed, to account for certain cases of monocular and binocular sudden blindness, but confirmation by morbid anatomy is wanting. According to Knapp, apoplexy between the sheaths of the nerve has been verified.

TUMOUR OF THE OPTIC NERVE.

A tumour, as seen in the disc by the ophthalmoscope, must be indeed rare, as I have not met with one, and but very few are on record.

Myxoma is the class to which this optic nerve tumour belongs. The new growth, so far as the optic nerve is concerned, is encapsuled by the optic nerve sheath, thrusts the eyeball forwards, limits

its movement, and produces blindness. In one case similar small analogous tumours were developed in the fatty tissue of the orbit.

The diagnostic mark by which it is to be distinguished from simple inflammatory tumefaction are, irregularity in disc prominence, variety in light and shade in the enlarged parts, distention of the sclerotic ring, and abruptness of the walls which separate the tumour from the neighbouring healthy retina.

CHAPTER XLVIII.

DISEASES OF THE RETINA.

NEURO-RETINITIS—RETINITIS ALBUMINURICA—RETINITIS SYPHILITICA — RETINITIS LEUCÆMICA — RETINITIS PIGMENTOSA — HYPERÆSTHESIA OPTICA—CYSTIC OR COLLOID DISEASE OF THE RETINA — EMBOLISM OF THE CENTRAL ARTERY OF THE RETINA — DETACHMENT OF THE RETINA FROM THE CHOROIDEA AND FROM THE VITREOUS BODY—HEMERALOPIA OR DAY BLINDNESS.

The retina, of all the ocular tissues, has been most investigated anatomically in its normal and abnormal states, both in ancient and in modern times, and with such success as to render it more than probable that, with no better appliances for research, nothing new will be discovered. I may say, too, that its functions, and its diseases in their clinical bearings, have received the fullest and most anxious attention of all physiologists and ophthalmologists. The literature of the latter is, from its extent, appalling to those who desire to look into it.

Reference to my "Anatomical Introduction" will show how largely modified collective tissue enters into the formation of the retina, and forms, as it were, its framework. This tissue is in largest proportion at the periphery of the retina, while at the centre the nerve element predominates.

I have shown, in treating of optic nerve neuritis, that the inflammatory changes begin, and are chiefly developed in the connective tissue, the other tissues of the nerve being mainly affected secondarily. In the retina we find a pathological parallel.

I think the least objectionable, and certainly the most convenient descriptive method of introducing the phenomena of retinitis, is to

treat of the effect of inflammation in the retina, and then the more marked alterations, or excess of changes, or prominence of any such, occurring in this or that tissue, as varieties under respective special heads.

ACUTE NEURO-RETINITIS IN FULL DEVELOPMENT, USUALLY CALLED INFLAMMATION OF THE RETINA.

This heading, which includes optic disc inflammation, is based on clinical fact. I never saw an unequivocal instance of retinitis in which the optic disc was not more or less involved in the surrounding inflammation. No degree of optic neuritis can occur without the retina participating, in at least as respects some blood-vessel abnormalities; since the retinal vessels pass through the optic nerve and disc; and occasionally retinal haze, or opacity just around the disc, and the most intense retinitis may be a sequel to optic neuritis. See page 1074. Still we may speak of optic neuritis as an entity. We cannot, however, in a like sense speak of retinitis, since in inflammation of the retina, not grafted on optic neuritis, and probably not therefore of cerebral origin, and developing in a proliferating process, the inflammatory action invariably spreads to the disc.

It is true that the disc is rarely so markedly affected as in original and isolated neuritis. I have said, at page 1075, that when a neuritis runs into a retinitis, or a retinitis into a neuritis, the morbid features of the part first attacked usually prevail. In this I recognise retrogressive neuritis. How far up the optic nerve the inflammatory action may travel, I know not.

It must ever be remembered, as respects this parcelling of diseases, that we are frequently dealing with arbitrary divisions absolutely necessary for methodical study, but which are scarcely otherwise sanctioned.

It has long been recognised in neuro-retinitis that, although none of the retinal layers escape in the attack—how could they in a structure so thin, so liberally, and generally supplied almost exclusively by one arterial trunk?—inflammatory proliferation of the connective tissue frame-work, fatty degeneration, and sclerosis are not usually equally spread through its entire thickness, but are more apparent, sometimes in one part, sometimes in another.

The limiting membrane, and what is called the external limiting membrane of Max Schultze, and described by him as "spongy connective tissue," neuroglia, lying between the external granular layer and the layer of rods and cones, but not noticed in the "Anatomical

Introduction," are often severally the focus of inflammation, and evince accordingly different local ophthalmoscopic signs. Where the former is involved, the vitreous body partakes in the excitement, and we have superadded hyalitis, a condition which I have elsewhere treated of. The choroidea may escape. This form of retinitis, which is the commonest met with, is often called parenchymatous, or diffuse. Where the latter and the posterior layers of the retina are the points of inflammatory selection, the choroidea is usually involved and the tapetum is affected, when arises a condition called exudative retinitis, which will be described. This comparative isolation supposes, in either case of course, a mild attack of retinitis, for in a furious one there is no such distinction, the entire retina, vitreous body, and choroidea suffer.

Ophthalmoscopic symptoms of acute neuro-retinitis.

Loss of disc and retinal transparency, to an extent varying from slight haziness to marked greyness or cloudiness, which might be called opacity. This haziness, &c., may be disposed over the retina, or occupy but a part; when partial, the region of the macula lutea would suffer. In either case it might be uniform or mottled. Partial retinitis is seldom elsewhere so well marked as at the macula lutea.

The disc is swollen, hyperæmic, and irregular, with loss of outline somewhat as in optic neuritis, only, as there is less exudation than in it, the pathological changes are less marked.

The retinal arteries may or may not be contracted, but the veins are always full, dark, and tortuous. Both of these systems of blood-vessels may be more or less hidden, and not capable of being traced to their ramifications. The manner in which they are obscured is a tolerable indication of the extent of the inflammatory products present in the retina and thereabouts. This may be said in explanation about it. Where the ramifications of the blood-vessels are chiefly obscured, and such divisions are mainly in the nerve fibre layer, it is certain that the limiting membrane and the anterior retinal layers are affected. Where the blood-vessels are seen tolerably in their courses, although blurred, lying as if on opacity, the posterior limiting membrane of Schultze and the posterior retinal layers are chiefly affected. Where the blood-vessels in general are very much obscured, the entire retina is uniformly inflamed, at which time their trunks appear to be reduced in number.

Haziness of the vitreous body, hyalitis, which varies in degree, will very much influence the ophthalmoscopic appearance of an inflamed retina, and may even hide the fundus altogether. It must always be assumed that with any degree of hyalitis the retina, at least the anterior portion, is inflamed. Hyalitis is never absent in retinitis,

which begins acutely. Where the hyalitis has not appeared, as in chronic retinitis, it may show itself if acute exacerbation arise.

If neuro-retinitis be not checked other transformations appear. The retinal cloudiness increases, whereby the choroidea is veiled so as to show only a faint redness, or is so hidden that the fundus is of a dull complexion, or yellow grey. With the increase of retinal opacity, the optic disc is always proportionately obscured.

Hæmorrhage is not uncommon. It is a very prominent symptom and must be well considered. It is rare in the disc as compared with its presence in the retina.

Extravasated blood, as seen under the ophthalmoscope, can scarcely be mistaken. Its aspect, whether bright red or dark red, is affected by its depth in the retina, the physical changes which it has produced in breaking up the retinal elements, the kind of blood effused, whether arterial or venous, and the age of the extravasation; for when undergoing absorption it displays hues, in a less degree, but analogous to those we observe during absorption of blood on the surface of the body.

The extravasation displays several forms. Dots or stippling. Splashes of striation; which streaking depends on, or is an effect of, the blood corpuscles disposed in rows between the bundles of nerve fibres. Irregular patches with sharp or blurred boundaries.

The bleeding may occur in any portion of the retinal area, but there is a tendency for it to issue near a blood-vessel, especially a large vein. It may, too, have its seat in any of the retinal layers; and this situation may be recognised by the relative position to the retinal blood-vessels, or to any deposits about the retina. The nerve fibre layer is its accustomed seat.

If the hæmorrhage increase the tendency is for the blood to pass backwards even to between the retina and the choroidea, where the effusion is always large, and but rarely forwards, although it might burst the membrana limitans and enter the vitreous body.

Hæmorrhage may be the chief observed ophthalmic symptom, and such an occurrence is generally described, I think incorrectly, as hæmorrhagic or apoplectic retinitis. Its symptoms are serous exudation, chiefly in and about the disc, dilatation and tortuosity of the veins, with extravasation of blood in one or several positions of the retina. In an exaggerated case of the kind, the disc is reddened and nearly hidden by the blood, while radiating and striated extravasation surrounds it and the region of the macula lutea. According to its cause, let me take an illustration rather digressively, say disease of retinal arteries, as a part of heart and arterial disease in general, atheromatous degeneration, when it is always sudden, the arteries

are hidden at the pole by the swollen retina, and appear fully at the equator, while the veins are astonishingly distended and enlarged and very dark, and tortuous to an extent which hides portions of them altogether.

All of the effused blood in the retina may be absorbed and leave no mark. A brownish or greyish spot may indicate where the clot lay, or fatty degeneration of the tissues immediately around, the effect of atrophy, because their nutrition has been interrupted. Pigmentation may ensue, after the manner I have described in the chapter on the Diseases of the Optic Nerve.

Pigmentation, irrespective of hæmorrhage, may occur as small spots in any part of an inflamed retina.

While on this subject, it would be a pity not to complete it, although so doing may seem to make a little digression in my text.

We may speak of two causes of hæmorrhage.

Intra-ocular. Such as inflammation of the disc and retina from whatever cause, whether it arise in the retina, or primarily in the optic nerve apparatus. Embolism of the central artery of the retina. Springing out of these, the hæmorrhage may appear at any period of life. Fatty degeneration of the retinal blood-vessels. Hæmorrhage does not arise from this till middle life, and for the most part till old age. There is no retinitis in such cases.

Extra-ocular. Chronic disease of the kidneys. Leucæmia. Disease of the heart and the arteries. Embolism of the central artery of the retina before it enters the eyeball. Hæmorrhagic diathesis, and, it is said, suppression of the menses.

Several of these states will be individually considered.

The question of pure retinal hæmorrhage in middle life and old age being a precursor of cerebral apoplexy, is one which I shall not enter into more than saying that such association has been verified on many occasions.

Marks or spots, incorrectly called exudations, occur in an inflamed retina. They look in the hazy or semi-opaque membrane like whitish dots scattered in groups, or as dull glistening patches. The disc may be partially obscured by them, and portions of the choroidea hidden. Their nature will be spoken of in the section "Retinitis Albuminurica," in which affection they are a marked characteristic.

Detachment of the retina from the choroidea ensues as an uncommon event at a late period of the neuro-retinitis.

There are no external objective symptoms so long as retinitis is not complicated with inflammation of any other ocular tissue, and we know that there may for a time be isolated retinitis, a single structure affection accounted for by the manner in which the retina

is supplied with blood. It is then found that the periphery of the retina suffers less than the centre. I repeat what I have said elsewhere, that the retina is the only constituent portion of the eyeball which is ever solely inflamed. As soon, however, as retinitis intensifies, other parts of the eyeball invariably participate, the whole of it may inflame, in either case abundant external objective symptoms are manifested. There is then ophthalmitis. I must take this, the earliest opportunity which occurs to me, to say that "Ophthalmitis," as described in Chapter XXXIV., should have been headed Ophthalmitis with Suppuration, because it does not include ophthalmitis without it, and such is common enough and frequently spoken of by me when I wish to express general inflammation of the eyeball, by some surgeons called pan-ophthalmitis.

Subjective symptoms. Retinitis is generally discovered only by these. They are, haziness or fogginess, which may so increase that by low illumination there is scarcely any useful sight. In equal step with this, the quality or acuteness of direct and indirect vision, is reduced. The visual field is contracted in proportion as the optic nerve fibre element in the retina is implicated. Blind spots in the visual field or scotomata, marked loss of vision in any particular zone of the field, whether centric or eccentric. Distortion of objects looked at, especially in their outline, and other subjective symptoms of neuritis of which I have spoken at p. 1077. Loss of visual range so that the eye and the object must be approximated. A rare symptom is minifying sight, by which objects look smaller than they really are. It is called micropsia. The cause is unknown although there are theories respecting it. At last only quantitative perception of sight may remain. The eyeball feels full and it may throb. Intolerance to light and pain are not necessary symptoms in pure retinitis. They are mostly complained of in the acute forms, and are developed in proportion as the retinitis becomes complicated.

But a few years ago it was taught that intolerance to light was a leading feature in retinitis. Now we know that the intolerance is due to ciliary irritation, something superadded to the retinitis. See p. 1062.

The effect of retinal changes on sight, be the cause what it may, will mainly depend on the region of the retina chiefly affected. Disturbance about the macula lutea, or extending over an area including the macula, always destroys the power of central sight, and it is just this part in which repair is least likely to occur. So long as the macula, the most sensitive spot, corresponding to the axis of vision, escapes, direct central or perfect vision may remain, although the

equatorial portion of the retina may be diseased. On the other hand, while direct vision is lost, there may be tolerably good peripheral visual power.

By pathological research are declared changes of the retinal elements in various ways, some of the essentials of which I will mention.

The gelatinous basis of the inflammatory product pervades all the retinal layers, but more particularly the granular ones.

In the connective tissue do we see the earliest and most extensive departure from health, in the form of proliferation, to which succeeds atrophy or fatty degeneration, the latter being very marked in the granular layers. The remaining nuclei, those which have escaped inflammatory destruction, become sclerosed or changed into fatty granules, and ultimately into choloid or amyloid bodies.

The nerve elements long resist destruction. Ultimately they suffer by fatty degeneration or sclerosis; the latter form of metamorphosis is especially seen in the nerve tubes.

Out of these alterations are formed the small and large marks above spoken of, so that they are composed partly of fatty degeneration, and partly of sclerosis of different tissues. During life, however, we cannot be sure of their composition; we may guess at it in so far as an anterior opacity is most probably due to sclerosis of nerve fibre.

The walls of the blood-vessels undergo changes analogous to those which occur in the connective tissue of the retina. Hypertrophy of these, the main trunks, produces a remarkable thickness, with occasional irregularity of surface. Sclerosis occurs, by which the calibre of the vessel is narrowed. The fatty degeneration is most apparent in the branches of the vessel. To these degenerations may be said, in general terms, is due the occasional abnormal appearance of white streaks bordering the vessels, which are seen in chronic retinitis, and to which I shall again refer in some of the many subdivisions of retinitis.

Complete atrophy of the retina. I have waited till now to speak of this transformation, the still further advance of the pathological phenomena just briefly given, and which may follow any form of intense retinitis. It is somewhat anticipated in my description of atrophy of the optic nerve, for there is no such thing as optic disc atrophy without the retina being more or less, or completely atrophied as well, and in nosological strictness the two states ought to be described together. In this final degeneration contracted connective tissue nearly takes the place of the late elaborate retina, for as the blood-supply is almost or quite lost, the metamorphosed tissues, or the inflammatory products, nearly or quite disappear.

Three conditions are indicative of the atrophy: 1st, Grey or white degeneration of the optic disc, with absence of the central blood-vessels of the retina, or reduction of them with attenuation and loss of most or all of their branches, white lines sometimes supplying the places of those which have disappeared. 2ndly, Loss of retinal reflection with thinness from attenuation, whereby the choroidea, which is always anæmic, is better seen. The loss of the entire system of blood-vessels is, I suspect, the chief cause of the transparency. Exceptionally there is a little thickening of the retina around the optic disc. 3rdly, Pigmentation on the external surface of the retina, in scattered shoots along the course of the remaining blood-vessels or their sites, or around the optic disc, and sometimes on the anterior part of the retina. Deposits of crystals of cholesterine have been seen.

Partial atrophy of the retina may ensue, by which some parts are unmistakably destroyed.

There is certainly no proportion between the ophthalmoscopic symptoms and the state of the sight. With much retinal alteration there may be useful vision, and, on the contrary, with little apparent disturbance, sight may be almost extinct. This is to be accounted for, I suppose, by the nerve fibres almost escaping while the connective tissue suffers severely.

The acute and chronic stages of neuro-retinitis have little difference in their vascular complexions beyond that, in the latter, the enlarged and tortuous veins have the most impressive effect. With much inflammatory product they are forced in different planes, as in the much thickened optic disc, in optic neuritis.

Slight attacks of retinitis occur, in which there is less retinal opacity, less vascular excitement, with less gorging of the retinal veins, in which too hæmorrhage is absent. The subjective symptoms are not very marked; perhaps there is only slight haziness of sight.

In the duration also of retinal inflammations there is much variation.

Causes of neuro-retinitis. Pure neuro-retinitis is a symptomatic affection depending on some general disorder, such as Bright's disease, or syphilis, &c.; but this must be understood to apply more to the commencement of the inflammation, for, except in Bright's disease and in leukæmia, other structures of the eye are soon implicated, and choroiditis, as well, is always prominent.

What is called functional irritation, that is the effect on the eye of direct sun rays, or the direct rays of artificial light, as experienced by cooks, stokers, &c., or the intense reflection of such rays, affects the retina chiefly as a part of the inflammation of the interior of the

eyeball, which is thereby set up. The same may be said of retinitis arising out of circumstances which affect the distinctness of retinal images, when minute vision is required to be long sustained under the disadvantages of imperfect or unsteady light, by eyes which are highly hypermetropic or myopic.

Neuro-retinitis from traumatic influence, whether arising out of the operation for solution of cataract, or indeed from any operation on the eyeball, or accidental wounds or blows, is scarcely more marked than the inflammation of the choroidea, a part of the ophthalmitis which is sure to be present. It would be a waste of time to attempt to discover whether, in such general ocular disturbance, the retinal or the choroidal inflammation have the priority.

Symptomatic retinitis, and retinitis from functional irritation, are for the most part binocular.

Relapse in retinitis is common, and points to the necessity of obtaining absolute recovery from an attack, of removing exciting causes, as well as protecting the eye from even an occasional exposure to them.

Expectancy of neuro-retinitis. The gradual manner in which neuro-retinitis is usually developed, especially when monocular, is apt to cause its existence to be overlooked. The progress is slow, what is called chronic, rather than quick, or acute. Besides this, the course is generally irregular, such as the symptoms intensifying, then becoming chronic and ending slowly.

The prognosis, as it is capable of being gathered from the ophthalmoscopic signs and the state of the vision, for these are to be regarded rather than the cause of the retinitis, may be expressed in this manner.

Where the inflammatory products are small, the retina is uniformly affected, and the inflammation has not been of months' duration, considerable, or even complete recovery may be expected. Where the inflammatory products are extensive, whether uniformly deposited or lying in spots, partial recovery only can be looked for, because the nerve elements will in all probability be much damaged. The longer the duration of inflammation the less the chance of preventing functional deterioration.

Impairment of vision, even to preventing discernment of small objects, such as the fingers, except when held close to the eye, is a far less threatening perversion than interruption in the visual field.

In many of the so-called cases of recovery from retinitis, while the eye is available for many employments, it is troubled with a mistiness of sight, which incapacitates it for the full exercise of distant or

of minute close sight, and for which relief cannot be obtained from optical appliance.

A perivascular retinitis, first described by M. Iwanoff and confirmed by two or three observers, must be noticed. It can only be a very exceptional state, as so few persons appear to have seen it. Its chief characteristic appears to be proliferation of the connective tissue in the course of the central blood-vessels and on the vessels, by which they assume the appearance of white lines with a central streak of blood. Varying the direction of the ophthalmoscope, so as to obtain a lateral view of the blood-vessels, is advantageous. The disc is cloudy, and cloudiness passes into the retina in the direction of the vessels. It is said that a true clinical picture has not yet been ascertained, that is, agreed on.

Dissection showed serous transudation in the retina which separates its elements without spoiling their function. The external layers of the central blood-vessels changed into round or fusiform nuclei, forming a distinct sheath which passed from the disc to their termination. The veins less thickly coated with nuclei than the arteries. The blood-vessels thus changed projected from the retina. It is attempted to be shown that this differs from fatty degeneration. The nerve elements slightly changed during the acute period.

A circumscribed retinitis has also been spoken of in systematic eye books. It is to be recognised by pathological changes round about the macula lutea. First hyperæmia, then ensues a yellowish blue or greenish hue. The retina around is partially cloudy. The objective symptoms are central scotomata. This is evidently but neuro-retinitis, in which the inflammatory effects are not uniformly deposited, and to which allusion has been made.

Treatment. We must attend to the so-called general principles, including rest to the body and to the eye, the reduction of preternatural heat in and about the eye by cold applications, alleviation of pain, by local anodynes applied cutaneously or subcutaneously, and attention to any prominent associated general symptom. We must further take as a guide for curative attempts, the cause of the retinitis. Under the several varieties, therapeutic measures will be discussed.

Traumatic retinitis, as a part of traumatic ophthalmitis, whether arising from operations or accidental injury, has been considered respectively in its proper place.

Retinitis from functional irritation should be met by the removal of the exciting cause and an endeavour to reduce any subjective or objective phenomenon.

RETINITIS ALBUMINURICA, OR NEPHRITIC RETINITIS.

Objective ophthalmoscopic symptoms. These display the many conditions of neuro-retinitis and neuritis, sometimes mixed, sometimes with strong individual markings. In whichever condition presides, there is variety while developing and while declining. Each of these inflammatory states has been described in detail, and need only be alluded to. There are, in addition to any of them which may be present, peculiar appearances which are definite and characteristic of this specific retinitis, and may be thus summed up. Hæmorrhage, or apoplexy, proliferation of connective-tissue, sclerosis of nerve-tissue and blood-vessels, fatty degeneration of the proliferated tissue and of parts of the normal retinal tissues. These must be fully described. The changes do not all occur at the same time.

At first the alterations in the fundus of the eye, however limited or extended, are those of congestion or hyperæmia, chiefly venous, and swelling. The tendency is to gradual and slow development of such symptoms, from the disc outwards, and so the disc and retina just around are first affected. The entire retina may be, but is not usually equally affected, the action lessening towards the circumference. To this hyperæmia and swelling follow greyish cloudiness, by which the disc-boundary, the central retina, and choroidal blood-vessels are obscured. The central retinal veins are enlarged, tortuous, and varicose, and are darker or lighter, as they are a little hidden or are plainly visible. The central retinal arteries are apt to lessen in calibre.

Hæmorrhage, about the first characteristic of the disease, now appears. It is always early; I have seen it even before the cloudiness. Its favourite positions are around the disc and in the macula lutea region. It occurs chiefly in the nerve-tissue or internal layer of the retina. It may extend into the outer layers, and even pass beyond them between the retina and the choroidea, as I have shown, according to the rules regulating retinal hæmorrhage in general. Parts of individual trunks of the central blood-vessels of the retina may be pushed forwards, and even concealed by the clots. The observer must be prepared for variation in the extent of hæmorrhage, from a mere point or two to large and numerous splashes. Subsequent hæmorrhages modify the appearance of previous ones. The presence of ecchymosis following partial blood absorption, and the bright redness of recent sanguineous outbursts, may coexist. In the intergranular layer blood has been found in distinct cavities.

Hæmorrhage is a symptom which I have met with alone, as the

only distinguishing mark of nephritic retinitis. Several of my patients have died from albuminuria, without any further eye mischief, because there has been no time for any other.

Whitish grey, or bright yellow, or buff-coloured, or absolutely opaque, and always slightly raised marks or spots, with irregular borders and some streaking, form in the cloudy and swelled retina around the disc. I have, it will be remembered, spoken of these as symptoms of neuro-retinitis, and promised to explain them. Some small brilliant dots, as constellations, round and about the macula lutea, and a few more widely scattered, generally coexist. They are mixed up with, and partially covered by the blood-effusion, which may modify their colour. Their posterior position in the retinal layers, is proved by their being behind the blood-clots, and behind the central retinal blood-vessels. Rarely only do they appear antecedent to hæmorrhage. These spots, or second retinal characteristics, ranging in size, number, and position, may increase, and some of them run together and form a large blotch, or they may unite in a belt around the disc. In any case of their presence, a little space generally intervenes between them and the disc. Their edges may be well defined. As an effect of contrast they make the disc look very red. The dots, too, in stellation, may coalesce into clumps and join the belt.

Fully developed optic neuritis may precede any retinal changes, or accompany them, but it is never a neuritis without complication at some time with the characteristics of the nephritic trouble.

There are no proper outward objective symptoms.

Subjective symptoms are, loss of acuteness of sight with cloudiness, or darkening of the visual field, with or without peripheral contractions of it, or marked interruptions in its area. They are sudden if hæmorrhage occur about the macula lutea. But there are no symptoms of this kind proper to the retinitis by which it can be properly known.

Both eyes invariably suffer, not necessarily simultaneously, and never in the same physical degree, but they are always typically alike.

Where the characteristics are not well marked, it may not be possible to make a correct diagnosis, unless the kidney symptoms be relied on.

The ocular complications are, hyalitis, not always present.

Morbid anatomy explanation. This need only be very short.

Enough has been said about hæmorrhage.

Serous and fibrinous, or at least coagulable fluid and proliferated connective tissue, cause the cloudiness of the disc and the retina, particularly its central parts.

Sclerosis of the nerve-fibres plays an important part. It attacks not only the fibres of the disc with ganglionic enlargements, but in an especial manner the radiating nerve-fibres around the macula lutea.

Sclerosis invades the small retinal blood-vessels and the capillaries.

The choroidea does not remain unchanged; besides hæmorrhage in it, opaque spots are found, and whitish spots of decolourized blood.

Partial sclerosis of the chorio-capillaries—the very minute capillaries which form the third choroidal layer, called the capillary layer, or tunica Ruyschiana—is very marked, in bright patches, whilst in contiguous portions of the fifth, or epithelial layer, the pigment is atrophied, or runs together in masses. These alterations, making allowance for the difference of structure in the two membranes, are analogous to those which are met with in the retina, but are quite independent of them as regards position.

The marks or spots are produced by fatty degeneration of the connective-tissue, a slight degree of fibrin, decolourized blood, and fatty change, or sclerosis of nerve-fibre and blood-vessel. Singly, or in combination, to such agency must all the varying markings be referred. The striation is no doubt due to the fatty change, or sclerosis of the nerve-fibres. The dotting around the macula is to be ascribed to similar causes, and it is said, too, to fatty change in the fibres of Müller.

Cause. This is, notoriously, Bright's disease. The kidney and the eye affections are directly associated; we cannot, however, say as cause and effect. Whether the two are consequent on some other cause we know not, nor can we tell why the eye sometimes escapes while the kidney is in its fullest disease.

The retinitis may appear while the kidney gives but very slight indication of implication, as gathered from the urine; this does not show that the kidney trouble, a necessary antecedent to that of the eye, has not long existed, though it is usually developed at a late and very marked stage of granulation.

It has occurred to me many times to discover the kidney disease by the retinitis, but then the albuminuria has crept on insidiously.

This question has arisen, Does retinitis occur in any other kidney disease than the granular, meaning the amyloid kidney, which in fact expresses parenchymatous nephritis with amyloid degeneration, such as occurs in persons with exhausting maladies? Evidence says yes. Direct proof has been supplied by Dr. Gowers. There are no kidney symptoms in addition to the albumen, and little or no alteration in the specific gravity of the urine, which is dark or yellowish brown. But, I may say, the difference between the two

kidney disorders is a matter of no practical interest to us as ophthalmologists.

Probably the next discovery in this subject will be structural alterations in the tract and in the post-ocular portion of the optic nerve, as in neuritis.

The frequent occurrence of hypertrophy of the heart in Bright's malady does not concern us in this inquiry.

Hæmorrhagic retinitis, that which I am considering, has been described as occurring in diabetes, but not sufficiently authentic for me to accept the report.

The course. It is confidently stated, I have no practical knowledge in the matter, that nephritic retinitis, in association with scarlatina, in which cloudiness and swelling of the disc and surrounding retina, with the alterations spoken of as occurring in the central blood-vessels of the retina, may be completely recovered from, if there be repair in the kidney. The same is said of retinitis in association with the albuminuria of pregnancy.

Inflammatory development from the beginning is commonly chequered by temporary arrests of progress, or even of repair, and by hæmorrhage. To this is the alteration in vision due, patients seeing some days better, some days worse.

After the fatty changes in the connective tissue, the whitish spots may so far clear up, and the blood-spots may so far be absorbed, as to allow the central retinal blood-vessels, and the choroidea with its changes to be seen. So-called anæmic disc and retina, but really an atrophic state supervenes. Sclerosed parts seem not to alter.

Detachment of the retina occurs. I have not seen it as a consequence of the atrophic state, but only during active inflammatory conditions of the retina.

Treatment. Of course degenerated tissue cannot be repaired, and there is nothing to be done for it. If there seem any reasonable scope for the application of the treatment which I have advised for neuritis or neuro-retinitis, it should be adopted.

TEMPORARY URÆMIC BLINDNESS AN EFFECT OF ALBUMINURIA.

The circulation of urine in the blood, one of the consequences of Bright's disease, may produce temporary dimness, and even loss of the perception of light. This was clearly understood, so far as associated with scarlatina, and made public by Dr. Wells in London in 1812, and the admirable report of his cases shows that he had discovered all the ocular and cerebral symptoms. After that, when

Bright's disease was announced, and clinical study became more extended, eye affections and granular kidney were found to be frequently associated; but, as the ophthalmoscope was not yet born, it was supposed that urea in the blood disturbed the eye. Now we know that physical changes in the eye are the usual cause of impaired sight, in association with the diseased kidney, and that uræmic influence alone is extremely rare.

The characteristics of this affection are subjective symptoms, namely, the rapid impairment of sight, and the nearly as rapid recovery. There may be expected the coexistence of other evidence of uræmic poisoning, such as headache, giddiness, convulsions, maniacal excitement, &c. The presence of albumen in the urine is the most confirmative proof of the nature of the case.

This oculo-uræmic symptom may occur without any objective symptom in the eye, although it may precede a retinitis. It may accompany and complicate, or mark the subjective symptoms of retinitis. Whether occurring alone or not, it may recur several times.

RETINITIS SYPHILITICA.

There is no prominent objective ophthalmoscopic symptom by which developing or recent retinitis, arising out of syphilis, may be honestly discriminated. Only from the precedence or presence of some other mark of constitutional syphilis, or evidence of syphilitic taint, or syphilitic history, can it be said with certainty that this or that internal ocular inflammation is syphilitic retinitis. This being the case, certainly I am not clinically justified in introducing the above heading. It is only from surrounding circumstances I venture to do so, and for the convenience, too, of discussing some points in association with syphilis of the eyeball.

So-called syphilitic retinitis is syphilitic inflammation in the fundus of the eye, which, in reaching its highest point, appears as what is usually known as iritis, that is general inflammation of the eyeball, or ophthalmitis (See p. 236). It is not easy to say where is the starting-point of the inflammation, whether it be in the choroidea or the retina, and it matters not in a clinical point of view, especially as the choroidea never escapes.

Symptoms of so-called syphilitic retinitis. Where the outward inflammatory symptoms are marked, and light may yet be thrown through the pupil, the vitreous body is nearly always too hazy to admit of a sufficient scrutiny of the retina and the choroidea. One

may be fortunate enough to examine an eye in which the internal inflammation is slowly developing. The signs then are a mild neuro-retinitis, with œdematous infiltration in the disc, but chiefly in the retina around the disc, thereby destroying transparency, by which the disc margin and the central vessels of the retina, both in the disc and far beyond it, are blurred. There are neither spots nor hæmorrhages. There is never at any stage the spotting so characteristic of the retinitis in Bright's disease, nor indeed the hæmorrhage. I tell students that these are the best cases for studying neuro-retinitis, and they are by far the most common of the class.

Already the sight is defective, and generally, in the centre of the visual field, to an extent far beyond what might be expected from the state of the retina and the choroidea. It was a sad puzzle in former times, when in a case of so-called iritis, with but the faintest iris changes, a patient had scarcely any useful vision, but still surgeons would persist in believing that the iris was the focus of the inflammatory action, and few in the present day are aware of the fallacy.

If treatment be neglected the vitreous body becomes hazy, first posteriorly, and then generally opaque, while the ophthalmitis develops. It is here that hyalitis is best studied. We may be fortunate enough to see its beginning, always, I believe, in the posterior part, as a very faint haze with dots, which soon collect in groups and are ultimately lost to view, as the body grows more hazy.

When the severity of the general ocular inflammation is reduced, and the fundus can be seen, effects of retinal degeneration and of exudative choroiditis are rarely absent.

I know that there may be a slight attack of syphilitic inflammation of the eyeball, almost confined to the choroid and retina; and that there may be a recurrence of such, as there sometimes is of the more advanced stage of general ophthalmitis, but this is very rare, as compared to the onward and forward movement of the inflammation, till we get marked outward objective symptoms. But it must be stated that syphilitic inflammation of the eye seldom relapses, the very contrary to rheumatic inflammation.

More varied and extensive pathological appearances, the effect of syphilitic inflammation of the optic nerve, the retina, and the choroidea, and the retinal blood-vessels, are met with than in any other form of inflammation of such parts, and this accounts for the many dissimilar ophthalmoscopic drawings which have been published to illustrate syphilis of the retina and choroid, and the supposed peculiarities said to have been met with in dissections. The well-known representation of Liebreich, Tab. x. Fig. 1, of

retinal syphilis, to my idea an uncommon appearance, though perhaps a portrait, is often described by writers and teachers—more frequently without acknowledgment of the author than with it—as a typical case. Liebreich himself says as to its exceptional form, "only in very rare instances do we notice such white streaks as those issuing from the optic disc." And, again, as to fulness of the arteries and emptiness of the veins, "it is but exceptionally that the vessels take so active a part in the process, as in the case represented."

I will quote a clinical remark from Liebreich.

In speaking of the punctiform, irregularly arranged opacities, which may appear about the macula lutea, he writes that they never reflect light so strongly as the brilliantly white spots in Bright's retinitis. He adds, the great mutability of the opacities is remarkable; he had seen them within the course of a few days vanish and reappear, the patient's sight undergoing corresponding fluctuations.

I advise in the matter of diagnosis that the nature of any supposed syphilitic retinitis be judged of solely by the concurrent symptoms of secondary or tertiary syphilis, and, in the absence of such, by the patient's history. Any one of the symptoms which we call secondary or tertiary may be the only ones to appear after primary inoculation, although, as a rule, many co-exist. The eye inflammation, whether we call it iritis or retinitis, may be, and often is, the only constitutional evidence of there having been primary syphilis. If a patient's conduct be decidedly such as to admit of the probability of a syphilitic origin in any case of inflammation of the retina not to be easily accounted for, where personal evidence of syphilis is wanting, so great is the perpetuation and attenuation of the syphilitic poison, and so general is it, that the existence of syphilis should be accepted. The assumption may be all the stronger if there be the kind of ocular pain spoken of at p. 946.

Treatment. This is efficiently expressed in what is said at p. 849 on the treatment of syphilitic iritis. Where there is not much outward inflammatory action, the persistence or decline of which is a chief guide for continuing or reducing the treatment, the state of the fundus of the eye, and that of the objective symptoms, must be the data relied on for the administration of our therapeutic means.

The prognosis is very favourable, so long as the treatment is undertaken while the inflammation is acute. The state of vision hardly helps us where there is much opacity of the vitreous body, as such opacity, including the exudations in it, may of itself be enough to shut out light, while the retina is not spoiled.

The alteration of colour sensibility in the eye, as the effect of

diseases of the retina or the choroidea, has been much investigated, but as nothing of a practical nature has been derived from it, I shall not enter into it.

RETINITIS LEUCÆMICA.

This is a rare accompaniment of that very scarce and fatal affection, known as leucæmica, which depends on disease of the spleen or the lymphatic glands, and a marked symptom of which is the preponderance of white corpuscles in the blood.

I have not met with this form of retinitis, and I am not surprised that the description which is given of it by Liebreich, its discoverer, has been but little verified by other ophthalmologists.

Liebreich tells us that he has seen six cases, and he speaks of the ophthalmoscopic diagnosis after this manner :—

1st. The pale colour of all the retinal and choroidal vessels, especially however of the retinal veins, which, notwithstanding their repletion and tortuosity, have a light pink shade, similar to that of the small apoplexies.

This is in contrast to the black-red tint of the veins in optic neuritis, and in glaucoma. Dr. Becker, of Heidelberg, who describes two cases, speaks of the indefinite outline or contour of the veins, and of those which were, in this respect, most changed, being bordered by small whitish margin, which made them look ribbon-shaped, and of the arteries being narrow and pale yellow, with a tolerably clear outline. He found the reflection from the fundus of the eye, obtained advantageously by the diffused light of day through a hole in a window shutter, to be of a pale orange-red.

The small apoplexies which Liebreich alludes to, are those which occur in the course of the retinitis.

2ndly. The paleness of the papilla, the striated cloudiness of the retina in its neighbourhood, and the irregular spots close to the macula lutea.

3rdly. A number of glistening white round spots, which in their form and colour are quite similar to those found in Bright's disease, but differ from them in their peripheral situation. It is added, in drawing attention to the difference between leucæmia and other forms of retinitis, that he does not merely allude to the colour of the vessels, and of the extravasations—for this depends exclusively upon the colour of the leucæmic blood—but also to the colour, shape, and distribution of the opacity. I suppose he means by the opacity the striated cloudiness. He concludes with the remark that he has

found in general the same appearances in all his cases, although modified in one way or another by the greater or lesser abundance of the extravasations, and by the degree of the repletion of the blood-vessels.

Dissections have been made of leucæmic retinas by Renicke, Roth, and others, from which I gather the following facts. The capillaries contained large quantities of the white corpuscles of the blood, especially in their varicosities. This is but an analogous state to what has been observed in the brain and the lungs of leucæmic persons. Some of these peripheral vessels were in fatty degeneration. In the central vessels of the retina, which also abounded in white corpuscles, there was scarcely any fatty change, but enlargement, with thickening of their walls. There were numerous small hæmorrhagic deposits. Renicke speaks of them as occurring in numbers towards the periphery, being round and prominent, and occupying all the retinal layers; red corpuscles of the blood forming their circumference, and white ones their centre. Other observers speak of the hæmorrhages as being confined to this or to that retinal layer. Considerable enlargement and a granular condition of the rods and cones seemed to be the only change which could account for the striated cloudiness, or diffusive opacity of the fundus. Nests of hypertrophied nerve fibres, near the macula lutea, seem to account for the white spots spoken of in that situation. The white lines skirting the large blood-vessels, are accounted for by Leber as due to hæmorrhage, consisting of an aggregation of white and red corpuscles of the blood, which in some places actually penetrated the wall of the vessel. The optic nerve appears to be normal, except being congested. Some of the vessels of the disc were compressed by closely packed lymph bodies. The choroidea was affected chiefly by hyperæmia.

No definite subjective symptoms are described by any author. In one case it is said that none existed.

RETINITIS PIGMENTOSA.

This name was given by Donders when he looked into an eye and saw the retina dotted with pigment, along with certain other fundus changes. As there is certainly as much of a choroiditis as a retinitis, if Donders' name be retained, it should have the prefix of chorio-neuro-retinitis pigmentosa, but it might scare beginners. I have, from the force of example, made my classification under diseases of the retina, and the justification, not my own, is on the score of the

retina being more affected than the choroidea. Spotted retina is a name sometimes applied.

It is thought by some physiologists, who base their opinions on the mode of development, that the fifth or epithelial layer of the choroidea, containing as it does a single layer of large, well-formed, hexagonal cells, each enclosing a nucleus surrounded by pigmentary matter, belongs more to the retina than to the choroidea.

In my description of acute neuro-retinitis, I have shown how inflammation has a selection for certain parts of the retina, and that when its posterior layers are attacked, the choroidea also suffers. This would seem to be exemplified here, if it be not rather that the retina and the choroidea are both simultaneously attacked.

Simple as retinitis pigmentosa is to be understood in its mere morbid anatomy aspect, yet owing to its origin, which is fœtal, and its not generally being detected in infancy unless a child be born blind with it, its insidiousness, and its occasional long course of years' duration before it causes enough trouble to be recognised, no one watches a case from beginning to end. Our knowledge is built up from the observation of cases occurring to ourselves and to others, and to some post-mortem examinations.

A few dots of pigment in the retina do not constitute retinitis pigmentation. Physiological pigmentation around the disc has been described, and I have not failed to speak of some acquired pigmentation in optic neuritis, and in neuro-retinitis.

I proceed, then, under this understanding, that the so-called retinitis pigmentosa is a fœtal chorio-neuro-retinitis, and, so far as the retina is concerned, is chiefly developed in its posterior layer. That the affection is almost always binocular, although the two eyes are seldom attacked with equal severity. That it has a centripetal progress, appearing at the nasal periphery of the fundus oculi, and extending inwards, which progress may be that of rapid development, or a very slow one, all the time of extending spoiling the sight, till about between the thirtieth and fortieth years of age, when it culminates in blindness, certainly in one eye, and sometimes in both.

Ophthalmoscopic symptoms. These are very characteristic and unmistakable, although no two cases correspond in their features. I will give those of an old patient whom I have just sent for and examined, which patient is thirty-two years old, has had defective sight from his birth, has lost all useful vision in his right eye, and sees but with a very small visual field with the left, and only at a short range, holding objects close to the eye.

Right eye. An astonishingly variegated appearance over the fundus of the eye, produced by black spots of most varied form, size, and relation to each other, and grey and shining white spots, the effect respectively of the loss of the pigment of the choroideal epithelium, and of the pigment, and of the stroma combined, by which the sclerotica is seen, fringed by a belt of very dark pigment. In proportion as pigment is removed so are the choroideal blood-vessels exposed. Where the second choroideal layer, the tunica vasculosa, can be recognised, it has a greyish or brownish aspect, and according as its pigmentation is reduced, or increased, will the blood-vessels be apparent or hidden. Here these vessels are tolerably intact; still those of the third, or capillary layer, are much atrophied. The retina is atrophied, and this again causes parts posterior to it to be the better seen. The optic disc is atrophic, and contains a few dots of pigment. Pigment is not deposited in the disc till a late period; when the pigmentation is generally very marked. The central blood-vessels of the retina are reduced in number; both arteries and veins are contracted. In atrophy of the disc, from whatever cause, these blood-vessels undergo like changes in proportion to the atrophy. Pigmentation of the retina may be very marked along the course of the large blood-vessels, at their bifurcation, and may even surround some of the branches, so that they look like black threads. In these situations a granular arrangement of the pigment is generally well marked. Such conditions are absent here.

Left eye. The fundus is altered chiefly by pigmentation, the greyish and white spots which were observed in the other eye are very few, and are entirely at the equator of the fundus. The optic disc is only a little impaired in transparency, and the central blood-vessels seem unchanged.

In both eyes the vitreous bodies and the lenses are clear.

The immunity which the vitreous body enjoys from disease is universally admitted, for only very rarely is the transparency affected, and then it occurs in the region of the optic disc, and obscures it.

The crystalline lens is prone to become opaque at its posterior and central parts, posterior polar cataract, which hardly ever increases to complete lenticular opacity; but this is a late occurrence, usually not appearing before the individual is thirty years of age.

There are no outward objective symptoms beyond a contracted or a slowly acting pupil, and a degree of arrest of development in the eyeball, microphthalmos, which is seen in those infants who are born blind with the affection, or in whom it is rapidly developing at the time of birth—I may add an oscillating movement, nystagmus,

which persons with a very limited visual field display in examining a large object.

Subjective symptoms. Those proper to the retinitis are feebleness of retinal power, so that full illumination is necessary for acute sight, hence by a bright light the eye may seem to be normal when it is really defective. This loss of function is often mistaken for hemeralopia, contraction of the visual field, a deficiency which will be best ascertained by an examination under artificial light. Central vision by day may long continue to be acute in association with severe peripheral contraction, but afterwards this seeing patch is prone to grow dim. It may be mentioned that in this regular contraction of the field we have a contrast to the irregular contraction arising from optic neuritis. Again, central vision is rarely so sharp in the neuritis.

The range of accommodation is seriously shortened when the visual field is much reduced. Myopia and astigmatism, are not uncommon complications.

It seems to be ascertained, without doubt, that the subjective symptoms may appear before the pigmentation. That the decrease in visual power is usually in equal step with the spotting is certain.

Varieties of retinitis pigmentosa are met with. The objective symptoms may be slight, while the subjective ones are severe, and *vice versâ*.

Cause. Syphilis has much laid to it, and perhaps not without just cause. In many cases syphilis has been traced to the one or the other parent. Intermarriage is largely blamed, but, as I believe, without any foundation. Modern investigation shows that healthy cousins who marry do not beget diseased offspring. Unhealthy cousins produce diseased children ; but surely less could not be expected from diseased parents, selected under any circumstances apart from consanguinity. But in general we cannot fathom the origin of it in any bodily disorder of the parents.

There is nothing peculiar in fœtal origin, since we know that all the diseases to which the body is liable, except those incidental to the full development of its organs, and to old age, have been found to exist at birth. It has invariably occurred to me, when in the first instance it has seemed that I have discovered an exception and been examining a case of acquired retinitis pigmentosa, ultimately to find that from childhood or youth there has been evidence of some visual disturbance.

There are records of several children by the same parents being afflicted with this disorder, of parent transmitting it to child, of other congenital defect, coexisting with it.

Morbid anatomy. I can only glance at this. First, as to the pigmentation, which is chiefly in the central layers of the retina. There has been a great deal written to account for it, and the explanations founded on dissection, in which Pope, Leber, and Wecker have had so much to do, run thus.

The proliferated tissue, which is most abundant in the external granular layer of the retina, throws out excrescences which embrace and envelope the pigment cells, and in returning carry the cells into the diseased retina. Of course this supposes the destruction of the layer of rods and cones, and I believe that such destruction is almost invariable. Again, the fourth choroidal layer, the elastic lamina, thickens, and gets warty, and drives the epithelial cells with the pigment into the retina. Again, from softening of the posterior retinal layers, and proliferation of the cells of the epithelial layer of the choroidea, the pigment enters the retina, according to the degree of the disorganization which it has undergone.

While retinal pigmentation is a marked object of this complaint it is really the least important event, for it has no spoiling influence. The presence of pigment within and between the histological elements of any tissue, does not affect the vitality or function of such part. If the pigmentation be not about the macula lutea, this of course means if the causes which produce the pigmentation have not spoiled that region, and if the optic nerve be sound, no matter how much pigment there may be elsewhere in the retina, vision is scarcely affected, and there is sure to be good central light.

Without denying the migration of the pigment from the choroidea to the retina, a point I think scarcely to be proved by dissection, unless thereby the pigment be found in the retina in its epithelial cell intact, I offer these remarks. I must eliminate from the consideration the formation of pigment out of extravasated blood, discussed in the chapter on Diseases of the Optic Nerve, p. 1089.

Pigment is frequently removed by absorption from the choroidal epithelial layer during the development of retinitis pigmentosa. Pigment is, indeed, absorbed under a variety of circumstances in posterior internal ocular disease. While we know that it is really renewed, we do not want to account for pigment in a wrong place, by saying that it has gone there from its right quarter, especially as the "running of the pigment into a mass," as the phrase goes, is more in quantity than such a disposition could account for. We know that there may be an increase of the pigment of the choroidal stroma under inflammation, while the pigment of the epithelial layer is partially removed.

Pigmentation is a very common form of degeneration of most of the tissues of the body. It is frequently, too, the effect of inflammatory action, brought about by some changes in the blood-vessels, or the circulation, and is often the only evidence of a preceding inflammatory process. A new growth forming in or about a naturally pigmented tissue, like the choroidea, possessing cells endowed with a special power of secreting colouring matter from the blood, and storing it up, is nearly always pigmented; for instance, the melanotic tumours of the choroidea. Taking these several circumstances into consideration, or some of them, and allowing sufficient credit or latitude for pigmentary formations, may we not account for pigment deposit in that part of the retina which abuts on the choroidea without resorting to the theory of its migratory origin? The physical disposition of the pigment carries signification. It is laid in a diffuse form, becomes darker and granular, hence the bone corpuscle-like form of it, to which I have above alluded.

Serous exudation, proliferation of connective tissue and sclerosis of the central blood-vessels complete the sum of the morbid anatomy changes. The greatest tissue destruction is in the posterior retinal layers, the supposed sensorial nerve elements, and which loss is replaced by connective tissue that shrinks and hardens. The nerve-tissue layer long resists destruction.

The arteries are more affected by sclerosis than the veins. By this process the calibre of the vessels is decreased, and the smaller branches become closed, and, apart from pigmentation, appear like white network. The general effect of sclerosis is to reduce the circulation and to give an atrophic appearance to the disc and the retina.

The choroidal changes are, more or less destruction of the fifth, or epithelial layer of the choroidea, with its pigment, thickening of the fourth layer, the elastic lamina, with outgrowths, generally described as warty excrescences, lymphoid cells in the choroidal stroma, exudative products either in the choroidal stroma, or between it and the sclerotica, and, according to Leber, prominent yellow whitish deposits in the region of the ora serrata, composed of connective tissue and fatty granules, by which the retina and the choroidea are glued together, and, ultimately, atrophy of the choroidal tissue. For fringed pigment around white choroideal spots, see Choroiditis Disseminata.

Treatment. Assistance may be obtained from optical appliances. To recommend with confidence definite therapeutic measures for certain of the retinal and choroidal changes, I am certainly unable; yet I do not think that retinitis pigmentosa is beyond the pale of treatment. I believe that I have checked it in young persons who have shown symptoms of inherited syphilis by attending to such

symptoms, and where there has coexisted a marked strumous habit, of which debility is a strong feature, by improving such.

HYPERÆSTHESIA OPTICA.

It can be said of the puzzling assemblage of symptoms classed under this name, that it occurs mainly under two conditions: 1st. Exalted sensibility, or excessive intensity and duration of the sensations, which may be caused by irritation of the optic nerve and the retina in association with ciliary irritation, which phenomena are supposed to be due to external influences acting on the retina, and distinct from such cases of reflex spasm as arise in surface ocular affections, having their seat in the conjunctiva and the cornea. 2nd. A kind of high excitement of the optic nerve and the retina, attended by symptoms which do not depend on external influences.

In the first condition there is lacrymation. Reflex spasm of the orbicularis palpebrarum muscle. See disease of this muscle, page 331. Pain in the eyeball, and pain in the course of one branch, or in several branches of the supra-orbital division of the fifth pair of nerves, so-called ciliary hyperæsthesia, or ciliary neuralgia. Intolerance to light, less than full illumination perhaps producing dizziness. The aggregate of these constitutes the effect usually described as photophobia.

Many of these subjective symptoms have been described as symptoms also of neuritis and neuro-retinitis, and it is exceedingly difficult in many instances of disease to say which classification should be adopted, namely, that of mild neuritis, or mild neuro-retinitis with complications, or hyperæsthesia optica.

Again, over and over, have I described hyperæsthesia optica as a part of the symptoms of several affections of the eyeball, without, of course, naming it as above.

But there is a milder form of hyperæsthesia optica, in which the lacrymation and pain are absent, only intolerance to light remains, the optic nerve and retina seem healthy, and there is no objective symptom of ciliary irritation. I meet with it in myopic and hypermetropic persons. It may remain long after such optical defects have been remedied, and persist in spite of every effort to overcome it. There is still a milder form, in which the intolerance to light does not appear unless the eye be used for minute work.

In the second condition there are merely subjective appearances and subjective effects, occurring with or without intolerance to light and dazzling.

By the subjective appearances is meant the so-called phosphenes, which include the sensation before the eye of sparks, bright, white, or coloured patches, flames, coloured rings, chromatic clouds, all of which may partially or entirely cover the visual field. These are frequently described as photopsia and chromatopsy. See p. 1077 for some further remarks on the subject.

By the subjective effects is meant duration of retinal impressions, especially from bright objects, for minutes, hours, days, or even months; or such duration that the impression of one object on the retina is not lost before another is received, by which confusion arises, and it may be that objects seem to dance, and so produce dizziness.

The first and the second conditions, although mainly separable, as I have just said, are sometimes mixed in varying intensity.

The treatment is not always to be rationally found, because many of the causes of the affection cannot be discovered. It is very reasonable to suppose that, in the absence of all objective symptoms, the malady has its origin in the optic-nerve apparatus posterior to the eyeball. We are always forgetting how much of this apparatus lies within the skull, and we may be sure that a great many subjective symptoms which we cannot account for, and I call functional, as if all symptoms were not evidences of loss of function, have their origin in the optic tract and in the brain. Whence arises the hyperæsthesia optica in concussion of the brain, in fever, in headache, in high mental excitement after the shock of fear, grief, and excessive fatigue, the eye all the while being natural.

Treatment. Save the eye from any influences which seem to affect it prejudicially, or to overtax its power, and endeavour to remove any state of system out of which it may seem probable that the ocular symptoms arise. So long as the eye cannot bear the full effect of light, it should be protected by some form of eye shade, for which full instructions will be found in the chapter on Eye Shades, p. 20.

CYSTIC OR CYSTOID DISEASE OF THE RETINA, ALSO CALLED ŒDEMA, AND COLLOID CYSTIC DISEASE.

Pathological conditions. To Iwanoff's researches and extensive dissections are we chiefly indebted for what we know in this matter. Nearly all, if not all, of the morbid change can be verified only as belonging to the affection by post-mortem inspection. By this I mean that the disease cannot be surely recognised in life.

The retina suffers partially, either peripherally or centrally. Very rarely is it implicated in the entire extent.

A retinal segment thickens, there is an increase in the length of the modified connective tissue, or framework of the same, and some atrophy of the granular layers. A space is developed, or several spaces are developed, in the external granular layer, between the hypertrophied fibres of Müller. Such development is after the manner of the independent formation of a cyst, by the enlargement and fusion of the spaces in the connective tissue, and the contained fluid material is serous or gelatinous. Soon after spaces are formed in the internal granular layer. The inter-granular or external molecular layer is as yet intact, but as soon as opposite cavities enlarge it is lost and a single cavity is formed; and so on it may be gradually removed, and one large cavity remain. The nerve-fibre layer is not readily diseased, but it may atrophy and be partially occupied by small cavities. The rods and cones are not destroyed till a late period. The ultimate cavities enlarge at the expense of the vitreous humour, which may be partially or entirely absorbed.

Cystic disease is chiefly met with in old people, and causes disorganization of the eye. In such instances the pathological explanation of Iwanoff, degeneration of the capillary blood-vessels, is highly probable.

Cystic disease is, besides, associated with, and I suppose arises out of disorganizing states of the eyeball, such as we meet with in glaucoma, and after the changes following traumatic injuries, by which sympathetic ophthalmitis is induced.

We find here, as elsewhere in cysts in the body, that there occur sometimes inflammatory changes in the cyst walls, called secondary action, by which surrounding parts are affected. This explains the thinning of the choroidea and the sclerotica by which they bulge just outside a cavity. This ensues without the retina being detached from the choroidea.

The objective ophthalmoscopic symptoms are not, as I have hinted, very definite, because it is generally impossible to say whether we have before us cystic disease or a partially detached retina. All that can be said differentially is that the former is more limited, stands out with sharper outline, and the separated retina is less opaque and does not tremble. Again, the development of cystic disease of the periphery of the retina, and the common complication of lenticular opacity, cataract, more or less present an efficient examination.

The subjective symptoms are deterioration or loss of sight, according to the extent and position of the part of the retina involved.

EMBOLISM OF THE CENTRAL ARTERY OF THE RETINA.

We must remember that embolism is the arrest of solid substances circulating in the blood, by blood-vessels which are too small to allow them to pass, and that such substances are numerous; namely, parasites, pigment granules, cancer cells, vegetations or calcareous or atheromatous masses set free from the valves of the heart, or the interior of the arteries.

The laws which govern embolism generally, will materially assist in elucidating the objective and subjective ocular phenomena. I will make some passing allusions to them in the course of the following remarks.

About twenty years ago Von Gräfe told the world that he had discovered embolism in the eye. Since then between thirty and forty cases have been publicly noticed; of course others have been detected, I include some which I myself have seen but have not reported. From an early period till now the correctness of their diagnosis has been very much questioned by some able ophthalmologists, because the mechanism of the embolism had not been to them satisfactorily demonstrated, and necessarily there followed lengthy and tedious controversy. Among the objections it is stated that the so-called embolic symptoms are but the effects of retrogressive neuritis, with abundant morbid products by which the central blood-vessels of the retina are compressed. That in pure embolus the intimate connection between the retinal arteries and the nutrient blood-vessels of the disc would prevent a permanent reduction of the retinal circulation to a minimum. That there is not even temporary want of blood in the choroidea, or any other parts of the eyeball. It is better to leave the theoretical objections, and tell that a post-mortem examination by Sichel, fils, has for ever settled the question that true embolism occurs in the central artery of the retina. "Archives de Physiologie," 1870.

It is related that there was sudden loss of sight. Examination of the eyeball revealed scattered retinal hæmorrhages, the largest of which occupied the macula lutea. The disc was healthy. After a short time peripheral sight was somewhat restored, so that the woman was able to read No. 17 of Jaeger's test type. Vision again rapidly declined. Then the central artery was found devoid of blood, its branches being like white cords, containing here and there slight coagula. The central veins were slightly dilated on the disc, but

natural in the rest of their course. Along with other retinal changes, there was considerable infiltration. The heart was diseased, there being an insufficient auriculo-ventricular opening. Cerebral symptoms caused death.

Post-mortem examination. Cerebral hæmorrhage, fatty degeneration of the posterior arteries of the brain, with central brain softening. A clot in the left central artery of the retina, three millimetres from the sclerotic entrance of the optic nerve, adhering to the walls of the artery, which it dilated in its middle part. At the corresponding spot the ophthalmic vein was completely obliterated.

Objective symptoms. We shall meet a diversity in these according to the positions of the embolism; that is, whether the stoppage be in the main artery, or in one of its branches, and the obstacles to the collateral circulation.

Ophthalmoscopic signs of embolism in the trunk of the central artery of the retina, before its entrance into the eyeball. This varies according to the time which has elapsed between the obstruction of the artery and the first examination of the patient.

In the beginning the papilla is pale but transparent. The arteries are reduced in size. Some of them, or all, are exsanguineous. In those which are not actually closed, a feebleness of circulation is unmistakable.

The greater or lesser check in the flow of the arterial blood depends directly on two conditions. First, the stopper-action of the embolus, whether this be entirely within the main arterial branch, or at the point of bifurcation. Secondly, on the nature of the embolus itself, whether derived from a soft recently-formed thrombus, in which case it will readily adapt itself to the blood-vessel, or consist of an irregular-formed calcified cardiac vegetation, when it is not likely to fill the blood-vessel. The same remarks apply in a mechanical sense to all other causes of arterial plugging. There may, therefore, be complete, or only partial plugging of the artery. Hence it is the arteries may be quite empty, and look like whitish threads, or a few only empty, while others are carrying some blood.

Small coagula are commonly seen in parts of the arterial branches in which some circulation yet remains. These are really thrombi. In embolism in general, thrombi frequently form in front and behind the plug; and usually, though not necessarily, extend as far as the entrances of the first large collateral vessels.

There are retinal vein changes, characterized by more or less emptiness, with irregularity in the distribution of the remaining volume of the contained blood. Sometimes the greatest fulness is

peripheral, sometimes central. Before the nutrition of the retina is interfered with, feeble undulatory movements of the venous blood may be seen in the peripheral vein branches. The occasional general fulness of the main trunks of the central vein is merely that of chronic congestion. It may occur with but the least possible degree of circulation.

Secondary thrombi, usually called clots, may form in the veins.

These venous conditions depend, as regards the arteries, on the amount of obstruction in the central artery, and the degree of anastomosis which exists between the nutrient blood-vessels of the disc and the branches of the central artery beyond the spot of obstruction; and as regards the veins, on the obstruction or not of the central vein in the optic nerve indirectly by the distention of the embolic artery, and on the facility by which collateral venous circulation is established.

The retina soon loses its transparency. A greyish cloud, I suspect merely œdema, covers the disc and the immediate neighbourhood, spreads around the macula lutea, and follows the course of the central blood-vessels, but does not affect the extreme equatorial parts.

Next follow very marked alterations at the site of the macula lutea. The macula itself looks like a hæmorrhagic spot, with a circling of grey. This is supposed to be the effect of contrast between the portion of the fundus of the eye not clouded and that which is so affected.

Later changes in the course of weeks or months occur, and depend on the re-establishment, in some degree, of the arterial circulation, or its continued obstruction. In the former case the arteries partly recover their calibre, the cloudiness, even that around the macula lutea disappears, and then only the loss of disc transparency marks the late departure from health. In the latter the disc atrophies, and so does the retina. The blood-vessels are more or less missing, and some of the thin threads, the traces of those which remain, may be bordered with white lines.

Subjective symptoms. Sudden cloudiness of sight, or contraction of the visual field, with more or less cloudiness of the field of direct, central, or perfect vision, generally quickly followed by blindness. But, as the affection is monocular, the short stage of impairment of vision may not be noticed, when blindness would be the first symptom discovered. Again, if the embolism occur in the night blindness may be revealed on waking. This rapid loss of retinal function, from the reduction or cessation of the retinal arterial blood supply, is but a parallel of what occurs under similar interruptions in

the arterial circulation elsewhere; for instance, on the occasion of the main nutrient artery of the part being plugged. Loss of consciousness and paralysis suddenly follow embolism of the larger cerebral arteries; embolism of the pulmonary artery produces sudden asphyxia, &c. In each instance the ultimate organic changes will depend on the structure of the organ attacked, and particularly on its blood-vessel arrangements.

Partial restoration of the arterial blood supply to the retina, whether temporary or permanent, is attended by corresponding improvement in the function of the eye, provided there has been no retinal spoiling. This again has its parallel in other organs.

Where there is obscurity in diagnosis, the course of the case, in a few days, will probably clear up the doubt.

In embolus, the retina is quickly deprived of blood, the occluded arteries soon contract, optic disc and retinal changes quickly follow. This is just the reverse of what occurs in optic neuritis.

The shrinking of the disc vessels in embolism causes paleness, which at first, at least, is characteristic, and rather different from either form of disc atrophy, the grey or the white.

A case has been published of incomplete obstruction of the trunk of the central artery of the retina, with more obstruction of the upper branch of the same than of the lower.

Cause. Ocular embolism is intimately connected with disease of the systemic arteries and capillaries, especially those of the brain, and with disease of the left cavities of the heart.

Ocular embolism has been followed by cerebral embolism.

Ophthalmoscopic signs of embolism of some of the branches of the central artery of the retina, the obstruction taking place within the eyeball. A few such cases are on record, and are quoted in the "Archives of Ophthalmology," &c., by H. Knapp. In one of them, which will serve as a type, the blood-vessels in the upper half of the retina and in the optic disc were normal. The inferior principal branch of the retinal artery displayed a slight intumescence, beginning at the margin of the optic disc, and extending thence about half the length of the diameter of the disc. From this swelling to the periphery of the retina, the artery appeared as a thin white thread. Nearly the entire lower half of the retina had a milky-white tint. The field of vision was affected in correspondence only to the retinal lesion, that is, in the upper part. The direct, or central sight, and that in the other parts of the visual field were uninfluenced. The patient noticed his defect only two days before; and his daily habit of using his right eye to shoot, proves the early detection of the disease. The opacity of the retina soon disappeared,

but the contracted artery and the defect in the visual field remained.

Knapp gives a case of his own, and runs on through seventeen pages of descriptive and clinical remarks. The tortuosity and enlargement of the veins corresponding to the occluded artery is mentioned, together with the seeming loss of continuousness of some of them at the disc.

A point on which he dwells much is the loss of pulsation in the retinal vessels, which happen to be obstructed from any cause. He argues after this manner: Pressure on the eyeball produces visible beating of the retinal arteries; obstruction of the arteries can only frustrate the experiment; consequently such obstruction may be safely assumed as existing whenever pressure on the eyeball fails to produce pulsation. He applies the argument to embolus. This requires a little qualification. Some arterial circulation might continue, provided it be feeble, without the possibility of inducing pulsation by pressure.

Retinal hæmorrhage producing apoplectic spots of different sizes. I have purposely waited until now to introduce systematically this contingency of embolism in the eye, already alluded to. Hæmorrhage is well known in the kidney, lung, and spleen, in association with embolism. Pathologically speaking, the bleeding arises from hyperæmia of the blood-vessels adjacent to the obstructed main artery, or to many obstructed secondary and tertiary arterial branches; the engorged capillaries are ruptured, and blood is extravasated. The bleeding occurs at a definite spot. The area over which there has been the stoppage of circulation, from the plugging of the embolus and the ensuing thrombosis, and which is more or less infiltrated with blood, is called the hæmorrhagic infarct.

Treatment. Where the central retinal artery is fully plugged the limited collateral arterial circulation is so poor that permanent loss of retinal power is inevitable. No help can be afforded. Where there is plugging of only a branch, the arterial anastomosis has proved available in some respects in partially restoring a part of the lost circulation, but not enough to vivify the retina, and re-establish sight. Some retinal repair does ensue. The œdema disappears. The hæmorrhagic deposits reduce and vanish. The veins become less tortuous and full. But partial disc and partial retinal opacity tell that complete recovery has not ensued. What can be done for this? Surgical prudence says, keep the eye quiet, and endeavour to relieve any distressing heart symptoms.

DETACHMENTS OF THE RETINA FROM THE CHOROIDEA AND FROM THE VITREOUS BODY.

Detachment by a choroidal tumour, and detachment by blood, have been described in the chapters on Cancer and other Malignant Affections of the Eye, and Injuries from Mechanical Agents.

Detachment by cysticerci has been considered in the chapter on Entozoa. Since writing that account, I have seen a sub-retinal cysticercus. It occurred in a man, aged twenty-six. The bluish paleness of the parasite, together with the raised retina just around, the yellowish choroideal change, in extent corresponding to the detached retina, and the course of the retinal vessels not being interrupted, although thrown forwards, were well marked. I am watching the case.

Detachments by the primary effusion of fluid, between the retina and the choroidea. This is not met with in children and young people, but in adults, and particularly after middle life. The separation may be very partial. It may be almost entire, there being freedom, except at the optic nerve entrance. It may be absolutely entire, by loss of the optic nerve connection. As the last does not occur except in eyes so disorganized that the lens is opaque, it will be no further noticed.

This stripping always has a small beginning, in a circular or linear form, without any point of selection, but occurs anywhere. A very marked separation always has its largest area in a depending position, because the gravitating fluid determines wide detachment in that direction.

It is said that effusion may quite change its place in a few months, and pass from an upper to a lower position; while the portion of retina originally raised recedes to its place.

The detached portion always projects to an extent, and in a form, which depends on a loss of vitreous body. Such loss must be in equal step with the sub-retinal effusion. The vitreous body is quickly absorbed under pressure, whether it be extra or intra-ocular. I am sure that it recovers itself when only partially reduced, and the influencing pressure is removed.

Some retinal opacity is, I believe, inseparable from detachment. Complete opacity may ensue. We meet with, as such effect in the raised retina, the appearances of slight veiling, dead-white cloudiness, striation, spotting. The proper aspect is modified by the colour of the effused fluid, when it is marked. With all, there is a brightness of reflection, due more to the whiteness and degree of the opacity

than to anything else. The older the detachment, the more opaque the retina becomes.

Objective symptoms. An extensively detached and markedly opaque retina, projecting well forward in the visual axis, may be indistinctly discerned with the naked eye, and better if the pupil be dilated. Yet the appearance is rather too indefinite to admit of a sure diagnosis.

Under ophthalmoscopic examination, with clearness of the dioptric media which implies no complication, advance of the retina from the choroidea is unmistakable. The raised membrane may at first sight be observed as a more or less opaque object at the fundus of the eye, or just as we catch a view of a healthy portion of the fundus, it may flit into view, and flit as quickly away. Hanging like a membrane in folds, and not infrequently with a definite edge, vertical or horizontal, it always trembles or waves with every movement of the eye, and its remaining in view, or passing out of view, depends on such movements, as well as on the position and extent of the detachment. The recognition of some of the retinal blood-vessels more fully declares that a detached retina is being looked at. These vessels might be traced in their radiation from the optic disc, but not always. Generally they appear and are lost as the retinal folds project or recede. They look darker, or are partially obscured, or even shine, as they may recline in shadows of the folds, or are masked by retinal deposits, or lie on flat and less clouded parts. Even under such conditions, the radiating arrangement is occasionally visible. We rely somewhat on the disposition of blood-vessels in distinguishing new growths from raised retina. See intra-ocular malignant affections.

The disc and other parts of the fundus may be seen by the side of the detachment, perhaps as in health, perhaps partially opaque, and the former may even be seen obscurely through a detachment in which there is yet much transparency. With almost complete detachment, which is always associated with very decided retinal opacity, nothing appears to view but the waving membrane.

Retinal exudation, pigmentation, and spots of cholesterine are not unusual on the detached portion of retina.

Cloudy media interfere with the examination. Haze of the vitreous body from hyalitis mostly obstructs. With or without the haze, exudations often float in the body.

A small retinal separation is not so easily judged of. Opacity, tortuosity, and interruption in the plane of the retinal blood-vessels, by which they are thrown forward, are the objective symptoms for our guides in diagnosis.

The acquired anterior position of the retina allows the direct ophthalmoscopic method of examination to be made at several inches from the eye. It is only by this method that the position and volume of an extensive attachment can be ascertained.

Subjective symptoms of detached retina. Interruption in the visual field. This is wider than can be accounted for mechanically by the extent of retina detached, a circumstance showing that the retinal function is affected beyond the actual point of separation. The nature of the interruption is determined by the condition and form of the detached piece. Some power of vision, not amounting, however, to anything which can be called accurate or definite, might be for a time retained in it. If the spoiling of such piece by inflammation or atrophy have not been perfected, a brightish spot or cloud, with definite coloured borders, is seen moving about. Distortion of bodies is not an unusual accompaniment, by which their outline is broken, or hidden, or bent. The appearance of corruscations, fiery wheels, dazzling lights, chromatic clouds, sheets of frosted silver, &c., occur as additional symptoms. Where spoiling has occurred and full opacity is established, a black streak or spot is observed, which also may seem to move a little, or there may be definite hemiopia, through any meridian.

Such interference with sight is always in direction contrary to the part of the fundus of the eye at which the retina is disturbed; from what I have said, it will therefore be understood that the visual interruption is for the most part in the upper section of the visual field.

For a long time, the normally-lying retina may be sensitive, and convey accurate impressions, but it is apt to lose its function, which invariably goes if the detachment increase quickly.

Cause. This is essentially inflammatory, although when confined to the interior of the eye it is generally overlooked. A strong reason for its being disregarded is the chronic type of it, for the accompanying irritation is not severe. To retinal and choroidal inflammation, singly or combined, must we look for such influence. High myopia, with staphyloma posticum, and any degree of posterior choroiditis, are agents so favourable to the end in question, as to force themselves on our attention. I blame the inflammation, and not the attending stretching of the sclerotica.

The sub-retinal fluid, according to what I have seen, bears evidence of inflammatory origin. Its frequent turbidity, with excess of salts, fibrinous material which occasionally adheres to the choroidea or retina as flocculi, together with pigment granules, free or in cells of new formation, blood corpuscles, hematine, &c., substantiate my view.

Opacity of the detached retina, already spoken of, occurring in the order, first, opacity, and then raising, is, I believe, an inflammatory effect, sometimes primary, sometimes secondary, and is by itself, one would suppose, enough to supply the fluid which does the fatal mischief.

Then detachment of the retina is a sequel of nephritic retinitis, and of general ophthalmitis, especially of a traumatic origin, of which I shall say more presently.

The frequent complication of hyalitis adds to the evidence of inflammatory causation. I have shown, elsewhere, that hyalitis points to retinitis of a severe kind.

It is not necessary that there be fluid in front of the retina, as some have supposed, and which they have attributed to partial fluidity of the vitreous body, to account for the manifestations of those tremblings or wavings already mentioned as seen by the ophthalmoscope, and called floating of the retina. The movement of the vitreous body, described in the chapter on Entoptics will account for small floating. But I believe that partial or complete fluidity of that body is requisite for extended retinal movements, and that detached retina and such fluidity are common associations I well know.

Retinal detachment from the vitreous body primarily, and the choroidea secondarily, is a variety of the affection under consideration, described by Iwanoff. His theory is based on dissections, by which he found separation of the membrana limitans from the vitreous body; he repudiates the existence of a hyaloid membrana; and inflammatory products on each side of the severed parts. He traces the origin of the evil to choroideal disturbance, whereby fluid is effused in front of the membrana limitans, and not to that of the vitreous body, as was long supposed. He explains the post-retinal fluid, as fluid escaped there from the front of the retina, necessarily by rupture.

Retinal detachment, in eyes disorganized from traumatic inflammation, is very common. The vitreous body is partially or entirely removed; it is always missing in eyes long disorganized; and the funnel-shaped retina holds by its optic nerve and ciliary attachments surrounded by turbid fluid.

The pathology of these disorganizations is not very clear. Iwanoff thinks, especially where there have been wounds or injuries of the sclerotica, that connective tissue degeneration of the vitreous body (see p. 978) is the cause of the separation, his detachment by "attraction." The vitreous body contracts and pulls up the retina, which occasionally becoming rent, allows some of the fluid which had formed behind it, in consequence of its separation, to pass in front.

The tension of the eyeball is more increased in detached retina. It decreases as soon as the detachment is well marked.

Treatment in cases of detachment of the retina from the choroidea. Spontaneous removal of the sub-retinal fluid does occasionally occur when the detachment is very small, and is monocular. It is said, I have not seen it, that the retinal transparency and even the function may be restored.

In nearly all the cases which I see, amelioration from treatment is out of the question, from the causes of the detachment which are irremediable, the general disorganization of the eye of which the retinal displacement is but a part, the extent of retina raised from its bed, the mechanical disturbances and necessarily partial spoiling of that part of the eye, consisting, as it does, of extremely minute, exquisitely delicate, and varied structure, and possessing the most exalted and complicated function. But all of them are not quite so utterly hopeless. I believe that in some of rather acute origin, with small and chiefly peripheral stripping and healthy surrounding retina, farther separation might be prevented, and some sight saved. If the region of the macula lutea be involved, as it may be, in small circular detachments around the optic nerve, vision will be lost, although the peripheral retina is not displaced. On the contrary, with very extended peripheral separation sight may be available even for reading, if the central retina remains intact.

I adopt general treatment and topical applications, according to the nature of any existing ocular inflammation, as in ophthalmitis, for instance. Besides this, I evacuate the sub-retinal fluid by tapping the eyeball posteriorly, and as early as possible.

The tapping only need be considered. It can scarcely be done except the vitreous body be tolerably clear, and general treatment will do much for clearing it where the opacity is recent. Without we can ascertain the exact position of the raised piece, we cannot puncture the sclerotica and the choroidea over it. It would never do to be stabbing the eyeball at random.

Having made up my mind where the puncture is to be made, I retract the eyelids with the double wire retractor, lay hold of the conjunctiva with a pair of forceps, pull the eyeball into the desired direction, and with my third-sized iris knife, make the desired puncture through the sclerotica and choroidea, and turn the knife-blade half round on its axis, to make the wound gape for the escape of the fluid, which swells the ocular tunic, and pushes up the conjunctiva, but is soon absorbed.

Sometimes the fluid has re-accumulated and been re-evacuated without benefit, the detachment of the retina remaining till the eye was spoiled. Sometimes the fluid was not re-secreted, the retina has fallen back retaining its degree of opacity, and the eye destruction has been arrested. In one of my cases I noticed the permanency of the result for thirteen years, till the death of the old gentleman.

Tapping may be applied even when sight is lost, and with the view of removing the inflammatory product in the effused fluid, to preventing farther disorganization of the eyeball through reaction, which is attended by symptoms of ophthalmitis. The iris inflames and adheres to the capsule of the lens, and the lens gets opaque. Sympathetic ophthalmitis is apt to be produced.

An operation for tearing through the raised retina and allowing the fluid to escape in front, as it is said into the vitreous body, is founded on the occasional spontaneous rupture of the retina, when of course such an occurrence of displaced fluid is more or less effected. It is done with needles introduced through the sclerotica. Judging from my own essays, and from the practice of others, and disregarding hospital reports, I look on it as a bungling, uncertain proceeding, usually damaging to the eye.

HEMERALOPIA, DAY SIGHT.

This word, of doubtful derivation and diversely applied, is employed by me to express binocular diurnal vision, or power to see things by day, and binocular nocturnal blindness, or inability to see by night.

Symptoms. Night-blind people see quite well by broad daylight, even to read fine print, and as this can be done for long without fatigue, it shows that the adjusting apparatus is intact. So far their eyes are equal to normal ones, but they see no longer, like a healthy person, when the sun goes down and twilight begins. That is, there is not a reduction in the acuteness of vision in proportion to the twilight, but with slight loss of luminous rays their visual field is very misty or darkly clouded, as by a London fog, and very exceptionally with some coloration, whereby the eyes may be said to be practically blind, or nearly so.

Yet there is no special relationship between the blindness and the time of the day, and any kind of light. It is merely the stimulus of bright light which the eyes want. Objects are no longer discerned whenever light is withdrawn, and diffused artificial light of a well-

illuminated room affords sight, or the direct light of a lamp or candle thrown on anything suffices for its recognition.

Variations are met with, and in chronic night-blindness the symptoms intensify. In saying this enough is expressed.

I do not believe that there is any external objective symptom. Alterations in the pupil, which are spoken of as regards dilatation, are quite within the range of health.

An ophthalmoscopic examination shows slight anæmia of the fundus of the eye. I have met with no exception.

Causes. Night-blindness is most commonly seen in this country among young European seafaring men, who have been attacked while they were in the tropics, or homeward-bound from such regions. That the glare from the sea is, in them, the exciting cause, cannot be doubted. If it do occur among Europeans in the tropics who do not lead a seafaring life, in creoles, and negroes, such occurrence must be very rare, since enquiry furnishes me with no examples.

But other agency besides the sun-glare, some remote or predisposing cause in the eye, the optic nerve, or the brain, must operate. General feebleness may have its influence, and the probability of this is strengthened if we find, as it is asserted we may, a co-existence between scurvy and the defect. The better sight of the hemeralope in shade, soon after rising in the morning, may be owing to his recruited powers at that time. Again, the rareness of night-blindness, as compared with the loss of acuteness of sight in association with hyperæmia of the fundus oculi and of the conjunctiva, intolerance to light and pain produced when minute sight is employed, the result of tropical glare on the sea and glare on land, or from snow-fields, directs us to seek for some peculiarity determining its development. The same kind of vascular and nervous irritation of the eye, induced by tropical weather, is seen here among those who work under the influences of bright light, heat, and dust, as in our factories, but I am sure that the workmen never have night-blindness.

In 1866 I published, with remarks, in the "Medical Times and Gazette" the particulars of an example which occurred in a sailor. I will reproduce a little of it.

The sailor youth had been at home more than a week. He was in robust bodily health. When he was coming from Calcutta, the return passage of his first trip to sea, and half seas over, he discovered suddenly one night after sunset that he could not see. He groped about with difficulty. A lamplight gave him scarcely any help. When within a week's sail of England, his vision returned. His eyes re-

mained well while at home, and even during a second outward voyage, but when at the Bombay Harbour, where he had been for five months, on came the night-blindness suddenly, and in a worse degree than before. The blindness lasted for four months, and disappeared, as at first, when near home.

That his day sight was good may be inferred from this fact. Up to the latest period prior to his attack during the first voyage he was often sent aloft, to keep a look-out. On the second passage home the glare from the water produced intolerance to light.

The acuteness of vision, and the accommodating power of the eye, were unimpaired.

Thus, from the attack coming on after the eyes had been used in a tropical glare, from its suddenness, from the day sight being perfect, and from the complication, the intolerance to light, when the affection may have been said to be chronic, is the chief history of these cases told.

Night-blindness is said to occur even among landsmen in Europe during summer, and epidemics of it are recorded. It would seem as if the fatigue which the harvesters and soldiers, the victims of it, were subjected to, were elements in its production. A very great deal of the marvellous records of outbreak of night-blindness which I find published by surgical writers is, I am sure, unreliable, from the absence of ophthalmological knowledge among the historians.

We know not the pathology of this ophthalmic affection.

There is often mistaken for night-blindness, such affections as optic neuritis, retinitis pigmentosa, and hyalitis; because with them high illumination is required for seeing well at any time. To this is to be attributed the accounts one hears of the contractions of the visual field, scotomata, loss of visual acuteness, showers of muscæ volitantes, &c., as hemeralopic symptoms.

The prognosis is most favourable; if the eyes be no longer submitted to heat and glare, visual function is restored. So great is the inconvenience of the affection that the afflicted soon seek relief, and amelioration soon follows. After a cure a relapse is likely, if the eyes be again subjected to the noxious influences.

Treatment. This is expressed in removing the eyes from the influence of the hurtful light, subduing any ocular complication, and attending to any general feebleness of the body. Absolute darkness for a few days or weeks, till the attack is overcome, I regard as more beneficial than shading the eyes, because it gives a quicker result. Shading is a proper precaution, and for long too, after the eye is apparently well.

NYCTALOPIA, NIGHT SIGHT.

It has been suggested that this is an affection invented as a companion one for hemeralopia, and the humour supplies all that need be said, since that is no complaint in which a person can see by night and not by day. Intolerance to light, so common to many ocular affections, is altogether a different affair. Even an albino cannot be called a nyctalope.

Students are much puzzled with the words nyctalopia and hemeralopia, because authors and teachers use them in different senses, and even in confusion.

CHAPTER XLIX.

DISEASES OF THE CHOROIDEA.

PHYSIOLOGICAL, ANATOMICAL, AND OPHTHALMOLOGICAL REMARKS—HYPERÆMIA OF THE CHOROIDEA—CYELITIS—CHOROIDITIS—TUBERCLE IN THE CHOROIDEA—RUPTURE OF THE CHOROIDEA—DETACHMENT OF THE CHOROIDEA FROM THE SCLEROTICA—COLLOID DISEASE OF THE CHOROIDEA—COLOBOMA OF THE CHOROIDEA—GLAUCOMA.

PHYSIOLOGICAL, ANATOMICAL, AND OPHTHALMOLOGICAL REMARKS.

Physiological conditions of the choroidea are likely to be mistaken for abnormal ones, solely on account of variations in the amount and in the arrangement of the pigment.

The student must remember that besides the fifth, or epithelial layer of the choroid, a specially and highly pigmented layer, frequently called the tapetum, the choroidal stroma contains a good deal of pigment. Perhaps he will refer to the "Anatomical Introduction," and read what is said under "Choroidea," or to p. 306, which a little anticipates what I am about.

The second choroideal layer, the tunica vasculosa, generally considered the choroidea proper, has a disposition of pigment, the stellate pigment cells, in relation to its blood-vessels, the venæ vorticosæ, calling for notice, but which must be deferred for a little.

The third, or capillary layer, it is certainly arbitrary to speak of it as a distinct layer, although convenient, is destitute of pigment.

To the blood in the choroidea, and the amount of it, and to the pigment, is the colour of the fundus of each individual eye due. All that is yellow red is derived from the tunica vasculosa and the

capillary layer. All that is brown is derived from the tapetum, the general pigmentation of the stroma, and from the first choroidal layer, or membrana Fusca, far back as it is. Where the pigment is removed in any part from the fundus of the eye, from any cause, the white sclerotica is seen. The more the pigment abounds the darker will the fundus appear, and necessarily, as it darkens, will the red reflex from the blood-vessels be shut out. Let it then be understood that the colour derived from the blood-vessels is always in an inverse ratio to the amount of pigment. Pigmentation in the eye has a proportion to pigmented tissues in other parts of the body; hence it is that in blondes, fair people, who have little pigment in their choroids, the reflex from the fundus is a light yellowish red colour; and in brunettes, who have a great deal of pigment in their choroids, the reflex from the fundus is of a light brownish red colour. In the negro's eye, as I have stated at p. 307, the fundus is almost black. In it the retina shines with a faint bluish film. I am repeating what has been written at p. 307, in order to give, as I now think necessary, more detail.

The pigmentation of the different parts of the choroidea also varies; so that while the tapetum is very dark, the stroma may be deficient in colour, and *vice versâ*. An excess of normal pigmentation, in a line around the optic nerve, has been spoken of; see p. 303, also retinitis pigmentosa. The region of the macula lutea is generally somewhat more deeply coloured, and occasionally has a marked shade of brown.

The degree of illumination which is used in an ophthalmoscopic examination, that is, the brightness or the dulness of it, the purity or impurity of the light, together with the kind of ophthalmoscope which is employed, see what is said on this subject in the short review on ophthalmoscopes, will very materially alter the character of the reflex from the fundus of any eye, and much of the detail of its several parts. When a strong light is employed the whole of the fundus is equally bright; when a weak one is applied the brightness of the same decreases from the centre to the circumference. The direct method of examination gives a brighter reflex than the indirect. A young eye illuminates fuller than an old one.

It is certain that the epithelial layer, with its pigment, the tapetum, while it checks the progress of some amount of light, does not altogether shut out all light from parts posterior. This is readily accounted for by the disposition of the pigment in the cells, and the manner in which they are set, so as to leave interspaces. To this partial interruption of light is due the well-known granular appearance of this layer.

The pigmented epithelial cells may be discerned in slightly pigmented eyes, under examination by the inverted method, with the magnifying power obtained from a low object-lens, and a high ocular or correcting one. See p. 299. These may be discerned about the equator of the retina, when they are not visible in other parts. By learning to recognise it, we avoid mistaking it for a morbid state. We are, too, enabled to ascertain from its position the exact locality of morbid changes, whether in the retina, or in the choroidea. In highly pigmented eyes the epithelium is invisible.

A few words, which I promised, about the pigmentation in the stroma of the second choroidal layer, the tunica vasculosa. It is in the interstices of the larger trunks of the blood-vessels here, especially the veins which are in front, that the pigment is apparent. Only where the epithelial layer, the tapetum, is very dark, can we not discern it. Under what may be called tolerably fair opportunities for examination, the choroidal vessels will appear of a uniform colour; like reddish bands in the region of the disc, alternating with light brown or black angular or roundish spots, with granular borders, really pigment marking, and about the equator, alternating with such marking of elongated form, with the long axis turned towards the disc. This stippling, or feathering, in its many but slight variations, where very marked, is sure to be mistaken for a diseased state, unless the student will take the trouble to study it in the living eye and to become familiar with it. Their forms, which really define the outlines of the venæ vorticosæ, prevent them from being mistaken for blood extravasations, or acquired pigmentation. They are best seen in a well pigmented choroid that is anæmic.

The extent to which the blood-vessel system of the fundus of the eye may be seen, under very reduced pigmentation, or absence of pigment in the epithelial layer and in the choroidal stroma, whether as a normal condition or the effect of disease, should be explained.

Fine ciliary arteries have been traced entering in the neighbourhood of the macula lutea, ramifying in a winding course, and partly passing on into the more direct vasa vorticosa. It is said too that in rarer cases, and with greater difficulty, it is possible to trace the anterior twigs of the ciliary arteries in their course in front of the veins.

The choroidal blood-vessels may readily be traced to their entire ramifications. These vessels are recognised first, and essentially, by their orange or orange red, or cinnabar colour. By their posterior position to the vessels of the retina, their trunks being in a direction just contrary to those of the blood-vessels of the retina and larger,

and being further unlike them in disposition, by frequent divisions, anastomoses, and intertwinings, especially about the macula, and band-like aspect, from the absence of dark margins and a central bright line. The veins, the vasa vorticosa, cannot be distinguished from the arteries. The more or less absence of pigment, the many physiological differences in the sizes of these blood-vessels in different persons, and the varying conditions in the circulation, must be taken into consideration, when reviewing their thickness. See lithograph in "Anatomical Introduction."

The third, or capillary layer, chorio capillaris, is only visible in unpigmented eyes. The influence which it exercises in the reflex from the fundus, is to add the orange to the redness of the vascular parts posterior to it.

Senile changes in the choroidea modify the appearance of the fundus of the eye more than senile alterations in the retina. Of course they occur at different times of life in different people, as is the case with all senile degenerations, for such they are, forms of atrophy.

That which is readily to be detected with the ophthalmoscope is the failing in the pigment, in patches, or even generally, especially that in the epithelial layer. According as this is removed can we see the choroidal blood-vessels, or the sclerotica. The epithelial pigment may be diminished in the cells, or be removed and replaced by fat, or it and the cells quite lost. Fatty degeneration and atrophy of the blood-vessels of the vascular layer and of the capillary layer ensue.

The other pigment cells undergo fatty change, or are quite absorbed.

The stroma cells long resist change, but they become fatty.

The elastic lamina becomes thickened and irregular, by hyaline material, which may project, and even at points pass through the epithelial layer, whereby they are surrounded by rings of pigment and molecules.

According to the expertness of the ophthalmoscopist, will more or less of these degenerations be discovered.

A great deal of the pigment may be removed, and that which remains may be reduced by bleaching several tints from its normal blackness. The first changes are usually in the immediate vicinity of the large vessels of the tunica vasculosa, hence the arborescent lightish streaks by the side of such vessels. As soon as the depigmentation produces a dirty greyish white the sclerotica is seen.

We cannot say in life whether the pigment be removed from the cells of the epithelial layer, or with them.

It is easy to understand how, from all the varying circumstances under which even a healthy eye is examined, a mistake may be made with respect to the condition of its vascular system.

IRIS.

The diseases of the iris have been disposed of. See Chapter XXXIII.

CHOROIDEA.

Hyperæmia of the Choroidea.

It cannot be said, by a glance at the choroidea, with anything like certainty, whether it be hyperæmia or not, on account of the varying conditions of its pigmentation. The nearest proof that can be got of its increased vascularity is the redness of the optic disc, without enlargement of its central vessels, or loss of its outline.

IRIDO-CYCLO-CHOROIDITIS.

This is not a frequent, but a very severe disease.

In my description of "Iritis," p. 937, I have shown that no one part or division of the uveal tract is ever alone inflamed. With equal emphasis I say that cyclitis and choroiditis are only parts of an inflammatory process which involve the entire uveal tract, and extend over the greater portion or the whole of the eyeball.

The same reasons under which I found shelter in making "iritis" a species, I hope my reader will refer to it, I claim for the above classification, that is in main only according to the situation of the intensity of the vascular action. In no other way could I thus nosologically proceed.

Inflammation, I repeat, is never confined to the uveal tract alone. It is well known that this is to be partly accounted for by the anatomical relations which exist between the blood-vessels of the choroidea and the neighbouring tissues, and partly by disturbances of the regulative influence which the choroidea and the ciliary body exercise upon the entire current of blood, and, through this, upon the nutrition of the interior of the eyeball.

I ought to say at once that I am about to describe a different form

of inflammatory attack to that which is denominated "iritis." So different is it, that at a glance I can diagnose the one from the other. Would that I could write a description so plain as to convey to my reader this appreciation. In each instance the same tissues are attacked, but in a different manner, and from different causes. Take the skin as an example of a pathological parallel, selecting the exanthemata. There we have inflammation of the cutis vera in all, but in each a dissimilar effect, because in each there is a different cause of disease.

CYCLITIS.

The term, a modern one, is used to express inflammation of the ciliary body, a pathological condition recognised half a century ago. Dr. Ammon went so far as to describe inflammation of its several parts. I do not know of the affection except in association with inflammation of the cornea or of the iris, and, in the latter case, necessarily, from what I have said, of the choroidea also. It will be, I hope, remembered that the basement membrane of the posterior elastic membrane of the cornea sends posterior fibres to the iris to form the anterior pillars of the same, anterior fibres to the sclerotica, and middle fibres to the ciliary muscle. I recapitulate this to show the connection with corneitis. Cyclitis is spoken of as occurring in an isolated form, very erroneously, and as a cause occasionally of iritis and choroiditis.

Its symptoms are declared in the ciliary region, that is speaking of the outer surface of the eye, in the sclerotic zone near to the cornea, the part which corresponds to the internal situation of the ciliary body, or the space extending from the ora serrata to the insertion or circumference of the iris. Where they are well marked, we find a redness, or hyperæmia, of the sclerotica and the conjunctiva, and a little chemosis, sensitiveness, or pain, when such region is touched. The eyeball is painful under pressure made on any part, but the ciliary region is by far the most sensitive. When the choroidea is much diseased or disorganized, the anterior ciliary veins become livid and enlarged, and form a coarse network. Yellowish and opaque shreds are said to occur in the vitreous body, just behind the crystalline lens. I never saw any exudation there except in general hyalitis. The hypopion, and hyperæmia of the retina, which are usually described as further symptoms, are respectively the effect of "corneitis" or of "iritis."

I recognise active and passive forms of cyclitis, and well know that

in them there may be a degree of independence from the co-existing contiguous inflammation of iris or choroidea. This means that with very severe iritis, &c., the cyclitis may be low; with a mild attack, it may be strikingly prominent. Occasionally in iritis, particularly the syphilitic variety, exudations are thrown out, see p. 945, whereby the sclerotica is bulged.

External objective symptoms. There is an absence of that lively inflammation of the iris which is so marked in the syphilitic and rheumatic forms of iritis, especially in the former. Very early and invariably, the iris loses colour, and the pupil adheres to the capsule of the lens in part or entirely, constituting complete synechia posterior, or even synechia posterior totalis, see p. 942, and in the beginning of the inflammation there may be some nodules on it, but these disappear as soon as atrophy of the tissue of the iris sets in. The pupil is always a little contracted, and necessarily more or less irregular. The veins in the surface of the iris are sufficiently enlarged to be seen by the naked eye. When hæmorrhages occur they are from such vessels. If there be synechia posterior totalis, the iris, now more discoloured, and the departures in this course depend on its natural colour, bulges forward uniformly in a circle, or irregularly at certain points, from posterior exudations, and lessens the anterior chamber, or actually destroys it by lying on the back of the cornea.

There is hyperæmia of the conjunctiva and of the sclerotica, which is never excessive, and often slight. Cyclitis is never absent, but there is not developed that active form of sclerotic hyperæmia which I have described and delineated at page 968; it is a passive kind. The colour produced by the cyclitis contrasts well with the dingy yellowish vascularity of the rest of the white of the eye.

The cornea is more or less hazy.

Internal objective or ophthalmoscopic symptoms. Haziness of the vitreous body, varying from a slight degree to that which prevents the fundus of the eye from being seen, and sometimes very marked hyalitis. Occasionally the pupil is too contracted, or has so much exudation in its area that the ophthalmoscope cannot be used.

I do not know whether it occurs to my reader that I have given no evidence of there being a "choroiditis" excepting what I have said about the enlargement of the anterior ciliary veins. Indeed, I cannot give any other, unless it be that of partial thinning of the sclerotica and choroido-sclerotic-staphyloma, necessarily a late occurrence, of which more will be said presently. But more must be spoken of choroiditis, and this shall be done under the next subdivision.

Subjective symptoms. These usher in the attack, throbbing and darting pains in the eyeball, and unilateral headache. The eyeball

is tender, especially in the ciliary region, and of slightly abnormal tension. This tenderness is traced to the nerve supply to the ciliary muscle, the only part of the uveal tract besides the iris which is supplied with nerves. Intolerance to light, and suffusion of tears prevail. Flashes of vivid reddish orange coloured light, or a luminous point constantly enduring in the axis of vision, are perceived.

Sight is always worse than the objective symptoms would seem to account for. A cloud overspreads the visual field, the acuteness of seeing is lost, and large bodies might not be correctly discerned.

Contraction of the visual field may exist in the latest course of the disease.

Only one eye is usually affected. If the two eyes suffer, it is rarely together, but consecutively.

Constitutional disturbance of a febrile kind is seldom absent, and may be very considerable.

Now and then we meet with a more sthenic form of irido-cyclo-choroiditis. In a short time all the symptoms reach their highest point, and lead quickly to permanent results.

Undoubtedly the tendency of the disease is to pass into a chronic course.

Certain alterations in the ciliary region are sure to follow long persistence of irido-cyclo-choroiditis. A ring of blackness surrounds the cornea after the manner expressed in the admirable wood

Fig. 293.

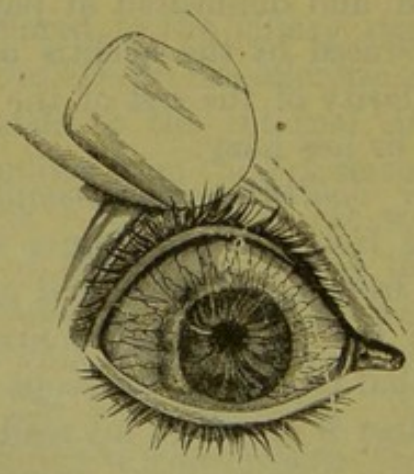

cut, Fig. 293, which also portrays an adherent pupil, atrophied iris, and hyperæmic eye.

More advanced pathological changes in the same region are apparent in thinning of the sclerotica and bulging, hence the anterior annular sclerotico-choroidal-staphyloma, described at p. 971. Another effect in an opposite direction is the result of contraction of the ciliary

region, whereby the eyeball is elongated a little in a conical form. This occurs only in milder but prolonged inflammation.

Posterior to the ciliary region, the sclerotica may become staphylomatous. At p. 971, a partial lateral sclerotico-choroidal staphyloma is delineated. In the chapter in which it occurs, the formation of staphylomata is discussed.

Further disorganization of the eyeball, the greatest which can occur, as severe as suppuration, is found in separation of the retina from the choroidea, elsewhere fully described, and atrophy.

We find then that, in reality, we have been considering a peculiar kind of inflammation of the eyeball.

Mild irido-cyclo-choroiditis.

This is by far the most common form of the two, whilst it is the most insidious and deceptive of ocular inflammations.

Symptoms. Almost without exception does the patient discover his malady by finding his sight hazy or dim, to which is soon added an unpleasant sensation of fulness in the eyeballs. To one not versed in eye matters nothing may be observed, for there need be as yet no hyperæmia, although already the pupil is partially adherent to the capsule of the lens, and a little of the iris lustre is lost. Soon a little redness appears about the ciliary region, and is nearly confined to the sclerotica. Even where hyperæmia is an early symptom, it is not severe. Haziness of the vitreous body is always present. Complete synechia posterior is not found in a first attack. So far, there might be no demonstrable evidence of cyclitis, or but very little, and we must rely chiefly on the objective testimony of tenderness in the ciliary region, to attest its presence. Still less can we judge of the presence of choroiditis, unless by analogy, or, as some would require, haziness of the vitreous body in the section corresponding to the ciliary body. But the general haze of the vitreous body, already alluded to, and the disturbance of the retinal function, due of course to retinitis, are not likely to appear without choroiditis.

The attack soon passes off, and may not affect the vision, or may damage it to a greater or lesser degree.

Relapse is tolerably certain. On each return more adhesions of the iris are formed, the pupil is more reduced, the body of the iris gets more discoloured and a little atrophic, and if the synechia be complete, falls slightly forward. Vision is materially damaged, and may be destroyed.

Patients who are sufficiently forewarned, notice the advent of the attack in the mistiness of the sight, or the further deterioration of it, when it has been already injured.

Staphylomata do not occur.

Cause. What this is I have not been able to satisfy myself. It certainly is not the result of traumatic injury. Disorganization of the eyeball from such a cause, has a different course, as I have explained in the proper place. It is true that the choroidea becomes inflamed in such cases, and we have staphylomata of it and the sclerotica. The term "choroiditis" is often loosely used in inflammatory affections of the eyeball. All that I can say is that the affection occurs about middle age, or after that, and most frequently in persons of a debilitated constitution. It is a prevalent belief among surgeons that over-use of the eyes is at least an exciting influence. It is said that syphilis is the most common origin of the malady. If so, in my cases at least, the eye affection has been the only secondary manifestation of such disorder. If inherited syphilis be claimed, as well as direct syphilitic infection, there is necessarily much in such a line to fall back upon.

Nor am I able to say what is the cause of the mild form of the affection. The inflammation certainly differs, if I may say so, from the other in appearing in persons earlier in life, even before adult age, and generally in those who might be selected for their appearance of health, and most commonly in women. As powerful a young man as ever I saw, and in whom I could trace no constitutional cause, no syphilitic origin, however remote, lost an eye after five or six attacks. The more slowly damaging power of this species is another difference.

Gräfe propounded the theory that adhesion of the pupil to the capsule of the lens, is a cause not only of the ciliary body and choroidea becoming inflamed, but of the repeated attacks of inflammation of which I have spoken. I have already at p. 952 noted my dissent from this. The cyclo-choroiditis, and the adhesions of the pupil, are parts of the same disease. I disbelieve in any disposing influence, which it is alleged adhesions possess of producing irritation of the eyeball, from stretching, to which it is said they are liable.

On the morbid anatomy changes, I must be very brief, especially as a good deal of the more advanced states is described in the chapter on the Diseases of the Sclerotica, in connection with staphylomata, and presently, under choroiditis, the subject must again be entertained.

Treatment. The measures propounded for iritis, p. 949, are those applicable to which I add tapping of the eyeball, paracentesis, corneæ, and frequently, that is daily, or not quite so often, till the tension of the eyeball is reduced. Loss of pain, and lessening of ciliary irritation, are proofs of the efficacy of the treatment, but still better is that of improvement in sight.

In the rapidly developing sthenic cases, vision is in some degree always early damaged. In the less severe cases, which have a tendency to pass into a chronic course, treatment may prevent the attacks, and save the sight.

The mild irido-cyclo-choroiditis is still more remediable. Local treatment is not often called for. I begin with the mercury pills at once, and reduce them as quickly as the symptoms lessen.

Iridectomy is much adopted for this affection, here and abroad. It does not prevent the recurrence of attacks, and if trusted to alone, as it often is, the eye will be the worse, instead of the better for it.

Where vision is destroyed, the eyeball more or less atrophic, and attacks of inflammation recur, extirpation of the spoiled organ should be adopted.

CHOROIDITIS.

We cannot describe this from observation, as we may a retinitis, if we desire to speak of developing inflammation. It has no visible vascular turgescence. This is prevented by the natural tension of the eyeball, for so long as the outer coats are healthy and have not yielded, and the vitreous body has not been reduced, an effectual barrier is placed to the over-filling of the blood-vessels of the choroidea, or, indeed, of any intra-ocular blood-vessels. Besides this, the choroidal pigment screens vascular excitement, and as soon as there is any disturbance in the epithelial pigment, which necessarily follows much choroidal inflammation, neuro-retinitis, and hyalitis, are developed enough to add to the obscuration. Remember, I said that inflammation was never confined to the uveal tract. We must look for outward objective symptoms to determine the affection in question, collateral and direct, such as the co-existence of iritis be it ever so slight, and the same of cyclitis. The sclerotica does not show much participation in early choroiditis, at most it may be faintly hyperæmic. Congestion of the anterior ciliary veins will be found. It is to the effects of inflammation that we must trust for ophthalmoscopic signs, in order to say that there is, or has been, choroiditis. These are effusion, hæmorrhage, atrophy.

Serous effusion. This is often spoken of, and if it mean infiltration of the stroma with such, it is assumed rather than proved, for we cannot see it. Effusion may separate the choroidea from the retina, but who can say that the retina does not play its part in such exudation?

CHOROIDITIS DISSEMINATA.

In describing this, I wish to represent chiefly what is called an exudative form of choroiditis; one in which there are plastic deposits.

Taking into consideration what has been said about retinitis pigmentosa, nosological difficulties at once present themselves. The retina, as well as the choroidea, is involved in it, as well as in choroiditis disseminata, indeed in both, the choroidea is the starting point of mal-action, and there is a strong subjective and objective resemblance between the two. Some authors think that the term retinitis pigmentosa is a mistake. Others class as choroiditis disseminata, conditions, which a third set, class as retinitis pigmentosa. Cases come under my notice which I am very much puzzled to classify.

Pigmentary changes in the fundus of the eye.

I desire to speak at once about the anomalies which are met with in the choroidal pigment, especially in that of the epithelial layer. It may clear up what might otherwise be a puzzle to the student when he looks into an eye and finds black dots, or black patches interspersed with lightish or white ones.

I have said in the chapter on Diseases of the Retina that congenital pigmentation may be found around the optic disc, and even in the retina; their congenital origin being assured by their limit, the perfect healthiness of the choroidea and retina around, and the normal condition of vision.

Pigment disturbance is always partial, as regards the extent of the choroidea.

The pigment may be removed partially, or entirely. Such deterioration is always spoken of as choroidal atrophy. The effect is respectively, tints of clearness in the fundus, till the full white shining of the sclerotica is seen. If the retina in the pale of the clear patch be sound, its blood-vessels will stand out in full distinctness (see p. 639). If the choroidal blood-vessels be not atrophied, they will be seen with corresponding clearness. In the reference given, I discover two blunders: line sixteen, the word "going" ought to be "shining;" in the last sentence of the paragraph, it should be written, the pigment of the epithelial cells.

There may be an increase of pigmentation, supplied by enlargement of the cells of the epithelial layer and augmentation in the quantity and the blackness of the pigment. This is called proliferation of the epithelial layer.

When choroidal atrophy ensues, be the cause mere stretching or

tearing, or effusion into it of a serous, plastic, or hæmorrhagic kind, and be the effect sudden or slow, the choroidea in the immediate vicinity of the atrophy is always abundantly pigmented, in the form of partial or complete rings, or spots, or streaks. The contrast between this blanching of one part, and deep pigmenting of another close by, produces the black and white spots with which we are now so much concerned.

Proliferation of pigment takes place over a choroidal exudation, and appears, for a while at least, as a very black spot.

I cannot escape describing several varieties of this affection, but before so doing, I must acknowledge how much we are indebted to Forster and Iwanoff for their pathological researches.

Areolar choroiditis disseminata of Forster. There are developed in the choroidal stroma small colourless cells. These are soon transformed into fibrillated tissue, from the particular areolar aspect of which, the disease has merited the name that Mr. Forster has given it. The retina over the deposit is depressed. In proportion as the new areolar tissue shrinks, the subjacent retina is drawn towards the cicatrix, and destroyed in isolated points. Immediately around these deposits, the choroidea inflames and adheres to the sclerotica, but outside of this, the retina and the choroidea are healthy.

Ophthalmoscopic symptoms. Black and white patches, of variable form and extent, are chiefly grouped around the macula lutea, and, with the exception of the smallest black spots, they all affect a roundish form.

The less voluminous black spots have a deep blackness, and are probably produced by a simple proliferation of the epithelial layer, but in proportion as the spot increases and the deposit behind is developed, its centre whitens, and the pigment is driven towards the border in roundish outlines. There is thus, at first, a black patch or spot, by the enlargement of which, and the whitening in the centre, the black and white patch is produced.

During these metamorphoses, the character of the exudation may be studied at the circumference, and its atrophy in the centre. A variety is described in which the spots have an intimate relation to the distribution of the retinal blood-vessels.

Second form. This differs from the above in that the inflammatory symptoms are more limited to the morbid centres, and leave the intermediate parts absolutely healthy. The morbid anatomy consists in a warty thickening of the elastic lamina of the choroidea, which thickening is out of all proportion to the little outgrowths which occur in old persons. These vitreous excrescences grow so large as to enter the retina, and destroy it in parts corresponding to their

pressure. It is probable that the nerve-fibres escape destruction by lateral displacement. The excrescences are surrounded by black pigment, some of which is enclosed in the retina. Of course I see the almost inappropriateness of placing this under an "exudative" heading.

The ophthalmoscopic image corresponds to the pathological changes, but unfortunately a variety is met with in the areolar form just described, in which there is more interspace of healthy retina, and we cannot always distinguish it from this form.

Later pathological changes take place in both forms. Neoplastic masses occur between the remains of the choroidea and sclerotica, and the retina and the vitreous body, followed by atrophy of the optic nerve, the retina, and the entire choroidea.

I have said that cases come under notice which are difficult to classify, according to the headings, retinitis pigmentosa, and choroiditis disseminata. In the phase of the latter, when the exudations are absorbed and the sclerotica is seen, who can tell the difference between it and a case of the former, where the choroidal atrophy alone, unpreceded by exudation, exposes the sclerotica?

A third form, described by Liebreich, consists of white exudative points in the neighbourhood of the optic disc, and in other parts, some with black borders, all deeply seated in the choroidea, and of large irregular white patches of exudations upon the inner surface of the choroidea, some of which have no pigmentary border.

Another form he describes, and particularly distinguishes by the groups of epithelial cells which are enlarged and filled with abnormally black pigment, forming black spots of most varied shapes, which are almost always surrounded by a narrow light-coloured border, in which the epithelium is either absent or deprived of its pigment. In the illustration which accompanies the description, there are atrophic portions of choroidea with pigmentary margins.

Choroidal hæmorrhage. This is an occurrence incidental to the blood-vessel degeneration of choroiditis.

Apart from wounds or blows which rent the choroidea singly, or along with other ocular tissues, it may safely be assumed that hæmorrhage is due to an abnormal condition of the chorio-capillaries, arising out of inflammation, so called inflammatory relaxation, whereby they become distended, or even sacculated, or undergo atheromatous change. Under such conditions of disease, any strain, as that arising from the check given to the blood returning to the heart, from coughing, sneezing, vomiting, stooping, or great exertion, is apt to cause hæmorrhage. So, again, pressure on the eyeball, or a slight blow, either of which would be nothing to a healthy eye, is

almost sure to produce the hæmorrhagic effect. Fortunately, where the tension of the eyeball is not reduced, the hæmorrhage is not large.

In speaking of the operation for the extraction of cataract, abscission of the eyeball, &c., I have alluded to the intra-ocular hæmorrhage which sometimes arises. It is from diseased chorio-capillaries. As soon as the eyeball is opened, and the capillaries lose their support, they burst and pour out blood. The hæmorrhage, as I have said, may be severe and even fatal. The conditions requiring such operations usually prevent the state of the choroidea and retina from being seen; but we may always suspect disease of the chorio-capillaries, if there be varicosity of the anterior ciliary veins.

The effused blood may be confined to the choroidea, pass between it and the sclerotica, or burst the retina and enter the vitreous body. Except where the extravasation is large, it is usually between the choroidea and the sclerotica, or partially in the true vascular layers. Several extravasations may occur. The rarest position is the last, but it is seldom acquired unless the rupture be near the ora serrata. There the nerve-elements of the retina are thinnest and the hæmorrhage more readily breaks through them to enter the vitreous body.

We must learn to discriminate these hæmorrhages. Small extravasations may be sufficiently near the extremity of the choroidea to elude detection, except by dissection. The rules which I have given for discriminating the positions of retinal hæmorrhage are partially applicable here. The anterior position of the blood-vessels to the hæmorrhage and their complete disassociation with it, which means that the trouble is posterior, is a characteristic of choroidal bleeding. It adds to the certainty of diagnosis of this symptom if it be ascertained that the retinal vessels are healthy, being free from degeneration, that there is no probability of the effused blood having come from them.

I forgot to say in my retinal hæmorrhage remarks that when extravasated blood is of certain thickness, and the central part blackish, it may be impossible to tell whether the retinal vessels pass over the blood, or the blood over them.

The very dark, uniformly coloured blood patch, regular or irregular in form, with defined or undefined edges, but without striation, are further marks of choroidal hæmorrhage. During the absorption of the extravasated blood we may sometimes be more sure of its position in the choroid, at which time, too, some surrounding pigmentation is not unusual. The binocular ophthalmoscope may now be advantageously used.

Persistence of the blood spot is much more common than in the

retina, where absorption begins quickly, and is soon finished, and so is degeneration into pigment spots.

Small choroidal hæmorrhages away from the macula lutea do not affect vision. Large apoplexies, which thrust back Müller's limiting membrane and compress the rods and cones, generally produce blind spots in the visual field. Hæmorrhage into the vitreous body necessarily impairs sight.

The subjective symptoms of defective sight, of choroiditis disseminata, are those of retinitis pigmentosa. The variations in vision are very great, owing, of course, to the contingent morbid changes in the vitreous body, the retina, the optic nerve, and the choroidea, so that we cannot assign any proper symptoms to either of these affections; hence, it is impossible to declare in any given case, from impaired sight alone, which of these are present. The greatest deterioration of sight goes with retinal and optic nerve alterations. Choroidal disorganization, provided it be not about the macula lutea, may be very extensive and yet impair sight but slightly; indeed, it might not affect it at all.

Causes. I have clearly ascertained that choroiditis disseminata may be found after the decline of irido-cyclo-choroiditis. I have learned that it may appear without any of the external tunics of the eye being involved. In the latter case I have seen it as a sequel of primary, and of inherited syphilis. But I am equally sure that I have seen it in adults, in whom there was no syphilis, either inherited or acquired.

I cannot give any differential objective ocular symptoms, from my own knowledge, by which a syphilitic case can be told from a non-syphilitic one, and I am sure that what have been pointed out as reliable in such diagnosis are not; no one would trust to them absolutely. To the history of a case and the presence or absence of constitutional syphilis must we rely for discrimination.

The treatment is that which I have recommended for retinitis pigmentosa, namely, the same as for "Iritis," p. 949.

TUBERCLE IN THE CHOROIDEA.

This has chiefly a pathological interest, since it is not seen among ophthalmic patients. I doubt whether an ophthalmologist will ever meet with an example, unless he seek it amongst those who are consumptive.

The association of ocular tubercle with acute miliary tuberculosis, particularly where tubercular meningitis is developed,

thanks especially to Colnheim, is now fully established, both by ophthalmoscopic appearance, and morbid anatomy inspection. By the latter only was the discovery first made. There is nothing very remarkable in this new pathological fact, for not an organ of the body, and scarcely a tissue, escapes being the seat of tuberculous deposit.

Symptoms. Both eyes usually suffer, and at the same time.

This new formation is generally developed in the vicinity of the optic disc, very rarely at any distance from it, in one or several points. When well developed, it appears as a round pale yellow, or yellow rose spot, the limit of which is lost in the parts around. In the earliest recognisable stage, when it just separates the choroidal epithelium a little, it is a spot of a palish grey. It may increase only a little, and not even push the epithelial layer forward, or grow sensibly and projecting, and show a diameter of from half to three millimetres. Very rarely is there any surrounding pigmentation, and in this we see a marked difference between it and any exudations or hyaline growths in choroiditis disseminata. The surrounding choroid is not inflamed, and the retina does not lose transparency. This is not quite in accordance with our modern ideas of such growths being inflammatory in their nature.

To sum up, then, the polar position of the growth near the disc, its increase, its peculiar colour, the almost absence of pigmentation around, in an eye otherwise healthy, are the characteristics. The recognition of the general tubercular disease unmistakeably confirms the ocular implication.

No subjective symptoms seem to have been noticed, the sight being perfect, and the visual field not contracted.

The starting or developing point of the growth is not quite settled, but I agree with Colnheim, that the lymphoid cell in the choroidal stroma is the primary seat. This agrees with the present belief of the development of tubercle from the tissues belonging to the lymphatic system. It is certain that the tubercle begins in the tunica vasculosa, and generally rests on the vessels. It is stated that a large tumour having a tuberculous character has been discovered in the choroidea.

RUPTURE OF THE CHOROIDEA.

Choroideal injury has been partially noticed in the chapter on Injuries from Mechanical Agents.

The causes of rupture are blows, or other mechanical damage

inflicted on the eyeball, on the orbit, on the face, or even on the head. See the fourth paragraph, p. 438.

Our knowledge of this lesion is generally not ascertainable until after the severe effects which nearly always accompany it have passed away. There is more or less opacity of the vitreous body, accompanied or not with ophthalmitis, the extent and intensity of which may be much influenced by any cutting or tearing of the outer ocular tunics and hæmorrhage.

Ophthalmoscopic symptoms. The clearing of the vitreous body and the absorption of extravasations need not be described. When the ophthalmoscope may be advantageously used we find one, two, or more streaks of tearing, and, whether single or many, the same characters exist. A single tear is rather exceptional, but I will select it for conciseness. It seems to stand out as a yellowish white rather than a dead white streak, of varying width, perhaps with serrations, which colour is due to the tunica fusca not being quite divided. Remains of the tunic may appear as a cloudy tracing or a little pigment. Wounds through the eyeball which divide the entire choroidea, leave the sclerotic shining, as we see it in complete choroidal atrophy.

Almost invariably the rent is at the pole of the fundus oculi, near to and at the outer side of the optic disc, with the axis vertical, or nearly so, and if curved, lying as a segment nearly parallel to the disc. The edges are sharp, everted, and much pigmented, or rough and reddish. Some choroid vessels may be seen in the breach. The retinal vessels pass over it, as across a staphyloma posticum. The superimposed retina may be clear or cloudy. The rest of the fundus oculi appears healthy.

Dissection has proved what the ophthalmoscope had determined, that the choroidea alone may be ruptured, and not infrequently, if we consider the epithelial layer as belonging to the choroidea. Rupture of the retina and choroidea are noticed elsewhere.

I have given a chromo-lithograph delineation of a case of double rupture, which is a beautiful representation of the original. It was taken from a man, twenty-seven years of age. The ruptures united at their lower edges. When there are several, there is usually an anastomosis.

The amount of extravasated blood is usually small. There may be no bleeding.

The rent seems to increase from shrinking and atrophy of its edges.

An outward objective symptom may appear in a sluggish, a dilated, or an irregular pupil, owing to tension or rupture of the ciliary nerves.

The principal subjective symptom is impaired vision, loss of acuteness of sight, which usually increases from inflammatory reaction and secondary changes, especially if the retina be secondarily damaged, for there may be but little intra-ocular irritation, or a great deal.

We know that it is possible, from the record of two cases, for sight to be restored after the rupture; but unfortunately we know also that there is permanent impairment of it, according as the retina is damaged; such as loss of visual acuteness, scotomata, distortion of objects, actual blindness. Sometimes the vision improves, but only to become worse. The very healing of the choroidea, during which the retina is drawn backwards and united to the sclerotica, by the cicatrized tissue in the choroideal gap, spoils the retinal elements.

I need not stop to consider the various theories which have been resorted to, whereby to explain this form of accident.

It is very probable that cases of this kind are frequently overlooked, because patients are examined before the conditions which mark the rupture have passed away, and no further inspection is made. No doubt they are sometimes mistaken for retinal hæmorrhage.

Knapp thinks that choroidal rupture is not always followed by hæmorrhage, and that evidence of such lesion would be shown by choroidal atrophy. Other observers consider atrophic patches near the disc as a kind of stretching of the choroid, short of actual tearing.

The treatment is the same as that recommended for internal traumatic ophthalmitis.

DETACHMENT OF THE CHOROIDEA FROM THE SCLEROTICA.

This has been described by Liebreich, who candidly admits that incipient intra-ocular tumours may produce similar ophthalmoscopic appearances. The symptoms are said to be a well-defined and tightly stretched tumour, which protrudes into the vitreous body, over which the retinal vessels run in a straight course, and immediately behind, indications of the choroidal blood-vessels, with their interspaces, are observed. See what I have written about the diagnosis of Choroidal Sarcomata, p. 987.

It is very questionable whether there be any such affection. Its existence could never be told except by dissection.

SUPPURATIVE CHOROIDITIS, OR PANOPHTHALMITIS.

I introduce this heading because some writers employ it. The affection it is meant to represent is that which I have described in Chapter XXXIV., "Ophthalmitis," p. 955, under the section "Ophthalmitis in General." I again refer to errors. Line 2, after "with," add "or without." "Suppurative" should be added to the headings of the second and third sections.

COLLOID DISEASE OF THE CHOROIDEA.

This has no relation to cancer. What we know of it is derived from microscopic research, chiefly in the disorganized eyeballs of very old people. It has escaped my notice in the living eye.

Ophthalmoscopic appearances. It is said that only late in the affection are there ophthalmoscopic signs, and then they appear in the periphery, rather than at the pole of the fundus. They are described as a blotched patchy appearance, due to the irregular distribution and partial atrophy of the choroidal epithelium. The choroidal vessels are hidden by cretaceous masses, which lie in front of them.

Mr. Hulke has written two papers on the subject in the "Royal London Ophthalmic Hospital Reports." After speaking of the investigations of Donders and Müller, he enters into details, from which I gather the following remarks. The inner surface of the choroidea is studded over with small, transparent, highly reflecting bodies, the largest compound, and looking like tiny seed pearls, the smaller ones simple; all being adventitious thickening of the elastic lamina. The appearance gives the idea of a forcible eruption, in which the colloid bodies start up from the inner surface of the choroidea, upheave and displace the epithelial layer.

The colloid bodies are prone to calcify, and form stony glandiform masses, or beads of a glassy aspect. Simultaneously with such calcification other structures of the choroidea undergo similar changes. Sometimes the retinal vessels as well undergo calcification.

Colloid disease is so frequently associated with inflammatory change, that inflammation may be considered a cause of it. It is almost always present in those shrunken eyeballs which have been repeatedly inflamed.

The globular form of the eyeball is completed about the third month of fœtal life, by the filling up of an opening in the lower part, which passes from near, and a little to the inner side of the optic nerve to the iris, and is known under the name of the fœtal fissure of the eyeball. The sclerotica first unites, then the choroidea, then the retina, the union commencing in front and proceeding backwards.

The failure in the completion of this work of growth, by which the fissure becomes permanent, constitutes coloboma.

Coloboma of the iris and of the choroidea usually coexist. The former may be present without the latter. The reverse is rare.

The iris deficiency is described among the diseases of the iris.

It is only to be told how coloboma of the choroidea is to be recognised, for it is an irremediable condition. This necessitates recounting of some of the several kinds, and a little explanation of the anatomical conditions.

All of the ocular tunics partake more or less in this congenital defect.

The only outward symptom is a protrusion of the sclerotica, staphyloma scleroticæ, which is in correspondence with the deficiency of the internal tunics. But the bulging, always irregular, may have very different depths.

There may be a mere escape from a coloboma, which is declared in thinning of the choroidea, the retina, and the sclerotica, in the line of the fœtal fissure, and attended by only the slightest bulging of the sclerotica.

The coloboma may extend through the ciliary processes, there being no interruption between it and coloboma of the iris to the side of the optic nerve. The optic nerve even may be included in the fissure. Usually, however, even in an extreme case, a process of choroidea forms a bridge at each extremity between it, the ciliary processes, and the optic nerve.

Partial and short colobomas are the most common, and may be situated in any part of the line of the fœtal fissure. I have a drawing of one, only two and a half lines long, mid space between the ciliary processes and the optic nerve. The sheath only of the optic nerve may be affected, and Liebreich has dissected such a case. Having made a longitudinal section of the optic nerve, he found its sheath to be dilated into a deep pocket below the disc, previous to its passing into the sclerotica.

Ophthalmoscopic effect. Reflection from the fundus of the eye is interrupted by an oval patch, of varying width, widest behind, of whitish grey, or dead white, according as the choroidea is merely attenuated, or nearly absent, or deficient, and shows the exposed sclerotica, with sharp edges, more or less pigmented. The retina lines the fissure, or partially lines it, and partially bridges over it, according to the varying depths. It is a question as to the membrane being really retina or not. The present conclusion is that if it be, the elements of the nerve tissue layer are miserably wanting. It has some of the characters of a detached retina, in its displacement, strong reflection, and some folding while a little hides the blood-vessels.

Where the optic disc is included in the coloboma, it is scarcely distinguishable from the bluish white sclerotica, except by the definition of its upper margin and its reddish tint. It has been seen as an ellipse, with the long axis horizontal. Where the sheath of the optic nerve is alone involved, Liebreich writes, in describing a case: "At the place of entrance of the optic nerve a clear round disc was seen, of the same greyish, transparent colour as the optic nerve, and separated, as it were, from the rest of the fundus oculi by those lines which I have described as the choroidal, sclerotic, and true nerve boundaries of the disc."

The mode of distribution of the retinal vessels is peculiar, chiefly on account of the manner in which they are thrown out of their natural plane, by more or less following the bulging of the sclerotica or foldings of the retina. Sharp angles, as well as curves and intermingling, are thus produced. Some choroidal blood-vessels may be discerned, being recognised by their coming out of the sclerotica, keeping close to it, and entering the choroidea, but it may be difficult to make them out from those of the retina. Some other congenital malformation may exist with the coloboma, especially microphthalmos or smallness of the eyeball, from imperfect development.

Subjective symptoms always exist in some form of defective sight.

The analogy to staphyloma posticum is striking.

GLAUCOMA.

While we retain this very old name, originally used by the ancients to signify opacity of the crystalline lens, and by modern writers to express a green or greenish colour of the pupil, the supposed distinctive characteristic of a particular disease, we do so without any reference to its etymology, and in a purely arbitrary sense.

I shall endeavour to show that we must recognise diseased conditions, some of them peculiar, of all the tissues of the eyeball, in fact, a combination of well recognised diseases, with some uncommon phenomena.

Glaucoma seldom appears till after the middle period of life, much oftener in females than in males, and in those of dark complexions, who are pale and unhealthy in appearance.

I shall class the symptoms of glaucoma, under the headings of acute and subacute.

Acute inflammatory glaucoma.

Premonitory symptoms. There may be definite premonitory symptoms, chiefly subjective. A halo or corona, grey or coloured, sometimes as one circle, sometimes as several, in the same or different colours, surrounds the flame of a candle or lamp, or any luminous object, which is looked at. Occasional dimness of sight, or dimness of a part of the visual field. Flashes or wheels of light, perceived in the dark as well as in the light, with or without intercurrent obscurations of sight. Rapid increase of presbyopia, together with reduction in the range of accommodation, ciliary neuralgia, headaches. There is no preference in the perception or order, where several occur, nor is there any usual time of duration, where they remit or intermit, nor of period over which they may extend, so that their occurrence may occupy hours, days, weeks, months, or years. The pupil may dilate.

Direct symptoms. After some, or all of the premonitory symptoms, or without any one of them, acute glaucoma appears as an inflammatory attack, ushered in by the subjective symptoms of sudden and severe, although alternating, ciliary neuralgia, popularly called, throbbing pain in the eyeball and corresponding side of the face. The eyeball is most intolerant to any touch. Flashes frequently appear, sometimes of a vivid red, sometimes of a deep orange colour, with intolerance to light. These are increased by exertion, or anything which quickens the heart's action, even the taking of food.

The outward symptoms declare ophthalmitis, or inflammation of the eyeball, in which the uveal tract is much implicated. We find lacrymation and intolerance to light, swelling and redness of the eyelids, slight conjunctivitis with serous chemosis, but scarcely any purulent discharge, hyperæmia of the sclerotica, and congestion of the anterior ciliary veins, which are much distended and livid. These disturbances vary very much in intensity. I am sure that my reader will gladly excuse my giving some of the variations. Who could describe all of them?

The surface of the cornea is hazy, like a slightly steamy glass,

and a little roughened, or even vesicular in spots. There may, too, be interstitial opacity. Some, or all of its sensibility is lost; there is much variety here, not only in the degrees of loss of sensation in the entire part, but in the manner in which, portions only of it, are so affected.

The entire cornea flattens, the iris inflames, loses its colour and fibrous look, acquiring a slate-like aspect, but rarely throws out exudation. It is pushed against the cornea, by which the anterior and posterior chambers are lessened, and the turbid aqueous humour is reduced. The pupil is dilated, irregular, and fixed. Its area, or pupillary aperture, differs from the normal greyish blackness of middle, and especially of old age, in showing less blackness and more drab colour; and sometimes it may be said, with a little imagination, a shade of green, but no tint of green is ever met with. This coloration, of which many varieties are described with considerable exaggeration, is to be accounted for by the natural amber coloration of the lens, see Senile Changes of the Crystalline Lens, p. 734, and the greater exposure of surface so changed by the dilated pupil, the colour of the aqueous humour, and the reflected light from the hazy vitreous body, to which is added, in later stages, slight atrophy, or opacity of the lens. Immature cataract is no uncommon association with advanced glaucoma.

The eyeball is harder than natural, and if other glaucomatous symptoms increase, so in all probability will the hardness, till the sclerotica is scarcely to be indented. It is an early symptom.

This hardness, or tension, as it is usually called, is rarely absent, and is the symptom, above all others, which the majority of surgeons rely on to substantiate the presence of glaucoma, and so much is it thought of, that some surgeons of deservedly high repute, define glaucoma as "tension of the eyeball." But this is saying a little too much, for I shall show that we may have glaucoma without abnormal tension, very exceptionally, I admit, and abnormal tension without glaucoma. The student must therefore learn, as far as it is possible, for he can at best get but a close approximation, to estimate what is the natural tension of an eyeball. Softness is as much a symptom of disease as hardness, and it is only by repeated practice that the amount of firmness and elasticity, indicative of a sound ocular state, can be tolerably ascertained. I must explain a little.

The natural resistance or tension of the eyeball, varies so much in youth, in the prime of life, and in old age, and in different individuals of the same age, that the extreme in the one direction might pass for abnormal softness, and in the other for abnormal hardness. This physiological variation is at times a little puzzling, and may be

a source of error, when we are taking into account slight softness or slight hardness, as indicative of disease.

Let me give a ready method for determining the resistance which, in any instance, the eyeball gives to pressure. The patient gently closes his eyelids and looks a little downwards. The examiner places the point of the forefinger of each hand on the upper part of the eyeball just beyond the cornea, one on the right side, the other on the left, and presses centrally, first with both fingers simultaneously, and then in alternation, all the while keeping them adapted. According as the eyeball yields or fluctuates, do we speak of its softness, and according as it resists, do we speak of its hardness.

It has been proposed to express degrees of glaucomatous tension, thus obtained, by numbers 1, 2, 3, to which are given certain ranges, to be represented by letters of the alphabet. But diseased gradations are too numerous to admit of any such tabulation, and normal tension in one eye may even exceed that of acquired or abnormal tension in another eye. Besides this, I know that no one could use any of the suggested formulæ, for there are several, with even an approximation to accuracy, any more than he could tell slight differences in the weight of bodies which he may take in his hand. How is he to get his unit? The other eyeball, if even healthy, may not, as I have shown from physiological variations, be sufficiently reliable. And then no two men would ever agree in their recognition of the degrees of tension. I think that we ought to be contented to be able to ascertain that a glaucomatous eyeball is a little harder than natural, or very hard, availing ourselves of the state of the other eye in comparison, and to express the same in simple words. Besides, we do not form our diagnosis of the extent of the glaucomatous changes, or our prognosis, by mere tension alone. We take into consideration other symptoms. I must not forget to tell that attempts have been made to take the glaucomatous tension by instruments, by Monik and others, which to my mind are inferior to the fingers. In Knapp's "Archiv. of Ophthalmology," &c., is a tedious paper of fifteen pages on Ophthalmotonometrie, by Dr. Pflüger.

Vision is always much deteriorated in acuteness, and generally declines in a gradual manner, and for a while, higher illumination and approximating the object to the eye, overcomes in a measure its deficiency.

It gets worse, a thick fog pervades the visual field by daylight, and a halo with prismatic colours surrounds objects by artificial light.

The visual field has already contracted, beginning at the inner

side, and the contraction may continue till only a diagonal slit of it remains, which is soon lost. Perhaps it never escapes reduction.

An ophthalmoscopic inspection is generally prevented by the hazy state of the vitreous body. When the fundus can be seen, the disc is hyperæmic, or much reddened. The arteries are normal, or reduced in size. The veins are always enlarged, generally tortuous, and some slight disc cupping may exist, although this is not generally met with on the occasion of a first inflammatory attack, unless it have been unusually severe.

Intra-ocular hæmorrhage is not uncommon, and proceeds from the disc, the retina, or the choroidea, singly or combined. Its presence is generally expressed by the term hæmorrhagic glaucoma. It is most common in the disc, as small apoplexies. It occurs next in frequency in the retina, and the extravasation is usually about the ora serrata. But it may occur about the optic disc and the macula lutea. It is like retinal hæmorrhage in neuro-retinitis, see p. 1097. We find round and well-defined blood-spots in the substance of the retina. Blood may pass into the vitreous body, or between the retina and the choroidea, where it is more copious. The choroidal hæmorrhage is as often about the macula lutea as the equatorial region of the fundus oculi. It, too, has the aspect of choroidal hæmorrhage in general, see p. 1149, exhibiting black or dark patches, with defined or undefined edges, without striation, occurring in the outer layers of the choroidea, or between the choroidea and the sclerotica. Hæmorrhagic effusions, when extensive, may interfere with, or even prevent ophthalmoscopic investigation.

Hæmorrhage is not so common nor so copious in subacute inflammatory glaucoma, which commences as such, except where the veins of the iris have become varicose, when blood may be effused into the aqueous chambers.

Glaucomatous cupping, or excavation, requires special consideration. At p. 308 I have spoken of physiological cupping. At p. 1086 I have dwelt on atrophic cupping, it remains for me to speak of this the third form of cupping.

Glaucomatous cupping occurs in two forms. As an excavation as large as the disc will admit of. It occupies the entire calibre up to its edge, is concave and flask-shaped, so produced by the stretching and falling back of the lamina cribrosa, and the falling outwards of the sides, so that they shelve under the edge of the disc. As an excavation with steep or straight sides without shelving. The latter is a slighter, as well as an earlier stage of disease.

This cupping produces a very marked effect on the course of the

central blood-vessels of the retina. The veins show the most physical change, because they are dilated, and more posterior than the arteries. All these vessels follow the sides or superficies of the cup, being separated from the lamina cribrosa and the nerve-sheath, by the nerve fibres, or whatever may remain of them, if atrophy has taken place, and by contracted proliferated areolar tissue. Therefore, to pass from the centre of the disc up to its edge, and over the sclerotic ring to the retina, they must go in a curved form, following the lateral excavation, or climb the steep sides where there is no excavation, and in both instances make a sharp elbow in clearing the sclerotic ring. The effect of the elbow, with lateral excavation of the disc, is to throw parts of the vessels, or segments of them, out of view under the disc edge, and so prevent the tracing of the continuity of some or all of them, particularly the veins. It may hence appear that, the portions of the vessels at the back of the disc, which may have an atrophic appearance and are sometimes difficult to be seen, do not belong to those at the edge. A little clever turning of the ophthalmoscope will enable more to be seen than would otherwise be visible. The elbowed portion of the vein is darker than the rest. Where there is no lateral excavation, but merely steep sides, the continuity of the vessels may be traced. The straight piece in each will necessarily, as I have shown in atrophic cupping, look very dark.

The central blood-vessels within the cupped disc, may undergo certain physical changes. Some of the small ones may, by interweaving and contortions, produce an effect likely to be mistaken for cavities. Later in the disease, most or all of the small central twigs are veiled. Even isolated branches may disappear. With this reduction in number, one or two which remain may be so unnaturally placed as to give the idea of being merely a collateral venous branch or branches. All the blood-vessels may be thrown aside from the porus opticus, a condition accounted for by pressure, in association with some physiological deviation.

Deeply excavated discs have a mottled aspect, the effect of the manner in which the incident rays of light necessarily fall, and of atrophic changes. The markings of the exposed lamina cribrosa are apparent, see p. 1086, and add to such effect. In the end the disc becomes grey, or greyish blue, or spotted with dirty grey, or absolutely white.

Cupped discs were supposed for a long time to be prominent. This mistake was the result of an optical delusion, and remained till we learned that their real shape is to be gathered from the shadow which the cupping forms, which is affected by any movement of the ophthalmoscope. The shadow surrounds the porus opticus, is ring-

shaped, indistinct in the central part, and sharply bounded towards the periphery of the disc.

Atrophy of the choroidal ring around the cupped disc is a fundus oculi change incidental to glaucoma. There is produced a yellowish-white arch or ring, which is generally wider as the cupping is the more marked.

Now and then we are very much puzzled to account for the little or no loss of acuteness of sight or reduction in the visual field, where marked glaucomatous cupping exists. It is supposed that a slight glaucomatous effect has been grafted on deep physiological cupping, and that, too, the nerve-fibres are as yet uninjured. It is said that it may be possible, at an early stage of the glaucoma, to recognise both forms of cupping, by the double sinking of the disc, and the double distortion and displacement of the central retinal blood-vessels.

Marked physiological cupping, with atrophy from optic neuritis, may be mistaken for glaucomatous cupping, where the feeble disc ring becomes pale and weakened, and the excavation tends more towards the sclerotic ring. The absence of atrophic choroidea around the disc, of pulsation in the central blood-vessels, or of its production by pressure, and the reduction in the size of the same vessels, will prevent a mistake.

Partial glaucomatous cupping is met with, by which only a portion of the disc is affected. In it the characteristic symptoms are readily discerned.

Pulsation of the central retinal vessels, already spoken of as an occasional physiological state, at page 304, is a very common pathological one in glaucoma, and verifies the glaucomatous condition nearly as well as the ocular tension. In the first instance the veins pulsate, and afterwards the arteries, in their disc course. If only the former beat, the latter will do so if the eyeball be slightly pressed by the finger.

Very marked constitutional disturbance accompanies acute glaucoma. The pain prevents sleep. The head is so tender that it cannot be laid on the pillow. Giddiness, foulness of tongue, nausea, and thirst exist.

There may be several slight glaucomatous attacks, before the eye is destroyed. Or the symptoms may remit, till the destruction ensues. Or one short and severe attack, may accomplish the spoiling.

Again, the inflammatory and other symptoms may not proceed so far as I have pictured them, nor be so destructive, for arrest may ensue with, or even without, treatment. The opacity of the cornea, the

cloudiness of the aqueous humour, and that of the vitreous body, may subside, the pain, too, disappear, and the sight so far return that a patient may think he has recovered since he can read small type; but the dilated pupil, some degree of abnormal ocular tension, and prominence of the iris, point to the damaged state of the eye. A relapse may never arise, but it is to be expected. Even then, destruction of sight may not be the consequence, unless they be frequent. They may become less severe, and so fall into the state which is called subacute or chronic glaucoma.

Subacute inflammatory glaucoma, usually called chronic glaucoma.

We meet with all the symptoms which have been enumerated as characteristic of the acute affection, but less definitely marked, although equally destructive to the eye. Those which are to be especially relied on, as demonstrating the subacute stage, are cupping of the disc, and reduction or contraction of the visual field.

We shall find more variety here, in the beginning, development, and termination, than in acute attacks. However diversified the several forms may seem, they are variously connected, and frequently pass into each other.

In some cases the vascular action shows no prominence. Inflammatory symptoms may be but faintly marked. They may never exist. Such exceptions have tempted some surgeons to make a subdivision of them. Under these circumstances, there is no sudden attack with pain. Whatever be the symptoms, they succeed each other slowly and insidiously, so that nothing is noticed till the eye is much affected. Both eyes are generally simultaneously involved, but in different degrees. There is a decline of acuteness of vision, sometimes for awhile noticed in distant vision, sometimes in near. The range of accommodation is reduced, and presbyopia or hypermetropia is acquired, the victims being usually about middle age. The pupil is generally, not always, dilated, but is dull in action. Undue ocular tension is perceptible, but not in excess. The dioptric media are clear, and ophthalmoscopic examination discovers some degree of optic disc cupping, with enlargement of the retinal veins and contraction of the arteries. Pulsation of the retinal vessels is scarcely seen, unless the eyeball be pressed on. A little ocular congestion might arise, but it is slight, and scarcely ever is there ophthalmitis, through which hyalitis occurs. Proceeding in this inactive manner, the pupil gets more dilated, the iris is thrust against the cornea, which retains its transparency, the disc gets more excavated, and the visual field, which has been all along contracting, is very much reduced. Disc atrophy follows, and vision is lost.

I lately watched a typical case of the kind. When I saw the

patient the symptoms were: in the right eye, deeply cupped optic disc, slightly dilated pupil, very much contraction of the field of vision, and dimness of central sight; in the left eye, sluggishness of the pupil, slight cupping of the disc, contraction of the visual field, reduction in the range of accommodation, and slight hypermetropia. In both eyes the dioptric media were clear, and in neither had inflammation or redness been noticed. Pain had not occurred. The right became blind, from atrophy of the disc and detachment of the retina. The other remained stationary, and with the aid of a convex cylindrical lens, No. 1 Jæger's test type could be deciphered, although a larger type could be more easily read. A striking clinical feature in this case, was an absence of abnormal ocular tension in both eyes. I was never able to detect any although I sought it frequently. It is said that it may intermit. A surgeon saw the case in consultation with me. He could not detect it, but he advised iridectomy in the better eye on account of the disc excavation. Another also saw the patient with me. When I told him that iridectomy had been suggested, he remarked, "There is not the slightest excuse for it, as the tension is normal in both eyes."

This form of glaucoma, which has been called "glaucoma simplex," may continue, as it remained in my patient's left eye, for months, or years, without any material change; and if it increase, it is by advance of disc excavation, by which, of course, the sight is more impaired. This is the variety by which an eye may be unconsciously blinded.

As a rule, however, in subacute inflammatory glaucoma, slight inflammatory symptoms are present from the first, and the disease progresses with perceptible objective and subjective symptoms, subject to temporary exacerbations, intermissions, and remissions, to which constitutional disturbance responds. In this way it may run on for years, apparently excited by external causes, or errors in diet, or fatigue of body or mind, exposure to strong light, sitting up late, &c.

The surface congestion becomes more palpable. The ciliary veins are more distended and tortuous. The sclerotica becomes of a mottled dirty reddish-yellow hue, generally called waxy. The ocular tension rises to its maximum. The cornea flattens more and becomes further anæsthetic. The crystalline lens and the much-discoloured iris are more pushed against the cornea, still more reducing the ocular chambers. The pupil is dilated far beyond what could be effected by atropine, there being a mere ring of iris. If it be possible to obtain a view of the fundus oculi, the disc will be found deeply cupped, with atrophic palor, and the retinal vessels much displaced at its margin. With this, the contraction of the visual field is greater, the

point of fixation more eccentric, while sight declines more and more, till absolute blindness ensues.

There is occasionally a sensation of illumination of the visual field which persons with subacute glaucoma experience, after blindness has ensued. It is of the nature of the subjective sensations spoken of in the chapter on the Diseases of the Optic Nerve, at p. 1077, last paragraph. Such persons often deceive themselves by supposing that their sight is returning, and with the addition of a little fancy, will declare that they see certain things, generally naming this or that of which they remember the place.

The occurrence of pain is very uncertain. It may be quite as severe as in the acute inflammatory form, and of longer duration.

The subacute state, more correctly then called a chronic process, may be the termination of a primary acute attack, in which the inflammatory symptoms have never quite declined, but merely remitted, springing up into activity, and oscillating for months or years, between exacerbations and remissions, till the extreme symptoms arrive.

Glaucoma always begins in one eye, and is very apt to be developed in the other, in the course of months or years. The second manifestation of it is not necessarily like the first, but may show the greatest possible variation, for while the first is acute, the second may be subacute, or so on.

That there is a family tendency to this disease I doubt not, in which case the attack occurs earlier in life.

Atrophy of the eyeball may succeed any form of glaucoma.

SECONDARY OR CONSECUTIVE GLAUCOMA.

This is understood to be the appearance of glaucoma in an eye which is already the subject of disease.

Abnormal tension of the eyeball is considered the sign which represents the presence of glaucoma.

Undue ocular hardness is very common. It is invariably produced by the operation for the solution of cataract, lasts all the while the cataract is being absorbed, and for a period afterwards. It becomes very exalted if the operation should be attended by ophthalmitis. It always appears, too, when traumatic cataract is induced, and remains till the cataract is absorbed or removed from the eye. It is brought about by all injuries which produce any degree of ophthalmitis, whether inflicted on the eyeball itself, on the ocular appendages, or on the surrounding parts, and especially where orbital cellulitis is set up. In the most marked examples which I have seen, I have not

known the optic disc to become excavated, nor the interior of the eye to become damaged from pressure, and therefore I cannot, in the undue tension alone, recognise glaucoma. An eye so affected may perish from the effect of ophthalmitis, or nerve damage, other than excavation of the optic disc. A few weeks ago Dr. Howard Barrett called me to see a patient, whose protruded and inflamed eyeball, of stony hardness, was so affected from orbital cellulitis, consequent on a palpebral wound. When the fundus of the eye could be seen, I discovered what is a usual occurrence in such cases, and elsewhere described in this book, that the optic nerve was inflamed. White atrophy, and of course blindness, soon followed, but there was no glaucomatous excavation of the nerve. Where, then, was the glaucoma?

In certain inflammatory diseases of the eyeball, abnormal tension is very apt to arise; for instance, parenchymatous corneitis, where I have ascertained over and over that the eye has not suffered from the pressure. Also in staphyloma of the cornea following penetrating ulceration, and staphyloma posticum. In the latter, Von Gräfe, to whom we owe so much for clinical exposition of glaucoma, tries to prove glaucomatous invasion, as confirmed by some disc cupping. I have never witnessed such disc excavation. In reading Gräfe's writings on the subject, it seems to me that this great observer was looking about him rather too loosely for such identity. This great man writes elsewhere that there is scarcely any inflammatory affection of the eyeball which may not be followed by glaucoma.

An ingenious but not satisfactory explanation of this escape of eye damage under increased ocular tension is that, the tension occurs in young people, in whom the sclerotica yields, and saves damage. If there were yielding, there would be no tension.

It is said that glaucoma attacks eyes affected with cataract. My observations tell me that in such instances the cataract is the effect of the glaucoma.

I do not say that an eye more or less diseased may not become glaucomatous, as it were, accidentally, like a normal eye.

It is undeniable that certain inflammatory actions of the eyeball, although very high, do not cause ocular tension. I do not know that I have ever seen this tension in syphilitic or rheumatic iritis, ophthalmitis, as I call it.

The practical bearing to be sought for in this consideration is, whether the treatment agreed on as beneficial in glaucoma should be applied to such cases of tension as I consider not glaucomatous. I will answer this when I am speaking of the treatment of glaucoma.

Cause of glaucoma. For aught that can be said under this head definitely, respecting the essential glaucomatous characteristics, I might as well and at once make the statement that I have nothing to tell. However, there is scope for a few relevant remarks, which may be made without dragging the reader through the large and dreary wilderness of speculative opinions on the subject.

For most of the phenomena of glaucoma we have some explanation, for others we have none. This agrees with what I said at first, that glaucoma is a combination of well recognised diseases, with some peculiar phenomena.

The pain in the eyeball, and tenderness to touch, are well known conditions in ophthalmitis.

The visual disturbances are those met with in optic neuritis, and neuro-retinitis, with the exception of the hazy visual field by day, and the halo with colour around luminous bodies, due to slight degrees of opacity of the vitreous body from hyalitis. When optic nerve atrophy sets in, then comes the contraction of the visual field.

The increase of any existing presbyopia, or the acquirement of hypermetropia, is to be accounted for, in the latter, by the flattening of the cornea, and, indeed, the shortening of the eyeball from before to behind, the effect of the more special form which it assumes, and in the former by loss of accommodation, from paralysis of the ciliary muscle, due perhaps to cyclitis.

Loss of corneal sensibility can only be from damage to the corneal nerves in their course, but hardly to be explained by attributing it to pressure on them.

A dilated and irregular pupil may certainly appear before the iris is pushed against the cornea, therefore pressure does not dilate it, as it is generally supposed. I know, on the contrary, from observation in other cases, that an iris may be pressed against the cornea and paralysed in action, while the pupil is no more dilated than its change in position rendered necessary. To disorder of the ciliary nerves, is the dilatation due, and the pupillary irregularity to implication of some nerve twigs more than of others. See Paralytic Affections of the Muscles of the Eye, especially p. 346.

Crystalline lens opacity, or cataract, is indisputably occasioned by loss of lens nutrition, a subject discussed in the chapter on Cataract. The cataract, or the unaffected lens, as the case may be, and the iris, are certainly pressed forward by some cause acting permanently and posteriorly to them.

Pulsation of the central blood-vessels of the retina is but a little excess of that which is known as a physiological condition, and then attributed to normal tension of the eyeball. It is easy to understand

how a little more tension would render an occasional condition a permanent one.

The constitutional disturbance is not met with unless the attack of glaucoma is markedly inflammatory. This is no more than what we meet with in ophthalmitis in general.

The nature of the glaucomatous tension has eluded our discovery. This preternatural hardness, as I have told, might be absent. Are we not then to consider glaucomatous excavation, with accompanying disturbances of sight, as true glaucoma. Such examples are not at all liked by those who insist on glaucoma and tension as synonymous, and they certainly make the least of them. It will not do to attribute the tension to blood turgescence, and blame the choroidea especially, saying that the venæ vorticosæ are obstructed in their afferent duty by this or that cause, for we know that there is glaucoma with tension with scarcely any or no inflammatory or congestive symptoms, and that therefore such symptoms, when they are present, may be called a complication. If tension be attributed, as it certainly may plausibly, to increased serosity of the vitreous body, due to loss of balance between secretion and absorption, or to perverted nutrition, in other words, to some disorder of the nerves presiding over secretion ; we shall be reminded that rigidity, or contraction of the sclerotica, may be as much concerned in the tension question, particularly, as I believe, that glaucomatous eyes become reduced in size.

The contradictory statements of experimenters on the lower animals, who have endeavoured to learn the respective influences of the sympathetic and fifth cerebral nerves in producing abnormal tension, is no more than what might be expected, since the experiments require a nicety hardly to be commanded, and the nervous system in man differs remarkably from that in the lower animals.

The glaucomatous cupping, usually ascribed to pressure, must have some other origin, else how can it occur, as we know it may, when abnormal ocular tension is absent. How it is induced is one of the glaucoma puzzles. I have seen it even where the lens and the iris have not been pushed forward. An attempt is made to meet this exception, by asserting that the cupping may be due to two causes, atrophy being one, and thrusting back of the disc from pressure being the other. My own impression, after much consideration, is, that the disc is primarily at fault, from neuritis and atrophy, and that the abnormal tension produces but a secondary, and, as such, an insignificant part.

Post-mortem examination of the disorganized eyeball shows nothing beyond varicose and enlarged capillaries, atrophy of the

several tissues, hæmorrhagic and other effusions met also with in eyes spoiled from other causes.

Treatment. I will speak first of acute inflammatory glaucoma. The premonitory symptoms afford scope for treatment where they arise from slight optic neuritis, or neuro-retinitis, or choroiditis. Besides the local and general measures requisite for such affections, the eye should be shaded, and saved from bright light and artificial heat.

Even when glaucoma is developed as an acute ophthalmitis, without the glaucomatous characteristics, especially the tension, being decidedly marked, the eye may be saved by attention to the inflammatory processes, through local and general measures.

Ever since the abnormal tension was discovered, a great many years ago, has it been thought a bad feature, and have surgeons been trying to reduce it, by letting out some of the contents of the eyeball, either from the vitreous or the aqueous chamber. The latter method was chiefly practised here and abroad. Three quarters of a century ago, Mr. J. Wardrop, one of the leading surgeons of his day, published a paper in the "Medico-Chirurgical Transactions," to show the beneficial effects of evacuating the aqueous humour in inflammatory affections of the eye, under which he includes glaucoma. It is a philosophical and practical essay. We find that everything of therapeutic efficacy which he claims for it, comprises what is attributed to iridectomy.

In 1864, when the treatment of glaucoma was much discussed in England, I contributed a long paper on Corneal Paracentesis, to the "Medical Times and Gazette."

V. Gräfe lately proposed the operation "Iridectomy," which he had been previously practising, for Irido-Choroiditis, &c. His papers are in the "Archiv. für Ophth." for 1856-7-8, and translated by the Sydenham Society. He removed a portion of the iris, because, he supposed, very erroneously, that this diaphragm was the source of the aqueous humour, and that by reducing its size less fluid would be poured out, and less tension produced, and accordingly if the operation were done in time, destruction of the retina would be completely arrested.

It is my duty, as an author, to say that, after all the controversies about Iridectomy, many ophthalmologists here and abroad, whether differing from or agreeing with Gräfe's theory of the operation, believe that the operation possesses some peculiar therapeutic value beyond any treatment yet practised. Besides reducing tension, it is supposed to materially influence the nutrition of the eyeball, where this is at fault, and apart from glaucoma, even to restore normal

tension where the eyeball has become soft. More than this, it is declared to be antiphlogistic, by which inflammatory action is reduced, or even prevented. Most exaggerated reports have been published respecting its potency, less however, lately, than some years ago. No ophthalmic operation has been so much abused, by application to cases which were not glaucomatous, and to disorganized eyeballs from all causes. Of course this does not touch the merit of the question.

It has been proved by Mr. Windsor, of Manchester, see "Ophthalmic Review," that acute glaucoma may occur where there is congenital absence of the iris.

It is my judgment that iridectomy possesses no advantage over any other operation practised for glaucoma, by which the tension of the eyeball is reduced, and through which the engorged intra-ocular blood-vessels are enabled to be relieved. I believe that this relief is best ensured by frequent tapping.

Paracentesis Corneæ, or tapping the cornea, is very simply performed with an iris knife. I introduce the point of the knife close by the margin of the cornea into the anterior chamber, and in withdrawing it extend the incision at the one or other extremity. The withdrawal should be gradual, so that the aqueous humour may escape slowly. Quick evacuation of it might too suddenly release the diseased intra-ocular blood-vessels from pressure, and produce severe intra-ocular hæmorrhage. See p. 1148, Choroidal Hæmorrhage.

The crystalline lens is apt to be wounded, where the iris is actually in contact with the cornea, unless the greatest care be exercised. The knife must not be pushed beyond the pupil margin. The iris may prolapse. The more aqueous humour there is, the greater will be the effect of its withdrawal. Only in the earlier stage of acute glaucoma is it not much diminished.

The operation for iridectomy, which is nearly the same as that for the operation for artificial pupil by excision when the pupil is free, is thus performed. After the eyeball has been sufficiently steadied, a keratome or an iris knife is pushed into the sclerotica, at the point selected for the operation, about half a line behind the cornea, and carried on slowly until the anterior chamber is opened, the incision being enlarged during its withdrawal, which should be done slowly. If the iris protrude it should be seized with a pair of forceps, drawn a little further out, and excised by a single cut with a pair of scissors, or by two or more cuts, if the operator should desire to remove very much, and at the same time to tear some from the ciliary attachment. Gräfe insists on excision quite up to the ciliary attachment, and directs a slight compression, through bandaging, to be applied to

the eye for half an hour or more, and to be gradually relaxed, in order to prevent hæmorrhage. Where there is glaucoma with synechia posterior, the operation must be done according to the rules given for making an artificial pupil by excision under such circumstances. The crystalline lens is prone to accidental wounding when the pupil is widely dilated, to avoid which it may be necessary to incise the cornea, as in the operation for extraction with a cataract knife, the point of which should not be allowed to pass beyond the margin of the pupil.

Surgeons are not agreed as to the amount of the iris to be removed. Some are satisfied with the excision of a mere speck, while others take a third, a quarter, or more. Some quickly resort to a second iridectomy.

The objections to iridectomy are these. The liability to cataract, from the violence done to a diseased eye in which the nutrition is much perverted, and in the immediate attachment of the crystalline lens; also to rupture of the capsule of the lens, and rupture of the zonule of Zinn. Intra-ocular hæmorrhage, especially into the vitreous chamber. There is always much bleeding in the anterior chambers, but this is of no consequence beyond what may arise from the long persistence of the blood. I have shown elsewhere that blood is never quickly absorbed, unless it be in an eye with a healthy aqueous humour. A dazzling sensation, and distortion of luminous bodies, the effect of a large lateral pupil, in association with the natural pupil. To endeavour to obviate this, iridectomy is usually performed at the upper part of the eyeball, the most difficult position, in the hope that the upper eyelid may partially cover the pupil. The formation of a cystoid cicatrix at the sclerotic wound, consisting of bridles, the interspaces of which are filled by a fine tissue, and which cicatrix protrudes, and gives way now and then, allowing the escape from time to time of a little of the aqueous humour. The consequence of which is irritation to the eye, and sometimes acute inflammation.

Von Gräfe makes this unexpected remark. If iridectomy be executed in the first stages of an acute inflammatory glaucoma, during or just after one of the first manifest attacks of inflammation, it hastens in a great percentage the appearance of glaucoma in the other eye. Notwithstanding, he recommends an early operation, believing such disadvantage to be outweighed by the greater benefit to the eye operated on, especially as the other eye may be operated on at an early period.

Mr. Hancock has introduced an operation for glaucoma. It is an excellent one for extracting blood from a congested eyeball; and in

my opinion if it be modified, as I have suggested at p. 920, whereby the aqueous humour is discharged, it is admirably adapted for glaucoma. Where the vitreous body is at all reduced in consistence some of it generally escapes.

Treatment by practical surgery alone is not enough; it should be but a part, an auxiliary of a therapeutic system, embracing those details which help so much in subduing the abnormal conditions which are common to other affections and to glaucoma. I allude, of course, to the abnormal conditions of inflammation of the uveal tract, particularly choroiditis, to neuro-retinitis, and hyalitis.

The vascular excitement in the eyeball and around it are further reduced by judicious local blood-letting. Exalted ocular temperature is lowered by the application of cold. Continuous pain, which might yield to nothing else, may give way under the subcutaneous injection of morphia at the temple. In a word, the system comprises the measures, subject to modifications according to the glaucomatous signs, and the general state of the patient, whether that of excitement or depression, as laid down at p. 949 for the treatment of iritis.

Glaucoma may prove to be beyond all control, or the treatment may be only a little salutary for a while, and this expresses the prognosis in the majority of cases. Fortunately it does not always pass to a destructive end at once, nor even after several exacerbations or attacks. Even when not treated, it may cease at any stage. If we can fortunately apply treatment before degenerative changes have been effected in the tissues of the eye, that is, where we have evidence that the visual field does not show any decided contraction and the sensitiveness to light is still acute, tolerable indications of the integrity of the optic nerve and of the retina, the function of the eye may be restored, or enough of it saved for practical purposes; and if the eye be sufficiently spared from minute work for some months, there may be an end of the glaucoma.

The diminution of pain and the decline of inflammatory symptoms show that the disease is yielding. The clearing of the hazy aqueous humour and of the vitreous body, and the absorption of effused blood may occupy weeks or months.

Normal ocular tension is extremely seldom restored, but I have seen it. The increased tension is frequently a little reduced. In general, it remains unaltered, unless the eyeball undergoes atrophy.

The iris never recovers. Therefore the pupil is always unnatural.

The crystalline lens never returns to its proper position, hence the anterior and posterior chambers are never restored to their proper size.

Where there is proof of the optic nerve and the retina having undergone degenerative changes, or where there has been much hæmorrhage prior to any operation, or where the eye strongly exemplifies the glaucomatous state, in association with great pain, treatment can do nothing beyond reducing the pain and the inflammatory paroxysm.

Subacute inflammatory, or chronic glaucoma, affords little latitude for treatment beyond the reduction of pain. How can an atrophied optic disc and a more or less atrophied choroidea be restored?

Where abnormal tension of the eyeball arises under the conditions expressed at p. 1165, as soon as the cataract is absorbed or extracted, or the ophthalmitis is reduced, the tension will decline. Where real glaucoma supervenes, in an eye already more or less diseased, the same treatment is applicable as where it is an original disease.

I am sure that where there is much intra-ocular degeneration any operation will make the eye worse, by causing intra-ocular hæmorrhage.

The glaucomatous pain may continue so perseveringly, in spite of all treatment, as to demand extirpation of the eyeball, or extraction of the lens and evacuation of some of the vitreous humour.

Where glaucoma is developed without ocular tension, treatment by operation is inadmissible; but I think that constitutional treatment may sometimes arrest it, where there is feebleness of constitution.

It remains for me to mention that incising the sclerotica, sclerotomy, has been revived in the treatment of glaucoma, by Wecker, Quaglino, and others.

In a paper published by Quaglino, in the Report of the Fourth International Ophthalmological Congress, held in London, in 1873, the author, in referring to other methods of treatment than iridectomy, writes thus:—"The conviction of these excellent practitioners, as well as my own persuasion, render it a matter of reasonable probability that the cure of glaucoma does not depend on excision of the iris; and the well-known fact that the efficacy of the operation bears no relation to the amount of the iris excised has led me to seek other explanations of the enigmatical cure of the affection. No one has, as yet, suggested any probable explanation of the mode in which iridectomy acts in glaucoma, and even its discoverer stated, with his usual candour, that it was only an empirical proceeding. But is it not true that, if we could discover the connection that exists between iridectomy and the arrest of glaucoma, we might make some progress in pathology and therapeutics? In other

diseases does it not hold good that the dispersion of error is as valuable as the discovery of truth?"

He describes his manner of incising the sclerotica, which is a simple incision carried through it, parallel to and close to the iris, so as freely to open the anterior chamber. He has had to repeat the operation. His result is thus given :—The hardness of the eye was diminished, and ultimately disappeared, just as if iridectomy had been practised, while the disorders of the dioptric apparatus, as well as the arterial pulsation and neuralgia, similarly vanished, either on the following day or soon after the operation. The anterior chamber also increased in depth. These effects were always produced when the sclerotic incision was made of a sufficient extent, three millemètres.

In Wecker's incision a bridge of sclerotica is left in the centre, to prevent prolapse of the iris.

All this is but tapping the chambers, on a more extended scale.

If in any of the tapping operations the iris should protrude, it had better be excised.

Where the eyeball is far advanced in degeneration, and the iris too atrophied for an iridectomy, and sclerotomy would be unavailing to relieve the pain, Wecker proposes to trephine through the sclerotica, close to the edge of the cornea, avoiding the lens and the ciliary body, He prefers this to extirpation. His paper is in "Annales d'Oculistique," 1872, and the trephine is depicted.

FINIS.

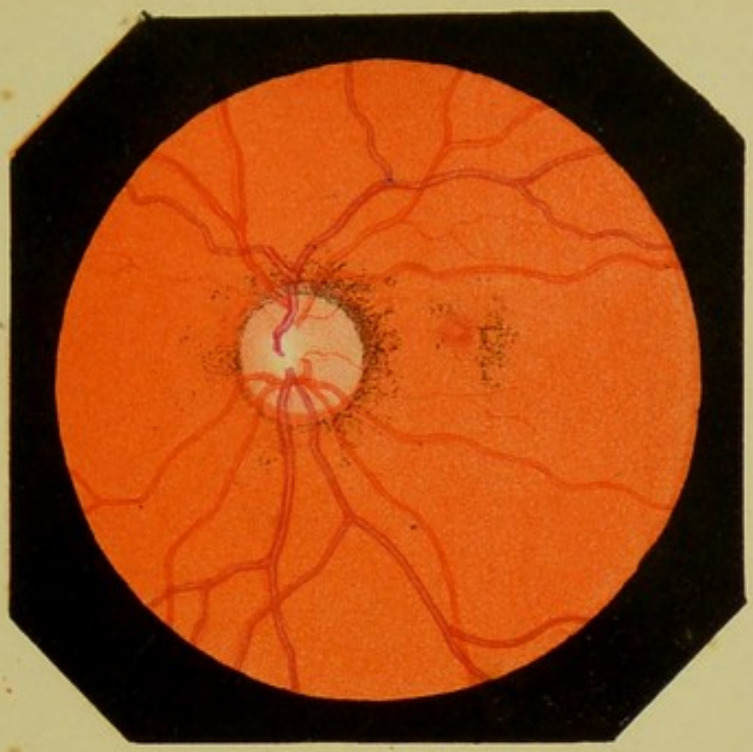

Normal fundus of the Eye.

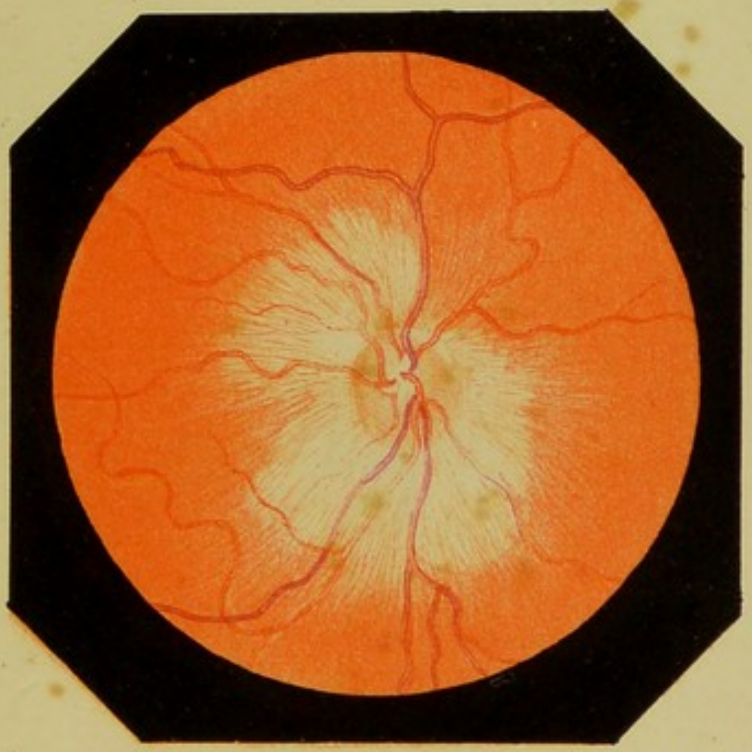

Opaque Optic nerve fibres.-Congenital defect.

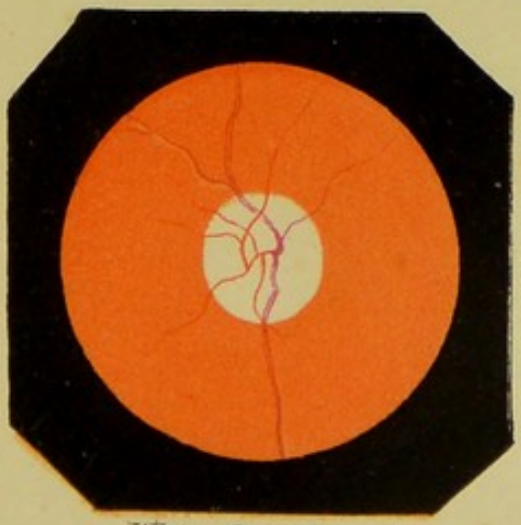

White disc Atrophy.



Grey disc Atrophy.

E. Burgess del et ch. lith.

W.W.

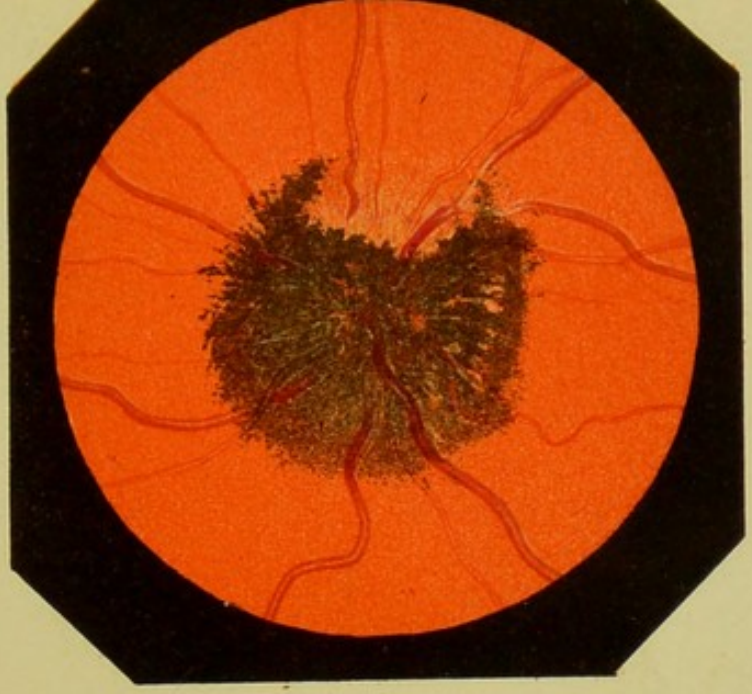

Optic Neuritis.



Retina&disc obscured by Iritis.



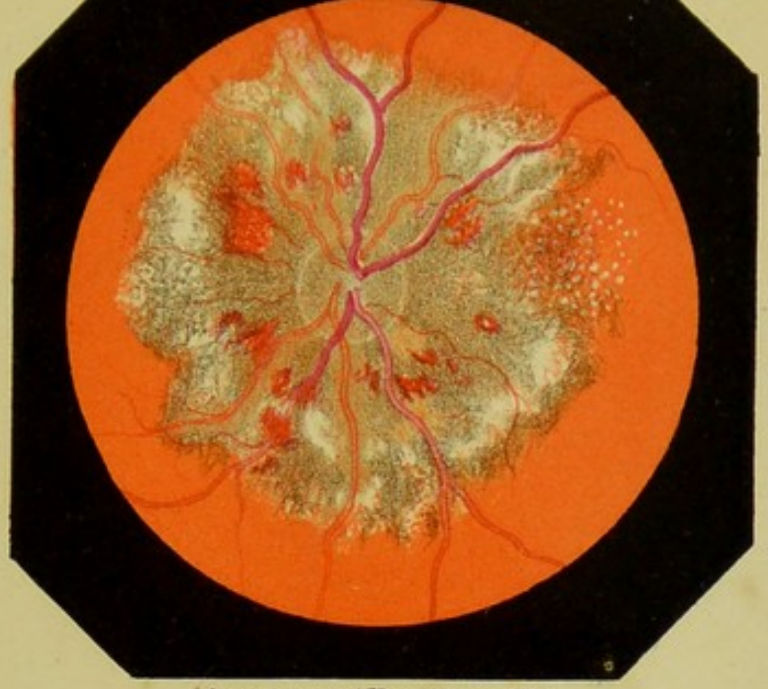

Retinitis Albuminurica.

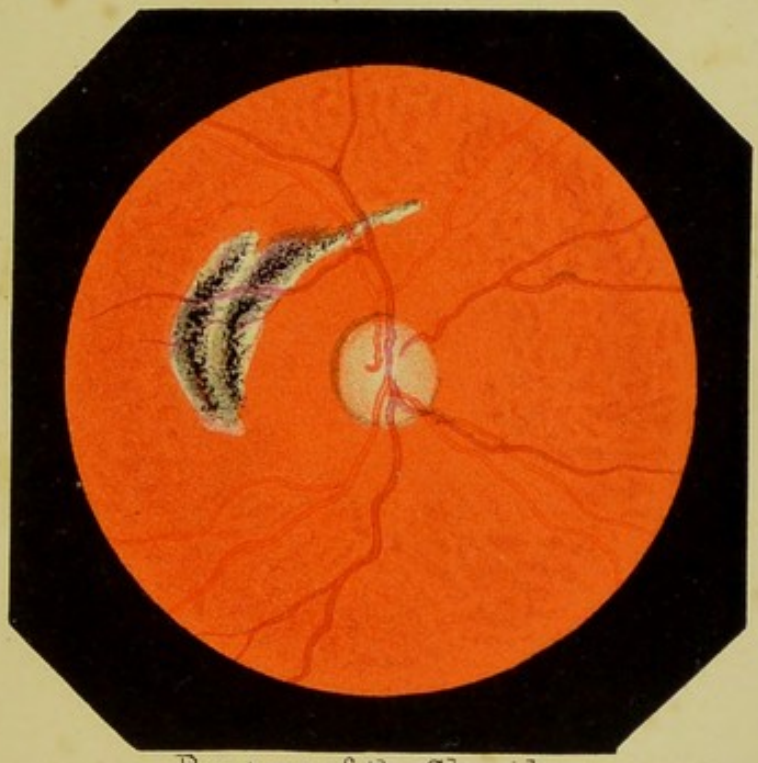

Rupture of the Choridea

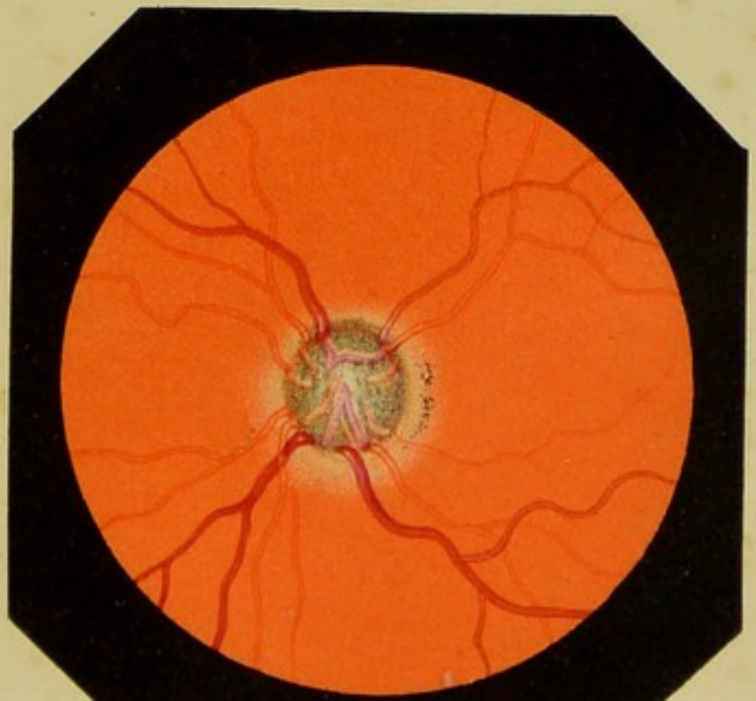

ERRATA.

Page 298. 16th line from top, read "direct" for "indirect."
„ 302. 8th line from bottom, read "sheaths" for "sheath."
„ 313. In the contents of the chapter, "Paralysis of the Sixth Cranial Nerve" should be inserted.
„ 607. 3rd line from top, the words, "which were formerly Roman, but are now square," are to be omitted.
12th line from top, read "expressed" for "measured."
„ 639. 16th line from top, read "shining" for "going."
In last sentence of same paragraph, it should be, "The pigment of the epithelial cells is removed."
„ 925. 6th line from the bottom, read "irido" for "iridis."
„ 955. 4th line from top, after "with" read "or without."
„ 956. 11th line from bottom, after the word "may," introduce the words "occur and."
9th line from bottom, read "suppurative ophthalmitis" "for it."
„ 971. The heading should be "Partial Lateral Sclero-Choroidal Staphyloma."

INDEX.

Abscess, of cornea after extraction of cataract, 798
interstitial, 915
surface, 919
from iridectomy, 952
in frontal sinus, 119
intra-orbital, 110
chronic indolent, 112
phlegmonous, 111
secondary from pyæmia, 111
of Meibomian gland, 724
within ocular tunic, 114
Abscission of eyeball, 928, 965
Accommodation, 598
classification of anomalies of, 617
paralysis of, 344
ranges of, 605
spasm of, 604
theory of, 599
squint arising out of forced, 912
Acephalocyst, 34
Acne, 132
ciliaris, 724
Amaurosis, 1092
Amblyopia, 1092
Amputation of eyeball, 928
Anæmia, of optic disc, 1063
of retina, 1063
Anæsthesia, 907
Anæsthetics, 11
Anchyloblepharon, 512
Aneurism, by anastomosis, 216
in orbit, 185, 217, 222
of central artery of retina, 234
of carotid, 230
of frontal branch of ophthalmic, 232
treatment by excision, 217
by ligature, 217, 219, 231
Apoplexy of optic nerve, 1092
Arcus and annulus adiposus, 928
Artery, embolism of, 1121
See also Aneurism
Atrophy, of optic disc, 1088
of nerve, 1085
colour-blindness in, 1089
facts in association with, 1089
of retina, 1088, 1100, 1101
Atrophy, white and grey, points in common, 1088
Atropine, 355, 453, 761
Asthenopia, 628
Astigmatism, abnormal, 651
forms of, 660
grades of, 656
normal, 650
methods of examination of, 657

Belladonna, use of, in diagnosis, 761
Bichloride of methyline, 15
Binocular, ophthalmoscope, 294
vision, 608
in strabismus, 610
Blepharospasm, 332
Blindness, colour, 1050, 1053
in optic nerve atrophy, 1089
night, 1131
temporary, 1091
uræmic, 1107
Blood, effusion of, from choroidea, 424
in frontal sinus, 122
in orbital cellular tissue, 108
spontaneous, 109
behind retina, 423
extravasation of, into cellular tissue about eyelids, 417
between choroidea and sclerotica, 426
about conjunctiva, 419
in retina, 1097
Blows and their results, 419
on the eye, 419
eyeball, 441
causing cataract, 427
eyebrow, 438
face, 439
forehead, 438
head, 439
about the orbit, 440
Bodies, foreign, adhering to conjunctiva, 490
in sinuses of, 491
in cornea, 486
imbedded in, 493
between conjunctiva and sclerotica, 494

Bodies impacted in crystalline lens, 504
in iris, 501
in chamber of eye, anterior, 497
posterior, 503
in lacrymal sac and duct, 560
in vitreous body, 505
on surface of eye, 485
within eyeball, 496
orbit, 71
sclerotica, 494
extirpation of eyeball on account of, 510
Body, ciliary, inflammation of, 1140
ossification of, 1011
vitreous, degeneration of connective tissue of, 978
detachment of, from retina and choroidea, 1126
diseases of, 975
dislocation of crystalline lens into, 431
encysting of a body in, 508
filaria in, 39
hæmorrhage into, 979
inflammation of, 975
liquefaction of, 978
lodgment of a body in, 505
loss of, while operating for cataract, 786
ossification of, 1012
spectrum of, 1029
suppuration of, 979
Brain, hydatids in, 37
Burns and scalds, 413

Calabar bean, 355, 453, 936
Calculi, in canaliculi, 525
in glands of caruncle, 1008
in lacrymal sac and duct, 560
in Meibomian apparatus, 1008
nasal, 1010
Canaliculus, congenital deficiency of, 525
contraction of, 526
dacryoliths in lower, 1009
division of, 471, 525
growths within, 528
obstruction of, 524
stricture of, 531
Cancer, 980
encephaloid, in eyelids, 988
in orbit, 992
epithelial, in eyelids, 989
in orbit, 993
scirrhus of eyeball, 981
of eyelids, 989
of orbit, 992
of lacrymal gland, 1020
treatment of, 995
Capsule of crystalline lens,
alteration in, from age, 735
injuries of, 455
opacity of, 428, 743, 753
Caries, 80
about orbit, 81, 83, 1037
Caries about obit, causing mal-position of eyelid, 89
deep-seated, 83
around lacrymal sac and duct, 550, 1037
Caruncle, calculi in glands of, 1008
enlargement of, 144
Cataract, 734
absorption of, after solution, 822
accidents likely to occur during operation, 811
acute inflammation after extraction of, 796
sub-acute, 797
adhesion of capsule to iris, 786
adjustment of corneal flap, 782
black, 738
capsular, 742, 770
method of lacerating, 832
capsulo-lenticular, 746
causes of, 427, 455, 459, 758
which interfere with success, 813
complications of, 762, 768
conditions, contra-indicating operation, 772
which retard recovery, 792
congenital, 751
anomalies of crystalline lens, 747
contingencies connected with extraction of, 783
corneal abscess, after extraction of, 798
diagnosis of, 748, 754
dilatation of pupil, 752, 778, 820
dislocation of, to be avoided, 819
spontaneous of hard, 815
division of cornea, 778
effect of, on eyesight, 756
entropium after extraction, 798
fluid, 754
hæmorrhage after extraction, 792
needle operation, 811
hard, 738, 749, 769
inadequate section of cornea, 784
irregularity of pupil after extraction, 799
lenticular, 736
loss of vitreous humour while operating, 786
non-union of cornea, 792, 793, 794
operation for displacement, 806
by depression, 807
by Egerton's plan, 810
by reclination, 808
for extraction, 776
by a crescentic corneal cut, 778
modified linear, 801
through a small section of cornea, 800
for solution, 775, 816
anterior operation, 818
posterior operation, 823
for capsular, 829
by extraction, 831
by partial separation, 832
for soft, by extraction, 826

Cataract, operation for soft, by suction, 835
partial, 748
position, of operator, 779
of patient, 778
preparation of patient for operation, 770
pressing out of the, 785
progress of, 747
prolapse of iris after extraction, 792
removal of, general considerations, 769
season of year most fitted for operation, 775
single and double, 748
soft, 736, 740, 747
spurious, 737
states of eye rendering extraction particularly difficult, 787
traumatic, 427, 455, 459, 741
treatment, general, 759
immediate after, 788
of traumatic, 839
vomiting after needle operation, 812, 813
Cellulitis, orbital, 42
chemosis in, 45
effects of, 50
Chancres about, conjunctiva, 1039
eyelids, 1038
Chemosis, after wounds of eyelids, 472
in catarrhal ophthalmia, 850
in orbital cellulitis, 45
incision of, 862
Chloroform, as an anæsthetic, 11
in liniments, 48
Choroidea, 1135
bleeding from, 424
coat of, 306
changes in coat of, 638
colloid disease of, 1154
coloboma of, 1155
detachment of from retina, 1126
sclerotica, 1154
diseases of, 1139
syphilitic, 1044
extravasation of blood between sclerotica and, 426
fluid between retina and, 1126
hæmorrhage in, 1148
hyperæmia of, 1139
laceration of, 436
ossific deposits between retina and, 1012
rupture of, 1152
sarcoma of, 986
senile changes in, 309, 1138
staphyloma of, 969
tubercle in, 1151
Choroiditis, 1145
disseminata, 1146
areolar of Forster, 1147
irido-cyclo, 1139
mild, 1143
suppurative, or panophthalmitis, 1154
Cilia. *See* Eyelashes
Colloid disease, of choroidea, 1154
Colloid disease of eyelids, 721
of retina, 1119
Coloboma, of choroidea, 1155
of eyelids, 724
of iris, 937
Colour-blindness, 1050
in optic nerve atrophy, 1089
colour, change of, in lens and pupil, 734
of fundus, to what due, 1135
Comedon, 127
Concretions, 1012
Conjunctiva, affections of, 847
anatomical sketch of, 845
ecchymosis of, 419
fibrinous growths in, 484
foreign bodies about, 490
between sclerotica and, 494
metallic, imbedded in, 493
fungus of, 143
inflammation of, 847, 848, 851
causing ptosis, 364
injury to, 465, 466, 472
inoculation of, 914
with a chancre, 1039
pemphigus of, 879
polypus of, 140
protrusion of, everting eyelids, 855
removal of zone of, 915
scarification of, 899
serous effusion in region of, 941
swelling of, 472
tumours of, 140
cartilaginous, 143
warts of, 140
wounds of, 473
Conjunctivitis, 847
catarrhal, 848
cuticular, 885
diphtheritic, 881
erysipelatous, 878
gonorrheal, 860
granular, 871
morbillous, 870
phlyctenular, 879
scarlatinous, 870
variolous, 870
Contusions in edge of orbit, 54
Cornea, abrasion of surface of, 446
abscess of, after extraction of cataract, 798
circular ulcer at margin of, 857
conical, 929
cretaceous deposits and ossific changes in, 1010
cysticercus in, 26
division of, 778
effect of rheumatic iritis on, 947
extraction of cataract by a crescentic cut of, 778
through a small section of, 800
fistula of, 1013
foreign bodies on, 486
incision through, for artificial pupil, 574

Cornea, inflammation of, 890
injury to, 465
interstitial abscess of, 915
non-union of, 792, 793, 794
opacity of, 910, 911, 912
from deposit of lead, 928
pannus of, 912
pathology of inflamed, 890
perforation of, 459, 897
pigmentation of, 902
rupture of, from blows rare, 444
staphyloma of, 923, 926
tapping of, 904, 920, 960, 1169, 1173
tumours of, dermoid, 151
fatty, 152
warty, 151
ulceration of, 857, 919
vasculo-nebulous, 912
wounds of, 447, 449, 452
Corneitis, diffuse, 901
neuro-paralytic, 907
phlyctenular, 894
punctiform, 904
simple, for the most part traumatic, 891
suppurative, 915
Counter irritants injurious, 48, 899
Cupping of optic disc, atrophic, 1086
glaucomatous, 1160
physiological, 308
Cyclitis, 1140
Cysts, in chambers of eyeball, 100
cutaneous proliferous, 130, 153
in walls of orbit, 116
Meibomian, 134
on sclerotica, 151
of lacrymal gland, 149
proliferous, 164
serous, 133, 163
Cysticercus cellulosæ, about ocular appendages, 25
behind retina, 31
implicating tunics of eyeball, 26
in cornea, 26
within crystalline lens, 31
within eyeball anterior part, 27
posterior part, 31
within orbit, 33

Dacryoliths, in lower canaliculus, 1009
in tear ducts of lacrymal gland, 1008
Dacryops, 149
Daylight, examination by, 311
Day sight, 1131
Derma, tumours arising from disease of, 137
Dermoid tumour, 150, 151
Detachment of iris, from blows, 433
with laceration, 434
from its circumference, 811
of retina from choroidea, 1126
vitreous body, 1129
Dilatation, of lacrymal duct, 537
of orbit from pressure within, 116
of pupil, 355, 752, 778, 820
Dilatation of pupil, excessive, from blows, 433
Diplopia, a consequence of squint, 384
after operation for squint, 411
from wounds of the cornea, 447
Disc. *See* Optic disc
Dislocation, of crystalline lens, 428, 431, 442
with capsule, 430
spontaneous, 841
of eyeball, 78
from blows, 446
from effused blood, 80
Displacement, of cataract, operation for, 806
of punctum, 529
Distoma, or fluke, 40
Dracunculus, or Guinea worm, 37
loa, 40
Duct, lacrymal calculi in, 560
congenital defects of, 561
diseases of, 530
inflammation of, acute, 543
chronic, 532
polypus in, 560
rhinoliths involving, 1010
Meibomian tumour of, 136
nasal, absence of, 561
bony deposits, occluding, 560
caries of bones, forming, 1037

Ecchymosis, of conjunctiva, 419
of eyelids, 417
Echinococcus, 37
Ectropium, 697
of under eyelid, 698
of upper eyelid, 708
from caries of the orbit, 89
from morbid changes in eyelids, 711
from paralysis, 716
from protruding conjunctiva, 855
from senile atrophy, 715
of lower punctum, 529
Eczema, 728
Effusion of blood, into cellular tissues of orbit, 108
into frontal sinus, 122
from choroidea, 424
behind retina, 423
fluid between retina and choroidea, 1126
serous in region of sclerotica and conjunctiva, 941
Emmetropia, 617
Emphysema, 722
Encephaloid cancer, 988, 992
Enchondroma, 1006
Encroachment of skin on corner of eye, 716
Enlargement of eyeball, 449
distinct from protrusion, 194
Entoptics, 1025
Entozoa, 24—41
Entropium, 685
after extraction of cataract, 798
with thickening of tarsal margin, 695

Entropium with trichiasis, 694
Enucleation of eyeball, 475
Ephidrosis, 723
Epicanthus, 716
Epiphora, 161, 895, 941
Epithelioma, or epithelial cancer, 989, 993
Erysipelas, 43, 364
Examination of eye, by lateral or oblique illumination, 310
by ophthalmoscope, direct method, 277
indirect method, 297
by ophthalmo-microscope, 312
Excavation, or cupping of optic disc, atrophic, 1086
glaucomatous, 1160
physiological, 308
Excision, artificial pupil by, 580
of cilia in trichiasis, 679
of cyst, 1005
of exostosis, 175
of portion of palpebral skin, 677
of upper maxillary bone, 552
Exophthalmos or Graves' disease, 90
Exostosis, of frontal sinus, 122
of regions round the eye, 189
within orbit, 173
excision of, 175
Extirpation of, eyeball alone, 475
for sympathetic ophthalmitis, 965
including entire contents of orbit, 474
on account of foreign bodies within, 510
lacrymal gland, 556, 1021
nævus maternus, 202, 213
tumour, 140, 144, 154, 162
warts, 142
Extraction, of hard cataract, 769
of soft cataract, 826
Extravasation. *See* Blood
Exudation from iris, 941
Eye, artificial, 479
cylindrical, 650
cysticercus about appendages of, 25
douches, 16
encroachment of skin on corner of, 716
erectile tumours in association with, 197
injury of surface of, from chemical agents, 462
injury to nerves connected with, 62
shades, 20
syphilitic diseases of, 1037
syringes, 18
watering of, 161, 895, 941
Eyeball, abscission of front of, 928, 966
adhesion of eyelids to, 515
appearance of fundus in healthy, 302
calcareous deposits in tissues of, 1010
cancer of exterior of, 981
conditions which conceal back of, 264
cysticercus within, 27, 31
dislocation of, from blows, 446
from effused blood, 80
Eyeball, dislocation of, in connection with orbital injury, 78
effects of blows on, 441
enchondroma within, 1006
enlargement of, 449
examination of, 277, 310
exfoliative effort on surface of, 494
extirpation, or enucleation of, 432, 475, 965
fistula of, 1013
fixed state of, 353
foreign bodies, within, 496
in anterior chamber of, 497
in posterior chamber of, 503
on surface of, 485
gunshot injuries to, 460
hæmorrhage in, 64, 421, 424, 426, 792, 811, 849, 979, 1097, 1148
inflammation of interior of, 436
malignant affections within, 981
muscles that move the, 315
neuralgia of, 1047
pressure on, from parasites, 36
protrusion of, or exophthalmos, 90
in a diagnostic point of view, 183
vascular, 229
rupture of, 441, 444
sarcoma on, 981
scirrhus of, 981
senile changes in, 309
severance of, from orbit, 80
softening of, 436
tenderness of, under pressure, 939
in connection with vascularity, 767
tension of, in glaucoma, 1158, 1159, 1165, 1167
trembling of, 351
tumours around, 158
in chambers of, 1001
wounds of, 446
Eyebrow, effects of blows on, 438
inflammation of, 718
ptosis from falling of, 363
Eyelashes, trichiasis of, 672
with entropium, 694
Eyelids, abscess of a Meibomian gland of, 724
acne of, 132
ciliaris of, 724
adhesion of edges of, 512
to eyeball, 515
blepharospasm of, 332
chancres of, 1038
comedon of, 127
congenital fissure of, 724
diseases of, 668
ecchymosis of, 417
eczema of, 728
emphysema of, 722
encephaloid cancer of, 988
epithelial cancer of, 989
eversion of, 697, 855
falling of, 358, 364
herpes of, 725

Eyelids, horns of, 131
hypertrophy of integuments of, 723
ptosis from, 362
inflammation of, 718
injuries of, 364, 417
inversion of, 685
after extraction of cataract, 798
larvæ of insects under, 495
malignant affections of, 988
mal-position of, from caries of orbit, 89
Meibomian cyst of, 135
duct, tumour of, 136
milium of, 129
molluscum of, 128
œdema of, 721
operation in connection with wounds of, 472
paralysis of muscles of, 323
restoration of, by plastic operations, 668
Italian, or taliacotian method for, 671
scirrhus of, 989
secondary syphilis about, 1038
serous cyst of, 133
steatozoon about, 41
sweating of, 723
swelling of, 943
syphilis about, 1038
tegumentary mole of, 138
tumours of, 126—140
twitching of, 331
ulceration of, 1039
warts of, 138
wounds of, 468
causing chemosis, 472
the surrounding integuments of, 473
xanthelasma of, 732

Face, effects of blows on, 439
Fifth cranial nerve, affections of, 1045
fibrous tumour on, 189
Filaria, 37, 38, 39
Fissure, congenital, of choroidea, 1155
of eyelids, 724
of iris, 937
Fistula, of eyeball, 1013
of lacrymal sac and duct, 547
of sclerotica, 1013
with prolapse of iris, 1014
Fluid, between choroidea and retina, 1126
cataract, 754
Fluke, 40
Forehead, effects of blows on, 438
Fossa, nasal, 188
zygomatic, 189,
Fourth cranial nerve, paralysis of, 349
Fractures of edge and wall of orbit, 58
Fundus, of eyeball, anomalies of, 307
appearance of, in healthy eye, 302
colour of, to what due, 1135
effect of pigment on colour of, 1136
Fundus of the eyeball, pigmentary changes in, 1146
Fungus of conjunctiva, 143

Gland, of caruncle, calculi in, 1008
lacrymal, cancer of, 1020
chronic enlargement of, 1017
cysts of, 149
dacryoliths in ducts of, 1008
diseases of, 1016
extirpation of, 556, 1021
fistulæ connected with, 1023
hæmorrhage of, 1024
inflammation of, 1016
morbid changes in, 1019
polypus in, 560
Meibomian, abscess of, 724
parotid, enlargement of, 330
pressure from causing paralysis, 326
thyroid, enlargement of, 94
Glandulæ congregatæ, acute inflammation of, 1015
hypertrophy of, 1015
Glaucoma, 1156
acute, 1157
constitutional disturbance in, 1162
cupping of disc in, 1160
deterioration in acuteness of vision in, 1159
tension of eyeball in, 1158, 1159
etiology, or cause of, 1166
incising the sclerotica, 1172
iridectomy, use of, in, 1169, 1170
objections to, 1170
secondary or consecutive, 1165
sub-acute or chronic, 1162
tapping the cornea, 1169, 1173
tension of eyeball in, 1165, 1167
treatment, 1168
Glioma, in orbit, 993
in retina, 982
Granulations, 942
Growths, within canaliculi, 528
on conjunctiva, 484
Guinea worm, 37

Hæmorrhage, after extraction of cataract, 792
after needle operation, 811
a result of hyperæmia, 849
behind retina, 423
between choroidea and sclerotica, 1149
from gunshot wounds, 64
into frontal sinus, 122
into orbit, 108
spontaneous, 109
vitreous body, 979
Hæmorrhage, intra-ocular, anterior, 421
posterior, 422
of choroidea, 424, 1148
of lacrymal gland, 1024
of retina, 1097

Head, effects of blows on, 439
Hemeralopia, or day sight, 1131
Hemiopia, 1066
Herpes frontalis, 725
Hordeolum, or stye, 137
Horns of eyelids, 131
Humour, aqueous, effects of escape of, 926
evacuation of, 459, 904, 920
Hyalitis, 975
Hydatids, 34, 167
ill effects of, 36
in brain, 37
in wall of orbit, 37
invasion of orbit from skull by, 195
Hydrocephalus, 1080
Hyperæmia, of choroidea, 1139
of retina, 1060
of disc, 1060
of sclerotica, 941, 967
of zone of sclerotica, 938
Hyperæsthesia optica, 1118
Hypermetropia, a cause of squint, 371
cause of, 620
degree of, 621
forms of, 620
treatment of, 626
vision impaired by, 624
Hyperostosis, 116
Hypertrophy, of glandulæ congregatæ, 1015
of integuments of eyelids, 723
ptosis from, 362
of orbital cellular tissue, 115
Hypopion, 916, 945, 947, 953

Incision, artificial pupil by, 573
through cornea, 574
of hard chemosis, 862
Infiltration of orbital tissues, 115
Inflammation, after extraction of cataract, 796
of ciliary body, or cyclitis, 1140
of conjunctiva, 847, 848, 851
causing ptosis, 364
of cornea, 890
of eyelids and eyebrow, 718
erysipelatous, 720
phlegmonous, 719
traumatic phlegmonous, 719
of interior of eyeball, 436
of lacrymal sac and duct, acute, 543
chronic, 532
syphilitic, 1041
of ocular tunic, 104
of orbital tissues, 184
of retina, 1095
of sinus, frontal, 119
of vitreous body, 975
traumatic, causing retinal detachment, 1129
Injuries, from chemical agents, 462
to conjunctiva, 466
to cornea, 465
mechanical agents, 413
Injuries, from mechanical agents, to capsule and crystalline lens, 455, 734
to conjunctiva, 472
to cornea, 444, 447
to eyeball, 419, 436, 441
gunshot, 460
to eyelids, 417
ptosis from, 364
to iris, 433
to orbit 440
gunshot, 63
to pupil, 433
to retina, 423
to nerves connected with the eye, 62
Inoculation of conjunctiva, 914
with a chancre, 1039
Instruments, canaliculus director, 523, 528
probe, 522
cataract knife, 776
secondary, 777
needles, 807, 817
cilia forceps, 672
curved needle and curette, 776, 817
guarded, 777
suction, 836
eye douches, 16
syringes, 18
grooved, needle, 840
iris hooks, 571, 588
knives 570
scissors, 569
canula, 572
keratome, 570
knife for dividing chemosis, 846
lacrymal duct, knife for, 530
probe, 539, 555
styles, 540, 548, 553
syringe, 549
wire, 539
miniature gouge, 485
optometer, 1068
ophthalmic, in general, 1
perimeter, 1070
ring forceps, 126, 127
screw syringe, 204
sharp canula forceps, 828
sharp lens hook, 777
Inversion of, eyelashes, 694
eyelids, 685
after extraction of cataract, 798
Iris, adhesion of capsule to, 786
alteration in colour of, 939
anomalies in colour of, 940
apparent loss of, after a blow, 435
bony deposits in, 1011
coloboma of, 937
congenital defects of, 936
detachment of, 433
with laceration, 434
discoloration of, 433
diseases of, 934
exudation on, 941
foreign bodies in, 501
granulations pervading, 942

Iris, paralytic influence of sympathetic nerve on, 320
prolapse of,
with fistula of sclerotica, 1014
with non-union of cornea, 792
with wounds of cornea, 452
staphyloma of, 924, 926, 927
tremulousness of, 348, 433, 937
tumour of, 1006
Iriddesis, 587, 931, 932
Iridectomy, in glaucoma, 1169, 1170
objections to, 1170
in iritis, 952
Iritis, 937
acute and chronic, 944
and sub-acute, 943
idiopathic, 944
rheumatic, 946
syphilitic, 945, 1041
iridectomy in, 952
pathological effects on iris of, 953
principles for treatment, 949, 952

Lacrymal, apparatus, diseases of, 522
from mechanical causes, 559
gland, cancer of, 1020
chronic enlargement of, 1017
cysts of, 149
dacryoliths in ducts of, 1008
diseases of, 1016
extirpation of, 556, 1021
fistulæ connected with, 1023
hæmorrhage of, 1024
inflammation of, 1016
morbid changes in, 1019
polypus in, 560
nerve, neuralgia of, 1046
sac and duct, calculi in, 560
nasal involving, 1010
caries of bones around, 1037
congenital defects of, 561
dilatation of, 537
disease of, 530
foreign bodies in, 560
fistula of, 547
with caries, 550
inflammation of, acute, 543
chronic, 532
syphilitic, 1041
opening of, 471
variations in size of, 532
secreting organs, diseases of, 1015
Lacrymation, 161, 895, 941
Larvæ of insects under eyelids, 495
Lens, crystalline, congenital anomalies of, 747
cretaceous, and bony deposits in, 1011
cysticercus within, 31
diseases and injuries of, 734
dislocation of, 428
external, 442
into vitreous body, 431
spontaneous, 841
displacement of, for hard cataract, 806
foreign bodies in, 504
Lens, reproduction of, 458
Lenses, 242
bi-cylindrical, 251
connecting, 299
cylindrical, 250
object, 299
orthoscopic, 251
spherical, 242
spherico-cylindrical, 251
figure of, 259
materials of which made, 260
rules in selection of, 645
Leucoma, 897
Liquefaction of vitreous body, 978
Luscitas, 353

Meibomian apparatus, calculi in, 1008
cyst or tarsal tumour, 134
duct tumour of, 136
gland, abscess of, 724
Melanoma, 1006
Membrane, hyaloid ossification of, 1011
Meningitis, 1080
Methylene, bichloride of, 15
Mole, 138
Molluscum, 128
Muscæ, causes and prevalence of, 1034
depending upon corpuscles between external surface and focal centre of the eye, 1028
entohyaloid, 1029
insulo-globular, 1031
muco-lacrymal, 1026
of delirium tremens and fevers, 1035
pathological, 1036
physiological, 1026
pearly, 1030
volitantes, 1025
watery, 1031
Muscles, action of, that move the eyeball, 315
ciliary, paralysis of, 344
resulting from diphtheria, 345
paresis of, 602
spasm of, 604
of eyelids, paralysis of, 323
orbital, 185
Mydriasis, 321, 346
Mydriatics, 355
Myeloid tumour, 993
Myocephalon, 897
Myopia, 617, 632, 912
loss of binocular vision in, 638
methods of examination for, 633
Myosis, 347, 935
Myotics, 354
Myxomata, 994

Nævus Maternus, cutaneous, 197
sub-cutaneous, 198
treatment by, caustic, 210
cutting and searing, 202
escharotics, 202
extirpation, 202, 213
injection, 203, 210 .

Nævus Maternus, treatment by, intense cold, 201
ligature, 204, 209, 213
pressure, 200
twisted suture, 204
Necrosis, 81
Nerve, affections of fifth cranial, 1045
fibrous tumour on, 189
syphilitic of third cranial, 1041
injury to, connected with eye, 62
neuralgia of lacrymal, 1046
paralysis of fourth cranial, 349
portio dura, 323
sixth cranial, 350
sympathetic, 320
third cranial, 335
ciliary, effect of damage to, 69
optic, apoplexies of, 1092
atrophy of, 1085
facts in association with, 1089
colour-blindness in, 1089
concretions in, 1012
damage to, 440
diseases of, 186, 1054
syphilitic, 1044
structure of, 1055
tumours of, 1092
Neuralgia, affecting the, eye, 1046
eyeball, 1047
lacrymal nerve, 1046
traumatic, 1048
Neurilemma, extension of, 307
Neuritis. *See* Optic neuritis
Nitrate of silver, 454, 467, 884
Noose for nævus, 206
Nyctalopia, 1134
Nystagmus, 351

Obstruction, of canaliculi, 524
of puncta, 523
Ocular tunic, 125
abscess within, 114
adhesion of, 107, 185
fibrous tumour within, 171
inflammation of, 104
Œdema, of choroidea, 1154
of eyelids, 721
of retina, 1119
sub-conjunctival, 887
Onyx, as distinguished from hypopion, 916
Opacity, of capsule, 743
in congenital cataract, 753
from injury to eyeball, 428
of cornea, 910, 911, 912
from deposit of lead, 928
from pterygium, 147
of crystalline lens from blow on eyeball, 427
partial repair of, 456
in lenticular cataract, 736
Opium, use of, 48
Optic disc, anæmia of, 1063
atrophy of, 1085
blood-vessels of, 1058
cupping of, atrophic or morbid, 1086
glaucomatous, 1160
Optic disc, physiological, 308
hyperæmia of, 1060
normal aspect of, 302, 1056
form of, 1057
pigmentation of, 303, 1089
size of, 1057
Optic nerve. *See* Nerve
Optic neuritis, 1072
from intra-cranial influence, 1080
from poison, alcoholic, 1083
lead, 1084
morbid anatomy of, 1078
ophthalmoscopic symptoms, 1073
subjective, 1077
tobacco, 1084
Optic tract, 1055, 1056
Optics, geometrical, 235
refraction and reflection, 237
mechanism of, illustrated, 601
Ophthalmia, catarrhal, 851
epidemic, 852
mild, 851
simple, 848
erysipelatous, 878
gonorrheal, 860
morbillous, 870
phlyctenular, 879
purulent, of adults, 845
of infants, 865
scarlatinous, 870
variolous, 870
Ophthalmitis in general, 955
pyæmic, 957
sympathetic, 961
syphilitic, in adults, 1041
in infants, 1042
traumatic, 956
treatment of, 959, 965
Ophthalmo-microscope, 312
Ophthalmoscope, binocular, 294
demonstrating, 1060
description of early, 283
directions for using, 296
discovery and use of, 264
general review of, 279
Orbicularis palpebrarum, disease of, 323
Orbit, abscess within, 110
aneurism of, 185, 217, 219, 222
blows about, 440
cancer in, 224
and other malignant affections of, 991
caries of, 80, 1037
cellulitis of, 43
contusions on edge of, 54
cysticercus within, 33
cysts in walls of, 37, 116
dilatation of, from pressure, 116
effusion of blood in cellular tissue of, 108
emphysema about, 116
excess of fat in, 186
extirpation of contents of, 474
foreign bodies within, 71
fractures of edge and wall of, 58
hæmorrhage of, 108
herpes of the skin of the region of, 725

Orbit, hydatid invasion of, 195
hyperostosis of bones of, 116
hypertrophy of cellular tissue of, 115
incised wounds of, 63
infiltration of cellular tissue of, 115
inflammation of tissues of, 184
injuries and wounds of, 63
injury of, in connection with dislocation of eyeball, 78
necrosis of, 81
paralysis of muscles of, 185
penetrating wounds within margin of, 68
periorbitis, 50, 1037
pus in cavity of, 184
syphilitic diseases of, 1037
tuberculous matter around, 156
tumours, cystic, 163
passing to, from cranial cavity, 195
within, 158—182
without, 153—158
Ossification, between choroidea and retina, 1012
of ciliary body, 1011
of hyaloid membrane, 1011
of sclerotica, 1012
of vitreous body, 1012
Osteophites, 181

Panophthalmitis, 1154
Pannus crassus, 912, 913, 914
phlyctenular, 881
tenuis, 912, 913, 914
traumatic, 913
Paracentesis corneæ, 904, 960, 1169, 1173
Paralysis, of muscles, ciliary, 344, 602
inferior, oblique, 340
orbicularis palpebrarum, 323
orbital, 185
rectus, inferior, 339
internal, 337
superior, 338
of nerves, fourth cranial, 349
portio dura, 323
sixth cranial, 350
sympathetic, 320
third cranial, 335
from division of nerve, 330
from enlargement of parotid gland, 326
from poisoning and hysteria, 341
ectropium from, 716
ptosis from, 358
Paraplegia, 1089
Pedunculate tumours, 138
Pemphigus of conjunctiva, 879
Perforation of cornea, 897
Periorbitis, 50, 1037
Phlegmon, sub-conjunctival, 888
Photophobia, 895, 905
Pigmentation, of optic disc, natural, 303
from choroidal peculiarities, 309
pathological, 1089
changes in, in fundus, 1146
effects of, on colour of fundus, 1136
Pigmentation, in choroidal stroma, 1135
in retinitis pigmentosa, 1116
in tunica vasculosa, 1137
of different parts of choroidea, variable, 1136
Polypus, of conjunctiva, 140
in frontal sinus, 123
in lacrymal duct, 560
Presbyopia, 612
Pressure, causing dilatation of orbit, 116
paralysis, 326
effect of, on eyeball, 191
of parasites on eyeball, 36
of pus on cornea, 916
on eyeball from bandages injurious, 921
one mode of treating nævus maternus, 200
tenderness of eyeball under, 939
Prolapse of iris, with fistula of sclerotica, 1014
with non-union of cornea, 792
with wounds of cornea, 452
Protrusion, of conjunctiva everts eyelids, 855
of eyeball, acute, 184
anæmic, 90
chronic, 186
vascular, 229
distinction between enlargement and, 194
extra-orbital causes of, 187
intra-orbital, 186
effects of on pupil, 191
Pterygium, 144
Ptosis, congenital, 360
paralytic, 358
senile, 360
simulated, 364
from erysipelas of conjunctiva, 364
from falling of eyebrow, 363
from hypertrophy of palpebral integument, 362
from mechanical injury to eyelid, 364
sign of paralysis of third cranial nerve, 336
operation for, 359
supplementary, 364
Puncta, affections of, 522
destruction of, from accident, 524
displacement of, 529
obstruction of, 523
Pupil, adhesion of, 941, 942, 953
agents that contract, 354
dilate, 355
aspect of, 934
contraction of, 347, 941
dilatation of, 752, 778, 820
excessive, from blows, 433
eccentric, 937
effect of protrusion of eyeball on, 191
gummy tumours surrounding, 942
irregularity of, after extraction of cataract, 799
movements of, 934

Pupil, loss of, 940
artificial, 562
choice in position for, 565
classification of morbid states of eyeball requiring, 573, 580, 582, 587, 589
form of, 567
operations, cutting or tearing through the adhesion, 589
excision, 580
iriddesis, 587
incision, 573
tearing away a bit of iris, 582
Pus, in connection with iritis, 943
inoculation of conjunctiva with, 914
in orbital cavity, 184
necessity of speedy evacuation from eyeball, 49
pressure of, on cornea, 916
Pustule of eyelid, 724

Quivering of eyelids, 331

Reflection, 237
Refraction, 237
difference of, in the two eyes, 609
diminution of, 612
mechanism of, illustrated, 601
Retina, anæmia of, 1063
aneurism in central artery of, 234
atrophy of, 1088, 1100, 1101
bleeding behind, 423
blood-vessels of, 302, 1054
cysticercus behind, 31
cystoid disease of, 1119
detachment of, from choroidea and vitreous body, 1126
diseases of, 1094
syphilitic, 1044
embolism of central artery of, 1121
extravasation of blood in, 1097
fluid between choroidea and, 1126
glioma in, 982
hyperæmia of, 1060
inflammation of, 1095
laceration of, 436
normal aspect of, 302
ossific deposits between choroidea and, 1012
Retinitis, acute neuro, 1095
expectancy of, 1102
albuminurica, 1104
circumscribed, 1103
leucæmica, 1111
perivascular, 1103
pigmentosa, 1112
syphilitica, 1108
Rhinoliths, 1010
Rupture, of choroidea, 1152
of coats of eyeball, 441, 444
of cornea rare, 444
of sclerotica, 441

Sarcoma, in choroidea, 986
on eyeball, 981
Sarcoma, on eyelids, 988
Scarification of conjunctiva, 899
Scirrhus, in orbit, 992
of eyeball, 981
of eyelids, 989
Sclerotica, colour of, 967
cyst on, 151
dermoid tumour of, 150
detachment of, from choroidea, 1153
diseases of, 967
extravasation of blood between choroidea, &c., 426
fistula of, 1013
with prolapse of iris, 1014
foreign bodies within, 496
hyperæmia of, 967
in iritis, 941
anterior zone of, 938
incision through, for artificial pupil, 575
ossification of, 1012
penetration of, 494
rupture of, 441
scrofulous tubercles in, 151
serous effusion in ciliary region of, 941
staphyloma of, 969, 970, 971
tapping of, 459
tumours of, 150
ulceration of, 974
wounds of, 459
Scotomata, or blind spots, 1069
Sequestrum, 88
Sessile tumours, 138
Severance of eyeball from orbit, 80
Sight, binocular, 608
day, 1131
disturbance of, 160
effect of cataract on, 756
of albuminuria on, 1107
monocular, 608
night, 1134
old, 612
temporary partial interruption to, 1091
Sinus, frontal, 118
effect of distension of, on eyeball, 188
effusion of blood in, 122
exostosis of, 122
inflammation and abscess of, 119
tumours in encysted, 121
in solid, 123
maxillary, effect of distension of, on eyeball, 188
sphenoidal, 189
Sixth cranial nerve, paralysis of, 350
Softening of eyeball, 436
Solution, operation for, 775, 816
Spectacles, construction of, 257
cataract, 262, 841
for myopia, 646
orthoscopic, 255
prismatic, 256
stenopæic, 256
Spectrum of vitreous body, 1029

Squint or strabismus, apparent, 367
binocular vision in, 610
lost in, 385
causes of, 375, 402
defects of operation for, 404
definition of, 366
degree of, 369
diplopia, a consequence of, 384
external, 399
forms of, 399, 402
sign of paralysis of third cranial nerve, 336
operation for, 403
internal, 370, 912
alternating single, 381, 382
double, 383
intermittent single, 380
paralytic or fixed, 379
operations for, 390
diplopia after, 411
traumatic, 387
true, 369
Staphyloma, anterior annular, sclero-choroidal, 971
cicatricial corneal, 923, 926
irido-racemosum, 925
of choroidea and sclerotica, 969
partial cicatricial, 926
iris, 924, 926
lateral sclero-choroidal, 971
posticum, 640
total iris and racemosum, 927
sclero-choroidal, 970
ulcerative corneal, 926
treatment, 973
Steatozoon folliculorum, 41
Strabismus. *See* Squint
Stye, 137
Suction, operation by, 835
Symblepharon, 515
congenital, 516
from quicksilver or mortar, 516
interrupted form, 516, 521
uninterrupted, 518
Synchysis oculi, 978
Syndectomy, 915
Synechia, 941, 942, 953
Syphilis, congenital or acquired, 1041
secondary, about eyelids, 1038
Syphilitic, diseases of the eye, 1037
acquired corneitis, 1044
affections of third cranial motor nerve, 1041
of optic nerve, retina, and choroidea, 1044
inflammation of lacrymal sac, 1041
ophthalmitis, adults, 1041
infants, 1042
periorbitis from nodes, 1037
primary sores, 1038

Tapping, the cornea, 904, 920, 960, 1169, 1173
the sclerotica, 459
Tarsal tumour, 134
Tattooing the cornea, 911
Tears, dacryoliths deposited from, 1008
morbid, 1024
yellow, 1024
Tenderness of eyeball under pressure, 939
Tenotomy, 388
Tension of eyeball in glaucoma, 1158, 1159, 1165, 1167
Tests for vision, 606
method of applying, 1067, 1068
Third cranial nerve, paralysis of, 335
Thyroid gland, enlargement of, 94
Tissues, corneal, wounds of, 447
orbital, effusion of blood in, 108
hypertrophy of, 115
infiltration of, 115
inflammation of, 184
sub-conjunctival affections of, 887
of vitreous body, degeneration of, 978
Tract, optic, 1055
Trembling of eyeball, 351
Trichiasis, 672
with entropium, 694
Trichnia spiralis, 41
Tubercles, growing from sclerotica, 151
in choroidea, 1151
Tumours, arising from diseases of derma, 137
of conjunctiva 140—149
of cornea, 151—153
of eyeball, 1001—1007
of eyelids, 126—140
of frontal sinus, 121—123
of iris, 1006
of nerve, fifth, 189
optic, 1092
of ocular tunic, 171
of orbit, extra, 153—158
intra, 158—182
passing to, from cranial cavity, 195
of sclerotica, 150
erectile or vascular, 197—221
gummy, surrounding pupil, 942
intra-cranial, 1080
sub-conjunctival, 149
Twitching of eyelids, 331

Ulceration, of cornea, 477, 857, 919
of eyelids, 1039
of sclerotica, 974

Vascularity in corneal ulceration, 921
Vision, acuteness of, 605
impaired by, glaucoma, 1159
hypermetropia, 624
binocular, 608
in squint, 610
loss of, in myopia, 638
in squint, 385
contraction of field of, 1069
direct and indirect, 1065, 1066
double, a consequence of squint, 384
after operation for squint, 411
general field of, 1064
hypermetropic, 624
imperfect, 1066

Vision, line of, 619
method of applying tests for, 1067, 1068
monocular, 1066
simultaneous, 610
strabismic, 385
temporary coloured, 1091
tests for, 606
Vitreous body, degeneration of connective tissue of, 978
detachment of, from retina and choroidea, 1126
diseases of, 975
dislocation of crystalline lens into, 431
encysting of a body in, 508
filaria in, 39
hæmorrhage into, 979
inflammation of, 975
liquefaction of, 978
lodgment of a body in, 505
loss of, while operating for cataract, 786
Vitreous body, ossification of, 1012
spectrum of, 1029
suppuration of, 979

Warts, 138, 140
Watering of eye, 161, 895, 941
Winking, morbid, 331
Wounds, of the conjunctiva, 473
of cornea, 447, 449, 452
of eyeball, gunshot, 460
causing cataract, 455
of eyelids, 468
of orbit, gunshot, 63
incised, 63
small shot, 67
within margin of, 68
of sclerotica, 459

Xanthelasma, palpebrarum, 732
Xerophthalmia, or cuticular conjunctivitis, 885

WELLCOME LIBRARY INSTITUTE

PARDON AND SON, PRINTERS, PATERNOSTER ROW, LONDON.

TEST-TYPES.

Corresponding in size to that of Prof. Jæger.

In the original the scale is graduated from 1 to 20, but my selection is enough for practical purposes.

I beg my reader to refer to p. 607, and read what I have said about test-types.

No. 1.

In the days when fairies lived and fairy gifts were plentiful, there was a worthy man who, for some good turn he had done one of the good folks, had received a very singular reward. This was nothing else than an extra pair of eyes, which he could slip on and off at pleasure. They were not exactly spectacles. He did not put them on his nose, nor could he say exactly where he did put them. All he knew was that

No. 3.

whenever he liked to have them on, there they were. And it was surprising what curious things he saw, whether he stayed at home or travelled abroad, by the help of these same extra eyes. When he

No. 5.

told people what he saw with them, or had seen in his travels and adventures, they would not believe him. And then he would bid them just slip them on for a minute,

No. 6.

or beg them to go to the various places he had been visiting, and try them on there. And they never failed to acknowledge that all he had described was

No. 8.

perfectly true, though somehow they had never been able to see it before. Does the reader possess a pair of these extra eyes? If he

No. 10.

do not, I advise him to use his best diligence to obtain a pair of such valuable optical appliances, and without

No. 12.

loss of time. Unfortunately they are not to be obtained for silver, or gold, or

No. 14.

precious stones, and yet they are within the reach of all classes

No. 15.

of the community, from the peer to the peasant.

No. 16.

They are exempt from all the diseases about which

No. 18.

so much has been said in

No. 19.

this big

No. 20.

book

The following stripe test for astigmatism from Donders, is a good addition to the figure tests given at pages 658 and 659.



Place the figure just beyond the range of distinct vision. As it is approached, the vertical or the transverse stripes will be first clearly discerned, according as the eye is astigmatic in its transverse or in its vertical meridian.