

A text-book of ophthalmology / by William F. Norris and Charles A. Oliver.

Contributors

Norris, William F. 1839-1901.
Oliver, Charles A. 1853-1911.

Publication/Creation

Edinburgh ; London : Young J. Pentland, 1894.

Persistent URL

<https://wellcomecollection.org/works/xfqzcgbk>

License and attribution

This work has been identified as being free of known restrictions under copyright law, including all related and neighbouring rights and is being made available under the Creative Commons, Public Domain Mark.

You can copy, modify, distribute and perform the work, even for commercial purposes, without asking permission.





Wellcome Collection
183 Euston Road
London NW1 2BE UK
T +44 (0)20 7611 8722
E library@wellcomecollection.org
<https://wellcomecollection.org>






22102345468









A
TEXT-BOOK
OF
OPHTHALMOLOGY.

BY
WILLIAM F. NORRIS, A.M., M.D.,
PROFESSOR OF OPHTHALMOLOGY IN THE UNIVERSITY OF PENNSYLVANIA, AND ONE OF THE
SURGEONS TO THE WILLS EYE HOSPITAL, PHILADELPHIA,

AND
CHARLES A. OLIVER, A.M., M.D.,
ONE OF THE SURGEONS TO THE WILLS EYE HOSPITAL, PHILADELPHIA, AND ONE OF THE
OPHTHALMIC SURGEONS TO THE PRESBYTERIAN HOSPITAL, PHILADELPHIA.

Illustrated with 5 Colored Plates and 357 Woodcuts.

EDINBURGH AND LONDON:
YOUNG J. PENTLAND,
1894.

[Orig. publ. Philadelphia: Lea & Febiger,
1893]

WELLCOME INSTITUTE LIBRARY	
Coll.	welM0mec
Call	
No.	WW100
	1893
	N86t

PRINTED IN AMERICA.

PREFACE.

IN preparing this volume, the main purpose of the Authors has been the presentation of such material as is necessary to convey a working knowledge of Ophthalmology to students and practitioners.

The work is not only representative of extensive research into the rich literature upon the subject, but is expressive of the result of careful clinical experience that has extended over many years of active practice.

The Senior Author takes this opportunity to acknowledge his indebtedness to his former teachers, Ferdinand v. Arlt, Eduard v. Jaeger, and Ludwig Mauthner, for many of the ideas inculcated in the following pages.

PHILADELPHIA, July, 1893.



CONTENTS.

CHAPTER I.	
Embryology	PAGES 19-26
CHAPTER II.	
Macroscopic and Microscopic Anatomy	27-79
CHAPTER III.	
Physiology	80-103
CHAPTER IV.	
Optics	104-141
CHAPTER V.	
Physiological Optics	142-162
CHAPTER VI.	
Examination of the Eye	163-202
CHAPTER VII.	
Ophthalmoscopy	203-223
CHAPTER VIII.	
Fundus-reflex Test. (Retinal Shadow-test)	224-234
CHAPTER IX.	
Methods of Determination of Errors of Refraction and Accommodation	235-259
CHAPTER X.	
The Correction of Errors of Refraction and Accommodation	260-280

CHAPTER XI.		PAGES
Injuries of the Orbits, Eyes, and Eyelids		283-299
CHAPTER XII.		
Sympathetic Ophthalmia		300-306
CHAPTER XIII.		
Diseases of the Conjunctiva		307-332
CHAPTER XIV.		
Diseases of the Cornea		333-350
CHAPTER XV.		
Diseases of the Sclera		351-352
CHAPTER XVI.		
Diseases of the Iris and Ciliary Body		353-367
CHAPTER XVII.		
Accommodation		368-381
CHAPTER XVIII.		
Emmetropia, Hypermetropia, Myopia, and Astigmatism		382-416
CHAPTER XIX.		
Cataract		417-438
CHAPTER XX.		
Diseases of the Retina		439-472
CHAPTER XXI.		
Affections of the Optic Nerve and its Internal Prolongations		473-495
CHAPTER XXII.		
Diseases of the Chorioid		496-510
CHAPTER XXIII.		
Diseases of the Vitreous		511-514

CHAPTER XXIV.

	PAGES
Glaucoma	515-533

CHAPTER XXV.

Affections of the Eye-Muscles	534-557
---	---------

CHAPTER XXVI.

Diseases of the Eyelids	558-567
-----------------------------------	---------

CHAPTER XXVII.

Diseases of the Lacrymal Apparatus	568-574
--	---------

CHAPTER XXVIII.

Diseases of the Orbit	575-582
---------------------------------	---------

CHAPTER XXIX.

Some of the More Common and Important Operations on the Eye	583-621
---	---------

TEST-TYPES	622-627
----------------------	---------

LIST OF COLORED PLATES.

- PLATE I. Diagram Illustrating the Relations of the Visual Apparatus
to the Cerebral Cortices.
facing page 80
- PLATE II. Diagram Illustrating the Chromatic-aberration Test for
Ametropia.
facing page 254
- PLATE III.
Fig. 1. Normal Eye-ground (average tint).
Fig. 2. Normal Eye-ground (brunette).
facing page 439
- PLATE IV.
Fig. 1. Ophthalmoscopic Appearances in Retinitis Leucæmica.
Fig. 2. Ophthalmoscopic Appearances in Retinitis Syphilitica.
facing page 458
- PLATE V.
Fig. 1. Ophthalmoscopic Appearances in Early Stage of Papillitis.
Fig. 2. Ophthalmoscopic Appearances in Regressive Neuritis.
facing page 474

PART I.

By CHARLES A. OLIVER, M.D.

EMBRYOLOGY.

MACROSCOPIC AND MICROSCOPIC ANATOMY.

PHYSIOLOGY.

OPTICS.

PHYSIOLOGICAL OPTICS.

EXAMINATION OF THE EYE.

OPHTHALMOSCOPY.

FUNDUS-REFLEX TEST.

METHODS OF DETERMINATION OF ERRORS OF REFRACTION
AND ACCOMMODATION.

THE CORRECTION OF ERRORS OF REFRACTION AND ACCOM-
MODATION.



ERRATA.

Page 80, line 23: for *blue* read *red*.

" " " 24: for *red* read *blue*.

" 397: Under illustration No. 245, for *Thinning and stretching of* read
Normal appearance of.

" 410, line 5: for *three* read *six*.

" 501, " 13: for *choroidal* read *vascular*.

" 581, " 44: for *tissues* read *fissure*.

" 588: In illustration No. 343 introduce the letter *b* at the apex of
dotted triangle.

" 617, line 25: for *hotkt* read *hook*.

" " " 27: for *maigne* read *magnet*.



CHAPTER I.

EMBRYOLOGY.

SCIENTIFIC observation has shown that the visual sense of the lowest animate forms has arisen from a diffused capacity for receiving sensations from waves of heat. This is proved by the fact that many of the simplest organisms display distinct peculiarities and differences in direct relation to variations of exposure to light and heat. In the apparent absence of special organs adapted to the reception of light-rays, we are compelled to the assumption that there is some generalized material which is capable of such action. Ascending in the scale of zoölogical forms, we find the organism manifesting a still more sensitive general surface, as it changes its habitat and mode of existence. Later, small isolated areas become more specially organized and are ready for the reception of higher stimuli. So-called eye-spots appear. Bundles of globules of pigmented epithelial cells show themselves, as may be seen in the peculiar end-organs in many of the lower invertebrata. For instance, each eye-spot of the star-fish is composed of several invaginated epithelial cells, containing a red pigment to which nerve fibres become connected. Such an organ is a light-receiver and a light-absorber, and can be considered as one of the primary examples of an eye.

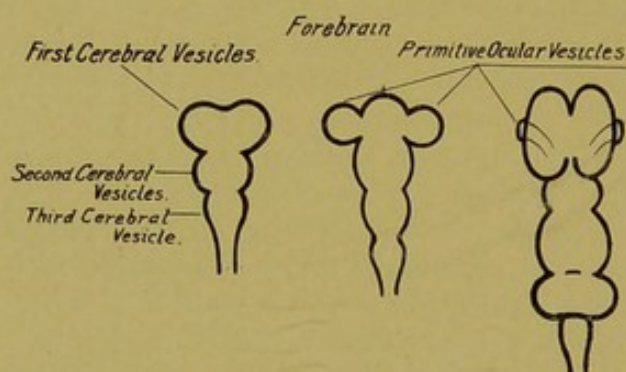
As advance is made into the life-form, these spots become more complex. The overlying cuticle raises itself into a curved plate and the raised tissue becomes transparent, so that now there is a material of such shape and quality as to possess the power of concentrating light. These simple eyes are found to be more numerous upon those parts which are the most necessary for the animal's existence, safety, and protection. Bases of tentacles become studded with them; margins of disks contain numerous dottings; the cephalic extremities hold the largest and the most specialized varieties; and peculiar movable foot-stalks, containing compound formation upon their distal extremities, appear. Certain parts become greatly increased, to exercise definite function in the animal's place of existence. Organic retrogradation of specialized parts shows itself. Protective apparatuses, adjusting mechanisms, and directing machinery, all become manifest. Formation of new and useful parts, abolition of old and useless portions, each adapted for some peculiarity of action, come and go, until at last the apparatus is brought to one of the most highly specialized varieties, as shown in man. To this variety, attention will be directed.

Roughly speaking, the human visual apparatus may be divided into three parts: The first, the peripheral or receiving portion, known as the eye proper, which consists of two separate surfaces of sensory material, termed the ocular retinae, which are placed at the focussing points of two compound systems of boxed lenses of changeable power: the

second, or transmitting portion, which, containing the combined nerve-material gathered into two masses that pass inward through the skull into the intra-cranial cavity, pursues its way backward in intermingled relation and connects at various points with the cerebral mass, until at last it is re-spread in the occipital region, to form a portion of the so-called cerebral cortex: the third, that area of the cerebral cortex which is composed of the outspread central terminations of this nerve-material, forming the so-called visual centres.

Whether the dual eye of the order Vertebrata is derived from the single median organ seen amongst the tunicates, or whether it is a derivative of the paired eyes of the annelids, it is impossible at present to hazard any more than a vague hypothesis. Embryologically, the foundation of the human ocular apparatus practically grows out, as a pair of lateral diverticula, from the first embryonic cerebral vesicles, which are a part of the three (really five) brain-sacs. These so-called

FIG. 1.



Formation of ocular vesicles. (BONNET.)

ocular vesicles or *diverticula* of the primitive cerebro-spinal canal, as seen in Fig. 1, are at first more or less globular, with a wide passage on their inner sides which communicates directly with the early neural cavity. As development proceeds,¹ the necks of these vesicles become elongated, narrowed, and solid.

In this way the optic nerve, the true retina, and the retinal pigment are developed. After the ocular vesicle has been pushed out so as to be brought in contact with the embryonic epidermis or ectoderm which, thickened in this situation, is to form the conjunctiva and covering of the cornea, the outer convexity of the vesicle is pressed inward by the rapid growth of the overlying ectoderm in such a manner that the outer half is thrust into the posterior half of the vesicle. Thus is formed a double-walled cup (*the ocular cup*) or *secondary ocular vesicle*. This is shown in Fig. 2.

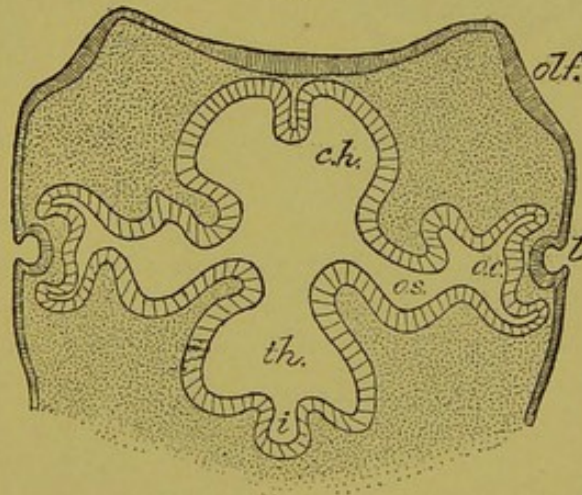
Later the exterior part of the cup becomes reduced in thickness and its cells are converted into pigment, into which the retinal rods and cones eventually dip. The inner part or interior layer of the cup, on the con-

¹ In order that the subject-matter might be kept more in harmony and the entire development of each part better understood, strict succession of development has not been adhered to.

trary, rapidly thickens to a depth of several layers of cells which, considered consecutively from its inner or concave face, may be differentiated as follows: ganglion layer, inner molecular layer, outer ganglion layer, external molecular layer, and layer of rods and cones. These several layers are supported and bound to one another by certain cells known as *Müller's fibres*, which represent the connective tissue of the retina proper. In the later stage, capillary blood-channels and lymph-spaces develop within the substance of the retina. These, however, do not reach their full development until one of the later periods of the post-embryonic stage.

The cortical strands of the optic nerve bundles develop peripherally from the ectodermic neuroblasts in the ganglionic layer of the retina along the walls of the hollow foot-stalks. They pass centripetally through these neural tubes to terminate in the occipital cortex. A

FIG. 2.



Invagination of lens. (Hrs.)

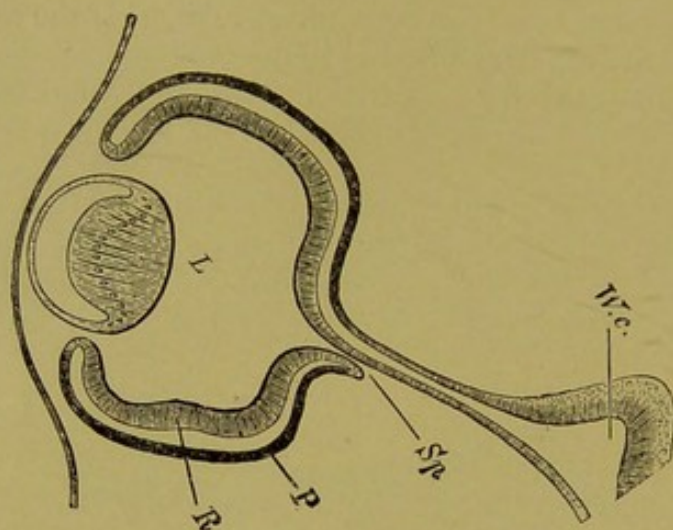
second series of strands, ganglionic in type, probably sensory-motor in character, and connected with the nuclei of the third, fourth, fifth (in part), and sixth pairs of intra-cranial nerves, seem to develop centrally in the nuclei of the ganglion cells of the optic tract and to pass centrifugally to the optic bulb. According to some authors, the median parts of the two stalks combine in a measure to form the chiasm. The posterior portions, or optic tracts, connect with the mid-brain.

Precedent to this involution of the retinal cup, there is developed from the external epithelium, immediately over it, a fold of the external embryonic epidermis, which has become thickened at this point. This fold, which subsequently forms the *lens vesicle*, is shut off from all connection with the exterior epidermis.

The anterior wall of the lens vesicle, or that portion lying next to the cavity of the retinal cup, begins to thicken before it is detached from the parent layer of epidermis. About the time of the detachment of this rudiment of the lens from the epidermis, its posterior wall has so greatly increased in size by nutrition derived from the vascular tunic of the lens, which is fed by the prenatal branches of the central

artery of the retina, as to cause the cavity in this epidermal vesicle to become crescentic in outline; the front wall of the lens-cavity in this stage being relatively thin. Fig. 3 shows this condition in a fourteen-

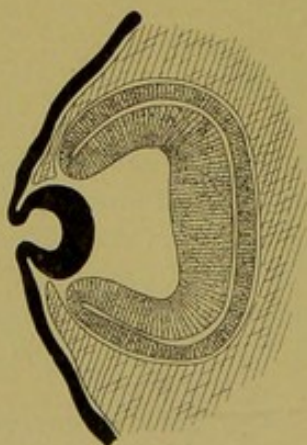
FIG. 3.



Isolation of lens and excentric position of optic stalk. (HIS.)

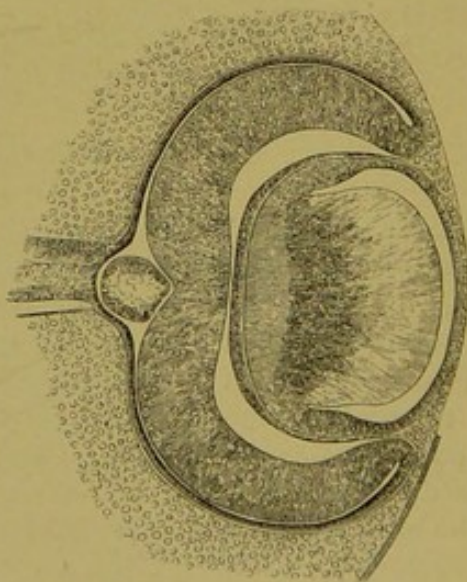
days-old rabbit embryo. This great thickening of the posterior wall is due to a lengthening of the component cells in an antero-posterior

FIG. 4.



Formation of optic cup and lens. (BONNET.)

FIG. 5.



Further evolution of lens vesicle. (KÖLLIKER.)

direction,¹ and proceeds until the crescentic cavity between the posterior and the anterior walls of the lens vesicle is entirely obliterated. The result of these processes, as can be seen in Fig. 4, is that the lens becomes a

¹ This lengthening of the cells and their subsequent cornification are said to give rise to the long fibres seen in the lens of the adult.

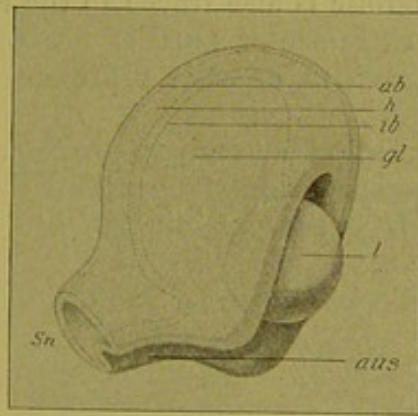
solid body composed of a posterior wall of elongated fibres and a thin adherent anterior wall made up of columnar epithelial cells, which at the margin become gradually elongated as they pass into the long fibres developed from the centre of the thickened posterior layer.

The lens capsule is probably either a derivative from a thin layer of mesoderm or a cuticular deposit from the lens cells themselves. Some authors assume that it is both.

The optic cup, as described above, must not be understood to assume a form with edges which are perfectly uniform in height; but, as shown in Fig. 5, there is a depression or groove of the edge upon the inferior side of the cup, in the same plane. (Fig. 6.)

This depression or notch on the inferior side of the optic cup is known as the *chorioid fissure* or *ocular cleft*, and in mammalia extends some distance along the optic stalk. Through this fissure, from beneath, embryonic connective tissue is proliferated to form not only the

FIG. 6.



Chorioid fissure. (BONNET.)

central artery and vessels of the vitreous, but also the vitreous humor itself. A little later, this cleft begins to close at its proximal end until at the time that the hyaloid vessels are all aborted, a small opening is left through which the central artery of the retina enters the optic nerve.

At first, owing to the relatively enormous size of the lens, the vitreous humor is small in amount, and it is only in the later stages, or in embryos beyond three and a half centimeters in length, that the latter attains any considerable size and importance, as in the adult eye. The hyaloid membrane is probably a derivative from the same source as the vitreous humor, being further differentiated into the suspensory ligament of the lens.

Simultaneously with the intrusion of the connective tissue through the chorioid fissure, there is an augmentation of the connective tissue between the anterior face of the lens and the external epidermis in front of it. This intrusion between the lens and the epidermis takes place in a ring-like manner from the margin of the optic cup toward the centre of what is to become the cornea; the epidermis of the cornea being formed of the embryonic epithelium and the intruding connective tissue described above. The connective tissue of the cornea, or *chorion*,

is continuous with the sclerotic, which has developed from embryonic connective tissue in contact with the outer or pigmented layer of the primitive optic cup. The chorioid and its vessels interposing between the sclerotic and the retina are likewise probably developed from embryonic connective-tissue cells.

With still further differentiation of the eyeball, the cornea becomes lifted off from contact with the lens; the space formed, now filled with a clear fluid, becoming the area into which the iris later protrudes. The iris is developed on its posterior face from the attenuated and degenerated portion of the anterior rim of the optic cup, which has gone to form the edge of the central opening known in after-life as the pupil; whilst the anterior face, containing more or less pigment, bloodvessels, and muscular fibres, is a derivative of embryonic connective tissue.

The apparatus for accommodation—the ciliary muscle and its attachments—is in like manner developed from embryonic connective tissue or mesoblast.

The origin of the sclerotic is also traced to the embryonic connective tissue. The attached extra-ocular muscles are probably derived from the walls of the head-cavities, or what represent head-cavities, in the mammalia.

The front of the eyeball of an embryo three and a half centimeters in length, with its large lens and the protruding cornea lying in contact therewith, is at this stage but slightly covered around its margins. (Fig. 7.)

This covering, which constitutes the rudimentary eyelids, consists of simple ridge-like folds of epidermis filled with embryonic connective-tissue cells, which gradually grow from above and below to unite over the eyeball by means of the surface-layer of cells. At birth, or immediately before, the palpebral fissures are formed by a splitting or separation of these surface-layers, caused by the rapid outgrowth of the cilia or eyelashes.

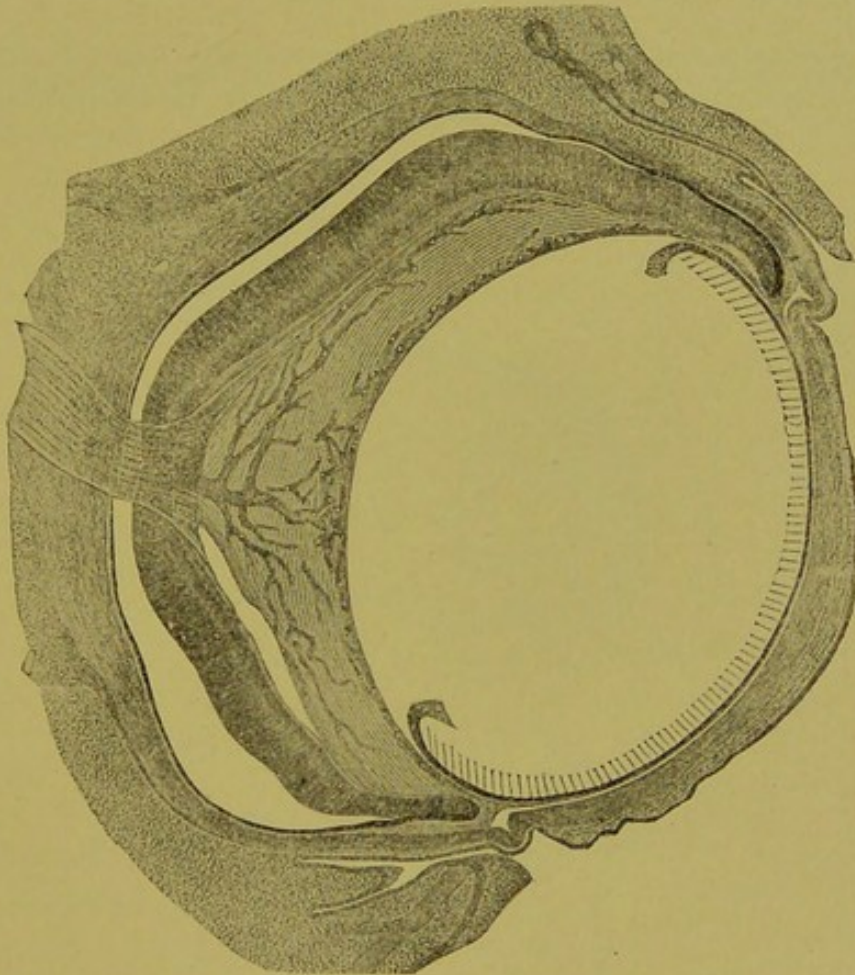
The third eyelid, or *plica semilunaris*, is developed as a fold covered by the external epithelium, in the same manner as the lids themselves.

The Meibomian glands are simple involutions of the embryonic epithelium or epidermis which cover the inner face of the eyelid and extend over the cornea as the corneal epithelium or epidermis. The lacrymal glands have a similar origin from the embryonic epidermis, especially from that near the outer angle of the upper eyelid, whilst the lacrymal canal is the result of the want of closure of the cleft which exists between the lateral plates of the fronto-nasal processes and their neighboring maxillary processes. The latter is lined by an epithelial tube, the production of a thickening of the rete mucosum, which sinks into the deep layer of the cutis along the fissural line.

The central artery of the optic nerve, in its early stages, lies in the depression on the under side of the hollow optic stalk, this depression being continuous at its outer extremity with the chorioid fissure. The vessels arising from the central artery of the retina and optic nerve are the earliest to enter the eye within the retinal surface. With the excep-

tion of the hyaloid branch, which, as can be seen in Fig. 7, runs across the vitreous chamber to furnish nutrition by numerous branches to the lens, they preserve all their essential characteristics in the adult.¹ Later the hyaloid and its stems rapidly abort, leaving the hyaloid canal as the only evidence of their existence.

FIG. 7.



Further development of the eye as shown by a section through an eye of a pig embryo. (KOLLIKER.)

Summary.—It will be seen that not only the optic nerve, but the retina itself, and the retinal pigment at one stage, are absolutely continuous with the walls of the embryonic cerebro-spinal nervous system. In fact, the cerebro-spinal nervous epithelium of the embryo passes uninterruptedly into the eye. The lens is entirely of epidermal origin, while the connective tissue of the sclerotic, the chorioid, the iris, and the cornea, are all derivatives from the primitive embryonic connective tissue or mesoblast. The voluntary muscles which move the eyeball are also derivatives from embryonic connective tissue.

¹ It will thus be seen that the intrusion of the bloodvessels into the optic nerve and into the eyeball, is similar to the intrusion of the connective tissue forming the vitreous into the eyeball through the chorioid fissure.

The three essential organs—the optic nerve,¹ the retina with its two layers (the retina proper and the pigmented layer), and the lens—are the first parts of the eye to be developed. All the remaining structures—the sclerotic, the vitreous, the aqueous humor, the iris, the muscles of accommodation, etc.—have grown either into or around the ball, or optic cup, secondarily. In other words, the retina and the lens are the essential primitive organs of the eye, being differentiated before any of the other organs are fully developed.

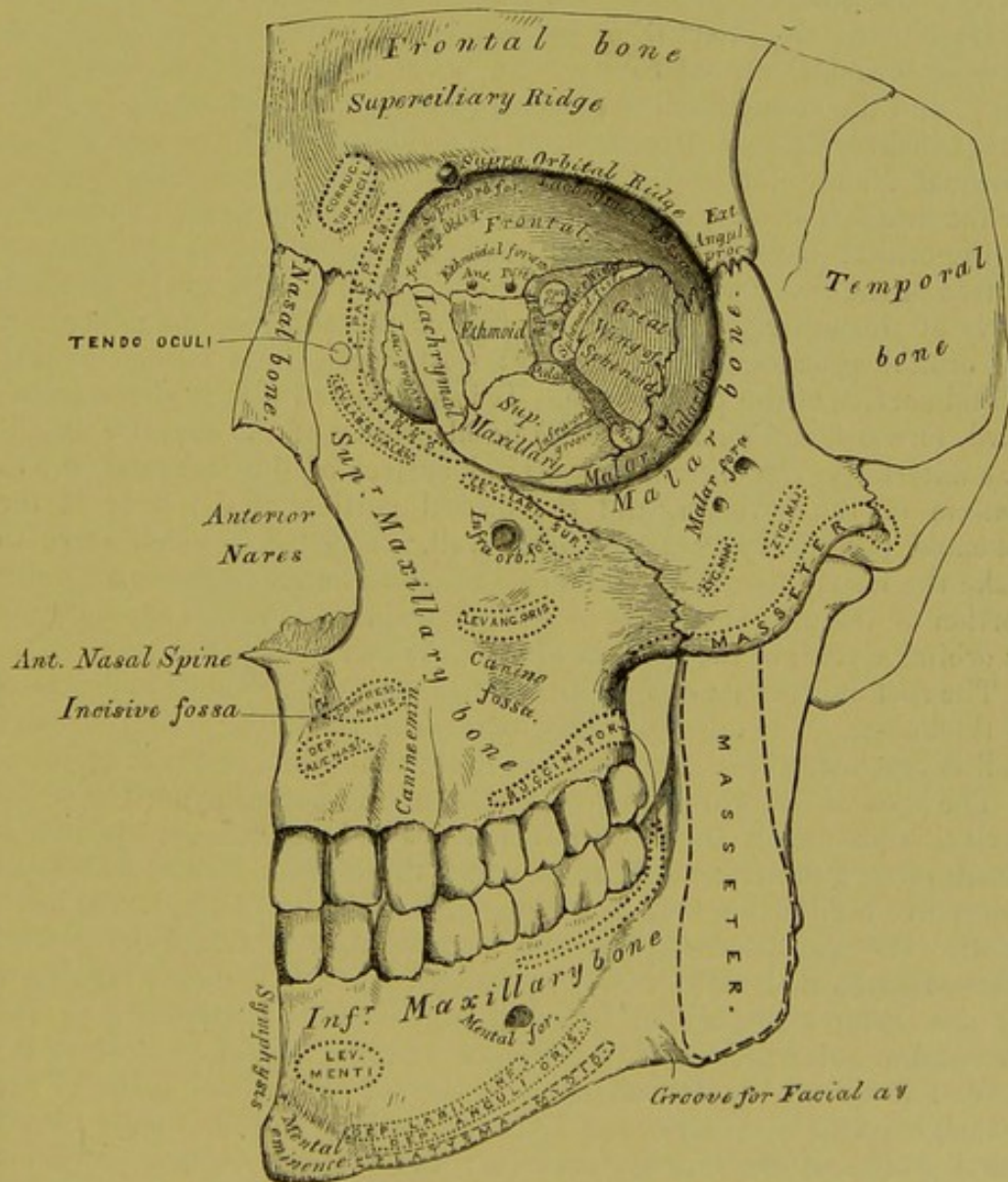
¹ It may be of interest to note that Miss Julia B. Platt, working on the chick, has shown it to be exceedingly probable that the optic nerve is dorsal in origin, thus reconciling this anomalous nerve with all the other sensory nerves, which are dorsal in origin in the embryonic medullary plate or first rudiment of the cerebro-spinal nervous system.

CHAPTER II.

MACROSCOPIC AND MICROSCOPIC ANATOMY.

THE eyes are imbedded in smooth sockets known as the orbits. These are composed of several associated bones placed on the upper outer facial aspect.

FIG. 8.



Bones of the orbit and face. (GRAY.)

They are irregularly quadrilateral, cone-like in shape, about forty-five millimeters (about one and three-quarters inches) deep, and situated on each side of the root of the nose, immediately beneath the forehead.

They are usually inclined to one another, as can be seen in Fig. 20, at an angle of about forty to forty-five degrees. The temporal borders of their circumferences project forward to a less distance than the nasal, which are almost parallel to one another. Their apices look upward and inward, so that, should their long axes be continued posteriorly, they would generally meet the middle of the anterior clinoid process of the sphenoid bone at about the position of the sella Turcica. As seen in Fig. 8, the bones entering into their construction are the frontal, the sphenoid, the ethmoid, the superior maxillary, the lacrymal, the malar, and the palate—the first three being common to both.

Six distinct portions of the cavity are recognized: the roof, or superior wall, which separates it from the frontal sinus and cranial cavity; the floor, or inferior wall, which forms the roof of the antrum of Highmore; the internal, or nasal, portion, which acts as a partition between it and the nasal cavity; the external, or temporal, wall; the apex; and the circumference, or base. The vault or roof, which is somewhat concave, shows a depression at its antero-temporal portion for the lacrymal gland, and a tuberosity or spicule at its antero-nasal portion for the attachment of the trochlearis muscle. It is formed anteriorly by the orbital plate of the frontal bone and posteriorly by the inferior surface of the lesser wing of the sphenoid. The floor is composed anteriorly of the superior or orbital surface of the superior maxillary and the orbital processes of the malar; posteriorly, it is formed by the orbital surface of the palate bone. It is so situated that it slopes downward, forward, and outward. The nasal process of the superior maxillary anteriorly, the external or orbital surface of the lacrymal, the os planum of the ethmoid, and the orbital portion of the body of the sphenoid posteriorly, form the inner wall. The bones which serve to make the nearly flat, firm, and most resisting outer wall, are the outer portion of the orbital process of the malar anteriorly, and the anterior or orbital surface of the greater wing of the sphenoid posteriorly.

The roof and the nasal wall are the thinnest. The inner wall is next in thickness. The other portions increase in thickness until the outer wall is reached, which is at least five to six times thicker than the inner.

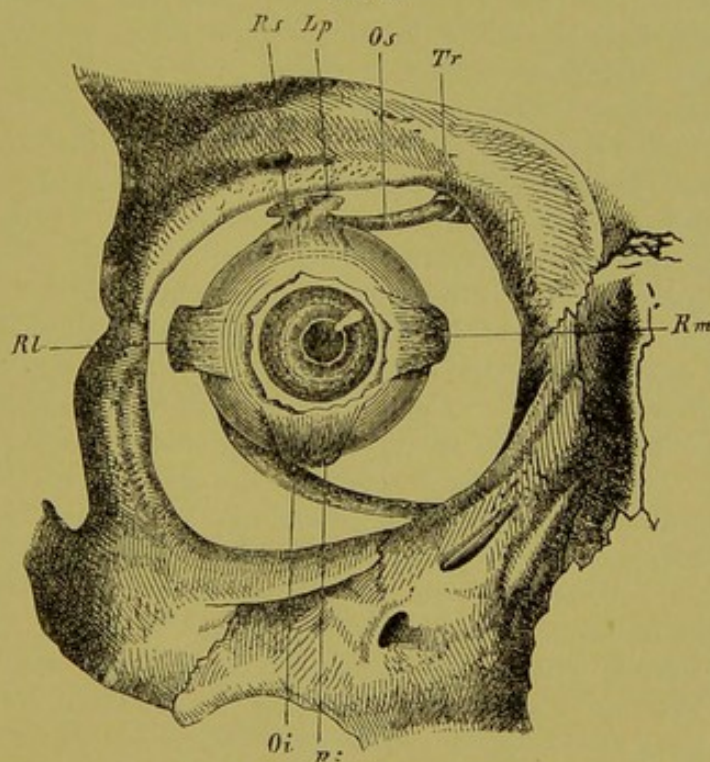
The apex of the orbit, which is situated at the posterior portion of the cavity, is practically the optic foramen. The base or facial opening is about forty millimeters (about one and three-fifths inches) wide, and thirty-five millimeters (one and three-eighths inches) high, in the adult skull. Its nasal border is generally situated about nineteen millimeters (three-fourths of an inch) from that of its fellow. It is bounded superiorly by the dense supra-orbital ridge of the frontal; externally by the external angular process of the frontal and the orbital process of the malar; inferiorly by the anterior border of the orbital plate of the malar, superior maxillary, and lacrymal bones; and internally by the nasal process of the superior maxillary and internal angular process of the frontal. These dense bony edges, which become less marked toward the median line, are known by some as the *orbital margin*. The inferior external angle is at a lower level than the inferior internal.

Each cavity presents four angles: the superior internal, formed by the junction of the roof and inner wall; the superior external, formed

by the roof and outer wall; the inferior external, formed by the floor and outer wall, and the inferior internal, made by the junction of the lacrymal and ethmoid with the superior maxillary and palate. The eyeball itself, as shown in Fig. 9, lies somewhat toward the superior external angle.

There are nine openings into each cavity, five of which are foramina, two are fissures, and the remaining two, canals. They are extremely variable in size, shape, and position. The first of these, about ten millimeters (three-eighths of an inch) long and about six millimeters (one-fourth of an inch) in calibre, is the *optic foramen*. It is situated on the edge of the body of the sphenoid bone, slightly to the nasal side of the apex of the orbit. It pursues its course upward and inward

FIG. 9.



Position of eyeball in orbit. (MERKEL.)

toward its fellow. Through it the optic nerve and ophthalmic artery make their exit from the cranial cavity. The second is the *supra-orbital foramen*, which is frequently nothing more than a mere notch or groove. It is generally found at the inner third of the supra-orbital arch of the frontal bone, at about six to ten millimeters (one-fourth to three-eighths of an inch) distance from the superior internal angle. It is intended for the transmission of the supra-orbital artery, vein, and nerve. The third, the *anterior ethmoidal foramen*, situated in or just above the suture of the superior internal angle, transmits the anterior ethmoidal artery and the nasal branch of the fifth nerve. The fourth, the *posterior ethmoidal foramen*, situated immediately back of the anterior, transmits the posterior ethmoidal artery and the corresponding vein. The fifth, the *malar foramen*, which in most instances is double, is situated in the outer wall of the orbit, on the upper surface or orbital

process of the malar bone. It is intended for the transmission of the orbital branch of the superior maxillary nerve and a twig from the lacrymal nerve, which communicates with the temporal filament before entering the foramen itself. The two fissures are known as the *sphenoid* and the *spheno-maxillary*. They are sometimes known as the *superior* and the *inferior orbital fissures*. The former, more properly termed the *anterior* or *superior lacerated foramen*, is the larger. It is just external to the optic foramen, at the posterior portion of the superior external angle, along which it extends anteriorly for some distance. It is in reality the slit between the greater and the lesser wings of the sphenoid bone, which has been converted into a foramen by association externally with the orbital plate of the frontal bone. It is triangular in shape, with its base down and in. Through it pass the third nerve, the fourth nerve, the frontal, the lacrymal, and the nasal branches of the ophthalmic division of the fifth nerve, the sixth nerve, a few small twigs from the cavernous plexus of the sympathetic, the superior and inferior ophthalmic veins, the recurrent lacrymal artery, and frequently some of the orbital branches of the middle meningeal artery. The latter fissure, which is situated in the inferior external angle, extends downward and outward from the sphenoidal fissure. It is formed superiorly by the inferior border of the orbital surface of the greater wing of the sphenoid; externally, as a rule, by the malar; inferiorly by the palate and external border of the orbital surface of the superior maxillary; whilst internally it connects at right angles with the pterygo-maxillary fissure. It generally serves as a passage-way for the superior maxillary nerve and its temporo-malar branches, the infra-orbital nerve, the ascending branches of the spheno-palatine ganglion, the infra-orbital artery, and the so-called facial ophthalmic vein.

The two canals are the *infra-orbital* and the *lacrymal*. The former commences as a groove at the centre of the external border of the orbital surface of the superior maxillary bone. Running forward from the spheno-maxillary fissure, it ends in a canal which divides into two branches. One of these, the infra-orbital, opens upon the facial surface of the bone about eight millimeters (about one-third of an inch) below the edge. The other, the *anterior dental canal*, passes into the substance of the bone itself and transmits the infra-orbital nerve and artery from the orbit outward.

The *lacrymal canal* begins as a groove in the lower inner portion of the circumference of the orbit. It is formed anteriorly by the inner surface of the supra-maxillary bone and posteriorly and on the side by the lacrymal groove of the lacrymal bone, and the lacrymal process of the inferior turbinated bone. It is lined by a fibrous tissue and is covered internally by a mucous membrane, which in the sac and duct is coated with ciliated epithelium. The canal serves as a passage-way for the tears to the nasal cavity.

The arteries found throughout the ocular tissues in the orbit are almost solely derived from the *ophthalmic artery*, which is given off from the cavernous portion of internal carotid. Entering the orbital cavity through the optic foramen to the outer and lower side of the optic nerve, and pursuing its way forward a short distance, it crosses

over the nerve toward the median line. Here it leaves the muscle-cone, and again passes forward beneath the superior oblique muscle to the inner angle of the eye, where it separates into its terminal branches—the *frontal artery* and the *nasal artery*.

The first, and one of the largest branches, is the *lacrymal artery*, which, generally appearing at or near the optic foramen, passes forward in company with the lacrymal nerve along the superior border of the external rectus muscle to supply the lacrymal gland. A few filamental twigs continue to the conjunctiva and the upper lid, where they anastomose with the palpebral arteries. During its passage forward it gives off a couple of so-called *malar* branches, which anastomose with both deep and superficial vessels.

The next most important branch, which is the largest, is the *supra-orbital artery*. It appears just as the main vessel crosses the optic nerve. Ascending through the muscle-cone, and passing forward with the frontal nerves above the levator palpebræ muscle, it goes through the supra-orbital foramen, and separates into a deep and a superficial branch. These distribute themselves to the pericranium and the muscular and integumental tissues of the forehead. A few filamental twigs anastomose with the temporal artery, a branch of the facial artery, and its opposite fellow. During its passage forward it gives off branches to supply the superior rectus muscle, the levator palpebræ muscle, and the tissues at the supra-orbital foramen and inner canthus.

The third and fourth are the *posterior ethmoidal artery* and the *anterior ethmoidal artery*. They appear as the main vessel goes along the inner wall of the orbit, and leave the orbit through the posterior and the anterior ethmoidal foramina, to be distributed to the intracranial and nasal structures about the cribriform plate.

The fifth and sixth are the *superior palpebral artery* and the *inferior palpebral artery*. They appear as the main vessel reaches the position of the pulley of the superior oblique muscle, and encompass the eyelids about their ciliary border. Beneath the orbicularis muscle they anastomose with the orbital branches of the temporal and infra-orbital arteries, and send a long filamental twig to the nasal duct.

The main vessel, continuing forward, terminates in the *frontal artery* and the *nasal artery*. The former ascends on the forehead from the inner angle of the orbit. It supplies the muscular and integumental tissues, and the pericranium, and anastomoses with the supra-orbital artery. The latter, after leaving the orbit just above the tendo oculi and sending a twig to the lacrymal sac, separates into two filaments. One of these anastomoses with the angular artery, and the other, called the *arteria dorsalis nasi*, supplies the superficial portion of the dorsum of the nose, and anastomoses with its fellow terminal.

Two small twigs, the *inferior muscular artery* and the *superior muscular artery*, appear, as a rule, somewhere within the muscle-cone. The former, which is the larger, and which furnishes most of the anterior ciliary arteries, passes forward beneath the optic nerve, and supplies the inferior rectus, the inferior oblique, and the external rectus muscles. The latter passes to the upper portion of the cavity, and sup-

plies the superior rectus, the superior oblique, and the levator palpebræ muscles.

Besides these so-called orbital branches, there are a number of important twigs known as the ocular branches. The first is the *central*

FIG. 10.

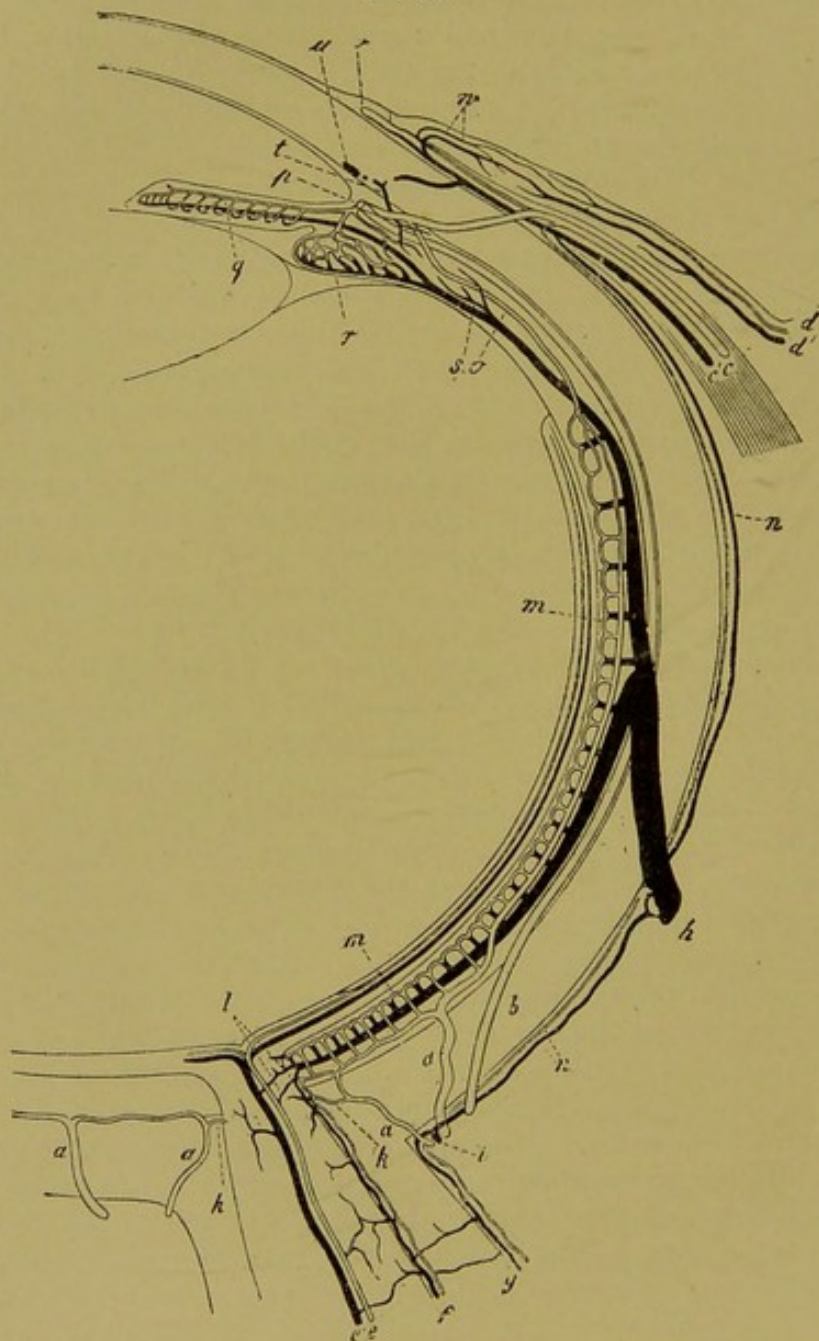


Diagram of a horizontal section of the circulation of the eye. (LEBER.)

The veins are made black and the arteries clear. *a a a* represent the short ciliary arteries; *b*, a long ciliary artery; *c c*, an anterior ciliary artery and vein; *d d*, a posterior conjunctival artery and vein; *e e*, the central retinal artery and vein; *f* and *g*, vessels of the inner and outer optic sheaths respectively; *h*, one of the vortex veins of the choroid; *i*, a short ciliary vein; *k*, a branch of the vein which passes into the optic nerve; *l*, an anastomosis of the chorioidal veins with the central vein of the retina; *m m*, the chorioidal capillaries; *n*, an episcleral branch; *o*, recurrent chorioidal artery; *p*, major arterial circle of the iris; *q*, vessels of the iris; *r*, vessels of the ciliary processes; *s*, venous branch passing from the ciliary muscle to the vortex vein; *t*, venous branch passing from the ciliary muscle to the anterior ciliary vein; *u*, venous plexus or circle; *v*, venous network at the corneal border.

artery of the retina, which is the smallest offshoot of the main vessel. It appears near the optic foramen at right angles to the parent trunk, and runs forward to obliquely penetrate the optic nerve at about ten millimeters (about three-eighths of an inch) behind the ocular bulb. Reaching here, it passes directly into the interior of the eye, as shown in Fig. 10 at *e*, and separates at or near the optic disk into a series of retinal twigs which terminate at or near the ora serrata.

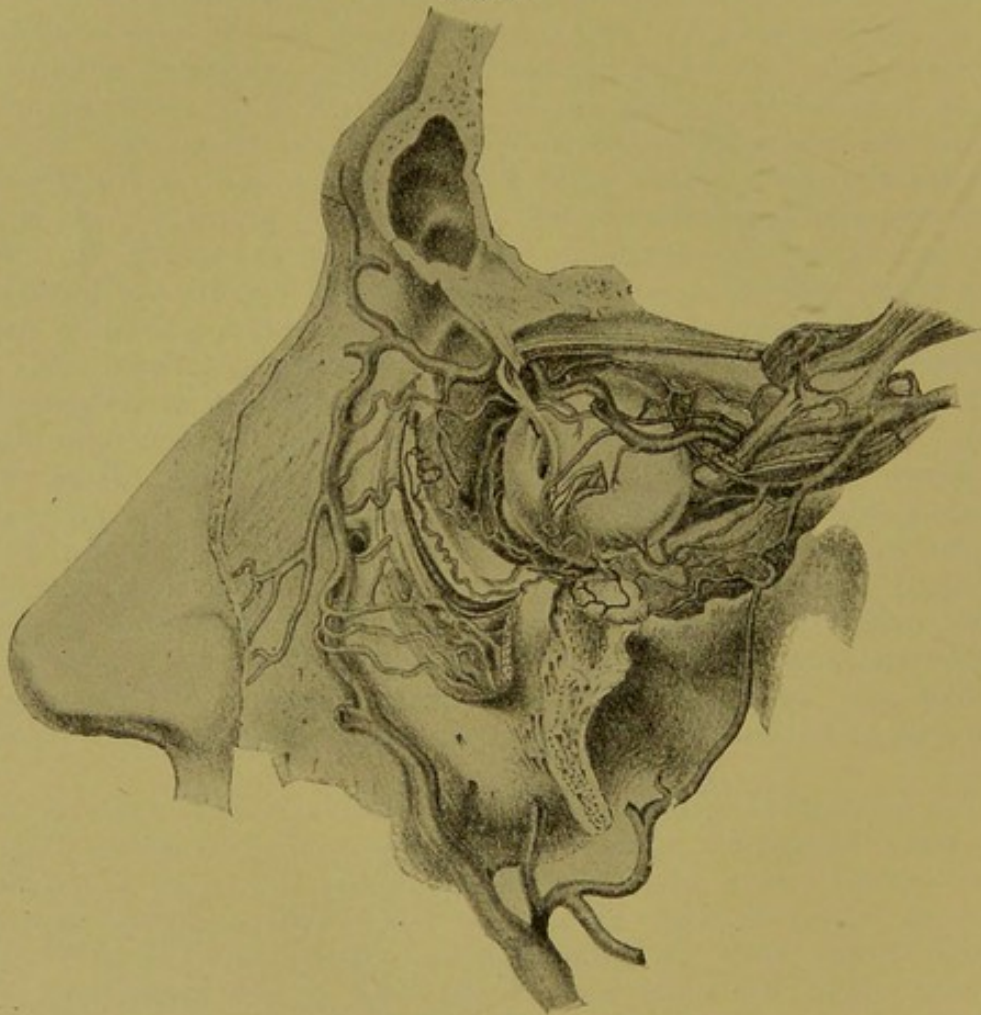
The second orbital branch is in reality a grouping, generally composed of three distinct and separate systems. These are known as the *short ciliary arteries*, the *long ciliary arteries*, and the *anterior ciliary arteries*. The first, which number ten to fifteen, appear as minute offshoots from the main trunk in the muscle cone, or one of its branches behind the ocular globe. Surrounding the optic nerve, and running forward, they penetrate the sclera, as shown at *a*, *a*, and *a* in Fig. 10, and pass around to supply the chorioid and the ciliary processes. At times they anastomose with one of the retinal twigs, as at *l* in Fig. 10. The long ciliary arteries, one of which is seen at *b* in Fig. 10, which are but two in number, appear from the main trunk or from a branch in about the same position as the short ciliaries. These pass forward—one on each side of the optic nerve—to perforate the sclerotic at its posterior part. Continuing onward between the chorioid and the sclerotic coats, as shown in the sketch, they supply the ciliary body. Here they separate into two branches, which form a circle around the periphery of the iris, shown at *p* in Fig. 10, from which a series of radiary filaments proceed through the iris-tissue to make an inner vascular circle around the pupillary border. The third series, shown at *c*, which are derived from the inferior and other muscular branches, run forward to pass into the sclerotic near the corneal limbus. Here they send branches to the ciliary body and to the greater vascular circle of the iris.

The veins which pass into the ophthalmic vein have more or less the same distribution as those of the corresponding arteries. Beginning centrally as a branch of the cavernous sinus, the *ophthalmic vein*, as shown in Fig. 11, can be followed through the superior orbital fissure into the orbital cavity, across the optic nerve and forward along the inner wall of the orbit to the inner angle of the eye. Here it forms a communication with the anterior facial vein, the frontal vein, the vena dorsalis narium, and the superciliary veins. Along its course it receives a number of branches, the first of which is the *supra-orbital vein*, which empties into it from behind, followed by the *lacrymal vein* and the *muscular veins*. The *palpebral vein* and the *vein of the lacrymal sac*, as a rule, are also included in the same. The *central retinal vein*, the *posterior ciliary veins*, and the *anterior ciliary veins*, and also the *vorticosae veins* with greater or less constancy, are strictly ocular in type. Related to their fellow arteries, and having the same distribution, no more than a mere summary of them, as given, is necessary. The frontal portion of the facial vein receives the *supra-orbital vein* as it descends upon the forehead, and sends a lateral branch, the *superior palpebral vein*, to the upper lid. Near the position of these two veins the *communicating vein*, with the

terminals of the ophthalmic vein, are found. The *inferior palpebral vein* passes into the facial vein just below the nasal branch at the junction of the wing of the nose and the cheek. This free anastomosis, as well as the great vascularity of the periphery of the orbit, is well shown in Fig. 12.

As the coloration of the blood would interrupt the passage of light, it becomes necessary that the ocular media should be nourished with

FIG. 11.



Distribution of ophthalmic vein. (GURWITSCH.)

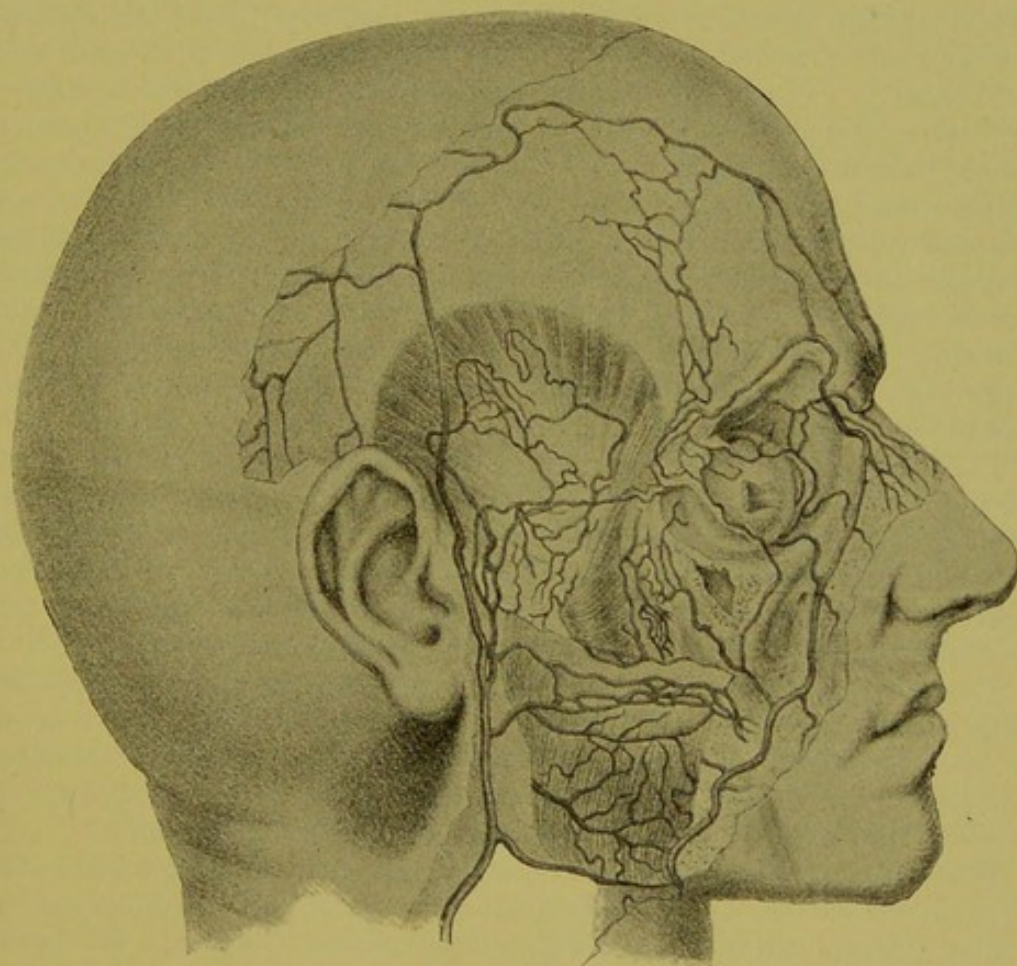
colorless lymph. This material, derived from the tissues of the eye, circulates through the cornea and the lens, and, in, fact, constitutes the aqueous humor, and probably the major part of the vitreous humor, before being discharged from the globe by one of three systems. These two large serous cavities or reservoirs placed in the paths of these systems of lymph streams serve many important purposes.

The aqueous humor, resembling in measure the fluid found in the cerebro-spinal system, is furnished as a secretion from the glands in the ciliary region. Possibly a small percentage of it, in modified form, is derived from the iris. This watery lymph secretion finds its way into the posterior chamber and then into the anterior chamber. Reaching this endothelial sac, it completely fills it, and constantly flows out through

the so-called canal of Schlemm and Fontana's spaces, situated just beyond the iris-angle, to connect with the fine stems of the anterior ciliary veins.

The vitreous humor—the second great reservoir, or, as Foster aptly puts it, “an attenuated mesoblastic sponge”—on the other hand, is practically a denser material, containing several streams of more fluid

FIG. 12.



Distribution of superficial veins. (GURWITSCH.)

lymph. One of these is slowly moving toward the optic disk, and the other is continually coming forward to get into the posterior chamber. The vitreous humor receives a portion of its lymph currents from the glands in the neighborhood of the zonule of Zinn and the ciliary bodies. A portion of this stream turns forward and goes directly into the humor of the posterior chamber, whilst a second great current for the retina is carried backward to the optic disk along the hyaloid canal. In fact, the vitreous humor serves in part as a vehicle or *menstruum*, through which the lymph currents are allowed to find their way.

These two large intercalaries, then, as it were, have several systems of current. The first, which is known as the *anterior lymphatic system*, is derived from the iris and the ciliary body. It serves to supply all of the tissues of the anterior segment of the eye. One portion of it, which

passes directly into the posterior and the anterior chambers to meet another current that leaves the ciliary bodies posteriorly, to penetrate a definite distance into the vitreous humor, comes forward and passes through the zone of Zinn directly into the posterior chamber. Here it combines with a third stream, belonging to the same system, which is found in the anterior chamber, and which oozes through the interstices of the pectinate ligament.

The second system, which might be termed the *middle lymphatic system*, though generally classified in the *posterior lymphatic system*, springs from a series of glands throughout the entire chorioidal area and passes to a space between the chorioid and sclerotic, which is filled with trabeculae and is lined with endothelium. The lymph secretion passes outward through the sclerotic by means of the perivascular lymph spaces of the venae vorticosae. Reaching this point, it encounters a second lymph area, which is situated between the outer surface of the sclerotic and the inner surface of Tenon's capsule. Here the current moves backward through Tenon's space until it reaches the outer boundary of the optic nerve, where the fluid goes directly into the supra-vaginal space, to pass back through the optic foramen into the arachnoid cavity.

The third system, or second series of the posterior lymphatic spaces, starting in the perivascular and other lymph cavities of the retina, passes back through the optic-nerve head, where, with numerous additions from the nerve itself, it flows into the sub-arachnoid cavity of the nerve, where an communication is effected with the second system. From this point the combined currents flow into the intra-cranial cavity.

The third, the fourth, the ophthalmic division of the fifth, and the sixth nerves enter the orbit through the sphenoidal fissure. The second, or optic nerve, reaches the orbital cavity through the optic foramen. The second, or the superior maxillary division of the fifth, appears in the orbit between the infra-orbital canal and the malar foramen.

The third, or oculo-motor nerve, after receiving a sympathetic filament in the cavernous sinus, bifurcates into a superior minor branch and an inferior major branch, which enter the orbit between the heads of the external rectus muscle. The upper branch distributes itself to the ocular surface of the superior rectus and levator palpebrae muscles by two twigs, and anastomoses with the nasal nerve. The lower branch distributes itself by three or four twigs to the inferior and internal rectus and inferior oblique muscles, and connects, by a short, thick twig from the last filament, with the inferior part of the lenticular ganglion. It also sends filaments to the sphincter muscle of the iris and to the ciliary muscle.

The fourth nerve, which at times receives filaments from the sympathetic and anastomoses with the fifth nerve, distributes itself to the ocular surface of the superior oblique muscle.

The ophthalmic, or first division of the fifth, divides into three branches—the frontal, the nasal, and the lacrymal nerves. The frontal branch, which is the largest, and is by some regarded as the continuation of the main trunk, enters the orbit through the sphenoidal fissure. It separates into the *supra-orbital* (the larger), which, after passing

through the supra-orbital foramen, terminates in cutaneous, muscular, and pericranial branches, and the supra-trochlear. After passing inward and giving an anastomosing twig to the infra-trochlear branch of the nasal nerve, it leaves the orbit between the pulley of the superior oblique muscle and the supra-orbital foramen, to distribute itself to the corrugator supercilii and occipito-frontalis muscles, and to be lost in the integument of the forehead. The nasal branch, which is second in size, enters the orbit between the two heads of the external rectus muscle, passes inward and forward between the optic nerve and the superior rectus and levator palpebræ muscles to the anterior ethmoidal foramen. Here it re-enters the intra-cranial cavity, to again leave it through a narrow chink, alongside of the crista galli, into the nose, where it divides into an internal and an external series of filaments. As it pursues its course across the orbit, it gives off three series of small twigs: first, the *ganglionic nerve*, which makes its appearance as the main branch passes between the heads of the external rectus muscle to form the superior or long root of the ciliary ganglion; second, the *long ciliary nerves*, which, appearing as the main branch goes over the optic nerve and piercing the back part of the sclerotic after anastomosing with the *short ciliary nerves*, given off from the ciliary ganglion, pass forward between it and the chorioid, to be distributed to the iris and ciliary muscle; and third, the *infra-trochlear nerve*, which appears just as the main branch is leaving the orbit. This branch traverses the orbital cavity along the superior border of the internal rectus muscle to the inner angle of the eye, to supply the palpebral and nasal integument, the orbicularis muscle, the mucus membrane of the conjunctiva, and the lacrymal caruncle and sac.

The lacrymal division, the smallest of the three branches, supposed by some to arise in measure from the trochlear nerve by a fine filament, enters the orbit at the narrowest part of the anterior lacerated foramen, and traverses this cavity along the superior border of the external rectus muscle to supply the lacrymal gland. It sends terminal filaments to the conjunctiva, the palpebral ligament, and the integument of the upper lid. At times it anastomoses with the facial.

Of the four associated ganglia connected with the various divisions of the fifth nerve, the *ophthalmic*, or *ciliary*, or *lenticular ganglion*, and the *spheno-palatine*, or *Meckel's ganglion*, are here of interest. The first, which is a reddish-gray, flattened, quadrate body of about one millimeter in diameter, is enclosed in adipose tissue and is situated in the external and posterior part of the orbit, beneath the external rectus muscle and the optic nerve. Its three roots or branches of communication, which pierce it posteriorly, are the *long ciliary nerve* and the *short ciliary nerve*. The latter is derived from the twig of the motor oculi which supplies the inferior oblique muscle, and the so-called *sympathetic nerve*, which springs from the cavernous plexus of the sympathetic. Ten to fourteen different twigs or branches of distribution appear at the anterior part of the ganglion and run irregularly forward in two groups. The superior bundle is composed of some four or five twigs. The inferior bundle comprises the remainder. These, with the long ciliary nerves, pierce the sclerotic, and run forward in grooves

between it and the chorioid, to be distributed to the iris and ciliary muscle.

The second ganglion is a minute aggregation of nerve-material, somewhat triangular in shape, of about four or five millimeters (about one-eighth or three-sixteenths of an inch) diameter in its wider part. It is deeply situated in the spheno-maxillary fossa, near the spheno-palatine foramen. We are interested here in the ascending branches alone, which penetrate the orbit through the spheno-maxillary fissure, and are distributed to the periosteum. It is by this twig that the connection between the spheno-palatine and the lenticular ganglia is established. By some it is stated that there is a connection between these twigs and the second and sixth nerves.

The sixth, or abducens nerve, first appears in the orbit through the sphenoidal fissure. It passes forward between the two heads of the external rectus muscle and distributes itself to the ocular surface of that muscle.

Each orbital cavity, which is smooth and polished, is lined by a periosteal layer, known as the *periorbita*. This is in direct connection with the intra-cranial periosteum and dura, principally through the canalis opticus and the fissura sphenoida. It directly connects with the periosteum of the facial portion of the skull through the spheno-maxillary fissure, the supra-orbital foramen, the infra-orbital canal, and the canalis zygomaticus facialis. The covering is thin and loosely adherent to the walls of the cavity, except at the various openings, where it becomes thickened and more condensed. Anteriorly, it gives off a fascial layer called the *tarso-orbital fascia*, which is intended for the eyelids. More posteriorly, it sends fibrous processes to Bonnet's and Tenon's capsule, the lacrymal glands, and the sac. Around the border of the optic canal it is condensed into an elliptical ring, known as the *annulus fibrosus*. Upon this ring several of the large extra-ocular muscles take their origin. At the sphenoidal fissure it splits into three divisions, which form openings or passage-ways for the nerves, arteries, and veins.

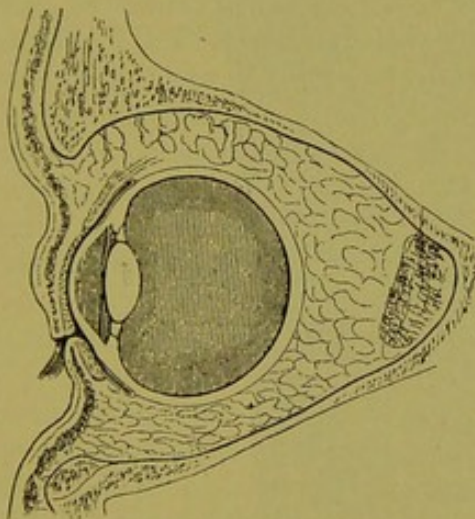
Immediately inside of this there is a thin membranous serous envelope, named the *tunica vaginalis oculi* or *bulbi*. It is divided into two parts. One of these is the *visceral layer*. It is loosely connected with the eyeball by fine connective tissue from the peripheral border of the cornea, where its tissues pass over into those of the ocular conjunctiva back to the optic nerve entrance. The second, or larger area, the *parietal layer*, lines the cavity of the fat-substance. The eyeball and optic nerve are imbedded in it, and move like a joint in a socket. The space between the two layers is known as *Tenon's space*. This space is continuous with the sub-arachnoidal and subdural spaces of the optic nerve. Just anterior to the equatorial region of the globe, the tissue is pierced by the extrinsic muscles of the globe, along which it sends sheath-like prolongations that blend with the ordinary sheaths of the muscles. Along these, with the exception of the superior oblique, where the sheath joins the periosteum at the trochlea, and the inferior oblique, where it is quickly lost in adipose tissue, they gradually disappear. The part anterior to the points of passage of the tendons is

known as *Tenon's capsule*. The posterior portion is spoken of as *Bonnet's capsule*. The anterior portion is much the thinner, and is the more closely adherent to the adjacent tissues. Small elastic and muscle fibres are said to be given off to the circumference of the orbit. These, in combination with the orbital fat and other tissues, serve to make the ocular capsule firmer and less yielding.

The first and the most important of the structures situated in front of the globe, is the muscular apparatus and coverings termed the *eyelids*, or *palpebræ*. They appear, as shown in Fig. 13, as two horizontal folds or crescents, the upper being larger than the lower. Each is covered anteriorly by skin, which is transformed into mucus membrane upon their inner surfaces.

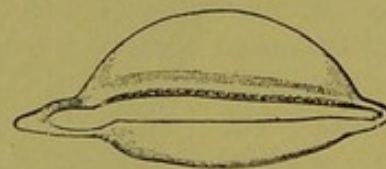Each lid has a disk-shaped framework of interlacing connective tissue, termed the *tarsus*. That of the upper lid is from six to ten

FIG. 13.



Relative positions and sizes of eyelids. (MERKEL.)

FIG. 14.



Shape and size of tarsus. (SCHWALBE.)

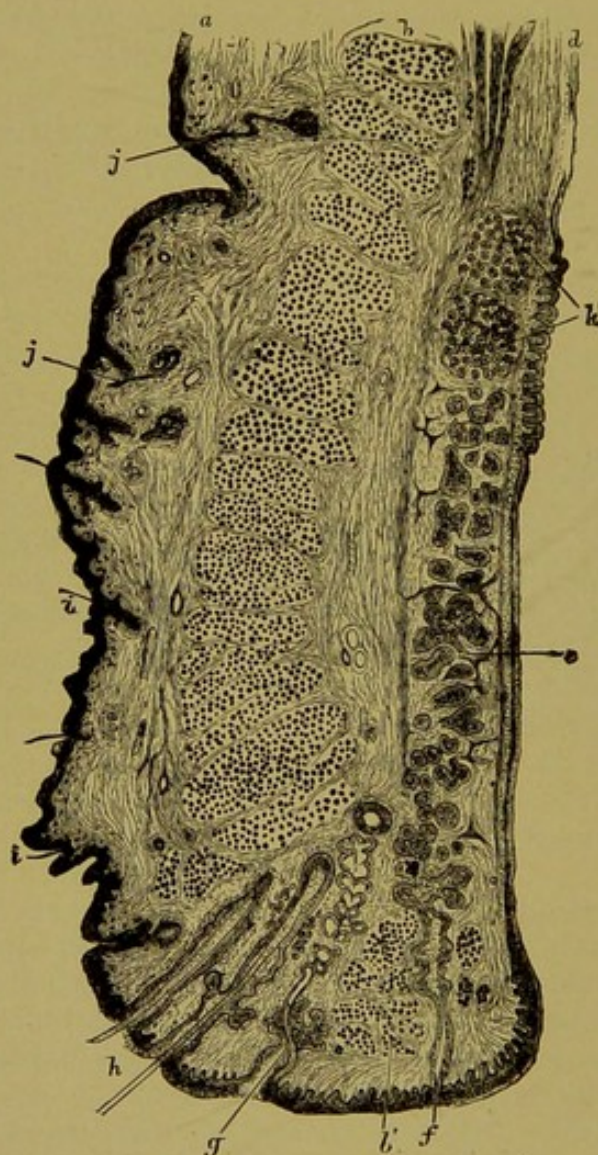
millimeters (about one-third of an inch) in width at its widest portion; and that of the lower lid is three to five millimeters (about one-eighth of an inch). Each tarsus is composed of dense, white fibrous tissue, disposed in all manner of directions and enclosing numerous elongated nuclei. As can be seen in Fig. 14, the upper tarsus is somewhat crescentic in shape, whilst the lower is fusiform.

Each is connected with the fascia of the orbit at its proximal extremity by what is generally known as the *tarsal* or *palpebral ligaments*. As shown in Fig. 14, they are connected at each extremity by narrow bridges of tissue termed the *ligamentum palpebrale internum* and the *ligamentum palpebrale externum*. The former is much smaller, narrower, and somewhat more pointed at its distal extremity. The connection of the tarsi at the inner canthus with the bones of the internal inferior angle of the orbit is made by the two branches of the *tendo palpebrarum* or *oculi*, which is about four millimeters (about one-sixth of an inch) long. In part, it is immediately subjacent to the skin.

The open space intervening between the upper and the lower tarsus,

which averages about thirty millimeters (about one and one-eighth inches) in length in the male adult, is termed the *palpebral fissure*. When the eyelids are open and the axis of vision is directed straight ahead, the vertical width of the fissure usually equals about twelve millimeters (about one-half an inch). The free edge of the upper lid covers about one or two millimeters (about one-twenty-fourth to one-twelfth of an inch) of the upper border of the cornea. This width increases to about

FIG. 15.



Vertical section through upper eyelid. (SCHÄFER.)

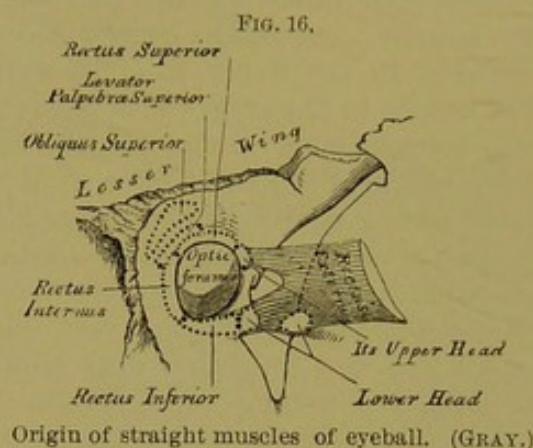
fifteen millimeters (about nine-sixteenths of an inch) when the eye is turned upward. It decreases to seven or nine millimeters (about one-third of an inch) when the eye looks downward. The nasal extremity, which is quite rounded, is known as the *internal canthus* or *internal commissure*. The more acute external angle, which is designated as the *external canthus* or *external commissure*, is generally situated at a higher level than the inner angle. The ciliary border of the upper lid is always the thicker, averaging about two millimeters (about one-

twelfth of an inch) in the centre of the lid and gradually thinning on each side.

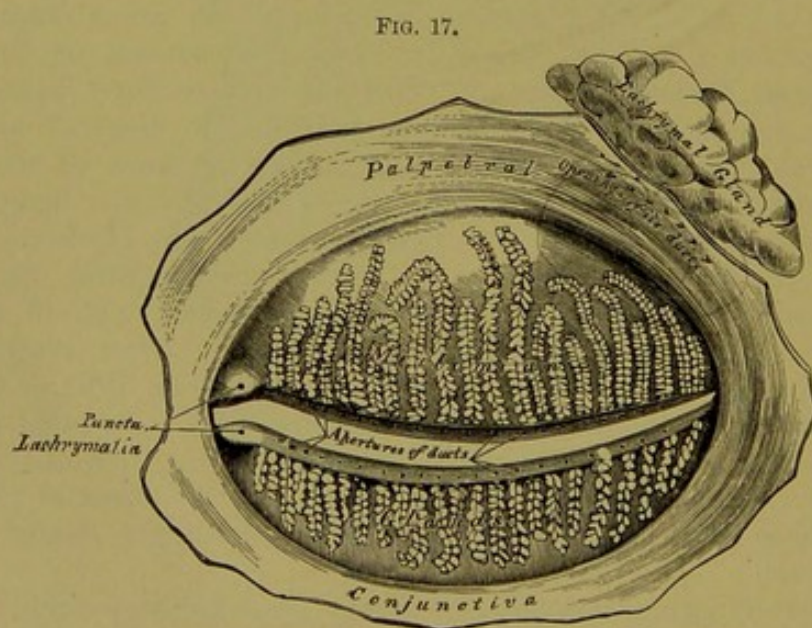
As can be seen in Fig. 15, the posterior surface of the tarsus is so intimately bound to the underlying conjunctival tissue that it is impossible to separate one from the other. Immediately overlying the anterior surface of the tarsus and imbedded in loose connective tissue, in which a few fat-cells can be occasionally recognized, several muscular structures, as can be seen in the sketch at *e*, are situated. The most important of these is known as the *orbicularis palpebrarum*. This is quite a large muscle, encompassing the palpebral fissure in a circular manner. In extent it embraces the entire area of the eyelids, and extends peripherally beyond the orbital rim or base, going outwardly for more than one and a half centimeters (one-sixteenth of an inch) distance beyond the external canthus. It may be divided into two portions, with several small accessory offshoots. The most peripheral, or orbital portion, is composed of a broad circular band of heavy fibres, which is connected with the corrugator supercilii and the occipitofrontalis. The more central portion, known as the *palpebral*, is composed of a series of concentric pallid fibres that take their origin from the anterior portions of the tendo palpebrarum, the crest of the lacrymal bone and adjacent bony wall, and the tissues in the vicinity of the lacrymal sac. It extends in concentric layers around the palpebral fissure to unite by cellular raphé at the external palpebral ligament. Near the free border of the upper lid and close to its inner surface, there are a number of muscular offshoots, which are a continuation of the muscle fibres. Collectively, these are known as the *musculus ciliaris Riolani*. The portion of the muscle fibres posterior to the tendo palpebrarum taking their origin from the posterior branch of the internal palpebral ligament, and passing in front of the lacrymal canal to extend into the most mesial and posterior ring of the orbicularis palpebrarum, is known as the *tensor tarsi* or *Horner's* muscle. A few of the fibres arising from the crest of the lacrymal bone crossing the lacrymal sac, and directed toward the great angle of the eye, are termed the *musculus lacrymalis posterior*. After reaching the latter point, the fibres divide into a superior and an inferior branch, which pass into the upper and the lower eyelids. Another portion, known as the *musculus lacrymalis anterior*, arising from the internal palpebral ligament and its vicinity, surrounds the tarsus at the same point, and extends to that portion of the eyelid which is devoid of connective tissue.

The next important muscle is the *levator palpebræ superioris*. As can be seen in Fig. 16, it arises at the upper portion of the *ligament of Zinn*, which partially surrounds the optic foramen at the apex of the orbit. Running forward along the orbital roof, it is inserted by three layers into and in the vicinity of the entire breadth of the upper edge of the tarsus of the upper eyelid. The fibres of the anterior insertion passing down as fibrous tissue in front of the tarsus, soon become associated with the aponeurotic layer from the superior orbital border, to at last mingle with the fibres of the orbicularis palpebrarum. The second insertion, which is about ten millimeters (three-eighths of an inch) long,

is made directly into the superior border of the tarsus. This branch, which is unstriped and involuntary, is sometimes known as the *musculus palpebralis superior* or the *muscle of Mueller*. An almost similar muscle, extending from the inferior rectus to the lower border of the inferior tarsus and conjunctival sinus, which has received the name *musculus*



palpebralis inferior, has been described. The third insertion, which is the most posterior, and back of the tarsus, attaches itself to the insertion of the superior rectus, and continues forward to the tissues just above the upper conjunctival sinus. It sends out a few lateral branches to the internal and the external orbital walls.



Imbedded in the tarsus of each lid there are, as shown at *f* in Fig. 15, a series of irregular, narrow, vertical tubes. These are known as *Meibomian* or *tarsal glands*. They number some twenty or thirty in the lower lid and thirty or forty in the upper lid. As can be seen in Fig. 17, they are situated in the posterior portion of the connective tissue, and can be plainly seen through the conjunctival tissues. Each gland consists of a number of small cul-de-sacs termed *acini*, which

enter indirectly or directly into a main channel that terminates at the inner edge of the free border of the lid back of the lashes. Both the central duct and some of the larger sacculations are lined with laminated and stratified epithelium. The cells of the walls of the deeper cells of the smaller cæcal appendages more especially, are somewhat columnar and contain roundish nuclei. At some portion of the course of the duct or gland it is embraced by the portion of the muscular fibres of the orbicularis palpebrarum known as the *musculus ciliaris Riolani*. This is shown at *b'* in Fig. 15.

There are numerous other glandular structures which are generally either tubular or racemose in character. They are found in many places throughout the entire lid substance. In the sub-epithelial tissue, in close proximity to the conjunctival sinuses, especially of the upper lid, and near the tarsal border, they are quite plentiful. Many of these are known as the *acino-tubular glands of Krause* (seen at *k* in Fig. 15). They are supposed to act as auxiliary lacrymal glands. At the free edge of the lids, usually between the line of the openings of the excretory ducts of the Meibomian glands and that of the cilia, or opening directly into an adjacent hair follicle, are situated the so-called *glands of Moll*; one of these is well shown at *g* in the same figure. Commencing peripherally as curved and rather broad tubes, they often rapidly become narrower and then wider, as they pass up into the substance of the lid. They either open into the follicles of the cilia or terminate in constricted bulbar or racemose extremities. Lined for the most part by epithelial scales of a cubical variety, which are arranged over a fibrous material in which spindle cells containing elongated nuclei are distributed, they at times are found to contain a mass of homogeneous and granular matter.

In a number of places throughout the skin area, as shown at *j* in Fig. 15, the coiled tubular congeries of the ordinary sudoriferous or sweat glands can be seen. Irregularly distributed throughout the overlying cutis, can be noticed numbers of very fine hairs (*i, i*), which project upon the delicate skin surface of the lids. Many of these are apparently devoid of any sebaceous glands at their follicles. Along the outer edge of the free margin or *ciliary border* of each lid, are situated one or more rows of short, strong hairs termed the *cilia* or *eyelashes* (shown at *h*). Slightly curved and more numerous and larger in the upper lid, they oppose one another in their convexities. Those of the upper rows average from eight to twelve millimeters (about one-third to one-half of an inch) in length. Their roots are about two or three millimeters (one-twelfth to one-eighth of an inch) long. The external edges of the ciliary border are rounded, whilst the bulbar edges are sharply angled.

The portion of the eyelids in apposition with the eyeball is covered with a mucus membrane called the *conjunctiva*. Closely attached to the posterior surface of the tarsus and to a submucus material where the tarsal tissue ends, it passes around a cul-de-sac known as the *fornix conjunctivæ*, to cover a part of the anterior surface of the globe.

The anterior surface of the lids is composed of extremely delicate skin, that of the upper lid being continued from the brow and that of

the lower lid from the cheek. It is loosely attached to the underlying cellular tissue, in which a number of minute sudoriferous glands and fine bulbar extremities of hairs can be found. Both the epiderm and corium are extremely thin, whilst the papillæ are very small. The surface of the skin is wrinkled into horizontal folds, the most important of which in each upper lid is the so-called *sulcus orbito-palpebralis superior*, produced by the superior border of the dense tissue of the tarsus pushing its way back into the orbit during the action of the elevator muscle of the upper eyelid. In the lower lid there is a corresponding, though less prominent, fold known as the *sulcus orbito-palpebralis inferior*. Beneath it, at varying distances, there is a second less marked fold known as the *sulcus palpebro-malaris*. The portion of the upper lid above the superior orbito-palpebral fold is known as the *orbital portion* of the lid, whilst the broad, elongated, curvilinear area above this, corresponding in position to the upper rim of the circumference of the orbit, is the *superciliary region*. In this region are found the *supercilia* or *eyebrows*, which consist of short, thick hairs that are directed obliquely up and out and then down and out from the median line.

Far to the nasal side of the free border of both the upper and the lower lids, at about five or six millimeters (three-sixteenths to one-fourth of an inch) distance from the inner canthus, there is a small elevation called the *papilla lacrymalis*. Upon this is situated the entrance into the excretory portion of the lacrymal apparatus—the *punctum lacrymalis*. This leads into a minute canal, known as the *canaliculus lacrymalis*, which passes through the substance of the lid to unite with its fellow and empty into the temporal side of the lacrymal sac.

The arterial circulation of the lids is chiefly obtained through the naso-frontal branch of the ophthalmic artery, which subdivides into the superior and the inferior median palpebral arteries. These branches, anastomosing with the lacrymal, the superficial temporal, and the angular—especially the last—form a series of loops or circles around the free edge of the lids.

The venous blood is carried off through the superior and the inferior palpebral veins, which are connected with the anterior facial vein on the median side and with the facial and the temporal veins on the temporal side.

The motor nerves of the lids are, with the exception of a few fibres from the sympathetic supplying Mueller's muscle, derived from the seventh or facial, which supplies the orbicularis palpebrarum, and the third, which supplies the levator palpebræ superioris. The sensory nerve fibres are offshoots from the trigeminus.

The *conjunctiva*, forming a sac known as the *conjunctival sac*, and receiving its name from the fact that it in reality serves in great measure to join the lids to the globe, practically divides itself into an upper and a lower portion. Each of these may be subdivided into a tarsal part, known as the *palpebral* or *tarsal conjunctiva*; an ocular part, which is termed the *bulbar* or *ocular conjunctiva*; and a third, or intervening orbital portion, connecting the two, known as the *fornix* or *sinus conjunctiva*.

Commencing at the free borders of the lids, and reflected into the lining membrane of the ducts of the Meibomian and lacrymal glands and the lacrymal canals, it extends over the entire inner palpebral surfaces from the upper and lower cul-de-sacs, and is reflected over the sclerotic (known by some as the scleral conjunctiva), just in front of the ocular equator, to cover the anterior face of the eye up to, at times, slightly beyond the margin of the cornea. It is continued across this portion of the eyeball as an epithelial layer alone. At the cul-de-sacs, or *folds of transition*, the membrane becomes thicker and forms two folds known respectively as the *plica palpebralis superioris* and *plica palpebralis inferioris*. The upper is much the deeper of the two. Near the inner canthus there is a thin, almost vertical fold, containing at times, according to some, cartilaginous material. It is semilunar in shape, with its concavity directed toward the cornea. This is known as the *plica semilunaris*, which is considered to be rudimentary to the third eyelid, or *membrana nictitans*, as seen in some animals. Just at the internal canthus, the mucus membrane forms, by a reduplication, a small, roundish, pale-red prominence lying on the semilunar fold and projecting forward toward the palpebral fissure. From its resemblance to a minute piece of flesh it is known as the *caruncula lacrymalis*. This prominence is composed of a congeries of follicles which are somewhat similar to the Meibomian glands and the glands of Moll. These are bound together by connective tissue, which is interspersed with sebaceous glands and fat-cells. The whole is covered with epithelium. Often a number of minute hairs can be found in its substance. This fleshy growth, with the underlying semilunar fold, rests upon the tendo oculi. It is bound rather tightly to the tissues lying beneath. Superficially, it encloses a small triangular area at the inner angle of the eye which is spoken of as the *lacus lacrymalis*.

The palpebral or *tarsal conjunctiva* is usually reddish-yellow in tint, the red hue being dependent upon its minute vascular channels. It is attenuated, translucent, and firmly adherent to the overlying tissue. Its substratum or framework consists of a peculiar glandular connective tissue, which becomes reticulated by forcing itself between the fibrillary cellular tissue of the inner surface of the cartilage and the overlying epithelium. Coetaneous with the appearance of the adenoid tissue, and more especially at the outer canthus and along the orbital edge, definitely outlined excrescences or papillæ, ridges, and folds (*Steida's system of grooves*, which are not well, or even at all, seen in the young), develop irregularly. The epithelial covering, which varies in different individuals, is composed of several layers of cells, the most superficial of which is pavement-like in appearance, whilst the deeper ones are generally cubical or cylindrical in form. Beneath this lowest layer, and tightly adherent to the tarsus, there is a thin stratum of fibrous tissue, which becomes looser and denser at the fornix. This epithelial layer is said to be rich in elastic fibres. In this fibrous layer, immediately underlying these excrescences and free spaces, and more abundant toward the orbit, are, in older subjects, according to some authors, a limited number of so-called lymph follicles, said to be like those described by Bruch, as seen in the eye of the ox. These are

composed of small ventless sacules, which contain a network of capillaries, and are infiltrated with pallid, round, nucleated cells.

The bulbar or ocular conjunctiva, which is more extensive over the superior portion of the anterior face of the eyeball, is very pallid. In most Caucasian subjects it presents an almost white, translucent appearance. It is so extremely thin and so loosely attached to the underlying Tenon's capsule that it is freely mobile over this membrane. As it passes toward the corneal edge over the front face of the globe, it becomes increasingly adherent and thinner. Near the border of the cornea it is quite dense and is tightly attached to the sclerotic as a broad band, which is two or more millimeters (one-twelfth of an inch or more) in width. It is wider above and below. This annulus, or ring, which in most instances extends beyond the corneal edge, is known as the *limbus conjunctivæ* or *limbus corneæ*. The conjunctiva, now reduced to its epithelial layer with an extremely thin underlying structureless membrane, forms the outermost covering of the cornea.

The entire bulbar conjunctiva, according to most authors, devoid of glands, excrescences, rugæ, and folds, is composed in greater part of superimposed plates of epithelium, with an underlying basement membrane. The portion over the sclerotic is sometimes termed the *scleral conjunctiva* in contradistinction to that which is over the cornea, which is designated the *corneal conjunctiva*.

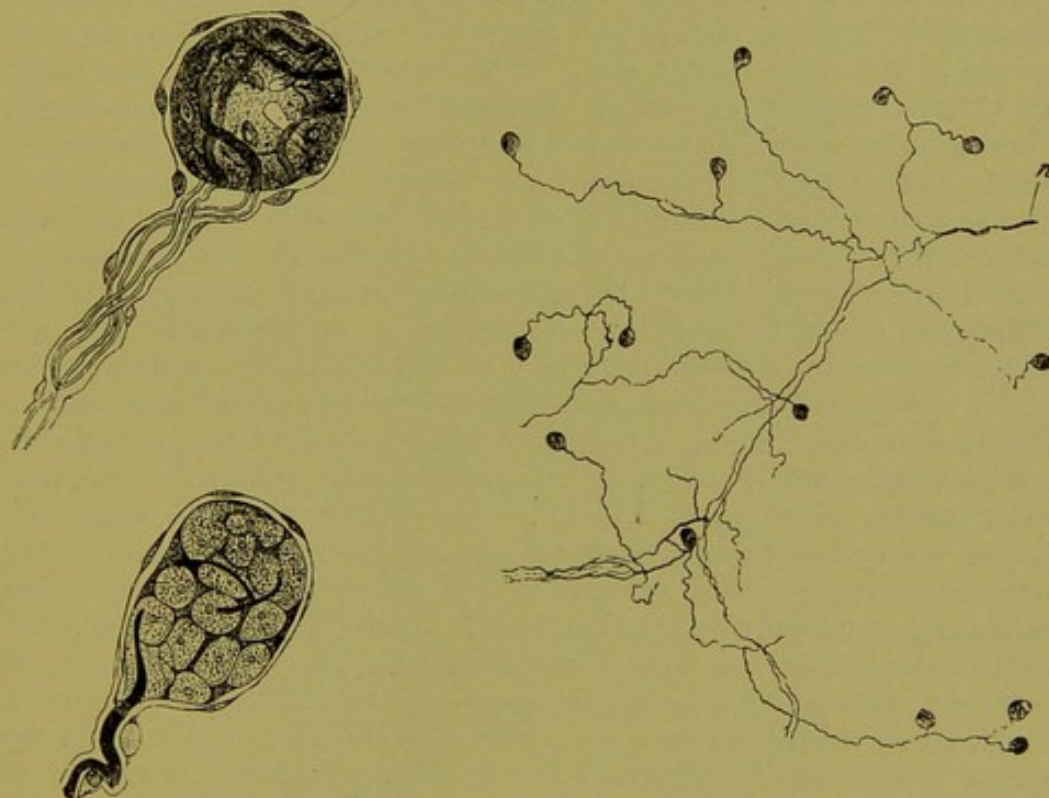
The conjunctival cul-de-sacs, or *palpebral sinuses*, are, in reality, exaggerations of the tarsal portions. The papillæ in these situations are more numerous, and at times are coalesced into fold-like prominences or plica. The connective-tissue material is also coarser, more widely separated, and contains many bundles of fine elastic fibres. Beneath the epithelial layer, with its outermost cylindrical, and underlying globular cells, a few large glandular structures, the so-called *acino-tubular glands of Krause*, are found. Especially is this so in the upper fornix, in close proximity to the orbital border of the tarsi. These, which are much more numerous in the upper cul-de-sac, are believed, as previously explained, to possess many of the anatomical and physiological characteristics found in the lacrymal gland. The excretory ducts of the lacrymal gland itself, six to twelve in number, pass through the tissues of the upper conjunctival fornix at its temporal part, near the external angle of the eye. This portion of the membrane varies greatly in size in different individuals, being much larger and deeper superiorly and laterally.

The vascular system of the conjunctiva, which freely communicates with that of the lids, and which is very rich in blood, obtains its arterial supply from the ophthalmic artery. This is done by means of branches from the lacrymal, which anastomose with the supra-orbital, the palpebrals, the frontal (one terminal), and the naso-dorsal (a branch of the other terminal), with some small twigs from the superior and the inferior muscular branches. The veins which return the blood from these tissues are the many small tributaries, more or less corresponding to the arterial branches, which are at last received into the ophthalmic and facial veins. At times there is a second ophthalmic trunk formed by the association of the venous branches and twigs along the orbital

floor, which either connects with the ophthalmic vein proper or pursues an individual course to the corresponding cavernous sinus.

The bulbar portion of the membrane around the limbus conjunctivæ is also supplied by the anterior ciliary arteries, thus offering a comparatively free arterial anastomosis of the so-called *anterior conjunctival vascular system* of Van Woerden, with the blood which circulates in the anterior segment of the globe. Mingled with the superficial vessels can be seen, more advantageously during the commencement of some acute conjunctival inflammation, large anastomosing conjunctival twigs, which

FIG. 18.



Spheroidal end-bulbs (clavate corpuscles) of Krause. (LONGWORTH.)

are outshoots (the so-called *posterior conjunctival vascular system* of Van Woerden) from the palpebral arteries. Intimately inosculating at these points, there is a corresponding series of fine veins. The lymphatics are prevalent. They are more numerous in the bulbar portion of the membrane, forming an irregular annulus near the corneal margin.

The nerves are the palpebral offshoots from the frontal, the lacrymal, and the sub-trochlearis. These are derived from the first division of the fifth pair. They, like many other afferent nerves of the mucus membranes in man, terminate in the so-called *spheroidal end-bulbs* (*clavate corpuscles*) of Krause. These, as can be seen in Fig. 18, are composed of a core-like mass of granular matter made up of polygonal and elongated cells, amongst which are the single or branched terminations of the axis-cylinders, the whole being enveloped in a connective-tissue capsule, which is practically a continuation of the sheath of Henle.

The *lacrymal apparatus* divides itself into a secretory and an excretory portion. The former consists of the lacrymal glands and a number of follicles situated in the outer part of the superior fornix. The latter is made up of the canaliculi, the lacrymal sacs, and the lacrymo-nasal ducts.

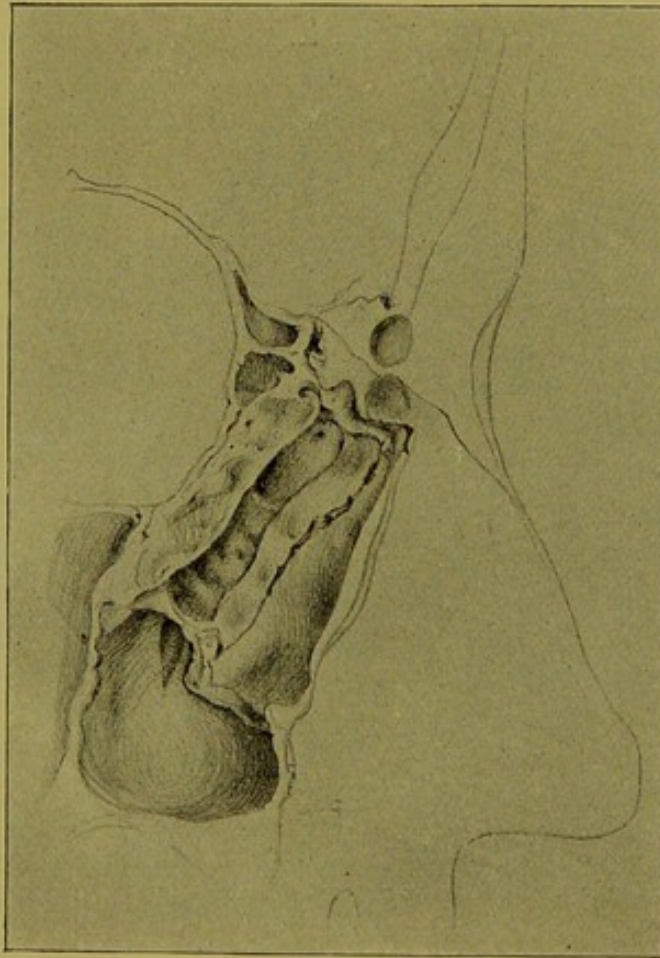
The *lacrymal gland* consists of two lobules—the *major*, or superior, and the *minor*, or inferior. These are separated by a thin wall of fascia that arises from the levator palpebræ superioris and is inserted into the temporal edge of the circumference of the orbit. The inferior, or smaller lobule, is known as the *accessory lacrymal gland*. It rests upon the superior cul-de-sac. The entire gland is situated in a depression called the *fossa glandulæ lacrymalis*. It is attached to the periosteum of the temporal extremity of the upper orbital base, just inside the external angular process of the frontal bone, by fine fibrous bands. These glands, which are enveloped in a common covering of connective tissue, and surrounded by numerous minute racemose structures of similar structure, are composed of alveoli somewhat similar to those found in the ordinary acino-tubular salivary glands. The larger cluster is about two centimeters (about three-fourths of an inch) long, ten to twelve millimeters (about three-eighths to one-half of an inch) wide, and five millimeters (about three-sixteenths of an inch) thick. It is yellowish-red in tint and almond-like in shape, with its concavity directed down and in. The smaller mass, which is about one-half the size of the main gland, and contains about one-third its volume, is tightly adherent to the posterior portion of the upper eyelid. It rests partly upon the upper surface of the eyeball and partly upon the upper edge of the fibres of the external rectus muscle. On account of the reflection of conjunctiva separating in measure a small portion of the anterior part of the gland from the main body, the mass thrust forward is sometimes known as the *palpebral portion of the lacrymal gland*. From both lobules combined, six to twelve fine tubules pass downward and forward under the mucus membrane, to perforate the upper conjunctival fornix at its outer part, through six to ten orifices arranged laterally. Each duct is composed of a basement membrane with numerous elastic fibres. Upon the inner surface of these there are layers of epithelium. The outer portions are covered with connective tissue which contains elongated nuclei. By some it is thought that there is an excretory duct connecting the two tubes. Others assert that some of the secretion finds its way into the lower cul-de-sac by a separate and special system of ducts, which come from the lower outer part of the combined gland.

In addition to these structures, the acino-tubular glands of Krause, situated, as previously described, in the conjunctival cul-de-sacs, with the general mucus surface of the conjunctiva itself, assist in the lacrymal function.

The watery secretion having served its purpose, is at last passed into the excretory portion of the apparatus. This part of the mechanism commences as two minute whitish openings, known as the *puncta lacrymalia*. Each is placed on the summit of two small elevations (the *papillæ lacrymalia*) situated on the free margin of the lids about six millimeters (one-fourth of an inch) from the inner canthus. They are known

respectively as the upper and the lower punctum, the latter being the smaller and situated more to the temporal side. Passing directly from these orifices, which are surrounded by a sphincter-like band of muscular fibres, and are in apposition with the ocular globe, are two fine tubules, termed the *canaliculi lacrymales*. The lower is the larger in calibre and the shorter in length. They extend respectively up, in and down, and down and in, to converge and unite, as may at times be seen in other excretory channels, into a common orifice which passes directly

FIG. 19.



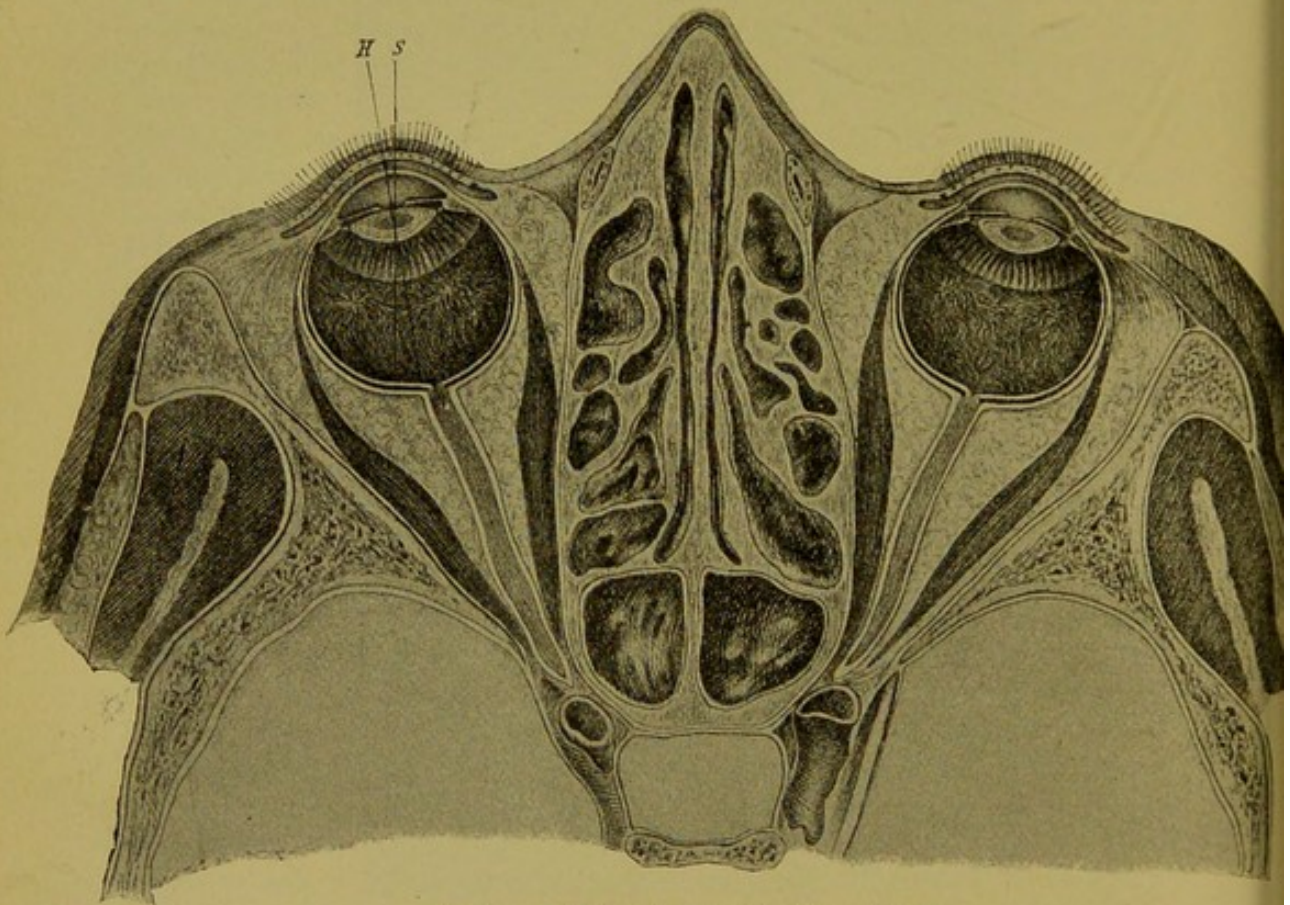
Section of lacrimal sac. (ARLT.)

into the lower outer wall of a receptacle or cavity known as the *lacrymal sac*. Their lining mucus membrane is much more pallid than any other part of the lacrymal tract. As can be seen in Fig. 19, the lacrymal sac forms an irregularly ovoid cavity, which though usually about twelve millimeters (one-half of an inch) in length, is of variable size. Lying immediately subjacent to the facial integument, it is lodged in a groove situated between the lacrymal bone posteriorly, and the nasal process of the superior maxillary bone, anteriorly. Practically serving as a receptacle for the tears, it is continued below into the *lacrymo-nasal duct*. It consists of a lining mucus membrane thrown into minute valvular folds which is continuous with that of the conjunctiva and the pituitary membrane of the nose. Covered by an

elastic fibrous coat, which is closely attached to the underlying periosteum, the whole is covered posteriorly with a muscle-structure termed the *tensor of the lid*. It is crossed anteriorly by a fibrous expansion from the *tendo oculi*, which is fastened to the crest of the unguis bone. These two structures, with the orbicularis, serve to keep the puncta directed against the globe. By many, the lining membrane, which, like that of the duct, is thick and rich in vascularity, is considered to be ciliated in its outer or cylindric layer.

The lacrimo-nasal duct extends irregularly downward, outward, and backward from the lacrymal sac to the inferior meatus of the nose.

FIG 20.



Relative positions of eyes and orbits. (ARLT.)

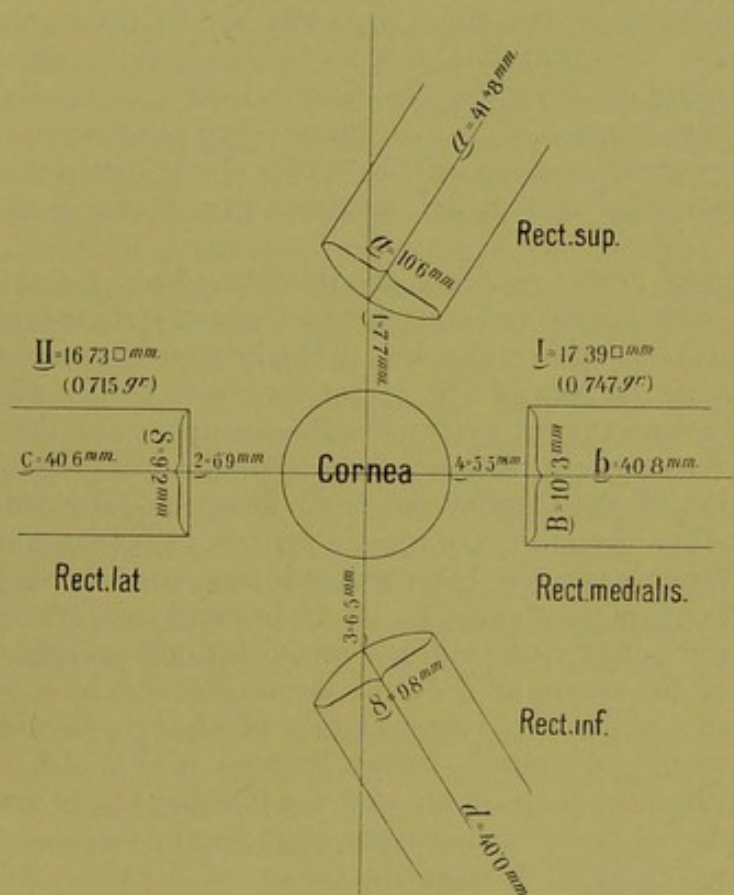
As can be seen in Fig. 19, it is, with the sac, about twenty to twenty-four millimeters (about three-fourths to one inch) in length, and from three to five millimeters (about one-eighth to three-sixteenths of an inch) in diameter. According to most authors it is composed of an internal layer of ciliated epithelium, which is covered with a fibrinous periosteal layer of the same character as that which is found in the lacrymal sac. Over this is a lamellated pavement-epithelium and many racemose glands. It lies in a bony canal formed by the lacrymal, the superior maxillary, and the inferior turbinated bones. Just after it leaves the lacrymal sac to enter the osseous canal, it is thrown into several folds. Narrowing as it goes through the bony canal, it again expands and is again thrown into folds after leaving the canal. It terminates in an oval

valve-like orifice which passes directly into the anterior wall of the inferior nasal meatus. Between the periosteum and the mucus membrane there is a dense venous plexus, which plays an important rôle in the pathological processes of the apparatus.

The arterial and venous circulations are mostly carried on through minute stems from the terminals of the ophthalmic and neighboring vessels.

The nerves are in great measure derivatives from the infra-trochlear and the first division of the fifth.

FIG. 21.



Relative positions of insertions of the straight muscles. (MAUTHNER.)

As shown in Fig. 20, and as explained on page 29, the eyeball is situated in the anterior portion of the orbit, and occupies an excentric position up and out. Resting on its soft cushion of orbital tissue, attached anteriorly to the broad expanse of freely yielding conjunctivæ, and supported posteriorly by the stiff, though slackened optic nerve, it is capable of much freedom in movement by a set of long, thin muscular structures which, with one exception, have their origin at or near the apex of the orbit, and their insertions on the forward portion of the globe.

Commencing with the most important and most powerful, the *internal rectus muscle*, which, as can be seen in Fig. 16, arises by a single tendon conjointly with the inferior rectus from the ligament of Zinn,

at the inner edge of the orbital border of the optic foramen. It passes directly forward and inward along the orbital wall and through the cellulo-fatty tissue of the orbit. Turning towards the equator of the globe, it pierces the capsule of Tenon at this point and follows the convexity of the globe as a broad tendinous band of about ten millimeters (three-eighths of an inch) in width. It is inserted into the sclerotic (as can be seen slightly modified in Fig. 21¹) at about five and a half millimeters (three-sixteenths of an inch) from the inner border of the cornea. The centre of the tendon is on a level with the centre of the cornea. The entire length of the muscle is about forty and eight-tenths millimeters (one and seven-eighths inches). As it passes forward, posterior to the globe, it sends a few bands of connective tissue through the orbital tissues to be attached to the periosteum. Whilst pursuing its way along the globe it throws out fascial prolongations into the capsule of Tenon, these being particularly pronounced around the superior and the inferior border of the insertions. Its ocular surface is covered with a smooth membranous extension of the fibrous envelope.

The *external rectus muscle* is the third longest of the entire straight series, being about forty and six-tenths millimeters (about one and three-fourths inches) in length, and is next in thickness to the preceding muscle. It arises, as can be seen in Fig. 16, at the outer border of the orbital edge of the optic foramen, by two heads—the upper and the lower. The latter head also arises in measure from a small bony prominence at the inferior border of the anterior lacerated foramen. Running along the temporal wall of the orbit, the muscle reaches the equator of the globe, perforates Tenon's capsule, becomes tendinous, and curves around the outer convexity of the eyeball. It is inserted into the sclerotic at about six and nine-tenths millimeters (about one-quarter of an inch) distance from the centre of the outer corneal border, by a band of nine and two-tenths millimeters (three-eighths of an inch) in width.

The *inferior rectus muscle*, as can be seen in Fig. 16, arises in the ligament of Zinn in conjunction with the internal rectus muscle, at the inferior border of the orbital margin of the optic foramen. It passes downward and forward through the tissues of the orbit, to curve upon the globe and penetrate the enveloping capsule in the same manner as the previously described straight muscles. It is obliquely inserted into the sclerotic at about six and a half millimeters (about one-fourth of an inch) distance to the median side of the anterior vertical meridian of the eye. It is inserted by a tendinous band of about nine and eight-tenths millimeters (slightly less than three-eighths of an inch) in width at about five to seven millimeters (about three-sixteenths to slightly less than one-third of an inch) from the lower border of the cornea. The external extremity of the tendinous attachment is about two millimeters (one-twelfth of an inch) further removed from the cornea than the internal. The entire length of the muscle is, as noted in the sketch, about four centimeters (one and five-eighths inches).

¹ It is here designated by the abbreviation Rect. medialis (rectus medialis of the European writers).

The *superior rectus muscle* is one of the thinnest, the longest (forty-one and eight-tenths millimeters—slightly more than one and three-fifths inches), and the narrowest in places. As can be seen in Fig. 16, it takes its origin from the superior portion of the ligament of Zinn, and passes forward and inward at about an angle of twenty degrees to the optic axis along the orbital roof. Penetrating Tenon's capsule near the ocular equator and giving off fascial prolongations, it follows the upper convexity of the globe to be obliquely inserted into the sclerotic about seven to eight millimeters (about seven-twenty-fourths to one-third of an inch) from the upper corneal border by a tendon ten and six-tenths millimeters wide (slightly more than three-eighths of an inch), which has its temporal border about two millimeters (about one-twelfth of an inch) further away from the cornea than the internal border.

The *superior oblique* or *trochlearis muscle* is fusiform in shape. It arises, as can be seen in Fig. 16, near the orbital apex, just up and in from the position of origin of the *levator palpebræ superioris*, and passes forward, upward, and inward along the upper inner angle of the orbit, to curve as a narrow tendinous cord through the trochlea, or pulley, which is situated in a depression just under the internal angular process of the frontal bone. After leaving the pulley it expands and is reflected backward and outward subjacent to the superior rectus muscle. It is inserted as a flat, tendinous band about six millimeters (one-fourth of an inch) in breadth, into the outer, upper, and posterior part of the sclerotic in such a position that the posterior extremity of the ocular insertion is situated about seven millimeters (about seven-twenty-fourths of an inch) up and out from the point of entrance of the optic nerve into the globe. As its tendon passes through the trochlear-like ring, it, as well as the inner surface of the fibro-cartilaginous pulley, is covered with a thin, delicate fibrous coat, which encloses a fine synovial membrane.

The *inferior oblique muscle* is also thin and narrow. It takes its origin at the anterior portion of the inferior internal angle of the orbit in a depression in the superior or orbital surface of the superior maxillary bone just external to the lacrymal canal. Passing for five or six millimeters (three-sixteenths to one-fourth inch) distance outward and backward along the orbital floor under the inferior rectus muscle, it changes its course upward so as to run between the external rectus muscle and the globe. It is inserted into the sclerotic by a broad and short tendinous band of about one centimeter (about three-eighths of an inch) in width, just beneath the insertion of the superior rectus muscle, in the upper posterior portion of the temporal side of the globe. The posterior and inferior ends of the insertion are but four or five millimeters (one-sixth to three-sixteenths of an inch) from the entrance of the optic nerve into the globe.

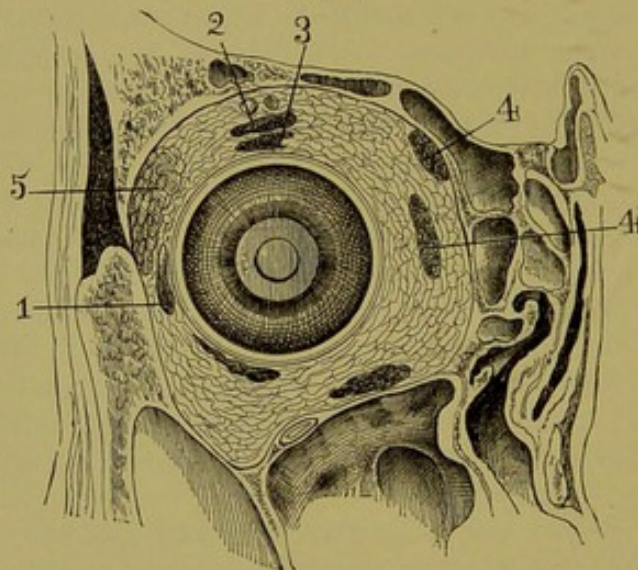
As the entire group of muscles pass through the orbital tissue just anterior to the ocular equator, they present in cross section the comparative sizes and positions as shown in Fig. 22. At this situation the internal rectus muscle, shown at the lower 4, is the largest, whilst the inferior rectus muscle is the next. The superior rectus muscle (3), the inferior obliquus muscle, and the levator palpebræ (2) are quite flat and

thin. It can also be noticed how compact and how close the superior oblique in this position (4) lies to the upper inner orbital wall. The comparative difference in size between the internal rectus and the external rectus (1) is also plainly manifest.

As before explained, the nerves that innervate these muscles are the third, the fourth, and the sixth. The third nerve goes to the internal, the inferior and the superior recti, and the inferior oblique. The fourth nerve supplies the superior oblique muscle. The sixth nerve goes to the external rectus muscle.

The deep origin of these nerves, from which nuclei fibres pass to the higher brain-centres in some portion of the motor area of the cerebral cortex, is to be found in the floor of the aqueduct of Sylvius. After passing through the pes pedunculi and encountering the substantia nigra and red nucleus of the tegmentum, the oculo-motor nerve roots, as can be seen

FIG. 22.



Relative positions of the ocular muscles just anterior to the ocular equator. (MERKEL.)

in Fig. 23, spread out from the thick nerve-trunk to form a series of nests of small nuclei which bear definite relations to one another. According to Starr, the grouping, commencing anteriorly, is as follows :

Sphincter iridis.	Musculus ciliaris.	Median line.
Levator palpebrae.	Rectus internus.	
Rectus superior.	Rectus inferior.	
Obliquus inferior.		

These several groups of multipolar ganglion cells are subdivided into an anterior, median, and posterior nucleus. The median nucleus, which is supposed to belong to the internal rectus muscle, crosses the median line, as can be seen in the illustration, to connect with the nuclei of its fellow, as well as with the nucleus of the external rectus. It is probable, however, that the various nuclei are connected in due proportion to the combined physiological workings of the peripheral muscles ; this being in measure proven by the facts that Edinger has recognized whole series of longitudinal fibres subjacent to the floor of the fourth ventricle that seem to connect all of the individual nuclei, and that

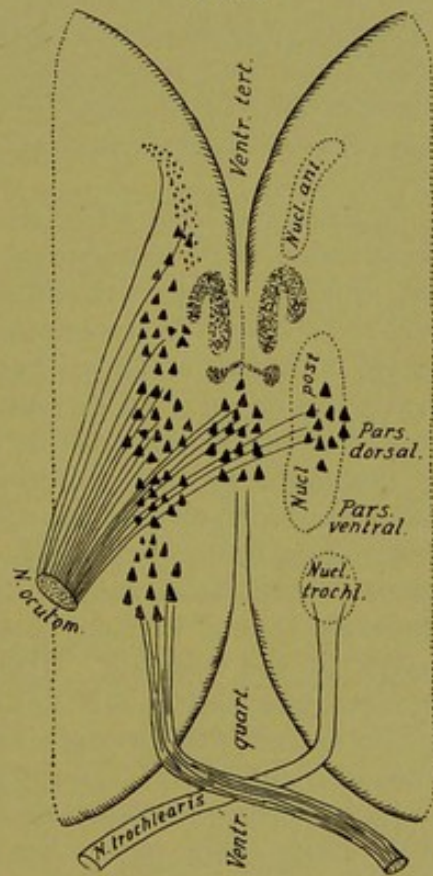
Spitzka has found a series of such fibres situated anteriorly which are crossed.

In front of the anterior portion of the aqueduct, the fourth nerve, as seen in Fig. 23, undergoes decussation and enters the opposite half of the floor to pass to its respective nuclear nest.

As above hinted, the nuclear nidus of the sixth nerve also lies on the floor of the fourth ventricle, just anterior to the centre of the median line.

We now come to the eyeball itself. The most external coat, the *sclerotic* or *sclera*, is so termed upon account of its hardness. In fact,

FIG. 23.



Nuclear origin of third and fourth nerves. (EDINGER.)

it is the skeleton of the eye. It is extremely tough and strong, being the thickest—one to one and a quarter millimeters (one-twenty-fourth of an inch)—posteriorly, and the thinnest—three-tenths to four-tenths of a millimeter (less than one-fiftieth of an inch) immediately behind the points of insertion of the external straight muscles. It is composed of a dense network of interlacing bundles of white fibrous tissue and elastic fibres, which are mingled together with a number of minute nucleated cells. These cells are of the spindle-shaped variety. At times they are pigmented, especially in the negro. These lie in cell-spaces, and are bound together by a homogeneous cement which holds a system of minute and irregular lymphatic channels.

Posteriorly, the external layers curve circularly around the optic-nerve entrance. Here the deeper of the two underlying ones passes

directly between the nerve fibres themselves and forms a sieve-like membrane—the *lamina cribrosa*. At this point, the middle layers coalesce with the sheath of the optic nerve. Anteriorly, around the limbus corneæ, there is a similar circular series of the inner layers, whilst other fibres pass directly into the cornea and are gradually converted into corneal tissue. Equatorially, the annular character of the posterior and anterior fibres becomes less and less marked, although, as a rule, the external striæ are said to be meridional and the inner ones equatorial throughout the entire coat.

Externally, the surface of the coat is comparatively smooth. It is separated anteriorly from the overlying conjunctival membrane by a loose layer of connective tissue, which is termed by some the *episcleral layer*. This layer becomes much thickened and increased in vascularity around the corneal limbus. At the position where the tendons of the extra-ocular muscles insert themselves, fine fibrillar prolongations, which perforate the scleral tissue at acute angles, can be seen. These are soon lost to view.

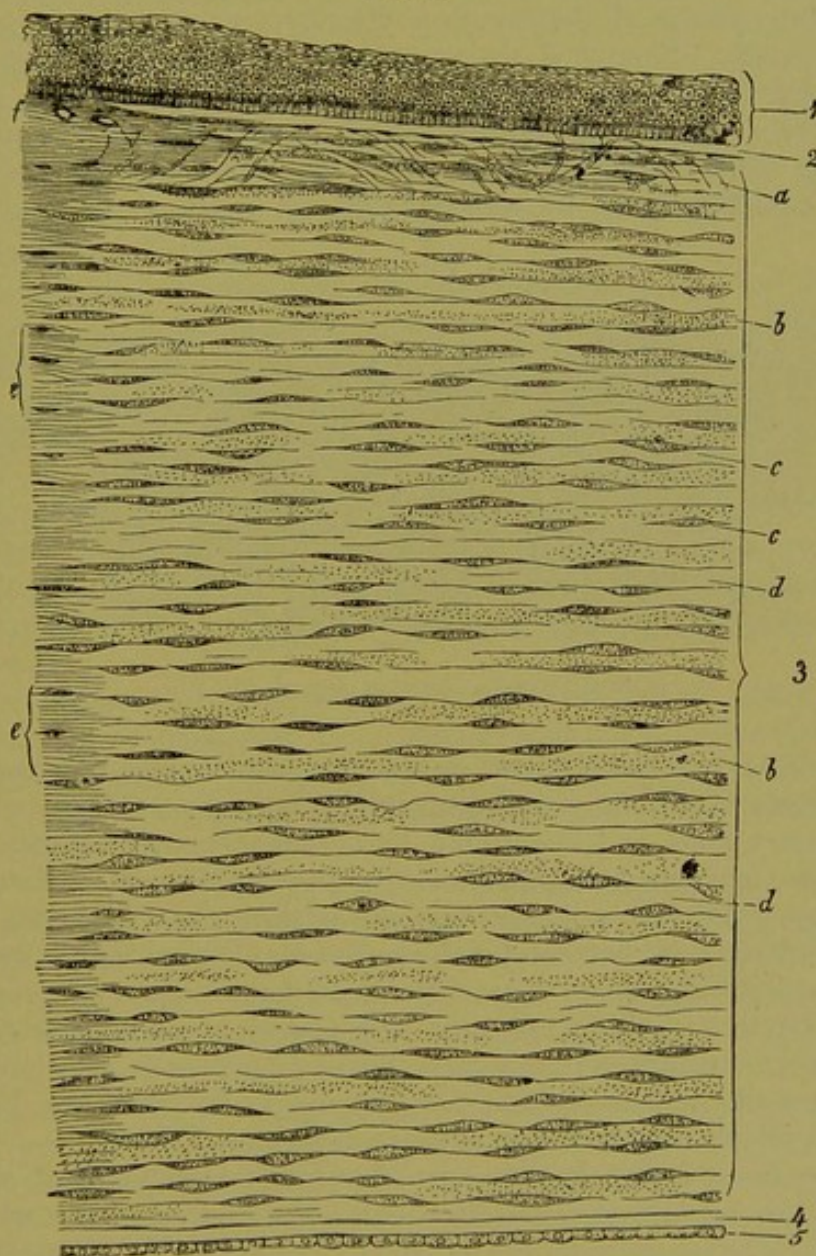
Internally, the coat is traversed by a series of fine grooves, which are intended for the transmission of the ciliary nerves. Beneath, there is a delicate endothelial lining of connective tissue, elastic fibres, and variously sized pigmented cells, known as the *lamina fusca*. The inner wall of this lining is coated with cells of an epithelial type. This thin membrane, which generally has its pigment increased around the internal borders of the optic-nerve entrance, forms the external wall of the so-called *perichorioidial lymphatic space*. Anteriorly, in the region of the ciliary processes, and posteriorly, around the optic nerve, the entire coat is tightly attached to the underlying chorioid. Posteriorly, about fifteen to eighteen degrees to the nasal side of the macula lutea and two to three degrees above the line of horizon, there is an aggregation of a series of fine openings in the sclerotic. These are comprised in an area of little more than one and a half millimeters (about one-thirty-sixth of an inch) in diameter. Through them, the optic-nerve bundle makes its entrance into the globe. In the centre of this sieve-like opening there is a larger aperture termed the *porus opticus*, through which the retinal vessels make their way. Besides these openings, there are a number of canals which afford entrance and exit to vessels and nerves, each of these canals being surrounded by a layer of elastic fibres. The two principal vascular circles of the membrane are the posterior and the anterior vascular zones or circles. The posterior surrounds the optic-nerve entrance. The anterior encircles the cornea. The entering nerves practically occupy the same position. Between these two great zones or circles, the texture of the membrane is permeated by a capillary network. It is perforated at points with small oblique canals which are intended for the transmission of deeper penetrating vessels and nerves. At the equator of the globe are the openings for the vorticosse veins of the chorioid, these, as the other vessels, being enclosed in their respective lymph-sheaths.

Just behind the corneal border, in the anterior part of the coat, there is an annular venous plexus lined by an elastic membrane of fine filaments. This is known as the *venous sinus of Leber*, or

Schlemm's canal. It contains a plexus of vessels that anastomose with the ciliary veins and those that are distributed to the outer scleral surface.

The transition from the scleral to the corneal fibres is not abrupt. The visible line of union is more peripherally situated at the internal surface of the membrane than at the external. This gives the point of juncture a bevelled appearance, with the sclerotic overlapping the cornea on the outer surface, similar to that seen in the fitting of a crystal to a watch.

FIG. 24.



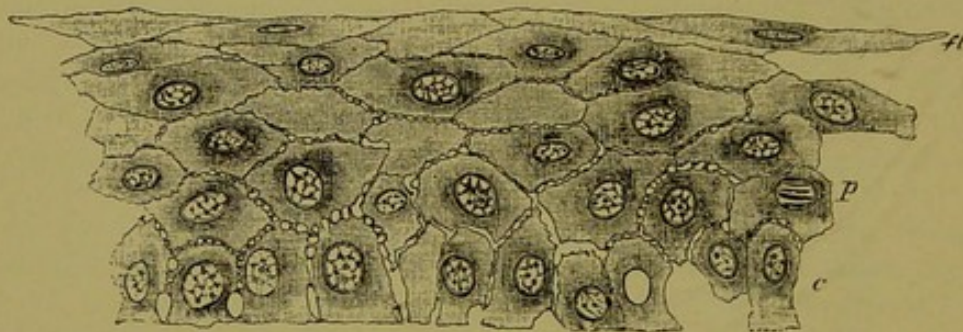
Sectional view of cornea. (SCHAEFER).

The *cornea* (or *pellucida*), as can be seen in Fig. 24, is ordinarily said to be composed of five strata or layers. These are the *anterior epithelial layer*, the *anterior elastic layer* or *Bowman's membrane*, the *substantia propria*, the *posterior elastic layer* or *Descemet's membrane*,

and the *posterior endothelial layer*. By others, the first stratum is termed the conjunctival; the next two strata are comprised under the generic term, the scleral; whilst the fourth and fifth are collectively known as the uveal portion. In the adult eye, its horizontal diameter is about twelve millimeters (about one-half inch) in length, and its vertical diameter is eleven millimeters (about eleven-twenty-fourths of an inch) in length. Its substance is thinnest in the centre. As can be seen in the profile sketch in the chapter on Physiological Optics, the curvature of the anterior surface is less than that of the posterior surface.

The tissue proper of the cornea is directly continuous with the fibres of the sclerotic. Stretched over anteriorly, and separated from it by a thin lamina, there is an epithelial layer which is a part of the anterior layer of the conjunctiva. Spread over it posteriorly, there is an elastic membrane which is covered in part by an endothelial layer that is in reality a modification of the anterior segment of the uveal tract.

FIG. 25.



Anterior epithelial layer of cornea. (QUAIN.)

The anterior epithelial layer, as can be seen in Fig. 25, consists of several strata of almost transparent nucleated cells. These are filled with a watery fluid and are united by a homogeneous cement. They decrease in thickness toward the centre of the membrane. Externally, they are very flat with a discoid nucleus as shown in the sketch. More deeply situated, they become polyhedral and spherical with a spherical nucleus, and finally show themselves as columnar and cylindrical with an ovoid nucleus. These last cells are placed perpendicularly to the surface of the membrane, and have fine prolongations which dovetail into one another and the surrounding tissues. In fact, they are the foster cells from which the successive anterior layers are formed.

Directly beneath this layer, and rather freely attached to it, there is in most instances the so-called Bowman's membrane. This, as can be seen in Fig. 24, is quite clear and but little fibrillated. Posteriorly, it is rather firmly fastened to the underlying layer of corneal tissue by a number of slender threads. This layer is denied by some, who suppose it to be either the anterior part of the cornea proper, or the post-natal remnants of a vascular covering.

The stroma, substantia propria, or tissue proper of the cornea, constitutes the next layer. It is composed of some forty to sixty super-

imposed strata of delicate and almost transparent fibres. These are formed into bundles by a cementing material. Its fibres cross one another in every conceivable direction (especially those of succeeding layers), and dip into the subjacent lamina. They become smallest and most oblique as they approach and penetrate the underlying membrane of Descemet. At many points they leave fusiform lacunæ between themselves, which are connected with one another by means of canaliculi. In addition to a number of minute wandering cells or leucocytes, these canals, which constitute the lymphatic spaces and canals and are continued into the tissue of the sclerotic, hold numerous fixed squamous cells with oval nuclei, which are termed the *corneal corpuscles*. Arranged in most instances in networks between definite strata, these channels branch and interlace directly up to the corneal borders, where they anastomose with the true lymphatic vessels of the conjunctiva. They thus carry lymph through the entire part of this portion of the cornea. By some it is stated that they possess a definite membranous covering.

Beneath this stratum comes the extremely thin *layer of Descemet* or *Demours*. It is transparent, homogeneous, and elastic. Thicker at the periphery, it breaks into a system of fibres which pass to both Schlemm's canal and the iris proper. The latter grouping is generally known as the *ligamentum pectinatum iridis* or *suspensory ligament of the iris*. By some it is asserted that there is a special central series which pass to the anterior part of the ciliary muscle. Between these combined series of fibres there are a number of spaces known as *Fontana's spaces* or *cavities*, which are said to be in communication with the canalicular systems of the cornea and sclerotic, and the venous sinus of Leber.

The deepest and most internal is the *endothelial layer*. In most instances it is composed of a single stratum of somewhat flattened polygonal cells with a large round or ovoid nucleus. At times these cells continue along the pectinate ligament and the anterior surface of the iris.

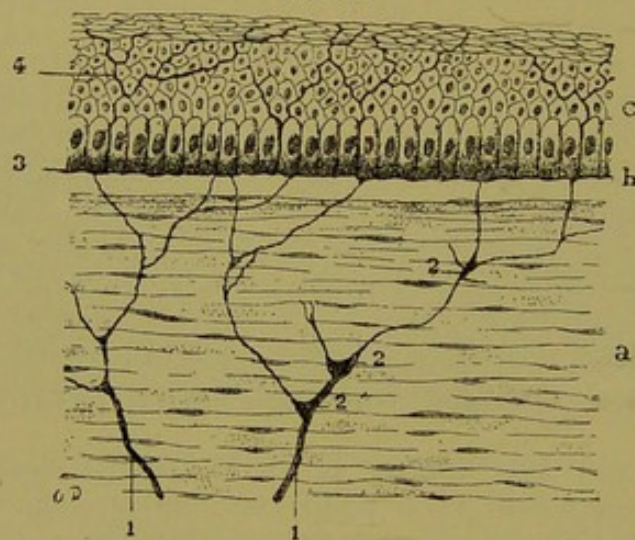
The nutrition of the cornea of post-natal existence is carried on by means of clear, colorless lymph and permeated aqueous humor. The corneal tissue contains bloodvessels only at its peripheral border. At this portion of the membrane, the capillary loops, which are derived mostly from the anterior ciliary arteries and veins, impinge into its substance to only a millimeter (one-twenty-fourth of an inch) distance.

The nerves of the cornea number from thirty to fifty main stems. They are derived from the anterior ciliary and the conjunctival. The ciliary branches form a plexus around the corneal border, and enter the membrane quite posteriorly. After losing their medullary sheaths and becoming transparent, they pass directly forward in special channels to be distributed to the various layers by means of superimposed networks. The deepest branchings, which appear in the substantia propria, are termed the *deep stroma* or *primary plexus*, whilst the finer second series, appearing beneath the anterior elastic membrane, is known as the *superficial stroma* or *secondary plexus*. The third, which is the most external, forms a network in the midst of the epithelial layer.

This network is designated as the *intra-epithelial plexus*. Finally, they terminate in minute bulbous expansions, presenting the same general characteristics as the larger tactile end-organs which lie in subcutaneous tissues. Fig. 26 shows these various plexuses and end-bulbs. The superficial fibrillæ, appearing as anastomoses and extensions from the conjunctival series, are quite few as compared with the posterior series. They are very minute in size.

The *iris* is practically the anterior termination of the *uvea* or *uveal tract*. It is the perforated curtain of tissue which is suspended in the aqueous humor. Commencing peripherally in association with the ciliary muscle at the internal wall of Schlemm's canal, it forms itself into an annular diaphragm which is situated just in front of the anterior capsule of the lens. Excentrically placed in it toward the nasal side, there is an opening which averages about three to three and a half millimeters

FIG. 26.



Corneal nerve plexuses. (GUTMANN.)

(slightly more than one-eighth of an inch) in its horizontal diameter. This is termed the *pupil*. Around this pupillary area, at about a millimeter (about one-twenty-fourth of an inch) distance from the border, an irregular concentric line can be recognized in the substance of the iris tissue. Between this line and the pupillary edge, a series of fine, circularly tending striæ which are more numerous posteriorly, can be plainly seen in the iris stroma. These constitute the muscular fibres of the *sphincter iridis*. Beyond this ring, in the same layer of the iris, the striæ, which are now more deeply seated in it, run peripherally directly out to the ciliary border. By some they are considered as muscular in type, and by others they are denied any such characteristics. They appear to arise from the sphincter by a number of overlapping fibrous arches. They divide into a superficial and a deeper layer, to again commingle as a narrow annular network at the ciliary margin. The more anterior, which are coarse, appear bifurcate and rejoin in many places. The deeper ones, which are more slender, pursue a sinuous course to the periphery. These peculiarities cause the tissue

to appear as if composed of innumerable striæ, pits, and crypts. Distributed over these, there is a varying amount of a brownish pigment which, by reason of the laws of interference, gives the iris its varied tints. Immediately in front of this fibre-layer, the vascular portion of the membrane is situated. Just anterior to this is a stratum of connecting and lymphoid cellular elements. All of these strata (the muscular, the vascular, and the cellular), belong to the true substance of the membrane.

The substantia propria of the iris is more or less covered with a delicate hyaline layer which is continuous with the cornea. Over this there is a thin layer known as the *anterior endothelial layer*. Immediately back of the tissue proper of the iris there is another stratum of hyaline matter termed the *membrana pigmenti*. This is said to be a continuation of the lamina vitrea of the ciliary processes and the chorioid. Posterior to this layer and in quite close apposition to the lens capsule at the pupillary border, there is a membrane which is popularly, though improperly, known as the *uvea*. It is composed of a couple of layers of polyhedral cells which contain an oval nucleus. On its back part it is covered by a layer of pigment. This, in many instances, curves around the pupillary border to form a narrow pigmented rim on the anterior portion of the diaphragm. It is sometimes described as the retinal portion of the iris.

The main arteries of the iris, which have their middle and external coats quite thick, are situated rather deeply in the stroma. Arising at the periphery, or just beyond, from an annulus formed by anastomoses between the long and the anterior ciliary arteries, they pass centrally to form a smaller and more superficial circle—the *circulus iridis minor*. After becoming capillary and forming an exceedingly minute plexus, they become venous in type, and pursue a corresponding reverse, though more posterior, course peripherally.

The lymph channels are also found in the substantia propria, in the vascular walls, and in the connective-tissue trabeculæ.

The nerve supply, which is abundant, is mainly derived from the three roots of the lenticular ganglion. It follows the vascular channels. The sensitive branches are the twigs from the ophthalmic branch of the fifth. The motor nerves, which go to the sphincter muscle, are derivatives from the third. The sympathetic is given off from the carotid plexus, and supplies the radiary fibres.

The space between the iris and the cornea is filled with aqueous humor. This is known as the *anterior chamber*. The space between the posterior surface of the iris and the anterior portion of the lens, which is also filled with the aqueous fluid, is known as the *posterior chamber*.

Practically, a continuation backward of the iris, and constituting the second portion of the uveal tract, we find the expanded *ciliary body*. It consists of the *ciliary processes* and the *ciliary muscle*. The former are in great measure in immediate juxtaposition with the vitreous humor. They are compressed into an annulus of almost seventy-five to eighty meridionally-placed ridge-like folds (the *pars plicata*). They take their origin as a narrow, smooth ring known as the *pars non*

plicata, at or near the anterior border of the chorioid. Rapidly increasing in height at this position until they have reached a point which is equivalent to the equator of the lens, they suddenly bend, forward and centrally, toward the peripheral border of the iris to project their free extremities into the posterior chamber. In texture they are composed of the same tissue proper, and limiting and pigmented membranes as the iris.

The posterior portion next to the vitreous is known as the *lamina vitrea*. It is covered with a hyaline layer, which is a somewhat thickened prolongation of that of the iris. Posterior to this, just as in the iris, and thicker nearer the chorioid, is a densely pigmented membrane, which is composed of ovoid cells containing brown pigmented granules. Overlying this layer, and situated directly against the vitreous humor, there is a stratum of anastomosing granular cells of columnar and cubical variety. These are known as the *pars ciliaris retinae*. The substantia propria or stroma of the ciliary body is like that of the iris, composed of a great mass of muscular and connective tissue with numerous irregularly sized and pigmented corpuscles.

The unstriped muscle tissue known as the ciliary muscle arises by a short tendinous ring from the pectinate ligament and the sclerotic. It passes backward and inward. It is roughly divided into three parts—the meridional, the radiatory, and the so-called annular, the first two being known as the *tensor chorioideæ*, or the *muscle of Brücke* or *Bowman*. As can be seen in the sketch by Arlt, in the section on Accommodation, the first is the largest, the longest, and the most external. It lies next to the sclerotic, and pursues a course longitudinally backward to give a stray fibre or two to the sclerotic. It terminates in a broad and irregular tendinous massing in the lamina fusca of the chorioid. The second is less compact, radiates more toward the ocular centre, and distributes itself over a broad fan-like area in the inner portion of the ciliary body. The third, sometimes known as the *circular muscle of Müller*, forms an annulus that is concentric with the equator of the lens. It is deeply imbedded in the forepart of the ciliary body. Between these fasciculi, as in the iris, the connective-tissue fibres and corpuscular elements of the stroma can be plainly seen.

The arterial blood of the ciliary body is principally carried by both the posterior ciliary arteries and the anterior ciliary artery. These pass directly through the ciliary muscle. The venous blood is mostly discharged through the posterior and the anterior ciliary veins. In their passage they are, as in the iris, more deeply situated, and are not practically interfered with by contraction of the fibres of the ciliary muscle.

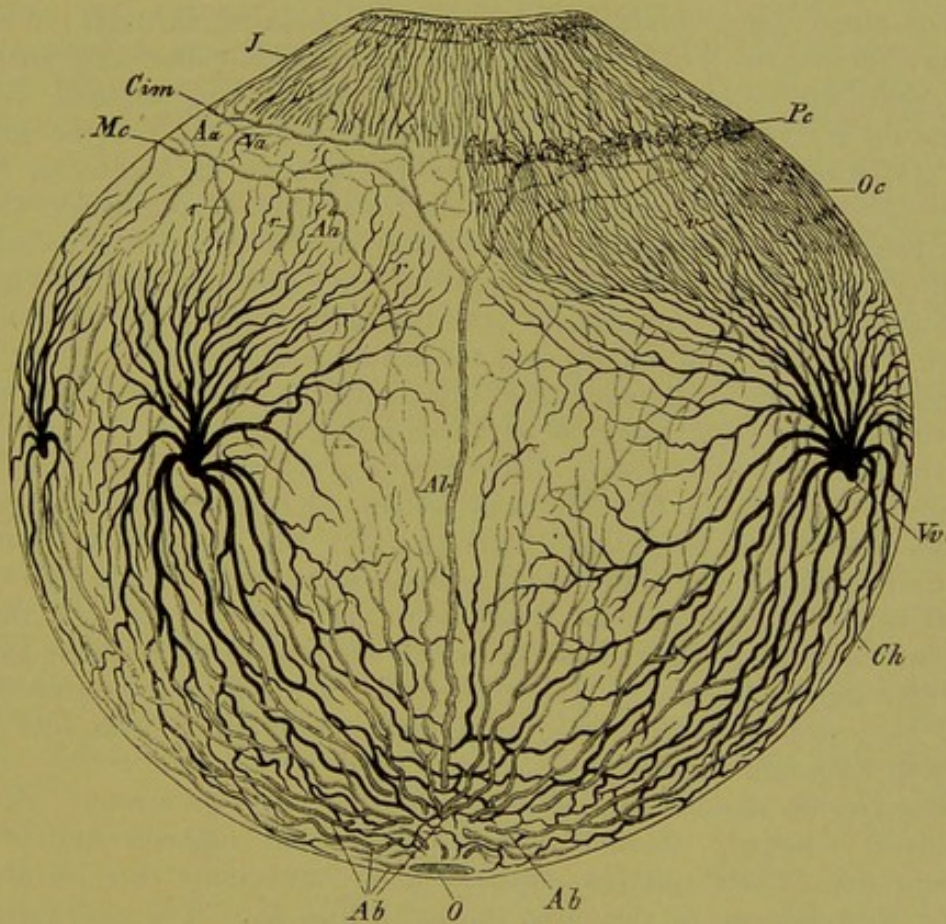
The nerve supply, like that of the iris, includes motor, sensory, and sympathetic fibres. It is in great measure derived from the short ciliary nerves. It is in intimate association with a localized plexus of ganglion cells in and around the ciliary muscle.

The *choroid*, or more properly *chorioid*, is the broad posterior terminal expansion of the uveal tract. It is the largest of the three subdivisions of the uvea. It extends as a sheet of pigmented and vascular tissue of about 0.08 to 0.16 millimeters in thickness, from the ciliary body back to the entrance of the optic nerve. It is thickest in the

neighborhood of the optic-nerve entrance, and gradually thins as it extends toward the ciliary body. At the optic-nerve entrance it resolves itself into a thin annulus, which surrounds the so-called *foramen opticum chorioideæ*, or opening in the membrane, through which the optic nerve enters—shown at *O* in Fig. 27.

The bulk or stroma of its tissue is known as the *tunica vasculosa chorioideæ*. It is composed of several layers of large arteries with their stems and twigs and veins. Associated with it are the so-called stellate pigment cells and elastic fibres; the rule being that the larger vessels

FIG. 27.



Vascular circulation in chorioid. (LEBER.)

are the more external. By some it is claimed that there are fine muscle fibres extending from the ciliary body back to the optic-nerve entrance. Internally to this layer, there is a thin layer of capillaries known as the *membrana Ruyschiana*. This is usually devoid of pigment, and disappears as it approaches the ciliary body. Just as with the ciliary body, there is a basal membrane against the vitreous. This is termed the *lamina vitrea chorioideæ* or *membrane of Bruch*. Although it is smoother and more transparent posteriorly, it is covered with minute elevations or glands, which are larger and more pronounced in the region of the ciliary body. Most externally, against the sclerotic, there is a brownish pigment layer. This is known as the *supra-chorioidea*. It lies immediately over the stroma chorioideæ.

As explained in the description of the sclera, there is a delicate and adherent portion known as the *lamina fusca*. In fact, the entire membrane, except anteriorly and posteriorly, is mainly held to the sclerotic by the vessels and nerves; this adherence being especially marked in the macular region, where numerous minute vessels pass between the two coats. Internally, at this point, the attachment of the chorioid to the retina is also very great.

Just behind the ciliary body all of these layers merge and intermingle. This situation, as shown at *Oc* in Fig. 27, and which, in reality, is the locality of the first appearance of the muscular elements of the ciliary body, is termed the *orbiculus ciliaris*.

The blood supply of the tunic is chiefly obtained through the short ciliary arteries, with recurrent branches from the so-called long anterior and posterior ciliary arteries. Thus, in Leber's diagrammatic representation of the chorioidal circulation—shown in Fig. 27—the letters *Ab Ab*, situated at the beginnings of the system of half-toned lines near the optic-nerve entrance *O* at the lower part of the figure, represent their commencements. It also shows how their channels become smaller, more numerous, and deeper as they pass forward to form a uniform network of capillaries (the *chorio-capillaris*) in the vascular layer of the tunic and extend over the entire chorioidal area. They are extremely minute in the regions of the macula and optic-nerve entrance, at which latter point there is an anastomosis with those of the optic-nerve head, as can be seen in Wolfring's diagram, shown further on, and as can be seen at *l* in Fig. 11. The letters *Al*, in the centre of Fig. 27, shows one of the long ciliary arteries which has entered the chorioid near the position where the short ciliaries come in. Running forward, as shown in the sketch, the artery does not bifurcate until it nearly reaches the ora serrata. Here branches are sent to the anterior part of the chorioid, the ciliary body, and the iris. In fact, there is a posterior and an anterior system of arterial distribution which form free connection with one another.

The venous blood is carried off by the four *venæ vorticosæ*.¹ A pair of these is usually situated in each inferior and superior half of the membrane. Their relative positions and connections can be understood by reference to the ones shown in Fig. 27. The peculiarity of distribution can be comprehended by a glance at Fig. 27, where the letters *Vv*, passing to the dead-black lines, indicate the position of exit of one of the main trunks from the chorioid. Here it will be seen that these main trunks are situated at the equator of the globe, and that they gather the blood in all positions throughout the entire membrane. Fig. 11 also shows this. A small amount of venous blood passes out by the anterior ciliary veins. All the chorioidal veins possess perivascular sheaths.

The nerve supply is by the ciliaries. Both branching from these and independent from them, there are numerous ganglionic cells and pale nerve fibres which are found in the stroma. Especially is this so in the chorio-capillaris near the macula and optic-nerve entrance.

¹ At times, on account of bifurcation, these may be six in number.

Leaving the vascular coat, we come to the *crystalline lens*. It is enclosed in an elastic, transparent, possibly striated envelope, which is known as the *capsule*. The anterior portion of the capsule, which is the thickest, is termed the *anterior capsule*, and the posterior half is known as the *posterior capsule*. The anterior portion is conveniently divided into a central region, or that which extends around the anterior pole of the lens, and the marginal region, which is peripheral and extends in every direction to the equator of the lens. The anterior capsule is said to be lined with a single layer of clear polygonal endothelial or epithelial cells. These hold oval and spherical nuclei that are larger in the central portion. They elongate and become more numerous and smaller as they reach the marginal portion. They are supposed to give origin to the lenticular fibres and to assist in osmotic action between the lens and one of the lymph streams in the anterior chamber; this being indirectly shown post-mortem by the presence of the so-called *liquor Morgagnii*, or fluid formed from the intra-ocular fluids, and a granular débris found between the lens substance proper and the capsular epithelium. According to most authors, the posterior capsule is devoid of an endothelial layer. It is quite thin and delicate, and lies in close contact with the lens substance and the vitreous humor.

The lens itself is a transparent biconvex body which measures about eight to ten millimeters (one-third to three-eighths of an inch) in diameter, and three and a half to five millimeters (one-eighth to three-sixteenths of an inch) antero-posteriorly. Although ordinarily increasing both in weight and volume as the subject grows older, it weighs about two hundred milligrammes during adult life. Its substance is composed of a great quantity of concentric layers which are roughly divided into three portions—the peripheral or external, the intermediate or middle, and the nuclear or inner. Each consecutive layer has a slight though significant increase of index of refraction. The average index is between 1.4371, as found by Helmholtz, and 1.4545, as determined by Listing.

FIG. 28.



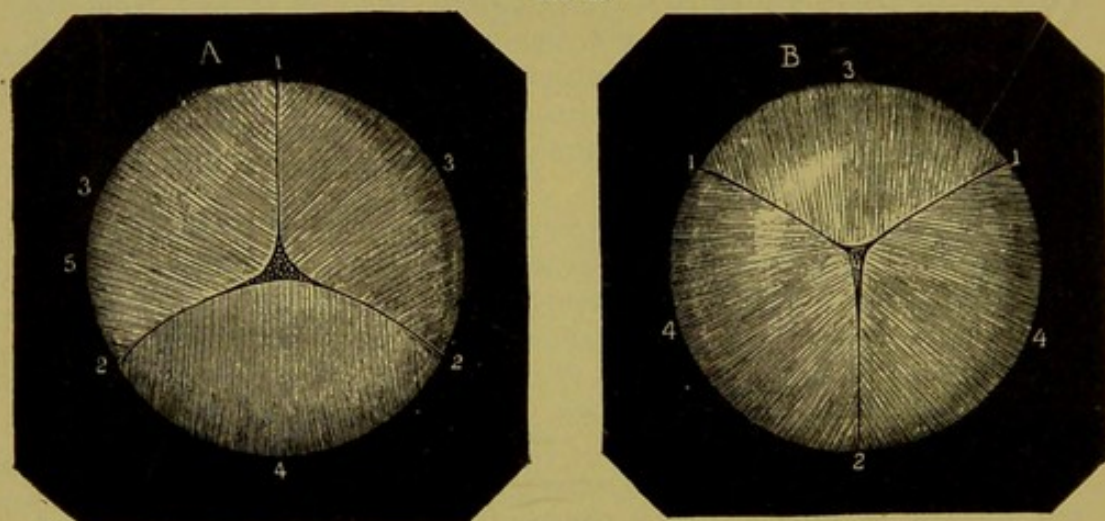
Hexagonal fibres of crystalline lens. (METZ.)

Each successive layer is merely a suppositional area of more greatly pressed and elongated embryonic cells. It is composed, as shown diagrammatically in transverse section in Fig. 28, of broadened hexagonal fibres. These, as younger smooth-edged cells, in the cortex or peripheral portions, contain granular nuclei which are imbedded in a clear, viscid, albuminoid material. Toward the inner, or so-called nuclear portion, the fibres through age and compression become more and more compact. Here they are somewhat yellowish, their nuclei gradually disappearing and their edges becoming serrated.

As the fibres, as a rule, run antero-posteriorly, and as they are subjected to great pressure in the equatorial region of the lens, their extremities meet at the anterior and the posterior poles. As shown in Fig. 29, they form, in the young, a Y-like figure in these situations, the anterior one being inverted. In mature subjects, the principal radii subdivide, causing numerous sectors whose apices are directed towards the anterior and posterior poles of the lens. These cells are cemented together by a clear homogeneous substance containing the so-called interfibrous channels which communicate near the lenticular equator.

Resting in the anterior part of the vitreous or so-called *hyaloid fossa* or *fossa patellaris*, and enclosed in its capsule and touching the posterior portion of the iris, the lens is held in position by the *suspensory ligament of the lens* or the *zone of Zinn*. This, after arising near the region of the ora serrata from the hyaloid membrane, and receiving

FIG. 29.



Sectors in crystalline lens. (TESTUT.)

fibres mostly from the elevations of the ciliary processes, divides into a series of fan-like radii to be irregularly inserted by three great groups into the posterior capsule, the circumference of the lens, and the anterior portion. It thus leaves a triangular space between the two portions, which is traversed by numerous interlacing fibres. This space is known as the *perilenticular space*, whilst the area between the fibres of the zonula and the equator of the lens is termed the *canal of Petit*. Behind the posterior wall of the zonule and the underlying vitreous, there is a supposed small annular space known as the *canal of Hannover*.

In post-natal existence, the crystalline lens is devoid of bloodvessels and nerves, receiving its nourishment by osmosis from the intra-ocular lymph streams.

Immediately behind the posterior capsule of the lens and contained in the space otherwise bounded by the suspensory ligament of the lens, the posterior portion of the ciliary bodies, the retina, and the optic-nerve head, there is a dense, gelatinous, transparent, and almost structureless body known as the *vitreous humor*. According to most authorities, it is enclosed in a membranous sac known as the *hyaloid*

membrane. At the optic nerve this sac turns in upon itself and runs forward to the posterior capsule of the lens to form the lining wall of a transparent canal, known as the *canal of Cloquet* or *Stilling*, which in ante-natal existence lodged the hyaloid artery. The area of this canal at the optic-nerve entrance, which is about two millimeters (one-twelfth of an inch) in diameter, is termed the *area of Martegiani*. Adherent posteriorly to the optic-nerve in this area, and fastened tightly anteriorly to the ciliary bodies by a series of plications, it forms a slight though firm rim-like attachment to the posterior capsule around the rim of the canal of Cloquet.

The humor itself is said by most authorities to be arranged in segments and concentric layers, which are probably somewhat, though of course relatively, similar to those of the lens. It is a viscid and jelly-like mass containing all manner of clear gelatinoid cell-forms, which, according to some, possess the power of amoebiform movements. These cells are better marked and less crowded together in the peripheral portions of the humor.

Just as the lens, the vitreous is utterly devoid of bloodvessels and nerves. According to some, it derives its nutriment in part from a system of minute tubular processes which are situated in the ciliary body and uveal tract.

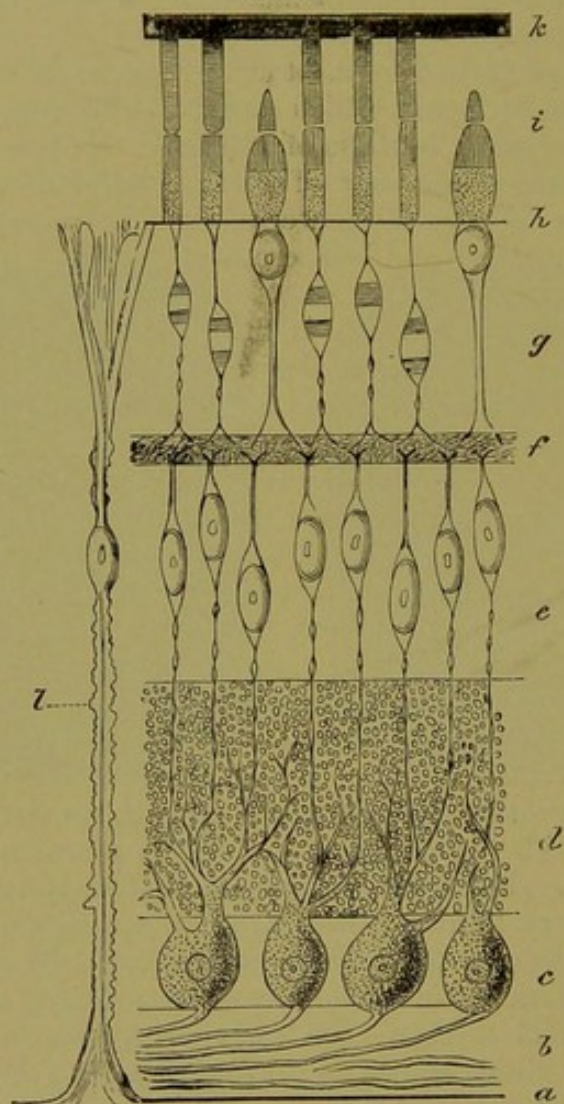
We now come to the first of the sentient structures. This is known as the *retina*. Spread out over the chorioid from its fastening at the ora serrata in front to its second principal point of fixation at the optic nerve entrance at the back, and held to a greater or less degree in position by the supporting vitreous, this broad sheet of nerve material practically serves as the sensitive plate of the ocular camera. As shown in Fig. 30, it consists of nine closely united layers with a special one of pigment (seen at *k*), which is spread out over and tightly adherent to the outlying chorioid.

Beginning internally at the vitreous humor, we first encounter one of the ordinary endothelial linings that are so prevalent in the deeper tunics of the eye. It is here known as the *membrana limitans interna*. This, which is very thin and lies in close apposition to the hyaloid membrane, extends over the whole retinal sheet. By some it is said to be continuous anteriorly with the *pars ciliaris retinae*, at which place it becomes denser and thicker. Its external surface is irregular, and, from it numerous fibres, known as the *limitary fibres of the retina*, pass into the deeper structures of the entire tunic, as shown at *a* in Fig. 30. Frequently, minute isolated nuclei connected by filiform fibrils can be seen within its substance between the various striæ. These become less and less pronounced, and the fibres become more and more obliquely placed as they approach the ciliary region. These connective-tissue fibrils, seen at *l* in the illustration, now generally known as the *fibræ of Müller*, and which in fact help to support and to keep the superimposed layers and individual nerve fibrils in position, really go quite a distance into the nervous sheet. They form loops and flame-shaped expansions, as seen in Fig. 30, in the internal limiting membrane, except in the macular region.

Overlying this endothelial sheet, the optic-nerve fibres, which are

identical with the pale fibres of the brain, first manifest themselves. Here they are so numerous and so large that this portion of the membrane is known as the *second*, or *nerve-fibre layer*. This layer is, as seen at *b* in Fig. 30, the lateral expansion of the individual fibres that have spread out in a definite anatomical manner from the optic-nerve entrance over the entire membrane as far forward as the ora serrata. They unite into variously sized fasciculi that are held and

FIG. 30.



Sectional view of retina. (SCHULTZE.)

bound together as shown in Fig. 30. Devoid of their opaque coverings after leaving the lamina cribrosa of the optic nerve, they pursue their way as axis-cylinders that are connected in places with some neuroglia. At the external surface of the layer, the individual fibres immediately turn at right angles and penetrate into the membrane as ganglion cells and granular layers. Here they terminate in club-like extremities which dip more or less into an albuminoid secretion popularly known as the *visual purple*. The variations of these fibres as they pass externally to their bacillary-like terminations, are so constant and so regular, that they form definite layer-like peculiarities, thus giving rise

to certain expressive groupings which are specially named. For instance, immediately after the bending of the fibre it becomes enlarged and globular. In fact, it becomes a ganglionic cell, thus giving rise to the *third*, or *ganglion-cell layer*. This layer, shown at *c* in Fig. 30, is composed of variously sized and differently developed multipolar and nucleated granular bodies, like those found in the cerebrum. These are bound together at many places by Müller's fibres, although at points, there are spaces through which some seemingly non-ganglionic fibrils make their way. Curiously, the larger the cell, the more peripherally is it situated in the retina, the smaller central ones being condensed and more compact. From the external portion of each ganglion cell, a parent trunk is given off which divides into several tree-like branches that go to form the *fourth*, or *internal molecular layer*. This layer, which is designated by a number of names, most prominent being the *granular* or *internal reticular layer*, is seen at *d*, in Fig. 30. It is practically composed of a great number of fine fibrils that are packed together longitudinally in such a manner that in section they appear like minute molecules, in which, at times, barely visible nuclei can be recognized.

Pursuing its way more exteriorly, the nerve fibre again becomes enlarged into an almost transparent, irregularly shaped body that is granular and contains nucleoli. The entire layer-grouping, a section of which is shown at *e* in Fig. 30, now forms what is known as the *fifth*, or *internal nuclear* or *internal granular layer*. Each nuclear cell is furnished with an external prolongation, which extends to the next outermost layer, thus making it bi-polar. Just as in the previous layer, there is an abundance of the radiating fibres, which are intermingled with the stems of the nucleated cells. The whole is bound together by a clear, gelatinous supporting cement. Although the external nerve-fibril stem is much the shorter, yet it is sufficient to give rise to a layer that is very much like the one produced by the opposite or internal fibril of the bi-polar cell—*i. e.*, the internal molecular layer. Upon account of this resemblance, therefore, and by reason of the more external situation, it is described as the *sixth*, or *external molecular layer* (shown at *f*).

The fibres again becoming granular in type, though smaller than were found in the internal granular layer, a new layer, termed the *seventh* or *external granular layer*, or the *external nuclear layer*, is formed. It is very dense and compact, being composed of fine nuclei or granules of various shapes, as shown at *g*, in Fig. 30. It divides itself into an external stratum, which is in main composed of the nuclei belonging to the retinal cones, and an internal stratum, which is connected with the retinal rods.

The next layer, the *eighth*, or *external limiting membrane*, seen at *h*, Fig. 30, is practically the external limit of the connective-tissue fibres and membranes which have given support to the various neural layers just described. It is composed of a narrow stratum of fine interlacing fibrils, with interstices through which the neural elements are permitted to pass into the layer beyond. It serves as a meshwork of binding-together tissue by which the several layers are held in close apposition.

The nerve elements passing through the fenestrated external limiting

membrane at last reach their rod and bulb-like terminations (*i*, in Fig. 30) in the *ninth*, or *bacillary layer*—the *layer of rods and cones*. The rods—the longer of the two—dip into their bath of visual purple, held in the more external or pigment layer of the retina. Each rod is a more or less straight cylinder which is divided into a rather narrow external segment that is apparently composed of superimposed disks, and a broader internal segment which, although similarly marked, is much denser, finely fibrillated, and not so liable to longitudinal cleavage. The cones, which, like the rods, are divisible into two segments, are, as named, coniform in shape. Here the more internal segment is the broader and the longer of the two. Both series of nerve terminations, then, are practically either a cylindrical or a conical expansion of the filament of neural tissue that is surrounded by a protective and an isolating membrane. Between these bacilli, there are fine processes which arise from the pigment cells.

Forming a matrix or bed, into which the bacillary tips of the nerve elements dip into a contained pigment-material known as the visual purple, the *tenth*, or *layer of pigment epithelium* (*k*, in Fig. 30), is next and lastly found. It consists of a thin sheet of irregularly polyhedral or more or less hexagonal cells of nuclear type. The outer or chorioidal portion of the cell is almost clear and is nearly devoid of pigment. The inner or retinal part is packed with a granular pigment which is similar in tint with that of the uveal tract. These cells are cemented together by a homogeneous intercellular material. They are more numerous and more closely adherent to the layer of rods and cones immediately behind the fovea centralis than at any other part of the membrane.

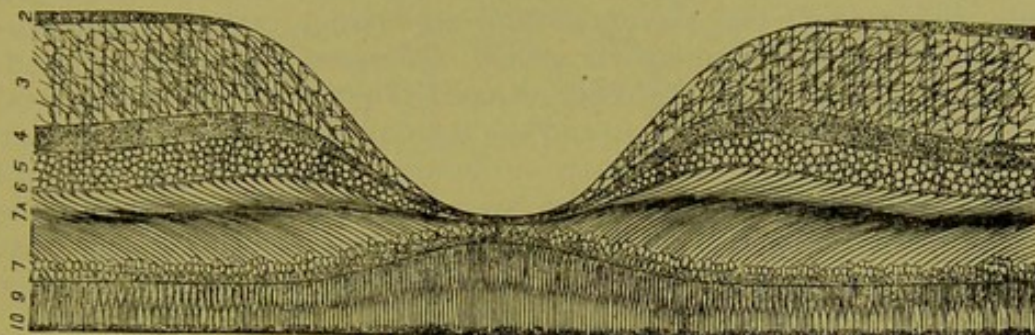
The *visual purple*, or *visual rose*, as it is at times called, is an albuminoid secretion which is supposed to be limited to the outer segments of the rods. It is practically a sensitive photo-chemical material of a purple tint, which, when exposed to light-stimulus, as will be explained in the next chapter, becomes rapidly bleached.

The retinal sheet is not of equal thickness throughout its extent, becoming very much thinner toward the ora serrata. As this point is approached, the neural elements terminate irregularly. The connective-tissue fibres continue forward as nuclear and almost transparent columns. The thickest portion of the retina is near the optic-nerve entrance. About two and a half millimeters (one-twelfth of an inch) to the temporal side of the optic disk, there is situated a horizontal oval area of about two or three millimeters (one-twelfth to one-eighth of an inch) in size. This is known as the *macula lutea*. It receives this name from the fact that it becomes yellowish immediately after death. At this portion of the fundus oculi, the membrane rises into a mound-like eminence, which contains a deep depression known as the *fovea centralis retinae*. This depression is the thinnest portion of the central area of the entire retinal sheet. Fig. 31 gives an excellent idea of what is meant.

Here it can be seen how the several layers of the retina become compressed at the fovea. Here the optic-nerve fibre layer disappears and the cones become increased, elongated, and thinned. In fact, the

neural elements increase enormously. In this region the rods are wanting, Müller's fibres lose their flame-shaped expansions, and, according to some, several layers of bi-polar ganglionic cells appear. This depression is generally horizontal-oval in shape and about two-tenths of a millimeter in its long diameter. It is not apparent at birth. The

FIG. 31.

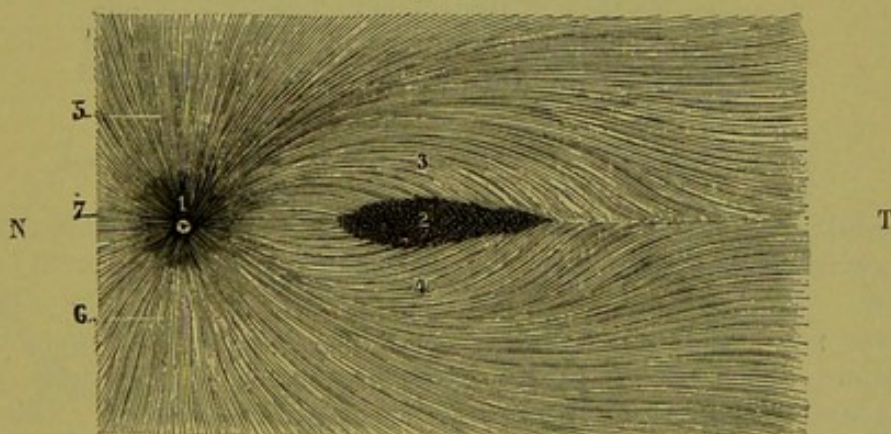


Retina in macular region. (STÜCKER.)

chromolithographs illustrating the normal fundus of the eye, show these peculiarities as they appear through the ophthalmoscope.

The nerve fibres themselves, after entering the interior of the globe through the optic-nerve entrance, distribute themselves, as a rule, over the retinal plane in a definite manner. By reference to Fig. 32 it will be noticed that there are practically two areas of distribution. One

FIG. 32.



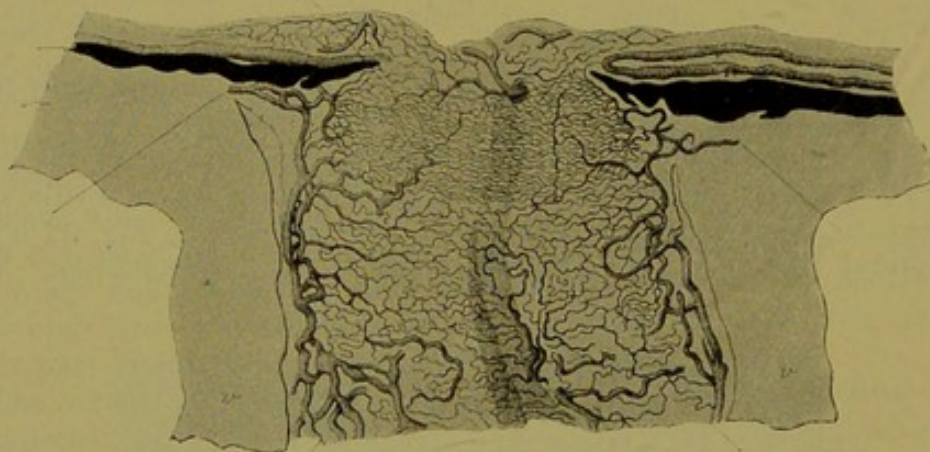
Distribution of fibres in retina. (KÖLLIKER.)

—the smaller—springs from a small portion of the fibres at the temporal portion of the disk. Its fibres pass in progressively lengthening curves to the macular region and the peripheral horizontal portion beyond. The other—a larger area coming from the remaining major part of the disk—passes radially to all the rest of the membrane. In this distribution the nasal shoots are the shortest, and the superior and inferior temporal stems the longest. Although the macular fibres are the most numerous—in fact, constituting at least one-fourth of the entire retinal fibre distribution—yet these fibres are the thinnest and the finest.

The arterial supply of the retina is mainly accomplished by the central artery of the retina, there frequently being, as shown in Fig. 33, an anastomosis with the short ciliary vessels near the optic disk.

Ophthalmoscopically, the main arterial trunk, as explained further on, bifurcates into several branches after pursuing its way through the head of the optic nerve. Extremely uncertain in its position of entrance on the disk and variable in the situation of its primary branching, it, as a rule, divides itself into a superior and an inferior branch, which subdivide into nasal and temporal stems. These are respectively known, as shown in Fig. 34, as the superior nasal (*ans*), the superior temporal (*ats*), the inferior nasal (*ani*), and the inferior temporal (*ati*) branches. In some instances, as can be seen in the same figure at *ame*, there are a few small medial branches which pass directly out into the nasal side of the retina. Generally there are a couple of rather larger stems that appear at the temporal portion of the disk and pass almost directly

FIG. 33.



Vascular supply in optic-nerve head. (WOLFRING.)

horizontally out, to curve around and in the macular region. These latter, which are known as the *macular arteries*, are seen at *am* in Fig. 34.

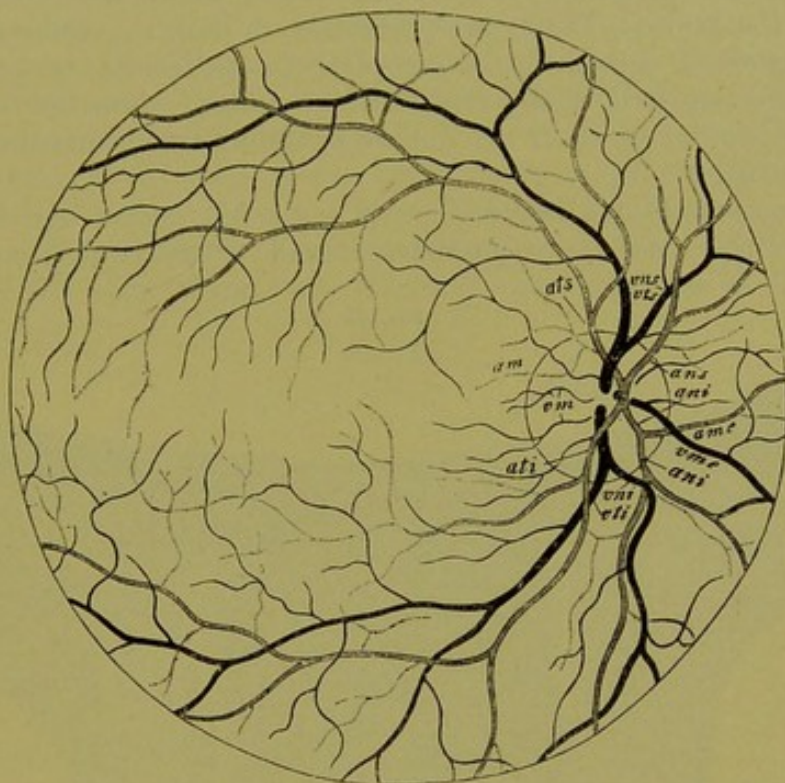
These main vessels, as a rule, occupy the nerve-fibre layer of the membrane, whilst their capillary offshoots pass at right angles to the parent stems as far externally as the inner granular layer. This gives rise to two series of networks—one in the outer part of the ganglionic layer, and the other in the same relative portion of the inner molecular layer.

Without any pronounced anastomosis they continue forward to near the ora serrata, where, after becoming finely capillary, they become venous in type. From here they pursue a backward course as ever-increasing and enlarging channels, to terminate in the *vena centralis retinae*, which, as can be seen in the last illustration by the appropriate initial letters, pass out of the eye in association with the entering central artery of the retina, as the central retinal vein.

The distribution of the circulation in the macular region is peculiar. Just as the neural portion of the retinal layers was crowded and

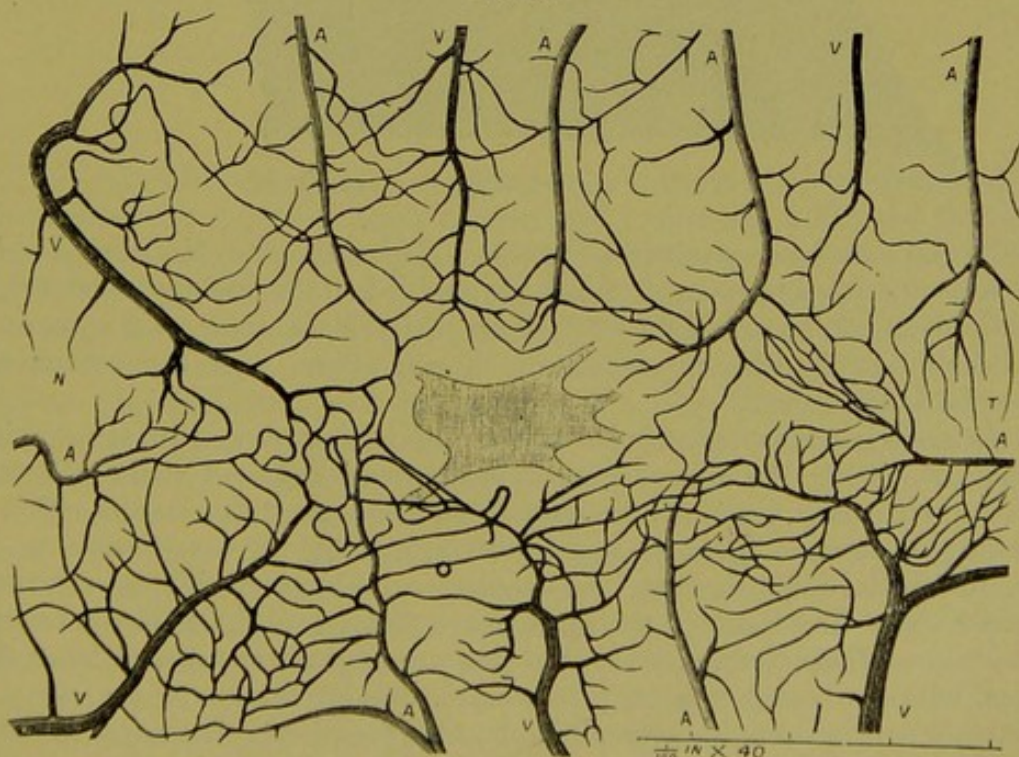
squeezed into a small compass in this area, so here the vessels, though externally rich in number, are very minute in size. The fovea itself is the only portion that is devoid of any visible circulation. As can

FIG. 34.



Distribution of retinal vessels. (JAEGER.)

FIG. 35.



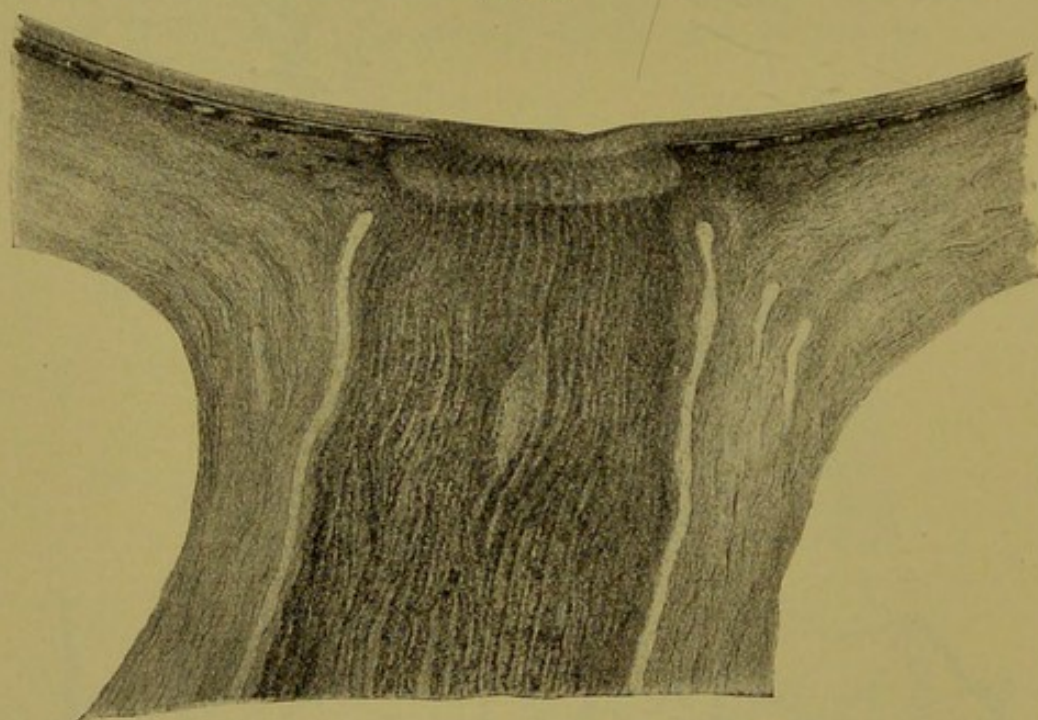
Retinal circulation in the macular region. (NETTLESHIP.)

be seen in Fig. 35, they form a corona or annulus, with a central apparently barren area. This crown or ring has been formed by the radiation of a great number of venous and arterial twigs.

Each vessel is surrounded by a lymph space, which is in communication with the lymph channels of the optic nerve that connect with those of the brain. This space, which is in both the arterial and the venous systems, though not so complete in the former, is situated between the outer wall of the vessel and an inner endothelial layer. In all of the capillaries, there are double cylinders which lie concentrically to one another.

The non-medullated nerve fibres of the retina gather together into a composite oval mass at the posterior pole of the eye known as the *optic*

FIG. 36.



Section of optic-nerve head. (JAEGER.)

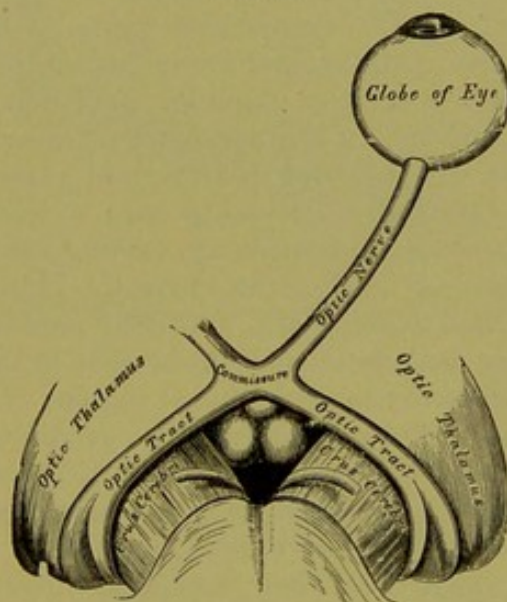
disk. This is shown partly in Fig. 36. The disk, or *optic-nerve head*, as it is at times termed, is about one and a half or one and six-tenths millimeters (about one-eighteenth of an inch) in diameter. Its apparent ophthalmoscopic size, as elsewhere shown, varies with the refractive constants of the eye.

Extending posteriorly as far as the lamina cribrosa, it presents ophthalmoscopically the appearances described and depicted in the colored plates in the first pages of the chapter on Diseases of the Retina. Continuing backward through the fenestrated tissue layer situated on a level with the sclerotic coat, and known as the *lamina cribrosa*—shown in the above illustration—the optic-nerve fibres lose their transparency and take on their medullations. At this point, numerous scleral fasciculi turn backward, and not only penetrate the interstices of the neural fibres, but form broad enveloping sheaths for their protection in the orbit. Upon account of this great increase in connective tissue, as can be

well seen in Fig. 36, the calibre of the nerve as it leaves the globe rapidly increases to four or five millimeters in diameter. As can be well understood, then, the retinal nerve fibres, which number nearly one-half million, after being gathered into a one-and-a-half-millimeter (about one-eighteenth of an inch) bunch at the posterior pole of the eye, perforate the chorioid coat, as previously explained, and pass through a sieve-like plate of scleral tissue to pursue their way backward as the so-called *optic nerve*, in a series of protective envelopes which have been formed from the sclerotic coat.

The outermost covering of the optic nerve is known as the *dural sheath of the optic nerve*. It is connected with the outer layers of the sclerotic, and passes backward around the nerve, to be lost in the periosteum of the optic foramen. The internal envelope is frequently

FIG. 37.



Optic chiasm. (BOWMAN.)

termed the *pial sheath of the optic nerve*. It is in direct continuation with the inner layers of the sclerotic, and continues backward through the optic canal to form the outer covering of the optic nerve within the cranium. This sheath, which is very delicate, sends numerous trabeculae through the tissues of the optic nerve. Between these envelopes there is a broad lymph space, which is lined by endothelium. It is in direct communication with the arachnoid of the brain. Subjacent to the inner sheath, between it and the optic nerve, there is a second, smaller and narrower lymph channel.

The entire structure, closely imbedded in fat and connective tissue and surrounded by the bellies of the extra-ocular muscles, pursues a sinuous course downward, outward, and backward, until it reaches a point at about eighteen millimeters (seven-eighths of an inch) behind the globe, where it is obliquely pierced by the central retinal artery and central retinal vein. Coming up and in, it reaches the optic foramen, when it has attained a length of nearly thirty millimeters (one and one-eighth inches). Entering the canal, it receives small vascular twigs,

and its outer sheath adheres tightly to the bony walls. After pursuing a distance of five or six millimeters (about three-sixteenths of an inch) through the canal, it flattens and curves up and in in the intra-cranial cavity for about ten millimeters (three-eighths of an inch), to reach its fellow nerve. Here a definite commingling of both the neural and the connective-tissue elements takes place. Here there is an interlocking, by which the nerve fibres intended for vision in the right fields of each eye pass to the left brain, and the nerve fibres used for vision in the left fields of each eye go to the right brain. This portion of the optic fibres terminating the optic nerve proper, which is known as the *optic chiasm* or *commissure*, appears, as in measure shown in Fig. 37, as a broad flattened X-like body. It rests on the sphenoid bone.

The distribution of the two series of nerve fibres in this connecting body is fairly certain. Starting from the retinae, each optic nerve at its exit from the eye has a small, compact wedge of temporal fibres which are in connection with the macular region. This wedge, holding by far the greater part of the retinal nerve tissues, remains in this situation, or probably falls to a lower plane for about ten millimeters (about three-eighths of an inch) along the nerve, where the retinal vessels enter it. Here it becomes vertical oval in form, and rises to the outer horizontal meridian. Gradually flattening into a horizontal oval as it reaches the optic foramen, and pursuing its way toward the centre of the nerve trunk, it at last reaches the chiasm. Here both series sink to the bottom, and both directly and indirectly pass inward and upward from each side, along each optic tract, to be sent to their respective portions of the cerebral cortex in each cuneal region.

The remaining nerve fibres, known as the *peripheral* and the *inter-medial*, which, as can be seen by reference to Fig. 32, constitute the remaining portion of the retinal distribution, occupy the rest of the neural portion of the optic-nerve bulk, until they reach the chiasm. Here those fibres which have been distributed over the nasal halves of the retinae and have gained the summit of the optic-nerve head, pass back and cross through the inner portions of the chiasm to the opposite tract, and pursue their way to the occipital cortex; whilst those which have been distributed over the temporal halves of the retinae take up the rest of the optic-disk area, and pass to the outer and probably upper portion of the chiasm, and pursue their uncrossed way directly back along the tracts of their own side.

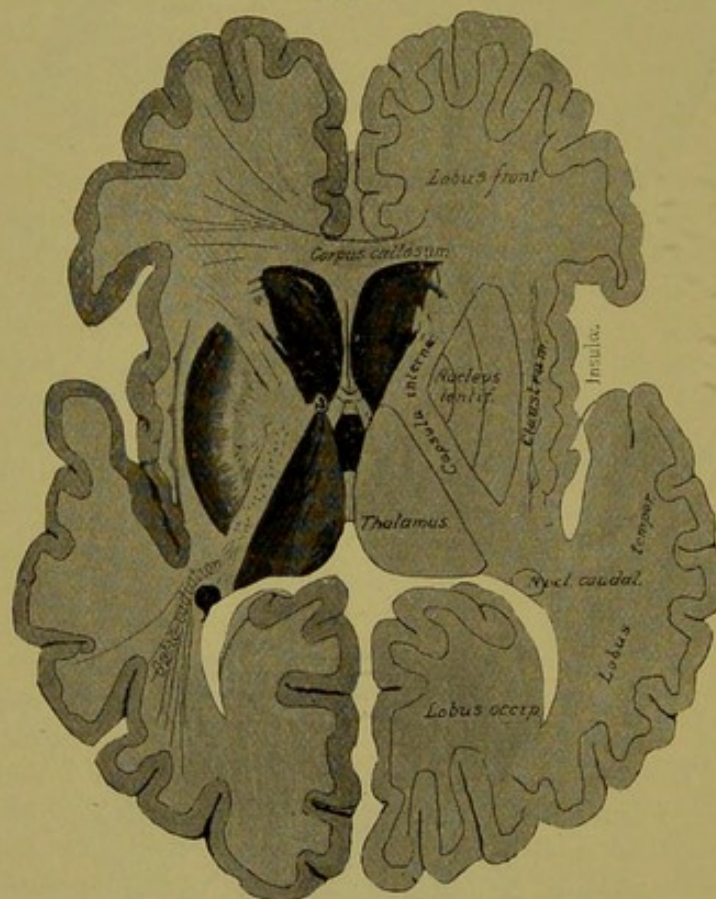
It will be thus seen that there are three series of fibres: the first, or macular grouping, which have a crossed and uncrossed series for each eye; the second, the remaining right temporal and all of the left nasal fibres, which, by interlacing in the chiasm, join at the commencement of the right optic tract to go to the right occipital region; and third, the remaining left temporal and all of the right nasal fibres, which, by the same anatomical arrangement at the chiasm, go to the left occipital cortex.

There is also an inter-retinal series of commissural type, which run from one eye to the other. These pass around the anterior portion of the chiasm. Further, in the posterior part of this region, there is another series of commissural fibres, as can be seen in Fig. 38.

protuberance on the posterior portion of the thalamus—the pulvinar. This can be seen in Fig. 39, where the right optic tract is seen coming around the infundibular lobe, just above the neck of the hypophysis, to curve upward, outward, and backward over the crista and beneath the thalamus to reach the pulvinar.

At the anterior brachium of the anterior quadrigeminal body, a large portion of the fibres of the lateral root of the optic tract enters and is spread out over the stratum zonale as a fine meshwork, which seemingly arises from many minute localized cells. Another series of this,

FIG. 40.



Optic radiations. (EDINGER.)

as can be seen in Fig. 39, passes into the lateral geniculate body; whilst a third grouping can be traced, as before said, and as well seen in Fig. 39, to the thalamus direct at the pulvinar. In the anterior quadrigeminal bodies there are also the terminations of a number of cortex fibres which have passed into their substance through the anterior brachium; this arm-like extension of the corpora also carrying nerve fibres up into the thalamus and to the internal capsule, where the optic radiations commence and pass backward to the cortex of the occipital lobe.

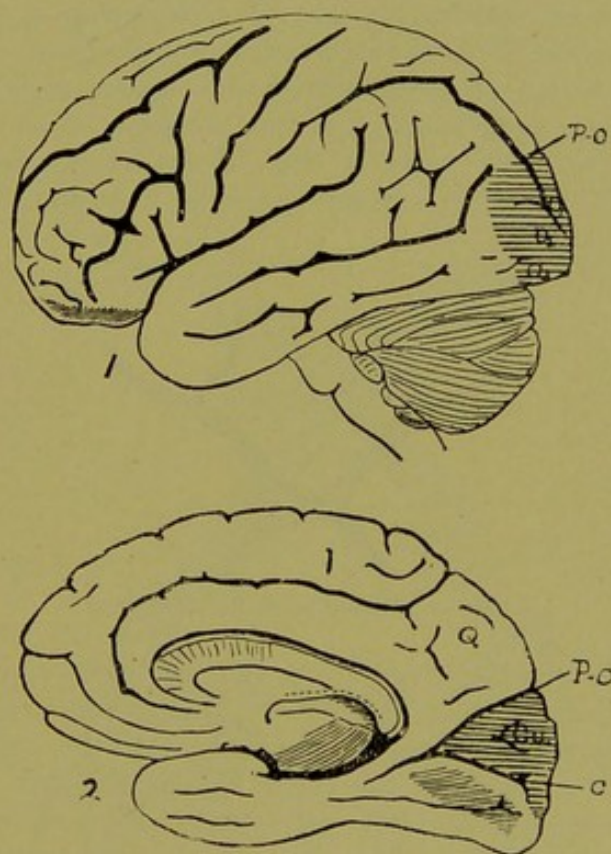
The fibres of the median root go to the internal geniculate body, at which place there is a connection made with the posterior quadrigeminal body.

In addition, there are small roots arising in the vicinity of the sub-thalamic body, and originating in the gray matter of the infun-

dibular region. Further, Stilling asserts the existence of another root which comes from the medulla oblongata to the pedunculus cerebri. There are also certain fibres that make their way to the nuclei of the oculo-motor nerves.

Backward and upward from these ganglia, the radiating visual *fibres of Gratiolet* proceed. Curving around that portion of the lateral ventricle which lies in the occipital lobe, and taking on the gray matter of that lobe when they reach the posterior portion of the internal capsule, they spread out fan-like in the occipital lobe to reach the cortex. These are fairly well shown in part in Fig. 40.

FIG. 41.



Visual cortex. (STARR.)

Practically, then, as can be seen by the colored drawing in the chapter on Physiology, each tract curves around the crus cerebri and terminates mainly in a series of ganglionic masses—the external geniculate body, the optic thalamus, and the anterior quadrigeminal body. Passing from these gray ganglia, a fresh series of nerve strands escape from the lateral portions of the thalamus, go into the internal capsule, and curve outward and backward around the posterior horn of the lateral ventricle and terminate in the occipital convolutions and cuneus.

As pointed out by Starr, the portions of the cerebral surface which hold the visual cortex are the occipital convolutions and the cuneus. Thus in Fig. 41, the first illustration represents the lateral surface of the left hemisphere, whilst the second illustration gives the median surface of the right hemisphere. The heavily shaded portions designate the areas occupied by the visual cortex.

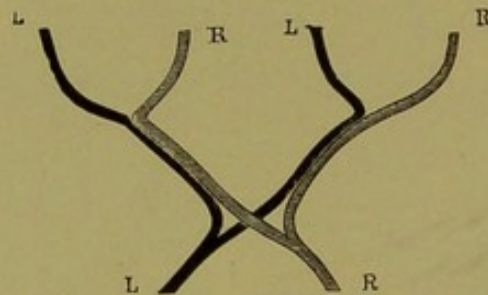
CHAPTER III.

PHYSIOLOGY.

SINCE the organ of vision is a structure for sensory purposes, possessing in its peripheral portion, the eye proper, the power of movement, the most satisfactory way of considering it physiologically is to study the action of its sensory and motor portions separately.

The sensory portion of the human ocular apparatus is so intertwined at the optic chiasm as to make the two portions of one ocular retina correspond with the two parts of that of the fellow-eye, showing that each ocular bulb contains sensory material intended for use on both sides.

FIG. 42.



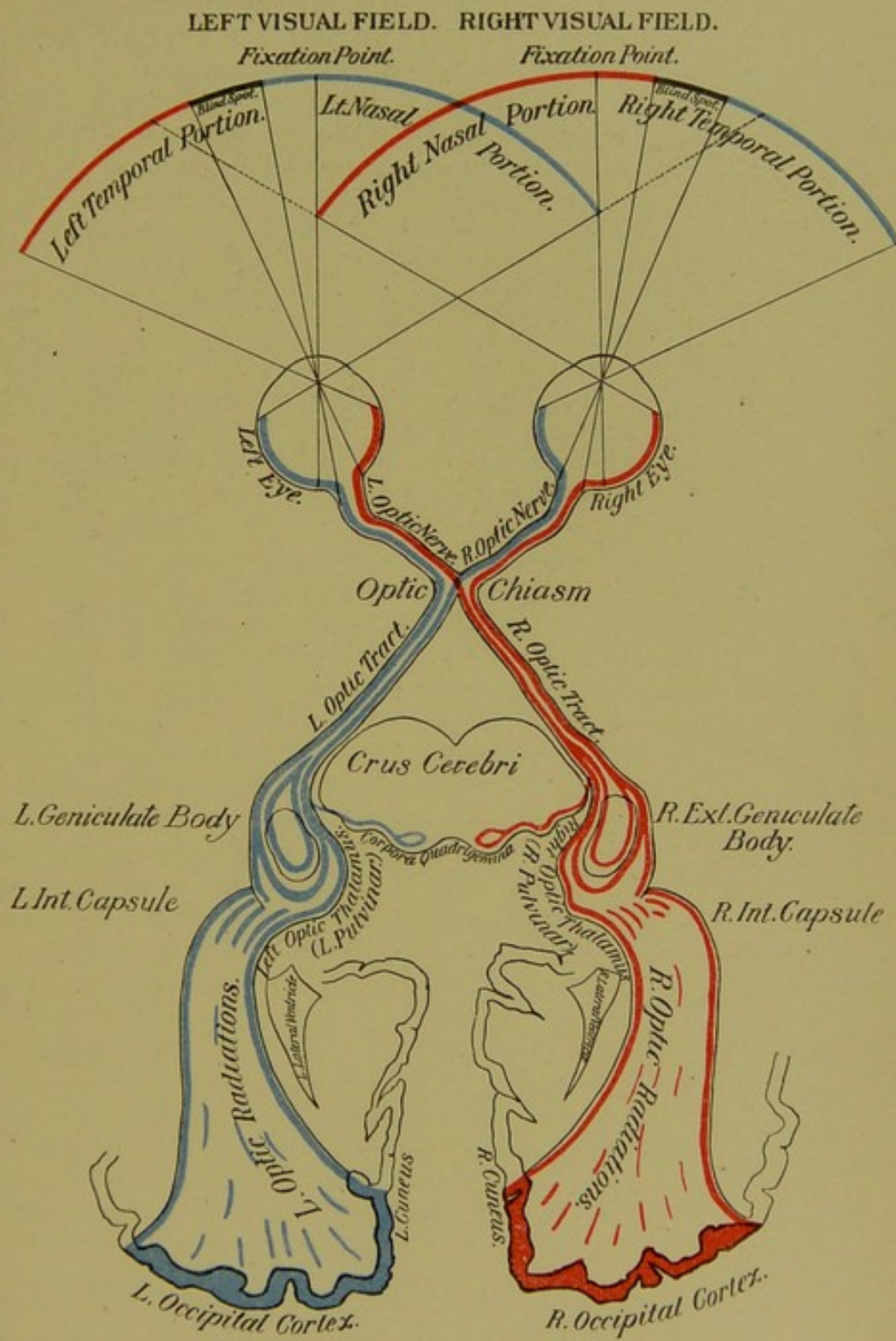
Decussation of optic-nerve fibers. (WELLS.)


In Fig. 42 the lightly shaded line at the lower right-hand corner of the figure, designated as R, which represents the right optic tract, divides into two portions, one of which goes to the outer side of the right eye, and the other to the inner side of the left eye; the same being relatively true of the left optic tract: thus showing that each eye contains a portion of the fibres from both optic tracts. It will also be noticed that the sensory material of the nasal portion of each retina is furnished by the opposite hemisphere.

Therefore, the visual apparatus for all objects seen in the right side of the visual fields is prolonged inward from the left side of each retina, and all that intended to receive impressions from the left side of the visual fields is found on the right side of each retina. Thus, in the colored plate, all visual objects situated in the parts of the visual fields that are tinted blue are sent to the right cerebral hemisphere for recognition, and all those in the red portions are sent to the left cerebral hemisphere.

Man enjoys both monocular and binocular vision, and in effecting either fully he must use both hemispheres. To use both eyes at the same time means to employ both cerebral cortices at the same moment. To use one eye properly means to employ the related portions of the two cortices.

PLATE I.





Further, should some intra-cranial mischief produce a loss of one-half of the visual function in each eye, which is designated as hemianopsia, the remaining portion of the visual field will include central, or as it is called macular, fixation. This shows either that the macular fibres of each retina have a special individual and crossed connection with the two cortices, or that there may be a true cortical association. From conjoined neurological studies and pathological data, it seems probable that the former is the case. In man, therefore, there appear to be two separate series of centres, one for the macular fibres and the other for the circum-macular fibres, each having connection with the cortex of its own side as well as with that of the opposite. Stimuli are thus allowed to be received by the macular fibres on both sides, even though connection with one cerebral cortex should be annihilated. Thus there is ordinarily simultaneous double action of the macular fibres.¹

Many theories been put forward to explain the working of the visual apparatus and the accomplishment of the sensory acts.

To perceive color, the mind must take cognizance of the action of color-sensation in the occipital cortex, a sensation which has been ever altering from the time when it was first formed from a peripheral impression of natural color-stimulus on the retina.

All that we can say is, that the innumerable retinal rods and cones placed side by side as a sheet of impressionable material at the bottom of the eye and dipping part-way into a layer of pigment, seem to possess some power of metabolism, which has been brought about by appropriate external stimuli, by which corresponding sensory impulses can be carried centripetally: in fact, there is a life-stuff in the material which helps to give origin to a molecular change—a species of motion. What the character of this kinetic force may be, is, at present, with our imperfect methods of observation, impossible to determine. We merely know that the mechanism presents peculiar appearances under different physiological conditions. Thus, when the eye has been exposed to strong stimulus, the irregular processes of the cells of the pigment epithelium are found prolonged far in between the outer segments of the rods and cones: whilst if the same part of the organ be examined when it has been kept unexposed to light, the processes will be found but slightly intruding. The component cells of these prolongations, which are as a rule studded with fine black pigment containing a material known as *fuchsin* or *melanin*, seem during exposure to constantly carry their pigment inward and outward from their nuclei to coat and recoat the outer segments of the rods and cones. The rapidity and intensity of this action is governed by the amount of light-stimulus which is poured in upon these retinal elements. The nuclei of the cells, therefore, seem to be workshops in which, during exposure to light, the crystallized pigment, which has been stored up in them during darkness, is being constantly painted upon the outer layer of the rods and cones by ever-moving and ever-changing tongues of cellular tissue.

¹ It must be distinctly understood that a central blind spot may coexist in some instances, seemingly invalidating this rule. To avoid illustrative complication, the semi-decussation of the macular fibres has been omitted from the colored diagram.

In addition, the outer segments of the rods, especially when unexposed to light-stimulus, are invested with a purplish pigment known as *rhodopsin*, which is extremely sensitive to both monochromatic and polychromatic light.¹ Of the office of this secretion, which is said to be an actual derivative of the fuchsin on these portions of the retinal terminals, nothing absolute is known. Though by no means certain, and even by some contradicted with much show of reason, it seems plausible to assert its connection with the visual act as a sensitizing preservative material.

Kuehne has found that he could produce more or less permanent colorless areas, or *optograms*, upon retinae which had been exposed during life to similarly shaped areas and objects possessing power of intense light-stimulation: as photographers would say, he fixed the image.

Each lateral combination of such retinal elements gives its compound expression of such points. Each related nerve-bundle carries the result to an equivalent cortex area. Each point ever changing, and each grouping ever differing, give the multitudinous and momentary impulses that are constantly carried to the visual centres. These sensations, associated in the visual centres with other related sensory and motor changes, form in connection with the higher mentalities, the ultimatum of the visual sense—*sight*.

For proper color-sensation, then, the neural cells of that portion of the occipital cortex must be rendered active. No matter whether the force be of external or of internal origin, if it acts upon these cells, or if it makes a new cell in this mass, it will cause color-sensation. Hence if there be mental recognition of this sensation of color—if the higher centres act and the mind take cognizance of this sensation, color-perception ensues, thus supporting the saying of Epicharmus, the old Greek poet:

" 'Tis mind alone that sees and hears;
All things beside are deaf and blind."

As we well know, there is a limit to this physiological action. The nerve-fibril accomplishes its work with a definite degree of celerity. Thus, Cattell has shown that with a unit of 0.001 sec., the average length of time necessary for the unfatigued eye to recognize a few of the most important colors under strong illumination equalled 0.82 sec. for orange, 0.96 sec. for yellow, 1.21 sec. for blue, 1.28 sec. for red, 1.42 sec. for green, and 2.32 sec. for violet. Here the same nerve-tips receiving different degrees of color-stimulus show results which not only serve to estimate the comparative strengths of the various color-vibrations received, but also give answer to the relative quickness of ability for perception of the several natural colors exposed—results which are in accord with the normal order of the visual fields to be described later on.

Both laboratory experiment and clinical example have taught us

¹ Albinos are the exception, though here, as Gunn remarks, the non-pigmented cells are evidently capable of performing the same functions, though in a minor degree.

that each optic-nerve fibril has its special amount of power in differentiating color. It manifests itself partly as a matter of education, as shown by the ability of Chevreul to distinguish and separate over fourteen thousand changes of color, and the increased ability of male workers in positions necessitating choice of minute color-differences, to differentiate such changes. It is made apparent by the higher color-sense of women, and the vast differences of power produced by racial and tribal characteristics. It exhibits itself partly as a matter of individual fibre strength, as shown in the dissimilarity of power of the macular and circum-macular distribution in the same retina. Partly, therefore, a matter of heredity, environment, and occupation of the containing organism; and partly a matter of position of the fibre in the organ—the question resolves itself into one of relative physical structure and physiological use.

For the average human macular fibril, it is probable that several hundred or thousand different color combinations can be separated from one another without the ability of verbal or oral designation.

Again, there is a difference in the amounts of color-area necessary to be exposed for recognition at certain distances under the same light-stimulus. In a series of experiments with a few of the most important colors on a black background and under diffused daylight exposure, the author has found that red requires two and two-thirds millimeters' exposure to be properly recognized at five meters' distance; yellow, a slightly increased area; blue, eight and three-quarters millimeters; green, ten and three-quarters millimeters; and violet twenty-two and three-quarters millimeters. In all these experiments the colors pass through different phases of faulty naming before being properly designated. Green almost invariably is termed whitish and bluish; red, whitish; orange, salmon color; blue, dirty white; yellow, whitish and lemon color; and violet, yellow, or even pink, after being termed dirty gray. Where artificial yellowish light (oil) was used, and the period-of-time method was employed, Cattell has found that orange, red, violet, and blue was the order of the colors named.

Just as there are differences of receipt in the individual fibril tip, so there are limits to the working capabilities of small areas in the recognition of form. Independently of changes in the power of focussing possessed by the eye in producing certain well-known peculiarities in image-formation upon the retinal plane, there is a difference in the grasping quality necessary for the correct perception of various objects, as, for example, the characters used in written language, ornamentation, and the minute distinctive points in letters of almost similar shape. The curved forms, the marks of punctuation and accent, etc., of many of the present styles of type are all more difficult to see and take a longer time for recognition than the simpler and more regularly arranged characters. This is well shown in the differences of recognition of the many similarly sized, though badly shaped test types daily used in ophthalmology—differences dependent upon improper letter-formation.

As the fibre becomes more peripherally situated in the retinal sheet, and less occupied in direct vision, it grows weaker, until at last it is able

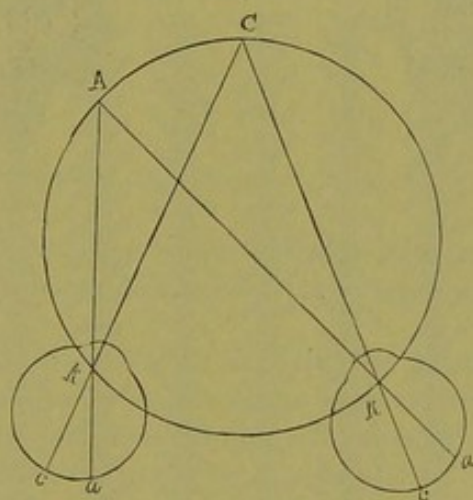
ordinarily to respond to but a few of the strongest color-stimuli. These losses, manifesting themselves by areal limitations, produce what are known as *fields of vision*. The order of a few of the most usually studied of these is green, red, blue, yellow, and white, their average relative extent being gauged to comparative sizes. Experiment teaches us, as is shown in the chapter on Examination of the Eye, that although the color-outlines are concentric, they extend further to the temporal and nasal sides than they do superiorly and inferiorly. Vertical and horizontal lines drawn through the fixation-points are known as the *lines of separation*, and are of value in designating the position of corresponding points.

The sensory elements are the most densely packed and the most highly evolutionized in the macular region or region for distinct vision, becoming more widely separated and less well developed as they pass peripherally on all sides. This intimate association, greatly increased number, and highest evolution in the region of the yellow spot, allow the finest points of object-rays to be received, transmitted, and perceived. Here the greatest detail of distant landscape or of near object can be obtained. Ever lessening from the veriest central cone, the most finely differentiated objects in the field are the first to go, until, getting out into a retinal area which includes about forty-five degrees of the visual field, small objects can no longer be separated from one another. This smaller central area is termed the *field of fixation*, or *qualitative field of vision*. This is the area in each eye in constant use for distinct vision—an area which upon account of a right and left duplication is not only greatly increased in lateral extent, but is also intensified throughout its binocular extent. Thus in the large color-diagram facing page 80, it will be noticed that the nasal and central portions of the right and the left field of vision lap.

A moment's reflection will show that any object in this combined portion of the two fields must give a double impression, one going to the right retina and the other to the left retina. Further, if we study the prolongation backward of the various fibrils embraced in this binocular area in the color-diagram, we shall find that a portion of them goes to each occipital cortex. Each brain is at work, yet ordinarily in the normal relation of the two eyes we know that the object is seen single. Should, however, one eye be but slightly deviated toward or away from its fellow, as in extra-ocular muscular disturbance, causing the external ray to fall upon some nerve-tips that probably have no cerebral relation; should the double impression of the single object be received upon two portions of the occipital cortex that are not physiologically related to one another, an immediate doubling will ensue, thus indirectly showing as one of the most probable causes that there must be a certain co-relationship, either peripheral or central—probably the latter—of the retinal nerve-tips in the two eyes, to produce *singleness of vision*. Popularly, these retinal points that are so related as to give single vision when simultaneously impressed, are known as *corresponding points* or *identical points*. In every possible field-projection there must be a limit to these corresponding points. The extent of this, which can be formulated for any given

position of the eyes, is known as a *horopter*. For instance, in Fig. 43, the large circle drawn in the plane of the visual axis $c c$ and $c c$ through the point of convergence C of the two axes and the nodal points $K K$ of the two eyes, represents the horopter for that plane. That is, no matter on what part of the circumference an object may be, as, for example, at A , the image-points on the two retinae will fall on identical points, and a single perception of the object will ensue. According to this doctrine, every singly seen object in the binocular field of vision must be situated on some horopter. Unfortunately, this rule will hold mathematically true only for certain geometrically situated points, there being numerous portions of the monocular visual field in which such objects cannot form a horopter with the two eyes. Such objects must be seen double, as can be shown by the experiment of holding two fingers up at different distances along the median

FIG. 43.

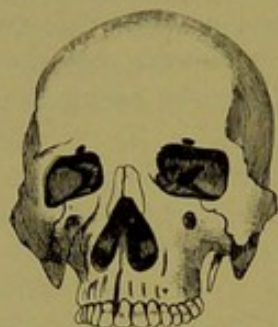


Extent of horopter. (FOSTER.)

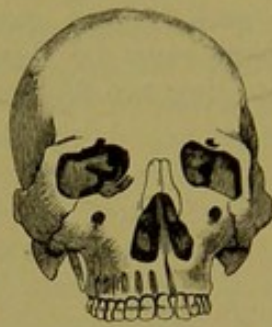line, when either can be made double by gazing at the other. To obtain a single cerebral response to such a double impulse, either one brain image must be ignored, as is so often done by expert microscopists and ophthalmoscopists—who, while using a monocular instrument, ignore the conflicting image of the unused open eye—or a new mental picture of the combined dissimilar retinal impressions must be made by the perceptive centres. That the latter is frequently the case is proved by the fact that ideas of solidity and relative projections are offered to those who possess binocular vision. Each relative impression, a flat one, so to speak, dissimilar in form from its fellow, in combination with previous tactile information, gives a double impression which stands out in space. Thus, in Fig. 44, of a skull as seen by the right and left eyes, where the right-hand figure has the right lateral aspect brought into view, and where, on account of the width of separation of the maculae luteae of the two eyes, the left-hand figure shows more of the left side, the binocular effect when the figures are gazed at with both eyes simultaneously through a double prism, termed a stereoscope, will be a full-face skull situated in the median line and projecting forward into space.

So it is with the visual apparatus. Here the mental combination of the two dissimilar flat pictures impinged upon the right and left retinæ, in association with previous information gained mostly by the sense of touch, produces the visual *perception of a solid object or form* standing out in space. Just as there are limits, however, to the perception of single and combined object-points, so there is a limit to this acquired power. Distant objects, such as isolated mountains or ships at sea, fail to present any ideas of solidity, appearing as if flattened against the background. Again, objects in the peripheral portion of the fields of

FIG. 44.



Skull as seen by left eye. (DALTON.)



Skull as seen by right eye. (DALTON.)

vision beyond the area of fixation have more or less of their solidity destroyed by indistinctness and by want of attention upon the part of the observer.

The *apparent size* of an object is theoretically dependent upon the width of the opening or visual angle which it subtends with the nodal point of the eye, thus causing the mental image of the object to diminish progressively in size as the object is removed from the eye. As the size of this visual angle is modified greatly in different positions and under different circumstances, varied estimates may be given as to the apparent magnitude of the object under these conditions. Thus, a ship at sea in a low dense atmosphere may appear quite large in comparison with a similarly sized object in a high altitude: or even during near vision, as in the complex illusory picture such as Zöllner has given, Fig. 45, where the broad black parallels seem to converge at the top when the short oblique lines point downward, and to diverge at the top when the latter point upward.

Again, possessing, as we do, a focussing apparatus which must be accurately adjusted upon the desired far-point, a certain muscular effort is necessary to be acquired, to make the retinal pictures sharp and clear for that point. Moreover, as it is with one eye, so, though to a greater degree, it must be with the two, in which case there is a superadded muscular effort to fix the two eyes upon the object. These changes of accommodation and convergence, as they are termed, in association with previous information and the present double sensation, give what is known as *ideas of distance*.

Thus, binocular fixation for the performance of certain manipulations is much more certain than monocular. Mental estimates of the distance of near objects are more sure the closer the object is brought to

the eyes. As the eyes, however, gaze at far-removed objects and approach so-called parallelism (convergence being almost lost and accommodative efforts gone), the power of differentiation of distance becomes less marked. This continues until when but little remains for comparison, as in the visual expression of the sun, moon, and planets, all estimation is ordinarily lost, and the distance, especially to an uneducated mind, becomes an unknown quantity.

The *actual size of an object* must in measure be dependent upon the mental estimate of the apparent size in association with a knowledge of the distance and previous information as to the object or its like. Thus, the apparently small size of a ship upon the horizon which we know to be at a definite distance, teaches us from previous information as to such ships that it probably is of a certain size.

FIG. 45.



Zöllner's lines. (CARPENTER.)

In spite of the efforts for supremacy and fusion in the two visual apparatuses when diverse objects are simultaneously presented to the two retinae, the results, as shown by many interesting scientific toys and natural changes, though often confusing, must be dependent upon some of the peculiarities of sensory and mental evolution here given. The majority of these, which need no special description in a book of this character, should not be confounded with those sensations and perceptions which most of us experience at times. These subjectivisms, which are known as *entoptic phenomena*, and which are numerous and varied, are dependent upon faults in the internal structure of the eye expressing themselves physiologically. Thus, the presence of minute opacities or unequal grades of density in any portion of the dioptric system, may cause shadows to be cast upon the retinal sheet, and give rise to entoptic images. Again, pressure of any kind upon the nerve-

elements, either peripherally upon the retina by artificial or pathological means, or by more deeply seated disturbance, may excite subjective phenomena of flashes of light, color, or even form-like manifestations, which are in exact physiological accordance with the degree, the character, and the position of the excitant cause. These are the opposite of the physiological expressions of nerve-fatigue, to be described further on.¹

Like all other nerve-elements, those of the visual apparatus show their decrease of action by corresponding decrease in physiological work. They also show their regains of ability to act by relatively increased expression of physiological results. These may be either seen at the time of fatigue and are popularly known as *simultaneous contrasts*, or are found immediately succeeding the overaction, and are designated as *after-images*. In all instances, they are mere physiological modifications dependent upon the condition and position of the nerve acted upon, and the character and degree of the impression.

For instance, if a definite number of nerve-tips tire for a spot of red, they will be unable for the moment to respond fully for an impression of natural white, but will give answer to their utmost ability at the time. In this instance it will be sufficient to give a sensation of the complement green. That is, the natural red impinged and perceived, plus the subjective after-color green seen when white stimulus was given, will equal the unfinished white sensation of the natural white. As with this red and green, so with any compound of color-vibration which will equal white. With white itself, or with its opposite so-called black, the experiment is interesting and instructive. In the first instance, if a white wafer on a neutral gray ground be gazed at intently for a moment under strong light-stimulus and then be suddenly removed and the light weakened, a corresponding area of black will be momentarily visible. This will be followed by weaker and weaker whites and blacks until the gray ground at this portion of the sheet is again assumed. The reason is plain: the nerve-tips exposed to the strong stimulation of white have had their physiological powers momentarily annihilated, and a blank area of non-perception, or "black" area, as it is termed, appears upon account of the continuance of the perception of the surrounding gray area, just as a hole is seen in a board. The after-alternations of apparent white and black with the definite order of coloration so often seen, continue in increasingly lessened degrees until the nerve-tips gradually regain their normal strength. If a black wafer be used upon a white ground and the whole brilliantly illuminated, the black area which has not affected the equivalent-sized retinal area will appear white upon suddenly removing the wafer and reducing the light-stimulus. This experiment proves that the tips supplying the area beneath the black wafer were fresh and active, whilst the surrounding ones were fatigued. Here the sequence of after-color change is just the opposite to that presented in the previous experiment.

As with *successive contrast* (as the after-images are sometimes termed), so it is with the simultaneous. Here the neighboring tips to

¹ It is interesting to note the many expressions of nerve-tire, and, in most instances, when the nerve apparatus is in healthy condition, the momentary regains during such fatigue.

the impinged ones seem to be affected by the natural color-stimulus and are only able to respond to the complements of the exposed color. Thus, if a red wafer is laid upon a white ground, there is a perception-area of red surrounded by a halo of green. That is, the surrounding nerve-tips are unable to respond properly to the white stimulus bordering the red. The red tips used for this area seem to have taken just that amount of strength from the bordering ones which are exposed to the white that will give a remaining amount of power which is equivalent to green. In other words, the nerve-tips have been weakened in strength to a degree equivalent to the perception of red, so that when a strong compound stimulus is given (composed, for example, of red and green to equal white), they are only able to give green perception to the white exposure.

This law of simultaneous contrast will also offer sufficient explanation for the visual phenomena of *irradiation* where colored fringes cause light-areas in juxtaposition to appear larger and stand out stereographically.

The length of time required for the impinged nerve-element to regain its accustomed strength can in most instances be measured. Clinically it can be prolonged by appropriate experiment, giving rise to interesting and instructive devices and mechanisms. For instance, a point of light revolved rapidly, will, as is well known, give a continuous line of light which exactly coincides with the direction of movement given to the illuminated point. This is beautifully shown in Mr. Roberts's so-called philosophical toy, in which the words on a disk that are made to revolve forty thousand times in a minute before a narrow slit, can be made visible and intelligible. The rotative disks of Müsschenbroeck perfected into the so-called "dazzling tops," where solid objects, such as bowls, cups, vases, etc., that are in reality mere outline representatives in some stiff metal, appear to revolve on top of the apparatus, are dependent upon the same condition. The well-known thaumatrope and zoëtrope, and the wonderfully ingenious praxinoscope of Raynaud, may also be cited as additional examples. This, which is known as *persistence of retinal impression*, depends upon the quality and quantity of the impinging stimulus and the condition of the receptive nerve-material. The rule is that the stronger and the more persistent the stimulus and the fresher and more active the nerve-element, the greater and longer will the persistence be.

A portion of the subject which has given rise to a vast amount of discussion, and which is more apparent than real, is *erectness of vision*. The retinal image, being inverted, was the one that the mind was supposed to take cognizance of: but now, as we are aware that the occipital cortex is the membrane in which the visually sensitized cell or image is situated, all that is necessary to imagine is that the simultaneously differently sensitized cortex cells give to the higher perceptive brain cells a mental image, as it were, of the cortex area so affected, so that it is not at all necessary to refer to the peripheral image or impression in the retinae. Again, as we know from the lines of visible direction, the image-points of the object are projected outwardly to their exact situations in the object itself, thus causing the entire object to appear

in its natural position. This latter explanation, in combination with other mental evidences, also offers conclusive answer for our ordinary ideas of *visual direction*.

There is one region in the retinal sheet that is incapable of impression from extraneous stimulus. This is the optic-nerve head, a portion of the fundus oculi that is devoid of nerve-terminals—the rods and cones with their sensitizing pigments. It thus, in reality, becomes a blind spot on the sentient membrane, and in consequence, leaves a hiatus or *scotoma* in the field of vision. This can be demonstrated clinically, as explained in the section on Perimetry, or can be shown subjectively by gazing in a definite manner at Fig. 46. Here upon closing the left eye whilst gazing intently at the cross with the right one when the

FIG. 46.

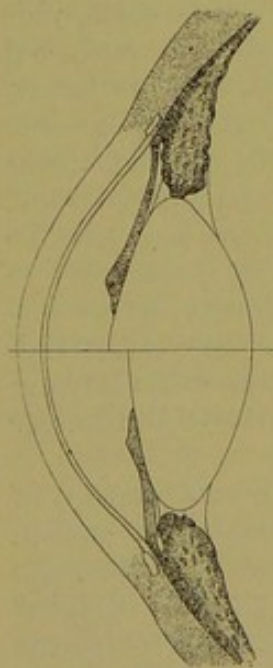


Diagram for subjective study of blind spot. (HELMHOLTZ.)

diagram is held some thirty to forty centimeters in front, the circle will disappear for a moment as the sketch is brought inward toward the

exposed eye. This momentary loss of physiological action is expressive of the time at which the image of the circular area fell upon the insensitive optic-nerve head. Fortunately, as can be understood from the colored diagram, the overlapping of the two fields of vision allows the nerve-fibrils of the opposite organ to take record of any images that may fall in the blind-field area of the fellow eye.

FIG. 47.



Mechanism of accommodation. (HELMHOLTZ.)

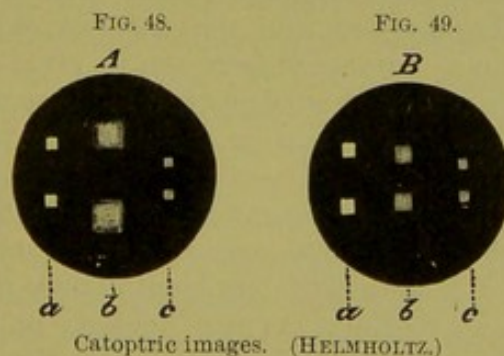
Besides this special sensory act of the apparatus, there is the power of motility given to a portion of both the internal and external structures of the end-organ—the eye itself. Here, especially in man, there are a series of intra-ocular and extra-ocular muscles which are intended for the government of both focussing and projection. Here there is a grouping of delicately balanced muscular tissues, so arranged as to allow binocular and monocular fixation upon any desired point. As has been shown in the previous chapter, the intra-ocular muscles are the ciliary and the iris groupings, whilst the extra-ocular series include the six attached muscles to the globe, and

the accessory ones governing the movements of the lids, etc. The former variety is intended for the regulation of lenticular power and the government of the size of the pupillary area. The external group-

ings are employed for the control of the movements of the globes and the associated ocular appendages.

The lens matter is supported and compressed by a ligament which is in direct relation with the ciliary bodies. These ciliary bodies constitute a ring or ridge in which is hidden a small annular muscular structure known as the ciliary muscle. In its action (according to Helmholtz), this muscle drags the ciliary processes with the posterior part of the chorioid toward the tissues around the so-called canal of Schlemm. By this action, the hill-like eminence over which the peripheral portion of the suspensory ligament of the lens is attached and stretched, is flattened. This flattening allows the zonule to advance and to be wrinkled or thrown into folds. Both the lens and the capsule fibres, however, possess an inherent elasticity by virtue of which they elongate the moment any decrease of tension is given to their tissues. This elasticity keeps the ligament taut and increases the antero-posterior diameter of the lens the moment the ciliary muscle contracts; the amount of increase being directly dependent upon the degree of muscle-action. As soon as the muscle ceases to act, the ciliary bodies resume their shape, the chorioid retreats, and the zonule is re-stretched and compresses the lens into its original flattened position. Thus, in Fig. 47, taken from Helmholtz, the upper half of which represents the relation of the parts during the accommodative act, the ciliary bodies are flattened and the antero-posterior diameter of the lens is lengthened. The simultaneous contraction of the pupil, as explained on page 92, is also seen.

These views are supported by the interesting studies in catoptrics made by Sanson, Cramer, Donders, and others. Thus, Figs. 48 and 49



are representative of the average position and relative size of the three so-called *catoptric images* or images of reflection, from the anterior face of the cornea at *a*, the anterior capsule of the lens at *b*, and the posterior capsule of the lens at *c*, that have been produced by allowing the bright glare from two vertically disposed square prisms to fall successively upon the three surfaces. Fig. 48 represents the relative situation of the reflexes when the eye is gazing at a distance (and hence not accommodating). Fig. 49 shows their changed position when the eye is fixed, and hence accommodated, upon some near object. Here the squares *b*, representing the reflexes on the anterior capsule of the lens, are much smaller and have approached one another vertically, thus evidencing an increase of curvature; whilst the squares

c, designating the small inverted reflexes from the posterior capsule, have undergone but little movement and change in size. The increase in thickness of the lens during the accommodative act, is also shown by the lateral separation of the images *b* and *c*.

These movements are conclusively proved by the experiments of Hensen and Völckers. They inserted pins and fine glass rods in various parts of the sclerotic of freshly enucleated eyes, so as to cause them to impinge either upon the front face of the anterior capsule of the lens, into the equator of the lens itself, or directly into the chorioid and retina just behind the ora serrata. By stimulating the ciliary region with electricity, accommodative movements could be recognized by movements of the pins. In every instance, there was a forward movement of the tissues in all these situations, as shown by a decided backward bending of the free extremities of the pins or rods. If the pin or rod had been made to touch the back face of the posterior capsule of the lens, its free end was immediately directed slightly forward, when the ciliary muscle was made to act. The greatest deviation always appeared at the point of irritation. Moreover, where the peripheral border of the lens and the tips of the ciliary bodies have been exposed by broad iridectomies, Coccius has been able not only to see the ciliary process increase in size and come forward, the zone of Zinn apparently broaden, and the peripheral border of the lens seemingly thicken, but he has been able to notice an increase in width of the striæ in the posterior capsule immediately back of the space of Petit. All these data serve to support the legitimacy of Helmholtz's supposition.

In extreme accommodation, which takes almost double the time that is necessary to relax from the same point, the centre of the anterior surface of the lens pushes forward into the anterior chamber sufficiently far to lessen its radius of curvature from ten to six millimeters. During the same act, the posterior surface of the lens moves backward into the vitreous only enough to lessen its radius of curvature from six to five and one-half millimeters. These two facts demonstrate that the forward portion of the lens bulges much more than the posterior. At the same time the extreme antero-posterior diameter of the lens increases four-tenths of a millimeter in length (that is, it becomes four millimeters long). In addition, as can be seen in Fig. 47, the peripheral border of the iris moves backward, and the centre of the iris plane is slightly bulged anteriorly. The pupillary area, as shown by Donders, decreases in size a moment later.

Next follow the pupillary changes. Study of these will show that there are two varieties of iris-motion—one causing involuntary pupillary contraction from light-stimulation upon the retina, and the other a similar, though voluntary contraction of the pupil which is connected with the acts of convergence and accommodation. The fact that, in the former, a point of light must be allowed to fall upon the retina to obtain contraction of the pupil, shows that there must be a communication between some of the ingoing fibres of the retina and the outgoing strands to the sphincter muscle of the iris. This communication is established upon the assumption of the existence of a series of fine

pupillary fibres which, in association with the true visual fibres of the second nerve, pass directly into the intra-cranial cavity. Here, as is explained in the chapter on Anatomy, the pupillary series leave the second nerve proper, and penetrate through the cerebral mass to reach the oculo-motor roots, where a sensory-motor combination is effected. Light-stimulus then, to produce pupillary contraction, causes an associated act to travel back through each optic tract until that portion of the stimulus that is carried along the reflex strands, separates from the main tract to meet the two light-reflex loops. At this situation a motor combination with the strands going to the sphincter muscle of both irides is made. This explains why there is pupillary contraction of an eye that is covered when its fellow is exposed to light-stimulus, and why there is failure of iris-response to light-stimulus thrown from hemianopic field areas.

The iris, besides responding to light-stimulus thrown upon the retina, or, what is practically the same thing, acting by irritation given to the fibres of the optic nerves themselves and thus making the pupil correspondingly small, acts similarly, though to a less degree, in associated movement when voluntary or semi-voluntary efforts for accommodation are made, either with or without convergence. This is not surprising when we take into account the fact that the central nuclei for the third, the fourth, and the sixth nerves, are not only placed in close proximity, but have an inter-related anatomical communication with one another, this communication being in direct relationship with the so-called associated movements of the two peripheral organs. For instance, as has been partially explained, there must be a physiological connection to allow the internal recti to act conjointly. There must be simultaneous central innervation of the internus of one eye and the externus of the fellow eye to allow these dissimilarly-placed muscles to respond together in so-called conjugate deviation. Again, the same must be true, as seen from the conjoined acts of the two internal recti with their compensatory obliques; as noticed with the simultaneous response of the ciliary muscle, the sphincter muscles of the irides, and the internal recti; and as expressed by the entire muscle-grouping whilst the eyes are performing any accurate double fixation upon a single object. In all these combinations of purposive action, there must be absolute anatomical connection to afford this beautiful harmony of irregular muscle-action. Moreover, these determinate proofs of physiological association and material connection are not only all distinctively shown by the fact that the motor groupings are in close relationship of action with one another, but are further proved to be a necessity in such a peripheral combination of sensory material as the two eyes, where a double impression is practically converted into a single perception.

Granting, then, the necessity, for proper image-formation, that there should be accurate and simultaneous placing of the two ocular globes with definitely related degrees of focussing, it is clear that every effort to obtain any desired point of fixation throughout the visual fields must mean a certain percentage of related muscle-action. So here, where accommodation, either monocular or binocular, is brought into play, and the related central nuclei are necessarily affected, the central nuclei in

connection with the sphincter pupillæ are also shown to have been brought into associated action by the fact that the pupils have become contracted during the accommodative effort; this being in obedience to the physiological law that, whenever two muscle-groupings learn to work in association, their central nuclei have been acting together to produce co-ordination of result.

This special combination of iris-action in accommodation is of value, as explained in another chapter, in placing a peripheral curtain around a central area which would ordinarily be too large to admit of clear definition of a very near object. Some authors, and especially Woinow and Adamük, associate this condition particularly with the act of convergence. That is, they associate it with the coetaneous innervation of the interni. Weber even goes beyond this in stating that pupillary contraction does not take place during accommodation alone. It is probable, however, that there is a common nuclear action when any one of the three peripheral endings of the reflex arcs is excited.

During sleep, which in part is expressed by physiological rest of the binocular focussing apparatus, the pupils will be found to be contracted and the eyeballs diverged slightly upward. This can be seen by exposing the globes of any somnolent person. Pupillary contraction is, therefore, merely expressive of the normal condition of all sphincter muscles during sleep.

The cause of pupillary dilatation is one of the moot points in ocular physiology. In view of the doubtful knowledge of the existence of the so-called radiary muscular fibres of the iris, and keeping in mind the correlation of this opening to both the conditions and the actions of the tissues of other communications with the interior of the body that are surrounded by more or less dense constricting muscular material, it seems most reasonable to look upon the pupil as an aperture having a surrounding muscular tissue which, whilst so arranged as to permit of its being lessened in area by constriction of these muscle fibres, has the average tone or condition of these fibres kept in abeyance under ordinary circumstances by a peripheral elastic tissue which is in reality merely inhibitory in its action. The so-called mydriatic nerves, which may be supposed to govern these radiary striæ, are probably derived from the second dorsal nerve, and, like all nerve strands which control the tonus of a sphincter, gauge the size of the pupillary opening by allowing the radiary fibres to act as a fulcrum, as it were, upon which the iris muscle can play. That is, it is a fulcrum which is made by the comparative innervation between the muscle-bearing nerve and the elastic-tissue nerves. If this be true, any departure from such a normality is dependent upon the relation between the two series of nerve-acts—the one an active impulse and the other an inhibitory influence. In the words of Schmeichler, "The pupil is like a fine balance: the slightest irritation produces a reaction, the slightest interference completely suspends its function."

Most interesting is the fact that the higher the possessor of an ocular apparatus belongs in the animal kingdom, the more certain is he to have fewer special end-organs. This is true, until at last, in the class vertebrata, but two peripheral bulbs, each of which is moved by four

straight and two oblique muscles, can almost universally be noticed. Here, superadded to the fact that the spheroidicity of the end-organ allows a greater increase of the visual field than that obtained, for instance, by the polymeniscous arthropods with their hemispherical corneal surfaces provided with myriads of lenses, we have the directive power of the organ's externally attached muscles which permit a single end-bulb to be capable of obtaining a broader working field than that which is gained by many of the shell-less mollusks by their entire combinations of simple eyes situated on their dorsal surfaces. Here, by a movable compound dioptric apparatus enclosed in a small rounded cavity, there is a focussing material which permits a wonderful degree of adaptive and penetrative powers to be given to the organ. Moreover, it must be remembered that each organ is so duplicated as to be able not only to work in association with its fellow, and thus give simultaneous sensation to contiguous and related cortex cells, but actually to add new peripheral field-areas in which useful vision can be obtained. Further, the numerous groupings of the small, delicate muscles of the neck which so unconsciously and yet so definitely respond with every series of monocular and binocular movement, play important rôles in the rapid increase of visible direction. The same must be true, though of course to a lower functional degree, for the trunk and lower-extremity muscles in the indirect motility of the organs of vision. All these related physiological acts and movements decidedly point toward central nuclear connections in greater or less degree.

During the first few months of infancy, the apparent movements of the eyes are so much at variance with what must be necessary to sustain binocular fixation upon single objects, that there cannot be any single-ness of result from the two organs at this time of life. This incompleteness of one of the most complex of the associated ocular movements, would seem to imply a similar incompetency of the purpose of the other associated acts of the two organs. It shows itself as one of the many incapacities of co-ordination in this incomplete mite of humanity. If proper progression of physiological action takes place, it will be noticed that the binocular motions necessary for synchronous action, gradually assume a purposed and definite change for every position desired.

If the two sensory structures act in harmony and give combined pictures of single projection, it becomes necessary, as has been previously explained, that every two related element-groupings should be simultaneously fixed upon the extraneous objects. Just here is one of the provinces of the muscles which are externally attached to the ocular globe. Remembering that the ocular globe is practically a sphere or spheroid set in a cavity of sufficient size to allow it an infinite variety of movements around a fixed centre, termed the *centre of motion* or *centre of rotation*, which is said to be situated intra-ocularly 1.77 millimeters behind the middle of the visual axis, we are immediately brought to the basis of the movements of these muscles. This basis, from which all ocular motion is estimated, is known as the *primary position*, which may be understood to be that position in which the two visual axes and the median plane are parallel to one another. It is assumed when

the eyes of a standing person are fixed upon a distant flat horizon.¹ All the other positions are known as the *secondary positions*. To effect these stations or positions, the eye is controlled by six attached muscles, which, upon account of the results of their various physiological actions, are divided into three separate groupings. The first and most important is that produced by the action of the combination of the external and internal rectus muscles. The associated acts of these two muscles are productive of a motion which is situated in a curve around an axis known as the *vertical axis*—that is, vertical to the horizon, thus giving a lateral curvilinear motion to the globe in a plane known as the *plane of the vertical axis*. The second, which is obtained by the combined acts of the superior and inferior recti with the obliques, gives the whole curvilinear movement in a plane known as the *plane of the horizontal axis*, around an axis which is made by drawing a line from the temple to the root of the nose. This axis, known as the *horizontal axis*, is inclined posteriorly and outwardly at an angle of sixty-three or sixty-seven degrees with the median line of the face or the anterior-posterior ocular axis. The third motion is made in a plane known as the *plane of the longitudinal axis*. It is accomplished by the action of the two obliques. The motion is said to be about an axis running from the ocular centre to the nucha. This axis is known as the *longitudinal axis*. It bisects both the median line and the antero-posterior axis of the globe at an angle of about thirty-five to thirty-nine degrees. These series of movements in their many combinations are, as a rule, regulated by a law known as *Listing's law*, which says that any movement to a secondary position is in reality one of rotation around a planal axis that, passing through the centre of motion, is perpendicular to the visual axis. Recession of the ocular globe is obtained by simultaneous action of the four recti (a power possessed to a marked degree by some of the amphibians—for instance, the frog—though but slightly noticeable in man). A forward movement of the eyes is obtained by a conjoined action of the two obliques. These constitute the sum-total of direct extra-ocular motions.

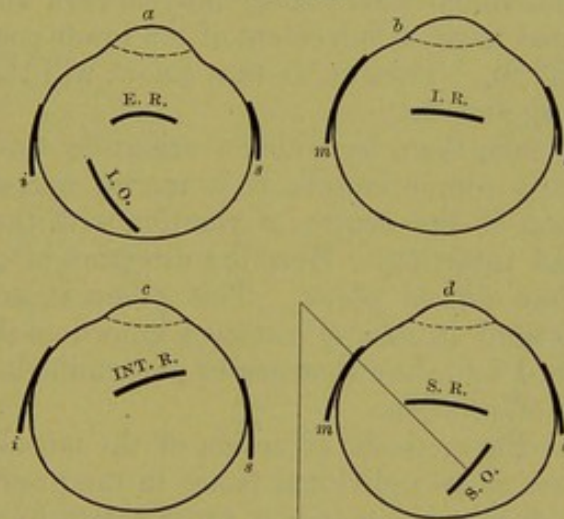
In the human ocular apparatus, both the monocular and the binocular motions are ordinarily limited to definite degrees which vary with the condition of the eyes and their co-relationship. These degrees of result may be the consequence of the peculiar method of movement of the muscle, either in its individual action or when working in combination with its fellow. They are also dependent upon the comparative shapes, sizes, and positions of the ocular globes themselves. Taking, for instance, a single superior rectus and analyzing its action, it will be found that its ordinary direction of pull is such as to roll the forward part of the eye—the cornea, with which we are most concerned—up and in: upward, because its tendon of insertion, as shown in *d* of the accompanying figures, slightly modified from that by Merkel, is situated above the cornea; inward, because its origin at the upper border of the optic foramen is placed relatively to the inner or nasal side of the same

¹ As the visual line of ordinary distant vision is situated a few degrees below the horizon, Meissner has assumed a downward inclination of about fifteen degrees to the horizon line for the height of the perspective point.

portion of the eye. This, however, does not fully fix the exact course of movement which is given to its muscular tissues during the contraction of the fibres from their insertion towards their origin. The shape of the globe, which determines in measure the position of the centre of rotation around whose axis the eye is made to revolve, the refraction of the organ, the position of the orbit in relation to its contained eye, and the condition of the nuclear equipose, all play important parts in the study of the precise angle of movement.

Just as the superiorly situated muscle of the globe has been analyzed, so the direction of pull for its antagonist, the inferior straight muscle, may be studied. Here, as its attachment of insertion is placed beneath the cornea, as shown in *b*, Fig. 50, and as the position of its origin is situated up and in from the point of the attachment, the cornea, or anterior segment of the globe, must be dragged down and in.

FIG. 50.



Points of insertion of extra-ocular muscles. (MERKEL.)

The letters *a, b, c, d* represent the globe in four different positions. The broad curved lines show the points of attachment of muscles. The situations of the related muscles, seen upon the circumference of the four figures, are noted by the initial letters *i* (inferior rectus), *s* (superior rectus), *m* (internal rectus), and *l* (external rectus).

A similar analysis of the internal and external rectus muscle actions will show that, as the points of the insertion and origin of these two muscles are situated in the same horizontal plane, their actions must be in this plane. For these reasons, the anterior segment of the organ is moved horizontally in the direction of the acting muscle; the amount of circumlinear motion given to the nasal or inner side of the front face of the globe being greater than that which is given to the outer or temporal face.

The action of the unassisted superior oblique draws the vertical meridian of the cornea down and out, giving it, at the same time, a rotatory motion from above below. A glance at Figs. 9 and 50 will make this clear. Here there is a double line of motion, the one extending from the position of insertion of the muscle on the globe to its pulley or turning-point, the other passing from the pulley to the origin of the muscle at the optic foramen. In consequence of this break in the

direction of contracture, the functional action of the muscle is limited to the portion that is situated between the globe and the pulley, and as this limited action must take place in the direction of the fibres which run from the globe to the pulley, the upper part of the globe back of the equator, to which the muscle is attached at its point of insertion, must be dragged upward and inward. Dragging this point of the ball, which is in the posterior segment of the globe, means a reversal of motion for all points that are anterior to the equator. For this reason we, who look upon the anterior face of the organ during the motions of the eye, notice a downward and outward motion.

The inferior oblique, in its action, gives the corneal summit a movement upward and outward, rotating it at the same time below upward. Remembering its attachment to the globe in the inferior portion of the orbit, as shown in the first illustration of Fig. 50, and its origin at the inner wall of the lower front edge of the orbit, as shown in Fig. 9, we see that its individual action diagonally inward across the inferior part of the eye, must mean a movement of the lower posterior portion of the globe down and in. This, as we now know, will throw the anterior face of the globe up and out.

To formulate a rule, then, by which a scientific study may be made of the action of any simple muscle, it is merely necessary to consider the relative position of the centre of rotation with the middle of the muscle's origin and insertion. Here the direction of motion is always in a plane called the *muscle plane*. This plane is made through the three positions, around an *axis of rotation* known as the *axis of turning*, which is formed by a line that passes perpendicularly to the plane through the point of rotation.

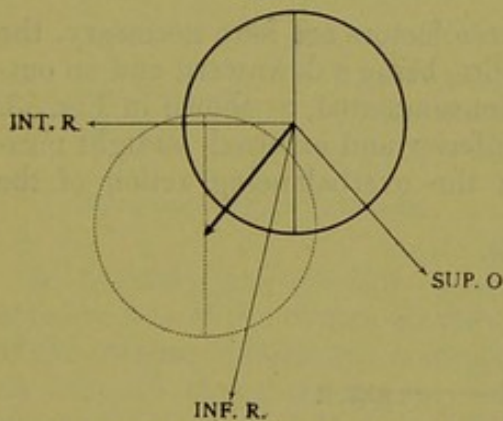
These constitute the methods of action of the muscles taken singly. Though each serves as an individual factor in the production of a definite result, yet each becomes modified in its action by some extraneous yet related condition, when it becomes necessary for it to work in harmony with its fellow. The combination of result is known as the *association of ocular movements*. Here each muscle gives its part to the movements of a muscular mechanism, thus allowing the combined apparatus to become adapted to an infinite variety of positions. As each individual muscle-impulse for some definitely chosen ocular movement has combined with it a commensurate impulse which has been relatively given to every related muscle, this combination of muscle-actions is at times exceedingly complex in character. For instance, the amount of innervation and action of any single muscle, which is measured by its steadiness of movement until the utmost tension has been reached (whilst the summit of the cornea is being carried over a definite arc of curvature), not only varies with the tone and power of the muscle itself, but also changes perceptibly with the connection of the muscle with one or more groupings at the time of impulse. Thus, the action of the two muscles necessary to produce an upward movement of the globe is very different from that required when there is an inward inclination given at the same moment—the inward movement, which necessitates the correcting active influence of a third muscle, changing the muscle balance and necessary pull. Or in one of the binocular motions, an internus

when associated with its fellow for binocular convergence, acts less powerfully than when it has the opposite externus in association, as in lateral deviation. Again, the combined action of the six muscles necessary to throw the two eyes simultaneously down and in, probably calls for a far greater amount of innervation and actual impulse than that which is required by the action of the four muscles which tend to throw the eyes directly up.

Briefly considering the various ocular motions in their monocular groupings, we shall find that we can properly enumerate them in their order of precedence sufficiently well for clinical purposes under eight types or classes. Starting with the primary position, where the muscles are in a state of equilibrium and equipoise, and the vertical meridian of the cornea is at its normal angle, we will consider:

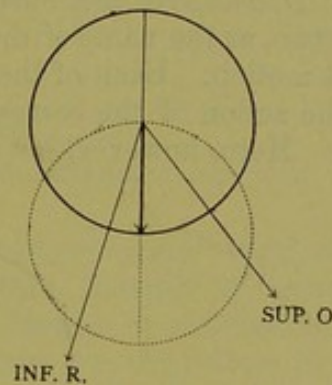
1. *Downward and inward.* Here there is a combined muscular movement tending to throw the anterior face of the organ obliquely toward the median line of the body and below the horizontal plane of the

FIG. 51.



Movement downward and inward.

FIG. 52.



Movement vertically downward.

organ. Here there is a movement which serves to deviate the line of sight into a position where it is of the greatest advantage—the position of vision of manual movements. This motion is accomplished, as shown in Fig. 51, by the active influence of the internal and inferior rectus muscles and the inhibitory influence of the superior oblique muscle. The inferior rectus, on account of its diagonal position, has, as can be seen in the figure, a tendency to drag the lower border of the vertical meridian of the cornea down and in, thus inclining the upper edge of the vertical meridian outwardly. Were these two meridians thus inclined in binocular fixation, they would not be parallel, and there would be double vision. To avoid this, an impulse is given to the superior oblique, which, from its relative position and action, antagonizes this too great action of the inferior recti, by tilting the lower border of the vertical meridian of the cornea outwardly. The too inward deviation being corrected in this way, the vertical meridians of the corneæ become parallel, and binocular vision becomes single.

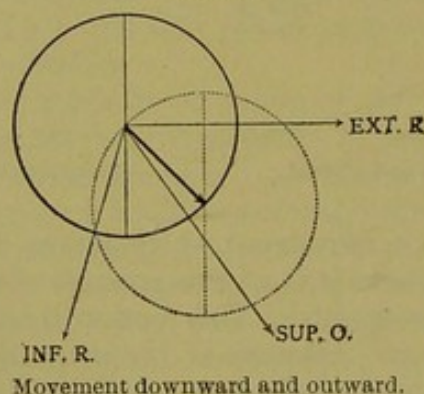
In Fig. 51, and in all the related succeeding ones, the heavy circle with the vertical diameter represents the anterior face of the right cornea with its vertical meridian. The dotted circle and its dotted vertical

diameter show the position of the same cornea and its vertical meridian after the desired movement has been made. The short, heavy arrow connecting the two centres of the circles, designates the line of resultant movement of the corneal plane. The fine arrows diverging from the circumference of the heavy circle, show the direction of movement given to the plane of the cornea by the muscle the name of which is printed at the extremity of the arrow.

2. *Vertically downward.* To effect this movement two active muscular contractions must take place. The first is made to carry the vertical meridian of the eye downward and slightly inward. This is accomplished, as shown in Fig. 52, by the inferior rectus. The second is done to neutralize the undue action of the inferioris in drawing the lower edge of the vertical meridian of the cornea to the nasal side. This is accomplished by the aid of the superior oblique, which, as in the previous case, exerts a compensatory downward and outward motion to this portion of the ocular globe. Here the problem is similar to that in the first type, except that in this class of action the internal rectus is not brought into play.

3. *Downward and outward.* Three factors are here necessary, the first two, as the name of the type implies, being a downward and an outward motion. Each of these two is consummated, as shown in Fig. 53, by the action of the corresponding inferior and external straight muscles. Here, however, not only must the overbalancing action of the

FIG. 53.



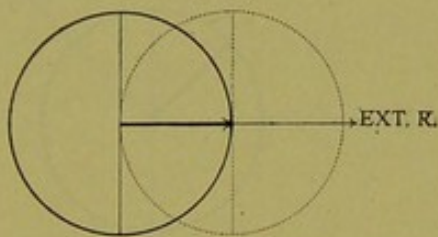
inferior recti in dragging the lower extremity of the vertical meridian inward be compensated for by a corrective contraction of the superior oblique, as in the previous action, but an additional impetus, which constitutes the third factor, must be given to this last muscle, so as to enable a further so-called *wheel motion*, or deviation of the vertical meridians of the corneæ, to take place in the same direction, so that the vertical meridian of the two eyes may be parallel in associated movement.

Fig. 53 shows the necessary muscular action. To recapitulate this motion: Remembering the physiological process necessary to produce the previous result of a downward motion, it will be seen that an additional impulse to carry the anterior corneal plane outwardly, is given in this type of movement. This outward movement is gained, not only by an impulse given to the external rectus, but also by an increased stimulus

given to the superior oblique, which helps to carry the anterior face of the cornea outwardly.

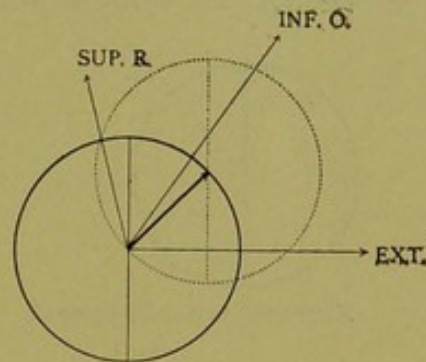
4. *Horizontally outward.* As the centre of the points of attachment of the external rectus and the centre of rotation are situated upon the same horizontal plane, any motion of the externus, from its insertion to its origin, will have a tendency to move the vertical meridian of the cornea more directly outward. As shown in Fig. 54, this is actually the case. Here the angle of pull of the muscle and the angle of the corneal movement coincide. The vertical meridian moves outwardly in a direction perpendicular to the line of motion.

FIG. 54.



Movement horizontally outward.

FIG. 55.



Movement outward and upward.

5. *Outward and upward.* An upward and inward movement of the anterior face of the cornea by the superior rectus, changed by the action of the inferior oblique into a directly upward motion, in association with an outward movement by the external rectus, are the factors in this action. Fig. 55 explains this. The line of traction of the superioris up and in, is deviated outwardly by the line of pull of the inferior oblique, which, when associated with the outward pull from the external rectus, throws the line of corneal drag still further downward and outward.

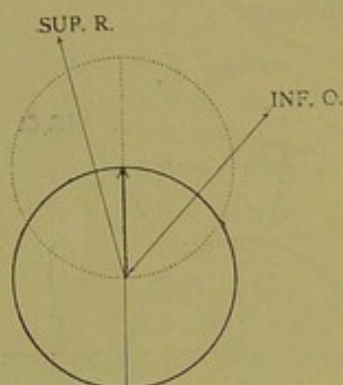
6. *Vertically upward.* In this type of movement the conditions are identical with those of the last class, except that the inferior oblique is less innervated, as it has only its correcting influence upon the superior rectus to perform, and the externus is unused as an active motor. In Fig. 56, the strong upward and inward impulse of the superior rectus, which would produce a movement of the vertical meridian of the cornea in its line of pull, is met by a slight upward and outward impulse from the inferior oblique. The resultant line of motion is a directly upward movement of the cornea in the direction of the vertical meridian.

7. *Upward and inward.* Here the internal rectus is not only brought into play to carry the vertical meridian of the cornea inward, but the superior rectus acts also to drag the anterior face of the cornea up and in. The superioris, however, deviates the upper edge of the vertical meridian inwardly, and thus throws the horizontal meridian down and in. To avoid this complication, the inferior oblique acts sufficiently to lift the combined line of pull upward, so as to bring the line of pull of the superior rectus exactly on the vertical meridian. Thus, having

the associated force of the three muscular actions arranged so as to give an equally combined upward and inward impulse, the result is an upward-inward movement of the corneal face, without deviation of the vertical meridian. Fig. 57 shows this very well.

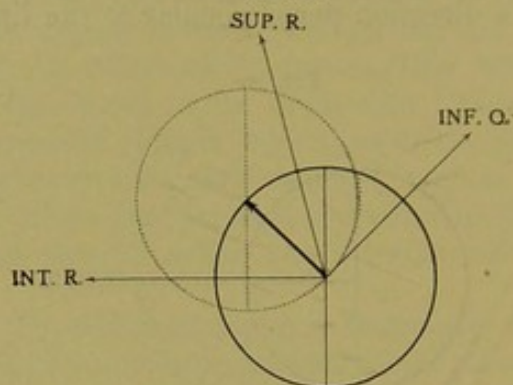
8. *Horizontally inward.* This, the antagonistic action of the outward movement, is produced by the uncombined action of the internus. This can be understood without recourse to a diagram.

FIG. 56.



Movement vertically upward.

FIG. 57.



Movement upward and inward.

We thus see that every peculiarity of movement described means a certain relative amount of co-operative muscular contraction. Not only is this so in reference to these gross manifestations of assistance and antagonism, but it is always present in any form of monocular or binocular action. It is present not only to obtain a definite regularity of extra-ocular muscle action, but also to give fixity to a highly movable globe for the proper consummation of such action, no matter in what relative positions the organ may be physiologically situated with its fellow. Hence, one of the most important fundamental principles of binocular vision, is, that the two foveæ centrales, or some other two corresponding points in the two retinae, must receive simultaneous impressions for singleness of vision.

A few words as to the eyes themselves: Both are so situated in the head as to give, in Porterfield's words, not only "greater facility" to "convey the image of external objects to the common sensorium," but are placed there "because the head is the most erect and most convenient part of the Body," and "that it is the most convenient Place for their Defence and Security." Each bulbus is freely movable in a large, roomy cavity of bone, so situated as to allow a wide lateral field of vision. Each end-organ is protected in front by a broad-fissured double shutter, which smoothly glides over its anterior face. Each eye is possessed of an apparatus by which an aqueous secretion is constantly ejected over its smooth, delicate front from one of the highest points, and each anterior face is continually washed by this secretion, which, aided by the movements of the lids and its own gravity, is alternately aspirated into and forced through a pair of minute excretory canals at the lower inner portion of the apparatus, so as finally to reach the nasal cavity. When we consider its dioptric apparatus, its separated and conjoined muscular

mechanism for focussing and fixation, its protective coats and nutrient channels of transparent fluid, and its sentient sheet gathered into a bundle, to be carried intermingledly to a combined centre for perception, we may well quote, in conclusion, the words of the great Porterfield: "From all which everybody may see, what a noble Piece of Geometry is manifested in the Fabric of the Eye, and the Manner of Vision. There is not one Part of the whole Body, that discovers more Art and Design than this Small Organ: All its Parts are so excellently well contrived, so elegantly formed and nicely adjusted, that none can deny it to be an Organ as magnificent and curious as the sense is useful and entertaining. Surely it cannot be said without betraying the greatest Ignorance, as well as Impiety, that the Eye was formed without Skill in Optics, or the Ear without the Knowledge of Sounds."

CHAPTER IV.

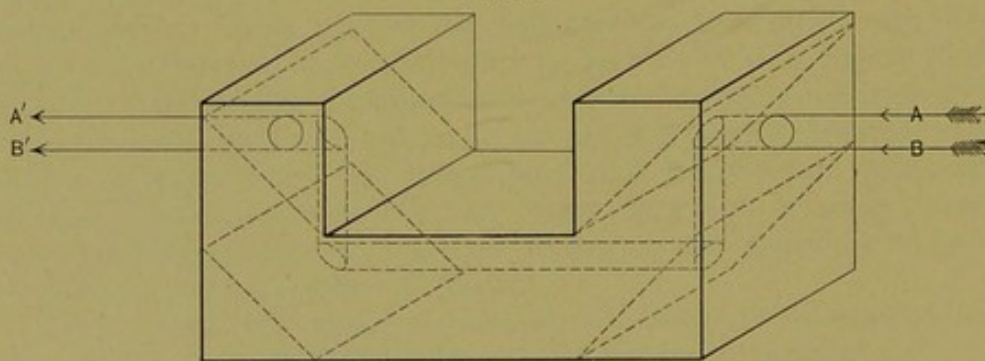
OPTICS.

OPTICS, from the Greek word *ὁπτομαι*, to "see," is that branch of science which treats of the laws of light and the phenomena of vision. That division which treats of the laws of light may be termed "physical optics," and that which treats of the phenomena of vision may be termed "physiological optics."

Nearly every form of natural material is, when placed under suitable conditions, capable of emitting what is characterized as light. Many such objects under ordinary circumstances are constantly giving forth such emanations, being designated as self-luminous, in contradistinction to non-luminous objects, which, under the same conditions, are incapable of acting in a similar way.

All natural light must have its source in some self-luminous body, no matter how frequently the result may be repeated from a series of non-luminous bodies. Thus, a beam of solar rays may be reflected many times from a combination of properly arranged mirrors or polished surfaces before its component parts become dissipated.

FIG. 58.



Reflection of rays of light from a series of boxed mirrors.

For instance, in Fig. 58, which is an adaptation of one of the old forms of the so-called magician's mirrors, the parallel lines of light A B, which make their entrance into the box through the small round opening at one end, emerge parallel in a similar direction at the other end of the box at A' B', by reason of repeated reflections from the four mirrors concealed within the apparatus.

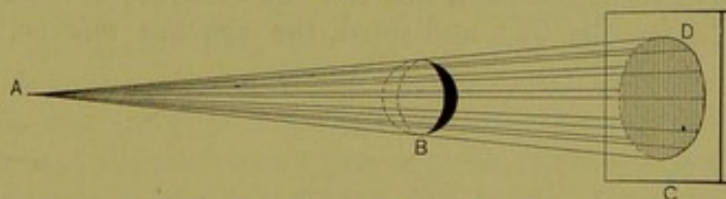
Primary luminosity is dependent upon what is known as *incandescence*—a condition that is produced by some form of molecular change—a species of motion. This light travels in an undulatory manner, in straight lines called *rays*, the undulations being termed *waves*. It moves with the velocity of about one hundred and eighty-six thousand miles in a second.

When the luminous emanation falls either directly from the incandescent mass, or indirectly by means of an illuminated material, upon any natural body, a portion of the beam is thrown back or *reflected* from the body; another part is lost or *absorbed* whilst penetrating it; and a third is *transmitted* or passed through the substance. If the natural body not only allows light to pass through it, but also permits the visibility of color and outline, it is termed *transparent* or *diaphanous*. If it is merely able to transmit light, it is called *translucent* or *opalescent*. If it does not allow any light to pass through it, it is said to be *opaque*. These differences, which are caused in the main by physical construction and condition of the impinged objects, as of texture, density, thickness, smoothness, etc., and the peculiarities in the character of light-stimulus, are subject to laws which, for our purpose, may be more readily studied by a division of the subject into two branches: *Catoptrics*, from the Greek *κάτοπτρον*, a "mirror," which treats of the changes which take place in the rays of light when they are reflected or thrown back from natural objects; and *Dioptrics*, from the Greek *διδόσθαι*, to "see through," which considers the changes in the rays of light produced during their passage through natural objects into which they have gained admission.

CATOPTRICS.

By experiments with shadows and projections of images through small apertures, it is shown that rays of light proceeding from either a luminous body or an illuminated object, traverse a homogeneous medium in straight lines in every uninterrupted direction. Three illustrations of this law, which can be repeated at all angles from the luminous body, may be cited. First: Let A, in Fig. 59, represent one of the

FIG. 59.



Shadow of sphere on a plane surface.

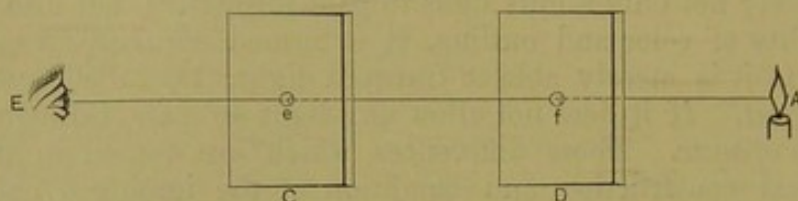
superficial points in a luminous ball, and B an opaque sphere situated between the point and the screen C. The sphere intercepts the passage of the rays, and hence casts a *shadow* or *umbra* of itself upon the screen. The outline of this shadow always bears a definite relation to the border of the sphere and the point of light. Disregarding for the present any small error from bending of the rays over the edge of the globe, the relationship is found to be governed by straight lines passing from A to D.

Second: The point A in the candle-flame (Fig. 60) can be seen by the eye E only when the holes e and f in the screens C and D are situated on the straight line drawn from the eye to the point.

Third: In Fig. 61 the inverted image B' A' of the candle-flame A

B has been produced upon account of the opening *e* in the screen *c* being smaller than the object itself—thus causing the straight lines proceeding through the screen from various parts of the object to cross one another in order to gain access to the screen *D*.

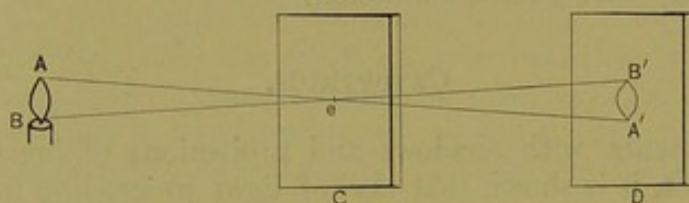
FIG. 60.



Visibility of candle-flame through two pin-holes.

As practically explained, if any obstacle possessing little or no receiving power should be placed at any point in this medium, it would not only interrupt the progress of the rays of light that fall upon its surface, but would bend a certain portion back upon themselves. If such obstacles have polished surfaces, and are used for the purpose of

FIG. 61.



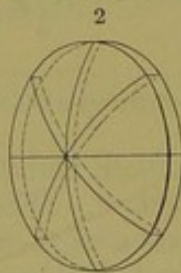Inverted image of candle-flame.

reflecting light, they are termed *specula* or *mirrors*. There are three principal varieties: first, the *plane mirror*, or one having a flat surface, as shown at 1 in Fig. 62; second, the *convex mirror*, in which the reflecting surface is curved outward, like the outer surface of a watch-crystal, as shown at 2 in Fig. 62; and third, the *concave mirror*, shown at 3 in Fig. 62.

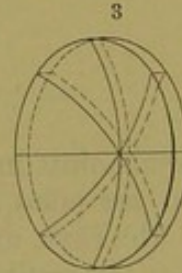FIG. 62.



Plane mirror.



Convex mirror.



Concave mirror.

The bending of the impinged ray from any of these mirrors is always accomplished in a definite manner: that is, an angle, known as the *angle of incidence*, which is formed by the impinging line or *incident ray* with a supposed perpendicular drawn from the impinged surface at the point where the surface is struck by the incident ray, is equal to the angle known as the *angle of reflection*, which is formed between

the departing line or *reflected ray* and the same assumed perpendicular; these two angles, the incident and the reflected ray, and the perpendicular, all being situated in the same *plane*.¹

Fig. 63 illustrates this very well. Here the incident ray, *A*, strikes the surface of the mirror, *M*, and is thrown off from it as a reflected ray, *A'*. If comparative measurement of the angle of incidence, which in this case may be designated as *A M P*, and the angle of reflection, *P M A'*, be made, as situated in the same plane, it will be found that they are equal to each other.

This proposition is true, not only for the single rays of light combining to form bundles, termed *pencils* and *beams*, but for all other massings which may fall upon any area of surface, no matter how irregular they or the surface may be; showing that the law of the single ray governs every compound of rays.

FIG. 63.

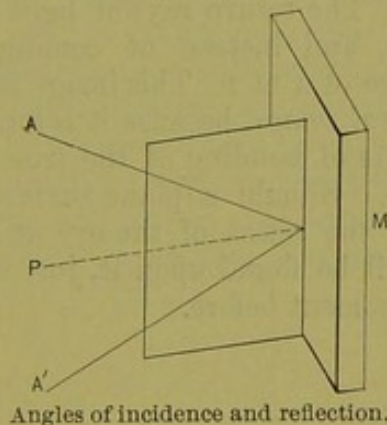
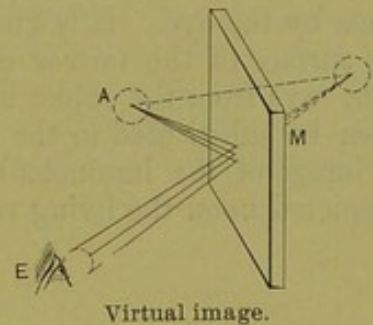


FIG. 64.



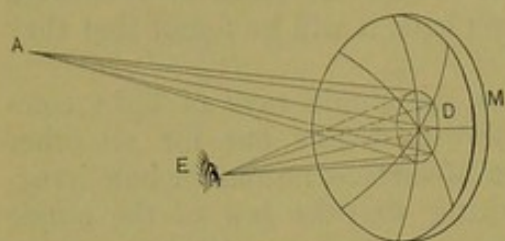
The usual effect of the return, or reflected ray, is to produce what is known as an *image*: thus, in Fig. 64, the divergent pencil of light from the luminous body, *A*, strikes the mirror, *M*, and is reflected with increasing divergence into the eye, *E*. The return rays of light, if perfect, proceed in accordance with the laws of visual projection, outwardly along the same lines upon which they entered the eye, and in consequence do not come to a focus until they have reached the point *I*, at which place the luminous point appears to stand. Similarly, every point of the luminous body strikes the mirror and proceeds to the interior of the eye, giving visual images at points seemingly situated as far behind the mirror as the true objective points are in front of it; thus producing a compound visual image of the entire luminous body, *A*, at *I*.

If the mirror has a plane surface, the image is known as a *virtual image*, since it is formed by the act of the observer in mentally projecting outward, through the substance of the mirror itself, a continuation of the lines received into the eye, sufficiently far forward to form an apparent, though unreal focus. Thus, in Fig. 64, the image, *I*, is an unreal or virtual image, having been produced by a mental projection of the converged lines from the eye to the mirror, through it, and beyond the reflecting material.

¹ If this law be studied and memorized, all the succeeding formulæ will be easily understood.

If the mirror has a concave surface, a divergent pencil of light from a luminous point, as for instance from A, in Fig. 65, strikes the mirror, M, at D, and there undergoes reflection. On account of the inward obliquity of the planes composing the surfaces of the mirror at the points struck,

FIG. 65.

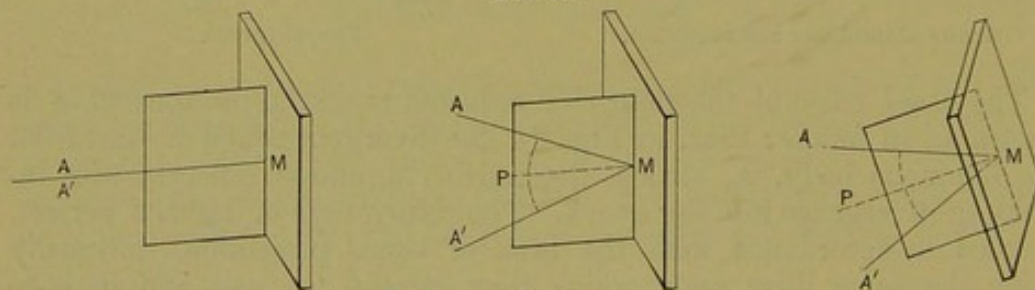


Real image.

the reflected rays are thrown together into a convergent bundle, and at last meet one another at the point E, known as the *focus*. This focus, as can be seen, is formed upon the same side of the mirror as that upon which the impinging rays fell. It is a *real focus*. If the eye be placed, for instance, at E, the reflected rays of light from the mirror will pass into it in a convergent manner. The return rays of light will

proceed outwardly along the same lines, and instead of coming to a focus, will form an erect magnified image of A at D. This image is the one seen by the eye. It is known as a *real image*, because it is formed on the surface of the mirror at the points of bending of the true and existent rays from the object into the eye. Should a plane surface or a screen be substituted in the position of the retina of the eye at E, a small image of the luminous body, A, will be found upon it, just as it was depicted upon the living retina the moment before.

FIG. 66.



Variations in lines of incidence and reflection.

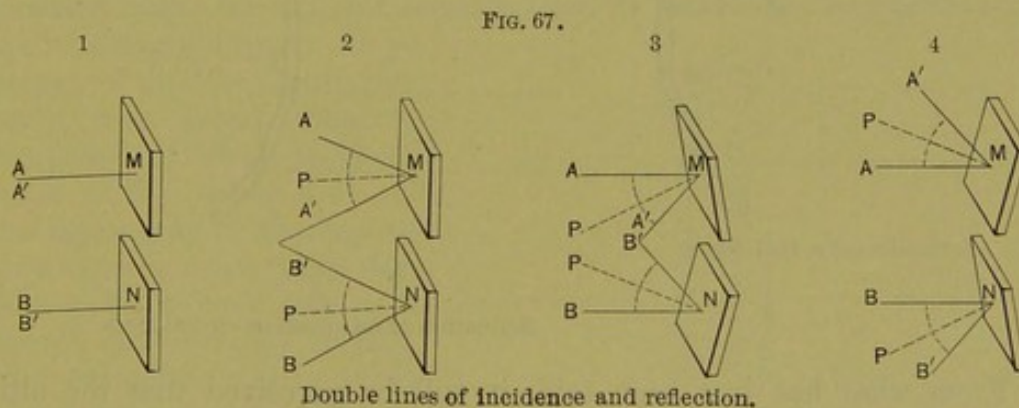
To analyze these facts, so that an adequate idea may be formed of the differences of image-formation produced by the various changes in angles of incidence and reflection through peculiarity in the impinged surface, it will be best to consider the mirror-surface as composed of an infinite number of small facets or planes which are inclined toward one another in definite directions. Commencing with the single facet or plane, we will study the effect of inclination of either the ray or the plane, so as to produce a departure of the impinging ray from an angle that is perpendicular to the surface of the facet. In Fig. 66, there are three illustrations. The first shows—as will be easily understood from the law demonstrated in Fig. 63—that, on account of the incident ray, A M (Fig. 66), being perpendicular to the plane of the impinged surface, M, the reflected ray M A' practically passes outward along the same line as that occupied by the incident ray. The reason for this is, that, as there has been no deviation from the perpendicular between the impinging ray and

the impinged surface, and as the angle of reflection must always equal the angle of incidence, the reflected ray must pass out along the perpendicular, which is the line of the incident ray. The angle of incidence and the angle of reflection equal nothing, and therefore, the line of incidence and the line of reflection coincide.

The second illustration shows, that although the impinged surface preserves the same position as in the first illustration, yet upon account of the line of incidence, $A M$, impinging upon the surface at an oblique angle, the line of reflection, $M A'$, is deviated from the perpendicular, P —according to the fundamental law given—at an angle equivalent to the one at which the incident ray impinges upon the surface of the facet, M . The angles of incidence, $A M P$, and reflection, $P M A'$, being equal, the lines of incidence and reflection diverge or separate equally.

The third illustration shows that although the line of incidence, $A M$, passes in the same direction as it did in the first illustration, yet upon account of the inclination given to the impinged surface, M , the incident ray, $A M$, in reality falls upon the mirror in an oblique manner, and, in consequence, the reflected ray, $M A'$, is deviated from the perpendicular, P , at an equivalent angle to the line of incidence, thus producing practically the same result as shown in the second illustration.

Applying these experiments to two similar facets placed in various relations, it will be noticed at 1, Fig. 67, that should two parallel perpendicular incidences, $A M$ and $B N$, strike the similarly situated facets,



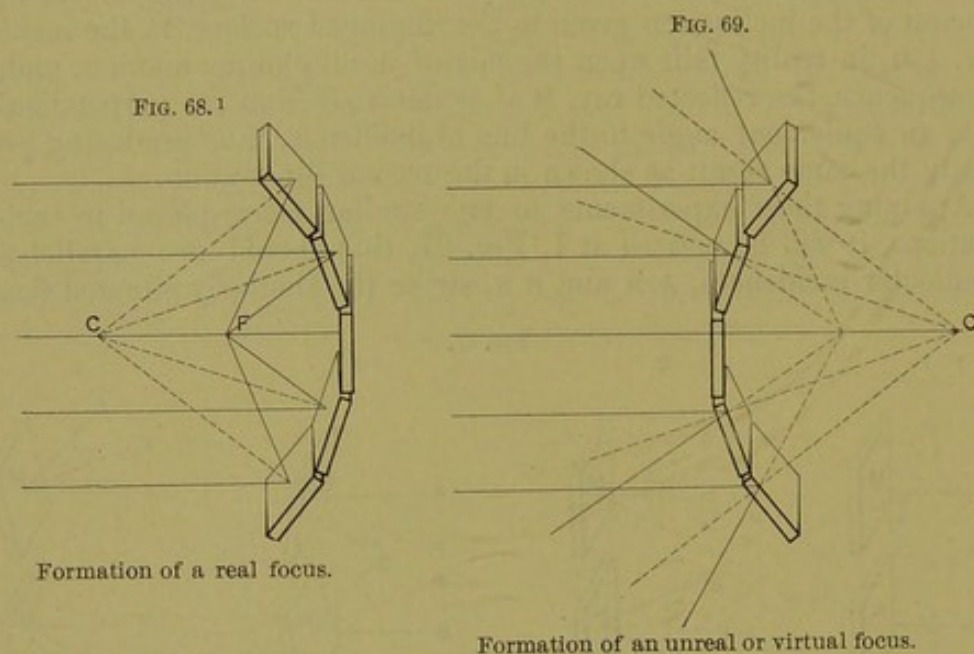
M and N , the reflected rays, $M A'$ and $N B'$, will return along the lines of incidence in a parallel manner.

Sketch 2, Fig. 67, illustrates that although the impinged surfaces, M and N , have not been changed in any way, yet on account of the incident rays, $A M$ and $B N$, striking the facets at equivalent oblique angles, the reflected rays, $M A'$ and $N B'$, really meet in front of the mirror; they have become convergent and come to a focus at a point that is dependent upon the angle of incidence and the lateral separation of the facets. If the reflected rays in this sketch had been considered the incident ones, the conditions would have been reversed, and the lines $M A$ and $N B$, which now would have become the reflected rays, would have widely separated as they passed outward; they would have become divergent.

At 3, Fig. 67, a similar effect of convergence is produced by the impinging of parallel rays upon surfaces which have been inclined

toward one another, thus rendering the impinging rays oblique. Here, although the incident rays, AM and BN , are parallel, the inclination given to the receiving facets, M and N , so alters the angles of incidence, AMP and BNP , and the angles of reflection, $PM A'$ and $PN B'$, that the reflected rays, MA' and NB' , are converged or brought to a focus. The converse, as explained by the second illustration, holds good here, except that the inward inclination of the facets renders the reflected rays less divergent—in fact, parallel.

At 4, Fig. 67, is seen how the parallel rays, AM and BN , falling upon the surfaces M and N , which have been deviated from each other, diverge in their passage outward as reflected rays in exact proportion to the amount of outward deviation given to the impinged facets. Here, too, the converse proposition holds good: should the rays be reversed, the convergent incident rays will pass into reflected parallelism.



From what has just been said, it will be perceived that the ultimate effect of the receipt of a ray of light upon a reflecting surface, is dependent upon the degree of obliquity which exists between the impinging ray and the impinged surface. It will be further seen, that this obliquity can be obtained either by causing the incident ray to fall in an oblique manner upon the receiving surface or by inclining the surface itself. Both these conditions will be associated with our future studies. In reality, every experiment in both catoptrics and dioptrics will have them as its essence and basis.

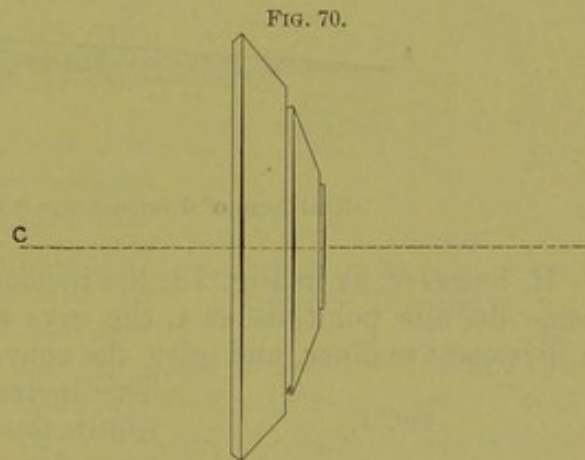
Pursuing the experiments, we are brought to Fig. 68. In this figure five facets are supposed to have been formed into a long, narrow concave surface, and parallel incident lines to have been reflected and converged to a common focus at F . By careful study of the figure, it will be noticed that each angle of reflection is equal to its angle of

¹ The position of the point F , in Fig. 68, is not absolutely correct for all of the series of parallel rays. Strictly speaking, each series of related parallel rays has its own principal focus.

incidence, and that the greater the inward inclination of the facet, the greater is the inward deviation of the reflected line. The principle of a focus has now been determined. It will also be noticed that the series of perpendiculars proceeding from the facets come to a common point on the perpendicular of the central facet at *c*. If measurement be made, it will be found that these perpendiculars are all of equal length, and that the common point is really the centre of a circle with the line of facets as the circumference. The distance, therefore, along any perpendicular from the point *c* to the line of facets, is equivalent to the radius of a circle, and is known as the *radius of curvature*.

Should the impinging surfaces of facets be constructed so as to deviate from one another, and the same character of parallel rays be made incident to these surfaces, as in Fig. 69, the study of the angles of incidence and reflection will immediately show that the reflected rays will never come to a focus: they will be dispersed or diverged. Thus, in Fig. 69, the parallel incident rays strike the system of deviated surfaces, and each facet sends off a reflected ray at an angle which is equivalent to the angle between the incident ray and the perpendicular from the facet. On account of the outward deviation, the perpendicular of the facet is thrown outward, which causes the reflected ray to be diverged. Such a system of facets acts as a disperser, and fails to bring the reflected rays to a focus.

Pursuing the researches still further, Fig. 70 is reached. Here the facets of Figs. 68 and 69 are supposed to have been revolved upon their principal axis, *c*. In so doing, a hollow, basin-like cavity has been produced, composed of an infinity of facets. The inner side of the figure may be assumed as a concave or converging surface, and the outer side as a convex or diverging surface. The evolution of two types of reflecting surface sufficient for our purpose—the *concave mirror* and the *convex mirror*—has been reached.



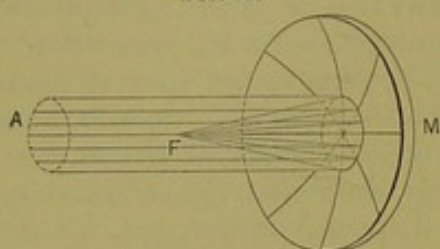
Evolution of a concave and a convex mirror.

The effect of the impinging of the three types of incident rays—the parallel, the convergent, and the divergent beams—upon the inner side or concave surface of the mirror is the first to be considered. It should be remembered that here all the facet-surfaces incline inwardly, and that the tendency of such a surface is to bring all the reflected rays together to a common focus. As shown with the double facet, the length of the focus varies according to the angle of incidence. Suppose, for instance, that a bundle of parallel rays, *A*, Fig. 71, strikes the concave mirror, *M*. Each ray in the composition of this bundle must strike a facet that is inclined inward. According to the law of double facets, as shown at 3, Fig. 67, the reflected rays must form a

convergent pencil of light which will come to a focus at F. In this instance, this point is known as the *principal focus*, as it represents the strength of the mirror for focussing parallel rays. It is situated on the principal axis, about midway or less between the centre of curvature and the central facet.

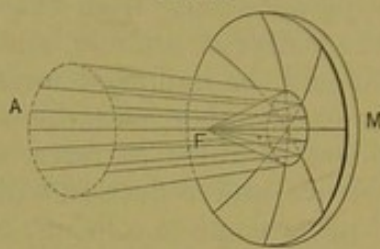
Should, however, already convergent rays of light, as in the convergent bundle, A, in Fig. 72, fall upon a concave mirror, as at M, the

FIG. 71.



Formation of principal focus from a concave mirror.

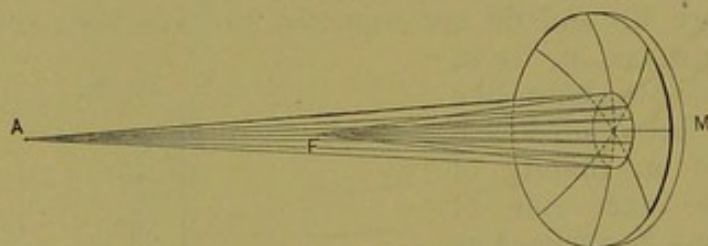
FIG. 72.



Real focus of convergent rays from a concave mirror.

reflected pencil of light will be more converged, and the focus will be much shorter and more intense. The incident ray has already indirectly accomplished some of the work of the mirror, and the final result is necessarily much greater.

FIG. 73.

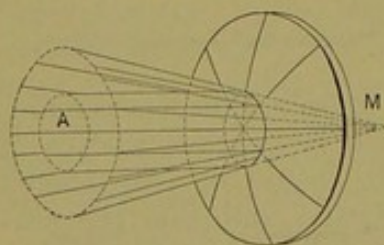


Real focus of divergent rays from a concave mirror.

If, however, as in Fig. 73, the incident pencil should proceed from some definite point, as at A, the rays will fall upon the mirror, M, in a divergent manner, and give the converging mirror more work to do.

This increase of work causes a diminished result, thus giving a longer and less intense focus.

FIG. 74.



Virtual focus of parallel rays from a convex mirror.

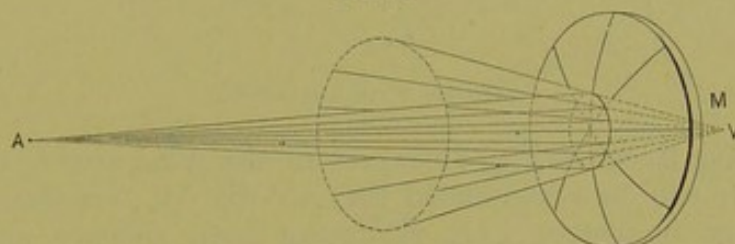
Using the opposite, or convex, surface of the mirror for the next series of experiments, it will be found that it, too, is governed by a series of definite rules. Here the facet-surfaces are all deviated from one another, and their tendency is to separate all the reflected rays. This separation or divergence, as we have

already learned with the double facets, depends upon the relation existing between the incident line and the reflecting surface. Take, for instance, Fig. 74. Here the parallel beam of light, A, strikes the convex, or diverging, surface of the mirror, M. Each individual ray of

light impinges upon the facet obliquely, and in such a manner as to deviate the reflected ray outward. Just as the single ray of the parallel bundle is diverged, so will the entire bundle be deviated, and in consequence there will be no focus: the reflected rays will be widely scattered.

Should the impinging rays be already divergent instead of parallel, the work of the reflector will be easier, and the result will be increased. Fig. 75 shows this very well. Here the divergent incident rays from

FIG. 75.

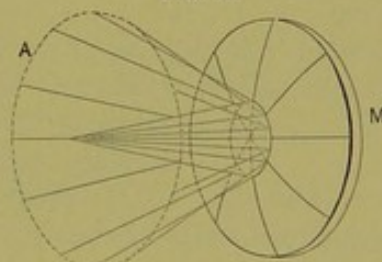


Virtual focus of divergent rays from a convex mirror.

the point A become more and more widely separated as they approach the mirror, consequently the reflector has less work to do, and the reflected rays leave the mirror in a more diverged manner.

Could a plan be arranged by which sufficiently convergent rays should be received upon the mirror, as in Fig. 76, a focus of reflected rays would be obtainable. As, however, rays having such incidence are ordinarily impossible in nature, convex mirrors may be said to fail to bring objects situated in front of them to a focus.

FIG. 76.



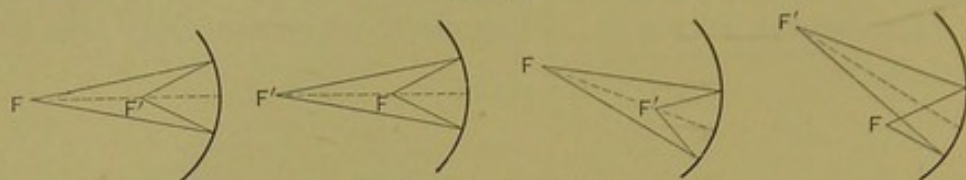
Real focus of highly convergent rays from a convex mirror.

Having shown that such surfaces are composed of a multitude of infinitesimal planes inclined regularly to one another, and that the receipt of varying impinging lines produces corresponding results in reflection, the variety of foci met with are next to be studied. In concave mirrors there are three, the first two of which are positive, whilst the third is negative in character. These are: First, the *principal focus*, which is formed in front of the mirror practically¹ at the point on its principal axis where all the incident parallel rays meet after reflection. This is shown at F, in Fig. 71. Its distance from the mirror is termed the *focal length* of the mirror. Second, the *conjugate focus*, which is purely reciprocal and mutual, and may be formed on any line from the object to the mirror upon which all the reflected rays from the mirror meet to form a focus. This can be represented by the following outline sections as seen in Fig. 77, where the dot F', in every instance, is the conjugate focus of the dot F. Third, a *virtual or unreal focus*, as previously explained, and as shown in Fig. 75, where the theoretical point, v, behind the mirror, is the virtual or unreal focus of the point A.

¹ As previously noted, the theoretical situation of this focus is always about one-half or less of the length of the radius of curvature of the mirror.

Just as both a concave and a convex spherical reflecting surface is evolved from the revolution of a series of plane facets about a common axis, so can the so-called cylindrical surface be evolved, and the effect of variously impinging rays, with the resultant positions and situations of independent and combined foci, be shown.

FIG. 77.

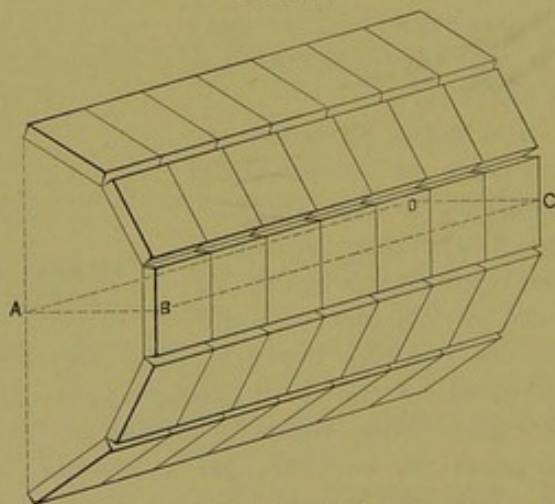


Varieties of conjugate foci.

Let the five facets in Fig. 78 represent the same section as noted in Fig. 68. It will be remembered that, in Fig. 70, this section was revolved about its centre line, producing both concave and convex spherical surfaces. If, instead of this, the section of facets in Fig. 68 should be moved along a common plane—as, for instance, along the axis, AD , in the plane, $ABCD$ —the diagram in Fig. 78 would be produced. The whole process, therefore, is simply to slide the section instead of rotating it.

It will be observed that this figure is practically the section of a cylindrical surface with its axial plane running from B to C , and its

FIG. 78.



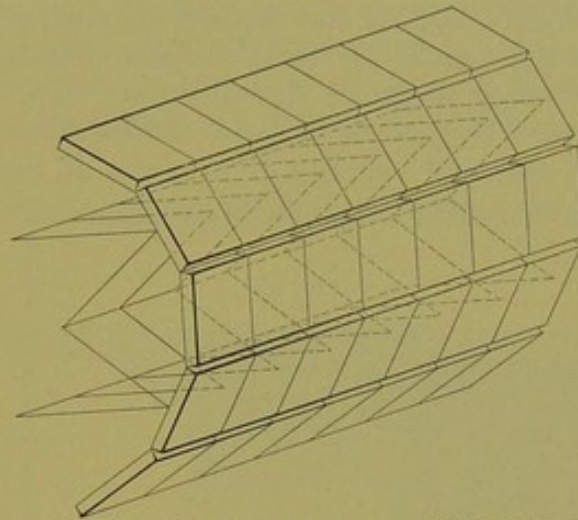
Evolution of a concave and convex cylindrical surface.

degree of curvature at right angles to that plane. It will also be noticed, that, like the spherical surfaces, it has both a concave, or converging, surface and a convex, or diverging, surface.

The effect of the receipt of parallel rays upon the concave surface of such a body, is next to be studied. A glance at Fig. 79 will show that should a series of rays which are parallel with the cylinder-axis fall at any point upon this surface, they will be reflected upon some point situated on a line running parallel with the axis of the mirror. In other words, the optical axis and the true axis of the mirror coincide. Therefore, instead of a resultant focal point, as in the spherical

surfaces, there is always a resultant *focal line*. The distance and position of this focal line in such mirrors are practically regulated by the same laws as those which govern the focal point of the spherical surfaces. The more convergent the impinging rays, the shorter will be the focus, and the nearer to the mirror will be the focal line. The more divergent the impinging rays, the longer will be the focus, and the further from the mirror will be the focal line.

FIG. 73.



Formation of focal line from a concave cylindrical surface.

Parallel rays, as before shown, place the line at or near the distance of the principal focus. The consideration of the effect of the receipt of planes of light at other angles will not be considered here. This one example is deemed sufficient for our present purpose.

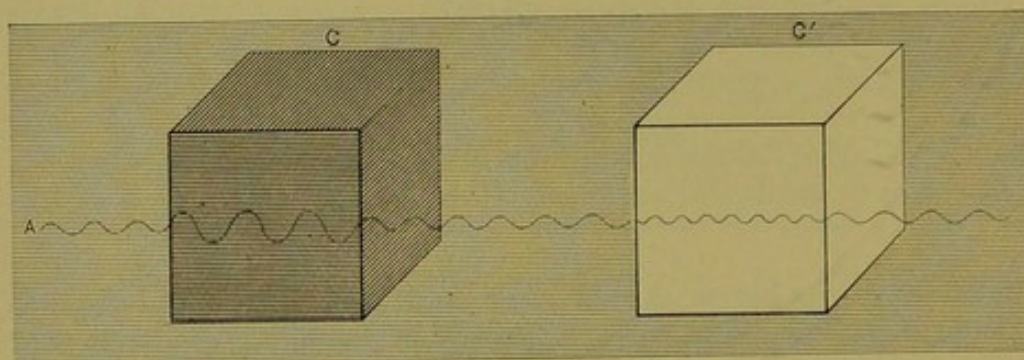
If the convex surface of the mirror be employed, the reflected rays will diverge under laws which are similarly dependent upon the degree of curvature and the angle of incidence.

DIOPTRICS.

When a ray of light is able to pass through a body of different density from that of the one from which it came, two important changes take place. The first, which is the more important for our purpose, consists in the change of velocity of the vibration constituting the ray. The second consists in the change of amplitude of the wave itself. Should the transmitting body be denser than the surrounding medium, the ray will have a more difficult task to perform whilst pursuing its course through the dense object than it had in the rare medium. The impediment to its progression is increased, and in consequence, it travels more slowly. Should the transmitting body be less dense than the surrounding medium, the ray will make easier progress than it did before, and will increase its velocity whilst passing through the object. The rule is, therefore, the denser the medium, the more slowly the ray of light passes through it, and the less compact the medium, the more quickly the ray penetrates it.

The second proposition, that there is a change in the amplitude of the wave when the ray passes through different media, is in reality a corollary of the former statement. The slower the velocity of the entering ray has become, the larger and coarser the wave must be, thus producing a change in the color-equivalent. Should the velocity of the ray have increased by its entrance into a less dense body, the wave will be made smaller. This, as well as the first proposition, is graphically represented by Fig. 80, where, in the first instance, the cube *c* is composed of material more dense than the surrounding medium. Here the incoming ray, *A*, has its wave heights and depressions enlarged, with a consequent decrease in the number of vibrations, the moment it is compelled to force its way through the more resistant mass. The second cube, *c'*, shows that the wave-lengths have been rendered smaller and more numerous by the ease and rapidity of progress of the ray through a medium of much less resistance than the medium through which it has

FIG. 80.



Passage of a ray of light through media of different densities.

come.¹ Here the cube, *c'*, is of less density than the surrounding medium.

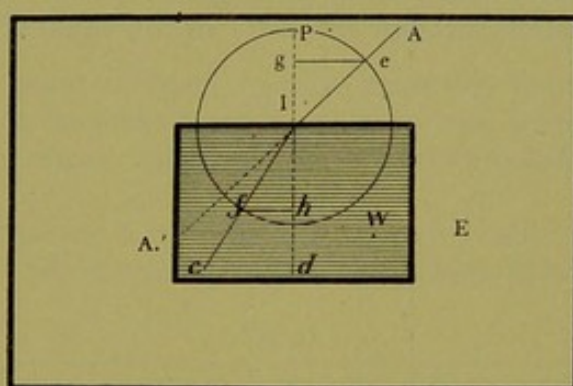
The relative degree of density, then, of any medium is known as its *index of refraction*, this being designated as the *absolute index of refraction* when it is compared with vacuum. As the difference, however, of the index of refraction between air and vacuum is so slight, and as the refraction of lenses is ordinarily studied in a medium of air, the index of refraction of air is generally assumed to be equivalent to that of vacuum. Assuming, then, that the index of refraction of air is equal to 1, we can readily determine the relative index of refraction of any denser or rarer medium by a simple rule of proportion. Thus, taking the most common example—that of water and air—all that is necessary to do, is to determine the comparative lengths of the sines of reflection and refraction, and the result will give the relative degrees of density. This is graphically shown in Fig. 81, where a circle has been drawn around a point of incidence, *I*. Here a line, *e g*, has been carried drawn around a point of incidence, *I*. Here a line, *e g*, has been carried at right angles to the perpendicular, *p d*, from the line of incidence, *A I*,

¹ The importance of these latter conditions is illustrated in another portion of this volume, in the description of a very ingenious color-test for the determination of the amount of refractive changes in ametropic eyes.

at the point where the circle cuts it, thus giving the sine, $g e$, of the angle of incidence, $A I P$. In the same way the sine, $f h$, of the angle of refraction, $c I d$, is evolved.

Two definitely sized ratios of sine are thus obtained, which, by the single rule of three, may be used to compare the known index of refraction of the one component (air), with the unknown one of the other (water). For instance, if the ratio of $g e$ and $f h$ be as 4 is to 3—in other words, if the former be longer in proportion as 4 is to 3—the two indices of refraction must bear the same relation to each other. Thus, by inverse proportion, knowing the index of refraction of air to be 1 and the proportionate length of the sines as 4 is to 3, we can make the following equation: as the length of the sine of the angle of incidence (4—indirectly representing the density of air) is to the sine of the

FIG. 81.



Geometrical figure illustrating the passage of an oblique ray of light from a rare to a dense medium.

angle of refraction (3—indirectly representing the density of water), so is the index of refraction of air (1) to the index of refraction of water; that is, $4:3::1.333:1$. The index of refraction of water is 1.333 as compared with that of air as 1.

The indices of refraction of several of the most commonly met with mediums employed in ophthalmological optics, as calculated in the same manner as given in the above example, are here borrowed from Brewster, for ready reference:

Vacuum	1
Air	1.000294
Water	1.333 to 1.336
Crown glass (used for spectacle lenses)	1.525 to 1.534
Quartz	1.547 to 1.548
Flint glass	1.578 to 1.580

Should the penetrating ray of light impinge upon the surface of the transmitting body at any other than a right angle, the course of the transmitted ray will be bent or refracted from the direction of the ray in the medium from which it came, giving rise to what is known as *refraction*, and the degree of refraction will be dependent upon the angle of incidence between the ray and the plane of the impinging surface and the ratio of density of the two media.¹ In other words, the laws

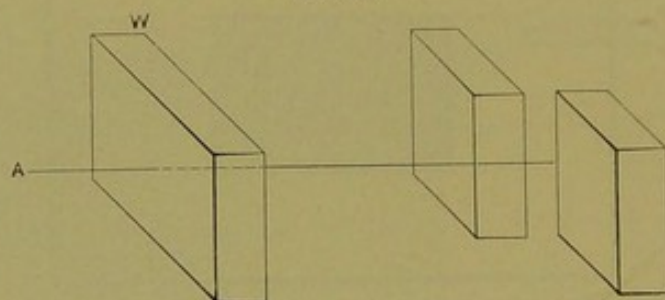
¹ It must, of course, be understood that the primary grade of wave-lengths of the impinging ray must be taken into account; but as all the studies are referable to diffuse daylight, the changeableness of this equation will be disregarded and considered as a fixed quantity.

of reflection, as shown in the previous section, and those of refraction here brought forward, are exactly the same, except that here there is an additional factor by reason of the ray passing through media of different densities. To illustrate the passage of these rays, it will be well to watch the progress of the ray through media of greater density. Beside being easier to understand, these are the conditions to which the eyes of ordinary land animals are subjected, and, of course, are those in which we are the most interested. Consequently, our studies will be confined to these, leaving to other treatises upon such subjects the consideration of the vexed problem of the refraction which, under certain circumstances, must be encountered by various water animals.

The influence of change in angle of incidence upon the passage of rays through denser media is the next point for consideration.

In Fig. 82, the ray of light, A, strikes the denser medium, W, at right angles to the surface. In the second diagram, which represents the same figure, the ray passes through the body in the same direction in which

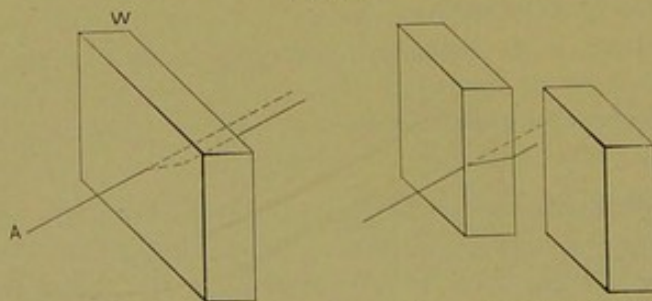
FIG. 82.



Passage of a right-angled ray through a medium of increased density.

it entered. Why is this? It is because the ray has been slowed and weakened in its progress through the body, and is therefore forced to seek its way in the easiest manner through the denser medium. Here the easiest way is the shortest: this, as the second diagram shows, is the continuation of the impinging line which has fallen perpendicularly upon the surface of the transmitting body.

FIG. 83.

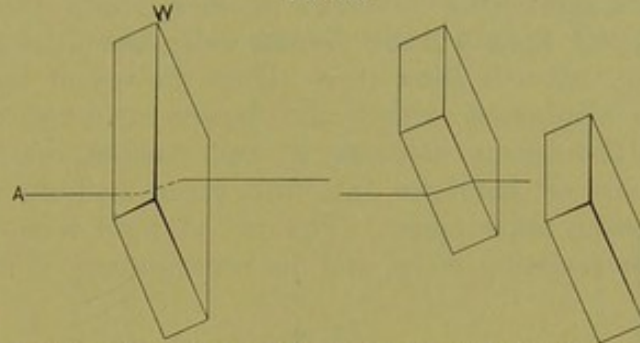


Passage of an oblique ray through a medium of increased density.

Should this perpendicular be deviated from, or should the impinging ray strike the body at an oblique angle, it would not only be weaker in itself, but would meet with more resistance, and its weakness would be shown by a constantly increasing departure from its original direction. Thus, in Fig. 83, the ray of light, A, which has struck the denser medium,

w, at an oblique angle, instead of pursuing its original course, as shown by the dotted lines, is more and more deviated, until at last it emerges at a much lower point than it would have done had the body been of the same density as the surrounding medium. So, too, in Fig. 84, the

FIG. 84.

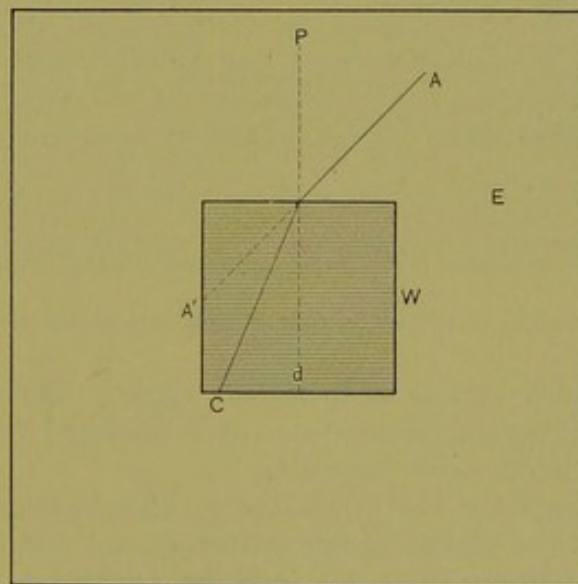


Passage of a ray through a medium of increased density which has been inclined.

denser body, w, being inclined so as to cause the impinging ray, A, to fall obliquely upon its surface, the ray is more and more weakened as it passes through the denser medium, and is thus deviated from its original line of motion.

In order to formulate a rule for this change of direction, the following profile (Fig. 85) may be employed. Here the ray of light, A,

FIG. 85.



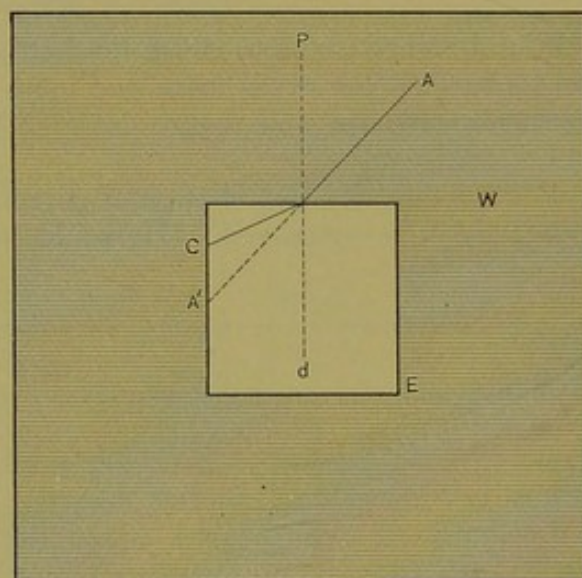
Refraction of a ray passing from a rare into a dense medium.

coming from the rarer medium, E, strikes the denser body, w, and, instead of going to A', is deviated to C. If a theoretical perpendicular be drawn from the surface of the denser body at the point where the impinging line strikes it and be continued into the body toward d, the transmitted portion of the ray will be found to have been deviated from the line AA', toward the perpendicular. The amount of deviation is dependent upon the ratio of the densities of the two media and the original obliquity of the impinging ray. The rule, then, is:

If a ray of light passes into a denser medium at any other angle than that which is perpendicular to the plane of the surface of the medium, the ray, instead of passing on uninterruptedly in the same direction, will be deviated toward the perpendicular of the surface of the denser medium.

Should the transmitting medium be rarer than the surrounding medium, the ray of light will be turned away from the perpendicular. A glance at Fig. 86 will show this. Here the ray of light, A, is supposed to have originated within the denser medium, W. The ray passes through the denser medium, W, and reaches the rarer medium, E. At the point of entrance into the rarer medium an immediate change of direction takes place. The ray of light is now thrust, as it were, into a less resisting body, and in consequence, it moves forward

FIG. 86.



Refraction of a ray passing from a dense into a rare medium.

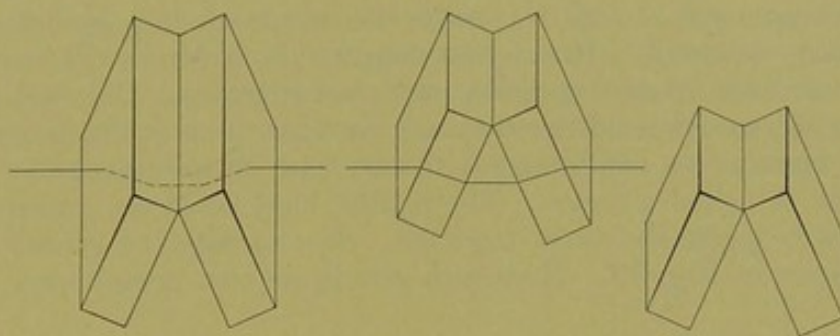
with greater velocity and at an increased angle. Therefore, instead of passing along its regular course, A A', it is deflected from the perpendicular, P d, and is deviated toward C.

Upon these few facts the whole theory of refraction is based. By applying them to a series of differences in position of the impinged surfaces and impinging lines, we shall be enabled to understand the entire scheme of lenticular action, which plays so important a part in physiological optics.

First, then, let the so-called lens be evolved. If a plain, transparent facet of denser material than the surrounding medium—as, for instance, a glass plate situated in the air—be taken, and a ray of light be allowed to impinge obliquely upon it by either rendering the ray itself oblique, as in Fig. 83, or having the surface of the glass plate at an angle, as in Fig. 84, a bending of the transmitted ray toward the perpendicular of the transmitting plate of glass will occur in each instance. Should two plates of glass be placed in such a position that they will incline

toward each other, the ray, as shown in Fig. 87, will deviate downward as it passes through the first plate, and then, on account of the surface of exit being parallel with the surface of entrance, it will be made parallel at a lower level as it passes between the two plates. Arriving at the surface of the second plate, which is inclined in a direction opposite to that of the similar surface of the first plate, it deviates upward to pass through the second plate, and at last pursues its way

FIG. 87.

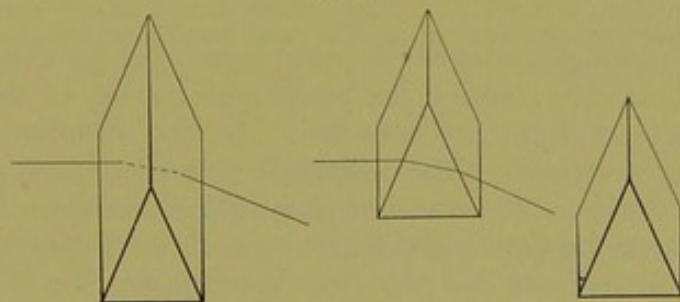


Passage of a ray through two dense media which have been inclined toward each other.

in the same direction as that given to it before any refraction whatever. Here the two different inclinations of the four surfaces of the two plates cause the ray of light to have four distinct bendings.

Suppose that two of these surfaces should be annihilated by filling the space between the two plates of glass in Fig. 87 with a glass-like material of the same density and transparency.¹ Fig. 88 would then be produced. Here the ray of light, after gaining entrance into the combined glass substance, continues in the same deviated direction, as

FIG. 88.



Passage of a ray through a prism.

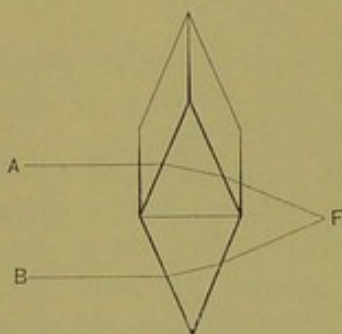
shown in the second diagram of the figure, until it meets the surface bordering the air medium. Upon account of its passage at this point into a rare medium, it is bent from the perpendicular of the surface, which, as can be seen, carries it still further toward the base of the substance. The so-called *prism* has been evolved. In optics, therefore, the prism is practically a transparent, wedge-like medium enclosed in part between two plane surfaces known as the *refracting surfaces*,

¹ The space above the plates is supposed to have been filled with glass up to the apex of the figure: the mode of representation here adopted is merely to avoid a complicated figure, and has no bearing upon this phase of the problem.

which are inclined toward each other, the point of meeting being known as the *apex* or *edge*, and the broad surface connecting their divergent extremities being termed the *base*. The amount of angular separation of the two refracting surfaces is known as the *refracting angle*, whilst the amount of deviation between the direction of the incident ray and that of the refracted ray is termed the *angle of deviation*.

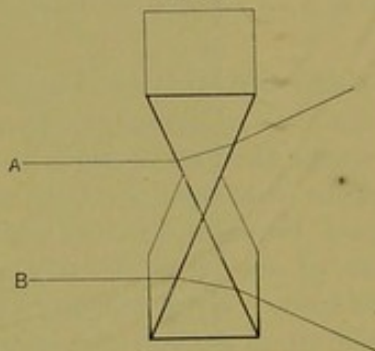
Let us pass to Figs. 89 and 90, in each of which we have two similar prisms, the first placed base to base, the second placed apex to apex. The entering rays, A and B, pierce the substance just as before and are similarly deviated. In the first diagram, however, it will be noticed that, on account of the entering rays being parallel and undergoing a similar degree of bending, they are brought to a common point, F, situated upon a line continuous with the base line of the two prisms: this point is called a *focus*. The prisms have acted as convergers—they have brought the lines together. Not so with the prisms placed apex to apex in Fig. 90. Here each acts in its own proper way. Each

FIG. 89.



Passage of parallel rays through two prisms placed base to base, forming a focus.

FIG. 90.



Passage of two parallel rays through two prisms placed apex to apex, causing a divergence.

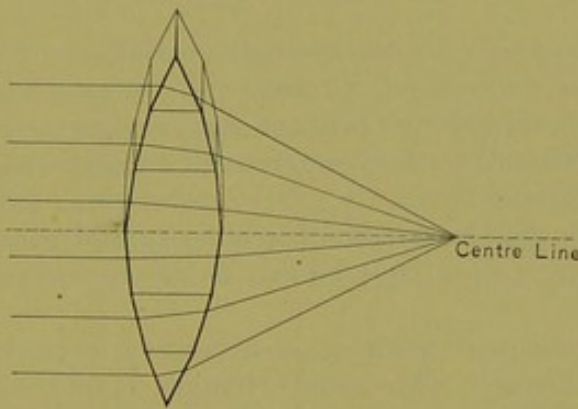
throws its ray of light toward its own base; but as these bases are separated, and as they occupy the peripheral border of the two substances, the rays of light are deflected. In this situation, the prisms fail to act as convergers. They separate the rays: they cause a dispersion; they weaken the force of the light-stimulus. In the first instance, we have the fundamental principle of a converging or convex lens. In the second, we see the first appearance of a dispersing or concave lens. No matter how intricate the surfaces of any series of lenses may be, the underlying principle of action is embraced in these few facts.

Proceeding further, we are brought to Fig. 91. Here is a series of six prisms, four of which are truncated so as to allow a sequence of exact apposition of base to truncated surface, thus practically making a complex modification of Fig. 89. Each section of prism receives its ray and deviates it toward its base, where, according to the laws just given, it is still further deviated in the same direction as it passes into the air beyond. Moreover, as the base of each prism in the series is situated toward the centre of the figure, every ray of light must in turn be deviated toward this centre, and, just as we had a focus formed by the

action of two prisms placed base to base in Fig. 89, so here we have a similar though denser focus formed by the six prisms. True as this is for two or six prisms, just as true it will be for a multitude of prisms: just as two or six prisms, placed base to base, converge and bring rays of light to a focus, so an infinity of such prisms must act. Each prism does its individual work, and every compound of the same nature will do greater, but similar, work.

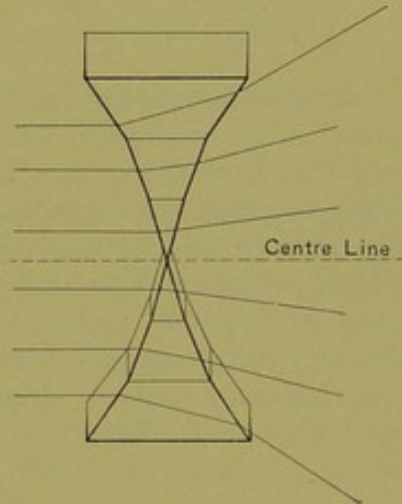
If the prisms are reversed and placed apex to apex, as in Fig. 92, a totally different result will be the outcome of similar action. The similar, though more powerful, result in this case, is the consequence of similar action to that of the two prisms placed apex to apex in Fig. 90. All the rays fall toward the base lines of the prisms, and, as these bases are situated peripherally in every case, every emergent ray will deviate toward the periphery of the figure. As with two or with six prisms,

FIG. 91.



Passage of six parallel rays through six truncated prisms with their apices pointing outward, forming a compound focus.

FIG. 92.



Passage of six parallel rays through six truncated prisms with their bases pointing outward, causing a divergence.

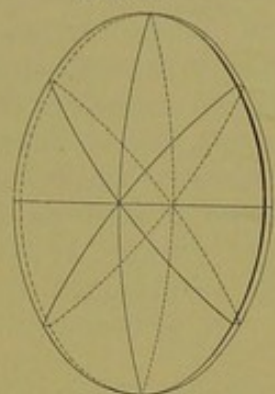
so with a hundred, or with an infinite number: every segment of prism acts as a disperser and tends to separate and weaken the rays of light. Every component prism exerts its individual action, and the combined result is one of general dispersion.

Figs. 91 and 92 are sections only. From these let us endeavor to evolve the so-called spherical lens. Just as the series of facets (in Figs. 68 and 69) were revolved upon a centre line to produce Fig. 70, whilst we were studying reflection from spherical surfaces, so here a definite section of a spherical body with either a convex or concave surface can be produced by revolving Figs. 91 and 92 about a similar centre line. Let the convex series be taken first. Suppose a line of axis to be drawn through the centre base line, as represented by the heavy dotted lines in Fig. 91, and that this line be used upon which to revolve the series of prisms. If this be done, it is evident that Fig. 93 will be produced. Here, then, is a figure composed of an infinite number of prisms—a figure that is bounded by two convex surfaces—a dense, transparent

medium, which will bring all manner of transmitted rays from a rarer medium to a series of common foci.

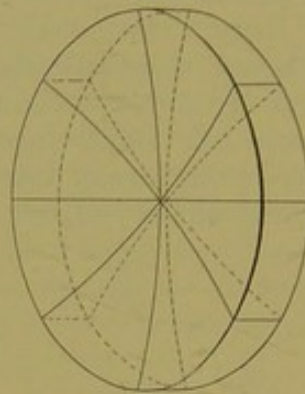
Likewise, should the series of prisms in Fig. 92 be revolved in a plane at right angles to the centre line, the compound figure, Fig. 94, composed of an infinite number of prisms with their bases turned away from the centre line, would be produced. A glance at Fig. 94 will

FIG. 93.



Bi-convex spherical lens.

FIG. 94.



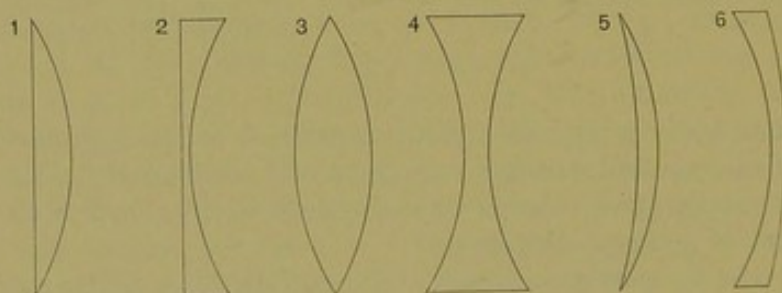
Bi-concave spherical lens.

show that here there is a body bounded by two concave surfaces—a dense, transparent medium, which will tend to separate all transmitted rays as they pass through its substance.

Upon account of there being a double surface of convexity and concavity in these two bodies, they are respectively known as the *bi-convex* lens and the *bi-concave* lens.

In ordinary routine ophthalmological work, it is necessary to have departures from these two set forms. The usual changes employed may be roughly specified in the following outline sketches—Fig. 95:

FIG. 95.

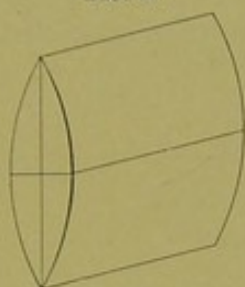


Profiles of lenticular forms.

The first, which has a convex border upon one side and a plane border upon the opposite side, is known, from these two surfaces, as a *plano-convex* lens. It acts as a weak converger, and will bring parallel rays which pass through it, to a long focus. The second, which is composed of a plane and a concave surface, is designated as a *plano-concave* lens. It is the opposite of the first lens, and causes rays to diverge and become dispersed. The third, which has a convex surface on each side, is termed a *bi-convex* or *double convex* lens. It is a converger of much greater strength than the first variety. The fourth, made of two

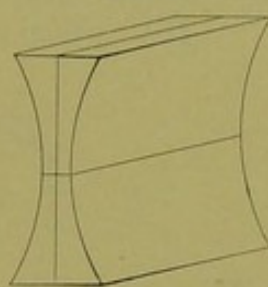concave surfaces, is the opposite of the third, and is called a *bi-concave* or *double concave* lens. It is a strong disperser, and separates rays with much greater facility than the plano-concave lens. The fifth is a combination of a concave and a convex surface, the convex surface being the greater of the two, thus making the lens act as a very weak converger. It is called a *concavo-convex* or *converging meniscus lens*. The last, which is the opposite of the fifth in action, is also made of

FIG. 96.



Bi-convex cylindrical lens.

FIG. 97.

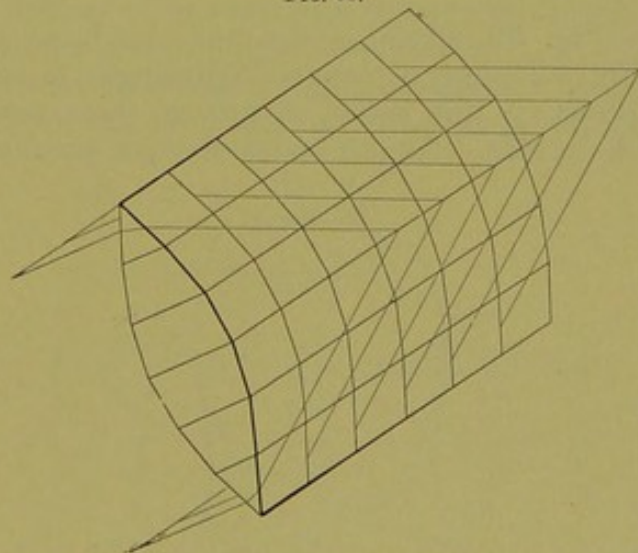


Bi-concave cylindrical lens.

two surfaces—a convex and a concave. Here the concave surface is the greater, thus making the lens act as a weak disperser. It is known as a *convexo-concave* or *diverging meniscus lens*.

In like manner the cylindrical lens is formed. Just as the series of reflecting facets in Fig. 68 were slid along a common plane in their axes to form the cylindrical reflector in Fig. 78, so here the series of truncated

FIG. 98.



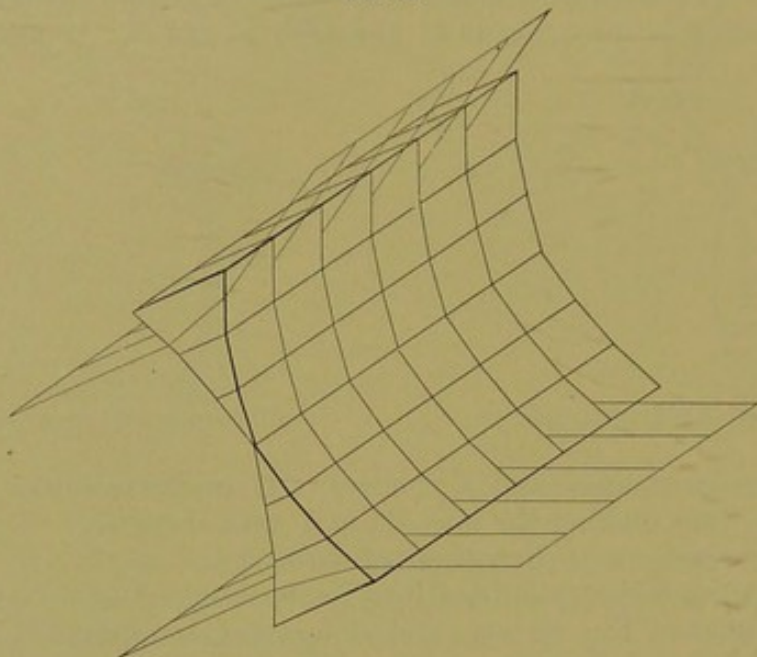
Formation of a focal line from two parallel planes, by a combination of truncated prisms, forming a bi-convex cylindrical lens.

prisms in Figs. 91 and 92 can be slid along a common plane at right angles to the centre line. A moment's thought will show that Fig. 96 will be the result of such motion given to Fig. 91, and that Fig. 97 will be the result of such motion given to Fig. 92.

The action of such lenses is quite simple. Just as the series of parallel rays were received and refracted to the common point in the single series of prisms in Fig. 91, so in Fig. 98 (which, as can be seen,

is merely a linear multiplication of such a series of prisms), the resulting convergent points of every individual series composing the row must make a line of convergence. This line is known as the *focal line* of the cylinder. It is shown in Fig. 98.

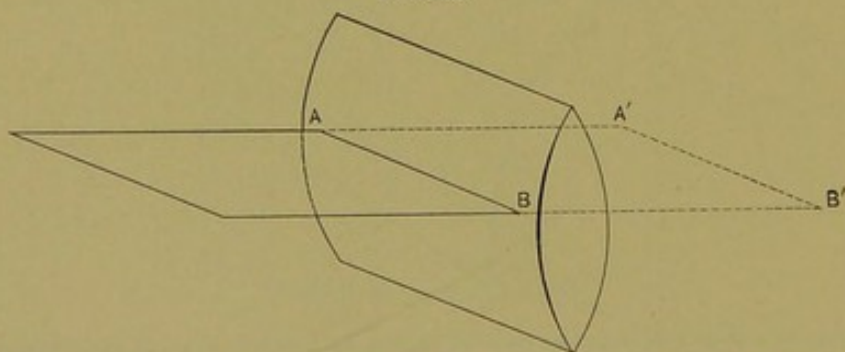
FIG. 99.



Dispersion of two parallel planes by a combination of truncated prisms, forming a bi-concave cylindrical lens.

The lens in Fig. 99, which is the body produced by the lateral movement of Fig. 92 along a plane at right angles to its axis, is composed of an infinity of the series of prisms, these series of prisms being placed side by side. As one series diverges parallel lines, so will

FIG. 100.



Plane of light passing undeviatingly through the mid-axis of a bi-convex cylindrical lens.

each successive series do the same, so that instead of the compound body forming two single rays of divergence, it will produce two long planes of such rays. This will be rendered clear by study of Fig. 99.

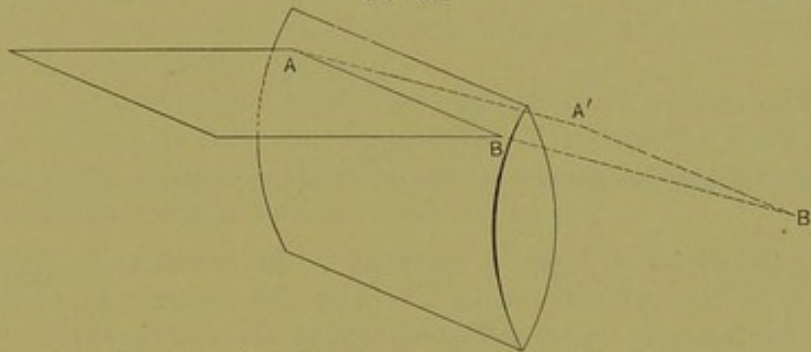
The next questions that arise are, In what direction are these focal lines formed, and with what part of the lens do they correspond? Let the illuminated points of sources of light be changed to illuminated lines for a moment, and these illuminated lines be considered as causing

planes of light to impinge upon these two varieties of cylinder lens and pass through them.

Commencing with the convex variety of lens, place the plane of light in the same meridian as the axis of motion given to the single series of lenses composing the body, as in Fig. 100. Here the plane of light, AB , merely passes through a certain thickness of glass in its entire length to $A'B'$, and there is no deviation.

Put the plane of light at another level in the same axis, and the only change will be a deviation of the entire plane inward, the autonomy of the plane remaining unaltered, as shown in Fig. 101.

FIG. 101.

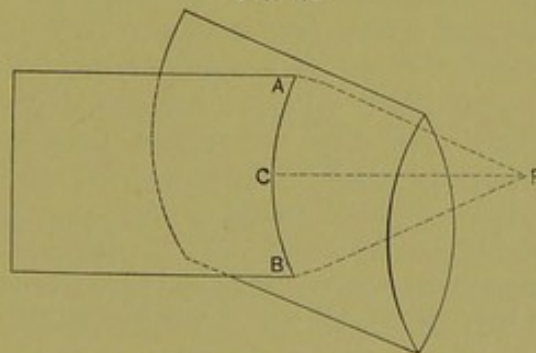


Plane of light uninterruptedly refracted through an excentric portion of the axis of a bi-convex cylindrical lens.

In both these instances, and in all similar examples, each ray of light composing any one of these planes goes through the same relative thickness and density of lens material throughout its entire length, and, in consequence, the plane of light is unbroken.

Should, however, the plane of light be situated in the meridian at right angles to the axis of motion given to the prisms in the formation

FIG. 102.



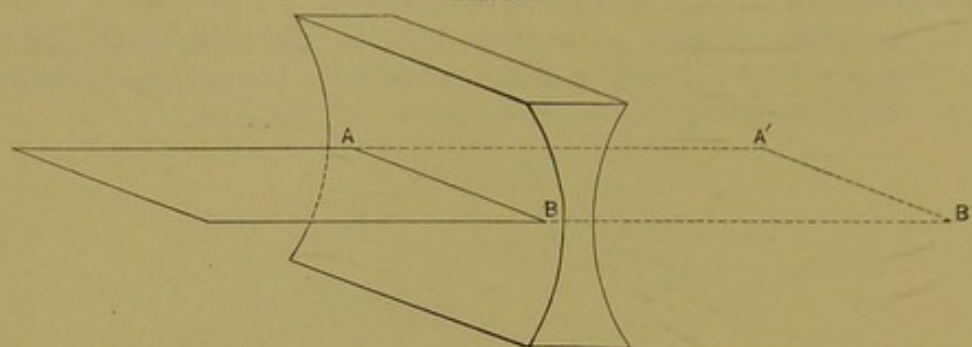
Plane of light passing through a bi-convex cylindrical lens in a meridian at right angles to the axis of the lens, refracted to a point.

of the cylinder lens, every portion of the plane will, as shown in Fig. 102, practically pass to a common point. Here the points A , C , and B in the impinging edge of the plane situated at right angles to the axis of the convex cylinder, are refracted to a common point, F .

These two experiments show that, in the convex cylinder, the plane of light which is at right angles to the axis of the cylinder is the one which is disturbed or broken by the lens.

So, too, with the concave variety of cylinder. Here, as shown in Fig. 103, there is no deviation in the plane of light when it passes through the axis of the cylinder. Here A passes to A', and B proceeds to B', making a line of refraction, A' B', which practically corresponds with the line of incidence, A B.

FIG. 103.

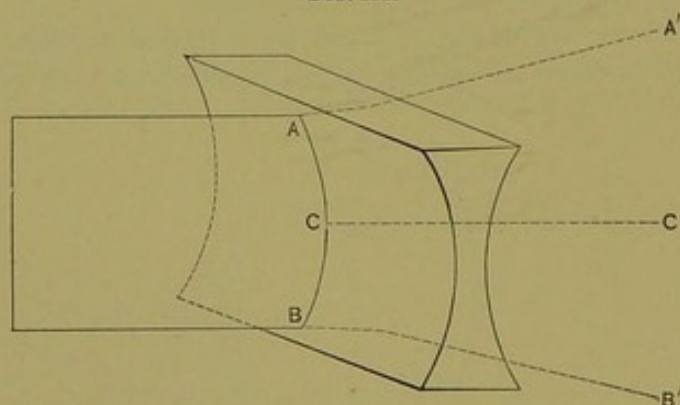


Plane of light passing undeviatingly through the mid-axis of a bi-concave cylindrical lens.

Should the plane of light be situated in the meridian at right angles to the axis of the cylinder, as in Fig. 104, the central ray of the plane, C C', will be the only one unaffected, whilst all others, as, for instance, A A' and B B', will be diverged and thrown toward the bases of the component prisms.

These two experiments, therefore, prove that the utmost refraction of a concave cylinder always occurs in the meridian at right angles to its axis.

FIG. 104.



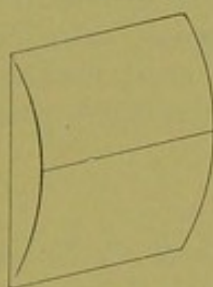Plane of light passing through a bi-concave cylindrical lens in a meridian at right angles to the lens, dispersed into more widely separate rays.

In ordinary ophthalmic practice, there are several varieties of cylinders employed. The first, which is shown in Fig. 105, is known as the *plano-convex cylinder*. It acts as a weak converger in a direction at right angles to its axis. The second, shown in Fig. 106, is composed of a concave cylindrical surface upon one side and a plane surface upon the opposite side. It is a weak diverger, the strength of the lens being in the meridian at right angles to the axis of the concave surface. It is known as the *plano-concave cylinder*. The third, shown in Fig. 96, is termed a *bi-convex cylinder*. It has double the converging strength

of the plano-convex variety. Its representative action is limited to the meridian at right angles to the axis of the lens. The fourth, shown in Fig. 97, is composed of two plano-concave lenses with their plane surfaces in juxtaposition. It is a strong diverger, ordinarily having double the strength of its progenitor, the plano-concave lens. Its action is that of a strong disperser, which is greatest, and therefore representative of the lens's strength, in the meridian at right angles to the axis of the lens. The fifth is composed of a plano-concave cylinder and a plano-convex cylinder, fastened at right angles to each other by their plane surfaces, thus making a concave meridian upon one side of the lens, and a convex meridian at right angles to the concave meridian, upon the opposite side. Fig. 107 shows this. Such a lens acts as a diverger and condenser. It disperses the rays of one meridian, and converges the rays of the opposite.¹

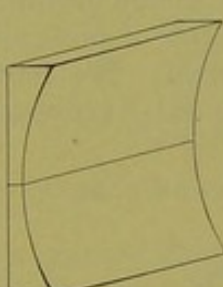
There are several other forms of lens employed in ophthalmology, but as they do not enter into the routine use of every-day work and are considered more or less as curiosities, it has not been thought worth while to describe them in such a text-book as this.

FIG. 105.



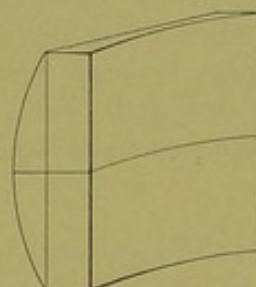
Plano-convex cylindrical lens.

FIG. 106.



Plano-concave cylindrical lens.

FIG. 107.



Crossed cylindrical lens.

Each lens has an axis, which, as can be seen in Fig. 110, is the line connecting the *centres of curvature* of the refracting surfaces. As will be understood from what has been said, every lens has a so-called *principal focus*, which represents the point on the external prolongation of the lens-axis, to which parallel rays, or those supposed to come from infinity, are united upon emergence from the opposite surface of the lens.² Thus, in Fig. 111 the point F is the principal focus of the parallel rays proceeding from A and B, after passing through the bi-convex lens, L. In a converse manner, if the point F be considered a source of light, the divergent rays, after passing through the lens, L, would be parallel.

The distance between the optical centre of the lens and the position of the principal focus on the axial ray, is known as the *principal focal distance*, and depends upon the refractive index of the lens and its degree of surface-curvatures. Every bi-convex lens thus has two principal foci, one for each surface; the one known as the *first principal focus*, which indicates the point on the axial ray where the

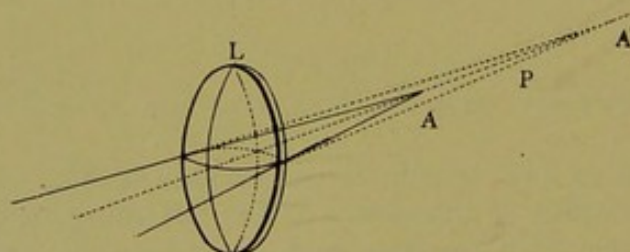
¹ In all these forms there may be, of course, all ratios of curves between the two surfaces, thus producing an infinite variety of resultant strengths of action.

² It should be remembered that, as has been already explained, this point in reality is merely theoretical, it being mathematically situated at different positions, for instance, in any convex or concave spherical lens, for every ring of light which is concentric with the central or axial ray.

rays of incidence should unite to produce a parallelism of the convergent rays with the axial ray on the opposite side of the lens; and the other, known as the *second principal focus*, which is the point of union of the emergent rays upon the axial ray which have been parallel with the axial ray during their incidence; the relative position of these points being *positive* or *negative* in accordance with the character of the lens, its surrounding medium, and the peculiarity of the incident ray. Thus, in Fig. 109, F is the second principal focus.

Should the lens be unequally curved upon its two refracting surfaces, these foci will be situated at proportionate distances on the axis. If the two surfaces are equally curved, they will be at the same distance. If the entering rays come from a point which is beyond that of the principal focus and nearer than infinity, there will always be points of relative foci which are correlated; those which are conjoined are termed *conjugate foci*. The rule as to their relative position, that the nearer the focus of entrance is to the lens, the farther removed is the focus of emergence, is based upon the fact that the more obliquely the impinging ray strikes the lens-surface, the harder is the work of the lens during the passage of the ray through it, and, in consequence, the less is the angle of deviation obtained. If the outline sections of mirrors in Fig. 77, illustrating the reciprocal foci of reflection, be supposed to be lenses, this can be very well understood. The letter F', in every instance, is the conjugate focus of F, the dot P representing the relative position of the principal focus.

FIG. 108.



Negative focus from a bi-convex spherical lens.

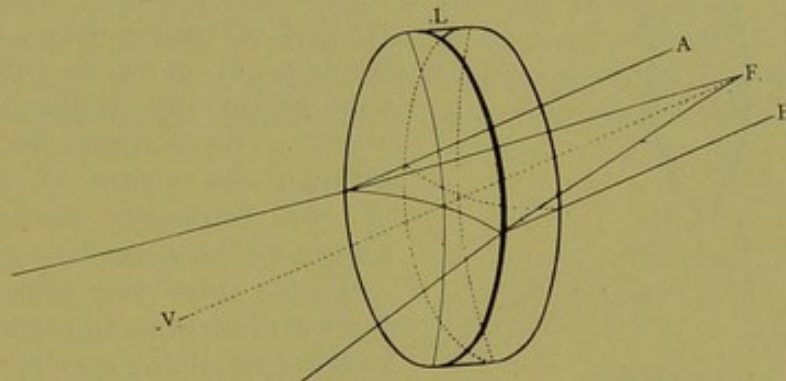
If the entering rays come from a point which is situated nearer the surface of the lens than the position of its principal focus, they can never be brought together, or even to parallelism, upon the opposite side of the lens. The angle of incidence has been too great, and the lens has been too weak. The outgoing refracted rays would continue to diverge, though to a lessened degree. The amount of this refraction is estimated by continuing the emergent lines backward until they reach the principal axis of the lens back of the principal focus, this point being known as the *negative, unreal, or virtual focus*. Thus, in Fig. 108, the rays from the point of light, A, which is nearer the surface of the lens, L, than the position of the principal focus, P, continue to diverge, though to a lessened degree, after emerging from the opposite surface of the lens. The amount of work performed by the lens is shown by the distance back along the principal axis that the unreal focus, A', is removed from the point of light, A.

As the concave lens serves as a disperser—a diverger, as it were—of

all forms of ordinary rays seen in nature (parallel and divergent), the foci here are all virtual in character, the rule being that the more divergent the impinging ray, the greater becomes the divergence of the emergent rays, and, in consequence, the shorter is the negative focus. If the impinging rays be parallel to one another, the negative focus will be situated at or slightly inside of the position of the so-called principal focus. If the point of light be at the principal focus, the virtual rays will pass away parallel.

Fig. 109 shows very well what is meant—where, for instance, the parallel lines, A B, impinging on the surface of the bi-concave lens L, diverge in proportion to the strength of the lens to form a virtual focus, F, which is practically situated at the position of the unreal principal

FIG. 109.



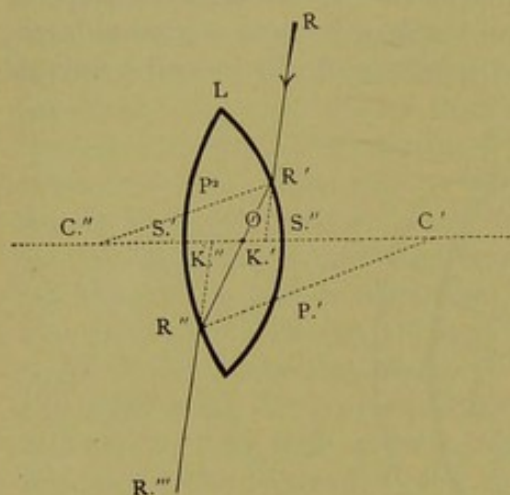
Negative focus from a bi-concave spherical lens.

focus of the lens. Were A B more divergent, the lens would have less to do, and the virtual focus, F, would be nearer the surface of the lens. Should A B be convergent, which is ordinarily impossible in nature, the point F would be more removed, and there might actually be formed a real focus upon the opposite side of the lens.

A glance at Fig. 109 will show that the central ray, which is coincident with the central perpendicular of the two refracting surfaces, is not bent or refracted; this ray is known as the *axial* or *principal ray*. At some position on this axial ray, within the lens-substance, there is a point which is known as the *optical centre*. The exact situation of this may be readily obtained by comparing the length of radius of one surface, drawn from the centre of curvature on the axial ray, with that of the other. Thus, for instance, were the two refracting surfaces of a bi-convex lens to have equal length of radii, the optical centre would be situated on the axis midway between the two surfaces; whereas, were one surface of greater curvature, and hence of shorter radius, the optical centre would approach that side of the lens. Again, were the lenses of either the plano-convex or the plano-concave variety, the optical centre would be at the curved surface, whilst in the meniscus forms of lenses it is external and on the side of the greater curvature. These broad rules must be especially remembered in the consideration of thick lenses of high convex power. The position of this centre is very important, because every incident ray passing through it becomes emergent in a direction which is parallel to the one received

into the lens. This is so on account of the formation of the same-sized angles with the radius of curvature of the two refracting surfaces. Thus, in Fig. 110, which might be multiplied in an infinity of ways, the incident ray of light, R , impinging upon the bi-convex lens, L , at R' , is, upon account of prismatic action, unequally refracted toward the central base-line or axis, $c'' c'$, through the optical centre, O , to the opposite surface, S' , of the lens, where, upon reaching a rarer medium and a position of lens-surface at R'' which is parallel to that where the

FIG. 110.



Optical centre.

incident ray entered, it is made parallel to the entering ray, though at a different level. A glance at the equality of the related angles, made more apparent by the dotted lines P' and P'' , which represent the radii of curvature drawn from the positions of entrance and emergence of the ray, shows this very clearly. Rays which do not pass through the centre of curvature of the refracting surfaces, are known as the *secondary axes*.

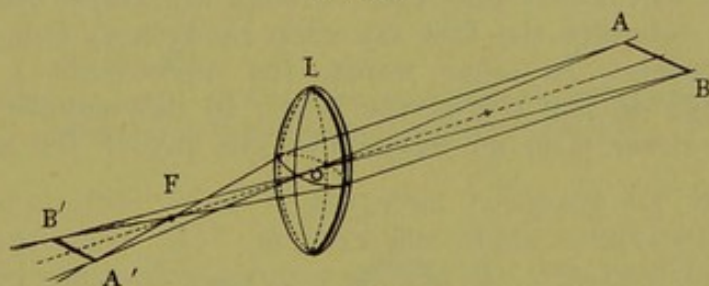
Beside these two principal foci, there are four other important points in every refracting system that must be considered. These are known

as the *first*, or *anterior nodal point*; the *second*, or *posterior nodal point*; the *first principal point*, and the *second principal point*. Collectively, together with the two principal foci, they are termed the *cardinal points*. There are also four planes. The two which pass through the principal points are known as the *first principal plane* and the *second principal plane*; and the two which pass through the principal foci are respectively termed the *first focal plane* and the *second focal plane*. The easiest way to realize the position of the two nodal points is to continue the direction of the emergent ray into the lens-substance until it reaches the lens-axis. Thus, in Fig. 110, the incident ray, $R R'$, prolonged without refraction until it reaches the lens-axis, $s'' s'$, gives the position of the anterior nodal point, K' ; whilst the emergent ray, $R'' R'''$, prolonged backward through the lens-substance without bending until it reaches the lens-axis, $c'' c'$, gives the position of the posterior nodal point, K'' . They represent the small amount of deviation (which can thus be measured along the lens-axis from the optical centre, or by triangulation) experienced by every secondary axis as it passes through the lens-substance. The two principal points also practically represent the average position of the curvatures of the two lens-surfaces on the lens-axis.

Just as these rules apply for a single ray of light, so they would for any number of rays. Just as the reflection and refraction of light-rays have been studied, so can those of object-rays be similarly studied. Just as one object-ray gives its single image, so would the entire collection of object-rays received from any object, give a composite image

of the object so reflected or refracted. Be the image of the object never so bent, distorted, enlarged, or diminished, the rules above given strictly apply. No matter what the image from any given object may result in, the laws are absolutely fixed. In fact, every such problem, however abstruse or complicated, can be solved with mathematical certainty. In other words, the study of any image produced by any form of lens, whether real or virtual, can be resolved, just as with light-rays, into the study of individual rays from a series of object-points. For example, if any object-ray be refracted through the optical centre, the image will be received upon that portion of the screen that is placed upon the opposite side of the lens at right angles to the line of incidence. Further, if the same object-ray, just as with the light-ray, passes through the lens parallel to the axial ray, it will be bent down to the principal focus of the lens on the axis. These two facts known, it is easy to calculate the size and position of any image formed by a lens. A graphic illustration is given in Fig. 111, which represents one of the simplest forms of convex lens—the bi-convex.

FIG. 111.



Position and size of reverse, real and diminished image formed by a bi-convex lens from an object situated beyond the principal focus of the lens.

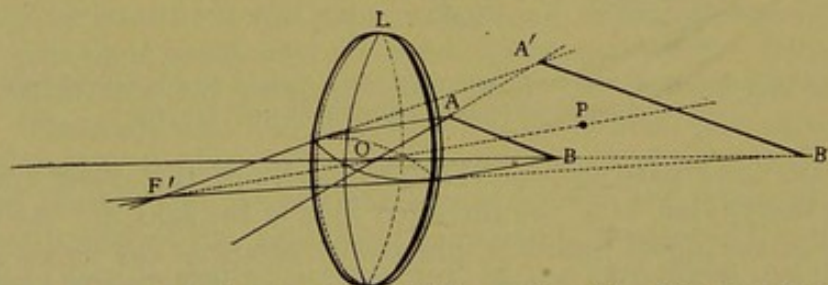
Here the rays passing from the peripheries of the object line, AB , form the image line, $B'A'$, on the other side of the lens, L . As the two extremes of the object line, AB , practically comprise the entire number of object-points between them, these two are sufficient for explanatory purposes. First let analysis of the refraction of the posterior point, A , be made. Remembering that the exact direction of a refraction-point from the object-point can be obtained by drawing a line from the object-point through and beyond the optical centre of the lens; and knowing that the position of the derived image-point is on this line (or in reality the prolonged secondary axis), and that it must be situated where the emergent ray of a line which has been drawn parallel to the axial line from the object-point coincides, it will be found by reference to the diagram, that the image-point must be at A' , which is in a reverse position to that of the object-point A . So also with the image-point B' , from the object-point B , and so with every intermediate point, thus giving a diminished reverse image, $B'A'$, of the object, AB . Moreover, as can be understood without further resort to diagrams, the magnitude and position of the image can be altered either by making a proportionate increase or decrease of distance of the object from the lens, or by keeping the object at a fixed point and employing lenses of varying focal lengths. If it is desired to brighten or strengthen the image,

all that is necessary to do is to increase the area of its refracting surface: for instance, a bi-convex lens of sixty millimeters diameter will concentrate double the number of rays that will be concentrated by one of thirty millimeters diameter.

As was explained while studying the laws of refraction of convex lenses, if the object be placed between the lens and its principal focus, the rays will so diverge that they cannot be brought to a focus upon the opposite side of the lens, and hence, no image of the object can be produced upon that side. Should the lines of the diverging emergent rays be continued directly backward (of course, with a slight necessary deviation) through the lens, they will meet upon the same side of the lens as the object, and produce a greatly magnified and erect virtual or unreal image of the object.

Thus, in Fig. 112, the object-point A, of the object, A B, sends its two rays of incidence to the lens. One, which is parallel with the axial ray, falls to a focus at the principal focus of the lens, F' , upon the opposite side. The other, the secondary ray (which, on account of the nearness of the object to the lens, has acquired so much divergence from the first ray as it is prolonged through the optical centre, O, that it can never intersect the first ray after emergence), fails to make a real image-point. In other words, the object-point A can never form an image on that side of the lens. In like manner, the object-point B can never form an image, nor can any of the intermediate

FIG. 112.



Position and size of erect, virtual and magnified image formed by a bi-convex lens from an object situated within the principal focus of the lens.

points except the single axial ray between A and B. From what has been learned, however, should all the corresponding lines of the emergent rays be carried backward through the lens, they will meet at A' and B' , and thus form a greatly enlarged and similarly positioned image of the object upon the same side of the lens as the object itself.

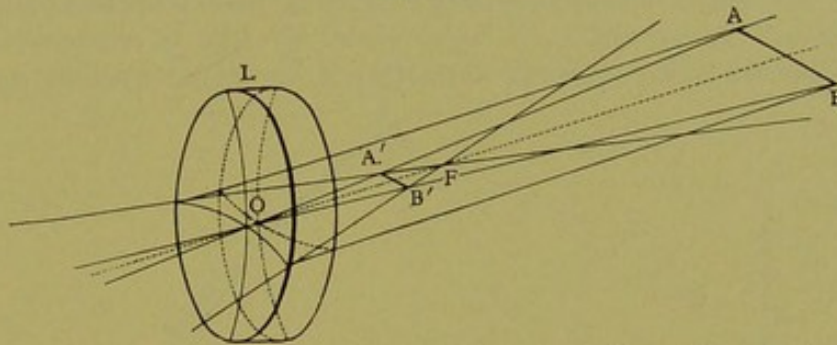
If any form of concave lens be employed, the image of any object formed by it will be virtual in character and diminished in size.

For instance, in Fig. 113, which represents a bi-concave lens of equal curvatures of surface, the rays of light from the two extremities, A and B, of the object, A B, can be followed along their special incident lines until they penetrate the lens, L, where they are markedly diverged by the dispersing power of the lens. Emerging as divergent rays, they can never come to a focus on the far side of the lens. If, however, these rays be followed backward, it will be noticed that now, acting as strong convergers, they come quickly to their points of intersection

between the lens and the object, each remaining on its own side, thus forming a small similarly-positioned image, $A'B'$, of the object, AB .¹

It must not be forgotten that in all these calculations there is a limit to the angle at which any ray that can undergo refraction, can form with the perpendicular of the refracting surface of the medium. This is known as the *limiting* or *critical angle of refraction*. It is different in different media, and varies with the relative indices of refraction of any two media, is reached when either the incident or the emergent ray passes one of the refracting surfaces in a direction parallel to it. Careful experiment has shown that the limiting angle for vacuum and for

FIG. 113.



Position and size of erect, virtual and diminished image formed by a bi-concave lens from an object situated beyond the principal focus of the lens.

water is equal to $48^\circ 27' 40''$; that that necessary for vacuum and for flint glass equals $38^\circ 41''$; and that that which is required for vacuum and for crown glass (this being generally the one used for spectacle lenses) is $40^\circ 39'$.

A quadrangular slab of ordinary crown glass situated in a medium of air expresses very well what is meant. Here the ever-increasing divergent rays of light emanating from any definite point in the interior of the dense medium, are refracted in increasing deviation until they reach certain points, at which situation the maximum deviation has been obtained—the limiting angle has been reached. Rays which are more divergent can never pass out into the air. They can do no more than reach the surface and be reflected internally back into the dense medium, thus producing what is known as *total reflection*.

The designation of the strength of prisms and lenses is best accomplished by the consideration of the deviation produced in the rays of light that pass through them: that is, they should be numbered according to their refractive powers.²

To accomplish this, three methods have been devised. The first, which is the original method of Jackson, designates the strength of the prism by the number of degrees, expressed by a small d , that a ray of light is deflected through it during *minimum deviation*—that is, when

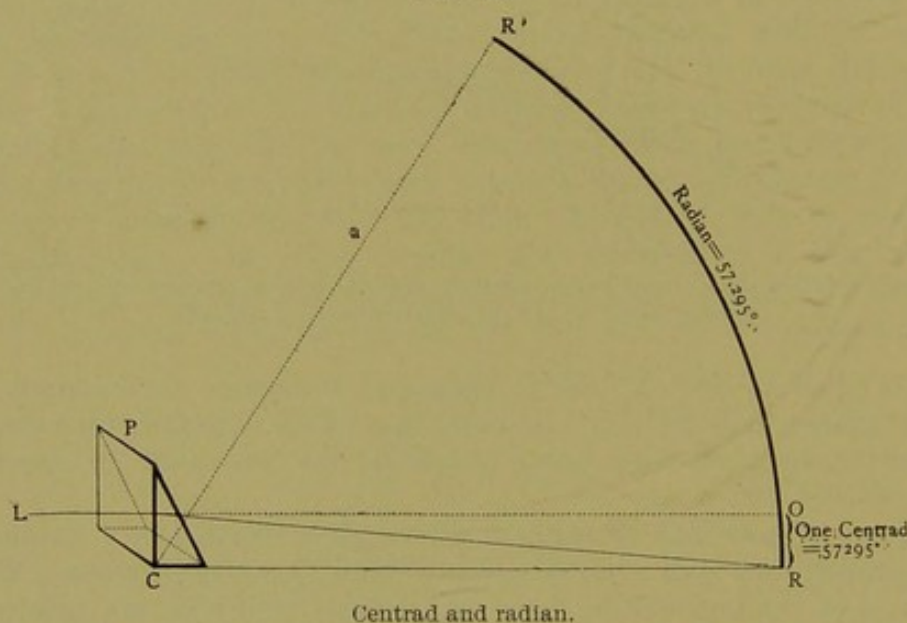
¹ The mixed forms of any variety of lens-formation can be similarly studied, and need no special explanation here.

² By most ophthalmologists at present, unfortunately, the amount of the angle between the two refracting surfaces of prisms is ordinarily used as designative of prism strengths. Until one of the newer and better plans of measurement by the amount of work done by the prism, as urged by Jackson, becomes more fully understood, both of the new methods, taking the prism diopter as the exponent of strengths up to twenty degrees, will be used throughout this portion of the text of this work. Beyond this strength, as suggested by Jackson, the deviation had better be studied, as explained further on, either on the arc or by equivalent tangents.

the angle of incidence and the angle of emergence of a ray of light are equal. The difficulty of readily determining these angles for any certain prism, so as to render it absolutely correct in all cases, has been so great as to cause two other methods to be proposed.

The first of these, known as that of the *centrad*, was introduced by Dennett. It consists in measuring, upon a so-called *radian*, the amount of linear deflection given to a ray of light which has entered any prism at right angles to its refracting surface, this radian, as it is termed in mathematics, being an arc of a circle which is equal to the radius. As the length of this arc is equivalent to an opening angle of 57.295° included between the two radii connecting its extremities with the centre of the circle, the author of the system proposes to use the

FIG. 114.

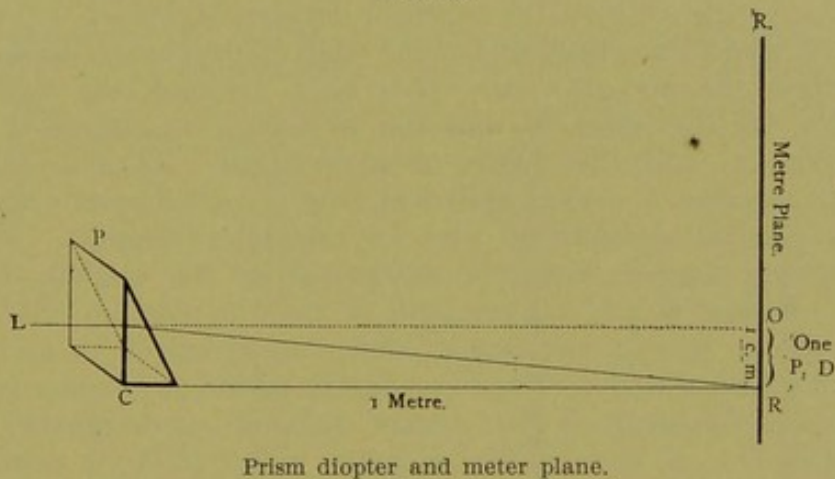


one-hundredth part of this radian, 0.57295° , known as the *centrad*, and expressed by the symbol CR, as a unit from which any number of prism strengths can be directly formulated without any complex calculation. In other words, the centrad is the one-hundredth part of the radius measured upon the arc, and any multiple of this strength is in strict mathematical proportion to this unit or standard.

Thus, for example, in Fig. 114, the prism, P, placed at C, the supposed centre of a circle, denotes the deflection of the incident ray of light, L, to one centrad's distance below the line L O, on the radian R R'. That is, had there been no prism placed at P, as in the diagram, the line L O would have remained parallel one centrad's distance on the radian above the base-line or radius, C R. That is to say, there has been an accurate measure of the amount of deflection caused by the intervention of the prism in the path of the ray of light. Knowing, then, the amount of work done by any prism, its value can be readily designated. Thus, in the diagram, the prism producing one centrad's worth of work can be called a prism of one centrad, and so on until the total number of prisms ordinarily used can be named.

In the second of the methods, known as that of the *prism diopter*, and suggested by Prentice, the unit is represented by a linear deflection which is equal to the one-hundredth part of the radius measured on the tangent. Here the standard of refractive power is obtained by terming that prism a *prism diopter*, which, situated at one meter's distance from a definite tangent plane, will deflect a ray of light exactly one centimeter along that plane. Thus, in Fig. 115, the supposed one centimeter's distance of deflection, OR , of the ray, LO , coming from the prism P , situated on the base-line, CR , at one meter's distance, is taken as a unit, and the prism is designated as a prism of one prism diopter. If another prism, situated at the same distance, deflect a ray two centimeters along the tangent plane, it is known as a prism of two prism diopters, etc. Of course, as will be made clear by a glance at the preceding diagram, as the strength of the prism is increased, the distance to the

FIG. 115.



prism or meter plane constantly increases, and the more peripherally the base-line is departed from, the greater will be the distance between the lens and the prism plane, thus making the various ratios of prism strengths reciprocal, and hence rendering it necessary either to memorize them, or to assume a series of average powers. This variation in ordinary ophthalmological work is, however, extremely slight, and the method is convenient for many purposes, such as the determination of the meter-angle, and the estimation of the amount of prismatic power produced by the decentration of lenticular strengths for the two eyes. Assuming, then, for prisms less than twenty degrees, that the standard prism is one that gives one centimeter's deviation at one meter's distance, and styling it the prism of one diopter (designated by P. D.), we can employ with certain minor restrictions any multiple of this unit up to twenty degrees, just as we do the multiple for the ordinary lens-strengths. Beyond twenty degrees it is better, as suggested by Jackson, either to study the deviations on the arc or to obtain the proper equivalent tangents. The following table, abstracted from Randall, gives the comparative strengths of a few of the most important centrads and prism diopters, with the relative degrees of opening angles of refraction :

TABLE SHOWING THE VALUES AND RELATIONS OF CENTRADS.

Centrads.	Tangent (P. D.)	Ref. Angle (Index 1.54).	Centrads.	Tangent (P. D.)	Ref. Angle (Index 1.54).
1	1.0000	1°.06	12	12.057	12°.34
2	2.0001	2°.12	14	14.092	14°.23
3	3.0013	3°.18	16	16.138	16°.08
4	4.0028	4°.23	18	18.196	17°.85
5	5.0045	5°.28	20	20.270	19°.45
6	6.0063	6°.32	30	30.934	26°.81
7	7.0115	7°.35	40	42.28	32°.18
8	8.0172	8°.38	50	54.514	35°.94
9	9.0244	9°.39	60	68.43	38°.31
10	10.033	10°.39			

The numeration of lenticular forms of refractive media is accomplished by the determination of focal distances.¹ For example, if the focal distance of either the bi-convex or the bi-concave lens, in the illustrations on page 124, is at one meter's distance, the lens, in accordance with this system of numbering, would be designated as one of one diopter's strength, using the sign 1.00 D. to represent it. If the lens be convex in variety, a plus or positive sign is prefixed (+1. D.); if it be concave, the minus or negative sign (—1. D.) is used. Should the lens be a spherical one, the sign S. is placed between the character and the strength-sign. If it be a cylinder, the sign C. is substituted for the letter S., and the axis-angle is expressed by the abbreviation ax., with the degree of angle added. Thus, for instance, +S. 1. D. signifies a convex spherical lens of one diopter's strength, whilst a concave cylindrical lens of the same strength, were its axis at ninety degrees, would be designated by the symbol—C. 1. D. ax. 90°. A lens of half the strength of the one diopter—that is, one which focusses at only two meters' distance—is known as an 0.50 D. lens; and a lens which is of but one-fourth of the one diopter strength—that is, one focussing at four meters' distance—is designated by the symbol 0.25 D. A lens of two diopters' power (2.D.) is double the strength of the one-diopter lens, and, in consequence, focusses at one-half of the meter. In other words, starting from the weakest lens, the stronger the power of the lens, the shorter is its focus, thus establishing the rule, which in a modified form is equally applicable to the linear deviation of prism-powers, that the refractive power of a lens is inversely proportional to its length of axial focus (short focus, strong lens; long focus, weak lens). Knowing, then, the number of diopters of dioptric power in a lens, it becomes easy to estimate its focal length. To do this, it is merely necessary to divide the number of diopters in the strength of the lens into one hundred centimeters (one meter). For example, a convex lens of four diopters' strength, which means that it is four times stronger than a similar form of lens that focusses at one meter (one hundred centimeters), has a focal length of twenty-five centimeters ($100 \div 4 = 25$); whilst one of ten diopters has a focal length of ten centimeters ($100 \div 10 = 10$).

The old system of numbering the various lens-strengths by their radii of curvature expressed in Paris inches, is known as the inch system. It had its unit of 1 assumed by the extremely strong lens of about one inch focus. As all the ordinary lenses used in spectacles

¹ At the present time most of the test-lenses in use are ground in strengths that are dependent upon their radii of curvature.

are weaker than this unit, the successive strengths had to be expressed by fractional parts of 1. For instance, a lens of two inches' focus is known as a $\frac{1}{2}$ lens; a lens of four inches' focus is designated as a $\frac{1}{4}$ lens; and a lens of forty inches' focus, as a $\frac{1}{40}$ lens. In consequence, this plan of numeration, which labors under the further disadvantages that there is a decided difference between the lengths of the German, French, and English inch which are employed, and that the lens-strengths ordinarily used, are so unequal in fractional interval, is being rapidly superseded by the easily calculated and substantially fixed metric system.¹

In daily use by the ophthalmic surgeon, there are a series of lenses, termed *test-* or *trial-lenses*, which are employed to determine the number of spectacle-lens needed by the patient. As these lens-powers have certain values, which although fixed in themselves, are reciprocal in the two systems, the following table is given as expressive of the designation and powers of convex and concave spherical lenses now in ordinary use:

Focal intervals between the diopter lens-strengths.	Number of lens in dioptric system.	Focal length in centimeters.	Focal length in Paris inches and corresponding lens in inch system. ²
0.12½ D.	0.12½	800	
"	0.25	400	144
"	0.37½	266	
"	0.50	200	72
"	0.62½	160	60
"	0.75	133	48
"	0.87½	114	42
0.25 D.	1.00	100	36
"	1.25	80	30
"	1.50	66	24
"	1.75	57	22
"	2.00	50	18
"	2.25	44	16
"	2.50	40	14
"	2.75	36	13
"	3.00	33	12
"	3.25	30	11
"	3.50	28	10
"	3.75	26	
"	4.00	25	9
"	4.25	23	
"	4.50	22	8
"	4.75	21	
0.50 D.	5.00	20	7
"	5.50	18	6½
"	6.00	16	6
"	6.50	15	
"	7.00	14	5½
"	7.50	13	5
1.00 D.	8.00	12	4½
"	9.00	11	4
"	10.00	10	3½
"	11.00	9	3¼
"	12.00	8	3
"	13.00	7.6	
"	14.00	7.1	2¾
"	15.00	6.6	2½
"	16.00	6.2	
"	17.00	5.8	
2.00 D.	18.00	5.5	2
"	20.00	5.0	
"	22.00	4.5	
"	24.00	4.1	

¹ It is of no consequence, so long as the plan is universal, that the French linear measurements are not yet absolutely accurate.

² In this column the nearest approach to the Parisian inch is assumed. If English inches had been employed, the one-diopter lens should have been considered as equivalent to 39.370 (practically 40) instead of 36, as the English inch is the shorter. This table, which is ordinarily expressed in fractions (1-72, 1-60, 1-10, etc.), does not pretend to be expressive of an exact equivalent of the corresponding lenses in the dioptric column. The index of spectacle-lens glass has been taken as 1.53 throughout.

For cylindrical lenses, as a rule, it is not necessary to have anything stronger than ten diopeters' strength. Prism strengths need not range higher than twenty P. D., there conveniently being one P. D. interval up to ten P. D., and two P. D. intervals between ten and twenty P. D. All such sets of test-lenses should contain graduated test-frames, a stop, a stenopæic slit, a pin-hole, a disk, a pair of differently tinted Maddox rods, and disks of red, green, blue, and cobalt glasses.

By reference to this table, it will be noticed that to convert any strength of diopter lens into an equivalent one of the old system, it is simply necessary to divide the number of diopeters in the lens into the meter, or thirty-six (Paris) inch length. Thus, a lens of one diopter strength is equivalent to a $\frac{1}{36}$ lens; a lens of one-half diopter strength is equal to a $\frac{1}{72}$ Paris inch lens; a two diopter lens, to a $\frac{1}{18}$ lens, etc.

With the dioptric system, the calculation necessary for any combination of lens-powers is very easy. For instance, a +S. 1. D. added to a +S. 6. D., gives a lens of +S. 7. D.; or, with unlike combinations, a +S. 6. D. and a -S. 1. D. added together, give a resultant of +S. 5. D., the minus one diopter having weakened the plus six diopter lens, one diopter's strength. That is, similarly formed lenses produce results equal to their added powers, whilst dissimilarly formed lenses give results equal to their differences. The same rule holds good for cylinders in similar axes, whilst prisms increase in strength when placed base to base, and decrease in strength when placed edge to base.

Of course, any combination of sphericals, cylinders, and prisms is subject to the same laws. All that is needed when formulæ for spectacle-lenses are written, as explained in the chapter on the Correction of Errors of Refraction, is to reduce the combination to its simplest form.

Careful consideration of all that has been said, will render it easy to understand that as every spherical and cylindrical lens is composed of varying multitudes of prisms, all varieties of prismatic action besides its expressive one, may be obtained when rays of light are allowed to fall through it in certain directions. Moreover, it is to be remembered that if any definite ray be made to impinge upon the surface of curvatures in a manner that will not allow it to pass through the optical centre, it will be deflected, the rule being that the greater the distance of the ray from the optical centre, the greater will be the degree of deflection. In other words, the farther the ray is from the optical centre, the greater becomes the prismatic action of the lens. This can be accomplished in two ways: First, by carrying the ray to an excentric position through the lens; second, by displacing the lens itself, so that the ray will pass excentrically. In spectacle lenses, therefore, it can be understood that any object-ray which pursues the same course as any light-ray, may be so deviated by a lens placed before the eye that almost any desired degree of deflection or prismatic action can be obtained by variation in the position and strength of lenses employed. To accomplish this clinically, two plans have been resorted to in spectacle lenses. One is by a separation or diminution in the bridge-width of the frames, which consists merely in displacing the optical centre of the lens, so that some excentric portion of the lens will come directly opposite the pupil. The other consists in grinding a

lens of the requisite size peripherally from a larger lens in such a manner that the so-called *geometrical centre* (which denotes merely a point equidistant from the circumference of any lens) is made at a different place from the optical centre of the lens from which the smaller one has been ground; the distance between the two centres, expressed in millimeters, giving certain amounts of difference of deflection or prismatic action in lenses of definite strengths. Thus in the accompanying table, abstracted from Maddox's series, the upper horizontal row of increasing strengths of millimeters, gives the amount of deviation necessary to be made for the various strengths of lens diopeters, shown in the first vertical column, to produce any definite desired prism action:

	1	2	3	4	5	6	7	8	9	10
	Mm.	Mm.	Mm.	Mm.	Mm.	Mm.	Mm.	Mm.	Mm.	Mm.
0.5 D.	1' 43"	3' 26"	5' 00"	7' 00"	8' 25"	10' 00"	12' 00"	14' 00"	15' 28"	17' 00"
0.75 "	2' 30"	5' 00"	8' 00"	10' 00"	13' 00"	15' 28"	18' 00"	20' 37"	23' 00"	26' 00"
1 "	3' 26"	7' 00"	10' 00"	14' 00"	17' 00"	20' 37"	24' 00"	27' 30"	31' 00"	35' 00"
1.5 "	5' 00"	10' 00"	15' 28"	20' 37"	26' 00"	31' 00"	36' 00"	41' 00"	46' 00"	52' 00"
2 "	7' 00"	14' 00"	20' 37"	27' 30"	35' 00"	41' 00"	48' 00"	55' 00"	1° 2'	1° 9'
3 "	10' 00"	15' 28"	31' 00"	41' 00"	52' 00"	1° 2'	1° 12'	1° 22'	1° 32'	1° 43'
4 "	14' 00"	27' 30"	41' 00"	55' 00"	1° 10'	1° 22'	1° 36'	1° 50'	2° 4'	2° 18'
5 "	17' 00"	35' 00"	52' 00"	1° 9'	1° 26'	1° 43'	2° 00'	2° 18'	2° 35'	2° 52'
6 "	20' 37"	41' 00"	1° 2'	1° 23'	1° 43'	2° 4'	2° 24'	2° 45'	3° 5'	3° 26'
7 "	24' 00"	48' 00"	1° 12'	1° 36'	2° 00'	2° 24'	2° 48'	3° 12'	3° 37'	4° 1'
8 "	28' 00"	56' 00"	1° 22'	1° 50'	2° 18'	2° 46'	3° 12'	3° 40'	4° 8'	4° 35'
9 "	31' 00"	1° 2'	1° 32'	2° 4'	2° 35'	3° 6'	3° 37'	4° 8'	4° 38'	5° 9'
10 "	35' 00"	1° 9'	1° 43'	2° 18'	2° 52'	3° 26'	4° 1'	4° 35'	5° 9'	5° 44'
12 "	41' 00"	1° 23'	2° 4'	2° 45'	3° 26'	4° 7'	4° 48'	5° 29'	6° 10'	6° 51'
14 "	48' 00"	1° 36'	2° 24'	3° 12'	4° 1'	4° 48'	5° 36'	6° 24'	7° 11'	7° 58'
16 "	56' 00"	1° 50'	2° 46'	3° 40'	4° 35'	5° 29'	6° 23'	7° 19'	8° 12'	9° 6'
18 "	1° 2'	2° 4'	3° 6'	4° 8'	5° 9'	6° 10'	7° 11'	8° 12'	9° 12'	10° 12'
20 "	1° 9'	2° 18'	3° 26'	4° 33'	5° 44'	6° 51'	7° 58'	9° 6'	10° 12'	11° 19'

Here the result is expressed in degrees, minutes, and seconds. It is inserted both to serve as a guide to what is meant, and for the benefit of those who still adhere to the ordinary degrees, minutes, and seconds method of prism-naming.

Should it be desired to estimate more accurately the amount of prismatic effect obtained in prism diopeters, all that is necessary for ordinary clinical work, is to remember the law laid down by Mr. Prentice, that "a lens decentred one centimeter will produce as many prism dioptries as it possesses lenticular dioptries of refraction." For instance, a one diopter lens, which is decentred one centimeter (ten millimeters), will produce one prism diopter of deviation at one meter's distance. Or, to modify this example by doubling the amount of decentring (thus doubling the effect), a five diopter lens, decentred two centimeters, will give ten prism diopters of deviation at the one meter plane. Of course, should the plane upon which the deviation takes place be changed, the size of the prism diopter at the meter plane would proportionately change.

Since the relative values of centrad and prism diopters are so nearly alike up to twenty, the rule may be applied to the former also. Where scientific accuracy is required, careful mathematical calculation is necessary for every point desired.

CHAPTER V.

PHYSIOLOGICAL OPTICS.

As is explained in the section on Anatomy, the eye is practically a series of boxed lenses, with a sentient membrane placed at their compound focussing-point. These lenses constitute the dioptric apparatus of the organ, and may be conveniently divided into those that are fixed and stable, and those that are movable and changeable: the one a focussing material that brings fixed rays of light, color, and form to their foci, and the other a focussing apparatus so contrived as to allow constantly-changing points of focus to fall properly upon the sentient sheet; the one termed the *refraction* of the eye, and expressed by the initial letter R, and the other known as the *accommodation* of the organ, and designated by the initial letter A: the one a fixed condition, the other a movable quantity.

This can be well understood if the focussing material of the ordinary photographic camera-box is compared with the dioptric apparatus of the eye. The camera is essentially a closed box, with a perforation containing a series of converging lenses so arranged as to permit the access of extraneous rays of light to a sensitized sheet of focussing material. Immovably fixed and devoid of any power of change of focus, it may be considered as equivalent to the eye in a state of rest. It may be understood as equal to the condition of that organ when its dioptric apparatus is in a state of physiological quiescence.

Should it, however, be desired that the camera focus accurately some other distant view at a much nearer point, say, than the one for which it is adapted: should it be desired to obtain an accurate picture of some other point than the one for which its lenses have been constructed, it will become necessary either to change the lenses themselves, or to move the sensitized sheet of material to a situation in the box corresponding to a new plane of focus. In the ordinary camera, as now made, this is generally accomplished by the latter method, a screw attachment so made as to alter the relative positions of the plate and of the lens, being the mechanical device used for the purpose. This, then, is the movable quantity of the instrument: it is the adaptation of the contrivance for changeable focus.

So with the eye: besides having its representative fixed focus, besides having its definite refraction, there is, just as in the camera, a power of changeability; there is an act of adaptability, as it were, which permits a series of points of ever-changing distance to be accurately focussed upon the retina. Here it is not accomplished by a lengthening and shortening of the diameter between the anterior surface of the series of lenses and the focussing sheet, as in the camera, but by a special muscular contrivance attached to an elastic lenticular body, which causes

a sufficient strengthening and weakening of lens-action to keep the entering rays always fixed upon the retinal elements.

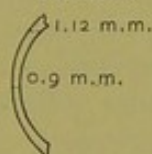
The only difference, then, between the two contrivances is, that in the artificial one (the camera), the focus is effected by a change in the form of the containing box, whilst in the natural one (the eye), the focus is obtained by giving the lens a movable and an equivalent action.

Confining our studies to the human eye, it now becomes necessary to inquire into the various component parts of this focussing material and to study their optical constructions and adaptabilities.

Commencing with the most external, the cornea is first encountered. Disregarding its physical constituents and considering only its optical qualities, it will be found to be a dense, transparent medium, which is bounded by two curved surfaces—the external surface being convex; the internal, concave.

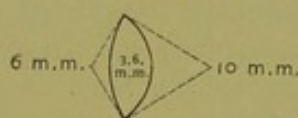In the human adult, the posterior surface is slightly more curved than the anterior, as shown by the fact that the thickness of the membrane is 0.9 millimeter at its summit and 1.12 millimeters at its periphery. The average radius of curvature, however, for convenience sake, is assumed as 7.6 to 7.7 millimeters.

FIG. 116.



Profile view of cornea.

FIG. 117.



Profile view of lens.

Leaving out of account the influence of the film of tears which overlies the medium, the entering ray of light may be said to strike a concave meniscus lens which has a density of 1.336.¹ The great difference of rarity between the air from which the ray comes and the aqueous humor into which the ray penetrates after passing through the membrane, far more than compensates for the slightly divergent effect produced by the shape of the membrane.

The moment the ray reaches any peripheral portion of the convex surface of the cornea, that moment it is converged—is bent inwardly. Passing on, it reaches the concave posterior surface of the membrane, and would now, if it again passed into air, diverge. Instead, however, of meeting such a medium, it encounters one of equal density with that from which it came; in consequence of which it pursues an uninterrupted course in the same converged direction for at least 2.7 millimeters,² until it reaches the anterior capsule of the lens. At this point it meets a lenticular structure of the bi-convex variety, which is not only unequally curved upon its two surfaces, but is also far from being homogeneous. Turning for a moment to the anatomy of the so-called crystalline lens of the eye, it will be found, as explained on page 65,

¹ As compared with distilled water 1.3358 (Brewster).

² 2.7 mm. is Krause's measurement of the depth of the anterior chamber opposite the corneal centre.

that it consists of superimposed layers, each less dense than the one which underlies it. Besides this, the radius of curvature of its anterior surface is, according to Helmholtz, equal to 10 millimeters, as shown in Fig. 117, whilst the posterior surface, as estimated by the same observer, is but 6 millimeters. The two poles of the substance are separated by a width of 3.6 mm. of lens-material, which, according to the same author's later views, has an average index of refraction of 1.437.

This gradual decrease of density from the centre of the lens to its periphery, and the inequality of the two refracting surfaces, have a great effect upon the passage of light-rays through its substance. No matter at what angle the incoming ray may strike the anterior capsule, it will progressively curve inward.¹ The effect upon the ray, which has now reached the lens, is to leave its direct convergent course, and to pursue a curvilinear inward direction toward the centre of the lens, and then to progressively, though slightly, change its course outward, although in the main to continue its convergence, until at last it reaches and passes through the posterior capsule of the lens.

The ray now reaches the largest body of humor in the eye—the vitreous. By looking at any profile view of the human eye, we shall see that this humor is a long, concave meniscus. On account of the discrepancy between the slight curvature of its surface and the great antero-posterior length of dense material composing its substance—which, according to Knapp, is about thirteen millimeters—its close apposition to the lens, and the slight relative average difference of density of these two structures,² it really acts as a converger.

Ordinarily, it is sufficient to consider but three points of change of deflection in the entering ray, viz., the anterior surface of the cornea, the anterior surface of the lens, and the anterior surface of the vitreous. In fact, for our purpose, the general effect of the converging property of the combined media from the anterior surface of the cornea back to the retinal plane itself, is all that will be necessary for demonstration. Preliminary to this, however, the following explanations will be useful.

Thus far, the entrance of a single peripheral ray of light into the organ and its passage through the various media, have been considered without any relation to angle of incidence, point of impingement, and exact direction of refraction. To obtain these, it is only necessary to fix a few points, lines, and angles of measurement which will apply to all eyes, and simplify the entering beams of light into two rays which are parallel to each other.

For this purpose the calculations of Gauss and Moebius, who demonstrated that the resultant focus from a compound system of lenses which are accurately centred upon the same optical axis, is in direct relation to the individual power of each lenticular component, may be taken. Just as one lens has two principal focal points, the first

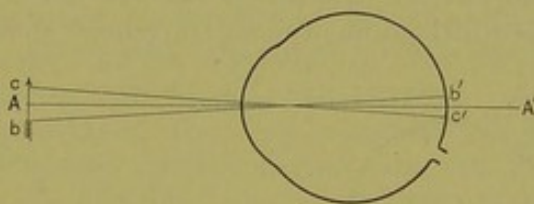
¹ This assertion is not strictly true, but is made here for the sake of simplicity. The fact is, the menisci forming the posterior cortical progressively decrease in density, which of itself has a tendency to give a slightly outward curvilinear deviation to the incoming convergent ray, even although all the menisci in this portion of the lens are of almost double the curvature of those in the anterior cortical.

² The density of the vitreous is about the same as, or possibly a trifle more than, that of the cornea and aqueous.

of which is represented by a point upon the optic axis from which all rays striking the denser medium are refracted in a direction parallel to the optic axis, and the second, by a point upon the optic axis beyond the lens, upon which all rays passing through the lens parallel to the optic axis will fall after having left the lens; just as one lens has its principal points, which are the points of meeting of the two lenticular surfaces with the optic axis; and just as one lens has its nodal points, which are practically the centres of curvature of the lenticular surfaces, so there are similar and related points in any system of lenses. As these, the so-called *cardinal points*, as explained on page 132, are obtainable in any series of artificial lenses, practically converting a complicated problem of optics into a simple equation, in the same manner with the eye—all the formulæ and necessary diagrams in explanation of this complicated apparatus are rendered more easy of comprehension by the reduction of its compound system of refractive material into a simple and easily understood mechanism.

Commencing with the explanation of the principal line upon which all these points are situated, the following illustration is made use of:

FIG. 118.



Principal and secondary axes.

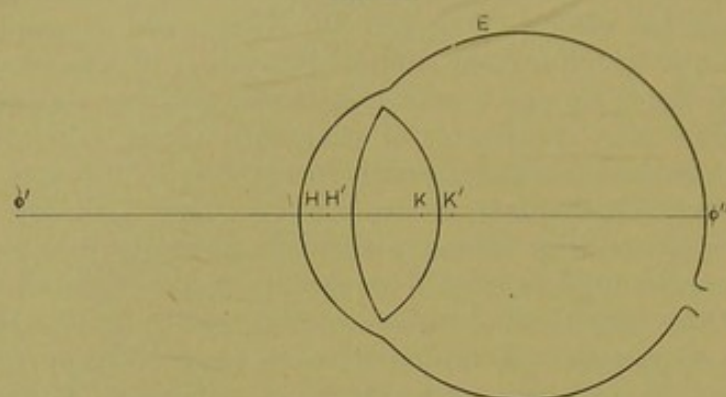
Here, there is supposed to be a horizontal section of the eye, so cut as to make a plane through the optic-nerve entrance and the macula lutea. The line A A' is known as the *optic axis* or *principal axis*. It passes through the centre of the cornea and the centre of motion, and emerges posteriorly at the posterior pole. All other axial lines proceeding from any given object are termed *secondary axes*, and upon account of the strong convergent power of the organ, are brought to a focus upon the principal axis in the interior of the eye, where they cross one another to pass on and form an inverted image upon the retinal focussing plane: thus, both b b' and c c' are secondary axes.

Having obtained the optic axis, the situation of what are known as the cardinal points of the dioptric apparatus are next to be studied. These are the *anterior* or *first principal focus*, the *posterior* or *second principal focus*, the *anterior* or *first principal point*, the *posterior* or *second principal point*, the *anterior* or *first nodal point*, and the *posterior* or *second nodal point*. A glance at Fig. 119 will show that they are all situated upon the principal axis.

The Greek letter ϕ' denotes the *anterior focus*. It is the point upon the principal axis, at 13.745 millimeters in front of the corneal apex, where all convergent rays from the eye which have been parallel with the principal axis within the eye and which have started from the retinal plane would fall to a focus. Fig. 120, which disregards the

various lenticular planes and their action, so as to avoid complication, is sufficiently accurate to explain what is meant.

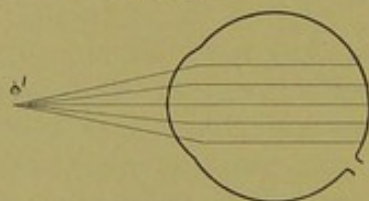
FIG. 119.



Schematic eye with cardinal points.

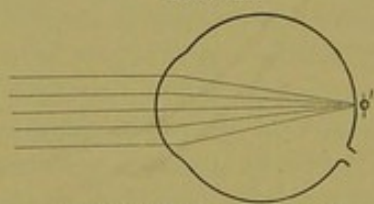
Careful examination of Fig. 120 will illustrate the fact that the divergent rays do not really pass into parallelism immediately upon reaching the anterior surface of the eye. This has been done intentionally to show that, on account of the interior of the eye not being homogeneous in structure, a theoretical point of commencement of focussing has been

FIG. 120.



Position of anterior focus.

FIG. 121.



Position of posterior focus.

assumed, which is the mathematical resultant of the coefficients of the several refracting elements contained in the media. This point, as explained before, and which is shown at H in Fig. 119, is the *anterior* or *first* principal point, and contributes toward the formation of the anterior plane. It is situated 1.753 millimeters behind the front of the cornea.¹

The *posterior principal focus*, represented by ϕ'' in Fig. 119 and in Fig. 121, is the point upon the optic axis in the dioptric apparatus of the same eye where incident rays which have been parallel to the principal axis in front of the eye are brought to a focus. This point, which is 22.823 millimeters behind the apex of the cornea, is situated at, or slightly anterior to, the posterior pole of the eye. Fig. 121, which, like the previous one, does not show the real bendings of the refracted rays, is sufficiently accurate for our purpose.

Here, the series of entering rays which are parallel with the central one (the principal axis) are all brought to a common focus upon (or near) the retina at the point of impingement of the principal axis.

Here it will be noticed that, just as before, the rays retain their original direction for a short distance after they have gained access to the interior

¹ In the figure, this distance is purposely exaggerated to give better effect.

of the globe. This plane is situated about 2.110 millimeters behind the outer corneal surface, and is known as the *second principal plane*. It is composed of an infinite number of points, termed the *second or posterior principal points*. In Fig. 119 it is shown at H' .

It will be remembered that the principal point of a lens is the point of meeting of the curvature of the surface and the optical axis of the lens. So here the combined system of lenses forming the dioptric apparatus of the eye, has its theoretical posterior surface of principal points situated in the aqueous humor slightly behind the first principal plane. In the human eye they are so close together that, for ordinary calculations, they may be supposed to be placed upon a third plane midway between the anterior and posterior planes, at a point in the aqueous humor 1.932 millimeters behind the posterior surface of the cornea.

The *first or anterior nodal point*, designated by the letter κ in Fig. 119, is the centre of curvature of the anterior principal point, H . In the human eye, it is situated 6.968 millimeters behind the cornea. This will cause it theoretically to fall in the posterior layers of the crystalline lens, about 0.231 millimeter in front of its posterior surface.

The *second or posterior nodal point*, κ' (Fig. 119), which represents the centre of curvature of the second principal point, H' , is situated, according to Landolt, 0.356 millimeter behind the posterior surface of the lens, thus causing it to fall into the vitreous.

In ordinary calculation, it is best to unite the nodal points into a single nodal point placed midway between the two, 7.146 millimeters—say, seven millimeters—behind the cornea, thus making it correspond to the single principal point. This plan greatly simplifies the whole procedure, theoretically reducing the eye to a homogeneous medium, in which H can be considered as equalling the theoretical surface of the dioptric apparatus, and κ as equivalent to its centre of curvature. The schematic eye of Listing is thus reached, without which dioptric formulæ would be both difficult and troublesome.

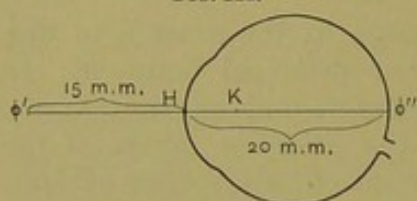
Adopting Donders's proposition to disregard all decimal fractions, the anterior focus can be considered to be equal to fifteen millimeters, the posterior focus to be equal to twenty millimeters, and the radius of curvature of the united principal points, H , which now becomes the anterior face of the reduced eye, to be equivalent to five millimeters. This is shown in Fig. 122. The coefficient of refraction, n as 1.333 ($n = \frac{20 \text{ mm.}}{15 \text{ mm.}} = \frac{4}{3} = 1.333$), which, as will be remembered, is practically that of water, is thus obtained.

Having from previous calculation, reduced the dioptric apparatus to a corneal surface, with a radius of curvature of five, or, according to some authorities, seven millimeters, placed in front of a homogeneous medium with an index of refraction of 1.333, which has a focussing plane situated roughly at twenty (or twenty-two for the latter radius) millimeters behind the centre of its anterior surface, a few of the most important of the remaining points, lines, and angles can be considered.

Were the eye a perfect optical instrument—were the axial planes of the cornea and the lens parallel, and did the centres of each lens com-

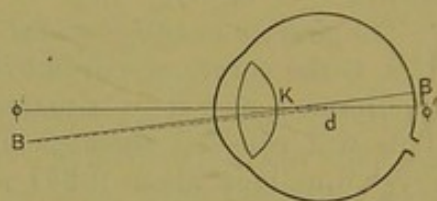
bination accurately coincide—the axis-ray would not be refracted. Unfortunately, careful experiments by Helmholtz, Knapp, Donders, and Doyer, performed by reason of the assertions of Wells, Mackenzie, and others, have made manifest that the corneal apex is generally situated to the nasal side of the lenticular summit. Further careful ophthalmometric observation has shown that the point of meeting of the optic axis and the corneal plane does not coincide with the corneal summit, the latter, as a rule, being to the outer side of the former. In view of these irregularities, and the fact that general distortion of the ocular tunics is so common, it becomes necessary to fix the position of some new points and lines before any degree of scientific accuracy in future calculation can be obtained.

FIG. 122.



Reduced eye.

FIG. 123.

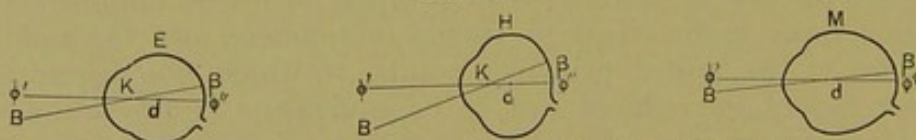


Visual line. Angles alpha and gamma.

Fig. 123, which, of course, is diagrammatic, though only sufficiently falsified to make the meaning plain, can be used.

The first important line is that which proceeds from an extraneous object directly through the nodal point to the macula lutea of the eye. It is known as the *visual line*, or *line of vision*. In Fig. 123 the line running from the point, B (the object), through the nodal point, K, situated upon the optic axis, forms its image, β , in the depression known as the fovea centralis in the posterior part of the globe. It will be noticed that it does not coincide with the optic axis, and that the only place of contact is at the nodal point, K. In reality, it is but one of the secondary axes of the system.

FIG. 124.



Relative sizes of angle alpha. (Modified from DONDERS.)

In the anterior portion of the figure, between these two lines, we can readily see that there is an angle, having the nodal point, K, for its apex. It is known as the *angle alpha* and is represented by the Greek letter α . It is denoted in the figure by $B K \phi'$. It varies considerably according to the many refractive and accommodative changes present. Fig. 124, modified from Donders, shows how eyes of normal length or of too short or too great an antero-posterior diameter affect the width and size of this angle.

It will be seen that this angle is very wide in the short, or hypermetropic, eye, H, and that it is extremely narrow in the long, or myopic, organ, M. Donders has shown that the angle in the hyper-

metropic eye is so broad that the point of impingement of the visual line upon the corneal surface is so far to the nasal side as sometimes to make an opening angle of eight or nine degrees—an amount almost double that found in the emmetropic organ. He has also shown that in the opposite condition (myopia), the opening angle may be annihilated, or even reversed, causing it in the latter instance to be designated as the *negative angle alpha*.

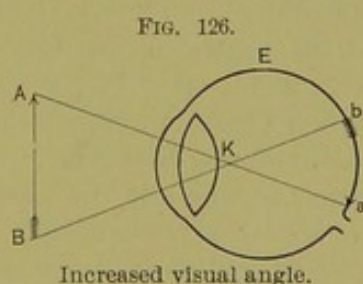
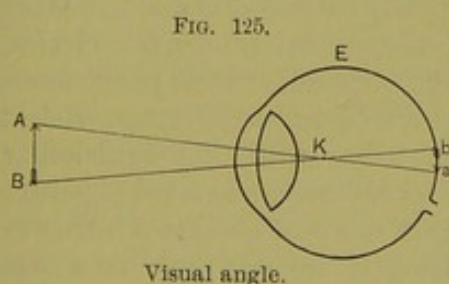
The most mooted point is that known as the *centre of motion* or *rotation*, a position, according to Donders, which is found in the vitreous at 1.77 millimeters behind the middle of the visual or optic axis. It is expressed by the sign d . A glance at Fig. 124 will show that although it lies more deeply in the vitreous of the myopic eye, yet it is situated more anterior to the retinal plane than in the hypermetropic organ, where it approaches very closely to the posterior pole.

The next line of importance is that known as the *line of fixation*. It is the straight line drawn from the point of centre of motion to the extraneous object. This is shown in Fig. 123 by the dotted line connecting the points B and d .

The angle included between the line of fixation and the optic axis, with the centre of motion as an apex, is termed the *angle gamma*. It is of value in the estimation of extra-ocular muscle changes. It is denoted in Fig. 123 by the angle $Bd\phi'$.

A fourth line, extending from the fixation-point through the centre of the pupil, has been noted by Helmholtz as the *visirlinie*, and termed the *line of sight* by Knapp.

The *visual angle* is the next to be considered. This is the angle which is subtended by the extremities of any visible extraneous object, and passes into the eye to form its apex at the nodal point of the organ. Reaching this point, the lines cross to diverge and form a reverse image of the distant object upon the retina, which image is sent to the cerebral centres for recognition. Fig. 125 explains what is meant.



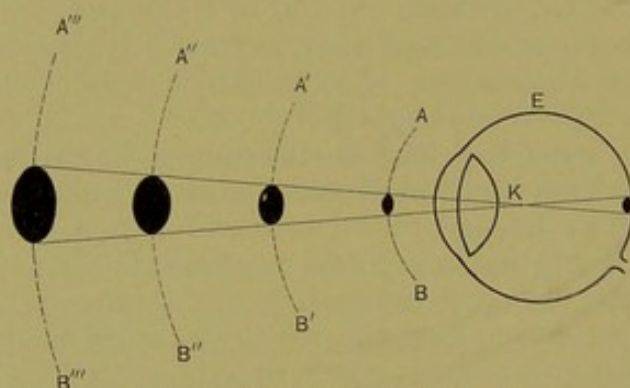
Here the eye, E , is adjusted for the upright arrow, AB , situated in the air. The convergent lines from the extremities of the object pass into the eye, and cross one another at the nodal point, K . Diverging, they fall upon the retinal plane, and make an inverted image, ba , of the arrow.

Should the same object be brought nearer, as in Fig. 126, the visual angle would be much greater, and the size of the retinal image would be increased. Or should the object itself be larger, the visual angle would be increased, and the inverted image would be larger. A very apt illustration is that of a small coin, which, if held near to the eye, will

hide from view a large area of the field of vision, but if removed several feet away, appears much smaller, and allows an enormous increase in the area of the field of vision; or, conversely, a distant tree, which appears small, and occupies but a limited portion of the landscape, becomes gradually larger as it is approached, until at last, when its surface is reached, the surrounding landscape is hidden.

Of course, there is a limit to the size of the angle. Volkmann and Snellen, who were long preceded by Hook and Porterfield in the estimation of the size of the angle, have determined that the smallest angle in which any terrestrial object can be properly recognized, is equivalent to about one minute's opening. By this, they mean that should the nodal point of the eye be situated at the centre of a circle, and objects placed upon any radius proceeding from it, the objects would be seen only when their height would reach to a second radius situated at an angle one minute higher than the one on which the object is standing, the same being true for all the other meridians of

FIG. 127.



Minimum limit of angle of vision.

the object. Thus in Fig. 127, the eye, E, has its nodal point, K, placed at the centre of the four segments of the theoretical concentric circles, A B, A' B', etc. Upon the segments of the circumferences, black areas which represent objects have been placed. To be properly recognized at one meter's distance, it will be necessary to have the dot sufficiently large to include the one-minute angle in every meridian at this point; to see it at two meters, it must be double the size of that which was seen at one meter; for the three-meter distance, the dot must be a size larger than that at two meters, and triple the size of that at one meter; whilst for four meters, the dot must be a size larger than that for three meters, and four times the size of that at one meter.

In ordinary ophthalmic practice, it will be seen that each specified distance has its appropriate size of test-type, this, as now understood, depending upon the distance of the component parts or dots from the nodal point of the observing eye. Thus, in the ordinary test-letters or *optotypi* of Snellen, the strokes of the letters are each embraced in the one-minute angle, the entire letter or character being kept within an angle of five minutes. Knowing that the tangent of a five-minute angle is equal to 0.001454, all that it is necessary to do, to obtain

the size of the letter which should be seen at any definite distance, is to multiply the length of the tangent by the number of centimeters' distance: thus, at one hundred centimeters, or one meter, the letter should be 1.454 millimeters square; at five meters it should be five times this size, or 7.270 millimeters square; each stroke being one-fifth of these sizes. With the simple form of letter-formation and under strong light-stimulus, the one-minute angle recognition, as spoken of by Hook, is frequently exceeded, giving rise to new and more difficult series for daily use by some ophthalmologists.

From what has been said, it must not be imagined that the eye is a perfect optical instrument. Helmholtz has justly said that "if an optician sent him an instrument so full of defects he would be justified in sending it back with the severest censure." Nevertheless, we can but feel, with Tyndall, that "as a practical instrument, and taking the adjustments by which its defects are neutralized, into account, it must ever remain a marvel to the reflecting mind."

Owing to the fact that the series of central and peripheral rays do not pass through the same amount and degree of focussing material whilst they pursue their way in the interior of the eye, we have an indistinctness of focus of one of these sets of rays the moment we obtain a clear image of the other: this is known as *spherical aberration*. In ordinary spherical lenses, it manifests itself either by a blur in the centre of the image, or by a clearly defined central picture with a peripheral indistinctness. In the eye, however, there are two contrivances which almost correct this: first, the iris, which cuts off the most peripheral rays; and second, the increase of density and curvature of lenticular material from the periphery toward the centre of the crystalline lens. The first is frequently imitated in nearly all optical instruments, but the second remains impossible of artificial construction.

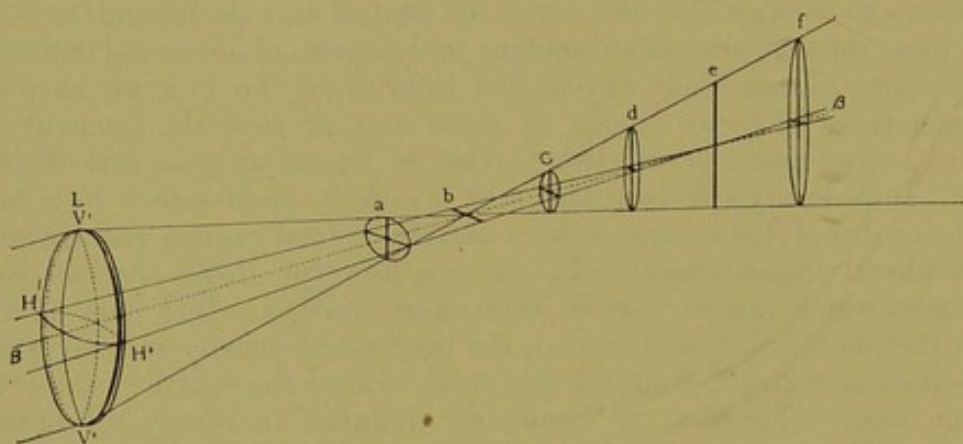
By reference to text-books on optics, it will be found that it is to Newton that the credit of determining "that light is not homogeneous, but consists of rays of different colors and unequal refrangibility," must be given. Moreover, the least change of the rate of speed of vibration causes a change in amplitude of wave-length, which necessarily produces a difference in color. So in the eye, if a series of definite wave-lengths impinge upon the cornea and are broken into different wave-lengths by encountering unequal degrees of resistance as they pass through the dioptric media, there will of necessity be a change in the colors produced in the different parts of the retinal image. In other words, there will be *chromatic aberration*—an aberration resulting from the lenses of the eye not being homogeneous, and from this inequality of material breaking the rays of light into different colors.

An apt illustration of the former defect is found in the limited capacity of the ingenious photographic camera called the "kodak." It is an instrument that can be used for distant views without the necessity of any special focussing. It is an imperfect artificial eye which allows the rays from the extraneous object to fall properly through its sensitized sheet only through the centre of the lens and a narrow surrounding area, thus limiting the picture to a small circle of two or three

inches' diameter. This is partly accomplished by a small central diaphragm. So is it, though to a greater degree, with the eye.

Again, as shown in the section on Astigmatism, there are, as a rule, in every human eye two principal foci in the refractive apparatus, one for the more bent and the other for the less bent rays, the rule being that the radius of the vertical meridian is shorter than that of the horizontal. Knowing that the amount of the deviation of a ray is dependent in due proportion upon the curvatures of the medium it strikes, it will be at once evident that should a homocentric beam of light pass through such unequal curvatures, there will be certain changes given to the image formed by this beam when received at different distances. Thus, in Fig. 128, which represents a bi-convex lens (L) that has the radius of its vertical curvatures ($V^1 V^2$) made shorter than its horizontal ($H^1 H^2$), the image of the beam of light, as it is gradually removed

FIG. 128.



Sturm's focal interval.

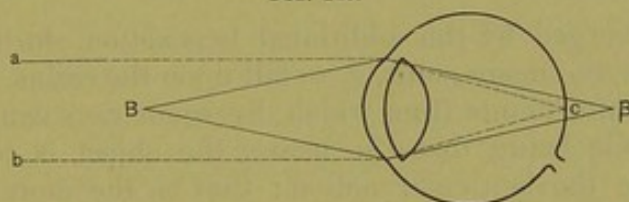
from the lens, first becomes horizontal oval in shape, at a, on account of the rays in the vertical meridian being the more greatly bent, until, at b, they have been brought together, making a horizontal band of light equal in width to the separation of the still unfocussed horizontal rays. The vertical rays crossing, diverge until, at c, their height equals the width of the separation of the horizontal rays, thus giving rise to a circle. The vertical rays still becoming progressively wider and the horizontal rays narrower, the image circle, c, is converted into a vertical oval at d, until at e, when the rays in the horizontal meridian having been brought together, the vertical oval image is changed into a vertical stripe. The horizontal rays undergoing their crossing, and the vertical rays becoming still more widely separate, give width to an image at f, which, in reality, becomes vertical oval in shape. The interval between the two foci at b and e, is generally known as *Sturm's focal interval*.

Further, it is a well-known fact, since *Scheiner's experiment*, that should we break the pupillary opening into two smaller apertures by means of a double perforation in a card or disk (*vide Thomson's device* in the chapter on the Determination of Errors of Refraction), that there will be two small *diffusion circles* for retinal impression instead of one

large diffuse one of any extraneous object-point that is not in exact focus. This is produced by the admittance of but two narrow bundles of rays which are sufficiently separated on the retinal sheet to be specially recognized.

Moreover, just as in every uncared-for optical instrument, so in the abused eye, an organ composed of the most delicate and changeable of structures, there are frequently found inequalities of lens-curvatures, irregularities and differences in the formation of the focussing-plane, floating opacities in the vitreous and aqueous, and fixed spots both in the lens and in the cornea, rendering the dioptric apparatus more or less imperfect. Still further, there are anatomical areas upon the retinal plane in which no image-formation can take place. The optic-nerve tip, the thickened and opaque nerve-coverings, and the large bloodvessels and their contents, all produce breaks in the field of vision, so that were it not for the dual organs being so placed as to act simultaneously upon the same object, the excessive freedom of ocular movement, and the quickness of visual perception, the organ's optical imperfections would become physiologically manifest.

FIG. 129.



Passage of parallel and divergent rays into an emmetropic eye.

Thus far, the fixed optical power of the eye has been considered. Our studies have been confined to what is termed refraction. Attention will now be devoted to the movable part of the apparatus—the portion that admits of change of focus, known as *accommodation*. Upon turning to the chapters on Anatomy, it will be found that there are several series of intra-ocular muscles which are devoted to the movement of the lens and the regulation of the pupillary area.

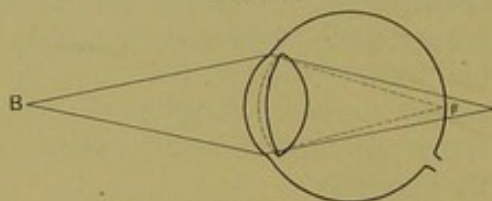
The physiological working of the lenticular series, which is the more important, will be considered first.

In the preceding chapter it has been learned that the hypothesis of Helmholtz in reference to accommodation is the one that is generally accepted. The influence of this mechanism upon the dioptric apparatus of the eye is now to be considered. It will be remembered that the emmetropic eye in a state of rest is intended for the focussing of extraneous parallel rays upon its retina. This being the case, it is plain that the stronger the action of its focussing material is rendered by the physiological action of the intra-ocular muscles, the more quickly will these parallel rays be focussed; in other words, their focus will fall into the vitreous. In consequence, however, of there being no necessity for increase of focussing effort from the normal state when the organ is adapted for distant vision, there is no extra effort for such sight. For objects which are nearer—for objects from which divergent rays instead of parallel ones proceed, as in Fig. 129—there must be an intra-ocular effort to bring

them upon the retinal plane. Here the divergent rays require much more focussing power to bring them to the point to which parallel rays have been brought. The eye, in its ordinary relaxed state, has not sufficient power to bring the image, β , of the object, B , to the correct focus, at c , upon the retina. It is unequal to the task of overcoming the divergent effect of the entering ray.

Fortunately, here accommodation comes into play. The change of lenticular shape, with the consequent increase of radial curvatures, permits a stronger action of the lens, and this additional physiological action is sufficient to compensate for the increased work given to it. Thus, in Fig. 130, the divergent ray from the aerial point, B , has been

FIG. 130.

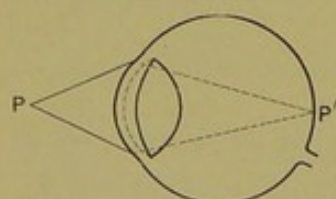


Effect of accommodation in bringing divergent rays to a focus.

sufficiently converged by the additional lens-action, during its passage into the eye, for its image-point, β , to fall upon the retina. This is true for almost all finite points from which divergent rays can proceed into the eye—the rule being that the nearer the object is to the eye, the greater must be the lenticular action: that is, the more divergent the ray, the more convex must the lens be made. The moment the object is situated inside of so-called infinity, that moment the entering rays become divergent, that moment accommodation becomes necessary, and increase of lenticular power is required.

The utmost power of the lens is represented by the nearest point at which an object can be properly seen. Thus, in Fig. 131, the point

FIG. 131.



Near-point.

P , which can be supposed to be situated eight centimeters in front of the eye, represents the total focussing strength of the dioptric media. It shows the *power of accommodation*. It is the objective expression of the total physiological action of lenticular change. This point, expressed as P , is termed the *punctum proximum*, or *near-point*. Its distance always expresses the strength of the focussing material.

Thus, should the near-point be situated at eight centimeters, it will be known that the increase of the lens-power has been equivalent to a convex lens which, in the air, would focus at eight centimeters. For the sake of convenience, it would be said that such an eye has an eight centimeters, or thirteen diopters lens-power.

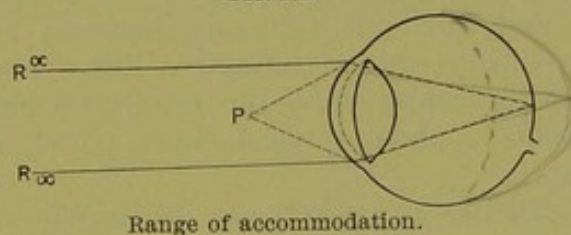
This brings us to the *region of accommodation*. The term as here written, signifies the linear distance over which accommodation has play. In the emmetropic eye, it is the distance between infinity and the near-point. In the ordinary eye, it is the distance between the furthest focussing-point when the eye is in a state of rest, and the

nearest focussing-point when the eye has assumed its utmost lenticular action. It is the total (linear) distance over which finite points of focussing are ranged.

As has just been said, in the almost unknown emmetropic organ, this range extends from what is known as infinity to the nearest point of focussing. Fig. 132 shows this.

The parallel rays of light fall exactly upon the retinal plane without any effort at accommodation. The moment the rays commence to diverge, accommodation begins. It must therefore be assumed that accommodative efforts begin the moment parallelism is departed from in a divergent manner. In this instance, parallel rays must be considered as the limits of accommodation: they are the far-points ($R R$), each being known as a *punctum remotum*. Suppose that the object has been brought into the nearest point at which it is clearly visible to the eye. In the diagram, this is shown at P . It is the nearest point of distinct vision; it represents the total lenticular strength. Having fixed these two situations (their degree of separation being known as the *region of accommodation*), the *power of accommodation*, which

FIG. 132.



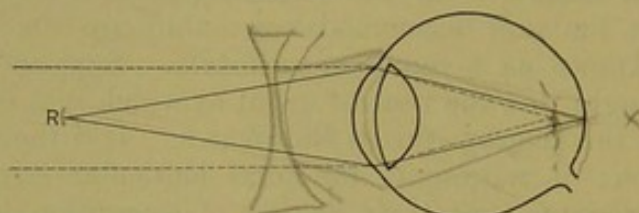
signifies the total strength of the accommodative act, no matter what or where its region may be, and which is designated by the symbol A , can be easily obtained: *i. e.*, $A = P - R$, expressing that the power of accommodation equals the difference between the states of refraction when the eye is focussing upon its near and upon its far points. Thus, assuming in any given case, A to be of a certain value in diopter strength, for instance, $A = 10. D$, $A = 5. D$, etc., the number of diopeters so written in every instance signifies the amount of power, expressed in lenticular strength, that the range of accommodation possesses. To obtain this by formula, all that is necessary to do is to obtain the distance of the far-point (R) and the near-point (P), and express them in diopter values, the difference between the two strengths giving the power of accommodation. For instance in emmetropia, if, as we know, the far-point (R) be at infinity, it can be represented by the appropriate symbol (∞), whilst if the near-point (P) be assumed to be at ten centimeters, P can be represented by the expression $10. D$: that is, $A = 10. D - \infty$, or $A = 10. D$, showing that the lenticular strength is equivalent to an artificial lens of ten diopeters' power.

In the average human eye, the parallel rays do not come to a focus exactly upon the retina. The eye is either too short or too long in its antero-posterior diameter, and, in consequence, infinity ceases to be the far-point. Just as before, the far-point must be considered as the aërial point from which rays would fall upon the retina when the eye is in a

state of rest. In the long or myopic eye, there is an abnormal increase of fixed focussing material, which necessarily adapts the eye in a state of rest for divergent rays. Fig. 133 shows this.

Here the eye is so long that the retinal focus can be obtained only when the entering ray is divergent—parallel rays, as is shown by the dotted lines, falling into the vitreous. This then brings the far-point to a fixed and finite distance, this point being representative of the refraction of the eye. Should it, for instance, be situated thirty centimeters in front of the eye, then the eye which is focussing at this

FIG. 133.

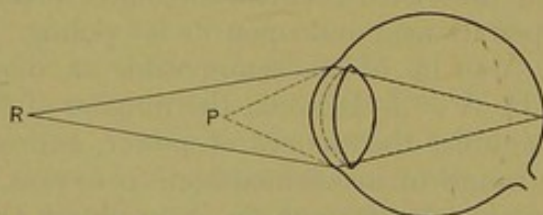


Far-point in a myopic eye.

point in a state of rest, and without any effort of accommodation, has sufficient stable and immobile focussing material to focus at thirty centimeters. It is in its state of refractive rest. Should the far-point be situated at thirty centimeters, the refractive material of the eye must be equivalent to about three diopters' power above that in the emmetropic organ.

Such an eye, just like any other, has its accommodative power, the utmost action of this power being manifested by the near-point. Thus, in Fig. 134, if R be at thirty centimeters, and the utmost accommodation be equal to ten diopters' power, the range, or region of accommodation,

FIG. 134.



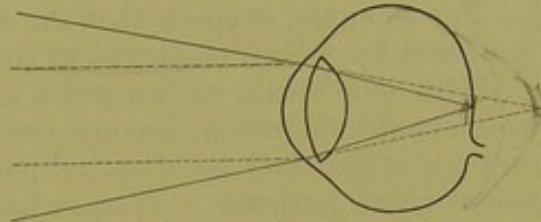
Range of accommodation in a myopic eye.

as may easily be perceived, is markedly diminished. It has been decreased, although the same ten diopters' strength has been resident in the focussing power. Here, however, the near-point has been brought closer to the eye than in the emmetropic organ, because it has had the advantage of the increased refractive power in the myopic organ, which in this case is equal to about three diopters, thus practically adding three diopters of strength to the ten diopters of lens-action, and making a total result of thirteen diopters, which will give a near-point of about eight centimeters instead of ten.

Should the organ be too short, as the vast majority of human eyes are constructed, the focussing material will be so shallow as to cause

insufficient focussing of even parallel rays upon its retinal plane, thus requiring a definite amount of the power to be employed in keeping distant objects in proper view. Figs. 135 and 136 show this. Fig. 135 explains how the eye, being short, is able to focus only very weak, or, in reality, already convergent rays upon its retina, the parallel rays,

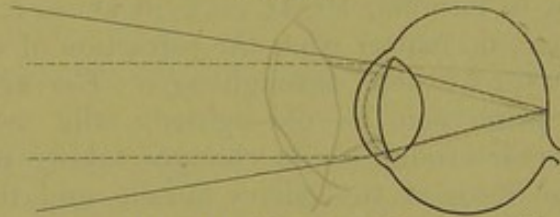
FIG. 135.



Inability to focus parallel rays on the retina of the hypermetropic eye.

which are here dotted, falling posterior to the plane of the retina. Fig. 136 demonstrates that it requires an addition to the convexity of the crystalline lens to bring these parallel rays upon the retina—the amount of additional convexity required being in direct ratio to the amount of shortening of the globe, or what is known as hypermetropia.

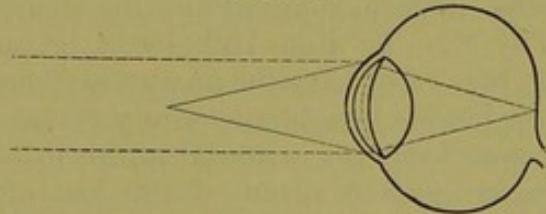
FIG. 136.



Accommodation necessary to bring parallel rays on the retina of the hypermetropic eye.

This additional convexity takes away a portion of the accommodative power merely to preserve proper distant vision, leaving more or less of a minimum for purposes of accommodation. Suppose, for instance, that one-fourth of the accommodative power has been employed in

FIG. 137.



Additional accommodative power necessary to bring an object at the near-point upon the retina of a hypermetropic eye.

obtaining distinct distant sight, then but three-fourths will be left for active accommodation. The result is that the near-point will be farther removed from the eye; there will be a weakening of what may be termed the dynamic or changeable power. Thus, in Fig. 137, the parallel dotted rays have been sufficiently converged to be received

upon the retina by the additional action of the lens, as shown by the dotted curve. A certain amount of lens-action has been lost in this procedure. The remaining portion (*i. e.*, the portion beyond the dotted portion of the lens) is useful only for accommodation. There being less dynamic play of lens strength, the near-point will be situated at a much greater distance than in either emmetropia or myopia. Here, therefore, both region and power of accommodation are affected: they are both decreased. For example, suppose that the same ten diopters of lens-power are used that have been employed in the emmetropic and the myopic organ. Here one-fourth, or two and a half diopters, have been employed to preserve distant vision, leaving but seven and a half diopters of lens-power out of the total ten diopters' power of lens-action to be used for accommodative purposes. This, as has been explained, must be taken away from the near-point, *P*, which represents the total lens-power: in other words, the near-point is removed two and a half diopters' strength of the lens-action away from the ten centimeters' distance; that is, it is pushed out to thirteen centimeters. The formula for the total power of accommodation would now read: Accommodating power, or 7.50 D., plus the corrected ametropia, or 2.50 D., equals 10 D. or A. That is, ten diopters of accommodative power, which, on account of two and a half diopters being used to bring the refraction to emmetropia (∞), are reduced to seven and a half diopters' play of accommodation, or in formula, $10. \text{ D.} - 2.50 \text{ D.} = 7.50 \text{ D.}$

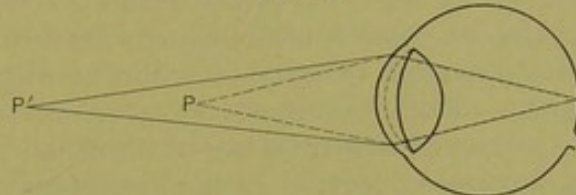
In every instance, no matter what the refraction of the eye may be, accommodative power weakens through age. The eye becomes what Donders calls "presbyopic" — old-sighted: the movable focussing apparatus is impaired through senile changes taking place in the lens-substance and the fibres of the ciliary muscle, and the action of the apparatus is consequently diminished. Both region and power of accommodation decrease, not at the near-point only, as is so often supposed, but in the hypermetropic eye at the far-point also: this being shown by the rendering manifest of hypermetropia which has remained more or less latent for many years. A glance at Figs. 138 and 139 will explain this.

In Fig. 138 the eye has, for example, a long time been able to bring objects in to the near-point, *P*. Through senile change the accommodative power lessens, and in consequence the near-point necessarily becomes removed to *P'*. In Fig. 139, let it be supposed that the extraneous parallel rays, *RR*, have for many years been allowed to fall upon the too shallow fundus by a compensatory action of the crystalline lens in furnishing more focussing material to the insufficient refraction of the eye. Here, as age has advanced, the loss of ciliary tone and the incapability of increase of lenticular power show themselves in the inability of the eye to focus the parallel rays upon its retina, and *RR* go to *R'R'*. The refraction of the organ has been robbed of its accommodative support, and the usual far-point is lost and carried beyond infinity; such rays, as before explained, being ordinarily unrecognizable in nature.

In the emmetropic organ, the far-point, which is infinity, and is intended for the reception of parallel rays upon the retinal plane, remains untouched. Here the near-point alone is affected.

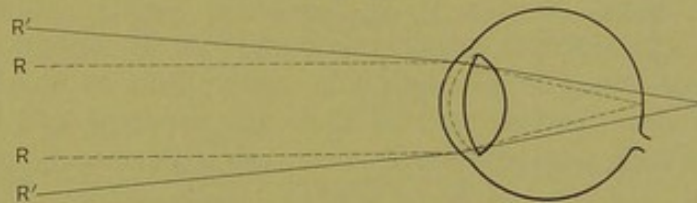
So with the myopic eye, as its far-point is at a finite distance, there is usually no exercise of accommodation to hold it. The increased refraction of the eye is generally sufficient to keep it in place. The near-point is the only one to go. If the far-point be situated at a comfortable distance for employment during near work, the eye will never require any artificial correction for such work, except it be for astigmatism.

FIG. 138.



The recession of the near-point in presbyopia.

FIG. 139.



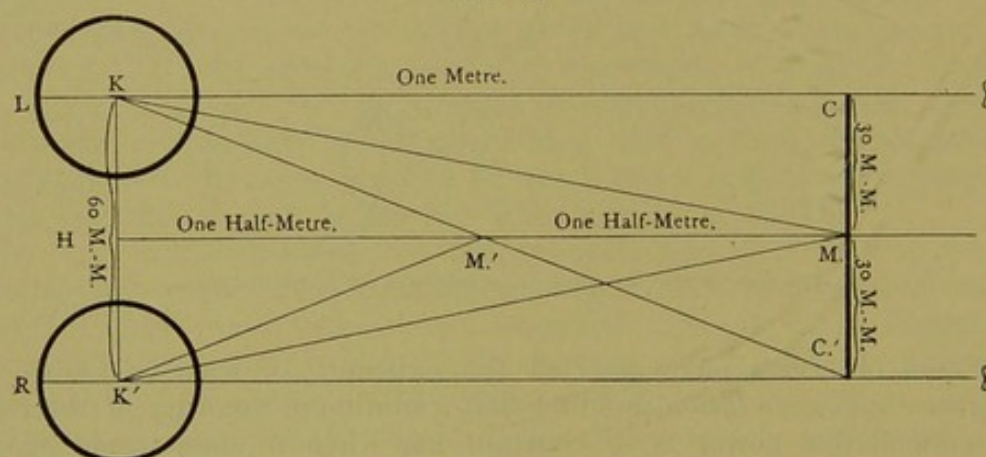
The loss of the far-point in presbyopia in hypermetropia.

Some observers have asserted the existence of what is known as *negative accommodation*, holding that a minimum quantity of the total accommodative power is in constant use when an emmetropic eye is being employed for distant vision, and supporting this opinion by the assertion that total ciliary paralysis by the use of a strong mydriatic, such as atropine, will render visible a quarter to a half diopter of accommodation more than can be found in the emmetropic organ when its intra-ocular muscle is untouched. Careful and repeated investigation with both emmetropic and ametropic organs is needed in this matter before the statement can be accepted as a certainty. Some suppose that this condition is produced by a dragging forward of the chorioid, producing a flattening of the lens.

It will be remembered that the fovea centralis is a situation on which ordinarily the image of any object looked at is formed. Again, it must be borne in mind that when using both eyes, there must be a double image of the object fixed upon—one for each eye; and yet, as such objects are seen singly, it must be conceded, as has been explained on page 84, that there must be single impressions from these two retinal visual points. Moreover, it has been shown that to obtain the best vision of an object, or, in other words, to make it the central or most important point to fix upon, the two eyes must be used in harmony, so as to have their foveæ in line with the object itself. Practically, on account of there being a definite distance between the two eyes, averaging in the Caucasian adult from sixty to sixty-four millimeters between the two

centres of motion, these so-called visual lines are parallel to each other when the two eyes are gazing at a distant object. When, however, any object gazed at binocularly is brought to some near distance, there is in every direction throughout the binocular field of vision, a movement inward of one or both of the globes. This, which is known as *convergence*, is best represented by that double inward motion given to the eyes when they are binocularly gazing at some near object situated on the median line. Thus, in Fig. 140, convergence takes place the moment the lines of vision leave the points, C and C' , respectively known as the *far-points of convergence*, and begin to be directed toward the median line, M ; this variation being included in an angle known as the *angle of convergence*. Each movement inward, or change in angular deviation, can be measured either along the median line, $H M$, or approximately along the plane $C M C'$. In the former plan, it is gauged by a unit designated as the *meter angle of convergence*, this being the

FIG. 140.



Far-points and angle of convergence.

angle included between the two visual lines of each eye when it is primarily fixed for distance, and when it is secondarily fixed upon the object situated on the median line at one meter's distance from the base-line connecting the two centres of rotation of the eye—using, of course, the nodal or turning-point in the eye as the apex. Thus, in Fig. 140, CKM is the meter angle, or unit of convergence. Should the object be brought still nearer along the median line, so as, for instance, to be at one-half meter's distance (at M') from the base-line, KK' , of the two eyes, the deviation, CKM' , will be twice as great as that of CKM ; it will equal two one-meter angles—showing that the distance diminishes in direct ratio with the increase of the angular deviation. Thus, any amount of inward motion of the two eyes, either separately or combinedly, can be studied, the total amount of convergence employed being known as the *power of convergence*, which is calculated by taking into account the number of meter angles contained in the convergence of any given case. Just as in accommodation, however, although the power of convergence may be alike in any two cases (for example, two meter angles or five meter angles of power of convergence), yet the position of the number of meter angles may be different, thus giving

rise to the term "*region of convergence*"¹—a term that tells where any definite number of meter angles (or power of convergence) is situated.

In the latter plan, where the amount and position of the angular deviations are studied along the meter plane, as, for instance, CMC' in Fig. 140, or, if more accurately desired, at equivalent centrad tangents, the calculation, although not absolutely correct, becomes quite easy and comprehensive enough for rough clinical purposes. Thus, given an average width of sixty millimeters between K and K' , or the centres of motion of the two eyes, L and R , in Fig. 140, it can be seen at a glance, that the amount of deviation along the meter plane, CMC' , is thirty millimeters for each eye: that is, the sine of each meter angle measured on the meter plane is equal to thirty millimeters. Should the visual line be extended along the meter plane, the distance will be doubled, tripled, quadrupled, etc. These intervals, however, becoming increasingly less true for every successive increase of visual deviation, necessitate careful calculation of equivalent tangents for every such increase made when scientific accuracy is required. Conversely, knowing the length of the sine of the angle for any definite distance, the number of meter angles contained in it can be easily obtained by dividing the length of the one-meter angle expressed in millimeters into the number of millimeters contained in the sine wished to be determined. For instance, the sine at four meters' distance must be as many times greater than the unit of convergence, as the number of meters' distance is increased. Thus, as there are one hundred and twenty millimeters of deviation at the four meters' distance, $120 \div 30$ (expressive of the number of millimeters in the one-meter sine) $= 4$, or four meter angles, or one meter angle deviation at four meters' distance.

Further, the number of meter angles, and therefore the length of the visual line in any given case being known, the amount of angular deviation at any desired distance, expressed in either prism diopters or centrads, can be calculated. This is done by simply taking the ratio between the number of millimeters in the sine of the one-meter angle and the number of millimeters in the median line from the point of fixation that it is desired to estimate to the base-line, and expressing them in hundredths, thus giving for ordinary clinical purposes the number of prism diopters or centrad strengths used to obtain the desired result. For example, in the previous figure, suppose that the fovea of the eye, R , be fixed upon the point, M' , on the median line, MH , situated at what we have determined to be equivalent to two meter angles or half a meter's distance along the median line, MH : in other words, the point of fixation being just at one-half meter or five hundred millimeters, and the sine of the meter angle being thirty millimeters in length, thirty (the length of the sine of the meter angle) is to five hundred (the number of millimeters on the median line from the base-line to the point of fixation) as six is to one hundred; that is, there are, roughly, six prism diopters or six centrads of power of convergence employed. The following abstract from Randall's tables will not only

¹ Here, just as in accommodation, the term "*region of convergence*" gives its true meaning in designating the positions of the meter angles, whilst the "*power of convergence*" represents strength expressed in the number of meter angles.

suffice to show the absolute and relative strengths of prism diopters and centrad action obtained by a few of the most important meter angles, but will also serve as a basis for the methods of obtaining any desired calculations :

TABLE OF METER ANGLES IN CENTRADS AND PRISM DIOPTERS, WITH AN INTEROCULAR DISTANCE OF SIXTY MILLIMETERS.

Meter angle.	Centrads.	Prism diopters.
1	3.000	3.0012
2	6.004	6.020
3	9.013	9.037
4	12.03	12.08
5	15.05	15.17
6	18.09	18.30
7	21.12	21.49
8	24.24	24.76
9	27.37	28.05
10	30.47	31.45
12	36.83	38.59
14	43.34	46.28
16	50.18	54.71
18	57.04	64.16
20	64.35	75.0

CHAPTER VI.

EXAMINATION OF THE EYE.

As the success of every variety of diagnostic procedure depends upon careful routine study of the existent conditions, so in ocular disease, definite paths must be followed, until every ordinary means of research has been exhausted. Each case is to be subjected to the most critical and painstaking examination of those conditions that may in any way tend to throw light upon the subject.¹ The visual acuteness and range and power of accommodation of each eye are to be tried in every instance possible. Extra-ocular muscle balance is to be obtained; the appearance of the lids, the conjunctiva, the cornea, and the iris is to be noted; the visible parts of the lens are to be studied; the intra-ocular tension is to be tested; and, lastly, every case is to be submitted to a most careful and systematic examination with the ophthalmoscope. All these conditions, in association with a concise family and personal history, should be carefully reported. In rarer cases, especially where there is gross local change dependent upon systemic lesion, the visual fields should be studied. In other instances, examination should be made for the detection of subnormal color-perception, particularly in cases that show indications of it in the visual field. Everything of any supposed value is to be recorded. The ridicule of those who fail thus to keep themselves thoroughly acquainted with the many evanescent changes to which diseased eyes are prone, is not to be regarded. Note of every passing condition is to be taken; by such observation not only will the mind be kept free from uncertain knowledge, but data will be secured for future answer as to prognosis and treatment. Let the ocular memory be one's case-book; trust the knowledge of passing changes to its leaves. Remember that nine-tenths of the success in diagnosis comes from careful routine observation, and that careful note-taking is of the very essence of such observation. Several times the author has seen cases in which dangerous symptoms have been dissipated by the repetition of what would have been lost empiricism had there been no noting of it in a case-book long laid aside. In so important a matter to the eye as a cataract, questions of character and methods of operative procedure have often been decided by a previous record. Time and again, the temporary conditions found in nerve disease, although at the moment they have seemed of no special value, have proved of great utility in the later history of the case. Frequently, the notings of reparative change and degenerative action in both local

¹ Although the subject-matter in this chapter has been placed as much as possible in its clinical order, yet on account of the various procedures having been made as entire as possible in their special situations, so as not to confuse the reader by needless repetition, it is not expected that anyone shall follow, in each particular instance, the routine examinations here given.

disorders and systemic disease, have given answers to questions as to treatment and the ultimate result of the disorder. Make it a rule, no matter of how little consequence a condition may appear to be at the time, to record it with every ocular symptom that may have any relevant significance. More than once, the author has found a rare pathological intra-ocular picture by using the ophthalmoscope in a case of slight ailment of the lid or conjunctiva. One of the most interesting eye-grounds that he has ever seen, was obtained by an ophthalmoscopic examination of a patient who had a piece of emery imbedded in the cornea of the opposite eye.

After procuring a succinct history of the patient's complaint, the examination is to be commenced, if possible, by obtaining the *acuteness of vision* by means of so-called test-types, as has been explained on pages 150 and 151. These types, which are arranged in consecutive order upon large cards, are so graded in size that each letter in its entirety subtends an angle of five minutes in all directions, at the distance marked above it. Thus, in the sheets of letters at the end of the volume, which have been modified by the author from those of Snellen and De Wecker, the largest letters, E and O, are intended to be seen at the distance of forty meters; the next in size should be recognized at thirty-five meters; and so on at five-meter intervals up to those which subtend an angle of five minutes at five meters.

By hanging a card of such letters on a wall opposite to a window, and having the patient sit with his back to the source of light at five meters' distance from the test-type, a convenient distance for a basis of calculations will be obtained, and any error that might arise from exposure of the eye to either direct light or to insufficient illumination will be avoided. The card should be hung so that the five-meter type shall be about one and a half meters above the floor; this will bring the type about on a level with the patient's eye. Each eye should be examined separately, care being taken that the patient does not press upon the fellow-eye during the examination. A different card for the opposite eye is to be used, or the patient is to read the lines backward for the second trial. The student should always begin with the supposed more defective eye, so that the patient cannot gain anything by memorizing. He should register these findings in the ordinary manner of fractions, employing the numerator (d) to express the distance used, and the denominator (D) for the size of the type seen: thus, should the patient read the five-diopter type at five meters, the fraction $\frac{5}{5}$, or, as sometimes written, $\frac{5}{V}$, would equal $\frac{d}{D}$, and would show that he had $\frac{1}{1}$ or normal vision. Should the patient, however, be able only to read the forty-diopter type at five meters' distance, the fraction $\frac{d}{D}$ would appear as $\frac{5}{40} (\frac{5}{XL})$, showing that there was but one-eighth of normal vision. If the forty-diopter type be unrecognized at this distance, the surgeon is to gradually carry the type toward the patient, or have him move toward the line of largest letters until it is seen. This new distance is to be measured or estimated, and made the numer-

ator of the fraction: thus, should it be necessary to have the patient approach to four meters from the forty-diopter type, the fraction will be $\frac{4}{40} \left(\frac{4}{XL} \right)$, which is equivalent to one-tenth vision. If two meters be the farthest point at which the type can be properly discerned, the fraction will be $\frac{2}{40} \left(\frac{2}{XL} \right)$, and the vision will be one-twentieth of normal. It is best in all the work to give the actual fractional value, as this shows both the type seen and the distance employed. If all the letters of any certain line, and possibly a couple of letters of the next smaller line, are seen, some surgeons place a plus mark after the fraction. If some of the letters of any line are improperly named, a minus sign is placed after the fraction. The author prefers the more exact method of giving the fractional value alone when every letter of any certain line is read, and placing as many interrogation signs after the fraction as there are miscalled letters in the line.

Among the illiterate and with young children, recourse can be had either to the many forms of geometrical figures constructed upon the same principal as the letters, or to the more difficult test-dots of Burchardt. If vision be more imperfect than can be judged or obtained by the card of letters, resort must be had to the methods for determining quantitative vision. Ordinarily, this is done by having the patient stand about five meters back of a large, open window, and walk gradually forward toward the outstretched hand, until he is able to designate how many fingers are raised. If there be good daylight in the room, or if there be artificial light, the patient can be placed at five meters' distance from the observer, who should stand in a bright place or beneath the light. The patient is then to approach gradually whilst the observer has his outstretched hand raised in front of his breast. It is a good plan to move the hand slowly from side to side over a limited area, and to change the number of fingers raised the moment the patient gives any answer as to their number. If the hand be held so near that its reflection can be seen upon the eye, the procedure can be facilitated by keeping its shadow opposite the pupillary space. Should the vision still be lower, the patient should be taken into a dark room and seated in front of a light in such a position that his face will be in shadow, and that the source of light will be upon the same side as the eye that is to be examined. Having him cover the fellow-eye with a handkerchief or bandage so as to exclude every particle of extraneous light from the organ, the light is to be turned down so as to make it equal to about one-half candle-power. The student is then to take a position in front of the patient and on the same side as the light. He is to tell the patient to keep his eye steadily fixed straight ahead, and that he must point to the direction in which he happens to see any light appear, without moving either his eye or his head. Next taking an ordinary concave mirror ophthalmoscope, by holding it a little beyond its focus a small pencil of light is made to play in various directions upon the exposed eye; this not only giving the amount of light-perception for the macular region, as is obtained when vision is got by the types, but also securing the advantages of the field of light-

perception with but little additional effort. If there are areas in which the amount of light is not seen, or if no definite field is obtainable, the light-stimulus should be strengthened sufficiently for perception. If this be impossible, the patient is to be wheeled around to face the light, and the very strongest and most concentrated beams possible by means of a twenty- or fifteen-diopter bi-convex spherical lens, are to be thrown in various directions upon the organ. Of course, if more scientific study of the light-sense be desired, resort can be had to one of the many devices which report the finest differentiation, or what is known as *light difference*, expressed as L. D., between two or more of the weakest intensities of illumination that are visible to the eye, or give the weakest illumination, known as *light minimum*, and designated by L. M., that can be recognized. At times, it may be useful to roughly test the degree of susceptibility of the eye to differences of intensity of light-stimulus. To do this readily, various test-letters are to be exposed whilst the strength of the illumination is being gradually lessened. This plan is ordinarily known as the method for the determination of the *minimum of differentiation*. For all ordinary purposes, however, the procedures above described will be found ample to give adequate answer in general clinical work and every-day office practice.

These results should also be recorded in full. If there is absolute blindness, the result is to be noted with the word "BLIND."

Having obtained the visual acuity, the power and region of accommodation should next be obtained. This is generally done by means of the smallest test-types which can be read at the farthest and the nearest distances possible with each eye separately. These two points give both the apparent region of accommodation, as shown by the space or difference between them, and the manifest power of accommodation, as evidenced by the position of the nearer point.

For ordinary use, there have been several cards of type employed, most prominent among these being Snellen's series, which have been so constructed as to remain in the one-minute minimum angle of distinct vision, and the selection of ordinary printers' type by V. Jaeger. By some, it is asserted that the Jaeger types are the better, as they place the patient during the examination under the same conditions that he will be situated in in after-work. Granting this, yet it is a fact that, as the Snellen basis is more scientific and carried throughout both the distance and the near-type, there is no break in the work, and the one becomes definitely related to the other, thus reducing error to a minimum. The series of accommodation tests placed at the end of this work, which have been constructed by the author so as to coincide accurately with the Snellen basis of letter-formation, give sufficient differences of size for all practical purposes. Commencing with 0.50 D. type, which has been made of a size sufficient to include the five-minute angle at one-half meter, the card is to be held at a point before one eye, whilst the other is excluded from view by having the patient cover it with the palm of his hand in such a way as not to press upon the organ. At first, care should be taken to bring the type so near the eye that there can be no accurate vision for the type: this is best done by placing the card against the patient's nose. By slowly moving the card away from

the eye, the moment the first word in the 0.50 D. type is recognized and properly named, the distance is to be registered in centimeters by an ordinary measure. For uniformity's sake, it is best to hold the end of the measure on a line at right angles to the apex of the cornea. After having obtained this (the near-point), the card is to be quickly removed beyond the limits of possible accommodation for the type—say to ninety centimeters—and then, whilst slowly bringing the card in toward the eye, the patient's attention is to be confined to the same word, and as soon as he says that he is able to read it, he should be immediately made to read the succeeding word, thus destroying any memorizing. If there is still doubt, the patient should be asked to continue reading the column of letters as the card is made to gradually approach the eye, until all the letters are clear and plain. This distance, which, as we know, is the far-point, is to be also registered. The findings may then be noted, for instance, as follows: "O. D. Acc. = Type 0.50 D., ten centimeters—fifty centimeters."

The same course is to be pursued with the other eye, and the results are to be noted in a similar manner. In some instances, having done this separately, and desiring, as we may sometimes find occasion, to obtain a most careful estimation of binocular efforts at accommodation, we can proceed in the same manner with the two eyes combined, taking care to place the type midway between the two eyes upon the median line. Should the patient be apparently presbyopic and unable to read the 0.50 D. type, a + S. 4. D. is to be placed before the eye, and the procedure continued in the same manner, taking care in the noting, that the artificial aid afforded by the lens be taken into account; thus: "O. D. Acc. + S. 4. D. Type 0.50 D., twenty centimeters—forty centimeters."

In daily ophthalmic examination, it will be found easier for computation, and less troublesome, to confine the artificial convex lens to a + S. 4. D. strength as much as possible, and to endeavor to have the patient read the 0.50 D., even though the lens over-corrects the accommodative failure; reserving the proper corrections of the fault for subsequent study and calculation. If the patient cannot see the 0.50 D. type, he should be asked to try the larger ones: these are to be registered in the same manner. For the illiterate and the uneducated, a series of small, properly sized geometrical figures can be employed.

As explained later on, when the two eyes accommodate in common, there is necessarily a limit to the amount of deviation or the power of the interni and their related helping muscles. To obtain this, which is not so often necessary, the easiest clinical plan is to simply bring a small test-object, such as a word printed in small type, in along the median line toward the nose whilst both eyes are gazing upon the test-type. The moment that diplopia is complained of, which shows that one or both of the interni have given out, the distance, which, as will be remembered, is known as at the punctum proximum, or point of maximum convergence, is to be registered. The punctum remotum, or point of minimum convergence, is obtained by having the patient, after being corrected in some cases, fix his vision upon a small distant flame, whilst prisms, with their edges placed outwardly, are successively tried until double vision

is complained of. The difference of strength of prisms expressed in meter angles, which can be readily obtained, as has been explained, with P. D. and Cr., on page 160, will give the power of convergence.

As an interesting subjective exposition of the power and region of accommodation (or even of the variety of ametropia when thus applied by appropriate apparatus, as in the clinical test proposed by Thomson, described later on) Scheiner's experiment deserves brief mention here. The eye to be examined should have a large opaque disk placed before it, in which two pin-holes, about one millimeter apart, have been made. By holding these holes horizontally before the eye to be examined, and having the patient look through them at a vertically placed needle some few centimeters away, the needle will, when accurately focussed upon, appear single. If the eye gaze at a distance beyond the needle, the needle-image will appear double, and if at this time one hole be blocked out, the image opposite to the blocked-out hole will disappear. The same thing occurs, if a shorter focus than that necessary to see the needle sharply, and hence greater accommodative effort, be made, except, that here, the disappearing image corresponds in position with that of the hole blocked out. In other words, the region of accommodation, and hence, indirectly, the power of accommodation, is determined by the distance between the farthest point of singleness of image and the nearest point.

A modification of the reversal method of the fundus-reflex test, as spoken of in the special chapter on that subject, may also be useful as an objective test amongst the illiterate and demented. The points of reversal of the reflex, as a plane mirror is made to gradually approach the patient's eye, gives an excellent guide as to position of the greatest and least accommodative actions.

Having obtained the acuity of vision, the power and region of accommodation, and the power of convergence, when desired, the *action of the extra-ocular muscles* is next to be tested. Generally, it will be necessary to employ several of the methods. By far the most common error, especially in cases of ametropia, is a condition known as *exophoria* (a tendency to external deviation). As elsewhere stated, muscle deviations may be of two varieties: the one, the result of paresis or lessening of action, which allows a normal or preponderant opponent to drag the eye away from the enervated side; and the other, a preponderance of action of an opposing muscle over the normal or weakened power of a muscle, also causing a deviation of the eye from the relatively weaker side; the latter of these two varieties, *i. e.*, the increased action of the opponent, being subdivided into that amount of error which is manifest, and that amount which is latent; the two added together, constituting the total amount of disturbance. Frequently in such cases, as pointed out by Stevens, the facial expression may give a clue to the existence and the variety of the muscle disturbance.

Clinically, the first plan to be employed in the estimation of the degree of these deviations, should be adopted when the acts of accommodation and convergence practically cease to be brought into play—a study of the muscle-balance, as it were, when these structures are the least employed, thus allowing a study to be made which is of equivalent value to the determination of those finer errors of astigmatism that are

fraught with so much discomfort to the uncorrected patient; a study that cannot fail, if properly made, to expose those slight latent disturbances which are so aggravated when the eyes are brought into combined action.

If at all pronounced, there is a very simple, though extremely coarse, way of making these deviations apparent. It can be readily understood that if the eye can be placed in a position where it is practically not used, and yet can be observed, there is, by reason of its muscles falling into their normal balance during such a time, a ready means of determining the degree of any muscular disturbance or want of balance. One of the easiest and quickest plans to accomplish this, is, to place the patient in a dark room at five or six meters' distance from a dimly-lighted gas-jet or a taper light. Being sure that the eyes are situated as nearly as possible upon the same level as the light, and seeing that he squarely faces it, a five- or ten-degree prism, or, better, an equivalent prism diopter or centrad, with its base placed vertically, is to be slipped in the left side of a test-frame and the frame is to be placed before the patient's eyes. Having him gaze at the light with both eyes open, he will probably assert that there are two lights, the one clear and bright and remaining stationary, the other, possibly, somewhat dim and swinging from side to side at a lower or a higher level. If the prism is placed base up, the false light will be upon a lower level. If the base of the prism be placed down, the false image will be upon a higher level.

Should there be doubt as to which is the false image, a red glass should be placed before the right eye, and, as its light will be made reddish, the differentiation becomes easier. The patient is next to be asked whether the false light is to the right or to the left of the true one. If he says that it is to the right, then he has what is known as *heteronymous diplopia*: that is, the muscle-balance of the two eyes is so unequal that when binocular vision is broken, and simultaneous, yet separate vision with the two eyes is secured by means of the prism, the images of the two eyes are on opposite sides, demonstrating that he has either a weakness of the internal rectus of the left eye or a spasm of the external rectus of the right eye. The amount of these conditions can be readily found by either substituting stronger and stronger prisms, with their bases in, before the right eye, or by employing stronger and stronger prisms, with their bases out, before the left eye, until the two images are made to appear upon the same vertical line. In some instances, the test-light may be advantageously placed immediately in front of a card so gauged by a series of properly separated marks indicative of the degrees of deviation at the distance employed, that the patient can read at a glance the character and the amount of deviation by means of the malposition of the false image in front of the gauge. Of course, however, as above mentioned, if such a gauge be used, the width of degree of separation must either be modified or calculated for every difference of distance from the eyes at which it is employed. After the horizontal deviation has been determined, the experiment may be repeated with a prism of sufficient power, with its base placed directly in, to produce a doubling of the dot on a horizontal line. If *orthophoria*, or perfect binocular equilibrium, in that meridian exist, the two lights will be situated upon the same line. If *hyper-*

phoria, or tendency for upward deviation of the visual line of one eye, be present, there will be a vertical deviation.

If further inequality in the extra-ocular muscle innervation be suspected, some modification of one or more of the following plans must be made use of. As a small, but certain amount of *esophoria*, or tendency toward increase of internal lateral deviation, for distance, is found in nearly every pair of hypermetropic eyes, this must be noted, and not assumed as normal in any case, because in most instances it becomes less apparent, less changeable, and less frequent, after careful correction of the refractive error. So, too, with the constantly changing, though nearly always evident, *exophoria*, or tendency toward increase of external lateral deviation, recognized during near-work, the rule is, that the better the correction of the optical error, the less liability there seems to be to its recurrence.

Often in the minor and latent forms of deviation, where this rough form of experimentation fails to reveal any disturbance of equilibrium, it may be possible to decide by subjective evidence alone, without recourse to any apparatus, whether there is enervation or increased tension, by having the patient assert whilst he alternately gazes at the light, whether there is movement of the light in any special direction. Of course, no absolute reliance can be placed upon this test alone. It should be used only in conjunction with the others. Duane terms it the *parallax test*, and says that he has found it a most delicate index of the character of disturbed muscle-balance. To gauge the amount of enervation or spasm, he superimposes correcting prisms before the eyes until the objects alternately looked at remain stationary and fixed.

Again, in some cases of high *heterophoria*, or imperfect binocular equilibrium, the mere placing of a plain red glass before one eye will be sufficient so to contrast the two images of a light, that a correctible degree of diplopia will be announced. Moreover, it may be sometimes noticed that when the prism is omitted, and a red glass placed before the eye for better differentiation, a horizontal diplopia may be readily and often unconsciously obtained by the patient; this doubling of the test-object being easily estimated in the usual way. Less frequently, a vertical diplopia or even an oblique position of the two images is superadded to the horizontal deviation—conditions that may be accurately determined by the superposition of prisms which will correct the faulty meridian.

These methods, of course, are subject to many disadvantages, which have induced various writers to employ other plans. One of the best and most favorably known methods, is, that by Maddox's ingenious glass-rod test, which in its perfected form, consists of a short cylinder of transparent glass, about a quarter of an inch (or, better, about an eighth of an inch) thick, fitted into a linear opening made in a disk of metal of the same size as an ordinary test-lens, thus forming a contrivance which can be placed in a test-lens frame so as to revolve the glass cylinder into any desired position before the eye without allowing any extraneous light to enter the pupil. The principle of the test depends upon the property of transparent cylinders, which are nothing but a combined series of prisms, to produce an apparent lengthening of anything seen through them, so that, for instance, with such a rod placed before one eye, a

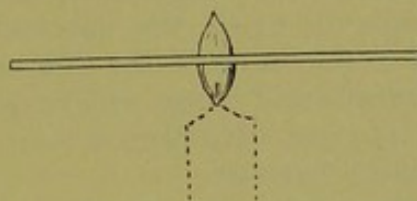
small distant flame will appear converted into a long, thin line of light. In other words, it tests the latent deviation of extra-ocular muscle by the alteration in the shape and the relative position of the two images. In testing, if the other eye views the flame at the same time, it is more or less properly asserted that there will be such dissimilarity between the two images, that there will be no tendency to fuse them, and consequently, if the impulse for fusion be lost, each set of eye-muscles will fall into its own state of equilibrium, and each image of the flame will be projected into its own true position, thus allowing prisms to be placed at various angles before the eyes, until the centre of the point of the flame seen with the one eye appears to be situated exactly midway in the length of the line of light, when the amount of muscle-action necessary to give binocular equilibrium, will be shown by one-half the amount of the correcting prisms used. In order to give a color-contrast between the two images, a red glass may be used before the fellow-eye.

FIG. 141.



Superposition of candle flame and vertical line of light.

FIG. 142.



Superposition of candle flame and horizontal line of light.

Commencing with the glass rod placed in a horizontal position, and having the patient gaze at a lighted taper or gas-jet about a fourth of an inch in diameter, a vertical line of light is produced, which, if it passes through the flame, shows that orthophoria for horizontal movements exists. Thus in Fig. 141, lateral orthophoria is proven by the fact that the candle flame and the vertical line of light exactly coincide. If, however, the line of light be separated laterally from the flame, there is either esophoria or exophoria. If the line of light be situated on the same side as the flame, the former condition exists, whilst if it be projected on the opposite side, the latter condition is present. The amount of these two deviations can now be readily tested by horizontally placed prisms with their bases situated outward for esophoria and inward for exophoria, and recorded, with a note to which eye it belongs, in the case-book.

To test for the presence of vertical deviation, the rod is to be rotated into the vertical position, thus producing a horizontal line of light upon which the flame-area as seen with the other eye will be situated, if there be no vertical displacement. This condition is plainly manifest in Fig. 142. If, however, the line be projected above or below the flame-area,

there is hyperphoria of the eye which sees the lower image. In order to measure this deviation, the prisms are employed with their bases vertically placed—base down if the line be above the flame, and base up if it be below the flame. A scale placed just behind the flame, may be useful for the patient to estimate the amount of deviation.

As a useful modification of this test for the detection of the slight angular deviations so often found in the various meridians, the author, finding that there seems to be little or no inclination to fuse a light-red and a yellowish-red line of light, has at times employed to advantage two glass rods, one of which has been made red, set in graduated metallic disks, at the same time. At times, two flames, a lateral grouping of rods, or an obliquely ground rod around which, as in Jackson's test, a prism is made to revolve, may be advantageously used.

Lately, Stevens has devised another method for the contrast plan. His contrivance consists of a small accurately-centred curved spherical lens of thirteen diopters' strength, which is carefully fitted into a three-millimeter opening made in a metal disk the size of a test-lens. This, which he terms a stenopæic spherical lens, being properly placed before an eye—which requires care and some patience—the image of a flame is converted into a large disk of diffused light, in the centre of which the untransformed image of the flame can be seen with the other eye. If orthophoria exists, the untransformed image of the flame will be situated in the centre of the disk of light. If heterophoria be present, the untransformed image will be situated excentrically in the disk of light. Its great advantage is that, by its use, compound deviations can be instantly detected.

Stevens' phorometer, especially his later instrument with its rotating prisms, is an excellent contrivance for the detection and estimation of heterophoria. By accurately adjusting it so that the prisms are situated at a few inches' distance from the patient's eyes (and seeing that his correction is properly placed, when confirmation work as to its influence upon muscle-balance is desired), the most useful and accurate data can at times be obtained. Risley's instrument, too, which can be readily adjusted for any desired distance, is a most convenient and valuable form of apparatus.

It must be remembered that these tests should be repeated at what is known as the "occupation distance," *i. e.*, the point employed by the patient during ordinary daily work, or the situation ordinarily used for reading, writing, and sewing, because, as has been explained, the extra-ocular muscle innervation necessary when the two eyes are fixed upon some object at these points, is very different from that which is required when the acts of accommodation and convergence practically cease to be brought into play. In fact, during distant vision, many of the muscular deviations here found, lessen or even reverse as a new muscle-balance comes into action. Care must always be taken, in the noting of these latter findings, to state that the work was done during accommodation and convergence.

If great care be taken in adjustment, Maddox's "obtuse-angled prism"—which consists of two three-degree prisms, placed base to base so as to give an angle of about one hundred and seventy-four degrees,

thus producing two images to compare with the single one of the fellow-eye—may be tried to advantage as an additional test. If, when its combined base is made horizontal, the true image of the fellow-eye between the two false images seen through the prisms, appears to one side of an imaginary vertical line drawn between the two false images, then there is a definite amount of lateral deviation, which can be easily estimated either in the more usual and simple way of substituting stronger and stronger prisms with their bases in or out as may be, until the three images are brought on a straight line, or by the more difficult plan of determining the deviation by the lines of rotation and deflection produced by a revolution of some prism of special strength. If the base be made vertical, vertical deviation can be studied, the same relative rule applying to any other meridian. In one of the newest forms of the apparatus, the prisms are made of red glass, so as to offer better differentiation between the true and the false images.

For the purpose of detecting the want of equilibrium of the oblique muscles, Savage has modified Maddox's prism by doubling its strength.

FIG. 143.



Relative positions of lines of light in want of equilibrium of oblique muscles.
(Slightly modified from SAVAGE.)

He has the patient look through the bases of the two prisms with one eye at a horizontal line situated about one-half a meter's distance. Of course, as we now know, there will be two parallel horizontal lines seen. By uncovering the naked eye, which is the one being tested, a third line, situated between the two, will make its appearance. If it is midway parallel with the others, orthophoria is said to exist. If, however, it be obliquely placed, the oblique muscles are inefficient in their action. Fig. 143, with the initial letters of the faulty muscle placed upon them, represents the appearances produced by the underacting muscles.

Frequently, especially if the patient complains of double vision, it is possible to determine the presence of proper action by simple inspection. One eye alone will be found to fix when a test-object is held at reading distance upon the median line, whilst its fellow is excluded from fixation. This is caused either by the overtaxed and incompetent muscle of the faulty eye permitting the antagonistic muscle to drag the eye in an opposite direction, or by a too strong and hypertrophic muscle overcoming the antagonist and carrying the organ beyond its proper position. This test can be accomplished by having the patient gaze at the finger-tip, or preferably, at the fine point of a pencil placed midway between his two eyes at the position he generally employs for near work. Having done this, one of his eyes should be quickly

covered with the surgeon's unused hand. Allowing the covered eye to remain excluded from vision for a moment or two, the hand is to be shifted so as to cover the fixing eye, when it will be found that the previously covered eye moves in to fix upon the unmoved pencil-tip. Repeating the act upon the opposite side, the same thing is found to occur to the fellow-eye. In other words, the covered eye in both instances has deviated outwardly whilst it has remained unused and been excluded from fixation, showing, for instance, that in their normal muscle-balance the external recti muscles have had a preponderant action. As the experiment has been partially made by a process of exclusion, the result may be noted in the record-book as "exophoria for convergence at . . . millimeters in exclusion." If there be no apparent deviation, it can be expressed by the term, "orthophoria for convergence at . . . millimeters in exclusion." If there be internal deviation, the expression "esophoria for convergence at . . . millimeters in exclusion" should be employed. If it is desired to ascertain roughly the associated muscle-balance of the two eyes in other relative positions, the same procedure may be repeated in other points of the combined field of vision, though in every instance care should be taken in the noting to express, as nearly as possible, the situation and the distance at which the experiment has been tried.

If the case be one of paralysis, it will be noticed that the movement of the sound eye will be greater in proportion than that of the one with the faulty muscle, this being caused by the muscle of the sound eye accomplishing more work with the same nerve-impulse than the fellow. If there is binocular fixation at this point, the patient, without moving his head, should follow the surgeon's upraised pencil-tip as it is moved in all directions in a plane before his eyes. Commencing at the median line, it should be carried up, down, to the right, and to the left, whilst the surgeon watches carefully to see if either eye lags during the excursions. In many instances, it is a good plan to have the patient at the same time help by stating the moment that the pencil-tip appears doubled. This examination should be repeated at the quarter angles, and, lastly, the internal recti should be made to act simultaneously by bringing the pencil-tip directly in, a little below or along the median line, toward the patient's face. Constant repetition of the procedure will soon make the student sufficiently adept to determine quickly which are the faulty muscles. Curiously, in some of these cases, especially where there is the faintest indication of extra-ocular paresis—as, for instance, in the second stage of general paralysis of the insane, where motor enervations are just beginning to manifest themselves; or in posterior spinal sclerosis, where the ataxic symptoms are just appearing—it will be found that the moment the muscle is made to return from its utmost limitation of excursion (its utmost tension), there are a series of to-and-fro movements, each one lessening in degree.

From what has been learned in the chapter on Physiology, it will be understood that there is a vast difference in the strength and action of the extra-ocular muscles, so that should an equal amount of loss of power be experienced by them, the visible results would appear at total variance. Recognizing this fact, certain empirical ratios can be made

use of to govern the amount of muscle-action in each instance. These are to be employed as bases upon which to formulate whether there is deficiency or overaction; the departures from these (expressed in degrees, prism diopters, or centrad) constituting the answers to the amount of error. As a guide, it should be remembered that the internal rectus muscles are the strongest, requiring a counteracting power of thirty to fifty degrees or more to overcome their action; followed by the external recti with about eight degrees; whilst the superior and inferior rectus muscles can overcome only about three or four degrees each, respectively. Employing these ratios, they can be made use of in any of the more common methods of prism-testing until the degree of muscle-balance in the various meridians is obtained: this done, the amount of strength for each muscle can be registered; each special amount and the average proportion obtained, at once demonstrating to a greater or less degree in what grouping the fault resides. Thus, for instance, if the internus withstands forty centrad of strength, "adduction = 40 cr." can be written. If the externus holds out against eight prism diopters, "abduction = 8 P. D." can be stated; and, if the superior and inferior recti require four degrees, "sursumduction = 4°" can be noted.

One of the best plans, knowing that the muscle normally overcomes a certain number of degrees, prism diopters, or centrad of prismatic action, is to place prism after prism with its apex pointing toward the muscle until double vision is complained of; the difference between this ratio and the normal one will give the amount of want of muscle-tone. Repeating the same procedure with the fellow-eye, the comparative relation between the two muscles becomes established. Each of the other straight muscles can be estimated in the same manner, and their power noted. Further information as to the comparative inequality of innervation and action of almost any grouping of physiologically related extra-ocular muscles may be thus obtained, which is not only of value for the actual series tested, but often affords distinctive signs of inequality of condition and work in other groupings. Thus, not only does the horizontally placed prism (which the author daily employs in his clinical procedures) show the balance of the lateral muscles, but, as previously noted, it often makes manifest an error of displacement of image in the vertical meridian by the fact that the double images are upon a different level, which error can be readily corrected by a superimposed prism with its base vertically placed. In fact, as before explained, this example is a mere repetition in a converse way of the plan in which a horizontal deviation is made evident by an artificially produced vertical displacement.

In all these studies, it should not be forgotten that errors of refraction, especially where there is astigmatism, play important rôles in extra-ocular muscle innervation and balance, so that all optical error should be carefully expunged before attempting to estimate correctly extra-ocular muscle-disturbance.

Briefly, then, no one test can be depended upon. Each case requires special combinations of procedures, which are to be discontinued only when the results seem to be certain and unvarying. On account of

variations in answer by reason of some peculiarity of instrumental precision or technique, control tests of all kinds, according to the ingenuity of the observer, are necessary, and each plan should be repeated sufficiently often to give an unequivocal answer. The student should not, on account of any presupposed rule or law, imagine that the condition is limited to any certain character of ametropia. He should remember, as has been frequently explained, that it may be but one of the visible expressions of general nerve debility. He must search for it in all cases. He should estimate it in every instance where found, and consider it in every ocular disturbance which seems to demand its correction.

The subjective method for the detection of the area of the field of fixation is as follows: The patient being placed in the ordinary position before a perimeter, a short test-word—the same that is used in determining the amount and range of accommodation—is placed upon the “traveller” of the instrument. The quadrant is rotated to the outside and the “traveller” is pushed as far peripherally as possible. Having made the patient look toward the temporal side as far as he is able without moving his head in the least, the surgeon should slowly move the “traveller,” with the test-word, in toward the centre of the perimeter. As soon as the patient can read the word properly, the surgeon should stop the “traveller,” and register the distance from the centre of the instrument. By pursuing this plan with different words in a number of positions around the circle of movement of the quadrant, a number of points shall have been obtained which may be connected by lines, thus giving an area in which macular vision may be accomplished without movement of the head.

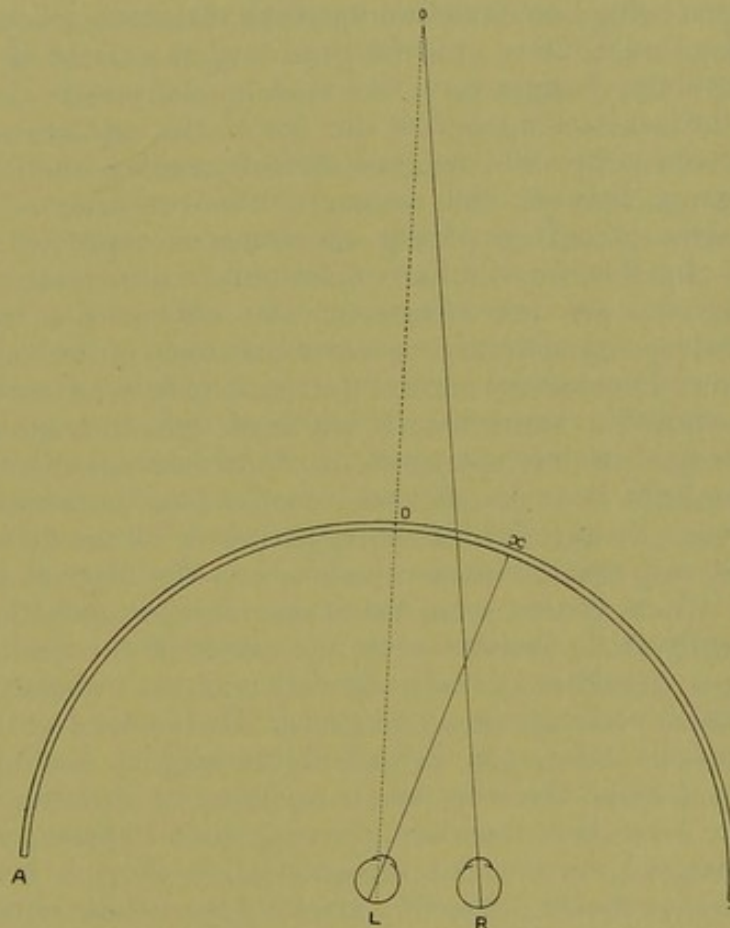
An example of this, the so-called angular method, is shown in Fig. 144, where the eye, *L*, placed before the perimeter arc, *AA*, has rotated inward so as only to allow the image of the object, *o*, to fall upon the centre of the cornea, should it be situated at thirty degrees' distance from the original point of fixation at ∞ . By repeating the procedure in every direction, and connecting the obtained points with one another, the surgeon shall have a fair idea of the field of fixation.

If desired, the arc of the instrument may be so constructed that the patient's eye is placed at the proper distance to give exact centrad deviations to any superimposed centrad prism. Or, if linear measurements at the meter plane or any of its multiples be desired, these can be readily made with ordinary prism diopters at the proper distances. In fact, any method of tangents can be used. By these methods, the surgeon may succeed in recognizing either muscular paresis or mechanical inability to full muscle-action, by a limitation of the excursion of the visual line. Tonic spasm or true hypertrophy of muscle-tissue, with or without undue capsular thickening, may be partially determined by the increase of the arc upon the quadrant over which the movement takes place.

Advantage may also be taken, as the author has frequently done, especially among the illiterate, the young, and the demented, of the comparative positions of the small bright reflex on the cornea when both eyes of the patient, who has been placed at some sixty to seventy-

five centimeters' distance, are alternately gazed at through the hole of an ophthalmoscopic mirror, whilst he is made to gaze steadfastly either into the aperture of the instrument, or, better, at the forehead of the observer. A little practice showing the relative symmetrical and asymmetrical placings of the little reflexes both during definite fixation and comparative movement of the eyes, will soon determine, in many instances, whether there is any deviation or not.

FIG. 144.



Field of fixation. (JULER).

Study of the relative situations upon the corneæ of the reflexes thrown from a small light held before the eyes, may also be employed as a rough-and-ready test.

By employing some one or more of these plans in various positions and during different combinations of physiological muscle-groupings, pareses and paralyses may often be readily estimated and differentiated from hypertrophies and spasmodic actions.

The student should next turn his attention to the condition of the pupils and the action of the irides. The patient is to be seated in front of the surgeon before a large window, and the patient should be made to look just over the top of the surgeon's head. Observation is then to be made whether there are any peculiarities of iris structure. Careful notes as to the color are to be obtained, remembering that it is almost always very little pigmented in early infancy. Sequelæ of past inflam-

mation should be looked for. The shape of the pupils should be examined both in separated and combined exposure, and measure of their apparent horizontal diameters, which ordinarily range from three and a half to four millimeters, should be made both monocularly and binocularly. To do this roughly, one of the many gauges or a millimeter measure may be employed, care being taken to state the character of light-stimulus under which the conditions are studied. All direct light-stimulus should be excluded from both the eyes, by holding the flat part of the hands in front of them : this will cause a partial dilatation of the patient's pupils. By quickly removing one hand and watching the contractile movements, repeating this several times until fairly sure of the extent of the excursion, the pupillary changes may, as a rule, be easily seen. The surgeon should do the same thing before the iris of the opposite side, by replacing his hand before this eye, and carefully noting whether there is any discrepancy between the actions of the two irides. He should pursue the same procedure during simultaneous exposure, and record the results. By this, he will have determined in a measure the condition of the reflex-arc controlling monocular and binocular iris-response to light-stimulus. A good plan to observe the action of the irides to light-stimulus thrown from various parts of the visual field, is to place the patient in a dark room and to throw narrow beams of light from an ophthalmoscopic mirror held in different positions. Commencing with the vertical meridian, the light is to be thrown into the pupil consecutively from numerous points throughout the entire periphery of the field of vision. This will not only serve to show whether the reflex is good throughout the field of vision, but in some instances may be useful as a rough guide, especially at the bedside, as to the extent of the field of vision.

The student should next study the action of the irides to accommodative effort with and without convergence. This is done by the surgeon asking the patient to fix upon a small object held at reading distance before one eye, whilst the other eye is excluded by covering it with his unused hand. As we have learned in the chapter on Physiology, the pupil becomes contracted the moment accommodative effort is brought into play. The surgeon should notice very carefully the amount of contraction, and compare it with that of the opposite eye. After this is done, both eyes are to be exposed to the object held at the same distance, but now on the median line, and observation made whether both pupils contract to the same size before they fall into their permanent size for the point chosen. It is of interest, and also of value, to note the series of secondary excursions made by the irides after they have received and obeyed their first impulse to contraction. In quite a number of neuroses, especially of the degenerative type, the secondary responses vary considerably and behave quite differently.

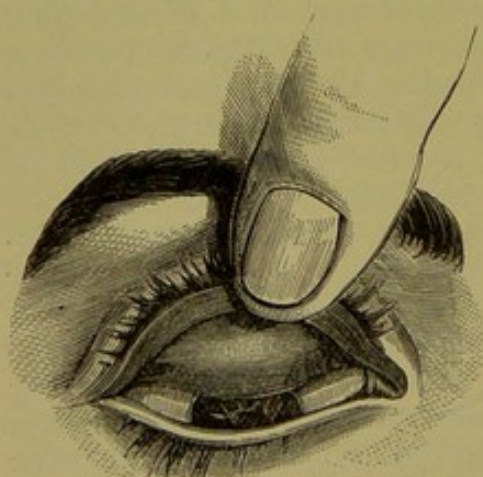
So far, the student has not touched the eyes ; he has done nothing to irritate them by handling. In the case of fretful and irritable children, much information can be obtained whilst attracting the little patient's attention to some gaudy or bright object held or dangled before its eyes. Nothing has been done to alarm the patient ; the examination has, as it were, been made at a distance. The surgeon should now proceed to make a most careful examination of the exterior of the organs. He

should see if the eyeballs are prominent or sunken, which may be fairly well gauged by the amount of sclerotic exposed to view. Notice must be taken if there are any malformations, peculiarities, or changes. He should compare the condition of one eye with that of the other, and make note of it in the record. Pressure upon the skin over the lacrimal sacs and lower canaliculi should be exercised, and careful watch made whether any mucoid material or tears can be expressed from the puncta. He should study the condition of the free borders of the lids, the state of the cilia, and the exact situation of the puncta. He is to look at the corneal limbus, and see whether fatty degeneration has taken place and produced a ring of opaque tissue. In subjects, especially the old, in whom there is any suspicion of glaucoma, additional evidence may be obtained by measuring the horizontal meridian of the cornea, which is said to be diminished in those who are prone to the disease. This can be quickly and fairly well done by holding a millimeter measure before the eyes so that the ruled edge shall be situated directly in front of the horizontal meridian of the cornea, when the width of the portion to be studied can be readily read off. Without causing pressure upon the globes, he should gently raise the upper lids; carefully examine the conjunctiva, its condition of vascularity; and look for the possible presence of small phlyctenulæ, etc. If there be marked vascular congestion and injection, he is to study their character. Note is to be made whether the finer vessels brought to view are situated in the conjunctiva or are more deeply placed. To do this, he is to move his forefinger lightly over the conjunctival membrane, and it will be found that its vessels glide with every movement given by the finger, whilst the deeper episcleral twigs, which should not be ordinarily seen, remain stationary. Again, the vessels of the conjunctiva appear quite tortuous, are superficial and bright red, and are more numerous in the looser and more peripheral portion of the membrane; whereas the episcleral arteries—which appear as very minute radiating stems, and seem to be limited to the ciliary region—have more of a decided pink appearance. Any venous engorgement in the same region, of course, appears much darker and denser. Further, he must remember that small superficial twigs encroaching upon the corneal limbus, or extending far over its surface, are of frequent occurrence, especially in localized lesions of this membrane.

He is next to lightly depress the lower lids, so as to expose the surface of the inferior portions of the conjunctivæ. In order to better bring the inferior cul-de-sac into full view, he will find it a good plan to have the patient look upward. He should now proceed to examine the conjunctival surface of the upper lid. After a little practice this may be readily accomplished by first having the patient look down, and then catching hold of the free margin of the lid or lashes with the index finger and the thumb of one hand, hold the lid away and down from the eye. When this is done, the surgeon is to place either the top of the forefinger or the thumb of the other hand, or, if he has become sufficiently expert, the second finger of the same hand, upon the upper lid about a centimeter above the point previously held. By now quickly and gently drawing the lid down and out and then up,

and at the same time firmly fixing the upper half of the lid in position by the finger held against it, the inferior portion of the lid will almost immediately evert and the conjunctival surface will become exposed to view. The moment this is accomplished, the patient is to be requested to look up with his opposite eye; this will cause the examined eye to look up—a manœuvre that will frequently make the everted lid remain in position without any further effort upon the surgeon's part to hold it. With the timid, or with children, he may find it desirable to substitute a probe or a pencil for the finger. Where the cilia have disappeared, as in many cases of chronic granular conjunctivitis and blepharitis, he can take hold of the lid by catching the entire lid-thickness. To do this, he should slip the tip of the thumb directly beneath the lid upon its conjunctival surface, and make the counter-grasp and the rest of the procedure in the usual way. Ordinarily, in these chronic cases, this will give but little discomfort. Should the palpebral fissure be very much shortened and the eye be painful, or, from some other local or general cause, should ordinary manipulation be impossible, and the case be sufficiently urgent, recourse must be had to local or general anæsthesia. In children the bromide of ethyl is an excellent agent for the latter purpose. After a little practice, the student will find himself able in all ordinary cases to evert the lid with one hand alone, using his right hand for the patient's left eye, and his left hand for his right eye. To do this, he should first place the index finger upon the lid and make a slight downward and backward pressure. He should next slip the thumb under the ciliary border, when, upon making an outward and forward movement with the thumb at the same time that the index finger is pressing down and in, the lid will quickly evert without any difficulty. If pain be complained of, a few drops of cocaine may be instilled beneath the upper lid. After having secured the lid in

FIG. 145.



Method of holding the upper eyelid.
(WELLS.)

the desired position, it can be retained there as long as desired, by pressing down instead of up upon the ciliary border, as shown in Fig. 145.

This manœuvre gives opportunity either to illuminate or magnify any portion that the surgeon wishes, by a convex lens held in the other hand. During the entire examination, the patient must be made to face the source of illumination. Having successfully accomplished the procedure, it only remains for the surgeon to study the condition of the surface, the state of the Meibomian glands, the cilia, etc.

Among children, especially where there are great photophobia, pain, and much discharge, it is an excellent plan to fix the child's head firmly between the surgeon's knees, whilst an assistant holds the child on his lap. This should be done in every case in which it may be found neces-

sary. To avoid staining the clothes with any of the solutions or washes used, a towel or rubber cloth should be spread upon the lap. The person holding the child should sit sideways in front of the surgeon, so that the body of the patient shall rest directly across his thighs, as this will give him opportunity to hold the little patient's hands with one hand and cross one leg over the child's legs at the same time, if necessary, thus leaving his other hand free to be of service in any manipulation required. By a little knack, the student will soon learn how either to expose the eye or cause the lids to evert whilst the patient is in this position. To accomplish the former, he should get the tip of the finger and of the thumb under the ciliary border before he attempts to widely separate the lids. To expose the conjunctiva alone, a quickly repeated lateral movement given to the border of the upper lid by the thumb of one hand, whilst the index finger of the hand with which he intends to hold the eye is placed upon the lid about half-way up its surface, will soon cause a free eversion. The lower lid can likewise be caught and held in position.

To expose the lower palpebral conjunctivæ means merely, as said before, a downward movement given to the lower lid. If the surgeon finds himself unable to expose the eye by his fingers alone, he can make use of one of the smaller-sized lid-elevators. He is not to misconstrue the little yellow-white nodules termed pinguecula, so often seen beneath the bulbar conjunctiva to the nasal side of the cornea, and not infrequently complained of, as something serious. He should take careful note of any apparent changes in the sclerotic, remembering that it is bluish pearly-white and exceedingly clear in youth, whilst in old age it may be normally yellowish and quite translucent.

This will bring us to *focal illumination*, which method of examination has also received the names of "*oblique illumination*" and "*lateral illumination*." It is of value in the detection of changes that may have taken place in the tissues of the anterior portion of the eye and its accessories. It should be employed in all cases where involvement of this part of the organ is suspected. In fact, it is so important a step in a critical study of any case of ocular disease, that it is advisable to include it in every ophthalmic examination. This cannot be too strongly impressed upon the student, as frequently, by recourse to it, he will be rewarded by the discovery of some minute change, or some delicate yet dangerous disturbance, the overlooking of which might lead to an imperfect and, perhaps, improper diagnosis. By it, slight inflammatory conditions of the conjunctiva or lids, minute opacities or faint nebulæ situated in the cornea, small superficial ulcers, particles of foreign substances which have become imbedded in the corneal substance, may all be made plainly visible. Where the areas of denuded cornea are extremely small, or where there has been a minute tear or break in the epithelium, the exposed portion may frequently be made more plainly recognizable by impregnating the corneal substance with a drop of a two per cent. solution of either the sodium or potassium salt of fluorescein. This is done by allowing a single drop to fall upon the corneal surface, following this immediately by a thorough washing with distilled water, when the exact point of the broken surface will

be made apparent by a deep greenish-yellow stain, which will remain visible for two or three hours. The drug causes conjunctival lesions to become quite yellow in tint.

Thickening, discolorations, and vascularity of iris-tissue, shape and size of pupil, lymph-extravasation into the pupillary space, plastic exudations attached either to the posterior surface of the cornea or to the anterior capsule of the lens, which should be compared with the condition of the related tissues in the fellow-eye, can all be seen. Even the faintest trace of disturbance or inflammatory changes in the lens or posterior capsule, morbid growths, detachments, blood- and lymph-effusions into the anterior portion of the vitreous chamber, may all often be brought into view.

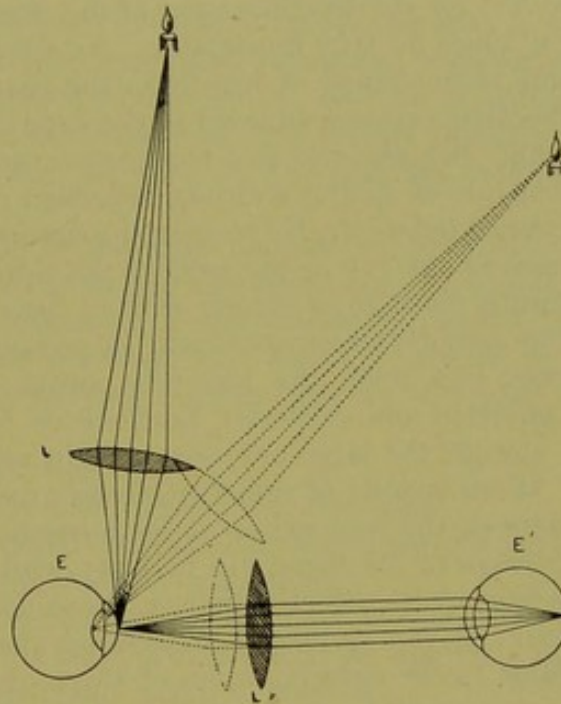
There are two methods, either of which may be employed, as circumstances permit. The first, which is the better, consists in placing the patient in a darkened room and exposing the eye to direct rays received from a single source of artificial light. The flame should be placed about one meter in front and to the outer side of the eye under examination. The light is to be situated on a higher level than the patient's eye, so as to avoid any shadows that may be cast by the arm and body of the operator whilst he is manipulating. A convex spherical lens of fifteen to twenty diopters' strength is needed.

The student should stand in front of the patient's opposite side and hold the lens between the light and the eye under examination. The lens should be held in the hand corresponding to the eye of the patient which is not being examined, and at a little more than its focal length from the portion of the organ to be studied. By this means, the focusing-point of a beam of concentrated artificial light is made to fall upon any of the above-named structures and to play over them to any requisite extent of area or degree of intensity. By looking back of the convex lens and gazing directly upon the illuminated part, he shall find an area of illumination surrounded by a more or less dense contrasting shadow, in which area of concentrated light the most minute changes can readily be seen. In order to secure a magnified image of the illuminated point, another lens, say of + S. 20. D., may be held in the surgeon's other hand, between his eye and that of the patient, at a distance from the observed eye at or within the focal length of the lens. If desired, a so-called "corneal loupe," which is practically a low-power microscope mounted in appropriate tubing, may be employed. Many extremely minute changes may thus be detected which would escape detection by the unassisted eye.

Fig. 146 explains the procedure very well. Here L is a bi-convex lens, known as the illuminating lens, which receives divergent illuminating rays from the upper candle-flame. After their passage through the lens, they are all brought to a point of concentration upon the cornea of the eye, E, which point of concentration can be made to alter its situation by changes of the relative position of the candle, the lens, and the eye (the dotted lines proceeding from the second candle through the dotted lens, so as to be focussed upon the posterior capsule of the lens, serving as another example). In the first instance, lens L', known as the magnifying lens, focusses the magnified image of the corneal point on the

observed eye upon the retina of E' , the observing eye. In the second instance, the dotted line passing from the deeper point on the posterior capsule of the lens of the observed eye, requires the movement of the lens, L' , to a point nearer the observed eye, in order to obtain a perfect picture upon the retina of the observing eye, E' .

FIG. 146.



Oblique illumination. (JULER.)

The second method is practically the same, and is conducted by having the patient seated before a large window which permits the entrance of plenty of diffuse daylight. The same relative positions are assumed as in the first method, and a similar plan is pursued, except that here the illuminating lens is held at its focal length from the part of the eye to be examined, instead of the distance beyond the lens-focus. The reason for this is, that now practically parallel rays of light are focussing upon the eye, instead of divergent ones.

For fear of injuring the eye by the concentration of too great heat, the student should avoid direct solar rays. In fact, care should be exercised that the eye shall not be subjected to any injurious glare. By having the observed eye turn in different directions, and by varying the intensity of the source of light and the positions of the two lenses, oblique or perpendicular incidences of any desired amount of light may be concentrated in such ways as to obtain the most decided contrasts between the beam of focal light and its surrounding shadow.

For ordinary inspection, the student begins by holding the condensing lens somewhat within its focal length from the part of the eye he wishes to study. On account of the most strongly condensed portion of light having been cut off by the ocular surfaces, this will cause a large area of rather weak illumination. By tilting the illuminating lens, the summit of the truncated cone of light may be played about

and carried in various directions. He should make the light play over the entire pupillary area, and focus accurately for any supposed capsular or lenticular change. If there be any doubt, he should not hesitate, after notifying the patient, to employ any proper mydriatic which will give a greater field of study and a more extended area of surface for answer.

A modification of the use of oblique illumination, in the study of the so-called *catoptric test* for the determination of the presence of the crystalline lens, may at times be very important. As shown in the chapter on Physiology, and as explained at length in the chapter on Cataract, there are three reflecting surfaces situated in the anterior segment of the eye, the corneal, and the anterior and posterior capsulars of the lens, each of which is capable of giving a strong reflection of any brilliantly illuminated body placed before it. By placing the source of artificial light at an angle and putting our eye in the path of the equivalent or reflecting angle, by looking through a strong convex lens, we can, if the patient's crystalline lens be transparent and in position, see the three images of the flame: one, upon the patient's cornea; and second and third, upon the anterior and posterior portions of his lens. If the patient's lens be absent, the large anterior upright corneal image will be alone visible. If an opacity of sufficient density and area to disturb the reflecting powers of the lens exists at its posterior pole, the small inverted posterior image of the flame will be lost; whilst if the anterior portion of the lens has lost its reflecting power, the middle upright image cannot even be seen. As can be readily understood, the plan thus offers a most valuable guide in the determination of these questions.

In some instances, advantage may be taken of the fact that the relative antero-posterior positions of many opacities in the ocular media cause a difference in apparent motion when a beam of light is cast upon them from the plane concave mirror of an ophthalmoscope through which they are being observed.

At times, where suspicion of so-called conical cornea is entertained, an accurate study of the corneal membrane, as seen in profile, is of great value.

The degree of *intra-ocular tension* should next be tested. As the student is aware, the contents of the eye are normally insufficient to fill the globe to its utmost, and, as the external coverings are not easily stretched, any decrease or increase of the contained material, either solid or liquid, will manifest itself by a corresponding decrease or increase of resistance offered to external compression. This resistance is known as tension. The best and simplest plan to ascertain its character and degree, is as follows: The patient should be directed to look steadily downward, and to close the lids gently. The student should apply the tips of his forefingers to the closed upper lids so as to press upon the globe just above the cornea. He is then to make a firm, but light downward and backward pressure. This is to be done first with one forefinger, and then with the other. To the novice, the procedure may at first be unproductive of any satisfactory answer, but by constant repetition in association with experts—upon healthy and diseased eyes of both young and old subjects, he will soon be made conversant with

what is clinically known as *normal tension*. Having this once established, there is no further difficulty in giving near and close estimations of the exact consistency of the globe in various pathological conditions. He should always test both eyes, and always make use of corresponding fingers. If uncertain at times, he should compare the results with those of other eyes which are seemingly alike in conditions, and make it a rule to study the condition in the normal eye as frequently as opportunity may be given. At times, as for instance in some cases where there are glaucomatous symptoms connected with disturbances situated in the anterior segment of the eye, it may be of value to ascertain the degree of intra-ocular tension at other points on the anterior surface of the globe. This can be done at any position desired, in the manner above described.

The abbreviation of the term tension is ordinarily written T, whilst the usual signs for registering the result are n (normal), — (minus), and + (plus) for the character of the condition; and 1, 2, and 3 for the degree; whilst the interrogation mark (?) serves to indicate uncertainty. Thus, the varying degrees may be indicated by the following signs:

T n, normal tension.

T — 1, slight, but perceptible decrease.

T — 2, decided decrease (the sclera can be very easily indented by ordinary palpation).

T — 3, great decrease (the sclera is so flabby and yielding that the least pressure changes the form of the globe).

T + 1, slight, but positive increase.

T + 2, decided increase (the sclera can still be indented by ordinary palpation).

T + 3, great increase (impossible to indent the sclera by firm pressure; "stony hardness").

From time to time, various contrivances known as *tonometers* have been devised in the hope of supplanting this empirical plan, and of giving greater certainty to the method of examination. Unfortunately, however, such instruments have not only been cumbersome and difficult to manage, but have proved extremely unreliable in result. The educated touch of the careful and experienced investigator is all that at present can be relied upon. By it, he can not only study intra-ocular pressure, but is enabled to differentiate this condition from rigidity or flaccidity of the tissues of the ocular walls themselves, which with the most improved present form of artificial tonometer is an impossibility.

The student must take care to avoid any inaccuracy that might arise from palpebral swelling or oedema, deeply-set and small-sized globes, or abnormally prominent or large eyeballs. He should remember, also, that not only may there be variations of the fluid contents of diseased organs, but also that changes in density of the ocular tissues may occur in many dyscrasiæ. Each case must be considered in association with its general conditions. Idiosyncrasy must be studied, because what might be normal for one could readily be abnormal for another.

In various forms of sensory nerve disturbance affecting the conjunctival and the corneal areas, and in many cases of glaucoma, it is of the

utmost clinical use to test the degree of sensibility. This may be readily done by touching the exposed membranes with a wisp of absorbent cotton, or, when greater accuracy is desired, by measuring the distances obtained between the blunted points of any ordinary æsthesiometer.

For the study of comparative conjunctival temperature-sense, the author has frequently found almost any of the well-known surface thermometers to give excellent results.

The student should next estimate the depth of the anterior chamber. He should notice whether there are any peculiarities of the iris-tissue. If there be any suspicion of abnormality or discrepancy in the relative positions of the two eyes in the orbits, measurements should be carefully made. If deep-seated orbital or ocular disturbances be suspected, palpation and auscultation may both prove of the greatest diagnostic value. Where the ciliary body is supposed to be implicated or inflamed, as is often the case in plastic iritis, it may be made more evident by gentle palpation upon the closed lid over the ciliary zone, revealing the presence of localized points and areas of tenderness; this is known as *ciliary tenderness*. The test is often of the utmost value in the determination of the probability of the presence of sympathetic irritation from long-standing irido-cyclitic stumps.

So far, the student has a very fair knowledge of the condition of the external appendages of the eye, and the visible appearance of the grosser changes in the anterior segment of the organ. It now becomes necessary to explore the interior of the globe, and bring to view the finer and less-pronounced changes in the lens, the condition of the vitreous, and the state of the chorioid, the retina, the optic nerve, and the intra-ocular surface of the sclerotic. This can be done by that most wonderful and valuable instrument of precision, the ophthalmoscope. So much is exposed by its means, and so much is dependent upon the structures that it brings into view, that the student should never fail to make its use a part of his routine examination.

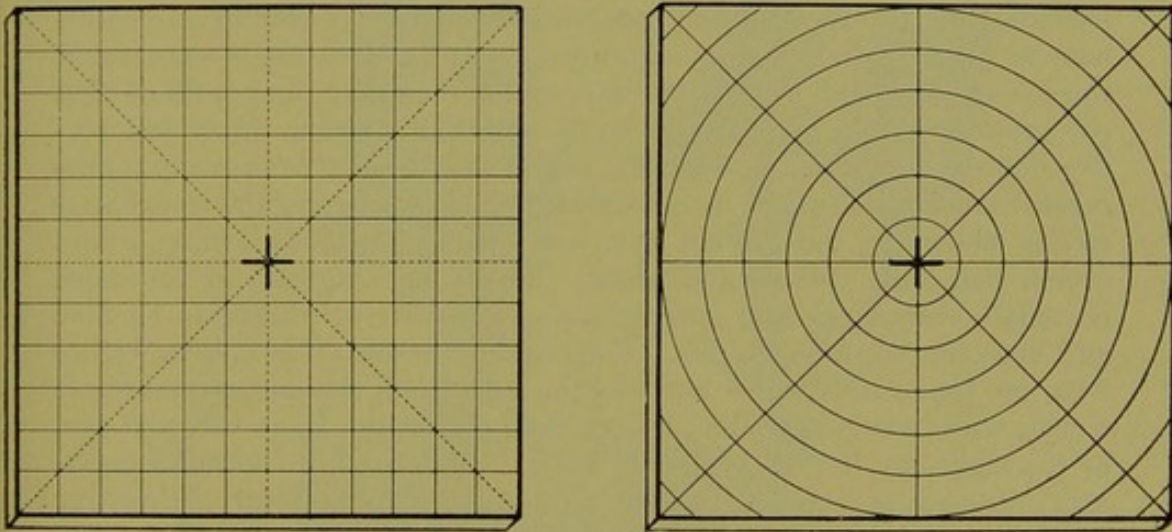
As shown in the chapter on Ophthalmoscopy, there are two methods, both of which are thoroughly explained in that place. The student should always make use of one or the other, as circumstances allow. From what is there told him, he can realize that the direct method of examination is the more advantageous of the two. He should use the best pattern of instrument that he can afford, since the most valuable results with the easiest work can be secured from the mechanism having the greatest facilities and the best workmanship. Personally, the author prefers the latest pattern of the refraction ophthalmoscope of Loring.

During such an examination, the surgeon should write a short description of the condition of the media, with a brief account of the shape, size, and long axis of the disk. He should note its tint and capillarity, the presence of physiological or pathological excavation, the position, width, and visibility of the scleral ring, and the character of the chorioidal ring and conus. He should give brief mention of the comparative size and tortuosity of the retinal vessels, with the apparent thickness of their walls and the color of the contained blood; and add a few words as to the situation of the greatest retinal striation, the state

of the chorioid, and the character and amount of refractive error, etc.¹ At first, this may seem irksome, and in many instances unnecessary. In spite of this, the advice of the author to the student is, do it, and the reward, as to the more exact knowledge of nerve and vascular change, the better interpretation of the many transient conditions of the optic nerve, retina, and chorioid, and the clearer recognition of those interesting visible expressions of harmful refractive error, will more than pay for the slight amount of extra work involved at the times of examination.

Leaving the methods to be detailed in the next chapter, where the subject is treated *in extenso*, those methods of ocular examination which are not absolutely necessary, except in special cases, will next be taken up. The first of these, which is the most frequently employed, is that of the determination of the so-called *fields of vision*.

FIG. 147.



Rulings and divisions of boards for use in determining the fields of vision.

As has been shown in the chapter on Physiology, every eye has a certain amount of indirect or peripheral vision, which in many instances of ocular disease it becomes desirable to estimate. Ordinarily there are three methods of accomplishing this: First, by the use of a flat, dead-black surface on which three-inch squares or concentric circles of five degrees' difference are ruled in some dark, almost black, or dark-blue color. In the centre of this black-board a white cross is painted, from which fine radiating dotted or solid lines at forty-five degrees' difference, extend in all directions, thus dividing the surface into eight equal sections. Fig. 147 shows the two characters of rulings and the divisions of the sections:

In addition to this, either a series of long, thin slips of ordinary dead-black cardboard, or, better, long, narrow, flat, flexible pieces of the blackened steel used in corsets, on which have been pasted at one end, small squares of unpolished green, red, blue, yellow, and white papers of one mm., two mm., four mm., or one cm., in each area, or a

¹ For an extended description of these appearances in the fundus, the student is referred to the beginning of the chapter on the Diseases of the Retina.

small black disk, fastened at the extremity of a long handle, will be necessary. This latter contrivance may be so arranged that graduated areas of any desired color may be exposed as wanted. The extent of the color-areas are graded by some surgeons, white being made somewhat more than double that of the green, red, blue, and yellow. The board, which is to be supported by a tripod or some similar arrangement, should be placed at a slight angle so as to face a window or a light. The patient should be seated before the board in such position that his eye will be on a level with the central cross. Care should be taken that the surface of the board has sufficient lateral inclination to escape any conflicting shadow from the patient's person. He is to be directed to fix his vision steadfastly upon the cross. One eye must be employed at a time, the other being excluded by means of one or two turns of a roller bandage. The test-colors are to be carried along the various meridians upon the surface of the board from the periphery toward the fixation-point in all manner of confusing ways, until the patient first recognizes their presence by correctly calling the color-names. Small chalk-marks significant of the colors used—preferably the initial letters of the colors—are to be placed at the points of first recognition. This procedure is to be repeated at from thirty to forty-five degrees' difference around the entire board. By connecting all the related marks, there will be completed a series of irregular concentric circles which, in the normal eye, will appear in the following order: green, red, blue, yellow, and white. These markings are to be copied on small blanks ruled in corresponding proportion, which can be filed and kept for future reference. For obvious reasons, it is always well to note on the charts which eye was the first tried, the author making it a rule, whenever practicable, to try first either the more affected eye, or the right eye if they be nearly alike. If desired, or if found necessary, though, of course, it is by no means so satisfactory, Priestley Smith's suggestion, as given in the accompanying arrangement, may be sufficient in some of the uncomplicated cases, for case-book record:

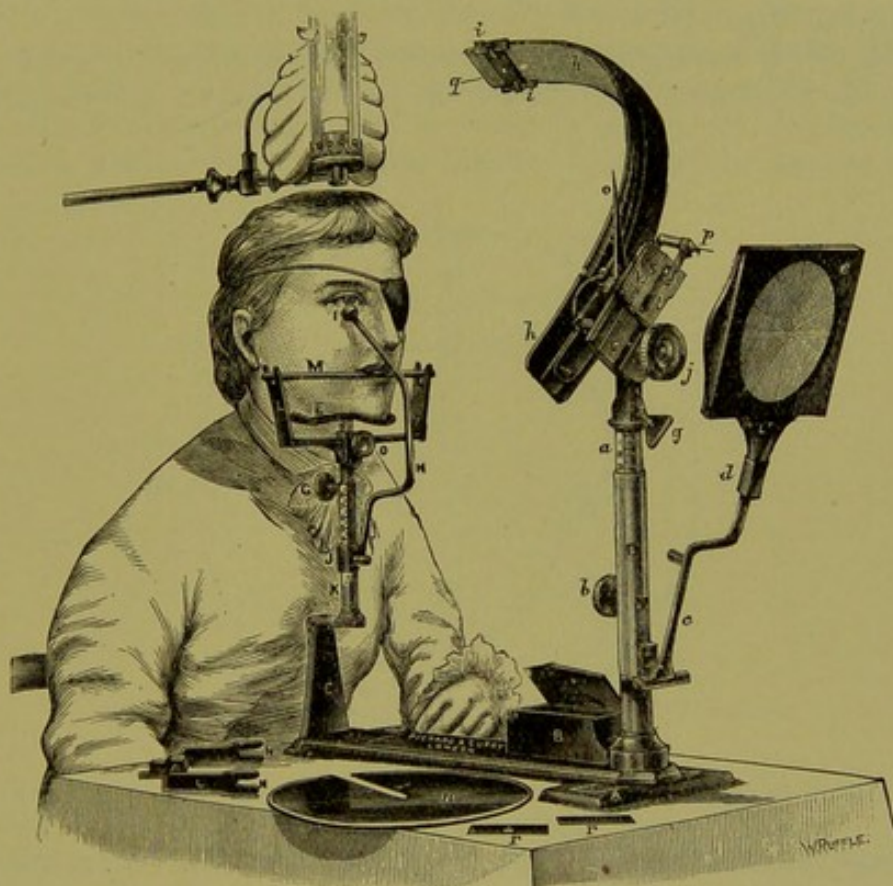
		55°			55°	
Fields :	90°	L	55°	55°	R	90°
		65°			65°	

If notings of the intermediate quarter meridians be desired, the number which expresses the degree of the special angle may be inserted in its proper position. If convenient, a slight modification of Bjerrum's plan, by having a square black screen two meters in size placed at two meters' distance from the patient, is very good when the student wishes to study very small scotomata situated near the centre of the field. The ordinary one-centimeter square or diameter test-color, fastened on the end of a long black rod, is to be used. By this means, the size of the blind spot can be most easily estimated. Of course, the distance used and the size of the test-object, should always be noted in connection with the amount of reduction made in field-blank used for record.

Second. This method, which, as a rule, is used by the most careful observers, consists in the employment of some one of the many forms

of perimeters, all of which are based on a mechanical contrivance for carrying small areas¹ of color inward upon a graduated metallic arc toward a fixed central point. Among the latest improvements that have been added to these contrivances is a small duplicature, which, by adjustment, can be made to register properly a copy of the field of vision being taken. One of the most recent and convenient is that of McHardy. It consists of a graduated quadrant upon which a small carriage containing various colors can be made to move inward from the

FIG. 148.



McHardy's perimeter. (JULER.)

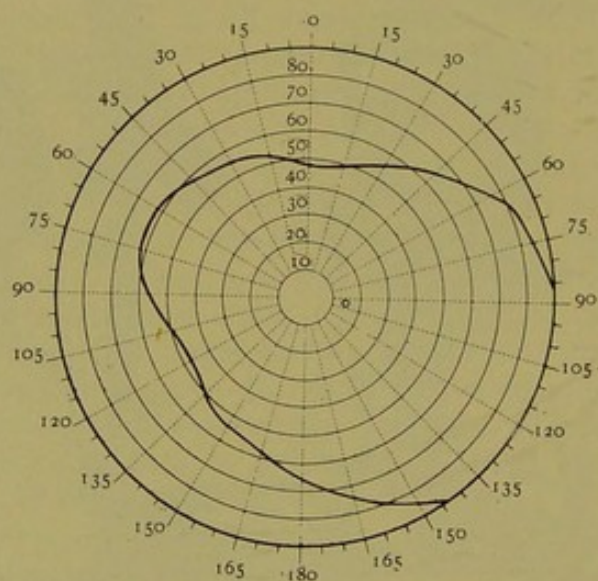
periphery. Back of the central fixation-point there is a small and ingenious mechanism for the registering of the result. In front, there is an adjustable chin-rest, by which the level of the patient's eye may be made to coincide with the centre of fixation. (Fig 148.) Other accessories intended for change of field-area and studies with the field of fixation, etc., accompany it. The quadrant, *h h*, having been adjusted so that it shall stand vertical, and the color-carriage having been removed to the extreme periphery of the arc, the patient is made to fix upon the central point, as shown in the illustration. The student standing behind the instrument, and slowly revolving the milled head, *j*, which acts simultaneously upon the color-traveller, *i i*, and the

¹ The smaller the better. The author prefers those which are but two and four millimeters square in size.

pointer, *P*, tells the patient to state the moment the area of incoming color is recognized. By stopping the motion and pushing the chart-box, *e*, against the pointer, *p*, the moment the color is recognized, a small hole is made in the registry blank at a point corresponding to the position of the color upon the quadrant. This procedure is repeated at any meridian desired, until a series of points are made upon the blank. The blank should then be removed, and the points on it connected with narrow ink lines, thus giving the desired charts of the field of vision. Repetition may be made with any chosen colors until the series of fields desired are completed. The appearance of a chart is shown in Fig. 149.

This, which corresponds to the entire field, is divided into concentric circles of five-degree differences from zero to ninety: it is intended for

FIG. 149.



Average size of field of vision for white. (Slightly modified from MCHARDY.)

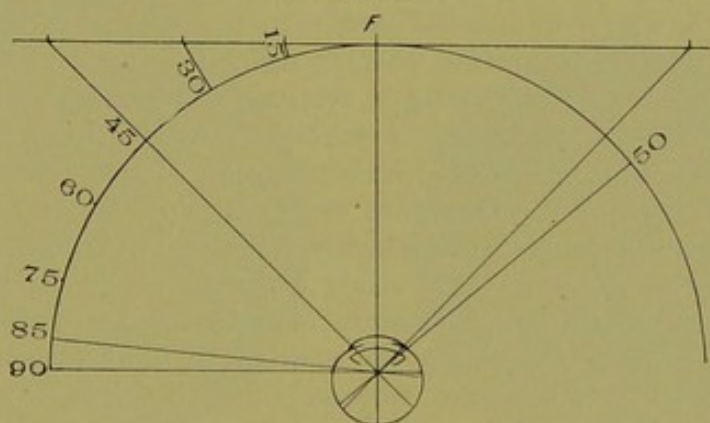
the registration of the changes in the whole color-area. A second chart, which extends peripherally to but forty-five degrees, may also be employed. This one, which thus gives twice the comparative measurement of the former, is to be used only for registering the changes which occur in the central portion of the fields.¹

In all examinations of this kind, there must be frequent interchange and substitution of colors, with sufficient repetition in all possible ways, to verify the correctness of each point chosen. Care should be taken to have the patient's eye constantly fixed on the central point, and to avoid fatigue of the eye by unnecessary repetition. After the principal boundaries have been obtained, it is desirable in all instances to search carefully throughout the fields for any areas of altered, diminished, or annihilated color-perception. This is done as follows: first, a similarly-sized piece of the color wished to be studied, is to be placed directly over the central cross, and then, while carrying a similar area of

¹ It will be noticed that the ninety-degree meridian is horizontal. Here, in the United States, the ninety-degree meridian is placed vertically.

the same color inward from the periphery to the fixation-point, the patient is to compare the two color squares without taking his eye from the central point. Any space or area, whether central or peripheral, in which the color is diminished or loses its identity, should be marked, care being taken not to confound it with the physiological blind spot, which should be searched for in every case and noted on the field blank, so as to insure the accuracy of the entire procedure. If greater certainty as to the exact conformation of these areas be desired, the patient may be removed double or treble the distance from the test-color, thus proportionately increasing their size. Of course, if a perimeter be used, the arc employed should be comparatively lessened in curvature. In some cases, as in the various hemianopsias, quadrant defects, etc., the line of demarcation between the blind and the seeing portions, especially around the fixation-point, should be carefully gone over, millimeter by millimeter, with a two- or a four-millimeter square of the desired colors.

FIG. 150.



Advantages of hemispherical over flat field. (NETTLESHIP.)

In the registry of the blind or dimmed areas, or *scotomata*, as they are called, it is a good plan to designate those that are positive, respectively either by black areas or cross-bars, and those that are negative by cross-bars or parallel linings. If scientific accuracy be desired, as in the study of incipient nerve disease, the color-square or circle, which should, as a rule, be quite small, can be fixed in the position of the partial scotomata on the field, and similarly-sized squares or circles, with numbers of related confusion-colors pasted upon them, substituted one after the other in the position of the central fixation-color, until the nearest match to the excentric color has been made. By this means, the student can obtain an idea of the appearance of the color in the affected area. Proportionate sizes of the matching confusion-colors may then be cut and pasted on the registry blank in this position and used for future comparison, thus giving better notions of prognosis than could otherwise be obtained. By fixing the test-color at various points upon the quadrant of the perimeter and revolving the arc around the central pivot, the ordinary procedure may be so altered as to produce lateral movements of the test-color along the concentric circle. This modified plan is particularly useful in studying scotomata and irregular

curvatures of bounding lines, as found in the color-fields of many cases of commencing optic-nerve atrophy and chorioiditis.

The great advantage of the hemispherical over the flat field is shown in Fig. 150. Here it will be seen that every point on the curved field is equidistant from the observer's retina, thus avoiding the double error in the flat surface of having the weakest portion of the retina given the most distant fixation. Further, as can be readily demonstrated in many cases clinically, especially in studying light-perception, the plane surface does not allow sufficient area upon which to project the most peripheral portions of the temporal field.

If desired, as when visiting a patient at his house, or when he is bed-ridden and cannot sit up, one of the small portable hand-perimeters, such as Schweigger's latest model, may be of value.

Third. The last method, which is the simplest and, of course, the crudest and least satisfactory, may be resorted to wherever the black-board or the perimeter is unobtainable. It consists in having the patient gaze steadily with one eye at a time (the other being covered) into the observer's eye, whilst he has his back turned toward a window or other source of light. The observer now, bringing his outstretched fingers, or a color square, inward along a vertical plane midway between his own eye and that of the patient in various directions from points in the periphery toward an imaginary line connecting the two eyes, is to notice the position at which the fingers or colors are first seen, being careful that the patient keeps his gaze steadily fixed upon his eye. Assuming that the observer's own field of vision is normal, he may compare the patient's answers with his own results obtained at the same time. It is a good plan to alter frequently the number of outstretched fingers or change the color of the card at various points in the field, in order that there may be more certainty as to the results.

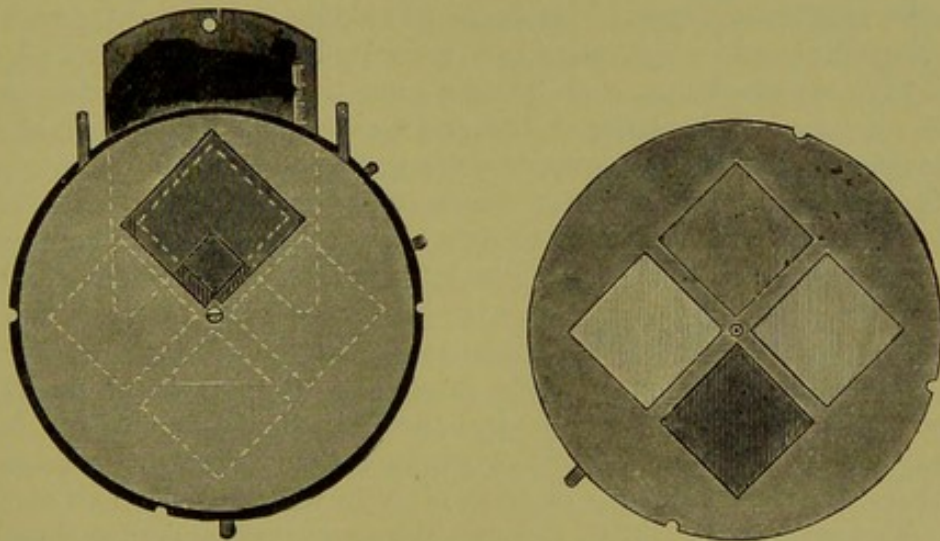
Should vision be very low, as in well-matured cataract, marked nerve disease, advanced glaucoma, etc., the extent of the visual field may be conveniently obtained by the employment of two candle-flames, or of a flame and the glare from the concave mirror of an ophthalmoscope. In each instance, one light is to be steadily gazed at and the other is to be moved inward from every side at short intervals toward the central light. If desired, two candle-flames might be attached to an ordinary perimeter, one at the fixation-point and the other on the carriage. An apparatus might be advantageously used by which graduated beams of electric-light stimulus could be substituted for the ordinary candle-flame. By this plan, not only would knowledge of the existence of quantitative light-perception be obtained, but also the grade and quality of the perception. Where central fixation is unobtainable, the author has many times secured steadiness of the patient's eye by repeatedly tapping upon the fixation-point, requesting, at the same time, that the patient endeavor to fix persistently upon the position from which he hears the noise.

The importance of the art of perimetry is very great, as the changes in the visual field assume such definite forms in various local disorders and systemic diseases as to render the full appreciation of the method an absolute necessity to every ophthalmic student. In the numerous

organic and functional neuroses, the different types of fields are often in many instances almost pathognomonic.

In rarer instances, it becomes necessary to study the character and amount of direct vision for colors. Many contrivances for both qualitative and quantitative measurement have been devised. For ordinary clinical purposes, where experimental and scientific accuracy is not absolutely necessary, a chart or disk of graduated colors, to be recognized at definite distances, is all that is necessary. As has been explained in the physiological division, red is the most easily recognized, green and blue coming next in order. Using these as rough standards until better grading and more definite estimates can be established, very fair notions of the comparative degree of color-vision, sufficient for all practical purposes, may be obtained. This can be easily done by having the colors

FIG. 151.



Color-sense measure. (OLIVER.)

placed upon a revolving disk situated at the back of a graduated opening so arranged that they can be exposed to the patient for recognition at a definite distance. Fig. 151 shows a form of such apparatus devised by the author.

It is to be hung on a wall in the same position as the test-type, and the patient is to be removed to the usual distance of five meters. The amount of exposure necessary for recognition, in millimeters, for each eye separately, should be noted in the case-book.

Should the case show any lowering of the color-sense, or should the student be led to suspect the existence of such a condition from the appearance of the optic-nerve tip, the retina, and the chorioid, or if the general symptoms indicate any grave neurosis, careful testing of color-perception becomes absolutely necessary. Of all the plans, that of Holmgren (really Wilson) is by far the best, where actual comparison of color is intended to be made among large numbers, this being accomplished by the use of cheap and easily-handled Berlin wools. Here there is no complicated apparatus, no doubts arising from imperfectly working machinery, and nothing dependent upon faulty naming. To

apply this method, the candidate is to be placed before a table. The series of small skeins of differently tinted wools chosen by Holmgren being thrown promiscuously in a heap upon the table, the candidate is handed a large test-skein of light pure green, and is requested to select the nearest matches and place them with the test-skein without attempting to name the color. Frequently, as Holmgren says, "If the person examined cannot succeed in understanding this by verbal explanation, we must resort to action." After the examination with this color has been done, the same thing is to be repeated with a purple and a red test-skein. If the first and second tests evidence decided lowering of color-perception, the third test need not be made.

For scientific, clinical purposes, and, in fact, even where large masses are to be examined, a plan modified from Holmgren and made use of by the author, is as follows: Broad diffuse daylight is necessary. A square of black muslin is placed upon a flat table about one meter away from the candidate's eyes. Five large test-skeins (pure green, pure red, rose, pure blue, and pure yellow) are separated from a collection of five small, pure match-skeins, each being a pure tint of definite intensity of one of the colors of the large skeins, and eighteen small confusion-skeins of the same intensity, each containing a mixture of certain definite percentages of two or more of the colors of the principal skeins. Each skein is colored with a vegetable dye, and each match- and confusion-skein is designated by a small black metallic bangle, upon which is marked the initial of the color and its degree of color-saturation, in such a manner as not to be understood by anyone but the examiner. One eye of the examinee is to be tried at a time. One of the large test-skeins (preferably the green) is handed to the candidate, and he is requested to select from the pile of wools the three nearest matches to this skein and to lay them alongside of it in the order of their matching. The surgeon should go through the procedure, and then show the candidate exactly what is wanted, taking care, however, so to disarrange his choice that it will be impossible for the candidate to gain any knowledge from his selection. The letterings upon the tags of the chosen wools are then to be registered, in the order of choice, upon a properly arranged blank. This finished, the selected wools are to be replaced among the general mass, and the same method of selection continued with the rose, the red, the blue, and the yellow.

By this plan one is able to obtain the proper registration of the color-sense with as few loop-holes of escape as possible. It prevents any chance of easy selection by the aid of skilful shading; it avoids the mistakes which might arise as to color, character of dye, and choice of material; it permits an easy and comprehensible method to any interested layman to be rendered unintelligible to the patient; and it allows a definite and exact grading of the amount of color-defect by which the registration may be made common property throughout the ophthalmic world.

For situations where proper color-perception is demanded at great distances, as among engineers, pilots, etc., it becomes requisite, for many reasons—such as, for instance, what Wilson aptly terms *chromic myopia*—to substitute contrivances by which a series of similar colors

to those used during near-testing can be promiscuously yet intelligently placed by the surgeon, so that comparison can be made while the visual apparatus is in the same position that it would be in during active employment. This may be done by the use of unpolished reflecting and transmitting color-areas, graded in size by previous experiment upon normal visual organs, so that they shall all be of one saturation of tint or shade. For this purpose, properly chosen colored lamps, flags, etc., can be used; but the best and most scientific method is the selection of loose and interchangeable reflected and transmitted color-areas of definite grades and intensities placed at as great a distance as will be compatible with safety when the eye is at work during its usual employment, and to have the testing done under the same circumstances that the visual apparatus is accustomed to during ordinary routine duty.

For railway service, as has been suggested by the author, five pure test-colors can be made into definitely sized color-areas of sufficient size to be properly recognized by the normal visual apparatus at the distance, say, of five hundred or a thousand feet. These areas can be arranged in the five faces of a revolving box placed several feet above a boxed series of twenty-three related pure and confusion tints of definitely graded sizes, situated along a horizontal beam about twenty feet above the ground. Each match-area is to be known to the surgeon by the initials of its contained color or colors. The colors can be placed in any order desired at the time, and this order marked upon a suitable blank. The candidate is then to stand at the specified distance from the testing apparatus, and, after an assistant has rotated one of the upper test-areas into position, the examiner is to request the examinee to register upon a blank, provided for the purpose, the nearest match upon the lower beam expressed in the number of its order at the time, to the exposed upper test-color. This is to be repeated with each test-color. If proper care be taken to guard against intercommunication, this can be done with a dozen or more candidates at a time. Experiments both by day and by night, during various kinds of weather, and under varying circumstances, can be made, thus placing the candidate in exactly the position and circumstances in which he is expected to serve.

For merchant and marine service, army signalling, etc., suitable modifications can be readily adopted.

In those rare cases of hemianopia in which it is desired to determine whether the failure of vision is due to an intra-cranial lesion situated in front of or behind the corpora quadrigemina, valuable aid is possessed in the movements of the iris to light-stimulus thrown upon the portions of the retinae from from which it is impossible to obtain any visual fields. As previously seen, the arc of light-stimulus follows the second nerves inwardly to loop with the outgoing strands of the portions of the third nerve controlling the sphincter pupillae. If the lesion be back of the loop—that is, if it be in the fibres from the second nerve back of the corpora, or in the occipital cortex—there will necessarily be no interference with the reflex act. Should the lesion, however, be situated anywhere in the path of the second nerve anterior to this situation and posterior to that portion of the optic-nerve prolongation which is anterior to the chiasm (that is, in the chiasm and optic tract), there will be

a failure of iris-response when the light is made to fall upon the retinae of the broken arcs. This may be termed *hemianopic pupillary inaction*.¹

To employ the method satisfactorily is most difficult, especially where there are disturbing collateral symptoms.

The method employed by the author is to place the patient—who has had one eye carefully excluded from all light-stimulus by a few turns of an ordinary roller bandage—in front of a light so arranged that the rays will fall over his head upon a small sheet of plain looking-glass, either held in the observer's hand, or better, fixed upon a stand. The mirror is to be so tilted that the reflection will fall directly upon the patient's eyes, causing a faint illumination of their exteriors of sufficient amount to render visible any movement of the irides. An ordinary concave-mirror ophthalmoscope is now to be held at or near its focal distance in front of the eye, thus producing a narrow beam of strong light-stimulus: this stimulus being the one intended to make evident the want of reaction. Should the case, for instance, be one of left lateral hemianopia, the beam of light is to be started from the extreme left, and gradually moved across the blind area of the left field until the central line is almost reached. If the iris remains immobile, and the pupil continues intact in size, there has been no pupillary response during the play of light upon the retina of the blind portion of the eye, showing distinctly that the lesion has encroached upon the second nerve somewhere within the sensory-motor arc, and hence, that the portion of the second nerve going to that side is involved at a point between the corpora quadrigemina and the beginning of the portion of the nerve anterior to the chiasma. Continuing the lateral movement of the light inward, we shall find that a moment or two before the central line is reached, the sphincter will act and the pupil will contract; this will continue as long as the stimulus is kept in the retinal field area. Reversing the bandage, and pursuing the same plan with the right eye—except that here it is best to begin to move the light outward from the nasal side, in order that the light-rays may fall upon the retina of the broken arc—no movement of the iris will be found until the light has reached the area of light-projection: thus showing that the right arc is involved also. Associating these two results, and remembering the anatomical division of the optic-nerve fibres (see colored diagram facing page 80), the student can readily see that the lesion must be situated in the right tractus between the optic chiasm and the right quadrigeminal body.

If the case be one of right lateral hemianopia, the play of light should commence from the extreme outer periphery of the right side of the patient. Should bi-nasal hemianopia be found, the play of light should commence from the nasal side of each eye, whereas, if there be bi-temporal hemianopia, it should commence from the temporal side of each eye. It should be remembered that the nerve-impulse soon tires in these cases, and that the response will soon cease to be either prompt or active.

In some cases of chorioidal inflammation, especially of the dissemi-

¹ Wernicke designates this as "hemipic pupillary reaction sign," but, as the word "hemipia" has been abandoned in ophthalmic nomenclature, the opposite condition of hemianopia, with its want of reaction, has been thought by the author to supply the better term.

nated variety, where the region of the macula is more or less involved, it may be at least of clinical interest to study the apparent distortion of objects caused by the bending and twisting of the perceptive elements of the retina.

The student will frequently find during the course of some ocular disease, such as a low grade of plastic iritis, and even irido-cyclitis, macular chorioiditis of low type, etc., where there is but little interfering exudate—conditions in which the optical constants are frequently modified—that valuable aid can be obtained from careful and repeated re-examination of refraction during the course of the disease. He will find that quite a number of cases may require, as they improve, weaker and weaker concave sphericals and cylinders, until at last, through the turnstile of mixed astigmatism, their ordinary compound hypermetropic astigmatism refraction is reached. Berry speaks of the plan, whilst Green, Mittendorf, and the author have called attention to these facts in cases of iritis, causing much argument to be raised as to the cause. Be this as it may, the facts are as stated, and, if properly used during ocular examination, may prove of great value in the study and treatment of disease.

In all the examinations, the student should avoid the use of mydriatics. He should confine their employment as much as possible to therapy. He should learn to depend upon his own skill as much as he can, and the time will soon come when he will find mydriatics unnecessary, except in rare cases. Should, however, instances present themselves in which it is necessary to examine the lens posterior to the ordinary position of the iris, or should a more detailed account of the vitreous chamber and fundus be required, he can resort to either homatropine or cocaine. The former is probably the better, as it acts more quickly and more powerfully, and hence is much more advantageous for study; the few additional hours of partial mydriasis and the slight increased loss of ciliary power from its action, not being of any practical importance.

Although simulated blindness is not so common here, it occurs sufficiently often to render necessary an explanation of a few of the more valuable methods for its detection. Before attempting any special plan, it will be advisable to write out a succinct account of the pretender's family and personal history without any reference to the eye symptoms. A concise statement of the time of the onset of the eye trouble, the manner of its appearance, and the progress of the affection is next to be obtained. Both distant and near vision for each eye separately, no matter of how little value the sight may seem to be, are to be noted, correcting them, if possible, as far as can be done without the use of a mydriatic. The pin-hole test, spoken of in the chapter on the Determination of Errors of Refraction and Accommodation, should be made use of. The action of the extra-ocular muscles is to be tested in order to ascertain whether there is binocular fixation or not. The action of the irides, both separately and conjoined, is to be observed, to learn whether the pupils contract to light-stimulus or when the patient is looking at near objects. If possible, the extent of the remaining fields, even though it be asserted that vision is limited to

mere light-perception, is to be obtained. The surgeon should see that there is proper relationship in their extent and size in various situations. Nothing should be taken for granted. The surgeon should proceed quietly, and obtain accurate records of all the necessary objective symptoms, with as careful an account as possible of all those subjective conditions that the malingerer may voluntarily or unintentionally furnish. Lastly, a critical ophthalmoscopic examination of each eye should be made, taking care to note any manifest error of refraction. Continuing unconcernedly, the surgeon is to pursue the investigation just as though the malingerer were unsuspected. He should tell the patient, if there be complaint of but one eye being defective, that the efforts will in the main be limited to the estimation of the power of the good eye. By now making use of one or several of the following plans, the actual possession of binocular vision, so as to be readily realized by competent witnesses, can often be conclusively shown.

First: *By the aid of prismatic glasses which are so placed as artificially to produce double and erroneous projections of natural objects.* Chief among these is the method of Von Gräfe. As this test is conducted before the good eye alone, it is one of the best, especially where one eye is declared to be absolutely blind. The surgeon, first seeing that both eyes are kept open, places a ten-degree prism, with its base held upward or downward, in front of the sound eye. Directing the patient to look either at a candle-flame held several meters away and on a level with the eyes, or at a dot on a piece of paper held at thirty or forty centimeters' distance, and taking care that he has not seen either of the test-objects before the prism was put on, the surgeon is to ask him, casually, whether the glass improves sight or not. If the patient says that he sees two candles or that there are two dots, he is necessarily using both eyes,¹ and has thus betrayed himself. The author prefers to make the paper holding the dot much larger in area than the combined visual fields, or, better, to employ the candle-test in the dark, because in both instances there is nothing else to be seen for comparison; for should the malingerer see the doubling of other objects that he knows to be single, he would undoubtedly declare that the test-object was single, even though it should appear double to him.


It is a good plan to drop a red glass in front of the prism for confirmation, and the prism may be rotated, to ascertain whether the false image rotates in a corresponding manner. The surgeon should never, if possible, use any of these tests on the affected eye, because if this be done, the malingerer's suspicions will be aroused, causing him to contradict himself in the most confusing manner, in his attempts to avoid the trap that he supposes to be set before him. By placing the prism before his good eye, his suspicions are disarmed, and the surgeon thus has him at an advantage.

If these methods do not succeed, it will then be advisable to try the stereoscope. Laurence says that "the test is certain if care is taken not to let the patient see the slide before putting it into the


¹ In a few rare cases of monocular diplopia this may not be so, but even here the fraud will be made manifest, on account of a tripling of objects.

stereoscope," and advises that the instrument "should be enclosed on all sides with ground glass." This advice is very good, provided the hood covering the face of the stereoscope be taken away, so that the surgeon may be positive that the patient is using both eyes simultaneously; for if the malingerer be allowed to open and close his eyes alternately, he will soon learn the correct and the falsified appearances of the test-objects, which knowledge will of necessity destroy the value of the experiment.

The pictures recommended in one of the most recently devised contrivances are many and varied, and are so arranged that their combinations give rise to entirely new and confusing results. If the examination be conducted properly, the malingerer will see before him a single picture which is the representation of three possibilities. This can be explained by the following example. Suppose a card of the ordinary size used for a stereoscope, to be arranged like the following, the field



for the right eye containing the letter F, and the field for the left having the letter L in a similar position in its area. Assume that the patient is pretending blindness in his left eye. Without allowing the card to be seen, adjust it correctly in the instrument. If the patient says that he sees a letter E, it is positive that he is using both eyes,



because such an impression must have been received binocularly, as this letter represents the combination of the two letters L and F; and as a consequence the cheat is discovered.

If he should assert that there is an L, the falsity of statement is manifest. If the letter F is the one stated to be seen, the patient has not allowed his deceit to be divulged, and his claims must be still further met with the more difficult and less comprehensive tests of the same series.

The great trouble with all stereoscopic tests, however, is that generally a moment or two elapse before fusion of the two pictures is made, during which time the malingerer becomes aware that there are two series of objects being fused into one.

Lippincott's plan, which is dependent upon the apparent elongation of objects produced by convex cylinder lenses, may also be mentioned. Possibly the easiest and most practical method for its ordinary employment in these cases is to hold a convex cylinder of two diopters with its axis at ninety degrees, and to have the subject gaze with both eyes open at a square card, about one-third of a meter in size, held at the ordinary distance used for near-work. Upon now asking him, without having allowed him to see the card before the cylinder has been placed before the good eye, to tell which vertical edge of the figure is the longer, he will, if he possesses vision in the fellow-eye, say that the side toward the eye before which the cylinder is placed is the longer. In that case the deceit is at once manifest, because the cylinder lens, having apparently increased the vertical length of the square which is visible through it, is unwittingly compared by the patient with the actual vertical length of the side of the square which is seen by the avowed blind eye. To verify this, the card may be removed from sight for a moment, and the cylinder-axis placed horizontally, and the experiment tried with the upper and the lower border of the square.

From what has just been said, it can be easily seen that the rod test, as explained on page 170, may also be taken advantage of in the detection of the simulation.

Should the case still not be clear, it will be advisable to change the mode of examination to the next plan.

Second: *Either by the aid of lenses or mydriatics, which so alter the focussing power of the two eyes as to render binocular fixation impossible, or by the employment of other contrivances by which the avowed good eye is secretly excluded from action.* This is one of the oldest methods, and embraces some of the most interesting and valuable experiments for the detection of the deceit. Foremost among these is a method made use of by Harlan. After first mentally eliminating the apparent amount of refractive error obtained by the use of the ophthalmoscope, and seemingly agreeing that nothing can be done for the bad eye, the patient is to be told that it is desired to see if any improvement can be made in the sight of the fellow-eye. Whilst both eyes are open, a strong convex spherical lens is to be placed in front of the good eye, of sufficient power to render proper distant vision with that eye impossible. The patient is now to be asked to state what he sees. If vision be found improved, it is certain that it has been accomplished by the aid of the defective eye.

A strong concave lens, or the instillation of several drops of a powerful mydriatic, may in the same way, and under the same plan, be tried instead. Rapidly repeated trials with various weak concave and convex lenses or similarly colored translucent and transparent glasses before each eye, may elicit an unintentional admission of visual improvement in the affected eye.

Recourse may be had to Javal's method, of first having the patient read some type with the good eye, whilst the eye which is said to be blind is covered by some opaque object, such as an ordinary ruler. During the reading, the position of the ruler is to be carefully shifted so as to exclude a portion of the context of the type from the good eye.

If the person continues to read properly, he is using the pretended defective eye.

A modification of Snellen's plan of having the letters of the word FRIEND painted alternately green and red on a white background, is very useful, when we are able to quickly place and substitute the same strength of red and green transparent plain glasses before the good eye; the word properly changing to FIN when the red glass is placed before the sound eye, but continuing as FRIEND if the supposed blind eye be acting; so with the green glass before the same eye, the word RED will alone be seen if there is no deceit, whilst the entire word FRIEND will be seen and so called, if the avowed non-seeing eye be acting.

If high myopia, or an exaggerated form of any variety of ametropia, be complained of, the study of the fundus-reflex test may prove of great service.

If the person has used a powerful mydriatic, the pupil is generally larger than that which is usually found in an ordinary case of nerve-disease, and the iris is totally insensible to stimulus directed toward it or the opposite organ. In such cases, where it is possible, the suspect should be kept under surveillance until the local effect of the drug is lost, making sure that he has no more secreted for continued use. If absolutely necessary, a portion of the aqueous humor may be withdrawn from the anterior chamber and instilled into the conjunctival cul-de-sac of another eye, to see whether any dilatation of the pupil will be thus produced. It must not be forgotten, however, that Fontana speaks of the possibility of the malingerer having the voluntary use of the iris-muscle, by which he may produce physiological mydriasis.

Artificial general anæsthesia, as proposed and successfully tried by Hutchinson in a case of feigned disease, may be of use. After the patient is anæsthetized, the sound eye is to be covered, so as to prevent any vision with it. Just as he is recovering from the effects of the anæsthetic, and before he has any command of his intellect, so as to allow him to resume his deception, the sight of the supposed blind eye is to be tested by the simplest measures, such as silently offering him various objects, or placing him apparently alone in seeming positions of immediate danger, etc. Keeping the good eye covered, whilst every action of the patient is constantly watched, often makes the imposture evident.

When binocular effect is feigned, the problem is somewhat difficult. Here, beyond a possibility of misstatements obtained, in cases where quantitative vision is affected, by rapidly placing various lenses before the eyes, no subjective ocular tests can be usefully applied. To an educated malingerer, the problem is much easier. He has simply to act like a blind man, or behave in a manner similar to one with indifferent sight. To the unintelligent or the uninformed malingerer, the deception is very difficult. As a rule, he fails to play the part properly: not groping, as in recent cases, with wide-open unconverged eyes and semi-dilated pupils, but quickly closing the eyes when sudden movements are made toward them, expressing great dread of light, and purposely gazing in opposite directions when asked to look at his own outstretched hands. He in some instances soon reveals his deceit.

In order to cope successfully with such a case, the patient must be quietly and persistently watched. Sudden feints of striking should be made, and notice taken if there is any resultant lid- or iris-reflex; the anæsthetic tests should have several trials; the patient should be placed in an embarrassing position, where good eyesight seems necessary for safety. No loop-hole should be overlooked, and sooner or later the reward will come in some unexpected discovery of deception.

Throughout the examination, the examiner must guard against asking unnecessary or self-answering questions, or exposing to the view of the patient any of the materials used for detection. He should not be misled by real, though slight, ailments. He should always have a series of proper working-instruments ready for action, and practise their use sufficiently often to be thoroughly acquainted with their manipulation whilst employed in a case. He should draw the conclusions not only from the faulty answers given to the confusion-tests, but also from the consistency of the patient's assertions and actions. He should note everything in writing, and keep the records in a safe place, so that all the data may be in readiness for future examination or testimony, because it is just this class of subjects that give the most trouble and annoyance to the busy practitioner, by taking him unawares, and misleading him by means of knowledge gained in the interval.

If the case be truly one of self-deception, as in some instances of hysteria, the psychic effect of a positive assurance that all is right, after a careful examination in which the patient is practically shown that he can see, or Harlan's plan of the application of a wooden imitation of a magnet, may be tried to advantage.

In all ocular examinations, no matter what the type of the case be, the student must remember that much of his success depends upon the care he gives to the study of the existent condition, and that more than half the battle is gained the moment he has fully determined what is the matter.

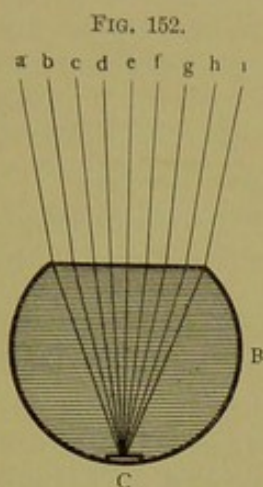
CHAPTER VII.

OPHTHALMOSCOPY.

It has been well observed that the art of using the ophthalmoscope to advantage is much more difficult to acquire than that of using any other instrument of precision which the beginner may have put in his possession. Many students imagine that their success is complete the moment that they have gained access to the interior of an eye. How vague and valueless such a belief! How much remains to be accomplished! Suppose, for a moment, that they had been placed before a small covered window situated in such a position as to overlook the Grand Bazaar at Constantinople, and that by a series of ingenious devices the curtain had been withdrawn so that many of the wonders of the world had been revealed to their gaze. What would this beautiful massing be but a heap of incongruity? Although cognizant of the general character of each article, they would yet be unable to designate the true value and significance of anything seen. So it is with the eye. The beginner in ophthalmoscopy has acquired, probably at the cost of no little practice and trouble, a fair knowledge of a few of the changes in the details of nerve, vessel, and tissue; yet variations are so perpetually found, slight but significant changes are so multitudinous, the normality of one eye is so closely allied in appearance to the gross pathological condition of another, and unrecognized obstacles and fresh pictures are so numerous, that even after many years of constant practice with this wonderful mirror, the conscientious observer still feels at a loss to understand the significance of the many new and ever-changing mysteries which present themselves to his view.

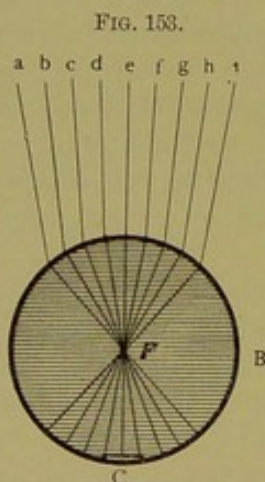
First, as to the instrument itself and the theory of its construction. We may recall the experiment of Mery, who, in 1704, converted the anterior curved area of a cat's refractive media into a plane, by immersing the animal beneath the still surface of clear water, this procedure allowing the experimenter to gaze into the interior of the animal's eye and see the fundus details just as he might have seen the peculiarities of structure of the bottom of a bowl filled with water; further, remembering the ease with which the myriad changes of marine growth are made visible by converting small areas of the irregular surface of the sea into perfectly smooth planes by means of the ingenious glass-bottomed boat used by scientific dredgers—we see that there is something necessary to be dislodged before the details of the living fundus oculi can be made apparent to the observing human eye. A moment's reflection will make it evident that there is some peculiarity in the surface of the anterior face of the organ that so persistently hides the interior of the eye from our view. On referring to the section upon Anatomy, we find that the front surface of the transparent portion of the eye, through which light penetrates and escapes, is convex upon its outer surface.

Let us for a moment study the course taken by light-rays that enter such an optical apparatus, and consider the changes that such rays undergo during their exit through this area from the organ. Were the cornea a plane flat surface, the entering rays of light, as can be readily imagined, would occupy a large area, and the return rays by which the bottom of the eye would be made visible would occupy an equally large area, thus allowing a view of some portion of the fundus of the eye from many extraneous points, just as in the case of the immersed eye of the cat, and in that of the bottom of the sea seen through the flat-bottomed boat. A glance at Fig. 152, will explain this.

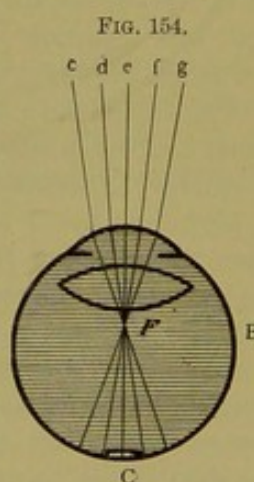


Area of visibility of coin in bottom of flat-topped medium of increased density.

Here the coin, c, in the bowl, B, will be visible to an eye situated at any one of the points a, b, c, d, e, f, g, h, and i, simply because the observing eye at any one of these points is in the direct line of the return ray which renders the coin visible; there being nothing to materially interfere with the passage into the eye of the rays which give rise to the reflected ray, or ray of vision. Were the impinged surface convex, as in Fig. 153, the same incoming rays would be brought to an earlier focus, F, within the bowl, B, and but few rays would reach the coin, c. Just as



Lessened area of visibility of coin in bottom of curved topped medium of increased density.



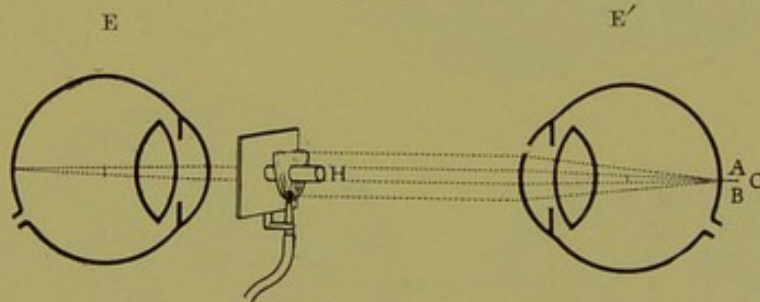
Greatly lessened area of visibility of coin in bottom of a more greatly curved topped medium of increased density—practically an eye.

before, the observing eye must place itself in the path of the return or reflected ray from the coin, to see the coin, c, and now, instead of the coin being visible at all the extraneous points, it can be seen only at the points d, e, and f. Again, if the area through which the light enters the bowl or globe be decreased, the convexity of the impinged surface increased, and an additional converging power placed in the interior of the globe, as in Fig. 154, which now represents the eye, the entering rays of light will be limited to still fewer central ones, in

which position it will be necessary for the observing eye to place itself before it can see the coin, *c*, in the fundus of the organ. Unfortunately, the beam of entering rays is so narrow that the observer's head casts such a shadow in front of the eye that it is ordinarily impossible for the eye in which the coin, *c*, is attempted to be seen, to receive any extraneous light into its interior; and consequently the fundus of the eye is in darkness, and fails to emit any ray of vision.

Given a hollow sphere filled with a material of strongly convergent power, a sphere with but a single opening covered by a curved surface, which thus necessarily can accurately receive but a few central rays—in other words, the human eye—the problem resolves itself into the question, How can an observing eye be placed in the line of the emitted ray without interfering with the impinging ray? If, as is known to be the case, the head of the observer interferes with the passage of light into the eye, the first thing that suggests itself is to place the source of light between the observed eye and the observing eye. Unfortunately, however, the light itself—as, for instance, a candle-flame or a gas-jet—is opaque, and the observing eye cannot see through it. The thought then comes: pierce a small hole through the flame or jet large enough to allow the observing eye

FIG. 155.

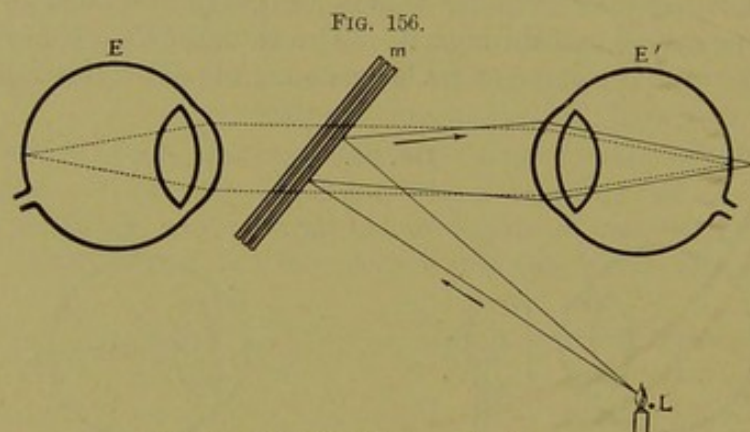


Visibility of fundus of eye through a tube piercing a gas-flame. (Modified from LORING.)

to have an area through the beam of concentrated light into the observed eye by which some return rays may enter it from the bottom of the illuminated eye, thus giving a retinal image of this intra-ocular point, and at the same time made sufficiently small to allow a ring of light from the candle to enter the observed eye for the purpose of illumination of its interior. This can be easily done by pushing a metallic tube (fastened to a screen to keep off glare and all extraneous rays) through the flame, as shown in Fig. 155. Here a small area, *A B*, of the observed eye, *E'*, may be rendered plainly visible to the observing eye, *E*, by the return rays which pass through the hole *H*, in the gas-jet. By substituting a reflector with a central hole in it for the gas-flame, tube, and screen, and placing the source of illumination in such a position as to allow the rays of light to fall upon its polished surface and to be reflected into the observing eye, we obtain all the essentials of an eye speculum or an ophthalmoscope.

It is interesting to study the mechanical evolution of the instrument. First, it is curious to reflect that even in spite of Mery's accidental discovery—studied in 1709 by La Hire, who showed that the inability to

see the cat's eye-ground under the ordinary condition of nature was due to refractive changes, which were neutralized by the overlying water—the scientific world should have been compelled to wait more than a century before Kussmaul, in 1845, by dissection of a sheep's eye, scientifically showed the correctness of La Hire's belief, by proving it to be dependent upon the presence of the cornea, the lens, and the vitreous humor. Second, come the experiments of Prevost, of Geneva, in 1810, who showed that the mirror-like reflections which were at times seen issuing from various animals' eyes were produced by light falling upon certain portions of the eye-ground (the tapetum lucidum to the temporal side of the optic nerve) and being reflected back into the eye of the observer (an observation which Rudolphi justly observed could be obtained only when the eyes were placed in certain positions). Third, Behr's experiment, in 1839, in which he saw a reddish-yellow reflex issuing from the aniridic eyes of a little girl; assisted by Cummings, in 1846, who disapproved of the strange and false hypothesis



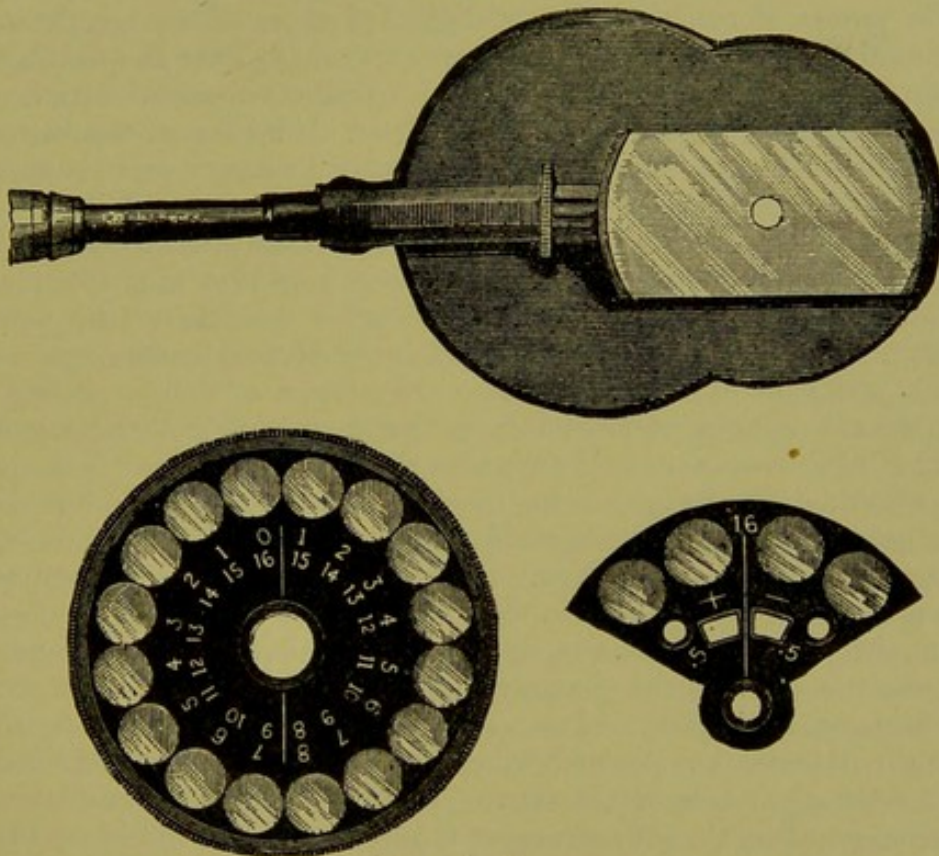
Theory of Helmholtz's ophthalmoscope.

which had gained general belief, that it was impossible to see into the interior of the human eye on account of the absorption of all the entering rays of light by the so-called chorioidal pigment; forestalled, though practically lost, by the imperfect deductions of an English ophthalmic surgeon from the study of an instrument made by Babbage in 1848, when he obtained a compound reflecting and refracting medium by scraping a small central clear space in a surface of silvered glass. And, fourth, thus assisted, disturbed, and even anticipated by experimental research, it remained for the genius of a Von Helmholtz, in 1851, aided by further evolvment in mechanical construction of the rudimentary instrument by others, to make the ophthalmoscope one of the most important pieces of instrumental precision ever given to the ophthalmic surgeon and general practitioner—a mastery of science which the then Professor at Königsberg gained not only by study of physiology in the laboratory, but also by careful analysis of both physics and mathematics; a result that has given us means to gain access to, to follow, and to see through those evanescent yet ever definite threads of light which pass through the narrow window of an eye and illuminate an area, access to which, by careful clinical research and post-mortem analysis, has enabled us not only to solve the true significance of local disease, but also to make

clearer the many mysteries of both general nerve and vascular disturbance.

Commencing in the hands of the practical physicist as three plates of unsilvered glass so arranged, as can be seen in Fig. 156, that there should be a thin stratum of air between the inner surfaces, a contrivance which possessed both refracting and reflecting powers, and which to-day has no superior in its powers when weak illumination is desirable, as in contracted pupils, or when study of the faintest opacities in the media, or of the slightest change in the tint of the optic-nerve head and the blood-columns of the retina is desired, the present form of perfected

FIG. 157.



Loring's ophthalmoscope.

machinery has passed through all manner of devices: mirrors, convex, plane, and concave, even combined in construction; varying sizes, shapes, and positions of sight-holes; clips, disks, slides, and even endless chains containing correcting lenses of all characters and combinations; prisms for reflecting light into the eye-ground; short handles, long ones, stands, head-bands, and attachments of all sorts; binocular instruments to observe with both eyes at once; and even auto-ophthalmoscopes for gazing into one's own visual organs: these mechanical changes which have brought the instrument to its present state of perfection, have all occupied the minds and called forth the powers of constructive ingenuity of a host of scientific and practical observers.

The best instrument is one, naturally, which combines the giving of the greatest amount of results with the simplest form of mechanism.

This may be obtained more or less in a number of instruments, but most prominent among these is the improved refraction ophthalmoscope of Loring. Although he has contrived special forms of the instrument, it will be merely necessary here to speak of the one that contains most, if not all, of the necessary requirements. The one most in use in the United States, and in fact the one generally preferred here, is that shown in Fig. 157.¹

Here it will be noticed that there is a perforated mirror attached by a joint or hinge to a post or screen upon which there is a disk containing a series of lenses so arranged as to afford a large number of lenticular strengths to be revolved before a sight-hole. First, and most important, is the mirror itself. Concave in variety upon account of its greater power of concentration of light,² of about fifteen centimeters' focus as the best strength for ordinary work, it is of the shape of a parallelogram, thirty-three millimeters high by nineteen millimeters broad, instead of being of the ordinary circular form. It is swung upon two pins which are attached to the screen, thus allowing a tilting motion of twenty degrees to the right or left to be given to the reflecting surface, and yet keeping the sight-hole quite near to the hole in the screen. The object of this last device is to allow any correcting lens that might be placed behind the sight-hole to act as a right-angled medium to the axis of vision, thus avoiding the production of artificial astigmatism with consequent distortion of the ophthalmoscopic picture, as well as getting rid of the loss of light by reflection from the surface of a correcting lens should it have been placed at any other than a right angle. The sight-hole, which is circular, is, as the result of experiment, made but three and a half to four millimeters in diameter, this giving the best field for the return or vision ray from the illuminated eye-ground. Practically there is no depth to the hole. This is done so as to avoid loss or distortion of light-rays. It is accomplished by bevelling the metal and the mirror at this point to the greatest degree of thinness that is compatible with firmness and safety. Revolving in a disk so placed as to wheel any desired lenticular power behind a screen with an aperture placed opposite the sight-hole of the mirror, there are fifteen lenses so minute in size and so thin that the strongest is less than half a millimeter thick. Seven of these lenses are convex spherical, and the remaining eight are concave spherical. Each successive lens in the two series is of one diopter difference in strength from its predecessor. The special strength of each contained lens is designated by an equivalent number—the number of the convex lens being painted white, and the number of the concave lens made red. A remaining aperture in the disk contains no lens. For the purpose of increasing the combination of these lens-strengths, there is a quadrant with four lenses—two minus and two plus; one of each

¹ It has been thought wise, in a text-book of this description, to avoid making any comparison between the several excellent patterns of working machinery now in use, reserving this for treatises and special books upon the subject. The present description is given not only because the author thinks that the above form is justly a representative instrument which combines all the essentials necessary for a comprehensive explanation of any good working model, but also because in his hands it has been productive of the best results even under the most difficult circumstances—a mere personal preference, however, which it is hoped will in no way bias the mind of anyone who desires such an instrument.

² Where weak illumination is desired, a plane mirror may be employed.

variety equalling a half-diopter strength, so as to give half-diopter difference between 0 and 7.50 plus diopters and 0 and 8.50 minus diopters,¹ and the other of each variety equalling sixteen diopters. The high plus lens serves to augment the plus series from eight diopters to twenty-three diopters by differences of one diopter, and the equivalent minus lens serves to increase the minus series by the same differences from nine diopters to twenty-four diopters. All the exposed parts of the instrument which come opposite the eyes and the light, with the exception of the reflecting and refracting portions, are made markedly absorbent of light-rays by being coated with dead-black pigment. The handle, which is light and long, is so constructed as to be easily held, and at the same time to give excellent balance to the entire mechanism when it is supported in an upright position.

Possessed of such an instrument—so light, so perfect in its construction, and so easily managed; so comprehensive in its workings as to admit of securing the best results from both the direct and the indirect methods of examination; that sets aside so many optical hindrances, and disregards so much of the ever-conflicting refraction changes; that not only acts as an ophthalmoscope, but also serves as one of the most useful ophthalmometers—it is no wonder that we exclaim, in the words of its lamented inventor, “In the whole history of medicine there is no more beautiful episode than the invention of the ophthalmoscope.”

Among the faults in teaching the art of ophthalmoscopy, the greatest is the one of omission—*i. e.*, where the student is never taught to obtain a normal basis upon which to place the pathological pictures that he will constantly meet with in his future practice. No healthy eye-grounds have been shown him, and hence nothing for comparison is ever associated with his ideas by which he can have a notion of the degree of disturbance of the tissues he may have spread before his uneducated eye. Do we ever hear of anyone attempting to study the pathology of a microscopical specimen before he has become fully acquainted with its normal histological appearance? How erroneous the decision of such an observer would be! In fact, here, just as elsewhere, it is the recognition of slight departures from health that renders the ophthalmoscopist the most successful; it is the minute and ordinarily unrecognized peculiarities in the incipient stages of disease that give the examination its greatest value.

Every beginner should commence the study of ophthalmoscopy by endeavoring to examine every normal eye-ground that may be thrown in his way. For this purpose the author has many times taken the advantage of selecting healthy children (these especially upon account of the largeness of the pupil and the clearness of the media) and adults who have presented themselves for some minor trouble not connected with the eye itself. He has thus been enabled to obtain a better idea of the tint of healthy nerve-substance, and to secure a more adequate notion of the character of normal vascularity, these serving as excellent foundations upon which to place for contrast the ever-varying changes

¹ Another half-diopter difference can be obtained by superposition of S. 16. D., making — S. 9. D.

of color, size, and condition presented by these materials when suffering from the effects of grave constitutional disturbance or local disease.

It must be remembered that age, condition, complexion, etc., play important parts in the objective appearance of the so-called eye-ground. A healthy child at six years of age has an optic-nerve ending which is totally different from that which the same subject will present after thirty years of wear and tear, even though he should remain perfectly strong and hearty to all appearances, and be practically free from any organic disease. Time will produce certain changes and will make such inroads upon the entire system, that here, where a nerve and a bloodvessel are laid bare to the unobstructed gaze, the retrograde metamorphosis will be strikingly visible.

The general pigmentation of the patient also causes remarkable peculiarities in the appearance of the healthy nerve and blood material. This can be exemplified in no better way than by contrasting the wonderful dissimilarity between the healthy eye-ground of a negro and that of a European albino—a dissimilarity so great that, were the body covered from view and our knowledge gained by observation of the fundus alone, we should find great difficulty in determining whether either eye was in an absolutely normal state or not.

Coming to the practical aspect of the question, there are many minute obstacles to be overcome, which give rise to incalculable trouble and often defeat the beginner in his attempts. To these, attention will now be directed.

We have seen that the instrument has been so contrived as to illuminate the interior of a windowed chamber—an eye—by a beam of reflected light, and that the observer has his organ of vision so stationed behind a screen as to allow him to gaze into this chamber through the interior of this beam of illumination. His first lesson, then, is to learn how to keep this beam of light directed into the window.

The room having been darkened, and having obtained a single source of steady illumination, which preferably should be an argand burner or a student lamp without a shade,¹ placed upon a table, or, better, fastened by a bracket to the wall, so as to allow free motion in every direction, the patient is to be seated on a straight-backed chair which will well support his back and head, and arranged so as to bring his eye upon a level with the light, about half a meter or one meter (eighteen or thirty-six inches) in front, and about one-third of a meter or one-half of a meter (about thirteen to eighteen inches) to the side of it, thus placing the light sufficiently far back to prevent any direct rays from falling upon the patient's cornea, and laterally at a sufficient distance to avoid any discomfort from heat. He should be told to keep both eyes open, and should be asked to fix the unused eye upon some distant object or some point upon the dark wall of the opposite side of the room. If the left

¹ If desired, a blue-tinted chimney, which can be made translucent in its upper two-thirds, so as to hide the movable tips of the flame, may be employed, so as to more closely simulate daylight. If ordinary daylight illumination is desired or is rendered necessary, it may be readily secured by allowing the entrance of a narrow diffuse beam into a darkened room, either by cutting a hole in a window-shutter or curtain, or by moving the edge of a window-shade slightly to one side. The employment of electric light for illuminating purposes has been frequently suggested. Usually, this source of illumination has been either a small incandescent loop attached to the ophthalmoscope, or one of the larger kind substituted for the lamp or gas-burner.

eye is to be examined, the patient is to be placed on the right side of the light. If the right eye is to be studied, the patient is to be seated to the left of the light. The student should then place himself in front of the patient, on the same side as the eye he wishes to examine, in such a position as to make an angle of about fifteen to thirty degrees opening between the patient's pupil, his own pupil, and the light.

This will cause him to use his right eye in examining the patient's right eye, and to employ his left eye in looking at the patient's left eye.

He should first try to get the level of the observed eye and the light a few centimeters below his own eye, which can be done by the use of an ordinary music-stool. When it is necessary to examine the fundus of a patient who is in a recumbent position, the best plan is to have him brought as near as possible to the side of the bed, and to have the light held in the same relative position as it would be were he erect. Often where the patient has been too ill to be moved from his position in a broad, double bed, the author has succeeded in examining the eyes with his opposite eye, either by leaning over a low head-board and having the light held in its proper place, thus studying the fundus upside down, as it were, or by kneeling on the bed alongside of the patient, and examining the eye-grounds in the usual way. If the patient is lying on one side of the bed, these latter procedures are necessary with only one eye.

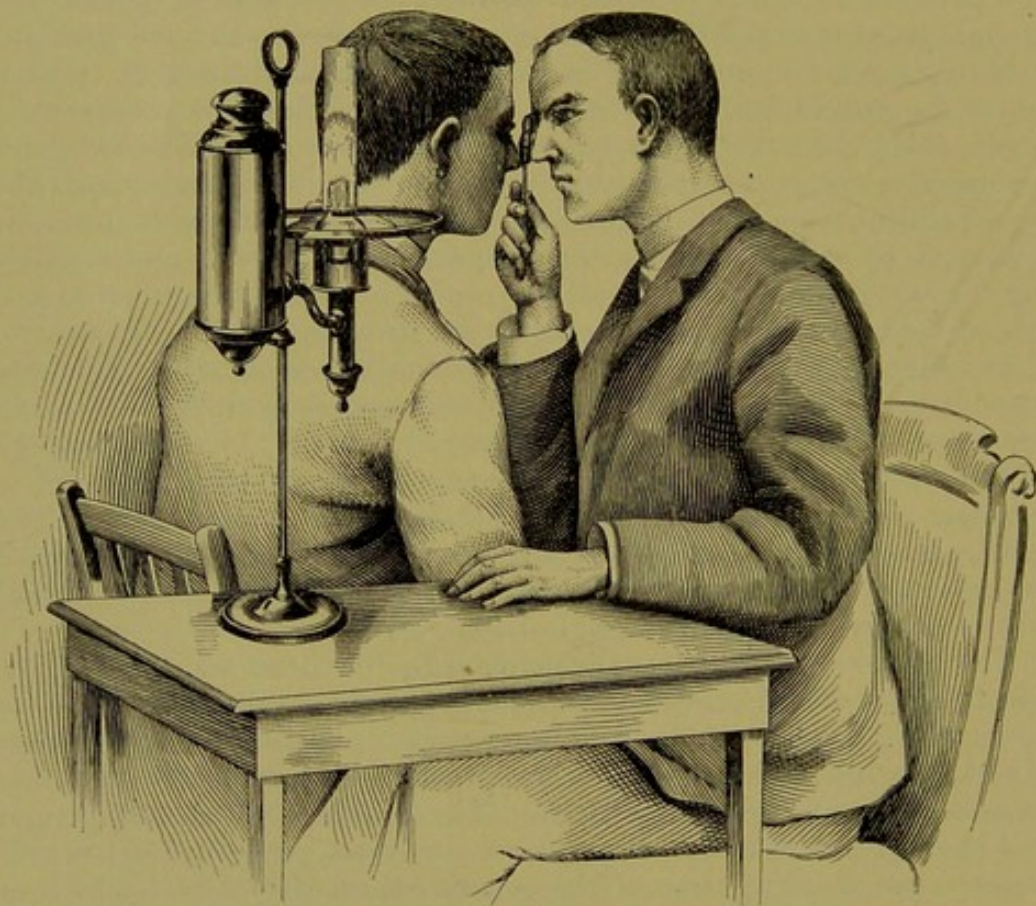In order to avoid leaning over the patient's person, the ophthalmoscope is to be held in the hand which corresponds with the eye to be examined. The instrument is to be grasped between the thumb and the middle, ring, and little fingers, the forefinger being left free in order to rotate any desired lens in the ophthalmoscope into position. The instrument is then to be held upright, with the mirror turned toward the patient's eye and the light, in such a way that the observer's pupil will come directly behind the sight-hole.

There are two methods usually employed—the *direct* and the *indirect*. The first is so named because the fundus of the observed eye is studied by direct rays proceeding from it. The second is so called because the rays of light are received indirectly from the observed eye and directly from an aerial image situated in front of it. The direct method of examination will be described first, not only because it is most generally used in this country, but also by reason of the general superiority of its results over those of the other. Here the difficulty of being compelled to determine in a measure any existent error of refraction, before accuracy of detail can be given, is more than compensated for by the additional precision through the increased magnifying power in obtaining knowledge of existent defects, and the great gain it gives us in the diagnosis and estimation of ametropia. Placing the patient in the position just described and holding the instrument as directed, bring it up to the eye to be examined, say from twenty to thirty millimeters (about three-fourths of an inch to an inch and a half) away, as in Fig. 158.

Do not gradually approach the patient's eye from a long distance after having got the centre of the beam into the pupil, as is ordinarily taught, but at once place the instrument as near as possible. The series of ocular gymnastics requisite to keep the reflecting beam of light from the ophthalmoscope steadily balanced and preserved in the pupillary area, whilst

the observer is approaching the organ, will thus be avoided. Keep both eyes open, so that the impulse for active accommodation with the observing eye may be lessened. Let the little circular shadow that is cast upon the patient's lids or eye, caused by the hole in the mirror not reflecting any light, fall directly into the patient's pupillary space, as it is through this area that the interior of the observed eye is seen. Moreover, the most useful portion of the illuminating surface of the mirror is that which immediately surrounds this area, and, in fact, constitutes the small ring of reflected light which gives the direct illumination of the eye-ground, the rest of the mirror-reflection being received upon the

FIG. 158.



Relative position of student and patient whilst employing the direct method.

iris and surrounding anterior surfaces. The student should now wheel a strong convex lens, preferably about S. 16. D. to S. 12. D., back of the sight-hole, and place his eye directly behind the instrument, so that he may look directly through the lens and sight-hole. If successful, he will obtain a reddish glare from the pupil of the observed organ. If this area of glare be uniform, presenting no hardness, blackis dots, spots, or striæ, and if the periphery be free from irregularity, he may feel assured that the portions of the cornea, aqueous humor, and lens thus illuminated are devoid of any marked disturbance. By rotating weaker and weaker spherical lenses into position, thus gradually lengthening the focus of the examining apparatus, the posterior portions of the lens and the increasingly deeper levels of the vitreous can be searched for variously

tinted¹ opacities and products of inflammatory change,² until at last the plane of the fundus is reached. When this has been found, search should be immediately made for the optic-nerve ending. This is the objective point on the fundus to be sought. To find it, the student should first see that the patient's eye is so directed as to place the disk in front of the mirror. To effect this, he should be made to look directly ahead, and then to turn his head slightly inward without changing the direction of his gaze. This manœuvre will bring his optic-nerve ending on a line projected directly back from the sight-hole of the instrument. Or, if desired, the patient may be told to direct his eye slightly to the nasal side without moving his head, which will bring the optic disk in a direct line with the ophthalmoscope. Here the surgeon, whilst looking through the mirror, has the macula of his eye fixed upon the optic-nerve entrance of the patient's right eye. If the pupil be very small, a slight enlargement of its area can be frequently obtained by either lowering the light to a single candle power or changing the mirror to a plane one, thus reducing the direct stimulus to pupillary contraction. It may also be accomplished by having the patient direct his eye far to the temporal side or even straight ahead, which partially removes any reflex stimulation by the third pair. Should the patient be a child, its attention may be attracted to some bright object or a gaudily colored ribbon or card held a few feet away, and kept in such position that the child's axis of vision will be directed to any desired point. Infants can frequently be made quiet by recourse to the gum nipple of a feeding-bottle, while being so held by an attendant that the head rests against the assistant's shoulder and arm of the same side as the eye to be examined. If the nerve cannot be found, search should be made for a vessel, and this followed down until the disk is reached.

As a rule, the disk appears as an irregularly bordered round or oval area of lighter or more grayish tint than the rest of the eye-ground, from which may be traced the passage of the retinal arteries into the retina, and into which may be seen entering the corresponding veins. Its size, shape and long axis, tint, and apparent condition should all be noted. To do this best, a certain routine, as it were, should always be followed. Remembering that its absolute anatomical size is about one and six-tenths millimeters, and that during the ophthalmoscopic examination it is placed at the bottom of a cup containing a transparent mass of magnifying material, we can thus readily see that we can determine the amount of the magnification by comparing the apparent ophthalmic size of the disk with its real size; the amount being expressed in diameters. Thus, should the disk appear to be about eleven millimeters in its horizontal diameter, and about thirteen millimeters in its vertical diameter, we would have a disk whose size would be roughly expressed by the words "disk 7×8 diameters in size." Should the nerve head appear about thirteen millimeters in every meridian, the noting would

¹ Black, reddish, golden-hued, and even whitish.

² The student can also readily, though roughly, determine the existence and position of changes in the vitreous, by merely withdrawing the ophthalmoscope to about twenty-five to thirty-five centimeters' distance from the eye, and tilting the mirror in various lateral and vertical directions. Advantage may also be taken of the various movements of the patient's eyes in such studies.

be, "disk eight diameters in size." If it be oval, its long axis should be written; thus, should it be at eighty degrees, the noting would read, "disk 7×8 , long axis at 80° ." Care should be taken to note whether there is any irregularity in contour and surface. This should be followed by a description of its tint and apparent condition, as well as the scleral ring, conuses, pigment splotchings, cuppings, and bordering haze. Study should be made of the comparative size and calibre of the retinal vessels (using the apparent size of the disk-area as a guide) their tortuosity, their reflexes, and the color of their contained currents. Every disturbance of nerve, retina, and chorioid (designated as at so many disk-diameters from the edge of the disk) that may be seen, is to be recorded.

Care, however, should be taken in every instance, never to prolong an examination where there may be either an active or a subacute inflammatory condition of the organ. The refraction at various points, such as the disk-edges and the region of the macula lutea, should be estimated. To realize more thoroughly the amount of lens-power necessary to be placed in the ophthalmoscope in order to give the exact focus of the apparent position of any intra-ocular point, the following table, taken in part from Loring, which shows approximately the differences of level of the fundus expressed in millimeters, as seen through various lens-strengths, may be used:

TABLE I., SHOWING THE EQUIVALENT OF SHORTENING IN HYPERMETROPIA.

+ 0.25 D.	=	0.70 mm.
+ 0.50 D.	=	0.14 "
+ 1. D.	=	0.29 "
+ 2. D.	=	0.56 "
+ 3. D.	=	0.83 "
+ 4. D.	=	1.09 "
+ 5. D.	=	1.33 "
+ 6. D.	=	1.57 "
+ 7. D.	=	1.80 "
+ 8. D.	=	2.03 "
+ 9 D.	=	2.24 "
+ 10. D.	=	2.45 "
+ 12. D.	=	2.84 "
+ 15. D.	=	3.38 "

TABLE II., SHOWING THE EQUIVALENT OF INCREASE IN MYOPIA.

- 0.25 D.	=	0.07 mm.
- 0.20 D.	=	0.15 "
- 1. D.	=	0.30 "
- 2. D.	=	0.61 "
- 3. D.	=	0.94 "
- 4. D.	=	1.28 "
- 5. D.	=	1.63 "
- 6. D.	=	2.00 "
- 7. D.	=	2.38 "
- 8. D.	=	2.80 "
- 9. D.	=	3.22 "
- 10. D.	=	3.67 "
- 12. D.	=	4.64 "
- 15. D.	=	6.27 "

By either employing it as a ready reference or memorizing it, the relation between the lenses that must be used, and the absolute anatomical position of the object to the retinal level at the point studied, can be known in an instant, thus giving valuable information as to the real lengthening and shortening of the globe, the elevation and depression of intra-ocular growths, detachments, and excavations, the comparative positions of vitreous opacities, etc. For example: a disk is found to be choked and so swollen that its extreme anterior part is seen with a convex lens which is five diopters stronger than that required for the apparently normal portion of the fundus, showing, by reference to the table, that the disk-head is pushed 1.33 millimeters forward into the vitreous; or the fibres of the head of the nerve may be so pushed backward against themselves in a case of glaucoma, by increased intra-ocular pressure, that a minus three-diopter lens may be required to see the head of the nerve in this position, showing that there has been a pathological cup formed which is 0.94 millimeter in depth.

A rough estimate may also be quickly obtained, especially in nerve-cupplings, or irregularities of level in the eye-ground, by study of the parallax displacement produced by quick successive movements of the convex lens during the employment of the indirect method. If, for instance, the bottom of a pathological excavation be focussed for, the edge of the nerve will move as a dim ring across the cupped area at a greater speed than the cup itself. So, too, with localized swellings; the summit of the mass, being nearer to the observer than the bottom, has a less excursion to perform, and, in consequence, moves the more quickly.

Rough sketches of the general appearance, not only for future use but also for present study, should be frequently made. Haab's sheets of plain eye-grounds, composed of uniform surfaces of cinnabar-red laid over a ground-color of yellow, are extremely valuable for such work. More accurate, even when roughly marked and scraped, than mere pencil-sketches; quicker as a means of obtaining the desired result than the ordinarily more difficult pen-drawings; easier to understand than the most extended explanatory detail, and less troublesome than the usual water-color drawings, by reason of a ready-prepared triple background or "wash," which partly represents the dominating colors of the retina, chorioid, and sclerotic in their anatomical order, it will be readily seen how such sheets, so easily prepared, can be made to become most excellent graphic data, either for hurriedly-made sketches for future reference, or for slowly-prepared drawings for permanent accurate representation. By this means, the appearances of the most minute changes, which in time will serve as valuable objective data upon which to formulate diagnostic and prognostic opinions, will soon be recognized. In order to appreciate thoroughly the peculiarities of coloration which constitute so essential a factor in the proper estimation of these sketches, they should be studied under the same conditions as those under which they were originally made: in other words, they should always be examined and criticised during exposure to the same character of illumination as was used when the eye-ground was looked at. Tiffany's plan of projecting and sketching the fundus-details upon a gauged sheet which is situated at a definite distance behind and to one side of the patient so as to be seen by the surgeon's fellow-eye, just as we do in sketching with the microscope, is very useful, provided that the observer is not presbyopic and is ambidexterous.

Thus far, photographic reproduction of the fundus oculi is so devoid of detail, the apparatus is so complicated and cumbersome in its mechanism, and the necessary manipulation is so difficult, that little advance has been made in the method. It is probable, however, considering the daily increasing facilities in the art of photography, and the likelihood of early success in obtaining color differentiation by this means, that the plan will, in the future, be successfully employed.

Remember that one hour spent in sketching a single eye-ground, no matter of how little apparent value the sketch may be, in association with an extended verbal description, is of infinitely greater value than would be a dozen hours occupied with "peculiar and interesting backgrounds," hastily and carelessly looked over. The author cannot

refrain from giving to every young reader of these lines a few words of advice: In your student days, learn to sketch, no matter how crude the picture may be.

Although not so frequently needed in this method as in the indirect, on account of the nearness of the observer's eye to the pupil of the patient, the use of mydriatics should be avoided as much as possible. The interior of the eye should be sought through Nature's ordinary window, and the frequent early disappointments will be amply repaid, later on, by the exceptional facility that will have been acquired through not being dependent upon artificial means, even in the most difficult of cases. Where it is absolutely necessary, as in the study of minute changes in the macular region (this region, upon account of its great sensitiveness to light, causing prompt pupillary contraction, thus lessening the aperture which is always occupied by the series of corneal reflections which surround the point of the visual axis), or in the peripheral portions of the eye-ground and lens, or in cases of myosis or central opacities in the media, the most evanescent of the mydriatics, such as cocaine or homatropine, should be used, so that the patient will not suffer many of the inconveniences from the after-effects of the drug. If homatropine be employed, the hydrochloride, on account of the large proportion of the alkaloid it contains, its extreme solubility, and its greater freedom from deliquescence, is much the best form of salt. The solution should be made in small quantities, and should be frequently changed. In every case, it is best to state plainly to the patient what is being done, and to describe the physiological effect of the material, so that there shall exist no chance for medico-legal action based upon the supposition that a failure of eyesight, which was previously present, has dated from the time of instillation, and in fact, has been caused by its use. A note should be added to the description that the drug has been used, and the amount stated, so that there may be distinct record of its employment in the case. Except under advice, where it may be important to have a critical examination of the eye-ground, do not use a mydriatic in old subjects with increased intra-ocular tension. If it becomes necessary to use it, employ one of the weaker forms, and be sure to instil sufficient eserine in frequently repeated and small amounts, until all danger of a glaucomatous outbreak has passed away.

At first, no endeavor should be made to see the eye-ground with the lens that is supposed to be the one that corrects the refractive error. Let the eye, as it were, act passively. Observe quietly, and imagine that the fundus is at a distance, just as though a landscape were being viewed through an open window. The fundus is to be obtained with any lens possible, and the observer will soon find that as the details of the picture become easier to see, the conscious effort to see lessens, and the mental desire to focus for an object which he knows is in reality very near, decreases, enabling him to approximate nearer and nearer to the refraction, until at last the difference between his ophthalmoscopic estimation and the true error will often be but trifling. A good plan to relieve oneself of undue accommodative effort in such work, is to take a rather strong convex spherical lens, say S. 5. D. ($+\frac{1}{2}$ sph.), or more, and endeavor to read fine type placed at its focal distance.

The observer must not expect, however, that he will be able to relinquish entire hold upon his accommodation. The finest work and most delicate approximation of one day will often be far outweighed by the great discrepancy of the next. To hope to estimate the refractive change of an eye with equal facility every day would be about as absurd as to expect to put the same number of steps into any definite distance repeatedly walked. Again, he must remember that, as a rule, an untaught and untaught patient is brought into a new field, and hence very frequently uses his accommodation, especially if the room be not very dark, and if he be enabled to fix upon some near object. Of course, this is greatly lessened when a well-trained patient is examined, so that possibly it would be well in some instances to exercise with this class of patients before an examination is attempted with the more difficult subjects. If the student possesses no clinical facilities for examining large numbers of patients, one of the many artificial eyes, such as Perrin's, may be employed to advantage. Here, by modifying the width of the pupillary aperture, and changing the refractive power of the contrivance, the different eye-grounds painted on the adjustable shells can be studied under a variety of conditions.

To obtain a view of the macula lutea when the pupil is undilated, the ophthalmoscope should be carefully moved slightly upward and inward toward the bridge of the patient's nose, so that the point of the line of the observer's vision upon the patient's eye-ground shall move about two to two and a half disk-diameters outward and somewhat downward from the temporal border of the disk itself. Where the pupil is dilated, or even in many instances, especially in the young, where it is not, a good view may be obtained of the same region by having the patient gaze directly into the sight-hole of the ophthalmoscopic mirror. The unused eye should always be kept open, so as to have full view of surrounding objects and to avoid any associated "nipping together" of the lids of the used eye. The observer will soon learn to disregard the images formed in the unused organ, just as he does in using the microscope.

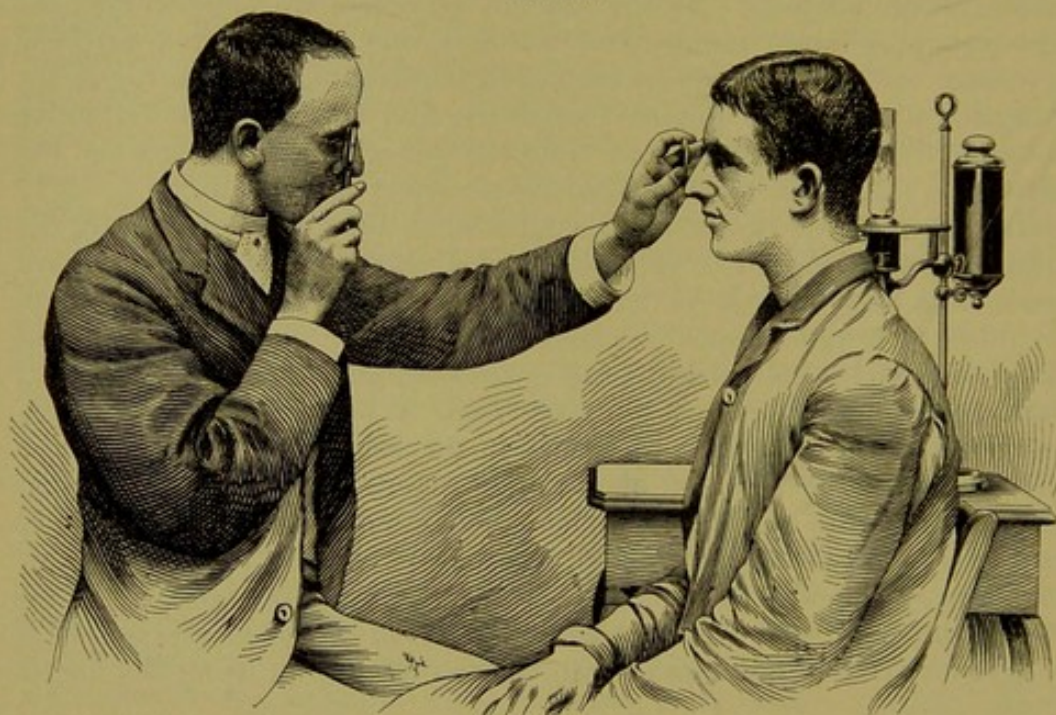If the observer has any optical error, it must be corrected by proper lenses, either worn at the time or placed in the sight-hole of the ophthalmoscope by some mechanical attachment. If he desires, he can resort to the more difficult plan of taking his own refractive error into account in every estimation of refraction that he may make—a method that becomes comparatively easy when the dioptric system of measurement is used. By this plan, he renders his eye emmetropic, which, when he has learned to disregard his accommodation, will permit him not only to estimate the patient's ametropia, but also to make absolute determination of measurements of heights of swellings, as in intra-ocular tumors and choked disk, amounts and degrees of neuro-retinitis, situations and extents of retinal detachment, depths of glaucomatous and atrophic excavations, etc.

The indirect method is of so much value in certain cases, as in high myopia, and gives so much larger field of vision in which coarse changes can be very quickly and conveniently located, that a detailed account of the procedure is necessary.

The same plan of examination is pursued as with the direct method, except that here the observer should sit about half a meter (about eighteen inches) in front of the patient. (Fig. 159.)

The ophthalmoscope is to be held with the hand corresponding to the eye to be examined, in the manner previously directed. If this be done correctly—which, if not very expert, the observer can readily determine by closing the unused eye for a moment—a reddish glare will be obtained from the pupillary area of the patient. After having secured this glare, a plain—or if preferred, a blue-tinted—convex lens of about eighteen diopeters ($\frac{1}{2}$ sph. focus) is to be held lightly between the thumb and forefinger of the unused hand. As this method of examination is infrequent in this country, the blue-tinted lens—which by its color filters


FIG. 159.



Relative position of student and patient whilst using the indirect method.

out, as it were, the irritating yellow rays of the artificial light and places the most sensitive eye in an area of illumination which can be better borne, at the same time so lessening the light-stimulus as to produce a larger pupillary area to work in—is but little used. By now placing the middle, third, and little fingers upon the outer part of the supra-orbital ridge of the patient's eye, the observer will be able to keep the focus of the converging lens wherever he desires, without disturbing the patient by placing his hand and arm across the patient's face. This plan has the additional advantage of allowing the surgeon to change readily to the direct method with the greatest rapidity, and permits the tip of the third finger to be of service in elevating the upper lid for better view, or in making pressure upon the globe to provoke venous or arterial pulsation. Endeavor should be made to keep the red glare from the pupil constantly in view, whilst the ophthalmoscope and object-lens should be inclined in various directions, and changes made in their distances from

each other, from the light, and from the patient's eyes. After having succeeded in this, the patient should turn his head and eyes slightly inward, which will not only bring the region of the disk into view, but will also allow a more ready relaxation of accommodation. If the instrument, the lens, and the eyes be in proper relative positions, the disk will be seen. Should this appear dim and badly defined, the lens and ophthalmoscope should be carefully moved backward and forward until there is a sharp and clear image. The observer must remember that this image is aerial, and is situated at or near the focal distance of the lens between the lens and the ophthalmoscopic mirror. It is to this point that he must direct his gaze. Moreover, he should understand that this image must be both reversed and inverted, thus explaining why everything seen in the fundus moves in an opposite direction to the motion given to the lens. To better understand this, the following arrangement of figures will show the relative positions of objects in the eye-ground in the two methods:



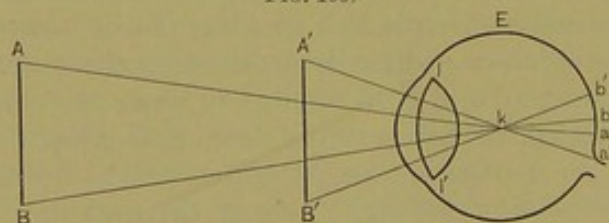
Care should be taken not to mistake any confusing corneal and lenticular reflexes for an imperfect picture of the eye-ground. A slight movement of the patient's eye, or the least tilt of the mirror or lens, will readily disclose their nature. By the employment of a convex lens weaker than twenty diopeters' focus, a much-increased size of the details of the fundus, though situated in a smaller or more faintly illuminated area, may be obtained. It is a good plan to make use of both a strong and a weak lens, employing the former for general study, and the weaker for accuracy of detail. Loring recommends a twenty-four-diopter ($1\frac{1}{4}$ sph.) lens in some instances where an area of highly condensed light is desired. Except for the purpose of re-magnifying the aerial image, which may be done either by a compound object lens situated between the aerial image and the mirror, or by a convex spherical lens of about four or five diopeters' focus behind the mirror, no correcting lenses need ordinarily be used by the observer. If, however, he be presbyopic, and is compelled to move the instrument so far from the aerial image in front of the lens that proper illumination of the interior of the patient's eye is impossible, a suitable convex lens must be wheeled back of the sight-hole of the mirror. This is done in order to permit a much nearer approach to the image, and to allow a stronger illumination. Should the observer be hypermetropic, especially if he be highly so, a convex lens is often just as necessary. If he should be laboring under a myopia greater (or even somewhat less) than the distance between the object-lens and the aerial image, a correcting concave lens becomes of service. If the myopia be less than this, he may be able to place his eye sufficiently far in front of the aerial image to see it properly without a correcting lens. The state of the patient's

refraction and power of accommodation also plays an important part in the technique, giving to each ocular condition a peculiarity of picture that distinguishes it from all others. After having obtained a good view of the disk, trial should be made to study the surrounding portions of the fundus; this can be easily done by counter-movements of both the object lens and the ophthalmoscope away from the side desired to be seen. If it be desired to examine the portion of the eye-ground which is anterior to the equator of the eyeball, or even that portion which is anterior to this, the magnifying lens may be ground to a prismatic surface. During use, the apex of the combination lens must be always directed away from the centre of the pupil, which in most instances should be dilated.

The student must not hesitate to make use of this method in every case that he may deem proper, as it may prove of great value both in association with the direct method, or when used alone in cases that may necessitate something more than the ordinary procedure in obtaining adequate answer. He should become thoroughly conversant with its workings, so as to give himself another means of precision; and his success in diagnosis from its employment will often be much greater than if he confined himself to the direct method. Each plan, however, has its capabilities, and hence, in doubtful cases, recourse must be had to both.

As has been shown in the preceding groupings of figures, the magnifying power, as well as the extent of fundus seen at a single glance, is very different in the two methods. In the direct plan, when the surgeon's eye and the observed eye are as near together during the examination as practicable, and when the patient's pupil is about four millimeters in size, the ophthalmoscopic field occupies an area of about two millimeters—an area sufficient to include a little more of the fundus than the width and the height of the optic disk. Of course, it can be readily understood that if the window—the pupil—through which the surgeon looks, be wider open—or dilated, as we ordinarily say—the field of view will be more extensive. Again, the extent of the illumination, the comparative distance between the two eyes, and the interplay of accommodative powers, all enter into the question.

FIG. 160.



Comparative sizes of retinal images.

One of the easiest plans, though not an absolutely accurate one, of estimating the magnifying power of the method as generally used, is first to know the distance at which any object is seen. Suppose, for instance, in Fig. 160, that an object, A B, which is situated eight inches from the nodal or crossing point, K, of the eye, E, produces a retinal image, b a, of a definite size, it will be seen that the same object, A B,

if brought to A' B' at two inches from the same nodal or crossing point, K, will produce an opening angle upon the retina which includes a retinal area, b' a', that will be four times greater than its predecessor, b a. By now using the eight-inch point as the one of "distant visual distance," it can be employed for comparison, provided the optical centres of the lenses in the eye exactly coincide, and that accommodative action be disregarded. Assuming that it is correct, and knowing that the magnifying power of the dioptric apparatus at the retinal plane can be obtained by dividing this assumed distance by the focal length of the combined strength of the lenticular system of the eye, which has been calculated to be equal to $6\frac{7}{10}$ Paris lines, all that is necessary to do is to divide the eight inches by the $6\frac{7}{10}$ lines, thus: $\frac{8''}{6\frac{7}{10}} = \frac{96'''}{6.7'''} = 14\frac{22}{67}$ ($14\frac{1}{3}$), showing that the refractive power of an emmetropic eye, is sufficient to give an apparent enlargement of the fundus-details to fourteen and one-third times their normal magnitude, thus allowing us to obtain at times very close actual measurements of fundus-details during life.

If the observed eye be short in its antero-posterior diameter, or if its refractive power be too weak, thus allowing less lenticular strength, as in hypermetropia or aphakia, for instance, the ophthalmoscopic picture will be smaller than that which is found in the emmetropic eye. On the other hand, if the dioptric systems of the eye be more than ordinarily great, as in myopia or in more marked density of the crystalline lens as seen in many cases of incipient cataract, the increase of refractive power will render the ophthalmoscopic appearance of the fundus much larger than ordinary.

Although these three general observations are in the main true, yet, as before noticed, ordinarily so many anatomical discrepancies may exist and so much is dependent upon the slightest variation of the optical constants assumed during the procedure, that they can be accepted only as general rules from which to formulate our, at times seemingly faulty, deductions. The details of the fundus are normally so variable in size, weakened lenticular power is so often associated with increased antero-posterior lengthening of the ocular globe, the actual position of the examining instrument is so changeable, the pupillary area is so inconstant, and the degree of illumination is so uncertain, that much variation must be expected.

In the indirect method, the visible area of the ophthalmoscopic field is greater, whilst the apparent enlargement of the details is less than in the direct plan of examination. The extent over which the surgeon can see at a single glance is dependent upon the size and strength of the condensing lens used in front of the eye. If the lens be of large size and very strong, the diameter of the area seen will be from five to eight times that of the disk itself. Should the lens be small and comparatively weak, the area will be more limited. So, too, with the magnifying power: the weaker the lens, the larger will the fundus-details appear; the general rule being that when a 13. D. lens is held at about seven and a half millimeters (about three inches) from the eye, there will be an enlargement of about $5\frac{3}{10}$ diameters of the normal size. Of

course, just as in the direct method, and as explained in the chapter on the Determination of Errors of Refraction, variations both as to the size and the extent of the ophthalmoscopic field occur in ametropia. Moreover, apparent discrepancies in answer must at times be expected upon account of peculiarities of structure, constant changeableness of physiological action, and almost unavoidable errors in technique.

Every student should provide himself with one of the simplest forms of the best-made instruments. He should avoid all cumbersome apparatus, as he would any other indifferent or hard-to-manage piece of workmanship. The primary expense will be lost sight of when he finds that he has a good mirror with a smoothly-working disk, a well-balanced handle, and all the requisites of a carefully made mechanism. Such an instrument, if properly cared for, will last a lifetime, and will give the best results.

As to the value of the recently revived and widely quoted experiment of Bellarminoff, in which he examines the eye-ground by pressing a plane glass against a cornea which has been cocainized—an experiment lately modified by Koller, who inserts plano-concave glass shells into the conjunctival sac, so that their flat surface is presented to the observer—very little can be said at present. The plan borrowed from Wharton Jones' studies, where sheets of plane glass were pressed against a cat's eye which had been atropinized, cannot, as now pursued, be of much clinical value except, as Koller states, for determining the position of foreign bodies in the vitreous. This is so, not only on account of the discomfort caused by the pressure of a foreign material against the globe itself, but also because alterations of the powers of the refractive constants of the eye are produced, rendering it more difficult to estimate properly any existent error. Further disturbances of the contained fluid, which may give rise to symptomatic and conflicting phenomena, are apt to be present. The use of a small glass chamber with flat sides, constructed so as to fit the face and keep the eye under water, obtains the same results. Moreover, the picture thus presented, although extremely large in area, is, on account of the great loss of magnifying power, so small that many of the ordinary mirror-details are practically invisible. These necessary faults in technique, and this inadequacy of results, make the method, as now pursued, untrustworthy and comparatively useless in many instances.

Having overcome all technical difficulties, the results and information gained with this instrument as a piece of working machinery, will compensate richly for all past anxiety and trouble. The student must not expect to become any more expert in its use than he would expect to do with any other instrument of precision, unless much more time should be vouchsafed him to give to its daily routine employment than he dares to hope for. He must rest content to use it as he does his stethoscope and his microscope. He should make it an absolute addition to his armamentarium. He should look upon it as another means of study. He should employ it in all cases of supposed organic disease, not in the spirit of affectation, but for the purpose of adding another distinctive series of clinical symptoms to his ordinary grouping of conditions. If he does this, he will often be unexpectedly rewarded by the discovery of

an intra-ocular lesion the knowledge of whose existence may prove of incalculable value in the study of his case. Still further, not only is the gain an individual one, but the knowledge so acquired, be it ever so little, will prove serviceable in special cases where the use of the instrument may become obligatory. If he uses it in this way, conscientiously and carefully, he will soon learn to recognize it as not only a valuable guide in the diagnosis and prognosis of local disease, but also as an indispensable adjuvant in the study of all related systemic lesions.

CHAPTER VIII.

FUNDUS-REFLEX TEST. (RETINAL SHADOW-TEST.)

THIS method of using the ophthalmoscopic mirror in the determination of errors of refraction has been known for some time under various names, prominent among them being keratoscopy, pupilloscopy, retinoscopy, and the shadow-test. The term keratoscopy was one of the first that was given to the test, on account of its being supposed that the different grades and areas of shadow, as well as the positions and intensities of the light-reflexes upon which the method depends, were due to variations in the form of the cornea. The name pupilloscopy, or more properly koroscopy, is hardly applicable, because it gives no idea of the rationale of the method. The incorrect and mongrel expression, retinoscopy, introduced by Parent, which would apply equally well to the employment of any instrument of precision intended to be used for observation of the retina alone, is the one by which the method is best known. Priestley Smith's term, "shadow-test," Hart-ridge's "umbrascopy," Egger's "skiascopy," and Chibret's "*fantoscopie rétinienne*," are all much better. The last term is the best, as it distinctly shows that the results are dependent upon the play of light and shadow through media of different powers, strengths, and curvatures, on the pigment coat of the retina. A better term would probably be "fundus-reflex test."

The earliest accounts of this test have been given by the English and French ophthalmic surgeons, among whom it seems to have taken an important position in daily practice. Bowman, as early as 1859, in speaking of the detection of the slighter degrees of conical cornea, tells us that he found that the play of light from an ordinary concave ophthalmoscopic mirror upon the various portions of the cornea always produced a shadow upon the side opposite to the instrument—an objective appearance, which is probably well known to every experienced ophthalmologist; moreover, what is much more pertinent to the present general bearing and application of the test, he, in the same communication, says: "It is a very useful one in discriminating the cause of slight defects of vision somewhat resembling myopia, and hitherto deemed anomalous." In 1864, Donders writes that his friend Bowman recently informs him "that he has been sometimes led to the discovery of regular astigmatism of the cornea, and the direction of the chief meridians, by using the mirror of the ophthalmoscope much in the same way as for slight degrees of conical cornea. The observation is more easy if the optic disk is in the line of sight and the pupil is large. The mirror is to be held at two feet distance, and its inclination rapidly varied, so as to throw the light on the eye at small angles to the perpendicular, and

from opposite sides in succession, in successive meridians. The area of the pupil then exhibits a somewhat linear shadow in some meridians rather than in others." It remained, however, for Cuignet, as late as 1873, to demonstrate that the direction of movement of the reflex indicated the character of the refraction error, thus giving it a place among the useful working methods to determine ametropia; whilst to Parent, who wrote upon the method seven or eight years later, is due the effort both in France and in England, to increase the value of the test by the employment of correcting lenses which might determine the degree of the refraction-error.

In the hope of bringing the method more prominently into favor, so that its practical bearing as an adjuvant in the diagnosis and correction of ametropia may be made more common, the author has been induced to enter quite fully into its explanation.

The principle of the test is, that when a beam of light is thrown into an eye from an ophthalmoscope held at a distance of little more than a meter, variations of light-reflex and shadow produced by the rotation of the mirror in different directions, serve as indices for the study of the differences in refractive errors, these variations being plainly seen by looking through the central opening of the instrument.

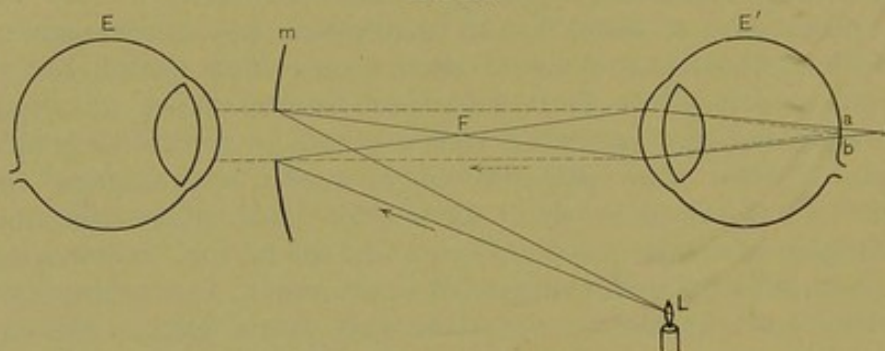
Two plans, each of which has its champions, may be pursued. The one in which a concave mirror of about twenty-five centimeters' focus or more is used, was the first to be described, probably on account of the more general employment of such a mirror in the ordinary ophthalmoscope. By the other plan, the plane mirror is substituted for the concave. That it is an excellent method for the objective detection and determination of ametropia there can be no doubt, but, as it requires as much practice as the direct method of examination, and ordinarily gives no better result, it cannot supersede this latter plan. Although it undoubtedly possesses the few special advantages of ease, certainty, and rapidity where subjective tests are impossible, yet it must be remembered that it merely resolves the ophthalmoscope into an optometer. With it, the fundus-details cannot be studied; the eye-ground is invisible, thus making the method of examination serve as a greatly inferior guide to the determination of the question whether the ametropia be remediable or not. It studies the optical condition of the dioptric apparatus of the eye, without giving any adequate reference to the pathological state of the organ. In the careful examination of the majority of cases of ametropia, it can never occupy any better position than that of an adjuvant—an assistant. It should be employed in every instance. No questionable case should be allowed to remain unexamined by this method. The necessary dexterity in manipulation is soon acquired, and constant repetition renders the results more certain and definite. The procedure takes but a few minutes' time, and the answers always prove of great value. It should never be used for the prescribing of correcting lenses, except where it is impossible otherwise to obtain proper subjective results, as among malingerers, foreigners, young children, the demented, etc. Here, combined with other optometric measures, it becomes almost indispensable. In ordinary use, it is probably best limited to the diagnosis of the error and the

verification of the correction, after carefully selected lenses from the test-set have been subjectively chosen. In these two particulars, especially in the latter, where the resultant vision is below normal, it becomes of value. It strengthens other diagnostic procedures, gives information of differences of so-called meridional refraction in different parts of the pupil, and acts as a check upon the subjective choice of correcting lenses. For these purposes, an endeavor should be made to master it thoroughly, and to make it a part of the working routine.

As already stated, there are two methods, one with the concave mirror, and the other with the plane mirror. Although, as will be shown, it is always preferable to employ the plane mirror, yet the concave-mirror plan is here given first, because, as all our past considerations have been limited to the concave mirror, it has been deemed better not to divert the student's train of thought by an intervening change of the optical conditions. The plane-mirror test, though easier to explain, has, therefore, been postponed for after-consideration.

We will first speak of the emmetropic eye. Should the concave mirror be used, as at *m*, in Fig. 161, the divergent rays from the light,

FIG. 161.



Employment of concave mirror in emmetropia.

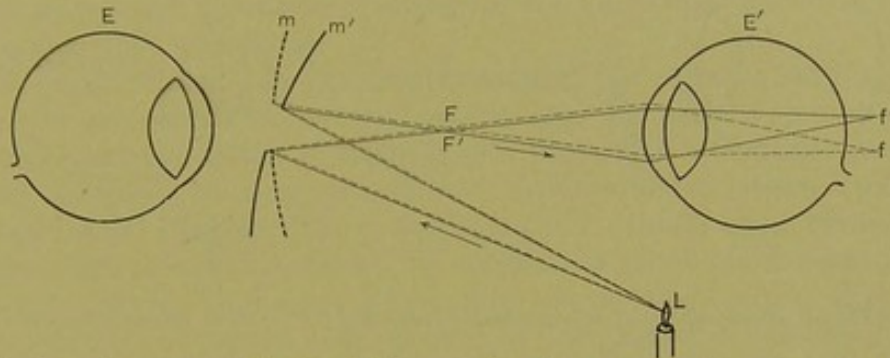
L, will strike the mirror, *m*, situated in front of the observing eye, *E*, and converge to their aerial focus at *F*, thus making an inverted aerial image of the flame, *L*. Here, they will diverge until they meet the anterior plane of the observed eye, *E'*, which brings them to a focus back of its fundus at *f*. Upon the retinal plane of the observed eye, there is a bright upright image, *a b*, of the light, this circular image being situated in the midst of an intense shadow.

If the mirror be rotated in any direction, as shown in Fig. 162, the inverted aerial focus of the flame at *F* will move in a similar manner, as shown at *F'*. The divergent pencil of rays of light from this point strikes the observed eye, *E'*, at a greater angle, and more excentrically than before, and, in consequence, it has a greater degree of refraction. This increase in the bend of rays throws the focus of the aerial image more peripherally upon the observed retina, as shown by the area in front of *f'*. This area or point, as can be seen by reference to the figure, must always move across the observed retinal plane in a direction that is contrary to the motion given to the mirror.

Should the observed eye be too short, as in hypermetropia, the entering rays of light from the aerial point will come less to a focus

than in emmetropia, whilst if the eye be too long, as in myopia, the rays, before meeting the retinal plane, will have crossed sooner than they did in the emmetropic organ. In each instance, as, for example, in Fig. 163, the reflex is larger and dimmer, and, in consequence, the associated shadow becomes more peripheral and crescentic than in the emmetropic eye.

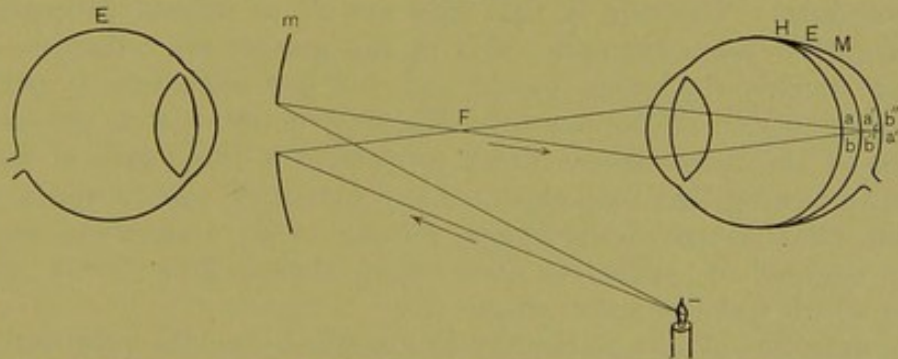
FIG. 162.



Direction of movement of reflex whilst employing the concave mirror in emmetropia.

In Fig. 163, the first retinal plane, H, representing the hypermetropic ground, cuts the incoming rays so as to form the large retinal reflex, $a\ b$. The second retinal plane, E, which represents the emmetropic ground, cuts the incoming rays so as to form the smaller retinal reflex, $a'\ b'$. The third retinal plane, M, is situated so far back that the incoming rays have crossed and produce a reversal of the image at $b''\ a''$. If astigmatism be present, the light-area will be bordered by badly defined outlines, and show the irregular edges of diffusion-circles.

FIG. 163.

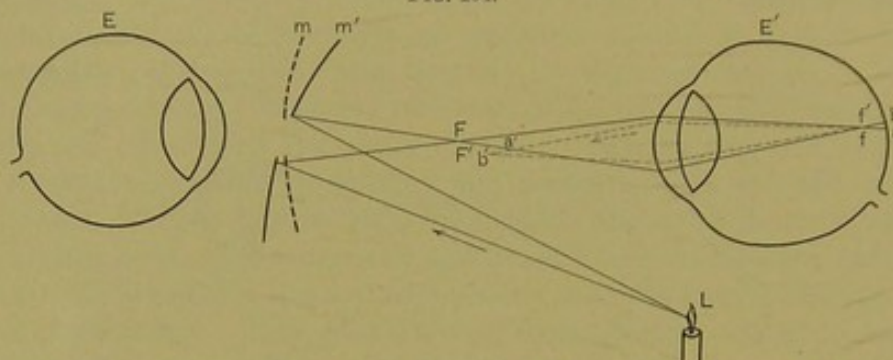


Relative areas and positions of retinal illumination whilst employing the concave mirror.

With the ametropic organ, every movement of the mirror affects the play of the light-rays in the same manner as in the emmetropic eye, except in one instance, namely, with the eye which has more than one diopter of myopia. Here the emergent rays from the observed eye, as explained in the description of the direct and indirect methods of examination, pass outward convergently and form an inverted aerial image. It is this image that we see and study. On referring to Fig. 164, it will be noticed that although the play of light across the patient's retina is in the same direction as in emmetropia and hyper-

metropia, yet the rays from b , after they emerge and form the aërial image-point at b' , are situated on the same side of the aërial image, F , of the candle-flame, L , as that to which the mirror, m , has been tilted. The movement of the aërial image, then, is with that of the mirror.

FIG. 164.



Direction of movement of reflex whilst employing the concave mirror in myopia.

If the myopia be less than one diopter, there is practically no aërial image of the fundus to study. The condition is the same as in hypermetropia and emmetropia. The reason for this is that our own eye occupies a position inside of the far-point or situation of the aërial image of the fundus of the observed eye. Our eye looks directly upon the fundus of the observed eye, just as it did in hypermetropia and emmetropia. To see such an aërial image, we must go beyond the patient's far-point; and this, if done when the concave mirror is used, causes so great a dispersion of light that the eye is too feebly illuminated for practical purposes.

In like manner, the amount and rate of movement of the light-reflex and the intensity of the associated shadows all play important parts in the procedure. The rule is, that they are all in inverse proportion to the amount of the ametropia; that is, the greater the refractive error, the less quickly the reflex moves and the less excursion it performs with every motion of the mirror. Keeping in mind that the size and dimness of the reflex are in direct proportion to the degree of ametropia, and knowing that both slowness and extent of motion are in direct relation with the size of the image, we can easily understand that the higher degrees of refractive error must always give slowly moving images which traverse short areas.

The detection of astigmatism by this method becomes quite easy. In fact, its application here is often invaluable. As the meridians of greatest and least refraction in the regular form are situated at right angles to each other, all that we have to do is to tilt the mirror in the direction of the various meridians until we succeed in finding the most ametropic. After having determined whether this is hypermetropic or myopic, and given our estimate of the amount of error, we should change the motion of the mirror to the meridian at right angles, and then study the new meridian in the same manner. By noting the difference of refraction between the two meridians, we may arrive at a very close estimate of the quality and degree of astigmatism.

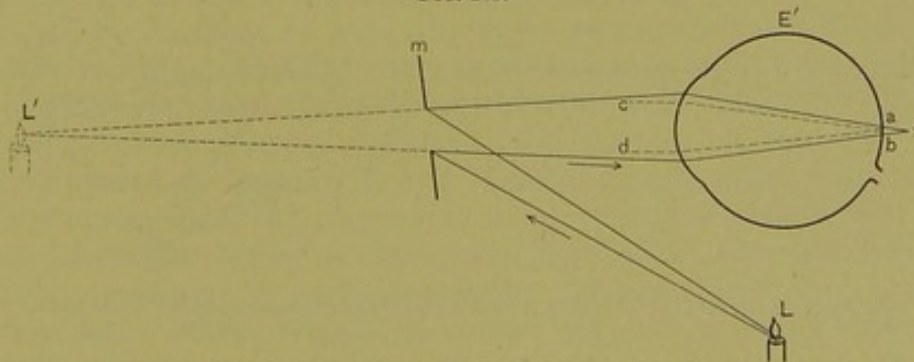
The angle of the principal meridians can be readily determined by

carefully watching whether the angle of apparent movement of the line of reflex corresponds absolutely with the real motion given to the mirror. If the line of reflex moves obliquely with the line of mirror movement, we may be assured that we are not tilting our mirror in one of the principal meridians. By studying the difference between the true and apparent motions, and changing the angles of the mirror's movement until the two motions coincide, we shall have placed our mirror in position to obtain answers for the ametropia which is resident in the principal meridians.

The great objection to the employment of the concave mirror is, that with it we are compelled to approach so near the patient that the power of active accommodation is brought into play, which destroys one of the optical constants of the method, and renders the answers unreliable. To avoid this, Chibret, Story, Jackson, and others, have made use of the plane mirror. This allows the surgeon to move much farther away from the patient, and thus avoid any errors that might arise from accommodative changes. On account of its greater simplicity in practice, and the fewer exceptions to be remembered, it is, indeed, the preferable plan for the diagnosis and estimation of ametropia.

We are now dealing with the upright reflex of the virtual image of the candle-flame, and not with the inverted reflex of the flame itself. This virtual image is situated as far back of the plane mirror as the luminous object is in front. From it the rays proceed in a divergent manner, and fall upon the retina of the observed eye. Thus, in Fig. 165, the divergent rays of light from the candle, *L*, strike the plane mirror, *m*, and are reflected into the eye, *E'*, in a divergent manner, just as though they had proceeded from *L'* (the virtual image of *L*) behind the mirror. After passing into the observed eye, they come to a

FIG. 165.



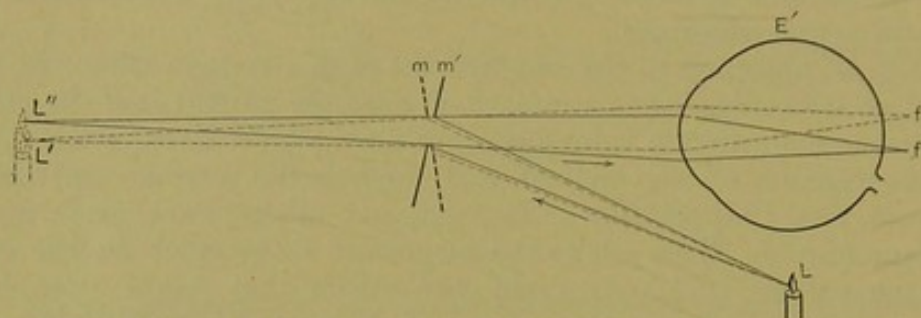
Employment of plane mirror in emmetropia.

focus behind the retinal plane at *f*, making a circle of intra-ocular illumination at *a b*. If the observed eye is emmetropic, the emergent rays, *c d*, pass out through its pupil, as previously explained, in a parallel direction, and fall upon the retina of the observer's eye, situated in its usual position, behind the aperture of the mirror. The farther the mirror is held from the observed eye, the more nearly parallel become the entering rays, and the nearer their focus falls upon the emmetropic plane of the observed eye. When the mirror is placed at about three meters' distance, the entering rays, which have now come

from a point at about six meters' distance in front of the eye, may be assumed to be parallel. Such rays will come to a focus upon the retinal plane, and give rise to a strong, clear, and well-cut reflex.

In both hypermetropia and emmetropia, the apparent movement of the reflex is in the same direction as the real movement of the mirror. This will be understood by reference to Fig. 166.

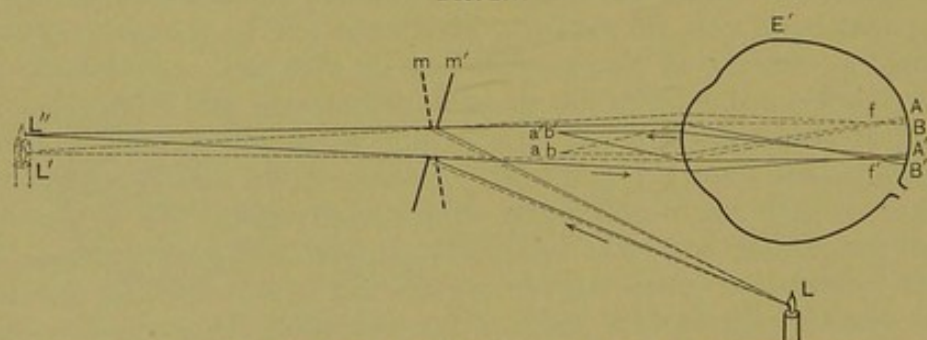
FIG. 166.



Direction of movement of reflex whilst employing the plane mirror in emmetropia.

Here the erect reflex of the virtual image of the candle-flame, L , is shown at f' . The mirror, m , has been tilted downward to m' , causing the virtual image, L' , of the light, L , to be lifted to L'' . The divergent rays proceeding from L'' into the observed eye, E' , now fall at a lower point behind the retinal plane, showing that every downward inclination of the mirror is accompanied by a downward movement of the illuminated retinal area. In other words, the movement of the mirror has caused a similar motion of the retinal image.

FIG. 167.



Direction of movement of reflex whilst employing the plane mirror in myopia.

If the observed eye is myopic, the apparent motion of the reflex is contrary to the movement given to the instrument. In Fig. 167, the mirror has been tilted downward into the position of m' : this, as just shown, causes the virtual image of the light to rise from L' to L'' . As we now know from the last illustration, the intra-ocular focus, f' , of L'' is situated on a lower level than the intra-ocular focus, f , of L' . In this instance, however, we consider the aerial images of these portions of the fundus. The reason for this, as has been several times explained in speaking of myopia, is that the far-point of the observed eye is situated between the patient and the mirror. It is this aerial image, then, that we observe. By following out the projection from the lower

focus area, $A' B'$, we find that its aerial image, $a' b'$, is higher than the aerial image, $a b$, of the original intra-ocular focussing area, $A B$. That is, the inferior portion of the eye-ground naturally gives its aerial image in the superior part of the visual field. Reference to the illustration plainly shows, then, that the aerial image of the reflex is lifted when the mirror is tilted downward, *i. e.*, it moves contrary to the direction of the "axis" of the motion given to the instrument. Fortunately, on account of the use of the plane mirror in this method, we can stand far beyond the far-point of any correctable myopia, and, in consequence, the movement of the reflex of the aerial image is always absolute. This makes the plan entirely trustworthy.

The degree of intensity of light, the movement of reflex, and the area of excursion, as seen in the various forms of ametropia, all play the same rôles as in the concave-mirror method; the only difference between the two plans being in the opposite direction of movement of the reflex. The procedure is quite simple. If we employ the concave mirror, an ordinary Loring ophthalmoscope may be used. If the plane mirror be preferred, it can either be obtained combined with the ophthalmoscope or made as a separate instrument. The best pattern for the plane form is one with a surface of forty millimeters' diameter and a central sight-hole of three or four millimeters.

When the concave mirror is used, we should seat ourselves about one hundred and twenty centimeters (about forty-eight inches) in front of the patient, who should be placed in the ordinary ophthalmoscopic position, except that the source of illumination is better placed above and back of him, at about an angle of 15° to 30° with a line drawn from our eye to his eye, so that the beam of light may shine over his head. The room is to be made quite dark, so that no extraneous and disturbing rays of light may fall into the eye to be examined. For better definition, and to avoid any conflicting rays, it is a good plan, as suggested by Jackson, to have the light surrounded by a black metal chimney in which a small circular opening, about eight or ten millimeters in diameter, has been cut at such a point as to come directly opposite the brightest part of the flame, the position of the hole being directed toward our examining eye. Care should be taken that the hole is not made so small that there will be an insufficient amount of light reflected from the region of the mirror surrounding the sight-hole. If we find it necessary to produce a larger pupillary field, and to avoid accommodative effort, though, of course, this will be at the expense of absolute accuracy, we can direct the patient to look to one side into darkness. With either method, especially with the concave mirror, the better plan is to use a mydriatic, in order to have the patient's macula lutea situated upon a line with our own, as this is the portion of the eye which he constantly employs for vision, and for this reason is the part to be studied. With the plane mirror held at three or four meters' distance there are no such complications, and the patient may be told to look directly at the sight-hole of the mirror.

On account of the diminished liability of the pupil to contraction during the use of the plane mirror, because of the great distance of the observed eye from the instrument and the less intense action of the focus

of illumination, mydriatics are here less frequently necessary than during the employment of the concave mirror. If, however, the pupil is small, so that it gives but little area through which to play the reflex, one of the weaker mydriatics should be used. At times, the employment of one of the more powerful drugs may be necessary in order to obtain the advantage of neutralizing the accommodating power of the patient. In every instance, the increase in the pupillary area has the additional value of permitting the light to be thrown more directly upon the macular region. If possible, the patient is to be directed to look straight ahead, and to endeavor as much as possible to disregard the surgeon's presence in his line of sight. The surgeon gazing through the sight-hole of the mirror, will notice a reflex of light occupying all or part of the patient's pupillary area. Following this by repeatedly tilting the mirror in various meridians in front of our eye, without either relaxing his gaze upon the patient's eye, or allowing any motion of his eye, the play of light and shade previously described will be made manifest.

After having determined the character, the amount, and the angle of error, it only remains, in some instances, to attempt to estimate with greater nicety the degree of the refractive condition. This is done by so changing the apparent play of light in its relative direction of motion, and the rapidity of its movement, that they may both coincide as nearly as possible with what is seen in so-termed emmetropia. To accomplish this, either different strengths of spherical and cylindrical lenses are to be dropped into a test-frame placed before the patient's eye, or an opaque disk containing a series of test-lenses is to be rotated before his eye, so as to bring successively any desired strength before the organ. To know when the lens which represents the refractive fault of the eye has been reached, the light is made to play through each superimposed lens until the proper relation between reflex and emmetropia is supposed to have been established.

For instance, if the case is found to be one of hypermetropia with astigmatism, increasing convex lenses are to be placed before the eye, the other eye being excluded from use by a stop-disk, and the mirror tilted in all meridians after each trial, until it is determined whether there are any angles in which the reflex still persists in moving contrary to the motion given to the mirror. If, after repeated essays, the student finds that there remains but one, a convex cylinder of, say, 0.50 D. is to be placed in the test-frame, in front of the spherical lens last chosen, with its axis set at right angles to the still faulty meridian. If, now, the reflex quickly moves in the same direction, or, better, if the slightest contrary motion remains throughout all the meridians, the total amount of the ametropia has been reached. If not, additions and subtractions of slight differences in spherical lenses and changes in the angles and amounts of cylinders, will soon enable the student to decide when he has reached the best obtainable conditions, at which point he may decide that he has obtained the proper correction. If the reflex is dull and its border moves slowly, no time is to be wasted with insignificant changes of correction, but a strong spherical lens is to be immediately placed in position, and, if it over-corrects, its strength is to be lessened in each meridian until the proper combination has been effected. If the first lens chosen

be insufficient, stronger and stronger ones are to be substituted until the desired result has been obtained. This method should now be repeated with the other eye. If the results of a subsequent examination—which should always be made twenty-four hours later, if possible—are identical, the trials may be stopped, and the accommodative powers and the extra-ocular muscle-balance with both corrections, carefully tried before the correction is ordered. If there be the slightest discrepancy, the work should be repeated sufficiently often to give unquestionable results.

In the other forms of ametropia, the work is to be pursued practically in the same manner, the only difference being, as we have already learned, that in the myopic meridians of the eye, the movements of the reflex are contrary to those that are found in the hypermetropic meridians.

The correction of mixed astigmatism, though subject to variations of answer through the slightest discrepancy, can, in many instances, be accurately effected by careful and repeated examination. Even in some cases of irregular astigmatism, the method may prove useful. Here, most prominent and very easily recognized, are the bright or dim central areas, with surrounding shaded or light circles, each having its individual direction and quickness of motion. In these cases, the same rules, of course modified, hold good, and the same method should be pursued. In all this work with the concave mirror, we must not forget that we have been seated about one hundred and twenty centimeters from the patient's eye, such a distance being nearer than the far-point of a myopia of less than about 0.75 to 1.00 diopter. In consequence of this, as has been explained, a myopia of that amount must give the movement of reflex as both emmetropia and hypermetropia. It becomes necessary, therefore, to take this exception into account. The rule in all such measurements with the concave mirror, is, that the distance between the two eyes must be subtracted from the result. Thus, if +4. D. be the apparent amount obtained, +3.25 D. or +3. D. must be the corrected answer. In myopia, on the other hand, if the patient's eye has not been rendered artificially myopic to 0.75 D. or 1.00 D., this amount must be added to the obtained result: thus, if -4. D. be the amount obtained, the revised reading must be set down as -4.75 D. or -5.00 D. This calculation either can be done mentally in each instance, or can be avoided by placing a + S. 0.75 D. or + S. 1.00 D. permanently in the test-frame or revolving disk behind the correcting lenses.

With the plane mirror, the surgeon is free to choose the distance at which to make his study. In fact, at times, he may, if he choose, be actually situated beyond the far-point of any myopia recognized as worthy of correction. With this form of test, all myopic reflexes move contrary to the motion of the mirror, whilst those of both emmetropia and hypermetropia move with the mirror. The surgeon should be stationed at from one to two meters' distance and make calculation for the distance used and the lens employed. The patient should be placed behind a disk of rotating lenses, which either he can revolve into position before his eye, or the surgeon can move by some mechanical contrivance. Should the surgeon wish to be as nearly theoretically correct

as possible, he can seat himself at three meters' distance. At this point there is nothing to compute, since the results at this somewhat inconvenient distance, give absolute answer as to the amount of any refraction-error that may be necessary for correction.

If he so desire, he may also find the distance between his eye and the patient's eye at which any reversals of movement take place, or he may place a rather strong convex lens before the eye to be examined, and calculate the distances at which the reverse movement of the reflex occurs. In both instances, a fair measure of the refractive error in any meridian desired can be secured.

If the surgeon wishes to check the correction-findings of the concave-mirror plan, or if it be desirable, as it almost always is, to verify the selection of lenses chosen by the patient in the ordinary subjective method, the plane-mirror method at one or two meters' distance is the one that should be pursued in every case, allowing, of course, in all instances, for the difference of strength between the lenses and the distance employed.

After a considerable trial with a number of unselected cases, we shall be better able to differentiate the various forms of refractive error. The border of the reflex is always to be studied. We should see whether it is equally well defined in all the principal meridians. Marked irregularity of the reflex edge is to be associated with astigmatism. Further, the student should make himself thoroughly acquainted with the intensity of the reflex and the density of the bordering shadow. He should remember the important rule, that the more nearly emmetropic the case is, the clearer will be the reflex and the more dense and distinct the surrounding shadow will become. He should also keep in mind that the nearer the case approaches emmetropia, the more quickly the edge of the reflex will move.

He should become thoroughly conversant with all the changes. He should study all cases, without selection, until he is able not only to designate the variety of ametropia, but also to make a fair estimate of the amount and the angle of error. This having been accomplished, the result should be noted with the previous work.

CHAPTER IX.

METHODS OF DETERMINATION OF ERRORS OF REFRACTION AND ACCOMMODATION.

A FAIR notion of the routine use and significance of the various procedures presented in the complete study of ophthalmic cases having been obtained, the student should proceed to the consideration of the special plans for the determination of anomalies connected with the focussing or dioptric system of the eye. The methods for determining these changes we shall now consider in detail.

In most instances, the patient, if an adult, will come complaining of gradual and increasing inability for continuous near-work, especially by artificial light. His eyes "give out," as he terms it, and near objects blur and "run together;" frontal and temporal headache, coming on after prolonged use of the eyes, ensue, whilst lassitude and inclination to discontinue work assert themselves with increasing frequency, until, at last, he is unable to employ his eyes with any degree of comfort for even the shortest length of time. Possibly glasses have been tried, which have acted as a temporary relief, but have soon been laid aside as useless and even disturbing. In this condition he comes as a patient. What has he told? That his eyes "give out" during near-work, and that near objects blur and "run together," these two symptoms being accompanied by headache and inability to use the eyes—a statement that practically says that the focussing apparatus for such work, the ciliary muscle, which, as we know, so regulates the action of the lens as to give the proper focus for any desired near-point—is overtaxed, and at last relinquishes its hold, giving rise to a blurring or fading of the object, and calling for additional and tiresome effort to regain it—a statement that plainly shows that the normal balance of extra-ocular muscles which should be found when the two eyes are brought to a single focus in binocular fixation, is disturbed by weakness of the converging muscles, this weakness expressing itself by repeated momentary losses of proper action, causing objects to appear to run together: the one known as accommodative asthenopia (*insufficiency of accommodation*), and the other as muscular asthenopia (more properly *insufficiency of convergence*). Still more, he has proved the existence of this disturbing muscle-action, by saying that the blur and the want of stability of the object looked at, constantly increase, with steady diminution of ability to use the organ, this often being followed by distressing neuralgias, especially in the frontal and temporal regions.

In other cases, the patient, especially if young, will complain of irritation and even inflammation of the external appendages of the eye. He will state that he is "subject to styes," that "the edges of the lids become red and sore," and that "the eyes feel hot, dry, and uncomfortable." To him, all objects may appear sharp and remain clear. Mus-

cular asthenopia may not be complained of. These statements prove, in measure, that both the intra-ocular muscles and extra-ocular muscles are in normal balance and proper working order, and that the brunt of the disturbance and discomfort has fallen upon the related tissues. These are usually the instances in which low grades of intra-ocular irritation and inflammation, with abnormal degrees of astigmatism at peculiar angles, are prevalent.

Frequently, a weak and overworked child is brought complaining of a progressive inability to see objects upon the black-board at school, associated with the necessity of bringing his books much closer to the eyes than formerly. The mother has, perchance, also noticed that the child nips its lids together in order to attain more distinct vision. Upon inquiry, the surgeon finds that other members of the family wear glasses, or that some blood-relations are said to have been "near-sighted." Here is the usual history of a myope.

Again, a boy or a girl with a history of inflammation of the eyes during infancy or childhood, comes upon account of increasing indistinctness of both far and near vision. Objects appear blurred, and even distorted, no matter at what distance they are situated. The lids and the eyes themselves are more or less uncomfortable, dry, and irritable. Intense cephalalgia, occurring more particularly during attempted near-work, sometimes aggravated by reflex-disorders and even by mental peculiarities, appears. In such a case, the surgeon is probably dealing either with some gross pathological change or with some form of astigmatism, in which all kinds of curious reflex-changes appear in consequence of strain and over-exertion of an abused and imperfect organ.

Each case presents its peculiar grouping of symptoms; each patient gives expression to his difficulty by some peculiar sign. Let attention be directed toward one of these types, and then, by a number of well-directed, leading questions, the surgeon will obtain the desired answer without troubling himself much about a series of long, rambling assertions to which he may occasionally be compelled to listen. Sometimes, especially in low grades of compound hypermetropic astigmatism in children where the astigmatism is marked, many of these conditions may be simulated by an undue and persistent action of the ciliary muscle keeping varying degrees of lens-action more or less constantly at work, associated at times with disturbed extra-muscle balance. This, however, may often be made evident by an examination of the eye-ground with the upright image, and can always be brought to light by the continued employment of a strong mydriatic, such as atropine.

Having obtained the family and personal history, it will be found most convenient, first, to determine the visual acuity for each eye separately, taking care, in so doing, that the lids are kept wide open. The student should proceed in the manner just explained. In this way the visual sense is examined, not only that it may give information as to the power of the sensory material of the visual apparatus, but also that it may afford a clue to the index of refraction. It can be readily understood that an eye may have indistinctness of distant vision—a lowering of visual acuity—through either faulty sensory structures or improper focussing material. It, therefore, becomes necessary to differentiate the

two conditions. If desired, this can be done by directing the patient to look at the distant type through a pin-hole in a black diaphragm placed before the eye. If the letters become clearer, and the patient is enabled to see smaller type, it is probable that the student is dealing merely with refractive error. If there is no change in the acuity of vision, the probability is in favor of other organic disease.

Assuming that the surgeon has thus found the case to be one of refractive error, it becomes necessary for him to understand the full significance of his findings. If the proper line of letters has been read without error at the necessary distance, the absence of any disturbing ametropia can only be fairly asserted. In such an instance, he is compelled to assume that there may be three possible conditions, any one of which can exist without exerting a detrimental influence upon vision: emmetropia, which is very rare and generally appears as an evanescent state between hypermetropia and myopia in a stretching globe; hypermetropia, which has been rendered latent by compensatory action of the accommodative power in supplying a correcting material to the lens; and, lastly, a minor degree of naturally corrected astigmatism, or an amount so slight that the patient is not troubled in readily distinguishing the ordinary test-type at the distance given, without the aid of an artificial correcting lens. If, however, the visual acuity should fall in the least below normal in such a case, there is manifestly some functional or real error of refraction.

The surgeon should next study the range and power of accommodation of each eye (see page 166), thus obtaining additional testimony as to the character of the refraction and further determination whether there is a functional or a real loss of ciliary and lenticular power. Should the patient be young, and have the nearest point of reading removed beyond what is considered to be natural for his age, suspicion should be directed toward a hypermetropia which is using accommodative power for the preservation of distant vision—in other words, a decrease of the region of accommodation through a functional use of accommodative power. Should the far-point of reading be brought nearer than ordinary, the surgeon is to suspect either a true or a functional myopia, which permits the letters to be recognized only at a shorter distance than normal; here, although the power of accommodation is intact, as shown by the proper situation of the near-point, the region or position of action is limited by the disturbing refractive error. Should the type appear indistinct at any point throughout the region of accommodation, it is presumable that there is an inequality of focussing in the different portions of this range—that is to say, there is astigmatism.

As has been explained in another part of this work, regular astigmatism assumes its greatest and its least curvature in two meridians, termed the *principal meridians*, which, as a rule, are at right angles to each other, and which, of course, will give the best and the most defective vision in these two axes. This may be taken advantage of by directing the patient to look at a disk or card which has a series of long, thin, equally black radii printed or engraved upon it. The best for this purpose is either the clock-face card of Green, or the long, narrow lines of Wallace. The test being hung upon the wall at the ordinary test-

type distance, and one eye being tried at a time, the patient is requested to state which is the clearest, the blackest, and the most distinct line. Comparing this with the line at right angles to it, and noting it in the record, the surgeon will often obtain valuable subjective data as to the meridians of greatest and least disturbance. Advantage may also be taken of the mistakes made during the reading of the test-types—the miscalling of letters which, by astigmatism, simulate others, giving quick answer as to the faulty meridians.

Upon account of senile changes, through which the lens becomes denser and less elastic, and the ciliary muscle, like all other muscular tissues, weakens, the conditions vary. As both the myope and the hypermetrope grow old, their near-points become removed; their focusing apparatus becomes weaker. Both region and power of accommodation lessen, whilst the refractive error becomes more and more manifest, until at last there may be absolutely no range of action, and the patient is compelled to read at his far-point alone, which can be done only by the myope. Not only does astigmatism become more apparent through a lessening of ciliary action, but a new astigmatic factor may arise through unequal thickenings and differences of increased density in the various portions of the lenticular apparatus.

The surgeon should next examine the external condition of the organ and the surrounding parts. He should note the shape of the skull and the relative situation of the orbits. He should look for any discrepancy in the level of the two orbital cavities. He should search for any inequality in the size and shape of their external borders. He should see if the palpebral fissures are identical in their long axes and are similar in length, and notice if the eyes themselves appear of different size or unequal shape. All these points will serve as important data for determining the probability of the presence of astigmatism, antimetropia, and anisometropia. He should next see if the corneal reflexes are regular. To do this, the patient is to be placed before a window at a few meters' distance from it, and, whilst he is made to look at the rectangular bars of the window-frame, he is to be told to move his eye in various directions. By closely observing the changes produced in the shape and size of the corneal image of the bars as they are reflected from the different portions of the membrane, the surgeon will soon be able to form a very good notion as to the presence of regular or irregular corneal astigmatism; the rectangles being shortened in the meridians of greatest curvature. If further and better evidence be wished for, recourse may be had to Placido's disk, or to one of the many forms of keratometers, or ophthalmometers, as they are called, which will be described later on. The apparent length of the antero-posterior diameter of the globe must be studied. To do this, the surgeon should direct the patient to look as far to the nasal side as possible without moving his head. This done, the patient's lids should be separated with the thumb and fingers, without pressing upon the eyeball, and observation made whether the apparent distance between the summit of the cornea and the probable position of the equator of the organ, is long or short. If it appears long, and if the anterior portion of the eye is prominent, the probability is in favor of myopia: if it seems short, hypermetropia is probably present.

As has been already explained, the size of the pupil bears an important relation to both the refractive condition and the state of accommodation. Independently of any pathological disturbance, it is always found much larger in near-sightedness than in emmetropia or far-sightedness—a fact that was known long before Porterfield's ingenious and, in many respects, correct description. Irregularity and relative inequality of pupil, also independently of local change, and associated nerve or vascular lesion, are of more frequent occurrence than is usually noted, and may, in a measure, denote some idiosyncrasy of refractive or accommodative change. High degrees of astigmatism, with their various axes of better vision, give rise to corresponding changes in different portions of the iris innervation; while anisometropia and antimetropia—especially the latter—are made more apparent by the unequal size of the pupils.

This done, attention is to be devoted to the action of the irides, both in separate and in conjoined action. The rules given on page 178 are to be followed, whilst the close connection between the action of the ciliary muscle, the iris muscle, and the converging muscles of the eyeball, in binocular refraction and accommodation, is to be remembered. Notings of their disassociated reaction to light-stimulus and accommodative effort should always be made, and study of their associated impulses to efforts at convergence should always be undertaken; for by these, not only are the conditions of the various sensory-motor arcs ascertained, but also further answer is obtained as to the character of refractive error and the power of single and combined focussing.

If the patient has worn glasses for any length of time, the fittings should be looked at. The surgeon should observe whether the plane of the lens has been bent away from the plane of the patient's face. He should see if there has been any vertical tilt given to the lenses, since often the most important data as to the meridians which the patient prefers to use, can be thus obtained. Frequently the author has carefully studied the faulty appearance in the fittings of improper lenses caused by the repeated efforts of the patient to bend his spectacle-frames in such a manner that he may see better, and has been rewarded by much valuable information as to the exact placing of a cylinder-axis. At times, patients voluntarily state that there is a decided gain in looking excentrically through their lenses: in such cases we should always suspect some uncorrected ametropia, especially astigmatism.

Thus far, however, the results have been uncertain. The student has been compelled to depend upon the patient's assertions and actions for the answer to his quest. There has been nothing absolute. Everything has been equivocal. At the same time, the task has been comparatively easy, and no instrument of precision has been required. Anyone with moderate skill and patience can get the same answer. It is to the meaning of each grouping of symptoms that he must give careful attention, and to the combined picture that he must devote his study. After having carefully done this, and formulated a fair conception of the significance of the findings, he should proceed to the more positive objective methods which, properly employed, give definite determination of the sought-for error. The foremost among these is

the ophthalmoscope. It must be used in every case. Nothing can be legitimately done without it. The eye-ground must be seen. How foolish it would be to attempt to correct the faulty physiological action of a structure without first looking at it in its entirety! The error may be guessed at, or even determined, but the interior of the organ, where the dioptric apparatus and the sensory material are situated, should be seen.

The study of shadows and light-reflexes, as in the excellent fundus-reflex test (see special chapter), can now be made, so as to obtain a more distinct idea of the character and amount of the supposed refraction and accommodation errors. These results should be recorded as a part of the clinical findings of the case. It is not this alone, however, that is wanted. The object is to know at once whether the error is a remediable one, or whether there is a disturbing intra-ocular change. This object can be properly attained only by the use of the refraction-ophthalmoscope.

Preferably, if possible, the student should begin with the upright image, because by it he obtains a double result in not only ascertaining the presence of any intra-ocular pathological change, but also in being at once made acquainted with the nature and amount of the refraction. He should make himself thoroughly conversant with its use. In such testing, he should always endeavor to keep the instrument at a fixed distance (preferably about thirteen or fourteen millimeters) from the observed eye—the position of the anterior or first principal focus, which is that ordinarily assumed by the lenses in the test-frame and spectacles. Always, if possible, he should employ the concave mirror, reducing the strength of the light-stimulus if he desires weaker illumination. He is to use that glass in the sight-hole which gives the most distinct view of the fundus that he desires to study, remembering to use the strongest plus lens and the weakest minus lens for this purpose. Repeating this experiment sufficiently often to get rid of any feeling of effort, he will at last be rewarded by finding himself able to see best the desired portion of the eye-ground with the lens that represents the refraction of the eye at that situation.¹ Two positions upon the fundus are generally sought for. The first, which is the easier to obtain, but which really does not represent the point desired, is the disk and its edges. The other, which is quite difficult to see, especially in the adult, is the region of the macula lutea, this being the part of the eye-ground that is used by the patient for direct vision.

In the student's early studies, both regions should be looked at, so that not only may a comparison in each instance be made, but also that he may become sufficiently adept in each to use afterward one or the other position in any particular case desired. On account of the great area of fundus covered by the disk, it serves as an excellent surface upon which to compare the distinctness of its different portions. Just as the fine radiating lines of the astigmatic card are so fashioned that the least indistinctness of vision in any particular meridian of an eye

¹ A good plan for practising the faculty to suspend one's accommodation is given on page 216. Of course, any strong convex lens can be employed, care being taken to keep the test-object at the principal focus of the lens.

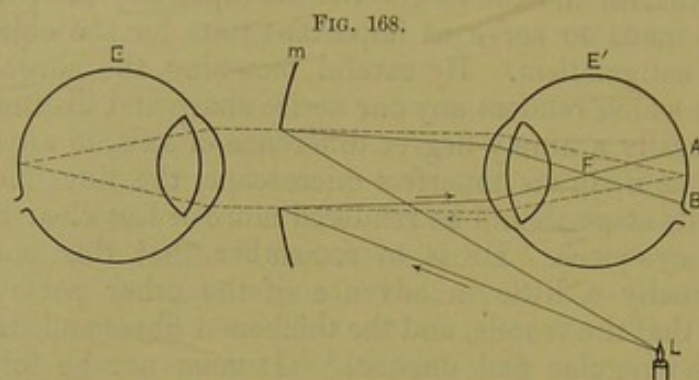
is made subjectively manifest, so in the eye, there is an area which has a series of lines—the capillaries, the small retinal vessels, or even the retinal striation at the border of the disk (if not too pronounced upon certain edges)—running in every direction, and so nearly alike, that, with the capillaries and the larger vessels, especially their light-streaks, they may be made to serve as important tests for the objective determination of astigmatism. By careful focussing, the surgeon will find that the lens which renders any one series sharp and distinct, will cause those at generally a ninety-degree difference of axis, to appear dull and diffuse; just as if, in an imperfect microscope, the fine lines of diatom placed upon its stage should be rendered more or less clear by a quarter-turn of the eye-piece. He is to remember that this portion of the fundus is usually a little in advance of the other parts of the eye-ground, and that the vessels, and the thickened fibres and striated retina, may be quite irregular and unequal.¹ It must not be forgotten, also, that, upon account of the many anatomical abnormalities and pathological peculiarities, the shape of the disk cannot alone be depended upon in the ophthalmoscopic determination of the presence of astigmatism. If possible, it is much better for the student to acquaint himself with the condition and appearance of the chorioid in the macular region. As has been said, this is the more difficult task of the two; and if sufficient practice in the method be not obtainable, he may arrive at a very fair approximation as to the amount of error by confining his estimations to the fine capillaries of the disk, making special study of those situated on its temporal side and at the long and short axes.

Let it be supposed, then, that he has made himself emmetropic,² and that he has acquired the ability to use the ophthalmoscope with total relaxation of his accommodation. Up to this point, he has carefully examined the patient with but one instrument of precision. Using now the ophthalmoscope in the way directed on page 212, he will cause its focus to fall through successive levels of the examined eye until the fundus is reached. If the eye-ground be indistinctly seen when there is no correcting lens back of the mirror, the patient is certainly ametropic. Thus, in Fig. 168, the observing emmetropic eye, *E*, placed behind the ophthalmoscopic mirror, *m*, looks through the hole of the instrument at the observed emmetropic eye, *E'*, with parallel rays which have emerged from the fundus of the observed eye just as though this latter were placed at a great distance before it. As the observing eye is emmetropic, it should focus these parallel rays upon its retina, and obtain a distinct view of the fundus of the observed eye without the interposition of a correcting lens behind the mirror. This will be clearly understood by reference to Fig. 168. The rays of light from the candle, *L*, which fall in a divergent manner upon the concave mirror, *m*, are reflected so as to impinge upon the observed eye, *E'*, in a convergent manner, and are brought to a focus in the interior of

¹ The author has seen a difference of several diopters between the levels of the macular and disk regions of an otherwise healthy eye.

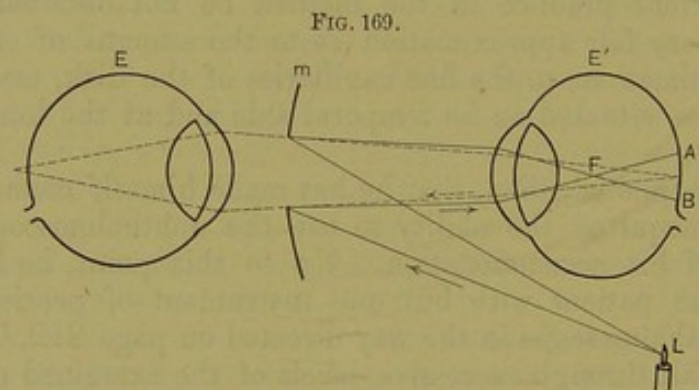
² It has not been thought necessary to risk confusing the student by an explanation of the changes produced by his own ametropia. He should correct his own error, especially if there be astigmatism, and employ the correction during the ophthalmoscopic examination.

the eye at F. They then cross and make a small focal area, A B, on the retinal plane. From all portions of this illuminated retinal plane, rays proceed outward, and, if the eye be emmetropic and unaffected by accommodative effort, must leave it in a parallel direction, as shown by



Direction of rays of light by the direct method in emmetropia.

the dotted lines. These rays pass through the sight-hole of the instrument, m, and strike the observer's eye, E, which now, if that eye be emmetropic and unaffected by accommodation, brings them to a focus upon its retina.

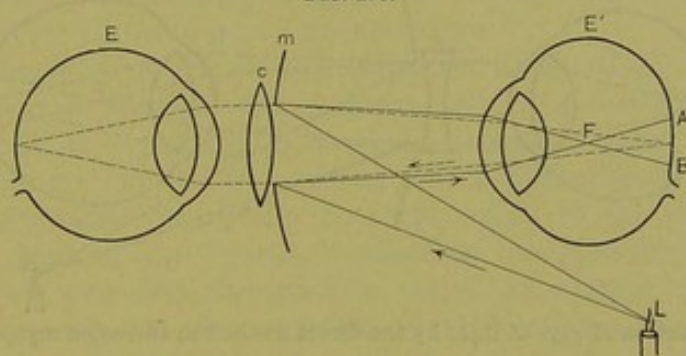


Direction of rays of light by the direct method in hypermetropia.

Should the observed eye be hypermetropic—that is, should it be too short or have insufficient focussing material in its antero-posterior diameter—it will not be able to emit parallel rays to the observing emmetropic eye. Thus in Fig. 169, the convergent rays from the ophthalmoscope, as before, theoretically come to a focus at F, which now, however, is situated much farther back in the interior of the observed eye, E'. In fact, there is less of a focus than before. The observed eye is not adapted for the emergence of parallel rays. It is so weak in its refractive apparatus that it is able to focus only already convergent rays, and, in consequence, the emergent rays from such a focus must leave the eye in an equally divergent manner. A glance at Fig. 169 will explain this. Here the reflected and refracted rays from the candle-flame, L, come to the focus, F. Upon account of the observed eye, E', being too short in its antero-posterior diameter, the illuminated focus-area, A B, is much smaller, and the divergent emerging rays have insufficient focussing material to bring the dotted

lines of exit into parallelism. They pass through the sight-hole of the mirror, *m*, and reach the observing eye, *E*, in a divergent manner. If the observing eye, *E*, be emmetropic and does not use any accommodative action to increase its focussing power, it will be too weak to focus such rays upon its retina, and in consequence there will be either a blurred picture of the observed fundus or no picture whatever. To make the fundus of such an observed eye clear and plain,¹ it will be necessary to wheel a convex lens behind the mirror until the divergent beams coming from the observed eye, *E'*, are strengthened into sufficient parallelism to fall upon the emmetropic plane of the observing eye, *E*. Thus, in Fig. 170, the convex lens, *c*, situated behind the mirror, renders the divergent rays from the observed eye, *E'*, sufficiently convergent (really parallel) to fall upon the emmetropic plane

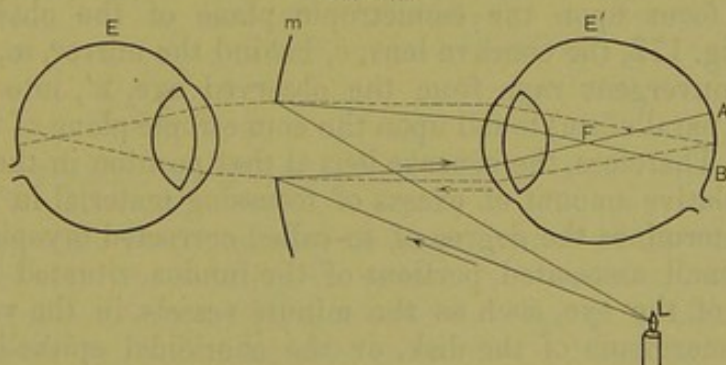
FIG. 170.



Direction of rays of light by the direct method in corrected hypermetropia.

of the observing eye, *E*. In other words, the convex lens situated in front of the observing eye, represents the relative want of focussing material in the observed eye. It determines the degree of so-called corrected hypermetropia.

FIG. 171.



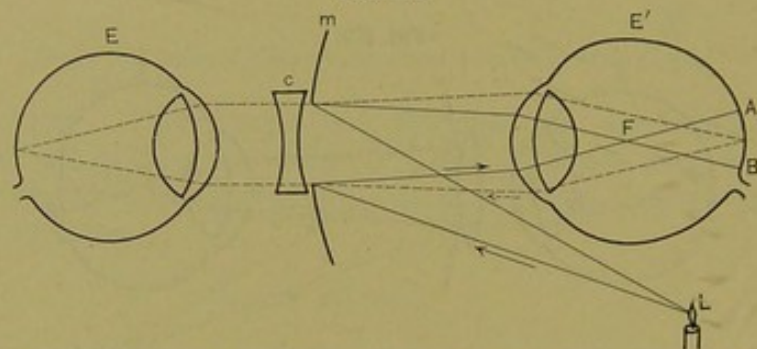
Direction of rays of light by the direct method in myopia.

Should the observed eye be myopic—that is, should it be too long or should it have too much focussing material in its antero-posterior diameter—its emergent rays, instead of being parallel, will be convergent as they fall upon the observing eye. Hence, parallel rays from the observing

¹ The question of the correcting influence of accommodation has been already discussed.

eye which are necessary for distinct distant vision, as in the present case, make their focus in the interior of the observed eye anterior to the myopic plane, and there is no clear view of the eye-ground. Thus, in Fig. 171, the solid lines, during their passage through the observed eye, E' , come in contact with more focussing material than heretofore, and in consequence, make a larger area of illumination at $A B$ than before. The emerging divergent rays from the retinal point in this situation, as shown by the dotted lines, have the same increased amount of focussing material given to them. This extra amount of refraction causes the emergent rays to pass out and impinge upon the observing eye, E , in a convergent manner, which, if the observing eye is emmetropic, causes them to come to a focus in its interior and not upon its fundus.

FIG. 172.



Direction of rays of light by the direct method in corrected myopia.

In other words, the observed eye is so powerful a focussing apparatus that it renders the observing eye incompetent to bring the too strongly focussed rays which have entered its interior, upon its retinal plane. The observed eye has acted as an over-correcting instrument. To make the fundus of such an eye clear and sharp, concave lenses must be wheeled behind the mirror until the convergent rays coming from the observed eye are weakened into sufficient divergence (really parallelism) to fall in proper focus upon the emmetropic plane of the observing eye. Thus, in Fig. 172, the concave lens, c , behind the mirror, m , has weakened the convergent rays from the observed eye, E' , into a sufficient divergence (parallelism) to fall upon the emmetropic plane of the observing eye, E . Therefore, the concave lens at that position in the air, represents the relative amount of excess of focussing material in the myopic eye. It determines the degree of so-called corrected myopia.

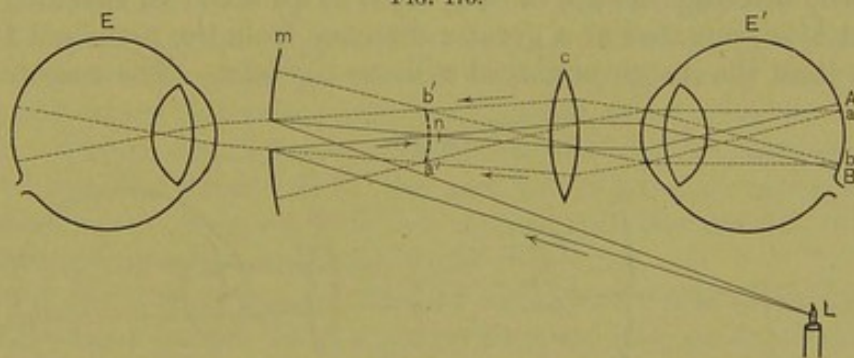
Should small associated portions of the fundus situated in the posterior pole of the eye, such as the minute vessels in the vertical and horizontal meridians of the disk, or the chorioidal epithelium in the vertical and horizontal axes of the macular region, require different lenses in the ophthalmoscope to render them equally distinct, it will be understood that these parts of the fundus are placed upon different planes—that they have different foci. Thus, under the conditions just given, should the vertical curves of the retinal vessels and the lateral borders of the disk be seen with a convex lens, and the horizontal curves of the retinal vessels and the superior and inferior margins of the nerve be seen with a concave lens, the presence of mixed astigmatism with the

myopia in the ninety-degree meridian, can be assumed. If both series of test-objects be seen with different convex or concave lenses, there is compound hypermetropic astigmatism or compound myopic astigmatism—the meridian of the greater error of refraction being usually situated at right angles to the meridian requiring the stronger lens behind the mirror. If one series of test-objects be seen without any correcting lens, there is either simple hypermetropic astigmatism or simple myopic astigmatism, according as a convex or a concave lens is required to correct the opposite meridian.

It will be seen from these several examples that the distinctness of the intra-ocular test-objects denotes that the equivalent refraction is in the opposite meridian. To many, this may seem perplexing, but it will become plain when it is considered that, although the lateral borders of the disk and the vertical curves of the vessels extend vertically, yet the distinctness of the lines depends upon their width, which is determined by the curvature of the horizontal meridians.

If the surgeon so desire, he can study the shape of the retinal image of some regularly formed opaque body, such as a revolving series of threads placed at right angles to one another, situated between the source of illumination and the mirror. If astigmatism be present, the image of the threads, which can be made to fall in any direction upon any desired part of the retina—preferably the macular region—will appear blurred, and even distorted, in certain meridians. To determine this more accurately, the most ametropic meridian found can be corrected, and constantly compared with the one containing the least amount of refractive error.

FIG. 173.



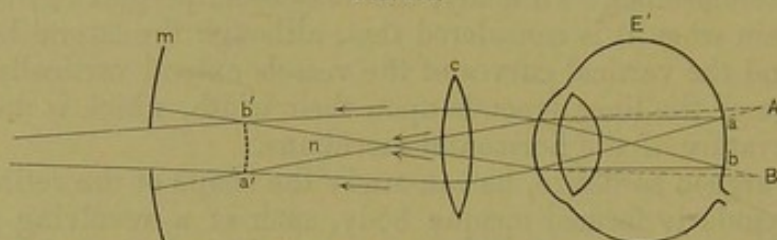
Lines of rays of light by the indirect method in emmetropia.

There are some cases, notably of high myopia, in which it becomes necessary to resort to the indirect method for better answer. In this plan, as has been seen, an inverted aerial image of a large portion of the eye-ground is made to appear in front of a bi-convex lens placed between the ophthalmoscope and the patient's eye. Although it is by no means so valuable as the former method, yet the student should have a full theoretical and practical knowledge of its workings, so that should any case arise that demands its use, he may be ready to employ it. If the observed eye be emmetropic, the inverted image will be practically situated at the principal focus of the lens. Thus, in Fig. 173, the dotted lines proceeding from *b*, in the lower part of the fundus of the observed eye, *E'*, pass through the dioptric apparatus of the eye, the air,

and the bi-convex lens, *c*, to form the upper portion of the aerial image, *b' a'*, situated on a plane at or near the focal point of the bi-convex lens, *c*. Likewise the dotted lines proceeding from the point *a*, form their aerial point of the same aerial image. The intervening points on the directly illuminated retina of the observed eye, *E'*, pass out similarly, and combinedly produce the reverse aerial image, *b' a'*.

Should the observed eye be hypermetropic, the aerial image will be usually larger and dimmer, and will be situated much farther in front of the bi-convex lens. Thus, in Fig. 174, the dotted lines proceeding outward from *a* and *b* are divergent. Such lines cannot form a focus

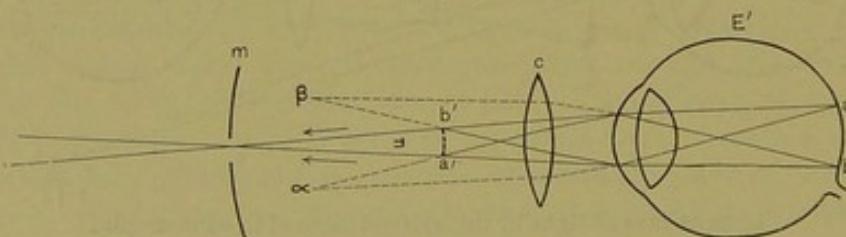
FIG. 174.



Direction of rays of light by the indirect method in hypermetropia.

in front of the eye, because the farther they are prolonged outwardly, the more separated they become. They can come to a focus only at theoretical points behind the eye at *A B*, which are made by prolonging the divergent line backward. By means of these theoretical points, we obtain our pictures: this is done by interposing a bi-convex lens in the path of the divergent rays passing outward from the eye, which causes a sufficient bending inward of the rays, to produce an inverted aerial image at *b' a'*, situated at a greater distance from the principal focus of the lens than the image produced without the lens. The reason of this

FIG. 175.



Direction of rays of light by the indirect method in myopia.

is, that the image-forming lens has had a more difficult task to perform in focussing the divergent rays from the hypermetropic eye than it had in focussing the parallel rays from the emmetropic eye. This difficulty leads to greater action with less result. It causes a less marked bending of the refracted rays, with a consequent longer focus and a larger, less plain image.

Should the observed eye be myopic, the inverted image will be ordinarily small, clear, and situated within the principal focus of the image-forming lens. Thus, in Fig. 175, although the principal focus is situated in its usual place at *n*, the rays from *a b*, in the myopic plane of the observed eye, *E'*, upon account of their emerging from the eye in a

convergent manner, cross and pass outward in the same manner to form inverted aerial points at β , ∞ . It is from these points that we obtain, by the use of the bi-convex lens, *c*, the small image at $b' a'$. Here, the bi-convex lens converges already convergent rays and brings them to a short focus inside of its principal focus. The work of the lens has been comparatively easy, and the result has been greater than in the other two instances. Here, there is a small, clear inverted aerial image, $b' a'$, of the portion *a b*, of the fundus.

Having ascertained the three positions and the comparative areas of the inverted aerial images—first, the emmetropic image, which, upon account of the lens practically focussing parallel rays from the eye, is situated at or near the principal focus of the lens; second, the large and faint hypermetropic image, which, upon account of the divergent rays from the observed eye imposing upon the lens a greater task and thus not allowing it to act so well, is situated beyond the principal focus of the lens and nearer the surgeon's eye; and third, the small, clear, myopic image, which, by reason of the bi-convex lens having but little work to perform in converging already convergent rays from the myopic eye, is situated near the lens and within its principal focus—it behooves the student to determine their significance not only as fixed ratios, but also as movable quantities. Should the image remain comparatively¹ unchanged in size whilst he moves the bi-convex lens backward and forward in front of the observed eye, emmetropia is indicated; the only change being that the farther we remove the lens from the observed eye, the less area of eye-ground is visible and the more feeble becomes the illumination. For instance, should the bi-convex lens in Fig. 173 be situated more forward than is there shown, the parallel outgoing rays will still remain parallel, so that no matter how far the lens may be removed from the eye, E' , they will, if it be sufficiently large in area, fall parallel upon its surface and be focussed at or near its principal focus, *f*. Ordinarily, however, the farther the lens is removed from the observed eye, the fewer will be the number of parallel rays that strike the surface of the lens, and the less intense will become the illumination, thus giving a less brilliantly lighted picture.

Should the image become smaller and clearer when the bi-convex lens is brought nearer to the surgeon's own eye, he is dealing with hypermetropia. If, in Fig. 174, the lens, *c*, should be removed to a greater distance from the position, *A B*, than is there shown, the emergent rays from *a b* would not be so difficult to focus, and hence, according to the law of conjugate foci, they would be brought to a shorter and a more detailed focus. The amount of the decrease in the size of the aerial image and its quickness of diminution, are thus practically in due proportion to the kind and degree of the refractive error.

Should the image become larger and dimmer whilst the surgeon brings the lens nearer his own eye, he is dealing with a case of myopia. If, in Fig. 175, the bi-convex lens, *c*, should be removed to a greater

¹ The author uses the qualifying word "comparatively" because, although there is no actual change in the size of the aerial image upon movement of the lens and eyes, yet, as Burnett tells us, there must be an apparent change, on account of the movement of the position of the aerial image upon our own visual axis; the image appearing larger as it approaches our eye, and decreasing upon removal, irrespective of the optical condition of the observed eye.

distance from the observed eye, E' , the rays from a b would be more difficult to focus, and hence, just as before, according to the law of conjugate foci (page 130), they would be brought to a longer focus. The image would be removed from the lens, and the aerial image would become fainter and larger—this increase in size of the aerial image, and its rapidity of enlargement, being in exact proportion to the kind and degree of ametropia.

These rules may be applied to cases in which any particular meridian of the eye-ground indicates a change in degree or kind of ametropia. In other words, the student will find that the movement of the bi-convex lens will serve as an additional method for the determination of astigmatism. From what has just been said, it will be easy to understand the few following principles. When the bi-convex lens is brought toward the surgeon's eye: simple hypermetropic astigmatism (Ah) is expressed by a diminution of size of one meridian of the aerial image, whilst the opposite meridian remains almost, but not absolutely, stationary in size—the meridian of movement corresponding with the ametropic meridian; should the meridians of movement decrease equally, the case is one of simple hypermetropia (H); should both meridians decrease in size, but one more decidedly than the other, there is an unequal degree of hypermetropia in the two meridians—that is, there is compound hypermetropic astigmatism ($H + Ah$), the greater amount of ametropia being found in the meridian of greater diminution of the aerial image; simple myopic astigmatism (Am) is shown by increase in size of one meridian, whilst the opposite meridian remains almost stationary—the meridian of ametropia corresponding with the meridian of increase in size of the aerial image; simple myopia (M) is shown by an equal increase in all the meridians; compound myopic astigmatism ($M + Am$) is designated by an unequal increase of two meridians at right angles to each other, the meridian of the greater ametropia being equivalent to the meridian of the greater movement and greater increase in size. Mixed astigmatism (either Ahm or Amh) is easy of recognition. In both Ahm and Amh , there are increases and decreases of the aerial image at the same moment; in the former, the decrease of the one meridian is greater than the increase of the opposite meridian, whilst in the latter, the increase of the one meridian is greater than the decrease of its fellow.

By means of an ordinary spring tape-measure fastened at one end to the ophthalmoscope and at the other end to a stiff graduated rod which holds the condensing lens at an unvarying distance from the eye to be examined, all the necessary measurements can be quickly made and read off at a glance.

In all these studies, it is a good plan for the student, in his earlier work, to confine his attention to the two meridians of the disk itself, until he is able to leave this questionable portion of the eye-ground and approach more nearly to the macular region of the fundus. The study of the disk, however, will serve him in helping to verify or correct the findings of astigmatism by the direct method.

The student now knows that in the indirect method, the aerial image of the fundus is both inverted and reversed, and, of course, the disk itself must appear so, as the result of the action of the object-lens held

in the air before the eye. If the lens be held within its focal length from the observed eye, it does more: it reverses and inverts the apparent meridians. Where, for instance, the disk has been enlarged into a vertical oval, it now becomes magnified into a horizontal oval, showing by comparison with the direct method that in the indirect plan the meridian of the greater refraction corresponds with the short axis of the disk. In order to understand this, the student has only to imagine that the optic disk is a perfect circle and that the dioptric apparatus situated in front of it has a greater amount of focussing material in the vertical meridian than in the horizontal. With the direct method, the disk will appear more magnified in this direction than in the opposite, and in consequence it will appear as a vertical oval. By now placing a strong bi-convex lens inside of its focal length before the observed eye and removing the ophthalmoscope sufficiently from the observed eye to allow him to view the aerial image situated between the lens and the ophthalmoscope, the more highly magnified rays of light, which formed the vertical meridian of the disk in the direct method, will strike and pass through the object-lens very divergently and come to a short focus in front of it, thus producing in the aerial image a narrowing of this meridian of the disk; whilst the less magnified rays, which formed the horizontal meridian of the disk in the direct method, will strike and pass through the object-lens more nearly parallel, and come to a much longer focus, thus producing a broadening of the previously narrow meridian of the disk. The rule, then, is, that in the direct method the optic disk appears largest in the direction of the meridian of greatest refraction, and in the indirect method it appears largest in the direction of least refraction. Should, therefore, the two meridians of the disk appear reversed in the two methods, the student may feel assured that there is a difference between the foci of the vertical and horizontal planes of that part of the dioptric apparatus—that is, that there is astigmatism. If, after careful trial with both methods, these changes do not take place, it is certain that any inequality of these planes is dependent upon the real shape of the disk.

In some cases, a third method offers itself, and may be combined with the other two in any instance where the surgeon finds such a procedure advisable. It is known as the *fundus-image test*, and will be explained in detail, so as to make more readily understandable the succeeding test—the fundus-reflex test (retinal shadow-test)—which so greatly depends upon it, and which is of so much importance in the detection and estimation of ametropia. In the fundus-image test, the surgeon sits about one meter in front of the patient, and directs him to gaze at a distance just to one side of the mirror. The surgeon now, placing his eye behind the aperture in the mirror and throwing the beam of light into the patient's pupil, obtains a small area of red reflex. If the case be devoid of any error of refraction, he will generally fail to observe any details of the eye-ground. The most probable reason for this is, that although the emergent rays from the observed eye pass out parallel and should form a focus upon his own retina, just as shown in Fig. 168 (direct method), yet the patient's eye is so far removed from his own, and the opening into the interior of the patient's eye—the pupil—becomes so small, that he ignores the deeper level of the fundus, and unconsciously focusses upon

the pupillary edge of the iris. The student can understand this by noticing the difference of facility in recognizing a distant landscape through a small aperture in a wall when the eye is brought directly up to the hole and when the organ is situated about a meter away. In the first instance, the eye plainly sees the distant view, whilst in the second, the edges of the hole are unconsciously focussed for, and the outside picture is lost. If the surgeon's eye be emmetropic, and should he totally relax his accommodation, or should it be artificially paralyzed by a mydriatic, thus taking away its focussing power, he will find in this experiment, that he will be able to recognize clearly the outside view, whilst the details of the edge of the aperture, will be indistinct and hazy. So, too, with the patient's eye, his fundus will appear clear and sharp, and the iris-edge will become faint and dim, if the surgeon's accommodation be either physiologically annihilated or artificially paralyzed.

With hypermetropia the problem is much simpler. In this case the emergent rays from the observed eye are divergent, and do not come to a focus in front of the eye. In this method, the observing eye, by bringing its accommodation into play, naturally adapts itself for such rays. The fundus of the observed eye, therefore, becomes easier to see than that of the emmetropic eye, because it is now necessary for the surgeon to bring his power of accommodation into play to make the divergent rays which pass through the aperture in the mirror fall upon his emmetropic fundus. The resultant fundus-image, however, although both clear and erect, will, upon account of the great distance between the two eyes and the character of the emergent rays, be extremely limited in area.

If the observed eye is myopic, the problem is wholly different. The emergent rays from the observed eye are convergent, and form an aërial image. The rays then, crossing, pass through the aperture of the mirror in a divergent manner into the observing eye, just as in the hypermetropic eye, and form an inverted picture of the observed fundus upon the retina of the observing eye. Upon account of the entrance of these divergent rays into the observing eye, the aërial fundus-image can be seen correctly only by the exercise of sufficient accommodative power to render the rays either parallel or convergent: this, as before shown, being the natural tendency, the fundus of such observed eyes, in most instances, becomes plainly visible. By studying the passage of the lines from the observed eye into the observing eye, the student will find that the resultant fundus-image will be both clear and inverted, and that the extent of the fundus of the observed eye will be in proportion to the nearness of the two eyes and the degree of myopia.

By reference to the figure illustrating the concave method in the fundus-reflex test, it can be easily understood that if the mirror is moved laterally in any direction before the hypermetropic eye, the image of the fundus will move with the motion given to the mirror, whereas a similar movement of the mirror in a case of myopia, will cause the now inverted image of the fundus to move in an opposite direction.

It will be well at this point to explain the workings of a few of the subjective and objective optometric methods for determining the error

of refraction, so that their significance may be understood when it is wished to add their testimony to the results thus far obtained. The simplest forms known, which are practically nothing but adaptations of single convex lenses mounted on graduated scales, are clinically useless for the careful determination of refraction-error. The varied relations and combinations of action produced by convex lenses in conjunction with stronger concave ones, first made use of by Von Graefe, and as now found in the ordinary opera-glass, may be more advantageously employed, if care be taken to avoid accommodation-efforts during the experiment. Starr has contrived a most ingenious optometer, in which not only is accommodation excluded, but the retinal images of all eyes examined by it remain uniform. It consists of a sixteen-diopter convex spherical lens, situated at its focal length in a tube. Beyond this in the tube, there is a movable concave spherical lens of the same strength. The amount of movement necessary to be given to the concave lens, so that the patient may see clearly ordinary test-type placed at five or six meters' distance, is registered in half-diopter differences. So, too, the movement and interplay of two convex lenses may be used to greater advantage; but here the intra-ocular muscles come into action, rendering the results far from correct.

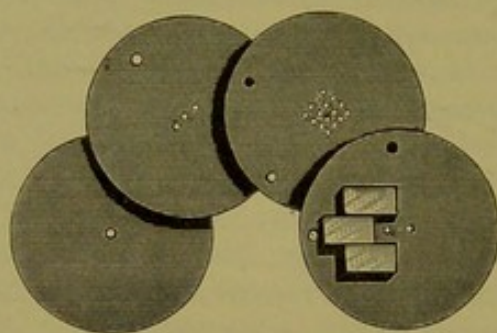
As already explained, when a compound ray of light proceeding from a single point of illumination falls upon the retina, there should be an accurate focus. If there is no distinct focus, a more or less circular area of diffused light is the result, which area, known as a *diffusion area*, which is composed of *circles of diffusion*, is the one perceived. It can hence be seen, that if any contrivance can be made by which the extent, shape, and intensity of this area can be studied, the surgeon will have an instrument by which he can determine the kind and degree of ametropia. On page 152, it is shown that the so-called Scheiner's experiment effects this purpose. Consequently, if an adjustment can be added to the apparatus thus employed, by which the method can be reduced to a more or less mathematical basis, or if a series of formulæ can be calculated to be used with the simpler forms of mechanism, answers can easily be obtained as to the kind and amount of refraction-error, thus rendering the plan both useful and practicable.

Beginning as a practical instrument in the hands of Porterfield, the forms of instrumentation underwent many modifications until 1870, when it was brought to its present form by the device of Thomson, consisting of four perforated disks, as shown in Fig. 176.

These disks are in reality four opaque screens, so made that each contains a certain number of perforations of one-half millimeter area in diameter. Each disk is so constructed that it can be set in a test-frame. If the patient, placed in a darkened room, look through these openings at a single source of illumination, the light will assume certain positions and sizes, move in definite directions, and be multiplied in exact proportion to the refraction of the eye. Estimating the distances between the lights, and calculating the angles at which they are best seen, the determination of which is greatly aided by the employment of a movable ruby glass placed in one of the screens, both the character and the degree of the error of refraction may be subjectively obtained. For instance, if the

flame be seen single, emmetropia is to be presumed. If two points of light be visible, one of which can be made to appear red by sliding the ruby glass into position, ametropia is apparent—the relative amount of crossing or non-crossing of the two images determining whether hypermetropia or myopia is present, and the widest and narrowest angles of separation giving the amount of greatest and least ametropia in the various meridians. By subjecting such a case to the careful estimation of the refractive error by means of the trial lenses, many interesting and valuable data can be added to the former results.

FIG. 176.



Perforated disks. (THOMSON.)

The circles of diffusion found in ametropia can also be measured by means of the same author's so-named "*ametrometer*," in which two gas-jets, about five millimeters each in diameter, are made to approach one another at any angle desired upon a bar which has been graduated into proportional differences of inches, centimeters, and diopters. By causing the patient to gaze with one eye at a time at the two lights somewhat separated, the presence or absence of ametropia can be instantly determined, according as the two jets are or are not identical in size and clear-cut. If they appear as large, irregular areas of diffused light, ametropia is present. To designate the variety, let the patient either exclude or color one-half of the circles by holding a card or a red glass vertically before the eye. If the corresponding halves of the diffusion circles are hidden or reddened, myopia is present; if the opposite halves are so lost or changed, hypermetropia is proved. Modification of these three rules applied in various ways, will soon make manifest not only the amount and variety, but also the angles of greatest and least disturbance. By study of the optical effects of the angles of greatest refraction upon circular areas of light, the meridians of greatest curvature can also be measured by an apparatus devised by Hotz—the so-termed "*astigmometer*," which consists of a graduated blackened disk upon which, by a mechanical contrivance, a four-millimeter illuminated opening is made to revolve around a stationary one of the same size until, if astigmatism be present, the longest diameters of the two lights coincide in direction when, by reading the index, the position of the greatest refraction meridian can be determined. Culbertson also has contrived an ingenious instrument termed a

"*prismometer*." It is composed of a revolving double prism placed in the centre of a large graduated disk, through which the patient is made to gaze at a large white area situated at about five meters' distance. If the patient be emmetropic, a double white area will appear to him, which will remain tangentially approximated throughout the entire revolution of the prism. If myopia be present, they will overlap. If there be hypermetropia, they will separate. The degree of separation or overlapping in the various meridians, gives the amount and the angle of astigmatism. A clip is placed just in front of the sight-hole, so that the ametropia thus subjectively found, can be determined and estimated.

As has been known since Wollaston's time, the optical constants are such that when a solid beam of homogeneous color of a specific number of undulations, as, for instance, red, is received upon the retina in a definite and determinate way, another and dissimilar beam, such as blue, will be received in a totally different manner; or, which practically amounts to the same thing, when an object capable of producing a compound color-stimulus is placed before such an eye, the color combination will be broken in a way that may be taken advantage of in the ready detection and rough estimation of refraction error. This, as has been repeatedly explained, is dependent upon the differences in refrangibility of the two colors. When a transparent prism intercepts a beam of solar light, the differences in the refractive power of the various portions of the prism through which the beam passes, cause the latter to break into a series of graded wave-lengths, each gradation being expressed by its representative color: in other words, the ordinary prismatic colors appear. If the prism did not thus break the compound ray into a series of colored ones; if the degree of power to separate the ray into its different parts were the same throughout the prism, the beam would pass through it practically unchanged. So with the lenses and the various adjustments of the eye. If they were perfect in construction and thoroughly adaptive, any entering homogeneous ray would reach the retinal plane without being disturbed, and there would be no so-termed aberration. Such is not the case, however, as has been shown in the chapter on the physiology of the organ. The rule is that there are discrepancies in greater or less degree. The eye acts prismatically and breaks the compound rays, more or less, into its elements—one eye being adapted for one series of rays to fall on its fovea centralis, and another eye for a different series.

If now, instead of the delicate beam of solar light, we allow the entrance of light-stimulus composed of a gross combination of two colors of great difference of refrangibility, for instance, blue and red, such as may be found in the ordinary cobalt glass of the shops, we have a simple guide for the ready clinical demonstration of the kind and degree of chromatic aberration resident in the eye. To effect this, all that is necessary is to surround a beam of artificial light with an opaque chimney in which there is a small round opening containing a rather thick piece of cobalt glass. A luminous area is thus obtained which contains a compound of blue and red. During the experiment, the patient

is to be seated about five meters from the color, which is to be so arranged that it shall be on a level with the eye to be examined. By reference to the accompanying colored diagram, it will be seen that the compound parallel beam of light, $A C$, is broken into its two component colors the moment it reaches the eye. The blue rays, which are the finer and the more easily broken, are refracted first, and come to an earlier focus, at b , than the more gross and less refrangible red ones at r . If the appearances of the diffusion circles in the planes of H and M be studied, it will be seen that in the too short, or hypermetropic eye, the blue rays, having come more nearly to a focus than the red ones, give a retinal image of blue surrounded by red, whilst in the too long, or myopic organ, the blue rays, having come to an earlier focus, become more widely spread apart than the red ones, which have been more tardy in their crossing, thus converting the image into one which has the red for its centre and the blue for its peripheral area. In the emmetropic plane, the two areas of blue and red—the one being too early in its focus, and the other equivalently too late—practically exactly coincide in density, and superimpose, thus giving a clear circular image of the cobalt. Reasoning from what has been already learned, that the retinal image is the one that is carried inward to be perceived, thus explaining that the differences of appearances shown, are those which the patient will assert to be present, the color-changes may, if so desired, be asked for. After determining the character and probable amount of the refraction-error, they may be carefully estimated and corrected by suitable test-lenses. By the aid of improvised contrivances, the author has found this method of optometric study, as well as the much better equipped previous subjective methods, not only extremely interesting for scientific study, but also very useful in a number of cases where he wished modifications of other forms of testing, especially among patients who, although illiterate, were quite intelligent.

If care be taken to effect lateral adjustment, binocular optometry may be practised. Unfortunately, however, no definite idea can be thus obtained as to which should be made the working eye, and which the helping eye.

Of the more common objective methods, the most prominent is Placido's *keratoscope* for the recognition of corneal astigmatism. As shown in Fig. 177, it consists of a round disk, twenty-three centimeters in diameter, containing a series of alternate white and black concentric bands, and having a central perforation one centimeter in width connecting with a tube three centimeters in length; the whole arrangement being held by a short handle.

Placing the patient, the light, and the face of the instrument in the same relative positions used during the employment of the ophthalmoscopic mirror, the patient is to be made to look directly into the aperture of the contrivance. On looking through the sight-hole, the student will then, as a rule, notice a series of regular or irregularly distorted reflexes of the concentric black and white circles on the cornea; each being graphically illustrative of a definite variety of corneal astigmatism. To obtain a slightly enlarged image and a more clearly cut view of the reflection of the circles, the author has found it most convenient

PLATE II.

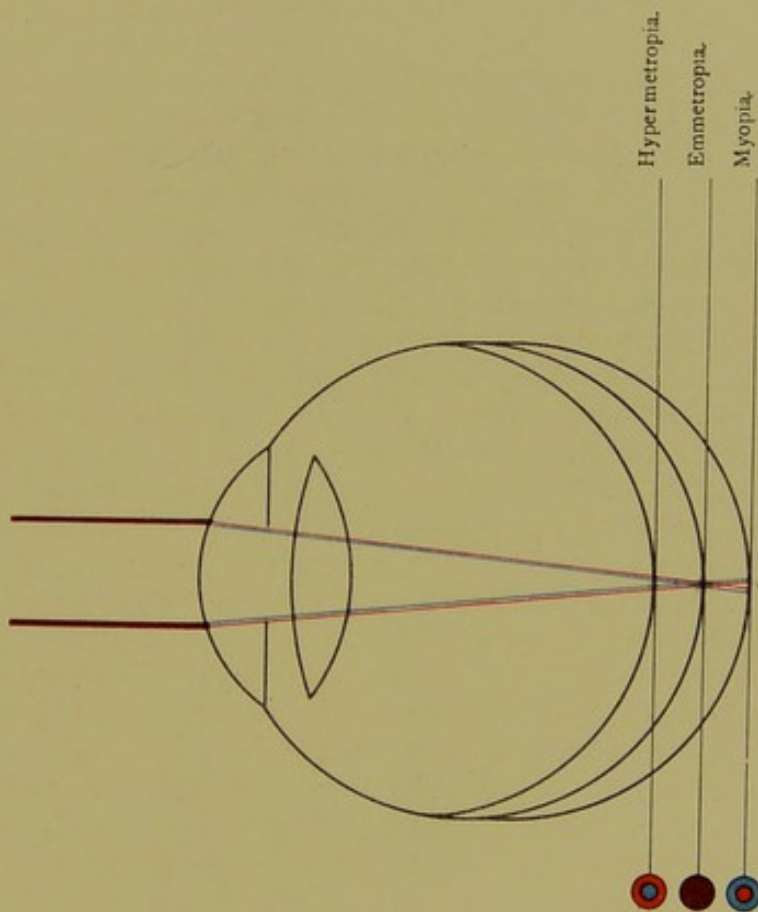



Diagram illustrating chromatic-aberration test for ametropia.



to make use of a small convex spherical lens, of about 6.50 D. strength, fastened against the sight-hole of the instrument.

If more accurate objective study as to the angle and the degree of corneal astigmatism be desired, especially in a central area (about five millimeters in diameter) of the membrane, the so-called *ophthalmometer*—more correctly *keratometer*—should be brought into use. Definite in its results when successfully applied, precise in its answers when

FIG. 177.



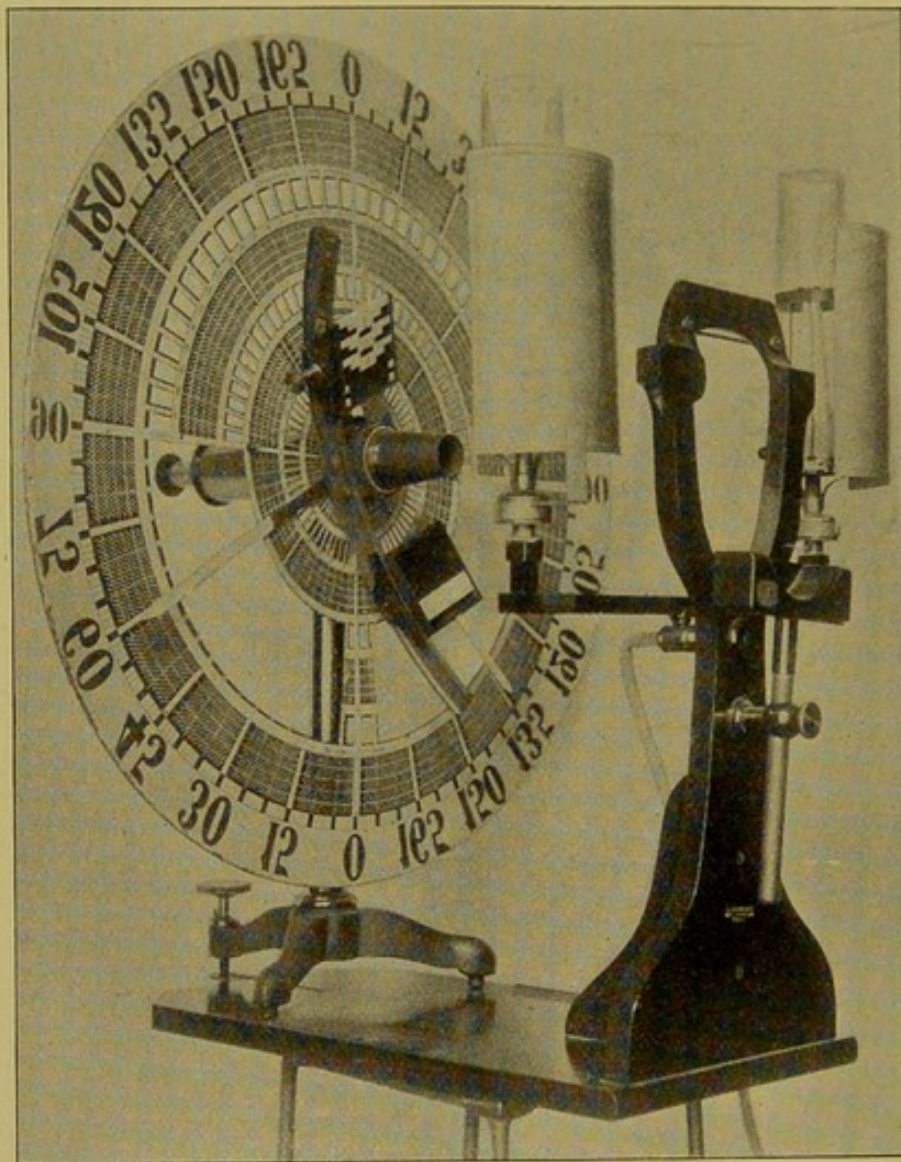
Placido's disk, or keratoscope.

skilfully adjusted, and easy of comprehension in its workings by any intelligent person, it is a most useful appliance not only for quick clinical work, but for scientific study. Unfortunately, however, its great cost, the difficulty of accurate adjustment to most students, and the discrepancy in its answers when incorrectly used, seem to hinder it in some degree, in its present form, from being more generally employed in ordinary clinical work. That it is one of the every-day working instruments of the future as well as of the present there can be no doubt, as the apparatus, although capable of great improvement, thus permitting further surety of action by greater simplicity in mechanism, must become more

general, thus rendering the technique easier and more comprehensible through the increased daily routine of employment.

As here explained, and as shown in Fig. 178,¹ the model of Javal and Schiötz consists practically of two adjustable reflecting surfaces, which can be so gauged that their corneal images may be accurately

FIG. 178.



Javal and Schiötz's ophthalmometer (model of 1889).

measured by a focussing apparatus placed between the patient's eye and the eye of the observer. This apparatus, which in reality is a contrivance intended for the measurement of catoptric images, therefore, becomes in fact an instrument by which variations in sizes of objects placed at finite points can be made so as to reflect images of certain equivalent areas from the anterior convex surface of the cornea. This obtained,

¹ The particular instrument shown in the illustration is one of the 1889 model, arranged for artificial illumination from two Welsbach gas-burners. One of the newest and best models has electric-light attachments, thus getting better and more evenly distributed artificial illumination with but little or no heat.

the measurements of the sizes of the test-objects necessary to accomplish this, furnish calculation by which the radius of corneal curvature can be readily obtained; the rule being, that every definite increase of size in the corneal images of the test-objects on the targets, corresponds in direct ratio with the amount of astigmatism.

As can be seen in Fig. 178, the contrivance is arranged like a perimeter. Upon the perimeter-bar, there are two black rectangular plates: one, which is fixed, contains a similarly shaped white test-object, known as a target, and the other, which is movable, two white figures bounded by three sides placed at right angles to one another; the upper side of the figure being shortened and connected with the far extremity of its lower side, by a series of steps. These targets are so arranged that they may be readily illuminated by diffuse daylight, preferably that from the north, or by two or four artificial lights from oil, gas, or better, electricity, that can be placed in front of reflectors which are situated on each side of the patient's head. In a position corresponding with the extremity of the radius of curvature of the bar, there is a perforated movable upright stage, so constructed that either eye of the patient can be placed exactly at the centre of rotation of the bar. At the centre of the perimeter-bar there is a telescopic arrangement, practically composed of two prisms of Iceland spar, so arranged that should the observer gaze through the far end of the telescope, the corneal images of the targets will appear doubled, greatly magnified, and displaced in the meridian of the bar. Peripherally situated around the telescope, just at the point where the perimeter-bar touches it, there is, as can be seen in the figure, a large disk-like area, which contains a graduated series of radiating lines and concentric circles.

By carefully adjusting the eye-piece of the instrument so that a pair of cross-wires or spider-webs in the telescopic arrangement are plainly visible to the student's own corrected eye, and placing the patient before the chin and head rests (by sighting through the transverse slit in the disk immediately over the tube) so that his eyes are exactly horizontal, he covers one of the patient's eyes with the little metallic shade, and sights the centre of the exposed cornea of the other eye through the notch on the upper side of the tube. He then directs the patient to gaze into the far end of the telescope, situated in front of the patient's eye. He then moves the disk-like portion of the instrument backward and forward, and upward and downward, until the central images of the two test-objects, which have been illuminated, are sharply defined on the spider-webs. He then moves the target along the bar until the aerial image of the corneal reflexes formed in the tube by the objective lens exactly coincides. This having been done, he notes the position of actual separation of the "mires" on the bar. By now turning the bar at right angles, the amount and exact angle of consequent overlapping or separation, if there be astigmatism, is to be noted; the difference between this and the other finding, giving the relative amounts of astigmatism in the two meridians. If the situation of the image in the second position assumes any obliquity as compared with that found in the original right-angled position, it is presumable that the two principal meridians of the cornea have not been used.

For verification of the correctness of the difference between the first and second positions, a good plan is to move the target in the second position until the images of the two targets again coincide, and note whether the targets again fall to their original situations as found in the first position; each step of deviation in the test-object representing one diopter of difference. If the corneal images remain in the same relative positions when the bar is rotated, all the corneal meridians are alike. If the aerial images in the tube separate in the vertical meridian, this meridian has the shorter radius, whilst, if they overlap in this meridian, it has the longer radius.¹

Davis says that the so-called "primary position," or position which represents that point at which the transverse lines of the reflectors become continuous, is the first to establish. To get this position properly and systematically, he places the long white pointer horizontally. If the lines are coincident, the primary position has been obtained. If not, the tube is to be revolved from right to left for about forty-five degrees and the same distance from left to right, thus causing the pointer to travel about forty-five or the requisite number of degrees above and below the horizontal meridian. Having obtained this axis, the test-objects are to be approximated, thus giving the axis and degree of ametropia at one meridian. Turning the long pointer ninety degrees to the left, which will give the secondary position, there will be astigmatism against the rule, if the untouched test-objects separate, and astigmatism with the rule, if they overlap; the number of steps of separation or overlapping, as compared with that of the primary position, representing the amount of difference of refraction in the two meridians. To prove this, a good plan is to correct the amount of displacement in the secondary position, and after turning the pointer back to the primary position, to notice the new amount of displacement; this new reading again giving the difference of ametropia between the two meridians. The first, supposing that there be an overlapping of two steps, can, as Davis says, be written, "Astigmatism with the rule, 2. D. $90^\circ +$ or 180° "; and the second, "Astigmatism against the rule, 2. D. $180^\circ +$ or 90° "; the long pointer in every instance showing the axis of the convex lens that is necessary to be worn, and the short right-angled pointer, the axis of the concave lens that should be worn.

The instrument, as now made, being gauged for the ordinary human corneal radius of 7.8 to 8 mm., the dioptric indices given by the little steps on the test-objects are about a quarter too large, thus necessitating the addition or subtraction of a definite fractional error² (0.50 D.) to the ophthalmometric reading; the rule being, as laid down by Javal, to add one-half a diopter to the finding, or to give the full correction when the findings are against the rule, and to subtract one-half a diopter when the results are with the rule. The instrument thus becomes one of the most accurate of objective contrivances for all practical purposes in the determination of the presence of ordinary corneal astigmatism, the exact positions of the angles of greatest and least curvatures, and the almost certain

¹ This description is correct for the special 1889 model here shown. In the more recent forms, the images are made to overlap in the shorter or more curved meridian.

² This error is said to be not so pronounced with the contrivance of Leroy and Dubois.

estimation of the amount of the error. Especially is this true, not only in every-day examinations of astigmatism, but in aphakia (markedly after cataract extraction), and even in irregular astigmatism and amblyopia. Further, by the process of exclusion in the after-correction by the trial lenses, we are allowed to state most definitely the presence of lenticular astigmatism, its angle, and its proportionate amount. The greatest advantages of the method in the determination of corneal astigmatism (which, as we know, often constitutes the major portion of disturbing ametropia), are its rapidity, and the fact that pupillary dilatation (ciliary paralysis) is never needed. Moreover, it estimates the astigmatism under the same circumstances as those in which the organ is employed during its ordinary work, thus giving a most excellent measure of the existent corneal astigmatism at the time. The student, however, should make it a rule to repeat his findings sufficiently often (just as was shown with test-lens selecting with a mydriatic) to guarantee some definite answer, thus insuring greater certainty of after-results by test-lens measurement.

In all the work, both subjective and objective, nothing should be neglected by the student that may seem to be of collateral value. Every detail should be studied. Nothing should be allowed to escape because it seems to be trivial and useless. - The error of "jumping at a diagnosis" from observation of a few salient points, is to be avoided, and, as the student's eye becomes better trained, he will find that what at first was irksome will at last give answers almost by intuition: the picture will appear, as it were, in a single grouping; and changes in the finer details, which otherwise might have been unnoticed, will now be readily recognized, and their significance almost unconsciously taken into account.

Having determined the character of the error and made a rough estimate of its degree, it becomes necessary to ascertain to the utmost nicety the degree of ametropia, and to correct it by appropriate lenses. This brings us to the methods of estimating errors of refraction and accommodation.

CHAPTER X.

THE CORRECTION OF ERRORS OF REFRACTION AND ACCOMMODATION.

HAVING satisfactorily determined the character of the refractive error, it becomes necessary to ascertain whether it is possible to correct the defect by the aid of suitable lenses. In many instances, this can be done by but one method—absolute annihilation of the power of accommodation. In many cases, especially among the young, no correcting lens can be conscientiously ordered until it is certain that every particle of the refractive error has been made manifest. Search must be made for the minute yet frequently disturbing remnants of unsuspected astigmatism. Care must be taken to exclude every iota of ametropia. By so doing, the case is, as it were, within the grasp; the total amount of error is made cognizable, and the condition can be more knowingly coped with; the error has been probed to its very foundation, and knowledge of it has been obtained in its entirety. Satisfaction with imperfect computation by hap-hazard selection from a test case, under the pretext that "this will do for the time being," or that "this seems good enough for the present," should not be sufficient. Every case should be treated with the utmost conscientiousness. Makeshifts are to be avoided. If certainty is felt that ciliary paralysis is necessary before proper lenses can be chosen, the surgeon had better be prepared to lose the patient than to give him imperfect work. If cases do arise where it is advisable to avoid the use of the drug, the patient should be told so, and if glasses are chosen under such circumstances, he should be made to clearly understand that the results obtained may be uncertain. Although these plans may often result in patients seeking advice from others who may rest content with an imperfect correction of some manifest error, yet in all such instances it is a far more than equivalent recompense to know that the steady, quiet reputation of many years of but little error in refraction-work, is infinitely better than the flash-like brilliancy of the moment in quickly giving corrections that may or may not be right. A few courteous refusals to compromise one's name with questionable work will be more advantageous than the acceptance of results that one feels may ultimately prove false and even detrimental.

To formulate a rule for the use of a mydriatic is almost impossible. Idiosyncrasy often determines its employment. Women nursing, susceptibility to the constitutional effects of the drug, age, contra-indicating local disorders, such as glaucoma, etc., all play important parts in the question. Some few cases seem not to need it at all for the correct estimation of their ametropia. Especially has the author found this so among the higher-class neurasthenics who daily employ their eyes in the recognition of minute differences between distant lines, points, and

angles—such as teachers and workers in draughting, geometry, astronomy, etc. In these rare instances, the eye often has readily got its proper angle and amount of astigmatism with the correct kind and grade of refraction-error, as has been proved by the after-use of the drug, without the aid of a mydriatic. In a number of these cases, as the patients recovered their full strength, the accommodative tone became stronger, and less convex spherical strengths were required.

The best rule is, to employ it in every case where individual judgment dictates that it is necessary, remembering, especially in young cases, that its non-use is seldom exceptional, and this for idiocratic reasons that must be determined at the time. Of course, it is unnecessary in aphakia.

Having, then, assumed that a mydriatic is to be employed, the next point is, what one shall be used. As has been explained in the clinical division, atropine is the best, the cheapest, and the most certain. The strength generally used is one grain of the sulphate to two fluidrachms of distilled water. Either three drops are to be instilled into the lower conjunctival cul-de-sac of each eye at about half-minute intervals, the evening before, at the time of retiring, and on the morning of the patient's visit, or, what is better, the surgeon should use the drug in the eyes himself, instilling the solution in such a manner that it may primarily come in contact with the superior limbus of the cornea, and then be allowed to flow gently over its surface; as much care as possible being taken to keep the lids separated. In order better to graduate the exact amount to be used, the point of the dropping-tube should be made extremely fine. Preferably, the instrument should be made with the point bent, so that the drops may be delivered directly downward. If absolute accuracy be desired, the pipette may be graduated. Definite percentages in oil, soluble disks, tabloids, and tablets containing graded quantities of the drug are, on account of the slow, steady absorption of the contained material, preferred by many ophthalmic surgeons. Often the ciliary border of the inner portion of the lower lid may be everted by the hand or temporarily closed by some appropriate contrivance with advantage, in order to prevent any of the material from passing into the lacrymal passages.

On account of the mydriatic effect of the drug, plain protective glasses of a medium grade, of "London smoke tint," preferably the large flat variety free from any blemish, or the coquille-shaped pattern, are to be worn during its employment. Care should be taken to state the poisonous character of the drops and to warn the patient against leaving them in insecure places. To guard against any future danger, instructions are to be given to throw the drops away and to destroy the bottle and dropper as soon as their use is discontinued. In cases where we do not find any disturbance of the chorioid and retina, we may employ frequently repeated instillations of varying percentages of hydrobromate of homatropine to advantage. In such instances, the best plan is to use four to six instillations of two to three drops of a four per cent. solution at intervals of from ten to fifteen minutes before each examination, taking care not to postpone the measurement for lenses longer than thirty minutes after the last instillation has been used. Personally, the author having long believed that atropine, daturine, and hyoscy-

amia have an actual therapeutic effect upon the condition of the generally disturbed chorioid and retina, independent of the intended ciliary paralysis, and that homatropine—even though neutral in reaction—seems to exert some visible disturbing influence upon the chorioid and retina, has always given the first three of these drugs, in their order of naming, the preference in all cases. To know when ciliary paralysis has been reached, the author often makes use of a minute test-word, which under such circumstances should be seen at some one fixed point when a strong convex-spherical lens (+S. 4. D.) is used; this point, as has been explained, giving the kind and degree of ametropia. Should the most decided paralyzant effect be desired with a ready return of ciliary action, solid mixtures of homatropine and cocaine, as proposed by Wood, are probably among the most reliable of these forms for employment. Should the student desire to use duboisia or hyoscyamia, he cannot be too careful to avoid any systemic effects, as both of these drugs are so powerful in action, that, if not used with discretion, unpleasant constitutional symptoms may appear. They should always be used by the surgeon himself, and in quantities just sufficient to produce the necessary paralysis of the ciliary muscle.

The patient is now ready. The student is now about to commence the estimation of the error.¹ The first subjective procedure is that with the test-lenses. These are so made as to be conveniently employed in a test-frame which contains a semicircular rim on each of its lower halves which is graduated into five-degree differences that run from the surgeon's left to his right. This plan of numbering the degree-marks on the test-frame is most common in the United States. This is probably due to the fact that the ordinary trial-frames commonly sold in the shops are so constructed. The validity of the method, both as to symmetry and unity, is questioned by many surgeons. Some, notably Knapp, consider the vertical meridian as zero (or vertical), and carry the degree-marks up to ninety (or horizontal), both toward the temple and the nose. Harlan starts at zero from the temporal sides for both the right and the left eyes.²

The case, for instance, having been diagnosed as one of compound hypermetropic astigmatism (H + Ah) of a certain probable amount, a convex-spherical lens which represents about two-thirds of the supposed entire amount of ametropia, should be placed in the test-frame before one eye—preferably the worst eye first—the other being covered or excluded from vision by an opaque disk set in the test-frame. We will suppose that this increases vision to about three-fourths of normal, and that the patient mistakes letters on the smallest lines of type that he sees. A weak convex cylinder of, say, about one-half diopter, with its axis at ninety degrees, should next be dropped into the frame in front of the spherical lens. Upon account of its convenience, equal efficiency, readiness, and ease, the author much prefers this plan to the use of the stenopæic slit. This probably will cause vision to rise to almost normal, the

¹ If the student desires, he can now re-study the fundus-reflexes under the most favorable circumstances. This will make him much more familiar with the method, and give him results which can be either controverted or proved by the test-lens selection.

² In all these methods of notation, the surgeon is supposed to be reading the degree-marks on the frames.

patient merely making errors in the line of type intended for the distance used. The axis of the cylinder being slowly shifted to each side of the ninety-degree notch in the frame, the patient is asked to state if the letter in which it is found that he is at fault, appears to change its shape, and to tell the name of the letter it now seems most like. If he names it properly, when, for instance, the axis of the glass is turned to the ninety-five-degree notch, we may feel fairly assured that we have found the meridians of greatest and least refraction. To be absolutely sure of this, however, the cylinder axis is to be wheeled several times to each side of the point chosen, and note made whether it comes at last to the same position. If a new point be chosen, the procedure is to be repeated, until it is certain that the proper place has been reached. Again having him read the smallest line upon the card in ordinary use, or upon another strange one, his attention is to be confined to any mis-called letters upon the line. Both spherical and cylindrical lenses are now to be added to and subtracted from the correction, until all the letters on the line are made clear and sharp. After this has been done, a + S. 4. D. is to be dropped into the test-frame in front of the chosen correction, and the patient directed to tell where either the smallest reading type upon the accommodation test-card or one of Burchardt's finest test-dot series, appears the plainest, and at what point he can either read or count the test-objects. If this be at about twenty-five centimeters, it is almost certain that the pre-existent ametropia has been properly eliminated. If the reading type be plainest inside of twenty-five centimeters, the error has probably been over-corrected, and if it be read beyond the twenty-five centimeters the correction is apparently insufficient. Verification by the direct method of ophthalmoscopic examination is next to be tried. If the case be properly corrected, the details of the fundus—especially in the macular region—will be seen clearly and sharply through the correction. This procedure should always be followed by further confirmatory evidence as given by the plain method of the fundus-reflex test. The rules given in the chapter on this test are to be employed, and if apparent emmetropia has been obtained, the opposite eye is to be studied. Here the work is to be repeated in precisely the same manner, and record of all the results accurately made.

In every case, the daily use of the drug should be continued until two sets of answers are made to agree.

The same care that has been taken to estimate the error of refraction whilst the eye has been under the full influence of the mydriatic, should be exercised in seeing that the after-work is sufficiently postponed until every vestige of the drug has disappeared; this being done so as to appreciate more thoroughly the new relationship which has been established between the refraction-error of a rested and less irritable eye, and the renewed, though now comparatively better-toned, intra-ocular and extra-ocular muscle-actions. In ordinary routine, if atropine, daturine, or hyoscyamine be employed, it is best to wait two weeks before ordering the correcting lenses. The loss of two or three days beyond the usually expected times of the dissipation of their actions, is more than compensated for by the assurance that there is no remnant of the effects of these drugs left. If homatropine should have been used,

the correcting lenses may be safely chosen and ordered in seventy-two hours after the last instillation of the drug.

Should the case have been one of compound astigmatism ($M + Am$), the same routine should be pursued, the only difference here being that, as a rule, the spherical lenses do not show such increase of vision so early in their selection, and that the astigmatic lens chosen is usually very much stronger, and its axis is generally situated at some peculiar meridian.

Simple hypermetropia quickly ignores the weakest cylinder, and simple myopia—which is very rare—does the same thing.

Simple hypermetropic astigmatism, as a rule, denies the spherical lens the moment it is dropped into the frame, whilst the patient expresses great satisfaction the instant the cylinder is used. In this case, just as before, $+ C. 0.50 D.$ axis at ninety degrees is to be commenced with, and, after the lens has been shifted until the best meridian has been obtained, appropriate cylinder-lenses are to be added and subtracted until every miscalled letter on the smallest line of type visible has been properly named.

The correction of simple myopic astigmatism demands the same procedure with concave cylinders, and soon manifests itself by the early refusal of spherical lenses and the almost instantaneous selection of cylinders of various strengths and angles.

Mixed astigmatism is soon estimated by commencing with the concave cylinders and increasing their strength and revolving their axes until the best possible vision is obtained. As a rule, it will be found that the correction of the entire ametropia, in some one meridian, will be quickly obtained. This is to be followed by dropping a weak convex cylinder before the chosen concave lens, at right angles to the minus cylinder, and gradually increasing the strength of the convex lens, until the highest visual acuity has been reached in the meridian at right angles to the minus one. The two lenses being held firmly together at exact right angles to one another, and the patient's attention being confined to some miscalled letter in the smallest line of type that is visible to him, the lenses are to be slowly and combinedly revolved about each side of the original axis chosen, until the outlines of the letters are rendered more distinct. By this means, the exact angles of greatest and least curvature are soon found. The patient's eyes being kept fixed upon the most difficult letters of the smallest line of type, additions and subtractions from both series of cylinders are to be made, until the best possible vision has been obtained. The result should then be tested by the artificial accommodation test with the $+ S. 4. D.$ and the retinal reflex test. If all seems right, the work is to be repeated at daily intervals until two sets of answers agree.

In aphakia, the requisite lens-strength is quickly chosen, the selection, in most instances, being greatly helped by an additional cylinder of generally one to two diopeters' strength, with its axis placed parallel with the length of the previous corneal incision.

Some cases, as said before, do not require that the ciliary muscle should be paralyzed. This is particularly the case among the aged, in whom the senile change has almost destroyed the activity of the muscle.

Again, the mydriatic may either be dangerous to the eye, or it may act unfavorably upon the general economy. These latter cases may frequently be fairly well estimated with an extremely weak and evanescent solution of one of the drugs sufficiently repeated to make almost certain the result. As before mentioned, a few cases where there is quick intelligence, with no local complications, may be tried without any drug at all.

With the feeble-minded, the demented, foreigners, the young, etc., where it is impossible to obtain any intelligent understanding as to what the patient sees, it becomes necessary to abandon the subjective method of determination for one of the most certain and easiest of the objective plans of estimation—the fundus-reflex test. This plan has proved of great service in such cases. The plane mirror plan, as has been explained, is by far the preferable method. As previously explained, lenses of various strengths and grades are to be placed in the test-frame, or preferably, some mechanical contrivance holding a series of correcting lenses which can be easily moved into proper position, is to be employed in the same way as just directed for the subjective method; each change of lens being verified or contra-indicated, by study of the movement of the consequent reflex, until, at last, emmetropia is supposed to have been reached: this done, the direct method of ophthalmoscopic examination should be preferably tried, and the details of the fundus, especially of the macular region, be sought for, and used as a confirmation-test for the lenses chosen by this method.

Even in ordinary cases, some surgeons of the present day prefer to make use of the quick and most easily recognized findings as to the degree and amount of correctable astigmatism of so-called ophthalmometric study in their formulæ for correcting lenses in preference to the time-taking, though absolutely certain, test-lens selecting. That the method, as before explained, is eminently useful in the objective detection of corneal irregularity and asymmetry, there can be no doubt; but as the results with the present forms of apparatus are so doubtful to most observers, and at times so at variance with those obtained from other instruments of equal precision, and further, as there is no check as to correctness except by test-lenses, which, to give adequate answers in such cases so studied, require as much, if not more, effort than if they had been primarily employed to subjectively correct any error, it thus necessarily fails much of its, by some, supposed value in the absolute correction of all the existent astigmatism in any given case, and resolves itself, in its present mechanical form, into a contrivance intended for the ready recognition of errors of corneal refraction. As intelligently used at present, therefore, and as previously shown, it is invaluable as an adjuvant in the careful and scientific detection of faulty curves and astigmatic meridians which are confined to the cornea: especially is this so with the ophthalmometer (keratometer) of Javal and Schiötz, which, as elsewhere described, can be readily made of the greatest use in many cases in the measurement and isolation of corneal astigmatism.

As a rule, it will not be necessary to employ the various ingenious optometers, intended for subjective use, that are devised from time to time. They should, however, always be used in scientific experiment and in doubtful cases. Unfortunately, in most of the subjective varieties

of measurement, as before hinted, differential distinction on the part of the patient is so delicate, and supposed optical constants are so inconstant and variable, that the least incongruity in answer and the slightest disturbance in working machinery will give rise to the most dangerous errors. To the intelligent and well-educated, and to the scientific observer, nothing can be more beautiful than to see the wonderful changes in aberration which appear to an ametropic organ of vision; but for practical purposes, in every-day public and private work, among the ever-varying grades of mentality brought before us, most of these methods cannot be used to advantage.

After having estimated the refractive error, it becomes necessary to order the correction of it. The point at which Donders deemed emmetropia to be present, is certainly scientifically incorrect, and cannot hold good when the wear and tear of tissue incident to the constant strain and hurry of the present age are considered. The abused eyes and their appendages will show the slightest organic or physiological fault, working at the rate to which they are daily subjected. All that can be said is that a definite correlation between the combined sensory and motor acts must be properly established before harmony of result can be expected in eyes which, if left uncorrected, would give local disturbance and even general discomfort. The optical portion of the apparatus must be in as perfect a condition as possible for the character of work it is to be used for, and the adjusting parts must be as evenly balanced and smoothly working as they can be, before unconscious action can be obtained. With this, then, the student will be daily brought face to face when errors of refraction, accommodation, and correlated extra-ocular muscle-action are to be corrected, which, although often of seemingly little consequence in themselves, he may find it necessary to give correction for, in order to relieve the patient of symptoms which have defied medication. The question is not, then, the simple one, Is there sufficient ametropia to correct? It is the complex one, What are the eyes used for? How are they employed? To how much strain are they subjected? What general symptoms might result from their abuse? Are such symptoms present? Such questions as these decide the answer. Remember, then, that the utmost attention must always be paid to both the condition of the refraction and the action of the ocular muscles, as it is to their combined workings that our treatment is directed. Moreover, it must be understood that there is probably no fixed standard at which to place the muscle-power of the eye, any more than there is for any other series of muscles in the body. The muscle-tone is not only in association with the amount and character of the refraction-error, but bears a direct relation to the general condition.

As to the amount of strength of lens to employ as compared with that which has been obtained under the mydriatic, rules of all sorts—from those that assert that total correction is necessary (which, theoretically, is correct and should be done in every instance possible), to those which maintain that the manifest error alone is sufficient—exist, and will continue to exist as long as individual thought and opinion hold their own.

Independently of a few broad formulæ upon which to base decision,

we must be governed by the case under examination. The correcting-lens of the ametropia of one patient who employs his eyes at the distance of a half-meter is a very different lens from that which should correct the same amount of ametropia in another patient who places his work at but one-third of a meter. The watchmaker and engraver, who need a most careful adjustment for twenty centimeters, are in a very different position from the bookkeeper and clerk, who almost constantly use their corrections at from forty-five to sixty-five centimeters. The strong adjustment necessary for the small woman with short arms, who can comfortably hold the work only at thirty-five centimeters away from her eyes, is a quite different problem from the weak adjustment sufficient to permit the large, long-armed man to hold it at fifty centimeters. Each case holds its own answer, and must be studied separately. The accommodative play and positions of desired working-points enter so much into the question of the selection of the primarily chosen lenses, that they must be taken into consideration in every instance, whilst the ever-related extra-ocular muscle-balance and movement necessary for proper binocular vision must be carefully ascertained and judiciously corrected and combined, whenever found markedly faulty or inharmonious.

The following directions may be useful in the selection of the corrections. The student should always begin by studying each eye separately. Suppose, for instance, that the case is one of compound hypermetropic astigmatism, with fair ciliary muscle power. First, the vision is to be gotten, which will probably be found to be but slightly below normal, or may even be normal. This is to be followed by obtaining the accommodation, in which the near-point will usually be situated too far from the eye. The work upon the correction is to be begun by slipping the previously chosen cylinder into the test-frame, and note taken whether there is improvement. Usually it will be found, especially if the astigmatism is slight, that the vision is bettered. A weak, spherical lens is next to be dropped in front of the cylinder, which will, especially in the left eye, probably further increase the distinctness of the smallest type visible. An increase of the strength of the spherical lens will now give apparent normal sight. This should be continued until the last and strongest possible selection produces a "faint, fog-like scum" before the eye, when the next weaker lens should be the one chosen for the purpose. After being repeated with the fellow-eye, the region and power of accommodation in each corrected eye are to be obtained. The two eyes are now to be tried simultaneously. As a rule, it will now be found that the binocular vision will be much clearer and better with the chosen lenses than when the eyes were tried separately, thus allowing stronger and stronger spherical lenses to be simultaneously substituted in front of the separately chosen sphero-cylinders, until again the smallest line of letters becomes slightly dim. The next weakest pair of lenses are the ones to stop at. Binocular accommodation for the nearest, the farthest, and the best points, must next be tried.

If the case is young or comparatively so, and does not use the eyes constantly for some near object, this combination of lenses will serve for constant wear, but should there be a decided weakness of ciliary

power or want of lenticular elasticity, caused by higher hypermetropia, more advanced age, or constant employment of the eyes at some very close point, it will be advisable to give the strongest combination of convex spherical lenses with the cylinder for the best vision at the desired accommodative point. This correction is to be used for near-work, in addition to the pair chosen for distance. Care must be taken, in each instance, to obtain a normal extra-ocular muscle-balance. This is done by giving that strength of spherical lenses, in combination with the cylinder lenses, which will produce the nearest degree of muscle-equilibrium for both the near and the far lenses—always, however, taking the general condition of the patient into consideration. If full correction is not employed, the patient should be so informed, and the lens may be made slightly thicker, so that any increase found necessary, may be easily ground on with but little expense to the patient.¹

The formula to be sent to the optician for such a case, should, for example, read as follows:

F.

O. D. + S. 1. D. \ominus + C. 0.50 D. ax. 45°.

O. S. + S. 1. D. \ominus + C. 0.50 D. ax. 135°.

(Centred at . . . mm.)

That is to say, "O. D." (opticus dexter, or right eye) is to have a "+S." (plus or convex spherical) lens of "1. D." (one diopter strength) " \ominus " (combined with) a "+C." (plus or convex cylinder) lens of "0.50 D." (one-half diopter strength) "ax. 45°" (axis at forty-five degrees); the same rules applying for "O. S." (opticus sinister, or left eye). It thus succinctly directs that the optician is to make for the right eye a compound lens, composed of a convex-spherical lens of one diopter strength, combined with a convex cylinder lens of a half-diopter strength, with its axis at forty-five degrees, and the same strength combination with its cylinder axis at one hundred and thirty-five degrees for the left eye; the optical centres of these two lenses to be placed . . . millimeters apart. Should the student prefer the plan of cylinder notation used by Knapp, the same formula when given in full would read:

O. D. + S. 1. D. \ominus + C. 0.50 D. ax. 45° T.

O. S. + S. 1. D. \ominus + C. 0.50 D. ax. 45° N.

That is, the axis of the right cylinder is inclined forty-five degrees temporally (T) from the vertical meridian, and the axis of the left cylinder is inclined forty-five degrees nasally (N) from the vertical meridian. If Harlan's method be used, the cylinder-axis of the left eye would be noted the same as that written for the right eye. Ordinarily, especially if the optician be at such a distance that the patient cannot have the frames properly adjusted by him, we should state the character of the frame desired, with the interpupillary and temporal distances, the bridge-height and width, the relative antero-posterior distance between the

¹ The author has found that one or two additional amounts of about one-half to three-fourths of a diopter are required in from one to two years' time in low degrees of hypermetropia. In the middle grades, higher corrections are immediately taken, and the remaining accommodative spasm is loath to go, thus allowing the patient to retain the original correction for a much longer period. In the high varieties, the greater part of the correction is readily received at first, and is held for many years.

apex of the nasal bridge and the plane of the lenses, and the wished-for inclination, directly beneath the formula. If through force of circumstances, the fitting must be personally done by ourselves, the formula as above given is complete.

In large cities, where there are expert and first-class ophthalmic opticians, it is always best to leave the entire fitting of the frames to them, merely stating on the formula that a reading- or a distance-frame is desired, so as to give a certain number of millimeters between the pupils when the eyes are binocularly fixed for some certain point that has been agreed upon in each individual case.

If we desire, we can adhere to the old inch system, which would make the above formula read :

$$\begin{aligned} \text{O. D.} &+ 1/36 \text{ sph. } \odot + 1/72 \text{ cyl. ax. } 45^\circ \\ \text{O. S.} &+ 1/36 \text{ sph. } \odot + 1/72 \text{ cyl. ax. } 135^\circ. \end{aligned}$$

If prisms are to be employed, the amount of P.D. or Cr. strength, with the direction of apex or base, is to be appended to the formula. If the strength of the prism has been determined by the old method of angular deviation, the degrees of opening can be substituted for the number of prism diopters or centrad.

Simple hypermetropic astigmatism demands the correcting convex cylinder for constant use if the case is young or has a strong ciliary muscle, but necessitates an additional spherical lens for near-work should ciliary action be weak or inefficient. When there is no additional spherical lens necessary, the formula reads, for instance, as follows :

$$\begin{aligned} \text{O. D.} &+ \text{C. } 0.50 \text{ D. ax. } 45^\circ \\ \text{O. S.} &+ \text{C. } 0.50 \text{ D. ax. } 135^\circ. \end{aligned}$$

If an additional spherical lens be required, the formula will practically be the same as that given to illustrate what is used for compound hypermetropic astigmatism.

If the case be one of compound myopic astigmatism, the problem is very difficult and requires accurate knowledge of the mode of employment of the eyes, the amount of ametropia, the character of the astigmatism, etc. The full cylinder should, as a rule,¹ be placed in the correction, but the spherical, although properly ordered in its entirety, in some instances may be reduced by an amount that is compatible with fair distant vision and the safety of the organ. This procedure is advisable in the higher forms. This is owing to the fact that the diminution of the size of the retinal images produced by the correcting lens induces the patient to enlarge them by bringing the object nearer to the eye, and to the unfortunate habit that most patients of this class possess, of using an acquired working-point, which represents, as a rule, their uncorrected best point of vision, though this practice has been rendered unnecessary by correction with proper lenses. Should the myopia be of sufficient quantity to allow a partial correction that is suffi-

¹ The author has seen departures from this. One case, seen several years ago, had so high a myopic meridian that it was found necessary, after several trials, to halve the cylinder-strength, after which the patient remained perfectly comfortable and free from all ocular strain, with cessation of further increase in the refractive error. The patient has been seen within a year.

cient for a safe and comfortable reading-point, the student should employ at first, for constant use, a weaker pair of spherical lenses with the cylinders which will give the best vision at this distance. Afterward, if possible, he is to give the fuller correction, reserving the first pair for near-work alone. If the myopia be very slight, or even if it be moderate, the full correction for distance, and the cylinders for near-work, are to be given. If the patient be old and the eyes are presbyopic, the amount of ciliary weakness and want of capsular elasticity, which may in a measure be corrected by a certain degree of lens-hardening, must be subtracted from the total correction given for distance, and the difference employed for near-work alone. This in many instances, among the slightly myopic, will require a weak convex spherical lens with a convex cylinder, with its axis at right angles to the axis of the original concave cylinder. The formulæ in all these instances are similar to those just given, except that a minus mark (—) to designate a concave lens, is to be used in place of the plus (+) sign.

In mixed astigmatism, the empirical plan for obtaining best vision, most comfort, and less liability to increase of refractive error, is first to increase gradually the concave cylinder until, as a rule, the entire strength is placed in the test-frame. This is to be followed by substituting stronger and stronger convex cylinders at right angles to the selected concave cylinder, until the best possible vision has been obtained. Having accomplished this with each eye separately, and with both eyes combinedly, monocular and binocular accommodation are to be tried, and if the eyes are still faulty and inefficient, correcting convex spherical lenses are to be placed before the chosen corrections, until the near object becomes distinct. If, by this plan, muscle-balance be established for near-work, and a very slight degree of horizontal deviation toward the same side as a vertically placed prism be produced for distance (just as in all the other instances), the lenses thus chosen may be ordered for near-work. The distance-glass made up of the cylinders alone is to be worn at all other times, whilst the reading-glass, corresponding to the corrected ametropia and faulty accommodation combined, should be employed in doing near-work. A pair of periscopic convex lenses in an eye-glass frame, representing the presbyopia, may be slipped in front of the permanent distance-correction when momentary near-work is attempted.¹

Presbyopia without refractive error is so rare that it is always best in cases of old sight, to obtain carefully the refractive error or inequality, and add this to the accommodative fault. A pair of spectacles and eye-glasses, the one for home or office use during prolonged near-work, and the other for momentary employment in situations where it would be uncomfortable and disturbing to search for spectacles and fit them on for use, are, as a rule, the most desirable for the patient. Often, if there be but little inequality between the refraction of the two eyes, the difference will be rejected by the patient. Again, minor degrees of astigmatism are frequently rejected where the lenses correcting the presbyopia are tried. In both of these instances, it may at times be

¹ This plan is often pursued to advantage in all kinds of ametropia where it is found necessary for the patient to change quickly from a distant to a near-work correction.

better to ignore them in the presbyopic correction. The many varieties of so-called "*Franklin glasses*," preferably those that have the plane of the lower half bent slightly inward, and the numerous patterns of *bi-focal* or *tri-focal lenses*, each contrived for some special peculiarity, are frequently of great value, and can often be satisfactorily adapted to cases where it is necessary to use both a far and a near glass, as in the many forms of ametropia with or without presbyopia. Especially is this so with artists, bookkeepers, and others who find it necessary to gaze alternately at objects that are situated at two or more definite points. The author has frequently employed them to great advantage in cases of aphakia following cataract extraction. The cemented lens, which can now be ground so thin as to be hardly perceptible, is, on account of the ease with which it can be removed and changed, much better than the doubly-ground single lens. Frequently, in cases where it is not necessary to correct any ametropia, the presbyopic lenses can be conveniently and advantageously cut into a smaller and flatter oval, or even into a crescent with the points turned upward, thus allowing the upper field for distant vision when the patient is alternately reading and speaking whilst standing on a high platform.

If exceedingly strong lens-powers are to be employed, much of the consequent weight may be reduced by resort to the so-called *lenticular lenses*, which consist either of small convex lenses, of such radii as to give the same strength as the larger ones cemented to one of the many forms of ordinary spectacle-glasses, as suggested by Loring, or of small-areaed deep cavities cut in the opposite surfaces of plane glasses, as proposed by Green. In all the forms of heavy concave lenses, the weight may be also greatly reduced by bevelling the edges of the lenses. In fact, it may be done, if so desired, as shown by Gould, in the more ordinary varieties.

In aphakia, the full lens-strength should always be ordered and constantly worn for distance, with either an extra pair containing an additional spherical strength adapted for use at any required near-point, or a bi-focal slip cemented to the lower portion of the distance-lens. If desired, as in many cases of single extraction, recourse may be had to the so-called reversible frames, which contain both the distance and near-work lens. The two most popular frames consist of a fitting with an X bridge and straight temples, which is to be reversed and inverted for near and far use respectively, and one which can be reversed by a change in the hinge of the temples, allowing the side-pieces to be swung forward and backward. It should always be remembered, and must sometimes be taken into consideration, that the spherical lens in these cases is so strong that the distance between it and the separated cylinder-lens in the trial-frame is at times sufficient to make a difference in the vision of the patient whilst employing the single compound lens made by the optician.

The corrections for the many cases of *anisometropia* and *antimetropia* (terms respectively designative of unequal degrees of the same kind of refraction in the two eyes, and unlike kinds of refraction in the two eyes) daily seen, which will give the most comfortable and the most satisfactory vision, are those which consider one eye as the working organ and the other as the helping, the latter being gradually trained

up to better work. A good empirical rule, is to put as much of the spherical with all of the cylinder upon the better eye, and to add that spherical to the cylinder before the fellow-eye which will give the easiest and best associated vision. To determine this latter point, the simplest plan is to try one of the muscle-tests in both horizontal and vertical directions at five meters' distance after the supposed proper lenses have been reached, and if muscle-balance be obtained, or if there be even a fraction of homonymous diplopia remaining, the correction may be safely ordered. If the lenses are intended for near-work alone, the muscle-balance test should be repeated at the desired distance. Though at times it is difficult to tell which to make the working eye, yet it is a good plan to choose the one which has the lesser ametropia, especially astigmatism, or the lesser amount of muscular or inflammatory disturbance. If binocular vision be impossible, the highest correcting lens compatible with the comfort and safety of each individual eye can be ordered, care being always taken to correct as much of the astigmatism as possible. Should the antimetropia be marked, the rule is to correct as much of the error in the hypermetropic eye, and as little of the spherical error in the myopic eye, as possible.

In the application of these rules, it must be distinctly understood that no hard-and-fast laws can be laid down for the government of each case. There are so many peculiarities in the shapes of the globes, in the conditions of the dioptric apparatuses, and in the actions of the intra-ocular and extra-ocular muscles, and so many disturbing elements when the two eyes are brought into combination at their usual working positions, etc., that beyond these few rules, little else than empiricism can ever be the guide in the selection of lenses that can conscientiously be considered as correct.

In some cases of irregular or meridional astigmatism and conical cornea, much improvement of both far and near vision, with a betterment of the, at times, concomitant distressing symptoms and even a retardation of the actual progress of the condition, may be obtained by repeated and careful lens-testing and correcting. Frequently, in such cases, the ophthalmometer may be made of incalculable use in the selection of the necessary lenses. No definite rules as to the procedure, beyond those just given, can be formulated, except that, here, paralysis of the accommodation should be avoided on account of the accompanying disturbance in exposing a large corneal area by the pupillary dilatation. Either artificial myosis or stenopæic holes and slits may at times be advantageously used while estimating the case, although in the author's experience the patient trial by lenses, with the eye in its ordinary condition, has given the best results. Dependent upon the position, altitude, and condition of the apex of the cone in conical cornea, the most bizarre results, and the most peculiar lenticular combinations, are at times obtained. Ordinary discrimination and care in the selection and use of the lens, with attention to both local and general hygiene, will often be of the utmost value to the comfort and usefulness of the organ. For the correction of irregular astigmatism, Fick has employed small transparent glass shells with the convex surface equal to that of the normal human cornea. These are known as *contact-lenses*. They are to be

placed in contact with the irregular surface of the cornea, and the intervening spaces are to be filled with a sterilized solution of grape-sugar. Patients have worn these for several hours at a time without suffering any inconvenience from clouding or irritation. The couple of instances in which the author has tried them, however, have not warranted his continuance of their use. Raehlmann's hyperbolic lenses with a deep concave hyperboloid surface to fit over the cone in conical cornea, may also be mentioned.

As it is always advisable, when ordering any of the above corrections, to have a proper formula, and as the difference between the lenticular combinations for near-work and for constant use frequently include both minus and plus forms, the best plan is to reduce all the lens-strengths, except in mixed astigmatism, to similar forms, and to place them upon the order-blanks in the most concise manner.

If it be necessary, for instance, to combine the formula for presbyopia with the representative lens signs for the amount of H, Ah, or $H + Ah$, the estimation of the proper formula is simple enough, merely requiring the addition of some convex sign representing the strength of the convex lens necessary to be added to the already chosen one which shows the amount of the correction of the refraction-error: thus, if there be a hypermetropia of one diopter, with which should be combined a correction for presbyopia of two diopters, the signs, + S. 1. D. and + S. 2. D. are to be united into a common representative sign, + S. 3. D.; or if the original formula reads, + S. 1. D. \subset + C. 0.50 D. ax. 45° , the addition of the + S. 2. D. will cause the new formula to read, + S. 3. D. \subset + C. 0.50 D. ax. 45° .

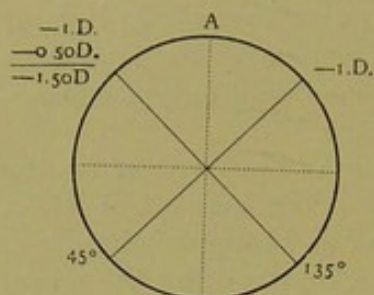
In M, Am, and $M + Am$ with Pr, however, the readings, if made in a similar manner, would appear very different, and not as they would be made by the optician. Here, each prescription should express the simplest and most effective mechanical device of lens that the optician can make use of to accomplish the purpose. Thus, if there be a myopia of one diopter and a presbyopia of two diopters, the formula for the near-work lens would read, + S. 1. D.; that is, the - 1. D. has been subtracted from the + 2. D., leaving a + 1. D.

Although, of course, the rule is the same if astigmatism be present, yet here the process of reduction is a little more complicated. Remembering, however, that a cylinder deals with one meridian only, and that this meridian is at right angles to the axis expressed, the work becomes comparatively easy: thus, if the refraction-formula should read, - S. 1. D. \subset - C. 0.50 D. ax. 45° it shows, as has been explained, that there is a compound lens of minus one diopter's strength at the forty-five-degree meridian and one of one and a half diopters' strength at the one-hundred-and-thirty-five-degree meridian. This is graphically shown in Fig. 179.

Let A represent a graduated circle, the dotted lines in which show the ninety- and the one-hundred-and-eighty-degree meridian. Drawing lines at right angles to one another through the points representing the meridians used in the lens, and noting the lens-strength employed in these two positions, the amount of lens-powers in the two meridians will be seen at once upon placing the representative signs in their

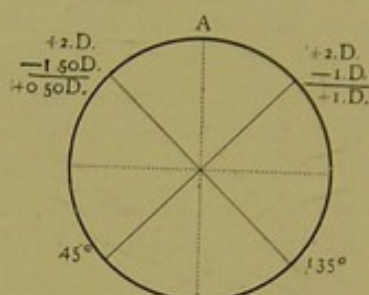
respective situations. For instance, in the diagram, as the spherical lens of minus one diopter has its strength in all meridians, its sign is to be placed at the extremity of both the forty-five- and the one-hundred-and-thirty-five-degree line; whereas, as the cylindrical lens of minus one-half diopter has its strength at right angles to its axis, which is forty-five degrees, its sign of strength is to be placed at the one-hundred-and-thirty-five-degree line, thus increasing the strength of the one-hundred-and-thirty-five-degree meridian to minus one and a half diopters.

FIG. 179.



Scheme for graphic determination of lens-powers.

FIG. 180.



Scheme for graphic determination of lens-powers.

If there is a presbyopic correction of two diopters to add to this correction, all that is necessary to do is to place the $+2.D.$ sign immediately over the $-1.D.$ sign at the forty-five-degree meridian, and over the $-1.50D.$ sign at the one-hundred-and-thirty-five-degree meridian. Thus, in Fig. 180, it will be readily seen that there is, as a result, $+1.D.$ in the forty-five-degree meridian, and a $+0.50D.$ in the one-hundred-and-thirty-five-degree meridian, which, being further reduced, will, without much calculation, give $+S. 0.50D. \subset +C. 0.50D. ax. 135^\circ$. Here the one diopter meridian practically holds two one-half diopters, one of which, given to the half-diopter in the opposite meridian, makes a half-diopter spherical in all meridians, with a remaining half-diopter cylinder strength in the forty-five-degree meridian: thus giving the above formula.

This example, which can be modified to suit any case, will be sufficiently illustrative of what is meant.

The work, however, does not cease here. In some instances, although, fortunately, not in many, as the mere correction of the optical error often restores imperfect muscle-balance and gives proper muscle-action, it may be necessary, in addition to the correction of the refractive error and accommodative fault, either to relieve some undue tension upon one of the extra-ocular muscles, or artificially to help the imperfect workings of a remaining weak, over-used, or diseased extra-ocular muscle. This, as has been shown in a previous section, is done by the use of prisms. Should the case continue to present any slight disturbing muscular element, even when corrected by the chosen lenses and proper attention has been given to the general health, it is probably best, if possible, to add a correcting prism to the correction. If the muscle-disturbance be more pronounced, operative procedure may be required. There are two ways of obtaining prismatic action by lens-action. The first, which is the easier, and often is very efficacious, consists in so

decentring the lenses used in correcting the refractive error and accommodative fault, that the combined lens-action shall be rendered sufficiently prismatic to correct the muscle-disturbance. This is readily accomplished, as previously explained, by moving the centres of the correcting lenses in or out from their ordinary positions, either by excentric grinding, or, if the disturbance be not very great, by altering the position of the frame. The second, which is the more difficult lens to construct, has the chosen prism ground into the correction. Sometimes, in high and peculiar cases, it may be advantageous to combine the plans.

After having obtained the proper correction for the ocular defect, the surgeon should see that all the conditions desired in the lens are fulfilled. A pair of correcting lenses should never be allowed to be worn unless the workmanship has been carefully verified. Absolute rule should be made that every lens ordered must be seen, as this will often save much anxiety, and frequently relieve the practitioner of an onus that might belong to the optician alone.¹

Even though the surgeon does his own adjustments, or, better, if he is able to send the patient to a first-class optician, such as is found in large cities, in whom, from constant experience, the utmost accuracy can be generally relied upon, yet he should take the utmost precaution that the mechanism of the fittings are looked at, and exercise the greatest care that they fulfil their purpose. If choice be offered by the patient, strong, durable gold spectacle-frames of good quality (ten to fourteen carat) for lenses which are to be worn constantly, should always be preferred. Should the lenses be desired for near-work, there is nothing better than accurately made rigid-steel frames, which are either burnished or bronzed; long, steady, straight temples being preferred for women with a profusion of hair. The fastenings of the mountings should be tight, and the joints should be smoothly mobile. Notice should be taken whether the bridge of the frame hugs the bridge and sides of the nose snugly without causing any decided pressure; and care must be exercised that the temples or sides of the frame press lightly, evenly, and continuously, as much as possible, throughout their entire length. The portions from the end-pieces to the ears must be as straight as possible, and their comparative lengths should be correct. Care should be taken that every part of the temples where they curve around back of the ears has been conformed to the irregularities, as frequently patients complain of pain in these situations from badly fitting wires.

The lens should be smoothly and evenly ground and polished, which may be determined by holding it at an oblique angle, and noticing whether there is uniform reflection; or, if desired, a straight, narrow object, such as a lead-pencil, can be placed against the under surface, whilst the lens is held in this position, and notice taken whether the object appears wavy, irregular, or crooked.

¹ This cannot be too strongly impressed upon the student. The author has, time and again, been compelled to have fittings remodelled, lenses reversed, and sometimes inverted; even too weak or too strong adjustments, etc., have been made. The exercise of proper care in this direction not only conduces to the comfort of the patient and the advantage of the physician, but is of infinite use to the scientific optician who takes the trouble to secure careful and proper work. The surgeon had better learn to do the work himself, than to trust to the results of some incompetent workman.

The strength of the lenses should be carefully gauged, which, in addition to the rough-and-ready method of measuring the focal distance necessary to give the clearest image of a distant object upon a piece of cardboard, is easily done by neutralization of the lenticular effect, by superimposing the same strength of the opposite variety of lens, thus rendering the surfaces parallel, and annihilating the action of the original lens. In addition to this, advantage should be taken of the fact that if a spherical lens be alternately moved in opposite directions in the same place, any object seen through it seems to move either with the direction of movement given to the lens, or contrary to that direction; the rule being that all objects move against the motion of the convex lens, and with the motion of the concave lens. This is dependent upon the ordinary converging and diverging powers of the lenses employed. Therefore, if, after placing the opposite-strength lens before the one to be determined, no motion of any object—such as a fine test-letter placed at about five meters' distance—is seen through the two glasses, it can fairly be concluded, especially in the weaker and ordinarily used lenses, that the correcting lens is properly gauged.

The neutralization of the cylinder lenses is done in the same manner, merely taking care that the axis of the lens to be gauged and that of the neutralizer are in exactly the same meridian. This can best be accomplished, by a novice, by placing them in a test-frame. Sphero-cylinders, or, in fact, any form of lens-combination, can be readily determined by these methods. In these experiments, it is best to hold the lenses at arm's length. If the lens be made of crown glass, which is ordinarily the case, recourse may be advantageously had to a little instrument lately devised by Mr. Brayton, by which, when it is in perfect order, not only can the power of any form of spectacle lens be accurately measured to one-quarter and even one-eighth diopter difference, but the axes of cylindrical lenses can be readily found. Practically, it consists of three steel points, the middle one of which, being connected with an index, can be easily moved up and down by pressure upon the surface of the lens that it is desired to estimate. By following certain simple rules, cylindrical, spherical, and plane surfaces can be quickly determined. If the lens be periscopic, the strength of one surface is to be subtracted from the other. If it be bi-convex or bi-concave, the strengths of the two surfaces must be added. It is also often extremely useful in determining whether cross-cylinders have been employed in the construction of a lens that has been directed to be so made.

Having found that there are no flaws, and that the lens has been properly gauged, it next becomes necessary to obtain what is known as its optical centre, or the position in the lens expressing its representative refraction. This is readily and satisfactorily done by looking at a long vertical line, such as the edge of a door-jamb, through the lens, and noticing whether the portion seen through the lens, when the line of jamb is made to fall through any one of the diameters of the lens, appears continuous with the rest of the edge of the jamb, or seems to be moved to one side. If it is continuous when this is done with a spherical lens, an ink-dot should be made at each extremity of the diameter

chosen and a fine line drawn from one point to the other. The same procedure should be tried in the meridian at right angles, by revolving the lens in a lateral direction. The situation at which the ink-lines cross each other will give the summit or the greatest depression of the lens, through which, necessarily, the principal axis containing the optical centre (which we are endeavoring to determine) passes. If there is no deviation, the lens is probably properly centred. In doubtful cases, it is a good plan to mark this point with a spot of ink, and then re-test, and see if the line of door-jamb always passes through the spot marked, when other meridians are tried. If the lens be of strong power, it is better to employ a cross made of fine lines placed at fifteen to twenty centimeters' distance. If care be taken to hold the face of the lens parallel with the face of a square card whose edges are of greater length than the width of the lens in its various meridians, an easy method to attain the same object can be pursued, by moving the lens before the card until two of its connected right-angled edges appear continuous when seen through the lens. When this occurs, the corner of the card will be found to exactly coincide with the optical centre of the lens. An ink-spot at this point fixes the desired result.

For the estimation of prisms, the neutralizing prism is to be placed exactly in the same meridian with its base situated toward the apex of the prism to be tested. This will throw the line of the door-jamb, which has been deviated toward the apex of the prism to be tried, directly into the combined centres of both prisms. This should be done whilst rotating them in every meridian, taking care, if the lens is a compound one, such as a spherical, a cylinder, and a prism, first to neutralize the cylinders. Another striking and plainly manifest deviated appearance of a vertical line can be produced by a single prism, by gazing at a right-angled cross through the prism in such a manner that the arms of the cross coincide with the apex of the prism. If the vertical stroke of the cross appears continuous and the entire figure seems perfect, the centre of the cross will give the summit or representative portion of the prism's apex; *i. e.*, the angle of the representative strength.

Advantage may also be taken of the fusion of the double lines of reflection to determine the axis of a prism. To do this, the observer simply looks at some reflected line (preferably a window-bar) that is situated behind him. Should the lens be cylindrical in its action, the object will be to obtain its line of representative action, which, as we have already learned, is at right angles to its axis. The examiner is to hold the line of supposed axis of the cylinder in such a manner as to correspond with the line of the jamb. Now, by slightly moving the lens in a lateral manner on each side of the supposed vertical line, he will find that the line of the door-jamb will be continuous and clear when it coincides with the axis of the lens. By drawing an ink-line through this part of the lens, he will thus locate the position of the axis. Changing the position of the lens so that the ink-line shall be at right angles to the line of the door-jamb, and pursuing the same course, he will be able to fix the point where the portion of the line of the jamb, as it passes continuously through the second line, cuts the axis of the lens. The new line, which is dimmer than the axis-line, represents the posi-

tion of the meridian of greatest refraction : it gives the line and angle of the representative strength of the lens. Combinations of sphero-cylinders are proved in the same manner, care being taken to hold the cylinder surfaces and the spherical surfaces respectively together while testing. If it be merely required to determine the degree of the opening or refracting angle of the prism, the angular separation rendered necessary for the legs of a pair of dividing compasses or calipers, measured on an ordinary mathematical protractor, will be sufficient. Should it be desired to register the amount of work done by the prism, actual measurement of the amount of deviation toward the apex of the prism can be made by a scale of graduated prism diopters or centradis intended for definite distances.

It will next be necessary to determine whether the optical centres come directly opposite the pupillary centres or at any other desired points, when the lenses are placed in position before the patient's eyes. For the determination of these points in distance-glasses, an ordinary millimeter measure is to be taken and estimates made (generally adding about one or two millimeters to the result), whether the intra-pupillary distance is correct, the surgeon gauging this from the centre of each pupil whilst he holds the measure at arm's length, or, better, by studying the distance from each pupillary centre to the summit of the nasal bridge of the patient while the latter is looking at a distance. If greater accuracy be desired, one of the many forms of pupilometer may be employed, each requiring some peculiarity of technique to obtain proper readings. Having had the optical centres of the lenses marked, the distance between the spots is to be measured, and then, having the patient fix upon some fine test-dot or letter, situated at the previously chosen distance and position for near-work, the distance between the two pupils when the eyes are adjusted for this point is to be measured, and notice taken if it agrees with the optical centres of the lenses. If it does, the lenses have been properly separated for such near-work. When decentring is desired, the same procedures hold good, except that the proposed amount of excentric placing must be taken into account.

The next thing to do, is to see if the lenses are situated upon their proper levels, and whether they are placed too near or too far from the eyes. To do this readily, a flat rule should be laid broadside against the anterior face of the lenses and measurements taken for any desired distance between the summits of the corneæ and the posterior faces of the lenses. During this examination, notice must be taken if the lashes have free movement without scraping against the lenses. Surety must be made, either personally by proper bending with fine pliers, or by the aid of an optician, that the lenses are made with sufficient inclination, and that their planes are situated as nearly as possible at right angles to the axis of vision—this generally requiring a downward and inward dip of about fifteen degrees to be given to lenses used for near-work. If these measurements must be made by the surgeon himself, nothing more than a very broad millimeter measure is necessary; the results becoming surer and easier by continued practice.

To meet the requirements of the almost innumerable shapes of the

nasal bridge, numerous so-called "*nose-pieces*" have been constructed, each adapted to some peculiarity of formation. To adjust such a nose-piece or bridge so that it may be comfortable and inconspicuous, and that it may fulfil all the necessary requirements, the ingenuity of the optician is often taxed to the utmost. One of the best plans for securing the shape of the nasal bridge that may be offered to the surgeon who does not pretend to do his own fitting, and where the patient is not under the immediate control of a first-class optician, has been the adapting of a small piece of malleable lead wire over the curve at the point where the nose-piece would naturally fall to rest, and then making a drawing, as it were, of all the irregularities by pressing the leaden mould upon a slip of paper and sketching in the details, or, better, sending the sample wire itself to the optician. A fairly good working model is thus secured, which can be used for measurement.

A good method for comparing the distance between the true centres of the lens with the distance between the optical centres, after having obtained the widths of separation of the optical centres and marked them, is to measure the width of one lens and the width of the nose-piece combined: this will give the distance between the true centres, which may be readily compared with the distance between the optical centres.

The existence of ametropia and accommodative fault having been carefully determined and corrected properly, there remain but a few words of advice beyond those just given. The student should always, if possible, especially if there be astigmatism or muscle-error, have the patient wear a carefully fitted spectacle-frame in preference to an eye-glass frame, so that any error or change of position from constantly repeated adjustment or weakening and stretching of the connecting spring may be avoided. If, as happens in many cases, the patient will not wear the spectacle-frames, the surgeon should see not only that the best, the most secure, and the most skilfully-made pattern of eye-glass frame is employed, but also that the mountings are frequently inspected by some competent optician. The patient should regularly visit the optician to have the fittings accurately readjusted, in order that it may be certain that the correction is properly placed before the patient's eyes: this is especially necessary with children's corrections and with lenses for near-work. Moreover, the patient should show the surgeon every new lens obtained, so that there may be a certainty that he is wearing the intended correction. The patient should be taught in a few words how to care for the spectacles or eye-glasses, how to remove and replace them (preferably with both hands) without straining the mountings, and how to cleanse them with a weak solution of ammonia water gently rubbed on with an old, soft, clean handkerchief.¹ Further, a rule should be made that the patient shall return every year, or at other stated intervals, so that watch may be kept over the progress of his case: this is particularly necessary in cases of used, irritated eyes, especially in the myopic eyes of young and growing children.

¹ Where cemented bi-focals are used, plain water is the best.

The student must always bear in mind that his success is in his own hands. As he has just been told, no inflexible rules of government can be laid down. Each case has its own series of peculiarities, and each peculiarity has its prototype in some past case. The grasping of one set of symptoms embraces the comprehension of many other sets. He should study each individual grouping in its entirety, and he will soon find himself both apt and efficient in obtaining what others have sought for in vain.

PART II.

BY WILLIAM F. NORRIS, M.D.

INJURIES OF THE ORBITS, EYES, AND EYELIDS.

SYMPATHETIC OPHTHALMIA.

DISEASES OF THE CONJUNCTIVA.

DISEASES OF THE CORNEA.

DISEASES OF THE SCLERA.

DISEASES OF THE IRIS AND CILIARY BODY.

ACCOMMODATION.

EMMETROPIA, HYPERMETROPIA, MYOPIA, AND ASTIGMATISM.

CATARACT.

DISEASES OF THE RETINA.

AFFECTIONS OF THE OPTIC NERVE AND ITS INTERNAL PROLONGATIONS.

DISEASES OF THE CHORIOID.

DISEASES OF THE VITREOUS.

GLAUCOMA.


AFFECTIONS OF THE EYE-MUSCLES.

DISEASES OF THE EYELIDS.

DISEASES OF THE LACRYMAL APPARATUS.

DISEASES OF THE ORBIT.

SOME OF THE MORE COMMON AND IMPORTANT OPERATIONS ON THE EYE.



CHAPTER XI.

INJURIES OF THE ORBITS, EYES, AND EYELIDS.

THE firm, bony margins of the orbits are admirably adapted to protect the eyes from blows. Their thin walls, however, render it possible for new growths from adjoining cavities to readily penetrate them, and afford foreign bodies ready access to the ethmoidal cells, antrum, and cranial cavity. Wounds of the orbital roof are always dangerous, and may be followed by intra-cranial hemorrhage, meningitis, or abscess of the brain. Where there is a fracture of the roof of the orbit, there may at first be no symptoms, but there is often a settling of blood, which, by spreading between the periosteum and the bone, follows down the tarso-orbital fascia, and may first show itself in the lids and under the bulbar conjunctiva a day or two after the injury. By reason of communication with the nasal cavities, fractures of the ethmoid plate or frontal sinus generally give rise to emphysema, and an attempt to blow the nose may so swell the eyelids as to cause them to close over the eye. A pressure-bandage generally diminishes this emphysema, and under its influence, combined with rest and abstinence from all attempts at forcible expiration, the fissure usually soon heals tightly enough to prevent the further entrance of air into the orbital tissues.

Large foreign bodies may be driven into the orbit, and whilst lying between its walls and the eyeball, or entering partly into the antrum or the nasal sinuses, may escape detection. Many curious cases of this sort could be recorded. Carter cites an instance where a patient, in going down stairs, fell and struck against an iron hat-peg secured to the wall, breaking it off from its base. It had entered on the nasal side of the right eye, and probably had perforated the antrum of the opposite side. Several days afterward it was removed. It measured three and a half inches in length and weighed twenty-five scruples. Nélaton removed the ivory handle of an umbrella, four centimeters long by one and a half centimeters thick, from the orbit of a man; where it had lain for three years, and where it had caused a button of granulation near the inner angle of the palpebral fissure. In this case, there were mydriasis and diminished inward mobility of the globe. The author once removed a large piece of iron from the inner and lower part of the orbit, which had remained unnoticed for several days. All these cases recovered with good eyesight. An instance of penetration of a foreign body into the nasal cavities through the orbit is recorded by White.¹ A piece of pipe-stem was driven through the lower lid into the orbit. The eye, which was luxated upward, was

¹ Cases in Surgery, pp. 131-132. London, 1770.

replaced, with the effect of restoration of vision. The patient experienced no further trouble, except a smell as if tobacco were in the nose, until two years later, when, during a paroxysm of coughing, he expelled a piece of pipe-stem two inches long from his mouth, followed two weeks later by another piece an inch long. After this, the patient entirely recovered.

Usually, however, foreign bodies in the orbit cause suppuration and abscess, with bulging of the eye and swelling of the eyelids and the surrounding skin of the face—symptoms which often subside upon evacuation of the abscess and removal of the foreign body. Frequently, eyesight is impaired or is destroyed. At times, life may be sacrificed, as is shown in the following cases recorded by Jaeger and Pagenstecher.¹ An instance of the former result is shown in the first, where a piece of tobacco-pipe, one inch long and four lines thick, which had been driven into the orbit, was removed after a year's time. During this interval it had caused orbital abscess and suppuration of the eyeball, with partial destruction of the cornea. In the second instance, which was followed by death, a knitting-needle was broken off within the orbit. After various attacks of subacute inflammation, there was presented, at a date seventeen years after the injury, an inflamed and shrunken globe, turned in toward the nose, and causing sympathetic irritation of the fellow-eye. Enucleation was attempted, but, owing to some hard substance which projected into the eye from the roof of the orbit, it was found impossible to remove the entire ball. On subsequent examination it was determined to remove this substance, and a fragment of rusty knitting-needle, one centimeter in length, was withdrawn. This operation was followed by nausea, vomiting, and fever. The patient recovered and left the hospital. Two months later there was a return of the cerebral symptoms, accompanied by deafness and dilated pupils. Sopor and death soon followed. The autopsy showed two abscesses, one on the left side of the medulla oblongata, and the other on the pons Varolii, between the arachnoid and the pia mater.

Contusions of the orbit may be followed only by ecchymosis of the lids. At other times, inflammation of the orbital fat and cellular tissue may appear; again, inflammation of the periosteum may occur. In the second of these conditions, an abscess, with severe pain and considerable swelling and exophthalmos, is apt to form rapidly. In the last, the symptoms develop more slowly. Blows upon the margin of the orbit, which apparently cause but little injury, are sometimes followed by blindness. This was formerly attributed to reflex action through the fifth nerve, but it is probable that in most instances, it is due to a fracture of the roof of the orbit, involving the optic foramen. Such a fracture may cause blindness by direct injury to the optic nerve, by interstitial inflammatory processes set up in it, or by hemorrhage into its sheath. Fractures of the base of the skull frequently involve the roof of the orbit, by extension forward. Where fractures of the roof are accompanied by sufficient hemorrhage into the orbital tissues to cause exophthalmos, the prognosis is most unfavorable.

¹ *Staar und Staar-Operationen*, Wien, 1864, Ss. 69-71.

The eyelids and eyelashes, which form mobile protecting coverings for the eyes, are exquisitely sensitive, and are endowed with highly developed reflex action. Their sudden closure is accompanied by the synchronous and reflex rolling up of the eyeball, so that when a blow is aimed at the eye, this reflex action is so prompt that a penetrating stab of the upper lid will sometimes enter the eyeball below the cornea. Owing, however, to the absence of the third eyelid, the eye of man is much less protected from injury and the entrance of foreign bodies than that of some of the lower animals. As previously explained, the eyelashes are curved outward, so that when the lids are partly approximated, and while we are still able to see, they form a screen or veil by touching one another with their convex surfaces, thus serving to keep dust and other foreign bodies out of the eye. When, in spite of these guards, a cinder, ash, or other substance enters the conjunctival sac, the eye waters, the lids close, and there is a sharp pain. If the foreign body is rough, or if it is of any considerable size, these symptoms persist until the substance is either washed away by the tears or is otherwise removed. Some bodies, however, especially when they lodge in the retrotarsal folds, where the conjunctiva is less sensitive, may remain for a long time, and give rise to symptoms of chronic conjunctivitis. Pieces of the beard of wheat and oats often lodge in such a position, and, becoming semi-transparent by maceration, and clinging tightly to the conjunctiva, require careful examination for detection. Cinders, and foreign bodies of like nature, can be readily removed by everting the lids and gently wiping off the foreign body with a wet handkerchief, the foreign substance becoming entangled in the meshes of the fabric. A small wisp of absorbent cotton also makes an efficient instrument.

FIG. 181.



Spud for the removal of foreign bodies from the cornea.

When a small foreign body lodges in the cornea, the eye not only waters, becomes painful, and is sensitive to light, but a pericorneal injection soon develops, which is usually most marked on the side that is nearest to the point of injury. To see such an object, the patient should be seated in front of a window, and the sound eye should be closed with a handkerchief. The patient should then be made to gaze at the movements of the surgeon's finger, as it is moved from one side to the other, or up and down. By this means an image of the window-bars may be successively reflected from all parts of the surface of the cornea, so that the slightest abrasion of the epithelium, or the presence of any minute body, will become easily visible. Especially is this so, if the examiner looks through a magnifying-glass. If the operator fails to see the inequality of the surface, or the foreign substance, by these methods, he should examine the cornea with a magnifying-glass behind the ophthalmoscope, when the depression of the minute particle will appear as a dark spot on a yellow-red ground. If still in doubt, he may resort to oblique illumination. When the foreign body has been located, a

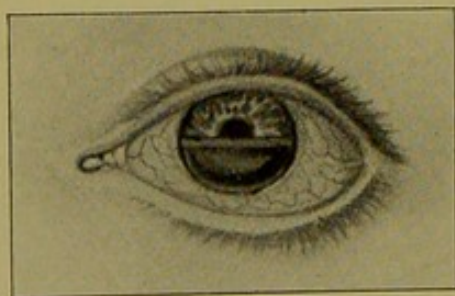
few minims of a two per cent. solution of cocaine muriate should be dropped into the conjunctival sac. This done, a cataract-needle or a spud of the variety shown in Fig. 181, should be gently inserted under the foreign body, so that the body can be lifted out of its bed. The hand of an assistant or the disengaged hand of the surgeon should be employed to lift the upper lid.

The eye should be washed with either a saturated solution of boric acid or with a weak solution of bichloride of mercury. It should be closed with a clean piece of linen that has been covered by a slight compress of cotton held in place by a bandage. Under this plan the epithelium will usually be regenerated in a few hours, and the eye will become quiet and comfortable, needing no further treatment. If, however, a considerable time has elapsed after the accident, or if the eye has been previously irritated by rough or unsuccessful attempts at removal of the foreign body, considerable ciliary injection will remain, persisting sometimes even after the reproduction of the epithelium. In such cases, a solution of homatropine should be instilled, and the pupil should be kept dilated for several days, till the eye has become white and quiet. The bandage should always be removed as soon as the epithelium has been reproduced, and the eye should be protected from irritants, by a dark glass. The cure will be much facilitated by forbidding the use of the fellow-eye for all near-work.

Abrasions of the cornea are injuries generally caused by some foreign body being roughly brushed across the eye. One of the most frequent causes is a scrape from the nail of an infant. The pain is often severe. It should be stilled by cocaine. The eye should be kept closed till the epithelium is reproduced. In the elderly and debilitated, abrasions of the cornea are often followed by serious results, such as creeping ulcers, or hypopyon-keratitis. These conditions are especially apt to occur where there is pre-existing catarrh of the lacrymal sac.

Blows and contusions often cause effusion of blood into the subcutaneous tissue of the lids and bulbar conjunctiva. These ecchymoses are

FIG. 182.



Hemorrhage into the anterior chamber.
(WHITE COOPER.)

frequently a cause of disfigurement, not only from the swelling, but also from the discoloration of the skin, which appears black and of various shades of green and yellow. As a rule, they disappear spontaneously. Their absorption may be materially hastened by hot compresses applied at half-minute intervals, for thirty minutes at a time, three or four times daily.

Hemorrhages into the anterior chamber, as shown in Fig. 182, are usually caused by rupture of the vessels of the iris or ciliary processes. In young and healthy subjects they are often readily absorbed, and such a chamber filled with blood may, within twenty-four hours, resume its normal appearance. A guarded prognosis should, however, always be given, as these injuries are often accompanied by similar ruptures of

bloodvessels in the retina and chorioid, which may permanently impair the functions of the eye. When these extravasations happen to be in the macular region, a central scotoma may remain throughout life. Effusions of blood into the vitreous humor are apt to leave remnants which cause floating muscæ. Where the vitreous is filled with blood, the eye almost invariably shrinks and becomes sightless.

Exophthalmos, or protrusion of the eyeball, may be due to any cause which increases the volume of the orbital contents. Oedema of the fat-tissue of the orbit in exophthalmic goitre; inflammation of the orbital contents in periostitis, cellulitis, or panophthalmitis; distention of the orbital bloodvessels; and new growths, are among the more common.

Enophthalmos, or the condition in which the eyeball sinks back into the orbit, and which is usually accompanied by a diminution in the size of the fissure of the lids, is produced when cellulitis induced by any of these processes is chronic, of low-grade type, and is accompanied by an absorption of the orbital fat.

Dislocations of the eyeball. After severe injuries and blows, the eyeball is sometimes forced forward, while the eyelids close spasmodically behind it and prevent its return. At times the eye is forced out of its socket by the insertion of the thumb into the orbit. Even a slight cause, such as straining when the upper lid is everted, may be sufficient to dislocate the eyeball in protuberant eyes. The optic nerve is thus put on the stretch, causing the patient to complain of distressing flashes of light. If the recti muscles have not been ruptured, and if there has been no hemorrhage into the capsule of Tenon, separation of the lids, with gentle pressure on the eyeball, will effect reduction. If we fail to replace the globe in this manner, division of the external canthus will loosen the lids, and enable us to bring them forward over the eyeball. If the stretching of the optic nerve has not been too severe, and if there has been no rupture of the eyeball nor intra-ocular hemorrhage, good eyesight may be recovered.

Tearing out of the eyeball may occur so as to completely separate it from its attachments and remove it from its socket. This may be effected by accident, as in the case related by Voerhaege,¹ where a drunken fisherman lost his balance in undressing, and fell against his bedroom door, so that a key, standing in the lock, divided the upper lid by a vertical wound. The key, acting as a curette, tore the eyeball so completely from its attachment, that the organ rolled upon the floor.

Injuries of the eyes by lightning are not infrequent. In instances of lightning-stroke where the patients have survived, Leber² has collected eighteen such cases. The injuries were exceedingly various in character. In nine, there was cataract. He also mentions ptosis, corneal haze, hemorrhages into the retina, and rupture of the chorioid, as some of the symptoms that were encountered. Sillex³ relates the case of a child who lay senseless for five hours, without other apparent injury than cloudiness of the cornea and of the lens. Eleven months later, the haziness of the media had partly disappeared.

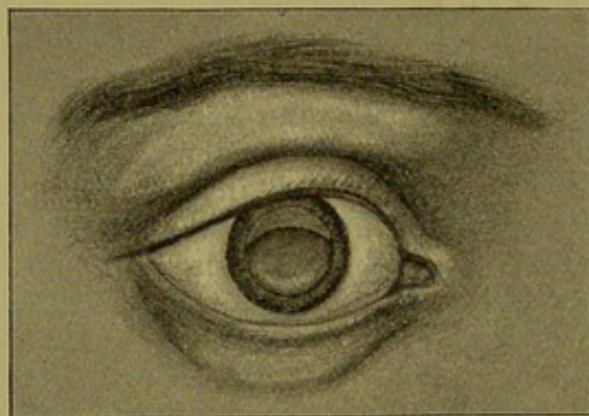
¹ Annales d'Oculistique, 1851, pp. 99-101.

² Arch. f. Ophthalmol., xxviii. 3, S. 255.

³ Archiv f. Augenheilkunde, xvii. 3, Ss. 335-340.

Dislocations of the lens are often caused by severe blows on the eye which rupture the suspensory ligament. The pupillary margin of the iris, deprived of its normal support, wobbles with each motion of the eye. If, as is usually the case, a part of the lens still remains opposite the pupil, as shown in Fig. 183, very great disturbance of vision is produced. Released from pressure of its suspensory ligament, the lens swells and becomes too convex. The rays of light passing through it are focussed before reaching the retina, making this portion of the eye myopic, while those passing through the remaining part of the pupil, are not focussed when they reach the retina, and consequently the eye, in this position, is hypermetropic. The lens usually assumes an oblique position, causing astigmatism. When the capsule is torn, the aqueous humor is admitted to the lens-substance, causing the lens to swell and to become opaque. In such instances, the rent is usually situated near the

FIG. 183.



Dislocation of lens. (JAEGER.)

equator, or is close to it on the posterior capsule. If the swelling of the lens be not so great as to cause decided increase of intra-ocular tension, or if pressure on the iris be not sufficient to cause inflammation of that organ, the traumatic cataract thus produced may be entirely absorbed, and leave the pupillary space clear. Most frequently, however, it leaves sufficient opacity to call for operative interference.

Iridodialysis is a tearing loose of the iris from its attachment to the ciliary body, and is not infrequently the result of severe blows on the eye. At times it is associated with dislocation of the lens or with rupture of the eyeball. This is shown in Fig. 184, where the condition is associated with traumatic cataract, the accident having been produced from a blow by a stick.

Burns of the eyelids and eyeballs are very frequent and serious injuries. In those caused by hot water, by splashes of molten metal, by the stronger mineral acids, or by caustic alkalies, the effects are usually so instantaneous and intense, that all attempts to limit the immediate destruction of tissue are useless, and we can treat only the results. When such agents strike the cornea and conjunctiva, they cause a dense whitish slough. Where the action is superficial, the epithelium is thrown off; regeneration taking place from the corneal edges. Fig.

185 represents a slough of the cornea after a burn, which was caused by a splash of caustic soda. Although a large permanent opacity of the cornea remained in this case, yet the patient had a useful eye.

FIG. 184.

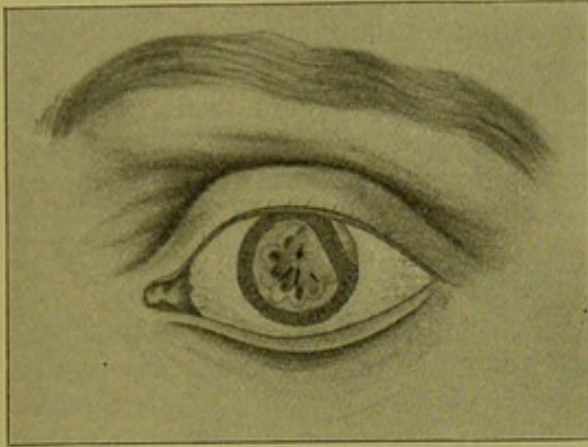
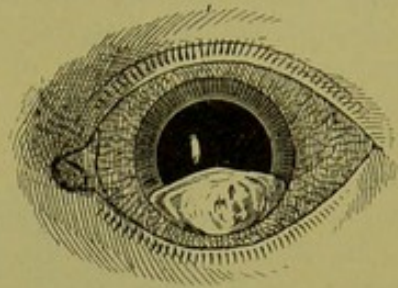


FIG. 185.



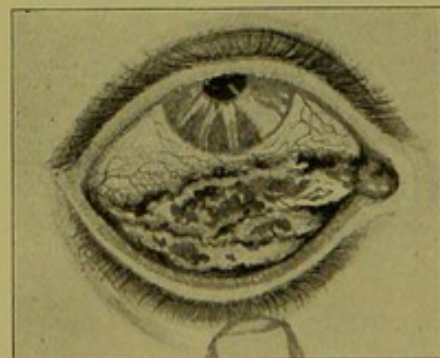
Iridodialysis with traumatic cataract. (JAEGER.) Slough of cornea after a burn. (RANDALL.)

Where the deeper layers of the cornea mortify, the eye is lost. In rare instances, small portions of molten metal enter the conjunctival sac, and in cooling, form a mould of the anterior surface of the eye, with wonderfully little injury either to the cornea or to the sclerotic. In such cases, it is supposed that the eye is saved by the non-conducting power of vapor; steam being formed and separating the hot metal from the eyeball. Long exposure to severe cold will sometimes cause a slough of the cornea which corresponds in extent with the fissure of the lids.

Burns from slaking lime leave very dense and contracting cicatrices. In such cases, the lids should be everted, while olive oil or other non-irritative fat is instilled to prevent the contact of water from causing further slaking of the lime. All foreign particles should be carefully removed from the conjunctival sac with a spud or a director. When no such appliances are at hand, much good may be effected by holding the eye open under a powerful stream of water, even though this favors the further slaking of the lime. All visible particles should be removed by the end of a match-stick or a handkerchief.

The instillation of vinegar is also recommended, so as to convert the lime into an acetate. Severe burns of the conjunctiva may be caused by the accidental contact or the careless application of some of the astringents. Fig. 186 shows a burn of the conjunctiva produced by nitrate of silver. When cicatrization sets in, burns of the skin of the lids are apt to cause ectropion and displacement of the lacrymal canaliculi, with

FIG. 186.

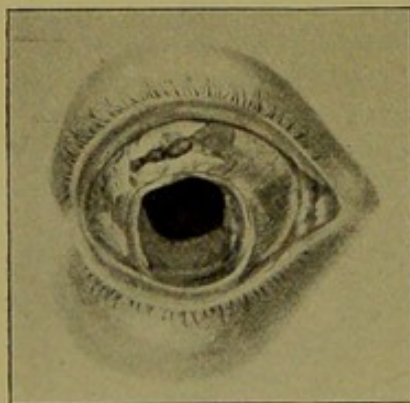


Burn of conjunctiva. (WHITE-COOPER.)

closure of their orifices. If both the bulbar and the tarsal conjunctivæ are burnt, the granulations from the opposing raw surfaces unite when the slough separates, and produce a firm attachment of the lids to the ball, thus forming what is known as a *symblepharon*. When the cornea has been involved, a fold of granulating conjunctiva may come in contact with the abraded cornea, causing firm union with it, thus producing a *traumatic pterygium*. The limitation of the motions of the eyeball thus caused by the adhesion between the eyeball and the lids, is a constant source of irritation, and the patient suffers from constantly recurring inflammation of the eyeball, with more or less corneal haze and marked conjunctivitis. All attempts to prevent union of the two surfaces by loosening the adhesion, or by the interposition of metal shields, are useless. The shields are gradually forced out from the bottom of the retrotarsal fold, by contraction and cicatrization.

In the treatment of burns, the eye should be kept clean by washing it with a weak bichloride solution. This should be followed by free instillation of boric acid. All shreds of necrosed tissue should be removed as they loosen. Keratitis and iritis call for the employment of atropine, while pain is combated by the frequent use of a solution of boric acid and cocaine. In the interval, the eye should be kept closed and covered with a soft rag that has been either saturated with carron oil or coated with iodoform ointment. When cicatrization is complete, an attempt may be made to divide the adhesions between the lids and the eyeball. They should be dissected from the cornea and sclera, and then, after the manner of Arlt, prevented from readhering by turning the outer or epithelium-covered surface of the dissected tissue toward the raw surface left on the eyeball. The raw bulbar surface should be diminished in extent as much as possible by loosening and stitching the cut edges of the bulbar conjunctiva together. The pyramidal mass of tissue dissected from the ball

FIG. 187.



Rupture of the sclerotic. (SICHEL.)

should have a thread with two needles passed through it. These should be carried to the bottom of the conjunctival sac and then passed out through the eyelid. The threads are then to be tied over a roll of antiseptic gauze or other soft material. The dissected flap is thus held securely in place. The suture should be left in position for three or four days, or until suppuration commences along its course.

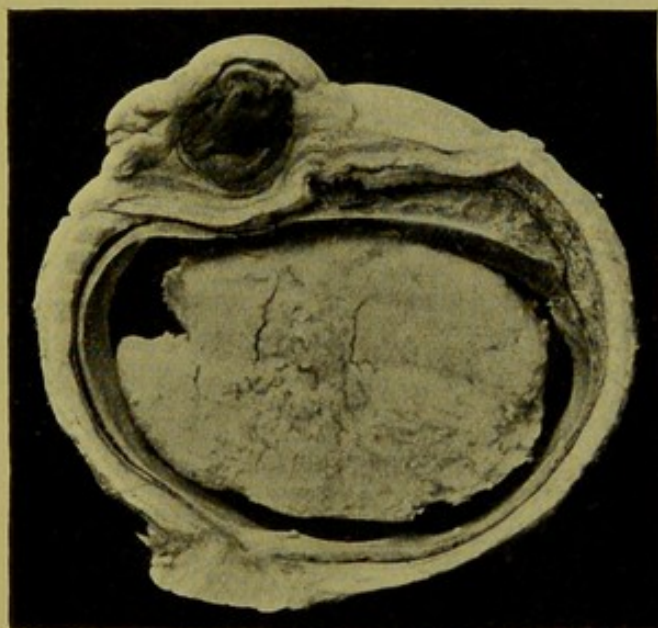Rupture of the sclerotic is, at times, produced as the result of a violent blow on the eye. The rent almost invariably takes place at right angles to the direction of the force producing it,

and generally occurs at a distance of from two to five millimeters from the border of the cornea. Thus, if the blow be from below and to the outside, the rent will be found above and to the inside. Although the sclerotic is thinnest behind the insertions of the recti muscles, yet, as it seems to be supported by them, the rent occurs in front of the muscle-

insertions. There is almost always prolapse of the iris, and frequently there is dislocation of the lens. Fig. 188 represents the latter condition.

In spite of the severity of the injury, the eye occasionally recovers with some degree of useful vision. In the vast majority of instances, it either shrinks or suppurates. White Cooper¹ reports a case from Bowman's practice, where a severe blow on the eye from the sudden opening of a carriage-door, caused a rupture of the sclerotic at its posterior part. He remarks, that such cases may be more frequent than they seem, as they cannot be diagnosticated till after enucleation of the eyeball.

FIG. 188.



Specimen showing rupture of eyeball with subconjunctival dislocation of lens.

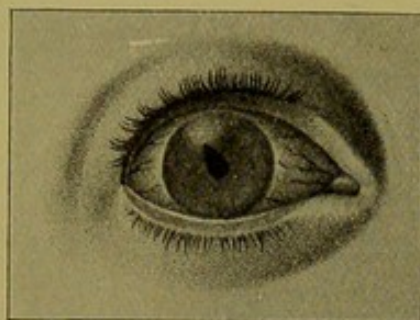
Rupture of the chorioid occurs at times, without any rupture of the sclerotic. In such cases, it usually appears as a rent which is parallel to one of the borders of the optic nerve. At first, its extent, and perhaps even its existence, cannot be determined by examination with the ophthalmoscope, on account of the effusion of blood. As the hemorrhage absorbs, a whitish or yellowish rent, often of considerable extent, and sometimes branched, is seen. If it does not invade the macular region, good sight may ensue. Temporary pigment-deposition between the disk and the macula may at times be the only recognizable ophthalmoscopic change.

Penetrating wounds of the eye with injury to the cornea and iris. The simplest examples of these, are those cuts of the cornea by which the anterior chamber is opened. If there is no prolapse of the iris, they generally heal rapidly, without impairment of vision. The purposive injuries made in the operation for discission of cataract, or in opening the anterior chamber to evacuate pus, are familiar examples. After the

¹ Injuries of the Eye, 1859, pp. 137, 198

operation, a slight clouding of the cornea is visible in and around the wound, but it soon clears away and cannot be seen by ordinary examination. It is, however, even for years afterward, demonstrable with a magnifying-glass and oblique illumination. Where incised wounds of the cornea are complicated with prolapse of the iris, they are much more serious. They leave larger and more extensive opacities, and are apt to result in anterior synechiæ, which often lead to chronic iritis or to increase of intra-ocular pressure and secondary glaucoma. Fig. 189

FIG. 189.



Anterior synechia with distortion of pupil. (DEMOURS.)

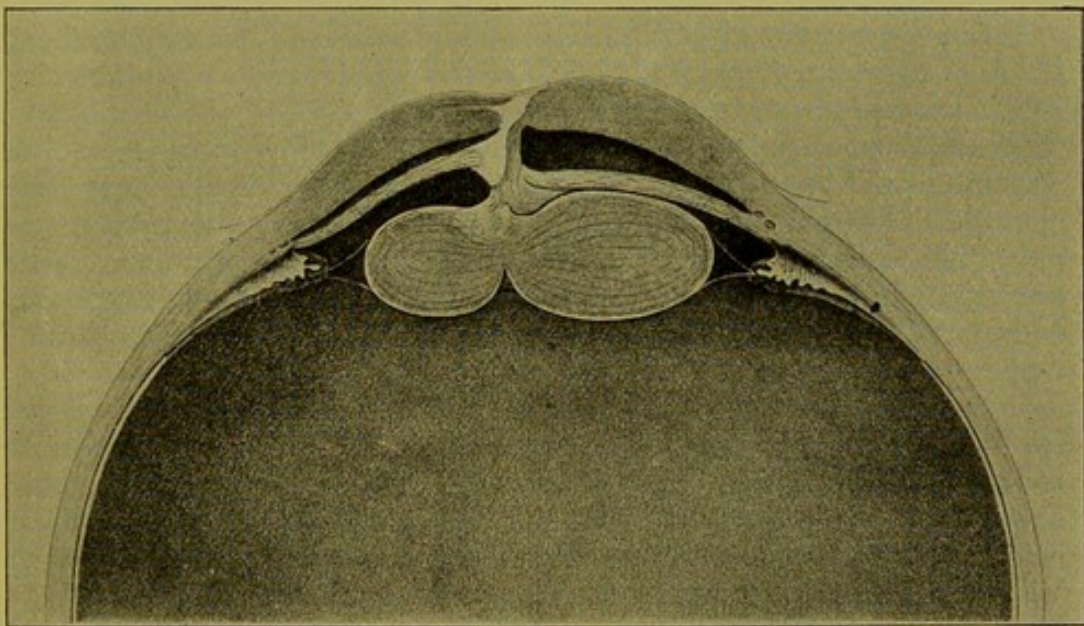
represents an anterior synechia following a punctured wound of the cornea. The distortion of the pupil and the permanent haze of the cornea around the wound are shown. When the prolapse is small, it should, after the eye has been washed with an antiseptic solution, be abscised by seizing it with the iris-forceps and cutting it off with a delicate scissors close to the cornea. The edges of the iris, if entangled in the wound, should be gently freed and replaced with a metal or horn spatula. In order to keep, if possible, the iris from again becoming entangled in the cut, a solution of atro-

pine should be instilled if the wound be central. If the wound be peripheral, a solution of eserine should be used. The eye is to be cleansed and a bandage is to be applied. This dressing should be repeated once daily, until firm union of the wound has taken place. Very large prolapses should not be cut off, as they reproduce themselves. In such cases, all that can be done is to try to prevent further protrusion by the use of a compress bandage.

Penetrating wounds of the eyeball with injury to the lens or its capsule. Wounds of the lens are always serious, and frequently lead to the loss of eyesight. Where the capsule is lacerated, it always results in swelling and opacity of the lens-substance, which generally continues until the entire lens has become opaque. In rare instances, the capsule closes, and the opacity remains partial. The prognosis is comparatively favorable only in those cases in which the wounding instrument has entered through the cornea and pupillary space, without injuring the iris and the ciliary body. In these instances, however, rapid swelling of the lens may take place, which may either cause inflammation of the iris from pressure on it, or lead to artificial glaucoma by augmenting the general intra-ocular pressure to such a degree that the nerve fibres of the retina are paralyzed and the head of the nerve is pushed back into its sheath. Owing to the greater softness and elasticity of the sclerotic and the greater dilatability of the pupil in early life, and to the slight tendency of the iris to inflammation, rapid swelling of the lens is much better borne in the young than it is in the old. In such persons, where the nucleus of the lens is still soft, a wound of this organ may lead to its entire absorption, leaving the eye in a state similar to that which is found after a successful cataract operation—that is, with a clear pupil

and entire absence of the lens. When the iris is involved, the prognosis is more grave. Inflammation of this organ keeps it congested, and its bloodvessels and those of the ciliary processes distended and full of blood, while the circulation at the periphery of the anterior chamber becomes more sluggish, and the absorption of the swollen lens-matter much slower. Moreover, exudation of lymph from its surface is apt to cause *posterior synechiae*, or attachments of the iris to the capsule of the lens. Further, continued contact with the aqueous is prevented by coating the wound in the capsule or the swollen lens-substance with lymph, and absorption is brought to a standstill, leaving a permanent traumatic cataract. Fig. 190 represents a section of an eye with traumatic cata-

FIG. 190.



Section of traumatic cataract. (BECKER.)

ract. The lens has undergone partial absorption and has become dumb-bell-shaped. The pupil is contracted and filled with lymph. The cornea is distorted and flattened.

Where large pieces of lens-substance swell out between the lips of the wound in the capsule and fall into the anterior chamber, they may cause local irritation of the iris. This complication is also evidenced by peri-corneal injection, which is much more intense at this point. In the most favorable cases of traumatic cataract, many weeks may elapse before the lens is absorbed and the eye becomes quiet. In complicated cases, we often wait many months for the same result. As sequences, we may have closure of the pupil by effusion of lymph, infiltration of the ciliary body and processes, and sympathetic inflammation of the fellow-eye. At other times, extensive chorioiditis or atrophy of the inner layer of the retina, with pressure excavation of the head of the nerve, may take place. During the entire process, the eyes should be kept shaded from strong light by smoked glasses, and all use of the fellow-eye for near-work forbidden.

While the wound of the capsule is open, the eye should be kept bandaged, and a neutral solution of sulphate of atropia should be instilled sufficiently often to keep the pupil dilated. Inasmuch as considerable reaction of the iris is usually accompanied by severe pain in the eye, forehead, and temple, free abstraction of blood from the temple, either by Heurteloup's apparatus or by natural leeches, should be resorted to. When there is pus in the anterior chamber (*hypopyon*), or when swelling of the lens is so extensive and so rapid as to threaten secondary glaucoma, much good may be done by tapping the anterior chamber with an iridectomy-knife or a broad needle, and evacuating the pus or softened lens-matter. If increase of tension recurs, the wound may be advantageously reopened by the introduction of an instrument, such as the small horn spud used to replace the iris, or a Daviel's spoon, between its lips.

When the inflammation runs high, and, in addition to great pain, there are swelling and oedema of the lids, the patient should be kept at rest in bed. Ice-compresses should be applied to the closed lids. Except in the cases above specified, operative interference is to be avoided, and no attempt should be made to remove a traumatic cataract till the eye has been entirely quiet. If the lens is mostly absorbed at this period, and only some opaque and wrinkled capsule be left in the pupillary space, discission may be attempted. If the pupil is closed with lymph, an iridectomy with some form of linear incision for the extraction of cataract is advisable.

Penetrating wounds of the eye with lodgment of a foreign body in the eyeball. When a foreign body enters the eyeball and remains in it, it usually excites sufficient inflammation to destroy the eye and to cause sympathetic irritation of the fellow. The prognosis will vary with the size and nature of the foreign body, and with the part of the eyeball in which it is lodged. When penetrating wounds of the eyeball are made by small metallic bodies travelling with great velocity, and the point of entrance is situated in the sclerotic, the detection of the wound of entrance is often very difficult, requiring careful search with a magnifying-glass and oblique light. Owing to the elasticity of the tunics of the eye, the wound is apt to be very small in proportion to the size of the body causing it. In all recent cases, a diminution of the intra-ocular tension will be manifested by careful palpation. Where, after an injury, there are repeated exacerbations of inflammation and a grade of disturbance that are disproportioned to the apparent severity of the injury, the presence of a foreign body in the eyeball may be suspected. Very small iron splinters in the anterior chamber may, in some instances, be entirely absorbed. Laurence, Wardrop, White Cooper, and Walton, have cited such cases, where small pieces of metal have been broken off from the ends of cataract needles. Dangerous inflammation, however, may ensue, as in an instance noted by Cunier,¹ where such an accident was followed by repeated attacks of inflammation, which eventuated in the minute particles of metal being glued fast to the iris by lymph. On attempting to remove this mass by an incision through the cornea, it

¹ *Annales d'Oculistique*, tome i. pp. 308, 309.

adhered so tightly to the iris and the capsule that the lens had to be evacuated. The patient recovered with fair sight.

There are also several examples given of encapsulation of foreign bodies in the anterior chamber, the eye remaining quiet. After a variable period of quiescence, however, such bodies are apt to become loose and to give rise to severe inflammation. A case is noted by Middlemore,¹ where, after two years' interval, a fragment of metal became loose, causing threatened suppuration of the eyeball, which was only averted by the extraction of the foreign body through a corneal incision. Small foreign bodies may remain for years in the anterior chamber without exciting any considerable and lasting irritation. Jacob² records an instance where a splinter of stone remained for four years in the anterior chamber. Jaeger³ reports one where a piece of gun-cap, one square millimeter in size, remained in a similar position for five years. Critchett states that he has removed a minute piece of glass from the anterior chamber of a useful and sharp-seeing eye, which had been in that situation for sixteen years. Cilia are sometimes carried into the anterior chamber by foreign bodies which enter it. At times, they are pushed in where the wounding body does not itself enter into the organ. Pagenstecher gives an instance in which a cilium remained in the anterior chamber for ten years without exciting any irritation. Very minute foreign bodies are sometimes spontaneously extruded from the eye. Usually, there are repeated attacks of inflammation, and during one of these the minute body ulcerates through the original place of entrance. Dixon records two cases where small metallic bodies were thus extruded, the organ retaining good vision. Unfortunately, in the majority of such cases, all vision is lost. In the first of Dixon's⁴ cases, the foreign body had remained in the eye for eighteen months. In the second, it had been imbedded for eight years before the first attack of inflammation occurred. In the latter instance, after an interval of three years, a second attack came on, which yielded to treatment. A third attack ensuing, the eye failed to become quiet. After protracted inflammation, a minute scale of metal protruded and was extracted. In both of these cases, the point of exit was at the corneo-scleral junction. Stoeber⁵ gives a case of gun-cap, which was spontaneously extruded through the same part of the eye. In this case there was repeated inflammation, which extended over a period of two years. Sight was lost. Small foreign bodies may remain imbedded even in the ciliary body itself for years, before they excite inflammation, as is shown in the case of Bowen's,⁶ in which a piece of iron of the size of a small pin's head was found between the fibres of the ciliary muscles, where it had remained for nine years. Finally, it excited inflammation, which led to enucleation of the eyeball and its discovery.

Foreign bodies lodging in the iris, if very small and causing no irritation, may be left in position, care being taken to watch the eye, and to warn the patient to return if inflammation sets in. Where they are

¹ A Treatise on Diseases of the Eye, vol. i. p. 664.

² Dublin Med. Press, Dec. 1846.

³ *Staar und Staar-Operationen*, Wien, 1864, S. 68.

⁴ Roy, Lond. Ophthal. Hosp. Rep., vol. i. p. 139.

⁵ Wounds and Injuries of the Eye, pp. 33, 59.

⁶ New York Medical Record, 1875, p. 207.

larger and excite irritation, an opening should be made into the anterior chamber with a broad needle and the object seized, and removed, either with a fine iris-forceps or with canula-forceps. It is, however, often impossible to extract the irritating object without pulling some of the iris with it, in which case the protrusion should be cut off. Where the foreign body lodges in the lens, it usually causes complete cataract. If the foreign substance is very small, the wound in the capsule may heal, and the body be extracted without difficulty at the time of the removal of the opaque lens. Where the foreign substance is of greater size, the rent in the capsule is frequently large enough to admit sufficient aqueous to cause complete softening and absorption of the lens. In such cases the foreign body may become dangerous by falling into either the anterior or the posterior chamber and exciting inflammation. An attempt should therefore be made to remove it, with the opaque lens, by some of the methods that are appropriate to the extraction of traumatic cataract.

Lodgment of a foreign body in the vitreous chamber or in some of the tissues that form its walls. Small fragments of metal may enter the vitreous, and, becoming encapsulated, remain in position for many years without exciting any irritation beyond that caused at the time of their entrance. As a rule, they are, however, liable to sink, and, by falling on the retina, the chorioid, or the ciliary body, give rise to destructive inflammation of the eye. Occasionally, foreign bodies in the vitreous may be spontaneously extruded after destroying sight. Mauthner¹ relates some cases where glass splinters were thus evacuated. One of these escaped entirely without assistance, whilst the other, which was detected presenting in the wound, was removed by enlarging the opening in the sclera and seizing the body with a forceps. White Cooper mentions a similar pointing, and attempt at spontaneous evacuation, by a large piece of iron in an inflamed and shrunken eyeball. In this case, the eye became quiet after extraction of the iron through an enlargement made at the point of the original wound. A good example of the lodgment of a chip of steel, which was encapsulated and which remained for years in the vitreous, while the eye still retained some degree of vision, is furnished by Jaeger. In this instance, there was only a slight trace of wound in the cornea and iris. The lens escaped injury, allowing the foreign body in the vitreous to be seen with the mirror. Detachment of the lower and outer part of the retina followed. At the end of three months, the metal had found its way into the centre of the vitreous, where, having at first been horizontal in position, it later became vertical.

When such small metallic bodies enter the vitreous chamber, the patient usually feels pain, sees a flash of light, and, sooner or later, notices a dimming of the vision. The last symptom may be dependent upon hemorrhage, retinal detachment, or general clouding of the vitreous. While the media remain clear, the ophthalmoscope offers opportunities to locate the body, the track through the vitreous being marked as a gray cord. If there be small rents in the iris, they may

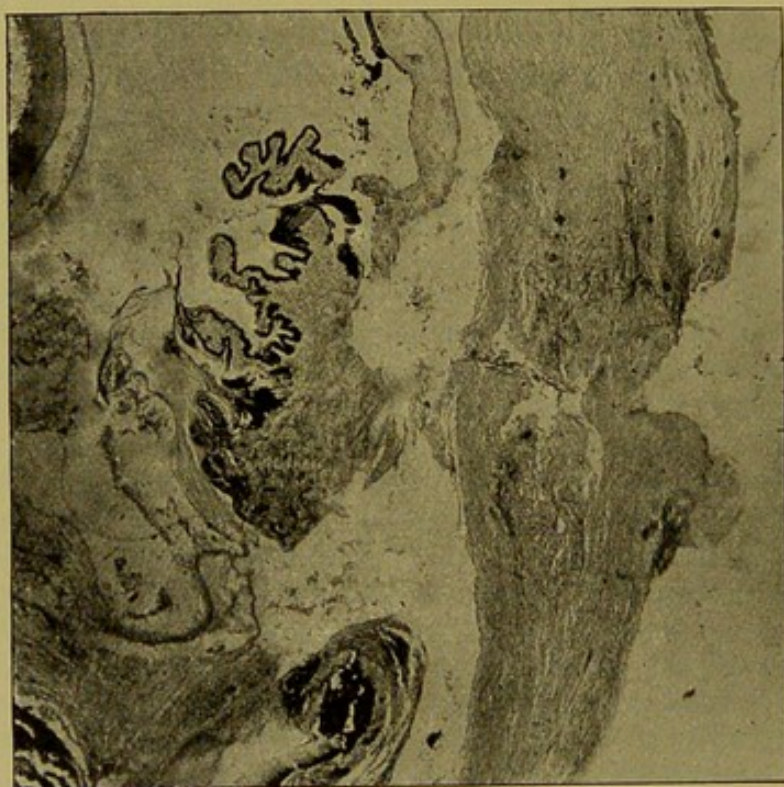¹ Mauthner; Vorträge aus dem Gesamtgebiete der Augenheilkunde, Band i. Ss. 10, 11.

often escape detection in examination by daylight, but when sought for by the mirror, they are readily seen as a red glare.

When we have located the body in the anterior part of the vitreous, we may sometimes attempt to remove it by first making a cut in an antero-posterior direction behind the ciliary muscle, and parallel to and between the straight muscles. Introducing a delicate pair of iris-forceps, we next endeavor to seize the body. Sometimes the foreign body is at once carried into the grasp of the forceps by a prolapse of the vitreous, which occurs during dilatation of the wound. If the body be of iron, our efforts to remove it will occasionally be much aided by a magnet. This should be composed of a blunt probe of soft iron, rendered magnetic by having an electric current passed through a wire coil, which surrounds its shank. This instrument is introduced, either through the wound of entrance or through such an incision as has been described. After having been brought in contact with the iron particle, it is to be gently brought out through the opening, when, at times, the foreign body will be found adhering to it. Where the body lies deep in the eyeball, our expectations may often be disappointed, even when the battery is in its best working order, and the magnet able to readily lift heavy iron objects outside of the eye. In such cases, we find that some fibres of the tough and gelatinous vitreous cling to the sharp rough edges of the foreign body on each attempt at withdrawal, and pull it away from the magnet. Even in an enucleated eye, where a foreign body has been left *in situ* and can be seen, we find, upon cutting it open, that we are, at times, unable to draw a foreign substance out of the vitreous. Nevertheless, as we are at times successful, and may save an eye which may at least be useful to get about with, and also relieve imminent danger of sympathetic inflammation, it is our duty to consider and try it in all appropriate cases. When the foreign body lies close behind a wounded lens, it may be removed either with a spoon or by the magnet, during an operation for the extraction of the lens. In a statistical paper on the result of magnet operation, Neese says that out of 154 cases, $10\frac{4}{5}$ per cent. recovered with nearly normal vision, $30\frac{1}{2}$ per cent. retained some degree of visual power, and $17\frac{1}{2}$ per cent. lost all perception of light. In these last cases, the form of the globe was retained. In $10\frac{3}{4}$ per cent., enucleation was inevitable, and in 37 per cent. the magnet operation was a failure from the beginning. On account of the large number of unsuccessful cases not ordinarily finding their way into literature, these statistics, however, present too favorable a view of the success of the operation. They are also faulty, because of the difficulty of obtaining knowledge of the permanent results. Still more recently, Hirschberg has given the results of one hundred electro-magnet operations. Of these, thirty-five were for fragments of iron lodged in the cornea, conjunctiva, sclerotic, iris, or lens, while in sixty-four instances, a piece had penetrated the vitreous chamber. Of these latter cases, four recovered with good vision, three with fair vision, and six with retention of the form of the eyeball. Of the remaining fifty-one, thirty-four underwent enucleation, one refused this operation, and fifteen, where the magnet failed to remove anything, recovered with the iron still in the eye.

All the above described operations are serious, and of themselves endanger the eyesight of the operated eye. We are nevertheless justified in attempting them, because, in the vast majority of instances, the presence of such a foreign body leads to loss of sight and inflammatory changes, which not only cause the organ to shrink, but also frequently give rise to sympathetic inflammation of the fellow-eye. In any case, where an attempt is made to remove the foreign body by any of the methods described, it should be previously agreed with the patient that, in the event of failure, the surgeon shall be empowered to enucleate the eyeball, if he deems such a procedure advisable. In all operations for the removal of foreign bodies from the anterior or the posterior chamber, the iris, the lens, or the vitreous, it is advisable to operate whilst the patient is in complete narcosis.

FIG. 191.



Section showing tearing and pulverization of tissues by a No. 8 shot.

Gunshot wounds of the eyeball. When a small-sized bird-shot has penetrated the eye, it causes so great destruction at the point of entrance (and of exit, if it passes through into the orbit), with so much intra-ocular hemorrhage that eyesight is always seriously impaired, and, usually, irretrievably lost. Fig. 191 gives an example of such an injury, where a No. 8 shot entered the ciliary region, rupturing the sclerotic at this point, and fairly pulverizing some of its fibres. The ciliary body and ciliary processes were torn and detached.

How near an eye can escape destruction is shown in a case treated by the author, where a No. 6 shot had lodged in the sclerotic, and

had caused a slight hemorrhage at corresponding points of the retina and chorioid, which was visible with the ophthalmoscope. The shot was removed from the sclerotic, and the eye recovered with perfect vision, which has now lasted many years.

When pistol or rifle bullets strike the eye directly, they usually destroy it. When they only graze it, they often cause ruptures of the chorioid, with sufficient intra-ocular hemorrhages to destroy sight.

Wounds of the optic nerve in the orbit are rare. This is owing to its deep position, its curved course, and its ready displacement. They have occurred by tearing off the nerve tissues through the forcing of blunt instruments into the orbit. At times, the nerve is cut by bird-shot, or by rifle- or pistol-balls. Schweigger records a case of immediate blindness caused by a bird-shot that struck the nerve near the optic foramen and entered the orbit without injuring the eyeball. If the injury is at the point of entrance of the central vessels, there is said to be immediate ischæmia of the disk. In any case, absolute atrophy ensues, even when the division of the nerve is made further back.

CHAPTER XII.

SYMPATHETIC OPHTHALMIA.

SYMPATHETIC OPHTHALMIA is a term that is applied to the inflammation of one eye that has been caused solely by a primary inflammation of the fellow. Such ophthalmias are frequently to be observed, and are in striking contrast with our every-day experience in inflammatory affections of other parts of the body. For instance, it is well known that where there is an inflammation of one hand, of one foot, of one side of the face, or of the trunk, no similar affection of a corresponding area on the other side of the body is ordinarily found. There are, it is true, a small number of well-observed cases in which it has been proved that, in consequence of some as yet not thoroughly explained action of the nervous system, an inflammation of one side of the body does exercise a marked influence on the nutrition of the corresponding area of the other side. This is well shown in rare cases of so-called reflex paralysis following gunshot wounds—a striking example of which is recorded by Mitchell, Morehouse, and Keen. In their case, complete anæsthesia of the external side of the right thigh developed after a gunshot wound of the corresponding area of the left thigh. Annandale relates a case of wound of the finger with painful cicatrix and glossy skin, which was followed by a similar condition of the corresponding finger of the other hand. Cenas has recorded a case of trophic changes in both hands, with contraction of the ring and adjacent fingers, that followed a gunshot injury of the right forearm, involving the ulnar nerve. Such instances, as well as occasional symmetrical disposition of new growths and of cutaneous eruptions on the two sides of the body, are comparatively rare, and in many such cases are not manifestations of sympathy, but are simply either evidences of disease in some of the ganglia of the cerebro-spinal system, followed by symmetrical affection of the nerves springing from them, or indications of peculiarities that are dependent upon similarity of tissue-formation in corresponding parts. In eye-diseases, however, when the ciliary body becomes involved, sympathetic affection of the fellow-eye is unfortunately a frequent occurrence. It is true that if such sympathetic disturbances are ever exhibited in the economy, we might reasonably expect them in the eyes, where there is so absolute an anatomical connection, and where both the motor and the sensory types of the physiological sympathies are so largely developed. In health, as previously shown, all movements of both eyeballs are in harmony with one another, so that, for instance, when one eye moves in a given direction, its fellow makes a simultaneous and equal excursion in the same direction. Further, as has been explained on page 93, the pupil of one eye, that has been screened from light, will contract and dilate consentaneously with that of its uncovered fellow, when the latter is exposed to varying light and shadow.

Wounds and inflammations of the ciliary region are the usual starting-points of sympathetic ophthalmias, it being very rare to have any manifestation of sympathy from any form of disease of the primarily affected eye unless this region becomes involved. There are two varieties of the disease. These are respectively known as *sympathetic irritation* and *sympathetic inflammation*. In the first, there is an irritation of the sympathizing eye, which is evinced by undue sensitiveness to light, and increase of lacrymation with speedy tiring of accommodation, thus producing inability to do near-work for more than a few minutes at a time. Further, any prolonged use of the organ not only causes blurring of the sight, but also brings on pain in the primarily affected eye. The exciting eye presents pericorneal and ciliary injections. There is marked tenderness of the ciliary region to the touch, while at times there are attacks of trigeminal neuralgia on the same side. The second is present, when, in addition to the symptoms already enumerated, there is a development of plastic exudations in the sympathizing eye. In it, we find a marked zone of ciliary injection, the eyeball in this region being exquisitely tender to the touch. There is a haziness of the media. The iris has lost its brilliancy and is changed in color, whilst plastic lymph is effused into its substance and thrown out on its posterior surface, glueing it firmly to the anterior capsule of the lens. Floating vitreous opacities become manifest on examination with the ophthalmoscope, and are visible to the patient as dark spots in front of the eye. As the disease progresses, lymph is effused into the pupil. At first, the tension of the eyeball is normal or slightly increased. Later, the eye becomes soft. Owing to retraction of effused lymph at this time, the ciliary margin of the iris is pulled back and the anterior chamber becomes deepened at its periphery. When exclusion of the pupil is complete, fluid accumulates in the posterior chamber, producing a bulging and thinning of parts of the iris. If the eye becomes quiet, it may, by involvement of the chorioid and the retina, with possibly complete detachment of the latter, become sightless; or, if the changes have been limited to the anterior part of the organ, it may retain a fair perception of light. We have, therefore, a secretory neurosis without any gross anatomical changes in the first form of the affection; while in the second, there is a malignant inflammation of the eye, which usually develops as a plastic cyclitis, and too often, in spite of all treatment, destroys the secondarily affected eye.

While these are the usual forms of sympathetic ophthalmia, an iridokeratitis or a serous iritis is occasionally encountered, as the visible expression of the sympathetic inflammation. In rarer cases, a sympathetic neuro-retinitis, accompanied by a marked swelling of the optic disk, may be met with. This form is often accompanied by vitreous opacities and other evidences of involvement of the ciliary region. Less frequently, the sympathetic affection takes the form of a violent and continuous blepharospasm, as in a case related by Donders and Maats, in which the spasm disappeared in a few hours after enucleation of the primarily affected eye. In a few rare cases, the cilia of both the primarily and the secondarily affected eye have turned gray consentaneously with the outbreak of the sympathetic cyclitis.

The most frequent causes of sympathetic disease are wounds of the ciliary region, and the presence of foreign bodies within the eye. The secondary changes induced by injury or inflammation, such as the development of anterior staphyloma, the shrinking of sightless eyeballs, the formation of bone between the chorioid and the retina, and the growth of intra-ocular tumors, are common, though less usual, causes of the same affection. In the latter cases, where the degeneration of sightless or impaired eyes leads to sympathetic disease, it is usually developed only when the secondary changes have caused inflammation of the ciliary body, and when the ciliary region has become exquisitely sensitive to the touch.

Sympathetic diseases may develop at any period after injury to the fellow-eye. The usual time for the first manifestation of sympathetic neurosis, where there has been a wound of the ciliary region, is from four to six weeks. Frequently, after the primary attack, both eyes become quiet for a time. After a variable period of rest, inflammation again sets in in the injured eye, and a renewed attack of sympathetic disturbance follows in its fellow. Often years elapse between an injury to an eye and the development of sympathetic disease, this being due to the fact that it is only at this late date that secondary changes have taken place in the ciliary region.

Although a wound of the ciliary region is the most common cause of sympathetic disturbance in the fellow-eye, yet any severe idiopathic inflammation of the ciliary body is also capable of producing the same condition. Thus, we sometimes see sympathetic inflammation when the development of a syphilitic gumma of the ciliary body has given rise to intense inflammation and final shrinking of the affected eye. Ulcers of the cornea which have produced staphyloma, and the inflammations which follow the degenerative changes in eyes that become blind from absolute glaucoma, are also not infrequent causes of sympathetic disease. In fact, any disease of the eye may give rise to sympathetic ophthalmia, if the accompanying or consequent inflammation of the ciliary body be only sufficiently intense. Noyes relates a case in which the kerato-iritis caused by herpes zoster frontalis, gave rise to sympathetic inflammation of the fellow-eye. Where, either from injury or disease of the primarily affected eye, sympathetic irritation has been established, the exciting eye has ordinarily lost all perception of light. In some cases, however, it may be necessary to sacrifice an eye which still retains some light-perception or even an ability to see to count fingers, by reason of the repeated and undoubted attacks of sympathetic irritation which it has produced in its fellow. In some instances, on account of the injury to the primarily affected eye, sympathetic irritation appears while the patient is still under treatment. It is then interesting to note the sudden development of tenderness in the ciliary region, the sensitiveness to light, and the great capillary congestion of the head of the optic nerve, in an eye in which, at the previous examination, the eye-ground appeared normal and the use of the ophthalmoscope caused no discomfort. At times, too, increased light-stimulus during an examination of the sympathizing eye, while giving little inconvenience to the eye examined, may cause pain and discomfort in the exciting organ.

While accidental wounds of the eyeball are frequently followed by sympathetic inflammation, the purposive wounds inflicted in operations on the eye, occasionally lead to the same unfortunate results. In some operations formerly much resorted to, such as iridodesis and depression or reclination of cataract, sympathetic inflammation was so frequent that they are now rarely performed. Occasionally similar inflammation following the extraction of cataract both by corneal flap and by peripheric linear incision may be found. Rarely, the operations for the solution of cataract and iridectomy lead to the same results.

When exudation of inflammatory products has once taken place in sympathetically affected eyes, we are no longer sure of stopping the disease by the enucleation of the primarily inflamed eye. If the latter retains any considerable amount of vision, its enucleation should not be resorted to, as frequently it will recover with better vision than the eye which is secondarily attacked. If the sympathizing eye should have become blind, we may, by judicious treatment and not enucleating the irritating organ, be able to save some remnant of sight in the primarily inflamed eye. Unfortunately, other treatment offers but little chance of success. Mackenzie, who was the first to recognize the disease, has most truly said: "Whenever I see sympathetic ophthalmitis, even in the first stage, I know that I have to contend with an affection which, however slight its present symptoms may be, is one of the most dangerous inflammations to which the organ of vision is exposed." The best treatment, which even usually fails, is the use of mercury pushed to ptyalism, followed by large doses of iodide of potassium. Such cases as those reported by Wecker¹ are so exceptional as only to prove the rule. This author gives an instance where a sympathetic cyclitis, caused by an inflamed and shrunken eyeball, set in so violently that on the second day after the outbreak, in spite of enucleation of the offending eye, there was only quantitative perception of light. After energetic mercurial treatment, the patient left the clinic with a vision of 20/xx.

Even after the sympathetically affected eye has become quiet, the iris, having been plastered down to the anterior capsule, remains fuzzy and soft, while the pupil is blocked with lymph. If under these circumstances, or later, when the iris has become tough and fibrous, an iridectomy is attempted, the operation is usually a failure.

The operation of enucleation, which was introduced in the treatment of this disease by Augustin Pritchard, of Bristol, England, in 1854, is undoubtedly proper when there is only sympathetic irritation and when no positive inflammation has appeared. In such cases, it may be asserted positively that the sympathetic irritation will be cured by the operation, and that usually no bad consequences will follow the operation itself. Of exceedingly rare occurrence, however, are erysipelas, secondary hemorrhage, or meningitis. Meningeal inflammation, though generally fatal, is so rare, that in 1866 Nettleship² had only twenty-nine cases to tabulate, while D'Oench,³ in reporting five hundred enucleations by

¹ Graefe u. Saemisch, Bd. iv. S. 528.

² Ophthalmic Review, February, 1866, p. 58.

³ Archives of Ophthalmology, June, 1887.

Knapp, had not one fatal instance to record. In six hundred enucleations, Wecker¹ had only two deaths—a mortality of one-third of one per cent.; while Becker² gives six hundred and forty cases without a single death out of statistics of other operators, and but two fatal cases in three hundred and sixty of his own, neither of which was due to meningitis. In fact, there is probably no serious surgical operation that is followed by so few bad results. Graefe attributes the fatal meningitis sometimes occurring after enucleation, to the presence of suppuration in the eyeball, and warns against operating in such circumstances. Of Nettleship's twenty-nine cases of meningitis, one-half occurred after enucleation, in which there had been no visible suppuration of the eyeballs. Moreover, it is the usual practice of the English hospital surgeons and of many surgeons in this country to enucleate suppurating eyeballs where necessary, regardless of the presence of pus, and without apparent evil results. The author has frequently enucleated eyeballs in full suppuration without any untoward consequences, believing that meningitis is just as likely to occur after enucleation for other causes. In considering the question of mortality after enucleation, it is only fair to remember that there are also deaths from panophthalmitis and from orbital abscess where no enucleation has been performed. Webster³ has recorded an instructive case where, after cataract operation, panophthalmitis appeared, which was followed by death, apparently due to meningitis, on the twelfth day.

In rare instances, as a consequence either of bruising the optic nerve or the ciliary nerves, or of healing the cut ends in the cicatrix, a tender stump may result which may give rise to sympathetic irritation of the other eye. This state is best remedied by cutting open the stump, and excising a piece of the tender cicatrix, together with the peripheral end of the optic nerve.

Cutting of the optic nerve and of the ciliary nerves of the primarily affected eye has also been considerably practised. In these operations the good results are often transitory, and, as the eye itself has usually been made unsightly by disease, we do not even improve the appearance of the patient, by allowing him to retain such an organ. The only advantage attained by such operations is in saving the patient the annoyance and expense of an artificial eye. In contradistinction, he runs the fearful risk of a return of the sympathetic disturbance in the good eye.

Evisceration of the eyeball (*exenteratio bulbi*) has been much practised of late years as a substitute for enucleation. Especially has this been done where there has been suppuration of the eyeball, it being considered that all danger of subsequent meningitis is avoided by this plan of treatment. Mules has urged that a better stump can thus be obtained for the insertion of an artificial eye. Following his teachings, small hollow globes of glass, unoxidizable metal, or ivory have been introduced into the cavity of the eyeball, and retained there permanently by the wound having been closed by sutures. In this way, an exceedingly movable stump is obtained. If the present theories of the causation and transmission of

¹ Annales d'Oculistique, xcv, p. 55.

² Die Universitäts Augenklinik in Heidelberg, 1888, s. 75-88.

³ New York Medical Record, February 11, 1888.

sympathetic ophthalmia are correct, it is evident that the operation cannot always be an innocuous one, as the optic nerve is left attached to the stump, furnishing a ready channel to transmit any infectious germs left behind in the remnants of the eyeball to the fellow-eye. Moreover, clinical experience shows that violent inflammation of the orbital tissues of the same side sometimes follows evisceration. Recently Schulek has reported two deaths following the operation. On the other hand, Bunge¹ reports two hundred and forty eviscerations performed at Alfred Graefe's clinic, in none of which was there any serious accident.

Mackenzie,² who, at the time he first described the disease, recognized the different channels through which it might be propagated, tells us that "It is not improbable that the bloodvessels on the side of the injured eye, being in the state of congestion which attends inflammation, communicate to those of the opposite side, with which they have connections within the cranium, a disposition to the same state in which they themselves are. The ciliary nerves also of the injured eye may be the means of conveying to the third and fifth nerves an irritation which may be reflected from the brain to the same nerves of the opposite side. I think, however, that the chief medium through which sympathetic ophthalmitis is excited, is the union of the optic nerves." In later years, the theory of communication through the optic nerves has been abandoned, because it has been found that the inflammation occurs where there could be no transmission of nerve-impulse, namely, in cases where there is complete atrophy of the optic nerve on the primarily affected side. The theory of reflex-irritation through the ciliary nerves has also been almost exclusively held, because the irritative symptom subsides so rapidly and completely after enucleation, and because where severe blepharospasm occurs, the symptoms so resemble those which are seen in that form of disturbance ordinarily produced by reflex action from the branches of the trigeminal nerve in the conjunctiva in phlyctenular keratitis, or in those cases in which a foreign body is present in the conjunctival sac. Moreover, in a certain number of instances, the ciliary tenderness provoked by pressure is manifest in exactly corresponding regions of the two eyes.

Recent writers, especially Deutschmann,³ consider the affection an *ophthalmia migrans*, caused by the wandering of micrococci and inflammatory products from one eye to the other. This author was unable to prove this completely by experiments, because the injection of pure cultures of staphylococcus pyogenes aureus into the vitreous of one eye of rabbits caused so violent an inflammation of the meninges that the animals died of meningitis before (in Deutschmann's opinion) there was time for the development of sympathetic ophthalmia. When, to avoid this accident, the same staphylococcus was injected between the dural and pial sheaths of an optic nerve, iritis and hypopyon on the same side developed on the third or fourth day. This author believes that when years intervene between a penetrating wound of the eye and the development of sympathetic ophthalmia, the micrococci

¹ Ueber Exenteration des Auges, p. 69. Halle, 1887.

² Mackenzie: Op. cit., p. 619.

³ Arch. f. Ophthalmol., xxx. 3, Ss. 77-122, u. S. 386.

have remained alive and have in some way been finally called into renewed activity. Gifford's¹ experiments, although pointing in the same direction, vary in detail. He proved that the infiltration of the vessels could not be traced in the optic nerve beyond the exit of the central retinal vessels, and that the micrococci themselves were limited to the vitreous of the eye into which they were injected. He found that the bacilli of anthrax or splenic fever were micro-organisms capable of living in the lymph without exciting intense inflammation, and that they could be carried by the lymph-stream from one eye to the space around the chorioid in the other. He thinks that the path taken by these organisms is from the vitreous of one eye along the chorioidal vessels into the orbit, thence along the central vessels into the cranial cavity, and finally down the intra-vaginal space of the optic nerve on the other side. More recently, Randolph,² experimenting on fifteen dogs by injection of staphylococcus aureus into the vitreous, failed in any instance to produce sympathetic ophthalmia. He usually provoked a suppurative panophthalmitis in the attacked eye, the infiltration extending but a short distance backward through the optic nerve.

¹ Archives of Ophthalmology, vol. xv. pp. 281-295.

² Ibid., vol. xvii. pp. 188-213.

CHAPTER XIII.

DISEASES OF THE CONJUNCTIVA.

Hyperæmia of the conjunctiva is very frequent in those subjects whose eyes are daily tasked with many hours of attentive observation of minute objects at short distances. The vessels which normally form a network with rather coarse, elongated meshes in the conjunctiva of the upper and lower tarsus, become wider, whilst those branches not ordinarily visible, are readily discerned. From the increased circulation in its papillæ, the upper part of the tarsal conjunctiva appears more velvety. In severe cases, there is a slight pericorneal flush, with an increase in the vascularity of the bulbar conjunctiva. The lids are heavy and they droop. Their bloodvessels swell and become prominent, and the edges of the eyelids along the roots of the lashes are reddened. There is increased secretion (*seborrhœa*) of the glands at the roots of the cilia, and at the orifices of the Meibomian glands. As a consequence of the seborrhœa, numerous white particles, consisting of dried secretion and epithelial scales, are found adhering to the lashes and adjoining skin. The eyes burn and feel hot. At times, they itch and become watery. Especially is this so when they are exposed to artificial light, tobacco smoke, or other irritants. Hyperæmia may not only appear from overwork of the eyes, especially in feeble or anæmic patients, but may be a sign of reflex congestion, caused by the strain undergone in attempting to overcome uncorrected ametropia.

Careful search should be made for optical defects, and if present, they should be corrected by proper glasses. Frequently, red and congested eyes which have resisted the use of salves and collyria, can be thus permanently cured. When the case is chronic, a salve of yellow oxide of mercury may be advantageously rubbed into the edges of the lids. Burning and discomfort may be allayed by the use of a wash of boric acid and cocaine. Diminution of the hours of labor, exercise in the fresh air, and the internal exhibition of iron and quinine, should be resorted to where overwork and anæmia are the causes.

Catarrh of the conjunctiva. The symptoms of this disease are redness and increased vascularity of the membrane, swelling at the retro-tarsal folds, serous infiltration, and a change in the character of the secretion. It usually attacks the tarsal conjunctiva and the retrotarsal and semilunar folds. The bulbar conjunctiva is affected only in severe cases. The conjunctiva of the lids may either have a slight increase in its injection, or a uniform scarlet tint. The retrotarsal folds are reddened and swollen, and the tears contain numerous shreds of flocculent mucus. Where secretion is abundant, the watery particles cause diffraction of light and an appearance of rainbows around bright points of illumination, as they float down over the cornea. Shreds of mucus become

entangled in the eyelashes during sleep, and, upon drying, form yellow crusts along the lids. These crusts, if not removed, often so mat the eyelashes of the upper and lower lids together, that, upon the patient's awakening after a long sleep, he may be unable to open the eyelids until he has softened and removed the secretion. Complaints are made of dryness, burning, and pricking, and of a feeling as if a foreign body were situated under the upper lid. All these symptoms become marked toward evening, and are aggravated by artificial light. In severe epidemic forms, where the bulbar conjunctiva is involved, there is marked pericorneal injection, with œdema around a slightly hazed cornea. At times, there are shallow ulcers on the cornea near the margin. These are caused by a loss of epithelium. The lids are swollen, and there are, at times, slight hemorrhages into the conjunctiva. In old people, the swelling of the bulbar conjunctiva is usually more marked. In chronic cases a condition known as *angular ophthalmia* is found. This consists in an excoriation of the temporal edges of the upper and lower eyelids. In such cases, the raw surfaces, being in apposition, are apt to unite and cause a diminution of the palpebral fissure. Another form, known as *pustular catarrh*, is sometimes encountered in young people. It is accompanied by the formation of small, yellowish-gray prominences near the cornea, which appear like pustules. When examined with a magnifying-glass, these are seen to be prominences with overlying shallow, infiltrated ulcers. The pustules are surrounded by an area of reddened and vascular conjunctiva. This form of catarrh does not differ materially in its course from other severe forms.

Consecutive catarrh. Symptoms of a low-grade catarrh due to an obstruction of the nasal duct and an inflammation of its lining membrane are frequently encountered. On account of the diminished calibre of the canal, the tears cannot readily flow into the nose. Consequently, they escape over the margin of the lid, and run down the cheek. In their passage through the conjunctival sac, they infect and irritate it. Unless the obstruction of the tear-duct be removed, treatment will be unavailing.

Follicular catarrh. By this term, many writers designate a catarrhal state of the conjunctiva in which there is a great development of the lymph follicles of the tissues, resembling trachoma, but differing from that affection, in that it does not go on to the formation of fibrous tissue and cicatrices. The prominences are oval in form, reddish-yellow in color, and are most abundant on the lower retrotarsal fold. It is the belief of the author that it is in no wise a special form of disease, but that it is rather a swelling of the lymph follicles, which may accompany either catarrh or granular conjunctivitis. It is usually found in young persons. He further believes that we must be in possession of a more complete knowledge of the bacteriology of the conjunctiva, before a proper place can be assigned it among the diseases of that membrane.

Pericorneal epithelial hypertrophy; Spring catarrh. The typical form of this affection occurs in children and adolescents. There is a pericorneal swelling of the conjunctiva, which is reddish-gray in color. This swelling is usually limited to the outer and inner sides of the

cornea over an area that corresponds with the fissure of the lids. Where the swelling of the limbus occurs above and below the cornea, it is usually paler in color. Horner has proved that this tumefaction is due to an increase of the epithelium of the conjunctiva, which often attains from one and a half to three times its normal thickness. Microscopic sections show that solid shoots, which are often branched like the fangs of a tooth, go down into the conjunctiva. There is hypertrophy of the connective tissue. The swelling at the limbus is accompanied by thickening of the tarsal conjunctiva in both the upper and the lower lid, and this membrane is often covered by a fine white haze, which resembles a thin layer of milk. The papillæ are enlarged, sometimes so much so as to assume a mushroom-like shape. At times, through mutual pressure, they assume a tessellated appearance. The disease generally appears in the spring, and often, in spite of all treatment, recurs annually at this season for many years. A similar state of affairs is often seen in women with irregular catamenia. At times it may be noticed in patients of both sexes who are affected with malarial poisoning, or who are living where intermittent fever is frequent.

In cases where there are pericorneal injection and slight corneal haze, the conjunctival sac should be frequently washed with a ten-grain solution of boric acid. Some mydriatic should be instilled until the pupil is dilated *ad maximum*, homatropine, on account of the transiency of its effects, being usually preferable for this purpose. The eye should be protected from light by smoked glasses; and all irritants, such as dust, tobacco-smoke, heat, or artificial light, should be carefully guarded against. When the oedema of the lids, the corneal haze, and the pericorneal injection have subsided (or where these have never been present), the best remedies are local stimulants. Among these, the most efficient is nitrate of silver. In acute cases, the lids should be washed with a solution of boric acid, to remove all adherent secretion. They should then be lightly brushed with a two-grain solution of nitrate of silver. A drop of a four-grain solution may be instilled into the conjunctival sac once every twenty-four hours. At first, after such applications, there is increased pain, with watering and smarting of the eye. This soon subsides, and in a few hours the eye becomes whiter and more comfortable. Iced compresses, constantly changed every few minutes and applied for from ten to fifteen minutes every three hours, are often agreeable, and diminish the burning and vascularity. They should be avoided when there is corneal haze with pericorneal injection. The burning and smarting of the first stage of acute catarrh are often promptly alleviated by the use of a collyrium containing one grain of muriate of cocaine and ten grains of boric acid. In more chronic cases, a ten-grain solution of nitrate of silver may be applied to the everted lids. As soon as its action is shown by slight superficial milkiness of the conjunctiva, the excess should be neutralized by a few drops of a solution of salt. With weaker collyria, the amount of chloride of sodium in the tears is sufficient for this purpose. When the patient cannot be seen frequently, a solution of bichloride of mercury (1 to 10,000), makes an admirable application. The conjunctival sac should be freely washed

with it. A stronger solution, such as the old-fashioned *Aqua Conradi*,¹ is excellent. It should be applied hot in compresses to the closed lids, a little being allowed to enter the palpebral fissure. The sulphates of zinc and cadmium in solution, two grains to the ounce, are effective, as is also the same strength of the acetate of zinc. Alum, either in crystal, wiped over the everted eyelids, or in solution of the strength of eight grains to the ounce, may be used. In such cases, poulticing is objectionable. As the popular applications of tea leaves, alum curds, or bread-and-milk poultices, if long and continuously applied, usually increase the swelling, redness, and discharge, and augment the tendency to secondary iritis, they should be discountenanced. Hot water, if used at a temperature of 115° to 120° Fahrenheit on the closed lids for short periods, often acts as a stimulant. The treatment of pericorneal epithelial hypertrophy should consist in the application of the mildest detergent washes to the conjunctiva, with the internal administration of quinine, iron, or arsenious acid.

If the eye be kept quiet and clean, and all irritants and near-work are avoided, uncomplicated cases of conjunctival catarrh will usually get well in less than two weeks' time. The duration will be diminished, and discomfort and pain much alleviated, by the treatment above laid down.

Croupous conjunctivitis is seen in children. The tarsal mucus membrane, and at times, the retrotarsal folds and bulbar conjunctivæ, are covered with a layer of yellow exudation, which, when stripped off, discloses a raw and perhaps bleeding surface. Usually, there is great swelling of the lids, causing the affection to simulate purulent conjunctivitis.

Hot-water compresses should be applied to the lids, and changed every few minutes, day and night. The conjunctival sac should be frequently washed with a solution of boric acid. Atropine should be applied sufficiently often to keep the pupil dilated. After the exudation has been thrown off, and the conjunctiva of the lids has become bright-red, the case should be treated like any ordinary catarrh. In all cases, some purgative that produces watery evacuations, should be administered. Tonic doses of quinine should be given, care being taken to improve nutrition by digestible concentrated food.

Purulent conjunctivitis. This dread disease may present only the symptoms of catarrh for the first twenty-four hours. During this brief period, lacrymation and photophobia, with burning pain and the sensation of a foreign body under the lid, may be its only symptoms. Clinical experience, as well as the direct experiments of Piringer, show, however, that when it is caused by inoculation with the discharge of another inflamed eye at the stage of full suppuration, or by inoculation with pus of an active gonorrhœa, the period of catarrh is usually of only six or eight hours' duration. According to this author, the disease that is caused by inoculation of contagious matter from the first stage of purulent ophthalmia is much slower in its development. In either case, commencing as a catarrh, red œdema and swelling of the lids with gray

¹ This is composed of one-eighth of a grain of bichloride of mercury with three or four drops of Sydenham's laudanum and a quarter of a drachm of quince-seed mucilage, to the ounce of distilled water.

infiltration of the conjunctiva lining, accompanied usually by intense pain and some fever, soon appear. The lids swell so as to form a projecting sensitive tumor, and are so tightly closed, that the patient cannot open them; while drops of yellow pus hang on the lashes to form crusts. Upon opening the eye, pus gushes out, and the bulbar conjunctiva is scarlet in tint. In severe cases, it is chemotic, projecting over the cornea so as to partly or entirely hide this membrane. On the third or fourth day, the disease attains its height. Later, the natural wrinkles in the skin of the eyelids, begin to return. In from four to six weeks, the disease will have run its course.

The inflammatory condition is dangerous in precise proportion to the amount of corneal inflammation and ulceration that is produced. In severe cases, ulcers form at the periphery of the cornea. These are especially found near the lower corneal border. They are usually semilunar in shape, and their bottom is generally yellowish-gray and opaque. The entire cornea is more or less clouded. When they ulcerate into the anterior chamber, the aqueous escapes. Coincident with this, there is generally a subsidence of the pain and decrease of the inflammation. With the escape of the aqueous, there is usually a prolapse of the iris into the wound. If the prolapse be small, it may heal with the presence of *anterior synechia* (attachment of the iris to the cornea). When it is larger, it becomes covered with a layer of lymph, which, giving way under intra-ocular pressure, forms a protrusion of the anterior portion of the eyeball. This is technically designated as an *anterior staphyloma*. When some remnants of corneal tissue and bands of lymph remain in the cicatrix, the thinned and dilated iris is pressed forward by the aqueous and projects between these bands. This form of staphyloma is said to be *racemose*. When the projection involves only a part of the cornea, it is described as a *partial staphyloma*. When it involves the entire area, it is said to be a *total staphyloma*. Every such projection, consists of the thinned and dilated iris with bands of newly-formed connective tissue and remnants of the cornea. Where the entire cornea is destroyed by inflammation, the anterior surface of the eyeball is found to be composed of a mass of granulations that sprout from the anterior surface of the iris. In such cases, and in many of the lesser forms, there may be a general purulent inflammation of the chorioid and of all the tissues of the eye (*panophthalmitis*), which even-tuates in a shrinking of the globe to a small and sightless stump.

If the eyelids are everted while the disease is at its height, intense swelling of the retrotarsal folds and an enormous development of the papillæ of the conjunctiva over both the upper and the lower tarsus, will be found. The papillæ are often found to be projecting and villous. At times, in consequence of mutual pressure, they are flattened. At this stage, the entire bulbar conjunctiva has a dark bluish-red hue, which is due to venous congestion. As the disease subsides, the circulation becomes more active, and the color of the conjunctiva becomes more scarlet. The secretion varies in amount, appearance, and character. At times, it is flocculent and plastic: again, it partly covers the lids with a yellow croupous exudation: in other cases, it is more yellow and fluid.

The patient should be put to bed, not only for the better application of the local dressings, but also to keep him at an equable temperature. The light in the room should be moderated. In the early stages, compresses, cooled by lying on a block of ice, should be applied to the closed lids, and renewed every half-minute, day and night. This treatment goes far to limit the amount of exudation. Compresses which have been used several times should be destroyed, so as to prevent them from becoming sources of inoculation. The lids should be gently separated every few hours (from one to three), and the conjunctival sac should be washed with the standard solution of bichloride of mercury. Sulphate of atropine should be instilled into the eye sufficiently often to keep the pupil dilated *ad maximum*. At times, if the cornea has ulcerated, cold compresses may be exchanged for hot ones. These should be wrung out of water brought to a temperature of 115° to 120° Fahrenheit, and should be applied in the same manner as the cold ones. When the swelling of the lids has somewhat diminished, and the secretion has become markedly purulent, the lids should be everted and their conjunctival surfaces brushed with a ten-grain solution of nitrate of silver. The silver solution should be allowed to remain sufficiently long to cause the formation of a faint whitish layer. The excess of the nitrate should be removed with a solution of salt. In cases where there is a great development of the papillæ, the mitigated stick of nitrate of silver, followed by flushing with a solution of common salt, is preferable to the solution.¹ To use it properly, requires skilled fingers and trained judgment, the object being not to destroy the conjunctiva, but to stimulate circulation and get rid of secretions. In the opinion of the author, the strength of the solution is far less important than the manner of its application. Thus, if the eye be thoroughly cleansed, and a ten-grain solution be passed lightly over the surface two or three times by a cotton swab freshly charged each time, the effect of a twenty- or thirty-grain solution as ordinarily applied, will be readily attained. On the other hand, if the brush be but moderately charged, and passed lightly and rapidly over, and instantly followed by the free application of the salt water, a very moderate effect will result.

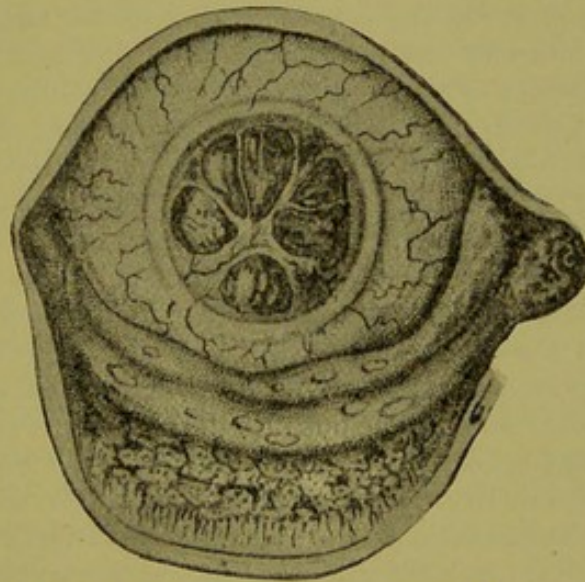
When pain is severe, it often becomes necessary to resort to subcutaneous injections of morphine in the temple, or to employ the internal use of opium. When one eye is affected, the fellow should be protected with a bandage, so as to prevent infection. A watch-glass, with adhesive plaster around its edges, forms a good shield, and at the same time allows the patient to see. As the discharge is eminently contagious, it is necessary that all handkerchiefs, rags, or sponges, that have been used should be burnt or thrown away. In washing such eyes, the surgeon and attendants should be careful not to get the secretion in their own eyes. Although the experiments of Piringer show that pus becomes innocuous when it is either dried on a rag or towel for seventy-two hours, or is freely diluted with water, nevertheless, it is best to boil all linen or cotton materials which may be soiled with the discharge. Care should be taken to wash and disinfect the hands by the free use of

¹ Prepared by fusing nitrate of silver with nitrate of potassium in the proportion of one-third to two-thirds.

soap and water and a solution of bichloride after dressing such cases. The finger-nails should be cleansed with a nail-brush. When the conjunctiva becomes smoother and less papillary, and the secretion diminishes, weaker solutions of the nitrate of silver, alum, and glycerole of tannin are beneficial. Later, the ointment of the yellow oxide of mercury is advantageous.

The prognosis in adults is always serious, even if the patient be seen at the outset and is skilfully treated. Under the most favorable circumstances, there will always be a considerable percentage of cases of total loss. Often great impairment of vision results from the formation of corneal maculæ and partial staphylomata. Out of 215 eyes affected with this disease and treated in Moorfields Hospital, 30 were lost entirely, while the cornea was badly damaged in 74.¹

FIG. 192.



Sequelæ of purulent conjunctivitis. (ARLT.)

Fig. 192, shows an eye where the cornea has been destroyed to the limbus. The iris is laid bare, and projects through whitish bands which consist of remnants of the cornea with lymph. The everted lower lid exhibits numerous wart-like papillæ. Several ovoid follicles can be seen in the retrotarsal fold.

Ophthalmia neonatorum. This form of purulent conjunctivitis is generally due either to infection during the passage of the head through the maternal passages, or to secretion, which has bathed the lids and adhered to the eyelashes, finding its way into the conjunctival sac immediately after birth. Where either of these occurs, a purulent inflammation of the eyes appears between the first and third days after birth. If the outbreak occurs later, the infection may usually be traced to some carelessness by which contaminated lochial secretion has found its way into the child's eyes. If the case occurs in a lying-in hospital, the transference of the disease may be from the eye

¹ W. T. Holmes Spicer : R. L. Ophth. Hosp. Reports, 1891, vol. xiii, p. 212.

of another child. When the mother has not had gonorrhœa or leucorrhœa, the lochial secretions are said not to produce any effect.

The symptoms are those described under purulent conjunctivitis, but here the swelling of the lids is more pallid than it is in the adult.

The disease is a frequent cause of blindness. The statistics of blind asylums show that from thirty to sixty per cent. of the inmates are there from this cause. In combined reports of various institutions, the percentage averages about forty in one hundred. Harlan¹ has found thirty-two per cent. in the blind asylum of this city. Inasmuch as young persons are always given the preference in admission, blind-asylum statistics, however, probably overstate the relative frequency of blindness from this cause.

Since ophthalmia neonatorum is so fruitful a source of blindness, every effort should be made to prevent its occurrence. As long ago as 1807, Gibson,² who believed that infection by the secretions of the vagina of the mother was the common cause of the affection, laid down three admirable rules for the prevention of the disease: "1. To remove, if possible, the disease of the mother during pregnancy. 2. To remove, artificially, as much of the discharge as possible from the vagina at the time of delivery. 3. To pay, at all events, particular attention to the eyes of the child, by washing them, immediately after delivery, with a liquid calculated to remove the offending matter and to prevent its noxious effects." For disinfection of the vagina, solutions of carbolic acid, of salicylic acid, and of borax have been usually employed. That careful and thorough washing of the eyes will go far to prevent infection, is shown by the experiments of Piringer, in which, even three minutes after the introduction of blennorrhœic pus into the conjunctival sac, careful and thorough washing prevented the development of the disease. In every case, clean water and fresh pads of absorbent cotton should be used to wash the eyes of the newborn child. The practice of using the same sponge or the same water to wash the eyes that has been employed in cleansing the body of the child, is reprehensible, and is likely to cause the disease. In the lying-in hospitals of Germany, Credé introduced the practice of first washing the eyes with water, following this by the instillation of a drop of a ten-grain solution of nitrate of silver from a clean glass rod. This practice has been highly successful in diminishing the number of cases in such institutions, and no better examples of its good effect can be given than those cited in the observations of Koenigstein,³ where the results obtained without treatment are compared with those obtained by the use of carbolic acid and nitrate of silver:

	No. of new-born children.	Per cent. of ophth. neonat.	Per cent. of catarrh.
No treatment	1092	4.76	14.5
One per cent. solution of carbolic acid	1541	1.42	6.00
Two per cent. solution of silver nitrate	1250	0.72	4.72

The child should be laid on its back, and its head placed between the knees of the person who undertakes to treat it. An assistant,

¹ Amer. Journ. Med. Sci., April, 1873, p. 410.

² Edin. Med. and Surg. Journ., 1807, vol. iii, pp. 159, 161.

³ Archiv f. Kinderheilkunde, Bd. iii., 1882.

seated in front, should hold its body in his lap and secure the hands. The fissure of the lids should be gently opened by pulling on the skin of the eyelids above the upper and below the lower tarsus. When the child cries and struggles, this manœuvre will often result in complete eversion of both lids. Where this fails to take place, the lids should be alternately everted and held open. The conjunctival sac should be thoroughly cleansed with the standard bichloride of mercury solution. This method of application should be repeated every hour. A four-grain solution of alum or a ten-grain solution of boric acid, also makes an efficient wash.

The physician should make these applications at least once daily. If there be no croupous exudation and there is no considerable gray infiltration, the conjunctiva can be thoroughly cleansed and a ten-grain solution of nitrate of silver applied freely to the everted lids. The excess should be neutralized with a solution of salt. If there be any corneal haze or ulceration, a four-grain solution of sulphate of atropine should be used sufficiently often to maintain full dilatation of the pupil. This treatment will, in the great majority of cases, cure the disease. In fact, we may say it will invariably save the eyes, if the patient be seen before ulceration has occurred. This result presents a marked contrast with that which is obtained in the treatment of purulent conjunctivitis of adults, where, even with the most careful treatment, a considerable proportion of eyes are lost. In most instances the disease has attacked both eyes. If but one eye is involved, it will be almost impossible to apply any proper protective dressing to the other and keep it in place. In such cases, it is obligatory to content oneself with carefully cleansing the affected eye, and preventing the child from rubbing the eyes. The attendants have instructions given to them as to the necessity of having separate cleansing materials for the use of the child.

Diphtheritic conjunctivitis is, fortunately, of rare occurrence in this country. In some cases, there are scattered patches of a dull gray color, which are surrounded by a swollen, reddened, and ecchymotic condition of the conjunctiva. Where the entire conjunctiva is invaded, the membrane loses its normal appearance, and is converted into a gray, gutta-percha-like mass, which resembles the condition seen after a burn from slaking lime or mineral acids. There is swelling of the lids, which, with the gutta-percha-like toughness of the infiltration, renders them so hard and board-like, that it is, at times, impossible to evert them without employing an anæsthetic. There is intense pain. At first, the secretion is thin, with sufficient flocculi of mucus and pus, and blood-globules to give it a slight, red tinge. When the disease advances, and the membrane is thrown off, the discharge becomes thicker and is more purulent. As in the purulent form of the disease, secondary involvement of the cornea, constitutes the main danger of the affection. Where extensive exudation occurs in the bulbar conjunctiva, there is a formation of large yellow infiltrated ulcers of that membrane. These, through their tendency to spread and perforate, at times, involve the deeper structures, and lead to the destruction of the eye. The secretion is extremely contagious. Where there are ulcers of the edges of the lids, or of the angles of the mouth, these situations become infiltrated with the same tough, gray exudation, which

always leaves permanent scars from cicatrization. At a period varying from the third to the fifth day of the affection, a slough of the affected conjunctiva occurs, which is thrown off piecemeal, leaving a raw, granulating surface. The disease generally affects children from two to ten years of age. It is seldom seen in adults. Should it attack older persons, complete infiltration of the conjunctiva is rare. If clouding and ulceration of the cornea set in early, the affected eye is usually lost. How fatal it is under the most skilful treatment, is shown by the fact that Graefe lost nine out of forty cases, and Hirschberg reports thirty-four losses in ninety-four cases.

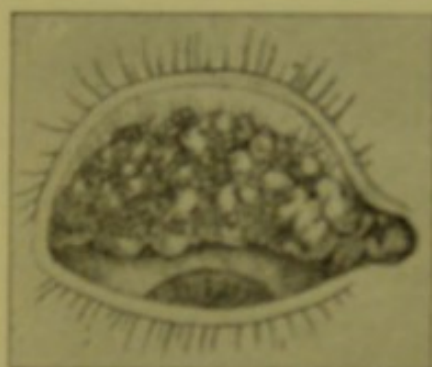When the lids are hard, infiltrated, and "burning," the treatment, with a view of limiting the amount of exudation, consists in the application of iced compresses. When the slough begins to separate, these should be exchanged for hot compresses, in order to stimulate the circulation of the blood in the conjunctiva. The eyes should be washed frequently with boric acid. All stronger collyria should be avoided, for fear of irritating the cornea. In the second stage, stimulating applications, such as a ten-grain solution of nitrate of silver, or tannin and glycerin, should be employed. Care should be taken to keep the eye thoroughly washed and cleansed with a weak solution of bichloride of mercury. When the cornea is affected, atropine should be instilled frequently. When there are raw surfaces, they at times grow together and produce symblepharon. Trichiasis and entropion may occur, as are commonly seen in the cicatricial stages of granular conjunctivitis. Graefe taught that vigorous employment of mercurials, carried to salivation, is advisable at the outset of the disease. Horner teaches that considerable doses of quinine should be employed.

Granular conjunctivitis; Trachoma. As Arlt has shown us, this disease exhibits two varieties, which may at times be found in the same individual. In the one, formerly described as *chronic blennorrhœa*, there is a thickening of the tarsal conjunctiva, with exudation into its substance, and a marked development of the papillæ, giving it a velvety appearance, especially at its outer and inner limits. In the other, usually designated as *trachoma*, the main symptom is a development of sago-like granules in the tarsal conjunctiva and the retrotarsal folds. At times, the limbus of the cornea and the bulbar conjunctiva are invaded. In most cases, we find that the granules develop simultaneously with the increase of the papillæ. The secretion is contagious.

The disease usually develops so quietly, that it at first attracts little attention. The lids become slightly thicker, droop, and look heavy. There is a secretion of mucus and pus, which accumulates in the inner canthus during sleep, and at times sticks to the lashes. These symptoms may be accompanied with a feeling of "burning" or "itching." There is abnormal sensitiveness to the action of irritants. On everting the lids, the conjunctiva is found to have lost its transparency from exudation into its substance, and there is a development of irregularly-rounded, yellowish, semi-transparent masses in it and in the tarsus. The disease may develop more acutely, with redness and swelling of the lids, and a considerable purulent secretion. In these cases, there is a sensation as though a foreign body were under the upper

lid. Superficial yellowish-gray gelatinoid masses may develop in the conjunctiva. These often escape attention unless looked for with a magnifying-glass and in a good light. From their resemblance to small blisters, they are known as *vesicular granulations*. The deeper-lying infiltrations develop in the conjunctiva, the tarsus, and the connective tissue, causing the conjunctival surface to have an appearance of small, irregular projections or granules, thus giving the name to the disease.

FIG. 193.

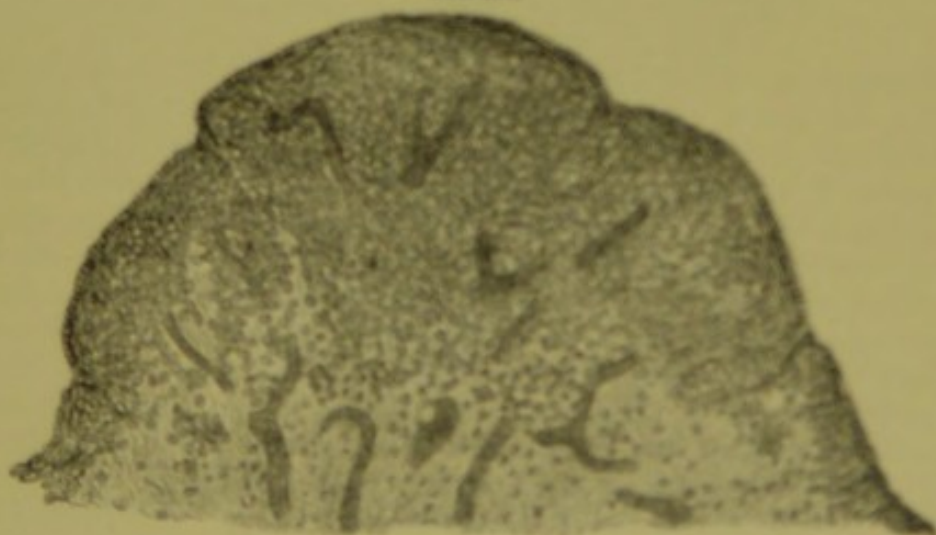

Conjunctiva of upper lid in chronic granular conjunctivitis. (ARLÉ.)

Fig. 193 shows the appearance of the conjunctiva of the upper eyelid in a chronic and marked case.

Fig. 194 shows the section of a granulation that is everywhere covered in front with a layer of epithelium, in which are folds and de-

FIG. 194.



Section of a granulation. (SAEMISCH.)

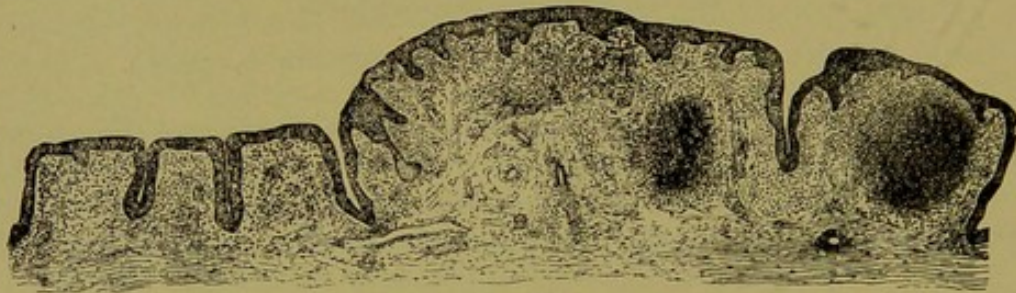depressions. The connective tissue at the posterior part, is continuous with the connective tissue of the tarsus. There are also sections of dilated bloodvessels and great cellular infiltrations of the tissue, which become more dense near the epithelial surface. These infiltrations have been demonstrated by Saemisch to be new formations, which at first, are masses of cells which subsequently become fibrillar in their contents,

and are closely connected with the connective tissue of the conjunctiva and the tarsus. They always degenerate into fibrous tissue, and leave permanent and contracting scars. They differ from the lymph-follicles which are found normally in the retrotarsal folds, in being irregularly round instead of oval. They also differ in the fact that they are covered by condensed epithelium only in front, this being continuous with the fibrous stroma of the conjunctiva in the deeper parts. The lymph-follicles, on the contrary, are surrounded by a delicate fibrous envelope.

The course of the disease is chronic. Pathology shows that with the original infection there is an appearance of the granules in the conjunctiva and tarsus which are accompanied by more or less catarrh and its attendant symptoms. The catarrhal symptoms diminish, and the granules lessen or apparently disappear, only to recur in a few weeks' time.

Fig. 195 shows a section of the conjunctiva from a case of granular conjunctivitis. At the left-hand end there are three papillæ which are covered by epithelium, and separated by sulci, thus giving them almost

FIG. 195.



Section of conjunctiva in granular conjunctivitis. (FUCHS.)

the appearance of tubular glands. To the right of these are larger papillæ, in which irregularly rounded bodies that are characteristic granules are imbedded. Everywhere, there is cellular infiltration of the mucus membrane, which is most marked near the bloodvessels.

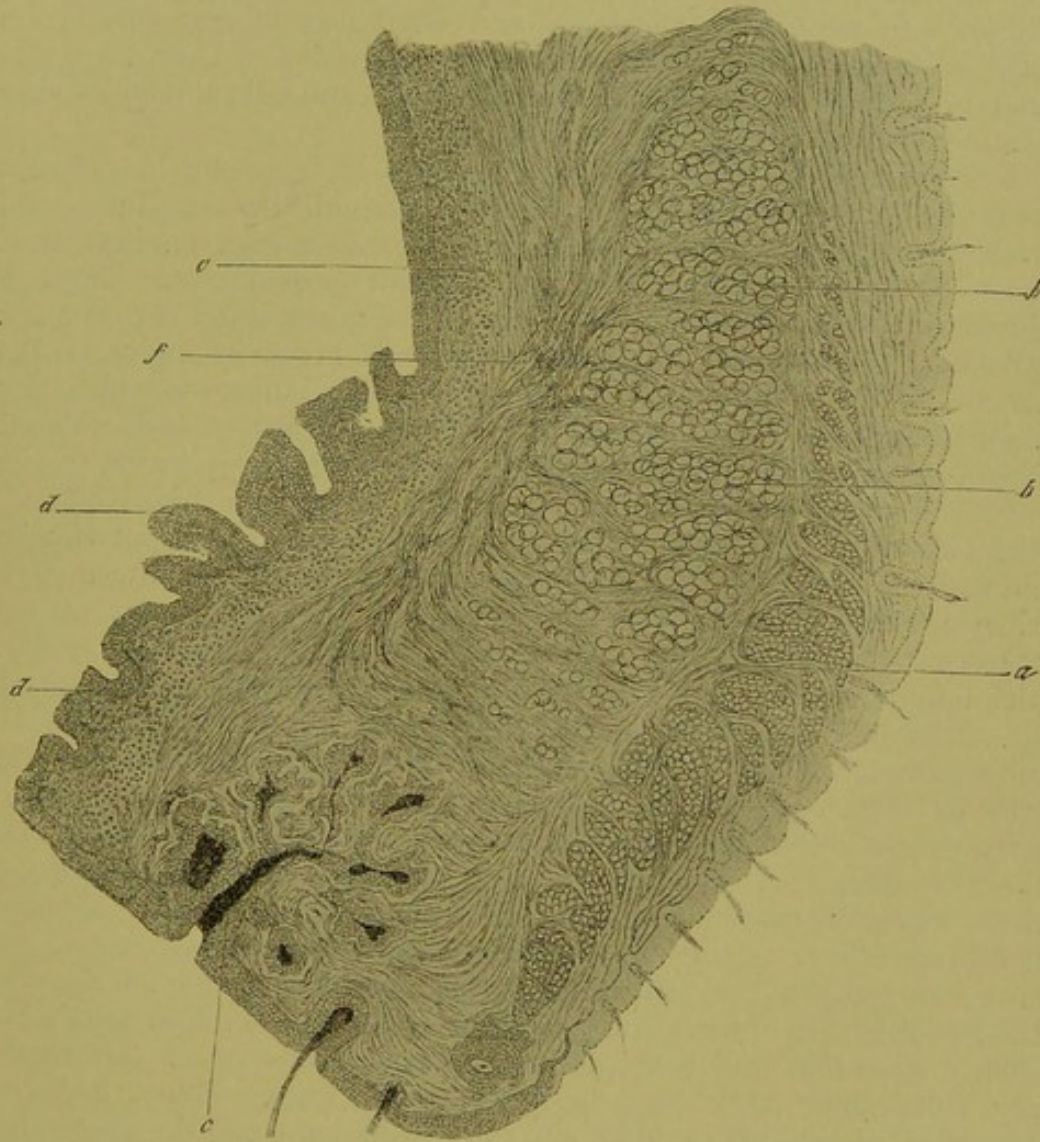
During a remission of the disease, the patient has, perhaps, believed himself cured, and has resumed his ordinary occupation, thus allowing him the opportunity to spread the disease by contact with other people, as, for instance, by using the same towel, handkerchief, or wash-basin.

When the granular deposition takes place in the limbus of the cornea, and under Bowman's membrane, it is generally accompanied by severe photophobia, lacrymation, and pain. This is also followed by the formation of bloodvessels in the cornea, which usually lie superficially between the epithelium and the corneal tissue proper. The pannus thus made, ordinarily appears at the upper part of the cornea—a circumstance which has given rise to the idea that it is caused by direct irritation from the lid-granulations.

During the regressive stage the vessels may disappear, but softening of the cornea may take place, causing this membrane to give way under intra-ocular pressure, and to bulge. If the pannus has been partial, great irregularity in the curvature of the cornea will be present. If it has pervaded the entire membrane, a globose state may result. Either

of these conditions greatly impairs the lenticular action of the cornea. Moreover, upon account of remaining opacities, which of themselves impair vision, complete transparency is rarely gained. In time, the granules become converted into fibrous tissue, and produce scars and bands in the conjunctiva. By contraction, these greatly diminish the size of the conjunctival sac. The cicatrices are first recognizable as

FIG. 196.



Section through upper eyelid in granular conjunctivitis. (SAEMISCH.)

bands running parallel to the edge of the upper lid, and at a little distance from its edge. This fibrous degeneration constricts the conjunctival bloodvessels, alters and diminishes the conjunctival secretion, and produces a fatty degeneration of the stroma and epithelium. These conditions cause the membrane to shed water and other fluids—a condition which is designated as *xeroma*. Fig. 196 represents a section through an upper lid affected with granular conjunctivitis in its cicatrizing stage. Here the lid is seen to be distorted and incurved. At *a* are the fibres of the orbicularis, *b* is the tarsus in a state of fatty de-

generation, *c* points to a shortened and shrunken Meibomian gland, *d* is a swollen and proliferating papilla of the conjunctiva, *e* cicatricial tissue in the conjunctiva, and *f* cicatricial tissue in the tarsus. The cicatrizing process destroys the inner edge of the lid, and causes the eyelashes to become inverted, and to rub against the cornea (*trichiasis*). This constant rubbing often produces a thickening and permanent opacity. When the contraction is more marked, it inverts the lids so strongly that the cutaneous surface touches the eyeball, producing a state which is known as *entropion*. Cicatrices and alterations of curvature in the cornea, always cause marked diminution of vision. They may also produce secondary inflammations in the iris and other deeper-lying tissues of the eye, leading on to blindness.

Granular conjunctivitis, although varying in frequency in different countries, forms the scourge of almshouses, children's asylums, and armies, throughout the civilized world, and causes such diminution of vision as to deprive thousands of all useful employment. Through ignorance and carelessness, this army of the unemployed is constantly spreading the disease. A few of the more noted examples of the ravages of the disease, will give an idea of the dangers to which any community is constantly exposed, and of the earnestness with which it should guard against dissemination. Its spread on a ship in the tropics is well described by Guillié.¹ The French slave-ship "Le Rôdeur," with twenty-two sailors and one hundred and sixty slaves, set sail on the east coast of Africa with all in good health. In about fifteen days, when nearly under the equator, it was observed that many of the negroes were suffering from red and inflamed eyes. They were treated with lotions of elder-flower water, and daily brought on deck for fresh air. Rather than endure their sufferings, many jumped overboard. In consequence, the others were confined below. The first man of the crew to be attacked was one who slept under deck, in a separate apartment near a grated partition which communicated with the hold. On the next day, a lad was seized with the disease, and in the course of three days, the captain and most of the crew were affected. Finally, it became almost impossible to navigate the vessel, as only one of the crew had escaped the contagion. About this time, they fell in with the Spanish ship "Lion," whose whole crew were so affected with the same disease that they could no longer navigate their ship. On reaching Guadeloupe, they were in a deplorable state. Many, however, improved rapidly under fresh air, fresh provisions, and the application of lime-juice and water to the eyes. Out of the crew of twenty-two, twelve lost their sight in both eyes, one of these twelve being the ship's surgeon; five lost one eye each, while four had considerable opacities in the cornea, with adhesions to the iris. Of the negroes, thirty-nine were entirely blind, twelve lost one eye each, and fourteen had corneal leucomata.

Of the ravages which granular conjunctivitis at times causes in civil life, the statement of Kirkpatrick² gives a striking example—where,

¹ Bibliothèque Ophthalmologique, par M. Guillié, tome i. p. 74. Paris, 1820. (Mackenzie.)

² Dublin Quarterly Journal of Medical Science, vol. xxi. p. 335.

out of a total population of 3,346,729 inmates in the workhouses of Ireland during the five years between 1849 and 1854, 134,848 persons were seized with the disease.

It is stated by many writers, that the disease was originally brought from Egypt by Napoleon's army, and so spread throughout Europe. There were, however, extensive epidemics of contagious ophthalmia in European armies before this date. Arlt quotes a passage from Celsus, in which there is an accurate description of the disease. It certainly ravaged both the French and English armies in Egypt, and prevailed extensively in most European armies during Napoleon's campaigns. Larrey tells us, that out of thirty-two thousand men landed in Egypt in July, 1798, every man was more or less affected in the course of two months. In the English army, in 1815, at Waterloo, from four hundred to five hundred men in one regiment of the Guards had diseased eyes, and in 1818 there were more than five hundred permanent invalids from granular conjunctivitis in the English military asylums. Between the years 1815 and 1817, over twenty thousand soldiers in the Prussian service were affected, of whom seven hundred and fifty became totally blind, and two hundred and fifty blind in one eye.¹ In the Russian army, seventy-six thousand eight hundred and eleven men were attacked by the disease between the years 1816 and 1839. Of these, six hundred and fifty-four became blind in both eyes, and eight hundred and seventy-eight in one eye. At present, the epidemics in the European armies are less virulent and are less widely distributed. It still prevails extensively in the Belgian army: according to Fuchs, if all recruits having the disease were rejected, the government could not obtain its quota of men in some districts.

An accurate account of its distribution would be interesting. It appears to exist throughout both the civilized and the uncivilized world, being less frequent in mountainous and sparsely populated countries. In the valley of the Rhine, it is rare at the head-waters, increasing constantly as the river gets into the lower and more densely populated districts. In certain races it is very common, being extensively prevalent among the Irish emigrants to this country. It is said, also, to prevail in Arabia, and, indeed, throughout Asia. In Africa, it is more frequent along the lower than along the upper Nile. Although generally assumed to be present to a greater extent in low and damp countries, yet, according to Russian writers, it is frequent in the Caucasus. In the United States, it is more common in the Western than in the Eastern States.

The disease is eminently contagious, and probably results originally more frequently than is generally supposed from inoculation with a gleet discharge; the subsequent transference being from eye to eye. It is also probable, that it is infectious through the medium of the air. This is shown from its rapid spread among large masses of men who have been confined in crowded and ill-ventilated rooms, when a heated and unchanged atmosphere becomes filled with the exhalations from the discharge of granular ophthalmia. The example cited of the slave-

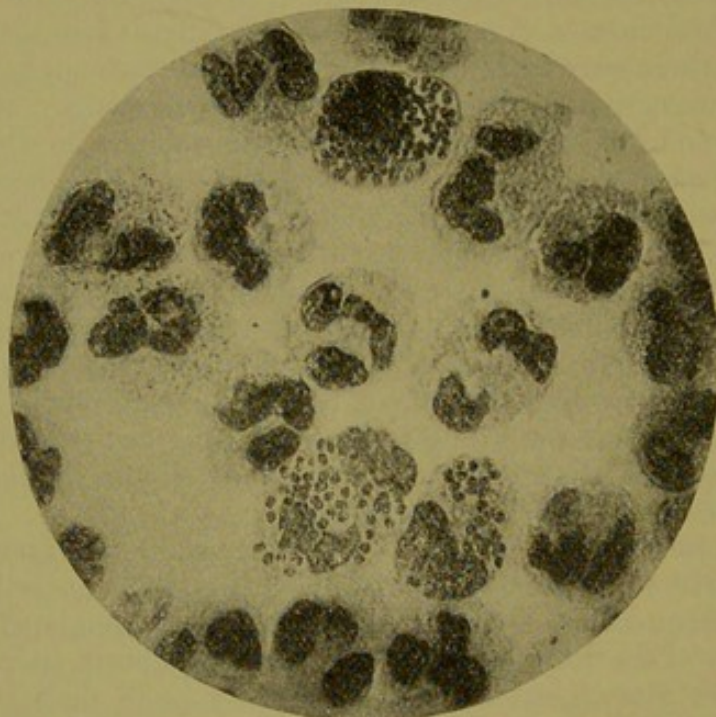
¹ Arlt: *Krankheiten des Auges*, Bd. i. Ss. 65, 66.

ship "Rôdeur," and the experience of military surgeons who have had charge of large numbers of cases during violent epidemics, favor this view.

Müller,¹ who had charge of the garrison at Mayence, states that he did not consider that his daily visit to the patients was dangerous, but state that he would have been unwilling to sleep in the close barracks at night, when the air was saturated with the exhalations from diseased eyes. It is probable that microscopic and bacteriological study will give us a better insight into the pathology.

Fig. 197 represents the gonococci as they appear in a fresh specimen of gonorrhœal pus that has been stained with fuchsin. The microbes

FIG. 197.



Gonococci enlarged 1000 diameters. (FRAENKEL and PFEIFFER.)

belong to the group of diplococci. They do not at first become spherical, but remain with their flattened sides turned toward each other as they were in the original mother-cell. They are often found in the interior of epithelial cells and leucocytes. The figure shows large multinuclear leucocytes that contain numerous specimens.

In order to take effective measures against the spread of the disease, it is necessary that medical men shall appreciate its contagiousness. They should also familiarize themselves with its clinical appearances, as well as do their best to abolish the use of the term "granulated eyelids" for phlyctenular conjunctivitis among the laity, as nothing goes further to prevent the public from having a just appreciation of the malady, than this misnomer. All applicants for admission to homes and asylums, as well as all recruits for the army and navy, should be examined. Careful eversion of the lids should be made, and

¹ Erfahrungen über die contagiose Augenentzündung, 1821.

the candidate should be rejected if any evidences of the disease be present. If, for other reasons, it becomes necessary to take patients suffering with the disease into charitable institutions, they should either be sent to the infirmary of the asylum, or assigned to separate dormitories. All such institutions should have lavatories with running water from a faucet, and every inmate should have his own basin and towel, which should be washed daily. The attendants should be made aware of the contagiousness of the disease, and trained to wash all eyes so affected, with a weak solution of bichloride of mercury or boric acid, several times daily.

The conjunctival sac should be thoroughly washed several times a day with a weak solution of bichloride of mercury. Where this seems to give pain and to produce irritation, boric acid may be temporarily substituted. If there be much corneal haze, photophobia, and pain, atropine should be instilled sufficiently often to keep the pupil dilated. Care should be taken to protect the eye by dark glasses. As inflammation subsides, tannin and glycerin (one drachm to the fluidounce), or boro-glyceride in glycerin (twenty per cent. solution), can be dropped into the conjunctival sac or lightly swabbed over the everted lids. A solution of bichloride of mercury, one part to two hundred and fifty, carefully applied to the everted lids with a cotton swab, is effective. The pain produced may be diminished by instillation of cocaine into the conjunctival sac both before and after the application. When the lids are velvety, nitrate of silver, ten grains to the ounce, applied once or twice daily to the everted eyelids, is an invaluable remedy. Care should be taken to remove the excess and not to continue its use sufficiently long to permanently stain the conjunctiva. Where staining occurs, the membrane assumes a characteristic brown hue, which is due to a deposit of oxide of silver. This condition is known as *argyrosis*. The accumulation is greatest in the adventitia of the small vessels. It is also said to be deposited in the yellow elastic fibres. In chronic cases of granular conjunctivitis, a two-grain ointment of the yellow oxide of mercury is an excellent application. When the disease reaches the cicatricial stage, the application of a smooth crystal of alum, or sulphate of copper, is useful. For patients at a distance, a weak solution of sulphate of copper in glycerin (from one-half to one grain to the fluidounce), or the glyceroles above mentioned, are good remedies. Where there is pannus, and the granulations are indolent, hot compresses form an admirable stimulant. These should be followed later, after a short course, by nitrate of silver. In the opinion of the author, all processes which aim at destroying the granulations, either by caustic or by scraping, are unjustifiable, and go far to augment any subsequent and inevitable cicatricial contraction.¹ *Peritomy*, or the circumcising of the cornea by cutting away a strip

¹ These views are not shared by most practitioners of the present day, and various methods of destroying the granulations are in favor. The best of these is, after gentle incision and scarification of the conjunctiva over the most prominent granulation-masses, to squeeze them out by pressure with Knapp's roller forceps. This process is very painful, and if the procedure be extensive it is best to etherize the patient. The immediate effect is to cause considerable reaction with the formation of fibro-purulent lymph on the surface of the conjunctiva. The application of iced compresses is therefore agreeable to the patient, and tends to control inflammation.

of bulbar conjunctiva two millimeters wide around its entire circumference, is advocated for the relief of dense pannus. Unfortunately, the vessels which have been thus cut off, repullulate, and the band which has been sacrificed is a loss to the already shrinking conjunctiva. For such desperate cases, the inoculation either of gonorrhœal pus or of pus from eyes affected from acute purulent conjunctivitis, has been practised—the resultant intense inflammation often clearing the cornea, and causing cicatrization of the granulation. The experiments of Piringer show that inoculations of the watery fluid of the first grade of acute blennorrhœa produce no result; that the secretion of the second stage is very active; and that the reaction produced by the secretion from eyes in the third stage is very intense. The condition is manifest in from six to eight hours. The extreme contagiousness of the secretion is shown by the facts, that it is still active when diluted with one hundred parts of water, and that it can be kept as vaccine material, for sixty hours. Drying destroys its powers. Of late years, the discovery of the property of the seeds of jequirity (*Abrus precatorius*), has given a more pleasant and more manageable remedy. An infusion of them, of the strength of two and one-half grains to the fluidounce of distilled water, macerated for twenty-four hours and filtered, should be gently but freely painted over the everted lid. For three hours, no effect is visible. An inflammation, which has all the appearances of a severe croupo-purulent ophthalmia, follows, attaining its height in sixteen hours. The lids are tense and swollen, and their edges are glued together by secretion, thus forming a tumor which often projects beyond the margin of the orbit. The skin of the lids is smooth, hot, and painful to the touch. The tarsal conjunctiva is covered by a thick, tightly adherent, yellowish-gray membrane. At times, in severe cases, the false membrane stretches from the lower retrotarsal fold to the edge of the upper lid, thus hiding the eyeball. The patient is restless and feverish. There are symptoms of influenza. The pre-auricular lymph-glands swell. On the fifth or sixth day, the membrane begins to separate from the tarsal conjunctiva, and is soon followed by that in the retrotarsal folds. Many weeks elapse before the redness and dirty-yellowish color of the conjunctiva have disappeared. Although much benefit may be derived from the use of jequirity in severe cases, it should never be resorted to unless there is pannus, as otherwise a corneal slough may be produced. In some instances a single application of the strength above mentioned proves insufficient. Where this is the case the application may be repeated every three hours till the desired effect is manifest. Where xerophthalmia has set in, the conjunctival dryness can only be palliated by frequent instillation of milk or glycerin.

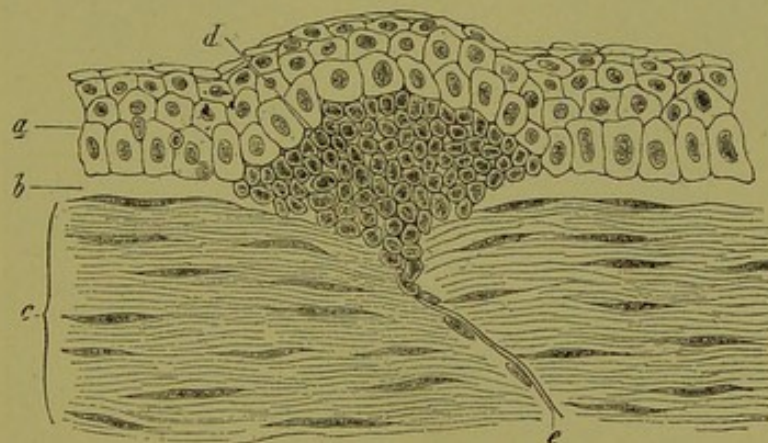
Phlyctenular conjunctivitis is characterized by an eruption of small rounded elevations in the epithelial layer of the conjunctiva or the cornea. According to the seat of eruption, it is spoken of under two distinct heads, *phlyctenular conjunctivitis* and *phlyctenular keratitis*. Inasmuch as the conjunctival stroma and epithelium are continuous with the corneal epithelium and Bowman's membrane, there is no good anatomical reason for this separation. Moreover, we constantly see eruptions which were originally in the conjunctiva invade the cornea,

in the same attack. The main reason for such separation seems to be, that the results are much more serious when the disease attacks the cornea.

The eruption consists primarily of minute rounded elevations which consist of a closely-packed mass of cells of about a millimeter or less in diameter.

Fig. 198 shows a phlyctenule in the corneal border, which is covered with epithelium and is everywhere densely packed with cells that are arranged around a terminal filament of one of the corneal nerves. There is so little fluid, that when a phlyctenule is pricked, its contents fail to exude. As the hillocks become older, they soften and form small blisters or abscesses. When this happens, either the contained material may be absorbed, or the epithelium may be thrown off, leaving small rounded ulcers with elevated margins. The ulcers either rapidly disappear, or become either vascularized or infiltrated and torpid. When

FIG. 198.



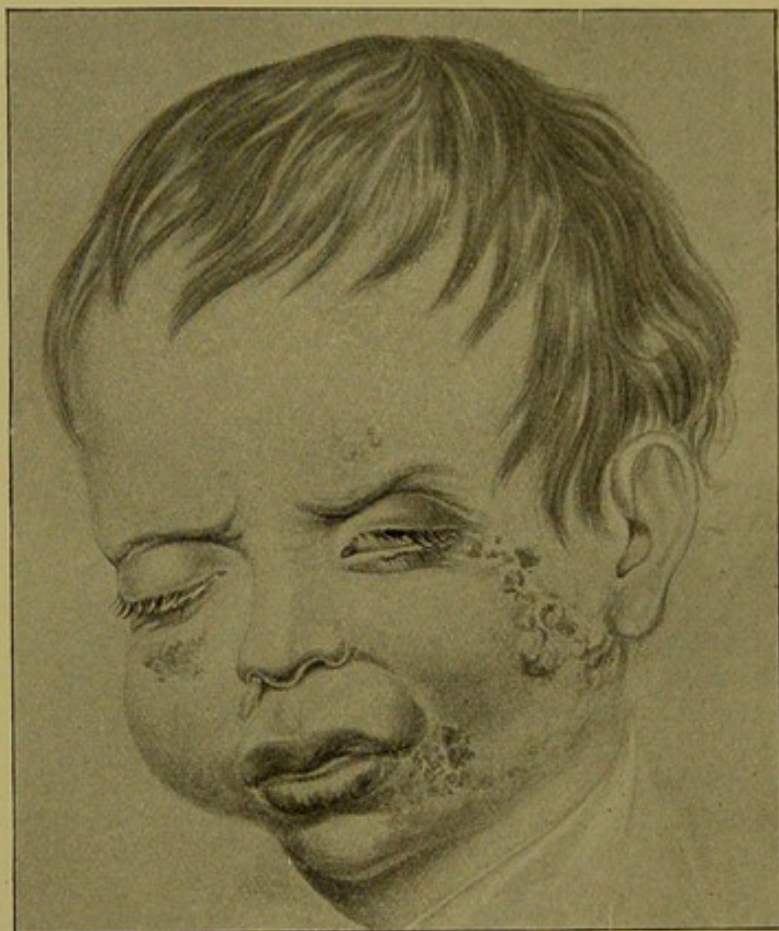Section of phlyctenule. (IWANOFF.)

they are seated in the cornea, they sometimes ulcerate through that membrane, and cause prolapse of the iris with anterior synechia. Where they are deep, and have marked gray or yellow infiltration of the tissue at their bases and sides, there is often a sinking of the pus which is secreted by them, between the layers of the cornea, producing a more or less semilunar-like accumulation at the lower margin of the cornea. This condition is called *unguis*. Sometimes there is an accumulation of pus at the bottom of the anterior chamber. This latter condition is known as *hypopyon*. When the eruption is seated either in the limbus or on the cornea, there is always pericorneal injection. This is general, when the phlyctenulæ are numerous, but is confined to their immediate vicinity when they are few in number. At times, ulcers form in the corneal margin and vascularize, while the innermost part of the ulcer broadens and progresses in a slightly-curved direction toward the corneal centre, thus giving the "rocket-shaped" appearance described by Arlt. Such ulcers never perforate. Both the ulcer and its leash of bloodvessels entirely disappear. Occasionally, there is a peculiar form of pannus, which consists of numerous minute opacities in the sub-epithelial layer of the cornea, to which bloodvessels run from the

limbus. These are confined to the superficial vascular layer in the corneal periphery. Iwanoff considers the affection analogous to herpes, while more recent writers classify it with eczema.

Phlyctenular conjunctivitis is one of the most frequent and important of eye-diseases. It is much more common among children than among

FIG. 199.



Phlyctenular conjunctivitis in a scrofulous subject. (DALRYMPLE.)

adults. In children, it constitutes one-fourth of all the diseases of the eyes. Its serious nature is shown by the fact that, according to Birch-Hirschfeld, six per cent. of the inmates in the blind asylums of Saxony owe their infirmity to this disease. This, however, gives a very inadequate idea of the number of eyes which are ruined by it for all fine work—an inability which is due either to corneal opacities or to alterations of corneal curvature from cicatrization and contraction of the ulcers.

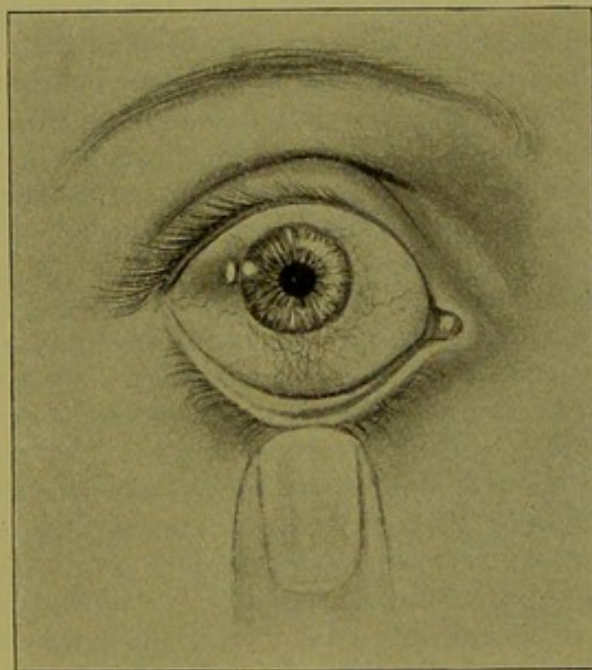
At times the eruption is limited to the conjunctiva and cornea. In many cases a large crop of phlyctenulæ develop in the mucus membrane of the roof of the mouth and upper part of the pharynx. The older writers called the disease *scrofulous conjunctivitis*. This they did with considerable show of reason, as a very large number of cases have enlarged glands in the neck and under the jaw, swelling in the upper lip and the alæ of the nose, and eczematous eruptions on the face. Fig. 199, which gives a representation of a severe case of

phlyctenular conjunctivitis in a scrofulous subject, shows this very well. The proof that this disease is one of lowered vitality and depraved nutrition, is, that it is frequently found after measles and scarlet fever. It also comes on after prolonged lactation, and other drains on the system. Moreover, it is seen at times in individuals who are simply feeble. Rarely, it appears in subjects who have no apparent decided departure from health. In the former class of subjects it is often associated with swelling of the follicles in the retrotarsal folds. As in most other diseases due to constitutional disturbance, relapses without any sufficient local cause appear.

It must be remembered also that secondary affections, such as iritis, anterior synechia with secondary glaucoma, corneal staphyloma, etc., may be produced by it.

The ordinary symptoms, are watering and burning of the eyes, and photophobia. The last is always present where the eruption is extensive, and is accompanied with pericorneal injection. At times it is seen in an excessive degree where the demonstrable local lesions are

FIG. 200.



Phlyctenular conjunctivitis. (DALRYMPLE.)

apparently of the slightest character. In severe cases there is an eczematous inflammation of the ciliary border of the lids, causing crusts to appear on their edges. Upon the removal of these, ulcerations are disclosed, which are usually located around a hair-follicle. Eczema of the lids and the adjacent skin is also frequent, and is much aggravated by scalding from lacrymation. In young children the dread of light is often so great that it is with difficulty that they can be prevented from burying their heads in their mother's breast, in pillows, etc. In adults, a handkerchief is generally folded and kept pressed on the eyes. Fig. 200 represents an eye with two large phlyctenulae. One is on the

cornea and the other is near its margin. There is great increase in the vascularity of the bulbar conjunctiva near the phlyctenulæ. The figure also shows a zone of pericorneal injection and the increased vascularity of the entire bulbar conjunctiva.

The eye should be frequently washed with solutions of boric acid, and protected from irritants by London-smoked coquilles. If there be much photophobia, with ciliary injection and ulcers on the limbus or cornea, some mydriatic should be instilled. Owing to its persistent effect, atropine is preferable. Cocaine will, at times, help to diminish the sensitiveness of the cornea. When blepharospasm is intense, it is often necessary to separate the lids with elevators, in order to obtain a view of the cornea, and to make it possible for the mydriatic to be retained in the conjunctival sac. When there is severe eczema of the lid-edges, the crusts should be first softened by warm water, then gently removed; the raw surface being touched with a ten-grain solution of nitrate of silver. If the skin of the lids is affected, an ointment of the yellow oxide of mercury, or calomel in vaseline, should be applied several times daily, after removal of the crusts by warm water. When the photophobia and blepharospasm are intense, immersion of the child's face for a few moments in cold water, with the purpose of diminishing the dread of light, and of obtaining a view of the eyes, is recommended. In the author's hands, the use of the elevators has proved more satisfactory. When the acute inflammation has diminished, and the ciliary injection has disappeared, the dusting of finely powdered calomel in the conjunctival sac is a most efficient measure. The drug is slowly decomposed and dissolved by the chloride of sodium of the tears, thus giving a prolonged and very dilute bath of bichloride of mercury to the affected eye. Care should be taken never to repeat the insufflation until all traces of the first application have disappeared from the conjunctival sac. Should this be done, the excess of calomel and the newly formed bichloride of mercury would accumulate in the lower retrotarsal fold, and act as an escharotic. In chronic cases, the salve of the yellow oxide of mercury may often be substituted for the calomel. Calomel, or yellow oxide of mercury, is contra-indicated whenever the patient is taking considerable quantities of iodine, because, in many such cases, the iodine is freely excreted by the tears, and converts the mercurial salt into an iodide, which is a most powerful irritant to the conjunctiva, and often produces an active localized inflammation. In the treatment of all phlyctenular disease, fresh air is beneficial. The room should be well ventilated, and the light should be tempered by shades. The eyes should be protected by smoked glasses, and a shade, like a cap-visor, should be employed, if necessary. The use of poultices or wet cloths, must be prohibited. When the patient is allowed to bury the head in the pillows, or to tie a handkerchief over the eyes, the tears soon saturate these coverings, which, by acting as cataplasms, increase any secretion, and augment the tendency to eczema. The most aggravated forms of the affection are usually seen among the poor. They are especially intractable where, either from washing, cooking, or from being partly underground, the living-room is damp, and where the air is vitiated by the exhalations of many

persons. It is an advantage, therefore, to such cases, to have them come daily for treatment. A marked change is often produced by taking such patients—especially children—into the better hygienic surroundings of a well-managed hospital-ward.

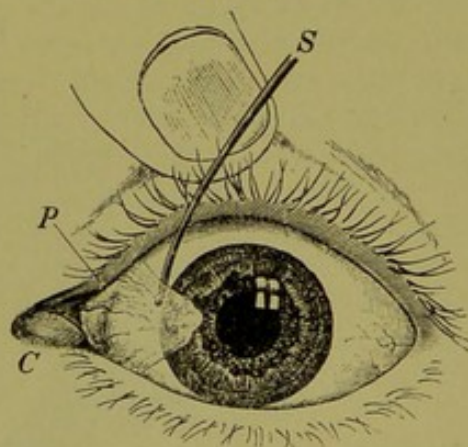
The skin should be kept secreting, and in good order, by hot baths and rubbings with a coarse towel. The diet should be regulated. As children are, of course, fretful, they are too frequently pacified by being repeatedly given cakes or candies. Not only should these articles be prohibited, but food should be given regularly, four times in the twenty-four hours, and the little patients allowed to get hungry during the intervals. Nutritious diet, rare-cooked beef and mutton, with abundance of eggs and milk, and a moderate amount of easily digested vegetable food, should be insisted upon. If the nutrition be much impaired, the appetite can be stimulated by quinine and small doses of milk punch. Digestion should be got into working order by the administration of from one-twelfth to one-eighth of a grain of calomel three or four times daily. Cod-liver oil and various ferruginous preparations, especially the iodide of iron, are of use. These may be assisted by either the phosphates or hypophosphites of calcium, sodium, and magnesium. If the child be nursing from a feeble and badly nourished mother, it should be either wet-nursed or weaned. In circumstances where this is impossible, the quality of the mother's milk may be improved by nutritious food, malt extract, and preparations of iron. To prevent relapse, the hygienic care, the medical treatment, such as dusting the conjunctiva with powdered calomel at regular intervals, should be continued for some time after the active symptoms have subsided.

Pterygium is the name given to that condition in which a fold of the bulbar conjunctiva grows over the cornea and unites with it. The head of the growth, which is at the corneal attachment, is usually rounded and is spread out in a triangular shape into the bulbar conjunctiva. It is firmly attached to the cornea, but at the limbus, and further back, a probe can be readily passed under the upper or lower edge of the growth as far as the median line. This is well shown in Fig. 201.

The growth is usually situated in the fissure of the lids, and is more frequently found on the nasal than on the temporal side of the cornea. Occasionally pterygia simultaneously develop both at the inner and the outer side of the cornea. If the head of the pterygium is pallid and non-vascular, it is usually stationary. If it is vascular, with an elevated edge, and a slight corneal erosion is visible in front of it, it is progressive. Pterygia are frequently seen in people of middle age.

In its usual form, it is produced by some catarrhal ulcer at the corneal edge, or by some slight wound of the cornea, due to the presence

FIG. 201.



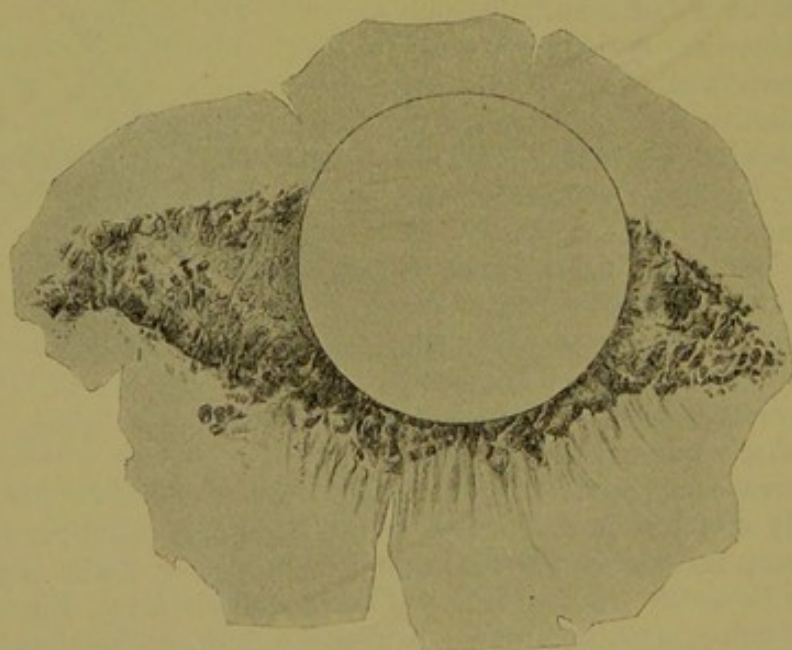
Pterygium. (FUCHS.)

of minute foreign bodies. In such cases, adhesive inflammation sets in, and the swollen conjunctiva of the ball is brought in contact with the raw corneal surface and unites with it. By a repetition of such processes, it may be pulled slowly on to the cornea. At times, it may become stationary. Such pterygia are innocuous, except where they grow out on the cornea so as to partly or completely cover the pupil. When they threaten to cover the pupil they should be removed, as they leave behind an opacity which never fully clears. Other forms of pterygium, which may grow in any direction, follow the positions of ulcers which result from burns, and purulent and diphtheritic conjunctivitis. Such forms of the growth are adherent throughout their extent to the subjacent tissues, and may produce cicatricial contraction sufficient to cause distortion of the cornea and to limit the motions of the eyeball.

To remove a pterygium, its head should be carefully dissected from the cornea, and the growth excised by converging incisions of the scissors. If desired, the head may be transplanted into some convenient part of the bulbar conjunctiva. Transplantation is usually preferable in large growths, as by this method no portion of the conjunctiva is sacrificed.

Pinguecula is the name given to a yellowish triangular patch of bulbar conjunctiva, which is slightly elevated and has its base directed

FIG. 202.



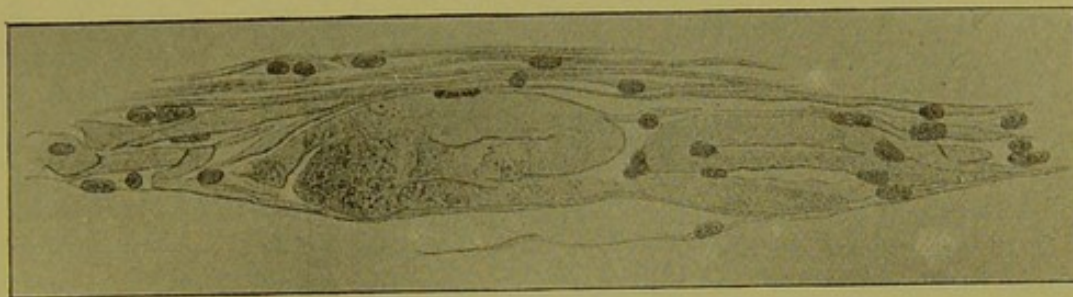
Dissection of bulbar conjunctiva showing pingueculæ. (FUCHS.)

toward the cornea. It is ordinarily found simultaneously in both the temporal and the nasal portions. It is harmless except as regards cosmetic appearance, although it may often precede and predispose to pterygium. According to Fuchs, it consists of a thickening of the conjunctiva with increase of its elastic fibres and an infiltration of hyaline into the tissue elements. He considers that it is a form of

senile degeneration in association with external irritant action. Fig. 202, showing the bulbar conjunctiva dissected from the ball and spread out, gives a representation of an eye with a pinguecula both at the inner and the outer sides of the cornea.

Fig. 203 gives the appearance of the hyaline degeneration of the sub-conjunctival connective tissue in the same condition. Overlying and adjacent to it, is an endothelial membrane with nuclei.

FIG. 203.



Minute structure of pinguecula. (FUCHS.)

Tuberculosis of the conjunctiva, always a rare disease, is seldom seen in this country. It shows itself as great thickenings and swellings of the lid, with a localized lump, which, on eversion of the lids, appears as a mass of granulations. Where the growth is young, these masses are red and exuberant. In other places there are ulcerations and lardaceous spots. The lymph glands in front of the ear and under the jaw of the same side are usually swollen. The disease frequently extends into the tear-passages, which then become filled with granulations. It is ordinarily found in the young and as part of general tuberculosis, although it may be primary and chronic. Arlt¹ says that it is impossible to diagnose it from lupus, epithelioma, syphilitic ulcer, and chronic blennorrhœa from local appearance alone, so that recourse to a careful history, and to microscopic examination of a portion of it, would be necessary for proper diagnosis.

For its treatment, Horner advises the scraping of the granulated surface, and the subsequent employment of yellow oxide ointment, with the administration of arsenic, cod-liver oil, and iodine-water internally.

Syphilitic affections of the conjunctiva are usually found as primary ulcers due to direct infection. They may also arise from softening and ulceration of conjunctival gummata. Such ulcers generally leave firm fibrous contracting cicatrices behind them.

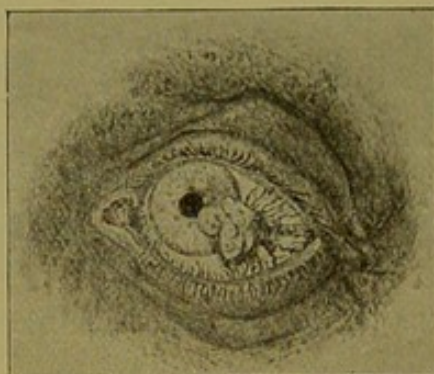
Lupus of the conjunctiva, according to Arlt, may be primary in this situation. More frequently it is secondary to lupus of the skin of the face and eyelids. It presents granulating ulcers which resemble those of tuberculosis. He describes a series of fibrinous bands as surrounding and separating the granulations, and says that after a thorough cauterization, a sieve-like mass of fibrous tissue may be seen at the

¹ Klinische Darstellung der Krankheiten des Auges, S. 98. 1881.

bottom of the ulcer. In its treatment, prompt cauterization should be resorted to. Koch asserts that it is advantageously treated by subcutaneous injections of a lymph as prepared by him.

Pemphigus of the conjunctiva is a very rare affection. The bullæ soon burst, and the raw surface appears grayish and covered with an adherent membrane. The condition may lead to shrinking of the conjunctiva, or to symblepharon.

FIG. 204.



Fibroid papilloma of conjunctiva. (QUINCY.)

Sarcoma of the conjunctiva occasionally, but rarely, has its primary seat in this membrane.

Fibroid papillomata of the conjunctiva form at times at the corneo-scleral junction, and recur after apparently complete removal.

Fig. 204 represents such a growth, as seen by the author, which recurred after abscission, and which was only permanently destroyed by a second operation in which nitric acid was used to cauterize the raw surfaces.

CHAPTER XIV.

DISEASES OF THE CORNEA.

LIKE most other fibrous tissues, the cornea is little disposed to take on idiopathic inflammation. Not infrequently, however, it manifests derangements in its nutrition which are due to constitutional disease. It is, moreover, very frequently the seat of pathological changes that are consequent upon disease of adjacent tissues. From such causes, and from its liability to injury, the affections of this membrane become one of the most common pathological conditions of the eye which we are called upon to treat. Inflammation not infrequently seriously interferes with vision, by so softening the tissue that it gives way to intra-ocular pressure; the consequent alteration of curvature impairing its action as a lens. A similar though converse result may be caused by contraction produced by cicatrizing processes. Moreover, ulcers and inflammation, leaving permanent opacities, interfere with transparency. Idiopathic inflammation is not usually accompanied by the formation of pus, while most of the traumatic and secondary inflammations are suppurative in character.

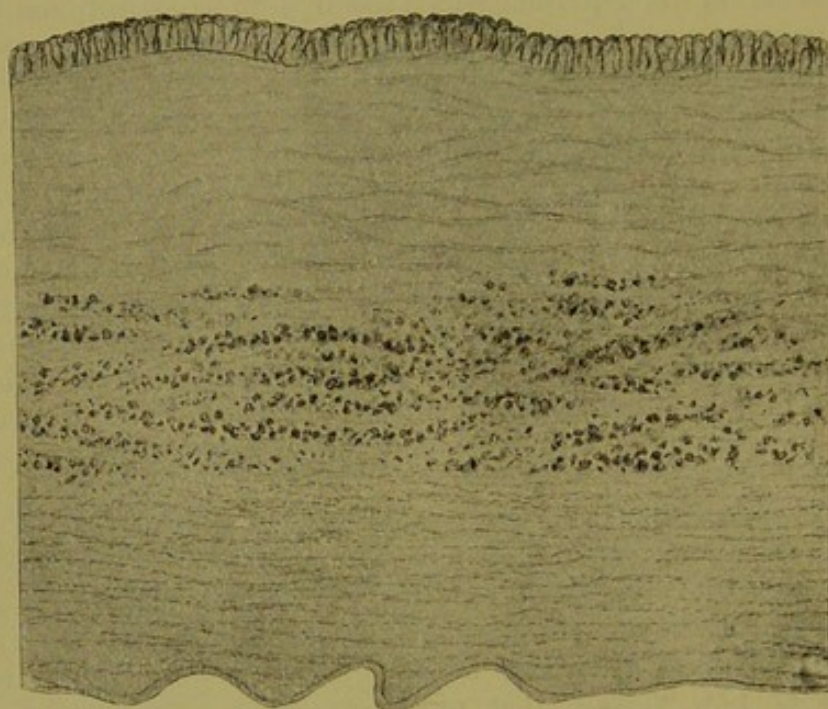
Interstitial keratitis, in its most usual form, is a disease of the young. It is generally an accompaniment either of scrofula or of inherited syphilis. It begins with irregularly rounded, whitish dots, which first appear in the centre of the membrane, or, at times, in its periphery. It is usually accompanied by diffuse haze, ciliary injection, and a marked formation of new vessels, that often present a raised yellowish-red crescent at the limbus. At times, the opacities are so completely confined to the interstitial lamina of the cornea, that the cloudy portion of the membrane looks as if it were covered with a layer of clear glass. At other times, the corneal epithelium appears rough, irregularly swollen, and needle-stuck. As the disease proceeds, the irregular whitish patches in the lamellæ grow larger by fusion, and the cornea sometimes becomes so opaque that vision may be reduced to mere perception of light. The clouding is frequently accompanied with intense ciliary injection, a constant flow of tears, and a great dread of light. The amount of vascularization varies largely in different cases. Vessels shoot in from the superficial and especially the deep loops, until at times the entire membrane becomes of a dark-red tint. Their formation, which is never primary, and always following a previous interstitial deposit, generally occurs in that part of the periphery that is nearest to the densest opacity. They may begin simultaneously in several places, and it is not uncommon to see two vascular patches make their appearance at the same time. When the disease subsides, the cornea clears from its periphery, the opaque white dots in the centre being the last to disappear. Often there is a development of iritis, with the formation of

posterior synechiæ, which may be recognized when the corneal haze partially subsides. Chorioidal degeneration and secondary retinitis may also at times be seen.

Fig. 205 shows the usual position of the interstitial deposit.

The subjects are usually between six and twenty years of age. Occasionally it develops as late as twenty-five or thirty years of age. Some of the most acute and obstinate attacks are those which appear at puberty. It is always chronic, lasting from two or three months to as many years. Generally both eyes are affected, the disease in the second eye

FIG. 205.



Section of interstitial keratitis. (WEDL.)

usually beginning a few weeks after its appearance in the first. Often, discouraging relapses occur after a period in which there has been marked improvement. Even in the most favorable cases it is rare to find a re-establishment of anything like perfect acuity of vision. Frequently, owing to softening through the chronic inflammation, the membrane undergoes distention, and the eye becomes myopic and irregularly astigmatic.

Almost all writers have recognized that the disease is frequently an exhibition of constitutional dyscrasia, but it remained for Hutchinson to show how often it is a manifestation of inherited syphilis. A very large proportion of the patients have a scaphoid face, with cicatrices at the angles of the mouth and alæ of the nose. There is a peculiar formation of the central upper incisor teeth, which are broader at the base than at the cutting surface. This surface presents slight irregular projections, which break off and leave marked vertical notches. These deformities in the central upper incisors are the only ones that are considered characteristic by Hutchinson. Sometimes, only one of them

presents this malformation; some of the neighboring teeth being but partly developed or even wanting.

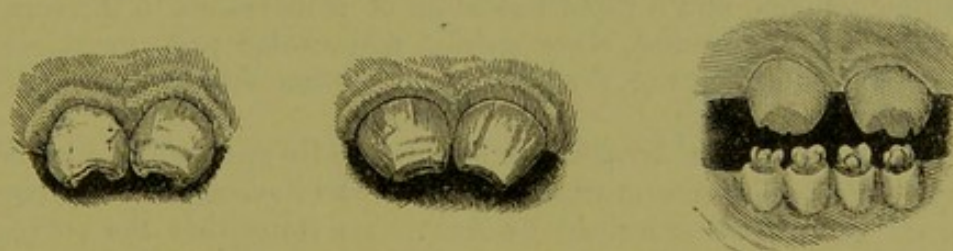
Fig. 208 shows two upper and four lower recently cut incisors (permanent) from a subject with inherited syphilis. The upper teeth are narrow from side to side at their edges, and show a thin middle lobe, that is bounded above by a crescentic line. The lower teeth are rounded and have foliated extremities. All of them are small, and spaces occur between them. In the upper ones, the crescentic, thin middle lobe, and in the lower ones the foliated extremities, will break away, and the upper teeth will be left in the state shown in Fig. 206. The teeth, where they are short, convergent, narrow from side to side at their edges, show vertical notches.

The teeth shown in Fig. 207 are almost similar in character to those in Fig. 206. Here, however, the notches are less deep, while the narrowing from side to side is quite marked.

FIG. 206.

FIG. 207.

FIG. 208.



Permanent incisors of inherited syphilis. (HUTCHINSON.)

Irregular projections from the lower incisors are also often found. These may be due to rachitis and to other vices of nutrition occurring during the growth of the permanent set. We must also distinguish the pegged and notched form of the central upper incisors from the horizontal striæ and grooves that are due to measles or to some other acute disease which has affected the system just before dental eruption.

If we accept the signs of facial development, cicatrices on the skin, and pegged and notched teeth, especially where they coexist with a series of miscarriages and dead-born children in the family history, as symptoms of inherited syphilis, then a large proportion of cases of interstitial keratitis is due to this disease. Many cases show general thickening of the periosteum of the tibia. Less frequently, nodes are present. We also encounter cases where these signs are wanting, and where we find only the thick, coarse skin and enlarged glands that are due to scrofula.

The eyes should be protected from irritants by light-tinted London-smoked coquilles. The conjunctival sac should be washed several times daily with a solution of boric acid. In the early stage of the disease, atropine is to be instilled, to prevent the development of secondary iritis. If there be much photophobia and ciliary injection, or if iritis be present, the atropine should be continued, and

cocaine added to the boric acid solution. We should not forget that the continued use of atropine in these cases may produce increase of intra-ocular tension. Inunctions of one drachm of mercurial ointment gently but persistently rubbed into the skin of the abdomen, twice in twenty-four hours, are of advantage. Under its use, the patient often loses his pallid appearance and becomes ruddy. The drug may usually be continued for months without salivation. When, for any reason, inunction is undesirable, the one-forty-eighth of a grain of bichloride of mercury dissolved in five or ten drops of tincture of perchloride of iron, is an admirable remedy. As nutrition is impaired, quinine, cod-liver oil, malt, good food, etc., are often called for. In the later stages of the disease, the moderate use of hot-water compresses is often beneficial in stimulating the circulation in and around the cornea, thus aiding to clear up the opacities. It is not, however, always well borne, and we are frequently obliged to remain satisfied, as regards local treatment, with keeping the eye cleansed from secretions and protected from light. When the attack comes on suddenly, with marked ciliary injection, great photophobia, and a rapid formation of bloodvessels in the cornea, and where there is frontal, circumorbital and ocular pain, great relief, with prompt subsidence of the symptoms, is often obtained by leeching the temple.

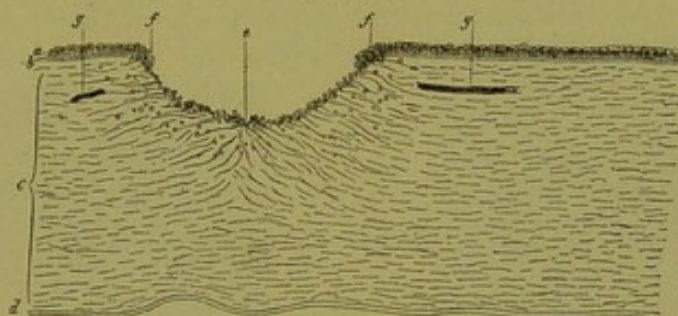
Malarial interstitial keratitis, occurs in middle-aged adults who have suffered from severe intermittent fever and who have acquired enlarged spleens. It was first described by Arlt. He states that the cornea is intact in its surface and curvature, while the opacity resembles paper which has been crumpled and oiled. In the cases which remained long enough under treatment, he found that the membrane cleared under the internal use of quinine, iron, and saline waters, such as Karlsbad.

Occasionally, we find a transient interstitial haze of the cornea resulting from acute conjunctivitis following exposure to cold.

Keratitis bullosa is a rare form of interstitial inflammation of the cornea. It occurs in eyes whose function has been impaired by glaucoma or by irido-cyclitis. In this disease, an increase of intra-ocular tension is accompanied by the formation of large bullæ in the cornea, which may be from four to five millimeters in diameter. The bullæ are situated on a base of grayish infiltrated and previously inflamed cornea, and are usually limited to the central or lower part of the membrane. They are only partly filled with fluid, which may readily be displaced by gentle pressure on the eyelids. Their walls consist of the epithelium and Bowman's membrane, and newly-formed tissue. Considerable pain, ciliary injection, and photophobia, usually accompany their formation. When they break, they leave a shallow but extensive ulcer. After they rupture, the eye should be cleansed with boric acid solution and a compress bandage should be applied. Any irido-cyclitic or glaucomatous symptoms should receive appropriate treatment. Where the disease is the result of glaucoma, an iridectomy will sometimes be of use. Often, however, intra-ocular changes are so far advanced that no advantage can result from it. Saemisch records a case in which, owing to repeated attacks, he was obliged to perform enucleation. The author has had two similar experiences.

Suppurative keratitis, in its various forms, is due to injury, or is secondary to disease affecting other tissues of the eye. It varies greatly, not only in form and appearance, but in the dangers with which the eye is threatened. A careful study of the principal varieties and of the processes of repair is necessary for successful treatment. In these, as in all the other varieties, the gray infiltration of the edges and bottom clears up when the ulcer begins to heal. The corneal epithelium grows in over the rough surface, dipping down into its sinuosities, and leaving an effusion of plastic lymph beneath, which long remains milky and translucent. In many cases, it becomes transparent, and assumes a structure which is more or less analogous to that previously destroyed.

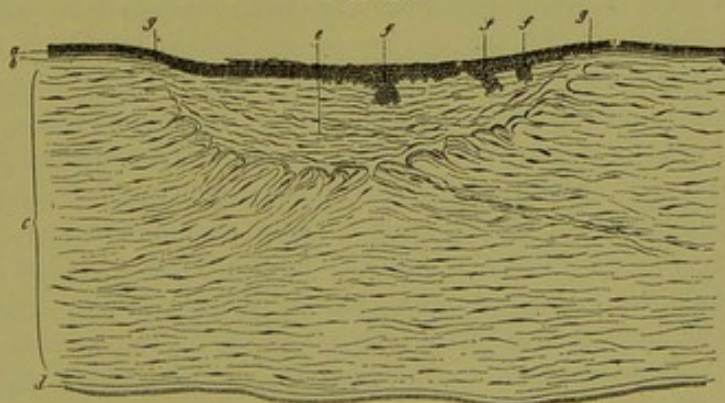
FIG. 209.



Corneal ulcer. (SAEMISCH.)

Fig. 209 represents a corneal ulcer which has destroyed the overlying epithelium, the anterior elastic lamina, and about one-third of the thickness of the corneal tissue. It is beginning to heal, and newly-formed bloodvessels have reached to its margins. There is still slight infiltration of the corneal fibres at the bottom and sides, which have become covered by an outgrowth of corneal epithelium.

FIG. 210.



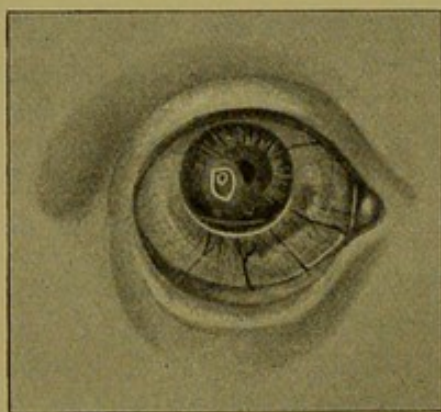
Cicatrix of corneal ulcer. (SAEMISCH.)

Fig. 210 shows a section through the resultant cicatrix of such an ulcer. The surface is slightly retracted. The anterior elastic membrane has not regenerated over the entire surface of the cicatrix. The previous cavity has become filled with lymph which has organized into

tissue that resembles healthy cornea. At its surface there are several places where plugs of epithelium shoot down into it.

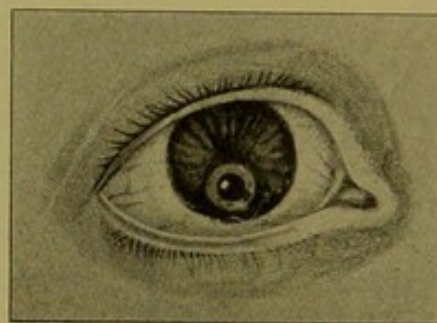
Simple perforations or clean-cuts of the cornea heal in a similar manner, leaving a scar which is always visible by a magnifying-glass and oblique light. The membrane of Descemet either remains with its end jutting into the anterior chamber, or some portion of it is rolled into the wound, to be united firmly with corneal tissue, and leave an open groove which extends into the true corneal tissue. When an ulcer is near the edge of the cornea, the formation of adjacent bloodvessel loops is a favorable sign, as fresh material for repair is thus brought to it. Fig. 211 represents a deep corneal ulcer with a gray halo in the corneal

FIG. 211.



Corneal ulcer. (SICHEL.)

FIG. 212.



Prolapse of iris. (DEMOURS.)

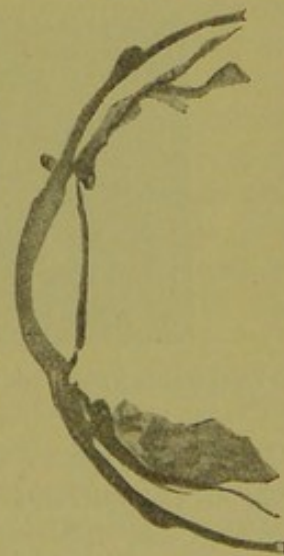tissue around it. There is also unguis and hypopyon. Secretion of pus in the chamber is frequently attended by the formation of posterior synechiæ, and tenderness of the eyeball. When these exist, they constitute positive evidence of the involvement of the iris and of the ciliary body in the inflammatory process. In such cases, it is justifiable to suppose that part of the hypopyon is produced by these conditions. Unguis and hypopyon are most frequently found in the deep ulcers that are due to phlyctenular inflammation and in corneal abscess.

The membrane of Descemet resists ulceration better than the corneal tissue itself, so that clear herniæ may be often seen projecting from the bottom of deep ulcers. Occasionally, when this protrusion gives way, as in small and deep ulcers, a corneal fistula forms. This apparently occurs because the ruptured ends of the membrane of Descemet are drawn outward and are applied to the edges of the wound, thus preventing any exudation from sticking to them and closing the opening. When this takes place, intra-ocular tension is lessened, and the eye is liable to recurrent attacks of inflammation. In such cases, rest in bed and the careful application of a pressure-bandage will often bring about closure of the wound. Sometimes it may be necessary to carefully cauterize the edges of the fistula with nitrate of silver or a fine red-hot metallic probe. Where the ulcer is large, contraction of the external muscles and the escape of the aqueous may bring the lens-capsule and the iris

in contact with it. Where it is small and central, sufficient lymph may be effused not only to fill the wound, but also to glue it to the lens-capsule. In all cases there is a gradual pressure on the anterior surface of the lens by the reaccumulation of the aqueous, as the closure of the wound becomes firmer and the new corneal tissue organizes. This, with the contraction of the elastic iris, often ruptures the connection of the anterior capsule to the cornea, thus causing the lens to resume its normal position. Sometimes the lymph on the capsule remains attached to the scar on the cornea by a thread. At times it is torn loose and persists as an elevated opaque mass on the capsule. This often gives rise to disturbance of the nutrition of the epithelial cells beneath it, causing the whole to appear as a more or less opaque pyramidal mass that projects into the anterior chamber. This constitutes what is known as *anterior central capsular cataract*. If the affection be congenital, the affected area is generally larger in size. When the ulcer is quite large, or is less central in position, a protrusion of the iris through the corneal opening is often met with. This constitutes what is termed *prolapse of the iris*. Fig. 212 represents a perforating ulcer of the cornea with prolapse of the iris. There is a halo of gray infiltration around the ulcer. The drag on the iris has caused displacement of the pupil.

If the prolapse be small and is conical in shape, it may, at times, by careful bandaging and abstinence from all muscular effort, be gradually pushed back from the cornea as the wound heals. Oftener, however, it remains incarcerated in the scar and pulls part of the iris forward across the anterior chamber, producing a condition to which the name of *anterior synechia* is given. Fig. 213 gives a good representation of a section through the anterior segment of a globe, showing the firm attachment of the iris to the cornea. On account of the constant pull on the iris in its incessant contraction in response to various intensities of light and with every act of convergence and accommodation, this condition constitutes a grave lesion. It is always disastrous when the corneal cicatrix is protuberant. In such a case it is sure to be followed by an increase of intra-ocular tension and secondary glaucoma, with complete excavation of the intra-ocular end of the optic nerve. Where there is an extensive ulcer with a large prolapse of the iris, a soft mass of exudation, composed of granulations from the iris and remnants of the corneal tissue, is apt to appear during the healing process. These, which slowly yield to intra-ocular pressure and form a projection from the front of the eye, are known as *staphyloma of the cornea*. They are either irregularly globose or pyramidal in shape. Where the staphyloma involves the whole cornea, it is said to be *total*. Where only a part of the cornea is affected, the protrusion is known as *partial*. Where, on account of intra-ocular pressure, the soft iris and exuda-

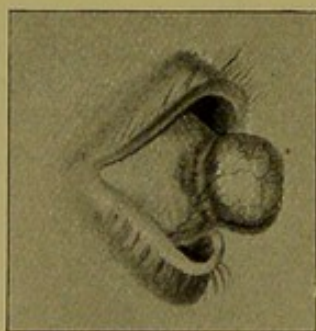
FIG. 213.



Section of anterior synechia.

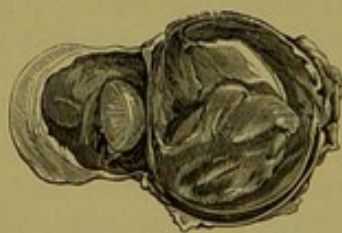tion-masses bulge through the comparatively resisting remnants of corneal tissue, it is designated as *racemose*. Partial staphylomata are apt to be conical in shape, while total staphylomata are generally irregularly rounded. At times the surface of the projection is covered with dense epithelium, and appears hard and horny. Rarely, some minute central portion remains sufficiently clear to temporarily give useful vision. Not unfrequently, all light-perception is lost; this being the result of pull on the iris and ciliary body, causing secondary glaucoma with complete excavation of the head of the optic nerve. Where a long-standing staphyloma has become large enough to project between the lids, there is often great thickening of its anterior walls. This is due both to effusion of plastic lymph and more particularly to a great increase and thickening of the epithelium from constant irritation by the air and minute foreign bodies. Behind the staphylomatous tissue, a space filled with fluid, which is often of considerable size, is found. This corresponds with the posterior chamber. The anterior chamber is obliterated by the union of the iris and the corneal tissue remnants. At times the lens remains in its proper position. More often it is dislocated and shrunken. In either case it is always opaque. Sometimes, no remnants of it are to be found, the lens having either been extruded through the ulcer, or having been absorbed after bursting of its capsule. As a rule the ciliary processes are atrophic, but may be enlarged in places and project into a bulge in the wall of the staphyloma. When, after long-standing inflammation of the ciliary region, the sclerotic at the periphery of the anterior chamber is distended by intra-ocular pressure and protrudes, the projection is known as *intercalary staphyloma*.

FIG. 214.



Total staphyloma of the cornea. (SICHEL.)

FIG. 215.



Section of total staphyloma.

Fig. 214 shows a total staphyloma of the cornea with great thickening of the anterior part.

Fig. 215 represents a section of a somewhat similar staphyloma from the eye of a child. It shows the thickening of the anterior wall, the plastering of the iris against its posterior surface, and the immense increase in the size of the posterior chamber. The divided lens has been slightly dislocated in cutting the eyeball.

Where the staphyloma is small and partial, a broad iridectomy opposite to the clearest part of the cornea, may give a degree of use-

ful sight. In addition, it may so reduce intra-ocular pressure as to enable the cicatrizing portion to contract more firmly and thus effect a partial cure of the disease. Usually, however, the staphyloma continues to grow, interfering with the action of the lids and causing dripping of tears over the cheeks. Recurrent attacks of inflammation may supervene, which may produce sympathetic irritation. If this last condition manifests itself, enucleation should be resorted to. If the staphyloma is merely an annoyance, and constitutes only a deformity, an operation for its removal may be resorted to. This consists simply in cutting it off and inserting a series of sutures around the opening, which, acting on the principle of a purse-string, will contract and thus help cicatrization. On account of the possibility of causing sympathetic disturbance, the method of putting sutures through the ciliary region is now abandoned. Should the sudden diminution of intra-ocular tension caused by abscission bring on chorioidal hemorrhage, the eye should be removed.

Instead of a protrusion of the anterior part of the eye after corneal ulceration, shrinkage may occur. This, which is known as *phthisis corneæ*, may appear when a considerable portion of the cornea has been destroyed. Here the corneal layers, which have become infiltrated with lymph, are glued to the iris by anterior synechia. Often, owing to contraction consequent upon panophthalmitis, a shrinking of the entire eyeball ensues, which, under the action of the recti muscles, becomes more or less quadrate in form. This condition is denominated *phthisis bulbi*.

Xerotic keratitis. In patients exhausted by prolonged fevers or debilitating maladies, the eyelids do not entirely shut during somnolency. Part of the cornea thus exposed dries, and is subjected to the irritation of dust and other minute foreign bodies. Under these circumstances the membrane becomes covered with a yellow crust which adheres to the lashes and to the dried cornea. If this crust be softened with warm water, and gently removed by a pair of forceps, the underlying cornea will be seen to be ulcerated. This ulcer has the characteristic gray infiltration of its walls. The only instances ever observed by the author occurred during the War of the Rebellion in the United States. All the patients were in the last stages of typho-malarial fever and of dysentery. Arlt reports recoveries, with entire clearing up of the ulcer.

Malacial keratitis is a term applied to a softening and sloughing of the cornea, which usually occurs in marasmic infants during the first few weeks of life. Here the membrane gradually softens, and is thrown off piecemeal, a result which is followed by hemorrhage into the vitreous chamber and panophthalmitis. In a number of interesting cases reported by Graefe, there was encephalitis. Arlt¹ has seen cases of recovery take place where there was a virulent small central opacity and an anterior-central capsular cataract.

Neuro-paralytic keratitis. It has long been known that when, owing to intra-cranial disease, there exists a paralysis of the trigeminus and a

¹ Klinische Darstellung der Krankheiten des Auges, 1881, S. 150.

loss of sensation in the parts supplied by it, hyperæmia of the conjunctiva, with an inflammation of the cornea, may be found. Here the cornea becomes irregularly hazy and has opaque spots scattered through its tissue. These are most frequent and dense at or near the centre. Ulceration often ensues. The condition is generally attributed to the fact that loss of corneal and conjunctival sensibility prevents the constant reflex lid-movements which ordinarily keep these membranes moist and free from irritants; that is, the action of foreign bodies, in conjunction with the dryness of the membranes, may excite inflammation. This is well shown in ordinary lagophthalmos, where, unless the lids be kept shut by a proper bandage, or the eye be protected by a watch-glass held in place by adhesive plaster, the organ becomes inflamed. With these precautions and by the aid of mild astringents, such eyes may be made white and quiet. The results of the most modern experiments in physiology point in the same direction.

Some experiments, however, such as those of Meissner and Schiff, seem to show that the cutting of the mesial (trophic) fibres of the nerve is attended with inflammation even if the cornea has not entirely lost its sensibility. The author has reported¹ a case undoubtedly of intracranial origin. Here, although the patient was seen soon after the beginning of the keratitis and the eye was carefully washed and bandaged, a central corneal slough formed.

Abscess of the cornea; Ulcer corneæ serpens; Hypopyon keratitis. This grave affection of the cornea is found almost exclusively in persons in middle life, and there is generally a history of preceding injury of the eye. Blennorrhœa of the lacrymal sac is, at times, a predisposing cause. According to Saemisch, it is found in thirty-two per cent. of serpiginous ulcers of the cornea. The patients are usually from the poorer classes, in whom the processes of nutrition and repair are below the normal standard.

In such cases we find a yellowish-gray, rounded spot, infiltrated with pus cells, with an area of swollen tissue around it, near the centre of the cornea. Later, the anterior wall being thrown off, an open ulcer, with prominent although undermined edges, is revealed. Usually one edge of the ulcer becomes more swollen and infiltrated than the rest of its margin. This portion increases more rapidly and the ulcerous mass loses its original round form. Soon cloudiness of the aqueous humor and hypopyon appear, which latter often increases in extent till it occupies from one-half to two-thirds of the anterior chamber. One would naturally suppose that this pus came from the corneal ulcer, and the fact that we can often observe a yellowish streak deep in the cornea, leading from the bottom of the ulcer to the commencing hypopyon, would, as pointed out by Horner and by Arlt, seem to confirm this theory. Some authors are, however, unwilling to believe that the pus cells can wander through the membrane of Descemet, and are, therefore, obliged to assume that it is furnished by the ciliary process and the iris. At the outset the process is often almost painless. Usually the iris and the ciliary body soon are involved in inflammation, and

¹ Trans. Amer. Ophth. Soc., 1871, pp. 138, 139.

the condition becomes one of the most painful of eye-affections. Should the abscess be opened, a tough slough of some of the lamellæ of the cornea, as well as pus from the ulcer and from the anterior chamber, is not infrequently evacuated. If left alone, the disease progresses till a large perforation of the cornea occurs, and the eye is lost by iridocyclitic processes.

Abscesses of the cornea during and after fevers. In severe cases of variola, corneal abscesses coming on during the stage of desquamation, or subsequent to it, are not uncommon. They are different from those which, as the consequence of a pustule forming in the conjunctiva at the edge of the cornea, arise at an earlier period of the disease. Saemisch gives an example of the occurrence of corneal abscesses in the seventh week of typhoid fever. These were coincident with abscesses in the scalp and in the skin of the back. In his case, an abscess formed in each cornea. One burst and caused a conical staphyloma. The other healed, leaving a central leucoma. Corneal abscesses also appear in pyæmic processes. They also coincide with the formation of abscesses in other parts of the body.

As all varieties of suppurative keratitis are serious and threaten the eyesight, we must watch them carefully, limit their progress, and bring about healing as promptly as possible. All ulcers should be carefully and repeatedly washed with some cleansing and antiseptic material. This is to be done by gently separating the lids and directing a stream of the solution against them from a pipette. Boric acid is the most useful. Where ulcers are indolent and there is but little pericorneal injection, weak solutions of chlorine water, of peroxide of hydrogen, of carbolic acid, of benzoate of sodium, or of bichloride of mercury, may be resorted to. A solution of atropine should be instilled sufficiently often to keep the pupil dilated and to diminish the tendency to hyperæmia and inflammation of the iris. If, in spite of this treatment, the ulcer spreads and remains gray, hot water applied to the closed lids by compresses often brings about a rapid healing. It may be applied at half-minute intervals, from ten to twenty minutes, three or four times a day. Where the symptoms are more urgent, it may be used continuously. Where the ulcer is deep and threatens to perforate, a compress bandage is often of advantage. In many cases, however, where there is much discharge from the conjunctiva, or where there is a high grade of eczema of the lids, we are compelled to desist from its application. If the ulcer is sluggish, or if its edges are undermined, local stimulation is at times advantageous. It is best performed by either placing a drop of laudanum on the ulcer by means of a fine brush, or by touching the bottom and edges of the ulcer with a button-pointed silver probe made red-hot by holding it in the flame of a Bunsen burner or an alcohol-lamp. A prompt whitening of the walls of the ulcer is the result of the latter application, which may be made almost entirely painless by the previous use of cocaine. It also has the two great advantages that its action is entirely under the control of the surgeon, and that it does not cause any irritation of the conjunctiva. Galvano-cauteries, although more complete, are more expensive and require care in their use. Where the ulcer is small and

deep, the membrane of Descemet at times projects into it as a hernia. In such cases it is advantageous to tap the hernia with a needle and to gently evacuate the aqueous humor. This should be done because the perforation so produced is of less extent and heals more rapidly than that which would result were the ulcer left to burst. A compress bandage, to facilitate closure of the wound and to prevent prolapse of the iris, should be applied after the operation. If perforation occurs, and a small and recent prolapse of iris tissue takes place, attempts to replace the iris by gently pushing it back with a horn spatula or a Daviel's spoon may be tried. Care should be taken to previously disinfect the conjunctival sac. A compress bandage should be applied after the operation. Where the ulcer is central, it is generally assumed that the application of atropine favors the retraction of the iris from the corneal wound. If it be peripheral, eserine is to be recommended for the same purpose. Under the use of a compress bandage, small prolapses will often heal nicely with a flat cicatrix. Where the prolapse bulges forward like a cyst, it is best to seize it with an iris-forceps and cut it off. If it is very large, we usually fail to attain any permanent result by abscission. In fact, a further portion of the iris may be forced into the wound, thus replacing that which has been excised. Where cicatrization is perfect, and a portion of the iris is retained in the scar and thus pulled forward out of its normal plane, the condition is designated as *anterior synechia*. Although this always displaces the pupil and puts a constant pull on the iris as it expands and contracts, it may, nevertheless, be innocuous, and the eye remain quiet for many years. Where the cicatrix is protuberant, it always leads to increase of intra-ocular tension. In such cases an iridectomy should be performed after the cicatrization has become complete and the eye has become free from ciliary injection. Should decided increase of tension come on before the eye gets quiet, it will be necessary to perform iridectomy. The result, however, will be much more certain if it can be postponed. In any case of prolapse, the compress bandage should be continued till the wound is firmly healed, the patient being enjoined to abstain during this period from straining and active exercise.

In all cases, we must remember that corneal ulcers heal more slowly in the old than in the young, and less readily in the feeble and those with impaired nutrition. We must look to hygienic surroundings, and, where necessary, order concentrated and digestible food with stimulants. In cases of corneal abscess and serpiginous ulcers, where they are large and threatening, and where there is not prompt and marked improvement under the use of hot water and atropine, operative measures should be proceeded to. The best is that proposed by Saemisch. This consists in first introducing a Graefe knife into the sound cornea on one side of the ulcer, the back of the instrument being held toward the centre of the eye and its edge being turned forward. While maintaining this position, the ulcer is to be bisected by bringing the knife out on the opposite side of the cornea. As the ulcer is apt to advance faster in the direction of the palpebral fissure, it is usually possible to slit it in its long axis whilst the lids are held apart. Where the long axis of the ulcer is oblique, the eyeball is to be seized with

the fixation-forceps and rotated sufficiently to render it possible to make the incision in a horizontal direction. By the use of cocaine, the incision can, in most instances, be made without fixation. In the opinion of the author, this is an advantage, as the cyclitis which accompanies these cases renders the ball sensitive to the touch or to any drug. The incision should be made slowly, and the knife carefully withdrawn, so that the aqueous humor may be gently evacuated and the iris not carried into the wound. Sometimes the exudation in the anterior chamber is not entirely evacuated. In such cases, it may be necessary to remove it with an iris-forceps. At times, we are obliged to remove the leather-like slough of corneal tissue which adheres to the sinuous and undermined edges of the abscess in a similar manner. When a small quantity of fluid pus remains at the bottom of the anterior chamber, it does not detract from the effect of the operation. The pain may still be severe after the procedure. In fact, it is often considerably augmented, but in a few hours is very much relieved. In order to promote prompt healing of the wound and to prevent prolapse of the iris, the patient should remain absolutely quiet in bed. Sometimes, on the following day the anterior chamber will be found partially refilled with pus, or the edges of the ulcer will be again swollen or infiltrated. In this case the wound should be reopened with a horn spatula, such as is used to replace an iris after prolapse. If the corneal wound has united too firmly to permit of this, a Graefe knife should be employed. By this treatment, we shall usually succeed in saving an eye with an indelible linear cicatrix and an adherent iris. In favorable cases, when a considerable portion of the cornea has been left intact and transparent, an after-iridectomy may afford useful vision.

The arrest of the sloughing process in the cornea brought about by the Saemisch operation, and the similar effect of the spontaneous perforation of smaller ulcers, have caused artificial evacuation of the contents of the anterior chamber to be tried in the treatment of ulcers. Such procedure is entirely inefficient in the creeping form and in abscesses, and frequently fails in smaller ulcers. The mere slitting of abscesses without opening the anterior chamber often fails to arrest the sloughing process. Arlt has suggested that more satisfactory results might be obtained, where the Saemisch operation fails, by using the electric cautery instead of reopening the wound. In some cases, thorough cauterization of the ulcer with the electric cautery may be advantageously substituted for the Saemisch operation.

Opacities of the cornea are sometimes congenital. Generally they are the result of inflammation or of ulceration occurring during extra-uterine life. According as they presented a slight haze, a decided spot, or a dense and permanent opacity, the older writers classified them as *nubeculae*, *maculae*, and *leucomata*. As the tissue in the cornea is resilient and inextensible, any loss of substance is made up by exudation, and subsequent organization of connective tissue and epithelium. Consequently, such scars are larger in comparison with the extent of the ulcer than they would be in the skin where the neighboring tissues are dragged into the original wound. Vision is affected not only according to their extent, density, and position, but by reason of the alterations which

they cause in corneal curvature. An absolutely dense opacity occupying a part of the pupillary area may be comparatively harmless, as its only effect would be to diminish the aperture in the diaphragm through which the patient sees. A similarly positioned opacity of the same size, though of less density, may be much more injurious to the vision. Here it not only diminishes the aperture, but causes such irregular diffusion of light as to fog the sharp retinal image obtained through the clear portion of the cornea. The reparative powers of corneal tissue are, however, great. It is wonderful to what an extent the effused lymph will sometimes clear, becoming organized into a tissue which closely resembles the original corneal fibres. This power of restitution not only varies with the extent and depth of the ulcer, but is still more influenced by the age and vigor of the patient. At times, deep and even perforating ulcers caused by ophthalmia neonatorum, become so clear, in time, that it is difficult to find a trace of them. In later life, and in enfeebled subjects, perforating ulcers, or even those that stop at the membrane of Descemet, leave indelible scars. Where there has been anterior synechia, or even any iris-pigment in the cicatrizing tissue, the prognosis is still more unfavorable. In leucomata from abscess, the corneal tissue is always incapable of becoming transparent. The cicatrices following pannus, and rubbing of intumed eyelashes, are also irremediable. Where the opacities are slight, they often give rise to myopia. This is owing to the feeble illumination of the retinal image and consequent increase of convergence and accommodation which is necessary when work is held near in efforts to obtain larger retinal images. In the same way they augment any tendency to squint. Where they are recent, and not very deep, even though dense in the centre, there is hope of their clearing so long as their edges are irregular and frayed. If they are of long standing, have sharp-cut edges, and extend into the deeper layers of the cornea, they will be permanent.

Band-like opacities are those which extend as narrow ribbons horizontally across the anterior layers of the cornea. They present a slightly whitish stippled appearance, and have tolerably sharp-cut upper and lower edges. Beginning in the centre or at the edge, they are separated from the corneal limbus by a narrow clear zone of substance. Although forming in eyes which are otherwise healthy, they are usually found where there is glaucoma, or chronic chorioidal disease, even where sight is entirely lost. Microscopically, they appear either as numerous colloid masses under the epithelium and in the anterior layers of the cornea, or as infiltrations of corneal tissue with deposits of the phosphate and carbonate of calcium. There is a difference of opinion as to their relation to other forms of eye-disease. Some hold that they are the cause of glaucoma, and others believe that they are evidences of foregoing pathological changes. In many instances it would appear as if they were the products of changes which had become stationary. Thus, Bowman, Dixon, Nettleship, and other English writers, have had good results, and have improved the eyesight by cutting and scraping them away. In some of these instances, the good results have been permanent, and have not been followed by any increase of intra-ocular

tension. Arlt relates a case where cataracts were successfully extracted whilst the opacities were present, leaving fair vision.

Arcus senilis, or *gerontoxon*, is an opacity of the cornea which is nearly always due to old age. It consists in a gray arc which runs parallel with the limbus. It is always separated from the limbus by a line of clear tissue of about a millimeter's width. It forms first at the upper corneal margin, then at the lower, extending from these situations so as to produce an opaque ring. It always remains broadest above and below. Microscopic examination shows that it consists of a fatty degeneration of the corneal fibres. In certain families it is of frequent occurrence. It may develop in youth and in middle life. Under these circumstances, Canton believes that it is apt to be associated with fatty degeneration of the external eye-muscles and the heart-muscles.

Congenital opacities of the cornea are apt to occur in partially developed, or microphthalmic eyes. They are generally coincident with coloboma of the chorioid, and are probably due to arrest of development. They may be caused by inflammation of the eye during foetal life. In many cases, they clear or diminish during the first few months after birth.

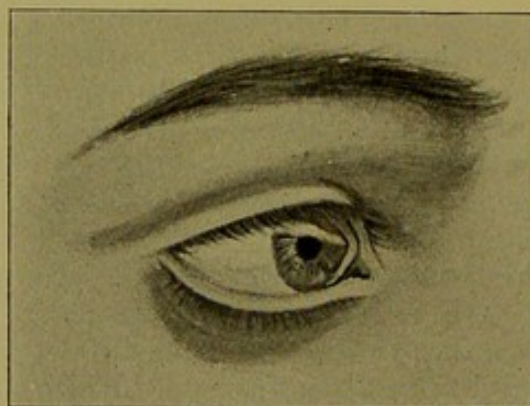
Many corneal opacities which follow ulceration may be much benefited after the inflammatory condition has ceased. The various remedies in vogue at different periods have been almost exclusively stimulant in character, causing temporary redness and watering of the eye. The vast number of these found in the older books, bear witness to their inefficiency. Here, as in corneal ulcer, the proper use of hot compresses is, in the author's opinion, often attended with good results. The other preparations usually employed are salves composed of some preparation of mercury. If the drug be dry, care should be taken that it be rubbed to the finest possible powder in an agate mortar before it is mixed with the excipient. The ointment of red or white precipitate and yellow oxide, of the strength of from one to five grains to the drachm, are favorite applications. The last named is the mildest and the least painful. Finely powdered calomel, or sugar mixed with bitartrate of potassium, or borax dusted into the eye, may also prove of benefit. Among the oleaginous preparations recommended, oil of turpentine with olive oil is one of the most efficacious.

During the last fifty years there have been constant efforts to excise permanent corneal opacities and replace them by portions of clear corneæ. Sometimes entire corneæ removed from animals have been employed. Both operations, however, have been followed by opacity or shrinkage of the graft. Von Hippel has devised a rotary trephine driven by a spring, by which a piece of cornea from one to four millimeters in diameter may be excised. The piece is to be dissected out and replaced by a graft cut with the same trephine from the clear cornea of some animal. He asserts that previous methods have been unsuccessful by reason of their cutting through the entire cornea, thus exposing the inserted plug and the adjacent corneal tissue to the action of the aqueous humor. He avoids this by stopping the trephine just in front of the membrane of Descemet and dissecting out the plug of tissue by a special knife. The operation is of too recent date to judge by expe-

rience of its results. It is evident that its range of application must be very limited, as it cannot be applied with advantage to cases with anterior synechia or to opacities lying in the deepest corneal layers.

Where the opacity lies opposite the pupil, vision may be benefited by an iridectomy, thus allowing light to enter through a clearer portion of the cornea. In cases of band-like opacities in which the anterior layers are infiltrated with lime, the opaque areas are best removed by scratching off the epithelium and introducing a cataract-knife parallel to the layers of cornea, so as to split and cut them off. Tattooing the cornea was introduced by Wecker. India-ink or other carbonaceous material in very fine division, is mixed with water and brushed over the leucoma. The opacity is stuck with fine needles till portions of the pigment have become entangled in its tissue. It is asserted that an unsightly deformity is thus removed, and that slight central opacities may be made perfectly opaque and rendered less disturbing to vision. The cosmetic effect is often readily attained. Its application is limited by the liability of exciting fresh attacks of irido-cyclitis in cases of anterior synechia, when the eye has become quiet and comfortable. Besides, the flow of blood tends to wash the carbon out of the tissue, and prevents it from becoming permanently imbedded in vascular cicatrices.

FIG. 216.



Conical cornea. (DALRYMPLE.)

Keratoconus; Staphyloma pellucidum. Conical cornea is a deformity in which, whilst the cornea gradually becomes thinner, its peripheral portion flattens and its central part projects as a pointed cone. The apex usually points inward and a little downward. The tissue remains transparent throughout, except in advanced cases, when the conical point becomes hazy. The cause of keratoconus is not known. It appears without apparent inflammation, and generally arises suddenly during youth. The author has twice noted its occurrence in several members of one family. Fig. 216 gives a good illustration of the condition.

The patients complain of dim vision, short-sightedness, and polyopia. At the apex of the cone there is a high degree of myopia. In every succeeding zone toward the base there is a different degree of diminished refraction, until, as a rule, there will be hypermetropia in the more peripheral parts.

In advanced cases, there is no difficulty in the diagnosis. Where the disease is not well marked, the distorted images which the cornea gives of distant window-bars, and the curious play of light and shadow along the base and sides of the cone when the membrane is lighted with the ophthalmoscope, often become valuable aids in its recognition.

As it has been found that the curves of such a cornea are parabolic, Raehlman has calculated definite formulæ and has had a series of parabolic glasses ground to remedy the defect. Their use is said to be sometimes satisfactory. We may, though of course more imperfectly, make use of cylinders or a stenopæic slit. Thus, when the cone points downward and its apex is below the centre of the pupil, the comparatively flat part above is often advantageously corrected by a convex cylinder with its axis placed horizontal. Such a lens creates for this portion of the membrane an even myopia, thus allowing more comfortable near-work. Strong concave cylinders may be employed to improve distant vision. In more advanced cases, a stenopæic slit, whilst diminishing the field, may facilitate near-work. Painting a concave glass with Brunswick black, so as to leave a one- to two-millimeter slit in the centre of the lens, is an excellent plan for accomplishing the same purpose. Operative measures have been employed.

For the more pronounced types, Graefe introduced the method of shaving the apex with a cataract-knife, so as to leave the deeper corneal layers intact. He followed this by repeatedly cauterizing the small ulcer thus obtained, so as to prevent healing and to cause more extensive cicatrization. Bowman attained the same end by the use of a small trepan. It has been supposed that the softened cornea gave way because its resisting-power was not sufficient to withstand ordinary intra-ocular pressure. Attempts have, therefore, been made to permanently lower tension by iridectomy. The author has seen admirable iridectomies fail to arrest the increase in the size of the cone, and produce much disturbance of vision by the glare and diffusion of light caused by a peripheral pupil. Where the patients are in feeble health, a roborant and nutrient treatment may be of service in altering the nutrition of the cornea and preventing further distention.

Tumors of the cornea. Dermoid tumors, which were first named by Ryba,¹ are opaque, yellowish-white hemispherical prominences, so seated in the corneal margin that the dividing line of the cornea and sclerotic passes nearly through their middle. They are usually solitary and are of small size. Rarely, they may be sufficiently large to almost cover the cornea. Saemisch records two in the same eye. Both Virchow² and H. Muller³ cite instances where they occurred in symmetrical positions in the two eyes. As the name implies, their structure resembles that of the skin. In fact, there is a thick layer of epidermis, below which there is a tough network of elastic fibres containing a few vessels and nerves. Occasionally, some hairs and hair-follicles are found.

They are benign, and there is no occasion for removal where they

¹ Prager Vierteljahrsschrift, 1853, X. Jahrgang, Bd. iii., S. 1.

² Virchow's Archiv, Bd. vi., Heft 4, S. 555.

³ Archiv f. Ophthalmol., ii., 2, S. 58.

are stationary, unless it be from deformity, or irritation that is produced by the rubbing of projecting hairs.

In removing them, they should be seized at their inner border with a toothed forceps and dissected off toward the periphery. Care should be taken not to attempt to remove too completely the underlying infiltrated layers, as the anterior chamber might be opened, thus converting an innocuous operation into one causing serious inflammation of the eye. Swanzy records a case at Graefe's clinic, where, during the removal of a large dermoid, the eye was so extensively opened that vitreous escaped.

Sarcoma, melanoma, and carcinoma of the cornea, have their origin in the conjunctiva.

CHAPTER XV.

DISEASES OF THE SCLERA.

Inflammation of the sclerotic ; Scleritis ; Episcleritis. The sclerotic, like tendinous structure, rarely takes on active inflammation. Although fatty and calcareous degenerations may appear, tumors push their cells between its fibres to fill the lymph-channels, and perforate its coats, and chronic inflammation of the chorioid produces thinning and bulging, yet no evidences of inflammation ever appear in it except in that variety of disease denominated *episcleritis*. This affection generally appears recurrently at different points either where the sclerotic is perforated anteriorly by the vessels which dip down through it from the conjunctival and subconjunctival tissues into the ciliary body or into some adjacent region. In elderly subjects, a small rounded lump can be seen deeply seated in the ciliary region, near the corneo-scleral junction. This appears of a dull purplish color, and is sensitive to touch. The overlying conjunctiva and its vessels are freely movable. When this mass diminishes and subsides, it leaves a depressed dirty-gray spot.

Usually, there is a feeling of burning and discomfort. At times, photophobia and sharp pain appear. Locally, the disease often remains unimproved by treatment, unless radical measures, such as the galvano- or actual-cautery, be employed. Remedies addressed to the general system, especially to the liver and the digestion, cause it to eventually disappear. Arlt records a case which was benefited by salicylate of sodium. Wecker recommends the subcutaneous injection of pilocarpine.

A more or less uniform discoloration and swelling over the ciliary zone is frequently an evidence of some chronic change in the ciliary body, ciliary processes, or anterior part of the chorioid. In such cases, known by Arlt as *uveoscleritis*, there is often a low grade of inflammation of the periphery of the cornea, which eventuates in irregular, jagged opacities near the limbus. Occasionally, there is intercurrent iritis. At times, a thinning of the sclera, which causes the cornea to project and the eyeball to become more or less pear-shaped, may occur. Again, there may be a positive projection of the sclerotic in the region of the ciliary body. Where the projection occurs in the periphery of the anterior chamber, it is called an *intercalary staphyloma*. When it is slightly farther back, it is termed *staphyloma of the ciliary body*. All operative interference with these secondary changes is to be avoided, except when the inflammatory processes have led to closure of the pupil. In high degrees of myopia, a thinning and distention in the macular region, and between it and the optic disk, known as *posterior staphyloma*, may be present.

In purulent panophthalmitis, ulceration of the surface of the sclerotic

may appear, if left to itself. If such cases be neglected, the pus usually evacuates itself through the thinnest portion of the sclera, close behind the insertion of the recti muscles.

Tumors are rare. Saemisch enumerates fibroma, sarcoma, cyst, and osteoma as of occasional occurrence. Watson relates the successful removal of an ivory exostosis as large as a good-sized pea, which originated in the sclerotic, between the insertions of the internal rectus and the superior rectus muscles.

CHAPTER XVI.

DISEASES OF THE IRIS AND CILIARY BODY.

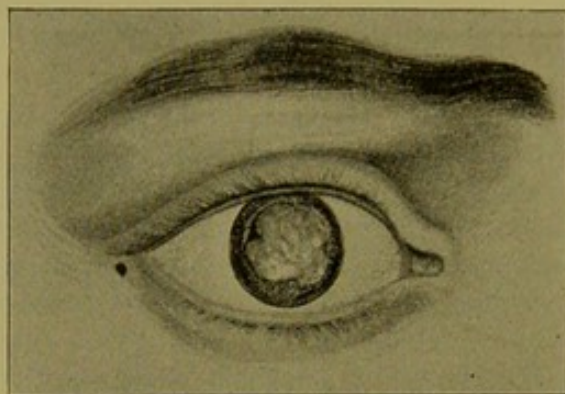
Hyperæmia of the iris is always a prelude of inflammation. It is frequently induced by inflammation and congestion of adjacent organs. For instance, it may be seen in intense conjunctivitis, keratitis, episcleritis, or congestion of the anterior part of the chorioid. The symptoms are pericorneal injection, sluggishness in movement, and change in color. The last symptom is dependent upon an increase of blood circulation in the iris, and probably serous infiltration of its tissue. The reddish-yellow color of the serum causes a bluish iris to appear greenish, and a hazel one to look reddish. A similar change of color in the iris may sometimes be due simply to infiltration of blood into the aqueous humor. In this case, the color disappears when the aqueous is evacuated. A hyperæmic iris frequently resists the action of mydriatics, requiring full doses and repeated applications to obtain full dilatation of the pupil. This is proved by subsequent examinations, where concentrated light and a magnifying-glass have failed to show traces of attachment to the capsule of the lens or exudation into the aqueous humor.

Iritis. This condition is said to be present when, in addition to sluggishness of the pupil, change of color, and pericorneal injection, there is inflammatory exudation. If the exudation appears in the pupillary space, on the uveal surface, and in the posterior chamber, and is tenacious, forming fibrous masses or sheets, the disease is termed *plastic iritis*. If the exudation is mainly found in the substance of the iris, the affection is called *parenchymatous iritis*. When the lymph is mostly effused into the aqueous humor, the disease is known as *serous iritis*. It is, however, not to be expected, when the anatomical configuration and the vascular supply of the iris are considered, that exudation will be limited accurately either to its surface or its parenchyma. Neither can it always be alike in all attacks or in different stages of the same attack. Accordingly, mixed forms are found which do not correspond with the anatomical standard assumed for classification. Unfortunately, also, constitutional diathesis fails, in most instances, so to influence the course of the inflammation as to produce appearances which are characteristic. We are, therefore, obliged to study the anatomical appearances, and to satisfy ourselves as to the diathesis by a careful examination of the history of the patient and the other symptoms.

In cases of acute iritis, there is generally severe pain, sometimes ocular, but more commonly referred to other branches of the trigeminus. Especially is this so to those fibres which are distributed to the temple, the forehead, and the upper jaw. At times, there is hemicrania. The pain varies much in different forms and stages of the disease. In acute attacks, it is often severe, preventing sleep and causing an increase in

temperature of from half a degree to one and a half degrees. Severe fever, with nausea, is rarely present, except when there is coincident inflammation of the ciliary body. Even if pain be not present, it may be readily produced by exposure of the eye. Use of it or of its fellow-

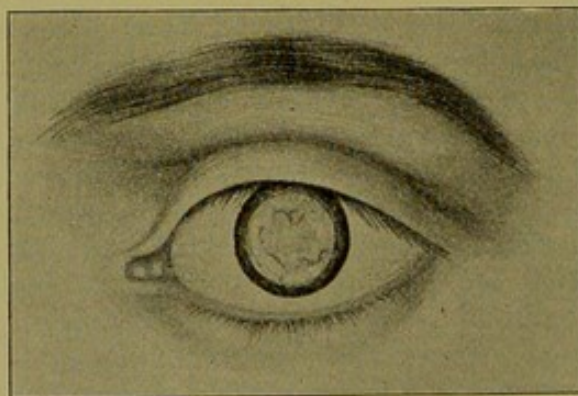
FIG. 217.



Posterior synechiæ. (JAEGER.)

eye in near-work, may also serve as causative factors. An early and important sign, are momentary blurrings of both distant and near objects. At times, the cramp of the ciliary muscle may be so great as to cause marked increases in the refractive power of the eye. Later, the acuity of vision is diminished in direct proportion to the haze produced by effusion into the aqueous humor. Except in serous iritis, the pupil

FIG. 218.



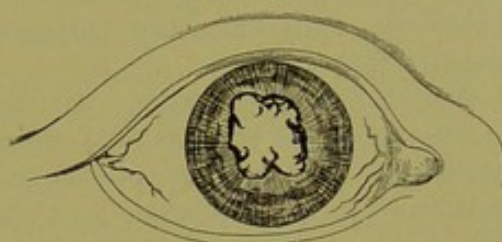Posterior synechiæ. (JAEGER.)

is usually small. Owing to the small size of the pupil and the immobility of the iris during sleep, plastic lymph has a favorable opportunity to fasten itself to the iris and capsule of the lens at that time. These adhesions are termed *posterior synechiæ*. As the lymph gravitates to the lower part of the pupil, they are, as a rule, most numerous in that position. When they are recent, and not too broad and too numerous, they can often be torn away by the action of a mydriatic, leaving behind gray spots of lymph on the lens-capsule, which may, at times, be tinted brown by the adherence of iris-pigment.

Figs. 217 and 218 give illustrations of posterior synechiæ, as seen by the ophthalmoscope, against a partially dilated pupil. In the first,¹ there are five synechiæ, four of which have been put on the stretch and have been partially detached by the action of a mydriatic. The effect of the drug on the broad and extensive one at the lower part of the pupil is almost imperceptible. The second¹ figure, shows the left eye of the same patient. Here the synechiæ have been entirely torn loose, leaving a fully dilated pupil. The black deposits in the anterior capsule of the lens, indicate the points at which the adhesions had been previously located. Fig. 219 shows a partially dilated pupil with numerous pigment-synechiæ. Here, owing to adhesions, the pupil has become irregularly quadrate with curvilinear extensions from the action of the drug at points where no synechiæ have formed.

When the pigmented spots are extensive and do not become absorbed, they often cause a change in the nutrition of the cells under the anterior capsule, and lead to permanent opacities of the lens. Where the synechiæ are hidden behind the iris, they may be demonstrated by the irregular motions of the pupil when the eye is alternately shaded and exposed to light. Sometimes, it is necessary to instil a mydriatic in order to ascertain their presence. If they are strong and broad, they are generally considered as one of the causes most apt to produce recurrences. They drag on the iris during its movements, and thus tend to irritate and interfere with its circulation. In severe forms of plastic inflammation, *ring-shaped synechiæ* which glue the pupillary margin of the iris to the capsule may appear. Where the entire posterior surface of the iris is fastened to the capsule, there is a *complete posterior synechia*. Either of these conditions cuts off the anterior from the posterior chamber. The secretion of aqueous humor by the ciliary processes pouring into the posterior chamber, causes a bulging of the thinner and more peripheral parts of the iris between the thicker radiating portions or pillars. The portions thus dilated form a series of prominences which bulge into the anterior chamber, while the pupil, which thus lies deeper and is fastened to the anterior capsule, presents a crater-like depression. When such exudations completely cut off communication between the anterior and posterior chambers, the condition is termed *exclusion of the pupil*. This condition leads either to increase of tension and glaucoma, or to inflammatory changes in the chorioid. Where lymph is effused into the pupil, almost filling it with a yellowish-gray cloud which projects into the anterior chamber, *occlusion of the pupil* takes place. It is the less dangerous of the two, as a good pupil can often be secured by an iridectomy. Moreover, there is frequently incomplete closure in occlusion, allowing circulation of fluid between the two chambers, and permitting sufficient access of light to give useful vision.

FIG. 219.



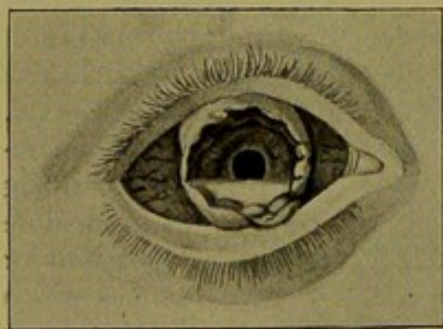
Pigment-synechiæ on the anterior capsule.
(JAEGER.)

¹ The process of reproduction in black and white, has caused the lens in the pupillary area to appear swollen and cataractous. This is, however, not the case.

Plastic iritis. Here, there is considerable effusion of organizable lymph, either causing posterior synechia or forming a fibrinous mass which fills up the pupil. The violence and rapidity of the attack vary greatly. In some cases, severe pain with marked ciliary injection and the formation of synechiæ, appear within a few hours. In others, there is discomfort for some days, with photophobia and watering when the eye is used or is exposed to bright light. At times, a slight swelling of the conjunctiva around the cornea, appears, which, upon subsiding, allows the ciliary injection to become manifest. In cases of traumatic iritis, especially after cataract operation, where the uveal surface of the iris comes in contact with the capsule, plastic iritis and the formation of adhesions, with but little pericorneal injection and discomfort, is frequently found.

Parenchymatous iritis. In this form, owing to exudation into the substance of the iris, there is either localized or general thickening and swelling. The surface appears spongy. Frequently, there is an entire change in its original color, and often there is a formation of new vessels. The tissue may become infiltrated with either lymphoid cells or aggregations of nuclei, or it may be permeated with extensive proliferations of connective tissue. The latter form is more frequent where the entire iris is involved, and where the pupil is firmly occluded with organized and vascular lymph. In those forms in which there is great lymphoid infiltration, lymph and pus in the anterior chamber are found. This condition is known as *hypopyon*. It varies greatly in its extent, as also in the rapidity of its formation and absorption. Fig. 220 shows a hypopyon,

FIG. 220.



Iritis with hypopyon and chemosis of bulbar conjunctiva. (DEMOURS.)

with considerable chemosis of the bulbar conjunctiva. In uncomplicated iritis, the pus is more fluid, less consistent, and less mixed with slimy and fibrinous exudates than it is in hypopyon keratitis.

Serous iritis. As clouding of the aqueous humor, and precipitates on the membrane of Descemet, often constitute the most prominent characteristics of this disease, this form of inflammation was termed *Descemetitis*, *Hydro-meningitis*, or *Aquo-capsulitis*. Here the pupil is often either of normal size or slightly dilated. Frequently, there is an

increase of intra-ocular tension. In this form there is almost invariably a contemporaneous inflammation of the ciliary body. Grayish or slightly brown precipitates on the membrane of Descemet are most numerous and largest at the lower part. They are frequently so minute as to require oblique illumination and the magnifying-glass for their detection. When they are of considerable size, they at times adhere quite loosely to the membrane of Descemet at the outset. In such cases, should increase of tension necessitate the performance of paracentesis, they may be evacuated with the aqueous humor. At times they irritate the membrane of Descemet and cause proliferation of its cells.

These becoming firmly incorporated with it, form hillocks that project into the anterior chamber. Long-standing descemetitis almost always produces opacity of the other layers of the cornea, giving origin to a variety of *sclerosing keratitis*.

To obtain a more complete idea of iritis and of its proper modes of treatment, its most prominent clinical varieties must be considered at length. These, named from the diseases which give rise to them, are as follows: Rheumatic iritis, syphilitic iritis, gonorrhœic iritis, and tuberculous iritis.

Rheumatic iritis. Here the disease may appear without other traceable cause than what is usually termed "taking cold." Although gouty and rheumatic subjects in middle life and old age are much more liable than others to attacks of iritis, yet the symptoms ordinarily found do not seem to indicate that there is any special variety that is developed in such persons. In fact, it presents no distinctive pathological appearances. It is rare in infancy and in youth. As a rule, it is mild in its outset, developing with slight conjunctival catarrh and with slight corneal haze. Sometimes, however, it originates violently, with severe pain, contracted pupil, and marked discoloration of the iris. In such cases, there is decided photophobia and lacrymation.

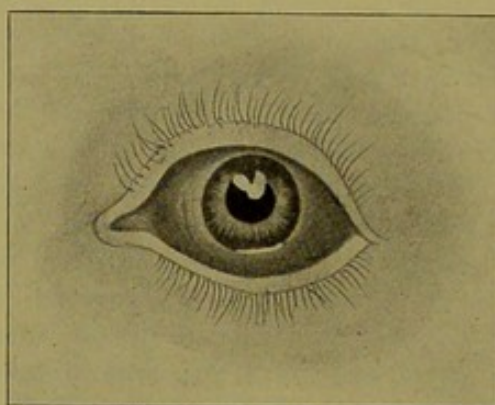
Syphilitic iritis. Attacks of iritis in children and infants, if not traumatic, are almost invariably due to inherited syphilis. In such cases, the disease may appear as a simple plastic iritis, but usually there is contemporaneous involvement of the ciliary body. The inherited form of the disease is rare, even in children, except as secondary to interstitial keratitis. In adults, the acquired form is frequent, generally developing as a plastic inflammation, or one which is accompanied by the formation of gummata. The plastic form is the more frequent variety. It is differentiated by its coincidence with other secondary symptoms, such as the various skin eruptions, falling of the hair, and development of mucus patches. Where the iritis precedes the other constitutional manifestations, there is no certain guide in the appearance of the eye itself that can conduct us to a proper diagnosis.

The disease is frequently insidious in its onset. Hyperæmia of the iris, with episcleral and pericorneal injection, may develop, and posterior synechiæ form, which attract but little attention from the patient. It is not until some slight dimness of vision or an attack of peri-orbital pain appear, that the patients search for relief. In some cases, acute pain, photophobia, and lacrymation, develop rapidly. The variety accompanied by the formation of gummata, is found at a later period of the general disease; that is, when the secondary symptoms are subsiding, or after they have passed off. As the gummous masses generally form over either the minor or the major circulus arteriosus, they are apparently influenced by the disposition of the bloodvessels of the iris. Sometimes, they develop slowly, appearing at first like whitish opaque cysts, that separate the fibres of the iris. An example of this, occurring in a Negro, is shown in Fig. 221.

Owing to numerous newly formed vessels surrounding the growth, it becomes yellow in the centre, with a border of red. Sometimes the gummatous masses are yellowish-gray from the outset. They are often

single. When multiple, they may almost fill the anterior chamber. They arise in the substance of the iris, and project both backward and forward. When large, they may form extensive adhesions to the anterior capsule. Usually, they are followed by partial atrophy of the portions of the iris in which they develop. When they grow from the periphery of the iris, they are, while small, almost hidden by the corneal limbus. Hypopyon frequently accompanies them. Their structure during growth, like that of other gummy tumors, consists of closely packed nuclei, with newly formed connective-tissue cells, which are imbedded in the gummy material. Later, caseous degeneration with absorption of the masses takes place, leaving atrophic spots on the iris.

FIG. 221.



Gumma of the iris.

Gonorrhœic iritis. Notwithstanding the prevalence of gonorrhœa, and the assertion of Förster that if the urethra be habitually inspected in every case of iritis, the two diseases would be found more frequently coinciding, yet, iritis due to gonorrhœa, clinically seems to be of comparatively rare occurrence. It does not generally occur as an immediate consequence of gonorrhœa, but develops in those cases where there are swelling of the joints and rheumatism. In such cases, renewed attacks of gonorrhœa are frequently accompanied by fresh exacerbations of iritis. Förster asserts that, even where there has been no new infection, there may be a fresh attack of iritis whenever from any cause there is a recurrence of a thin gleet discharge from the urethra.

Tuberculous iritis. This form of the disease is a rare affection in this country. Ordinarily, it is developed in scrofulous children or in adolescents with enlarged lymphatic glands. Sometimes it is seen in those subjects who have a development of tubercle in the lung. At times, however, it occurs in persons who are apparently free from any other localizations of the disease. Haab has given a good description of the disease as it has been observed in Zurich. He says that it begins as ordinary iritis, with dread of light, pain, ciliary injection, and posterior synechiæ. Later, small gray nodules develop and enlarge. At times, these may disappear, as the inflammation subsides. In other cases, plastic irido-cyclitis, with shrinking of the eyeball, may ensue. Where the tuberculous nodules are large, they are yellow in color. Frequently

there is a red vascular border, causing them to resemble gummata. Where they continue to grow, the cornea gives way and the eyeball shrinks; no general symptoms of tubercular disease appear, and the patient apparently gets well. In this respect, tuberculosis of the iris, which is often primary, presents a strong contrast to tuberculosis of the chorioid, where almost invariably there is an accompaniment of general tuberculosis.

If the eye be protected from irritants, and the patient is prevented from using the other eye for near-work, many mild cases of iritis will get well with local treatment by atropine. As there is a flow of blood to the ciliary region of each organ, and a contraction of the ciliary muscles, irides, and internal recti in reading or other near-work, when but one eye is used, the non-use of the uninflamed eye should be insisted upon even though the inflamed eye be bandaged. Both eyes should be protected from strong light, either by smoked glasses and a shade when the patient is compelled to go out, or by moderation of the surrounding light by blinds and screens when he is in the house. In all forms of the disease, the eyes are so sensitive to the action of strong wind, changes of temperature, and other irritants, that, although such patients can be treated satisfactorily at our offices or in dispensary service, yet they would recover more promptly if they could be cared for in hospitals or at their homes. In many severe cases, it is necessary to put the patients to bed and to employ sudorifics. Where synechiæ have formed, atropine should be used energetically until full dilatation of the pupil is obtained. In outdoor practice, it is always best to detain the patient at his first visit until this result is gotten. Where, owing to synechiæ or inflammatory conditions which resist mydriatics, it seems impossible to obtain dilatation, blood should be taken from the temple, either by a Heurte-loup apparatus or by natural leeches. The effect of the mydriatic is thus greatly increased by the local bloodletting. The simultaneous instillation of cocaine is also of value.

To avoid obstruction of the pupil by lymph, and to guard against its deleterious influence on the nutrition of the lens, as well as to prevent relapses, it is important that all adhesions to the anterior capsule should be broken. Where this cannot be done by the means just detailed, it is well, whether the case be syphilitic or not, to bring the patient sufficiently under the influence of mercury to cause slight sponginess of the gums. Nothing in clinical surgery can be more instructive, than to see adhesions which have hitherto resisted all efforts, begin to give way as soon as the signs of mercurial action become evident. When full dilatation is obtained, the atropine must be applied sufficiently often to keep the pupil dilated until inflammation and ciliary injection subside. If full dilatation be obtained, the worst may be generally considered to be over. Where there is considerable effusion of lymph, and where there is pus in the anterior chamber, hot compresses (from 100° to 120° F.) are often beneficial in hastening absorption. These should be applied by wads of absorbent cotton, applied at half-minute intervals, for from fifteen to twenty minutes at a time, every three or four hours.

If the pain be excruciating, it can generally be much relieved by the use of atropine and local leeching. When, in spite of this, it continues

to be severe and keeps the patient awake, injections of morphine into the temple may be useful. Dover's powder internally, or suppositories of the aqueous extract of opium, may also afford relief. In cases of high inflammatory reaction with intense pain, hydrobromate of hyoscyne may prove valuable. It sometimes relieves pain, when instilled into the conjunctival sac, where atropine has failed. The solution employed should be four grains to the fluidounce. In doses of one-hundredth of a grain, either by the mouth or by subcutaneous injection, it has at times proved useful in allaying pain. If the patient is vigorous and well nourished, free purgation by the employment of magnesia, or of saline cathartics, may be advantageous. When, in consequence of neglect or repeated attacks of inflammation, the pupil is so firmly bound down that it entirely fails to respond to the measures previously detailed, it often becomes necessary to desist from the use of any mydriatic. In fact, all such applications apparently make the eye worse. In such cases, we are forced to content ourselves with hot compresses and proper internal medication.

Where there is increase of tension with the severe pain, prompt relief may be often obtained by paracentesis of the cornea. This relief, however, lasts until the wound has closed and the aqueous has reaccumulated sufficiently to reincrease intra-ocular pressure. In the same way, it may be advantageous to give egress to an hypopyon by an incision with a broad needle. Where all other measures fail to free adhesions, iridectomy, in spite of the inflammation, has been advised. In such cases, the iris is often spongy and rotten, and only small parts of it can be pulled out with the forceps, leaving the plastic lymph and uveal pigment sticking to the lens-capsule. Moreover, the results are often unsatisfactory in obtaining any remission of the inflammation. For these reasons, the author looks upon the operation as a last and exceptional resort. If there be occlusion of the pupil after all inflammatory symptoms have subsided, iridectomy is necessary to obtain an artificial pupil for optical purposes. In case of exclusion, the same operation is advisable to prevent increase of intra-ocular tension and glaucoma.

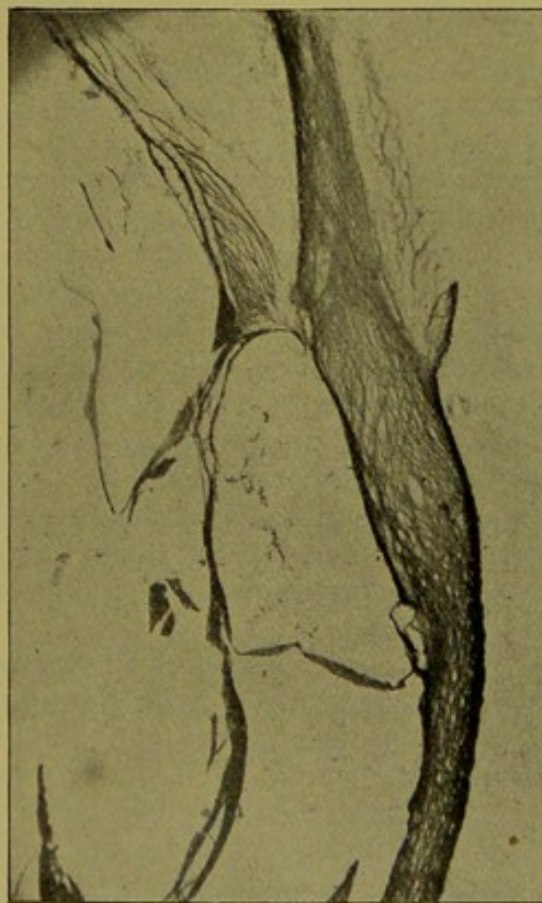
While the general outline of treatment in syphilitic iritis should be that above indicated, it is advantageous to use mercury more freely, and to continue its administration longer. In the majority of cases, inunction is the most valuable method of administering the drug. One drachm of mercurial ointment should be gently and thoroughly rubbed into the skin of the abdomen, night and morning. In the interval, a binder, to hasten absorption and to prevent soiling of the clothing, should be applied over the part. If the skin of the abdomen becomes irritated, the groins and the inside of the thighs, or the arms and the axillæ, should be selected for the application. Oleate of mercury is more cleanly, but is much more apt to produce local irritation. Often, it is sufficient to repeat the inunction but once in twenty-four hours. Where, for any reason, inunction cannot be efficiently carried out, the internal administration of calomel, in doses of from one-twelfth to one-half grain, as often as may be found suitable in each individual case, is indicated. Protiodide of mercury, in equivalent doses, is also an efficient preparation. When the urgent symptoms have ceased, bichloride of

mercury, in doses of from one-forty-eighth to one-sixteenth grain, three times daily, either alone or in combination with iodide of potassium, is useful. To prevent relapse, the drug should be continued for a considerable time after the eye has become quiet. When gummata are developed, and their growth is so rapid as to threaten destruction of the eye, iodide of potassium in large doses, frequently repeated, is probably the most effective remedy. Some patients will bear from two hundred to two hundred and fifty grains daily, without the production of any marked iodism. In patients who have become debilitated and cachectic from long-standing syphilitic disease, the energetic use of the mercurials and of the iodides is often not well borne. Here, we are obliged to administer them in small doses, and at the same time try to improve the nutrition by digestible food and tonics.

The gonorrhœic variety does best when treated by iodide of potassium and by considerable doses of quinine, with or without morphine. This treatment, conjoined with the use of hot sulphur-baths, is both agreeable and effective in eradicating any accompanying rheumatic joint-affections.

The tuberculous form of the disease should be treated with cod-liver oil, iron, the hypophosphites, and good diet.

FIG. 222.



Section of cyst of iris. (RISLEY AND RANDALL.)

Cysts of the iris are almost invariably developed after wounds which have carried a cilium, with its hair-bulb or epidermis-cells, into the

tissue of the iris. They sometimes develop rapidly before the irritation of the wound has entirely subsided. Usually, however, after the eye has become quiet, there is a grayish projection on the anterior surface of the iris. This grows with so little irritation that patients sometimes seek relief only when it is large enough to interfere with the pupil. Less frequently, they ask for advice because they are alarmed at its appearance and its increase in size.

Fig. 222 shows a section of an interstitial cyst of the iris.

If left alone, they generally keep enlarging, and may give rise to violent irido-cyclitis, which in turn may produce sympathetic ophthalmia.¹ It is best, therefore, to remove them. This is done by making an incision in the cornea with a Graefe knife, or with a triangular iridectomy-knife, adjacent to the cyst. Then seizing the unbroken cyst and dragging it out of the wound with an iris-forceps, its wall, with the adhering iris, may be excised with a fine scissors. In this way, the cyst may often be removed entire.

Closely allied to cysts, are the *epidermoid* or *pearly tumors*, which form in the iris-substance. They consist of closely-packed epidermoid cells, which have sometimes so far undergone degeneration that the interior of the tumor is slimy and semi-fluid. These growths should be treated in the same way as cysts.

Congenital pigment-spots and melanomata. The former are frequent on the iris and are of no significance. They usually remain unchanged during life. Larger, dark, congenital tumors of the iris are classed by Graefe and by Knapp, as simple *benignant hyperplasia of the iris-tissue*.

Sarcomata and melanotic carcinomata rarely occur primarily in the iris. They have been treated by iridectomy and excision. Kipp reports the successful removal of one that attained the size of $7 \times 5 \times 4$ millimeters. When the patient was seen, one year later, there had been no return of the disease. Arlt² refers to two cases, and Knapp³ cites three. All were successfully removed without enucleation. We cannot, however, always be sure of thus removing the entire tumor. Enucleation is, therefore, usually safer, and hence is more desirable.

Granuloma of the iris is now considered to be a form of tuberculosis.

Iridodonesis is that condition in which there is a wobbling of the iris with the various motions of the eye. It takes place either when the vitreous is fluid, or when the lens is displaced or its suspensory ligament loosened.

Iridodialysis is a separation of a part or all of the periphery of the iris from its ciliary attachment. This is usually the result of a violent injury. When partial, it makes a second pupil, and also changes the shape of the central one—the pupillary margin opposite the detachment being pulled straighter, and the pupillary area being diminished on the affected side. This is seen in Fig. 223. In this instance, the injury, as explained and shown on pages 184 and 185, has produced traumatic cataract. Arlt records a case in which, after almost complete

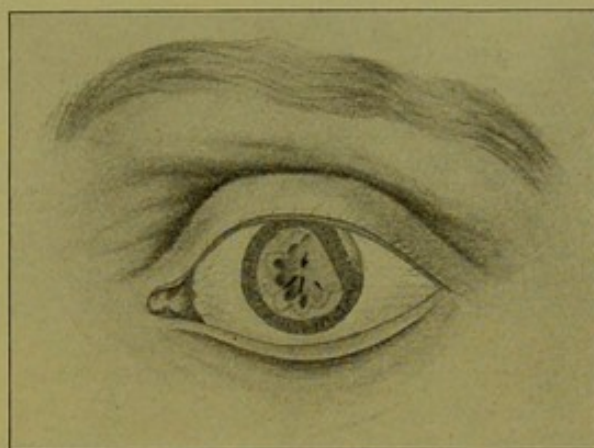
¹ Hulke: Roy. Lond. Ophthal. Hosp. Rep., vol. i., vi., p. 12.

² Graefe und Saemisch, Bd. iii. S. 420.

³ Archives of Ophthalmology, vol. viii. p. 82.

iridodialysis, the shrunken iris was visible as a grayish mass at the bottom of the anterior chamber. The patient could still count fingers and was able to distinguish colors. The entire iris has sometimes been torn out in cataract-operation, the patient nevertheless recovering with useful vision.

FIG. 223.



Traumatic iridodialysis. (JAEGER.)

Albinism. This want of pigment in the iris is a most striking anomaly. Here the iris-tissue is so thin that red light is reflected through it from the fundus, giving the eyes a pink appearance. Owing to the deficiency of pigment in the iris and chorioid, strong light is very annoying to such subjects, who avoid it to some extent by partial closure of the lids. Marked nystagmus is usually associated with the defect. In some cases, the iris is so transparent that the ciliary processes and the edge of the lens can be seen through it.

Irideremia or *aniridia* is a total absence of the iris. This is frequently accompanied by opacity of the lens. Although the cataract in such cases may be successfully removed, yet vision is apt to be subnormal, as the other parts of the eye are often imperfect. Such patients suffer from over-stimulation of light and fogging from diffusion to a higher degree than albinos. In partial irideremia, the iris is generally imperfectly developed in its upper segment, and is wanting below. This should not be mistaken for the condition in which sometimes, in consequence of a blow, the vitreous comes forward and the iris is turned back and hidden from view.

Polycoria is a state of the iris in which there are two or more pupils.

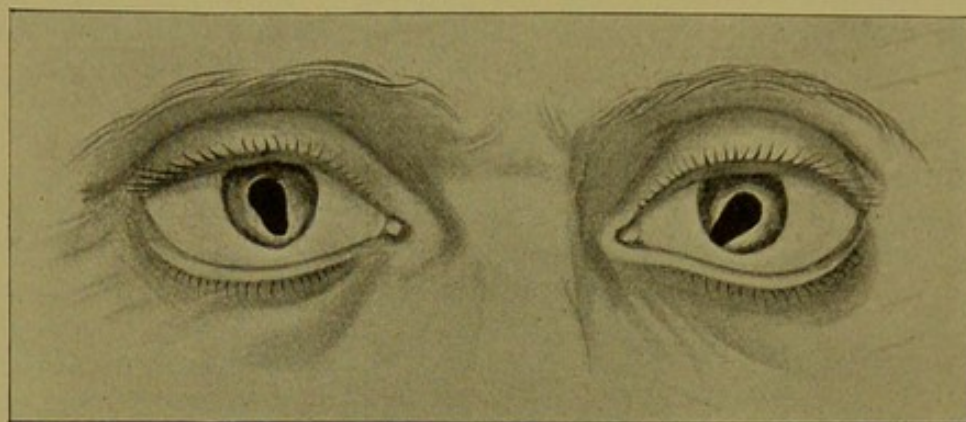
Corectopia is the term given to a pupil which is congenitally misplaced.

Coloboma of the iris is an arrest in the development of the iris which leaves the pupil more or less pyriform, the small end of the opening, as a rule, being directed downward and inward, or downward. It is generally binocular. If so, the colobomata, as a rule, are in corresponding directions.

Fig. 224 gives a good representation of a case of this anomaly. Coloboma of the chorioid, and at times a slight notch in the equator of

the lens at its lower part, known as coloboma of the lens, are frequently found with it. At times, it is associated with microphthalmus. It is often hereditary.

FIG. 224.



Coloboma of iris. (SICHEL.)

Persistent pupillary membranes and tags consist of elastic brown bands, which extend across the pupil from one side to the other. They are sometimes sufficiently numerous to form a network. They are never attached to the pupillary margin or to the sphincter muscle of the

FIG. 225.

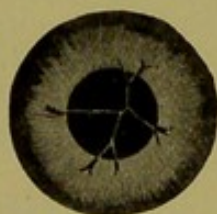
Remnants of pupillary membrane.
(RANDALL.)

FIG. 226.

Remnants of pupillary membrane;
pupil dilated. (RANDALL.)

iris, but pass in front of the pupil, and are inserted just beyond the outer periphery of the sphincter. Owing to their elasticity and position, they never materially interfere with the movements of the pupil.

Fig. 225 shows a case of remnants of the pupillary membrane which stretch as bands across the pupil. Fig. 226 exhibits the same pupil dilated by a mydriatic.

DISEASES OF THE CILIARY BODY.

Cyclitis, or inflammation of the ciliary body, in any of its forms, is a serious affection. When it is extensive and severe, it leads to impaired vision, and often to entire loss of eyesight. Besides, it frequently becomes the starting-point of sympathetic inflammation. As the iris and ciliary body are so intimately connected anatomically, receiving a common blood-supply, severe inflammation of either organ is apt to involve the other. This is almost invariably the case when the inflammation

starts in the ciliary body. Such an order of inflammatory sequelæ is in strong contrast with what takes place in the posterior part of the uveal tract. Here the ophthalmoscope often shows inflammatory processes which are limited to it, or which, if they spread, have a tendency to attack the retina and sclerotic rather than to extend forward to the ciliary body and iris. The fact that the posterior ciliary arteries are distributed exclusively in the chorioid, seems to account for the comparative immunity of the anterior portion of the uveal tract when the chorioid is inflamed. Besides, although most of the venous blood of the iris and the ciliary body joins that of the chorioid, and escapes through the vortex veins, the recurrent branches of the greater arterial circle of the iris form the only common vascular supply. These anatomical peculiarities seem to explain why inflammatory changes in the uveal tract are most apt to travel backward.

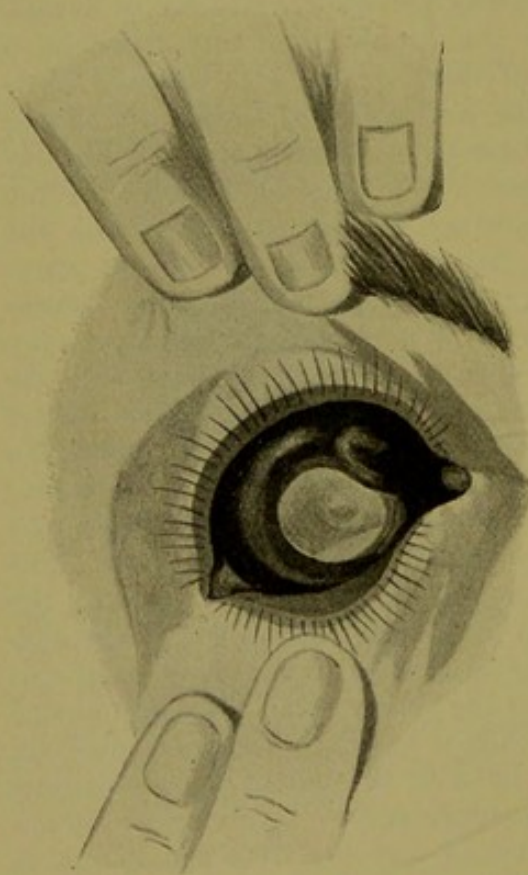
Plastic cyclitis is said to exist when the eye is red and watery, with marked ciliary injection, and tenderness to touch over the ciliary region. Here the iris is hyperæmic, though still mobile. If the eye is examined with a plane mirror, before there is any perceptible effusion of lymph into the pupil, and before there is the formation of any synechiæ, a strong reflex from the anterior part of the vitreous, with diffused haziness of it, may be seen. Owing to the contraction of the lymph effused upon the iris and upon the ciliary processes in an early stage of the disease, retraction of the iris at its periphery may be found. If the inflammation runs high, and it continues, further exudation into the vitreous, with the formation of large flocculi and filaments, takes place. This effusion of lymph, however, like that of pus in the more severe cases, may either be limited to the anterior part of the vitreous, or may infiltrate the whole of it. The iris always becomes involved, and the pupil is closed by effusion and extensive synechiæ. In the earlier stages, tension is increased, but as the inflammation subsides and the vitreous becomes disorganized, it sinks below normal. Where the exudation is limited to the anterior part of the eye, the lens and iris may be pulled forward, causing the anterior chamber to become shallow. This may also ensue from large effusions of lymph between the iris and the lens-capsule. If the whole vitreous has been infiltrated, it shrinks. Being fixed at the ora serrata and the head of the optic nerve, it gradually pulls the membrana limitans and the retina with it, away from the chorioid. The shape of the retina when it has thus become completely detached, has been aptly compared by Arlt to that of a convolvulus-flower, its stem being at the optic entrance and its open end at the ora serrata. The space between the chorioid and the detached retina, is usually filled with serous fluid. Where there has been secondary inflammation of the chorioid, the effused fluid is at a still later date, gelatiniform in character. Finally, degenerative changes in the effusion may convert it into a fibrous or a dense cartilaginous tissue, or even into layers of bone. In some instances, the eye may become quiet much earlier, having either a moderately clear pupil, or such a closure as can be remedied by an iridectomy.

Serous cyclitis is present when the ciliary injection is less marked and extensive, the pupil sluggish and slightly dilated, and intra-ocular ten-

sion increased. In such cases, the ophthalmoscope shows numerous flocculent vitreous opacities lying close behind the lens. Later, there is descemetitis, which is most marked at the lower part of the cornea. In such cases, owing to the irregular shedding of the outer layer of the cells of the anterior epithelium, the nutrition of the cornea becomes deranged and its anterior surface is needle-stuck. Ordinarily, the symptoms develop slowly. At any time, however, there may be an outbreak of plastic cyclitis with an increase of violent inflammation.

Parenchymatous cyclitis, as its name implies, is, perhaps, best exemplified in cases where there is a formation of syphilitic gummata in the ciliary body. Gummous masses in this position are, fortunately, much less frequent than in the iris. Here they produce a violent plastic and suppurative inflammation with intense pain, which usually results in the loss of the eye. Fig. 227 shows the external appearance of an eye in which

FIG. 227.



Gumma of ciliary body.

there is a high grade of parenchymatous cyclitis due to a gumma on the ciliary body. Here there is marked corneal haze with a considerable hypopyon. The growth forms a rounded prominence which projects at the upper inner periphery of the cornea.

Sympathetic irido-cyclitis is an affection in which the inflammatory changes in the iris and ciliary body of one eye cause a similar outbreak in the other. By this, it is distinguished from other varieties of irido-cyclitis. It is also characterized by its great tendency to the effusion of plastic and vascularizing lymph in the tissue and over the surface of the iris and ciliary processes. A circular synechia, with bulging of the peripheral parts of the iris into the anterior chamber, sometimes ensues. Continuance of effusion, however, converts this into a complete posterior synechia, the pupillary part of the iris being the most prominent, and its margin the most

retracted. Owing to the great amount of exudation and its subsequent contraction, there is shrinking and degeneration of the bloodvessels in the ciliary processes, with fluidity and decrease of the vitreous humor. This is often accompanied by total detachment of the retina, and atrophy of the entire anterior part of the eyeball. In some cases, in spite of the partial atrophy of the anterior portions of the globe, there may be sufficient absorption of the pupillary and vitreous exudation to permit

some useful vision, thus enabling the patient to guide himself in moving about.

All cases should be put to bed. The skin should be kept at an even temperature and its action should be stimulated by sudorifics. Active cathartics, which insure watery evacuations, should be administered. The temples are to be freely leeches, while atropine is to be instilled. Pain is to be controlled by hydrobromate of hyoscine, or the watery extract of opium. In the endeavor to diminish the amount of plasticity of the exudation, mercury should be administered energetically. It should be carried to a point in which slight touching of the gums is to be noticed. This is to be followed by the administration of iodide of potassium. In serous cyclitis, mydriatics are often to be avoided. In such cases, eserine should be used locally; and, at times, jaborandi should be employed internally. When the ciliary region has lost its tenderness, and when the eye has become quiet and no longer flushes when seized with the forceps, an iridectomy is the only means which offers some hope of improving eyesight and of preventing the steady continuance of degenerative processes. Owing to the dense membrane plastering the iris to the capsule of the lens, it is often necessary to remove the lens at the same time. The healing of the wound is usually rapid, and is favored by the diminished tension of the eyeball and by the tendency to plastic exudation. The gap made in the iris, however, always contracts considerably, and too often closes completely. When the field of vision is contracted, we are at times forced to try an iridectomy before the eye has become entirely quiet, in the endeavor to save it from total destruction. Here the results are usually far from satisfactory.

CHAPTER XVII.

ACCOMMODATION.

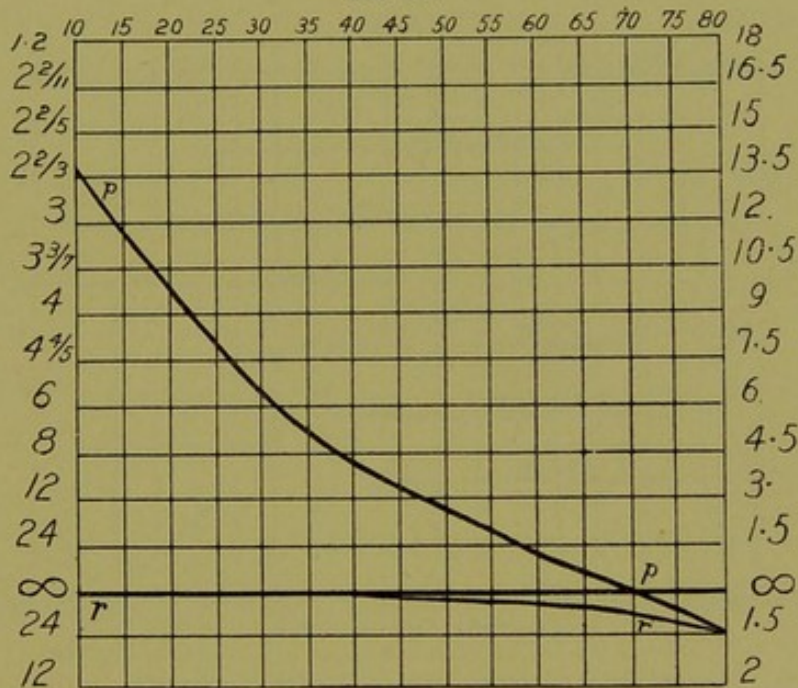
As has been explained, if a lens retains the same curvature and the same index of refraction, it can have but one principal focus. Should our eyes possess such a lens alone, various eyes might be adapted for different distances, but this adaptation would depend on the relation between the position of their principal focus and their retinal rods and cones: that is, they would be adapted for certain set and fixed distances. Thus, according as the principal focus fell either on the rods and cones, as in emmetropia, in front of them as in myopia, or behind them as in hypermetropia, the eye would be adjusted for some single point in space. Experience shows that, although these three forms of eye actually occur, they all have a power of changing their focus. From infancy we are so habituated to such changes of focus, and they take place so easily and so promptly, that we are generally unconscious of them.

How is this change of focus accomplished? As explained in the chapter on Physiology, observation of the images formed upon the anterior and the posterior capsules of the lens, has taught us that this organ changes its curvature. This change of form of the lens-substance, which has been carefully studied by Cramer, Donders, and Helmholtz, by the use of the ophthalmometer (as explained on page 91), is apparently due to its innate elasticity and the action of the ciliary muscle. In practice, as shown on page 164, we usually determine the far-point, and find whether the eye is focussed for parallel rays of light, or for converging or diverging rays, by means of Snellen's test-type placed at six meters' distance. In the former case, it is adapted for infinite distance; whilst in the other instances, the appropriate convex or concave glass which gives good distant vision gives the far-point. In myopia, this can also be readily determined by the farthest distance at which print of definite size can be read. To determine the near-point, it is most convenient, as shown on page 166, to take some print of about the size of No. 1, as furnished in Jaeger's test-types (the "brilliant" of printers), and, after placing this almost in contact with the nose of the person tested, gradually remove it until it can be read, and until its outlines appear sharp and distinct. The refractive power of the lens which the eye has been able to add to its refractive apparatus, is then found. The result is usually stated, as previously shown, in the formula $\frac{1}{A} = \frac{1}{P} - \frac{1}{R}$.

The lens of the newborn child, which is colorless, transparent, and soft, rapidly becomes more dense (especially the nucleus and

the parts immediately surrounding it) in youth, until, after twenty years of age, it acquires a faint straw-yellow color, which darkens as age increases. This continues, even though the lens is transparent, until it has become almost of an amber color; the nucleus increasing at the expense of the cortical substance. The result of this is a diminution in the elasticity, so that, even in early youth, the lens is less capable of swelling and changing its curvature than it was in infancy. The range of accommodation is therefore diminished long before the body in general has attained its maximum of growth and vigor. Fig. 228 shows the actual fall of the accommodative power with age and the range

FIG. 228.



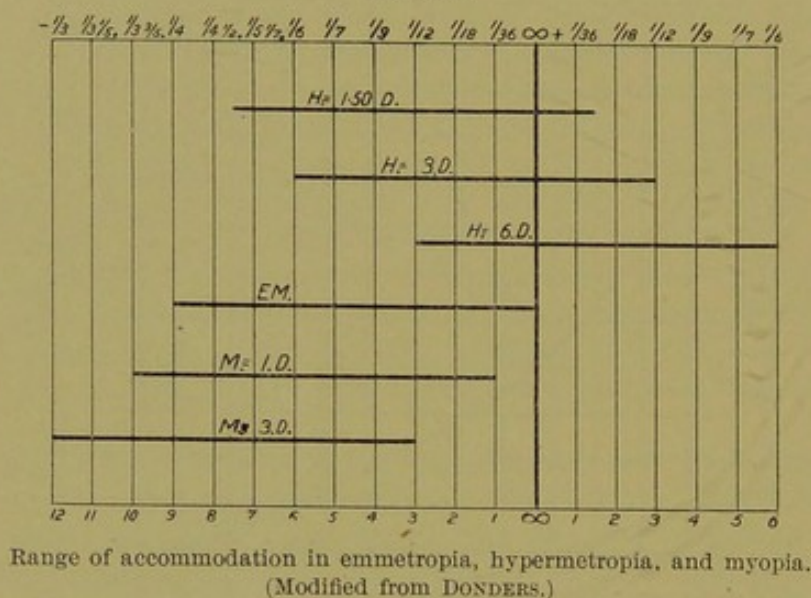
Fall of accommodative power with age and range of accommodation for various periods of life. (Modified from DONDEES.)

of accommodation for each period of life. The figures on the left give the respective distances for which the eye can be accommodated; those below infinity being so marked as to express the distance at which the convergent rays, for which the eye is adapted in old age, would come to a focus behind its nodal point. The black curved line indicates the actual position of the near-point at each time of life, as specified in numbers at the top of the table. The vertical lines joining the near and the far points, give the entire range of accommodation. On the right-hand side are the equivalents in diopters. Thus, at ten years, an emmetrope can see sharply an object which is removed but two and two-thirds inches from the nodal point of his eye. At fifteen, his near-point has receded to three and one-eighth inches, and at twenty it has fallen to three and three-fourths inches, showing a considerable loss during adolescence. At thirty, the eye has lost about one-half of its accommodative power.

Fig. 229 shows the range of accommodation in emmetropia, hypermetropia, and myopia. The thick, black, horizontal lines represent

the range of accommodation. The figures at the top of the vertical lines show this range in inches, and those at the bottom express it in diopters. For instance, an amount of accommodation equal to nine diopters gives a range of distant vision from infinity to four inches from its nodal point to a young emmetropic eye, while the same power of accommodation in a hypermetropic eye of one and a half diopters would give a range from infinity to but four and four-fifths inches. A hypermetropic eye of three diopters would give a range from infinity to six inches, and a hypermetropic eye of six diopters would give a range from infinity to twelve inches. On the other hand, a myopic eye of one diopter would see from thirty-six inches to three and three-

FIG. 229.



Range of accommodation in emmetropia, hypermetropia, and myopia.
(Modified from DONDEES.)

fourths inches, while one of three diopters would have a near-point at three and one-fourth inches, and a range of accommodation only from this point to twelve inches.

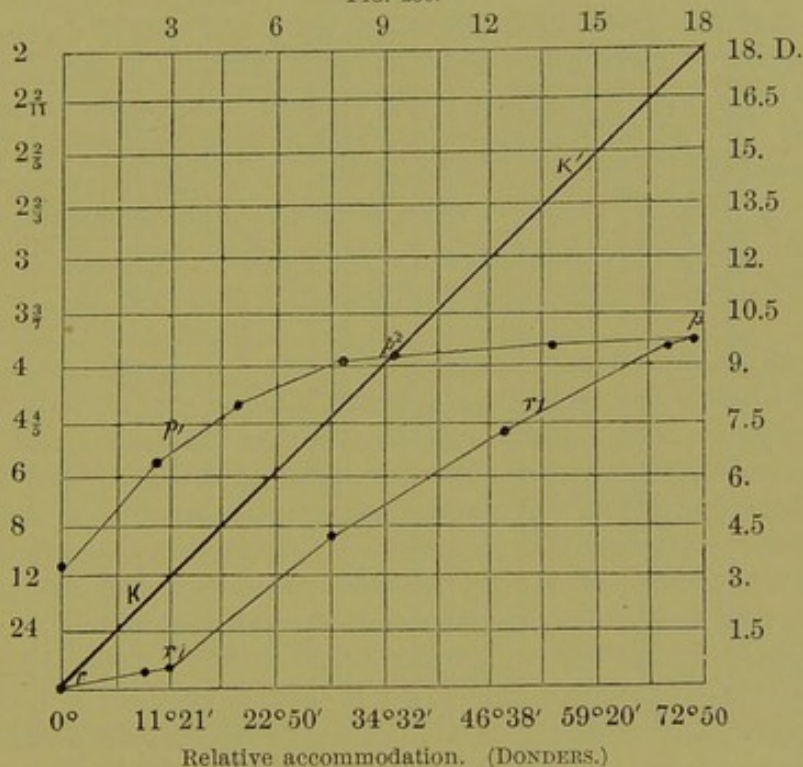
As a rule, as has been before shown, there is a simultaneous and corresponding innervation of the ciliary muscle and the internal and external recti muscles, so that the more the eye-axes are converged, the more vigorously can the eyes accommodate. A proof, however, that this rule is not inflexible, can readily be obtained by holding alternately weak concave and convex glasses before the eyes. If whilst doing this, some point for which the eyes are converged can continue to be seen sharply, the accommodation has been altered without changing convergence. If, on the other hand, weak prisms, with their bases outward or inward, be alternately held before the eyes, convergence can be altered without changing accommodation.

The power to alter the accommodation without changing the point of convergence, is termed the power of *relative accommodation*. Fig. 230 shows its extent in inches for different degrees of convergence in a healthy emmetropic eye of fifteen years of age.

The diagonal line, $\kappa \kappa'$, cuts the horizontal lines on which the distances of accommodation are given in Paris inches. At the foot of the

vertical lines, the corresponding angles of convergence, measured from a base-line of sixty millimeters (the distance between the pupils of the individual who was tested), are shown. At the top of the vertical lines, the figures designate the amount of convergence as expressed in meter-angles. From this diagram, it can be seen that, with parallel eye-axes, an emmetropic eye at this time of life, can accommodate up to twelve inches. Further, it will be noticed that when convergence for twelve inches is made, the accommodative power is increased, so as to bring the near-point in to five inches. If convergence be made for six inches, the

FIG. 230.



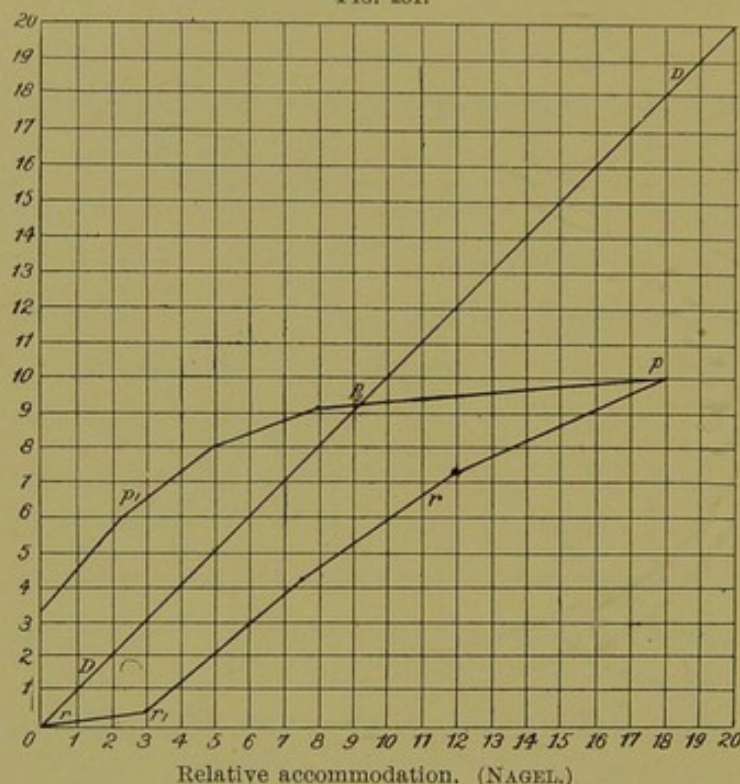
near-point is brought in to four and one-fourth inches. At the point where the line $p p^1$ cuts the diagonal of convergence, p^2 is situated. This represents the point of strongest binocular accommodation. If the convergence is still further increased, accommodation becomes monocular, until at about three inches, where the maximum of convergence (seventy degrees) is reached, the near-point has come a trifle closer (3.8''), and there is no longer any variation of either accommodation or of convergence: the lines $p p^1$ and $r r^1$ come together.

Ordinarily, the eye is accommodated for the point toward which the visual axes converge, but the figure shows that the eye there given, while still converging for twelve inches, can strain its accommodation more tensely, so as to bring its near-point to five inches. Moreover, it shows that it can relax its accommodation to seventy-two inches, thus giving a total range of relative accommodation of 1/4.6. Further, it can be seen, that as the convergence increases, the near-point approaches the eye, and the power to accommodate more strongly with unaltered visual axes steadily diminishes. On the other hand, the range over which accommodation can be relaxed, increases with the convergence.

As explained on page 160, Nagel has assumed the meter-angle as a convenient standard for the measurement of convergence.

Fig. 231 shows a modified table of relative accommodation, similar to that given by Donders. The figures on the left-hand side denote the accommodation in diopters. Those at the bottom give the convergence in meter-angles. That portion of the accommodation which lies between the far-point and the point of convergence is termed the *negative accommodation*, because it has already been employed to obtain distinct vision at this distance. That part which lies between the near-point and the line

FIG. 231.



of convergence is termed the *positive* part of the range of accommodation, because it is still at disposal. Loring¹ has added much to the knowledge of this subject, having proved that if a Snellen's test-card and a candle-flame be placed at six meters' distance, and weak concave glasses be held in front of the two eyes of a young emmetrope, the six-meter type can still be sharply seen and without doubling. If, under these circumstances, a colored glass be slipped before one eye, this eye immediately moves inward, causing a convergent squint with homonymous double images of both the candle-flame and letters. He has further shown that the distance apart of the double images is in proportion to the strength of the concave glass that is overcome by the accommodation. This in his own case was equal to twenty-three inches with a -2.25 D., twelve inches with a -1.75 D., and three inches with a -1.25 D. If a -1 D. was used, the images overlapped. He has thus proved that for every degree of accommodative impulse sent to the ciliary muscle, there is a corresponding amount of convergent impulse set in action.

¹ Trans. Amer. Ophth. Soc., 1868, pp. 40-58.

Up to a certain point, however, when both eyes are equally sharp-seeing, this tendency can be resisted by a corresponding amount of innervation of the externi, which is caused by a desire for binocular vision. In experimenting on the range of the relative accommodation, Loring also found, that if he fixed a point at eighteen inches, he could relax his accommodation by a convex 1.75 D. and still see the object sharply. He also showed that he could span his accommodation more tensely by looking through a concave 2.50 D. without blurring of the object, thus giving, with his ability of relaxation, a total power for the relative accommodation, of 4.25 D, with a convergence for eighteen inches. Further, should he, whilst fixing the same point, hold prisms of 5° bases outward before his eyes, he could only relax his accommodation by a glass of convex 1.50 D., and could span it more tensely by the use of a glass of concave 3. D., thus showing that the total amount of the accommodation was now equal to 4.50 D. In this latter experiment, he obtained an increase in the range, and brought the region in which it was exerted nearer to the eye, proving that the prisms with the base out, caused an additional converging strain on the interni, by which a corresponding increased tension was transmitted to the ciliary muscle.

Just as we are but slightly conscious of the action of any of our voluntary muscles in a state of health, the subjective sensations called forth by the act of accommodation are, under such circumstances, slight. Purkinje, however, has called attention to phosphenes and transient flashes of light seen in the periphery of the field of vision when, after accommodative efforts have been made in the dark, accommodative tension is suddenly relaxed. These cannot be called forth by all observers. Nagel describes similar appearances in his own eyes at the beginning of every effort at accommodation. Almost all observers are conscious of a cloud at or near the fixation-point, produced by strong and continued accommodative effort. When, during such experiments, Purkinje made slight pressure on the eye, he could observe the circulation on each side of the central cloud, while Nagel, under similar conditions, was conscious of a momentary clearing of certain portions of the cloud, so that the lighter areas formed a sort of network—this phenomenon coinciding with the pulse-beat.

The rapid relaxation of the accommodation and the ability to see distinctly distant objects immediately after strong accommodative efforts, have led many observers to look for some apparatus for *negative accommodation*. Up to the present time, however, there is no positive proof of the existence of any such mechanism, and we are hence obliged to assume an elasticity of the zonula which is capable of promptly overcoming the elasticity of the lens.

As shown more at length on page 92, in all efforts of accommodation there is an accompanying contraction of the pupil. This is easily proved by the experiment of Hering,¹ in which a screen with two holes in it is so placed before the eyes that the holes will appear as one. If an additional opening be made above that looked at by the one eye, and

¹ Die Lehre von binocularen Sehen, 1869, S. 114.

another made below that observed by the fellow-eye, the small circles of light will become visible in a vertical line, one over the other. If an accommodative effort without change of direction of the visual axes is now made, all these circles of light will at once diminish in an equal degree.

Mydriatics and myotics. The first of these agents diminishes or temporarily suppresses the power of accommodation, whilst the latter stimulate the ciliary muscle to action, and, if pushed, produce spasm of accommodation. Of the stronger mydriatics, there are practically four which are readily attainable, and in common use. Two, atropia and daturia, act comparatively slowly, and their influence passes off slowly. The other two, duboisia and hyoscyamia, are more rapid and more transient in their action. In homatropia, we have an atropine derivative whose action is weaker and less lasting. These drugs are invaluable, not only for purposes of temporarily paralyzing the ciliary muscle for ascertaining the true state of the refraction of the eye, but they are useful for holding for a time the accommodation at absolute rest, thus allowing low grades of irritation and inflammation of the retina and chorioid a chance to pass off. This latter office they perform by preventing congestion of those membranes which would physiologically occur with every effort of accommodation. For these purposes, it is usual to employ a stronger mydriatic in a solution of one part to one hundred and twenty, or four grains to the ounce, so that three minims instilled into the conjunctival sac will contain the one-fortieth of a grain of the drug.

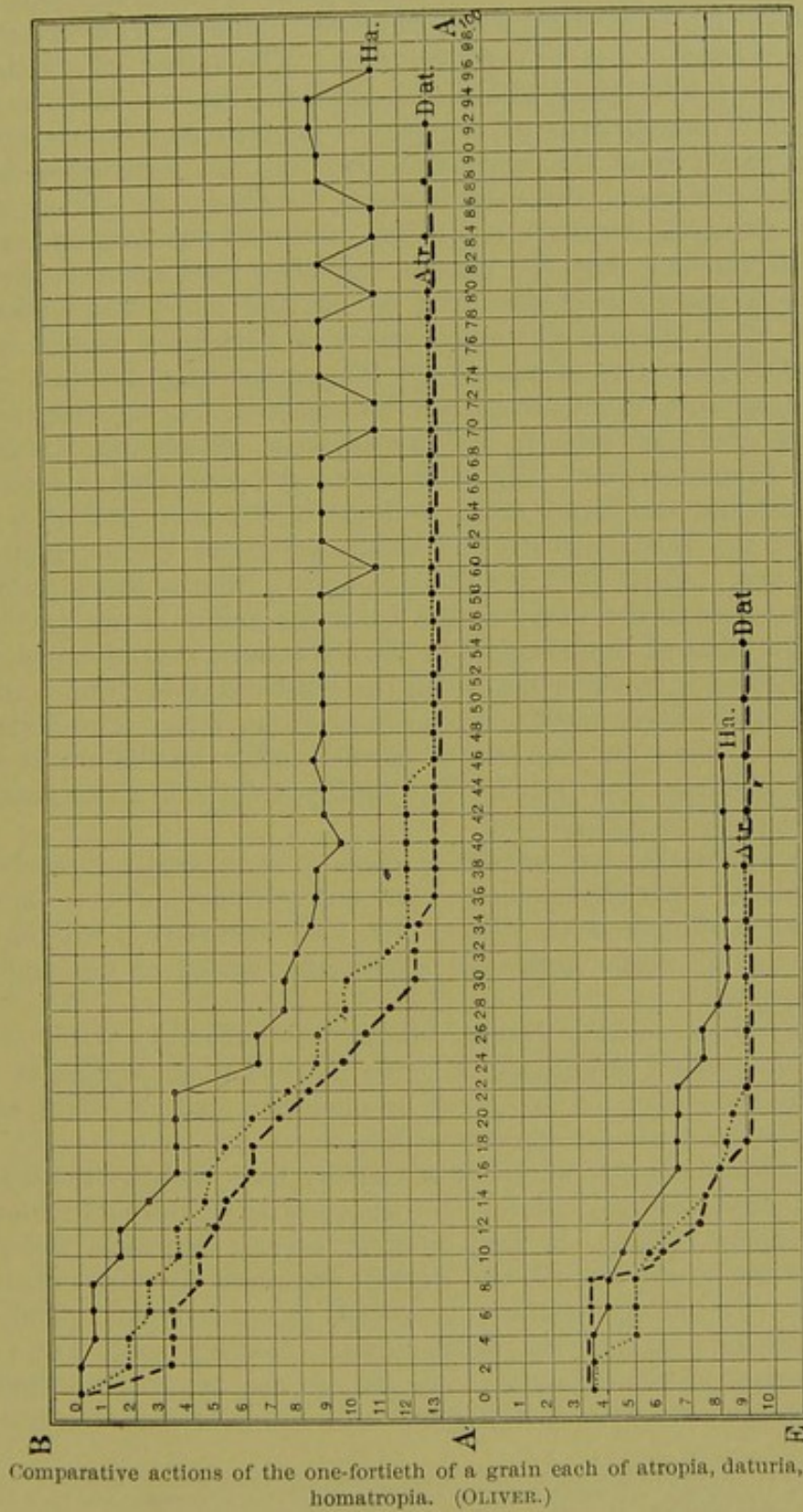
All such solutions are absorbed by the cornea and by the blood-vessels of the corneo-scleral junction. They thus find their way into the anterior chamber, where they act directly on the muscles of the ciliary body and iris, as well as on the imbedded nerves and ganglia. If the anterior chamber of an eye, which has thus been brought under the influence of any of the strong mydriatics, be tapped, and the escaping aqueous humor caught in a watch-glass and dropped into another eye, the pupil of the second eye thus treated will dilate from the dose of the mydriatic that is contained in the aqueous humor.

Upon account of constitutional effects, great care should be exercised in applying strong mydriatics to the eye. Especially is this so with duboisia and hyoscyamia. Many persons are very susceptible to these drugs, and even careful use will produce a slight feeling of dizziness on suddenly rising from a chair, and a sensation as if the legs were giving way. In many cases, considerable and unpleasant dryness of the throat occurs. In some few subjects, or where the drugs are carelessly applied, a rapid pulse, flushed face, brilliant eyes, slight rise in temperature, and even a low grade of delirium, may be produced. In severe cases of such constitutional effects, it may become necessary to administer some preparation of opium. Preferably, the one-eighth to the one-fourth of a grain of morphia by subcutaneous injection, should be used.

In a young emmetropic and healthy eye where absorption is active, one-fortieth of a grain of sulphate of atropia will, as shown by Oliver, produce, *ad maximum*, dilatation of the pupil (from eight to nine millimeters) in twenty-two minutes, whilst a similar quantity of daturia will

produce the same effect in eighteen minutes. The author has found that the one-fortieth of a grain of duboisia will cause full dilatation in

FIG. 232.



fifteen minutes. According to Oliver, an equal amount of hyoscyamia will do it in ten minutes. The latter author finds that it takes the one-

fortieth of a grain of hydrobromate of homatropia thirty minutes to accomplish the same thing. The action on the accommodation is in each case slower than that on the pupil. Thus, as shown in Fig. 232, atropia (in the dose above mentioned) paralyzes the accommodation in forty-six minutes, daturia in thirty-six minutes, and homatropia gains its utmost action in sixty minutes. The author also finds that duboisia takes but thirty minutes. According to the table, a single application of one-fortieth of a grain of homatropia does not produce complete paralysis of the accommodation, its maximum effect lasting only a few minutes. We can, however, as shown by Oliver, obtain complete paralysis by early repetition of the instillation, and, as the effect is so transient that the patient can often read again on the next day, it is a most convenient drug to use for all determinations of refraction where there is not much spasm of the ciliary muscle or congestion of the interior of the eye.¹ By augmenting the dose of the mydriatic, a more rapid action can be obtained, but the risk is run, with such drugs as duboisia and hyoscyamia, of making the patient seriously uncomfortable. Fig. 233 shows the comparative actions of atropia, daturia, and homatropia, in doses of one-twentieth of a grain each, upon the unirritated iris and ciliary muscle of a functionally emmetropic eye. Figs. 232 and 233, compiled from a paper published by Oliver, show in the finely dotted lines the action of atropia, in the long dashes that of daturia, and in the solid lines that of homatropia, in normal eyes. In these tables, on the left-hand side, from B to A, is given the loss of accommodation expressed in diopters. The horizontal lines, A to A', show the number of minutes after instillation at which the accommodation was tested. The figures from A to E designate the size of the pupil in millimeters.

Where hyoscyamia or duboisia is used, it is generally three or four days before the patient is able to read any ordinary print. In using atropia, we may reckon on five or six, but ordinarily it will be from ten days to two weeks before all appreciable action of the mydriatic has disappeared.

All mydriatics, to some extent, benumb the sensibility of the corneal nerves, but corneal anæsthesia is most marked when cocaine is used. The mydriatic action of this drug is moderate, and its effect on the accommodation is almost inappreciable.

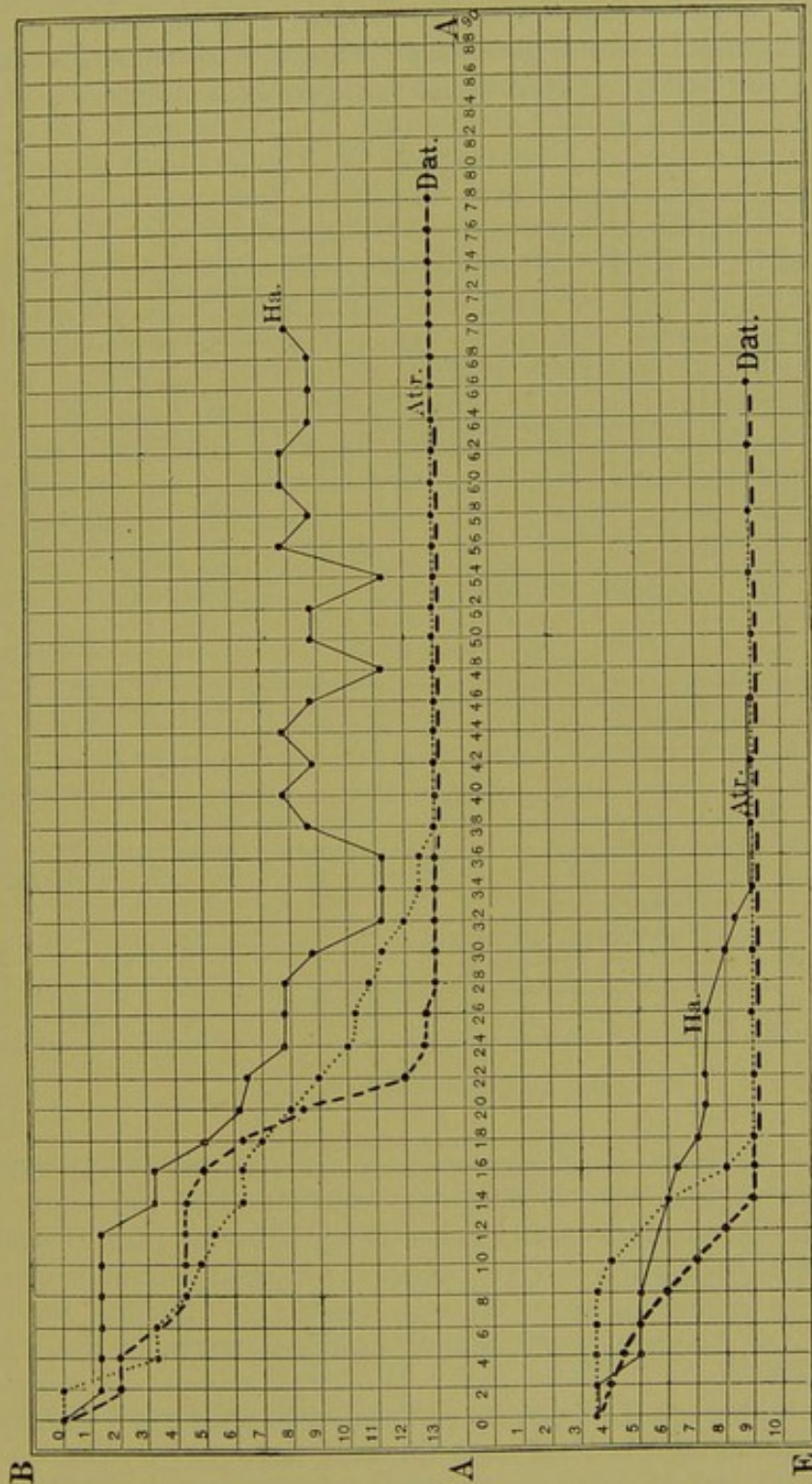
Of all the myotics, the alkaloids of Calabar bean and jaborandi-leaves have furnished the most useful contractors of the pupil and stimulants to the accommodation. In weak solution, eserine contracts the pupil, stimulates the ciliary muscle, and slightly augments the range of accommodation. In strong solution, it causes accommodative spasm, and brings both the near and far points closer. Jaarsma² says that a solution of eserine of the strength of one part to one hundred instilled into an emmetropic eye with a near-point and range of accommodation of

¹ While the above statements are true of young emmetropic and healthy eyes, we must not forget that in testing the refraction in cases of astigmatism and hypermetropia, in which we have to deal with hypertrophy of the ciliary muscle, spasm of accommodation, and great congestion of the ciliary processes, retina, and chorioid, it often necessitates repeated instillations on successive days to arrive at a true result.

² Over de Werking van eenige Mydriatica en Myotica op de Accommodatie en de Groote der Pupil. Leiden, 1880, p. 21.

eight diopters (12.5 centimeters), had, in a quarter of an hour, a range of only 7.5 D., the near-point being at 8 centimeters (equal to 12.5 D.),

FIG. 233.



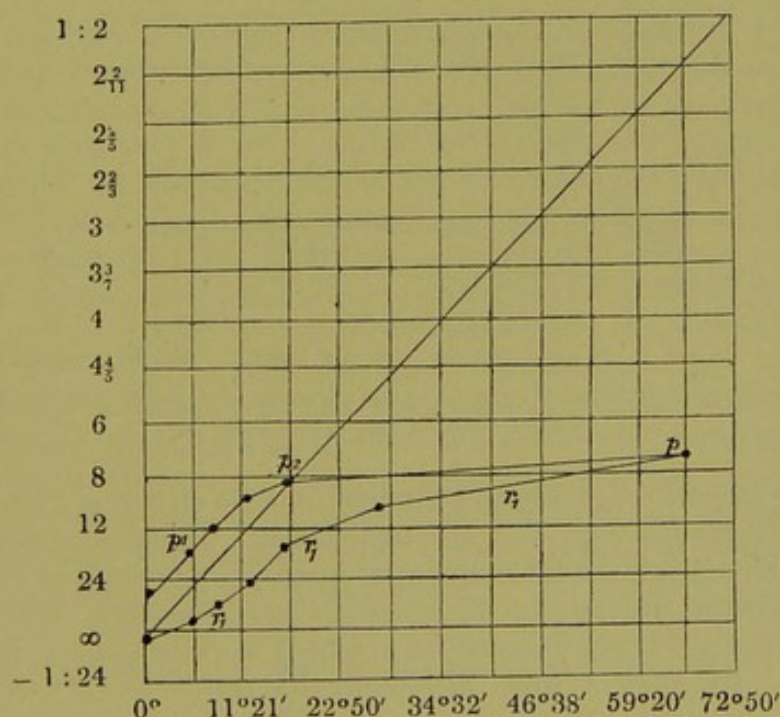
Comparative actions of the one-twentieth of a grain each of atropia, daturia, and homatropia. (OLIVER.)

and the far-point at 20 centimeters (equal to 5. D.). The eye had, therefore, become myopic, and had diminished its range of accommodation

of myotic action. The drug, therefore, becomes weaker when kept for a long time, although often remaining reasonably active long after the solution has become tinted. The salicylate is said to be less irritating to the conjunctiva than the sulphate. Pilocarpine is usually employed either as a muriate or a nitrate. It is an active myotic, but to get the same effect that is obtained from eserine, the solution must be nearly of double strength. According to Jaarsma, in an emmetropic eye, with a near-point of ten and a half centimeters (9.5 D.), while the far-point is at eighty centimeters (1.25 D.), a quarter of an hour after instillation of a solution of one part to fifty, P is at nine and a half centimeters (10.5 D.). In two hours and three-quarters, the far-point has again receded to infinity, while the accommodation is 10.2 D. Muscarine is another myotic, which is obtained both from the *amanita muscaria*, and from the albumen of the hen's egg. It is said to act irregularly and feebly in contracting the iris, but works very energetically on the ciliary muscle. Krenchel tells us that it always causes cramp of the ciliary muscle, and diminishes the amplitude of the accommodation. The action of opium as a myotic is too well known to need comment here.

Presbyopia is the name given to the loss of accommodation which ensues in old age. By reference to Fig. 228, the gradual decline of this power from childhood throughout life, may be seen. Fig. 235 gives

FIG. 235.

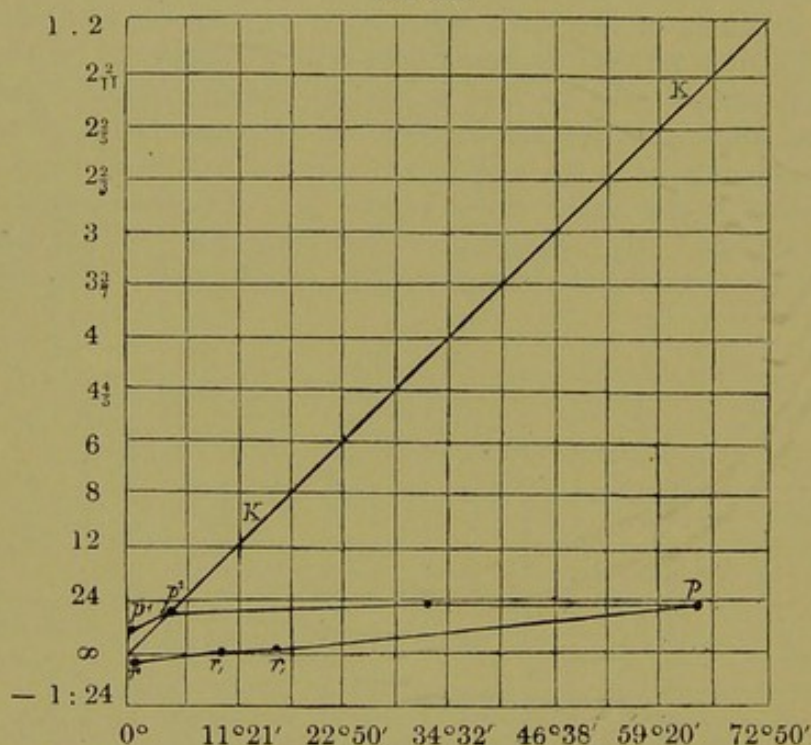


Relative accommodation in a presbyopic emmetrope of forty-four years of age. (DONDEES.)

a graphic representation of the diminished value of relative accommodation in a presbyopic emmetrope of forty-four years of age. Fig. 236 shows that in an eye of the same optical build at sixty years of age, the power to change accommodation with unaltered convergence has almost disappeared.

Practically, in emmetropic eyes, the age at which the loss of accommodation will be felt, will vary with the vigor of the individual and the claims which his occupation makes on his eyes in near-work. Donders has fixed the limit of presbyopia empirically at that time at which an emmetropic eye has its binocular near-point at eight inches. As ordinarily we cannot work for any considerable length of time at our near-point, any near-work will be held considerably farther off—probably from fourteen to eighteen inches. The individual thus affected will seek a very strong light, complaining even of ordinary print. Often, he may either hold the letters between the light and himself, or so place them that a strong light shall fall both on the eye and on the printed page; thus

FIG. 236.



Almost total disappearance of relative accommodation in a presbyopic emmetrope of sixty years of age. (DONDERS.)

causing the pupil to contract and diminishing the circles of diffusion that are produced by his imperfect accommodation. Usually, glasses should be given which bring the binocular near-point to from eight to ten inches. Stronger glasses are apt to be uncomfortable, because, owing to the stiffening lens, great strain, even for ordinary work, is put on the accommodation. In such a case, although the result is very slight, the exertion of the ciliary muscle is intense. The book is therefore held at a distance at which the print is distinctly seen—a distance which makes a much greater strain on the weakened accommodation than it does on the unimpaired convergence. A strong convex glass reverses all this. It enables the eye to see distinctly without accommodative effort at a distance which makes considerable demand on the convergence. Such patients are, therefore, usually better suited with moderately strong convex glasses so mounted that their optical centres are set a little closer

together than the centres of the pupils, thus allowing them to act as weak prisms with their bases inward. Such glasses diminish the convergence necessary for binocular fixation, while they lessen the strain on the accommodation and bring the near-point closer. The giving of glasses in which the centres are farther apart than the pupils, will result in great discomfort, by augmenting the tension on the interni whilst diminishing the strain on the accommodation. Orthoscopic lenses have been proposed, of such strength that they may enable the patient to read at the far-point of the glass without effort of either the accommodation or the convergence. Their strong prismatic action is, however, uncomfortable, causing a flat surface to appear curved with the convexity toward the patient, and making the vertical lines of any rectangular figure appear as if curved outward.

The following table, from Donders, shows the strength of glass required by emmetropic presbyopes :

Age.	Glasses necessary in emmetropia.	Distance of distinct vision in inches.	Age.	Glasses necessary in emmetropia.	Distance of distinct vision in inches.
48	$\frac{1}{60} = 0.65$	14"	65	$\frac{1}{13} = 2.75$	12"
50	$\frac{1}{40} = 0.75$	14"	70	$\frac{1}{10} = 3.25$	10"
55	$\frac{1}{30} = 1.25$	14"	75	$\frac{1}{9} = 4.00$	9"
58	$\frac{1}{22} = 1.75$	13"	78	$\frac{1}{8} = 4.50$	8"
60	$\frac{1}{18} = 2.00$	13"	80	$\frac{1}{7} = 5.00$	7"
62	$\frac{1}{14} = 2.50$	13"			

While the table is correct for emmetropia, low grades of myopia or of hypermetropia will cause considerable variation in the near-point. Thus, the presence of 0.75 or of 1. D. of myopia, will often postpone the time when it is necessary to wear glasses for old sight from two to seven years, because the binocular near-point will not have receded to eight inches before this period. Myopes of higher grades—for example, those who have their far-point from ten to seven inches—will never need glasses for reading, inasmuch as they will always be able to read at their far-point. Presbyopia in such eyes forces the myopic patient to hold his book at this point, and the loss of accommodation is manifest in the fact that he cannot read fine print inside of this distance. While myopes of low grade, as above stated, are eventually compelled to wear convex glasses for reading, those of high grade will be obliged to resort to weaker concave glasses, so as to make less demand on their failing accommodation. On the other hand, hypermetropia of low grade causes the early recession of the near-point and the premature wearing of glasses. All presbyopic hypermetropes should have a glass which represents the sum of the presbyopia and the hypermetropia.

CHAPTER XVIII.

EMMETROPIA, HYPERMETROPIA, MYOPIA, AND ASTIGMATISM.

EMMETROPIA.

Emmetropia is that state in which the rods and cones of the retina are placed exactly in the principal focus of the combined lenses of the eye. Therefore, such an eye in a state of rest focusses sharply all distant objects which send to it parallel rays of light. While this is the mathematical definition of emmetropia, there are very few absolutely emmetropic eyes, and any practitioner could count on the fingers of one hand the number of cases in which, after paralysis of the ciliary muscle under repeated doses of a strong mydriatic, the distant vision of apparent emmetropes could not be perceptibly improved by the use of a weak cylindrical or spherical convex or concave glass.

In the reduced eye, the simplest method of calculating the size of the retinal images, circles of diffusion on the retina in imperfect accommodation, astigmatism, or the position of conjugate foci, can be obtained. Fig. 125, on page 149, explains how conveniently we may arrive at such results, representing the size of the retinal image produced, for instance, in an emmetropic eye at five meters' distance. As before explained, Donders and others have assumed the existence of a normal tone in the ciliary muscle, the temporary annihilation of which by a mydriatic causes every emmetropic eye to become slightly hypermetropic. In fact, the existence of small degrees of ametropia does not prevent the eye from having a vision of 5/5 or better. Nevertheless, we are obliged to limit our clinical definition of emmetropia to cases in which the ametropia is less than 0.25 D., because, especially in hypermetropic eyes, such a defect, when there are asthenopia and feeble health, is at times sufficient to cause considerable inconvenience to the patient. In such cases, we find that a cylinder of this amount adds perceptibly to the comfort of the patient. Thus, although emmetropia is really a mathematical definition—a delicate knife-blade of a balance, on one side of which lies hypermetropia, and on the other myopia—nevertheless there are quite a number of cases in which the ametropia is so slight that they may be practically reckoned as emmetropes. It should be understood that this definition of emmetropia differs very much from that adopted by numerous authors—indeed, by many who have instituted and published extensive studies of the refraction of the eyes of school-children. Frequently in such statistics, all eyes having a vision of 5/5 are classified as emmetropic, even when ophthalmoscopic examination shows a hypermetropia of 0.25 D. to 0.75 D., and where there is a marked sinking of the acuity of vision under atropinization, which rises to normal with the correcting glass. So, too, on the other side, young myopes of a grade of 0.25 D., can often readily see the 6/6 of Snellen's table.

It is evident that an eye in which the principal focus of its combined lenses falls on the retina, may vary in its dimension, this being according to the radius of curvature of its lenses and their indices of refraction. The shorter the radius of curvature of the cornea or of the lens, and hence the higher the indices of refraction, the closer the retina would have to be to the combined lens-system, to make an emmetropic eye.

According to Donders, a great many measurements of emmetropic eyes have shown that there is little variation in the optical constants. Taking the same view of the comparatively small variation of emmetropic eyes, Listing and Helmholtz, and several later writers, have, as shown on page 146, constructed *schematic eyes* for the easier calculation of the course of rays of light in their passage to the retina, etc. Following Listing and Donders, we have in the *reduced eye*, as shown on page 148, a still further simplification of the optical processes involved.

If to Listing's assumption, that the length of the visual axis of the schematic emmetropic eye is equal to 22.647 millimeters, or Helmholtz's assertion that it is equivalent to 22.834 millimeters, we add 1.3 millimeters for the average thickness of the sclerotic at the fovea, we obtain, in the first case, 23.947 millimeters, and in the latter, 24.134 millimeters, as the absolute diameter of an emmetropic eyeball at the visual axis. After a careful discussion of this subject, Mauthner assumes considerable variation in the axis of emmetropic eyes, which may have either a sharply curved cornea, with a correspondingly shorter diameter of the globe, or a less curved cornea, with a greater diameter of the eyeball. As extremes, he states that we may have an emmetropic eye with a corneal radius of 6.95 millimeters and a visual axis of 20.95 millimeters, or one with a corneal radius of 8.04 millimeters and an axis of 24.94 millimeters. If we add 1.3 millimeters for the thickness of the sclerotic, we obtain 22.25 millimeters as the diameter of the smaller eyeball, and 26.24 millimeters as that of the larger. Donders¹ has given 7.785 millimeters as the average radius of curvature of the cornea in twenty-seven emmetropic males, and 7.719 millimeters as the average in eleven emmetropic females. All these were carefully measured with the ophthalmometer. Arlt² adopts a corneal curve of 7.6 millimeters and an axis of 24 millimeters as the average standard in emmetropia, and considers any axis over 26 millimeters as myopic.

Numerous investigations have shown that infants are almost universally born with hypermetropic eyes, while daily clinical experience teaches us that the majority of eyes of adults which have not been overworked, retain some degree of hypermetropia. Nevertheless, like the rest of the body, the eye has grown, and its diameter on the visual axis, as well as the horizontal and vertical meridians, has increased. Our anatomical knowledge in this direction is still defective. The most complete measurements are those of Jaeger's,³ which show that in newborn babes the average diameter in the visual axis is 17.495 millimeters, the average horizontal diameter 17.2 millimeters, and the average vertical

¹ Defects of Refraction and Accommodation, New Sydenham Soc., 1864, pp. 89, 90.

² Die Ursachen und Entstehung der Kurzsichtigkeit, Wien, 1876, S. 2.

³ Einstellung des dioptrischen Apparates im menschlichen Auge, Wien, 1861, Ss. 12, 13.

diameter 16.38 millimeters. The same author states that the average visual axis in adult eyes which are not much used for near-work, is 24.3 millimeters; the average horizontal diameter being 23.395 millimeters, and the average vertical diameter, 23.535 millimeters. We must remember that this growth of the eyeball is accompanied by a thickening of the sclerotic (especially of the dural layer), by a decrease in the curvature of the lens, and by a retention of the proper relations between the visual, and the vertical and the horizontal axes of the eyeball. If there be pathological changes in a diminishing hypermetropia or a commencing and increasing myopia, there will be a thinning of the ocular coats, a disturbance of the relations between the inner and outer layers of the sclerotic, and a marked variation in the different axes, with an undue increase in the sagittal and horizontal diameters.

Theoretically, the emmetropic eye is probably the best adapted for comfort. With it, distant objects are seen sharply without effort, and when it focusses near ones, the normal relation between convergence and accommodation is, as a rule, undisturbed. Emmetropes, however, have the disadvantage, as compared with myopes, of being obliged to put on glasses for near-work at forty-six to forty-eight years of age.

HYPERMETROPIA.

Hypermetropia (hyperopia) is the name given to that condition in which the recipient elements of the retina lie inside of the principal focus of the combined lenses of the eye. Consequently, in a state of rest, all parallel and divergent rays would, if not intercepted by the retina, be brought to a focus behind it. Only convergent rays would focus on that membrane. Inasmuch as all objects reflect either divergent or parallel rays, as previously explained, such an eye is unable in a state of rest to see distinctly, unless by using its accommodation it can cause its lens to become more convex and thus refract the rays more strongly, thus causing the principal focus to be thrown on the retina. Having thus used a part of its accommodative power to convert itself functionally into an emmetropic eye in order to see objects emitting parallel rays distinctly, it has that much less power to focus near objects which furnish divergent rays. Therefore, the nearest point of distinct vision lies farther from such an eye than it would in an emmetropic one with the same power of accommodation. This retrocession of the near-point, causing an inability to accommodate properly for the time of life, is one of the most certain and characteristic symptoms of hypermetropia, so that if a patient be in full vigor, has had no recent attack of acute sickness, and no astigmatism, we may look on it as complete evidence of hypermetropia. As this state of refraction can often be masked by the accommodation, it is evident that the symptoms of its presence will depend on the relation existing between the amount of hypermetropia and the power of accommodation. In the young, moderate degrees of the defect may be completely concealed by the accommodation, in both near and distant vision. The hypermetropia is then said to be *latent*. If the degree of the defect is higher or if the power of accommodation is lessened, there is painful or indistinct vision

of near objects, or even misty outlines of distant ones. The hypermetropia is then said to be *manifest*.

Manifest hypermetropia is, by systematic writers, divided into three categories: 1. *Facultative hypermetropia*, in which the patient can overcome the refraction error, both for near and for distant objects, by voluntary effort. 2. *Relative hypermetropia*, in which there is only sufficient accommodation to neutralize the defect by an undue effort at convergence. 3. *Absolute hypermetropia*, in which the patient, even if he accommodate to his utmost, cannot, upon account of the great amount of refraction-error or the failure of the accommodation, see distant objects distinctly; this being more pronounced for near ones. In relative hypermetropia, the visual axes, instead of meeting on the point looked at, cut one another between the point of fixation and the eye—resulting in the production of convergent squint.

It is evident that an individual, retaining the same degree of hypermetropia, might pass through all these stages, having facultative hypermetropia while young, relative in mature years, and absolute as he approaches old age. The feebleness of accommodation produced by severe or exhausting disease, is a frequent cause of similar changes in the range of distinct vision. The clinical symptoms are protean in form. They may be advantageously studied under three heads: First, early fatigue; second, disturbances in the circulation in the eye and its appendages; and third, neurotic disturbances.

1. We constantly meet with examples of early fatigue in middle-aged people, who find that they get sleepy, their lids become heavy, their eyes itch or burn, and the print begins to blur, during continued near-work. In order to avoid these discomforts, they press or rub their eyes and foreheads with their hands. This bringing a sense of relief, they resume their work for a time, only to be again annoyed by a recurrence of the symptoms. Upon examination, their eyes appear healthy. They generally have perfect vision for distance, but their range of accommodation is diminished. The ophthalmoscope shows a healthy hypermetropic fundus. Such patients may still have a vision of 5/5 through weak convex glasses, while stronger ones give the normal range of accommodation, enabling them to read with comfort as long as they desire.

2. It is a well-known law of physiology that the use of any organ is accompanied by an increased flow of blood to it, causing a certain amount of congestion of the parts. The eye is no exception to the rule, its tissues becoming congested from use. In a hypermetropic eye, this congestion is more marked. This is upon account of the extra exertion which the ciliary muscle is called upon to put forth to overcome the optical defect of construction, thus causing more than the normal flow of blood to it. The ciliary body and uveal tract become congested, the bloodvessels of the retina carry more than a normal amount of blood, and the lymph-spaces are distended by serum; while similar processes take place in the bulbar and tarsal conjunctivæ and in the eyelids. In many cases, therefore, we find red and heavy eyelids with the congestion especially marked in the ciliary margin, and an increase and perversion of the

secretion of the sebaceous follicles at the roots of the cilia and Meibomian glands. The congestion of the conjunctiva may be slight, or may manifest itself as a *symptomatic conjunctivitis* with marked increase of secretion and smarting and burning of the eye. Any pre-existent low grade of catarrhal or of phlyctenular conjunctivitis, is thus continued and increased, so that such chronic inflammation, while persistently relapsing after treatment by astringents, and augmented by every attempt to use the eyes, will frequently yield to a mydriatic and the employment of convex lenses which correct the hypermetropia.

Examination with the ophthalmoscope shows a varying degree of haze of the retina, with fulness and tortuosity of the retinal veins, which is most marked around the optic disk. Numerous yellowish-white and silvery reflexes may be seen following the course of the central vessels, or running off from them at an angle and coming out into the fibre-layer above. These reflexes shift with each motion of the mirror. The normal finely-stippled appearance of the epithelium of the chorioid is exaggerated. It appears woolly and ill-defined. At times, its pigment is so disturbed and concentrated, that it looks as if it were sprinkled with black pepper.

The eyes in this state feel swollen and uncomfortable. They often itch, smart, and burn when used for near-work. These symptoms are more pronounced when artificial light is employed, objects fixed upon becoming misty and blurred. If, in spite of these discomforts, work is persisted in, headache over the eyebrows and temples generally appears.

All these symptoms, especially those affecting the interior of the eye, rapidly diminish under absolute rest. This is obtained by the persistent application of any one of the stronger mydriatics. If the use of the mydriatic is followed by the employment of the proper correcting-glasses, these symptoms will not recur in uncomplicated cases. Where these precautions are neglected, and the use of the eyes for near-work is persisted in, the congestion becomes chronic. The envelopes of the eye gradually lose their tonicity and become softened until, under the influence of the intra-ocular pressure, the globe undergoes slow and gradual distention. Here, there is a *diminishing hypermetropia*, which may, when excess of near-work is avoided, become stationary at any grade. Often, however, such an overtaxed eye may gradually and slowly distend, until by almost imperceptible gradations its refraction creeps on into myopia. These conditions are most marked in the medium and lower grades of hypermetropia, as in this class of cases only can will-power and muscular effort correct the defect sufficiently to permit continuance of work. When the refraction-error is greater, the individual is obliged, upon account of blurring of near-work, either to discontinue or to resort to the use of convex glasses. This, associated with the fact of the greater thickness of the sclerotic in high hypermetropia, shows why the refraction of such cases often remains unchanged.

3. In high degrees of hypermetropia, the ciliary muscle is so little able to persistently combat the eye-defect, that any effort at continued near-work is relinquished, unless the strain is relieved by the use of appropriate convex glasses. In healthy young people, with a hypermetropia of between two and three diopters, the eye

is able to temporarily overcome its uncorrected defect by severe and persistent effort. As the hours of work, however, cannot long be maintained continuously, the sclerotic remains rigid, and the congestion becomes less marked; the frequent and obligatory intervals of rest allowing any increased vascularity to subside. The effort and strain on the part of the ciliary muscle, are shown by pain in the eye or temple and forehead. In aggravated cases, the pain shoots through the top of the head and to the junction of the occiput with the spine. If the patient complains of such symptoms in their most marked form, he may be obliged to discontinue all useful occupation. In some cases, he may even be in great distress, through fear of subsequent blindness. Often, the neuralgia is so intense that any change of tension in the ciliary muscle becomes painful, and reflex disturbances, usually consisting in sensations of dizziness and nausea, are developed. These are especially called forth by any rapid change of focus of the eye, as, for example, in bookkeepers who are almost momentarily compelled to look from a day-book to a ledger, or pianists who alternately glance at a sheet of music and the keyboard. On testing such patients, we find that they usually have perfect vision for distance for a few moments only; a blur then comes before the eyes. In some cases, the act of accommodation is so painful that it is difficult to induce any efforts to read. When encouragement, however, is made to make the attempt, fine print may be read for a few moments. In such cases, the ophthalmoscope shows clear media with a hypermetropia of from two to three diopters. The disk, retina, and chorioid appear nearly normal. Less severe but somewhat similar symptoms, with marked congestion of the interior of the eye, are constantly encountered in low grades of hypermetropia. These occur either in persons who are convalescent from acute disease, or in those who have an enfeebled and broken-down nervous system. At times, the same conditions are found in women suffering from chronic congestion of the mucus membrane of the uterus, uterine displacement, or those shrinking and atrophic changes of the organ which accompany the menopause. In this class of patients, pain in the back and top of the head, accompanied by great discomfort and dull pain deep in the orbits immediately back of the eyes, is frequently complained of. Here, the symptoms are often most severe soon after rising in the morning, before the eyes have had any near-work, and when one might expect them to be refreshed by sleep. Such patients complain of a feeling as if the eyes were sticking to the eyelids, and as if they could not, therefore, open the eyes; this latter symptom being more marked during the irregular menstruation which often precedes the menopause. The ready fatigue of the eye on very slight use, and the neuralgia, discomfort, and blur caused by slight and moderate degrees of hypermetropia in cases showing the very earliest irritative and ataxic symptoms of posterior spinal sclerosis, may fairly be classed as among the earliest signs of that disease.

Aphakia. When absorption of the lens is produced by discission, or when the lens is removed from the eye by extraction, a high degree of hypermetropia is generally produced. The want of the lens in such an eye, gives a dioptric system which is composed of but one refracting surface

(the cornea). In front of this surface is air, and behind it are the aqueous and vitreous humors. As both of these have nearly the same index of refraction as water, the conditions for calculating the length of axis, the size of retinal images, etc., are almost as favorable as in the schematic eye. Experience has shown that, where the eye is nearly emmetropic before operation, a glass of 4'' focus (*i. e.*, $1/3\frac{1}{2}$, $1/4$) held half an inch in front of the organ, will correct the hypermetropia. It also teaches that when a much weaker lens is required, we have to deal with an organ which was originally myopic. If a stronger lens be required, there has been previous hypermetropia. The only exception to these rules is, where there is an abnormally short radius of corneal curvature. Very rarely do we meet with myopia so high that after extraction of the lens the eye becomes emmetropic. Donders has related such a case. He has calculated that the length of axis that is requisite to produce emmetropia in aphakia must be 30.58 millimeters. Mauthner¹ has shown by measurement of several aphakic eyes, that the length of the axis in emmetropia varies from 22.4 to 24.9 millimeters. Förster has endeavored to prove that in lensless eyes there is still a power of accommodation which is dependent upon the action of the ciliary muscle in diminishing the radius of curvature of the cornea. The apparent accommodation found in some cases after cataract operation is, however, probably due either to a slight shifting of the correcting lens, causing an increase in the distance between the glass and the eye, or narrowing of the pupil in the effort to see near objects, with consequent diminution of the circles of diffusion. We can readily recognize how great an effect can be produced by this latter manoeuvre, by placing a very small diaphragm in front of a photographic lens, and observing the images which are formed on the ground-glass screen of objects that are placed at different distances. Moreover, Donders and Coert have shown that every movement of a distant object, causes a blurring of the sight in the aphakic eye, which can be corrected by the addition of either minus or plus glasses to the spectacles. Mauthner has seen a case where a patient who was tested with Burchardt's dots, claimed a blurring of the image for every change given the distance of the test-object. Again, where print is used as a test, a knowledge of the letters and quick intelligence, will often permit correct conclusions to be drawn even though the images be blurred and imperfect.

In cases of very high hypermetropia, it may be desirable to prove the presence or absence of the lens. Where the cornea is clear and the pupil is wide, the catoptric test, as explained on page 91, will at once enable us to decide as to its existence. Where the cornea is cloudy and the pupil is small, the modification of Scheiner's test invented by Thomson, as explained on page 251, will often enable us to arrive at a correct conclusion.

According to Donders, a shortening of the visual axis of half a millimeter would give a hypermetropia of $1/21.43$; of one millimeter, would give a hypermetropia of $1/10.34$; of one and a half millimeters, would give a hypermetropia of $1/6.649$; and of two millimeters, would give a hyper-

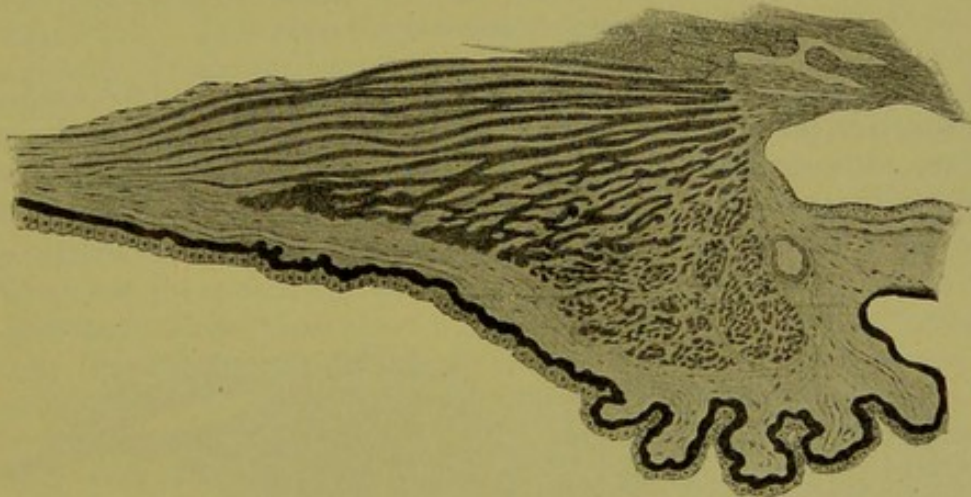
¹ Die optischen Fehler des Auges, Ss. 240-248.

metropia of $1/4.302$. Mauthner says that if H equal $1/40$, the corneal radius will equal 7.77 millimeters, and the diameter of the eyeball in the visual axis will equal 24.70 millimeters; if H equal $1/12$, the corneal radius will equal 7.62 millimeters, and the diameter of the eyeball in the visual axis will equal 23.67 millimeters; if H equal $1/6$, the corneal radius will equal 7.48 millimeters, and the diameter of the eyeball in the visual axis will equal 22.56 millimeters; and if H equal $1/4.5$, the corneal radius will equal 7.43 millimeters, and the diameter of the eyeball in the visual axis will equal 21.85 millimeters.

The difference between these estimates is so slight that for all practical purposes, they may be assumed as identical. They agree nearly with the post-mortem measurement of axes of eyes in which the degrees of hypermetropia have been previously known.

The objective symptoms of high degrees of hypermetropia are quite marked. Generally, there is an apparent divergent squint. When the eyeball is rolled strongly inward, the shortness of its axis is revealed by

FIG. 237.



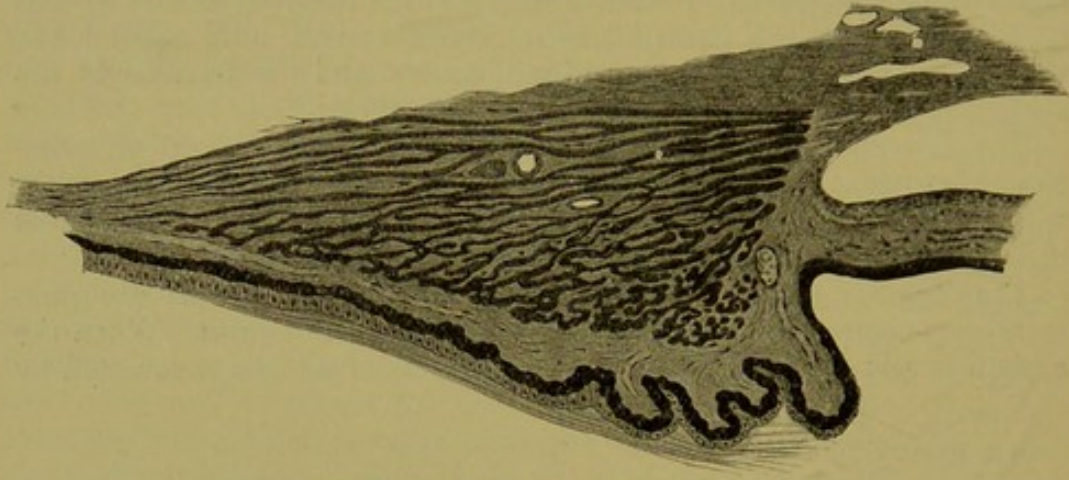
Ciliary muscle in hypermetropia. (ARLT.)

a sharp curvature in the equatorial region. The anterior chamber is often shallow, and the pupil is small. The shortness of the visual axis which produces the seeming external deviation of the eye, causes a greater divergence between the visual axis and the major axis of the corneal ellipse than usual. This is so, even if the distance from the macula to the disk should be slightly less than in the emmetropic eye. Donders has proved that the angle α averages $7^\circ 55''$ in hypermetropic eyes, while in emmetropic organs it is usually equal to $5^\circ 82''$. In hypermetropic eyes, dissection shows an axis which varies from nineteen to twenty-three millimeters. This shortening produces a much more rapid curve at the equator. The sclerotic is thicker and is more dense.

In high degrees of hypermetropia, the circular fibres of the ciliary muscle are so hypertrophied that there is either a right angle or an obtuse one formed at the junction of the anterior and the external surfaces. This is less so in emmetropia. In high myopia, the angle is often quite acute. Section of such a muscle, as was first pointed out

by Iwanoff, will often, without other evidence, show that an eye is hypermetropic. Figs. 237, 238, and 239, of the ciliary muscle, taken from hypermetropic, emmetropic, and myopic eyes, will serve to make the differences evident.

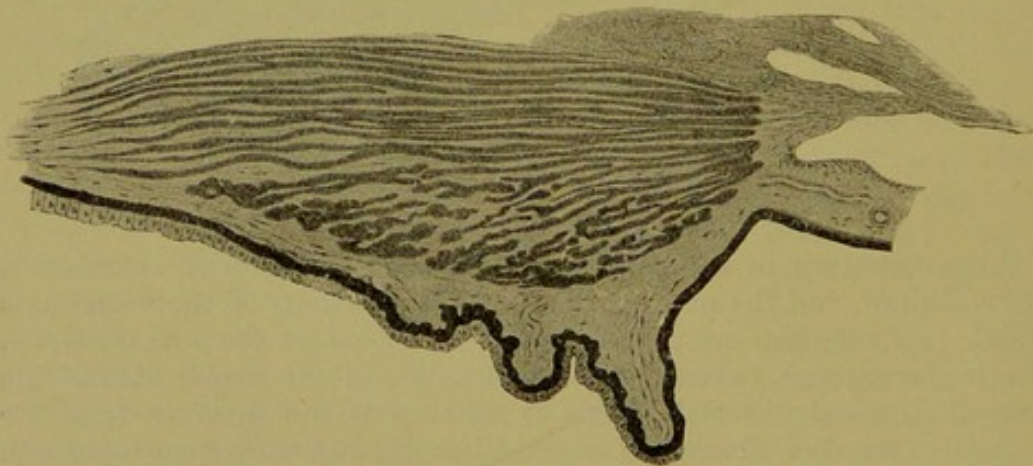
FIG. 238.



Ciliary muscle in emmetropia. (ARLT.)

In many cases of hypermetropia, the form of the face is different from that which is characteristic of emmetropia and myopia. The orbits are shallow, with edges which project but little, and the measurement from corresponding points on their outer rims, is unusually great. The eyes are wide apart, the nose is flat, and the cheeks are but little rounded. If

FIG. 239.



Ciliary muscle in myopia. (ARLT.)

this is accompanied with apparent divergence of the visual axis, a shallow anterior chamber, a narrow pupil, and a sharp curve of the eyeball at the equator, the characteristics of pronounced hypermetropia are present.

It follows from the explanation given of latent hypermetropia, that its existence may sometimes be difficult to prove. The chronic congestion of the lids or the conjunctiva, or the marked asthenopic symptoms, may be due to other causes, and when we examine such

an eye functionally, the great power of the ciliary muscle masks the defect. Such patients not only reject the weakest convex glasses, but even prefer weak concave ones, as making the images for distant vision sharper and clear. In such cases, the upright method of examination with the ophthalmoscope and the shadow-test, may fail also. In cases of spasm, the inability to relax the accommodation entirely, with the consequent diminution of the range of distinct vision in reading, may convince us of the probability of the presence of hypermetropia. In both instances, nevertheless, it often becomes necessary to instil a mydriatic to prove the presence of the refraction-error.

In middle life and old age, these difficulties of diagnosis are relieved by the diminished accommodative power being no longer sufficient to hide the defect. In such cases, convex glasses improve the distant vision, whilst the retrocession of the near-point beyond its usual situation at the patient's time of life, makes the diagnosis easy. If necessary, additional evidence by means of the retinal shadow-test, or an examination of the eye-ground with the direct method, can be obtained.

Hypermetropia of low grade is the normal state in the eyes of all the human race which are not excessively and constantly used for near-work. It is also the condition of the adult eye in all the lower animals. In the former, the slight effort of accommodation that is sufficient to give sharp distant vision and to enable a moderate amount of near-work to be done without discomfort, is not perceived by healthy and vigorous individuals. In youth, low-grade, uncomplicated hypermetropia does not need any correction by glasses. It is only when old age approaches such subjects, that the failing accommodation is no longer fit to overcome the defect, and that they are obliged to resort to spectacles for near-work earlier than those who have emmetropic organs. Later, they may require them to see sharply at a distance. In young people whose complaint is of early fatigue of the eye, it will usually be sufficient to order a glass which corrects the total hypermetropia for the accustomed near-work, allowing them to go uncorrected for distance as long as they see distant objects comfortably and distinctly. Theoretically, the best course would be to convert such an eye into an emmetropic one, by giving it a full correction to wear habitually. Practically, we find that this is undesirable, and that such patients will reject such glasses as long as they can see distinctly at a distance without asthenopia. This arises from the fact that eyes which, since childhood, have been accustomed to strain their accommodation and convergence in the effort to see distinctly, and have thus acquired hypertrophy of the ciliary muscles and of the internal recti, are unable at once to reverse their habits of work with comfort. In addition, it must be remembered that any glass, no matter how well fitted to the eye and face, is a nuisance by giving rise to circles of diffusion which arise from reflecting images of brightly illuminated objects striking its posterior surface, thus making the edges and rims of the glasses unpleasantly apparent. Disagreeable feelings in the nose, temples, and ears are also often occasioned by the weight of the glasses and pressure of their frames. Of course, if distant vision is made much more distinct with the glasses, or if headache and eye-strain is relieved by their use, the advantages resulting from their employment lead the

patient to habituate himself to them and to neglect the inconveniences. As such persons become older, the glass correcting the manifest hypermetropia is only able to give sharp distant vision, thus necessitating a second and stronger pair of glasses for near-work.

In the second class of hypermetropes, where the constant strain on the ciliary muscle causes reflex disorders of the circulation, and there is blepharitis or catarrh of the conjunctiva, the correcting-glasses should be advised to be constantly worn. This should be done so as to prevent not only discomfort, but also to avoid the chronic congestion of the interior of the eye and of its walls, which, by permitting softening and stretching, gives rise to a diminishing hypermetropia and paves the way to myopia. In many instances, on account of the unsightliness of glasses and the annoyances caused by their constant wear, this advice will be persistently rejected. In such cases, we shall be obliged to content ourselves with combating the external inflammation by weak astringents, detersive eye-waters, or some of the mercurial or other ointments, taking care to give the patients full corrections for near-work. These measures may be pursued with safety as long as the ophthalmoscopic appearance of congestion of the interior of the eye is inconsiderable, and there are no evidences of diminishing hypermetropia.

In the third class of cases, in which there are eye-strain, headache, and other neurotic disturbances, the total hypermetropia should be carefully ascertained. We should insist on our patients wearing habitually as strong glasses as are possibly consistent with the obtaining of normal binocular vision for distance and the giving of good range of accommodation. By reason of hypertrophy of the ciliary and the internal recti muscles, a total correction will, when accommodation returns, blur distant objects. Owing to the diminished necessity for work of the interni when a smaller demand is made on the accommodation, it will also cause a disturbance in the muscle-balance both for near and far vision. Where, owing to the extremely hyperæsthetic state of the nervous system, such a correction cannot be worn for constant use, it must be adhered to for near-work. In these cases, we should supply the strongest glasses for distance which can be worn habitually. Watch should be kept over the patients, and stronger glasses supplied from time to time, according as their hypertrophied ciliary muscle becomes weaker, and as they learn to moderate the strain on their straight muscles, to which they have for years been habituated in efforts to see distinctly. In correcting such cases, we must never lose sight of the fact that we should be guided not solely by the amount of hypermetropia, but also by the constitutional state of the patient. It is a matter of everyday observation, though, unfortunately, not sufficiently insisted on by writers on the subject, that persons who are convalescent from acute disease, or those who have feeble health and impaired nutrition, as well as those who have hyperæsthesia of the nervous system, suffer acutely from low grades of hypermetropia which would produce no symptoms of discomfort at the same time of life were they in robust health. In many cases of nervous debility, in the hyperæsthetic state preceding central nerve degeneration, and in the various disturbances of health accompanying uterine or ovarian disease, adolescence, or the change of life, we

daily see that the correction of a hypermetropia of 0.25 to 0.50 D., or equivalent changes in glasses already worn, relieve headache and nervousness, and enable the patients to perform their daily tasks with less discomfort. Again, individuals who, in an enfeebled state of health, have found spectacles absolutely necessary for comfort, can, perhaps, lay them aside when they have regained their accustomed vigor. In prescribing glasses without the use of a mydriatic, it is usually desirable to order for distance use, the strongest lens which will give perfectly sharp vision for Snellen VI, at six meters. For near-work, the strongest glass should be given which allows a range of accommodation to correspond to the age of the patient.

In the opinion of the author, a correction should be prescribed in all cases of marked local vascular disturbance, or where there is asthenopia. To ascertain this in young people, it is necessary to obtain the absolute amount of refraction-error. This is done either by placing the ciliary muscles under an apparently full influence of one of the stronger mydriatics, or by instilling repeatedly, at short intervals, solutions of weaker ones, such as homatropine. Without such drugs it is impossible, in such cases, except in the middle-aged and in the old, to ascertain the total hypermetropia, either by test-glasses, by the ophthalmoscope, or by the shadow-test. Ordinarily the efficient use of a mydriatic is rendered difficult by the fact that it obliges the patient to temporarily abandon his occupation. Where asthenopia is considerable, he is well repaid by the result. Where there is marked congestion of the interior of the eye, the use of the drug is absolutely curative, as the persistent use of strong mydriatics under these circumstances will often, without other medication, be followed by complete subsidence of the retinal and chorioidal irritation, thus leaving a quiet and healthy state of the fundus oculi. In employing these agents, we must never forget that, owing to the wide expansion of the pupil, the retina is often exposed to many times the amount of light which Nature ever intended to reach this delicate structure. In order, therefore, to reduce the amount of light which enters the eye to somewhere near the normal, we should protect it by causing the patient to wear a pair of London-smoked glasses. A neglect of this precaution will often cause additional haze and congestion of the retina, instead of aiding the eye to return to a state of quiet. Occasionally, it will produce a low grade of chorio-retinitis, which is far easier to call into existence than to cure.

MYOPIA.

Myopia, or *short-sightedness*, is that state in which the principal focus of the refracting lenses of the eye falls in front of the retina. Here the rays of the light from distant objects, having already crossed, diverge to form circles of diffusion, these becoming larger in proportion to the increase of the distance between the principal focus and the receptive retinal screen. Such an eye is capable only of receiving sharp images of near objects, which send to it divergent rays. The distance at which rays from any given point are the least sufficiently divergent to be sharply focussed on the retina, gives the far-point of distinct

vision. Consequently, it indicates the grade of myopia. The correcting-lens of such an eye is that concave glass which, held immediately in front of the eye, causes parallel rays of light to diverge so strongly that they appear to come from this, its natural far-point. According to the refracting power of the necessary correcting-glass, we speak of the grade of the myopia.

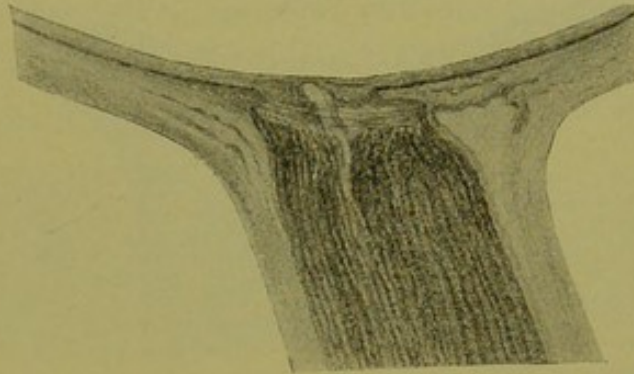
It is evident that, in any emmetropic eye arranged so that, in a state of rest, its principal focus shall fall on the retina, myopia may be produced either by an increase in the curvature of the cornea or of the lens, or by an elongation of the visual axis. Although the principal focus of the eye falls in front of the retina in all these cases, yet they are not all technically termed myopia. For instance, myopia is practically produced by an increase in the curvature of the cornea in staphyloma of the cornea and conical cornea. It may be caused by an increase in the curvature of the lens in the early stage of cataract, or it may be produced by a spasm in the muscle of accommodation. In fact, there is a production of temporary short-sightedness every time that accommodation is made for a near object. It is only where there is an elongation of the visual axis which is due to a stretching of the coats of the eyeball, that there exists what is usually classified as myopia. The greater the elongation of the axis, the nearer does the far-point approach to the eye, and the smaller becomes the range of distinct vision. The affected individual sees the moon and other distinct and brilliant objects, of larger size than natural and fogged with hazy outlines. Small distant objects, which are less brilliantly illuminated, are invisible to him. False estimates of magnitude and distance are thus formed, and he lives within a narrow circle of vision, thus being placed at a great disadvantage in most outdoor pursuits and sports when competing with those who have emmetropic or hypermetropic eyes. If this state of affairs be not corrected by glasses, the youthful myope will acquire distinct mental habits and peculiarities. He will become brusque in his manner and unduly self-reliant. Perhaps, at times, he may be hesitant in positions where it is necessary to judge properly of his surroundings or to appreciate the feelings and changes of countenance of those whom he is addressing.

In myopia that is due to increase of the visual axis of the eye, many characteristic tissue-changes are encountered. The cornea usually retains its normal curvature, but, according to Donders, it may sometimes be flatter. The anterior chamber is deeper, the pectinate ligament of the iris is thinner, and the pupil is generally wider. Owing to the greater development of the longitudinal fibres and the small number of the circular fibres, the ciliary body has, as was shown in Fig. 239, a peculiar shape.

The retina, chorioid, and sclerotic are stretched, causing a thinning of the ocular walls in that part which has undergone the greatest elongation, this being usually most marked in the neighborhood of the macula lutea. At times, however, the optic-nerve entrance, or part of it, forms the deepest part of the eyeball. Occasionally, the greatest protuberance may lie to the nasal side of the disk. In 1853, Arlt published four cases of myopia, in which the degree of short-sight, as indicated by the

correcting-glass, was compared with careful measurement of the visual axis after death. Soon after, Jaeger augmented the knowledge in this respect, by publishing ophthalmoscopic drawings of the eye-grounds of several cases of carefully-corrected ametropia where subsequent dissection showed the structures of the ocular coats, the length of the visual axes, and the condition of the optic-nerve entrances and their vicinity.

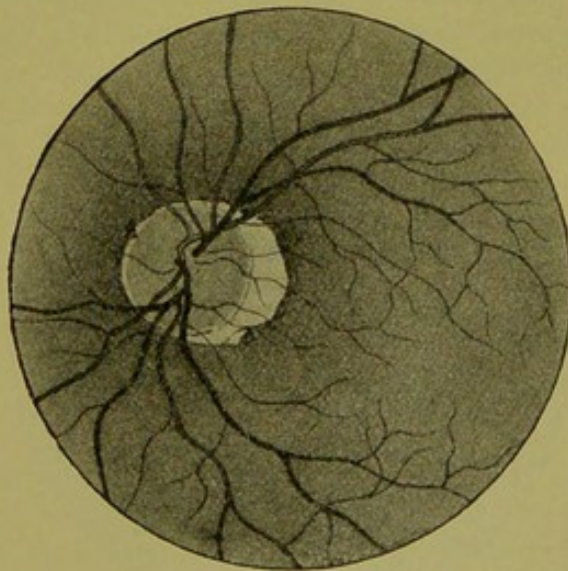
FIG. 240.



Section of change in shape of discal end of the intervaginal space. (JAEGER.)

He thus proved that myopia which is equivalent to one twenty-fourth, had a visual axis of 25.7 millimeters; that myopia which is equivalent to one-twelfth, had a visual axis of 27.7 millimeters; that myopia which is equivalent to one-tenth, had a visual axis of 28.0 millimeters; that myopia which is equivalent to one-eighth, had a visual axis of 29.7

FIG. 241.

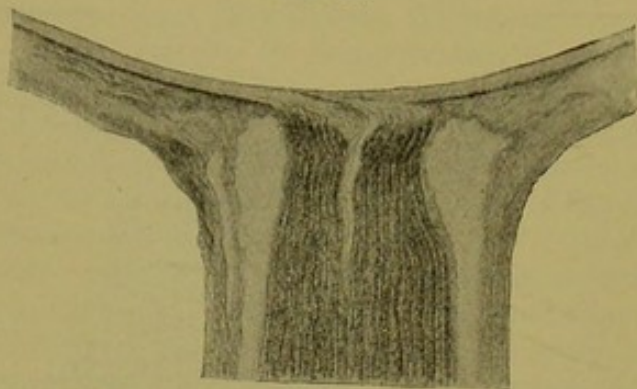


Ophthalmoscopic view of change in shape of discal end of the intervaginal space. (JAEGER.)

millimeters; that myopia which is equivalent to one-fifth, had a visual axis of 30.6 millimeters; and that myopia which is equivalent to one-fourth and a half, had a visual axis of 32.6 millimeters. Later anatomical data prove, in the main, the correctness of these tables. Yet, as has been shown in speaking of emmetropia, these values are

not necessarily absolute. The slight variations here, as there, are dependent upon the greater length of the axis being partly compensated by a flatter cornea. At the same time, Jaeger pointed out that the displacement of the inner layer of the sclerotic upon the outer, produces a change in the shape of the discal end of the intervaginal space. He

FIG. 242.

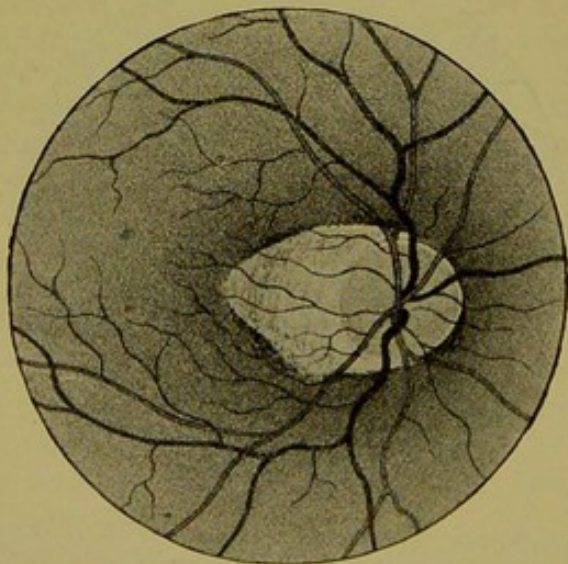


Section of changes in dilatation of both discal ends of the intervaginal space. (JAEGER.)

found it to become enlarged and club-shaped on the nasal side and slit-like on the temporal side, in those cases where the maximum distention of the eyeball is in the visual axis. This is seen in Figs. 240 and 241.

He moreover proved that both ends of the space were dilated in those cases where the greatest stretching was in the position of the optic axis. This is shown in Figs. 242 and 243.

FIG. 243.

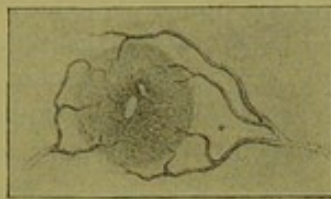

Ophthalmoscopic view of dilatation of both ends of space. (JAEGER.)

He further demonstrated, as shown in Figs. 244 and 245, that there is a thinning and stretching of the vessels which constitute the arterial anastomosis between the short ciliary arteries and the central retinal artery, at the head of the optic nerve.

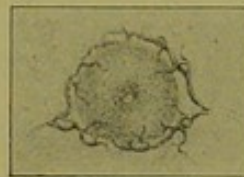Jaeger has called attention to the inequality which exists between the vertical and horizontal equatorial axes in myopic eyes, showing that the latter is always disproportionately the greater. He has found that these axes are nearly equal in emmetropic or slightly hypermetropic eyes. Lately, Stilling¹ has laid stress on the enlargement of the horizontal diameters of the eyeball, attributing it, as well as the backward protuberance in the macular region, to the action of the superior oblique. Weiss has proved that in some myopic eyes, with marked elongation of the axis, the optic nerves are short and are put on the stretch by the inward and downward movements of the eye.

FIG. 244.



Thinning and stretching of anastomosing arteries at the head of the optic nerve. (JAEGER.)

FIG. 245.



Thinning and stretching of anastomosing arteries at the head of the optic nerve. (JAEGER.)

Normal appearance

When the eyeball thus undergoes distention, either the vitreous must enlarge or a space must form which soon becomes filled with serum. In the majority of such eyes, softening of the posterior part of the vitreous, with a breaking down of its structure and the formation of floating filaments, occurs. These filaments often throw shadows on the retina, and are perceived by the patient as muscæ. At times, there is a detachment of the vitreous, the space between it and the retina being filled with fluid. Usually, the thinning and atrophy of the chorioid are most marked at the outer side of the optic entrance, presenting either a meniscoid or a conical shape. The area of atrophy may, however, encircle the nerve-head and be more developed either to the nasal side or above or below. It may extend out irregularly, often following the retinal vessels, and having its greatest diameter in the direction of the upper or lower temporal branches. The affected area may become atrophic, or have pigment-spots and some unobliterated vessels of the chorioid remaining in it. Besides these changes (as well as in other states of refraction), a horizontally ovoid disk, with retinal vessels entering obliquely from above, is occasionally found. Such a nerve-head is bordered below by a broadened scleral ring and a completely atrophic area, beyond which there is an area of partial or complete atrophy of the chorioid.

In some rare cases, even of high myopia, there is but little that is abnormal, except a slight thinning of the chorioid coat and its contained pigment, to be seen with the ophthalmoscope. Generally, even in moderate myopia, there is a narrow band or a meniscus at the outer side of the optic nerve, where the chorioid is lighter-colored than in other parts, and in which, at times, heapings of pigment or some of the larger vessels of the

¹ Untersuchungen über die Entstehung der Kurzsichtigkeit, 1887, S. 212.

chorioid, can be seen. This loss of chorioid-pigment may continue till the entire meniscus becomes white. The area of disturbed or absorbed pigmentation is generally bounded toward the macula lutea, by a more or less complete black rim. In cases of myopia of higher degree, the meniscus assumes a more or less conical shape, with the apex of the cone generally pointing toward the macula. At times, the *conus* may be so dotted with concentric pigment-rings as to show the various stages in its growth. The atrophic area is frequently not confined to the temporal side of the disk, but surrounds the disk. Often, in cases of high-grade myopia in patients toward middle life, where the disease is of long standing, groups of irregular pigment-splotches and white atrophic patches appear in the chorioid. They seem, by preference, to form in the macular region, or between it and the disk. In some advanced cases, besides the formation of *conus*, there is an absorption of epithelial pigment throughout the eye-ground. This loss so affects the rods and cones, as to cause great reduction in visual acuity. It is often accompanied by the production of numerous vitreous opacities. These changes in the vitreous, chorioid, and retina, frequently prelude a detachment of the retina, which may gradually lead to absolute blindness. Many cases of high myopia, however, retain fair peripheral vision for years after macular changes have caused the appearance of absolute central scotoma.

Patients with slight degrees of myopia often scarcely recognize any deterioration of their sight, and are surprised to find that their distant vision can be bettered by concave glasses. Those with moderate degrees complain of inability to see objects clearly at a distance; while those with high degrees, thoroughly realizing their near-sightedness, complain either of increase of the affection, or of inability to recognize objects clearly at the distance at which they are compelled to work. In young people who see badly at a distance, perfect acuity of vision is usually found at some point near the eye. If, under such circumstances, letters of double size are no longer read at double the distance, the existence of myopia may be assumed. Especially is this so, if the patients still have the full amount of accommodation which is proper for their age, and the entire range of accommodation is brought nearer to the eye. In such cases, concave glasses will improve the distant vision. The one which corresponds with the far-point of the eye, is the one that will give $5/5$, and will allow the range of accommodation to approach that of emmetropia.

In advanced cases, the retinal vessels appear dragged, being straighter in their course. The main trunks diverge more at right angles. When the direct method of ophthalmoscopic examination is used, not only are the appearances of the fundus oculi made visible, by that concave lens which allows a distinct image of the macula, or the region between it and the disk, but an approximate measure of any needed correcting-glass is obtained.

Spasm of the accommodation in hypermetropic eyes gives transient symptomatic myopia. The diagnosis between it and true myopia is evident from the peculiarities of the range of accommodation, and from the fact that no concave glass gives full acuity of vision for any length of time in the former. Further, in the functional variety, there is a dis-

proportion between the glass chosen and that with which the eye-ground can be best seen. In cases of doubt, a few drops of any of the stronger mydriatics will soon unmask any spasm. The simulation of myopia by some patients with high degrees of hypermetropia, who hold their work close to their eyes, so as to obtain large, although blurred, images, can be detected by the improvement of vision by convex glasses, and the information obtained by the use of the ophthalmoscope.

The vision of myopes offers some peculiarities. Owing to the fact that the eye has a finite far-point, objects which are more distant are seen through circles of diffusion, which are all the more annoying, because the pupil is generally large. Points of light, such as the larger stars and planets and the moon, appear as irregular shining disks, which are much larger in diameter than they are to the normal eye. These optical defects are, to some extent, remedied by a partial closure of the lids. This not only allows the lids to act as stenopæic slits, thus permitting a diminution of the circles of diffusion by allowing entrance to the more central rays alone, but may cause some flattening of the cornea or produce a diminution of the antero-posterior axis of the eye, by their temporary pressure upon the globe. Upon account of the horizontal position of the palpebral fissure, the diameter of the circles of diffusion is most diminished in the vertical direction, thus rendering horizontal lines more plainly visible. The cilia, however, act to some extent as vertical linear objects, and give rise to duplication of lines in the same direction. This closure of the eyelids is a striking peculiarity in the physiognomy of myopes who either do not wear correcting-glasses, or whose corrections are inadequate.

Inasmuch as, with an equal tension on the accommodation, myopes are able to hold objects nearer than emmetropes, they see them under a larger angle of vision, and consequently, such objects appear of larger size. Moderate degrees of myopia, therefore, give their possessors some advantages for near vision. Again, owing to the range of accommodation being situated near the eye, myopes can read longer without the aid of glasses when they become presbyopic. In some fortunate cases, where they have a far-point of from eight to twelve inches, they are able to dispense with glasses. Failing accommodation, however, deprives them of the power of approaching their work any nearer to the eye than the far-point. In this respect, their vision is like that of the presbyopic normal eye armed with a strong glass, where there is but little deviation from the artificial far-point given by the glasses. Inasmuch as some grades of myopia do not need presbyopic spectacles until late in life, while others never require any, a widely disseminated popular impression exists that myopes have strong eyes. This belief has been strengthened by the fact that upon account of the narrowing of the pupil which appears with old age (with consequent diminution of circles of diffusion), distant vision may, to some extent, be even improved.

From the foregoing description of the anatomy and ophthalmoscopic appearance of myopic eyes, it will be seen that Donders's statement, that "the myopic eye is a sick eye,"¹ is correct; and, notwithstanding

¹ *Anomalien der Refraction und Accommodation des Auges*. Wien, 1866, S. 288.

the advantages enjoyed in old age by near-sighted eyes of a medium grade, the fact remains, that where the condition is progressive and is of high grade, there is serious impairment of vision later in life. In the lower grades, this consists in increasing myodesopia, and in such changes in the vitreous and the lens as tend to impair the nutrition of the latter and favor the production of cataract. In the graver forms, there is not only local atrophy round the disk, causing an increase of Mariotte's spot in the field of vision, but also such changes in the epithelial layer as will affect the function of the rods and cones. Moreover, local atrophies in the deeper layers of the retina, especially in the region of the macula lutea, only too often destroy central vision. In such cases, the chorioidal and vitreous changes favor the occurrence of retinal detachment, which frequently produces a loss of the last remnants of vision.

Whilst discussing emmetropia and hypermetropia, it has been stated that the eyes are usually hypermetropic at birth. It has also been shown that the eye starting with a visual axis of from seventeen and one-half to nineteen millimeters, increases during the growth of the body, at least 2.75 millimeters in the same direction, even though it remains with a very short axis, producing a high hypermetropia ($H = 1/4$ to $1/2$)—while if it becomes emmetropic, the growth of the eyeball must be even more considerable. In that portion of the community whose occupations are sedentary, and where continued near-work is involved, many eyeballs can be noticed which, by stretching, have acquired still larger dimensions, and have consequently become myopic. On inquiry, it will be generally found that there has been a change in refraction, which occurred in childhood or youth. Let consideration, for a moment, be taken of the circumstances in which this change takes place, the appearances of the interior and the exterior of the eye, and the discomforts occasioned to the individual in whom the changes are in progress. When the soft, elastic, and bluish sclerotic of the young is looked at, it can be readily perceived how, under any softening influence, it would give way slowly even to normal intra-ocular pressure.

Transient congestion is the universal law of physiological activity. If our muscles are used, more blood circulates in them, and, for the time, they become tense and swollen. If convergence and accommodation is attempted, more blood flows into the acting muscles. Here the vascular network of the chorioid, as well as that of the ciliary muscle and ciliary processes, occupy more space and transiently raise the intra-ocular pressure; this pressure being augmented by the tension of the straight and oblique muscles in directing the visual axis inward and downward. The retina shares in the general excitement, becoming thicker and less transparent, and presenting a faint pinkish hue in its thicker parts, thus causing it to veil the upper and lower margins of the disk. The walls of the larger bloodvessels at or near the disk become visible, whilst numerous yellowish or silvery reflexes may be seen in various parts of the eye-ground near the smaller vessels; these reflexes being probably due either to a similar cause or to an infiltration of the vascular lymph-sheaths. The condition is identical with that which has been so well described and pictured by Jaeger, as retinal irritation. Even the dense sclerotic coat carries more blood, and its lymph-spaces, as well as those

of the cornea, become more distended by serum. In healthy individuals who have sufficient intervals of rest and sleep, the bloodvessels contract, the increased exudation of serum becomes absorbed, and the eye subsides into a state of quiescence. If, however, the period of work be too prolonged or be too often repeated, the capillaries and lymph-spaces remain dilated, and there is never a period during which there is complete contraction and quiet. The reflex-action which determines a normal flow of blood to the eye and its appendages, becomes disturbed, and the result is a congestion of the eyelids and of the tarsal and bulbar conjunctivæ, accompanied by an itching, burning, and watering of the eye, with a feeling of "sandiness" or "sleepiness." Whenever the exertion is pushed still further, the weary muscles ache, and there is pain in and back of the eye, which shoots through the temples and the forehead. Even under the normal intra-ocular pressure, frequent repetitions of this process cause the congested, serum-infiltrated, and softened tissues to give way. This yielding generally occurs at the posterior pole, where the sclerotic is best supplied with blood, and where it is weakened by the numerous perforations for the entrance of the posterior ciliary arteries and nerves. A gradual lengthening of the visual axis is thus produced, which results first in a diminishing hypermetropia, and finally in the production of increasing myopia. Any constitutional dyscrasia which makes the circulation sluggish and the tissues less tense and resisting—notably those morbid processes which are usually grouped under the name of scrofula—greatly augments the tendency to change. Feebleness of the constitution after eruptive and continued fevers, often produces the same change. Any continued low-grade inflammation of the chorioid, may lead to softening, and cause the eye to give way to normal intra-ocular pressure on the slightest attempt at near-work, thus producing the myopia which is occasionally encountered among unlettered people. Myopia once produced during adolescence, may either continue progressive or come to a standstill. When the latter occurs, it is apt to take place somewhere between the ages of twenty and twenty-five years, when the body has completed its development and growth.

Where myopic eyes have become stationary in their refraction and have not attained a high degree of near-sightedness during their youth, they often remain comfortable and capable of doing much hard work. They may also enjoy the advantage of not having to resort to spectacles for near-work until late in life, and perhaps, if the far-point lies between twelve and eight inches, they will never require them. Where, however, the myopia has attained to a higher grade in youth, or where, owing to feebleness and overwork in adult life, unusual strain is put upon the eyes, it may gradually increase. In such a case, it may be accompanied by the previously described changes in the macular region, which so often, when the patient is about fifty years of age, produce a central scotoma which renders him incapable of all useful work; and indeed practically blind. In many cases, the failure of sight is so great that the patient can with difficulty get about. Where detachment of the retina sets in, the condition is apt to result in blindness.

In view of the importance which the subject of near-sightedness has

assumed in modern life, where almost every child is sent to school, and where it is rare to encounter anyone who cannot read and write, it is worth while to examine somewhat in detail the writings of those who in various countries have made the average refraction of the human eye the subject of careful and laborious investigation. Jaeger, in 1861, was one of the first to call attention to this matter, and Randall, in 1888, reported one hundred and five studies, in which 165,000 (165,384) eyes had been examined. Of these, 92,435 (58.8 per cent.) were emmetropic, 32,343 (19.5 per cent.) were myopic, and 36,347 (21.9 per cent.) were hypermetropic; while 4259 were remarkably astigmatic or amblyopic. In this series, it must be remembered that in many young cases, myopia was perhaps only apparent, being due to spasm of accommodation, while the slightly greater number of hypermetropes represented only manifest hypermetropia, and should really be increased by a vast number of those apparently emmetropic, in whom a hypermetropia was rendered latent by accommodation. As will be seen in the accompanying compilation by Randall, the vast majority of the eyes of the newborn are hypermetropic:

Date.	Investigator.	Infants.	Eyes.	Hypermetropia.	Emmetropia.	Myopia.
1861	Jaeger,	[100 x]	100	17 = 17 per ct.	5 = 5 per ct.	78 = 78 per ct.
1880	Ely,	111	154	106 = 69 "	21 = 14 "	27 = 18 "
1880	Horstmann,	20	40	28 = 70 "	8 = 20 "	4 = 10 "
1881	Koenigstein,	281	562	552 = 98.2 "	10 = 2 "	
1884	Schleich,	150	300	300 = 100 "		
1884	Ulrich,	102	204	204 = 100 "		
1884	Bjerrum,	87	[87]	61 = 70.1 "	23 = 26.4 "	3 = 3.4 "
1884	Horstmann,	50	100	88 = 88 "	10 = 10 "	2 = 2 "
	Total,	901	1547	1356 = 87.6 "	77 = 5 "	114 = 7.3 "

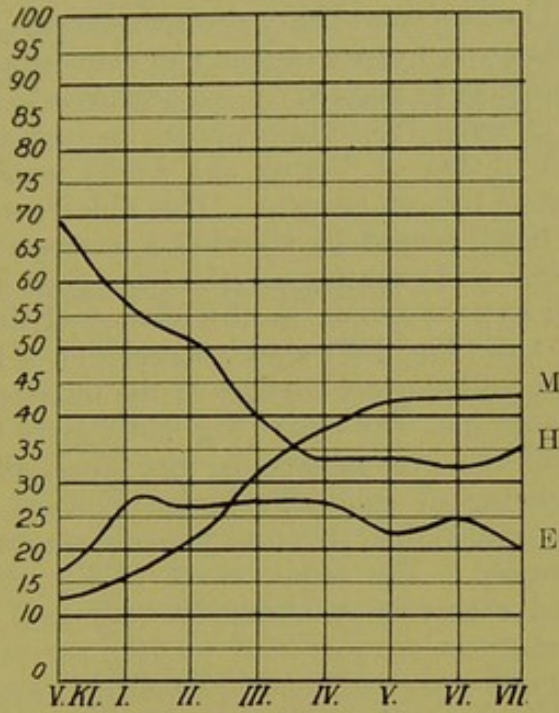
In considering this compilation, the extreme difficulty of the task must be remembered where it is necessary to rely absolutely on the ophthalmoscope for determination, whilst the child is constantly moving its head and eyes. In fact, absolute accuracy can be attained only by a thorough abolition of accommodation by the instillation of a strong mydriatic in the eyes of both the examiner and the examined. Owing to a want of attention to these precautions, it is probable that the above statistics contain a great overstatement of the amount of myopia. It must be remembered, however, that Jaeger attributes the prevalence of myopia to the greater curvature of the lens during the first two days of life.

As to the average refraction of the human eye during school-life, a very different picture is obtained. From the numerous examinations made on this subject, the author has selected for reproduction three tables by different writers, as giving a correct view of some of the best and most careful work on this subject:

In two (Figs. 246 and 247), the relative proportion of hypermetropia, emmetropia, and myopia in the different classes is given. In the other (Fig. 248), there is an attempt to indicate the number of manifest hypermetropes. The results agree, in so far as they

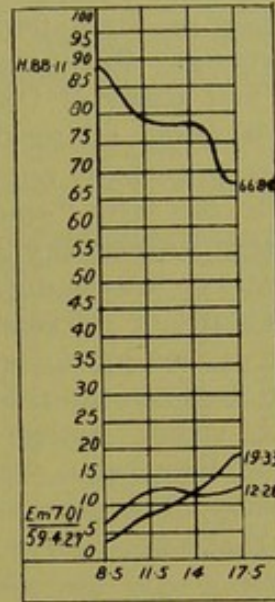
show a marked increase of the myopia and a decided diminution of hypermetropia during school-life, while emmetropia runs with compara-

FIG. 246.



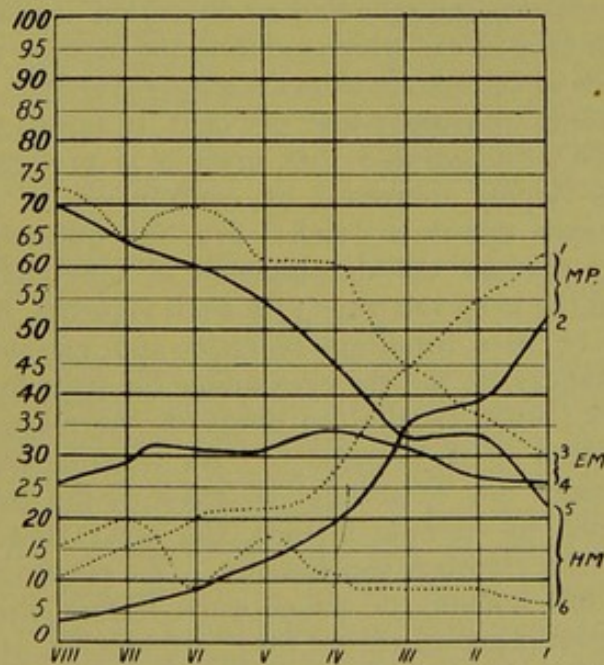
Relative proportion of M, H, and E.
(ERISMANN.)

FIG. 247.



Relative proportion of H, Em, and M.
(RISLEY.)

FIG. 248.



Relative proportion of M, Em, and HM. (CONRAD.)

tively little variation through the entire period. In all three diagrams, the figures on the left, indicate the percentages. Those at the foot of the vertical lines, show either the class or age of the pupils examined.

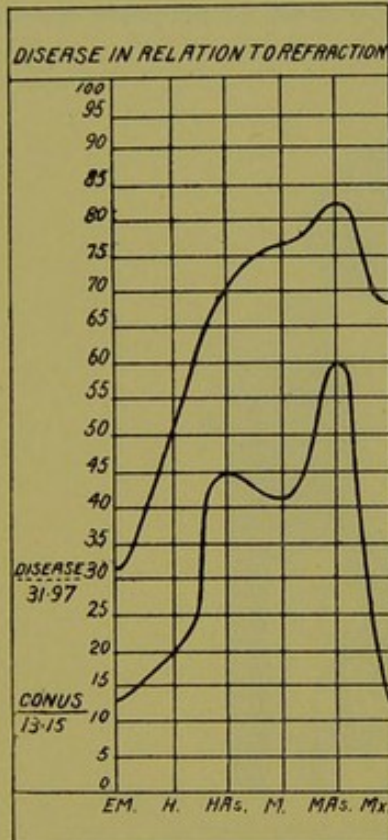
The grades and the ages of primary classes and youngest scholars are put on the left, and those of the oldest are placed at the extreme right. In Conrad's table, the punctate lines mark the refraction-curve as indicated by the test-letters, while the continuous black lines show the determinations by the ophthalmoscope. The two sets of curves are almost parallel in myopia, but their great variation in hypermetropia and emmetropia, shows how readily hypermetropia may be masked by the accommodation in the young. In the statistics of some other observers, as, for instance, in the first paper of Cohn, and in that of Loring and Derby, emmetropia is found taking the place of hypermetropia. This difference of result is principally apparent, being caused by allowing a pretty wide limit for the term "emmetropia," and counting all who have good distant vision without any manifest hypermetropia in this class. Risley¹ has given two interesting tables. One (Fig. 249), shows the relation of the various states of refraction to the pathological changes of the interior of the eye as seen by the ophthalmoscope. The other (Fig. 250), gives the relation between the refraction of the eye, asthenopia, and diminished acuity of vision. Among the pathological conditions, he has included all grades of disturbance, extending from retinal irritation to neuro-retinitis, chorioiditis, and chorioidal atrophy. The upper curve of Fig. 249, shows that while thirty-one and ninety-seven-hundredths per cent. of emmetropic eyes are affected, there is a rapid rise to fifty per cent. for hypermetropia, and to seventy-five per cent. for hypermetropic astigmatism. The same curve also shows a falling to seventy-four per cent. for mixed astigmatism, to eighty-one per cent. for myopia, and to eighty-seven per cent. for myopic astigmatism. Here the fall is probably due to the giving way and alteration of curvature in the cornea, which to some extent relieves the tendency to distention at the posterior pole. The second table (Fig. 250), which exhibits the amount of asthenopia in the various states of refraction, shows a steady rise from twenty-one per cent. in emmetropia to seventy-four per cent. in mixed astigmatism.

It having been demonstrated that myopia is produced during adolescence, and is largely increased by continuance of near-work, and also that a myopic eye is a "sick" eye, the question arises, What can be done to prevent the development of near-sightedness? The answer is: First, to keep the young in such vigorous health that their eye-tissues will be in a condition to resist any reasonable strain put upon them; secondly, to put the eyes under the most favorable circumstances for work; and, thirdly, to diminish the amount of work, or to temporarily stop it if necessary. As regards the first proposition, we must learn not to attempt to exact of the feeble, scrofulous, and those affected by chronic disease, the tasks that may be safely demanded from the vigorous and healthy. We should take care never to require the full amount of school-work from a child immediately after recovery from measles, scarlet fever, diphtheria, or other exhausting acute disease. Better, that six months of schooling should be

¹ Dr. Risley informs the author that this percentage is higher than that shown by his subsequent investigations, because in this series in one class in a dark school-room, every one of the eighty children had retinal irritation. In these tables, MAs, is equivalent to Am of Donders; HAs to Ah; and Mx to Ahm and Amh.

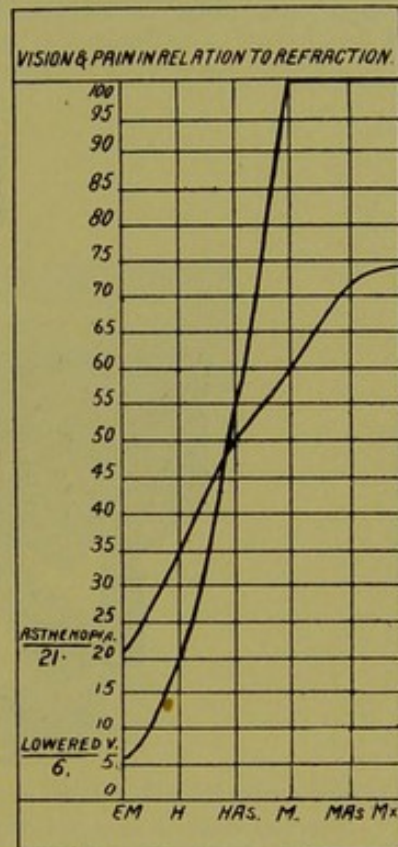
lost, and the child set back in a lower class, than that he should be encouraged to work until his eyes have entered upon the down grade of diminishing hypermetropia, or the still steeper decline of increasing myopia. Good food, fresh air, and exercise, with attention to the functions of the skin, the digestive organs, and the alimentary canal, should be insisted on; while, in addition, iron, quinine, and cod-liver oil, should be freely administered to the feeble. As regards the second proposition, the question is a much more complicated one, and it is

FIG. 249.



Pathological condition in relation to refraction.
(RISLEY.)

FIG. 250.

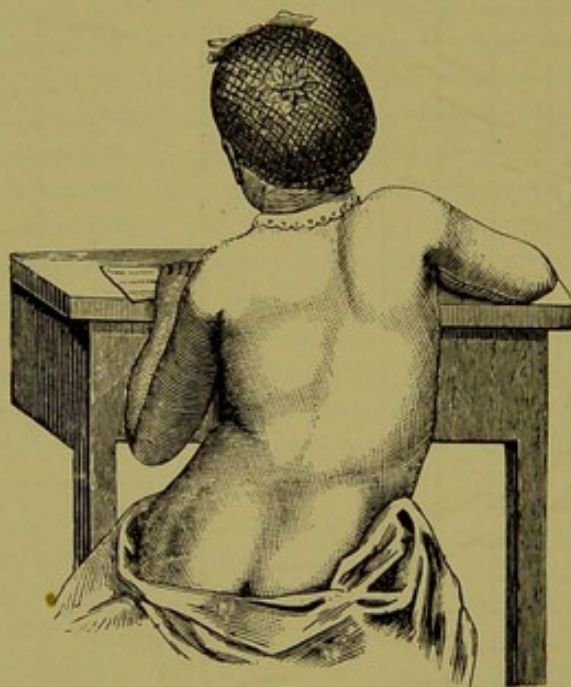


Vision and pain in relation to refraction.
(RISLEY.)

often out of our power to do much to improve the faulty hygienic conditions under which such young eyes are doomed to labor. The school-room should be well lighted and properly ventilated, and there should be some arrangement of the studies that will permit the tasks to be frequently interrupted by short intervals of rest, so that the eyes, after accommodation for reading or writing, shall be rested by relaxation of the ciliary muscles and the interni by looking at some distant object, such as a blackboard or a chart in the lecture-room. As a general rule, a school-room cannot have too much light, because, where it is excessive or falls in undesirable directions, it can be readily moderated and controlled by suitable window-shades, curtains, and screens. If there is too little daylight, it is not possible to replace it advantageously by any known means of artificial illumination. Wherever practicable, the strongest light should come over the left shoulder, so that in writing

the shadow of the hand shall not be in the way. If possible, there should always be windows in more than one wall, as, otherwise, the side away from the windows, if the room be a large one, will be insufficiently illuminated. When there is a choice, the best arrangement, in our climate, is a room with the main light coming from the north, and with the seats made to face properly-curtained windows looking east. A skylight in a slanting roof which faces the north, also furnishes a desirable situation for the entrance of light into a school-room. If practicable, side-windows should be used both for ventilation and for additional light. A southern exposure is bright, cheerful, and warm in winter, and the direct sunlight may, with care, be properly screened

FIG. 251.

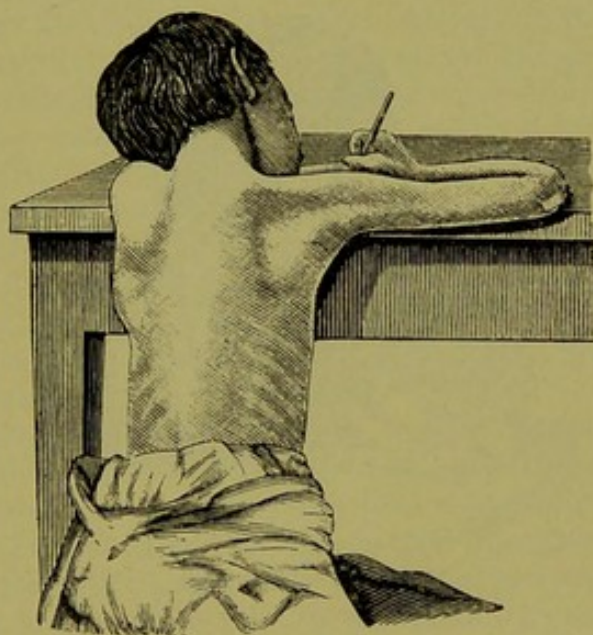


Improper position assumed upon account of badly contrived desk. (COHN.)

out, but the room is apt to become intolerably hot in summer. In situations not shadowed by trees or by other houses, one square foot of glass to every five square feet of floor-surface, is considered sufficient. This is a good general proportion for construction. In buildings already occupied as schools, perhaps the readiest test is to try to read small print in the darkest corner of the room on a dark day. When the light is insufficient, we can utilize it to the best advantage by coating the walls and ceiling of the room with some dead-white material. When an adjoining house comes close to the windows, its walls, if practicable, should also be whitened. When artificial light is used, it should, even if it be electric, be placed low and near the desk or table. The direct rays should be excluded from the eyes by means of porcelain or tin shades, the latter being painted white on the inside. With feebler illumination, such as that produced by gas or by the higher grades of oil, this position of the light is all the more important. One student's-lamp for every two pupils, is the minimum that should be allowed.

It is a familiar fact that in order to read even coarse print in twilight or in feeble light, we are obliged to hold it very near the eyes, thus obtaining large retinal images. At the same time, however, it is necessary to strain the accommodation and convergence in order to see such objects sharply. Stooping over work causes the neck to be bent forward, which interferes with the return circulation through the jugulars, thus damming up the blood in the head, eyes, and orbits; this tendency being further aided by the faulty position interfering with the full play of the chest and the proper expansion of the lungs. It is, therefore, very important that the height of the seat of the chair should be so proportioned to the stature of the individual occupying it, that his feet shall rest firmly either on the floor or on a foot-stool; while the height

FIG. 252.



Improper position assumed upon account of badly contrived desk. (COHN.)

of the desk-top, which should be sloping, should be so arranged that the work can be comfortably carried on, while the body is held erect, and the print or writing placed at a suitable distance from the eye. Figs. 251 and 252 show how badly proportioned school-furniture will tend to strain the eye by necessitating its too near approach to the work, and at the same time encourage the habit of leaning on the desk, which in some instances, especially in the feeble and scrofulous, will tend to produce spinal curvature. Fig. 253 shows a very ingenious head-rest, devised by Kallmann, so constructed as to prevent the pupil from unduly bending the head forward, and to compel him to sit straight. There is probably, however, no better corrective than the careful supervision of an intelligent teacher.

The print of all school-books should be large, the type broad-faced, and the ink black, so that even to eyes with slightly diminished acuity of vision, the letters will be readily legible. It is usually out of our power to alter or abridge the curriculum; but it is our duty to protest against the modern tendency to send children to school at too early an

age and to teach them too many branches, thus overburdening the mind, and unduly taxing and distending the soft eyes natural to this period of development and growth. Suitable recesses and sufficient exercise in the fresh air during daylight, are all-important, and should be insisted upon.

As myopia depends on the lengthening of the visual axis, we have no means of radical cure at our command. Our first endeavor, therefore, must be to prevent its production by careful attention to the hygienic rules above laid down. If the condition becomes once established, we should endeavor to arrest its progress by the strictest care of the eyes, which should be constantly protected by the employment of proper concave glasses, so as to render any necessary

FIG. 253.



Head-rest. (KALLMANN.)

use more comfortable and less dangerous to the patient. In the selection of a glass for distant vision, and still more so of one for habitual wear or for reading, great care, as shown on page 269, is necessary. This is so, inasmuch as a strong glass is often preferred upon account of the clear, sharp-cut images it gives of distant objects, and the improvement of vision caused by the diminution of the circles of diffusion, as the pupil contracts in its effort to overcome such an improper lens. Moreover, in many cases of progressive myopia, where the whole interior of the eye is in a state of chronic congestion, there is spasm of the ciliary muscle, which temporarily increases the real refraction of the eye, and gives the appearance of a higher degree of myopia.

If we give a glass in the slightest degree too strong, the myopic eye is converted into a functionally hypermetropic one, and consequently to get clear images on the retina, accommodation and convergence must be unduly strained. In testing the patient, therefore, across the room with the test-type, as shown in the chapter on the Determination of Errors of Refraction, the weakest glass which will give good vision, should be selected. Even then, the result is doubtful unless the glass which produces this acuity, corresponds in strength with the distance of the far-

point, as determined by the range of accommodation in the reading-test. As explained on pages 240 to 249, such examination should be controlled by one with the ophthalmoscope used as an optometer for the determination of the refraction-error, and as a guide to the condition of the media and the fundus. In all young people in whom the accommodation is still active, the eyes should be placed under the influence of a solution of atropia, duboisia, or hyoscyamia sufficiently strong to produce absolute loss of accommodation power. The weakest glass which, under these circumstances, gives the patient good vision, should be the one selected for use during the correction for distance. If any astigmatism be present, it should also be corrected. In cases where there is much retinal haze and chorioidal woolliness, it is doubly necessary to use mydriatics. Here, as well as in cases with spasms of accommodation, repeated instillations should be made on successive days, as explained in detail on page 263, till it is sure that the eye is in a state of rest. Under this treatment, the true refraction of the eye is not only ascertained, but the congestion of the retina and chorioid is diminished. A persistence in this method of treatment, re-enforced by abstinence from all near-work, will often result in the interior of the eye becoming quiet and losing all signs of retinal and chorioidal congestion. Where mydriatics are used, the eyes should be protected from excessive light during the entire period of pupillary dilatation, by smoked glasses. When by repeated testing, the lens which makes parallel rays sufficiently divergent to appear to come from the far-point is found, the full correction has been ascertained.

The full correction thus determined, the question arises, How shall the patient be allowed to use it? In many cases, where the myopia is slight, as, for example, where it varies from one-fourth to three-fourths of a diopter, he will not, as a rule, wish to wear the glass habitually. In such instances, the patient may safely be allowed to wear it as a lorgnette, or eye-glass, on any occasion when it is desirable to see distant objects, and to read and write without it if there be no astigmatism. In myopia ranging from one to three diopters, the patient, if he be young, the acuity of vision be perfect, the range of accommodation suitable to his age, and the balance of the external eye-muscles good, may be allowed to convert his eye into an optically emmetropic one, by wearing his correcting-glass habitually, both for near-work and for distance. When the patient is older and the grade of myopia is from two to four diopters, it is generally best to let him use his full correction for distance, and to read uncorrected at his far-point. Where there is insufficiency of the internal recti, the use of prisms with their bases inward to diminish the strain on convergence, is often advisable. If the occupation of the patient makes it necessary for him to see distinctly near objects lying somewhat farther off than his uncorrected far-point, a partial correction should be given to enable him to do this. For example, if a myope of three diopters finds it necessary to read music-notes at twenty-four inches, he should be provided with a glass of -1.50 D. for that purpose. Myopes of higher degrees than four diopters, are almost always better off for having a correction both for near-work and for distance, even though they are subjected to the inconvenience

either of carrying two pairs of spectacles or of wearing split or bi-focal glasses. In these cases, the glass for near-work is determined by finding the distance at which the work is to be done, and subtracting a corresponding number of diopters from the strength of the distance-glass. For instance, if a myope of three diopters desires to read at twelve inches, a glass of -3 . D. may be given. If his work be at eighteen inches, a glass of -4 . D. should be employed. Many myopes of high grade who desire to avoid the necessity of continually changing glasses, prefer to wear their reading-glasses habitually, becoming accustomed to the lessened degree of haziness of objects beyond their reading-distance as compared with that produced by their unassisted eye. Such patients may be permitted to do this without harm to their eyes, as they thus, to some extent, avoid the serious inconveniences of great reduction of the size of the images produced by strong lenses, and the distortion of objects arising from prismatic action of such lenses as soon as their optical centres cease to be looked through.

Insufficiency of the interni in myopia is often a cause of asthenopia. This is in measure due to the elongation of the eyeball and its consequent greater prominence in the orbit, making it harder for the straight muscles to move the globe. Further, as the far-point lies close to the eye, the interni are obliged to work harder to converge the visual axes sufficiently to obtain binocular fixation. Moreover, as such eyes see distinctly at their far-points without accommodation, the internal recti muscles are deprived of the aid which is usually afforded by the simultaneous innervation of the ciliary muscle. There is, therefore, a decided tendency to divergence and divergent strabismus. In marked cases of insufficiency, crossed double images for both near and distance are found when vertical diplopia is produced by a prism. When the insufficiency for distance amounts to ten or twelve degrees, and that for reading distance to a correspondingly larger amount, great relief of the asthenopia is often obtained by dividing one or, if necessary, both of the externi. The division of the externi was supposed, by Graefe, to be a means of stopping progressive myopia. Apparently it sometimes succeeds, but it often fails to produce this result. Lesser degrees of insufficiency are frequently satisfactorily remedied by decentring the glasses, so that their centres shall be farther apart than the centres of the pupils; the action of a prism with its base inward being thus practically obtained. In many cases of high myopia, especially where there is marked diminution of the acuity of vision, it is best for the patient to relinquish all attempts at binocular vision with reading-glasses, and to use the eyes alternately. High-grade myopes readily accustom themselves to this, and, availing themselves of their tendency to divergence, hold the book toward the side of the better eye, thus reading for hours without difficulty or any strain on either the interni or ciliary muscles. Of course, the constant use of the eyes in this manner, augments the tendency to divergent squint. High myopes should avoid all excessive physical exertion, as well as any prolonged stooping or straining, because such procedures flush and congest the eye, and thus augment intra-ocular pressure and tend to produce retinal detachment in predisposed eyes. The congestion of myopic eyes often causes a most unpleasant feeling of tension

and burning. This may be much relieved by washing the lids with hot water freely several times daily. The circulation in the orbit and the anterior portion of the eyeball is thus stimulated, and any local congestion is relieved.

ASTIGMATISM.

In the chapter on Physiological Optics, we have seen that if an emmetropic eye be taken as representing the optical normal standard, there are but two variations from this state of refraction. One is where the principal focus falls in front of the retina, and the other is where the cone of rays, if continued, would come to a focus behind the retina. If attention be turned to the defects of the lenses of the eye, we find that there are, as described on page 151: 1, spherical aberration; 2, chromatic aberration; and 3, irregularity of radius of curvature. Either of the last two, is of such a nature that homocentric light falling on the lens, no longer remains homocentric. Instead of all the rays being again gathered to a single focus, the lens has two principal foci, one for the more bent, and the other for the less bent rays. This condition may also be produced by a want of the proper relative positions of the optical centres of the combined lenses of the eye. Whewell designated these effects as *astigmatism*, to express the fact that homocentric light is not gathered to a central point or focus.

The first variety, in which there is unequal curvature in any one meridian, is called *irregular astigmatism*. It is probably universal in the human eye, causing points or disks of light to appear to have irregular projections from them; in a word, to look "star-shaped." "Stars," therefore, in all languages, have appellations of synonymous meaning, showing the universality of the optical defect. Careful ophthalmometric measurements have demonstrated that the seat of this variety of astigmatism is usually in the lens. When it is in the cornea, it is generally the result either of irregular contraction or cicatrization from previous ulceration, or of softening and stretching from some pathological process, such as conical cornea.

Where there is a difference in the curvature of different meridians, there is *regular astigmatism*. This is usually due to asymmetry of the cornea. It is present in all eyes. Although there may be a variation of half a millimeter in the radius of curvature of different meridians, nevertheless there still may be normal acuity of vision (5/5). In consequence of this, Donders reckoned even eyes with an astigmatism varying from $\frac{1}{100}$ to $\frac{1}{60}$ as normal; giving the following variations as consistent with emmetropia: radius at 105° , 7.36 millimeters; at 15° , 8.28 millimeters; at 90° , 7.43 millimeters; at 180° , 8.38 millimeters; at 75° , 7.62 millimeters; and at 165° , 8.17 millimeters.

Later experience, however, has proven that although under this definition many asthenopic cases would be classed with emmetropia, yet the asthenopic symptoms are relieved by correction of astigmatism of $\frac{1}{144}$ (0.25 D.), or of $\frac{1}{72}$ (0.50 D.); such corrections often increasing vision to 5/4 or 5/3.

When even emmetropic eyes are carefully examined, it will be found

that the vertical meridian is usually more sharply curved than the horizontal, and that therefore fine vertical and fine horizontal lines are not seen sharply at the same distance. It will also be found that in the immense majority of eyes, horizontal lines must be approached more closely than vertical ones, in order to be seen with equal distinctness. A point of light outside of the range of distinct vision, is seen as a vertical oval, while if situated inside of it, the horizontal diameter is the longer. Rays of light striking an astigmatic lens will be most sharply bent by the most curved meridian, and will come to a focus nearer the lens than the rays which pass through the meridians of less curvature. If, therefore, a cone of homocentric light be thrown through such an astigmatic lens (arranged, as usually the human eye is, with its most curved meridian vertical), and a ground-glass screen be brought close behind it and gradually removed from it, we shall, as explained on page 152, have a horizontal oval, then a horizontal line of light, followed by a circle and a vertical line of light; the interval between the two foci being known as *Sturm's focal interval*.

It is thus evident that the inequality of meridians producing astigmatism, may take place either in a functionally emmetropic eye or in a hypermetropic or a myopic one. In the first form, one meridian will be emmetropic and one ametropic, the latter being either too much or too little curved; that is, it may be either myopic or hypermetropic. If the ametropic meridian be hypermetropic, a convex cylindrical lens with its axis made parallel to the emmetropic meridian and its curve situated in the hypermetropic meridian, will correct the defect. If the ametropic meridian be myopic, a concave cylinder with its axis parallel to the emmetropic meridian and its curve in the myopic meridian, will be required. When astigmatism occurs in hypermetropia or in myopia, the least defective meridian may be made emmetropic by a proper convex or concave spherical glass, while the difference between its curvature and the curvature of the most ametropic meridian, may be corrected by the addition of a cylinder that is equal to the difference between these two curvatures. The ellipses of diffusion may thus be gotten rid of, and the homocentric light gathered to a single focus. When one meridian is hypermetropic and the other is myopic, crossed cylindrical lenses, the axis of the convex cylinder being parallel to the myopic meridian and the axis of the concave cylinder parallel to the hypermetropic meridian, will correct the astigmatism and bring the rays to a focus on the retina. The defect may also be corrected by a combination of a spherical and a cylindrical glass. To do this, a concave spherical of sufficient power to correct the myopic meridian can be selected, and a convex cylinder of a strength equal to the corrective lenses of both meridians added together to it, can be added, or a convex spherical to correct the hypermetropic meridian, to which a concave cylinder equal to the combined refractive power of the two meridians is added, can be employed. Where one meridian is emmetropic and the other is either myopic or hypermetropic, the condition is termed *simple myopic astigmatism* or *simple hypermetropic astigmatism*. When both meridians present the same kind of ametropia, varying only in degree, it is designated either as *compound myopic astigmatism* or *compound hyper-*

metropic astigmatism. When one meridian is myopic and the other is hypermetropic, the condition is called *mixed astigmatism*.

Having studied the ellipses of diffusion produced in astigmatic eyes, their effect on vision of horizontal and vertical lines, can be considered. To see a horizontal line clearly, every ray of light passing through the vertical meridian of the eye, must come sharply to a focus in its retinal image, while the ovals of diffusion passing through the horizontal meridian, will blur the image but little, because in this direction, the ovals lap one another and are lost in the line of light. To see a vertical line distinctly, every ray coming through the horizontal meridian of the lens must focus sharply, and the overlapping of the vertical diffusion-ovals coming through the vertical meridian is lost in the continuous light-line of the horizontal rays. We have seen that in the vast majority of human astigmatic eyes, the strongest refracting meridian is vertical, and that the rays in this meridian form a horizontal linear focus in front of the focal point of their fellows, while farther back, after their crossing and divergence, a vertical line of light from the less bent rays in the horizontal meridian is obtained. Therefore, in every hypermetropic eye in a state of accommodative relaxation, distant horizontal lines will be seen more sharply than vertical ones, while in the passive myopic eye, vertical lines will be seen more distinctly than the horizontal ones. Where, by strain of accommodation, the hypermetropic eye makes itself emmetropic, the vertical lines will be seen the most distinctly. As has been explained in speaking of the lines, distant points of light will, where the most strongly refracting meridian is vertical, appear vertical-oval in myopic and emmetropic eyes, and horizontal-oval in hypermetropic eyes, in a state of rest. On these two facts, depend most of our tests for the presence of astigmatism.

The ellipses of diffusion produce the appearance of distortion and blurring of print to astigmatic eyes. As it is impossible for such eyes to see simultaneously the strokes of letters which are at right angles to one another with absolute sharpness, the astigmatic individual, therefore, makes characteristic errors in reading the Snellen test-card, mistaking C for O, O for Q, F for P, Z for E, B for R, etc. The blurring of the image also greatly diminishes the range over which the patient can read small type. In many cases, the object can be deciphered only at some one distance where, by straining the accommodation to the utmost, a large retinal image is obtained, and by diminishing the size of the pupil, the ellipses of diffusion are lessened. This combined intra-ocular muscle-effort may cause symptomatic conjunctivitis, redness of the lids, congestion of the interior of the eye, a feeling of weariness and sleepiness, and, finally, pain in the eye, in the temple, and in the forehead, which, at times, shoots into the back of the head. Such cases, besides making characteristic mistakes in naming letters of Snellen's five or six meter table, assert, that certain radiating lines in some one of the astigmatic charts, hung at the same distance, are the most plainly seen. If a stenopæic slit of one-half millimeter in width be placed before the eye so that the opening shall be parallel to the line best seen on the dial-plate, and if attention be directed to the letters, the visual acuity will be found to be less with the slit so situated, than it would be were the slit placed at

right angles to this direction. If the patient is advanced in life, or if his accommodation be paralyzed by a strong mydriatic, the glass which brings vision to the normal standard for each meridian can be found; the difference between the glasses chosen in the two meridians, giving the astigmatism. If the eye is not myopic, it can be made so by a convex glass, and the foregoing method of examination can be repeated at any artificial far-point desired, by causing the eye to look at finer radiating lines or to gaze at parallel fine-drawn wires. By using the radiating lines constructed for testing at five or six meters' distance, we can also determine what spherical lenses make the line which has been best seen by the naked eye, sharpest, and what one brings out distinctly the line at right angles; the difference giving the amount of astigmatism. These findings can be confirmed by correcting the general ametropia, and then determining what cylinder renders the lines all equally sharp.

High degrees of regular and irregular astigmatism can be recognized at the first inspection of the patient, by observing the image of the window-bars on the cornea, or, better, by the use of the disk of Placido. These tests, as explained on pages 238 and 254, are everywhere accessible. In the latter test, if the cornea is astigmatic, the circles appear as ellipses with their long diameters parallel to the least curved meridian. In conical cornea, the distortion on the sides of the cone is striking and characteristic.

The ophthalmometer, which rendered such brilliant services to the study of refraction in the hands of Donders and Helmholtz, still offers a most reliable method of measuring the curves of the cornea. Of late years, Javal and Schiötz have invented an admirable contrivance (*vide* p. 256), and every eye-surgeon hoped to find in the use of this instrument, an invaluable aid in correcting asthenopic eyes. In the author's hands, however, the results obtained by it have usually failed to agree accurately with those arrived at by the use of test-lenses; the variation often amounting to one-half or three-quarters diopter, and at times even as much as one diopter. Burnett,¹ Bull (of Paris), and Story² have all published detailed accounts of the use of the instrument in considerable numbers of cases, and unite in admitting these discrepancies, although they consider it a valuable method of controlling the results arrived at in other ways. Of course, part of these discrepancies may be due to an irregularity in the curvature of lens, or an obliquity in its position, which may either increase or diminish the total astigmatism of the eye. It is probable, however, that at least part of the discrepancy is dependent upon inherent defects in the instrument itself. Thus Oswalt³ claims that, owing to the manner of its construction, the results obtained by it are necessarily erroneous, and that the real corneal astigmatism amounts always only to three-fourths of that indicated by the instrument. He further states, that the ophthalmometer of Leroy and Dubois affords much more accurate results. With this instrument, however, the author has not had any experience.

The appearances of the corneal images of Placido's disk when used

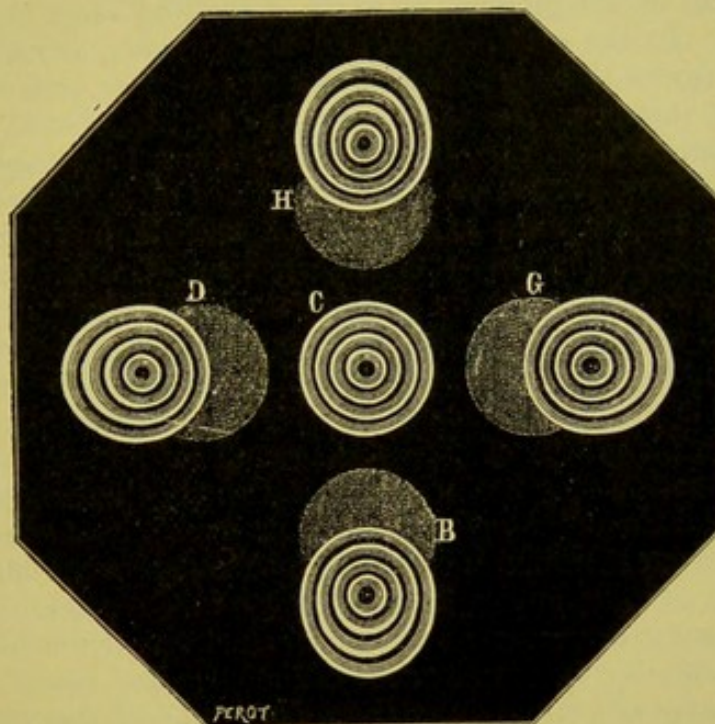
¹ Journ. Amer. Med. Assoc., Chicago, Sept. 8, 1891.

² Ophthalmic Review, July, 1891.

³ Revue générale d'Ophthalmologie, 1891, tome x., No. 3, p. 115.

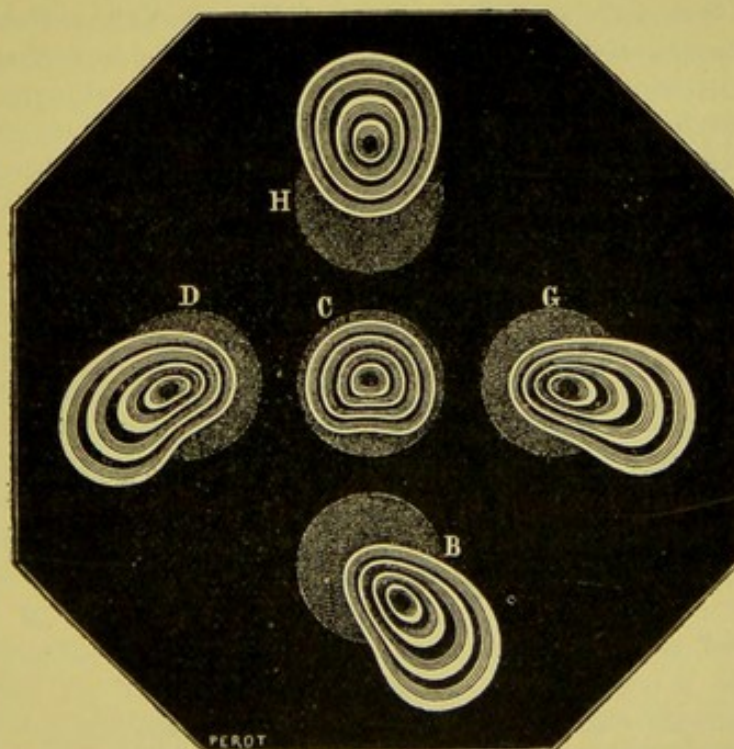
in Javal's optometer, are well shown in the accompanying figures. Fig. 254 exhibits the images of a normal cornea and the distortion which exists in the peripheral portions. Fig. 255 shows the distortion of the images

FIG. 254.



Placido's disks as they appear at various portions of an approximately normal cornea. (JAVAL.)

FIG. 255.



Placido's disks as they appear in conical cornea. (JAVAL.)

in a case of conical cornea. At times, as spoken of on page 239, the knowledge of the fact that tilting of strong spherical lenses will produce artificial astigmatism may be used as an additional diagnostic means, by studying the angles at which the patient has bent his spectacle-frames in efforts for betterment of vision.

Every case of astigmatism is worth correcting when it gives rise to asthenopia. In the weak, sickly, and neurasthenic, asthenopia is produced by degrees of astigmatism which would pass unnoticed in the healthy and vigorous. In such cases, the system should be built up with appropriate food, rest, tonics, exercise, and necessary work made bearable by the correction of even low grades of the affection. High grades are so distressing to the patient, and diminish the acuity of vision so much, that they compel correction. Uncomplicated, simple myopic astigmatism or simple hypermetropic astigmatism is corrected by a concave or convex cylinder, with its axis placed at right angles to the faulty meridian. Compound myopic astigmatism or compound hypermetropic astigmatism is ordinarily corrected by a plano-spherical glass, on the plane side of which is ground an appropriate cylinder. Mixed astigmatism may be corrected by crossed cylinders, one of which is concave and the other convex; or, if preferred, by a sphero-cylinder lens in which one meridian is corrected by an appropriate spherical lens, and the one at right angles by a cylinder which must be made sufficiently strong to overcome the additional ametropia artificially produced in this meridian by the employment of the spherical lens.

As the astigmatism produced by a flattening of the corneal tissue from cicatrization after operation—for instance, cataract-extraction and iridectomy—generally takes place in the meridian at right angles to the direction of the length of the incision, either a slight antero-posterior tilting of the spherical lens in the same meridian, or an additional cylinder with its axis at right angles to the meridian, will be found of greater service than the employment of the ordinary correcting spherical lens placed in its usual position. When, owing to presbyopia, or to high degrees of myopia or hypermetropia, we are compelled to give reading as well as distance glasses, the cylinder should, as a rule, be of the same strength and be placed at the same angle in each. Sometimes, however—as, for example, in compound myopic astigmatism or in mixed astigmatism—it is desirable to correct the defect by increasing the refraction of the weakest meridian. To do this, an appropriate convex cylinder, with its axis placed parallel to the most curved meridian, should be used. In ordering correcting-glasses, it must be remembered that, in some cases, owing to the distortion of the cornea, the visual axis in reading or other near-work, passes through a corneal area which is curved differently from that which is encountered in the primary position of the eye, and that, therefore, the correcting-cylinder for distance will not always be appropriate in the reading-glass.

CHAPTER XIX.

CATARACT.

IN modern ophthalmology, the word "cataract" has come to mean an opacity of the lens, being applied to any want of transparency, whether partial or complete. It may be congenital, or it may occur at any time during the life of the individual. It is often produced by wounds of the lens or of its capsule (see chapter on Injuries of the Eye), or may be caused by any disease of the eye that seriously interferes with the nutrition of the lens. The most common form of uncomplicated cataract is that occurring in old age; and to understand its pathology it is necessary to consider the growth of the lens. At birth this organ is soft, elastic, and perfectly transparent—so transparent, and so nearly of the same index of refraction as the aqueous humor, that in children, it is often difficult, and sometimes impossible, to demonstrate its presence by means of oblique light. In the adult, the striation of the cortical substance is readily visible, and in middle life the nucleus can be easily recognized. The gradual growth and hardening of the nucleus are accompanied by change of its color, causing it to appear of a pale straw-yellow in middle life, and darker as age advances. The layers of the lens adjoining the nucleus gradually increase in darkness and hardness, causing a corresponding loss of elasticity, with consequent decrease in the power of accommodation. When the normal increase of the nucleus at the expense of the cortical substance ceases, the first step is taken toward the formation of cataract. Opacities, usually commencing at the equator, form in the anterior and posterior corticals, and gradually encroach on the pupillary space in a more or less pyramidal form. This change is accompanied by a swelling of the cortical substance, which pushes the iris forward and narrows the anterior chamber. The anterior fibres become mother-of-pearl-like in appearance, and the pupillary space appears gray. Gradually the gray tint becomes tinged with yellow, the mother-of-pearl glitter disappears from the anterior surface of the lens, and the visible portion of the lens in the pupillary space, assumes a hue that resembles yellowish wax. The lenticular swelling disappears, and the anterior chamber resumes its normal depth. At this stage, vision has generally become so impaired that the patient can see only the motions of the hand when it is held between him and a light. When a lens has resumed its normal size and has become evenly opaque to the capsule, the cataract is said to be ripe. As the cataract becomes older, the cells of the anterior capsule grow larger and undergo degeneration, forming dense whitish spots on the surface of the lens. The anterior cortical commences to liquefy and to absorb, and, owing to fatty degeneration and the formation of cholesterine crystals, again becomes whitish, and even

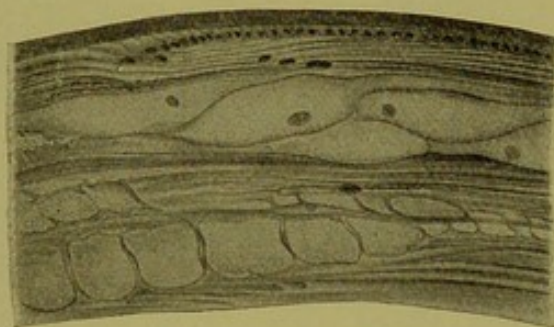
milky in appearance. In some lenses, this softening process goes so far that the yellow nucleus moves freely in the liquefied cortical, settling to the bottom of the capsular sac when the eye is at rest. This is known as *Morgagnian cataract*. Rarely, this process continues so long that the yellow nucleus moves in an almost clear yellowish fluid in the thickened capsule. In such cases, there is an improvement in the vision. Other forms of degeneration are occasionally found, the cataractous lenses, for instance, becoming denser and harder, and finally undergoing calcification. In such cases, owing to accompanying changes in the chorioid, vision is usually abolished. Senile cataract invariably attacks both eyes, although it rarely comes on simultaneously in each; a period of several months often elapsing before the second eye is affected. When the pupils of old people are dilated, and careful search for lenticular opacities is made with the ophthalmoscope, it is so frequent to find slight pyramidal shoots in the periphery of the lens, that the term *gerontoxon lentis* has been used—a condition that has been compared with the arcus senilis of the cornea. Indeed, in pre-ophthalmoscopic times, Walther declared that cataract was not a disease, but was a sign of old age, which was existent in every one to whom death did not come prematurely. Notwithstanding the frequency of these peripheral lenticular striæ, it is doubtful whether there is ever what, strictly speaking, can be called *primary cataract*, and whether, in all cases, these striæ are not a symptom of previous pathological alterations in the vessels of the ciliary processes and chorioid. Such slight opacities in the periphery of the lens are often stationary for a long time. Jaeger has noticed a considerable clearing up of them in two cases, but has never seen them totally disappear. Becker speaks of cases in which they remained unchanged for fifteen years, and cites one instance in which he witnessed their complete disappearance in a patient of sixty years of age.

In many instances, cataract is secondary—a manifestation of imperfect nutrition of the lens caused by foregoing pathological changes in other parts of the eye. The forms of it, such as are frequently found after separation of the retina, extensive chorioiditis, pigmentary retinitis, and glaucoma, are familiar examples. That endosmosis continues, even in cataractous lenses, is shown by the experiments of Bence Jones, where he injected solutions of carbonate of lithium subcutaneously into the tissues of patients who were soon to be operated on for cataract. In these cases, however, it was found that, although the lithium salt was demonstrable in all other tissues in a few minutes' time, it was not to be found in all portions of the lens until after two and a half or three hours. In those cases in which operation was deferred until the fifth day, the drug had commenced to disappear from the lens. Where the eyes were not operated upon until the seventh day, scarcely a trace of the drug could be found. In animals, it was found in the normal lens in twenty to thirty minutes after injection. From these experiments, it appears that while endosmosis in the cataractous lens still continues, it is much slower than it is in healthy tissues. The fact that sugar has also been demonstrated in the lens in diabetic cataract, offers additional proof of the continuance of endosmosis.

More recent experiments by Deutschmann, show that after the administration of iodide of potassium to rabbits, this drug was first demonstrated and in greatest quantity near the equator of the lens, and between this location and the posterior capsule. Magnus has produced cataract by feeding naphthalin to animals, and has always found the effects most marked in the lens-matter at the equator and just behind it. In support of this, clinical observation in man points to the same region of the lens, as that in which most active nutritive processes take place. Further, Fuchs mentions that whenever he has been able to observe any clearing of cortical opacities in traumatic cataract, it has been in the posterior layers.

The pathological changes in cataractous lenses are characteristic. As has been intimated, the commencement of cataract seems to be preceded by a stoppage of growth in the lens-fibres and a consequent cessation in the increase of the size of the nucleus. The fibres constituting the nucleus

FIG. 256.



Jointed bamboo-like spaces between the cortical fibres. (BECKER.)

become denser, more yellow, and more homogeneous. They also lose their serrated outlines. This stoppage of growth seems to precede for some time any loss of transparency. The fact that Priestley Smith has shown that even when lenses are but slightly cataractous, they are smaller and weigh less than transparent lenses at the same time of life do, offers further evidence. As the lens becomes more cataractous, the nucleus gradually shrinks, causing the cortical fibres to separate irregularly from one another. The spaces thus formed, become filled with an albuminous fluid, which is at first transparent, but afterward becomes coagulated. Sometimes, the fibres form continuous masses which are contracted at points, giving rise to a jointed alga or bamboo-like appearance, as shown in Fig. 256.

Later, the lens temporarily imbibes water and swells, but as the cataract becomes older, it diminishes in size. At this stage, oil-globules, cholesterine crystals, and granular detritus, form from the degenerating lens-fibres and the albuminous coagula between them. These changes are most marked in the cortical substance, the nucleus remaining comparatively clear.

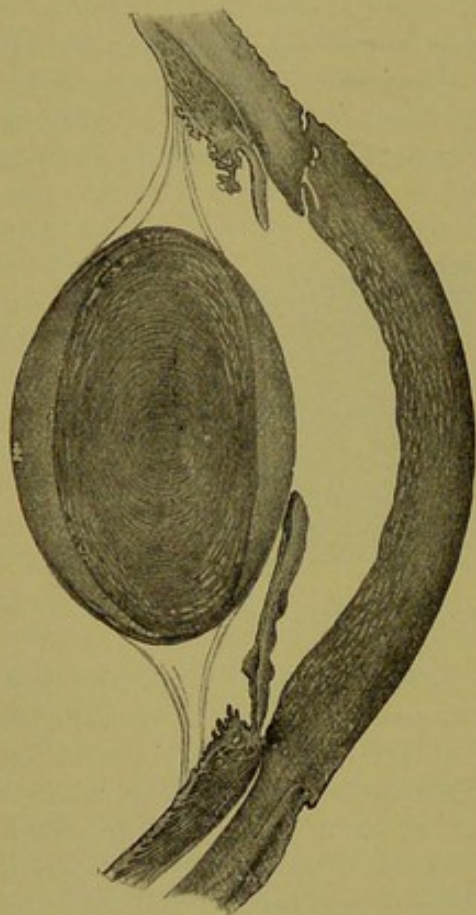
Fig. 257 shows the œdematous cornea and partly closed wound in a case where preliminary iridectomy had been performed on a patient with diabetes mellitus. The patient soon afterward died of diabetic coma. The lens exhibits the shrinking of its substance, the interspaces between

the fibrillæ in the anterior and posterior corticals, and the layer of albuminous material between the capsule and the cortex.

Fig. 258 shows a section through a Morgagnian cataract where the comparatively clear and resistant nucleus has fallen out of place and is surrounded by the remnants of the degenerated cortical material.

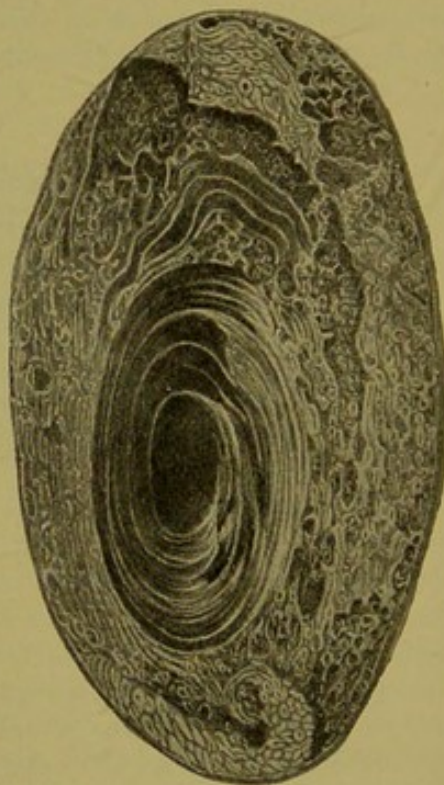
Both this figure and Fig. 259, show some of the formative changes which take place in degenerating lenses, and which, in these instances, consist mainly in the production of colloid masses and large vesicular,

FIG. 257.



Edematous cornea and partly closed wound following preliminary iridectomy in a patient with diabetes mellitus. (BECKER.)

FIG. 258.




Section through Morgagnian cataract. (BECKER.)

nucleated cells near the equator of the lens. The other changes of this character, consist mainly of proliferation of the epithelium under the anterior capsule, which, by pressure, forces its way backward. When the equatorial lens-fibres have been partly or entirely destroyed, the growing cells push their way backward till they sometimes form an epithelial lining for the entire posterior capsule.

Diabetic cataract. It has long been noticed that cataract is found with unusual frequency in diabetic patients. Graefe considered that it occurred in about one-fourth of all such cases. Gerhardt, however, who examined one hundred and fifty diabetics, found only six affected with the disease—about 4.28 per cent. From the experiments of Kunde,

Kuhnhorn, Mitchell, and Deutschmann, it appears that injections of large quantities of salt or syrup into the tissues of lower animals, will cause opacity of the lens. This is probably due to the abstraction of water from the substance of the lens, and interference with endosmosis and nutrition. The fact that, in the case of frogs, the lenses again become transparent after the animals have been allowed to remain in water for several hours, tends to confirm this view. The rare but well-authenticated instances of the spontaneous disappearance of diabetic cataract in man, would appear to serve as additional evidence in sup-

FIG. 259.



Formative changes in a degenerating lens. (BECKER.)

port of this statement. In these instances, the clearing up of the lens-substance coincided with an improvement in the general health of the patient and with a diminution of the amount of sugar in the urine, as shown by Seegen and Tannahill.

Nephritic cataract. It is quite common to encounter opacities of the lens in the advanced stages of Bright's disease, thus causing many writers to speak of nephritic or *albuminuric cataract*. It is doubtful whether disease of the kidneys has any specific action on the production of cataract further than through the general impaired nutrition caused by it, and the tendency to œdema of the lids, face, and orbital tissues, which may hinder, to some extent, lymph-circulation within the eye. Only a very small percentage of the cases of ripe cataracts which have presented themselves to the author for operation, have had either casts or albumin in the urine.

Rothmund has reported a series of curious cases of hereditary skin diseases accompanied by cataract. Although Mooren asserts that chronic skin eruptions may favor the development of cataract by causing creeping inflammatory processes within the eye, yet the usual diseases of the skin do not appear to produce lenticular opacity. Foerster thinks that chronic skin affections may favor the development of marasmus, thus giving rise to cataract by alterations in the nutrition of the lens. Ergotism, also, is said to produce cataract.

Posterior polar cataract is very common in chorioidal affections. Both anterior and posterior cortical opacities are found almost without exception in cases of pigmentary retinitis of long standing, the cataract often becoming complete in the later stages of the disease. In some instances, dissection shows that the opacity is primarily seated either in the fossa patellaris or in the vitreous immediately behind the lens. Later, correspondingly situated posterior cortical opacities form, which in time, often spread throughout the lens. As posterior polar cataracts, even though of limited extent, are situated in the visual axis, they are very annoying to the patient. In such cases, the progress toward general involvement of the lens with complete ripening of the cataract, is often exceedingly slow.

Congenital cataracts and the cataract of infancy. The former are frequently unnoticed until some time after birth. They are often accompanied by nystagmus and partial atrophy of the optic nerve. That form which is designated as *axial cataract*, in which a spindle-shaped opacity runs antero-posteriorly through the lens, is very frequently accompanied by these defects. When the opaque spindle is narrow, regular in shape, and occupies only a part of the pupillary area, it may sometimes interfere so little with vision as to escape detection in early life. When it is sufficiently thick to obscure most of the pupil, or if it is so irregular in shape as to cause increased diffraction of light, it very much diminishes the acuity of vision. Another common form of congenital cataract is the so-called *zonular cataract*. The first description of the anatomy of this variety was given by Jaeger. In this form, the nucleus of the lens remains clear, and is surrounded by an opaque band or zone, outside of which there is clear lens-substance. Arlt, looking on such cases as acquired, has called attention to the fact that they are frequently subject to convulsions in infancy. Horner has shown that zonular cataract is often accompanied by horizontal striæ on the enamel of the teeth, and other manifestations of rhachitis. J. Arnold has demonstrated that the development of the enamel of the teeth and that of the layers of the lens affected in zonular cataract, occur at the same period of foetal development.

Sometimes there are no other opacities in the lens. At times, radiating striæ can be seen extending outward from the opaque zone. In the latter cases, it is not common to find the lenses becoming completely opaque as the patient becomes older, although in some instances—usually in those in which no peripheral striæ exist—sufficient vision may be retained to allow the subject to perform many sorts of coarse manual labor, and to read, laboriously, large print. The opaque zone always diminishes the elasticity of the lens. Becker states that there is never

more than the twentieth part of normal accommodation in such patients.

Total congenital cataract is frequently hereditary. It usually rapidly undergoes degeneration and often shrinks materially. At times, anterior synechiæ, which are probably due to inflammation during foetal life, are found.

In the variety which forms in adolescence, it may be concluded that the more bluish the lens and the deeper one can see into its clefts with focal illumination, the softer is the cataract. Degenerated cataracts are often milky and semi-fluid, becoming denser and more opaque in their lowest portions; the heavier portions naturally settling to the bottom of the lens-capsule when the patient is erect and quiet. In congenital cataracts, the capsule is often unduly tough, while the zonula is less resistant, causing such lenses to dislocate readily in attempts at dissection.

Capsular cataracts. It has been mentioned that in most over-ripe cataracts, there is a formation of opacities in the capsule. This is due to a proliferation of the cells which underlie and form an essential part of its anterior portion. Wedl and Becker have both seen such cell-growth taking place and projecting into the lens-tissue proper, while the lenticular substance was transparent. Fig. 260 represents such a capsular cataract with its proliferation of the capsular cells, which have invaded the true lens-substance.

FIG. 260.



Capsular cataract. (BECKER.)

This has been described by Iwanoff as *phakitis*. It is frequently accompanied by an inflammation of the iris and chorioid, and a development of bloodvessels on the anterior surface of the capsule.

Central anterior capsular cataract is generally the result of a perforating central ulcer of the cornea. When the aqueous escapes in such cases, the lens is pushed against the opening, and, as the wound heals, the part of the capsule thus brought into contact with the cornea, becomes covered with exudation. When the corneal wound is healed, the aqueous reaccumulates, and the lens is gradually pushed back into place, leaving a layer of exudation on the anterior capsule. Sometimes, careful examination will show a thread-like band that runs from the capsular opacity to the corneal leucoma. In either case, this process leads to a disturbance of the nutrition of the capsular cells which underlie the exudation, causing them to proliferate and push the opaque portion of the capsule forward into the anterior chamber, where it frequently appears as a small cone. The pathological changes may stop at this stage, or may continue till total opacity of the lens is produced. According to Hulke, this form of cataract may sometimes appear in children,

where, without absolute perforation, a plug of lymph is formed in the anterior chamber by severe suppurative corneal inflammation.

Elderly people, whose lenses are commencing to become opaque, usually complain that they no longer see well when they use their spectacles. They think that they need stronger pairs, but even with these, the eyes become fatigued after reading for a few minutes. Many such patients see spots or *muscæ*, and notice that the moon or any bright point of light fails to present its usual appearance, being either seen doubled or as having projections or bulgings. These phenomena are described as *monocular polyopia*, and are due to an irregular swelling of the lens-substance, causing light to be refracted differently in the various sectors. In rare cases, this swelling is very great, while there is but little opacity. Owing to the greater curvature of the lens, such persons are able to use much weaker convex glasses, or to lay them aside altogether. They are then said to have acquired *second sight*. The myopia thus produced, causes a failure of vision at a distance, which may be approximately corrected by appropriate concave lenses. Owing to the fact, however, that there is a slight clouding of the lens, the corrected acuity of vision is less than normal. In such cases, ordinary type is easily read without the aid of a glass; small print readily fatiguing the eye, even when a weak convex lens for magnifying purposes is employed. Arlt has called attention to the fact that in some cases of nuclear cataract, myopia is produced by the rays which form the retinal image entering through the periphery of the lens alone, and therefore, being more refracted, come to a focus nearer to the posterior surface of the lens.

Passing from the consideration of these unusual cases, it will be found that in the early stage of cataract, the lens is swollen, the iris is pushed forward, and the anterior chamber is narrowed. This pressure provokes the iris to become irritable, usually making the patients exhibit a slight degree of photophobia, and causing them to complain when exposed to bright sunlight. Moreover, as brilliant illumination contracts the pupil, and therefore, owing to the decrease in the quantity of light which the hazy lens permits to pass through it, diminishes the sharpness of the retinal images, such patients see badly in situations where there is much light-stimulus. They therefore usually derive comfort from the use of light and medium-tinted smoked glass when out of doors or when facing a bright light. At this time, there is always a strong pupillary reflection; but, as this effect may be the result of a narrow pupil and a yellow lens, a diagnosis of incipient cataract must not be made unless opacities can be demonstrated in the lens by the use of oblique light, and the diagnosis confirmed by the employment of the mirror. The extension of the lenticular opacities continues at a varying rate in different individuals. In some, the lens becomes entirely opaque in the period of a few months. In others, the process of ripening lasts for years before the cataract is mature. We speak of a cataract as mature when the primary swelling of the lens has subsided, and when the opacity has extended throughout the lens-substance and the anterior cortical has become opaque out to the anterior capsule. At this time, the iris rests immediately upon the opaque portion of the lens, while in unripe

cataracts, a transparent rim of substance separates it from the opaque matter beneath. Owing mainly to the extent to which the sclerosis of the nucleus has advanced, the cataract at this stage varies much in appearance. In most cases, a grayish layer overlies the amber-colored nucleus, which, in some instances, is so dense that it becomes distinctly visible only by oblique light. In others, there is scarcely any of the gray opacity left in the anterior cortical, and the lens appears yellowish and waxy.

At times, where the sclerosis has invaded the entire lens, the pupil looks so dark that it is only by careful focal illumination that the presence of a dark-yellow cataract is recognized. From the blackness of the pupil, and the extremely dark color of the lens after its extraction, such cataracts have received the appellation of *cataracta nigra*. The same term is applied by some writers to that form of complicated cataract which sometimes ensues after chorioidal disease and hemorrhages into the eye. In such instances, the lens is said to owe its dark color to the imbibition of hæmatin. If the retina and the optic nerve are healthy, the cataract, even when thoroughly formed, is never sufficiently dense and opaque to cause entire blindness, the patient being able to see the motions of the hand in a good light, and to distinguish the presence of a lighted candle in a dark room at a distance of twenty feet. In milky and in Morgagnian cataracts, the reflection of light is often so great that a lighted candle is seen only at a distance of from ten to twelve feet. In all cases where the patient is made to fix one candle-flame, he should be able to detect the presence of a second one at any point within the usual field of vision. Should he fail to do this, there is probably some diminution of the visual field. Large defects in the field, such as are due to advanced glaucoma or separation of the retina, are thus generally readily recognized. Owing to the diffusion of light by the opaque lens, small lesions cannot be detected. For instance, attempts to map out Mariotte's spot, invariably fail. Such patients are usually able to distinguish colors when they are exhibited in large masses and are brightly illuminated. Owing to the great absorption of the blue rays by the yellow lens, such subjects are apt to be slightly blue-blind.

It has long been realized that any means of so influencing the nutrition of the lens as to cause it either to absorb or to again become transparent, would be a great boon to humanity. Up to the present time, however, all efforts to attain this object have been fruitless—the older books presenting a long list of remedies which were once supposed to be efficacious, but which have since been demonstrated to be absolutely useless. Nevertheless, the author is of the opinion that many cases of cataract, when seen at their very commencement, may be retarded in their progress by improving the general nutrition of the patient, and by the moderate use of such salines as promote watery discharges from the bowels and increase the secretion of urine.

Internal medication having proved valueless to stop the disease, we must resort to surgical means to secure a free ingress of light into the eye. For this purpose, three different methods have been devised: 1, discission; 2, couching; 3, extraction.

Discission (*scleronyxis* and *keratonyxis*) is probably a modern

operation. Although certain passages in the writings of the ancients are by some interpreted to be descriptive of discission, the differential diagnosis between cataract, hypopyon, and other pupillary obstructions was so uncertain, and the descriptions are so inaccurate, that it is difficult to decide whether the operation was really practised. Among the first to introduce it systematically was Percival Pott, who, in 1787, accurately described and extensively practised the method. All operations for discission have for their aim, not only the rupture of the capsule of the lens and the partial cutting and breaking of the lens-substance, but also the admission of aqueous humor to the lens. This is done because this fluid has the property of causing the lens-substance to swell, become more opaque, and finally to undergo dissolution. When the puncture is made from the sclera (*scleronyxis*), a needle is inserted into this membrane about three or four millimeters behind the corneal border, and is carried through the posterior chamber till the point reaches the upper inner part of the pupillary space. The instrument is then rotated on its axis and made to bore into the lens-substance, while its cutting edges are employed to still further divide the tissue. Care must be taken to avoid any injury to the iris. Scleronyxis was at one time extensively practised as a general method of operation on cataract both in England and in this country, Dr. Isaac Hays, of this city, inventing an ingenious knife-needle so arranged as to cut and break up more thoroughly hard and senile lenses. Discission through the cornea (*keratonyxis*) is performed by puncturing the cornea with a needle and carrying the instrument through the anterior chamber and pupillary space into the lens. By rotation, and by using the instrument as a lever with the fulcrum in the cornea, the lens is bored and cut through its anterior surface.

In the performance of either operation, the pupil should be dilated to its maximum, and the needle should be introduced at right angles to the surface of the cornea and sclera, so as to make the wound-canal as short as possible. After entering the anterior chamber, the instrument should be directed to the desired point. An oblique wound causes more tearing and bruising of the tissues when the needle is used as a lever. As it is desirable that no aqueous should escape until the completion of the operation, the instrument should be so constructed that its neck will fill the canal made by the cutting edge. To prevent the intra-ocular pressure from driving the aqueous out with a rush, the needle should be withdrawn slowly. Moreover, the sudden emptying of the anterior chamber in eyes in which there is degeneration of the bloodvessels, may give rise to intra-ocular hemorrhages.

In both keratonyxis and scleronyxis, we rely on the aqueous humor to gradually dissolve the lens-matter, which, by rupture of the capsule, has been brought in contact with it. The success and rapidity of this absorption depends on the free circulation through the vessels in the neighborhood of Schlemm's canal and at the periphery of the anterior chamber. So long as the membrane of Descemet remains intact, there is no filtration through the cornea. Great care should be taken not to do too much at one operation, but to be satisfied with a moderate cutting of the lens and capsule. If the discission be too free, the lens

will swell rapidly, and large masses will fall into the anterior chamber, which, pressing on and irritating the iris, will produce congestion of its bloodvessels and those of the ciliary processes. Absorption and filtration are thus much diminished, and the swollen masses lie for days in the pupillary space or anterior chamber without apparent change. At times, they may give rise to positive inflammation of the iris, with consequent exudation. When the discission has been carried too far, the operation may be followed by nausea and vomiting, and there may even be a violent and sudden increase of tension, with the production of secondary glaucoma. Frequently, where the nutrition of the parts is impaired, or where the lens is unusually hard, it may be necessary to repeat the operation several times, before a clear pupil is obtained. During the entire period of absorption, the eye should be kept steadily under the influence of atropine. Although experience has shown that excellent results may be obtained from careful and repeated discissions in senile cataract, yet, owing to the slowness of absorption in such hard lenses, the necessary repetition of the operation, and the danger of exciting irido-cyclitis, this method of operation is generally undesirable in such cases. Discission, therefore, has its proper field in children and in young persons (under twenty-five years), in whom the nucleus of the lens has not yet become hard and dense.¹

Keratonyxis is usually to be preferred to scleronyxis, because, in the former operation there is only a slight wound made in the cornea, and the iris and ciliary body are not touched or disturbed by the needle. The wound in the cornea, although healing readily, always leaves a scar, which, even years afterward, is often demonstrable by a magnifying-glass and oblique light. To favor the healing of the wound, both eyes should be bandaged for the first twenty-four hours after the operation. On the next day, the bandage may be replaced by medium-tint smoked glasses, and the patient kept under the influence of atropine. As long as the slightest pericorneal injection is manifest, he should be placed in a room with but a moderate amount of diffuse daylight. Even when this has long disappeared, the occasional use of atropine is indicated, if the eye, although having fair acuity of vision, waters on exposure to strong light or flushes during attempts at near-work. The eye should be protected from heat and glare. Entire abstinence from attempts at near-work, should be insisted on.

Couching of cataract—reclination and depression, or the removal of an opaque lens from its usual position behind the pupillary space by dislocating it into the vitreous humor, is an operation which has been practised among many nations from the earliest times. Celsus² gives an excellent description of it, recognizing the necessity of having the cataract hard and mature, and stating that some varieties are incurable. He also gave instructions as to diet and after-treatment. His method consisted in introducing a needle through the cornea and pressing the lens directly downward into the vitreous. In 1785, Willburg entered the needle through the sclera, laid its head on the anterior surface of

¹ Fifty years ago, in Philadelphia, under the teachings of Hays and Littell, almost all cataracts were operated by discission, and in many cases with excellent results.

² Lib. vii., c. vii., 14.

the lens, and pressed it backward and downward, so that the anterior part of the lens looked upward. In 1801, Scarpa perforated the sclera below the median line back of the ciliary body, and pressed the lens outward and backward, so that its anterior surface looked upward and inward, toward the glabellum frontis.

In successful cases, where the lens is of proper consistence, the immediate results of the operation are almost magical. Without loss of blood or of any of the contents of the eyeball, and almost without pain, the opaque lens is pushed out of the visual axis. The cornea retains its curvature, and the space occupied by the lens is at once filled by clear aqueous and vitreous humor, so that the patient, who was a few moments before blind, can see fine print distinctly with the aid of a proper lens. The disadvantages are, however, numerous. All lenses cannot be so displaced in their entirety, many breaking up, causing the pupillary space to become filled with large masses of cortical, which, pressing on the iris, cause it to inflame; or the pupil becomes closed from inflammation, and the eye is often lost from resultant irido-chorioiditis. Moreover, lenses once depressed will not unfrequently rise up again after a time, and partially or entirely obstruct the pupillary area. Further, in some cases, it will be found that the lens which has been dislocated into the vitreous, is entirely absorbed, except perhaps a few particles of chalky matter or of fat. Usually, however, when eyes which have been thus operated on in this manner are examined ophthalmoscopically, or by dissecting them, the lens is found lying on the ciliary body. Still worse, in many cases, the dislocated lens acts as a foreign body, and excites recurrent inflammation of the chorioid and ciliary body, which often not only destroys the eye, but also excites sympathetic inflammation in the fellow-eye. On account of these dangers, and because of the improved technique of the operation of extraction with its consequently diminished risks, reclinatio has been abandoned by most surgeons of the present day.

In the performance of couching, the pupil should always be well dilated by a mydriatic, so as to give a large pupillary space and thus diminish the chance of injury of the iris by the needle. The dilatation also allows any portion of the lens which may remain in its original position, and thus press upon the iris, an opportunity to swell with less irritation to this membrane. The after-treatment should be the same as that directed for discission.

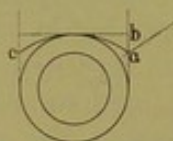
The operation of extraction of cataract is said by Anagnostakis to have been known to the ancients, and described and practised by Galen. If so, it was lost sight of and forgotten, to be reinvented by Daviel in 1748. Daviel made his incision entirely in the cornea. He used a triangular knife for the purpose, and then enlarged the wound, either with a knife or with a scissors, until he had separated a little more than one-half of the circumference of the cornea from its attachment to the limbus. In 1752, he reported two hundred and six such extractions, with one hundred and eighty-two favorable results. Since that day, almost all conceivable variations in the position and extent of the incision have been made by different surgeons, the cut varying in size from four millimeters, for the linear extraction,

to ten and twelve millimeters, for the peripheric linear and the flap; and extending to still larger dimensions in the scleral method of extraction. The rule is, that the larger the flap, the easier is the exit of the lens, but the greater is the disturbance in the nutrition of the cornea, and the more difficult it is to secure accurate apposition with prompt and firm union of the wound. Moreover, when the incision is large, the success of the operation depends largely on the quietude of the patient, so that anything which makes him hold his breath and strain, or any coughing, sneezing, sudden rising in bed, or straining at stool, may cause a reopening of the wound, with loss of the eye; this occurring from prolapse of the iris and slow inflammatory processes from escape of vitreous, inducing intra-ocular hemorrhage, or from suppuration of the flap, with consequent panophthalmitis. The tendency to suppuration and iritis was supposed by Mooren to be largely obviated by an iridectomy performed from two to six weeks before the extraction of the lens. The frequent prolapse of the iris in any flap operation, especially when the cut was a very peripheral one, was an additional argument in favor of iridectomy. Besides, it facilitated the ready exit of any particles of cortical matter that might be left in the posterior chamber behind the iris. To secure the easy evacuation of such masses, and of the lens proper, Jacobson made the incision still more peripheral, placing it entirely in the vascular limbus. Moreover, he maintained that the union of the lips of the wound was more perfect and rapid in this vascular tissue than it was in the cornea. Of course, prolapse of the iris was inevitable in this incision, and to be avoided only by iridectomy, while the dangers of a rupture of the hyaloid and prolapse of the vitreous were so great, that it was necessary to perform the operation during the relaxation of complete chloroform narcosis. Out of one hundred operations by this method, he had only one total loss. Notwithstanding these various modifications of the flap operations, the frequent accidents which accompanied and followed them, led other surgeons to adopt a plan of procedure which was diametrically opposite in theory.

The so-called linear incision had been adopted by Palluchi, Rosas, and Fr. Jaeger, for the extraction of degenerated and shrunken cataracts, while the same method had been extensively employed by Gibson and Travers for traumatic and for soft cataracts. Graefe introduced a modified linear extraction, in which, after making an incision at the edge of the cornea extending through one-quarter of its circumference, and performing an iridectomy, he removed the lens with a spoon. A very similar method was adopted in England by Bowman and Critchett, the latter sometimes detaching one-third of the corneal periphery, and making a wound so little curved that "it had rather the attributes of a slit than of a flap." In 1865, Graefe perfected his method, and introduced the peripheric linear section, which for many years was practised by the majority of eye surgeons, almost to the exclusion of other forms of extraction. The incision is made by a thin and narrow knife, which is introduced with its cutting edge directed toward the situation of the proposed incision, at the point designated as *a* in Fig. 261; this point being on the line of a vertical tangent to the cornea, about two millimeters below the point, *b*, where a horizontal tangent to the upper border of the

cornea would meet it, thus causing the point of the knife to enter the eye about one and a half millimeters from the corneal edge. The blade of the instrument is then carried into the anterior chamber and across it, making the counter-puncture at a similar point, *c*, on the other side. The edge of the knife is now turned slightly forward, and brought out by a sawing motion, so as to make a very slightly curved wound, the outer part of which lies in the sclerotic and the inner part in the cornea. The minute flap thus formed has the depth of only half a millimeter. A piece of iris is then excised, the capsule is opened, and the lens and any remaining cortical matter are gently coaxed out by stroking the cornea, either with a smooth spoon or with the finger acting through the medium of the eyelid.

FIG. 261.



Peripheric linear section (actual size).

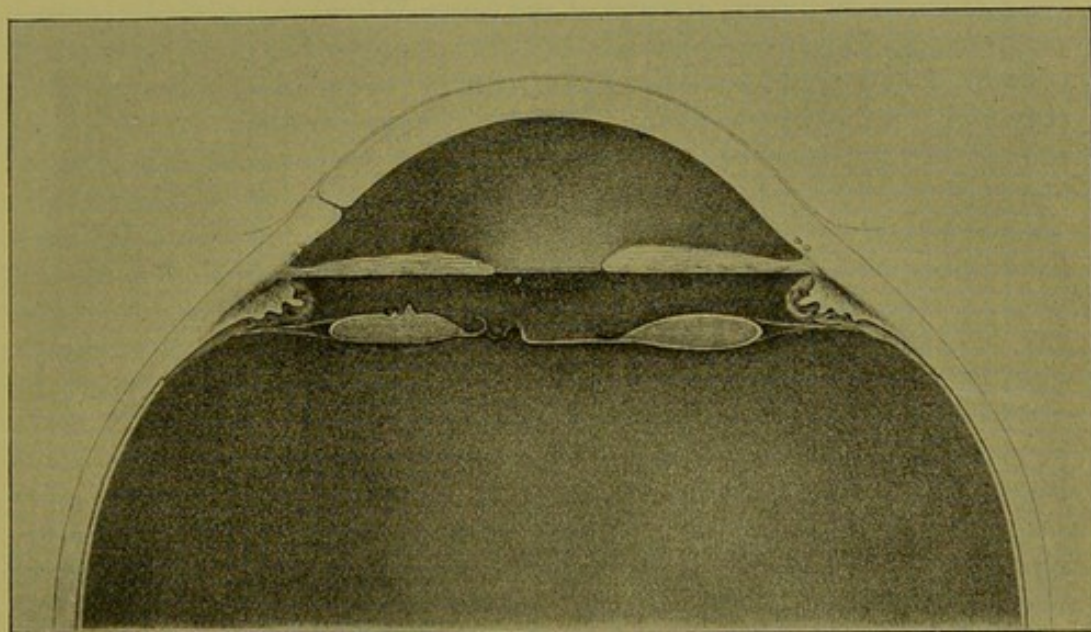
All these flap and linear operations may be performed upward or downward, each method of making the cut having its advocates. When the incision is made downward, the operation is much easier of performance in case of eyes that are deeply set in their sockets, and the escape of the lens and cortical matter is favored by the position of the eyelids and by gravity. On the other hand, the upward cut is better splinted and is better held in apposition when the lids are closed. In all cases where an iridectomy is performed, it is advantageous to have the cut made above, so that the upper lid may cover the artificial pupil, and prevent the blinding effect of the great quantity of light which otherwise would be admitted to the eyeball. In cases of extraction without iridectomy, the iris, owing to the absence of the lens, lies at a deeper level in the eye. Where we are fortunate enough, however, to have healing without inflammatory processes, and without the formation of synechiæ, a mobile pupil is secured which, by its alternate contraction and dilatation, is capable of adapting the eye to the amount of light. Besides, the eye has a much more normal appearance.

In all these methods, in order to evacuate the lens, the anterior capsule is cut or torn by some form of cystitome. Portions of it and of the entire posterior capsule, however, remain behind in the eye, as shown in Fig. 262, which represents a section of an eye which had been unsuccessfully operated on by Arlt six years previously. Here the torn remnants of the capsule are retracted in folds, and the anterior and posterior capsules are united at the periphery of the capsule sac to enclose the remaining portions of lens-substance. This zone, with its enclosed opaque lens-matter, is always found in eyes which have been operated on for cataract, and may sometimes be seen during life by widely dilating the pupil. The more central portions of the anterior and posterior capsules, especially if they have become attached to the iris, often proliferate and form a veil just behind the pupillary space: this is known as *secondary*

cataract. These membranes, even if thin, interfere very much with vision by becoming folded and thus distorting the retinal images.

To avoid secondary cataract, Beer, and other older writers, advocated the removal of the entire capsule. More recently, Pagenstecher has advised the extraction of the lens in its capsule, by a traction instrument, as an essential factor in every operation for senile cataract which is not traumatic in its origin. The loss of vitreous usually following this method of operation, its prolapse into the incision, the clouding of the entire string of it leading from the wound, and the formation of opacities, as well as the increased probability of inflamma-

FIG. 262.



Encapsulated zone of opaque lens-matter. (BECKER.)

tion and the inability to remove many cataracts in this way without rupture of the capsule, have seemed to most operators the disadvantages that outweigh its advantages. In many over-ripe lenses, however, the lens may be removed in its thickened and toughened capsule, either by gentle manipulations of the ball through the closed lids or by the introduction of a wire loop, without the loss of a drop of vitreous. Pagenstecher¹ has lately published the results of many years' experience with his method of extraction. While maintaining that the visual acuity is superior to that obtained when the capsule is left in position, he admits that the skill of the operator is shown in his choice of cases, as in many instances it is impossible to get the lens out without rupturing its capsule. Soon after the Graefe peripheric linear method of extraction had become common, many operators found that the small amount of gaping of the linear wound, and the quantity of cortical matter consequently scraped off during the exit of the lens, together with the near approach of the cut to the ciliary body, with the increased liability of this region

¹ Arch. f. Ophthalmol., xxxiv., 2, Ss. 145-166.

to inflammation, were sufficient objections to cause them to make a larger incision and a deeper flap, and to place the wound itself more within the limits of the cornea. For these reasons, and in the belief that by strict antiseptic precautions, suppuration of the flap can be prevented, most operators of the present day, although still using the narrow knife of Graefe, have abandoned his method of operation, and make a flap of greater or less extent, either in the cornea itself or in the corneo-scleral junction. Many surgeons prefer an incision in the cornea, detaching from one-third to one-half of its periphery, and try to effect the exit of the lens without cutting the iris. Where this is attempted, the flap should be entirely in the cornea, and cocaine should have been previously instilled, so as not only to render the eye insensible, but to dilate the pupil and thus facilitate the exit of the lens. Where there is a fully ripe, hard, waxy, and uncomplicated senile cataract, with a healthy iris and a pupil which readily dilates *ad maximum*, excellent results are often obtained. At times, however, there is prolapse of the iris, and we are obliged either to perform iridectomy or to have the eye heal with an anterior synechia, and perhaps also a cystoid cicatrix. In all cases of complicated cataract, the operation is best performed with iridectomy. Where there is any suspicion of chronic glaucoma, the excision of the iris should be made from two to three months previous to the extraction of the cataract. In the opinion of the author, the flap operation, combined with iridectomy, is usually safer, and will give an average of better results in any large number of consecutive cases, not selected especially for the form of operation, but taken as they ordinarily present themselves. The main disadvantages of the combined extraction are the deformity produced by the iridectomy and the blinding effect of a large quantity of light coming through the periphery of the pupil. These, however, can be largely remedied by making the incision upward, thus bringing the artificial pupil under the upper lid.

When cataract cases present themselves, the eye should be carefully inspected as to the presence of any chronic catarrh or other conjunctival disease, as to the promptness and completeness of the motions of the iris, and as to the tension of the eyeball. Both central and peripheral light perception and projection should be carefully tried, and if these are good, and the patient, although old, is in fair general health, the case may be considered as a proper one for operation. Complicated cataract, if present on both sides, and if offering any reasonable chance of success, should not always be refused, but the increased dangers should be carefully explained to the patient. No cases with lacrymal obstruction should be operated on till an attempt has been made to cure the disease by the means recommended in the chapter on the subject, because such a patient is very likely to have infection of the wound by pus regurgitating into the eye from the lacrymal canals. The urine should be examined for sugar, albumin, and casts. A moderate purgative—preferably one acting on the liver—should be given, care being taken to obtain thorough evacuation of the alimentary canal. The patients should not be debarred from their usual fresh air and exercise, and any reasonable digestible food should be permitted. When the time has arrived for operation, the patient is to be undressed and put to bed in such a position that the eye

may be thoroughly illuminated by a light from a window so arranged that any shadow from the surgeon's hands and instruments may not be cast upon it. The patient should be propped up by pillows, so as to enable the surgeon readily to operate when seated on a chair alongside of the bed or when kneeling by the side of it. In hospital practice, the author is in the habit of operating while standing beside his patient, who is placed on a bed, the height of which is easily regulated by a screw. The face should be carefully washed with Castile soap and water, and the conjunctival sac freely flushed with the standard solution of bichloride of mercury (gr. j to Oj). It is very important to test the sharpness of the knife and other instruments, inasmuch as the ability to produce a clean and properly shaped wound without contusion or dragging of the tissues, will largely depend upon this. The surgeon's hands should be absolutely clean, and his instruments, which have been freshly washed with absolute alcohol and wiped on a clean linen or on absorbent cotton, should be put upon a tray held by an assistant or laid within reach. Prior to the introduction of cocaine, it was advisable, in most instances, to place the patient under the influence of ether, pushing it to absolute insensibility of the cornea and relaxation of the eye-muscles, but at present, the instillation of a few drops of a two per cent. solution of muriate of cocaine into the conjunctival sac, is sufficient to produce anæsthesia of the conjunctiva and cornea. If a previous instillation has been made from twenty minutes to half an hour before operating, dilatation of the pupil and a dulling of the sensibility of the iris is obtained. If the surgeon be alone, the lids should be separated by a spring speculum. If not, his assistant should carefully lift the upper lid with an elevator, taking care not to press upon the eyeball with it. If it be decided to do an operation without iridectomy, the knife should be so directed as to detach one-half of the circumference of the cornea from the limbus, the entire incision lying in the corneal tissue.

If an iridectomy be intended, the points of entrance and exit should be in the inner part of the limbus, and the incision so completed that a small conjunctival flap shall be left at the upper part of the wound. To some extent, the flap is in the way, both in cutting the iris and in preventing a view of it and of the anterior chamber. It adheres so tightly to the subjacent sclera when replaced in its proper position, however, that the anterior chamber is very soon restored, and the wound is much less likely to be sprung by any incautious movement on the part of the patient. At times, there may be free hemorrhage from the conjunctival flap, its occurrence constituting one of the objections to this method of operating. If this happens, the eye should be shut and the hemorrhage arrested by gentle pressure on the closed lids with a wad of cotton. When a clear view of the iris has once more been obtained, a delicate pair of forceps should be carefully introduced into the anterior chamber, and the iris seized a little distance from its pupillary margin and gently pulled out of the wound. While held in this position and in a state of slight tension, it should be divided by a single upward cut of the scissors. If the iris lies prolapsed in the wound, it is sufficient to seize the extended portion and cut it off. If bleeding occurs into the anterior chamber, an endeavor should be made to stop it by gentle pressure or by

ice-cold or very hot compresses. After removing any clot which is lying in the wound, with the iris-forceps, the blood in the anterior chamber is to be gently stroked out by pressure on the closed lid with the finger. If the cataract be over-ripe, or if the capsule be thickened, the same lid-mancœuvre should be repeated to see whether the posterior part of the latter is sufficiently loosened from the hyaloid to enable the lens to be extracted in its capsule. If, as will be the case in most instances, we fail to do this, and find that the lens does not dislocate, we should take a cystitome, and by a triangular or quadrangular incision try to cut out a portion of the capsule. If this be unsuccessful, we should endeavor to make a large opening in it. Removing the cystitome, we should press gently on the lower edge of the cornea in a direction backward and upward, either with a smooth and elastic tortoise-shell curette or by means of the finger on the closed lid. If the capsule has been sufficiently opened, the lens will present its edge in the wound, when it, together with any remaining fragments of cortical, can be gently coaxed out, by a continuance of the same mancœuvres. We should persist in our endeavors until a clear and black pupil is obtained. The patient should then be able readily to count fingers held at a distance of one foot in front of the eye. If, however, after cutting the capsule, a clear black space at the opposite side of the pupil is seen upon the first attempt at pressure on the eye, it may be certain that the suspensory ligament has given way, and that a loop of vitreous is presenting. Persistence in attempts to evacuate the lens by pressure will then be futile, causing more vitreous to prolapse, and dislocating the lens and pushing it still farther from the wound. A wire loop should be then introduced behind the lens, and, by gently bringing it forward and toward the wound, the cataract is to be removed. Such an accident is usually very disadvantageous, because it prevents the removal of all the lens-fragments from the anterior chamber, where, by their swelling and pressure, they are likely to irritate and inflame the iris. If, however, we have succeeded in removing the lens without rupture of the hyaloid membrane, the anterior chamber should be carefully examined to see if any fragments of cortical matter remain in it. If they are present, an endeavor to get rid of them by a continuation of the usual mancœuvres should be made. At this stage, Panas and many other operators take a small syringe with a blunt beak, and, placing the latter in the lips of the wound, endeavor to wash any cortical from between them, and also thoroughly to disinfect the cut edges with a weak solution of bichloride of mercury. Some surgeons attempt thus to wash out the anterior chamber. In the opinion of the author, it is better to remove any cortical by the methods previously indicated, and to disinfect the wound by instilling a warm solution of boracic acid into the conjunctival sac and diffusing it by manipulating the lids with the fingers. If the iris has prolapsed, it should be gently replaced by a horn or tortoise-shell spatula, and a solution of eserine instilled. If iridectomy has been performed, and the cut edges of the iris are caught in the wound, they should either be seized with the iris-forceps and cut off, or be carefully replaced with the spatula whilst the iris is stimulated to contraction by gently rubbing the cornea with the fingers placed on the closed lid. Inasmuch as the sphincter has been

destroyed, but little can be expected from the instillation of eserine. If there has been any previous tendency to glaucoma, the eserine instillation should never be omitted. On the other hand, where there has been previous inflammation of the iris, or where the existence of posterior synechiæ renders iritis probable after the operation, atropine should be at once dropped into the conjunctival sac. When the anterior chamber has been cleared of all blood or lens-remnants, or, at least, of all that can be removed without risking rupture of the hyaloid and loss of vitreous, the conjunctival flap should be carefully replaced. If no such flap has been made, it should be seen that the lips of the wound are in apposition. After cleaning the conjunctival sac, the eye should be gently closed. Small pieces of aseptic gauze, freshly saturated with a solution of bichloride of mercury 1:4000, should then be placed over each eye, and upon this enough disinfected absorbent cotton to fill out the orbit should be placed. These wads are to be gently held in position by light turns of a flannel roller bandage. If the patient be in bed, the pillows should be so adjusted as to make him comfortable. If he be on an operating-table, he should be carefully lifted into bed.

The light of the room should be so tempered and arranged that no direct rays shall fall on his face. At the same time there should be sufficient light to enable the attendants to move about comfortably, and to read to the patient if desirable. For several hours there is usually some slight smarting, or a feeling as if sand were in the eye. Sometimes the tears accumulate and give discomfort till they find their way out of the conjunctival sac. If severe pain sets in, the bandage should be removed, the lower lid gently pulled down, a solution of atropine or of hyoscine instilled, and the bandage replaced. It is very important that the patient should remain quiet for the first twenty-four hours. He should resist any inclination to cough or to blow the nose, and should avoid any efforts to raise himself in bed, to strain at stool, or to chew hard food. These injunctions should be strictly enjoined, as any such motions have a tendency to open the wound and delay healing, or perhaps to cause hemorrhage, prolapse of the iris, or even loss of vitreous humor. When a conjunctival flap is made, or when the incision is linear, all such accidents are much less likely to occur, as the wound has less tendency to gape. The enforced quiet, however, is very distressing to many patients, and they get backache, and feel the necessity of changing their position. To do this properly the nurse takes the patient's two hands in his one hand, and puts his other behind the patient's neck, and then gently raises him. At the same time, an assistant places pillows or a bed-chair behind him, so that the patient may sit up in bed. Male patients should be encouraged to use the urinal within a few hours after the operation, as retention of urine and the use of a catheter may thus be often avoided. If the patient has no pain, the bandage should be removed at the end of twenty-four hours, and, while he keeps the lids closed, they, with the lashes and brows, should be gently washed with a stream of boracic acid solution from a large pipette. Any mucus or discharge adhering to the lashes, should be carefully removed by a wad of absorbent cotton wet with the same solution. If there be no swelling of the lid nor increase of secre-

tion from the conjunctival sac, the surgeon may usually be quite sure that the eye is doing well. Inasmuch, however, as there may be considerable inflammation of the cornea without these symptoms, in many feeble and debilitated patients, the author is in the habit of gently pulling down the lower lid, while the patient is told to open his eye, thus enabling him to inspect the cornea and anterior chamber. In such cases, he gently flushes the conjunctival sac with a lukewarm solution of boracic acid, followed by an instillation of a few drops of atropine. It is important to have these and all other collyria warmed to a blood-heat, the patient not being so apt to start or strain as he would were they used of the temperature of the room. Care should be also taken to see that all mydriatic and myotic solutions are absolutely neutral to litmus-paper, as otherwise they might cause much discomfort and smarting. If the patient be feeble, his strength should be supported by meat essence and milk-punch, and he should be got out of bed and allowed to sit in a chair alongside of it. If he bears confinement well, it is better that he should remain quiet in bed till the third or fourth day. The eye should be washed daily. The bandage should be reapplied at each dressing, but should not be removed permanently till the fifth to the seventh day. When, owing to the chronic conjunctivitis, the eye bears bandaging badly, and the conjunctiva secretes any considerable quantity of mucoid or mucopurulent matter, the bandage should be removed as soon as the wound is healed, and a pair of dark glasses given; the patient being sheltered from direct light falling on the eye. If, owing to delayed union of the wound or prolapse of the vitreous accompanied by an increasing mucopurulent discharge from the conjunctiva, it becomes desirable to remove the bandage permanently before the incision is finally united, a strip of isinglass plaster, half an inch in breadth, applied vertically over the upper and the lower lid about the median line, may be used instead. Although it is advantageous to have a room where the light can be regulated by shades, yet it is not at all necessary. In confirmation of this fact, the author has for many years treated all his cases at the University Hospital in the general surgical ward, where each bed has a screen at its foot to prevent direct light from the opposite windows from falling on the patient's face. In every case, the eyes were protected by bandage, dark glasses, or a forehead-shade, according to the stage of the healing and the degree of irritation following the operation. Patients are usually able to go out into the fresh air in from two to three weeks. They should be watched, however, and some mydriatic should be occasionally instilled into the eye as long as a walk in the wind, or other slight irritant, causes the eye to flush and water. To judge the progress of the case, vision may be tested at almost any time after a week. No spectacles should be given, nor any reading allowed, until two months after the operation, as the congestion of the eye necessarily dependent upon convergence and near-work, has a marked tendency to augment and keep up any low grade of inflammatory action in the capsule, and thus favor the formation of secondary cataract.

Notwithstanding the vast mass of statistics published on the subject, we are still far from having a satisfactory solution of the average results of the operation for cataract. The standards of success among

different operators are widely different, the manner in which acuity of vision is determined is in many cases unsatisfactory, and the date of its determination is often not mentioned. Further, a statement as to the amount of astigmatism developed, the accidents during convalescence, and the result six months or a year after operation, are often entirely wanting. Arlt¹ has given, as the result of his vast experience, the following statement: Of nine hundred and fifty-four eyes operated upon by the old-fashioned flap extraction, there were 69.70 per cent. of successes, 24.24 per cent. which could probably have been bettered by a secondary operation, and 6.06 per cent. of absolute loss. The same author states that out of one thousand and seventy-three cases of extraction by the peripheric linear method of Von Graefe, there were 83.72 per cent. of successes, 10.61 per cent. that could probably have been bettered by secondary operations, and 5.67 per cent. of total loss. More recently, Knapp² has reported one thousand cases of extraction with iridectomy, with 85.4 per cent. of successes, 8.3 per cent. of half-successes (*i. e.*, vision 6/60 or less), and 6.3 per cent. of absolute loss. Becker,³ adopting the same standard of success, has reported eleven hundred and thirty-four operations of extraction with iridectomy. He gives 86.3 per cent. of successes, 9.4 per cent. of half-successes, and 4.2 per cent. of absolute loss. In Knapp's statistics, 13 per cent. of the operations, and in Becker's, 14.7 per cent., were done in cases of complicated cataract.

Amongst some of the accidents which may occur during the operation, are: 1. Loss of vitreous. This may take place, where myopia or other pathological process has caused fluid vitreous and weakening of the zonula, no matter how carefully and skilfully the operation is performed. It is also often produced by straining on the part of the patient, or through carelessness or clumsiness of the surgeon. If it occurs during the completion of the corneal incision, the operator has the choice of bandaging the eye and abstaining from any further attempt to remove the lens, or of going on with the operation. If, however, the loss of vitreous occurs after the opening of the capsule, it is necessary to extract the lens by a wire loop or spoon, the risks ensuing from the additional loss of vitreous being less than those from allowing the dislocated and lacerated lens to remain in the eye. If the prolapse of the vitreous be small, it will often of itself draw back into the eye within the first few hours after operation. Where it is large, it is best to excise it with a scissors. If it is allowed to remain, it renders the cicatrization slower; the protruding portion gradually becoming opaque and being finally thrown off. The bursting of the hyaloid is not of itself necessarily deleterious. Some operators, such as Hasner, have even recommended its puncture with a needle after the completion of the operation, to allow the vitreous to come forward into the space left by the extraction of the lens. Loss of vitreous, if moderate, often does not materially interfere with the result of the operation, but it is always an element of danger. Where it is considerable, it may lead to chorioidal hemorrhage and

¹ Graefe u. Saemisch, Bd. iii. S. 818.

² Trans. Amer. Ophthalmolog. Soc., 1887.

³ Die Universitäts Augenklinik in Heidelberg, 1888, Ss. 55, 56.

detachment of the retina. It may also open the road to infection, and give rise to panophthalmitis.

2. Hemorrhage. In operations in which the iris is cut, hemorrhage from its divided vessels into the anterior chamber obscures the field of operation, and renders the capsulotomy more difficult and less accurate. Although blood remaining in the anterior chamber delays convalescence, it is usually readily absorbed. If hemorrhage from behind the iris appears during the operation, it is a sign of degeneration of the vessels of the chorioid, and is fatal to the eye. It is a rare accident where there has not been some previous evidence of glaucoma.

3. Collapse of the cornea. As Arlt has pointed out, this takes place ordinarily where, owing to absorption of the orbital fat, the recti and orbicularis muscles exercise less pressure on the eyeball than usual, allowing atmospheric pressure to drive the cornea inward. In consequence of the absolute relaxation of these muscles in complete narcosis, it is also more frequent when the operation is performed under this condition. Wrinkling of the cornea prevents the surgeon from seeing properly to cut the capsule, and the general flabbiness of the globe renders the subsequent expulsion of the lens and remaining cortical fragments, difficult. These manœuvres, however, can be facilitated, and the influence of the muscles be replaced, to some extent, by gentle pressure on the eyeball by means of the fixation forceps.

4. Remnants of cortical matter. If these are not readily removed by stroking manipulations on the cornea, either through the lids or by a spatula acting on it directly (while the posterior lip of the wound is gently depressed with a second spatula), it is best to leave them *in situ*. This should be the rule except where they are situated at the upper part of the anterior chamber. If they are in this position, they may be removed either by the careful use of the Daviel spoon, or by irrigating the lips of the wound by the introduction of the beak of a suitable syringe and gently washing the wound with a weak solution of biniodide of mercury according to the method of Panas, or, preferably, with one of boric acid. The use of even a weak (1 to 10,000) solution of bichloride of mercury, clouds the cornea. The author believes that thorough washing of the anterior chamber, so as to free it and the capsular sac of all loose remnants, is in most instances injudicious and dangerous. Fragments at the bottom of the anterior chamber, which are not readily evacuated by manipulation, are best left in position, trusting to their subsequent absorption by the aqueous humor.



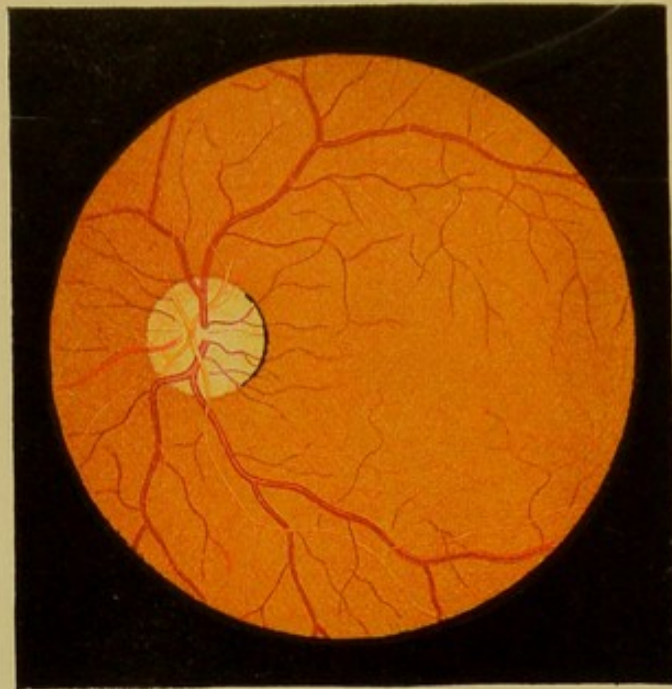


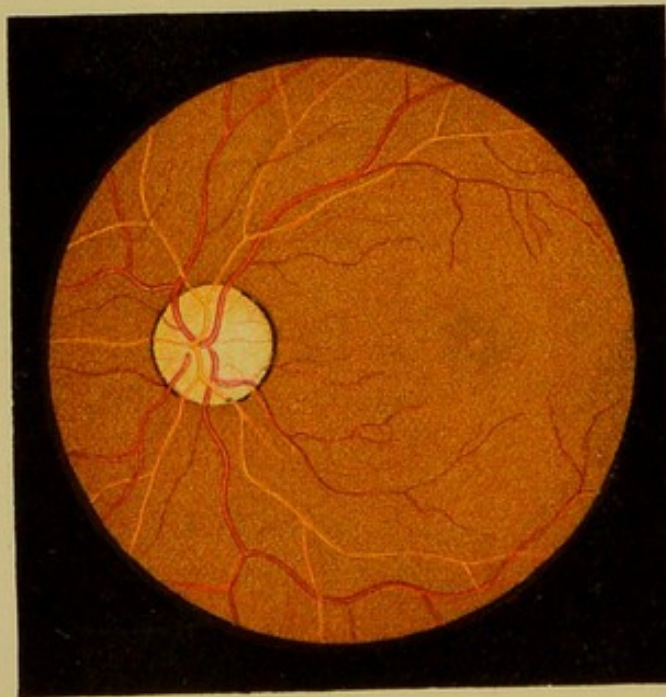
PLATE III.

FIG. 1.



Normal eye-ground (average tint).

FIG. 2.



Normal eye-ground (brunette).

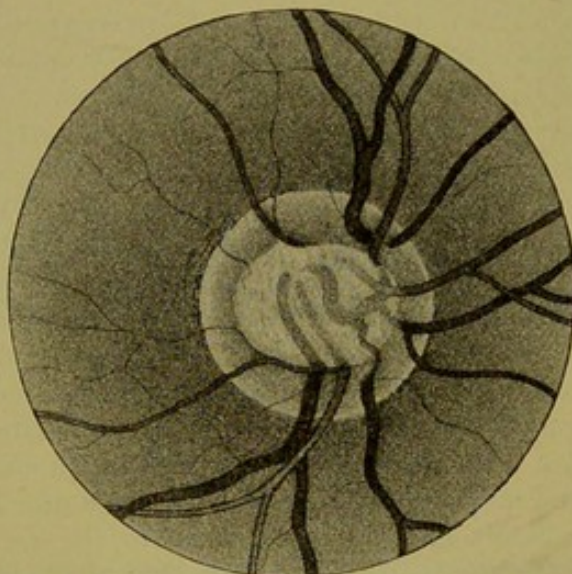
CHAPTER XX.

DISEASES OF THE RETINA.

OWING to the transparency of the retina and its abundant supply of bloodvessels, as well as to the delicacy of its fibre-layer and that of the head of the optic nerve, frequent and admirable opportunities are obtained, not only to study changes of transparency and color in these organs, but also to note alterations in their bloodvessels and in the color of the blood that circulates within them. Although these delicate tissues are protected from sudden variations in temperature and from wounds by the eyelids and the more superficial parts of the eye (thus comparatively seldom giving opportunity for the study of purely local inflammation), yet, as a matter of fact, there are but few severe diseases or dyscrasiæ in which pathological changes in the retina and the optic nerve are not frequently encountered. In order to note them and to get a rapid and correct idea of their location in the eye-ground, our attention is usually first turned to the optic disk. This, which, as previously shown, measures from one and a half to two millimeters, in reality appears from nine to eighteen millimeters in diameter, as seen under the compound magnifying-glass of the cornea and lens. Although anatomically it is rarely circular, yet, owing to the frequent presence of astigmatism and to the fact that the shorter curve of the cornea is ordinarily approximately vertical, it is generally seen as an upright oval. As a rule, its color is yellowish-white, with a pinkish or reddish tinge. This is due to the varying capillarity of its nerve-fibres. Its peripheral edge is indicated by a narrow white line, more or less completely encircling it, which in turn is bounded by broken lines or massings of pigment. The white line is termed the *sclerotic or connective-tissue ring*. The pigmented line is called the *chorioidal ring*. The surface of the disk is frequently not curved to correspond with the curve of the surrounding retina, being generally more prominent, and hence called the *optic papilla*. Ophthalmoscopically, it varies much in aspect according to the manner in which the nerve-fibres divide in it as they pass into the retina, causing it in some instances, when they turn abruptly in its level without separating into bundles, to appear nearly flat and to correspond in curvature with that of the retina. Frequently, there is a so-called pit or excavation, which, on account of the reflection of light from its sides and bottom, appears whiter and more luminous than the surrounding nerve-tissue. This is owing to the nerve-fibres dividing into bundles as they enter the eye, and diverging from one another before they reach the retinal level. These physiological excavations vary greatly in size. Sometimes they form conical pits, and at other times, they are larger, with sharp-cut, undermined edges. On focussing for the bottom of them, they appear spotted when

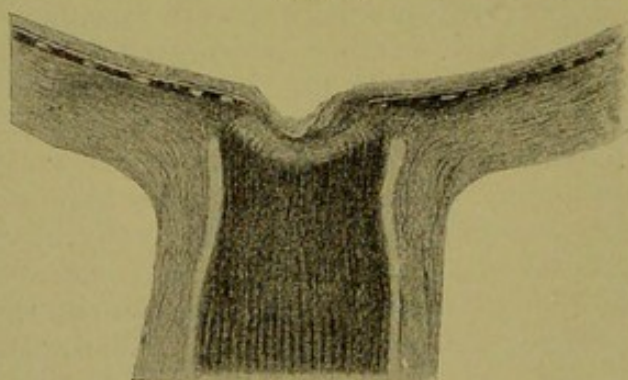
they are wide and deep. This is caused by the meshes of the lamina cribrosa reflecting more light than the nerve-fibres which pass through them. As there must always be room for the bundles of nerve-fibres which branch out in the retina in every seeing eye, no physiological excavation can ever extend out to the connective-tissue boundary of the disk or scleral ring. Owing to the extreme transparency of the nerve-fibres in some instances, it becomes difficult to recognize the exact extent of the excavation ophthalmoscopically. As is shown by anatomical investigation, these depressions often appear larger, especially to the temporal side, where the fibre-layer is thinnest.

FIG. 263.



Ophthalmoscopic view of physiological excavation. (JAEGER.)

FIG. 264.

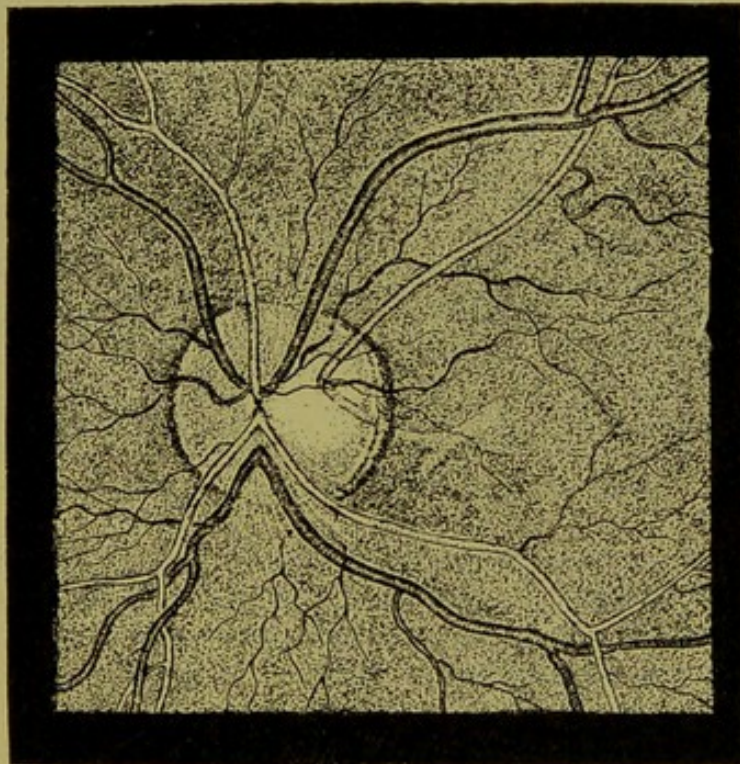

Section of physiological excavation. (JAEGER.)

Figs. 263 and 264 represent a large physiological pit as seen by the ophthalmoscope during life, and in the retina under the microscope after death. It is deepest near the upper temporal margin. The retinal vessels, having pierced the nerve behind the globe, enter the eyeball nearly in the centre of the optic disk. If there be a physiological pit, the vessels generally enter in it or at one of its borders. Owing to the

fact that the vessels often divide deep in the optic nerve, their apparent number is variable. At times, they become visible to the ophthalmoscope as two trunks, and do not divide until they have nearly reached the retinal level. The variations and anomalies in the distribution of these arteries and veins are as great and as frequent as those found in other organs of the body. Study of the reproduction of Jaeger's plate of normal eye-grounds numbered 1 and 2, facing page 439, will make the average distribution, as shown on page 73, readily understood. Just inside of the cribriform fascia, the central retinal artery gives off branches which form an arterial circle which anastomoses with the short ciliary arteries that enter the chorioid near the optic nerve. By reference to Figs. 244 and 245, showing the sclerotic arterial

FIG. 265.



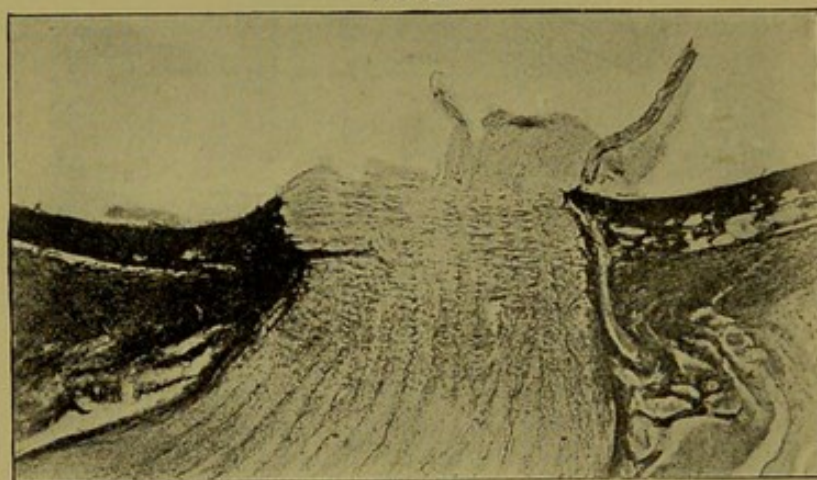
Ophthalmoscopic appearances of a cilio-retinal artery. (RANDALL.)

anastomoses found in the healthy eyes of a child and of an adult, it will be seen that a small but important anastomosis is here formed between the circulation of the retina and that of the chorioid, which in congestion and inflammation of the latter membrane, causes the increased vascularity of this circle and its branches to be seen as a dull, deep-lying redness of the optic nerve. Besides this anastomosis, a so-called "errant vessel" may be found at the outer side of the disk, which, springing from the short ciliary arteries, enters obliquely through the optic nerve and is distributed through the retina. Fig. 265 gives an excellent representation of the ophthalmoscopic appearances, whilst Fig. 266 shows a microscopic section through such a vessel. Beyond this point, the central artery of the retina is strictly an "end-

artery," and does not communicate with any of the vessels that supply the other tunics of the eye or its envelopes.

The color of the retinal blood-columns is yellowish-red in the arteries, and purplish-red in the veins. On both sets of vessels in their larger branches, but more plainly seen in the arteries, is a lighter streak or line of light running along their convexities. This phenomenon has given rise to much discussion, being held by some to be a reflection of light from the wall of the vessel. By others, for instance, by Loring, it is said to be a line of concentrated light which, reflected from the underlying chorioid and retina, is concentrated by the blood-column as by a cylindrical lens. Others, such as Jaeger, assert that in ordinary circumstances, the walls of the vessels have so nearly the same index of

FIG. 266.



Section of a cilio-retinal artery. (RANDALL.)

refraction as the retina, that they are invisible, the line of light being reflected from the blood-column itself. They state that it is therefore more intense and better marked in states of chlorosis, than it is when the blood is rich in albuminous elements.

Pulsation of the retinal bloodvessels. Probably one of the most striking circumstances noted, when for the first time one looks at the retinal circulation, is, that there is so equable a flow of blood, that no apparent current and no variation in the size of the vessels can be seen. This is due to the minute size of the vessels, their distance from the heart, and the inhibitory and regulating effect of the intra-ocular pressure. Where, however, from any cause, the cardiac impulse is increased, or there is slight increase in the intra-ocular pressure, the so-called venous pulse can be noticed. This is manifested by a momentary emptying of one or more of the main venous trunks near their points of disappearance in the substance of the optic nerve. Here, the vein collapses for a short distance and the blood retreats from the optic nerve toward the periphery, to be followed by a return rush of blood from the periphery toward the optic nerve again. This phenomenon can be usually produced by slight pressure on the eyeball with the finger. The explanation of its production appears to be, that where the intra-venous and intra-ocular pressures are nearly balanced, a slight increase of the

latter may cause the impulse of the entering arterial blood to be transmitted to the vitreous. From here it is thus extended directly to the proximal extremity of the veins, where the intra-venous pressure is lowest, before the entering blood-column has found its way through the capillaries into the veins. When this occurs, the pressures are once more equalized, and the current flows steadily till the entrance of the next arterial pulse-wave, when the phenomenon is repeated and continues until the intra-venous pressure becomes equal to or higher than the intra-ocular pressure.

Arterial pulse in the retina. While the venous pulse is of common occurrence in subjects in whom both the constitutional and the local conditions are healthy, the occurrence of arterial pulse is always a sign of serious disturbance either in the eye itself or in the general circulation. It may, however, be artificially produced at all times, by exercising considerable pressure on the eyeball with the finger. When spontaneous, it indicates a great disproportion between the intra-arterial and the intra-ocular pressures. Where it is found, we may be sure of the presence of something which causes undue diminution of the first or augmentation of the second beyond the normal standard. In short, wherever the intra-ocular pressure is much above the intra-arterial pressure, the heart has only the power to force the blood into the eye during its systole; while during the period between the pulse-waves, the intra-ocular pressure closes the calibre of the artery, and thus, by momentarily preventing the passage through the artery, gives rise to the formation of a visible pulsation in the vessel. We may, therefore, with a normal intra-ocular pressure, find a pulse in the retinal artery from any cause which materially reduces the intra-arterial pressure. Thus, it is frequently seen in cases of marked aortic insufficiency with regurgitation, in aneurism of the arch of the aorta or of the carotids, or temporarily, in the failure of the heart-impulse during an attack of syncope. On the other hand, where there is a marked increase of intra-ocular pressure, as in those cases of glaucoma where blood is excluded from the eye except during the maximum of intra-vascular pressure, it may also be found.

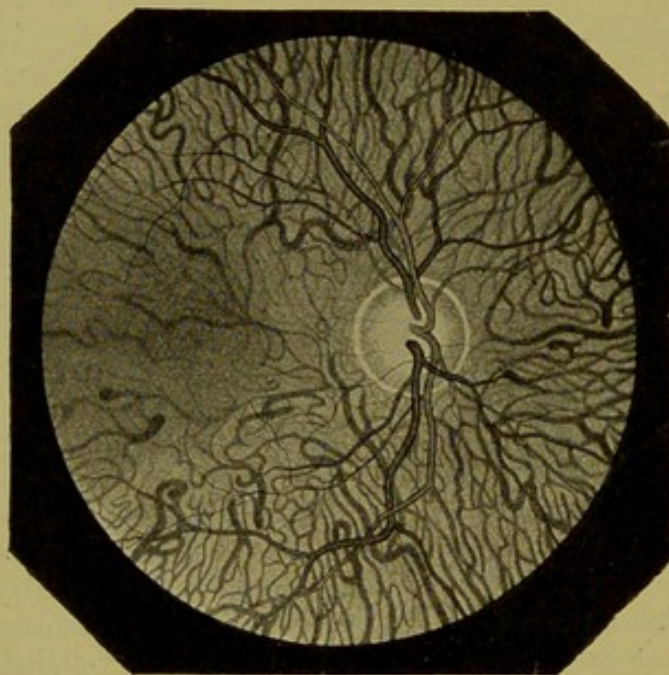
The remainder of the eye-ground presents a yellowish-brownish red color. This is due to the reflection of light from the pigment in the epithelial layer of the retina and the vascular interspaces of the chorioid, as well as from the red blood circulating in those vessels and capillaries of the latter membrane, which are too small to be visible under the magnifying power of the lenses of the eye. The chorioid appears granular, not because the individual pigment cells are seen, but by reason of the observer's ability to appreciate their grouping within a capillary loop. By careful focussing with weak light, he can distinguish the thin, whitish veil of the retina spread out over the chorioid. It can be recognized most easily near the disk, where its fibre-layer is the thickest. In this position, the disposition of the retinal fibres can almost always be followed by careful focussing. In cases of disease, they often become readily manifest. In consequence of the contrast with a darker fundus, the retina is also much more plainly visible in darkly-pigmented races.

According as the region of the yellow spot is viewed in the upright

or in the inverted image, it appears very different. With the upright image, the entire macular region is found to be generally more darkly pigmented, its centre being free from any vessels of a size that are visible with the ophthalmoscope. The fovea centralis is often marked by a yellowish reflex. When the same region is studied by the inverted image, with dilated pupil, the macula, especially in the young, appears as an oval area, which is decidedly darker than the rest of the eye-ground. At times, it is surrounded by a light-yellowish curvilinear reflex.

Anomalies often encountered and consistent with good vision. Very slight variations in the amount and distribution of the pigment within the eye, make marked differences in the appearances of the eye-ground. Thus, in the dark races and in persons with very dark hair and skin,

FIG. 267.



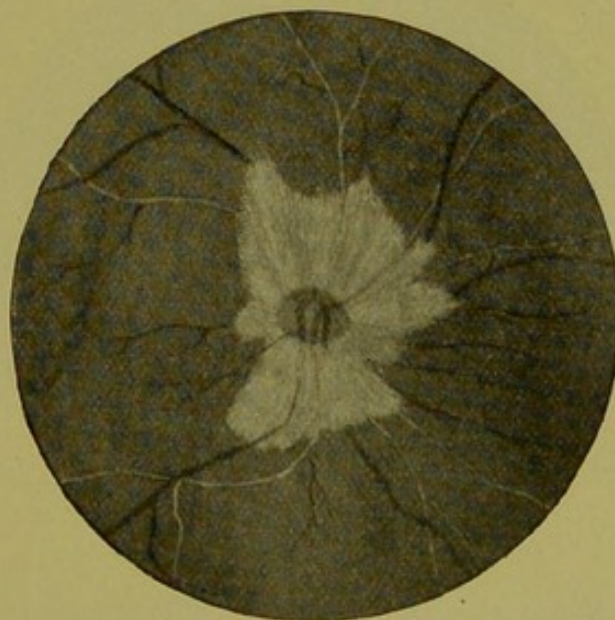
Ophthalmoscopic representation of an eye-ground of an albino. (JAEGER.)

the general color of the fundus is brownish, as shown in Plate facing page 439 (No. 2). In very blonde subjects, the larger chorioid vessels toward the periphery of the eye-ground can almost always be seen. In some cases, they are visible throughout the entire fundus, as shown in Fig. 267. In albinos, there is so little pigment in the stroma of the chorioid at times, that white light reflected from the sclerotic between the vessels is found. In more pigmented individuals, the sclerotic is hidden by the pigment in the chorioidal stroma, and this again by that in the epithelial cells of the retina.

Less frequent are the anomalies in the character of the fibres of the optic nerve as they bend over into the retina. Occasionally, it is found that after they have, as usual, lost their marrow sheath at the lamina cribrosa, they become once more ensheathed in it in the head of the nerve, or as they pass into the retina. When the medullary covering thus reinvests the nerve-fibres, they appear ophthalmoscopically as dense white and strongly light-reflecting bundles, instead of a delicate

and almost transparent tissue. Generally, they are fringed at their distal end, as they once more die out in their retinal distributions. In exceedingly rare instances, the sheath reappears further on in the periphery, making a detached white patch in the retina. These bundles of opaque nerve-fibres are apt to accompany the larger retinal vessels in their course. At times, they partially or completely hide them. Owing to their opacity, they prevent definite images from being thrown on to the rods and cones beneath them. Accordingly, they manifest their presence either by an enlargement of the blind-spot in the field of vision, when they occupy the ordinary situation around the optic nerve, or by the appearance of scotoma which correspond to the positions of the peripheral patches. Inasmuch as they never invade the macular region, central vision remains unaffected. Fig. 268 gives a representation of a large development of such opaque patches around the optic disk.

FIG. 268.



Opaque optic-nerve fibres.

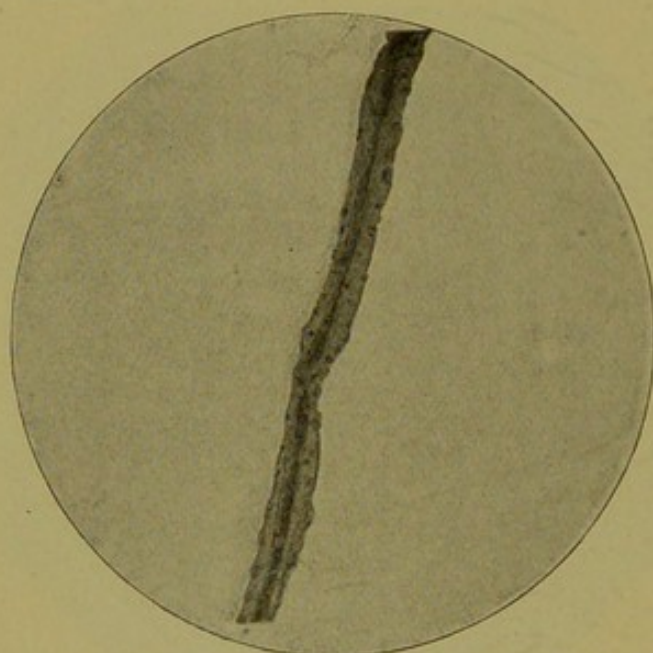
There is a marked difference in the appearance of the eye-ground in childhood and in old age. In the former, the fibres in the head of the nerve are more transparent, allowing the observer readily to focus through them on the meshes of the lamina cribrosa. They are also more capillary, giving the head of the nerve a rosy tint. The retinal vessels stand out and are sharply defined from the surrounding tissues. In old age, the capillarity is diminished, and owing to the haziness of the nerve-fibres, the lamina becomes less visible. Moreover, the vessels at the nasal side of the disk are more or less veiled by the overlying semi-opaque retinal fibres.

At times, variations in the color of the optic nerve, which may appear slightly bluish or greenish without any demonstrable loss of acuity of central or peripheral vision, and without any history of previous disease, are found. In the opinion of the author, these variations, especially when they consist in a dull-gray appearance of the nerve, with perhaps

a brickdust hue in the capillary portions—which may be either superficial or situated at the chorioidal level—are to be looked upon with suspicion; they serving either as traces of foregoing ill-health, of which there has been a failure to obtain a history, or as harbingers of impending trouble. In this, however, as in most other clinical matters, experience is the only safe guide, and it cannot be too strongly impressed on the student, that men's eye-grounds are as various as their faces, and that he who hopes to succeed must study carefully hundreds of either of them, before he will be in condition to make up his mind as to the presence of slight pathological changes.

In almost all eyes which are steadily tasked with near-work, the increased tissue-changes in the retina become visible, permitting the

FIG. 269.



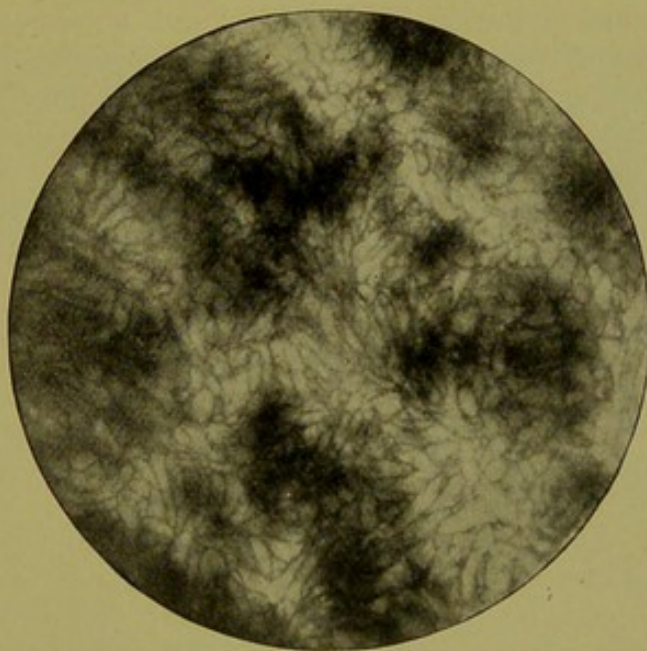
Retinal bloodvessel and lymph-sheath. (PIERSOL.)

normal striation of the retinal fibre-layer to be more plainly seen, and to be followed to a greater distance toward the periphery. The fibres themselves become more opaque and grayer. When, owing to over-work and slow distention of the eyeball, the refraction in young eyes is steadily increasing, these appearances are still more marked; the fibre-layer becoming sufficiently opaque and swollen to obscure the normal outlines of the optic disk, and often so great as to entirely hide the nerve-head at the inner margin, where the fibres are thickest. The main venous trunks become slightly distended and are more tortuous. Their walls undergo tissue-change, their lymph-sheaths infiltrate with fluid, and the cells of the sheaths become granular: each of which is sufficient to render the above conditions visible to ophthalmoscopic examination. At times, grayish or whitish masses can be seen encasing the blood-columns on the optic disk, or extending, in gradually lessened degree, to considerable distances beyond. Fig. 269 shows a retinal bloodvessel from a human retina, with its lymph-sheath, isolated

by tearing. Fig. 270 gives a more highly magnified view of some of the lymph-channels of the retinal tissue after treatment of the tissue by nitrate of silver.

In some cases, especially in the young, bright reflexes along the smaller vessels are obtained with each turn of the mirror. These are especially visible where the vessels bend or turn, giving an appearance which has been likened by some English writers to "shot silk." At the same time, the cells of the retinal epithelium have become swollen, so that each group lying within a capillary loop becomes visible, causing the chorioid to appear abnormally granular, and giving it, at times, a honeycombed appearance where part of the pigment has been absorbed. When the pigment has been aggregated in spots, parts of it may appear

FIG. 270.



Lymph-channels of retina.

as if sprinkled with black pepper. These symptoms are found to a greater or less extent in almost all asthenopic eyes. That they are due to the congestion caused by the eye-strain or over-work, is shown by the fact that they frequently either decidedly diminish or disappear after the eyes have been set at rest by some strong mydriatic or have had their strain relieved by the use of proper glasses. In some rare cases, there seems to be so much exudation and swelling, that a distinct papillitis occurs. Such cases, when accompanied by worrying neuralgia and headache, may become so marked as to give rise to difficulty of diagnosis, and producing, at times, serious apprehensions of intra-cranial disease.

Hyperæmia of the retina. This condition may be frequently seen in cases of commencing acute iritis and cyclitis before the media have become sufficiently opaque to obscure the view of the fundus. In confirmation of this, either hyperæmia or inflammation of the retina is almost always found in eyes that have been enucleated for cyclitis. Here, as in many other tissues of the body, it is difficult to draw the exact

line between irritation and inflammation—a difficulty which is increased by the fact that while one can often see distinctly the morbid processes in the retina, he is obliged to trust to the sense of sight alone, and is unable to measure the local increase of temperature in them; it being only where the conjunctiva is alone affected, or where the entire eyeball is inflamed, that an increase of temperature can be demonstrated. In consequence, many morbid appearances which possibly would be more accurately defined as hyperæmia with œdema, are, for convenience sake, classed as retinitis. Where the foregoing appearances are of high grade, especially if there is any marked impairment of function, and where the tissue-changes are accompanied with hemorrhages, the condition is usually spoken of as *retinitis*.

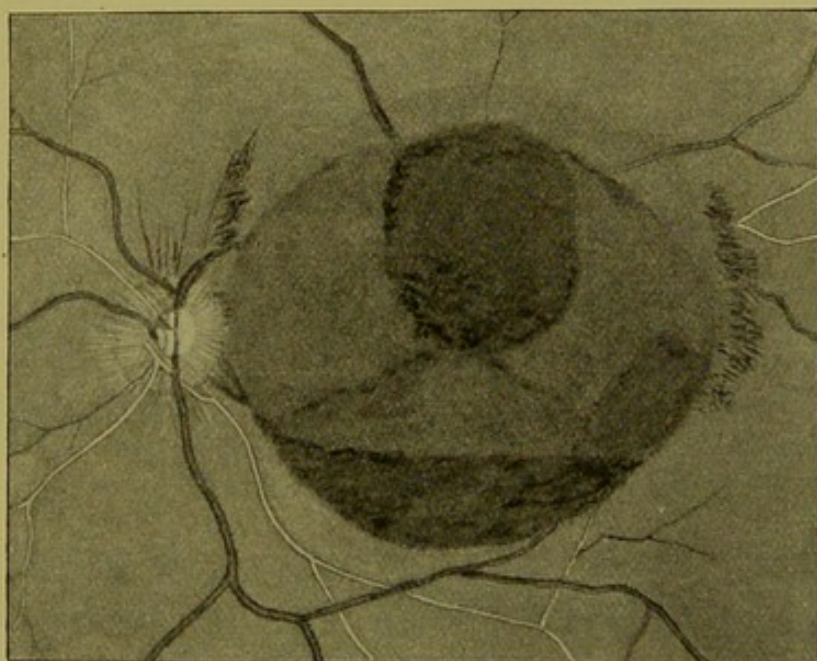
Retinal hemorrhage. This does not necessarily imply accompanying inflammation, but when the hemorrhages are numerous and are accompanied by marked dilatation of the veins and serous swelling of the retina, the morbid process is usually denominated *retinitis hæmorrhagica*. Where the retinal hemorrhages occur in the fibre-layer, they are usually irregularly linear in outline, the blood following the course of the fibres. In the deeper layers, they assume a more or less globular shape, this being dependent upon the fact that the extravasation meets resistance to its course from the radiating connective-tissue fibres of Müller. At times, small hemorrhages may remain confined within the lymph-sheath of the bloodvessels, encasing the vessels for a short distance. When the escape of blood is large, it sometimes breaks through the retina and hyaloid membrane into the vitreous. At times, a little clot is found caught in the passage thus forced, lying directly over the ruptured vessel and pointing to it. Generally, however, it is impossible, with the magnifying power at command, to trace any rupture of the vascular walls. For this reason, Leber is inclined to believe that most retinal hemorrhages are due to diapedesis. In some rare cases, large hemorrhages, after escaping from the fibre-layer, find their way between the retina and the hyaloid, and spread out as a concave sheet over the face of the retina. Such hemorrhages, even when they invade the macular region, may be entirely absorbed without any impairment of vision. Large hemorrhages which have taken place in the retinal tissue proper, do direct damage to the nervous elements at the time of their escape from the vessels or during subsequent cicatricial change. If they occur in the macular region, they may cause demonstrable and permanent central scotoma.

Fig. 271 shows a large hemorrhage in the macular region which came on apparently without cause in a healthy woman of forty, and found its way between the retina and the hyaloid membrane. It eventually cleared up entirely, leaving a vision of 20/xx.

Probably because of fatty degeneration, hemorrhages generally lose color, and become transformed into yellowish or whitish patches, which may, in time, be so nearly absorbed that no trace of them remains visible with the ophthalmoscope. More rarely, they leave spots of brownish-black pigment behind them. In elderly people, retinal hemorrhages are often visible signs of a degeneration of the coats of the bloodvessels that cannot be detected during life by the ordi-

nary methods of examination. Where degenerative changes have occurred in the cerebral bloodvessels, hemorrhages in the retina are not unfrequently the forerunners of apoplexy. They are also common accompaniments of albuminuric retinitis, and may be very frequent in many diseases of malnutrition where the character and composition of the blood have undergone marked changes. At times, though fortunately very rarely, recurrent hemorrhages appear in young people from about puberty up to the age of twenty or twenty-five years. The pathology of this type has not been made clear. Although generally occurring in feeble and scrofulous subjects, they may be found in apparently healthy people. Ordinarily, they have been attributed to some functional derangement, such as constipation or suppression of the

FIG. 271.



Hemorrhage in macular region.

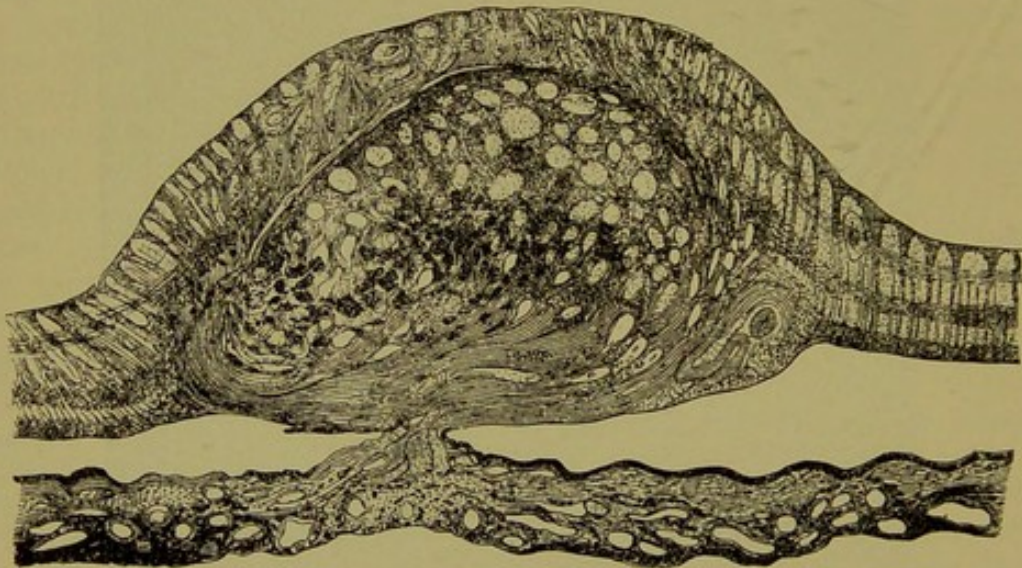
menses. The former condition, however, is often absent, and either sex may be affected. Although, when extensive, their effects are usually most disastrous, yet, fortunately, they are often confined to one eye.

Hemorrhages breaking through into the vitreous, destroy its stroma, and so impair the nutrition of the eye, that either the organ shrinks, or an attack of increased pressure and glaucoma is superinduced. When the effusion of blood is small and is situated in a peripheral and superficial part of the retina, the subjective symptoms of retinal hemorrhage are either slight or wanting. At times, however, the pressure of the blood on the sensitive elements gives rise to flashes of light. When such effusions are situated in the macular region, they are visible as dark spots or scotomata in the centre of the field of vision. Should they cause pressure and dragging on the layer of rods and cones, *metamorphopsia* or distortion of visual objects may exist. When the blood-extravasation invades the vitreous and is extensive,

objects may seem as if seen through a reddish fog, while smaller blood-clots often appear as black spots, which move with every motion of the eye. In many instances, when the hemorrhages are small or are favorably situated, they are gradually absorbed, and leave no visible traces. In others, they cause partial destruction of the retinal tissue, with the formation of pigmented fibrous cicatrices.

Fig. 272 shows such a fibrous cicatrix, where the hemorrhages had caused secondary glaucoma. In this case, the chorioid was little affected, but there were fibrous bands connecting it with the retina, which became continuous with the radiating connective-tissue fibres of Müller, toward the periphery of the cicatrix. After absorption of the retinal hemorrhages, partial or total atrophy of the retina, with blanching of the disk, is sometimes found. At times, this condition is associated with thickening of the walls of the bloodvessels or with obliteration of their lumen.

FIG. 272.



Pigmented fibrous cicatrix. (LEBER.)

Treatment of retinal hemorrhage should vary with its cause and with the state of health of the individual. A light pressure bandage will often hasten the absorption of the effused blood, whilst much may be accomplished in stimulating tissue-change and osmosis, by watery cathartics and diuretics. In the feeble, these measures should be aided by good food and tonics, in order to alter the composition of the blood and render diapedesis less probable. All violent exercise, such as lifting, or anything tending to unduly increase congestion of the head and face, such as stooping, should be avoided.

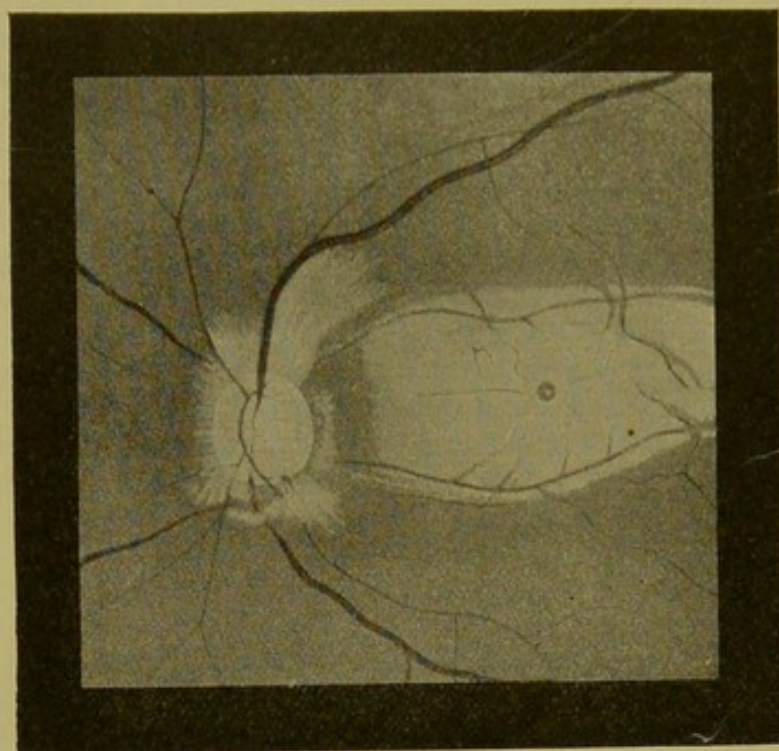
In studying the various morbid states of the system, physicians are in the habit of looking at the skin of the face, at the lips, the tongue, and the finger-nails, for evidences of the color of the blood and of the state of the circulation. In many instances, however, they can better appreciate such changes by observing the retina and the head of the optic nerve with the ophthalmoscope,

where not only the general tint of the part is seen, but the blood-columns lie open to view and are studied under a magnifying-glass. For instance, in pneumonia and pleurisy, the insufficient aëration of the blood becomes evident in the retinal veins, by the darker color of their contents; while in various states of anæmia and chlorosis, the hæmoglobin appears to hold on to its oxygen and not give it up to the tissues in the capillary circulation, thus causing the venous blood to appear very much like the blood that is found in the arteries. Again, in leucocythæmia and pernicious anæmia, where the constitution of the blood is gravely altered, the color-changes are manifest also in the chorioidal circulation, giving the eye-ground a yellowish tint.

Embolism and thrombosis of the retinal bloodvessels. Von Graefe, in 1859, was the first to diagnosticate embolism of the central artery of the retina with the ophthalmoscope, the diagnosis being proved by Schweigger, who found the embolus lodged in the artery just behind the lamina cribrosa. Since that time, numerous cases have been described, several of them having been substantiated by autopsies. The affection, which generally appears as an accompaniment of extensive valvular disease of the heart, is a rare one—rarer than in other parts of the body. Mauthner has pointed out that this rarity is probably due to the fact that the internal carotid gives off the ophthalmic artery nearly at a right angle; this, in turn, giving the central retinal artery in the same manner, so that floating emboli are readily carried past the orifices of these channels into other branches.

The most pronounced symptom of embolism of the main trunk of the central retinal artery, is rapid and complete blindness. In some cases, this is instantaneous. In others, it comes gradually as a fog which moves from the periphery toward the centre of the field of vision. Ophthalmoscopically, the arteries appear to be lost to view in places within a few hours after the lodgment of the embolus. In others, they seem to be much diminished in calibre, while the veins are lessened in diameter; the latter being usually more full of blood in the periphery of the eye-ground than on the disk. Under such circumstances, owing to complete stoppage of the artery, it is impossible to produce either venous or arterial pulsation by artificial pressure on the eye. As the nutrition of the retina soon becomes deranged, and the membrane partially opacifies, a thick whitish veil is formed over the eye-ground. In this veil, the fovea centralis appears, by contrast, as a cherry-red spot. Fig. 273 represents the eye-ground of embolism of the central artery, as seen twenty-four hours after the lodgment of the embolus. This condition is followed by one of gradual atrophy of the retina and of the head of the optic nerve; the latter becoming white and shrunken, with marked reduction in the size of the branches of the central vessels. The retinal haze gradually disappears. In some cases where the stoppage of the circulation by the embolus is incomplete, the blood in the veins and arteries is broken into short cylinders, with empty interspaces, as the current begins to re-establish itself. This irregular and slow circulation of the blood is manifest to the ophthalmoscope by an alternate filling and emptying of the calibre of the vessel at any given point by the blood-cylinder.

FIG. 273.



Embolism of central artery of the retina. (LIEBREICH.)

Embolism of a branch of the arteria centralis retinae. This form of the affection presents somewhat different symptoms. Here the blood is cut off from only one part of the retina, and this part alone becomes cloudy, or has the calibre of its supplying arteries diminished. Hemorrhages and infarction of the affected area with blood, are often met with. Probably because the retina still draws nutritive supplies from the subjacent choroid, the sphacelus which is observed in other tissues following embolus of a terminal artery, does not occur. Upon account of the intra-ocular pressure being sufficient to prevent regurgitation of blood into the eye from the main venous stems, hemorrhagic infarction never occurs in cases of embolus of the main artery. In embolus of a branch, however, regurgitation into the capillary area supplied by the obstructed branch, readily takes place, this being so, because all other unaffected branches are under the same pressure.

The prognosis of embolism of the central artery of the retina is most unfavorable. This is so, because the stoppage of the circulation is soon followed by atrophy of the retina and of the head of the optic nerve. In some instances, the scotoma produced by an embolus in one of the branches of the main artery, may be materially diminished by the development of collateral circulation.

Various plans of treatment have been proposed, all of which are generally ineffective. Iridectomy and paracentesis have been suggested with a view of promptly diminishing intra-ocular pressure, thus aiding the enfeebled retinal circulation. Massage of the eye has also been resorted to in the hope of dislodging the embolus.

Thrombosis of the central retinal vein is a rare affection. It usually occurs in elderly people. The blindness, which comes on almost as suddenly as that in embolism, is said never to be so complete as it is in that affection. According to Michel, the ophthalmoscopic appearances consist in a diffuse and intense reddish haze in the fibre-layer of the retina, which, hiding the outlines of the disk, extends one and a half disk-diameters from it. This area shows numerous small linear hemorrhages which run in the direction of the retinal fibres. Beyond the cloudy area, the retinal arteries and veins again become visible, the latter being very tortuous and turgid with dark, blackish blood. In the periphery of the retina, the hemorrhages are rounded and splotchy, while a dark rounded clot occupies the fovea centralis. Zehender makes two classes of these cases—one, the *marasmic*, which he found in old people; and the other, the *phlebitic*, which he has seen in young persons. Thrombi are of fairly common occurrence in the branches of the central retinal veins. Especially is this so in severe cases of hemorrhagic retinitis.

Prognosis is unfavorable. If the thrombus be large and if it become fully organized, the case must result in atrophy of all the structures of the retina.

Treatment should consist in regulation of the diet and digestion, and in keeping the skin and its secretions in good order. It is said that the subcutaneous injection of strychnia, is often advantageous.

Peri-vasculitis (so called) is that condition in which the retinal vessels appear as white cords, this being produced on account of their walls becoming so dense and opaque, in places or throughout, as to hide the underlying blood-columns. Although it may show itself after simple neuritis, it is more frequently seen in violent cases of inflammation, such as that which occurs in the course of severe erysipelas, when the eyes are swollen shut and a high grade of exophthalmus develops.

The prognosis is usually unfavorable, being dependent upon the degree of the affection. If the changes be extensive, they surely lead to atrophy of the retina.

Purulent retinitis either forms a part of panophthalmitis, or, in the vast majority of cases, is secondary to suppuration of the chorioid. In some septic cases, however, the retina is either solely or principally involved. Virchow was the first to call attention to such a septic form of inflammation, which he found to be produced by small emboli in the vessels. Heiberg and Roth have demonstrated that these emboli contained numerous micrococci in some cases. More frequently, purulent retinitis has been found as a consequence of wounds of the eye. Berlin, Nettleship, and recently Schöbl, have cited three cases. Each instance was caused by a fragment of gun-cap being driven into the eye, the foreign body making its entry through the cornea, the lens, and the vitreous without wounding either the iris or the chorioid. In every case, the foreign substance was found lying at the bottom of the vitreous chamber. In such cases, the suppuration is either situated mainly in the retina or is exclusively limited to it. It is most marked in the fibre-layer and near the large vessels. In more advanced cases, a sheet of pus is found between the retina and the hyaloid. In this

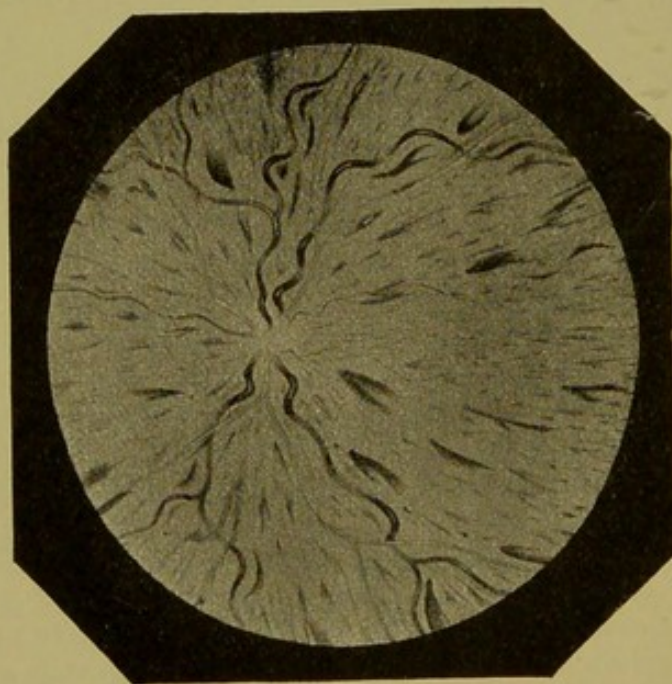
stage, the layer of ganglion cells is affected and many of them are destroyed, while the pus is accumulated in masses between the radiating fibres of Müller. Schöbl has cited two interesting cases where chronic purulent retinitis gave the clinical aspect of glioma. In these, the autopsy failed to show any involvement of the chorioid or any new growth.

As regards the eye, prognosis is always unfavorable, as the disease is often followed by a general panophthalmitis. When it is embolic in its origin, the causes giving rise to it, always threaten life. If the eyeball shrinks, the usual dangers of such degenerative processes to the fellow-eye, lurk in the sightless organ.

Treatment in those cases where the constitutional condition is not grave enough to threaten life, should as a rule consist in prompt enucleation of the eye.

Hemorrhagic retinitis is a term that is generally applied to those cases of retinal inflammation in which, with considerable swelling of the retina

FIG. 274.



Hemorrhagic retinitis. (JAEGER.)

and numerous hemorrhages, no systemic affection, such as Bright's disease or diabetes, can be found. Fig. 274 shows the ophthalmoscopic appearances very well. In many cases, hypertrophy of the left ventricle of the heart, consecutive to insufficiency of the aortic valves, has been noted. The fact, however, that such affections are often one-sided, seems to show that there must be other predisposing causes to account for the condition, such as degeneration of the walls of the retinal vessels or the occurrence of emboli in the smaller branches of the central artery.

The prognosis will not only depend upon the size and the position of the hemorrhages, but also upon the patient's constitutional state. The

immediate dangers are from pressure on the rods and cones. The consecutive ones are due to cicatricial contracture.

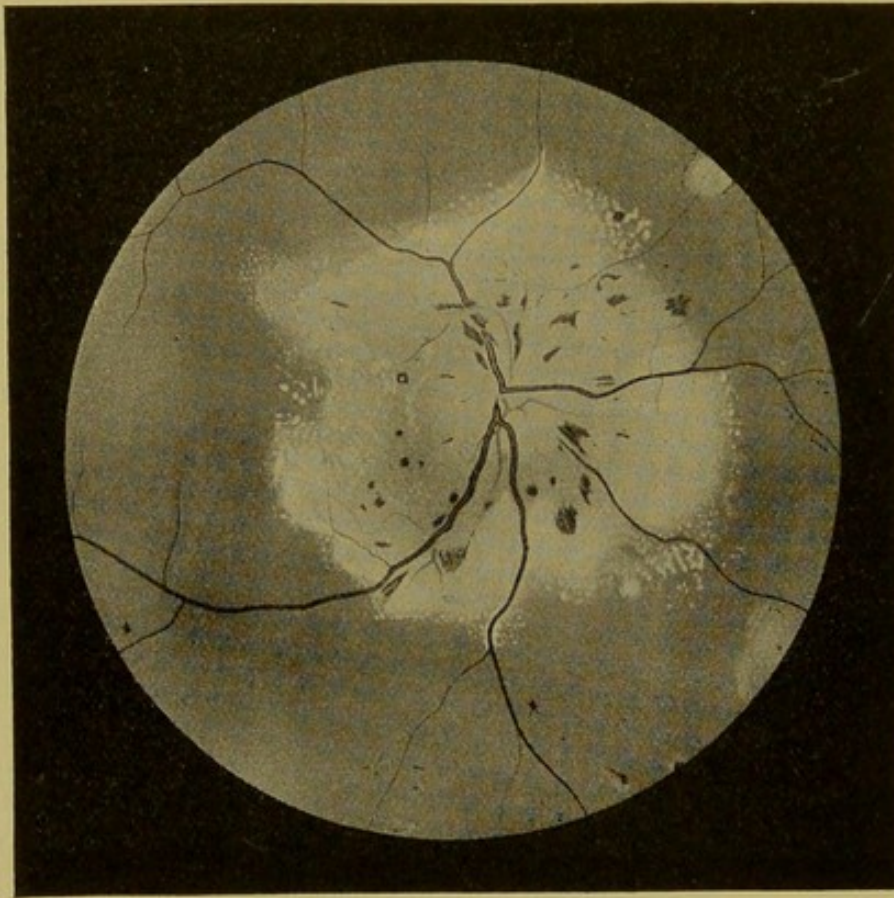
When, as in the case above represented, the retinitis occurs in a patient in middle life, who is full-blooded and a hard drinker, he should be put to bed and have an active mercurial purge administered to him. This is to be followed by a sufficient subcutaneous injection of pilocarpine to produce a good sweat. Local bloodletting from the temple is also advantageous. Subsequently, he should have a course of saline purgatives, such as Bedford or Hathorne water, in order to diminish the blood-pressure and to regulate the liver. Where the hemorrhages are of small extent and are few in number, and where the patients are old and feeble, there is little to be done beyond regulating the diet, digestion, and exercise.

Retinitis from Bright's disease. That dimness of vision is an occasional attendant in this affection, was observed soon after the clinical recognition of the general disease. Bright,¹ whilst discussing eleven cases, "illustrating some of the more insidious attacks which attend a fatal termination," in his second paper on the subject, reports four instances of failure of vision, which occurred from four to six weeks before death. Subsequent experience has shown that the condition often appears at a much earlier stage of the disease. It must always be regarded as an unfavorable symptom. As seen with the ophthalmoscope, it presents very various aspects. These are dependent on the stage of the development of the disease. It distinguishes itself mainly from other forms of inflammation of the nervous sheet, by a greater tendency to fatty degeneration of the tissues involved. As found in dispensary services, it usually presents a type that is very different from that which predominates in the wards of a general hospital. In the former class of cases, the disease seems to fall with peculiar intensity on the nervous system. The patients come, complaining of headache, dizziness, and dim vision, these being the only marked expressions of the malady. Here, the anæmia, dropsy, and other symptoms which are so common to hospital cases, either are absent, or are present in so slight a degree, that the patients do not suppose themselves to be suffering from any constitutional malady that is of sufficient moment to need medical advice. In such cases, the retinal changes are generally very extensive, and it is probable that were we able to examine the living cerebrum as accurately as we can examine the retina, similar and equally developed changes would be here found. Among hospital inmates, a few white splotches, either with or without hemorrhages, in the retina, are often seen. Occasionally, a slight atrophy of the optic disk and retina is the only sign of a previous retinitis. Such patients, whose waxy skin and general appearance indicate how seriously their nutrition has been impaired by the disease, usually suffer from dropsy and dyspnoea. Occasionally, in long-standing cases, where the affection has not been markedly relieved by rest and treatment, there is an opportunity of seeing the development of the typical form of the retinitis. Here, the retinal changes, which begin with slight oedema and striation of the

¹ Guy's Hospital Reports, 1836, pp. 338-380.

disk and surrounding retina, are associated with a few irregular white splotches and striated hemorrhages in the fibre-layer. Although these white patches multiply and extend, they are usually confined within an area of two or three disk-diameters from the optic entrance. In high grades of the ocular affection, they coalesce and form a broad zone around the disk. The disk itself is swollen and prominent, whilst its boundaries are hidden by diverging opaque nerve-fibres. From time to time, fresh hemorrhages occur, which are striated when in the fibre-layer, but assume more or less rounded forms when they invade the

FIG. 275.



Albuminuric retinitis. (LIEBREICH.)

deeper portions of the retina. At the same time, a new series of irregularly linear or quadrate white splotches which radiate throughout the macular region from the fovea centralis, are developed. These, however, which were supposed to be characteristic of the affection, have been observed in a few cases of neuro-retinitis caused by basilar meningitis without any accompanying disease of the kidney. Nevertheless, in the immense majority of cases, Bright's disease can be safely diagnosed where the foregoing typical symptoms are found; whilst a careful investigation of the urine will usually confirm the diagnosis. Generally, the hemorrhages soon lose their characteristic blood-color, fade, turn white, and often undergo absorption. When the lower grades

of retinitis are found in the advanced stages of the disease, the color of the fundus and the blood-columns in the arteries becomes abnormally yellow, while the venous blood loses its pronounced red-purple tint, causing the eye-ground to resemble that which is seen in cases of leucocythæmia and pernicious anæmia.

Although the foregoing description gives a fair idea of the appearance of ordinary cases, instances are sometimes seen where there is only a transient hemorrhagic retinitis without distinctive marks. In rarer cases, the sole lesion may consist of a temporary intense choking of the disk, similar to that so frequently found in cases of brain-tumor. As regards the frequency of retinitis in Bright's disease, statistics vary, some fixing the percentage as low as 7.64 per cent, while others rate it as high as 30 per cent. Although it may accompany any form of Bright's disease, yet it is a concomitant of the advanced stage of cirrhotic kidney in the vast majority of cases. We sometimes, however, find it even in the early stages of the kidney-affection which accompanies scarlet fever, or in the albuminuria of pregnancy.

The acuity of vision in albuminuric retinitis may be either much impaired or but little affected. Ordinarily, the failure of vision is confined to an inability to recognize either colors or form (which require larger areas of exposure) with the same degree of quickness as a healthy eye. In the early stages, the field of vision is generally not materially contracted. Where there are extensive white patches or hemorrhages, there are corresponding scotomata, which are most noticeable when the lesions are seated in the macular region. In rare cases, the retina becomes detached, causing a corresponding defect in the field of vision.

Uræmic amaurosis is much more rare in Bright's disease than albuminuric retinitis. It is often accompanied by convulsions. It is rapid in its development and subsidence, and is without any retinal changes that are demonstrable by the ophthalmoscope. The blindness is evidently due to some transient affection of the cerebral sight-centres. In some instances, it develops where albuminuric retinitis pre-exists.

Dissection of the diseased retina in albuminuric retinitis, shows a great multiplicity of changes. These are found both within this membrane and in its bloodvessels. The fibre-layer is swollen. There is a hyperplasia of the connective-tissue elements, while an albuminous exudation, sometimes nearly homogeneous and sometimes granular or fibrillar in appearance, exists between the fibres. The fibres themselves exhibit spindle-shaped swellings, which are generally aggregated in nests. This condition, which is also found in other retinal inflammations, is known as *varicose hypertrophy of the nerve-fibres*. The hyperplasia of the connective tissue extends through the retina. The radiating fibres of Müller become markedly visible. Those that are situated in the macular region often have a collection of fat globules at their inner ends, giving rise to the appearance of white spots and striæ. Compound granule cells, either disseminate in character or distributed in masses throughout the retina, are also found. These are especially noticeable in the outer and the inner nuclear layers. The former is often thick-

ened and swollen near the disk. In the early stages, the veins and the capillaries sometimes appear dilated. Later, they may appear contracted. The vessel walls exhibit fatty degeneration. This is often most marked in the adventitia. At times, so-called sclerosis, consisting in a transparent thickening of the walls, resembling amyloid degeneration, but not responding to the action of iodine, may be seen. The chorioid often exhibits changes in its bloodvessels that are similar to those described in the retina. H. Müller has especially called attention to a sclerosis of the chorioidal capillaries that is associated with fatty degeneration of their endothelium. This subject has been lately discussed by the Archduke Charles. He holds that the process consists in an obliterative inflammation of the vessels of both the retina and the chorioid; this being accompanied by degenerative changes and swelling, which start either in their fibrous envelopes or in the large vessels that are situated between the muscular coat and the intima. He further says, that as the proliferation increases, the intima is pushed forward in folds and the calibre of the vessel is first narrowed and then obliterated. He considers these changes in the bloodvessels as the forerunner and the probable cause of many others in the retina.

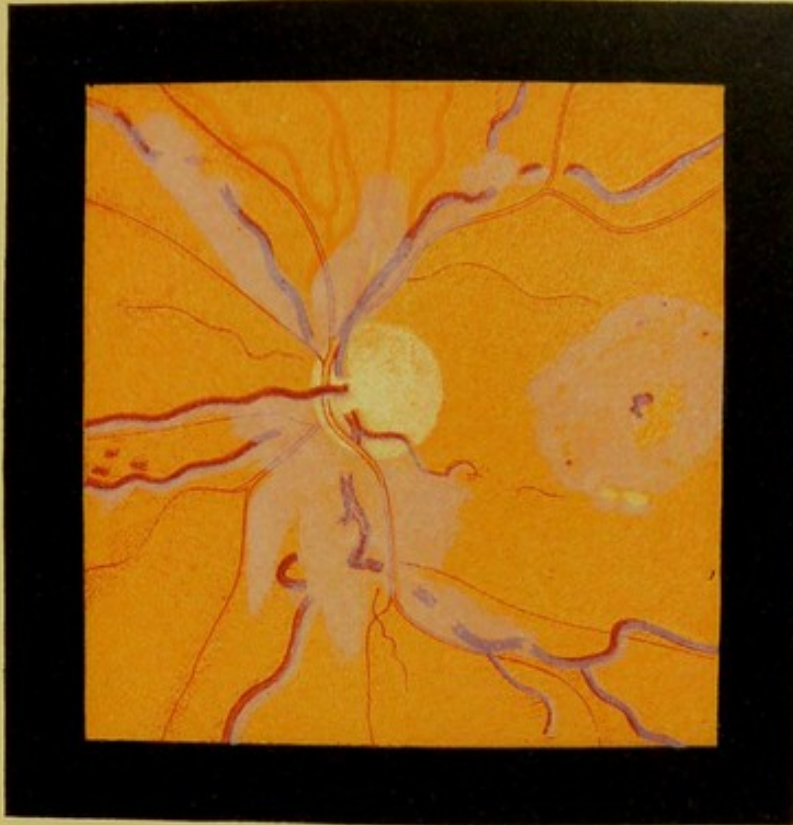As the condition is usually a sign of advanced chronic disease of the kidney, the prognosis is always grave except in acute cases, and although death may generally be expected within a few months, it is sometimes possible to better the acuity of vision very materially. Thus, for example, the author recalls a case which he twice admitted to a hospital. Each time, the patient's eyesight was so blurred that she was unfitted for all useful work, but after a few weeks of treatment, vision improved sufficiently to allow her to return home and attend to her household duties. Within a few weeks after her second return home, she suddenly died of pleuro-pneumonia supervening on the kidney disease.

The walking cases should, if possible, be put to bed and given hot sponging or hot baths. If the patients are sufficiently strong, they should be treated by watery purgatives. Jaborandi in doses that are sufficient to cause sweating and salivation, should also be administered. Ordinarily the latter remedy is best given either by enemata in fluid-extract form or by subcutaneous injections of pilocarpine. This treatment, with a nutritious and unirritating diet composed largely of milk, will generally lead to a marked visual improvement. In more chronic cases, where the symptoms are less urgent, small frequently-repeated doses of bichloride of mercury or some form of Basham's mixture, may be advantageously employed.

Retinitis leucæmica. Liebreich was the first to call attention to this form of retinitis. He gives an interesting picture of it in his Atlas, stating that he has had six cases, all of which occurred in the splenic variety of the disease. Chromo-lithograph No. 1, Plate IV., shows a diffuse retinitis with scanty hemorrhages and marked change in the color of the eye-ground and blood-currents. The blood-columns, especially in the retinal veins, are less intense in color, and have acquired a slight rose-tint. The hemorrhages appear slightly redder than usual. He also describes the existence of white splotches which resemble those that are found in Bright's

PLATE IV.

FIG. 1.




Ophthalmoscopic appearances in retinitis leucæmica.

FIG. 2.



Ophthalmoscopic appearances in retinitis syphilitica.

To face page 458.]



disease, differing from them only in the fact of their more peripheral situation. In one case, these white patches were examined by Recklinghausen, who found them to consist of nests of degenerated nerve-fibres that had undergone sclerosis. Becker¹ has pictured two interesting cases, in which, besides the diffuse retinitis with scanty hemorrhages, the main characteristics were a yellow color of the eye-ground, and large white plaques with red hemorrhagic borders that were situated in the periphery. In the few cases which the author has had the opportunity of studying, the most striking peculiarity has been the change in the color of the eye-ground and blood-columns. In none of these were there either the white patches with the red borders or any extensive hemorrhages. It is probable that the ophthalmoscopic appearances vary in different cases and in various stages. Leber states that the disease sometimes assumes the form of hemorrhagic retinitis.² Gowers thinks that there is a much greater tendency to hemorrhage in leucocythæmia than there is in simple anæmia. He also says that the effused blood is of a pale chocolate color, and that the white or yellowish splotches, which are often edged by a halo of blood-extravasations, are commonly present. Immermann has seen the affection occurring in myelogenous leucæmia, but in most of the cases above cited, it accompanied the splenic variety of the disease.

In cases with but little hemorrhage or exudation into the retina, the prognosis as to eyesight would be favorable, were it not for the fact that the disease of which the retinitis is a symptom, usually proves fatal in a few months or years.

Treatment consists in good diet, with the exhibition of arsenic, quinine, and iron. Mental and physical rest should be strictly enjoined.

Retinitis in pernicious anæmia. Biermer, in 1871, was the first to call attention to the retinal changes found in this grave and comparatively rare disease. Since that time, Horner³ and Quincke⁴ have carefully studied a considerable number of cases. The former records thirty, and remarks that the color of the blood, the distention and tortuosity of the veins, and the numerous hemorrhages, recall the appearances of leucæmic retinitis. He also asserts that the disks are entirely white. The latter, in his latest paper on the subject, records seventeen instances, giving a chromolithograph of one of the retinae. He describes the affection as an œdema of the retina, with numerous hemorrhages. He says that many hemorrhages have white or grayish centres. He finds that others envelop the bloodvessels, causing them to appear varicose by irregularly distending their lymph-sheaths. He says that the œdematous condition produces an ophthalmoscopic appearance, as if a thin bluish-white film had been spread over the eye-ground. The author has examined three cases of this disease. In all, there was not only a diffuse retinitis with distended veins and pallid blood, but the disk appeared dirty-white with a faint greenish tinge, and the eye-ground seemed decidedly yellow in hue. In one, there were no other patholo-

¹ Archives of Ophthalmology, vol. i. pp. 341-358.

² Graefe und Saemisch, vol. v. S. 599.

³ Klinische Monatsblätter für Augenheilkunde, 1874, Ss. 458-459.

⁴ Deutsche Archiv f. klinische Medicin, 1877, Ss. 1-31.

gical appearances. In the second, there were only a few small hemorrhages in the lymph-sheath of some of the vessels near the macula. In the third, there were numerous irregularly round or ovoid hemorrhages that had yellowish-white centres. It is evident, however, from the statements of Quinke, that any one case might, in various stages, present all these phases.

From the impaired nutrition of the retina and the optic nerve, as well as the tendency to low-grade atrophic processes in these tissues, the outlook as to vision is threatening. The disease itself is frequently relapsing and is often fatal.

According to Osler,¹ the best treatment for pernicious anæmia is rest in bed, with light nutritious diet and massage. These measures are to be aided by increasing doses of arsenic.

Retinitis in diabetes mellitus is of occasional occurrence. In a few of the recorded cases, the urine has been so carefully examined as to exclude any coexisting Bright's disease. In some instances, both affections simultaneously exist with retinal changes. Frequently, the retinal disturbance bears a close resemblance to that which occurs in Bright's disease. It is distinguished from it mainly by the fact that the changes are more uniformly distributed over the retina and that they are less confined to the area around the disk. Vitreous opacities are common, and are very often dense. Sometimes, the media remain clear. Jaeger gives an admirable picture of such a case, in which there was not only sufficient retinal swelling to hide the outlines of the nerves, but there were numerous hemorrhages and yellow splotches. In his description, he mentions that there was a marked central scotoma, which consisted of a dense area that was surrounded by a lighter one. In such cases, it is not clear whether these blind spots are due to retinal changes in the macular region, or whether they are dependent upon a coexisting affection of the optic nerve; such affections in diabetes being much more common than the retinitis. In Jaeger's case, the periphery of the retina was but little affected, since the patient could still decipher the letters of No. 18 of his test-type when they were placed excentrically.

Retinal changes in oxaluria are rare. They consist of hemorrhages with a low grade of retinitis. Fig. 276 gives a picture of a retinitis which was associated with formation of new vessels in the vitreous. This occurred in a case where there was an abundant deposit of oxalate of lime in the urine.

Retinal changes in diseases of the liver. In congestion of the liver and abdominal plethora, Förster has called attention to a hyperæmia of the retina that coexists with a diminished range of accommodation. Here the ophthalmoscope often shows premature senile degeneration of the lens with faint striæ in its extreme periphery. This state of affairs can be best benefited by proper exercise and baths, with the use of saline aperients, such as Saratoga, Vichy, and Karlsbad. Occasionally, retinal hemorrhages occur in cases of grave disease of the liver. Litten² says that for ten years he has examined every case of liver

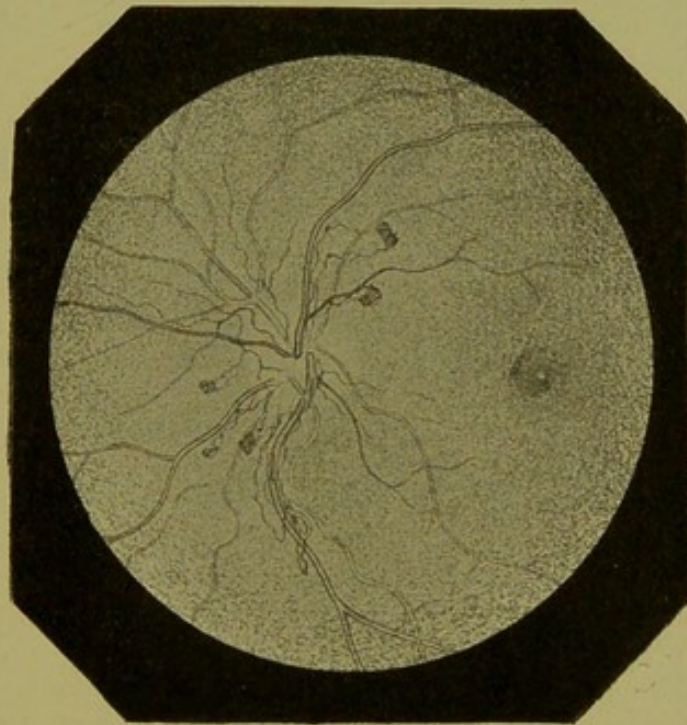
¹ The Principles and Practice of Medicine, 1892, p. 996.

² Deutsche med. Wochenschrift, 25. März, 1882, Ss. 179-182.

disease that came under his charge with the ophthalmoscope, with the result of finding retinal hemorrhages but fifteen times. They are said to occur only when jaundice is present, and to be more frequent in the deeper layers of the retina.

Xanthopsia is a rare complication of liver-disease. Rose¹ cites a case in which the violet end of the spectrum was shortened in the same manner as is found in santonin-poisoning. The blue-blindness was so marked in this case, that a few days before the patient's admission to the hospital, he had excited the astonishment of his fellow-workmen by mistaking the color of a door which had been freshly painted blue. The autopsy showed that the cornea was stained deep yellow. The

FIG. 276.



Retinal changes in oxaluria. (JAEGER.)

lens and the vitreous were colorless. Jaeger has called attention to the light-yellow color of the eye-ground and retinal blood in cases of jaundice.

Retinitis syphilitica. Although haziness and congestion of the retina are not infrequently observed in syphilitic iritis, yet the term above used is generally applied to a characteristic form of retinal inflammation, which appears after the condylomata, the mucous patches, and the skin eruptions have disappeared. It may even be present when, perhaps, periostitis has not yet been developed. At this stage, a diffuse retinitis, usually without hemorrhages, is found. It looks as if a gray cloud had been spread over the disk to some two or three disk-diameters into the retina. This cloud extends farthest and is densest near the larger vessels. These, however, retain nearly their usual calibre. When the cloud extends to the macular region, the fovea, as

¹ Die Gesichtstäuschungen Icterus, Virchow's Archiv, xxx. Ss. 442-447.

shown in the chromo-lithograph No. 2, Plate IV., appears as a pale reddish spot that is imbedded in the area of grayish retina. Hemorrhages which are apparently due to thrombosis that has been caused by disease of the coats of the bloodvessels, sometimes occur in some limited area. In many instances, chorio-retinitis is found in the equatorial region of the eye. This is commonly accompanied by numerous point-like opacities in the vitreous, which sometimes appear as if they had been dusted on thin separated layers. The above appearances often allow a probable diagnosis of the general disease to be made. This is strengthened by accompanying cicatrices in the skin and mucous membranes, or by enlargement of the cervical or submaxillary lymphatic glands. Generally, the retinal affection causes very great diminution of the acuity of vision, which, even under energetic treatment, is usually slow to improve. At times, there are discouraging relapses. Another rare variety of syphilitic retinal disease, is the so-called *central recurrent retinitis*. In this form, the most noticeable symptom is a dense central scotoma, that is apparently caused by a gray infiltration of the macular region with whitish spots. If it were not that these macular changes have been accurately described by Graefe, and several other competent observers, the alternate recurrences of the scotoma would incline us to look for a *rétro-bulbar neuritis* as the cause.

The best treatment for syphilitic retinitis is that by mercurial inunction—a drachm of mercurial ointment being rubbed into the skin twice daily. When improvement has been thus obtained, this drug should be followed by ascending doses of iodide of potassium. If, however, the patient becomes anæmic under treatment, or if he has been so, iodide of iron is a valuable remedy. Light but nutritious diet with hot baths and mild saline purgatives, are often useful adjuvants.

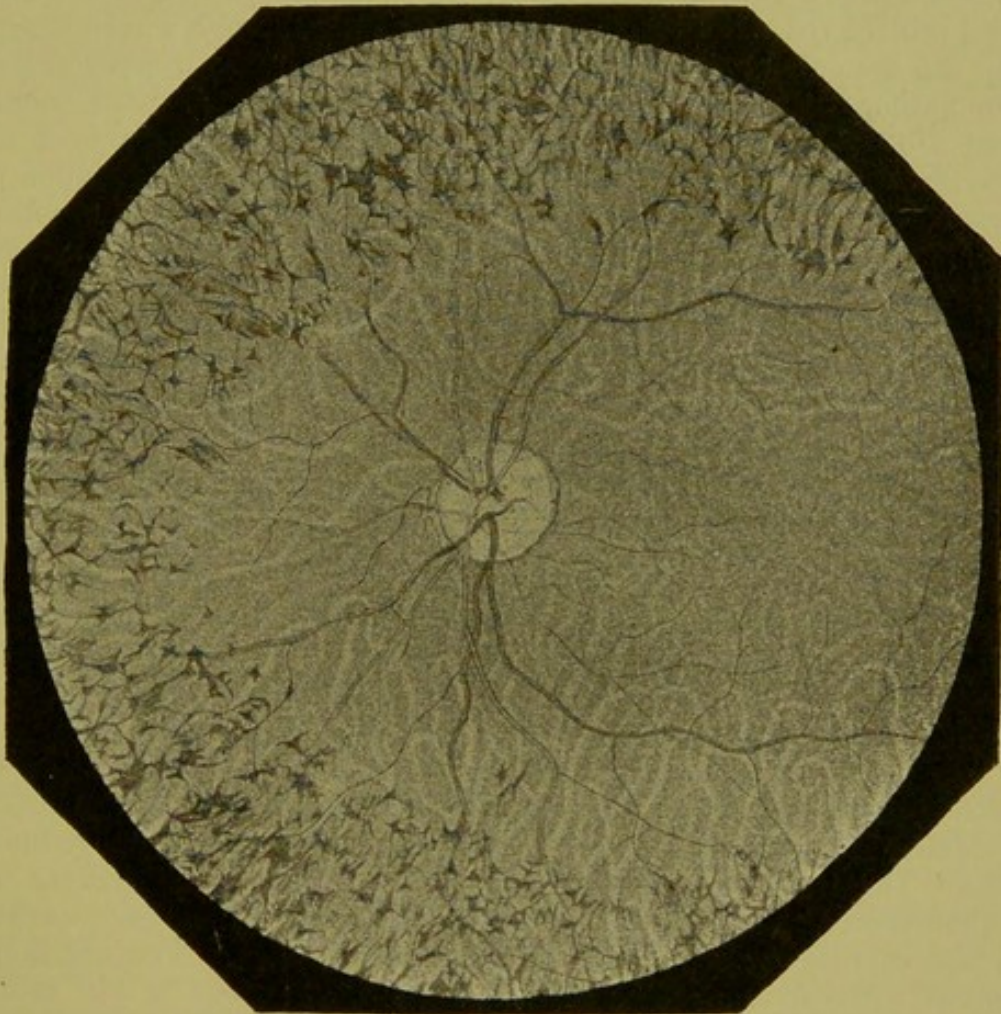
Pigmentary degeneration of the retina (retinitis pigmentosa). Many of the symptoms of the typical form of this affection were well known even in the pre-ophthalmoscopic days—especially night-blindness. In these cases, the ophthalmoscope shows that the disease is accompanied by a progressive atrophy of the retina, and by a formation of irregularly stellate pigment-patches. These patches are first deposited in the equatorial region. As the disease advances, they augment in numbers and gradually extend as an ever-broadening band, toward the macula lutea.

Fig. 277 represents a typical case of the disease in a young subject, with a myopia of $1/32$. There is almost complete absorption of the epithelial pigment, allowing the large tortuous vessels and dark interspaces of the chorioidal stroma to be seen. A considerable portion of this pigment has wandered into the inner layers of the retina and has been deposited at the forks of the smaller vessels. The optic disk is still capillary and the main branches of the central retinal vessels are nearly normal in calibre. The acuity of vision was considerably impaired and the field of vision was so contracted that, taken at eighteen inches, it measured eleven inches to the nasal side, fifteen inches above and below, and eighteen inches to the outside.

In moderately developed cases, the disk and the central bloodvessels are normal in appearance and character. When the epithelial pigment

has been partially absorbed, there is a deposit of it in the inner retinal layers. As the disease advances, this gradual absorption of pigment advances throughout the eye-ground, laying bare the large and tortuous vessels of the chorioidal stroma, which appear as yellowish bands. At times, the epithelial layer which has been robbed of its pigment, appears as a delicate reddish stippling. In other cases, the epithelium takes on a whitish, almost silvery sheen before the pigment is absorbed, this being usually seen in patches. Later, the pigment-area extends farther

FIG. 277.



Typical pigmentary degeneration of the retina. (JAEGER.)

in toward the disk and macula. This is accompanied by a marked diminution in the calibre of the retinal vessels and a gradual atrophy of the retina and the intra-ocular end of the optic nerve.

The disease is frequently hereditary, and may occasionally be traced back for several generations. It attacks many members of the same family. The males are the more frequently affected, although the daughters seem the more likely to transmit the defect. Cunier, in a memoir published by the Société de Médecine de Gand (1838), has related the history of a family in the commune of Vendémian near Montpellier, in which the hereditary transmission could be traced for two centuries (six generations). Out of six hundred and twenty-nine

individuals descended from one Jean Nougaret, eighty-five were affected with hemeralopia, while no others of the surrounding population presented any similar symptoms. It is said also to be one of the results of intermarriage of near relatives. This, however, is probably true only in the sense that in any case of in-and-in breeding, the tendency to reproduce family peculiarities is much strengthened.

The eyes present no external peculiarities. The main symptom consists in varying degrees of night-blindness, with contraction of the field of vision, which constantly becomes worse as the disease advances. This continues, until in many instances, while the patient still retains good central vision, he becomes like one looking through a narrow tube, and can see only those objects which are situated directly in front of him. The author has seen several cases in which, with central vision ranging from 20/XXX to 20/XV, the form-field was limited to from ten to fifteen degrees, from the point of fixation. Throughout the field, sensation for form and color was fairly good. This great narrowing of the field of vision, causing an inability to see but a portion of an object at a time, not only debars the patient from most useful work, but makes reading, for instance, both laborious and difficult. Further, it renders walking in crowded thoroughfares dangerous. The symptoms vary considerably as to the time of life at which they become pronounced, but are generally marked between twenty-five and thirty years of age. At forty-five or fifty, the patient is often rendered practically blind from narrowing of the field of vision and the diminution of the visual acuity. In many cases, the development of posterior polar cataract hastens the failure of vision. Such patients are generally very shy, averse to any prolonged ophthalmoscopic or perimetric examination, and are reluctant to talk about their family history. Allied to this form of disease, are cases of *congenital atrophy of the retina and optic nerve*. These are infrequent, and have been insufficiently studied, to admit of being properly classified.

Anatomical examination shows that there is an increase, with subsequent contraction of the connective tissue of the retina. This starts in the external layers of the membrane and extends through its entire thickness. There is also a migration of pigment from the epithelium into its substance. This, by preference, accumulates in the lymph-sheaths of the capillary vessels and small arteries and veins. The accumulation of pigment is apt to be massed at the bifurcations of the retinal vessels, and thus gives rise to linear or stellate patches. The blood-vessels thicken, become contracted in calibre, and often appear semi-transparent. Later, their tissue-elements become ill-defined. In the further progress of the disease, the epithelium loses its pigment, and the nerve-fibres, the ganglion-cells, and the rods and cones become atrophic.

Pigmentation of the retina frequently occurs in various forms of chorio-retinitis and chorioiditis. Though presenting clinically a different history, yet it exhibits symptoms which sometimes, inasmuch as there is absorption of pigment from the epithelium and a massing of it in the sheaths of the vessels, present somewhat similar ophthalmoscopic appearances. In this form, the changes are generally accompanied by atrophic patches which are situated in the tissue of the chorioid proper.

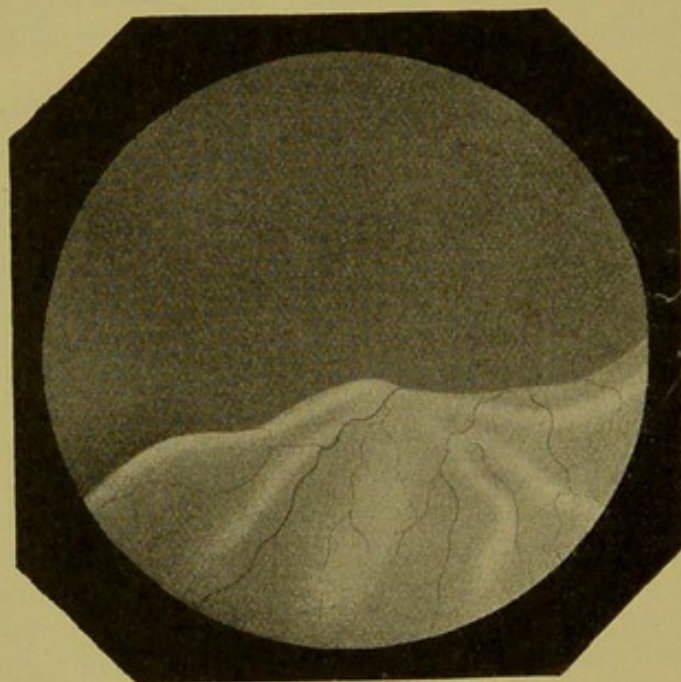In this grouping of cases, the increase of connective tissue is more confined to the outer layers of the retina.

While there is no known way to arrest the march of the malady and to prevent the final blindness, a little can be accomplished to comfort the patients and add for a time to their usefulness and ability in pursuing their vocations. In the hands of the author, the occasional employment of small quantities of bichloride of mercury, aided by strychnine in doses varying from one-sixtieth to one-sixteenth of a grain and continued until some physiological effect is produced, has been of considerable service. The strychnia appears to act by augmenting the blood-pressure and thus driving some nutriment to those portions of the retina which are starved by vascular contraction. This is shown by the fact that there is often a slight extension of the form-field under its use, which is frequently agreeably appreciated by the patient. H. Derby and Standish assert that the use of the constant galvanic current will accomplish the same result.

Detachment of the retina. Where this formidable affection occurs primarily in eyes not bearing the marks of previous active inflammation, it usually appears suddenly. The patients notice a cloud in some part of the field of vision, this being at times accompanied by flashes of light, and by a distortion and an apparent motion of objects. In the majority of instances, the detachment takes place somewhere between the equator and the posterior pole. If it comes forward toward the ciliary body and lens, this result is due to an after-extension. In some instances, ophthalmoscopic examination of recent detachments shows a slight rounded hill or prominence in the retina. Behind this, the details of the chorioid can be only dimly seen. Where the retina retains its transparency, and exhibits no marked change except in its displacement, the detachment may readily be overlooked during a careless examination. Generally, however, a grayish or whitish cloud on which the retinal vessels ramify, can be seen at some portion of the eye-ground. On the prominence, the vessels become darker, lose their central light-reflection, and at times, appear smaller in calibre. The last peculiarity is probably due to the fact that they lie nearer to the nodal point of the combined lenses of the eye, and are, therefore, less magnified. The detachment represented in Fig. 278 came on suddenly in the emmetropic eye of a clerk, while seated at his desk and writing. An ophthalmoscopic examination about half an hour later, showed a large detachment of the retina, which, commencing near the horizontal meridian, about a disk-diameter outside of the disk, extended into the equatorial region. Six days later, the effused fluid had settled to a lower part of the eye-ground and had extended forward to the ciliary region. The picture represents the detachment as it then appeared. At times, a rent or tear in the retina, which is most apt to take place near the equator, may be seen. Through this tear the details of the chorioid are plainly visible. Where the retina is thrown into a number of folds, there is liability to mistake the valley between them for a tear in the membrane. In most cases, vitreous opacities are present. When the detachment has taken place in the upper or in the lateral portions of the retina, it is apt to gradually gravitate toward the bottom of the eyeball, and when the

lesion has existed for any length of time, there is almost invariably a detachment of the lower part of the retina. In the majority of instances, the detached retina ceases to function, thus causing a defect in the corresponding part of the field of vision. Occasionally, however, light-perception is retained for some time. When the effusion has gravitated to the lower part of the eye, the portion of the retina originally detached often reappplies itself to the chorioid and sometimes resumes its functions. It is doubtful, however, whether its physiological action is ever fully re-established. When the parts near the macula are uninvolved, central vision is often good. There is, however, always a certain torpor of the retina, which causes a necessity for bright illumination to obtain good vision. Moderate-sized detachments, which either have originated in

FIG. 278.



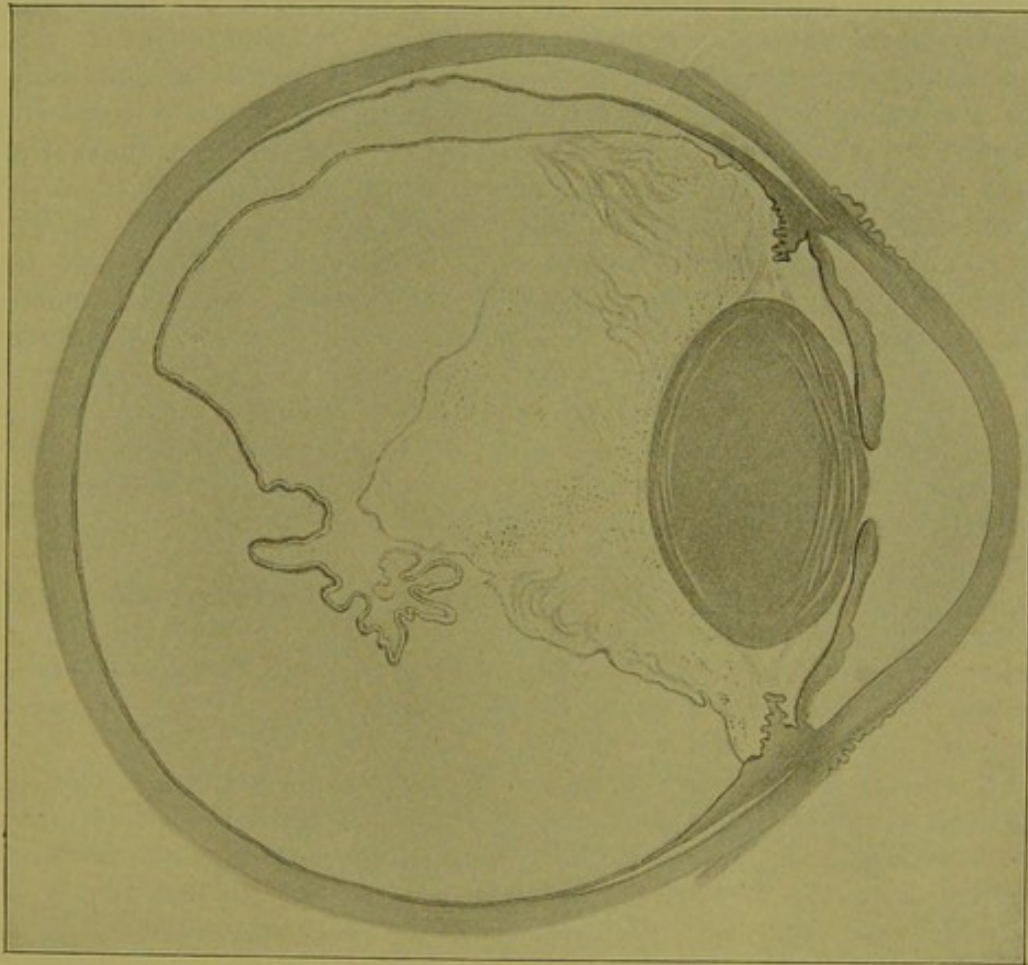
Detachment of the retina. (JAEGER.)

the bottom of the eye or have gravitated to this position, may, at times, remain quiescent for years without appreciable change. Generally, however, there is a tendency for them to become larger and to invade the anterior part of the eye. Sometimes, they come so far forward as to be visible by oblique light. In cases where the detachment is total, the ophthalmoscope shows only gray clouds without any reddish reflex. When the detachments are extensive, and when they invade the anterior parts of the eye, the lens usually becomes cataractous. Plastic iritis, producing a closure of the pupil, or infiltration of the angle of the iris, causing a secondary glaucoma, may also appear. Even in posterior detachment of small extent, there is a marked interference with the nutrition of the lens and a tendency to the development of cataract.

In many cases where there is an inflammation of the anterior part of the eye that is sufficient to prevent ophthalmoscopic examination, it is necessary to rely on the rational symptoms for a diagnosis. These consist mainly in those which are usually found in all cases of detach-

ment—loss of vision ordinarily in the upper part of the field and diminished tension. The amount of mobility of the detached retina is very various. In some cases, the ophthalmoscope shows marked wave-like movements with every change of position of the eyeball. In others, there is little or no perceptible motion. As will be seen in discussing the pathology of the affection, detachment of the retina is always secondary to some disorder in the nutrition of the eye. Ordinarily, where not traumatic, it is a sequence of myopia, of an intra-

FIG. 279.



Detachment of retina, showing communication between sub-vitreous and sub-retinal spaces.
(NORDENSON.)

ocular tumor, or of some form of chorioiditis, or cyclitis. Traumatic detachment, which is apt to appear either as a primary or a secondary change where there has been any large wound of the eyeball that permits of a considerable loss of vitreous humor, is probably either directly caused by sub-retinal hemorrhage from bursting of the chorioid vessels, or may appear as a sequence to retractive processes produced during cicatrization.

As detachment of the retina occurs suddenly in the vast majority of cases, without any increase of intra-ocular tension, and often with but little visible change in those parts of the chorioid that are accessible to

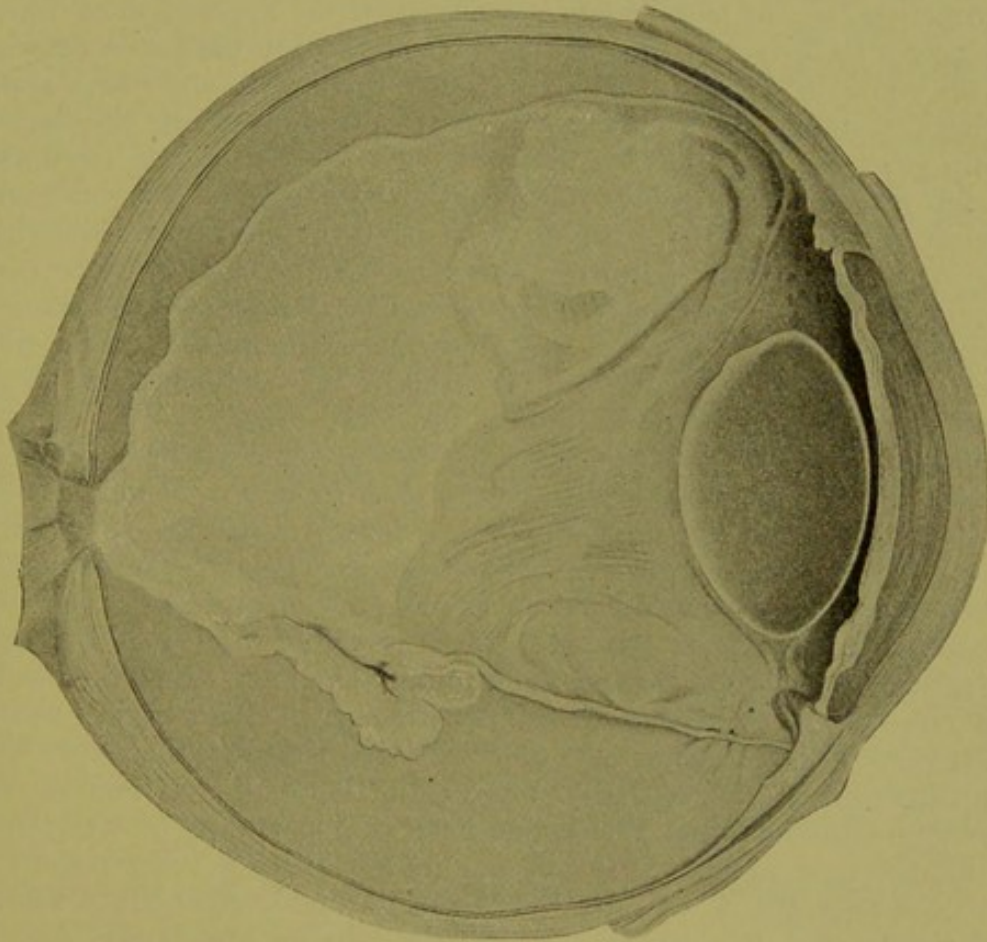
ophthalmoscopic examination, it cannot be supposed that either any considerable quantity of the eye-contents suddenly exudes from the globe to make room for sub-retinal effusion, or that such effusion occurs suddenly without increase of intra-ocular tension. Until the recent careful studies of Leber and Nordenson threw light upon the subject, the pathology of the affection was therefore a riddle. They proved that retinal detachment is usually preceded by coarse fibrillation of the vitreous humor, which, pulling from the ciliary processes, causes detachment of the vitreous and its separation from the inner surface of the retina; the space thus left being filled by a serous exudation. As the vitreous in front of the equator is much more firmly attached to the retina, the detachment is generally situated posteriorly. Continuation of this drag finally causes the retina to tear, this usually occurring somewhere near the ocular equator. The fluid contained in the space formerly occupied by the vitreous, can now suddenly find its way under the retina and there lift the layer of rods and cones away from the pigment layer. The detached portion of the retina now floats forward on the entering fluid, and, inasmuch as there is fluid both behind it and in front of it, it waves with each motion of the eyeball. Fig. 279 represents a spontaneous detachment of the retina which occurred in a myopic eye ($M = 1/12$). The retina is thickened and folded at its posterior part. It thins rapidly between the equator and the ciliary body. The vitreous, which is also detached, is enclosed in it as in a funnel. The posterior part of the vitreous lies in the equator of the eye and its substance is thickened and fibrillated, this being most markedly noticeable in the anterior portion.

Fig. 280 shows the position of a rupture in the retina, which was located by the ophthalmoscope during life. The folding and retraction of that membrane, thus leaving a large opening between the sub-vitreous and sub-retinal spaces, can be plainly seen. The figure also shows the fibrillation of the vitreous.

All retinal detachments do not originate in this manner. This is well seen where the affection forms slowly and is accompanied by great local swelling of the retina, as, for instance, in some cases of albuminuric retinitis, or in the detachment which occurs in the earliest stages of chorioidal sarcoma. In such cases, fluid gradually accumulates behind the retina and pushes this membrane forward against the comparatively intact vitreous. Of course, such detachments do not move freely with the motions of the eye. Later, however, as the vitreous shrinks, a retinal rupture may occur, allowing fluid to be found both in front and behind the retina, and permitting free mobility of the detached membrane. When the detachment is of long standing, the nutrition of the retina is impaired. The interstices contain effused lymph and softened nerve-substance. Its connective tissue increases. In this way, cysts are formed in the retina. The increase of connective tissue is often found most marked along the larger vessels, giving rise to cicatricial bands in this situation. Raehlmann has produced detachment of the retina by injecting strong saline solutions into the vitreous, thus causing great effusion of a dense albuminous fluid from the chorioidal vessels. From this experiment, he reasons that the retina, acting like any other

dialyzing membrane, offers more resistance to fluids in proportion to their density, and that, therefore, a portion of the effused fluid accumulates behind the retina and pushes it from the chorioid. Where the retinal detachment is complete, the retinal sheet is found stretching as a funnel across the eye from the optic nerve to the ora serrata, and containing the shrunken vitreous within it. This funnel-like form is surrounded by a clear yellowish albuminous fluid, which, in the majority of cases, is transparent and free from flocculi and contains, at most, a

FIG. 280.



Spontaneous detachment of retina. (NORDENSON.)

few macerated retinal rods and cones. This has been abundantly proved by the autopsies of Arlt and of Leber, and by the repeated tappings of the eyeball in the living subject as executed by Wecker.

From what has been said of the pathology, it follows that unless some means are found to prevent the further thickening and condensation of the anterior part of the vitreous, and thus do away with the mechanical pull on the retina, all plans tending toward a permanent cure, must usually be illusory. In fact, even if temporary amelioration is obtained, all attempts to remedy this state of affairs are generally in the long run ineffective.

In recent cases, a diminution of the detachment, and sometimes a complete reapplication of the retina to the chorioid, may be secured by

putting the patient at rest on his back in bed, bandaging the eye, and giving him injections of pilocarpine in the temple. Unfortunately, in most instances, this lasts only so long as the patient is kept in a recumbent posture. Graefe proposed perforating, tearing, and cutting the detached retina with needles, thus allowing the sub-retinal fluid to find its way into the vitreous. Drainage of the fluid through an incision in the sclera and chorioid, or aspiration with a subcutaneous syringe, have often been practised. In order to secure permanent drainage, Wecker has inserted gold wires and canulas to prevent the wounds from closing. In order to cause adhesive chorioiditis with cicatricial contraction, he has more lately recommended the application of white-hot points to the sclera, hoping thus, if possible, to produce a drawing of the retina into place. He recommends that six or eight such applications, by means of a galvano-cautery, be made beneath the detachment after rotating the eye upward. He performs the operation as far back as practicable, repeating it every eighth day. Schoeler advocates the injection of two or three drops of tincture of iodine into the vitreous humor. Although these procedures have in some cases produced improvement in the field of vision, and caused the retina to reapply itself to the chorioid, yet these effects are only too often transient. Moreover, the continued invention of new methods points to the inefficiency of those which have been previously used.

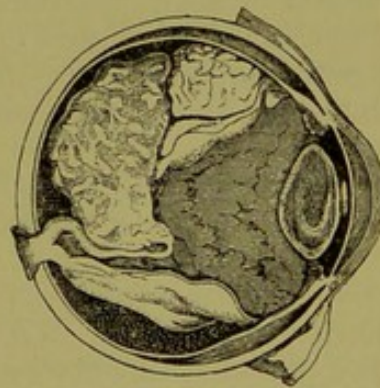
Glioma is a malignant tumor of the retina, which exclusively affects young children and adolescents. It is most frequently found between the ages of six months and four years. Several instances are reported where it has attacked several children in one family. Infrequently, there has been a history of similar trouble in the previous generation. Fortunately, it is a rare disease. At Arlt's clinic there were five cases of glioma out of eight thousand four hundred and fifty-one patients. At Coccia's clinic, there were three out of seven thousand eight hundred and ninety-eight patients. At the Wills Eye Hospital, there have been but nineteen out of one hundred and eight thousand five hundred and seventy-eight patients. We seldom have an opportunity of studying it in its incipency, as the little patients are not likely to complain of dim vision. It is only when the pupil begins to dilate, and when a whitish reflex behind it becomes visible, that the parents first notice that the eyes are affected.

The ophthalmoscope reveals a whitish tumor of the retina, which is covered by blood-bearing retinal vessels. Occasionally, it is sprinkled with minute hemorrhages that project into the vitreous chamber. The growth itself is usually yellowish-white, with spots which are more opaque and are more saturated in color. Sometimes, other little whitish spots of commencing retinal infection may be seen. During this stage, there is neither increase of tension nor pain. As the mass grows, the eyeball becomes hard, and the pericorneal veins become injected. There is cloudiness of the cornea and aqueous humor. At times, there may be the formation of cataract. The increasing tumor infiltrates the chorioid and the ciliary body, and, either by displacement of the peripheral insertion of the iris or by proliferation through the pupil, reaches the anterior chamber. Later, the cornea has

its nutrition so greatly interfered with, that it sloughs, causing rupture of the eyeball. Owing to the low-grade inflammatory processes set up in this stage, a shrinking of the globe (partial phthisis bulbi), with an apparent halt in the progress of the disease, is sometimes seen. This cause is usually of short duration; though Wadsworth¹ records a case in which the period of indolence lasted for twenty months. If episcleral growths have not already occurred, they are now apt to take place. The disease may also extend backward through the optic nerve toward the brain. The eyeball again increases in size. Masses of vascular granulations sprout from its anterior part, push aside the lids, and form a large mushroom-shaped growth, which is covered with small sloughs and bleeds at the slightest touch. The child becomes feverish and emaciated. At this time, it is frequently found that the infiltration has extended back into the brain, sometimes forming either a diffuse tumor in its substance or rounded lumps between the dura mater and the cancellous bone-tissue of the calvarium. Metastases are also apt to appear on the outer side of the skull, between it and the periosteum. They are very prone to form at the angle of the jaw. They are also recorded as having been found in the clavicle, the ribs, and the humerus. When the internal organs are attacked, the disease is most frequently found in the liver. Death ensues from exhaustion and the deleterious effects of the absorbed portions of the degenerating tumor masses.

When opportunity for enucleating the eyeball during the first stage of the disease is offered, a whitish tumor situated in the retina, projecting backward through the outer layers and raising them from the chorioid, as shown in Fig. 281, is found. At times, the growth may spring from the inner layers of the retina, and, by extending inward, may increase to a considerable size without producing retinal detachment. As the growth is of extremely rapid development, it soon attains a considerable size. This is quickly followed by the formation of yellowish patches of fatty degeneration in it, with frequent granular deposits of carbonate and phosphate of calcium. The exact starting-point of the growth does not always seem to be the same. It often appears to originate in the outer nuclear layer. At other times, the inner nuclear layer is found the most affected, while even the fibre-layer has been reported by both Manfredi and Iwanoff as being the seat of its commencement. Microscopic examination of any peripheral part of the tumor, shows a delicately fibrillated reticulum, with numerous bloodvessels and round tumor cells. The cells themselves, which are small, and at times appear slightly polygonal in hardened specimens, contain large nuclei. Where they are mixed with any considerable number of spindle-shaped cells, the growth is generally described as glio-sarcoma.

FIG. 281.

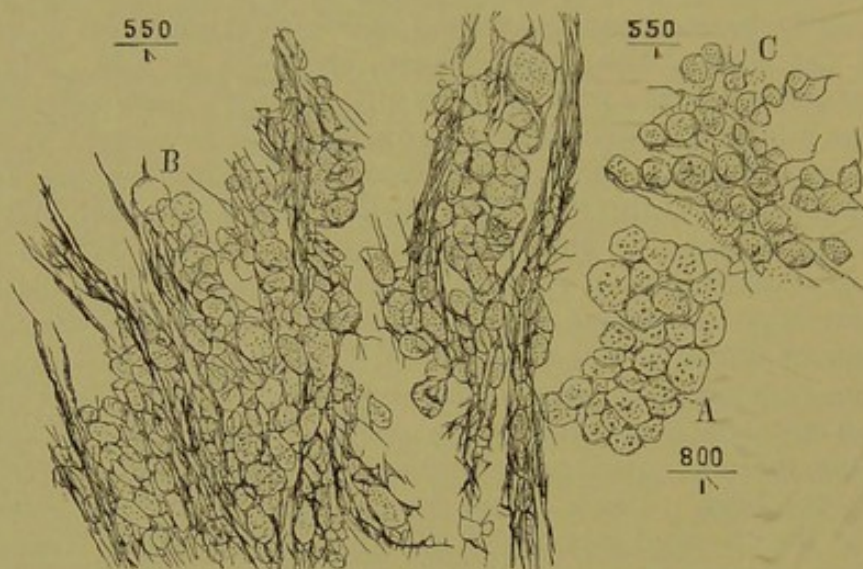


Glioma of the retina. (LEBER.)

¹ Trans. Amer. Ophthal. Society, 1873, pp. 11-23.

Fig. 282 gives a representation of the microscopic appearances usually encountered in glioma. The cells from the intra-ocular tumor are shown at A. B shows a section where the growth has infiltrated the sclerotic and passed into the orbit. C exhibits a section of a secondary tumor, which had formed between the dura mater and the skull.

FIG. 282.



Glioma of the retina.

The cells of glioma have frequently been likened to those of the nuclear layers of the retina. Delafield,¹ however, has shown that the resemblance holds good only in hardened specimens examined with low powers, and asserts that fresh specimens examined under high magnifying power without reagents, bear close resemblance to ordinary lymphoid cells.

As soon as the diagnosis is reasonably sure, enucleation should be advised as the only hope of either curing the patient or preventing a lethal issue. This should be done even if the eye still retains some vision. Although cases of permanent cure following enucleation are reported by Knapp, Carter, Hirschberg, Manfredi, and Agnew, in which no recurrence took place nor any development of the disease in other organs occurred for periods of from twenty months to fifteen years, yet, in the vast majority of instances, the disease soon reappears. In performing enucleation, the optic nerve should be cut off far back, and, if any infiltration of the proximal end of the cut surface be apparent, the remaining portion should be severed close to the optic foramen. Where any episcleral growth is found, exenteration of all the orbital tissues should be performed. The periosteum should be removed, and any doubtful spots in the bare bone should be touched with chloride of zinc paste, hot iron, or the galvano-cautery.

¹ Archives of Ophthalmology and Otology, ii. p. 61.

CHAPTER XXI.

AFFECTIONS OF THE OPTIC NERVE AND ITS INTERNAL PROLONGATIONS.

OWING to the fact that the nerve-fibres lose their investing marrow-sheath before passing the lamina cribrosa, the head of the optic nerve is sufficiently transparent to often allow the whitish appearance of the meshes of the lamina and the darker color of the nerve-fibres that pass through them, to be recognized. The superficial fibres of the nerve are sufficiently capillary to give it a pink tinge. Apart from this, the color is yellowish-white in the majority of cases. In others, it is grayish, with a slight bluish-green tinge. In childhood, especially in cases of hypermetropia, the pink hue is very marked. As old age advances, the disk becomes less pink, assuming a grayer tint and becoming less transparent.

Congestion of the retinal vessels is generally accompanied by an increase of the superficial capillary flush, while congestion of the chorioidal vessels often manifests itself by a more deeply situated and duller red color in the nerve. In fact, it is situated at, and just in front of, the lamina cribrosa. Almost all inflammations of the ciliary bodies, of the chorioid, and of the retina are accompanied by an increased vascularity, œdema, and swelling of the head of the nerve—a true neuritis ascendens. This condition, although usually soon hidden from view by increasing opacity of the media, is invariably confirmed by autopsy.

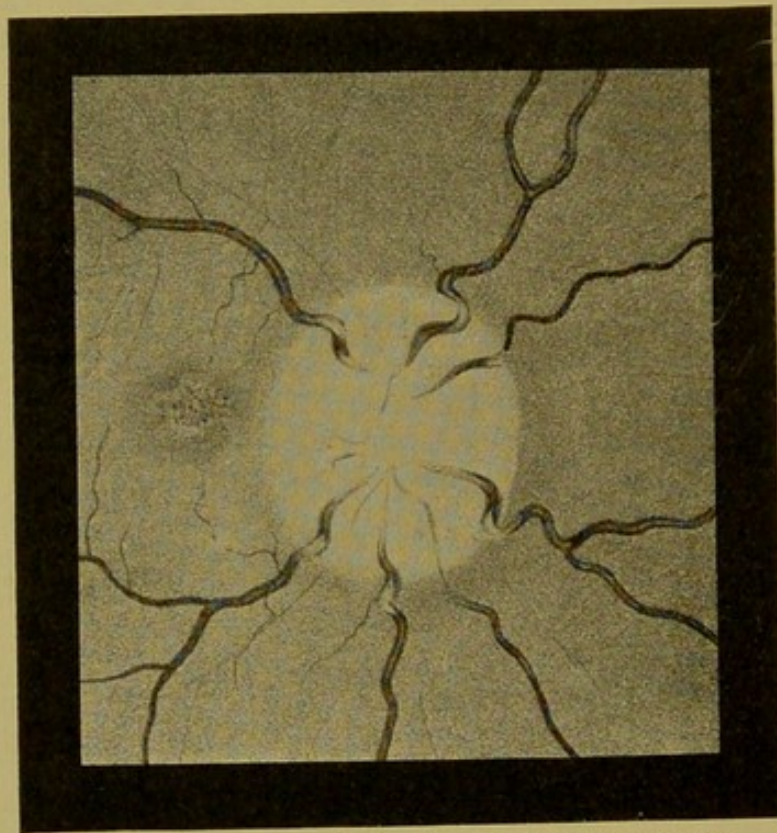
Neuritis from eye-strain. Every effort at accommodation and convergence is normally accompanied by an augmented flow of blood to the eye, and an increase in the circulation of the ciliary body, of the retina, and of the chorioid. Where these efforts are unduly repeated and prolonged, an infiltration of these tissues with serum, a persistent dilatation of their capillaries, and a loss of transparency in the fibre-layer of the retina result, which is most marked where it is thickest just after leaving the disk. The head of the nerve itself becomes redder and slightly swollen, the ophthalmoscope often showing a prominence of 0.50 D. Its boundaries appear hazy from increased opacity of the fibre-layer, frequently being lost to view at the nasal side, where the numbers of the nerve-fibrils are the greatest.

If the eye be rested, especially if this be made absolute by the use of atropia, the retinal opacity will clear up and the nerve-head resume its normal appearance in a few days to a few weeks. In some exceptional cases, the swelling increases. The normal boundaries of the nerve become hidden, and the capillarity and œdema of its intra-ocular end increase so far as to cause a projection of its summit to 1. D. to 1.50 D. In very rare cases, it may become as much as 2. D. The author has several times had an opportunity of examining cases in which this

neuritis was so marked as to cause grave doubts whether it might not be the herald of intra-cranial disease. By observation for many months, however, and under rest of the eye and the use of proper lenses, the patient's good health continued, and the swelling partially or completely subsided. Nevertheless, in the majority of cases where there is a prominence of two diopters or over, the conditions are far more serious, betokening intra-orbital or intra-cranial disease.

Papillitis (Choked disk—Stauungs-Papilla.) By this term is designated a decided swelling of the intra-ocular end of the optic nerve, which forms a small convex tumor that projects into the vitreous. In many

FIG. 283.

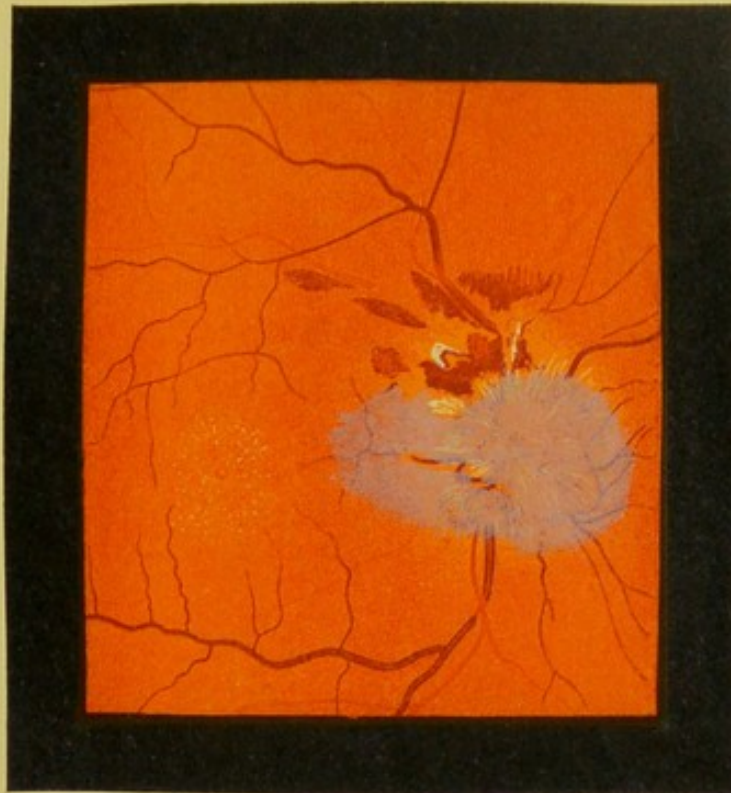

Swollen disk in a case of chronic meningitis. (LIEBREICH.)

instances, it is so marked that its antero-posterior diameter or height becomes equal to the width of the original area of the disk itself in the plane of the retina. On the surface, engorged capillaries, which permeate the swollen head of the nerve, are visible. These are often accompanied by small superficial hemorrhages. The nerve-fibres are swollen and oedematous. They have also lost their transparency. In consequence of this, the following conditions may appear: obliteration of the physiological excavation, a hiding of the branches of the central retinal artery to reappear in the periphery of the eye-ground, and a veiling or entire disappearance, at times, of the more superficial veins for a short distance, by the swollen and opaque nerve-fibre, to again become tortuous, dilated, and rendered visible as dark bluish-red cylinders which run

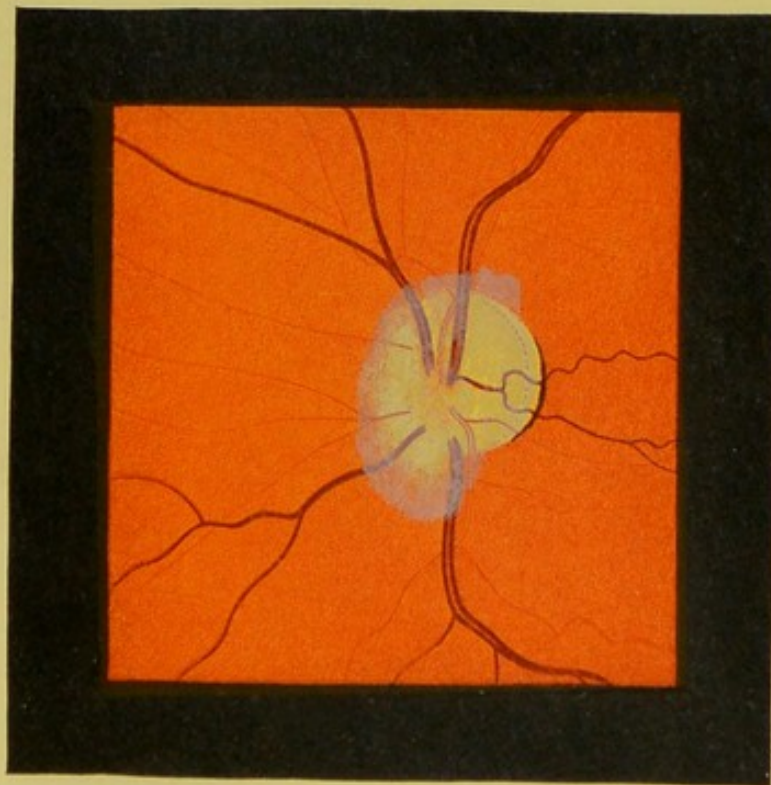
PLATE V.

FIG. 1.



Ophthalmoscopic appearances in early stage of papillitis.

FIG. 2.



Ophthalmoscopic appearances in regressive neuritis.

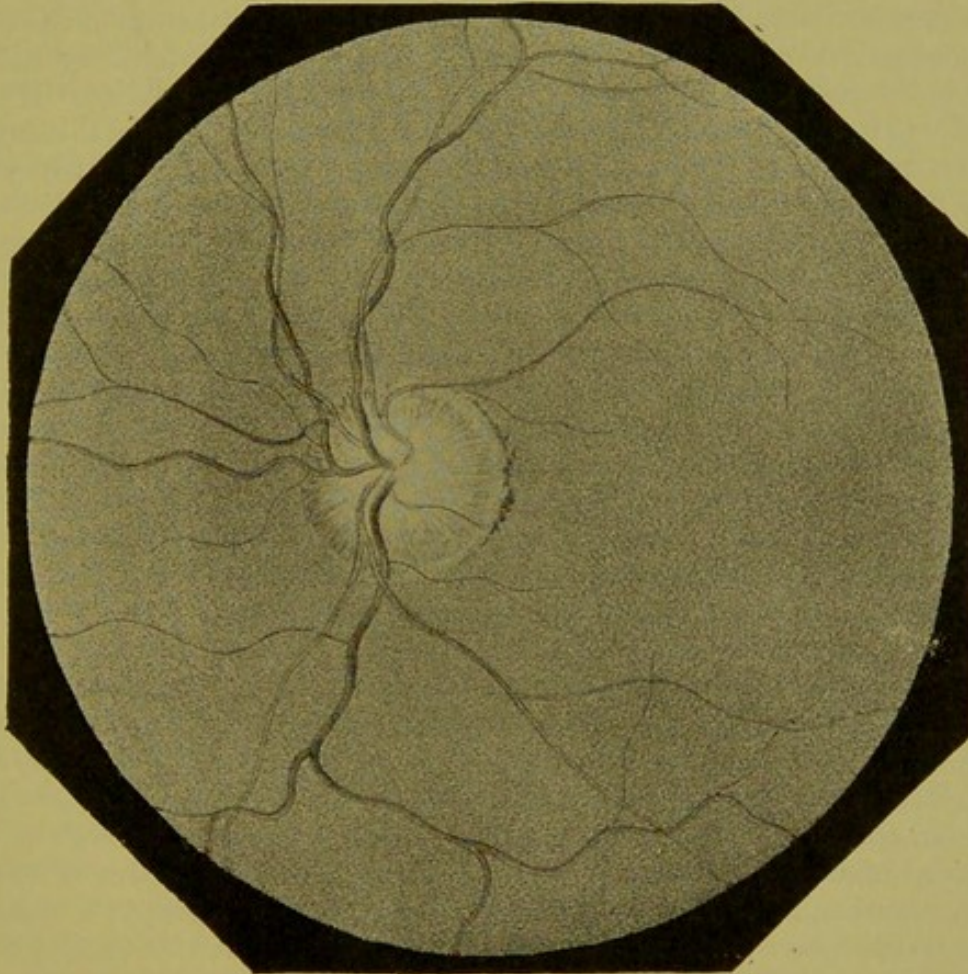


down the sides of the swollen disk before regaining their normal level in the retina. The disk is also swollen laterally. This is shown in Fig. 283, which represents a swollen disk found in a case of chronic meningitis.

Chromo-lithograph No. 1, on Plate V., showing the ophthalmoscopic appearance of the early stage of papillitis in a case of Bright's disease, gives a more vivid picture of the condition.

The lateral swelling of the disk can often be best appreciated by the fact that the distance between its temporal border and the fovea centralis

FIG. 284.



Regressive neuro-retinitis. (JAEGER.)

is less than usual. In such cases, there is an enlargement of the blind-spot in the field of vision. In some instances, the disk will remain nearly in the same state of swelling for many months. Gradually, however, it assumes a more pallid tint, and often a bluish-gray hue. The superficial capillaries disappear, and the swollen nerve-head begins to shrink both vertically and laterally. In short, a process of cicatrization sets in, which gradually leads to contraction of the disk, atrophy of its nerve-fibres, and a diminution in the calibre of the central artery and vein. When the atrophy is complete, the disk generally becomes bluish- or greenish-gray in tint. Sometimes, it may become even whitish. In either instance, a haze that fringes its margins may remain for months,

bearing evidence of the foregoing inflammation. Fig. 284 shows a regressive neuro-retinitis. The previously swollen disk has shrunk nearly to the retinal level. The retinal bloodvessels are constricted, and the hazy nerve-fibres everywhere hide the scleral ring and lamina cribrosa. In the early stages of papillitis, there are often no associated symptoms that can be used to indicate its presence. The author has seen cases where, for months, in spite of a high degree of swelling and increased vascularity, there was nearly normal vision. Mauthner, Blessig, and Schiess-Gemuseus have recorded instances in which, although there has been a high grade of choking of the disk, normal vision was retained till death. As the vascularity diminishes, a gradual diminution of acuity of vision for both form and color, with concentric contraction of the field of vision, generally ensues. At first, this is not demonstrable by strong light, it being made manifest only by reducing the illumination. If this be done, it will be found that the patient's visual acuity diminishes much more rapidly than our own. A little later, this becomes evident with any method of testing. Eventually, the vision may become so lowered that only a mere ability to see the motions of the hand, for instance, will remain. At times, it may continue until there is absolute loss of light-perception. Even in eyes where the disk appears quite atrophic, sufficient sight may remain to enable the patient to grope about unassisted. In the majority of instances where there is marked papillitis in each eye, it is due to some intra-cranial disease. Where the other symptoms leave doubt as to the existence of a brain-tumor, the occurrence of double choked disk is always strong evidence of its presence. When this symptom is absent, however, and where there are others that point to intra-cranial trouble, it must be remembered that papillitis is not to be expected in all cases and at all stages of the complaint. In fact, as Hughlings-Jackson has told us, choked disk is essentially a transitory symptom, and may develop late in the progress of the disease. So long as the absorption of cerebral tissue keeps pace with the growth of the tumor, there will be no decided increase of intra-cranial pressure and no effusion into the sub-arachnoid space. When, however, there is a sudden congestion of the surrounding parts, with rapid growth of the tumor, exudation, increase of pressure, and the development of papillitis, may ensue. In rare cases of lead-poisoning, Bright's disease, and severe intermittent fever, there may be the production of choked disk. In these instances, it is probably dependent upon intra-cranial effusion.

Five years after the invention of the ophthalmoscope, Graefe had diagnosed papillitis and differentiated it from other forms of optic neuritis. He considered it an evidence of intra-cranial pressure, which, by damming the return blood in the cerebral sinuses, caused impeded circulation and increased intra-venous pressure in the ophthalmic and central retinal veins. In this explanation, he compared the rigid tissue of the lamina cribrosa to a "multiplier," which, by its constriction, tended to augment any existing plethora in the head of the nerve. In consequence of the anatomical investigations of Seesemann and of Merkel, which have demonstrated the free anastomosis between the orbital and the facial veins, the first part of this theory has been abandoned. The theory of vasomotor paralysis is a most attractive one,

but it is difficult to explain why paralysis of the sympathetic should always be limited to the branches which supply the head of the nerve and not involve those going to the peripheral parts of the retina, to the iris, the ciliary body, and the chorioid. Granting that there is some special filament of the carotid plexus that is distributed exclusively to the head of the nerve, it is hard to understand how it can so frequently be involved by intra-cranial tumors of all sizes and situations, to the exclusion of other branches. Since the anatomical researches of Schwalbe and of Retzius have given a clear understanding of the lymphatic circulation in the eyeball and the optic nerve, attention has been directed to the many cases in which papillitis was diagnosticated during life, and in which autopsy showed a pyriform distention of the dural sheath of the nerve just behind its junction with the eyeball. These researches have given rise to the most interesting lymph-space theory. It has been found that the space so distended was filled by lymph, and that the delicate trabeculæ covered with endothelial cells, which normally exist in the space between the dural and pial sheaths of the nerve, were more dense and were increased in amount. In some cases, the presence of fluid has been demonstrated during life by the evacuation of a few drops of lymph, from incisions made through the dural sheath of the nerve. By many, it has been supposed that where there has been effusion into the sub-dural and sub-arachnoid spaces of the brain, any sudden congestion of this organ or of an intra-cranial cerebral tumor, would increase the contents of the cranial cavity and force fluid to the distal extremity of the nerve and into the lamina cribrosa—thus exciting inflammation of the head of the nerve. The experiments of Rumpf and Kuhnt have added to the probability of this mode of causation, by showing the deleterious influence of lymph on the axis-cylinders of nerves. The ease with which the intra-vaginal space of the optic nerve can be filled by post-mortem injections into the sub-dural and sub-arachnoid spaces within the cranium, has also added weight to this view. Although it is true that this distention of the sheath and accumulation of fluid in the peripheral part of the nerve, have at times been unsuccessfully looked for at autopsies, yet it is unreasonable to suppose that they, like the papillitis itself, may not be transient symptoms and not absent at some stages of the affection. Leber has more recently suggested, and Deutschmann seems to have proved experimentally, that it requires something more than the mere infiltration of the head of the nerve with serum to produce papillitis, and that this "something" is to be found in the infection of the sub-arachnoid fluid by the products of the intra-cranial tumor, as, for instance, in the actual transport of tubercle-bacilli in cases of tuberculosis. It has also been demonstrated that new growths in the distal end of the optic nerve, such as psammomata and tubercle, may produce choked disk.

Lower grades of intra-ocular neuritis: Interstitial neuritis. Descending neuritis. Such varieties of neuritis are frequently encountered in various forms of intra-cranial disease. This is notably so in cases of meningitis. Here the intra-ocular end of the nerve becomes dull red, oedematous, and hazy. Its normal outlines are entirely hidden. There are, however, much less swelling, prominence,

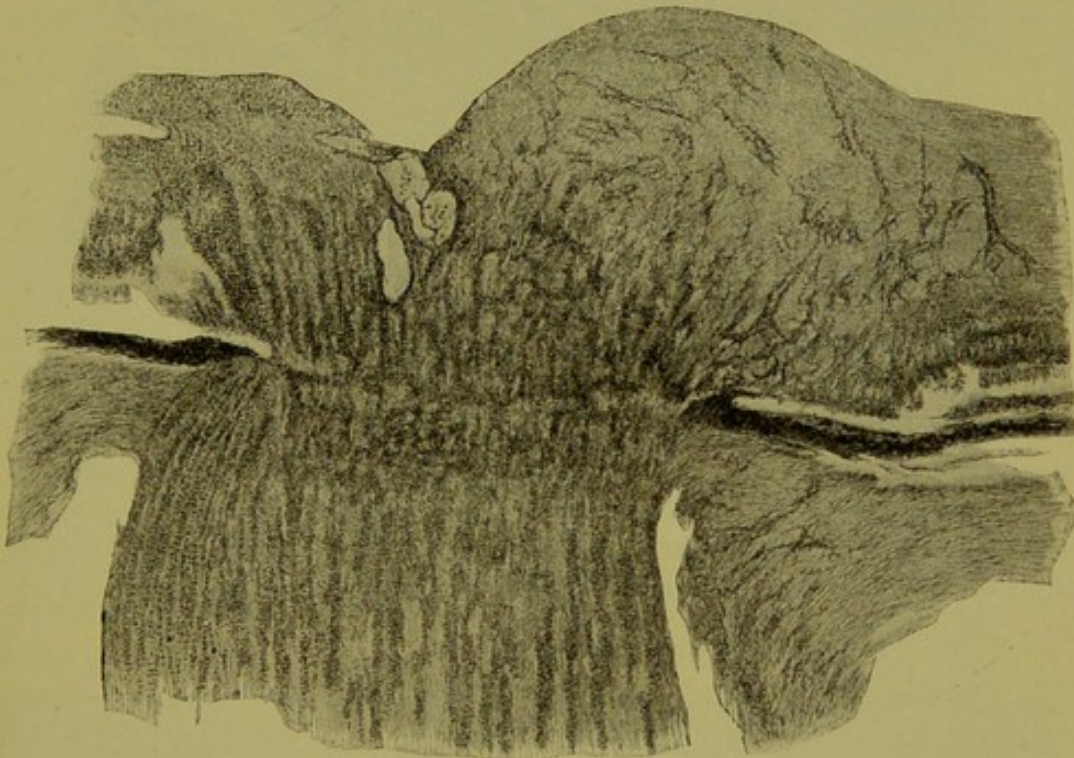
and development of capillaries than in the higher grades of neuritis. In some cases, these symptoms indicate the first stages of what subsequently develops into a marked papillitis. In others, however, the nerve never increases its swelling. In the latter variety, just as in cases where the swelling has become more marked, cicatrizing processes set in and a gradual atrophy ensues. Where there is an interstitial neuritis in the whole length of the nerve, there is generally a diminution of visual acuity that is out of all proportion to the visible changes in the disk. Where the changes in the head of the nerve are due to degenerative processes of a low grade, as, for instance, from pressure upon some part of the nerve's course by an intra-cranial tumor, the ophthalmoscopic appearances are usually limited to a slight swelling of the disk, with a grayish or whitish cloud in it and the surrounding retina. Here there is an absence of all red color that might be produced from either exudation or increase of capillarity.

Post-neuritic atrophy. After severe neuro-retinitis has persisted for many months, the disk, though still swollen, begins to change color, loses its dull-red tint, and assumes a bluish-gray hue. Subsequently, the nerve-fibres commence to shrink, and gradually, if the patient lives, the summit of the disk sinks, and eventually passes beyond the retinal level. The prominence is now replaced by a shallow cup, in which capillarity has been entirely lost, and in which there has been sufficient contraction of tissue to diminish materially the calibre of the central retinal artery and vein. Often for many months after the subsidence of the swelling, the opaque striation of the retinal fibres fringing the edges of the disk, reveals its inflammatory origin. Chromo-lithograph No. 2, on Plate V., gives an admirable picture of such a regressive neuritis, in which the disk is swollen and hazy on the nasal side. The retinal ring is visible on the temporal side, and the nerve-fibres have so far atrophied in this position, that a shallow excavation has formed at this point. This gradual contraction impairs the ability of the nerve-fibre to conduct light-impressions from the retina to the brain-centre, and the patient thus often becomes blind. In some few cases, however, especially where the neuritis is due to syphilis and where treatment has been energetic and carried out faithfully for a long period of time, sufficient transmitting power to enable the patient to get about by himself, may persist for years, in spite of the ophthalmoscopic appearances of well-marked atrophy.

Even in pre-ophthalmoscopic times, the frequency of impaired vision as a concomitant of intra-cranial affections, was well known. Abercrombie noted failure of vision in seventeen (thirty-eight and five-tenths per cent.) out of forty-four cases, while Ladame, in a study of three hundred and thirty-one cases, estimated that there was a disturbance of vision in fifty per cent. Since the invention of the ophthalmoscope, statistics show a higher percentage. It must be remembered furthermore, however, that there is usually little or no impairment of vision in the earlier stages of choked disk, and that, therefore, unless every case of suspected intra-cranial disease be carefully and repeatedly examined with the ophthalmoscope, many instances of such condition of the optic-nerve head will escape detection. In eighty-eight cases, forty-three of

which have been recorded by Annuske,¹ and forty-five by Reich,² double optic neuritis was present in ninety-three per cent. Gowers³ maintains that it is present in four-fifths (eighty per cent.) of all cases of cerebral tumor; Edmunds and Lawford,⁴ on a basis of one hundred and seven autopsies of brain-tumor, give sixty-three per cent. of optic neuritis. The last-named authors also state that the intra-ocular condition is most frequently found where the tumor is in the cerebellum. They believe that it appears next in frequency in those cases of growth involving the motor ganglia. They also say that it is less frequent in growths of the convexity of the brain, asserting its presence in seventy-four per cent. of tumors of the base, and in fifty per cent. of tumors of the convexity.

FIG. 285.



Section of papillitis in the stage of incipient contraction.

Basilar meningitis rarely runs its course without producing changes in the intra-ocular end of the optic nerve. These changes vary from a slight oedema of the disk, with dilatation and tortuosity of the veins, to a dense opacity of its fibres, which hides its normal outlines. In some cases, the condition may amount to marked papillitis. If the meningitis be limited to the convexity of the cerebrum, however, there may be an absence of all ophthalmoscopic appearances, this continuing as long as the meningitis remains in this region. According to Allbutt⁵, twenty-nine (seventy-six per cent.) of thirty-eight cases of basilar tubercular meningitis showed changes in the optic disks. Heinzl⁶ states, that in sixty-three cases of

¹ Archiv f. Ophthalmologie, xix., 3, S. 165.

² Klinische Monatsblätter f. Augenheilkunde, 1874, S. 274.

³ Medical Ophthalmoscopy, 1879, p. 133.

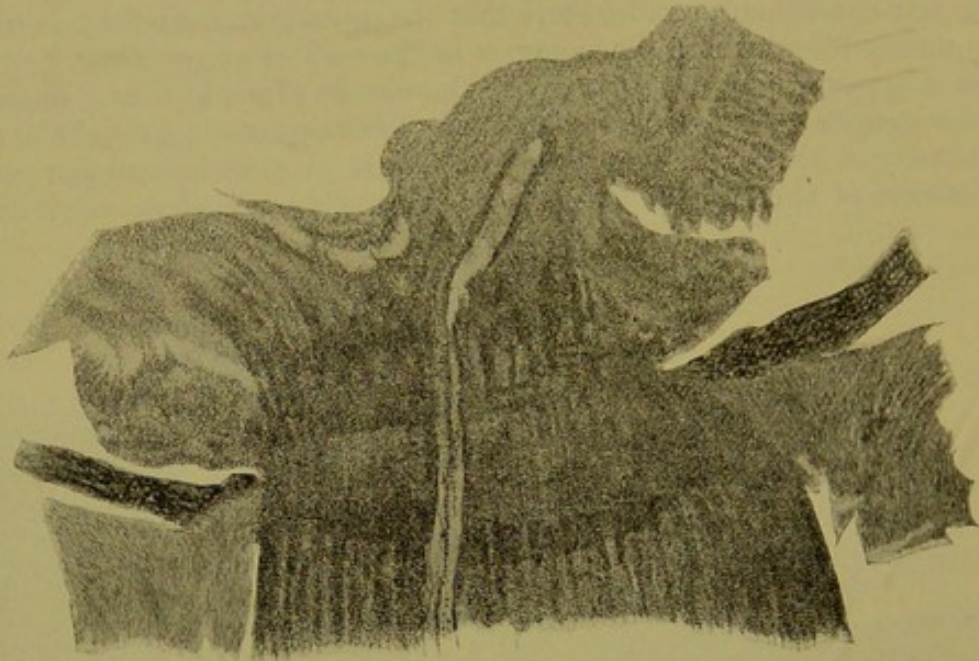
⁴ Trans. Ophth. Soc. of the United Kingdom, 1884, pp. 172-186.

⁵ Use of the Ophthalmoscope, 1871, p. 95.

⁶ Jahrbuch der Kinderheilkunde, vol. viii., 1875.

brain-disease in children, seventy-four per cent. showed ophthalmoscopic changes, while in thirty-three cases of tubercular basilar meningitis, twenty-seven (eighty-one per cent.) exhibited signs of either neuritis or

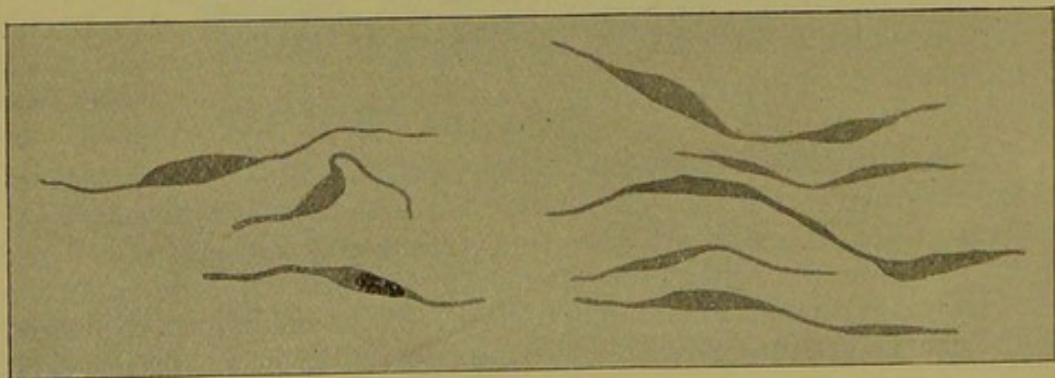
FIG. 286.



Section of later stage of papillitis.

atrophy. Garlick¹ tells us that out of twenty-six carefully watched cases, fifty per cent. evidenced distinct swelling and neuritis, while many others exhibited only slightly increased redness of the disk, with dilatation and tortuosity of the veins.

FIG. 287.



Spindle-shaped swellings.

If opportunity is given to examine a disk anatomically in the early stage of papillitis, a state of serous infiltration of the head of the nerve, with swelling of the nerve-fibres and marked dilatation of the capillaries, will be found. Studied at a later stage, when the disk is becoming

¹ Observations on the Ophthalmoscopic Appearances in the Tubercular Meningitis of Children. Trans. Roy. Med.-Chir. Soc., London, 1879, p. 444.

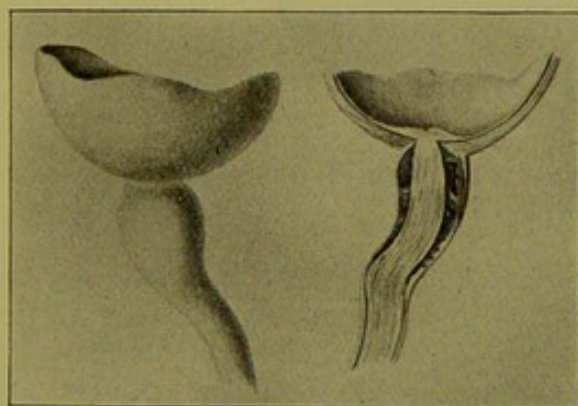
bluish-gray, increase in the neuroglia, infiltration with lymphoid cells, and nests of spindle-shaped swelling and degeneration of the nerve-fibres, will be seen. Figs. 285 and 286 show these conditions very well, whilst Fig. 287 exhibits tracings from a nest of the spindle-shaped swellings.

In most cases of recent origin, there is a pyriform dilatation of the dural sheath at its peripheral end, with proliferation of the endothelial tissue in the sub-vaginal space.

Fig. 288 shows a section of an eyeball through the optic-nerve entrance in a case of papillitis. The mushroom-like swelling of the head of the nerve and the pyriform distention of the dural sheath, can be plainly seen.

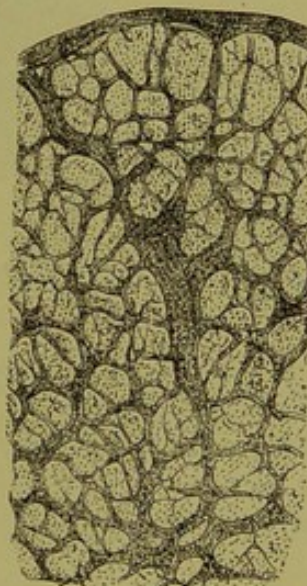The pathological changes are much more marked near the disk. Often, however, there is an increase in the nuclei of the connective tissue

FIG. 288.



Pyriform enlargement of peripheral end of optic nerve.
(PAGENSTECHER and GENTH.)

FIG. 289.

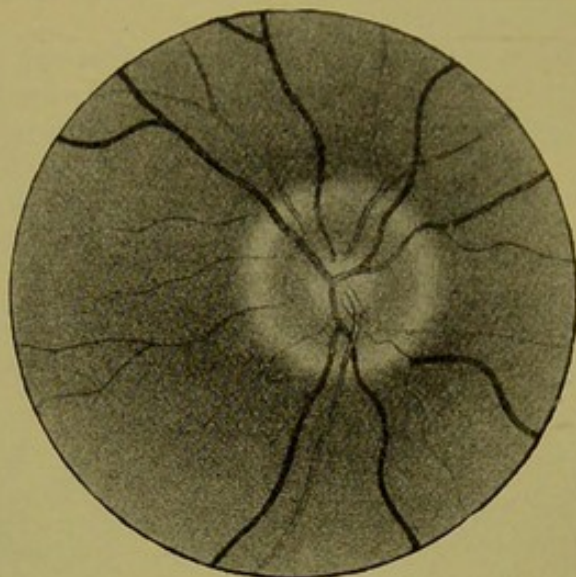


Interstitial neuritis. (LEBER.)

between the bundles of nerve-fibres, this proliferation extending a considerable distance along the course of the nerve. In some cases, where there is basilar meningitis, an interstitial neuritis with thickening of the connective-tissue trabeculae throughout the length of the nerve, is found. This is especially the case where the meningitis is syphilitic in its origin. Fig. 289 represents a marked interstitial neuritis with thickening of the connective-tissue trabeculae. It also shows an infiltration of the trabeculae with lymphoid cells. If purulent meningitis exists, marked perineuritis is generally present, the pial sheath and the trabeculae nearest to it showing marked thickening and infiltration. In proportion as atrophy progresses, the connective-tissue bundles increase and contract, while the nerve-elements degenerate and are absorbed. Finally, in place of the normal nerve a fibrous cord, with but little nerve-tissue left in it, will be found; this atrophic remnant of the optic nerve being so shrunken that it no longer occupies its normal position, thus leaving a wide space between the pial and the dural sheaths.

We will next consider *those forms of atrophy of the optic nerve which are preceded by anæmia of the optic disk (from hemorrhage, from the action of cold, and quinine-poisoning)*. Jaeger has given careful clinical histories, with admirable colored illustrations of the *atrophies which follow hemorrhage*. He says that soon after the loss

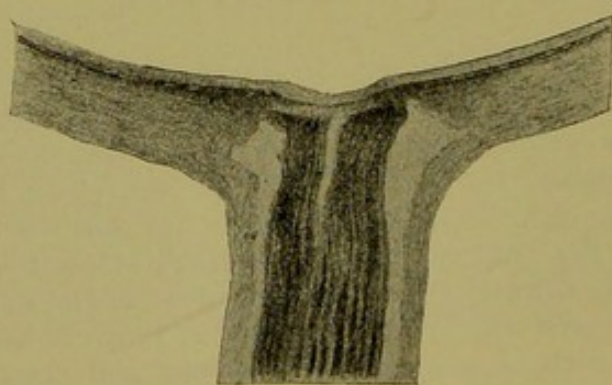
FIG. 290.



Ophthalmoscopic appearance of disk in atrophy following hemorrhage. (JAEGER.)

of blood, vision becomes temporarily hazy, this being followed by partial clearing, which is dependent upon improved nutrition of the patient. He has found, however, that the eye remains easily fatigued by any near-work, and that in the event of subsequent hemorrhages, the recurrent amblyopia augments with each loss of blood, until all useful

FIG. 291.



Section of nerve-head of same. (JAEGER.)

vision is lost. Ophthalmoscopically, the anæmia shows itself by the pallor and bluish color of the disk. Its sclerotic boundary is too broad and too pronounced, whilst the remaining eye-ground becomes paler and the central bloodvessels appear smaller in calibre than normal. In one of Jaeger's cases, the nerve remained in this condition for six years,

when, after severe headaches, it became fuzzy, assumed a dirty-greenish color, and showed a shallow atrophic excavation. The fuzziness of the disk and the commencing atrophic excavation in this case, are shown in Fig. 290.

Fig. 291 exhibits a cut section of the same optic-nerve head and adjacent tissues. Here, a saucer-like excavation, with a dense felting together of the meshes of the lamina cribrosa, which occupy less space than usual, can be seen. In this section, the bundles of nerve-fibres in the scleral foramen are seen to be shrunken so as to pull the pial sheath away from the dural sheath and form a large irregular cavity where there is normally only a narrow lymph-space with nearly parallel walls. These cases were due to hemorrhage after labor. In a later work on "The Results of Investigation with the Ophthalmoscope," Leber tells us that he has repeatedly seen such instances. Fries,¹ in his monograph on the subject, says that thirty-five and a half per cent. of such cases are due to hemorrhage from the stomach and intestines, twenty-five per cent. to uterine hemorrhage, twenty-five per cent. to abstraction of blood, seven and three-tenths per cent. to epistaxis, five and two-tenths per cent. to bleeding of wounds, and one per cent. each to hæmoptysis and urethral hemorrhage.

Jaeger² cites several instances of intense *anæmia of the disk from the action of cold*. The affected individuals had been exposed in an open sleigh for hours to a violent snow-storm, causing their eyes to feel like pieces of ice in their sockets. After recovering from the exposure, a considerable dimness of vision was immediately noticed. This dimness remained unchanged without material alteration for years.

Marked *ischæmia of the disk* is also produced by *quinine-poisoning*. In some cases, this condition is associated with entire blindness. Central vision usually slowly improves, and at times gradually approaches the normal standard. The contraction of the field of vision is said to be permanent. De Schweinitz has shown that toxic doses of quinine in dogs will produce optic atrophy, and has occasionally found thrombosis of the central retinal vein.

The degenerations of the optic nerves which accompany tabes dorsalis and other forms of gray degeneration of the central nervous system are quite constant. Almost all cases of posterior spinal sclerosis exhibit marked eye-symptoms some time during their course, whilst a large proportion, if carefully examined, show impaired nutrition of the optic nerve even in the early and pre-ataxic stage of the affection. In the early period of the disease, this impairment manifests itself as a reddish-gray haze of the optic disk, which becomes still grayer in the deeper layers of the nerve-head. In such cases, while central vision may remain unaffected, slight but demonstrable contraction of the field of vision for form and color, can be noticed. The eye is readily fatigued, and when kept constantly applied to near-work, gives out, often finding comfort in the correction of small degrees of astigmatism and hypermetropia which have previously caused no inconvenience. As the symptoms of ataxia become manifest, a gray degeneration of the

¹ Klinische Monatsblätter f. Augenhellkunde, 1878.

² Ergebnisse der Untersuchung mit dem Augenspiegel, 1876, S. 88.

optic disk, with marked contraction of the field of vision, is found. At times, this may be associated with decided reduction of visual acuity and even complete blindness. Among the earliest symptoms of this stage, paralysis of the external muscles of the eye, giving rise to annoying diplopia, may be noticed. Although this is usually a transient symptom, yet a recurrence of the paresis in the same muscle may occur. Associated with, or more generally following the development of the ataxic symptoms, irido-cycloplegia, causing diminution of the pupillary movements and the power of accommodation, may appear. At this time, the so-called *Argyll-Robertson symptom* is ordinarily present: a condition in which the irides, though irresponsive to the action of light on the retina, retain their motility upon convergence of the eyes for near objects. In this condition, the pupils are usually small and cannot be dilated *ad maximum* by the energetic use of strong mydriatics. In the pre-ataxic stage of the disease, there is an exaggeration of the knee-jerk. In the ataxic stage, the knee-jerk is either diminished or abolished. In some exceptional instances, complete atrophy of both nerves may occur years before the development of the ataxic symptoms. Förster and Charcot cite such cases. Central scotoma is unusual at any stage of the disease.

Sections of the optic nerve show similar lesions to those which are found in the spinal cord. Owing to a degeneration of the medullary sheaths, the nerve-fibres reflect less light and appear gray. Compound granule cells are found between the fibres. The nerve-substance has disappeared, the connective tissue is shrunken, and the nerve-trunk is decidedly diminished in size. In such sections, the degenerative process does not usually appear to have travelled continuously either down or up the nerve, but seems to be localized in isolated spots.

The optic nerve degeneration that is accompanied by central scotoma (retrobulbar neuritis, tobacco- and alcohol-poisoning, diabetes, and hereditary atrophy), is of great clinical interest. In some forms of nerve-degeneration, those fibres of the optic nerves which supply the macular region are the first and the most severely affected. In fact, they often remain diseased, with but slight implication of their adjacent nerve-bundles, for a long time. In more advanced stages, a cloud is thrown over everything looked at, causing a great diminution of central vision, whilst peripherally situated objects can be seen fairly well. Probably, because of pupillary contraction which cuts off light from the periphery of the retina—the only part which remains serviceable in such cases—the patients are much annoyed by a strong light. Although, owing to obliteration of central vision, little or no visual improvement results (as measured by the test-letters) from allowing the comparatively healthy peripheral parts of the retina to act by exposing such eyes to lessened light-stimulus, yet it is a clinical fact that such patients see much better toward evening and move about more comfortably with semi-dilated pupils in moderately dark rooms. In consequence of the former fact, they are said by some authors to be nyctalopic. In the early stages, appreciable ophthalmoscopic signs are variable. In advanced cases, a general pallor of the disk, which is much more marked in the temporal half, is often

found. The careful observations of Samelsohn,¹ Vossius,² and Ulthoff³ have shown that the above symptoms are due primarily to an affection of the macular fibres of the nerve, which may be often traced through their entire length up into the chiasm and optic tracts.

Where opportunity offers of studying these cases from their origin, it is generally found that the symptoms begin with slight dimness of vision and ready fatigue of the eye. Careful examination of the fields of vision at this time, shows that, except at the centre of fixation, they are normal for both form and color. In this position, small squares of green gradually fade and appear whitish, while similar areas of red become dimmer and brownish. In a slightly higher grade of the affection, these colors may disappear from view, although there may still be sufficient conducting power in the macular region to allow a fair perception of form at this point. Such scotomata are called *relative*. As the affection progresses, the power of distinguishing form in this region is lost. The scotoma is then said to be *absolute*. This condition causes every object whose image falls on the macular region of the retina, to appear as though it was more or less enveloped in mist or fog. In some instances, the scotoma may become so dense that a point of light used for fixation, cannot be perceived. Any change in the circulation of the head and face, causing congestion of the eye, is apt to temporarily increase the density of the cloud.

In the early stages, there are often no ophthalmoscopic signs. Later, a blanching of the temporal side of the disk, that is due to the atrophy of the macular fibres in the head of the nerve, is occasionally found. Sometimes, as pointed out by Sachs, a triangular area of atrophy may be seen, the sides of which gradually fade into healthier tissue. Owing to the fact that the temporal half of the disk is naturally the more pallid, and to the frequency of shallow physiological excavations in this portion, the diagnosis is difficult even to the expert. Indeed, in slight cases, a diagnosis is impossible. Furthermore, all observers must have seen instances of a decided contrast in the vascularity of the outer and the inner halves of the disk, in which there were no central scotomata. The investigations of Ulthoff upon scotoma due to alcohol-poisoning, confirm this statement, and Wecker⁴ states that in the early stages of the same disease, he has often seen marked hyperæmia of the temporal halves of the disks. Upon account of the atrophic tissue gradually shading off into the healthy, the line of demarcation in central scotoma is not abrupt. In some forms, the lesion may continue for years without any extension to the adjacent nerve-fibres. In many, however, notably in those that are due to tobacco- and alcohol-poisoning, there is a tendency to general involvement of the nerve, causing an atrophy of the nerve-fibres, with increase of connective-tissue elements throughout its length.

The investigations of Samelsohn demonstrate the course of the degeneration throughout the nerve. He has found that a section of the

¹ Archiv f. Ophthalmologie, xxviii., Heft i., S. 1.

² Ibid., xxviii., Heft iii., S. 201.

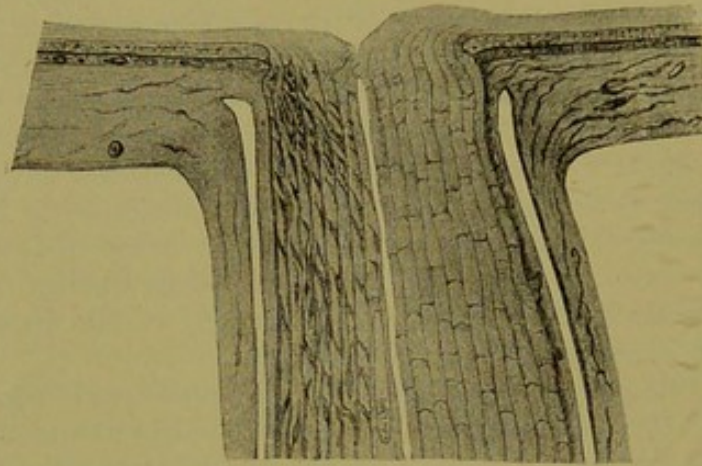
³ Ibid., xxxii., Heft iv., S. 95; xxxiv., Heft i., S. 257.

⁴ Traité complet d'Ophthalmologie, tom. iv. p. 511.

nerve anterior to the entrance of the central vessels, shows a triangular area of atrophy with its base turned outward and its apex pointing toward the centre of the nerve. The shape of the bundle of atrophic fibres posterior to the entrance of the central vessels, appears in cross-section as more or less zonular, its concavity being turned toward the centre of the nerve. As the atrophic fibres ascend, they gather together in the centre, so that, at the optic foramen, they form a central bundle which is everywhere surrounded with healthy nerve-fibres.

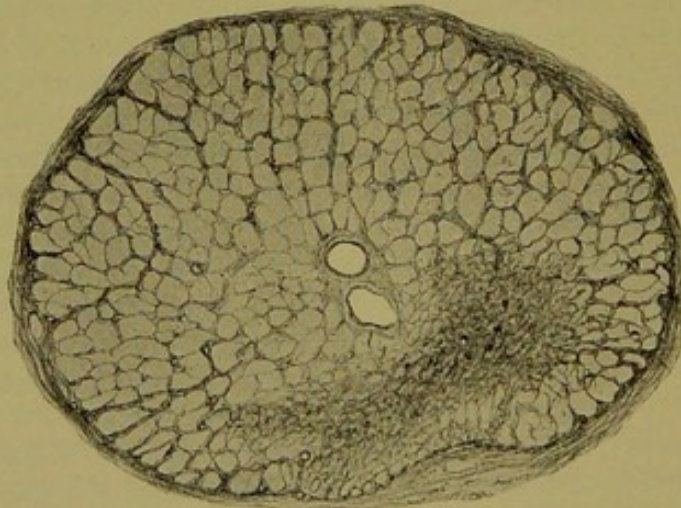
Fig. 292 shows a longitudinal section of such a nerve at the optic entrance; Fig. 293 exhibits a cross-section of the same nerve just after

FIG. 292.



Longitudinal section of optic-nerve head. (SAMELSOHN.)

FIG. 293.

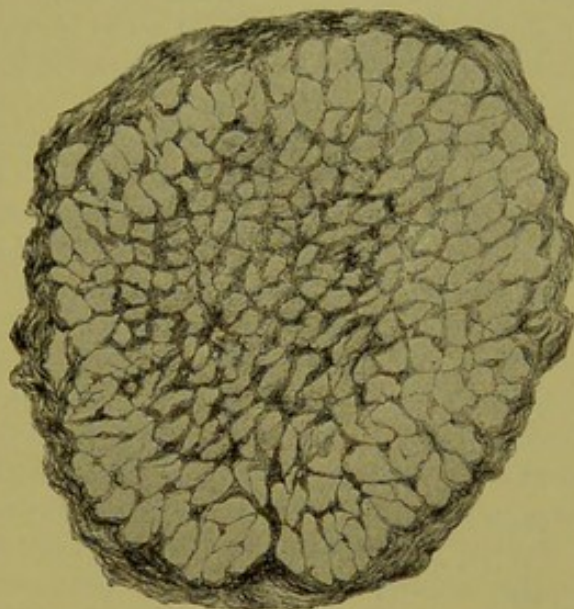


Cross-section of optic nerve just posterior to situation of entrance of the central vessels. (SAMELSOHN.)

the entrance of the central vessels; Fig. 294 shows a cross-section at the posterior part of the orbit, and Fig. 295 gives a view of a section at the optic foramen. In every figure, the shaded part represents the degenerative portion of the nerve. These investigations have been amply confirmed by Vossius, Nettleship, and Ulthoff. The last-quoted author shows that a section of the atrophic fibres within the cranium,

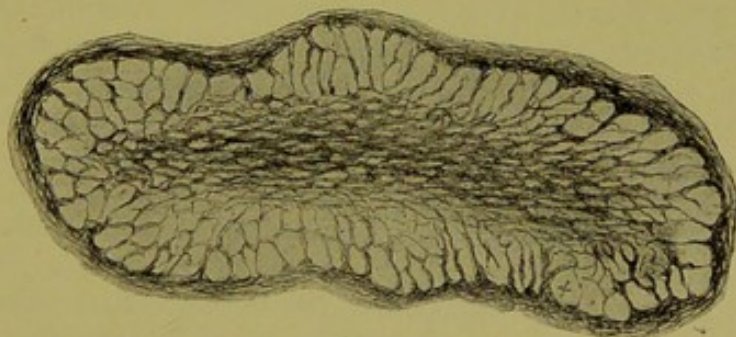
becomes horizontal oval in form, and extends somewhat obliquely in direction from above and out, and down and in. He further describes the degenerated strands as occupying symmetrical positions in the anterior part of the chiasm, whilst in the middle of the chiasm, they approach

FIG. 294.



Cross-section of optic nerve at posterior part of orbit. (SAMELSOHN.)

FIG. 295.

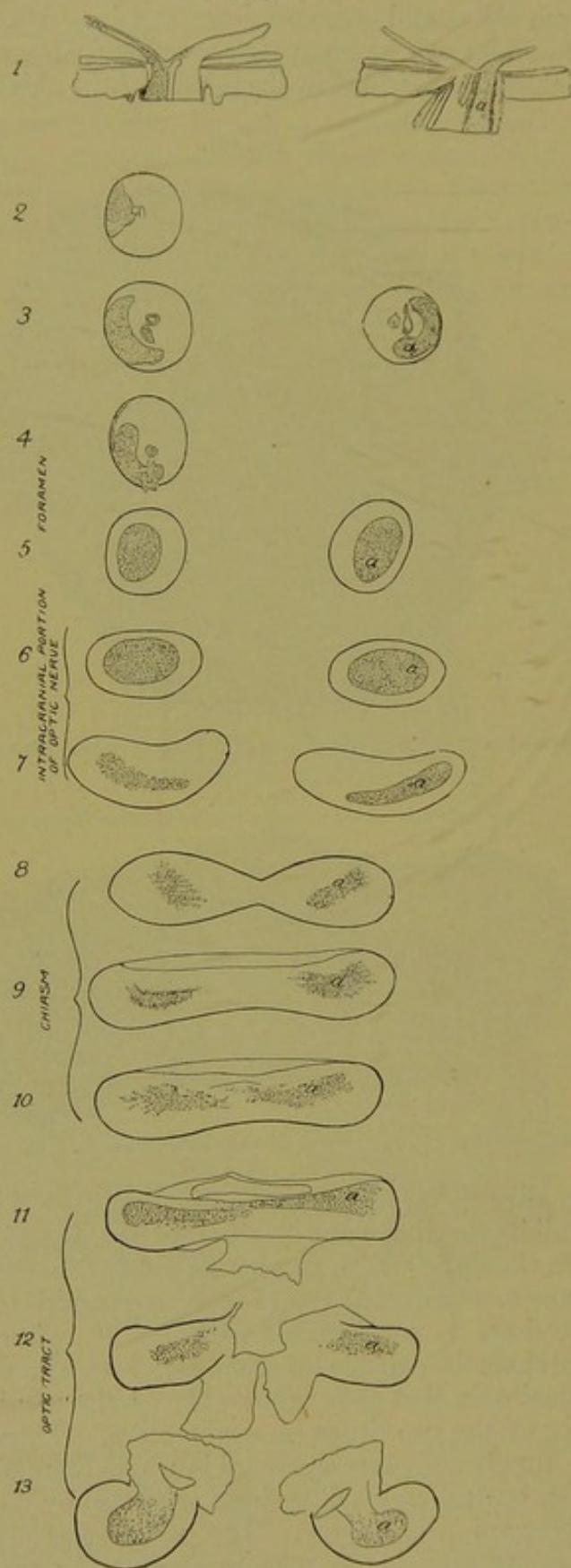


Cross-section of optic nerve at the optic foramen. (SAMELSOHN.)

and join, to diverge again in the optic tracts as they issue from it. Fig. 296 exhibits the shape and position of the degenerated areas from the eyeball to the optic tracts, as seen in successive cross-sections.

In reference to *degeneration of the optic nerves due to abuse of tobacco and alcohol*, there is considerable diversity of opinion. Some hold that tobacco alone is capable of giving rise to the above symptoms, and others maintain that they occur only as the result of either alcoholic abuse or of the two drugs in combination. There are, however, a considerable number of cases on record in which there can be no reasonable doubt that central scotoma has been produced by the exclusive use of alcohol or tobacco, respectively. The writer has seen several cases which were apparently due to tobacco alone. As there are few hard drinkers who do not smoke, and few hard smokers who do not use

FIG. 296.



Relative shapes and positions of degenerated areas in optic nerves, chiasms, and tracts.
(ULTHOFF.)

alcoholic beverages, there is mixed poisoning in the majority of instances. On the other hand, there are many who consume vast amounts of tobacco or alcohol for years without sensible impairment of vision: a fact which shows that the occurrence of central scotoma is probably due to some predisposing cause, such as impaired health or over-sensibility of the nervous system to one or the other of the drugs. In many instances, especially in those that are due to abuse of alcohol, the symptoms show that there is a marked tendency to general degeneration of the optic nerves.

Degeneration of the optic nerves in diabetes is an affection that is both peculiar and interesting. The fact that diabetes at times produces cataract and retinitis with hemorrhagic and degenerative spots, has already been referred to, but it seems probable, since the researches of Leber, that it may be the cause of central scotoma. Bresgen¹ has reported cases of this peculiar form of affection, in which, however, there is no mention as to whether the patient was a smoker or not. Since then, a *résumé* of these cases, with nine additional ones, has been given by Nettleship and Edmunds.² These authors state that both eyes are affected, and that, although the fields of vision are of full size, yet there is impaired acuity of vision over an area which extends from the fixation-point to the blind spot, and often beyond it. In this area, red and green are either lost or are distinguished with difficulty. They do not, however, consider it proved absolutely that the affection exists in cases where tobacco has not been used.

Hereditary atrophy of the optic nerves is a remarkable and a fortunately rare disease. Frequently it may be traced back for several generations, thus reminding us of the hereditary transmission of typical pigmentary degeneration of the retina and color-blindness. Like these diseases, it is more prone to affect the males than the females, although the latter, even when unattacked, may transmit it to their children. In 1882 and 1884, the author reported to the American Ophthalmological Society detailed histories of two such families, in which the course of the disease, with careful transcripts of the fields of vision, was given. In the first family, the history of the disease extended through five generations, and in the second, it passed through four. In the latter grouping, a mother in the third generation, not suffering from the disease, had seven affected children.

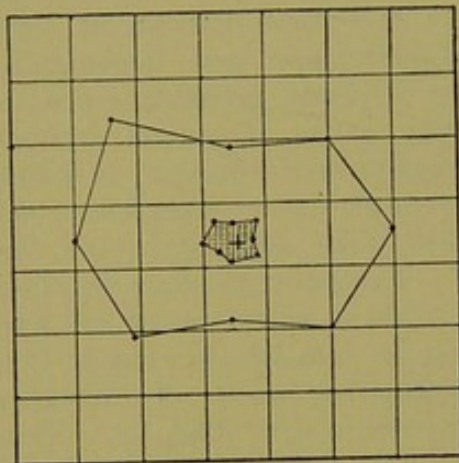
The first subjective symptom is the production of a central scotoma for color, which may gradually become so pronounced as entirely to prevent light-perception in the affected area. The disease may develop as early as seven years or as late as thirty-five, but is most likely to manifest itself about puberty. Frequent frontal headaches, and a cloud in front of the eye which obscures direct vision, are the most prominent symptoms. In a few cases, spontaneous improvement has been recorded, although the resultant vision was far from normal. Generally, the central scotoma becomes sufficiently dense to prevent all useful employment of the eye. It often remains unchanged throughout life. Although the form-field is contracted in most instances, yet it is extremely rare to find complete blindness.

¹ Centralblatt f. Augenheilkunde, 1881, S. 31.

² Trans. Ophth. Soc. of the United Kingdom, 1883, vol. iii. p. 165.

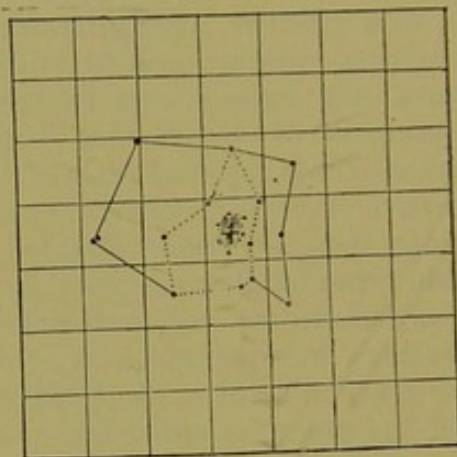
The disease is essentially a neuritic atrophy. As seen by the ophthalmoscope, the head of the optic nerve presents three stages: First, that of cloudy swelling and oedema; second, that of lymph-reflexes; and third, that of gradual death of the nerve tissue. Figs. 297, 298, 299, and 300 graphically show the fields of vision of the left eye of A. S., aged fourteen (one of the members of the second family seen by the author), for form, and for yellow, blue, and red, respectively. They were taken at the time when the ophthalmoscope showed that the nerve

FIG. 297.



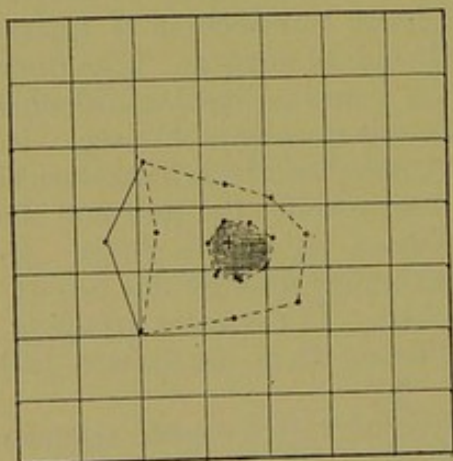
Left field for white.

FIG. 298.



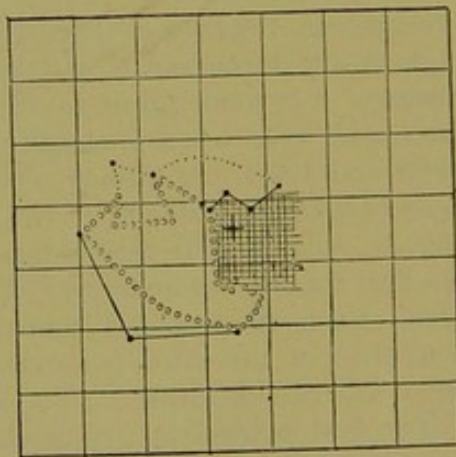
Left field for yellow.

FIG. 299.



Left field for blue.

FIG. 300.



Left field for red.

was passing through the second stage of its inflammation into degeneration, vision for form being reduced to one-sixtieth. The test-objects used were one-centimeter squares of white and colored paper. These were carried toward a central fixation-point on a ruled blackboard placed at twenty-five centimeters' distance from the eye. In the accompanying diagrams, each square of ruling on the board has been reduced to one-twelfth of its original size. In all the fields, the innermost ruled lines show the extent of the central scotoma. In Fig. 298, the dotted lines represent the boundaries of the yellow field; in Fig. 299,

the ruled lines show the boundaries of the blue field; the small circles in Fig. 300 designate the boundaries of the red field. In each field, the apparent changes in color, simulating any of the other colors named, are marked in the same manner as that intended for the designation of the true color. In every instance, the central scotoma was so dense that a point of light had to be employed for fixation. In one case, the scotomata were paracentral.

The irregular areas of color-perception and the varying rate of the ability to distinguish color-changes, give a most instructive picture of a low-grade neuritis, and the difficulty of conduction in aggregations of nerve-fibrils, which have undergone greater degeneration or have been more compressed than their neighbors. The subjective projections of the visual fields give an excellent clinical representation of the position of the greatest amounts of pathological change which, in this peculiar form of neuritis, a post-mortem examination would bring to view. In fact, they designate, in a general way, how closely related all such clinical evidence is to the physical demonstration of optic-nerve disturbance, as found under the microscope.

Amblyopia without ophthalmoscopic changes either in the retina or in the optic nerve (hemeralopia, uræmic amaurosis, congenital color-blindness, and hemianopia) is so often seen that a detailed account of the symptoms is desirable. *Hemeralopia*¹ or *day vision*, or, as it is also termed, *night-blindness*, has been spoken of as a symptom of pigmentary degeneration of the retina. At times, it develops without any ophthalmoscopic symptoms. It often affects considerable numbers of people, such as sailors and soldiers, whose nerve energies have been lowered by long exposure to glare of light and to the weather, and who have had insufficient and improper food. Impaired nutrition is sufficient for its development, as may be seen in hospitals for the convalescent. Blessig tells us that it is frequent in Russia during the rigorous Lenten fasts of the Greek Church. It is accompanied by depraved nutrition. A peculiar xerosis of the ocular conjunctiva corresponding with the palpebral fissure, often develops with it. It usually forms a dry anæsthetic patch at the outer border of the cornea. In many instances, the patch becomes iridescent and silvery, and dry scales can be readily detached from it. This state of affairs is sometimes preceded by disease of the liver. At times, jaundice may be associated with it. The principal symptom is rapid failure of vision in dim light. This can be readily noticed and contrasted with the vision of the normal eye, either at the approach of nightfall or whenever the patient is placed in a situation where there is but little light. The treatment consists in rest, alteratives, tonics, and a generous diet.

Nyctalopia, or *vision by night*, is generally a symptom of central scotoma, the cloud in front of the eye being less annoying when objects are only dimly illuminated, and when the consequently dilated pupil allows more light to reach the peripheral parts of the retina.

Uræmic amaurosis is occasionally seen. It is especially found in the severe forms of the disease which are accompanied with convulsions.

¹ The terms hemeralopia and nyctalopia are here used in accordance with their present sanctioned meaning and not with their derivation.

There is either great temporary impairment of vision or temporary absolute blindness without any ophthalmoscopic symptoms; these conditions being evidently due to some transient affection of the cerebral sight-centres. It must be remembered, however, that the conditions may be developed where the disease of the kidneys has already caused the retinal changes.

Congenital color-blindness has been discussed in its various aspects on pages 82, 83, 193, 194, and 195.

Hemianopia (Hemianopsia), or the not seeing half of an object, is usually unaccompanied by any characteristic pathological alterations that can be demonstrated with the ophthalmoscope. When *hemiopia*, or *visus dimidiatus*, is spoken of, the affection is named from the act of seeing but half of an object. The term *hemianopia* is preferable, as it distinctly states the true relationship between the defect in the field of vision and the blind portion of the retina. Slighter symmetrical defects in both visual fields, which often have analogous significance, may at times be found. Most frequently, *hemianopia* is of the homonymous lateral variety. This signifies that condition in which all points in the field of vision of each eye, lying either to the right or to the left of the point of fixation, are lost to view. Thus, in *right homonymous hemianopia*, everything to the right of the binocular fixation-point is invisible, showing that there is a break in the functioning power of the nerve-fibres distributed in some portion of the visual apparatus intended for the left halves of the retinae. The reverse is the case in *left homonymous hemianopia*. (See large colored diagram of visual fields facing page 80.) In the remaining half of the field, the boundaries of vision for color retain their usual relation to those for form, although the total size is less than normal. The line of demarcation between the blind and seeing halves of the field is usually nearly vertical. In some forms of the affection, it is absolutely so, touching the fixation-point in its course. The homonymous lateral variety of *hemianopia* generally develops suddenly, and is often associated with hemiplegia. At times, there is a diminution of the cutaneous sensibility on the same side. When the condition is on the right sides of the fields, it is sometimes accompanied by aphasia. Clinically, the field of vision does not show any considerable contraction. Neither do irregularities nor zig-zags develop in it.

Contrasted with homonymous lateral *hemianopia*, there is a temporal variety (*heteronymous lateral hemianopia*). This is caused by a loss of power of conduction through that part of the visual apparatus which is in direct physiological connection with the nasal halves of the retinae. In this form, sensation is carried on through the temporal halves only. Here the combination of the remaining nasal fields renders the binocular field of vision nearly normal, while the nasal halves of the retinae are physiologically blind, thus causing a failure to perceive any object that lies to the outside of the fixation-point. The dividing-line between the seeing and blind halves of the field of vision is often irregular. It may vary from time to time. The development of this form of *hemianopia* is usually less sudden than that of the homonymous lateral variety.

In *heteronymous nasal hemianopia*, the nasal half of each field is

wanting upon account of the external half of each retina being blind. Consequently, there is loss of binocular vision in this variety of the affection.

Superior and inferior hemianopia shows itself by a dividing-line that is horizontal. At times, this variety may be monocular in type. In such cases, the line of demarcation does not run through the fixation-point.

Symmetrical and monocular defects in other parts of the field of vision are occasionally encountered.

Transient hemianopia is of frequent occurrence in individuals enjoying fair health, and is generally homonymous-lateral in type when the attack has fully developed. Ordinarily, it is followed by severe headache, and rarely by vertigo, tinnitus aurium, difficulty of speech, etc. Even in intelligent patients, it is seldom recognized as half-vision, but, as in the permanent variety, is apt to be described as a dimness or blindness of the eye which corresponds to the side on which the field of vision is defective. Some cases of transient hemianopia are accompanied by peculiar zigzag flickerings of light in the defective portions of the field of vision—a circumstance which has caused this variety to be termed *scotoma scintillans*. Förster, who has frequently experienced a definite variety of the affection in his own person, has given an accurate account of the symptoms. In his case, the phenomena last from fifteen to twenty-five minutes. They begin with a dimness in both eyes, which gradually increases until a complete defect, embracing everything lying in the field of vision to one side of the fixation-point, is formed. These symptoms are soon followed by a flickering, which begins in a zone around the scotoma, and increases centrifugally till it assumes the form of an arc with its convexity directed outward. This scintillation rarely extends beyond the vertical line which separates the two halves of the field of vision. When the flickering has reached the outer limits of the field, it gradually fades away. Other varieties of the affection may be accompanied by irritation phosphenes, which often assume the form of showers of luminous particles, etc.

The explanation of the various forms of hemianopia, especially that of the homonymous lateral variety, has, ever since the time of Newton, been a fruitful source of investigation and discussion. In the hope of further study upon the subject, this author informs us that it is probable that the fibres from the right half of each retina so unite at the chiasm as to go together to the right half of the brain, while those from the left half of each retina pursue a similar course to the left hemisphere; and he further remarks that, if he is "correctly informed, the optic nerves of such animals as have a binocular field of vision join at the chiasm, while those of animals who have no binocular vision, such as the chameleon and some fishes, do not so join." Förster has since remarked that this decussation of the optic nerves at the chiasm, does not violate the ordinary rule of the total crossing of other nerves, because in the binocular field of vision, the partial crossing causes all objects to the right of the fixation-point to be seen by the left hemisphere, and all those to the left of the fixation-point to be seen by the right hemisphere.

In fact, while the theory of partial crossing of the optic nerves in the chiasm has been in the main satisfactory both to physiologists and to

clinicians, it has been very difficult to prove such semi-decussation by anatomical demonstration. From time to time, therefore, there have appeared advocates for the theory of the total crossing in the higher animals and in man. Consequently, according to the views of Biesiadecki, Mandelstamm, Schwalbe, Scheel, and Michel, who believe in total decussation of the optic nerves, homonymous lateral hemianopia would be produced by pressure upon one of the outer angles of the commissure; pressure at the anterior angle would paralyze the fibres going to the inner half of each retina, and produce temporal hemianopia; while pressure at the posterior angle would give rise to blindness of the temporal half of each retina, as shown in nasal hemianopia. The most convincing proofs of semi-decussation, however, are the experiments which have been made upon some of the higher animals that possess binocular vision. In these, it has been found by Gudden that where an eye is extirpated and the animal is allowed to live until central atrophy sets in, there results an ascending atrophy of the nerve of the enucleated eye, which may be followed up into both optic tracts; the larger bundle of atrophy crossing to the opposite side, and the smaller one continuing up the tract of the same side. Woinow, Schmidt-Rimpler, and Manz assert that a similar state of affairs is attested by autopsies in man. To the clinician, however, the evidence of careful post-mortem examinations in cases of strictly localized intra-cranial lesions, has of late years become convincing, and sufficient reports of such localizations have been made by competent observers to show that homonymous lateral hemianopia may be caused by interference with the conducting fibres in the optic tract, in the thalamus opticus, in the radiating fibres, and in the sight-centre situated in the cortex of the occipital lobe of the same side. If the evidence of the dissecting-table as to the causation of homonymous lateral hemianopia by lesion of these localities be admitted, there must be a partial and not a total crossing of the fibres in the chiasm.

Where the hemianopia is produced by pressure in the optic tract or by disease in the chiasm itself, an important localizing symptom is obtained in *Wernicke's sign*. This consists, as previously shown, in the fact that a small, bright image thrown on the blind part of the retina does not cause pupillary contraction, thus proving that where the reflex is found in such cases, the arc is complete, and the lesion must be situated behind the corpora quadrigemina.

Temporal hemianopia is accounted for by pressure or disease at the anterior or posterior angles of the commissure, or the inner strands of the optic nerves just before reaching the chiasm. This has been proved by autopsy.

Crossed amblyopia has been reported by Charcot in his "Studies of Hystero-epilepsy," but is scarcely substantiated by those cases in which he had the eye-grounds and visual fields carefully studied by Landolt, who, although finding a considerable amount of amblyopia on the opposite side, always obtained an accompanying contraction of the fields of vision in the comparatively sound eye.

Tumors of the optic nerve, which are rare and generally occur in young people, are sometimes developed either from the dural and pial sheaths or from the nerve itself. If of moderate size and situated in

the anterior part of the orbital portion of the nerve, they may for a considerable time cause but little disturbance of the motions of the eyeball. As they increase in size, exophthalmus gradually develops, and a limitation of the motions of the ball, which may become absolute in some directions, ensues. They are usually either sarcomatous or myosarcomatous in variety, although cases of tubercle and of comparatively benignant tumors, such as fibroma, psammoma, and neuroma, have been reported. As patients rarely submit to operation till the exophthalmus is decided and the vision is either impaired or lost, enucleation of the eyeball, with exenteration of the orbit, is generally necessary. It is possible, however, in some cases to enucleate the tumor and save the eyeball, as in those instances recorded by Knapp, Schiess-Gemuseus,¹ and Gruening. Knapp² has also removed a tumor of the nerve with retention of the eyeball. In this case, the cornea sloughed, and the growth extended into the interior of the cranium. Ayres³ says that although there have been but few returns *in loco*, where these tumors have been extirpated, yet an unusual number of cases of meningitis have followed the operation, with metastases within the cranial cavity, which sometimes manifest themselves only after an interval of several years.

¹ Archiv f. Ophthalmologie, Bd. xxxiv., 1888, Abth. iii. S. 226.

² Trans. Amer. Ophthal. Soc., 1879, pp. 557-560.

³ Trans. Amer. Med. Assoc., 1889.

CHAPTER XXII.

DISEASES OF THE CHORIOID.

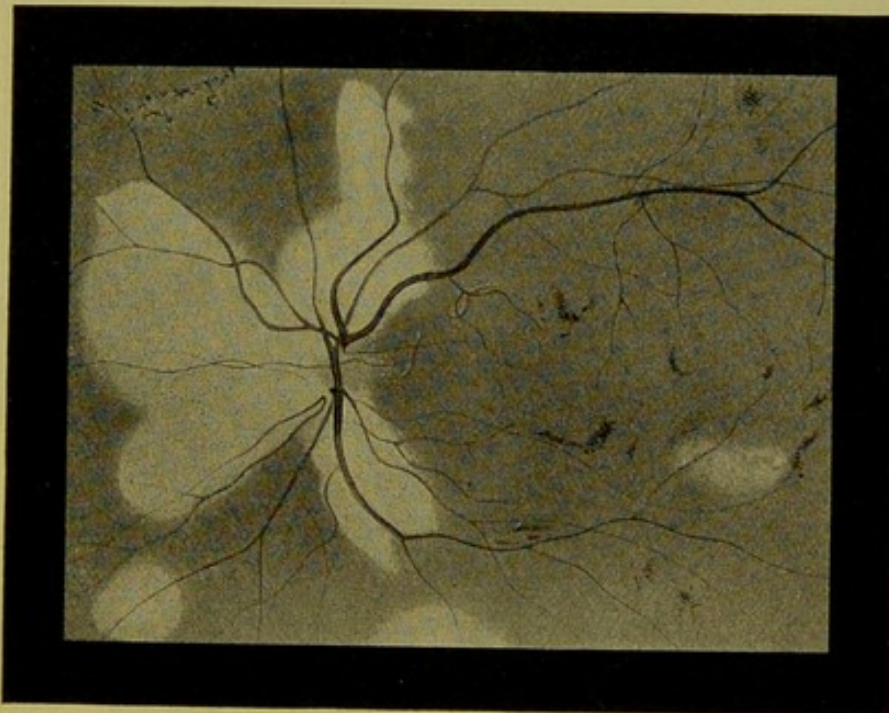PRIMARY disease of the chorioid is generally due to degenerative changes taking place in some part of its vascular network, or to some constitutional affection, such as syphilis. At times, such degeneration is either senile or is the result of impaired general nutrition. Secondary disease of the chorioid is exceedingly frequent. It often follows inflammations of the iris or ciliary body. More rarely, it appears as the result of embolic or pyæmic processes.

Hyperæmia of the chorioid, when slight in degree, is not readily recognized, as the dense pigmentation of the pigment cells and intervascular spaces beneath them, renders it impossible to judge accurately of any increase of vascularity in the membrane. Often, chronic congestion of the chorioid is revealed by the state of the optic disk, which, owing to the congestion of the arterial anastomosis between the central retinal and short ciliary arteries, becomes of a dull-red hue, with well-marked outlines. This redness of the optic-nerve head lies at a deeper level, and is quite different in appearance from the flush of the disk that is caused by increased vascularity of its true tissue. More intense hyperæmia of the chorioid produces a granular or woolly appearance of its pigment layer, which is probably due partly to the swelling of the individual cells and partly to the dilatation of the capillary meshes surrounding the cell groups. This is constantly seen in eyes which have become uncomfortable from excess of near-work. Especially is it developed in school-children, among whom it is often associated with slight haziness along the main vessels of the retina, and such exudations into the sheaths and walls of the finer vessels, that silvery reflexes, which play over the retinal surface with each motion of the mirror, appear. Both the woolliness of the chorioid and the retinal reflexes often disappear entirely when the eye is kept at perfect rest for some weeks under the use of a solution of atropia.

Chorioiditis. Where there is positive inflammation of the chorioid, with exudation of lymph, the affected areas become more prominent. In a great majority of instances, however, these prominences are so small that the magnifying power of the upright method of ophthalmoscopic examination is insufficient to demonstrate their presence. In all cases, a difference in the color of the eye-grounds over such elevation can, nevertheless, be noticed. These patches become fawn-colored and yellowish, while the pigment covering them is either absorbed or piled in masses at the periphery of the inflamed spot. Where the retina over the spot is also inflamed, a snowy-white or a bluish-white patch is found. After the retinal cloud has been absorbed, the stroma of the chorioid is laid bare to inspection. If the inflammation has

been high and the exudation has been considerable, a depressed white spot, which is due to the sclera shining through the remnants of atrophic chorioid, is found beneath. Where the inflammation mainly involves the capillary layer of the chorioid and the overlying epithelium, the result is either to lay bare the large red vessels that ramify in the black stroma of the chorioid, or to render them visible as red streaks which cross partially atrophic white patches. Frequently, the inflammation glues the epithelial layer to the retina proper, and the pigment-granules, wandering along the lymph-sheaths of the retinal bloodvessels, become especially abundant where the small vascular branches are given off.

FIG. 301.



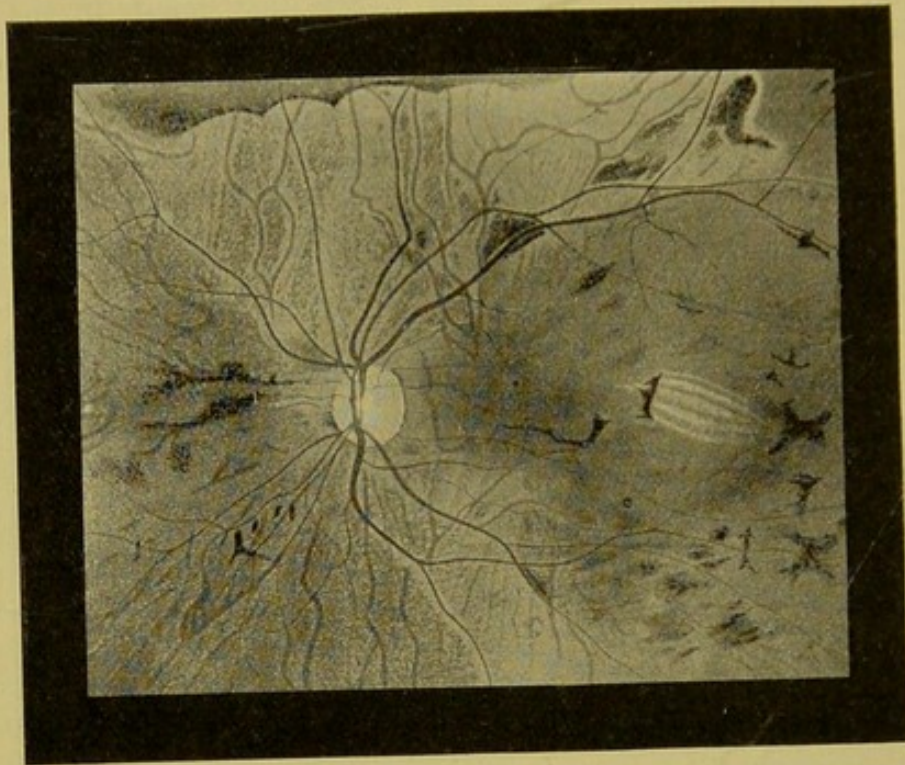
Early stage of chorio-retinitis. (LIEBREICH.)

The above-described changes in chorio-retinitis are well illustrated in Figs. 301 and 302. They represent the same eye-ground sketched at different stages of the disease. The white patches seen in Fig. 301 have entirely disappeared in Fig. 302, which was taken some months later. The subsequent changes in the chorioidal pigment are well shown in Fig. 302. Vision, which in this case had been very dim at first, improved very much under rest of the eye and the administration of corrosive sublimate.

Chorioiditis disseminata is distinguished by the appearance of numerous small atrophic spots in the equatorial and anterior portions of the chorioid. These, though sometimes rounded, are usually stellate or irregular in form. They may be developed in the deeper part of the chorioid. While small, they have indistinct margins and may be more or less covered and hidden in the only partially changed epithelium. Many of the diseased areas lie in the mere superficial layers and

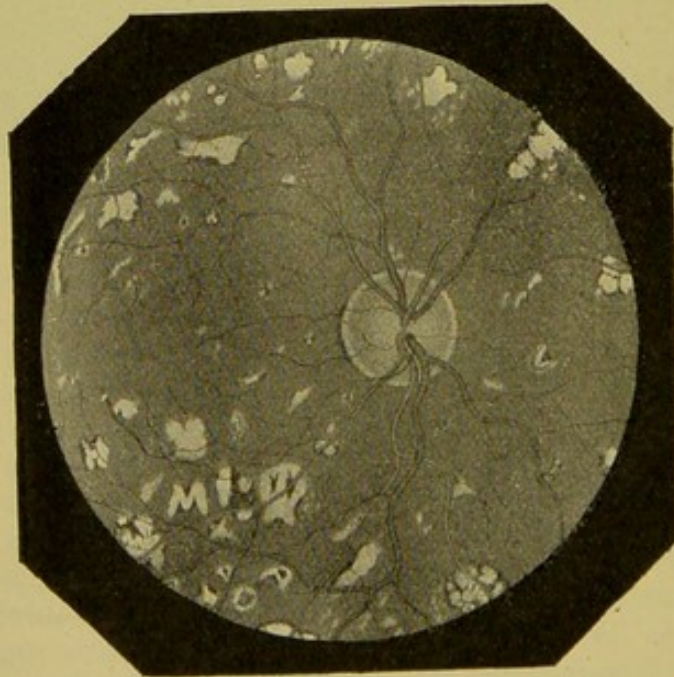
project beyond the chorioidal level. Owing to their small size, their frequent development without vitreous opacities, and the part of the

FIG. 302.



Late stage of chorio-retinitis. (LIEBREICH.)

FIG. 303.



Disseminated chorioiditis. (JAEGER.)

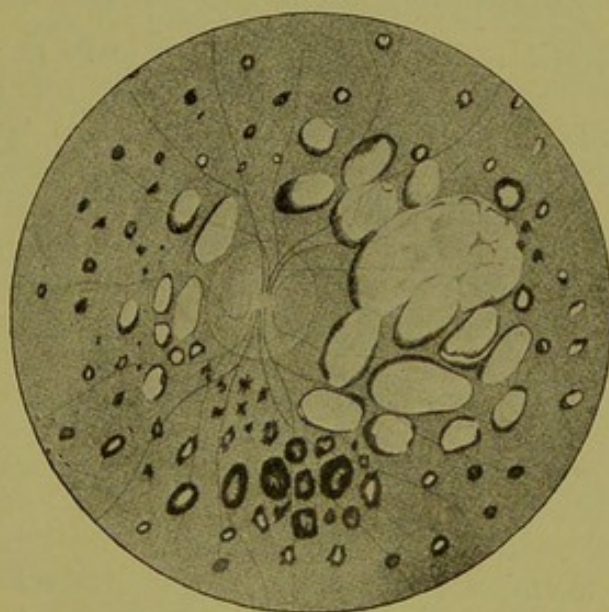
chorioid that is affected, marked changes in the eye-ground may exist for months without decided impairment of vision. A good representation

of this form of disease is given in Fig. 303. This case occurred in a patient aged forty-one years, who presented no evidences nor gave any history of syphilis. He had noticed a gradual failure of sight for six months. Notwithstanding the fact that the media were clear and that the central retinal vessels were normal in calibre at the date of examination, vision was so far reduced that fingers could barely be counted.

As the disease progresses, the patches often become more numerous, coalesce with adjacent ones, and gradually extend into the exterior part of the chorioid.

Chorioiditis areolata, to which attention has been especially called by Förster, is characterized by the development of atrophic spots in the region of the disk and around the macula. Owing to the fact that these spots primarily affect the vessels of the stroma of the chorioid, they are

FIG. 304.



Areolated chorioiditis. (FOERSTER.)

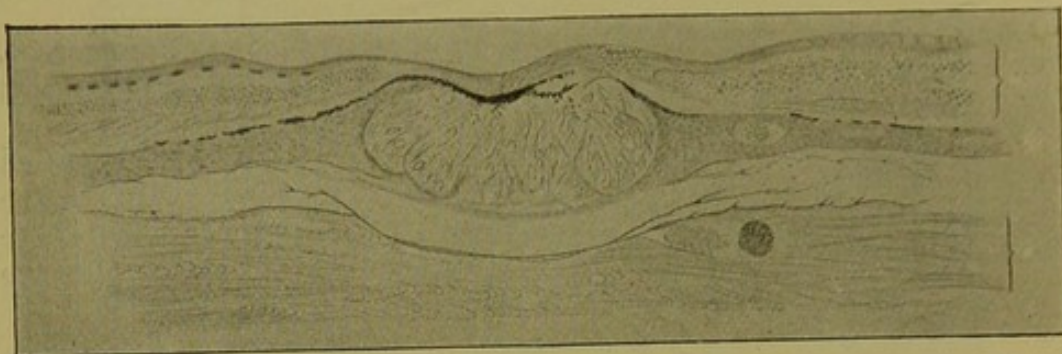
usually larger in size, and are more vivid in color than those that are found in disseminate chorioiditis. Each area is generally black-rimmed, this being caused by a massing of pigment at its border. Where the inflammatory process does not run high, a gradual fading of the chorioid to a brownish-yellow, and later to a white color, can often be seen. Often, also, owing to the greater atrophy of the underlying stroma, the edges of the areolæ appear undermined.

Fig. 304 gives an ophthalmoscopic view of a case where the disease is far advanced, and where, consequently, the lesions are of long standing.

Fig. 305 shows a section through one of the atrophic areas of the chorioid. The retina above the patch is thinned, and the inner layers of the underlying sclera have undergone partial absorption. The umbilicated depression on top, shows that the patch is beginning to shrink and undergo absorption. At first the process is so sharply localized, that the rods and cones, except at the affected points, remain intact. They thus function perfectly, allowing the patient to enjoy excellent vision for years. As the patient becomes older, a general degeneration

of the chorioid, associated with numerous opacities in a fluid vitreous, sets in. At times, this is accompanied with sufficient alteration in the nutrition of the lens, to cause cataract.

FIG. 305.



Section through an atrophic area. (FOERSTER.)

Chorioiditis centralis (*chorioiditis circumscripta*) is that variety of the disease which localizes itself in the macular region. The patient complains of a gray cloud situated immediately in front of every object looked at. Vision is so reduced that there is an inability to read even coarse print, except when the book is held close and the head to one side. The ophthalmoscope shows one or more yellowish prominences in the macular region. These are covered by a grayish layer of retina. The rest of the eye-ground presents nearly its usual appearance. Later, complete atrophy, which is marked by a sharply-cut white spot that is due to the sclera showing through, appears in the affected area.

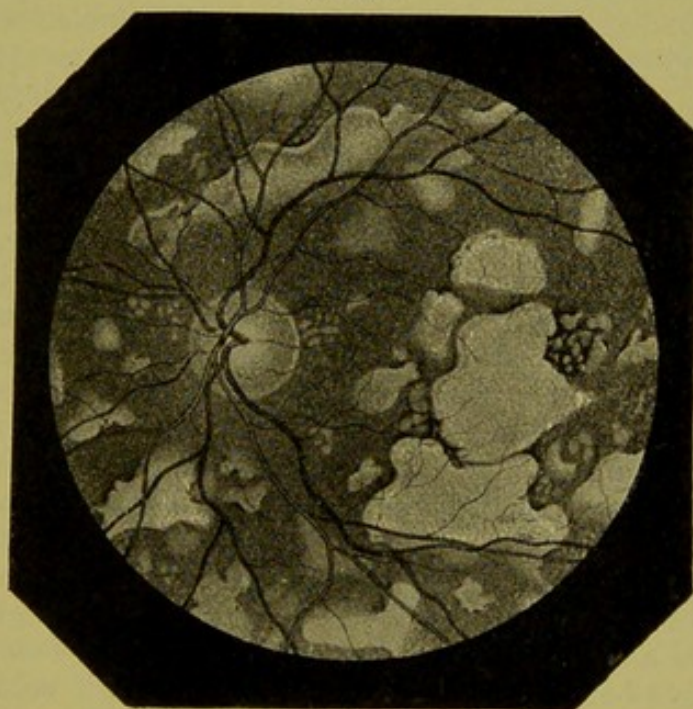
Chorioiditis syphilitica, or, more properly, *chorio-retinitis syphilitica*, is an affection which primarily attacks the epithelial layers, the overlying retina, and the adjacent vitreous. Only in cases of some duration is disseminate chorioiditis developed. At first, there is distortion of objects looked at, and flashes of light. This is followed by rapidly clouding eyesight, which is more pronounced when the patient is situated in feebly-lighted localities. At times, zonular defects in the field of vision can be demonstrated. The ophthalmoscope shows a marked haze in the vitreous humor, which lies immediately in front of the disk, and extends to often two or two and one-half disk-diameters around the nerve-head. In this area, the retina is clouded. There are no hemorrhages. In bad cases, the vitreous-haze may extend throughout its substance, especially to the anterior part. The patients are usually affected with tertiary stage of syphilis. The eye-disease is frequently very obstinate in resisting treatment.

Fig. 306 gives a good idea of the advanced stages of the affection as it appeared in a patient about five years after the primary infection and about four and a half years after sight had commenced to grow dim. In this instance, there was never any inflammation of the exterior of the eyes, the patient complaining of gradually increasing clouding of the vision which soon compelled abandonment of all fine work. This was accompanied by flashes of light, which, when further excited

by the stimulus of artificial illumination, appeared as reddish-yellow circles of light that moved and gradually melted into one another. For two years before the sketch was made, the patient had been able only to distinguish day from night. The fellow-eye, which was affected in the same way to a less degree, allowed the patient sufficient vision to find the way about the streets with difficulty.

Chorioiditis suppurativa is not unfrequently observed after wounds and injuries of the eye. Where they involve the cornea, there is a rapid clouding of this membrane, which becomes opaque. This is followed by yellowish-white plastic effusion, with the formation of posterior synechia and narrowing of the anterior chamber. The iris is swollen, and its stroma is dissected and pushed apart by small accumulations of

FIG. 306.



Syphilitic chorioiditis. (JAEGER.)

pus, that are distributed throughout the chorioidal interspaces. This is accompanied by oedematous swelling of the lids, more or less protrusion of the eyeball, and intense pain in the eye and around the orbit. The patient soon loses all light-perception. Frequently, there is fever. In rare cases, there may be a partial suppuration of the eyeball, with the formation of an abscess in the anterior part of the vitreous, and subsequent shrinkage of the globe. Usually, however, every part of the eye is involved, and the chorioid is everywhere infiltrated with pus, which dissects up the stroma and pushes its fibres apart. The retina is also infiltrated with pus, and is generally lifted up and separated from the chorioid by a large layer of pus. The vitreous humor becomes converted into an abscess.

Besides the traumatic form, *metastatic suppurative chorioiditis* accompanying severe fever, such as typhoid fever, variola, and puerperal pyæmia, is sometimes met with. It is very rarely found in pyæmia

from wounds and injuries, though Weiss¹ records a double metastatic chorioiditis as the only metastasis that occurred in a case of compound fracture. In the majority of such cases, the disease is probably caused by emboli. In purulent meningitis, however, it is supposed that the pus travels down between the sheaths of the optic nerves, and then passes into the sub-chorioid space, thus directly infecting the chorioid.

The atrophic changes of the chorioid that frequently develop in myopic eyes, and are often designated as *posterior staphyloma* and *sclerotic-chorioiditis posterior*, are described in the section on Myopia.

In hyperæmia of the chorioid, a cure can be confidently expected from rest of the eye and the use of depletory and alterative measures. In the various forms of inflammation, the expectations of a cure will vary materially with the location and grade of the changes, and with the stage of the disease. Where there has been considerable disturbance of the meshes of the chorio-capillaries and of the pigment in the retinal epithelium, causing the latter to aggregate in spots and to wander into the inner layers of the retina, the outlook is more dubious than in simple hyperæmia. In spite of this prognosis, however, a degree of vision may exist which is much higher than the ophthalmoscopic appearances would lead one to suppose, even where such changes invade the macular region. Moreover, such cases, even when accompanied with white patches of exudation in the overlying retina, often improve beyond the most sanguine expectations, under prolonged rest of the eye and the continued use of mercurial and iodic alteratives. In all forms of inflammation, where there has been a large amount of plastic exudation, atrophy of the chorioid-stroma and pressure or drag upon the rods and cones of the retina, are apt to follow. In such cases, a scotoma that corresponds more or less accurately to the affected area, may be demonstrated. Where such atrophic spots exist only in the periphery of the eye-ground, there may not be any perceptible diminution of the central vision. If the spots are developed at or near the macula lutea, they are apt to impair or destroy useful eyesight. The prognosis of any form of syphilitic chorioiditis, if seen at an early stage, is always more favorable than similar changes that are due to other causes. Suppurative chorioiditis is generally fatal, both to the eyesight and to the integrity of the eyeball.

In most cases of metastatic chorioiditis much will be done if the life of the patient is saved, even if the eyesight be lost. Fortunately, as far as sight is concerned, this form of the disease is often monocular.

In hyperæmia of the chorioid, the eye should be protected from the light by smoked glasses, and atropia should be instilled to set the ciliary muscle at rest and to diminish the congestion of the uveal tract. Where necessary, these measures may be advantageously aided by the abstraction of blood from the temple by natural or artificial leeches, and by the moderate use of some mercurial or iodic resolvent. In disseminate and areolate chorioiditis, there is, unfortunately, little to be done in long-standing cases, or in those that develop slowly. Where these forms of the disease are more acute, and where there is a development of vitreous

¹ Bericht der Ophthalmologischen Gesellschaft, Heidelberg, 1875, Ss. 393-403.

opacities, the local abstraction of blood, with the alterative and depletory measures that have been detailed in the treatment of iritis, should be used. As the syphilitic form of chorio-retinitis usually occurs in the advanced stage of the disease, the most energetic and persistent anti-syphilitic measures should be resorted to. The treatment of metastatic chorioiditis must, of course, be mainly influenced by the general state of the patient. When suppurative chorioiditis has fairly set in, the surgeon will generally do well to alleviate the suffering of the patient by either enucleating the eyeball or evacuating its contents. Most Continental European writers hold that enucleation under these circumstances endangers the life of the patient by tending to produce suppurative meningitis. This view, however, is not held by many English surgeons, and in the opinion of the author, enucleation is the best treatment, and does not involve any additional danger to the life or well-being of the patient, where the case is of traumatic origin.

Detachment of the chorioid from the underlying sclerotic takes place in some states of chronic inflammation of the chorioid. Inasmuch as the chorioid is fastened down posteriorly by the short ciliary arteries, and at the ocular equator by the vortex veins, the separation generally appears in the anterior portion of the coat. Ophthalmoscopically, the detachment appears as a rounded prominence, that is covered by a more or less opaque retina, which has been pushed up in front of it. The color of the prominence varies partly with the amount of retinal haze, and partly with the amount and distribution of the pigment in the epithelial cells. As a rule, the tumor can be differentiated from simple detachment of the retina by the fact that the chorioid is close behind it, and by the absence of any vibrating and tremulous motions in it, when the eye is moved. It is to be distinguished from pigmented sarcoma of the chorioid by its less rapid growth and change of shape, and by the diminished tension of the globe. In detachment of the chorioid, tension is usually below normal, while in intra-ocular growths it is often increased. Eyes affected by detachment of the chorioid, generally undergo atrophy. This condition also ensues after wounds and operations on the eye, in which there has been marked loss of vitreous. Knapp¹ reports a case of cataract with fluid vitreous, in which, after operation, three brownish rounded tumors, which were supposed to be sarcomatous, developed. They were visible with the ophthalmoscope, and appeared velvety on their surface.

Rupture of the chorioid, as the result of severe blows upon the eyeball, usually occurs at the posterior portion of the membrane, near the insertion of the optic nerve.²

Disseminate or miliary tubercle of the chorioid is always primarily deposited in the capillaries of the chorioid. It may subsequently become interstitial, infiltrating the entire thickness of the membrane, and separating its fibres as pus does in suppurative processes. Generally, however, it appears ophthalmoscopically in distinct spots or nodules, that are situated in the posterior part of the chorioid near the optic entrance and macula. The tubercular masses appear as whitish-yellow spots in the stroma of the chorioid. They vary in size from one-eighth of the

¹ Intra-ocular Tumors, pp. 261-269.

² This condition has been fully described in the chapter on Wounds and Injuries of the Eye.

diameter of the optic disk to the size of the disk itself; and may, by confluence of adjoining growths, aggregate into larger masses. These spots are prominent, and may be surrounded by a narrow border of chorioid which shows slight change of color by reason of disturbance in its pigmentation. It is rare, however, to have any black boundary of pigment around a prominent area. There is an additional variety of tubercular infiltration which is an accompaniment of tubercular meningitis. This variety has a marked retinitis and swelling of the head of the nerve associated with it.

Solitary tubercle of the chorioid is very rare. It manifests itself to the ophthalmoscope as a large nodule, which resembles sarcoma. It causes detachment of the retina. In some chronic cases, the intra-ocular tubercular mass is the primary seat of the disease.

Tubercles of the chorioid often occur in children suffering from acute miliary tuberculosis. In consequence, however, of the difficulty of careful ophthalmoscopic examination in sick and restless children, their occurrence often escapes detection. Their frequency in this situation is variously estimated by different observers. Cohnheim, who has made many autopsies in cases of acute miliary tuberculosis, declares that tubercles of the chorioid are to be always found. Many other observers, however, assert that they are exceptions. Thus, Allbutt¹ states that he has examined ten individuals so affected, with the ophthalmoscope, and has made two autopsies, all with negative result. Garlick,² during a two years' experience at a children's hospital, has found them but once. Heinzl³ reports ten autopsies of children with general tuberculosis. In none of these were tubercles of the chorioid present.

In miliary tuberculosis of the chorioid there are rarely any observable symptoms, the patients dying of the general affection before the disease of the eye has advanced very far. Solitary tubercle always threatens the existence of the eye, and if left alone, is said sometimes to work its way through the sclerotic. Most patients affected with it die of tuberculous disease of the brain or other organs.

In the solitary form, enucleation is the proper treatment. This is to be done with a view of preventing infection of other parts of the body.

Sarcoma of the chorioid, though originating in a densely-pigmented matrix, is sometimes white and free from pigment. The latter variety is more apt to occur in young subjects in the anterior part of the eyeball. The growth is, however, usually densely pigmented, and sometimes consists so entirely of small spindle cells as to become almost fibrous in character. At other times, mixed spindle and round cells, and sometimes small round cells, form the bulk of the tumor. Knapp maintains that the spindle-celled forms are outgrowths of the outer layers of the chorioid, and that the round-celled varieties are developed from the inner layers and the chorio-capillaris. These growths commence as small, rounded prominences, with an overlying detachment of the retina. They can only be diagnosticated with certainty as tumors by watching them for some time, and seeing either that they become

¹ Use of the Ophthalmoscope, 1871, p. 99.

² Trans. of Roy. Med.-Chir. Soc., London, 1879, 2d series, vol. xlv. pp. 441-465.

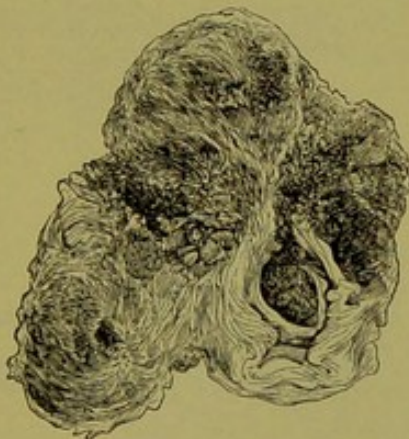
³ Jahrbuch für Kinderheilkunde, 1875, Bd. viii. S. 355.

increased in size or that new, smaller prominences are developed on them. When they are large and have advanced toward the region of the lens, the newly-formed vessels ramifying in the tumor proper can sometimes be distinguished from those of the overlying retina by oblique light, or by a strong magnifying-glass placed behind the ophthalmoscopic mirror. By this means, the diagnosis is frequently rendered more certain.

The detached retina is often irregularly pigmented. As the tumors increase in size, they may cause sufficient irritation to the surrounding tissue or enough obstruction to its circulation, to produce an effusion of serum and an increase of intra-ocular tension. This condition of affairs is attended by clouding of the cornea, injection of the pericorneal veins, and severe pains in the temple and forehead; in fact, all the ordinary symptoms of a glaucoma that originate from other causes.

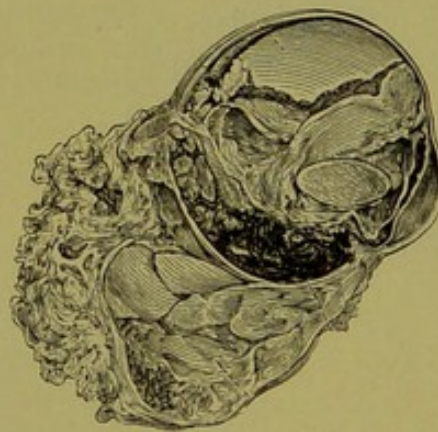
As the new growth increases, it works its way into the sclerotic and separates and pushes aside the fibres. Having thus found entrance

FIG. 307.



Section of spindle-celled sarcoma of chorioid.

FIG. 308.



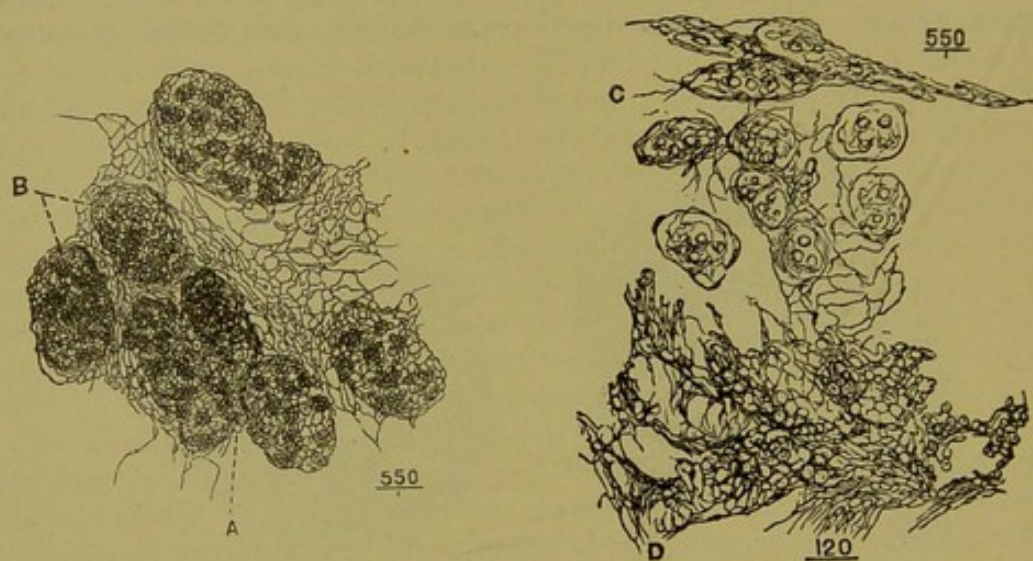
Pigmented sarcoma of chorioid.

into the orbit, it grows rapidly, forming an episcleral tumor that is often much larger than the original growth within the eyeball. Fig. 307 shows a tumor that was the size of a hen's egg. It was hard and nodulated to the touch, and was composed of masses of small spindle cells which grew from a cicatrix that was left by the removal of staphyloma of the cornea, some years previously. The tumor completely filled the shrunken eyeball. The large secondary episcleral growth is also represented in the figure. Fig. 308 represents a pigmented sarcoma of the chorioid. This growth had caused suppurative chorioiditis, and, having found its way through the sclerotic, had formed a non-pigmented episcleral mass of considerable size. The intra-ocular tumor was composed mainly of large polynucleated pigmented cells that were mixed with pigmented spindle cells. The episcleral growth exhibited similar cells, which were non-pigmented. These conditions are well shown in Fig. 309.

As soon as the diagnosis is assured, immediate enucleation of the eyeball is the best treatment. This is so, because the tumor in its early stages has not yet infiltrated either the sclerotic or the optic nerve,

thus offering the best possible chance for escape of the orbital tissues. Notwithstanding these favorable circumstances, growths of a similar character, as for instance in the liver, are often found from one to three years after the operation. While this is frequently the case, it is possible to hold the disease in abeyance for many years. The author has followed the after-history of a case of finely-felted, spindle-celled, pigmented sarcoma for a period of thirteen years after enucleation, during which time there has never been any local or general recurrence of the disease. In several other instances, he has seen death from early appearance of the disease in the liver. Many cases, however, are lost sight of for the purpose of studying the natural history of the disease. For example, if disease of the liver should manifest itself after a period of some years, the patient may pass into other hands, and neither the

FIG. 309.



- A. Large polynucleated pigmented cells from intra-ocular tumor.
- B. Other large cells lying in a slightly deeper layer, the nuclei being hidden by the numerous superficial pigment granules.
- C. Round and spindle cells from the orbital growth.
- D. Stroma of orbital growth as seen under a lower power

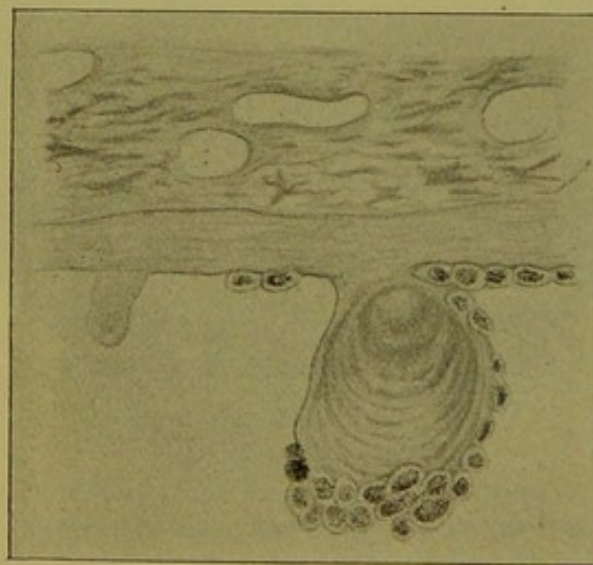
patient nor the practitioner suppose that a previous tumor of the eye had anything to do with the development of the disease of the liver.

In all cases of sarcoma, the cut end of the optic nerve in the orbit should be carefully examined after enucleation of the eye, and if it be infiltrated by pigment, it should be again seized and resected. Where the tumor has gradually pushed its way through the inner spaces between the scleral fibres, a smaller extra-ocular lump in a corresponding position is often found. If this lump appears to have infected the orbital tissues, the periosteum of the orbit should be dissected off and the entire contents of the orbital cavity removed. If any attachments have formed to the bones of the orbit, the points of adhesion should be seared with a red-hot iron. When the disease is far advanced, the prognosis is in every way serious, and the probability of a return in the same locality is very great.

Metastatic neoplasms in the chorioid. Although primary sarcoma of the chorioid is usual, yet secondary deposits in this membrane are rare. Virchow says that in the eye, as in other organs where "protopathic tumors are common, metastasis is infrequent." The experience of every practitioner bears witness to the accuracy of this observation. Pfluger¹ describes a metastatic sarcoma of the chorioid, the original seat of the disease being a nævus of the neck which had undergone sarcomatous degeneration. Perls, Hirschberg, Schöler, Manz, and Schapringner have each recorded cases of metastatic carcinoma of the chorioid.

Formation of bone, as a result of chronic and long-standing irritation in degenerated and shrunken eyes, is often met with. It appears in the form of sheets of bone, with well-developed canaliculi and lacunæ. It is generally found in the inner layers of the chorioid, and in the fibrous exudate that has formed between the chorioid and the retina. These new growths occur as a thin layer of varying thickness, which is situated either near the insertion of the optic nerve into the eyeball or in the ciliary region. Occasionally, they are found sufficiently extensive to form an incomplete hollowed shell. They are not infrequently encountered in phthisical globes. They have no particular significance, except so far as by their presence or growth, they may give rise to sympathetic ophthalmia.

FIG. 310.



Colloid growths. (PAGENSTECHER.)

Hyaline colloid growths are little projections from the lamina vitrea of the chorioid, which project up toward the retina and sometimes invade its tissue. They are usually covered with the pigment epithelium. They are most frequently met with in the equatorial region.

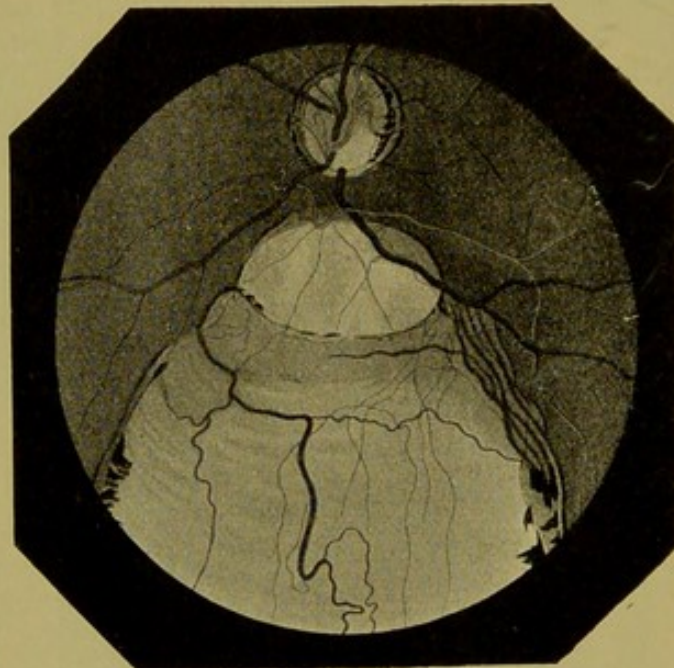
Fig. 310 shows two such growths. The larger one exhibits a concentric striation of its tissue, and is mostly covered by pigment epithelium.

¹ Arch. f. Ophthalmol., xxx. 4. S. 113.

Although they generally constitute one of the forms of senile degeneration of the eye, yet Wecker states that they are sometimes developed as a consequence of chronic chorioidal disease both in the old and young. If so, they are then visible with the ophthalmoscope.

Coloboma of the chorioid is the name given to a congenital defect which generally involves both the retina and chorioid. It may be accompanied by a similar faulty development of the iris. It usually affects both eyes, and may be hereditary. The defect, which sometimes involves the optic nerve, is generally situated in or near the vertical meridian, and extends from before backward. Its greatest breadth is often placed posteriorly, and it runs to a point anteriorly. At times, however, it may be broader in the middle. Its edges are irregular, and frequently have projections into which the chorioid runs. Ophthalmoscopically, it appears as a bright white area, which corresponds in size to

FIG. 311.



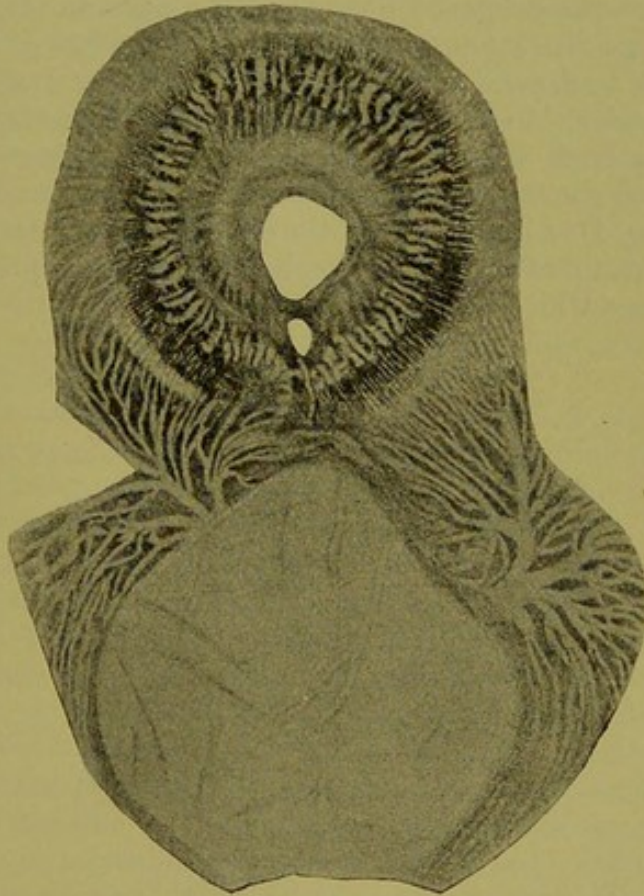
Coloboma of the chorioid. (JAEGER.)

the defect of the epithelial layer and the chorioidal stroma pigment. This defect lies at a much deeper level than its edges. Over it, blood-bearing retinal vessels run with a sharp bend, sometimes to rise to the retinal level on the other side, and again to disappear into the chorioidal stroma at the edges of the coloboma. If the defect be large, irregularities in its outer wall, which are scaphoid and bulging outward at points, can generally be seen. The optic disk is either round or horizontal oval, while the central artery and vein have a distribution, which, although variable, is quite different from that which is ordinarily seen. In some instances, the coloboma solely affects the macular region. In such cases, its borders are nearly round, irregularly curved, or rhomboid. There is always a fault in the field of vision which corresponds in general form with the defect in the retina and chorioid. In

some cases of macular coloboma, the amblyopia, however, is so great as to render an accurate mapping of the field impossible.

Fig. 311 gives an excellent representation of a well-marked coloboma of the chorioid. Here, the optic disk is almost vertical oval with a peculiar pyramidal excavation at its lower part, that extends to the scleral ring. Over the edge of the scleral ring, the lower retinal vein bends sharply, as is so often seen with the retinal vessels in glaucoma. The whole distribution of the retinal vessels is anomalous, they sending small branches into a delicate whitish membrane which overlies the coloboma. The excavation is divided into three portions of different depths—the deepest being nearest the disk. The edges of the coloboma

FIG. 312.



Post-mortem appearance of a coloboma of the iris, ciliary body, and chorioid. (WEDL and BOCK.)

are bounded by an irregular black stripe covered in places with pigment massing. At the right-hand edge, the pigment of the chorioid is wanting in places, thus enabling a view of some of the vessels of its stroma to be obtained.

The post-mortem appearance of an interesting case is shown in Fig. 312. Here, the pupil is ovoid with its long axis in the direction of the coloboma. Beneath it, separated by some of the circular fibres of the iris, there is an ovoid coloboma which communicates with the defect in the chorioid by a slit-like cleft in the ciliary body. The ciliary processes are distorted in the vicinity of the cleft and one of the vorti-

cose veins stops abruptly at the edge of the coloboma. A few vessels are seen lying deeply in the colobomatous area.

Although many ophthalmoscopic cases have been reported, yet there have been so few in which the eyeball has been dissected, that the statements as to the character of the tissue found in the coloboma, are at variance. Two of the most careful autopsies are those reported by Arlt.¹ In the second of these, a membrane, which was continuous with both the retina and the chorioid, could be seen crossing the coloboma. In this membrane, all of the retinal structures were found imperfectly developed and scattered. A few specks of pigment in a fibrous tissue, was all that remained to represent the chorioid.

The defect is often accompanied by microphthalmus. At times, a string of fibrous tissue and bloodvessels can be seen running from the posterior part of the coloboma forward to the position of the lens. So far as embryology has given an insight into the nature of this affection, it would appear to depend upon a failure of the foetal slit in the secondary eye-bladder, to close. According to Von Ammon, the foetal slit closes normally from before backward, thus accounting for those instances in which there is a coloboma of the chorioid without involvement of the iris. Our knowledge of the development of the macula lutea is not sufficient to offer a good explanation of the presence of the form of coloboma which occurs in that region.

¹ Krankheiten des Auges, S. 129.

CHAPTER XXIII.

DISEASES OF THE VITREOUS.

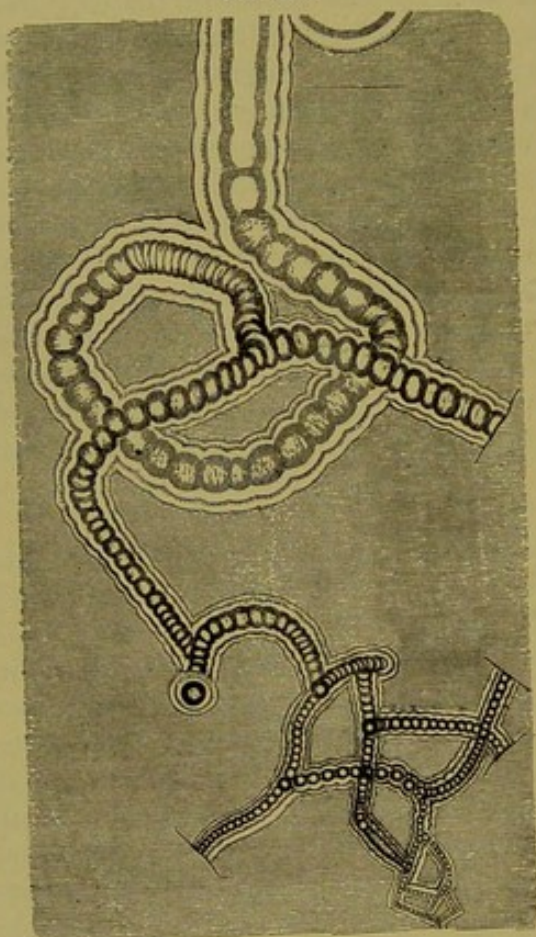
Hyalitis. Inasmuch as the vitreous is devoid of bloodvessels and nerves, being simply a mass of transparent mucoid material that derives its nutriment from the bloodvessels of the ciliary processes, retina, and chorioid, by endosmosis, its pathological changes are few, being mostly secondary to other inflammatory or degenerative processes in the tissues of the eye. Entopic examination shows that there are groups of cells, beaded filaments, and membranous expansions in every vitreous, which, according to Jago, are so disposed that there is a central bag with septa leading out from it that are so arranged as to divide the rest of the vitreous into smaller bags. The ophthalmoscope fails to reveal these cells and septa, which, although throwing sufficient shadow on the retina to be readily noticed by the individual, are invisible when the fundus is illuminated by the mirror. In fact, it is only when the structures of the vitreous become thickened by proliferation, or when they undergo degeneration and become more opaque, that they can be discerned ophthalmoscopically.

The majority of the opacities of the vitreous are, however, dependent upon either the wandering of lymph-cells into the tissue (which are visible as a delicate cloud), or the changes that are undergone by them during their transformation into fibrous tissue or degeneration into pus. At times, they may be due to hemorrhages from the vessels of the ciliary processes or of the retina into the structure of the humor with subsequent changes in the effused blood. Where there is a wound of the eyeball, any bead of vitreous which has been caught in the point of injury, can often be seen becoming gray from infiltration with wandering cells. In many instances, a gray streak running back into the wound made in the vitreous by the perforating body, may be observed with the ophthalmoscope. At times, a fine cloud-like mass may be recognized at the termination of this gray streak, thus indicating the presence of a foreign object. Sometimes, minute splinters of metal or small shot become encapsulated and remain in the vitreous for years without producing any serious disturbance. Usually, however, such bodies gradually find their way to the bottom of the eyeball, where they may produce purulent chorioiditis or give rise to sympathetic ophthalmia. At times, a local abscess forms around them, which, pointing through the sclera, allows them to be thus evacuated. In some cases, a wound of the vitreous gives rise to a proliferation of fibrous tissue that is sufficient to cause a depressed cicatrix in the sclera with detachment of the retina.

As previously pointed out, hyalitis, when not traumatic, is necessarily secondary. Ophthalmoscopically, it manifests itself either by a fine clouding and delicate stippling of the vitreous, by the formation of filaments, membranes, and irregularly rounded masses (*flocculi*), or by a

disintegration and softening of its tissues (*synchysis*). The various opacities, in whatever manner produced, throw shadows on the retina, causing the patients to complain of seeing such objects as "flies," "spiders," or "networks of filaments." This symptom is denominated *myodesopia*. *Muscae volitantes* are by no means always caused by serious change in the vitreous, being frequently found to disturb feeble patients with normal vitreous humors, whose retinae are hyperæsthetic from overwork. Anyone who has not been annoyed with such objects

FIG. 313.



Entopic images. (JAGO.)

during reading or in looking into the field of a microscope, can readily get an idea of what is seen and complained of by his patient, by holding a visiting-card which has had a hole pricked into it, close in front of his eye. By now giving the card a series of shaking movements so as to cause the pin-hole to pass across his field of vision, while he looks at the blue sky, or some brightly illuminated object, he will notice a series of entopic images and shadows. Fig. 313 represents the beaded filaments which are to be seen entopically in every vitreous, by the use of a small pencil of divergent light. The upper end of the filament being further from the retina, throws a larger shadow and therefore appears of greater size. Such filaments form a network throughout the vitreous. The light-centres of the individual beads may be made to appear black when they are examined in a beam of convergent light, such as can be easily obtained by placing a convex lens of half-inch

focus in front of the eye and varying the distance at which it is held as it is desired to throw the focus in the more superficial or the deeper-lying parts of the vitreous.

The very fine, diffuse, dust-like opacities in the vitreous that are so often associated with specific chorio-retinitis, are much less frequently encountered than the filaments and flocculi. These dust-like opacities may be either diffused throughout the humor or condensed into ball-like masses. The filaments and flocculi are generally found most developed in either the anterior or the posterior part of the vitreous. They are usually accompanied with sufficient breaking down of the tissues of the vitreous to allow them to float freely about with the various movements of the eye. When the vitreous opacities develop suddenly and when they are situated in the anterior part of the eye, they are generally caused by hemorrhages which have originated in the ciliary processes. If they are situated in the back part of the humor, they result from breakages in the bloodvessels of the retina. Under ophthalmoscopic illumination, they appear blackish or brownish. When situated in the anterior portion of the vitreous, their red color can be frequently demonstrated by oblique illumination. They are often absorbed, but at times, undergo fatty degeneration and leave cholesterin crystals behind them. More frequently, permanent muscæ remain. When there is extensive softening or fluidity of the vitreous, the opacities can be seen making considerable excursions through it. When cholesterin or tyrosin crystals are present, a brilliant silvery or golden shower can be noticed moving about in the vitreous with every motion of the eye. When there is acute inflammation of the eye, the vitreous opacities are apt to be filamentous and membraniform in character. Especially is this so in those opacities which are produced in inflammations of the ciliary body. In many cases of myopia with thinning and staphyloma of the posterior part of the globe, the adjacent vitreous becomes fluid. This shows why myopes are especially likely to be annoyed by muscæ volitantes. By some anatomists, this condition is not accepted as a breaking down of any part of the vitreous humor, but is considered to be a detachment of the vitreous from the retina, allowing the intervening space to be occupied by effused serum and lymph.

New growths in the vitreous, consisting of pillars and coils of connective tissue and newly-formed vessels, are occasionally met with in cases of proliferating retinitis. A representation of such vessels before they have attained any very great size, is given in Fig. 276. It is only in rare cases of chronic inflammation, whilst the vitreous remains comparatively clear, that such new growths can be seen and studied.

Persistent hyaloid artery. In studying eye-grounds with the ophthalmoscope, a little tag of tissue attached to the sheath of the retinal vessels at the porus opticus, and floating about with the motions of the eye, is frequently seen. More rarely, whitish strings, which lead out from the same point and branch in the vitreous, can sometimes be followed to the posterior pole of the lens. In the latter form, these are evidently thickened remnants of the foetal hyaloid artery and its branches, the main stem of which thus demonstrates the position of the vitreous canal. Several cases of persistent hyaloid artery, which

remained blood-bearing, are reported. Knapp¹ has recorded one in which the condition was present in both eyes.

Parasites in the vitreous. Numerous cases of the development of cysticercus in the vitreous humor are reported in Germany. The affection is much rarer in Austria, England, France, and this country. If seen soon after the development of the parasite and its entrance into the vitreous, before it has excited sufficient inflammation to produce much opacity, it presents a very striking picture, which, with full dilatation of the pupil, is generally easily recognized. A bluish ball with translucent walls, which not only moves in the vitreous with the motions of the eye, is seen, but the parasite has an independent peristaltic motion, and at times exhibits a curious iridescence on its surface. Occasionally, the little bladder-like form will thrust out its head, when the characteristic quadrate form with its suctorial pores and the construction of the neck, leaves no doubt as to the diagnosis. Becker records a case in which the point of entrance through which the animal worked its way into the vitreous could be observed. Jaeger has given a masterly picture of a cysticercus whilst it remained partly imbedded in the retina. Becker has reported a case in which two cysticerci were found in one eye.

The diagnosis of vitreous opacities with the eye-mirror is usually easy. Ordinarily, they are best studied by the upright image with a strong magnifying-glass placed behind the hole in the mirror. For those which lie immediately behind the lens, a convex spherical lens of five to six diopeters' strength should be employed. Weaker lenses can be used for those that lie deeper. If fine dust-like opacities be present in the vitreous, a magnifier is not only needed, but a weak-light mirror must be employed to appreciate them properly. Dense opacities can sometimes be best seen with the strong light of the inverted image, taking care to hold the condensing lens first near the eye, and then gradually to withdraw it until the inverted image of the edge of the pupil is obtained. By this means, the entire thickness of the vitreous humor can be explored.

In case of fluid vitreous caused by long-standing and chronic disease of the chorioid or ciliary body, little can be expected from treatment. In acute forms, which are accompanied by inflammation, however, depletory and alterative measures, with rest of both eyes, will frequently accomplish a great deal.

Even in desperate cases, either chronic or acute, where there has been a recent and sudden increase of the opacities, remedies should be given a fair trial, as frequently, considerable improvement will result. When there is ciliary injection, without increase of tension, atropine should be instilled, blood taken from the temple, and the patient put under the influence of some preparation of mercury, or of mercury in combination with iodide of potassium. In more chronic cases, where the patient is not too feeble, he should be put to bed, and given either fluid extract of jaborandi by the rectum, or muriate of pilocarpine by subcutaneous injection, in doses that are sufficient to cause profuse sweating. Later, when the patient is permitted to go about, benefit may be derived from the employment of Turkish baths.

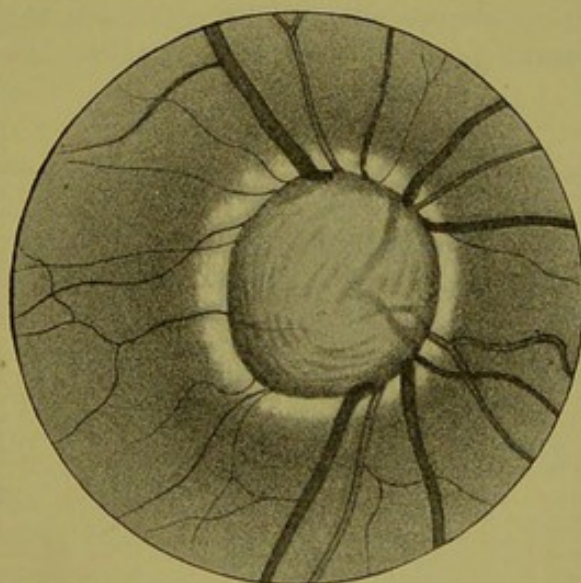
¹ Archives of Ophthalmology, vol. iii. p. 190.

CHAPTER XXIV.

GLAUCOMA.

GLAUCOMA is the name given to a group of eye-symptoms that is characterized by periodical obscurations of vision and a diminution of the range of accommodation, in association with an increase of intra-ocular tension, haziness of the cornea, dilatation of the pupil, pericorneal venous injection, fulness of the anterior scleral veins, and a dull-purplish discoloration that is situated around the margin of the cornea. At times, these symptoms are accompanied with but little discomfort beyond the gradual loss of vision. At other times, they are associated with an agonizing pain in the eye and forehead. In this latter type,

FIG. 314.

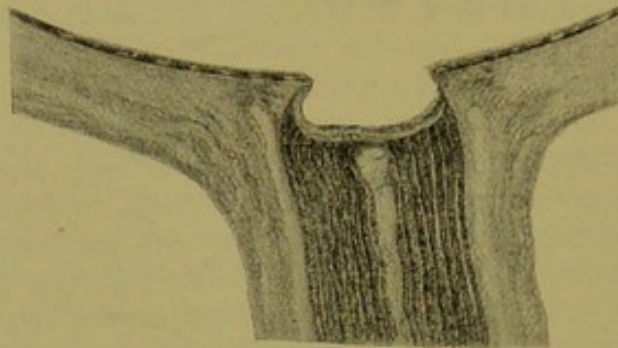


Ophthalmoscopic appearance of absolute glaucoma. (JAEGER.)

there is intense vascular injection of the conjunctiva of both the lids and eyeball. After recurring attacks, permanent contraction of the field of vision, with excavation of the intra-ocular end of the optic nerve, takes place. When the disease has lasted for a long time, a degeneration of the eyeball, ending in atrophic shrinking of the globe, ensues. Fig. 314 gives a view of the ophthalmoscopic appearances of the head of the optic nerve in the eye of a seventy-three-year-old female, who had been blind from glaucoma for three years. The halo around the disk and the appearances caused by the pressure of the vessels against the edge of the excavation, are well shown. Fig. 315 shows a section of this nerve magnified half as much as the ophthalmoscopic picture. In it, the tissue which constituted the head of the nerve

can be seen to be pushed back into the sheath between the scleral edges and massed against the lamina cribrosa. The lamina cribrosa itself has been displaced backward. When these symptoms arise without any

FIG. 315.

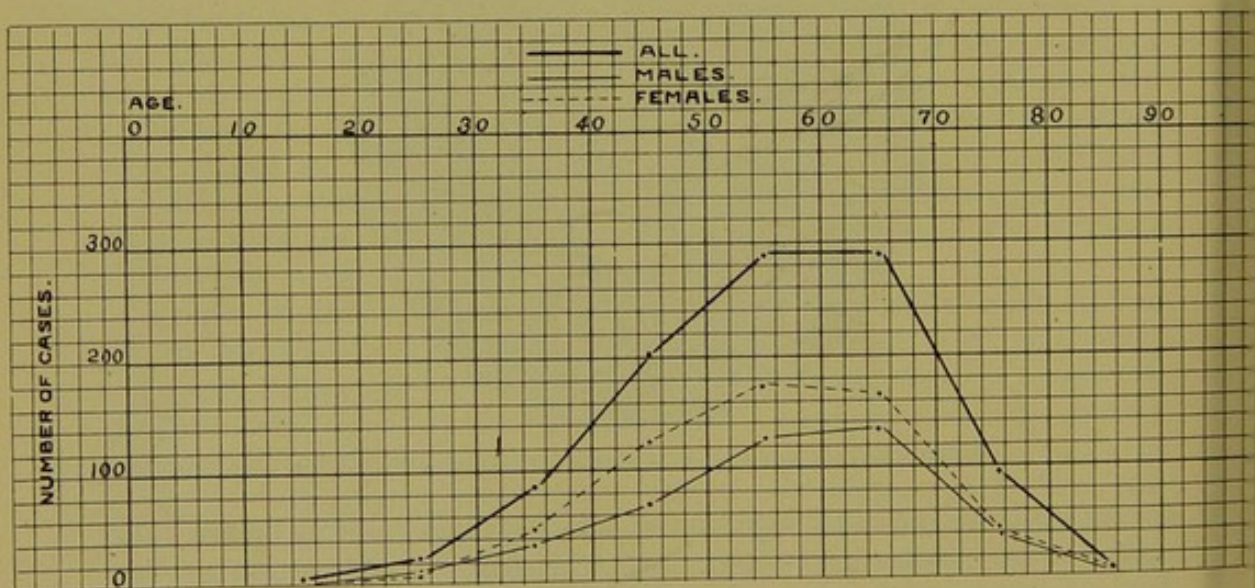


Section of optic-nerve head of same. (JAEGER.)

known cause, the affection is called *primary glaucoma*. When they follow lesions or inflammatory changes in the eyeball, the condition is termed *secondary glaucoma*.

Primary glaucoma always affects both eyes, although there may be an interval of several years between the attacks. It is usually a dis-

FIG. 316.



Frequency of primary glaucoma at different life-periods. (PRIESTLEY SMITH.)

ease of later middle life, being very exceptional in the young. Out of three hundred and eighty-eight patients admitted for operation for glaucoma, in a period of ten years, at Arlt's clinic, in Vienna, ninety-three were between forty and fifty years of age, one hundred and twenty-nine between fifty and sixty, one hundred and ten between sixty and seventy, and seventeen over seventy. Of the remaining thirty-nine under forty years of age, thirty-four were found to be

between thirty and forty years, four between twenty and thirty years, and one was aged sixteen years. More lately, Priestley Smith has published a table (Fig. 316) showing the frequency of primary glaucoma at different life-periods. From this, it appears that this form of the disease is most frequent in the decade from fifty-five to sixty-five years, and that it is more prevalent in females at any age than it is in males.

A manifest hereditary predisposition to it exists in many families. By most European writers it is asserted to be more frequent in some races, notably among the Jews. Moura has found the disease at Rio de Janeiro much more common among the negroes than among the whites. The eyes affected by it are usually hypermetropic. The feeble and cachectic are more liable to the disease, and any great mental depression predisposes to an attack.

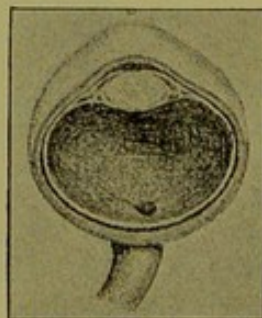
Simple glaucoma (glaucoma simplex) in some cases is most insidious in its onset. Except temporary obscurations of sight, slight recurrent congestions of the eyeball, and tendencies to see rainbows around lights, there is nothing to alarm the patient. Gradually, however, the field of vision is diminished, a halo forms around the optic disk, a deep and complete excavation of the head of the nerve is produced, and sight slowly vanishes, never to return.

Fig. 317 gives a good view of the advanced stage of this form of the disease. The eyeball is represented of its natural size. It was stony hard. The anterior chamber is almost obliterated. The iris is much atrophied, and the head of the optic nerve shows a complete and characteristic excavation.

Subacute glaucoma (glaucoma subacutum). It is rare to have the whole course of the disease pass without some acute or subacute inflammatory exacerbations. These, which are expressive of this type of the disease, are accompanied by marked redness of the eyes, intense haze of the cornea, dilatation of the pupil, and great hardness of the eyeball. During the attack, there is severe neuralgic pain in the eye, forehead, and temple, which, at times, extends to the side of the nose and the angle of the jaw. The attack, if left alone, subsides, and vision improves, to be followed, at intervals of some weeks or months, by another seizure. In fact, in all its forms, glaucoma is essentially a disease of remissions, and even patients who have been long blind from it, have their light and their dark days. The eye is always better after sleep.

Acute glaucoma (glaucoma acutum, glaucoma fulminans). In rare cases, where previous obscurations of the field of vision and rainbows around lights have either not existed or have escaped attention, the patient is suddenly seized with agonizing pain in the eye, temple, and forehead. This is accompanied by congestion of the conjunctiva, slight swelling of the lids, and great dimming of sight. The eyeball becomes stony hard, the cornea gets steamy, needle-pricked, and anæsthetic. These conditions continue until, in severe cases, a single attack will in a

FIG. 317.

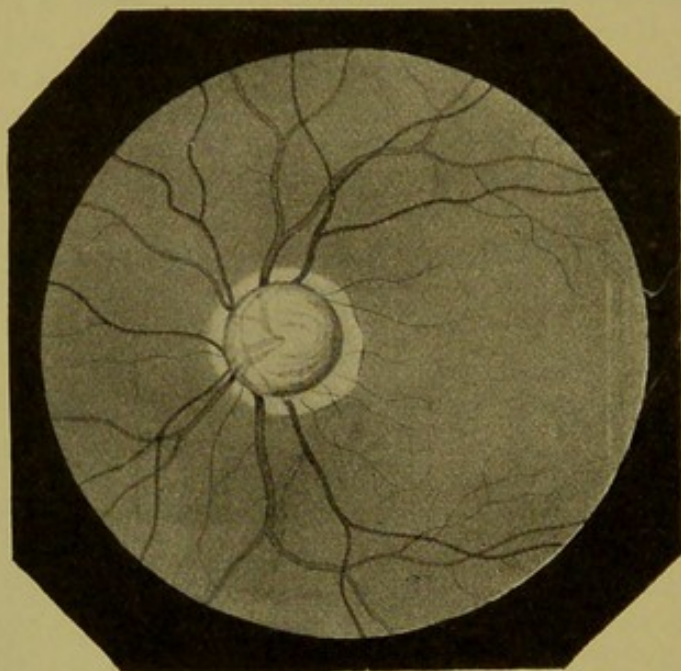


Section of eyeball in the advanced stage of simple glaucoma. (MAGNI.)

few hours entirely destroy vision. Later, a condition known as *glaucomatous cataract* may develop.

If an eye suffering from acute or subacute attack of glaucoma be examined with the ophthalmoscope, and the media have not become sufficiently cloudy either to prevent or to materially impair a view of the fundus, it will be frequently seen that the central artery markedly pulsates. In cases where this pulsation is not present, the slightest pressure with the finger on the tense eyeball will call it forth. This phenomenon is due to the fact that the increased intra-ocular tension prevents the arterial blood from entering the eye except during the maximum of intra-vascular pressure. The veins are usually tortuous and enlarged. In some cases, there are extravasations of blood into the

FIG. 318



Ophthalmoscopic appearance of chronic glaucoma. (JAEGER.)

retina. After repeated attacks, or long duration, it will be found that the vessels in the head of the nerve have altered their position, and that they present a sharp bend at the edge of the disk, and then disappear from sight, to reappear generally at a deeper level. Here they penetrate the lamina cribrosa and are lost to view. In many long-standing cases with complete excavation of the head of the nerve, the differences of level between the bottom of the excavation and the edge of the disk is so great that, while the vessels in the retina, before they bend over the edge of the disk, may be seen either without a correcting lens or with a convex glass of one or two diopters' strength, they can only be sharply seen at the bottom of the excavation with a concave glass of from one to four diopters. In most cases, except those of very long standing, the excavations are very unequal in depth, generally being the deepest near the centre or in the neighborhood of the entrance of the central vessels. In many cases of commencing glaucoma, and in all cases of complete glaucoma, a broad yellowish band,

which is either evenly developed on all sides, or extends farthest to the temporal side, is found at the place that is usually occupied by the scleral ring, and beyond it. It is more dense and pronounced in color near the disk, and is fainter and tinged red-brown on the outer side. Fig. 318 gives a life-like representation of the ophthalmoscopic appearance of a marked case of chronic glaucoma which occurred in the eye of a school-mistress aged sixty-four, who had been affected by the disease for two years. In this instance, the halo around the disk is unusually broad and distinct. Although the patient had never suffered any pain in the eye, there had been a gradual clouding of the sight, which became so bad that she could only see the motions of the hand with difficulty. At the time of examination, and for some months afterward, there was a very marked spontaneous arterial pulse. This gradually disappeared, and could only be called forth by pressure.

In the earliest stages of glaucoma, failure of accommodation, causing a rapid and irregular increase of any existing presbyopia, is generally found. When this symptom is accompanied by occasional clouding of vision, or by a "sickly" appearance of the optic disk with broadening of the scleral ring, this symptom should always arrest attention.

During the first, or, as Arlt terms it, the congestive stage of the disease, there are periodical obscurations of vision, which become less marked and sometimes disappear entirely after sleep. Rainbows around lights are seen; this being probably due to clouding of the media, principally of the cornea. As focal illumination of the cornea shows a marked haze which is densest in the centre, this symptom is probably dependent upon disturbance in this membrane. Opacities may develop in the vitreous humor. There may also be haziness of the aqueous humor, as has been demonstrated by Mauthner and others, who found that the incision made in the corneo-scleral junction preliminary to iridectomy, caused the eye to become bright and clear. The haze of the cornea resembles that produced by breathing on glass. Examination with a magnifying-glass shows the haze to be uniform and not resolvable into minute points. In acute cases, some of the epithelial cells are shed, and the corneal surface appears "needle-stuck."

Total or partial loss of the sensibility of the cornea, dependent upon impaired nutrition of the membrane, which varies greatly in different individuals, may involve the entire area or isolated portions.

Venous congestion shows itself mostly in the dull-bluish pericorneal zone and in the tortuosity of the sub-conjunctival veins which emerge from the sclera in the neighborhood of the insertions of the straight muscles of the eye.

Dilatation of the pupil is generally irregularly oval in outline, except in acute cases. In such instances, the tissue of the iris is at times swollen and cloudy. In the advanced stages, it is discolored and atrophic. At times, the iris is so shrunk as to form a band, which in some places may be but a millimeter in width. Narrowing of the anterior chamber and the development of a greenish reflex from the pupil, are well marked in all advanced cases. These have been described by Beer, Fischer, and many of the older writers; the first-named author giving admirable colored plates of these conditions and of glaucomatous cataract.

Increase of tension, though always present in the attacks of acute and the exacerbations of subacute glaucoma, is often absent in simple glaucoma. It varies much in degree. In chronic forms of the disease, it may remain materially unchanged for many weeks at a time. The ball may be stony hard, or its hardness may be but slightly increased. Besides the actual increase of tension, there is a change in the consistence of the scleral tissue. This becomes rigid, especially in old and gouty subjects, and seems at times, on palpation, to possess more or less the texture of tough parchment, rather than the pliant suppleness of the healthy sclerotic. The author recalls a case of the absolute form of the disease, with the development of cataract occurring after an acute attack of glaucoma, in which, during an iridectomy undertaken to alleviate the intense pain in and around the blind eye, the tissue fairly "cried" under the puncture with a lance-knife, just as is sometimes found on incising dense scirrhus growths.

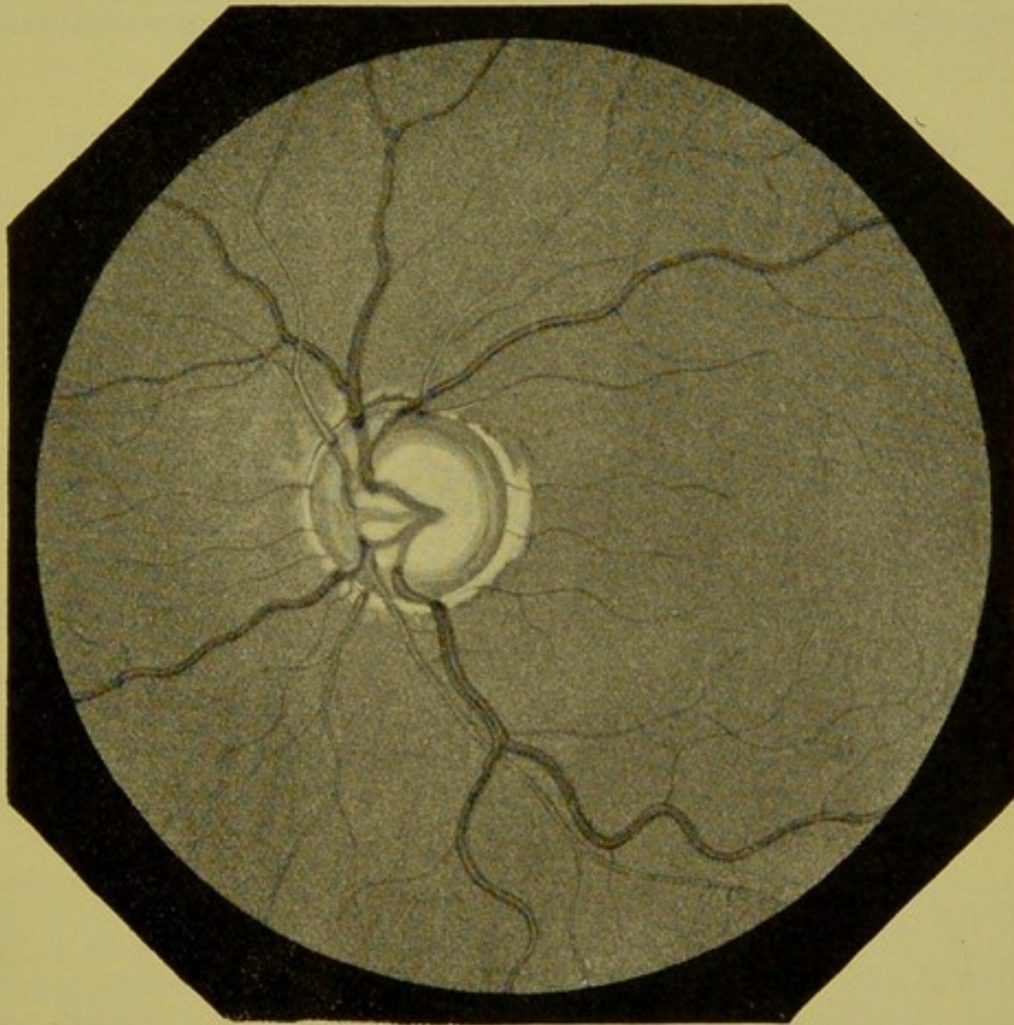
Field of vision diminishes as the disease advances. In the majority of cases there is some general contraction in the form-field, which, though much more marked to the nasal side, usually has its greatest loss situated in and down. At a later stage, even when the disease has attacked the fixation-point, the field still shrinks most rapidly from this side, until finally, vision exists only in the temporal field. While these statements hold good in the majority of cases, many marked exceptions are found, central vision not unfrequently being attacked before any great lessening of the field is manifest. In cases of typical contraction, the color-fields retain their usual relations to the form-fields, while in neuritic and essential atrophies, the color-fields frequently shrink much faster than the form-fields. Laqueur, who has carefully studied this subject, informs us that he has examined the fields in one hundred and seventy-five cases, and of these, fifty-six presented nearly normal extent, with greatly diminished central vision. Of the remaining one hundred and nineteen cases, ten showed contraction exclusively in the temporal field. With one exception, central vision was also much impaired. Twenty-four cases exhibited concentric limitation of the field, which in some instances was so great as to make it difficult for the patients to get about; in these central vision remained fair (*e. g.*, $3/4$). Ninety-five cases showed contraction of the nasal field, the greatest shrinkage being at times situated in and up, and sometimes in and down.

All typical glaucomatous excavations begin at the position of the scleral ring, where the vessels are sharply bent as they dip into the excavation. Beyond this, there is a broad whitish-yellow band, which is described as the glaucomatous halo. Where central vision remains fair, while the cup appears to be complete, it must be concluded, with Mauthner, that, owing to the diaphanousness of the nerve-fibres, the extent of the excavation is overestimated. It always extends to the scleral ring. In cases where it is incomplete, and is taking place in eyes where there is already a physiological excavation, a most instructive picture is obtained. Here, as shown in Fig. 319, the double bend of the central vessels—one at the scleral ring and a second in the head of the nerve at the edge of the physiological excavation—can be plainly seen.

The double excavation here shown, occurred in the eye of a day-

laborer, aged fifty-five years, who was affected with subacute glaucoma. Seven months previously, after severe headache, most marked in the forehead, which lasted eight days, and was accompanied by flashing of light, his vision rapidly failed, so that at the time of examination, all perception of light was lost. In many cases of incipient glaucoma, before the excavation fairly commences, a dull red-gray clouding of the head of the nerve, followed by a reddish, waxy transparency of its tissue, is found. In such instances, it is very difficult to be sure when the

FIG. 319.



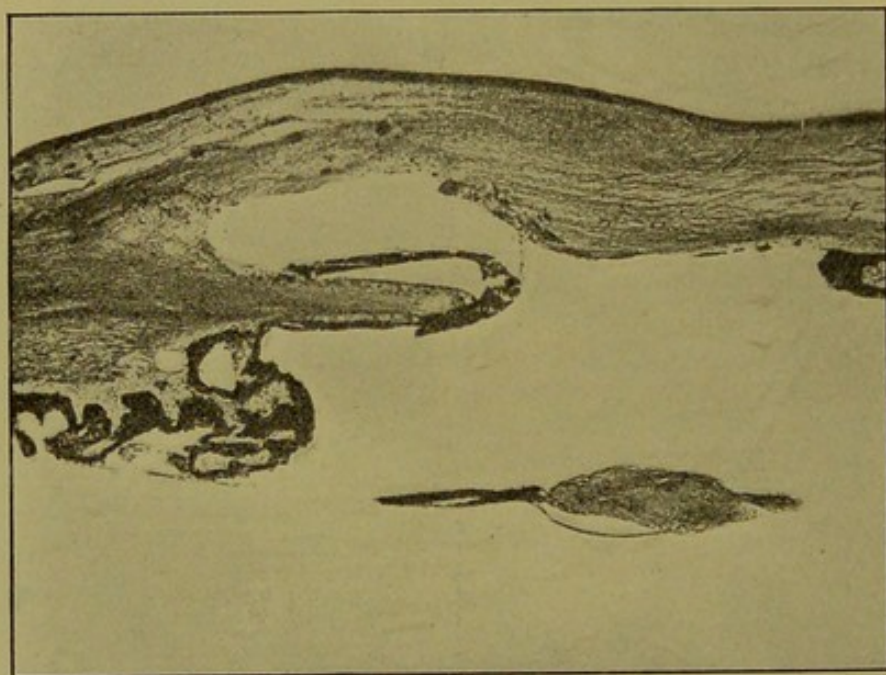
Glaucomatous excavation taking place in an optic nerve with a physiological excavation.
(JAEGER.)

excavation first makes its appearance, and it is only by most careful study of the fine branches of the retinal vessels that run over the temporal side of the disk, that the diagnosis can be made certain. Where there is incipient opacity of the lens, or haziness of the cornea, it becomes impossible to diagnosticate an excavation in its early stages. For several days or weeks, the head of the nerve and the lamina cribrosa may retain a considerable degree of resiliency. Further, there are cases recorded by competent observers, in which a glaucomatous cup of from three to four diopters in depth, is said to have filled out, and the head of the nerve to have regained its normal level after iridectomy. In

cases of hemorrhagic glaucoma, the excavation may be filled with a blood-clot. Immediately to the outside of the scleral ring, a yellowish-white band, which is generally denser and more intense in color at its inner part, and at times slightly stippled, and of yellowish-brown hue at its outer part, is found. Sometimes, this is nearly uniform in breadth all around the disk. Oftener, however, it is broader to the temporal side, and at times, may be developed at this point only.

Hemorrhagic glaucoma; Glaucoma hæmorrhagicum; Glaucoma apoplecticum. According to Laqueur,¹ this form occurs in about three per cent. of all cases of the disease (seven cases out of two hundred and sixty-eight). Whether the retinal and vitreous hemorrhages are looked

FIG. 320.



Cystoid cicatrix.

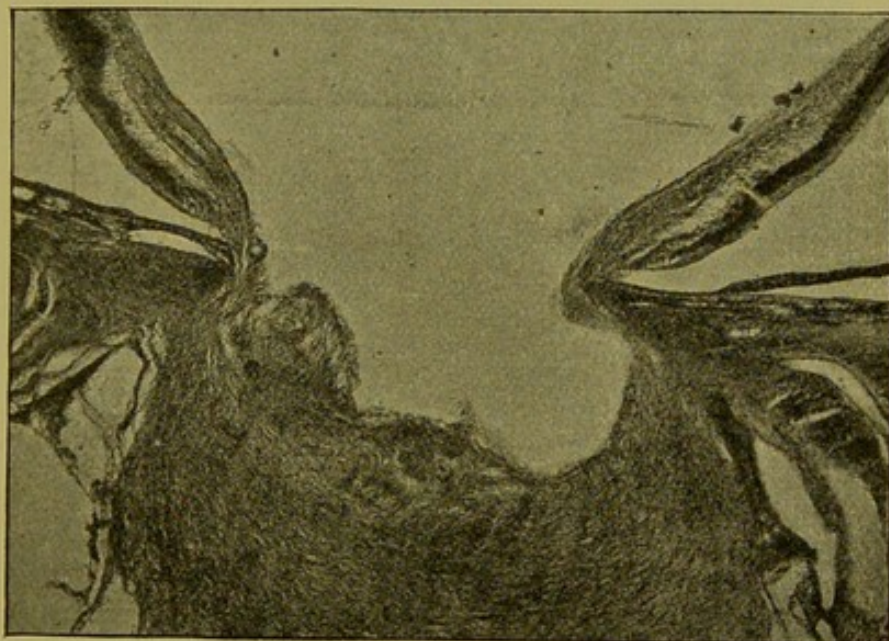
upon as the early symptoms of the disease, or, as most writers assert, that they are the cause of the glaucomatous outbreak, this form of the affection deserves special attention upon account of its clinical importance, and from the fact that iridectomy usually fails to give relief, and even hastens the loss of sight. As noted by Coccia and Pagenstecher, the increased pressure and the ciliary neuralgia may occur in from two to five days after the retinal hemorrhages, but, as Von Graefe says, they ordinarily develop from four to ten weeks later. The hemorrhagic extravasations may appear either with the symptoms of acute glaucoma, or with but slight indications of inflammation. The attack is generally accompanied, or followed within a few weeks, by hemorrhagic retinitis in the fellow-eye. This may not, however, be associated with any decided rise of intra-ocular tension. In such cases, ciliary neuralgia is usually severe.

Secondary glaucoma; Glaucoma secundarium. Where, after any

¹ Annales d'Oculistique, 1889, pp. 32-58.

disease of the eye, or operation upon it, there is a permanent rise of intra-ocular pressure, with diminution of the field of vision and excavation of the intra-ocular end of the optic nerve, secondary glaucoma is said to exist. Its most frequent causes are protuberant corneal cicatrices, with anterior synechia; complete circular posterior synechia; serous iritis and cyclitis; traumatic cataract when there is excessive and rapid swelling of the lens; and partial dislocation of the lens, which is either congenital or acquired. The disease being produced by some lesion of one eye, is limited to it, and, unlike spontaneous glaucoma, there is no increase of tension in the other. In most of the lesions above enumerated, the irritation caused by them in the iris and ciliary

FIG. 321.



Section of deep and irregular glaucomatous excavation.

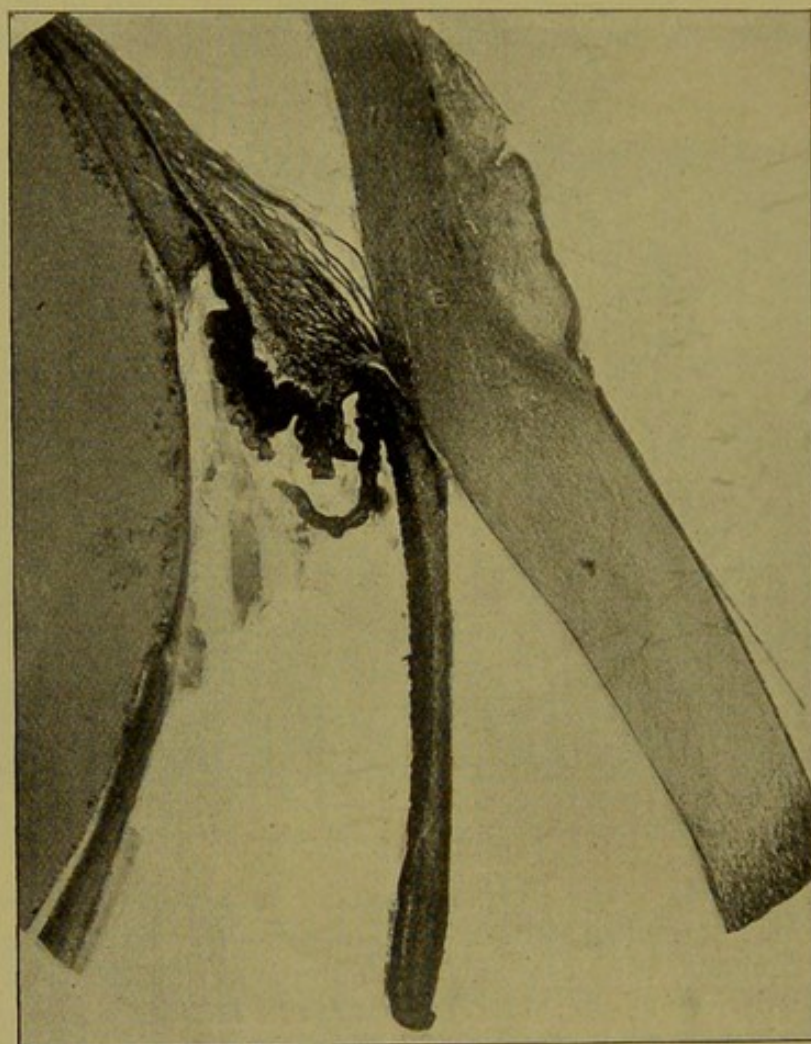
processes, seems to produce hypersecretion and increase of intra-ocular tension, which, in some instances, is doubtless aided by a stoppage of the spaces of Fontana, with consequent hindrance to the escape of lymph from the periphery of the anterior chamber. In most cases of intra-ocular tumor, there is also some period of the growth, at which irritation and hypersecretion of the chorioid and the iris, with obstruction of the filtration angle, produce glaucomatous symptoms. Figs. 320 and 321 are from photographs of a section of an eye that was affected with secondary glaucoma supervening after a peripheric linear operation for cataract. Fig. 320 gives a view of the inflammatory changes in the ciliary processes, the closure of the filtration-angle, the entanglement of the stump of the iris in the wound, and the extensive cystoid cicatrix. Fig. 321 shows a view of a section of the deep and irregular glaucomatous excavation in the head of the optic nerve.

During an attack of glaucoma the cornea becomes anæsthetic and hazy, looking at times like glass which has been breathed upon. Again, from shedding of the superficial epithelial scales, it may appear as if

needle-stuck. This haze is densest at the centre, and is not resolvable into distinct points by the magnifying-glass. According to Fuchs,¹ this condition is due to an oedema of the cornea which is most pronounced between the anterior epithelium and Bowman's membrane.

Owing to a forward protrusion of the lens and iris, and to the contact of the latter with the cornea at its periphery, the anterior chamber is ordinarily very shallow. In some cases, however, there is a deepen-

FIG. 322.



Section through the corneo-scleral junction in secondary glaucoma.

ing of the anterior chamber. In such instances, there is generally serous iritis with precipitates on the membrane of Descemet, the iris being usually congested and the pupil semi-dilated. In acute cases, this dilatation is tolerably regular. In chronic ones, however, where there have been repeated subacute attacks or where there has been a long preceding period of glaucoma simplex, the mydriasis, owing to a partial atrophy of parts of the iris structure, is irregular. In time, the entire iris may become so atrophic that no pupillary reaction can be obtained.

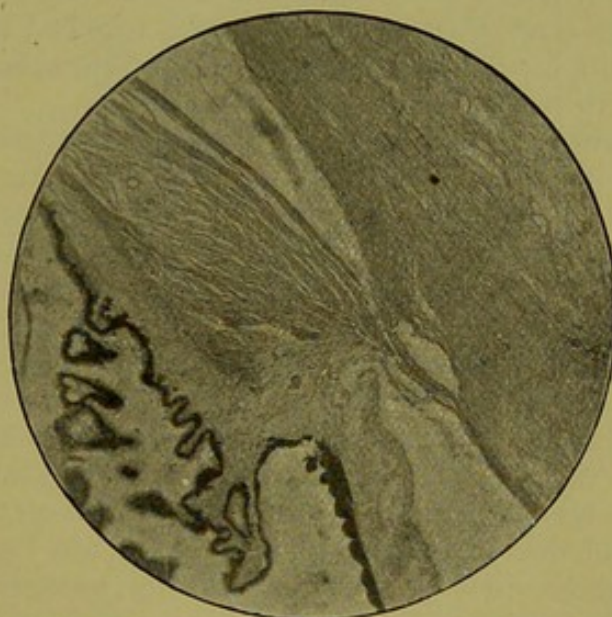
¹ Arch. f. Ophthalmol., xxxvii., 3, 66.

In the early stages of the disease, the pupil can be readily still further dilated by mydriatics, or contracted by the energetic use of myotics.

Fig. 322 represents a section through the corneo-scleral junction and adjacent parts in an eye with secondary glaucoma. It shows how the base of the iris and the pectinate ligament are pressed against the cornea at the periphery of the anterior chamber, and how the filtration-angle is thus closed.

Fig. 323 shows a section through the same region of a healthy eye. It is given here to exhibit at a glance the great changes which have taken place in the section of the glaucomatous eye reproduced in the previous figure.

FIG. 323.



Section through corneo-scleral junction in a healthy eye.

The lens is pushed forward, but rarely becomes opaque, except in long-standing cases, where extensive degeneration of the ciliary processes and chorioid has taken place. As glaucoma is pre-eminently a disease of middle life and old age, commencing opacity of the lens is often found, which, in many instances, probably pre-existed when the disease began. Priestley Smith has shown that the equatorial diameter of the lens is frequently increased in glaucomatous eyes.

Owing to the clouding of the cornea, the state of the vitreous humor is difficult to study during life. Skilled observers, like Graefe and Arlt, maintain that they have seen vitreous opacities, while others with extensive opportunities for observation, such as Schweigger and Schnabel, deny their existence. Autopsies of such cases by Arlt, however, show that they are sometimes present. The fact also that shrinking of the anterior part of the vitreous, with detachment of the retina, is found in some advanced cases of the disease, makes their previous presence probable.

In many cases of acute glaucoma, when seen at the beginning of the attack, there is no excavation of the head of the optic nerve. In

advanced cases of the disease, however, there is a complete excavation, the fibres previously occupying that space having undergone atrophy, and their remnants being pressed backward against the lamina cribrosa and the sides of the cavity. The bottom of the excavation is irregularly concave, and is often deepest at the point of entrance of the central vessels. In fact, a bulging backward of the lamina cribrosa is not infrequent even in cases where there is only a partial excavation and where the head of the nerve still contains considerable masses of nerve-fibre. The central retinal vessels usually branch so as to approach the nasal side of the disk, and are therefore applied against this wall of the excavation. The pushing back of the head of the nerve and of the lamina cribrosa, causes atrophy of the zone of anastomosing arteries at the periphery of the optic nerve. This degeneration causing interference with circulation in the tissue-area supplied by these vessels, probably accounts for the glaucomatous halo and the subsequent atrophy of the chorioid in this region.

The changes in the ciliary processes and the chorioid, are found to be very similar in character to those in the iris which have been already described, namely, congestion followed by slight exudation of lymph-corpuscles, and later, atrophy and wasting of the tissues. According to Arlt, at times, there are secondary changes in the uveal tract which are caused by a shrinking of the sclerotic coat on the vortico-se veins and lymph-channels which ensheath and accompany them.

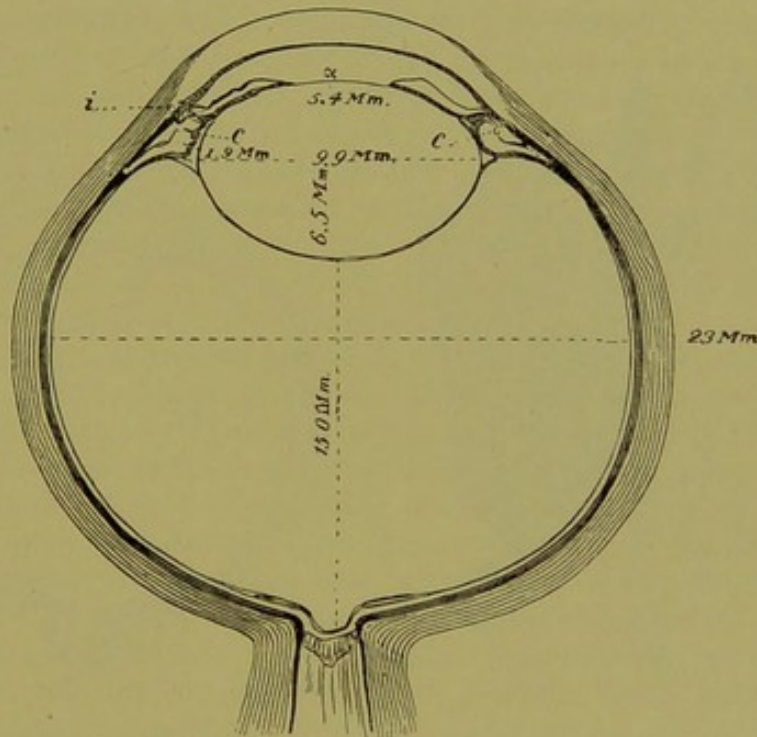
As has been shown by Magni, the ciliary nerves are frequently atrophied. In fact, they are often considerably degenerated in eyes which still retain fair vision. The sclerotic has its tissue condensed and its intra-fascicular spaces narrowed. In many instances, areas of fatty degeneration and deposits of phosphate of lime are found. There is congestion of the vessels which dip into its anterior part and the episcleral vessels around the cornea.

The theories of the origin of glaucoma are so numerous and so varied as to present a true labyrinth, with innumerable paths leading in different directions. In the main, they may be divided into three classes: first, those theories which see in glaucoma an evidence of primary nerve-disturbance, leading to increased intra-ocular secretion, which in a certain number of cases is followed by inflammatory symptoms; second, those theories in which the condition is looked upon as a mechanical result consisting in an interference with the normal egress of fluids from the eye, either by a narrowing of the spaces of Fontana which prevents proper drainage at the periphery of the anterior chamber, or by a diminution of the lymph- and blood-exits where the vortico-se veins perforate the sclerotic (thus regarding all inflammatory symptoms as secondary to such interference with the circulation); and third, those theories which regard the process as a low-grade serous chorioiditis, in which stoppage of the spaces of Fontana or of the vortico-se veins with their surrounding lymph-channels, is looked upon as an accident that occurs as a sequence of the primary chorioidal inflammation.

As regards the causation of the two most prominent symptoms, viz., the increased intra-ocular pressure and the excavation of the head of

the optic nerve, it is evident that there are two possibilities. The increased tension might be produced either by a narrowing of the blood- and lymph-outlets, with a normal supply of fluids, or by an increased secretion of intra-ocular fluids while the efferent channels remain normal. The excavation of the intra-ocular end of the optic nerve, in like manner, might be produced from increased pressure with normal resistance on the part of its tissues, or from normal pressure accompanied by pathological softening of the lamina cribrosa and the head of the nerve. It is also evident, that although the absolute atrophy of the nerve-fibres in the head of the nerve, which is found in cases of long-

FIG. 324.



Section through glaucomatous eye. (KNIES.)

standing glaucoma, would necessarily produce blindness by cutting off all communication between the retinal rods and cones and the brain-centres, yet nevertheless, this cannot be the cause of blindness in cases of acute glaucoma, as here serious impairment or absolute loss of eyesight is found before the excavation of the head of the nerve has occurred, or still oftener, before the cupping has become complete. In such cases, the diminution of sight and the contraction of the nasal field, must be due either to a starvation of the retina that is dependent upon pressure interfering with conduction of blood to it, or to some change that affects the function of the rods and cones.

That increase of intra-ocular pressure is often caused by obstruction of the spaces of Fontana has been abundantly proved by Knies¹ and by Weber.² The experiments of Schöler,³ in which increase of pres-

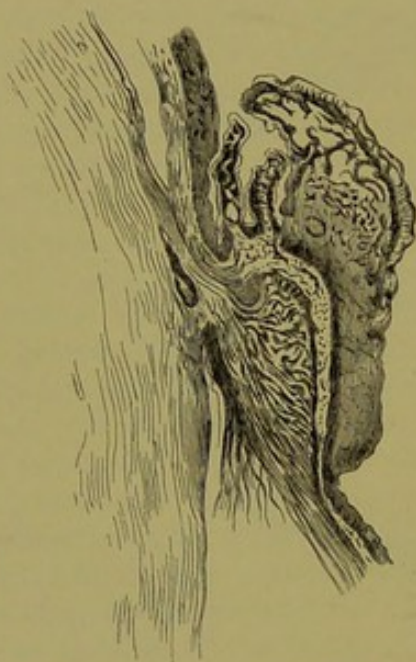¹ Arch. f. Ophthalmol., xxii., 3, Ss. 163-201.

² Ibid., xxiii., 1, Ss. 1-91.

³ Ibid., xxv., 4, Ss. 63-111.

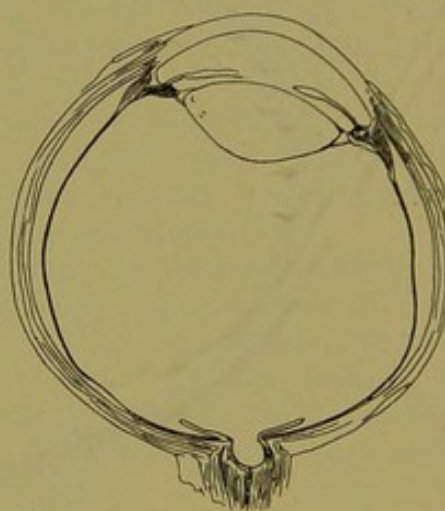
sure was obtained by burns of the corneo-scleral junction in rabbits, and the statement of Mooren,¹ that he has frequently seen glaucoma produced by burns of the ciliary region in man, point in the same direction. Fig. 324 represents a section through a glaucomatous eye in which there was an excavation of the optic nerve, and narrowing of the anterior chamber, with closure of the filtration angle. Fig. 325, from the same case, shows the swollen and congested ciliary processes which have pushed the iris against the pectinate ligament and the cornea. Weber and Priestley Smith think that the filtration-angle is usually closed by this mechanism, while Birnbacher and others suppose that local inflammatory processes in the pectinate ligament around the canal

FIG. 325.



Swelling and congestion of ciliary processes. (KNIES.)

FIG. 326.

Section of glaucomatous eye.
(PRIESTLEY SMITH.)

of Schlemm, are the main causes of the infiltration. On the other hand, it has been abundantly proved by Pagenstecher, Brailey, and Priestley Smith, that many cases of glaucoma occur in which the spaces of Fontana are patulous and the anterior chamber is deep. Fig. 326 shows a glaucomatous eye with deep excavation of the nerve, deep anterior chamber, and widely opened filtration-angle. In the clinical history of the case, it is noted that high tension supervened during the course of a serous cyclitis. Priestley Smith considers that filtration is retarded by serosity of the aqueous humor in such cases, thus causing this fluid to pass more slowly through the animal tissues at the filtration-angle.

Further, the experiments of Leber² and Exner,³ of ligaturing one or more of the vorticosae veins, show a prompt and marked increase of intra-ocular tension, thus authorizing the inference that either shrinking

¹ Fünf Lustren ophthalmologischer Wirksamkeit, 1882, S. 169.

² Arch. f. Ophthalmol., xix, 2, S. 145.

³ Quoted by Arlt, Glaucom, 1884, S. 113.

of the scleral canal through which the vessels make their escape from the eye, or atheroma or thrombosis of the vessel-walls, would readily cause increase of intra-ocular tension. In either case, whether due to stoppage of the anterior or of the posterior lymph and blood channels, it can be seen that any cause, either mental or physical, that would produce a relaxing effect on the sympathetic nerve, would increase the circulation in the ciliary vessels and exudation from them, and thus, by making still greater demands on the already-narrowed channels of exit, temporarily augment the increased intra-ocular tension.

The rôle played by the nervous system in the increase of the intra-ocular pressure in man is not well understood. Mooren,¹ however, relates an interesting case of double glaucoma, with a subsequent attack of interstitial keratitis, which was apparently produced by a myelitis of the spinal cord near the junction of the cervical and dorsal portions. In this case, the glaucomatous condition was cured by an iridectomy which was supplemented by the use of mercurial inunctions. He states that he has seen four other somewhat similar cases. Magni has pointed out the frequency of degeneration of the ciliary nerves in glaucoma. He has also proved by autopsy, that there may be marked atrophy of several of these nerves in eyes which, although unmistakably glaucomatous, could still be used to see fine print.

That local degenerative processes of the head of the optic nerve have much to do with the formation of the characteristic glaucomatous cup, has been pointed out by Mooren—a fact that will be readily granted by every attentive student of eye-grounds where the disease is in its incipency. In such cases, a slight haze of the disk, and, later, a semi-transparent waxy appearance of the tissue composing it, are often seen. These appearances seem to have been fully appreciated by Graefe, when he speaks of “amaurosis with excavation of the optic nerve,” and by Jaeger, when he describes “glaucomatous degeneration of the optic nerve.” Mooren² declares that the cupping cannot be the direct consequence of pressure, as there are numerous recorded observations in which, in spite of the greatest possible increase in pressure, no excavation formed. Moreover, he says that he has seen other cases “unnumbered times,” where there was no cup at the time of operation, but, nevertheless, an excavation formed after the lapse of months or years, in spite of a successful iridectomy which resulted in a permanent lowering of the intra-ocular tension.

In consequence of degenerative changes in the cornea, which are sometimes owing to the formation of a structureless membrane that is situated between the epithelium and Bowman's membrane, the cornea becomes opaque after repeated attacks of acute or subacute glaucoma. At times, large bullæ appear on the cornea, their development being often accompanied by severe pain. The iris undergoes degeneration, this usually first appearing at some point of its periphery, causing the pupil to become irregularly ovoid. The iris-tissue appears bluish-gray, and at times, loses its fibrillation and becomes semi-transparent in places. Later, the entire iris shrinks and atrophies, so that a rim of it can be

¹ Loc. cit., Ss. 171-175.

² Loc. cit., S. 179.

barely recognized at the peripheral margin of the anterior chamber. Arlt has pointed out that where staphyloma of the sclera occurs, it is often found in the same meridian in which the greatest atrophy of the iris and dilatation of the pupil previously existed. In this stage of the disease, bluish enlargements at the exit of the vorticosse veins are generally found. More rarely, local thinning of the sclerotic, with staphylomatous projections in the equatorial region, is present. In this stage of the disease, a deep and complete excavation of the head of the optic nerve—usually ampulliform, or broader posteriorly than at the sclerotic level—with absolute atrophy of the nerve-fibres and bulging backward of the lamina cribrosa, is found.

Treatment in acute glaucoma consists in the prompt performance of a broad and peripheral iridectomy, this being the most reliable means of alleviating the pain and restoring the eyesight. Mauthner and Snellen assert that a sclerotomy, even in acute attacks, yields just as favorable results. In such critical conditions, however, the author has always preferred to practise that operation whose value has been proved in the thousands of cases that have fallen into the hands of ophthalmic surgeons in all quarters of the globe. Moreover, in his judgment, sclerotomy is far from having had so complete a trial. Owing to the clouding of the cornea and the narrowing of the anterior chamber in such cases, either operation is difficult of performance, rendering it best at times to instil a four-grain solution of eserine into the conjunctival sac, and to wait for twenty-four hours, until the chamber has become deeper, before attempting any operative procedure. In subacute exacerbations of the chronic form of the disease, iridectomy also gives excellent results. In acute cases, a restoration of good vision may be expected. In the subacute attacks of chronic cases, vision as good as that which was enjoyed before the exacerbation, may usually be looked for. In any case, care should be taken to see that the cut edges of the iris are properly replaced, and that they are not entangled in the wound. Our endeavors to do this may be much aided by the free use of eserine, both previous and subsequent to the operation. Where the wound heals promptly without entanglement of the iris, the anterior chamber soon becomes deeper, the media become clearer, and vision improves, these changes often bettering for some weeks after the operation. Frequently, such eyes remain quiet and retain their sight for years. In some cases, however, the wound does not unite for several days after the operation, and when it does heal, there is apt to be an incarceration of the iris and a cystoid cicatrix with a recurrence of the symptoms. Where tension does not promptly subside at the time of the opening of the anterior chamber, so-called *malignant glaucoma* is said to be present. In such a case, it is certain that there has been a hemorrhage in the interior of the eye which has resulted from rupture of some of the chorioidal vessels whose walls have been weakened by degenerative processes. Sometimes, the blood collects between the chorioid and sclerotic. In bad cases, it may be in sufficient quantity to flow out of the wound. Every ophthalmic surgeon has seen such cases. One of the saddest is that recorded by Arlt, in which, after the operation had failed in one eye, the other eye, which became attacked a year later, followed the same course,

in spite of all possible precautions during its treatment. That slight hemorrhages from the sudden relaxation of pressure on the weakened walls of the vessels, are not infrequent, is evidenced by those which are occasionally seen in the retina after a successful iridectomy. It is also well known that during and after iridectomy for glaucoma, hemorrhage into the anterior chamber is more likely to occur than after a similar operation made to meet other indications. Both Mauthner and Schweigger emphasize the fact that in some rare cases, an unaccountable deterioration of the vision, which is not due to the astigmatism produced by the wound, or to any other demonstrable cause, appears after apparently successful iridectomies for glaucoma.

FIG. 327.



Cicatrix in iridectomy.

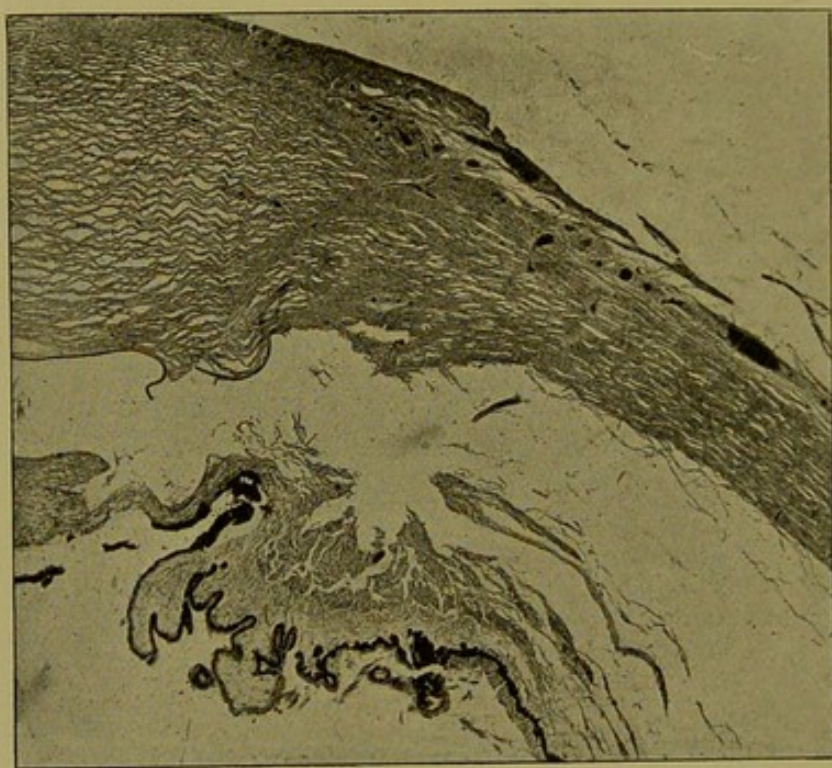
It has also been found that where there is marked contraction of the field of vision, and when the limits of the field run near the fixation-point, central vision, at times, is rapidly extinguished after the operation. This, however, is not always the case, the author having operated on chronic glaucoma where vision remained for many months as good as before the operation, and the disease was apparently arrested; this being so in spite of the fact that the field of vision showed contraction to a dangerous proximity with the point of fixation before operation. The results of operation in simple glaucoma are much less reliable. Here, too frequently, the atrophy of the nerve progresses, the excavation increases, and vision steadily diminishes. Unfortunately, more-

over, inasmuch as eserine and pilocarpine also fail, such cases are, so far as at present known, irremediable.

Where, owing to entanglement of the iris in the wound, the operation is a failure, this may often be successfully corrected by the performance of a second iridectomy immediately alongside of the first. Where a faultless operation fails to relieve the symptoms, success may sometimes be attained by making an iridectomy diametrically opposite to the first.

The statistics of Horner's clinic at Zürich, as given by Sulzer,¹ probably give as accurate an idea of the effect of iridectomy in glaucoma as any now possessed. In one hundred and three cases of simple glaucoma, twenty-two and three-tenths per cent. showed an improve-

FIG. 328.



Cicatrix in sclerotomy.

ment in vision; in thirty-seven per cent. vision remained the same as before the operation; in twenty-three and three-tenths per cent. there was fair vision, although less than before the operation; while in thirteen and six-tenths per cent. there was, in spite of favorable healing of the wound, a marked decline in vision. In three and eighth-tenths per cent. there was absolute loss of sight. On the other hand, out of one hundred and forty-nine cases of inflammatory glaucoma, seventy-two and one-half per cent. showed an improvement in vision; in eleven and one-half per cent. the previous degree of sight remained unaltered; in ten and one-tenth per cent. vision was impaired to a slight degree; while in four and eight-one-hundredths per cent. an immediate diminution

¹ Die Iridectomie bei primären Glaucom, Inaug. Dissert., 1882, Ss. 42-105.

of sight followed the operation. In two and two-one-hundredths per cent. there was a subsequent decline in visual acuity.

Sclerotomy is usually performed by the method described by Wecker. A narrow knife is entered in the corneo-scleral junction, and thrust out at a similar point on the other side of the anterior chamber, the incision being made as if an extraction of cataract with large scleral flap were intended, except that the cut is not completed, thus leaving a large undivided bridge. Figs. 327 and 328 show the positions of the cicatrices in an iridectomy and a sclerotomy as performed by Wecker's method.

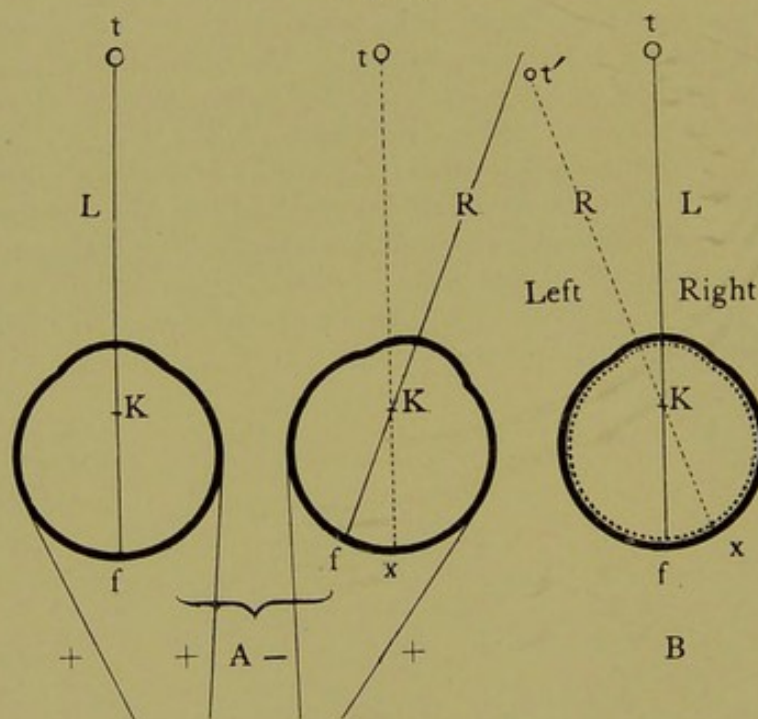
The operation of sclerotomy has been used mainly by the author and many others in chronic or subacute cases, and is often successful in reducing intra-ocular tension. To prevent prolapse of the iris in the wound, eserine should always be used freely, both before and after the operation. Some surgeons, as Quaglino and Snellen, who have extensively practised sclerotomy, prefer to perform it with a broad lance-shaped knife, making the incision as if for iridectomy. In fact, it should always be remembered that when iridectomy is properly performed, it includes a sclerotomy, and that the real question is, whether excision of a part of the iris is necessary to the success of the operation. In chronic cases, where the tissue of the iris has undergone atrophy, it is a notorious fact that iridectomy is unsuccessful, and the best is probably done for the patient by limiting the operation to a careful sclerotomy. Mooren has given warning that in cases with marked concentric contraction of the field of vision, and in which there is albumin in the urine from Bright's disease, serous iritis is likely to follow the performance of iridectomy.

CHAPTER XXV.

AFFECTIONS OF THE EYE-MUSCLES.

WHEN any pair of normal eyes in a state of health look at any given point, the visual axes, if prolonged, would intersect at that point. Consequently, the point thus doubly fixed, has its image projected on each fovea centralis, and is seen singly, whilst the images of

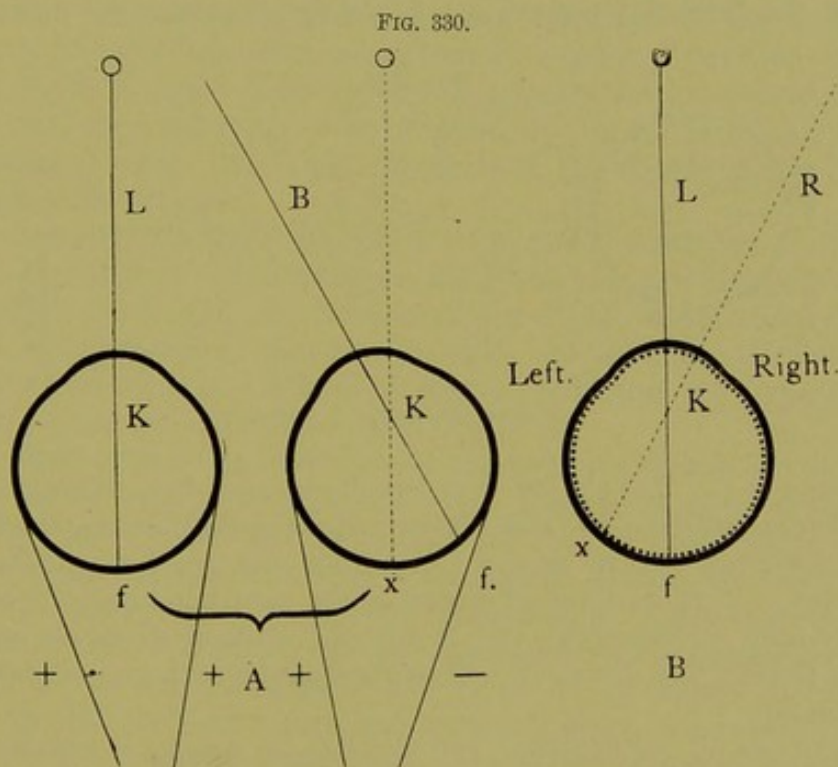
FIG. 329.



Paralysis of the right internal rectus muscle. (Modified from MAUTHNER.)

all other objects are ordinarily disregarded by the brain-centres, and are thus habitually suppressed. If experiment is made, however, by holding a pen's point about twelve inches in front of the face, and a candle is set a few feet beyond this in the same line, two candles will be seen when the pen-point is looked at, and two pen-points when the candle is looked at, when the eyes are converged first for the one and then for the other. Consequently, owing to the habitual suppression of peripheral double images, by reason of the dulness of perception throughout the retina except in the macular region, and to the constant changes in the direction of the visual axes, it will be found difficult, except under favorable conditions, to realize this physiological double vision. On the other hand, when, owing to partial or complete paralysis of one of

the extra-ocular muscles, all efforts fail to direct the visual axis of the affected eye to the point which it is desired to look at, the double images thus produced become very annoying. In these circumstances, the faulty muscle is unable to pull the visual axis so as to properly decussate the visual axis of the healthy eye at the point of view in the object looked at. The eye, therefore, lags, and the retinal image of the object, instead of falling on the fovea, is received on some portion of the retina that is situated between the fovea and the insertion of the antagonistic muscle. The image is, therefore, always projected toward the side of the paralyzed muscle. Thus, in paralysis of the superior rectus muscle, the image is formed on the retina below the fovea and is projected upward; while in paralysis of the inferior rectus muscle, the retinal image, being above the fovea, is projected downward. In case



of paralysis of an internal rectus muscle, the retinal image falls to the outside of the fovea and is projected inward. The image, being thus seen on the side of the sound eye, is said to be crossed.

In Fig. 329 the heavy circles representing the right and the left eye respectively, with their lines of visual projection, distinctly show that the internal rectus muscle of the right eye (—) is so paralyzed, that the point of projection of its false image, which has been received from the true object too far to the temporal side of the retina, is crossed to the left side. This is further shown in the third diagram, which gives the combined eyes.

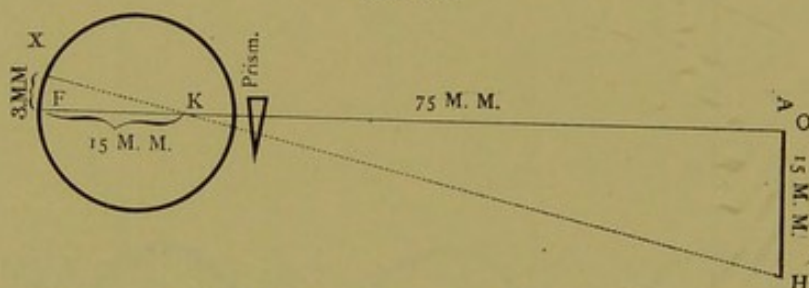
In case of paralysis of an external rectus muscle, as shown in Fig. 330, the image falls on the median side of the fovea, and being pro-

jected outward, is thus seen on the side as the paralyzed eye. This form of diplopia is termed homonymous.

So far as the apparent position of the object is concerned, it is indifferent whether the double vision is obtained by the deviation of one eye when using both eyes, or whether double vision is produced in one eye by covering one-half of the pupil with a prism. Should the prism be used in the latter manner, double vision can be produced in any desired direction by rotating it, and causing the double images either to come close together or to get farther apart by varying its strength.

Fig. 331 shows how the deviation which any given prism will produce, can be readily calculated. Taking the reduced eye with its twenty millimeter axis and its distance of fifteen millimeters from the nodal point *K* to the fovea *F*, and a prism with deflecting power of three millimeters on the retinal plane, we have: *OH*, the desired amount of deviation, is to *XF*, the deflecting power, as *OK*, the distance from the point looked

FIG. 331.



Deviation produced by prism.

at (*O*), is to *KF*. That is, if *OK* equals seventy-five millimeters, *KF* equals fifteen millimeters, and *FX* equals three millimeters, the distance of the projected double images (*OH*) from one another will be fifteen millimeters. If these lines of projection be continued on to five meters (five thousand millimeters), this being the ordinary distance employed in prism-testing, the deviation will be increased one thousand millimeters or one meter.

If paralysis of the external eye-muscles be recent, it usually causes sensations of dizziness and discomfort, with double vision when attempts are made to turn the eye in a direction which would bring the paralyzed muscle into action. When the paralysis is either complete or is of high grade, it frequently produces squint, the deviation of the visual axes becoming more marked when the patient is made to fix any object which is moved toward the side of the affected muscle. In lesser degrees, where it is impossible to detect any deviation of the optic axes, it may be necessary to study the so-called secondary deviation of the sound eye, as explained on pages 173 and 174, to discover which is the paralyzed muscle. If the eye under the covering-hand remains quiet during this experiment, the equilibrium of the eye-muscles is perfect. If the eyes deviate equally, there is concomitant squint. If the deviation is greater in one eye, there is, as explained on page 174, a paresis of one muscle in the eye which has the lesser deviation. This increased deviation at once enables us to distinguish the healthy from

the faulty eye. While in this way the affected muscle may often be detected, yet in order to form an accurate diagnosis, it becomes necessary in many instances, to resort either to the more delicate tests of double vision or to the relative positions of the images of the two eyes in different parts of the field of vision, as described in full in Chapter VI.

Paralysis of the sixth nerve (rectus externus). The paralysis of the abducent nerve is much more frequent than that of any of the others supplying the external muscles of the eye. When permanent, it is at times, accompanied by affections of the base of the brain. Especially is this so if such affections are located in the middle fossa of the skull. In such instances, it is often associated with paralysis of the facial nerve of the same side. In many cases of the nuclear form, permanent loss of power also remains. The transient variety is often designated as rheumatic, although it is not infrequently, as spoken of on page 174, an early symptom of tabes dorsalis, and of general paralysis of the insane. A temporary form of it is often encountered in patients between sixty and seventy years of age. This variety disappears in the course of a few months, and does not seem to be followed by any marked disturbance of the nervous system. At times, this form of the disease is accompanied by retinal hemorrhages.

Féréal and Graux have described a variety of paralysis of the sixth pair, which is due to an affection of the filament connecting the nucleus of the sixth nerve and the nucleus of the third nerve, supplying the internal rectus muscle of the opposite side. In this form of the disease, secondary deviation is much diminished, producing the appearance of an ordinary concomitant convergent squint.

In marked cases, in consequence of the loss of power in the paralyzed muscle, the affected eye is incapable of having its vertical meridian carried beyond the median line. If efforts be made to move the eye toward the paralyzed side, the only result will be that the superior and the inferior oblique muscle, though incapable of exercising sufficient simultaneous innervation to roll the eye outward, will cause slight upward and downward rotations of the globe on its axis. In all such cases of absolute or nearly complete paralysis, there is a marked inward squint, which increases in proportion as the sound eye is called to fix objects in the temporal field of the paralyzed one.

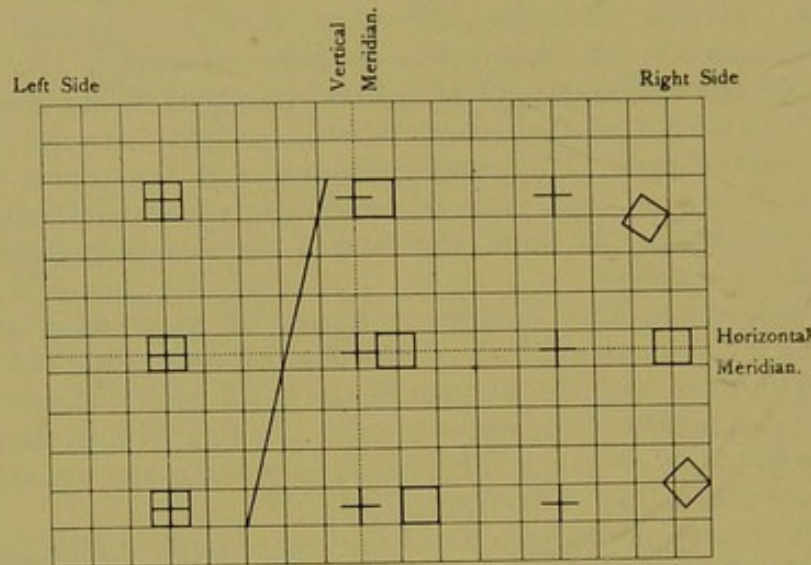
In Fig. 332¹ are represented the positions of the double images in a case of paralysis of the external rectus muscle of the right eye as they would be seen if projected on the blackboard in case our own right eye were the one that was affected.

This diagram shows that in the left field, there are single images which become double at or near the centre and farther apart as the patient moves toward the side of the paralyzed muscle in the right field. In the horizontal meridian, these images remain at the same height and are parallel. When the visual axes are directed upward and outward, or

¹ In each figure, the comparative points of projection are shown throughout the entire visual-field areas. Here the situations of the projection-points have been similarly shaped. All the images for the right eye are made like squares, and all those for the left eye are made cruciform in shape. The combined image-points are composed of crosses and squares in combination. In order to avoid confusion, the muscles of the right eye are, in all these sketches, assumed to be the affected ones. In affections of the left eye, all that is necessary to do is to reverse the rules and diagrams here given.

downward and outward, the image of the paralyzed eye is no longer vertical. It also shows that when the patient looks up and out, the image of the affected eye is lower than that of the sound one, and is tilted so that its upper end diverges from that of its fellow. This is so, because the sound eye, acting normally under the influence of its internal rectus muscle, its superior rectus muscle, and its inferior oblique muscle, has its visual axis directed properly to the fixation-point, and is thus rotated upward and to the right; the upper end of its vertical meridian being tilted to the right. The affected right eye, however, having lost power over its external rectus muscle, and having only the superior

FIG. 332.



Paralysis of the right external rectus muscle. (Modified from MAUTHNER.)

rectus muscle and the inferior oblique muscle to guide it upward and outward, goes directly upward, thus allowing its vertical meridian to remain vertical. The image of the fixation-point therefore falls in the upper inner quadrant of its retina, and consequently is seen below and to the outside of the image that is projected by the sound eye. In the lower outer field—that is, in positions to the right of the affected eye and below it—the reverse is the case. Here the visual axis of the sound eye, under the conjoint action of its internal rectus, its inferior rectus, and its superior oblique muscles, is properly directed toward the fixation-point, and has the upper end of its vertical meridian tilted outward, whereas, under the combined influence of the inferior rectus and superior oblique muscles alone, the vertical meridian of the affected eye remains vertical, causing the retinal image to be formed in the lower outer quadrant of the affected eye and to be projected higher than normal. In this case, the upper end of the false image is tilted toward the upper end of the image of the fellow-eye: so here, just as in looking obliquely upward and downward with sound eyes, the image of any vertical object fixed, no longer remains parallel to the vertical meridian, but is inclined at various degrees to it. Daily experience, however, teaches that either the sensorium unhesitatingly regards the images as in their true position or that

there are correcting motor impulses. So in paralysis of the eye-muscles, although the tilting of the meridians really takes place, nevertheless the image of the sound eye is regarded as the standard, and the tilted one is referred to the paralyzed eye.

Fig. 332 also shows that double vision does not commence exactly in the centre of the field of vision, but follows a line which is nearer the vertical meridian above, and farther from it below. This is due to the fact that in looking up at distant objects, the muscles normally used, cause the visual axes to diverge materially, giving the antagonistic muscles more work to do, thus bringing the projected images more closely together. In looking downward, however, they to some extent, cause the visual axes to converge, giving the antagonistic muscles less work to do, and thus causing the projected images to seem farther apart. In addition, it must be remembered that, owing to the great lessening of physiological action in the peripheral part of the retina in which these images fall in the extreme right and upward, or right and downward directions, even intelligent patients often fail to perceive the tilting of the images.

Paralysis of the third nerve. The third nerve, supplying three of the straight and one of the oblique muscles of the eye, besides innervating the ciliary muscle and the sphincter muscle of the iris, may give rise to most varying symptoms in its affections.

Owing to the position of its nucleus, as shown on pages 54 and 55, and to its great extent, there is a good opportunity for proliferative and pressure-changes in its various parts to cause an interference with the innervation of its muscles. This is well shown by the consequent paralyzes of the separate branches of the nerve. Moreover, owing to the long course of its trunk at the base of the skull and in the orbit, it is very easy for tumors or exudations either within the cranium or at the sphenoidal fissure, to give rise to compression that is sufficient to cause its total paralysis. Where palsy of the third nerve occurs with hemiplegia of the opposite side of the body, it is generally produced by pressure on the nerve where it passes beneath the cerebral peduncle. According to Nothnagel,¹ this localization of the disease is still more certain when paralysis of the facial and hypoglossal nerves exists on the same side as the hemiplegia. In cases of hemiplegia, transient associated movements of the eyes and head are often found. Prevost² says that the lesion in such cases may be localized in accordance with the following rules: "I. When the hemiplegic looks toward his lesion and away from the paralyzed side, the lesion is hemispherical. II. If he looks toward his paralyzed side, the lesion is situated in the mesencephalon." Landouzy³ and Coingt⁴ assert that these rules are reversed in irritative lesions.

Double third-pair paralysis is rare. It may be produced by a growth or an effusion in the median line that presses on both nerves as they pass under the peduncles.

¹ Topische Diagnostik der Gehirnkrankheiten, 1879, S. 198.

² De la Déviation conjuguée des Yeux et de la Rotation de la Tête dans certains cas d'Hémiplégie. Thèse de Paris, 1868, p. 140.

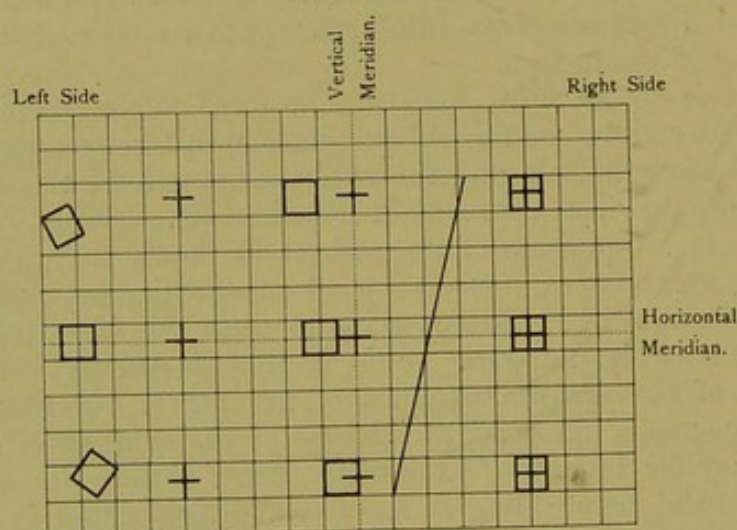
³ Symptômes oculaires dans les Maladies du Système Nerveux central. Thèse de Paris, 1878.

⁴ Des Convulsions et Paralysies liées aux Méningo-encéphalites frontal-pariétales. Paris, 1876.

Complete paralysis of the third nerve presents a striking picture. The skin of the upper lid loses its folds. The lid falls down over the eye, and can be only partly raised by the increased action of the occipitofrontalis muscle. When the lid is lifted, the eye is generally found turned outward and slightly downward; this being due to the combined influence of the external rectus and the superior oblique muscles. The action of the latter muscle in rotating the meridians of the eye, becomes very apparent, when the patient is made to endeavor to look farther downward. The pupil is semi-dilated and immobile, while the power of accommodation is entirely lost.

In many cases, all the branches are not affected. When the paralysis has been caused by degenerative changes in the nucleus of the nerve (*exterior ophthalmoplegia*), the pupillary and the ciliary muscles are especially apt to escape.

FIG. 333.

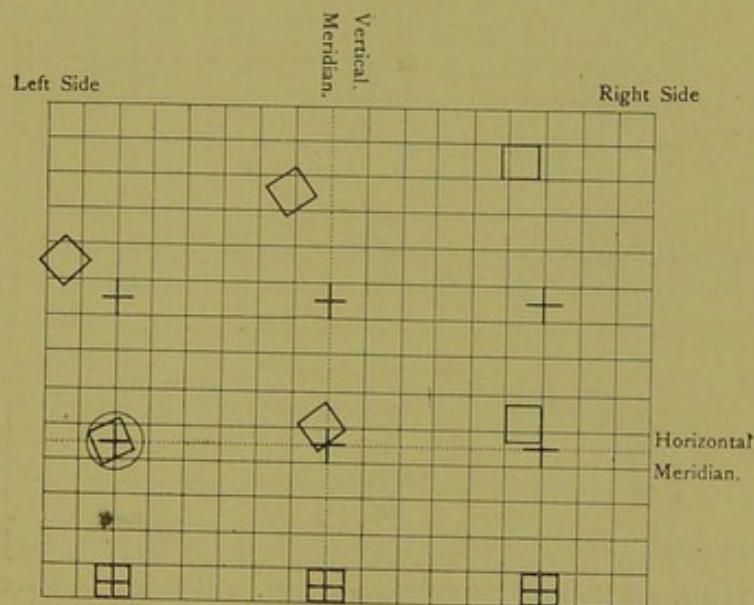


Paralysis of the right internal rectus muscle. (Modified from MAUTHNER.)

Paralysis of the rectus internus is one of the most frequent forms of third-nerve paralysis. When marked in degree, there is a slight divergence of the visual axes, which becomes greater as the fixation-object is carried into the field of the sound eye. If the paralyzed eye be forced to fix by covering the unaffected eye, there will be marked secondary deviation of the good eye. Fig. 333 shows the positions of the double images in a case of paralysis of the right internal rectus muscle. As shown by the combined cross and square, there is single vision throughout the right portion of the field. When the eyes are fixed in the primary position (*vide* page 95), the images separate, and remain upright and on the same horizontal plane; the image of the right or affected eye crossing over beyond that of the left eye. In the entire left field, the images get farther apart. Further, owing to the fact that when looking upward the eye-axes normally diverge, the images are situated farther apart in the upper field and begin to separate before the fixation-object reaches the centre. In the lower field, where the visual axes normally converge, they are closer together, and double

vision begins only at or near the median line. In the left upper field, the crossed image of the paralyzed eye is the lower, and has its upper end tilted to the left. This is due to the fact that, owing to the loss of the power to turn the eye inward, when the affected organ looks upward to the left, its vertical meridian remains vertical under the influence of the superior rectus and inferior oblique muscles, the upper end of the vertical meridian of the sound eye being tilted outward. It also shows that in looking below and to the left, the crossed image stands higher and has its upper end tilted to the right. In this form of paralysis, the head is usually turned to the left, so as to bring the objects as much as possible into the right half of the visual field. This is done in order to make less demands upon the paralyzed muscle.

FIG. 334.



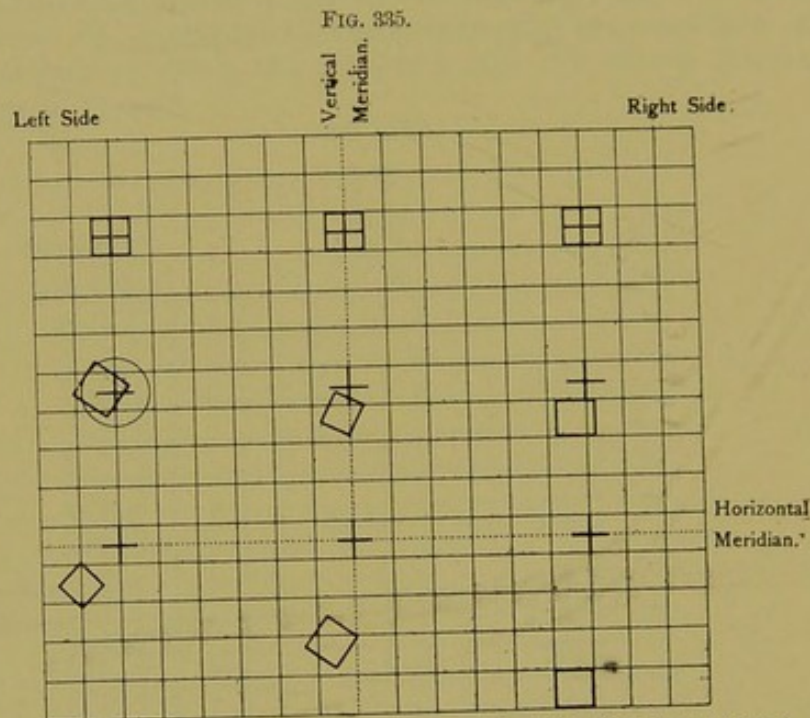
Paralysis of the right superior rectus muscle. (Modified from MAUTHNER.)

Paralysis of the rectus superior. Here, the patients complain of double vision when looking upward, the head being generally thrown far back, in order to fix the visual axes on any object above them. The vertical distance between the double images increases as the fixation-object is carried farther into the upper part of the field, and the patient will hit too high in endeavoring to strike the object.

Fig. 334, which supposes a tolerably complete paralysis of the superior rectus muscle of the right eye, shows that single vision is everywhere present throughout the lower part of the field. In the horizontal meridian, the images are crossed and are at a slightly different level. In the upper part of the field, the images are further crossed, and there is a more marked difference of level; this difference being greater in the right field than in the left. At the vertical meridian and to the left of it, the image of the affected eye is tilted so that its upper end diverges from that of the sound eye. Further examination shows that the double images are everywhere crossed, this being dependent upon the fact that,

owing to the paralysis of the superior rectus muscle, the inferior oblique muscle rolls it slightly outward, whilst assisting to raise the eye.

In complete paralysis, there will be double images in the horizontal meridian, because, owing to loss of power in the paralyzed muscle, the tonic contraction of the inferior rectus muscle, even whilst in the primary position, pulls the eye slightly downward. Above the horizontal line, the vertical difference of level is greater in looking to the right than it is in looking to the left. This is so, because in the former position, the paralyzed muscle, having normally the greater influence in rolling the right eye upward, lags behind. Further, the double images are not parallel,



Paralysis of the right inferior rectus muscle. (Modified from MAUTHNER.)

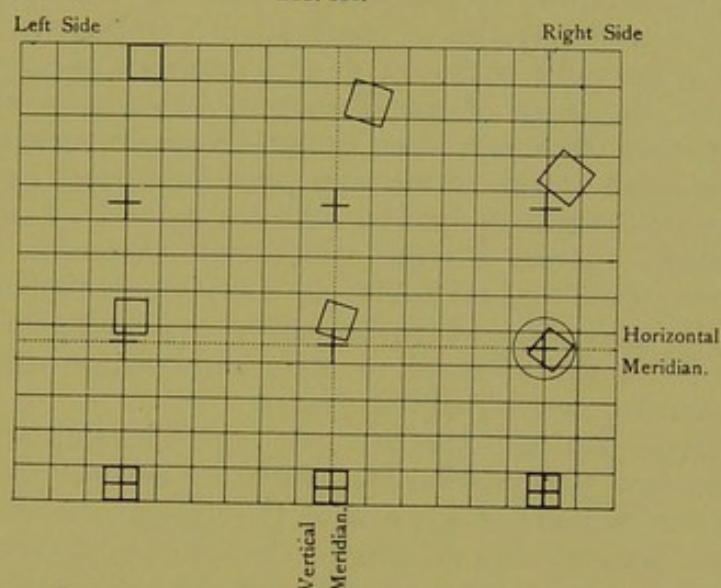
the crossed image of the affected eye diverging at the top. This is owing to the fact that the cornea of the paralyzed eye is rolled up and out by the inferior oblique muscle in attempting to elevate the eye. If the sound eye be covered, when the paralyzed one attempts to fix an object slightly above the horizontal line, a marked secondary deviation of the sound eye upward will be produced.

Paralysis of the rectus inferior. This form is extremely annoying, the patient holding his head down and tilted toward the side of the body on which the paralyzed muscle is situated, thus causing him to stumble in walking. Especially is this so in going up and down stairs. Here, double images are found throughout the lower portion of the field, the image of the paralyzed eye being the lowest. It is also crossed, and its upper end is tilted toward the image of the sound eye. Fig. 335, representing paralysis of the right inferior rectus muscle, shows the position of the double images in the different portions of the field. In the right field, they are situated farthest apart vertically. This is so, because in this position, the influence of the paretic muscle in rolling the eye downward is greatest, and the superior oblique muscle tilts the vertical meridian

inward (*i. e.*, to the left), causing the upper edge of its projected image to point to the right.

Paralysis of the obliquus inferior is one of the rarest of eye affections. It is doubtful whether it is ever encountered without involvement of the other eye-muscles that are supplied by the third nerve. Mauthner reports a traumatic case which followed an injury to the muscle during an operation on the orbit. As the muscle rotates the eye upward and outward, its paralysis causes homonymous double images in the upper part of the field. These have their greatest vertical distance in the median part of the field, where the influence of the muscle in rolling the eye upward is the greatest. This is well shown in Fig. 336.

FIG. 336.



Paralysis of the right inferior oblique muscle. (Modified from MAUTHNER.)

Paralysis of the levator palpebræ, like that of the inferior oblique muscle, is almost invariably associated with paralysees of other branches of the third pair. When it occurs singly, it is probably due to some affection of the nucleus of the third pair. According to Grasset, however, it may be cortical in origin, the lesion being located in the parietal lobe in advance of the angular gyrus.

Paralysis of the sphincter pupillæ and of the musculus ciliaris (*Ophthalmoplegia interna*) is usually made evident by an inability of the patient to focus properly for any form of near-work, and by partial dilatation of the pupil. The power of accommodation is either greatly lessened or is lost, and the movements of the irides are extremely sluggish. In such instances, pupillary enlargement never reaches *ad maximum*, and can always be increased by instillation of a mydriatic. In cases of nuclear paralysis, these muscles often escape. As might be expected from the location of the nucleus of the internal rectus muscle just behind the nuclei for pupillary motions and accommodation, paralysees of these muscle-groupings are often associated. In gray degeneration of the posterior column of the spinal cord, and probably in some cases of nuclear disease, the pupil, although contracting

strongly with convergence of the eye-axes, often fails to respond to light-stimulus on the retina. Such pupils, which are known as *Argyll-Robertson*, cannot be fully dilated by even repeated instillation of the most powerful mydriatics. After diphtheria, especially of the fauces, there is often a temporary paralysis of the ciliary muscles, which prevents any employment of the eyes for near-work. Here, the sphincter muscle of the pupil is usually but little affected. The paralysis generally passes off under tonic treatment as the patient gets stronger.

Notwithstanding the vast mass of material written on the changes in the pupil as a part of general symptomatology, both in ancient and in modern literature, most perplexing confusion and contradiction exist. This is partly due to imperfect knowledge of the anatomy of the brain, to the great difficulty of accurately estimating pupillary changes, and to lack of a proper system of observation. Ordinarily, the data have been hastily compiled, without a minute statement of concomitant symptoms or of the stage of the disease in which they were developed. Moreover, they often have been made without proper means for illuminating the pupil or without any apparatus for correctly magnifying and observing the motions of the iris. Again, the lack of knowledge of the more common sources of error, such as a difference in the size of the pupils, owing to individual peculiarities in the refraction of the two eyes, pupillary irregularity, and impairment of iris-movement from posterior synechia, with the presence of other intra-ocular changes, have in many instances, invalidated the results.

Nystagmus is a term that is applied to an involuntary oscillatory or rotary motion of the eyeballs. The oscillatory movements are due to rapid alternate contractions of one pair of the straight muscles. The rotary, which take place around the axis of the oblique muscles, are due either to the action of the oblique muscles alone or to a combination of their action with that of the straight muscles. The horizontal form is the more common. The vertical variety is rare. The condition may be either congenital or acquired, the latter form being the more frequent. The congenital form is generally accompanied either with cataract or with imperfect development of the optic nerve and the retina. It is also frequently associated with albinism and typical pigmentary degeneration of the retina. The acquired form often develops in the first few months of life, where, by reason of corneal opacities that result from ophthalmia neonatorum, efforts to see are hindered.

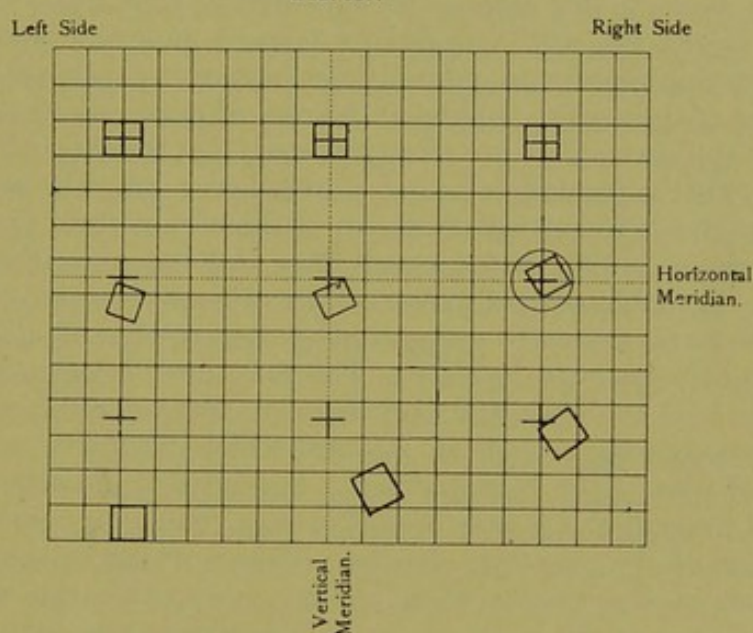
The nystagmus that is observed among coal-miners is one of the most interesting of the acquired forms. At first, the lights in the mines and other objects on which the miners fix their attention, begin to dance, these movements ceasing when work is quitted and when the men come up into the fresh air. If work be persisted in, the nystagmus becomes permanent. The motions are usually lateral, but at times, they are rotary, causing the miner to see a circle of light. The affection is probably due to the fatigue of the eye and its nerve-centres in the endeavor to see in a dim light, and to the strained position which the miner is obliged to maintain. Perhaps the enfeeblement of the nerve-centres by the action of fire-damp, aids in the production of the condition.

In any form of nystagmus, the motions generally become more rapid

when the eyes are used for near-work. It is not infrequent to observe slight nystagmic movements, when feeble patients, without any well-defined disease of the nervous system, are examined by the ophthalmoscope. In some very rare cases, the condition may be produced at will. Charcot says that it is a valuable symptom of disseminate sclerosis, it being present in about one-half of such cases. According to Hammond, it may precede all other symptoms for the period of a year. The former observer states that it is exceptional in locomotor ataxia. It is said to occasionally accompany Ménière's disease and severe purulent otitis.

Paralysis of the fourth nerve (*Paralysis of the obliquus superior or trochlearis*) is much less frequent than that of the sixth and the third nerves. Very frequently, the deviation of the eye is so slight that the lesion cannot be detected except by subjective examination of the

FIG. 337.



Paralysis of the right superior oblique muscle. (Modified from MAUTHNER.)

behavior of the double images. If it can be determined by outward inspection alone, this may be accomplished by noticing the secondary deviation of the sound eye downward and inward when the paralyzed eye is forced to fix by covering the good eye. Fig. 337 shows the position of the double images in various parts of the field. Here, there is single vision in the upper part, with homonymous double images in the horizontal meridian. Below this latter situation, they acquire a vertical distance which is greater toward the left side (median line). The image of the paralyzed eye is tilted toward that of its fellow in the right field, where the action of the paralyzed muscle, in rotation of the eyeball, is normally the greatest. Owing to this paralysis, the inferior rectus muscle will have greater play, causing the vertical meridian of the affected eye to roll outward, and to diverge from its fellow above, thus making the retinal images appear to converge at their upper ends. Upon account of the double images it produces in the lower field, paralysis of this muscle is exceedingly confusing to the patient. It is

to be distinguished from paralysis of the inferior rectus muscle by the fact that in palsy of the superior oblique muscle, the double images have their greatest vertical distance apart when the fixation-object is carried toward the median line, while in paralysis of the inferior rectus muscle, the greatest vertical deviation of the images is in the outer lower field of the affected eye.

Paralysis of the seventh nerve. As the innervation of the sphincter muscle of the lids depends upon the facial nerve, paralysis of this nerve may exercise a most important influence on the eye.

When the orbicularis muscle becomes paretic, its normal contraction during sleep is more or less lost, allowing the levator of the lid to pull the fissure of the lids a little open by its inherent tonic contraction. This action permits the lower lid to fall from its own weight, thus exposing the lower portion of the cornea and a part of the conjunctiva to the air, and allowing them to dry and to become irritated by dust. Even during waking hours, the same conditions may be produced by the lessened ability of the muscle to move, thus preventing proper washing and cleansing of the organ. In higher degrees of paralysis of the orbicularis muscle, these symptoms are so aggravated, that there is inability to close the lids, with a decided drooping of the lower lid. In consequence, a characteristic localized inflammation of the cornea or of the conjunctiva readily ensues, which, if neglected, may lead to severe ulceration of the cornea. Minor degrees of paresis of the orbicularis muscle, especially in the senile form, are easily recognized by the presence of *epiphora*, or the trickling of tears over the cheek. This may ensue because the lower lid is no longer held up in position, and there is a want of action of that portion of the muscle (the muscle of Horner) which normally tends to empty the upper part of the lacrymal sac. Paralysis of the orbicularis muscle does not prevent the levator of the lid from producing marked variations in the size of the palpebral fissure. This is owing to the fact that the relaxation of the levator when looking down, with the weight of the upper lid, causes the latter to partly fall, only to rise again through the action of the levator when the patient looks upward. Where the facial paralysis is central in its origin, there is apt to be an impairment of the sense of taste. In these cases, the ala of the nose is not affected. On the other hand, as the branch of the vagus which supplies the ala of the nose runs close to the stylo-mastoid foramen, this portion of the face is often implicated in palsies of the facial nerve that are due to peripheral causes. Where the palsy is dependent upon caries of the petrous portion of the temporal bone, it is apt to be accompanied by paresis of the auditory nerve, causing an impairment of hearing upon the same side.

Blepharospasm, or Spasmodic closure of the lids, is frequently found in corneal and conjunctival affections. Especially is this so in the phlyctenular varieties. It is also often due to the lodgment of a foreign body in the conjunctival sac or in the cornea. In these cases, it is evidently reflex in origin, it often being entirely out of proportion to the amount or severity of the conjunctival or corneal disease. Twitching of the lids as a part of general or local chorea is also encountered. The same conditions may be frequently found in feeble patients with eye-strain, who have no choreic manifestations.

It is evident from the foregoing descriptions of the symptoms and causes of eye-paralysis, that prognosis will vary in different cases. As a rule, it is serious; so much so, in fact, that it becomes a duty, if the slightest trace of any form of ocular paresis exists, to study the case carefully in the minutest detail. While some of the paralyses are temporary, being due to rheumatic affections of the sheaths of the nerves, or to some slight hemorrhage or effusion in or near the nuclei, which may eventually disappear without leaving any traces, nevertheless even these transient paralyses are too often the forerunners of serious nerve disease, such as locomotor ataxia. When they are dependent upon syphilitic new growth or thickening of the membranes at the base of the brain, or to exudation accompanying acute basilar meningitis, reasonable hopes for improvement under treatment may be given. Sarcomata and other malignant tumors make the prognosis lethal.

Treatment varies with the cause. The iodides and the mercurials are the internal remedies which usually accomplish the most good. In some cases of nuclear paralysis due to slight degenerative changes, the continued employment of small doses of bichloride of mercury and suitable tonics, with a regulated mode of life, is of marked advantage. There is considerable diversity of opinion as to the advantages to be derived from the use of electricity, and as to the proper time for its application. Benedict and many other electricians have advocated its early and systematic employment. In the opinion of the author, electricity is best employed in cases of not too recent origin. Here, it is of value to stimulate the affected muscle during convalescence, and thus improve its nutrition and increase its circulation of blood.

Operations to remedy any annoying diplopia that may accompany paralysis of the external eye-muscles, are usually unsatisfactory. They should never be attempted until sufficient time has elapsed to be sure that the paralysis is not a transient one or one which is slowly progressive. When the loss of power is complete, advancement of the paralyzed muscle and division of its antagonist, are useless, as they cannot supply nerve-force to make the affected muscle work. Further, when the degree of paralysis is a changeable quantity, an operation which corrects a present position of the eye will soon produce either too great or too little an effect. The diphtheritic form of paralysis of the ciliary muscle will generally disappear as the patient gets stronger. The duration of the affection, however, may be shortened by the administration of iron, quinine, and strychnine. Sometimes, the instillation of a weak solution of eserine ($\frac{1}{32}$ ad f5j) into the conjunctival sac is of advantage to slightly stimulate the convalescent muscle. Blepharospasm, when severe, may demand division of the orbicularis muscle, with enlargement of the fissure of the lids at the outer canthus.

In the primary position of the eyes, the muscles should be nearly in a state of physiological rest. If they are properly balanced in power for the various deviations which they are called on to make from this position, single vision and comfort in the use of the eyes ensue. It frequently occurs, however, that one of the eyes, while not sufficiently weakened to cause deviation of the visual axes with diplopia, is able to counterbalance its opponent only by great effort and greatly-increased

innervation. Under such circumstances, the use of the eyes is accompanied with headache, dizziness, and discomfort; and if work be persisted in, there will be burning of the eyes, with a blurring and overlapping of the letters. In fact, the well-known symptoms of muscular asthenopia manifest themselves. At times, these symptoms may be quite as severe and as painful as those that are found in any form of asthenopia that has been caused by ametropia. If such a patient be made to fix his visual axes upon a lighted candle at the usual distance at which the test-letters are placed (five or six meters), and one eye be covered by the hand or a piece of slightly-ground glass, as explained on page 169, the desire for binocular vision will be removed, and the covered eye will deviate in the direction of the opponent of the feeblest muscle. Where this weakness lies in either the internal or the external rectus muscle, even though it is too slight in degree to be noted by the naked eye, it becomes readily apparent by a lateral deviation of the test-object, when a weak prism, which is held base downward before one of the eyes, produces vertical diplopia. If, as previously shown, there be equilibrium, the double images will be directly vertical. If, owing to insufficiency of the internal recti, there be outward deviation, crossed diplopia will manifest itself. If, owing to insufficiency of the external rectus muscles, there be inward deviation, homonymous diplopia will be present. If there be insufficiency in the superior or inferior rectus muscles, a prism held with its base down alternately before each eye, will cause a difference of level in the vertical images. These images will be nearer together when the direction of the base of the prism coincides with the direction of the weakened muscle, and will be farther apart when the direction of the base of the prism agrees with the direction of movement of the sound coadjutor on the other side. Want of equilibrium of the muscles which roll the eyes upward or downward, is still more easily diagnosticated by using a pair of eight degree to ten degree prisms, with their bases placed inward, and noticing whether there is any vertical deviation of the images in the horizontal diplopia thus produced.

Having ascertained the state of equilibrium of the eye-muscles in the primary position by the above means, or by one of the more delicate and recent tests, such as Maddox's rod-test described on page 170, it is best to see whether any existing insufficiency for distance is augmented or diminished when the eyes are put into the position in which the patient uses them during his habitual work. This can be done by employing what is usually known as *Von Graefe's test*. This test consists in having the patient notice whether the double images produced by fixing his axes of vision upon a small dot that is situated at the end or at the middle of a vertical line, whilst he is looking through a vertically placed prism of from ten to fourteen degrees before one eye, are vertical or not. In many cases, more accurate results are insured by using a short word of some small type, like Jaeger No. 1, as the test-object, and insisting that the patient shall not only look at it, but also read it, thus giving proof that he is using his accommodation. In either case, whether the dot and line or the printed word be employed, the test should be

made at the ordinary distance used for reading or writing—from ten to sixteen inches.

We are indebted to G. T. Stevens for a new and better nomenclature to express the various defects of the eye-muscles. The condition of proper equilibrium is designated as *orthophoria*, while all other states are classed as *heterophoria*. The tendency for the eye to deviate inward is termed *esophoria*, and the tendency for the eye to deviate outward is termed *exophoria*, while its tendency to deviate upward or downward is called *hyperphoria*. If there be a tendency inward and upward, the condition is designated *hyperesophoria*. If there be a tendency upward and outward, it is termed *hyperexophoria*.

Of these faulty actions of the different muscles, those which are due to the internal rectus muscle or to the inferior rectus muscle, are generally the most embarrassing. This will be understood when it is considered that the patient is to a certain extent obliged to converge and roll the eye downward to be sure of his footing in moving about, whilst in reading, writing, or the performance of other near-work, it becomes necessary for him to still further call these muscles into action. In most cases, a refraction-error will be found. This should be carefully corrected under a strong mydriatic, and the lenses thus determined, given for habitual wear before any operative treatment is attempted. This becomes necessary, because in the effort to overcome any optical defect, a temporary extra tension is frequently developed in some of the external muscles which may, as hinted at on page 274, subside under the use of the correcting-glass. At times, it is advantageous also to make sure that thorough relaxation of any increased tension in the extra-ocular muscles is attained, thus developing any latent insufficiency. This can be done by giving a pair of prisms with their bases pointing toward the insufficient muscle for temporary wear.

Insufficiency of the interni. Slight but annoying degrees of insufficiency of the internal rectus muscles are often developed in presbyopic patients by putting on spectacles which are so strong as to bring the near-point inconveniently close to the eyes. The reason for this is, that whilst such glasses relieve the strain on the accommodation, they call for increased convergence by bringing in the near-point, thus reversing the habits of relative accommodation. Insufficiency of the same muscles may also be produced by placing the optical centres of the lenses wider apart than the pupillary centres. When these are placed too far apart, they act as prisms with their bases outward, and thus increase any strain on the internal rectus muscles. In the same way, when a full correction is given in hypermetropia, it will often be found that the relative near-point is brought too close, and the internal rectus muscles fail to perform the extra work thus thrown upon them, upon account of the hypertrophied and over-tense ciliary muscle not being at once relaxed. Insufficiency of the interni is also a frequent accompaniment of myopia. Here it is caused by the near-point being brought too close to the eye with a relatively less effort on the part of the accommodation, thus producing a simultaneous increase in the demands on the convergence. This, with the great lengthening and the ovoid shape of the ball (especially in cases of high myopia) mechanically increases the

work of the internal rectus muscles, and makes it more difficult for them to roll the eyes inward. In cases of high myopia, the demands on convergence are relieved either by using only one eye at a time, or by the wearing of concave lenses which give an artificial far-point that is situated at a greater distance from the eye than it is in the uncorrected organ; this latter plan being aided, if necessary, by decentring the lenses outward, so that they may act as prisms with their bases placed inward. Where the degree of myopia is slighter, and the patient is young, the insufficiency may frequently be remedied by giving a full correction for habitual wear. Where this is impracticable, reading-glasses can be combined with prisms.

As previously mentioned, the ordinary power of the straight muscles varies greatly. On account of this inequality of action, we can often afford to neglect an amount of tendency to lateral deviation which we should be called upon to correct if it existed in an upward or a downward direction. Further, a weak prism, with its base down, placed before one eye, and reinforced by one of similar grade, base up, before the fellow-eye, is a welcome relief in some cases of hyperphoria.

The severe asthenopic symptoms caused by insufficiency and heterophoria are of frequent occurrence, and are familiar to all practitioners. Of late years, it has been held by Stevens and many others, that in addition to the frequent and distressing asthenopia, these disturbances of the ocular muscles are often the cause of severe nervous affections, which are purely reflex in their nature. These, they assert, can be cured by restoration of the ocular balance effected by partial tenotomies. The most prominent of this class of diseases are reflex-chorea and reflex-epilepsy.

While every ophthalmic surgeon has daily opportunities for observation of exquisite reflex action in the eye and its surroundings excited by disease affecting some other part of it, and is, therefore, prepared to look for reflex disturbance elsewhere, and while the experiments of Dercum and Parker show that long-continued and slight strain on some of the muscles of the body may be followed by general convulsions, nevertheless it is the experience of the author, that cases of reflex-chorea or reflex-epilepsy due solely to eye-strain are very rare. He has often seen cases of facial chorea, especially of twitching of the orbicularis muscle in children, much benefited by the correction of hypermetropia or hypermetropic astigmatism, but has rarely observed permanent and complete cure from such a plan of treatment. As regards the graver forms of chorea and epilepsy, and their reported cure by operations on the eye-muscles, it must be remembered how little is known about the pathology of these affections, how irregular at times is the course of the latter disease, and how often a cure has been erroneously supposed to be effected either by therapeutic measures or by surgical operation.

Operative treatment of insufficiency and heterophoria. Although tenotomy of the external recti muscles in cases of increasing myopia with insufficiency of the interni, has not given as favorable results as were thought possible by Von Graefe when he introduced the operation, it nevertheless acts most beneficially in relieving the resultant muscular insufficiency and asthenopia, in many instances. As a rule, no operative interference

upon any of the eye-muscles should be resorted to until careful correction of any existing refraction or muscle defect by proper lenses, has been tried and faithfully worn for a time. If after thorough trial (the eyes having been carefully measured under a strong mydriatic) these measures fail, and if the grade of insufficiency be high enough to warrant it, and if there be fair abductive and adductive power, a tenotomy may be resorted to. The amount of facultative divergence at a distance (that is, the ability to overcome prisms, base in, at six meters) should be taken as the limit of the operative interference. If there be power to overcome prisms of from twelve to sixteen degrees, base inward, division of the external rectus muscle may be safely proceeded with, but if there be less than this amount, a tenotomy will probably produce convergence with homonymous diplopia for distance. A careful division of the muscle alone, without disturbing the attachments to Tenon's capsule, will usually give about fourteen degrees correction. If necessary, this effect may be lessened by sutures. The result of the same operation, however, will vary in different cases, being greater where a very thin and delicate Tenon's capsule permits the divided muscle to retract farther than usual, and less where a dense firm capsule limits the retraction—the immediate effect being nearly double that of the permanent. The amount of correction gained should be tested immediately after the operation, by holding a candle in the so-called "*place of election*"—*i. e.*, at an angle of about fifteen degrees from the median line toward the side of the divided muscle, thus giving the muscle a better chance to act. It is necessary to allow the healing process to proceed for about a week before the results of the tests with prisms will correspond approximately with the results to be finally obtained. When there is less than this amount of facultative divergence for distance, operative interference must be declined, or a partial division of the muscle resorted to. This latter operation is best performed according to Stevens's method, by making a small opening through the conjunctiva, exactly over the insertion of the tendon. After this is done, the tendon is seized by an extremely fine pair of forceps, and divided in each direction, thus preserving the extreme outer fibres, or at least, the reflection of the capsule of Tenon, which serves as an auxiliary attachment.

Owing to the comparative weakness of the vertically acting muscles, partial tenotomy is better adapted to the treatment of hyperphoria than it is to that of esophoria or exophoria. One of the great difficulties in the way of the adoption of the operation, is, that in slight cases of heterophoria, a little excess of operative interference is a great disadvantage. Besides, it is extremely difficult to calculate the probable result with accuracy. Owing to individual peculiarities in the strength of the muscle, and to the density or feeble development of the capsule of Tenon, the same amount of division will, even in competent hands, give varying effects. The amount of cicatricial contraction following, is likewise an unknown quantity. Although the variation in result is held by the advocates of partial tenotomy to be due simply to the subsequent development of heterophoria, which was latent at the time of the operation, certain it is that, even in the hands of those who practise it the oftenest, repeated operations are frequently necessary for favorable results.

Concomitant strabismus. Strabismus, or squint, is said to exist when the visual axes no longer meet in the object looked at. If they meet before reaching the object to which they are directed, the condition is termed *convergent squint*. If they meet beyond the object, or deviate from each other, the condition is known as *divergent squint*. In the preceding sections, the squint that is due to paralysis of the eye-muscles has been discussed. There it was seen that in this form, the angle included between the visual axes varies, and that the squint or primary deviation of the eyes is greater in proportion as the fixation-object is moved toward the side of the paralyzed muscle. It was also noticed that if under these circumstances, the sound eye was covered and the lame eye attempted to fix, the associated movement of the sound eye, or the *secondary deviation*, was greater than the primary. On the other hand, in non-paralytic squint, the angle between the visual axes remains nearly the same in all parts of the field, and if the fixing eye be covered and the squinting eye be made to fix, the arc of movement made by the deviated eye in coming to fixation, will be equal to the arc that is described by the visual axis of the covered eye. Thus, if the squint is a convergent one, and the deviated eye turns outward, say two lines, in fixing, the covered eye will make a movement of equal extent inward. Conversely, in divergent squint, if the deviated eye comes in two lines to fix, the covered eye will make an equal and simultaneous excursion outward. This condition is termed *concomitant squint*. In short, the squinting eye acts as if one of its muscles had been slightly shortened, the innervation of the affected muscle and that of its fellow, remaining as before.

In the vast majority of cases of concomitant squint, the eye-axes converge. Less frequently, they diverge. Very rarely, there is a vertical deviation. In convergent squint, the relative amounts of the deviations can be measured by noting either the position of the inner margin of the pupil in comparison with the lacrymal point of the lower lid, or the position of the inner margin of the cornea and of the caruncle. In divergent squint, the same purpose can be accomplished by noting the position of either the outer corneal or the outer pupillary margin as compared with the position of the external commissure of the lids. If more accuracy is desired, a millimeter rule can be held along the margin of the lower lid of the squinting eye, and after the division which corresponds with the centre of the pupil is noted, the number of divisions of deviation, either in or out, when the fixing eye is alternately covered and directed toward the object looked at, can be quickly read. For rough results, as explained on page 173, it answers very well to use one hand as a cover for one eye, and a finger of the other hand, or better, a pen's point or other minute object, as the fixation-object, whilst bringing the accommodation of the eye into play by urging the patient to make an effort to force the point into distinct view. If it be desired to obtain more accurate answers as to the character and the degree of the deviation, recourse can be had to some of the plans described in the chapter on the Examination of the Eye.

It is instructive also to experiment on sound eyes with prisms, and to watch the corrective squint which ensues to remedy the double vision

thus provoked. For instance, a prism with the base placed outward before one eye, throws the image of a fixation-point to the outer side of the macula of this eye, producing a convergent squint as the effect of the effort of the internal rectus muscle to pull the fovea out far enough to receive the image. With a prism base inward, on the other hand, an extra exertion of the external rectus muscle is obtained, giving rise to a corrective divergent squint.

As shown on pages 98 and 175, the power of the several eye-muscles in correcting the diplopia caused by prisms, varies greatly, this not only being so in different people, but also in the same individual. The power of the internal rectus muscles to overcome prisms, base outward, is termed the power of *adduction*. The power of the external rectus muscles to overcome prisms placed base inward, is termed the power of *abduction*.

Concomitant squint may be either *alternate* or *monolateral*. In some cases, there may be *periodic squint*, this form usually depending on the use of the eyes for near-work. In the alternate variety, if the squinting eye is made to fix, the fellow-eye makes an associate movement under the covering hand, this inward deviation often remaining after removal of the hand. Here the fellow-eye has thus become the deviating eye. In such cases, good acuity of vision in each eye is apt to be found. When the covering hand is removed from the sound eye, in monolateral squint, the sound eye promptly comes back into fixation, while the primarily deviated eye resumes its squinting position.

One of the most curious characteristics of squint, is that although the visual axes deviate from the fixation-point, the patient rarely complains of double vision, and in many instances, especially in the monolateral variety, it is impossible, even with the addition of vertically deviating prisms, to make him aware of the presence of double images. In such cases, the acuity of vision in the deviating eye is as a rule very much impaired. The reason of this non-perception of the double image has been much discussed, causing theories of anatomically pre-existent corresponding retinal points, and of the physiological development of corresponding portions by continued use and by experience, to be propounded. Certain it is that the foveæ centrales really correspond anatomically, and that the construction of the retina permits good acuity of vision in these regions only. The fact is that the association necessary for proper binocular vision is often lost by disturbance only in certain portions of the retina of the affected eye. Especially is this so in those portions which are not only anatomically correspondent with the central portion of the retina of the fixing eye, but which by the faulty position of the deviated eye, are excited simultaneously with the central portion of the retina of the sound eye. As has been pointed out by Alfred Graefe, there are three classes of cases of amblyopia in squint: First, those in which double images can be readily produced, these standing in the positions in which, judging from the apparent deviation of the eyes, they would be expected. Second, those in which the images are produced with more difficulty, and do not correspond with the apparent deviation of the eye, appearing nearer together than should be expected. Third, those cases in which double images cannot

be produced. It has always appeared to the author that voluntary and long-practised mental suppression of the images, is the real cause of the amblyopia. Thus, in using the ophthalmoscope or the microscope, we have all at first found it difficult to keep both eyes open and to suppress the images of objects before the unemployed eye. With practice, however, this is very readily learned. For instance, in using the latter instrument, we can by an effort of the will bring both eyes into action simultaneously, and, seeing with one the divisions of the rule and with the other the magnified image of the object, can compare and measure the sizes of the two retinal impressions of the object under observation. Squint usually begins in infancy, giving the individual an opportunity for long practice of suppression of the retinal images of the unused eye at a time of life that is most favorable for the formation of the habit. In case of paralysis, however, the deviation generally appears later in life, when the habits of observation are fixed, and when the effort to bring the deviated eye into fixation, often causes discomfort and dizziness; this being so even when the double images are entirely done away with by covering the sound eye. As has been already stated, when the squint is monolateral and of long standing, it is generally found that the vision of the squinting eye is much impaired, this being true even when the media are clear and the ophthalmoscope fails to reveal any disease or abnormality. This state of affairs has given rise to the theory of amblyopia from disuse. Many writers, however, maintain that the amblyopia is congenital. Inasmuch as squint generally begins at so early an age that proper determination of the acuity of vision is impossible, and accurate ophthalmoscopic examination is difficult, the question cannot be easily decided. The fact, however, that the presence of corneal or lenticular opacities, in many cases of squint, apparently determines which eye should deviate, would appear to indicate that often, at least, there is an unrecognized anatomical peculiarity that produces the appearance of congenital amblyopia.

In judging of the presence of squint, we are often deceived by the fact that the visual axes do not correspond with the axes of the corneæ, because, as has been explained in the chapter on Physiological Optics, the visual axes often form an angle of five degrees with another in emmetropia, and frequently increase to seven degrees in hypermetropia. Consequently, while the position of the antero-posterior axes of the eyes can be readily detected and their situation properly judged, no criterion as regards the direction of the visual axes is obtainable, and therefore, when the angle between these two axes is greater than usual, the eye has an apparent divergent squint. In such cases, we are surprised to find that on alternately covering each eye, there is no deviation, the covered eye remaining steady in its fixation.

Prognosis as to the result of operation is better where the power of binocular vision is retained. In many instances of alternating squint, operation is unnecessary, permanent cure being effected by the habitual use of proper correcting-glasses.

Convergent squint. The true pathology of concomitant convergent squint was first pointed out by Donders, who showed that it was usually connected with and due to hypermetropia. As has been explained in

the chapter on Accommodation, the more the power of convergence, the better the ability to accommodate. The hypermetrope, having the retina inside of the principal focus of his combined lenses, can see distant objects distinctly only by bringing his ciliary muscle into action, and thus rendering his lens more convex. He has, therefore, less accommodation left to spend in focussing near objects, and in endeavoring to use this remainder to full advantage, he innervates both the ciliary and the internal rectus muscles vigorously and simultaneously. He thus puts a high tension on the latter, which reveals itself in many instances by a deviation of one of the visual axes inward, thus causing them to cross one another before reaching the fixation-object, and hence producing convergent squint. When Donders advanced this theory, he pointed out the fact that at least seventy-five per cent. of all eyes with convergent squint are hypermetropic. It has since been shown that the percentage is still higher, Wecker placing it at eighty-five per cent., while the experience of the author, which includes many hundreds of cases whose refraction was tested by atropine, gives even a higher ratio.

Knowing that convergent squint develops in infancy, and that the vast majority of eyes are hypermetropic in early life, it would be naturally asked, If the state of refraction is a cause of convergent strabismus, and is not an accidental accompaniment of it, why are there not more squinting eyes? and why do not all hypermetropes squint? Donders has answered these questions by pointing out that the vast majority of patients with convergent squint have only a low degree of hypermetropia, and that it is possible for them to overcome this by undue convergence and accommodation. On the other hand, he has shown that patients with high degrees of hypermetropia would gain no advantage from undue convergence, and that hence they do not exercise it. Further, he states that many hypermetropes prefer binocular vision with slightly-blurred images to clearer images that are associated with diplopia. In addition to the above-mentioned causes, there may be a congenital want of equilibrium in the eye-muscles, with undue preponderance of the internal rectus muscles. Further, double vision has fewer inconveniences and is more easily suppressed when there is a difference in the visual acuity of the two eyes, such, for instance, as may be due to the following conditions, which seem to be among the most active and predisposing causes: great difference in refraction, congenital amblyopia, corneal opacity, and opacity of the lens.

Prognosis is more favorable when the treatment is undertaken during adolescence, and when visual acuity is good in both eyes. In some few cases, a spontaneous cure of squint is seen in adults who have had decided convergence in childhood. In the majority of instances, however, the deviation remains permanent unless properly treated. An attack of phlyctenular conjunctivitis or other slight inflammatory condition of hypermetropic eyes in children whose general condition is lowered, may at times, call forth a transient or a permanent convergent squint.

There has been considerable diversity of opinion among writers as to the proper time of beginning the treatment of squint in young people. It has been the author's practice to begin treatment by carefully atropinizing the eyes and putting spectacles for habitual wear on the child

as soon as it knows its letters. Much, however, will depend on the intelligence of the patient and on the care exercised by its parents. By thus waiting, we are enabled to secure the quiet which is necessary for an accurate determination of the refraction during an ophthalmoscopic examination, and are aided by the child's ability to properly name the test-letters. At the same time, the prognosis is materially assisted by knowing whether there is amblyopia or not. In any case, young or old, the first step should be to examine the refraction carefully under a strong mydriatic, and, if hypermetropia and astigmatism be present, to prescribe full correction for habitual wear. After the effect of the mydriatic has passed off, the full correction, on account of the slight blurring of distant vision, is often somewhat disagreeable to the patient. As it takes away to a considerable extent, however, the desire of accommodation for distant objects, and thus relaxes any concomitant tension in the internal rectus muscles, it should always be employed. By this plan, accommodation and convergence for near-work are performed under conditions in which it is possible for the patient to bring the internal rectus and ciliary muscles into normal relation with each other. In a few cases of concomitant squint, especially where the main defect is an astigmatic one, the visual axes become straight simply under the influence of a pair of correcting-glasses. In the majority of instances, however, a portion of the squint persists, necessitating operative interference. In some cases of inveterate squint, where there is a high degree of amblyopia in the deviating eye, but little aid can be expected from the use of glasses. Operative results in such cases are generally much less satisfactory. When the deviation is not greater than from four to five millimeters, we may content ourselves with a simple tenotomy of the internal rectus muscle of the squinting eye. If it exceeds this, it is usually better to divide the effect between the two eyes by operating on both the squinting and the sound eye. For a moderate effect, the incision should be made in the conjunctiva near the border of the cornea, and, after Tenon's capsule is divided, the muscle is to be brought forward on a hook and divided at its insertion into the sclerotic, thus causing the muscle to retract and to get an insertion farther back on the sclerotic. In all cases, even before a new insertion by attachment to Tenon's capsule has taken place, the muscle is able to move the ball inward to a considerable extent. If a greater effect than the division of the tendon and Tenon's capsule is desired, oblique incisions can be made into the latter, and the cut end of the muscle thus enabled to still farther retract. This procedure, however, makes it much more difficult to judge of the final result of the operation, and is much more likely to be followed by a retraction of the caruncle. To prevent the latter occurrence in cases where extensive incisions are made into Tenon's capsule, it is sometimes advantageous to dissect up the bulbar conjunctiva with the scissors as far back as the caruncle before dividing the muscle. Where too great an effect is obtained, it can be diminished by suturing the conjunctiva at the completion of the incisions. When such free division on both sides still leaves residual squint, advancement of the external rectus muscle must be resorted to to remedy it. In most of such cases, it is best to give preference for the operation to the eye that has been primarily operated upon.

The orthopædic treatment of squint by cultivating and confirming the power of any existent binocular vision, is often useful after operation and the prescription of proper glasses. In many instances of well-established squint, the stereoscopic field in front of the squinting eye remains a blank and fails to form or to fuse any images. Where, however, stereoscopic images can be called forth, special slides which have dots or lines so placed as to form letters or figures when the two retinal images are fused, constitute useful devices for exercise.

Convergent strabismus with myopia is rarely encountered. These cases generally have the peculiarity that they have binocular vision inside of their far-point or inside of their usual reading-distance, while for objects beyond these points, a convergent squint, that is often accompanied with annoying double vision, sets in. According to Von Graefe, this is due to an increased tension, which, existing in the internal rectus muscles in all cases of myopia, is eventually followed by a diminution of the ability of the muscles to relax. In time, positive shortening appears. At first, most of these cases are periodic, and if left untreated, are apt to become permanent. In young people with a good power of accommodation, this variety of convergent squint may often be relieved by giving the patient a full correction, thus removing the far-point farther from the eye and relieving the internal rectus muscles of unduly increased work at short distances. If necessary, the desired effect may at first be aided by decentring the correcting concave glasses inward, thus obtaining the action of weak prisms with their bases out. When, in spite of these procedures, convergent squint persists, a careful tenotomy in one eye will generally afford relief.

Divergent strabismus, though occurring occasionally in hypermetropic eyes, is usually associated with myopia. When the far-point lies quite close to the cornea in very high degrees of myopia, the eyes cannot be made to converge for it, and there is divergence at this, the usual working distance. In addition, the ellipsoidal form of the eyeball in these cases, very much increases the difficulty of the muscles in turning the eye inward. Further, as the visual axes are normally parallel in a state of rest, and tension of the internal rectus and ciliary muscles makes distant vision worse, there is consequently, under these circumstances, a disposition to allow the eyes to be readily turned out by the external rectus muscles, especially if these muscles happen to be unusually strong.

When the defect is slight and the myopia is high, the outward tendency of the eyes can often be remedied by prescribing a fully correcting concave glass for distance and a weaker one for near-work. This is so, because, by so doing, the excessive amount of work called for on the part of the interni is diminished by putting the near-point farther from the eye. Where, owing, for instance, to the formation of cataract or to disease of the optic nerve or retina, acuity of vision is much impaired, the eye may frequently be seen to turn in various directions under the influence of its own muscle-equilibrium. When glasses that are used as above directed, fail to relieve the squint, careful division of one or both external rectus muscles is sometimes indicated.

Strabismus with vertical deviation is rarely seen in its pure and simple form. In convergent squint, however, the eye is often found also turned slightly upward.

CHAPTER XXVI.

DISEASES OF THE EYELIDS.

Congenital ptosis, which may be either one-sided or bilateral, consists in a drooping of the lid. The tissues of the lid, which hang down loose and fail to present any superficial folds in the skin, can be elevated only by a wrinkling of the forehead through the action of the occipitofrontalis muscle. Occasionally, the total absence of the levator palpebræ muscle has been observed. This anomaly, as shown by Steinheim¹ and Horner,² is sometimes associated with deficient innervation of the superior rectus muscle.

Although no treatment has ever been successful in entirely removing the peculiar deformity, yet various operations have been suggested to palliate it, the object of each being to raise the edge of the upper lid sufficiently high, so as to clear the pupillary space when the eye is directed forward in the horizontal plane. The advancement of the tendon of the levator muscle has been unsuccessfully tried by many skilful operators, including Bowman and Von Graefe. Snellen claims to have been successful by shortening the muscle. The operation generally practised is the removal of a horizontal oval piece from the skin of the lids and the underlying orbicularis, thus shortening the lid and diminishing the power of its sphincter at the same time. Great care should be taken not to remove such an amount of the skin as would prevent total closure of the lids during sleep. In bringing the lips of the wound together during the operation, the edges of the cut muscle should be included in the sutures that are passed through the skin.

Epicanthus is the name given to a fold of skin which projects outward over the inner canthus from the internal angles of the lids. A slight degree of it is present in many flat-nosed children for a few months after birth. With the increasing development of the nasal bones, however, it gradually disappears, so that when the child has reached the age of five or six years, the affection may have ceased to be visible. Marked degrees of it which persist, require operative treatment. The operation generally performed, is that of Von Ammon, who recommends the excision of a vertical oval piece of skin from the upper median part of the nose, followed by suturing the edges of the wound together. This procedure should be carefully performed, for if the strain is too great and the sutures give way, an ugly scar will result. Arlt advises the removal of a part of the epicanthal fold of skin, and the suturing of the cut edges.

Coloboma of the lids, which is a rare deformity, is usually monolateral

¹ Klin. Monatsblätter f. Augenheilkunde, 1877, S. 99.

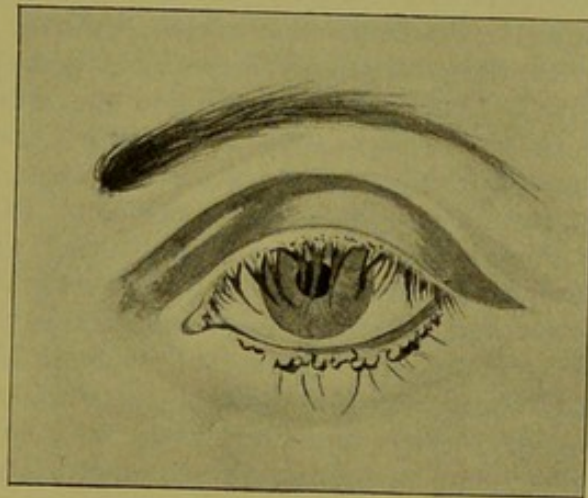
² Handbuch d. Kinderkrankheiten, v. S. 225.

in type. The upper lids are more frequently affected than the lower ones.

Blepharitis is a term that is, at the present time, restricted to an inflammation that occurs at the edges of the lids. The enlarged palpebral vessels give the edges of the lids a red color. Between and entangled in the cilia, lie numerous whitish particles. These are due to an excessive formation and exfoliation of the epithelial scales, and an over-secretion of sebum, from the glands of the hair-follicles and the skin. At times, these particles collect into thin whitish scales. In severe cases, they form yellowish crusts. Fig. 338 shows these conditions very well.

The nutrition of the structures about the edge of the lid is affected. The cilia are more rapidly shed, and come out readily when an attempt is made to remove the adherent secretion. The patients complain of

FIG. 338.



Blepharitis. (DALRYMPLE.)

slight itching. The eyes burn and redden easily on exposure to wind and dust, or when the patient faces the glare and heat of artificial light. In the vast majority of such cases, this local congestion of the eyeball and edge of the lid is primarily a reflex vascular disturbance that is due to the strain of the ciliary and converging muscles of a hypermetropic eye in its endeavor to neutralize its deficient power in focussing near-work. All such cases get better with rest. Where the refraction is not properly corrected by convex glasses, the symptoms are aggravated and made chronic by persistent use of the eyes for near-work. Such a state of chronic congestion and thickening, which has lasted a lifetime, is often seen in literary men, watchmakers, and sewing-women.

In treatment, the first duty is to examine the eyes and correct any hypermetropia or astigmatism by appropriate glasses, for without such correction all local applications lead to but temporary improvement. Locally, the adhering epidermic masses should be softened either by washing the edges of the lid with warm water or by the application of

hot compresses to them for ten minutes at a time. The softened crusts should be removed by rubbing them with a linen rag that has been pulled over the forefinger, or with the cilia-forceps. A minute portion of an ointment of vaseline or lanolin containing two grains of ammoniated chloride of mercury to the drachm, or a similar strength of red or yellow precipitate, should then be gently rubbed into the roots of the eyelashes with the finger. Care should be taken that none of the ointment reaches the conjunctival sac, as it would thus give rise to unnecessary burning and pain.

Eczematous or *ulcerous blepharitis* is a much more severe affection. It is far more commonly found in feeble, ill-nourished, scrofulous children than it is in adults. In the former, it is frequently accompanied by phlyctenular inflammation of the conjunctiva and cornea. In the milder forms, a few cilia that are imbedded in dried pus and epithelial scales, the whole forming a conical mass with its point outward and toward the edge of the lids, can be seen. A part of the ciliary border of the lid that is comparatively normal, next follows, this being succeeded by another mass of cilia that is coated with a yellowish crust. In the severer forms, the entire edge of the lids is attacked. Often, all four lids are involved. In these latter forms, the entire margins are covered with a thick yellowish crust, through which the cilia protrude. The lids are oedematous, and their edges are reddened. On lifting the crust, the edge of the lid is found to be ulcerated. Little pits surround the cilia, the protruding lash often appearing "sickly" and ill-developed. Either the ulceration frequently goes so far as to destroy the hair-bulbs, or subsequent processes of cicatrization may cause them to protrude in an abnormal position and to rub against the eyeball. Where repeated attacks of this kind occur, a proliferation of the connective tissue, with thickening of the lids, which has been designated as *tylosis*, results. Cicatrization of the tissues in this condition, often leads to slight ectropion of the lower lid and to eversion of the lower tear-point.

The first step in the treatment, as in the milder form, is to remove the crusts. This should be done either at once with the cilia-forceps, or by means of hot-water embrocations, after the crusts have been softened. The patient should then be directed to close his lids, and the raw and ulcerated surface should be lightly brushed with a ten-grain solution of nitrate of silver, the excess being neutralized with a solution of salt in water applied with another swab. A small amount of the astringent thus applied, finds its way also into the fissure of the lids, and thus acts favorably on any inflammation of the conjunctiva. This treatment should not be repeated till the crusts begin to loosen, as any rough handling augments inflammation. For the same reason, epilation is objectionable. The later stages of the disease may be treated by the mercurial ointments that have been recommended for the lighter form of blepharitis. When there is much thickening of the lid, Horner paints the remaining excoriations and a two-millimeter band of the lid beyond with tincture of iodine. He uses a small brush made almost dry, so as to prevent the entrance of any excess of the solution into the conjunctival sac. Treatment should always be continued till the lids have lost their redness and swelling, and the crusts have disappeared.

Hordeolum, or *stye*, is a localized inflammation of the connective tissue of the tarsus, which is tender to the touch, and is accompanied by a varying amount of redness and swelling of the lid. Where the inflamed tissue lies deep in the tarsus and is situated near the outer angle of the lids, so as to interfere with the circulation in the veins that empty into the facial vein, there may be so much œdema and swelling of the lids and conjunctiva as to give the appearance of erysipelas or incipient purulent conjunctivitis. Serous chemosis of the bulbar conjunctiva may even take place. In such extreme cases, diagnosis is rendered easier by rapidly moving the finger over the closed lid, thus usually revealing the existence of a tender spot of localized inflammation. Sometimes, a small abscess forms and points at the edge of the lid. This should be punctured and the contents evacuated by pressure. When the patient is unwilling to have the abscess opened, the exit of the pus may be generally facilitated by the employment of hot compresses used every two or three hours for ten minutes at a time.

Abscess of the lid is generally the result of inflammation that follows injury. In scrofulous children, it is often accompanied by caries of the margin of the orbit. It sometimes follows attacks of facial erysipelas in which the orbital tissue has become involved. The lids are greatly swollen, infiltrated, reddish, and feel hard to the touch; these symptoms being often accompanied by pain and fever. In bad cases, there may be sloughing of the skin of the lids, giving rise to extensive cicatrices, with *lagophthalmus*, or inability to close the eyes, and *ectropium*, or eversion of the eyelid. Where, although the skin is intact, a depressed cicatrix, and at times, a fistula leading to carious bone, is present, the orbital tissue is affected.

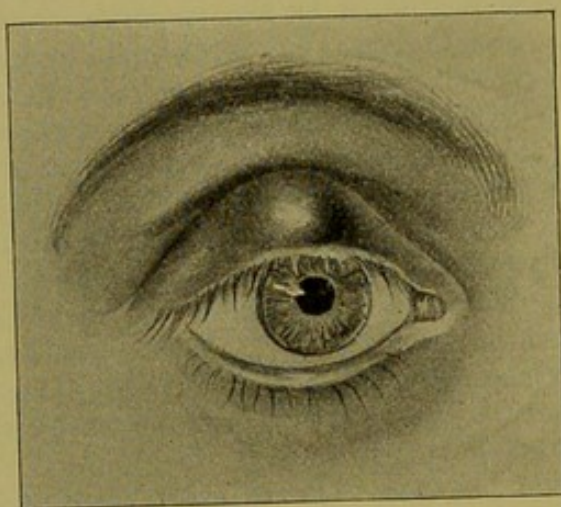
If, after a blow on the eye, there is great swelling of the lids, iced compresses will often be effective in reducing inflammation and preventing suppuration.* As soon, however, as an abscess is diagnosticated, it should be opened and its cavity very gently syringed with a dilute solution of bichloride of mercury.

Chalazion is the term that is applied to a small tumor that is caused by chronic inflammation of a Meibomian gland or some of its follicles. The growth varies in size from that of a split-pea to that of a small olive. It is situated deep in the tarsal tissue. It is hard and tense to the touch, and the skin moves freely over it. The contents of the sac consist either of a gelatinous mass of cells in the process of fatty degeneration, or of pus. Fig. 339 represents a moderate-sized chalazion.

If chalazia are allowed to develop, they become firmly attached to the conjunctiva of the tarsus by persistent periglandular inflammation, and cause the surface over the affected area to become unduly red and inflamed. Finally, the conjunctiva gives way, and granulations from the underlying connective tissue sprout on its surface. Where the growth has reached this advanced stage, it is best to incise it from the conjunctival surface, press out the contents, and cauterize or scrape its walls so as to produce adhesive inflammation. Care should be taken not to cauterize it so freely as to cause contraction that will be sufficient to produce partial entropium. Where the adhesion to the conjunctiva is less extensive, the lids should be compressed by a clamp, to prevent

hemorrhage. An incision should be made in the skin over the tumor parallel to the course of the fibres of the orbicularis muscle. The muscle-fibres should be divided in the same direction and pushed to one side, laying bare the yellowish-white and shining walls of the sac. The growth is next to be pulled gently forward by a tenaculum and then carefully dissected out. When it lies deep, and is firmly attached to the conjunctiva, it is impossible to remove it completely without making a button-hole in the mucous membrane, an accident that should always be avoided as far as possible, so as to prevent cicatrization which might cause deformity of the lid. If the incision be of any size, two or three sutures had better be applied. A chalazion, being purely a local condition, never returns, if once thoroughly removed.

FIG. 339.



Chalazion. (DALRYMPLE.)

According to Fuchs,¹ a chalazion is primarily a chronic inflammation of some of the lobules of a Meibomian gland, causing hyperplasia of the epithelium and retention of the secretion. The connective tissue outside of the affected lobules continues to proliferate until it forms a mass of granulation-tissue which fuses together the contiguous lobules and forms a firm lump. The contents of the tumor at this stage consist of granulation-tissue. Later, this tissue takes on colloid degeneration. Giant cells are always present, some arising from the epithelium and others from the granulation cells.

Vaccinal eruption on the eyelids, when generally seen, presents itself as an ulcer with an indurated border and yellowish floor. It is accompanied by considerable swelling of the lids and face and by enlargement of the pre-auricular gland. According to Schirmer,² a deep keratitis and curious concentric circles of corneal haze, which seem to be at a deeper level in this membrane, are sometimes associated with it.

Epithelioma of the eyelids generally develops in the skin near the ciliary margin. It first makes its appearance in the form of small, hard

¹ Archiv f. Ophthalmologie, xxiv. 2, Ss. 121-155.

² Klinische Monatsblätter, 1891. Bericht der Heidelberger Ophthl. Gesellschaft.

excrescences that soon show a tendency to ulcerate. The edges of the ulcer are indurated, and the walls are undermined. When it is situated near the inner angle of the lids, it is prone to spread to the caruncle and the nose. It usually occurs in middle-aged and elderly people. With the exception of a sense of itching after ulceration, it produces but little discomfort. If it is kept clean, and is not scratched or irritated by caustics, it often remains almost stationary for many years. If it exhibits a tendency to spread, it is best treated by excising the portion of the lid that includes the tumor, and replacing the lost tissue. When it has attacked the bulbar conjunctiva, any operation that does not include enucleation of the eyeball, usually fails to prevent recurrence. The disease is sometimes difficult to distinguish from indurated chancre. The latter, however, generally occurs in younger subjects and is often accompanied by other symptoms of syphilis. Tuberculous ulcers, which closely resemble the syphilitic and the epitheliomatous types, appear almost exclusively in the young. Moreover, some of the deeper-seated tuberculous tissue that has been snipped from the walls or bottom of the ulcer, will generally exhibit the characteristic bacilli.

Lupus may at times attack the eyelids. If it is seen in its early stages, it should be cauterized. If the growth is more advanced, it should be excised and the lid-tissue replaced by some plastic operation.

Lepra, as a part of the ocular manifestation, frequently attacks the lids. Fortunately, it is quite rare here, being only seen in countries where the disease is endemic. Tumors in the region of the eyelashes and in the eyebrows, form in the tubercular variety. These cause a falling of the cilia before the lashes are sufficiently developed to be visible to the naked eye.

Phthiriasis of the eyelashes was so seldom seen here before the vast emigration of some of the races of Eastern Europe, that it sometimes became a puzzle to physicians of considerable experience. More lately, however, it is said to not be infrequently found in dispensary practice that admits a large contingent of the lower classes of these nationalities. The cases which the author has observed, have been in children who were in charge of uncleanly people. The disease is due to crab-lice which have found lodgment in the hair of the pubes and thence ascend or are carried by the hands, etc., to the palpebral cilia to lay their eggs. The edge of the lids appears "scabby," and is strewn with minute black points. If a cilium is pulled out and laid under the microscope, the ova can often be readily recognized, firmly attached to the hair. The infected parts should be thoroughly washed with warm water and weak solution of bichloride of mercury. Dilute citrine ointment or an ointment of ammoniated mercury should be subsequently rubbed into the infected areas three times daily.

Xanthelasma, or *xanthoma*, is a disease of the skin which often makes its first appearance on the eyelids of persons in middle life. It is more frequent in females than in males. Small opaque yellowish patches appear, which are slightly elevated above the surrounding skin. These usually vary in tint from a light buff to an orange. Occasionally, they are lighter in hue—almost cream-colored. The disease, as it appears

in the eyelids, is painless, innocuous, and slow in growth. Where, upon account of cosmetic effect, removal is desired, this may be easily accomplished by excision. According to Duhring,¹ the disease sometimes becomes general, invading the palms, the soles of the feet, the face, the ears, the flexures of the joints, the extremities, and, lastly, the trunk. Occasionally, the macular form of the disease attacks the mucous membrane of the lips, gums, tongue, palate, and trachea. Similar opaque patches have been found in the spleen and lining membrane of the gall-ducts. The disease, when confined to the skin, consists of a new growth of the connective tissue of that covering, which undergoes molecular fatty degeneration.

Trichiasis is a term that is applied to an inversion of the eyelashes, which causes them to rub against the eyeball and irritate it. A long continuance of the disease often produces irremediable scars in the cornea. The faulty position of the cilia is usually produced by cicatrices situated in the conjunctiva. These cicatrices may be the result of burn or other injury, but are generally due to granular conjunctivitis. In slight cases, where but a few pale and ill-developed cilia are thus deflected, it sometimes requires careful search to find the cause of the recurring corneal inflammation. If there be but a few incurved hairs, epilation is a temporary remedy. Destruction by galvanism, however, although a painful procedure, is effective, being permanent in its results. To perform electrolysis, a fine needle, connected with the negative pole of a battery, is introduced into the hair-follicle which it is wished to destroy, and the positive electrode, being covered with a wet sponge, is either applied to the temple or to the hand of the patient. The moment that the bulb is pierced, the patient is requested to squeeze the sponge or the sponge is pressed hard against the temple. This causes considerable pain. In a moment or two, the hydrogen liberated by the destruction of the watery parts of the tissue, causes a fine foam to exude along the cilium. The needle is then withdrawn, and the hair may be either extracted or allowed to fall out. In the majority of cases, if the hair-follicle has been thoroughly destroyed, the eyelash is not reproduced. When the entire or any considerable part of the row of lashes is turned inward, some operation for transplanting the cilia is called for.

Distichiasis is said to exist where one row of cilia still points outward, while the inner row is drawn in against the eyeball. Its causes are essentially the same as those of trichiasis. Treatment is also the same as for that disease. Occasionally, it appears as a congenital defect in an otherwise normal lid.

Entropium is the term used to denote the condition in which the entire edge of the lid is turned inward, and the skin-surface is brought in contact with the eyeball. Like trichiasis, it is most generally due to the degenerative and cicatricial changes that follow granular conjunctivitis. A slight degree of it is always seen after the enucleation of an eyeball. In such cases, the support of the lid has been removed, thus allowing the orbicularis muscle to turn the free edge of the lid inward. This form of entropium is corrected by the insertion of an artificial eye. In old

¹ Diseases of the Skin, 1882, p. 465.

people, whose skin is lax and thin, and in whom, owing to the conformation of the face or disappearance of orbital fat, the eye lies deep in the orbit, a spastic entropium is often produced by bandaging the eye. Here the irritation of the conjunctiva causes a spasmodic contraction of that portion of the orbicularis muscle that is near the edge of the lid, thus turning the free edge of the eyelid against the eyeball.

Ectropium is often produced by any cicatrix which shortens the skin of the upper or the lower lid. When there is complete eversion, the conjunctiva becomes inflamed, and shows a marked contrast in vascularity and velvety appearance between its tarsal portion which is papillary and its retrotarsal part which is non-papillary. The cornea becomes dry and is exposed to dust and foreign bodies, by being no longer bathed with tears through the constant winking of the lid. Occasionally, where the lids are stiff and infiltrated from chronic inflammation of the conjunctiva, there are slight degrees of spastic ectropium. This tendency to eversion is augmented by an undue contraction of the peripheral bundles of the orbicularis muscle. In old people, owing to defective innervation of this muscle, the lower lid sometimes drops away from the eyeball, thus allowing the tears to flow over the cheek. In paralysis of the orbicularis, there is a still more marked sinking of the lower lid. In fact, the flow of tears over the cheek is frequently the first sign of facial palsy.

Division of the canaliculus sometimes helps to better drain the tears. The use of the constant current of electricity, with proper alterative medicine, often helps the paralytic form. In many such cases, however, and in all ectropiums of cicatricial type, operative measures are necessary.

Ankyloblepharon is a name that is given to the growing together of the two eyelids. It is generally the result of burns or sloughs. From the nature of the injuries causing it, it is often accompanied by *symblepharon*, or adhesion of the lid to the ball. Where the entire edges of both lids are adherent, the ankyloblepharon is said to be total.

If the condition exists without symblepharon, a simple division of the adhesions suffices to remedy it. When it is accompanied by extensive adhesions to the globe, efforts to permanently free the lids from the ball are frequently nugatory. Where symblepharon is but slight, the elasticity of the bulbar conjunctiva may be made use of to prevent reunion of the cut surfaces.¹

Blepharophimosis is a term that is generally applied to a narrowing of the outer end of the palpebral fissure. It is generally caused by ulceration and subsequent cicatrization of the margin of the lid in subjects who have chronic disease of the conjunctiva. It is easily remedied by canthoplasty.

Lagophthalmus is an inability to completely close the fissure of the lids. In slight cases, although strong effort of the orbicularis muscle will approximate the edges of the lids, a normal tension, such as that taking place during sleep, fails to do so. In consequence, the lower parts of the cornea and bulbar conjunctiva are frequently exposed to

¹ This subject has been referred to in the chapter on Injuries to the Eye and its Appendages. The operations for its relief are described in the chapter on Operations.

dust and drying. The usual causes of the condition are complete or incomplete paralysis of the orbicularis muscle, cicatrices in the skin of the lids, and the relaxation of the muscle and insensitiveness of the conjunctiva, which appear in the very ill. Sometimes, too, it may be due to exophthalmus, where, owing to undue prominence of the eye, the lids fail to completely cover the eyeball during sleep.

In mild cases, it is sufficient to bandage the eye during sleep. In more pronounced ones, it becomes necessary to diminish the fissure of the lids by some form of tarsorrhaphy.

Blepharospasm is a cramp-like closure of the lids. It is a frequent symptom of the various diseases of the conjunctiva and eyeball. Examples of it are daily seen in cases of phlyctenular disease, trichiasis, and cases of lodgment of small foreign bodies in the cornea and conjunctival sac. In all such instances, it is manifestly reflex, being produced by irritation of the peripheral branches of the trigeminus. All grades of twitching of the orbicularis muscle, from a barely perceptible movement of its superficial fibres to a series of most violent contractions, as seen in pronounced cases of facial chorea, are also frequently encountered. Often there is no demonstrable cause of the reflex irritation. The condition is quite common in children. In this class of subjects, the removal of any cause that tends to congest the bulbar conjunctiva, such as suitable glasses in cases of hypermetropia or astigmatism, or the cure of any slight conjunctivitis, is often of marked benefit and diminishes the frequency and the violence of the spasmodic attack. It generally fails, however, to cure it. The twitching in such cases is usually one-sided. If it be bilateral, it is much more frequent and more pronounced on one side. In hysterical subjects, a cramp of the orbicularis muscle may be found. This variety is of much longer duration and has complete closure of the lids associated with it. The frequent blinking seen in old people is ordinarily either a part of some form of tic, or is due to conjunctival irritation, producing a low-grade spasmodic action of the lids.

Paralysis of the orbicularis. Inasmuch as the orbicularis muscle is innervated by the facial nerve, it may be either partially or completely paralyzed by disease of the related cerebral centres or of any portion of the nerve itself. By far the most common cause of the condition is either a neuritis or a pressure upon the nerve in the aqueduct of Fallopius or in the vicinity of the stylo-mastoid foramen. Where the paralysis is due to intra-cranial disease, the fibres of the nerve supplying the muscles about the mouth are more affected than those supplying the orbicularis muscle. From their close proximity to the auditory nerve also, such intra-cranial affections are apt to produce deafness. In some cases, the uvula is deviated to the sound side. This occurs when the lesion is situated anteriorly to the point where the larger superficial petrosal nerve is given off. If the conditions be accompanied by hemiplegia, the facial palsy may be on either side. When it is on the same side, the disease is frequently located in the optic thalamus or corpus striatum of the opposite side of the brain; this form of paralysis being apt to be partial. If it is on the opposite side to the hemiplegia, the lesion is probably to be found in the pons on the same side as the facial paralysis. The most

common causes of orbicular palsy are exposure to cold, injury to the facial nerve either by disease or by operation in the parotid region, disease of the temporal bone, and thickening of the lining membrane of the aqueduct of Fallopius or similar thickening of the dura mater within the cranium. According to Bull and Hansen, paralysis of the orbicularis muscle is of common occurrence in leprosy.

The treatment varies with the cause. When the condition has been produced by cold, hot compresses and irritating ointments (such as veratria) are of advantage, and are often aided by alterative and the absorbent influence of small doses of iodide of potassium. Where syphilitic disease is present, appropriate treatment is indicated. In all cases, the eye should be protected from injury by bandage so arranged as to close the lids during sleep. In advanced cases, where the lower lid droops and falls away from the ball, tarsorrhaphy is indicated.

Paralysis of the levator palpebræ, when complete, shows itself by a drooping of the upper lid to such an extent, that the patient is unable to lift the lid above the pupil, even by wrinkling the forehead through the aid of the occipito-frontalis muscle. Where there is simply paresis, the wrinkling of the forehead with the throwing back of the head in the effort to bring the pupil opposite to the narrow lid-fissure thus obtained, is quite characteristic. The condition is usually associated with paralysis of other branches of the third pair. When it manifests itself without involvement of the other branches of the nerve, or when it is coincident with hemiplegia of the opposite side, it is generally held to indicate that there is a cerebral lesion that is either situated in the cortex or in the nucleus of the nerve.

CHAPTER XXVII.

DISEASES OF THE LACRYMAL APPARATUS.

As described in the chapter on Anatomy, the lacrymal apparatus is composed of two parts—a secretory and an excretory portion—which are separated by the conjunctival sac. The first portion is but little liable to disease, and rarely calls for surgical interference. The latter is frequently affected, furnishing constant occupation to the surgeon.

Except as part of general abscess of the orbit, acute or chronic inflammation of the gland is rare. Although Becker¹ has described a cylindroma of the gland, yet new growths originating strictly in the gland-substance are but seldom seen. According to Schmidt,² most tumors of the gland originate in the connective tissue of the surrounding orbital fat. The substance of the gland has also been found in a state of fatty degeneration and atrophy, which had been caused by obliteration of its ducts by cicatricial processes that have accompanied granular conjunctivitis.

Amongst the most prominent diseases of the lacrymal passages, the canaliculi are frequently misplaced by swelling of the edge of the lids or by cicatrices of the skin of the lids and face. At times, they may be misplaced by an *enophthalmus*, or retraction of the eyeball, that is due to an absorption of the orbital fat, thus depriving the edge of the lid of its accustomed support. Again, there may be stoppage of the canaliculi by fungoid growths, such as *leptothrix*. If the displacement or the stoppage is likely to be permanent and the epiphora be persistent and annoying, the resulting condition may be generally relieved by converting the canaliculus into an open drain by slitting it. Where the puncta have been closed and part of the canaliculi have been obliterated by cicatrices, especially those that follow burns, it becomes exceedingly difficult to find the canals and dilate them, or in any way to re-establish permanent communication with the lacrymal sac.

Catarrh of the lacrymal passages (Blennorrhœa lacrymalis), when chronic, is a disease which, though frequent in adults, is rare in children. When it occurs in subjects that are under ten years of age, it is usually an evidence of inherited syphilis. The symptoms are watering of the eye, swelling of the upper part of the lacrymal sac, frequent chronic catarrh of the conjunctiva, and a low-grade blepharitis. The amount of swelling varies very much in different cases. Sometimes, it is barely perceptible, and at others, it forms a large tumor at the inner angle of the eye. Pressure on the sac with the finger, gives a sensation of elastic resistance, which usually disappears if the pressure be con-

¹ Ueber Adenom der Thränendrüse, Bericht der Wiener Augenklinik, 1863-67. S. 162.

² Krankheiten des Thränenorgans, 1893, S. 130.

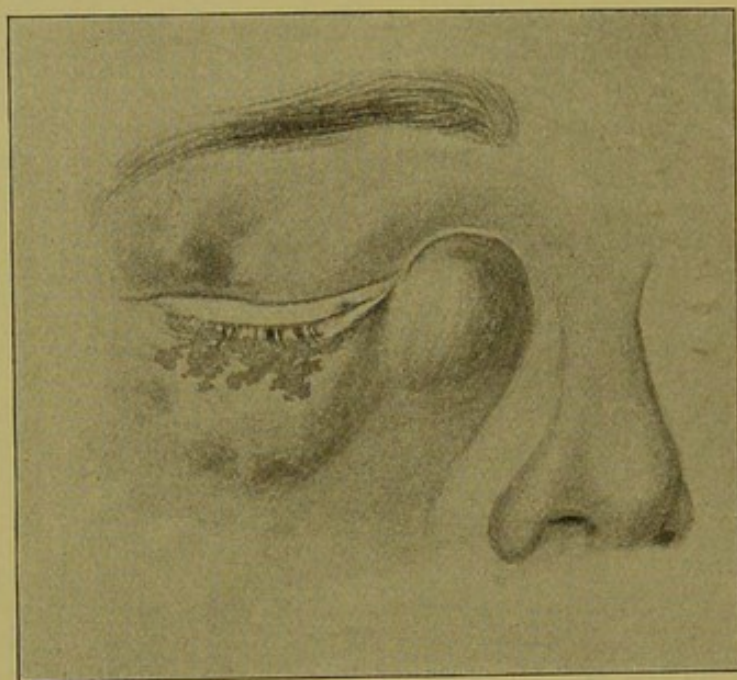
tinued. The reason for this is, that the contents of the sac either as a rule escape through the canaliculi into the conjunctival sac, or more rarely are evacuated into the nasal cavity. The fluid which regurgitates into the conjunctival sac, is generally yellowish. It is often capable of being drawn into threads. The amount of pus in the discharge varies greatly. In many chronic cases, it is ropy and transparent, resembling the white of an egg.

When the mucous membrane is inflamed, it is dull reddish-brown in color, and presents numerous folds and crypts. Sometimes it is infiltrated with granulations, such as are found in granular conjunctivitis. Where the sac is thinned and distended through chronic inflammation, it is much less vascular, and looks like a serous membrane. If the granulations have infiltrated the tissue, they undergo fibrous degeneration, and produce cicatrices and strictures. These latter may also result from ulceration of the mucous membrane. At times, partial or complete obliteration, from a growing together of ulcerating folds of the swollen lining membrane, ensues. Arlt says that he has several times found the lower part of the nasal duct converted into a fibrous cord, in cadavers where there have been ulceration and destruction of the *alæ* of the nose which has probably been syphilitic in nature. The amount of dilatation of the sac varies greatly. In some instances, it is sufficient to form a tumor large enough to interfere with the field of vision. In cases of considerable distention, it is often very difficult to evacuate the contents by pressure through the canaliculi. This is so, because these fine tubes are so arranged that they always enter the sac obliquely, thus causing the fold of membrane at the entrance to become almost valve-like when any distention is brought to bear upon the walls of the cavity. It is by no means necessary that there shall be complete closure of the lower part of the duct to have very great distention of the sac, as the walls of the latter, being softened by inflammation, give way readily to slight pressure in those parts where they are covered only by the orbicularis muscle, and by the muscle of Horner. Owing to obstruction of the lower part of the duct, the sac is insufficiently emptied into the nose at each act of winking, so that as soon as each pressure of the orbicularis muscle relaxes, fresh fluid flows in from the conjunctival sac to replace the small quantity that has been driven out. It has long been known that the regurgitation of the mucoid and purulent fluid contained in catarrhal lacrymal sacs into the conjunctival sac exercises a deleterious influence in many inflammations of the eyes. Especially is this so in those conditions, where there is any ulceration of the cornea or where any cut has been made into its substance, either accidentally or as part of an operation—as, for instance, cataract and iridectomy. The researches of Sattler have shown that this harmful effect is probably due to the fact that the contents of the distended lacrymal sac form a favorite breeding-place for various sorts of micrococci—especially for the *staphylococcus pyogenes aureus*, thus giving an excellent opportunity for directly infecting any corneal abrasion.

The formation of the face has a great deal to do with the calibre of the lacrymal passages, and with the liability to obstruction. It is asserted that individuals with the flat scaphoid type of face, and eyes

that are widely separated, are peculiarly disposed to lacrymal disease. It is certain, however, that such affections are often found in subjects with narrow faces and prominent noses. Nevertheless, it is evident, at times, that anatomical formation favors the development of such diseases, because in cases where the face is unevenly developed and the nose is turned to one side, lacrymal obstruction is often found on the side where the ducts are the narrower; the other side remaining free. It has long been known that catarrh of the nasal passage frequently precedes and causes a similar condition of the lacrymal duct, but chronic inflammation of the conjunctiva may often exist, however, for a considerable time without any evidences of lacrymal obstruction. In some cases,

FIG. 340.



Abscess of lacrymal sac. (DALRYMPLE.)

catarrhal distention of the lacrymal sac lasts for years without causing the patient any marked annoyance beyond weeping of the eye and the occasional necessity of evacuating the contents of the sac by pressure. In other instances, owing either to gradual extension of inflammation to surrounding parts or to ulceration of the sac itself and the sudden infection of the surrounding connective tissue, rapid swelling is found at the inner angle of the eye, with redness and tumefaction of the lids that is associated with intense pain in the inflamed region and its vicinity. Fig. 340 represents an example of this form of disease.

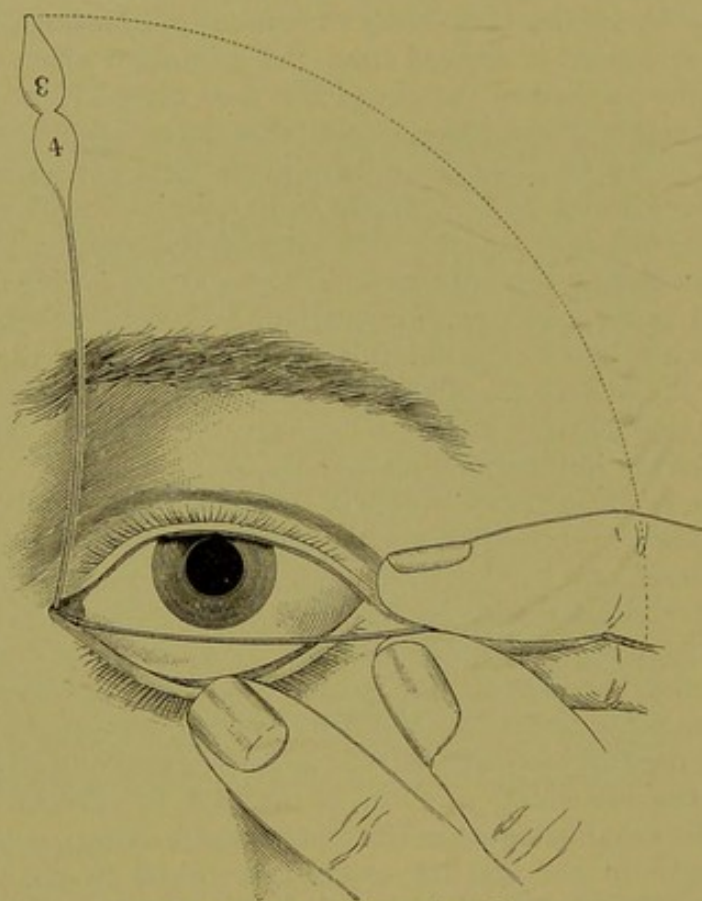
In such cases, purulent inflammation may be established, the abscess usually pointing just below the tendon of the orbicularis muscle. This is known as *dacryocystitis*, or *lacrymal abscess*. If the inflamed parts in such a condition are undisturbed, the skin ulcerates over the point just indicated, and a portion of the contents of the sac escapes through the opening, leaving an irregular and tortuous passage between it and the lacrymal sac. This is known as *fistula of the lacrymal sac*.

Treatment should begin by gentle pressure on the lacrymal sac with the pulp of the finger, thus forcing the contents of the sac either into the nose or into the conjunctival sac. The conjunctiva should then be thoroughly cleansed with a solution of boracic acid or bichloride of mercury, the lids being manipulated with the finger so as to induce some of the fluid to enter the lacrymal sac. This procedure is to be followed by the employment of some of the astringents that are ordinarily used for chronic conjunctivitis, such as sulphate of zinc and baborate of sodium. Where there is conjunctival blennorrhœa, the application of one- or two-grain solutions of nitrate of silver to the membrane by means of a swab of cotton, is advantageous. In many cases, much benefit is derived from the stimulant effect of heat. This can be easily applied on the closed lids over the position of the lacrymal sac, by pledgets of absorbent cotton that have been immersed in hot water. The applications should be made for a period of ten minutes two or three times daily. If the Schneiderian membrane be simultaneously affected with catarrh, advantage may be derived from cleansing it and stimulating the mucous membrane at the orifice of the duct, by carrying a probe armed with a small wad of cotton that has been saturated with a solution of bichloride of mercury, along the lower meatus back into the pharynx. The effect thus obtained, may often be advantageously augmented by the astringent action of the fluid extract of sumach berries, applied in a similar manner.

In cases of long duration, it will be necessary to aid these measures by the stimulating effect of small probes on the mucous membrane of the duct itself, and by the direct application of astringent washes. The probing should always be done gently and with Nos. 1 to 4 of Bowman's series. If the application be followed by even a few drops of blood, it is certain that the delicate and inflamed mucous membrane has been injured, or that the time of application has been improperly chosen—while the lining membrane of the duct is still too vascular and inflamed. To facilitate the introduction of the probe, and to prevent torsion of the tissue of the canaliculus when the instrument, having passed the distance of its length in the smaller conduit, is raised to enable it to follow the course of the lacrymal duct, it is best to slit either the upper or the lower canaliculus by the introduction of a probe-pointed Weber's knife. The canal is thus converted into an open groove, which is hidden from view and is immersed in the tears that accumulate in the lower part of the conjunctival sac upon the lower canaliculus when the lid is in place. This operation can be best done by raising the handle of the knife and cutting through the upper inner part of the canal into the conjunctival sac. When the upper canaliculus is to be cut, the handle of the knife should be depressed and the incision made down and in. In many cases, the procedure presents no difficulty. In some instances, however, the lacrymal point is so contracted that a magnifying-glass must be used to find it before it can be dilated with a pin or small conical probe. In any case, the opening of the duct is more easily effected when the orbicularis muscle is put on the stretch by pulling on the overlying skin at the outer canthus. Most surgeons prefer to open the lower canaliculus. The slitting of the canaliculus having been accomplished,

and the lid still being kept on the stretch, one of Bowman's probes should be so introduced that its point slides along the anterior wall of the little artificially-made groove, till it reaches and enters the lacrymal sac. The sensation of the hand guiding the probe usually gives information as to when entrance into the sac has been made. If there is any uncertainty, the instrument may be advanced till it comes in contact with the inner wall of the sac, at the groove of the lacrymal bone. When this situation has been reached, the point of the instrument is

FIG. 341.



Method of inserting Bowman's probe.

slightly retracted, its outer end elevated and its inner extremity gently coaxed down into the nose through the nasal duct. The course of the duct and the proper position of the instrument is best ascertained by the operator drawing an imaginary line from the centre of the tendon of the orbicularis muscle to the fold of skin that is situated between the ala of the nose and the cheek. He should remember that when the point of the probe is in proper position, it will lie on the floor of the nose about one and a quarter inches behind the lower extremity of this line. When the operation is carefully done, a small quantity of tears generally flows into the nose alongside of the probe, causing many patients to use their handkerchief and to be conscious that that side of the nose has become wet. The probe should be allowed to remain in position for from five minutes to half an hour, the time varying with the sensitiveness of the canal and the feeling of pressure and discomfort. It should

be withdrawn slowly and gently. Fine probes may ordinarily be introduced through the intact punctum and canaliculus. This method of treatment was advocated and practised by Travers and by Hays. The disadvantages consist in the torsion of the tissues surrounding the canaliculus, and the fact that as the patient usually contracts the orbicularis muscle and thus grips the probe and holds it with more or less force, accurate judgment as to how much of the resistance is due to this cause and how much to stricture of the duct itself, is hindered to some extent. The method of introducing a lacrymal probe through the lower canaliculus is graphically shown in Fig. 341. The lower lid having been firmly but gently pulled downward and outward, so as to put the lower canaliculus on the stretch, the point of the probe is engaged in the punctum. This having been accomplished, the distal end of the probe is lowered and the point pushed upward and toward the median line until it enters the lacrymal sac. The lower lid is then released and the handle of the probe is rotated upward (as shown by the dotted lines) till the instrument assumes a vertical position. The point is then gently pushed downward in the direction of the lacrymal duct until it reaches the floor of the nose.

In many instances, much can be done to hasten a cure by careful and thorough washing of the duct. This is best effected by introducing a hollow probe that is equivalent in size to a No. 2 or No. 3 of Bowman's series, and forcing fluid through it from the nozzle of a small syringe that has been inserted into its upper end. Then, whilst gently withdrawing the probe into various positions, the syringe should be repeatedly filled and emptied, thus insuring a thorough cleansing of the entire length of the sac. Solutions of chloride of sodium, boracic acid, bichloride of mercury, sulphate of zinc, peroxide of hydrogen, and dilute glycerole of tannin, are among the best applications. In very chronic cases, where there is a persistent purulent discharge, a one-half-grain solution of nitrate of silver is admissible. It should be remembered, however, that this drug is likely to cause severe inflammatory reaction in cases that are not properly selected. In any case, the solutions should be of less strength than those which can be safely applied to the conjunctiva. This is so because the mucous membrane of the sac cannot be inspected and any excess of the application cannot be readily washed off.

In most instances, the disease is chronic and relapses are frequent. The patients, as a rule, are much less annoyed in summer by the tears running over the cheeks. In winter or in bleak, blustery weather, there is an aggravation of the affection.

In the scrofulous, much may be gained by improving the general nutrition of the patient by iodide of iron and other appropriate tonics. In the syphilitic, and even in many cases where no such taint is demonstrable, iodide of potassium is useful. Several writers, notably Weber in Germany, and Theobald in this country, have advocated the use of large probes in the treatment of lacrymal affections. The author does not share their views, and would advise the avoidance of all probes larger than No. 6 of the Bowman series. He believes that such affections are best treated by the means above indicated, and that, in most cases, a

No. 4 probe is sufficient. Where the patient cannot be seen frequently, the introduction of styles of lead wire or catgut into the lacrymal duct is sometimes advantageous. As dacryocystitis is usually accompanied by intense pain, that can be promptly allayed by evacuation of the abscess, this in many instances can be readily accomplished by slitting the canaliculus with a Weber's knife and freely dividing the entrance into the lacrymal sac. In cases where the abscess has pointed, it is best to open it from the outside. This may be done by making a small incision with a scalpel or a straight bistoury just under the tendon of the orbicularis muscle. In performing this, the handle of the instrument is held so as to bisect an imaginary line that is drawn from the ala of the nose to the external canthus. The knife is then carried back till its point touches the lacrymal bone, and is slightly retracted, thus causing its outer end to be elevated almost to a vertical position and permitting the blade to readily slip into the nasal duct. The suppurating sac should be carefully washed daily. The fistula on the cheek is to be kept open till the inflammation subsides. After inflammation has ceased, careful probing should be attempted, and the treatment previously described, instituted. As soon as the swelling of the mucous membrane has disappeared and the duct has become patulous, the opening in the skin will readily close.

When treatment of confirmed and chronic cases is unavailing, and the patients are subject to recurrent inflammation, it is customary to attempt obliteration of the sac. This may be performed by either dissecting out the upper part of the sac, or destroying it by nitrate of silver, caustic potash, or the galvano-cautery. Treatment by any method, however, gives rise to subsequent retraction which is apt to leave an unsightly scar. To remedy this disfigurement and to put a permanent stop to lacrymation, Zachariah Lawrence advised the extirpation of the tear-gland. Most surgeons, however, think the severity of the operation to be disproportioned to the results that are obtained. Of late years, Wecker has proposed a substitute for this operation which seems to promise as good results from a less extensive procedure. He everts the lids, seizes the conjunctiva which covers the prolapsed subsidiary gland with toothed forceps, and dissects it off. After this is done, he excises the little lobules and the emissary ducts of both the subsidiary and the main glands, with a hook, as they successively make their appearance. In this operation, the wound is confined to the conjunctival sac and heals readily.

CHAPTER XXVIII.

DISEASES OF THE ORBIT.

ALTHOUGH diseases of the orbit form but a small proportion of those that come under the notice of the ophthalmic surgeon, yet they are important by reason of the difficulties of diagnosis and the danger with which many of them are fraught to life and eyesight.

By reference to Fig. 20, it can be seen how a very slight increase in the volume of the orbital contents will, by pressure on the unyielding walls, cause the eyeball to push the eyelids forward, and how, if the swelling be continued, the eyeball will separate the lids and project in front of them.

Periostitis of the orbit may be either acute or chronic. The latter form is the more frequent, being especially seen among young scrofulous subjects. The symptoms consist in dull pain in and around the orbit, swelling of the lids, and painful or impeded motion in the eyeball. The eyeball itself is prominent and tender to the touch, this tenderness being usually intensified and localized near the diseased portion of the bone. In the acute variety, these symptoms are more intense, and are frequently accompanied by general disturbance, such as dizziness, fever, and vomiting. In severe cases, there is a marked tendency to the involvement of the entire orbital tissues and to the formation of abscess. When the disease is chronic, the swelling is often hard to the touch, but slightly movable on its base, and accompanied with moderate exophthalmus. On opening the abscess, exit is given to a small quantity of thin sanious pus. If a probe be introduced into the opening, it will encounter thickened periosteum, and at times, some small areas of bare carious bone.

In acute cases, hot fomentations should be used. If pus be present, an incision should be made with a bistoury so as to give vent to it, the opening thus produced being kept patulous by drainage-tubes. In cases which have been either intentionally or spontaneously opened, the same free drainage, accompanied by frequent cleansing with warm solutions of boracic acid, should be resorted to. If probing be necessary, great care should be taken to have the instrument and the fingers chemically clean. Care should also be exercised to avoid all violence during the use of the probe, and in the removal of small sequestra, as there may be a likelihood of thus inducing general orbital cellulitis or meningitis. Constitutionally, quinine should be freely administered. Where there is caries in the young and scrofulous, iron and cod-liver oil should be exhibited.

Cellulitis of the orbit. Inflammation of the connective tissue of the orbit may be either slight or severe. In the former variety, there are only slight protrusions of the eye and diminution of mobility; such

cases often ending in resolution. In the latter form, there is intense pain in and around the orbit and in the branches of the trigeminus of the affected side. The lids are swollen, oedematous, and of a dusky red hue. The eyeball protrudes either in the direct axis of the orbit, or, more often, is pushed over to the lower inner side by the swelling of the lacrymal gland. There is dizziness and fever. When the exophthalmus is great, there often is partial dilatation of the pupil and diminished sensibility of the cornea. This is owing to involvement of the ciliary nerves. In the early stages of the disease, sight is usually but little affected. Later, it is frequently much lessened, and often is entirely lost.

According to the part of the optic nerve that is most involved, there will be relative variations in the ophthalmoscopic appearances. If the nerve-disturbance be far back, any recognizable intra-ocular changes are often wanting during the first stages of the disease. If the nerve be affected at the entrance of the central vessels or at its insertion into the ball, there may be intra-ocular neuritis. If the central vessels are mainly affected, thickening of their coats, with hemorrhage into the retina, may manifest itself. Should the point of attack be situated farther back, the appearances of retro-bulbar neuritis are more generally present. In any case, complete atrophy of the optic nerve may follow at a later stage.

In some instances, the eyeball is destroyed by sloughing of the cornea. In others, a general suppurative inflammation of its interior takes place. Again, in some fortunately rare cases, gangrene of the lids, eyeball, and orbital tissues ensues. Almost every practitioner has had occasion to observe that there are oedema and swelling of the lids and orbital tissues in all cases of suppurative panophthalmitis. Although this may be slight in degree, yet its existence points to the danger of the disease spreading along the vessels and giving rise to thrombosis of the ophthalmic veins and of the sinuses of the dura mater: conditions that may be followed by fatal meningitis. This sequence of events is sometimes reversed, the orbital cellulitis being produced by intra-cranial disease causing thrombosis of the ophthalmic and retinal veins. Septic infection, as, for instance, in the course of puerperal fever or after surgical operations, is one of the causes of severe orbital cellulitis. As already stated, it often follows periostitis of the orbit, and may be caused by fractures of the orbital walls or by punctured wounds of this region. Facial erysipelas is one of the most frequent causes of orbital cellulitis, and even after comparatively slight attacks, vision may be found either much impaired or entirely abolished after subsidence of the swelling of the eyelids. Fortunately, however, swelling and inflammation of the eyelids are usually the principal ocular symptoms in facial erysipelas, it being exceptional to find the disease attacking the connective and fat tissues of the orbit and giving rise to orbital cellulitis.

If the inflammation has reached the suppurative stage, warm fomentations, with early but careful incision into the abscess, followed by drainage and frequent washing with warm boracic acid solutions, is the best treatment. The utmost gentleness is requisite in cleansing the

suppurating tract. In making the incision, the bony walls of the orbit cannot be too carefully followed, as disregard of this precaution may readily lead to a wound of the eyeball; an accident that would destroy all chances of recovery with good eyesight, and perhaps render immediate enucleation of the eyeball necessary.

Tenonitis (*inflammation of the oculo-orbital fascia*) is characterized in some cases by pericorneal injection, thickening of the sub-conjunctival tissue, slight prominence of the eyeball, and pain on moving the eye or on pressing it back into the orbit. In such cases, the media remain clear, and there is no trace of iritis or chorioiditis. The disease is rare, seemingly following colds or slight attacks of idiopathic facial erysipelas. Wecker¹ speaks of a case of gummatous capsulitis. The traumatic variety is the most frequent, it being exceptionally encountered after operations for strabismus. Several instances are reported by Mooren, Bull, Wecker, and Noyes.

Hæmatoma, or spontaneous hemorrhage into the orbit, is so rare as to be among the curiosities of ophthalmic literature. One of the most noted is the case reported by J. N. Fischer,² in which an amaurotic eye that had been exophthalmic for several years, was removed on account of increase of proptosis and excessive pain. The exophthalmus first appeared after suppression of the menses. The enucleated orbital tissues were examined by Rokitansky, who found them to be infiltrated with recent and old hemorrhages, some of the latter being encapsulated in dense cysts. Effusion of blood into the orbital tissues following traumatism are not uncommon. Almost every operator has occasionally seen sufficient hemorrhage occur when the optic nerve is divided in enucleation, to fill the capsule of Tenon and to cause the lids to become prominent and closed. Similar symptoms are recorded as having taken place during operations for strabismus. Hemorrhagic effusions may follow penetrating wounds of the orbit, which are either with or without fracture of the orbital walls. They are frequent and early symptoms in cases of the latter affection. Where there is fracture of the walls of the orbit, there is sudden exophthalmus, that varies in degree with the sanguineous suffusion of the retrotarsal fold and conjunctiva. On the other hand, the late appearance of the ecchymosis of the upper lid, as previously described, is a frequent symptom of fracture of the roof of the orbit. According to Friedberg,³ hemorrhages into the orbits and eyelids without any fracture of the orbital walls, are frequently found in the bodies of infants that are born in severe labors. Especially is this so where the forceps has been employed. Bergmann⁴ asserts that such hemorrhages are frequent after blows on the eye or on the frontal or maxillary regions. According to Berlin,⁵ they exist almost invariably wherever a fracture is more than a mere fissure. This assertion is confirmed by statistics of Hölder, which show that in one hundred and twenty-four wounds of the cranium, examined by him,

¹ *Thérapeutique Oculaire*, 1879, p. 721.

² *Lehrbuch der gesamten Entzündungen und organischen Krankheiten des menschlichen Auges*, 1846, S. 359.

³ *Zur Entstehung und Diagnose der Fractur des Orbitaldaches*, Virchow, Archiv, xxxi, S. 362.

⁴ *Verletzungen der Knochen des Schädels*. Im Handbuch der allgem. Spec. Chirurgie, Billroth, iii, 1.

⁵ *Graefe u. Saemisch*, vi, 569-572.

there were seventy-nine orbital fractures. Sixty-nine of these had intra-orbital hemorrhage, while the remaining ten showed only thin layers of blood that were situated between the bone and the periosteum. Almost all authors agree with Berlin, when he insists on the great prognostic importance of such hemorrhages, and asserts that all such cases are serious, and that those accompanied by fracture of the roof of the orbits almost invariably end fatally.

Tumors of the orbit, although most diverse in character, have this in common, that as soon as they acquire any considerable size, they cause protrusion of the eyeball and limitation of its movements. Encephalocele and angioma are congenital. The most common malignant varieties are sarcoma, carcinoma, fibro-sarcoma, and myxo-sarcoma. Cylindroma and enchondroma are rare. Osteomata, which may be periosteal, of either the cancellous-tissue or the dense-ivory variety, are seldom encountered. Echinococcus and the cysticercus are the most frequent of the parasitic tumors. Vascular tumors also present themselves, the most common being angioma, and that which is characterized as pulsating exophthalmus. Where prominence and limitation of the movements of the eye, with absence of inflammatory symptoms, give suspicion to the presence of a tumor, careful note as to the extent of protrusion of the eye, and the degree and direction of limitation of its movements, should be made. The tissues should be palpated to ascertain if the eye can be pushed back into the orbit to any degree.

Note should be taken whether there is any pulsation, or purring feeling communicated to the palpating finger. Careful auscultation should be made to determine whether any bruit can be detected. In some instances, palpation will reveal in which part of the orbit the growth is most prominent. Occasionally, where the tumor has attained considerable size, it will determine whether the growth is hard or soft, and whether its surface is smooth, bossellated, or rough.

As the starting-point of such tumors is often found in some of the adjoining cavities of the skull, such as the antrum or the ethmoidal sinuses, an extended and rigid examination of the nose and the roof of the mouth is necessary. Where no tumor can be felt, and where the eye is projected directly in the axis of the orbit, there is ground for supposing that the growth is situated within the funnel-shaped space enclosed by the straight muscles of the eye. In such a case, it is possible that the growth springs from the optic nerve. In all cases of orbital tumor, where the media are not too cloudy, an ophthalmoscopic examination should be made, as the data thus obtained, frequently aid in forming a correct diagnosis. In the opinion of the author, all exploratory incision, even if done with the aspirating-needle and under aseptic precautions, should be avoided unless both patient and physician are prepared, if necessary, to enter at once upon more serious operative procedures. Perhaps no more illustrative example can be cited of the difficulty of diagnosis in these cases than the famous instance of the Austrian Field-Marshal Radetsky.¹ At the age of seventy, the patient had undergone considerable fatigue and exposure in the autumn manœuvres of troops.

¹ Friederich Jaeger : *Annales d'Oculistique*, xxiii. 14.

At this time, he was seized with fever and violent pain in the forehead and temples, which was accompanied by inflammation of the right eye and eyelids. Upon the subsidence of these symptoms, a tumor formed at the inner angle of the orbit. This was followed by another growth that presented itself at the outer angle. Three months later, Flarer and Jaeger were consulted. At that time, they found complete exophthalmus, with an orbital tumor which was stony hard, and uneven, and bossellated. The conjunctiva was inflamed and bathed in sanious mucus. Both the above-mentioned experts decided that the conditions were probably dependent upon a malignant scirrhus growth. The course of the case, however, showed it to be an abscess, which, after breaking and discharging its contents, allowed the eye to sink back into its socket.

Angioma and pulsating exophthalmus. Angiomata are usually congenital. They are often associated with naevus of the eyelids. They do not pulsate, have no bruit, are painless, and increase in size slowly. When, however, the patient is made to hold the head for some time in a dependent position, they become decidedly larger. They are thus distinguished from cases of pulsatile exophthalmus, where, in addition to pulsation, a purring and thrill which are perceptible both to the finger and to the ear, simulating aneurism, are often found. Anatomical examination of cases of pulsatile exophthalmus, by Nunneley and Sattler, has generally shown the existence of a rupture of the internal carotid artery in the cavernous sinus, and not an aneurism of the orbit. Such a rupture enormously distends the ophthalmic and other orbital veins, causing them to pulsate.

Digital compression of the main trunk of the carotid artery in the neck should always be thoroughly tried before ligature of the artery is resorted to. One of the most instructive cases of cure is that reported by G. C. Harlan. The patient, a railroad conductor, would sit down in the car and compress his own carotid during every interval that relaxation from duty would allow. In the course of a year, a perfect cure was obtained. Not only all pulsation and thrill disappeared, but all subjective noises ceased. Sattler, however, asserts that while intermittent pressure will, at times, effect a cure in idiopathic cases, no result can be obtained in traumatic ones except by rest and prolonged and continuous compression.

Osteomata of the orbit are comparatively rare. They are usually painless, and of very slow growth. Consequently, they do not urgently call for removal, except for consequent deformity, or for the ocular pain and inflammation that they exceptionally produce. When the latter symptoms set in, the patient may sometimes be relieved of his discomfort by removing the eyeball without touching the tumor. This procedure is more apt to be advisable where the tumor is situated far back in the roof of the orbit. Any attempt to remove a growth from the roof of the orbit is likely to fracture the exceedingly thin plate of bone composing this portion of the cavity, and to produce a meningitis that is apt to be fatal. Where such growths spring from the floor of the frontal sinus, operative interference is much less dangerous. Berlin¹ has

¹ Graefe u. Saemisch, vi., S. 730.

collected thirty-two cases in which extirpation of orbital osteomata has been performed. Of this number, eight died (*i. e.*, twenty-five per cent.). In the sixteen cases of this series, in which the growth was situated in the roof of the orbit, six died, thus giving a mortality of thirty-eight per cent. The cause of death in these latter cases was a meningitis and an encephalitis, that were often associated with a considerable abscess in the brain-substance near the seat of operation. In the remaining sixteen, but two died, thus showing a decrease of mortality to twelve and one-half per cent. These facts, except in those cases where fracture of the orbital plate would simply result in opening the frontal sinus, make the author agree with this writer, when he advises that an operation for the removal of an osteoma should be avoided when the growth is situated on the upper wall of the orbit. Osteomata on the floor of the orbit, especially if of sufficient size to have produced exophthalmus and blindness from atrophy of the optic nerve, may be readily removed. This is to be done by first enucleating the eyeball, then dissecting the periosteum from the base of the orbit and breaking up the tumor with light and repeated blows by the chisel and mallet. If preferred, a dental engine may be used to drill holes into the growth before it is broken up. Where the growth is situated more anteriorly, the eyeball may, at times, be successfully retained. If the growth is dense and ivory-like, it may sometimes be shelled out with more readiness than supposed, after opening and dissecting off the periosteum and enveloping fibrous capsule. More frequently, however, the attached base is of such considerable extent, and the tissue is so extremely hard, that it is difficult to separate the tumor. In making the incision to lay bare the tumor, injury to the intra-orbital nerves and to the tissues of the orbicularis and levator palpebræ muscles should, as far as practicable, be avoided.

Dermoid cysts of the orbit are generally congenital, unilocular, and of slow growth. As a rule, they contain fatty matter of various degrees of consistence, this sometimes being mixed with hairs. They are ordinarily supposed to be of foetal origin, caused by the infolding of the external layers of the embryo. Wecker, however, considers them as having their development as retention-cysts in the substance of the skin, and mentions two cases in which he has seen a fibrous band connecting them with the integument. They are benign, and, upon account of their situation in the orbital fat outside of the funnel formed by the external muscles of the eyeball, they are generally readily removed. It is said that where they are neglected and are allowed to become very large, they may form attachments to the eye-muscles or the eyeball. At times, they may even invade some of the neighboring cavities. No instance, however, is recorded of their having worked their way into the cranium.

The prognosis of orbital tumors depends upon their character, position, and size. In some instances, where the growth is small and benign—as, for example, in the dermoid cysts just described—it may be removed without material damage to the eyelids or any danger to the eyeball. In the majority of instances, however, where it has attained a considerable size, enucleation of the eyeball or exenteration of the orbit is necessary. In some desperate cases, the eyelids or

large portions of them will, in addition, have to be sacrificed. In such an event, a plastic operation, to cover in as best able the gaping cavity left by the operation, must be resorted to.

Exophthalmic goitre; Cardiac exophthalmus (Graves's disease; Basedow's disease) is a most serious malady. Its principal symptoms may be divided into three groups: First, increased action of the heart, with a tendency to dilatation of the veins of the face and the neck; second, protrusion of the eyeballs, with diminished frequency of the natural winking motion; third, enlargement of the thyroid gland. Not all of these groupings are necessarily present in any given case. Sometimes, the rapid and tumultuous action of the heart with exophthalmus is found without goitre. In other instances, the disturbance of the heart's action and the goitre are present without the exophthalmus. In fully-developed cases, the symptoms are very striking. The eyes are protuberant. The upper lids are so retracted that the conjunctiva above the corneæ becomes apparent, giving the patient a peculiar stare and a frightened look. Enlargement of the thyroid, with marked pulsation in the carotids, a rapid feeble pulse that becomes more frequent and is accompanied by increased rapidity of respiration, and a tendency to flushing of the face on any slight mental or physical exertion, are also present. In the early stages of the disease, the eyeball is usually moderately protruded, though it can be replaced into position by gentle pressure on the closed lids. As soon as the pressure is removed, however, it again comes forward. In more advanced cases, probably owing to increased density of the orbital fat and of the connective tissue, this mobility is lessened.

Under these circumstances, a loud bruit from the enlarged vessels within the orbit can often be heard by placing the ear on the closed lid. Even where the exophthalmus is slight and the motions of the eyes are nearly normal, the retraction of the upper lids gives the countenance a most peculiar aspect. The relation between the action of the muscles turning each eye downward and that of the orbicularis muscle in closing the lid, is altered, causing the upper lid to lag when the patient looks downward. This is known as *Graefe's sign*. The diminished frequency of the ordinary involuntary closure of the lids, allows the conjunctiva to become red and irritated, thus producing a low grade of conjunctivitis and complaints of dryness of the eyes. If the exophthalmus be more pronounced, the lids often fail to close over the eyes during sleep. In such cases, the corneæ become irritated, inflamed, and may ulcerate from drying and from the presence of minute foreign bodies. The inflammation may even spread to the iris and chorioid, producing panophthalmitis. Basedow relates a case in which both eyes were thus lost, the sightless stumps, which were covered with crusts of dried mucus and pus, projecting into the palpebral tissues. When the cornea has not become inflamed from exposure, the pupil is normal in size, the iris is prompt in action, and accommodation remains unimpaired. In some cases, the ophthalmoscope shows perfectly normal disks. In others, there is an undue dilatation of the arteries and veins, the former being the more affected. Becker describes cases in

which there was an arterial pulse, with an increase in the tortuosity of the arteries at each systole of the heart.

The vessels of the neck are enlarged and beat violently. The thyroid is swollen in greatly varying degrees, and a pulsatile movement and a distinct purring sensation can be felt in most cases when the hand is gently applied over the gland. This form of goitre is usually softer, freer from cysts and hard masses, and is less in size than thyroid tumors that are due to other causes. The heart is tumultuous in its action, and the cardiac dulness often extends over a larger area than usual. A blowing systolic sound is heard most distinctly over the apex of the organ, and the heart-beats generally range from ninety to one hundred and twenty in the minute. The radial pulse is usually feeble. The patients are weak and cachectic, and, although very acute cases have been recorded by Mackenzie, Förster, Trousseau, and others, the disease is ordinarily slow in development. Females and adults are more frequently affected than males and children.

In spite of the fact that many complete recoveries are reported, prognosis is serious. Death seems to be less frequently due to the progress of the disease than it does from intercurrent affections. According to Sattler, the lethal causes ordinarily recorded are general debility, dropsy, apoplexy. Less frequently, hemorrhage from the lungs or the intestines is given as the cause of death.

The pathology of the disease is not yet well made out by autopsies. That it is primarily a disorder of the nervous system, with paresis of the sympathetic fibres causing dilatation of the bloodvessels, which is usually most marked in the orbit and in the neck, seems probable. That there may be a diminution of the inhibitory action of the vagus on the heart, is plausible. Thus far, however, no characteristic changes have been found in the regions of the cerebrum that give origin to these nerves. The sympathetic ganglia of the neck have sometimes been found to be enlarged and unduly vascular.

Treatment of the eye-symptoms consists in first combating the conjunctivitis by the use of solutions of boracic acid. Should the eye remain open during sleep, closure of the lids should be effected by a proper bandage. In chronic cases, permanent diminution of the fissure of the lids by tarsorrhaphy tends not only to protect the cornea, but also to free the patient from the peculiar expression of alarm that is so common in such cases.

The constitutional treatment consists in mental and bodily rest, with change of air and surroundings. Nutritive food, iron, quinine, and heart and bloodvessel tonics, such as digitalis and strychnine, should be exhibited. Many authorities assert that iron should be avoided where the increased action of the heart is very decided. Trousseau advocates the use of digitalis in doses that are sufficient to reduce the pulse markedly below normal.

CHAPTER XXIX.

SOME OF THE MORE COMMON AND IMPORTANT OPERATIONS ON THE EYE.

IN order to avoid useless repetition regarding the operative treatment of various eye-diseases, a concise description of those operations on the eye which are most frequently performed is here presented, with a few remarks as to the difficulties and accidents which are liable to be met with in undertaking them.

Before performing any operation on the eye or its appendages, strict aseptic precautions should be observed. The hands of the operator and his assistants should be thoroughly washed with Castile soap and water. The nails should be cleansed with a brush, and the hands should be rinsed with a one-part-to-four-thousand solution of bichloride of mercury. The instruments, which are to be kept always clean, sharp, and polished, should have their edges tested and be immersed in a bath of absolute alcohol until needed. During the operation, as the instruments are removed from their bath and handed to the operator, they should be wiped dry with absorbent cotton that has been wetted with alcohol. Some surgeons prefer to disinfect their instruments by keeping them in an oven containing dry heat that is sufficient to destroy bacilli. This, however, is apt to interfere with the keenness of the delicate cutting edges of the knives.

The face of the patient should be well washed with Castile soap and water, this being repeated with a solution of one part to four thousand of bichloride of mercury. In operations on the eyeball, and in those involving the conjunctiva, the conjunctival sac should be thoroughly cleansed by the free use of a ten-grain solution of boracic acid, followed by a one-to-eight-thousand solution of bichloride of mercury. In many cases, it is necessary to repeat this proceeding either during the operation or at its close.

As a rule, in major operations on the ball of the eye, where it is desirable to keep the eye quiet after the operative procedure, it is best to close both eyes by the use of bichloride gauze and cotton, and to immobilize them by a light bandage. A single bandage placed over the operated eye is sufficient for many cases of minor character. For operations on the eyelids, iodoform, aristol, lint saturated with carbolized oil, or colorless vaseline dusted and smeared under an antiseptic bandage, are generally the best applications.

It must, however, be admitted that the eye is a very unfavorable field for the practice of aseptic surgery. This is mainly owing to two causes: first, the canaliculi place the conjunctival sac in direct communication with the lacrymal sac and the nasal cavities, so that the field of operation is constantly liable to infection by the bacilli and micrococci which inhabit

these situations; second, the great sensitiveness of the anterior segment of the eyeball and of the conjunctiva renders it impossible to use bichloride of mercury and other antiseptics in the strength that are employed on other parts of the body, without producing pain, irritation, and congestion. The influence of the first cause, which has become well understood since the rise of aseptic surgery and the study of the micro-organisms of the tear-passages and conjunctival sac, has long been familiar to eye-surgeons, however, through the increased risk of operations for cataract and iridectomy in the presence of lacrymal obstruction.

In removing *chalazia*, it is generally best to allay pain by instilling cocaine into the conjunctival sac. At the same time, a quantity of the anæsthetic may be injected under the skin of the lid by the aid of a hypodermatic syringe. A Desmarres forceps is then to be placed over the lid so that the imperforate blade is situated in the conjunctival sac, and the growth surrounded by the fenestrated blade. The two blades of the instrument are now sufficiently approximated by the screw as to compress all the surrounding bloodvessels, and thus prevent hemorrhage. An incision, parallel with the fibres of the orbicularis muscle, and extending a slight distance on each side of the growth, is next to be made over the tumor with a scalpel. The orbicularis muscle is seized with the forceps and divided. The cut edges of the skin and muscle having been pushed to one side, and the glistening, whitish sac of the chalazion laid bare, a sharp hook is introduced into the growth, which is then slightly pulled forward, thus enabling the tumor to be readily dissected out. The cut edges of the skin are united by two or three sutures of fine black silk. The clamp is now removed, this procedure being followed by the escape of a few drops of blood, which are readily stopped by slight pressure.

In cases where a red spot with enlarged papillæ is seen on the conjunctival surface, it is certain that the adhesions to the conjunctiva are so close that it will be impossible to dissect the chalazion out without button-holing that membrane. Where the tumor has opened into the conjunctival sac, the incision into the growth should be made through this membrane. This should be done in the direction of the Meibomian glands. The contents can then be pressed out with the fingers, and the walls scraped with a curette. Some surgeons prefer this method of treatment in all cases. Where the operation is done by external incision the wound should be dressed with bichloride gauze that has been freshly steeped in a one to four thousand solution of bichloride of mercury. This dressing should be covered with aseptic cotton, the whole being retained in place by a tight bandage. The sutures may be removed on the second day.

Trichiasis; Distichiasis. To relieve the discomfort caused by the misplaced lashes, epilation is often successfully resorted to by the patients or their friends. The operation requires frequent repetition, and often it is very difficult to see and seize the small whitish and distorted cilia. Splitting the lower lid into two layers at the point where the faulty lashes grow, and excising the outer layer in which they are imbedded, is often practised. The resultant cicatrization, however, is apt to cause irregularity in the position of the remaining cilia. Where the misplaced

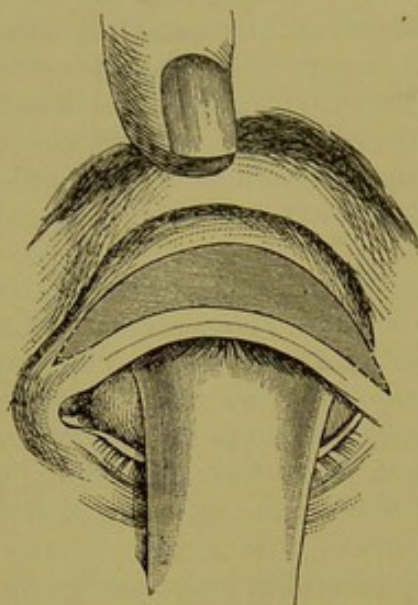
lashes are few in number, electrolysis is probably the best means of getting rid of them. A fine needle attached to the negative pole of a galvanic battery is introduced carefully into the hair-bulb. The circuit is completed by causing the patient to grasp a wet sponge connected with the positive pole, or by applying it to his temple. If the operation be properly performed, a slight bubbling and escape of white froth along the needle will show that the intended purpose is accomplished. The hair is then to be seized with a pair of forceps and quickly withdrawn. In the majority of instances, a single operation will suffice. Occasionally, however, it becomes necessary to repeat the procedure. Electrolysis thus applied, appears to cause more pain than when performed in any other part of the face.

Snellen has introduced an ingenious method of snaring misplaced cilia and making them grow out of the skin of the lid above their normal position. To effect this, a needle armed with a loop, made by carrying both ends of a silk thread through its eye, is carried into the aperture of the hair-follicle and brought out through the skin above. Before pulling the loop through, care is to be taken to see that the cilium is caught in it, so that the lash may be imbedded in the desired position in the skin.

Entropium. As this condition is usually caused by contracting cicatrices in the tissues of the conjunctiva and tarsus that are due to granular conjunctivitis, severe cases are difficult to remedy by any operation. In fact, the imperfect success which often attends even the best-directed efforts, is shown by the numerous operations that are brought forward by different surgeons. Usually, these procedures are intended either to transplant or remove the entire portion of the lid which carries the eyelashes, or to turn it outward and upward. The operator will have to decide on the plan of treatment which, in his judgment, is best adapted to remove the deformity in each case. The operation which, in average cases, has yielded the best and most lasting results in the hands of the author, is the Jaesche-Arlt method of transplanting the outer margin of the lid. To perform it, a horn spatula is introduced beneath the lid and held by an assistant in such a manner as to keep the lid in a state of slight tension. The operator, with the thumb of one hand, now pulls gently on the skin, so that the position of the cilia and the orifices of the Meibomian glands can be seen. While the lid is held in this position, a Beer's knife is entered at one margin, at a point on the bluish line that is visible just outside of the orifices of the Meibomian glands. This done, the edge of the knife is gradually carried onward, so that the lid is split into two layers, in a position corresponding with the curvature of the tarsus. The incision is carried up into the substance of the tarsus for a distance of three millimeters. The lid has thus been divided at its lower end into two layers. The outer layer contains the ciliary margin, the skin, and the fibres of the orbicularis muscle, whilst the inner layer is composed of the tarsus, with the Meibomian glands imbedded in it, and the conjunctiva. When this has been accomplished, and it is certain, by careful inspection, that no hair-bulbs are left behind in the inner layer of the split lid, the removal of a semi-lunar piece of skin from the operated lid is the next step in the procedure. To effect

this, the lid is spanned over a horn spatula by the fingers of the surgeon. An incision parallel to the free margin of the lid, is made through the skin at a distance of from three to four millimeters above the ciliary

FIG. 342.



Jaesche-Arlt operation on the upper eyelid. (ARLT.)

border. This should extend about four millimeters farther on each side than the cut at the margin of the lid. The skin of the eyebrow being raised by an assistant, while the surgeon steadies the skin of the lid at its cut portion, the two edges of the horizontal cut are united by a curved incision, which, at its most convex portion, is removed about five or six millimeters above the horizontal cut. This is represented in Fig. 342, which shows the appearance of the wound made by the two incisions, and its relation to the cut in the ciliary border.

The semi-lunar piece of skin thus circumscribed, is dissected off from the underlying orbicularis muscle with either a knife or a pair of scissors. The upper and lower margins of the incisions are approximated by sutures. Five or six stitches are necessary. These should be

inserted at the upper lip of the wound through the skin only. At the lower lip, however, the needle should pass behind the detached ciliary border and be brought out in the free margin of the lid just above the eyelashes, so as to set the lashes well out. The drawback to this method of operating, is that occasionally, when the incisions have been made so as to interfere with the nutrition of the little bridge of tissue by encroaching on its blood-supply at the outer and inner ends, there is a tendency for it to slough. If there should be such a tendency, the flap can generally be saved by the free use of hot-water compresses. Reaction is usually slight, and the wound heals kindly.

Green's method¹ yields excellent results. Here the lid is everted, and the incision is made through the conjunctiva and tarsus, two millimeters from the border of the lid and parallel to it. A strip of skin about two millimeters in width and one and a half millimeters from the free edge of the lid is removed. The fibres of the orbicularis muscle are left intact, so as to aid in preserving the blood-supply of the ciliary border. A threaded curved needle is introduced through the free edge of the tarsus just below the cilia and brought out at the skin-wound. The thread is now pulled through. The needle is next re-entered at the upper edge of the cut in the skin and is carried along the outer margin of the tarsus to a point about half an inch above. Here it is again brought through the skin. Three or four such sutures are applied, and the threads are tightened and tied, thus closing the skin-wound and everting the eyelashes. In dressing the wound, the cilia are further

¹ Trans. Amer. Ophthal. Soc., 1880, p. 167.

held in position by the application of a thin band of gauze that has been painted with collodion. The stitches may be removed on the second or third day. The wound in the conjunctiva and tarsus gapes, and is left to granulate.

The operation of Hotz¹ is performed by first seizing the lid at its middle, between the thumb and the finger. While it is thus kept on the stretch, an incision is made horizontally in the skin from one side of the lid to the other at about two millimeters' distance above the cilia. When the lid is released, the skin contracts, causing the upper edge of the incision to become curvilinear. The muscular fibres are then carefully dissected and pushed away from the upper third of the tarsus. Three or four threads are next carried through the skin at the lower margin of the wound, the needles being again inserted through the outer fibres of the tarsal cartilage at its upper part and the threads passed through the tarso-orbital aponeurosis and brought out through the skin at the upper edge of the wound. As the object of the procedure is to cause the skin to become adherent to the upper edge of the tarsus and the tarso-orbital fascia, care should be taken not to include any muscular fibres. Considerable reaction usually ensues. The stitches should be removed on the second day.

The operations of Streatfeild and of Snellen contemplate the excision of a wedge-shaped piece from the deformed tarsus. The latter is probably the more frequently performed. It is accomplished in the following manner: After immobilizing the lid, and preventing hemorrhage by the application of a Snellen clamp, an incision is carried through the skin the entire length of the lid. This incision should be made three millimeters above the ciliary margin and parallel to the border. The skin is pushed and dissected back, and a strip two millimeters broad is cut out of the orbicularis muscle thus laid bare. A wedge-shaped piece with its base placed outward is then carefully dissected out of the tarsus, its breadth depending on the effect that is desired to be produced. Three metallic sutures with a needle at each end are introduced through the upper part of the tarsus, so that three loops are made in the tarsal tissue. The needles are again introduced into the ciliary border, and brought out just above the eyelashes. The sutures are then tightened. It is not necessary to suture the two cut edges of skin.

In any form of operation for entropium, the strictest antisepsis should be observed. At its close, the eye should be dressed with gauze recently wetted with a one-to-four-thousand solution of bichloride of mercury. The field of operation is to be covered with aseptic cotton and the eye is to be immobilized by a bandage. Sutures may be removed in three to five days.

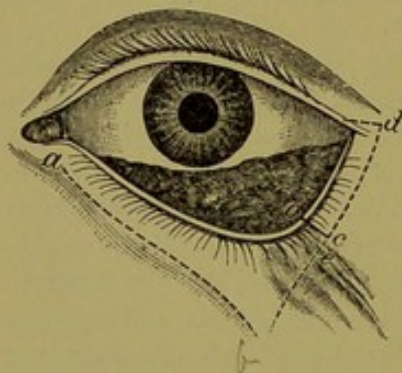
The treatment of *ectropium* varies with its degree and cause. In the sarcomatous or fleshy variety, the use of a mild astringent and a carefully-applied compress bandage will often afford relief. Those of slightly higher degree require that either a strip of conjunctiva, or a V-shaped piece be excised from the entire thickness of the lid, near the

¹ Archives of Ophthalmology, 1879, p. 249.

outer commissure. Ectropium that is due to extensive cicatrices or to other causes which produce complete eversion of the lid, requires much greater operative measures. Where the cicatrix is not very extensive, and where it is not adherent to the bone, the removal of a V-shaped piece from the middle of the everted lid and a careful reunion by hare-lip pin sutures, as originally proposed by Adams, will often be sufficient. In other cases, good results may be obtained by a method that was originally recommended for the upper lid by Wharton Jones. This method, however, gives better results when it is applied to the lower lid. In either case, the cicatrix is included in a triangular flap whose base is formed by the free edge of the lid, the gap left by its contraction being closed by sutures pulling on the adjacent skin. In operating on the lower lid, the flap should be dissected up as far as necessary toward the tarso-orbital fascia. The gap should be united by hare-lip pins.

Arlt's operation yields excellent results. In this method, as shown in Fig. 343, a triangle is formed by the cuts ab and bc , and a piece from two to three millimeters deep, containing the hair-bulbs at the external angle of the lid, is removed. The extent of this excised portion depends on the amount of the ectropium. The triangular flap is loosened as far as necessary, and the wound is sutured so that c comes up to d , and the side of the flap marked bc , lies against the skin-wound cd . The gap left by the raising of the flap, is to be diminished or closed by hare-lip pins. If necessary, the edge of the adjacent skin should be undermined.

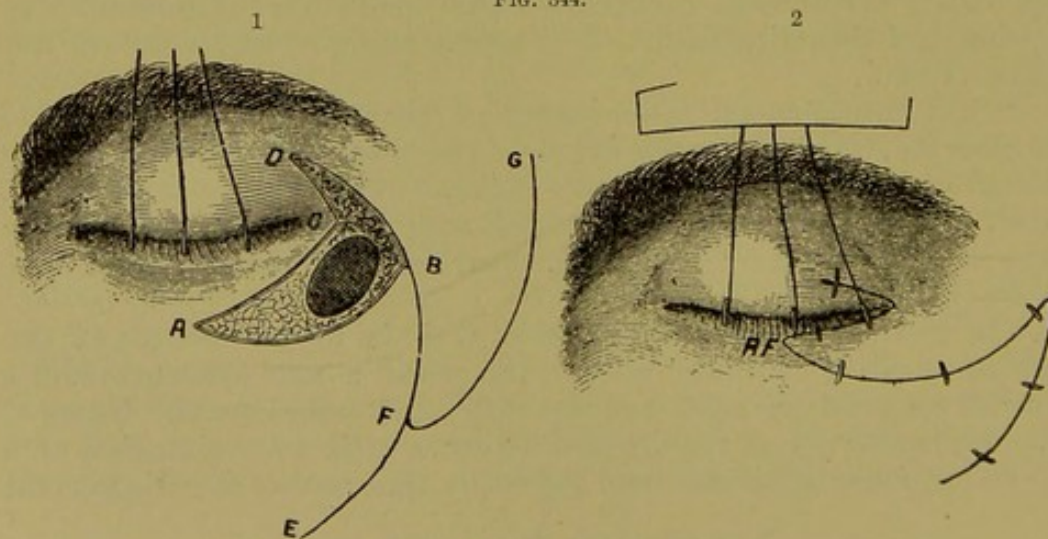
FIG. 343.



Arlt's operation for ectropium. (ARLT.)

by scars at the outer lower part of the lower lid. As shown in Fig. 344, the cicatrix is excised by three curvilinear cuts, one, BA , at the

FIG. 344.

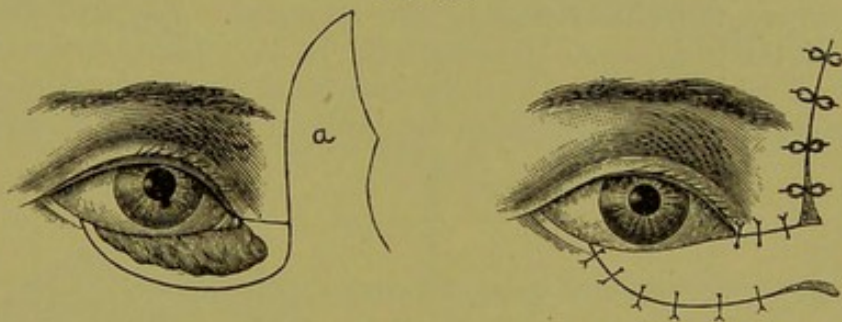


Richet's operation for ectropium. (ARLT.)

orbital margin below the scar, one, *CA*, between the scar and the margin of the lid, and one, *DE*, which, starting on the upper lid, is carried in a curve down on to the cheek, so as to touch the temporal end of the second cut at *B*. The scar is dissected out, and the lid is replaced and held in position, as shown in the first figure, by temporary sutures passing through the margins of both lids. A fourth curved cut, *FG*, starting from about the junction of the upper two-thirds with the lower third of the last incision, and extending upward in the temple, is next made. The last flap, *DFG*, is sewed on the defect caused by the excision of the cicatrix, thus bringing *F* to *A*, as shown in the second figure. The lower flap, *ABE*, is loosened and pulled up to cover-in the gap left in the skin of the temple.

Blepharoplasty, or plastic operation on the lids, is frequently necessary after the removal of epitheliomata, or other tumors of the eyelids. It is also useful to avoid or mitigate keratitis and other inflammatory conditions of the eyeball and conjunctiva in the severer forms of ectropium, such as those following extensive burns or sloughing of the skin

FIG. 345.



Fricke's method of blepharoplasty. (ARLT.)

and cellular tissue due to erysipelas or to caries of the bony walls of the orbit. The operations may be divided into two classes: 1. Those in which, after the tumor or cicatrix has been excised, its place is supplied by a flap that has been shifted from the cheek, the temple, the forehead, or the nose.¹ In all these cases, one part of the transplanted tissue is left in connection with its natural sources of blood-supply. 2. Those in which the skin taken to replace the defect is directly removed from some other part of the body. In the first class, the various possible methods of operating vary much with each case, and with the ingenuity of the operator. They may, however, be subdivided into three groups: First, those in which a more or less tongue-shaped flap is made, such as in the method of Fricke;² second, those in which a quadrilateral flap is moved over so as to cover-in a triangular defect; and third, those in which the surrounding skin is extensively incised and undermined, and the flaps thus obtained, are made to cover the defect. Fig. 345 shows how tongue-shaped flaps may be taken from the temple and sutured in place, and how the gap left in the temple is filled by dragging

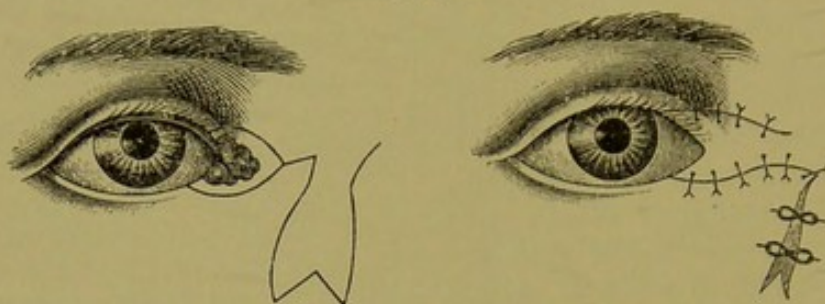¹ In some cases, as in the Tillacotian operation, the skin of the arm has been used to supply the defect.

² *Bildung neuer Augenlieder, Blepharoplastice*, Hamburg, 1829.

on the surrounding skin. Fig. 346 explains how a growth may be removed from the canthus and be replaced by a flap from the cheek.

In operations on the upper lid, it is generally necessary to resort to some modification of the tongue-shaped flap. Where they are made on the lower one, however, the method of Dieffenbach may often

FIG. 346.



Arlt's method of removing growth from canthus. (ARLT.)

advantageously replace these plans. This method yields admirable results in replacing the substance of the lower lid. Especially is this so in cases where the ciliary margin can be saved. Fig. 347 shows the position of the incisions. These should be so made that the distance from *c* to *d* will be greater than the horizontal measurement of the defect, thus making the transplanted flap larger than the area of the excised

FIG. 347.

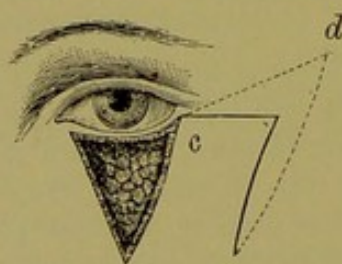
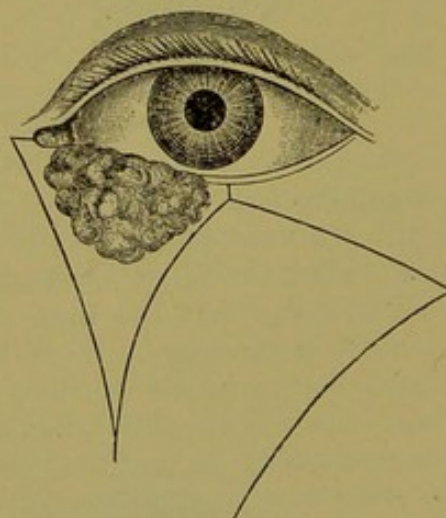
Dieffenbach's method of blepharoplasty.
(ARLT.)

FIG. 348.

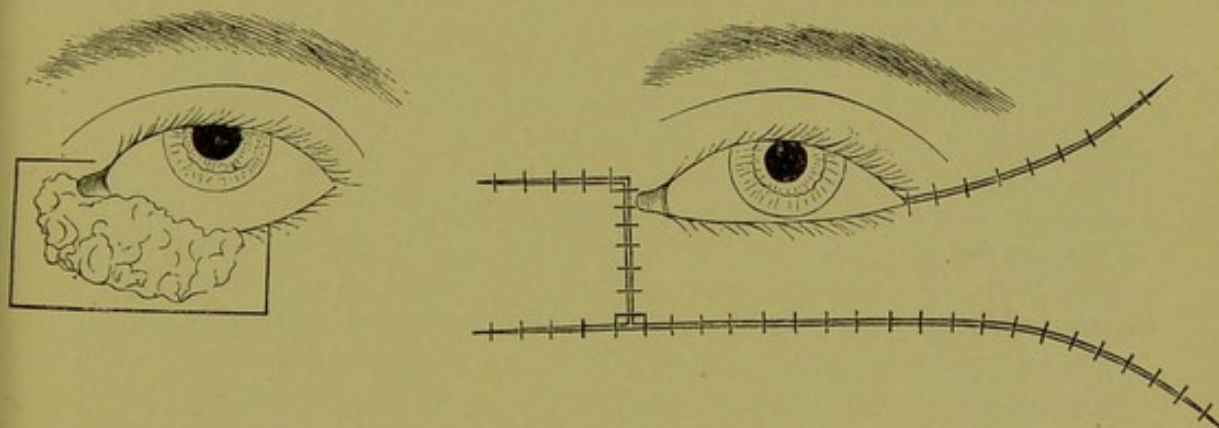
Arlt's method when a portion of the eyelid is
to be sacrificed. (ARLT.)

portion. The point, *d*, representing the upper outer part of the flap, should be selected on the temple a little higher than the external canthus. When the flap is sutured in place, a more or less triangular defect remains on the cheek or temple, which may be much diminished at its upper part by ordinary sutures. The gaping wound at the apex of the triangle is best closed by the use of a hare-lip pin. Fig. 348 shows how this method may be advantageously practised in cases where it becomes necessary to sacrifice a part of the margin of the lid.

The method of Knapp,¹ by which a more or less quadrangular piece of skin surrounding the new growth is cut out, and its place supplied by a sliding flap made by an extensive dissection of the skin of the face and temple, is shown in Fig. 349.

The principal methods of transplanting entire portions of skin from other parts of the body are those of Wolfe² and Riverdin.³ In the former, the size and shape of the defect are accurately cut out in paper. A piece, which is similar in outline, but considerably larger in every diameter, is next removed from the inside of the arm. The skin to be transplanted, is dissected off cleanly, leaving the subcutaneous cellular tissue and fat behind. The flap is now gently sutured in its new position, and is covered with gold-beater's skin and a bandage. The bandage may be removed on the second day. The gold-beater's skin, however, must remain in position a much longer time, it having sufficient transparency to allow inspection of the underlying flap. The epidermis is always thrown off, and the grafted portion at first looks whitish.

FIG. 349.



Knapp's method of blepharoplasty. (KNAPP.)

In Riverdin's method, small pieces of epidermis with the superficial part of the true skin are shaved off some part of the body and applied to the raw surface. These are kept in place and dressed in the same manner as in Wolfe's method. Where it is desired to replace lost conjunctiva in this way, small pieces can be removed from the inside of the lip and the mucous membrane of the mouth. Care should be always taken that the hemorrhage has ceased and that all clots are removed before the flaps are permanently adjusted. Wadsworth⁴ and others report favorable cases treated by the Wolfe method. The author has had no personal experience with it. The results that he has acquired in the practice of the Riverdin method have not been encouraging. Where, in any of the plans of transplantation with a pedicle, the circulation in the flap is not promptly re-established, and on examination on the following day, it threatens to slough, its vascularity may often be improved and the flap saved, by the free use of hot compresses.

¹ Archiv für Ophthalmologie, xiii. 11, Ss. 183-85.

² Bristol Medical Journal, September 18, 1875.

³ Bulletin de la Société Impériale de Chirurgie de Paris, 1869, pp. 493, 511.

⁴ Report of the Fifth International Ophthalmological Congress, 1876, p. 237.

Symblepharon, when involving a large lateral extent of the conjunctiva at the retrotarsal fold, defies operative treatment. Operative procedure should never be undertaken until any inflammation has disappeared and all cicatrices have consolidated. Where the base of the cone of cicatricial tissue is not too extensive, Arlt's operation will sometimes give good results. To perform this, the tissue is seized with the forceps at its point of attachment to the cornea. It is now dissected away from the eyeball, either with scissors or a knife, the incisions being carried well back into the retrotarsal folds. The two ends of a silk thread, each attached to a curved needle, are carried through on each side of the apex of the flap. They are now passed downward into the retrotarsal fold and out through the skin of cheek, and tied over a piece of rubber tubing or buckskin. The raw surface of the flap is thus turned toward the epithelial surface of the lid. The gap in the bulbar conjunctiva is closed by two sutures, the one just below the cornea, and the other lower down near the retrotarsal fold.

For more extensive adhesions, the old plan of Himly may be resorted to. This consists in perforating the base of the attachment in the direction of the conjunctival cul-de-sac and placing a lead wire in it. The wire is allowed to remain till the fistula is covered with epithelium. The adhesion is then divided. If the symblepharon be of small extent, small flaps of conjunctiva to fill the gap may be dissected off the eyeball. This procedure was originally practised by Teale. More lately, both this writer and Noyes have recommended the slipping of a band of conjunctiva down over the bared surface in severe cases. This band is taken from the sides and upper part of the eyeball by an incision that is made sufficiently curving downward at each outer end, as to give a strip from four to five millimeters in width, with a gradually broadening base. The method of Riverdin, which consists in filling the gap with small pieces of the mucus membrane taken from the mouth, may also be employed. Transplantation of the rabbit's conjunctiva is said to be at times successful. Noyes reports an instance in which the result was permanently satisfactory after two operations, enabling the patient to wear an artificial eye over the stump.

Ankyloblepharon, which is almost always accompanied by symblepharon as the result of burns, can be remedied by division of the adhesions between the lids and the dissection of the lids from the cornea only when the adherent surface of the lid at least can be covered by conjunctival or other mucus membrane flaps.

Canthoplasty, or division of the external canthus, is generally performed either to lessen pressure of the lids upon the eyeball and to relieve pathological narrowing of the palpebral fissure in cases of granular conjunctivitis with pannus, or to gain room for enucleation of orbital tumors and the removal of the contents of the orbit. To perform this operation, one blade of a strong pair of scissors is inserted into the conjunctival sac at the outer canthus. The skin and conjunctiva are now cut through in a horizontal direction with a single snip, making a wound about half an inch in length. The upper lid being seized, is to be gently pulled toward the nose, thus putting the tarso-orbital fascia on the stretch. The fascia is also to be divided. This is

to be done either with the scissors or with a small scalpel, if the edge of the tissue can be felt. Some operators prefer to make the incision by introducing a curved bistoury into the conjunctival sac, and cutting outward, after pushing the point of the instrument through the skin at the outer commissure. By retraction of the conjunctiva and skin, the wound becomes rhomboidal in shape. The conjunctiva is united to the skin by sutures in such a way that the mucous membrane prevents the cut edges of the skin from uniting at the point of the divided commissure and farther out. This is generally done by three stitches—one through the conjunctiva and the extreme end of the incision in the skin, and the other in the same manner at equidistant points above and below.

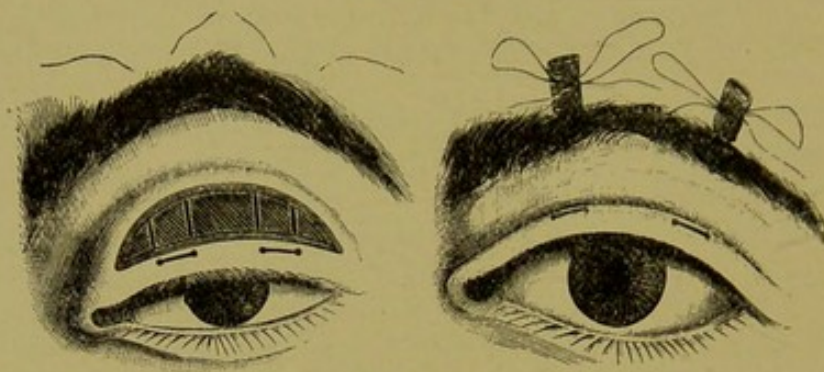Tarsorrhaphy is an operation that, in opposition to canthoplasty, is intended to diminish the extent of the palpebral opening. It is chiefly of value where the lids are not able to protect the cornea, as in cases of paralysis of the facial nerve and exophthalmic goitre. Provisionally, it is of use in plastic operations, where it is desired to keep the palpebral fissure closed during the commencement of the healing process. When the procedure is designed to give a permanent effect, it is advisable to split the ciliary margins of both the upper and the lower lids into two parts for a distance of five or six millimeters, and to excise the portions that carry the hair-bulbs by a cut made parallel to the edge of the lid at about two millimeters from its margin. The inner margin of each lid should be pared away and freshened. This should be done not only over a space that corresponds to that which has been deprived of its lashes, but should extend to a slight distance to its nasal side. The wounded portions should then be brought into coaptation by sutures. The lids are immobilized by a bandage for a few days' time. When a lesser effect is desired, it will often be sufficient to pare away the internal margin of both lids and leave the hair-bulbs in position.

In cases where the operation is intended for temporary purposes, only a small portion, not extending to the canthus, should be operated on. This precaution is to be taken so that the newly-formed bridge may be easily divided and that the edges of the lid shall remain sufficiently separated to prevent reunion.

Ptosis in its congenital form, necessitates operative interference. In acquired cases, proper constitutional treatment should be first tried. If this fails, operation should be resorted to. The usual procedure consists in cutting out a semilunar piece of skin of the upper lid and suturing the cut edges. When this is insufficient, resort may be had to a plan that has been suggested by Wecker. This consists in passing two threads with a double needle through the portion of skin left standing at the ciliary margin in such a manner that each puncture is separated by a space of about three millimeters. Each needle is then carried up under the skin of the upper lid and brought out just above the eyebrow. The two threads are each tightened over a piece of rubber drainage-tube. One suture is inserted at the junction of the inner and middle thirds of the lid. The other is placed at the union of the outer and middle thirds. Fig. 350 shows this very well. It

must never be forgotten that much more can be readily done than is designed. In fact, the lid can be so much shortened that it will not close entirely during sleep. In no case, except perhaps in the lipomatous form, can the fissure of the lids be made to look like its fellow. The best that can be expected, is to raise the lid by the shortening of the skin and the action of the frontalis muscle so as to partially or entirely clear the pupil.

FIG. 350.



Wecker's operation for ptosis. (WECKER.)

Foreign bodies in the conjunctiva and cornea. Small particles in the conjunctival sac, which usually lodge in the tarsal surface of the upper lid, or in the upper retrotarsal fold, are easily removed by a piece of clean wet linen used as a swab, or by a spud. If they have lodged for some time in the retrotarsal fold, they may be found imbedded in granulations, which must be excised before the foreign body can be extracted. Before removing any foreign body, it is generally best to instil a few drops of cocaine solution. This is always advisable when the substance is lodged in the cornea. Small metallic splinters are often so firmly imbedded in the dense fibrous tissues of the cornea that it is necessary to cut or scrape them out with a spud or a spear-pointed cataract-needle. When they are exceedingly minute, it is frequently necessary to employ a magnifying-glass and oblique illumination. The little wound should always be scraped clean, and no rust allowed to remain in it. In refractory patients, it is often best to raise the upper lid with the thumb of one hand, the eyeball being pressed through the lower lid with the little and ring fingers of the other hand. The thumb, index and middle fingers can then be reserved for the use of the spud. Where a long and irregular splinter becomes imbedded in the cornea, the corneal tissue over it must be incised with a sharp knife, so that the object can be seized with a forceps. When the foreign body, although still sticking fast in the cornea, has penetrated the anterior chamber, it is generally best to make a small incision about a millimeter distant from the corneal border in such a position that either a Daviel's spoon or the instrument with which the incision had been made, can be introduced behind the foreign body so as to press the foreign substance forward at the moment that an attempt is made to seize it with the forceps. In all cases where the cornea is scraped, the patient will be more comfortable and the wound

will heal better if, after the conjunctival sac is cleansed with boracic acid solution, the eye be kept closed till the epithelium is re-formed over the abraded surface.

Scraping of the cornea (abrasio corneæ) over a considerable extent may often be successfully resorted to where there is a deposit of lead in its substance. It is also useful in cases where, after previous disease of the eye, there is a band of opacity—dependent upon a deposition of phosphate and carbonate of lime—over the part that corresponds to the fissure of the lids. This method is not applicable to the removal of ordinary maculæ and leucomata, because here the resulting cicatricial tissue generally becomes more opaque than that which was removed.

The method of *grafting* a piece of clear *corneal tissue* taken from one of the lower animals—an operation devised by Von Hippel—has not been performed with sufficient frequency to enable any judgment to be offered as to its average success. In this operation, the entire thickness of the membrane is not removed, the trepanation being carried down only as far as the membrane of Descemet. According to Von Hippel, the method is not applicable to opacities where the iris is adherent.

Tattooing the cornea, or the method of rendering permanent opacities of the cornea less noticeable, is sometimes resorted to. To effect this purpose, India-ink is introduced beneath the epithelium covering the cicatrix and deposited in the underlying anterior corneal layers. This is generally done by either applying the pigment directly into the leucoma by a grooved needle or working it in by pricking the opaque spot with three or four needles placed side by side in a holder after having covered the overlying surface of the cornea with a drop of fluid holding the India-ink in suspension. By repeated applications, a central opacity may sometimes be made so dark as to give the appearance of a natural pupil. Some cicatrices, however, do not readily hold the little grains of coloring matter, because if they are vascular and the vessels are pricked, the escaping blood tends to wash the pigment away. Tattooing should never be performed until the cicatrix is perfectly quiet and all tendency to ciliary congestion has passed away.

As *dermoid tumors of the cornea* are always congenital, they may generally be safely removed by careful dissection. They should be seized with a toothed forceps and separated from the cornea by gentle strokes with a cataract-knife. When this has been accomplished, they are to be pulled downward and forward by the forceps, and carefully removed from their scleral attachments by a pair of curved scissors. The cornea heals with a permanent white opacity situated over the spot that was occupied by the tumor.

The operations for *pterygium* are usually limited to either abscission or transplantation. In the former procedure, the growth should be seized with toothed forceps at the part just over the margin of the cornea, and the head should be carefully dissected away from the cornea by means of a sharp knife. The neck, or part adhering to the limbus, and the portion immediately beyond, should also be detached, and the underlying surface of the ball scraped till the white sclerotic is laid bare. This having been accomplished, a V-shaped piece should be cut out of the

substance of the growth, the point of the V being directed away from the cornea and situated on the middle line of the pterygium. If the growth be small, the surface thus exposed may be left to heal by granulation. If it be large, it will be better to bring the conjunctiva together with sutures. The eye should be kept closed and bandaged for a few days. Large pterygia are often advantageously treated by transplantation. To effect this, the head of the growth is to be dissected from the cornea and firmly sutured to the apex of a conjunctival wound that is obtained by making a vertical cut in the bulbar conjunctiva about three millimeters from the corneal border. Following the procedure of Knapp, large pterygia are sometimes divided into two parts by a median incision, one part being inserted in the upper and the other in the lower part of the ocular conjunctiva.

Partial staphyloma of the cornea, where there is still some anterior chamber, is best prevented from increasing by an iridectomy. The apex, or a portion of it, is sometimes shaved off and the wound left to heal under a compress bandage. Where there is secondary glaucoma, with absolute loss of eyesight, it is generally better to enucleate the eyeball. In *total staphyloma*, an improvement by iridectomy is impossible. Even where there is a small partly clear margin at the periphery that allows the iris to be seen, the choice must lie between abscission and enucleation. The old method of performing the former operation consists in transfixing the staphyloma horizontally with a triangular cataract-knife at the middle line of its base. A downward cut, which detaches its lower half from the cornea, is then made. Next telling the patient to look up, the remnant is gently seized with the forceps and the other half of the base of the staphyloma is detached by a few clips of the scissors. If the lens is present, an incision is made into its capsule and it is evacuated. When cocaine is used, this operation is almost painless. No stitches are inserted. A compress bandage is applied, and the patient is confined to bed for two or three days. The dangers attending this method of operating are, that straining may cause loss of the vitreous, or that degeneration of the chorioidal vessels may, in the absence of intra-ocular pressure, give rise to hemorrhage. If this latter accident should occur at the time of the operation, either the remainder of the globe should be enucleated, or the eyeball should be eviscerated by scraping out its contents and baring the inner surface of the sclerotic. In uncomplicated cases, if the patient remains quiet for several days after the operation, an excellent stump is obtained. Although the Critchett method of putting sutures through the ciliary body is now abandoned, most surgeons of the present day prefer the use of sutures after the staphyloma has been excised. To do this, the conjunctiva is dissected back from the cornea before the cornea is excised and is pierced in several places by a purse-string suture. The conjunctiva is thus pulled over the gap, and the edges of the wound in the sclerotic drawn closer together after the operation. When there is increase of intra-ocular tension, enucleation is always to be preferred to abscission.

The fact that cocaine in the operations for *strabismus* and for *insufficiency* enables a general anæsthetic to be dispensed with, thus allowing the effect of the operative procedure in any reasonably resolute and

obedient patient to be immediately tested, has rendered the employment of this drug a great aid in the proper performance of these procedures. In children and nervous patients, it is necessary to resort to ether. Before proceeding, the acuity of vision, the optical defects, and the amount of deviation of the eyes, should be tested. The equilibrium of the eye-muscles, both for near and for distance, in all cases of insufficiency, is to be studied by means of prisms. In all such cases, it is a material aid to remember Arlt's practical division of squint into three grades: first, slight, where the inner edge of the cornea of the deviating eye reaches a vertical line that unites the lacrymal puncta; second, moderate, where the inner edge of the cornea reaches the caruncle; and third, high grade, where the inner edge of the cornea is hidden beneath the caruncle. In the first instance, careful division of the tendon on one eye alone will suffice; in the second, a similar moderate division of both tendons will usually answer; in the third, a double operation, with the addition of cuts in the capsule of Tenon in one or both eyes, is necessary. Slight periodic or alternating convergent squint should not be operated on until the effect of thorough atropinization and the use of proper glasses have been tried. In all cases, the habitual use of correcting-glasses after the operation, goes far to insure the permanency of the effect obtained and to correct the causes that have originally produced the squint.

Although many operations have been devised for the correction of squint, yet those described by Arlt and Graefe furnish the types on which most of them are based. In all cases, it is well to remember, as explained on page 51, the centres of the insertions of the internal, the external, the superior, and the inferior rectus muscles of the eye, as it is frequently impossible to determine the exact site of tendon-implantation by visual examination alone.

The operation described by Arlt consists in first directing the patient to look toward the outer commissure of the eye to be operated on, or, if anæsthesia is employed, the eye should be held in the position of outward rotation by an assistant. The operator then seizes a fold of the conjunctiva about four millimeters inward from the corneal border with a pair of fine-toothed forceps, and incises this fold with a pair of scissors in such a manner as to make a vertical wound of about seven millimeters' extent in it. The forceps, with its points closed, is next introduced along the ball from two to three millimeters farther back than the conjunctival incision, and is so raised that it points almost at right angles against the eyeball at the place of contact. It is now opened to about eight millimeters' width and closed, taking care to keep the points always pressed against the sclerotic. The muscle which is thus seized, is separated from the sclerotic at its insertion by repeated clips of a pair of delicate scissors that is curved on the flat, one blade of the instrument, with its convexity turned toward the eyeball, being introduced under the muscle. If, on moving the ball outward, the white, shining sclerotic is distinctly seen, most of the muscle-insertion has been severed. Any remaining attachments, above or below, are easily detected by the insertion of a small blunt hook. These can be divided by the scissors. The motion of the eye is then to be tested. If the eyeball can be rolled in

nearly to its normal extent, the desired result has been attained. If the eye can be rolled in until the edge of the cornea is buried, oblique incisions should be made up and down into Tenon's capsule, and the result again tested by making the patient fix upon some object situated in the median line at about twelve inches' distance. If the visual lines converge properly, or even if there be slight residual convergence, the object of the operation has been attained. If the operated eye deviates decidedly outward whilst the patient fixes, at twelve inches' distance or less from the fixation-point, the muscle has been unduly weakened, and the effect must be immediately diminished by introducing sutures in the conjunctiva and in Tenon's capsule near the divided end of the muscle. These sutures must be fastened firmly in the conjunctiva near the cornea. When the sutures are applied crosswise, one going in a direction from in and down, outward and upward, and the other from in and up, downward and outward, an increased effect is obtained. If the visual axes become parallel or slightly divergent after division of the muscle, when an anæsthetic is used, it will be certain that there will be a small amount of residual convergence when the patient recovers from the influence of the drug.

The operation by *Graefe's method* is commenced by making a vertical incision in the conjunctiva near the cornea. The exposed portion of Tenon's capsule at the lower border of the muscle is next seized with the forceps, and is incised with a pair of scissors. Through the hole thus made, a large blunt hook is inserted and carried upward so as to grasp the entire muscle. This is pulled forward and divided at its insertion with the scissors. Any fibres that have escaped severance, are sought for with a smaller hook, and are divided with the scissors.

In the *sub-conjunctival operation*, an incision parallel to the muscle to be divided is made at its lower border. A hook is slipped under the muscle, which is thus rendered tense, and the tips of a pair of scissors are inserted beneath the conjunctiva so as to follow the hook and divide the insertion of the muscle by repeated small cuts.

Snellen has proposed that after the conjunctiva in the median line over the insertion of the muscle has been divided and this membrane dissected up, the centre of the insertion should be grasped with the forceps and a hole cut in it. The remaining fibres above and below are then seized with a small blunt hook and alternately divided.

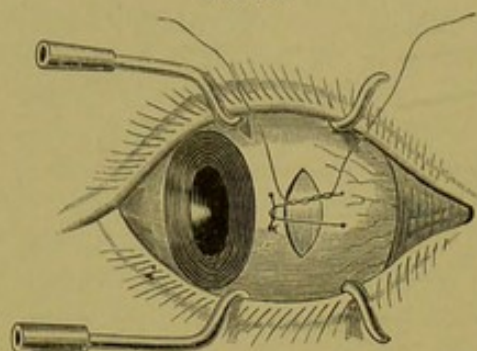
Partial tenotomy has, in some instances, been performed by Graefe, who left one-quarter or one-third of the insertion of the muscle undivided. The effect, however, is apt to be transitory, and it is always difficult to estimate the ultimate result. Stevens has revived partial tenotomies. By the use of a pair of fine forceps and scissors, a button-hole is cut in the insertion of the muscle, and, when necessary, the fibres on each side are divided. He has also introduced the system of *graduated tenotomy*. Here, repeated operations, where a portion of the tendon is divided at each sitting, are performed, in the expectation to attain more accurate results than have hitherto been considered possible. That it is difficult to accurately foresee any desired effect, is evident from the number of times that even experts in the method are obliged to repeat the procedure.

Operations for insufficiency, are of two sorts. In the one, the tendon of the antagonist is cut, thus indirectly strengthening the weakened muscle. In the other, the tendon of the weakened muscle is dissected from its insertion, so as to bring it forward toward the cornea, thus enabling the muscle to act to greater mechanical advantage. Frequently, both methods are combined. Before operating, it is necessary to carefully study the muscle-balance when the eyes are made to fix alternately upon a near object and upon a distant one. It is advantageous to employ cocaine during the operation, and to test the effect obtained both during and after the operative procedure with prisms.

In the *operation of advancement*, a vertical incision is made in the conjunctiva about the position where the weakened muscle is normally inserted. The conjunctiva is then dissected backward till the insertion of the muscle is laid bare. The eyeball being held rotated toward the side of its antagonist, a good-sized silk thread armed with a needle at each end is passed through the muscle (if possible, dipping into it two or three times, to secure a good hold), and the tendon is carefully divided at its insertion, the threads being laid to one side. The antagonist is now divided. After dissecting up the conjunctiva of the eye in which the muscle is to be advanced, the end of the muscle is brought up against the cornea and is fastened to the conjunctiva and capsule of Tenon by the needled suture, so that one end of the thread passes up under the conjunctiva and capsule of Tenon to the vertical meridian, and the other passes to a corresponding position below. If necessary, the muscle may be shortened by clipping the divided end in advance of the suture. Where the deformity is very great, it is best to put a suture through the tendon of the antagonist and divide the muscle just behind it, so that the eye can be pulled over as far as is desired toward the side of the muscle to be advanced, and fixed in this position by carrying the thread through the skin at the outer commissure. This suture can be left in place for a period varying from six hours to two days. As there is apt to be considerable reaction, any operation for advancement is a far more serious procedure than that of simple division of the muscle. The patient should be kept quiet, both eyes bandaged for two or three days, and ice compresses, either simple or charged with small amounts of boracic or salicylic acid, employed. An excellent mode of performing advancement, known as the "pulley method," has been lately introduced by Prince. A stay suture or pulley is introduced vertically into the bulbar conjunctiva a short distance from the cornea, a deep hold being taken to get a good grip of the conjunctiva, capsule of Tenon, and episcleral tissue. An incision slightly in advance of the insertion of the tendon of the muscle which is to be brought forward, is made into the conjunctiva. A strabismus-hook is slipped under the muscle so as to enable one blade of a specially constructed toothed forceps to be introduced under the muscle. The forceps is then closed and held fast by a spring clamp, so as to prevent the muscle slipping from its grasp. Two curved needles on a single thread are introduced under the muscle, and after being carried some distance back, are made to pierce the muscle and overlying tissues, so that one is brought out near its upper, and one near the lower margin of the muscle. One end

of this suture is now laid over the pulley-suture and the two ends of the latter are tied fast over it. The two ends of the loop passing through the muscle are then tightened and tied. Fig. 351 gives a good idea of the eye as it appears with the sutures in position, the pulley having been drawn tight and tied, while the other loop is ready to be tied.

FIG. 351.



Prince's operation for advancement.
(PRINCE.)

Division of the externus is done in the same manner as division of the internus. Where there is excessive divergence, the division of both the external rectus muscles frequently gives less effect than is desired. In such cases, the plan of pulling the eyes toward the nose by

sutures, leaving the threads in place for from six to twenty-four hours, is often effective.

Division of the superior or of the inferior rectus muscle is attended with some difficulty. This is owing to the stronger attachments to the capsule of Tenon and to the thickening of the latter by the leaflet of the tarso-orbital fascia. Graefe says that when there is an upward squint, the inferior rectus muscle of the sound eye should be divided, and if the squint is a downward one, the superior rectus muscle of the sound eye should be divided. When the deviation is very great, it is necessary to divide the effect between the two eyes by cutting the inferior rectus muscle of the one, and the superior rectus muscle of the other eye.

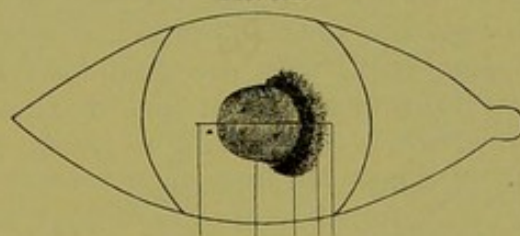
The dangers of the operation for strabismus, where strict asepsis has been observed and where the eye is subsequently properly protected from external irritants, are very slight. An occasional case of severe tenonitis, with suppuration of the cornea, has, nevertheless, been recorded. The author, in a series of many hundred operations, which in the vast majority of cases were treated at dispensary services, has never been unfortunate enough to have any considerable reaction follow. When the contracted muscle and its attachments have been too freely severed, the eye will sometimes turn in the opposite direction. With care in the operation, and the use of sutures when necessary, high degrees of divergence can always be avoided. The author, however, usually does not make use of any conjunctival sutures, being content to bandage the operated eye. Such sutures, nevertheless, favor more rapid union, and granulation buttons are less apt to sprout from the stump of the divided tendon—a condition that is more liable to occur when the sclerotic is not shaved very cleanly and closely. If such a granulation be left undisturbed, the conjunctiva gradually tightens around its base, causing the granulation to shrink. When such constriction has commenced, healing may be hastened by excising the growth with a pair of scissors. It is useless to cauterize or cut it before shrinkage.

Paracentesis of the cornea is generally performed by making an incision in the cornea near the limbus with a broad needle or a lance-

shaped knife. The object of the procedure is to evacuate pus which has accumulated in the anterior chamber, to tap a hernia of the membrane of Descemet, and to temporarily diminish intra-ocular pressure in glaucoma and traumatic swelling of the lens.

Slitting of the cornea (Saemisch operation) is resorted to with great advantage in many cases of corneal abscess or in ulcers with undermined edges that have resisted milder treatment. After the ulcerous surface and the entire conjunctival sac have been thoroughly cleansed by the use of a weak solution of bichloride of mercury warmed to blood heat, a solution of cocaine should be freely dropped upon them. The bulbar conjunctiva is gently seized with fixation-forceps, and a Graefe cataract-knife, with its back to the eyeball, is entered in the clear cornea at the margin of the ulcer. The knife is then carried into the anterior chamber, pushed across the long diameter of the ulcer, and the point made to emerge in the sound margin of the cornea on the other side. Fig. 352 gives a graphic representation of the proper position of the

FIG. 352.



Splitting of the cornea. (SAEMISCH.)

incision. The fixation-forceps having been laid aside, the knife is made to cut out by gently pushing it forward, aiding this, if necessary, by slight sawing motions. In this, as in all other operations in which the anterior chamber is opened, the aqueous humor should be allowed to escape slowly. As a rule, most of the pus will flow out. The small portions remaining in the periphery of the anterior chamber, will soon absorb. Any sloughs of the corneal tissue should be carefully removed with an iris-forceps. The eye is to be washed with warm boracic acid, atropine instilled, and a light pressure bandage applied over both eyes. On account of the severe pain which is apt to follow such operations, an opiate is often indicated. When practicable, it is best to operate on the patient in the bed in which he is to remain. Care should be taken that he be kept quiet in bed for several days afterward. Should pus reaccumulate, it is advisable to reopen the wound with a thin horn spatula. If, by reason of too firm cicatrization, this is impossible, a Graefe knife must be employed. Although, owing to the advanced disease of the cornea and the involvement of the ciliary body in the inflammation, convalescence is necessarily slow in most of the cases in which it is necessary to employ this operative procedure, the results, however, are usually very satisfactory.

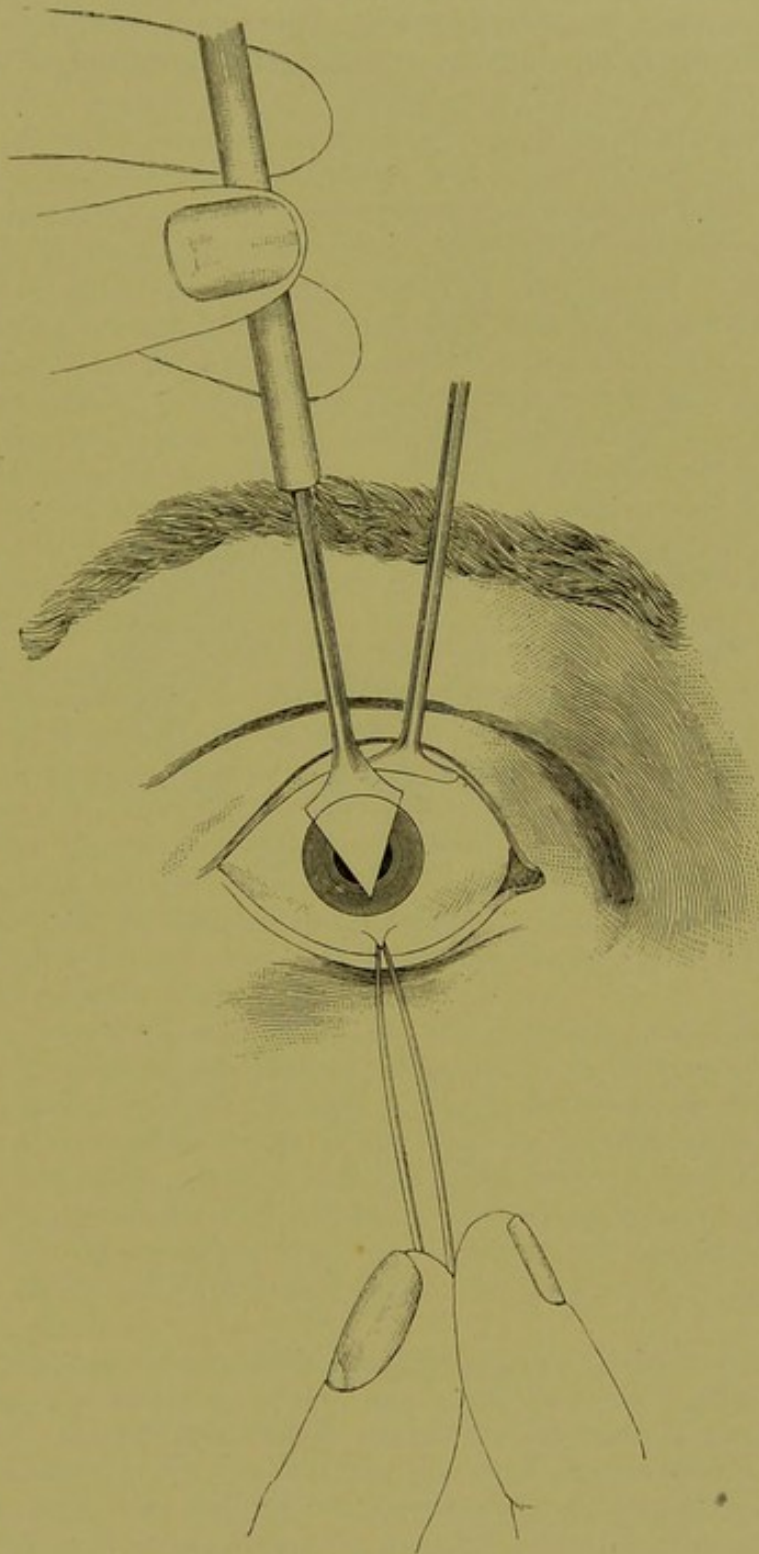
The application of the actual cautery in ulcers of the cornea is often followed by a limitation of ulcerative tendency, and by a disposition in indolent corneal ulcers, and in those deep erosions which are accompanied by a sinking of pus between the corneal layers, to heal. When

the galvano-cautery is applied, great care should be taken in the manipulation, as the slightest touch of the white-hot platinum end burns and cuts with extreme rapidity. Moreover, owing to the weight and stiffness of the thick connecting-wires necessary to obtain a white heat, it is very difficult to manipulate the instrument with as much lightness and precision as can be attained by the use of a cataract-knife or a spud. After evacuation of a corneal abscess by the Saemisch incision, and the removal of the sloughs of corneal tissue, it is often a good plan to carefully cauterize the eroded edges with light but repeated touches of the white-hot platinum. Where a proper galvano-cautery is not obtainable, a very satisfactory substitute may be made in cases of deep ulcers of moderate size, by heating an ordinary strabismus-hook in an alcohol flame or a Bunsen burner. This may be used while its tip is glowing hot. The head of a silver pin, heated in the same manner, makes a still more satisfactory instrument.

Iridectomy, or the cutting out of a piece of the iris, is one of the most common and most important of the operations on the eyeball. It was at first performed only for optical purposes—to provide a substitute for a closed pupil, and to admit light to the retina through some clearer part of the cornea. To Von Graefe must the credit for the knowledge of its uses in diminishing intra-ocular tension and in altering the nutritive processes of the tissues within the eyeball, be given. Not only is it the best means of reducing excessive intra-ocular pressure, but it acts most favorably in modifying the nutrition of the eye in exclusion of the pupil. In cases where long-standing inflammation has caused the eyeball to become softer than normal, this operative procedure, by its influence on the intra-ocular circulation, will also often bring about a return of normal tension. Its successful performance requires considerable skill in the surgeon, a thorough knowledge of the size and anatomy of the parts to be operated on, and steadiness and quietude on the part of both the surgeon and the patient. In reasonably courageous patients, cocaine is sufficient. In some rare cases, however, where even repeated instillations of the drug fail to make the iris insensitve, it becomes advisable to employ a general anæsthetic. The eyelids being held open by a spring speculum, or by a Desmarres elevator in the hands of an assistant, and the head carefully steadied, an incision is made into the cornea with a lance-shaped knife having a moderately bent shank. The point of the knife is held at an angle of about sixty degrees to the part of the cornea in which it is desired to enter. The instrument is gently pushed in this direction till it is felt to have perforated the tissue, and penetrated the anterior chamber. As soon as the glittering point can be perceived in the chamber, it is turned toward the cornea. The knife is then gently pushed forward so that the point crosses the anterior chamber, the wedge shape of the knife thus introduced, preventing any loss of aqueous humor as it advances. When the incision is completed, the handle should be slightly pushed back, so as to cause the point to come close to the posterior surface of the cornea. The instrument is then gently and slowly withdrawn. Perhaps the best idea of the action of the knife is obtained, by keeping in mind Arlt's direction, that it is to be employed as a curved needle. When the knife has been properly used and gently

withdrawn, the iris, as a rule, will not prolapse. Light but firm iris-forceps, closing neatly at and near the point, but not quite touching at

FIG. 353.

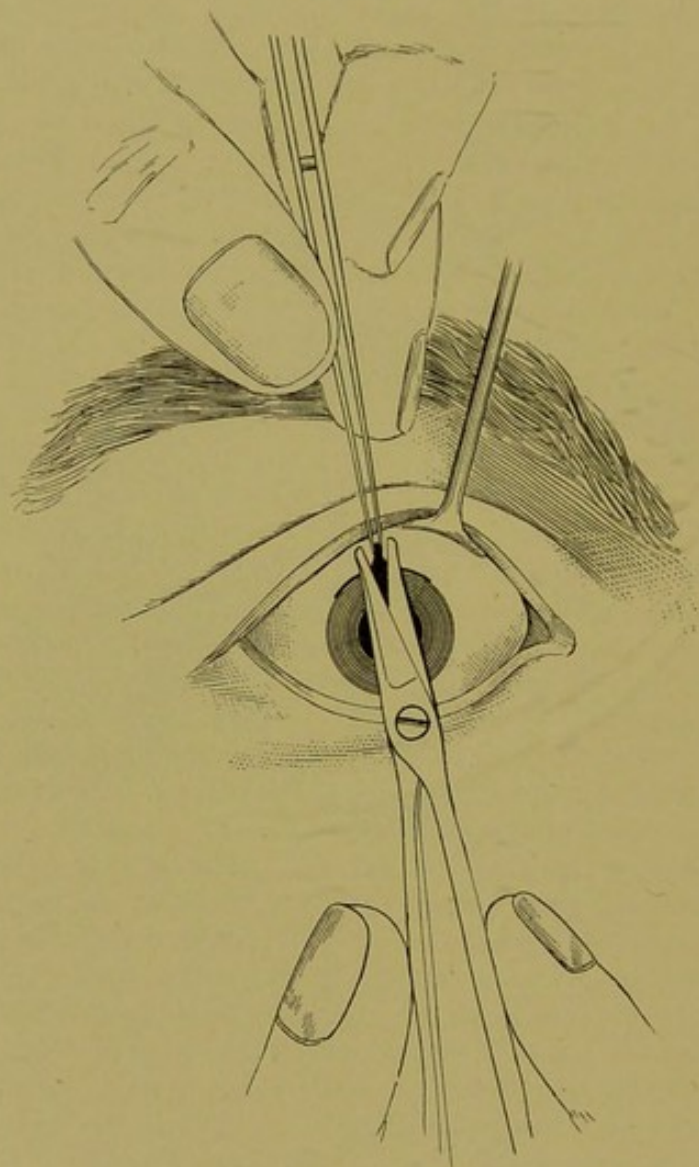


The corneal incision in iridectomy.

the heel, should then be introduced closed into the wound. When in position, the points are allowed to separate and close so as to grasp the

sphincter of the iris near its outer border. The forceps are gently withdrawn, pulling a fold of the iris out of the wound. As soon as this fold is rendered fairly tense it should be divided with the scissors as close to the lips of the wound as practicable. This is the critical part of the operation, because any quick movement of the eye or head of the patient may cause a drag on the opposite side of the iris, producing a partial or

FIG. 354.



The excision of the protruding portion of the iris in iridectomy.

total loosening of the muscle from its ciliary attachment. In restless patients, it is necessary to have an assistant hold the eye with a fixation-forceps while the operator seizes and cuts the iris. In quiet patients, it is best to dispense with any fixation. The seizure and incision of the iris, however, constitute the painful part of the operation, causing many to wince who have previously held still. It is important to seize the iris as directed, because, if the forceps are not introduced far enough, the sphincter may be left and a button-hole cut in the iris. On the

other hand, if the forceps are introduced too far, there is a risk of wounding the anterior capsule. Fig. 353 shows the position of the knife on the completion of the incision just before it is withdrawn from the anterior chamber. Fig. 354 shows the iris where it is being seized and dragged out of the wound so as to be cut with the scissors, which are in position. Too much care cannot be taken in looking after the cut edges of the iris. If they become entangled in the wound, they should be seized with the forceps and excised. If they are but partially engaged in it, they should be gently stroked out of the wound by the use of a thin tortoise-shell spatula. It is exceedingly important that the corneal wound should be made entirely clean, as a cystoid cicatrix or low grades of irritation of the iris or ciliary body may often appear months after the operation, as the results of the healing of the iris in the wound.

In cases where the operation is done for glaucoma, Von Graefe says that "any healing of the iris in the wound gives harbor to the enemy we are fighting against—viz., the secretory irritability of the eye." When the sphincter muscle, or any portion of it, is left undivided, the bridge, or a portion of it, should be seized with a forceps or a blunt hook, and drawn out of the wound and cut off. Blood in the anterior chamber may be coaxed out by pressing on the upper edge of the wound and gently stroking the cornea below with the lower lid. Any small clots lying in the wound may be removed with the forceps. Many surgeons prefer to use a Graefe cataract-knife to make the incision. In fact, in some cases of glaucoma, when the lens and iris are so pushed forward as to obliterate the anterior chamber, it is the safest instrument to employ. In ordinary cases, the author much prefers the lance-knife, because the smooth and even wound made by it, coaptates instantly and heals more rapidly than the incision that is made with the Graefe knife. The eye should be cleansed and bandaged. The patient should be confined to bed till the wound has firmly healed, this taking from twenty-four to forty-eight hours.

Where there is a choice of position, the iridectomy should be performed at the upper part of the cornea. This should be done so as to have the enlarged and non-contractile artificial pupil covered in part by the upper lid, thus avoiding any excess of light and undue diffraction. In operations for optical purposes, the incision is to be made in the limbus or in the cornea just in front of it. It should be about four millimeters in extent. Where the object is to reduce tension, the wound, which should be about seven millimeters in extent, should be made where the limbus joins the sclerotic.

When the operation is performed for glaucoma, the anterior chamber should become deeper as soon as the wound is firmly healed. Should it fail to do this, it is probable that but little has been effected. In such a case, the surgeon may be called upon to perform another iridectomy. This is usually best done at a point diametrically opposite to the first. Delayed healing of the wound is a most unfavorable symptom in glaucoma. Where the operation is performed for chronic iridocyclitis, especially for that variety which is due to sympathetic disease, there is often a failure to obtain a satisfactory result. This is owing to the altered condition of the tissues. The soft and fuzzy tissue tears out in

the grasp of the forceps, rendering it impossible to excise any large portion of the iris. If there is much plastic adhesion between the anterior capsule of the lens and the iris, the lens is usually opaque, rendering it frequently desirable to evacuate it.

Korelysis is an operation that is performed at times to free the iris of adhesions to the anterior capsule of the lens. The best method of performing it is that of Passavant. An incision is made into the cornea as if for iridectomy. The iris is then seized in the grasp of the forceps over the adhesion which it is desired to loosen. The adhesion is now torn from the capsule by a series of very gentle lateral and forward pulls. Only one synechia is to be detached at each operation.

Iridodesis is a most ingenious operation which was devised by Critchett. After opening the anterior chamber by an incision in the cornea just inside of the limbus, a pair of forceps is introduced and the iris is seized between the outer edge of the sphincter and the periphery. The membrane is then gently drawn into the wound and tied in this position by a thread on the outside. The slight loop of iris thus produced, is either snipped off after an interval of forty-eight hours or allowed to heal in the cornea without interference. A mobile but somewhat distorted pupil is thus obtained, which can be placed opposite to any clear or properly curved portion of the cornea at pleasure. Should the case be one of dislocated but transparent lens, the central part of the lens may be thus utilized. In cases of zonular cataract, the pupil may be likewise placed opposite to the clear part of the lens. The fact that iridocyclitis sometimes occurs months or even years after the operation, and in some instances excites sympathetic inflammation, has led to the abandonment of the procedure.

Iridotomy consists in a division of the fibres of the iris. It is frequently resorted to after cataract operations, or after injuries of the lens, where the pupil has been obliterated by the iris drawing up into the wound. In many instances, a Hay's knife-needle passed through the tense iris in a direction at right angles to the line of greatest tension, is sufficient to make an admirable pupil. If desired, a lance-knife may, after passing through the cornea, be thrust into the iris. Where a dense membrane is situated behind the iris, these procedures will not be sufficient. Here, a lance-knife is entered through the cornea so as to make a wound of four millimeters in extent, and the point of the instrument is thrust through the iris. It is then withdrawn. A Wecker's scissors is next introduced into the anterior chamber, one blade being thrust behind the iris and the other in front of it. The instrument is gently pushed along as far as necessary. The blades are then closed, and the iris is cut. Where, however, the cut edges of the iris either do not retract or retract but little, it sometimes becomes necessary to follow the procedure by a second incision made at an angle to the first one. The second operation will often secure a satisfactory result.

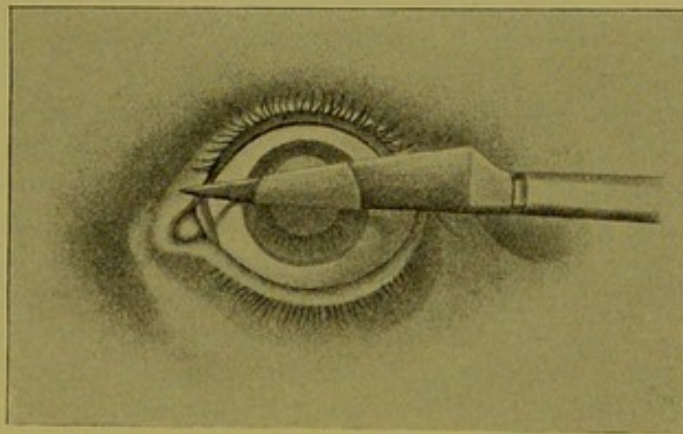
Cataract is removed from the pupillary space by three methods: I. *Extraction*, done by cutting the eyeball open and taking out the opaque lens. II. *Discission*, made by cutting the anterior capsule and some of the superficial lens-fibres, so as to allow the entrance of the aqueous humor into the substance of the lens in order to exercise its

solvent action upon it for the gradual removal of the lens material.

III. *Reclination* or *Couching*, accomplished by pushing the lens out of the pupillary space, and forcing it to assume another position in the vitreous humor.

I. In the performance of the *flap operation without iridectomy* (*simple extraction*), the bed on which the patient is to remain after the operation should be so placed that a good strong light from the upper part of a window (if possible, light that is reflected from the sky) will fall upon the patient's face when he is placed in the recumbent position. If the head of the bed is high, the patient may be reversed, so that an assistant at the foot of the bed may stand behind the patient to steady the head and raise the upper lid with a wire or a Desmarres elevator. Many operators prefer a spring speculum. This is a great advantage if there are no skilled assistants. Unless the speculum is very carefully

FIG. 355.

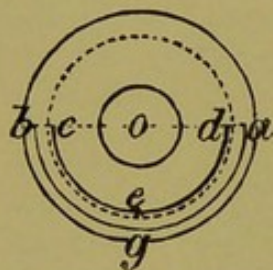


Corneal incision with triangular knife. (SICHEL.)

watched, however, it is apt to cause unnecessary tension on the eye; and further, if loss of vitreous occurs, it is impossible to remove the instrument as quickly and as gently as the elevator can be removed. The bulbar conjunctiva is then seized just below the cornea with toothed fixation-forceps. If this membrane is too friable to bear a pull with the forceps, as it sometimes is in the old and badly-nourished, the instrument is made to grasp the fascia over the insertion of the inferior rectus muscle. With a broad Graefe's knife, or with a triangular knife, such as Beer's or Sichel's, an incision is made into the cornea just in advance of the limbus, at a point immediately above the horizontal median line. Passing the blade of the instrument across the anterior chamber, the counterpuncture is made by its point at a corresponding position on the other side. If the Graefe's knife is used, its point should be made to cut upward with tolerable rapidity, and in drawing it back it should cut at the heel, so as to get it well into the upper part of the anterior chamber before any aqueous humor escapes. If this manœuvre is not properly done, the iris may fall forward on the edge of the knife. If this should happen in either case, the bridge which is left, should be divided by a gentle sawing motion until the incision is completed, the edge of the knife having everywhere been

kept just in front of the limbus. If the triangular knife has been used, it must be remembered that after a proper counterpuncture has been made, the instrument cuts like a wedge by being simply pushed forward. Fig. 355 shows how the corneal incision is performed when an upward flap is being made with a triangular knife. In any case, the operation cannot be too gentle. All pressure on the eyeball, either with the fixation-forceps or with the knife, should be avoided, and the aqueous humor should be allowed to escape slowly as the cut is completed. The incision, thus made, lies in the clear cornea, about one millimeter distant from the limbus, so that in detaching the flap, a rim of corneal tissue is everywhere left at the junction with the sclerotic. When the anterior chamber is shallow, the making of the incision is facilitated by having the pupil previously dilated with cocaine. If this be insufficient, homatropine should be used. Fig. 356 represents the position of

FIG. 356.



Position of downward section. Double natural size. (ARLT.)

the incision when the section is made downward, as was usual with most of the older operators. The figure, made double normal size for more ready discrimination of the lines, is here given to aid the reader in understanding the position of the incision. *a* is the outside puncture; *d* is the point where the knife enters the membrane of Descemet; *e* is the point of counterpuncture in Descemet's membrane, and *b* is the counterpuncture on the surface of the cornea; *d e c* is the line of the completed incision in the membrane of Descemet, and *a g b* the line of the completed incision at the surface of the cornea. The curved

dotted line indicates the position of the margin of the lens. If the Desmarres elevator be used, it is advisable to let the patient close the eye and rest it before proceeding to cut the capsule. This may now be done by making either a cross-cut in it with a double edged needle or a V-like cut with a cystitome. Many operators have advised attempting to cut a piece out of the anterior capsule either with a cystitome or with a toothed forceps. In the opinion of the author, an endeavor should be made to make the opening large and central, and to push aside and tuck away the torn flaps of the capsule. Knapp recommends a horizontal division of the capsule by a single slit, making this behind the iris. He does this in the belief that such an incision prevents contact of cortical matter with the iris, thus tending to prevent inflammatory reaction from this sensitive blood-bearing muscle. On the other hand, the capsule thus left in the pupillary space is sure to thicken, and thus make a secondary operation necessary. In over-ripe cataracts where the anterior capsule is thickened, it may be perforated with a sharp hook, and the lens and the entire capsule drawn out of the eye. Upon the completion of the capsulotomy, the lens generally comes forward. The surgeon is now ready to dispense with fixation-forceps and to deliver the lens. To do this, he, with the thumb of one hand on the upper lid, and two fingers of the other on the lower lid, gently tilts the upper edge of the lens forward by slight pressure backward over its lower margin. The lens is then coaxed out of the wound by stroking the cornea upward.

Should he prefer, the fixation-forceps may be kept in position. Slight pressure backward at the lower corneal margin so as to tilt the upper equatorial edge of the lens forward, can be made with a tortoise-shell or hard-rubber spoon, the same stroking manœuvre being repeated with the spoon as that described to be executed on the lower lid by the fingers. For beginners, the latter method of delivering the lens is the safer, as they are less likely to exercise undue pressure on the eyeball, and thus rupture the hyaloid membrane. If, owing to absence of orbital fat and a want of proper pressure on the globe from the orbicularis and straight muscles, the lens and the vitreous do not come forward against the cornea, the cystitome should be reintroduced, so as to be certain that the capsule is divided. This procedure should be accompanied by slight pressure on the lower part of the ball. If the capsule has been divided, the pressure will cause the upper edge of the lens to present in the wound. If the lens still fails to come forward, the corneal incision is probably too small, and should be carefully enlarged with the scissors. If vitreous presents, appearing as a dark line at the upper part of the wound, all attempts at stroking out the lens should be abandoned, as such efforts will usually cause more vitreous to come forward, allowing the escaping bead to force the lens downward and backward into the posterior chamber. Under these circumstances, a wire loop is to be carefully introduced behind the lens. When this has been accomplished, the handle of the instrument is raised so as to throw its upper end slightly backward, thus causing the loop to catch the lens. By now pressing the instrument gently forward toward the cornea, the lens is readily brought out of the wound. Some operators prefer to draw out the lens by a sharp hook thrust through the posterior surface of the lens-substance.

If there has not been any rupture of the hyaloid, escape of vitreous, or other accident, it becomes necessary to endeavor to evacuate all loose cortical matter and to obtain a perfectly clear and black pupil, so that the patient can readily count fingers held at a distance of eighteen inches. This may, at times, be done by repeated stroking. In order to still more thoroughly remove all cortical matter from the anterior and the posterior chambers, various means of washing out these recesses have been devised. The solution usually used is distilled water or a weak solution of boric acid, that has been carefully warmed to blood-heat. The instrument of Lippincott, by which a stream of water impelled by gravity can be readily regulated as to size and force of stream, is admirably adapted for this purpose. It has the disadvantage, however, of introducing another instrument into the anterior chamber and thus giving additional opportunity for accident in restless or nervous patients. Furthermore, it seems to the author, that even when carefully managed, it always causes some disturbance in the nutrition of the cornea. As the introduction of weak solutions of bichloride of mercury always causes clouding of the cornea, they should be avoided. Panas recommends a weak solution of the biniodide of mercury as the proper agent for washing out the anterior chamber.

If the iris has its proper resiliency, it will allow its pupillary opening to be stretched to permit the exit of the lens; drawing back into

place after the lens is extracted. If the pupil is displaced toward the incision, the iris may be gently stroked back into place by a small tortoise-shell spatula. If, however, the iris prolapses and remains prolapsed, the protruding portion should be seized with the forceps and excised. Care should be taken that the angles of the coloboma are stroked back into place. If the corneal incision has been properly made and placed, there will usually be no prolapse of the iris. If it be placed too far back, this accident is almost unavoidable. If the incision be made as directed, the wound at the membrane of Descemet, measuring horizontally about nine millimeters, will gape antero-posteriorly to three or four millimeters, thus giving ready exit to the lens. No greater mistake can be made than either to introduce the knife too obliquely or to place the incision too far forward, thus causing the inner edge of the corneal wound to be too small to permit the easy exit of the lens. If the operator makes these mistakes, he should immediately enlarge the wound at each end with a pair of fine scissors. After the completion of the operation, two or three drops of a quarter of a grain solution of sulphate of eserine, to insure contraction of the pupil, should be instilled. The method of operating above given, is nearly the same as that described by Daviel, Beer, and the older operators. Most surgeons of the present day make the flap a little smaller, so as to comprise about two-fifths of the cornea. If the incision be made in the limbus of the cornea, where the tissues, being vascular, heal more readily, its position, though facilitating the exit of the lens, necessitates an iridectomy and disposes to loss of vitreous. A lesser degree of periphericity in the cut, although giving a conjunctival flap which is liable to bleed, insures an earlier closing of the wound. In the opinion of the author, the more peripheral cut should always be avoided if it is desired to perform the operation without iridectomy. In the simple flap operation for extraction as invented by Daviel, and practised by many later surgeons, the incision was made downward. Other operators preferred making the cut upward—a practice that is followed by the author, who believes that the flap so placed is better splinted by the upper lid.

In the flap operation with iridectomy, the incision, except when it is desired to include but two-fifths of the cornea, is performed in a manner that is similar to that which is made for simple extraction. If a conjunctival flap is desired, the incision may be placed a little nearer to the periphery of the cornea. The iris-forceps are introduced into the anterior chamber, and the iris is seized and cut as has been described in the operation for iridectomy. Often, there is sufficient hemorrhage from the cut iris to prevent a good view of the pupillary area and a proper cutting of the capsule of the lens. When this occurs, the eye should be closed, hot-water compresses applied, and endeavors made to secure the exit of the blood by pressure on the upper lip of the wound, while the cornea is gently stroked upward. The opening of the capsule and the delivery of the lens are accomplished as described under the rules for the performance of the simple flap operation. Just as before stated, care must be taken to see that the cut edges of the iris are properly replaced, and not left entangled in the wound. The cleans-

ing of the anterior chamber from cortical remnants is then proceeded with in the same manner as explained for the simple method of extraction.

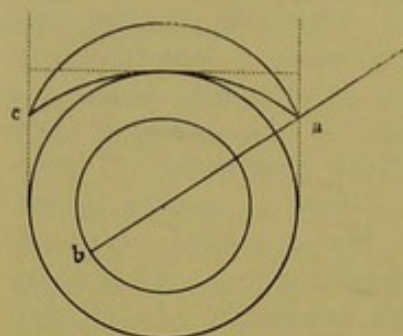
After completion of all flap operations, either with or without iridectomy, the eye should be gently washed with lukewarm boracic acid solution. This is done in order to remove any traces of lens-matter or blood from the conjunctival sac. If the eye is otherwise healthy, a slight amount of blood remaining in the anterior chamber is of little consequence, as it is generally absorbed in from twenty-four to forty-eight hours' time. In all cases, both eyes should be gently closed, covered with antiseptic gauze wet with a one-to-four-thousand solution of bichloride of mercury, and a light pad of antiseptic cotton. After these have been applied, the eyes should be carefully bandaged. In all flap operations, there is great danger of the patient's opening the wound during the first few days by ill-considered efforts at coughing, straining at stool, or moving in bed. The patient should be warned of the danger of putting his hands to his head or of touching the bandages. The restlessness and backache which generally arise from his being obliged to remain long in one position, may be allayed after the first few hours, by having him gently raised to a sitting posture in bed and slipping a best-rest behind him.

Linear extraction is a proceeding that is adapted only to fluid or partly fluid cataracts, or to such cataracts as have undergone considerable shrinking. The pupil should be dilated to its utmost before performing the operation. An incision from six to nine millimeters in extent at a point about half-way between the centre and the periphery, is made in the cornea with a lance-shaped knife. The aqueous humor should be evacuated slowly, so as to retain at least part of the pupillary dilatation. If the cataract is shrunken, a sharp hook is introduced into it, and the lens drawn out of the opening. In semi-fluid cataracts, the capsule is opened with a cystitome, the fluid cortical is evacuated through the wound, and the nucleus of the lens is gently stroked out. In soft cataracts, a discission may be done a few days previously, to further soften and liquefy the lens-matter that is to be extracted.

In the *peripheral linear operation*, which was first adopted by von Graefe, the pupil having been dilated, the incision is made with a knife whose blade is two millimeters broad and three and a half centimeters long. The knife is introduced with its point directed to the centre of the pupil at a point in a line which is coincident with a vertical tangent to the outer border of the cornea, one and a half millimeters from it, and two millimeters below the horizontal tangent of the upper border. When it has penetrated to about six millimeters, the handle is lowered, thus carrying the point up and across the chamber. The counter-puncture is now made at a corresponding position on the other side, the knife being made to cut out just at the upper border of the cornea by a gentle sawing motion. The incision of the wall of the eyeball being completed, the conjunctiva in front of the knife is cut by turning the edge of the instrument forward and cutting out slowly, so as to form a conjunctival flap of two to three millimeters' width. If the heel of the

knife be raised, the conjunctiva may be divided more rapidly. Fig. 357 graphically explains the method of operating. The dotted lines

FIG. 357.



Peripheral linear incision. (ARLT.)

indicate the vertical and horizontal tangents of the cornea. *a* is the point of puncture, and *c* is that of the counter-puncture. The straight solid line, *ab*, indicates the original direction of the knife. The curved line, *ac*, shows the position of the wound in the eyeball, and the curve, *cda*, indicates the situation of the conjunctival flap. The conjunctival flap is now pushed back on the cornea, and a portion of the iris is seized with the iridec-tomy-forceps and cut off accurately at the outer margin of the wound with the iris-scissors. A V-shaped or quadrilateral opening is then cut in the anterior capsule with a cystitome. While the fixation-forceps still retain their grasp on the eyeball, pressure is made with a rubber or tortoise-shell spoon at the lower edge of the cornea. The upper margin of the lens equator is next gently pushed forward into the wound by a gradual stroking motion of the spoon on the cornea, and the lens is extruded from the eye. By a continuation of similar stroking movements, either with the fingers on the lids or with the spoon on the cornea, all remnants of cortical matter are removed from the anterior chamber. As deep-lying fragments sometimes elude these manipulations, it is usually better to leave them to absorb, rather than to risk any loss of vitreous by attempting to effect their removal with a spoon. Any clot of blood is to be removed from the wound with the iris-forceps. The cut edges of the iris are disentangled from the incision and stroked back into place with a thin horn-spatula. The conjunctival flap is carefully replaced, thus concluding the operation.

II. *Discission* is effected in two ways: either by introducing a needle through the cornea, or by carrying it through the sclerotic coat. The first method is known as *keratonyxis*, and the second is termed *scleronyxis*. In either plan, the pupil is to be previously dilated to its maximum by repeated instillations of a four-grain solution of atropine. The former operation is the one that is usually to be preferred. To perform it, a double-edged sharp needle, with its cutting portion made from two to three millimeters in length, fastened to a stout cylindrical shaft that fills up the cut made by its point so as to prevent loss of aqueous, is required.

This is plunged preferably through the lower outer quadrant of the cornea, about half-way between the centre and the periphery. A cut is then made in the anterior capsule by using the instrument as a lever with its fulcrum in the cornea. The needle is then slightly drawn backward and rotated, and another incision, preferably at right angles to the first cut, is made across the first capsular incision. The capsule and some of the anterior fibres of the lens are thus divided. As the lens capsule holds the lens in a state of tension, when it is intact, it allows the swelling lens to force a little mass of lenticular substance

into the anterior chamber when it is divided. As this portion of the lens-matter is acted upon by the aqueous, it becomes more opaque. Sometimes, portions of it drop off and fall to the bottom of the anterior chamber. At the conclusion of the operation, atropine is to be re-instilled, and both eyes are to be closed. Great care should be taken not to do too much at the first sitting, as otherwise such swelling of the lens may arise as to press the iris against the cornea and to sufficiently interfere with intra-ocular circulation as to bring on an attack of glaucoma. If this should occur, the atropine must be stopped and tension diminished by tapping the anterior chamber and allowing the escape of some of the lens-matter. If necessary, this procedure should be followed by an iridectomy.

The operation is well adapted to the soft cataracts of infancy and childhood, yielding excellent and perfect results. As a rule, it must be repeated several times. As the process of absorption is slow, a period of not less than ten to twelve weeks must be counted on for complete clearing of the opaque lens. When the capsule is hard and the lens is tough, the needle should be bored into the lens-substance by rotary motions, as otherwise the lens might often be dislocated instead of making an efficient slit in the capsule. The pupil is to be kept dilated by the free use of atropine during the entire after-treatment.

In the operation for *scleronyxis*, a double-edged needle with the cutting part made slightly curved on the flat, or better, a Hay's knife-needle, is introduced into the sclerotic about four millimeters behind the cornea and just below the horizontal median line of the globe. When the point of the instrument is placed on the outer side of the sclerotic, it is directed toward the centre of the eyeball. After entering the globe, however, it is turned forward and gently slid up between the posterior surface of the iris and the anterior capsule of the lens. After it has attained the upper inner portion of the pupil, slight incisions in the anterior capsule and the anterior lens-fibres are to be made by gentle lever motions. In withdrawing the instrument, a reversal of the motions made during the entrance of the knife, is to be observed. In this way, Hays, Littell, and others in Philadelphia frequently operated on senile cataract, often obtaining absorption of the lens with good eyesight. The operation for this purpose, however, has been properly superseded by the various methods of extraction.

III. The now rarely performed operation of *reclination* is most easily done whilst the patient is placed in the sitting posture, care being taken that there is good fixation of the head and eyelids. Previous thorough dilatation of the pupil with atropine, is necessary. A double-edged reclination-needle, with a lance-shaped blade about one millimeter broad and three millimeters long, slightly curved on the flat, is passed through the sclerotic on the outer side of the eyeball just below the horizontal median line and about four millimeters behind the margin of the cornea. At first, the cutting edge is held horizontally, and the needle is directed toward the centre of the eyeball. As soon as the lance-shaped head has passed through the sclerotic, the instrument is rotated so that its cutting edges shall be vertical. It is then turned forward, and brought up in the posterior chamber between the

iris and the lens, to the upper inner part of the pupillary space. The handle is now raised upward and inward toward the glabella, thus pressing the lens downward, backward, and outward into the vitreous. The needle is held in position for a moment, to allow the vitreous to settle around it. It is then carefully withdrawn by a reversal of the motions that attended its introduction. Hard, dense cataracts are the only ones which can be operated upon successfully by this method. This is so, because if similar attempts be made with softer ones, they will frequently break up and leave large lens-flocculi in the anterior and posterior chambers and in the vitreous. If the operation is successfully executed, the lens lies over the posterior part of the ciliary body, where it becomes encapsulated. Should the patient move at the critical moment, the lens may be displaced into the anterior chamber. In this case, it should be removed by a flap operation. If carefully executed, the immediate results are often astonishingly good. A moderate degree of ciliary injection supervenes, which soon subsides under atropine, and in the course of two or three weeks the eye again becomes perfectly white and quiet. Frequently, however, the operation is followed by such changes in the vitreous as to superinduce detachment of the retina. Still oftener, the lens lying on the ciliary body becomes a starting-point for inflammatory changes in the uveal tract. Such pathological alterations often take months or years to become perfectly developed, but nevertheless are clearly due to the operation. These after-results have led to the almost entire abandonment of the procedure, except in feeble and simple-minded old people who cannot be trusted to keep quiet in the after-treatment of extraction. It is also employed for the removal of the shrunken hard lenses from the pupillary space that are often found obstructing vision in children.

Secondary cataract. In all forms of cataract operations in which the entire lens in its capsule is not removed from the eye, definite changes take place in the capsule, as shown on page 430. The resultant pupillary opacities are designated as secondary cataract. For those cases in which there is a thin and delicate web, the best method of treatment is to tear or cut a hole in it with a discission-needle or a Hay's knife-needle. When the membrane is denser, two Bowman's stop-needles may be introduced in the same opening in the capsule. By separating them from one another, a hole can be torn in the secondary cataract without pulling on its attachments to the ciliary processes. Such membranes are sometimes removed from the eye in their entirety. This is done by making an incision in the cornea just in front of the limbus, inserting a sharp hook into the membrane, and pulling the membrane out of the opening. The principal objection to this method of proceeding is, that severe inflammatory reaction is likely to be produced by dragging on the ciliary processes. Noyes has suggested an ingenious and useful operation in such cases. A Graefe's knife is thrust through the cornea just in advance of the limbus and carried through the anterior chamber and out on the other side at a corresponding point, thus making an incision two millimeters in extent on opposite sides of the cornea. As the knife is withdrawn through the first incision, its point is made to cut a vertical hole in the mem-

branous cataract. Two blunt hooks are carried into the anterior chamber through the two openings in the cornea, and are made to catch on each side of the hole in the membrane. This hole is now enlarged by separating the extremities of the hooks. Denser membranes may be cut by passing a Graefe's knife or a lance-knife through them. If it be desired to enlarge the opening, a Wecker's scissors can be employed in the same manner as described, under the head of iridotomy.

Amongst some of the accidents that occur during and after cataract-extraction are :

1. Collapse of the cornea. In deep-seated eyes, with diminution of the orbital fat, where the action of the orbicularis and straight muscles is not sufficient to push the lens and the vitreous sufficiently forward to support the cornea, collapse of this membrane readily ensues. The consequent wrinkling of the cornea is annoying, as it prevents the contents of the anterior chamber from being clearly seen during the operation. Sometimes, this want of resistance makes it difficult to divide the capsule of the lens. Slight pressure on the eyeball with the fixation-forceps, however, is often sufficient to remedy this defect.

2. Loss of vitreous. This often ensues from want of skill and care on the part of the operator. It may be due to making too much pressure on the eye. It may also occur during the performance of a cystotomy which is too peripheral or too violent, thus pressing back the lens sufficiently to rupture the suspensory ligament and the posterior capsule. Owing to pathological thinning of the zonula and fluidity of the anterior portion of the vitreous, it is, however, at times, unavoidable. If the accident occurs at the completion of the first cut, or while the capsule is being torn, it will generally be necessary to introduce a wire loop and remove the lens. When it occurs during the expulsion of the lens, or after its extraction, it often prevents the anterior chamber from being freed from detached cortical. When the prolapse is small, it may retract of itself in a few hours. If it remains in the wound, its outer part turns yellowish-gray and sloughs off as the wound closes. Although a considerable portion of vitreous may be often lost and recovery with good eyesight take place, yet the accident certainly predisposes to those secondary changes that at times result in retinal detachment.

3. Hemorrhage. This frequently occurs in operations in which the iris is cut or where a conjunctival flap is made. At times, it renders the making of the incision of the capsule a matter of difficulty. If there be considerable hemorrhage, gentle pressure on the eye for a few minutes with a wad of cotton, or the use of hot-water compresses, will generally be sufficient to check it. Where the incision is made in the cornea, there are not any cut vessels to contend with. Here there cannot be hemorrhage except in those fortunately quite rare cases where there have been foregoing glaucoma and disease of the coats of the vessels of the chorioid. In such instances, the hemorrhage comes from the interior of the eyeball. If the wound gapes slightly at the completion of the operation, it is due to the presence of remnants of cortical matter, lens-capsule material, or iris-tissue in the wound. If cortical matter be present, it should be removed with the spoon or spatula, followed by washing with boracic acid solution. If opaque and thickened capsule be found,

it should be seized and cut off. If a portion of the iris be caught in the wound, it should be carefully replaced with the spatula. When the prolapse of the iris recurs, the prolapsed portion should be seized and excised. Sometimes, in over-ripe cataracts, the cystitome dislocates the lens instead of tearing the capsule. In this case, the lens may sometimes be removed entire in its capsule by stroking manipulations, or by catching a sharp hook into its anterior capsule. The rule is, the larger the flap is made, the greater is the danger of subsequent bursting open of the wound by any straining on the part of the patient or by pressure on the eye. Sometimes, the break may simply allow the aqueous humor to leak out for a time and thus delay healing. Oftener, however, the iris will prolapse into the wound, causing at times, the sequelæ of iritis and iridocyclitis. When severe inflammatory reaction does not set in, it is well to excise the prolapse on the fifth or sixth day. Sometimes, the healing of the wound may be further advantageously stimulated by gently touching the lips of the wound with a galvano-cautery. Post-operative inflammation is best combated by the employment of cold compresses and atropine. In the feeble, however, heat must be substituted for cold, and the general circulation and nutrition aided by the administration of stimulants.

Inasmuch as Daviel's method is now often done with a rather smaller flap and the operation is performed with the observance of strict antiseptic precautions, most surgeons of large experience, prefer the flap operation without iridectomy. By resorting to such measures, it has been hoped to get rid of one of the most formidable objections to the old operation—sloughing of the cornea—which, in the hands of the best operators by the old method, occurred from six to eight times in every one hundred cases. It is beyond dispute that, when the operation is successful, it is the ideal one, as it leaves an eye which, to actual inspection—except in the depth of the anterior chamber—almost exactly resembles its fellow. It also has the advantage of giving the patient a round pupil and a mobile iris. Even in the hands of the most expert operators, however, prolapses which require to be cut off, will occasionally occur. Moreover, there is more likelihood that the wound will open, thus allowing the iris either to prolapse or to become adherent to the cicatrix. Again, the position of the iris mechanically renders the complete emptying of the cortical matter out of the posterior chamber at the time of the operation, difficult. On the other hand, iridectomy often causes a hemorrhage at the time of operation, thus rendering the further steps in the procedure more difficult to perform properly. In prominent eyes, where the coloboma is not well covered by the upper lid, an annoying diffusion of light is produced when the patient is out of doors or is facing some source of light, such as a window or a lamp. Under favorable circumstances (such as in moderate illumination), the acuity of vision is not materially affected by the coloboma.

In complicated cases, where there is any suspicion of chronic inflammation in the uveal tract, or where there appears to be a tendency to glaucoma, a preliminary iridectomy performed six weeks or two months before the operation, produces marked improvement in the nutrition of the eye, and offers greater chances for a successful result. In any case,

the iridectomy renders the cleansing of the anterior and the posterior chambers from any remaining cortical much easier to perform. Further, it enables the corneal wound to be made smaller. As to the question of suppuration of the cornea or infectious inflammation of the iris, the present antiseptic methods ought to render either method of procedure equally efficacious. The author, therefore, while fully realizing that the subject is still *sub judice*, is inclined to believe that out of any considerable number of consecutive cases taken as they occur in hospital practice, and operated on by the same individual, the operation with iridectomy will, in the average, give the better results. In consequence, he is disposed to reserve the operation by the corneal flap without iridectomy for those cases in which there is but little soft cortical, where the iris is still elastic and dilatable *ad maximum*, and where reasonable quietude can be expected for at least three or four days after the operation.

Paracentesis bulbi, or *opening of the eyeball through the sclerotic*, is, occasionally made. This is done either to enable some foreign body—such as a cysticercus or a piece of metal, to be extracted from the vitreous chamber, or to evacuate sub-retinal fluid. Where there is a choice of situation, it is best, so that the edges of the wound may lie in close apposition, to make the incision in the direction of one of the antero-posterior meridians of the eye, at the outer and lower part of the ball, between the external and the inferior straight muscles. In cases where it is desired to extract a parasite or foreign body, it is well to disassociate the conjunctiva and pull apart the opening by small sharp hook, so that the foreign body may not be scraped off during extractions. Where there is a piece of iron or steel in the eye, the forceps or *maigne* should, as a rule, be introduced through the wound of entrance. If necessary, the wound should be slightly enlarged. In cases of retinal detachment, attempts were formerly made to allow the fluid to gain access into the vitreous by scleronyxis with one or two needles. Now, when an operation for this purpose is undertaken, it is generally performed by either drawing off the fluid with an aspirating syringe, or allowing it to escape through a scleral incision.

In performing *enucleation*, the patient having been etherized, and a spring speculum inserted between the eyelids, the conjunctiva is seized at the outer side of the cornea with toothed forceps, and an incision is made into the fold thus raised with the scissors. Picking up the cut edges of the membrane, and slipping one blade of the scissors beneath it for some distance, the conjunctiva is completely detached from the cornea as close as possible to its border by repeated cuts. The straight muscles are then taken up in succession on a hook and divided at their insertions into the sclerotic. The external rectus muscle is severed so as to leave a little stump. This stump is seized with the forceps, and the eyeball is rotated toward the nose. A strong pair of scissors curved on the flat is now introduced along the sclerotic back to the optic nerve, which, thus placed within easy reach, is snipped off with a single cut made some two or three millimeters behind the globe. If desired, the assistant may at the time of the cutting of the nerve, press the spring speculum backward, so as to make the eye come forward in the socket.

This manœuvre often facilitates this part of the procedure. The eyeball being then luxated onto the cheek, the tendons of the oblique muscles are divided at their insertions into the sclerotic. Arlt advises that the operation be commenced by seizing the conjunctiva at the outer side, and cutting this portion of the membrane away from the cornea as far above and below as the insertions of the superior and inferior rectus muscles. The external rectus muscle is next divided, so as to leave a stump. This is seized by the forceps. The scissors are made to glide along the sclerotic with one blade under the inferior rectus muscle. This muscle is then separated from its insertion. A similar procedure is followed for the superior rectus muscle. The eye is next rolled inward toward the nose, and the scissors, with closed points, are carried back to the optic nerve. This is now divided. The ball being pulled forward out of the orbit, is seized by the fingers of the operator, and the oblique muscles cut away from their insertion. Lastly, the internal rectus muscle and the overlying conjunctiva are divided.

In all cases, the cavity should be well washed with a solution of bichloride of mercury and dusted with iodoform or aristol. A firm pressure bandage is applied over the eye. In a few hours, when all danger of further infiltration of the orbital tissues or of the eyelids has passed off with the cessation of hemorrhage, this dressing should be removed and replaced by a looser one. It is important to save as much conjunctiva as possible, so as to insure a good socket for the application of an artificial eye.

Exenteratio bulbi, or removal of the contents of the eyeball, is best performed as recommended by Alfred Graefe. After the most thorough antiseptics of the conjunctival sac, the eyeball is seized at the limbus by a pair of powerful toothed forceps. An assistant grasps the conjunctiva and episcleral tissue at a point five millimeters distant and further back on the eyeball with a similar pair. The sclerotic is now carefully divided by repeated cuts between these two points with a sharp knife, and thus the anterior portion of the ciliary muscle is laid bare. One branch of the forceps is gently introduced into the supra-chorioid space and the cornea is cut off by successive clips of the scissors. This having been accomplished, the sclerotic is again seized by the two pairs of forceps, separated this time about ten millimeters apart. The globe is thus held firmly. A sharp curette, curved so as to adapt itself to the inner surface of the sclerotic, is employed to cut the attachments of this membrane to the chorioid; the vorticosse veins, the posterior chorioid arteries, and the neck of the optic papilla, constituting the main points of attachment, and offering the firmest resistance. The inner surface of the sclerotic have been thus carefully freed, as far as possible, from all adhering tissues, the cavity of the globe is most thoroughly washed with a strong solution of bichloride of mercury. The cut edges of the sclerotic are united by from three to five catgut sutures. These sutures are intended to keep any oozing blood within the eyeball. An aseptic but organizing ball is thus formed on the inside of the globe, thus obtaining a large and prominent stump. Mules, and some English surgeons, have advocated the placing of a glass ball within the scleral cavity before the wound is sutured.

Exenteratio orbitæ, or removal of the orbital contents, is generally necessitated by large orbital growths that involve the eyeball. The operation is commenced by slitting the outer canthus and dissecting the lids back from the growth, so as to save them should they not be invaded by the neoplasm. With a pair of blunt scissors and a bone elevator, the growth is gradually worked free on all sides, and is detached as far back as possible. Finally, the mass is pulled forward by a tenaculum, and the optic nerve and the origins of the straight muscles at the optic foramen, are divided by the scissors. When it becomes necessary to remove the periosteum, this membrane should be divided with a sharp scalpel at the edge of the orbit. It may then be readily worked loose and separated from the bone by a bone elevator and scissors. When the growths are small and lie outside of the straight muscles, they may sometimes be dissected out. This is done by working carefully in ward from the conjunctival cul-de-sac, cutting the conjunctiva at the retro-tarsal fold, thrusting this membrane aside, and gradually enucleating the tumor, without disturbing the eyeball. If after removal of all of the orbital contents and the periosteum, the growth appears to have infiltrated the bony walls, it is best to singe the parts so affected with a hot iron or a galvano-cautery, remembering, however, that severe cauterization, either in this way or by the employment of zinc paste, may cause exfoliation of bone, or possibly bring on meningitis. In complete exenteration, the orbit should be thoroughly washed with a solution of bichloride of mercury, and the wound should be packed with small pellets of antiseptic gauze that have been well greased with vaseline and infiltrated with iodoform. If the lids have been preserved, they should be closed and stitched together at the divided external canthus. They should be covered by gauze that has been freshly wrung out in a solution of bichloride of mercury, and a roller bandage should be applied. The packing is to be removed on the second day, and the orbit again washed and dusted with iodoform. This should be repeated at least once daily till the cavity heals.

When the growth has perforated the roof of the orbit, the operation is apt to be followed in a short time by death. If the growth has invaded the lids, and it is necessary to partly or wholly sacrifice them, it becomes desirable to perform some form of plastic operation to supply their place.

Operations on the lacrymal apparatus are both important and frequent. Most cases of obstruction of the lacrymal passages are best treated by the introduction of probes combined with the injection of weak astringents so as to wash the lining mucous membranes free from any mucoid or purulent secretion, and thus bring about altered action. The probe may be introduced either from the lower or from the upper canaliculus. This is easily effected in the lower canal, as explained on page 572. If necessary, the punctum can be dilated by a small conical probe and the probe-point of a Weber's knife introduced into it. The handle of the knife is lowered till it is made parallel with the margin of the lid, and then it is slowly thrust forward in the canaliculus in a direction toward the median line, and slightly upward, till its point enters and crosses the lacrymal sac and is felt to touch the unguis bone.

While the lid is still held stretched, the blade is made to cut out by raising the handle, the cutting edge of the knife being turned slightly inward toward the conjunctival sac, and the incision being carried to the edge of the caruncle. A No. 2 or No. 3 sound of Bowman's series is introduced along the slit canaliculus till its inner end touches the inner wall of the sac. It is then raised nearly to the vertical position and coaxed down in the direction of a point in the inferior meatus of the nose that lies about an inch deeper than the junction of the ala and the cheek; this being done so that the final direction of the probe corresponds with a line drawn from this point to the middle of the tendon of the orbicularis muscle. When the probe is in the canaliculus, and it is desired to raise it to bring it in the direction of the lacrymal duct, the patient should be directed to look up, as the relaxation of the orbicularis muscle thus induced, favors its introduction. The probing should be frequently repeated. If there is much mucus in the sac, the duct should be cleansed with an astringent solution, which can be introduced through one of the hollow probes that is attached to an Anel's syringe. An ordinary glass hypodermic syringe makes a good substitute. The probes with bulbous ends, as spoken of by Travers and H. W. Williams, are often serviceable. Although many surgeons prefer the larger probes of Weber or Theobald, the author, believing that a small opening in a duct clothed with healthy mucous membrane is sufficient to carry off the tears, prefers frequent probing and syringing with small hollow probes, as much more likely means to bring about a normal state of affairs, than forced dilatation with large ones. Many surgeons advocate cutting strictures of the lacrymal sac. This is best effected by introducing a Weber knife through the entire length of the canal and cutting through the obstruction by pressing the edge of the knife against the bony wall as the instrument is withdrawn.

Abscess of the lacrymal sac should always be promptly opened. In its early stages, this is best done by incising it from the inside by carrying a Weber's knife through the canaliculus. In the later stages, however, it is better to open the sac with a scalpel or bistoury that has been introduced from the outside. In the latter operation, the point of the instrument is placed at right angles to the convex surface of the sac and about its middle, just below the tendon of the orbicularis muscle. The knife is then carried inward into the sac, when by raising its handle, the point drops readily into the duct. If the inflammation has subsided under the use of hot-water compresses and frequent evacuation of the contents of the sac by pressure with the finger or by gentle syringing from the outside, it is time to commence syringing by the canaliculus. This is to be followed by treatment with probes and astringents, as previously described.

Obliteration of the sac may be performed either by laying the sac open from the cheek or by freely slitting the conjunctival surface from the upper and the lower canaliculus. The walls of the sac are then to be seized with forceps and dissected out as far as they can be reached. The remaining portions should be cauterized by such an amount of nitric acid as will adhere to a piece of soft wood that has been dipped into it.

Prothesis oculi, or the application of an artificial eye, should never be done till the wound that has been caused by enucleation or evisceration is well cicatrized and the stump has lost all tenderness to the touch. The eye is inserted by gently raising the upper lid with one hand, while with the other, the thick end of the shell which has been moistened with water or vaseline, is slipped under the lid and rotated so as to cause it to slide into the outer corner. The edge of the lower lid is then pulled outward and downward, and the lower edge of the shell slid into the lower conjunctival cul-de-sac, where it is firmly held, when the lower lid is allowed to come back into place. To remove the eye, the lower lid is slightly pulled downward and the head of a pin is inserted under its lower edge. The shell is then slightly pulled forward so as to readily slip out. Artificial eyes should be carefully washed with water and wiped dry each time that they are removed from the socket. Even the best soon become rough and must be laid aside. Celluloid eyes, though cheap and not easily broken, corrode readily and become very offensive. A well-made glass eye should, with proper care, last about two years.

TEST-TYPES.

D-050

LEET
COOL
FUEL
ROLL

COOF
FUEL
FUEL
FUEL

FOOB
LOLL
BOFE
CHLY

D-150

CODE
FLED
COLD

DOLT
LOOT
DOLL

D-075

COO
TEE
ODD
ELL

LEE
COB
HEL
DOT

OLD
LET
TOO
FOE

ELL
TOD
OFF
COT

D-200

FED
ODE
LOT

LOO
TOE
OFT

D-100

LEET
FOLD
TOLL
DOLE

COLT
FEED
TOLD
FELL

LOFT
DELL
FOOL
FLOE

D.=V.

E O F C T D L

D.=VII[†].

C T O E D F

D.=X.

F D F C T L

D.=XV.

O L C F

D.=XX.

T

D

F



D.=XXV.

D

F


C

D.=XXX.






D.=XXXXV.

E



D.=XL.





INDEX.

- ABDUCTION**, 553
A Abrasio corneæ, 595
 Absorption of light, 105
 Accommodation, 142, 153, 368
 determination of, by Scheiner's experiment, 168
 by the fundus-reflex test, 168
 power of, 166
 hypothesis of Helmholtz, 153
 insufficiency of, 235
 in emmetropia, 369
 in hypermetropia, 369
 in myopia, 369
 mechanism of, 90, 91
 negative, 159
 power of, 154
 range of, 155
 in a hypermetropic eye, 157
 in a myopic eye, 156
 region of, 154
 Accommodative power, fall of, with age, 369
 Acini, 42
 Actual cautery, application of, 601
 size of an object, 87
 Acute glaucoma, 517
 Acuteness of vision, 164
 Adduction, 553
 Advancement, operation for, 599
 Prince's operation for, 599
 pulley method of operation for, 599
 After-images, 88
 Albinism, 363
 ophthalmoscopic appearance in, 444
 Alcohol as a cause of optic-nerve degeneration, 487
 Amaurosis, uræmic, 491
 Amblyopia, crossed, 494
 without ophthalmoscopic changes, 491
 Ametrometer, 252
 Ametropia, action of irides in, 239
 apparent length of antero-posterior portion of globe in, 238
 behavior of, during mydriasis, 262
 chromatic aberration, test for, 253
 determination of, by test lenses, 262
 estimation of, by ophthalmometer, 257
 facial asymmetry in, 238
 formula for lenses in, 268
 fundus-image test in, 249
 optometric methods for determining, 250
 presbyopia in, 238
 range and power of accommodation in, 237
 Scheiner's experiment in, 251
 size of pupil in, 239
 strength of lens to employ in correction of, 266
 theory of ophthalmoscope in estimation of, 241
 value of ophthalmoscope in detection of, 240
 visual acuity in, 237
 Anæmia of disk from action of cold, 483
 Anæsthesia of cornea in glaucoma, 519
 Anatomy, macroscopic and microscopic, 27
 Angioma, 579
 Angle alpha, 148
 gamma, 149
 Aniridia, 363
 Behr's experiment in, 206
 Anisometropia, 271
 Ankyloblepharon, 565
 operation for, 592
 Annulus fibrosus, 38
 Anterior chamber, 61
 encapsulation of foreign bodies in, 295
 hemorrhages into, 286
 nodal point, 132, 145, 147
 principal focus, 145
 point, 145
 Antimetropia, 271
 Apex of prism, 122
 Aphakia, 387
 amount of lens-strength to be worn in, 271
 Apparent size of objects, 86
 Aqueous humor, 34
 Aquo-capsulitis, 356
 Arcus senilis, 347
 Argyll-Robertson symptom, 484, 544
 Argyrosis, 323
 Arteria dorsalis nasi, 31
 Arterial pulse in retina, 443
 Artery, persistent hyaloid, 513
 Astigmatism, 411
 appearance of optic disk in, 240, 241
 compound hypermetropic, 412
 myopic, 412
 corneal reflexes in, 238
 correction of, 416
 irregular, 272
 detection of, by fundus-reflex test, 228
 determination of, 414

- Astigmatism, determination of, by ophthalmometer, 414
 improper spectacle-frames in, 239
 irregular, 411
 meridional, correction of, 272
 mixed, 413
 principal meridians in, 237
 regular, 411
 simple hypermetropic, 412
 myopic, 412
 symptoms of, 236, 413
 tests for, 237
 use of Placido's disk in, 414
- Astigmometer, 252
- Atrophy of optic nerve, from action of
 cold, 482
 from hemorrhage, 482
- Atropia, action of, 375, 377
- Axial ray, 131
- Axis of cylinder, 126, 128
- B**ABBAGE'S compound reflecting and refracting instrument, 206
- Bacillary layer of retina, 70
- Base of prism, 122
- Basedow's disease, 581
- Bellarminoff's experiment, 222
- Bi-concave cylindrical lens, 125
 lens, 125
 spherical lens, formation of, 124
- Bi-convex cylindrical lens, 125, 128
 lens, 124
 spherical lens, formation of, 124
- Bi-focal lenses, 271
- Blennorrhœa, chronic, 316
 lacrymalis, 568
- Blepharitis, 559
 eczematous, 560
 treatment of, 559, 560
 ulcerous, 560
- Blepharophimosis, 565
- Blepharoplasty, Arlt's method of, 590
 Dieffenbach's method of, 590
 Fricke's method of, 589
 Knapp's method of, 591
 Riverdin's method of, 591
 Wolfe's method of, 591
- Blepharospasm, 546, 566
- Bone, formation of, 507
- Bonnet's capsule, 39
- Bowman, muscle of, 62
- Bowman's membrane, 57
 probe, method of inserting, 572
- Bruch, membrane of, 63
- Brücke, muscle of, 62
- Bulbar conjunctiva, 44
- Burns of eyelids and eyeballs, 288
 treatment of, 290
- C**ALABAR extract, action of, 378
- Canaliculi lacrymales, 44, 49
- Canaliculus, setting of, 620
- Canthoplasty, operation for, 592
- Canthus, Arlt's method of removing
 growths from, 590
 external, 40
 internal, 40
- Capsule of crystalline lens (anterior), 65
 (superior), 65
- Cardiac exophthalmus, 581
- Cardinal point, 132, 145
- Caruncula lacrymalis, 45
- Cataract, 417
 absorption of, 425
 albuminuric, 421
 anterior central capsular, 339
 capsular, 423
 cases, examination of, 432
 central anterior capsular, 423
 congenital, 422
 couching of, 427
 depression of, 427
 diabetic, 420
 etiology of, 417
 extraction of, 428
 accidents in operations for, 437
 accidents occurring during, 615
 after-treatment of, 435
 details of method for, 433
 flap operation with iridectomy
 for, 610
 without iridectomy, 607
 linear, 611
 peripheral linear operation for,
 611
 removal of entire capsule in, 431
 statistics of results of, 437
 glaucomatous, 518
 history of extraction of, 428
 linear incision in extraction of, 428
 modified linear extraction of, 429
 Morgagnian, 418
 nephritic, 421
 of infancy, 422
 operation for couching of, 607
 for discission of, 606, 612
 for extraction of, 606
 for reclinacion of, 607, 613
 for simple extraction of, 607
 operations for, 425
 preparation of patient for, 433
 pathological changes in, 419
 peripheric linear section in extraction
 of, 429
 posterior polar, 422
 primary, 418
 reclinacion of, 427
 secondary, 418, 430
 symptoms of, 424
 traumatic, 293
 with hereditary skin disease, 422
 zonular, 422
- Cataracta nigra, 425
- Catarrh, consecutive, 308
 follicular, 308
 pustular, 308
- Catoptric images, 91
 test, method of making, 184

- Catoptrics, 105
 Centrad, 136
 Centrads, values and relations of, 138
 Central artery of retina, 33
 retinal vein, 33
 Centre of motion, 149
 of rotation, 149
 Chalazia, removal of, 584
 Chalazion, 561
 operation for, 562
 Chiasm, anatomy of optic, 76
 Choked disk, 474
 in intra-cranial disease, 476
 Chorio-capillaris, 64
 Chorioid, anatomy of, 62
 coloboma of, 508
 detachment of, 503
 diseases of, 496
 disseminate tubercle of, 503
 fissure, 23
 hyperæmia of, 496
 metastatic neoplasms in, 507
 miliary tubercle of, 503
 rupture of, 291, 503
 sarcoma of, 504
 solitary tubercle of, 504
 tubercles of, 504
 Chorioidal ring, 439
 Chorioiditis, 496
 areolata, 499
 centralis, 500
 circumscripta, 500
 disseminata, 497
 metastatic suppurative, 501
 suppurativa, 501
 syphilitica, 500
 Chorion, 23
 Chorio-retinitis, early stage of, 497
 late stage of, 498
 syphilitica, 500
 Chromatic aberration, 151
 Chronic myopia, 194
 Cilia, 43
 Ciliary arteries, anterior, 33
 long, 33
 short, 33
 body, anatomy of, 61
 diseases of the, 364
 gumma of, 366
 retention of foreign bodies in, 295
 staphyloma of, 352
 border of lid, 43
 ganglion, 37
 muscle, 61
 development of, 24
 nerves, long, 37
 short, 37
 paralysis, determination of artificial, 262
 processes, 61
 pars non plicati, 61
 plicati, 61
 tenderness, 186
 veins, anterior, 33
 posterior, 33
 Cilio-retinal vessel, 441
 Circles of diffusion, 251
 Circulus iridis, minor, 61
 Cleft, ocular, 23
 Cloquet, canal of, 67
 Colloid growths, hyaline, 507
 Coloboma of chorioid, 508
 of lids, 558
 Color-blindness. (See Sub-normal color-perception.)
 -perception, 81
 -sense measure, 193
 Commissure, external, 40
 internal, 40
 Communicating vein, 33
 Complete posterior synechia, 355
 Compound focus, formation of, 123
 Concave mirror, 106, 111
 Concavo-convex lens, 125
 Congenital atrophy of retina and optic nerve, 464
 "color-blindness," 492
 Conical cornea, 348
 correction of, by lenses, 272
 Conjugate foci, 130
 focus, 113
 Conjunctiva, 43, 44
 catarrh of, 307
 diseases of, 307
 fibroid papillomata of, 332
 foreign body in, 285
 hyperæmia of, 307
 lupus of, 331
 pemphigus of, 332
 removal of foreign bodies from, 594
 sarcoma of, 332
 syphilitic affections of, 331
 tuberculosis of, 331
 Conjunctival thermometry, 186
 Conjunctivitis, croupous, 310
 diphtheritic 315
 prognosis of, 316
 treatment of, 316
 granular, 316
 contagiousness of, 320, 321
 development of, 316
 distribution of, 321
 gonococci in, 322
 treatment of, 323
 phlyctenular, 324
 symptoms of, 327
 treatment of, 328
 purulent, 310
 prognosis of, 313
 treatment of, 312
 scrofulous, 326
 Connective-tissue ring, 439
 Contact-lenses, 272
 Contrasts, simultaneous, 88
 successive, 88
 Convergence, 160
 angle of, 160
 determination of maximum, 167
 of minimum, 167
 far-points of, 160

- Convergence, insufficiency of, 235
 meter angle of, 160
 power of, 160
 region of, 161
- Converging meniscus lens, 125
- Convex mirror, 106, 111
- Convexo-concave lens, 125
- Co-ordination of extra-ocular muscles, 95
- Corectopia, 363
- Cornea, abrasions of, 286
 abscess of, 342
 during and after fevers, 343
 treatment of, 343
 band-like opacities of, 346
 congenital opacities of, 347
 treatment of, 347
 diseases of, 333
 foreign bodies in, 285
 opacities of, 345
 pellucida, anatomy of, 57
 perforation of, 338
 removal of foreign bodies from, 594
 scraping of, 595
 staphyloma of, partial, 339
 total, 339
 treatment of, 340
 tattooing, 348, 595
 tumors of, 349
 treatment of, 350
- Corneal conjunctiva, 46
 tissue, grafting of, 595
 ulcer, 337
 ulceration, treatment of, 338
- Correlation of ocular movements, 96
- Corresponding points, 84
- Cortex, visual, 79
- Couching of cataract, 427
- Critical angle of refraction, 135
- Crystalline lens, dislocation of, 288
 subconjunctival dislocation of, 291
- Cummings' hypothesis, 206
- Cup, formation of optic, 22
 the ocular, 20
- Curvature, centres of, 129
 radius of, 111
- Cyclitis, 364
 parenchymatous, 366
 plastic, 365
 serous, 365
 sympathetic, 301
- Cylindrical surface, evolution of, 114
- D**ACRYOCYSTITIS, 570
 Datura, action of, 375, 377
- Day-vision, 491
- Decussation of optic nerve fibres, 80
- Demours' layer of cornea, 59
- Dental canal, anterior, 30
- Depression of cataract, 427
- Dermoid tumors of the cornea, removal of, 595
- Descemetitis, 356
- Descemet's membrane, 57
- Descending neuritis, 477
- Detachment of retina, 465
- Deviation, angle of, 122
- Diabetes, degeneration of optic nerve in, 489
- Diaphanous, 105
- Diffusion area, 251
 circles, 152
- Dilatation of pupil, 94
- Dioptries, 105, 115
- Direct method, advantages of, 217
 compared with indirect method, 219
 magnifying power in, 220
 determination of, 221
- Discission, 425
- Disk, optic, 74
- Disseminated chorioiditis, 498
- Distance, ideas of, 86
- Distichiasis, 564
 operation for, 584
 Snellen's operation for, 585
- Distortion of objects in chorio-retinitis, 196
- Diverging meniscus lens, 125
- Diverticula, 20
- Division of the externus, 600
 of inferior rectus muscle, 600
 of superior rectus muscle, 600
- Double concave lens, 125
 convex lens, 124
 third-pair paralysis, 539
- Downward and inward motion of globe, 99
 and outward motion of globe, 100
- Duboisia, action of, 376
- Dural sheath of the optic nerve, 75
- E**CTROPIUM, 561, 565
 Arlt's operation for, 588
 Richet's operation for, 588
- Edge of prism, 122
- Elastic layer of cornea, anterior, 57
 posterior, 57
- Electrolysis, 584
- Embolism of retinal arteries, 451
 symptoms of, 451
 artery, ophthalmoscopic appearances of, 451
 of branch of central retinal artery, 452
 of central artery of retina, prognosis of, 452
 treatment of, 452
- Embryology, 19
- Emmetropia, 382
 ciliary muscle in, 390
 definition of, 382
 standard of, 382
- Endothelial layer of cornea, posterior, 58
- Enophthalmus, 287, 568
- Entoptic images, 512
 phenomena, 87
- Entropium, 320, 564

- Entropium, Green's method for relief of, 586
 Hotz's operation for, 587
 Jaesche-Arlt method of transplantation for relief of, 585
 operations for, 585
 Snellen's operation for, 587
 Streatfeild's method for relief of, 587
 Enucleation, Arlt's method of, 618
 for sympathetic ophthalmia, 303
 operation of, 617
 Epicanthus, 558
 Episcleral layer, 56
 Episcleritis, 352
 Epithelial layer of cornea, anterior, 57
 Epithelioma of eyelids, 562
 Erectness of vision, 89
 Errant vessel, 441
 Eserine, action of, 376
 Esophoria, 170, 549
 Ethmoidal artery, anterior, 31
 posterior, 31
 foramen, anterior, 29
 posterior, 29
 Examination of eye, 163
 Exenteratio bulbi, 304, 618
 orbitæ, 619
 Exophoria, 168, 170
 Exophthalmic goitre, 581
 Exophthalmus, 287
 External granular layer of retina, 69
 limiting membrane of retina, 69
 molecular layer of retina, 69
 nuclear layer of retina, 69
 rectus muscle, action of, 97
 anatomy of, 52
 Extraction of cataract, 428
 Eye, penetrating wounds of, 291, 292, 294
 Eyeball, blows and contusions of, 286
 dislocations of, 287
 gunshot wounds of, 298
 rupture of, 291
 tearing out of, 287
 Eyebrows, 44
 Eyeground, method of describing normal, 186
 normal, peculiarities in, 210
 Eyelashes, 43
 Eyelids, anatomy of, 39
 development of, 24
 diseases of, 558
- F**ACIAL expression, in extra-ocular muscle disturbance, 168
 Fantoscopie rétinienne, 224
 Far-point, 155
 in a myopic eye, 156
 -sightedness, 384
 Fibres, Müller's, 20
 Field of vision, advantage of hemispherical over flat field, 192
 chart for registration of, 190
 in glaucoma, 520
 for white, average size of, 190
- Fields of vision, 187
 Bjerrum's method of obtaining, 188
 determination of by use of black-board, 188
 methods of determining, 187
 First focal plane, 132
 nodal point, 132, 145
 principal focus, 129, 145
 plane, 132
 point, 132
 Fixation, field of, 84
 determination of, 176
 Fluorescein, employment of, 181
 Focal illumination, 181
 length, 113
 line, 115, 126
 formation of, 98, 115
 Focus, 108, 122
 evolution of, 121
 Folds of transition, 45
 Fontana's spaces and cavities, 59
 Foramen opticum chorioideæ, 63
 Form, perception of, 86
 Fornix conjunctivæ, 43, 44
 Fossa glandulæ lacrymalis, 48
 patellaris, 66
 Fourth nerve, paralysis of, 545
 Fovea centralis retinæ, 70
 ophthalmoscopic appearance of, 444
 Franklin glasses, 271
 Frontal artery, 31
 Fuchsin, 81
 Fundus-details, Tiffany's plan of projecting and sketching, 215
 -image test, 249
 oculi, photographic reproduction of, 215
 -reflex test, 224
 advantages of plane mirror in, 229
 of concave mirror in, 225
 method of employment of concave mirror in, 226
 of plane mirror in, 229
 plane mirror in, 225
 principle of, 225
 theory of concave mirror in, 226, 227, 228
 of plane mirror in, 229, 230, 231
 reversal method in, 234
- G**ANGLION-CELL layer of retina, 69
 Ganglionic nerve, 37
 Geometrical centre, 141
 Gerontoxon corneæ, 347
 lentis, 418
 Gland, accessory lacrymal, 48
 major superior lacrymal, 48

- Gland, minor or inferior lacrymal, 48
 Glass shells of Koller, 222
 Glaucoma, 515
 acutum, 517
 apoplecticum, 522
 at different life-periods, 516
 fulminans, 517
 hæmorrhagicum, 522
 malignant, 530
 nervous system in, 529
 ophthalmoscopic appearances in, 521
 pathology of, 522, 523, 526, 527
 secundarium, 522
 simplex, 517
 subacutum, 517
 swelling and congestion of ciliary processes in, 528
 symptoms of, 519
 theories of, 526
 treatment of, 530
 vitreous humor in, 525
 Glaucomatous cataract, 518
 Glioma of retina, 470
 Graduated tenotomy, 598
 Graefe's sign, 581
 test for heterophoria, 548
 Granular layer of retina, 69
 Granulation, section of, 317
 Gratiolet, fibres of, 79
 Graves's disease, 581
- H**AAB'S plates, 215
Hæmatoma, 577
 Hannover, canal of, 66
 Head, optic-nerve, 74
 -rest, 408
 Hemeralopia, 491
 Hemianopia, 492
 heteronymous lateral, 492
 nasal, 492
 inferior, 493
 left homonymous, 492
 right homonymous, 492
 superior, 493
 temporal, 494
 transient, 493
 Hemianopic pupillary inaction sign, 195
 method of obtaining, 196
 Hemianopsia, 492
 Hemiopia, 492
 Hemorrhagic glaucoma, 522
 Hereditary atrophy of optic nerves, 489
 Heteronymous diplopia, 169
 Heterophoria, 170, 549
 operative treatment of, 550
 Homatropia, action of, 375, 377
 Hordeolum, 561
 Horizontal axis, 96
 plane of, 96
 Horizontally inward motion of globe, 102
 outward motion of globe, 101
 Horner's muscle, 41
 Horopter, 85
- Hutchinson's teeth, 335
 Hyalitis, 511
 Hyaloid artery, origin of, 25
 fossa, 66
 membrane, 66
 Hydro-meningitis, 356
 Hyoscymia, action of, 375
 Hyperbolic lenses of Raehlmann, 273
 Hyperesophoria, 549
 Hypermetropia (*hyperopia*), 384
 absolute, 385
 ciliary muscle in, 389
 clinical symptoms of, 385
 determination of by fundus-reflex test, 232
 facultative, 385
 latent, 384
 loss of far-point in presbyopia in, 159
 manifest, 385
 relative, 385
 treatment of, 393
 Hyperphoria, 169, 549
 Hypopyon, 294, 325, 356
 keratitis, 342
- I**DENTICAL points, 84
 Image, 107
 Incandescence, 104
 Incidence, angle of, 106
 Incident ray, 106
 Indirect method, magnifying power in, 221
 Inferior oblique muscle, action of, 98
 anatomy of, 53
 rectus muscle, action of, 97
 anatomy of, 52
 Infra-orbital canal, 30
 -trochlear nerve, 37
 Injuries of orbits, eyes, and eyelids, 283
 Insertion of extra-ocular muscle, points of, 97
 Insufficiency, operations for, 596
 operative treatment of, 550
 Intercalary staphyloma, 340, 352
 Internal granular layer of retina, 69
 molecular layer of retina, 69
 nuclear layer of retina, 69
 reticular layer of retina, 69
 rectus muscle, action of, 97
 anatomy of, 51
 Interni, insufficiency of, 549
 Interstitial neuritis, 477
 Intra-ocular tension, 184
 Iridectomy, 602
 cicatrix in, 531
 Irideremia, 363
 Irides, determination of movements of, 177, 178
 Iridocyclitis, sympathetic, 366
 treatment of, 367
 Iridodesis, 606
 Iridodialysis, 288, 362
 Iridodonesis, 362
 Iridotomy, 606
 Iris, anatomy of, 60

- Iris and ciliary body, diseases of, 353
 anterior endothelial layer of, 61
 coloboma of, 363
 congenital pigment-spots of, 362
 cysts of, 361
 epidermoid tumors of, 362
 granuloma of, 362
 gumma of, 358
 hyperemia of, 353
 lodgment of foreign bodies in, 295
 melanomata of, 362
 melanotic carcinomata of, 362
 pearly tumors of, 362
 prolapse of, 338, 339
 sarcomata of, 362
 suspensory ligament of, 59
 tissue, benignant hyperplasia of, 362
- Iritis, 353
 gonorrhœic, 358
 parenchymatous, 353, 356
 plastic, 353, 356
 rheumatic, 357
 serous, 353, 356
 sympathetic, 301
 syphilitic, 357
 treatment of, 359
 tuberculous, 358
- Irradiation, 89
- Ischæmia of disk from quinine poisoning, 483
- J**ACKSON'S test for heterophoria, 172
 Jequirity in granular conjunctivitis, 324
- K**ERATITIS bullosa, 336
 interstitial, 333
 symptoms and course of, 334
 teeth in, 335
 treatment of, 335
 malacial, 341
 malarial interstitial, 336
 neuro-paralytic, 341
 phlyctenular, 324
 sclerosing, 357
 suppurative, 337
 xerotic, 341
- Keratoconus, 348
 treatment of, 349
- Keratometer, 255
- Keratonyxis, 426
 operation of, 612
- Keratoscope of Placido, 254
- Keratotomy, 224
- Korelysis, 606
- Koroscopy, 224
- Krause, acino-tubular glands of, 43, 46
 clavate corpuscles of, 47
 spheroidal end-bulbs of, 47
- L**ACERATED foramen anterior, 30
 foramen inferior, 30
- Lacrymal apparatus, anatomy of, 48
- Lacrymal apparatus, diseases of, 568
 operations on, 619
 artery, 31
 canal, 30
 diseases, treatment of, 571
 gland, anatomy of, 48
 palpebral portion of, 48
 glands, origin of, 24
 passages, catarrh of, 568
 sac, 49
 abscess of, 570
 fistula of, 570
 obliteration of, 574
 operation for obliteration of, 620
 slitting of abscess of, 620
 vein of, 33
 vein, 33
- Lacrymo-nasal duct, 49
- Lacus lacrymalis, 45
- Lagophthalmus, 561, 565
- La Hire's experiments with a cat's eye-ground, 206
- Lamina cribrosa, 56, 74
 fusca, 56, 64
 vitrea, 62
 chorioideæ, 63
- Lateral illumination, 181
- Leber, sinus of, 56
- Lens, anatomy of crystalline, 65
 invagination of, 21
 isolation of, 22
 measure, description of, 276
 powers, scheme for the determination of, 274
 strength required by emmetropic presbyopes, 381
 strengths, estimation of, 140
 suspensory ligament of, 66
 systems, conversion of, 140
- Lenses, combinations of formulæ for, 273
 numeration of, 138
- Lenticular ganglion, 37
- Lepa of eyelids, 563
- Leptothrix, 568
- Leucomata corneæ, 345
- Levator palpebræ superioris, anatomy of, 41, 53
- Lid, abscess of, 561
- Lids, coloboma of, 558
 epithelioma of, 562
 lepra of, 563
 lupus of, 563
 method of eversion of, 179, 180
 plastic operations on, 589
 spasmodic closure of, 546
 vaccinal eruption on, 562
- Ligamentum palpebrale externum, 39
 internum, 39
 pectinatum iridis, 59
- Light difference, 166
 minimum, 166
 -streak on retinal vessels, 442
- Lightning, injuries of eyes by, 287
- Limbus corneæ, 46
 conjunctivæ, 46

- Limit of color-perception, 82, 83
 Limiting angle of refraction, 135
 Line of fixation, 149
 of sight, 149
 of vision, 148
 Listing's law, 96
 Longitudinal axis, 96
 plane of, 96
 Lupus of eyelids, 563
 Lymphatic system, anterior, 35
 middle, 36
 posterior, 36
- M**ACULA lutea, 70
 method of observing, with ophthalmoscope, 217
 Maculæ corneæ, 345
 Macular region, hemorrhage in, 448
 ophthalmoscopic appearance of, 444
 Maddox's glass-rod test, 170
 Malar foramen, 29
 Mariotte's blind-spot, 90
 Martegiani, area of, 67
 Meckel's ganglion, 37
 Medullary sheaths of retinal fibres, retention of, 444
 Meibomian glands, 42
 development of, 24
 Melanin, 81
 Membrana limitans interna, 67
 nictitans, 45
 pigmenti iridis, 61
 Ruyschiana, 63
 Meridional refraction, fundus-reflex test in, 226
 Méry, experiment of, 203
 Metamorphopsia, 449
 Meter plane, 137
 Minimum angle of vision, 150
 deviation, 135
 of differentiation, 166
 Mirror, evolution of, 111
 Mirrors, 106
 Mixed astigmatism, determination of, by fundus-reflex test, 233
 Moll, glands of, 43
 Monocular polyopia, 424
 Morgagnii, liquor, 65
 Motion, centre of, 95
 Müller, circular muscle of, 42, 62
 Müller's fibres, 21, 67
 Muscæ volitantes, 512
 Muscarine, 379
 Muscle, paralysis of ciliary, 543
 of external rectus, 535, 537
 of inferior oblique, 543
 rectus, 542
 of internal rectus, 534, 538, 540
 of levator palpebræ, 543, 567
 of orbicularis, 566
 of sphincter pupillæ, 543
 of superior oblique, 545
 rectus, 541
 Muscle plane, 98
 Muscles, affections of eye, 534
 determination of extra-ocular, 168
 diagnosis of paralysis of eye, 548
 treatment of paralysis of, 547
 Muscular artery, inferior, 31
 superior, 31
 veins, 33
 Musculus ciliaris Riolani, 41
 lacrymalis anterior, 41
 posterior, 41
 palpebralis inferior, 42
 superior, 42
 Mydriatics, action of, 374
 use of, in examination of eye, 197
 Myodesopia, 512
 Myopia, 393
 ciliary muscle in, 390
 convergent strabismus with, 557
 correction of, 408
 determination of, by fundus-reflex test, 233
 increase of, 401
 pathological changes in, 394
 statistics of, 402
 symptoms of, 236, 394
 simulated, 236
 vision in, 399
 Myotics, action of, 374, 376
- N**ASAL artery, 31
 Near-point, 154
 determination of, 368
 -sightedness, 393
 Negative accommodation, 373
 angle alpha, 149
 focus, 130
 Nerve-fibre layer of retina, 68
 fibres, varicose hypertrophy of, 457
 Nerves, deep stroma of corneal, 59
 intra-epithelial plexus of corneal, 60
 primary plexus of corneal, 59
 secondary plexus of corneal, 59
 superficial stroma of corneal, 59
 Neuritis, retrobulbar, 484
 Neuro-retinitis, sympathetic, 301
 Night-blindness, 491
 Normal tension, 185
 method of obtaining, 185
 Nose-pieces, 279
 Nubeculæ corneæ, 345
 Nuclear origin of third, fourth, and sixth nerves, 54, 55
 Nyctalopia, 491
 Nystagmus, 544
 of coal miners, 544
- O**BLIQUE illumination, 181
 Ocular conjunctiva, 44
 movements, association of, 98
 Oculo-orbital fascia, inflammation of, 577

- Opalescence, 105
 Opaque optic-nerve fibres, 445
 Opaqueness, 105
 Operations on eye, preparations for, 583
 Ophthalmia, angular, 308
 migrans, 305
 neonatorum, 313
 prophylaxis of, 314
 symptoms of, 314
 treatment of, 314
 Ophthalmic artery, 30
 ganglion, 37
 vein, 33
 Ophthalmometer, 255
 description of Javal-Schiötz's model, 256
 Ophthalmoplegia interna, 543
 Ophthalmoscope, description of Loring's, 208
 mechanical evolution of, 207
 methods of using, 210
 theory of, 204, 205, 206
 Ophthalmoscopic appearances, value of sketching, 215
 determination of position of intra-ocular objects, 214
 Ophthalmoscopy, 203
 art of, 209
 direct method of, 211
 method of employing, 212
 homatropine in, 216
 importance of studying normal eye-ground in, 209
 indirect method of, 211
 method of employing, 218
 use of mydriatics in, 216
 Optic axis, 145
 commissure, 76
 disk, anæmia of, 482
 anatomical size of, 213
 apparent ophthalmoscopic size of, 213
 description of ophthalmoscopic appearances of, 214
 ophthalmoscopic appearances of, in direct method, 213
 foramen, 29
 nerve, anatomy of, 75
 and its internal prolongations, affections of, 473
 atrophy of, 482
 from quinine poisoning, 482
 degeneration accompanied by central scotomata, 484
 accompanying tabes dorsalis, 483
 from diabetes, 484
 from retrobulbar neuritis, 484
 from tobacco and alcohol poisoning, 484
 pyriform enlargement of peripheral end of, 481
 tumors of, 494
 variations in color of, 445
 Optic nerve, wounds of, 299
 neuritis from eye-strain, 473
 interstitial, 481
 papilla, 439
 Optical centre, 131
 Optics, 104
 Optograms, 82
 Optometer of Starr, 251
 Optometry, binocular, 254
 Optotypi of Snellen, 150
 Orbicularis palpebrarum, 41
 paralysis of, 566
 Orbiculus ciliaris, 64
 Orbit, anatomy of, 28
 cellulitis of, 575
 contusions of, 284
 dermoid cyst of, 580
 diseases of, 575
 foreign bodies in, 283
 fracture of roof of, 283
 osteomata of the, 579
 periostitis of, 575
 tumors of the, 578
 Orbital fissure, inferior, 30
 superior, 30
 margin, 28
 portion of lid, 44
 tumors, prognosis of, 580
 Orthophoria, 169, 549
 Outward and upward motion of globe, 101
- PALPEBRÆ, 39**
 Palpebral artery, anterior, 31
 superior, 31
 conjunctiva, 44
 fissure, 40
 ligaments, 39
 vein, inferior, 34
 superior, 33
 veins, 33
 Panophthalmitis, 311
 Papilla lacrymalis, 44, 48
 Papillitis, 474
 in basilar meningitis, 479
 ophthalmoscopic appearances of, 474
 theories of causation of, 476
 Paracentesis bulbi, 617
 of cornea, 600
 Parallax displacement, 215
 Parallax test, 170
 Parietal layer, 38
 Pars ciliaris retinæ, 62, 67
 Partial staphyloma of cornea, operations for, 596
 tenotomy, 598
 Perception of a solid object, 86
 Perforated disks of Thomson, 251
 Perichorioidial lymphatic space, 56
 Pericorneal epithelial hypertrophy, 308
 Perimeter, description of McHardy's, 189
 Perimetry, 188
 Periorbita, 38
 Peritomy, 323
 Perivasculitis, 453

- Perrin's artificial eye, 217
 Persistent pupillary membrane and tags, 364
 Petit, canal of, 66
 Phakitis, 423
 Phlyctenule, section of, 325
 Phorometer, 172
 Phthiriasis, 563
 Phthisis bulbi, 341
 cornese, 341
 Physiological excavation, 440
 optics, 142
 Pial sheath of optic nerve, 75
 Pigment-epithelium layer of retina, 70
 Pigmentary degeneration of retina, 462
 Pigmented fibrous cicatrices from retinal hemorrhages, 450
 Pinguecula, 330
 Placido's disk, 255
 corneal images of, 415
 Plane mirror, 106
 Plano-concave cylinder lens, 128
 lens, 124
 -convex cylinder lens, 128
 lens, 124
 Plica palpebralis inferioris, 45
 superioris, 45
 semilunaris, 45
 development of, 24
 Polycoria, 363
 Porus opticus, 56
 Posterior chamber, 61
 nodal point, 132, 145, 147
 principal focus, 145, 146
 point, 145, 147
 staphyloma, 352, 502
 synechiæ, 293, 354
 Post-neuritic atrophy, 478
 -operative astigmatism, 416
 Presbyopia, 158, 379
 recession of near-point in, 159
 Prevost's experiments on mirror-like reflections, 206
 Primary glaucoma, 516
 position, 95
 Principal axis, 145
 focal distance, 129
 focus, 112, 113, 129
 ray, 131
 Prism, 121
 deviation produced by, 536
 diopter, 137
 evolution of, 121
 Maddox's obtuse-angled, 172
 strengths, estimation of, 141
 Prismatic action of lenses, 140
 result by lens action, 274
 Prisms, determination of axis of, 277
 estimation of strength of, 277
 power of muscles to overcome, 175
 Prisoptometer, 253
 Profiles of lenticular forms, 124
 Prothesis oculi, 621
 Pterygia, Knapp's method of removal of, 596
 Pterygium, 329
 removal of, 330, 595
 traumatic, 290
 Ptosis, operation for, 593
 Wecker's operation for, 594
 Pulsating exophthalmus, 579
 Pulsation of retinal bloodvessels, 442
 Punctum lacrymalis, 44, 48
 proximum, 154
 remotum, 155
 Pupil, 60
 Argyll-Robertson, 484, 544
 dilatation of, in glaucoma, 519
 during sleep, 94
 exclusion of, 355
 occlusion of, 355
 Pupillary changes, normal, 92, 93
 Pupilloscopy, 224
 Purple, visual, 68
- Q**UALITATIVE fields of vision, 84
- R**ADIAN, 136
 Radiations, optic, 78
 Range of accommodation, positive portion of, 372
 Rays, 104
 Real focus, 108
 formation of, 110
 image, 108
 Recession of ocular globe, 96
 Reclination of cataract, 427
 Reduced eye, 148, 383
 Reflected ray, 107
 Reflection, 105
 angle of, 106
 Refracting angle, 122
 Refraction, 117, 142
 absolute index of, 116
 and accommodation, choice of mydriatic in, 260
 correction of errors of, 260
 methods of determination of errors of, 235
 ophthalmometer in, 265
 use of mydriatic in, 260
 coefficient of, 147
 determination of manifest, in iritis, 196
 from a dense into a rare medium, 120
 from a rare into a dense medium, 119
 index of, 116
 of newborn, 383
 ophthalmoscopic changes in increasing, 446
 Regressive neuro-retinitis, 475
 Relative accommodation, 370
 in presbyopia, 379, 380
 Retina, anatomy of, 67
 and optic nerve, congenital atrophy of, 464
 detachment of, 465

- Retina, detachment of, etiology of, 468
 ophthalmoscopic appearance of, 465
 pathological changes in, 467
 prognosis of, 469
 treatment of, 470
 diseases of, 439
 distribution of nerve fibres in, 71
 glioma of, 470
 microscopic appearances in, 472
 ophthalmoscopic appearances in, 470
 prognosis of, 471
 symptoms of, 471
 treatment of, 471, 472
 hyperæmia of, 447
 limiting fibres of, 67
 lymph-channels of, 447
 ophthalmoscopic appearances of
 normal, 439
 rupture of, 468
 Retinal bloodvessel, lymph-sheath of, 446
 changes in diseases of liver, 460
 in oxaluria, 460
 hemorrhage, 448
 treatment of, 450
 hemorrhages, absorption and degeneration of, 448
 images, comparative sizes of, 220
 impression, persistence of, 89
 shadow-test. (See Fundus-reflex test.)
 vessels, congestion of, 473
 distribution of, 73
 Retinitis, acuity of vision in albuminuric, 457
 central recurrent, 462
 from Bright's disease, 455
 ophthalmoscopic appearances of, 456
 pathological changes in, 458
 prognosis of, 458
 treatment of, 458
 hemorrhagic, 454
 prognosis of, 454
 treatment of, 455
 in diabetes mellitus, 460
 in pernicious anæmia, 459
 leucæmica, 458
 prognosis in, 459
 treatment for, 459
 pigmentosa, 462
 heredity in, 462
 ophthalmoscopic appearances of, 462
 prognosis of, 465
 symptoms of, 462
 treatment of, 465
 purulent, 453
 syphilitic, 461
 treatment of, 462
 Retinoscopy, 224
 Rhodopsin, 82
 Ring-shaped synechiæ, 355
 Rods and cones, layer of, 70
 Rose, visual, 70
 Rotation, axis of, 98
 Rotation, centre of, 95
 Rubeserine, 378
 SAC, conjunctival, 44
 Saemisch's operation, 601
 Savage's method for determination of equilibrium of oblique muscle, 173
 Scheiner's experiment, 152
 Schematic eye, 383
 of Listing, 147
 Schlemm's canal, 57
 School-hygiene, 406
 Sclera, diseases of, 351
 tumors of, 352
 Scleral conjunctiva, 46
 Scleritis, 352
 Scleronyxis, 426
 operation of, 612, 613
 Sclerotic (sclera), anatomy of, 55
 inflammation of, 352
 origin of, 24
 ring, 439
 rupture of, 290
 Sclerotico-chorioiditis posterior, 502
 Sclerotomy, cicatrix in, 532
 Scotoma, optic nerve degeneration accompanied by central, 484
 scintillans, 493
 Scotomata, absolute, 485
 methods for finding, 190, 191
 registry of, 191
 relative, 485
 Seborrhœa, 307
 Second focal plane, 132
 nodal point, 132, 145, 147
 principal focus, 130, 145
 plane, 132, 147
 point, 132, 145, 147
 sight, 424
 Secondary axis, 132, 145
 cataract, operation for, 614
 deviation, 174, 552
 glaucoma, 516, 522
 corneo-scleral junction in, 524
 positions, 96
 Sensation of color, 81
 Separation, lines of, 84
 Seventh nerve, paralysis of, 546
 Shadow-test, 224
 Short-sightedness, 393
 "Shot-silk" opacities, 447
 Sight, 82
 Simple glaucoma, 517
 Simulated blindness, artificial general anæsthesia in, 201
 fundus-reflex test in, 201
 Harlan's method in, 200
 Javal's method in, 200
 Lippincott's plan for detection of, 200
 methods of determination of, 197

- Simulated blindness, Snellen's plan in, 201
 use of mydriatic in, 201
 use of stereoscope in, 198
 von Graefe's method of detection of, 198
 Singleness of vision, 84
 Sinus conjunctiva, 44
 Sixth nerve, paralysis of, 537
 Skiascopy, 224
 Slitting of cornea, 601
 Space, peri-lenticular, 66
 Spectacle-frames, choice of, 279
 fitting of, 275
 lens, determination of optical centre in, 276, 278
 estimation of true centres of, 279
 gauge of strength, 276
 neutralization of cylinder, 276
 position of, before eyes, 278
 smoothness of, 275
 Specula, 106
 Sphenoid fissure, 30
 Spheno-maxillary fissure, 30
 -palatine ganglion, 37
 Spherical aberration, 151
 Sphincter iridis, 60
 Spring catarrh, 308
 treatment of, 309
 Squint, alternate, 553
 concomitant, 552
 convergent, 552, 554
 prognosis of, 555
 diagnosis of, 554
 divergent, 552
 etiology of, 553
 monolateral, 553
 operative treatment of, 555
 periodic, 553
 Staphyloma, anterior, 311
 partial, 311
 pellucidum, 348
 total, 311
 Stauungs-Papilla, 474
 Steiba's system of grooves, 45
 Steven's stenopæic spherical lens, 172
 Stilling, canal of, 67
 Strabismus, Arlt's operation for, 597
 convergent, 552
 divergent, 557
 Graefe's operation for, 598
 operations for, 596
 Snellen's operation for, 598
 subconjunctival operation for, 598
 with vertical deviation, 557
 Sturm's focal interval, 152, 412
 Styte, 561
 Subacute glaucoma, 517
 Subnormal color perception, 193
 determination of, at great distances, 194
 Holmgren's method of obtaining, 193
 Oliver's method for determining, 194
 Substantia propria of cornea, 57
 Sulcus orbito-palpebralis inferior, 44
 superior, 44
 palpebro-malaris, 44
 Supercilia, 44
 Superciliary region, 44
 Superior oblique muscle, action of, 97
 anatomy of, 53
 rectus muscle, action of, 96
 anatomy of, 53
 Supra-chorioidea, 63
 -orbital artery, 31
 nerve, anatomy of, 36
 vein, 33
 Surfaces, refracting, 121
 Symblepharon, 290, 565
 Arlt's operation for, 592
 Himly's operation for, 592
 Noyes' operation for, 592
 Riverdin's operation for, 592
 Teale's operation for, 592
 Sympathetic inflammation, 301
 irritation, 301
 ophthalmia, 300
 causes of, 302
 cutting of ciliary and optic nerves in, 304
 development of, 302
 enucleation in, 303
 evisceration of eyeball in, 304
 symptoms of, 301
 theories of, 305
 treatment of, 302
 Symptomatic myopia, 398
 Synchysis, 512
 Synechia, anterior, 311


TARSAL conjunctiva, 44
 Tarsal glands, 42
 ligaments, 39
 Tarso-orbital fascia, 38
 Tarsorrhaphy, operation for, 593
 Tarsus, 39
 Tendo oculi, 39
 palpebrarum, 39
 Tenometers, 185
 Tenonitis, 577
 Tenon's space, 38
 Tension, increase of, in glaucoma, 520
 Tensor chorioideæ, 62
 tarsi, 41, 50
 Test-frames, enumeration of, 262
 or trial lenses, 139
 -type, method of using, 164
 -types, 622
 Third nerve, complete paralysis of, 540
 Thrombosis of central retinal vein, 453
 treatment of, 453
 Tobacco as a cause of optic-nerve degeneration, 487
 Total reflection, 135
 staphyloma of cornea, operations for, 596
 Trachoma, 316
 Transmission, 105

- Transparency, 105
 Trichiasis, 564
 operation for, 584
 Tri-focal lenses, 271
 Trochlearis muscle, anatomy of, 53
 paralysis of, 545
 Tunica vaginalis bulbi, 38
 oculi, 38
 vasculosa chorioideæ, 63
 Turning, axis of, 98
 Tylosis, 560
- U**LCER, "rocket-shaped," 325
 Ulcus corneæ serpens, 342
 Umbrascopy, 224
 Unguis, 325
 Unreal focus, 113, 130
 Upward and inward motion of globe, 101
 Uræmic amaurosis, 457, 491
 Uvea, 60
 Uveal tract, 60
 Uveo-scleritis, 352
- V**ACCINAL eruption of eyelids, 562
 Van Woerden, anterior conjunctival
 vascular system of, 47
 posterior conjunctival vascular sys-
 tem of, 47
 Vena centralis, retinal, 72
 Venous congestion in glaucoma, 519
 pulse in retina, 442
 Vertical axis, 96
 plane of, 96
 Vertically downward motion of globe, 100
 upward motion of globe, 101
 Vesicle, lens, 21
 evolution of, 22
 secondary ocular, 20
 Vesicles, ocular, 20
 formation of, 20
 Vesicular granulations, 317
- Virtual focus, 113, 130
 formation of, 110
 image, 107
 Visceral layer, 38
 Vision, determination of power of, 165
 fields of, 84
 by night, 491
 Visirlinie, 149
 Visual angle, 149
 direction, 90
 line, 148
 Visus dimidiatus, 492
 Vitreous chamber, lodgment of foreign
 bodies in, 296
 removal of foreign bodies from,
 297
 diseases of, 511
 hemorrhages into, 449
 humor, 35
 anatomy of, 60
 in glaucoma, 525
 new growths in, 513
 parasites in, 514
 Von Graefe's test, 548
 Von Hippel's operation, 347
 for grafting corneal tissue, 595
 Vorticose veins, 33
- W**AVES, 104
 Wernicke's sign, 494
 Wheel-motion, 100
- X**ANTHELASMA, 563
 Xanthoma, 563
 Xanthopsia, 461
 Xeroma, 319
- Z**INN, ligament of, 41
 zone of, 66
 Zöllner's lines, 87









YOUNG J. PENTLAND'S PUBLICATIONS.

18mo, Cloth limp, pp. xii., 120, Price 3s.

SYNOPSIS OF THERAPEUTICS

ARRANGED FOR THE USE OF PRESCRIBERS:

WITH POSOLOGICAL TABLE AND AN ARRANGEMENT OF THE POISONS.

BY R. S. AITCHISON, M.B., EDIN.

(1886.)

EXTRACT FROM THE PREFACE.

The object of this short work has been to collect and to group in synoptical form, the agents comprising the *Materia Medica*. Instead of a natural history or alphabetical arrangement, a therapeutic classification has been adopted. This consists in grouping the drugs, according to their physiological action and their uses in practice—a plan which has the obvious advantage of enabling the prescriber readily to see the various remedies available for any morbid condition, and to make his selection accordingly.

8vo, Cloth, pp. x., 220, with 9 illustrations, Price 7s. 6d.

THE TREATMENT OF EPILEPSY.

BY

WILLIAM ALEXANDER, M.D., F.R.C.S.,

HONORARY SURGEON, ROYAL SOUTHERN HOSPITAL, LIVERPOOL; VISITING SURGEON,
LIVERPOOL WORKHOUSE HOSPITAL; ACTING HONORARY CONSULTING
SURGEON, EPILEPTIC INSTITUTION, MANOR HOUSE, MAGHULL.

(1889.)

EXTRACT FROM PREFACE.

A description of the effects of removal of the cervical ganglia of the sympathetic for epilepsy forms the chief feature of this book, and is the cause of the book being written. Other methods of treatment are, however, touched upon, but only as far as the light of my own experience enables me to speak. The tenth chapter I consider of great importance, and I trust it may be useful in bringing about in Britain a more organised, rational, and successful method of dealing with epileptics.

FOR SALE BY SUBSCRIPTION ONLY.

In Three handsome volumes, Royal 8vo, containing about 1000 pages each, with fully 1700 elaborate Illustrations, Price 30s. per volume nett.

THE AMERICAN SYSTEM OF
DENTISTRY,
IN TREATISES BY VARIOUS AUTHORS.

EDITED BY

WILBUR F. LITCH, M.D., D.D.S.,

PROFESSOR OF PROSTHETIC DENTISTRY, THERAPEUTICS, AND MATERIA MEDICA,
IN THE PENNSYLVANIA COLLEGE OF DENTAL SURGERY, PHILADELPHIA.

EXTRACT FROM THE PROSPECTUS.

"Dentistry, although as old as history itself, yet owes its practical and scientific advancement mainly to the labours and researches of the last two generations. Within this brief period its progress has been so rapid that to understand and expound the whole extent of the subject is far beyond the powers of any single mind and pen. To the further dissemination of dental learning, the gathering of this widely scattered mass of knowledge into a compact and orderly body is essential, and a work which will accomplish this end promises to mark an era in the science by reflecting its present position and indicating the direction in which future research is likely to prove most successful.

"Such a work—THE AMERICAN SYSTEM OF DENTISTRY—has for some years been in preparation, under the co-operation of a large corps of writers, and its publication places the profession throughout the world under renewed obligations to the Authors.

"The distinguished editor has chosen those men who, by long experience in practice, teaching, or original research, have proved themselves abundantly competent to treat their several subjects, and a consideration of the plan as a whole will show that the scope and arrangement of the work are such as to present a complete and systematic exposition of the entire Science and Art of Dentistry. So vast has been the amount of indispensable material obtained, that it has been impracticable to present it in less than three extra sized octavo volumes of about 1000 pages each. The series of Illustrations, numbering about 1700 Wood Engravings, have been executed under the supervision of the Authors themselves, and may be relied on for entire accuracy. In every particular of Type, Paper, Printing, and Binding, the Publisher has studied to make the work a pleasure to the reader, and a lasting ornament to his library.

"In short, 'THE AMERICAN SYSTEM' forms a complete Encyclopædia of the whole Science and Art of Dentistry."

A Detailed Prospectus will be sent to any address on application.

For Sale by Subscription only. Re-issue in monthly volumes.

*In 8 very handsome volumes, Royal 8vo, Cloth, of about 400
pages each, fully illustrated with Engravings and
Coloured Plates, Price 12s. 6d. each.*

SYSTEM OF
GYNECOLOGY & OBSTETRICS,
BY AMERICAN AUTHORS.

EDITED BY

MATTHEW D. MANN, A.M., M.D.,

PROFESSOR OF OBSTETRICS AND GYNECOLOGY IN THE MEDICAL
DEPARTMENT OF THE UNIVERSITY OF BUFFALO, N.Y.

AND

BARTON COOKE HIRST, M.D.,

ASSOCIATE PROFESSOR OF OBSTETRICS IN THE UNIVERSITY OF PENNSYLVANIA;
OBSTETRICIAN TO THE PHILADELPHIA MATERNITY HOSPITALS;
GYNECOLOGIST TO THE ORTHOPÆDIC HOSPITAL.

EXTRACT FROM THE PROSPECTUS.

The Publisher has much pleasure in announcing to the Profession that this enterprise, which has been long and carefully elaborated, is now completed.

The subjects treated are those which American Medicine has made peculiarly its own, and in which it has won its greatest triumphs.

That the time has arrived for the presentation of these subjects is shown by the readiness with which the foremost men of the country engaged to contribute to this work, so planned as to call forth their best efforts. It was thus possible to frame a scheme embracing all departments of Gynecology and Obstetrics, and to assign each topic to the authority recognised by universal consent as most competent to treat it. In developing the various subjects it has been the aim of the Authors and Editors to make the articles complete monographs, to which the practitioner may at all times turn with full certainty of finding what he needs in its most recent aspect, whether he seeks information on the general principles or minute guidance in the practical treatment of special disease.

No expense has been spared in presenting the system in a dress worthy of a work of so great importance. The arts of the Engraver and Chromolithographer have been generously employed wherever illustrations would really serve to illustrate the text, but no space is occupied by superfluous pictures. Each volume is copiously indexed and the final volume of each section contains a general index to the entire subject.

The success which has attended the original issue has induced the Publisher, at the request of many members of the Profession, to re-issue the work in divisions at monthly intervals.

The first volume is now ready and subscribers' names can be received.

A Detailed Prospectus will be sent to any address on application.

Second edition, 8vo, Cloth, pp. viii., 374, with 408 Illustrations, finely engraved on Wood, and 4 analytical tables, Price 5s

TEXT-BOOK OF GENERAL BOTANY

BY
DR. W. J. BEHRENS.

TRANSLATION FROM THE SECOND GERMAN EDITION.

REVISED BY
PATRICK GEDDES, F.R.S.E.,
PROFESSOR OF BOTANY IN THE UNIVERSITY OF DUNDEE

(1891.)

EXTRACTS FROM PRESS NOTICES.

"The work now before us is written in such a plain and simple style, and withal is so interesting, as to invest the study with a charm which makes it difficult for one to put down the book; and we are not surprised to hear that it has rapidly attained wide circulation. It only requires to be known to become a popular class-book."—*Students' Journal*.

"A most useful addition to the list of text-books on this subject, and one that may be highly recommended to teachers of the science. The illustrations are original and exceedingly good."—*Journal of Microscopy*.

"We have no hesitation in stating our belief that this is the best Botanical Text-Book for medical students in the English language."—*Bristol Medical Journal*.

"To a rare faculty for simple exposition the author adds a wide acquaintance with the latest developments of the science, and he contrives to carry the student along with him from the enunciation of its most rudimentary phenomena and principles to the consideration of its highest problems. These characteristics of the work have been faithfully preserved in the present translation. . . . Altogether the work is not only an excellent text-book, but is admirably adapted to serve the purposes of the lay reader."—*Scotsman*.

"A fascinating book on a fascinating subject is Mr Geddes' translation of Dr Behrens' 'Text-Book of Botany.' The author of this volume has contrived to invest its learned aspects with something of the romance attaching to its sentimental associations. He builds up the science from its elementary facts to its most complicated problems in a manner interesting to follow and easy to master. The fertilisation of flowers forms the subject of a delightful section. Those who care nothing for Botany as a science can scarcely fail to enjoy the account of such things as given in these pages; while students of the science may rest assured that, popular as the style of this work is, it is yet thoroughly trustworthy."—*Literary World*.

"In every respect the work is an excellent class-book, and we have no doubt that it will speedily find favour with teachers and students."—*Glasgow Herald*.

Crown 8vo, Cloth, pp. xii., 83, Price 3s. 6d.

THE ELEMENTS OF OPHTHALMOSCOPIC DIAGNOSIS, *FOR THE USE OF STUDENTS ATTENDING OPHTHALMIC PRACTICE.*

BY
GEORGE A. BERRY, M.B., F.R.C.S.ED.,

OPHTHALMIC SURGEON, EDINBURGH ROYAL INFIRMARY; LECTURER ON
OPHTHALMOLOGY, ROYAL COLLEGE OF SURGEONS, EDINBURGH.

(1891.)

*Ready this day, Second Edition, 8vo, pp. xvi., 730, thoroughly revised and illustrated with many additional coloured plates. Cash price,
19s. 5d., post free.*

DISEASES OF THE EYE.

*A PRACTICAL TREATISE FOR STUDENTS
OF OPHTHALMOLOGY.*

BY

GEORGE A. BERRY, M.B., F.R.C.S.ED.,

OPHTHALMIC SURGEON, EDINBURGH ROYAL INFIRMARY; SENIOR SURGEON,
EDINBURGH EYE DISPENSARY; LECTURER ON OPHTHALMOLOGY,
ROYAL COLLEGE OF SURGEONS, EDINBURGH.

(Pentland's Medical Series—Volume Second.)
(1893.)

PRESS NOTICES OF THE FIRST EDITION.

"This is a good book, written by a competent man. It presents the novelty of coloured illustrations introduced into the text. On the whole the illustrations are good. In regard to the text, the usual topographical arrangement is followed. Special chapters are devoted to the important subjects of Glaucoma, Foreign Bodies in the Eye, and Sympathetic Ophthalmia. The operations are relegated to the end of the volume. We have much pleasure in recommending Mr. Berry's work, considering it to be a valuable addition to Ophthalmic literature."—*The Lancet*.

"This handsome volume is one of the most attractive, both externally and internally, of the many text-books of Ophthalmology which adorn our bookshelves. With very few exceptions the drawings are the best that we are able to find in any corresponding handbook. . . . We wish to recommend this book as one which can be read with both pleasure and profit, not only by the student beginning the subject, but also by the specialist practising Ophthalmology. It must be regarded as a decided and creditable addition to British Ophthalmic literature."—*Dublin Medical Journal*.

"We have no hesitation in saying that in many respects this is the most advanced text-book which has yet appeared in this country in the department of medicine of which it treats.

"The clinical descriptions are clear, and for the most part well proportioned to the practical importance of the subjects treated. One of the best chapters is that on Glaucoma. The various forms of this mysterious affection, and the symptoms and signs upon which the diagnosis rests, are all carefully passed in review; in each case their causation is explained or discussed; plates illustrative of the typical, external, and ophthalmoscopic appearances, as well as a characteristic chart of the field of vision, are judiciously introduced. . . . Not less interesting is the chapter on Amblyopia, Amaurosis, and other anomalies of vision.

"Section II. treats of Errors of Refraction and Accommodation, Affections of the Oculo-Motor Muscles, and the Examination of the Eye. The concluding section is devoted to operations. The descriptions are concise and thoroughly practical. Mr. Berry has succeeded in conveying his meaning in direct and vigorous language, and the whole work is one which must add fresh lustre to

In two very handsome Imperial 8vo volumes, containing about 1600 pages.

Price 50s. nett, carriage free.

THE NATIONAL MEDICAL DICTIONARY

Including English, French, German, Italian, and Latin Technical Terms
used in Medicine and the Collateral Sciences, and a Series of
Tables of useful data.

By JOHN S. BILLINGS, A.M., M.D.,

LL.D., HARV. and EDIN., D.C.L., OXON.,

MEMBER OF THE NATIONAL ACADEMY OF SCIENCES, SURGEON U. S. A., ETC.

WITH THE COLLABORATION OF

W. O. ATWATER, M.D.
FRANK BAKER, M.D.
C. S. MINOT, M.D.

JAMES M. FLINT, M.D.
R. LORINI, M.D.
WASHINGTON MATTHEWS, M.D.

S. M. BURNETT, M.D.
J. H. KIDDER, M.D.
J. H. KIDDER, M.D.

H. C. YARROW, M.D.
WILLIAM LEE, M.D.
W. E. COUNCILMAN, M.D.

(1890.)

EXTRACTS FROM PRESS NOTICES.

From THE LANCET, 5th April 1890.—"There is, perhaps, no medical scientist in the civilised world more competent for the task of undertaking a work such as the one under notice than the accomplished author whose name stands first upon the title-page of the 'National Medical Dictionary.' That Dr. Billings, whose ripe scholarship and familiarity with general medical literature are universally acknowledged, should bestow his *imprimatur* upon a work, especially of the class to which this belongs, is sufficient to guarantee its excellence. The object of this Dictionary, as set forth in the Preface, is to furnish to students and practitioners of medicine a clear, concise definition of every medical term in current use in English, French, German, and Italian literature, including the Latin terminology of all these languages.' Its scope, therefore, is one which will at once satisfy the student, and meet all the requirements of the medical practitioner. Clear and comprehensive definitions of words should form the prime feature of any dictionary, and in this one the chief aim seems to be to give the exact signification, and the different meanings of terms in use in medicine and the collateral sciences, in language as terse as is compatible with lucidity. The utmost brevity and conciseness have been kept in view. The work is remarkable, too, for its fulness, dealing, as it does, with the definitions of no less than 84,844 words and phrases, of which number 25,496 are Latin, 9158 French, 16,708 German, and 6514 Italian. The enumerations and subdivisions under each word-heading are strikingly complete, as regards alike the English tongue and the languages chiefly employed by ancient and modern science. It is impossible to do justice to the Dictionary by any casual illustration. Apart from the boundless stores of information which may be gained by the study of a good dictionary, one is enabled by the work under notice to read intelligently any technical treatise in either of the four chief modern languages. There cannot be two opinions as to the great value and usefulness of this Dictionary as a book of ready reference for all sorts and conditions of medical men. So far as we have been able to see, no subject has been omitted, and in respect of completeness it will be found distinctly superior to any medical lexicon yet published."

From THE INTERNATIONAL JOURNAL OF THE MEDICAL SCIENCES, April 1890.—"Without disparagement of the other valuable medical dictionaries already in use, this one may be fairly said to be the most desirable for possession and reference by both students and practitioners. Dr. Billings would have been the choice of the profession for such a task, could it have been submitted to suffrage; not only because of his ability and medical scholarship, recognised with the highest honours at home and abroad, but also because the immense experience of the superintendence of the *Index Medicus* has afforded a special preparation for this work. The judiciousness of his selection of collaborators is shown by the general excellence of the definitions given throughout the two volumes. Cardinal virtues in a dictionary are clearness and sufficient fulness, without redundancy. Generally, the definitions in this work are clear. . . . Proportion has been, almost throughout, well preserved; it does not, as some others have done, show a constant ambition to grow into a cyclopædia. With very little exception, indeed, the orthography and pronunciation of medical terms in this Dictionary are beyond question. We could render no higher compliment to such a work than to give it a minute, if it even seem a hypercritical, examination. It is well worthy of it; as it is also of a place near the elbow of every medical student, and on a low-down shelf in the library of every practitioner."

A detailed Prospectus will be sent to any Address on application.

Large 8vo, Cloth, pp. xvi., 783, Price 25s. Illustrated with 226 Wood Engravings, and 68 pages of Lithograph Plates, exhibiting 91 Figures—317 Illustrations in all.

DISEASES OF THE HEART AND THORACIC AORTA.

BY

BYROM BRAMWELL, M.D., F.R.C.P.ED.,

LECTURER ON THE PRINCIPLES AND PRACTICE OF MEDICINE, AND ON PRACTICAL MEDICINE AND MEDICAL
DIAGNOSIS, IN THE EXTRA-ACADEMICAL SCHOOL OF MEDICINE, EDINBURGH;
ASSISTANT PHYSICIAN EDINBURGH ROYAL INFIRMARY.

(1884.)

EXTRACTS FROM PRESS NOTICES.

From the LANCET.—"In this elegant and profusely illustrated volume, Dr. BRAMWELL has entered a field which has hitherto been so worthily occupied by British authors; and we cannot but admire the industry and care which he has bestowed upon the work. As it stands, it may fairly be taken as representing the standpoint at which we have arrived in cardiac physiology and pathology, for the book opens with an extended account of physiological facts, and especially the advances made of late years in the neuro-muscular mechanism of the heart and blood-vessels. Although in this respect physiological research has outstripped clinical and pathological observation, Dr. BRAMWELL has, we think, done wisely in so introducing his treatise, and has thereby greatly added to its value. . . . A chapter on thoracic aneurism terminates a work which, from the scientific manner in which the subject is treated, from the care and discrimination exhibited, and the copious elaborate illustrations with which it is adorned, is one which will advance the author's reputation as a most industrious and painstaking clinical observer."

From the MEDICAL TIMES.—"Among the host of text-books and monographs which come now from the medical press, it is thoroughly gratifying to occasionally find some which do not bear obvious marks of being written either to order or for the mere sake of writing. Neither inaccuracy nor airing of crotchets—two faults which so largely disfigure our literature—can be charged against the work which is now before us. Those who have read Dr. BRAMWELL's previous book on the Spinal Cord would rightly expect to find the result of careful labours set forth with systematic clearness in anything that came from his pen; and they will not be disappointed in their perusal of this treatise on the Diseases of the Heart. Although this book deals systematically with the subject, and therefore contains much that is to be found in other works, it has two characteristics which entirely preclude the objection that it is superfluous, and, moreover, give it a right to rank among the most useful of English text-books. In the first place, the matter is arranged with great clearness, and the style is particularly intelligible, being neither redundant nor over-condensed. In the second place, there are signs throughout the work that it is not simply a careful compilation, but that the author has thought out for himself the problems he discusses, and has made the subject his own by assiduous work, both clinical and pathological. The book ends with a most valuable one (chapter) on Diseases of the Aorta, in which good use is made of rich pathological material. The illustrations are of great merit, and cannot fail to give a vivid idea of the conditions underlying the often obscure symptoms of intra-thoracic disease. A careful perusal of this work will well repay the student and refresh the memory of the busy practitioner."

8vo, Cloth, pp. xvi., 270, with 116 Illustrations, Price 14s.

INTRACRANIAL TUMOURS.

By BYROM BRAMWELL, M.D., F.R.C.P.ED.,

LECTURER ON THE PRINCIPLES AND PRACTICE OF MEDICINE IN THE EXTRA-ACADEMICAL SCHOOL OF MEDICINE, EDINBURGH; ASSISTANT PHYSICIAN TO THE EDINBURGH ROYAL INFIRMARY.

(1888.)

Crown 8vo, Cloth, pp. 154 with 5 Illustrations, Price 4s. 6d.

DISEASES & INJURIES OF THE EAR:

THEIR PREVENTION AND CURE.

By CHARLES HENRY BURNETT, A.M., M.D.,

AURAL SURGEON TO THE PRESBYTERIAN HOSPITAL; ONE OF THE CONSULTING AURISTS TO THE PENNSYLVANIA INSTITUTION FOR THE DEAF AND DUMB; LECTURER ON OTOTOLOGY, WOMEN'S MEDICAL COLLEGE OF PENNSYLVANIA, IN PHILADELPHIA.

(1889.)

Crown 8vo, Cloth, pp. xvi., 520, illustrated with Charts. Price 10s. 6d.

DISEASE IN CHILDREN:

A Manual for Students and Practitioners.

By JAMES CARMICHAEL, M.D., F.R.C.P.ED.,

PHYSICIAN, ROYAL HOSPITAL FOR SICK CHILDREN; UNIVERSITY LECTURER ON DISEASE IN CHILDREN, EDINBURGH.

(Pentland's Students' Manuals.)

8vo, Cloth, pp. xii., 102, with 4 Illustrations, Price 5s.

SUPPURATION AND SEPTIC DISEASES.

THREE LECTURES DELIVERED AT THE ROYAL COLLEGE OF SURGEONS OF ENGLAND.

By W. WATSON CHEYNE, M.B., F.R.C.S.,

HUNTERIAN PROFESSOR; SURGEON TO KING'S COLLEGE HOSPITAL; EXAMINER IN SURGERY AT EDINBURGH UNIVERSITY.

(1889.)

In press, to be issued in Fasciculi at Intervals of Two Months.

ILLUSTRATIONS OF THE DISEASES OF THE SKIN,

IN A SERIES OF PLATES FROM ORIGINAL DRAWINGS
WITH DESCRIPTIVE LETTERPRESS.

By H. RADCLIFFE CROCKER, M.D., F.R.C.P.,

PHYSICIAN TO THE DEPARTMENT FOR DISEASES OF THE SKIN, UNIVERSITY COLLEGE HOSPITAL;
PHYSICIAN TO THE EAST LONDON HOSPITAL FOR CHILDREN; EXAMINER
IN MEDICINE AT APOTHECARIES' HALL, LONDON.

* * * Subscriber's Names can now be received.

Royal 4to, illustrated with a series of 27 Coloured Plates from Original Drawings, and numerous Figures throughout the text. Price 50s. nett.

ILLUSTRATIONS OF THE NERVE TRACTS
IN THE
MID AND HIND BRAIN
AND THE
CRANIAL NERVES ARISING THEREFROM.

By ALEXANDER BRUCE, M.D., F.R.C.P. Ed.,

LECTURER ON PATHOLOGY IN THE SCHOOL OF MEDICINE, EDINBURGH; ASSISTANT
PHYSICIAN (FORMERLY PATHOLOGIST), EDINBURGH ROYAL INFIRMARY;
PATHOLOGIST TO THE ROYAL HOSPITAL FOR SICK CHILDREN.

(1893.)

*8vo, Cloth, pp. xii., 245, with Characteristic Illustrations of the Disease.
Price 10s. nett.*

BERI-BERI:
Its Etiology, Symptoms, Treatment, and Pathology.

By ARTHUR J. M. BENTLEY, M.D., M.R.C.S.,

FORMERLY COLONIAL SURGEON, STRAITS SETTLEMENTS; MEDICAL ADVISER TO THE
JOHORE GOVERNMENT, ETC.

(1893.)

*In 2 Vols., Crown 8vo, fully Illustrated with Wood Engravings. An entirely
new and thoroughly Revised Edition, with a new section on
the Brain completing the work. Price 25s.*

MANUAL
OF
PRACTICAL ANATOMY.

By D. J. CUNNINGHAM, M.D., F.R.S.,

PROFESSOR OF ANATOMY AND CHIRURGERY, TRINITY COLLEGE, DUBLIN.

(Pentland's Students' Manuals.

(1893.)

THE "COMPEND" SERIES.

A Series of Handbooks to assist Students preparing for Examinations.

Compend of Human Anatomy, Including the Anatomy of the Viscera. By SAMUEL O. L. POTTER, M.D., M.R.C.P. (Lond.), Cooper Medical College, San Francisco. Fifth Edition, revised and enlarged, Crown 8vo, pp. 233, with 117 engravings and 16 full-page plates. Price 5s.

Compend of the Practice of Medicine. By DANIEL E. HUGHES, M.D., late Demonstrator of Clinical Medicine in the Jefferson Medical College of Philadelphia. Fourth Edition, revised and enlarged, Crown 8vo, cloth, pp. 328. Price 7s. 6d.

Compend of Obstetrics. By HENRY G. LANDIS, A.M., M.D., late Professor of Obstetrics and Diseases of Women in Starling Medical College. Fourth Edition, thoroughly revised, enlarged, and improved, Crown 8vo, cloth, pp. 118, with 17 illustrations. Price 4s. 6d.

Compend of Human Physiology. By ALBERT P. BRUBAKER, A.M., M.D., Demonstrator of Physiology in Jefferson Medical College. Fourth Edition, thoroughly revised, Crown 8vo, cloth, pp. 174, with 16 illustrations and a Table of Physiological Constants. Price 4s. 6d.

Compend of Surgery. By ORVILLE HORWITZ, B.S., M.D., Chief of the Outdoor Surgical Department, Jefferson Medical College Hospital. Fourth Edition, revised, Crown 8vo, cloth, pp. 272, with 136 illustrations. Price 5s.

Compend of the Diseases of the Eye, Including Refraction and Surgical Operations. By L. WEBSTER FOX, M.D., Ophthalmic Surgeon to the Germantown Hospital, and GEORGE M. GOULD, M.D. Second Edition, thoroughly revised, Crown 8vo, cloth, pp. 164, with 71 illustrations. Price 4s. 6d.

Compend of Gynæcology. By HENRY MORRIS, M.D., late Demonstrator of Obstetrics and Diseases of Women and Children, Jefferson Medical College, Philadelphia. Crown 8vo, cloth, pp. 178, with 45 illustrations. Price 4s. 6d.

Compend of Diseases of Children. By MARCUS P. HATFIELD, A.M., M.D., Professor of Diseases of Children, Chicago Medical College. Crown 8vo, cloth, pp. 186, with coloured plate. Price 4s. 6d.

Compend of Dental Pathology and Dental Medicine. By GEO. W. WARREN, D.D.S., Clinical Chief, Pennsylvania College of Dental Surgery. Crown 8vo, cloth, pp. 109, illustrations. Price 4s. 6d.

FOR SALE BY SUBSCRIPTION ONLY.

*In 8 Vols. Royal 8vo, of about 500 pages each, Illustrated with
Wood Engravings in the Text, and numerous full-page Plates.
Price 12s. 6d. per Volume, Carriage Free.*

CYCLOPÆDIA
OF THE
DISEASES OF CHILDREN,
MEDICAL AND SURGICAL.

*THE ARTICLES WRITTEN ESPECIALLY FOR THE WORK BY
AMERICAN, BRITISH, AND CANADIAN AUTHORS.*

EDITED BY

JOHN M. KEATING, M.D.

THE aim of the Editor of these volumes has been to present a Practical Work, appealing to the Practitioner who comes in daily contact with disease in all its forms, as well as a Cyclopædia, embodying in its many articles the Science of Medicine and Surgery so far as they relate to the subjects in view.

Authors on both sides of the Atlantic have written articles on the subject with which they are most familiar, and their views will be accepted as the latest expression of scientific thought and practical knowledge. The endeavour throughout has been to present valuable material in a well-digested, practical style, written to entertain as well as instruct the reader. A brief consideration of the subject-matter will at once show that the general plan of the work has been so framed as to render it a complete and invaluable Text-book, as well as an unfailing Work of Reference, to which the Practitioner may at all times turn with the certainty of finding what he needs in its most recent aspect.

The Contributors have been allowed to introduce such Illustrations as they have considered would add to the value of their contributions. These have been reproduced in great part from original drawings and photographs, and have been printed upon a specially prepared plate paper and inserted as separate sheets. A large number of original Illustrations and Diagrams are also included in the text.

As a work of which every Physician may feel proud, and in which every Practitioner possessing it will find a safe and trustworthy counsellor in the daily responsibilities of practice, the Publisher reasonably anticipates a large demand.

Royal 8vo, Cloth, pp. xx., 1016, Illustrated with 7 Full-page Plates, some Coloured, and 97 Engravings throughout the text. Price 31s. 6d.

HYGIENE AND DISEASES OF WARM CLIMATES,

IN A SERIES OF ARTICLES BY EMINENT AUTHORITIES.

EDITED BY

ANDREW DAVIDSON, M.D., F.R.C.P.ED.,

LATE VISITING AND SUPERINTENDING SURGEON, CIVIL HOSPITAL; PROFESSOR OF CHEMISTRY,
ROYAL COLLEGE, MAURITIUS; AUTHOR OF "GEOGRAPHICAL PATHOLOGY."

(1893.)

SUMMARY OF CONTENTS.

- CHAPTER I.—Influence of Warm Climates on the Constitution. By EDWARD A. BIRCH M.D., F.R.C.P., Surgeon Superintendent, General Hospital, Calcutta.
- CHAPTER II.—Hygiene of the Tropics. By J. LANE NOTTER, M.A., M.D., Professor of Military Hygiene, Army Medical School, Netley.
- CHAPTER III.—Tropical Naval Hygiene. By Fleet-Surgeon R. W. COPPINGER, M.D.
- CHAPTER IV.—Malarial Diseases. By the Editor, ANDREW DAVIDSON, M.D., F.R.C.P.ED.
- CHAPTER V.—Tropical Typhoid Fever. By H. R. WHITEHEAD, F.R.C.S.
- CHAPTER VI.—Malta Fever. By Surgeon-Captain DAVID BRUCE, M.B., Netley.
- CHAPTER VII.—Yellow Fever. By GEORGE M. STERNBERG, M.D., Deputy-Surgeon General, U.S. Army.
- CHAPTER VIII.—Dengue. By ANDREW DAVIDSON, M.D., F.R.C.P.ED.
- CHAPTER IX.—Plague. By MONTAGU LUBBOCK, M.D., F.R.C.P., Physician, Out-Patients, Charing Cross Hospital.
- CHAPTER X.—Cholera. By N. C. MACNAMARA, F.R.C.S., Surgeon-Major, Bengal Medical Service; Surgeon, Westminster Hospital.
- CHAPTER XI.—Leprosy. By N. C. MACNAMARA, F.R.C.S., &c.
- CHAPTER XII.—Beri-beri. By PATRICK MANSON, M.D., M.R.C.P., LL.D., late Medical Officer, Seamen's and Chinese Hospitals, Amoy.
- CHAPTER XIII.—Negro Lethargy. By PATRICK MANSON, M.D., M.R.C.P., LL.D., &c.
- CHAPTER XIV.—Framboesia or Yaws. By WILLIAM T. PROUT, M.B., C.M.
- CHAPTER XV.—Tropical Diarrhoea. By Surgeon-General Sir JOSEPH FAYRER, K.C.S.I., LL.D., M.D., Q.H.P., F.R.S.
- CHAPTER XVI.—Dysentery. By Surgeon-Captain D. M. DAVIDSON, M.B., C.M., and ANDREW DAVIDSON, M.D., F.R.C.P.ED.
- CHAPTER XVII.—Tropical Diseases of the Liver. By HENRY CAYLEY, F.R.C.S., Professor of Clinical and Military Medicine, Army Medical School, Netley.
- CHAPTER XVIII.—Tropical Liver Abscess. By Surgeon-General Sir JOSEPH FAYRER, K.C.S.I., LL.D., M.D., Q.H.P., F.R.S.
- CHAPTER XIX.—Sunstroke. By Surgeon-General Sir JOSEPH FAYRER, K.C.S.I., LL.D., M.D., Q.H.P., F.R.S.
- CHAPTER XX.—Goitre. By FRANCIS NOTTIDGE MACNAMARA, M.D., late Professor, Medical College, Calcutta.
- CHAPTER XXI.—The *Filaria Sanguinis Hominis* and Filaria Disease. By PATRICK MANSON, M.D., M.R.C.P., LL.D., &c.
- CHAPTER XXII.—Distomum Ringeri Vel Pulmonale. By PATRICK MANSON, M.D., M.R.C.P., LL.D., &c.
- CHAPTER XXIII.—Intestinal, Hepatic, and Portal Entozoa, and Associated Diseases. By Professor PROSPERO SONSINO, M.D., Pisa.
- CHAPTER XXIV.—Diseases of the Skin in Tropical Climates. By PATRICK MANSON, M.D., M.R.C.P., LL.D., &c.

In 2 Volumes, large 8vo, Cloth, pp. xvi., 1008, illustrated with Maps and Charts. Price 31s. 6d.

GEOGRAPHICAL PATHOLOGY.

An Inquiry into the Geographical Distribution of Infective
and Climatic Diseases.

By ANDREW DAVIDSON, M.D., F.R.C.P.Ed.,

LATE VISITING AND SUPERINTENDING SURGEON, CIVIL HOSPITAL; PROFESSOR
OF CHEMISTRY, ROYAL COLLEGE, MAURITIUS.

(1892.)

EXTRACTS FROM PRESS NOTICES.

"In these two large handsome well printed volumes Dr. Davidson essays a laborious and difficult task, viz., a general survey of the distribution of infective and climatic diseases throughout the globe. Only those who have personally worked in this field of inquiry can adequately realise the immense difficulties which beset the task to which Dr. Davidson has addressed himself, difficulties arising out of scanty, imperfect, and often untrustworthy sources of information, different methods of registration, anomalies in medical nomenclature, and from other causes. We have carefully studied Dr. Davidson's volumes, and we regard them as an important contribution to the study of a vast and complex subject, and likely to find a useful and honourable place in medical literature. The style is easy and clear, the information is well marshalled, the writer seems laudably free from bias, and the printing and appearance of the work leave nothing to be desired. . . . He has made a very substantial contribution to the study of the geographical distribution of disease, and has produced (so far as we know) the best work on the subject hitherto published in the English language."—*The Lancet*.

"The gigantic task—how gigantic this is, those who have engaged in similar studies alone can form any conception—Dr. Davidson set himself has been admirably carried through. His work is a credit to English medical literature. The labour involved in the production of this work must have been prodigious; no less remarkable are the literary skill, the scientific spirit, and the temperance and clearness of judgment in collecting and arranging material and drawing inferences. Dr. Davidson may be congratulated, not only on having written a very learned work, but also on having written a very useful one, whose place on the bookshelf is, beside *Hirsch*, to which it forms a worthy and very necessary companion."—*Practitioner*.

EXAMINATION QUESTIONS

*Set for the Professional Examinations in Edinburgh University
during the past ten years, selected from the Calendars.*

By W. RAMSAY SMITH, M.B., B.Sc.,

DEMONSTRATOR OF ANATOMY, EDINBURGH SCHOOL OF MEDICINE, MINTO HOUSE;
LATE SENIOR ASSISTANT TO THE PROFESSOR OF NATURAL HISTORY,
UNIVERSITY OF EDINBURGH.

NATURAL HISTORY, arranged and annotated, price 1s.

BOTANY, arranged and annotated, price 1s. 6d.

CHEMISTRY, answered and annotated, price 2s.

ANATOMY, answered and annotated, price 2s.

MATERIA MEDICA AND THERAPEUTICS, answered and
annotated, price 2s.

PHYSIOLOGY, answered and annotated, price 2s.

MIDWIFERY AND GYNÆCOLOGY, answered and annotated,
price 1s. 6d.

* * * OTHER VOLUMES TO FOLLOW.

VOLUME FIRST NOW READY.

*To be issued annually, 8vo, pp. xvi., 650 or thereby, handsomely
printed, illustrated with full-page Plates and Engravings.
Price per Volume, 12s. 6d. nett. Carriage free.*

EDINBURGH HOSPITAL REPORTS.

Published under the supervision of an Editorial Committee elected by the Medical
and Surgical Officers of the Royal Infirmary, Royal Hospital for Sick
Children and Royal Maternity and Simpson Memorial Hospital.

EDITED BY

G. A. GIBSON, M.D., D.Sc., C. W. CATHCART, M.A., M.B.,
JOHN THOMSON, M.D., and D. BERRY HART, M.D.

EXTRACT FROM PROSPECTUS.

AS in the case of other hospitals actively engaged in medical education, many original observations are made, and much original research is carried out every year in the teaching hospitals of Edinburgh. Many of the results of these investigations are laid before those studying in connection with the different departments of the hospitals, and become in this way part of the current teaching of the day. A certain, but variable, proportion of this work finds its way into medical literature by means of the professional and scientific journals, or through the medium of the medical societies. There is, however, always a considerable residue of observation and investigation of real value which never reaches the general medical public, and it is the aim of the Edinburgh Hospital Reports to provide a means of bringing such results before a wider circle, and to furnish an opportunity of placing them permanently on record.

The contributors to the Reports comprise past as well as present members of the Edinburgh School, occupied in many fields of scientific work, and the results of their labours should be of wide interest to the medical profession. Their contributions will be rigidly arranged according to the nature of their subjects, and there will thus be a systematic grouping of the contents of the volume.

The statistics of the hospitals, embodying the classification of the diseases and the results of the treatment, have not hitherto been accessible to the public, or available for comparison with those of similar institutions; but, owing to the enlightened liberality of the Managers of the Royal Infirmary, of the Directors of the Royal Hospital for Sick Children, and of the Directors of the Royal Maternity and Simpson Memorial Hospital, complete statements of these facts will be presented in the forthcoming volume.

With regard to the production of the Reports, no effort will be spared to make the volumes in every way worthy of their contents. The text will be printed in a beautifully clear type, from a new fount specially cast for the purpose. Many of the contributions will be accompanied by drawings and photographs of clinical and pathological appearances, as well as by diagrammatic sketches, explanatory of the facts stated or views held by their authors. These illustrations will be reproduced in the best manner possible, so that their merit, from the artistic point of view, will be such as their intrinsic value demands.

In the publication of the Reports, Contributors and Editors have worked loyally together, under the supervision of the Editorial Committee, to bring out a work representative of the most modern teaching, and the Publisher submits the first volume to the Medical Profession with the confident expectation that it will meet with their approval and support.

8vo, Cloth, pp. xvi., 498, with 30 Illustrations, Price 16s.

DISEASES OF THE STOMACH.

By DR. C. A. EWALD,

EXTRAORDINARY PROFESSOR OF MEDICINE AT THE UNIVERSITY OF BERLIN;
DIRECTOR OF THE AUGUSTA HOSPITAL.

AUTHORISED TRANSLATION, WITH SPECIAL ADDITIONS
BY THE AUTHOR,

By MORRIS MANGES, A.M., M.D.,

ATTENDING PHYSICIAN, MOUNT SINAI HOSPITAL, NEW YORK CITY.

(1892.)

8vo., Cloth, pp. 54, Illustrated with 16 Coloured Maps, Price 5s.

ON THE GEOGRAPHICAL DISTRIBUTION OF SOME TROPICAL DISEASES AND THEIR RELATION TO PHYSICAL PHENOMENA,

BY

R. W. FELKIN, M.D., F.R.S.E., F.R.G.S.,

LECTURER ON DISEASES OF THE TROPICS AND CLIMATOLOGY, SCHOOL OF
MEDICINE, EDINBURGH.

(1889.)

*Second Edition, Crown 8vo, Cloth, pp. xvi., 383 with 109 Illustrations,
many coloured. Price 10s. 6d.*

PHYSICAL DIAGNOSIS,

A Guide to Methods of Clinical Investigation.

By G. A. GIBSON, M.D., D.Sc., F.R.C.P.Ed.,

ASSISTANT PHYSICIAN, EDINBURGH ROYAL INFIRMARY; LECTURER ON THE PRINCIPLES
AND PRACTICE OF MEDICINE IN THE EDINBURGH MEDICAL SCHOOL.

AND

WILLIAM RUSSELL, M.D., F.R.C.P.Ed.,

ASSISTANT PHYSICIAN, EDINBURGH ROYAL INFIRMARY; LECTURER ON
PATHOLOGY AND MORBID ANATOMY IN THE EDINBURGH
MEDICAL SCHOOL.

(Pentland's Students' Manuals.)

(1893.)

8vo, pp. xvi., 204, with 34 full page Coloured Plates, Price 16s.

HYDATID DISEASE

IN ITS CLINICAL ASPECTS.

By JAMES GRAHAM, M.A., M.D.,

LATE DEMONSTRATOR OF ANATOMY, SYDNEY UNIVERSITY; MEDICAL SUPERINTENDENT,
PRINCE ALFRED HOSPITAL, SYDNEY.

(1891.)

8vo, Cloth, pp. 624. Price 16s.

A TEXT-BOOK

OF

PRACTICAL THERAPEUTICS,

WITH ESPECIAL REFERENCE TO THE
APPLICATION OF REMEDIAL MEASURES TO DISEASE AND
THEIR EMPLOYMENT UPON A RATIONAL BASIS.

By HOBART AMORY HARE, M.D. (UNIV. OF PA.), B.Sc.,

CLINICAL PROFESSOR OF THE DISEASES OF CHILDREN AND DEMONSTRATOR OF THERAPEUTICS
IN THE UNIVERSITY OF PENNSYLVANIA; PHYSICIAN TO ST. AGNES'S HOSPITAL AND
TO THE MEDICAL DISPENSARY OF THE CHILDREN'S HOSPITAL.

(1890.)

8vo, Cloth, pp. 362, illustrated with 60 Photographic Reproductions,
Price 12s. 6d.

PRACTICAL PATHOLOGY

AND

MORBID HISTOLOGY.

By HENEAGE GIBBES, M.D.,

PROFESSOR OF PATHOLOGY IN THE UNIVERSITY OF MICHIGAN; FORMERLY LECTURER ON HISTOLOGY
IN THE MEDICAL SCHOOL, WESTMINSTER HOSPITAL, LONDON.

(1891.)

Crown 8vo, Cloth, pp. xvi., 260, with 164 Illustrations and a series of Flora
Diagrams, Price 6s.

BOTANY,

A Concise Manual for Students of Medicine and Science.

By ALEXANDER JOHNSTONE, F.G.S.,

LECTURER ON BOTANY, SCHOOL OF MEDICINE, EDINBURGH.

(Pentland's Students' Manuals.)

*Fourth Edition, Revised, 8vo, Cloth, pp. 172, with 16 Wood Engravings,
Price 7s. 6d.*

A PRACTICAL TREATISE ON
IMPOTENCE, STERILITY,
AND ALLIED DISEASES OF THE MALE SEXUAL ORGANS.

By SAMUEL W. GROSS, A.M., M.D., LL.D.,

PROFESSOR OF THE PRINCIPLES OF SURGERY AND CLINICAL SURGERY IN THE
JEFFERSON MEDICAL COLLEGE OF PHILADELPHIA.

FOURTH EDITION REVISED BY F. R. STURGIS, M.D.

(1890.)

*Crown 8vo, Cloth, pp. xvi., 216, with Coloured Plate and 29 Wood-
Engravings, Price 5s.*

HANDBOOK OF OBSTETRIC NURSING.

By FRANCIS W. N. HAULTAIN, M.D., F.R.C.P.ED.,

PHYSICIAN TO THE ROYAL DISPENSARY; LATE CLINICAL ASSISTANT TO PHYSICIAN FOR DISEASES
OF WOMEN, ROYAL INFIRMARY, EDINBURGH.

AND

J. HAIG FERGUSON, M.B., F.R.C.P.ED.,

PHYSICIAN TO THE NEW TOWN DISPENSARY; LATE RESIDENT PHYSICIAN,
ROYAL MATERNITY HOSPITAL, EDINBURGH.

(1889.)

8vo, Cloth, pp. xii., 285, Price 9s.

PULMONARY PHTHISIS,
ITS ETIOLOGY, PATHOLOGY, AND TREATMENT.

By ALEX. JAMES, M.D., F.R.C.P.ED.,

LECTURER ON THE PRINCIPLES AND PRACTICE OF MEDICINE IN THE SCHOOL OF MEDICINE,
EDINBURGH; ASSISTANT PHYSICIAN, EDINBURGH ROYAL INFIRMARY.

(1888.)

8vo, Cloth, pp. xii., 170, illustrated with 79 Engravings, Price 8s. 6d.

THE
TECHNIC OF LING'S SYSTEM
OF
MANUAL TREATMENT,
AS APPLICABLE TO SURGERY AND MEDICINE.

BY

ARVID KELLGREN, M.D. (EDIN.).

(1890)

In quarterly Volumes, of about 350 pages each, 8vo, handsomely printed, illustrated with full-page plates reproduced from photographs, and numerous engravings throughout the text. Price per Volume, 12s. 6d. nett, carriage free. Subscriptions are only received for 4 Volumes, or one year's issue, the Volumes being payable as delivered.

INTERNATIONAL CLINICS

A QUARTERLY COLLECTION OF CLINICAL LECTURES

ON

*MEDICINE, SURGERY, GYNÆCOLOGY, PEDIATRICS,
NEUROLOGY, DERMATOLOGY, LARYNGOLOGY,
OPHTHALMOLOGY, AND OTOTOLOGY.*

BY PROFESSORS AND LECTURERS IN THE LEADING
MEDICAL COLLEGES OF THE UNITED STATES,
GREAT BRITAIN, AND CANADA.

EDITED BY

JOHN M. KEATING, M.D.,
J. P. CROZER GRIFFITH, M.D.,
PHILADELPHIA.

J. MITCHELL BRUCE, M.D., F.R.C.P.,
DAVID W. FINLAY, M.D., F.R.C.P.,
LONDON.

THE editors are impressed with the belief that many members of the profession will be glad of the opportunity of having, in a digested form, the views and teachings of the most distinguished professors and lecturers expressed in such a way as to meet their every-day requirements. There are but few physicians or surgeons, taking an active interest in their profession, but would be glad of the opportunity of post-graduate clinical instruction. The present enterprise is expected to afford, at a small cost, the opportunity desired.

The aim of the publishers and editors is, through the medium of the International Clinics, to afford to practitioners the advantages of practical post-graduate instruction, and to present the most valuable of these lectures in the form of concise and well-digested articles, systematically arranged.

A large mass of useful and valuable matter has been collected, which the editors are now arranging and preparing for publication.

These lectures, reported by competent medical stenographers, are put into correct form by the editors, and are then returned to the authors for revision and correction. It is the intention of the editors to select only the best, that is to say, the most really valuable of the lectures which are offered for publication. The reader is thus put in possession of the approved thoughts and the latest ideas of the most eminent teachers, men who, by their ability, are shaping out the progress of medicine in its rapid development.

The contributors are men of established reputation, who recognise the necessity and importance of devoting special attention to Diagnosis, and it is expected that Differential Diagnosis, Prognosis, and Treatment—more especially the latter—will, in every instance, be fully and clearly discussed.

Most of the prominent teachers in the Medical Schools of the United States, Great Britain, and Canada, have promised their hearty co-operation and support to make the venture a success.

The work will be issued at quarterly intervals, and each volume will consist of 350 pages, or thereby, 8vo, handsomely printed in a beautifully clear type. Photographs illustrating the more important cases will be introduced as occasion demands. They will be printed on a specially prepared paper of fine quality, and inserted as separate leaves.

Subscriptions are received for one year, or for four volumes, at the subscription rate of 12s. 6d. per volume, carriage free. The volumes payable as delivered.

FOR SALE BY SUBSCRIPTION ONLY.

In 3 Volumes, Royal 8vo, of about 1000 pages each. Uniform with the "Cyclopædia of Children's Diseases" and "Systems of Gynæcology and Obstetrics." Price per Volume 22s. 6d., carriage free.

A SYSTEM OF PRACTICAL THERAPEUTICS

BY VARIOUS AUTHORS.

EDITED BY

HOBART AMORY HARE, M.D.,

CLINICAL PROFESSOR OF DISEASES OF CHILDREN, AND DEMONSTRATOR OF THERAPEUTICS IN THE
UNIVERSITY OF PENNSYLVANIA; PHYSICIAN TO ST. AGNES' HOSPITAL, PHILADELPHIA.

LIST OF CONTRIBUTORS.

- | | |
|-------------------------------|------------------------------|
| I. E. ATKINSON, M.D. | C. J. KIPP, M.D. |
| S. C. AYRES, M.D. | BENJAMIN LEE, M.D. |
| HENRY B. BAKER, M.D. | ALFRED L. LOOMIS, M.D. |
| H. M. BANNISTER, M.D. | EDWARD MARTIN, M.D. |
| ROBERT BARCLAY, M.D. | RUDOLPH MATAS, M.D. |
| SIMON BARUCH, M.D. | CHARLES K. MILLS, M.D. |
| A. D. BLACKADER, M.D. | JOHN K. MITCHELL, M.D. |
| T. LAUDER BRUNTON, M.D. | WILLIAM F. MITTENDORF, M.D. |
| E. N. BRUSH, M.D. | JOHN H. MUSSER, M.D. |
| F. BULLER, M.D. | FREDERICK A. PACKARD, M.D. |
| CHARLES H. BURNETT, M.D. | ROSWELL PARK, M.D. |
| SWAN M. BURNETT, M.D. | CHARLES B. PENROSE, M.D. |
| J. CHALMERS CAMERON, M.D. | B. ALEXANDER RANDALL, M.D. |
| WALTER CHRYSTIE, M.D. | JOSEPH RANSOHOFF, M.D. |
| JEROME COCHRAN, M.D. | JOSEPH P. REMINGTON, PHAR.D. |
| S. SOLIS-COHEN, M.D. | C. EUGENE RIGGS, M.D. |
| H. RADCLIFFE CROCKER, M.D. | A. D. ROCKWELL, M.D. |
| T. D. CROTHERS, M.D. | B. SACHS, M.D. |
| D. BRYSON DELAVAN, M.D. | C. E. SAJOUS, M.D. |
| F. X. DERCUM, M.D. | SAMUEL SEXTON, M.D. |
| GEORGE E. DE SCHWEINITZ, M.D. | FREDERICK C. SHATTUCK, M.D. |
| R. L. DICKINSON, M.D. | WHARTON SINKLER, M.D. |
| GEORGE DOCK, M.D. | ANDREW H. SMITH, M.D. |
| MANUEL DOMINGUES, M.D. | J. LEWIS SMITH, M.D. |
| H. GRADLE, M.D. | E. S. SOLLY, M.R.C.S. |
| LANDON CARTER GRAY, M.D. | HORATIO N. SPENCER, M.D. |
| WALTER D. GREEN, M.D. | M. ALLEN STARR, M.D. |
| JOHN B. HAMILTON, M.D. | GEORGE M. STERNBERG, M.D. |
| W. A. HARDAWAY, M.D. | D. D. STEWART, M.D. |
| EDWARD M. HARTWELL, M.D. | J. S. STEWART, M.D. |
| M. B. HARTZELL, M.D. | ROBERT W. TAYLOR, M.D. |
| FREDERICK P. HENRY, M.D. | WILLIAM H. THOMSON, M.D. |
| BARTON C. HIRST, M.D. | T. J. WATKINS, M.D. |
| LUCIEN HOWE, M.D. | WILLIAM M. WELCH, M.D. |
| JAMES NEVINS HYDE, M.D. | J. WILLIAM WHITE, M.D. |
| EDWARD JACKSON, M.D. | JAMES T. WHITTAKER, M.D. |
| W. W. JAGGARD, M.D. | HORATIO C. WOOD, M.D. |
| HOWARD A. KELLY, M.D. | I. BURNEY YEO, M.D. |
| CHARLES B. KELSEY, M.D. | |

*Third Edition, Revised and Enlarged, 8vo, Cloth, gilt top, pp. xx., 641,
with Woodcut and 9 double-page coloured Illustrations.
Cash Price 16s. 8d. post free.*

DISEASES OF THE SKIN.

A Manual for Students and Practitioners.

BY

W. ALLAN JAMIESON, M.D., F.R.C.P.ED.,

EXTRA PHYSICIAN FOR DISEASES OF THE SKIN, EDINBURGH ROYAL INFIRMARY; CONSULTING PHYSICIAN
EDINBURGH CITY HOSPITAL; LECTURER ON DISEASES OF THE SKIN,
SCHOOL OF MEDICINE, EDINBURGH.

(Pentland's Medical Series, Volume First.)

(1897.)

EXTRACTS FROM PRESS NOTICES.

"This is the first volume in *Pentland's Medical Series*. It does credit to the author, and is an excellent book of its kind, sound in matter, thoughtful, and practical. The work is especially noticeable for the excellent style of the author's writing, and for a more complete exposition of the uses of many remedies and methods of treatment brought forward in recent years than is to be found in any other work. Dr. Jamieson is an enthusiastic supporter of Unna's methods and preparations, and not without good reason. The author's experience on this matter will be very acceptable to the profession in these islands. After a careful perusal of the work, we can heartily recommend it."—THE LANCET.

"The chief charm of the work, as a whole, is its literary style. It is refreshing to read such vigorous, lucid English, without one ambiguous line. It reminds us more of Watson's *Physic* than any more recent work. We have had the greatest possible pleasure in reading this book. It was Lord Bacon who said that 'some books are to be tasted, others to be swallowed, and some few to be chewed and digested.' This classical work, by Dr. Jamieson, is one of the last class, and as such we strongly recommend it to the profession."—BRITISH MEDICAL JOURNAL.

"Dr. Jamieson's work on *Diseases of the Skin* appears as the first volume of *Pentland's Medical Series*, and it is difficult to imagine that a series of medical manuals could have been introduced more successfully and with greater promise. So many manuals on diseases of the skin have lately been published, that a new one, to possess any claim to be read, must afford evidence of individuality. A strong claim to individuality may successfully be made in connection with the book before us. Whilst one of its leading features is that it contains references to the most recent works on dermatology, even up almost to the very date of publication, it also illustrates types of skin disease and methods of treatment that have been observed and studied by Dr. Jamieson himself. It was becoming that the Edinburgh school should produce a work of this kind, and the industry and ability of the author have contributed to the production of a book which does that ancient school of medical learning credit. We must refer the reader to the work itself, which we cordially recommend to his consideration and study."—PRACTITIONER.

"Dr. Allan Jamieson is well known to all our readers by his most valuable periscope of Dermatology, which so often adorns our pages, as well as by much excellent original work. The book seems to fulfil, in a very admirable way, all the purposes for which it is intended. It is full, yet concise enough not to be unwieldy. It is arranged in a thoroughly scientific manner, and yet is severely practical. Without undervaluing the labours or neglecting the classifications of other writers, Dr. Jamieson gives his own opinions, and in his own way. Excellent illustrative cases give a personal interest to the descriptions, and each variety of disease is so carefully painted in words as to render recognition easy; and then the treatment, both local and constitutional, of each is given in the plainest and easiest terms. We congratulate Dr. Jamieson and the Edinburgh School, in which he is such a favourite teacher, on his admirable work."—EDINBURGH MEDICAL JOURNAL.

"If the practitioner's library is to contain only one book on diseases of the skin, it would be well furnished with this book."—BRISTOL MEDICAL JOURNAL.

"In the limits of a short review, it would be impossible to do full justice to this important treatise on dermatology. We can strongly recommend the work as a standard textbook on diseases of the skin, and one which will not only prove useful to the student, but will also serve as an excellent work of reference for the practitioner. All the illustrations are well executed."—LIVERPOOL MEDICAL JOURNAL.

*Second Edition, Revised and Enlarged, oblong Cr. 8vo, Cloth, pp. 65
with 28 Illustrations, Price 4s.*

THE URINE AND THE COMMON POISONS,

Memoranda, Chemical and Microscopical, for Laboratory Use.

By J. W. HOLLAND, M.D.,

PROFESSOR OF MEDICAL CHEMISTRY AND TOXICOLOGY, JEFFERSON MEDICAL COLLEGE,
OF PHILADELPHIA.

(1889.)

Handsome 8vo, Cloth, pp. 818, Price 18s.

A NEW PRONOUNCING DICTIONARY

OF

MEDICAL TERMS.

By JOHN M. KEATING, M.D.,

FELLOW OF THE COLLEGE OF PHYSICIANS OF PHILADELPHIA; VISITING OBSTETRICIAN TO THE
PHILADELPHIA HOSPITAL, AND LECTURER ON DISEASES OF WOMEN AND CHILDREN.

12mo. Cloth, pp. 52, Price 2s.

THE ESSENTIALS OF MEDICAL ANATOMY.

By H. R. KENWOOD, M.B., C.M., L.R.C.P.(Lond.)

(1889.)

Crown 8vo, Limp Cloth, pp. 64. Price 2s.

THE MINERAL WATERS OF HARROGATE.

By JOHN LIDDELL, M.D.,

HONORARY PHYSICIAN, HARROGATE ROYAL BATH HOSPITAL.

(1893.)

New Edition, 18mo Cloth, pp. 303, Price 4s.

STUDENTS' POCKET MEDICAL LEXICON.

Giving the correct Pronunciation and Definition of all Words and
Terms in general use in Medicine and the Collateral Sciences,

By ELIAS LONGLEY.

(1889.)

*Large 8vo, Cloth, pp. xvi., 600, with 147 Illustrations, some Coloured,
Price 30s.*

THE REFRACTION AND ACCOMMODATION OF THE EYE, *AND THEIR ANOMALIES.*

BY

E. LANDOLT, M.D.,
PROFESSOR OF OPHTHALMOLOGY, PARIS.

TRANSLATED UNDER THE AUTHOR'S SUPERVISION

BY

C. M. CULVER, M.A., M.D.,
FORMERLY CLINICAL ASSISTANT TO THE AUTHOR; MEMBER OF THE ALBANY
INSTITUTE, ALBANY, N.Y.

(1886.)

*Large 8vo, Cloth, pp. xxviii., 772, Illustrated with 404 Engravings,
Price 31s. 6d.*

THE PARASITES OF MAN

AND THE DISEASES WHICH PROCEED FROM THEM.

A TEXT-BOOK FOR STUDENTS AND PRACTITIONERS.

BY

RUDOLF LEUCKART,

PROFESSOR OF ZOOLOGY AND COMPARATIVE ANATOMY IN THE UNIVERSITY OF LEIPSIK.

Translated from the German with the Co-operation of the Author,

By WILLIAM E. HOYLE, M.A. (Oxon.), M.R.C.S., F.R.S.E.,
CURATOR OF THE MUSEUMS, OWENS COLLEGE, MANCHESTER.

*NATURAL HISTORY OF PARASITES IN GENERAL.
SYSTEMATIC ACCOUNT OF THE PARASITES INFESTING MAN.
PROTOZOA—CESTODA.*

(1886.)

8vo, Cloth, gilt top, pp. xvi., 640, with coloured Illustrations from Original Drawings, Price 25s.

DISEASES OF THE THROAT, NOSE, & EAR.

A CLINICAL MANUAL FOR STUDENTS AND
PRACTITIONERS.

By P. McBRIDE, M.D., F.R.C.P. ED.,

LECTURER ON THE DISEASES OF THE EAR AND THROAT, EDINBURGH SCHOOL OF MEDICINE;
AURAL SURGEON AND LARYNGOLOGIST, ROYAL INFIRMARY, EDINBURGH;
SURGEON, EDINBURGH EAR AND THROAT DISPENSARY.

.(Pentland's Medical Series. Volume Third.)

(1892.)

EXTRACTS FROM PRESS NOTICES.

"Dr. McBride's views on many points connected with the subjects embraced in the title of this book are so well known and valued for the authoritativeness with which they are expressed, that all will welcome a text-book from his pen. We expected something above the meagre average of similar productions, and we are not disappointed. The general appearance of the work reflects great credit upon the care of the printers and the liberality of the publisher. The paper and typography could not be better; and although these are very small matters in discussing the value of a work, yet accuracy and elegance generally prove as attractive to the reader as they doubtless are to the author. We hope to see many editions of this valuable book."—*Lancet*.

"In this handsome and well-printed volume, the author has gathered together under one cover all the main facts of modern laryngology, rhinology, and otology; and it is obvious that such an arrangement will present many distinct advantages to the students and practitioners for whom the work is primarily designed. In the main, Dr. McBride gives a complete account of all methods which he has found to be beneficial in his own experience with cases; and at the same time, while showing an impartial consideration for the opinions of other authorities, he is careful to point out any procedure which he himself holds to be either unnecessary or harmful. The whole work is well and clearly written, and may be commended to all those who desire to have a sound and judicial guide to the present state of our knowledge in these branches of medicine."—*Practitioner*.

"The third volume of Pentland's Medical Series appears under the above title, and bids fair, we think, to have a success equal to, or greater than that obtained by the previous volumes on the skin and the eye. The author is well known to our readers as a shrewd observer, an original thinker, and a man who has established a reputation, both in this country and abroad, as an able writer and a successful practitioner; and it is not too much to say that anything coming from his pen is sure to be worth reading. But this volume is of special interest, for it is, so far as we know, the only manual that has appeared by one writer dealing with all three subjects—the throat, the nose, and the ear. The coloured plates are in most cases excellent, and they are conveniently placed throughout the text. The whole book is written in clear and vigorous style, and the writer conveys his meaning in forcible, lucid, and intelligible language. We congratulate the author and the publisher respectively on the contents and the appearance of the volume."—*Edinburgh Medical Journal*.

"Lecturers on diseases of the ear, throat, and nose, will welcome Dr. McBride's latest volume. To recommend a text-book to students engaged in the study of the diseases affecting those closely associated organs has hitherto been a difficulty with teachers. This volume solves the difficulty. In some 600 pages of a clearly-printed book, we have the main facts of laryngology, rhinology, and otology placed before us. The book is written up to date, and is by no means a replica of other works dealing with the same subjects. Of 38 illustrations given, the majority are in colour, and are original; and for the most part they are not only beautiful pictures, but very accurate representations of the diseased conditions described. It will prove to be not only a useful text-book for students, but a convenient and reliable guide to those regions for the graduate."—*Glasgow Medical Journal*.

*In Ten Parts, Price 6s. each ; or complete in one handsome Royal 4to Volume,
Extra Cloth, Price 63s. nett.*

ATLAS OF VENEREAL DISEASES.

*A Series of Illustrations from Original Paintings, with Descriptions
of the varied Lesions, their differential Diagnosis
and Treatment.*

BY

P. H. MACLAREN, M.D., F.R.C.S.E.,

SURGEON, EDINBURGH ROYAL INFIRMARY; FORMERLY SURGEON IN CHARGE OF THE LOCK
WARDS, EDINBURGH ROYAL INFIRMARY; EXAMINER IN THE ROYAL
COLLEGE OF SURGEONS, EDINBURGH.

THE Work consists of a series of Life-size Plates, exhibiting Forty-five Figures, illustrating all the essential types of the disease in the Male and Female, including those rarer varieties met with occasionally.

The Illustrations, without exception, are original. They are copied from paintings of cases which have come under the Author's observation during the past few years.

The chief aim of this Work is to offer to the Medical Profession a series of Illustrations which may prove useful as a reference in the Diagnosis of Venereal Diseases.

To Medical Students who have not sufficient time nor opportunity afforded them in their curriculum for the systematic study of the multifarious expressions of Venereal Diseases, it is hoped that this Atlas will be specially serviceable.

In the production of the Plates neither labour nor expense have been spared to reproduce the original paintings with accuracy and finish.

Each is accompanied by a concise and clear description of the conditions portrayed.

The Atlas is printed on a thick specially prepared paper, Folio size, 15 × 11.

To afford those members of the Profession who may desire to secure the Work in its Serial form another opportunity of acquiring it, the Publisher has decided to re-issue it in Ten Fasciculi, at Monthly intervals. Each Fasciculus will contain three Illustrations, with descriptive Letterpress, and along with Fasciculus X. the Title Page, List of Illustrations, &c. will be supplied. As but a limited number of the original copies remain for sale, early application is recommended.

FOR SALE BY SUBSCRIPTION ONLY.

VOLUME SECOND, JUST READY.

In two handsome 4to Volumes, of over 350 pages each, illustrated with upwards of 100 full-page Facsimile Chromo-Lithographic Plates, reproduced from Photographs taken by the Author of his own Dissections, expressly designed and prepared for this Work, and coloured by him after Nature. Price per Volume, 42s. nett.

REGIONAL ANATOMY

IN ITS RELATION TO

MEDICINE & SURGERY.

BY

GEORGE McCLELLAN, M.D.,

LECTURER ON DESCRIPTIVE AND REGIONAL ANATOMY AT THE PENNSYLVANIA SCHOOL OF ANATOMY;
PROFESSOR OF ANATOMY AT THE PENNSYLVANIA ACADEMY OF THE FINE ARTS,
PHILADELPHIA.

NOTWITHSTANDING the recent and great advances in medical education and the necessarily resulting increase of specialism in medical practice, little has been done to present the practical aspects of Anatomy in a manner commensurate with the requirements of the physician and surgeon, and in accordance with the existing state of the science.

In the present work the Author has undertaken to afford to the practitioner and student the opportunity of seeing carefully and scientifically made dissections of the human body, with the various parts displayed in their natural relations.

While expressing his profound belief that the best text-book on the Anatomy of the Human Body is, and always will be, the body itself, he has endeavoured to place before his readers a series of facsimile representations with a view to exhibiting the exact Anatomy of each region.

The text is full and complete, and its materials represent the teaching of the science of to-day in its most advanced and best approved style.

The arrangement of the subject matter is novel and striking.

The one object which the Author has had before him has been the teaching of Anatomy by the most effective and correct method. The old system viewed the bones, the muscles, the vessels, and the nerves as so many distinct structures, and this method is still very generally adhered to. The student in the dissecting-room, and the young graduate in his early practice, are thus compelled to co-ordinate the acquired anatomical facts as best they may, and to bring them into some practical shape, usually, however, in a manner more or less imperfect. Yet nothing can be more important to either surgeon or physician than a just appreciation of the relations which the various parts and organs bear to one another, and the application of this knowledge to questions of diagnosis and treatment.

While it cannot be fairly said that a knowledge of any one part of the human economy is intrinsically more valuable than that of any other part, there are still matters of prime importance in anatomical study, such as the interdependence and the mutual relation of associated organs; and such knowledge can be obtained only by conscientious regional study to which this work opens the way.

VOLUME FIRST NOW READY.

*To form 6 Divisional Volumes, Large 8vo, of about 550 pages each, fully
Illustrated. Price 14s. each nett.*

A SYSTEM OF
GENITO-URINARY DISEASES,
SYPHILOLOGY, AND DERMATOLOGY.

EDITED BY
PRINCE A. MORROW, M.D.

*Second Edition, Revised and Enlarged, 18mo, pp. xvi., 315, in flexible leather
binding, Price 6s. 6d.*

PRESCRIBING AND TREATMENT IN THE
DISEASES OF INFANTS AND CHILDREN.

By PHILIP E. MUSKETT,
LATE SURGEON TO THE SYDNEY HOSPITAL; FORMERLY SENIOR RESIDENT MEDICAL OFFICER,
SYDNEY HOSPITAL. (1893.)

8vo, pp. xvi., 212, with 3 Illustrations. Price 9s.

MALIGNANT DISEASE
OF THE
THROAT AND NOSE.

By DAVID NEWMAN, M.D.,
LARYNGOLOGIST TO THE GLASGOW ROYAL INFIRMARY; ASSISTANT SURGEON TO THE WESTERN
INFIRMARY; EXAMINER IN PATHOLOGY IN THE UNIVERSITY OF GLASGOW. (1892.)

8vo, pp. xii., 122, with 32 Illustrations, mostly in colours, Price 10s. 6d.

LEAD POISONING,
IN ITS ACUTE AND CHRONIC FORMS.

*THE GOULSTONIAN LECTURES, DELIVERED IN THE ROYAL
COLLEGE OF PHYSICIANS, MARCH 1891.*

By THOMAS OLIVER, M.D., F.R.C.P.,
PROFESSOR OF PHYSIOLOGY, UNIVERSITY OF DURHAM; PHYSICIAN TO THE
ROYAL INFIRMARY, NEWCASTLE-ON-TYNE. (1891.)

Large 8vo, pp. xvi., 1080, illustrated with Charts, Price 24s.

THE PRINCIPLES & PRACTICE OF MEDICINE

Designed for the Use of Practitioners and Students
of Medicine.

By WILLIAM OSLER, M.D., F.R.C.P.,

PROFESSOR OF MEDICINE IN THE JOHNS HOPKINS UNIVERSITY, AND PHYSICIAN-IN-CHIEF TO
JOHNS HOPKINS HOSPITAL, BALTIMORE.

(1892.)

THE work is an eminently practical one, deals with diseases from the most modern scientific standpoint, and is in every way thoroughly up to the times. In it the etiology, symptoms, diagnosis, prognosis, treatment, and pathology of diseases are fully set forth, making it one of the most thorough and scientific text-books on the subject ever presented to the profession. Dr. OSLER's reputation as a writer, clinician, and teacher insures to the reader of this work a fund of information so arranged and classified as to make it easily available.

OPINIONS OF THE PRESS.

"The English-speaking student has been fortunate in his text-books of medicine, both in this and in the past generation. Still, the number of such text-books of the first rank is limited, and the announcement that Dr. William Osler had a systematic work on general medicine in the press raised expectations that we might be presented with another real text-book. The reviewer is supposed in theory to come to his task with a perfectly unbiassed mind, but with Dr. Osler this is not quite possible. He has done such good work that the reader is prejudiced in his favour; we expect a masterly production. Have we received such a work? Only time can answer this question, but we suspect that the reply will be in the affirmative.

"Dr. Osler has written throughout from the standpoint of modern pathology and of the most modern methods of clinical examination. . . . There are not many novelties of classification, which is well, but there are some not without significance. For instance, we find tuberculosis treated, as a whole, under one heading, and placed, as it ought to be, among specific infectious diseases. In this way, the reader, whether student or practitioner, finds a complete picture of this vastly important disease placed before him in a continuous essay.

"As a rule, the style of the book is business-like though distinctly readable, but the author allows us to see that he is not wanting in a feeling for literary form.

"Diseases of the Nervous System are fully treated. The customary mode of arrangement has been generally followed. There are good articles on cerebral and spinal localisation, and altogether this part of the book is of a thoroughly practical character, well suited to the needs of the working physician.

"The book is provided with a copious index, and appears to be very free from misprints and errors of arrangement."—*British Medical Journal*.

"The publication of few books of recent times has been awaited with so much interest as that of the present volume, and few works upon medicine have so well satisfied those who consulted their pages.

"A dedicatory tribute to the memory of his teachers gives evidence of the author's appreciation of the value and responsibility of the relation of teacher and pupil. He strikes the key-note of his own methods in Medicine in the platonic statement which says 'that this is an art which considers the constitution of the patient, and has principles of action and reason in each case.' He then proceeds at once to the discussion of the specific infectious diseases, and first of these typhoid fever. His treatment of this subject is a fair illustration of his method in others. The definition and history are followed by etiology, and then comes a description of the specific germ and its modes of conveyance. The morbid anatomy of the disease is considered with reference to 64 autopsies conducted by the author, and also the records of 2000 at Munich. It is rare to find a more satisfactory picture of disease than that afforded by these pages.

"For those who wish to know the facts of Modern Medicine, as such are attained by skilful observation and logical deduction, this is the most interesting and valuable book in the English language.

"Dr. Osler has laid those in the profession, who find enjoyment in the study of Medicine upon a rational basis, under a lasting obligation in the present volume."—*International Journal of the Medical Sciences*.

Second Edition, thoroughly revised, large 8vo, Cloth, pp. 701, with 214 Wood Engravings, and a Coloured Plate, Price 18s.

THE SCIENCE AND ART OF OBSTETRICS.

BY

THEOPHILUS PARVIN, M.D., LL.D.,

PROFESSOR OF OBSTETRICS AND DISEASES OF WOMEN AND CHILDREN IN JEFFERSON
MEDICAL COLLEGE, PHILADELPHIA, AND ONE OF THE OBSTETRICIANS
TO THE PHILADELPHIA HOSPITAL.

(1891.)

OPINIONS OF THE PRESS.

"So many obstetric manuals have been lately issued that a fresh one is apt to be very critically received. This book, however, will at once assume a high rank amongst the literature of this department of medicine. The enormous amount of labour and research that has been expended on it is visible in every chapter.

"To the obstetrician one cannot over estimate the advantage of having such a book for reference, containing as it does almost every important question expressed or written.

"The diagrams are most excellent, many being refreshingly new and original, and as accurate as they are graphic.

"In conclusion, we cordially congratulate the author on the result of his labours, which is likely to be of such real and lasting benefit to his fellow-practitioners in all countries."—*Practitioner*.

"The work proper commences with a very elaborate description of the anatomy and physiology of the female reproductive organs. It is very carefully done, and the illustrations are numerous and suggestive.

"The various stages of development of the foetus from the impregnated ovum are particularly well described, and in addition to the stock drawings with which every student of obstetrics is familiar, there are several which are new to us, which aid greatly in the comprehension of this complicated process.

"Questions such as the nutrition of the foetus *in utero* are discussed and elucidated by frequent references to the most recent discoveries and hypotheses, and the whole is worked up in a pleasant style, which is humorous without ever being trivial.

"It is satisfactory to see that the advantages of abdominal palpation as an aid to the diagnosis of position are beginning to be appreciated. The details of the procedure are given, and the *modus operandi* is made clear by several woodcuts. Hitherto this valuable method has been dismissed with a few words, and we are glad to see the lapsus filled.

"In conclusion, the book is considerably above the average work on obstetrics, and is valuable both for study and reference. There are no less than 215 illustrations, many of which are new, and the index is unusually complete."—*British Medical Journal*.

"Dr. PARVIN is to be congratulated on the general style of his book, which displays extensive reading as well as sound practical knowledge. The woodcuts, 214 in number, are lucid and well executed."—*Medical Press and Circular*

PRACTICAL LESSONS IN NURSING:

A NEW SERIES OF HANDBOOKS.

Now ready, Crown 8vo, Cloth, each 4s. 6d.

THE NURSING AND CARE OF THE NERVOUS AND THE INSANE.

By CHARLES K. MILLS, M.D.,

PROFESSOR OF DISEASES OF THE MIND AND NERVOUS SYSTEM IN THE PHILADELPHIA
POLYCLINIC AND COLLEGE FOR GRADUATES IN MEDICINE; LECTURER ON
MENTAL DISEASES IN THE UNIVERSITY OF PENNSYLVANIA.

MATERNITY, INFANCY, CHILDHOOD.

Hygiene of Pregnancy; Nursing and Weaning of Infants;
The Care of Children in Health and Disease.

*Adapted especially to the use of Mothers or those intrusted with the bringing up
of Infants and Children, and Training Schools for Nurses, as an
aid to the teaching of the Nursing of Women and Children.*

By JOHN M. KEATING, M.D.,

LECTURER ON THE DISEASES OF WOMEN AND CHILDREN, PHILADELPHIA HOSPITAL.

OUTLINES FOR THE MANAGEMENT OF DIET:

Or, The Regulation of Food to the Requirements of Health and
the Treatment of Disease.

By E. T. BRUEN, M.D.,

ASSISTANT PROFESSOR OF PHYSICAL DIAGNOSIS, UNIVERSITY OF PENNSYLVANIA;
ONE OF THE PHYSICIANS TO THE PHILADELPHIA AND UNIVERSITY HOSPITALS.

FOR SALE BY SUBSCRIPTION ONLY.

To be issued at Intervals of Two Months, in Eight very handsome Volumes, Imperial 8vo, Cloth, of about 800 pages each, illustrated with Engravings and Coloured Plates. Price per Volume 25s. Carriage free.

Volume I. now ready.

A REFERENCE HAND-BOOK OF THE MEDICAL SCIENCES,

*EMBRACING THE ENTIRE RANGE OF SCIENTIFIC AND PRACTICAL
MEDICINE AND ALLIED SCIENCES BY VARIOUS WRITERS*

EDITED BY

ALBERT H. BUCK, M.D.,
NEW YORK CITY.

The Publisher has pleasure in announcing that this Work, differing from all others issued in this country, and calculated, as he believes, from its character and the high reputation of its very large staff of learned Contributors (over 300 in number), to be the most practical and generally useful work to all classes of the Medical Profession of any hitherto presented to their notice, is so near completion that the First Volume is now ready for delivery, and the others may be expected to appear at regular intervals of two months.

The HAND-BOOK consists of a collection of concisely written Essays on all the important topics belonging to the broad domain of Medicine, Surgery, and the allied Sciences. Its subject-matter is alphabetically arranged, admitting of instant and ready reference, and is designed to cover so wide a field and embrace such a variety of subjects as to render it of the greatest practical utility, not only to general Practitioners, but also to those who are interested in Special Departments of Medical Science. The various Articles have been assigned to writers who are recognised by universal consent as most competent to handle them.

Illustrations have been freely introduced wherever they will serve to elucidate the text, and special pains have been taken to secure as large a proportion of Original Woodcuts as possible.

The following summary of the leading Subjects dealt with in THE HAND-BOOK will afford an idea of the extent and scope of the Work, but it is impossible within the limits of a Prospectus to do more than give a general outline of the contents. To secure the highest order of excellence, no labour or expense has been spared.

SUMMARY OF CONTENTS.

Applied Anatomy.—Biology, Histology, and Experimental Physiology.—Physiological and Pathological Chemistry.—Toxicology.—Pathological Anatomy.—Hygiene and Public Health.—Military and Naval Medicine, Hygiene and Sanitary Science.—Climatology, Health Resorts, and Mineral Springs.—Life Insurance.—Medical Jurisprudence.—General Pathology and Therapeutics, and Physical Diagnosis.—Materia Medica, Medical Botany, and Pharmacology.—Poisonous Insects and Reptiles.—Surgical Pathology and General Surgery.—Orthopædic Surgery.—Dental Pathology and Therapeutics.—Diseases of the Mind and Nervous System.—Dermatology and Syphilis.—Laryngology and Diseases of the Nose and Throat.—Ophthalmology.—Otology. &c. &c.

8vo, Cloth, with Coloured Illustrations from Original Drawings.

B E R I - B E R I :

Researches Concerning its Nature and Cause and the Means of its Arrest.

By C. A. PEKELHARING,

PROFESSOR IN THE FACULTY OF MEDICINE, UNIVERSITY OF UTRECHT;

AND C. WINKLER,

LECTURER IN THE UNIVERSITY OF UTRECHT.

TRANSLATED BY JAMES CANTLIE, M.A., M.B., F.R.C.S.

(1893.)

*8vo, Cloth, pp. xvi., 271, with Coloured Plates and 35 Engravings,
Price 10s. 6d.*

THE CAUSES AND TREATMENT
OF

A B O R T I O N,

By ROBERT R. RENTOUL, M.D., M.R.C.S.,

FELLOW OF THE OBSTETRICAL SOCIETY, LONDON.

WITH AN INTRODUCTION BY

LAWSON TAIT, F.R.C.S.,

(1889.)

REPORTS FROM THE LABORATORY

OF THE

ROYAL COLLEGE OF PHYSICIANS, EDINBURGH.

EDITED BY

J. BATTY TUKE, M.D.,

G. SIMS WOODHEAD, M.D.,

AND

D. NÖEL PATON, M.D.

VOLUME FIRST, *8vo, Cloth, pp. 212, with 23 full page Plates, and 19 Engravings. Price 7s. 6d. nett.*

VOLUME SECOND, *8vo, Cloth, pp. xiv., 280, with 43 full page Plates, consisting of Lithographs, Chromo-Lithographs, and Micro-Photographs. Price 10s. 6d. nett.*

VOLUME THIRD, *8vo, Cloth, pp. xii., 304, with 11 Plates and Folding Charts. Price 9s. nett.*

VOLUME FOURTH, *8vo, Cloth, pp. xii., 254, with 25 full page Plates, many coloured, and Folding Charts. Price 10s. 6d. nett.*

8vo, Cloth, pp. xii., 302, with 5 Wood Engravings, Price 9s.

DISEASES OF THE MOUTH, THROAT, AND NOSE,

INCLUDING

RHINOSCOPY AND METHODS OF LOCAL TREATMENT.

BY

PHILIP SCHECH, M.D.,

LECTURER IN THE UNIVERSITY OF MUNICH.

TRANSLATED BY

R. H. BLAIKIE, M.D., F.R.S.E.,

FORMERLY SURGEON, EDINBURGH EAR AND THROAT DISPENSARY; LATE CLINICAL ASSISTANT,
EAR AND THROAT DEPARTMENT, ROYAL INFIRMARY, EDINBURGH.

(1886.)

EXTRACTS FROM PRESS NOTICES.

"We have read this book with great interest. It is altogether a work of much practical value, and will well repay perusal by the practitioner."—*The Practitioner*.

"We can heartily recommend this work."—*Birmingham Medical Review*.

"The translator has succeeded in rendering available to English readers a manual most useful for their guidance, and which has long been a desideratum. It is handsomely produced, and is furnished with a very good index."—*Hospital Gazette*.

Crown 8vo, Cloth, pp. xii., 173, with 60 Illustrations, Price 5s.

MANUAL OF CLINICAL DIAGNOSIS.

BY DR. OTTO SEIFERT,

PRIVAT DOCENT IN WURZBURG,

AND

DR. FRIEDRICH MÜLLER,

ASSISTENT DER II. MED. KLINIK IN BERLIN.

THIRD EDITION REVISED AND CORRECTED. TRANSLATED WITH THE
PERMISSION OF THE AUTHORS,

By WILLIAM B. CANFIELD, A.M. M.D.,

CHIEF OF CLINIC FOR THROAT AND CHEST, UNIVERSITY OF MARYLAND.

(1887.)

EXTRACT FROM TRANSLATOR'S PREFACE.

The favour with which this book has been received in Germany, and its eminently practical and concise manner of dealing with the different important points in diagnosis, seem to justify its translation into English. It has been brought down to the latest acquisitions of science, thus representing the most advanced views. For the sake of clearness, the figures relating to weight, measure, length, etc., as well as the dose table at the end of the book, have been modified to conform to the system used in England and America.

*Large 8vo, Cloth, pp. 270, Illustrated with 13 Plates, mostly Coloured.
Price 9s.*

SURGICAL BACTERIOLOGY.

BY

NICHOLAS SENN, M.D., PH.D.,

PROFESSOR OF PRINCIPLES OF SURGERY AND SURGICAL PATHOLOGY, RUSH MEDICAL
COLLEGE, CHICAGO.

(1889.)

Crown 8vo, Cloth, pp. xii., 226, Price 6s.

SURGICAL ANATOMY:

A MANUAL FOR STUDENTS.

By A. MARMADUKE SHEILD, M.B. (CANTAB.), F.R.C.S.,

SENIOR ASSISTANT SURGEON, AURAL SURGEON, AND TEACHER OF
OPERATIVE SURGERY, CHARING CROSS HOSPITAL.

(Pentland's Students' Manuals.)

(1891.)

Crown 8vo, Cloth, pp. xii., 67, Price 2s.

ON THE NATURAL AND ARTIFICIAL FEEDING AND CARE OF INFANTS.

By JOHN SERVICE, L.R.C.S. & P., ED.,

AUTHOR OF THE "LIFE AND RECOLLECTIONS OF DOCTOR DUGUID OF KILWINNING."

(1890.)

Crown 8vo, Cloth, pp. xvi., 222, Price 3s. 6d.

THIR NOTANDUMS,

Being the Literary Recreations of Laird Canticarl
of Mongrynen (of kittle memory),

TO WHICH IS APPENDED A BIOGRAPHICAL SKETCH OF

JAMES DUNLOP, ESQ., F.R.S.S., LOND. & ED.,

*Astronomer-Royal at the Observatory of Paramatta,
New South Wales, 1831-47.*

By JOHN SERVICE, L.R.C.S. & P., ED.

(1890.)

Second Edition, Crown 8vo, extra Cloth, pp. xvi., 287, Price 3s. 6d.

THE LIFE AND RECOLLECTIONS OF
DOCTOR DUGUID
OF KILWINNING.

WRITTEN BY HIMSELF, AND NOW FIRST PRINTED FROM THE
RECOVERED MANUSCRIPT.

BY

JOHN SERVICE, L.R.C.S & P. Ed., Sydney.
(1888.)

Second Edition, Post 8vo, Cloth, pp. 396, with 12 Illustrations, Price 10s.

DISEASES OF THE DIGESTIVE ORGANS IN
INFANCY AND CHILDHOOD,

WITH CHAPTERS ON THE INVESTIGATION OF DISEASE,
THE DIET AND GENERAL MANAGEMENT
OF CHILDREN, AND MASSAGE
IN PEDIATRICS.

By LOUIS STARR, M.D.,

LATE CLINICAL PROFESSOR OF DISEASES OF CHILDREN IN THE HOSPITAL OF THE UNIVERSITY
OF PENNSYLVANIA; PHYSICIAN TO THE CHILDREN'S HOSPITAL, PHILADELPHIA.

(1891.)

*Crown 4to, extra Cloth, gilt top, with 70 Plates exhibiting
over 400 Figures, Price 12s. 6d.*

ILLUSTRATIONS OF ZOOLOGY,
INVERTEBRATES AND VERTEBRATES.

By WILLIAM RAMSAY SMITH B.Sc.,

DEMONSTRATOR OF ZOOLOGY IN THE UNIVERSITY OF EDINBURGH.

AND

J. STEWART NORWELL.

(1889.)

EXTRACT FROM PREFACE.

This book is a companion to a course of Systematic Zoology. In it the student will find illustrated by Diagram or Drawing, the structure of forms selected from all the great classes of Vertebrates and Invertebrates, and the illustrations arranged in systematic order. Our design is to help the student of Comparative Anatomy in the most important and most difficult part of a systematic course of lectures.

8vo, cloth, pp. xii., 223, with 7 Illustrations, Price 9s.

ELEMENTS OF PHARMACOLOGY.

BY

DR. OSWALD SCHMIEDEBERG,

PROFESSOR OF PHARMACOLOGY, AND DIRECTOR OF THE PHARMACOLOGICAL INSTITUTE,
UNIVERSITY OF STRASSBURG.

TRANSLATED UNDER THE AUTHOR'S SUPERVISION BY

THOMAS DIXSON, M.B.,

LECTURER ON MATERIA MEDICA IN THE UNIVERSITY OF SYDNEY, N.S.W.

(1887.)

*In two Handsome Volumes, royal 8vo, cloth, gilt tops, pp. xxiv., 140, profusely
Illustrated with Engravings throughout the text, and full-page
plates, Price, 30s. nett.*

TEXT-BOOK OF SURGERY.

BY AMERICAN AUTHORS.

EDITED BY

WILLIAM W. KEEN, M.D.,

AND

WILLIAM WHITE, M.D.

The articles are contributed by C. H. BURNETT, M.D.; P. S. CONNER, M.D.; F. S. DENNIS, M.D.; W. W. KEEN, M.D.; C. B. NANCREDE, M.D.; ROSWELL PARK, M.D.; LEWIS S. PILCHER, M.D.; NICHOLAS SENN, M.D.; F. J. SHEPHERD, M.D.; LEWIS A. STIMSON, M.D.; J. COLLINS WARREN, M.D., &c. &c.

(1893.)

Crown 8vo, cloth, pp. viii., 239, Price 6s.

APPENDICITIS AND PERITYPHLITIS,

BY

CH. TALAMON,

PHYSICIAN TO THE TENON HOSPITAL, PARIS.

TRANSLATED FROM THE FRENCH BY

RICHARD J. A. BERRY, M.B., C.M.,

LATE PRESIDENT OF THE ROYAL MEDICAL SOCIETY, EDINBURGH.

(1893.)

Crown 8vo, cloth, pp. xvi., 642, with 32 full-page Illustrations, Price 12s. 6d.

OUTLINES OF ZOOLOGY,

BY

J. ARTHUR THOMSON, M.A.,

LECTURER ON ZOOLOGY, SCHOOL OF MEDICINE EDINBURGH.

(1892.)

(Pentland's Students' Manuals).

Subscription One Guinea per annum, in advance, post free.

THE JOURNAL OF PATHOLOGY AND BACTERIOLOGY

EDITED, WITH THE COLLABORATION OF DISTINGUISHED BRITISH AND
FOREIGN PATHOLOGISTS,

By GERMAN SIMS WOODHEAD, M.D.,

DIRECTOR OF THE LABORATORIES OF THE ROYAL COLLEGES OF
PHYSICIANS (LONDON) AND SURGEONS (ENGLAND).

ASSISTED IN SPECIAL DEPARTMENTS BY

SIDNEY MARTIN, M.D. (LOND.) (*Pathological Chemistry*);
M. ARMAND RUFFER, M.D. (OXON.) (*Morbid Anatomy and Histology*);
G. E. CARTWRIGHT WOOD, M.D. (EDIN.) (*Bacteriology*);
C. S. SHERRINGTON, M.D. (CANTAB.) (*Experimental Pathology*).

IT has been felt for some time that the want in this country of a Journal dealing specially with General and Experimental Pathology has militated most seriously against the free interchange of ideas, not only between English-speaking pathologists, but also between British and Foreign workers.

Although the Transactions of the Pathological Society deal with communications which are brought before its members, there is no medium in which longer articles, and especially those from workers throughout the United Kingdom and abroad, can be brought before a less limited circle of readers. It has been thought desirable, therefore, to found a Journal specially devoted to the publication of original contributions on General Pathology, Pathological Anatomy, and Experimental Pathology, including Bacteriology. These articles will, of course, be mainly from British Laboratories and Hospitals; but the co-operation of many distinguished Continental, American, and Colonial Patho-

EDINBURGH AND LONDON: YOUNG J. PENTLAND.

logists has been obtained, and papers written or edited by them will be placed before our readers.

In order to increase the interest and extend the usefulness of the Journal, it is intended that, in addition to original articles, critical summaries of work done in special departments of Pathology and Bacteriology shall from time to time be published. All articles appearing in the Journal will be signed.

The Journal will appear at least four times a year, but it will be issued more frequently if necessary, in order to ensure publication of all papers as early as possible after they are received.

The numbers issued throughout the year will form a volume, royal 8vo, of about 500 pages. It will be printed on good paper, and will be freely illustrated with Woodcuts and Chromolithographs.

Amongst those who have already promised to collaborate are the following :—

Sir HENRY ACLAND, Bart, Oxford.
J. G. ADAMI, Montreal.
S. ARLOING, Lyons.
B. BANG, Copenhagen.
ALEX. BARRON, Liverpool.
W. H. BARRETT, Belfast.
J. ROSE BRADFORD, London.
CH. BOUCHARD, Paris.
H. BUCHNER, Munich.
ANGELO CELLI, Rome.
Sir CHARLES CAMERON, Dublin.
A. B. CHARRIN, Paris.
A. CHANTEMESSE, Paris.
A. CHAUVEAU, Paris.
W. WATSON CHEYNE, London.
H. CHIARI, Prague.
Sir ANDREW CLARK, Bart., London.
JOSEPH COATS, Glasgow.
W. T. COUNCILMAN, Baltimore.
G. F. CROOKE, Birmingham.
D. D. CUNNINGHAM, Calcutta.
D. DRUMMOND, Newcastle.
S. DELÉPINE, Manchester.
J. DRESCHFELD, Manchester.
VON ESMARCH, Koenigsberg.
CH. FIRKET, Liege.
R. H. FITZ, Boston.
P. GRAWITZ, Griefswald.
W. S. GREENFIELD, Edinburgh.
E. H. HANKIN, Agra.
H. HEIBERG, Christiania.
VICTOR HORSLEY, London.
F. HUEPPE, Prague.
J. W. HULKE, London.
O. ISRAEL, Berlin.
E. H. JACOB, Leeds.

E. KLEBS, Zurich.
ALFRED LINGARD, Poonah.
Sir JOSEPH LISTER, Bart., London.
O. LUBARSCH, Rostock.
P. MARIE, Paris.
E. METCHNIKOFF, Paris.
F. W. MOTT, London.
E. NOCARD, Alfort.
T. OLIVER, Newcastle.
J. ORTH, Göttingen.
WM. OSLER, Baltimore.
T. MITCHELL PRUDDEN, New York.
J. F. PAYNE, London.
J. M. PURSER, Dublin.
C. S. ROY, Cambridge.
J. C. SALOMONSEN, Copenhagen.
A. M. STALKER, Dundee.
J. BURDON SANDERSON, Oxford.
S. G. SHATTOCK, London.
J. LINDSAY STEVEN, Glasgow.
H. STILLING, Lausanne.
I. STRAUS, Paris.
T. P. ANDERSON STUART, Sydney.
R. THOMA, Dorpat.
J. BATTY TUKE, Edinburgh.
L. VAILLARD, Paris.
RUD. VIRCHOW, Berlin.
H. MARSHALL WARD, Cooper's Hill.
C. WEIGERT, Frankfort a/M.
A. WEICHELBAUM, Vienna.
W. H. WELCH, Baltimore.
SAMUEL WILKS, London.
A. E. WRIGHT, Netley.
VON ZENKER, Erlangen.
E. ZIEGLER, Freiburg.

LIST OF PAPERS ALREADY PUBLISHED.

INTRODUCTION.

- VIRCHOW, RUDOLF, Transformation and Descent.
- METCHNIKOFF, E., On Aqueous Humour, Micro-Organisms, and Immunity.
- MARTIN, SIDNEY, A Chemical Examination of a Case of Anthrax in Man.
- DEAN, HENRY PERCY, Cerebro-Spinal Pressure (3 Wood Engravings and 7 Charts).
- MACKENZIE, JAMES, Pulsations in the Veins, with the Description of a Method for graphically recording them (48 Wood Engravings).
- HALLIBURTON, W. D., Mucin in Myxœdema—Further Analyses.
- GRAWITZ, PAUL, Hæmorrhagic Infarcts of the Lung.
- MILES, ALEX., On the Microscopic Pathology of Cerebral Traumatism (5 Coloured Figures).
- SPENCER, H. R., On Hæmatoma of the Sterno-Mastoid Muscle in New-Born Children (2 Wood Engravings).
- PRINGLE, A., Paraffin Infiltration by Exhaustion.
- WRIGHT, A. E., A Note upon the Relations between Plasma and Serum, &c.
- MUIR, R., Observations on Leucocythemia (Coloured Plate, 5 Figures).
- KANTHACK, A. A., Madura Disease (Mycetoma) and Actinomycosis (3 Plates, 25 Figures).
- BOYCE, R., Remarks upon a Case of Aspergillar Pneumonomycosis (Coloured Plate, 7 Figures).
- HALDANE, J., and J. L. SMITH, The Physiological Effects of Air Vitiating by Respiration (6 Wood Engravings).
- GARROD, A. E., On Hæmatoporphyrin as a Urinary Pigment in Disease.
- RUFFER, M. ARMAND, and J. HERBERT WALKER, On some Parasitic Protozoa found in Cancerous Tumours (3 Coloured Plates, 37 Figures).
- COATS, JOSEPH, The Pathology of Sudamina and Miliaria (1 Plate, 5 Figures).
- BOYCE, R., & CECIL F. BEADLES, Enlargement of the Hypophysis Cerebri in Myxœdema; with Remarks upon Hypertrophy of the Hypophysis, associated with Changes in the Thyroid Body (2 Coloured Plates, 5 Figures).
- HANKIN, E. H., On the Method of Testing the Bactericidal Power of Alexin Solutions (4 Wood Engravings).
- CATHOART, C. W., Papier Mâché Casts of Pathological Specimens.
- CHEATLE, G. L., A Rapid Method of Dehydrating Tissues before their Infiltration with Paraffin (1 Wood Engraving).
- ADDRESS OF CONGRATULATION TO PASTEUR.
- SHERRINGTON, C. S., Experiments on the Escape of Bacteria with the Secretions.
- GILLESPIE, A. LOCKHART, The Bacteria of the Stomach.
- HARRIS, A. BUTLER, On a New Micro-Organism of Spreading Œdema (7 Engravings from Micro-Photographs).
- HALDANE, J., and J. L. SMITH, The Toxic Action of Expired Air.
- MARTIN, SIDNEY, Multiple Neuritis (5 Engravings from Micro-Photographs).
- MACKENZIE, J., Herpes Zoster, and the Limb Plexuses of Nerves (17 Engravings).
- FABER, KNUD, The Part Played by Giant Cells in Phagocytosis (1 Coloured Plate, 8 Figures).
- BOYCE, R., & CECIL F. BEADLES, A further Contribution to the Study of the Pathology of the Hypophysis Cerebri (1 Coloured Plate, 3 Figures).
- CARTER, E. C., A Case of Cylindroma of the Brain, with Remarks (1 Coloured Plate, 3 Figures).
- MIDDLEMASS, J., An Improved Form of Injection Apparatus (2 Wood Engravings).
- GULLAND, G. LOVELL, The Application of OBREGIA'S Method to Paraffin Sections for Class Purposes.
- RUFFER, M. A., and H. G. PLIMMER, Further Researches on some Parasitic Protozoa found in Cancerous Tumours (1 Plate, 12 Figures).
- NOCARD, ED., Coccidial Tumours from the Small Intestine of the Sheep (1 Coloured Plate, 4 Figures).
- BERKLEY, H. J., The Intrinsic Nerves of the Kidney (2 Plates, 17 Figures).
- FENWICK, W. SOLTAU, The Pathology of Acute Perforating Ulcer of the Stomach in young Adults (2 Plates, 7 Figures).
- WRIGHT, A. E., A Contribution to the Study of the Coagulation of the Blood.
- HOPKINS, F. GOWLAND, On the Estimation of Uric Acid in the Urine.
- COATS, JOSEPH, A case of Tuberculosis in an organised Blood-clot on the Dura Mater.
- SLATER, CHARLES, A Bacteriological Investigation of Artificial Mineral Waters.
- WOODHEAD, G. SIMS, The Position of Pathology among the Biological Sciences.

Demy 4to, Cloth, illustrated with 26 full-page Coloured Plates from Original Drawings. Price 30s.

RESEARCHES IN FEMALE PELVIC ANATOMY.

BY

J. CLARENCE WEBSTER, B.A., M.D., M.R.C.P.ED.,

ASSISTANT TO THE PROFESSOR OF MIDWIFERY AND DISEASES OF WOMEN
AND CHILDREN IN THE UNIVERSITY OF EDINBURGH.

(1892.)

UNIFORM WITH THE ABOVE.

Demy 4to, Cloth, illustrated with 11 full-page Plates, exhibiting numerous Figures. Price 16s.

TUBO-PERITONEAL ECTOPIC GESTATION.

BY

J. CLARENCE WEBSTER, B.A., M.D., M.R.C.P.ED.,

ASSISTANT TO THE PROFESSOR OF MIDWIFERY AND DISEASES OF WOMEN
AND CHILDREN IN THE UNIVERSITY OF EDINBURGH.

(1892.)

EXTRACTS FROM PRESS NOTICES.

"The want of precise knowledge regarding the anatomical changes in the pelvis during the puerperium has been a subject of regret, especially to those called upon to teach students the normal condition of the rapid alterations which take place during the first two weeks subsequent to childbirth. Dr. Clarence Webster has succeeded in obtaining many specimens of the post-partum pelvis, which he has described faithfully in this volume. Fortunately, the author has not restricted himself to mere sectional investigation, but has also observed by dissectional study as well. A great mass of facts is accumulated in the first part of the book, and its value is enhanced to practitioners by the statement that Dr. Webster had seen and examined all the cases during life. In a *résumé* he brings together some important information of great interest to the practical obstetrician. We congratulate Dr. Webster on the production of such a book, which will prove of great advantage to all interested in the progressive development of scientific midwifery. It is a record of careful investigation carried on in the laboratory of the Royal College of Physicians of Edinburgh, and contains twenty-six full-page illustrations, the majority of the plates having been drawn from nature by the author."—*Lancet*.

"Dr. J. C. Webster's *Researches in Female Pelvic Anatomy* is a scientific work of a high order of merit. It consists of three parts. The first contains an account of the sectional appearances of six specimens of the pelvis and its contents from patients who died during the puerperium, and is illustrated by a series of beautiful coloured plates, most of which are reduced by one-third from the natural size; the second is a monograph upon the female pelvic floor; and the third part is devoted to the investigation of the pelvis in a case in which a woman at the fifth month of pregnancy died nine days after the removal of a dermoid tumour of the left ovary. The great value of the book consists in the minute and accurate descriptions of the relations of the various soft structures to the pelvic walls, and in the deductions bearing upon the regional anatomy of the puerperium which are drawn from these."—*Edinburgh Medical Journal*.

"All who are really jealous of the honour of the profession must approve of any work which strengthens the scientific basis of obstetrics. Dr. Webster's two publications deserve equal praise on account of the principle on which they are written, and on account of their intrinsic value. Twenty-six beautiful engravings illustrate *Female Pelvic Anatomy*. A good feature in this work is the index, which gives references to each mention of individual pelvic structures. The author's opinions on the support of the uterus are of much interest."—*British Medical Journal*.

*Large 8vo, pp. xvi., 700, with 178 Fine Engravings, many in Colour,
Price 18s.*

CLINICAL TEXT-BOOK OF
MEDICAL DIAGNOSIS,

FOR

PHYSICIANS AND STUDENTS.

BASED ON THE MOST RECENT METHODS OF EXAMINATION.

By OSWALD VIERORDT, M.D.,

PROFESSOR OF MEDICINE AT THE UNIVERSITY OF HEIDELBERG.

*TRANSLATED, WITH ADDITIONS FROM THE SECOND ENLARGED
GERMAN EDITION, WITH THE AUTHOR'S PERMISSION.*

By FRANCIS H. STUART, M.D.,

MEMBER OF THE MEDICAL SOCIETY OF THE COUNTY OF KINGS, NEW YORK.

In this work, as in no other hitherto published, are given full and accurate explanations of the phenomena observed at the bedside. *It is distinctly a clinical work by a master teacher, characterised by thoroughness, fulness, and accuracy, it is a mine of information upon the points that are so often passed over without explanation.*

Post 8vo, Cloth, pp. 498, with 403 Wood Engravings, Price 12s. 6d.

MINOR SURGERY AND BANDAGING,

INCLUDING THE

TREATMENT OF FRACTURES AND DISLOCATIONS, TRACHEOTOMY,
INTUBATION OF THE LARYNX, LIGATIONS OF ARTERIES,
AND AMPUTATIONS.

By HENRY R. WHARTON, M.D.,

DEMONSTRATOR OF SURGERY AND LECTURER ON SURGICAL DISEASES OF CHILDREN IN THE UNIVERSITY OF PENNSYLVANIA; SURGEON TO THE PRESBYTERIAN HOSPITAL, THE METHODIST EPISCOPAL HOSPITAL, THE CHILDREN'S HOSPITAL, AND THE DREXEL HOSPITAL FOR CHILDREN; CONSULTING SURGEON TO THE RUSH HOSPITAL FOR DISEASES OF THE CHEST, ETC.

*Second Edition, Revised and Enlarged, Crown 8vo, Cloth, pp. 766, with
150 Illustrations. Price 16s.*

HANDBOOK OF DISEASES OF WOMEN,

Including Diseases of the Bladder and Urethra.

By DR. F. WINCKEL,

PROFESSOR OF GYNÆCOLOGY, AND DIRECTOR OF THE ROYAL UNIVERSITY CLINIC FOR WOMEN IN MUNICH.

AUTHORISED TRANSLATION EDITED BY

THEOPHILUS PARVIN, M.D.,

PROFESSOR OF OBSTETRICS AND DISEASES OF WOMEN AND CHILDREN IN JEFFERSON MEDICAL COLLEGE, PHILADELPHIA.

(1890.)

*Royal 8vo, Cloth, pp. 927, Illustrated with 190 Engravings,
mostly original, Price 28s.*

TEXT-BOOK OF OBSTETRICS,

INCLUDING THE PATHOLOGY AND THERAPEUTICS OF
THE PUERPERAL STATE.

DESIGNED FOR PRACTITIONERS AND STUDENTS OF MEDICINE.

By DR. F. WINCKEL,

PROFESSOR OF GYNÆCOLOGY AND DIRECTOR OF THE ROYAL HOSPITAL FOR WOMEN;
MEMBER OF THE SUPREME MEDICAL COUNCIL AND OF THE FACULTY
OF MEDICINE IN THE UNIVERSITY OF MUNICH.

TRANSLATED FROM THE GERMAN UNDER THE SUPERVISION OF

J. CLIFTON EDGAR, A.M. M.D.,

ADJUNCT PROFESSOR OF OBSTETRICS IN THE MEDICAL DEPARTMENT OF THE
UNIVERSITY OF THE CITY OF NEW YORK.

(1890.)

*Second Edition, Post 8vo, pp. xii., 208, with 47 Coloured Illustrations,
Price 10s. 6d.*

A PRACTICAL GUIDE TO MEAT INSPECTION.

By THOMAS WALLEY, M.R.C.V.S.,

PRINCIPAL OF THE EDINBURGH ROYAL (DICK'S) VETERINARY COLLEGE;
PROFESSOR OF VETERINARY MEDICINE AND SURGERY.

(1891.)

*8vo, Cloth, pp. xii., 174 with 60 Illustrations, mostly Original (34 in Colours)
Price 8s. 6d.*

PATHOLOGICAL MYCOLOGY:

AN ENQUIRY INTO THE ETIOLOGY OF INFECTIVE DISEASES.

By G. SIMS WOODHEAD, M.D., F.R.C.P. ED.,

DIRECTOR OF THE LABORATORIES OF THE ROYAL COLLEGES OF PHYSICIANS
(LONDON), AND SURGEONS (ENGLAND).

AND

ARTHUR W. HARE, M.B., C.M.,

FORMERLY PROFESSOR OF SURGERY, OWENS COLLEGE, MANCHESTER.

SECTION I.—METHODS.

(1885.)

*Third Enlarged and thoroughly Revised Edition, 8vo, Cloth, pp. xxiv., 652,
Illustrated with 195 Coloured Plates from original drawings, price 25s.*

PRACTICAL PATHOLOGY.

A MANUAL FOR STUDENTS AND PRACTITIONERS.

By GERMAN SIMS WOODHEAD, M.D., F.R.C.P.ED.,

DIRECTOR OF THE LABORATORIES OF THE ROYAL COLLEGES OF PHYSICIANS (LONDON)
AND SURGEONS (ENGLAND).

PUBLISHER'S NOTE.

The recent advances in Pathology have rendered it necessary that in the third edition of this work the scope should be somewhat enlarged and altered in several important respects.

The Chapter on Methods has been brought well up to date; a Chapter on Inflammation and Healing of Wounds has been added, and much new matter, especially as regards the naked eye appearances of diseased tissues and organs, has been incorporated with the other sections; greater attention has been paid to the arrangement of descriptions and details; repetition has been avoided as much as possible; and the references to methods of hardening, preparing, and staining, have been so arranged as to interfere as little as possible with the continuity of the descriptions. The whole work has been revised; much of it has been re-written and so recast as to make it available for both practical class-room work and home study. Many of the old plates have been re-drawn, and the number of illustrations has been increased from 162 to 195.

EXTRACTS FROM PRESS NOTICES.

"There is no better index of the progress of science than that which is afforded by the successive editions of a Standard Text-book. The author of such a work, if he wishes his book to maintain its popularity, is compelled to keep pace with advancing knowledge, and must perforce enlarge the limits of his manual. To do this well requires much skill and judgment, as well as an intimate acquaintance with the growing literature of his subject, and practical familiarity with modern methods. Those who remember the advent of Dr. Woodhead's manual nine years ago, and the freshness with which the details of morbid histology were described and illustrated, will find in the latest edition a considerable amplification and revision of the text, as well as many new coloured engravings, which form a notable feature of the book. Thus the work has much increased in bulk, without losing any of its characteristic points. In a word, the book cannot fail to be of the greatest service to the worker in the pathological laboratory, and Dr. Woodhead may be congratulated upon the success with which he has managed to render it one of the most useful and practical manuals of its kind."—*Lancet*.

"The merits of Dr. Woodhead's *Practical Pathology* are already so well known to the profession that but few words are required on our part to commend it anew to their attention. The present edition retains all the good features of its predecessors, with a number of additional good qualities of its own. Great care has obviously been taken throughout in its preparation. It has been almost entirely re-written, much of it altered and re-arranged, and a great deal added. It forms now a volume of 652 pages, as compared with the 484 pages of the first edition. A notable feature of this work from the very first has been the great beauty of its coloured illustrations. In this respect, also, the merits of the book have suffered no abatement in the present edition. A large number of new illustrations have been added; and in every case where new ones have replaced those in the earlier editions, the change is an improvement. Both author and publisher are to be specially congratulated on this portion of their work. We can confidently recommend this work as one of the best practical treatises dealing with the subject of morbid histology that have appeared in this or any other country."—*British Medical Journal*.

"Woodhead's *Practical Pathology* has become one of the standard text-books for students of human pathology; indeed it may be said to have occupied that position ever since its first appearance nine years ago. For some time past the work has been out of print, and that fact must have caused considerable inconvenience to medical students, inasmuch as there is not in the market any book at all approaching it in usefulness as a guide to practical pathology. The scope of the work has been enlarged, the matter has been partially re-arranged, and the illustrations have been improved and increased in number. Taking text and illustrations together, the book is a model work of its class, and medical students of the present day are to be congratulated on having at their disposal such an admirable aid to the practical study of pathology. We strongly recommend it to both veterinary practitioners and students as the best book on the subject that is obtainable in the English language."—*Journal of Comparative Pathology and Therapeutics*.





