

**Renal growths : their pathology, diagnosis and treatment / by T.N. Kelynack.**

**Contributors**

Kelynack, T. N. 1866-1944.

**Publication/Creation**

Edinburgh : Young J. Pentland, 1898.

**Persistent URL**

<https://wellcomecollection.org/works/er48qhft>


**License and attribution**

This work has been identified as being free of known restrictions under copyright law, including all related and neighbouring rights and is being made available under the Creative Commons, Public Domain Mark.

You can copy, modify, distribute and perform the work, even for commercial purposes, without asking permission.




Wellcome Collection  
183 Euston Road  
London NW1 2BE UK  
T +44 (0)20 7611 8722  
E [library@wellcomecollection.org](mailto:library@wellcomecollection.org)  
<https://wellcomecollection.org>





22101804598

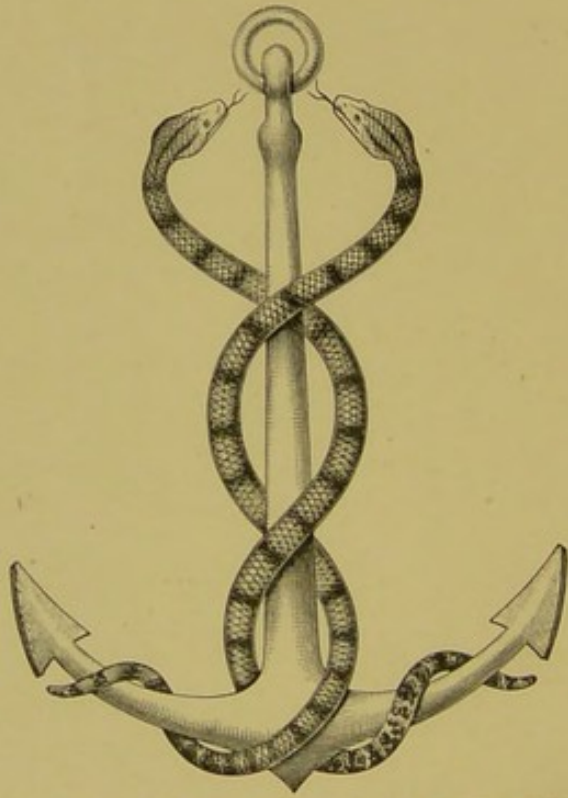


63  
—  
d  
—  
22

Presented to  
The Library of the Royal College  
of Physicians  
by the Author.

20. vi. 98

RENAL GROWTHS.



NUNQUAM ALIUD NATURA, ALIUD SAPIENTIA DICIT.

63  
d 22


# RENAL GROWTHS

*THEIR PATHOLOGY, DIAGNOSIS, AND  
TREATMENT*

BY

T. N. KELYNACK, M.D. (VICT.), M.R.C.P. (LOND.)

PATHOLOGIST, MANCHESTER ROYAL INFIRMARY; DEMONSTRATOR AND ASSISTANT  
LECTURER IN PATHOLOGY, THE OWENS COLLEGE, MANCHESTER



*WITH NINETY-SIX ILLUSTRATIONS*

EDINBURGH AND LONDON  
YOUNG J. PENTLAND

1898



15400

11417

-4990102

EDINBURGH: PRINTED FOR YOUNG J. PENTLAND, 11 TEVIOT PLACE, AND  
38 WEST SMITHFIELD, LONDON, E.C., BY MORRISON AND GIBB LIMITED.

M18901

WELLCOME INSTITUTE LIBRARY	
Coll.	welMOMec
Call	
No.	WJ300
	1898
	K29r

## PREFACE.

---

No systematic treatise on growths of the kidney has as yet appeared in this country. The present work is an attempt, at least in some measure, to supply this want. As far as possible I have endeavoured to indicate the work already accomplished, and to suggest lines for further research.

It is a pleasing duty to acknowledge the valuable assistance that has been afforded me in my investigations. I am specially indebted to the members of the staff of the Manchester Royal Infirmary, for full opportunities of examining a number of cases, and to Professor Delépine for permission to avail myself of material in the Pathological Department of the Owens College. My best thanks are due to Mr. Targett, late Curator of the Museum of the Royal College of Surgeons of England, for his most generous kindness in placing at my disposal his valuable collection of photographs, with notes of many rare forms of renal growth. Mr. Paul, of Liverpool, has also greatly assisted by allowing me to examine his collection of microscopic specimens, and permitting me to have photographs taken of several.

I have also to express my obligations to the kind courtesy of Dr. Affleck and Dr. Leith, Dr. Rolleston and Professor Kanthack, Professor Cunningham, Dr. Warthin, and Mr. Henry Morris, and the editors of the *Journal of Anatomy and Physiology*, for their kindness in granting me the use of certain illustrations.

Among the Museums visited during the course of my researches, I must in particular express my indebtedness to that of the Royal College of Surgeons of England.

My thanks are also due to my Colleague, Dr. Moore, for several drawings; to one of our old students, Dr. Bythell, for the preparation of the photo-micrographs; and to my brother, Mr. W. S. Kelynack, for photographs of many of the macroscopic specimens.

To the numerous gentlemen who have assisted me by sending specimens, or in other ways, I also beg to offer sincere thanks.

T. N. KELYNACK.

3 ST. PETER'S SQUARE,  
MANCHESTER, *May* 1898.

# CONTENTS.

## CHAPTER I.

### INTRODUCTION.

	PAGE
Objects and Methods of Investigation—Early Literature—Nomenclature— Confusion in Terms—References—Recent Papers—Cases at Pathological Society of London . . . . .	1

## CHAPTER II.

### CLASSIFICATION.

Old Grouping—Paul's Divisions—Harrison's Classification—Newman's Grouping—Histogenetic Arrangement . . . . .	13
---	----

## CHAPTER III.

### FREQUENCY OF RENAL GROWTHS.

Data—Manchester Records—Proportion—Old Terms—Proportion of Primary to Secondary Growths—Melanotic Sarcoma . . . . .	18
--	----

## CHAPTER IV.

### ETIOLOGY OF RENAL GROWTHS.

Embryonic Defects—Heredity—Traumatism—Calculi—General Causes—Pre- disposing Influences—Race—Sex—Age . . . . .	23
--	----

## CHAPTER V.

### GENERAL CHARACTERS OF RENAL GROWTHS.

Size—Weight—Extent—Shape—Colour—Consistency—Cystic Formation— Condition of Capsule—Affected Side—Nature . . . . .	38
--	----

## CHAPTER VI.

## METHODS OF EXTENSION OF GROWTH.

	PAGE
Direct Continuity of Tissue—Lymphatic Involvement—Venous Invasion— Secondary Deposits—Distribution of Metastases—Changes in the Growth —Duration—Cause of Death . . . . .	48

## CHAPTER VII.

## RELATIONSHIP OF RENAL GROWTHS.

Confusion from Nomenclature—Variations in Histological Structure—Mixed, Complex, and Compound Forms—Transitional Varieties—Multiple Malignancy . . . . .	56
---	----

## CHAPTER VIII.

## SIMPLE OR BENIGN GROWTHS.

Frequency—Varieties—Fibroma—Lipoma—General Characters—Cases . . . . .	60
---	----

## CHAPTER IX.

SIMPLE OR BENIGN GROWTHS—*continued*.

Myxoma — Chondroma — Osteoma — Angioma — Lymphangioma — Lymphadenoma—General Characters—Cases . . . . .	71
---	----

## CHAPTER X.

## SARCOMATA.

Classification—General Characters—Period of Development—Sarcoma in Foetal Life—Sarcoma in Infancy and Childhood—Influence of Age— Size—Weight—Duration—Side Affected—Sarcoma in Adults—Origin and Seat—Regional Classification—Capsular Growths—Parenchymatous Growths—Hilum Growths—General Characters—Cases . . . . .	80
---	----

## CHAPTER XI.

## SARCOMATA CONSIDERED ACCORDING TO THEIR HISTOLOGICAL CHARACTERS.

Histological Features—Combined Forms—Round and Spindle-celled Sarcoma — Rhabdo-Myo-Sarcoma — Angio-Sarcoma — Adeno-Sarcoma—Alveolar Sarcoma — Myxo - Sarcoma — Lipo - Sarcoma — Melanotic Sarcoma — Lympho-Sarcoma . . . . .	95
---	----

## CHAPTER XII.

## ADENOMATOUS GROWTHS.

Simple Adenomata—Single—Multiple—Solid—Cystic—Papillary—Alveolar —General Characters . . . . .	112
---	-----

# CONTENTS.

ix

## CHAPTER XIII.

### MALIGNANT CYST-ADENOMA.

	PAGE
Cystic Trabecular Form—Papillomatous Structure—Hæmorrhagic Character—Origin—Typical Case—General Characters—Nephrectomy Cases . . . . .	116

## CHAPTER XIV.

### ON THE RELATION OF RENAL GROWTHS TO ADRENAL STRUCTURES.

Historical References—Simple Adrenal "Rests"—Characters—Nephrectomy Cases—Sex—Age—Side Affected—Duration—Secondary Deposits—General Characters—Cases . . . . .	131
--	-----

## CHAPTER XV.

### CARCINOMATA.

Types—Frequency—Sex—Age—Varieties—Origin—Consistency—Microscopical Structure—Encephaloid—Scirrhus—Colloid—Epithelioma—Cylindroma—Secondary Deposits—Malignant Adenoma . . . . .	152
---	-----

## CHAPTER XVI.

### ADRENAL GROWTHS.

Frequency—Adenoma—Cases—References to Cases—Fibroma—Lipoma—Glioma—Angioma—Lymphangioma—Malignant Growths—Frequency—References to Cases—Carcinoma—Sarcoma—Cases—Clinical Features . . . . .	162
--	-----

## CHAPTER XVII.

### PERIRENAL GROWTHS.

Retroperitoneal Lipomata—Cases—General Characters—Difficulties in Diagnosis . . . . .	187
---	-----

## CHAPTER XVIII.

### SYMPTOMATOLOGY.

Tumour—Frequency—Situation—Shape—Relation to Intestines—Mobility—Ballottement—Fluctuation—Pulsation—Murmur. Hæmaturia—Frequency—Age—Time—Quantity—Variability—Association with other Symptoms—Varieties—Pain—Frequency—Character—Seat—Import. Varicocele—Uræmia—Pressure Symptoms—Urine—General Symptoms—Icterus—Temperature—Cachexia—Secondary Growths—Latent Forms . . . . .	192
--	-----

## CHAPTER XIX.

### DIAGNOSIS.

Methods of Examination—Exploring Needle—Cystoscope—Vaginal Examination—Rectal Insufflation—Radiography—Hot Bath—Differential Diagnosis—Adrenal Growths—Perirenal Growths—Omental Tumours	
--	--

	PAGE
—Mesenteric Tumours—Peritoneal Growths—Peritonitis—Cystic Kidney —Tuberculosis—Gummatous Enlargement—Hydronephrosis—Pyo- nephrosis—Abscess—Nephrolithiasis—Movable Kidney—Ureteral Growths—Hydatid—Lesions of Liver and Gall Bladder—Splenic En- largements—Pregnancy—Ovarian Tumour—Uterine Growths—Ascites— Fæcal Accumulation—Phantom Tumour—Pathological Diagnosis . . . . .	204
CHAPTER XX.	
TREATMENT.	
Surgical—Statistics—Cases—Relations of Kidney—Medicinal Measures— Bacterium Therapy—Electrolysis—Palliative Treatment . . . . .	214
CHAPTER XXI.	
BIBLIOGRAPHY.	
Preliminary Remarks—References to Renal Growths—References to Adrenal Growths . . . . .	231
GENERAL INDEX . . . . .	263

## LIST OF ILLUSTRATIONS.

FIG.	PAGE
1. Melanotic Sarcoma of Kidney, Secondary Deposits . . . . .	22
2. Malignant Adenoma . . . . .	38
3. Malignant Adenoma, Growth Divided . . . . .	39
4. Sarcoma in Kidney removed by Nephrectomy . . . . .	41
5. Sarcoma, Sections of Growth . . . . .	42
6. Malignant Growth involving One End of Kidney . . . . .	43
7. Cysto-Sarcoma . . . . .	44
8. Malignant Adenomatous Growth . . . . .	45
9. Sarcoma . . . . .	49
10. Diffuse Fibrosis of Kidney, probably Syphilitic . . . . .	61
11. Lipomatous Growth . . . . .	64
12. Microscopic Section of Lipomatous Growth . . . . .	66
13. Angioma, Naked-Eye Characters . . . . .	73
14. Angiomatous Growth, Microscopical Character . . . . .	73
15. Angiomatous Growth, Microscopical Appearances . . . . .	74
16. Angiomatous Growth, Tubular Structures . . . . .	75
17. Angiomatous Growth, Glomeruli . . . . .	76
18. Angiomatous Growth, Epithelium and Pigment . . . . .	77
19. Angiomatous Growth, Pigmentary Deposit . . . . .	78
20. Congenital Sarcoma . . . . .	82
21. Capsular Sarcoma . . . . .	89
22. Sarcoma removed by Nephrectomy . . . . .	90
23. Sarcoma springing from Convex Border of Kidney . . . . .	91
24. Sarcoma, Complete Section of . . . . .	92
25. Sarcoma invading Hilum . . . . .	93
26. Sarcoma, Mixed-Cell . . . . .	93
27. Hilum Growth . . . . .	94
28. Sarcoma, Round-Cell . . . . .	96
29. Sarcoma, Round and Spindle-Cell . . . . .	97
30. Sarcoma, Tuberculated . . . . .	99
31. Myo-Sarcoma . . . . .	101
32. Adeno-Myo-Sarcoma . . . . .	102
33. Adeno-Myo-Sarcoma, Striated and Round Cells . . . . .	103
34. Adeno-Myo-Sarcoma . . . . .	103
35. Rhabdo-Myo-Sarcoma, Left Kidney . . . . .	104
36. Rhabdo-Myo-Sarcoma, Right Kidney . . . . .	104




FIG.	PAGE
37. Myo-Sarcoma . . . . .	105
38. Angio-Sarcoma . . . . .	106
39. Adeno-Sarcoma . . . . .	108
40. Melanotic Sarcoma . . . . .	110
41. Melanotic Sarcoma . . . . .	111
42. Cystic Adenoma . . . . .	114
43. Adenoma . . . . .	115
44. Cyst-Adenomatous Growth in Liver . . . . .	121
45. Malignant Cyst-Adenoma of Kidney . . . . .	122
46. Malignant Papilliferous Cyst-Adenoma, Irregular Tubular Spaces . . . . .	123
47. Papilliferous Cyst-Adenoma, Cyst with Intracystic Papilla . . . . .	124
48. Papilliferous Cyst-Adenoma, Complex Intracystic Papillomatous Growth . . . . .	125
49. Papilliferous Cyst-Adenoma, Cyst containing Blood . . . . .	126
50. Papilliferous Cyst-Adenoma, Growth in Liver . . . . .	127
51. Papilliferous Cyst-Adenoma, Deposit in Liver . . . . .	128
52. Papilliferous Cyst-Adenoma, Deposit in Vein . . . . .	129
53. Cyst-Adenoma removed by Nephrectomy . . . . .	129
54. Malignant Growth, possibly of Adrenal Origin . . . . .	136
55. Section of Growth (Fig. 54) . . . . .	137
56. Adenomatous Growth . . . . .	139
57. Accessory Adrenal . . . . .	140
58. Adrenal "Rest" . . . . .	141
59. Adrenal "Rest" . . . . .	141
60. Malignant Adenoma . . . . .	142
61. Malignant Growth, possibly of Adrenal Origin . . . . .	146
62. Malignant Renal Growth . . . . .	147
63. Malignant Adenoma . . . . .	148
64. Malignant Adenoma . . . . .	149
65. Section of Large Adenomatous Growth . . . . .	151
66. Carcinoma . . . . .	154
67. Secondary Epithelioma . . . . .	155
68. Malignant Papilloma . . . . .	156
69. Malignant Papilloma . . . . .	157
70. Carcinoma . . . . .	159
71. Malignant Adenoma . . . . .	160
72. Adrenal Adenoma . . . . .	164
73. Adrenal Adenoma . . . . .	165
74. Adrenal Adenoma . . . . .	166
75. Adrenal Adenoma and Kidney . . . . .	167
76. Adrenal Adenoma . . . . .	167
77. Adrenal Adenoma . . . . .	168
78. Adrenal Adenoma . . . . .	168
79. Adrenal Adenoma . . . . .	169
80. Malignant Adrenal Growth . . . . .	176
81. Sarcoma of Adrenal . . . . .	177
82. Adrenal Sarcoma . . . . .	178
83. Adrenal Sarcoma . . . . .	179
84. Adrenal Sarcoma . . . . .	180
85. Adrenal Sarcoma . . . . .	182
86. Adrenal Sarcoma . . . . .	183
87. Perirenal Sarcoma . . . . .	191


*LIST OF ILLUSTRATIONS.*

xiii

FIG.	PAGE
88. Relation of Colon and Small Intestine to Sarcoma of Kidney . . . . .	194
89. Normal Blood-supply of Kidneys . . . . .	224
90. Accessory Renal Arteries . . . . .	225
91. Relations of Kidneys . . . . .	226
92. Relations of Kidneys to Adjacent Organs . . . . .	227
93. Relation of Peritoneum to Kidneys and Adrenals . . . . .	228
94. Relations of Kidneys as viewed in Transverse Section . . . . .	228
95. Transverse Section at level of First Lumbar Vertebra . . . . .	229
96. Transverse Section at level of Second Lumbar Vertebra . . . . .	230



RENAL GROWTHS.



# RENAL GROWTHS.

---

## CHAPTER I.

### INTRODUCTION.

VERY considerable uncertainty and confusion still exists in our knowledge of renal growths. Their pathology is, by general admission, very obscure. Large numbers of individual cases are on record, and yet there is little or no general agreement as to their nature. The origin, character, and relationship of neoplasms of the kidney have up to quite recent years received but scant attention. The subject, however, is rapidly becoming one of pressing importance. The majority of renal growths are now allowed to run their malignant course unopposed, for surgical interference has hitherto met with very indifferent success. A scientific basis for our practice is urgently demanded. Clinical progress halts for an advance in pathology. The indiscriminate removal of renal growths is neither reasonable nor reassuring.

As Bland Sutton well says: "It is particularly necessary to subject these tumours to a rigid analysis, clinical and pathological, for the purpose of discovering which may be removed with the best hope of prolonging life, and to obtain, if possible, evidence which will enable us to diagnose, with a reasonable amount of confidence, the nature of the tumour from the physical signs."

Keener scrutiny of details, as revealed by microscopical research, may well be expected to lead to more precise clinical differentiation.

The early literature of renal growths consists in little more

than a bare record of cases. Some few important papers, chiefly by German pathologists, have appeared during the last few years, dealing with certain forms of new growth of the kidney. The subject has also from time to time been dealt with in theses and dissertations. Nevertheless, even in the most recent works devoted to a study of the diseases of the kidney, the question of new growths is only very inadequately discussed. As far as I know, there is no convenient work which deals with the subject as a whole.

The present time seems suitable for a review of our available knowledge as to renal growths in general. The modern spirit of research demands that clinical deductions shall, as far as possible, be based upon pathological facts; and scientific treatment can only rest upon accurate knowledge. A diagnosis of renal "tumour" will not now suffice. Means must be found for early discrimination and practical differentiation, not merely on theoretical grounds, but in order to afford the necessary guides to successful interference. As Newman very truly says: "It is only by a careful study of these growths on the lines laid down by modern pathology, that a satisfactory foundation of facts can be accumulated upon which the surgeon can base his diagnosis." The neoplasms of the kidney very forcibly indicate the necessity, as Butlin has well pointed out, for a separate and independent study of the growths of each organ, if any true advance is to be made. In these pages I desire to make the accumulated experience of the past accessible to the workers of the present, and, if possible, to indicate lines for extended observation and research in the future. And, in the scientific study of these renal neoplasms, it is encouraging to remember that some light may be thrown on the origin and nature of new growths generally. A deeper appreciation of the influence of developmental defects in the etiology of new growths must necessarily be the outcome of a study of certain forms of renal growth.

The present work is a plea and an attempt for a more scientific investigation, and a more satisfactory grouping of renal growths. A more perfect practice lags for want of more certain knowledge. Such can only be accomplished by a thorough study of a large number of cases, by modern methods of investigation, and their comparison according to our more recent views on neoplastic formations.

It is earnestly to be hoped that in future full details of every

case may be recorded, until sufficient accurate data shall have accumulated to allow of the formation of satisfactory pathological generalisations.

*Nomenclature.*—At the very outset we are baffled by the confusion resulting from the use and misuse of terms. Much of the material accessible is rendered almost useless for satisfactory comparison in great measure through faulty and misleading nomenclature. Until recent years, careful microscopical examination was but seldom resorted to, and many of the growths reported by older writers appear to have been named in a very haphazard fashion. Most of the malignant forms were simply described as “cancer.” A very favourite appellation was “encephaloid growth.” Not infrequently we get nothing better than “fungus hæmatodes,” applied generally to soft, pulpy, vascular growths, but often undoubtedly sarcomatous in nature. After an extensive search through much of the literature of the subject, I have sorrowfully convinced myself that most of the earlier cases on record, although presenting much of clinical interest, are of but little value in assisting to any rational and scientific grouping of renal growths. It is only within the last few years that renal carcinomata and sarcomata have been differentiated. Up to quite recently they were almost invariably considered under one head. Mr. Paul in 1884, in attempting to bring some order out of this confusion, had to deplore “the very inefficient manner in which the ground had been previously covered.” Well-known writers still describe these growths under the generic name of “cancer.” Many hardly mention sarcomata. Birch-Hirschfeld and others have even acknowledged that renal sarcomatous growths have been questioned by many. Rindfleisch declared that “in the kidney there is found true carcinoma only.” Jacobi, as recently as 1884, at the International Medical Congress at Copenhagen, was able to say, without fear of contradiction, that “the very best literature of modern times, with the exception of but few instances, make no difference between carcinoma and sarcoma.” Even Sir William Roberts, in the last edition of his work “On Urinary and Renal Diseases,” describes malignant disease of the kidney mainly under the head of “cancer,” referring only very briefly in an appendix of two pages to cases of sarcoma. He, however, admits that many of the cases referred to under the head of “cancer” were observed before the differentiation between carcinoma and



sarcoma had been generally demonstrated. He also states that a considerable number of the older cases would now be classed as sarcomata.

Many authors do not sufficiently distinguish between enlargements of the kidney, due to inflammatory processes or mechanical conditions, and those due to new growths proper. In some of the classifications of "tumours" adopted in modern text-books, such lesions as hydatid, tubercle, gumma, and leukæmic nodules are included. This only tends to perpetuate a needless confusion. Many use the term "tumour" in a very loose fashion; at one time indicative of new growth, but often merely to convey the idea of "swelling." In many instances it is only by the context that one can obtain the true sense in which the word is employed. In these pages I have avoided the term "tumour" as far as possible, or used it only as a convenient clinical expression. As a term for enlargement of the kidney, appreciable on clinical examination, irrespective of the strict pathological condition giving rise to such increase in size, it is doubtless of service, and may be well retained. The term "growth" should always be allowed to signify a true neoplasm. It will thus be clear that while many renal "tumours" are due to "growths," all "growths" at one period of their development could not be detected as "tumours"; and indeed, in many instances, a new formation may never reach sufficient dimensions to render it recognisable as a "tumour" during life. It is very greatly to be regretted that much of the confusion has arisen, and is still perpetuated, by the loose and negligent way in which the terms "tumour," "growth," and "neoplasm" are used. Some authors, however, like Tuffier, have gone so far as to defend and justify the inclusion of all forms of malignant growth under one common title, chiefly on the grounds that these growths act in the same way, that they progress similarly, and that the differential diagnosis is impossible. It is needless to say that such a view is quite at variance with modern scientific principle.

The catalogues of our large museums bear ample evidence to the limited and oftentimes inaccurate terminology applied to specimens of renal growth. The label "cancer" seems generally to have been intended to be synonymous with "malignant disease"; and, in referring to such specimens, it is well mentally to read it as such. In 1888, Newman wrote: "By inquiry into the literature of the subject, and by examining

specimens already classified in museums, I am much struck by the fact that a large number of malignant growths, which should properly be placed under the sarcomata, are still classified as cancers." In the statistics drawn from his collected cases, he appears, however, to have arranged the growths as they were named in the published records.

In very many instances it would seem that the early writers did not clearly distinguish between primary and secondary growths. This point alone makes the early statistics far from reliable.

The present position is forcibly put by Bland Sutton, who, writing in 1893, in his work on "Tumours," says:

"It has been so much the fashion with surgeons to describe malignant tumours of the kidney, under the meaningless title of 'encephaloid,' that we have no histological data to guide us in determining the nature of such tumours." He goes on to add that "I am convinced from my own investigation that a large proportion of such tumours are in reality sarcomata, but I am equally certain that in a few 'encephaloid' tumours of the kidney abnormal development of epithelium is a distinguishing feature." I am heartily in agreement with Mr. Sutton when he says: "It is impossible to write an account of carcinoma of the kidney until surgeons are more alive to the interest of the question, and take steps to place malignant tumours of the kidney, while fresh, in the hands of experienced pathological histologists."

There is no doubt more rapid advance would be made in our knowledge of the growths of the kidney, if surgeons would, to use Mr. Malcolm's words, "look for guidance in treatment to a careful study of clinical histories and of the microscopic structure of the specimens removed."

*References.*—A short reference to the literature of the subject, and especially to the articles of some of the early writers, may not be without interest, and will serve to indicate the lines along which investigation has progressed up to the present day.

Only a very few vague and doubtful allusions to growths of the kidney can be found previous to the present century. Sennert in 1650 speaks of scirrhus of the kidney, but, as was pointed out by Rayer, very probably these early cases were not examples of growth at all. The references made by Morgagni and Chopart also seem very doubtful.

Corvisart and Leroux in 1804 reported what seem to have been true growths in the kidney.

Muriel in 1810 met with a most interesting renal "cancer" in a woman, *æt.* 35, which simulated, and was evidently mistaken for pregnancy.

Carraud in 1813 reported the case of a woman, *æt.* 58, where a growth of the right kidney was mistaken for disease of the liver.

Chomel in 1814 recorded a case which was apparently primary, as it was limited to the kidney, and occurred in an old man, *æt.* 60.

Rance in 1815 reported the case of a growth in a female child, *æt.* 17 months. This is probably the first case of congenital sarcoma on record.

Beclard and Cloquet in 1816 brought a preparation of "cancer" before the Faculty of Medicine in Paris. The growth occurred in a man, *æt.* 50, involved the right kidney, and was of the size of a child's head.

Wilson in 1817 drew attention to the occurrence of renal growths, and briefly indicated their characters.

Houssard in 1818 met with "cancer" in the right kidney of a woman, *æt.* 28.

Rostan in 1819 published a case met with in a woman, *æt.* 64, but apparently secondary to gastric carcinoma.

Norris in 1820 published a case of "fungus hæmatodes" in an old woman, but this too was probably secondary.

Darwall in 1823 recorded two cases, one in a young man *æt.* 22, and another in an old woman. It seems doubtful if these were really primary.

Recamier in 1824 met with "cancer" of the left kidney in an old woman, in whom also there were secondary deposits in the lungs.

Vallerand de Lafosse in 1825 published a case evidently of primary growth in a man, *æt.* 30, with secondary deposits in the lungs.

Koenig in 1826 endeavoured to indicate the more important differences between the various kinds of growth, but apparently without sufficient pathological evidence for his views.

Velpeau in 1826 also mentioned cases of renal growth.

Bouilland in 1828 met with growth of the right kidney in an old man of 60.

Gairdner in the same year published a case of "fungus hæmatodes" in a female child, æt. 3. Both kidneys were affected, the left weighed 5 lb. 3 oz. and the right 1 lb. 3 oz.

Cruveilhier in 1829, in his classical work on pathological anatomy, dealt with the whole question of renal growths in a more or less scientific manner.

Roques in 1829 also published a case where the right kidney was involved, but apparently the growth was secondary.

Gintrac in 1830 recorded the case of a man, æt. 54, in whom the left kidney was transformed into an encephaloid mass, with secondary deposits in the lungs.

Dance in 1831 referred to a case where nodules of soft growth were found in the kidneys, but these were apparently secondary to cancer of the intestines.

Bennet in the same year recorded a case of growth, evidently a sarcoma, affecting the right kidney of a child of 4.

Cazeaux in 1833 described the chief characters of renal "cancer."

Renauldin also in 1833 met with a growth of the left kidney in a woman, æt. 65, in whom there was also a cancerous nodule in the heart.

Cramer in 1837 recorded a case of malignant disease of the kidney.

Warren in 1838, in his work on "Surgical Observations on Tumours," very briefly refers to renal growths, and mentions a case occurring in a woman of 50.

Gorham also in 1838 published his report on a case of "fungoid disease" of the kidney.

Rayer in 1841 reviewed the subject up to that date, and gave references to many of the earlier cases. He also described the chief characters of some thirteen growths, but several of these are manifestly secondary.

Husson in 1843 published a case in which a growth of the right kidney had extended into and plugged the inferior vena cava.

Matice in 1844 recorded an example of renal "cancer."

Walshe in 1846, in his work on "The Nature and Treatment of Cancer," devoted considerable attention to renal growths. He was able to collect some forty cases, including his own and those of Rayer. He, however, did not clearly distinguish between primary and secondary growths.

Rokitansky in 1849 described renal growths with considerable accuracy, and declared that "carcinomatous growths occur frequently in the kidney and in the primary form."

Lees also in 1849 recorded a case of renal "cancer."

Lebert in 1851, in his "Traité des maladies cancéreuses," described the chief pathological characters, but he failed to satisfactorily distinguish between primary and secondary growths.

Moreau in 1852 called attention to the occurrence of "cancer" in young children.

Eves in 1854 recorded the case of a male, *æt.* 38, in whom phosphatic calculi were found in the kidney opposite to that affected by growth.

Hawkins in 1856 met with malignant growth occurring in a young child.

Hullman in 1857 wrote his dissertation on renal "carcinoma."

Brinton in 1857 also published a case of "encephaloid" of the kidney.

Totland in the following year, 1858, recorded another example of "encephaloid."

Doderlain in 1860 took renal growths as the subject of his dissertation.

Walcott in 1861 performed nephrectomy on a man, *æt.* 58. This is the first recorded case of removal of a kidney with malignant growth.

Grisolle in 1862, in his "Traité de pathologie interne," only very briefly referred to growths of the kidney.

Johnson also in 1862 published his work on "Diseases of the Kidney," but devoted very little space to the consideration of "cancer."

Roberts in 1865, in the first edition of his well-known work on "Urinary Diseases," reviewed the whole question, and based his description on fifty-two collected cases.

Bezold in 1865 published an account of a specimen he considered to be a myxoma.

Faludi in 1865 met with "cancer" in a child *æt.* 5.

Von Franque also in 1865 records a similar case in a child *æt.* 8.

Gay in 1868 met with "encephaloid" weighing  $36\frac{1}{2}$  lb. in a boy *æt.*  $8\frac{1}{2}$ .

Neubert in 1868 also recorded a case of double-sided "cancer."

Lulkens in 1869 wrote a dissertation on renal "carcinoma."  
Rosenstein about the same time described malignant disease of the kidney.

George in 1869 met with "cancer" in an infant.

Braidwood in 1870 published cases occurring in children.

Gairdner and Coats in 1870 recorded an interesting case of "soft cancer."

Jerzykowski in 1871 wrote his dissertation on this question of renal growths.

Eberth in 1872 first drew attention to the occurrence of muscular tissue in certain growths occurring in children.

Hahn in the same year met with a case of sarcoma, the right kidney being affected, in a child, *æt.* 10 months.

Hansen in 1873 described "cancer" in an infant 10½ months old.

Neumann in the same year, 1873, gave a most useful résumé of the work done up to that date, and furnished a good bibliography.

Von Perewerseff published the results of his investigations on the development of "cancer" in 1874.

Rohrer also in 1874 recorded the results of his observations.

Menger in 1875 was the first to prominently draw attention to the forms of growth having an adenomatous arrangement.

Sturm also in the same year published his admirable paper on adenomata.

Cohnheim also, in 1875, drew attention to the myo-sarcomata, and indicated their probable origin.

Ferreol in 1875 published an interesting case of malignant growth, probably sarcoma, met with in a negro child.

Langenbuch in 1877 performed nephrectomy for renal growth.

Landsberger in 1877 published the results of his researches on malignant growths, probably of congenital origin.

Koch in 1878 issued his dissertation on the origin of sarcomatous growths of the kidney.

Marchand in 1878 published his important researches on the myo-sarcomata.

Huber and Boström also in 1878 drew attention to the rhabdo-myomata.

Monti, also in 1878, gave an admirable summary of the then known views as to the origin and nature of these growths, in Gerhardt's "Handbuch der Kinderkrankheiten."

Kocher and Czerny both recorded cases of nephrectomy for growth in 1878.

Geddings in 1878 met with a sarcoma weighing  $13\frac{1}{2}$  lb. in a negro girl, æt.  $3\frac{3}{4}$ .

Lossen in 1879 recorded the case of a pregnant woman, æt. 37, on whom nephrectomy was successfully performed.

Osler in 1879 drew attention to the myo-sarcomata, and recorded cases.

Barker in 1880 reviewed the question of nephrectomy for growth, and gave tables of the recorded cases.

Whitehead in 1881 performed nephrectomy on a man æt. 45.

Israel in 1881 recorded a case of "fungating carcinoma."

Newman in 1882 gave a résumé of the subject up to that date, dealing particularly with the more important historical points.

Abeille in his thesis, published in 1883, gave numerous references.

Bergmann and Kessler, both in 1883, took this question as the subject for their dissertations.

Grawitz in 1883 published his important paper, in which attention was drawn to the importance of adrenal inclusions as a cause of renal growth.

Windle in 1883 published cases of sarcoma, and gave tables of collected cases.

Alloway also in 1883 drew the attention of American pathologists to the occurrence of renal growths in children.

Hornaus in 1883 collected the cases in which nephrectomy had been performed.

Weichselbaum in 1884 carefully described the adenomata.

Sabourin also in 1884 pointed out the association of adenomatous formations with renal sclerosis.

Paul in 1884 attempted to formulate a more satisfactory classification, and gave the results of an important microscopical investigation.

Brosin in 1884 described the congenital myo-sarcomata.

Cremer in 1884 published a case of "cancer" he believed due to traumatism.

Pughe in 1885 performed nephrectomy for sarcoma.

Godlee in the same year removed the kidney from a child nearly 2 years old. There was recovery from the operation, but recurrence subsequently occurred.

Bieck in 1886 wrote his dissertation on renal growths.

Ribbert also in 1886 published a paper on myo-sarcomata.

Skene Keith in 1886 performed nephrectomy unsuccessfully in two cases, one a male *æt.* 61, the other a female *æt.* 49.

Prudden in 1888 described multiple adenomata of the kidney.

Newman in 1888 published his work on "Surgical Diseases of the Kidney," in which he collected all the recorded cases of nephrectomy for growth.

Long in 1888 met with sarcoma in a child *æt.* 16 months.

Special reference must be made to the admirable thesis of Guillet which appeared in 1888, entitled "Des tumeurs malignes du rein." He gave an excellent bibliography and tables of nephrectomy cases.

During the last ten years a considerable number of cases have been recorded, and more or less valuable articles written on the subject of renal growths. It is impossible to refer to them here in detail, but reference to them will be found in the bibliography. Chief among these, however, may be mentioned the following:—

Tuffier in 1888 published a useful bibliography of seventy nephrectomy cases.

Dumont in 1889 wrote his thesis "On Malignant Growths in Children."

Schutz in 1889 published his paper "On the Origin and Development of Epithelial Growths."

De Paoli in 1890 called attention to the angio-sarcomata.

Goebel in 1890 wrote a dissertation on the myo-sarcomata.

Beneke in the same year published a valuable criticism on the different views as to the origin of renal growths.

In 1891 important contributions appeared from Ambrosius, Horn, and Lusard. Chevalier especially drew attention to the chief points in connection with surgical intervention.

In 1893 the work of Askanazy, Pick, and Bland Sutton appeared.

In 1894 important articles were contributed by Abbe, Lubarsch, and Sudek. Targett in this year delivered his Erasmus Wilson Lectures on "Tumours connected with the Kidney in Children."

In 1895, Brock and Ulrick's papers appeared, and in this year Fruitnight treated sarcoma in an infant with the so-called "erysipelas toxin."



In 1896 important papers appeared by Allen and Cherry, Gatti, Kayser, Lewi, Macweeney, Manasso, Targett, Wentworth, and Witte.

Among the most recent contributions, special reference should be made to those of Ricker and Walker, and also Küster's work, "Die Chirurgischen Krankheiten der Nieren."

A number of very interesting cases will be found recorded in the *Transactions of the Pathological Society of London*, by such observers as—

Abercrombie, Balding, Ballard, Beadles, Bristowe, Coupland, Croft, Dickinson, Dowse, Drew, Eve, Fagge, Fenwick, Fisher, Hebb, Holmes, Leared, Lunn, MacCormac, Malcolm, Moore, Murchison, Obre, Pollard, Sharkey, Thornton, Trotter, Tyson, Van der Byl, Weber, Wells, Whipham, Wilks, and Williams.<sup>1</sup>

<sup>1</sup> Full references to most of the above-mentioned writers will be found in the Bibliography at the end of this volume.

## CHAPTER II.

### CLASSIFICATION.

THERE can be no doubt the time is rapidly approaching when a mere clinical grouping of renal "tumours" must give way to a division based upon pathological characters. Such a classification, to be perfectly satisfactory, necessitates a complete acquaintance with the life-history of each growth. This can only come by careful and thorough investigation of individual cases. A histogenetic arrangement for the time being is to be aimed at. Beyond details of structure lie truths which, when more clearly recognised, may lead to a still more scientific classification, based possibly on an intimate knowledge of etiological factors and developmental influences. At the present time our pathological grouping is not always in accord with clinical facts. It is not uncommon for a new growth, having a structure which we are accustomed to consider indicative of its local and benign character, to become disseminated, and the subject dies to all intents and purposes from malignant disease. In other cases, a growth which, judged from its histological characters, would be declared most malignant, shows little or no tendency to become generalised, and with complete removal does not recur. These difficulties are well illustrated by our experience of such forms of growth as are often spoken of as "adenomata," "endotheliomata," and "alveolar sarcomata." Still, at the present time, a grouping dependent on histological characters seems the most scientific and serviceable. In far the majority of cases an examination of the microscopical structures will allow one to form a fairly accurate opinion as to the development of the growth, and to foretell the course of the case. And yet, as I have endeavoured to show, too little attention is at present given to the minute structure of these growths by surgeons, and indeed by pathologists generally.

It is unnecessary to dwell at length on the different classi-

fications that have been suggested. Most are mere convenient arrangements for purposes of description. Some are based on clinical characters only. In many instances, completely different "tumour" formations are brought into close association. Some include the rare gummata of the kidney, and the more common caseous nodules of local tuberculosis in their "tumour" formations. Many also place "true cystic disease" alongside of cystic growths. Even Bland Sutton makes the surprising statement that "the only tumour of the kidney to which the term renal adenoma is applicable is that peculiar condition known as congenital cystic kidney." True cystic kidney has a distinct pathology of its own, and is probably in no way allied to renal neoplasms, and I have consequently omitted all reference to it in these pages.

In 1884, Mr. Paul of Liverpool, with the assistance of a number of British pathologists, attempted to place the grouping of new growths, arising in connection with the urinary system, on a rational and scientific basis. Their researches certainly greatly assisted to a more accurate perception of the nature and relationship of several of the forms of renal growth, especially the sarcomata. Mr. Paul's classification is as follows:—

1. OF CONGENITAL ORIGIN—

Sarcoma	·	{	Round-celled.
			Fibro-sarcoma.
			Striped myo-sarcoma.
			Adeno-sarcoma.

Dermoid tumours.

2. OF ADULT ORIGIN—

Cysts.

Cavernous tumours.

Sarcoma	·	{	Round-celled.
			Other varieties?

Adenoma	·	{	Cystic.
			Tubular.

Carcinoma	·	{	Pelvic—like the bladder.	
			Glandular	Cystic.
				Tubular.

This grouping was an immense advance on previous attempts, and has stood the test of years so well, that Dr. Ord even in 1896, when writing his articles on "Renal Affections,"<sup>1</sup> practically adopts the same arrangement, merely adding lymph-adenoma to the end of the second group.

<sup>1</sup> *Practitioner*, London, 1896.



4. Hæmatangiomatica.
5. Adenomata . . (a) Papillary.  
(b) Alveolar.
6. Papillomata.
- B. MALIGNANT . 7. Carcinomata . . (a) Encephaloid.  
(b) Scirrhus.  
(c) Colloid.  
(d) Epithelioma.  
(e) Cylindroma.
8. Lymphadenomata.
9. Sarcomata . . (a) Round-celled.  
(b) Spindle-celled.  
(c) Alveolar sarcoma.  
(d) Angio-sarcoma.  
(e) Adeno-sarcoma.  
(f) Myo-sarcoma.  
(g) Myxo-sarcoma.

The old clinical divisions, however, are not to be wholly cast aside. They have assisted greatly in the past, and our perception in the present is in great measure dependent on the light from former days. But grafted on to the clinical divisions must be a true discernment of pathological differences and likenesses. At the present time no perfect classification can be suggested. As a means to a more desirable end, I believe a division very similar to, if not identical with, that recommended by the Royal College of Physicians of London,<sup>1</sup> in which tumours are classified according to their structure and the type of normal tissue they most closely resemble, would, if generally adopted, soon lead to a distinct increase in our present information as to renal growths, and speedily bring order and knowledge where now confusion and ignorance exist.

It must be honestly admitted that no perfect classification seems possible at the present time. As Newman well says, "There are equivocal cases which, so far as we know, do not follow any recognised type, either in their clinical history or in their histological appearance." Much further research will be necessary before our histogenetic classification can be considered satisfactory. And yet, as Newman says, "A classification based on the minute structure is at present the only one available for practical men; it is the only one in which clinical characters of the tumours justify the anatomical distinctions."

Especially in the study of renal growths is it necessary to bear in mind the important fact, well brought out by Bland

<sup>1</sup> "The Nomenclature of Diseases," 1896, p. 335.

Sutton: "It may be regarded as a postulate, that the histology and embryology of an organ enable an experienced oncologist to predict the various genera of tumours and cysts to which it is liable," nevertheless "this knowledge will not enable us to predict the liability or the relative frequency with which tumours attack particular organs."

## CHAPTER III.

### FREQUENCY OF RENAL GROWTHS.

It is very difficult to obtain reliable data for forming any satisfactory opinion as to the frequency with which primary growths occur in the kidney.

Tanchou, according to Ebstein, found only three examples among 8300 cases of carcinoma obtained from the mortality returns of the Department of the Seine during the years 1830-1840.

Marc d'Epine gives the proportion as 0.3 per cent. He found two fatal cases among 889 deaths from cancer. His figures are based upon the returns of the Canton of Geneva during thirteen years.

Steiner, according to Ebstein, seems to have found only four cases among 100,000 children admitted to the Children's Hospital at Prague.

Ebstein also states that in Frerich's clinique at the Charité Hospital at Berlin, only three cases of renal cancer were recorded in ten years.

Virchow, from his experience of the examination of malignant neoplasms during four years at Würzburg, gives the rate as 0.5 per cent.

Willigk, from his observations at Prague, gives 4.6 per cent., but his numbers are manifestly fallacious, as secondary growths were evidently included.

Rokitansky in 1849 was of the opinion that "carcinomatous growths occur frequently in the kidneys and in the primary form." He noted the co-existence of growth in the kidney and testicle of the same side.

Morris, in an investigation of 2610 post-mortem inspections, found five primary and twenty-five secondary cases of malignant disease.

As indicating the comparative rarity of primary renal growths, Dr. Rolleston tells me he has only met with one

example in six and a half years at St. George's Hospital; although, in the ten years 1880-1890, five cases were met with in the pathological department.

In a careful search through the pathological records of our hospital of the last 4505 cases, I can only find reports on nine cases of primary renal growth. This gives a proportion to all cases dying from very various causes of 0.19 per cent. This does not include recent cases where the growth has been removed by operation.

Among 1400 cases examined, while pathologist to the Manchester Royal Infirmary, six cases of primary renal growth have come under my observation. This would give a percentage of 0.42. I have recently had opportunities of investigating a further case of growth removed by operation by Mr. Thorburn at the Infirmary; also specimens of congenital sarcoma from a patient of Dr. Wilkinson's.

With regard to the proportion between these cases of primary malignant growth of the kidney and malignant disease elsewhere, the percentage is between 2 and 3 per cent. Possibly this may be a little high, as I believe my experience has been somewhat exceptional; but for a large general hospital, where a certain proportion of children are admitted, it is perhaps not much too high.

As indicative of the relative frequency of the different forms of renal growth, I believe no returns of sufficient accuracy are at present forthcoming.

In England and America, at the present time, it seems customary to consider sarcomata much commoner than carcinomata. This is probably a correct view. I am convinced, however, from my own experience, that it is often quite impossible to differentiate between these two groups without careful microscopical examination. This I have proved again and again. One case which macroscopically seemed to me undoubtedly a sarcoma, from its distribution and general characters, I found, on examining with the microscope, was a very typical papilliferous cyst-adenoma. The malignant adenomatous growths often resemble the sarcomata in their naked-eye characters. Many of the illustrations in this volume clearly indicate the impossibility of ascertaining the essential nature of a growth without careful histological examination. After a little personal experience, one may well excuse much of the confusion that



has arisen in the past between these different forms of growth, when minute examination was often impossible. Even with our modern methods of investigation, it is by no means always easy to distinguish between the different varieties, and not infrequently skilled pathologists differ considerably in their views as to the precise nature of these growths.

Minges, in an analysis of sixty-two cases, gives the proportion as follows—thirty sarcomata, thirty carcinomata, one adenoma; one fibro-cystic growth. Twenty-one of the carcinomata were described as “encephaloid cancer,” but probably most of them should be placed under the sarcomata.

I have attempted to roughly group a number of collected cases under the published headings; and the result, although of no real value, may not be without interest. A very large number of the “carcinomata”—and under this heading I have placed all those termed “cancers”—are undoubtedly sarcomata. Many of the old cases are simply spoken of as “malignant,” “fungus hæmatodes,” or “encephaloid.”

In 306 cases occurring in both sexes at all ages, the proportion is as follows:—115 sarcomata, twenty-two myo-sarcomata, 142 carcinomata, fifteen fibromata or lipomata or mixed, and twelve adenomata.

The benign forms of growth are so rare, generally so limited in extent, and usually give rise to such slight general disturbance, that, in comparison with the malignant varieties, they are of but little significance.

*Proportion of primary to secondary growths.*—In the earlier cases sufficient care was not always taken in distinguishing between primary and secondary growths. In this way many of the figures generally given are palpably erroneous.

Primary renal growths are, as compared with growths generally, rare. Secondary involvement of the kidney is also comparatively infrequent.

In order to ascertain the proportion of cases in which secondary deposits occur in the kidney, I have analysed a number of cases which have come under observation in our pathological department during the period I have acted as pathologist.

Among 1400 cases I have collected 195 of malignant disease. This gives a percentage of nearly fourteen for malignant disease, as compared with all forms of disease as met with in a large general hospital. Doubtful cases have been excluded. I

have also passed over the cystic growths of the ovary, and have omitted some exceptional cases—such, for instance, as two examples of growth of the pituitary body associated with acromegaly. These 195 cases may be roughly divided into sixty-nine sarcomata and 126 carcinomata. I use the term "carcinoma" here in its widest sense, and include all epitheliomata. It seems unnecessary to further divide these growths for present purposes.

Of the 126 carcinomata only ten presented secondary deposits in the kidneys. Of these ten, in seven there was undoubted secondary deposition. In two the involvement was so slight as to be considered somewhat doubtful. In one the renal affection was apparently due to direct extension. In only two were both kidneys affected. The right was clearly involved in four, doubtfully affected in two, and invaded by direct extension from the liver in one. In one case the left kidney only was affected. Of the ten cases all were adults, the average age being nearly 48. As regards sex, six were males, with an average age of 49, and four were females, with an average age of nearly 46 years.

Of the sixty-nine sarcomata ten presented secondary deposits in the kidneys. Of these ten, in eight there was undoubted secondary deposition. In two the involvement was apparently due to direct extension. In one case the kidney was atrophied, but uninvolved by growth, although its ureter was infiltrated with sarcomatous tissue. In six both kidneys were affected. The left was alone involved in three, but in one of these it appeared to be affected by direct extension of the growth. Of the ten cases all were adults. The age was obtained in eight, and averaged nearly 40 years. As regards sex, six were males and four females.

In the carcinoma cases the primary growth was situated in the stomach in four, in the pharynx in two, in the œsophagus in two, and one each in uterus and lung.

In the sarcoma cases the primary growth was situated in the mediastinum in five, and in abdominal, retroperitoneal or pelvic glands in five.

These figures tend to show that the kidney is an organ which is but seldom involved by secondary growth. Of the 126 carcinomata, the primary growth originated in the alimentary canal in eighty-nine, but of these only eight showed deposits in the kidneys.

We can therefore venture to say that secondary deposits are met with in the kidney in about 8 per cent. of all cases of carcinoma and nearly  $14\frac{1}{2}$  per cent. of all cases of sarcoma.

Secondary deposits do not usually reach any considerable size, and are generally not numerous. The kidney differs in this respect very greatly from the liver.

Primary malignant growths are usually unilateral, while secondary are generally, although by no means always, bilateral. The latter do not, as a rule give rise to symptoms independent of the primary growth. Generally they are only detected at the autopsy.

Reginald Harrison gives it as his opinion that "secondary sarcoma and carcinoma are less frequent in the kidney than in the lungs or liver, and the growths rarely attain sufficient size to seriously impede the functions of the organ, except in the case of the direct infiltration of a neighbouring tumour."



FIG. 1.—Melanotic sarcoma of kidney. External surface of one-half of kidney, showing a number of secondary melanotic growths, varying in size from a pin's head to a pea.

Wood and Fitz state that "secondary cancer owes its origin to disease in the vicinity, and particularly to primary malignant disease of the testis." They also add that "the right kidney is more often diseased than the left in secondary cancer of the kidney."

Secondary melanotic sarcoma occurs in the kidney occasionally. Some time since I examined a growth originating apparently in a small pigmented wart. It proved to be a melanotic sarcoma. The patient, a young female, died from more or less general dissemination, and Mr. Coats, the patient's medical attendant, informs me the kidneys contained numerous pigmented nodules.

In our College Museum we have a beautiful example of secondary melanotic sarcoma, the nodules being very numerous and scattered through the kidney, and varying in size from a pin's head to a pea (Figs. 1, 40, 41).

## CHAPTER IV.

### ETIOLOGY OF RENAL GROWTHS.

THE origin of renal growths, like that of growths elsewhere, is very obscure, and shrouded in mystery. We are almost completely ignorant of the true etiological factors.

Certain influences may, however, be mentioned, although with some it is difficult to know to what extent they should be considered as more than merely predisposing.

*Embryonic defects.*—The development of the kidney is highly complex, and it is very probable that mal-development may lead to unnatural activity in certain of the abnormally environed cells. It would appear to be almost impossible to explain the presence of certain elements in these growths without reference to the evolution of the organ.

The urinary and generative organs, according to Schäfer's description, in the last edition of Quain's "Anatomy," originate in connection with the intermediate cell-mass: "A portion of mesoblast, which is seen in sections of the early embryo, lying between the para-axial mesoblast and the pleuro-peritoneal cleft, and abutting against the external epiblast." The permanent kidney arises—(1) As protrusions from the posterior end of the Wolffian ducts—these form the ureters and part of the collecting tubules; (2) from portions of the intermediate cell-mass posterior to the Wolffian body—these form the convoluted tubes, the Malpighian bodies, and the remaining parts of the uriniferous tubules.

Cohnheim seems to have been the first to suggest that certain growths met with, especially in infants and young children, are due to a faulty segmentation of the pro-vertebral somites, whereby some cells become included with those of the primitive kidney.

Eberth strongly supports the view that sarcomata develop from heteroplastic remnants of the Wolffian bodies.

There can be but little doubt that some of these sarcomatous growths develop during foetal life, and, existing in the renal tissue at birth, quickly develop and manifest themselves clinically.

Cohnheim's suggestion of embryonic inclusions is strongly borne out by such observers as Wentworth, Osler, Gardner, Jacobi, Kocher, Little, Monti, and Williams, who have described growth present at birth. Geddings and Landsberger have met with sarcoma in 7-months foetuses. The fact that most of these growths develop within the first few years of life is also in favour of this view.

Mr. Targett also strongly supports the Wolffian origin of certain of the renal growths. The Wolffian bodies atrophy from before backwards, and hence the part nearest to the kidney would be the last to disappear, and therefore most likely to become included. It is also stated that the Wolffian bodies are less used up in the female, explaining, as my statistics as regards young subjects would seem to show, the somewhat greater liability of the female sex to the development of renal growths.

But little information is forthcoming as to the exact site of the congenital growths in the kidney. Should they prove to be most frequent at the cephalic end, or towards the ventral surface, this would be an additional argument in favour of their Wolffian origin. It is interesting to remember that, as Mr. Targett has so clearly shown, growths in connection with the hilum in children are more likely to contain muscle cells. Possibly they may be derived from the myotomes in close contact with the developing ureter. The growths arising in the cortex are more likely to have a glandular structure. This is suggestive of an origin from the Wolffian body. Rudimentary glomeruli are said to be abundant in the Wolffian bodies. Some of the congenital growths have presented similar structures.

In some instances it seems very possible that embryonic inclusions may lie dormant until later periods of life, and then under influences at present unknown commence active growth.

We are indebted to Manasse for one of the best studies on the histogenesis of renal growths.

In recent years the researches of Grawitz and others, to whom I shall have to allude later, have clearly shown that growths, generally of an adenomatous type, arise from adrenal inclusions or accessory suprarenals.

These adrenal inclusions, or "rests," as they have been

termed, may, as Ziegler and many other pathologists believe, under certain circumstances take on indefinite growth, and manifest such characters as we are wont to associate with the designation "malignant."

Sudeck and others have thought it possible that certain of the renal growths may arise from "rests" of hepatic origin. It is also reasonable to believe that separated fragments of renal parenchyma may become the seat of indefinite growth.

*Heredity.*—As far as can be gathered from recorded cases, hereditary predisposition to renal growth is by no means a marked feature. No stress need be laid upon it, and for purposes of differential diagnosis it is useless.

It is true, however, that in some few instances a distinct family history of malignant disease has been noted, but, considering the frequency of malignant growth in some parts of the body, such association is not surprising.

Ballard gives the case of a lady, *æ*t. 70, who died from "encephaloid cancer" of the kidney. Her daughter, *æ*t. 40, died from cancer of the tongue; and a son about the same age had malignant disease of the leg, necessitating amputation.

In Beadles' case of primary renal growth there was also a strong history of neoplasms in the family.

Walker, in an analysis of 145 collected cases of sarcoma in children, found only eight with any family history of malignancy.

Strümpell mentions a case where two brothers were affected.

*Traumatism.*—Considering the deeply-placed and well-protected position of the kidneys, it would seem most unlikely that these organs should be affected to any considerable extent by external mechanical irritation.

A number of writers, however, have sought to connect the development of growths with blows or other injuries. The association is, without doubt, in most instances nothing better than a coincidence. Many persons, anxiously seeking for the explanation of so striking and seemingly unreasonable an occurrence as rapid development of a "tumour formation," eagerly seize on any trivial injury received, as a sufficient explanation for its origin. In many of the recorded cases, I feel convinced that the blow or injury received did little more than draw attention to the part, and so led to the detection of an enlargement which doubtless had been present for some time previously. In some instances it would seem as though the trauma might have pro-

duced some contusion of the growth, and so led to hæmaturia, pain, and possibly more rapid development. In some of the cases where traumatism has been the alleged cause, the growth has not appeared until some years after the injury. In most of the recorded cases, any etiological relationship is exceedingly doubtful. Still, traumatic malignancy is known to occur elsewhere in the body; and it is possible that in some exceptional instances it may account for the rapid development and advance of some renal growths.

Chomet, as far back as 1829, met with a case of "cancer" which was considered to have been due to a blow.

Bright<sup>1</sup> records the case of a young woman who fell downstairs while pregnant, striking her side somewhat severely. Soon after her confinement a tumour was noticed in the right hypochondriac region. After death, a large "encephaloid tumour" of the right kidney was found united to the colon and duodenum.

Brinton in 1857 recorded the case of a man, æt. 40, who "ricked" himself on the right side, and for two days his urine contained blood. Eighteen months later he discovered a swelling in his abdomen, which proved to be a malignant growth of the right kidney.

Manzolini in 1856 reported the case of a boy who was kicked on the left side. Hæmaturia occurred, and lasted fourteen days, and a distinct enlargement was detected shortly after.

In the case of a man, æt. 36, met with by Andrew in 1877, and described as "cancer," there was a history of traumatism. Distinct tumour and hæmaturia existed for fourteen years, and death ultimately took place from phthisis. From the description of the specimen, it seems probable that the renal enlargement was due rather to chronic tuberculosis than new growth.

Jerzykowski records the remarkable case of a lady who fell down a number of steps. She had hæmaturia for some weeks. After six months a tumour was noticed, which gradually increased in size and led to death, eighteen years after the fall, from "carcinoma" of the kidney.

In Vogelsang's case of sarcoma, occurring in a girl of 3, a fall was considered to be the exciting cause.

In Elben's case the growth was also ascribed to traumatism.

<sup>1</sup> *Guy's Hosp. Rep.*, London, 1839, vol. iv.

Davis and Lawson met with a growth occurring in a woman, *æt.* 49, and first noticed shortly after a fall. In one of Alloway's cases there was also a history of injury. Chapman has recently recorded two cases in which there was a distinct history of injury to the affected side.

Walker states that out of the 142 cases of sarcoma in children, trauma was noted in thirty, consisting principally of falls, kicks, strokes in the side, jumping, and fright; and even violent vomiting is made responsible for three instances.

Rindfleisch seeks to explain these cases by injury done to the regulating nerve fibres, thus permitting abnormal growth.

Cases might doubtless be multiplied, but they are very probably of no scientific value and of comparatively little practical service.

*Calculus.*—The view that there is an etiological connection between cancer and calculi merits consideration.

Renal calculi have been met with in association with growth in a number of cases, and many authors hold that there is sufficient evidence to indicate a clear etiological connection. In the case of gall stones and growth of the gall bladder, such a relation undoubtedly occurs. I myself have met with a number of examples.

Certainly chronic irritation in many parts of the body leads to malignant disease, and there seems to be no reason to doubt but that in certain cases the presence of renal calculi may lead to the development of morbid growth in the pelvis, or perhaps even in the parenchyma of the kidney.

Bright recognised the co-existence of renal calculus and "cancer," and mentions a case.

Eves in 1854 met with a large "encephaloid cancer" of the left kidney, weighing 3 to 4 lb., in a man of 38. The right kidney contained a phosphatic calculus.

Brodeur records the case of a female, *æt.* 36, in whom a calculus was considered to have led to the formation of a cylindrical-celled epithelioma.

Walsham, at a meeting of the Pathological Society of London, mentioned a remarkable instance where epithelioma was present in a case where he performed nephro-lithotomy for calculous pyelitis. He also referred to a similar specimen in the Museum of St. Bartholomew's Hospital.



MacCormac has also met with epithelioma in association with calculus.

Morris mentions the case of an old man of 76, where the growth weighed 49 oz. and contained irregular calculi, which he considered had probably been the exciting cause.

A number of other cases where calculi and growth were associated have been recorded by Coupland, Cullingworth, Davy, Dickinson, Eves, Gluge, Hartmann, Israel, Jessop, Lucas, Moore, Papavoine, Pollard, Rokitansky, and Schuppel. Full references to these authors will be found in the bibliography.

In the Museum of Guy's Hospital there is an interesting specimen (1652), where a villous carcinoma has developed in an organ, the seat of hydronephrosis and calculus. In the same collection there are several other preparations showing the association of growth and hydronephrosis.

Butlin seems to endorse the view as to the etiological connection, for he says "the frequency with which renal calculus has been found in cases of renal cancer has led to the belief that cancer is induced by the presence of calculus."

Wilks, Frerichs, and other well-known pathologists also regard calculus as a causal agent in some cases.

Morris goes so far as to say that "renal calculus and injury, and the irritation of pyelitis or retention of urine, are the most frequent exciting causes."

It seems clear, however, that calculus can only very exceptionally lead to new growth. I have met with a considerable number of cases of renal lithiasis, but in none was there any indication of growth. In the cases of renal growth which have come under my notice, there was no evidence of calculus.

In none of Walker's 145 collected cases of renal sarcoma in children did any calculus precede the growth. In one a wandering kidney was noticed some months before the development of the growth.

In some of the recorded cases it is very probable that the stone was secondary in formation, and in some instances this has been the opinion of the reporter. In some instances the calculus has been stated to have been of a phosphatic nature.

*General causes.*—Little can be said respecting the other causes which have been alleged as instrumental in the development of renal growths.

Morris says: "Sometimes a malignant growth is engrafted

upon a serous cyst." Such a statement would appear to be difficult to prove. I know of no case which would seem to warrant it.

Ordinary chronic inflammatory conditions of the kidney appear in no way to predispose to the development of malignant disease.

The multiple adenomatous formations, described by Sabourin as occurring in connection with cirrhosis of the kidney, hardly come within the grouping of true growths, and are more of the nature of a simple hyperplasia of the renal cells. An analogous condition I have met with in the liver in the form of the so-called "nodular" or "adenomatous" cirrhosis.

As far as I have been able to ascertain, growths are not specially prone to develop in kidneys showing any of the ordinary malformations. I have met with a number of horseshoe kidneys and other abnormalities, but in no instance was there any evidence of growth.

Walker, in his 145 collected cases of renal sarcoma in children, found that in five instances the malignant growth was preceded by one of the exanthemata. It is possible, as Weigert has suggested, that such occurring in a subject where the kidney contains foreign tissue, the latter may be stimulated to proliferate by the irritation of the disease, and, the inhibitory influence of the kidney being lowered, the abnormal growth is enabled to develop.

The view that these neoplasms may be the result of parasitic invasion has but little support from pathologists of the present day.

#### PREDISPOSING INFLUENCES.

Brief reference may be made to certain influences which appear, although perhaps only remotely, to predispose to neoplastic development:—

*Race.*—On the influence of racial characters we have but little evidence. As far as is known, race would appear to have no influence in the development of renal growths. Several cases have been met with in black subjects. Geddings records the case of a negro girl, æt. 3 $\frac{3}{4}$ , where a sarcoma reached the weight of 13 $\frac{1}{2}$  lb. Ferreol also met with a growth in a negro child.

*Sex.*—Almost all authors agree in stating that malignant

growths of the kidney are met with oftener in the male than in the female. Roberts says: "The male sex is considerably more liable to renal cancer than the female." Of sixty-six cases, he found forty-seven to be males and nineteen females. Of twenty-four children, fifteen were boys and nine girls. Of forty-two adults, thirty-two were men and ten women.

Walshe also states that males are more frequently affected than females, in the proportion of three to two.

Snow says: "Males appear slightly more liable than females to cancerous growth in the kidney in both the periods of life at which these prevail—old age and infancy."

Ebstein, in fifty-six cases, found thirty-eight to be males and eighteen females. Among children he found but little difference. Of fifteen subjects, eight were boys and seven girls.

White and Martin, quoting Senator, state that of 305 cases, 199 were males and 106 females; while of ninety-six children under 10, fifty-eight were boys and thirty-eight girls.

Of Walker's 130 sarcoma cases, fifty-five were boys, fifty-one girls, and of twenty-four the sex was not stated.

Of the cases which have been met with in the post-mortem room of our hospital, the majority have been males.

In order to obtain more accurate evidence on this point, I have collected and analysed 142 cases, including those which have come under notice in our pathological department. The result is indicated in the following table:—

INFLUENCE OF SEX AT ALL AGES.

Sex.	No. of Cases.	Per Cent.
Males . . .	70	49.29
Females . . .	72	50.70

These numbers are somewhat in opposition to what has generally been taught. The cases have, of course, not been in any way specially selected. Apparently the supposed greater frequency of growths in the male is not in accordance with facts. Indeed, there seems to be no clear reason why one sex should be more liable to be affected than the other.

Birch-Hirschfeld, however, claims that these growths do

occur more frequently in girls, and he endeavours to explain it by the earlier disappearance of the Wolffian body.

In order to ascertain the influence of sex in young subjects, I have tabulated sixty-six cases in which growth was met with below 10 years of age, and the result of my analysis is as follows:—

## INFLUENCE OF SEX IN INFANCY AND CHILDHOOD.

Sex.	No. of Cases.	Per Cent.
Male . . . .	30	45.45
Female . . . .	36	54.54

For an indication of the influence of sex in active and adult life, I have grouped twenty-three cases, occurring between 21 and 40. The numbers come out as follows:—

## INFLUENCE OF SEX IN ADULT LIFE BETWEEN THE AGES OF 21 AND 40.

Sex.	No. of Cases.	Per Cent.
Male . . . .	8	34.78
Female . . . .	15	65.21

Above the age of 40, malignant disease again becomes more frequent, and of forty-six cases the proportion of the sexes is indicated as follows:—

## INFLUENCE OF SEX AT AGES ABOVE 40 YEARS.

Sex.	No. of Cases.	Per Cent.
Male . . . .	27	58.69
Female . . . .	19	41.30

The influence of sex in connection with the different forms of growth is very difficult to estimate with the present uncertainties as to the nature of many of the growths. It is quite impossible, in a very large number of the recorded cases, to venture on any accurate grouping. I have, however, attempted an analysis of some 138 of the cases, but make no claim for their being strictly

comparable. The results may, perhaps, be of passing interest if nothing more:—

INFLUENCE OF SEX IN DIFFERENT FORMS OF GROWTH.

Probable form of Growth.	Sex.	No. of Cases.	Per Cent.
Sarcoma . . . . .	Male.	31	38·75
	Female.	49	61·25
Myo-sarcoma . . . . .	Male.	10	58·82
	Female.	7	41·17
Carcinoma . . . . .	Male.	26	63·41
	Female.	15	36·58

The exact proportion between the sexes at different periods of life must at present be left open until a sufficient number of individually investigated cases shall allow of sufficient data being available.

*Age.*—The relation of the age of the subject to the development of growths is a question of much interest in throwing light on at least one large group of these new formations.

It is generally stated that renal growths occur particularly in early childhood and in advanced life.

Walshe in 1846 published the following table, which shows the ages at which thirty-one cases died from so-called "cancer":—

Age.	No. of Cases.
0- 1 year . . . . .	1
1- 2 years . . . . .	1
2- 9 „ . . . . .	0
10-19 „ . . . . .	1
20-29 „ . . . . .	3
30-39 „ . . . . .	3
40-49 „ . . . . .	1
50-59 „ . . . . .	10
60-69 „ . . . . .	9
70-79 „ . . . . .	2

Setting aside the two cases occurring before the tenth year, he found the mean age at death in the twenty-nine remaining cases to be 52·14 years.

Rohrer states that of all cases, over one-third occur in childhood. Of 115 collected cases, thirty-seven occurred before the age of 10 years, and thirty-one of these were below 5 years.

Mr. Paul, writing in 1893, says: "Between the ages of 5 and 30, malignant disease of the kidney is extremely rare. Cases are certainly on record, but they are only very occasionally met with. I have seen many on each side of this limit, but never any within it."

Pick says, 60 per cent. of all cases are met with below 5 years of age.

Ebstein gives the following table of his collected cases:—

Age.	No. of Cases.
Under 1 year . . . . .	5
1- 5 years . . . . .	11
5- 8 „ . . . . .	4
16 „ . . . . .	1
21-30 „ . . . . .	3
31-40 „ . . . . .	6
41-50 „ . . . . .	6
51-60 „ . . . . .	10
61-70 „ . . . . .	16

Basham, writing in 1862, says: "Cancerous or malignant disease of the kidneys occurs for the most part in the middle or later period of life."

Roberts gives the following tables. Among twenty-five children under 10, the cases were as follows:—

Age.	No. of Cases.
Under 1 year . . . . .	2
1- 2 years . . . . .	6
2- 3 „ . . . . .	6
3- 5 „ . . . . .	8
7- 8 „ . . . . .	2
10 „ . . . . .	1

In thirty-six adults the distribution was as follows:—

Age.	No. of Cases.
19 years . . . . .	1
20-30 „ . . . . .	7
30-40 „ . . . . .	5
40-50 „ . . . . .	4
50-60 „ . . . . .	9
60-70 „ . . . . .	9
Above 70 „ . . . . .	1

Newman gives a slight enlargement of the numbers compiled by Labadie-Lagrave, from figures which were taken from

several authorities who had themselves collected their cases. He points out that if these returns be taken collectively, they show that 48 per cent. of the cases occur under 10 years of age. The succeeding 30 years claim only 19 per cent., while the remaining 33 per cent. occur in individuals between the ages of 40 and 70 years.

Ebstein in fifty-two of his collected cases found twenty to be children.

Roger Williams, speaking of renal growths in young subjects, states that "tumours of this kind are invariably sarcomatous, although in the older reports they are often described as 'cancers,' owing to the occasional presence of epithelial structures of simple tubular or papillary cystic type in the sarcomatous matrix."

White and Martin give the following table from Senator:—

Age.	No. of Cases.
0-10 years . . . . .	157
10-20 „ . . . . .	15
20-30 „ . . . . .	34
30-40 „ . . . . .	45
40-50 „ . . . . .	42
50-60 „ . . . . .	96
60-70 „ . . . . .	57
70-80 „ . . . . .	13
	<hr/>
	459

Monti, from an analysis of fifty cases in young subjects, gives some interesting figures as regards the frequency in infancy and childhood. The following is his table:—

Age.	No. of Cases.
2 months . . . . .	1
3 „ . . . . .	1
4 „ . . . . .	1
5 „ . . . . .	1
7 „ . . . . .	2
9 „ . . . . .	3
10 „ . . . . .	2
1 year . . . . .	3
1½ „ . . . . .	6
2 years . . . . .	6
3 „ . . . . .	8
4 „ . . . . .	8

Age.	No. of Cases.
5 years . . . . .	2
6 „ . . . . .	1
7 „ . . . . .	2
8 „ . . . . .	2
9 „ . . . . .	1

Rosenstein's thirty cases of sarcoma, including adults, were as follows:—

Age.	No. of Cases.
Under 1 year . . . . .	6
1- 2 years . . . . .	3
2- 8 „ . . . . .	8
8-10 „ . . . . .	1
10-20 „ . . . . .	4
40-60 „ . . . . .	6
60-80 „ . . . . .	1

Starr, in a series of fifty-four cases of sarcoma, gives the following:—

Age.	No. of Cases.
Under 1 year . . . . .	9
1- 3 „ . . . . .	17
3- 5 „ . . . . .	18
5- 8 „ . . . . .	6
8-12 „ . . . . .	4

Walker's analysis of 138 cases of sarcoma in children gives the following results:—

Age.	No. of Cases.	Percentage.
7-8 months embryonic life . . . . .	3	2·17
At birth . . . . .	9	6·52
Under 6 months . . . . .	7	5·07
6 months to 1 year . . . . .	18	13·04
1- 2 years . . . . .	27	19·56
2- 3 „ . . . . .	19	13·76
3- 4 „ . . . . .	20	14·49
4- 5 „ . . . . .	13	9·42
5- 6 „ . . . . .	10	7·24
6- 7 „ . . . . .	6	4·34
7- 8 „ . . . . .	3	2·17
8- 9 „ . . . . .	...	...
9-10 „ . . . . .	1	·72
10-12 „ . . . . .	...	...
12-14 „ . . . . .	2	1·44



With a view to ascertaining more exactly the influence of age, I have analysed 160 collected cases of what appeared to be undoubted malignant growth, although of course of different varieties.

The result is indicated in the following table:—

Age.	No. of Cases.	Age.	No. of Cases.
Stillborn . . . . .	1	Brought forward,	99
2- 3 months . . . . .	1	35-36 years . . . . .	1
3- 4 " . . . . .	1	36-37 " . . . . .	2
5- 6 " . . . . .	1	37-38 " . . . . .	4
6- 7 " . . . . .	2	38-39 " . . . . .	3
7- 8 " . . . . .	1	39-40 " . . . . .	2
9-10 " . . . . .	3	40-41 " . . . . .	1
10-11 " . . . . .	1	42-43 " . . . . .	1
11-12 " . . . . .	1	44-45 " . . . . .	3
1- 2 years . . . . .	23	45-46 " . . . . .	4
2- 3 " . . . . .	16	48-49 " . . . . .	3
3- 4 " . . . . .	17	49-50 " . . . . .	2
4- 5 " . . . . .	6	50-51 " . . . . .	3
5- 6 " . . . . .	6	51-52 " . . . . .	2
7- 8 " . . . . .	1	52-53 " . . . . .	6
8- 9 " . . . . .	3	53-54 " . . . . .	1
18-19 " . . . . .	1	54-55 " . . . . .	1
19-20 " . . . . .	1	56-57 " . . . . .	3
20-21 " . . . . .	2	57-58 " . . . . .	2
21-22 " . . . . .	2	58-59 " . . . . .	4
24-25 " . . . . .	1	59-60 " . . . . .	3
28-29 " . . . . .	1	60-61 " . . . . .	2
29-30 " . . . . .	1	62-63 " . . . . .	1
30-31 " . . . . .	1	64-65 " . . . . .	3
31-32 " . . . . .	1	65-66 " . . . . .	3
32-33 " . . . . .	1	69-70 " . . . . .	1
34-35 " . . . . .	3		
	—	Total . . . . .	<u>160</u>
Carry forward,	99		

Jacobson states that sarcomata occur in children before 10 years, and usually much earlier, before 5 years. Carcinomata are usually met with in persons past middle age.

Roger Williams says that "next to the eye the kidney is the locality in infants whence malignant neoplasms most frequently arise."

My investigation would seem to show that while the years of

adolescence are almost exempt from the tendency to develop renal growths, infancy and childhood are the particular periods when such occur. In young adult life growths are rare, becoming more frequent towards the end of mature life. In old age they are not common.

It will be noted that eighty-four out of the 160 cases, or over 52 per cent., occurred below the age of 10 years. No less than seventy-four were met with below 5 years.

Some pathologists have denied the occurrence of malignant growths in the foetal kidney, but the researches of Jacobi, Paul, and other observers already mentioned have clearly shown that such are actually met with. Growths have not only been found at birth, but have been observed in stillborn premature infants. Through the kindness of Mr. Paul, I have been enabled to give an illustration of a sarcomatous growth met with in a seven-months' foetus (Fig. 20).

## CHAPTER V.

### GENERAL CHARACTERS OF RENAL GROWTHS.

BEFORE proceeding to the study of the different forms of renal growth, it may be best briefly to refer to several of the more important of the general characters of these formations.

*Size, weight, and extent.*—The growth may be so small as to

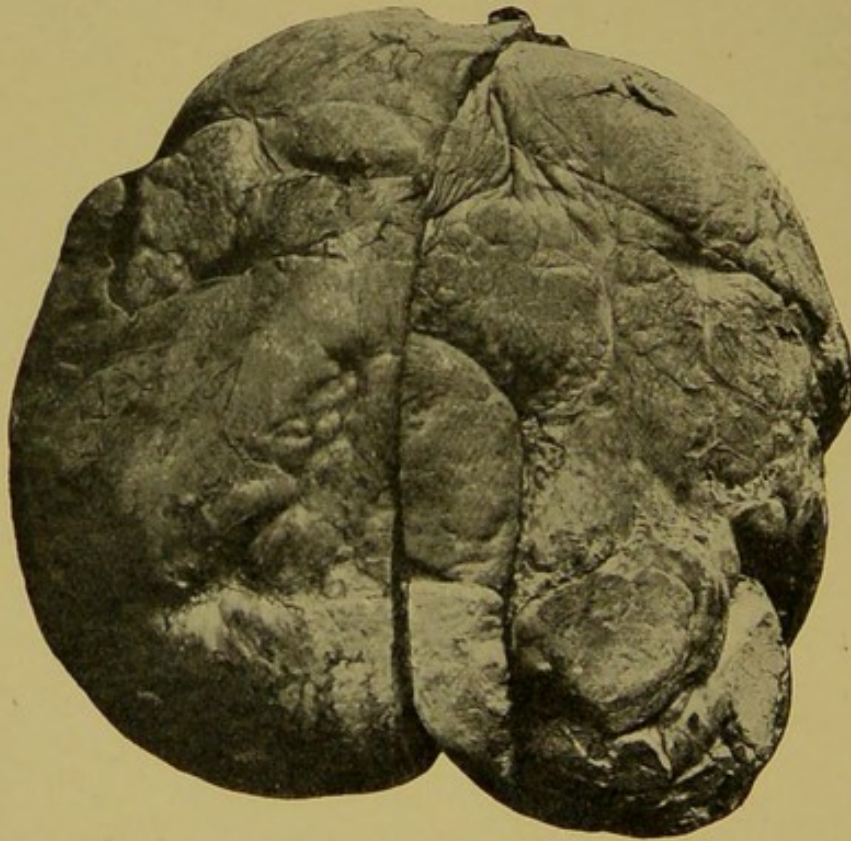


FIG. 2.—Malignant adenoma in a child. Weight, after hardening in spirit, 8 lb. 9 oz.

be undetected by physical signs indicative of any enlargement of the kidney, and yet lead to death from hæmorrhage. This, however, is exceptional. Occasionally a growth is found accidentally, in a patient dying from injury or some disease in no way connected with the kidney. In one of our hospital cases, a man,

æt. 52, dying from cerebral disease, a growth was found in the left kidney, of the size of a large walnut. Generally, however, the growth more or less rapidly reaches a size appreciable on palpation. In some instances the size and weight is enormous, and in extent it may almost fill the abdominal cavity before proving fatal. As a rule, it is both comparatively and absolutely largest in children. In one of our museum specimens the growth occurring in a child was as large as a man's head.

In a case of bilateral myo-sarcoma, which I have recently



FIG. 3.—Malignant adenoma occurring in a child. Growth (indicated as a whole in Fig. 2) has been divided and the parts separated.

investigated for Dr. Wilkinson, occurring in an infant of one year, the right kidney weighed 6 lb. 12 oz. and was  $8\frac{1}{2}$  in. long.

Roberts found the weight in fifteen adults averaged  $9\frac{1}{2}$  lb. Spencer Wells mentions the case of a child of 4, in whom the growth weighed 16 to 17 lb.

The size and general appearance of a huge malignant growth met with in a child, and presented to our College Museum by Dr. Hutton, are shown in Figs. 2 and 3.

Abbe records a case which, after it had been growing for only six weeks, weighed  $7\frac{1}{2}$  lb.

According to Morris, the Middlesex Hospital Museum contains the left kidney of a boy of 8, who, together with the tumour, weighed 131 lb., the growth contributing 31 lb. of this.

The size and extent are points of very considerable importance to the surgeon. Cases have been operated upon, where the growth exceeded 30 oz., by Albert, Barker, Homans, Lucke, Walcott, Wells, and others.

Reczey removed a carcinomatous kidney weighing 8 lb.

It is usually stated that growths may reach the weight of 30 lb. in children and 40 lb. in adults.

In fifty-one cases, which I have tabulated on this point, I find the following results come out:—

## WEIGHT OF MALIGNANT GROWTHS.

Form of Growth.	Sex.	No. of Cases.	Average Weight.
Sarcoma.	Males.	17	100 oz.
	Females.	19	108 „
Carcinoma	Males.	10	$90\frac{1}{2}$ „
	Females.	5	67 „

I have attempted to indicate the influence of age on the weight of the growth in the following table:—

No. of Cases.	Average Age.	Average Weight of Growth.
Twenty-four below 10 years.	3 years.	$124\frac{3}{4}$ oz.
Nineteen above 21 years.	50 „	85 „

In the case of ten children at or below 2 years of age, the average weight was 63 oz.

The actual size thus varies immensely. Sometimes the growth may appear to fill the whole abdominal cavity. Rindfleisch considered that cancerous kidney growths might attain the dimensions of 12 by 6 in.

Walker, in his analysis of 145 cases of sarcoma in children, found the tumour varied from the size and shape of a normal kidney up to a huge pyriform and oblong ovoidal. It measured from  $3 \times 2 \times 2$  cms. up to  $50 \times 40 \times 30$  cms., the average being

15 × 11 × 9 cms. Weight and size ranged from that of a hazelnut up to 36½ lb. In Abbe's case the tumour weighed 7½ lb., the remaining child 15 lb.; in Mackenzie's, the tumour 22 lb., the remaining child 39 lb.; in Buchanan's, the tumour 6 lb., the remaining child 10 lb.

*Shape.*—In a large number of the cases the general outline of the kidney is retained. When the tumour is distinctly reniform without irregularities or notches, and especially when occurring on the left side, the shape may prove of some assistance in diagnosis.

Frequently the mass presents no resemblance in its outline

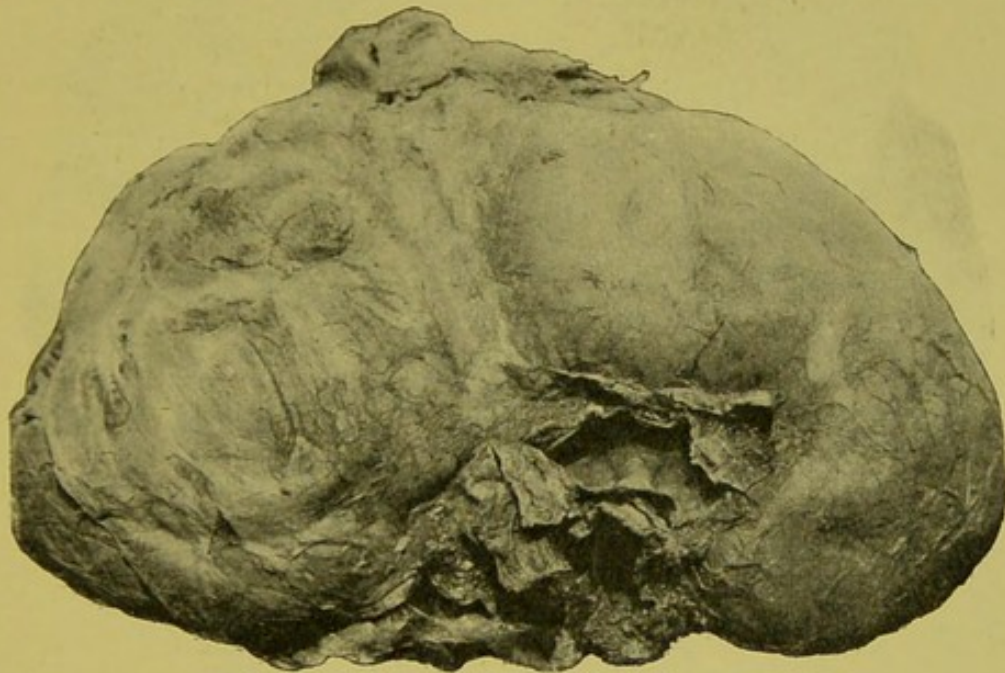


FIG. 4.—Sarcoma, removed by nephrectomy from man æt. 45. Weight, 8 oz.; length, 5½ in.; breadth, 3½ in. Extensive growth towards left. Adhesions between kidney and adjacent structures.

to the kidney. It is often irregular, and the nodules or bosses of extending growth may sometimes be felt through the abdominal walls.

The variation in shape depends mainly on whether (1) the growth is irregular in its distribution and rate of increase, when nodules are usually present; or (2) more or less uniformly infiltrating and diffused through the kidney, when a smooth and distinctly reniform mass results; if (3) cystic, it is probable that the tumour will be irregular, the cystic portion usually projecting beyond the more solid parts.

The accompanying illustration (Fig. 4) of a specimen in the

Museum of the Manchester Royal Infirmary shows how an organ, although extensively involved by growth, often tends to retain more or less of its normal form. The kidney was removed by nephrectomy by Mr. Jones from a man *æt.* 45, whose chief symptom had been hæmaturia and pain lasting eight months. The organ was increased in size, and at one end the seat of extensive growth.

*Colour.*—The differences in colour depend mainly upon the

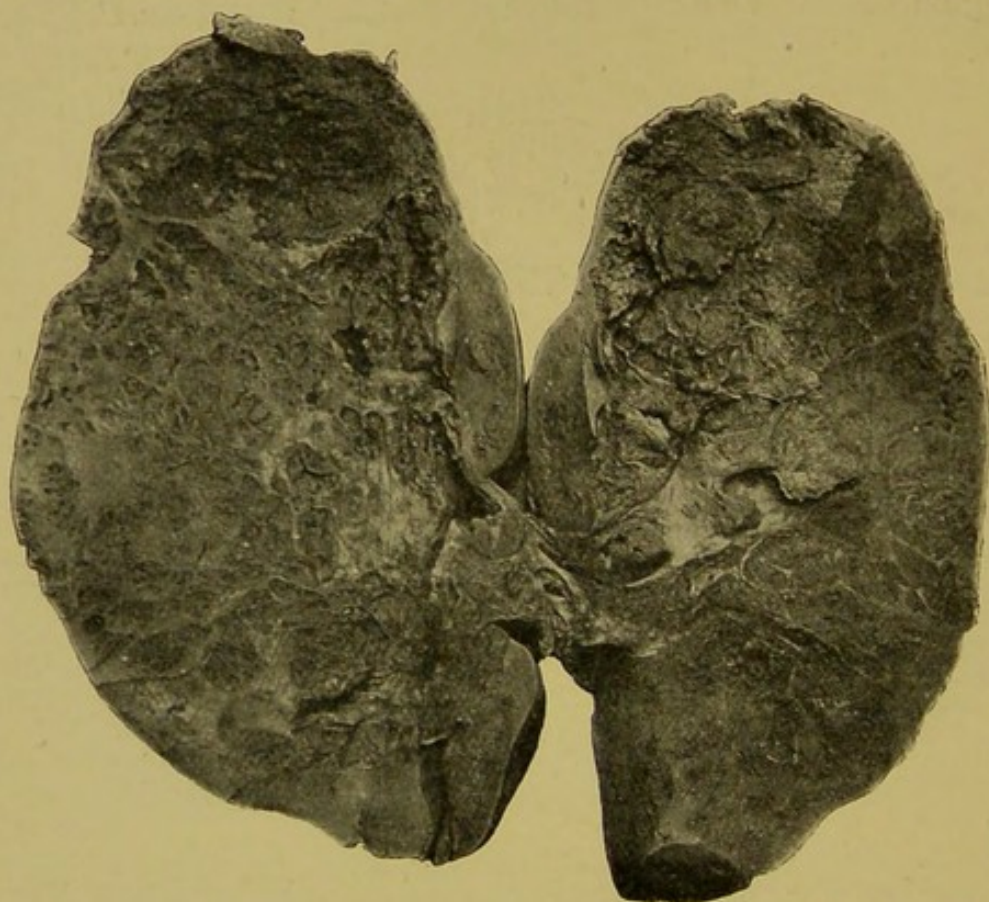


FIG. 5.—Sarcoma. Weight,  $17\frac{1}{2}$  oz.; size,  $7\frac{1}{2}$  in. by  $4\frac{1}{4}$  in. A little renal cortex remaining at lower end. Stroma divides growth into irregular areas filled with soft growth. At upper end, mass of growth size of orange, of exceedingly soft, spongy consistency, with little or no trabecular framework.

varying vascularity and the occurrence of degenerative changes. Sometimes the growth appears of a yellowish-white colour. In others it has a mottled pink or plum-coloured appearance. In some of the cases I have met with, dark purplish areas alternated with lighter-coloured yellowish-pink patches. In some instances the thin-walled vessels giving way allow of considerable hæmorrhage into the soft texture of the growth. The extravasated blood undergoes changes, and thus are obtained colours varying from red, ruddy-brown, to yellow and ochre. In some of the

forms of growth a yellowish white appearance may be met with.

The Museum of the Royal College of Surgeons contains a specimen (3594), obtained from the collection of Mr. George Langstaff, in which the kidney is filled and blackened with melanotic deposit, although not altered in size or form.

*Consistency.*—This varies considerably. Usually the growth, especially when sarcomatous, is soft and of the consistency of brain tissue. The old writers have likened it to the milt of fish. In some cases the growth may be semidiffluent. Often it has a sodden, œdematous, or gelatinous appearance.

In the case of some adenomata and carcinomata the new growth may be fairly dense, firm, and elastic

The illustrations (Figs. 2 and 3) from photographs of a

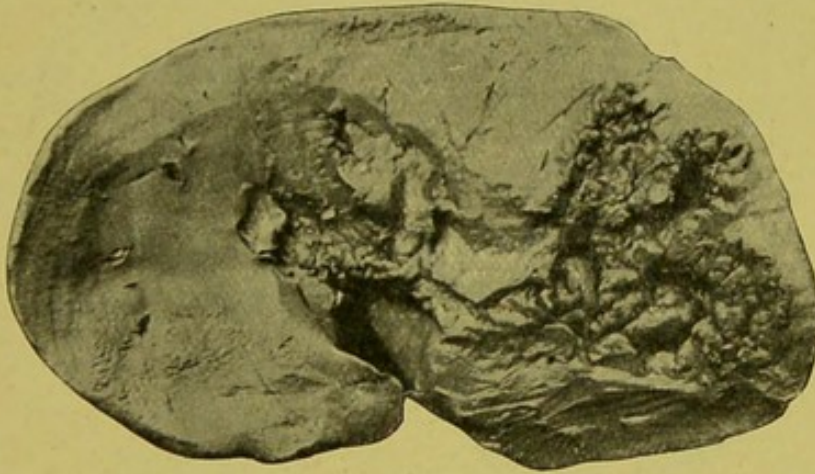


FIG. 6.—Half of kidney with malignant growth at one end. Central parts of growth have softened to form irregular nodular walled cavity.

remarkable adenomatous growth, from a child, presented to our museum by Dr. Hutton, illustrates very clearly the fact that even these rapidly developing growths, in young subjects, may be of a more or less dense and solid consistency. Microscopically, the growth presented a typically adenomatous structure.

A considerable number of renal growths have a more or less trabeculated arrangement. In some instances the growth presents almost a honeycomb appearance. More frequently the stroma has an irregular distribution, and forms spaces, varying greatly in size and shape, which are packed with cells of the growth. The appearance is well indicated in the illustration from a photograph of a specimen in the museum of the pathological department of Owens College (Fig. 5).



Mr. Timothy Holmes has described a specimen, now in the Museum of the Royal College of Surgeons (3591), where the whole growth was of a spongy nœvoid character, with a network of fibres enclosing spaces filled with soft vascular growth and blood clot. The same collection contains another interesting specimen (3584G), presented by Mr. Reginald Harrison, which well illustrates certain of the macroscopic features of renal malignant disease. The growth forms a spongy mass at the

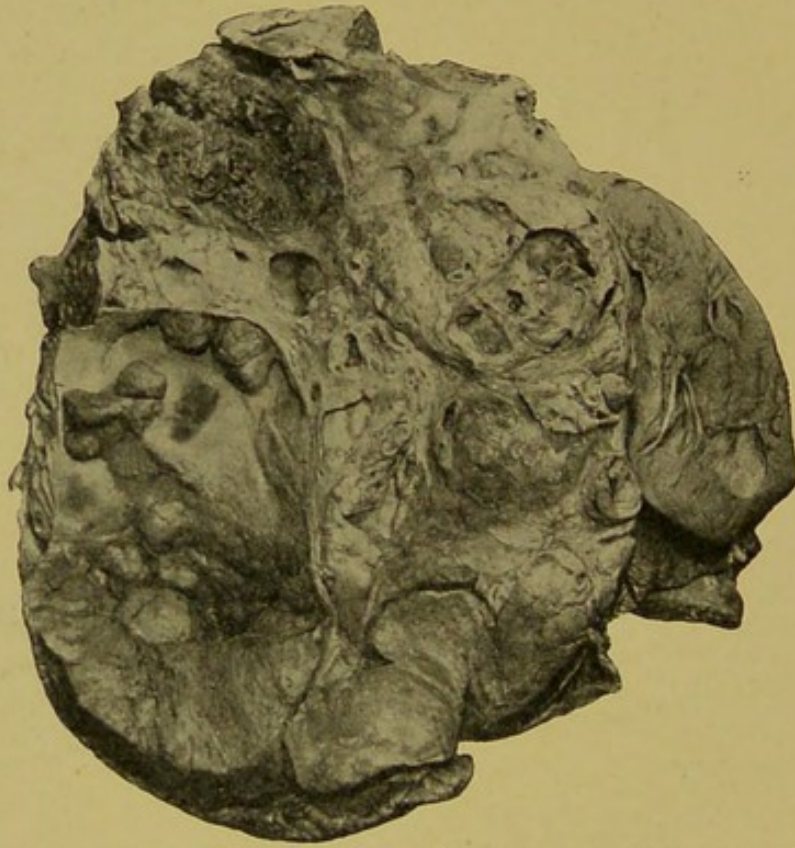


FIG. 7.—Cysto-sarcoma from a child. Shrunken kidney  $3\frac{1}{2} \times 1\frac{1}{2}$  on right side of growth, with small deposit of growth at one end. Size of growth  $8 \times 5\frac{1}{4}$  in. Weight of specimen 32 oz. (about half the growth). Nodular and cystic growth. Largest cyst,  $3 \times 2\frac{1}{2}$  in., presents several nodular growths on wall. Honeycomb appearance in places due to aggregation of cysts. Several large spaces filled up with soft vascular growth. Extensive adhesions between growth and pericapsular tissue.

lower end of the left kidney. It has a coarsely alveolated appearance, and the spaces present evidence of hæmorrhage. It has spread into the pelvis. It is stated to be a soft carcinoma.

Not infrequently the growth remains for some considerable time limited in extent. In not a few instances it undergoes degenerative changes, giving rise to irregular cavities, which often have a rough or nodular appearance. This form is

illustrated in Fig. 6, taken from a specimen in Owens College Pathological Museum.

The cystic tendency of many of these rapidly growing malignant neoplasms is a striking feature. The cysts vary greatly both in size and number. Sometimes they are almost filled with soft vascular ingrowths. In other cases the cyst wall may be almost smooth. In one specimen, of which I here give an illustration, the intracystic development was of a curious nodular form (Fig. 7). The preparation was presented to Owens College Pathological Museum by Dr. Hutton.

In not a few cases the cysts are rather spaces in a trabecular

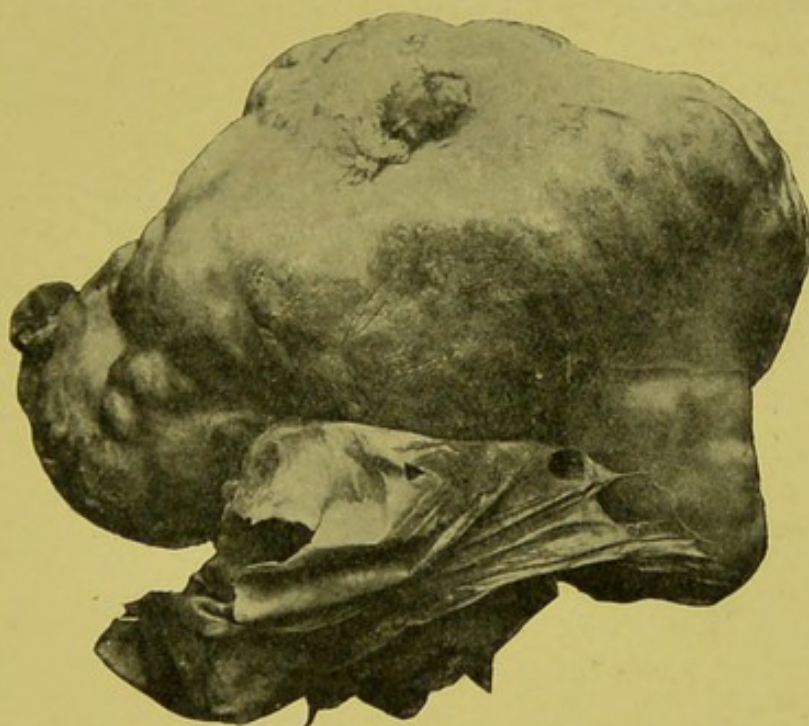


FIG. 8.—Malignant adenomatous growth. Diffuse growth has produced nodulation of surface. Capsule stripped off from greater part readily, and is shown drawn to one side. Removed by operation from a man, *æt.* 48.

network. These have been termed the "trabecular cystomata." Some appear to be comparatively benign, but others present malignant characters, and give rise to secondary deposits, which recapitulate the structure of the primary growth (Figs. 44–52).

Sometimes, even when the greater part of the kidney is the seat of growth, the enlarged organ can be detached from the capsule with little or no difficulty. This is shown in the accompanying figure of a malignant adenomatous growth recently removed from an adult male at the Manchester Royal Infirmary by Mr. Thorburn (Fig. 8).

In all such cases the practical importance of examining the capsular tissues, the adjacent peritoneum, and the neighbouring glands, for evidences of growth, must be self-evident to the surgeon.

I have met with calcareous plates and strands of dense fibrous tissue in the midst of some sarcomatous growths. These, on section of the tissue, can be detected by grating on the knife. Where the growth is undergoing cystic degeneration, the contents of the cysts may be almost if not quite fluid.

*Affected side.*—It is of interest, and indeed of some slight clinical importance, to know the side most frequently involved by growth. In some instances both organs have been so similarly affected as to strongly suggest a simultaneous development. In many of these cases it is manifest that the one is really secondary. In some of the older cases, I am inclined to believe that both might be considered secondary to extrarenal growth.

Ebenezer Gairdner, in 1828, mentions the case of a female child, *æt.* 3, in whom both kidneys were the seat of "fungus hæmatodes," the left weighing 5 lb. 3 oz., and the right 1 lb. 3 oz.

Walshe, in thirty-five collected cases, found both organs affected sixteen times; the right alone, thirteen times; the left alone, six times. Evidently many of his cases were secondary.

Guillet found that of seventy-two cases sixty-five were unilateral and seven bilateral.

Klebs says the left kidney is most frequently affected. Most authors seem to think the right manifests a slightly greater tendency to growth than does the left.

According to Rohrer, in childhood the left kidney is most commonly affected.

Morris says "primary malignant growths, except the myosarcoma, are never bilateral."

Treves declares that "renal sarcomata of the adult rarely affects both kidneys. Congenital renal sarcoma as often as not affects both kidneys."

With a view to throwing fresh light on this point, I have analysed a large number of cases.

In 118 cases of malignant disease of which I have details as to the side affected, I find the following distribution:—

Side affected by Growth.	No. of Cases.	Per Cent.
Right . . . . .	52	44·07
Left . . . . .	54	45·76
Both . . . . .	12	10·16

In 114 of the cases the sex was ascertained and influenced distribution, as is shown in the next table—

Sex.	Side.	No. of Cases.	Per Cent.
Male . . . . .	Right.	26	22·80
" . . . . .	Left.	32	28·07
" . . . . .	Both.	4	3·50
Female . . . . .	Right.	24	21·05
" . . . . .	Left.	20	17·54
" . . . . .	Both.	8	7·01

I have still further endeavoured to gain some information as to the form of growth by an analysis of 114 cases, but the result can only serve as a very rough indication, as in many of the cases the nature of the growth could only be indirectly ascertained.

Probably several of the carcinomata were really sarcomata, and possibly some of the sarcomata may have been myo-sarcomata. The returns, however, such as they are, may be tabulated as follows :—

Nature of Growth.	Side.	Sex.	No. of Cases.	Per Cent.
Sarcoma . . . . .	Right.	Male.	12	10·52
" . . . . .	"	Female.	17	14·91
" . . . . .	Left.	Male.	17	14·91
" . . . . .	"	Female.	13	11·40
" . . . . .	Both.	Male.	2	1·75
" . . . . .	"	Female.	5	4·38
Myo-sarcoma . . . . .	Right.	Male.	3	2·63
" . . . . .	"	Female.	1	0·87
" . . . . .	Left.	Male.	4	3·50
" . . . . .	"	Female.	...	...
" . . . . .	Both.	Male.	...	...
" . . . . .	"	Female.	3	2·63
Carcinomata . . . . .	Right.	Male.	12	10·52
" . . . . .	"	Female.	6	5·26
" . . . . .	Left.	Male.	11	9·65
" . . . . .	"	Female.	6	5·26
" . . . . .	Both.	Male.	2	1·75
" . . . . .	"	Female.	...	...

## CHAPTER VI.

### METHODS OF EXTENSION OF GROWTH.

It is often quite impossible to suggest in what part of the kidney the growth originated. Some have thought that the upper extremity was more often affected than the lower. According to the seat of origin, so will the rate and manner of extension vary somewhat.

Renal growths may spread locally or infect generally. The more important channels of extension are—(1) By direct continuity of tissue, (2) lymphatic involvement, and (3) venous invasion.

Usually the development of the growth remains local until the bulk of the tumour is considerable. The growth encroaching on the peritoneal cavity often gives rise to the formation of extensive adhesions, which would appear in some measure to resist its advance. In some cases the growth bursts through into the peritoneum, and secondary deposits are rapidly formed in the serous membrane. The immediately adjoining tissues are frequently invaded by direct spread of the growth. The liver, adrenals, and spleen may thus become affected. Often, however, the adjacent organs seem to be pushed aside rather than infiltrated. In the case of an immense growth affecting the left kidney of an adult woman, I found the atrophied spleen adherent to the mass but not itself involved. In several of the figures illustrating sarcomata originating in the hilum, it will be observed that much of the kidney itself is pushed aside and atrophied. A renal growth has been known to ulcerate into the duodenum and other parts of the intestinal tract. Abele records a remarkable case where the growth extended through the abdominal walls, forming a large fungating mass.

The direction and extent of the local spread explains many of the pressure symptoms, to which reference will be made later. In some instances there is extension into the renal pelvis,

the growth passing downwards along the ureter, which may be completely blocked. In several of the illustrations extension of the growth into the calyces and pelvis of the kidney is clearly indicated. Extension to the lower urinary passages seems to be rare, and may be accounted for by the course taken by the lymphatics. Involvement of the kidney, when the primary growth affects the bladder or urinary passages, is said to be common, but personally I have not found it so.

In some cases the growth reaches such immense dimensions as to practically fill the abdomen. This is especially noticeable

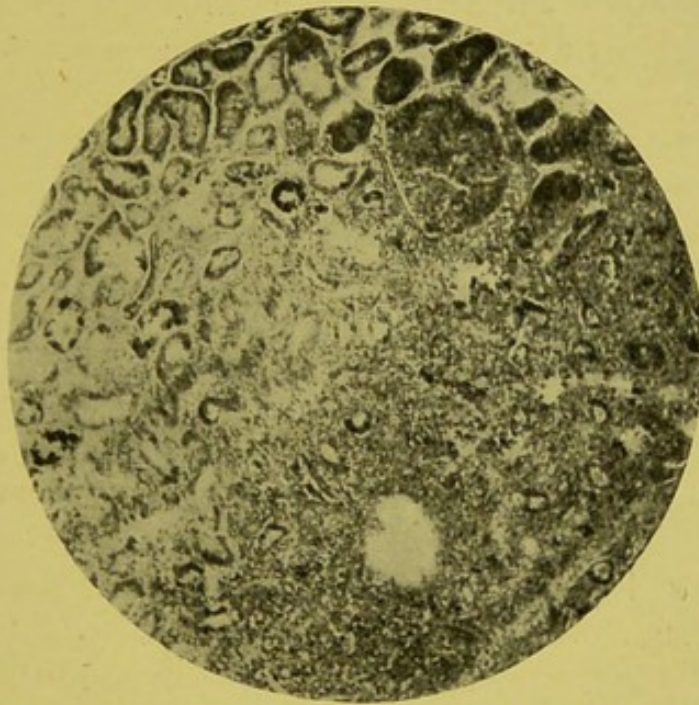


FIG. 9.—Sarcoma. Renal tubules in various stages of atrophy and degeneration, above and to the left. Round sarcomatous cells below and to the right encroaching on renal tissue and spreading between the renal tubules. ( $\times 60$ .)  
— From a specimen lent by Mr. Paul.

in children. Extension into the true pelvis may even occur. Erichsen<sup>1</sup> states that "in adults sarcoma of the kidney usually runs a less rapid course than in infants." This is no doubt generally the case.

Spread by lymphatic infection does not generally occur early, and, as far as I can gather, is comparatively rare. The lymphatic glands in the immediate neighbourhood may be affected, but as a rule the retroperitoneal and other glands are not extensively involved. In some cases secondary deposits occur in the glands at the hilum of the kidney, in the vertebral and mesenteric

<sup>1</sup> Erichsen's "Surgery," 10th edition, London, 1895.

glands, and I have even seen deposits in the glands of the neck and axilla. The involvement of the glands in the immediate neighbourhood of the kidney is a point demanding the most careful attention of every operative surgeon.

Dissemination of the growth mainly occurs through the channel of the blood. The arteries are more or less resistant, and though they may be compressed they are but seldom invaded. The veins, on the other hand, are readily encroached upon. The growth penetrates into the lumen, along which it extends often in a thrombus-like form. It would appear in many instances as though the vein became thrombosed, the coagulum acting as a ready support for the soft encroaching growth. I have found the renal vein invaded in several instances. In one case, that of a child, the sarcomatous growth appeared almost like a thrombus in general appearance, extending along the renal vein, thence into and along the inferior vena cava, and was finally traced to the right auricle of the heart, into which it was projecting.

It is interesting to note that Walshe in 1846 wrote: "It is not uncommon to find the renal veins plugged with cancerous masses, or with coagula, exhibiting in some parts the encephaloid aspect; such coagula extend not infrequently into the vena cava inferior and sometimes even to the right auricle." The same facts seem to have been known to Velpeau and Moritz as early as 1835. In an interesting case recorded by Gairdner and Coats, the soft growth extended along the renal vein, and there was growth within the cavity of the heart and pulmonary artery. Guillet says he found the inferior cava invaded twice in forty-seven cases. Rohrer found it encroached upon twelve times in fifty cases. Gintrac has seen extension into the vena azygos. It is said that the growth has been known to invade the iliac vein.

Rindfleisch in 1873 clearly showed that "soft cancer of the kidney is especially prone to invade the efferent canals, veins, and calyces, a tendency which occasionally gives rise to very serious clinical symptoms; for, should the tumour extend along the renal vein, it must ultimately reach the inferior cava."

Osler records the case of a striated myo-sarcoma of the left kidney in a child *æt.* 3½ years, where the growth had extended into the renal vein and inferior vena cava; portions of the sarcomatous thrombus had become detached, and a mass 2.5 by

1.2 cm. had plugged the tricuspid orifice, and another the size of a hazel-nut the orifice of the pulmonary artery.

Secondary deposits may occasionally involve the bones. In the case of man, æt. 39, with sarcoma of the right kidney weighing 48 oz., Dr. Delépine, who conducted the pathological examination at St. George's Hospital, found involvement of the twelfth dorsal and first lumbar vertebræ.

In some very exceptional and most remarkable cases, a tumour believed to be a malignant growth of the kidney has disappeared spontaneously. Lawson Tait mentions the case of a young lady, æt. 24, where a mass as large as a cocoa-nut, and what he considered to be undoubted malignant growth, almost entirely disappeared, and he states: "I gladly gave my sanction to the marriage of the patient, at a time when I fully expected she would have been in her grave."

*Secondary deposits.*—From the methods of extension it might be expected that the occurrence of secondary deposits would be common. This, however, does not seem to be altogether so.

I am led to believe that in a great majority of the cases the growth remains practically local for some time after a tumour has been first observed. Even in fatal cases the number and extent of the secondary deposits is often small. The practical bearing on operative interference is self-evident.

Guillet collected 294 cases—probably not all primary—and found 168 secondary deposits, most frequently in the lungs and liver. The lungs were involved in seventy-five, the liver in seventy-one, and the lumbar glands in fifty-three.

Jacobi says:<sup>1</sup> "Metastatic deposits in the other kidney take place, if at all, at a late period of the development of the pseudoplasm." Sometimes deposits, which are apparently secondary, are found in the second kidney, and none elsewhere."

Lunn mentions the case of a man, æt. 57, where there was what seemed to be a secondary deposit in the kidney opposite to that affected by growth, although no deposits could be found elsewhere.

In some of the cases where both kidneys have been involved, the growth has undoubtedly originated simultaneously, but in others the growth was probably at first extrarenal, and had extended into both organs. But little attempt has hitherto been made to indicate the seat, extent, and order of involvement

<sup>1</sup> "Therapeutics of Infancy and Childhood:"



by secondary deposits. Alloway, writing in 1883, says there have been found secondary deposits in about 60 per cent. of all reported cases.

Roberts gives the following table to show the distribution of secondary deposits:—

*Distribution of Secondary Deposits in Renal Growths.*

Organ Affected.	Number of Cases.
Kidneys alone affected . . . . .	20
Secondary deposits found elsewhere . . . . .	31
Seat of secondary deposits—	
Lumbar, mesenteric, and vertebral glands . . . . .	15
Lungs . . . . .	14
Liver . . . . .	14
Suprarenal capsules . . . . .	4
Omentum . . . . .	3
Heart . . . . .	3
Vertebræ and rib . . . . .	3
Costal surface of pleura . . . . .	1
Bladder, uterus, penis, and testicle, each . . . . .	1

Windle found records of secondary deposits in seventeen out of his forty-one collected cases, affecting the organs in order of frequency as follows:—Liver, retroperitoneal glands, mesenteric glands, heart, diaphragm, adrenals, spleen, lungs, pancreas, intestines, pleura, renal vein, orbit, and elbow. Dickinson found secondary deposits in fifteen out of nineteen cases.

Following the general rule, the secondary deposits tend to repeat the structural form of the original growth.

Tuffier has described the secondary nodules as they develop in the renal parenchyma. They appear like miliary granulations around the arteries of the cortex. The groups of cells in the intertubular substance appear as an intrusion, which soon leads to conversion of the adjacent renal tissue into a large area of growth.

In one of the cases mentioned in the "Pathological Reports" of the Manchester Royal Infirmary, where the primary growth, weighing 36 oz., occurred in the left kidney of an old man of 63 years, secondary deposits were found in the opposite kidney, the lungs, and the brain. In another case, where the growth weighed 7 lb., and affected the left kidney of a man æt. 58, there were secondary deposits in the mesenteric glands, liver, lungs, and pleuræ.

Reference to secondary deposition, as met with in other cases, will be noted in connection with the cases themselves as referred to later.

*Changes in the growth.*—These renal growths undergo changes much as do other tissues. They not infrequently become the seat of certain well-recognised pathological processes. Degenerative changes are common. Fatty changes sometimes occur; and there are a considerable number of cases on record in which either the growth has undergone this conversion or has been associated with fatty deposition. Myxomatous changes may also be met with. As far as I have seen, it is somewhat common, especially in the sarcomata. Calcareous infiltration may occur, not only in the simpler growths, but even in connection with some of the more rapidly developing sarcomata. I have met with sarcomata where, on section, the knife could be heard grating on the parts infiltrated with lime salts.

Hæmorrhage frequently occurs, especially in connection with the soft and vascular forms of sarcoma. Blood is also abundant in the general texture of the growth in the so-called malignant papilliferous cyst-adenomata.

Necrosis, or actual death of the new-formed tissue, occurs, but to a very varying degree. In many cases small areas of necrosis can be readily detected with the microscope. Occasionally larger portions of the growth may slough, but this condition of molar death or gangrene is rare.

Softening may occur, either by myxomatous changes in the tissue or by localised necrosis in portions of it. Parts of the growth may become semidiffuent. As previously indicated, irregular cavities may be produced in the growth from processes of softening.

Inflammatory changes, though rare, may result from injury, exploratory puncture, or local irritation. Suppuration is rare, but occasionally pyogenic organisms may be introduced or gain access from the neighbouring intestinal tract.

Atrophy occurring spontaneously is so exceptional that many doubt if it is ever met with. Some few cases are on record where a growth, believed to be malignant, has gradually undergone involution. As far as is known at present, the tendency for renal malignant growths is almost invariably to progress.

*Duration.*—Considerable difference of opinion exists as to the comparative duration of malignant renal growths.

Walshe, writing in 1846, seems to have thought that "cancer" of the kidney ran a more rapid course than did any other form of internal growth. He says: "I am inclined to believe that the kidney is one of those organs in which the disease, reckoning from the first appearance of symptoms, runs a relatively rapid course." He gives the mean duration as eight months.

Braidwood, apparently quoting from Roberts, says the mean duration in children is from seven to eight months.

Newman gives the following table taken from Dickinson:—

DURATION OF MALIGNANT GROWTHS.

From First Symptoms to Death.	Children. 13 months to 4 years.	Adults, 25 to 58 years.	Total.
Under 6 months . . . . .	4	2	6
From 6 months to 1 year . . . . .	2	4	6
" 1 year to 2 years . . . . .	...	1	1
" 2 years to 3 years . . . . .	...	1	1
" 3 years to 4 years . . . . .	...	1	1

The rate of growth depends in great measure on the essential nature of the growth. As regards the sarcomata, the more embryonic the character the more rapid the growth. Probably in children the maximum time may be said to be two and a half years, and the minimum six to eight months. Snow says that "life ends in from eight months to two years."

There are, however, cases where children only a few months old have died from growth. In these the development originated evidently during foetal life. Growth has been met with in several instances at birth. Possibly the myo-sarcomata which usually occur in children run a somewhat longer course than the simple round and spindle-celled forms. Carcinomata certainly appear to develop more slowly than the sarcomata. Some of the malignant adenomata may exist for a few years.

Much doubt necessarily exists concerning the nature of those growths which have been reported as existing for many years. Walcott mentions a case of "encephaloid cancer" which was known to have been present for six years. Andrew, of St. Bartholomew's Hospital, had a case of renal "cancer," which he thought had existed for fourteen years. From his description it seems very probable that the case was really one of chronic

tuberculosis. The patient died from phthisis. Sometimes, as I have myself seen, it is impossible to exclude the presence of growth in some of the forms of chronic local tubercle of the kidney without careful microscopic examination. Czerny mentions a case which he apparently considered had existed for thirty years.

The simple or benign growths, which, however, are very rare, and many of which, being of insufficient size to be appreciable during life, may exist for many years without visible detriment to the patient.

*Cause of death.*—The immediate cause of death varies considerably. In some the close appears to be due simply to exhaustion. Involvement of the gastro-intestinal tract may occur from ulceration into the bowel, or partial occlusion of the intestines may result from pressure. In many, either secondary pneumonia or malignant deposition in the lungs terminates the case. Extension of the growth into the chambers of the heart may hasten the end. Compression of the spinal cord and death from paraplegia has been recorded. Bright mentions a curious case where intraperitoneal hæmorrhage occurred from rupture of the growth. Braidwood also points out that "death is sometimes induced suddenly by rupture of the tumour." Uræmia is rare. Should, however, the active kidney become involved by secondary deposits or become the seat of an inflammatory process, death from suppression of urine or uræmia may occur. In one of our hospital cases the man died comatose, and distinct nephritic changes involved the kidney unaffected by growth. Sometimes pyelitis and abscess formation may be associated with the growth.

Usually the unaffected kidney shows marked hypertrophy, but, according to Ebstein, in rare cases lardaceous changes ensue. The affected kidney sometimes shows evidences of a diffuse nephritis in the portions uninvaded by growth.

## CHAPTER VII.

### RELATIONSHIP OF RENAL GROWTHS.

UNFORTUNATELY but little can definitely be said as to the true relationship of renal growths. As already shown, much confusion has hitherto existed in the nomenclature of renal growths. This has almost completely prevented any satisfactory attempt at a comparative study of the relationship of these neoplasms. Much careful investigation will be necessary before we can fully realise the import of structural arrangement. Already it is clear that many forms not infrequently occur, the exact nature of which would be differently interpreted by different pathologists. Some of the difficulty arises from our imperfect knowledge of the embryonic elements from which certain of the growths would seem to develop. Our views, also, as to formations purely of a connective tissue type and structures of an epithelial type may possibly have to undergo considerable modification. It is certain, at least, that epithelioid cells not infrequently arise from connective tissue elements, and cells undoubtedly sarcomatous may sometimes be arranged, according to a manner closely resembling glandular structures. Again, growths apparently having a sarcomatous or carcinomatous structure may be wanting in nearly all those characters which we are wont to associate with the term "malignant." As Allen and Cherry very well point out, "a histological structure closely resembling carcinomata, with alveolar arrangement, large epithelial cells, and bold nuclei, is compatible with clinical innocence." They also show that the inactive neoplasms are often multiple, while the active ones are usually single. A marked feature of the inactive forms seems to be the presence of many thick-walled vessels immediately around them. It must also be remembered that these inactive tumours are sometimes associated with other forms of morbid growth.

Allen and Cherry, in their recent valuable investigations on the relationship of these growths, clearly show that the typical

adenoma and the typical sarcoma both pass insensibly into pseudo-carcinomatous structures. Their work is so suggestive that I have no hesitation in quoting from the reprint of their paper, which they have kindly furnished me with. In these complex types they show that the following appearances may be met with:—

1. Tubes variously dilated and lined or filled with epithelium.
2. Cysts lined by one or many layers of possibly huge epithelioid cells, and perhaps more or less completely filled by papillary growths.
3. Solid epithelial cylinders with basement membrane.
4. Vague epithelial growths, the epithelial cells filling large areas, not being as a rule closely applied to one another, and being in intimate relations with embryonic blood vessels.
5. Similar epithelial growths, but with fibrillar matrix between the individual cells.
6. Alveolar formations, in which, however, the epithelial cells are not always in contact, having in many cases distinct out-runners, and being evidently in close connection with the alveolar walls.
7. Tubular or alveolar formations, in which the cells have a decidedly endothelial type, being developed in connection with the alveolar walls, and merging into diffuse epithelioid formations which are not alveolar, and which have no likeness to carcinoma.

Many authors definitely declare that they have met with mixed forms of combined carcinoma and sarcoma. Ebstein, for example, says "sarcoma may occur as a mixed tumour, simultaneously with carcinoma of the kidney." To these the name of sarcoma carcinomatodes has been given. Some authors speak of cases approximating to this type, under the term "adeno-sarcoma." Cases have been described by Abbe, Paul, Allen and Cherry, and others. Abbe says of his case, that it looked like "an adeno-carcinoma, in which the stroma was formed of spindle-celled sarcoma." In such cases the following arrangement is usually met with:—Imperfectly formed renal tubules. Columns of cells closely resembling that lining the normal tubules. Cysts which sometimes show intracystic papillomatous development. A matrix made up of fibrillar and spindle cells, with a variable quantity of round cells. In some instances secondary deposits have been found elsewhere, notably in the lungs, which have

reproduced the general arrangement found in the kidney. An example of an adeno-sarcoma is illustrated by Fig. 39.

Further study will doubtless throw much light on the nature of these neoplasms. Some of them evidently belong to the class of adenomata, to which reference will be made presently. Others, and possibly the majority, are really sarcomata. As Allen and Cherry well say, "As far as new growths are concerned, the renal epithelium behaves as a mesoblastic and not as an epiblastic formation, and that the tumours most closely resembling carcinoma in structure are not carcinomatous in nature or history."

Richer has recently attempted to indicate the gradual transition between simple renal cysts and the complex trabecular cystomata. He believes that a study of these intermediate forms will show indisputably their close relationship, and demonstrate their origin from true renal elements. It is admitted, however, that the trabecular cystoma has certain affinities with the growths of adrenal origin, and also with the perivascular sarcomata, or "peritheliomata," as they have been termed.

Until recently growths originating from adrenal inclusions have been confused chiefly with the carcinomata, and their differentiation and true relationship is still often difficult and obscure. It is remarkable how greatly a growth may vary in structure and general arrangement of the cells taken from different parts. In examining a doubtful growth, it is always well to prepare sections from different parts. In a specimen kindly sent me by Dr. Nathan Raw, I found at one part that nothing presented but typical round sarcomatous cells. In an adjoining area the growth consisted of fine spindle cells. In other areas, numerous fibres, having the general characters of muscle cells, were abundant. Near the border of the growth were glandular elements. In some parts the epithelial cells were so closely applied to each other as to form immense masses, in which little definite structure could be made out. In other places a few epithelial cells lay in distinctly alveolar spaces, formed by a fine connective tissue stroma. In parts the stroma was very abundant, and the epithelial elements were isolated as well-defined tubular structures. There were large thin-walled vascular spaces in several districts of the growth. The specimen had been removed from a child.

Thus in the same specimen one part had the typical structure of the most embryonic form of a connective tissue

type of growth, while another manifested a highly developed glandular form.

A considerable number of the specimens which I have been enabled to examine have presented a compound structure and often a complex arrangement.

Very rarely a primary malignant growth of the kidney may be associated with a primary malignant growth elsewhere. Allen and Cherry mention a case where malignant adenoma, or endothelioma as they call it, occurred in a subject in whom there was also a mixed-celled sarcoma of the stomach.



## CHAPTER VIII.

### SIMPLE OR BENIGN GROWTHS.

#### *FIBROUS AND LIPOMATOUS FORMS.*

GROWTHS of a simple and usually benign character are occasionally found in the kidney. They form but a small minority. Aldibert collected fifty-one cases, which were operated upon; forty-eight were malignant, and only three benign. Generally they are found in the course of a pathological examination, and but seldom give rise to symptoms during life.

Although of but little practical importance, brief reference must now be made to them.

#### FIBROMA.

A fibroma is generally met with in the form of a small, hard, rounded nodule. Laboulbenè says, they are not very rare, and occur within the renal parenchyma, or beneath the capsule. It is very probable that many of these so-called fibromata are really adenomata, and possibly due in some cases to inclusions of accessory adrenal tissue.

Ebstein says fibromata are found in connection with diffuse interstitial nephritis. This seems to be the form spoken of by Virchow as nephritis interstitialis tuberosa. It is very doubtful if they should be considered as fibromata at all. Many of them, as Sabourin has shown, are really of an adenomatous nature, and consist of glandular tissue resembling true renal parenchyma.

Several interesting cases of so-called fibroma are on record. Wilks in 1869 described the case of a man, *æt.* 53, where the right kidney was converted into a mass the size of a child's head. "It was remarkably hard, and was translucent in appearance, so that the impression at first conveyed to the eye was that it consisted of fibro-cartilage." It was softened in the

centre, and, microscopically, was found to consist of nothing but fibrous tissue. Hæmaturia and pain had existed for ten years.

Dickinson records a case where a perceptible tumour existed in the right hypochondrium. It weighed 6 lb. 7½ oz. It had a complex arrangement of white fibrous tissue, thick masses giving off branching septa, which, dividing and subdividing, held a considerable quantity of fat.

Bristowe also met with growths consisting of fibrous tissue and fat. He does not express any opinion as to the nature of these formations, but definitely states that they were




FIG. 10.—Diffuse fibro-cellular infiltration of kidney. From a man, æt. about 50 years. Weight, after hardening, 1 lb. 8 oz.; size, 6¼ by 4 in. Closely adherent to adjacent parts. Considerable deposit of fat in layer around one-half of growth. Consistency firm and rigid. Surface has fibroid aspect, and was of pink colour, with irregular areas of yellow and orange. No distinct softening or cystic formation.

not tubercular or cancerous. He describes the growth as irregular, or globular, lobulated, soft, buff-coloured, yielding a cream-like juice, and affecting only part of the kidney, and covered with large and tortuous veins. The growth was also divided into segments, varying in size from a walnut to a bean, by fibrous septa.

Billroth removed a large growth by operation from a woman, æt. 35, who suffered for three years. The tumour weighed nearly 40 lb., and was found to be composed of muscular and fibrous tissue. The patient died apparently from peritonitis.

Thomas successfully removed a huge fibro-cystic growth from a woman, æt. 21, in whom the tumour had reached "the

size of the uterus at the eighth month of gestation." The growth had apparently originated from the capsule of the kidney.

Bruntzel also successfully removed a fibrous growth weighing  $37\frac{1}{4}$  lb. Somewhat similar forms of fibrous formation have been removed by nephrectomy, by Peaslee, Wahl, and Bardenheuer. Probably several of the cases recorded as renal fibromata might more strictly be placed with the perirenal fibro-lipomata.

The fibromata may undergo degenerative changes, and in some instances simple softening would seem to have led to considerable cystic formation.

Somewhat recently, through the kindness of my friend Dr. Percy Cooper, I have been enabled to investigate a remarkable case of diffuse fibroid induration of the kidney (Fig. 10).

At first sight the appearance much resembled a diffuse malignant growth. Microscopic examination showed the condition to be due to extensive fibrous development, with much cellular infiltration. A somewhat similar patch in the liver consisted of gummatous material. The preparation was removed, post-mortem, from a man of about 50, with no definite history of syphilis; but was undoubtedly an example of diffuse syphilitic cirrhosis of the kidney.

#### LIPOMA.

True lipomata are extremely rare. Small aggregations of fat, however, are sometimes found in a subcapsular position. Lobulated masses of fatty tissue are occasionally met with, but they seem to be more of the nature of an irregular deposition than a true neoplasm.

Some of the so-called lipomata, as described by Robin and Virchow, have been clearly shown by Grawitz and others to be small adenomata, arising from aberrant adrenal tissue.

Lipomata have also been described as arising in connection with the renal pelvis. Thoma states that "in the kidney lipoma is found extending along the large divisions of the vessels, at the boundary between medulla and cortex, or between the connective tissue layer of the capsule of the kidney, as flat, disc-shaped tumours."

It is also necessary to remember that frequently an atrophied kidney, so small and shrunken as to be almost indistinguishable, may become surrounded by immense masses of indurated adipose

tissue, and still retain a more or less reniform shape. I have met with several such.

Undoubtedly a considerable amount of fat may be associated with true sarcomatous elements. True malignant growths also undergo fatty degenerative changes. Fagge describes a variety of cancer, which he speaks of as carcinoma lipomatosum.

Manasse describes two cases of lipo-myoma, one in an old woman of 86, and another in a woman *æt.* 44.

Warthin has recently recorded a remarkable case of fibro-lipoma of the kidney; and as he has very kindly allowed me to reproduce his illustrations of the specimen, I venture to quote his communication somewhat at length.

“Mary L., native American, *æt.* 31. The patient always had good health previous to the beginning of the present trouble. Her periods have been regular and normal up to the onset of the present condition, since which time they have been small and light-coloured, lasting six days, and attended with great pain.

“The patient was very ill after her first delivery. In 1888 she had an abortion, and six weeks later she began to flow. This continued with more or less severity for several months, when a second abortion occurred. She recovered after this, and in 1889 and 1892 bore children at full term. In 1894 her fourth child was born after a most difficult labour. This child died two weeks after birth, its death being said to have been caused by injuries received during delivery. An instrumental delivery had been necessary, because of obstruction to labour caused by a large abdominal tumour which was first discovered at this time. This tumour was most prominent at the level of the umbilicus, to the left of the median line. To it was ascribed all the difficulty attending labour. The tumour seemed to increase slowly in size, and as the patient became pregnant again in 1895, her physician, fearing complications, induced abortion. From the effects of this the patient recovered slowly, and has been miserable ever since. Three months later another abortion was brought about, and her condition became worse. Nevertheless, she became pregnant again, and in August 1895 a 2-months old foetus was removed. This last abortion was accomplished with great difficulty, and was followed by severe endometritis. At this time the tumour seemed to break away from the left side and to become fixed in the median line. According to the patient's

statement, it has grown slowly but steadily. On 3rd April 1896

a physical examination was made.

"The patient is well built and in fair condition. In the median line there is an irregular mass about the size of a child's head, passing to the left to the pelvic wall and extending below beyond the reach of palpation. The mass is fixed and very sensitive, so that examination was difficult. Cervix patulous, the lips everted. Uterus anteverted, measuring  $2\frac{1}{2}$  in.; it is very sensitive. The vaginal wall on the left is very tense. Examination of the urine is negative.

"A definite diagnosis was not made, and the patient was prepared for an exploratory operation. On the 19th May a laparotomy was performed; the tumour was found to be retroperitoneal, occupying the position of the left kidney, of which no other trace could be found. There was but little fat about the tumour; on the right the atrophied renal vessels passed into the mass, and from its lower portion the dilated ureter emerged, apparently containing some solid mass extending half-way to the bladder. It was at once evident that the mass re-

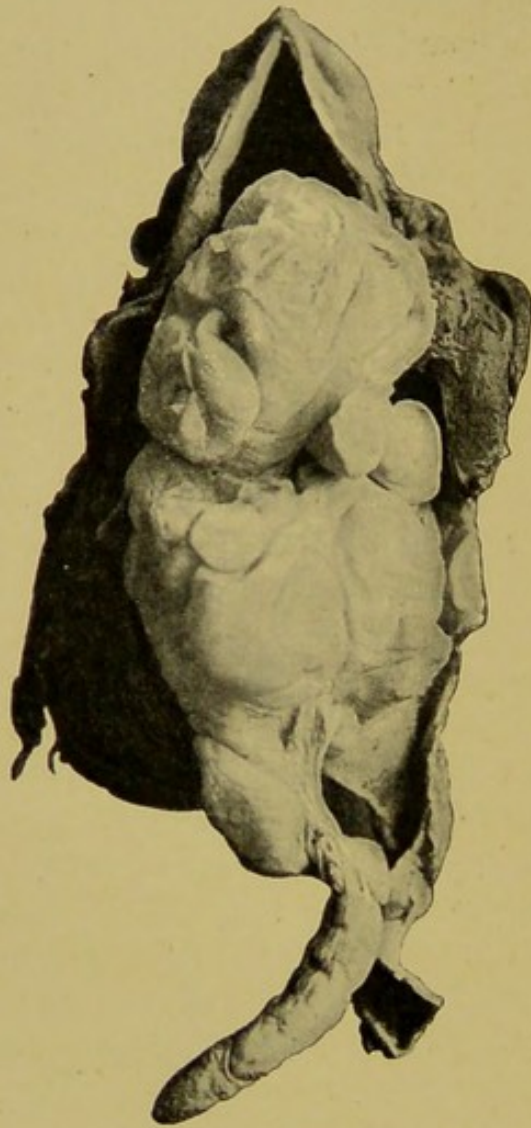


FIG. 11.—From a photograph of a specimen, which is suspended by a string fastened in the cystic kidney, which formed a capsule to the tumour growing in its pelvis. At the lower right hand is the dilated and thickened ureter, slit open along its entire length. To its left is the prolongation of the tumour which extended into it, completely filling its lumen. The kidney pelvis is opened along the hilum, exposing the tumour, which falls forward by its own weight, showing that it is not attached above. The point of attachment is shown at the extreme lower left hand by the cut into the capsule. The lobular appearance of the tumour, the curious raphé on the ureter prolongation, with the pearly areas on the surface, are well shown in the illustration. The drawing Fig. 12 is made from a section taken from the surface of the main mass.—WARTHIN.

presented the kidney, and it, together with the dilated portion of the ureter, was removed. On examination of the right

kidney it showed slight enlargement; otherwise it seemed normal.

“The patient entirely recovered.

“GROSS APPEARANCE.—The tumour was 14 in. long, 8 in. wide, and 6 in. thick; it weighed 2 lb. Externally it gave the appearance of a dilated cystic kidney and ureter, filled with some solid elastic mass. Its form still suggested that of the kidney; on its anterior surface were several nodular elevations of different sizes, the largest covered with the thinned, almost transparent capsule, through which the colour of the tissue underneath showed yellowish. One of these largest elevations gave distinct fluctuation. The external surface of the capsule resembled that of the kidney capsule, presenting no fat tissue, but covered with stringy portions of the perinephritic connective tissue from which it had been separated. The posterior surface was more nearly flat than the anterior, but also presented several round nodules.

“The tumour was opened by slitting up the ureter and along the capsule in a line corresponding to the hilus. In the dilated and thickened ureter was met, first, the remarkable prolongation, as seen in Fig. 11. This consisted of a round cord-like structure, 6 in. long and 1 in. in diameter, terminating in a smooth, blunt end resembling the glans penis. It had no attachment whatever to the ureter walls, though apparently completely filling its lumen. It was firm but elastic, yellowish-white in colour, and having a smooth, shining surface, covered, especially near its end, with areas of pearly-white flakes, which could be scratched off by the finger without difficulty. The cord was marked off slightly into lobular divisions, and along its inner surface there was a raphé-like collection of connective tissue. Cut surfaces of the growth gave the characteristic shining appearance of adipose tissue. The mucous membrane of the ureter was thickened and uneven, presenting to the eye small cyst-like papillæ, yellowish to brownish in colour.

“On following up the ureter into the cavity of the pelvis, the cord-like mass was found to pass into a large, irregular, and nodular tumour, completely filling the cavity of the dilated pelvis. This tumour resembled the prolongation in the ureter in every respect. Its surface was smooth and shining, with the same pearl-like flakes; its colour was yellowish white, in some areas quite yellow; its consistency firm and elastic, except over

several of the nodules where fluctuation could be obtained. There were no adhesions between its surface and that of the mucous membrane of the pelvic cavity, except in a few places where they were easily separated; the surface of the tumour at these places being covered with the pearly film. The mass was lobulated and nodular, the nodules corresponding to the external elevations in the capsule, and from these the tumour was shelled out with ease. By extending the cut through the hilus along the entire length of the mass, the whole mass of the tumour was shelled out of the capsule, with the exception of an area about

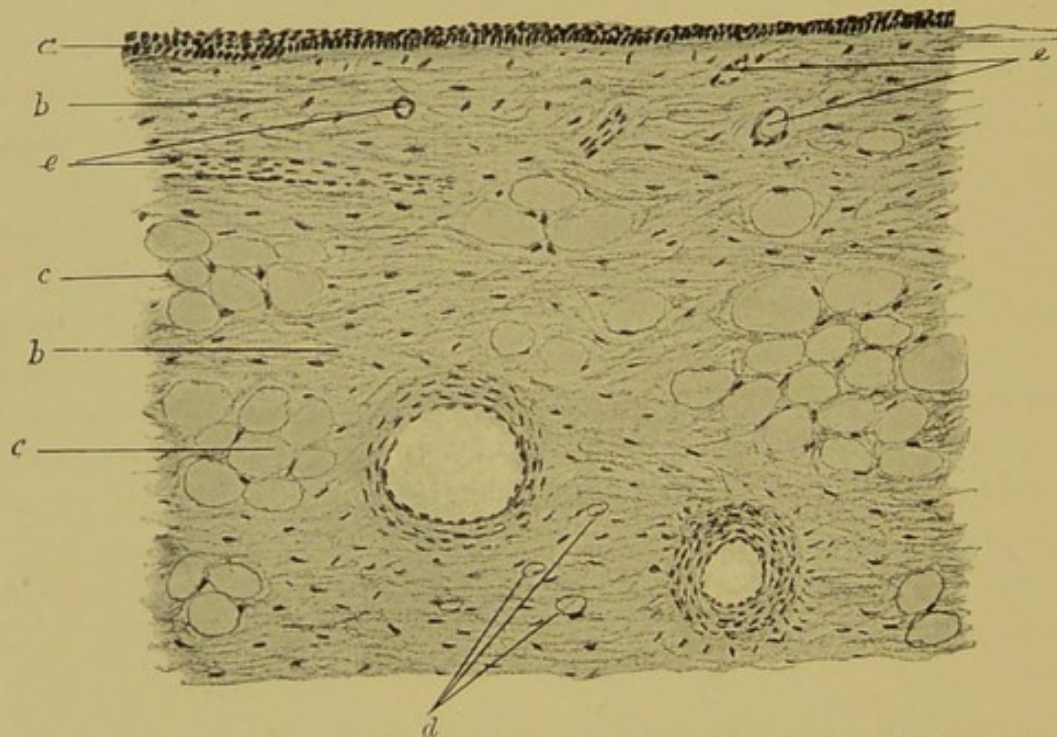


FIG. 12.—Section from outer surface of tumour. (Obj. Seibert, No. 3, Oc. 0,  $\times 75$ .)  
*a*, surface layer of transitional epithelium; *b*, fibrous connective tissue;  
*c*, fat cells; *d*, connective tissue cells containing small fat droplets;  
*e*, small blood vessels.—WARTHIN.

1½ in. in diameter in the outer posterior inferior portion of the pelvic cyst, where the tumour passed by a firm white pedicle into the structure of the capsule.

“The growth thus exposed resembled a large lobulated lipoma, while the turned-back capsule gave the appearance of a cyst of a hydronephrosis, with dilated calyces into which the nodules of the tumour had fitted. Two of these nodules were degenerating; the largest one giving fluctuation had fitted into the cavity covered by the thin and transparent capsule. It was opened, and about 1 oz. of clear fluid was obtained. This gave the

reactions for mucin. At its inferior portion the tumour was divided by a deep fissure running upwards, almost separating it into two halves, giving it the appearance as if the growth had first increased upwards, and had then curved on itself along the hilus down to the ureter into which it had sent the prolongation. It would seem, then, that the growth of the tumour had been peripheral and not central. The inner surface of the cyst resembled that of the kidney pelvis, but it was more uneven and thickened.

“MICROSCOPICAL APPEARANCE.—*Tumour*.—Small pieces taken from all parts of the growth showed that the tumour in all of its parts was essentially of the same structure. The main ground-work consisted of connective tissue fibres; in many places these were very large and coarse, with few nuclei, thus giving the picture of a hard fibroma. In other places the fibres were finer, with more abundant nuclei, but in no portion of the tumour were these numerous. There was, therefore, nowhere any resemblance to sarcoma, the tumour on the whole being poor in cells. Among the connective tissue fibres, in the greater portion of the mass, there were numerous large fat cells, usually in groups of six or eight, but also scattered singly throughout the tissue. In many areas, especially in the sections taken from the yellowish portions of the tumour, the fat cells predominated over the fibrous tissue, so that sections from these parts gave the typical appearance of adipose tissue, resembling, perfectly, sections taken from an ordinary simple lipoma. At its pedicle, and in the portion of the tumour passing into the kidney structure, there were but few fat cells, the character of the sections being that of a hard fibroma. Sections of the prolongation in the ureter showed fewer fat cells and more abundant nuclei. Here the transition of the connective tissue cell into a fat cell could be clearly seen; all stages, from the cell containing a minute fat droplet up to the large fat cell, could be found.

“Though in many areas the fibrous tissue of the tumour was solid and compact, especially near its origin, the greater part was œdematous, or showed mucous degeneration. This was most marked on the surface of the tumour, where there were numerous small cystoid cavities filled with mucin-containing fluid. Examination of the larger cysts presenting on the surface in several places, showed them to be not true cysts but only



degenerated areas of the tumour tissue filled with the same fluid. The œdematous areas were like those of any œdematous fibroid, the connective tissue fibres being pushed apart by a finely granular substance, the fibres being either swollen and stringy, or becoming indistinct, as if being gradually dissolved in the fluid bathing them. The mucous degeneration in places involved also the fat tissue. No true mucous tissue was found in any part of the mass, neither was any adrenal or tissue of any other kind found in any section. The blood vessels were rather numerous and large, with thick walls. Neither hyalin nor amyloid degeneration was observed in these. No areas of hæmorrhage and no pigment deposits were found. In the firmer portions of the tumour there were numerous large lymph spaces, resembling those in uterine fibroids.

“The surface of the tumour, both of the external portion and of the inner cavity, as well as that of the prolongation in the ureter, was covered with a layer of stratified transitional epithelium (Fig. 12), corresponding to that lining the pelvis of a kidney. In the places covered with the pearl-like coating the sections showed a hyperplasia of the epithelium; over the thin cyst-like areas which were in intimate contact with the thinned capsule it was reduced to a mere line; in a few places, where the tumour had been adherent to the wall of the kidney pelvis, it was torn away, but usually at these points of adhesion the epithelium was hyperplastic. There could be no doubt, therefore, that the tumour had grown from the kidney substance out into the pelvis, pushing the pelvic epithelium before it, so acquiring a surface layer of transitional epithelium of the same kind as that of the pelvis.

“In its outer posterior inferior portion the tumour passed by a thick cord-like pedicle about  $1\frac{1}{2}$  in. in diameter into the structure of the atrophied kidney. Sections made here showed that the tissue of the tumour passed directly into the connective tissue underlying the pelvic epithelium, and through the medullary portion into the connective tissue surrounding the large blood vessels in the boundary between cortex and medulla.

“As far as could be determined, it seemed that the tumour had arisen here, or in the interstitial tissue of the medullary pyramid, and had grown toward the pelvis away from the cortex. That it did not arise from the kidney capsule is certain, as between the tumour tissue and the capsule a thin layer of

atrophied cortex could still be made out, and there was no connection at all between the tissue of the tumour and that of the capsule. Evidently the growth of the tumour into the surrounding kidney tissue had been slight, but in the medullary portion, for some distance around the point of insertion of the pedicle, there was a thick mass of tissue of the same character as the tumour, and insensibly passing into it, fairly well defined from the neighbouring tissue of the kidney, but not possessing any well-marked capsule. In the kidney tissue around this there was a narrow fibro-blastic zone with small-celled infiltration and hæmorrhage.

“*Kidney.*—Sections of the capsule of the cyst-like cavity in which the tumour lay showed it to be the atrophied renal substance, exhibiting the changes of chronic nephritis, with amyloid degeneration, accompanied by fresh hæmorrhages into the capsule and some of the convoluted tubules.

“The mucosa of the pelvis showed in many places marked inflammatory changes, with œdema and hæmorrhage beneath the epithelium. The thickness of the latter varied very much, in places being reduced to a single line of nuclei; but in the areas corresponding to the pearl-like coating on the surface of the tumour it was hyperplastic.

“*Ureter.*—Sections of the enlarged ureter showed a great thickening of all of its coats, especially of the muscularis. The blood vessels were greatly enlarged, with thickened walls, and everywhere through the muscle and connective tissue there were areas of leucocyte infiltration. The submucosa was œdematous, infiltrated, and in many places hæmorrhagic. The appearance of the mucosa coincided with that described by Litten as *ureteritis chronica cystica polyposa*. The mucous surface was uneven, small papillæ, corresponding to the naked-eye prominences, projecting into the lumen. The submucosa of these papillæ showed various stages of œdema or mucous degeneration, so that some of them appeared as cysts filled with a hæmorrhagic granular substance in which a few connective tissue nuclei or leucocytes could be seen. The epithelial covering was in every case preserved; and the sections presented these papillæ in every stage of development, from a small elevation, in which the submucosa was only slightly swollen through œdema and hæmorrhage, to the larger cyst-like collections of fluid and blood beneath the epithelium.

Litten, who found in the greatly dilated ureter of a case of cystic degeneration of the kidney a condition similar to this, thought that these cyst-like elevations were retention cysts, due to the closure of mucous glands in the mucosa of the ureter. His description corresponds so closely to my finding, that I take the two conditions to be the same, and reject his explanation, as my specimens show the cysts without doubt to be formed by the collection of exudate and blood beneath the epithelium; some of the papillæ were formed of granulation tissue, the epithelium over them being in some cases atrophied, in others hyperplastic."

Weir has recently recorded the case of an adult female, where a calculus was associated with what was considered to be a fibro-lipomatous growth. The kidney was removed successfully.

Godard mentions a case where half the kidney was converted into a mass of fat. There was a calculus in the pelvis. Hullett Browne also describes a somewhat similar case, associated with calculus, pyelitis, and left renal fistula. These cases are apparently not to be considered as true growths. Fatty deposition is exceedingly common around an old unilateral septie pyelo-nephritis.

Sir Spencer Wells successfully removed tumour masses, probably circumrenal in origin, which, according to Eve, were of a fibro-lipomatous nature.

Ebstein records the case of a lipoma occurring in an old woman, who died of marasmus. The left kidney was enlarged to more than double its natural size. The entire organ consisted of fatty tissue without a trace of kidney substance. Rayer also mentions a somewhat similar case.

Cases of growth containing fatty elements have also been described by Halle, Hartmann, Lacrampe, Lousteau, Sturm, and others.

It will thus be seen that fibrous and fatty elements when they occur as renal neoplasms are often combined. In many instances it is very probable the growth originates rather in the capsule or perirenal tissue than in the renal parenchyma. Reference to these so-called "perirenal lipomata" will be made in a subsequent chapter (Chapter XVII.).

## CHAPTER IX.

### SIMPLE OR BENIGN GROWTHS—*continued.*

BESIDES the fibromata and lipomata, a number of other benign growths have been met with. They are, however, very rare, and of interest chiefly as pathological curiosities.

#### MYXOMA.

Myxomatous growths are referred to by some few authors. Bezold describes and illustrates a case where several small opalescent bluish white nodules of mucous-like tissue were found in the cortical substance of the kidney. Myxomatous changes may also occur in other forms of growth, and may sometimes be met with in the sarcomata.

Mr. Henry Morris<sup>1</sup> mentions a case occurring in a man *æt.* 39, causing death within a year from the first discovery of the tumour, without metastasis or hæmaturia, and with symptoms only of pressure and wasting with some abdominal pain.

#### CHONDROMA.

Cartilaginous growths are practically unknown. Gluge, however, mentions a case where, associated with hydronephrosis, there was what he considered to be a growth mainly composed of cartilage.

#### OSTEOMA.

Bony growths have been described, but probably all those described as being of a bony nature were merely depositions of lime salts in other forms of growth, or in old inflammatory and degenerate tissues. As Newman says, "the occurrence of true bony tumours has been doubted by most writers on the subject,

<sup>1</sup> Allbutt's "System of Medicine," vol. iv.

many of the so-called bony growths being in reality calcified inflammatory products."

Roberts states that "sometimes a fibrous or cartilaginous tumour grows in the substance of the kidney and subsequently ossifies, transforming a large mass of the organ into a bony mass."

Rayer met with a specimen in which the linea propria and pelves from an elderly man formed two bony-like shells.

#### ANGIOMA.

Vascular growths of the kidney are not infrequently found. They are usually sarcomata. Occasionally true angiomata are met with, and are said to be practically identical in structure with the cavernous angiomata met with in the liver. They occur, according to Virchow, most frequently beneath the capsule, and sometimes in the uppermost portion of the medullary substance. They appear as encapsulated bright red masses, varying in size from a cherry-stone to a walnut.

Simple "nævus" of the kidney, in my experience, is very rare. It must be carefully distinguished from the hæmorrhagic forms of cystic adenoma and from simple hæmorrhage.

Allen and Cherry state that "true angioma of the kidney may show all grades of capillary dilatation, until networks of intercommunicating vascular spaces are formed. In the neighbourhood of a simple angioma the epithelial cells of the renal tubes may be active, with deeply staining nuclei."

Morris says that cavernous angiomata, though distinct formations of reticulated cavernous tissue, are of quite small size, not exceeding that of a marble, and the affected portions of the kidney are often shrunken, rather than projecting or enlarged.

In some specimens of trabecular cystoma which I have investigated, the spaces, although lined with a single layer of columnar-celled epithelium, contained blood in a condition which manifested little or no degenerative change.

Rolleston and Kanthack have described a very curious form of vascular growth, which may perhaps be best referred to in this section. As these authors have very generously permitted me to reproduce their illustrations,<sup>1</sup> taken from drawings by Dr. R. J. M. Buchanan, I venture to record their case somewhat at

<sup>1</sup> *Journ. Path. and Bacteriol.*, Edin. and London, 1894, vol. ii. p. 80.

length, quoting from their report, a copy of which they have kindly placed at my disposal.

"The growth was met with in the body of a man, *æt.* 62 years, who died with epithelioma of the lower part of the pharynx. The left kidney had, projecting from its convex border and embedded in it, an irregular lobulated tumour (Fig. 13) about the size of a walnut. The tumour lay under the capsule, and was not adherent to it. On section it was very vascular to the naked eye, and from the large quantity of blood in it, it was thought to be a cavernous angioma. It extended into the cortex of the kidney, from which, however, it appeared to be marked off by a fibrous capsule.

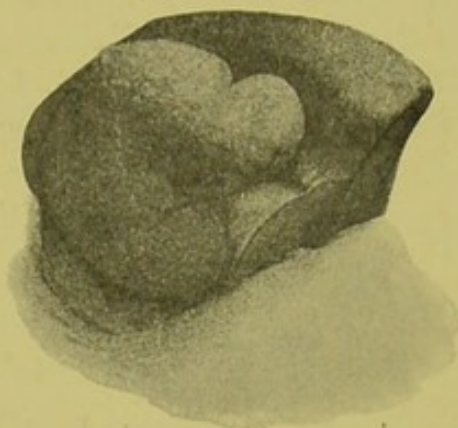


FIG. 13.—Naked-eye appearance of the tumour protruding from the convex border of the left kidney. Half the tumour has been removed. (Natural size.)

"The left kidney weighed 8 oz., its surface was somewhat granular, and the branches of the renal artery were much thickened. There were no cysts under the capsule or in the

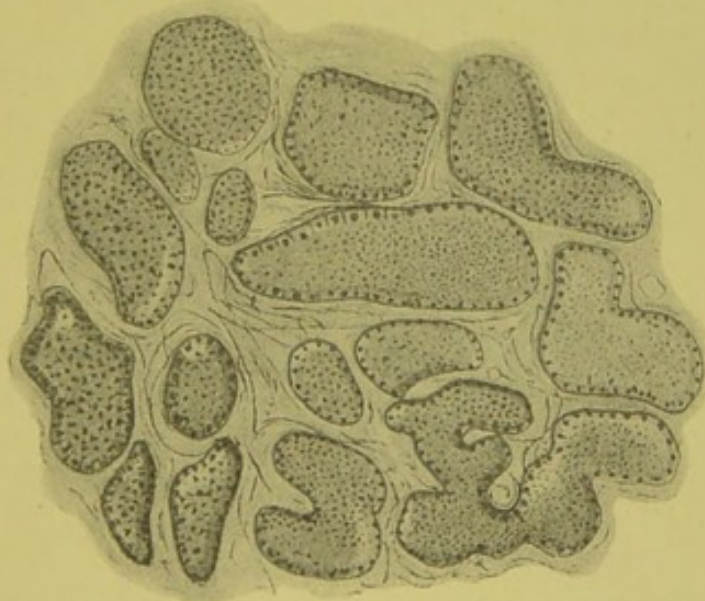

FIG. 14.—Section through the tumour. (Zeiss A, Oc. 4.) Shows the irregular spaces, lined by epithelium in a state of fatty degeneration and containing blood.

substance of the cortex. The right kidney weighed 7 oz., and, excepting some of the changes of chronic interstitial nephritis, presented nothing abnormal.

“At first sight the tumour (Fig. 14) appeared to consist of spaces full of red blood corpuscles lined by cubical epithelium. The spaces were of various sizes and shapes, and were bounded by strands of well-formed fibrous tissue. No thrombi or fibrin filaments were seen in any of these spaces, which were filled with red and white corpuscles in about their normal ratio. It may be inferred that the blood had been freely circulating up to the time of death. The cells lining the spaces were distinctly epithelial in type, formed a continuous

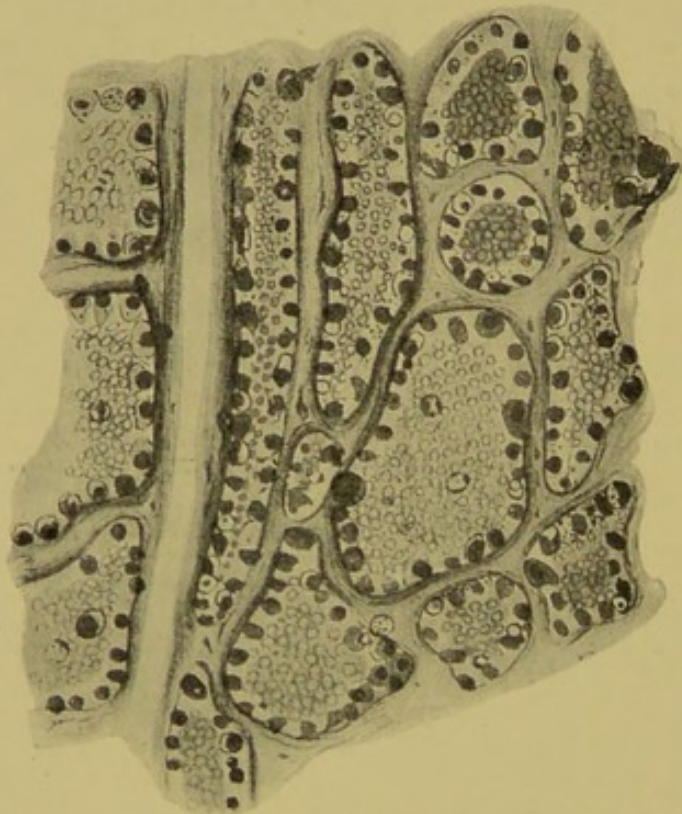


FIG. 15.—Section through tumour. (Zeiss D, Oc. 4.) Shows an empty vessel and a cylindrical tube. All the spaces lined by fatty epithelium are full of blood. The cylindrical space is lined with fat epithelium. The vessel shows no fatty degeneration.

layer (Figs. 15 and 18), and were more or less cubical. In picro-carmin and hæmatoxylin stained specimens the nuclei were well preserved, and every cell was occupied by a clear highly refractive sphere, which refused to take the stain (Fig. 17). This appearance suggested either globules of fat or vacuolation. Gram's method, acid fuchsine, carbol fuchsine, and Ehrlich-Biondi staining left the appearance unchanged. Osmic acid stained these globules uniformly black (Figs. 15, 16, 18). The tumour then was com-

posed of spaces full of fresh blood, the walls of which were lined by cubical epithelium, each cell containing a large fat globule.

“It being quite clear, from the presence of epithelium lining the spaces, that the tumour was not a nævus, the next step was to determine its nature and origin. As mentioned above, the size and shape of the spaces varied considerably. Most commonly the spaces were round or irregularly oval, an appearance which might result from the transverse section of tubes. But here and there long cylindrical spaces, resembling tubes cut in their long

axis, was seen (Figs. 15 and 16). The epithelium lining the cylindrical spaces was more flattened than that lining those of round or oval outline (Fig. 15). In places, groups of the round and cylindrical spaces were seen to alternate (Figs. 15 and 16), an appearance compatible with the view that the cylindrical tubes are the straight tubes of the medullary rays, and the round or oval spaces the convoluted tubes of the kidney, both of which have undergone a quite exceptional fatty degeneration, and have become distended with blood. The correctness of this view manifestly depends on the presence of glomeruli, as their presence would show that the tumour was composed of altered renal parenchyma, and was not a neoplasm. According to this view, the blood distending the tubes must have been derived from the capillaries of the tufts, and so have first distended and rendered the Malpighian bodies prominent.

“In parts of the tumour the remains of Malpighian bodies (Figs. 16 and 17) may be made out, but they are few in number, and in many sections none are visible, while in the kidney substance outside the limits of the tumour they are normal in number. The epithelium lining the inner

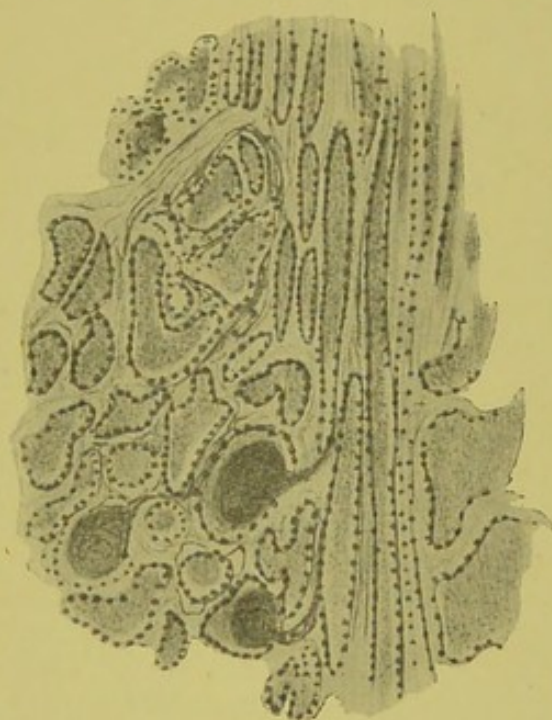


FIG. 16.—Specimen prepared as above. (Zeiss A, Oc. 4.) Shows the alternate groups of irregular, round, or oval tubes, and of cylindrical tubes; and also three Malpighian bodies.

surface of Bowman's capsule contains large fat globules, while the epithelium covering the capillary tufts is unchanged (Fig. 17). The presence of these bodies, together with the characters of the spaces described above, and the general resemblance of the lining epithelium to that of the kidney (Fig. 18), go to show that the tumour is composed of renal parenchyma distended with circulating blood, and is not a new growth. The comparative rarity of the Malpighian bodies in the sections may be explained in two ways—first, the extravasation of blood into the cavity of Bowman's capsule may



have taken place to such a degree as to destroy the tuft of capillaries; and, secondly, when the capsule has been greatly distended by blood, the glomerulus becomes shrunken and compressed, and so, being pressed to one side, does not appear in the majority of sections taken, while the distended capsule appears as a large round tube lined by epithelium, containing fat globules. It is well to notice that there was no hæmorrhage worth speaking of between the spaces, and that the extravasated blood was found only in these spaces and in the vessels between

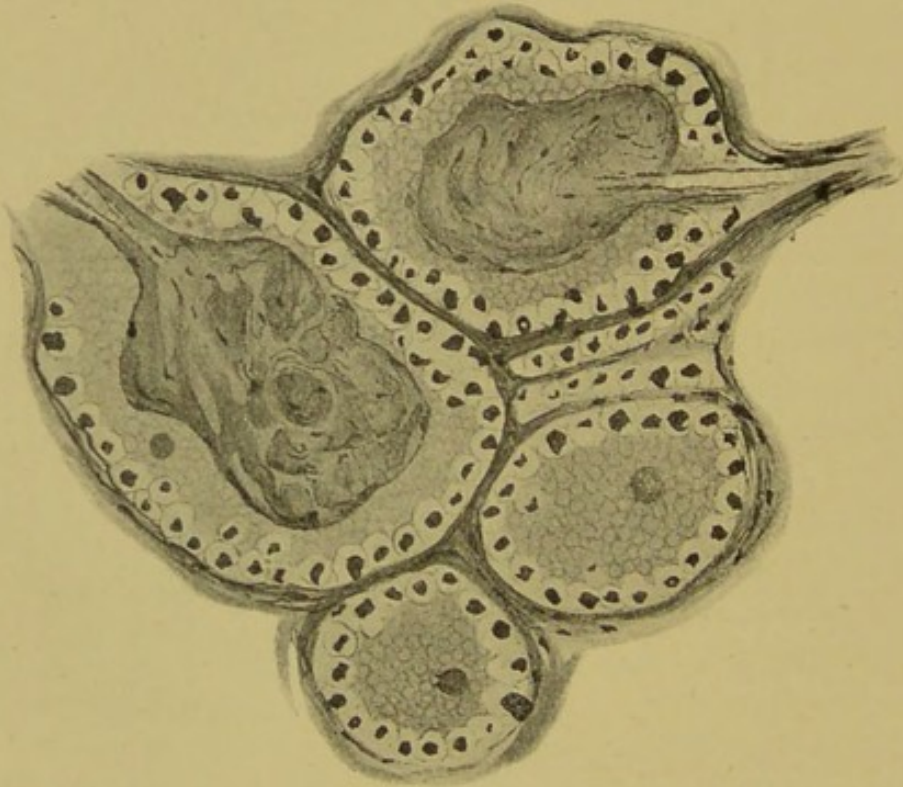


FIG. 17.—Vascular renal growth. (Zeiss D, Oc. 4.) Shows two distinct glomeruli. The epithelium over the tufts is not degenerated, the epithelium lining Bowman's capsule shows clear spaces (fat). The nuclei are all well stained.

them, the endothelium of which was quite normal, and showed no signs of any fatty degeneration. From what has been said, it is evident that this condition has nothing in common with an hæmorrhagic infarct, but has, *mutatis mutandis*, certain features of resemblance to pulmonary apoplexy.

“Perhaps one of the most striking points is the universal presence of fat globules in the epithelium lining the spaces throughout the tumour. At the periphery of the tumour, near its fibrous capsule, tubes are found, not distended by blood, the epithelium of which is nevertheless in the same degenerate con-

dition as that of the tubes which are distended by blood, while the remainder of the kidney showed no marked degeneration.

"It would appear, then, that the local degeneration is due to some special cause affecting this region of the kidney alone. That it is not due to the presence of blood in the tubes, is shown by the fact of fatty degeneration occurring in collapsed tubes, especially at the periphery of the tumour. The circulation in the region of the tumour appears to have been partly through the vessels and partly through the renal tubes, a disturbed condition of the circulation which it is not unreasonable to suppose may well have impaired the vitality of, and thus have led to a fatty degeneration of, the epithelium. It

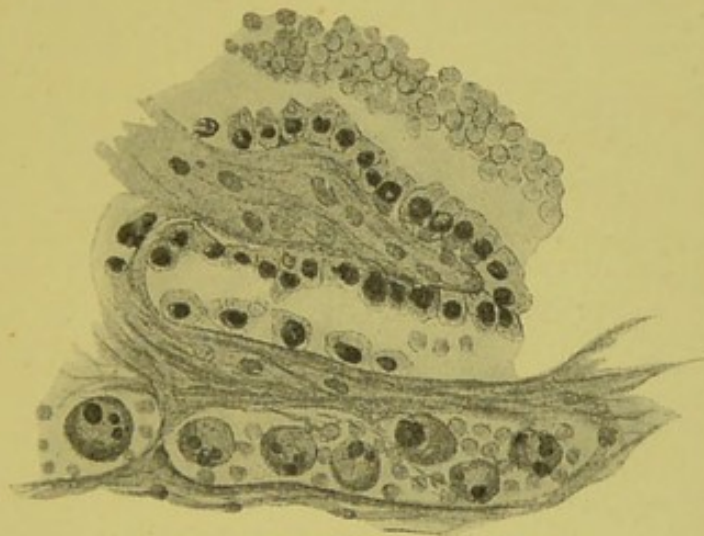


FIG. 18.—Specimen stained with osmic acid. (Zeiss  $\frac{1}{2}$ , oil immersion, Oc. 4.) Shows the structure of the epithelium, especially the striation. Note the large round and oval cells containing pigment masses.

might, indeed, have been expected that such a copious extravasation of blood into the renal tubes would have destroyed them altogether.

"Although the fatty degeneration is extreme, a condition approaching it is occasionally met with in cases of interstitial nephritis. Cornil and Ranvier have figured and described a somewhat similar condition.

"On examining sections stained with osmic acid, with an oil immersion (Zeiss  $\frac{1}{2}$ ), cells in which the degeneration was not too far advanced (Fig. 18) showed the typical renal striation, so that there could be no doubt as to their nature.

"In parts of the kidney, especially near the periphery in the fibrous capsule, pigment masses, golden-yellow in colour,

are present in considerable quantity (Fig. 19). Some of these, the smallest, are irregularly scattered about; somewhat large, round masses appear to be enclosed in round or oval cells (Fig. 18), while the greater part of the pigment is arranged in streaks or clumps between the layers of the fibrous capsule (Fig. 19). The pigment masses are not crystalline. A piece of tissue containing them in large quantity did not give the murexide reaction, and hence the pigment is probably derived from the blood. No pigment was found in other parts of the kidney outside the tumour. The assumption that the pigment is

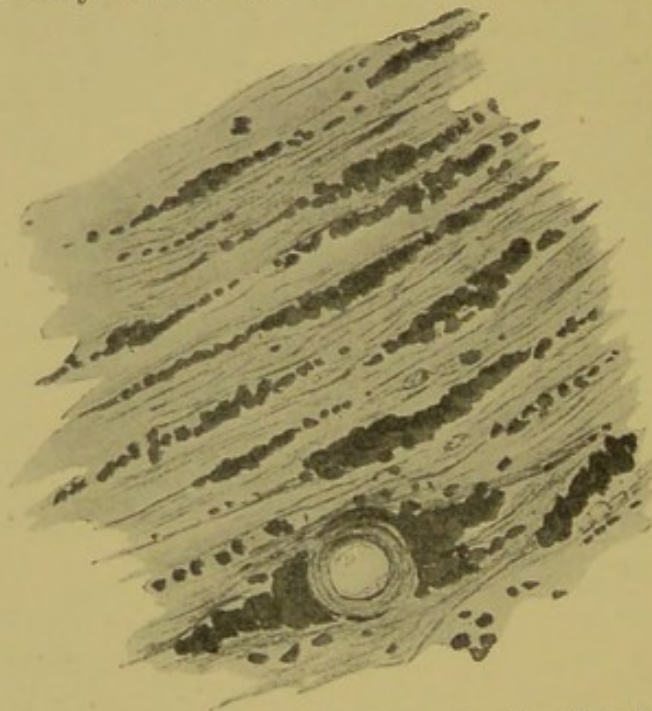


FIG. 19.—Specimen stained with osmic acid. (Zeiss D, Oc. 4.) Shows the arrangement of the pigment in the fibrous capsule. Note the heaping up around the vessels, and the arrangement of the pigment in streaks.

derived from extravasated blood, and the fact that it is limited to this part of the kidney, render it probable that the escape of blood into the renal tubes had been of some standing.

“The surrounding parts of the kidney show to a marked degree the changes of arterial sclerosis, the tubes are not dilated or cystic or distended with blood. The interstitial substance in the region of the tumour is less evident, though its presence may be masked by the distension

of the renal tubes. The tumour is marked off by a thick fibrous capsule containing vessels (Fig. 19). Two explanations as to the origin of this capsule offer themselves; in the first place, it may have been formed of the wedges of fibrous tissue which occur in the cortex, and are characteristic of chronic interstitial nephritis. Considering, however, the size of the tumour, it seems more probable that the capsule in this case is homologous to that so frequently met with around innocent tumours.”

It is very doubtful if the true angiomas should be included among the growths, as they appear to be more of the nature of vascular ectases. Custom, however, sanctions the inclusion.

LYMPHANGIOMA AND LYMPHADENOMA.

Lymphatic growths are usually secondary or associated with leucocythæmia. The naked-eye characters are not distinctive, and their essential structure can only be ascertained by microscopic examination. They must not be confounded with round-cell sarcoma.

Murchison describes a case occurring in a man *æt.* 24, where the liver, lymphatic glands, intestine, and other parts were also involved. The kidneys contained "numerous opaque white deposits, raised above the outer surface and also embedded in the cortical tissue and pyramids. They were for the most part rounded, and some were as large as a small cherry."

Wilks describes a case of lymphadenoma in a woman of 43; but there seems good reason to believe that this and some of the other cases on record were probably of the nature of growths originating in adrenal "rests." Cases have also been described by Virchow, Friedreich, Böttcher, and others. Heschl has recorded a case of lymphangioma.

## CHAPTER X.

### SARCOMATA.

To this group undoubtedly belong the majority of the malignant growths of the kidney. And yet, as already shown, up to comparatively recent years they were not distinguished from the other forms of so-called "cancer."

In attempting a study of the renal sarcomata, one is confronted by a difficulty in determining on any satisfactory method of grouping. A completely satisfactory classification seems almost impossible at the present time. The growths generally considered to be sarcomatous differ so widely in their distribution and in their structural characters, that their true relationships must for a long time afford a wide field for discussion and much difference of opinion.

For purposes of convenience a division of the subject may be approached in three principal ways:—

1. According to the period of life at which the growth develops.

2. According to the situation in which it arises.

3. According to its histological characters.

Before attempting any such division, it may be well to consider some of the more important characteristics of the sarcomata as a class.

*General macroscopical characters.* — The sarcomata form tumours which vary very considerably in their general characters. Occasionally they are comparatively small, but usually they tend to assume enormous proportions. Ebstein makes the somewhat surprising statement that "they generally present themselves as not very extensive tumours." They may occur as more or less spheroidal or oval masses, and often are at first distinctly encapsuled. In some instances they are distinctly separable from the surrounding kidney substance. Often the growth consists of numerous nodules, and gives to the tumour

mass a bossed and irregular surface. Generally the renal capsule forms a kind of sheath for the growth, and for a time resists its spread. This is well shown in many of the accompanying figures. In many instances it invades and extends through the capsule and spreads irregularly, attacking adjoining structures, and forming adhesions with stomach, intestines, omentum, mesentery, spleen, liver, diaphragm, and abdominal walls.

Some have a roughly trabecular structure, the irregular spaces being filled up with soft and frequently very vascular growths. An example of such is shown in Fig. 24. In some cases the growth has a diffuse appearance, affecting in a more or less uniform manner the greater part of the organ. In some instances, as already indicated, it would seem as though the growth originating in the connective tissue of the pelvis or adjacent parts, insinuated itself into the renal parenchyma, and, as it were, opened out the organ. Sometimes nodules may be observed projecting into the renal pelvis, still covered with a layer of mucous membrane. In colour, the growths vary greatly. Sometimes they are of a chocolate or dark brown tint. Often there is a mottled appearance, areas of a pinkish-yellow irregularly alternating with others of a much darker colour.

In our museum we have a specimen where black nodules of secondary melanotic sarcomata are scattered through the kidney (Figs. 1, 40, 41).

The consistency is very variable. Some growths are solid throughout, as indicated in some of the accompanying illustrations.

The majority of sarcomata present evidence of cystic formation, the cysts containing serous, sanguinolent, or colloid matter. Many of the sarcomata are exceedingly soft and of the consistency of brain tissue.

#### SARCOMATA CONSIDERED ACCORDING TO THE PERIOD OF DEVELOPMENT.

Sarcomatous growths in the kidney have been met with at three different periods of life. We have—

1. Sarcomata in foetal life.
2. Sarcomata in infancy and childhood.
3. Sarcomata in adult life.

## SARCOMATA IN FETAL LIFE.

For a long time it was denied that sarcomata ever occurred during intra-uterine development. Now, however, it has been conclusively shown that these growths may not only manifest themselves within a few weeks of birth, but may be of conspicuous size some time before the full period of pre-natal development.

Jacobi has more particularly investigated these cases of congenital sarcomata. He has himself met with a typical

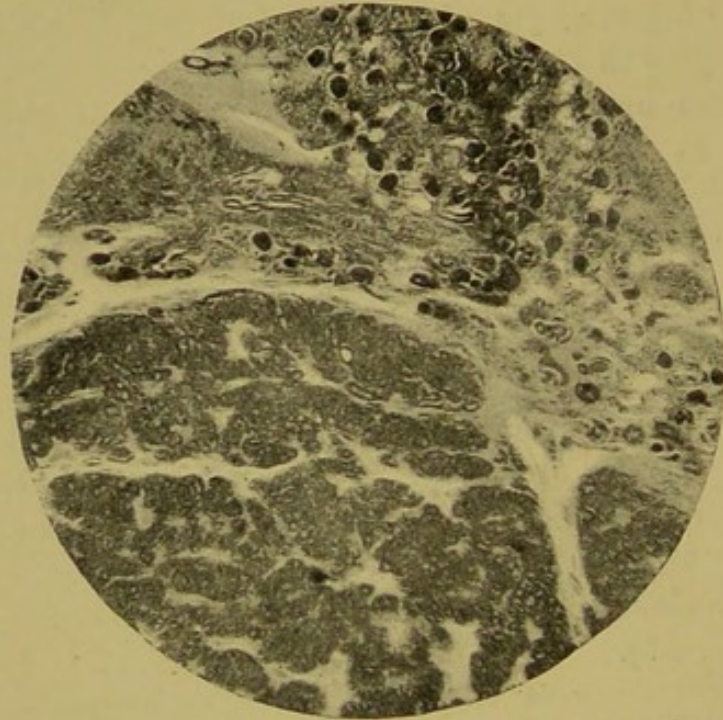


FIG. 20.—Congenital sarcoma. From a 7-months' foetus. (Zeiss, Oc. 2, Reichert, Obj. No. 2,  $\times 40$ .)—From a specimen lent by Mr. Paul.

sarcomatous growth in a still-born female child. Other cases have been recorded by Brosin, Kocher, Little, and Van der Byl.

Through the kindness of Mr. Paul, I am enabled to give an illustration of the histological characters of a sarcomata met with in a 7-months' foetus (Fig. 20).

A very considerable number of cases have been recorded where the tumour was first noticed within a short time of birth. In a large proportion of these the growth in all probability originated during foetal existence. There can be no doubt that most of the rhabdo-myomata commence their growth at a very early period.

## SARCOMATA IN INFANCY AND CHILDHOOD.

Early life is the period specially selected for sarcomatous growth in the kidney. From an analysis of a large number of cases, I find the greater number of cases occur under 5 years of age. In consequence of the uncertainty as to the precise nature of some of the growths occurring in early life, slight-differences of opinion still exist as to the exact ages at which this class of growth is most frequent.

Butlin states that "sarcoma occurs in infants, children, and adults, but is uncommon in the young and middle period of adult age." Newman gives the average of his collected cases as "a trifle under 10 years and 2 months."

The following analysis of ninety-six cases may be of interest in illustrating the comparative frequency of sarcoma at different ages:—

INFLUENCE OF AGE IN DEVELOPMENT OF SARCOMA.

Sex.	No. of Cases.	0-5 Years.	5-10 Years.	10-21 Years.	Above 21 Years.
Male . . .	41	25	6	...	10
Female . . .	55	31	4	1	19

It is therefore very clear that sarcoma must be considered as particularly prone to affect the kidney in the early periods of existence. The late Mr. Greig Smith has stated that nearly 40 per cent. of renal growths occur in children, and undoubtedly most, if not all, of these are sarcomatous. My own researches show that, of 160 cases of malignant growths occurring at all ages, over 52 per cent. were met with below 10 years. Formerly, all forms of malignant renal growth in children were simply named "cancer," "fungus hæmatodes," or the like.

Lancereaux in 1876 was one of the earliest to clearly show that many of the so-called "cancers" met with in infants were really of a sarcomatous nature.

Monti also in 1880 prominently advocated the same view.<sup>1</sup>

Eustace Smith in 1884 was definite in stating that "sarcoma of the kidney constitutes the ordinary form of cancer met with in the child." The occurrence of renal growths in children has, of course, been long recognised, but satisfactory

<sup>1</sup> Gerhardt's "Handbuch der Kinderkrankheiten," 1878, Bd. iv. Abth. iii.



advance in the knowledge of these growths has been long delayed by the teaching that "cancer of the kidney was the most common form of growth met with in childhood." Generations have been satisfied with this dictum. Braidwood of Liverpool, writing as late as 1870 on "Cancerous Degeneration of the Kidney in Children," well reflects the teaching of his day when he states that "renal cancer occurring in children is almost exclusively encephalous in character."

As already indicated, present experience would tend to show that nearly all the malignant growths originating in early life are really sarcomatous. Power says<sup>1</sup> "malignant tumours of the kidney in children are nearly always sarcomata."

Walker's critical review on the "Renal Sarcomata of Children," published at the end of last year, must be mentioned as one of the most recent and thorough contributions to the subject.

I find that over 46 per cent. of the cases met with in childhood occur under 3 years of age. In a large proportion of these, the growth in all probability should be considered as of "congenital" origin.

The rhabdo-myomata in particular are associated with infancy and childhood. Indeed, they are almost confined to the period of infancy. Newman's average is 1 year and 3 months. They are essentially the sarcomata of infancy. It is very rare to meet with them in adults. They are not so frequently met with as the more simple forms of sarcoma.

I have collected and analysed a small number of recorded cases of myo-sarcoma, with a view to indicate the influence of age:—

INFLUENCE OF AGE IN RHABDO-MYO-SARCOMATA.

Sex.	No. of Cases.	Under 1 Year.	1-2 Years.	2-3 Years.	3-4 Years.	Above 4 Years.
Male . . .	9	...	3	2	3	1
Female . . .	7	1	3	...	1	2

As far as I can ascertain, sex has some little influence in directing the development of sarcomata in young subjects. I have analysed a number of cases in connection with this point:—

<sup>1</sup> "Surgical Diseases of Children."

INFLUENCE OF SEX IN RENAL SARCOMA  
OF INFANCY AND CHILDHOOD.

Sex.	No. of Cases.	Per Cent.
Male . . .	30	46·15
Female . . .	35	53·84

These figures seem to show that in childhood the female sex is a little more liable to be affected than the male. Should this be really the case, it raises a point of considerable developmental interest.

*Size and weight.*—According to Jacobi, 36 lb. is the largest weight reported as occurring in the young subject. In adults it may reach a very considerable size, but usually sarcomata in children are proportionally and also actually considerably larger than in men and women. Paul describes a case where the growth weighed 6 lb. and the rest of the body only 10 lb. Roberts mentions the case of a child *æt.* 6, where the growth reached 31 lb.

In twenty-three cases of sarcoma in children under 10 years of age, and many of them infants, I found the average weight to be a little over 126 oz.

The question of size has already been dealt with in considering malignant growths generally.

*Duration.*—Usually the sarcomata developing in children grow with very great rapidity. Jacobi, however, takes a different view. Speaking of sarcoma in childhood, he says: "Growth is generally slow, rapid only when hæmorrhage takes place either into the tissue of the tumour or into a cyst, which grows very unexpectedly under such circumstances. One required at least six, probably eight, years until its final fatal termination."

Hahn mentions the case of an infant, 10 months old, in whom the growth reached the size of a child's head in four weeks.

*Side affected.*—Both sides are more or less equally affected. Sometimes the growth seems to originate simultaneously in both kidneys.

Jacobi in forty collected cases of sarcoma occurring in childhood found involvement to be—right, 13; left, 19; both, 8.

Mr. Paul sums up the chief characteristics of the congenital renal sarcomata as follows:—

1. They show themselves during the first five years of life, and are probably invariably of congenital origin.

2. They are primarily extra-renal, though usually intra-capsular, and they distend or surround the kidney in preference to infiltrating it.

3. In about half the cases they are bilateral.

4. They rarely cause marked urinary symptoms, or much pain, and are usually fatal by exhaustion or pressure effects.

5. They only occasionally give rise to metastatic growths; but some kinds freely infiltrate the kidney, and all recur when removed.

6. They frequently contain striped muscular fibre, and embryonic renal tissue, and almost constantly various kinds of adult connective tissue, such as white fibrous tissue, yellow elastic tissue, areolar tissue, and fat.

#### SARCOMATA IN ADULT LIFE.

Renal sarcoma may develop at any age. Whilst particularly associated with the period of rapid growth, it occasionally appears in mature life, and an increased liability appears with increasing years. Sarcomatous growths have been observed as late as 76 years.

Bland Sutton points out that the years from 5 to 30 are peculiarly free.

As regards sex it is usually stated that such has no distinct influence. Bland Sutton says "they seem to occur equally in men and women."

In adults the female sex appears to be distinctly more liable to renal sarcoma than is the male. In thirty cases, all occurring in persons above 21 years of age, exactly double the number of women were affected as compared to the men, as shown in the following table:—

INFLUENCE OF SEX IN ADULT LIFE.  
ALL AGES ABOVE 21.

Sex.	No. of Cases.	Per Cent.
Male .	10	33·33
Female .	20	66·66

In order to test the question of the influence of sex, I have

collected and analysed ninety-seven cases of sarcoma, including of course the myo-sarcomata. The result is shown in the following table:—

INFLUENCE OF SEX, AT ALL AGES, IN DEVELOPMENT OF SARCOMA.

Sex.	No. of Cases.	Per Cent.
Male .	42	43·29
Female .	55	56·70

These figures clearly show that on the whole the female sex is most predisposed to sarcomata. My numbers, although taken from a collection nearly three times as large as that of Newman's, strange to say give, in round numbers, exactly the same percentage.

Newman found, out of a total of thirty-seven cases, twenty-one were females and sixteen males, that is, a percentage of 56 for females and a percentage of 43 for males. Amongst the spindle-celled sarcomata, five were males and three females; round-celled, four males and eight females; rhabdo-myomata, seven males and four females.

#### SARCOMATA CONSIDERED ACCORDING TO THE SEAT OF ORIGIN.

One of the most practical groupings of renal sarcomata would be that depending upon the point of origin. Both to the pathologist and to the surgeon this question of seat is of profound interest and practical importance. Unfortunately, however, the affected organ does not usually come under observation until the growth has assumed such proportions as often to make it exceedingly difficult to definitely ascertain its starting point.

In many instances, however, a regional classification may be safely adopted.

Without attempting too fine a distinction, at least three chief groups may be distinguished—

1. Capsular growths.
2. Parenchymatous growths.
3. Hilum growths.

In some cases it is possible to identify a further group, namely, those arising in connection with adrenal inclusions, but these can hardly be considered as true sarcomata, and will be referred to later (Chapter XIV.).

## SARCOMATA ORIGINATING IN THE RENAL CAPSULE.

A certain number of sarcomatous growths involving the kidney undoubtedly arise in connection with the capsule or the subcapsular connective tissue, in much the same way as similar growths arise in the periosteum or capsule of bone. They are, however, undoubtedly rare.

When the growth has reached considerable dimensions, much difficulty may be experienced in arriving at a definite opinion as to its exact relation to the capsule. Indeed, in many instances, no opinion can be safely ventured upon.

In some cases the growth early penetrates through the capsule, while in others, where presumably it originates in the deeper layers of the capsule, it tends rather to invade the renal parenchyma.

Day records a case probably belonging to this group. The subject was a female child, *æt.* 4. "The tumour did not involve any part of the kidney, but lay entirely between the anterior surface of that organ and the capsule which was stretched over it, but could readily be traced from the surface of the tumour on to the back of the kidney. The tumour was chiefly composed of a soft, encephaloid material, which broke up easily, with here and there patches of softer and more fluid matter. It weighed  $9\frac{1}{4}$  lb." Microscopically the growth consisted of round and spindle sarcomatous cells. Dr. Day seems to have considered it probable that the growth originated in the lymphoid tissue lying beneath the capsule.

The Museum of the Royal College of Surgeons contains a very interesting specimen (3590), in which the growth seems to have originated in the deeper part of the renal capsule, or, if not in the cortex itself, at all events in a part close to the capsule.

The preparation was taken from a female child, *æt.* 3. Two months before death she had complained of pain in the region of the right ilium. Growth was exceedingly rapid. The relation of the growth to the kidney is indicated in Fig. 21. Mr. Targett's description of the specimen is as follows:— "The tumour measures 8 in. in length, and on section the kidney may be recognised as a triangular mass wedged into the substance of the growth. The base corresponds with the inner border of the kidney, and the apex is formed by a conical projection of the cortex. Towards the upper end of the organ the

cortex is very narrow, yet it can be separated from the capsule of the growth; and at the very extremity the renal tissue is prolonged over the tumour for more than an inch. Here, too, the fibrous capsule of the kidney can be traced over the tumour. The lower end of the organ, however, is flattened by pressure, and separated from the growth by the ordinary fibrous capsule. From these relations it is clear that the neoplasm originated beneath the capsule, probably at the periphery of the cortex, and, having perforated the capsule, gradually enveloped the remainder of the kidney.

"Histologically it is composed of round sarcomatous cells, with large extravasations of blood and numerous varicose capillaries. No glandular or other elements were found, though sections from five different parts of the tumour were examined."

Maidlow has recently published a case in which a subcapsular "mixed-celled sarcoma, with patches of mucoid change," was removed by nephrectomy. The patient was a woman, *æt.* 25. The operation was undertaken three weeks after the first confinement. The growth weighed 7 lb., and had an average diameter of  $6\frac{1}{2}$  in. The capsule of the growth was continuous with that of the kidney. The kidney except for about  $\frac{1}{4}$  in. subjacent to the point of attachment of the growth seemed normal. Three months after operation she was well.

#### SARCOMATA ORIGINATING IN THE RENAL PARENCHYMA.

A considerable proportion and perhaps the majority of the renal sarcomata originate either in the cortex or medullary portion of the organ. They arise apparently in connection with the intertubular connective tissue, but a certain number possibly originate from the peri-vascular and peri-lymphatic structures.

The growth may arise at one part of the organ and assume



FIG. 21. — Round-cell sarcoma, probably originating in the renal capsule. Kidney appears as wedge-shaped mass on the left side of the growth. The base corresponds to its inner border, while the apex is formed by projection of cortex. Vessels and ureters indicated by bristles. Calyces much dilated. Fibrous capsule of kidney continued over growth. Cavity in lower end of growth due to degenerative changes. Length of growth, 8 in. From a girl, *æt.* 3. History of pain about the right ilium first noticed two months before death.— From a photograph lent by Mr. Targett.

considerable proportions before the pelvis becomes blocked, or the secretory function of the remaining part arrested. This is indicated in the illustration taken from a photograph of a specimen in the pathological collection of the Manchester Royal Infirmary.

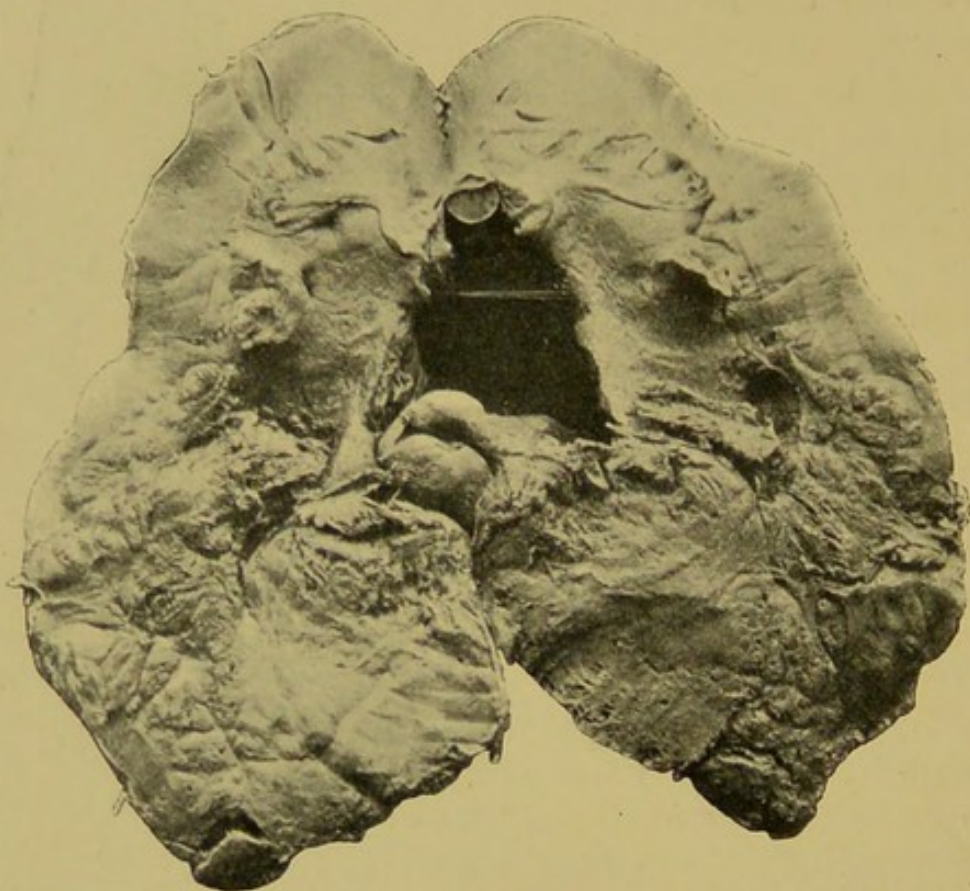


FIG. 22.—Sarcoma.—Mass of growth infiltrating lower half of kidney. Weight, 8 oz. Length,  $5\frac{1}{2}$  in. Breadth of growth,  $3\frac{1}{2}$  in. Removed by nephrectomy from male, *æt* 45. *Chief symptoms*—Hæmaturia and slight pain for eight months.

The growth was removed by nephrectomy, by Mr. Jones, from a man *æt*. 45. As will be seen, the growth replaces a considerable portion of the renal parenchyma, and has even extended into the pelvis as a large nodular mass. The half of the kidney with remainder of pelvis is not involved. The chief symptoms were pain and hæmaturia, occurring over eight months. Long fine clots were sometimes passed. Death occurred from the shock of operation (Fig. 22).

An example of sarcomatous growth, originating in the cortical portion of the renal parenchyma, is illustrated in Fig. 23, taken from a specimen in the Royal College of Surgeons (3597c).

The growth appears to spring from the convex border of the

right kidney. It is more or less rounded in form, and at its upper and lower portions is overlapped by renal tissue and fibrous capsule. The hilum of the kidney is distinct, and the pelvis and infundibula have been dissected out. A strip of renal parenchyma intervenes between growth and hilum. The growth was very soft and friable, but fairly uniform in consistency. Areas of hæmorrhagic infiltration are distinctly marked in two places.

According to Mr. Targett's report, the growth is a round-cell sarcoma. The capillaries consist of a single layer of nucleated endothelial cells. A delicate stroma consisted of tailed connective tissue corpuscles. Here and there were a few ducts, lined by columnar epithelium, and situated either in the connective tissue or mingled with the sarcoma cells.

The appearance, as indicated in the figure, rather suggests the possibility of the growth having arisen in the capsule or in the tissue immediately between the capsule and cortex. Careful examination, however, shows that the kidney tissue extends over the growth, and that the latter actually extends into the cortical substance. The fact also that renal tubules occur in the growth is strongly in favour of its origin in renal tissue rather than in the capsule.

The growth was removed by operation from a child æt. 19 months. An abdominal tumour had only been observed for three weeks.

When the growth reaches extensive proportions, it is often extremely difficult to be sure of its exact starting point. In the preparation, a slice of which is shown in the accompanying illustration, Fig. 24, the growth seems to have originated in the substance of the kidney and extended outwards to




FIG. 23.—Round-cell sarcoma of right kidney. Coronal section. Anterior half of preparation removed. Sarcomatous growth springing from convex border of kidney. Enclosed by capsule. Overlapped by kidney substance. Kidney compressed. Band of compressed kidney tissue between growth and hilum. Hilum uninvolved. Pelvis and infundibula dissected out. Growth slightly torn at upper part. Patches of extravasated blood in growth. (From a photograph lent by Mr. Targett.)



the capsule and inwards and downwards along the urinary passages.

#### HILUM GROWTHS.

In not a few instances the renal substance proper is but little affected, or, if involved, manifestly only by a local encroachment. Sometimes the kidney is small and atrophied, and as it were a mere appendage to the growth. From a consideration of

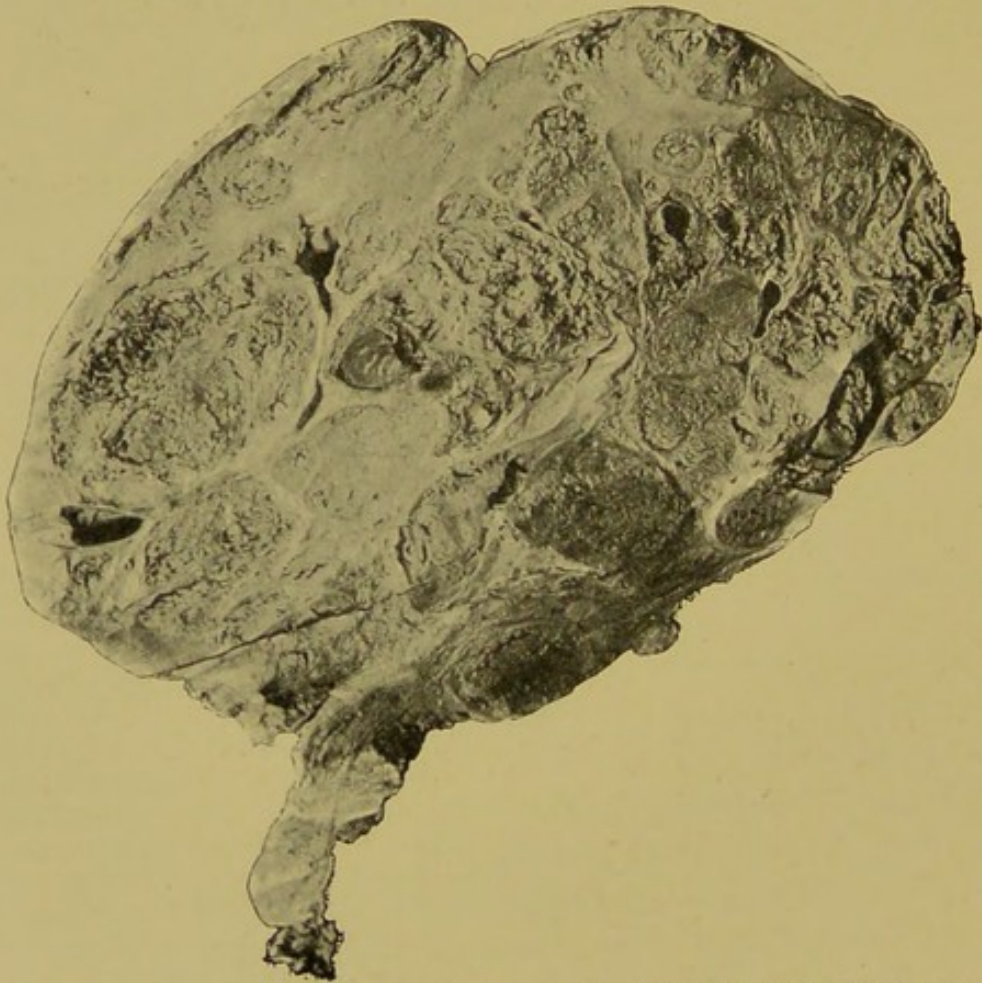


FIG. 24.—Slice from centre of renal sarcoma. Trabecular stroma with abundant aggregation of soft sarcomatous cells.

the relation of growth to organ, one is driven to the conclusion that the former must have originated externally to the kidney tissue proper.

Most of the sarcoma originate within the kidney. Ashby and Wright<sup>1</sup> state that "in the majority of cases a new growth involving a kidney is a round-celled sarcoma, which begins outside the kidney, gradually displacing and compressing

<sup>1</sup> "Diseases of Children," 1896.

the kidney itself. It is difficult to say exactly where these growths begin, presumably in lymphatic tissue."

From a study of a number of museum specimens there can be no doubt that a certain proportion of these cases originate near the pelvis.

In 1880, Abercrombie drew attention to the development of growth in connection with the hilum. All his cases were young children, and in each both kidneys were involved by sarcomatous growth, which had invaded the organ at the hilum.

Hilum growths have been specially investigated by Mr. Targett, and fully dealt with by him in his Erasmus Wilson Lectures before the Royal College of Surgeons. He shows that they are generally situated outside the pelvis in

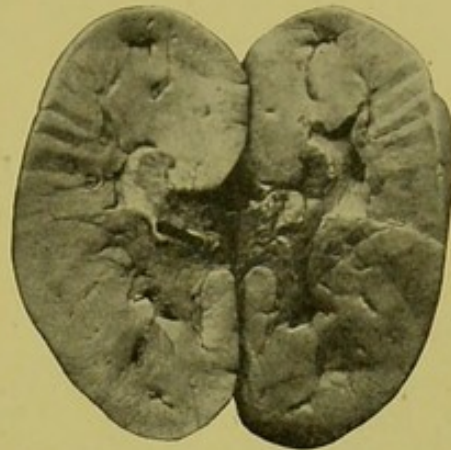

FIG. 25.—Fibro-sarcomatous growth invading and spreading along hilum of kidney. The growth can be distinguished by its darker colour. Rod indicates ureter which is compressed but not blocked.—From a photograph lent by Mr. Targett.

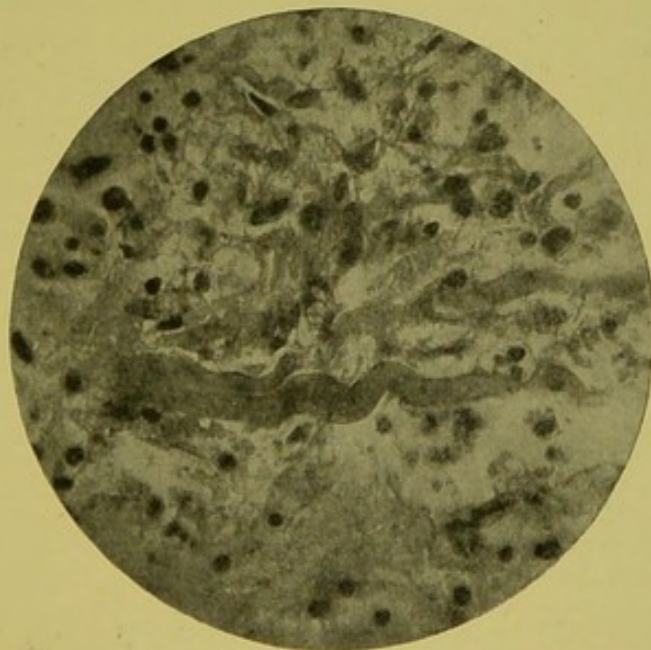

FIG. 26.—Photomicrograph of mixed cell sarcoma. Fine fibrous tissue. Round sarcomatous cells. Blood corpuscles. Large wavy fibres passing transversely, and possibly of the nature of imperfectly developed muscle cells. From case of which Fig. 25 is the macroscopic representation.—From a photograph lent by Mr. Targett.

the cellular tissue around the vessels and ureters. After pene-

trating the hilum the kidney becomes encroached upon, expanded, and finally a considerable portion of the gland becomes replaced, or so diminished as to be almost inconspicuous. In many instances the remnant of the kidney lies flattened out over the surface of the growth.

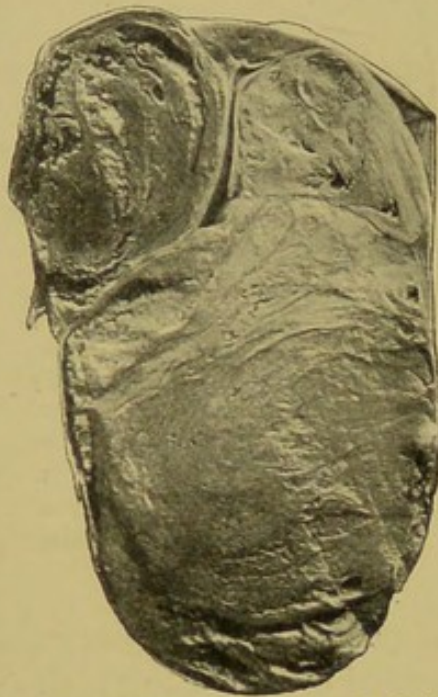

FIG. 27.—Growth of kidney. Probably originating in hilum. At upper end, portion of healthy kidney quite separate from adjacent lobule of growth to the left. Vertical slit represents compressed and elongated pelvis with calyces and papillæ. Large lobules of growth present dark areas, due to extravasation of blood. Whole growth enclosed with fibrous capsule, apparently the true renal capsule. Size of growth, 8 × 5 in. From a boy, æt. 3, who died of exhaustion and emaciation.—From a photograph lent by Mr. Targett.

Sometimes the renal parenchyma becomes so infiltrated with growth as to be unrecognisable. Through the kindness of Mr. Targett, I am enabled to illustrate the way in which growths at the hilum encroach upon the kidney proper (Fig. 25). The preparation was obtained from a girl æt. 4, and is preserved in the Museum of the Children's Hospital, Great Ormond Street.

"The kidney is normal as regards its special structure, but there is a firm, dark, new growth surrounding the pelvis and ureter, which forms a perfect mould of the hilum. Spreading along the outside of the infundibula, it enters the medullary substance in company with the vessels between the papillæ. The cut surface shows small, apparently separate, nodules of growth, at the junction of the cortex and medulla, but in reality these are extensions from the hilum along the vessels."

A further example of growth, probably originating in the hilum, has been placed at my disposal by Mr. Targett. It was removed from a boy æt. 3. The specimen is preserved in the Pathological Museum of St. Mary's Hospital (Fig. 27).

The Museum of Guy's Hospital also contains a preparation (1663) where a sarcomatous growth, evidently originating outside the organ, is invading the hilum.

## CHAPTER XI.

### SARCOMATA CONSIDERED ACCORDING TO THEIR HISTOLOGICAL CHARACTERS.

THE most satisfactory grouping of the renal sarcomata is that based upon their structural characters. The true nature and relationship of these growths can only be ascertained by a careful consideration of their histological features. And according to the variations in the microscopical appearances, so in some degree at least can clinical differences be distinguished. Accumulated experience, it is to be hoped, may before long more clearly indicate the exact association of clinical features with structural arrangement.

Still it is necessary to retain an open mind in attempting the interpretation of many of these growths. The combinations of connective tissue types with glandular forms often lead to much perplexity in allocating special examples to definite groups. The complex varieties seem to be much commoner than is usually believed.

Mr. Paul has particularly insisted upon the peculiar and complex histological structure of many of these growths, especially the so-called "congenital sarcomata." "The term sarcoma," he rightly says, "as applied to these growths, is in a certain sense misleading, for glandular elements are frequently present in them. However, in their mode of growth, and in their histological structure, they resemble the sarcomata, and even when markedly of the adenomatous type, we have less reason than usual for excluding them from this group, when we bear in mind that the kidney itself is purely of mesoblastic origin."

#### ROUND AND SPINDLE-CELLED SARCOMATA.

The majority of sarcomata consist chiefly of round and spindle cells. Usually one form of cell preponderates. In

some instances almost the whole growth consists of round cells. This has been the case in a number of specimens I have examined. Sometimes the round cells lie in disseminated clusters (Fig. 28). They usually grow very rapidly, and are extremely malignant. In some the growth contains large numbers of fusiform cells, which vary considerably in size. All, however, have a well-marked nucleus, and there is generally distinct evidence of rapid proliferation. Sometimes large areas of the sarcomatous tissue undergo degenerative changes, usually of a fatty or myxomatous nature, or actual necrosis may occur.

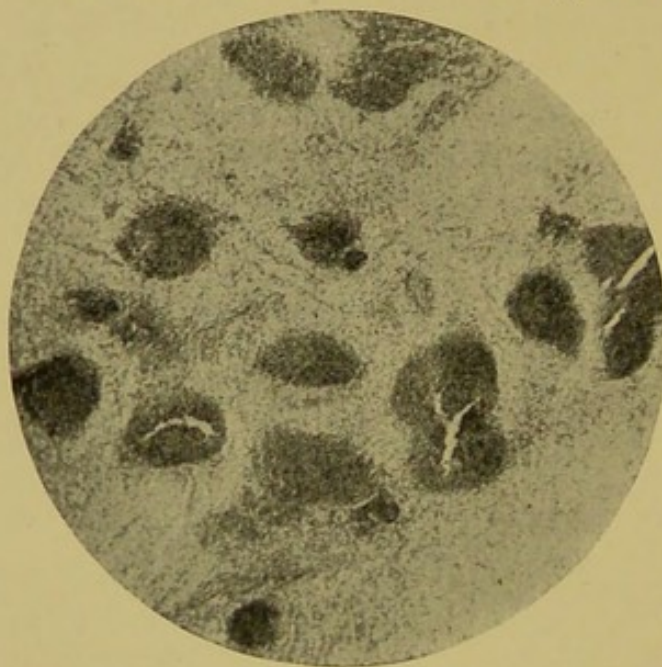


FIG. 28.—Round-celled sarcoma. ( $\times 60$ .)—From a very young child.

In some cases much difficulty is experienced in regard to the exact position which these growths should occupy in our classification of the sarcomata. This has been well indicated by Allen and Cherry, who point out that "some sarcomata of the kidney, especially of the fibrifying spindle-celled variety, may remain small and inactive." Some of these indolent growths are encapsuled, but others are not.

A specimen sent me by Mr. Paul consisted

almost entirely of round cells with only here and there a few very elongated spindle-shaped cells, evidently embryonic fibrous tissue.

In another of Mr. Paul's specimens of "congenital sarcoma" the growth consisted mainly of round and spindle cells, with extensive and thin-walled blood spaces (Fig. 29).

Brief reference may here be made to certain of the sarcomatous cases, which I have recently been enabled to investigate at the Manchester Royal Infirmary, in so far as they illustrate points of clinical or pathological importance.

R. P., male,  $\text{aet. } 1\frac{1}{2}$  years; admitted into hospital, under Dr. Harris, with history of progressive enlargement of abdomen. Tumour seems to have been noticed early in the first year. Symptoms were characteristic of renal growth.

*Autopsy.*—Greater part of abdominal cavity was filled by a large oval growth, 8 by 5 in., reaching from the right loin downwards, inwards, and forwards into the left iliac region. The growth was covered by peritoneum. Intestines were pushed inwards to the left, so that the cæcum with its appendix lay to the inner border of the lower end of the growth, and the ascending colon passed upwards along the inner border. The ureter was compressed and thinned out into a riband-like structure.

Growth consisted of soft, vascular, pinkish yellow masses, and extended along the renal vein into the inferior vena cava, thence as a thrombus-like extension projected into right auricle. No deposit in lungs. Left kidney normal, weight 1 oz.

*Microscopic.*—Growth consisted of aggregations of round cells in which lay large, thin-walled blood vessels and vascular spaces. A fine fibrous stroma formed a kind of network in some places, in the meshes

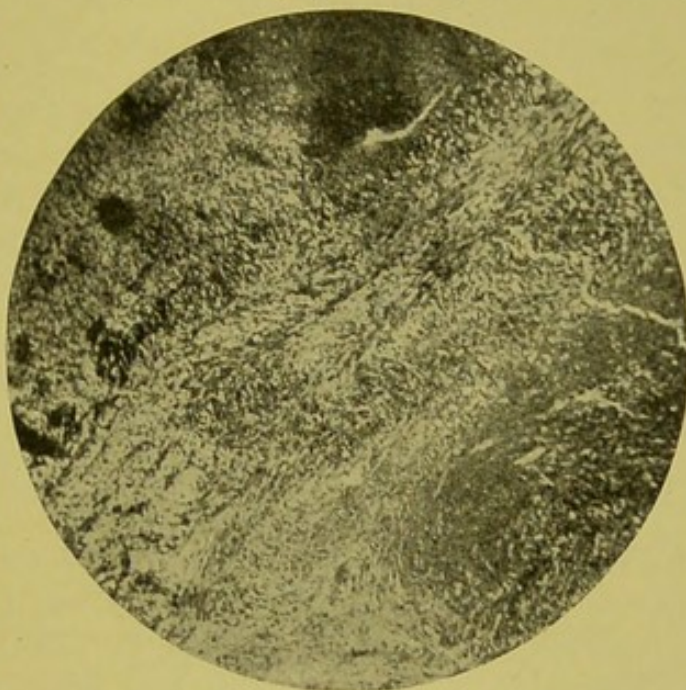


FIG. 29.—Round and spindle-celled sarcoma. Parts appearing very dark indicate vascular areas or vessels distended with blood. (Zeiss, Oc. 2, Obj. A,  $\times 50$ .) From a specimen lent by Mr. Paul.

of which round cells were grouped. There were numerous areas of necrosis in the mass of the growth. The growth was a very vascular round-celled sarcoma.

In the previous case, as well as in the following, the growth manifested itself at a very early age, and there seems much to warrant the view adopted by many pathologists, which permits the application of the term "congenital" to this class of sarcoma in infancy.

A. J., female, *æt.* 2 years; admitted to the Manchester Royal Infirmary under Dr. Harris.

*Clinical history.*—Was quite well up to three months before death. Pain in the abdomen was the first symptom. Became listless and readily tired, and lost weight. About a month before

death the child's mother first noticed tumour in left flank. Admitted to hospital with distinct tumour in left renal region. Rapidly got weaker, and died in ten days.

*Autopsy.*—Great enlargement of abdomen. Circumference,  $1\frac{1}{2}$  in. above umbilicus, 21 in. A large tumour mass occupied the left flank, reaching upwards to the diaphragm, and bulging the lower ribs outwards; downwards to level of anterior superior spine, forwards to anterior part of abdominal cavity, occupying greater extent of cavity, and passing  $2\frac{1}{2}$  in. to right of median line.

Descending colon passed over growth. To right of growth lay the displaced intestinal coils. Below, sigmoid and rectum. Above, growth was crossed by the transverse colon, and partly covered by the stomach. In front it was covered by omentum, to which it was in places adherent. Pancreas pushed forward in front of growth.

At upper part of growth, at outer part, sheet of renal tissue; cortex and medulla compressed to mere marginal strip, and separated from the great mass of growth by slit-like remnant of pelvis. At upper and lower parts kidney directly continuous with growth. Weight, 3 lb.  $4\frac{1}{2}$  oz.; size,  $7 \times 5$  in. Growth, dark red and pink colour, exceedingly soft and friable, and very vascular; in parts, yellowish white patches of firmer consistency.

Right kidney.—Normal; no growth; weight, 2 oz. Spleen.—Pushed upwards and outwards, but directly continuous with growth, although not involved by growth. Weight, nearly 1 oz. Liver.—Displaced upwards; no growth. Lungs.—Very anæmic; no growth. Mediastinum, recent hæmorrhage.

*Microscopic examination.*—The growth proved to be a typical round-celled sarcoma. The cells were grouped in masses, varying considerably in size, and surrounded by a fine fibrous stroma. In places remains of renal tubules could be detected.

The following case is of much interest, since it occurred at an unusual age, although the characters of the growth placed it undoubtedly among the most embryonic forms of the sarcomata.

E. R., female, æt. 19; admitted to the Royal Infirmary under Dr. Harris. About five months before death patient first complained of pain in the right loin, which increased in about six weeks, so that she had to take to bed. Tumour appeared shortly after.

On admission to hospital the patient was very pale and

wasted. Weight, 5 stones; temperature slightly raised. Large tumour mass was detected, reaching downwards to level of anterior superior spine of ilium, inwards to umbilicus, and above this to left side of body. Tumour hard and exceedingly tender. Exploratory aspiration showed granular looking material, containing round sarcomatous cells. Urine scanty—20 oz., sp. gr. 1022; acid, albumin, blood, phosphates. Temperature continued irregular, sometimes reaching 102° F. Shooting pains and difficulty in breathing. Superficial veins over abdomen became

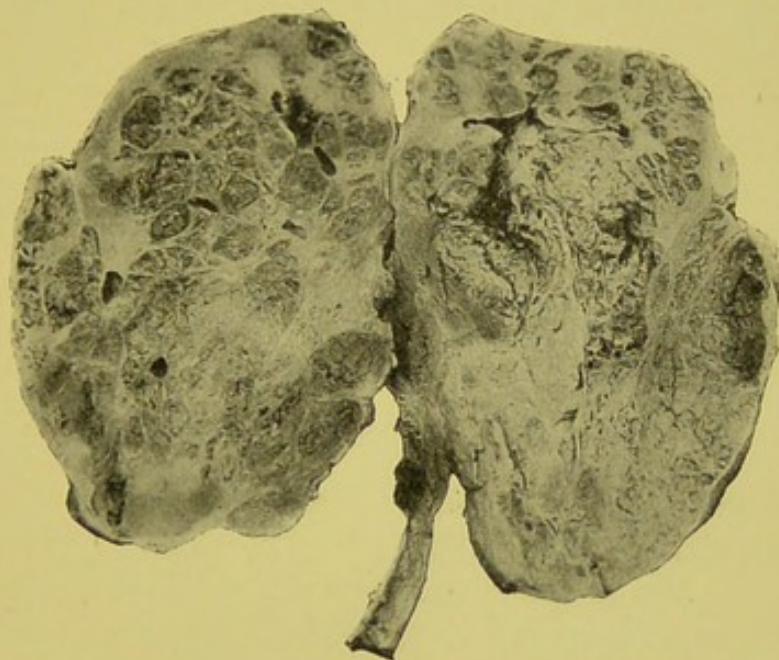

FIG. 30.—Sarcoma of kidney. Traces of renal cortex at both ends. Irregular strands of fibrous tissue, pink in colour, homogeneous in appearance, dividing growth into irregular spaces filled with soft cellular growth; some pink, others yellow, and a few red, like blood. Honeycomb appearance, of spongy consistency in parts. Hemorrhagic areas. Extension of growth along ureter.

distended, and jaundice appeared. Renal growth extended to become continuous with liver. Death from exhaustion.

*Autopsy.*—Abdominal cavity partly filled by huge tumour mass, extending from right loin upwards beneath liver, forwards to median line, and downwards to brim of pelvis. Growth firmly adherent to lower surface of anterior border of liver. Cæcum immediately below lower end of growth. Ascending colon pushed downwards, inwards, and forwards, and thus lay in oblique direction over inner portion of tumour. Transverse colon under cover of stomach, which was pushed downwards and assumed vertical position. Intestines adherent to growth. Size of growth, 9 by 6½ in.



Growth, soft, red-brown colour; parts had gelatinous appearance. No cysts; no evidence of kidney tissue; thrombus in renal vein. Left kidney healthy. Meckel's diverticulum present, 43 in. above ileo-cæcal valve.

Lungs.—Old caseous nodules in right lower lobe; no growth.

Heart.—Mitral sclerosis and recent vegetative endocarditis.

*Microscopic examination.*—Consisted chiefly of round and spindle cells. Numerous thin-walled vessels, closely surrounded by sarcomatous tissue. No intercellular stroma. Some parts very distinctly myxomatous. The growth was a round and spindle-celled myxo-sarcoma.

The general character of many of these sarcomata is well shown in Fig. 30, photographed from a specimen which we have in our hospital museum. The clinical history of the case I have been unable to obtain. It is unnecessary to describe the growth in detail. Microscopically, it proved to be a very vascular, round, and spindle-celled sarcoma.

#### MYO-SARCOMA.

The rhabdo-myoma is a form almost special to young subjects. Mixed with the round and spindle cells, which may be present in very variable proportions, are elongated and transversely striated cells. The cells are generally thinner than true muscle cells, and have no sarcolemma. They vary in size and in the distinctness of the striation. It is usually best marked in the larger fibres, but there is the greatest variation and gradation in these muscle-like cells. The nuclei are said to be generally placed rather more to the walls of the fibres than enclosed in the midst of the cell. Haycraft, Sutton, and others have thought that possibly the fibres may not be true muscular elements, but ribbings of the surface of a tissue which is not contractile. Spaces lined with cells and resembling kidney tubules are usually present in these growths. The epithelium frequently shows proliferative change. The myo-sarcomatous elements have an intertubular position. These growths are said often to contain glycogen. There is sometimes a considerable amount of freely formed connective tissue, which some state occasionally contains elastic fibres (Figs. 26, 31, 33).

Rhabdo-myomata appear to have been first recognised by Rokitansky in 1848. They were more particularly investigated

by Eberth in 1872, and later still in 1875 by Cohnheim. In the papers of Neumann, Ribbert, and Wolfensberger will be found useful references to the history of the early cases.

As previously indicated, the origin of these growths is probably dependent upon inclusions of the muscle elements, consequent upon faulty segmentation of the primitive muscle plates, and which become, as it were, entangled in the intermediate cell mass. Similar growths are said to occur, although only rarely, in the testicle. These growths have been met with between

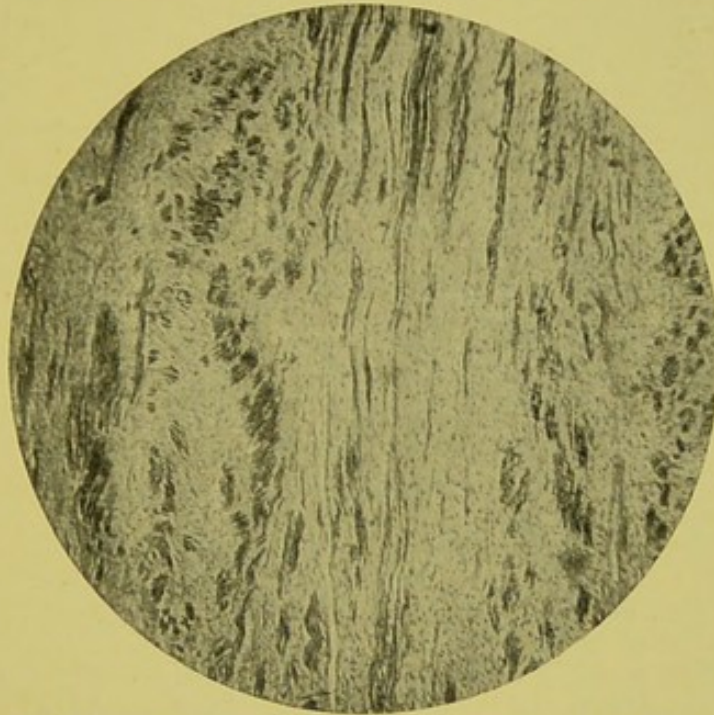


FIG. 31.—Striated myo-sarcoma. (Zeiss, Oc. 2, Obj. A,  $\times 50$ .)—From a specimen lent by Mr. Paul.

6 months and 3 years, but most frequently they occur under 2 years of age.

Paul and many other modern pathologists think they should be grouped under the teratomata.

The growths may be limited to one kidney, but they are sometimes bilateral.

Box describes such a case occurring in a male infant of 11 months. The kidneys formed two large tumours, practically filling the abdomen; the right weighed  $35\frac{1}{2}$  oz., the left  $11\frac{1}{2}$  oz. In each the kidney substance was replaced by an encapsuled mass of whitish glistening growth, which microscopically proved to be a very vascular round-celled sarcoma, with a few intermixed fasciculi of striated muscle fibres and large areas of necrosis.

They remain for some time encapsuled and separable from the kidney substance. The lymphatic glands are not early affected. Secondary deposits are uncommon, although they have been met with in the liver.

Jacobi says, metastases, if they do occur, appear late and are not very extensive.

These growths may reach enormous dimensions. One has been recorded by Paul which weighed 6 lb., in a female infant, the rest of the body weighing 10 lb. Dawson Williams met with an example in a male child *æt.* 13 months, weighing 1 lb. 13½ oz., or one-sixth of the total weight of the body.

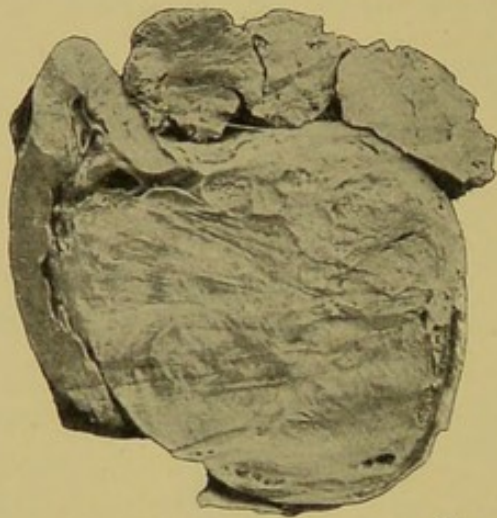


FIG. 32.—Adeno-myosarcoma. Compressed and atrophied kidney to the left. Large rounded mass of growth projecting into hilum. Renal capsule enclosing both kidney and growth. Masses of soft growth at upper part, which have apparently burst through capsule. Main mass of growth presenting interlacing bundles of fibrous-looking tissue, enclosing spaces filled with softer growth. Removed by operation from a child 10 months old, in whom an abdominal swelling had been noticed shortly after birth.—From a photograph lent by Mr. Targett.

Through the kindness of Dr. Wilkinson, I have been enabled to investigate a very interesting case of bilateral myo-sarcoma from an infant of one year. The child had been under observation for some three months, and the growths had evidently formed distinct "tumours" soon after birth. The specimens were shown at a recent meeting of the Manchester Pathological Society. The right kidney formed a huge mass 9½ in. transversely, 8½ in. long, and 6 in. from back to front, and weighed 6 lb. 12 oz. Almost the whole organ was replaced by growth. The left kidney was

much smaller. It was 2¾ in. transversely, 4¾ in. long, and 3½ in. back to front, and weighed 1 lb. 12 oz. What seemed to be about half the normal kidney still remained. Microscopically the growths consisted of round and spindle cells with large wavy striated muscle-like elements. There was a fine fibrous stroma. Some parts stained very badly and were apparently semi-necrotic. In some areas were curious fine duct-like structures lined by a single layer of cells.

A considerable number of cases are on record, the chief

being those published by Abbe, Brock, Brodawski, Brosen, Cohnheim, Eberth, Eve, Heidemann, Hoisholt, Huber, Kocher and Langhans, Landsberger, Osler, Manasse, Marchand, Paul, Ribbert, Smith, Virchow, Williams, Windle, and Wolfensberger.

One of the photographs so kindly placed at my disposal by Mr. Targett admirably illustrates the appearance of a myo-sarcoma, originating in or near to the hilum (Fig. 32). I quote from Mr. Targett's notes —“The outline of the

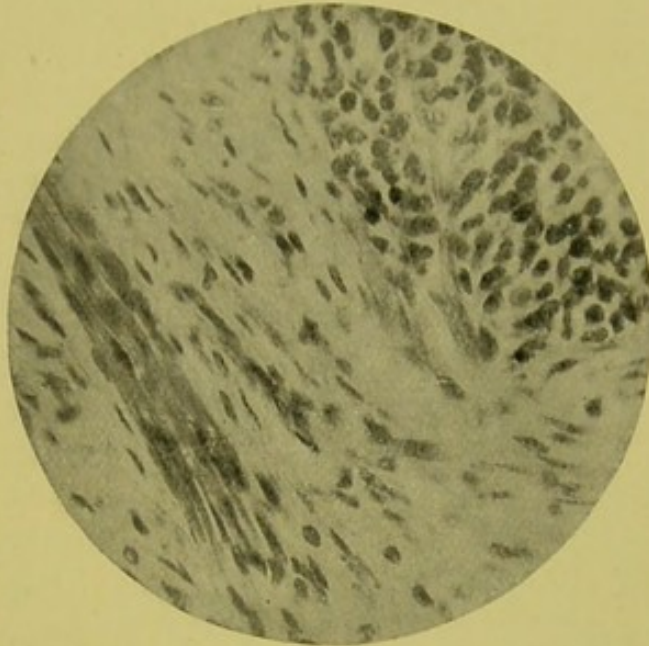


FIG. 33.—Section from main mass of growth shown in Fig. 32. Bundles of muscle cells at lower and left side of photograph, some of which show striation. Collection of sarcomatous cells at upper and right side.—From a photograph lent by Mr. Targett.

healthy renal tissue is well seen, forming a kind of cap to the

rounded tumour which projects into its hilum. The tumour is in contact with the renal pelvis, but does not invade the glandular tissue. Superiorly the cortex can be traced for a short distance over the kidney ; inferiorly it is only represented by a thin layer of compressed parenchyma, hardly distinguishable from the tumour. Over all the fibrous capsule of the kidney is laid, and can be easily followed from the convex border of the kidney to the right-hand margin of the tumour. This capsule, after

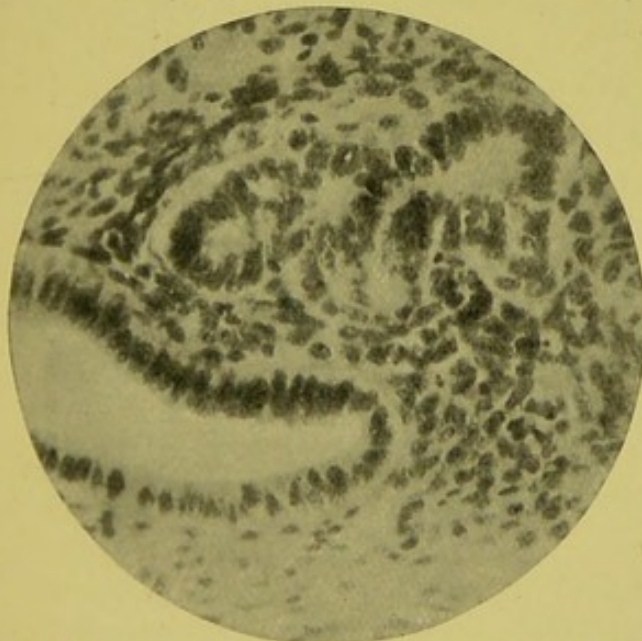

FIG. 34.—Section from nodules at margin or in extra-capsular portion of growth, Fig. 32. Round and oval sarcomatous cells. Spaces lined by columnar epithelium.—From a photograph lent by Mr. Targett.

the right-hand margin of the tumour. This capsule, after

considerable stretching by the growth, has at length yielded to

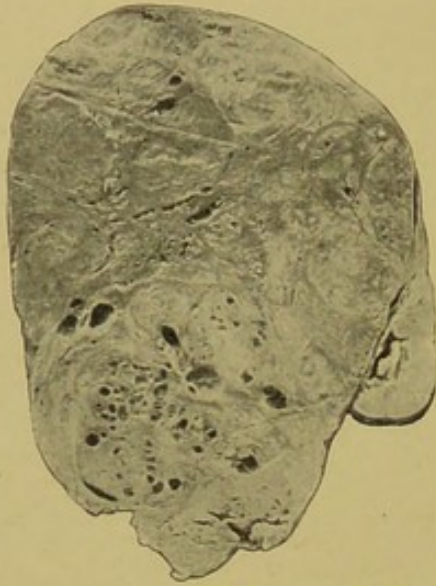

FIG. 35.—Rhabdo-myo-sarcoma of left kidney. Remnants of kidney on right side of photograph. Hilum and posterior half of kidney flattened out by growth. Anterior half of kidney replaced by growth. Fibrous capsule includes all. Growth consisting of irregularly distributed fibrous-looking tissue, with numerous cysts at lower part. From a child.—From a photograph lent by Mr. Targett.

the pressure within. In consequence, lobules of soft growth are seen at the top of the preparation, and still more abundantly upon its reverse. The ureter does not seem to have suffered compression, for the calyces are not dilated. The appearance of the cut surface of the growth shows some differences in its structure. To the left a large arc of the tumour is streaked with interlacing white bundles like fibrous tissue. To the right, and more especially in the extra-capsular portion, its substance is more granular and friable, and permeated by some large vessels. Microscopic examination of the fibrous portion showed intercut in various directions. On lacing bundles of muscle cells cross section the dotted appearance of muscle fibres was very obvious, and in longitudinal section they show either cross striation or only fibrillation in the long axis of the cell. Each cell is nucleated either at the middle, or at the periphery (Fig. 33). The appearances of a piece from the margin are represented in Fig. 34. They comprise scattered bundles of muscle cells with myophan striation, ordinary oval and spindle-celled sarcomatous tissue, and very distinct masses of glandular epithelium. In the softer parts, especially that outside the boundary of the tumour, the tissue consists almost entirely of

the pressure within. In consequence, lobules of soft growth are seen at the top of the preparation, and still more abundantly upon its reverse. The ureter does not seem to have suffered compression, for the calyces are not dilated. The appearance of the cut surface of the growth shows some differences in its structure. To the left a large arc of the tumour is streaked with interlacing white bundles like fibrous tissue. To the right, and more especially in the extra-capsular portion, its substance is more granular and friable, and permeated by some large vessels. Microscopic examination of the fibrous portion showed intercut in various directions. On



FIG. 36.—Rhabdo-myo-sarcoma of right kidney. Growth springing from anterior surface of kidney, and lying as it were in a cup of renal tissue. Second nodule in lower end of kidney, probably secondary, presenting several cysts. Main growth consists of interlacing bands, yellowish or of faintly brownish white colour. Capsule of kidney enclosing all. From a child.—From a photograph lent by Mr. Targett.

the tissue consists almost entirely of

masses of glandular epithelium, with acini and large dilated ducts lined with columnar epithelium. A little loose embedding tissue is seen above. The tumour is described as an adeno-myosarcoma."

The growth was removed by operation from a child *æt.* 10 months. An abdominal swelling was detected soon after birth. The specimen is preserved in the Museum of St. Mary's Hospital.

These myo-sarcomatous growths vary considerably in size, form, and general appearance. Even when bilateral, the two growths may differ considerably on macroscopic examination. This is shown in Figs. 35, 36.

The original specimens are preserved in the pathological collection of the Royal College of Surgeons of England (3584 and 3584A).

In the one kidney the growth is of considerable size, the organ only being apparent as a crushed and flattened structure along the convex border of the tumour (Fig. 35).

The opposite kidney shows the growth projecting from the surface of the organ, but at a much earlier stage than in the other (Fig. 36).

The specimens were obtained from a young child. The adrenals in the case were normal. These specimens seem to suggest that the development of these so-called "congenital" sarcomata do not always originate simultaneously.

A further example of myo-sarcoma is illustrated in Fig. 37, photographed from a specimen met with in the Great Ormond Street Children's Hospital. The growth forms an oval mass, with the remains of the expanded kidney on one side. On section, a part of the growth presents lobules composed of interlacing bundles of fibres, which consist of cross-shaped muscle cells. Large blood extravasations had occurred in several places (Fig. 37).

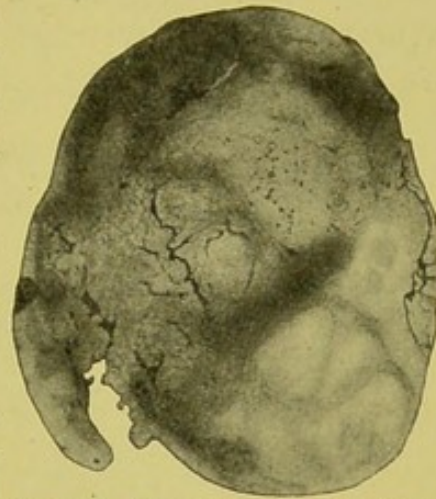


FIG. 37.—Myo-sarcoma. Remains of kidney on the left. Mass of growth on right, expanding kidney. Trabeculae divide it up into lobules. Spaces filled with sarcomatous tissue, which has fallen out in several places, leaving small cavities. Large extravasations of blood. Lighter coloured lobules at lower right extremity, having somewhat whorled appearance, consist of striated cells.—From a photograph lent by Mr. Targett.

## ANGIO-SARCOMA.

Many sarcomata are very vascular. The researches of de Paoli and others, however, seem to show that there is a distinct variety, meriting the name of angio-sarcoma. They generally form dark mulberry-like projections of soft consistency. At first they may be encapsuled. The general form of the kidney is preserved at least for a time. The growths tend to extend throughout the organ. They have a more or less alveolar structure. Cystic changes are liable to occur. Hyalin changes are also common in the walls of the vessels and in the con-

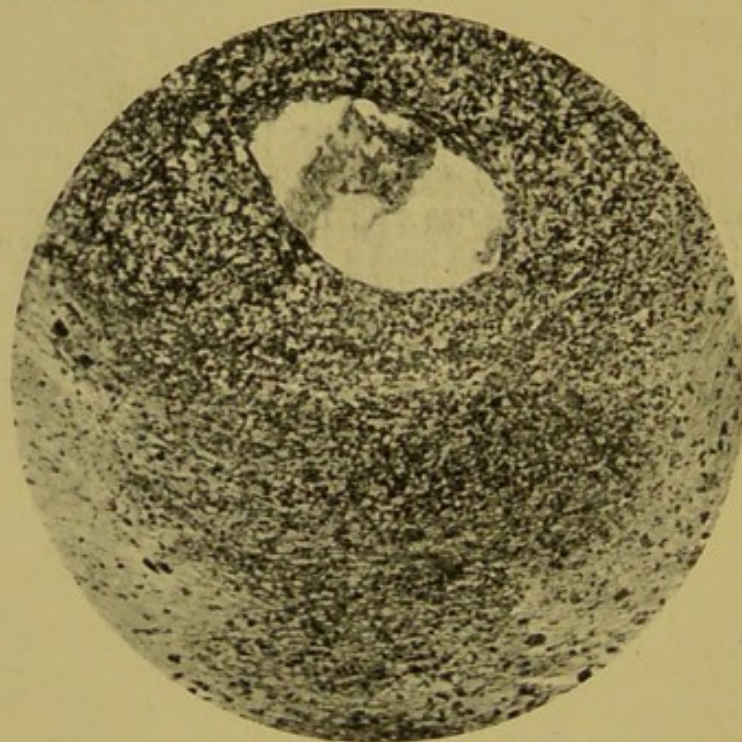


FIG. 38.—Angio-sarcoma. Preparation stained with osmic acid. Large vascular space containing blood. Surrounding tissue consisting of sarcomatous cells. (Zeiss, Oc. 4, Obj. A,  $\times 110$ .)—From a specimen lent by Mr. Paul.

nective tissue stroma. De Paoli, in his illustrations, shows cylinders formed of cells, in which considerable hyalin changes have taken place. Such changes occur chiefly in the walls of the blood channels. Between these columns of cells is fine connective tissue infiltrated with blood.

These growths would appear to originate from the perivascular tissue. Sometimes they seem to arise near the hilum of the kidney. Death may result from hæmorrhage. In some of the recorded cases no secondary deposits have been found elsewhere.

Wilson records an interesting case where, in an adult male,

the chief and almost only symptom was profuse intermittent hæmaturia. It was thought that the growth might have been in the bladder, and cystotomy was performed.

Under the heading of angio-sarcoma, Manasse would place the blood vessel endothelioma, the lymph endothelioma, and the perivascular sarcoma.

Mr. Paul has sent me a most interesting specimen, which appears to belong to this group. The growth occurred in a female, æt. 46. The greater part of the growth consisted of columns of epithelial cells, arranged around, and apparently originating in, the walls of a blood vessel. The lumen was usually not completely obliterated, and often contained blood elements. In some parts cells appeared to project into the central space. Much of the growth consisted of spindle cells and fine fibres. Many parts were infiltrated with blood corpuscles. Throughout the whole sections were irregular areas showing a hyalin change, and in which no definite structure was apparent.

Another of Mr. Paul's specimens also appears to belong to this group. The most embryonic of the sarcomatous cells were grouped around spaces filled with blood, as indicated in Fig. 38.

#### ADENO-SARCOMA.

In certain of the sarcomatous growths a variable amount of glandular-like tissue may be present. In some it consists of little more than stranded elements. In others, however, it forms an essential part of the growth, as can be plainly seen from the relationship of the glandular portions to the more distinctly embryonic cells.

Allen and Cherry clearly recognise this form. They describe "large epithelial developments, with distinct tubes or columns of epithelial cells, or masses of epithelioid cells, arranged in sarcoma fashion, or even an alveolar structure resembling carcinoma, but without any sign of active spread."

The general arrangement of these adeno-sarcomata is indicated in the accompanying illustrations, but it must be remembered that there is very great variation in the proportion and general arrangement of the component elements of these growths. Usually the adenomatous portions are less conspicuous than the typical sarcomatous parts, but considerable variety



occurs in the proportion between the two parts. It seems quite possible that some growths of adrenal origin may have been described under this term. Occasionally muscular elements may also be present, as in a specimen previously referred to (Figs. 32-34).

Mr. Paul has sent me particulars of an interesting specimen of adeno-sarcoma of the kidney of a little girl, *æt.* 2 years and 4 months. The growth was removed by nephrectomy by Mr. Pughe.

"The tumour with the remains of the kidney weighed 2 lb. It had the usual soft, juicy, brain-like appearance and consist-

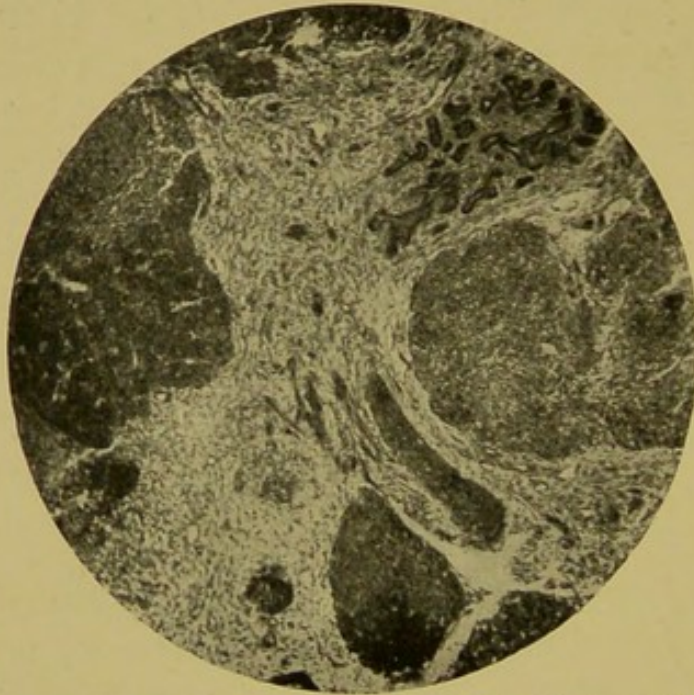


FIG. 39.—Adeno-sarcoma. (Zeiss, Oc. 2, Obj. A,  $\times 60$ .)  
—From a specimen lent by Mr. Paul.

ence, but contained no cysts. It had evidently originated between the pelvic membrane and the substance of the kidney, for the pelvis, filled with cheesy pus, was still to be seen at the inner part of the tumour, while the kidney itself was stretched over its external aspect.

"The microscope showed that the bulk of the growth consisted of broad trabeculae of rounded cells, supported by a delicate

cellular connective tissue (Fig. 39). The latter was freely supplied with well-developed blood vessels, which did not penetrate the trabeculae of round cells. The arrangement, in fact, was much like what one meets with in carcinoma of the antrum or nasal mucous membrane. Here and there in the connective tissue, groups of tubes lined with perfect cubical epithelium were met with, which exactly resembled the tubules of a foetal kidney, and when the trabeculae of rounded cells were examined with a high power, it was quite easy to see that they had a general tendency to form tubular structures, and that every gradation could be traced, from perfect tubes with a considerable lumen, to the more simple trabecular masses of round cells. An

examination of the connective tissue shows that it consists of, at various parts, round cells, spindle cells, branched cells, well-formed white fibrous tissue, and yellow elastic tissue; that the blood vessels are fully developed, and even small ones have a muscular coat; and that here and there are bands of spindle cells staining deeply with eosin, unlike the connective tissue spindle cells, and which are probably very young striated muscle fibres. Then, although nearly the whole of the epithelial structures of the tumour are of the type already described, still there are to be met with in some parts solitary cylinders of large, clogged, squamous epithelial cells, which can have no affinity whatever with the other variety. Altogether it will be seen that this tumour has a very complex structure, although the mass of it is of the nature of developing renal tissue."

#### ALVEOLAR SARCOMA.

Much doubt seems to exist in the minds of pathologists as to the nature of the so-called alveolar sarcomata. Those spoken of as endotheliomata are certainly closely related, and by some are considered as identical with alveolar sarcomata.

These growths probably originate in connection with the endothelial lining of lymphatic or vascular channels or spaces. They are thus probably very closely related to the angiosarcomata already referred to. I believe some of the forms described as carcinoma sarcomatosum really belong to this group.

The growths consist of cells forming groups or alveoli, and separated from each other by a variable amount of connective tissue. They closely resemble a glandular type, and doubtless many have formerly been considered to be true carcinomata. The cells are not of epithelial origin, but spring from the connective tissue stroma. These growths are distinctly malignant.

#### MYXO-SARCOMA.

The soft, whitish, jelly-like structure of these growths is dependent upon the abundant quantity of sarcomatous cells which are combined with cells of a mucous nature, and which form, as it were, a network or stroma in which the cells lie.

Eberth mentions a case occurring in a female child of 17 months.

Ebstein also records a case of a myxomatous sarcoma of the right kidney in a woman *æt.* 70, which reached the size of a small apple. Cases have also been published by Billroth, König, and others. I have also in several instances met with considerable myxomatous changes in renal sarcomata.

#### LIPO-SARCOMA.

Fatty elements, though rare, have been met with in association with sarcomatous tissue.

Allen and Cherry record a case, and state that "in an apparently simple lipoma of the kidney there are tracts of embryonic cellular tissue, mostly resembling round-celled sarcoma, but partly epithelioid. Some lipomata are progressive and infiltrating, and then contain a considerable admixture of sarcoma tissue, either round or spindle-celled. Islets of well-formed fatty tissue may be present in tumours which histologically resemble sarcoma, but the presence of such islets indicates comparative innocence.

As will be shown later, the so-called lipomatous growths originating in the perirenal tissue sometimes present sarcomatous elements and run a malignant course (Chapter XVII.).

#### MELANOTIC SARCOMA.

As already indicated, these growths, although occasionally met with in the kidney, are invariably secondary.

The characteristic naked-eye appearance and distribution,



FIG. 40.—Melanotic sarcoma. Numerous black rounded secondary nodules scattered throughout kidney, in both cortex and medulla. Longitudinal section. Only one-half of kidney shown.

and lines of extension of the pigmented sarcomatous cells, are indicated in the accompanying illustrations taken from a speci-

men now in the Pathological Museum of Owens College (Figs. 1, 40, 41).

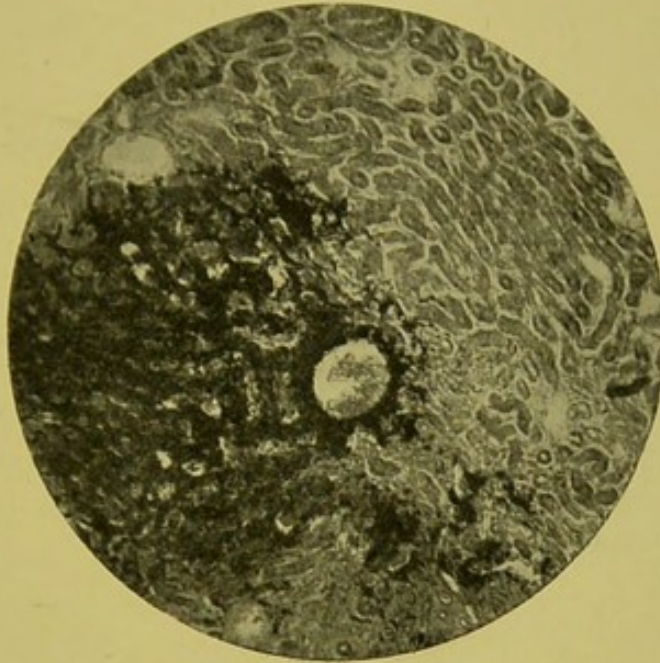


FIG. 41.—Melanotic sarcoma. Pigmented cells around vessel and infiltrating parenchyma at left and lower part of section. (Zeiss, Oc. 1, Obj. A,  $\times 60$ .)

#### LYMPHO-SARCOMA.

Cases of so-called lympho-sarcoma of the kidneys have been described. Usually both organs are affected, and at first sight they sometimes resemble very "large white kidneys."

Dr. Parkes Weber has somewhat recently reported a case of diffuse symmetrical sarcomatous infiltration of both kidneys in a girl *æt.* 5. Other abdominal viscera were also the seat of growth.

If thoroughly investigated, I believe all these cases would prove to be secondary, the primary growth usually originating in the mesenteric or retroperitoneal glands.

## CHAPTER XII.

### ADENOMATOUS GROWTHS.

IN the adenomatous group are placed certain growths which, while more or less distinctly glandular in general structure, are probably very different in origin and nature. Considerable further investigation will be necessary before their true relationships can be hoped to be made clear.

#### SIMPLE ADENOMATA.

These growths may appear as single or multiple nodules, and are usually sharply circumscribed. They consist of tubes and irregular spaces lined by cubical or columnar epithelium, closely resembling that of the normal tubules. Ziegler describes them as "well-defined white nodes, of the size of a walnut or less, and with a structure like that of ovarian adenomata."

Even the simple adenomata would appear to present great variability.

As regards number of growths, we have—

1. Single adenoma.
2. Multiple adenomata.

According to structural arrangement—

1. Solid, glandular adenomata.
2. Cystic adenomata.

Weichselbaum and Greenish and other pathologists further divide them into—

1. Papillary forms.
2. Alveolar forms.

The *papillary* variety is thought to originate in the collecting tubules, and consists of tubules and acini with papillary formations, and lined with cylindrical epithelium.

The *alveolar* variety is said to arise in the convoluted tubes, and closely resembles the true secretory epithelium. Harrison

says "adenoma occurs as small more or less encapsuled tumours, having a tubular or cystic structure."

Illustrations of the papillary and glandular types are given by Delafield and Prudden,<sup>1</sup> and also by Birch-Hirschfeld.<sup>2</sup>

The simple adenomata generally appear to the naked eye as small nodules in the cortex of the adult kidney, and vary in size from a pin's head to a small marble. They are generally rounded and of whitish colour, and by some observers are said to be most frequently met with in subjects over 40 years of age. Sometimes they occur in both kidneys of the same case.

Thoma says it is possible to see single urinary tubules pass into the tumour from the surrounding tissues, and sometimes these are in direct connection with the epithelial cells of the adenoma. He states, moreover, that there is always a distinct difference between the epithelium of the adenoma and that of the urinary tubules, although the latter may also have begun to proliferate.

Conolly Norman has described an interesting case of adenoma in a man, *æt.* 53.

The new growth existed in the right kidney. "It projected 9 mm. from the convex exterior border of the kidney, just below the middle of that surface. Externally it was closely covered by the capsule of the kidney, wherein, in this position, ran a great number of vessels—some encircling the base, others running over the surface of the growth. The tumour from the outside showed an expansion above the base, thus approaching to the pedunculated form.

"The surface of the new growth was nodular. It was of a lighter colour than the rest of the kidney. When the capsule of the kidney was removed, which adhered closely to the tumour, the latter showed a dirty white tint.

"On section, the tumour was seen to project into the substance of the kidney for about the same distance as it projected beyond the surface of the organ. The tumour was marked off from the kidney structure by a thin fibrous-looking, dark-coloured capsule, from which thicker bands extended into the new growth. In these dissepiments the openings of minute vessels were here and there distinguishable. On the projecting surface of the tumour this fibrous structure seemed to become continuous with the thickened capsule of the kidney."

<sup>1</sup> "Handbook of Pathological Anatomy and Histology," 1897.

<sup>2</sup> "Lehrbuch der Pathologischen Anatomie," 1887, Bd. ii.

Microscopically, the growth presented a distinctly adenomatous structure. Many alveoli strongly resembled uriniferous tubules. In some places the cells seemed to fill up the alveoli, leaving no distinct lumen. Towards the centre of the growth the structure became more confused. The alveolar mass presented numerous hæmorrhages.

"Throughout were numerous cavities which had contained blood, and to which a few blood corpuscles still adhered—some were mere holes surrounded by broken-down epithelial cells, others were cavities lined as above described."

The exact origin of the true simple adenomata is obscure. Probably, in not a few instances, they arise from "rests" of the renal tubules. It is very interesting to note that Ricker has met

with adenomatous formations in the central parts of infarction cicatrices in the kidney. He even mentions cases where a trabecular cystoma has apparently originated from such isolated elements.

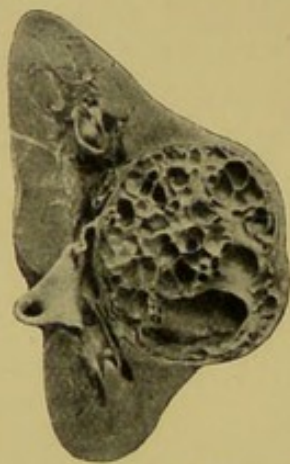


FIG. 42.—Localised cystic growth of kidney. Dr. Edmund's case.—From a photograph lent by Mr. Targett.

Dr. Edmunds has described a most interesting specimen of what appears to be a trabecular cystoma, which was removed by operation from a girl æt. 18, in whom a movable tumour had been noticed for two years occupying the left lumbar region. The specimen is in the Museum of St. Thomas's Hospital. Mr. Bland Sutton has also referred to the same specimen as an "adenoma" in his work on "Tumours"; and as the growth appears to have been of a benign character, it may perhaps be best referred to here (Fig. 42).

The growth was 2 in. in diameter, and consisted of an aggregation of cysts, varying in size from a small walnut downwards. It projected about an inch above the level of the convex border of the kidney, but a thin layer of renal tissue intervened between it and the capsule. At the hilum the growth blended with the wall of the pelvis, and was in contact with the vessels. The renal tissue both above and below was pushed aside, but otherwise normal. The spaces were smooth, and with the septa exceedingly thin and delicate.

Microscopically, the cysts were found to be lined with epithelial cells, columnar or cubical in shape.

In the simple adenomata there may be considerable variation in the proportion between cells and stroma. Sometimes the connective tissue is very abundant. Some of the adenomata are very vascular. These growths also sometimes contain glycogen in very appreciable amount. They may undergo fatty degeneration, and sometimes present areas of distinct necrosis.

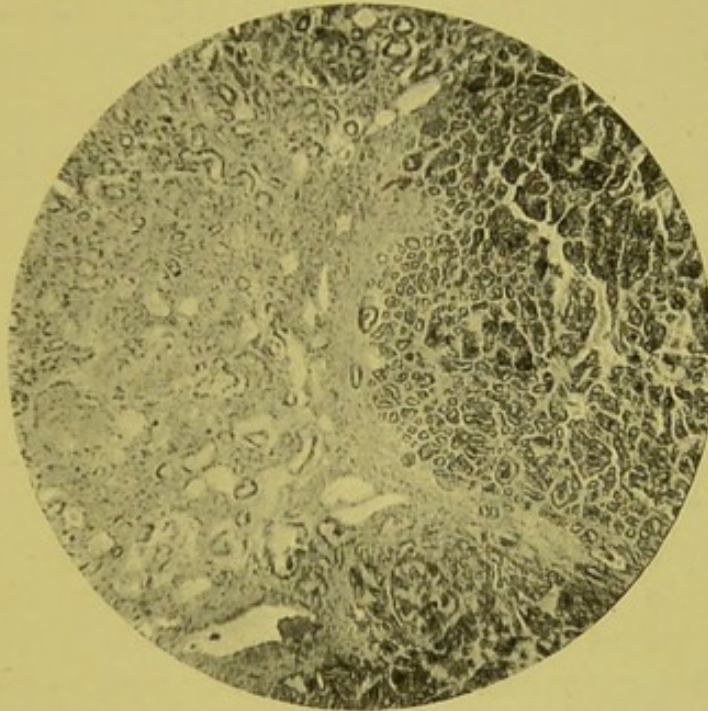


FIG. 43.—Adenoma. Renal tubules to the left. Adenomatous tissue on the right. Fine fibrous capsule separating the two. (Zeiss, Oc. 2, Obj. A,  $\times 60$ .)—From a preparation lent by Mr. Paul.

Sabourin and Cettinger describe adenomata in connection with interstitial nephritis, but these are probably more of the nature of a glandular proliferation rather than true growths. As will be shown presently, many of the simple adenomata are probably of adrenal origin.

Hufschmidt, von Kahlden, Nauwerk, and Sutton are inclined to include "true cystic disease" under the cyst-adenomata. This appears to me to be neither justifiable nor convenient.

Is it possible Wedl was referring to nodular adenoma when, in 1845, in his article on Renal Cancer, he makes the following somewhat surprising statement: "The more consistent nodules, not infrequently connected with Bright's disease, occasionally exhibit, notwithstanding they may have attained to a considerable bulk, an apparently homogeneous structure without a trace of vascularity"? The adenomatous forms of growth are further considered in Chapters XIII. and XIV.



## CHAPTER XIII.

### MALIGNANT CYST-ADENOMA.

No very definite line can be drawn between the various forms of adenomatous growth. They shade off one into another. Some, especially the "trabecular cystomata," as they have been termed, with papillary ingrowths, are particularly prone to take on indefinite growth and to manifest malignant characters. This seems to have been recognised by several pathologists.

Delafield has pointed out that sometimes adenomata behave like malignant growths, especially those forms which are very vascular. As he well says, "the adenomata which run a malignant course, with the formation of metastatic tumours, are often called carcinomata." Ricker has also met with a malignant form of trabecular cystoma. It is of very great practical importance to remember that, although from their microscopical characters they might be considered simple, yet frequently they prove malignant. This was well illustrated in a case recently recorded by Willet.

Klebs seems to think that the simple growths may develop into malignant forms. Thoma also says: "It appears that this transition of adenoma into a malignant variety of tumour is the more frequent in proportion to the degree in which the structure of the adenoma differs from the normal type." Ziegler also admits that it is very probable that the adenomatous growths may develop into carcinomata.

The cystic forms are especially prone to develop papillary ingrowths which project into the tubes and spaces, each covered with a single layer of cylindrical or cubical epithelium. Thoma gives excellent illustrations of such development. The cystic arrangement would seem to be an essential or elemental character in this form of growth. The varying extent and degree of the papillary ingrowths are probably more of a secondary

character, dependent in great measure upon rate of growth and adaptation to the surrounding structures.

The hæmorrhagic character of many of these cyst-adenomata is often very marked. In some instances the growth has an almost angiomatous appearance. The blood, at least in some instances, has so normal an appearance as almost to suggest that it had been freely circulating up to the time of death. Certainly the absence of distinct degenerative changes is a striking feature. There may be almost complete absence of true blood vessels. Reginald Harrison is perhaps referring to this class of growth when he says: "Some very interesting specimens of a vascular or hæmorrhagic tumour of the kidney have been recorded, and it is not decided whether they should be called angio-sarcoma or hæmorrhagic carcinoma."

It is generally stated that these growths, like the simpler adenomata, originate in connection with the convoluted tubules. It seems possible that they may develop from inclusions of aberrant glandular elements, or from remnants of the Wolffian bodies; although I believe it much more likely that they arise in connection with the renal tubules. Possibly the tubules from which they develop may be the seat of some congenital defect; although even this view is almost purely speculative.

Allen and Cherry have met with growths belonging to this class. In one instance the growth was met with in a man *æt.* 58, and formed an oval, well-defined, and partly encapsuled tumour. The microscopical examination showed "tubules and cystic spaces bounded by basement membrane, and lined or filled with active epithelioid cells. These seemed to arise from the inner surface of the cysts, with outrunners prolonged along the basement membrane, and others somewhat pyriform in shape retaining a narrow connection with the membrane. In some parts there were masses of nucleated endothelial plates, arranged somewhat in sarcoma fashion, with vascular spaces between them; in other parts, the cells have become branched and united into a kind of open myxomatous tissue with embryonic vessels." In another specimen, taken from an old man, the growth formed a rounded mass, 4 cms. in its greatest diameter, bulging both beneath the capsule and into the dilated pelvis. It was encapsuled, moderately soft, and had a grey, finely pitted appearance, with more homogeneous patches which seemed to be undergoing necrosis. Microscopically, the growth consisted of

cystic spaces bounded by fibrillar tissue, with processes which extended into the spaces. The spaces and processes were lined by epithelial cells. The papillæ in some instances filled the spaces and fused into a pseudo-alveolar tissue.

The same observers also record a remarkable case, where a multiple papilliferous adenoma of the kidney was associated with multiple cavernous angiomata in the liver and lymphomatous growths in the groins, axillæ, and spleen.

The papillary forms are said to originate in the medulla, but there is good reason to doubt if this is always the case.

Thoma figures an excellent example of papilliferous cyst-adenoma, which consisted of a number of nodules, and was obtained from a woman *æt.* 49.

Mr. Paul has sent me a specimen which he terms an "angeio-sarcoma of the kidney." It consists of cyst-like spaces, many of very considerable size, and appearing as distinct cavities to the naked eye. Many of the cysts are quite small. All, however, are lined by a single layer of columnar epithelium, but there was no intracystic papillary growth; many contain much blood. Distinct transitional stages can be distinguished, from the more or less normal renal tubule to the large cysts. Perhaps the best descriptive term would be "vascular trabecular cystoma."

The specimen described by Edmunds, and already referred to, consisting of a congeries of cysts lined with cubical epithelium, may possibly have near relationships with the class we are now considering (Fig. 42).

Somewhat recently I have had the opportunity of investigating an example of a malignant cyst-adenomatous growth, which illustrates so many of the more important features of this class of formations that I here venture to record it somewhat fully.

The patient was a married woman, *æt.* 33, and was admitted to the Manchester Royal Infirmary under the care of Dr. Dreschfeld.

CLINICAL HISTORY.—The patient had been healthy up to 16 years of age, when she was confined, and in her opinion the present illness dated from that time. She was married shortly after, and has since had six miscarriages. For many years she experienced periodic attacks of illness occurring at about intervals of six months, each consisting in swelling and pain at the lower part of the abdomen, with loss of appetite and vomiting. About

ten months before her death she experienced a worse attack, when the pain was of a shooting character and "went through to the back." A little later she first noticed two "lumps," one on each side, in the region of the lower ribs, each about the size of the hand, but hard and painless. In about a month, according to the patient's account, these enlargements disappeared somewhat suddenly. After this the lower part of the abdomen increased in size, and the pain became more severe; and the patient gradually got worse. The family history was good. Patient had kept a public-house, and had been in the habit of taking beer, but denied any indulgence in spirits.

On admission the patient was much emaciated, and very anæmic. The abdomen was much enlarged, the circumference at the level of the umbilicus being 32 in. The umbilicus slightly protruded. There was considerable ascites. The superficial veins were dilated. The enlarged liver reached to a level midway between the ribs and the anterior superior iliac spine. It was painful, and nodules could be detected over its surface. There was also considerable dulness in the left flank, due to a large tumour which reached almost to the crest of the ilium. Palpitation and dyspnœa caused much discomfort. The apex beat was in the fourth left intercostal space and outside the nipple line, with distinct pulsation over the second, third, and fourth intercostal spaces. A systolic murmur was heard at the apex. The pulse was regular, and there was undue pulsation of the subclavian artery. The veins over the chest wall were prominent. Proportion of white to red corpuscles, 1 to 513. Hæmoglobin reduced to 20 per cent. Respirations were chiefly thoracic in type. A few rhonchi could be detected at the base of the left lung. Vocal fremitus was diminished on the left side. The tongue was clean, but there was little or no appetite, and marked thirst. Pain was experienced over the whole abdomen, and worse after food, with occasional vomiting. Constipation very troublesome. Urine scanty, acid, sp. gr. 1014; no sugar, but a trace of albumin, some glandular casts and blood corpuscles. Menstruation had been arrested for four months. There was leucorrhœal discharge.

During her residence in hospital there was practically no improvement. The temperature was somewhat irregular, but mostly subnormal. Her weight on admission was 8 stones. After a short stay in hospital she left for home. A month

before her death she was readmitted, manifestly much worse. There was slight jaundice of face. The lips were coated with brownish crusts, and the tongue was red and furred. The abdomen was immensely distended. A large tumour occupied the left flank. The liver was larger than before, irregular and very tender. The urine was scanty, alkaline, sp. gr. 1010; contained albumin, but no sugar. There were also red corpuscles, leucocytes, and endothelial cells. There was much œdema of the lower extremities.

The peritoneal cavity was at once "tapped," and 2 gallons of fluid withdrawn. The patient steadily got worse. Twenty days before death the girth at umbilicus was 40 in. Large quantities of ascitic fluid were withdrawn on several occasions. Death occurred from asthenia.

AUTOPSY.—I made a pathological examination the following morning, and the following is an abstract of my report:—

*Macroscopical examination.*—Extremely emaciated middle-aged female. Considerable abdominal distension. Œdema of lower extremities. Slight jaundice. Rigor mortis passing off.

Abdomen.—On opening abdominal cavity, large quantity of ascitic fluid liberated, and large tumour mass on left side, with enormously large liver exposed.

Peritoneum.—Extensive adhesions over enlarged liver and renal growth.

Liver.—Extended upwards to third rib, and downwards almost to level of umbilicus. Antero-posterior diameter, 8 in.; transverse, 13 in. Surface roughened by numerous nodules of growth, which also infiltrated all parts of organ. One large mass, 6 in in. diameter, in right lobe, immediately below ribs. Growths of soft creamy consistency, very vascular, of pinkish-yellow colour, and of peculiar honeycomb appearance. Weight, 111 oz. Gall-bladder not involved.

Spleen.—Not enlarged. Size,  $3\frac{1}{4} \times 2\frac{1}{2}$  in. No growth. Placed along ribs, seventh to ninth partly under cover of left lobe of liver, and in contact with liver above and renal growth below. Weight, 3 oz.

Pancreas.—Anæmic, and with tail attached to inner part of renal growth.

Kidneys (right).—Slightly enlarged; weight, 5 oz. A little congested, but otherwise normal. (Left).—Seat of extensive diffuse growth. Size, that of child's head,  $9\frac{1}{2} \times 5\frac{3}{4}$  in.

Weight, 41 oz. The lower border at level of crest of ilium. Tumour more or less smooth, except anteriorly, where there was raised, rounded, nodular mass, 4 in. in diameter, situated immediately below spleen. One part of growth somewhat resembled outline of kidney. On section.—Growth involved practically whole of organ, leaving very little evidence of renal tissue. In a few places traces of cortex. Pelvis could be distinguished, but growth extended into it and blocked ureter. Growth also extended along renal vein into inferior vena cava. It was exceedingly soft, in parts almost diffluent, very vascular, and in greater part of purplish brown colour. In places irregular, hard gritty tissue, upon which the knife grated. Peculiar spongy appearance, which after hardening gave to growth distinct honeycombed aspect. Almost whole growth made up of cysts, with, in many instances, intracystic proliferation apparent even to the naked eye.

Ureters.—Both slightly distended; left blocked by growth at upper part.

Bladder.—Normal.

Thorax.—Whole cavity much diminished in size by extreme elevation of diaphragm consequent on upward pressure exerted by abdominal growth and ascitic accumula-

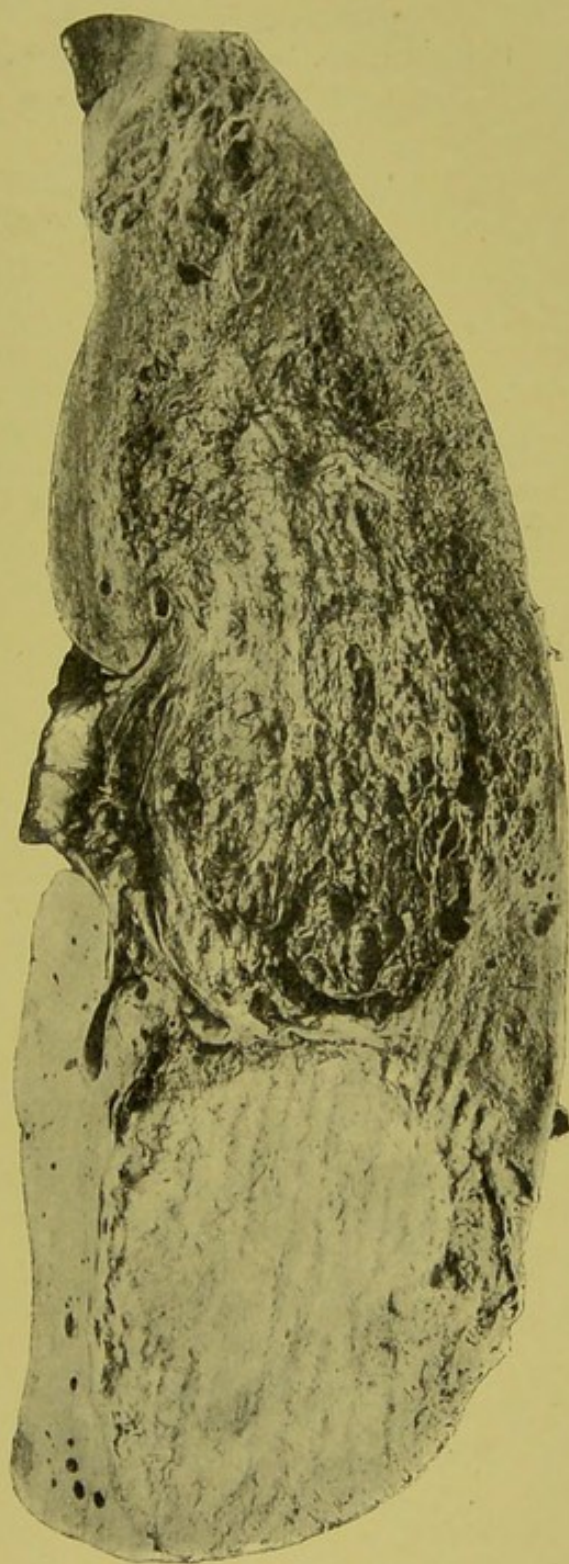


FIG. 44.—Slice of liver showing cyst-adenomatous growth identical in structure to that occurring in kidney (Fig. 45). Spongy vascular growth in left two-thirds (upper part of illustration); soft light-coloured mass of growth in right lobe (lower part of illustration).

tion. On right side diaphragm reached to lower border of third rib, and on left upper border of fourth.

Pericardium.—Small, and with heart displaced upwards.

Heart.—Weight,  $5\frac{3}{4}$  oz. ; valves, orifices, and cavities normal.

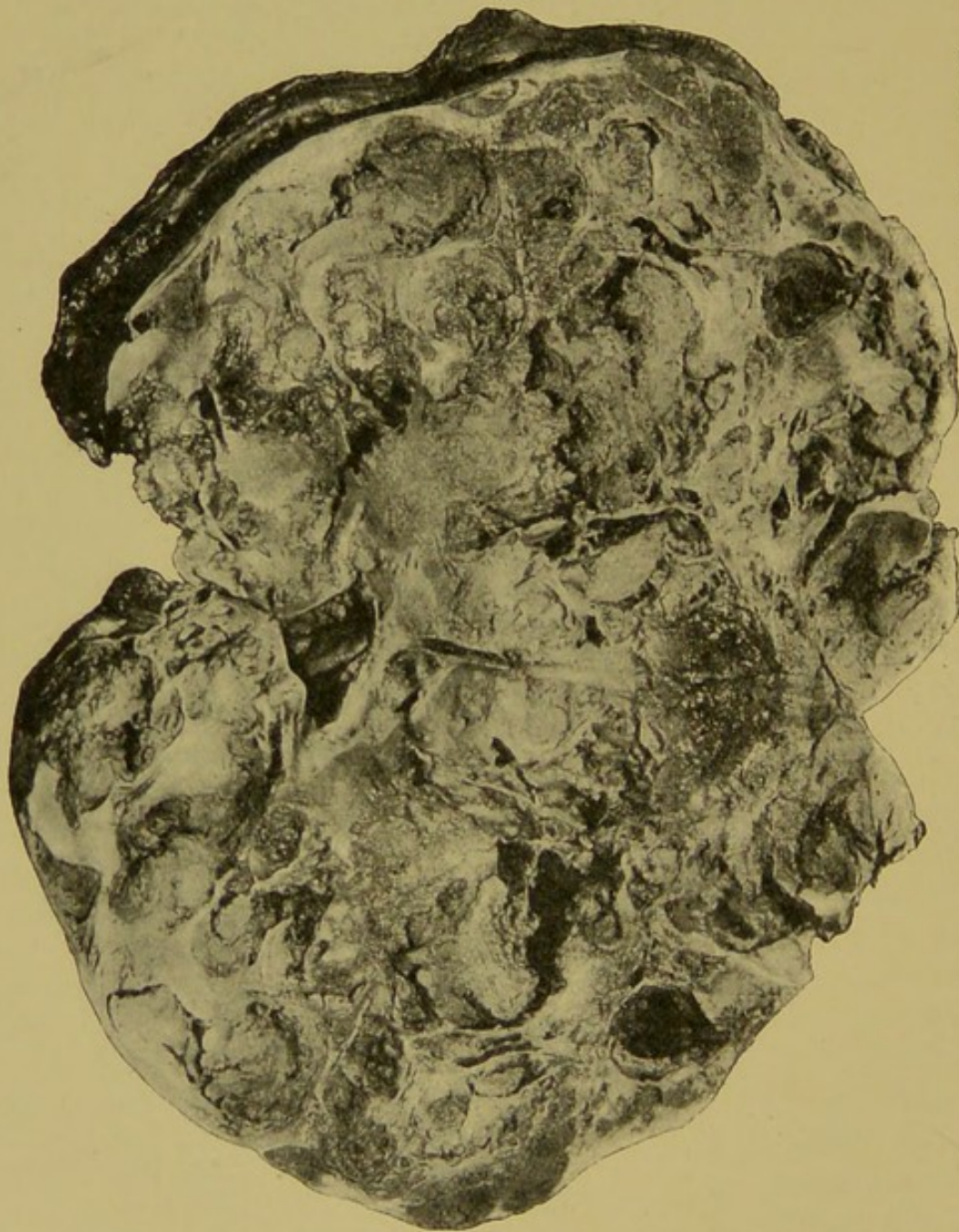

FIG. 45.—Malignant cyst-adenoma of kidney. Diffuse spongy vascular growth with slight remains of renal cortex beneath capsule.

Pleuræ (right).—Slight collection of serous fluid. (Left).—Extensive adhesions at base.

Lungs.—Both small, compressed, congested, and with one or two small rounded secondary nodules of growth. Weight, right, 15 oz. ; left, 18 oz.

The remaining organs presented nothing noteworthy.

*Microscopical examination.*—Kidney.—Sections taken from different parts of the renal growth. All parts presented adenomatous structure, with varying degrees of cystic arrangement.

The more important features are well illustrated in the accompanying figures taken from drawings kindly prepared from my sections by my friend and colleague, Dr. F. C. Moore.

Cysts.—These varied much in size. Some were no larger than an ordinary renal tubule, while others were of considerable

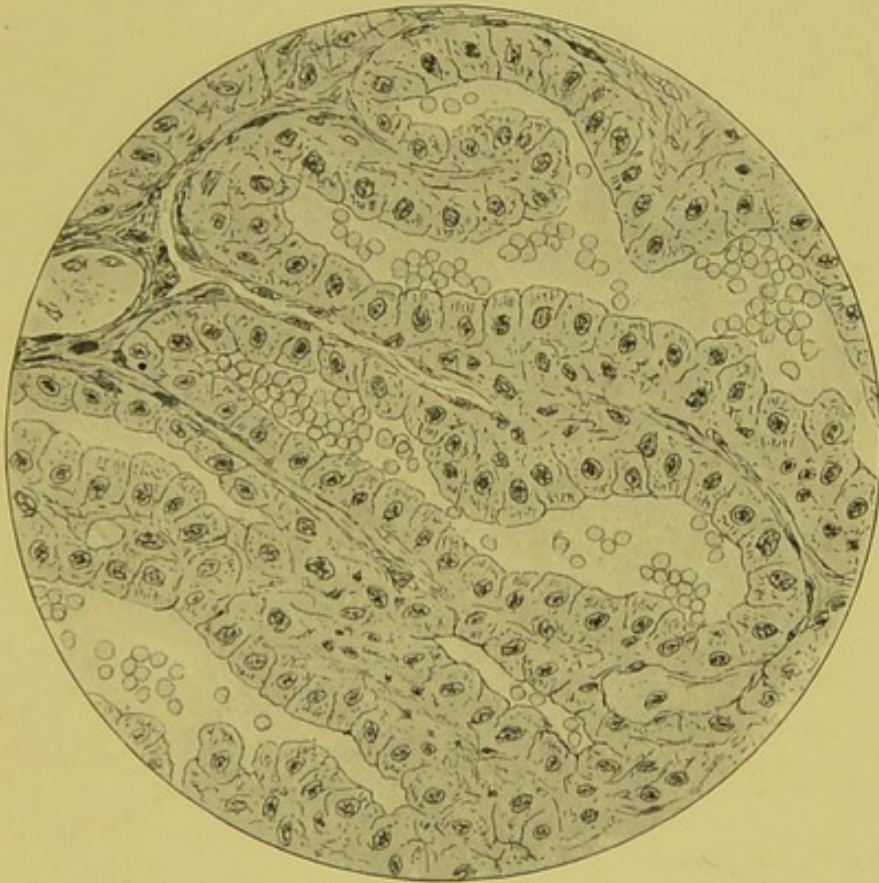


FIG. 46.—Section of malignant papilliferous cyst-adenoma of kidney. Irregular tubular-like spaces, lined by a single layer of epithelium and containing blood. (Zeiss, Obj. D, Oc. No. 2,  $\times 240$ .)

extent. Some could be readily distinguished with the naked eye. The cystic arrangement in the greater part could be clearly made out with an ordinary hand lens. The cysts also varied in shape. Many were more or less circular, others oval, elongated, irregular, and even tubular-like spaces. Each cyst was lined by a single layer of cylindrical epithelium, which stained exceedingly well and presented little or no evidence of degenerative changes. The epithelial cells were placed upon a basis of fine spindle-shaped embryonic connective tissue cells,



which, however, could hardly be said to form any distinct basement membrane (Fig. 46).

Intracystic papillomata.—While many of the cysts were minute cavities lined by a single layer of cylindrical epithelium, the majority showed distinct intracystic papillomatous growth. In some the papillomata were mere bud-like prominences, formed as it were by a slight indentation of the epithelial lining (Fig. 47).

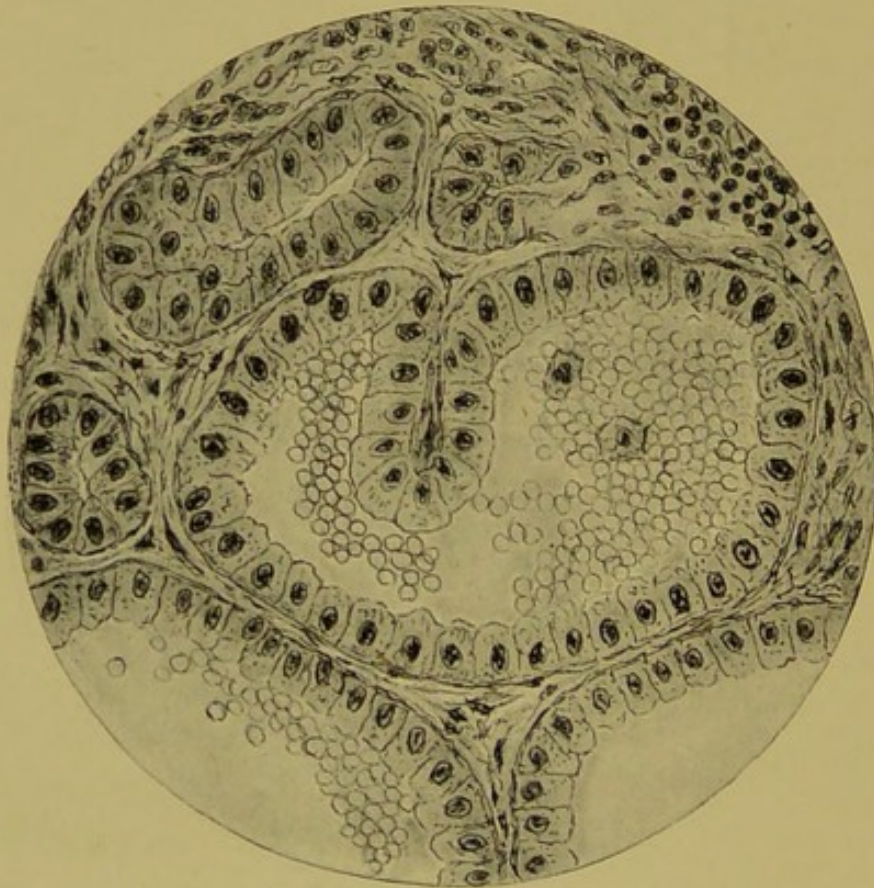


FIG. 47.—Section of kidney tumour. Cyst lined with single layer of columnar epithelium, and containing quantity of red blood corpuscles and one or two leucocytes. Papillary ingrowth shows first stage in the formation of intracystic development. Portions of adjacent cysts. Irregular tubules of distinctly renal type. Intercystic embryonic connective tissue. (Zeiss, Obj. D, Oc. No. 2,  $\times 240$ .)

These papillæ looked little more than a double row of cylindrical cells, the intervening stroma being so exceedingly scanty. In many cysts the papillæ were much more extensive, branched, and in some instances practically filling the whole space with proliferative epithelial ingrowth. In some the papillomatous growth was so considerable as to almost obliterate the original cyst cavity, which was indicated merely by a few slits or fissures (Fig. 48).

Distribution of blood.—Many of the cysts showed accumu-

lation of blood. Some were so crowded with red corpuscles as to give quite an angiomatous appearance. Many cysts, even where the intracystic epithelial development was considerable, contained much blood; and even cysts in which the cavity was practically obliterated by papillomatous growth still showed

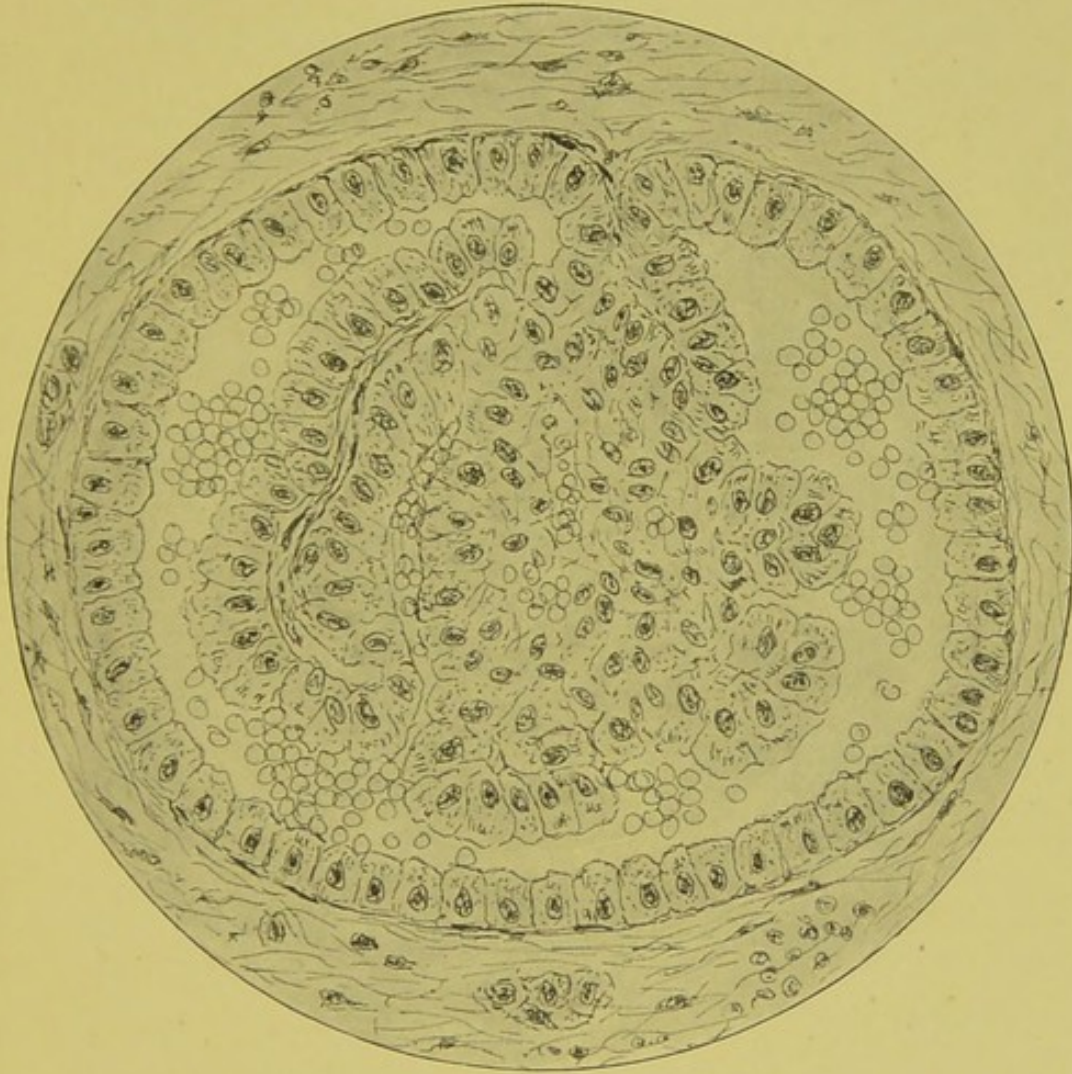


FIG. 48.—Section of malignant papilliferous cyst-adenoma of kidney. Large cyst lined by single layer of epithelium. Complex intracystic papillomatous projections. Remains of original cavity between and around intracystic papillomatous development containing blood corpuscles. Embryonic connective tissue around cyst. (Zeiss, Obj. D, Oc. No. 2,  $\times 240$ .)

blood in the spaces which represented the original cyst cavity. Extreme vascularity seemed an essential feature of the growth. The blood in most parts showed little or no indication of degenerative change, and the epithelial lining of the cysts presented no such effects as might be expected from the pressure of an ordinary hæmorrhagic extravasation (Fig. 49).

Intercystic tissue.—The structures between the cysts consisted of embryonic connective tissue, chiefly spindle-shaped cells, and numerous columns of cells of a distinctly renal type, and having in many parts a clearly tubular arrangement. There were also some few blood vessels, but these were by no means conspicuous.

Liver.—The hepatic growth closely resembled that of the kidney.

Cysts.—The cysts were most abundant, and readily discernible

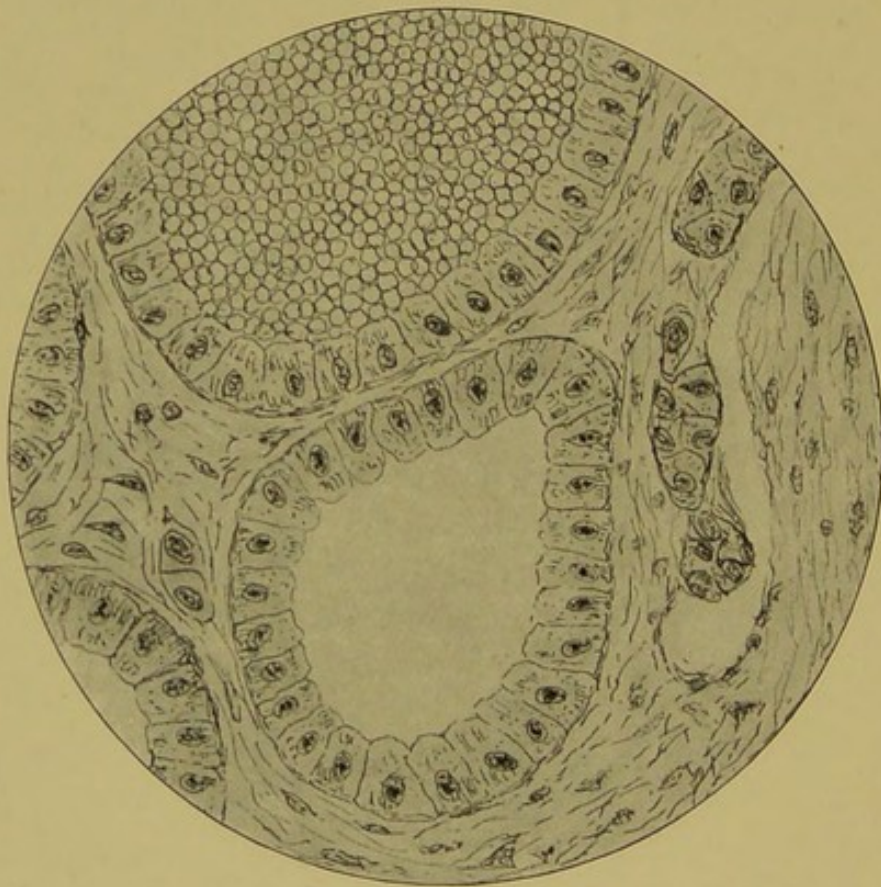


FIG. 49.—Section of papilliferous cyst-adenoma of kidney. Simple cysts lined by single layer of epithelium. No papillomatous formation. One cyst filled with well-defined blood corpuscles. Cellular intercystic tissue. (Zeiss, Obj. D, Oc. No. 2,  $\times 240$ .)

with the naked eye. They varied much in size, but generally assumed larger proportions than those in the kidney. Each cyst was lined by a single layer of cylindrical cells (Fig. 50).

Papillomata.—The intracystic papillomatous growth was well marked in many of the cysts, but as a rule was not so extensive or so complicated as in the kidney (Fig. 51).

Blood.—There was accumulation of blood within many of the cysts, just as in the kidney, but not so abundant.

Growth in vein.—A portion of the thrombus, taken just at the junction of the left renal vein with the inferior vena cava, showed distinct adenomatous invasion, cylindrical cells in more or less papillomatous form lying embedded in the clot (Fig. 52).

Glands.—Some of the small glands close to the main mass

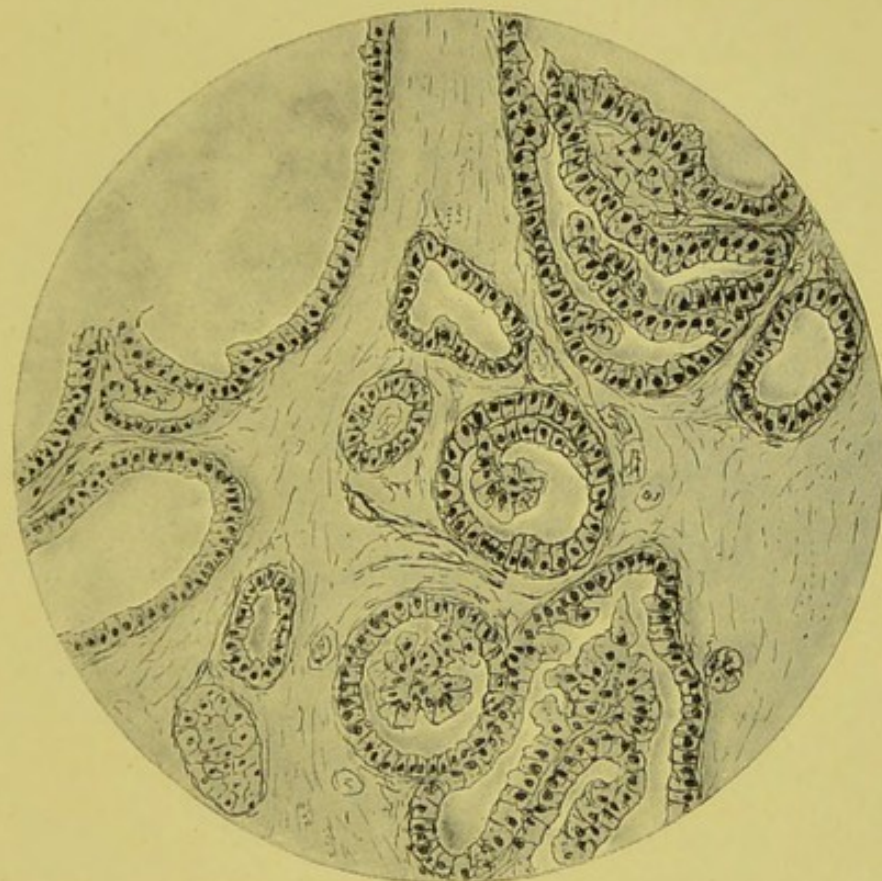


FIG. 50.—Section of liver. Cysts lined with single layer of epithelium, and showing intracystic papillomatous development similar to that in the kidney. The liver substance forming intracystic portions has, for convenience of illustration, not been defined in the drawing. (Zeiss, Obj. A, Oc. No. 2,  $\times 50$ .)

of the growth presented a similar appearance to that in the original neoplasm.

Although the above case presents several special features, it is perhaps undesirable here to discuss them further. The whole case may, however, be considered a good example of such growths as, I venture to think, are best designated by the term "malignant papilliferous cyst-adenoma."

Thoma records a case which, although somewhat different, is of interest in connection with mine. An adeno-cystoma

developed in the kidney of a woman, *æt.* 38. It was accompanied by a similar growth in the vaginal wall. Both were removed by operation. It was considered to be a case of primary multiple tumour formation, possibly dependent on an anomaly of development in the genito-urinary tract.

A somewhat similar case to the above is recorded by Mr.

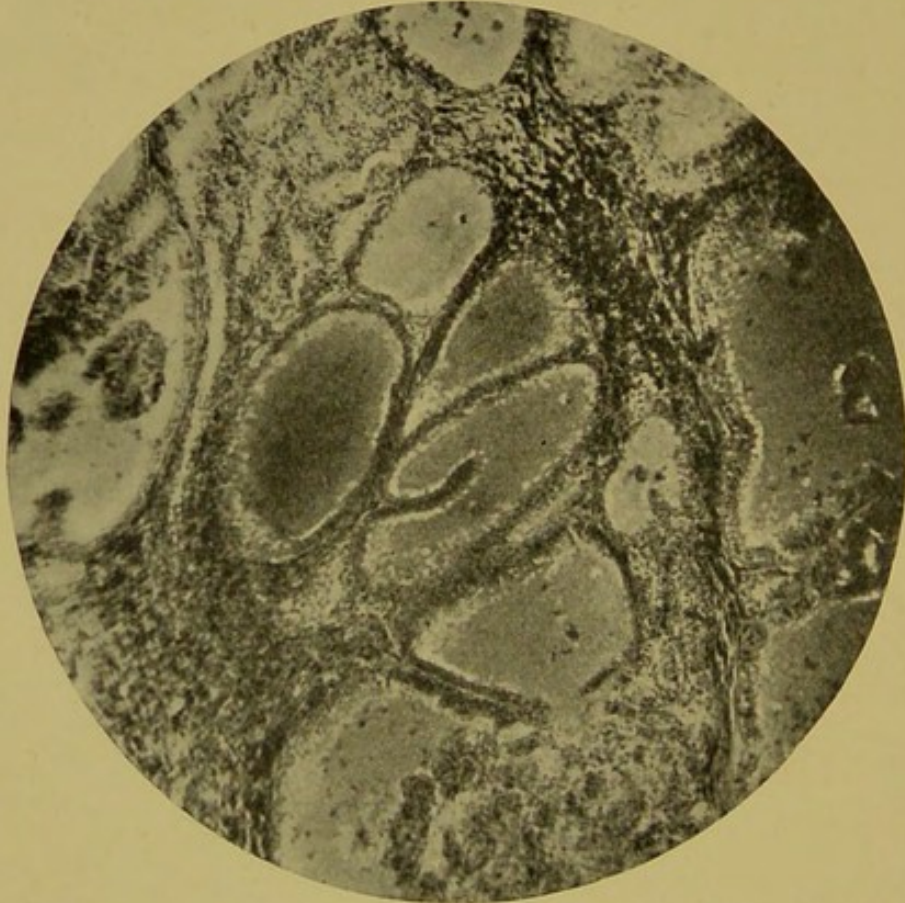


FIG. 51.—Photo-micrograph of growth in liver, from case of primary malignant cyst-adenoma of kidney. Structure identical with that of kidney growth. Cysts lined by epithelium. Cavities filled by blood. Intracystic growth commencing in central cyst. Liver tissue below and to the left. (Zeiss, Obj. A, Oc. 2,  $\times 50$ .)

Edgar Willett. The patient was a young man, *æt.* 19. He had noticed a tumour in the right loin for six months. The swelling rapidly increased. He experienced no pain, and the urine was always normal. Mr. Thomas Smith removed the whole kidney through the right linea semilunaris. A good recovery followed, "and the patient was able to hunt regularly throughout the following winter, and remains in good health at the present time."

The chief naked-eye characters of the growth are shown in Fig. 53. Microscopically, the growth presented the appear-

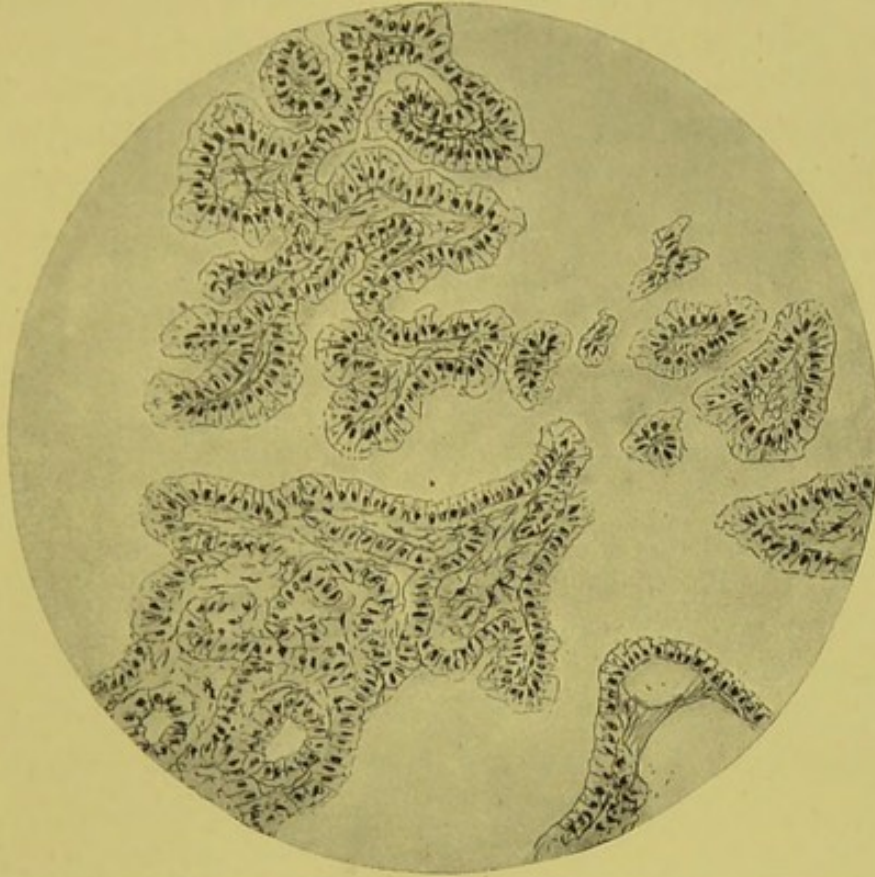


FIG. 52.—Section through clot close to left renal vein. Characteristic adenomatous structure similar to that in the kidney. The blood elements in the thrombus have been purposely omitted in the drawing. (Zeiss, Obj. A, Oc. No. 2,  $\times 50$ .)

ance of a trabecular cystoma. The spaces were lined by columnar cells, and there was extensive and complicated intracystic development.

Mr. Littlewood of Leeds has kindly sent me notes of a remarkable adenomatous growth which apparently belongs to this group. The growth was recently removed by nephrectomy from a woman *æt.* 55. The first symptoms were observed two years ago. She then had paroxysmal pain in the left lumbar region. Six months before admission to hospital, hæmaturia was first noted, and continued for four months. The growth

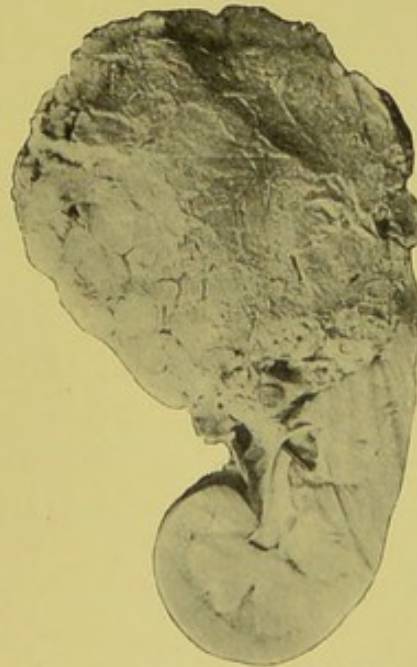


FIG. 53.—Cyst-adenoma of right kidney. Large nodulated mass involving upper end of kidney, consisting of a number of irregular cysts filled with soft vascular growth. From a man, *æt.* 19. Removed by nephrectomy. Recovery.—From a photograph lent by Mr. Targett.

was about the size of an orange, formed a prominence on the outer surface of the kidney, and was surrounded by a capsule. It extended to the renal pelvis. Microscopically, the growth consisted of cysts and spaces lined by cubical epithelium. In some parts there were processes covered with cubical epithelium, which appeared to project into the cysts.

## CHAPTER XIV.

### ON THE RELATION OF RENAL GROWTHS TO ADRENAL STRUCTURES.

THE present place seems to be the most convenient for a brief consideration of growths originating in connection with adrenal inclusions.

It is only of recent years that the importance of adrenal "rests" has been fully realised.

Adrenal "rests" have been met with in connection with the peri-adrenal fat, in the tissues near to the solar plexus, in the mesentery, in the broad ligaments adjoining the ovaries, and within the kidney.

Mr. Targett has recently described a case of multiple adrenal bodies in the broad ligaments of a foetal uterus.

Grawitz in 1883 was one of the earliest to indicate the relationship between certain forms of renal growth and aberrant adrenal tissue. These adrenal inclusions had been referred to by Robin in 1853, and Virchow in 1863, under the name of "lipomata." Grawitz proposed the somewhat cumbersome name of "*strumæ lipomatodes aberratæ renis*." They may for the present be conveniently spoken of simply as "adrenal rests."

The subject has been carefully investigated by such observers as Ambrosius, Askanazy, Beneke, Gatti, Horn, Lubarsch, Lowenhardt, MacWeeney, Manasse, Marchand, and Ulrich, and their researches go far to establish the correctness of Grawitz's original views.

Driessen, Sudeck, and a few other pathologists still strongly oppose the adrenal origin of any of the renal growths.

Rupprecht in 1890 described a growth, removed by operation from a child of  $2\frac{1}{2}$  years, having a structure which Neelsen declared to resemble adrenal tissue. This would appear to be the youngest case on record. Most of the cases belonging to this class have hitherto been met with in adults.



Our present position is fairly clearly indicated by Bland Sutton when he says: "Much uncertainty must exist in drawing conclusions from old records of renal sarcomata, because it is now clear that many tumours of the kidney in adults, which have been described as sarcomata, were in many instances composed of tissue similar, if not identical, in structure with that which forms the zona fasciculata of the adrenal." He also adds: "It is quite certain that some specimens regarded as sarcomata of the kidney turn out on critical investigation to be tumours of the adrenals."

Although these growths may for convenience be placed in the large class of adenomatous forms of renal growth, it is clearly to be remembered that the cells of the suprarenal, although morphologically epithelial, are strictly of mesoblastic origin; and growths arising in adrenal "rests" appear to be sarcomatous in general characters rather than carcinomatous.

These growths are generally situated just beneath the capsule, or near the surface of the cortex. Grawitz has figured one of these growths lying in the left kidney immediately below the capsule, but distinct from the main portion of the kidney. They are usually encapsulated, at least in an early stage of their development. The nature of the tissue, and the structure and arrangement of the cells, closely resemble the adrenal bodies. The cells are generally arranged in rows or columns or line spaces, just as occurs in ordinary suprarenal tissue, and their relation to the blood vessels is not that of the kidney cells, but agrees with that of the adrenal. Certain of the growths are practically identical with ordinary adrenal adenomata.

In these renal growths the cell protoplasm is similar to that of the adrenal, and the nucleolus and nuclei stain, according to such methods as those of Weigert, in a similar manner. The cell substance is rich in fat, which often is found in large drops, as occurs in the normal adult adrenal. Glycogen, it is said, may also often be found within the cells, and sometimes around them.

English and American pathologists have hitherto devoted very little attention to the study of these growths. In 1894 the subject was briefly discussed at the Pathological Society of London by Willett, Targett, and Newton Pitt. Pitt, speaking of "embryonic renal tumour," which term of course includes other forms of growth besides those of adrenal origin, stated that in eight years, at Guy's Hospital, they had met with seven speci-

mens. "The small nodules showed a glandular structure, the tubes being lined with cylindrical epithelium without a central cavity. Others were merely small fibromata, and in these, perhaps, the adenomatous elements had atrophied and disappeared. None of them showed signs of active growth or malignancy."

MacWeeney has recently recorded two important cases where nephrectomy was performed, and to which brief reference must here be made.

CASE 1.—Mrs. B., a thin, delicate looking woman, *æt.* 53, mother of seven children, had suffered for nine months from night sweats, vomiting, and abdominal pain. She had been operated on by Mr. Reeves, at the Soho Hospital, for movable kidney. Further operation for the removal of the organ was proposed and declined. There was now a tumour on the left side of the abdomen; no hæmaturia. On March 4th, 1892, abdominal section was performed by Mr. Coppinger, and a smooth tumour as big as a large melon exposed in the situation of the left kidney. It fluctuated; and after an unsuccessful attempt to aspirate its contents it was slit open, and a bowlful of brain-like hæmorrhagic material evacuated; Mr. Coppinger remarking that all previously reported cases of soft sarcoma of the kidney which had been opened had proved fatal by hæmorrhage. The cavity at once filled with blood, but the hæmorrhage was successfully dealt with, and the tumour removed. The patient, who recovered without a bad symptom, is still alive and well.

CASE 2.—Patient, female, *æt.* 38, admitted, in September 1895, to the Maternity, under the care of Mr. Lentaigne. Had been suffering for six months from abdominal pain and a tumour in left side of abdomen. No disorders of micturition. Patient looked cachectic and emaciated. Laparotomy revealed a large lobulated tumour of the left kidney extending to the middle line. The size and connections of the growth rendered the operation very difficult and prolonged. Death followed in nine hours from shock. Necropsy refused.

Microscopically, both presented "rows and groups of large columnar or cubical cells of obviously epithelial characters." Towards the degenerate parts many of the groups contained a central space. The cells were flattened, and the nuclei lay close to or actually projected into what corresponded to the lumen. In one of the cases there was extensive deposition of glycogen in the form of intracellular granules, and also large extra-

cellular masses. The resemblance to the adrenal was unmistakable, the zona fasciculata and zona glomerulosa being both represented.

It seems very probable that many of the anomalous cases on record, and doubtless some of those described as angiosarcoma, endothelioma, lymphadenomata, or adenoma, really belong to this class. Such specimens as those described by Sturm, Klebs, de Paoli, Weichselbaum and Greenish, Rumpell, Driessen, Sudek, Brunn, and Virchow, and referred to in the Bibliography, may perhaps have been of adrenal origin.

It is somewhat remarkable, however, that true adenomata of the adrenals should be so rare; indeed, they would seem to occur less frequently even than do the renal growths resembling them.

Lubarsch has subjected the whole question to a most searching criticism. He gives tables forming a summary of some twenty-nine cases.

Mr. Targett has also recently contributed an important article to the *Transactions of the Pathological Society of London*.

The number of clear cases are at present so few, and many of them are so dissimilar that it is very dangerous to attempt to draw any safe general conclusions. The following may, however, be tentatively advanced—

*Sex.*—Males seem to be more often affected than females. Of thirty-two cases probably belonging to this class, twenty were males and twelve females.

*Age.*—This varies greatly. They certainly occur in children. Walsham's case was only 9½ months when the growth was removed. Several have been met with in young adults. They also occur in elderly subjects. If such are really due to adrenal inclusions, it is surprising how long they may remain quiescent. Myo-sarcomata, as already shown, almost always develop very early in life. In thirty-two cases the ages averaged—males, 50; females, 45.

Lubarsch found twenty were between 40 and 79 years, and eight between 2½ and 39 years.

*Side.*—Both kidneys seem to be about equally affected. Usually only one organ would seem to be involved.

*Duration.*—This varies immensely. In some instances the growths have reached a very considerable size in a few months, while in others they seem to have existed from two to ten years.

Askanazy's patient noticed a tumour in early life, but reached the age of 53.

*Secondary deposits.*—Metastases occur in the majority of cases. Lubarsch found secondary deposits in twenty of his collected cases. In some cases, however, the growth long remains local, and may be removed successfully, as MacWeeney showed.

The obscurity which still exists as regards the nature of these growths is well summed up by Delafield and Prudden when they say: "The relationship between true adenoma of the kidney, adenomata which appear to develop from strayed adrenal elements, and similar tumours which are regarded by some observers as endotheliomata or endothelial sarcomata, and certain forms of angio-sarcoma, is not yet altogether clear."

In considering some of the growths of the kidney of supposed adrenal origin, one is compelled to agree with Mr. Targett in his opinion that "not a few writers have been carried away by the ingenuity of the theory, and have been led to refer many ordinary renal carcinomata to this extraordinary class."

There can be but little doubt that this form of renal growth is very rare.

Two cases have come under my observation which I venture to think may have originated in adrenal inclusions. Certainly both presented elements closely resembling the appearance of normal adrenal tissue. In both, however, the growth was not uniform throughout, and in parts had little or no likeness to suprarenal structure. According to some, I have no doubt, these examples would be considered of a true carcinomatous nature, and, indeed, I myself am not prepared to deny that they may have arisen in connection with true renal tissue. Brief reference, however, may here be made to these cases.

CASE 1.—F. G., male, æt. 44, ropemaker, was admitted to the Manchester Royal Infirmary, under the care of Dr. Thomas Harris, complaining of pain in the left loin, and with blood in the urine. A distinct tumour occupied the left renal region. Secondary deposits rapidly appeared in the thorax and in the glands of the neck and axillæ. The left vocal cord became paralysed, and much fluid accumulated in the left pleura. Paracentesis was performed three times, but he sank and died within two hours of the last tapping.

AUTOPSY.—Wasted middle-aged male. Enlarged glands in neck and left axilla.

Abdomen.—Tumour in left lumbar region. Spleen above and to outer side. Descending colon crossed directly in front of it. Much adhesion to surrounding tissues. Kidneys (left).—Seat of growth. Mass more or less rounded, size of infant's head; surface somewhat irregular and nodulated. On section, appearance as shown in illustrations (Figs. 54, 55). Outline of kidney at lower part of mass. The upper part of kidney infiltrated by growth, but still presenting renal outline. Immediately

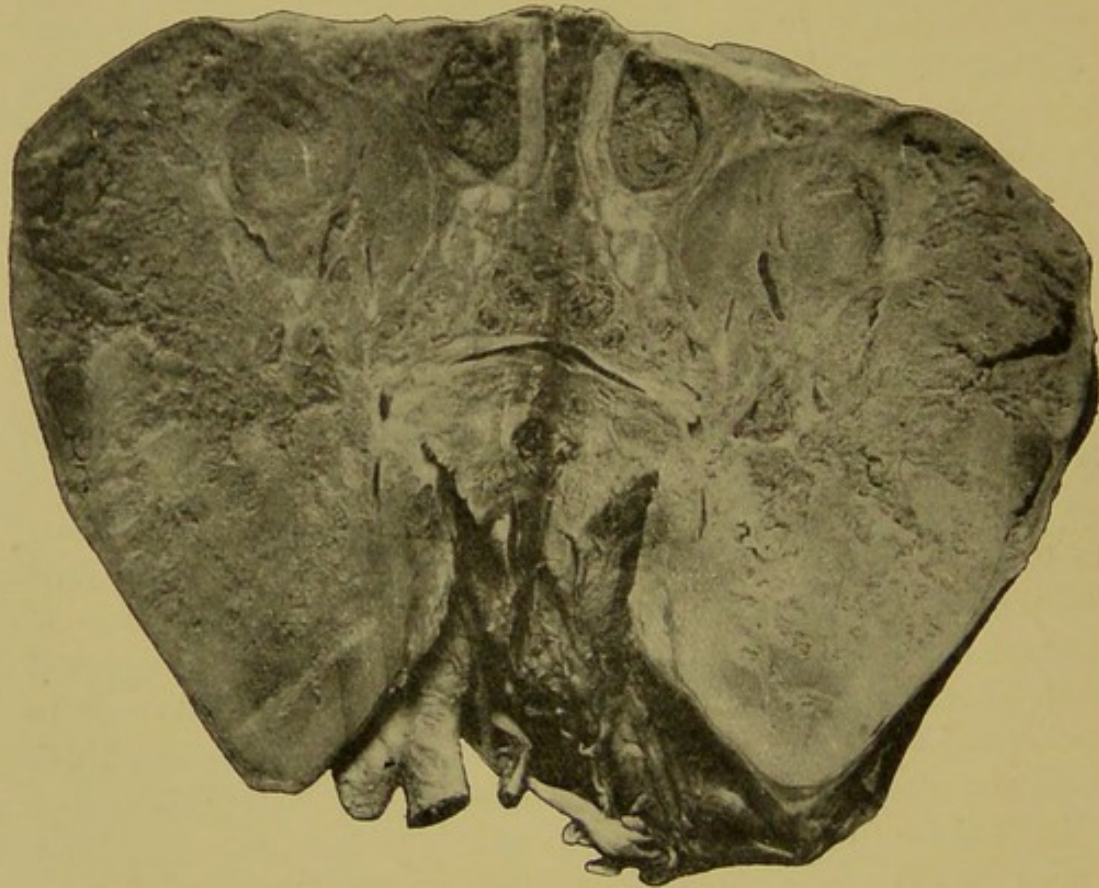


FIG. 54.—From a photograph of malignant renal growth, from male, *æt.* 44. Growth affected left kidney. Size, 6 × 4 in. Remains of kidney at lower end. Growth had yellowish white appearance. Ureter blocked by growth, which also extended along renal vein. Aorta dividing into common iliac also shown at lower part of illustration.

above, and practically continuous with embedded kidney, immense mass of yellowish white growth with darker pinkish areas, and fibrous looking septa. Upper end of ureter blocked by growth, which also extended along renal vein almost reaching inferior vena cava. (Right).—Normal in appearance. Weight, 4½ oz.

Bladder.—Normal. Liver.—Enlarged; weight, 5 lb. 5½ oz. Presented a few secondary deposits. Spleen.—Small; size,

4½ × 3 in; weight, 3¾ oz. No growth. Intestines.—Normal. Lungs.—Numerous secondary deposits. Pleuræ.—Nodules of growth most numerous on left side, which contained blood-stained fluid. Mediastinum.—Glands seat of secondary growth. Pericardium.—Nodules projecting into upper part of sac from mediastinum. Heart.—Normal. Glands.—Secondary deposits of growth in glands in neck and left axilla. Spine.—Meningocele over body of third lumbar vertebra.

*Microscopic.*—Sections taken from junction of kidney and growth. Masses of cells, more or less distinctly of epithelioid



FIG. 55.—From a photograph of slice of growth through centre of tumour mass. From F. G., male, ropemaker, æt. 44. Remains of kidney at lower extremity (left end of illustration). Mass of growth at upper end (right side of figure).

type. Some large and cubical or columnar; others crushed, elongated, or irregular. Each had distinct round nucleus. Cells arranged in clusters or rows; where grouped, closely resembled hepatic tissue; where in columns, very similar to adrenal. Between cells little or no stroma. Cells seemed to be placed directly on the capillaries. The kidney tissue was much altered, the essential elements being greatly atrophied.

CASE 2.—T. G., male, æt. 45, labourer; admitted to the Manchester Royal Infirmary, under the care of Dr. Leech.

*Clinical history.*—Some six months before death, patient was first troubled with sick headache, weakness, sleeplessness, dizzi-

ness, and staggering. Later he became very anæmic. On admission the urine was scanty, pale, acid, sp. gr. 1020, and containing little albumin. There was a slight puffiness about the eyes. He had several attacks of uræmic convulsions, and died comatose.

*AUTOPSY.*—Middle-aged male; general wasting; anæmia; œdema of lower extremities. Left kidney, seat of growth; weight, 25 oz.; size, 6 × 4 in. Upper and anterior part still retained renal outline. Below and behind, large, rounded dark-pink mass, closely adherent to post-renal, muscular, and cellular tissue.

On section, strip of renal tissue at upper part, fairly healthy in appearance. Lower, 4½ in. in vertical extent, consisted of growth of yellowish white appearance, moderately firm, and with number of well-defined cysts. At lower end, large cyst containing mucous-like material. Renal vein blocked by growth and blood clot. Growth extending into renal pelvis and upper part of left ureter, which is somewhat dilated.

Right kidney.—Slightly enlarged; weight, 7½ oz. No growth. Cortex increased, and in condition of parenchymatous nephritis. Liver.—No growth; weight, 40 oz. Pleuræ.—Double hydrothorax. Lungs.—Small number of more or less rounded nodules, about size of peas, yellowish white in colour, chiefly situated near pleura, and most abundant in left lung.

*Microscopic examination.*—The structure varied considerably. In some parts there were nodular areas of epithelioid cells closely resembling, both in appearance and arrangement, the cells of the suprarenal cortex. The cells were arranged in groups or columns, end to end and sharply defined from the adjoining tissue. In other places there was extensive hæmorrhagic infiltration, the tissue being hardly visible for the excessive accumulation of blood corpuscles. In some parts the cells were evidently of an embryonic connective tissue type, very suggestive of sarcoma. Tubular structures, and irregular and sometimes branching columns of epithelial cells, were plentiful in many parts, and in places epithelial elements aggregated within alveolar spaces gave a very carcinomatous appearance. Myxomatous degenerative changes were very conspicuous in several places.

Mr. Malcolm has recorded a remarkable case of successful removal of an adenomatous growth, which, whether originating from an adrenal "rest" or not, may perhaps be best referred to

here. The patient was a male child, *æt.* 23 months. The tumour, in the right side of the abdomen, had been noticed for six months. The urine was normal, and the child otherwise in good health. The growth could be easily defined. It was fixed in the right loin, and reached to the middle line, a little below the level of the umbilicus. Percussion gave a dull note over all the front and outer part of the growth. A resonant note was elicited to the left, and between the liver dulness and that of the growth. The kidney was removed through a longitudinal incision outside the right rectus abdominis muscle. The posterior layer of peritoneum was opened outside the colon. Strong bands of connective tissue had to be divided before the growth could be removed. The ureter, which appeared healthy, was cut close to the growth and its end fixed outside the incision. A mass of enlarged glands around the renal vessels was removed by the aid of scissors. The vessels were secured close to the vena cava. The patient rapidly recovered, and three years after the operation was known to be well. The specimen is now in the Museum of the Royal College of Surgeons (3597E). Fig. 56 well indicates the macroscopic characters. A large oval tumour springs from the anterior part of the kidney. It lies entirely within the fibrous capsule of the kidney. The hilum, pelvis, vessels, and greater part of the kidney appear healthy. The surface of the divided growth indicates division into lobules. Fibrous strands extend inwards from the capsule and compressed renal tissue.

Microscopic examination showed that the growth had everywhere an adenomatous structure. "There were tubules and solid masses or follicles of epithelial cells. These follicles varied considerably in size, and forcibly recalled the follicles in the foetal thyroid body. Some of the larger follicles were undergoing central softening, and thus cystic spaces were formed. These

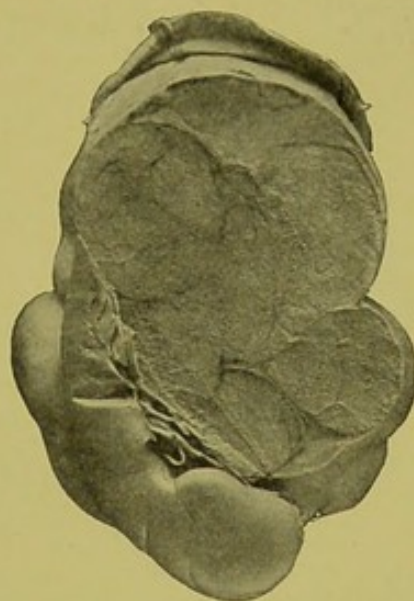


FIG. 56. — Adenomatous growth. Probably originating from adrenal inclusion. Large oval growth springing from upper and anterior surface of kidney. Posterior surface, convex border, and lower end of kidney free. Renal capsule encloses growth. Removed by operation from child, *æt.* 23 months. Good health three years afterwards. — From a photograph lent by Mr. Targett.



differed from the tubules, in that the latter were lined with distinct columnar epithelium. The meshwork supporting the neoplasm was likewise very delicate and scanty. No evidence of sarcomatous tissue."

Dr. Newton Pitt has described an admirable example of an accessory adrenal in close connection with the left kidney. The general appearance is shown in the accompanying illustration (Fig. 57). The accessory adrenal is situated upon the anterior surface of the organ, towards its upper end. The renal capsule

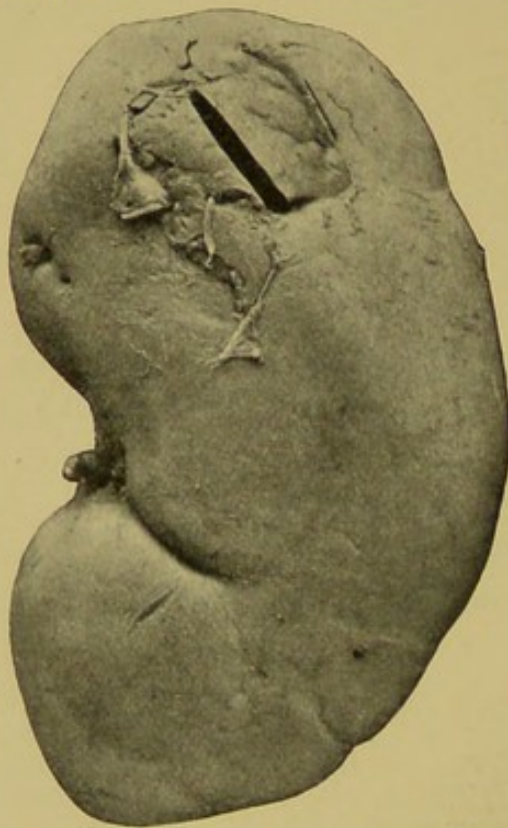


FIG. 57.—Accessory adrenal. A small portion has been removed from the centre for microscopic examination.—From a photograph lent by Mr. Targett.

has been stripped off up to the edge of the adrenal "rest," and here it passes between it and the kidney. The suprarenal bodies were normal in size, structure, and position.

Sections taken from the portion indicated in the figure presented internally the characteristic form and arrangement of the renal convoluted tubes; while externally there were columns of cells of typical adrenal form and grouping. Between the two portions there was, in parts, a scanty amount of connective tissue, but in places the renal and adrenal structures appeared to have blended (Fig. 58).

Dr. Rolleston has sent me an interesting specimen, which appears to be a good example of an adrenal inclusion in the kidney. The formation appeared as a small tumour in the cortex of the kidney of a man who died from an accident. As shown in Fig. 59, the growth is demarcated from the true renal tissue by a layer of fibrous tissue, which practically acts as a capsule for the growth. The structure is distinctly adenomatous. The growth is made up of columns of cells closely resembling those of the normal adrenal. Between the columns and aggregations of cells is a fine connective tissue stroma.

One of the illustrations from Mr. Targett's photographs

(Fig. 60) shows a remarkable malignant adenomatous growth. It is possible, however, that the growth may have arisen from included adrenal tissue. The specimen was removed by nephrectomy through a median abdominal incision by Sir Wm. Maccormac from a girl *æt.* 3. A tumour had been noted for nine months. There was never any hæmaturia observed, and the child complained of but little pain. The preparation may be best described in Mr. Targett's own words: "The tumour consists of three large lobules and some smaller ones, all of which are distinctly

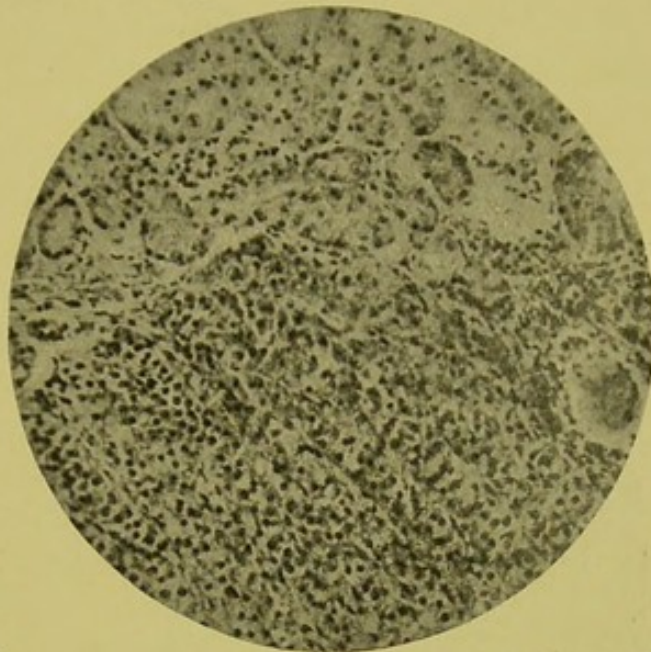


FIG. 58.—Adrenal "rest" in kidney. Above are the characteristic renal tubules. Below, more or less vertical columns of adrenal cells. Between the two a small amount of fine connective tissue, except at central part, where renal and adrenal tissues blend.—From a photograph lent by Mr. Targett.

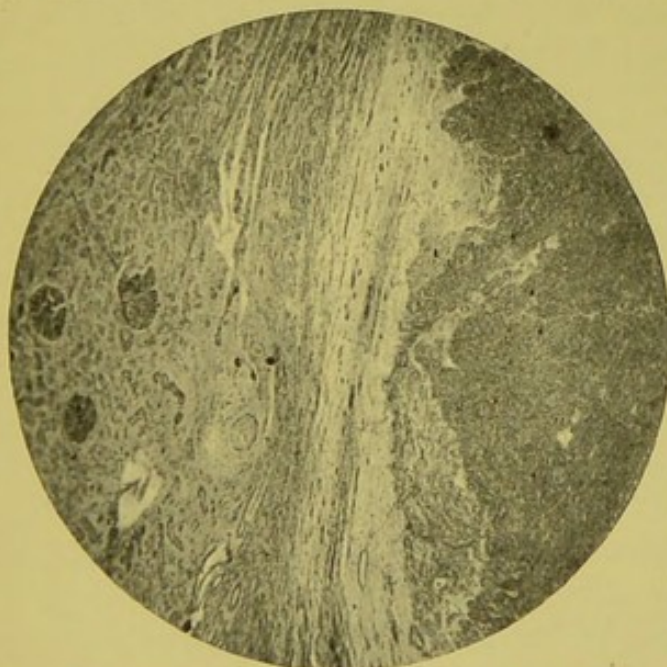


FIG. 59.—Adrenal "rest" in kidney. Renal tubules on the left. Adrenal tissue on the right. Fibrous tissue intervening. (Zeiss, Oc. 2, Obj. A,  $\times 50$ .)

separated from each other by kidney tissue at the periphery, and by strands of fibrous tissue towards the centre of the mass. The vessels traverse these strands chiefly, and very few are visible in the central parts of the lobules. The space at the top of the tumour shows the compressed calyces and vessels of the hilum. The centre of each lobule of the growth has undergone a fibrous transformation, like

that seen in carcinomatous nodules in the liver. These areas

have a semi-transparent aspect, and trabeculae radiate from them towards the periphery of the lobules. They are composed of loose connective tissue, and their central position suggests that they are due to rapid growth at the periphery, and the blood supply being thereby impaired a lower form of tissue growth is induced. Microscopical sections taken from different parts of the tumour agree in showing an adenomatous structure. They are composed of tubules cut in various directions with a distinct

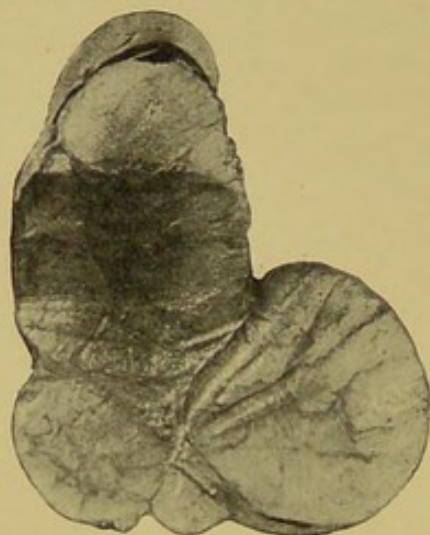

FIG. 60.—Malignant adenomatous growth of kidney. Probably originating in hilum. Cap of healthy renal tissue at upper end, with compressed calyces and vessels of the hilum. Growth consists of three large lobules, with some smaller ones. Renal tissue around and between each mass. Strands of fibrous tissue running towards centre of each lobule, which have semi-translucent aspect from fibrous transformation. From a girl, aet. 3.—From a photograph lent by Mr. Targett.

lumen, and lined with columnar epithelium. Around these are placed solid follicles of all sizes, consisting of small spheroidal epithelial cells. There is a very delicate meshwork, forming a stroma which holds the tubules and follicles together. Nowhere is there evidence of sarcomatous tissue or of striped fibres." The specimen is now in the Museum of the Royal College of Surgeons (3597F).

Ricker has met with six well-marked examples of renal growth of adrenal origin. The smallest was found in the healthy kidney of a youth, aet. 16, and appeared as a slightly prominent yellow nodule smaller than a pea, and in its greater part cystic. It consisted of a zone of solid cell columns separated and surrounded by capillaries. The cells were polygonal, and contained large masses of fat. A few cellular trabeculae crossed the central cavity. The cylindrical cells contained a large fat globule in their outer part. Another growth was rounded, of yellow colour, and the size of a cherry. A third specimen was of the size of a nut, and of a brownish red colour.

Occasionally it would seem that renal parenchyma may be included by true adrenal tissue. Ricker has met with a case where kidney and adrenal were firmly united over an area of several cms. The tissue of each organ extended into the territory of the other. Characteristic renal cysts, lined by a single layer

of cubical epithelium, were present on the suprarenal side of the separating connective tissue. In this connective tissue layer was a nodule made up of adrenal elements. In another case the adrenal cortex was the seat of a small cystic growth consisting of a single layer of cubical epithelium, resting on a connective tissue basis and containing distinct trabeculae, each with a capillary and covered by cubical epithelium.

Ribbert has described a growth connected with the outside of the capsule of the kidney, near the renal pelvis, in a child *æ*t.  $8\frac{1}{2}$ , which apparently originated in an aberrant adrenal.

It is easy to understand how incomplete development of the capsules of the adrenals and kidneys may allow of penetration of a part of one organ into the substance of the other. Adrenal tissue has even been found beneath the capsule of the liver. Usually it is adrenal which becomes entrapped within renal parenchyma. Occasionally adenomatous tissue having adrenal structure is found directly adjoining the apparently normal suprarenal. Dr. Eurich has recently recorded a well-marked example. The specimen was obtained from a man, *æ*t. 38. He has kindly sent me the following report of his case:—

“Kidney and suprarenal body were separated from each other to the distance of a couple of inches. While the latter occupied its usual place, there was a slight but distinct downward displacement of the former—insufficient, however, to account for the gap. This was due to a congenital atrophy of the kidney, which measured 2 in. in length,  $1\frac{1}{2}$  in. in breadth, and  $\frac{3}{4}$  in. in thickness. The left kidney showed compensatory hypertrophy, but was otherwise healthy. The above mentioned interval between kidney and suprarenal body was occupied by a tumour, almost spherical, measuring somewhat more than an inch in diameter, of a livid purple, tense to the feel, and encapsulated. Upon its upper pole was perched the suprarenal body, apparently healthy in every respect, and in no wise involved by the tumour mass, from which it was separated by the aforesaid thin capsule. This capsule of fibrous tissue, over the anterior surface of which a few veins were seen to course, was prolonged at the lower pole of the tumour to form a short but broad pedicle, by which it was continuous with the capsule of the kidney. This tumour, therefore, departing from the usual course of its kind, had not encroached upon any organ—either by direct involvement or by compression, but had, as it were, served to fill a gap. A section

of the tumour showed it to be very dark, pulpy, and vascular. Part of the growth was hardened in bichromate, part in spirit. Microscopic examination revealed, with certain differences, according to the hardening solution employed, the following appearances.

“The greater mass of the tumour is formed of glandular looking cells without a distinct cell-wall, and irregular in shape, the polygonal form prevailing; they contain an oval nucleus centrally situated, and varying considerably in size—being of moderate dimensions in the centre of the growth, but often three or four times that size towards the periphery, where, too, it was sometimes horseshoe-shaped, sometimes vacuolated. The outermost cells, however, differed somewhat from the rest, being smaller, almost cubical, and containing a moderately sized, nearly spherical nucleus, staining deeply with the usual nuclear dyes. Spirit preparations show the cell protoplasm as slightly granular; but if bichromate has been the hardening agent, then most of the cells appear to contain a diffuse yellowish brown pigment; but not all—for here and there, standing out clearly from among the rest, are cells with pale, clear protoplasm, only faintly dyed by the stains employed, but otherwise like their fellows.

“The arrangement of these cells is very irregular, and is determined by an intricate network of capillaries, veins, sinuses, and blood channels, between which the cells are placed. A double row of cells usually separates the vascular passages from each other, but larger clusters are seen in places, while in others but a single layer appears to intervene. How far these differences were due to the line of section could not be determined. The capillaries are lined by flattened endothelial cells. Almost the only fibrous tissue in the body of the tumour is found forming the walls of the veins, and lining an old hæmorrhagic cavity. This is situated somewhat excentrically, and contains blood pigment and fibrinous clot; a little blood pigment is also found among the cells bordering upon the cavity. The sinuses and blood channels attain their maximum development towards the centre of the growth; they show no, or almost no, endothelial lining, the glandular cells themselves forming their walls, and projecting into them here and there in the shape of buds of varying size. Single cells, or groups of cells, are not unfrequently found lying apparently loose in the

lumen of these sinuses, according to the direction of the plane of section. A few thrombosed veins and small blood channels are also found beneath the capsule, but in size they are inferior to those towards the centre. So far the spirit and bichromate preparations have agreed in all essentials. We would now pass to an appearance found only in the latter. This is a peculiar homogeneous, hyalin-looking material, lying in the veins and its branches, but apparently not in the larger sinuses. It stains yellowish brown with picro-carmin, pale red with lithium-carmin, faintly with alum-carmin, and not at all with hæmatoxylin. It does not always quite fill the vessels, but may leave a gap filled with blood corpuscles. Blood cells are also found embedded in the mass itself. Where there is no lining endothelium, the tumour cells frequently lie in apparent contact with this substance; and this appearance may, if the vessel be small, and if the cells themselves present a yellow tint, closely simulate a giant cell. Prolonged contact with alcohol completely destroys it; and though hyalin-like in appearance, it cannot be considered hyalin in nature. To complete the description, we should add that no traces of fat or of glycogen could be detected within the tumour cells by the usual methods.

“In structure, therefore, the growth closely resembles that of the medulla of the suprarenal body, though we were unable to convince ourselves of the presence of ganglion cells or nerve fibrils. The absence of all nerve elements may seem, at first, a serious objection to this view. The history of peripheral accumulations of nerve cells meets this objection: they reach their final positions by emigration, and their axis cylinders, as centrifugal outgrowths from the cell bodies, insinuate themselves between tissues and cells, according to laws as yet not fully understood, till they reach their destination. The nerve cells and fibres within the suprarenal medulla are no exception. It seems to us quite reasonable to suppose that, with the abnormal development and position of this piece of suprarenal medulla, nerve elements may be altogether wanting.”

Dr. Eurich believes his specimen owes its origin to an aberrant adrenal fragment—not of suprarenal cortex but of suprarenal medulla; and conceives it possible that its first germs might have lain beneath the capsule of the kidney had that organ attained to its full development. He believes it

very probable that medullary residues may explain the development of certain of the anomalous growths. His suggestions are at least of speculative interest.

"It is more difficult to assign distinguishing characteristics to such supposititious growths. That they must be tumours of the glandular type is evident. Glycogen, and especially glycogen plus fat, should be absent from the cells; fatty contents alone, particularly if of local occurrence, would not exclude a medullary origin, for there are few growths which do not exhibit fatty changes at some period of their life-history. Extensive vascularity would probably be another characteristic.

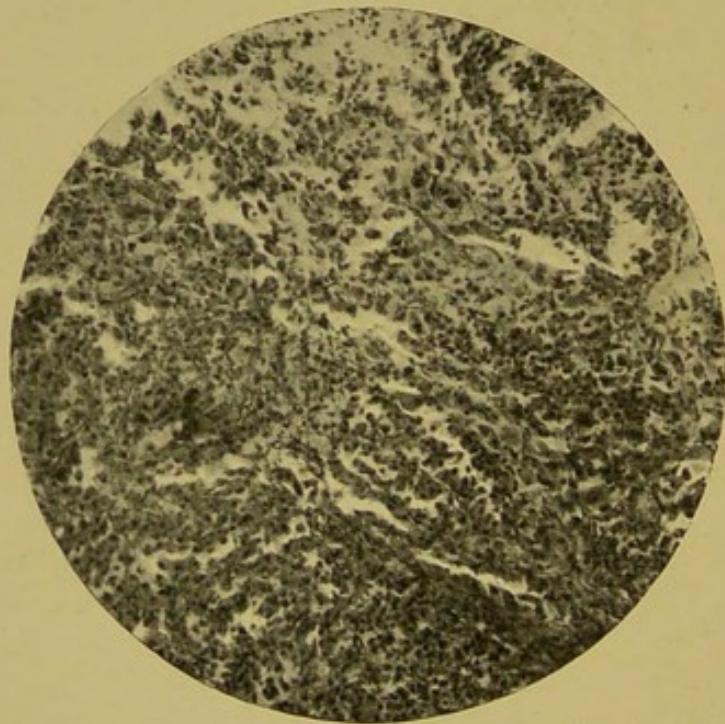


FIG. 61.—Malignant growth of kidney, possibly originating from an inclusion of adrenal tissue. (Zeiss, Oc. 4, Obj. A,  $\times 110$ .)—From a specimen lent by Mr. Paul.

But the most distinguishing feature would possibly be that homogeneous, hyalin-looking substance above described."

Mr. Paul has sent me a remarkable specimen obtained from an adult subject (Fig. 61). The structure in places appears to me to somewhat resemble that of the adrenal, and I am inclined to look upon the growth as possibly originating in an adrenal "rest." While, however, some portions simulate suprarenal tissue, other parts closely resemble an alveolar sarcoma (Fig. 62), and some districts have an appearance which, I believe, many would be inclined to term carcinomatous.

At present our knowledge as to the various forms assumed

by members of this class of renal growth is so meagre that there is very great difficulty in venturing, even with the greatest diffidence, and with all caution, to declare a growth as undoubtedly arising from inclusions of adrenal tissue. Doubtless, in time, further and more certain indications will be apparent than is the case at present.

An interesting example of the difficulty in "placing" a renal growth is illustrated by the curious adenomatous growth investigated by Mr. Edgar Willett, through whose kindness I am enabled to make full reference to it in these pages.

This specimen is also referred to by MacWeeney as possibly belonging to the group of growths derived from suprarenal "rests." It has probably, however, no true etiological connection with adrenal structures, but since its exact position is disputed, and its structure certainly in many respects anomalous, I venture to describe it in this chapter.

The growth occurred in an infant of 9½ months.

The clinical features of the case were originally pub-

lished by Dr. Ilott and Mr. Walsham. A tumour had been noticed in the left side of the abdomen for a month. It grew very rapidly, had a semi-fluctuating feel, and was freely mobile. The child seemed to be in good health. A little blood had been passed in the urine. The whole growth, together with an enlarged lumbar gland, was removed. One year later recurrence was noted, and a large rapidly growing mass soon occupied the greater part of the abdominal cavity.

The macroscopic characters of the growth are well shown in the accompanying illustration (Fig. 63).

Mr. Willett considered the growth to be a "congenital cystic adenoma." Microscopically, the growth "consists of numerous minute cysts of various sizes, each of which is lined by a single layer of short cubical epithelium. The cavity of the larger cysts

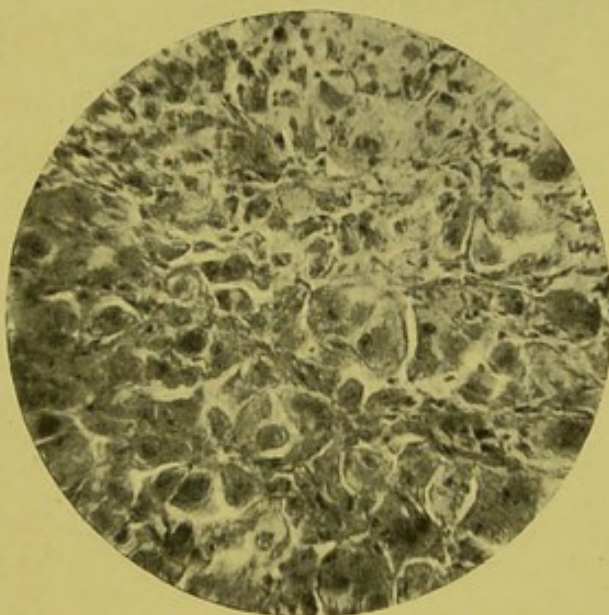


FIG. 62.—Malignant renal growth. High power of Fig. 61. (Zeiss, Oc. 4, Obj. D, ×435.)



seems to have contained a fine granular material; in many places there is an appearance as though the thin cyst wall had ruptured, but nowhere are any intracystic growths or tufts to be seen." The specimen was considered by a committee of the Pathological Society of London to be "a glandular carcinoma." They prepared sections from the junction of the growth and the kidney, and describe large angular alveoli "packed with masses of immature glandular epithelium." At the margin of the




FIG. 63.—Malignant adenoma, originating in cortex or from capsule. Spherical growth embedded in cortex of convex border of kidney. Enclosed by fibrous capsule of kidney. Overlapped by kidney tissue. Compressed kidney tissue between growth and hilum. Holes like pin-pricks indicate spongy character of growth. Fine fibrous trabeculae throughout growth. From an infant, *æt.* 9½ months. Removed by nephrectomy. Recurrence within a year.—From a photograph lent by Mr. Targett.

growth they found "a layer of dense fibrous stroma in which the remains of secretory tissue can still be traced."

Mr. Willett tells me that in his first set of specimens tubular-like structures, apparently in transverse section, were present, and suggested renal tubules in section. Another set of sections was taken at right angles to the others, for "if the first set had been tubes in cross-section, the second set must have shown the tubes in longitudinal section." The two sets of specimens, however, were identical, and it therefore seemed that the spaces were really cavities, more or less spherical in form, and not tubules at all.

This remarkable specimen has been thoroughly investigated by Mr. Targett. I quote from his notes kindly sent me.

"Microscopic sections, taken from the junction of the tumour and kidney, are composed of large angular alveoli held together by strands of nucleated connective tissue. These alveoli are filled with masses of glandular epithelial cells without obvious arrangement, and running through most of the alveoli may be seen a duct having a distinct lumen and lined with columnar epithelium. This duct is situated either in the centre of the mass or at its periphery. The cells in the stroma have oval

and elongated nuclei, and this tissue is permeated by capillary vessels, and shows here and there a separate duct. Between the tumour and the kidney there is a broad zone of fibrous tissue, in which may be recognised a few compressed renal tubules and wasted glomeruli. Beyond this capsule the substance of the kidney is perfectly normal.

“On turning to the sections taken from the centre of the tumour, we find that the scene has changed, and in place of the solid alveolar masses, each with its single duct, we have a series of cysts embedded in a fibrous stroma. The alveoli have not entirely disappeared, hence it is possible to trace the stages by which the present condition has been formed. Some of them are undoubtedly dilated ducts, such as those described above. But the majority of the spaces are due to softening of the central cells of the alveoli and conversion into granular débris. When such spaces are in close apposition they eventually coalesce, and occasionally one observes a cavity, due to softening, which has then formed a communication with a duct. The pathological process would seem to be some interference with the nutrition of the growth, possibly by thickening of the stroma and compression of the vessels as well as the ducts. This would lead to dilatation of the ducts, and at the same time account for the degenerative changes in the centre of the alveoli” (Fig. 64.)

Weigert has described a case of what he considers to be “congenital adeno-carcinoma,” and gives drawings showing masses of epithelial cells lying in spaces, and having in their midst, or in close proximity, tubules of ordinary renal type. In some of the aggregations of cells there were numerous thin-walled vessels. As this specimen seems to have resembled

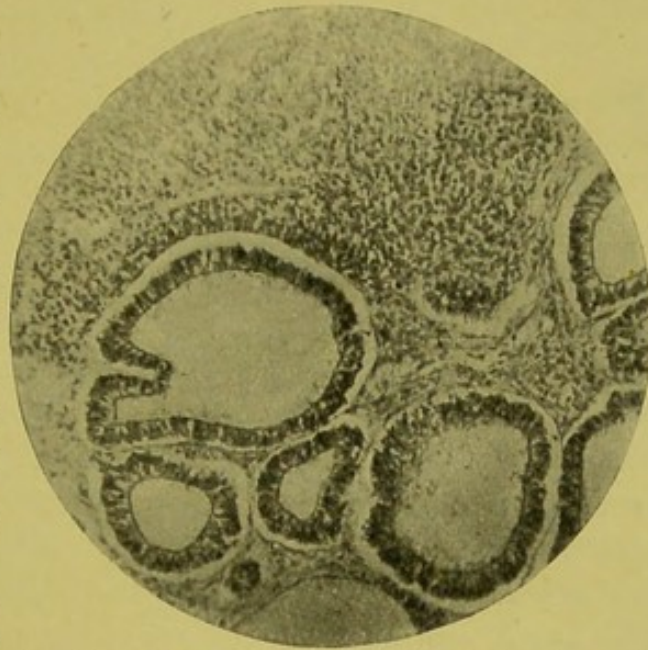


FIG. 64.—Photo-micrograph of growth shown in Fig. 63. Masses of cells at upper part of photo. Cysts or tubular structures embedded in fibrous tissue, and lined by epithelial cells. From a photograph lent by Mr. Targett.

the one of Mr. Willett, in some points at least, I venture to refer to it in this place.

Dr. Eurich has very kindly sent me notes of a case he has recently investigated, which appears to me to be very similar to the above. The specimen is now in the Museum of the Royal Infirmary, Bradford. The patient was a child, *æt.* 2. The tumour was first noticed about six months before death. The growth originated in the left kidney, and "apparently from the 'sinus' of that organ." The kidney was compressed from before backwards, and the growth involved part of the upper pole of the kidney. Most of the kidney substance seemed normal. The left adrenal could not be found. The growth was very soft. "On section it presented beneath the capsule a rind about  $1\frac{1}{2}$  in. thick, like the fat layer of a ham. Further in, streaks of this whitish substance could be seen, but the main mass was taken up by pinkish red tissue, firmly fibrillar, with numerous hæmorrhages. In the centre of the tumour was a hard, semi-cartilaginous nodule, the size of a filbert, which microscopically proved to consist of somewhat densely packed striped muscle fibres in sarcomatous tissue. The main mass of the tumour, save where destroyed by hæmorrhages, consisted of round and spindle cells, arranged in large groups, separated from each other by strands of more elongated and less densely packed spindle cells. Within the groups were vessels lined with cubical endothelium, some of which had proliferated. One had the impression that here and there the sarcoma cells had originated from the adventitia. Within the groups were also seen what appeared to be duct-like structures, cylindrical cells circularly arranged around a distinct lumen. Some of these gland or duct-like structures seem to have contained blood. There was no trace of fat in the cells of the tumour, save in the centre around the hæmorrhages. The growth weighed 6 lb., and almost filled the abdomen."

In some of the cases it seems possible the duct-like structures, described as lying in the mass of the growth, may have been derived from vascular structures. Others, no doubt, originated from renal tubules.

The whole question of the adenomatous growths met with at all periods of life requires the most thorough investigation; but until all specimens of renal growth are submitted to thorough microscopical investigation, our knowledge of this important and probably very complex adenomatous group will not advance far.

In the mere naked-eye characters, the adenomatous forms of growth often closely resemble the sarcomata, as will be evident

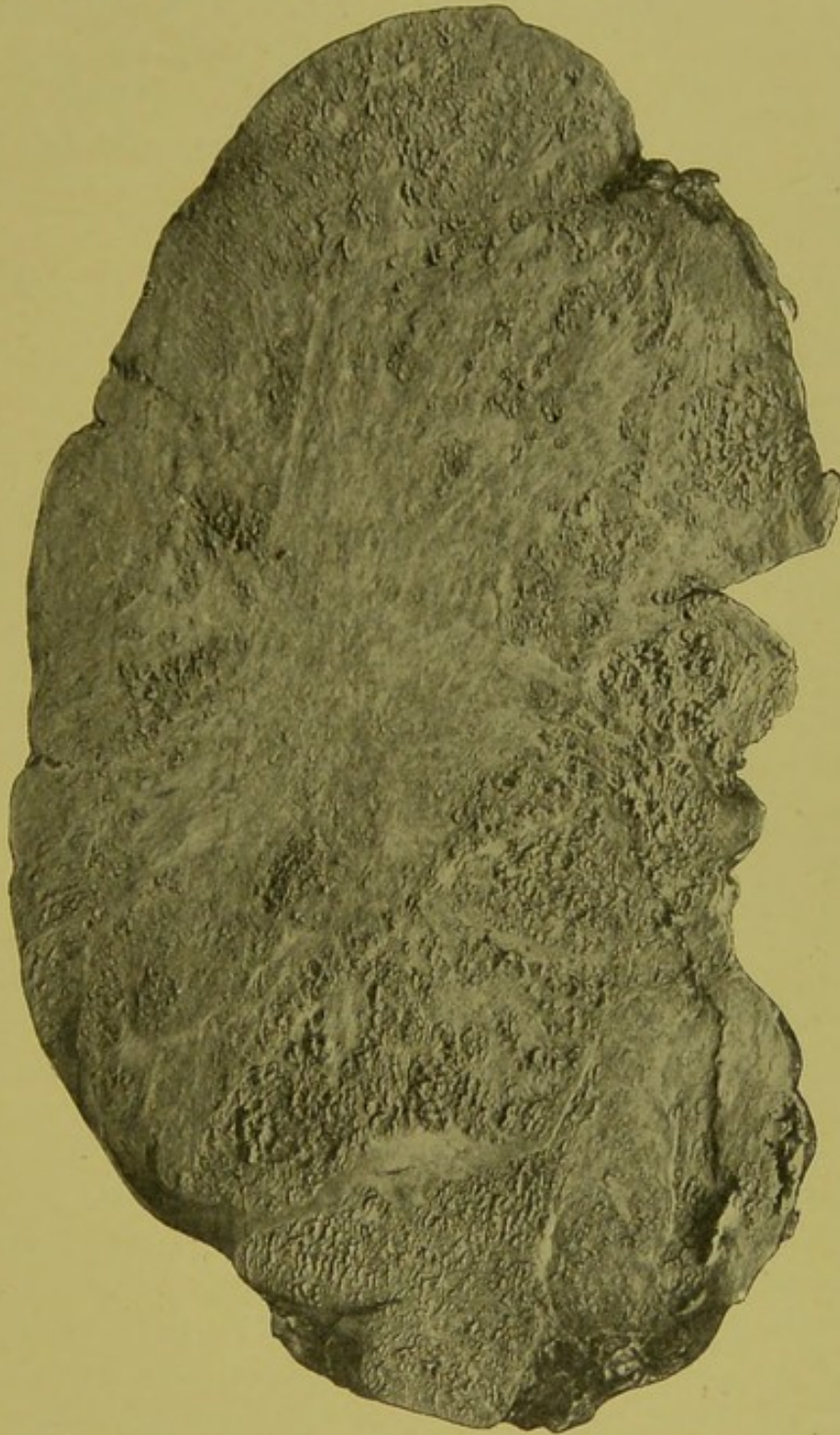

FIG. 65.—Slice taken from centre of large adenomatous growth which developed in a child.

from the accompanying illustration of a large adenomatous growth, now preserved in the Pathological Museum of the Owens College (Fig. 65).

## CHAPTER XV.

### CARCINOMATA.

MALIGNANT growths of an epithelial type occur in connection with the kidney, as—

1. Glandular, epithelial type,—the true carcinomata.
2. Surface epithelial type,—the epitheliomata.

Many continental pathologists use the term epithelioma in the wider sense, to embrace all forms of neoplasm of a true epithelial type. I prefer to limit it, according to English and American custom, to the malignant growths originating in connection with epithelial surface membranes.

As already shown, most cases of malignant growth of the kidney were formerly considered to belong to this group. Since many of the "cancers" have been shown to be sarcomata, attention seems to have been in great measure withdrawn from the true carcinomata. Hence the study of these malignant growths has been much neglected. At the present time it is only possible to indicate approximately the general characters of this class.

Reginald Harrison, in his recent article,<sup>1</sup> bluntly acknowledges the limitations of our present knowledge when he says: "The typical carcinoma is tubular and sometimes cystic, but there is at present no satisfactory account of the pathological varieties which may occur in this region."

*Frequency.*—True primary carcinoma is undoubtedly rare. Lebert, out of a total of 447 cases of "cancer" of different organs, found renal "cancer" in only twelve, and probably several of these were not true carcinomata.

Even secondary carcinoma is not common. In 111 cases of carcinoma which have come under observation in the pathological department of our hospital during the last few years, only eight showed distinct involvement of the kidneys by

<sup>1</sup> "The Twentieth Century Practice of Medicine."

secondary growth. In two others there were also doubtful nodules. In one of the eight the growth had probably reached the kidney by direct extension. In only seven, or a little over 6 per cent., was secondary deposition in the kidney certainly present. Epithelioma is rarer still. Roberts says he only knows of two recorded cases. It sometimes, however, is met with as a secondary deposit.

*Sex.*—As far as I have been able to ascertain, sex has but little or no influence in predisposing to the development of carcinoma.

*Age.*—It is generally stated that carcinomata are met with usually in elderly persons. Butlin states definitely that they occur only in adults. The Fenwicks, in the last edition of their "Medical Diagnosis," state that primary cancer is met with at a late period of life, and usually affects only one kidney. Probably they never occur in children. Brault says: "Sarcoma of the adult is less frequent than cancer; it is much less hæmorrhagic than epithelioma." The average age is said to be about forty. They are specially liable to occur between forty and sixty. Newman found the mean of twenty-three cases was a little over forty years, but deducting several doubtful cases he arrived at an average of forty-eight and a half years. Adenomatous forms of growth, some of which are undoubtedly malignant, and such as might be considered carcinomatous by some pathologists, occur in young as well as adult subjects, as already indicated.

*Varieties.*—The growth may occur in two chief forms—

1. Nodular or circumscribed.
2. Infiltrating or diffuse.

The nodular forms appear as definite, clearly circumscribed yellowish nodules. They have no distinct capsule. Coats figures a case where the growth formed a rounded mass at the upper end of the kidney. In some of the infiltrating forms there is an abundant stroma of a fibrous nature, from which the meagre amount of cells have to be pencilled out in order to render them distinct.

*Origin.*—Careful observations by Pereverseff, Newman, and others seem to show that these growths arise in the cortical and subcortical region, the urinary passages only being involved later. The growth originates in the epithelium of the tubules.

Sharkey has recorded and figured a specimen, from a woman, æt. 28, in which he believed the growth originated in the epithelium of the Malpighian tufts.

At the borders of the growth the proliferation of the epithelium may be best studied. At first the epithelium is enclosed within the basement membrane, and transitional forms may be seen within the tubules. Soon the intertubular tissue also becomes infiltrated. The villous papillomata met with in the pelvis are generally epitheliomatous. In one case, where the papilloma was removed by one of our surgeons, the growth recurred and proved fatal. Several cases recorded as due to the irritation of calculi have been true epitheliomata. Such, for example, as those recorded by Walsham and Brodeur.




FIG. 66.—Carcinoma of right kidney. Healthy kidney substance, with hilum, vessels, and ureter on the right. To the left, bun-shaped mass of growth projecting through capsule. Between these, oval mass of very soft, vascular growth, with considerable part infiltrated with blood. Well-defined capsule to growth. Diameter of growth, 5 in. From female, æt. 43. Growth removed by operation. Recurrence and death in eight weeks.—From a photograph lent by Mr. Targett.

Herringham, Garrod, and Gow<sup>1</sup> make the somewhat surprising statement, that carcinoma “most often originates in the lymphatic glands, or parts of the hilum, invading the kidney substance later, or not at all”; and a little later they speak of sarcoma occurring in “a not uncommon

form as lympho-sarcoma, beginning in the glandular tissue of the hilum.”

*Consistency.*—The general characters vary much. Some are very soft and vascular, others are hard and look almost like fibrous tissue. In some the growth is almost entirely cellular, in others the stroma is excessive. The more cellular the growth the more malignant it is, as a general rule. In the same growth the proportion between cells and stroma may vary greatly in different parts.

*Microscopical characters.*—According to the histological characters, the following forms have been described:—

<sup>1</sup> “Handbook of Medical Pathology.”

1. Soft or encephaloid.
2. Hard or scirrhus.
3. Colloid.
4. Epithelioma.

Considerable difficulty is often experienced, as has been shown in a previous chapter, in distinguishing the true carcinomata from certain other forms of growth. Thoma has put the case well when he states: "In such organs as the kidneys, which are developed comparatively late in foetal life, epithelial cell growths form tumours which in their general

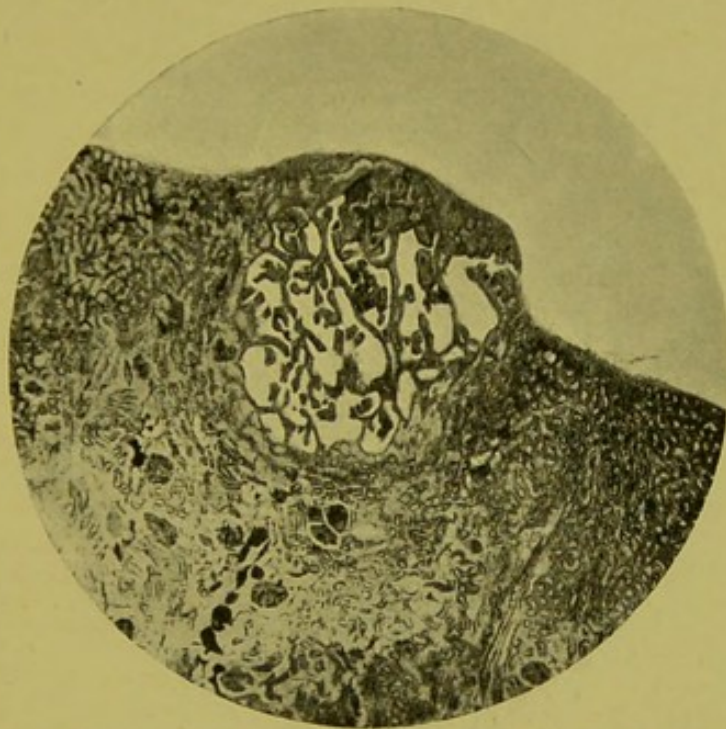


FIG. 67.—Secondary epithelioma of the kidney. (Zeiss, Oc. 2; Reichert, Obj. No. 2,  $\times 30$ .)—From specimen lent by Mr. Paul.

appearance are not easily distinguished from very cellular tumours arising in connective tissue."

It is particularly necessary to remember that it is sometimes almost impossible to decide which should be considered a carcinoma and which an adenoma, judging merely from microscopic appearances. Difficulties also arise in connection with some of the adeno-sarcomata and alveolar sarcomata. Although some cases present the appearances usually associated with ideas of malignancy, it is nevertheless necessary to recognise the fact that in a number of these cases apparent recovery has resulted after nephrectomy. It seems quite possible that some of the cases were really forms of growth originating in adrenal "rests."



Greenfield and Goodhart figure an interesting example of medullary cancer of the right kidney, from a man, *æt.* 37. A somewhat similar specimen is preserved in our College Museum.

The carcinomata vary comparatively little in their minute structure. The proportion between cells and stroma, of course, varies to some extent, but the general arrangement does not vary so much as in the sarcomata. Degenerative changes frequently occur in the carcinomatous cells. In one specimen sent me by Mr. Paul, the central parts of the microscopic masses

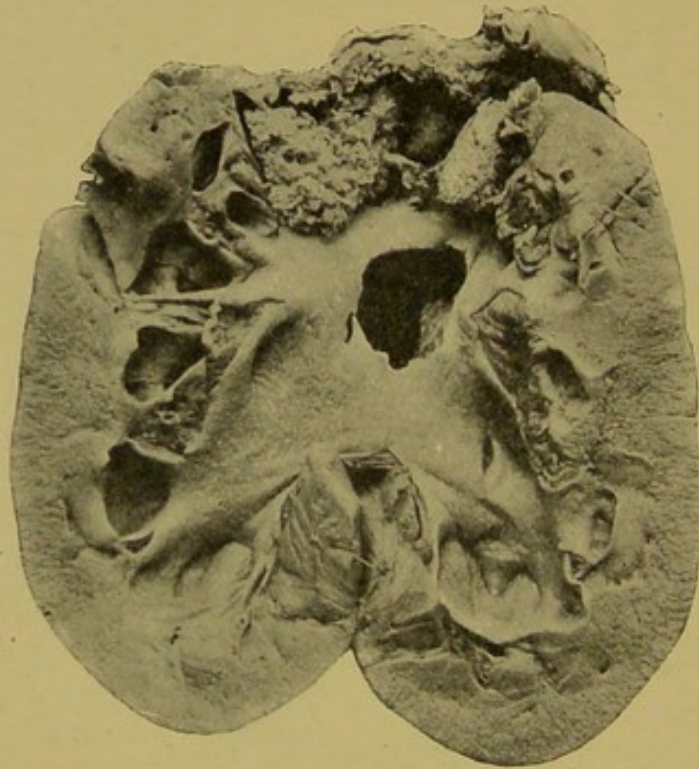


FIG. 68.—Malignant papilloma. Mass of soft papillomatous growth at upper part of kidney, filling space size of pigeon's egg. Area of growth,  $1\frac{3}{4}$  in. diameter. Length of kidney,  $5\frac{1}{2}$  in. Weight,  $6\frac{1}{2}$  oz. Pelvis and calyces dilated. Renal parenchyma normal. Removed by nephrectomy from male, *æt.* 56.

of epithelial cells had undergone such change as to make the individual cells indistinguishable.

Growths apparently of an epitheliomatous nature, and probably originating in connection with the pelvis of the kidney, have been recorded by Battle, Billroth, De Morgan, Drew, Gaucher, Hartmann, Israel, Jones, Murchison, Robin, Thornton, and Windle.

Billroth removed a growth, three times the size of the closed hand, from a man, *æt.* 33, which was considered to be a papilloma. In Drew's case a villous carcinoma involved the pelvis of the

left kidney and ureter, and also the bladder, and led to hydro-nephrosis. The patient was a male, *æt.* 56, and the chief symptoms were attacks of pain resembling renal colic associated with hæmaturia.

De Morgan's case was a female, *æt.* 76, who died from strangulated hernia. At the lower part of the renal pelvis were masses of papillomatous growth. Mr. Thomas Jones has also removed a papilloma from the renal pelvis (Figs. 68, 69). The specimen is preserved in the Museum of the Manchester Royal Infirmary. It was obtained from a man, *æt.* 55. The papilloma was removed, but recurrence took place within nine months, and

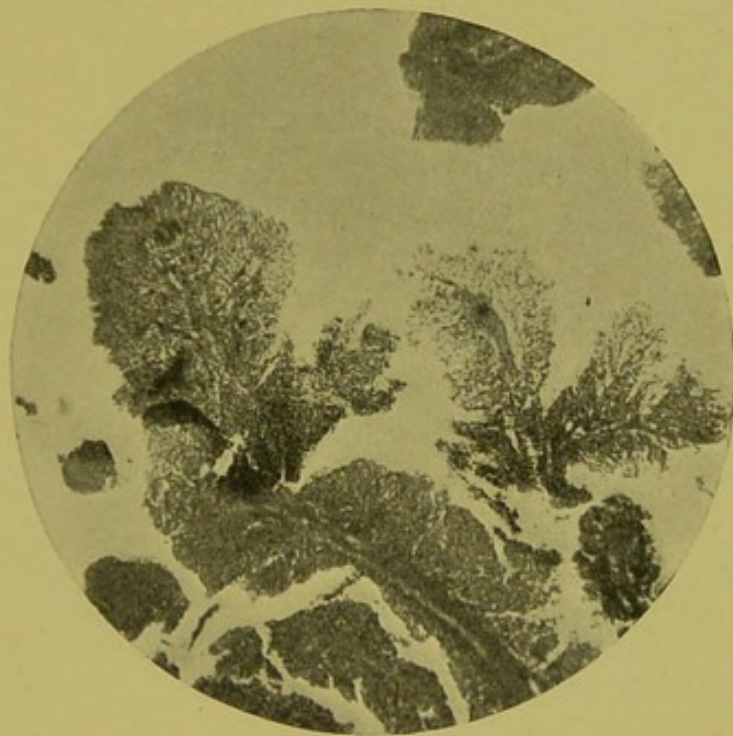

FIG. 69.—Malignant papilloma. (Zeiss, Oc. 2, Obj. A,  $\times 60$ .)

the whole kidney was then removed. Murchison records the case of a man, *æt.* 65, where the pelvis of the kidneys were occupied by villous growths, similar papillomata being situated in the bladder at the orifice of each ureter. Sutton gives an illustration of this specimen, which is preserved in the Museum of Middlesex Hospital, in his work on "Tumours."

In a specimen of carcinoma of the pelvis of the kidney sent me by Mr. Paul, there was an abundant fibroid stroma, with aggregations of large epithelial cells in masses, columns, and small alveolar-like groupings, but presenting no distinct papillomatous structure.

Reginald Harrison, while admitting that "the renal pelvis,

like the vesical bladder in structure, is sometimes the seat of growths similar to those met with in the latter," believes that villous growths are rare, and that "squamous-celled epithelioma is the usual kind of carcinoma met with in this locality." In some instances the villous growths have been associated with calculus formation.

In Battle's case, where the patient was *æt.* 51, the kidney was explored, and a calculus detected and the growth scraped.

Knowsley Thornton's patient was a female, *æt.* 32. A papilloma existed at the junction of the ureter and pelvis with a calculus adherent to it.

Drew states that specimens of papillomata associated with calculus formation, are to be found in the Museums of University College and Guy's Hospital.

It is probable that some growths originating in the renal substance extend into the renal pelvis and project in a somewhat papillomatous form.

Rundle has recorded a remarkable case of epithelioma of the ureter in a man *æt.* 46.

Colloid forms are rare. Newman describes a case met with in the Glasgow Royal Infirmary. The patient was a woman, *æt.* 45. The growth projected from the convex margin of the right kidney, and on section was found to be composed of a soft, almost disintegrated tissue, which towards the hilum merged into normal renal tissue. Microscopic examination showed considerable colloid change in the epithelial cells, and the form of the stroma was characteristic. There is a somewhat similar specimen in Guy's Hospital Museum.

Dickinson has met with colloid cancer associated with calculi. Schueppel has recorded a colloid cancer weighing 26½ lb. Cases of colloid growth have also been recorded by Rokitansky and Gluge.

The cylindroma is not a carcinoma but a special form of sarcoma. This form of growth has been described under such different names as "tubular tumour," "tubular sarcoma," or "siphonoma." It is very rare in the kidney. Wagner mentions two cases. Cylindroma evidently has close relationships with the alveolar sarcoma and endotheliomata.

Sometimes the primary growth may be quite overshadowed by the symptoms arising from secondary deposits. This was

well illustrated by a case in the Manchester Royal Infirmary some years ago, under the care of Dr. Simpson.

James W., æt. 49, five weeks before admission, whilst washing himself, suddenly found his right arm becoming weak. In three or four days it became quite useless. A week later the right leg failed. He then experienced some difficulty in speaking.

On examination, evidences of cerebral tumour were unmistakable. No abdominal growth was noted. The urine appeared normal. He remained under observation for nearly six weeks, the cerebral symptoms increasing, and died comatose.

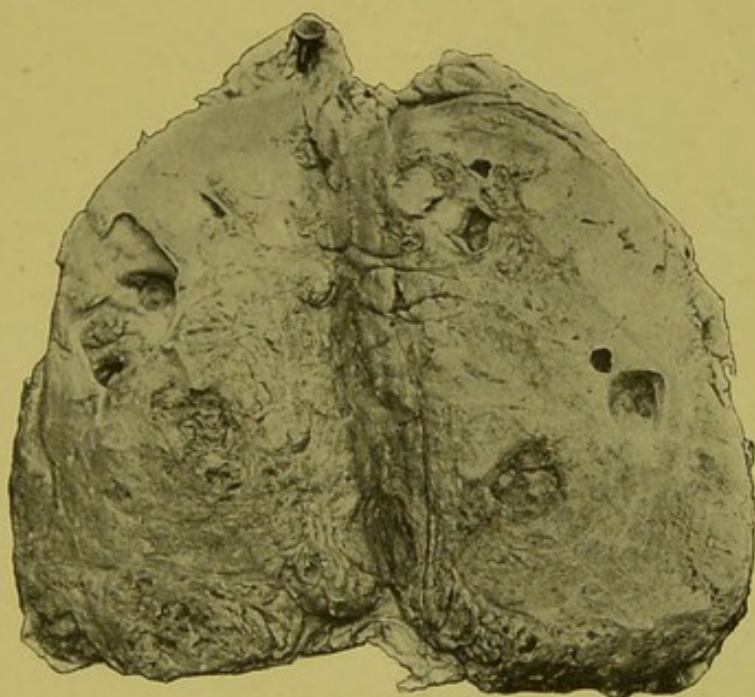


FIG. 70.—Carcinoma of kidney. Remains of kidney at one end. Diffuse growth having in parts honeycomb appearance, and presenting several cysts showing intracystic growth. Extensive adhesions between kidney and perirenal fat. Weight (after hardening), 16 oz.; size,  $5\frac{1}{2} \times 3\frac{1}{2}$  in.

The post-mortem examination was conducted by Dr. Thomas Harris. "In the substance of the left cerebral hemisphere, close to and involving the cortex, was a tumour the size of a large walnut. This growth was seated so as to involve chiefly the upper extremity of the ascending parietal convolution. It was of a dull red colour in the greater part of its substance, whilst elsewhere there were signs of considerable recent hæmorrhage having ensued into its substance. In the anterior part of the right frontal lobe was a focus of black recent hæmorrhage, but no evidence of growth could be seen around it. Elsewhere the brain presented no abnormal appearances."

The left kidney was the seat of extensive growth. Weight, 24 oz. At one extremity a portion of kidney cortex remained uninvolved (Fig. 70). The growth at the periphery was fairly firm in consistency, and of a mixed red and grey colour. The centre was very soft, and of a yellow appearance. The right kidney weighed 8 oz., and appeared normal. The liver presented a small secondary nodule the size of a walnut in the substance of the right lobe. Both lungs were the seat of several secondary nodules.

Microscopically, the growth presented an alveolated struc-

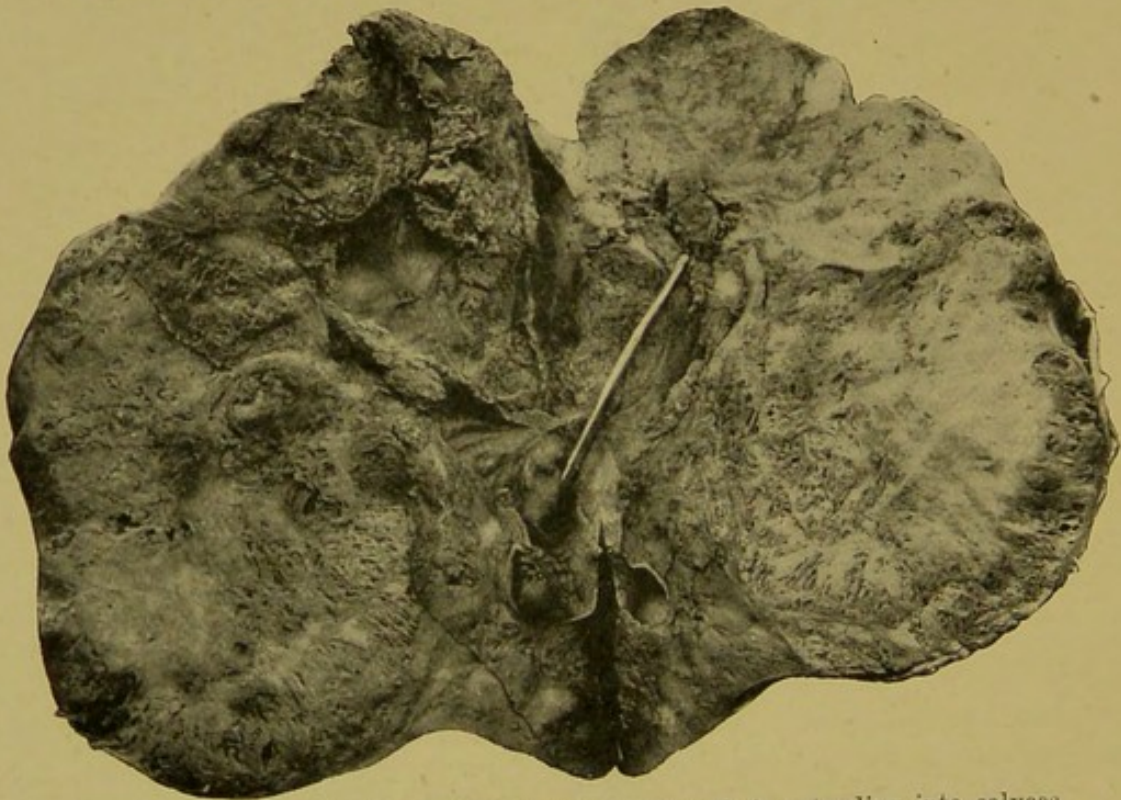


FIG. 71.—Malignant adenomatous growth. Growth is extending into calyces and pelvis. A probe is passed into the pelvis from the ureter. Remains of kidney tissue at one end. Removed by operation from a man, æt. 48.

ture, with abundant epithelioid cells; and, although in some respects approximating to a sarcomatous form, may perhaps be best included in this group.

In connection with this chapter, perhaps the following somewhat remarkable example of a malignant adenomatous growth may be referred to.

The adenomatous features of the growth were very marked, but its rapid development and secondary involvement of adjacent glands seemed to clearly indicate its malignant nature.

J. W., æt. 48, warehouseman, was admitted to the Manchester

Royal Infirmary, 1st Sept. 1897, under Mr. Thorburn. Patient had always enjoyed good health up to 1895. In October of that year he first felt sharp pain in the region of the left kidney, and blood appeared in the urine. Blood continued to be passed at intervals of a few months. Clots were sometimes passed, and gave rise to much pain. Patient gradually became worse. On admission, a distinct swelling was detected in the left loin, extending inwards and downwards as far as the umbilicus. Urine was slightly alkaline, sp. gr. 1010; contained albumin, blood, and phosphates. On lumbar exploration a renal growth was found. No calculi were present. The growth was removed, but patient died the same day from hæmorrhage. No post-mortem examination was permitted.

The macroscopic characters of the growth are illustrated in Fig. 71. The specimen has been added to the Pathological Museum of Owens College.

Externally, the mass had a nodular or bossy appearance, but the capsule could be detached with moderate ease. On section, the growth had a somewhat spongy appearance, and involved the greater part of the organ, and was extending into the pelvis.

Microscopically, the structure was in places almost typically adenomatous. In other parts the proliferation of the tubular epithelium had led to considerable accumulation of cylindrical epithelium. A tendency to cystic formation was but little marked. One of the small glands removed from the immediate neighbourhood of the kidney presented a similar structure to the original growth.

## CHAPTER XVI.

### ADRENAL GROWTHS.<sup>1</sup>

BEFORE leaving the consideration of the different forms of renal growth, it seems desirable, both on pathological and clinical grounds, to briefly refer to growths arising in connection with the suprarenal capsules. As Reginald Harrison very truly points out, "tumours of the adrenal are often so intimately connected with the kidney that it is impossible to differentiate them clinically."

Neoplasms occurring in connection with accessory adrenals, or arising from structures derived from the Wolffian body or intermediate cell mass, and included in the renal parenchyma, will not be dealt with in the present chapter, as they have already been sufficiently referred to.

Growths of the suprarenal bodies have received but scant attention. Individual cases have from time to time been recorded more or less briefly, but few attempts have been made to systematise our knowledge. And yet the subject is of the greatest interest and importance. A study of adrenal growths is of value in several respects. In the adrenals we have glandular organs fulfilling very important functions. Replacement by growth not infrequently gives rise to general symptoms which may quite overshadow in importance any local manifestation due to the growth itself. The occurrence also of indefinite growth in connection with adventitious adrenal tissue, such as is sometimes met with in several important abdominal structures, and more especially the kidney, widens the etiological view of neoplastic development, and explains much that has until recently appeared anomalous in certain tumour formations. Moreover, a consideration of the various types of growth met with in the adrenals seems capable of throwing much light, not

<sup>1</sup> This chapter has been extended from an article which I first published in the pages of the *Manchester Med. Chron.*, Sept. 1897.

only on the relationship of growths generally, but in suggesting connections between a localised hyperplasia and such formations as we are accustomed to speak of as true neoplasms.

Adrenal growths are by no means of common occurrence. Roger Williams, in a collection of 8378 consecutive cases of malignant disease, only found one example primary in the adrenal.

#### BENIGN GROWTHS.

*Adenoma.*—Glandular-like formations are the most frequent form of simple growth met with in the suprarenals. Virchow and others have shown that the adrenals, like the thyroid, may undergo a diffuse or general enlargement, apparently due to pure glandular proliferation. Some pathologists have even gone so far as to speak of such cases as "adrenal goitre." Such a term, however, would seem to be most undesirable.

Adrenal adenomata, according to Rolleston, are met with in two forms:—

"1. Multiple small yellowish nodules situated on the cortex of the organ; they are not marked off by any capsule from the surrounding tissue, but differ from it in being the seat of very advanced fatty change. In other respects the cells composing them are like the cells of the suprarenal cortex.

"2. Large adenomata are almost always found singly in the suprarenal capsule, though they may be bilateral. They do not involve the whole of the organ, but form distinctly localised tumours, which may attain a very considerable size. They arise as a rule in the cortex, either from one or from more of its zones, and project usually from one side, though the whole thickness of the organ may be affected."

Among modern pathologists, Letulle in particular has recently drawn attention to the adrenal adenomatous group in his paper entitled "Surrénalite nodulaire hyperplastique et adénomes de la capsule surrénale." He clearly shows that the normal arrangement of the adrenal elements may undergo considerable perturbation, by which their topographical and functional relationships are much altered. This occurs not infrequently in the course of other diseases, such as pulmonary tuberculosis and gastric cancer. This nodular form of adrenal hyperplasia, according to Letulle, sometimes occurs in connection with similar developments in the liver, such as have been described by Kelsch,



Kiener, and Sabourin. There is undoubtedly a more or less gradual transition from the forms of mere glandular hyperplasia to the true adenomata, or benign epitheliomata, as some continental pathologists prefer to call them. The similarity between the localised adrenal adenomata and the adenomatous formations in so-called "nodular" cirrhosis of the liver is certainly striking. Since Sabourin and others have clearly shown that the latter adenomatous formation of the liver cells is usually secondary to some irritant, there is reason to believe

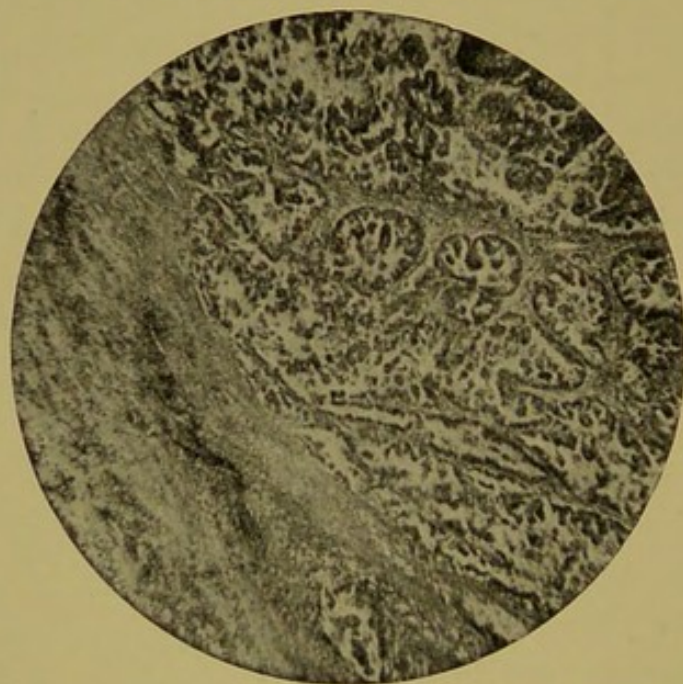


FIG. 72.—Adrenal adenoma (from Case 1). Fibrous stroma infiltrated with small round cells. Irregular spaces, several of which show papillomatous ingrowth, degenerated epithelial cells, and granular material in alveoli. (Zeiss A, Oc. No. 2,  $\times 50$ .)

that some at least of the adrenal adenomata may be found to arise as reactions to definite irritation.

Adrenal adenomata of any conspicuous size are by no means common. During the last few years, in examination of over 1500 cases in the Pathological Department of the Manchester Royal Infirmary, I have only met with three well-marked examples.

The general characters of this class of growth, and some of their more important variations in arrangement, are illustrated in Figs. 72-79.

CASE 1.—Male, *æt.* 63. Death from cerebral hæmorrhage. Right adrenal—much enlarged; pyramidal in shape; weight,  $1\frac{1}{2}$  oz. Consisted of soft, pinkish white, vascular, glandular-looking tissue.

*Microscopically.*—Abundant fibrous stroma, infiltrated in places with small deeply staining round cells. Spaces irregular in size and shape, lined or filled with more or less cubical cells, each with a large well-defined nucleus. Some spaces presented slight papillomatous ingrowth. In some parts the columnar

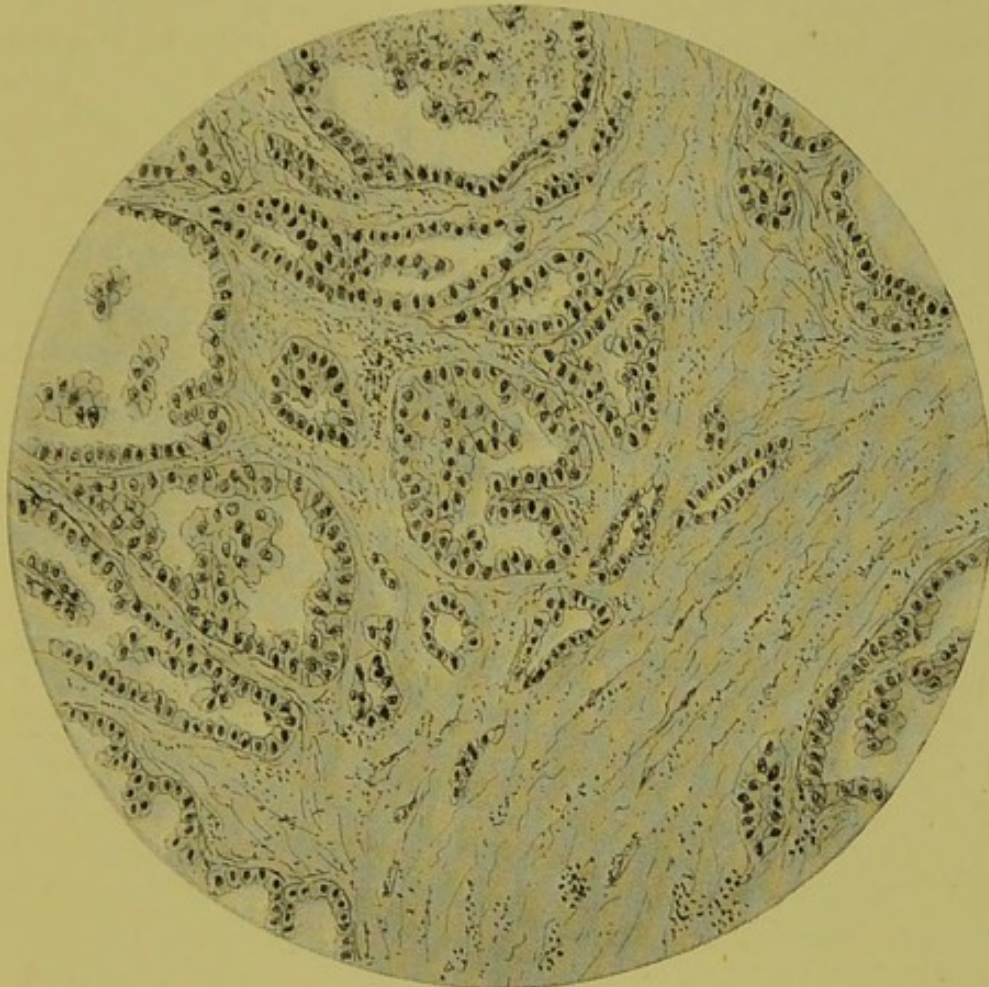


FIG. 73.—Section of adrenal adenoma, showing stroma of fine fibrous tissue; clusters of round cells in the stroma; spaces lined by and containing cubical epithelial cells; one cyst-like space shows tendency to intracystic papillary growth; one large space shows granular material, consisting in part of degenerated cells. (Zeiss, Oc. 2, Obj. A.)

arrangement of the cells closely resembled the zona fasciculata of the normal adrenal (Fig. 72).

CASE 2.—Male, æt. 56. Death from cerebral softening. Left adrenal—much enlarged; weight,  $3\frac{1}{2}$  oz.; length,  $3\frac{1}{2}$  in.; breadth,  $2\frac{1}{2}$  in.; antero-posterior diameter,  $1\frac{1}{2}$  in. Yellowish white colour. Surface a little irregular. Upper end of kidney united to growth. The naked-eye characters are shown in the accompanying illustration (Fig. 75).

*Microscopically.*—Growth very closely resembled normal

adrenal tissue. Abundant fine fibrous stroma, infiltrated in places with small round cells staining deeply with nuclear dyes. Extensive aggregations of epithelial cells. These varied considerably in their general arrangement. In some parts the cells were closely approximated in rows or more or less distinct columns (Fig. 76). In other places the columnar form was very conspicuous, the elongated masses of cells appearing to branch or

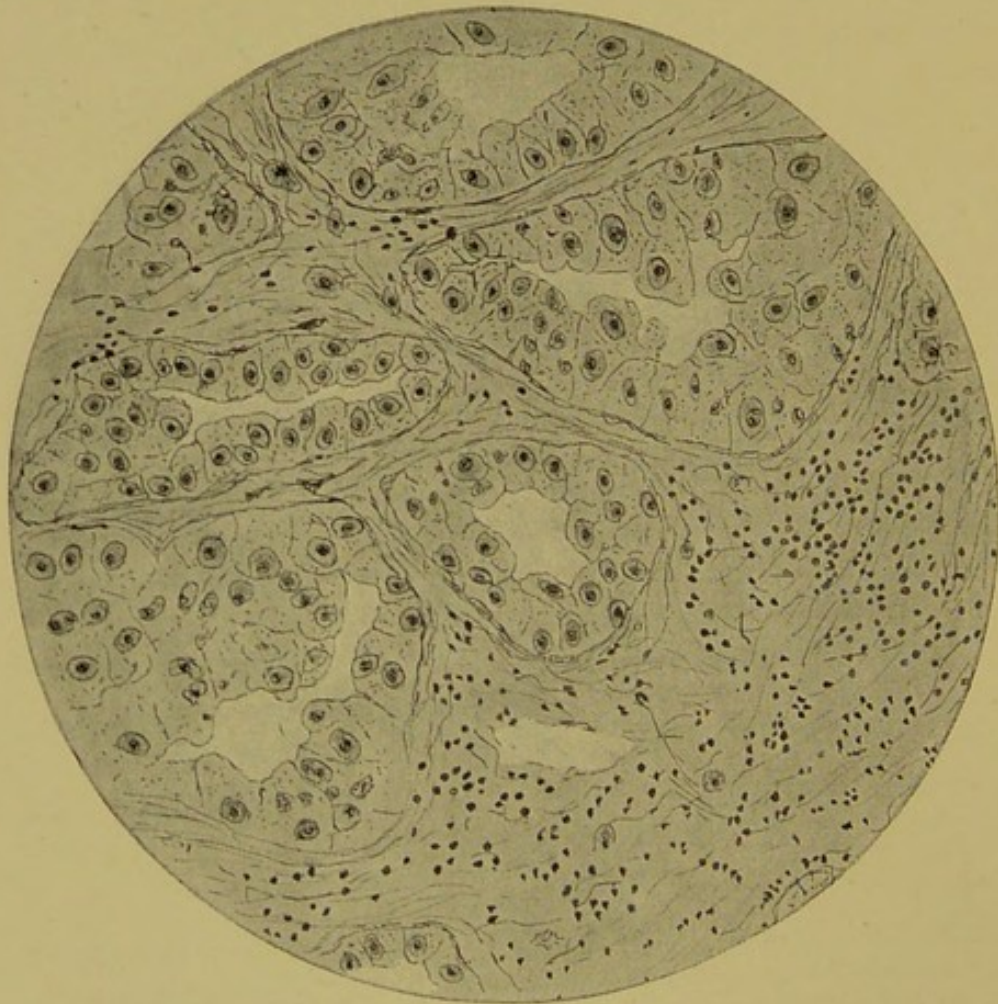

FIG. 74.—Section of adrenal adenoma, showing stroma of fine fibrous tissue; round cells scattered through stroma; irregular spaces lined with epithelium. (Zeiss, Oc. 2, Obj. D.)

divide in a somewhat irregular and indefinite manner. In some regions the cells were packed together, forming large, round, or oval masses. There was but little tendency to form spaces, as in the previous specimen. Well-marked distended vessels ran in the stroma.

CASE 3.—Female, *æt.* 60. Death from chronic interstitial nephritis. Left adrenal—elongated, and presenting at its central part a rounded slightly elevated mass, of the size of a

small walnut. Weight,  $\frac{1}{2}$  oz. The growth was more or less localised, but had no distinct capsule. It was yellowish white in colour, and very similar in general appearance to normal adrenal cortex, but with areas in its midst having a more or less homogeneous appearance.

*Microscopically.* — Presented more distinctly glandular type than even the two preceding preparations. There was a very abundant fine fibrous stroma, exceedingly rich in vessels distended with blood. Alveolar spaces filled with large epithelial cells of distinctly glandular type. In some places the masses of cells became elongated into columns closely resembling those of the normal adrenal. The cells in the more superficial parts of the growth presented distinct characters of adrenal tissue. In the deeper parts irregular areas appeared to be undergoing degenerative change, had an indistinct appearance, and failed to stain (Figs. 77, 78, 79).

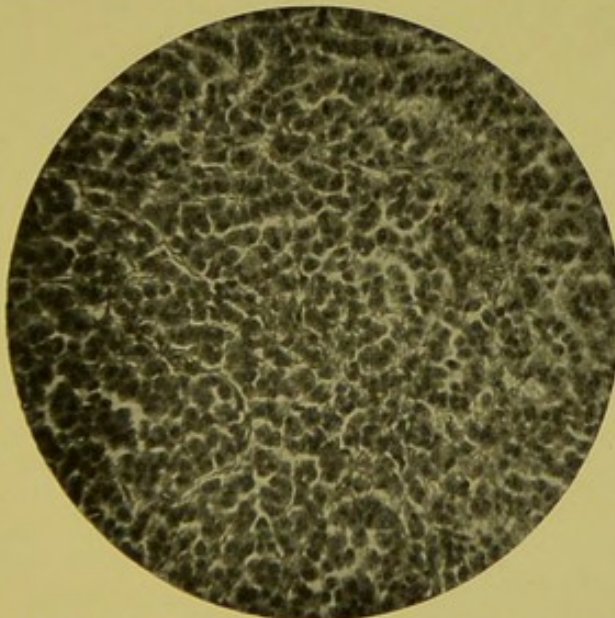


FIG. 76.—Adrenal adenoma (from Case 2). (Zeiss D, Oc. No. 2,  $\times 240$ .)

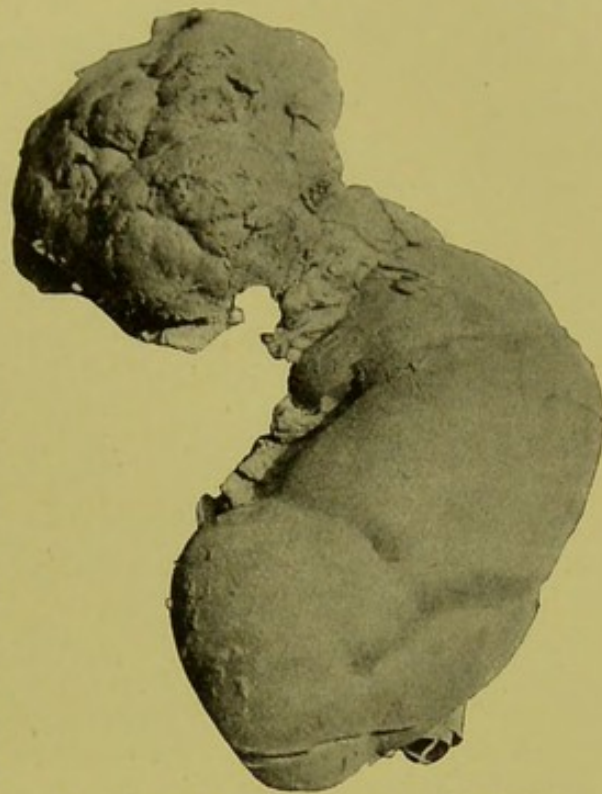


FIG. 75.—Adrenal adenoma and left kidney (from Case 2).

suprarenal body. On section, it was of a dark brownish red colour. It was discovered in the body of a man, *æt.* 54, who

rather larger than a walnut, and localised to the upper part of the left suprarenal body. On section, it was of a dark brownish red colour. It was discovered in the body of a man, *æt.* 54, who

Rolleston, in 1894, reported an interesting example of adrenal fibroadenoma. The growth was rather larger than a walnut, and localised to the upper part of the left

died from granular kidneys. Microscopically, "the suprarenal

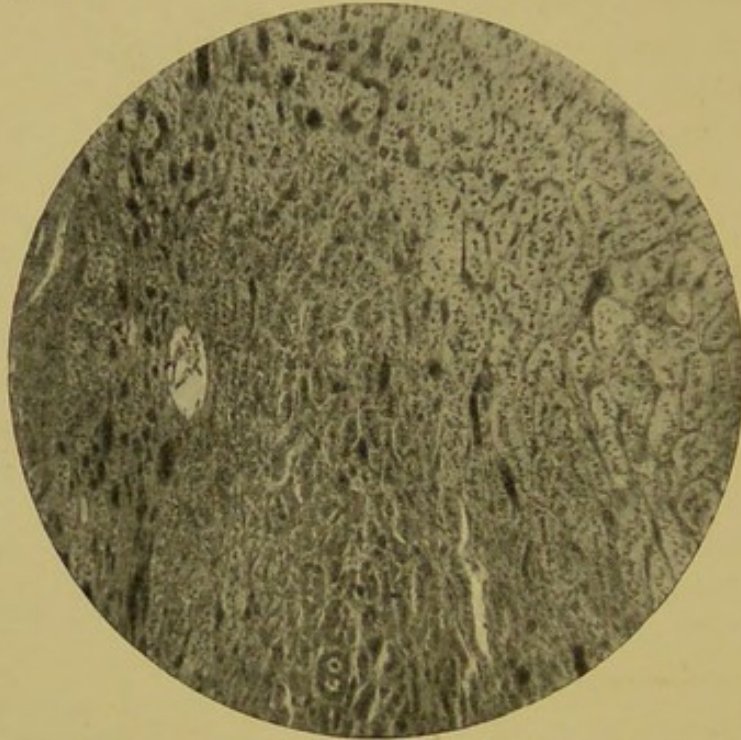


FIG. 77.—Adrenal adenoma (from Case 3). Darker areas indicate vessels of stroma distended with blood. Between vessels, columns and round or elongated masses of epithelial cells. (Zeiss A, Oc. No. 2,  $\times 70$ .)

tissue, though altered, could be easily recognised; the normal arrangement of the layers in the cortex was somewhat obscured,

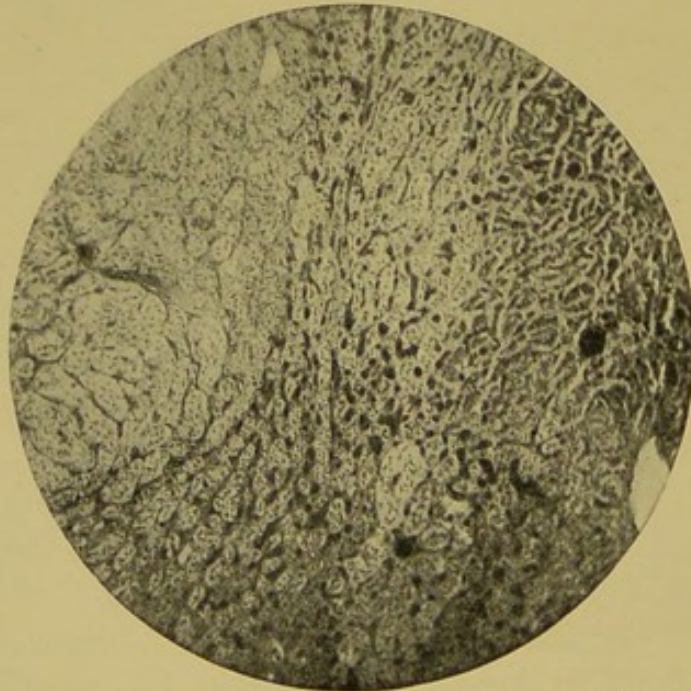


FIG. 78.—Adrenal adenoma. Section from another part of Case 3. ( $\times 60$ .)

but not entirely lost. The columns of suprarenal cells were separated and compressed by strands of well-formed fibrous tissue,

so as to produce an appearance homologous to cirrhosis of the liver. There was more fibrous tissue in the deeper parts of the tumour than on the surface. Running in this fibrous tissue were well-formed and large blood vessels. The suprarenal cells were somewhat atrophied, but did not show any fatty infiltration. No caseous areas were found, and tubercle bacilli were not discovered."

Usually these adrenal adenomatous growths do not reach large dimensions. Sometimes, as in one of the above cases, the growth assumes a distinctly localised nodular form. As far as my experience goes, and as far as I can judge from the descriptions given by other observers, the macroscopic characters are generally very similar.

The adenoma appears as a diffuse or localised growth of a yellowish white colour, very similar in general appearance to the normal adrenal cortex. Some are pink or red, according to the varying degree of vascularity. Occasionally the deeper parts have a homogeneous or gelatinous appearance. I believe they occasionally undergo sufficiently

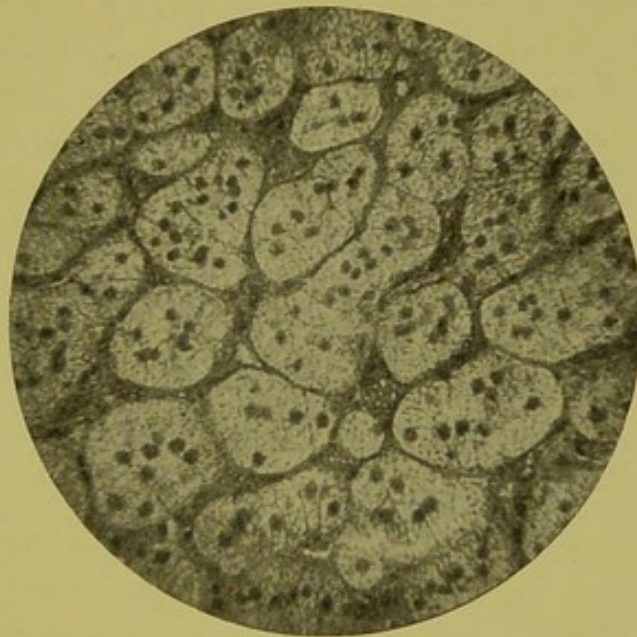


FIG. 79.—Adrenal adenoma (from Case 3). Glandular-like aggregations of cells, with fine and very vascular stroma. (Zeiss D, Oc. No. 2,  $\times 250$ .)

extensive degenerative changes to form small cysts. The surface is generally fairly smooth, and the customary shape is often retained even when the adrenal is greatly enlarged. Sometimes they are firmly adherent to the adjacent kidney.

Adrenal adenomata vary considerably in structural arrangement. There is always a fibrous stroma, but this is very variable in extent. In some instances it is very abundant. In others it is scanty in amount, and more or less embryonic in character. Generally the trabeculae are larger and more abundant than in the normal adrenal. In one of my cases the stroma contained numerous and very large vessels distended with blood. Sometimes the stroma is the seat of an extensive small round-cell infiltration.

The cellular elements between the fibrous strands vary greatly both in amount and in general arrangement. Frequently the appearance is almost identical with normal adrenal tissue. Generally the columnar arrangement is more or less followed. In some the elongated masses of cells branch in rather indefinite manner. Often the cells are closely packed together in irregular masses. In one of my cases the epithelial elements were collected together in more or less definite spaces. The cells in some filled the cavity, while in others they formed a lining one cell deep. In some there was slight but distinct intracystic papillomatous growth.

Many of the cells show very marked degenerative changes. Some may be fatty. Occasionally they may present slight pigmentation. In some instances the cells are seen to have broken down. In one of my specimens considerable areas showed little but granular débris. Letulle never noticed hæmorrhage into the interior or at the periphery of the nodular adenomatous masses he describes.

It is interesting to speculate on the influence of the products of these adenomatous growths on the system generally. In the cases coming under my observation, the cause of death was such as to prevent any inference being made on this point. Analogy with the condition of the thyroid in exophthalmic goitre suggests the desirability of more careful observation in all adrenal adenomatous cases. In several of the published cases of adrenal growth cretinoid characters have been noted, and also a condition of hypertrichosis.

In studying the records of adrenal growths, it has seemed to me that a number of the doubtful examples really belong to this adenomatous group. Brief reference may here be made to several.

Ogle in 1857 brought before the Pathological Society of London specimens which he termed "Two suprarenal capsules of a remarkably unusual form, and occupying a very unusual position. Substance of these organs healthy." Judging from the description, and the illustration accompanying it, there can be little doubt but that the specimens were true adenomata.

Sibley in 1859 examined a man, æt. 66, dying from epithelioma of the tongue, in which the only secondary growth involved the right adrenal. It was enlarged to nearly double the size of the left. Microscopic examination showed the

growth to consist of fibrous elements and large numbers of cells, which "closely resembled epithelial cancer cells. They were very irregular in form and size, but were mostly flattened and nucleated."

Walter Smith in 1877 met with a large growth in the body of an elderly male in the dissecting room. The growth formed a large round elastic tumour on the left side. The left kidney projected behind it; flattened but otherwise normal. The growth was  $8 \times 3\frac{1}{2}$  in. in size, and embedded in a loose capsule of connective tissue. There were no adhesions. On section, the outer part was of a homogeneous red appearance, the inner portion being buff-grey in colour. There were numerous cysts. The growth was considered to be a sarcoma, which had undergone colloid and cystic degeneration.

Wiglesworth in 1891 reported a case of what he considered to be primary carcinoma of the right adrenal. The specimen was obtained from a woman, æt. about 60, who died in the Rainhill Asylum. The growth was of the size of a small ovary, and weighed 2 oz. On section, it was of firm consistency, and had a somewhat marbled appearance, due to the alternation of buff-coloured and reddish portions. The central part had much the appearance of a partially decolorised blood clot. Microscopically, the greater part consisted of altered blood, but the cortical portions presented a well-marked alveolated structure.

Bland Sutton has described and figured a growth in the adrenal of a marmot which he considered to be an adrenal adenoma. There were, however, similar nodules in the liver.

Cohnheim, Morris, Coats, Howard, and Villy have shown that adenomatous types of thyroid growth may give rise to secondary growths which repeat the normal structure. It seems reasonable to believe that a like form of growth may occur in the adrenals, but, with the exception of Sutton's case, I know of no example. Besides the adenomatous growths, simple tumours of the adrenal are exceedingly rare.

*Fibroma.*—According to Laboulbène, small fibromata have been met with in the medullary substance by Saviotti. It, however, seems possible that these were really fibro-adenomatous formations or examples of Letulle's nodular hyperplasia. Mattei also refers to fibroid growth in the adrenal.

*Lipoma.*—Fatty growths have been described, but most of



these have undoubtedly been adenomata, in which the cells have undergone extensive fatty change. Virchow termed such, *struma lipomatosa suprarenalis*.

*Glioma*.—Virchow has referred to certain minute growths in the suprarenal bodies under this term. He describes them as globular, pale red nodules, about the size of a millet seed.

*Angioma*.—Payne has met with a very vascular growth in the adrenal of a female, æt. 25, dying from exhaustion due to hæmorrhage from a uterine polypus. There were similar nævoid formations in the ovaries and liver.

*Lymphangioma*.—Klebs mentions the occurrence of cavernous lymphangiomata, and, according to Laboulbène, Vogel and Seitz have observed lymphatic formations in the adrenals.

#### MALIGNANT GROWTHS.

It is exceedingly difficult to obtain satisfactory information as to the nature and frequency of primary malignant disease in the suprarenal bodies.

In many of the recorded cases the growth is manifestly secondary, and frequently details as to its microscopic characters are only conspicuous by their absence. In a considerable number of the cases which have been published, and especially those about the middle of the century, the only point which has seemed to interest the observers was the relationship between lesions of the adrenals and Addison's disease. Hence a large number of the cases of adrenal growths are rendered almost worthless by their very incompleteness.

Rolleston has attempted to indicate the frequency of secondary involvement of the adrenals. In 1050 post-mortem examinations, carcinoma of various parts of the body occurred sixty-three times, and in seven of these the suprarenal bodies were the seat of growths. There were twenty-four cases of sarcoma, and of these only two cases showed metastatic growths. These figures would seem to show that secondary deposits only occur in about 11 per cent. of carcinoma, and 8 per cent. of sarcoma.

The adrenals may be involved by direct extension, or by vascular deposition. In retro-peritoneal sarcoma they are liable to be involved, as I have myself seen.

Roger Williams, in thirty-six collected cases of malignant

growth of the adrenals, found that more than one-third belonged to the periods of infancy and childhood. They may even be met with at birth. The same author says: "They are invariably sarcomatous, although often described as cancerous."

Of the recorded cases, it is certainly difficult to distinguish between sarcoma and carcinoma. Many were evidently not subjected to microscopic examination. A considerable number are merely described as "cancer." Brief reference may be made to some of these.

Peacock and Bristowe in 1856 met with what they considered to be adrenal cancer in a young woman of 18. Judging from the description, the growth was only secondary in these organs. The same authors, in the same year, recorded a case of secondary cancer in a man *æt.* 55.

Gibb in the same year recorded the case of a woman, *æt.* 33, the subject of proliferous ovarian cyst, where there were deposits in one adrenal.

Haldane in 1861 published a case of adrenal cancer occurring in a man, *æt.* 36. The growth was apparently secondary.

Pitman in 1865 recorded a remarkable case of malignant growth in a female child, *æt.* 3, where there was general malasma and short hair over the entire body, while the external genitals resembled those of an adult. The growth weighed 2 lb. 5 oz., and was attached to the kidney. "It was manifest from its connections, as well as from the absence of any other representative, that this was the left suprarenal capsule. A secondary nodule was found in the liver." Microscopically, it consisted of "a collection of cells which were very fatty, while at the same time they had the character of cancer cells."

Cayley in 1865 reported a case of cancer of the right suprarenal the size of a large pea, but undoubtedly secondary to primary medullary cancer of the uterus. The woman was *æt.* 45, and the symptoms of cancer of the uterus began about a year before death.

Greenhow in 1866 recorded a case of cancer of both suprarenal capsules in a man *æt.* 56. This was apparently secondary. In 1867 he publishes a case of cancer of one adrenal in a girl *æt.* 12. This case, judging from the description given, seems to have been a simple adenoma. In 1873 he recorded a further case, met with in a man of 56.

In Greenhow's special report on diseases of suprarenal capsules to the Pathological Society of London in 1866, a table of twenty-four cases of cancerous affection is given. In at least two the involvement was probably not really due to growth.

Arnott in 1868 met with a specimen of adrenal cancer in a man *æt.* 47. The growth had an epitheliomatous arrangement, and was secondary to growth of the tongue.

Bristowe in the same year observed a case where adrenal cancer was associated with similar growths in the brain, liver, and kidney of a man *æt.* 62.

Murchison, also in 1868, noted a case of secondary cancer of one adrenal, and reported because the patient presented no symptoms of Addison's disease.

*Carcinoma.*—As already indicated, it is by no means always easy to distinguish between adenoma and carcinoma of the adrenal. After excluding the doubtful adenomata, and setting aside the undoubtedly secondary carcinomata, one is driven to admit that primary carcinomata of the adrenal is excessively rare.

Ritchie and Bruce in 1890 reported a case of what they considered to be primary adrenal carcinoma in a female, *æt.* 73. There were also deposits in the lungs.

*Sarcoma.*—This is the usual form of primary malignant growth in the adrenal. Even these are exceedingly rare. Affleck and Leith, in the most complete article yet published on adrenal sarcomata, succeeded in finding references to only some sixteen cases. In many of the recorded cases the primary are not always sufficiently separated from the secondary sarcomata. The earliest recorded case of adrenal sarcoma, according to Affleck and Leith, was published by Kussmaul in 1863. The growth, a melanotic sarcoma, was evidently secondary. It involved the right adrenal, and was as large as a man's head. It produced thrombosis of the inferior vena cava, and death by embolism.

Meckel in 1877 briefly refers to a case of adrenal sarcoma met with by Zenker in a male the subject of tubercular meningitis and chronic pneumonia.

West in 1878 recorded the case of a man, *æt.* 57, in which the right adrenal was the seat of a primary sarcoma. There were secondary deposits in the lungs.

Rosenstein in 1881 met with sarcoma in both adrenals of a

man *æt.* 40, with what he considered to be metastatic deposits in the left kidney, pancreas, and heart.

Fox in 1884 describes a sarcoma the size of a cocoanut in a child *æt.* 2.

Hale White in 1885 recorded a case of adrenal sarcoma weighing 20 oz. The growth was secondary to a sarcoma of the posterior mediastinum.

Charleswood Turner in 1885 recorded a case of a man, *æt.* 25, where both suprarenals were the seat of a medullary sarcoma. There was also a mediastinal sarcoma.

Fox in 1885 met with primary sarcoma in the left adrenal of a female child *æt.* 2. There was extensive thrombosis of the vena cava inferior. The growth was about the size of a cocoanut, uniformly ovoid, soft and fluctuating, and weighed  $1\frac{1}{2}$  lb. It rested on and flattened the healthy left kidney. The capsule of the growth was adherent to but otherwise quite distinct from the kidney.

Fränkel in 1886 described sarcomatous growths in the adrenals of a girl *æt.* 18.

Pilliet in 1888 published the case of a man, *æt.* 56, with a huge sarcoma of the right adrenal which had led to thrombosis of the inferior vena cava.

Perry in 1889 reported a case of primary sarcoma, originating in a man of 23. His skin was muddy, although there was no distinct bronzing; he complained of great pain in the abdomen, which he referred to the region of the gall-bladder, and to the pit of the stomach; there was distinct tenderness over the lower dorsal vertebræ; he had constant vomiting, occasional diarrhœa, and profuse perspiration; his temperature was slightly raised. The autopsy showed that both adrenals were the seat of growth, which microscopically proved to be spindle celled sarcoma.

Berdach in 1889 recorded the case of a man, *æt.* 55, whose left adrenal was the seat of what appeared to be primary spindle celled sarcoma.

Mr. Henry Morris in 1893 published the case of a man, *æt.* 43, from whom he removed a large adrenal growth which was invading the kidney. He has very kindly lent me the accompanying illustration of the specimen from his case (Fig. 80). Hæmaturia had been observed for two years. General wasting then became marked, and finally a distinct tumour was noted on

the right side of the abdomen. The patient recovered from the operation, but general dissemination quickly appeared, and deposits were noted in the liver, and over a considerable area of skin. As regards the growth removed, "in structure it resembles the medullary part of the suprarenal capsule, and it is a tumour of the suprarenal body which has encroached upon and absorbed into itself the upper half of the right kidney. As is seen by the figure, the kidney has been completely divided across, opposite its hilum, in the process of growth of the tumour. The surface section is perfectly smooth and concave, and is covered by a

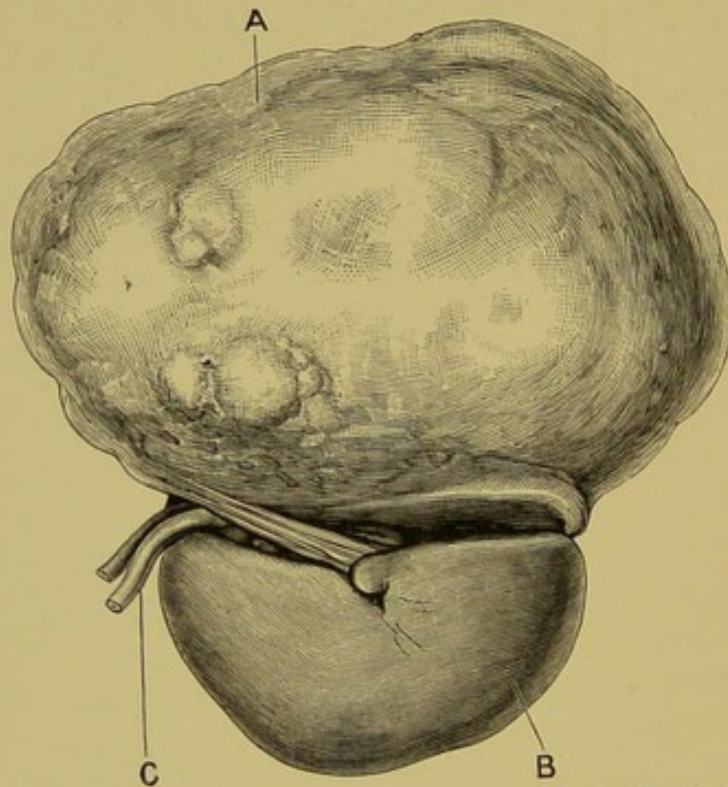


FIG. 80.—Malignant adrenal growth. A, Adrenal growth; B, kidney; C, ureter.—From a block lent by Mr. Henry Morris.

thin fibrous envelope which holds it to the lower part of the tumour. The ureter is bifurcated near the renal pelvis, one part coming from the portion of kidney into which the tumour has grown, and the other from the unaffected half of the organ.

Mr. Morris tells me that as no post-mortem examination could be obtained, the secondary deposits could not be submitted to microscopical examination. Bland Sutton refers to this specimen in his work on "Tumours" as "originating in an accessory adrenal."

Lazarus in 1894, according to Affleck and Leith, recorded a

case in a child, *æt.* 3½, where the growth replaced the left adrenal, and weighed 12½ lb.

Cohn, also in the same year, met with a sarcoma of the right adrenal, composed of round and polygonal cells, in a child of 9 months. There were extensive secondary deposits situated in the liver, kidneys, ovaries, skull, and costo-chondral junctions of ribs.

Mr. Targett has very kindly drawn my attention to a most interesting specimen of adrenal growth in the Museum of the Royal College of Surgeons of England (No. 3518D). The preparation was presented by Dr. R. E. Scholefield, and was removed from a boy *æt.* 5, who died of scarlet fever. No tumour was noted during life. I am indebted to Mr. Targett, formerly curator of the museum, for the following description:—"The tumour, with the kidney, has been divided longitudinally. The kidney is normal in structure, but its upper end is much flattened in consequence of the pressure of the growth, from which it is sharply limited by means of its capsule. The capsule has been readily detached from the kidney, leaving a healthy surface, but it is firmly blended with the tumour.

Above, the tumour is bounded by the diaphragm, the substance of which is already invaded.

"The cut surface of the tumour has a distinctly triangular shape, like that of the normal adrenal, and shows the soft friable nature of the growth, as well as large blood extravasations into it. Its anatomical situation between the kidney and the diaphragm, outside the capsule of the former, and its peculiar shape, are good evidence that the tumour has originated in the adrenal body, though no trace of that structure can be found upon it. Microscopical examination showed that it was composed of small cells, with round nuclei remarkably uniform in size, like sarcoma

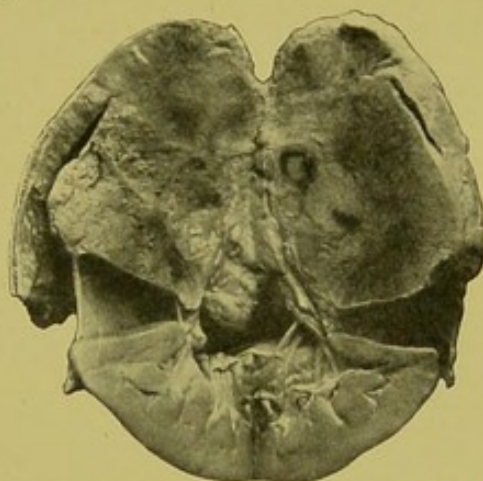


FIG. 81.—Sarcoma of the suprarenal body. Whole of adrenal replaced by growth. Several areas of blood extravasation. Diaphragm adherent to and invaded by growth. Kidney much flattened at its upper end from pressure of growth, from which it is sharply separated by its capsule. From a boy, *æt.* 5. Growth and kidney divided longitudinally, the latter drawn away from its capsule, which is adherent to growth.—From a photograph lent by Mr. Targett.

cells. The section was permeated by many strands of connective tissue and vessels, and in the deeper part of the tumour several nerve fibres belonging to the sympathetic system were cut across. The growth is undergoing caseation in parts, and there is much extravasation of blood."

Mr. Targett has kindly supplied me with the photograph of a further example of adrenal sarcoma (Fig. 82). The growth was found in the body of a girl, *æt.* 12, who died from pneumonia. The specimen has been added to the Middlesex Hospital Museum (1664). The kidney was flattened, but not invaded by growth. Kidney and tumour were separated by a fibrous capsule, which could be readily detached from the former, but was closely

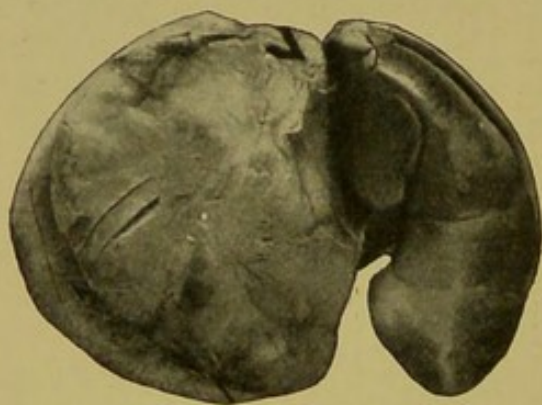

FIG. 82.—Flattened but healthy kidney on the right, surrounded by its capsule. Adrenal growth to the left. Small angular flap at upper part, beneath which a piece of black paper represents extremity of suprarenal body, the rest of which is lost in the growth.—From a photograph lent by Mr. Targett.

united to the latter. The remnant of the adrenal body was stretched out over the growth. The growth was very spongy in consistency, and on microscopic examination proved to be a medullary sarcoma. There were no secondary deposits.

stiffness in the back and limbs. There was great lassitude and increasing emaciation. Pulmonary tuberculosis developed, and death occurred one month after admission to hospital.

Through the kindness of these authors, I am enabled to reproduce their illustrations of the specimens (Figs. 83–86). The following is Dr. Leith's report:—

"The position of the right suprarenal body was occupied by a large mass of a yellowish white colour, mottled with red, in which no trace of normal suprarenal tissue could be discovered. It covered over more of the kidney than usual, and was adherent in part to the surrounding structures, especially to the vena cava, behind which it had grown, and to the under surface of the liver. In the latter region the growth was continuous with a growth in

Affleck and Leith in 1896 described a case of primary adrenal sarcoma, occurring in a man of 46. He came under observation complaining of great and increasing weakness, together with severe pain and

the liver over an area of about 3 in. After separation therefrom, and from its other attachments, except about  $1\frac{1}{2}$  in. of the inferior vena cava, which was removed *in situ*, it, along with its kidney, weighed 1 lb. 12 oz. The growth was fairly smooth on the surface, more rounded than the natural suprarenal body, and measured 5 in. transversely by 4 in. vertically, and about 3 in. antero-posteriorly. Its capsule was thin, and the growth

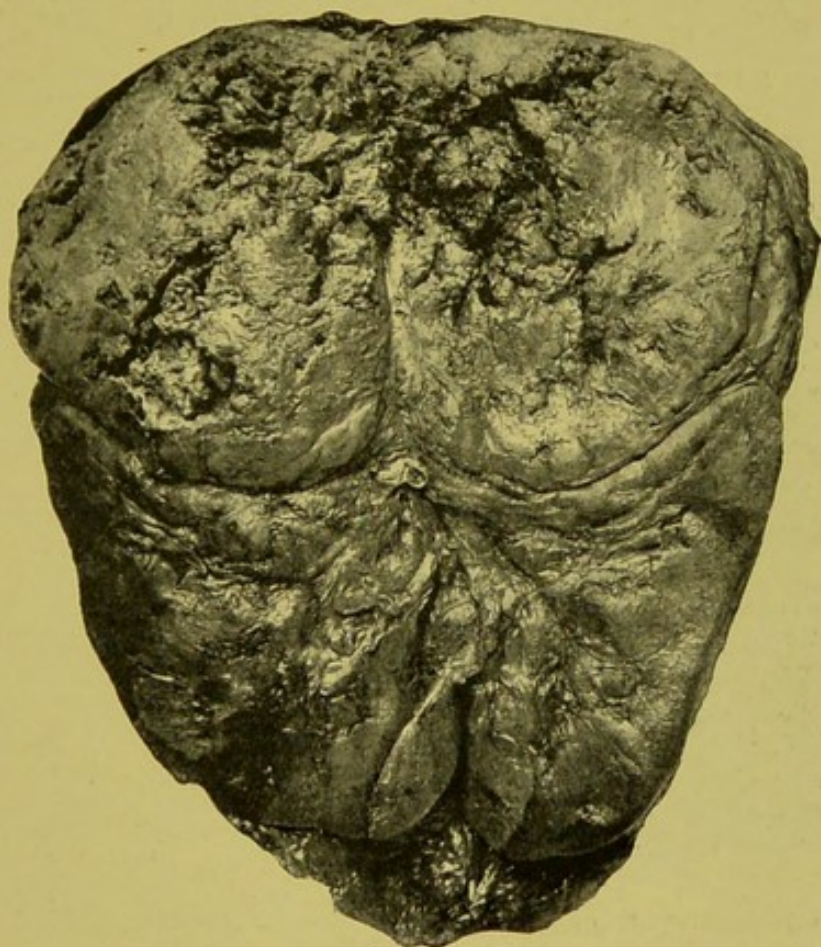


FIG. 83.—Sarcoma of right adrenal. Large mass of growth above and compressing upper part of kidney.—Affleck and Leith.

itself was of a soft consistence. On section, it showed a pulpy centre, with a firmer peripheral part. The former looked like a soft whitish tumour growth mixed up with blood clot. The latter was of a pale yellowish white colour, showing patches of degeneration of a darker yellow, and some varying sized hæmorrhages. It was very vascular in parts, showing large blood sinuses. There was no appearance of a fasciculated or acinal arrangement even in its peripheral parts, which represented the more characteristic structure of the tumour (Fig. 83).

“The kidney was normal, its capsule everywhere separating



it from the growth. The inferior vena cava was also seen to be normal, the tumour having become adherent to its posterior wall, and bulged it forwards, thus encroaching somewhat upon the tumour, but not further implicating its coats; but it had caused an extensive thrombosis of the vessel, extending upwards nearly to the heart, and downwards for some distance into both iliac veins. The clot was only slightly adherent. The left suprarenal body was also affected. Normal suprarenal structure was, as in the case of its fellow, quite unrecognisable, its place being taken by a tumour growth closely resembling that on the other

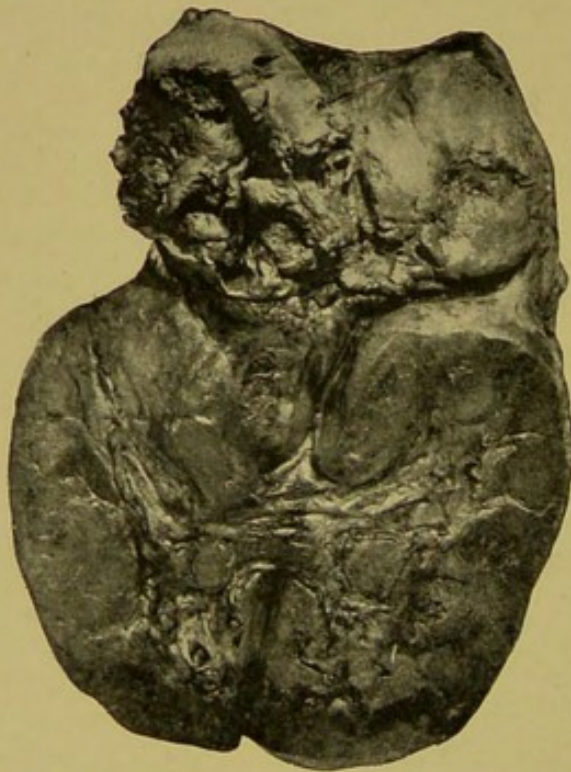

FIG. 84.—Sarcoma of left adrenal.—Affleck and Leith.

side, with which it was practically in contact across the middle line. It measured  $4\frac{1}{2}$  in. transversely by  $2\frac{1}{4}$  in. vertically, and about 2 in. antero-posteriorly. It was not adherent to the surrounding tissues, except at its inner part, where both tumours, with the enlarged glands, encroached upon the position of the solar plexus, which was undiscoverable in the mass. Along with its kidney it weighed 12 oz., from which it was everywhere separated by the capsule, as on the other side. Its appearance very closely resembled the other (Fig. 84).

“The liver was enlarged. It weighed 5 lb. 4 oz., and the increase was chiefly due to a large growth on the under part of the right lobe. It measured fully  $3\frac{1}{2}$  in. at its widest part, just above the surface, where it was adherent and continuous with the right suprarenal growth over an area nearly 3 in. transversely by 2 in. antero-posteriorly. This mass projected into the liver for nearly 3 in. at its deepest part. On section, it closely resembled the peripheral part of the growth in the suprarenal bodies, but was considerably firmer. There were no other tumour growths in the liver substance in its immediate neighbourhood, but the general substance of the organ, which was

acutely congested, showed a few small, pale, yellowish white nodules scattered through it.

“The lymphatic glands, both mesenteric and retroperitoneal, in the region of the suprarenals, were enlarged, firmer, and paler than normal.

“The spleen weighed 15 oz., and showed much congestion. The pancreas and other abdominal organs, except the stomach, were practically healthy. This organ showed a small pea-like nodule, white, and fairly firm on its anterior wall, immediately beneath its peritoneal coat. It also showed a slight contraction about its middle. When opened, it disclosed two small ulcers exactly in this position, one on the anterior and the other upon the posterior wall, opposite one another. They were a little larger than threepenny pieces, almost exactly circular, with well-defined, raised, pinkish white margins and roughish looking floors of a yellowish colour, showing hæmorrhagic points. The floors were situated in the submucous coats, but the muscular coats did not appear to be exposed. A few other tiny ulcers, with similarly raised margins of a white colour, and not so deep, were seen in the neighbourhood. They recalled the appearance of caseous tubercular foci in the process of ulceration. The general mucous membrane of the stomach was somewhat congested.

“*Thorax.*—The pleural surfaces of both lungs were closely studded with whitish flat nodules, varying in size from that of a pin-head to a sixpence, and showed, in addition, much recent pleurisy over the bases. The thickened pleura reached  $\frac{1}{8}$  in. in places. There were no nodules in the interior of the lungs, the bronchi were congested, and the bronchial glands were only slightly affected. The apex of the right lung, about  $\frac{3}{4}$  in. from the surface, showed a tiny, acutely congested patch, which contained three or four miliary tubercles, showing early caseation, and there were at least other two miliary foci of a tubercular nature in the neighbourhood. This indicated a tubercular infection of a very recent nature. The periosteum of the sternum was studded in places, especially in its upper part, with similar white flat nodules, and several of the ribs also showed them.

“The heart was healthy, but the aorta showed a subacute atheroma of a somewhat extensive nature.

“The brain and its membranes were healthy.

" *External appearances.*—The skin was pale, and there was no trace of any pigmentation. The body was much wasted.

" *Microscopic appearances.*—Parts of the growth in both suprarenals, in the liver, lymphatic glands, in the stomach ulcers, in the pleuræ, sternum, and ribs, were selected for examination; and in all of them it was of a precisely similar character. The sections show a very cellular growth, with, in places, many blood vessels and little or no stroma (Fig. 85). The cells were of an irregular shape, and varied greatly in size, there being every transition between a small nucleated speck of proto-

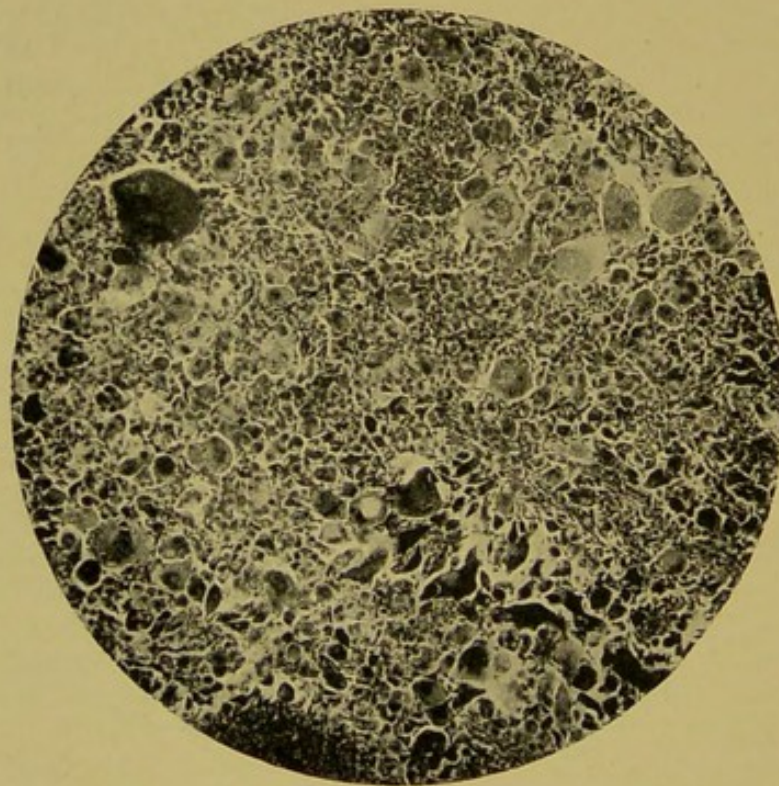


FIG. 85.—Sarcoma of suprarenals. ( $\times 70$ .)

plasm and very large multinucleated giant cells. Very few of them showed any signs of degeneration, even in the softest and most discoloured parts, towards the centre of the tumour. They stained well, and the multinucleated forms were mostly clearly traceable to lobations of a single large nucleus still showing connecting links with one another. A few showed many nuclei at different places of the cell, but from the unequal size and appearances of these nuclei it is probable that they were similar to the others (Fig. 86). A glance at the photomicrographs will show how easily the tumour might be mistaken for a myeloid sarcoma. The giant cells are, however,

quite different from those of a myeloid sarcoma, and the other cells also differ, not only in their appearances, but in their relation to the giant cells. It is not at all uncommon to meet with such giant cells in ordinary spindle-celled sarcomata, though not usually in such numbers as here. Although many spindle cells were present in the sections, the tumour could not be regarded as a spindle-celled sarcoma. The very varied shapes and characters of the cells preclude it from being classified under any one form, and it must therefore be regarded as a mixed or irregular-celled sarcoma. The intercellular substance was very

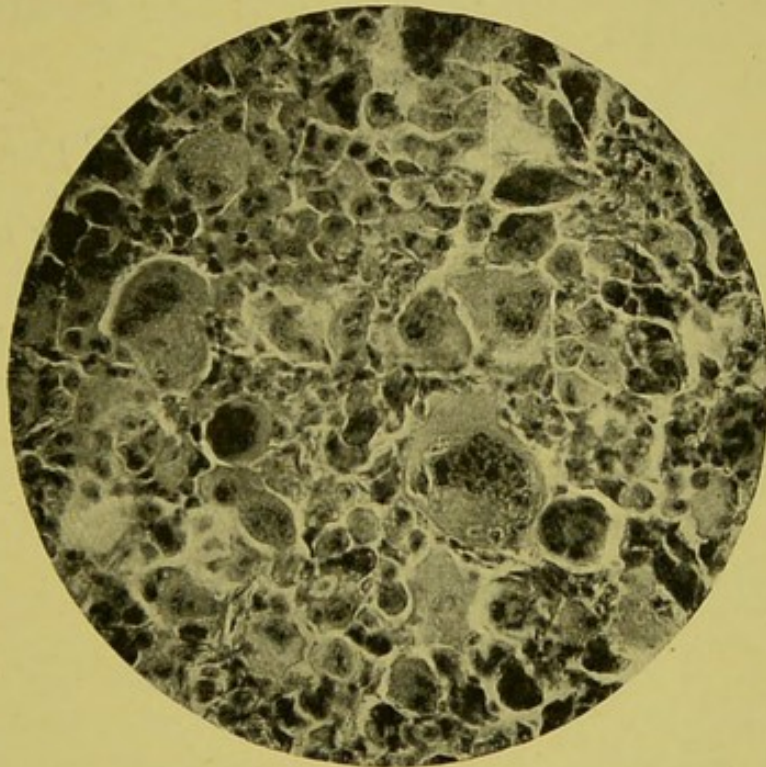


FIG. 86.—Sarcoma of suprarenals. ( $\times 200$ .)

scanty, appearing as an indefinite granular material in places, quite unrepresented in others. There were numerous and extensive hæmorrhages into it. The blood vessels were most irregularly distributed throughout the tumour, being very numerous, large, sinus-like, and distended with blood in some places, small and numerous in others, and absent in other areas of quite considerable extent."

In considering the case, Dr. Leith remarks: "In a case like the present, where both suprarenals and where other organs (the liver and stomach) were also affected, there may be some difficulty in deciding as to which was the primary seat. There is little or no

room for doubt, however, in this particular case, that the primary growth was that occupying the position of the right suprarenal body. Its continuity with the growth in the liver supports this view, for tumours of the right suprarenal have probably a greater tendency to grow upwards into the liver than have those of the liver to grow downwards into the suprarenal. The degenerative changes of this suprarenal growth were greater than those of the hepatic one, and also greater than those of the left suprarenal. This and its larger size point to its longer existence. The number, small size, and recent-looking appearances of the ulcers in the stomach, were strongly suggestive of their being metastatic. All the indications therefore point to the case as being a primary, irregular-celled sarcoma of the right suprarenal capsule, with secondary growths in the left suprarenal, liver, stomach, and abdominal glands. Primary sarcomata of the suprarenals are extremely rare. I have had an opportunity of seeing other two cases which may, I think, with justice be so regarded. One was in 1893, in a man *æt.* 31, in whom there was an enormous growth, in the position of the right suprarenal, continuous with a huge growth in the liver and a small one in the kidney. It was of a very soft consistence, almost diffuent, of a yellow colour, and weighed, along with the liver and kidney, 20 lb. 4 oz. It was a small round-celled sarcoma with little stroma, few blood vessels, and many hæmorrhages. After careful dissection, Dr. Muir, who did the post-mortem, came to the conclusion that the growth had originated in the right suprarenal capsule. The left suprarenal was healthy, and there was no growth elsewhere. The other case was in 1895, in a woman *æt.* 50, also a case of Dr. Affleck's. The position of the left suprarenal was occupied by a somewhat rounded tumour which measured  $5 \times 4 \times 3$ , of a firm consistence and pale colour, showing irregular yellowish areas separated by fibrous stroma. Continuous with it there was a huge retroperitoneal tumour weighing  $35\frac{1}{4}$  lb., filling up most of the abdominal cavity. Both growths were of the nature of a cystic sarcoma, and Dr. Muir, who also did the *sectio* in this case, decided that the older growth was in all probability that in the suprarenal capsule."

Professor Mayo Robson of Leeds has kindly sent me notes of two cases of adrenal growth which were removed by operation. One was at first thought to be an enlarged gall bladder, as, on distending the bowel with air from the anus, it was

pushed up towards the liver. The growth proved to be a sarcoma, and was removed with the kidney. The patient made a good recovery from the operation, but subsequently died from recurrence. The second case was a lady, *æt.* 62, on whom in 1893 cholecystotomy was performed for gall stones. She remained perfectly well for six years, and then began to have pain in the right side, neuralgic in character. A growth was found midway in the adrenal. It was removed, together with a wedge-shaped piece of the top of the kidney. The patient made a good recovery and is now quite well. The growth appeared to be a true adenoma.

#### CLINICAL FEATURES.

Unfortunately little can be definitely stated as to the symptomatology of adrenal growths. The number of cases on record, and the descriptions of many of the same, are so meagre, that our knowledge of the clinical features is necessarily exceedingly small.

Simple growths, like the adenomata, appear to give rise to no definite symptoms; and even growths having the histological structure of sarcoma have been found in subjects dying from causes in no way connected with the growth.

Usually adrenal neoplasms, when of sufficient size to give rise to a distinct "tumour," are not distinguishable from renal growths. In some cases, however, certain features may suggest the origin of the growth in suprarenal tissue.

In some instances manifestations of a profound nutritional derangement have been conspicuous. Cases have been described by Fox, Ogle, and others, where children, the subjects of adrenal sarcomata, have presented a marked cretinoid appearance, with abundant growth of hair over the greater part of the body. Targett has also met with this condition of hypertrichosis in an adult female, a lunatic, with primary sarcoma of the suprarenal.

Some have thought that adrenal growths have a less tendency to develop bilaterally than renal growths, which, especially in children, not infrequently develop simultaneously on both sides. It is very doubtful if this is really so.

Adrenal growths are not associated with marked urinary symptoms. When the growth, breaking through its capsule, invades the adjacent kidney, the urine may assume such characters as are met with in a certain proportion of the cases of

primary renal growth. It must, however, be remembered that not a few cases of renal growth run their course without producing any appreciable change in the urine.

In Cohn's case a distinct transverse groove was observed during life crossing the tumour. At the autopsy this was found to indicate the junction between adrenal growth and kidney.

In some instances the growth displaces the kidney downwards and outwards. Possibly in some exceptional cases the kidney might be palpated separately from the main mass of the growth. The kidney may be directly invaded or becomes crushed or stretched over the rapidly developing adrenal growth.

Generally the growth would seem to assume considerable proportions before giving rise to secondary deposits; but this is by no means always so. In Cohn's case, a child 9 months old, the appearance of secondary nodules in different parts of the body first attracted attention.

Thrombosis of the vena cava and its branches may be produced through the pressure or direct invasion of the growth, as in cases recorded by Kussmaul and Fox. The growth also tends to invade the diaphragm, as illustrated in Fig. 81.

## CHAPTER XVII.

### PERIRENAL GROWTHS.

BRIEF reference must here be made to perirenal growths. Clinically, they closely resemble true renal tumours. Pathologically, they are generally very different.

The most interesting group is formed by the so-called perirenal lipomata. These have been quite recently the subject of an important investigation by a former Manchester student, Professor Adami, now of Montreal. Dr. Adami having kindly furnished me with a copy of his work, I venture to give an outline of the same.

The fat normally present around the kidney is liable to great overgrowth when those organs are diseased. There is, however, a condition of excessive hyperplasia, leading to the development of enormous neoplasms when the kidneys are primarily unaffected. These retroperitoneal lipomata seem to occur most frequently around the kidneys, but may be met with in the mesentery or radix mesenterii, or elsewhere. Dr. Adami, after an extensive study of the literature of the subject, has collected and analysed the recorded cases. Two specimens which have come under his own observation he describes in detail. They illustrate the important features of these cases so well that I here mention them in outline.

CASE 1.—Male, *æt.* 45, a harness-maker. Strong, and in excellent health until January 1892. Then noticed abdominal enlargement and general wasting. In April, medical examination detected large tense abdomen more enlarged to the left, and with distinct fluctuation from side to side. The girth at the level of the umbilicus was 37 in. Aspiration yielded no fluid. An exploratory incision was made on 2nd May, and a solid uniform growth was found occupying the whole abdominal cavity. No attempt was made to remove the tumour. The patient recovered from the operation, and in a fortnight returned



home. The growth continued to grow steadily, the body becoming emaciated. There was no pain, and the appetite remained good. In October the circumference at the umbilicus was 47 in. In the middle of the month there was noticed an apparent softening, about the size of a saucer, in the umbilical region, which, on aspiration, yielded 9 pints of sweet pus. From this time aspiration was practised every week or ten days, and in all close upon 60 pints were removed. Six weeks before death the pus became offensive, and there were evidences of septicæmia. Towards the end slight anasarca of the legs appeared. Death occurred on 9th February 1893.

On opening the abdomen the bowels were found to be behind and to the right side of the tumour, with the exception of the descending colon, which was stretched over the growth, and which during life could be felt passing across towards the right side and front of the tumour. This was covered by expanded mesentery and peritoneum. Some slight adhesions existed, but breaking down with the finger allowed the tumour to come away readily. With it came the left kidney and the spleen. The kidney was adherent to and embedded in the growth, its lower extremity being atrophied by pressure, and flattened. The ureter passed down along the back of the growth to the bladder, and was pervious. The spleen was partially embedded, but could be easily separated. The liver was pressed upwards. The pancreas was loosely adherent to the growth. The right kidney was healthy. The growth weighed 41 lb., but, allowing for escape of pus and serum, probably weighed 44 lb. or 45 lb. It presented a coarsely lobate appearance, the lobes being bound down and covered by several irregular and thin layers of fibrous tissue. On section, well-marked bands of connective tissue could be seen passing between the large lobes, which varied in size from that of a man's fist to that of a man's head. On the anterior surface were three or four lenticular lobes that appeared to be composed exclusively of fatty tissue, and were completely cut off from the main mass by loose connective tissue, and then were capable of being moved to a slight extent over the surface of the rest of the growth. Within the lower and anterior portion of the tumour was a large cavity, of which the front wall had fallen in. It contained greyish green pus, and the tissue around was necrotic, and presented patches of old hæmorrhages and thrombosed vessels. On microscopic

examination, the growth was found to be composed mainly of pure and typical fatty tissue. In parts it was undergoing mucoid degeneration. In some regions the fat had almost wholly disappeared, the myxomatous cells being very distinct. Well-marked connective tissue generally separated the fatty lobes, but at one place, near the lower end of the growth, and not far from the abscess, an oat-shaped growth replaced the fully formed connective tissue, and had a markedly sarcomatous appearance.

CASE 2.—Male, æt. 60. Tumour noticed in February 1869, about the size and shape of an ostrich egg, movable and painless. During the next two years it steadily increased in size without affecting the general health. The patient was a regular attendant at church up to a fortnight before his death. Three weeks before his death he walked a long distance to attend a friend's funeral. He there caught cold, and died in February 1871. The autopsy revealed a large abdominal growth, weighing  $41\frac{1}{2}$  lb., of irregular flattened shape, and everywhere adherent. The liver and intestines were pushed upwards. The stomach was compressed and adherent to the diaphragm. The right kidney contained one large and some smaller cysts. The left kidney was atrophied and flattened by the growth, to which it was adherent, and in which it was fairly embedded. It contained a cyst the size of a walnut. Microscopically, the growth consisted "largely of adipose tissue in a voluminous stroma of embryonic connective tissue, with abundant nuclei between the fat cells."

Both cases presented a similar history—long duration, slow growth, very little general disturbance, no pain, and extreme emaciation. In both the growth consisted of fatty tissue, in which the kidney was embedded. Both were retroperitoneal in position, and crossed by a length of large intestine.

Retroperitoneal lipomata are rare. The greatest number have been recorded in France. The fullest studies have been made by Terrillon, Josephson and Vestberg, and Salzer.

A large number, probably a third of those recorded, originated in the neighbourhood of one or other kidney, but others seem to have started lower down.

The largest collection of retroperitoneal fat occurs physiologically around the kidney, and here, naturally, is the most likely place for lipomata to originate. These growths are met with more frequently in the female than in the male, in the propor-

tion of 25 to 16. Where the relationship to the kidney is recorded, the growth is found as frequently on the left as on the right. Middle and later life are the usual periods at which they occur. Lauwers met with a growth fourteen days after birth, which grew steadily and attained such a size, and led to such emaciation, that when removed, at the age of 7, it weighed 6 lb., the total weight of the child being 20 lb.

Growth is always slow. Generally two to three years elapse between the first recognition and the death of the patient. It has been known to exist seven or eight years. The size is enormous—the majority of recorded cases weighed more than 20 lb.; five were above 50 lb.; one was 63 lb. In many the definite presence of fluctuation has led to an erroneous diagnosis. Intestine usually passes in front of the growth. Eventually œdema of the lower extremities appears, due to venous obstruction in the abdomen.

Microscopically, the growth, as would be expected in a connective tissue type of tumour, varies somewhat. We then have pure lipoma, fibro-lipoma, fibro-chondro-osteo-lipoma, lipoma myxomatodes, and lipo-sarcoma. The tendency is for the growth to be a myxo-lipoma, or, as some term it, lipoma myxomatodes.

Windle has described a lipo-sarcoma surrounding the right kidney, and weighing 50 lb. The specimen is in the museum of the Royal College of Surgeons (3595).

Roger Williams mentions the case of a male child, æt. 2, where the left kidney was surrounded by "a mass of soft ecchymosed myxo-sarcomatous new growth, which had evidently sprung from the perirenal fatty envelope, for it was distinctly outside the renal capsule, and the kidney itself was unaffected." He mentions having seen a similar case in an adult.

Mr. Leopold Hudson has described a perirenal lipoma weighing 12 lb. 4 oz., which developed during five years in a fox-terrier bitch. The specimen is in the Museum of the Royal College of Surgeons (3596A).

A certain number of the rapidly growing round-celled sarcomata and lympho-sarcomata, originating in retroperitoneal structures, probably start in perirenal tissues; but, as far as my experience goes, it is rarely that one can venture, at the pathological examination, when the growth has usually reached considerable dimensions, to decide upon the exact point of origin.

Mr. Knowsley Thornton has presented a large perirenal

sarcoma, taken from a woman *æt.* 36, to the Museum of the College of Surgeons (3597B).

The accompanying illustration (Fig. 87), photographed from a specimen now in the Museum of the Children's Hospital, Great Ormond Street (462), well indicates how a retroperitoneal growth may simulate a renal tumour.

The great difficulty in distinguishing between a true renal growth and one arising in the retroperitoneal tissues in the vicinity of the kidney, is well illustrated by a case recorded by Dickinson, where malignant disease of the left lumbar glands simulated a renal tumour. The patient was a boy of 9 years. At the post-mortem examination the growth was found to be situated entirely behind the peritoneum. The kidney lay upon the upper surface of the growth, in a horizontal position, with its anterior surface looking upwards, and its lower extremity pointing forwards. The descending colon passed in front of the tumour.

The Museum of Guy's Hospital contains an interesting preparation (1662), where the perinephritic tissue is infiltrated with a melanotic sarcomatous growth.

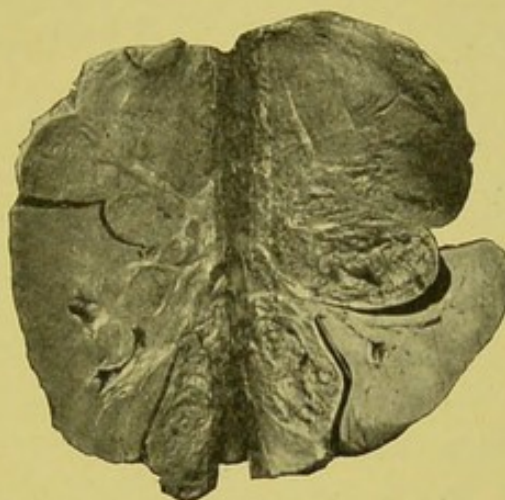


FIG. 87.—Retroperitoneal round cell sarcoma invading kidney. Mass of growth above kidney and surrounding infundibula and calyces, and extending to medulla.—From a photograph lent by Mr. Targett.

## CHAPTER XVIII.

### SYMPTOMATOLOGY.

WE are now in a position to proceed to the consideration of the signs and symptoms of renal growth. The more important may be considered separately.

#### TUMOUR.

Enlargement, or tumour, is in the majority of cases detectable at some period in the history of the case. Roberts says "abdominal tumour is by far the most constant sign of renal cancer, and usually the earliest one noted." It is certainly very often the first physical sign of any morbid condition. In many instances it remains for a considerable time the sole sign. In large tumours there is conspicuous or visible enlargement. Sometimes the enlargement is so great as to practically fill the whole abdominal cavity.

The chief points with regard to the character of renal tumours were well indicated and illustrated by Bright, in his article, published as far back as 1839, in *Guy's Hospital Reports*.

*Frequency.*—Chevalier shows that it is the first indication of growth in 60 per cent. of cases occurring in children, and 26·6 per cent. in adults. Rohrer found tumour present sixty-seven times out of his 115 collected cases.

Guyon, in 133 observations, found signs of enlargement to be absent in four cases only.

Dickinson, in nineteen cases, states that in three the tumour was not discovered during life, and points out that this was due to either one or more of the following causes—extreme sensibility of the abdomen produced by peritonitis, want of thorough abdominal examination, or the occurrence of cerebral symptoms which drew away the attention from the abdomen.

Ebstein found enlargement absent in only three out of fifty-two cases.

Roberts found tumour was present in sixty-one out of sixty-four cases. In the remaining three there was hæmaturia.

The presence of tumour is to be carefully sought for according to the usual methods of inspection, palpation, percussion, and auscultation. Inspection and palpation are of the greatest service. Mensuration may prove of assistance in some cases. A careful bimanual examination usually proves the most satisfactory method of investigation, one hand to be placed over the loin and the other over the abdominal wall. In some instances a thorough examination can only be made when the subject is under the influence of an anæsthetic. Exploratory puncture, and even exploratory section, may be justifiable in some cases. By upward extension of the growth, or by elevation of the liver or spleen, dulness may extend high up into the thorax.

*Situation.*—The tumour always occupies the lumbar region, except in those very rare instances where a movable kidney has been the seat of growth. It tends to extend forward into the abdominal cavity. It generally lies between the ribs and the iliac crest, and does not usually pass up into the thorax or extend into the pelvis. The fingers cannot be got behind it. There is no resonance between the tumour and the vertebral spines, and no space between it and the mass of the spinal muscles. There is generally a greater resistance posteriorly on the affected side, although a distinct bulging is very rare.

Sir William Jenner goes so far as to declare that renal tumours “do not cause distinct posterior bulging.” A genu-pectoral, or simply a ventral posture, is convenient for comparison of the two sides. When the tumour is of large size there may be bulging of the flank, distension of the lumbar region, prominence of the ribs, or a general projection of the parietes on the affected side. Sometimes the fulness reaches well down into the iliac fossa. Holmes has recorded the case of a man with “pulsating cancer” of the kidney, where the growth appears to have produced a distinct swelling over the sacrum and extensive œdema of the back. As a general rule, it may be safely stated that the growth extends in the direction of least resistance.

It is necessary to remember that spinal curves in the lower dorsal and lumbar regions may cause the tumour to be unduly prominent. On the other hand, it must not be forgotten that a kidney growth may occasionally be obscured by a large overlapping liver.

The enormous size to which these growths may reach is well indicated by an illustration figured by Ashby and Wright.<sup>1</sup>

*Shape.*—The tumour has usually a more or less reniform outline. It is often quite smooth. In many cases it is irregular and nodulated. It never presents a distinct notch like an enlarged spleen. Jenner would seem to be a little too dogmatic

when he says that the kidney "is rounded on every side and in disease never loses this peculiarity."

It is necessary to bear in mind that a part only of the kidney may be involved, especially in the case of some of the so-called "adenomata."

*Relation to intestines.*—The relation of the tumour to the intestines, and especially to the colon, is a point of considerable importance. Roberts appears to have been one of the earliest observers to lay stress upon this sign. He says: "The colon is invariably found in front of the growth, although sometimes flattened and empty." Morris declares that renal tumours "have bowel in

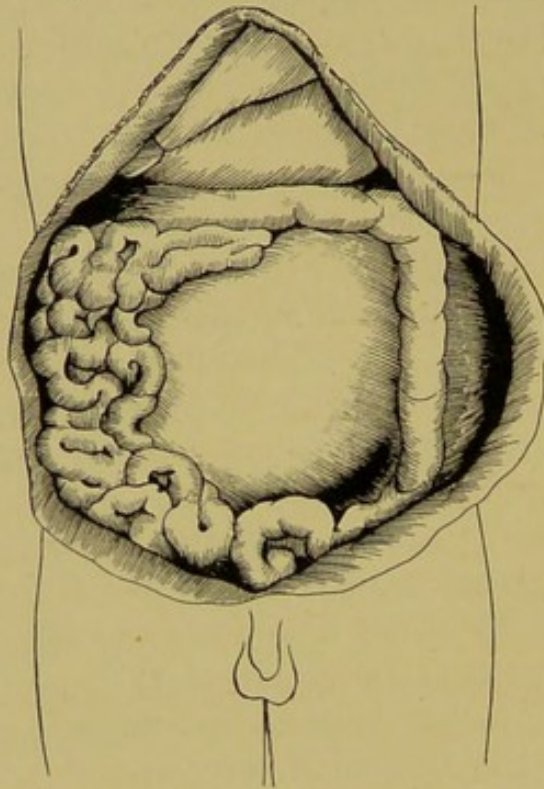


FIG. 88.—Relation of sarcoma of kidney to colon and small intestines. From girl æt. 2.—From sketch taken by Mr. Roney Schofield in the post-mortem room of the Manchester Royal Infirmary.

front of them with only the rarest exceptions." This relation is indicated in the accompanying sketch of a case which I had the opportunity of investigating pathologically (Fig. 88).

When the growth is on the right side, the cæcum and ascending colon may be much displaced inwards, as I have myself seen, and, instead of lying in front of the mass, may lie along its inner border, to which it is sometimes firmly adherent.

Ballard says: "A yielding portion is commonly perceived at some period on the surface of the tumour, either lying vertically along it, or crossing it more or less obliquely; it is sometimes so marked as to give rise to the idea that there are two tumours in place of one. This is due to the intestine which lies in front of

<sup>1</sup> "Diseases of Children."

the kidney, and the deception is similar to that which I have noticed as of more rare occurrence in the case of the liver."

When on the left side, the growth may extend forwards and inwards, pressing the descending colon to its outer side. In some few cases the colon, although empty and non-resonant, has been evident as a roll-like structure on the anterior surface of the tumour. The colon is practically never found in front of any enlarged spleen, and only in rare cases overlaps an enlarged liver, unless ascites be present. In some instances the tumour may drag its moorings, and become floated forwards in front of the colon and small intestine. In such it may readily be mistaken for an ovarian growth.

It must also be remembered that the colon is not infrequently displaced congenitally.

*Mobility.*—It has often been stated that renal growths are not influenced by respiration or manipulation, but are fixed tumours. Musser, in his recent work on "Medical Diagnosis," speaks of renal growths as "immovable either by the hands or with respiration." This is by no means always so. They are often distinctly, though only slightly, mobile. Almost every operating surgeon with experience of renal cases can testify to the effect of respiration in influencing the position of the kidney.

Guyon in 1888, and others since, have shown that the descent of the diaphragm with respiration undoubtedly does affect the position of the kidneys.

It may now be admitted that the mobility of the kidney is influenced by respiratory movements, by alteration in attitude, and by pressure on the abdominal walls, or by pressure from the lumbar region. Renal enlargements, however, are usually much less affected by respiratory movements than hepatic or splenic tumours. When there are extensive adhesions; it is easy to understand that the growth may become fixed.

*Ballottement.*—Guyon has laid considerable stress upon this sign, which, he states, can generally be obtained before adhesions take place. The growth is often of more or less uniform consistency, and sometimes quite hard and resistant; and it is evident that this sign may occasionally be of service.

*Fluctuation.*—A sense of fluctuation may sometimes be obtained in solid growths. This is especially the case with rapidly growing sarcomata. Power says malignant tumours are



“often so soft as to be mistaken for chronic abscesses.” This deceptive sense of fluctuation must be distinguished from true fluctuation, which sometimes occurs in connection with the cystic forms of growth, more particularly the cystic sarcomata.

*Pulsation.*—Some remarkable examples of renal growths, in which pulsation occurred synchronous with the cardiac beats, have been recorded by Bristowe and Langstaff.

*Murmur.*—Occasionally a soft-blowing systolic murmur has been heard over the tumour. Cases have been reported by Alloway, Ballard, Byrom Bramwell, and Holmes. A bruit heard over a renal tumour may lead to the impression that an aneurysm is present.

#### HÆMATURIA.

The presence of blood in the urine, and absence of the ordinary symptoms of nephritis, or involvement of the bladder or urinary passages, is a sign of the greatest moment.

*Frequency.*—Hæmaturia is by no means so common an indication as tumour. It is said to occur in 50 per cent. of all cases.

Rohrer, in 115 cases, found hæmaturia in thirty-seven. Roberts, in fifty-nine, mentions it as occurring in thirty-one; but in five of these there also existed other possible cause for it. Ebstein, in fifty cases, gives hæmaturia as present in twenty-four. Lebert, in fifty collected cases, found that in thirty-six a tumour appeared first, while in nineteen hæmaturia was the first symptom. Monti, in eight, noted it only in three. It thus seems to occur in about 40 per cent. of all cases.

*Age.*—As far as can be gathered, hæmaturia appears to be more frequent in adults than in children. Hurry Fenwick shows that in children it does not usually appear until a tumour has been recognised.

*Time of appearance.*—In some cases it is the first indication. In a few it persists throughout the whole case. In many it is more or less intermittent in its appearance. In some instances it has only been met with near the close of the case.

It usually appears spontaneously. In some it has been noticed shortly after a blow or injury had drawn attention to the renal enlargement. It often occurs without any pain or discomfort. Distension or examination of the bladder does not influence the hæmaturia. Movements generally appear to have but little effect in varying its amount.

*Quantity.*—This varies greatly. It may be so abundant as to appear almost as pure blood, and large clots may be passed. Sometimes blood casts of the ureter are formed. In many cases the quantity of blood is small, sometimes only sufficient to slightly colour the urine.

*Variability with different growths.*—The benign growths probably never give rise to conspicuous hæmaturia.

Hæmaturia is an important sign of malignant disease. Some have thought that hæmaturia was more persistent in carcinomata than in sarcomata. Tyson says definitely: "Hæmaturia is more frequent in carcinoma than sarcoma." In the former it is said to occur in over half the cases. Certainly in some carcinoma specimens the growth may be observed extending through the medulla, and projecting into the calyces, without uniformly infiltrating the whole organ—a condition seemingly favourable for the production of hæmaturia.

*Association with other symptoms.*—In some instances hæmaturia may precede all other evidences of growth. Sooner or later other signs generally become manifest.

Tuffier, in thirty-six collected cases where symptoms had been carefully noted, found hæmaturia had preceded the appearance of tumour by two to three years in six cases.

Fenwick records the case of a man, æt. 58, whose only symptom was abundant hæmaturia. Similar cases have been recorded by other observers.

*Varieties of hæmaturia.*—According to the presence or not of these two most important evidences of growth, tumour and hæmaturia, it has been stated that the majority of cases may be divided into—

1. Tumour with hæmaturia.
2. Tumour without hæmaturia.
3. Hæmaturia without tumour.
4. Absence of both tumour and hæmaturia.

Further, with regard to the character of the hæmaturia, the following varieties may be recognised—

1. Uncontrollable.
2. Persistent.
3. Variable.
4. Recurrent.
5. Intermittent.

Hurry Fenwick has suggested tying the renal artery to

check hæmorrhage in cases of growth. He, however, lays great stress on the dangers attending vesical exploration in cases of renal growth.

In interpreting the important symptom of hæmaturia, it is very necessary to examine the case by all other means available. In one case, where the preparation seemed to be of a syphilitic nature, hæmaturia had been a striking feature. Hæmaturia occasionally lessens the pain in a case of growth. Sometimes the sudden arrest of hæmorrhage may be due to impaction of a clot in the ureter. Clots of a vermicular form should always be searched for in these cases. Hæmaturia in cases of growth, like the hæmorrhage associated with calculus, is sometimes brought on by slight exercise.

#### PAIN.

This is generally a symptom of but little value. In some few cases, however, it may be the first indication drawing the patient's attention to the abdomen.

*Frequency.*—Often no pain or discomfort is complained of until the tumour has formed adhesions to adjacent structures, or reached such proportions as to produce considerable pressure on adjoining organs. It is indeed remarkable how tolerant the abdomen appears to be to growths, even when they reach very considerable dimensions. In children especially, pain is but seldom a marked feature.

Walter Smith mentions the case of a man, æt. 53, a brass-finisher, who worked up to six months before his death, although growth had been slowly increasing during the previous two years. Children are often able to play about to within a few weeks of their death.

*Character and seat.*—The pain is generally experienced as a dull aching in the loin. Usually it is little more than a sense of discomfort on one side of the abdomen. Aching in the lumbar region is sometimes complained of. In some cases it is of a shooting or lancinating nature. In a few instances it has extended to the hip, thigh, and even leg. Occasionally it shoots down into the testicle. It may simulate colic. Patients sometimes are unable to lie on the affected side.

Brault describes the case of a man, æt. 41, where intense pain was the only sign of the growth. When blood clots are being passed, renal colic may occur, and occasionally slight

attacks of vesical tenesmus. Sometimes the clots are distinctly "worm-like."

In one case recently operated on in the Manchester Royal Infirmary, the history of the pain was practically identical with that usually given by a typical renal calculus subject.

Too much importance must not be given to this symptom of renal pain. Although it may exist as the chief symptom of many morbid conditions in the kidney, and, as above admitted, may sometimes be the only indication of a growth, yet pain in the renal region may be experienced even when no permanent lesion of the kidney exists. Habershon many years since showed that aortic valvular disease led to pain radiating into the hypochondrium. Ralfe finds an "aching kidney" in young women who wear tight corsets while playing tennis or when engaged in other forms of violent exercise. It is said that renal pain may result from the irritation of hard scybalous masses in the colon.

#### SYMPTOMATIC VARICOCELE.

The occurrence of a secondary or symptomatic varicocele cases of renal growth appears to have been first noted by Guyon. According to this observer, it is often an early sign. When occurring on the right side it may be of distinct service. It does not appear to have been looked for in most of the recorded cases. In examining for it the patient should be in the erect attitude, as it is not apparent in the horizontal position. He should be directed to walk about for a short time before the spermatic veins are examined. The varicocele develops rapidly. The veins are supple and less knotted than in the common form of varicocele. The veins in the front group are said to be more affected than those behind. Pain and hydrocele are uncommon.

Morris thinks varicocele of the left side more likely to develop in renal than in splenic enlargements. He mentions a case where a large varicocele of the left side had been gradually increasing with the growth of the tumour. At the operation it was found to be due to distortion and distension of the spermatic vein, which, with the inferior mesenteric vein curved over the front and inner side of the tumour, was enlarged to the size of the ring finger.

Morrow, while admitting that this sign may sometimes be of

service, cautiously points out that "varicocele is so common an affection on the left side that it is significant only when on the right."

Hauser, in his Paris "Thesis," published at the end of 1897, fully discusses the importance of this sign. He proves that varicocele may result from the compression by glands, the seat of secondary growth, and is therefore inclined to consider the sign as an important indication to the surgeon, as showing the need for the removal of the glands as well as the main mass of the growth.

#### URÆMIA.

Toxic symptoms are but rarely met with in connection with renal growth. This was well recognised by Walshe, who, writing in 1846, says: "It is a curious fact that patients afflicted with cancer of the kidneys do not, as so commonly happens when the organ is affected with diseases of other kinds, die comatose; on the contrary, the intellectual faculties sometimes remain clear to the last, even in the worst cases."

When the second kidney also becomes the seat of growth, or involved by inflammatory processes, uræmia may sometimes occur. I have examined a case in which for several days before death there were undoubted uræmic manifestations, due to a tubular nephritis supervening in the kidney uninvolved by growth.

#### PRESSURE SYMPTOMS.

According to the size and extent of the growth, so will the pressure effects on the surrounding structures vary. Where the bulk is considerable, much displacement will necessarily occur. The stomach may be pushed upwards, and, especially when the growth is on the left side, upwards and inwards. The small intestines are often somewhat compressed, and in many instances adhere to each other and to the growth.

Reference has already been made to the displacement of the colon.

The liver becomes elevated, pushed to the left when the growth is on the right side, or twisted on its transverse axis.

The spleen is generally elevated on the growth, lying on its upper and outer side, immediately beneath the diaphragm and ribs. The diaphragm may be elevated, and the thoracic cavity consequently much diminished in size.

The omentum and mesentery are often much thickened, and attached to the growth. The inferior cava and other vessels may occasionally be compressed. Engorgement of the abdominal cutaneous veins sometimes occurs. In some exceptional cases the vertebræ have been pressed upon and eroded, and even involvement of the cord has been noted.

#### URINE IN RENAL GROWTHS.

Examination of the urine in cases of renal growth is often of comparatively little value. When taken into consideration with the previous symptoms, it may, however, sometimes afford considerable assistance in diagnosis. The most important and most frequent morbid element is of course blood. Albumin is rare, except in connection with the presence of blood. Pus occasionally occurs when the growth is associated with calculi or suppurative conditions in the renal pelvis. Acetone has been noted in advanced cases. Particles of gravel have been passed in some instances. Examination of the urine for characteristic cells is usually very unsatisfactory. Cells from a growth, even if they reach the bladder, will probably have undergone such degenerative changes as to make identification in their altered condition almost impossible. The absence of organised material is therefore of but little diagnostic importance. Epithelium and casts are sometimes met with, but characteristic elements of growth are very exceptional. Sometimes a soft sarcomatous growth will invade the pelvis and ureter, and fragments becoming detached may be conveyed into the bladder and expelled during micturition.

Allen and Cherry say that "when a malignant tumour of the kidney fungates into the pelvis, large cylindrical processes may come away in the urine, and be mistaken for villous growths from the bladder." They also add, that this is especially the case in "sarcoma carcinomatodes."

Ebstein says: "Melano-sarcomata of the kidney which escape palpation may be suspected when the urine in such cases assumes a dark colour, because this colour is due to the black elements of sarcoma which are washed out."

Usually there is no marked alteration in the normal quantity of urine passed. In the final stages there will probably be considerable diminution. Sometimes there is fre-

quent micturition, but often subjective urinary symptoms are completely absent.

#### GENERAL SYMPTOMS.

In many cases, especially in children, the appearance is almost characteristic. The abdomen is generally much enlarged, but usually most marked on one side. Varicose veins appear on the abdominal walls, and may extend upwards into the axilla.

The general health may suffer but little until the growth has assumed conspicuous proportions. In many instances the appetite is particularly good. In some cases there has been a voracious or morbid appetite and craving for drink. Gairdner, writing in 1828, mentions a curious case, where a girl of three years would eagerly swallow large quantities of porter, and even eat chalk taken from the walls. In cases where the growth is extensive, or rapidly advancing, there may be anorexia, nausea, vomiting, diarrhœa, or constipation.

Ascites, due to pressure on the portal vein or involvement of the peritoneum, may occur; and sometimes varices and anasarca of the lower extremities may be present.

Poncet has recently removed a kidney, the seat of malignant growth, by transperitoneal nephrectomy, from a woman, æt. 47, in whom the earliest symptoms were gastro-intestinal, with urticaria of the lower extremities.

*Icterus*, when it occurs, is usually due to invasion of the hilum of the liver, or to involvement of glands pressing on the bile ducts. Sometimes it may arise from the pressure exerted by infiltration of the liver itself. Snow states that "when the right kidney is attacked jaundice may follow, and the lesion be regarded as of hepatic origin."

*Temperature*.—Renal growths are not generally associated with febrile manifestations until secondary inflammatory processes are set up.

*Cachexia* is not common in the sarcomata, but may occur in advanced cases, and is also met with in carcinoma in adults. In the sarcomata of children the general nutrition may not be markedly affected, until pressure on the abdominal organs leads to interference with the introduction and absorption of food. Cachexia seems to be most frequent in the carcinomata. Emaciation in some instances has been extreme.

When *secondary growths* occur early in the liver or other

organs, the primary growth is often in danger of being overlooked. I have known a case in which the secondary deposits in the glands of the neck and axillæ, with signs of intrathoracic involvement, gave somewhat the appearance of Hodgkin's disease. The renal growth was not suspected until the post-mortem. In another case, already referred to, the secondary deposit in the brain gave rise to such prominent symptoms that the primary growth was completely overlooked.

#### LATENT FORMS.

Brief reference must be made to the so-called latent forms of malignant renal disease. In some very exceptional cases, growths certainly do seem to develop without giving rise to any distinct symptoms. A latent form was recognised and described by Walshe in 1846. Many of the cases described as "latent" have doubtless been secondary. This, however, will not explain all cases.

Tuffier divides the latent forms into two classes—(1) The latent primary "cancers," which are very rare; (2) the latent secondary "cancers," which are comparatively common.

The insidious development of many of these cases is very remarkable. The Keiths say:<sup>1</sup> "In children there may be no symptoms at first, or even when the tumour is of some size, and during the whole course of the growth there may be nothing to draw one's attention to the existence of renal disease." Latent cases have been recorded by Fleming, Lebert, and others.

<sup>1</sup> "Text-book of Abdominal Surgery."



## CHAPTER XIX.

### DIAGNOSIS.

EARLY diagnosis is essential for successful operative interference. And yet diagnosis is often exceedingly difficult. Treves says: "Renal tumours are among the most difficult of abdominal enlargements to diagnose correctly." They certainly are the cause of many errors.

At the present time considerable difficulty is experienced in early differentiation between enlargements due to growths and those due to other causes. And further, if we are ever to distinguish with any degree of certainty between the different varieties of growth, as is most desirable we should do, it can only be by a minute and detailed account of the clinical and pathological features of every case coming under observation, until the accumulated facts shall allow of safe generalisations.

In forming a complete diagnosis it is desirable to distinguish—

1. Renal from non-renal enlargement.
2. Renal growths from other forms of renal enlargement.
3. Different forms of renal growth.

In referring to the pathological characters and symptoms, I have already indicated indirectly many of the points of diagnostic importance. These must be the basis of all considerations as to differential features.

It will be unnecessary to describe the best methods of conducting an examination, as these are sufficiently indicated in most modern works on clinical medicine. Suffice it to say that a thorough examination must be made in every case. In many cases an accurate diagnosis can only be arrived at after a careful investigation, conducted according to the method of exclusion.

The assistance of the aspirator, or exploring needle, must not be rashly accepted. Such means are not without danger. An exploratory incision may sometimes be safer. The cystoscope

has rendered considerable aid in not a few instances. Vaginal examination may occasionally help in the correct diagnosis of renal growths in the female. Rectal insufflation of gas has proved useful in indicating the relation of the colon to the tumour. Radiography may possibly before long prove of real service in the diagnosis of some renal growths.

Schuster has recently strongly recommended an examination by palpation in the hot bath for renal and other difficult abdominal tumours. Lennhoff also strongly supports such a method. The patient rests on some support slung from the sides of the bath. After remaining some minutes in water, as hot as can be borne, the abdominal wall will be found soft and the muscles relaxed. The abdomen can then be thoroughly palpated. This method has the advantages of a general anæsthetic, without the disadvantage of losing the patient's voluntary assistance, which is sometimes needed, as in growths affected by respiratory movements.

It will be sufficient at the present time to briefly indicate the more important conditions which may be confused with renal growths.

*Adrenal growths.*—These have been dealt with at length in a former chapter. They are much rarer than renal growths, and only very exceptionally reach any considerable size. The cases which have come under my own observation gave rise to no symptoms during life.

When they are of large size and malignant nature, it is practically impossible, and indeed unnecessary, for practical purposes, to differentiate them from renal growths. The malignant forms, which are usually of a sarcomatous nature, seem to develop more slowly than do the renal sarcomata. They are seldom bilateral, as is sometimes the case with the renal growths met with in young subjects. Hæmaturia and other urinary symptoms are of course absent until the kidney becomes involved. It may be well to remember that in some of the recorded cases curious general symptoms have been observed, such as pigmentation, overgrowth of hair, and cretinoid characters, to which we have already referred in Chapter XVI.

*Perirenal growths.*—These have been sufficiently dealt with in a previous chapter. It is only necessary here to again indicate the great difficulty in clinically distinguishing between a growth originating in the kidney itself and one arising in the

immediate vicinity. Usually it is impossible to differentiate between them. As the fibro-lipomatous forms often manifest for some time more or less benign characters, it is most desirable that no time should be lost in removing them when once a diagnosis of renal or perirenal growth has been made. Some of them, as we have already indicated, present sarcomatous elements. The rapidly growing perirenal sarcomata are exceedingly malignant, sometimes infiltrate both kidney, and generally complete removal is impossible. In all cases, however, at least an exploratory incision should be ventured on.

*Omental tumours.*—Occasionally growths of the omentum may closely resemble a renal growth. Usually, however, their shape, position, and relation to the intestines will indicate their true localisation. Generally omental growths tend to assume a flattened or cake-like form. Often such a tumour may be distinctly palpated as a band, or elongated mass, passing transversely across the abdomen.

*Mesenteric tumours.*—Solid and cystic formations in the mesentery may sometimes resemble a renal growth. Among recent writers, Moynihan and Harris and Herzog have specially drawn attention to the tumours of the mesentery.<sup>1</sup> The absence of urinary symptoms and the characters of the tumour will usually enable a differentiation to be made readily.

Mesenteric tumours are generally rounded in form. The most prominent part is usually near the umbilicus. They are almost always freely mobile. A cyst can be pushed over from one side of the abdomen to the other. Sometimes it can be twisted round its central axis. Fluctuation is often detected. It may be confounded with the elasticity of a lipomatous growth. In hydatid cysts the "frémissement hydatique" has been obtained. Generally there is a zone of complete resonance around the cyst. Intestinal symptoms may arise from pressure. General wasting may be a characteristic feature, due probably to obstruction to the lacteals. The small and large intestines may lie in front of mesenteric growths, while in omental they are probably always behind or below.

Harris and Herzog record the case of a boy, *æt.* 5, where the abdomen was partially filled by a large tumour. In some respects it was suggestive of a renal growth. The growth,

<sup>1</sup> *Ann. Surg.*, N.Y., July 1897, pp. 1-30, 66-82; abstract in *Med. Chron.*, Manchester, Sept. 1897.

a lympho-sarcoma of the mesentery, was successfully removed, although a length of gut had to be taken with the tumour.

*Peritoneal growths.*—Occasionally growths in other parts of the peritoneum besides the mesentery and omentum may give rise to such conspicuous growth as to suggest their origin in the kidney. On careful investigation, however, most of these would appear to rise in connection with the retroperitoneal tissue. Occasionally sarcomata, possibly arising in the peritoneum, simulate renal growth, but their position, form, and general characters are usually sufficient to readily distinguish them.

*Peritonitis.*—In some exceptional cases of local chronic peritonitis, such extensive inflammatory thickening may occur as to give rise to the appearance of new growth. The position, however, is usually such as to exclude involvement of kidney.

*Cystic kidney.*—True cystic disease of the kidney sometimes reaches a considerable size, and forms a distinct tumour. Both sides are often affected. The progressive nature of the case, together with the general symptoms, generally readily indicate the character of the lesion.

Höhne, in a recent case, found on microscopic examination of the puncture fluid from the cysts containing dark brown fluid, a number of brown round bodies, which varied from the size of a lentil to that of a sixpence. The centre was structureless. They also presented one to five concentric rings, and had a radiating striation from centre to periphery. They have also been figured by Förster and Beckmann. The presence of these peculiar rosette-like bodies, if found in the puncture fluid from a supposed renal growth, would strongly suggest the enlargement being due to cystic kidney.

*Tuberculosis.*—Local renal tuberculosis sometimes closely simulates growth. Several of the cases recorded as “fibrofatty” tumours seem to me very probably to have been examples of chronic renal tuberculosis. Barclay in his case goes so far as to speak of “the yellowish material of which the growth mainly consisted had much the appearance of crude tubercle.” I have myself seen a specimen where it was impossible to decide whether growth was not associated with the local tuberculosis, without microscopic examination.

Clinically, the difficulty may be a very real one. Repeated search may be necessary for pus and tubercle bacilli. The lungs should be carefully examined for active or quiescent tubercle.

Some little time since I examined our post-mortem records of cases of the so-called "serofulous" kidney. I found it to occur in about 0.5 per cent. of all cases submitted to pathological examination. It was commonest in men. The proportion of males to females was as four to one. The average age was 34. Both organs were generally involved. Tuberculous lesions were present elsewhere in the body in 90 per cent. of the cases. The lungs presented evidence of either latent or active tuberculosis in 70 per cent. The genital organs or urinary bladder was involved in 75 per cent.

*Gummatous enlargement.*—Bowlby recently showed a specimen at the Pathological Society of London, of gummatous enlargement of the kidney in a woman, *æt.* 40. She had a tender tumour in the right loin. There was slight albuminuria. Growth was diagnosed, and the tumour removed by lumbar nephrectomy. It weighed over 1 lb. The patient recovered.

Israel has twice performed nephrectomy, under the impression that a gummatous infiltration of the kidney was growth.

Hurry Fenwick also recognises the importance of unilateral renal syphilis. Renal gummata are usually limited to one side. They vary in number, from twenty (Cornil) to eighty (Axel Key) in number, and are said to most frequently involve the cortex.

In a previous chapter I have referred to a case of syphilitic cirrhosis of the kidney which closely simulated growth (p. 62).

*Hydronephrosis and Pyonephrosis.*—At a casual examination these conditions may resemble growth, but a consideration of the history and a careful investigation of the general characters of the enlargement usually quickly clear up any doubt as to the nature of the case.

In difficult cases of diagnosis exploratory puncture may be of service, but is somewhat risky in very vascular growths. In one of our hospital cases exploratory aspiration allowed of the demonstration of characteristic sarcomatous cells.

Hurry Fenwick has recently published cases, with illustrations, in which the electric light cystoscope proved of great service in assisting the diagnosis.

*Abscess.*—Nephritic and perinephritic abscesses have simulated renal growths. A consideration of the history, together with careful general as well as local examination, will usually readily clear up all difficulty. In cases of doubt an exploratory incision should be made without unnecessary delay. Psoas abscess

very occasionally may resemble a tumour of the kidney, but the cause will usually be readily apparent.

*Nephrolithiasis.*—The history of hæmaturia and renal colic—sudden in onset, irregular in its attack, and occurring over a considerable period—may sometimes point more in favour of renal calculus than growth. Recently I had the opportunity of investigating a case where all the points in the early development of the case strongly pointed to nephrolithiasis. Ultimately the kidney became considerably enlarged, was removed by operation, and found to be almost completely replaced by malignant growth.

*Movable kidney.*—A displaced kidney, especially when enlarged, may suggest growth, and it is necessary to bear in mind that there is no reason apparent why a movable kidney may not become the seat of malignant disease.

*Ureteral growths.*—These are excessively rare. In that they may produce profuse hæmaturia, renal growth may be suggested. Voelcker has recently recorded a case of primary carcinoma of the ureter.<sup>1</sup>

The patient was a man æt. 68. Four months before his admission to hospital he noticed discoloration of the urine. When examined the urine was found to contain blood. He complained of nausea and pain across the loins. The liver was enlarged, tender, nodular, and evidently the seat of growth. Much blood continued to be lost in the urine; but there was no blood present during the last week. At the autopsy the left ureter in its lower two inches was found to be the seat of a growth which projected into the lumen of the tube, in the form of delicate villous processes covered with blood. On the outer side of the ureter was a mass of growth the size of a cherry. There was no growth in the bladder. The left kidney was atrophied and hydronephrotic. Secondary nodules were found in the liver, abdominal glands, and lung. Microscopic examination showed the growth to be a villous carcinoma. A delicate branching stroma of nucleated fibrous tissue was covered with numerous layers of large pyriform epithelial cells having large nuclei. The growth invaded the muscular coat as a fibrous alveolated stroma containing epithelial cells.

Rundle<sup>2</sup> has also described and figured another case where an epithelioma originated at the lower end of the right ureter

<sup>1</sup> Voelcker, *Trans. Path. Soc. London*, 1894, vol. xlvi. p. 133. Illustrations given.

<sup>2</sup> Rundle, *ibid.*, 1896, vol. xlvii. p. 128. Photograph given.

in a man *æt.* 46, and led to extensive hydronephrosis. The specimen is in the Museum of the Portsmouth Royal Hospital.

*Dilated bladder.*—Such a condition could only very rarely simulate a renal growth. I have, however, conducted a post-mortem examination on a case where an enormously dilated bladder, secondary to latent prostatic abscess on some occasions during life, very closely resembled a cystic condition of the left kidney.

*Hydatid.*—Parasitic cysts in the kidney or its immediate neighbourhood may closely resemble true growth. I have met with an old hydatid cyst retroperitoneal in position, and lying close to the right kidney, which during life simulated a renal tumour. In many instances careful aspiration and microscopical examination of the fluid obtained will make the diagnosis clear.

*Liver and gall bladder.*—Tongues of liver tissue and an enlarged and calculus blocked gall bladder have been confounded with renal growth. Hydatid cysts of the liver projecting from the lower surfaces may lead to error. Ballard shows that a renal growth “often appears rather as a tumour growing from the under surface of the liver (when on the right side) than as one of the kidney.” I have performed autopsy on a number of cases of malignant growth of the gall bladder, but, as far as I know, only in one instance was there any suspicion of the tumour being of renal origin, and here there was a calculous pyelonephritis as well as an epithelioma of the gall bladder.

Mayo Robson points out that—“In the case of renal tumour as well as in movable kidney, by distending the intestine with gas the kidney will be pressed back into the loin, but the gall bladder will be pushed up towards the liver and made more prominent. The last test is usually also sufficient to enable a diagnosis to be made between a distended gall bladder and a tumour of the right suprarenal body.” An interesting case is mentioned where, on inflating the colon, the tumour was pushed upwards, but on performing abdominal section a sarcoma of the adrenal was found, the explanation being that the colon was fixed below the growth and pushed up when the bowel was distended with gas.

The differential diagnosis of tumours of the gall bladder I have fully discussed elsewhere.<sup>1</sup>

<sup>1</sup> “Growths of the Gall Bladder and Bile Ducts,” *Med. Chron.*, Manchester, 1897, vol. viii. pp. 81-124.

*Splenic enlargements.*—Primary growths of the spleen are rare. In practically all cases an enlarged spleen has no intestine in front of it. A well-defined border, often notched, is usually distinct. Splenic tumours do not seem to give rise to varicocele. There is nearly always a line of resonance between the dulness and the spinal column.

*Pregnancy.*—Most abdominal tumours have at some time been confounded with pregnancy. Renal growths form no exception. The mistake has doubtless not infrequently been made. At all events a number of cases are on record where the conditions have been confused.

Miriel in 1810 published the case of a woman, *æt.* 33, who was thought to be pregnant; but the abdominal enlargement proved to be due to an enormous growth of the right kidney.

Walshe, writing in 1846, refers to a case in which growths in both kidneys were present, and the woman was thought to be pregnant. He considerably adds, "the error could not have been committed at the present day."

Greenhalgh also mentions a remarkable case, where a growth weighing 27 lb. 3 oz. was noticed in association with two pregnancies. It had been looked upon as of ovarian origin.

*Ovarian tumour.*—A number of cases have been mistaken for ovarian tumour. In one case the affected kidney was so movable as to be readily mistaken for an ovarian growth, and operation was undertaken. Alexander of Liverpool records the case of a female, *æt.* 50, where a growth involving the left kidney and weighing 5 lb., was removed by nephrectomy. It had been diagnosed as an ovarian tumour or pediculated fibroid.

The above mentioned case of Greenhalgh's is a striking example, and similar cases have been recorded by Davis and Lawson Tait and others.

*Uterine growths.*—Renal cystic sarcomata may occasionally somewhat closely resemble large pediculated cystic growths of the uterus. The indications for a discrimination between tumours connected with the female genital organs and renal and other abdominal growths have been recently well summarised by Playfair.<sup>1</sup>

*Ascites.*—It would hardly have been imagined that confusion should arise between renal growth and ascites. Dickinson, however, mentions a case where a fluctuating sarcoma occurring in a girl of 3 years was actually mistaken for ascites.

<sup>1</sup> Allbutt's "System of Gynæcology."



*Fæcal accumulation* does not often simulate renal growth, and confusion could only occur from insufficient inquiry or careless examination. Sometimes a real difficulty may arise. The patient may be pale, wasted, and ill-developed. Investigation of the intestinal tract must be thorough. Gersang has recently described a sign he considers of much differential value. If the tumour be pressed upon by the finger, the intestinal mucous membrane adheres to the sticky fæcal masses. On removing the pressure, the mucous membrane separates slowly, and the sign consists in the detection of this gradual separation.

*Congenital dilatation of colon.*—Cases of so-called idiopathic dilatation of the large intestine have a superficial resemblance to renal growth. Careful physical examination at once detects the difference. The distended abdomen is usually highly tympanitic, but accumulation of fæces may give rise to lateral dulness. I have recently had opportunities of watching a typical case—a boy æt. 5, under the care of Dr. Wilkinson—and investigating the same by post-mortem examination. An admirable summary of recorded cases has recently been published by Martin.<sup>1</sup>

*Phantom tumour.*—A so-called “phantom” tumour of the abdomen may readily simulate a number of abdominal lesions. Dr. Donald of Manchester has met with considerable swelling of the abdomen, secondary to pelvic inflammatory conditions, and expresses the opinion that similar affections of the abdominal organs might occasionally give rise to similar phantom-like tumour formations. He mentions having met with a case in which, after the abdominal muscles had been completely relaxed by the administration of chloroform, a distinct tumour, probably renal, was found in the left lumbar region.

At the present time our knowledge of the life-history of the individual growths of the kidneys is too limited to allow of our making anything like a reliable diagnosis as to the essential nature of the formation, as indicated by its structural arrangement during life. We may, however, safely venture on the following statements:—

A rapidly increasing growth of the kidney is almost always of a malignant nature. The forms usually met with in early life are sarcomata. Striated-celled sarcomata are almost confined to the period of infancy. Adenomatous growths occasionally

<sup>1</sup> *Montreal Med. Journ.*, 1897, vol. xxv. pp. 697-708; abstract, *Med. Chron.*, Manchester, 1897.

occur in early life, and do not readily give rise to secondary deposits.

In adult life almost any form of growth may occur. Carcinomata are practically limited to adults. Growths developing from adrenal "rests" are commonest in adults. The various forms of cystomata are especially common in fully developed subjects. Sarcomata do occur, but much more rarely than in young life. Malignant development of the adrenal is commonest in adults. Perirenal growths are generally met with in adults.

It is to be hoped that fuller investigations and accumulation of fully described cases may enable us before long to make a more precise diagnosis as to the probable nature of the growth before it reaches the laboratory of the pathologist.

## CHAPTER XX.

### TREATMENT.

SUCCESSFUL treatment must be based upon sound pathological knowledge. At the present time too little is known as to the etiology and nature of these growths to allow of any prophylactic measures, even if such were possible.

Up to recent years, cases of renal growth when diagnosed as such were considered hopeless and generally left alone. Only the most meagre efforts to palliate were attempted.

Not so long since, Sir William Lawrence was able to say to his students, at St. Bartholomew's Hospital: "The kidney, gentlemen, is fortunately beyond the reach of the surgeon." The wheel of fortune has now turned, and the kidney is almost as accessible as any other abdominal organ. Extreme conservatism is, however, yet manifest in dealing with malignant growths of the kidney.

Knowsley Thornton in 1889, when writing on renal sarcomata in children, says: "Removal is commonly followed by such speedy recurrence that the operation is barely justifiable. Such recurrence, moreover, is very extensive in its outbreak, and usually leads to an amount of suffering altogether beyond that which is seen when the disease is allowed to run its natural course in the kidney."

Bland Sutton in 1893 also gives it as his opinion that "nephrectomy for renal sarcoma in children is absolutely unavailing, and is fast falling into disfavour."

The Keiths in 1894 wrote: "In young children it is doubtful whether it is ever right to operate."

Curtis,<sup>1</sup> writing as recently as 1895, shows an effort to break away from the do-nothing policy, when he says: "Formerly a hopeless condition, it would appear that at last surgeons are beginning to make some advance in treatment."

<sup>1</sup> Ashurst's "International Encyclopædia of Surgery."

Malcolm, writing in 1894, after recording the details of a successful nephrectomy for growth in a female child under two years of age, gives his opinion that, "if nephrectomy is to be performed for new growths in children, a very careful selection of cases ought to be made; and it would seem that as a rule the surgeon should absolutely refuse to interfere. His difficulty is to pick out the few cases in which he may be justified in advising an operation."

Ashby and Wright in 1896 believe that "removal of a sarcomatous kidney is usually followed so rapidly by recurrence that this [nephrectomy] the only possible treatment is hardly justifiable."

Jacobson in 1897 directs that "an operation should only be performed in an early stage, while the growth is still internal to the capsule, and while the strength, health, and condition of the viscera are satisfactory."

Wood and Fitz, also in 1897, declare that "only in very rare cases can the diagnosis be reached sufficiently early in true cancer to justify excision"

Manifestly the only effective treatment at present known is total removal, which, in order to be effectual, should be performed as early as possible. Delafield puts the case reasonably when he says: "If the kidney be removed while the growth is still small, the prognosis is fairly good. If it be not removed until the tumour is large, or until metastatic tumours have formed, the prognosis is bad."

America has the honour of claiming the surgeon who first removed a renal growth by nephrectomy. Walcott in 1861, from a man, *æt.* 58, removed a growth considered to be "encephaloid cancer," affecting the right kidney. The growth weighed  $2\frac{1}{2}$  lb., and had existed for six years. The ventral incision was adopted, as the case had been diagnosed as one of hepatic cyst. The patient died fifteen days after the operation, apparently from sepsis. The second growth was also removed by the American surgeon Peaslee in 1868, from a woman in whom ovarian growth had been diagnosed. The patient died shortly after the operation. The earliest operations, avowedly undertaken for the removal of renal growths, were performed by Langenbuch, Kocher, Jessop, Byford, Martin, and Czerny.

Langenbuch in 1875 removed the left kidney from a female *æt.* 32, by lumbar incision; but as there appears to have been

no definite microscopical examination, and as the patient recovered, it is possible that the case may not have been a true growth after all.

Kocher seems to have been the first to perform nephrectomy by the ventral method for a diagnosed renal growth. His case was a woman, *æt.* 35, and death occurred in three days, from peritonitis.

Hueter in 1876 removed a sarcoma of the right kidney, weighing 5 lb., from a female child, *æt.* 4, in whom he had diagnosed splenic or ovarian growth. Death occurred from hæmorrhage.

Jessop of Leeds, in 1877 successfully removed a growth of the left kidney by the lumbar method, from a male child, *æt.* 2½. Recurrence took place in nine months.

Kocher, also in 1877, removed an adeno-sarcoma, weighing 3 lb., by the ventral method, from a male child, *æt.* 2½ years. There was much loss of blood at the operation, and death occurred on the second day from peritonitis.

Byford in 1878 scored one of the first early successes. He removed a growth of the right kidney, weighing 4½ lb., by the ventral method. The patient was a woman *æt.* 39.

Martin, also in 1878, had a successful case, in a woman *æt.* 53. He removed a carcinomatous right kidney by the ventral method.

Czerny in 1879 attempted the removal of a soft sarcoma from a man *æt.* 50, but the hæmorrhage was so severe that the aorta had to be ligatured.

Lossen in 1879 reported the remarkable case of a woman, *æt.* 37, pregnant three months, from whom a large angio-sarcoma of the right kidney was successfully removed.

Barker, of London, in 1880 recorded a fatal case, in which a "cancer" involving the right kidney, and weighing 30½ oz., was removed by the ventral method. He reviewed the whole subject, and tabulated all cases up to that date.

Cullingworth in 1886 successfully removed a large renal sarcoma. The case is one of great interest, and, being a Manchester one, I make no apology for quoting Dr. Cullingworth's report at length—

"Elizabeth B., *æt.* 43, had enjoyed exceptionally good health until twelve months ago, when she first became conscious of a swelling in the abdomen, and of a sensation of a heavy mass

moving from side to side when she turned in bed. She had been married upwards of seven years, but had never become pregnant. For some time previous to the first appearance of the swelling she had suffered from a dull heavy pain in the lumbar region, to which she had paid little attention. There had been no urinary symptoms. Menstruation had become somewhat irregular during the last three years. Lately she had lost flesh and appetite, and the swelling in the abdomen and pain in the back had both rapidly increased. On admission, she appeared, notwithstanding her complaint of having lost flesh, to be in good health. She was fairly stout, and had a ruddy, healthy complexion. The abdomen was distended by a large movable tumour, more prominent on the right side than on the left, and giving on palpation an obscure sense of fluctuation. There was dulness on percussion over the whole abdomen, except in the epigastrium, left hypochondrium, and flanks, where the note was tympanitic. No interval of resonance could be obtained, either above the pubes or in the groins. The greatest girth of the abdomen was  $38\frac{1}{2}$  in. Per vaginam the uterus was found normal in size, and retroverted, being displaced by the lower end of the tumour, which lay in front of it. The urine was normal in colour, acid in reaction, of sp. gr. 1020, without deposit, and free from albumin or other morbid constituent. There was slight elevation of temperature in the evening,  $99^{\circ}$  to  $100^{\circ}$ .

“Abdominal section was performed, with antiseptic precautions, on 14th April. It was immediately evident that the tumour was not ovarian, inasmuch as its anterior surface was entirely covered by a highly vascular layer of peritoneum. This proved to be the posterior parietal peritoneum, pushed forwards until it was in close contact with the anterior layer. The peritoneal investment was torn through by the fingers, and the cyst tapped, a large quantity of thick, grumous, chocolate-coloured fluid being withdrawn. The incision was now enlarged to a length of about 6 in., and the tumour separated from its attachments and drawn forwards. It was then seen that it sprang from the left kidney, and that the upper and lower ends and pelvis of the kidney, though inseparable from the cyst, were not implicated in the disease. The renal vessels and ureter together formed a pedicle, which was transfixed, tied with a double ligature of strong carbolised silk, and divided. The

cyst wall, with kidney attached, weighed 1 lb. 14 oz.; its fluid contents weighed 9 lb. 8 oz., and measured 4 quarts. The divided edges of the peritoneum were simply placed in contact, without sutures, the ligatured vessels and ureter lying behind them.

“On examining the pelvic organs, the left ovary was found enlarged to the size of a pigeon’s egg, and cystic; it was therefore removed. A glass drainage tube was inserted at the lower angle of the abdominal incision, and the wound was closed with carbolised silk sutures. Dry dressings, consisting of pads of sublimate wood-wool, were applied, and maintained in position by a many-tailed flannel bandage, as usual. The patient vomited several times during the same afternoon, and once next day. The dressings were changed twice a day for four days, when the tube was removed, the quantity of blood stained serum having by that time decreased, from being sufficient to saturate the dressings to an accumulation of not more than  $1\frac{1}{2}$  drms. in the twelve hours.

“Menstruation commenced on the fourth day, and lasted three days. The temperature at 6 P.M. on the day of operation rose to  $101^{\circ}\cdot4$ ; on the three following days it was under  $100^{\circ}$ ; on the fourth day it only reached  $100^{\circ}\cdot4$ . 19th April (fifth day).—The three deep sutures were removed. The temperature varied between  $98^{\circ}\cdot4$  and  $100^{\circ}\cdot6$ . 20th April.—The bowels acted for the first time, after an enema, and the urine from this time was passed voluntarily. 21st April.—The two superficial sutures were removed. 22nd.—The general condition remained satisfactory, but the temperature in the evening rose to  $101^{\circ}$ . Next morning (23rd April) the temperature was  $99^{\circ}\cdot8$ , and the patient appearing well and complaining of being very hungry, she was ordered a small meat dinner. In the evening, however, the temperature rose to  $101^{\circ}\cdot8$ . 24th April (tenth day).—The temperature at 2 P.M. again suddenly rose from normal to  $102^{\circ}\cdot2$ , and at 2 A.M. on the 25th reached  $102^{\circ}\cdot4$ . There was no pain or discomfort, but during the night of the 24th–25th vomiting occurred. The temperature during the next three weeks was very irregular, varying from  $98^{\circ}$  to  $103^{\circ}$ . Vomiting took place about once every twelve hours during the early part of this period, and during the latter part at intervals of several days. Thinking it highly probable that these symptoms were to be accounted for by the occurrence of sloughing of the pedicle,

and suppurative inflammation in the connective tissue surrounding it, I examined the loin carefully from time to time. At first the note over the left renal region was tympanitic, and the part felt soft and yielding. Gradually the tissues became firmer and more resistant, and the percussion note dull. On 15th May, a month after the operation, I was able, for the first time, to assure myself of the presence of fluid, deeply seated in the loin.

“On the following day, 16th May, the patient was placed under chloroform, and a small incision was made, with antiseptic precautions, at the spot where fluctuation had been detected. A small quantity of pus made its escape. An indiarubber drainage tube was inserted in the wound. In the evening a much more copious discharge of matter took place, and with it a small quantity of fæcal matter. It was evident that I had accidentally wounded the bowel. Fæces continued to pass from the wound until the 18th, when a portion of the sloughed pedicle, with one of the ligatures attached, came away, accompanied with a large quantity of pus. From this time there was no further escape of fæces. Next day (19th May) the remaining portion of the pedicle, with its ligature, appeared on the dressings, and the wound now rapidly healed. The tube was removed on the 21st, and on the 26th all discharge had ceased, and the temperature was normal. The patient was able to sit up a little on the 29th, and on 12th June she went home, convalescent.

“I rather feared, from the peculiarly self-centred and desponding disposition of the patient, that on leaving the hospital she would lapse into the condition of a bedridden invalid. In the month of August I received a letter from Mr. Stelfox of Middleton, her medical attendant, in which he informed me that she had then been five weeks in bed, complaining of pain along the anterior crural nerve, but was now improving and beginning to sit up a little. I visited her to-day (16th Oct.) at her home, and found her in a condition far from satisfactory. She is lying in bed, complaining of great weakness. There is no pain or pyrexia; the skin is harsh and dry; and there is some loss of flesh. There is nothing abnormal in the condition of the abdomen; but during the last few weeks an oval swelling has made its appearance in the back, over the lower ribs on the right of the spine, extending from the



eleventh rib upwards, and measuring about 3 in. in length by  $2\frac{1}{4}$  in. in breadth. The swelling is smooth, firm, and elastic, and has a uniform elevation of about  $\frac{3}{8}$  of an inch. Just above the scar of the lumbar incision on the left side there is a small movable body beneath the skin, about the size of an almond. A similar body has made its appearance in the scar itself. There can be little doubt that these appearances indicate a recurrence of the disease. Over the left renal region, the tissues, with the exception of the two gland-like bodies just described, are normal, and the note elicited on percussion is tympanitic. The area of dulness over the right renal region is normal.

“The specimen was examined by Dr. Dreschfeld, who reported as follows:—

“The specimen consisted of a large globular cyst. One end of the cyst terminated in a mass which was found to be kidney, measuring 7 in. in length; the lower portion of this consisted of the rounded lower border and a part of the hilum of the kidney. In the hilum large veins and small arteries were found, but no ureter was made out. The part adjacent to this kidney mass was flattened out and formed a portion of the cyst, beyond which was another solid mass consisting of a portion of the normal upper extremity of the kidney.

“The outer surface of the cyst was smooth and shiny, and showed a large quantity of large and small rounded elevated masses. On microscopic examination, these were found to consist of round cells and spindle cells, disposed in an irregular manner, without any alveolar arrangement. The thickness of the cyst wall varied; in some places it was a few lines, in others a quarter of an inch. Its inner side was irregular, had no distinct lining membrane, and showed again, corresponding to the nodules seen outside, rough, villous, or granular masses of the same structure (spindle cells and round cells).

“The cyst was closed on all sides, and showed no communication with the remaining kidney substance.

“The contents of the cyst consisted of a thick grumous fluid. Microscopically, there were found in it blood cells, large and small granule cells, and spindle cells. The tumour must therefore be considered as a mixed sarcoma that had undergone cystic degeneration.’

“Before the operation the growth had been considered to be in connection with the right ovary.”

Newman in 1887 was able to collect seventy-four cases in which nephrectomy had been performed. Of these, only thirty-eight seem to have recovered, and there is reason to believe that recurrence took place in several of these.

Tuffier gives references to nearly all the nephrectomy cases up to 1887. In forty-six collected nephrectomies, he found a mortality of 65·2 per cent. He also collected sixteen cases in children, with a mortality of 62·5 per cent.

These figures seemed to warrant Butlin, in 1887, expressing an opinion that the results of nephrectomy for carcinoma "do not appear to justify a continued trial of the operation." Although admitting that the removal of sarcomatous kidneys in children had not been so fatal as for cancer in adults, he nevertheless then thought that "the operation will fall into disrepute." He, moreover, says that "although nephrectomy for sarcoma in adults has hitherto afforded the best results, the mortality is so large that the operation is not likely to find favour in the eyes of either surgeons or their patients."

Sigrist considers the results discouraging. He collected sixty-four cases of nephrectomy for malignant disease, with thirty-two deaths from operation. Recurrence took place in nine, within a year and a half; in five, in a little over two years; and one was well at four years.

Guillett, in his admirable thesis, published in 1888, gave tables of nephrectomy cases—twenty-eight for carcinoma, and thirty-seven for sarcoma.

Guilleman in 1891 gives the following numbers, apparently based on Chevalier's observations. In sixty-six cases of transperitoneal nephrectomy there was a mortality of 59 per cent. In twenty-one lumbar nephrectomies the mortality was 24 per cent. In children, 70 per cent. of the operations were unsuccessful, and in adults, 58 per cent.

Barth has collected the statistics of 100 nephrectomies, performed for malignant disease, up to June 1892. Of these, forty-two died from operation, twenty from metastases, and thirty-eight were reported as "cured." As regards those returned as "cured," the word must be used in a very modified sense. Recurrence seems generally to take place within three years.

Minges gives sixty cases, with a mortality of forty-six.

Fischer collected thirty cases of nephrectomy for growths

in children, and found a mortality of 56 per cent. in the earlier cases, while in the later it had fallen to 48 per cent.

Bland Sutton in 1893, in his work on tumours, published a table of twenty-one nephrectomy cases for renal sarcoma in children under 6 years of age, with nine recoveries and twelve deaths, but of those who recovered from the operation all were dead within a year.

In a further table of fourteen cases of nephrectomy for sarcoma in adults, there were six recoveries and eight deaths; but of those who survived the operation, all died from recurrence within a year.

Israel in 1894 published six cases treated by nephrectomy; three recovered. He gives useful tables and illustrations.

Coley states that Lotheisen found that of eleven patients operated upon for malignant tumour of the kidney, only one was well beyond two years, and the growth was an adeno-carcinoma. Of the five cases of sarcoma all the patients died of recurrence.

Martin says recurrence takes place in 40 per cent. of the cases. Gross believes recurrence occurs in about one-third of the cases.

Mr. Henry Morris, in his recent article on renal growths,<sup>1</sup> is cautiously hopeful. "In cases which are diagnosed early, before secondary infection has occurred, nephrectomy may be performed with some hope of cure.

Osler says: "When the growth is small and the patient in good condition, removal of the organ may be undertaken, but the percentage of cases of recovery is very small."

It must be remembered that recurrence may be slow. In one of Abbe's cases it was more than four years after operation.

Lewi in 1896 collected sixty cases of nephrectomy for renal sarcoma, with a mortality of  $28\frac{1}{2}$  per cent., but recurrence took place in nearly all the cases which survived the operation.

References to nearly all the cases will be found in the Bibliography, so that it is unnecessary to dwell at length on the individual cases. The following brief references may, however, not be without interest and value.

Nephrectomy for simple fibrous growths has been successfully performed by Bardenheuer, Bruntzel, Thomas, and Wahl.

Sir Spencer Wells twice successfully removed from the kidney or its immediate neighbourhood fibro-lipomatous growths, one weighing  $16\frac{1}{2}$  lb., and another  $14\frac{1}{2}$  lb.

<sup>1</sup> Allbutt's "System of Medicine."

Monod has recently removed an enormous capsular lipoma. Alsberg in 1892, and Warthin in 1897, published cases where lipomatous growths were removed by nephrectomy.

Papillomata have been removed from the pelvis by Billroth and Thomas Jones. Mr. Jones tells me his case ultimately died with all the symptoms of malignant disease, so evidently the growth was of a malignant nature.

Adenomata have been successfully removed by Schonborn from a child *æt.* 2 years; and by Weir from a man *æt.* 35 years.

Quite recently Mr. Thorburn removed a large malignant adenomatous growth from an adult male, in the Manchester Royal Infirmary, by the lumbar incision. Illustrations from photographs of the specimen are shown in Figs. 8 and 71.

Sutton refers to a case recorded by Ris, where a tumour, stated by Klebs to be an adeno-sarcoma, was removed from a woman *æt.* 56 years, by Krönlein of Zurich, and the patient was alive and well five years after.

Cases in which nephrectomy has been performed for sarcoma have been recorded by—Abbe, Adams, Albert, Alexander, Alsberg, Bardenheuer, Barker, Barth, Bérard, Bergmann, Billroth, Bokai, Braum, Brokaw, Buchanan, Chadwick, Charon, Cossen, Croft, Cullingworth, Czerny, Dandois, Danforth, Döderlein, Dohrn, Fischer, Girard, Godlee, Halstead, Heydenreich, Hicquet, Hornaus, Hunter, Higuët, Hume, Imlach, Israel, Jessop, Keith, Kocher, Koenig, Krönlein, Langenbuch, Lewi, Little, Lossen, MacBurney, M'Donald, Maguer, Martin, Meredith, Pughe, Rawdon, Roberts, Steele, Stetter, Thiriar, Thomas, Thornton, Trendelenburg, Weir, and others referred to in the Bibliography.

As far as I can ascertain, nephrectomy has been performed for a myo-sarcomatous growth in only a very few cases.

Nephrectomy has been performed for growths described as "cancerous," but evidently in some instances sarcomatous, by—Albert, Barker, Bokai, Clementi, Czerny, Davy, Gross, Homans, Israel, Jessop, Lucke, Martin, Novaro, Pean, Poncet, Réczey, Steller, Thelwall Thomas, Wahl, Walcott, Wells, and others.

De Pauli records a case of successful extirpation of the right kidney for angio-sarcoma in a man, *æt.* 30. He also mentions the case of a man, *æt.* 37, with angio-sarcoma of the left kidney, where nephrectomy was performed, but with a fatal result.

Growths probably originating in adrenal "rests" have been removed by Coppinger and Lentaigne, as recorded by MacWeeney.

Leguen has recently recorded a case of nephrectomy in a movable kidney, the seat of a cystic carcinoma.

Tuffier has recently shown that partial nephrectomy may be successfully performed for the removal of benign growths.

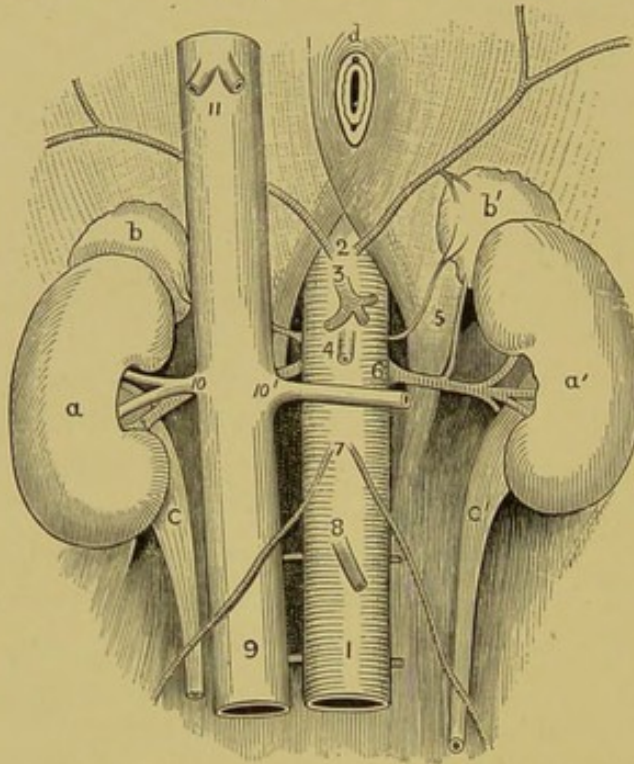


FIG. 89.—Diagram of the normal blood supply of the kidneys. 1, Abdominal aorta; 2, phrenic arteries; 3, coeliac axis; 4, superior mesenteric artery; 5, middle suprarenal artery (left); 6, renal artery (left); 7, spermatic (or ovarian) arteries; 8, inferior mesenteric artery; 9, inferior vena cava; 10, 10', renal veins; 11, hepatic veins; *a, a'*, kidneys; *b, b'*, suprarenal capsules; *c, c'*, ureters; *d*, oesophageal opening in diaphragm.—HEPBURN.

It is not my intention to enter into any discussion upon the question of the mere technique of nephrectomy, which is ably dealt with in the ordinary text-books of surgery, and by such writers as Hurry Fenwick, Jacobson, Morris, Newman, and Treves.

Neither is it necessary to stay to consider the relative advantages of the intraperitoneal or lumbar methods, for, as Tait says, "the kidney is best reached by the most likely-looking road," and this decision rests with the operator, who will act in accordance with the requirements of the case.

The present attitude may be indicated very briefly by two quotations, which fully express the author's opinions.

Osler writes: "A very large proportion of the cases come first under the care of the physician, whose province it is to recognise the condition; but to do justice to his patient he should be thoroughly familiar with the advances which have been made in the department of renal surgery." And to this may be added the view of Aldibert, that "the results of operation during recent years have been so encouraging, that no case should be abandoned, no matter how young the patient."

The accompanying illustrations will sufficiently indicate to the diagnostician, as well as to the operating surgeon, the necessity for a clear perception of the relation of the kidney.

In all cases of nephrectomy for growth, the whole of the fibrous capsule should be removed. Some advise that the capsule should, if possible, be opened, and any growth enucleated. This is not acting up to pathological experience. Even when there is no general dissemination, and the growth appears per-

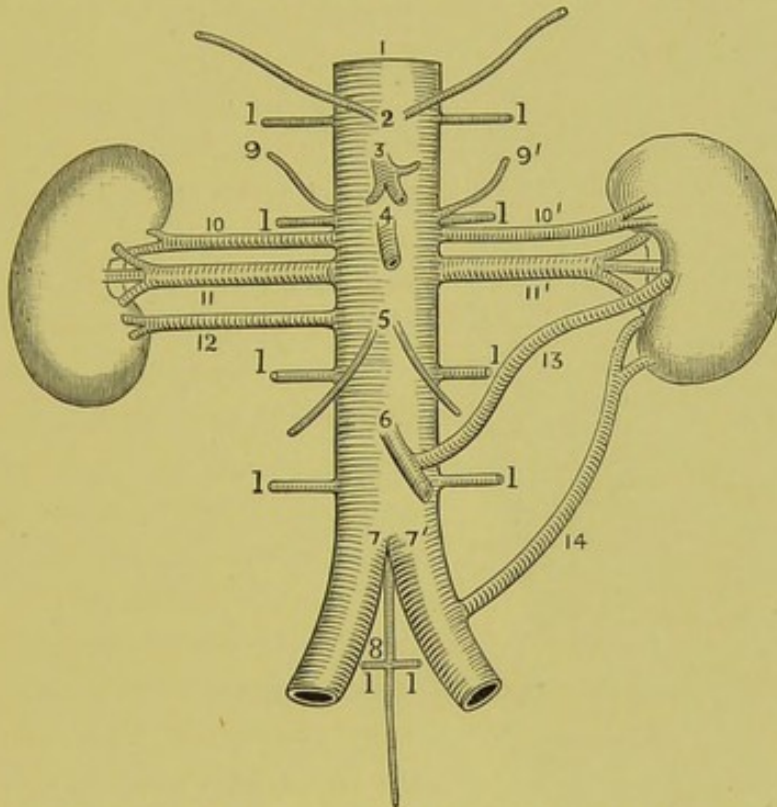


FIG. 90.—Diagram of the accessory renal arteries. 1, Abdominal aorta; 2, phrenic arteries; 3, coeliac axis; 4, superior mesenteric artery; 5, spermatic (or ovarian) arteries; 6, inferior mesenteric artery; 7, 7', common iliac arteries; 8, middle sacral artery; 9, 9', middle suprarenal arteries; 10, 10', superior accessory renal arteries; 11, 11', renal arteries; 12, inferior accessory renal arteries; 13, accessory renal from 6; 14, accessory renal from 7'; 1, 1, lumbar arteries.—HEPBURN.

fectly local, careful search will often show affected glands, especially in the neighbourhood of the hilum.

My special desire is to most strongly oppose the present very pessimistic view taken by the majority of practitioners. After a careful study of many of the cases subjected to nephrectomy, I am convinced that the mortality may be considerably lowered. At present about 50 per cent. die from the operation. Delayed interference is undoubtedly the chief cause of this excessive mortality. Hesitation to deal with a process which, if untouched,

must of necessity prove fatal, is in great measure due to a too cautious conservatism on the part of the physician under whose observation and care these cases are usually first placed.

Nephrectomy for growth must always be a very serious undertaking, but the records may undoubtedly be greatly improved; and, as Jacobson points out in the last edition of his work on "The Operations of Surgery," general opinion is too pessimistic with regard to the future.

If operation be delayed, extensive adhesions will almost certainly be present, and glands, and possibly veins, will have been invaded by growth. The risks of the operation can only be increased by delay, and, unless undertaken before the growth has become extensive, will in all probability prove ineffectual, from its necessary partial character.

Abbe's brilliant results show conclusively that operative interference may be successful even in very young subjects. In a child *æt.* 2, nephrectomy was performed, and good health was reported five years later. In an infant of 14 months the growth was successfully removed, and four years after the child was quite well.

Operation is, of course, useless when there are evidences of secondary deposition. Before proceeding to nephrectomy, the condition of the opposite kidney should be investigated, according to such modern methods as are admirably indicated by the late Greig Smith in his work on abdominal surgery. When the growth is very large, and extensive adhesions exist, the idea of nephrectomy will probably have to be abandoned.

Medicinal treatment is practically useless. Some have

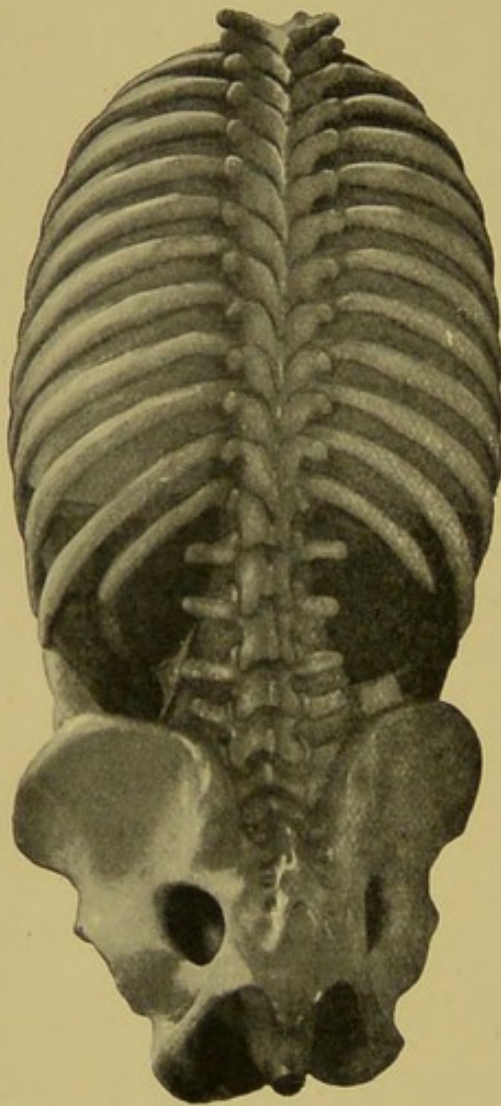


FIG. 91.—Relations of kidneys. Abdominal viscera *in situ*, seen from behind.—From a model.—WARING.

thought that arsenic, given with plenty of water, and continuously administered, tended to delay the rate of growth. Iodide of potassium, Chian turpentine, and other drugs have been given by some practitioners constitutionally hopeful.

During the last few years attempts have been made to influence the development of malignant growths by the introduc-

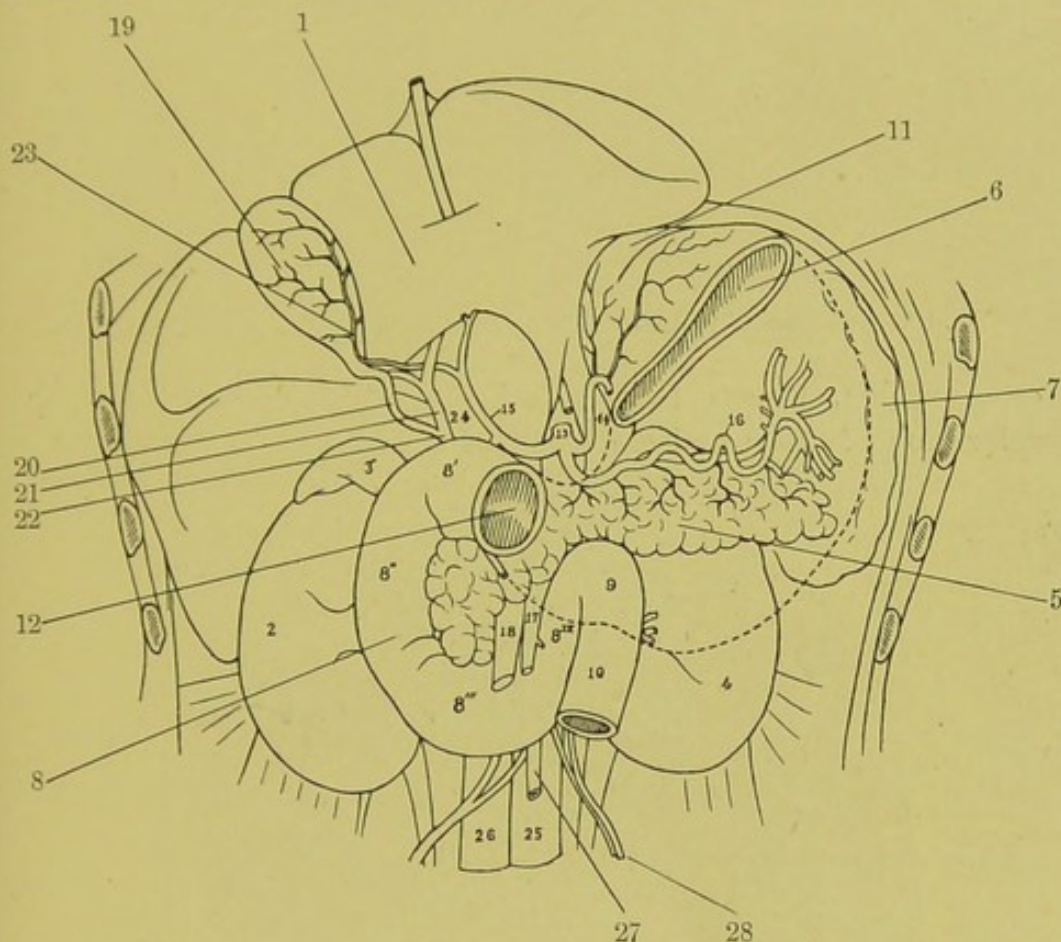


FIG. 92.—Relations of kidney to adjacent organs. Diagrammatic view. 1, Inferior aspect of liver; 2, right kidney; 3, right adrenal; 4, left kidney; 5, pancreas; 6, cardiac portion of stomach; 7, spleen; 8, duodenum; 8', duodenum, 1st part; 8'', duodenum, 2nd part; 8''', duodenum, 3rd part; 8'v, duodenum, 4th part; 9, junction of duodenum and jejunum; 10, jejunum; 11, cardiac orifice of stomach; 12, pylorus; 13, cœliac axis; 14, arteria gastro-duodenalis; 15, hepatic artery; 16, splenic artery; 17, superior mesenteric artery; 18, superior mesenteric vein; 19, gall bladder; 20, cystic duct; 21, common hepatic duct; 22, common bile duct; 23, cystic artery; 24, portal vein; 25, aorta; 26, inferior vena cava; 27, inferior mesenteric artery; 28, spermatic artery.—After TESTUT.

tion of powerful toxins. Fruitnight has introduced the toxins of *Streptococcus erysipelatis* and *Bacillus prodigiosus* in a case of renal sarcoma occurring in an infant, æt. 13 months. A large tumour had been noted in the right lumbar and hypochondriac regions for three weeks. The toxins were injected daily into the



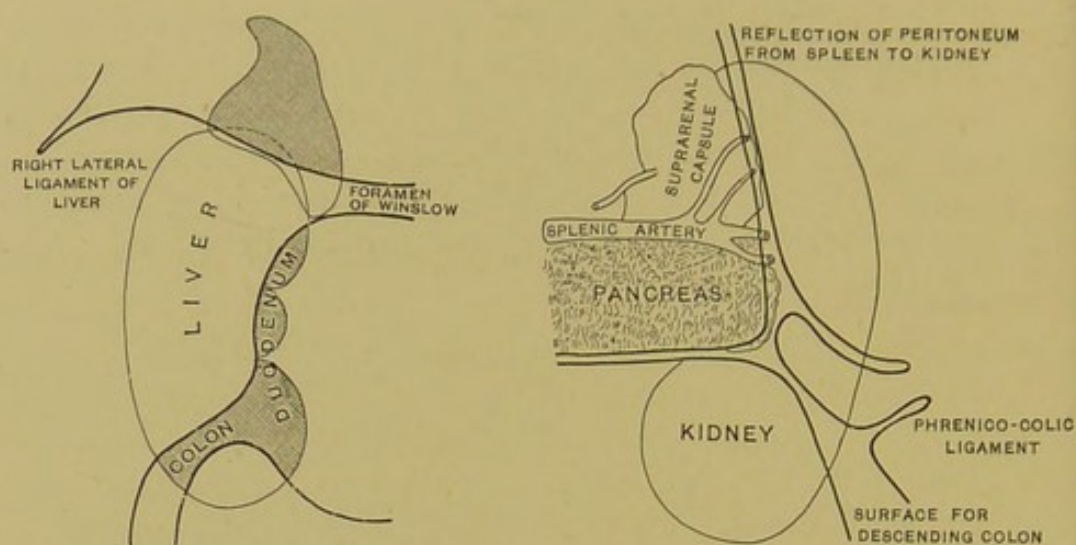


FIG. 93.—Relations of peritoneum to kidneys and adrenals.—CUNNINGHAM.

gluteal region, fifteen injections being administered. A slight acceleration of pulse and elevation of temperature followed each

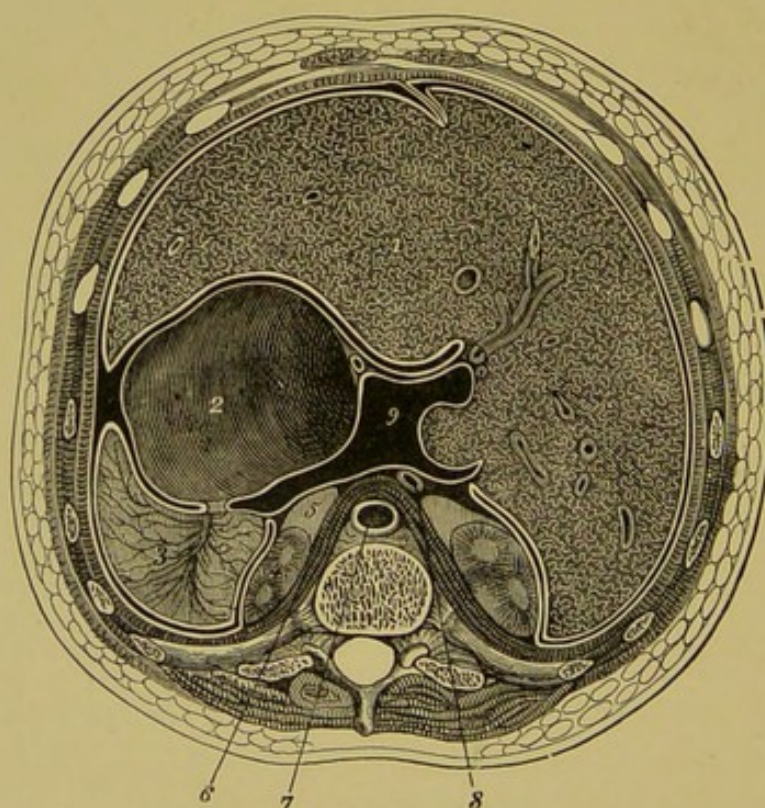


FIG. 94.—Section through the abdominal cavity of a young subject at the upper border of the twelfth dorsal vertebra, above the level of the foramen of Winslow. From this it will be seen that the lobus Spigelii is the only part of the posterior surface of the liver which is clothed by the liver sac. 1, liver; 2, stomach; 3, spleen; 4, kidney; 5, suprarenal capsule; 6, diaphragm; 7, aorta; 8, vena cava; 9, lesser bag of peritoneum.—From LUSCHKA.

injection, but the temperature never rose above 102° F. There was no appreciable effect upon the size or course of the growth. The tumour weighed 4½ lb. Microscopically, it consisted of sarcomatous elements, with striped muscular fibres and adenomatous tissue.

Coley in 1894 removed a mixed-cell sarcoma by the transperitoneal method from a girl, æt. 5. Recurrence took place in seven months. Injections of the filtered and sterilised "Coley's fluid" were then administered, with apparent benefit. The growths, however, increased, and ultimately almost filled the abdomen.

Petersen,<sup>1</sup> who has recently published a critical survey of

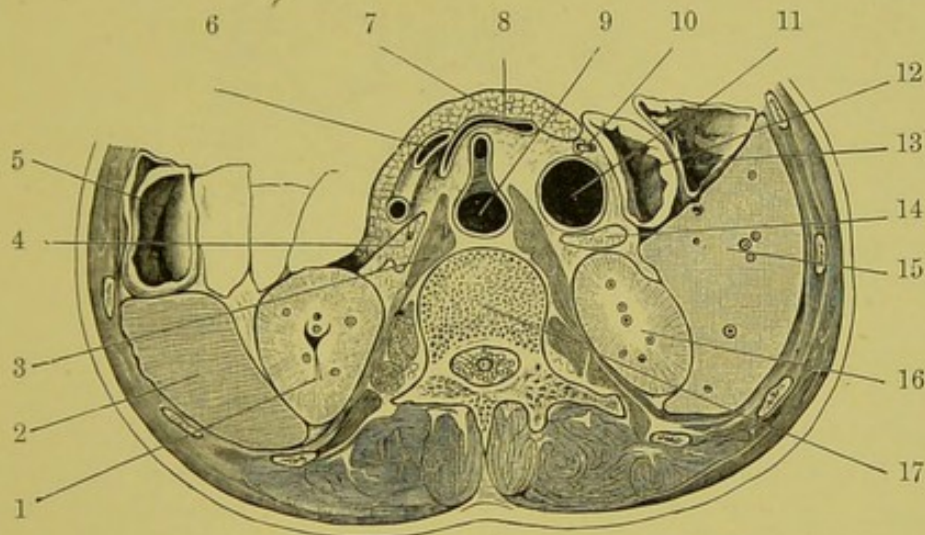


FIG. 95.—Transverse section through abdomen, at the level of the first lumbar vertebra. 1, left kidney; 2, spleen; 3, crus of diaphragm; 4, suprarenal capsule; 5, colon; 6, splenic artery; 7, pancreas; 8, splenic vein joining the portal vein; 9, aorta giving off the superior mesenteric entry; 10, rod in bile duct; 11, inferior vena cava; 12, duodenum; 13, colon; 14, suprarenal capsule; 15, liver; 16, right kidney; 17, first lumbar vertebra.—CUNNINGHAM.

bacterium therapy of malignant growths, based upon a consideration of thirty-eight cases treated by toxins, antitoxins, or serums, gives but little encouragement to this form of treatment. In no case was a carcinomatous growth improved. With some sarcomata, however, the progress of the growth seemed to be delayed, and in two instances there was a decided decrease in size. "Coley's serum," which consists of the mixed toxins of the *Streptococcus erysipelatis* and *B. prodigiosus* seems to depend almost entirely upon the activity of the toxin of the former. At present

<sup>1</sup> Petersen (Walther), "Beiträge zur klinische Chir.," 1896, Bd. xvii. Heft 2, S. 341.

the use of such agents should, at least, be limited to inoperable cases. Mansell Moullin<sup>1</sup> has recently fully discussed the question of treating extensive sarcomatous growth by "Coley's fluid."

Attempts have been made to treat malignant inoperable growths by electrolysis and cataphoresis, but there is little to encourage any such extension to renal malignant growths.

In cases where operative interference is manifestly inadmissible, and in those instances where recurrence has followed

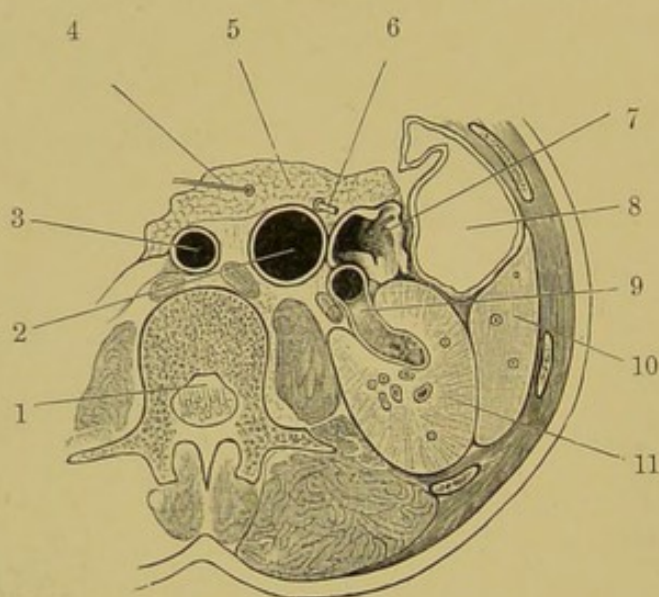


FIG. 96.—Section through abdomen at the level of the second lumbar vertebra. 1, cauda equina; 2, vena cava; 3, aorta; 4, pancreatic duct; 5, pancreas; 6, common bile duct; 7, duodenum; 8, colon; 9, renal vein; 10, liver; 11, right kidney.—CUNNINGHAM.

nephrectomy, palliative treatment is alone possible. This must be carried out along general lines. Snow recommends the continuous administration of cocaine, and states that antipyrin is also useful in subduing the neuralgic-like pains. Strange to say, he believes that opium is "necessarily contra-indicated." Most clinicians will believe that the judicious administration of morphia is not only justifiable but desirable where there is much pain.

<sup>1</sup> Moullin, "The Treatment of Inoperable Sarcoma by means of Coley's Fluid," *Lancet*, London, 1897, vol. i. p. 354. Bibliography given.

## CHAPTER XXI.

### BIBLIOGRAPHY.

IN the body of this monograph I have abstained from burdening the pages with references, which, however, can be readily obtained by consulting the list of authors, alphabetically arranged and here appended.

In compiling this, I trust fairly complete, Bibliography, I have endeavoured to make it useful and convenient for subsequent workers. As far as I am aware, no such collection exists in any language. I trust it may be of service to those who desire to make independent study of the subject.

In making myself acquainted with the literature of the subject, I have made much use of the admirable libraries belonging to our Manchester Medical Society and Royal Infirmary. I have also largely availed myself of the libraries of the Royal College of Physicians of London, the Royal College of Surgeons of England, and the British Medical Association.

I am also greatly indebted to the invaluable "Index Catalogue of the Library of the Surgeon-General of the United States," and the volumes of the "Index Medicus," to the *Revue des Maladies Cancereuses*, edited by Duplay, Lannelongue, and Cornil, the *Annales des Maladies des organes genito-urinaires*, Paris, and to numerous references given in many of the works mentioned in my list.

In order to avoid useless repetition, I have not given the full titles of the papers, but have endeavoured to indicate, by the names placed in brackets, the main object of the author's essay, or the probable nature of the case, or cases, described.

In giving dates, I have kept to that of the volumes in which the article appears rather than attempted to indicate the exact year—often the one previous to that given—at which the communication may have been brought forward.

I much regret that it has been impossible for me to verify

my references in all cases. Some of the works named have not been in the libraries to which I have had access. In some instances I have been obliged to rest content with giving the reference to a readily accessible abstract. Where thought desirable, I have given reference both to the original article and to the available abstract.

I have also attempted to indicate by brief notes some of the more important cases and those submitted to operation, with the recorded results.

### I. RENAL GROWTHS.

ABBE.—(Sarcoma) *Ann. Surg.*, St. Louis, 1894, vol. xix. pp. 58-69.

Cases with photographs. •

CASE 1.—Female, æt. 2. Right; weight, 2½ lb.; nephrectomy; recovery; perfect health five years later. Carcinoma sarcomatosum.

„ 2.—Female, æt. 14 months. Right; weight, 7½ lb.; nephrectomy; recovery; perfect health four years later. Rhabdomyo-sarcoma.

„ 3.—Male, æt. 65. Right; weight, 3 lb.; nephrectomy; death in fourteen hours. Sarcoma.

ABEILLE.—(Malignant Growths) “Étude sur le cancer primitif du rein,” Paris, 1883. Thesis.

ABERCROMBIE.—(Sarcoma) *Trans. Path. Soc. London*, 1879-80, vol. xxxi. pp. 168-174.

Cases of bilateral renal growth, possibly due to direct invasion from without.

CASE 1.—Male, æt. 3¼.

„ 2.—Female, æt. 2.

„ 3.—Female, æt. 4.

„ (Sarcoma) *Trans. Path. Soc. London*, 1880-81, vol. xxxii. p. 205.

CASE 1.—Male, æt. 1½. Bilateral growth, considered to be of extra-renal origin.

ADAMI.—(Perirenal lipomata; males, æt. 45 and 60) *Montreal Med. Journ.*, Jan. and Feb. 1897.

ADAMS.—(Carcinoma) *Med. Times and Gaz.*, London, 1882, vol. ii. p. 678.

CASE 1.—Adult, æt. 39. Right; nephrectomy; death in six weeks; growth probably sarcomatous; secondary deposits.

AGNEW.—(Carcinoma) “Principles and Practice of Surgery,” 1881, vol. ii. p. 710.

ALBERT.—(Carcinoma) *Soc. de méd. de Vienne*, Feb. 15, 1885.

CASE 1.—Female, æt. 40. Right; weight, 2½ lb.; nephrectomy; recovery.

ALDIBERT.—(Growth) *Rev. mens. d. mal. de Venf.*, Paris, Nov. 1893.

ALESSANDRI.—(Renal growths from Adrenal “Rests”) *Policlin.*, Roma, 1896, tome iii. pp. 393-415.

ALEXANDER, C.—(Adrenal growths) *Beitr. z. path. Anat. u. z. allg. Path.*, Jena, 1891, Bd. xi.

ALEXANDER, W.—(Sarcoma) *Liverpool Med.-Chir. Journ.*, 1888, vol. viii. p. 257.

CASE 1.—Female, æt. 50. Left; weight, 5 lb. Growth thought to be ovarian or pedunculated fibroid; nephrectomy; death.

ALLEN.—(Cancer) *Austral. Med. Journ.*, Melbourne, 1880, vol. ii. p. 173.

ALLEN AND CHERRY.—(Primary renal growths) *Internat. Med. Journ.*, Australia, 1896, vol. i. pp. 274, 644.

Reports of microscopical examinations of twenty-nine cases; eight illustrations.

- ALLING.—(Cancer) *Bull. Soc. anat. de Paris*, 1869, tome xlv. pp. 278–280.
- ALLOWAY.—(Malignant Growths in Childhood) *Am. Journ. Obst.*, New York, 1883, vol. xvi. pp. 881, 993.  
 CASE 1.—Female, æt. 5. Right; round cell sarcoma; illustrations.
- ALSBERG.—(Sarcoma) *Deutsche med. Wchnschr.*, Leipzig, Oct. 6, 1886, Bd. ii.  
 CASE 1.—Child, æt. 5. Right; nephrectomy; recurrence and death in eleven months.  
 „ (Lipoma) *Arch. f. klin. Chir.*, Berlin, 1892, Bd. xlv. S. 458–462;  
 and *Verhandl. d. deutsch. Gesellsch. f. Chir.*, Berlin, 1892, Bd. xxi. S. 96–99.  
 Illustrations.
- AMBROSIUS.—“*Beitr. z. Lehre von den Nierengeschwülsten*,” Marburg, 1891. Diss.
- ANDERSON.—(Cancer) *Brit. Med. Journ.*, London, 1881, vol. i. p. 806.  
 CASE 1.—Male, æt. 59. Right; weight, 5 lb. 12 oz.
- ANDERSON AND COATS.—(Cancer) *Glasgow Med. Journ.*, 1887–88 (4), N. S., vol. xxix. pp. 10–16.
- ANDREW.—(Cancer of Fourteen Years' Duration) *Lancet*, London, 1877, vol. i. p. 194.  
 CASE 1.—Male, æt. 36. Trauma; tumour and hæmaturia for fourteen years. Probably chronic renal tuberculosis; death from phthisis.
- ASKANAZY.—(Malignant Growths) *Beitr. z. path. Anat. u. z. allg. Path.*, Jena, 1893, Bd. xiv. S. 33–70.  
 Discussion on growths probably developed from adrenal “rests.”  
 Illustrations.  
 „ (Growths of Adrenal Origin) *Virchow's Archiv*, 1894, Bd. cxxxvi. S. 568.
- AUDAIN.—(Sarcoma) *Union méd.*, Paris, 1875, Sér. 3, tome xix. pp. 702–706.  
 CASE 1.—Infant, æt. 10 months.
- AUDAIN AND FÉREOL.—(Sarcoma) *Bull. et mem. Soc. méd. d. hôp. de Paris*, 1875, pp. 52–55.
- AUSTIN.—“*Diagnostic précoce néoplasms du rein et de la vessie au moyen du cystoscope*,” Thèse de Paris, 1890.
- BACCELLI.—(Carcinoma) *Gior. internaz. d. sc. med.*, Napoli, 1879, tome i. pp. 686–693.  
 „ (Carcinoma) *Gazz. d. osp.*, Milano, 1882, tome iii. pp. 114, 122, 130.
- BAGINSKY.—(Sarcoma) *Deutsche med. Wchnschr.*, Berlin, 1876, Bd. ii. S. 113;  
*Verhandl. d. Berl. med. Gesellsch.*, 1875–76 (1), Bd. vii. S. 65.  
 CASE 1.—Infant, æt. 7 months. Left kidney.
- BALDING.—(Encephaloid Cancer) *Trans. Path. Soc. London*, 1856–57, vol. viii. p. 286.  
 CASE 1.—Female, æt. 5½. Right; weight, 4½ lb. Probably sarcoma; deposits in lungs.
- BALLARD.—(Diagnosis of Renal Growths) “*The Physical Diagnosis of Diseases of the Abdomen*,” 1852, p. 97.  
 „ (Encephaloid Cancer) *Trans. Path. Soc. London*, 1858–59, vol. x. p. 188.  
 CASE 1.—Female, æt. 70. Left kidney.
- BALLET.—(Adenoma) *Bull. Soc. anat. de Paris*, 1879, tome liv. pp. 446–449;  
*Progrès méd.*, Paris, 1880, tome viii. p. 152.
- BANTL.—(Sarcoma) *Arch. di anat. norm. patol.*, Firenze, tome v. p. 2; Abstract, *Jahresb. ii. d. Fortschr. d. ges. Med.*, Erlangen, 1890, Bd. i. S. 255.
- BARBACCI.—(Growths) *Morgagni*, 1891, tome xxxiii. pp. 497–511.
- BARBIERI.—(Cancer) *Ippocratico*, 1866, Sér. 3, tome ix. pp. 305–312.

- BARCLAY.—(Fibro-fatty Growth) *Lancet*, London, 1863, vol. ii. p. 563.  
 CASE 1.—Male, æt. 35. Part of right; weight, 5 lb. 7½ oz. Probably tuberculous.
- BARDENHEUER.—(Sarcoma) *Berl. klin. Wchnschr.*, 1887, p. 257.  
 CASE 1.—Female, æt. 22. Right; nephrectomy; death from septicæmia.  
 „ (Fibroma) quoted by Newman.  
 CASE 1.—Female, æt. 51. Nephrectomy; recovery.  
 „ (Sarcoma) Quoted by Newman.  
 CASE 1.—Male, æt. 3. Left; nephrectomy; recovery.  
 „ (Sarcoma) *Mitth. das Kolner Bürger Hosp.*, 1890, Heft 5.  
 CASE 1.—Male, æt. 3. Left; weight, 2 kilos.; lumbo-abdominal nephrectomy; death on fourteenth day from peritonitis.
- BARETTE.—(Malignant growth; child, æt. 26 months) *Année méd.*, Caen, 1896, tome xv. p. 4.
- BARKER.—(Sarcoma) *Med.-Chir. Trans.*, London, 1880, vol. lxxiii. pp. 181–215.  
 CASE 1.—Female, æt. 21. Right; weight, 30½ oz.; nephrectomy; death. Illustrations; tables of nephrectomy cases.
- BARRIE.—(Epithelioma) *Bull. Soc. anat. de Paris*, 1889, tome lxiv. pp. 24–28.
- BARTH.—(Cancer) *Bull. Soc. anat. de Paris*, 1851, tome xxvi. p. 28.  
 „ (Malignant growth) *Bull. Acad. de méd.*, Paris, 1870, tome xxxv.  
 „ (Adeno-sarcoma) *Deutsche med. Wchnschr.*, Leipzig, 1892, S. 531.  
 CASE 1.—Female, æt. 5. Right; nephrectomy; recurrence and death in four months.
- BARTHOLOMEW.—(Sarcoma) *Chicago Med. Rec.*, 1896, vol. ix. pp. 10–15.
- BASHAM.—“On Dropsy connected with Diseases of the Kidneys (*Morbis Brightii*), and on some of the Diseases of those Organs associated with Albuminous and Purulent Urines,” London, 1862.
- BAUCHET.—(Lipoma) *Bull. Soc. anat. de Paris*, 1859.
- BEADLES.—(Carcinoma) *Trans. Path. Soc. London*, 1892–93, vol. xlv. pp. 98–100.  
 CASE 1.—Male, æt. 57. Right; weight, 69½ oz.; secondary deposits in lungs.
- BÉCLARD AND CLOQUET.—(Cancer) *Bull. Fac. de méd. de Paris*, 1816–17, tome v. p. 114.  
 CASE 1.—Male, æt. 50. Right kidney.
- BEER.—“Die Bindesubstanz der Niere,” Berlin, 1859.
- BÉHIER.—(Cancer) *Union méd.*, Paris, 1875, tome ii. pp. 810, 822.
- BELFIELD.—(Encephaloid Cancer) *Med. Journ. and Exam.*, Chicago, 1878, vol. xxxvi. pp. 347–349.
- BELLATI.—(Adeno-Carcinoma) *Arch. prov. de chir.*, Paris, tome v. p. 216.
- BENEKE.—(Growths) *Beitr. z. path. Anat. u. z. allg. Path.*, Jena, 1891, Bd. ix. S. 440–487.  
 Discussion on aberrant adrenals in kidney, and growths originating in same. Cases.
- BENNETT.—(Fungus Hæmatodes) *London Med. Gaz.*, 1831, vol. viii. p. 182.  
 CASE 1.—Female, æt. 4. Weight, 4 lb. 2 oz.
- BÉRARD.—(Sarcoma in Infant) *Lyon méd.*, 1894, tome lxxvii. pp. 360–363.  
 „ (Encephaloid; adult male; nephrectomy) *Prov. méd.*, Lyon, May 1895.
- BERGER.—(Cystic Epithelioma) *Abeille méd.*, Paris, 1896, June 20, p. 193.  
 Abstract: *Rev. d. mal. Cancereuses*, July 1896, p. 242.
- BERGMANN.—(Sarcoma) *Diss.*, Dorpat, 1883.  
 CASE 1.—Female, æt. 41. Nephrectomy; death from suppression of urine.

- BERGMANN.—(Sarcoma) *Berl. klin. Wchnschr.*, 1885, Bd. xlv. S. 711.  
 CASE 1.—Female, æt. 54. Right; nephrectomy; recovery.
- BERNER.—(Sarcoma) *Norsk Mag. f. Lægevidensk.*, Christiania; abstract, *Jahresb. ii. d. Leistung. . . . d. ges. Med.*, Berlin, Bd. xvi. S. 207.  
 CASE 1.—Male. Right; weight, 5800 grms.
- BEYERLEIN.—“Das Carcinom der Niere,” Erlangen, 1867.
- BEZOLD.—(Myxoma) *Virchow's Archiv*, 1865, Bd. xxxiv. S. 229.  
 Case with Illustration.
- BIECK.—“Beitr. z. Casuistik der Nierengeschwülste,” Marburg, 1886. Diss.
- BIERMER.—(Lymphoma) *Virchow's Archiv*, 1857, Bd. xix. S. 537.
- BIGGS.—(Growth) “Reference Handbook of the Medical Sciences,” New York and Edinburgh, 1887, vol. iv. pp. 292–298.
- BILLROTH.—(Myxo-sarcoma) *Wien. med. Wchnschr.*, 1884, S. 773.  
 CASE 1.—Female, æt. 38. Duration, five years; nephrectomy; recovery.
- ” (Myo-sarcoma) *ibid.*, 1883.  
 CASE 1.—Child, æt. 3.
- ” (Fibro-myoma) *ibid.*, 1880, Bd. xxviii.  
 CASE 1.—Female. Left; nephrectomy; death; probably of extra-renal origin.
- ” (Epithelioma) *ibid.*, 1884, No. 25, S. 774.  
 CASE 1.—Male, æt. 33. Left; nephrectomy; recovery.
- BIRCH-HIRSCHFELD.—“Lehrbuch der Pathologischen Anatomie,” 1887, Bd. ii. S. 692–700.
- BOCCARDI.—(Enchondroma) *Progresso med.*, Napoli, 1888, tome ii. pp. 737–746.  
 Illustration.
- BOETTCHER.—(Lymphoma) *Virchow's Archiv*, 1858, Bd. xiv. S. 483–501.  
 Lymphatic formations in leukæmia. Illustrations.
- BOINET AND ASLANIAN.—(Fibro-cysto-sarcoma) *Rev. de méd.*, Paris, 1893, tome xiii. pp. 727–732.  
 CASE 1.—Male, æt. 66. Left kidney; twelve calculi, consisting of phosphates and oxalates; obliteration of ureter; pyo-nephrosis.
- BOKAI.—(Sarcoma) *Orvosi hetil.*, Budapest, 1884, Bd. xxviii. S. 446–449.  
 CASE 1.—Male, æt. 1½.
- ” (Myo-sarcoma) *Orvosi hetil.*, Budapest, 1883, Bd. xxvii. S. 157–163;  
 also *Pest. Med.-chir. Presse*, Budapest, 1883, Bd. xix. S. 217–219.  
 CASE 1.—Male, æt. 5½. Left; nephrectomy; death from septic peritonitis.
- BOKAI, A., AND BABES.—(Adeno-carcinoma) *Orvosi hetil.*, Budapest, 1881, Bd. xxv. S. 1109–1113; also *Pest. med. Chir. Presse*, Budapest, 1882, Bd. xviii. S. 6.
- BORCHARD.—(Alveolar Sarcoma) *Deutsche med. Wchnschr.*, Berlin, 1893, Bd. xix. S. 860.  
 CASE 1.—Child, æt. 2½.
- BOSCHETTI.—“Di un cancro molle del rene destro complicati da vizio cardiaco,” Firenze, 1873.
- BOSTROM.—“Beitr. z. pathologischen Anatomie der Nieren.”  
 (Rhabdo-myoma) *Deutsches Arch. f. klin. Med.*, Leipzig, 1878, Bd. xxiii. S. 209.  
 Microscopical Report on Huber's case.
- BÖSARTIGE.—(Growth) *Ärztl. Ber. d. k. k. allg. Krankenh. zu Wien*, 1862, S. 163.



- BOTT.—“Ueber das quergestreifte muskelsarcom der Niere,” Giesen. Diss.
- BOUILLAND.—(Cancer) *Journ. compl. du dict. d. sc. méd.*, Paris, 1825, tome xxii. pp. 193–203.
- ” (Cancer) *Ibid.*, 1828, tome xxxi. p. 18.
- CASE 1.—Male, æt. 60; right kidney.
- BOX.—(Bilateral Myo-sarcoma) *St. Thomas's Hosp. Rep.*, London, 1896, N. S., vol. xxv. p. 258.
- BOYCE (Growths) “Text-Book of Morbid Histology,” 1892, p. 278.
- BRAIDWOOD.—(Cancer) *Med. and Surg. Rep.*, Philadelphia, 1870, vol. iv. pp. 45–54.
- Malignant growths in children, probably sarcoma.
- CASE 1.—Male, æt. about 2. Left; weight, 10 lb.
- ” 2.—Female, æt. about 1½. Left; weight, 8 lb.
- ” 3.—Male, æt. 8 months. Right; weight, 25 oz.
- BRAMWELL.—(Growth) *Lancet*, London, 1878, vol. i. p. 166.
- CASE 1.—Male, æt. 49. Solid growth; no micro-characters.
- BRANDT.—(Sarcoma) Quoted by Walker.
- CASE 1.—Male, æt. 1. Right; abdominal nephrectomy; well four months later.
- BRAULT.—(Cancer) *Semaine méd.*, Paris, 1891, tome xi. p. 249.
- ” “Maladies des Reins,” art. in “Traité de médecine,” Charcot, Bouchard, Brissaud, tome v. 785–811.
- BRAUM.—(Sarcoma) *Deutsche med. Wchnschr.*, Leipzig, 1881, Bd. i. Nos. 31, 32, 33.
- CASE 1.—Adult, æt. 51. Nephrectomy; recovery.
- BRAUN.—“Des tumeurs malignes du rein chez l'enfant; considérations sur leur traitement chirurgical,” Nancy, 1897. Thesis.
- BRIGHT.—“Clinical Memoirs on Abdominal Tumours,” *New Syd. Soc.*, 1861.
- ” (Growths) *Guy's Hosp. Rep.*, London, 1839, vol. iv. pp. 208–264.
- Illustrations of renal tumours, most of which are not neoplasms.
- BRINTON.—(Encephaloid) *Brit. Med. Journ.*, London, 1857, pp. 493–495.
- CASE 1.—Male, æt. 40. Weight, 9½ lb. Diagram given.
- BRISTOWE.—(Cancer) *Trans. Path. Soc. London*, 1853–54, vol. v. pp. 185–194.
- Illustration.
- ” (Fibro-lipomatous Growth) *Trans. Path. Soc. London*, 1862–63, vol. xiv. pp. 190–192.
- CASE 1.—Male, æt. 53. Left.
- ” “Theory and Practice of Medicine,” 1890, p. 870.
- BROCK.—(Myo-sarcoma) *Virchow's Archiv*, 1895, Bd. cxl. S. 493–502.
- Illustrations of microscopical characters.
- BRODEUR.—“De l'Intervention chirurgicale dans les affections du rein,” Paris, 1886, pp. 143–226.
- Numerous cases. References. Illustrations. Tables of Nephrectomies for carcinoma, sarcoma, and fibroma.
- BROKAW.—(Myxo-sarcoma) *Med. News*, Phila., 1891, vol. lxii. p. 313.
- CASE 1.—Male, æt. 3 years, 8 months. Right nephrectomy; recurrence and death in four months.
- BRONSON.—(Encysted growth) *Trans. Ohio Med. Soc.*, Columbus, 1853, vol. viii. pp. 41–43.
- BROSIN.—(Myo-sarcoma) *Virchow's Archiv*, 1884, Bd. xevi. S. 453–461.
- CASE 1.—Male, æt. 3. Left; weight, 580 grms.
- BROWNE.—(Lipoma) *Trans. Path. Soc. London*, 1862, p. 131.
- BRUEN.—(Malignant growth) *Maryland Med. Journ.*, Baltimore, 1884–85, vol. xii. pp. 312–314.

- BRUNTZEL.—(Perirenal Fibro-lipoma) *Berl. klin. Wchnschr.*, 1882, No. 49, S. 744.  
 CASE 1.—Female, æt. 33. Weight, 37½ lb.; nephrectomy; recovery.
- BRYANT.—(Melanotic Carcinoma) *Trans. Vermont. Med. Soc.*, 1879, pp. 62–64.
- BUCHANAN.—(Sarcoma) *Med. and Surg. Rep.*, Philadelphia, 1895, vol. xxii.  
 CASE 1.—Female, æt. 2. Left; nephrectomy; recovery.
- BUHL.—(Sarcoma) *Ztschr. f. Biol.*, München, 1865, Bd. i. S. 263.
- BULLENS.—(Cancer) *Ann. Soc. d'anat. path. de Bruxelles*, 1880, tome xxix. pp. 112–115.
- BURT.—(Sarcoma) *Canadian Pract.*, Toronto, 1890, vol. xv.
- BUTLIN.—“The Operative Surgery of Malignant Disease,” 1887, “Kidney,” pp. 249–255.
- BUTTE.—(Cancer) *Bull. Soc. anat. de Paris*, 1883, tome lvii. pp. 420–423; also *Progrès méd.*, Paris, 1883, tome xi. p. 391.
- BYFORD.—(Cancer) *Trans. Am. Gynec. Soc.*, 1880, p. 71; also *Med. Times and Gaz.*, London, 1880, vol. ii.  
 CASE 1.—Female, æt. 39. Right; weight, 4½ lb.
- CABOT.—(Growth) *Boston Med. and S. Journ.*, 1860, vol. lxii. p. 126.
- CACCIOLA.—(Sarcoma) “Un caso di capsula surrenale accessoria aberente al rene,” Padova, 1885.
- CAIRD.—(Adenoma) *Scot. Med. and S. Journ.*, Edinburgh, 1897, p. 698.  
 Illustrations.
- CALMETTES.—(Cancer) *Bull. Soc. anat. de Paris*, 1868, vol. xliii. pp. 276–282.
- CARLISLE.—(Encephaloid Cancer) *New York Med. Journ.*, 1877, vol. xxv. pp. 41–44.  
 CASE 1.—Infant, æt. 2.
- CARO.—(Encephaloid Cancer) *Trans. New York Path. Soc.*, 1879, vol. iii. pp. 174–178.
- CARRAUD.—(Cancer) “Sur la nephrite,” Paris, 1813, tome xxi. Thesis.  
 CASE 1.—Female, æt. 58. Right kidney.
- CARSON.—(Cancer) *St. Louis Cour. Med.*, 1879, vol. ii. pp. 610–615.
- CATTANI.—(Cancer) *Gazz. d. osp.*, Milano, 1880, tome i. pp. 433–449.  
 ” (Cancer) *Arch. per le sc. med.*, Torino, 1882, tome vi. pp. 83–112.
- CAUDMONT.—(Cancer) *Bull. Soc. anat. de Paris*, 1847, tome xxii. pp. 40–44.
- CAZEAUX.—(Cancer) *Ibid.*, 1833, tome viii. pp. 201–208.
- CHADWICK.—(Sarcoma) *Boston Med. and S. Journ.*, 1881, vol. ii. p. 338.  
 CASE 1.—Nephrectomy; death.
- CHAPMAN.—(Sarcoma) *West London Med. Journ.*, July 1897, p. 201.
- CHARON.—(Cancer) *Journ. de méd., chir. et pharmacol.*, Bruxelles, 1874, tome lix. pp. 435–441.  
 ” (Sarcoma) *Ann. Soc. belge de chir.*, Bruxelles, 1897, pp. 43–46.  
 CASE 1.—Male, æt. 19 months. Nephrectomy.
- CHEVALIER.—“De l'intervention chirurgicale dans les tumeurs malignes du rein,” Paris, 1891. Thesis.
- CHIENE.—(Sarcoma). Quoted by Newman.  
 CASE 1.—Nephrectomy; death.
- CHOMEL.—(Cancer) *Journ. de méd., chir. et pharmacol.*, Bruxelles, 1814, tome xlv. p. 81.  
 CASE 1.—Male, æt. 60.
- CLARKE.—(Encysted Growth) *Edin. Med. and S. Journ.*, 1808, vol. iv. pp. 273–275.
- CLARKE, W. M.—(Cancer) *Med. Times and Gaz.*, London, 1860, vol. ii. p. 154.
- CLEMENTI.—(Carcinoma). Quoted by Newman.  
 CASE 1.—Female, æt. 30. Nephrectomy; recovery.

- COATS.—“Manual of Pathology,” 3rd ed., 1895, pp. 972-976.  
General considerations; references; illustration.
- COHNHEIM.—(Myo-sarcoma) *Virchow's Archiv*, 1875, Bd. lxxv. S. 64-69.  
CASE 1.—Female, æt. 1½. Both kidneys involved.
- COLEY.—(Sarcoma, girl, æt. 5; nephrectomy; recurrence) *Med. News*, Phila., Oct. 9, 1897, p. 467.
- COLLEVILLE.—(Carcinoma) *Bull. Soc. anat. de Paris*, 1883, tome lviii. pp. 55-58; also *Progrès méd.*, Paris, 1883, tome xi. p. 387.
- COMEGYS.—(Encephaloid Cancer) *Cincin. Lancet and Obs.*, 1875, vol. iii. pp. 247-250.  
CASE 1.—Child, æt. 3. Probably sarcoma.
- CORNIL.—(Hæmorrhagic Epithelioma) *Progrès méd.*, Paris, 1887, Sér. 2, tome v. p. 336.
- CORNIL AND BOUSSEAU.—(Growth) *Journ. de l'anat. et physiol. etc.*, Paris, 1868, tome v. pp. 570-572.
- CORVISART AND LEROUX.—(Growths) *Journ. de méd., chir., pharm., etc.*, Paris, 1804, tome vii. pp. 387-430.
- COSSE.—(Sarcoma) *Centralbl. f. Chir.*, Leipzig, 1879, S. 175.  
CASE 1.—Female, æt. 37. Nephrectomy; recovery; abortion.
- COTTON.—(Sarcoma) *Med. and Surg. Rep.*, Philadelphia, 1896, No. 20, vol. lxxv.  
CASE 1.—Infant, æt. 9 months. Right; nephrectomy; eight months later, living and well.
- COUPLAND.—(Medullary cancer) *Trans. Path. Soc. London*, 1881-82, vol. xxxiii. p. 219.  
Association with calculi.
- COYNE AND TROISIÈRE.—(Cancer) *Bull. Soc. anat. de Paris*, 1871, tome xlvi. pp. 239-243.
- CRAMER.—(Medullary Growth) *Wchnschr. f. d. ges. Heilk.*, Berlin, 1837, S. 316-319.
- CREMER.—“Nieren carcinom nach einem Trauma,” 1884. Diss.
- CRISP.—(Fungus Hæmatodes) *Brit. Med. Journ.*, London, 1860, vol. ii. p. 959.
- CROFT.—(Sarcoma) *Trans. Path. Soc. London*, 1884-85, vol. xxxvi. p. 274.  
CASE 1.—Male, æt. 3. Right; nephrectomy; recurrence in two months; death in four months.
- CRUVEILHIER.—(Growth) *Bull. Soc. anat. de Paris*, 1829, tome iii. p. 77.  
“ (Malignant growths) “Atlas d'Anatomie pathologique,” 1829, tome i. plate iv.
- CULLINGWORTH.—(Sarcoma) *Med. Chron.*, Manchester, Nov. 1886.  
CASE 1.—Female, æt. 43. Left; weight, 11 lb. 6 oz.; nephrectomy; recovery; recurrence.
- CURTIS.—(Cancer) *Bull. méd. du nord*, Lille, 1893, tome xxxii. pp. 137-145.
- CZERNY.—(Sarcoma) *Centralbl. f. Chir.*, Leipzig, 1879, No. 45.  
CASE 1.—Male, æt. 50. Nephrectomy; hæmorrhage; death in ten hours.
- “ (Sarcoma). Quoted by Newman.  
CASE 1.—Female, æt. 46. Right; weight, 4 lb.; nephrectomy; death.
- “ (Carcinoma) *Centralbl. f. Chir.*, Leipzig, 1878, S. 738.  
CASE 1.—Adult, æt. 50. Nephrectomy; hæmorrhage; ligature of aorta; death from shock.
- “ (Sarcoma) *Trans. Internat. Med. Cong.*, 1881, vol. ii. p. 261.  
CASE 1.—Male, æt. 46. Left; nephrectomy; death from tetanus.
- “ (Sarcoma) *Arch. f. klin. Chir.*, Berlin, Bd. xxv.  
Associated with hydronephrosis; nephrectomy; death from shock.

- CZERNY.—(Sarcoma) *Arch. f. Kinderh.*, Stuttgart, 1889-90, Bd. xi. S. 247-250.  
 CASE 1.—Child, æt. 3½. Right; nephrectomy; death from shock.
- „ (Angio-sarcoma) *Deutsche med. Wchnschr.*, Leipzig, 1881, No. 32.  
 CASE 1.—Adult, æt. 51. Nephrectomy; death in six months with generalised growth.
- „ (Adeno-sarcoma) *Deutsche med. Wchnschr.*, Leipzig, 1881, Bd. xxxi. S. 422.  
 CASE 1.—Female, æt. 11 months. Nephrectomy; death from peritonitis.
- D'AINTOLO.—(Adrenal "Rest" in Kidney) *Bull. d. sc. med. di Bologna*, 1886, tome xvii.
- DALTON.—(Sarcoma) *King's College Hosp. Rep.*, London, 1897, vol. iii. p. 270.  
 CASE 1.—Girl, æt. 2.
- DANCE.—(Cancer) *Arch. gén. de méd.*, Paris, 1831, tome xxv. p. 45.  
 CASE 1.—Male, æt. 78. Probably secondary.
- DANEL.—(Epithelioma; male, æt. 23) *Journ. d. sc. méd. de Lille*, May 17, 1896, p. 478.
- DANDOIS.—(Adeno-sarcoma) *Bull. Acad. roy. de méd. de Belg.*, Bruxelles, 1885, No. 12, p. 830.  
 CASE 1.—Male, æt. 25 months. Nephrectomy; recovery.
- DANFORTH.—(Growths) Loomis and Thompson's "System of Practical Medicine," 1897, vol. ii. pp. 789-794.
- DANNER.—(Encephaloid) *Bull. Soc. anat. de Paris*, 1856, tome xxxi. p. 170.
- D'ANTONA.—(Growths) *Morgagni*, 1887, tome xxix. pp. 65-74.
- DARWALL.—(Growths) *Edin. Med. and S. Journ.*, 1823, vol. xix. p. 160.  
 Two cases, old woman, and man æt. 22.
- DAVIES.—(Sarcoma) Abstract, *Trans. Hunterian Soc.*, London, 1889-90, pp. 110-112.
- DAVIS AND LAWSON.—(Sarcoma) *Lancet*, London, 1865, vol. i. p. 285.  
 CASE 1.—Female, æt. 49. Left; mistaken for ovarian tumour.
- DAVY.—(Carcinoma) *Brit. Med. Journ.*, London, 1884, vol. ii. p. 757.  
 CASE 1.—Adult, æt. 53. Left; calculus in growth; nephrectomy; recovery with recurrence, and death in two years with generalised growth.
- DAY.—(Sarcoma) *Trans. Path. Soc. London*, 1880-81, vol. xxxii. pp. 142-145.  
 CASE 1.—Female, æt. 4. Right; weight, 9¼ lb.
- DEAN.—(Lipoma) *St. Louis Med. and Surg. Journ.*, 1877, vol. xiv. pp. 424-427.
- DELAFIELD.—(Growths) "Pepper's Text-Book of the Theory and Practice of Medicine," 1894, vol. ii. p. 668.
- DELAFIELD AND PRUDDEN.—(Growths) "Pathological Anatomy and Histology," 5th edition, 1897, pp. 677-680.
- DELÉTRE AND RAIMONDI.—(Cancer) *Bull. Soc. anat. de Paris*, 29th Jan. 1897.
- DELORME.—(Cancer) *Union méd. du Canada*, Montreal, 1890, N. S., tome iv. p. 176.  
 CASE 1.—Child, æt. 3½. Probably sarcoma.
- DENMAN.—(Growths) *Buffalo Med. and Surg. Journ.*, 1873-74, vol. xiii. pp. 50-52.
- DENTI.—(Medullary Cancer) *Gazz. med. ital. lomb.*, Milano, 1883, Sér. 8, tome v. pp. 337, 347, 357.
- DENTON.—(Lipoma) *Med. Arch.*, St. Louis, 1871, vol. v. pp. 273-277.
- DE PAOLI.—(Angio-sarcoma) *Beitr. z. path. Anat. u. z. allg. Path.*, Jena, 1890, Bd. viii. S. 140-166.

Cases: illustrations; references.

DE PAOLI.—(Angio-sarcoma) *Osservatore*, Torino, 1888, tome xxxix. pp. 679, 700, 729. Abstract, *Jahresb. u. d. Fortschr. d. ges. Med.*, Erlangen, 1890, Bd. i. S. 255.

Cases; illustration.

D'ESPINE AND PICOT.—"Man. prat. des mal. de l'enfance," 3rd edition, 1884, p. 698.

DICKINSON.—(Fibro-lipoma) *Trans. Path. Soc. London*, 1862-63, vol. xiv. pp. 187-190.

CASE 1.—Male, æt. 55. Right; weight, 6 lb. 7½ oz. Illustration.

" (Growth) *Trans. Path. Soc. London*, 1861-62, vol. xiii. pp. 137-139.

" (Growth) *Lancet*, London, 1885, vol. i. p. 526.

DIEULAFOY.—(Growth) "Manuel de Pathologie Interne," 1884, tome ii. p. 358.

DÜDERLEIN.—"Zur Diagnose der Krebs geschwülste im rechten Hypochondrium, insbesondere der Niere und Nebenniere," Erlangen, 1860.

" "Embryonale Drüsengeschwülst der Nierengegend im Kindersalter," 1894.

CASE 1.—Female, æt. 8. Left; adeno-sarcoma; nephrectomy; well five months later.

DOE.—(Growth) *Boston Med. and S. Journ.*, 1879, vol. ci. pp. 412-414.

DOHRN.—(Sarcoma) *Centralbl. f. Gynäk.*, Leipzig, 1890, Bd. xvi. S. 273.

CASE 1.—Female, æt. 3. Right; nephrectomy; recurrence and death in four months.

DONKIN.—(Sarcoma) *Brit. Med. Journ.*, London, 1882, vol. i. p. 157.

DONOVAN.—(Growth) *Trans. Maine M. Ass.*, Portland, 1884, vol. viii. pp. 350-353.

DOWSE.—(Sarcomatous Carcinoma) *Trans. Path. Soc. London*, 1874, vol. xxv. p. 172.

DREW.—(Villous carcinoma) *Trans. Path. Soc. London*, 1896-97, vol. xlvi. p. 130.

References to papillomata of renal pelvis.

DRIESSEN.—(Malignant Growths) *Beitr. z. path. Anat. u. z. allg. Path.*, Jena, 1892, Bd. xii. S. 65.

Discussion on growths from adrenal "rests."

DRUGMAND.—(Encephaloid Cancer) *Ann. Soc. d'anat. path. de Bruxelles*, 1867, tome xiii. pp. 3-5.

DUFAN.—(Cancer) *Bull. Acad. de méd.*, Paris, 1870, tome xxxv. pp. 783-785.

CASE 1.—Male, æt. 52. Left; weight, 5½ kilos.

DUMONT.—"Des tumeurs malignes du rein chez l'enfant," Paris, 1889. Thesis.

DUNLOP.—(Cancer) *Lancet*, London, 1877, vol. i. p. 567.

DURANTE.—(Sarcoma) *Pediatria*, Naples, 1896, tome iv. pp. 237-247.

CASE 1.—Female, æt. 2. Secondary deposits in thorax and brain.

DUTIL.—"Du cancer primitif du rein," Paris, 1874. Thesis.

Bibliography.

DUZAN.—(Cancer in Infancy) Paris, 1876. Thesis.

EBERHARD.—"Ueber carcinom der Niere," Tübingen, 1869. Diss.

EBERTH.—(Myo-sarcoma) *Virchow's Archiv*, 1872, Bd. lv. S. 518-520.

CASE 1.—Female, æt. 17 months. Both kidneys affected.

" (Melanotic Sarcoma) *Virchow's Archiv*, 1873, Bd. lviii. S. 58.

EBSTEIN.—Article in "Ziemssen's Cyclopædia of the Practice of Medicine," 1877, Bd. xv. S. 635-638; 658-685.

General descriptions; references.

- EBSTEIN.—(Cancer) *Deutsches Arch. f. klin. Med.*, Leipzig, 1881-82, Bd. xxx. S. 399-406.  
 CASE 1.—Male, æt. 66. Left; deposits in right kidney, glands, lung, pleura.
- EDES.—(Cancer) *Boston Med. and S. Journ.*, 1878, vol. xcix. pp. 788-793.
- EDGERLEY.—(Sarcoma) *Ibid.*, 1881, vol. civ. p. 131.
- EDMUNDS.—(Adenoma) *Trans. Path. Soc. London*, vol. xxxvii. p. 287.  
 Illustration.
- VON EISELSBERG.—(Fibro-lipoma) *Wien. klin. Wchschr.*, 1890, Bd. iii. S. 438.
- ELBEN.—(Myxo-Sarcoma) *Med. Cor.-Bl. d. württemb. ärztl. Ver.*, Stuttgart, 1880, Bd. l. S. 105-108.  
 CASE 1.—Male, æt. 5. Left; weight, 8 lb. History of trauma.
- ENGSTRÖM.—(Carcinoma) *Förh. v. Svens. Läk.-Sällsk. Sammank.*, Stockholm, 1868, pp. 269-272.
- ERBE.—“De pyelitide ejusque casu quodam cum renis carcinomate conjuncti,” 1851. Thesis.
- ESMARCH.—(Carcinoma) *Centralbl. f. Chir.*, Leipzig, 1882, S. 72.  
 CASE 1.—Nephrectomy; death from intestinal perforation.
- EVE.—(Rhabdo-Myomata) *Trans. Path. Soc. London*, 1881, vol. xxxiii. pp. 312-317.  
 CASE 1.—Male, æt. 16 months. Right.  
 ” 2.—Child. Specimen from Hunter's Collection.—*Roy. Coll. Surgeon's Museum.*
- EVES.—(Cancer) *Assoc. Med. Journ.*, London, 1854, vol. i. p. 53.  
 CASE 1.—Male, æt. 38. Left; weight, 3 to 4 lb. Phosphatic calculus in right.
- EWALD.—(Growths) “Real-Encyclopädie der gesammten Heilkunde,” 1888, Bd. xiv. S. 405.
- FAGGE.—(Cancer) *Trans. Path. Soc. London*, 1870, vol. xxi. pp. 249-252.  
 CASE 1.—Child, æt. 4½.  
 ” (Carcinoma Lipomatosum) *Trans. Path. Soc. London*, 1876, vol. xxvii. pp. 204-206.
- FAGGE AND PYE SMITH.—“Principles and Practice of Medicine,” 1891, vol. ii. p. 549.
- FALUDI.—(Cancer) *Jahrb. f. Kinderh.*, Leipzig, 1865 (3), Bd. vii. S. 67-73.  
 CASE 1.—Child, æt. 5.
- FEARON.—(Growth) *Med. Communicat.*, London, 1784, vol. i. pp. 416-420.
- FENOGLIO.—(Sarcoma) *Gazz. d. osp.*, Milano, 1882, tome iii. pp. 570-573.
- FENWICK, E. H.—(Encephaloid Cancer) *Trans. Path. Soc. London*, 1887, vol. lxxviii. p. 166.  
 ” (Growths) “Urinary Surgery,” 1894, pp. 37-40.  
 ” (Diagnosis: Gummata of Growths) *Treatment*, London, May 27, 1897, p. 135.
- FERRALL.—(Growths) *Dublin Journ. Med. Sc.*, 1842-43, vol. xxii. p. 401.
- FERRARESI.—(Cancer) *Gazz. med. di Roma*, 1884, tome x. pp. 133-137.
- FERRARO.—(Carcinoma) *Gior. internaz. d. sc. med.*, Napoli, 1890, N. S., tome xii. pp. 241-262.
- FERREOL.—(Sarcoma) *Bull. Soc. méd. d. hóp. de Paris*, 1875, tome xii. p. 52.  
 CASE 1.—Negro infant, æt. 10 months. Left.
- FERRETTI.—(Sarcoma) *Atti. d. xi. Cong. med. internaz.*, Roma, 1894, Chirg., tome iv. p. 555.
- FINCK.—(Cancer) *Med. Cor.-Bl. d. württemb. ärztl. Ver.*, Stuttgart, 1869, Bd. xxxix. S. 329.

- FINNEY.—(Sarcoma) Quoted by Walker.  
 CASE 1.—Female, æt. 13. Left; weight, 3.5 kilos.; nephrectomy; death from shock.
- FISCHER.—(Sarcoma) *Deutsche Ztschr. f. Chir.*, Leipzig, Bd. xxix. S. 590.  
 CASE 1.—Male child, æt. 4½. Left; nephrectomy; recurrence and death in four months.  
 „ 2.—Female, æt. 7. Nephrectomy; recurrence and death in year.
- FISHER.—(Bilateral Sarcoma of Hilum) *Trans. Path. Soc. London*, 1895-96, vol. xlvii. p. 115.
- FLEMING.—(Cancer) *Dublin Q. Journ. Med. Sc.*, 1867, vol. xlv. pp. 235-237.
- FOLKER.—(Medullary Enlargement) *Lancet*, London, 1853, vol. ii. p. 576.
- FOLLIN AND DUPLAY.—(Growths) "Traité élémentaire de path.," 1883, tome vi. p. 631.
- FORGET.—(Growth) *Gaz. méd. de Strasbourg*, 1845, Bd. v. S. 246.
- FOTHERBY.—(Sarcoma) *Brit. Med. Journ.*, London, 1882, vol. i. p. 157.  
 CASE 1.—Female, æt. 2½. Right; round-celled sarcoma.
- VON FRANQUE.—(Cancer) *Journ. f. Kinderkr.*, 1865, Bd. xlv. S. 42-45.  
 CASE 1.—Child, æt. 8. Probably sarcoma.
- FRISSELL.—(Encephaloid Cancer) *Trans. Med. Soc. W. Virginia*, 1875, pp. 113-116.
- FRONMÜLLER.—(Cancer) *Memorabilien*, Heilbronn, 1876, Bd. xxi. S. 158.
- FRUITNIGHT.—(Sarcoma) *Arch. Pediat.*, N.Y., 1895, vol. xii. pp. 881-898.  
 CASE 1.—Infant, æt. 13 months; treated with toxins.
- FÜRTH.—(Growth) *Wien. med. Presse*, 1866, Bd. vii. S. 80-83.
- FUSSELL.—(Malignant Growth) *Lancet*, London, 1873, vol. i. p. 131.
- GAIRDNER.—(Fungus Hæmatodes) *Edin. Med. and S. Journ.*, 1828, vol. xxix. pp. 312-315.  
 CASE 1.—Female, æt. 3. Left; weight, 5 lb. 3 oz. Right; weight, 1 lb. 3 oz.
- GAIRDNER AND COATS.—(Cancer) *Glasgow Med. Journ.*, 1870-71, vol. iii. pp. 221-229.
- GATTI.—(Growths) *Gior. d. r. Accad. di med. di Torino*, 1896, Sér. 3, tome xlv. pp. 233-246; *ibid.*, tome xlv. pp. 630-638; also, *Virchow's Archiv*, 1896, Bd. cxliv. S. 467-497.  
 CASE 1.—Development of renal growths from adrenal "rests." Cases; references; illustrations.
- GAUCHER.—(Cancer) *Bull. Soc. anat. de Paris*, 1881, tome lvi. p. 40; also, *Progrès méd.*, Paris, 1881, tome ix. p. 527.
- GAY.—(Encephaloid Growth) *Buffalo Med. and Surg. Journ.*, Dec. 1868.  
 CASE 1.—Male, æt. 8½. Left; weight, 36½ lb.
- GEDDINGS.—(Sarcoma) *Trans. Am. Gynec. Soc.*, 1878, vol. ii. pp. 479-481.  
 CASE 1.—Negro female, æt. 3¾. Left; weight, 13½ lb. Illustration.
- GEORGE.—(Cancer in Infant) *Boston Med. and S. Journ.*, 1869, N. S., vol. iii. p. 249.
- GERHARDT.—"Lehrbuch der Kinderkrankheiten," 4th edition, 1881, S. 556.
- GINTRAC.—(Cancer) *Mem. et obs. de méd. clin. et d'anat. path.*, Bordeaux, 1830, pp. 109-125.  
 CASE 1.—Male, æt. 54. Left.  
 „ 2.—Male, æt. 59. Right.  
 „ (Cancer) *Journ. de méd. de Bordeaux*, 1856, Sér. 2, tome i. pp. 692-694; also, *Gaz. d. hôp.*, Paris, 1857, tome xxx. p. 22.
- GIORDANO.—(Cancer) *Ann. d. mal. d. org. génito-urin.*, Paris, 1892, tome x. pp. 584-592.  
 CASE 1.—Female, æt. 57. Nephrectomy by Novaro; references.

- GIRARD.—(Sarcoma; child, æt. 3; nephrectomy) *Dauphiné méd.*, Grenoble, Jan. 21, 1897.
- GLUGE.—“Atlas der Path. Anat.,” 1840, Bd. ii. S. 170.
- GNÄNDINGER.—(Cancer) *Jahrb. f. Kinderh.*, 1880–81, Bd. xvi. S. 452–456.
- GODARD.—(Fat in Kidney) *Compt. rend. Soc. de biol.*, Paris, 1858–59, tome v. p. 261.
- GODLEE.—(Sarcoma) *Trans. Clin. Soc.*, London, 1885, vol. xviii. pp. 31–36.  
 CASE 1.—Male, æt. 22 months. Weight, 1 lb. Nephrectomy; recovery; recurrence and death in six months.
- GOEBEL.—“Myo-sarcoma striocellulare des Nierenbeckens.” Bonn, 1890, Diss.
- GOODE.—(Growth) *Cincin. Lancet and Obs.*, 1871, vol. xiv. pp. 208–215.
- GORHAM.—(Fungoid Disease) *London Med. Gaz.*, 1838, N. S., vol. i. p. 764.
- GOULD.—(Capsular Myxoma) *Lancet*, London, 1888.
- GRAWITZ.—(Lipoma) *Virchow's Archiv*, 1883, Bd. xciii. S. 39–63.  
 Cases; illustrations.
- ” (Origin of Growths from Adrenal “Rests”) *Verhandl. d. deutsch. Gesellsch. f. Chir.*, Berlin, 1884 (2), Bd. xiii. S. 28–38; also, *Arch. f. klin. Chir.*, Berlin, 1884, Bd. xxx. S. 824–834.
- ” (Origin of growths) *Berl. klin. Wchnschr.*, 1884, Bd. xxi. S. 740; also, *Deutsche med. Wchnschr.*, Leipzig, 1884, Bd. x. S. 719; also, *Verhandl. d. Berl. med. Gesellsch.*, 1885, Bd. xv. S. 283–288.
- GREENFIELD AND GOODHART.—“Atlas of Illustrations of Pathology,” *New Syd. Soc.*, 1879.
- GRON.—(Sarcoma) *Festschr. med. Prof. Heiberg*, Kristiania, 1895, pp. 90–99.
- GROSS.—(Cancer) *Med. News*, Phila., 1883, vol. xlii. p. 646.  
 CASE 1.—Female, æt. 59. Right; weight, 18 oz.; nephrectomy; death from peritonitis.
- ” (Cancer) *Am. Journ. Med. Sc.*, Phila., 1885.
- GROVE.—(Malignant Growth) *Progress*, Louisville, 1888–89, vol. iii. p. 438.
- GUEMBEL.—(Medullary Carcinoma) *Jahrb. f. Kinderh.*, Leipzig, 1871–72, Bd. v. S. 428–434.  
 CASE 1.—Child, æt. 3½. Probably sarcoma.
- GUILLEMAN.—(Diagnosis and Treatment of Malignant Growths) *Gaz. hebdom. de méd.*, Paris, Dec. 26, 1891.
- GUILLET.—“Des tumeurs malignes du rein,” Paris, 1888.  
 Thesis; excellent bibliography; tables of nephrectomies.
- GUITERAS.—(Cancer) *Trans. Path. Soc.*, Phila., 1879, vol. viii. pp. 112–114; also, *Phila. Med. Times.*, 1878, vol. viii. p. 592.  
 Growth of left kidney extending along renal vein and into ascending part of inferior vena cava. Probably sarcoma.
- GULL.—(Malignant Growth) *Lancet*, London, 1864, vol. i. p. 184.
- GUSSENBAUER.—(Sarcoma) *Arch. f. Kinderh.*, Stuttgart, Bd. xi. S. 247.
- GUYON.—(Semeiology and Examination of Growths) *Ann. d. mal. d. org. génito-urin.*, Paris, 1888, tome vi. pp. 641–656.  
 ” (Malignant Growths) *Ibid.*, 1890, tome viii. pp. 329–344.
- HAHN.—(Sarcoma) *Berl. klin. Wchnschr.*, 1872, Bd. ix. S. 269.  
 CASE 1.—Child, æt. 10 months. Right; duration, four weeks.
- HALSTED.—(Sarcoma) Quoted by Walker.  
 CASE 1.—Female, æt. 6. Left; nephrectomy; recurrence and death in four months.
- HARE.—(Diagnosis) *Lancet*, London, 1857, vol. ii. p. 580.
- HARRISON.—(Growths) “Twentieth Century Practice of Medicine,” vol. i. pp. 165–171.
- HARTMANN.—(Cancer and Calculi) *Bull. Soc. anat. de Paris*, 1886, p. 576.



- HAUSEMANN.—(Adeno-Myxo-Sarcoma) *Berl. klin. Wchnschr.*, 1894, Bd. xxxi. S. 717.
- HAUSEN.—(Cancer) *Ibid.*, 1873, Bd. x. S. 387.  
CASE 1.—Infant, æt. 10½ months. Probably sarcoma.
- HAUSER.—(Sarcoma) "Pathogénie du varicocele symptomatique des tumeurs malignes du rein," Paris, Dec. 28, 1897. Thesis.
- HAUSHALTER.—(Cancer) *Rev. méd. de l'est*, Nancy, 1895, tome xxvii. pp. 274–282.  
CASE 1.—Child. Illustration; probably sarcoma.
- HAUSMANN.—(Cancer) *Berl. klin. Wchnschr.*, 1876, Bd. xiii. S. 648–651.
- HAWKINS.—(Growth) *Lancet*, London, 1856, vol. i. p. 626.
- HAWTHORNE.—(Carcinoma) *Trans. Glas. Path. and Clin. Soc.*, 1893–95, vol. v. p. 35; also, *Glasgow Med. Journ.*, 1894, vol. xli. p. 148.
- HAYEM.—(Encephaloid Cancer) *Bull. Soc. anat. de Paris*, 1864, tome xxxix. pp. 521–529; also, *Union méd.*, Paris, 1864, Sér. 2, tome xxiv. pp. 495–499.
- HEATH.—(Sarcoma) *Brit. Med. Journ.*, London, 1882, vol. ii. p. 100.  
CASE 1.—Young child. Nephrectomy; death from shock.
- HEBB.—(Lympho-Sarcoma) *Trans. Path. Soc. London*, 1888–89, vol. xl. pp. 153–159.  
" (Malignant Growth) *Westminster Hosp. Rep.*, London, 1895, vol. ix. pp. 121–126.
- HEDENIUS.—(Cancer) *Upsala Läkaref. Förh.*, 1878, tome xiii. pp. 322–325.
- HEIDEMANN.—(Myo-Sarcoma) *Ann. d. mal. d. org. génito-urin.*, Paris, 1893, tome vi. p. 154.  
CASE 1.—Male child, æt. 1½.
- HEINLEIN.—(Sarcoma) *Centralbl. f. d. Krankh. d. Harn-u. Sex.-Org.*, Leipzig, 1894.  
CASE 1.—Male, æt. 8 months. Right; nephrectomy; well two months later.
- HEITLER.—(Growth) *Ärztl. Ber. d. k. k. allg. Krankenh. zu Wien*, 1876, S. 27.
- HERRINGHAM, GARROD, AND GOW.—(Growths) "Handbook of Medical Pathology," 1894, p. 193.
- HERZ.—(Sarcoma) *Virchow's Archiv*, 1864, Bd. xxx. S. 468.  
" (Growth) *Ibid.*, 1866, Bd. xxxv. S. 211.
- HESCHL.—(Lymphangioma) *Wien. med. Wchnschr.*, 1866, Bd. xvi. S. 489–491.
- HEUROT.—(Cystic Alveolar Cancer) *Bull. Soc. méd. de Reims*, 1877, No. 15, pp. 127–132.  
Illustration. Mistaken for cystic malignant growth of liver.
- HEYDENREICH.—(Sarcoma) *Rev. méd. de l'est*, Nancy, Jan. 26, 1897.  
CASE 1.—Child, æt. 5. Nephrectomy; death.
- HEYDER.—(Lipoma) *Arch. f. Gynaek.*, Berlin, Bd. xxxviii.  
Review of twenty-two cases.
- HICQUET.—(Adeno-Sarcoma) *Bull. Acad. roy. de méd. de Belg.*, Bruxelles, Jan. 28, 1882.  
CASE 1.—Male, æt. 6. Left; weight, 5000 grms.; nephrectomy; recurrence and death in sixteen months.
- HILDEBRAND.—(Adenoma) *Arch. f. klin. Chir.*, Berlin, 1894, Bd. xlvii. S. 225–273.  
" (Growths) *Ibid.*, 1894, Bd. xlviii. S. 343–371.
- HILTSCHER.—(Sarcoma) *Österr. med. Wchnschr.*, Wien, 1847, S. 705–707.

- HIRNE.—(Sarcoma) *Bull. et mem. Soc. méd. d. hôp. de Paris*, 1875, Sér. 2, tome xii. pp. 100-103.  
 CASE 1.—Female, æt. 2½.
- HOFFMAN.—(Carcinoma) *Maryland Med. Journ.*, Baltimore, 1888-89, vol. xx. pp. 263-265; and *New York Med. Press*, 1888, vol. vi. pp. 7-9.
- HOISHOLT.—(Chondro-Myo-Sarcoma) *Virchow's Archiv*, 1886, Bd. civ. S. 118-121.
- HOLLEN.—“Zur Casuistik der Nierengeschwülste,” Greifswald. Diss.  
 Cases of lipomata, fibromata, sarcomata, adenomata, and carcinomata.
- HOLLIS.—(Sarcoma) *Brit. Med. Journ.*, London, 1886, vol. i. p. 210.
- HOLMES.—(Pulsating Cancer) *Trans. Path. Soc. London*, 1873, vol. xxiv. pp. 149-151.
- HOLT.—(Growths) “Diseases of Infancy and Childhood,” 1897, pp. 623-627.
- HOLTZ.—(Growth) *Berl. klin. Wchnschr.*, 1879.
- HOMANS.—(Myxo-Sarcoma) *Boston Med. and S. Journ.*, 1883, vol. cix. p. 567.  
 (Carcinoma) *Ibid.*, 1884.  
 ”  
 CASE 1.—Male, æt. 29. Left; weight, 3½ lb. Nephrectomy; death.
- HORN.—(Histogenesis of Growths) *Virchow's Archiv*, 1891, Bd. cxxvi. S. 191-217.
- HORNAUS.—(Cancer) *Boston Med. and S. Journ.*, 1883, vol. ii.  
 CASE 1.—Nephrectomy; growth adherent to colon; death.  
 ”  
 (Sarcoma) *Ibid.*, 1883, vol. ii.  
 CASE 1.—Child; nephrectomy; recovery.
- HOUEL.—(Lipoma) “Manuel d'anatomie pathologique,” 1857.
- HOUEL AND GODARD.—(Lipoma) *Gaz. méd. de Paris*, 1859.
- HOWARD.—(Encephaloid Cancer) *Ohio Med. and S. Journ.*, Columbus, 1852-53, vol. v. pp. 415-419.
- HUBER.—(Rhabdo-Myoma) *Deutsches Arch. f. klin. Med.*, Leipzig, 1881, S. 359.
- HUBER AND BOSTRÖM.—(Rhabdo-Myoma) *Deutsches Arch. f. klin. Med.*, Leipzig, 1878-79, Bd. xxiii. S. 205-209.  
 CASE 1.—Male, æt. 3½. Left; weight, 11 lb. Illustration.
- HÜE.—(Fibroma) *Bull. Soc. anat. de Paris*, 1882, Sér. 4, tome vii. p. 85.
- HUETER AND SCHULLER.—(Sarcoma) *Deutsche Ztschr. f. Chir.*, Leipzig, 1878, Bd. ix. S. 527.  
 CASE 1.—Female, æt. 4. Right; weight, 5 lb. Duration, one year; nephrectomy; death from hæmorrhage during operation.
- HÜLLMANN.—“Monographia de carcinomate renum,” Halle, 1857. Diss.
- HUME.—(Sarcoma) *Med. Press and Circ.*, London, 1897, vol. i. p. 111.  
 CASE 1.—Adult, æt. 53. Nephrectomy.
- HUNTER.—(Sarcoma) *Deutsche Ztschr. f. Chir.*, Leipzig, 1878, Bd. ix. S. 527.  
 CASE 1.—Female, æt. 4. Right; weight, 2200 grms.; duration, one year; nephrectomy; death from hæmorrhage.
- HUSSON.—(Cancer) *Gaz. d. hôp.*, Paris, 1843, Sér. 2, tome v. p. 419.  
 Probably sarcoma. Extension along right renal vein to inferior cava.
- HUTCHINSON.—(Malignant Cystic) *Arch. Surg.*, London, 1893-94, vol. v. p. 302.
- HUTCHINSON, J., Jun.—(Carcinoma) *Brit. Med. Journ.*, London, 1885, vol. ii. p. 871.
- IKIN.—(Malignant Growth) *Brit. Med. Journ.*, London, 1867, vol. i. p. 663.
- ILLIOT AND WALSHAM.—(Malignant adenoma) *Brit. Med. Journ.*, London, 1893.  
 CASE 1.—Male, æt. 9½ months. Left; nephrectomy; recurrence and death a year later.
- IMLACH.—(Sarcoma). Quoted by Newman.  
 CASE 1.—Female, æt. 25. Right; nephrectomy; recovery.

- ISRAEL.—(Carcinoma) *Virchow's Archiv*, 1881, Bd. lxxxvi. S. 359-362.  
 „ (Sarcoma) *Berl. klin. Wchnschr.*, 1890, Bd. ii.  
 „ (Diagnosis, Gumma from Growth) *Deutsche med. Wchnschr.*, Leipzig, 1892, No. 1.  
 „ “Erfahrungen ueber Nierenchirurgie,” Berlin, 1894, S. 4-29.  
     Tables of nephrectomies for growth. Illustrations.  
 „ (Sarcomata) *Arch. f. klin. Chir.*, Berlin, 1894, Bd. xlvii.  
     CASE 1.—Female, æt. 4. Right; nephrectomy; recurrence in two months.  
     „ 2.—Male, æt. 14. Right; extra-peritoneal nephrectomy; well five years later.
- JACCOUD.—(Growth) “*Traite de pathologie interne*,” 1871, tome ii. p. 524.
- JACKSON.—(Encysted Growth) *Med. and Phys. Journ.*, London, 1816, vol. xxxv. pp. 1-3.
- JACOBI.—(Sarcoma) *New York Med. Journ.*, 1879, vol. xxx. p. 524.  
 „ (Sarcoma) *Ibid.*, 1880, vol. xxxi. p. 532.  
 „ (Sarcoma) *Am. Journ. Obst.*, N. Y., 1881, vol. xiv. pp. 113-115.  
 „ (Primary Cancer) *Med. Rec.*, N. Y., 1881, vol. xix. p. 217.  
 „ (Sarcoma) *Am. Journ. Obst.*, N. Y., 1884, p. 1006.  
 „ (Primary Sarcoma of Fœtal and Infantile Kidney) “*Congrès periodique international des sciences medicales*,” Copenhagen, 1884, Sec. 8. “*Pediatrics*,” tome iii. pp. 16-40.  
     Critical Summary. Personal cases.  
     CASE 1.—Male, æt. 2 years 8 months. Left; myo-sarcoma.  
     „ 2.—Male, æt. 2½. Left; weight, 6 lb.; sarcoma.  
     „ 3.—Female, still-born. Left; sarcoma.  
     „ 4.—Male, æt. 2. Right; round-cell sarcoma.
- JACOBSON.—(Growths) “*Operations of Surgery*,” 1897, 3rd edition.
- JEANNE.—(Teleangiectatic Sarcoma) *Bull. Soc. anat. de Paris*, 1896, tome xii.
- JEANNEL.—(Growths) “*Cong. franc. de chir.*,” Paris, 1887, tome ii. pp. 154-165.
- JEANTON.—(Cancer) *Progrès méd.*, Paris, 1886, Sér. 2, tome iv. p. 618.
- JERZYKOWSKI.—“*Beitr. z. Kenntniss der Nierenkrebse*,” Breslau, 1871. Diss.
- JESSOP.—(Encephaloid Growth) *Lancet*, London, 1877, vol. i. p. 889.  
     CASE 1.—Male, æt. 2½. Left; weight, 16 oz.; nephrectomy; recovery; recurrence and death in nine months.
- JOHNSON, G.—(Growths) “*Diseases of the Kidney*,” 1852, p. 475.  
 „ F. W.—(Carcinoma) *Boston Med. and S. Journ.*, 1896, vol. cxxxv. p. 59.
- JOLLY.—(Growth) *Lancet*, London, 1870, vol. i. p. 212.
- JONES.—(Growth) *Med. Times and Gaz.*, London, 1854, p. 613.  
 „ (Adenoma) *Deutsche med. Wchnschr.*, Leipzig, 1894, S. 209.
- JONES, H. B.—(Malignant Disease) *Brit. Med. Journ.*, London, 1858.
- JONES, T.—(Malignant Papilloma) *Med. Chron.*, Manchester, July 1891, p. 267.
- VON KAHLDEN.—(Congenital Adenoma) *Beitr. z. path. Anat. u. z. allg. Path.*, Jena, 1894, Bd. xv. S. 626-632.
- KAHLER.—(Carcinoma) *Allg. Wien. med. Ztg.*, 1889, Bd. xxxiv. S. 356-358.
- KAJSER.—(Malignant Growths) *Hygiea*, Stockholm, 1896 (2), tome lviii. pp. 1-28; Abstract, *Rev. d. mal. Cancereuses*, April 1897, p. 174.
- KAMMERER.—(Cancer) *New York Med. Journ.*, 1891, vol. liii. p. 79.
- KANN.—(Sarcoma) “*Ein Fall von Nierensarcom*,” Erlangen. Diss.
- KAST AND RUMPEL.—(Adenoma-Sarcomatosum pseudo-papillare) *Jahrb. d. Hamb. Staatskranken-anst.*, Leipzig, 1894 (5), Bd. ix. S. 506.  
 „ (Secondary carcinoma) *ibid.*, 1897, Bd. v. Heft 15, p. 21.
- KEITH, SKENE.—(Encephaloid Cancer) *Edin. Med. Journ.*, 1886, vol. ii.  
     CASE 1.—Male, æt. 61. Right; nephrectomy; death in fifty hours.

- KEITH, SKENE.—(Sarcoma) *Edin. Med. Journ.*, Oct. 1886.  
 CASE 1.—Female, æt. 49. Nephrectomy; death from peritonitis in six and a half days.
- KELYNACK.—(Malignant Papillomatous Cyst Adenoma) *Journ. Path. and Bacteriol.*, Edin. and London, 1896, vol. iv. pp. 236-241.  
 Illustrations; references.
- KESSLER.—“Ein Sarkoma myxomatosum reinis sinistri, ein Beitr. z. Kenntniss der primären Nierensarkome,” Marburg, 1883. Diss.
- KEYES.—(Adenoma) *Am. Journ. Med. Sc.*, Phila., 1890, vol. ii.  
 “The Surgical Diseases of the Genito-Urinary Organs,” 1888, pp. 347-350.
- KLEBS.—“Handbuch der Pathologischen Anatomie,” 1868-76.
- KOCH, E.—“Beitr. z. Kenntniss d. primären Nierentumoren besonders der Sarcome,” Halle, 1878. Diss. Abstract, *Jahresb. ü. d. Leistung. . . d. ges. Med.*, Berlin, Bd. xiii. S. 273.
- KOCHER.—(Sarcoma) *Deutsche Ztschr. f. Chir.*, Leipzig, 1878, Bd. ix. S. 312.  
 CASE 1.—Male, æt. 2½. Left; weight, 3 lb.; nephrectomy; death in two days from peritonitis.
- KOCHER AND LANGHANS.—(Myo-Sarcoma) *Deutsche Ztschr. f. Chir.*, Leipzig, Bd. ix. S. 312.  
 CASE 1.—Female, æt. 35. Nephrectomy; death in three days from peritonitis.
- KOENIG.—(Myxo-Sarcoma) *Centralbl. f. Chir.*, Leipzig, 1885, No. 24.  
 CASE 1.—Child, æt. 2. Nephrectomy; recovery; recurrence.  
 ” (Sarcoma) Abstract, *Semaine méd.*, Paris, 1887, p. 157.  
 CASE 1.—Nephrectomy; death.
- KRONLEIN.—(Sarcoma) *Centralbl. f. Chir.*, Leipzig, 1885, Bd. ix.  
 CASE 1.—Female, æt. 58. Nephrectomy; recovery.
- KÜHN.—(Cancer in Childhood) *Deutsches Arch. f. klin. Med.*, Leipzig, 1875, Bd. xvi. S. 306.
- KUMMEL.—(Perirenal Lipoma) *Deutsche med. Wchnschr.*, Leipzig, 1886.  
 CASE 1.—Male, æt. 38. Nephrectomy; death from pneumonia.
- KUSTER.—(Growths) *Centralbl. f. d. krankh. Harn-u. Sex.-Org.*, Leipzig, 1897, Bd. viii. S. 583-593.
- LABADIE-LAGRAVE.—“Dict. de méd. pratique,” 1882, tome xxxi.  
 General description; references.
- LABOULBENE.—(Cancer) *Compt. rend. Soc. de biol.*, Paris, 1855, tome ii. p. 51.  
 CASE 1.—Female, æt. 63. Left.  
 ” “Anatomie pathologique,” 1879, pp. 751-756.  
 General description; references.
- LABRIC.—(Hæmorrhagic Growth) *Bull. Soc. anat. de Paris*, 1851, tome xxvi. p. 206.
- LACHER.—(Carcinoma) *München. med. Wchnschr.*, 1886, Bd. xxxiii. S. 817, 835, 854.
- LACHMANN.—“Das primäre Nierencarcinom. und seine Metastasen,” Würzburg, 1883.
- LACRAMPE, LONSTAN.—(Lipoma) “Essai sur l'adipose du rein,” 1881.
- LANCEREAUX.—(Cancer) *Gaz. d. hôp.*, Paris, 1889, tome lxii. pp. 169-171.  
 ” (Epithelioma) *Union. méd.*, Paris, 1890, Sér. 3, tome xlix. pp. 289-294.  
 Clinical study; diagnosis; prognosis; treatment.  
 ” “Dict. ency. des sc. médicales,” 1875, tome iii.

LANDSBERGER.—(Congenital Myo-Sarcoma) *Berl. klin. Wchnschr.*, 1877, Bd. xiv. S. 497.

CASE 1.—Female, æt. 7 months. Both kidneys; no secondary deposits.

LANE.—(Cancer) *Texas Health Journ.*, Dallas, 1896-97, vol. ix. pp. 63-67.

LANGENBUCH.—(Sarcoma) *Berl. klin. Wchnschr.*, 1877, No. 34.

CASE 1.—Female, æt. 32. Nephrectomy; recovery.

LANGHANS.—(Histology of Renal Cancer) *Deutsche Ztschr. f. Chir.*, Leipzig, 1878, Bd. ix. S. 312-328.

LANTZENBERG.—(Sarcoma) *Bull. Soc. anat. de Paris*, 1895, tome lxx. p. 592.

LAURENT.—(Fibro-Myoma) *Progrès méd.*, Paris, 1876, tome iv. p. 593.

LAUWERS.—(Sarcoma; children, æt. 6 and 3; nephrectomy) *Ann. Soc. belge de chir.*, Bruxelles, Dec. 1895, p. 313.

LEARED.—(Cancer) *Trans. Path. Soc. London*, 1870, vol. xxi. p. 252.

LE BARILLIER.—(Cancer) *Mém. et bull. Soc. de méd. et chir. de Bordeaux*, 1869, tome iv. pp. 113-118.

LEBERT.—“*Traité d’anatomie pathologique*,” Paris, 1855, tome ii. p. 355.

” “*Traité des maladies cancéreuses*,” Paris, 1851, p. 867.

LE DENTU.—(Growths) “*Affections chirurgicales des reins, des uretères et des capsules surrenales*,” Paris, 1889, pp. 536-567.

References.

LEES.—(Cancer) *Med. Times and Gaz.*, London, 1849, vol. xix. p. 90.

” (Encephaloid Disease) *Dublin Quart. Journ. Med. Sc.*, 1848, vol. vi. p. 451.

LEMAIRE.—(Multilocular Cyst) *Bull. Soc. anat. de Paris*, 1863, tome xxxviii. p. 411.

LÉPINE.—(Cancer) *Mém. et compt. rend. Soc. d. sc. med. de Lyon*, 1883, tome xxii. pp. 123-129; also, *Lyon méd.*, 1882, tome xli. pp. 226-232.

CASE 1.—Primary growth in left kidney, extending along inferior vena cava to entrance of hepatic vein.

” (Cancer) *Rev. de méd.*, Paris, 1888, tome viii. p. 1024.

LEQUEN.—(Varicocele Symptom) *Presse méd.*, Paris, 1895, p. 321.

LEVADOUX.—“*Étude anatomo-pathologique sur le cancer épithélial du rein chez l’adulte*,” Paris, 1892. Thesis.

LEVY.—(Growth) *Rev. med. de l’est*, Nancy, 1878, tome x. pp. 15-19.

LEWI.—(Sarcoma in Children) *Arch. Pediat.*, N. Y., 1896, vol. xiii. pp. 81-100.

CASE 1.—Female, æt. 2½. Left; nephrectomy; recovery; well three months later.

LINCOLN.—(Cancer) *Journ. Am. Med. Ass.*, Chicago, 1889, vol. xii. p. 423.

LISSARD.—“*Die primäre Krebskrankung der Nieren*,” Würzburg, 1891. Diss.

LITTLE.—(Growth) *Dublin Journ. Med. Sc.*, 1873, p. 101.

LITTLE, J. T.—(Sarcoma) *New York Med. Journ.*, 1884, vol. i.

CASE 1.—Female, æt. 4. Right; nephrectomy; death from shock.

LITTLEWOOD.—(Cystic Adenoma) *Brit. Med. Journ.*, London, 1898, vol. i. p. 492.

LOEWE.—“*Ueber einen Fall von Malignem Nierentumor, bei einem Kinde*,” Berlin, 1884. Diss.

LOFTWICH.—(Cancer) *Lancet*, London, 1876, vol. ii. p. 461.

LONG.—(Sarcoma) *Trans. Med. Soc. New Jersey*, 1888, p. 192.

CASE 1.—Child, æt. 16 months.

LONGSBRETH.—(Alveolar Sarcoma) *Phila. Med. Times*, 1884-85, vol. xv. p. 366.

LOOMIS.—(Carcinoma) *Ann. Med. Times*, N. Y., 1862, vol. iv. p. 124.

” (Cancer) *Ibid.*, 1863, vol. viii. p. 208.

- LOSSEN.—(Angio-Sarcoma) *Deutsche Ztschr. f. Chir.*, Leipzig, 1879, Bd. xiii.; also, *Centralbl. f. Chir.*, Leipzig, 1879, Bd. xlv. S. 715.  
 CASE 1.—Pregnant female, æt. 37; right; abdom. nephrectomy; recovery; other fatal cases.
- LOTZBECK.—(Cancer) *Aerztl. Int.-Bl.*, München, 1860, Bd. vii. S. 606.
- LOUVEAU.—(Cancer) *Ann. de la Polyclin. de Bordeaux*, 1897, tome v. pp. 403–413.
- LÖWENFELD.—(Carcinoma) *Wien. med. Presse*, 1873, Bd. xiv. S. 656–658.
- LÖWENHARDT.—(Cystic Growth) *Deutsche Ztschr. f. Chir.*, Leipzig, Bd. xxviii. S. 583.  
 CASE 1.—Male, æt. 46. Right; deposits in liver and lung.
- LÖWENSTEIN.—(Growth) *Journ. f. Kinderkr.*, 1846, Bd. vii. S. 1–5.
- LUBARSCH.—(Growths from Adrenal "Rests") *Virchow's Archiv*, 1894, Bd. cxxxv. S. 149–223.  
 Critical review; references; illustration.
- " (Growths) *Virchow's Archiv*, 1894, Bd. cxxxvii. S. 191.
- LUCKE.—(Cancer) *Deutsche Ztschr. f. Chir.*, Leipzig, 1880, Bd. xv. S. 519.  
 CASE 1.—Adult, æt. 60. Right; nephrectomy; death from uræmia.
- LULKENS.—"Ueber Carcinoma renale," Würzburg, 1869. Diss.
- LUNA.—"Sur les formes clin. du cancer renal," Paris, 1884. Thesis.
- LUNDIE.—(Scirrhus) *Edin. Med. Journ.*, 1887–88, vol. xxxiii. p. 456.
- LUNN.—(Carcinoma) *Trans. Path. Soc. London*, 1890–91, vol. xliii. pp. 186–188.  
 CASE 1.—Male, æt. 57. Right; weight, 4½ lb.; secondary deposits in left kidney; no deposits elsewhere.
- MAIDLAW.—(Sarcoma) *Brit. Med. Journ.*, London, 1898, vol. i. p. 426.  
 CASE 1.—Female, æt. 25. Left; nephrectomy three weeks after parturition; well five months later.
- McBURNEY.—(Sarcoma) *Ann. Surg.*, St. Louis, 1894, vol. xx.  
 CASE 1.—Male, æt. 10. Right; weight, 5000 grms.; nephrectomy; death in few months.
- M'CARTHY AND MARTIN.—(Carcinoma) *Montreal Med. Journ.*, 1894–95, vol. xxiii. pp. 490–496.
- M'CASEY.—(Sarcoma) *Kansas City Med. Rec.*, 1890, vol. vii. p. 87.
- McCULLOM.—(Cancer) *Boston Med. and S. Journ.*, 1872, vol. ix. pp. 152–154.
- MACCORMAC.—(Epithelioma and Calculus), *Trans. Path. Soc. London*, 1888. Abstract, *Brit. Med. Journ.*, London, 1888, vol. i. p. 533.
- MCDONALD.—(Sarcoma) *Albany Ann.*, May 1897.  
 CASE 1.—Male, æt. 3. Left; weight, 2 lb.; nephrectomy; recurrence in five months.
- MACKENZIE.—(Growth) *Illus. Med. News*, London, 1888, vol. ii. p. 269.  
 " (Growth) *Cincin. Lancet and Obs.*, 1875, vol. xviii. p. 20.
- MACKINTOSH.—(Sarcoma) *Lancet*, London, 1895, vol. i. p. 1371.  
 CASE 1.—Child, æt. 11 months.
- MACLAGAN.—(Cancer) *Brit. Med. Journ.*, London, 1881, vol. i. p. 806.  
 CASE 1.—Male, æt. 59. Right; weight, 8 lb. 12 oz.
- MCWEENEY.—(Growths from Adrenal "Rests") *Brit. Med. Journ.*, London, 1896, vol. i. pp. 323–326.  
 CASE 1.—Female, æt. 53. Left; nephrectomy; recovery; well three and a half years after.  
 " 2.—Female, æt. 30. Left; nephrectomy; death in nine hours.  
 Illustrations; critical summary; references.
- MADER.—(Sarcoma) *Ber. d. k. k. Kranken. Anst. Rudolph Stiftung in Wien*, 1891, S. 277.
- MAGARTH.—(Encephaloid) *Lancet*, London, 1876, vol. ii. p. 461.

- MAGUEUR.—(Sarcoma) *Journ. de méd. de Bordeaux*, Feb. 1888.  
 CASE 1.—Male, æt. 2. Right; nephrectomy; death from shock.
- MALASSEZ.—(Cancer) *Bull. Soc. anat. de Paris*, 1870, tome xlv. p. 147.
- MALCOLM.—(Sarcoma) *Trans. Path. Soc. London*, 1895-96, vol. xlvii. p. 119.
- MALHERBE AND RANVIER.—(Cylindrical Epithelioma) *Bull. Soc. anat. de Paris*, 1872, tome xlvii. pp. 303-305.
- MANASSE.—(Histology and Genesis of Renal Growths) *Virchow's Archiv*, 1896, Bd. cxliii. S. 278-323; Bd. cxlv. S. 113-157.  
 Full account of adenomata and myomata; illustrations and references.
- MANBY.—(Growth) *Lancet*, London, 1885, vol. i. p. 661.
- MANZOLINI.—(Cancer) *Ann. univ. di med. e chir.*, Milano, 1856, vol. clviii. p. 66.
- MARCHAND.—(Myo-Sarcoma) *Virchow's Archiv*, 1878, Bd. lxxiii. S. 289-301.  
 " (Sarcoma) *Ibid.*, 1873, Bd. liv.  
 CASE 1.—Male, æt. 17 months. Right; deposits in liver.  
 " (Adenoma) *Festschr. Rudolf Virchow*, Berlin, 1891.
- MARTIN.—(Growth) *Austral. Med. Journ.*, Melbourne, 1873, vol. xviii. pp. 302-304.  
 " (Sarcoma) *Berl. klin. Wchnschr.*, 1879, Bd. xxiii.  
 CASE 1.—Female, æt. 53. Right; nephrectomy; recovery; recurrence.  
 " (Sarcoma) *Lyon méd.*, 1896, tome lxxxii. pp. 326-330.  
 CASE 1.—Infant, æt. 5 months.
- MARTINEAU.—(Cancer) *Bull. et mém. Soc. méd. d. hôp. de Paris*, 1875, tome xii. p. 100.  
 CASE 1.—Female, æt. 2½ years. Left; probably sarcoma; illustration.
- MATICE.—(Cancer) *Bull. Soc. anat. de Paris*, 1844, tome xix. pp. 303-309.
- MAUDERLI.—"Sarcombildung im Kindersalter," 1895, Basel. Diss.
- MAX.—(Sarcoma) *Clinique*, Bruxelles, 1894, tome viii. pp. 705-710.
- MAYROTH.—(Cancer) *Lancet*, London, 1876, vol. ii.
- MENDELSON.—(Secondary Sarcoma) *New York Med. Journ.*, 1886, vol. xliii. p. 669.
- MENGER.—"Ueber das Adenom der Niere eine neue Geschwulstform," Leipzig, 1875. Diss.
- MEREDITH.—(Sarcoma) *Med. Times and Gaz.*, London, 1884, vol. ii. p. 627.  
 CASE 1.—Female, æt. 4. Weight, 3½ lb.; nephrectomy; death from ligation of vena cava.
- METZNER.—"Beitr. z. Kenntniss der primären Nierengeschwulste," Halle. Diss.
- MICHEL.—(Sarcoma) *Bull. Soc. anat. de Paris*, 1892, p. 118.  
 " (Cancer) *Ann. Soc. d'anat. path. de Bruxelles*, 1874, tome xxiii. pp. 120-125.
- MICHELS.—"Ueber Carcinom der Niere," Berlin, 1872. Diss.
- MILLIGAN.—(Medullary Carcinoma) *North-West Med. and S. Journ.*, St. Paul, 1871, vol. ii. pp. 110-112.
- MINERVINI.—(Congenital Growths) *Clin. chir.*, Milan, 1897, vol. v. pp. 181-210.
- MINGES.—(Malignant Growths) *Journ. Am. Med. Ass.*, Chicago, 1885, vol. iv. pp. 618, 650.
- MIRIEL.—"Reflexions sommaires sur l'importance du diagnostic," Paris, 1810, p. 13.  
 CASE 1.—Female, æt. 35. Right; mistaken for pregnancy.
- MOHL.—(Cancer) *Memorabilien*, Heilbronn, 1867, vol. xii.
- MONOD.—(Perirenal Lipoma; male; laparotomy; recovery) *Ann. d. mal. d. org. génito-urin.*, Paris, 1893, tome xi. p. 229; and *Rev. de chir.*, Paris, 1892, tome xii. p. 1047.

- MONTANÉ.—(Encephaloid Cancer) *Crón. med.-quir. de la Habana*, 1875, tome i. pp. 175-179.
- MONTGOMERY.—(Growth) *Am. Med. Compend*, Toledo, 1897, vol. xiii. pp. 139-141.
- MONTI.—(Growth) "Gerhardt's Handbuch der Kinderkrank.," 1878, Bd. iv. Abth. iii. S. 449-446.  
General description ; critical summary ; references.
- MOORE, N.—(Growth) *Trans. Path. Soc. London*, 1884-1885, vol. xxxvi. p. 272.  
" (Cancer and Calculus) *Ibid.*, 1881-1882, vol. xxxiii. p. 199.  
" (Cancer) *Lancet*, London 1879, vol. i. p. 770.
- MOREAU.—(Cancer in Young Children) *Bull. Soc. anat. de Paris*, 1852, tome xxvii. pp. 237-241.
- MORGAGNI.—(Perirenal Lipoma ; female, æt. 60) "De sedibus et causis Morborum," Epist. 39, 5.
- MORRIS.—(Growth) "Surgical Diseases of the Kidney," London, 1885, pp. 483-500.  
" "Keating's Cyclopædia of Diseases of Children," vol. iii. p. 579.  
" (Renal and Adrenal Growth) "Surgery of the Kidney," *Brit. Med. Journ.*, London, 1893, vol. i. p. 2.  
" "Allbutt's System of Medicine," 1897, vol. iv. pp. 445-450.
- MORROW.—(Growths) "System of Genito-Urinary Diseases," 1893, vol. i. p. 823.
- MOXON.—(Probably Syphilitic Gumma) *Guy's Hosp. Rep.*, London, 1868.
- MOYNIER.—(Perirenal Lipoma ; female, æt. 47) *Compt. rend. Soc. de biol.*, Paris, Sér. 1, tome ii. p. 139.
- MÜHLIG.—(Medullary Cancer) *Gaz. méd. d'Orient*, Constantinople, 1860, tome iii. pp. 70-73.
- MURCHISON.—(Papilloma of Pelvis) *Trans. Path. Soc. London*, vol. xxi. p. 241.  
CASE 1.—Male, æt. 65 ; illustration in Sutton's "Tumours."
- MURRAY.—(Sarcoma) *Maritime Med. News*, Halifax, 1893, vol. v. p. 33.
- NEISLEY.—(Cystic Sarcoma) *Ann. Gynec. and Pædiat.*, 1891, vol. iv. p. 311.  
CASE 1.—Female, æt. 3. Right ; weight, 5 lb. ; nephrectomy ; well some months after.
- NEPVEN.—(Colloid Epithelioma) *Bull. et mém. Soc. de chir. de Paris*, N. S., 1890, tome xvi. p. 224.
- NETTER.—(Cancer) *Progrès méd.*, Paris, 1886, Sér. 2, tome iv. p. 891.
- NETZEL.—(Growth) *Hygiea*, Stockholm, 1882, vol. xliv. pp. 81-94.
- NEUBERT.—"Ein Fall von primæren doppelseitigen Nierenkrebs," Leipzig, 1868. Diss.
- NEUMANN.—"Essai sur le cancer du rein," Paris, 1873. Thesis.  
Bibliography.
- " (Sarcoma) *Deutsches Arch. f. klin. Med.*, Leipzig, 1881-1882, Bd. xxx. S. 377-397.  
Historical survey ; collected cases.
- NEWMAN.—"Surgical Diseases of the Kidney," London, 1888.  
General description ; tables of nephrectomy cases.
- " (Cancer) *Glasgow Med. Journ.*, 1896, vol. xlv. pp. 179-187.
- NICHOLS.—(Encephaloid) *New Jersey Med. Reporter*, Burlington, 1851, vol. iv. p. 93.
- NICOLADONI.—(Carcinoma) *Wien. med. Presse*, 1886, Bd. xxvii. S. 673-675.  
CASE 1.—Adult, æt. 35 ; nephrectomy ; death in fourteen hours.
- NORMAN.—(Adenoma) *Trans. Roy. Acad. Med. Ireland*, Dublin, 1892-1893, vol. xi. pp. 377-386.  
Critical survey ; illustrations.



- NORRIS.—(Cancer) *Edin. Med. and S. Journ.*, 1820, vol. xvi. p. 562.  
 CASE 1.—Male, æt. 59; probably secondary, as other organs affected.
- NOWLAN.—(Encephaloid) *Dublin Hosp. Gaz.*, 1857, vol. iv. p. 373.
- OBRE.—(Sarcoma) *Trans. Path. Soc. London*, 1846-48, vol. i. p. 119.  
 " (Cancer) *Ibid.*, 1852-53, vol. iv. p. 191.
- OLIVER.—(Lymphadenoma) *Lancet*, London, 1879, vol. ii. pp. 829-831.
- OLLIER.—(Sarcoma) *Rev. de chir.*, Paris, 1883, p. 898.  
 CASE 1.—Child, æt. 4. Nephrectomy; death from shock.
- OLLIVIER AND RANVIER.—(Growth) *Compt. rend. Soc. de biol.*, Paris, 1866, Sér. 4, tome iii. p. 253.
- OPPOLZER.—(Growth) *Allg. Wien. med. Ztg.*, 1861, Bd. vi. S. 236.
- ORD.—"Lectures on Renal Diseases," *Practitioner*, London, 1896, vol. ii. p. 470.
- ORLOWSKY.—(Cancer) *Deutsche Ztschr. f. Chir.*, Leipzig (1), Bd. xxii. S. 2.  
 CASE 1.—Female. Nephrectomy; recovery.
- ORR.—(Cancer) *Glasgow Med. Journ.*, 1879, vol. xi. p. 53.  
 CASE 1.—Infant, æt. 6 months. Probably sarcoma.
- ORTH.—"Lehrbuch der Speciellen Pathologischen Anatomie," 1893, Bd. ii. S. 113.

## References.

- OSLER.—(Myo-Sarcoma) *Canada Med. Rec.*, Montreal, 1879, vol. vii. p. 164.  
 " (Sarcoma) *Montreal Gen. Hosp. Rep.*, 1880, vol. i. pp. 325-328.  
 " (Myo-Sarcoma) *Journ. Anat. and Physiol.*, London, 1879, vol. xiv. pp. 229-233.  
 CASE 1.—Male, æt. 19 months.  
 " 2.—Female, æt. 3½ years.
- OUCHTERLONG.—(Cancer) *Journ. Am. Med. Ass.*, Chicago, 1886, vol. vii. pp. 281-286.
- PAPAVOINE.—(Cancer and Calculus) *Chir. d. hôp.*, Paris, 1829, tome iv. p. 13.
- PAQUET.—(Angio-Sarcoma) *Bull. méd. du nord*, Lille, 1886, tome xxv. pp. 235-237.
- PARKER.—(Encephaloid in Children) *New York Med. Journ.*, 1850, vol. v. p. 206.
- PARODI AND CONI.—(Cancer) *Rev. de méd.*, Paris, January 1877-78, tome xiv. pp. 196-200.
- PATINO-LUNA.—"Étude sur les formes cliniques du cancer renal," Paris, 1884. Thesis.
- PATURAND AND GARSAUX.—(Sarcoma) *Bull. Soc. anat. de Paris*, 1875, Sér. 3, tome x. p. 262. Abstract, *Schmid's Jahrb.*, Leipzig, 1879, Bd. clxxxiv. S. 89.  
 CASE 1.—Female, æt. 6. Right; weight, 1300 grms. Deposits in lungs and liver.
- PAUL.—(Classification of Growths) *Brit. Med. Journ.*, London, 1884, vol. i. pp. 48-51.  
 Records of private collective investigation, in which author was assisted by several British and American pathologists. Presented to Fifty-first Annual Meeting, British Medical Association.
- " (Congenital Sarcoma) *Ibid.*, 1884, vol. i. p. 766; also *Liverpool Med.-Chir. Journ.*, 1885, vol. v. p. 217.  
 CASE 1.—Female, æt. 1. Tumour noticed at 6 months. Left; weight, 6 lb.
- " (Congenital Adeno-Sarcoma) *Brit. Med. Journ.*, London, 1886, vol. i. p. 546.  
 Same case as recorded by Pughe.
- " (Congenital Sarcoma) *Liverpool Med.-Chir. Journ.*, 1894, vol. xiv. pp. 102-110.

- PÉAN.—“Diag. et traitement des tumeurs de l'abdomen et du bassin,” 1880, tome i. p. 215.  
 ” (Epithelioma) *Gaz. d. hôp.*, Paris, 1885, tome xxxix. p. 307.  
 CASE 1.—Female, æt. 45. Right; weight, 12 lb.; nephrectomy; recovery.
- PEARSON.—(Growth) *Med. Obs. Soc. Phys.*, London, 1784, vol. vi. pp. 236–245.
- PELTIER.—(Cancer) *Bull. Soc. anat. de Paris*, 1833, tome viii. pp. 155–160.  
 Extension of growth along right renal vein to inferior cava.
- PEPPER.—(Cancer) *Trans. Coll. Phys. Phila.*, 1850, N. S., vol. i. pp. 100–103.  
 ” (Encephaloid Cancer) *North Car. Med. Journ.*, Wilmington, 1881, vol. vii. pp. 261–274.  
 ” (Growth) *Buffalo Med. and S. Journ.*, 1884–85, vol. xxiv. pp. 57–61.
- VON PEREWERSEFF.—(Development of Cancer) *Virchow's Archiv*, 1874, Bd. lix. S. 227–236.  
 Histological investigation; illustrations.
- PÉRIER.—(Cancer). Quoted by Newman.  
 CASE 1.—Male, æt. 65. Right; nephrectomy; death from uræmia.
- PICCARD.—(Growth) *Kansas Med. Journ.*, Topeka, 1895, vol. vii. p. 214.
- PICK.—“Das primäre Nierensarkom,” Würzburg, 1893. Diss.  
 Statistical and historical résumé.
- PIERCE.—(Growth) *Boston Med. and S. Journ.*, 1831–32, vol. v. pp. 127–129.
- PIERSON.—(Carcinoma in Infant) *Trans. Med. Soc. N. Jersey*, 1863, pp. 57–59.  
 ” (Carcinoma) *Med. Rec.*, N. Y., 1892, vol. xli. p. 463.
- POLLARD.—(Carcinoma and Calculi) *Trans. Path. Soc. London*, 1884, vol. xxxvi. pp. 272–274.  
 CASE 1.—Female, æt. 47.
- PONCET.—(Cancer—Transperitoneal Nephrectomy) *Lyon méd.*, May 23, 1897, p. 122.
- PORTER.—(Sarcoma) *Bull. New York Path. Soc.*, 1881, Ser. 2, vol. i. pp. 343–345; also, *Med. Rec.*, N. Y., 1882, vol. xxi. p. 48.
- PRIESTLEY.—(Sarcoma) *Iowa State Med. Reporter*, Des Moines, 1883, vol. i. p. 4.
- PRUDDEN.—(Multiple Adenomata) *Proc. New York Path. Soc.*, 1888, p. 109; also, *Med. Rec.*, N. Y., 1887, vol. xxxii. p. 84.
- PUGHE.—(Sarcoma) *Liverpool Med.-Chir. Journ.*, 1885.  
 CASE 1.—Female, æt. 2½. Nephrectomy; death from intestinal strangulation.
- PUGHLIESI.—(Etiology of Growths) *Morgagni*, Milano, 1893, tome xxxv. pp. 57–60.
- QUÉNU.—(Cancer) *Bull. Soc. anat. de Paris*, 1878, tome liii. p. 436; also, *Progrès méd.*, Paris, 1879, tome vii. p. 165.
- RABAGLIATI.—(Lympho-Sarcoma) *Med. Times and Gaz.*, London, 1885, vol. i. p. 114.
- RABL.—(Growth) *Arch. f. mikr. Anat.*, Bonn, 1891, Bd. xxxviii. S. 492.
- RAGOT.—(Cancer) *Bull. Soc. anat. de Paris*, 1866, tome xli. p. 40.
- RALFE.—“Diseases of the Kidneys and Urinary Derangements,” London, 1885.
- RAMMI.—(Sarcoma) *Norsk Mag. f. Lægevidensk.*, Christiania, October 1896.
- DE LA RANADA.—(Growth) *Monit. d. hôp.*, Paris, 1853, tome i. p. 415.
- RANCE.—(Fungus Hæmatodes) *Med. and Phys. Journ.*, London, 1814, vol. xxxii. pp. 19–25.  
 CASE 1.—Female, æt. 17 months. Probably sarcoma.
- RATHERY.—“Essai sur le diagnostic des tumeurs intra-abdominales chez les enfants,” Paris, 1870. Thesis.
- RAWDON.—(Sarcoma) *Liverpool Med.-Chir. Journ.*, Sept. 1882.  
 CASE 1.—Female, æt. 16 months. Left; weight, 14 oz.; nephrectomy; death in fifteen hours from carbolic poisoning.

- RAYER.—“*Traité des maladies des reins*,” 1841, tome iii. pp. 675–723.  
Historical references; cases, many of which are secondary.
- ” (Cancer of Sheep) *Compt. rend. Soc. de biol.*, Paris, 1864, Sér. 3, tome v. p. 57.
- RAYMOND.—(Carcinoma) *Gaz. d. hôp.*, Paris, 1880, tome liii. p. 1041.
- RECAMIER.—(Cancer) *Rev. méd. franc. et étrang.*, Paris, 1824, vol. ii. p. 18.  
CASE 1.—Aged female. Left.
- VON RECKLINGHAUSEN.—(Adenomata) *Festschr. Rudolf Virchow*, Berlin, 1891.
- RECZEY.—(Sarcoma) *Centralbl. f. Chir.*, Leipzig, 1883, No. 31.  
CASE 1.—Male, 5½. Weight, 8 lb.; nephrectomy; death in three days.
- REES.—(Growth) *Brit. and For. Med.-Chir. Rev.*, London, 1856, vol. ii. p. 390.
- RENAULDIN.—(Cancer) *Arch. gén. de méd.*, Paris, 1833, tome ii. p. 588.  
CASE 1.—Female, æt. 65. Left.
- RENAULT.—(Encephaloid Carcinoma) *Bull. Soc. anat. de Paris*, 1872, Sér. 2, tome xvii. p. 371.
- RETZIUS.—(Cancer) *Journ. f. Kinderkr.*, 1860, Bd. xxxv. S. 426–428.
- RIBBERT.—(Rhabdo-Myo-Sarcoma) *Virchow's Archiv*, 1886, Bd. cvi. S. 282–295.  
” (Myo-Sarcoma) *Ibid.*, Bd. cxxx. S. 249.
- RIBBERT AND SCHEVEN.—(Sarcoma) *Berl. klin. Wchnschr.*, 1886.
- RICKER.—(Growths) *Centralbl. f. allg. Path. u. path. Anat.*, Jena, June 1897.
- RINDFLEISCH.—“*Manual of Pathological Histology*,” *New Syd. Soc.*, 1893, vol. ii. p. 169.  
” “*Die Elem. der Pathologie*,” 1883, S. 71.
- ROBERTS, F. T.—“*Reynolds' System of Medicine*,” London, 1879, vol. v. pp. 608–638.
- ROBERTS, W.—“*Urinary and Renal Diseases*,” London, 1865; *Ibid.*, 4th edition, 1885.
- ROBERTS, W. O.—(Sarcoma) *Am. Pract. and News*, Louisville, 1888, vol. vi.  
CASE 1.—Child, æt. 5. Weight, 3½ kilos.; nephrectomy.
- ROBERTSON AND DALZIEL.—(Cancer) *Glasgow Med. Journ.*, 1886, Ser. 4, vol. xxvi. pp. 307–311.
- ROBIN.—(Epithelioma) *Compt. rend. Soc. de biol.*, Paris, 1855, tome ii. p. 41; also *Gaz. d. hôp.*, Paris, 1855, tome xxviii. pp. 186, 194, 202.
- ROBSON, MAYO.—(Sarcoma) *Brit. Med. Journ.*, London, 1876, vol. i. p. 659.  
CASE 1.—Female, æt. 52. Left; deposits in lungs.  
” (Sarcoma) *Clin. Journ.*, London, 1895–96, vol. vii. pp. 98–102.
- RODDICK.—(Cancer) *Canada Med. and S. Journ.*, Montreal, 1884–85, vol. xiii. pp. 715–717.
- ROHRER.—“*Das primäre Nierencarcinom*,” Zurich, 1874. Diss.
- ROKITANSKY.—(Cancer) “*Manual of Pathological Anatomy*,” *Syd. Soc.*, 1849, vol. ii. p. 208.
- ROLLESTON AND KANTHACK.—(Hæmorrhagic Growth) *Journ. Path. and Bacteriol.*, Edin. and London, 1893–94, vol. ii. pp. 80–83.
- ROQUES.—(Cancer) *Bull. d. sc. méd.*, Paris, 1829, tome xvii. p. 133.  
Probably secondary to testicular growth.
- ROSENSTEIN.—“*Die Pathologie und Therapie der Nieren-Krankheiten*,” Berlin, 1870.
- ROSTAN.—(Cancer) *Nouv. Journ. de méd.*, Paris, 1819, tome vi. p. 215.  
CASE 1.—Female, æt. 64. Probably secondary to gastric cancer.
- ROTCH, T. M.—(Growth) “*Pediatrics*,” 1896, vol. ii. p. 939.
- ROVSING.—(Malignant Growths) *Hosp.-Tid.*, Kjobenhaven, 1894, tome ii. pp. 469, 493, 517.
- ROWE.—(Cancer) *Am. Journ. Obst.*, N. Y., 1881, vol. xiv. pp. 484–489.
- RÓZSAY.—(Cancer) *Magy. orv. és term.-vizsg.*, Pest, 1869, S. 145–148.
- RUGE.—(Growth) *Berl. klin. Wchnschr.*, 1877, S. 190.

- RUNEBERG.—(Cancer) *Finska läk.-sällsk. handl.*, Helsingfors, 1878, vol. xx. pp. 324–327.  
 „ (Cancer) *Ibid.*, 1881, vol. xxiii. pp. 161–163.
- RUPPRECHT.—(Growth) *Centralbl. f. Gynäk.*, Leipzig, Bd. xiv. S. 592.  
 CASE 1.—Child, æt. 2½. Right; probably of adrenal origin.
- RUSSELL.—(Growth) *Prov. Med. and S. Journ.*, London, 1844, p. 219.
- SABOURIN.—(Hæmorrhagic Adenoma) *Ibid.*, 1884, tome iv. pp. 874–886.  
 „ (Multiple Adenomata and Renal Cirrhosis) *Ibid.*, 1884, tome iv. pp. 441–465.
- SABOURIN AND ETTINGER.—(Adenoma) *Rev. de méd.*, Paris, 1885, tome v. pp. 889–908.
- SAHLMEN.—“Ueber einen Fall von paranephritischen Sarcom bei einen 5 Jahre alten Kinde,” Greifswald, 1877. Diss.
- SALZER.—(Perirenal Lipomata) *Wien. klin. Wchnschr.*, 1888, Bd. i. S. 199, 224, 238.  
 CASE 1.—Male, middle-aged. Laparotomy; death.  
 „ 2.—Female, æt. 53. Laparotomy; death.  
 „ 3.—Male, æt. 40. Laparotomy; death.
- SANCEROTTE.—(Fibroma) *Mém. Soc. de méd. de Nancy*, 1879, tome xxx.
- SANDERSON.—(Fibrocellular Growth) *Trans. Path. Soc. London*, 1862–63, vol. xiv. p. 195.
- SANDWITH.—(Fungus Hæmatodes) *Edin. Med. and Surg. Journ.*, 1820, vol. xvi. p. 381.
- SCHEDE.—“Meine Erfahrungen ueber Nieren Extirpation,” Hamburg, 1889.  
 CASE 1.—Male, æt. 2½. Right; nephrectomy; recurrence; operation; death.
- SCHIBBYE.—(Sarcoma in child æt. 13 months) *Norsk Mag. f. Lægévidensk.*, Christiania, 1894, vol. ix. p. 201.
- SCHMIDT.—(Cancer) *Med. Ann.*, Heidelberg, 1848, Bd. xiii. S. 285–292.
- SCHNELLER.—(Sarcoma) *Deutsche Ztschr. f. Chir.*, Leipzig, Bd. ix.  
 CASE 1.—Female, æt. 4. Left; probably of extrarenal origin.
- SCHÖNBORN.—(Adenoma) *Bull. Acad. roy. de méd. de Belg.*, Bruxelles, 1885, No. 12; and *Semaine méd.*, Paris, 1885, p. 157.  
 CASE 1.—Child, æt. 2. Nephrectomy; recovery.
- SCHRÖDER.—“Ein Fall von paranephritischen Carcinom,” Kiel, 1874. Diss.
- SCHUPPEL.—(Sarcoma) *Arch. d. Heilk.*, Leipzig, 1868, S. 386.
- SCHÜTZ.—“Untersuchungen ueber den Bau und die Entwicklung der Epithelien Geschwülste der Niere,” Dorpat, 1889. Diss.
- SEILER.—(Growth) *Trans. Path. Soc. Phila.*, 1882, vol. x. p. 187; also, *Phila. Med. Times*, 1879–80, vol. x. p. 123.
- SEVERI.—(Lipoma) *Bull. d. sc. med. di Bologna*, 1873, Sér. 5, tome xvi. pp. 225–230.
- SHARKEY.—(Development of Cancer from Malpighian Bodies and Tubules) *Trans. Path. Soc. London*, 1881, vol. xxxiii. pp. 195–198.  
 „ (Cancer) *Ibid.*, 1883, vol. xxxv. p. 235.
- SHATTUCK.—(Growth) *Boston Med. and S. Journ.*, 1887, vol. cxvi. p. 273.
- SHAW AND PERRY.—(Carcinomata and Sarcomata) *Guy's Hosp. Rep.*, London, 1895, vol. ii. pp. 192, 195, 199, 201.
- SHEPHERD.—(Encephaloid) *Am. Journ. Med. Sc.*, Phila., 1858, N. S., vol. xxxv. p. 291.  
 CASE 1.—Male, æt. 4. Right; weight, 10 lb.; probably sarcoma.
- SHORT.—(Cancer) *Birmingham Med. Rev.*, 1896, vol. xxxix. pp. 159–163.
- SHRADY.—(Cancer) *Bull. New York Path. Soc.*, 1881, Ser. 2, vol. i. p. 193.  
 CASE 1.—Child; probably sarcoma.  
 „ (Cancer) *Trans. New York Med. Ass.*, 1886, vol. ii. pp. 441–447.

- SIREDEY.—(Carcinoma) *Bull. Soc. anat. de Paris*, 1882, Sér. 4, tome vii. pp. 86-89.
- SIRLEO.—(Multilocular Adeno-Cystoma) *Policlin.*, Roma, 1897, tome iv. pp. 357-367.
- SKENE.—(Sarcoma in Child) *Am. Journ. Obst.*, N. Y., 1879, vol. xii. p. 741.
- SMITH, D.—(Cancer) *Am. Med. Times*, N. Y., 1863, vol. vi. p. 293.
- SMITH, H.—(Growth) *Trans. Path. Soc. Lond.*, 1871, vol. xxii. pp. 174-176.
- ” (Encephaloid of Left Kidney in Child) *Trans. Phila. Obst. Soc.*, 1870, vol. i. pp. 24-27; also, *Am. Journ. Obst.*, N. Y., 1870, vol. iii. pp. 476-479.
- SMITH, L.—(Myxo-Sarcoma) *Med. Rev.*, N. Y., 1880, vol. xviii. p. 326.
- SMITH, T.—(Growth) *Trans. Path. Soc. London*, 1864-5, vol. xvi. p. 171.
- SMITH, W.—(Sarcoma) *Brit. Med. Journ.*, London, 1885, vol. ii. p. 105.
- CASE 1.—Male, æt. 53. Right; weight, nearly 4 lb.; spindle cells; no deposits.
- SMITH, W. G.—(Sarcoma) *Am. Journ. Med. Sc.*, Phila., 1886, vol. xci. pp. 143-151.
- SNOW.—(Growths) “On Cancer and the Cancer Process,” 1893, pp. 321-325.
- SOUQUES.—(Adenoma) *Bull. Soc. anat. de Paris*, 1889, vol. lxiv. pp. 615-618.
- SOULIÉ.—(Growth) *Ibid.*, 1860, vol. xxxv. p. 130.
- SPALDING.—(Melanotic Sarcoma) *New Eng. Med. Gaz.*, Boston, 1883, vol. xviii. pp. 355-358.
- SPEE.—(Adenomata) *Arch. f. Physiol.*, Leipzig, 1884, S. 89.
- STEDMAN.—(Sarcoma) *Boston Med. and S. Journ.*, 1881, vol. cv. p. 440.
- CASE 1.—Female, æt. 4. Both kidneys involved.
- STEELE.—(Sarcomata in Children) *Ann. Gynec. and Pædiat.*, Jan. 1896.
- ” (Sarcoma) *Chicago Med. Rep.*, 1894, vol. vi.
- CASE 1.—Male, æt. 16 months. Left; weight, 4000 grms.; nephrectomy; well four months later.
- STEELE, G. M.—(Medullary Cancer) *Trans. Med. Soc. Wisconsin*, 1880, vol. xiv. pp. 174-179.
- STEELE, D. A. K.—(Sarcoma in Children) *Med. and Surg. Reporter*, 1896, vol. lxxiv. pp. 136-143.
- STEINER.—(Malignant Growth) *Berl. klin. Wchnschr.*, 1896, Bd. xxxiii. S. 565.
- STEINMANN.—“Ueber primäres Nierencarcinom,” Leipzig, 1889. Diss.
- STETER.—(Carcinoma) *Centralbl. f. Chir.*, Leipzig, 1887, No. 25.
- CASE 1.—Female, æt. 51. Nephrectomy; recovery.
- STILLER (Diagnosis of Renal Growths) *Verhandl. d. Cong. f. innere Med.*, Wiesbaden, 1888, Bd. vii. S. 462-472; and *Wien. med. Wchnschr.*, 1888, Bd. xxxviii. S. 1113, 1145.
- STINTZING.—(Carcinoma) *Aerztl. Int.-Bl.*, München, 1883, Bd. xxx. S. 185.
- STOLTZ.—(Cancer) *Förh. v. Svens. Läk.-Sällsk. Sammank.*, Stockholm, 1870, pp. 52-55.
- STRICKER.—(Cancer) *Virchow's Archiv*, 1867, Bd. xli. S. 291.
- STROUP (Primary Carcinoma) *Rev. méd. de l'est*, Nancy, 1895, tome xxvii. p. 182.
- Associated with round ulcer of stomach; case simulated gastric cancer.
- STRÜBING.—(Adenomata) *Deutsches Arch. f. klin. Med.*, Leipzig, Bd. xliii.
- STURM.—(Adenomata and other Growths) *Arch. d. Heilk.*, Leipzig, 1875, Bd. xvi. S. 193-237.
- SUDEK.—(Adenomatous Growths) *Virchow's Archiv*, Bd. cxxxiii. S. 405.
- ” (Growths) *Ibid.*, 1894, Bd. cxxxvi. S. 293-301.
- Histology of growths; references.
- SULLIVAN.—(Growth) *Journ. Gynec. Soc. Boston*, 1870, vol. iii. pp. 347-350.
- SUTTON, BLAND.—“Tumours: Innocent and Malignant,” London, 1893.
- ” ” (Growths) *Clin. Journ.*, London, vol. iii. p. 4.

- TAIT, LAWSON.—(Growth) *Brit. Med. Journ.*, London, 1889, vol. ii. p. 1085.  
Cases; statistics.
- TANNER AND BROADBENT.—(Growths) "Practice of Medicine," 1875, p. 279.
- TARGETT.—(Congenital Growths) *Lancet*, London, 1894, vol. ii. p. 1095.  
Microscopic characters of a series of embryonic growths.
- " (Growths of Adrenal Origin) *Trans. Path. Soc. London*, 1895-96,  
vol. xlvii. pp. 122-128.  
Cases. Illustrations. Criticism.
- TAYLOR, H. L.—(Malignant Growths in Infancy) *Am. Journ. Med. Sc.*,  
Phila., 1887, vol. xciv. pp. 461-475.
- TERRILLON.—(Epithelioma) *Bull. et mém. Soc. de chir. de Paris*, 1891, N. S.  
tome xvii. p. 116.
- TESSIER.—(Encephaloid) *Bull. Soc. anat. de Paris*, 1834, tome ix. p. 154.
- THIRIAR.—(Sarcoma) *Rev. de chir.*, Paris, 1881, tome i.  
CASE 1.—Male, æt. 48. Right; weight, 610 grms.; nephrectomy;  
recovery.
- " (Perirenal Lipoma, female, æt. 63) *Cong. Franc. de chir.*, quoted  
by Banby and Daunic, *Midi méd.*, Toulouse, 1893, tome ii. p. 542.
- THOMA.—"Text-Book of General Pathology and Pathological Anatomy,"  
London, 1896, vol. i. p. 575.
- THOMAS.—(Fibrocystic Growth) *New York Med. News*, 1882, vol. i. p. 9.  
CASE 1.—Female, æt. 21. Weight, 10 lb.; nephrectomy; recovery.
- THOMAS (THELWALL).—(Carcinoma, male, æt. 39; nephrectomy; recovery)  
*Med. Press and Circ.*, London, 3rd Nov. 1897, p. 455.
- THORNTON.—(Alveolar Sarcoma) *Trans. Path. Soc. London*, 1882-83, vol. xxxiv.  
pp. 141-143.  
CASE 1.—Female, æt. 53. Weight, 7 lb.; nephrectomy; recovery.
- THOROWGOOD.—(Malignant Growth) *Med. Times and Gaz.*, London, 1868, vol.  
ii. p. 529.
- TILLMAN.—(Perirenal Lipo-Sarcoma, female, æt. 28; laparotomy; recovery;  
recurrence) *Hygiea*, Stockholm, 1891, tome i. p. 277.
- TODD.—(Growth) *Med. Times and Gaz.*, London, 1853, vol. i. p. 541.
- TOPHAM.—(Encephaloid) *Lancet*, London, 1851, vol. i. p. 156.
- TOPLIFF.—(Encephaloid Cancer) *Denver Med. Times*, 1884-85, vol. iv. pp. 161-  
163.  
CASE 1.—Male, æt. 7 years. Probably sarcoma.
- TORLEY.—"Ueber einen Tumor des Nierenbeckens," Bonn, 1891. Diss.
- TOTLAND.—(Encephaloid) *Pacific Med. and S. Journ.*, San Francisco, 1858,  
vol. i. pp. 302-305.
- TOWNSEND.—(Cancer) *Dublin Quart. Journ. Med. Sc.*, 1868, vol. xlv. pp. 219-221.
- TRENDELENBURG.—(Sarcoma) *Berl. klin. Wchnschr.*, 1886, Bd. ii.  
CASE 1.—Child, æt. 9. Nephrectomy; recovery.
- TREVES.—(Growth) *Lancet*, London, 1887, vol. ii. p. 603.  
" "System of Surgery," 1896, vol. ii. p. 858.
- TROTTER.—(Encephaloid) *Trans. Path. Soc. London*, 1871, vol. xxii. p. 173.
- TROVANELLI.—(Carcinoma in a man, æt. 24) *Gior. di med. mil.*, Roma, 1885,  
tome xxxiii. pp. 1345-1354.  
Critical review; bibliography of seventy nephrectomy cases.
- TUFFIER.—(Malignant Growths) *Ann. d. mal. d. org. génito-urin.*, Paris, 1888,  
tome vi. pp. 65-93.  
" (Epithelioma) *Mercredi méd.*, Paris, 1894, tome v. p. 593.
- TURNER.—(Malignant Growth) *Trans. Path. Soc. London*, 1884-85, vol. xxxvi.  
p. 275.

- TYSON.—(Encephaloid Cancer) *Trans. Path. Soc. Phila.*, 1876, vol. v. pp. 148–150.  
 ” (Growths) “Practice of Medicine,” 1896, p. 682.
- ULRICH.—(Adrenal Growths) *Beitr. z. path. Anat. u. z. allg. Path.*, Jena, 1895, Bd. xviii. S. 589–655.
- URAG.—(Cancer) *Wchnbl. d. k. k. Gesellsch. d. Aerzte in Wien*, 1856, Bd. ii. S. 829–834.
- VALLERAND.—(Cancer) *Nouv. bib. méd.*, 1825, tome viii. p. 42.
- VAN-DER-BYL.—(Cancer) *Trans. Path. Soc. London*, 1855–56, vol. vii. pp. 268–270.  
 CASE 1.—Male, æt. 8½. Left; weight, 31 lb.; history eight years; probably sarcoma.
- VAN TILLIMANN.—(Capsular Fibro-Myxoma) *Hygiea*, Stockholm, 1891.
- VELPEAU.—(Growth) *Rev. de méd.*, Paris, 1826, tome iv. p. 219.
- VERSTRÆTEN.—(Cancer) *Ann. Soc. de méd. de Gand*, 1878, tome lvi. pp. 31–65.
- VIGLA.—(Growth) *Bull. Soc. anat. de Paris*, 1838, tome xiii. p. 305.
- VILLENEUVE.—(Cancer) *Marseille méd.*, 1892, tome xxiv. pp. 674–683.
- VIRCHOW.—(Myo-Sarcoma) “Die Krankhaften Geschwülste,” 1865, Bd. iii. S. 106.
- VOGELSANG.—(Medullary Carcinoma) *Memorabilien*, Heilbronn, 1876, Bd. xxi. S. 66–69.
- VOLKMANN.—(Growth) *Deutsche Ztschr. f. Chir.*, Leipzig, Bd. xli. S. 1.
- WAGGENER.—(Encephaloid) *St. Louis Med. and S. Journ.*, 1880, vol. xxxviii. p. 301.
- WAGNER.—(Complex Growths) *Arch. d. Heilk.*, Leipzig, 1860, Bd. i. S. 313–321.  
 ” (Sarcoma) *Centralbl. f. d. Krankh. d. Harn-u. Sex.-Org.*, Leipzig, 1894, Bd. v. S. 267–279.  
 CASE 1.—Female, æt. 4½. Both kidneys involved.
- WAHL.—(Growths) *St. Petersb. med. Wchnschr.*, 1885, tome xlv.
- CASE 1.—Female, æt. 11. Nephrectomy; recovery; fibroma.  
 ,, 2.—Female, æt. 49. Nephrectomy; recovery; carcinoma.
- WALCOTT.—(Encephaloid Cancer) *Med. and Surg. Reporter*, 1861, vol. vii.  
 CASE 1.—Male, æt. 58. Right; weight, 2 lb. Duration, six years; nephrectomy; death.
- WALKER.—(Sarcoma in Children) *Ann. Surg.*, New York, 1897, Bd. lix. p. 529.  
 Critical review. Abstract of nephrectomies. Bibliography.
- WALSHAM.—(Epithelioma and Calculus) *St. Barth. Hosp. Rep.*, London, vol. xxi.
- WALSHE.—“Nature and Treatment of Cancer,” London, 1846, pp. 377–394.  
 Pathological and clinical study; references to early cases.
- WALTZ.—(Carcinoma) *Mag. f. d. ges. Heilk.*, Berlin, 1821, Bd. xi. S. 179–202.
- WARDELL.—(Growth) *Trans. Path. Soc. London*, 1848–50, vol. ii. p. 76.
- WARE.—(Cancer) *Boston Med. and S. Journ.*, 1859–60, vol. lxi. p. 280.
- WARNER.—(Sarcoma) *Trans. Am. Pediat. Soc.*, Phila., 1891, vol. ii. pp. 65–69.  
 ” (Sarcoma) *Arch. Pediat.*, N. Y., 1890, vol. ii. pp. 817–821.
- WARTHIN.—(Fibro-Lipoma) *Journ. Path. and Bacteriol.*, Edin. and London, March 1897, p. 404.
- WEAVER.—(Sarcoma) *Lehigh Valley Med. Mag.*, Easton, Pa., 1890, vol. ii. pp. 109–111.
- WEBER.—(Symmetrical Lympho-Sarcoma) *Trans. Path. Soc. London*, 1895–96, vol. xlvii. p. 117.
- WEDL.—(Cancer) “Rudiments of Pathological Histology,” *Syd. Soc.*, 1845, p. 586.
- WEHR.—“Ein Fall von primären Alveolarsarcom der Niere,” Greifswald, 1893. Diss.

- WEICHELBAUM.—(Adenoma) *Ber. d. k. k. Krankenhant., Rudolph-Stiftung in Wien*, 1884, S. 384.
- WEICHELBAUM AND GREENISH.—(Adenoma) *Med. Jahrb.*, Wien, 1883, S. 213-248.
- WEIGERT.—(Adeno-Carcinoma) *Virchow's Archiv*, 1876, Bd. lxxvii. S. 492-500.
- WEIR.—(Adenoma) *Ann. Surg.*, St Louis, 1887.  
 CASE 1.—Male, æt. 35. Weight, 30 oz.; nephrectomy; recovery.  
 „ (Fibro-Lipoma and Calculus; adult female; nephrectomy; recovery) *Ann. Surg.*, New York, July 1897, p. 128.
- WEISS.—(Cancer) *Bull. Soc. anat. de Paris*, 1851, tome xxvi. p. 148.
- WEISSETHANNER.—(Growth) *Union méd. d'Orient*, Constantinople, 1880, tome vii. p. 200.
- WELLS.—(Fibro-Lipoma). Quoted by Newman.  
 CASE 1.—Female, æt. 48. Nephrectomy; recovery.  
 „ (Perirenal Lipoma) *Trans. Path. Soc. London*, 1868, vol. xix. p. 243.  
 CASE 1.—Female, æt. 43. Laparotomy; death.  
 „ (Cancer) *Ibid.*, 1862-63, vol. xiv. p. 179.  
 „ (Cancer) *Med.-Chir. Trans.*, London, 1883, p. 305.  
 CASE 1.—Male, æt. 58. Nephrectomy; death in five days.  
 „ 2.—Female, æt. 38. Nephrectomy; death on twenty-fifth day.
- WENTWORTH.—(Malignant Growths) *Arch. Pediat.*, N. Y., 1896, vol. xiii. pp. 321, 341.  
 CASE 1.—Female, æt. 20 months. Left; weight, 220 grms.; nephrectomy; death in sixty-one hours.  
 „ 2.—Female, æt. 3 months. Right; weight, 400 grms. Illustrations; histological characters; bibliography.
- WERDER.—(Rhabdo-Myo-Sarcoma) *Am. Lancet*, Phila., 1894, vol. iii.  
 CASE 1.—Female, æt. 2. Left; weight, 1250 grms.; nephrectomy; well six months later.
- WHIPHAM.—(Lymphadenomata) *Trans. Path. Soc. London*, 1871-2, vol. xxiii. pp. 166-168.
- WHITE, H.—(Growth) *Guy's Hosp. Gaz.*, London, 1897, vol. xi. pp. 385-388.
- WHITE AND MARTIN.—(Growths) "Genito-Urinary Surgery and Venereal Diseases," 1897, pp. 842-848.
- WHITEHEAD.—(Sarcoma) *Brit. Med. Journ.*, London, 1881, vol. ii. p. 741.  
 CASE 1.—Male, æt. 45. Right; nephrectomy; death on fourth day.
- WIEFEL.—"Ueber Adenoma der Nieren." Diss.
- WIGGLESWORTH.—(Perirenal Lipoma; female, æt. 43) *Lancet*, London, 1883, vol. i. p. 1121.
- WILKS.—(Fibrous Growth) *Trans. Path. Soc. London*, 1868-69, vol. xx. pp. 224-226.
- WILLET.—(Growths) *Lancet*, London, 1894, vol. ii. p. 1095.  
 CASE 1.—Cystic adenoma. Child, æt. 11 months. Nephrectomy; recovery; recurrence.  
 „ 2.—Carcinoma. Male, æt. 19 years. Nephrectomy; recovery; well eighteen months later.
- WILLIAMS.—(Myo-Sarcoma) *Trans. Path. Soc. London*, 1881, vol. xxxiii. pp. 317-320. Abstract, *Brit. Med. Journ.*, London, 1881, vol. ii. p. 744.  
 CASE 1.—Male, æt. 13 months. Right; weight, 1 lb. 13½ oz., or one-sixth of whole body.
- WILSON.—(Encephaloid) *Med. and Surg. Reporter*, 1871, vol. xxv. pp. 548-551.
- WILSON, A.—(Angio-Sarcoma) *Brit. Med. Journ.*, London, 1886, vol. i. p. 1109.  
 CASE 1.—Adult male. Left; profuse hæmaturia; cystotomy.
- WINDLE.—(Sarcomata) *Journ. Anat. and Physiol.*, London, 1884, vol. xviii. pp. 150-170.  
 Personal cases; table of collected cases; critical analysis; references.



- WISING AND BLIX.—(Cancer) *Hygiea*, Stockholm, 1878, tome lx. pp. 468–476.  
 WITTE.—“Erworbenes multiloculares adenokystom und angeborene cystische Entartung der Nieren,” Königsberg, 1896. Diss.  
 WOLFENSBERGER.—“Myo-Sarcomata,” Zurich, 1894. Diss.  
 WOLLCOTT.—(Encephaloid Growth) *Med. and Surg. Reporter*, 1861, vol. vii. p. 126.  
 WOLLESTEIN.—(Rhabdo-Myo-Sarcoma) *Med. Rec.*, N. Y., 1893, vol. xliii. p. 90.  
 WOOD AND FITZ.—(Growths) “The Practice of Medicine,” 1897, p. 1043.  
 WOODHOUSE.—(Malignant Disease) *Assoc. Med. Journ.*, London, 1853, p. 1011.

## II. ADRENAL GROWTHS.

- ADDISON.—(Cancer) “On Disease of the Supra-Renal Capsules,” 1855, p. 30.  
 AFFLECK AND LEITH.—(Sarcoma) *Edin. Hosp. Rep.*, 1896, vol. iv. pp. 278–293. Illustrations; references.

- ARMANNI.—(Neuroma) *Movimento*, Naples, 1874, tome vi. pp. 533–536.  
 ARNOTT.—(Cancer) *Trans. Path. Soc. London*, 1867, vol. xix. p. 418.  
 AVERBECK.—(Primary Cancer) “Die Addison'sche Krankheit,” 1869.  
 BALL.—(Cancer) *Bull. Soc. anat. de Paris*, 1858, vol. xxxiii. pp. 423–429.  
 BAMBERGER.—(Growths) “Krankheiten des chylo-pæetischen Systems,” 1855.  
 BENEKE.—(Sarcomata) *Schmidt's Jahrb.*, Leipzig, 1888, Bd. cccix. S. 232.  
 BERDACH.—(Primary Sarcoma) *Wien. med. Wchnschr.*, 1889, Bd. xxxix. S. 357, 385.

### References.

- BERDEZ.—(Growths) *Arch. de méd. expér. et d'anat. path.*, Paris, 1892, tome iv. pp. 412–415.  
 BESNIER.—(Cancer) *Bull. Soc. anat. de Paris*, 1857, tome xxxii. pp. 85–92.  
 BLACKBURN.—(Sarcoma) *Journ. Am. Med. Ass.*, Chicago, 1888, vol. x. p. 389.  
 BOUCHARD.—(Growths) “Traité de pathologie générale,” 1895, vol. i.  
 BRISTOWE.—(Cancer) *Trans. Path. Soc. London*, 1868, vol. xix. p. 415.  
 BYFORD.—(Fatty Tumour) *Obst. Gaz.*, Cincinnati, 1889, vol. xii. pp. 84–86.  
 CADE.—(Sarcoma) *Forh. Norske med. Selsk. i Kristiania*, 1886, p. 33.  
 CAILLE.—(Sarcoma in an Infant) *Arch. Pediat.*, N. Y., 1895, vol. xii. p. 594.  
 CAYLEY.—(Cancer) *Trans. Path. Soc. London*, 1864–65, vol. xvi. p. 250.  
 CHAUFFARD.—(Adenoma) *Bull. et mém. Soc. méd. d'hôp. de Paris*, 1896, Sér. 3, tome xiii. pp. 777–784.  
 COATS.—(Growths) “Manual of Pathology,” 3rd edition, 1895, p. 811.  
 COHN.—(Primary Sarcoma in Infant) *Berl. klin. Wchnschr.*, 1894, Bd. xxxi. S. 266–268.  
 DA COSTA.—(Secondary Cancer) *Proc. Path. Soc. Phila.*, 1857–60, vol. i. p. 153.  
 DELPIERRE.—(Cancer) *Gaz. d. hôp.*, Paris, 1856, p. 393.  
 DI MATTEI.—(Adenoma) *Gior. d. r. Accad. di med. di Torino*, 1886, tome xxxiv. p. 127.  
 DUCLOS.—(Cancer) *Bull. gén. de thérap.*, Paris, 1863, tome lxiv. p. 97.  
 EARLE.—(Malignant Growths, æt. 3) *Journ. Am. Med. Ass.*, 29th Dec. 1894.  
 EURICH.—(Adenoma) *Journ. Path. and Bacteriol.*, Edin. and London, Jan. 1896, p. 504.  
 FEREOL.—(Growth) *Bull. Soc. anat. de Paris*, 1857.  
 FORMAD.—(Growth) *Trans. Path. Soc. Phila.*, 1884, vol. xi. p. 184.  
 FOX.—(Primary Sarcoma in a Child) *Trans. Path. Soc. London*, 1884–85, vol. xxxvi. pp. 460–463.  
 FRÄNKEL, F.—(Growth) *Virchow's Archiv*, 1886, vol. ciii. pp. 244–263.  
 GAIRDNER, W. T.—(Growth) *Month. Journ. Med. Sc.*, London and Edin., 1850, vol. x. p. 382.  
 GATTI.—(Growths in Aberrant Adrenals) *Morgagni*, Milano, 1897, vol. xxxix. pp. 474–497.  
 GREENHOW.—(Malignant Growth, æt. 12) *Trans. Path. Soc. London*, 1867, p. 303.

- GREENHOW.—(Cancer and Table of Cases) *Ibid.*, 1865–66, vol. xvii. pp. 303, 332.
- ” (Cancer) *Ibid.*, 1866–77, vol. xviii. pp. 260–262.
- ” (Cancer) *Ibid.*, 1872–73, vol. xxiv. pp. 238–241.
- HABERSHON.—(Growth) *Guy's Hosp. Rep.*, London, 1866, vol. xii. p. 423.
- HADDEN.—(Carcinoma) *Trans. Path. Soc. London*, 1885–86, vol. xxxvii. p. 515.
- HALDANE.—(Cancer) *Edin. Med. Journ.*, 1861, vol. vii. p. 586.
- HAMILTON.—(Growths) “Text-Book of Pathology,” 1894, vol. ii. part 2, p. 783.
- HEITLER.—(Cancer) *Wien. med. Presse*, 1875, Bd. xvi. S. 809, 833.
- KELYNACK.—(Adenoma) *Journ. Anat. and Physiol.*, London, 1896, vol. xxx. p. 539.
- ” (Adenomata) *Edin. Med. Journ.*, Sept. 1897, p. 263.
- ” (Growths) *Med. Chron.*, Manchester, Sept. 1897, pp. 401–412.
- KLEBS.—(Growths) “Handbuch d. Patholog. Anatomie,” 1876, Bd. i. S. 580.
- KUSSMAUL.—(Melanotic Sarcoma) *Würzb. med. Ztschr.*, 1863, No. 24.
- LANCEREAUX.—(Growths) “Dictionnaire Encyclopédique des sciences médicales,” Paris, 1875, tome iii. p. 161.
- LAZARUS.—(Sarcoma, æt. 3½) *Berl. klin. Wchnschr.*, 21st May 1894.
- LETENNEUR.—(Growths) *Journ. de la sect. de méd. Soc. acad. Loire-Inf.*, Nantes, tome xxxiii. p. 341; and *Gaz. hebd. de méd.*, Paris, 1858, p. 618.
- LETULLE.—(Fibroma) *Bull. Soc. anat. de Paris*, 1888, tome lxiii. pp. 302–304.
- ” (Adenoma) *Ibid.*, 1892, p. 334.
- ” (Adenomata) *Gaz. hebd. de méd.*, Paris, 1892, tome xxix. p. 306.
- ” (Adenomata) *Arch. d. sc. méd. . . . de Bucarest*, Paris, 1896, tome i. pp. 80–86.
- LUBET-BARBON.—(Cancér) *Bull. Soc. anat. de Paris*, 1885, tome lx. p. 136; and *Progrès méd.*, Paris, 1885, part 2, p. 556.
- MACGILLIVRAY.—(Cancer) *Austral. Med. Journ.*, Melbourne, 1868, tome xiii. p. 294.
- MANKIEWICZ.—(Malignant Growth, æt. 2) “Ueber die bösartigen Tumoren der Nebennieren,” Strassburg, 1887. Diss.
- MARTIN.—(Malignant Growth, æt. 5 months) *Lyon méd.*, July 1896.
- MARTINEAU.—(Cancer) “De la Maladie d'Addison,” p. 67.
- MATTEL.—(Growths) *Gaz. hebd. de méd.*, Paris, 1864, p. 588.
- MECKEL.—(Sarcoma) “Ziemssen's Cyclopædia of Practice of Medicine,” 1878, vol. viii. p. 653.
- METTENHEIMER.—(Cancer) *Deutsche Klinik*, Berlin, 1856, S. 483.
- MORRIS.—(Growths) *Brit. Med. Journ.*, London, 1893, vol. i. p. 2.
- MOXON.—(Adenoma) *Trans. Path. Soc. London*, 1868–69, vol. xx. p. 385.
- MURCHISON.—(Cancer) *Ibid.*, 1857–58, vol. ix. p. 400.
- ” (Cancer) *Ibid.*, 1867–68, vol. xix. pp. 416–418.
- NUNO PORTI.—(Primary Encephaloid Carcinoma) *Med. contemp.*, Lisbon, 1884, part 2, pp. 188–190.
- OGLE.—(Carcinoma in a Child) *Trans. Path. Soc. London*, 1864–65, vol. xvi. pp. 250–252. (Same case as Pitman's.)
- ” (Adenoma) *Ibid.*, 1858, vol. ix. p. 406.
- PALAMIDESSI.—(Growth) *Arch. ital. di clin. med.*, Milano, 1895, tome xxxiv. pp. 80–102.
- PAYNE.—(Angioma) *Trans. Path. Soc. London*, 1869, vol. xx. p. 203.
- PEACOCK AND BRISTOWE.—(Cancer) *Ibid.*, 1856, vol. viii. pp. 333–337.
- PERRY.—(Sarcoma) *Brit. Med. Journ.*, London, 1888, vol. i. p. 1382.
- ” (Primary Sarcoma) *Ibid.*, 1889, vol. ii. p. 1766.
- PILLIET.—(Primary Sarcoma) *Bull. Soc. anat. de Paris*, 1888, tome lxiii. pp. 716–728.
- ” (Adenoma) *Ibid.*, 1889, tome lxiv. pp. 199–201.
- ” (Adenoma) *Ibid.*, 1889, pp. 423–425.
- PITMAN.—(Cancer in Female Child, æt. 3) *Lancet*, London, 1865, vol. i. p. 175. (Same case as Ogle's.)

- PITT.—(Accessory Adrenal) *Trans. Path. Soc. London*, 1894, p. 141.
- PYE-SMITH, P. H.—(Suprarenals and Lymphatic Growths) *Brit. Med. Journ.*, London, 1887, vol. i. p. 99.
- RITCHIE AND BRUCE.—(Carcinoma) *Trans. Med.-Chir. Soc.*, Edin., 1889-90, vol. ix. pp. 67-72; and *Edin. Med. Journ.*, 1890-91, vol. xxxvi. pp. 12-17.
- ROBSON.—(Sarcoma and Adenoma) *Brit. Med. Journ.*, London, 1898, vol. i.
- ROLLESTON.—(Fibro-Adenoma) *Trans. Path. Soc. London*, 1895, vol. xlv. p. 150.
- ” (Growths) “Goulstonian Lectures on the Suprarenal Bodies,” 1895.
- ” (Secondary Carcinoma) *Trans. Path. Soc. London*, 1896-97, vol. xlviii. p. 209.
- ROSENSTEIN.—(Sarcoma) *Virchow's Archiv*, 1881, Bd. lxxxiv. S. 322-324.  
Illustrations.
- SAPÉLIER.—(Primary Carcinoma) *Bull. Soc. anat. de Paris*, 1881, tome lvi. pp. 264-266; and *Progrès méd.*, Paris, 1881, tome ix. p. 793.
- SCHARAGO.—(Sarcoma) *Médecine*, St. Petersburg, 1893, tome v. pp. 82, 98.
- SIBLEY.—(Cancer) *Trans. Path. Soc. London*, 1858-59, vol. x. p. 272.
- SIPPY.—(Growths from Aberrant Adrenals) *Chicago Med. Rec.*, 1897, vol. xxiii. pp. 307-315.
- SLOUKOVENTOFF.—(Growth) *Gaz. méd. de Paris*, Dec. 7, 1895, p. 581.
- SMITH, W.—(Cystic Sarcoma) *Dublin Journ. Med. Sc.*, 1877, vol. lxiv. p. 555.
- STYBR.—(Primary Carcinoma) *Sborn lék.*, v. Praze, 1890, tome iv. pp. 84-100.
- SUTTON, BLAND.—(Adenomata) “Tumours, Innocent and Malignant,” 1893, p. 98.
- THOMA.—“General Pathology,” 1896, trans. by Bruce, vol. i. p. 567.
- TROISIER.—(Cancer) *Bull. et mém. Soc. d. hôp. de Paris*, 1890, vol. vii. pp. 266-268.
- TURNER.—(Sarcoma) *Trans. Path. Soc. London*, 1884-85, vol. xxxvi. p. 464.
- VIRCHOW.—(Growths) “Die Krankhaften Geschwulste,” 1862-65.
- WALLIS.—(Growth) *Hygiea*, Stockholm, 1884, vol. xlvi. p. 557.
- WEIMBERG.—(Double Adenoma) *Bull. Soc. anat. de Paris*, 1895, tome lxx. p. 630.
- WEST.—(Primary Sarcoma) *Trans. Path. Soc. London*, 1878-79, vol. xxx. pp. 419-421.
- WHITE.—(Sarcoma) *Ibid.*, 1884-85, vol. xxxvi. p. 464.
- WIGLESWORTH, J.—(Primary Carcinoma) *Liverpool Med.-Chir. Journ.*, 1892, vol. xii. p. 254.
- WILKES AND HUTCHINSON.—(Cancer) *Trans. Path. Soc. London*, 1856-57, vol. viii. p. 340. (Report on Gibbs' specimen).
- ZIEGLER.—“Text-Book of Pathological Anatomy” (MacAlister's translation) 1886, part 2, p. 87.

GENERAL INDEX.



## GENERAL INDEX.

	PAGE		PAGE
Aberrant adrenal tissue . . . . .	145	Adrenal lipoma . . . . .	171
Abscess, diagnosis from growth . . . . .	208	"    lymphangioma . . . . .	172
Accessory renal arteries . . . . .	225	"    malignant growths of . . . . .	172
"    adrenals . . . . .	140	"    mesoblastic organ of . . . . .	132
Adeno-carcinoma . . . . .	149	"    "    "    rests " . . . . .	131
Adenoma, adrenal . . . . .	163	"    sarcoma . . . . .	174
"    alveolar . . . . .	112	Adults, sarcoma in . . . . .	86
"    classification . . . . .	112	Affected side . . . . .	46
"    congenital cystic . . . . .	147	Age, influence generally . . . . .	32
"    cystic . . . . .	112	"    in carcinoma . . . . .	153
"    malignant cystic . . . . .	116	"    "    growths of adrenal origin . . . . .	134
"    malignant . . . . .	38	"    "    rhabdo-myo-sarcoma . . . . .	84
"    "    nephrectomy for . . . . .	45	"    "    sarcoma . . . . .	83
"    microscopic characters . . . . .	115	Alveolar sarcoma . . . . .	109
"    multiple . . . . .	112	Angioma, adrenal . . . . .	172
"    nodular . . . . .	115	"    renal . . . . .	72
"    papillary . . . . .	112	Angio-sarcoma . . . . .	106
"    simple . . . . .	113	Antipyrin for pain . . . . .	230
"    solid . . . . .	112	Arsenic, treatment by . . . . .	226
"    transitional forms . . . . .	116	Ascites, diagnosis . . . . .	211
"    with interstitial nephritis . . . . .	115	Atrophy of growths . . . . .	53
Adenomatous formation in infarct . . . . .	114	Ballottement, sign of tumour . . . . .	195
"    growths . . . . .	112, 160	Benign growths of adrenal . . . . .	163
"    "    macroscopic characters . . . . .	151	"    "    kidney . . . . .	60
"    "    need for investigation . . . . .	150	Bibliography . . . . .	231
"    "    nephrectomy for . . . . .	161	Bilateral renal growths . . . . .	51
"    "    simple . . . . .	112-115	Bones, secondary deposits in . . . . .	51
Adeno-myo-sarcoma . . . . .	150	Broad ligament, adrenal "rests" in . . . . .	131
Adeno-sarcoma . . . . .	107	Calcareous infiltration . . . . .	53
Adhesions of growth . . . . .	41	Calculi and epithelioma . . . . .	158
Adrenal, aberrant . . . . .	145	"    "    growths generally . . . . .	27
"    accessory . . . . .	140	"    "    capsular sarcoma . . . . .	88
"    adenoma . . . . .	163	Capsular sarcoma . . . . .	225
"    angioma . . . . .	172	Capsule, removal of . . . . .	174
"    benign, growths of . . . . .	163	Carcinoma, adrenal . . . . .	153
"    carcinoma of . . . . .	174	"    age in . . . . .	158
"    character of growths of kidney . . . . .	132	"    calculi in . . . . .	158
"    originating in . . . . .	185	"    cases . . . . .	156
"    clinical features of growths of . . . . .	205	"    circumscribed . . . . .	153
"    diagnosis of growths of . . . . .	171	"    colloid . . . . .	155, 158
"    fibroma of . . . . .	163	"    consistency of . . . . .	154
"    frequency of growths of . . . . .	172	"    degeneration in . . . . .	156
"    glioma . . . . .	163	"    diagnosis, histological . . . . .	155
"    "    goitre " . . . . .	143	"    diffuse . . . . .	153
"    hepatic capsule and tissue of . . . . .	131	"    epithelioma . . . . .	156
"    historical references to "rests" . . . . .	131	"    frequency . . . . .	152
"    of . . . . .	131	"    fungating . . . . .	10
"    investigation of "rests" of . . . . .	131	"    glandular . . . . .	152
		"    hard . . . . .	155

	PAGE		PAGE
Carcinoma, histology . . . . .	154	Deposits, secondary, in lumbar glands .	51
"  infiltrating . . . . .	153	"  "  in lungs . . . . .	51
"  lipomatosum . . . . .	63	"  "  percentage of . . . . .	52
"  nodular . . . . .	153	"  "  structure of . . . . .	52
"  origin of . . . . .	153	"  "  table of distribu-	
"  papilloma . . . . .	156	tion of . . . . .	52
"  scirrhous . . . . .	155	Diagnosis . . . . .	204
"  secondary deposits in .	159	"  of abscess . . . . .	208
"  in kidney . . . . .	152	"  "  adrenal growths . . . . .	205
"  sex in . . . . .	153	"  "  ascites . . . . .	211
"  soft . . . . .	155	"  "  cystic kidney . . . . .	207
"  surface . . . . .	152	"  "  dilated bladder . . . . .	210
"  varieties of . . . . .	153	"  "  dilatation of colon . . . . .	212
Cataphoresis, treatment by . . . . .	230	"  "  faecal accumulation . . . . .	212
Changes in growths, atrophy . . . . .	53	"  "  gumma . . . . .	208
"  calcareous . . . . .	53	"  "  hepatic diseases . . . . .	6
"  degenerative . . . . .	53	"  "  histological difficulties . . . . .	147
"  fatty . . . . .	53	"  "  hydatid . . . . .	210
"  hæmorrhage . . . . .	53	"  "  hydronephrosis . . . . .	208
"  inflammation . . . . .	53	"  "  liver and gall bladder,	
"  myxomatous . . . . .	53	lesions of . . . . .	210
"  necrosis . . . . .	53	"  "  mesenteric growths . . . . .	205
"  softening . . . . .	53	"  "  movable kidney . . . . .	209
"  suppuration . . . . .	53	"  "  nephrolithiasis . . . . .	209
Characters of growths . . . . .	38	"  "  nature of growth . . . . .	212
"  affected side . . . . .	46	"  "  omental growth . . . . .	206
"  colour . . . . .	42	"  "  ovarian tumour . . . . .	211
"  consistency . . . . .	43	"  "  phantom tumour . . . . .	212
"  extent . . . . .	40	"  "  pyonephrosis . . . . .	208
"  shape . . . . .	41	"  "  perirenal growths . . . . .	205
"  size . . . . .	38	"  "  peritoneal growths . . . . .	207
"  weight . . . . .	38	"  "  peritonitis . . . . .	207
Chian turpentine, treatment by . . . . .	227	"  "  pregnancy . . . . .	6
Childhood and sarcoma . . . . .	83	"  "  splenic enlargements . . . . .	211
Chondroma . . . . .	71	"  "  tuberculosis . . . . .	207
Classification of growths . . . . .	13	"  "  uterine growths . . . . .	209
"  Harrison's . . . . .	15	"  "  uterine growths . . . . .	211
"  histogenetic . . . . .	13	Dilatation of colon, diagnosis from	
"  Newman's . . . . .	15	growth . . . . .	212
"  Paul's . . . . .	14	Dilated bladder, diagnosis . . . . .	210
Cocaine for pain . . . . .	230	Duration, growths generally . . . . .	53
Coley's fluid, treatment by . . . . .	227	"  growths of adrenal origin . . . . .	134
Colloid carcinoma . . . . .	158	"  sarcomata . . . . .	85
Congenital sarcoma . . . . .	86	"  table showing . . . . .	54
Cylindroma . . . . .	158	Electrolysis, treatment by . . . . .	230
Cyst-adenoma, hæmorrhagic characters .	117	Embryonic defects . . . . .	23
"  histological characters . . . . .	117	"  growths . . . . .	132
"  malignant . . . . .	116	Encephaloid carcinoma . . . . .	155
"  of kidney and liver . . . . .	118	"  term objectionable . . . . .	3
"  origin of . . . . .	117	Endothelioma of kidney, with gastric	
Cystic formation in growths . . . . .	45	sarcoma . . . . .	59
"  kidney, diagnosis . . . . .	207	Epithelioma . . . . .	152
Cystoma, adeno- . . . . .	117	Etiology . . . . .	23
"  local trabecular . . . . .	114	"  age . . . . .	32
"  papillary . . . . .	116	"  calculi . . . . .	27
"  trabecular . . . . .	58, 116	"  embryonic defects . . . . .	23
"  transitional forms . . . . .	58	"  general . . . . .	28
Cysts in adenoma . . . . .	147, 149	"  heredity . . . . .	25
Death, causes of . . . . .	55	"  predisposing influences . . . . .	29
Degenerative changes in growths . . . . .	53	"  race . . . . .	29
Deposits, secondary, development of . . . . .	52	"  sex . . . . .	29
"  "  distribution of . . . . .	52	"  traumatism . . . . .	25
"  "  frequency . . . . .	51	Exhaustion, death from . . . . .	55
"  "  in bone . . . . .	51	Extension by continuity . . . . .	48
"  "  in brain . . . . .	52	"  "  lymphatics . . . . .	49
"  "  in growths of ad-		"  "  veins . . . . .	50
renal origin . . . . .	135	"  methods of . . . . .	48
"  "  in liver . . . . .	51	"  to inferior vena cava . . . . .	7, 50

	PAGE		PAGE
Extension to renal vein . . . . .	50	Heart, extension of growth to . . . . .	55
"    right auricle . . . . .	50	Hepatic lesions, diagnosis . . . . .	210
"    vena azygos . . . . .	50	Heredity, influence of . . . . .	25
Extent of growths generally . . . . .	38	Hilum, sarcoma in . . . . .	92
"    "    in children . . . . .	40	Histological diagnosis, difficulties . . . . .	155
Faecal accumulation, diagnosis . . . . .	212	Hydatid, diagnosis . . . . .	210
Fibro-lipoma . . . . .	63	Hydronephrosis, diagnosis . . . . .	208
Fibroma, adrenal . . . . .	171	"    and villous carcinoma . . . . .	156
"    renal . . . . .	60	Infancy, sarcoma in . . . . .	83
Fluctuation in tumours . . . . .	195	Inflammation in growths . . . . .	53
Foetal sarcoma . . . . .	82	Intestinal obstruction . . . . .	55
Fungus hæmatodes . . . . .	3	Intestines, relation to tumour . . . . .	194
Gall-bladder lesions, diagnosis . . . . .	210	Intracystic growth . . . . .	45
Gastro-intestinal complications . . . . .	55	Iodide of potassium, treatment by . . . . .	227
General causes of growth . . . . .	28	Kidney, accessory arteries of . . . . .	225
Glioma, adrenal . . . . .	172	"    adeno-carcinoma of . . . . .	149
Glycogen in adenomata . . . . .	115	"    "    -myo-sarcoma of . . . . .	150
Growths adenomatous, renal . . . . .	112	"    "    -sarcoma of . . . . .	107
"    adrenal . . . . .	162	"    adenomatous growths of . . . . .	12
"    angioma, renal . . . . .	71	"    adhesions around growth of . . . . .	41
"    benign, adrenal . . . . .	163	"    adrenal rests in . . . . .	131
"    "    renal . . . . .	60	"    alveolar sarcoma of . . . . .	109
"    carcinomatous, adrenal . . . . .	174	"    angioma of . . . . .	72
"    "    renal . . . . .	152	"    angio-sarcoma of . . . . .	106
"    capsular sarcoma, renal . . . . .	88	"    benign growths of . . . . .	60
"    chondroma . . . . .	71	"    capsular sarcoma of . . . . .	88
"    classification . . . . .	13	"    carcinoma of . . . . .	152
"    colour of . . . . .	42	"    changes in growths of . . . . .	53
"    combined . . . . .	57	"    character of growths of . . . . .	38
"    comparative study of . . . . .	56	"    chondroma of . . . . .	71
"    complex . . . . .	58	"    classification of growths of . . . . .	13
"    consistency of . . . . .	43	"    complex forms of growth of . . . . .	58
"    developed from adrenal "rests" . . . . .	131	"    congenital sarcoma of . . . . .	86
"    diagnosis of . . . . .	204	"    cylindroma . . . . .	158
"    etiology of . . . . .	23	"    cyst-adenoma . . . . .	116
"    fibroma, renal . . . . .	60	"    cystoma . . . . .	116
"    foetal sarcoma . . . . .	81	"    deposits, secondary in growths of . . . . .	52
"    frequency of . . . . .	18	"    diagnosis of growths of . . . . .	204
"    general characters . . . . .	38	"    duration . . . . .	53
"    historical references . . . . .	5	"    etiology . . . . .	23
"    latent . . . . .	39	"    extension methods in growth of . . . . .	48
"    lipoma, renal . . . . .	62	"    fibro-lipoma . . . . .	63
"    lymphadenoma . . . . .	79	"    fibroma . . . . .	60
"    lymphangioma, renal . . . . .	7, 9, 11	"    foetal, sarcoma of . . . . .	82
"    malignant adrenal . . . . .	172	"    frequency of growths of . . . . .	18
"    "    cyst, adenoma . . . . .	116	"    hilum, growths of . . . . .	92
"    methods of extension . . . . .	48	"    histological diagnosis . . . . .	210
"    myo-sarcoma . . . . .	100	"    hypertrophy of . . . . .	55
"    myxoma . . . . .	71	"    lipoma of . . . . .	62
"    osteoma . . . . .	71	"    lipo-myoma of . . . . .	63
"    perirenal . . . . .	187	"    "    -sarcoma of . . . . .	110
"    sarcomata, adrenal . . . . .	174	"    lymphadenoma . . . . .	79
"    "    renal . . . . .	80	"    lymphangioma . . . . .	79
"    "    simple . . . . .	60	"    lympho-sarcoma . . . . .	111
"    symptomatology . . . . .	192	"    melanotic sarcoma . . . . .	22, 110
"    treatment . . . . .	214	"    myxoma . . . . .	71
Gummatous kidney, diagnosis . . . . .	208	"    myxo-sarcoma . . . . .	109
Hæmaturia, age . . . . .	196	"    nephrectomy for growths of . . . . .	214
"    association . . . . .	197	"    nomenclature of . . . . .	3
"    frequency . . . . .	196	"    papilloma . . . . .	158
"    quantity . . . . .	197	"    peritheliomata . . . . .	58
"    time of appearance . . . . .	196	"    rhabdo-myo-sarcoma . . . . .	100
"    variability . . . . .	197	"    sarcomatous growths of . . . . .	80
"    varieties . . . . .	197	"    symptomatology of growths of . . . . .	192
Hæmorrhage into growth . . . . .	53	"    treatment . . . . .	214
"    intraperitoneal . . . . .	55		





	PAGE		PAGE
Lardaceous changes . . . . .	55	Perithelioma . . . . .	58
Latent growths . . . . .	203	Peritonitis, diagnosis . . . . .	207
Lipoma, adrenal . . . . .	171	Phantom tumour, diagnosis . . . . .	212
"    renal . . . . .	62	Pneumonia, death from . . . . .	55
Lipomata, retro-peritoneal . . . . .	189	Predisposing influences . . . . .	29
Lipo-myoma . . . . .	63	Pregnancy, diagnosis . . . . .	211
"    -sarcoma . . . . .	110	Pressure symptoms . . . . .	200
Lymphadenoma . . . . .	79	Proportion of primary to secondary growths . . . . .	20
Lymphangioma, adrenal . . . . .	172	Pulsation in tumours . . . . .	196
"    renal . . . . .	79	Pyonephrosis, diagnosis . . . . .	208
Lympho-sarcoma . . . . .	111		
		Race, influence of . . . . .	29
Malignant growths, adrenal . . . . .	172	Recovery, spontaneous . . . . .	51
Manchester Royal Infirmary, cases at . . . . .	19, 96	References, bibliographical, adrenal . . . . .	260
Medicinal treatment . . . . .	226	"    "    renal . . . . .	232
Melanotic sarcoma . . . . .	22, 110	"    "    historical, adrenal . . . . .	173
Mesenteric growths, diagnosis . . . . .	206	"    "    renal . . . . .	5
Mesentery, adrenal "rests" in . . . . .	131	"    "    recent cases . . . . .	11, 12
Microscopical examination, need for . . . . .	5, 19	Relations of kidneys . . . . .	226-230
Movable kidney, diagnosis . . . . .	209	Relationship of growths . . . . .	56
Murmur over renal tumours . . . . .	196	Renal tissue included by adrenal . . . . .	142
Myxoma . . . . .	71	Rhabdo-myo-sarcoma, bilateral . . . . .	101
Myxomatous changes . . . . .	53	"    cases . . . . .	103
Myxo-sarcoma . . . . .	109	"    dimensions . . . . .	102
		"    early references to . . . . .	100
Nævus . . . . .	72	"    metastases in . . . . .	102
Nature of growth, diagnosis . . . . .	212	"    origin . . . . .	101
Necrosis in growths . . . . .	53	"    weight . . . . .	102
Nephrectomy, adenomatous growths . . . . .	129, 139, 141, 223	Round-cell sarcoma . . . . .	95
"    adrenal "rests," growths . . . . .	131, 224	Rupture of growth . . . . .	55
"    from . . . . .	131, 224		
"    cancer . . . . .	223	Sarcoma, adeno- . . . . .	107
"    capsular lipoma . . . . .	223	"    adrenal . . . . .	174
"    carcinoma in movable . . . . .	223	"    adult, renal . . . . .	86
"    kidney . . . . .	224	"    age in renal . . . . .	83
"    early cases . . . . .	216	"    alveolar . . . . .	109
"    fibrous growths . . . . .	222	"    angio- . . . . .	106
"    first case . . . . .	8, 215	"    capsular . . . . .	88
"    methods . . . . .	224	"    carcinomatodes . . . . .	57
"    papillomata . . . . .	223	"    characters, general . . . . .	80
"    partial . . . . .	224	"    classification . . . . .	80
"    pregnancy with growth . . . . .	10	"    congenital . . . . .	6, 82
"    recurrence after . . . . .	221	"    cystic formation in . . . . .	81
"    sarcomata . . . . .	223	"    cysto- . . . . .	44
"    statistics . . . . .	221	"    differentiation from "cancer" . . . . .	80
"    technique . . . . .	224	"    duration of renal . . . . .	85
"    value of, opinion on . . . . .	214	"    foetal . . . . .	82
Nephritis interstitialis tuberosa . . . . .	60	"    hilum . . . . .	92
Nephro-lithiasis, diagnosis . . . . .	209	"    histological characters of . . . . .	95
Nomenclature . . . . .	3	"    renal . . . . .	86
		"    in adults . . . . .	83
Omental growths, diagnosis . . . . .	206	"    in infancy and childhood . . . . .	10
Origin of growths generally . . . . .	23	"    in negro . . . . .	110
"    carcinomata . . . . .	153	"    lipo- . . . . .	111
"    sarcoma . . . . .	87	"    lympho- . . . . .	96
Osteoma . . . . .	71	"    Manchester cases . . . . .	110
Ovarian tumour, diagnosis . . . . .	211	"    melanotic . . . . .	109
		"    myxo- . . . . .	41
Pain, character . . . . .	198	"    nephrectomy for . . . . .	100
"    frequency . . . . .	198	"    rhabdo-myo- . . . . .	84
"    seat . . . . .	198	"    "    age in . . . . .	95
"    treatment . . . . .	230	"    round-cell . . . . .	87
Palliative treatment . . . . .	230	"    seat . . . . .	87
Papilloma and calculi . . . . .	158	"    sex at all ages . . . . .	86
Paraplegia, death from . . . . .	55	"    "    in adult life . . . . .	85
Parenchymatous sarcoma . . . . .	89	"    "    childhood . . . . .	85
Perirenal growths . . . . .	187	"    side affected . . . . .	85
"    "    diagnosis . . . . .	205	"    size . . . . .	85

	PAGE		PAGE
Sarcoma, size in children . . . . .	40	Tables, sex, in sarcoma at all ages . . . . .	87
" spindle-cell . . . . .	95	" " " " in adult life . . . . .	86
" tubular . . . . .	158	" " " " early life . . . . .	85
" weight . . . . .	85	" weight of growth in relation to	
" " in children . . . . .	41	age . . . . .	40
Scirrhus . . . . .	155	" malignant growths . . . . .	40
Seat of sarcoma . . . . .	87	Traumatism, etiological effects . . . . .	25
Secondary deposits . . . . .	20	Treatment . . . . .	214
" renal carcinoma . . . . .	152	" antipyrin . . . . .	230
Sex, influence in growths generally . . . . .	29	" arsenic . . . . .	226
" " of adrenal origin . . . . .	134	" bacterium therapy . . . . .	229
" " carcinoma . . . . .	153	" capsule, removal of . . . . .	225
" " sarcoma . . . . .	86	" cataphoresis . . . . .	230
Shape of tumour, diagnosis . . . . .	194	" Chian turpentine . . . . .	227
of growth . . . . .	41	" cocaine . . . . .	230
Side affected in growths of adrenal		" Coley's fluid . . . . .	229
origin . . . . .	134	" early nephrectomy . . . . .	226
affected in sarcoma . . . . .	85	" electrolysis . . . . .	230
Simple growths, adrenal . . . . .	163	" iodide of potassium . . . . .	227
renal . . . . .	60	" medicinal . . . . .	226
Simultaneous origin of growths . . . . .	51	" nephrectomy . . . . .	215
Siphonoma . . . . .	158	" " opinions on . . . . .	214
Situation of tumour . . . . .	193	" palliative . . . . .	230
Size of growths generally . . . . .	38	" scraping . . . . .	158
sarcomata . . . . .	85	" statistics . . . . .	221
Softening in growths . . . . .	53	" surgical . . . . .	215
Solar plexus, adrenal "rests" near . . . . .	131	" toxins . . . . .	227
Spinal cord, compression by growth . . . . .	55	Tubercular kidney, diagnosis . . . . .	207
Spindle-cell sarcoma . . . . .	95	Tubular growth . . . . .	158
Splenic enlargements, diagnosis . . . . .	211	sarcoma . . . . .	158
Spontaneous cure . . . . .	51	Tumour, ballottement of . . . . .	195
Strumæ lipomatodes aberratæ renis . . . . .	131	" definition of . . . . .	4
Subcapsular growths of adrenal origin . . . . .	132	" diagnostic sign . . . . .	192
lipoma . . . . .	62	" fluctuation in . . . . .	195
Suppuration in growths . . . . .	53	" frequency . . . . .	192
Surface epithelial type of growth . . . . .	152	" mobility . . . . .	195
Syphilitic fibrosis of kidney . . . . .	61	" murmur . . . . .	196
Symptomatology, general . . . . .	202	" pulsation . . . . .	196
" hæmaturia . . . . .	196	" relation to intestines . . . . .	194
" latent cases . . . . .	203	" shape . . . . .	194
" pain . . . . .	198	" situation . . . . .	193
" pressure symptoms . . . . .	200	Uræmia . . . . .	55, 200
" tumour . . . . .	192	Ureter, epithelioma of . . . . .	158
" uræmia . . . . .	200	Ureteral growths, diagnosis . . . . .	209
" urinary alterations . . . . .	201	Urine in growths . . . . .	201
" varicocele . . . . .	199	" diagnosis . . . . .	211
Tables, affected side, frequency . . . . .	47	Varicocele, symptomatic . . . . .	199
" " relation to sex and		Varieties of carcinoma . . . . .	153
growth . . . . .	47	" hæmaturia . . . . .	197
" age, influence in growths gener-		" growth . . . . .	14-16
ally . . . . .	32-36	" sarcoma . . . . .	80
" in rhabdo-myo-sarcoma . . . . .	84	Villous growth in renal pelvis . . . . .	156-158
" in sarcoma . . . . .	83	Weight of growths . . . . .	38
" classification of growths . . . . .	14-16	" age influence . . . . .	40
" distribution of secondary de-		" in adults . . . . .	39
posits . . . . .	52	" in children . . . . .	39
" duration of malignant growths . . . . .	54	" table of . . . . .	40
" sex, in growths generally . . . . .	30	" sarcomata . . . . .	85
" " adult life . . . . .	31	" " surgical aspects . . . . .	40
" " advanced life . . . . .	31		
" " infancy and childhood . . . . .	31		
" " relation to forms of			
growth . . . . .	32		









CATALOGUE  
OF  
YOUNG J. PENTLAND'S  
PUBLICATIONS.

EDINBURGH: 11 TEVIOT PLACE.  
LONDON: 38 WEST SMITHFIELD, E.C.

OCTOBER 1897.

CATALOGUE

YOUNG & PENTLAND'S

PUBLICATIONS

PRINTED BY THE UNIVERSITY PRESS, EDINBURGH  
AND BY WATSON & WATSON, LTD., LONDON

CATALOGUE  
OF  
MEDICAL PUBLICATIONS  
ISSUED BY  
YOUNG J. PENTLAND,  
EDINBURGH and LONDON.

---

**Aitchison, Robert S., M.B., C.M., F.R.C.P.Ed.,**

Visiting Physician, St. Cuthbert's Poorhouse Hospital, Edinburgh.

SYNOPSIS OF THERAPEUTICS. Arranged for the use of Prescribers. With Posological Table and an arrangement of the Poisons. 18mo, cloth, pp. xii., 120. Price 3s.

**Alexander, William, M.D., F.R.C.S.,**

Honorary Surgeon, Royal Southern Hospital, Liverpool; Visiting Surgeon, Liverpool Workhouse Hospital; Acting Honorary Consulting Surgeon, Epileptic Institution, Manor House, Maghull.

THE TREATMENT OF EPILEPSY. 8vo, cloth, pp. x., 220, with 9 illustrations. Price 7s. 6d.

**Behrens, Dr. W. J.**

TEXT-BOOK OF GENERAL BOTANY. Translated from the Second German Edition. Revised by PATRICK GEDDES, F.R.S.E., Professor of Botany in the University of Dundee. 8vo, cloth, pp. viii., 374, with 408 illustrations, finely engraved on wood, and 4 analytical tables, new and cheaper edition. Price 5s.

**Berry, George A., M.B., F.R.C.S.Ed.,**

Ophthalmic Surgeon, Edinburgh Royal Infirmary; Senior Surgeon, Edinburgh Eye Dispensary; Lecturer on Ophthalmology, Royal College of Surgeons, Edinburgh.

DISEASES OF THE EYE. A Practical Treatise for Students of Ophthalmology. Second Edition, 8vo, cloth, pp. xvi., 730,



**Crocker, H. Radcliffe, M.D., F.R.C.P.,**

Physician to the Department for Diseases of the Skin, University College Hospital, London.

**ATLAS OF THE DISEASES OF THE SKIN.** In a series of Illustrations from Original Drawings with Descriptive Letterpress. Complete in Sixteen Fasciculi, containing 96 plates, exhibiting 238 figures printed in colours, from original drawings specially prepared for the work. Price 21s. each Fasciculus, and sold only by subscription. Also in 2 vols., handsomely bound in half morocco, gilt tops, the plates mounted on linen guards,—Price 18 Guineas, nett.

**“Compend” Series, The.**

**A Series of Handbooks to assist Students preparing for Examinations.**

**COMPEND OF HUMAN ANATOMY, INCLUDING THE ANATOMY OF THE VISCERA.** By SAMUEL O. L. POTTER, M.D., M.R.C.P. (Lond.), Cooper Medical College, San Francisco. Fifth Edition, revised and enlarged, crown 8vo, cloth, pp. 289, with 117 engravings and 16 full-page plates. Price 5s.

**COMPEND OF THE PRACTICE OF MEDICINE.** By DANIEL E. HUGHES, M.D., late Demonstrator of Clinical Medicine in the Jefferson Medical College of Philadelphia. Fourth Edition, revised and enlarged, crown 8vo, cloth, pp. 328. Price 7s. 6d.

**COMPEND OF OBSTETRICS.** By HENRY G. LANDIS, A.M., M.D., late Professor of Obstetrics and Diseases of Women in Starling Medical College. Third Edition, thoroughly revised, enlarged, and improved, crown 8vo, cloth, pp. 118, with 17 illustrations. Price 4s. 6d.

**COMPEND OF SURGERY.** By ORVILLE HORWITZ, B.S., M.D., Chief of the Outdoor Surgical Department, Jefferson Medical College Hospital. Fourth Edition, revised, crown 8vo, cloth, pp. 272, with 136 illustrations. Price 5s.

**COMPEND OF DISEASES OF CHILDREN.** By MARCUS P. HATFIELD, A.M., M.D., Professor of Diseases of Children, Chicago Medical College. Crown 8vo, cloth, pp. 186, with coloured plate. Price 4s. 6d.

**COMPEND OF PATHOLOGY AND MORBID ANATOMY.** By H. NEWBERY HALL, Ph.G., M.D., Professor of Pathology and Medical Chemistry, Post Graduate Medical School; Surgeon to the Emergency Hospital, &c., Chicago. Crown 8vo, cloth, pp. 204, with 91 illustrations. Price 4s. 6d.

COMPEND OF DENTAL PATHOLOGY AND DENTAL MEDICINE. By GEO. W. WARREN, D.D.S., Clinical Chief, Pennsylvania College of Dental Surgery. Crown 8vo, cloth, pp. 109, illustrations. Price 4s. 6d.

### Cunningham, D. J., M.D., F.R.S.,

Professor of Anatomy and Chirurgery, Trinity College, Dublin.

MANUAL OF PRACTICAL ANATOMY. Second Edition. In 2 vols., crown 8vo, cloth, illustrated with 372 wood engravings, and 2 coloured plates. Vol. I.—Upper Limb, Lower Limb, Abdomen; Vol. II.—Thorax, Head and Neck. Price per volume, 12s. 6d. (*Pentland's Students' Manuals.*)

### Davidson, Andrew, M.D., F.R.C.P.Ed.,

Late Visiting and Superintending Surgeon, Civil Hospital; Professor of Chemistry, Royal College, Mauritius.

GEOGRAPHICAL PATHOLOGY. An inquiry into the Geographical Distribution of Infective and Climatic Diseases. In 2 vols., large 8vo, cloth, pp. xvi., 1008. Illustrated with maps and charts. Price 31s. 6d.

HYGIENE AND DISEASES OF WARM CLIMATES. In a Series of Articles by Eminent Authorities. Edited by ANDREW DAVIDSON, M.D., F.R.C.P.Ed., Late Visiting and Superintending Surgeon, Civil Hospital; Professor of Chemistry, Royal College, Mauritius; Author of "Geographical Pathology." The Articles are contributed by Sir JOSEPH FAYRER; Drs. MACNAMARA; PATRICK MANSON; LANE NOTTER; E. A. BIRCH; R. W. COPPINGER; DAVID BRUCE; G. M. STERNBERG; MONTAGUE LUBBOCK; HY. CAYLEY; SONSINO; THE EDITOR; &c. &c. One volume, royal 8vo, cloth, pp. xx., 1014. Illustrated with engravings and full-page plates. Price 31s. 6d.

### Davis, Edward P., A.M., M.D.,

Professor of Obstetrics and Diseases of Infancy in the Philadelphia Polyclinic; Clinical Professor of Obstetrics, Jefferson Medical College, Philadelphia.

A TREATISE ON OBSTETRICS FOR STUDENTS AND PRACTITIONERS. Large 8vo, cloth, pp. 553, illustrated with 217 engravings and 30 plates in colours and monochrome. Price 16s. nett.

### Dentistry, The American System of.

In Treatises by Various Authors. Edited by WILBUR F. LITCH, M.D., D.D.S., Professor of Prosthetic Dentistry, Therapeutics,

and *Materia Medica*, in the Pennsylvania College of Dental Surgery, Philadelphia. In three handsome volumes, royal 8vo, cloth, containing about 1000 pages each, with fully 1700 elaborate illustrations. Price 30s. per volume, nett. For Sale by Subscription only.

### **Dercum, Francis X., A.M., M.D., Ph.D.,**

Clinical Professor of Nervous Diseases, Jefferson Medical College, Philadelphia; President of the American Neurological Association.

A TEXT-BOOK ON NERVOUS DISEASES. By American Authors. Royal 8vo, cloth, pp. xvi, 1056. Illustrated with 341 engravings and 7 coloured plates. Price 25s. nett.

\* \* \* The list of contributors includes the following well-known names:—

N. E. BRILL, M.D.	JAMES HENDRIE LLOYD, M.D.
CHARLES W. BURR, M.D.	CHARLES K. MILLS, M.D.
JOSEPH COLLINS, M.D.	S. WEIR MITCHELL, M.D., LL.D.
CHARLES L. DANA, M.D.	CHARLES A. OLIVER, M.D.
F. X. DERCUM, M.D.	WILLIAM OSLER, M.D.
E. D. FISHER, M.D.	FREDERICK PETERSON, M.D.
LANDON CARTER GRAY, M.D.	MORTON PRINCE, M.D.
C. A. HERTER, M.D.	G. E. DE SCHWEINITZ, M.D.
GEORGE W. JACOBY, M.D.	WHARTON SINKLER, M.D.
W. W. KEEN, M.D., LL.D.	M. ALLEN STARR, M.D.
PHILIP COOMBS KNAPP, M.D.	JAMES C. WILSON, M.D.

### **De Schweinitz, G. E., A.M., M.D.,**

Professor of Ophthalmology in the Philadelphia Polyclinic; Clinical Professor of Ophthalmology in the Jefferson Medical College, Philadelphia.

TOXIC AMBLYOPIAS; their Classification, History, Symptoms, Pathology, and Treatment. Royal 8vo, cloth, pp. 238, with 46 figures in the text, and 9 full-page plates. Price 16s. nett.

### **Edinburgh Hospital Reports.**

Edited by G. A. GIBSON, M.D., D.Sc.; C. W. CATHCART, M.A., M.B.; JOHN THOMSON, M.D.; and D. BERRY HART, M.D. Issued annually, 8vo, cloth, pp. xvi., 650 or thereby, handsomely printed. Illustrated with full-page plates and engravings. Price per volume, 12s. 6d. nett. Carriage free. Volumes I. II. III. IV. and V. now ready.

**Edinburgh Medical Journal.**

Edited by G. A. GIBSON, M.D., D.Sc., F.R.C.P.Ed., Assistant Physician, Edinburgh Royal Infirmary.

*Assisted in Special Departments by :—*

- A. LOCKHART GILLESPIE, M.D., F.R.C.P.Ed., Medical Registrar, Edinburgh Royal Infirmary (*Medicine*).
- ALEXIS THOMSON, M.D., F.R.C.S.Ed., Assistant Surgeon, Edinburgh Royal Infirmary (*Surgery*).
- FRANCIS W. N. HAULTAIN, M.D., F.R.C.P.Ed., Physician for Diseases of Women, Deaconess Hospital, Edinburgh (*Obstetrics and Gynaecology*).
- RALPH STOCKMAN, M.D., F.R.C.P.Ed., Professor of Materia Medica in the University of Glasgow (*Therapeutics*).
- R. F. C. LEITH, M.A., M.B., B.Sc., F.R.C.P.Ed., Assistant Physician, Edinburgh Royal Infirmary (*Pathology*).
- D. J. CUNNINGHAM, M.D., D.Sc., F.R.S., LL.D., D.C.L., Professor of Anatomy in the University of Dublin (*Applied Anatomy*).
- THOS. H. MILROY, M.D., B.Sc., Demonstrator of Physiology, University of Edinburgh (*Physiology*).
- J. BATTY TUKE, M.D., D.Sc., F.R.C.P.Ed., Physician Superintendent, Saughton Hall Asylum; and J. MACPHERSON, M.B., F.R.C.P.Ed., Medical Superintendent, Stirling District Asylum (*Insanity*).
- W. ALLAN JAMIESON, M.D., F.R.C.P.Ed., Physician for Diseases of the Skin, Edinburgh Royal Infirmary (*Diseases of the Skin*).
- P. M'BRIDE, M.D., F.R.C.P.Ed., Aural Surgeon and Laryngologist, Edinburgh Royal Infirmary; and A. LOGAN TURNER, M.D., F.R.C.S.Ed., Surgeon for Diseases of Ear and Throat, Deaconess Hospital, Edinburgh (*Diseases of the Ear, Throat, and Nose*).
- GEORGE A. BERRY, M.B., F.R.C.S.Ed., Ophthalmic Surgeon, Edinburgh Royal Infirmary; and W. G. SYM, M.D., F.R.C.S.Ed., Senior Assistant Ophthalmic Surgeon, Edinburgh Royal Infirmary (*Diseases of the Eye*).
- G. H. MELVILLE DUNLOP, M.D., F.R.C.P.Ed., Extra Physician, Royal Hospital for Sick Children, Edinburgh (*Diseases of Children*).
- C. HUNTER STEWART, M.B., D.Sc., F.R.S.E., Demonstrator of Public Health and Medical Jurisprudence, University of Edinburgh (*Public Health*).

**The Volumes begin with the Issues for January and July.**

*Subscription One Guinea per annum (in advance) post free. For the Colonies and Abroad, Twenty-four Shillings per annum (in advance) post free. Single Numbers Two Shillings each.*

**Ewald, Dr. C. A.,**

Extraordinary Professor of Medicine at the University of Berlin; Director of the Augusta Hospital.

**DISEASES OF THE STOMACH.** Authorised translation, with special additions by the author, by MORRIS MANGES, A.M., M.D.,

attending Physician, Mount Sinai Hospital, New York City. Large 8vo, cloth, pp. xvi., 498, with 30 illustrations. Price 16s.

### Felkin, R. W., M.D., F.R.S.E., F.R.G.S.,

Lecturer on Diseases of the Tropics and Climatology, School of Medicine, Edinburgh.

GEOGRAPHICAL DISTRIBUTION OF SOME TROPICAL DISEASES AND THEIR RELATION TO PHYSICAL PHENOMENA. 8vo, cloth, pp. 54. Illustrated with 16 coloured maps. Price 5s.

### Frost, W. Adams, F.R.C.S.,

Ophthalmic Surgeon and Lecturer on Ophthalmic Surgery, St. George's Hospital; Surgeon, Royal Westminster Ophthalmic Hospital, London.

THE FUNDUS OCULI, with an Ophthalmoscopic Atlas, illustrating its Physiological and Pathological Conditions. In one handsome 4to volume, extra cloth, gilt top, with 47 plates, exhibiting 107 beautifully coloured figures, and numerous engravings in the text. Price 63s. nett.

### Fuller, Eugene, M.D.,

Instructor in Genito-Urinary and Venereal Diseases, Post-Graduate Medical School, New York.

DISORDERS OF THE MALE SEXUAL ORGANS. Large 8vo, cloth, pp. 242. Illustrated with 8 plates and 25 figures in the text. Price 9s.

### Gibbes, Heneage, M.D.,

Professor of Pathology in the University of Michigan; formerly Lecturer on Histology in the Medical School, Westminster Hospital.

PRACTICAL PATHOLOGY AND MORBID HISTOLOGY. 8vo, cloth, pp. 362. Illustrated with 60 photographic reproductions. Price 12s. 6d.

### Gibson, G. A., M.D., D.Sc., F.R.C.P.Ed.,

Lecturer on the Principles and Practice of Medicine in the Edinburgh Medical School; Assistant Physician, Edinburgh Royal Infirmary.

DISEASES OF THE HEART AND CIRCULATION. 8vo, pp. xvi., 550, or thereby. Illustrated with 100 figures in the text. In Press. (*Pentland's Medical Series, Volume Sixth.*)

TEXT BOOK OF MEDICINE. By British Teachers. Edited by G. A. GIBSON, M.D., D.Sc. In Press, royal 8vo, pp. xxiv., 1250, with illustrations.

\* The following, among others, will contribute:—Professors W. T. GAIRDNER, Sir T. GRAINGER STEWART, THOMAS OLIVER; Sir

WILLIAM R. GOWERS, DOCTORS J. MITCHELL BRUCE, R. MAGUIRE, F. W. MOTT, STEPHEN MACKENZIE, HECTOR MACKENZIE, HALE WHITE, LAUDER BRUNTON, SIDNEY MARTIN, W. PASTEUR, A. A. KANTHACK, PATRICK MANSON, J. W. MOORE, WM. HUNTER, W. ALLAN JAMIESON, J. O. AFFLECK, WILLIAM RUSSELL, ALEX. BRUCE, R. W. PHILIP, the EDITOR, &c. &c.

**Gibson, G. A., M.D., D.Sc., F.R.C.P.Ed.,**

Lecturer on the Principles and Practice of Medicine in the Edinburgh Medical School; Assistant Physician, Edinburgh Royal Infirmary;

and

**Russell, William, M.D., F.R.C.P.Ed.,**

Assistant Physician, Edinburgh Royal Infirmary; Lecturer on Pathology and Morbid Anatomy in the Edinburgh Medical School.

PHYSICAL DIAGNOSIS. A Guide to Methods of Clinical Investigation. Second Edition, crown 8vo, cloth, pp. xvi., 376, with 109 illustrations, some coloured. Price, 10s. 6d. (*Pentland's Students' Manuals.*)

**Graham, James, M.A., M.D.,**

Late Demonstrator of Anatomy, Sydney University; Medical Superintendent, Prince Alfred Hospital, Sydney.

HYDATID DISEASE IN ITS CLINICAL ASPECTS. 8vo, cloth, pp. xvi., 204, with 34 full-page coloured plates. Price 16s.

**Hall, H. Newbery, Ph.G., M.D.,**

Professor of Pathology and Medical Chemistry, Post Graduate Medical School; Surgeon to the Emergency Hospital, &c., Chicago.

COMPEND OF PATHOLOGY AND MORBID ANATOMY. Crown 8vo, cloth, pp. 204, with 91 illustrations. Price 4s. 6d.

**Hare, Hobart Amory, M.D., B.Sc.,**

Clinical Professor of the Diseases of Children and Demonstrator of Therapeutics in the University of Pennsylvania; Physician to St. Agnes's Hospital and to the Medical Dispensary of the Children's Hospital, Philadelphia.

SYSTEM OF PRACTICAL THERAPEUTICS. By Various Authors. Edited by HOBART AMORY HARE, M.D. In 6 volumes, royal 8vo, cloth, of about 500 pages each. Uniform with the "Cyclopædia of Children's Diseases" and "Systems of Gynæcology and Obstetrics." Price per volume, 12s. 6d. nett, carriage free.

Supplement, bringing the work up to date, in two volumes, royal 8vo, cloth. Price 25s. nett, carriage free.

**Hatfield, Marcus P., A.M., M.D.,**

Professor of Diseases of Children, Chicago Medical College.

COMPEND OF DISEASES OF CHILDREN. Crown 8vo, cloth, pp. 186, with coloured plate. Price 4s. 6d.

**Haultain, F. W. N., M.D., F.R.C.P.Ed.,**

Physician to the Royal Dispensary; late Clinical Assistant to Physician for Diseases of Women, Royal Infirmary, Edinburgh; and

**Ferguson, J. Haig, M.D., F.R.C.P.Ed.,**

Physician to the New Town Dispensary; late Resident Physician, Royal Maternity Hospital, Edinburgh.

HANDBOOK OF OBSTETRIC NURSING. Second Edition, revised and enlarged, crown 8vo, cloth, pp. xvi., 244. Illustrated with 33 wood engravings. Price 5s.

**Hayem, Georges, M.D.,**

Professor of Clinical Medicine in the Faculty of Medicine of Paris.

PHYSICAL AND NATURAL THERAPEUTICS: the Remedial Uses of Atmospheric Pressure, Climate, Heat and Cold, Hydrotherapeutic Measures, Mineral Waters, and Electricity. Edited by HOBART AMORY HARE, M.D., Professor of Therapeutics and Materia Medica, Jefferson Medical College, Philadelphia. Large 8vo, cloth, pp. 426, with 113 illustrations in the text. Price 14s.

**Hirst, Barton Cooke, M.D.,**

Professor of Obstetrics in the University of Pennsylvania; and

**Piersol, George A., M.D.,**

Professor of Embryology and Histology in the University of Pennsylvania.

HUMAN MONSTROSITIES. In handsome folio, containing about 230 pages of text, illustrated with engravings and 39 full-page photographic plates from Nature. In four fasciculi. Price 25s. each nett, carriage free. The edition is limited, and is for sale only by subscription.

**Holland, J. W., M.D.,**

Professor of Medical Chemistry and Toxicology, Jefferson Medical College, Philadelphia.

THE URINE AND THE COMMON POISONS, MEMORANDA, CHEMICAL AND MICROSCOPICAL, FOR LABORATORY USE. Second Edition, revised and enlarged, oblong crown 8vo, cloth, pp. 65, with 28 illustrations. Price, 4s.

**Horwitz, Orville, B.S., M.D.,**

Chief of the Outdoor Surgical Department, Jefferson Medical College Hospital, Philadelphia.

COMPEND OF SURGERY. Fourth Edition, revised, crown 8vo, cloth, pp. 272, with 136 illustrations. Price 5s.

**Hughes, Daniel E., M.D.,**

Late Demonstrator of Clinical Medicine in the Jefferson Medical College, Philadelphia.

COMPEND OF THE PRACTICE OF MEDICINE. Fourth Edition, revised and enlarged, crown 8vo, cloth, pp. 328. Price 7s. 6d.

**Hygiene and Diseases of Warm Climates.**

(See DAVIDSON.)

**James, Alex., M.D., F.R.C.P.Ed.,**

Lecturer on the Principles and Practice of Medicine in the School of Medicine, Edinburgh; Assistant Physician, Edinburgh Royal Infirmary.

PULMONARY PHTHISIS. Its Etiology, Pathology, and Treatment. 8vo, cloth, pp. xii., 285. Price 9s.

**Jamieson, W. Allan, M.D., F.R.C.P.Ed.,**

Extra Physician for Diseases of the Skin, Edinburgh Royal Infirmary; Consulting Physician, Edinburgh City Hospital; Lecturer on the Diseases of the Skin, School of Medicine, Edinburgh.

DISEASES OF THE SKIN. A Manual for Students and Practitioners. Fourth Edition, revised and enlarged, 8vo, cloth, pp. xvi., 676, with coloured illustrations. Price 21s. (*Pentland's Medical Series, Volume First.*)

**Johnstone, Alexander, F.G.S.,**

Lecturer on Botany, School of Medicine, Edinburgh.

BOTANY. A Concise Manual for Students of Medicine and Science. Crown 8vo, cloth, pp. xvi., 260, with 164 illustrations and a series of floral diagrams. Price 6s. (*Pentland's Students' Manuals.*)

**Journal of Pathology and Bacteriology.**

Edited, with the Collaboration of Distinguished British and Foreign Pathologists, by GERMAN SIMS WOODHEAD, M.D., Director of the Laboratories of the Royal Colleges of Physicians (London) and



Surgeons (England), Assisted in Special Departments by Sidney Martin, M.D. (Lond.) (*Pathological Chemistry*); S. G. Shattock, F.R.C.S. (*Morbid Anatomy and Histology*); G. E. Cartwright Wood, M.D. (Edin.) (*Bacteriology*); C. S. Sherrington, M.D., (Cantab.) (*Experimental Pathology*). Subscription, One Guinea per annum (in advance), post free.

It has been felt for some time that the want in this country of a Journal dealing specially with General and Experimental Pathology has militated most seriously against the free interchange of ideas, not only between English-speaking pathologists, but also between British and Foreign workers.

Although the Transactions of the Pathological Society deal with communications which are brought before its members, there is no medium in which longer articles, and especially those from workers throughout the United Kingdom and abroad, can be brought before a less limited circle of readers. It has been thought desirable, therefore, to found a journal specially devoted to the publication of original contributions to General Pathology, Pathological Anatomy, and Experimental Pathology, including Bacteriology. These articles will, of course, be mainly from British Laboratories and Hospitals; but the co-operation of many distinguished Continental, American, and Colonial Pathologists has been obtained, and papers written or edited by them will be placed before our readers.

In order to increase the interest and extend the usefulness of the Journal, it is intended that, in addition to original articles, critical summaries of work done in special departments of Pathology and Bacteriology shall from time to time be published. All articles appearing in the Journal will be signed.

The Journal appears at least four times a year, but it will be issued more frequently if necessary, in order to ensure publication of all papers as early as possible after they are received.

The numbers issued throughout the year form a volume, royal 8vo, of about 500 pages. They are printed on good paper, and freely illustrated with Woodcuts and Chromolithographs.

Amongst those who collaborate are the following:—Sir Henry Acland, Bart., Oxford; J. G. Adami, Montreal; S. Arloing, Lyons; B. Bang, Copenhagen; Ch. Bouchard, Paris; R. Boyce, Liverpool; J. Rose Bradford, London; H. Buchner, Munich; Sir Charles Cameron, Dublin; Angelo Celli, Rome; A. Chantemesse, Paris; A. B. Charrin, Paris; A. Chauveau, Paris; W. Watson Cheyne, London; H. Chiari, Prague; Joseph Coats, Glasgow; W. T. Councilman, Boston; D. D. Cunningham, Calcutta; S. Delépine, Manchester; J. Dreschfeld, Manchester; D. Drummond, Newcastle; Von Esmarch, Koenigsberg; Ch. Firket, Liége; R. H. Fitz, Boston; P. Grawitz, Griefswald; W. S. Greenfield, Edinburgh; E. H. Hankin, Agra; H. Heiberg, Christiania; Victor Horsley, London; F. Hueppe, Prague; O. Israel, Berlin;

E. Klebs, Zurich ; Alfred Lingard, Poonah ; Lord Lister, London ; O. Lubarsch, Rostock ; P. Marie, Paris ; E. Metchnikoff, Paris ; F. W. Mott, London ; E. Nocard, Alfort ; T. Oliver, Newcastle ; J. Orth, Göttingen ; William Osler, Baltimore ; J. F. Payne, London ; T. Mitchell Prudden, New York ; J. M. Purser, Dublin ; J. C. Salomonsen, Copenhagen ; J. Burdon Sanderson, Oxford ; A. M. Stalker, Dundee ; J. Lindsay Steven, Glasgow ; H. Stilling, Lausanne ; I. Straus, Paris ; T. P. Anderson Stuart, Sydney ; R. Thoma, Dorpat ; J. Batty Tuke, Edinburgh ; L. Vaillard, Paris ; Rudolf Virchow, Berlin ; H. Marshall Ward, Cambridge ; A. Weichselbaum, Vienna ; C. Weigert, Frankfort a/M ; W. H. Welch, Baltimore ; Samuel Wilks, London ; A. E. Wright, Netley ; Von Zenker, Erlangen ; E. Ziegler, Freiburg.

### Keating, John M., M.D., LL.D.,

Fellow of the College of Physicians of Philadelphia ; late Visiting Obstetrician to the Philadelphia Hospital, and Lecturer on Diseases of Women and Children, Philadelphia Hospital.

CYCLOPÆDIA OF THE DISEASES OF CHILDREN, MEDICAL AND SURGICAL. The Articles written especially for the work by American, British, and Canadian Authors. Edited by JOHN M. KEATING, M.D. In 8 vols., royal 8vo, of about 500 pages each. Illustrated with wood engravings in the text, and numerous full-page plates. Price 12s. 6d. per volume nett, carriage free. Detailed prospectus on application.

A NEW PRONOUNCING DICTIONARY OF MEDICAL TERMS. Handsome 8vo, cloth, pp. 818. Price 18s.

### Keating, John M., M.D., LL.D.,

and

### Coe, Henry C., M.D., M.R.C.S.,

Professor of Gynæcology, New York Polyclinic.

CLINICAL GYNÆCOLOGY, MEDICAL AND SURGICAL. By American Teachers. 2 vols., royal 8vo, cloth extra, gilt tops, pp. xviii., 994. Illustrated with 34 full-page plates and 377 engravings in the text. Price 25s. nett.

### Keith, Skene, F.R.C.S.,

Assisted by

### Keith, George E., M.B., C.M.

TEXT-BOOK OF ABDOMINAL SURGERY. A Clinical Manual for Practitioners and Students. 8vo cloth, gilt top, pp. xvi., 508. Price 16s. (*Pentland's Medical Series, Volume Fourth.*)

**Kenwood, H. R., M.B., C.M., L.R.C.P. (Lond.).**

THE ESSENTIALS OF MEDICAL ANATOMY. 12mo, cloth, pp. 52. Price 2s.

**Landis, Henry G., A.M., M.D.,**

Late Professor of Obstetrics and Diseases of Women in Starling Medical College.

COMPEND OF OBSTETRICS. Third Edition, thoroughly revised, enlarged, and improved, crown 8vo, cloth, pp. 118, with 17 illustrations. Price 4s. 6d.

**Lawless, E. J., M.D.,**

Surgeon-Major, 4th V.B. East Surrey Regiment.

FIRST AID TO THE INJURED AND MANAGEMENT OF THE SICK. An Ambulance Handbook and Elementary Manual of Nursing for Volunteer Bearers and Others. Crown 8vo, cloth, pp. xvi., 262, with plate and numerous wood engravings. Price 3s. 6d.

**Leuckart, Rudolf,**

Professor of Zoology and Comparative Anatomy in the University of Leipsic.

THE PARASITES OF MAN AND THE DISEASES WHICH PROCEED FROM THEM. A Text-Book for Students and Practitioners. Translated from the German with the co-operation of the Author by WILLIAM E. HOYLE, M.A. (Oxon.), M.R.C.S., F.R.S.E., Curator of the Museums, Owens College, Manchester. Natural History of Parasites in General.—Systematic Account of the Parasites Infesting Man.—PROTOZOA.—CESTODA. Large 8vo, cloth, pp. xxviii., 772. Illustrated with 404 engravings. Price 31s. 6d.

**Liddell, John, M.D.,**

Honorary Physician, Harrogate Royal Bath Hospital.

THE MINERAL WATERS OF HARROGATE. Cr. 8vo, limp cloth, pp. 64. Price 2s. nett.

**Lockwood, Charles Barrett, F.R.C.S.,**

Hunterian Professor, Royal College of Surgeons of England; Assistant Surgeon to St. Bartholomew's Hospital; Surgeon to the Great Northern Central Hospital, London.

TRAUMATIC INFECTION. Hunterian Lectures delivered at the Royal College of Surgeons of England. Crown 8vo, cloth, pp. xii., 138. Illustrated with 27 wood engravings in the text. Price 3s.

ASEPTIC SURGERY. Crown 8vo, cloth, pp. xvi., 233. Price 4s.

**Longley, Elias.**

STUDENTS' POCKET MEDICAL LEXICON. Giving the correct Pronunciation and Definition of all Words and Terms in general use in Medicine and the Collateral Sciences. New Edition, 18mo, cloth, pp. 303. Price 4s.

**McBride, P., M.D., F.R.C.P.Ed.,**

Lecturer on the Diseases of the Ear and Throat, Edinburgh School of Medicine; Aural Surgeon and Laryngologist, Royal Infirmary, Edinburgh; Surgeon, Edinburgh Ear and Throat Dispensary.

DISEASES OF THE THROAT, NOSE, AND EAR. Second Edition, revised and enlarged, 8vo, cloth, pp. xvi., 682, with coloured illustrations from original drawings. Price 25s. (*Pentland's Medical Series, Volume Third.*)

**McClellan, George, M.D.,**

Lecturer on Descriptive and Regional Anatomy at the Pennsylvania School of Anatomy; Professor of Anatomy at the Pennsylvania Academy of the Fine Arts; Member of the Academy of Natural Sciences, College of Physicians, &c., of Philadelphia.

REGIONAL ANATOMY IN ITS RELATION TO MEDICINE AND SURGERY. In 2 handsome volumes, large 4to of over 350 pages each. Illustrated with 100 full-page facsimile chromo-lithographic plates, reproduced from photographs taken by the Author of his own Dissections, expressly designed and prepared for this Work, and coloured by him after Nature. Price per volume, 42s. nett. Carriage paid. Sold only by subscription.

**Maclaren, P. H., M.D., F.R.C.S.Ed.,**

Surgeon, Edinburgh Royal Infirmary; formerly Surgeon in charge of the Lock Wards, Edinburgh Royal Infirmary; Examiner in the Royal College of Surgeons, Edinburgh.

ATLAS OF VENEREAL DISEASES. A Series of Illustrations from Original Paintings, with Descriptions of the Varied Lesions, their Differential Diagnosis and Treatment. In 10 fasciculi, price 6s. each; or complete in one handsome royal quarto volume, extra cloth, price 63s. nett.

**Maguire, Robert, M.D., F.R.C.P.,**

Physician to, and Joint Lecturer on Pathology, St. Mary's Hospital; Assistant Physician, Consumption Hospital, Brompton, London.

DISEASES OF THE KIDNEYS. 8vo, pp. xvi., 500, with illustrations in the text. In Press. (*Pentland's Medical Series, Volume Seventh.*)

**Martin, Sidney, M.D., F.R.S., F.R.C.P.,**

Assistant Physician and Assistant Professor of Clinical Medicine at University College Hospital; Assistant Physician to the Hospital for Consumption and Diseases of the Chest, Brompton.

FUNCTIONAL AND ORGANIC DISEASES OF THE STOMACH. 8vo, cloth, pp. xx., 506. Illustrated with numerous engravings throughout the text. Price 16s. (*Pentland's Medical Series, Volume Fifth.*)

**Mills, Charles K., M.D.,**

Professor of Diseases of the Mind and Nervous System in the Philadelphia Polyclini and College for Graduates in Medicine; Lecturer on Mental Diseases in the University of Pennsylvania.

THE NURSING AND CARE OF THE NERVOUS AND THE INSANE. Crown 8vo, cloth, pp. 147. Price 4s. 6d.

**Morrow, Prince A., M.D.,**

Clinical Professor of Genito-Urinary Diseases; formerly Lecturer on Dermatology in the University of the City of New York; Surgeon to Charity Hospital, New York.

SYSTEM OF GENITO-URINARY DISEASES, SYPHILOLOGY, AND DERMATOLOGY. By VARIOUS AUTHORS. Edited by PRINCE A. MORROW, M.D. In 6 divisional volumes of about 550 pages each. Royal 8vo, cloth extra, gilt tops, illustrated with coloured plates and engravings throughout the text. Price per volume, 14s. nett. Sold only by subscription.

**Muir, Robert, M.A., M.D., F.R.C.P.Ed.,**

Lecturer on Pathological Bacteriology, and Senior Assistant to the Professor of Pathology, University of Edinburgh; Pathologist, Edinburgh Royal Infirmary;

and

**Ritchie, James, M.A., M.D., B.Sc.,**

Lecturer in Pathology, University of Oxford.

MANUAL OF BACTERIOLOGY. Crown 8vo, cloth, pp. xvi., 519, with 108 illustrations. Price 12s. 6d. (*Pentland's Students' Manuals.*)

**Murray, R. Milne, M.B., F.R.C.P.Ed.,**

Assistant Physician Royal Maternity and Simpson Memorial Hospital; Lecturer on Midwifery and Diseases of Women, School of Medicine, Edinburgh.

MANUAL OF MIDWIFERY. Crown 8vo, with numerous illustrations, pp. 500, or thereby. Preparing.

**Muskett, Philip E., L.R.C.P. & S.Ed.,**

Late Surgeon to the Sydney Hospital; formerly Senior Resident Medical Officer, Sydney Hospital.

PRESCRIBING AND TREATMENT IN THE DISEASES OF INFANTS AND CHILDREN. Third Edition, revised and enlarged, 18mo, pp. xx., 336, in flexible leather binding for the pocket. Price 6s. 6d.

**Musser, John H., M.D.,**

Assistant Professor of Clinical Medicine in the University of Pennsylvania; Physician to the Philadelphia and the Presbyterian Hospitals, &c.

PRACTICAL TREATISE ON MEDICAL DIAGNOSIS. For Students and Physicians. Royal 8vo, cloth, pp. viii., 882. Illustrated with 162 engravings and 2 coloured plates. Price 24s.

**Newman, David, M.D.,**

Laryngologist to the Glasgow Royal Infirmary; Assistant Surgeon to the Western Infirmary; Examiner in Pathology in the University of Glasgow.

MALIGNANT DISEASE OF THE THROAT AND NOSE. 8vo, cloth, pp. xvi., 212, with 3 illustrations. Price 8s. 6d.

**Norris, W. F., A.M., M.D.,**

Professor of Ophthalmology, University of Pennsylvania;

and

**Oliver, C. A., A.M., M.D.,**

Surgeon to the Wills Eye Hospital, Philadelphia.

TEXT-BOOK OF OPHTHALMOLOGY. Royal 8vo, cloth, pp. viii., 622. Illustrated with 5 coloured plates and 357 woodcuts. Price 25s.

**Oliver, Thomas, M.D., F.R.C.P.,**

Physician, Royal Infirmary, Newcastle-on-Tyne; Professor of Physiology, University of Durham; Honorary Physician, Newcastle-on-Tyne Dispensary and Industrial Schools.

LEAD POISONING, IN ITS ACUTE AND CHRONIC FORMS. 8vo, cloth, pp. xii., 122, with 32 illustrations, mostly in colours. Price 10s. 6d.

**Osler, William, M.D., F.R.C.P.,**

Professor of Medicine in the Johns Hopkins University, and Physician-in-Chief to the Johns Hopkins Hospital, Baltimore.

THE PRINCIPLES AND PRACTICE OF MEDICINE. Second Edition, thoroughly revised and largely re-written. 8vo, cloth, pp. xvi., 1143, with charts and illustrations. Price 24s.

LECTURES ON ANGINA PECTORIS AND ALLIED STATES. 8vo, cloth, pp. viii., 160. Price 6s. nett.

### **Park, Roswell, A.M., M.D.,**

Professor of the Principles and Practice of Surgery and of Clinical Surgery in the Medical Department of the University of Buffalo, Buffalo, New York; Surgeon to the Buffalo General Hospital, etc.

A TREATISE ON SURGERY, by American Authors, for Students and Practitioners of Surgery and Medicine. Edited by ROSWELL PARK, A.M., M.D. 2 volumes, large 8vo, cloth, pp. 1603. Illustrated with 807 engravings and 38 full-page plates in colours and monochrome. Price 34s. nett.

### **Parvin, Theophilus, M.D., LL.D.,**

Professor of Obstetrics and Diseases of Women and Children in Jefferson Medical College, Philadelphia, and one of the Obstetricians to the Philadelphia Hospital.

THE SCIENCE AND ART OF OBSTETRICS. Third Edition, thoroughly revised, large 8vo, cloth, pp. 701, with 269 wood engravings and 2 coloured plates. Price 18s.

### **Pekelharing, C. A.,**

Professor in the Faculty of Medicine, University of Utrecht;

and

### **Winkler, C.,**

Lecturer in the University of Utrecht.

BERI-BERI: Researches concerning its Nature and Cause and the Means of its Arrest. Translated by JAMES CANTLIE, M.A., M.B., F.R.C.S. 8vo, cloth, pp. xvi., 160, with coloured illustrations from original drawings. Price 10s. 6d. nett.

### **Potter, Samuel O. L., M.D., M.R.C.P. (Lond.),**

Cooper Medical College, San Francisco.

COMPEND OF HUMAN ANATOMY, Including the Anatomy of the Viscera. Fifth Edition, revised and enlarged, crown 8vo, cloth, pp. 289, with 117 engravings and 16 full-page plates. Price 5s.

### **Rentoul, Robert R., M.D., M.R.C.S.,**

Fellow of the Obstetrical Society, London.

THE CAUSES AND TREATMENT OF ABORTION, with an Introduction by LAWSON TAIT, F.R.C.S. 8vo, cloth, pp. xvi., 271, with coloured plates and 35 engravings. Price 10s. 6d.

## Reports from the Laboratory of the Royal College of Physicians, Edinburgh.

Edited by J. BATTY TUKE, M.D., G. SIMS WOODHEAD, M.D., and D. NÖEL PATON, M.D.

VOLUME FIRST, 8vo, cloth, pp. 212, with 23 full-page plates and 19 engravings. Price 7s. 6d. nett.

VOLUME SECOND, 8vo, cloth, pp. xvi., 280, with 43 full-page plates, consisting of lithographs, chromo-lithographs, and micro-photographs. Price 10s. 6d. nett.

VOLUME THIRD, 8vo, cloth, pp. xii., 304, with 11 plates and folding charts. Price 9s. nett.

VOLUME FOURTH, 8vo, cloth, pp. xii., 254, with 25 plates and folding charts. Price 10s. 6d. nett.

### Rotch, Thomas Morgan, M.D.,

Professor of Diseases in Children, Harvard University.

PEDIATRICS. The Hygienic and Medical Treatment of Diseases in Children. For Students and Practitioners. 2 vols, royal 8vo, pp. xvi., 1124. Illustrated with 8 full-page coloured plates and about 400 engravings in the text. Price 25s. nett.

### Schäfer, E. A., F.R.S.,

Jodrell Professor of Physiology, University College, London.

TEXT-BOOK OF PHYSIOLOGY. By British Physiologists. Edited by E. A. SCHÄFER, F.R.S., Jodrell Professor of Physiology, University College, London. In Press. 2 vols, royal 8vo, pp. xxiv., 950 each or thereby, with numerous illustrations in the text.

\* \* The following among others will contribute:—Professor BURDON SANDERSON (Oxford), Professor GAMGEE, Dr. GASKELL (Cambridge), Professor GOTCH (Oxford), Professor SHERRINGTON (Liverpool), Professor M'KENDRICK (Glasgow), Professor HALLIBURTON (King's College), Professor HAYCRAFT (Cardiff), Dr. PEMBREY (Charing Cross), Dr. STARLING (Guy's), Dr. RIVERS (Cambridge), J. N. LANGLEY (Cambridge), Professor WAYMOUTH REID (Dundee), B. MOORE (University College), F. G. HOPKINS (Guy's), LEONARD HILL (London Hospital), W. H. R. RIVERS (Cambridge), the Editor, etc. etc.

### Schech, Philip, M.D.,

Lecturer in the University of Munich.

DISEASES OF THE MOUTH, THROAT, AND NOSE. Including Rhinoscopy and Methods of Local Treatment. Translated by R. H. BLAIKIE, M.D., F.R.S.E., formerly Surgeon, Edinburgh Ear and Throat Dispensary; late Clinical Assistant, Ear and Throat Department, Royal Infirmary, Edinburgh. 8vo, cloth, pp. xii., 302, with 5 wood engravings. Price 9s.



**Schmiedeberg, Dr. Oswald,**

Professor of Pharmacology, and Director of the Pharmacological Institute, University of Strasburg.

**ELEMENTS OF PHARMACOLOGY.** Translated under the Author's supervision, by THOMAS DIXSON, M.B., Lecturer on Materia Medica in the University of Sydney, N.S.W. 8vo, cloth, pp. xii., 223, with 7 illustrations. Price 9s.

**Seifert, Dr. Otto,**

Privat Docent in Wurzburg; and

**Muller, Dr. Friedrich,**

Assistent der II. Med. Klinik in Berlin.

**MANUAL OF CLINICAL DIAGNOSIS.** Third Edition, revised and corrected. Translated with the permission of the Authors by WILLIAM B. CANFIELD, A.M., M.D., Chief of Clinic for Throat and Chest, University of Maryland. Crown 8vo, cloth, pp. xii., 173, with 60 illustrations. Price 5s.

**Sheild, A. Marmaduke, M.B. (Cantab.),  
F.R.C.S.,**

Senior Assistant Surgeon, Aural Surgeon and Teacher of Operative Surgery, Charing Cross Hospital.

**SURGICAL ANATOMY: A Manual for Students.** Crown 8vo, cloth, pp. xii., 226. Price 6s. (*Pentland's Students' Manuals.*)

**Skene, Alexander J. C., M.D.,**

Professor of Gynecology in the Long Island College Hospital, Brooklyn, New York.

**MEDICAL GYNECOLOGY: A Treatise on the Diseases of Women from the Standpoint of the Physician.** 8vo, cloth, pp. vi., 530, with illustrations in the text. Price 21s.

**Smith, W. Ramsay, M.B., B.Sc.,**

Formerly Demonstrator of Anatomy, Edinburgh School of Medicine, Minto House; Late Senior Assistant to the Professor of Natural History, University of Edinburgh.

**EXAMINATION QUESTIONS.** Set for the Professional Examinations in Edinburgh University during the past ten years, selected from the Calendars.

**NATURAL HISTORY,** arranged and annotated. Price 1s. nett.

**BOTANY,** arranged and annotated. Price 1s. 6d. nett.

**CHEMISTRY,** answered and annotated. Price 2s. nett.

**ANATOMY,** answered and annotated. Price 2s. nett.

**MATERIA MEDICA AND THERAPEUTICS,** answered and annotated. Price 2s. nett.

**PHYSIOLOGY,** answered and annotated. Price 2s. nett.

MIDWIFERY AND GYNÆCOLOGY, answered and annotated.  
Price 1s. 6d. nett.

PRACTICE OF PHYSIC, answered and annotated. Price 1s. 6d.  
nett.

SURGERY, answered and annotated. Price 1s. 6d. nett.

MEDICAL JURISPRUDENCE AND PUBLIC HEALTH,  
answered and annotated. Price 2s. nett.

*\*\* Other Volumes to follow.*

**Smith, W. Ramsay, M.B., B.Sc.,**

and

**Norwell, J. Stewart, B.Sc.**

ILLUSTRATIONS OF ZOOLOGY, INVERTEBRATES AND  
VERTEBRATES. New and cheaper Edition, crown 4to, extra  
cloth, gilt top, with 70 plates exhibiting over 400 figures. Price  
7s. 6d.

**Snell, Simeon, F.R.C.S.Ed.,**

Ophthalmic Surgeon, Sheffield General Infirmary.

EXAMINATION OF THE EYE. Crown 8vo, pp. xvi., 172, with  
88 illustrations. Price 5s.

**Starr, Louis, M.D.,**

Late Clinical Professor of Diseases of Children in the Hospital of the University of  
Pennsylvania; Physician to the Children's Hospital, Philadelphia.

DISEASES OF THE DIGESTIVE ORGANS IN INFANTS  
AND CHILDREN. With Chapters on the Investigation of  
Disease and on the General Management of Children. Second  
Edition, post 8vo, cloth, pp. 396, with illustrations. Price 10s.

**Stephenson, Sydney, M.B., F.R.C.S.Ed.,**

Surgeon to the Ophthalmic School, Hanwell, London.

EPIDEMIC OPHTHALMIA: Its Symptoms, Diagnosis, and  
Management. 8vo, cloth, pp. xvi., 278. Illustrated with a coloured  
plate and numerous figures in the text. Price 9s. nett.

**System of Gynecology and Obstetrics.**

By American Authors. Edited by MATTHEW D. MANN, A.M.,  
M.D., Professor of Obstetrics and Gynecology in the Medical  
Department of the University of Buffalo, N.Y.; and BARTON  
COOKE HIRST, M.D., Associate Professor of Obstetrics in the  
University of Pennsylvania; Obstetrician to the Philadelphia and

Maternity Hospitals; Gynecologist to the Orthopædic Hospital. In 8 very handsome volumes, royal 8vo, cloth, of about 400 pages each. Fully illustrated with engravings and coloured plates. Price 12s. 6d. each nett. For Sale by Subscription only.

### **Talamon, Ch.,**

Physician to the Tenon Hospital, Paris.

APPENDICITIS AND PERITYPHLITIS. Translated from the French by RICHARD J. A. BERRY, M.B., C.M., Late President of the Royal Medical Society, Edinburgh. Crown 8vo, cloth, pp. viii., 240. Price 6s.

### **Taylor, Robert W., M.D.,**

Clinical Professor of Venereal Diseases at the College of Physicians and Surgeons (Columbia College), New York; Surgeon to Bellevue Hospital, and Consulting Surgeon to City (Charity) Hospital, New York.

THE PATHOLOGY AND TREATMENT OF VENEREAL DISEASES. Royal 8vo, cloth, pp. 1002. Illustrated with 230 engravings in the text and 7 coloured plates. Price 22s. nett.

### **Text-Book on Nervous Diseases. By American Authors.**

See DERCUM.

### **Text-Book of Physiology. By British Physiologists.**

See SCHÄFER.

### **Text-Book of Medicine. By British Teachers.**

See GIBSON.

### **Thomson, J. Arthur, M.A.,**

Lecturer on Zoology, School of Medicine, Edinburgh.

OUTLINES OF ZOOLOGY. Second Edition, revised and enlarged, crown 8vo, cloth, pp. xx., 820, with 266 illustrations in the text. Price 15s. (*Pentland's Students' Manuals.*)

**Vierordt, Oswald, M.D.,**

Professor of Medicine at the University of Heidelberg.

CLINICAL TEXT-BOOK OF MEDICAL DIAGNOSIS, for Physicians and Students. Based on the most Recent Methods of Examination. Translated, with additions from the second enlarged German edition, with the Author's permission. By FRANCIS H. STUART, M.D., Member of the Medical Society of the County of Kings, New York. Large 8vo, cloth, pp. xvi., 700, with 178 fine engravings, many in colour. Price 18s.

**Walley, Thomas, M.R.C.V.S.,**

Late Principal of the Edinburgh Royal (Dick's) Veterinary College; Professor of Veterinary Medicine and Surgery.

A PRACTICAL GUIDE TO MEAT INSPECTION. Third Edition, thoroughly revised and edited by J. M'FADYEAN, Principal and Professor of Comparative Anatomy, Royal Veterinary College, London. Post 8vo, cloth, pp. xvi., 198, with coloured illustrations. Price 10s. 6d.

**Waring, H. J., M.S., B.Sc.Lond., F.R.C.S.,**

Demonstrator of Operative Surgery, and Senior Demonstrator of Anatomy, St. Bartholomew's Hospital; Senior Assistant Surgeon, Metropolitan Hospital; Surgeon to the Belgrave Hospital for Children, London.

DISEASES OF THE LIVER, GALL BLADDER, AND BILIARY SYSTEM; their Pathology, Diagnosis, and Surgical Treatment. 8vo, cloth, pp. xvi., 385, with 58 engravings. Price 12s. 6d. nett.

MANUAL OF OPERATIVE SURGERY. In Press. Crown 8vo, pp. 650 or thereby, with 400 illustrations in the text.

**Warren, Geo. W., D.D.S.,**

Clinical Chief, Pennsylvania College of Dental Surgery.

COMPEND OF DENTAL PATHOLOGY AND DENTAL MEDICINE. Crown 8vo, cloth, pp. 109, illustrations. Price 4s. 6d.

**Webster, J. Clarence, B.A., M.D., F.R.C.P.Ed.,**

Demonstrator of Gynæcology, M'Gill University; Assistant Gynæcologist, Royal Victoria Hospital, Montreal; Late Assistant to the Professor of Midwifery and Diseases of Women and Children in the University of Edinburgh.

ECTOPIC PREGNANCY: its Etiology, Classification, Embryology, Diagnosis, and Treatment. 8vo, cloth, pp. xvi., 240, with 22 pages of plates and figures throughout the text. Price 12s. 6d. nett.

RESEARCHES IN FEMALE PELVIC ANATOMY. Demy 4to, cloth, illustrated with 26 full-page coloured plates, from original drawings. Price 30s. nett.

TUBO-PERITONEAL ECTOPIC GESTATION. Demy 4to, cloth, illustrated with 11 full-page plates, exhibiting numerous figures. Price 16s. nett.

PRACTICAL AND OPERATIVE GYNECOLOGY. Crown 8vo, cloth, pp. xvi., 295. Illustrated with 54 engravings. Price 7s. 6d.

MANUAL OF DISEASES OF WOMEN. In Press. Crown 8vo, pp. 650 or thereby, with 300 illustrations.

### **Williamson, Richard T., M.D., M.R.C.P.,**

Medical Registrar, Manchester Royal Infirmary; Assistant to Professor of Medicine, Owens College, Manchester.

DIABETES MELLITUS, its Symptoms, Pathology, and Treatment. 8vo, pp. xvi., 400 or thereby. In Press.

### **Winckel, Dr. F.,**

Professor of Gynæcology and Director of the Royal Hospital for Women; Member of the Supreme Medical Council and of the Faculty of Medicine in the University of Munich.

TEXT-BOOK OF OBSTETRICS, including the Pathology and Therapeutics of the Puerperal State. Designed for Practitioners and Students of Medicine. Translated from the German under the supervision of J. CLIFTON EDGAR, A.M., M.D., Adjunct Professor of Obstetrics in the Medical Department of the University of the City of New York. Royal 8vo, cloth, pp. 927. Illustrated with 190 engravings, mostly original. Price 28s.

### **Woodhead, G. Sims, M.D., F.R.C.P.Ed.,**

Director of the Laboratories of the Royal College of Physicians (London) and Surgeons (England).

PRACTICAL PATHOLOGY: A Manual for Students and Practitioners. Third enlarged and thoroughly revised Edition, 8vo, cloth, pp. xxiv., 652, with 195 coloured illustrations, mostly from original drawings. Price 25s.

### **Woodhead, G. Sims, M.D., F.R.C.P.Ed.,**

and

### **Hare, Arthur W., M.B., C.M.**

PATHOLOGICAL MYCOLOGY: An Enquiry into the Etiology of Infective Diseases. Section 1.—Methods. 8vo, cloth, pp. xii., 174, with 60 illustrations, mostly original (34 in colours). Price 8s. 6d.

## CLASSIFIED INDEX.

<b>Abdominal Surgery,</b> . . . . .	KEITH.
<b>Abortion</b> (Causes and Treatment), . . . . .	RENTOUL.
<b>Abscesses</b> (Treatment), . . . . .	CHEYNE.
<b>Ambulance Lectures,</b> . . . . .	LAWLESS.
<b>Anatomy</b> (Practical), . . . . .	CUNNINGHAM.
" (Medical), . . . . .	KENWOOD.
" (Regional), . . . . .	M'CLELLAN.
" (Compend of), . . . . .	POTTER.
" (Surgical), . . . . .	SHEILD.
" (Examination Questions), . . . . .	SMITH.
" (Female Pelvic), . . . . .	WEBSTER.
<b>Angina Pectoris,</b> . . . . .	OSLER.
<b>Appendicitis,</b> . . . . .	TALAMON.
<b>Aseptic Surgery,</b> . . . . .	LOCKWOOD.
<b>Atlases</b> (Brain), . . . . .	BRUCE.
" (Eye), . . . . .	FROST.
" (Skin), . . . . .	CROCKER.
" (Venereal Diseases), . . . . .	MACLAREN.
<b>Bacteriology,</b> . . . . .	MUIR & RITCHIE.
" . . . . .	WOODHEAD & HARE.
" and Pathology, Journal of.	
<b>Beri-Beri,</b> . . . . .	PEKELHARING.
<b>Bones and Joints</b> (Disease of), . . . . .	CHEYNE.
<b>Botany</b> (Text-Book), . . . . .	BEHRENS.
" (Manual), . . . . .	JOHNSTONE.
" (Examination Questions), . . . . .	SMITH.
<b>Brain</b> (Tumours), . . . . .	BRAMWELL.
" (Illustrations of Nerve Tracts), . . . . .	BRUCE.
<b>Chemistry</b> (Examination Questions), . . . . .	SMITH.
<b>Children</b> (Diseases), . . . . .	CARMICHAEL.
" (Compend of Diseases), . . . . .	HATFIELD.
" (Cyclopædia, Diseases of), . . . . .	KEATING.
" (Treatment of Diseases), . . . . .	MUSKETT.

Children (Diseases), . . . . .	ROTC.
„ (Digestive Organs in), . . . . .	STARR.
Clinical Diagnosis, . . . . .	SEIFERT & MULLER.
„ Gynæcology, . . . . .	KEATING & COE.
„ Medicine (Studies in), . . . . .	BRAMWELL.
„ „ . . . . .	GIBSON & RUSSELL.
„ „ . . . . .	MUSSER.
„ „ . . . . .	VIERORDT.
Cyclopædia of the Diseases of Children, . . . . .	KEATING.
Dental Pathology, . . . . .	WARREN.
Dentistry (System of), . . . . .	LITCH.
Dermatology (Atlas), . . . . .	CROCKER.
„ . . . . .	JAMIESON.
„ . . . . .	MORROW.
Diabetes Mellitus, . . . . .	WILLIAMSON.
Diagnosis (Ophthalmoscopic), . . . . .	BERRY.
„ (Physical), . . . . .	GIBSON & RUSSELL.
„ (Medical), . . . . .	MUSSER.
„ (Clinical), . . . . .	SEIFERT & MULLER.
„ (Medical), . . . . .	VIERORDT.
Dictionary of Terms (5 languages), . . . . .	BILLINGS.
„ „ . . . . .	KEATING.
„ „ (Pocket), . . . . .	LONGLEY.
Diet, . . . . .	BRUEN.
Digestive Organs in Children, . . . . .	STARR.
Ear (Diseases), . . . . .	BURNETT.
„ „ . . . . .	M'BRIDE.
Ectopic Gestation, . . . . .	WEBSTER.
Edinburgh Hospital Reports.	
Edinburgh Medical Journal.	
Epidemic Ophthalmia, . . . . .	STEPHENSON.
Epilepsy, . . . . .	ALEXANDER.
Examination Questions, . . . . .	SMITH.
Eye (Diseases), . . . . .	BERRY.
„ (Atlas), . . . . .	FROST.
„ (Diseases), . . . . .	NORRIS & OLIVER.
„ (Examination of), . . . . .	SNELL.
„ (Ophthalmia), . . . . .	STEPHENSON.
„ (Toxic Amblyopias), . . . . .	DE SCHWEINITZ.
First Aid to Injured, . . . . .	LAWLESS.
Genito-Urinary Diseases, . . . . .	MORROW.
Geographical Pathology, . . . . .	DAVIDSON.

Gestation (Ectopic), . . . . .	WEBSTER.
Gynæcology (Text-Book), . . . . .	KEATING & COE.
" (Medical), . . . . .	SKENE.
" (Examination Questions), . . . . .	SMITH.
" (Practical), . . . . .	WEBSTER.
" (Manual), . . . . .	"
" and Obstetrics (System of), . . . . .	MANN & HIRST.
Harrogate Waters, . . . . .	LIDDELL.
Heart (Diseases), . . . . .	BRAMWELL.
" " . . . . .	GIBSON.
" (Angina Pectoris), . . . . .	OSLER.
Hospital Reports (Edinburgh).	
Human Monstrosities, . . . . .	HIRST & PIERSOL.
Hydatid Disease, . . . . .	GRAHAM.
Hygiene and Diseases of Warm Climates, . . . . .	DAVIDSON.
Infective Diseases, . . . . .	LOCKWOOD.
Intracranial Tumours, . . . . .	BRAMWELL.
Joints (Tuberculous Disease), . . . . .	CHEYNE.
Journal of Pathology.	
" (Edinburgh Medical).	
Jurisprudence, Medical (Examination Questions),	SMITH.
Kidney (Diseases of), . . . . .	MAGUIRE.
Laboratory Reports (R. C. P., Edinburgh).	
Lead Poisoning, . . . . .	OLIVER.
Liver (Diseases of), . . . . .	WARING.
Malignant Disease of Throat and Nose, . . . . .	NEWMAN.
Materia Medica (Examination Questions), . . . . .	SMITH.
Meat Inspection, . . . . .	WALLEY.
Medical Anatomy, . . . . .	KENWOOD.
" Diagnosis, . . . . .	MUSSER.
" " . . . . .	VIERORDT.
" Dictionary (5 languages), . . . . .	BILLINGS.
" " . . . . .	KEATING.
" " (Pocket), . . . . .	LONGLEY.
" Gynæcology, . . . . .	SKENE.
" Jurisprudence (Examination Questions),	SMITH.
Medicine (Text-Book of), . . . . .	GIBSON.
" (Compend of), . . . . .	HUGHES.
" (Text-Book of), . . . . .	OSLER.



<b>Medicine</b> (Examination Questions)	SMITH.
<b>Midwifery</b> (Treatise on), . . . .	DAVIS.
"    (Compend of), . . . .	LANDIS.
"    (Manual of), . . . .	MURRAY.
"    (Text-Book), . . . .	PARVIN.
"    (Examination Questions), . . . .	SMITH.
"    (System of), . . . .	MANN & HIRST.
"    (Text-Book of), . . . .	WINCKEL.
<b>Mineral Waters</b> (Harrogate), . . . .	LIDDELL.
<b>Monstrosities</b> (Human), . . . .	HIRST & PIERSOL.
<b>Morbid Anatomy</b> , . . . .	HALL.
<b>Mouth, Throat and Nose</b> (Diseases), . . . .	SCHECH.
<b>Natural History</b> (Examination Questions),	SMITH.
"    "    (Illustrations), . . . .	SMITH & NORWELL.
"    "    (Text-Book), . . . .	THOMSON.
<b>Nervous Diseases</b> (Epilepsy), . . . .	ALEXANDER.
"    "    (Text-Book), . . . .	DERCUM.
"    "    (Nursing), . . . .	MILLS.
<b>Nose</b> (Diseases), . . . .	MCBRIDE.
"    (Diseases), . . . .	SCHECH.
<b>Nose and Throat</b> (Malignant Disease of), . . . .	NEWMAN.
<b>Nursing</b> (Obstetric), . . . .	HAULTAIN & FERGUSON.
"    (First Aid), . . . .	LAWLESS.
"    (Insane), . . . .	MILLS.
<b>Obstetric Nursing</b> , . . . .	HAULTAIN & FERGUSON.
<b>Obstetrics</b> (Text-Book of), . . . .	DAVIS.
"    (Compend of), . . . .	LANDIS.
"    (Manual of), . . . .	MURRAY.
"    (Science and Art of), . . . .	PARVIN.
"    (System of), . . . .	MANN & HIRST.
"    (Text-Book of), . . . .	WINCKEL.
<b>Ophthalmia</b> (Epidemic), . . . .	STEPHENSON.
<b>Ophthalmology</b> (Text-Book of), . . . .	NORRIS & OLIVER.
<b>Ophthalmoscopic Diagnosis</b> , . . . .	BERRY.
<b>Ophthalmoscopy</b> (Atlas of), . . . .	FROST.
<b>Parasites of Man</b> , . . . .	LEUCKART.
<b>Pathological Mycology</b> , . . . .	WOODHEAD & HARE.
<b>Pathology</b> (Geographical), . . . .	DAVIDSON.
"    (Practical), . . . .	GIBBES.
"    (Compend of), . . . .	HALL.
"    (Dental), . . . .	WARREN.
"    (Practical), . . . .	WOODHEAD.

<b>Pathology and Bacteriology</b> (Journal of),	
<b>Pediatrics,</b>	CARMICHAEL.
"	HATFIELD.
"	KEATING.
"	MUSKETT.
"	ROTCH.
"	STARR.
<b>Pharmacology,</b>	SCHMIEDEBERG.
<b>Phthisis</b> (Pulmonary),	JAMES.
<b>Physical Diagnosis,</b>	GIBSON & RUSSELL.
<b>Physiology</b> (Examination Questions),	SMITH.
" (Text-Book),	SCHÄFER.
<b>Poisoning</b> (Lead),	OLIVER.
<b>Practice of Medicine</b> (Text-Book of),	GIBSON.
"    " (Compend of),	HUGHES.
"    " (Text-Book of),	OSLER.
"    " (Exam. Questions),	SMITH.
<b>Pregnancy</b> (Ectopic),	WEBSTER.
<b>Prescribing and Treatment of Children's Diseases,</b>	MUSKETT.
<b>Regional Anatomy,</b>	McCLELLAN.
<b>Reports, Edinburgh Hospital.</b>	
"    R. C. P. Laboratory, Edinburgh.	
<b>Septic Diseases,</b>	CHEYNE.
<b>Sexual Organs</b> (Diseases),	FULLER.
<b>Skin Diseases</b> (Atlas of),	CROCKER.
"    "	JAMIESON.
"    "	MORROW.
<b>Stomach</b> (Diseases),	EWALD.
" (Diseases),	MARTIN.
<b>Suppuration,</b>	CHEYNE.
<b>Surgery</b> (Compend of),	HORWITZ.
" (Abdominal),	KEITH.
" (Aseptic),	LOCKWOOD.
" (Examination Questions),	SMITH.
" (Operative),	WARING.
<b>Surgical Anatomy,</b>	SHEILD.
<b>Syphilology,</b>	MORROW.
"	TAYLOR.
<b>System of Dentistry,</b>	LITCH.
"    Genito-Urinary Diseases,	MORROW.
"    Gynæcology and Obstetrics,	MANN & HIRST.
"    Therapeutics,	HARE.

<b>Therapeutics</b> (Synopsis), . . . . .	AITCHISON.
" (Principles of Treatment), . . . . .	BRUCE.
" (System), . . . . .	HARE.
" (Physical and Natural), . . . . .	HAYEM & HARE.
" (Examination Questions), . . . . .	SMITH.
<b>Throat</b> (Diseases), . . . . .	SCHECH.
" and <b>Nose</b> (Malignant Disease of), . . . . .	NEWMAN
" <b>Nose and Ear</b> (Diseases), . . . . .	MCBRIDE.
<b>Toxic Amblyopias</b> , . . . . .	DE SCHWEINITZ.
<b>Traumatic Infection</b> , . . . . .	LOCKWOOD.
<b>Treatment</b> (Principles of), . . . . .	BRUCE.
<b>Tropical Diseases</b> , . . . . .	DAVIDSON.
" " . . . . .	FELKIN.
<b>Tumours</b> (Intracranial), . . . . .	BRAMWELL.
<b>Ulcers</b> (Treatment), . . . . .	CHEYNE.
<b>Urine</b> , . . . . .	HOLLAND.
<b>Venereal Diseases</b> , . . . . .	MACLAREN.
" " . . . . .	MORROW.
" " . . . . .	TAYLOR.
<b>Warm Climates</b> (Diseases), . . . . .	DAVIDSON.
<b>Women</b> (Diseases of), . . . . .	KEATING & COE.
" (Diseases), . . . . .	SKENE.
" (Diseases of), . . . . .	WEBSTER.
<b>Wounds</b> (Treatment), . . . . .	CHEYNE.
<b>Zoology</b> (Examination Questions), . . . . .	SMITH.
" (Illustrations of), . . . . .	SMITH & NORWELL.
" (Outlines of), . . . . .	THOMSON.

