

Manual of operative surgery / by H.J. Waring.

Contributors

Waring, H. J. Sir, 1866-1953.

Publication/Creation

Edinburgh ; London : Young J. Pentland, 1898 (Edinburgh : Morrison and Gibb.)

Persistent URL

<https://wellcomecollection.org/works/hjbwf8ks>


License and attribution

This work has been identified as being free of known restrictions under copyright law, including all related and neighbouring rights and is being made available under the Creative Commons, Public Domain Mark.

You can copy, modify, distribute and perform the work, even for commercial purposes, without asking permission.



Wellcome Collection
183 Euston Road
London NW1 2BE UK
T +44 (0)20 7611 8722
E library@wellcomecollection.org
<https://wellcomecollection.org>





22101762776



H x $\frac{20}{w}$

With the Publisher, Compts.

MEDICAL CHRONICLE,
OWEN'S COLLEGE

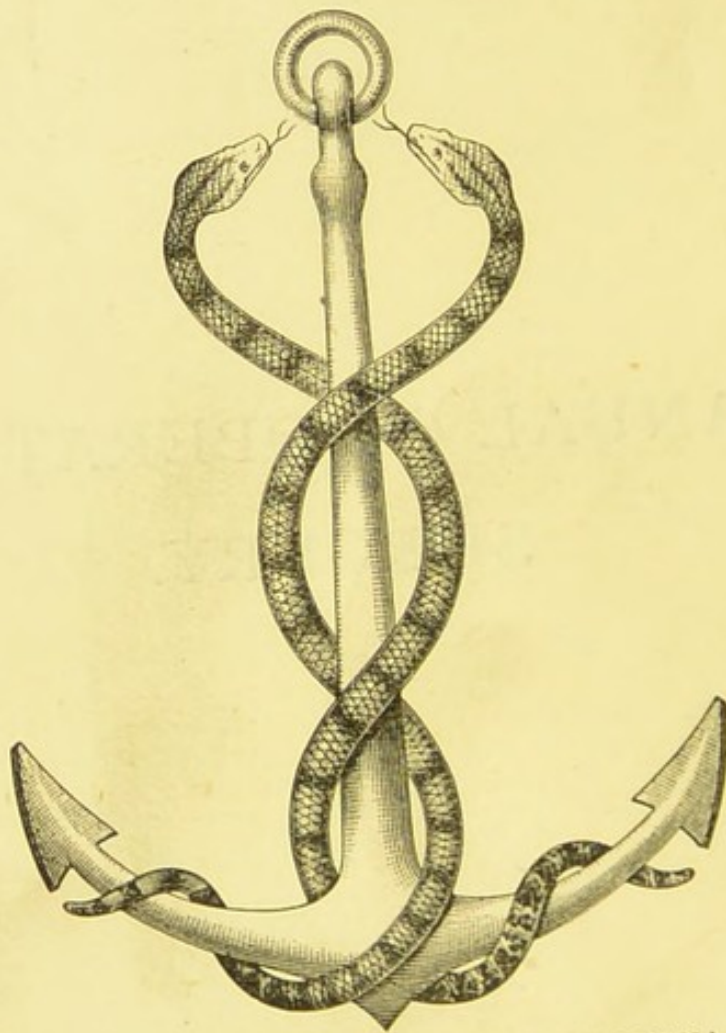


Digitized by the Internet Archive
in 2015

<https://archive.org/details/b20408997>

Pentland's Students' Manuals.

MANUAL OF OPERATIVE
SURGERY.



NUNQUAM ALIUD NATURA, ALIUD SAPIENTIA DICIT.

MANUAL
OF
OPERATIVE SURGERY

BY

H. J. WARING, M.S., M.B., B.Sc. (LOND.), F.R.C.S.

DEMONSTRATOR OF OPERATIVE SURGERY AND SURGICAL REGISTRAR, LATE SENIOR
DEMONSTRATOR OF ANATOMY, ST. BARTHOLOMEW'S HOSPITAL; SURGEON
TO THE METROPOLITAN HOSPITAL; SURGEON IN CHARGE OF THE
THROAT AND EAR DEPARTMENT, METROPOLITAN HOSPITAL;
SURGEON TO THE BELGRAVE HOSPITAL FOR CHILDREN;
AND ERASMUS WILSON LECTURER TO THE ROYAL
COLLEGE OF SURGEONS, ENGLAND.

EDINBURGH & LONDON
YOUNG J. PENTLAND

1898

14802931

EDINBURGH: PRINTED FOR YOUNG J. PENTLAND, 11 TEVIOT PLACE, AND
38 WEST SMITHFIELD, LONDON, E.C., BY MORRISON AND GIBB LIMITED.

19515

WELLCOME INSTITUTE LIBRARY	
Coll.	we1MOmec
Call	
No.	W0500
	1898
	W27m

[All rights reserved.]

PREFACE.

THIS book has been written with the object of serving as a text-book for the classes held in the Operative Surgery Department of St. Bartholomew's Hospital.

In order to make it a complete handbook for the use of students, a description of many operations which cannot readily be performed on the dead subject, has been added.

Previous to the description of an operation, or a group of allied operations, a short account of the main indications for the performance of the operation or operations under discussion is given. This, in my opinion, is an advantage, especially to junior students who are doing a course of Operative Surgery for the first time.

The order in which the different operations have been described may seem peculiar. It is that which is adopted in the practical courses at St. Bartholomew's Hospital, and which has been found to be the most useful, when, as is generally the case in England, only a small amount of material is available for carrying out a course of Operative Surgery on the dead subject.

Most of the illustrations have been prepared specially for this work; where they have been borrowed from other works, the origin has in every case been given.

The illustrations of instruments are taken from blocks kindly lent to me by Messrs. Arnold & Sons, except Figs. 107, 110, 111, 112, 395, and 396, which are from blocks lent by Messrs. Down Brothers.

I take this opportunity of thanking those friends who have helped me in the preparation of the book, especially Mr. Walter H. Jessop, for the chapter on "Ophthalmic Operations"; Dr. C. Hubert Roberts, for the sections on "Vaginal Hysterectomy" and "Rupture of the Female Perineum"; my colleagues in the Operative Surgery Department, Mr. D'Arcy Power and Mr. M'Adam Eccles, for many valuable suggestions and corrections; Mr. A. T. Compton and Mr. Cecil Beadles, for the drawings from which the illustrations have been made; Mr. P. G. Harvey and Mr. A. R. Tweedie, for a number of photographs; and Mr. J. S. Sloane, for much help in reading the proofs and making the index.

I also beg to thank all those who have kindly given me permission to use illustrations from their works.

I shall be grateful for suggestions and corrections from those who may use the book.

H. J. WARING.

9 UPPER WIMPOLE STREET,
CAVENDISH SQUARE, W.,
January 1898.

CONTENTS.



CHAPTER I.

INTRODUCTORY.

Indications for the performance of operations—Preliminary preparations—Selection of instruments—Operation table—Positions of patient, operator, and assistants—Actual operation—Methods of holding a knife—Arrest of hæmorrhage—Closure of wounds—Needles, sutures, and knots—After-treatment page 1

CHAPTER II.

OPERATIONS UPON THE STOMACH AND INTESTINES.

Stages of an abdominal operation—Methods of intestinal suture—Operations upon the stomach: Gastrostomy, gastrotomy, pyloroplasty, gastro-enterostomy, pylorectomy, and operative treatment of perforated gastric ulcer—Operations upon the small intestine: Closure of perforating wounds, resection of the intestine (by suture, and with the aid of a mechanical appliance), formation of an artificial anus—Operations upon the large intestine: Removal of vermiform appendix, excision of cæcum, resection of large intestine, colotomy (inguinal and lumbar)—Operations upon the rectum: For hæmorrhoids, for fistula in ano, excision of part of rectum (perineal method and sacral method) page 18

CHAPTER III.

OPERATIONS FOR THE TREATMENT OF HERNIA.

Operations for the radical cure of inguinal hernia: Bassini's, Kocher's, and Macewen's operations—Operation for the radical cure of femoral hernia—Operation for the radical cure of umbilical hernia—Operations for strangulated hernia: Inguinal, femoral, umbilical, and obturator herniæ page 95

CHAPTER IV.

OPERATIONS UPON THE LIVER AND BILIARY
SYSTEM.

Upon the liver: Hepatotomy (for hydatid cysts, and for abscess),
hepatectomy. Upon the biliary system: Cholecystotomy,
cholecystectomy, cholecyst-enterostomy, choledochotomy
page 119

CHAPTER V.

OPERATIONS UPON THE SPLEEN.

Splenectomy—Splenotomy page 140

CHAPTER VI.

OPERATIONS UPON THE URINARY SYSTEM.

Operations upon the kidneys: Nephrolithotomy, nephrotomy, nephrec-
tomy (lumbar and abdominal operations), nephrorrhaphy—Opera-
tions upon the urinary bladder: Puncture of the bladder, litho-
lapaxy, suprapubic cystotomy, lateral lithotomy, median lithotomy,
treatment of rupture of the bladder—Operations upon the urethra:
External urethrotomy page 145

CHAPTER VII.

OPERATIONS UPON THE MALE GENITAL ORGANS.

Operations upon the penis: Circumcision, amputation (partial and
complete)—Operations upon the testicle: Castration, radical cure
of hydrocele page 186

CHAPTER VIII.

OPERATIONS UPON THE FEMALE GENITAL ORGANS.

Operations upon the ovaries and broad ligaments: Ovariectomy,
salpingo-oöphorectomy—Operations upon the uterus: Hysterectomy,

abdominal (with intraperitoneal and extraperitoneal treatment of the pedicle) and vaginal (partial and complete)—Operations upon the perineum : Operation for repair of partial rupture, and operation for repair of complete rupture page 196

CHAPTER IX.

OPERATIONS UPON THE RESPIRATORY SYSTEM.

Operations upon the larynx : laryngotomy, thyrotomy, excision of the larynx (partial and complete)—Operations upon the trachea : Tracheotomy (high and low), laryngo-tracheotomy—Operations upon the lungs : Pneumotomy—Operations upon the pleuræ : paracentesis, incision of the pleura page 221

CHAPTER X.

OPERATIONS UPON THE PERICARDIUM.

Paracentesis, incision page 244

CHAPTER XI.

OPERATIONS UPON THE THYROID GLAND.

Excision of one lobe, excision of cysts and adenomata page 246

CHAPTER XII.

OPERATIONS UPON THE ŒSOPHAGUS.

Œsophagotomy—Œsophagostomy—Œsophagectomy page 252

CHAPTER XIII.

OPERATIONS UPON THE TONGUE.

Excision of the tongue, through the mouth and by the submaxillary method (Kocher)—Excision of a "wedge-shaped" portion page 256

CHAPTER XIV.

OPERATIONS UPON THE CRANIUM.

Trephining : For fracture of the skull, for extradural abscess or hæmorrhage, for cerebral tumour or cyst, for cerebral abscess, for cerebellar tumour or cyst, for cerebellar abscess, tapping and drainage of the lateral ventricle, removal of foreign bodies, for epilepsy—Temporary resection of the skull—Craniectomy page 263

CHAPTER XV.

THE LIGATURE OF ARTERIES.

Indications for operation—Instruments—General method of operating—Exposure and ligature of individual arteries page 292

CHAPTER XVI.

OPERATIONS UPON VEINS.

General considerations—Exposure of lateral sinus—Ligature of internal jugular vein—Operation for varicocele—Varicose veins—Venesection—Injection of saline fluids—Transfusion page 361

CHAPTER XVII.

OPERATIONS UPON NERVES.

General considerations—Neurorrhaphy—Nerve-stretching—Neurotomy—Neurectomy—Excision of ganglia—Exposure of individual nerves page 374

CHAPTER XVIII.

OPERATIONS ON TENDONS, MUSCLES, LIGAMENTS, AND APONEUROSES.

The subcutaneous method—The open method—Special operations—Suture of divided tendons—Lengthening of tendons page 395

CHAPTER XIX.

OPERATIONS UPON THE SPINAL COLUMN AND SPINAL CORD.

Laminectomy—Operations for spina bifida : By injection, by excision—
 Operations for spinal caries page 410

CHAPTER XX.

OPERATIONS ON THE TONSILS.

Incision of a tonsillar abscess—Removal of the tonsil : For simple
 enlargement, for malignant growth page 417

CHAPTER XXI.

OPERATIONS UPON THE NOSE AND ITS ACCESSORY CAVITIES.

Removal of nasal polypi—Rectification of deviated nasal septum—
 Plugging the nares—Passage of a Eustachian catheter—Removal of
 naso-pharyngeal polypi—Removal of adenoid growths—Exploration
 of frontal sinus—Exploration of antrum of Highmore page 422

CHAPTER XXII.

OPERATIONS ON THE EAR.

Extraction of foreign bodies—Removal of growths from the external
 auditory meatus : Polypi, exostoses—Incision of membrana tympani
 —Exploration of mastoid antrum and cells page 439

CHAPTER XXIII.

OPERATIONS ON THE BONES.

Osteotomy—Operations for ununited fractures—Excision of bones and
 portions of bones page 447

CHAPTER XXIV.

EXCISION OF ARTICULATIONS.

Methods of operation—Indications for operation—Excision of individual joints page 489

CHAPTER XXV.

AMPUTATIONS.

General considerations—Methods of amputation—Modes of fashioning flaps—Indications for amputation—Amputations in the upper extremity—Amputations in the lower extremity page 524

CHAPTER XXVI.

OPERATIONS UPON THE MAMMARY GLAND.

Operation for mammary abscess—Removal of localised non-malignant growths—Amputation of the breast: Without removal of the lymphatic glands from the axilla; with removal of the lymphatic glands from the axilla page 593

CHAPTER XXVII.

PLASTIC OPERATIONS.

Hare lip: Single and double—Cleft palate: Of soft palate, and of both soft and hard palate—Operation for extroversion of the urinary bladder—Operation for epispadias—Operation for hypospadias—Skin grafting: By ordinary method, by Thiersch's method page 602

CHAPTER XXVIII.

OPHTHALMIC OPERATIONS.

General considerations—Slitting up the canaliculus—Passage of lachrymal probe—Advancement of a muscle—Paracentesis—Iridectomy—Sclerotomy—Extraction—Discission—Excision page 629

INDEX page 645

LIST OF ILLUSTRATIONS.

FIG.	PAGE
1. Operation table (Arnold)	4
2. Scalpel (Arnold)	5
3. „ held in “dissecting” position	6
4. „ held in “fiddle-bow” position	6
5. Knife held in “dinner-knife” position	7
6. Amputation knife held in “grasping” position	8
7. Pressure forceps (Arnold)	9
8. Artery forceps „	9
9. Rubber bandage for rendering a limb bloodless (Arnold)	10
10. Elastic tourniquet (Arnold)	10
11. Needle, fully curved	11
12. „ half curved	11
13. „ straight	11
14. Needle-holder (Arnold)	11
15. Combined needle and needle-holder (Arnold)	12
16. Method of introduction of “interrupted” sutures	12
17. Appearance of wound when closed with “interrupted” sutures	12
18. Method of inserting a “continuous” suture	13
19. Appearance of wound when closed by a “continuous” suture	13
20. Method of tying a “reef” knot	13
21. A “granny” knot	14
22. True “surgical” knot, first stage	14
23. „ „ „ completed	15
24. Wound closed by “interrupted” sutures, each being the double hitch of a “surgical” knot	15
25. Section of the gut wall, showing method of insertion of Lembert’s suture	20
26. Section of intestinal wall, showing manner of approximation by a Lembert’s suture	20
27. Incision showing a series of embert’s sutures inserted	21

FIG.		PAGE
64.	Removal of vermiform appendix, external incision	66
65.	„ „ „ first stage	67
66.	„ „ „ second stage	68
67.	„ „ „ operation completed	68
68.	Excision of cæcum	70
69.	Inguinal colotomy, external incision	72
70.	Section of sigmoid flexure, showing method of suturing	73
71.	Inguinal colotomy, operation completed	74
72.	„ „ truss (Arnold)	75
73.	Transverse section of abdomen	77
74.	Lumbar colotomy, external incision	78
75.	„ „ operation completed	80
76.	Clover's crutch (Arnold)	82
77.	Curved sharp-pointed bistoury (Arnold)	85
78.	Vertical section through male pelvis (Cunningham)	87
79.	Excision of rectum, perineal method, first stage	88
80.	„ „ „ „ second stage	88
81.	Rectal bougie, Harrison Cripps (Arnold)	90
82.	Excision of rectum, sacral method	91
83.	Radical cure of inguinal hernia (Bassini), external incision	97
84.	Hernia needle	98
85.	Radical cure of inguinal hernia (Bassini), second stage	99
86.	„ „ „ „ third stage	100
87.	„ „ „ „ (Kocher), first stage	100
88.	Long forceps for drawing hernial sac through the canal (Arnold)	101
89.	Radical cure of inguinal hernia (Kocher), second stage	102
90.	„ „ „ „ third stage	102
91.	„ „ „ „ fourth stage	103
92.	„ „ „ „ (Macewen), method of folding the sac	104
93.	Macewen's hernia needles (Arnold)	104
94.	Radical cure of inguinal hernia (Macewen), method of transfixing the sac	105
95.	Radical cure of inguinal hernia (Macewen), method of transfixion of the conjoined tendon	106
96.	Radical cure of inguinal hernia (Macewen), suture ready for tying	107
97.	Femoral hernia, line of incision	109
98.	„ „ fixation of sac	110
99.	Umbilical hernia	111
100.	Inguinal hernia	114
101.	Hernia director, Skey's (Arnold)	115

FIG.	PAGE
102. Hernia knife (Arnold)	116
103. Obturator hernia	117
104. Resection of liver	126
105. „ „	127
106. Cholecystotomy	129
107. Cholecystotomy forceps, Anderson (Arnold)	130
108. Cholecystotomy scoop	131
109. "Purse-string" suture	134
110. Cholecyst-enterostomy (Down)	135
111. „ „	135
112. „ after Murphy (Down)	136
113. Gastro-hepatic omentum	138
114. Transverse section of trunk showing the relations of the spleen	141
115. Lumbar nephrectomy	146
116. Transverse section of trunk showing relations of kidneys	147
117. Large abdominal retractor (Arnold)	148
118. Calculus forceps (Arnold)	150
119. Pedicle needle „	155
120. Abdominal nephrectomy	156
121. Lithotrite (Arnold)	163
122. Evacuating catheter (Arnold)	164
123. Bigelow's evacuator „	165
124. Rectal bag	167
125. Suprapubic cystotomy	168
126. Mesial section through male pelvis (Cunningham)	169
127. Lithotomy forceps (Arnold)	171
128. Lateral lithotomy, staff (Arnold)	174
129. „ perineal incision (Arnold)	175
130. Lithotomy knife (Arnold)	176
131. Wheelhouse's staff (Arnold)	178
132. Lateral lithotomy, external incision	179
133. Probe-pointed gorget (Arnold)	180
134. Circumcision, skin incision	187
135. „ operation completed	188
136. Amputation of penis, incision	189
137. „ „ operation completed	190
138. Castration	193
139. Ovariectomy	197
140. „ trocar (Arnold)	198
141. „ cyst forceps (Arnold)	199
142. Pedicle needle (Arnold)	200
143. Female pelvic viscera (after Testut)	204

FIG.	PAGE
144. Myoma screw, Tait (Arnold)	207
145. Structures in broad ligament (after Testut)	208
146. Large pressure forceps (Arnold)	209
147. Sims' vaginal speculum (Arnold)	212
148. Vaginal hysterectomy	213
149. Rupture of perineum (partial)	216
150. „ „ „	216
151. „ „ (complete)	217
152. „ „ „	217
153. „ „ „	218
154. „ „ „	218
155. Laryngotomy	222
156. „ tube (Arnold)	223
157. Thyrotomy	225
158. Excision of larynx. Gussenbauer's artificial larynx (Arnold)—	
<i>A.</i> Complete instrument	229
<i>B.</i> In section	229
159. Intubation apparatus, O'Dwyer (Arnold)	231
160. Transverse section through the neck	233
161. Tracheotomy	234
162. Blunt hook for use in tracheotomy (Arnold)	235
163 (<i>a</i>). Tracheotomy dilators (Arnold)	236
163 (<i>b</i>). „ tube, Parker (Arnold)	237
164. Aspirator (Arnold)	240
165. Incision of pleura	241
166. Drainage tube (Arnold)	242
167. Excision of thyroid gland	247
168. Mouth gag, Ackland (Arnold)	257
169. Excision of tongue (Kocher)	259
170. Trephine (Arnold)	264
171. Skull showing bony points	265
172. „ „ position of cerebral fissures	266
173. Fissures and convolutions of right cerebral hemisphere (after Eberstaller)	268
174. Fissures and convolutions of left cerebral hemisphere (after Eberstaller)	269
175. Horsley's periosteal elevator (Arnold)	270
176. Straight-edged chisel (Arnold)	271
177. Grooved chisel (Arnold)	272
178. Wooden mallet (Arnold)	273
179. Depressed fracture of skull	276
180. Head showing position of cranial sutures (Cunningham)	279

FIG.	PAGE
181. Trephining for motor centres	280
182. Trephining for temporo-sphenoidal abscess	283
183. „ cerebellum	285
184. Gun-shot probe (Arnold)	287
185. Temporary resection of the skull (after Wagner)	289
186. Hoffman's bone forceps (Arnold)	290
187. Hey's saw (Arnold)	291
188. Serrated forceps (Arnold)	293
189. Double-curved aneurysm needles (Arnold)	294
190. Retractor (Arnold)	295
191. Method of opening the sheath of an artery	296
192. Simple-curved aneurysm needle (Arnold)	297
193. Transverse section of neck	302
194. Ligature of common carotid artery	303
195. „ internal and external carotid arteries	305
196. „ lingual artery	308
197. „ facial and superficial temporal arteries	309
198. „ occipital artery	311
199. „ anterior and posterior branches of middle men- ingeal artery (after Krönlein)	312
200. Ligature of main trunk of middle meningeal artery	313
201. „ subclavian artery	317
202. „ internal mammary artery	320
203. „ axillary artery—first part	323
204. „ arteries of upper extremity	324
205. Transverse section of upper arm	326
206. „ „ arm at bend of elbow	328
207. Ligature of ulnar artery	329
208. „ radial artery at wrist	332
209. „ abdominal aorta	334
210. „ common iliac artery	336
211. „ external iliac artery	339
212. „ deep epigastric and circumflex arteries	341
213. „ common femoral artery and superficial femoral in Scarpa's triangle	343
214. Transverse section of thigh	344
215. Ligature of superficial femoral artery (in Hunter's canal), and upper part of popliteal artery	345
216. Transverse section through middle of thigh	346
217. „ „ thigh (popliteal space)	347
218. Ligature of popliteal artery (lower part)	349
219. „ posterior tibial artery	350

FIG.	PAGE
220. Transverse section through middle of leg	351
221. Ligature of peroneal artery	353
222. „ anterior tibial artery	354
223. „ dorsalis pedis artery	357
224. „ gluteal and sciatic arteries	360
225. Exposure of internal jugular vei	362
226. Operation for varicocele	365
227. Apparatus for intravenous injection of fluids (Arnold)	370
228. Transfusion apparatus, Aveling (Arnold)	372
229. Primary suture of nerves	376
230. Secondary suture of divided nerves	378
231. Blunt hook for nerve-stretching, (Arnold)	379
232. Exposure of supra-orbital and infra-orbital nerves	381
233. „ spinal accessory nerve	385
234. „ musculo-spiral and ulnar nerve	387
235. „ musculo-spiral nerve (at bend of elbow) and ulnar nerve (at wrist)	388
236. Exposure of median nerve	391
237. „ great sciatic nerve	392
238. Sharp-pointed tenotome (Arnold)	396
239. Blunt-pointed tenotome (Arnold)	397
240. Suture of divided tendons	407
241. Lengthening of a tendon	408
242. „ „ by alternate incisions	409
243. Laminectomy	411
244. „ forceps, Waring (Arnold)	412
245. Spina bifida	413
246. Tenotomy knife, "guarded"	418
247. Tonsil guillotine, Mackenzie (Arnold)	419
248. Vulsellum forceps (Arnold)	420
249. Nasal speculum (Arnold)	423
250. Polypus snare (Arnold)	424
251. „ forceps (Arnold)	425
252. Forceps for rectification of deviated nasal septum, Walsham (Arnold)	425
253. Nasal plugs, Walsham (Arnold)	426
254. Bellocq's cannula	427
255. Method of plugging posterior nares (after Esmarch and Kowalzig)	428
256. Eustachian catheter (Arnold)	429
257. Method of surrounding a naso-pharyngeal polypus (after Esmarch and Kowalzig)	430

FIG.	PAGE
258. Ring-shaped knife, Meyer (Arnold)	434
259. Gottstein's curette (Arnold)	434
260. Forceps for removing adenoid growths, Walsham (Arnold)	434
261. Exploration of frontal sinus	435
262. Drainage of frontal sinus (after Esmarch and Kowalzig)	436
263. Perforation of antrum through tooth socket	437
264. " " " its external wall	437
265. Aural forceps, Cumberbatch (Arnold)	440
266. " syringe (Arnold)	440
267. " scoop (Arnold)	440
268. " polypus snare (Arnold)	442
269. " speculum (Arnold)	443
270. Knife for incision of membrana tympani (Arnold)	444
271. Opening of mastoid antrum and cells, skin incision	445
272. " " " " incision in bone	445
273. Grooved chisel or gouge (Arnold)	446
274. Chisel (Arnold)	447
275. Osteotome (Arnold)	447
276. Supracondylar osteotomy of femur (Macewen)	448
277. Macewen's osteotome (Arnold)	449
278. Ossification of femur	450
279. Osteotomy of femur, external incision	451
280. " saw, Adams (Arnold)	452
281. " of femur (Ogston)	453
282. " " " " " "	453
283. " " subtrochanteric	455
284. " of tibia	457
285. Operation for fracture of patella	459
286. " " " method of inserting sutures	460
287. " " " sutures inserted and fixed	460
288. " " " sutures as seen from the front	461
289. Excision of upper jaw	463
290. Lion forceps (Arnold)	464
291. Excision of lower jaw	467
292. Removal of "wedge-shaped" piece from lower jaw	469
293. Excision of clavicle	470
294. " rib	475
295. Relation of structures in an intercostal space	476
296. Excision of part of chest wall	477
297. " patella	480
298. " astragalus	485
299. Cuneiform tarsectomy	487

FIG.	PAGE
300. Resection knife and periosteal elevator (Arnold)	492
301. Excision of shoulder-joint	493
302. „ elbow-joint	496
303. Ossification of humerus	498
304. „ radius and ulna	499
305. Excision of elbow-joint (Kocher)	500
306. Synovial membranes of carpus	502
307. Excision of wrist	503
308. Splint for use after excision of wrist	506
309. Excision of hip-joint (posterior incision)	508
310. „ „ (anterior incision)	510
311. „ knee-joint	512
312. Butcher's saw (Arnold)	513
313. Ossification of tibia and fibula	514
314. Howse's splint, for use after excision of knee	515
315. Excision of ankle-joint	518
316. Synovial membranes of tarsus and metatarsus	520
317. Excision of metatarso-phalangeal and interphalangeal joints of great toe	521
318. Excision of temporo-maxillary joint	522
319. Stump of a limb after a circular amputation	525
320. Elliptical incision	526
321. Forms of amputation flaps	527
322A. Circular incision	528
322B. Racket-shaped incision	528
323. Finger, showing manner of insertion of flexor and extensor tendons	530
324. Amputation of distal phalanx by a long palmar flap	531
325. Finger from which last phalanx has been removed	532
326. Amputation of a finger through second phalanx	534
327. „ „ „ metacarpo-phalangeal joint	536
328. Amputation of a finger with its metacarpal bone	537
329. Removal of the thumb at the carpo-metacarpal joint	538
330. Amputation at the wrist, long palmar flap	540
331. „ „ „ equal dorsi-palmar flaps	541
332. „ „ „ external flap	542
333. „ of the forearm, antero-posterior flaps	544
334. „ at the elbow-joint (elliptical method)	548
335. „ through upper arm (circular method)	549
336. „ „ „ formation of circular flap	550
337. „ at the shoulder-joint	552
338. „ of the upper extremity	554

FIG.		PAGE
374.	Operation for single hare lip (W. Rose)	605
375.	" " " "	605
376.	" " (Nélaton)	605
377.	" " " "	605
378.	" " " "	606
379.	" " (Malgaigne)	606
380.	" " " "	606
381.	" " " "	606
382.	" " (Giraldès)	607
383.	" " " "	607
384.	" " " "	607
385.	" double hare lip (W. Rose)	609
386.	" " " "	609
387.	" " (Maas)	609
388.	" " " "	609
389.	" " " "	610
390.	Mouth gag (Sir Thomas Smith)	611
391.	Cleft palate ; complete	612
392.	Periosteal elevator for operations on palate (Arnold)	613
393.	Long forceps for operations on palate (Arnold)	613
394.	Tubular cleft palate needle, T. Smith (Arnold)	614
395.	Needle-holder and small needles for palate operations, Arbuthnot Lane (Down)	615
396.	Needle-holder and small needles for palate operations, Arbuthnot Lane (Down)	615
397.	Operation for cleft palate (complete)	616
398.	Wire twister (Down)	616
399.	Operation for cleft palate (complete)	617
400.	" " (partial)	617
401.	" " " "	618
402.	" " " "	618
403.	Extroversion of the urinary bladder (Wood)	620
404.	Operation for epispadias, Thiersch (after Esmarch and Kowalzig)	622
405.	" " " " " "	623
406.	" " " " " "	623
407.	" " " " " "	624
408.	Skin grafting knife, Thiersch (Arnold)	627
409.	Canaliculus knife, Weber's (Arnold)	631
410.	Lachrymal probe (Arnold)	632
411.	Fixation forceps (Arnold)	633
412.	Curved scissors (Arnold)	633
413.	Spring speculum (Arnold)	633

FIG.	PAGE
414. Strabismus hook (Arnold)	634
415. Keratome (Arnold)	636
416. Curette and cystotome (Arnold)	636
417. Iridectomy forceps (Arnold)	637
418. „ scissors (Arnold)	637
419. Stop-needle (Arnold)	638
420. Graefe's knife (Arnold)	643

MANUAL OF OPERATIVE
SURGERY.

THE UNIVERSITY OF CHICAGO

LIBRARY

PHYSICS

1911

MANUAL OF OPERATIVE SURGERY.

CHAPTER I.

INTRODUCTORY.

THE present "Manual of Operative Surgery" has for its object the consideration and description of the various surgical operations which may be performed upon the human organism for the alleviation or radical cure of those malformations, diseases, or injuries amenable to direct surgical interference.

Before any surgical operation is performed, the surgeon should give careful consideration to the following details:—

- (a) The indications for its performance.
- (b) Preliminary preparations—(1) For asepsis; (2) For anæsthesia.
- (c) Selection of instruments.
- (d) Position of patient, operator, and assistant or assistants.
- (e) Actual operation.
- (f) After-treatment.

Indications.—The chief indications for the performance of each operation, or group of operations, will be mentioned in the present work, but a complete and detailed discussion of them will not be attempted, since this belongs to a text-book on surgery proper. It is, however, advisable, in my opinion, that, in a text-book intended for the use of students, an outline of the indications for the perform-

ance of the operation which is under discussion should be given.

Preliminary preparations.—(a) *For asepsis.*—That portion of the body which is about to be operated upon, if it is covered with hair, should be well shaved on the day previous to the operation. The skin should next be rendered as aseptic as possible by washing it with soap and hot water, next with ether or absolute alcohol, and finally with a solution of perchloride of mercury (1 in 500), or carbolic acid (1 in 40). A sterilised dressing is then applied and left on until the time of operation. Immediately before the operation is commenced, and after the patient has been anæsthetised, it is advisable to repeat the disinfection of the skin by the method just described.

(b) *For anæsthesia.*—An aperient medicine should be given, if possible, on the day preceding the operation, and an enema on the morning of the operation, so as to evacuate the intestines; this is especially necessary before operations on the abdominal portion of the alimentary canal, or upon the rectum. No food should be given by the mouth for three or four hours before the operation is performed. Proper observance of these precautions tends to avoid vomiting during the administration of the anæsthetic, and also involuntary evacuation of the fæces. When the alimentary canal is the seat of operation, it is of great advantage that it should be as empty as possible, so that the possibility of soiling the peritoneum with intestinal contents may be minimised. In many abdominal operations, especially those which involve the pelvic viscera, it is advisable to empty the bladder immediately before or after the commencement of the administration of the anæsthetic. This can be done either by directing the patient to pass water shortly before coming to the operation room, or by passing a catheter when the anæsthetic has been given.

In operations of emergency, such as for strangulated hernia, acute intestinal obstruction, or severe injuries, it is

generally impossible to carry out effectually these preliminary precautions, owing to the necessity for the immediate performance of the operation. In these cases the skin in the neighbourhood of the field of the operation is shaved so as to free it from hair, and then made as aseptic as possible by washing it with soap and water, ether, and then with perchloride of mercury solution, after the manner already mentioned.

Selection of instruments.—Before a surgical operation is commenced, all instruments which may be required during its performance should be selected and rendered sterile. In order to make this selection satisfactorily, it is necessary to review mentally the different stages of the operation, and to decide what instruments are requisite for each stage. Thus, whenever an incision through the skin has to be made, a cutting instrument, such as a scalpel, is requisite; if the wound is deep, or the anatomical structure upon which it is proposed to operate is not readily exposed, retractors are required; if blood vessels are to be divided, pressure forceps are necessary; and if a bone requires section, a saw of appropriate shape, or bone forceps must be taken. As a general rule, it is advisable to use as few instruments as possible.

Needles and suture material will also be required if it is wished to close up the external wound, and ligatures for the arrest of hæmorrhage. The best ligature or suture material for general use is sterilised silk of different thicknesses. Catgut is preferred by many surgeons for all buried sutures or ligatures. If its sterility can be relied upon, there is no objection to its use. Silk-worm gut and horsehair are very useful for the approximation of the margins of a skin incision. Whatever ligature material is selected, great care must be taken to ensure that it is in an aseptic condition. Silk can be boiled immediately before the commencement of every operation, and, on this account, its freedom from micro-organisms can be guaranteed.

Operation table.—A table which stands firmly upon its supports should be selected for the purpose. Fig. 1 is a representation of the form of table which is used in St. Bartholomew's Hospital. It has an arrangement for warming by means of hot water, so that chilling of the patient is avoided when the operation is a prolonged one, or a considerable amount of exposure of the patient is necessary.

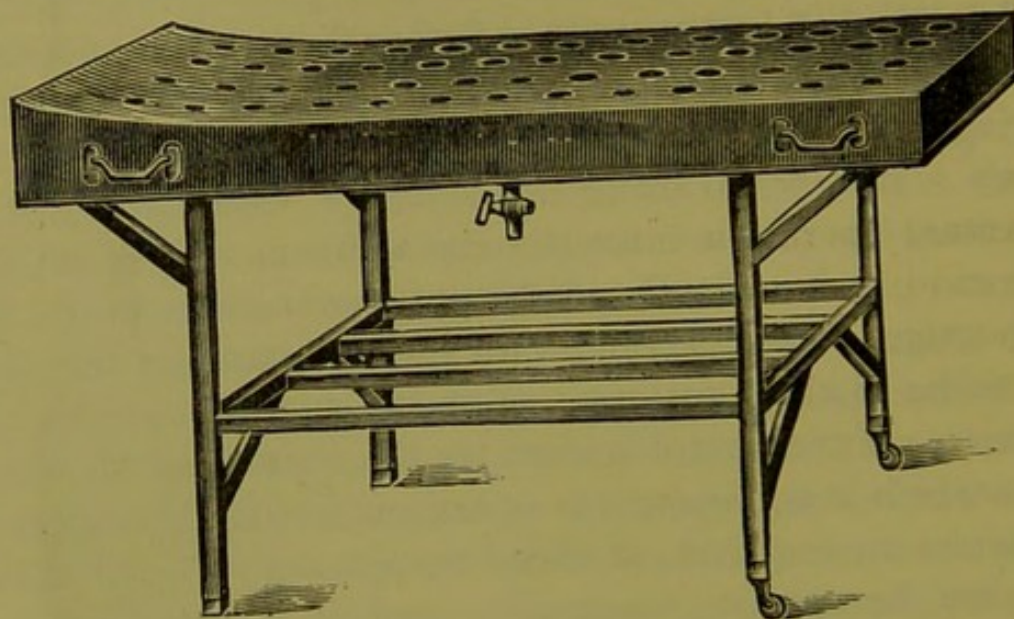


FIG. 1.—Operating table, with zinc water reservoir and perforated top.

In emergency cases, however, any form of firm support can be utilised for the purpose, care being taken that it is of suitable height and stability, and that it is made as clean as possible.

Position of patient, operator, and assistants.—The patient should be placed in a position that will at once ensure the greatest possible advantage being taken of all available light, afford a complete exposure of the field of operation, and in no way hamper the movements of the operator and his assistant. Care, however, must be taken that the respiration is not interfered with, and that room is allowed for the administrator of the anæsthetic.

The operator places himself in such a position that he can easily and readily get at the region which is to be

operated upon, whilst the assistants are so placed that they can afford the greatest help to the surgeon without impeding his movements.

The assistant or assistants, especially when not well acquainted with the technique of surgical operations, should receive explicit instructions from the surgeon as regards their duties. A good assistant in a surgical operation does what is required of him at the right moment, but otherwise does not interfere with the course of the operation.

Actual operation.—Every surgical operation can be conveniently divided into several stages, the number of which varies somewhat according to the class of operation which is being performed. In nearly all cases the first stage is the *skin incision*. This is made with a cutting instrument, usually a scalpel. In some forms of operation, however, such as tenotomy, a special knife called a tenotome is used; or, in amputations, an amputation knife of suitable shape is employed; whilst in those cases in which the skin is not divided, such as the removal of a nasal polypus or the excision of laryngeal growths by the intra-laryngeal method, no knife is necessary, a special form of instrument suitable for the individual operation being made use of. Fig. 2 is a representation of a good form of scalpel. This form of knife is recommended for making most skin incisions which are of moderate length, and for carrying out any dissections which may be necessary during the further stages of the operation.

Method of holding a knife.—Several different methods of



FIG. 2.—Scalpel of good shape, with a metal handle.

holding a knife, when performing a surgical operation, are adopted. These may be classified as follows, namely :—

- (a) "Dissecting" position.
- (b) "Fiddle-bow" position.
- (c) "Dinner-knife" position.
- (d) "Grasping" position.

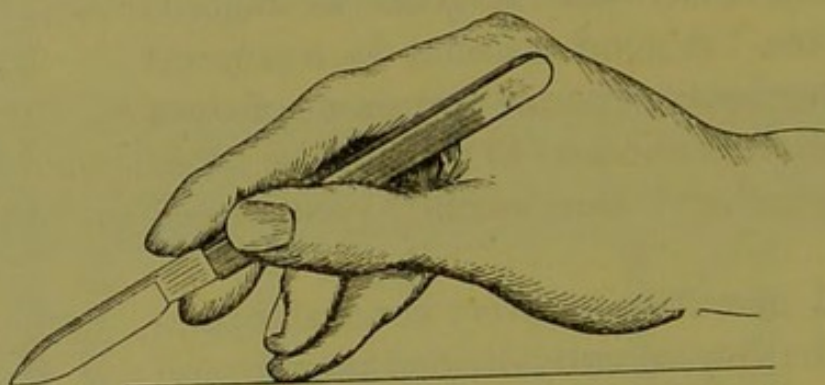


FIG. 3.—"Dissecting" position of holding a knife.

(a) Fig. 3 is an illustration of the manner in which a scalpel ought to be held in the first or "dissecting" position. This is sometimes called the "pen" or "writing" position.

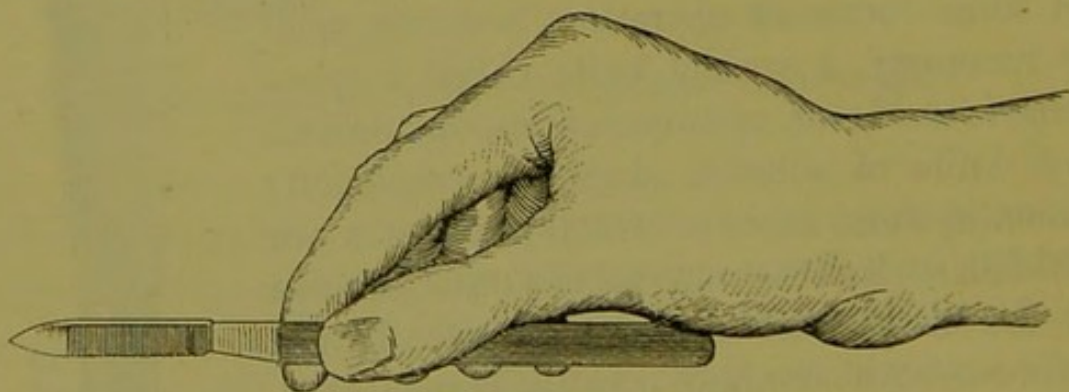


FIG. 4.—"Fiddle-bow" position of holding a knife.

This method ought to be adopted in making nearly all incisions which are not more than 3 or 4 in. in length, and in all cases where any fine or delicate dissection is necessary, such as the exposure of an artery, nerve, or vein, or when separating any new growth or other pathological formation from its connections with important structures.

(b) Fig. 4 is a representation of a scalpel held in the "fiddle-bow" position.

This method of holding a knife is made use of by some surgeons when making skin incisions and rough dissections, but its adoption is not recommended, since the instrument is not held so firmly as in Fig. 3, and consequently greater risk is incurred, in the performance of a delicate dissection, of doing damage to the adjacent structures.

(c) When it is desired to make a long incision, as in the removal of a large tumour or the formation of the flaps in an amputation, or to separate soft tissues from their connection with bone as in excision of a joint, the knife should be held in the so-called "dinner-knife" position. This method of holding a knife is shown in Fig. 5.

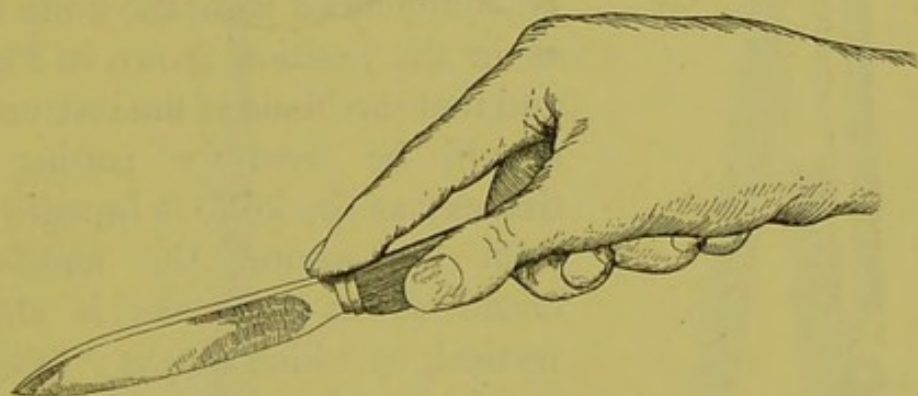


FIG. 5.—"Dinner-knife" method of holding a knife.

(d) When it is necessary for the surgeon to make a long sweeping cut, as in performing an amputation by the "circular" method, the knife is usually held in the position shown in Fig. 6. This position is sometimes called the "grasping" position.

Great care must be taken, when making an incision through the skin and underlying soft tissues, to avoid what is called "tailing" of the incision. By the term "tailing" in operative surgery is understood making the central part of an incision deeper than either one or both extremities. In order to avoid this, some surgeons advise that the knife should be held in a vertical position at the commencement of the incision, thus making this part of the operation of the nature of a stab. There is a decided

objection to this method of commencing an incision. The skin is much tougher and more resistant than the underlying soft tissues, and, owing to this fact, it sometimes happens, when the scalpel is entered in this manner, that the point penetrates much more deeply than is wished,

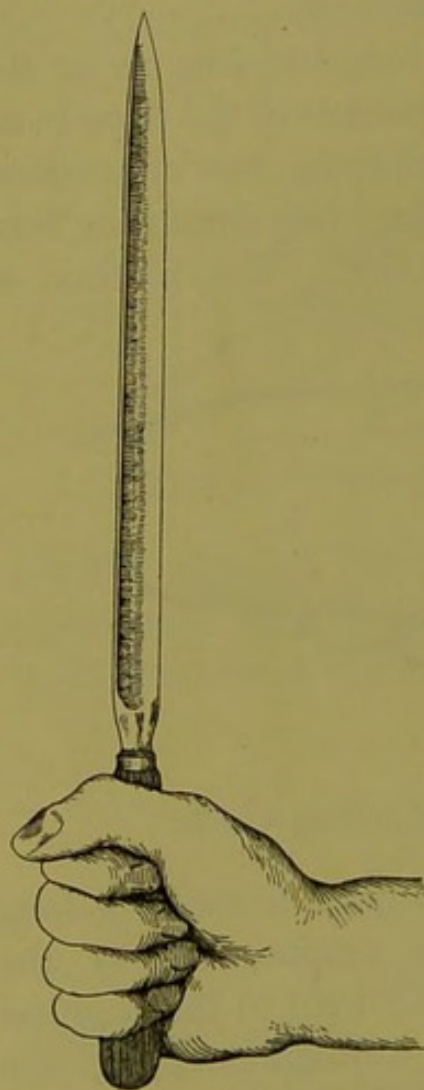


FIG. 6.—Long amputation-knife, held in the "grasping" position.

and perforates an important blood vessel, or divides an adjacent nerve trunk. On this account the "vertical" method of commencing an incision is not recommended. It is advised that all ordinary incisions which are of moderate length should be commenced with the knife held as in the position shown in Fig. 3, and that the blade of the instrument should be used for cutting the tissues; as the knife is brought out from the wound, the handle is raised so as to make it almost vertical, by which means "tailing" in this part of the wound is avoided. A beginner in operative surgery usually has a tendency to use the point of the knife too much, instead of the blade, whilst making the main part of the incision. The wound is maintained of equal depth for its entire length, until the anatomical structure sought for is

laid bare. In order to do this, it is usually necessary to make an occasional extra light stroke with the knife in the upper part of the incision, since there is a tendency to slightly tail this portion of the cut.

The further stages of each operation differ according to the procedure which is being carried out. They will be described in connection with the individual operations.

Arrest of hæmorrhage.—During the performance of every surgical operation which necessitates the division of blood vessels, attention must be paid to the arrest of hæmorrhage.

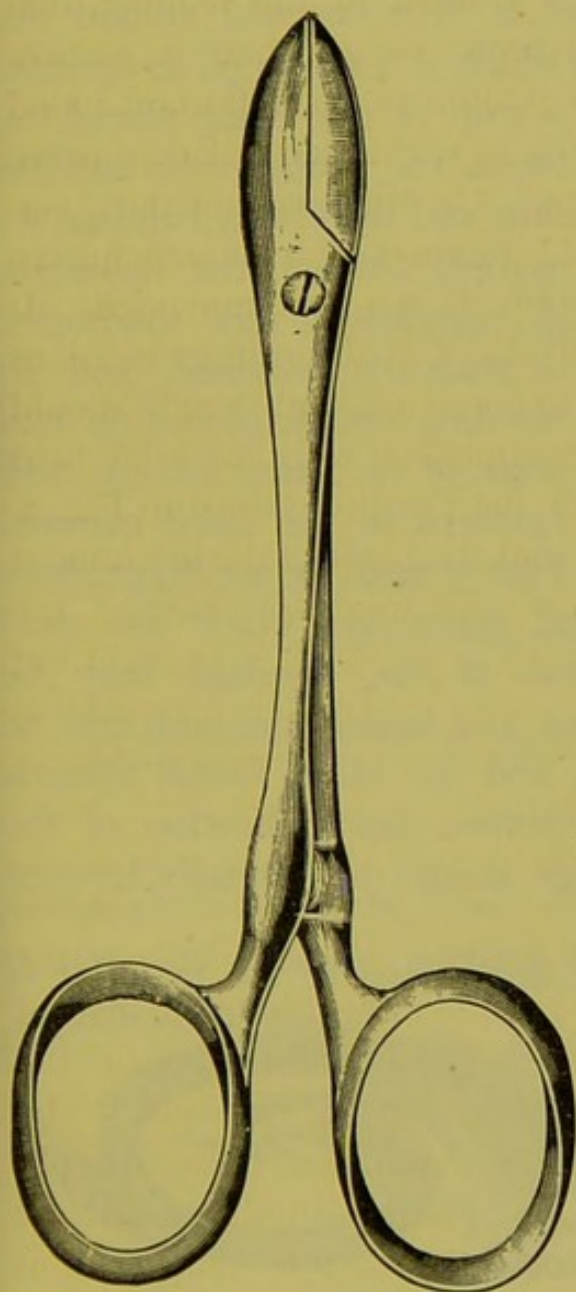


FIG. 7.—Pressure forceps.

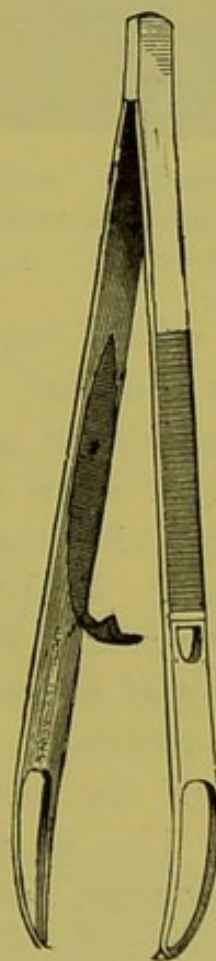


FIG. 8.—Artery forceps.

This is effected by seizing each bleeding point with a pair of pressure or artery forceps, and then applying a ligature. Figs. 7 and 8 are illustrations of pressure and artery forceps. Occasionally it is desirable to operate by what is called the "bloodless" method. In this case an elastic bandage is

wrapped around the affected limb, commencing below, and applied sufficiently tightly to force the blood upwards, and to arrest the circulation in the arteries which supply the part. An elastic tourniquet is then fastened around the limb above the region upon which it is proposed to operate,

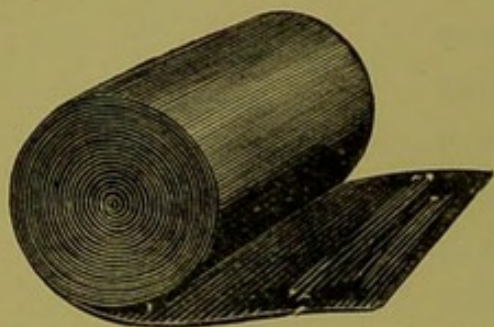


FIG. 9.—Rubber bandage for rendering a limb bloodless during an operation.

a strip of lint being placed between the rubber tube and the skin, and the elastic bandage removed. When the operation is completed, this tourniquet is gradually loosened, and all bleeding vessels picked up with pressure or artery forceps and ligatured in the usual manner.

Figs. 9 and 10 are illustrations of the rubber bandage and tourniquet which are used for this purpose. The use of the bandage may be dispensed with in many cases, and instead the limb may be elevated for a few minutes, and the blood forced towards the trunk with the hands before the application of the tourniquet. All hæmorrhage should be carefully arrested before a wound is closed.

Closure of wound.—The final stage of the majority of surgical operations is the closure of the external wound. This is usually effected by the introduction of some form of suture or sutures. The two commonest and most

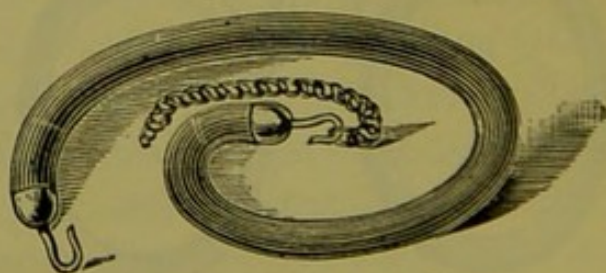


FIG. 10.—Elastic tourniquet.

useful methods are the "interrupted" and the "continuous" suture. The instruments which are necessary for this proceeding are needles, a needle-holder, and suture material. Figs. 11, 12, and 13 are illustrations of fully-curved, half-curved, and straight surgical needles. The shape of the needle which ought to be used for closing an incision

depends upon the depth and accessibility of the wound. In deep wounds, or wounds which are not readily accessible,



FIG. 11.—Fully-curved needle.




FIG. 12.—Half-curved needle.




FIG. 13.—Straight needle.

curved needles will be found to be most useful, whilst for shallow cuts straight needles will be most convenient.

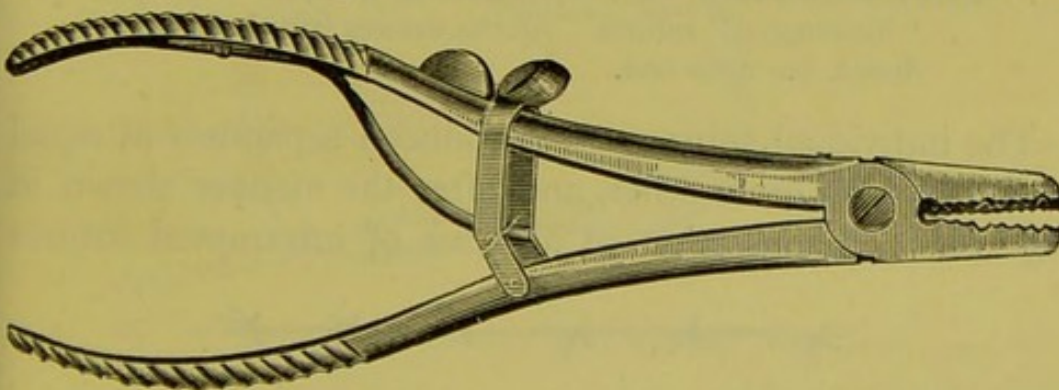


FIG. 14.—Needle-holder suitable for all kinds of surgical needles.

Fig. 14 represents a useful and simple form of needle-holder. The instrument shown in Fig. 15 will occasionally be found to be very useful in sewing up external wounds.

The needle is passed through the tissues, the suture slipped into the slot near the apex, and the needle withdrawn. The use of this form of needle obviates the necessity of

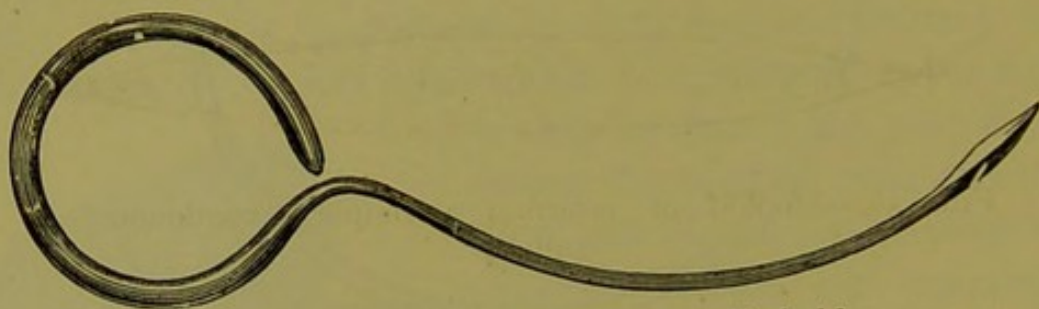


FIG. 15.—Combined needle and needle-holder.

threading each suture, and also the use of a needle-holder. It will be found most useful for closing long incisions.

Closure of an incision by a simple interrupted suture.

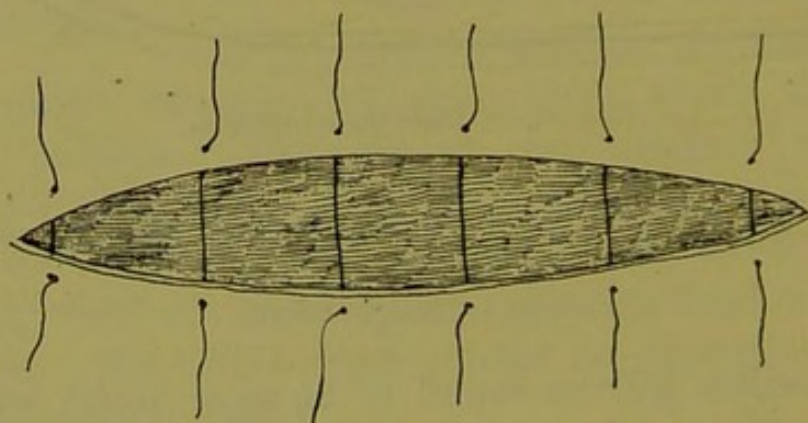


FIG. 16.—Method of introduction of a series of simple "interrupted" sutures. All the sutures have been introduced, but none tied.

—The individual sutures are introduced separately at equal distances from each other, and after the manner shown in Fig. 16. The insertion of a series of interrupted sutures



FIG. 17.—Row of simple "interrupted" sutures inserted, tied, and ends cut short.

can be facilitated by the assistant placing a blunt hook in each extremity of the wound, and exerting traction in opposite directions so as to render the margins taut.

When all the sutures have been inserted, each one is tied and the ends cut short. Fig. 17 shows the appearance of

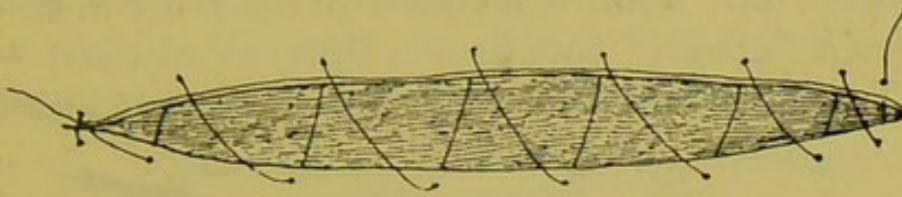


FIG. 18.—Method of inserting a simple "continuous" suture.

an incision which has been closed by the insertion of a row of simple "interrupted" sutures.

Closure of an incision by a continuous suture.—This form



FIG. 19.—Appearance of an incision when closed by a "continuous" suture.

of closure of a skin incision is a very good one, since by its adoption the margins of the wound can be very readily brought into exact apposition and kept there until union

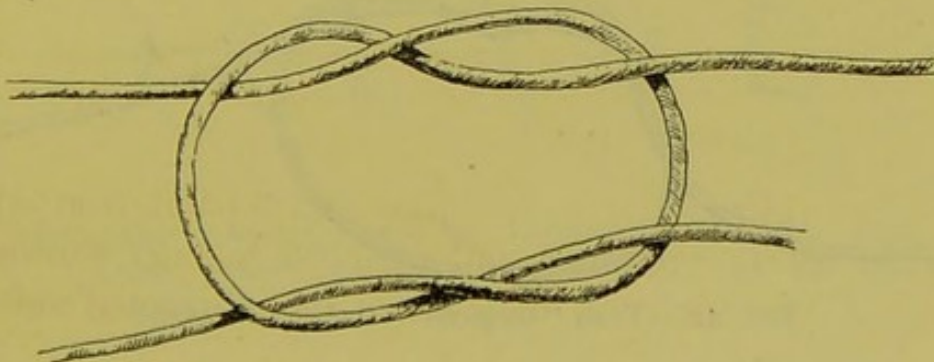


FIG. 20.—Method of tying a "reef" knot.

has taken place. A little more care, however, is required than when the "interrupted" suture is inserted. Fig. 18 shows the method of inserting a continuous suture, and Fig. 19 its appearance when the margins of the incision have been approximated and the ends secured.

When a series of sutures has been inserted for the closure of an external wound, each one should be tied separately by making a "reef" knot. Care must be taken not to tie what is called a "granny" knot, as it is liable to slip, and hence allow the margins of the cut to become slightly separated.

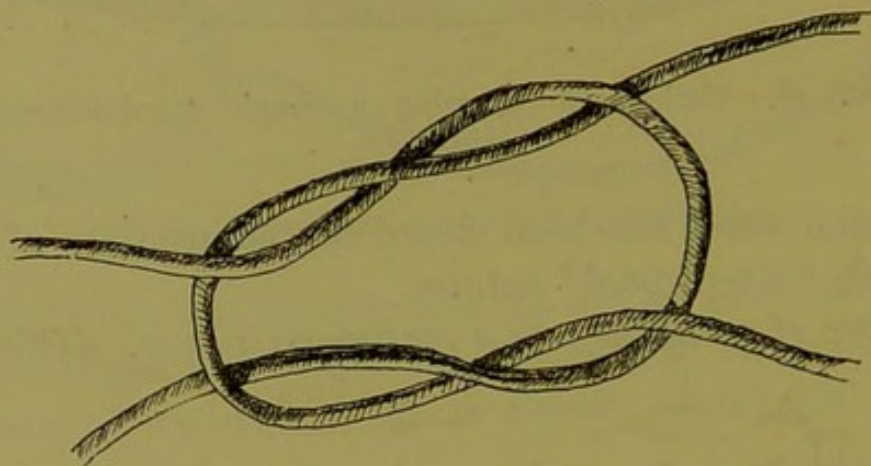


FIG. 21.—A "granny" knot.

Fig. 20 shows the method of tying a "reef" knot, and Fig. 21 a "granny" knot. When silk-worm gut is used for closing an external wound, the best method of tying it is by the first stage of a so-called true surgical knot. Fig. 22 is an illustration of this method of tying a suture, whilst

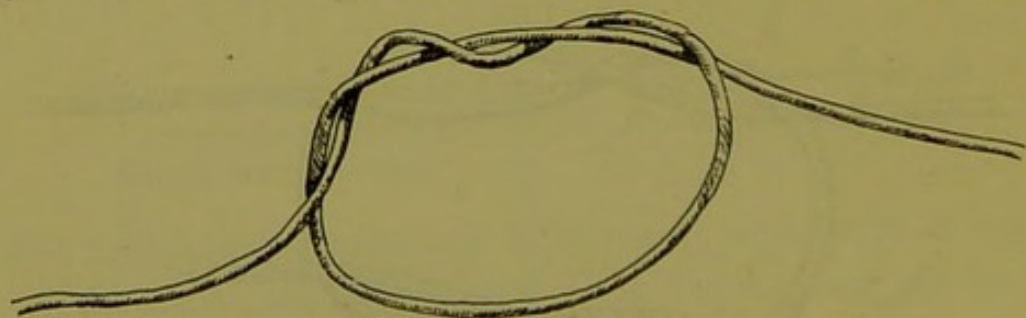


FIG. 22.—True "surgical" knot, first stage.

Fig. 23 shows the completed knot. This method of tying sutures will also be found to be very useful in those cases in which it is somewhat difficult to keep the margins of the incision in exact apposition during the making of the second "hitch."

Fig. 24 is a representation of a wound closed by a series of "interrupted" sutures of silk-worm gut, each

suture being secured by the double "hitch" of the surgical knot.

When a suture is tied, care should be taken not to fasten it too tightly, otherwise the suture may cut out, or an unnecessary amount of scarring may result. Each suture

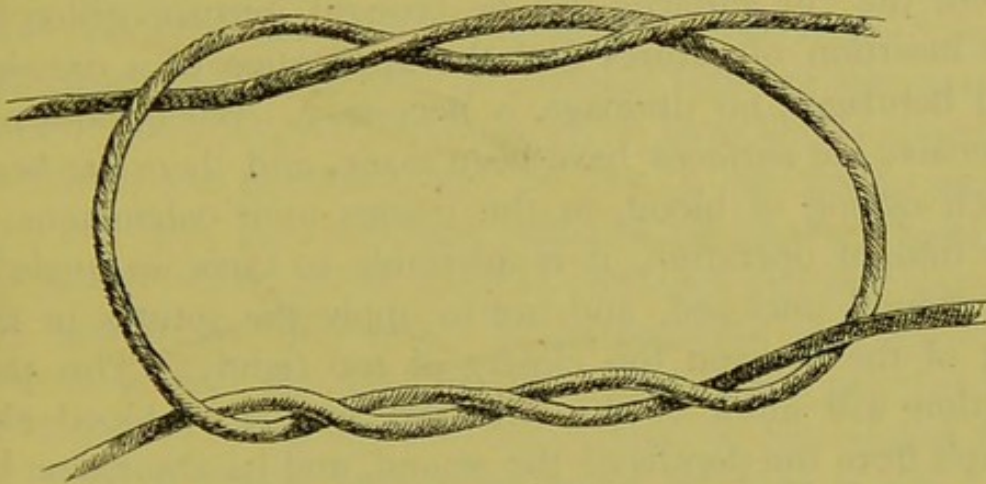


FIG. 23.—True "surgical" knot, completed.

should be tied only tight enough to keep the margins of the wound in exact apposition. When the incision is a deep one, or the cut surfaces are very extensive, the above

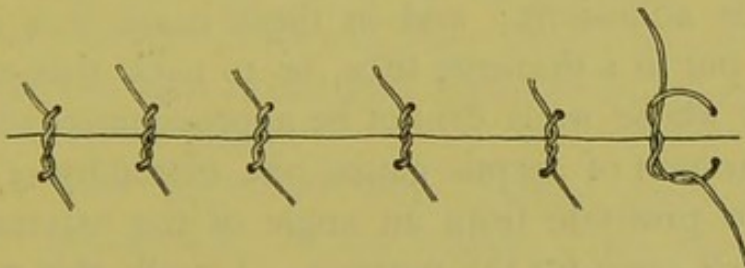


FIG. 24.—A wound closed by "interrupted" sutures, each being secured by the "double hitch" of the true "surgical" knot.

methods of closing a wound are insufficient, since the deeper parts of the cut are not brought together by the sutures. In order to avoid non-approximation of the deeper parts of an incision, "buried" sutures are sometimes inserted. This method is of much use in closing wounds of the abdominal walls; but in the extremities, as after amputations or the removal of tumours,

the cut surfaces can in nearly all cases be brought into exact apposition by the careful application of bandages.

Introduction of drainage tubes.—A drainage tube is rarely required in the treatment of a wound which has been made by a surgical operation. In all cases of clean incised wounds, where the cut surfaces can be brought into apposition by the insertion of sutures and the application of a dressing and bandages, no drainage is necessary. When, however, extensive cut surfaces have been made, and there has been much oozing of blood, or the tissues were œdematous at the time of operation, it is advisable to leave an angle of the wound unclosed, and not to apply the sutures in the rest of the incision too closely or too tightly. This precaution will allow of the necessary escape of blood and lymph from the depths of the wound, and its absorption by the overlying dressing. It occasionally happens that it is not possible to effect complete approximation of the deeper portions of a wound, as after the extirpation of a large tumour with deep connections, or after the removal of abdominal or pelvic tumours which had extensive connections or adhesions; and in these cases it is advisable either to put in a drainage tube, or to pack that portion of the cavity whose walls cannot be approximated with a long strip or tampon of aseptic gauze, one extremity of which is allowed to protrude from an angle of the external wound which is left open for the purpose. Usually this method of packing with gauze will be found more efficacious than the use of a drainage tube. In both cases the strip of gauze or the drainage tube is removed at the end of twenty-four or at most forty-eight hours, unless some complication such as hæmorrhage or suppuration has occurred.

A drainage tube or a tampon of gauze ought to be placed in those wounds which are the seat of septic processes at the time of operation, and also in cases in which a fistula is very liable to result, as after certain operations on the alimentary canal and the urinary system.

After-treatment.—The treatment which ought to be adopted after the performance of a surgical operation can be considered from two aspects, namely—(a) The after-treatment of the wound, and (b) the after-treatment of the patient generally.

(a) *The after-treatment of the wound.*—When the wound is of an aseptic nature, and no drainage tubes or tampons of gauze are inserted, the dressings which have been applied at the end of the operation can be left on for five to seven days, and then removed and replaced by others. If, however, much oozing occur, and the dressings become soaked with exudations, they ought to be removed and replaced by fresh ones. The sutures which have been inserted for the closure of the external wound should be removed at the end of five or seven days, especially if they are of silk. If silk sutures are left longer than this they are very liable to cause the development of “sutural” or “stitch” abscesses. When silk-worm gut is used it can be left longer—ten days or a fortnight—without an abscess of this nature being formed. When drainage tubes or tampons of gauze are inserted in an operation wound, they should be removed at the end of twenty-four hours, and replaced by others if it is considered to be necessary.

(b) *The general after-treatment.*—Careful attention must be paid to the feeding of the patient, and also to the hygienic conditions and surroundings. The part of the body which has been the seat of operation should be kept at rest, either by simply keeping the patient in bed, or by applying some form of splint or stiff apparatus. The air should be allowed to circulate freely in the neighbourhood of the dressings, so as to prevent the atmosphere becoming moist, foul, and contaminated with the exhalations from the skin. This can be effected by raising the bed-clothes from the affected portion by means of a cradle.

CHAPTER II.

OPERATIONS UPON THE STOMACH AND INTESTINES.

THE majority of operations upon the stomach and intestines are carried out through an incision in the anterior abdominal wall. In lumbar colotomy, however, the incision is made in the loin; and in operations upon the rectum, the posterior half of the perineum or the region of the sacrum is the seat of the incision.

Hence the *first stage* in most operations upon the stomach or intestines is the making of an incision through the abdominal parietes, and the opening of the peritoneal cavity. This incision is often made in the middle line, through the linea alba, so as to avoid the division of nerves, and to minimise the risk of occurrence of a ventral hernia at a later period. If it is not possible or convenient to make the incision in the middle line, it should be so placed that the nerves which supply the muscles of the anterior abdominal wall are exposed to as little injury as possible. These nerves run for the most part in an oblique direction from behind downwards and forwards. The large blood vessels of the anterior abdominal wall—the deep epigastric artery which runs from opposite the mid-point of Poupart's ligament to the umbilicus, and the superior epigastric artery which runs from the seventh costal cartilage to the umbilicus—should also be avoided.

The length of the parietal incision varies according to the nature of the operation. The longer the incision the

greater is the liability to a subsequent ventral hernia. It is, however, most important that the surgeon should have an unobstructed view of the organs upon which he proposes to operate, and sufficient room for the easy performance of the necessary manipulative procedures.

When the skin, fasciæ, and muscular strata of the abdominal wall have been divided, all hæmorrhage should be arrested by the application of ligatures to the bleeding points, and the wound sponged dry. Next, the peritoneal cavity is opened. The parietal peritoneum can usually be recognised by the loose fatty tissue layer—subperitoneal fat—which lies between its external aspect and the transversalis fascia, and also by the arborescent arrangement of the blood vessels upon its surface. The peritoneal cavity is most safely opened by picking up a piece of the membrane with dissecting forceps, and cutting upon the points with the scalpel. When this has been done, the aperture is enlarged by pushing through it the points of a pair of dissecting forceps, and cutting between them. The fingers of the left hand may then be introduced, and the opening further enlarged by cutting between the fingers, which serve as a director and keep the intestine and omentum out of the way. When a piece of the parietal peritoneum is picked up with the dissecting forceps, the underlying intestine or omentum slips away, if the normal peritoneal cavity has not been obliterated by peritonitis and the formation of adhesions.

The *second stage* of an abdominal operation of this kind is the finding of the anatomical structure upon which it is proposed to operate, and the performance of whatever procedure may be necessary.

When the object of the operation has been effected, in some cases, such as the resection of a portion of the alimentary canal or the establishment of an intestinal anastomosis, the parietal wound is closed, whilst in others, such as the creation of an artificial anus or the drainage of

a purulent collection, it is left open, so as to allow of the insertion of a drainage tube or packing with strips of gauze.

Washing out, or irrigation of the peritoneal cavity.—Before the closure of the wound in the parietes, care must be taken to remove by sponging or irrigation all traces of

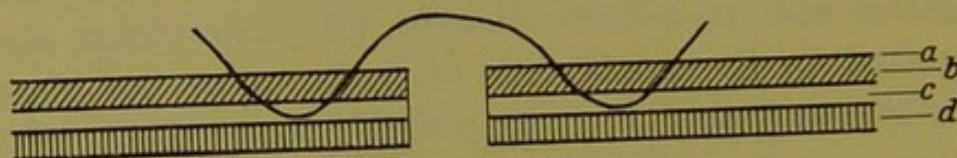


FIG. 25.—Diagrammatic section of a portion of gut wall, showing the method of insertion of a Lembert's suture.

<i>a.</i> Peritoneum.	<i>c.</i> Submucous coat.
<i>b.</i> Muscular coat.	<i>d.</i> Mucous coat.

blood or any kind of extraneous matter from the peritoneal cavity. In all cases where the peritoneum has been soiled by septic material from the alimentary canal, or by pus, it is advisable to thoroughly irrigate the contaminated area.

Methods of intestinal suture.—For the performance of

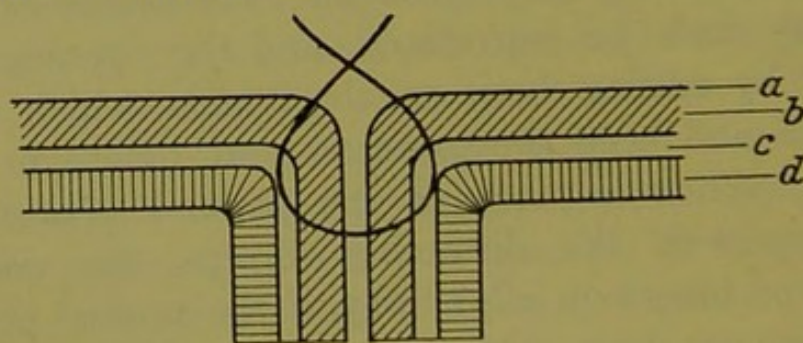


FIG. 26.—Diagrammatic section of a portion of intestinal wall, showing method of approximation by Lembert's suture.

operations upon the stomach and intestines, it is necessary for the surgeon to be familiar with some of the methods of intestinal suture. The principal of these will now be described. The most important of these are—

- (a) Simple continuous suture.
- (b) Simple interrupted suture.
- (c) Lembert's suture.
- (d) Czerny's suture (Czerny-Lembert).

- (e) Gussenbauer's suture.
- (f) The Czerny-Lembert-Wölfler suture.
- (g) Chaput's suture.
- (h) Halstead's mattress or quilted suture.

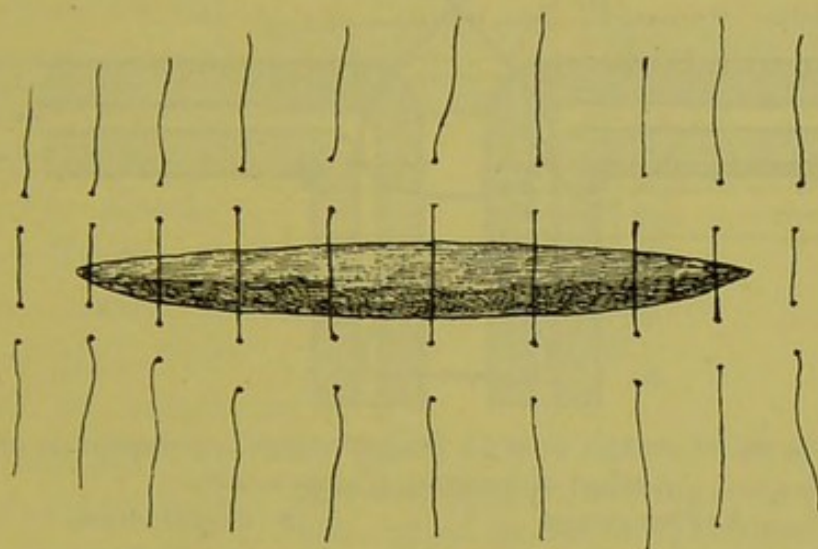


FIG. 27.—Illustration of an incision, with a series of Lembert's sutures inserted but not tied.

(a) and (b) *The simple continuous and simple interrupted sutures* have already been described on pp. 12, 13.

(c) *Lembert's suture*.—Fig. 25 shows the mode of inserting a suture by Lembert's method, and Fig. 26 the manner in which the serous surfaces are brought together.

Fig. 27 is an illustration of an incision for the closure of which a series of Lembert's sutures has been inserted.



FIG. 28.—The same incision, with the sutures tied and the ends cut short.

Fig. 28 shows the appearance of such an incision when the sutures have been tied and the ends cut short.

In inserting a Lembert's suture, the needle is made to transfix the serous and muscular coats and penetrate the submucous coat of the intestine on one side of the wound, and then the same proceeding is repeated on the other side, care being taken not to pierce the mucous coat.

(d) *Czerny's suture* really consists of two superimposed tiers of Lembert's sutures; the first tier unites the serous and muscular coats of the margins of the wound, whilst the

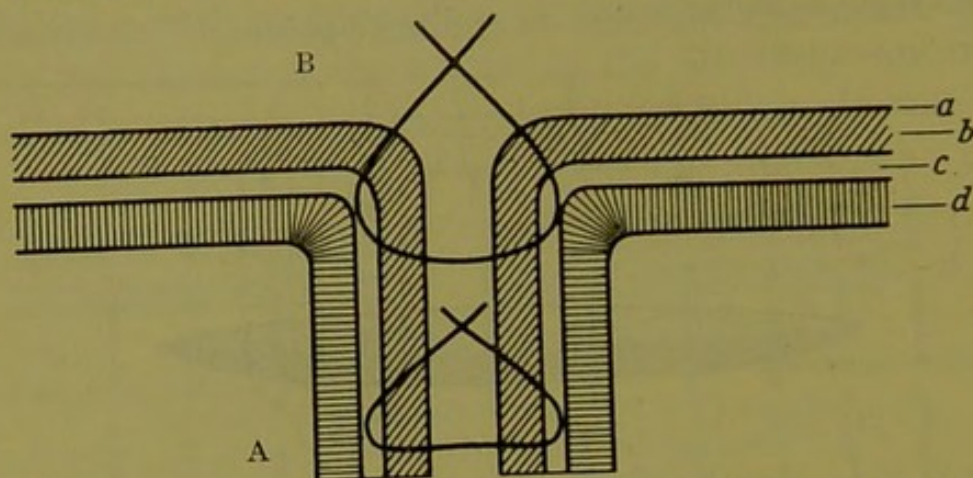


FIG. 29.—Czerny's suture: Diagrammatic representation of method of inserting Czerny's suture.

A. First suture. | B. Second suture.

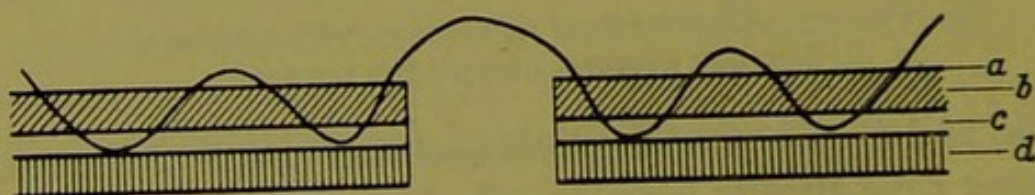


FIG. 30.—Gussenbauer's suture: Section of gut wall, showing method of insertion.

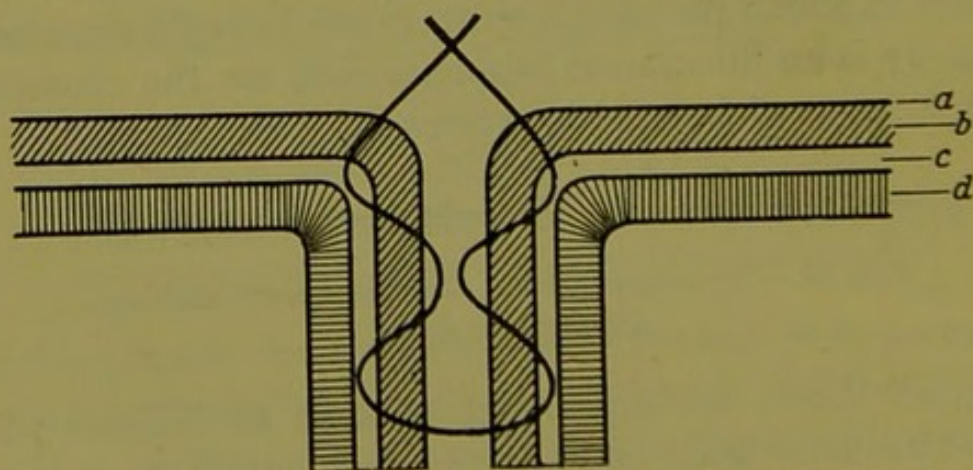


FIG. 31.—Gussenbauer's suture: Section of gut wall, showing manner of approximation as suture is tied.

second is placed a short distance beyond. All the sutures of the first tier are inserted, tied, and cut short before any of the second tier are passed.

Fig. 29 shows the method of inserting this variety of suture.

(e) *The suture of Gussenbauer* is in reality a double Lembert (or Czerny) suture, inserted with one thread at the same time (Figs. 30 and 31).

(f) *The Czerny-Lembert-Wölfler suture, or suture in three stages.*—This method of suture is essentially a Czerny's suture, with the addition of a tier

of sutures which unite mucous membrane to mucous membrane, as shown in Fig. 32.

(g) *Chaput's suture.*—The essential point in this suture is the preliminary separation for a short distance of the mucous membrane from the muscular and serous coats.

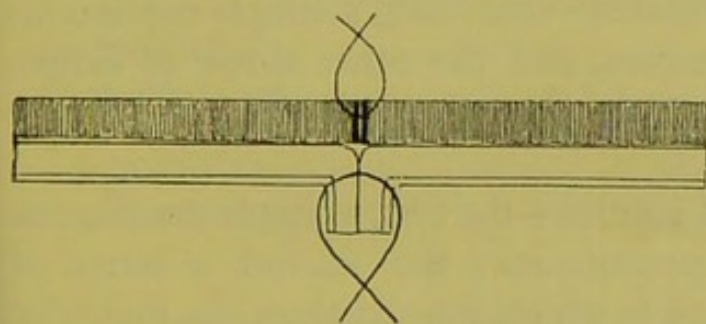


FIG. 33.—Chaput's suture: Section of intestine, showing method of insertion and manner of approximation.

and fixed in apposition by a series of simple interrupted sutures, according to the method shown in Fig. 33.

(h) *Halstead's quilted or mattress suture* is inserted according to the method shown in Fig. 34, care being taken

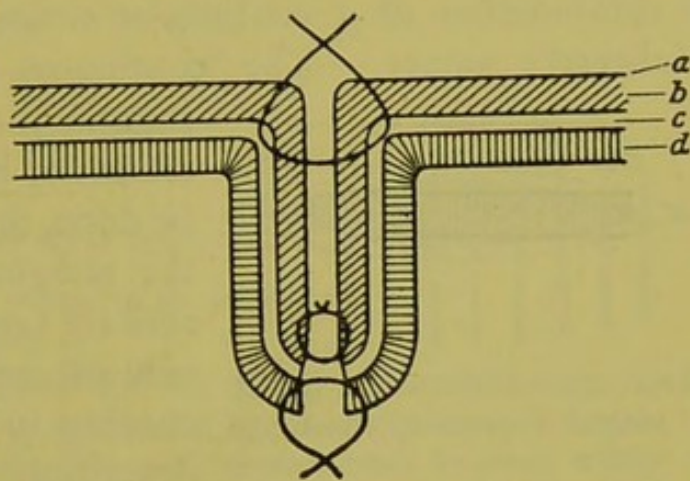


FIG. 32.—Czerny - Lembert - Wölfler suture: Section of intestine, showing manner of insertion, etc., of the three tiers of sutures.

When this has been done, the margins of the mucous membrane are united by the insertion of a series of simple interrupted sutures.

Next, the serous and muscular coats are slightly everted

to ensure that the needle passes through the muscular coat and pierces part of the submucous layer.

Of these methods of intestinal suture the best is probably a combination of a continuous suture with Lembert's or Halstead's suture. The continuous suture is made to

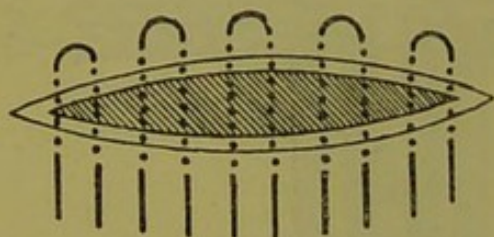


FIG. 34.—Halstead's quilted suture: Appearance of a wound with a series of these sutures inserted.

transfix the mucous membrane alone, or, if this cannot readily be done, the whole thickness of the margin of the wound; a series of Lembert's or Halstead's sutures are then inserted, according to the manner already described.

This method of closure of intestinal wounds produces less puckering of the tissues, and hence causes the minimum of contraction.

Method of closure of the parietal wound.—The incision through the abdominal wall may be closed in the following ways:—

1. By one row of simple interrupted sutures, each suture passing through all the layers of the abdominal wall.
2. By two tiers of sutures—one being a simple continuous suture for the peritoneum, and the other a row of simple interrupted sutures which pass through the rest of the abdominal wall.
3. By three tiers of sutures—the first, a simple continuous suture through the peritoneum; the second, a series of buried interrupted sutures which approximates the muscular strata; and the third, interrupted or continuous, for the fasciæ and skin.

When more than one tier of sutures is inserted, the deep ones are tied and the ends cut short before the next row is inserted.

The following operations upon the stomach and intestines will now be described:—

OPERATIONS UPON THE STOMACH.

Gastrostomy.
Gastrotomy.
Pyloroplasty.
Gastro-enterostomy.
Pylorectomy.
Operation for perforated gastric ulcer.

OPERATIONS UPON THE SMALL INTESTINE.

Closure of perforating wound of the intestine.
Resection of the intestine—
1. Suture methods (circular enterorrhaphy, Maunsell's method).
2. With the aid of a mechanical appliance (Murphy's button, a bone tube, or a bone bobbin).
Formation of artificial anus.

OPERATIONS UPON THE LARGE INTESTINE.

Removal of vermiform appendix.
Excision of cæcum.
Resection of large intestine.
Colotomy—
1. Inguinal.
2. Lumbar.

OPERATIONS UPON THE RECTUM.

For hæmorrhoids.
For fistula in ano.
Excision of part of rectum—
1. Perineal method.
2. Sacral method.

OPERATIONS UPON THE STOMACH.

Gastrostomy.—The operation of gastrostomy has for its object the establishment of a permanent fistulous communication between the cavity of the stomach and the surface of the body.

The stomach is situated in the upper part and on the left side of the abdomen, but its exact extent and relations depend upon the amount of its distension. In every con-

dition, however, the main part of the viscus occupies the left hypochondrium and the left half of the epigastrium.

Indications.—Undilatable fibrous strictures of the œsophagus, and carcinoma of the œsophagus, when life will probably be prolonged by the operation.

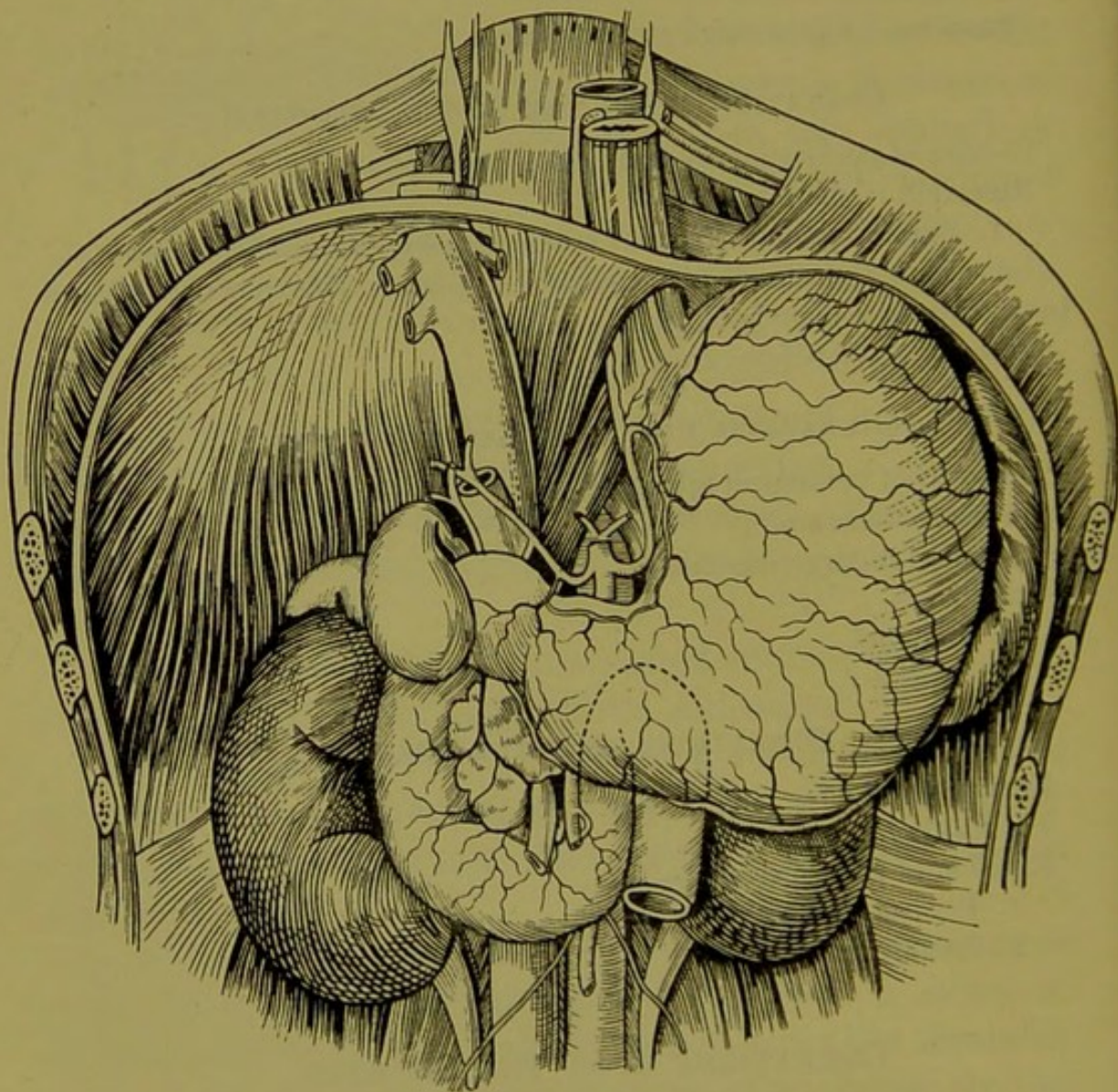


FIG. 35.—Stomach and its relations as seen from the front when the liver has been removed.—After TESTUT.

Instruments.—Scalpel, dissecting forceps, scissors, retractors of moderate size, pressure forceps, curved needles, needle-holder, and ligature silk (two sizes, fine and medium).

Position.—The patient is placed in the dorsal position, near the left side of the table. The operator stands on the

left side and the chief assistant on the other side directly opposite to him.

Many varieties of operation have been described; the best of these appear to be those which have been proposed by, and are known as the operation of Frank (or Albert), and that of Witzel.

Frank's operation.—The operation itself may be divided into three stages, namely—

(a) Incision of the abdominal wall; (b) exposure of the stomach and fixation of a portion of the viscus in the abdominal wound; (c) incision of the thoracic wall immediately above the costal margin, suture of the stomach to the margins of this opening, and formation of a gastric fistula.

(a) *Incision of the abdominal wall.*—An incision from 2 in. to $2\frac{1}{2}$ in. in length is made in the abdominal wall, parallel to and 1 in. below the costal margin, and opposite the costal cartilages of the seventh, eighth, and ninth

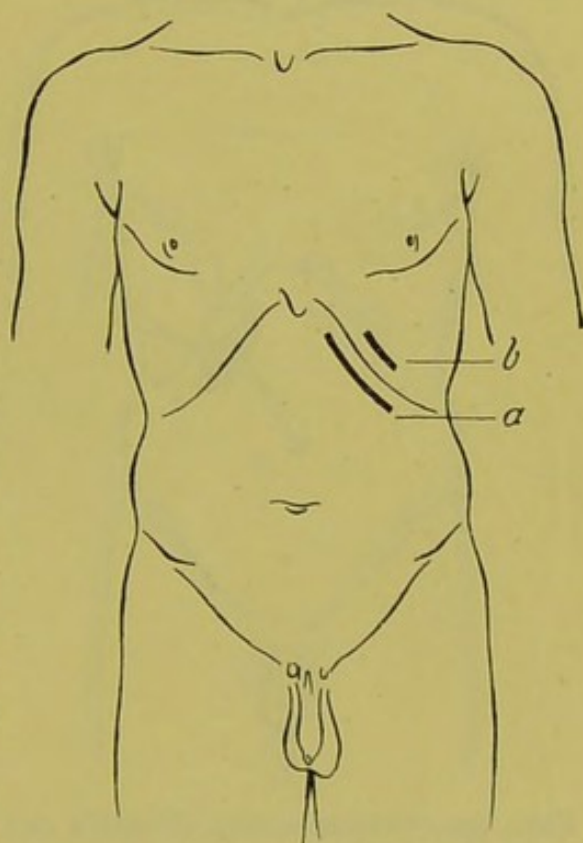


FIG. 36.—Gastrostomy (Frank's or Albert's method): Position of incisions.

a. First or abdominal incision.

b. Second or thoracic incision.

ribs of the left side (Fig. 36). The scalpel is made to divide the skin, fasciæ, and anterior layer of the sheath of the rectus abdominis muscle, and when the surface of the muscle is exposed its fibres are separated in a vertical direction for about 1 in., the separation being about one finger's-breadth from the linea semilunaris. By this means the posterior wall of the sheath is exposed. This is now

divided in the line of the original incision, the margins of the wound in the rectus being retracted, together with the underlying transversalis fascia, subperitoneal fat, and peritoneum.

(b) *Exposure of the stomach and fixation of a portion of the viscus in the abdominal wound.*—The stomach is sought for by passing the fingers of the right hand into the peri-

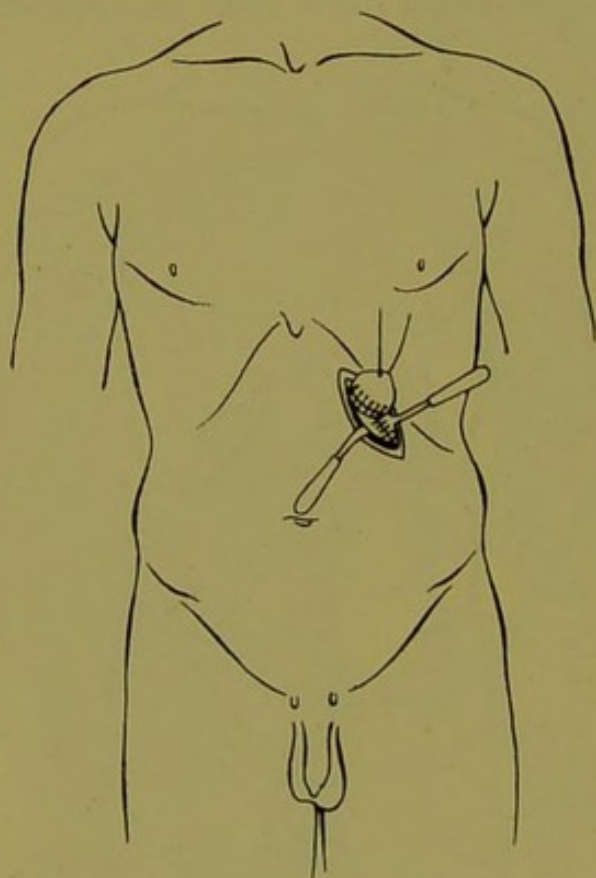


FIG. 37. — Gastrostomy (Frank's or Albert's method): Cone of stomach brought out of first incision and sutured to serous and muscular strata of abdominal wall.

toneal cavity. It can be recognised by the thickness of its walls, the attachment of its superior margin to the liver by means of the gastro-hepatic omentum, the smoothness of its surface, and the absence of sacculations and appendices epiploicæ. When the stomach has been recognised, a portion of it is brought into the wound, and a point selected upon its anterior aspect opposite to the parietal incision and about $1\frac{1}{2}$ or 2 in. above the greater curvature. A thick suture is passed through the serous and muscular coats of the organ at the point selected, and

this is left long and used to lift up the stomach during the later stages of the operation. A cone of the anterior wall of the stomach (Fig. 37) is lifted up into the abdominal wound, and its base sutured to the margins of the incision by the insertion of a ring of fine silk sutures. Each suture passes through the serous, muscular, and submucous portions of the wall of the stomach, and also the serous and muscular strata of the anterior abdominal wall. These

sutures are inserted at intervals of about one-third of an inch, and all are introduced before any are tied. The cone of the stomach which is brought out in this manner in most cases is about $1\frac{1}{2}$ in. in length, but this depends upon the thickness of the anterior abdominal wall. If the abdominal incision is larger than the portion of stomach, the ends of the incision are closed by the insertion of sutures in the usual manner.

(c) *Incision of the thoracic wall, etc.*—An incision three-quarters of an inch in length is now made over the costal margin, opposite the middle of the first incision and parallel to it. This is deepened until the deep fascia has been divided and the surface of the external oblique exposed (Fig. 36, *b*). The bridge of skin and fascia which separates the two incisions is lifted after the deep fascia has been detached from the muscle.

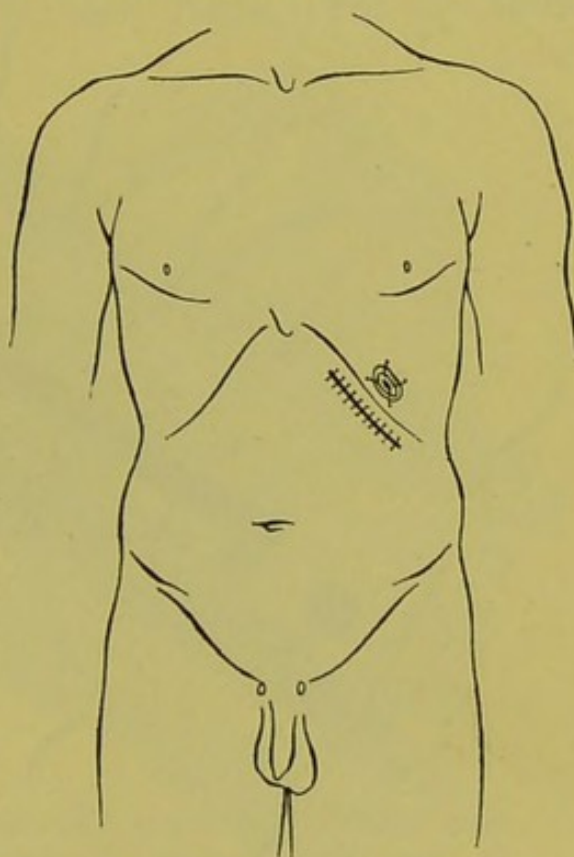


FIG. 38. — Gastrostomy (Frank's or Albert's method): Operation completed. The opening in the stomach is attached to the upper incision.

The long loop of silk which is fixed to the stomach is passed underneath this bridge of skin, and brought out through the second incision and traction exerted upon it. The cone of the stomach is thus drawn underneath the cutaneous bridge.

A small aperture about half an inch in length is then made in the wall of the protruded part, and the margins of this incision are fixed to those of the wound in the skin by the insertion of sutures. Each suture passes through the skin and

fascia, and then through the entire thickness of the wall of the stomach (Fig. 38). The margins of the first incision are then united by a continuous suture. The advantages of this operation are: The stomach can be opened at the time of operation, the margins of the aperture and the walls of the fistula can be held in apposition during the intervals

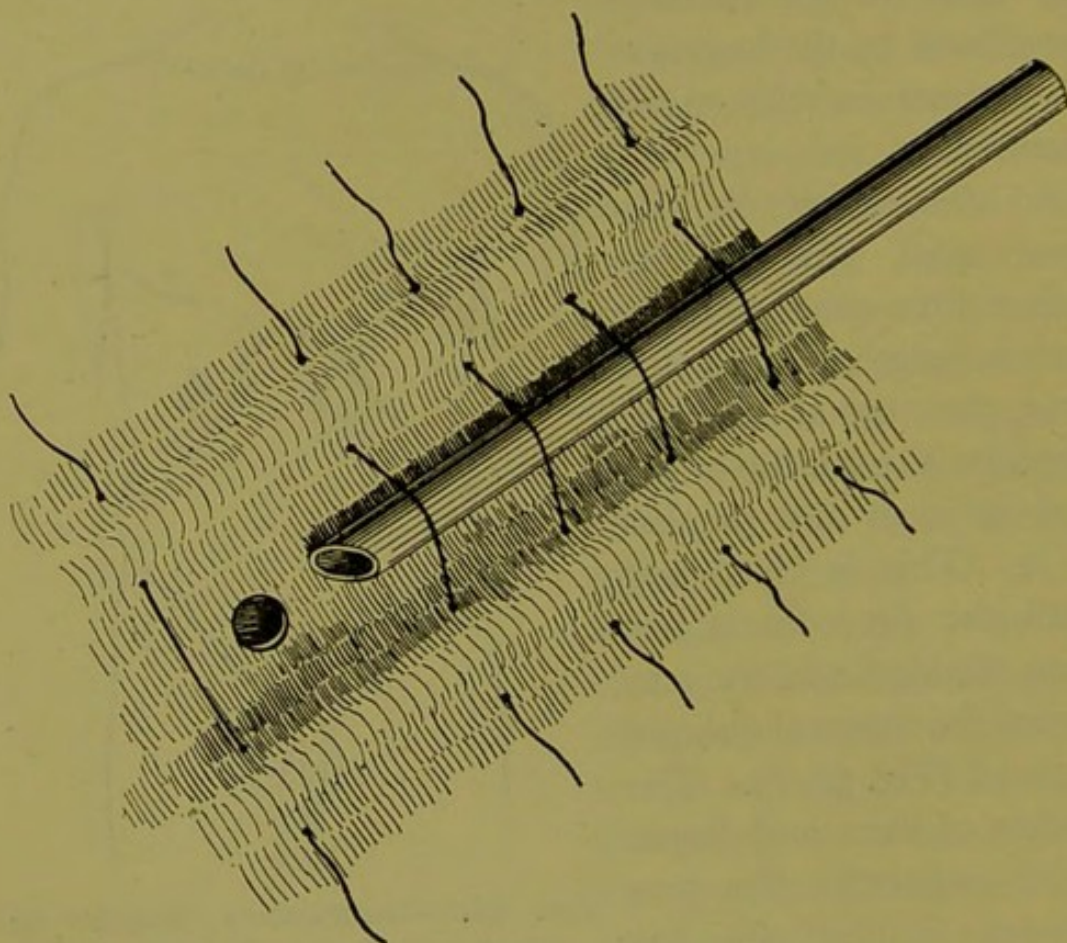


FIG. 39. — Gastrostomy (Witzel's operation): Method of opening stomach and fixing tube in a groove formed from anterior surface of viscus.

between feeding, regurgitation of food is prevented, and peritonitis is not likely to be induced.

Witzel's operation. — The peritoneal cavity is opened as in the preceding operation. When this has been done, a portion of the anterior wall of the stomach is brought into the wound, and a point selected about $1\frac{1}{2}$ in. above the greater curvature. With a tenotomy knife or scalpel an aperture is made in the stomach wall,

sufficiently large to admit a rubber tube, as shown in Fig. 39. The dark circle indicates the position of the incision.

Next, a series of Lembert's sutures are inserted in the stomach in such a manner that they pass over the tube, and when they are tied they convert a portion of the anterior wall of the stomach into a canal, commencing at the aperture which has already been made. Fig. 40 shows

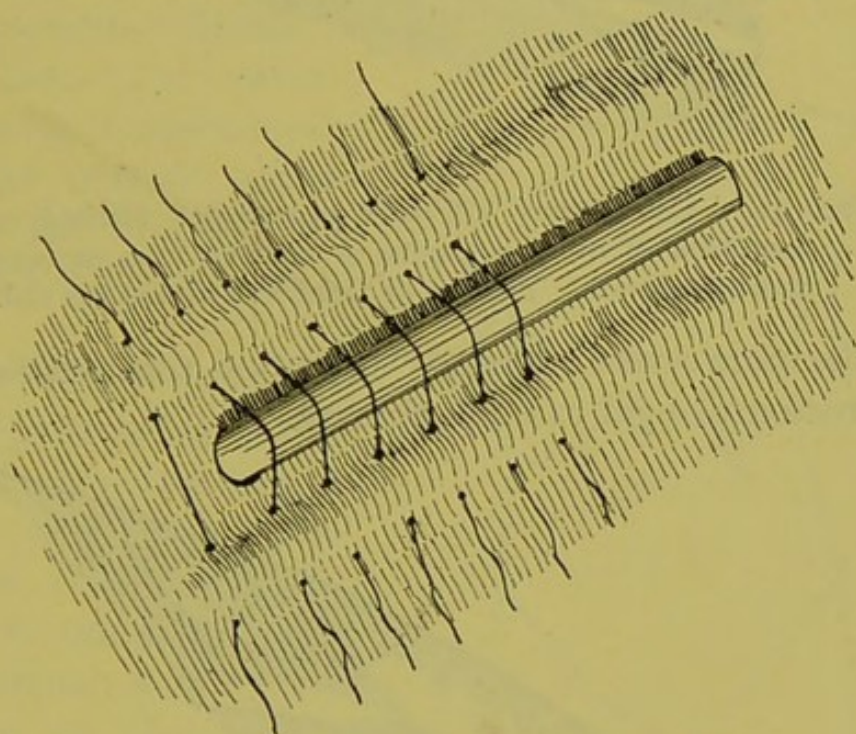


FIG. 40.—Gastrostomy (Witzel's operation): Rubber tube passed through aperture in stomach, and row of Lembert's sutures inserted.

these sutures inserted and not tied, and Fig. 41, tied, and the ends cut short.

The margins of the upper portion of the canal are united to those of the abdominal wound, and the remaining portions of the parietal incision closed. Figs. 42 and 43 illustrate these stages of the operation.

The advantages of this operation over the preceding one are, it does not cause so much constitutional disturbance, and it is easier to bring the requisite amount of stomach wall into the wound. The disadvantage is that it is not quite so easy a matter to prevent regurgitation.

When there is any difficulty of bringing the stomach into the external wound, or it is thought that the patient will not

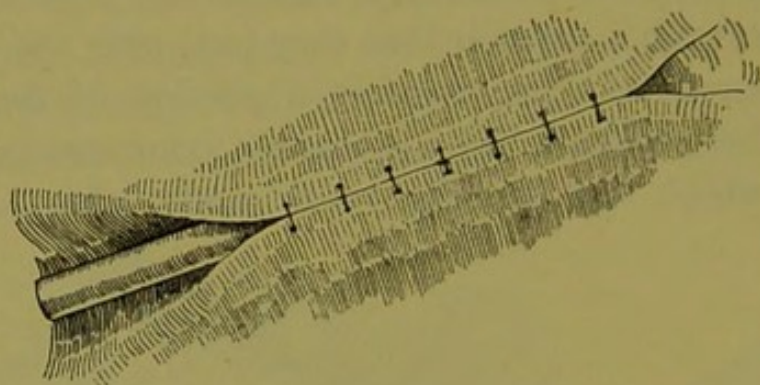


FIG. 41. — Gastrostomy (Witzel's operation): Method of formation of oblique groove or channel from anterior wall of stomach. The row of Lembert's sutures are tied.

stand the more severe "Frank's" operation, this modification of gastrostomy ought to be performed.

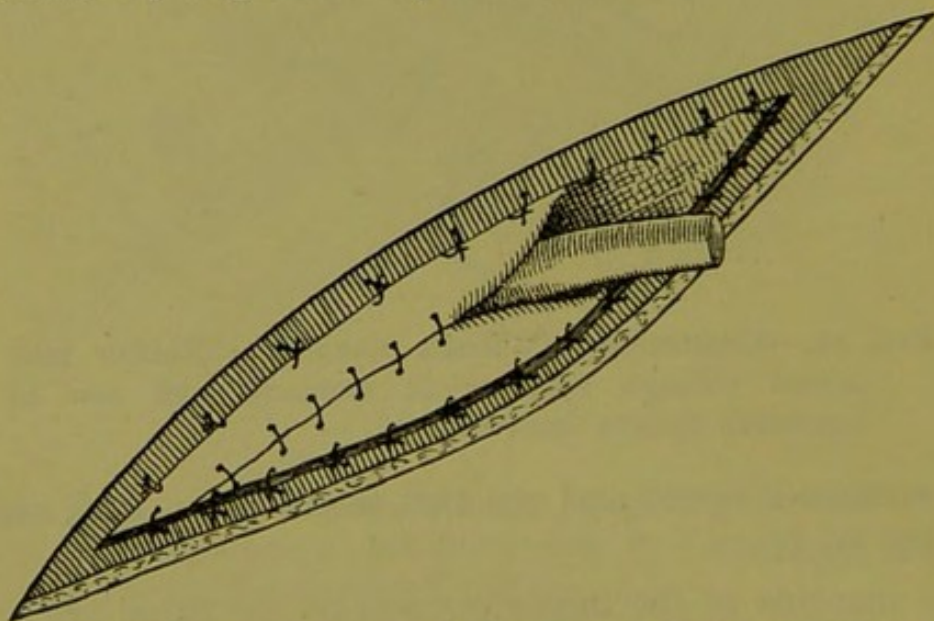


FIG. 42. — Gastrostomy (Witzel's operation): Method of fixation of margins of aperture of artificial channel in wall of stomach to margins of external wound.

Gastrotomy.—The term gastrotomy implies the making of an opening through the wall of the stomach. This opening is usually closed immediately after the object of the operation has been attained.

Indications for operation.—Gastrotomy has been per-

formed for the following conditions:—(a) The presence within the stomach of a foreign body which will not readily pass through the pylorus; (b) fibrous constriction of the pylorus, or of the lower portion of the œsophagus; (c) localised malignant growths of the stomach, which are limited to the mucous membrane; (d) impaction of a foreign body in the lower part of the œsophagus.

Instruments.—Similar to those for gastrostomy.

Position.—The patient is placed in the dorsal position, the operator stands on the left side, and the chief assistant opposite to him.

Operation.—The operation of gastrotomy may be divided into four stages, namely—(a) Abdominal incision; (b) finding of the stomach, bringing it into the parietal wound, and location of the foreign body or other pathological condition; (c) incision of the stomach wall, and removal of the foreign body, or treatment of the special pathological condition for

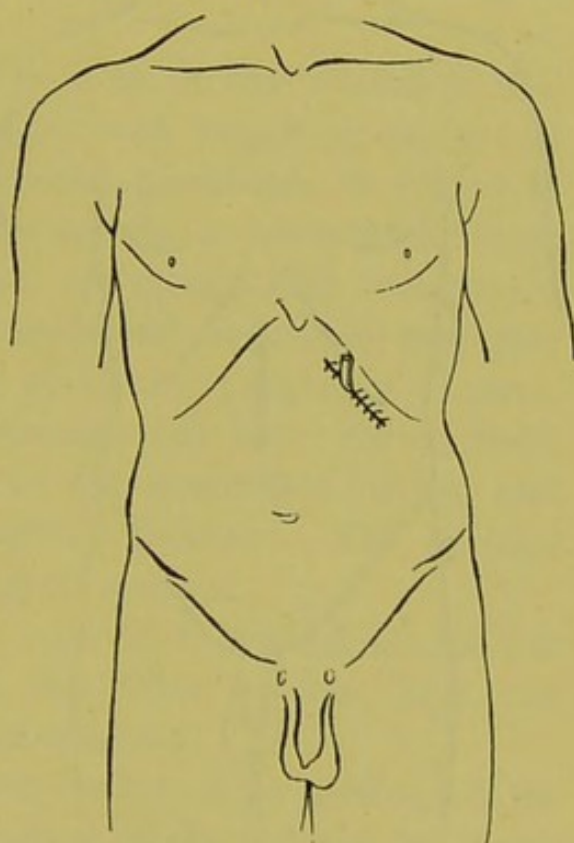


FIG. 43.—Gastrotomy (Witzel's operation): Appearance of abdomen when operation is completed.

which the operation is undertaken; (d) closure of the incisions in the stomach and in the abdominal wall.

Before commencing the operation, it has been advised that the stomach should be washed out with a dilute alkaline solution, so as to render it as aseptic as possible, and diminish the risk of the occurrence of peritonitis.

(a) *Abdominal incision.*—An incision 3 in. in length is made parallel to the left costal margin, and $1\frac{1}{2}$ in.

below it, commencing on the left, opposite the tip of the ninth costal cartilage, and extending upwards and towards the middle line. This incision is deepened until the peritoneal cavity has been opened. If the operation is performed for the removal of a foreign body, and the situation of this structure can be felt, the incision is usually made over it; and if it is being done for the relief of a

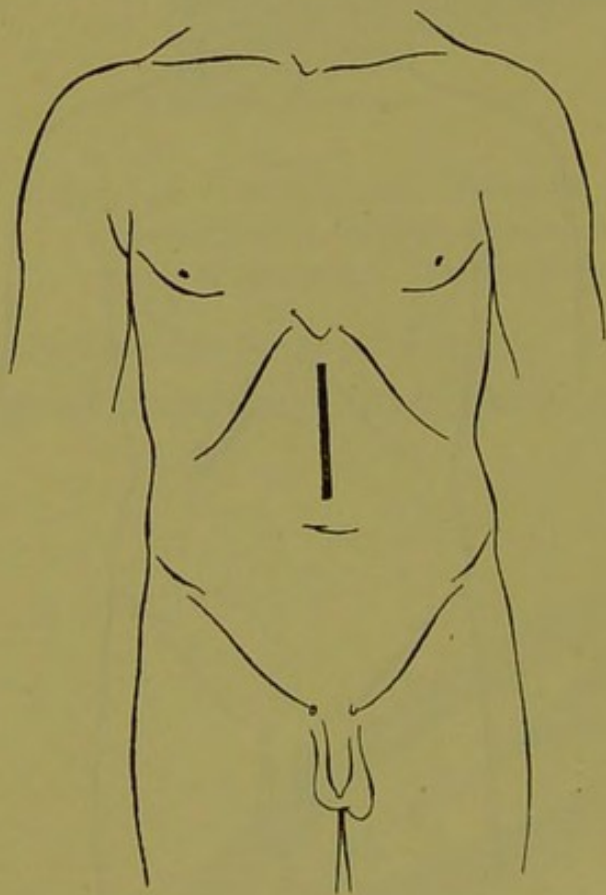


FIG. 44.—Gastrotomy: Abdominal incision.

fibrous constriction of the pylorus, the incision is made in the linea alba, according to Fig. 44.

(b) *Finding of stomach, etc.*—The fingers are introduced into the wound, and the stomach felt for, and also the locality of the foreign body, fibrous constriction, or growth. Care must be taken when palpating the stomach not to cause injury to the walls, if a sharp foreign body is present. The stomach is then brought into the parietal wound, and the surrounding por-

tion of the peritoneal cavity packed with aseptic Turkey sponges.

(c) *Incision of the stomach wall, removal of foreign body, etc.*—An incision is made through the stomach wall in a direction at right angles to the long axis of the viscus, so as to avoid injury to the chief blood vessels. The length of this incision varies according to the size of the foreign body which it is wished to remove, or to the nature of the constriction, or the size and locality of the malignant growth.

The foreign body is removed through the aperture made, care being taken not to lacerate or damage the walls of the stomach. If the operation is performed for the relief of a fibrous stricture, either of the pylorus or the lower portion of the œsophagus, the forefinger of the right hand is passed into the cavity of the stomach towards the seat of the constriction, and the narrowed portion of the canal dilated by gently forcing the finger through the stenosed part.

(d) *Closure of wound*.—The area of the wound in the stomach wall is carefully sponged with aseptic sponges, and the aperture closed. The mucous membrane is joined to mucous membrane by the insertion of a continuous suture of catgut, the muscular coats are united with interrupted sutures of fine silk, and the serous and superficial muscular coats by the insertion of a series of Lembert's sutures. When the incision in the stomach has been closed thus, all sponges are removed from the peritoneal cavity, and the exposed peritoneum carefully cleansed. The parietal wound is then closed in the usual manner.

In the after-treatment of a case of this kind, no food is given by the mouth for the first three or four days, the patient being fed with nutrient enemata.

The operation of gastrotomy, when it is performed for the dilatation of a fibrous stricture of the pylorus, has been called "Loreta's operation."

Pyloroplasty.—This operation has been recommended by Heineke and Mikulicz as superior to digital dilatation, in cases of fibrous stricture of the pylorus or the upper part of the duodenum.

Operation.—The abdomen is opened by an incision in the linea alba, as in the preceding operation, and the pylorus and the constricted portion of the duodenum brought into the parietal wound. The exposed portion of alimentary canal being protected by aseptic flat sponges, an incision is made on the anterior aspect of the constricted gut in its long axis,

according to the method shown in Fig. 45. The margins of this incision are then approximated as in Fig. 46, and

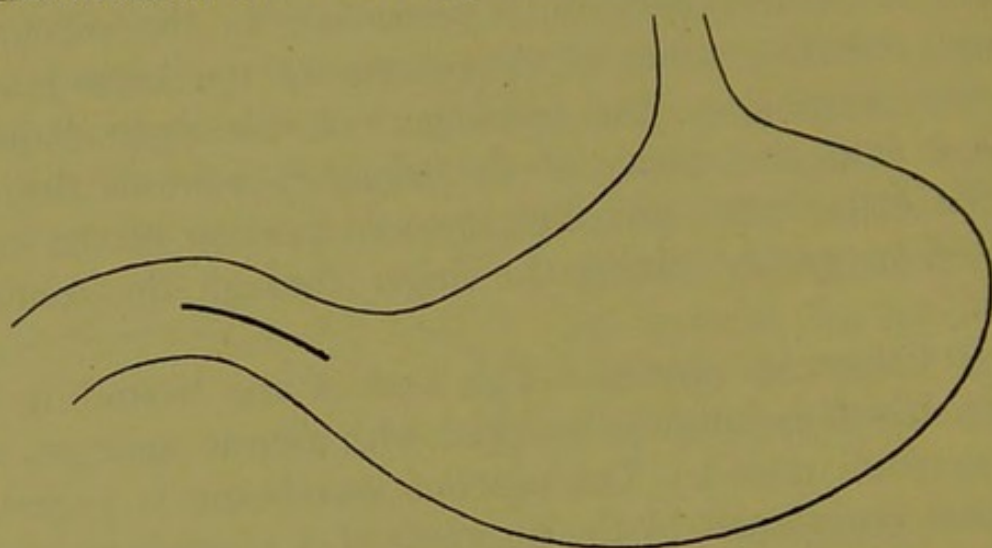


FIG. 45.—Pyloroplasty: Stomach and duodenum with line of incision in gut wall.

fixed by the insertion of sutures. Three tiers of sutures are inserted, the first uniting the mucous membrane, the second the muscular coat, and the third the peritoneum.

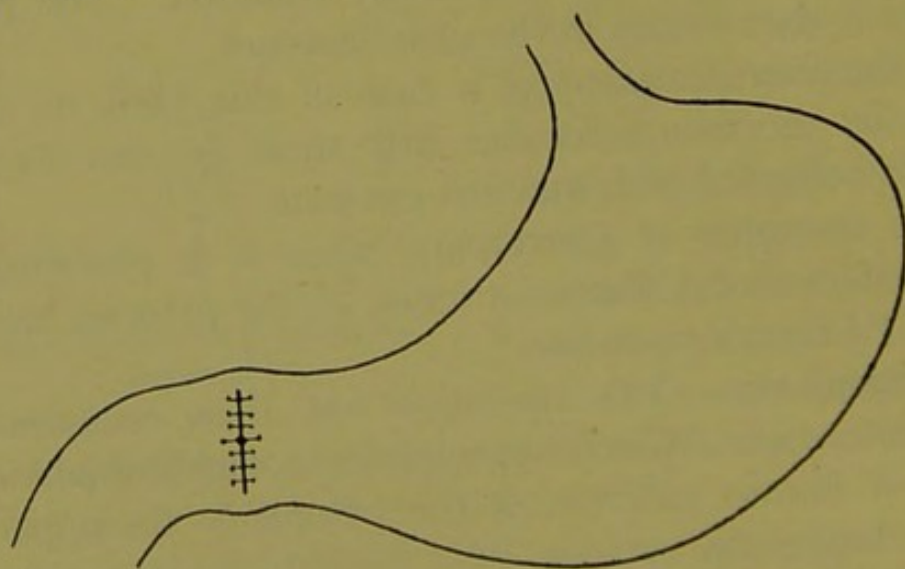


FIG. 46.—Pyloroplasty: Appearance of incision when sutures have been inserted and tied.

When the operation is completed, the margins of the incision are at right angles to the long axis of the affected part of the intestine.

The pylorus and duodenum are returned into the

peritoneal cavity, and the external wound closed in the usual manner.

Gastro-enterostomy.—The establishment of an artificial communication between the cavity of the stomach and that of the intestine is called “gastro-enterostomy”; if the duodenum is the part of the intestine to which the stomach is attached, the operation is known as “gastro-duodenostomy”; if the jejunum, “gastro-jejunostomy”; if the ileum, “gastro-ileostomy”; and if the colon, “gastro-colostomy.”

Indications.—The operation of gastro-enterostomy is indicated in the following clinical conditions, namely:—

(a) In those cases of malignant disease of the pylorus, in which it is not advisable to attempt local removal of the growth, and in which it is probable that life will be prolonged by the establishment of an artificial communication between the stomach and the intestine.

(b) In certain cases of severe fibrous stricture of the pylorus or duodenum, which cannot be satisfactorily treated by “pyloroplasty.”

Position.—The patient is placed in the dorsal position, the surgeon stands on the right side of the patient, and the assistant on the left.

Instruments.—Scalpel, retractors, intestinal clamps, dissecting and pressure forceps, scissors, (anastomosis “button,” “tube,” “bobbin,” or Senn’s plate, if it is proposed to make use of one of these contrivances), needles, needle-holder, and suture and ligature material.

Operation.—The operation of gastro-enterostomy may be conveniently divided into the following stages:—(a) Parietal incision; (b) finding of stomach and required portion of intestine, and bringing them out through the external wound; (c) establishment of anastomosis between stomach and intestine; (d) closure of external incision.

(a) *Parietal incision.*—An incision from 3 to 4 in. in length is made in the linea alba, commencing a short distance below the ensiform cartilage, and extending

to the umbilicus. This incision is extended until the peritoneal cavity has been opened.

(b) *Finding of stomach and required portion of intestine, and bringing them out into the external wound.*—The portion of the intestine which is usually selected is the jejunum, a short distance beyond the termination of the duodenum. The great omentum is turned upwards and towards the right, then a coil of small intestine, which lies upon the vertebral column and at the level of the apex of the left kidney, is taken and traced upwards; if it is the jejunum, it will be found to have a short mesentery at its upper part, and to turn upon itself and become continuous with the duodenum. If this is verified, the coil is traced downwards, until a loop can be readily brought into the external wound

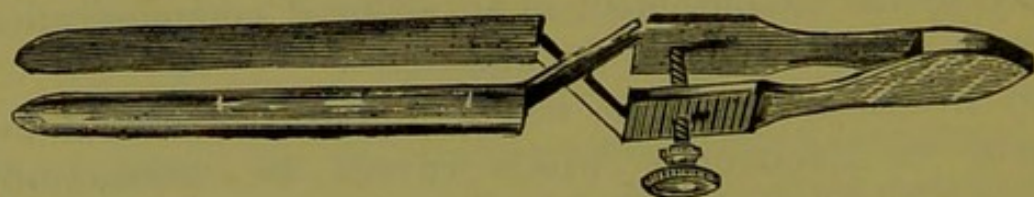


FIG. 47.—Intestinal clamp.—MAKINS.

and applied to the stomach. This loop is emptied of its contents by passing it between the fingers, and then two intestinal clamps are applied at a distance of about 3 in. from one another. The stomach is next brought into the external wound, and an area selected on the anterior surface, about 1 in. above the greater curvature and nearer to the pyloric than the cardiac extremity. These portions of stomach and intestine are surrounded with warm sterilised towels and sponges. The formation of the anastomosis may now be performed.

(c) *Formation of anastomosis between stomach and intestine.*—The stomach and intestine may be united in a variety of ways. These methods, however, may be divided into two classes—union by *suture*, and union by *sutures* aided by a *mechanical appliance*, such as Senn's plate, a Murphy's button, or a bone "tube" or "bobbin." If the

"suture" method is well performed, it probably is the best. Of the mechanical appliances for this operation a "bone plate" or an anastomosis "button" are the most suitable.

Union by sutures.—The loop of intestine is applied to the stomach in such a manner that, when the communication has been established, the contents of the stomach will flow into the intestine in a direction corresponding to that of the normal peristaltic movements. This is said to be effected by twisting the intestine "half a turn" on its long axis.

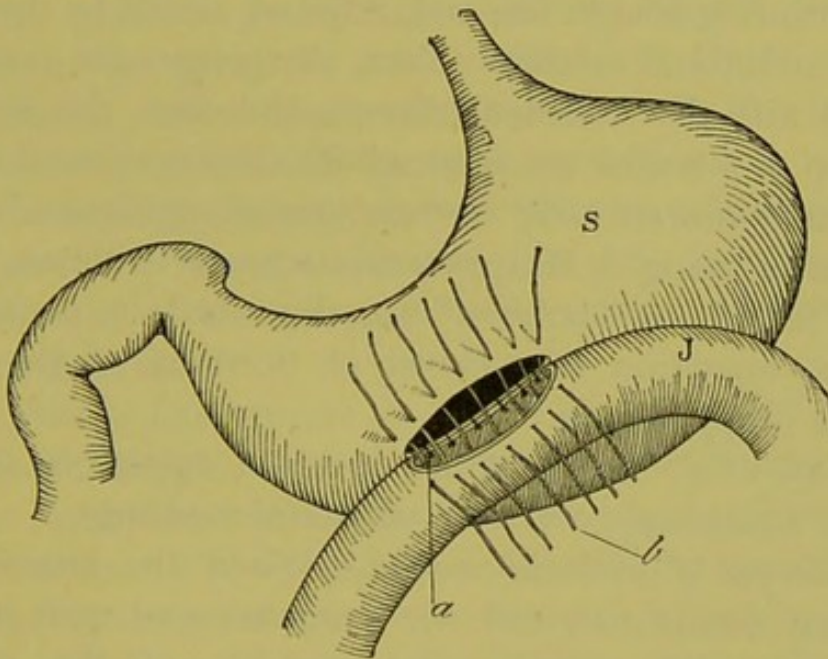


FIG. 48.—Gastro-Enterostomy: Stomach and a coil of Jejunum approximated and the margins of the incision closed on one side.

S. Stomach; J. Jejunum. *a*. The sutures of the second row tied and their ends cut short; *b*. The sutures of the third row inserted but not tied.

When this has been done, incisions $1\frac{1}{2}$ in. in length are made through the serous and muscular coats of both stomach and intestine. These incisions are so placed that they correspond with one another, and the one in the intestine is in its long axis. A series of Lembert's sutures of fine silk is now introduced at the lower margins of the incisions, and each suture tied. Next, the mucous membrane of each viscus is divided at the bottom of the

incision, and the cut margins united all round by numerous fine interrupted silk sutures. When this has been done, the serous and muscular coats on the upper margins of the incisions are united with Lembert's sutures in a manner similar to that adopted for the lower margins. When this has been done, the communication between the stomach and intestine is established, two circles of sutures preventing escape of intestinal contents into the peritoneal cavity. The area of operation is well sponged, and any weak points in the suturing sought for, and, if found, closed by the insertion of additional sutures. Next, all sponges are removed, together with the intestinal clamps, and then the stomach and loop of intestine are returned into the peritoneal cavity.

Union by sutures aided by "mechanical appliances."—The methods of using a Murphy's anastomosis "button," or a bone "tube" or "bobbin," are described in connection with the operation of removal of portions of the small intestine on pp. 59–62.

The use of a "Senn's plate" does not appear to present material advantages over that of careful suturing.

(d) *Closure of external wound.*—When the anastomosis has been completed, and the contaminated part of the peritoneum well sponged, the margins of the parietal incision are united in the ordinary manner by the insertion of one or more tiers of sutures, as described on p. 24.

Pylorectomy, or removal of the pyloric portion of the stomach.—In this operation the pyloric extremity of the stomach, together with the adjacent parts of the duodenum and stomach, are removed through an abdominal incision, and then the opening in the stomach is partially closed, and that part which is left open is united to the open extremity of the duodenum.

Indications.—Removal of the pylorus is rarely justifiable, but in those cases of malignant disease of the pylorus in which the pathological process is strictly localised to this part of the alimentary canal, and there are no secondary

deposits elsewhere, it may be advisable to attempt the removal of the growth, with the hope of affecting a cure, or at least prolonging life for a period. The operation should only be attempted in patients who are very good subjects for surgical interference.

Preliminary preparations.—For several days before the operation the stomach should be washed out with a dilute antiseptic solution, and during this period easily digestible food, which has previously been sterilised, should be given. The day previous, an aperient medicine should be administered, so as to empty the intestines as far as possible. Immediately before the patient comes into the operation room the stomach should be again washed out.

Instruments.—Scalpel, pressure forceps, retractors (large), large intestinal clamps, scissors, dissecting forceps, needles (half-curved, of two sizes), needle-holder, and suture and ligature material.

Position.—The patient is placed in the dorsal position, and near the right edge of the table. The operator stands on the right side, and the assistant directly opposite to him.

Operation.—The operation of pylorectomy may be divided into the following stages:—(a) Parietal incision; (b) localisation of tumour, separation of it from surrounding structures, and bringing it out through the abdominal wound; (c) removal of pylorus and affected portions of stomach and duodenum; (d) partial closure of wound in stomach, and union of other part to duodenum; (e) return of stomach and intestine into abdomen, and closure of external wound.

(a) *Parietal incision.*—An incision 4 in. in length is made in the linea alba or in the right linea semilunaris, usually the former, and situated over the most prominent part of the tumour. The various strata of the abdominal wall are divided in the usual manner until the peritoneal cavity has been opened.

(b) *Localisation, separation, and delivery of tumour and adjacent portion of alimentary canal.*—The fingers of the

right hand are introduced into the peritoneal cavity, and the position of the affected pylorus defined. The adjacent coils of intestine and the great omentum are pushed out of the way, and protected from injury by packing the region of the tumour with flat sponges. The pylorus is next brought out through the external wound. If its attachments to the great and lesser omenta do not allow this to be done, these structures are divided for a sufficient distance along the greater and lesser curvatures of the stomach, and the cut edges tied with ligatures so as to arrest hæmorrhage. When the tumour has been brought well forward into the external

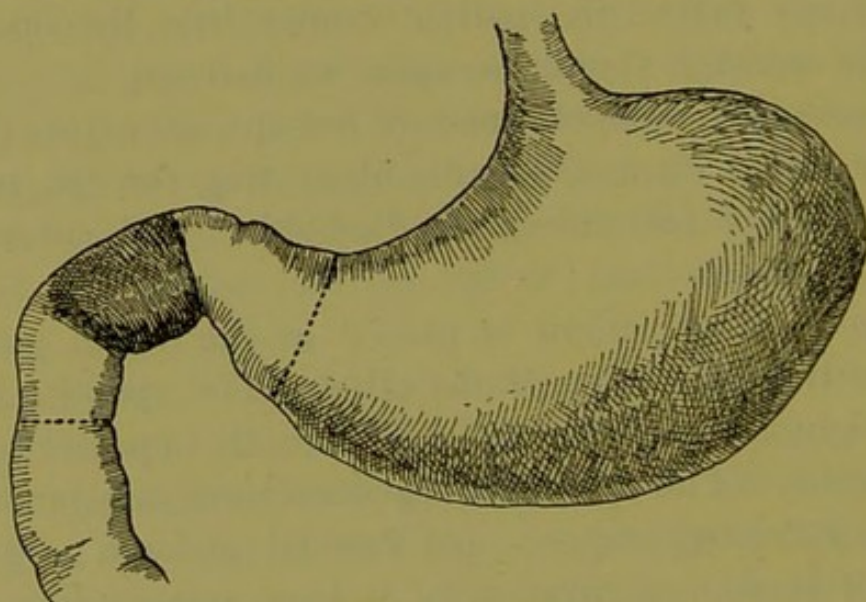


FIG. 49.—Pylorotomy: Lines of incision in stomach and duodenum. The dark portion represents the extent of the growth.

wound, its relations are determined. If it is found to be localised, and there are no signs of secondary growths in the lymphatic glands of the gastro-hepatic omentum, in the liver, or in the region of the head of the pancreas (or elsewhere), it may be decided to effect its removal.

(c) *Removal of tumour, etc.*—Before commencing to remove the tumour, the contents of the adjacent portions of the stomach and duodenum are pushed onwards (if any are present), and then an intestinal clamp is applied to the stomach about three-quarters of an inch above the limits of

the growth, and a second clamp to the duodenum an equal distance below it. These clamps prevent the escape of intestinal contents into the field of operation, and help the surgeon to control hæmorrhage without much difficulty. When the clamps have been applied, both the stomach and duodenum are divided with strong scissors or a scalpel, and the tumour freed from any other connections which it may have. Care must be taken in making these sections, that the common bile duct, the portal vein, and the hepatic artery are avoided. They lie behind the first portion of the duodenum, and then between the two layers of the gastro-

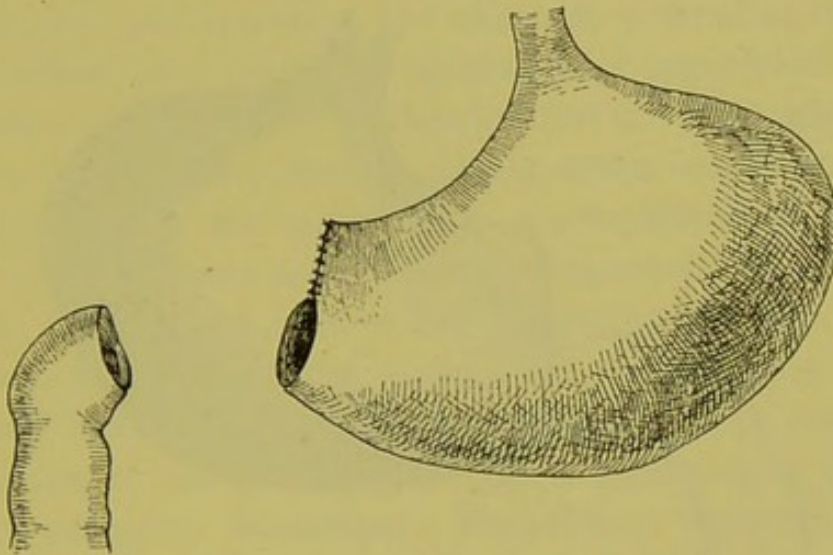


FIG. 50.—Pylorectomy: Affected portions of gut removed, and part of incision in stomach closed by sutures.

hepatic omentum. The tumour having been removed, the cavities of the exposed parts of the stomach and duodenum are carefully sponged so as to render them as aseptic as possible, and then the clamps are slightly loosened by the assistant, in order to allow hæmorrhage to take place from the divided vessels, and so facilitate the application of ligatures to them.

(d) *Partial closure of wound in stomach, and union of other part to cut end of duodenum.*—A part of the divided end of the stomach is united, according to the method shown in Fig. 50. The best method of doing this, is by the insertion

of a continuous silk suture to the margins of the wound, a firm hold of the mucous membrane being taken; and when this has been done, a series of Lembert's sutures are inserted, as in Fig. 50. The next stage is the union of the remainder of the wound in the stomach to the open extremity of the duodenum, and hence the re-establishment of the continuity of the alimentary canal. This can be done either by means of sutures alone, or by sutures aided by a mechanical appliance, such as Murphy's "button," a bone tube, or a bone bobbin.

(1) *Sutures only*.—The mucous membrane and the mus-

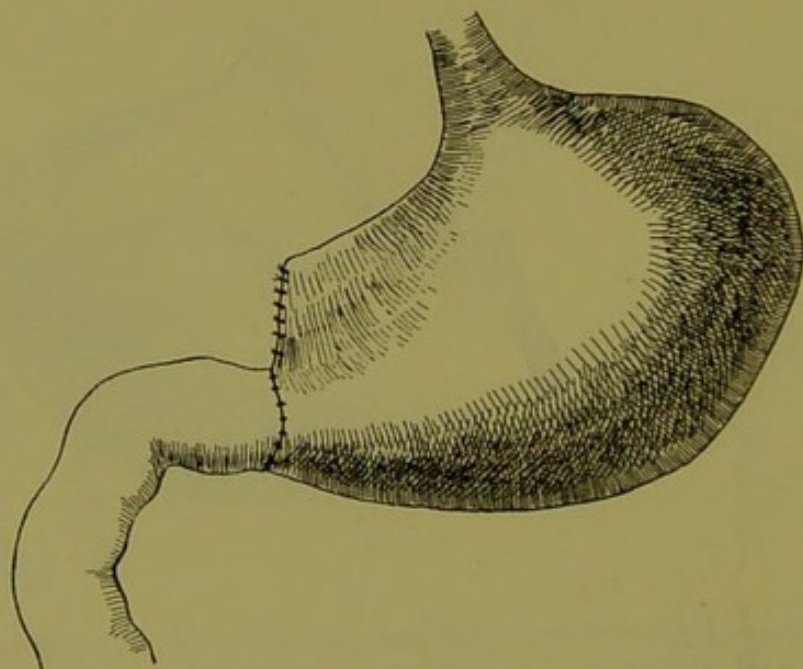


FIG. 51.—Pylorotomy: Stomach and duodenum united by sutures.

cular coat of the stomach are united to the corresponding portions of the duodenum by a series of interrupted fine silk sutures. The insertion of these is commenced posteriorly, and continued forwards until the entire circumference of the bowel has been sewn up. As these sutures are inserted, each one is tied and cut short, the knot being towards the lumen of the gut. Next, the line of suture is well sponged so as to remove all traces of blood or stomach contents, and then the line of approximation is further united by the insertion of a circle of Lembert's sutures,

which transfix the serous, muscular, and submucous coats only. When these have been tied and the ends cut short, the union is completed. If there is any doubt as regards the security of the sutures, it has been recommended that a graft of omentum should be fastened to the suspected portion.

(2) *Sutures aided by a mechanical appliance.*—When the portion of stomach which is not required for suture to the duodenum has been closed, the remaining portion may be united to the open end of the duodenum by the insertion of a Murphy's "anastomosis button," or a bone tube or bobbin, into the lumen of the alimentary canal at the point of junction, and then the operation is completed by the insertion of a circle of Lembert's sutures. The advantages of this method over that of simple suture are—the greater ease with which the suturing is accomplished, the shorter time which is necessary for the operation, and the less liability there is of incomplete apposition of the divided surfaces, and hence the leakage of the contents of the stomach afterwards. The disadvantage is the liability of the button or bobbin to give rise to obstruction at a later period, owing to impaction. Probably a decalcified bone tube or bobbin is safer than a Murphy's button.

(e) *Return of stomach and duodenum into abdomen, and closure of external wound.*—After the approximation of the divided portions of the alimentary canal has been completed, all the sutures are cut short, the region of operation and the adjacent part of the peritoneal cavity are well sponged with an aseptic solution so as to remove all blood and other material which has escaped, and then the stomach and duodenum are returned within the abdomen. The external wound is finally closed by sutures in the usual manner. No drainage is necessary.

After-treatment.—No food should be given by the mouth for the first twenty-four or thirty-six hours, the strength of the patient being maintained during this period by the

administration of nutrient enemata. Afterwards, feeding by the mouth is commenced, small quantities being given at first. Only fluid foods should be given, and these should be rendered sterile, if possible, before administration.

Treatment of perforated gastric ulcers.—Ulcers of the stomach which lead to perforation of the walls may be either of the "acute perforating" or the "chronic" variety. The perforation usually occurs suddenly without any premonitory symptoms having been manifested. Immediately the diagnosis has been made that an ulcer of this kind has perforated the stomach wall, an operation for the relief of the condition ought to be carried out.

Some surgeons have suggested that, in certain forms of gastric ulcer, an operation should be performed before perforation has occurred, in order to avoid the dangers of general peritonitis. Owing, however, to the fact that only a small percentage of gastric ulcers cause perforation, and to the severity of the operation for the cure of a non-perforated ulcer, it does not seem advisable to adopt this method of treatment.

The symptoms of shock, which in all cases supervene immediately after the occurrence of perforation, must be combated by the administration of stimulants, such as strychnine given hypodermically, in order that the patient may not be too collapsed to withstand the further shock due to the operation.

Position.—The patient is placed in the dorsal position on the operation table, the surgeon stands on the right side, and his assistant on the left.

Instruments.—Scalpel, retractors, dissecting and pressure forceps, scissors, irrigation apparatus, drainage tubes, needles, needle-holder, and ligature and suture material.

Operation.—The operation may be divided into several stages, namely :—(a) External incision; (b) finding of stomach and the seat of perforation in it; (c) closure of

perforation; (d) washing out of peritoneal cavity; (e) establishment of drainage and closure of external wound.

(a) *External incision.*—An incision is made in the linea alba, commencing immediately below the lower border of the ensiform cartilage, and extends downwards towards the umbilicus for a distance of 3 or 4 in. This incision is deepened until the peritoneal cavity has been opened, all hæmorrhage from the parietal vessels being arrested.

(b) *Finding of stomach and perforation.*—The anterior surface of the stomach can usually be seen at the bottom of the wound.

The adjacent coils of small intestine, if they protrude, are held aside by packing with flat sponges. If a perforation has taken place, and the contents of the stomach have passed into the peritoneal cavity, it generally happens, when the peritoneum is incised, that gas and particles of food escape.

The stomach having been found, search is made for the perforation. This, in most instances, is situated either on some part of the anterior surface of the viscus, or in the vicinity of the lesser curvature. If it cannot be at once seen, the stomach is palpated with the finger, and often a localised hardness will indicate the region of the ulcer which has caused perforation. In order to examine the lesser curvature, it is necessary for the liver to be lifted up by the assistant. As the liver is lifted up, adhesions between its inferior surface and the stomach will often become manifest. The presence of adhesions of this kind usually indicates the seat of the perforation. If the perforation cannot be discovered on the anterior aspect, or in the region of the lesser curvature, it will be necessary to carefully break through the gastro-hepatic omentum on the left side of the portal vessels, and then examine the posterior aspect. A similar examination may be made by dividing the anterior lamina of the great omentum, about half an

inch below the greater curvature. This, in my opinion, is a better method.

Occasionally, when the perforation is on the posterior aspect of the viscus, its position may be located by passing the finger through the foramen of Winslow into the cavity of the lesser sac, and then palpating the posterior part of the organ.

When the perforation has been located by one of these methods, it must, if possible, be closed. Before doing this, the region of the perforation must be well irrigated with an aseptic solution, so as to remove all stomach contents which may have escaped. If the aperture in the stomach wall is large, a tube should be passed through it, and all food washed out from the interior of the stomach by irrigation.

(c) *Closure of perforation.*—The aperture is then closed by the insertion of a number of Lembert's sutures, each suture taking up the submucous, muscular, and serous coats only. If possible, that portion of the stomach which is the seat of the perforation should be brought into the parietal wound during the insertion of the sutures. All the sutures should be introduced before any are tied.

When the margins of the ulcer are indurated and irregular, it is advisable to excise the hardened portion before introducing the sutures. In this case the margins of the mucous membrane are united first by a continuous suture, and then the remainder of the coats as above. Care must be taken that each Lembert's suture takes up some of the submucous coat.

The sutures are now tied, their ends cut short, and the region of the perforation well sponged. The stomach is then dropped back into the peritoneal cavity. Occasionally it will be found impossible to close the aperture with sutures. In some of these cases it may be possible to close the aperture by stitching over it a piece of the great omentum. When this cannot be done, the margins of the perforation

must be sewn to the parietal incision, so as to make a gastric fistula, or, failing this, a drainage tube must be passed down to the perforation, and the part of the peritoneal cavity around the tube packed with long strips of aseptic gauze, one extremity of each strip protruding from the external incision.

(d) *Washing out of peritoneal cavity.*—When the aperture in the stomach wall has been dealt with by one of the methods mentioned above, the sponges are removed from the peritoneum, and the entire cavity irrigated with an aseptic solution, if there has been a general escape of stomach contents into the peritoneum. Care must be taken to remove all débris from the pelvis, and in order to do this it may be necessary either to enlarge the incision in the abdominal wall, or to make a second one below the umbilicus. If the stomach contents have only contaminated the region of the perforation, it is not necessary to irrigate the general peritoneum.

(e) *Establishment of drainage and closure of external wound.*—In most cases of perforation of a gastric ulcer it is necessary to drain the peritoneal cavity after the perforation has been closed. This is done by the insertion of one or two glass or rubber drainage tubes, which are passed through a part of the external wound which has been left open for the purpose. When the depths of the pelvis have been contaminated with stomach contents, it is advisable to pass a tube into this part.

The external wound is closed in part, or entirely, by the insertion of one or more tiers of sutures in the usual manner.

When the aperture of perforation has been shut off from the rest of the peritoneum by the presence of adhesions, it may be advisable to close the entire external wound, but this is of rare occurrence.

After-treatment.—The patient should not be fed by the mouth for several days after the closure of the perforation,

but the strength should be maintained by the administration of nutrient enemata. Small quantities of ice or warm water may, however, be given by the mouth. The state of general nutrition of a patient who is suffering from a perforated gastric ulcer is usually good; hence, for the first few days, little food is required.

OPERATIONS UPON THE SMALL INTESTINES.

Closure of perforating wounds.—Perforating wounds of the small intestine may be made—(a) By the surgeon, as in the removal of an impacted gall stone or a foreign body; or (b) as the result of an injury, such as stab with a knife, a fall upon sharp railings, a gunshot wound, or a bayonet wound.

The wound may penetrate either the abdominal parietes or the thoracic wall and the diaphragm.

In order to locate the position of the perforation of the intestine, it is usually necessary to perform an abdominal section, either through the linea alba, or by enlargement of the original wound. It occasionally happens that a coil of intestine is protruded through the aperture in the parietes, and the perforation in it can be at once seen.

In these cases, however, it is nearly always necessary to examine the other coils of intestine, so as to be certain that a second perforation is not passed undetected.

When the wound has been discovered, the injured loop of intestine is brought through the parietal incision, and surrounded with warm aseptic sponges or towels, and the region of perforation well washed or irrigated, so as to remove all dirt or intestinal contents. In many cases, the mucous membrane will be found to be protruded through the aperture in the intestinal wall. An attempt should be made in every case to unite the margins of the mucous membrane with a continuous fine silk ligature. The perforation is again sponged clean, and the margins of the

aperture in the muscular and serous coats approximated and fixed in apposition by a series of Lembert's sutures of fine silk, introduced about one-fifth or one-eighth of an inch apart. Care must be taken in the insertion of these sutures, that one is placed beyond each extremity of the aperture in the intestinal wall. If other perforations be present, they must be treated in a similar manner.

When all have been closed, the area of perforation is irrigated with an aseptic solution, the injured coil or coils returned into the peritoneal cavity, and the wound in the parietes closed in the ordinary manner.

The after-treatment of these cases is similar to that mentioned in connection with "resection of the intestine."

When the perforations are very large or numerous, it is usually necessary to remove the injured coil or coils according to the method which is described later.

Removal of a portion of intestine.—Removal of a portion of the small intestine is generally called "enterectomy," of the large intestine "colectomy."

Indications.—Excision, resection, or removal of a portion of the intestines is indicated in the following conditions, viz. :—

(a) *Strictures.*—Strictures of the intestines, either simple or malignant, especially the latter. Simple growths of the intestines rarely cause obstruction which necessitates resection of the affected part, but occasionally such a procedure is called for. Malignant growths usually involve the large intestines, and when they can be localised, and there are no signs of secondary affections elsewhere, resection is indicated.

(b) *Gangrene of intestine.*—Gangrene of a portion of the intestine is usually due to some form of strangulated hernia ; removal of the gangrenous portion is then necessary. The method of treatment, after the dead portion has been removed, depends upon the situation of the diseased tissue, and the general condition of the patient. If the strength of

the patient is good, or if the gangrenous portion is situated high up in the small intestine, anastomosis of the divided ends must be performed, whilst, if the condition of the patient is so serious that it is probable that a prolonged and severe operation will not be borne, the dead portion is removed and the open extremities of the divided gut fixed in the abdominal wound. If the patient survive this stage, the anastomosis and restoration of the canal can be effected at a later period.

(c) *Intussusception*.—Certain cases of intussusception in which the invaginated portion cannot be reduced, or gangrene has taken place.

(d) *Injuries*.—Those forms of injuries of the intestines where extensive laceration of the walls of the gut has taken place.

(e) *Tuberculosis*.—Some forms of intestinal tuberculosis, when the affection is localised to one portion of the alimentary tract, as in tuberculosis of the cæcum.

(f) *Adhesions*.—Occasional cases of fibrous stricture following an injury, and due to extensive and tight adhesions.

(g) *Fistulæ*.—Intestinal fistulæ which are not curable by less severe measures.

Varieties of operation.—A number of different methods of resection of a portion of the alimentary canal have been adopted by surgical operators. The most important may be divided into two distinct classes, viz. :—

(a) Methods in which the approximation of the divided extremities is accomplished by means of some form of *suture*. Two forms of this operation will be described—(1) Union by *circular enterorrhaphy*; (2) union by *Maunsell's method*.

(b) Methods in which the approximation is accomplished with the aid of a *mechanical appliance*, such as a *Murphy's anastomosis button*, a *bone tube*, or a *bone bobbin*.

All these methods of union are available in what is called "end-to-end" anastomosis, but in some cases it is

advisable to establish a lateral anastomosis or union, a result which may be accomplished by one of the above methods, or can be readily brought about with a contrivance known as *Senn's plates*. The method of using *Senn's plates* will be considered in the operation of "lateral anastomosis," p. 62.

Instruments.—Scalpels (one of ordinary shape and one with a long narrow blade like a finger knife), scissors, retractors, pressure forceps, dissecting forceps, intestinal clamps, Murphy's "anastomosis button," a bone tube, or a bone bobbin (whichever it is wished to use), needles, (straight and half-curved), needle-holder, suture and ligature material (Chinese twist and silk-worm gut are the best).

Position.—The patient in nearly all cases is placed in the dorsal position, but the position of the operator depends upon the situation of the parietal incision. The chief assistant stands directly opposite the surgeon, and the second assistant on his left hand.

Operation.—In all cases of resection of the intestines, the actual operation may be divided into five stages, which are the following:—(a) Parietal incision; (b) finding of diseased portion of intestine, and bringing it out through the wound in the abdominal wall; (c) removal of the affected piece; (d) union of the divided ends of the intestine; (e) closure of the external wound. The first two and the last stages are similar in all forms of intestinal resection, but stages c and d differ in details, according to the individual procedure which is being adopted. The first two stages, a and b, will be first described, then the modifications which occur in stages c and d, and finally the method of closure of the external wound.

(a) *Parietal incision.*—The situation of the incision in the parietes depends upon the locality of the tumour or the part of the intestine which it is intended to remove. As far as possible, it ought to be made in the linea alba, or

directly over the tumour. In the case of a strangulated hernia, it is not possible to decide whether the gut will require resection until it has been exposed through the usual hernial incision, and when it is found to be gangrenous, the incision is enlarged sufficiently to enable the coil of gut to be brought out of the wound, and to allow of its return after the resection has been performed. Usually an incision from 3 to 4 in. in length will be long enough to enable the surgeon to readily perform all the manipulative procedures which are requisite.

(b) *Finding of diseased portion, etc.*—The fingers of the right hand are introduced into the peritoneal cavity, and the affected portion of gut is sought for, and when found it is brought out through the external wound and surrounded with large flat sponges which have been wrung out of a warm antiseptic solution, preferably of boracic acid. If there are any adhesions which hold down the affected coil or loop, they are either broken down with the fingers or they are tied in two places with silk ligatures, and divided. The intestine having been delivered in this manner, the contents are forced onwards with the fingers until the lumen of the affected part is quite empty. Two intestinal clamps are taken and applied to the intestine 2 in. above and below the lines where it is intended to make the section. If these clamps are placed too near the lines of section, they interfere with the insertion of the sutures, and with the application of measures which have for their object the asepticity of the area of operation.

In cases of malignant disease, it is advisable to examine the mesentery for enlarged lymphatic glands, which, if found, must be removed.

(c) *Removal of the affected piece.*—The intestinal tube is divided transversely to its long axis and well beyond the diseased tissue. This can be done, either with strong scissors, or, better, by transfixing the mesentery close to the intestine with a long narrow-bladed scalpel, and cutting

outwards. When this has been done, the portion of mesentery which is attached to the separated piece of intestine is divided along the line of attachment of the gut (Fig. 52). As this is done hæmorrhage from many small blood vessels occurs, and is arrested by picking up each bleeding point with a pair of pressure forceps.

The advantage of this method of division of the mesentery is, that a better blood supply is left than when a wedge-shaped piece is removed. If, however, the disease or growth has involved the mesentery, it must be removed by making

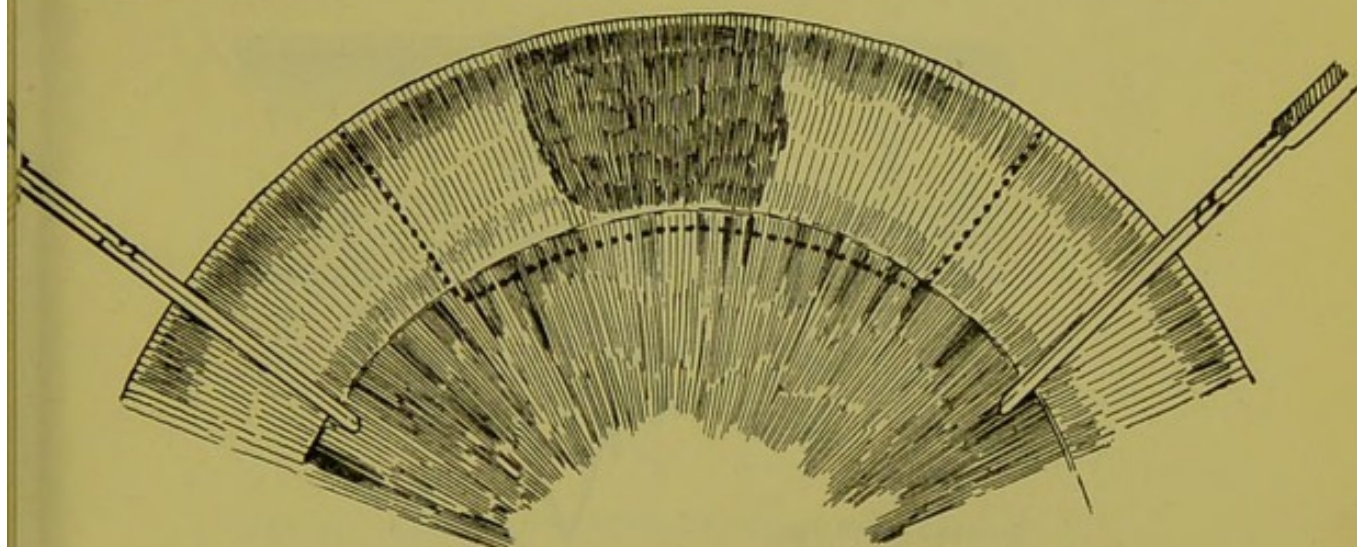


FIG. 52.—Enterectomy: Lines of incision in bowel and mesentery.

a wedge-shaped incision, as shown in Fig. 53. In Maunsell's method of operation, also, a wedge-shaped piece must be removed. When all hæmorrhage has been arrested, and the cut ends of the intestine well washed with an aseptic solution, approximation and union can be performed.

(d) *Union of the divided intestine.*—By *circular enterorrhaphy*.—Four sutures are first inserted so as to hold the margins of the divided intestine in apposition and ensure exact approximation. The first one is passed at the mesenteric attachment, the second at the convexity of the gut opposite the attachment of the mesentery, and the third and fourth half-way between the mesentery and the

convex border, one on each side. Each of these sutures is made to transfix the mucous and submucous coats, and is left long. These are given to the assistant to hold, whilst the surgeon inserts a series of similar sutures which shall approximate and fix in apposition the mucous and submucous coats for the entire circumference of the bowel. When this has been done, all the sutures are cut short except the first four, which are left long to help in the insertion of the next series. A circle of Lembert's sutures is now inserted about one-sixth or one-eighth of an inch

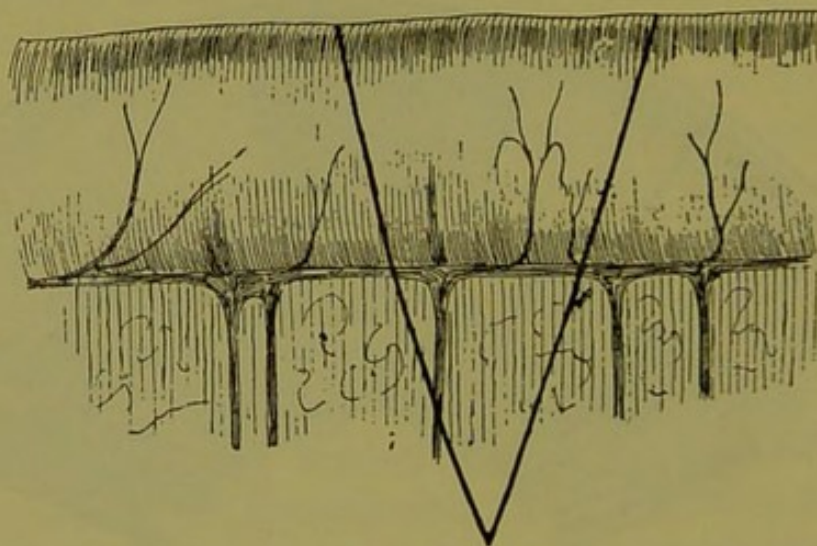


FIG. 53.—Enterectomy: Lines of incision in bowel and mesentery, when a V-shaped piece is removed from the latter, as in Maunsell's operation.

apart. Each long suture is cut short as soon as the neighbouring Lembert's sutures have been inserted. These Lembert's sutures are introduced according to the method shown in Fig. 27. When the complete circle has been introduced and tied, the approximation of the intestine is finished, and nothing remains but to fold the mesentery in the form of a "pleat" and fix it as in Fig. 60. If there is any doubt as to the security of the stitches in the part of the intestine near the mesentery, it may be advisable to stitch the mesentery over this portion, in order to give a little extra security. In most cases, however, this is not requisite.

The line of approximation of the two ends of intestine is now carefully washed, together with any soiled portion of peritoneum, the clamps are removed, and the gut returned into the peritoneal cavity.

(2) *By Maunsell's method.*—The portion of the intestine which it is wished to remove, together with a V-shaped piece of the mesentery, is detached, according to the method shown in Fig. 53. This having been done, two sutures, one at the mesenteric attachment and the other at the convex

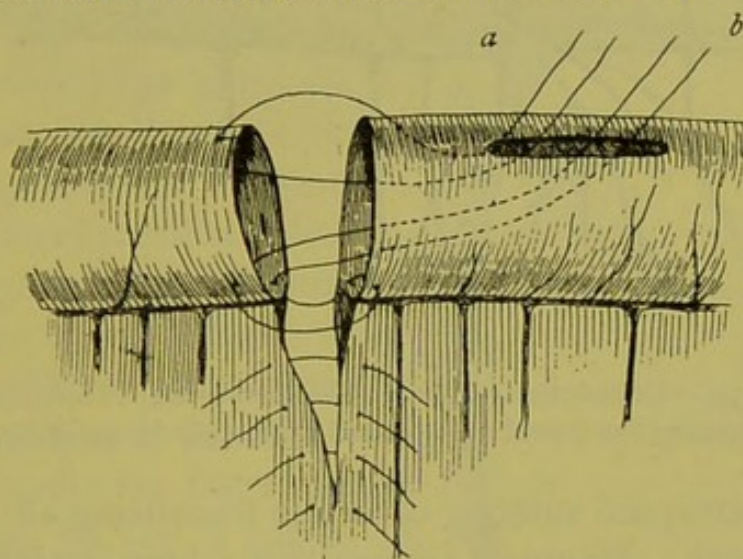


FIG. 54. —Enterectomy (Maunsell's operation): Method of insertion of two long sutures, after the segment of gut has been removed and before invagination. The manner of insertion of sutures into the mesentery is also shown.

border, are inserted as in Fig. 54, and the ends left long. Next, an incision is made in the long axis of the bowel on the convexity, as in Fig. 54. The length of this incision varies with the calibre of the gut which is being operated upon, but in every case the extremity of the incision nearest to the divided end of the intestine is 1 inch beyond it. This incision should be made in that portion of the bowel which has the larger calibre. A pair of pressure forceps is passed through this longitudinal incision, and the two long threads, *a* and *b*, are pulled through, as in Fig. 54, and the smaller segment of the gut invaginated within the larger.

Next, the margins of the two divided ends of intestine are fixed in apposition by the insertion of a number of

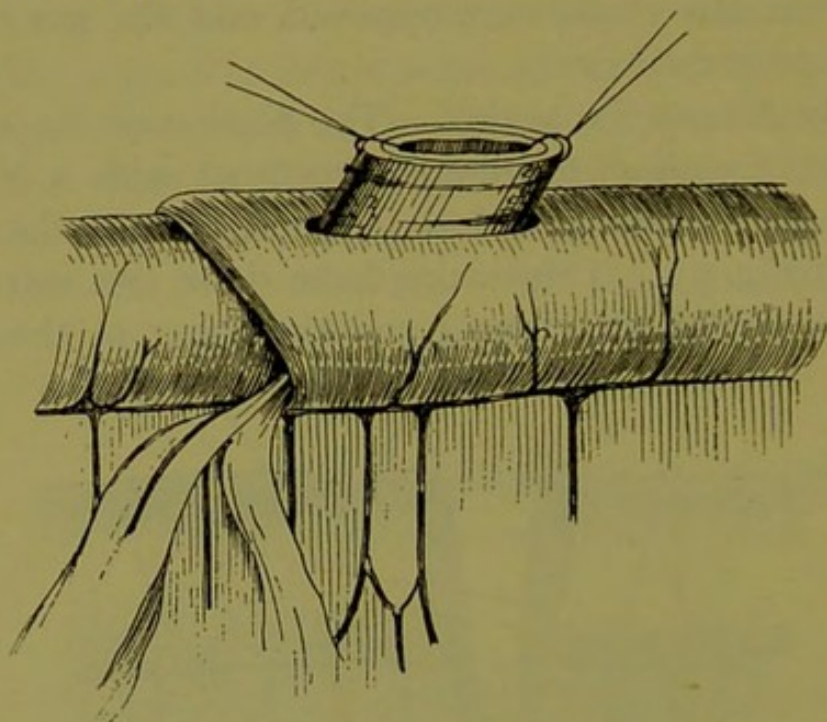


FIG. 55.—Enterectomy (Maunsell's operation). Third stage, showing the bowel invaginated and ready for suturing.

simple interrupted sutures, each one transfixing all the coats of the bowel. Maunsell advises that a long straight needle

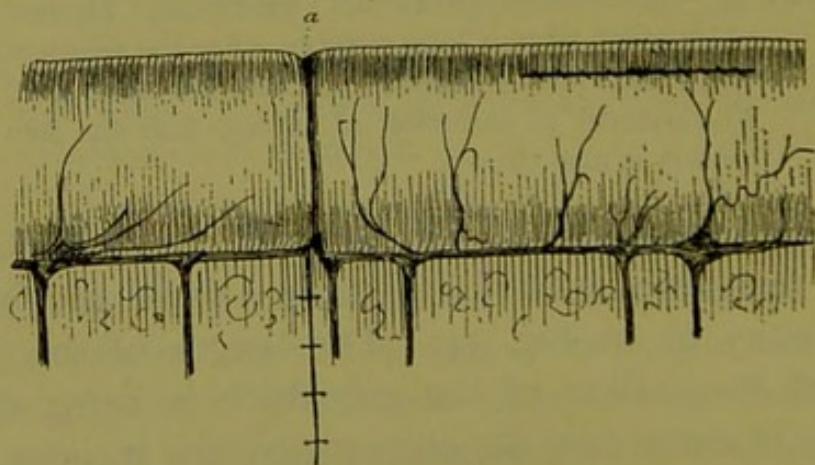


FIG. 56.—Enterectomy (Maunsell's operation). Operation according to Maunsell's method completed. *a.* Line along which series of Lembert's sutures should be inserted.

should be passed through both walls of the bowel at the same time, and the thread hooked up from the interior of

the gut, and cut across. It is better, however, to pass each suture separately, and to perforate the walls of the gut from the serous to the mucous surface. When all these sutures have been inserted, tied, and the ends cut short, the area of operation is well washed, so as to render it aseptic, and then the sutured portion of intestine retracted, as in Fig. 56. The longitudinal cut is again cleansed and closed by the insertion of five or six Lembert's sutures. The margins of the incision in the mesentery are next united by sutures, and the approximation and union is completed. This is Maunsell's own operation; but in my opinion it is safer and better to unite the line of union *a*, in Fig. 56, by a circle of fine silk sutures, introduced after Lembert's method.

The coil of intestine and the exposed peritoneum having been cleansed from all blood and intestinal contents, the bowel is returned into the abdomen.

(3) *By the aid of Murphy's "anastomosis button."*—The diseased portion of intestine having been removed according to the method shown in Fig. 52, all bleeding from the mesenteric border is arrested. Next, the exposed lumen of the gut and the margins of the divided ends are thoroughly washed with an antiseptic solution. A "purse-string" suture is inserted

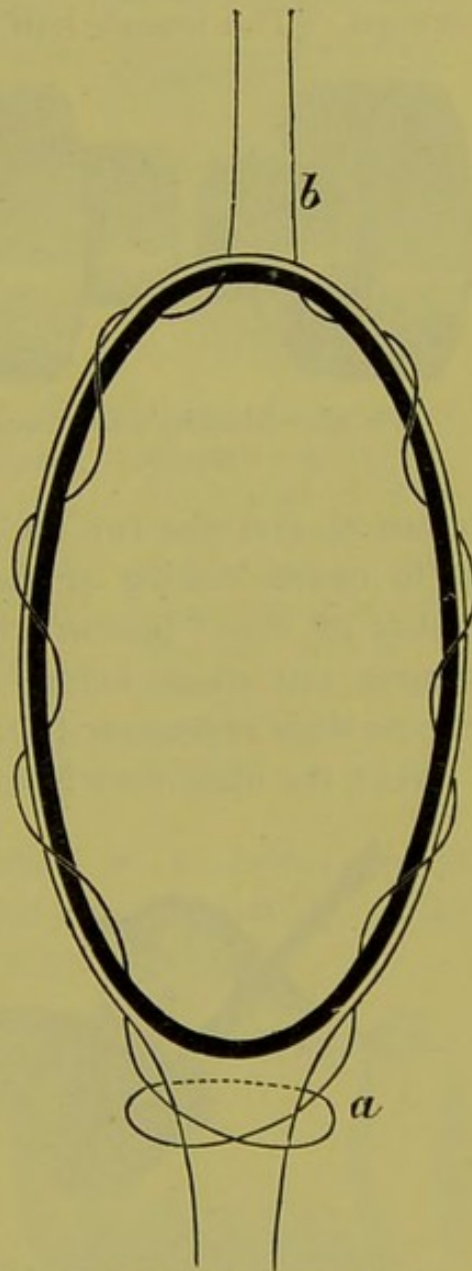


FIG. 57.—Enterectomy (Murphy's operation). Method of inserting "purse-string" suture into divided extremity of gut. *a*. Mesenteric border of bowel. *b*. Free border of bowel.

around the margin of each divided end, in the manner illustrated in Fig. 57. Next, the two halves of the anastomosis button are taken, and each grasped with a pair of pressure forceps. The female half of the "button" is placed in the

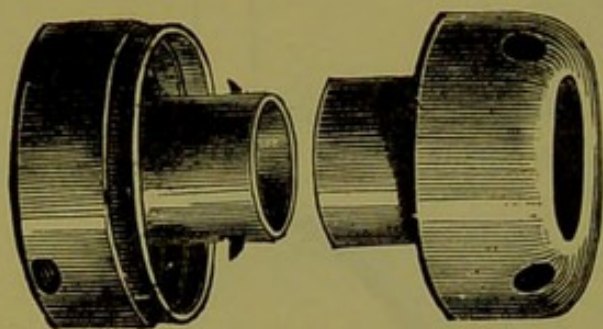


FIG. 58.—Murphy's anastomosis "button."

lower half of the gut (if this is known), the "purse-string" suture is tied, and the ends cut short. The male half is then placed in the upper segment of the gut, and the suture tied in a similar manner. The pressure forceps are now

removed, and the two ends of the gut pressed together so as to cause locking of the "button." Fig. 59 shows both halves of the "button" inserted, and the "purse-string" sutures cut short before the ends are approximated, and Fig. 60 their appearance when the union has been completed.

Next, the mesentery is folded in the form of a "pleat," and

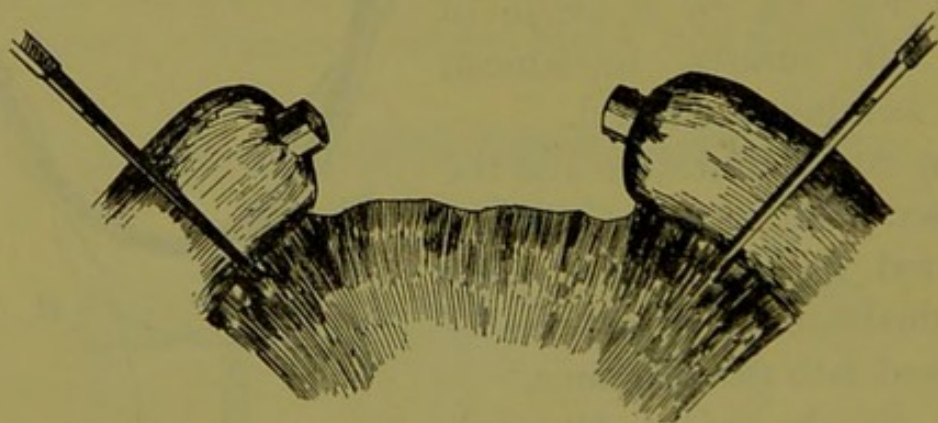


FIG. 59.—Enterectomy (Murphy's operation): Segment of gut removed, and two halves of "button" inserted and ready for approximation.

fixed by the insertion of a few points of interrupted suture. Murphy does not advise any further suturing, but in my opinion it is advisable to fix the margin of the approximated serous surfaces by the insertion of a circle of fine silk sutures after Lembert's method. The pressure of the "button"

upon the included margins of the intestine causes a pressure-gangrene, which sets free the button itself and allows it to pass along the alimentary canal, and be passed per anum. The insertion of a row of Lembert's sutures gives additional support, and helps to prevent giving way of the line of union in the early stages. Each of these sutures should pierce only the serous, muscular, and submucous coats. One of the objections to the use of these "buttons" is their small lumen. If they are used in cases of strangulated hernia, a condition which does not allow the intestine to be emptied by purgatives before operation, there is always a possibility of any large piece of undigestible food becoming impacted there and causing a fresh attack of obstruction.

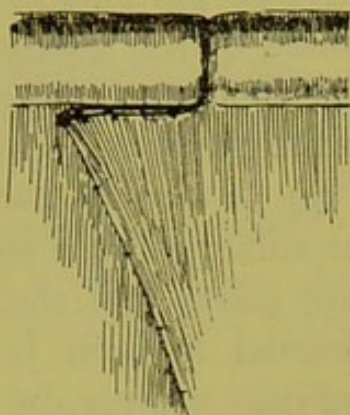


FIG. 60. — Enterectomy (Murphy's operation): Appearance of intestine when the operation is completed. The mesentery opposite the resected portion is folded upon itself, and fixed by a few points of suture.

(4) *By the aid of a bone tube or a bobbin.*—The methods of operation in these cases are very similar. Figs. 61 and 62 are illustrations of these contrivances.




FIG. 61. — Decalcified bone tube.—BAILEY.

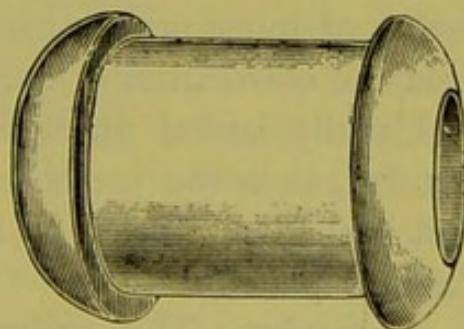


FIG. 62. — Decalcified bone bobbin.—ROBSON.

When the two divided ends of the intestine have been freed from all contamination with blood and intestinal contents, a continuous suture, which pierces the entire wall of the gut, or a circular ligature, which surrounds it, is

inserted and tied, by which means the divided ends are fixed in close approximation. Next, the serous surfaces of the two portions of intestine in the region of section are united by the insertion of a circle of Lembert's silk sutures. The treatment of the mesentery is similar to that mentioned in the previous operation.

(e) *Closure of the external wound.*—When the loop of intestine has been returned into the abdominal cavity, and care taken that the bowel is not twisted upon itself, the external incision is closed. This is carried out in the ordinary manner, by the insertion of one or more tiers of interrupted sutures. Drainage is not usually required.

After-treatment.—The after-treatment of a patient from whom a portion of the alimentary canal has been removed, has for its object the maintenance and improvement of the patient's general condition, combined with rest to the alimentary canal. It is advisable to give small quantities of opium by the mouth every few hours, and to see that the food is liquid, easily digestible, and peptonised if possible. If these points are attended to, few complications will arise.

For the first two or three days it may be advisable to administer nutrient enemata.

Lateral intestinal anastomosis.—In this operation two loops of intestine are fixed in apposition in such a manner that the convexities of the coils are close together.

Usually lateral anastomosis is established by means of sutures, as in the method described for gastro-enterostomy, but it may be effected by the use of decalcified bone plates (Senn's plates).

Operation.—The abdomen having been opened by a median or other incision, the seat of obstruction in the alimentary canal is sought for. A coil of intestine is selected above and below the seat of obstruction, and a short distance from the diseased segment. Each loop is emptied of its contents, by passing it between the fingers. Intestinal clamps are applied to the upper and lower

extremities of each loop, as in "intestinal resection." The exposed intestines are well surrounded with warm sterilised towels, and then an incision long enough to readily allow the introduction of the "bone plate" is made on the convexity of the bowel opposite the mesenteric attachment. The interior of each loop of intestine is cleaned out by careful

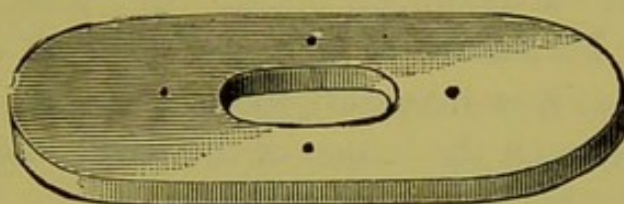


FIG. 63A.—Senn's decalcified bone plate for operation of lateral intestinal anastomosis.

sponging. Next, the plates are introduced already threaded, and the lateral or fixation sutures, and the end or apposition sutures tied. The peritoneal surface of the gut, which overlies the plates, is scarified with a needle or the point of a

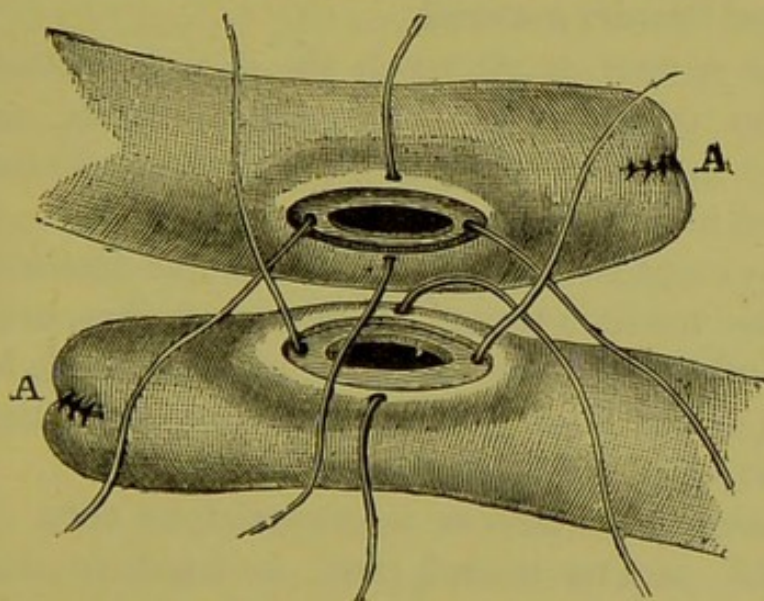


FIG. 63B.—Lateral intestinal anastomosis: Two coils of intestine, partly approximated with Senn's plates.

scalpel, and the two openings brought into approximation.

The sutures of the two plates are now tied, and the ends cut short. The serous membrane over the margins of the approximated plates is united with a few

points of interrupted suture, the intestine washed free from all traces of intestinal contents, and returned into the abdomen. The external wound is then closed. Fig. 63A is an illustration of a "bone plate," and Fig. 63B of two coils of intestine when they have been fixed in apposition with the aid of this mechanical appliance.

The technique of this operation is complicated, and the results do not appear to be better than those which have been obtained by careful suturing, or after the use of an "anastomosis button" or "tube."

Formation of an artificial anus.—It only rarely happens that it is necessary to establish an artificial communication between the lumen of the small intestine and the surface of the body.

Indications.—(a) Acute intestinal obstruction of some part of the small intestine which cannot otherwise be relieved.

(b) Strangulated hernia, in which the herniated portion of gut has become gangrenous, and the condition of the patient will not allow of the performance of an intestinal anastomosis.

Instruments.—Scalpel, scissors, retractors, dissecting and pressure forceps, trocar and cannula, or aspirator, needles, needle-holder, and ligature material.

Position.—The patient is placed in the dorsal position on the operation table, whilst the operator stands on whichever side is the more convenient; and the assistant stands opposite to him.

Operation.—In cases of strangulated hernia the incision will necessarily be made in one of the hernial regions, and in other cases of intestinal obstruction it will usually be made in the linea alba or the linea semilunaris, according to the supposed position of the obstruction.

The loop of intestine which it is proposed to open is brought into the parietal wound, and is fixed to the margins of this by the insertion of a series of sutures, each suture passing through the serous, muscular, and submucous coats of the intestine, and then through the serous, fascial, and cutaneous strata of the abdominal wall. In practice it will usually be found advisable to open the intestine and allow the escape of the fluid or gas with which it is distended, before an attempt is made to attach it to the abdominal wall, or, in the case of gangrene, it may be requisite to remove the dead portion before this is done.

The exact method of inserting the sutures is described in connection with "Inguinal Colotomy" (p. 75).

OPERATIONS UPON THE LARGE INTESTINE.

Removal of the vermiform appendix.—The vermiform appendix is attached to the postero-internal aspect of the cæcum, a short distance, usually about half an inch, below the lower border of the ileo-cæcal valve. The length of the appendix varies considerably. It usually measures 3 or 4 in., but in some cases it is not more than 2 in. long, whilst in others it may be even 10 in. The position of the free extremity varies: usually it hangs over the pelvic brim, in front of the commencement of the external iliac vessels, and then has a distinct mesentery formed by a double fold of peritoneum, in which is a small artery, the vermicular twig from the ileo-cæcal branch of the superior mesenteric artery. The corresponding vein is a tributary of the portal vein. In other cases the appendix is located behind some part of the cæcum, or it may be situated in the iliac fossa immediately above the middle part of the Poupart's ligament of the right side.

Indications for removal.—Removal of the vermiform appendix is indicated in the following circumstances, namely—

- (a) Perforation of the appendix.
- (b) Ulceration of the interior of the appendix, leading to a collection of pus in the interior, to localised destruction of its wall and perforation.
- (c) Certain cases of relapsing appendicitis, in which each successive attack is worse than the previous one, or in which serious inconvenience is caused.
- (d) Those pathological conditions which necessitate removal of the cæcum.

Instruments.—Scalpel, dissecting and pressure forceps, retractors, scissors, needles (fine, half-curved, and straight), needle-holder, and suture and ligature material.

Position.—The patient is placed in the dorsal posture, and near the right edge of the table; the surgeon stands on the right side, opposite the iliac region, and the assistant on the left.

Operation.—Removal of the vermiform appendix may be divided into three stages, namely—(a) Parietal incision; (b) finding, separation, and removal of the appendix; and (c) closure of the external wound.

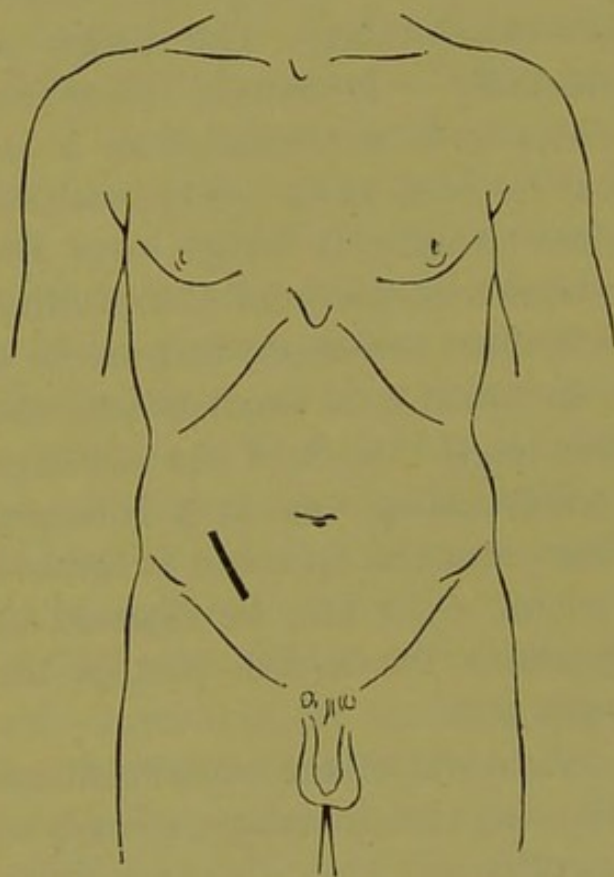


FIG. 64.—Removal of vermiform appendix. Position of patient and line of parietal incision.

(a) *Parietal incision.*—An imaginary line is drawn from the anterior superior iliac spine of the right side to the umbilicus, and a point a third of the distance from the iliac spine selected. When there is reason to believe that many adhesions exist, the selected point should be half way between the anterior superior iliac spine and the umbilicus. An incision 3 in. in length is made at right angles to the imaginary line, and passing through the selected

point. One-third of this incision is above the line, and two-thirds below it. Care must be taken, however, not to prolong the lower limit of the incision as far as the deep epigastric vessels. The skin, fasciæ, and muscular strata of the abdominal wall are divided in the usual manner; next, the fascia transversalis is incised, and then the peritoneal cavity opened.

(b) *Finding, separation, and removal of appendix.*—The

coils of the small intestine and the lower margin of the great omentum are pushed over towards the left, and kept there by packing with a large flat sponge. If no adhesions are present, the cæcum is lifted upwards and towards the right, and then the appendix will be partially or entirely exposed. The appendix having been found by the method mentioned above, its mesentery is defined. When this has been done, the mesentery is transfixed at its base, close to the cæcum, with a needle armed with a silk ligature. This ligature is tied, and the line of attachment of the mesentery to the appendix divided with a pair of scissors. By this means the appendix is freed from its connections, except where it is attached to the cæcum. The apex of the appendix is seized with pressure forceps, and with the scalpel the serous and muscular (or fibrous) coats are divided in a circular manner, about

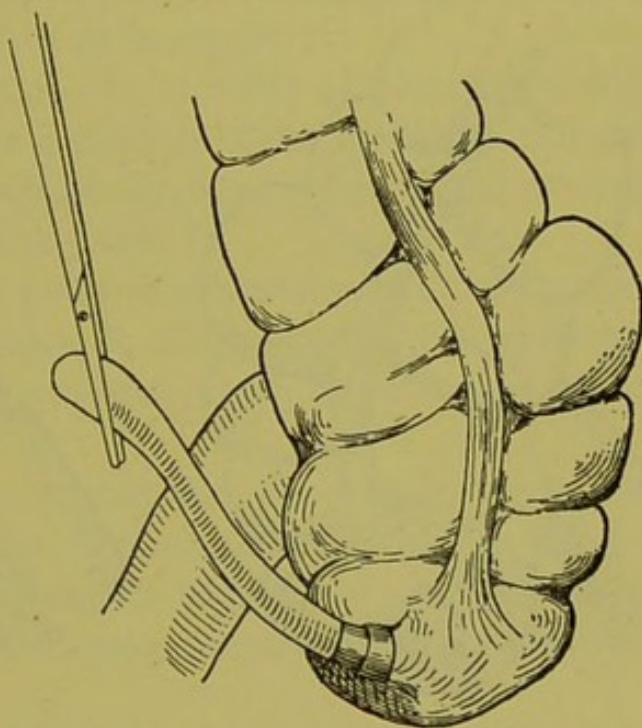


FIG. 65.—Removal of vermiform appendix. Line of incision through serous and fibrous coats, with a "cuff" of serous and fibrous coats turned back.

two-thirds of an inch from the cæcum, and a "cuff" of tissue stripped back until the cæcum is reached (Figs. 65 and 66). Care must be taken not to divide the mucous membrane during this procedure. A fine silk ligature is then tied around the mucous membrane, just beyond its junction with the cæcum; the tube of mucous membrane immediately distal to the ligature is cut across with scissors, and the appendix removed. The ligature which surrounds the mucous membrane of the stump of

the appendix is cut short, and the stump itself inverted into the cæcum. The "cuff" of peritoneal and fibrous coats is pulled over the base of the inverted stump, and sewn up by the insertion of two or three points of Lembert's suture.

If, owing to adhesions or inflammatory changes, it is not possible to dissect back a "cuff" of serous and fibrous coats, a silk ligature is applied around the entire appendix

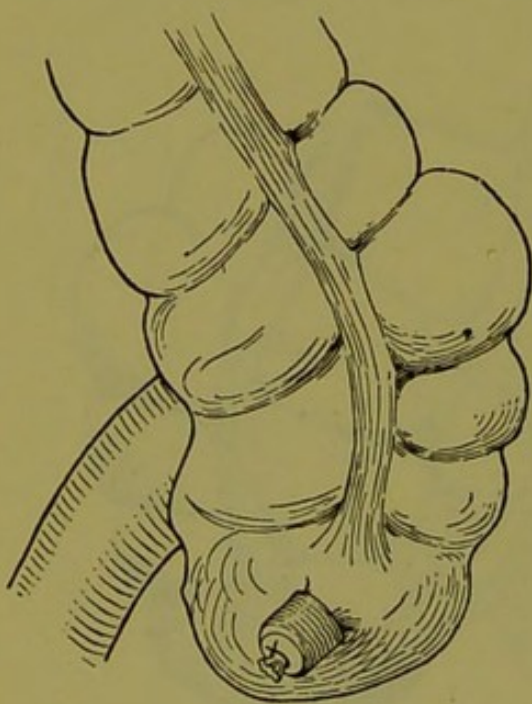


FIG. 66.—Removal of vermiform appendix. "Cuff" of serous and fibrous coats dissected back, and mucous coat ligatured close to its attachment to cæcum.

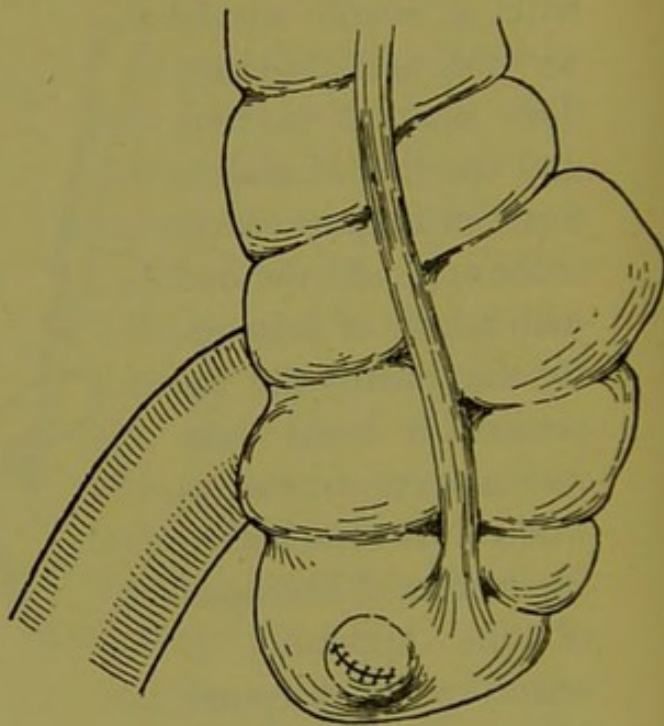


FIG. 67.—Removal of vermiform appendix. "Cuff" of serous and fibrous coats sewn over stump of appendix.

at its junction with the cæcum, and the structure removed. Next, the mucous membrane in the middle of the stump is either cauterised or well washed with an antiseptic, and then the stump is inverted into the cæcum and held in that position by bringing the adjacent portions of the serous and muscular coats of the cæcum together, by means of two or three fine silk Lembert's sutures.

(c) *Closure of the external incision.*—The region of operation is well washed with an aseptic solution, especially

where there has been any soiling of the peritoneum, the sponges are removed, and the external wound closed by the insertion of one or more tiers of sutures, according to the method described on p. 24.

When the affection of the appendix has resulted in the formation of a localised collection of pus, the overlying portion of the peritoneal cavity will usually be obliterated by adhesions, and the external incision may be made through the most prominent part of the swelling, care being taken to avoid opening the peritoneum.

Excision of the cæcum.—In excision of the cæcum it is also necessary to remove a portion of the lowest part of the ileum. The vermiform appendix is attached to the cæcum, and hence is removed along with it.

Indications.—Certain cases of tuberculosis of the cæcum, when the disease is localised to this portion of the intestine; and primary malignant growths which have not involved adjacent structures.

Removal of the cæcum may also be necessary in cases of inveterate fæcal fistula, communicating with the interior of this part of the gut; and in occasional cases of cæcal hernia when inseparable adhesions with the hernial sac have formed.

Instruments.—As for section of small intestine. If, however, a mechanical appliance is used, it must be of suitable size. It should be so made that the segment which fits into the ileum is smaller than that for the colon.

Position.—The patient is placed in the dorsal posture, near the right side of the table. The operator stands on the right side, and the assistant on the left.

Operation.—The operation of removal of the cæcum may be divided into stages, as in the previous operation—(a) Parietal incision; (b) finding, separation, and removal of cæcum; (c) union of the divided ends of ileum and colon; (d) closure of external wound.

(a) *Parietal incision.*—An imaginary line is drawn from

the anterior superior spine of the ilium to the umbilicus, this is bisected, and an incision 3 to 4 in. long made at right angles to the imaginary line, one half being above, and the other half below, the selected point. This point has been called M'Burney's point. The incision is deepened until the peritoneal cavity has been opened.

(b) *Finding, separation, and removal of cæcum.*—The

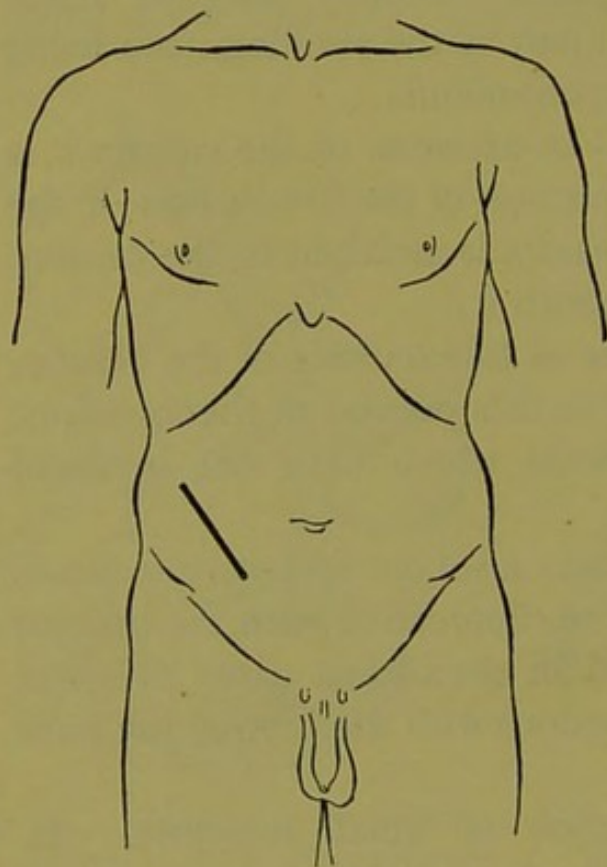


FIG. 68.—Excision of cæcum. Line of parietal incision.

coils of small intestine and the lower portion of the great omentum are pushed upwards out of the way, and held there by packing the peritoneal cavity just above and internal to the right iliac fossa with flat sponges. This having been done, the cæcum will be exposed as it lies in the right iliac fossa. The last 3 in. (or more, if necessary) of the ileum is exposed. An intestinal clamp is then placed on the ileum 3 in. above the ileo-cæcal valve. The contents of the portion of the ileum below the clamp are forced

with the fingers into the cæcum, and a pair of pressure forceps placed on the ileum at its junction with the cæcum.

With a pair of scissors or a long-bladed scalpel the ileum is divided immediately above the pressure forceps, and then the peritoneum, which is reflected from the iliac fossa to the cæcum, is divided by a series of snips with the scissors. As the cæcum is freed in this manner, it is lifted up from the iliac fossa, and all bleeding vessels are seized with pressure forceps, and tied. When the cæcum and diseased portion of

the ascending colon have been sufficiently separated (that is, when the limits of the disease have been passed), an intestinal clamp is placed on the ascending colon about 2 in. above the proposed line of section of the bowel. A second clamp or a pair of pressure forceps is then placed on the colon at the line of section, the intestinal contents being previously forced into the cæcum or onwards into the distal part of the colon. The ascending colon is now divided transversely, immediately above the clamp nearest to the cæcum, and the cæcum, together with the vermiform appendix and the adjacent parts of the ileum and ascending colon, removed. When all hæmorrhage has been arrested by ligature, the field of operation is well sponged out, and especial care taken to disinfect the cavities of the ileum and colon beyond the clamps.

(c) *Union of the divided ends of ileum and colon.*—The anastomosis of the ileum and colon is effected by one of the methods described in connection with “resection of small intestine.”

The same precautions must be observed as in dealing with the small intestine. Some surgeons have advised that the free end of the colon should be sewn up, and then the extremity of the ileum implanted in the lateral aspect of the ascending colon a short distance above its divided end. This method does not appear to present any advantages over end-to-end anastomosis.

When the union of the two portions of the intestine has been effected, all the sponges are removed from the peritoneal cavity, and the contaminated area well washed with an aseptic solution.

(d) *Closure of the external wound.*—This is effected in the usual manner.

Resection of the large intestine.—The methods which are adopted for the removal of portions of the large intestine are similar to those which have been already described in connection with the surgery of the small intestine,

The chief indications for removal of portions of the large intestine are—localised malignant growths, gangrene in connection with strangulated hernia, severe lacerations, and some forms of severe localised ulceration.

Colotomy—Inguinal colotomy.—Inguinal colotomy has for its object the creation of a fistulous communication between the lumen of the colon and the surface of the abdomen in the inguinal region. The operation is usually performed on the left side, the sigmoid flexure becoming the seat of the fistula; but occasionally the artificial anus is made on the right side, and the ascending colon is opened.

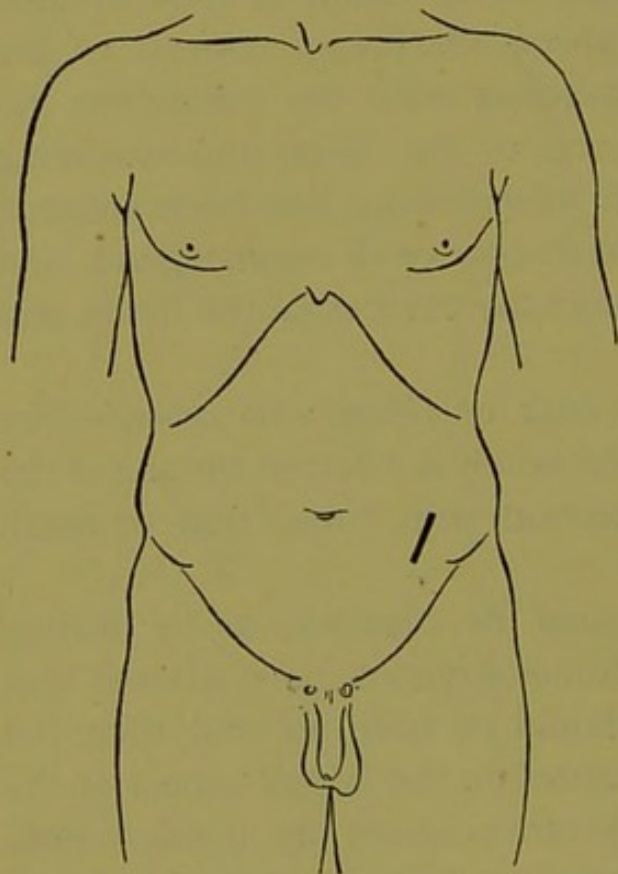


FIG. 69.—Inguinal colotomy. Position of patient and line of incision.

Indications.—The operation may be performed, either as a radical measure for the cure of a disease, or as a palliative procedure for the prolongation of life, the prevention of impending death, or the ameliora-

tion of a patient's condition. As a radical operation it is performed in recto-vesical fistula which cannot be closed by a local operation, in certain varieties of non-malignant ulcerations of the rectum, and in congenital malformations in which the anus and rectum are absent. As a palliative proceeding it is most commonly performed on patients suffering from cancer of the rectum when the growth cannot be locally removed.

Instruments.—Scalpel, dissecting and pressure forceps,

scissors, retractors, needles, needle-holder, and suture and ligature material.

Position.—The patient is placed in the dorsal position, near the left side of the operating table. The surgeon stands on the left side of the patient, and the chief assistant opposite to him.

Operation.—Inguinal colotomy may be divided into three stages, namely—(a) Parietal incision; (b) finding of the bowel and fixation to the abdominal wall; (c) opening of the gut and making an artificial anus.

(a) *Parietal incision.*—An incision from 2 to 3 in. in length, according to the obesity of the patient and the thickness of the abdominal walls, is made in the following manner:—An imaginary line is taken from the left anterior superior iliac spine to the umbilicus, and a point is selected along this line one-third of the distance from the iliac spine. The incision is made to pass

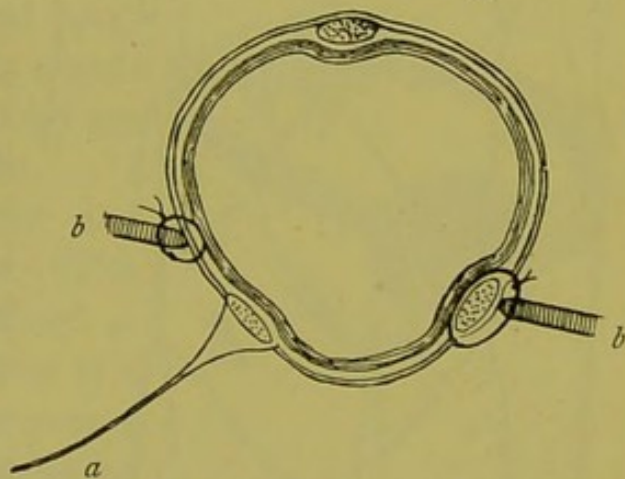


FIG. 70.—Inguinal colotomy. Diagrammatic section through the sigmoid flexure, showing line of insertion of sutures. a. Mesentery. b. Abdominal wall.

through this point at right angles to the imaginary line, one-half of this incision being above, and the other half below the line (Fig. 69). This incision is made to divide all the strata of the abdominal wall until the peritoneal cavity is opened.

(b) *Finding of the bowel and fixation to the abdominal wall.*—The colon may at once protrude in the wound, but if not, the fingers are passed into the peritoneal cavity and the large intestine sought for. It will usually be found a little below and external to the incision. In abnormal conditions it may be found over the brim of the pelvis and towards the

right side. The large intestine can be recognised by its sacculations, the presence of appendicæ epiploicæ upon its surface, and the arrangement of its longitudinal muscular coat in the form of three distinct bands, one of which is directly opposite the mesenteric attachment. In order to prevent prolapse, the sigmoid flexure is drawn down from above until the upper segment is quite taut, the coils being

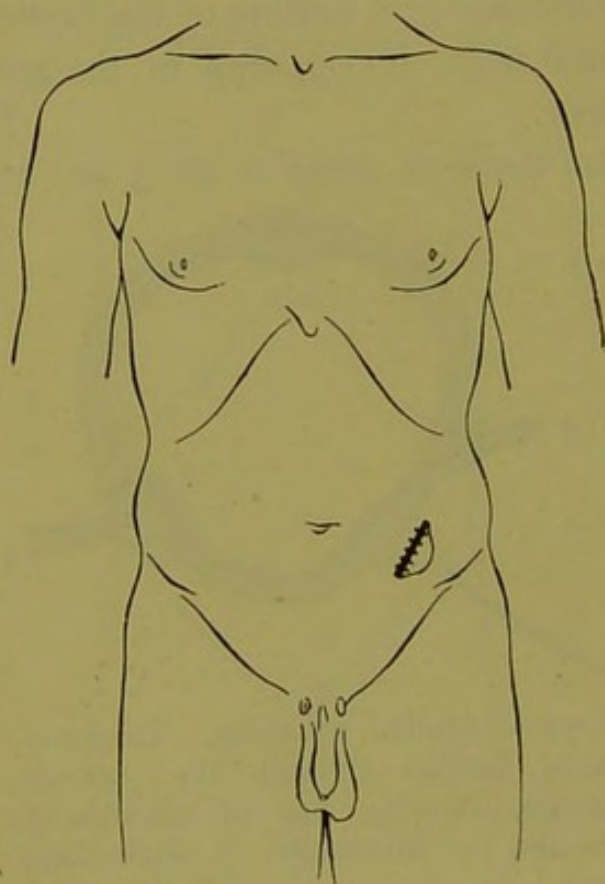


FIG. 71.—Inguinal colotomy. Operation completed, but the gut has not yet been opened.

passed in again below. A loop of intestine is then selected as near the descending colon as possible, and into the convexity two guiding sutures are passed, $1\frac{1}{2}$ in. apart, and through the serous and muscular coats. These sutures are left as loops, one knot being placed on the upper and two on the lower, in order to enable the surgeon to recognise the exact position of the intestine when it is opened in the third stage of the operation. The loop of intestine is returned into the peritoneal cavity, and the parietal peritoneum fixed

to the skin on each side of the incision by the insertion of two silk sutures on each side. The loop of intestine is again brought out into the wound, and fixed to the margins of the incision by seven or eight sutures on each side, the terminal suture at each extremity going from one side to the other, and picking up the intestine half an inch beyond the guiding sutures. The sutures are so inserted that two-thirds of the circumference of the bowel are distal to the

lines of insertion and one-third between them. The sutures on the inferior and left side of the bowel are passed through the posterior longitudinal band, and the upper ones just beyond the mesenteric attachment (Fig. 70). Each suture is made to pass through the skin, fasciæ, and peritoneum of the abdominal wall, and through the serous, muscular, and submucous coats of the intestine, care being taken not to perforate the mucous membrane.

After all the sutures have been introduced, they are tied and the ends cut short. If the parietal wound has been made larger than the protruded loop of intestine, the portions to which the intestine is not attached are closed in the usual manner.

(c) *Opening of the gut and making an artificial anus.*—The intestine may either be opened at the time of the operation or at a subsequent date. If the symptoms are not urgent, it is advisable to leave it for three to five days, an aseptic dressing being applied in the meantime. In opening the bowel the two guiding sutures

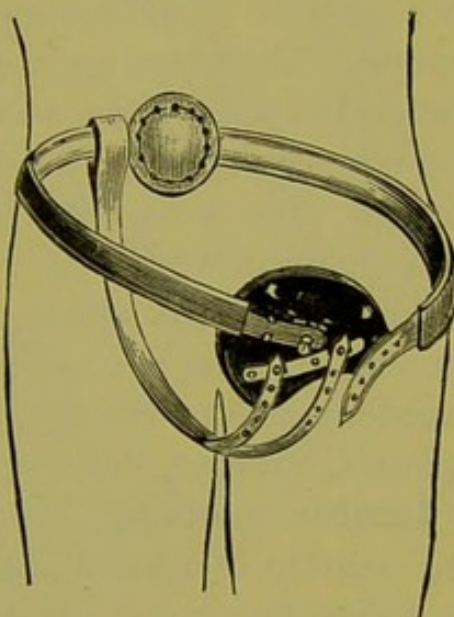


FIG. 72.—Inguinal colotomy.
Truss for use after this operation.

are taken, one is given to an assistant to hold, and an opening is made into the interior of the gut by cutting between these sutures with a scalpel. The superfluous portions of the gut around the artificial anus are trimmed away with scissors, and all bleeding points ligatured.

Prolapse of the mucous membrane of the portion of the intestine immediately above the external aperture very rarely follows this variety of operation. In order to control the escape of fæces, it is advisable to fit up the patient with a truss similar to the one figured in Fig. 72.

Inguinal colotomy without sutures (Maydl and Reclus'

operation).—The early stages of this operation are exactly similar to those of the operation above described. When the loop of sigmoid flexure has been brought into the parietal wound, and made taut above, a small aperture is made in the mesentery immediately behind the bowel and in the middle part of the loop, and through this a glass rod, about 4 or 5 in. in length, is passed, and fixed to the abdominal wall by two pieces of strapping. The rod is so placed that the loop of intestine lies above it, and it is fixed in a position at right angles to the long axis of the external wound. Dressings are applied in the usual manner, and at the end of a few days, according to the urgency of the case, the bowel is opened in a manner similar to that described above. The glass rod should be left in position for a week, and then removed.

The advantages which are claimed for this operation are the short time necessary for its performance, and the excellent results which have followed its adoption. In my opinion, however, the "suture" method is the best.

Lumbar colotomy.—The term lumbar colotomy implies the creation of an artificial opening in either the ascending or descending colon, through an incision made in the right or left lumbar region.

Indications.—The indications for the performance of this operation are for the most part similar to those enumerated in connection with inguinal colotomy, and by a few surgeons it is preferred to the latter. The inguinal variety of colotomy is, however, generally preferred, on account of the fact that the artificial anus is in a position where it can be more easily managed by the patient, fewer difficulties are likely to be met with in the performance of the operation, and septic cellulitis is not so liable to be established in the region of the wound. The lumbar operation has the advantage that the opening in the intestine is placed further above the focus of the disease in cases of cancer of the rectum, the condition for which the operation of

colotomy is most frequently performed. The anatomy of the parts concerned in the operation of lumbar colotomy is shown in Fig. 73.

Instruments. — Scalpel, dissecting forceps, retractors, pressure forceps, hare-lip pins, ordinary curved needles, needle on a handle, blunt hook, needle-holder, and suture and ligature material.

Position. — The patient is placed in a semiprone position, lying on the sound side. A hard round pillow or a sandbag is placed under the loin, so as to separate as far as possible the crest of the ilium from the lower margin of the last rib. The surgeon stands behind the patient opposite the loin, and the chief assistant opposite to him.

Operation. — The line of the colon is marked out on the surface of the body, by drawing a line vertically upwards from a point half an inch behind the centre of the crest of the ilium to the lower border of the last rib.

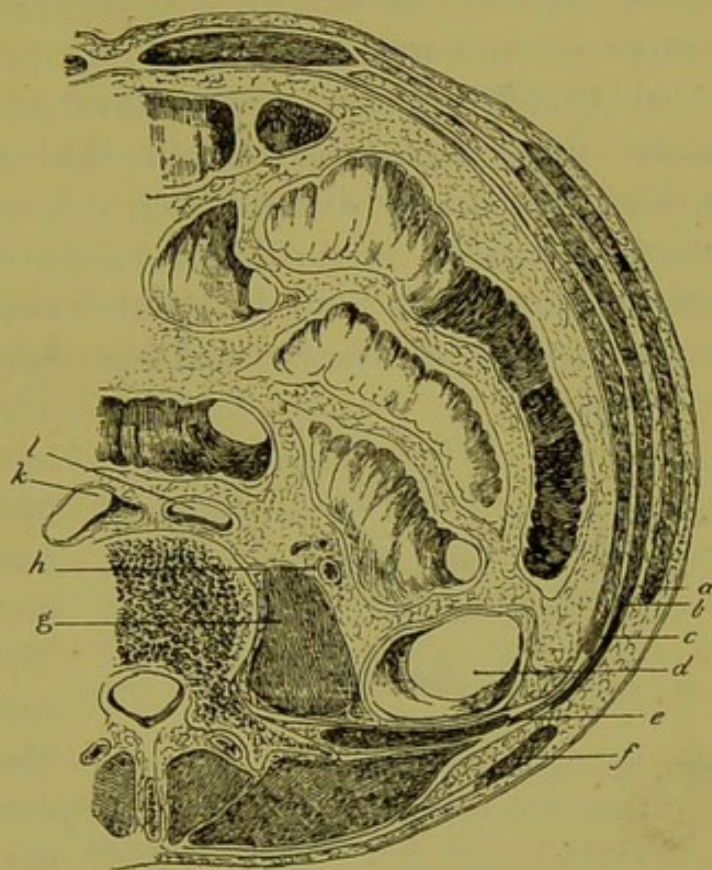


FIG. 73.—Diagrammatic representation of a transverse section through the trunk at the level of the upper portion of the third lumbar vertebra, showing relations of anatomical structures concerned in lumbar colotomy.

- | | |
|-----------------------------|------------------------|
| a. Obliquus externus. | f. Latissimus dorsi. |
| b. Obliquus internus. | g. Psoas magnus. |
| c. Transversalis abdominis. | h. Ureter. |
| d. Colon. | k. Abdominal aorta. |
| e. Quadratus lumborum. | l. Inferior vena cava. |

The operation may conveniently be divided into three stages, namely—(a) Parietal incision; (b) finding of the colon, bringing it into the external wound, and fixation of it; (c) opening of the exposed portion of intestine. When the intestine is opened at once, stages (b) and (c) are performed concurrently.

(a) *Parietal incision*.—The central point of the line which marks out the colon between the iliac crest and the last rib is taken, and an incision from $2\frac{1}{2}$ to 3 in. in length is made, which is parallel to the lower border of the last rib and passes through this point. A little more of the incision is made posterior to the vertical line than anterior (Fig. 74).

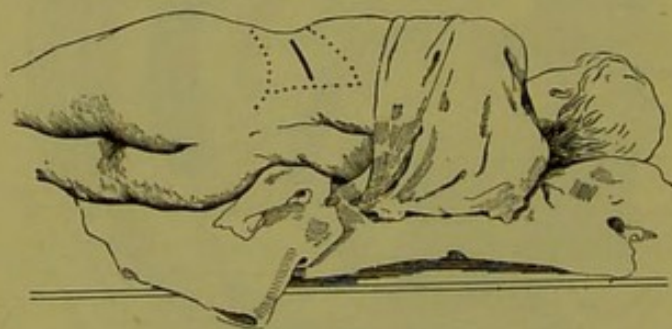

FIG. 74.—Lumbar colotomy. Position of patient and line of incision in lumbar colotomy. The dotted lines represent the lower border of the last rib, the iliac crest, and the outer border of the erector spinae muscles.

The incision commences in front, and passes upwards and backwards. The skin and fasciæ are first divided, and then in succession the anterior fibres of the latissimus dorsi and the posterior fibres of the external oblique, the internal oblique, the lumbar fascia, the external

portion of the quadratus lumborum, and the posterior portion of the transversalis, and its continuation inwards as the anterior layer of the lumbar fascia, and lastly the fascia transversalis. The loose connective tissue, containing a quantity of fat in its meshes, which covers that portion of the colon devoid of peritoneum, is now exposed. This is carefully broken down or teased away with the fingers or dissecting forceps, so as to expose the posterior aspect of the colon.

(b) *Finding of the colon, etc.*—When the connective tissue surrounding the colon is being teased away, care must be

taken not to make a hole into the peritoneum. The colon can best be recognised by feeling for it, the tissues in the bottom of the wound being grasped between two fingers. The colon is more resistant, and feels thicker than either the peritoneum or a coil of small intestine. It is not often possible to distinguish the longitudinal arrangement of the fibres of its muscular coat. In many cases the colon at once bulges into the external wound when the fascia transversalis has been incised. If difficulty is met with in finding the colon, its discovery may be facilitated by the assistant exerting pressure from the front so as to lift the gut backwards, or by inflating the intestine with air through the anus. It occasionally happens that the colon has a complete mesentery (on the left more commonly than on the right), or it may have an abnormal position within the abdomen. In these cases it will be impossible to find the gut without opening the peritoneal cavity; and if this becomes necessary, it is better to close the lumbar incision and perform an inguinal colotomy, unless the colon can be readily felt at the bottom of the lumbar incision and connected to the posterior abdominal wall by a mesentery, in which case the operation will be completed either by stripping off the peritoneum from the colon, or by opening the peritoneal cavity and bringing out the gut through the aperture thus made. When the intestine has been exposed and brought into the wound, an area about $\frac{3}{4}$ in. square is laid bare, through which the fistulous aperture can be made. If it is desired to open the bowel at once, two moderately strong silk sutures are taken, and threaded with a needle at each end. One suture is passed into the cavity of the intestine at one angle of the exposed area and out again at the other angle of the same side, and the second ligature is passed in a similar manner at the other side. These ligatures are given to an assistant to hold whilst the surgeon makes an incision into the bowel at right angles to its long axis, and in the middle of the area included

within the ligatures. A blunt hook is passed into the interior of the gut, and the loops of ligature are brought out. These are cut in the middle, and then the margins of the opening can be held apart by two ligatures on each side. The free end of each ligature to which a needle is attached is made to pass through the tissues bounding the external incision, and come out through the skin. Next, a suture is passed from one side of the incision to the other, a short distance beyond the sutures already introduced, and taking up the intestine just beyond the angle of the opening in it, but not passing into the

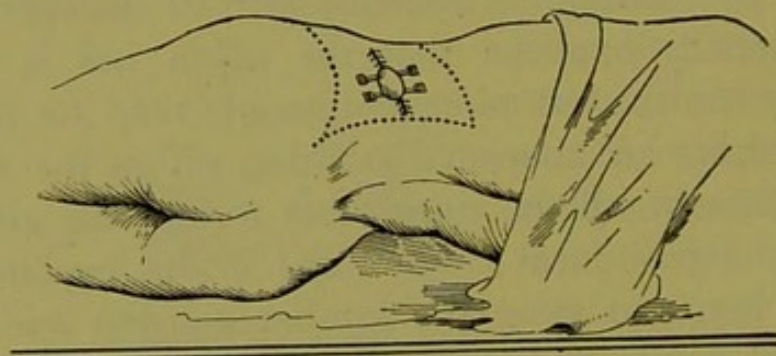


FIG. 75.—Lumbar colotomy. Loop of large intestine fixed in a lumbar colotomy wound by two hare-lip pins. The remainder of the wound is closed by sutures.

interior of the gut, the muscular and submucous coats alone being seized. The sutures having been introduced in this manner, all are tied and the ends cut short. The margins of the incision in the bowel are lifted well over the margin of skin of the parietal wound as the ligatures are being tied. If any part of the external wound remains open, it is closed in the usual manner. When there is no urgency as regards opening the bowel, the exposed area is fixed in the external wound by passing two long hare-lip pins through the muscular coat in the manner shown in Fig. 75. The other parts of the wound are approximated by the insertion of silk sutures. Dressings are applied, and the final stage performed several days later.

(c) *Opening of the gut.*—The intestine is opened by making an incision with a scalpel through that portion of tissue which lies between the hare-lip pins. After the incision has been made, it is sometimes possible to remove large masses of fæces from the adjacent parts of the colon, a proceeding which often gives great relief to the patient. No anæsthetic is necessary for the opening of the intestine. It is advisable to fit up the patient with a bandage or truss which will be of use in controlling the evacuation of fæces.

OPERATIONS UPON THE RECTUM AND ANUS.

Hæmorrhoids.—Hæmorrhoids or piles frequently require surgical treatment. The varieties of operation which may be adopted are the following, namely—(a) Treatment by ligature, (b) treatment by excision, (c) treatment by crushing. The method of treatment by ligature appears to be the most satisfactory, and moreover it is the easiest to carry out. The three operations will be described in order.

(a) *By ligature.*

Instruments.—Clover's crutch, scissors, vulsellum or pile forceps, pressure and artery forceps, and ligature material (thick and fine silk).

Position.—The patient is placed in the lithotomy position, Clover's crutch being used, and the buttocks made to project slightly over the end of the operation table. The surgeon sits opposite the perineum, and the assistant stands on his right hand.

Operation.—As a preliminary to most operations upon the lower part of the rectum which are carried out from its interior, it is necessary to dilate the anus and cause temporary paralysis of the sphincters. This is done by introducing the index fingers or thumbs of both hands through the anal aperture, and exerting continuous and firm traction,

until the sphincter is felt to relax or give way. When this occurs, the pressure from within is diminished so as to avoid laceration and tearing of the muscle. In order to thoroughly dilate the anus in this manner, it is usually necessary to exert traction for three or four minutes. When the anus has been sufficiently dilated, the hæmorrhoids prolapse and become evident.

Application of the ligature.—The most prominent pile at the posterior margin of the anus is seized with the vulsellum

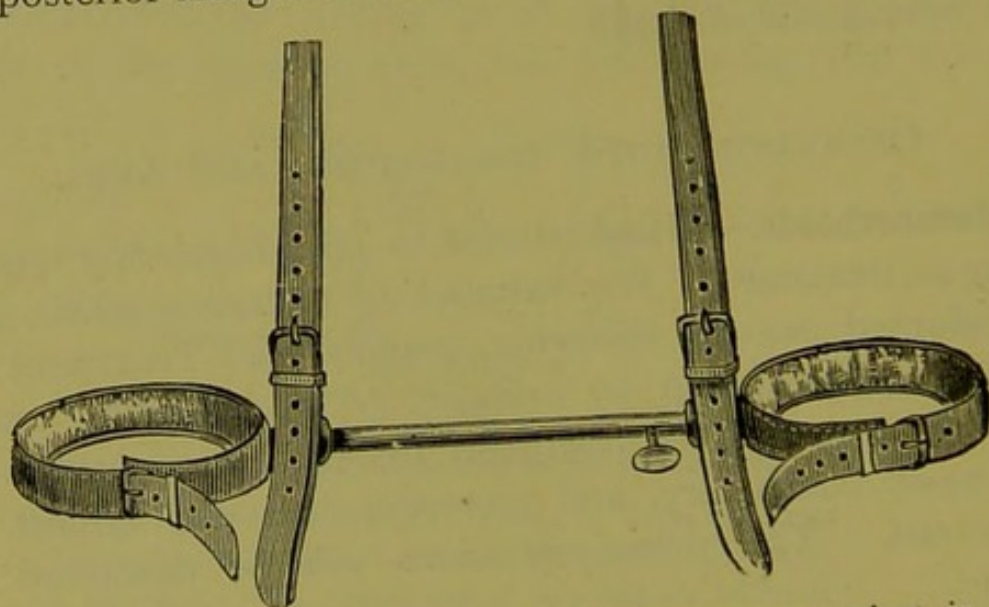


FIG. 76.—Clover's crutch, for maintaining a patient in lithotomy position.

forceps and drawn inwards towards the middle point of the enlarged anal aperture. This renders apparent the junction of the skin and the mucous membrane. The scissors are taken, and a cut is made at the base of the pile and along the muco-cutaneous junction; and the hæmorrhoidal mucous membrane, with the attached pile, dissected upwards for a short distance until a distinct pedicle to the pile has been made. It is only necessary as a rule to make a few snips with the scissors in order to effect this. A strong silk ligature is then placed in the groove between the pile and the skin, the forceps and attached pile are pulled slightly outwards and downwards, and the ligature is tied in such a manner that all the blood vessels going to the pile

are obstructed, and the knot is so placed that it lies upon the mucous membrane of the rectum. Any other piles which may be present are treated in a similar manner, but it is not necessary even in severe cases to apply more than four ligatures. When all the ligatures have been tied, the distal portions of the piles are cut away, care being taken to leave a distinct button of tissue which shall prevent the ligature slipping. The ligatures are cut short, the area of operation washed with an aseptic solution, and an aseptic dressing applied and held in position by a perineal bandage.

Care must be taken in this operation not to include any of the skin of the anal margin, otherwise much pain may be induced, or it is possible that a stricture of the anus may afterwards develop.

(b) *By excision (Whitehead's operation).*

Instruments.—These are similar to the instruments required for ligature, with the addition of dissecting forceps and suture needle with needle-holder.

Position, as for ligature.

Operation.—The mucous membrane of the rectum is divided with scissors at its junction with the skin for the entire circumference of the anus, any irregularities of the skin being followed. By dissection, the hæmorrhoidal portion of the mucous membrane is separated from the submucous tissue which lies between it and the adjacent tissues, and then the ring of piles and mucous membrane is pulled down below the level of the anus. The mucous membrane is now divided just above the “hæmorrhoidal area,” and the diseased portion removed. The cut edge of the mucous membrane is united to the free margin of the skin by the insertion of a number of sutures. This is best done in stages; as a portion of the mucous membrane is divided, it is stitched to the free margin of the skin.

All the ligatures are cut short and a dressing applied, as in the previous operation.

(c) *By crushing.*

Instruments.—The instruments for this operation are the same as for ligature, with the addition of the special form of "pile-crushing clamp" preferred by the operator.

Position.—The position of the patient and operator are the same as for ligature.

Operation.—The anal sphincter is dilated in the usual manner, so as to allow of free access to the piles. The most prominent pile is selected, and the aperture in the clamp placed over it. A pair of vulsellum forceps is passed through this aperture, and the pile seized and drawn through the opening. Whilst it is held in this position, the clamp is quickly screwed up tightly and the contained pile crushed. The clamp is left on for two or three minutes, and the projecting portion of the pile removed with scissors or a cautery. The clamp is then unscrewed and removed, and if any bleeding points appear they are picked up with pressure forceps and tied. Any other piles which may be present are treated in a similar manner. When this has been done, the region of the anus is freed from blood clot, and a dressing applied.

This operation does not appear to present any advantages over the "ligature," it takes much longer to perform, and is moreover more likely to be followed by hæmorrhage.

Operation for "fistula in ano" (Rectal Fistula).—*Instruments.*—Clover's crutch, probe-pointed director, sharp-pointed curved bistoury, scissors, pressure forceps, and ligature material.

Position.—The patient is placed in the lithotomy position, Clover's crutch having been applied, with the buttocks projecting just beyond the end of the operation table. The operator sits opposite the perineum, and the assistant stands on his right hand.

Operation.—If the fistula has an external opening, a probe-pointed director is pushed through it, made to pass along the track of the fistula and emerge in the cavity of the rectum through the internal aperture, if one is present; or, if

not, the point is forced through the thinnest portion of the mucous membrane which intervenes between the fistulous track and the lumen of the bowel. When the internal opening is only a short distance above the anal margin, the point of the director is brought out through the anus. If this can be done, a sharp-pointed bistoury is passed along the groove in the director, and all the tissues between the fistulous track and the surface divided. When the internal aperture is situated so high within the bowel that this cannot be done, the forefinger of the left hand is passed into the rectum to the point of the director as it protrudes through the internal opening, and with a pair of scissors the intervening tissues between the track of the fistula and the lumen of the intestine are divided. Some surgeons in these cases pass a rounded piece of soft wood into the rectum as far as the internal opening of the fistula, and then a sharp-pointed bistoury is pushed along the fistulous track, until the point pierces the piece of wood within the rectum. The bistoury and the piece of wood are next withdrawn together, and the tissues divided. When the chief fistulous track has been opened by one of these methods, an examination of its upper extremity should be made, to ascertain whether there is a sinus extending further upwards, and if so, as is usually the case, it is opened up with scissors on a director, unless it extends so far that there is danger of hæmorrhage occurring where it cannot readily be controlled. Next, the lateral prolongations of the fistula are opened up. Care must be taken not



FIG. 77. — Curved sharp-pointed bistoury.

to divide the external sphincter in more than one place, otherwise incontinence of fæces may follow the operation. The necessity for division in more than one place can be avoided in most instances, by opening the superficial portion of the sinus until the director has a straight track into the lumen of the bowel. In those rare cases in which there are two internal openings, it is better to open up the more extensive and larger fistula and to scrape out the interior of the other one with a fine Volkmann's spoon, since in most cases this second track will then close, while the one which is laid open is granulating up. When the fistulous aperture is situated in the central part of the female perineum, the sphincter should not be divided at this point, since incontinence generally follows, owing to the interlacement of the fibres of the external sphincter ani and the sphincter vaginæ at this point. The best method of treatment in these cases is to treat the fistulous track by scraping, and then to divide the external sphincter in the middle line behind. The fistula will generally heal after this has been done, since the contractions of the muscle do not force fæcal matter into the sinus, and the walls are allowed to remain at rest. When the fistula has been opened up by one of these methods, any projecting portions of unhealthy skin or granulation are removed with the scissors, and all bleeding points seized with pressure forceps and ligatured. The area of the operation is washed so as to free it from blood clot, and then a piece of lint, upon which some boracic ointment has been smeared, is placed in the bottom of the track, and an aseptic dressing is applied.

After-treatment.—The ultimate success of this operation depends upon the careful after-treatment. The wound should be kept as clean and aseptic as possible by daily irrigation, and after this has been done a strip of lint is placed (as above) between the cut surfaces, so as to ensure healing up from the bottom and prevention of bridging over, which may be the cause of the development of

secondary fistulæ. If any union of the granulations of the two sides is noticed, it ought to be broken down with a probe.

Excision of the rectum (from perineum).—*Indications.*—Excision of a portion of the rectum by the perineal method is indicated in cases of carcinoma which involves the lower

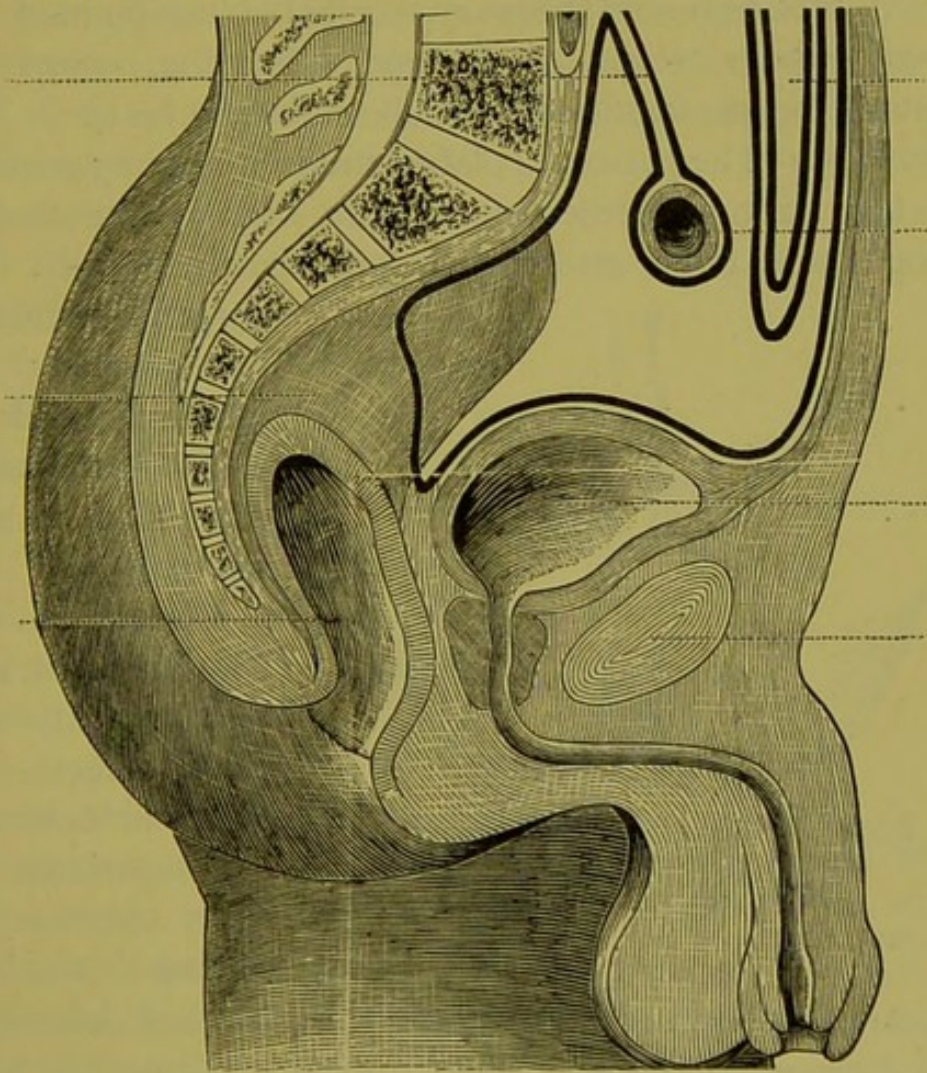


FIG. 78.—Vertical section through the male pelvis. The dark line shows the extent of the peritoneal covering of the rectum.
—After CUNNINGHAM.

three inches of the bowel, and does not extend to the adjacent structures except to a limited extent. The finger ought to be passed beyond the region of the growth and be able to feel healthy mucous membrane above.

When there is extensive infiltration of the surrounding

tissues, or there are signs of secondary growths in other parts, the operation is contra-indicated.

The anatomical relations of the rectum, and its relations to the surrounding structures are shown in Fig. 78, which is a representation of a vertical section through the pelvis.

Instruments.—Strong, curved, sharp-pointed bistoury, straight probe-pointed bistoury, scalpel, blunt-pointed and curved scissors, vulsellum forceps, dissecting, artery, and pressure forceps, ligatures (fine silk make the best).

Position.—The patient is placed in the lithotomy position, with the buttocks projecting slightly beyond the end of the operation table, and raised somewhat by a pad. The

surgeon stands or sits opposite the perineum, and the assistant stands on his right hand.

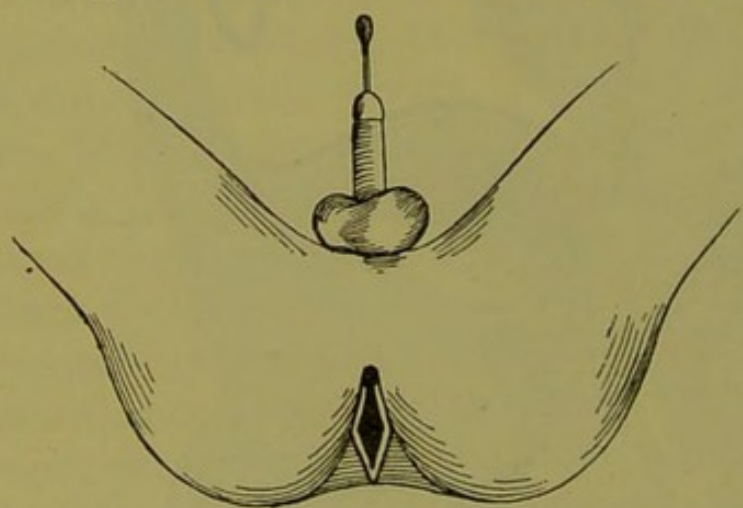


FIG. 79.—Excision of rectum (perineal method). First incision, showing tissues between posterior margin of anus and tip of coccyx divided.

Operation.—The operation may be divided into three stages—(a) External incisions; (b) separation of lower portion of rectum; and (c)

removal of portion of bowel along with diseased tissues.

(a) *External incisions.*—The forefinger of the left hand is passed into the rectum, until the tip of the coccyx can be felt (beyond the growth, if possible). A sharp-pointed curved bistoury is taken, passed into the rectum along the curve of the finger, and made to transfix the posterior wall of the rectum and all the tissues which lie between it and the tip of the coccyx, until the point emerges through the skin at the apex of the coccyx. A cut is made towards the anus with the bistoury, so as to divide all the tissues between

the tip of the coccyx and the median line of the posterior margin of the anus. It is important to keep in the middle line, so as to avoid unnecessary hæmorrhage. A semi-circular cut is next made around each lateral margin of the anus, commencing at one side of the median posterior incision, and terminating at a point in front of the anal aperture. This cut should be made through the mucous membrane and not the skin, if the extent of the growth will allow of this being done, and should extend well into the ischio-rectal fossa on each side.

(b) *Separation of the lower portion of the rectum.*—With the fingers the posterior and lateral portion of the rectum are separated from the surrounding tissues,

until the levator ani is reached. This structure is divided with scissors. The bowel is next separated from its connections in front. If the patient is a male, a No. 12

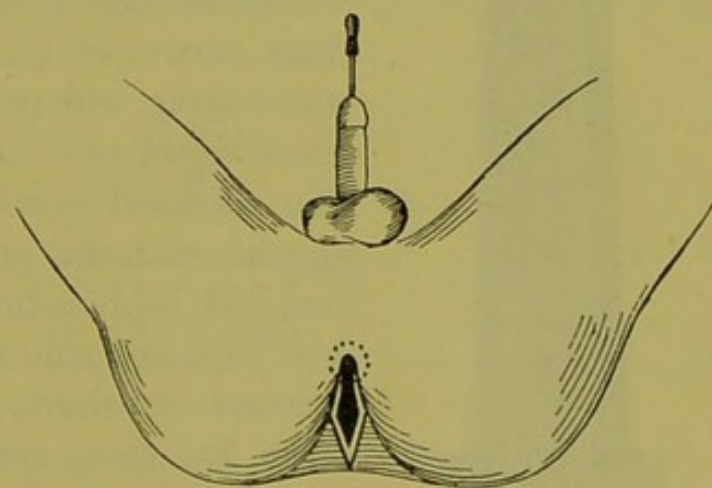


FIG. 80.—Excision of rectum (perineal method).
Line of incision around anus.

bougie or catheter is passed into the bladder, and held in position by the assistant. The anterior wall of the rectum is seized either with vulsellum forceps or the fingers of the left hand, and drawn backwards. The connections between the anterior wall of the rectum and the structures in front of it are divided by careful dissection with the scissors or scalpel, or both, until the upper limits of the disease have been passed. The catheter or bougie can be readily felt, and any damage to the urethra easily avoided. If the patient is a woman, the finger of the assistant should be placed in the vagina, so as to facilitate the separation and avoid

making an aperture through the posterior vaginal wall. The plane of separation is made through the vaginal submucous tissue. When the dissection has been carried beyond the limits of diseased tissue, the affected portion of the bowel can be removed, the line of division being through healthy tissue above the growth.




FIG. 81.—Excision of rectum. Bougie for use after excision of rectum by perineal method.—HARRISON CRIPPS.

(c) *Removal of the bowel.*—The lower portion of the rectum is seized with vulsellum forceps, and drawn downwards. With a strong pair of scissors the rectal wall is cut through transversely at the upper limit of the wound. As the division is effected free hæmorrhage occurs, which is controlled by at once seizing, with pressure forceps, each blood vessel as it commences to bleed. The diseased portion of the rectum, together with the growth, having been removed, all bleeding points are ligatured with fine silk, and the ends of the ligatures cut short. When all hæmorrhage has been arrested, the field of operation is examined, so as to make sure that no diseased tissue has been left behind. It is of no advantage to bring down the divided edge of the mucous membrane and stitch it to the margin of the lower portion of the wound, since it has been found that the sutures

always cut out, and serve no practical purpose. A rubber tube is now passed into the cavity of the rectum, and allowed to project through the external aperture. The space around is packed with aseptic gauze and wool, and a perineal bandage applied. The tube allows the passage of blood and gas from the rectum, and so removes a source of discomfort to the patient.

After-treatment.—This has for its object the prevention of septic processes and the development of cicatricial contraction. The first complication is avoided by attention to cleanliness, and the avoidance of the accumulation of any discharge which may undergo decomposition. The occurrence of cicatricial contraction is prevented by the daily passage of a rectal bougie, during the process of healing of the wound. Mr. Harrison Cripps advises that the passage of this instrument should be commenced immediately signs of contraction appear. Contraction usually commences within two to four weeks from the time of the operation. The bougie should be left in for three or four hours each day, if it does not cause discomfort. When the wound has healed, a process which takes about two months, the bougie is passed every other day, for about a year. The instrument is simply passed in and out, and not left for any length of time within the rectum.

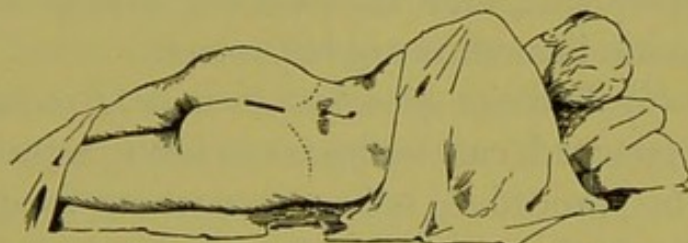

FIG. 82. — Excision of rectum. Position of patient, and line of incision for excision of rectum by sacral method.

Excision of the rectum by the sacral method (Kraske's operation).—Removal of a portion of the rectum by this method is indicated in those forms of carcinomatous growths of the viscus, which are situated at a level at once too high up for removal by the perineal method, and too low down to allow of removal through an abdominal incision; that is to say, when the growth is located at or near the junction of the upper and middle thirds of the rectum.

Instruments.—These are similar to those required for the "perineal" operations, with the addition of a small saw, a chisel, a mallet, a spatula, and bone forceps.

Position.—The patient is placed in the right lateral and semiprone position. The surgeon stands behind the patient, opposite the sacrum, and the assistant on his left hand.

Operation.—The operation of excision of the rectum by the sacral method may be divided into the following stages, namely—(a) External incision; (b) Excision of coccyx, division of sacrum, and exposure of affected portion of rectum; (c) Separation and removal of growth and adjacent portion of bowel; (d) Union of proximal and distal portions of rectum; and (e) Closure of external wound.

(a) *External Incision.*—An incision is made in the middle line, commencing above at the spine of the second sacral vertebra, and extending downwards to within an inch or so of the posterior margin of the anus, stopping short of the external sphincter ani. The soft structures are reflected as far as the lateral margins of the sacrum and coccyx on either side, and all bleeding vessels secured. The sacro-sciatic ligaments are left intact.

(b) *Excision of coccyx, division of sacrum, etc.*—The coccyx is resected, care being taken not to injure the underlying gut. This procedure is best carried out by introducing the index finger of the left hand into the rectum, and so following, by the sense of touch, each successive stroke of the knife. The bleeding is not excessive, though one or two vessels may require ligature.

The sacrum is now divided transversely, by means of an Adams' saw, at the level of the third sacral spine, the connective tissue attachments of the rectum to the anterior aspect of the bone having been previously torn asunder. This transverse cut through the bone must be done gradually and carefully, so as to avoid, if possible, any splintering. The detached portion is firmly held aside by the assistant, and a spatula having been placed along the anterior aspect of the bone, to protect the underlying structures, a longitudinal cut is made through the bone a little to the left of the middle line, so as to avoid entering the neural canal. This avoidance of the neural canal is necessary, not for the preservation of the contained nerves, as these have already been divided in the transverse cut, but in order to

facilitate subsequent wiring of the fragments, since, if the vertical cut extends into the canal, it is more difficult to fix the bony fragments together. The lateral segments of the sacrum are now held aside, the attachments of their respective sacro-sciatic ligaments serving as hinges.

A good view of the rectum having been thus obtained, the exact extent of the growth must be made out, since the precise character of the subsequent steps in the operation depends upon this. As an examination through the anus may not allow the finger to pass high enough up, it is always advisable to make an opening through the rectal wall posteriorly, immediately below the lowest limit of the growth, taking care not to carry it further downwards than is necessary for the introduction of the finger. Having made out the exact limits, the next stage of the operation can be decided upon. This is usually the separation of that portion of the bowel which is involved in the growth from the surrounding structures.

(c) *Separation and removal of growth.*—The gut is freed from its attachments all round, care being taken in the performance of this to avoid unnecessary laceration and damage to the tissues. In those cases in which the growth extends anteriorly, there may be considerable adhesion to the capsule of the prostate. If such exists, the prostatic capsule may be stripped off the gland, with little risk of bleeding or other injury. The portion of the gut containing the growth is now excised, care being taken to make the sections well above and below the diseased segment. The division of the bowel is most conveniently made with strong scissors. This having been done, a search is made for any enlarged lymphatic glands in the vicinity, two or three usually being found lying in the hollow of the sacrum, on a level with the first sacral vertebra, in which case they must be removed. Should it be necessary to open the peritoneal cavity in the removal of the diseased bowel, the aperture must be closed by the insertion of a series of sutures.

(d) *Union of proximal and distal portions of rectum.*—If the growth is fairly limited, and the upper portion of the gut can be sufficiently drawn down to allow of circular “rectorrhaphy,” this can be proceeded with, after the manner which has been already described in connection with circular “enterorrhaphy” of the small intestine. When this can be done, it is not advisable to make the anastomosis complete, but rather to leave a gap posteriorly, to allow of the escape of fæces during the process of repair. If the anastomosis is completed, the bond of union will not, in most instances, be sufficiently firm to overcome the resistance of the external sphincter, and consequently there will be in all probability escape of fæces through the line of sutures, resulting in perirectal inflammation and abscess. When a gap is left, fæces can readily escape, and in time the fistulous track will be closed by cicatricial contraction. Should this, however, not take place, a plastic operation may be performed for its closure.

When the suturing has been completed, the bone flaps are placed in apposition, and united by the insertion of stout silk or wire sutures.

When the disease is too extensive to allow of approximation of the two ends of the gut, the upper end must be drawn out of the wound and sutured to the margins of the upper portion of the skin incision. In this case the bone flaps cannot be replaced, and must be removed, a circumstance which at once does away with one great advantage of the operation, namely, preservation of the natural support of the floor of the pelvis.

Closure of external wound.—This consists in closing the skin incision by the insertion of interrupted silk-worm gut sutures as far as is practicable. When circular “rectorrhaphy” has been performed, the skin incision must not be closed opposite the gap left in the posterior aspect of the rectal wall. The wound is then dressed with antiseptic dressings in the usual manner; strips of strapping will be useful for keeping them in position.

CHAPTER III.

OPERATIONS FOR THE TREATMENT OF HERNIA.

- I. OPERATION FOR THE RADICAL CURE OF INGUINAL HERNIA.
 - A. Bassini's operation.
 - B. Kocher's operation.
 - C. Macewen's operation.
2. OPERATION FOR THE RADICAL CURE OF FEMORAL HERNIA.
3. OPERATION FOR THE RADICAL CURE OF UMBILICAL HERNIA.
4. OPERATIONS FOR STRANGULATED HERNIA.
 - A. Inguinal hernia.
 - B. Femoral hernia.
 - C. Umbilical hernia.
 - D. Obturator hernia.

OPERATION FOR RADICAL CURE OF INGUINAL HERNIA.

NUMEROUS operations have been devised for the cure of an inguinal hernia. Some of them are very complicated, whilst others are correspondingly simple. The operations which will be given are similar to the one devised by Bassini, and to those practised by Kocher and Macewen.

Indications.—(a) Some cases of irreducible inguinal hernia; (b) those cases of strangulated hernia which are operated upon for the relief of the strangulation, and in which it is safe to perform a prolonged operation; (c) cases of reducible hernia in young people, in order to obviate the wearing of a truss. A number of other indications might

be given, but for a discussion of these the student is referred to a text-book of surgery.

Instruments.—Scalpel, dissecting and pressure forceps, scissors, retractors, blunt hooks, strong curved needle on a handle, needles, needle-holder, and suture and ligature material.

Position.—The patient is placed in the dorsal posture; the surgeon stands on the affected side of the patient, and his assistant directly opposite to him.

Anatomical considerations.—The inguinal canal is a space lying between the different strata of the anterior abdominal wall, which commences internally at the internal abdominal ring—an aperture in the fascia transversalis—and terminates at the external abdominal ring—an aperture in the external oblique muscle. It is bounded *anteriorly* by the external oblique for its entire extent, and by the lowest fibres of the internal oblique for the external inch; *posteriorly* by the fascia transversalis for the entire extent; and behind this, the deep epigastric vessels externally; and then in succession the middle inguinal pouch, the obliterated hypogastric artery, and the outer part of the internal inguinal pouch. Internally, in front of the fascia transversalis, is the conjoined tendon of the internal oblique and transversalis. The *floor* of the canal is formed by the grooved upper surfaces of Poupart's and Gimbernat's ligaments. The *roof* is formed by the arching fibres of the internal oblique and transversalis. The contents of the canal in the male are the constituents of the spermatic cord, together with the coverings of this structure which are derived from the fascia transversalis and the internal oblique. These are known as the infundibuliform fascia and the cremaster muscle respectively. The inguinal branch of the ilio-inguinal nerve lies in the superficial part of the canal, and emerges through the external abdominal ring.

In the female the inguinal canal contains the round ligament of the uterus, and the process of peritoneum known as the canal of Nuck, together with coverings similar to those of the spermatic cord.

A. Bassini's operation (radical cure of inguinal hernia).

—The area of operation should be well shaved on the day previous to operation, and rendered aseptic in the manner recommended on p. 2. It is essential that very strict aseptic precautions be observed, as much of the success depends on the non-occurrence of suppuration.

The operation may be divided into the following stages, namely—(a) External incision; (b) opening up of inguinal canal, definition of sac of hernia and spermatic cord, and separation of these two structures; (c) removal of hernial sac, and union of internal oblique and transversalis muscles to Poupart's ligament; (d) replacement of spermatic cord, and union of external oblique to Poupart's ligament; (e) closure of external wound.

(a) External incision.—

An incision from 3 to 4 in. in length is made parallel with and about half an inch above Poupart's ligament, commencing nearly an inch

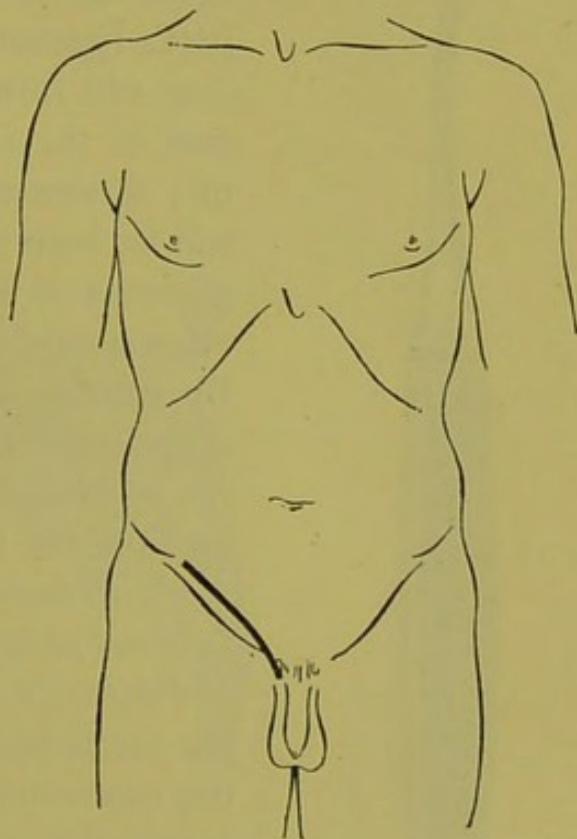


FIG. 83. — Inguinal hernia; radical cure. Line of external incision. — BASSINI.

internal to the anterior superior iliac spine, and terminating over the middle of the external abdominal ring. The skin and fasciæ are divided; one or two small arteries, the superficial epigastric and the ascending branches of the superficial circumflex iliac, requiring ligature. The aponeurosis of the external oblique muscle is next divided for the entire length of the incision.

(b) Opening of inguinal canal, etc.—The aponeurosis of

the external oblique is dissected upwards and inwards as far as the outer border of the rectus abdominis, and downwards to the grooved upper aspect of Poupart's ligament. Next, those portions of the internal oblique and transversalis which cross the bottom of the incision, are divided a short distance above their attachments to Poupart's ligament. The internal abdominal ring will now be exposed in the outer part of the incision, and extending from this downwards along the inguinal canal will be seen the hernial sac and the constituents of the spermatic cord, which are often spread out over the sac of the hernia. By careful dissection the hernial sac is separated from the structures composing the spermatic cord, the latter being lifted up from the sac by blunt hooks.

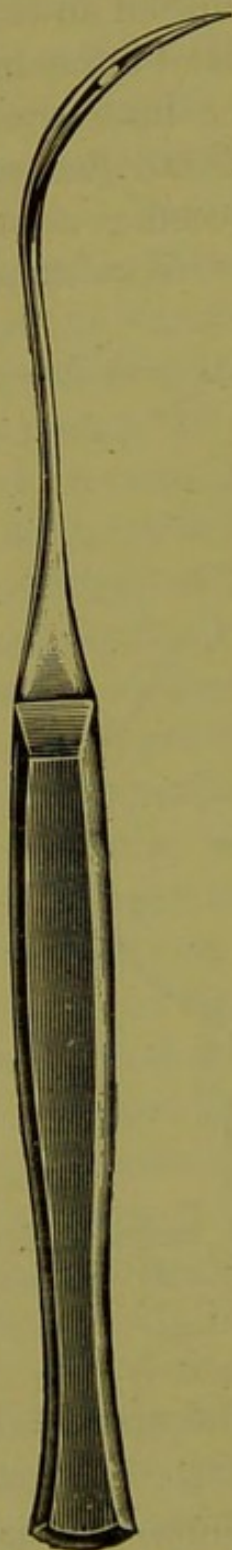


FIG. 84.—Radical cure of inguinal hernia. Long needle on handle for transfixion of hernial sac, and introduction of sutures.

(c) *Removal of hernial sac, and union of internal oblique and transversalis muscles to Poupart's ligament.*—The distal part of the sac is laid open, and if any portion of the omentum, intestine, or other viscus, is inside, this is returned into the abdominal cavity, any adhesions which may be present being ligatured and divided. The sac is now held up, and the region of the neck where it lies within the internal abdominal ring separated from the surrounding tissues, and transfixed at the base with a blunt hernia needle which carries the loop of a silk ligature. This ligature is cut into two, and the needle withdrawn; each half of the ligature is tied around one-half of the sac and one

around the entire stump. The distal part of the sac is removed with scissors and the stump pushed inwards towards the abdomen. When the hernia is of the congenital variety and the sac is continuous with the tunica vaginalis testis, it is necessary to cut across the sac first a short distance above the testis, and then to proceed as above.

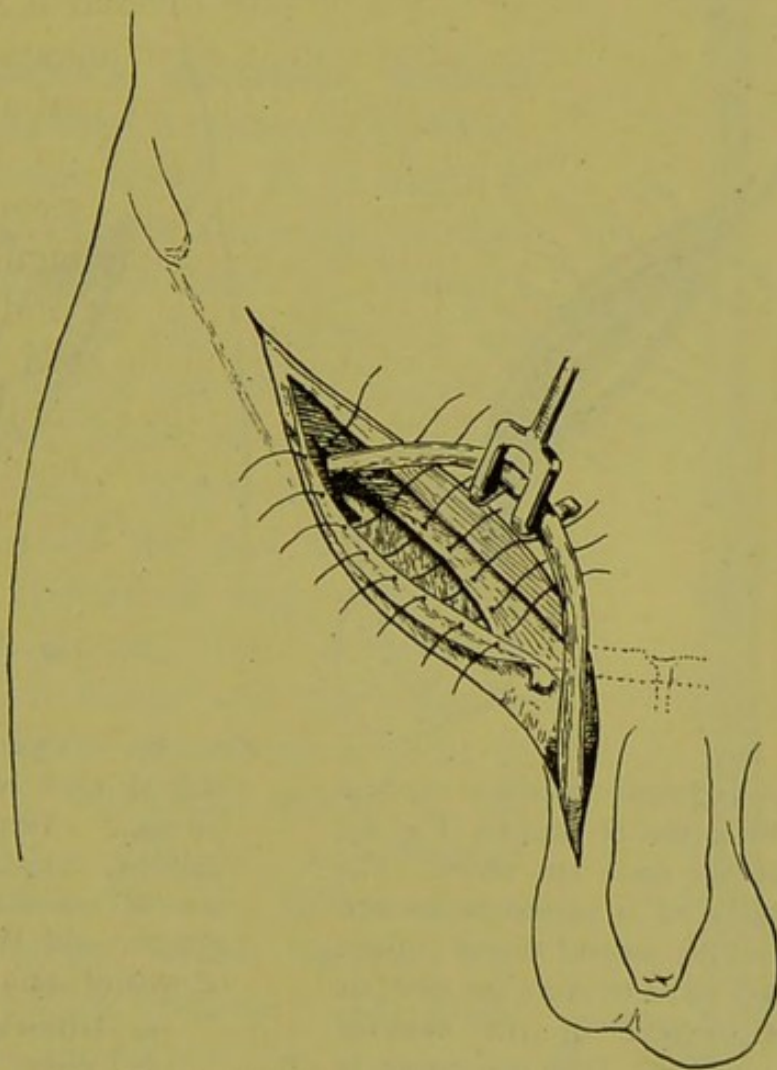


FIG. 85.—Inguinal hernia; radical cure. Entire inguinal canal open, spermatic cord lifted up, and first tier of sutures inserted but not tied.—BASSINI.

The cut margins of the transversalis and internal oblique muscles are now fixed to the upper margin of Poupart's ligament by the insertion of a row of interrupted silk sutures, according to the method shown in Fig. 85. During this procedure the spermatic cord is held out of the way by an assistant.

(d) *Replacement of spermatic cord, and union of external oblique to Poupart's ligament.*—The spermatic cord is placed on the external surface of the internal oblique just above the line of its attachment to Poupart's ligament, and hence it comes to lie in a new canal. The aponeurosis

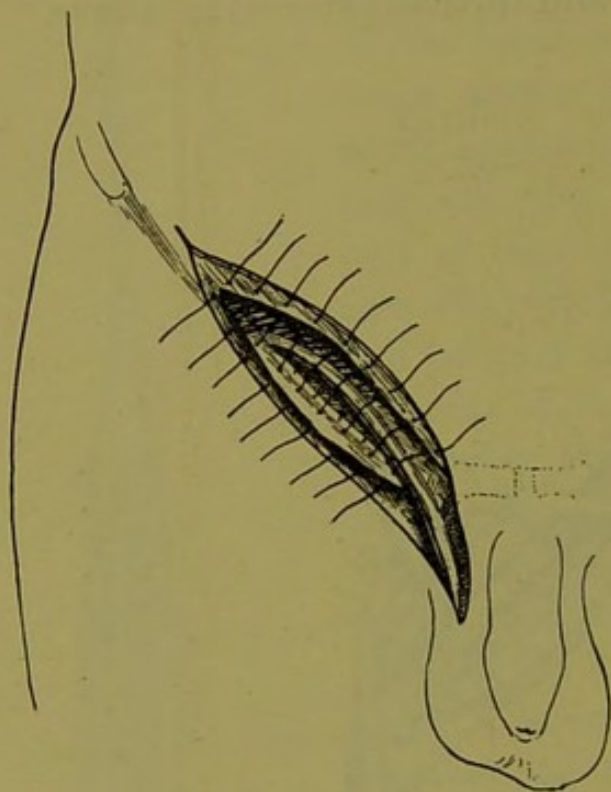


FIG. 86.—Inguinal hernia; radical cure. First tier of sutures (Fig. 85) tied, and the ends cut short. The spermatic cord is placed in its new canal, and the second tier of sutures is inserted so as to unite the margins of the incision in the external oblique muscle. They are ready to be tied.—BASSINI.

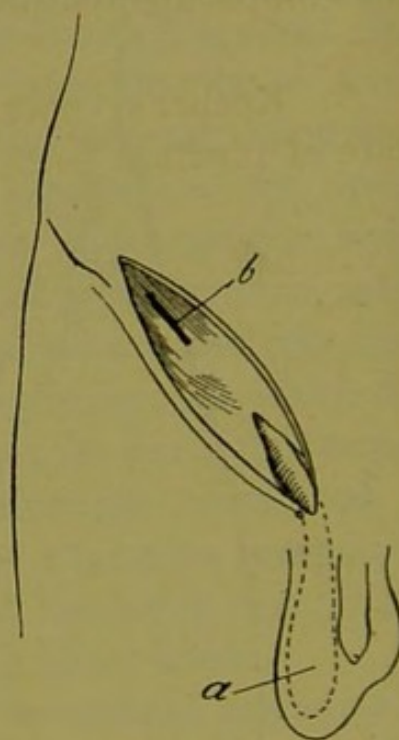


FIG. 87.—Operation for radical cure of inguinal hernia. First stage: External incision, exposure of external oblique muscle, and laying bare of neck of sac.—KOCHER.

a. Hernial sac.
b. Incision in external oblique.

of the external oblique is placed over the spermatic cord, and the cut margins united to Poupart's ligament by interrupted silk sutures.

(e) *Closure of external wound.*—This is closed in the usual manner.

The advantages which this operation is said to possess are the easy and complete access which is given to the

herniated structures, and the non-liability to relapse afterwards. The latter advantage, however, has been very much exaggerated. The disadvantages are the long incision which is necessary, and the complicated nature of the operation.

B. Kocher's operation (radical cure of inguinal hernia).—Operation.

—An incision about 3 in. in length is made half an inch above and parallel to the inner two-thirds of Poupart's ligament. The skin and fasciæ are divided, and the superficial epigastric and external pudic vessels cut across and ligatured. Next, the coverings of the hernial sac just beyond the external abdominal ring—the intercolumnar fascia, the cremasteric muscle and fascia, and the infundibuliform fascia—are incised, so as to expose the superficial aspect of the hernial sac. This sac is separated by dissection from its surroundings, and its fundus, which occupies the scrotum, pulled upwards. The distal part of the sac is now free.

The upper margin of the wound is strongly retracted upwards, and an opening made in the aponeurosis of the external oblique immediately above and external to the internal abdominal ring, that is, above and external to the mid-point of Poupart's ligament. This opening is usually about 1 in. in length, and is large

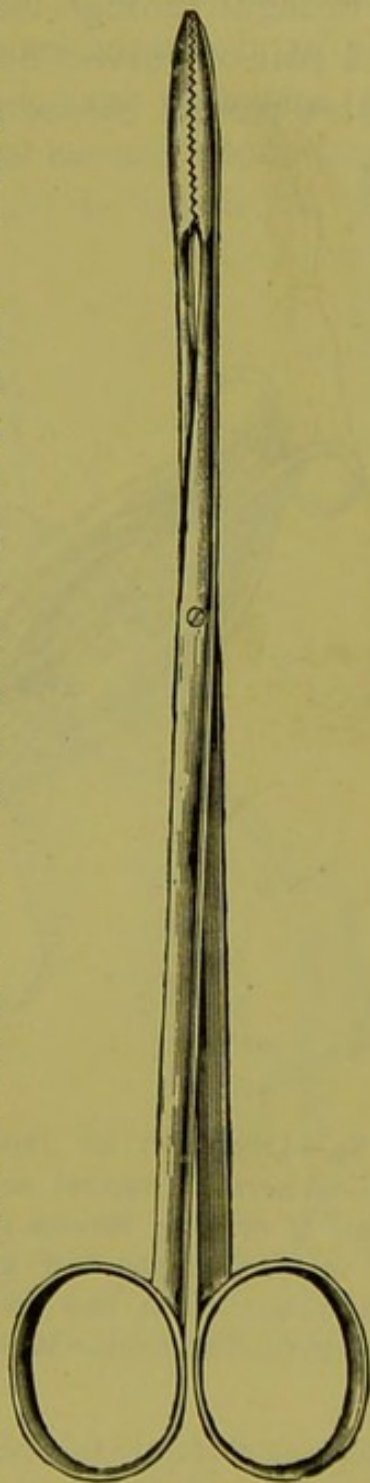


FIG. 88. — Kocher's operation for radical cure of inguinal hernia. Dressing forceps for drawing hernial sac along inguinal canal and through aperture in external oblique.

enough to allow the fundus of the empty hernial sac to be brought through it (Fig. 87).

A pair of curved dressing forceps (Fig. 88) is taken, the blades passed through the opening in the external oblique,

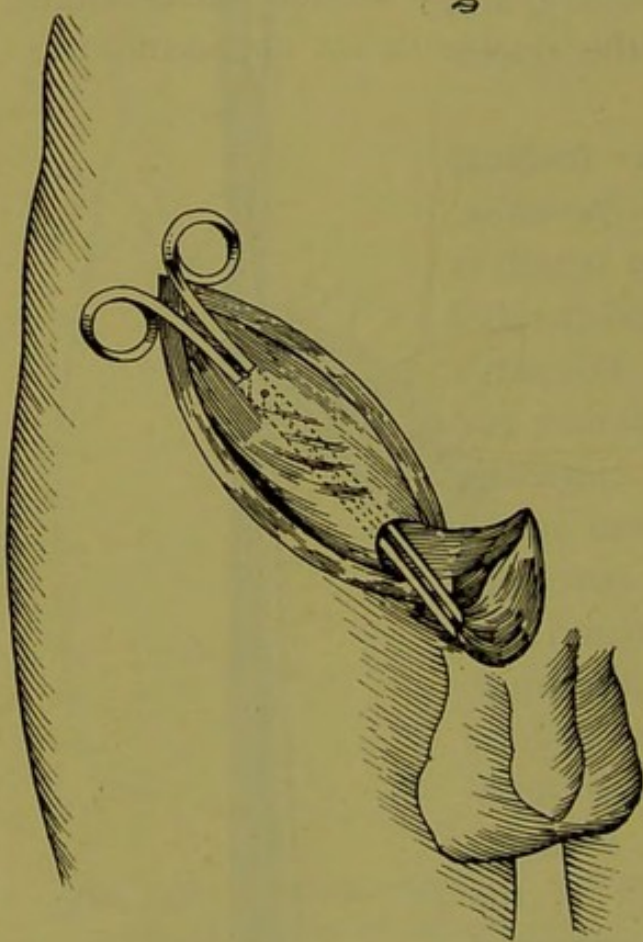


FIG. 89.—Operation for radical cure of inguinal hernia. Second stage, showing a pair of dressing forceps passed along the inguinal canal and grasping the hernial sac, which has been separated from its surroundings.—KOCHER.

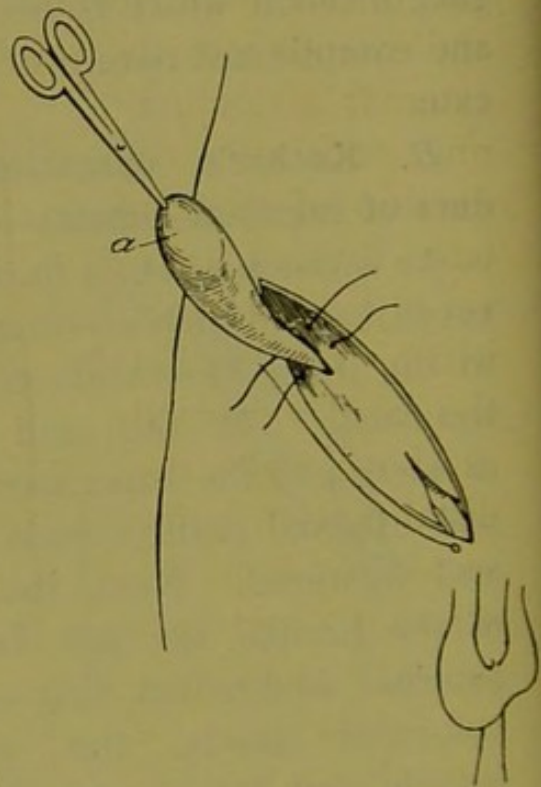


FIG. 90.—Operation for the radical cure of inguinal hernia. Third stage, showing the hernial sac drawn upwards through the aperture in the external oblique muscle. Two sutures are shown passing through the neck of the sac and the interior abdominal wall (muscular and fascial layers).—KOCHER.
a. Hernial sac.

then through the lowest fibres of the internal oblique into the inguinal canal, and thence along this canal anterior to the spermatic cord, until the points emerge from the external abdominal ring at the inner part of the first incision (Fig. 89).

The fundus of the hernial sac is next seized with the dressing forceps and drawn along the inguinal canal until it

emerges through the aperture in the external oblique, by exerting traction in an upward and outward direction (Fig. 90).

An opening is now made at the distal extremity of the sac, and its interior examined so as to make sure that no gut or omentum is within. When the hernial sac is large and extends into the scrotum, it should be opened at the external abdominal

ring, and, after reduction of its contents, divided transversely. The part which lies within the canal is treated as above, whilst the distal portion is dissected out from the scrotum and removed. The sac is then pulled downwards and outwards, in order to draw down as much as possible of the neck and the peritoneum in the region of the internal abdominal ring. It is then transfixed with a needle carrying a

strong ligature, tied in two halves, and the portion distal to the ligature removed with scissors.

The stump of the sac is now reduced through the aperture in the external oblique, and anchored to the deep aspect of this muscle by sutures which pass through the muscular and fascial layers of the abdominal wall, and also transfix the stump of the sac (Fig. 90). A deep suture is passed through

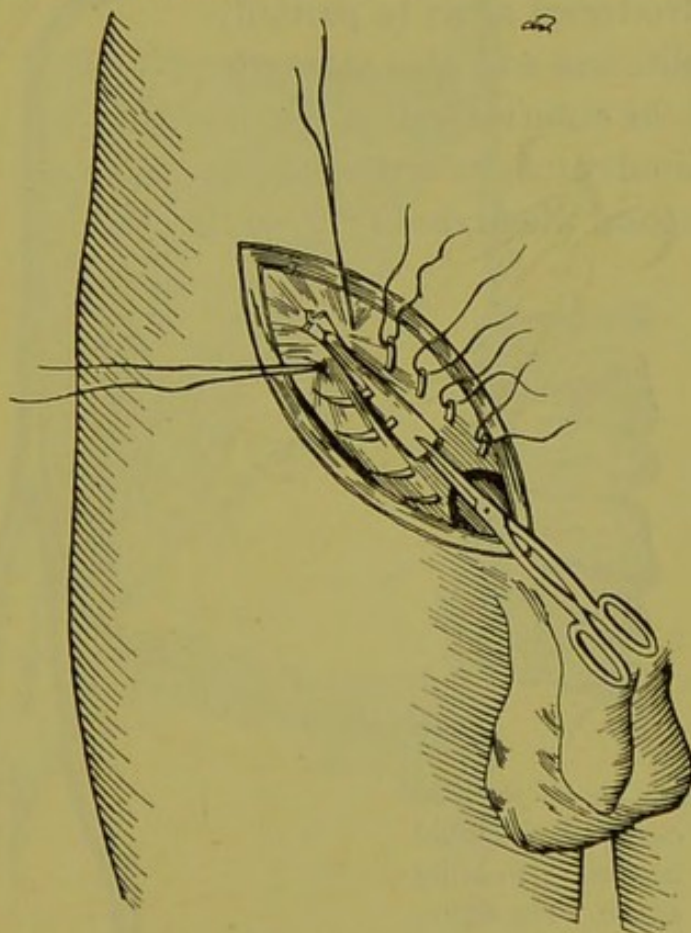


FIG. 91.—Operation for the radical cure of inguinal hernia. Fourth stage, showing the method of introduction of "canal sutures" in partial obliteration of the inguinal canal.—KOCHER.

the margins of the internal abdominal ring immediately below the neck of the hernial sac. The remainder of the incision in the external oblique is then closed in the usual manner by the insertion of one or two points of simple suture.

"Canal sutures" are now introduced so as to partially obliterate and also strengthen the anterior wall of the inguinal canal, according to the method illustrated (Fig. 91).



FIG. 92. — Radical cure of inguinal hernia. Folding of sac. The figure shows the sac transfixed with a ligature, and thrown into a number of folds. —MACEWEN.

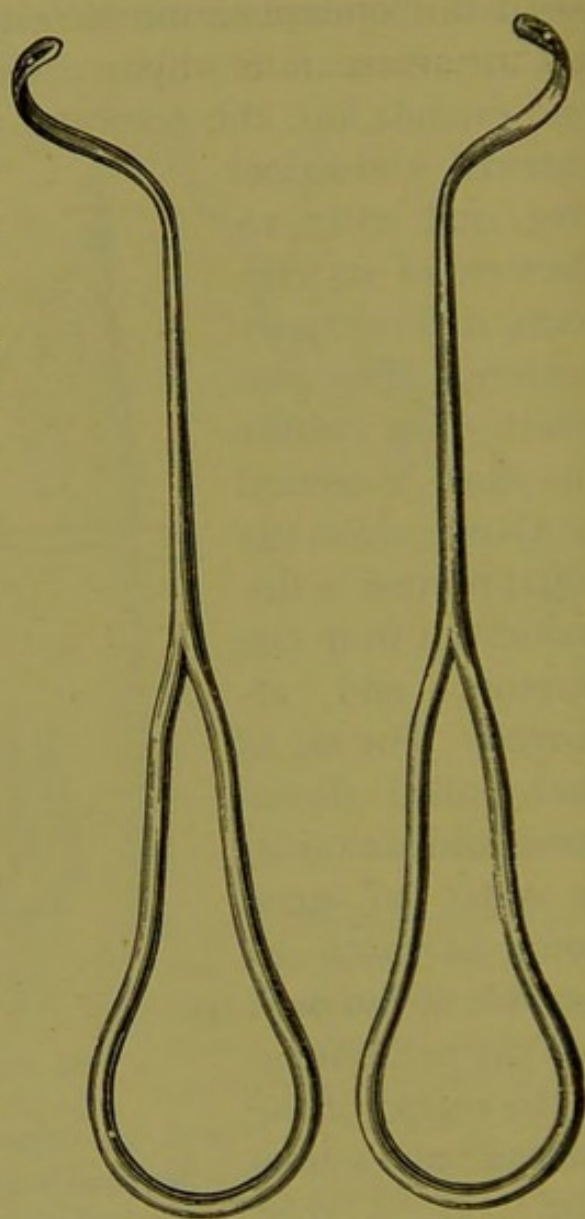


FIG. 93. — Radical cure of inguinal hernia. Hernia needle. — MACEWEN.

The external incision is then closed by the insertion of a row of interrupted sutures of silk-worm gut, and aseptic dressings applied.

The advantage of this operation is that the muscles which form the anterior boundary of the inguinal canal are not cut through, and the canal is not opened up for its entire extent.

The spermatic cord is not interfered with as in Bassini's operation.

C. Macewen's operation (radical cure of inguinal hernia).

—In this operation the hernial sac is thrown into a series of transverse folds, by means of a suture which passes

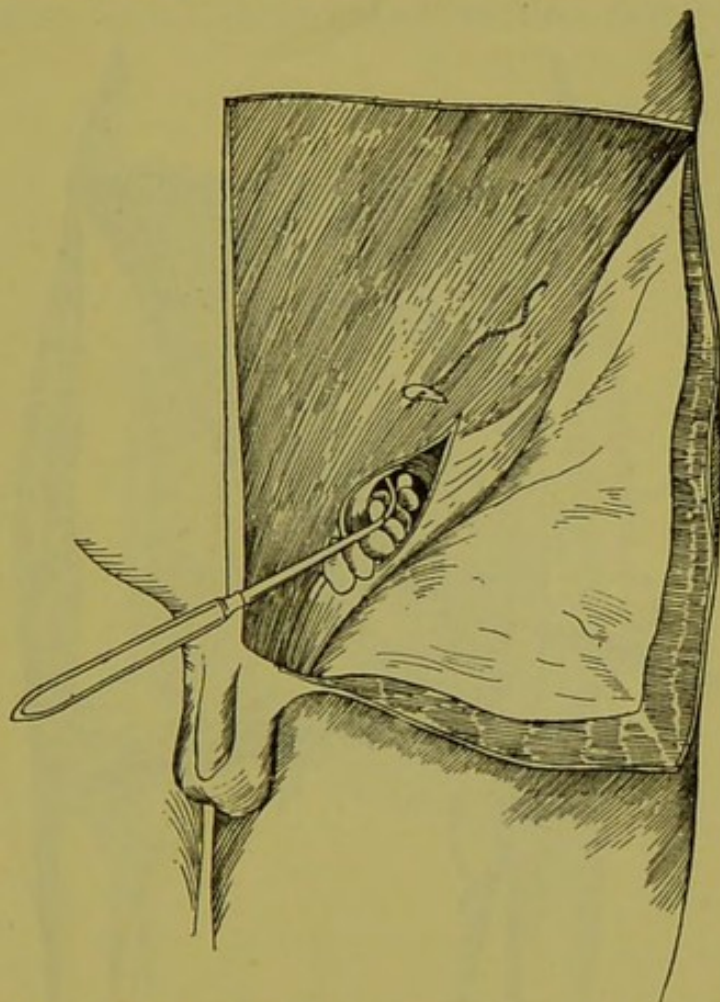


FIG. 94.—Radical cure of inguinal hernia. Manner of transfixing the sac. The hernia needle has passed through the sac in several places, and pierced the abdominal muscles from behind forwards, emerging about an inch external to and a little above the internal abdominal ring.—MACEWEN.

through it several times. The sac is then reduced, and fixed in position opposite the internal abdominal ring, and the inguinal canal is closed by the insertion of a number of sutures.

Operation.—The positions of the patient, surgeon, and assistant are similar to those in the preceding operations.

External incision, exposure, and treatment of hernial sac.—An incision is made in the inguinal region, directly over the external abdominal ring. This is deepened until the external ring and the neck of the hernial sac have been well exposed. The contents of the sac are then

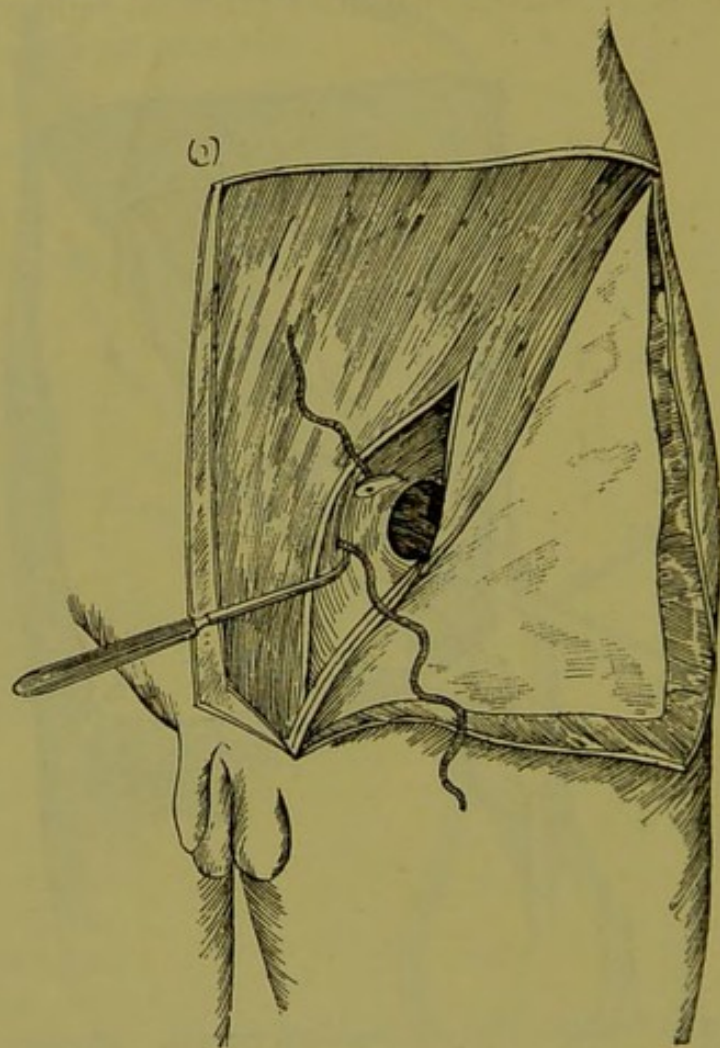


FIG. 95.—Radical cure of inguinal hernia. Method of transfixion of conjoined tendon in two places, with hernial needle carrying a suture.—MACEWEN.

reduced into the peritoneal cavity, the fundus of the sac is separated from the scrotum, and the neck from the wall of the inguinal canal as far as the internal abdominal ring. This is done by the point of the forefinger, care being taken to separate it freely around the margins of the internal ring, and to define the position of the deep epigastric artery. The fundus of the sac is pulled out from

the scrotum, and then the entire sac is folded upon itself as in Fig. 92, and transfixed with a hernial needle of the shape shown in Fig. 93, the point of the needle emerging through the external oblique a little above and external to the position of the internal abdominal ring (Fig. 94).

The needle is withdrawn, and traction being exerted on

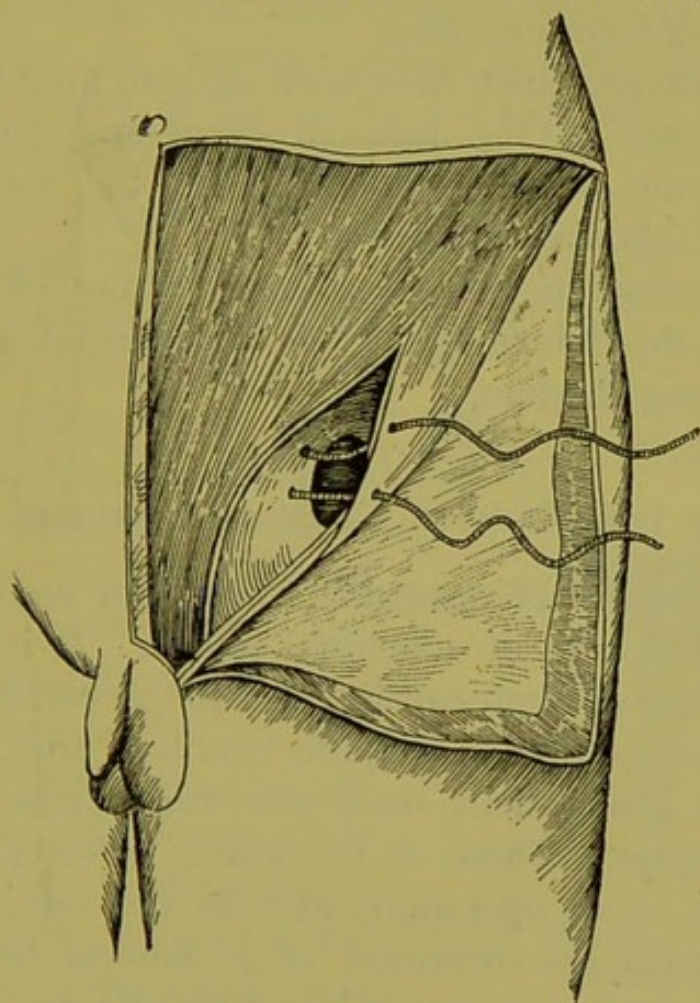


FIG. 96.—Radical cure of inguinal hernia. Suture ready for tying, after the conjoined tendon has been pierced in two places, and also Poupart's ligament.
—MACEWEN.

the thread, the sac is drawn upwards along the inguinal canal, and fixed opposite the external aspect of the internal abdominal ring.

Closure of inguinal canal. — The conjoined tendon is pierced with the hernial needle, carrying a suture, in two places as in Fig. 95 ; and the needle withdrawn, leaving the suture in position.

Next, each extremity of this suture is carried separately through Poupart's ligament, as in Fig. 96.

A sufficient number of sutures are introduced in this manner; usually two or at most three are necessary. Each suture is then tied in a reef knot, and the ends cut short.

The external wound is then closed in the usual manner, and aseptic dressings applied.

The advantages which have been claimed for this method are the closure of the inguinal canal and the internal abdominal ring which is effected, and the good results which have followed the operation.

A disadvantage is the complicated nature of the procedure, and the difficulty which is experienced in carrying it out in young children.

OPERATION FOR RADICAL CURE OF FEMORAL HERNIA.

Several varieties of operation have been recommended for the radical cure of a femoral hernia. It is doubtful, however, if any of them can be regarded as certain in their results, since recurrence is quite common after their performance if the patient does not wear some form of truss or support. There is no doubt, however, that the performance of an operation, such as the one described later, facilitates the retention of a femoral hernia, and allows the patient to wear a lighter form of truss.

Position.—The patient lies in a dorsal position with the limb of the affected side slightly flexed, abducted, and rotated outwards, a pillow being placed under the knee. The surgeon stands on the affected side of the patient, and his assistant on the opposite one.

Instruments.—Scalpel, hernia knife, scissors, retractors, dissecting and pressure forceps, hernia needle, needles, needle-holder, and suture and ligature material.

Operation.—The operation may be divided into four stages, which are—(a) External incision and exposure of

sac; (b) treatment of sac; (c) treatment of femoral ring and canal; (d) closure of external wound.

(a) *External incision and exposure of sac.*—An incision is made in the long axis of the hernial swelling, commencing in front of Poupart's ligament, and half an inch outside the pubic spine, and extending downwards for about 2 in. The skin, superficial fascia, cribriform fascia, and the fascia of the femoral sheath, are divided, and the superficial aspect of the hernial sac exposed. This can be recognised by its tenseness, its slaty-blue colour, the arrangement of the blood vessels upon its surface—these are said to be arborescent—and by the fact that the sac itself can be picked up, and made to glide over the contents. The sac is carefully divided up to the femoral ring. The surgeon can often recognise that he has divided the sac wall by the escape of a quantity of clear fluid (blood-stained in the case of a strangulated hernia). The contents of the sac are next examined, and

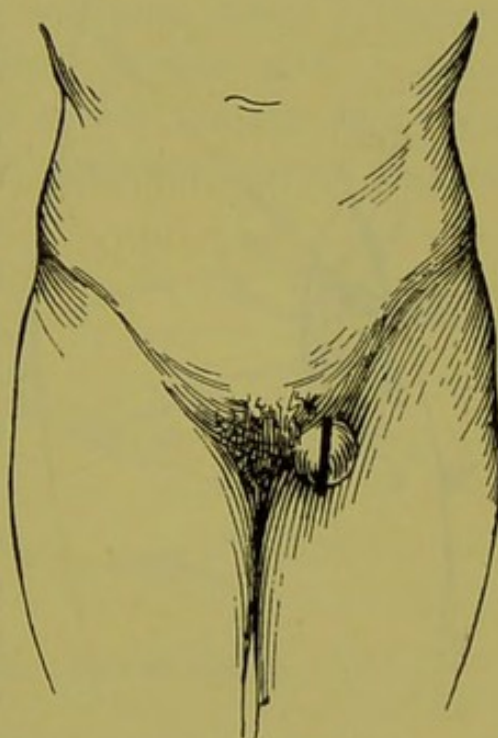


FIG. 97.—Femoral hernia. Line of incision.

dealt with as is considered proper. If any adhesions are met with, they are separated either by breaking them down with the finger if they are recent, or by ligature if of old standing.

(b) *Treatment of sac.*—When the sac has been exposed and opened, and the contents returned into the abdominal cavity, its neck is well separated with the finger from the surrounding tissues above the femoral ring. Traction is exerted upon it, and a ligature applied around its neck as high as possible. If the sac is small, the ligature may simply

surround the neck, but in most instances it is advisable to transfix the neck as high as possible, and to tie it in two halves, as in the case of inguinal hernia. When these ligatures have been tied, the ends are kept long, and the sac removed beyond the line of application of the ligature,

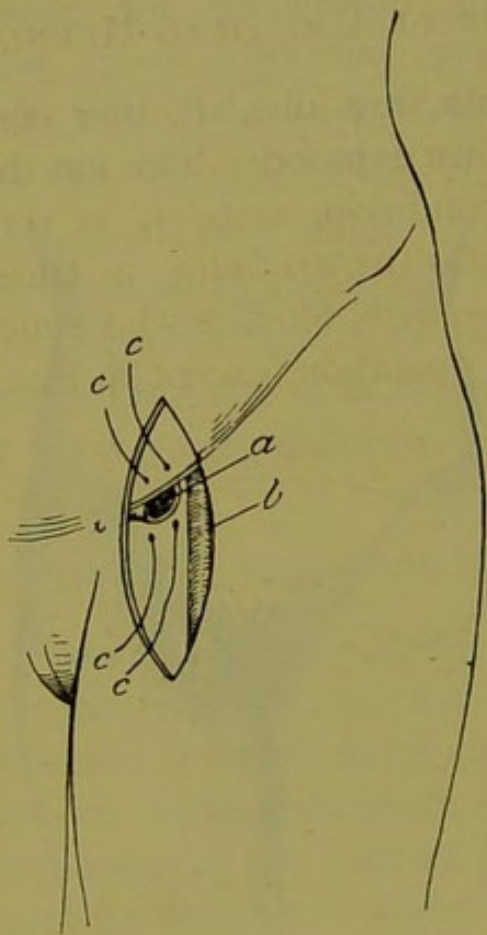


FIG. 98. — Femoral hernia.
Method of fixation of neck of
sac to Poupart's ligament.

- a. Stump of hernial sac.
- b. Common femoral vein.
- c. Sutures.

sufficient being left in the stump to ensure non-slipping of the ligature. The stump is now pushed upwards into the abdomen, and one end of the ligature, which has been left long, passed through Poupart's ligament and tied to the other extremity, and cut short. This helps to anchor the stump to the abdominal wall, and to keep it immediately above the aperture of the femoral ring.

(c) *Treatment of femoral ring and canal.*—The femoral ring can be closed by passing one or two ligatures through that portion of Poupart's ligament which lies in front of the ring, and then through the attachment of the pectineal fascia to the ilio-pectineal line (Fig. 98). Two ligatures of this kind are usually enough. Care must be taken

not to perforate the common femoral vein, which lies immediately outside the femoral ring. The femoral canal can be, in part, obliterated by dissecting up a flap of the pectineus muscle and its fascia,—the convexity of the flap being below, and the attached base above,—and fixing this to Poupart's ligament by the insertion of a few interrupted silk sutures.

(d) *Closure of external wound.*—The margins of the aperture in the deep fascia are united by a continuous suture, and the skin wound is closed in the usual manner.

OPERATION FOR RADICAL CURE OF UMBILICAL HERNIA.

Many cases of umbilical hernia in adults, if other conditions allow, ought to be submitted to operation for the radical cure of the abnormal condition, since it is very difficult to keep up an umbilical hernia with a truss. Often, however, the patients are elderly females who suffer from bronchitis, and in these an operation, except in cases

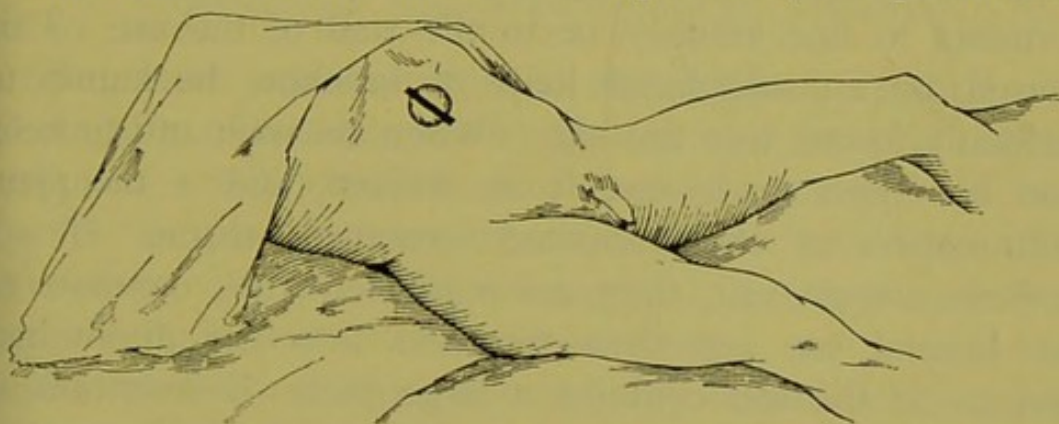


FIG. 99.—Umbilical hernia. Line of incision.

of emergency, is not desirable. The small umbilical herniæ of children can usually be cured by the application of a suitable pad.

Position.—The patient is placed in the dorsal posture, the surgeon stands on the right side of the patient, and the assistant directly opposite to him.

Instruments.—As for inguinal hernia.

Operation.—The stages of the operation are—(a) External incision, and exposure and opening of sac; (b) treatment and return of contents of sac within abdomen, and removal of that portion of sac which lies beyond the aperture in the aponeurosis; (c) closure of hernial ring and wound in abdominal wall.

(a) *External incision, etc.*—An incision is made in the middle line of the abdomen over the tumour (if this is large, over its lower part), and deepened until the sac has been opened. Care must be taken when making this incision, since it often happens that the wall of the hernia is very thin, and the contents of the sac may be easily injured owing to the presence of adhesions. It is not always easy to demonstrate the wall of the sac before opening it, but this should be done if possible.

(b) *Treatment and return of contents of sac.*—The sac having been opened for a distance of about 1 in. or more, the contents are examined, and the constriction, if any, made out. This may be due to adhesions of the contents to one another, or to the wall of the sac, or be caused by an additional loop of intestine having been suddenly forced into the sac. When the seat of constriction has been made out, it is divided, and a complete examination of the herniated structures made. If adhesions are present, they are separated; the contents of the hernial sac are then returned into the abdominal cavity. If the sac contains a large piece of omentum, it is usually advisable to unravel it, transfix it in several places, tie it in segments, and then remove the distal portion. The contents of the sac having been dealt with, the aperture in the aponeurosis is temporarily plugged with a flat sponge, which will prevent the further escape of intestines.

The sac is now dissected from its connections with the surrounding tissues until the neck is reached. If possible, the peritoneum which forms the sac should be separated from the margins of the aperture in the aponeurosis, and then sewn up with a continuous silk suture, the sponge plug being first removed. The portion of the sac beyond the line of suture is removed with scissors, and the stump pushed inwards towards the abdominal cavity.

(c) *Closure of aperture in aponeurosis, and external incision.*

—The margins of the aperture in the aponeurosis are pared away until the sheath of the rectus abdominis muscle on each side is opened. Next, the margins of the aperture are united together by the insertion of interrupted sutures. This may be done in one or more tiers. Usually the cut margins of the posterior layer of the sheath of the rectus are united to one another, then the margins of the two recti are approximated, and finally the anterior layers of the sheath.

The margins of the incision in the skin and fasciæ are united in the usual manner.

OPERATIONS FOR STRANGULATED HERNIA.

The most common herniæ are inguinal, femoral, and umbilical; obturator, sciatic, gluteal, and internal herniæ are rare. All varieties may become strangulated and require surgical intervention in order to save life. The operations for the relief of inguinal, femoral, umbilical, and obturator herniæ will be described.

Instruments.—Scalpel, hernia knife, hernia director, pressure and dissecting forceps, scissors, retractors, intestinal clamps, needle on handle, needles, needle-holders, and suture and ligature material. In those cases in which resection of bowel is necessary, Murphy's "anastomosis button," or a bone "tube" or "bobbin," will also be required, if the surgeon wishes to use one of these mechanical appliances.

Preliminary preparation.—The skin in the hernial region is shaved, and then rendered aseptic by washing it with soap and water, ether, and solution of perchloride of mercury (1 in 500), before the operation is performed. Care, however, must be taken not to injure the contents of the hernial sac by rough treatment.

A. Inguinal hernia.—*Position.*—The patient is placed in the dorsal posture, with the thighs slightly flexed so as to

relax the tissues in the region of the external abdominal ring. The surgeon stands on the affected side, and his assistant opposite to him.

Operation.—The operation itself may be described as consisting of the following stages, namely—(a) External incision and exposure of the sac; (b) opening of the sac, examination of its contents, and division of the stricture which causes the strangulation; (c) treatment of the herniated viscus, and return of it into the abdominal cavity; (d) closure of the hernial aperture, and closure of the external wound.

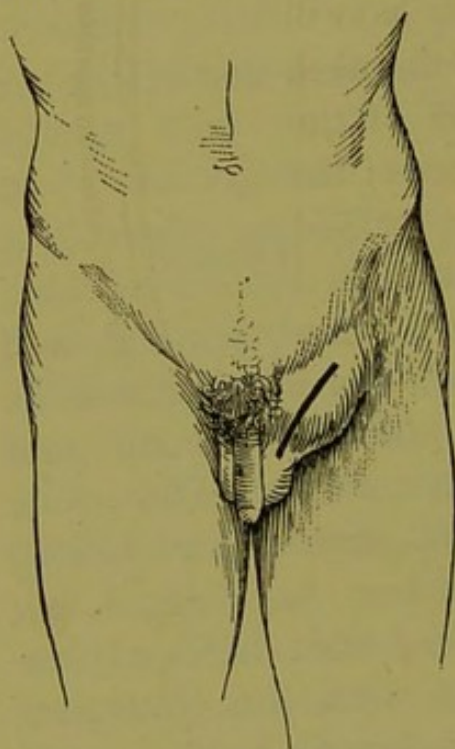


FIG. 100.—Inguinal hernia.
Line of external incision in
a case of strangulation.

(a) *External incision and exposure of the sac.*—An incision is made over the prominent portion of the hernial swelling, parallel to its long axis, and so situated that it extends a short distance above the external abdominal ring. This incision divides the skin and the fascial layers which cover the sac. It is not usually possible to recognise all the anatomical strata which form the coverings of a hernia,

but often the intercolumnar fascia and the cremasteric layer can be distinguished. The wall of the sac can generally be recognised by its tenseness. When all hæmorrhage from the superficial pudic arteries has been arrested, a small piece of the sac wall is picked up with forceps and carefully divided with the scalpel. An escape of fluid indicates the opening of the sac. This fluid is generally blood-stained serum, but it may be purulent or consist of intestinal contents, though the latter condition is very uncommon. Often, however, this fluid contains septic

micro-organisms, hence it is advisable to irrigate the interior of the sac with an antiseptic solution before dividing the constriction. A director is passed through the aperture made in the wall of the sac, and the opening is enlarged until the contents of the hernia are fully exposed. An examination of the intestine, omentum, or other viscus, is now made, and its condition determined. If it is in a moderately healthy condition, such as will justify its return into the abdomen, the neck of the sac is freed and the situation of the stricture made out. The forefinger of the left hand, or a hernia director, is passed to the stricture, and when a director is used it is passed through it. The hernia knife is now passed along the finger or the director, and one or two small notches made into the tissue forming the constriction, until the opening is made large enough to allow the return of the herniated structure. This having been done, the director or finger is withdrawn, and in the case of intestine the loop is pulled downwards so as to allow the surgeon to make a visual examination of the gut wall which has been nipped in the stricture. If this is found to be non-gangrenous, the contents are gradually and gently manipulated back into the abdominal cavity. It should be drawn downwards, unravelled, and then transfixed in several places, tied in sections, and the distal portion removed.

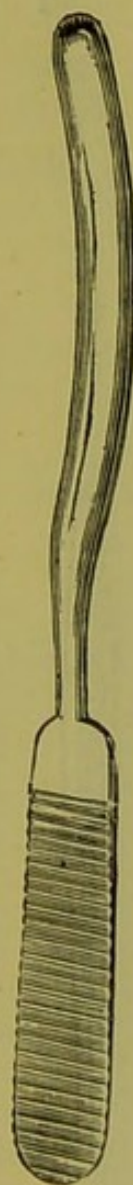

FIG. 101.—Hernia director.

When the contents of the hernial sac are in a condition of gangrene, the further treatment depends upon the general condition of the patient. If the gangrenous portion is a loop of intestine, and the patient is much collapsed

and not likely to survive a prolonged operation, the lumen of the gut should be opened so as to allow the escape of intestinal contents, and drainage established. When, however, the general condition of the patient is good, the gangrenous loop of intestine should be brought well into the wound, surrounded with warm sterilised towels, and the dead portion removed by performing intestinal resection, after the method described on pp. 55 *et seq.* It is advisable to allow the intestinal contents to escape before completing the anastomosis.

(d) *Closure of the hernial aperture and suturing of the external wound.*—These stages of the operation are similar to those described in connection with the radical cure of an inguinal hernia (pp. 97 *et seq.*).

B. Femoral hernia. — *Position.* — The patient is placed in the dorsal position, with the leg of the affected side slightly flexed. The surgeon stands on the affected side, and his assistant directly opposite to him.

Operation.—The stages of the operation are similar to those described in connection with inguinal hernia (*q.v.*).

An incision about 2 in. long is made in the long axis of the hernial swelling, and is so situated that the upper extremity is a little below and half an inch external to the pubic spine. This incision is in most cases on the inner aspect of the hernial swelling. The incision is deepened until

FIG. 102.—Operation for strangulated hernia. Hernia knife.



the sac has been opened. In dividing the stricture the

cut must be made upwards and inwards, so as to notch the free edge of Gimbernat's ligament, and to avoid the common femoral vein, which is on the outer side. In a small number of cases, 1 in 70, the obturator artery is given off from the deep epigastric, and runs in front of the neck of the sac. When this abnormality occurs, it may be divided, in which case the wound must be enlarged and a ligature applied to the cut extremity. The treatment of the hernial contents is similar to that mentioned in inguinal hernia, whilst the treatment of the sac and closure of the ring and wound are the same as in the radical cure of a femoral hernia (*q.v.*, p. 110).

C. Umbilical hernia.—

When an umbilical hernia becomes strangulated, the sac must be opened by a vertical incision over it.

The contents are dealt with according to the methods described in the chapter on inguinal hernia, and this having been done a radical cure is performed, as described on p. 112. When the condition of the patient will not allow of resection of gangrenous bowel, the dead portion is opened and the loop fixed in the external wound, an artificial anus being established. If the patient recovers, this opening can be closed at a later period, and the hernial aperture closed as in the radical operation.

D. Obturator hernia.—In the treatment of a case of strangulated obturator hernia, an incision is made in the long axis of the swelling and on the inner side of the femoral vessels. This is deepened, the pectineus muscle

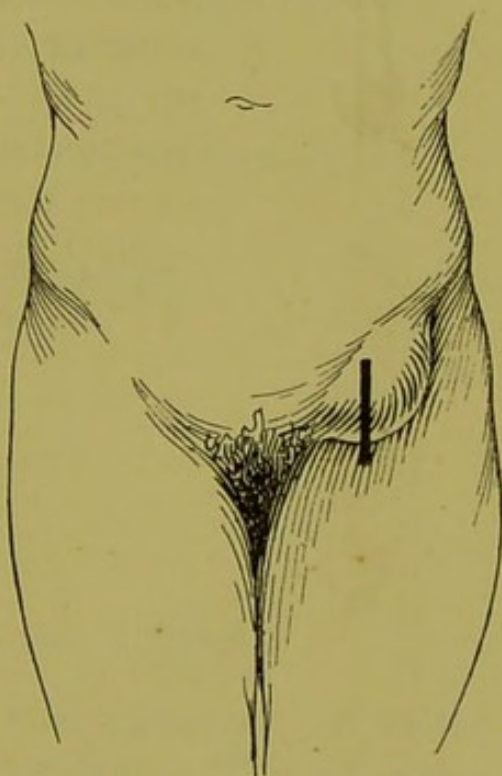


FIG. 103. — Obturator hernia.
Line of external incision.

and fasciæ being incised until the hernial sac is reached, which structure is opened in the usual manner. The stricture can be relieved by notching the obturator membrane at the inferior margin of the aperture. When the intestine is gangrenous, or when perforation has taken place, it is necessary to open the abdomen by an incision in the corresponding linea semilunaris, and to perform the requisite procedures from within the peritoneal cavity.

CHAPTER IV.

OPERATIONS UPON THE LIVER AND BILIARY SYSTEM.

THE following operations will be described, namely :—

1. UPON THE LIVER.

- A. Hepatotomy (1) for hydatid cysts.
- B. Hepatectomy (2) for abscess.

2. UPON THE BILIARY SYSTEM.

- A. Cholecystotomy.
- B. Cholecystectomy.
- C. Cholecyst-enterostomy.
- D. Choledochotomy.

OPERATIONS UPON THE LIVER.

Hepatotomy.—By the term “hepatotomy” is understood making an incision into the liver. This operation is indicated in the following classes of cases—(a) In cases of hepatic suppuration ; and (b) in cases of cystic disease of the liver, especially in hydatid disease.

Position.—The patient is placed in the dorsal position, or lying somewhat on the sound side if it is proposed to make an incision on the lateral aspect of the trunk ; the surgeon stands usually on the right side of the patient, and his assistant on the left.

Instruments.—Scalpel, dissecting and pressure forceps, retractors, exploring syringe or aspirator, dressing forceps, scissors, drainage tube, needles (large fully-curved), needle-holder, and ligature and suture material.

Operation.—The operation of hepatotomy may be divided into four stages, namely—(a) Parietal incision ; (b) exposure of liver, finding of diseased portion, incision of liver substance, and evacuation of pus or other fluid ; (c) union of margin of hepatic incision to that of parietes ; (d) establishment of drainage.

(a) *Parietal incision.*—An incision, about 3 in. in length, is made over that portion of the liver which is supposed to be the seat of the abscess. It may be necessary to puncture with an exploring needle or the needle of an aspirator before this can be determined. The incision usually commences at the costal margin, and extends downwards. This incision is deepened until the peritoneal cavity has been opened. If the inflammation has caused obliteration of that part of the cavity which lies between the affected part of the gland and the abdominal wall, the peritoneum is left untouched, but this condition is of rare occurrence in cases of hepatic suppuration.

(b) *Exposure of liver, incision of wall of abscess, and evacuation of pus.*—The liver lies exposed in the bottom of the wound after the peritoneum has been divided, and the margins of the parietal incision held aside. The adjacent portion of the peritoneal cavity is packed with flat aseptic sponges, so as to avoid septic contamination when the abscess is opened.

The location of the pus can usually be determined, either by the presence of a swelling on the surface of the liver, or by the presence of fluctuation. If there is any uncertainty as to the position of the abscess, the exploring syringe should be used.

The situation of the hepatic abscess having been determined, an incision, about $1\frac{1}{2}$ in. in length and parallel to the external wound, is made in the hepatic substance over the abscess. When the abscess has been reached, all hæmorrhage is arrested from any hepatic vessels which may require ligature, and then the opening is dilated with the

finger, or a pair of dressing forceps, and the pus allowed to escape. As the pus is escaping, the assistant should be directed to press the anterior abdominal walls against the liver, so as to prevent pus passing into the peritoneum. In some cases it will be found convenient to pass the forefinger into the cavity of the abscess and to hook the gland forwards. When the pus has been evacuated, the interior of the abscess cavity is examined with the finger so as to determine whether any other abscesses are present. If any are found, the intervening tissue is broken down with the finger, and the contents allowed to escape. The interior of the cavity is next irrigated with an antiseptic solution, and the aperture temporarily plugged with a sponge.

(c) *Union of margins of hepatic incision to those of parietal wound.* — All sponges are removed from the peritoneal cavity, and the peritoneum in the region of the hepatic incision is well sponged, or irrigated if much contamination has taken place.

Next the margins of the incision in the liver are united to those of the incision in the abdominal wall, by the insertion of a ring of interrupted silk sutures. Each suture is entered at the lower part of the incision in the liver, and traverses the hepatic substance until it emerges about half an inch from the margin, and then it is passed through the tissues of the abdominal wall and made to emerge one-third of an inch from the margin of the parietal wound. The sutures are introduced at intervals of about one quarter of an inch.

Just beyond the upper and lower extremities of the hepatic incision a suture should be passed through the abdominal wall, then through the liver substance beyond the angle of the wound, and finally through the abdominal wall on the other side of the incision. When all these sutures have been inserted, they are tied and the ends cut short, the two sutures at the extremities being tied last. That portion of the wound in the parietes to which the

margins of the hepatic incision are not attached is closed in the usual manner.

(*d*) *Establishment of drainage*.—When the cavity of the abscess is not very large, the interior should be packed with a long strip of aseptic absorbent gauze, one end of which protrudes from the external wound. This should be removed daily, and replaced by a similar strip. Some prefer to insert a drainage tube, one end of which passes out from the external wound. An objection to the employment of this, at least immediately after the operation, is that it allows venous oozing to take place from the walls of the abscess. Another objection, if the tube is too long or too stiff, is that the lower extremity may lacerate the walls of the abscess cavity during the movements of respiration.

Hepatotomy for hydatid cyst of the liver.—This operation does not differ essentially from that for “abscess.”

When the abdomen has been opened and the cyst exposed, the peritoneum in the neighbourhood is packed with flat sponges and the cyst wall incised. The contents are evacuated, and the margin of the cyst wall stitched to those of the parietal incision, and drainage established. In these cases, as a rule, no septic complications are present.

Some surgeons have advised that after the cyst wall has been incised and the contents evacuated, the cyst should be dropped back into the peritoneal cavity and the abdominal incision closed. The aperture in the cyst wall may or may not be closed. This method of treatment has not as yet become well established. There are several objections to its adoption, such as deposit of calcareous matter in the wall of the cyst, and the possibility of infection of the peritoneum with the parasite.

Hepatectomy.—It is only during recent years that surgeons have successfully removed portions of the liver by operation. The operation has been called “resection of the liver,” or hepatectomy. In those cases in which portions of the liver have been removed a fair amount of

success has been met with, and it is to be hoped, by the introduction of improved details of technique, that this operation may become a recognised and justifiable one, since there are many affections of the liver which only admit of a cure being obtained by a complete and radical removal of the diseased tissue. All operations of this nature which involve the liver are limited to the removal of a portion of the organ, since it is not possible for a person to live when the entire organ has been taken away, even if this operation were possible from a merely operative point of view. The removal of portions of the liver can be effected according to one of the following methods, each of which has been used and recommended by surgeons of repute:—

(a) *Fixation of the diseased portion of the liver in an abdominal wound, and application of an elastic ligature to its base, so as to cause sloughing of the parts distal to the ligature.*—*Operation.*—An incision from 4 to 6 in. long is made through that portion of the abdominal wall which overlies the affected portion of the liver, commencing above at the costal margin and extending downwards in a vertical direction. This incision is deepened until the parietal peritoneum is reached, when it is divided for the entire length of the wound. All hæmorrhage from blood vessels in the incised abdominal walls is arrested, and then that portion of the liver which it is wished to remove is brought well into the wound, and made to protrude externally, so that the base of the diseased part can be brought into good apposition with the margins of the wound in the abdominal parietes. A series of silk sutures is next passed through the liver substance, well beyond the diseased area, and then through the abdominal wall a short distance from the margins of the incision, so that when these are tied the liver is firmly fixed to the abdominal wall, and the diseased portion protrudes externally. That portion of the abdominal wound which lies below the protruded part of the liver is closed in the ordinary manner with silk sutures.

An elastic ligature is placed around the base of the protruded piece of liver, but distal to the ring of sutures which fix the organ to the anterior abdominal wall. This ligature is allowed to remain in position for three or four days, the area of the operation being protected by the application of aseptic dressings. About the third day the elastic ligature is replaced by a second one, which is more tightly applied, and, if requisite, this in its turn is also replaced by a still tighter one. By these means the portion of the liver which lies beyond the elastic ligature is made to undergo a necrotic change, and in a short time it becomes separated as a slough or mass of gangrenous tissue.

When the constricted portion has separated from its connection with the remainder of the liver, the base of the protruded portion will cicatrise and heal. The separation of the protruded portion may be hastened by the use of the actual cautery on the tenth or twelfth day after the application of the elastic ligature. If the gangrenous portion remains too long in connection with the liver, putrefactive changes are very liable to become established, and the abdominal wound, or the liver itself, may become the seat of suppuration.

(b) *Fixation of the diseased portion of the liver in an abdominal wound, and removal of the affected part after the liver has become adherent to the margins of the incision (operation à deux temps).—Operation.*—The early stage of this operation is exactly similar to that of the preceding. The portion of the liver which it is desired to remove is fixed by its base to the margins of a wound in the anterior abdominal wall, where it is left for several days or more. When the liver has formed adhesions to the margins of the abdominal wound, the second stage of the operation is performed. The portion of the liver which protrudes is detached from the remainder of the gland, either by cutting it away with a knife or with a Paquelin's cautery. As the piece of liver is removed the cut surface should be covered

with a sponge, and pressure applied so as to arrest temporarily any hæmorrhage which may occur, and to prevent the possibility of the entrance of air into the open mouths of the intrahepatic veins, and thereby to avoid air embolism. When the portion of the liver has been detached, the sponge pressure is relaxed, and all bleeding points upon the cut surface are ligated with silk. After hæmorrhage has been arrested in this manner, the cut surface of the organ is irrigated so as to remove all traces of blood and débris, and then an aseptic dressing is applied and is firmly fixed in position by strapping and a bandage. In order to avoid the exposure of a large cut surface of the liver, after the resected portion has been removed, it appears to me that in the second stage of the operation it would be preferable to resect the part of the liver which is to be removed, by the employment of a "wedge-shaped" incision, such as is described later.

If this form of incision in the liver were adopted, it would be possible to bring together the margins of the hepatic wound, and fix them in apposition by the insertion of sutures. All fears of the occurrence of hæmorrhage and air embolism may thus be avoided. In all cases of exposure of a cut area of the liver, great care must be taken to prevent the entrance of air into the hepatic veins, since in these structures the venous blood pressure is negative, and air may be drawn inwards by suction.

Some authors have recommended that, after the portion of liver has been detached with the knife, the actual cautery should be applied to the cut surface, so as to arrest hæmorrhage and prevent the occurrence of air embolism. If it is wished to make use of the cautery, it appears to me to be preferable to remove the piece of the liver with the knife of a Paquelin's cautery, and so arrest all hæmorrhage as the operation proceeds. The objection to the use of the cautery in these cases is the necessary necrosis of charred tissue which must follow, and the liability to suppuration as the dead tissue is being separated or absorbed.

(c) *Removal of tumours and cysts from the liver by dissection, and subsequent closure of the wound in the liver by sutures, together with simultaneous closure of the abdominal incision.*—Tumours of the liver which are completely encapsuled, or hydatid and other forms of cysts which are embedded in the gland, may be removed by dissection. After the surface

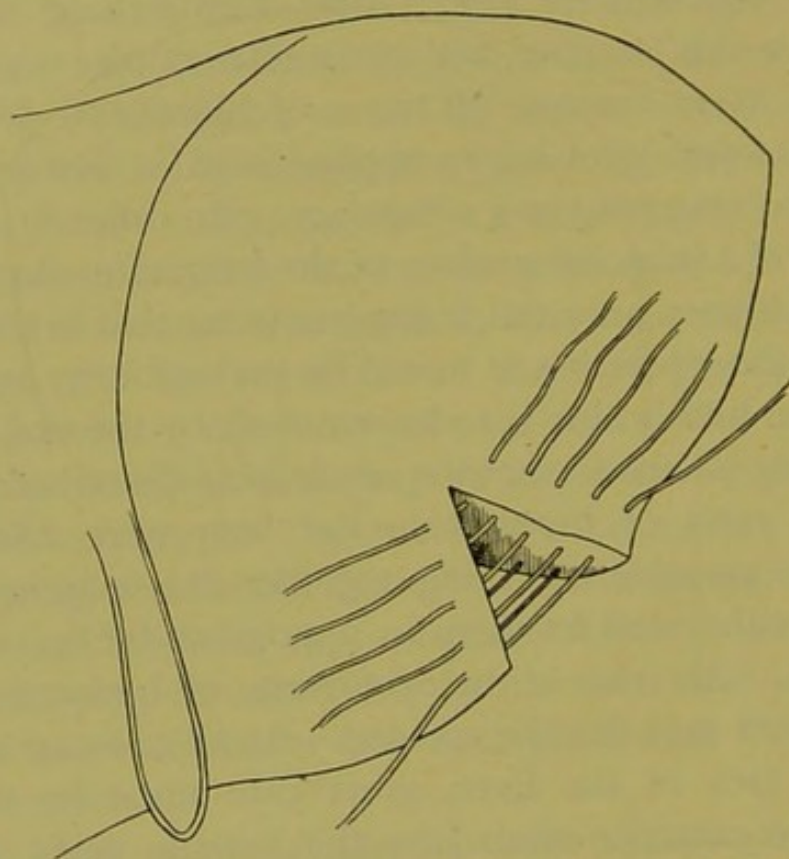


FIG. 104.—Resection of liver. Method of inserting sutures into the liver after a "wedge-shaped" portion has been removed. This diagram shows all the sutures in position before any have been tied. In this case the portion of the gland which has been resected has been from the antero-inferior margin, and the adjacent parts of the inferior and anterior surfaces of the left lobe.

of that portion of the liver which contains the tumour or cyst has been exposed by an incision in the abdominal wall, the surrounding portion of the peritoneal cavity is packed with aseptic sponges, so as to avoid contamination of the peritoneum with blood or foreign material, or injury to the intestines, and then an incision is made into the hepatic substance, until the superficial portion of the tumour is

exposed. The tumour or cyst is then separated from the normal hepatic tissue by a process of careful dissection.

The surfaces of the wound left by the removal of the cyst or tumour are approximated and fixed in apposition by the insertion of a number of interrupted deep sutures. The external wound is closed in the usual manner.

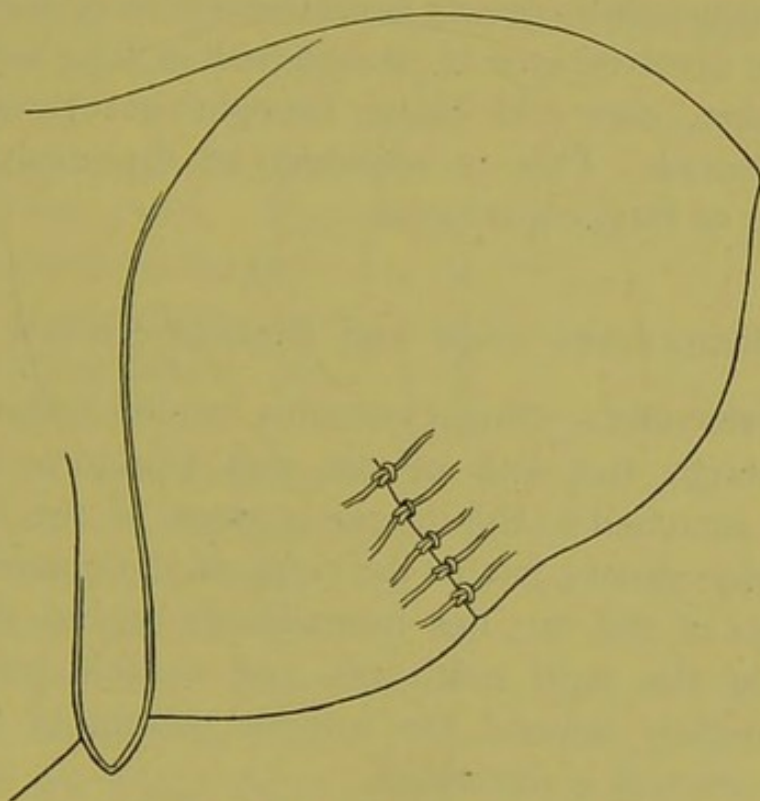


FIG. 105.—Resection of liver. Same as Fig. 104, but with all the sutures tied and the ends cut short.

(d) *Excision of a portion of the liver by the employment of a "wedge-shaped" incision.*—*Operation.*—The abdomen is opened and the liver exposed as in the previous operation. The diseased area is defined, and an elastic ligature made to encircle the base a short distance beyond the limits of the growth. If this cannot be conveniently done, an assistant ought to pass his hand into the abdominal cavity in such a manner that his forefinger is in the foramen of Winslow and the thumb on the anterior surface of the gastro-hepatic omentum, in front of the hepatic artery and the portal vein. By exerting compression upon both these structures, the circulation can be controlled.

The affected portion of the liver is then removed, according to the method shown in Figs. 104 and 105.

When the wound in the liver has been completely sutured, and its margins brought together, the gland is dropped back into the abdominal cavity, all blood sponged away, and the incision in the parietes closed in the ordinary manner. If there is much venous oozing from the region of the hepatic wound, the involved area is packed with a long tampon of aseptic gauze, one end being brought out through the external wound. This is removed at the expiration of twenty-four or forty-eight hours.

OPERATIONS UPON THE BILIARY SYSTEM.

Cholecystotomy.—Cholecystotomy implies making an incision through the wall of the gall bladder. The gall bladder is attached to the inferior surface of the liver, and lies in a wide groove just to the right of the quadrate lobe. The fundus of the sac lies immediately behind the costal cartilage of the right ninth rib, and at this point often projects slightly beyond the inferior margin of the liver, especially when it is distended.

Indications.—The operation is performed for the following conditions, namely—(a) Gallstones within the gall bladder, which are giving rise to trouble which cannot be alleviated by other measures; (b) collections of pus or fluid in the gall bladder, which are due to impaction of gallstones, or to inflammatory conditions of the mucous membrane of the gall bladder dependent upon septic micro-organisms; (c) the removal of gallstones impacted in the cystic duct.

The operation may be divided into the following stages, namely—(a) Incision of the abdominal parietes; (b) finding of the gall bladder and bringing it into the external wound; (c) incision of the gall bladder and removal of pathological collections from its interior; (d) fixation of

the margins of the wound in the gall bladder to those of the abdominal incision, and closure of the other portion of the external wound.

Instruments.—Scalpel, dissecting and pressure forceps, retractors, cholecystotomy forceps and scoop, scissors, needles (fully curved and half curved), needle-holder, suture and ligature material, and rubber drainage tube.

Position.—The patient is placed in the dorsal position, and near the right side of the table. The surgeon stands on the right side of the patient, the chief assistant directly opposite to him.

Operation.—(a) *Parietal incision.*—An incision from 3 to $3\frac{1}{2}$ in. long is made through the anterior abdominal parietes, commencing above at the margin of the ninth right costal cartilage, and extending downwards towards the right pubic spine. The incision is deepened until the peritoneal cavity has

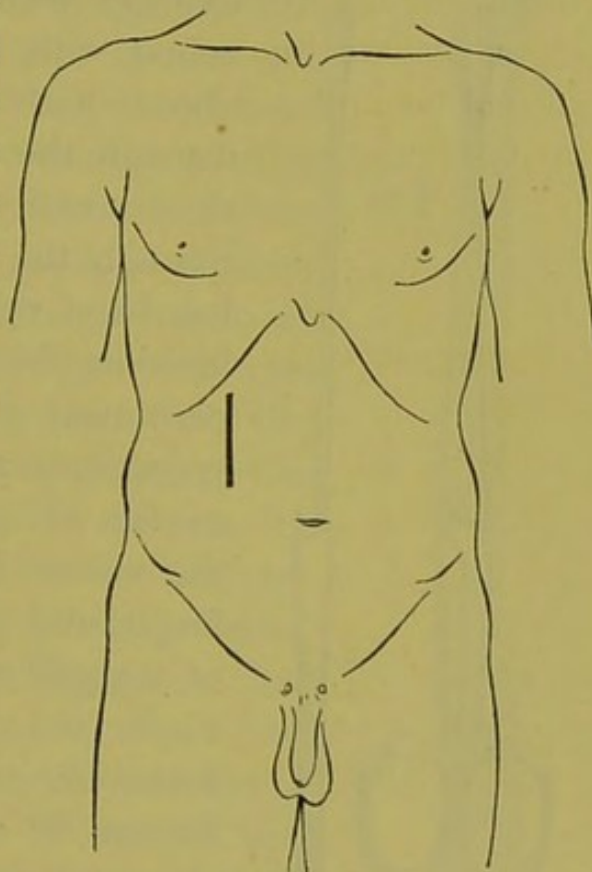


Fig. 106.—Cholecystotomy Line of parietal incision.

been opened, care being taken to avoid notching the liver or injuring the intestines.

(b) *Finding of gall bladder and bringing it into external wound.*—If the gall bladder does not at once protrude, the margins of the incision are held apart with retractors, and the fingers of the right hand are introduced into the peritoneal cavity, and the viscus is sought for, on the lower aspect of the liver. In many cases it will be found to be enlarged, and often attached to the adjacent structures by

strong adhesions. When the situation of the organ has been made out, it is brought into the wound, any adhesions which prevent this being divided if requisite.

(c) *Incision of gall bladder, and removal of calculi, etc.*—

If the gall bladder is very large, owing to distension with fluid, part of the fluid contents may be evacuated by aspiration with an aspirator. The margins of the perforation with the aspirator needle are seized with forceps, and an incision about half an inch in length made through the wall of the gall bladder on the convexity of the fundus, and passing through the seat of perforation, if one has been made. Before making this incision, the surrounding portion of the peritoneal cavity is packed with flat sponges, so as to prevent contamination as far as possible. The interior of the viscus is next examined with the finger, and the size, shape, and locality of any gall stones which may be present made out. These bodies are then removed, either with cholecystotomy forceps or a scoop, whichever may be the more convenient. When the gall

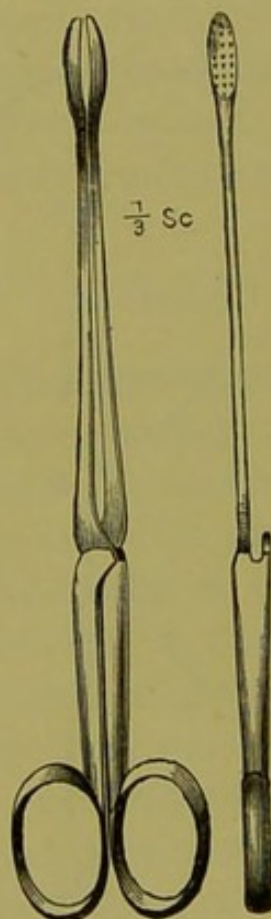


FIG. 107. — Cholecystotomy forceps.
—ANDERSON.

bladder has been emptied, the cystic duct is examined from the interior of the viscus, and if any calculi are present they are removed. The interior of the organ is washed out by irrigation, and a small sponge placed in the aperture, which will serve as a temporary plug, and prevent the escape of fluid into the peritoneum. The sponges which have been placed around the organ in the peritoneal cavity are removed, and the course of the extrahepatic bile ducts examined with the finger. If these do not contain calculi, and are otherwise normal, the region of the gall bladder is thoroughly

cleansed by sponging, and the margins of the incision in the fundus attached to those of the parietal wound.

(d) *Fixation of gall bladder, etc.*—The margins of the gall bladder incision are brought into apposition with those of the upper portion of the parietal wound, and fixed there by the insertion of sutures. The sutures are best introduced in the following manner. On each side of the incision in the gall bladder a row of sutures are inserted, one-third of an inch apart, each suture passing through the fascial, muscular and serous strata of the abdominal wall, and then through the wall of the gall bladder into its interior. At the upper and lower extremities a suture is passed from one side of the parietal incision to the other, taking up the gall bladder just beyond the incision by passing through its muscular and serous coats. The portions of the parietal wound above and below the sutured part of the gall bladder are closed by sutures in the usual fashion. All the sutures are introduced before any are tied. When all the sutures have been inserted, they are tied, and the sponge plug removed from the interior of the gall bladder, and a small rubber tube passed down into the cavity of the viscus, so as to act as a drain.

The above operation is the ordinary one adopted in the removal of gall stones from the interior of the gall bladder and the cystic duct. It will be seen, however, that a fistula is established, through which the bile from the gall bladder drains for a time. In favourable cases this fistula closes within three to five weeks. On account of



FIG. 108.—Cholectomy scoop.

the formation of a fistula, many surgeons call the operation "cholecystotomy."

Cholecystendysis.—In a few favourable cases, where the walls of the gall bladder are in a perfectly healthy condition and at the same time are thick and muscular, it is possible to close the incision in the gall bladder at the time of operation, and to drop the viscus back into the peritoneal cavity and then to close up the external wound. This form of operation is called "cholecystendysis," or "ideal cholecystotomy."

Cholecystectomy.—Removal of the gall bladder is known as cholecystectomy. The operation has been performed for the following conditions:—(a) Localised malignant growths; (b) rupture and perforation, when the region of the neck has been involved or the injury has been extensive; (c) in cases of mucus fistula, associated with obliteration of the lumen of the cystic duct.

Operation.—The instruments and the early stages of the operation are similar to those employed in cholecystotomy. When the peritoneal cavity has been opened, the gall bladder is separated from the inferior aspect of the liver by dividing the peritoneum on each side of the groove in which it lies, and also around its fundus in the region of the anterior inferior border. When this has been done, the organ is separated from the liver with the fingers, all bleeding vessels which are met with being tied as the operation proceeds. By this means the gall bladder is separated from the liver until the cystic duct is reached. With a needle on a handle, a moderately stout silk ligature is passed around the cystic duct and tied. The duct is then cut across and the gall bladder removed. If possible, the mucous membrane of the divided portion of the cystic duct should be removed by scraping, especially when the gall bladder is the seat of an inflammatory process. When this has been done, the margins of the wound in the peritoneum on the inferior surface of the liver are brought together and

fixed in apposition by the insertion of a continuous silk suture. The stump of the cystic duct is covered over with a flap of peritoneum as the continuous suture is being inserted. The area of operation is irrigated and cleansed, and the parietal wound closed in the usual manner. If there is much bleeding, it may be necessary to pack the wounds with plugs of aseptic gauze, the ends of which are brought out in an angle of the external wound, which is left open for the purpose.

Cholecyst-enterostomy.—Cholecyst-enterostomy is an operation which has for its object the creation of an artificial communication between the gall bladder and the intestine, usually the duodenum.

Indications.—The operation of cholecyst-enterostomy appears to be indicated in the following conditions:—

(a) In all cases where the common bile duct is permanently obstructed or occluded by adhesions, inflammatory processes, or malignant growths, the cystic duct remaining patent. The forms of new growth include those which are primary in the common bile duct and those which commence in the head of the pancreas and spread to it by direct extension. In cases where the common bile duct is occluded as the result of secondary malignant growths, it is not advisable to perform the operation.

(b) In all cases of complete division of the common bile duct as the result of injury or operative measures.

(c) In cases of chronic biliary fistulæ which cannot be cured by the performance of a plastic operation, or in which the fistulæ are due to obstruction of the common bile duct and are not amenable to direct surgical interference.

(d) In all cases of perforation of the common bile duct which result from an ulcerative process.

(e) In cases of kinking of the common bile duct which are due to the presence of fibrous adhesions, and cannot be remedied by operation.

Instruments.—Scalpel, scissors, dissecting and pressure

forceps, retractors, intestinal clamps, needles, needle-holder, small "anastomosis button" (Murphy's), and ligature and suture material.

Position.—The patient is placed in the dorsal posture, the surgeon stands on the right side of the patient, and the assistant on the left.

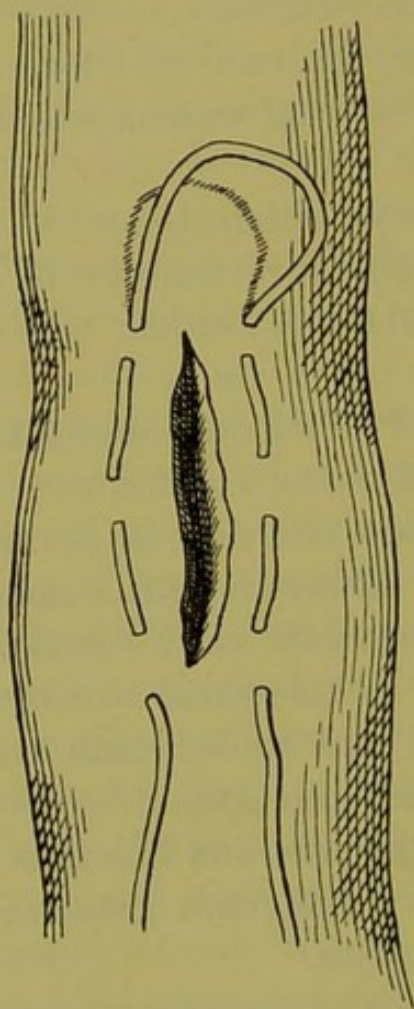


FIG. 109.—Method of inserting "purse-string suture" into intestine in the operation of cholecyst-enterostomy.—After MURPHY.

Operation.—The operation may be divided into the following stages:—(a) Parietal incision; (b) finding and bringing into the external wound the gall bladder and the duodenum, and the union of the gall bladder and the duodenum; and (c) closure of the external wound.

(a) *Parietal incision.*—An incision is made in the right linea semilunaris, commencing at the edge of the ribs and extending downwards for two or three inches. This is extended until the peritoneal cavity has been opened.

(b) *Finding and delivery of gall bladder and duodenum, and union of same.*—The gall bladder and the duodenum are drawn into the wound; a needle threaded with 15 in. of silk is inserted into the duodenum, directly opposite the

attachment of the mesentery; and at a point near the head of the pancreas a stitch is taken through the entire bowel, one-third of the length of the incision to be made; the needle is again inserted one-third the length of the incision from its outlet, in a line with the first, and embracing the same amount of tissue as the first. A loop, 3 in. long,

is held here, and the needle is inserted in a similar manner, making two stitches parallel to the first in the reverse direction, and one-fourth of an inch from it, coming out at a point near the insertion of the needle. This forms a

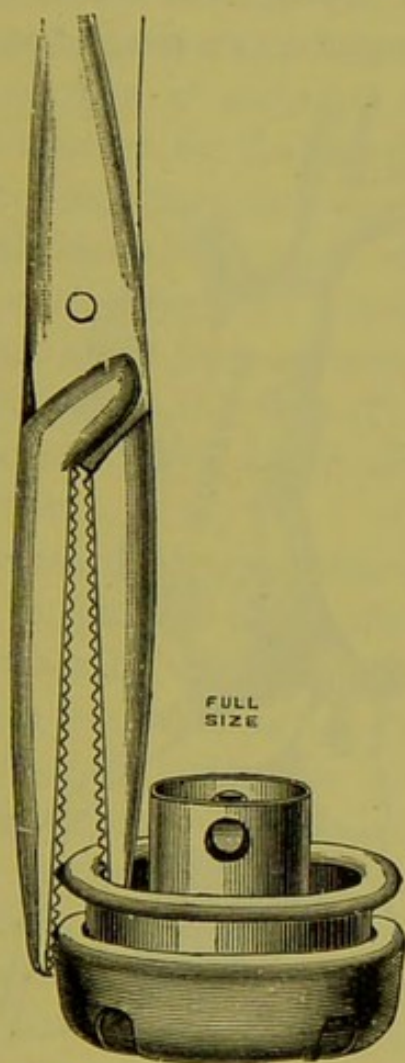


FIG. 110.—Cholecyst-enterostomy. Method of holding male portion of anastomosis button for insertion.

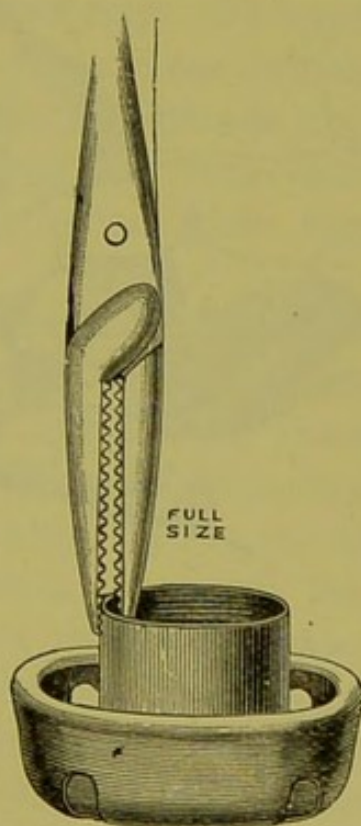


FIG. 111.—Cholecyst-enterostomy. Method of holding female portion of anastomosis button for insertion.

running thread, which, when tightened, draws the incised edge of the bowel within the cup of the button. A similar running thread is inserted in the gall bladder. An incision which is two-thirds of the diameter of the button to be used, is now made in the intestine, care being taken to avoid cutting the running thread when making the incision ;

the male half of the "button" is slipped in, the running thread tied firmly around the central cylinder, and then the button is given to an assistant to hold with forceps, so as to prevent it slipping into the cavity of the bowel. An incision is now made in the gall bladder, the same length as the one in the intestines, between the two rows of suture.

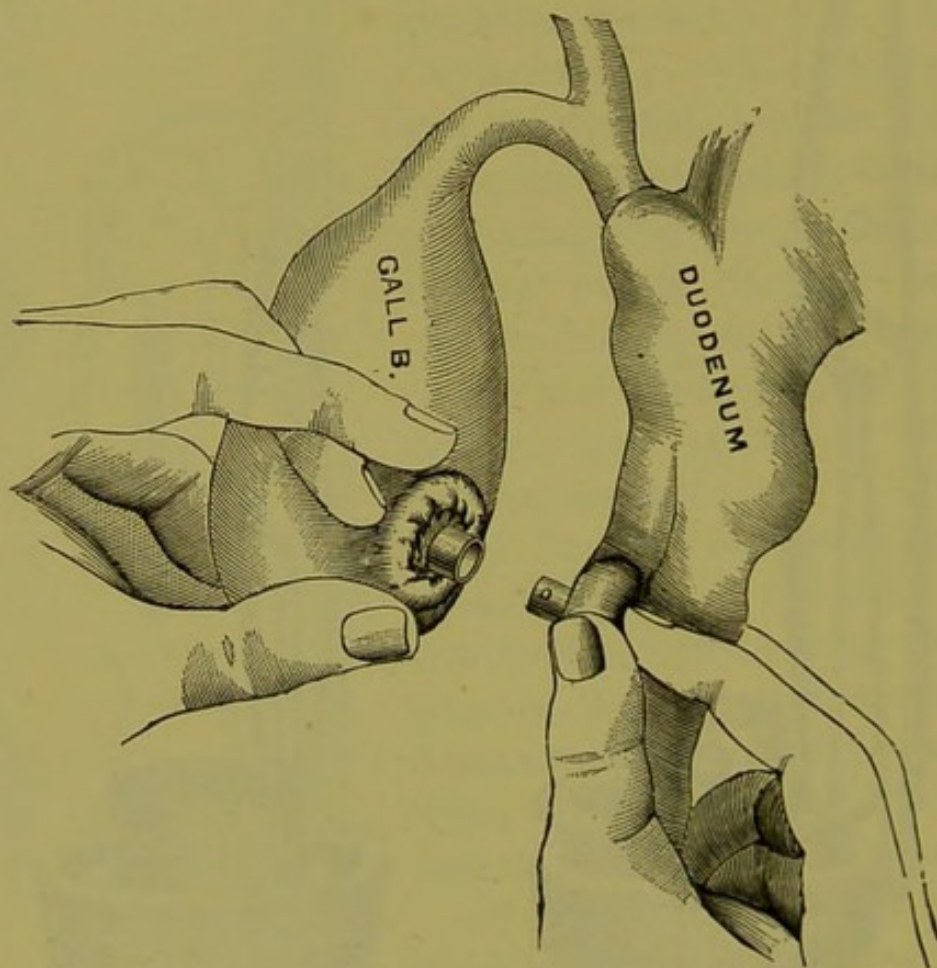


FIG. 112.—Cholecyst-enterostomy. Gall bladder and duodenum, showing two halves of anastomosis button introduced, with the "purse-string" sutures tied, and ready for fixing together.—After MURPHY.

The gall stones and fluid contents of the gall bladder are removed; the female half of the "button" inserted, and the running thread tied. The forceps are then removed, the two halves of the "button" are held between the fingers and slowly pressed together. A sufficient degree of pressure must be used to bring the serous surfaces of the gall bladder and intestine firmly in apposition and

compress the tissues. The elastic pressure of the spring cup of the "button" produces a pressure atrophy of the tissues embraced by it, and leaves an opening which is larger than the "button." When the "button" is liberated, it passes on through the bowel, and is voided per anum, from eight to fourteen days after the operation.

(c) *Closure of external wound.*—This is closed in the usual manner by the insertion of interrupted silk sutures. One or more tiers may be introduced.

Choledocho-lithotomy—choledochotomy.—This operation has for its object the removal of one or more calculi from the interior of the common bile duct, in cases in which an obstruction to the flow of bile along this canal has been established, or in which severe symptoms result from the impaction.

Operation.—In performing the operation the abdominal cavity is opened by an incision which is made either in the linea alba, commencing above immediately below the ensiform cartilage, or in the right linea semilunaris, commencing just below the costal margin. It is not always possible to make an exact diagnosis as regards the seat of the impacted calculi, and when this is the case it is better to make the incision in the linea semilunaris. When the abdominal cavity has been opened, the course of the biliary tract is examined with the finger; the gall bladder should be examined first, then the cystic duct, and then the common bile duct, both as it lies in the gastro-hepatic omentum and in its course behind the first part of the duodenum, and where it lies between and behind the head of the pancreas and the left aspect of the second portion of the duodenum. In many cases, placing the examining finger in the foramen of Winslow will be found to be of diagnostic value, since in this position a considerable extent of the common bile duct can be palpated, and if there is a calculus in its interior its position can be at once made out. When a stone is discovered in the

common bile duct, the gastro-hepatic omentum and the common bile duct are drawn into the abdominal wound. The peritoneal cavity around these structures is packed with sponges, and an incision is made in the common bile duct over the calculus, this incision being parallel to the long axis of the duct. Through this incision the impacted calculus is extracted, care being taken to damage the walls of the duct as little as possible. In order to facilitate the

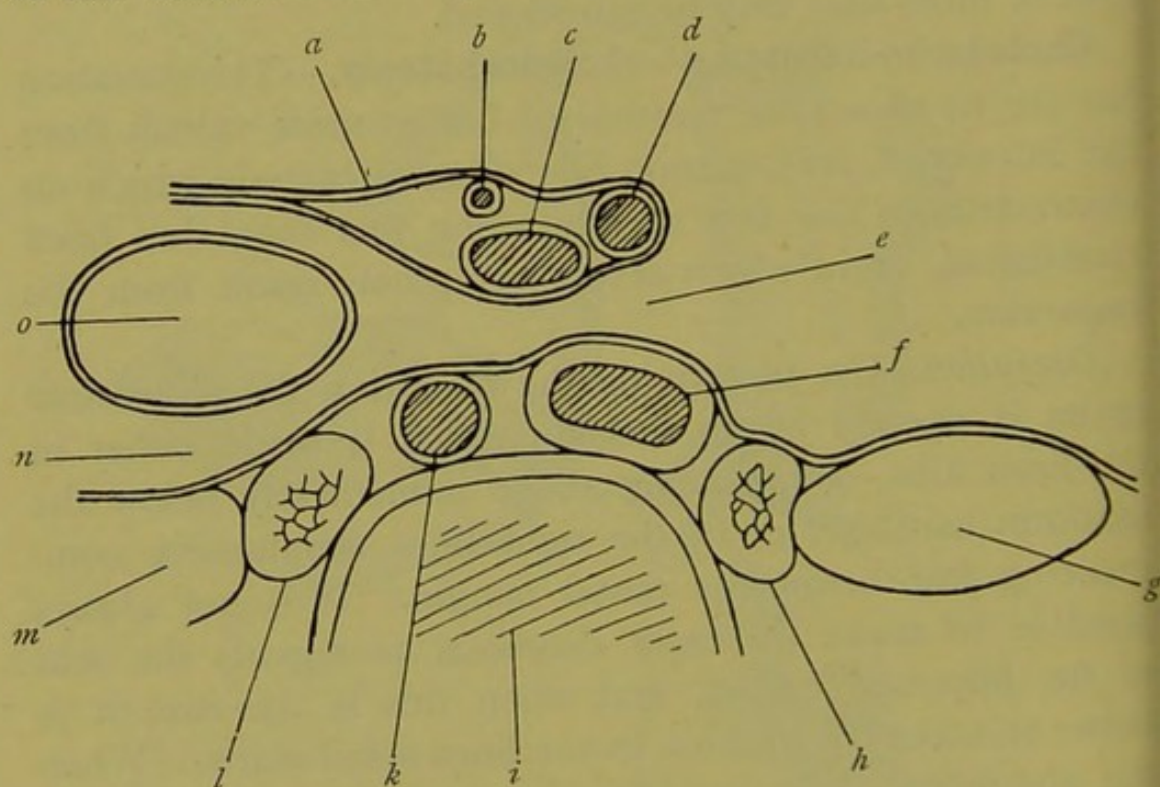


FIG. 113.—Relation of structures in gastro-hepatic omentum. *a*. Gastro-hepatic omentum; *b*. Hepatic artery; *c*. Portal vein; *d*. Common bile duct; *e*. Foramen of Winslow; *f*. Inferior vena cava; *g*. Right kidney; *h*. Right supra-renal capsule; *i*. Dorsal vertebra; *k*. Aorta; *l*. Left supra-renal capsule; *m*. Left kidney; *n*. Lesser sac of peritoneum; *o*. Stomach.

removal of the calculus, it is found in some cases to be advantageous to break up the stone with crushing forceps and to extract it in several fragments. When the stone has been removed, the area of the operation is thoroughly irrigated, and the margins of the incision in the common bile duct are then approximated and fixed in apposition by the insertion of two tiers of fine silk sutures. The first

unites the mucous membrane, and the second the muscular and serous coats. If the peritoneum which forms the anterior layer of the gastro-hepatic omentum has been dissected from the bile duct, it may be united separately from the muscular walls of the common duct, in which case three tiers of sutures will be requisite. In many cases of this operation it will be found advisable to pack the region of the incision in the common duct with a strip of aseptic gauze, and to bring out the end of this strip through an angle of the abdominal wound, which is left open for the purpose. This strip is removed after one or two days, and if there is no sign of leakage from the duct, the abdominal wound is entirely closed. The strip of gauze is replaced by a similar one when any small quantity of fluid escapes. It is sometimes found that the impacted calculus lies behind the duodenum, and then it is necessary to lift up this structure and open the common bile duct, as it lies behind it. If the calculus is a small one, or the common bile duct is considerably dilated, an attempt may be made to manipulate the calculus into the duodenum, by forcing it along the duct and through the orifice on the biliary papilla.

CHAPTER V.

OPERATIONS UPON THE SPLEEN.

Removal of the spleen, or splenectomy.—In this operation the spleen is removed through an incision in the anterior or antero-lateral abdominal wall.

Indications.—Removal of the spleen is indicated in the following clinical conditions:—(*a*) Certain cases of rupture of the organ, due to some form of injury, such as a blow upon the abdomen, or a stab, or to spontaneous rupture, in which hæmorrhage cannot be arrested by milder measures; (*b*) some forms of cystic affections which are not amenable to drainage; (*c*) some forms of “movable” or “wandering” spleen, in which the viscus cannot be retained in position by a suitable belt, or cannot be fixed in its usual place by a surgical operation; (*d*) some forms of hypertrophy, either simple or malarial in nature, which cannot be relieved by other measures; (*e*) occasional cases of suppuration or inflammation. Malignant disease of the spleen and leukæmic hypertrophy appear to contraindicate removal.

Location.—The spleen is a solid viscus, situated upon the anterior aspect of the posterior abdominal wall. It lies in the left portion of the epigastric region and upper part of the left hypochondrium, about one-third being in the former and two-thirds in the latter. It lies obliquely, its upper extremity being nearer the middle line than the lower. The diaphragm and the posterior inferior margin of the left lung and pleura intervene between it and the inner surfaces of

the ninth, tenth, and eleventh ribs. The splenic artery enters, and the splenic vein emerges, from the hilum. The viscus is attached to the left margin of the stomach by the gastro-splenic omentum, and to the diaphragm by the phrenico-splenic ligament. The tail of the pancreas lies in close relation to the hilum.

Instruments.—Scalpel, dissecting, pressure, and large

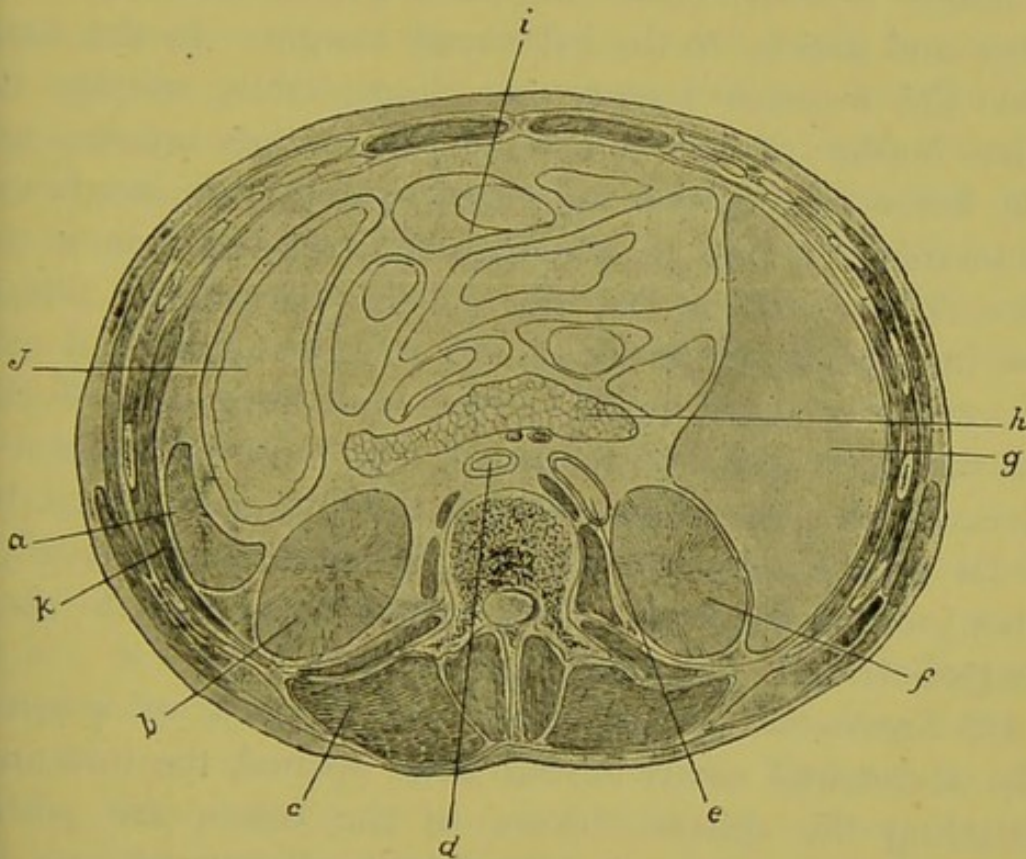


FIG. 114.—Transverse section of body to show relations of spleen to adjacent viscera. *a.* Spleen; *b.* Left kidney; *c.* Erector spinae; *d.* Aorta; *e.* Inferior vena cava; *f.* Right kidney; *g.* Right lobe of liver; *h.* Pancreas; *i.* Colon; *j.* Stomach; *k.* Transversalis abdominis.

clamp forceps, retractors, scissors, sponge-holders, needle on handle with blunt point, needles, needle-holder, and ligature and suture material.

Position.—The patient is placed in the dorsal position, or, when the antero-lateral incision is employed, lying slightly upon the right side. The surgeon stands on the left side, and the first assistant directly opposite to him.

Operation.—Removal of the spleen may be divided into several stages, which are—(a) Parietal incision; (b) separation of the spleen, and bringing it out into the parietal incision; (c) transfixion and ligature of the pedicle, and removal of the organ; and (d) closure of the external wound.

(a) *Parietal incision.*—An incision from 4 to 5 in. in length is made either in the left linea semilunaris, or below and parallel to the left costal margin. In the latter case the incision commences immediately outside the outer border of the left rectus abdominis muscle, and 1 in. below the costal margin, and extends downwards and backwards in a line parallel with the costal margin to the interval between the last rib and the iliac crest. Whichever incision is made use of, the wound is deepened until the various strata of the abdominal wall have been divided and the peritoneal cavity opened. In most instances it is advisable to adopt the incision in the linea semilunaris, but in fat and emphysematous people with deep chests the other incision will enable the operator more easily to get at the pedicle and apply a ligature to it.

(b) *Separation of adhesions and delivery of spleen.*—The abdominal cavity having been opened, the intestines, including the splenic flexure of the colon, are pushed downwards and towards the right, and covered with flat sponges. If any adhesions are present, they are defined, surrounded with ligatures in two places, and divided between. When all adhesions have been divided, the spleen is carefully lifted up from its position underneath the ribs into the external wound. Its pedicle is then defined. Usually this will be found to be broad and extensive, and have important connections. It consists of four laminae of peritoneum—the two layers which form the gastro-splenic omentum and the two layers of the lieno-renal ligament.

(c) *Ligature of pedicle and removal of spleen.*—The structures which require careful attention in ligature of the

pedicle are the blood vessels ; in the gastro-splenic omentum are the gastro-epiploica sinistra artery and vein ; and in the lieno-renal ligament, the splenic artery and vein. The pedicle needle is pushed through the pedicle from its posterior aspect, so as to avoid damage to the large splenic vein. In order to do this the spleen should be turned towards the right, so as to expose its posterior surface ; the positions of the artery and vein are defined, and the needle pushed between the two, and its point made to emerge through the gastro-splenic omentum half-way between the stomach and spleen. The needle is threaded with a double ligature of silk, and withdrawn. The two ligatures thus introduced are locked and tied, one around one half of the pedicle and the other around the other half. Finally, the second ligature is made to surround the entire pedicle, and is again tied in a knot. When the pedicle is very broad it will be necessary to transfix it in several places, and to tie the ligatures in the form of a locked chain.

In passing the pedicle needle through the posterior aspect of the pedicle, great care must be taken not to transfix the tail of the pancreas, and in tying the ligature not to include any part of this structure. In some cases it may be necessary to apply, first of all, ligatures to the splenic artery and vein, an inch from the hilum of the spleen, and then by dissection to separate the tail of the pancreas from its connections with the hilum of the spleen and the lieno-renal ligament.

The ligatures having been applied to the pedicle, this is cut through on the splenic side of the ligatures and about two-thirds of an inch from them, and the spleen removed. The stump of the pedicle is carefully sponged, in order to render evident any bleeding points, which are at once ligatured. When all hæmorrhage has been arrested, the stump of the pedicle is returned into the abdomen, and the exposed portion of the peritoneal cavity freed from blood, etc., by careful sponging with an aseptic sponge.

All sponges are next removed from the peritoneum, and the intestines are allowed to fall back into their usual position.

(d) *Closure of external wound.*—This is effected in the usual manner by the insertion of several tiers of sutures. If there is much oozing, it is advisable to pack the space from which the spleen has been removed with a long strip of aseptic gauze, one extremity of which is brought out through an angle of the external wound which is left open for the purpose.

The chief danger in the operation of splenectomy is the liability to the occurrence of severe hæmorrhage. The most favourable cases are those in which the viscus is removed for injury.

Splenotomy, or incision of the spleen.—This operation may be necessary in some cases of abscess of the viscus in which the inflammatory process has extended to the surrounding tissues and caused the formation of numerous adhesions. An incision is made through the abdominal wall over the most prominent part of the inflammatory swelling, until the abscess cavity is reached.

CHAPTER VI.

OPERATIONS UPON THE URINARY SYSTEM.

THE following operations upon the urinary system will be described, namely :—

1. OPERATIONS UPON THE KIDNEYS.

- A.* Nephrolithotomy.
- B.* Nephrotomy.
- C.* Nephrectomy.
 - 1. Lumbar operation.
 - 2. Abdominal operation.
- D.* Nephrorrhaphy.

2. OPERATIONS UPON THE URINARY BLADDER.

- A.* Puncture of the bladder.
- B.* Litholapaxy (lithotrity).
- C.* Suprapubic cystotomy.
- D.* Lateral lithotomy.
- E.* Median lithotomy.
- F.* Treatment of rupture of the bladder.

3. OPERATIONS UPON THE URETHRA.

- A.* External urethrotomy (Wheelhouse's operation).

Nephrolithotomy. — Nephrolithotomy is an operation which has for its object the removal of a calculus from a kidney. It is usually carried out through an incision in the lumbar region of the affected side, and on this account is sometimes called "lumbar nephrolithotomy."

Indications.—The performance of the operation is indicated in all cases in which there is reason for thinking that a calculus is situated either in the kidney sub-

stance itself or in the pelvis, when this calculus gives rise to severe symptoms, and cannot be got rid of by other measures.

Instruments.—Scalpel, dissecting, pressure, and artery forceps, retractors (wide), scissors, lithotomy forceps and scoop, dressing forceps, long straight round needle on handle, long-bladed tenotome, small bladder sound (No. 3), syringe, needles (straight and curved), needle-holder, drainage-tube, and ligature material.

Position.—The patient is placed in the semiprone position, lying upon the sound side with the back near the edge of

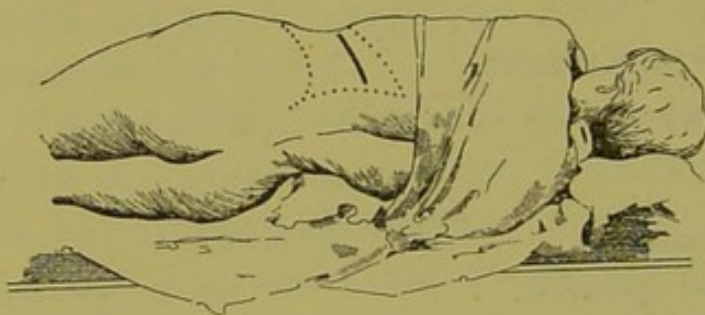

FIG. 115.—Lumbar nephrectomy and nephrolithotomy. Position of patient and line of external incision. The dotted lines show the lower border of the last rib, the iliac crest, and the outer border of the erector spinæ.

the operation table. A moderate-sized sandbag, or hard pillow, is placed underneath the loin. The surgeon stands behind the patient, and the chief assistant on the opposite side.

Operation.—The operation of nephro-

lithotomy may be conveniently divided into the following stages, namely—(a) Parietal incision; (b) exposure of the kidney; (c) examination of the kidney for the detection of the calculus; (d) removal of the calculus; (e) treatment of the wound in the kidney, and closure (partial or complete) of the parietal wound.

(a) *Parietal incision.*—An incision is made in the lumbar region, from 3 to 4 in. in length at first, which is parallel to the lower border of the last rib and half an inch below it, commences in front and terminates at the outer border of the erector spinæ group of muscles, usually about 2 in. or $2\frac{1}{2}$ in. from the dorsal spine. Care must be taken to make certain of the position of the last rib by counting

them from above. It occasionally happens that the twelfth rib is very short and rudimentary, and the eleventh is mistaken for it. In these cases, if the incision is made half an

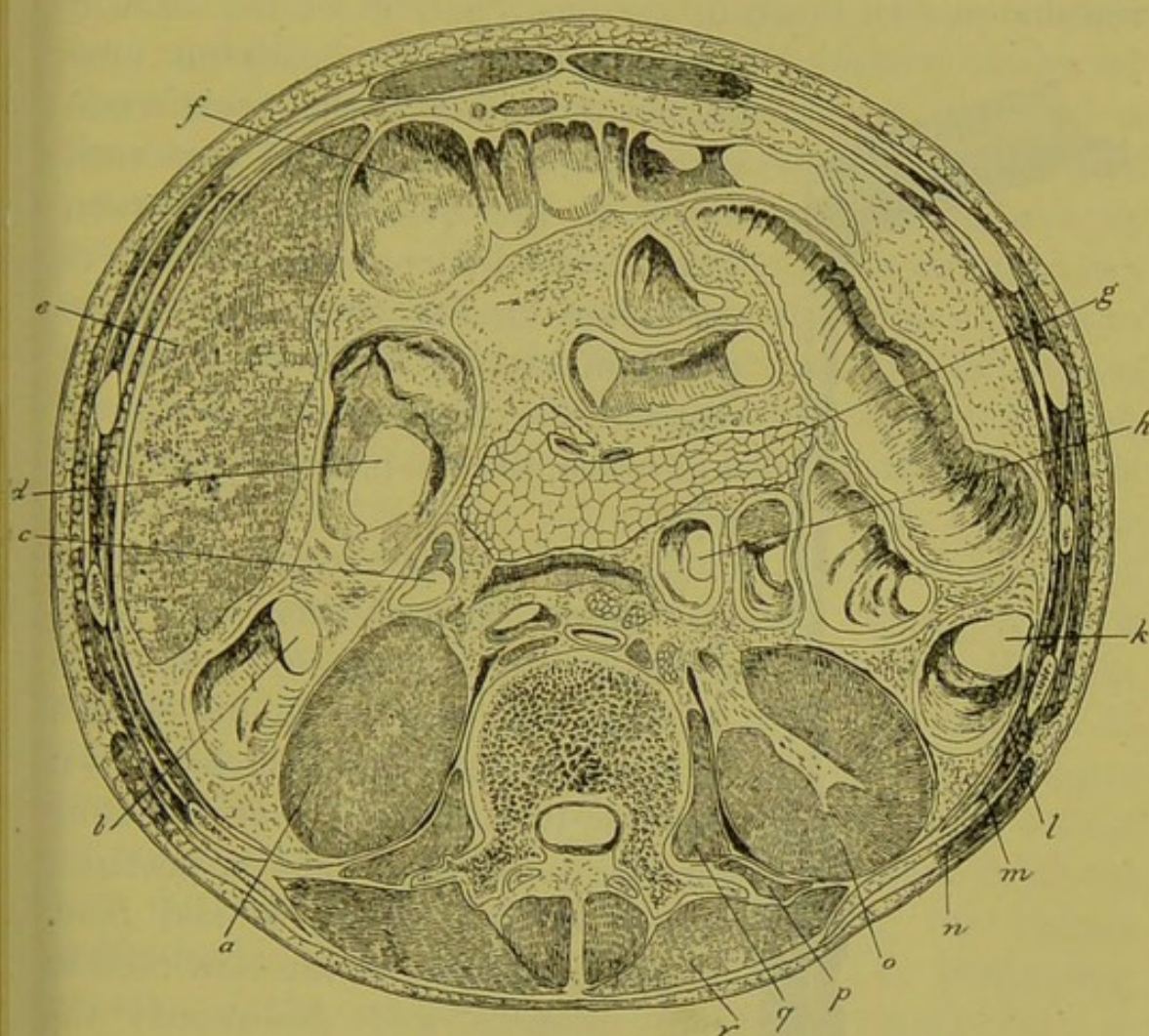


FIG. 116.—Transverse section through abdomen, showing anatomy and relations of the kidneys.

- | | |
|-------------------------------------|------------------------------------|
| <i>a.</i> Right kidney. | <i>k.</i> Descending colon. |
| <i>b.</i> Ascending colon. | <i>l.</i> Transversalis abdominis. |
| <i>c.</i> Duodenum. | <i>m.</i> Obliquus internus. |
| <i>d.</i> Hepatic flexure of colon. | <i>n.</i> Latissimus dorsi. |
| <i>e.</i> Right lobe of liver. | <i>o.</i> Left kidney. |
| <i>f.</i> Transverse colon. | <i>p.</i> Quadratus lumborum. |
| <i>g.</i> Pancreas. | <i>q.</i> Psoas magnus. |
| <i>h.</i> Small intestine. | <i>r.</i> Erector spinæ. |

inch below the eleventh costal arch, the lower portion of the pleura will in nearly every case be injured. The incision is deepened, the fasciæ being first divided and then the muscular strata. The anterior fibres of the latissimus dorsi and

the posterior fibres of the external oblique—both of them almost vertical in direction—are divided first; next, the internal oblique and the posterior aponeurosis of the transversalis muscle, which in the inner portion of the incision



FIG. 117.—Flat broad abdominal retractor.

splits to enclose the quadratus lumborum; and, finally, the fascia transversalis, and if requisite the outermost fibres of the quadratus lumborum. The subcostal nerve and a branch of the upper lumbar artery may be exposed in making the incision, and if met with they are pulled upwards with a retractor, so as to preserve them from injury.

(b) *Exposure of the kidney.*—When the fascia transversalis has been divided, the perinephric fatty connective tissue appears in the bottom of the wound. This is broken down with the tip of the finger or dissecting forceps, and by this means the posterior aspect of the kidney is laid bare. Large flat retractors are now used to pull upwards and downwards the margins of the parietal incision, so as to more fully expose the surface of the kidney. If the kidney is movable in the perinephric tissue, it may tend to fall forwards, and so render its full exposure somewhat difficult. This

difficulty may be avoided by directing the assistant to press backwards the anterior abdominal wall with the clenched fist of one or both hands. By this means the kidney can often be forced into the bottom of the wound.

(c) *The examination of the kidney for the detection of the calculus.*—The kidney being supported from the front, either

by the assistant or the hand of the surgeon, the whole of the posterior aspect is systematically palpated with the finger, and any irregularities or points of resistance noted. If a calculus is present, it can often be felt as a resistant body through the kidney substance. If nothing can be felt abnormal on the posterior aspect, the patient is placed in the dorsal decubitus, the forefinger of the surgeon is passed round the external border of the organ, and the anterior surface examined. If nothing indicating the presence of a calculus is discovered by these manipulations, the kidney may be grasped between the forefinger and the thumb, and each part of it squeezed, and any point of increased resistance noted. Next, the pelvis of the organ is examined from behind, the patient being again turned into the semiprone position. If any hard or resistant area has been discovered during the digital examination, a needle on a handle is taken and forced into the hard spot so as to determine the presence or absence of a calculus in the suspected part of the viscus. If the above digital examination fails to locate the calculus, the kidney is fixed in the bottom of the wound by pressure from in front, and then its substance explored with the needle on a handle by puncturing the kidney methodically from upper to lower end. The perforating portion of the needle ought not to be longer than 2 or $2\frac{1}{2}$ in. At each thrust of the needle the point should be directed towards the hilum. If all these measures fail, Mr. Henry Morris recommends that an incision should now be made into the posterior surface of the gland with a long-bladed tenotome or scalpel. This incision is inclined inwards and forwards, until the cavity of one of the calyces has been opened. The interior of the calyces and the pelvis of the kidney is now examined, first with a small steel sound, and then with the forefinger of the surgeon. This examination should be made in a systematic manner, commencing above and gradually working downwards until the commencement of the ureter has

been reached. By one or other of these measures a calculus, if within the kidney or its pelvis, will generally be discovered. Some surgeons—among whom may be men-

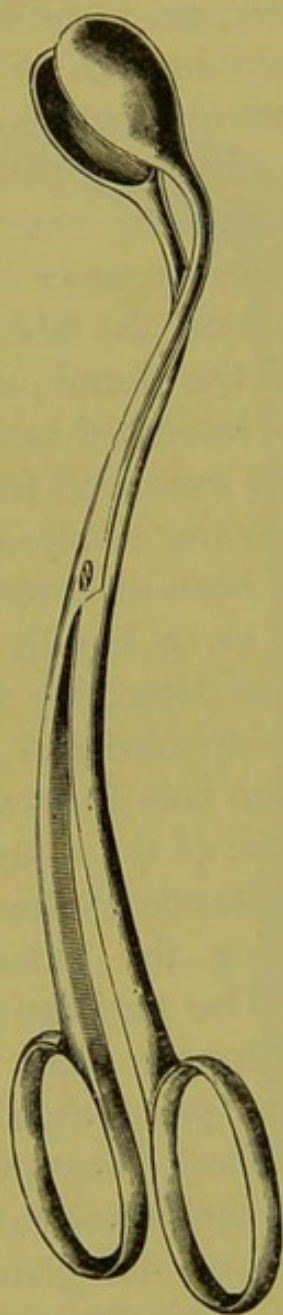


FIG. 118.—Calculus forceps for extracting calculi from the pelvis of kidney.

tioned Mr. Knowsley Thornton and Mr. Jacobson—advise that the pelvis of the kidney should be opened by incising its posterior surface, instead of incising the kidney substance. A wound of the pelvis of the kidney, however, is said to be more frequently followed by a urinary fistula than when the incision is made through the renal substance, though hæmorrhage is more likely to follow the latter procedure. The stone, having been located by one of the above methods, must be removed.

(d) *Removal of the calculus.*—If the kidney has not already been incised in the detection of the stone, an incision is made directly over the calculus with a scalpel or bistoury, the forefinger is passed into the wound, and the stone lifted out if possible. When this cannot readily be removed with the finger, a small pair of lithotomy forceps or a scoop is passed down to the region of the calculus, which is then seized and extracted. If the calculus is a branching one, it should be broken up into several fragments, each one being removed separately, to avoid unnecessary injury to the renal tissue. When the stone is within the pelvis of the kidney, it may be removed either through

the incision in the renal tissue, or through an incision made through the posterior aspect of the pelvis itself; if the stone obstructs the commencement of the ureter, difficulty is

often experienced in its extraction. By careful manipulation, however, it can usually be successfully removed.

When all fragments of the stone or stones have been removed, the wound in the kidney and the entire area of operation is irrigated with an antiseptic solution, so as to remove all blood, portions of calculus, and débris. If any distinct bleeding points become apparent, they are ligated with fine silk. General venous oozing can be controlled and arrested by packing with tampons of iodoform gauze.

(e) *Treatment of the wound in the kidney and the closure of the parietal incision.*—The wound in the kidney is packed with tampons of iodoform gauze, one extremity of each being brought into the angle of the abdominal incision. A rubber drainage tube is next passed down to the region of the incision into the kidney, but not into it, and fixed in position by suturing it to the margin of the parietal incision. Next, the external wound is closed by the insertion of sutures of silk or fishing-gut, except at the angle where the drainage tube and the end of the gauze tampon have been brought out, and aseptic dressings applied. The tampons of gauze can usually be removed at the end of twenty-four hours.

Nephrotomy.—The term nephrotomy implies the exposure of the kidney and the making of an incision into its substance.

Indications.—The operation is indicated in the following conditions of the organ:—(a) In cases of suppuration of the kidney, due to renal tuberculosis or other pathological condition; (b) in certain cases of hydronephrosis and pyonephrosis; (c) in calculus suppression of urine; (d) in the treatment of certain cases of simple or hydatid cyst of the kidney.

The term exploration of the kidney is sometimes used to indicate the exposure of the organ by a surgical operation, when it is wished to make a digital examination without making an incision into the renal substance.

Operation.—The instruments necessary for the performance of the operation, and the individual stages of the operation itself, are similar to those described in the preceding operation up to the stage of exposure of the gland. An incision is then made into the diseased portion of the organ, and any fluid collections which may be present are evacuated. Drainage is nearly always requisite after this operation.

Nephrectomy.—The removal of a kidney by the performance of a surgical operation is called nephrectomy. The organ may be removed, either through an incision made in the lumbar region of the diseased side, which does not open the peritoneal cavity, or through an incision made in the anterior abdominal wall which opens the peritoneum. The former operation is known as “lumbar nephrectomy,” and the latter “abdominal nephrectomy.”

Indications.—Removal of the kidney may be necessary in the following pathological conditions, namely—(a) Certain cases of hydronephrosis, pyonephrosis, suppurative and cystic affections which are not amenable to treatment by nephrotomy; (b) some cases of ureteral and renal fistula; (c) diseased conditions of a floating kidney which cannot be remedied by other means; (d) some cases of severe injury of one kidney; and (e) certain cases of malignant disease of the kidney. Unless it is known that the opposite kidney is not seriously diseased, and is capable of performing its normal functions, in no case would nephrectomy be justifiable. When secondary deposits have formed in other organs, as a result of a primary malignant disease of one kidney, removal of the affected organ should not be taken into consideration. As regards the choice of method, in most instances the lumbar operation is to be preferred, the abdominal variety being carried out only in cases of large solid tumours of the kidney or in cases of extensive cystic disease.

1. **Lumbar nephrectomy.**—*Instruments.*—Scalpels (large

and small), scissors, retractors, artery, pressure, dissecting, and clamp forceps, pedicle needle, needles (straight and curved), needle-holder, and ligatures (thick and thin silk, and silk-worm gut).

Position.—The patient is placed in a semiprone posture, lying on the sound side, with the back near the edge of the table, and a hard pillow or sandbag underneath the loin, so as to separate the last rib and iliac crest as far as possible. The surgeon stands behind the patient, and the assistant on the other side and opposite to him. A second assistant stands on the right hand of the surgeon.

Operation.—The operation may be divided into the following stages, namely—(a) Parietal incision; (b) enucleation of the kidney; (c) separation of the pedicle, and the application of a ligature to it; (d) removal of the kidney; (e) treatment of the ureter, and closure of the external wound.

(a) *Parietal incision.*—The incision is made in the lumbar region, parallel with and about half or two-thirds of an inch below the inferior margin of the last rib. It measures in length from 3 to 5 in., according to the obesity of the patient and the size of the organ to be removed, commences in front, and terminates at the external border of the erector-spinae muscle. The various strata of the abdominal wall are divided as in the operation of “nephrolithotomy,” until the posterior aspect of the kidney is exposed. In some cases it will be necessary to make a second incision, so as to enlarge the field of operation and facilitate the manipulations of the surgeon. This can be best effected by making a short vertical incision downwards, commencing about an inch external to the posterior angle of the oblique wound.

(b) *Enucleation of the kidney.*—In most cases the organ should be separated from its surrounding perinephric pad of fatty connective tissue. This may be accomplished in many instances by the fingers, but it occasionally happens when there has been much inflammation—especially in

old - standing suppurative cases—that this cannot be done. If the kidney cannot be separated from its surroundings in this manner, it is advisable to open the capsule proper, and then enucleate it. Usually, however, small portions will remain behind, adherent to the fibrous capsule. In very difficult cases, where the exact extent of the renal tissue cannot be made out, the removal may be effected either by cutting with a scalpel or a pair of curved scissors. Sometimes a combination of these methods enables the surgeon to separate the kidney from its surroundings. When the enucleation has been completed, the organ is lifted up in the wound by an assistant, so as to allow of the separation and ligature of the pedicle.

(c) *Separation and ligature of the pedicle.*—The margins of the parietal wound are held well apart with wide flat metal retractors, whilst the surgeon defines the pedicle and separates it into two parts, an upper containing the blood vessels, and a lower the ureter alone. The portion of the pedicle containing the renal vessels should be carefully separated from the surrounding tissues for a short distance towards the abdominal aorta. This will give more room for the application of the ligature, and there will be less chance of it slipping afterwards. This having been done, a pedicle needle threaded with medium silk is passed between the two halves of the pedicle, and tied around that portion which contains the blood vessels, the point of application being an inch or more from the hilum of the kidney. A pair of clamp forceps is then placed on the lower half of the pedicle, or ureter.

(d) *Removal of the kidney.*—The kidney is lifted up into the parietal wound by an assistant, who takes great care not to exert traction upon the blood vessels; and then the surgeon, with scissors, divides both portions of the pedicle, the upper half, about two-thirds of an inch on the distal side of the ligature—that is to say, in most cases at the hilum of the kidney—and the lower half, on the kidney

side of the clamp forceps. The organ is then removed. When it is difficult to separate the upper half of the pedicle, owing to extensive inflammatory adhesions, a small button of renal tissue may be left on the distal side of the ligature, so as to prevent any tendency which it might otherwise have to slip, owing to the nearness of the ligature to the cut surface of the pedicle stump. The pedicle is now sponged dry and examined, and if any bleeding points become visible, they are picked up with artery forceps and ligatured with silk.

(e) *Treatment of the ureter and closure of the external wound.*—When the ureter is apparently healthy, a ligature is applied to it, and it is dropped back into the wound. The entire field of operation is next irrigated, and the parietal incision closed by the insertion of sutures of silk-worm gut, which are so introduced that they approximate as far as possible the incised surfaces. If there is much oozing, or there has been recent inflammation, a drainage tube is passed down into the bottom of the wound, and one extremity brought out through an angle of the external incision which has been left open for the purpose. If the ureter is dilated and filled with pus or tuberculous material, its interior should be well scraped with a small, sharp Volkmann's spoon; and then, if all the diseased tissue has been got rid of, a ligature may be applied as low down as possible, the part distal to this removed, and the

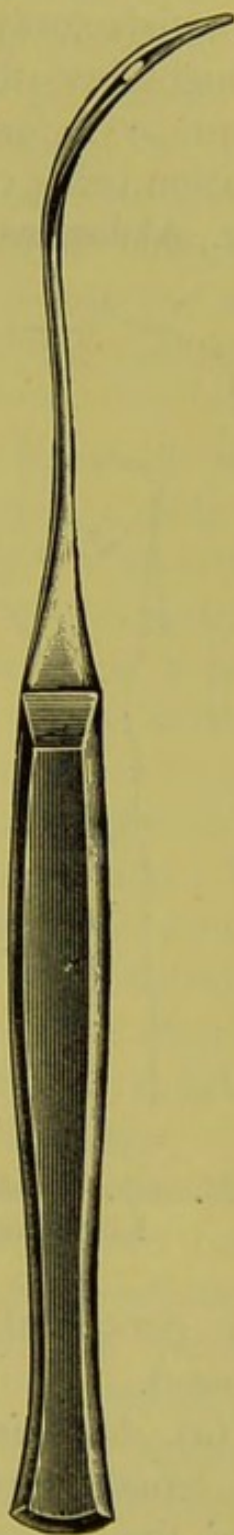


FIG. 119. — Large needle on handle for passing ligature through pedicle of kidney in nephrectomy.

ligatured end dropped back into the wound. The external incision is then closed as before. If all traces of pus cannot be satisfactorily removed, the open end of the ureter is brought into the angle of the parietal incision, and fixed there by a few points of suture, the other parts of the incision being closed in the usual manner.

2. **Abdominal nephrectomy.**—*Instruments.*—The instru-

ments are the same as those required for the "lumbar" operation.

Position.—The patient is placed in the dorsal position on the operating table, the surgeon stands on the affected side, the chief assistant opposite to him, and a second assistant at his right hand.

The stages of the operation are—(a) Incision of the abdominal parietes; (b) exposure of the kidney; (c) separation and ligature of the pedicle; (d) removal of the kidney; (e) the performance of

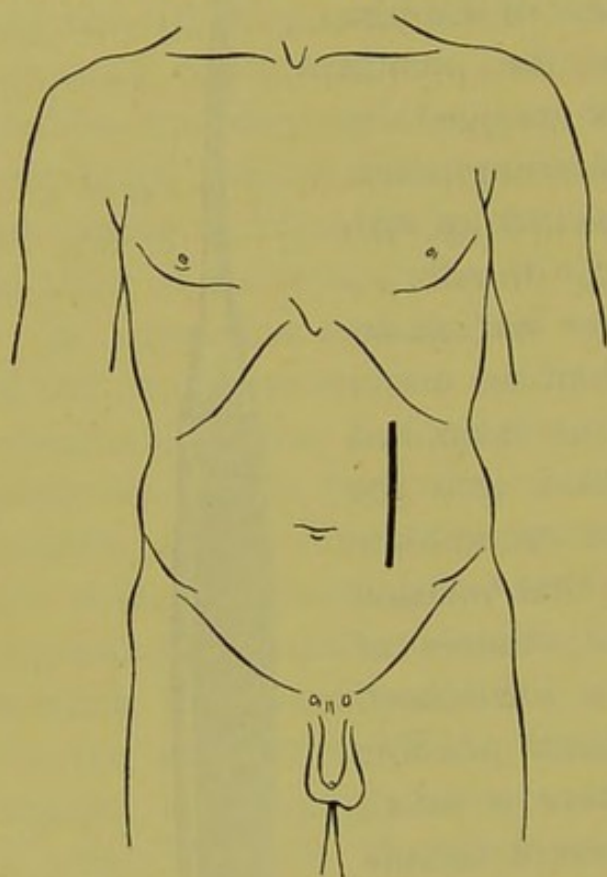


FIG. 120. — Abdominal nephrectomy.
Line of external incision.

the peritoneal "toilet," and the closure of the external wound.

(a) *Abdominal incision.*—An incision from 4 to 6 in. in length, according to the size of the diseased kidney and the thickness of the abdominal walls, is made in the linea semilunaris of the affected side, the centre of the incision being at the level of the umbilicus. This is deepened until the peritoneal cavity has been opened for the entire length of the incision. The hand of the surgeon

is then introduced through the aperture, and the size and connections of the diseased organ made out, and, in addition, the kidney of the opposite side is examined by passing the hand over to that side. If the patient is fat, considerable difficulty may be experienced in distinguishing the healthy kidney, owing to the large amount of perinephric fat which surrounds it. If it is found advisable and possible to remove the diseased kidney, and the one on the opposite side is present and healthy, the operation is proceeded with.

(b) *Exposure of the kidney.*—The small intestines and omentum are pushed over towards the opposite side of the abdomen, and held out of the way by the insertion of one or more flat sponges. The margins of the external wound are held apart with retractors, and the outer aspect of the colon on the diseased side defined. The parietal peritoneum, on the outer side of the colon and just beyond it, is divided, or, better, torn with the fingers until an aperture 2 or 3 in. in length has been made. By tearing the tissues with the fingers, the peritoneum on the anterior aspect of the posterior abdominal wall, together with the colon, is lifted up and separated from the anterior surface of the kidney and its blood vessels. A number of blood vessels may require ligature during this stage.

(c) *Separation and ligature of the pedicle.*—When the anterior aspect of the kidney and its blood vessels have been exposed, the vessels are separated from the adjacent tissues with the finger, and a blunt aneurysm needle passed around them, 1 in. or more from the hilum of the kidney. The needle is withdrawn, and the ligature securely tied. The ureter is next either seized with clamp forceps, or ligatured.

(d) *Removal of the kidney.*—The ureter is severed on the kidney side of the clamp, the blood vessels are divided, and then any connections between the kidney and the surrounding tissues are broken down with the finger. The

organ can now be lifted out of the wound, and removed. If it is doubtful whether the ligature on the blood vessels will hold, a second one ought to be applied a short distance nearer the aorta, taking care to avoid the inferior vena cava on the right side. All bleeding points in the field of operation are picked up with artery forceps, and ligatured. If the ureter is healthy, a ligature is applied to it and it is dropped back; but if it is dilated and filled with pus or tubercular material, it is best to scrape away as much of the purulent matter as possible, and then to make a small incision in the lumbar region, and bring it out through this opening, the margins of its open end being sutured to the external wound.

(e) *The performance of the peritoneal "toilet," and closure of the external wound.*—The space from which the kidney has been taken is thoroughly sponged out and irrigated with an aseptic lotion (or hot salt solution), so as to remove all blood clots, etc., and render evident any bleeding vessels which may have escaped ligature. When this has been done, the peritoneum and the intestines are allowed to fall back into their former positions, and the external wound is closed in the usual manner. It is not necessary to unite the margins of the wound in the peritoneum on the outer side of the colon.

Nephrorrhaphy, or Nephropexy.—The operation which has for its object the fixation of an abnormally movable kidney to the posterior abdominal wall is called nephrorrhaphy or nephropexy, the former term being the one which is more commonly used.

Indications.—The operation is indicated in cases of movable or floating kidney which are not amenable to less severe measures, and are a source of serious annoyance and inconvenience to the patient, or are even a danger to life.

Instruments.—Scalpel, dissecting and pressure forceps, retractors, scissors, needles (straight and large curved

Hagedorn's), needle-holder, and ligatures (fine silk and thick catgut or kangaroo tendon).

Position.—The positions of the patient, surgeon, and assistants are the same as in lumbar nephrectomy.

Operation.—The stages of the operation are—(a) Parietal incision; (b) exposure of posterior aspect of kidney; (c) fixation of kidney to tissues in lumbar region, and (d) closure of external wound.

(a) *Parietal incision.*—An incision, 3 in. in length, is made in the lumbar region, parallel to and half an inch below the inferior margin of the last rib. It commences at the outer border of the erector spinæ and extends downwards and forwards. This is deepened until the posterior surface of the kidney has been reached, or at least until the perinephric fat becomes visible.

(b) *Exposure of the kidney.*—The loose perinephric fat and connective tissue is torn away, until the posterior aspect of the kidney has been laid bare. It is advisable to remove entirely the layer of fat which lies between the kidney and the fascial covering of the posterior abdominal muscles. Some difficulty may be experienced in finding the kidney, especially in those cases in which the organ has a distinct mesonephron. It can, however, usually be made to protrude in the bottom of the wound, by the assistant making strong pressure from the front so as to force the organ backwards. When it has been found by any of these methods, it is brought into the bottom of the lumbar incision, and its posterior aspect thoroughly exposed. Some surgeons have advised that a portion of the capsule should be detached from this surface, or that it should be scarified. Both procedures have for their object the creation of firm adhesions as the result of plastic inflammation. It is doubtful, however, whether either of these methods ought to be adopted, since it is said that they may induce interstitial nephritis; and the organ can be fixed in position without having resort to such measures.

(c) *Fixation of kidney to tissues in lumbar region.*—Mr. Henry Morris advises that this should be done in the following manner:—"Three kangaroo tendons are passed through the posterior surface of the kidney—one near the upper, another near the lower end, and the third midway between the other two, but nearer the hilum. Each suture is buried for a length of three-quarters of an inch within the kidney substance, and penetrates about half an inch into the thickness of the organ. The upper suture passes through the upper edge of the shortened adipose tissue capsule, the transversalis fascia, and the muscles, and is tied to them; the lower suture is similarly passed through and tied to the lower edges of the cut structures; and the intermediate suture is passed through both edges of the divided capsule, fascia, and muscles, and laces all up together."

If the periosteum on the internal aspect of the last rib (or the last two ribs) can be readily made accessible, the sutures which are used for anchorage of the kidney should be passed through this tissue before they are tied. This will help to fix the organ more securely.

(d) *Closure of external wound.*—The kangaroo tendon sutures are cut short, and then the various structures divided in the parietal incision are brought into apposition by the insertion of silk sutures in the usual manner. It is advisable, in most cases of nephrorrhaphy, to pass a drainage tube of moderate size to the bottom of the wound and leave it there for a few days, in order, if possible, to incite increased plastic inflammation.

Puncture of the bladder.—*Indications.*—Puncture of the bladder is indicated in cases of acute distension of the bladder which cannot be relieved by the passage of a catheter, as in some forms of acute gonorrhœa; in some forms of enlargement of the prostate, when a catheter cannot be passed; and in cases of retention of urine dependent upon a stricture through which a catheter cannot be passed, and in which there is urgent need of relief of

the distension. In gonorrhœal cases and in distension due to stricture, it is a temporary measure, and relieves the patient whilst other measures, such as a hot bath, the administration of opium, passage of a catheter, etc., are being carried out.

It is often requisite in cases of enlarged prostate to keep the puncture-opening permanent, and to pass inwards a trocar or catheter, which serves afterwards for the evacuation of urine.

When the puncture is intended as a temporary measure for the relief of an acute condition, the bladder should be punctured with the needle of an aspirator; and when it is intended to create a suprapubic urinary fistula, a trocar and cannula should be used.

(a) *Puncture with the needle of an aspirator.*—The hypogastric region of the abdomen is rendered aseptic by shaving, and then washing with soap and water, ether, etc., in the usual manner. Next, the bladder is steadied by an assistant placing one hand on each side and applying pressure in an inward direction. A point is then selected immediately above the pubes, and the needle of the aspirator (Fig. 164) forced inwards until the point has entered the cavity of the bladder. The urine is allowed to flow out, the flow being aided by gentle, continuous pressure from above.

Care should be taken that the point of the needle passes well into the interior of the bladder; otherwise, as the bladder contracts and diminishes in size, the needle may slip out before all the contained urine has been drawn off.

This proceeding may be repeated at intervals, but it is not advisable to trust to this method of evacuation for any considerable length of time. When the wall of the bladder has once been punctured by this method, the urine should not be allowed to collect so as to considerably distend the organ, otherwise the point of puncture may leak, and urine pass into the adjacent tissues.

(b) *Puncture with a trocar.*—The hypogastric region is prepared as above, a point is selected, and then a trocar and cannula pushed into the bladder through the abdominal wall. The trocar is withdrawn, leaving the cannula in position, and through the lumen of this a soft rubber catheter is passed into the bladder. The cannula may be fixed in position for a few hours and then removed, the catheter being left.

Litholapaxy.—The term litholapaxy implies the removal of a stone from the urinary bladder at one sitting, by crushing it with an instrument called a "lithotrite" (which is introduced into the cavity of the bladder along the urethra), and immediately evacuating the fragments. The name "lithotrity" is often given to the operation, but this term ought to be limited to that form of operation in which the calculus is crushed at several sittings, and the fragments are allowed to be evacuated along with the stream of urine.

Removal of urinary calculi by crushing has replaced to a considerable extent the operation of lithotomy.

Indications.—Litholapaxy is indicated in all cases of calculus in the urinary bladder in which the stone can be readily grasped with the blades of the lithotrite, and is of a consistency which will allow crushing without danger of breaking the instrument. In some cases of oxalate of lime calculi the stone is so hard that it cannot be safely crushed with the lithotrite. When very large stones are present, it is only possible to remove them by lithotomy, but it may be said that in the majority of cases in which the calculus can be grasped between the blades of the lithotrite, it will be possible to remove it by crushing, unless it is very hard and dense. Some surgeons have said that the operation ought not to be performed on young boys, but this statement appears to have been made without sufficient data, since it has been clearly shown that calculi can be easily and safely removed from the interior of the bladder of young male children by crushing.

Preparatory treatment.—The patient should be kept at rest for a few days previous to the operation, and fed on light, non-stimulating food. If a stricture of the urethra is present, it should be gradually dilated until a full-sized catheter can be easily introduced. The patient should be directed to retain his urine for an hour or more before the time of operation.

Instruments.—Scalpel (to enlarge meatus if necessary), lithotrites of different sizes, evacuator and evacuating catheters, rubber catheter, and injection syringe (or a funnel and rubber tube).

Position.—The patient is placed in the dorsal position near the right side of the operating table, with the buttocks slightly raised, and the legs extended and slightly separated; the surgeon stands on the right side, and the chief assistant opposite to him.

The actual operation of litholapaxy can be divided into two stages, namely—(a) The introduction of the lithotrite, and crushing the stone into small fragments; and (b) removal of the fragments from the interior of the bladder with the evacuator.

(a) *Introduction of lithotrite and crushing of stone.*—A catheter is passed and the fluid contents of the bladder evacuated. With the injection syringe from 4 to 6 oz. of warm boracic solution are introduced, and then the patient is ready for the introduction of the lithotrite. The instrument is warmed and oiled, and then carefully passed along the urethra, care being taken not to allow the tip to catch against the anterior layer of the triangular



FIG. 121.—Litholapaxy. Lithotrite.

ligament, this accident being obviated by allowing the instrument to pass along the urethral canal chiefly by its own weight, and not lifting the handle until the prostate has been reached. When the lithotrite has entered the bladder, it is allowed to pass lightly over the trigone, so as to detect the locality of the stone. If the calculus can be felt on one side, the blades of the instrument are turned to the other side, the male blade is carefully separated from the female one, and then they are turned towards the stone and closed gradually, so as to fix the stone between the blades. If the stone is not felt at first, the blades of the lithotrite should be separated, the handle slightly raised so as to depress the blades, and then often the stone will fall in between them, in which case they are closed. If these manœuvres fail, the blades are opened and carefully turned from side to side, so as to explore the area of the trigone and the adjacent portions of the bladder; and if these measures are not successful, the handle should be depressed so as to raise the point of the instrument into the middle of the cavity of the bladder, and then turned round, and the floor examined with the blades in the reversed position. If these directions are systematically

FIG. 122.—Evacuating catheter, for use with Bigelow's evacuator.

carried out, it will rarely happen that the surgeon fails to grasp the stone with the blades of the lithotrite. When the calculus has been fixed by the lithotrite, it is lifted towards the centre of the cavity of the bladder,

and then the blades are screwed home and the calculus broken into fragments. These usually fall into the position where the calculus was first found, and hence it is an easy matter to repeat the procedure of seizing a portion of the calculus, lifting it to the centre of the cavity of the bladder, and then crushing it. This is repeated until the

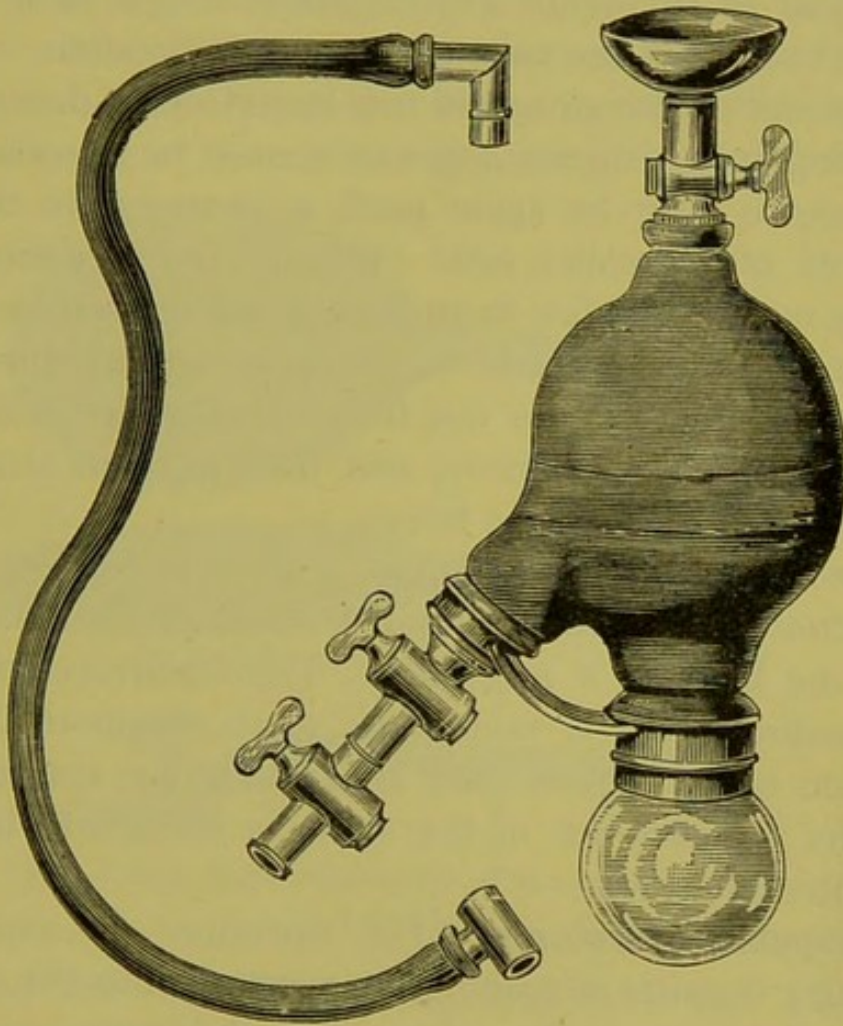


FIG. 123.—Bigelow's evacuator, for use in litholapaxy.

entire calculus has been reduced into small fragments, and then the blades are closed and the instrument withdrawn.

(b) *Removal of the fragments.*—An evacuating tube is next introduced, and the evacuator filled with a dilute solution of warm boracic acid, and connected with the tube. Pressure is now carefully and gradually applied to the bag of the evacuator, and 2 or 3 oz. of fluid are forced into the bladder.

Pressure is then relaxed, and the fluid is drawn back into the bag of the evacuator, carrying with it a number of the fragments. This procedure is repeated until all the fragments of the calculus have been removed. After each relaxation of pressure on the bag of the evacuator, a short time should be allowed to elapse before pressure is again exerted, so as to permit any fragments which have passed into the interior of the tube to pass out if possible. If any of the pieces of the stone are too large to pass through the evacuating tube, either a larger tube must be introduced or the lithotrite must be again used, so as to reduce them to fragments of a smaller size. When there is difficulty in washing out the last few fragments, it will often be found to be advantageous to detach the evacuator and allow as much fluid as possible to pass out from the bladder, aiding the flow by suprapubic pressure, and then to again attach the evacuator and wash out as before.

After-treatment.—The patient is kept at rest for a few days after the operation, and a catheter is passed to empty the bladder, if necessary. The occurrence of rigors and urethral fever is said to be more common after the operation of litholapaxy than after lithotomy, and by some surgeons a recurrence of the stone is thought to be more frequent.

Suprapubic cystotomy.—The operation of suprapubic cystotomy consists in making an aperture into the bladder through the hypogastric region of the abdomen.

Indications.—This variety of operation is indicated in the following conditions:—(a) The presence of calculi within the bladder which are too large or too hard to be easily crushed by the lithotrite, or when the local conditions of the bladder wall, or the general condition of the patient, are not favourable for the performance of a prolonged operation. (b) The presence of an encysted calculus of the bladder. (c) The removal of certain forms of intravesical tumour. (d) The removal from the interior of the bladder

of foreign bodies which cannot readily and with safety be extracted through the urethra. (*e*) In some cases of ulceration of the walls of the bladder (tuberculous), so as to allow of direct treatment of the ulcerated areas. (*f*) In some cases of enlarged prostate.

Instruments.—Scalpel, dissecting forceps, pressure forceps, sharp hooks, catheter, injection syringe or irrigation apparatus, rectal bag, scissors, retractors, needles, needle-holder, and ligature material. When the operation is performed for stone, or the removal of a foreign body, lithotomy

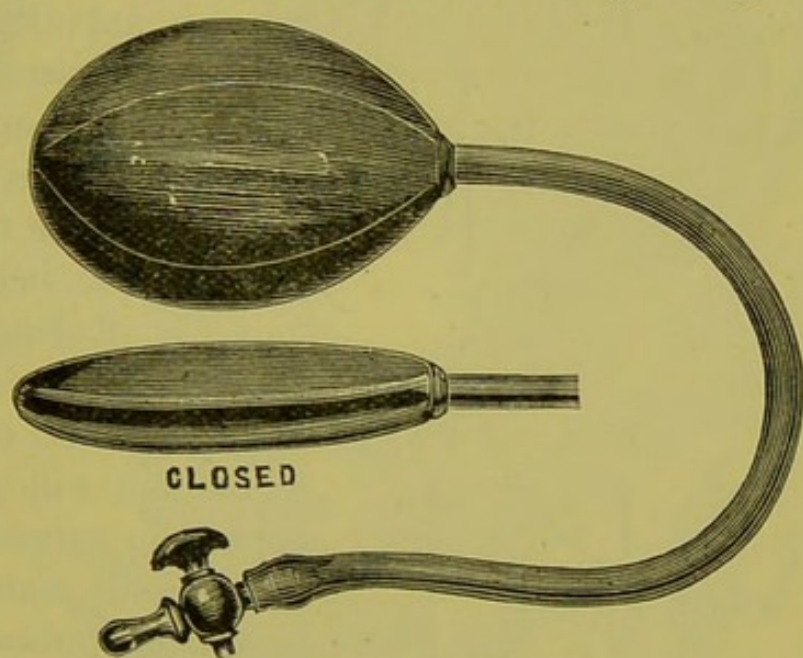


FIG. 124.—Rectal bag for dilatation of rectum in suprapubic cystotomy.

forceps and scoops will also be required; and when a tumour is being removed, curettes and cutting forceps are necessary.

Position.—The patient is placed in the dorsal position, the surgeon stands on the left side of the patient, and the chief assistant opposite to him.

Operation.—The operation may be divided into the following stages, namely—(*a*) Evacuation of the bladder and distension with an aseptic fluid; (*b*) introduction of the rectal bag and its distension; (*c*) incision through the abdominal parietes; (*d*) opening of the bladder; (*e*) per-

formance of the intravesical manipulations; (f) closure of the wound in the bladder and the wound in the parietes.

(a) *Evacuation of the bladder and distension with aseptic fluid.*—When the patient has been anæsthetised, the hypogastric region having been previously shaved and rendered aseptic, a catheter is introduced into the bladder, and all the fluid contents drawn off. An injection syringe or irrigation

apparatus is filled with warm boracic acid solution, and usually about 8 to 12 oz. are injected, but this amount varies according to the condition of the bladder walls, in many cases of cystitis not more than 3 or 4 oz. being introduced. Enough fluid should be injected into the bladder (if the condition of its wall will allow) to enable the surgeon to feel the fundus halfway between the pubes and the umbilicus. The catheter is removed, and a bandage tied around the penis, so as to prevent the escape of the fluid.

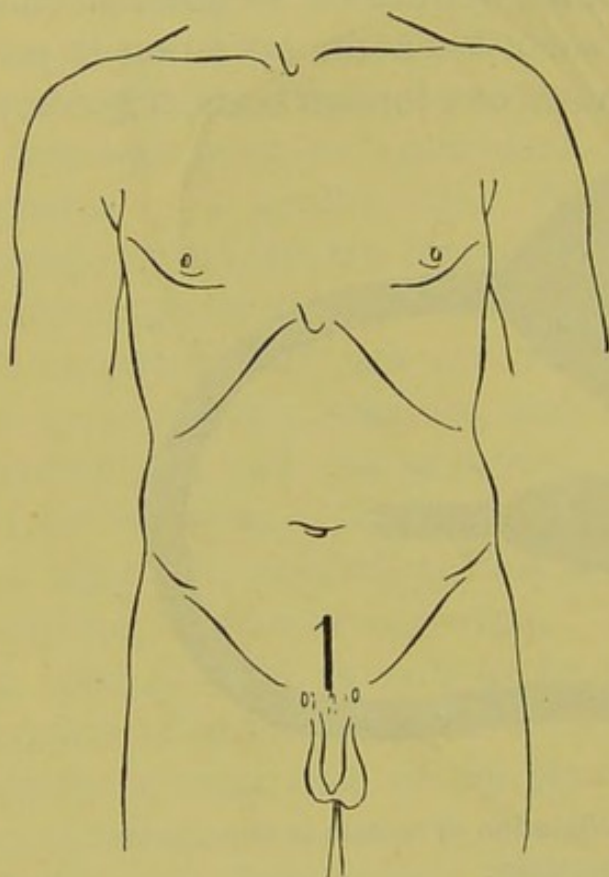


FIG. 125.—Suprapubic cystotomy. Position of patient and line of abdominal incision.

(b) *Introduction and distension of rectal bag.*—The rectal bag, after it has been oiled and rolled up in the form of a cone, is passed into the rectum by an assistant, and afterwards distended with about 10 oz. of warm fluid. It is better to introduce the rectal bag immediately before distending the bladder. In many cases it will be found better to distend the rectal bag after the cavity of the bladder has been opened.

The use of the rectal bag can be dispensed with in a

considerable number of cases ; it is of much use in patients with fat abdominal walls and a deep pelvis.

(c) *Parietal incision*.—A vertical incision from 2 to 3 in. in length is made, which commences about half an inch below the upper border of the pubic symphysis, and extends

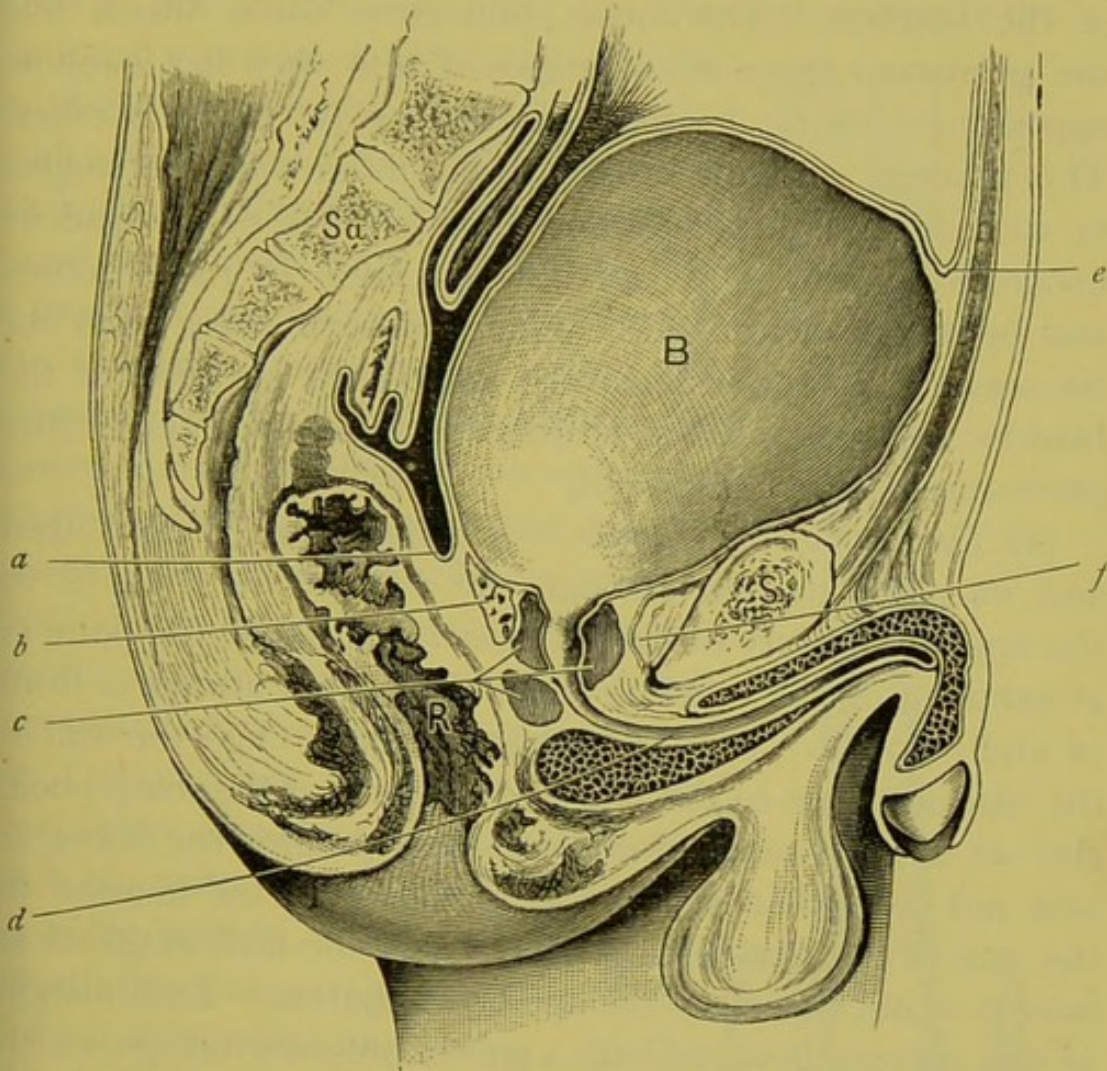


FIG. 126.—Mesial section through a male pelvis, in which the bladder is greatly distended.—CUNNINGHAM.

a. Reflection of peritoneum, from bladder to rectum ; *b.* Vas deferens ; *c.* Prostate ; *d.* Urethra ; *e.* Peritoneal reflection from fundus of bladder to anterior abdominal wall ; *f.* Retro-pubic or ante-vesical pad of connective tissue and fat. B. Urinary bladder ; R. Rectum ; S. Symphysis pubis ; Sa. Sacrum.

upwards towards the umbilicus. The abdominal wall is divided, if possible, through the interval between the two recti muscles ; and in order to make this distinct, when the deep fascia has been cut through, an incision may be made

transversely in the line of the pubic crests. The interval between the muscles is incised, and the margins of the wound held apart with retractors. The fascia transversalis is then divided for the entire length of the incision, care being taken not to notch the peritoneum in the upper part of the incision. The loose connective tissue which fills the prevesical space is now exposed, and often has a yellow appearance, owing to the presence of fat in its meshes. This tissue is carefully broken down either with the fingers or with dissecting forceps, and then the wall of the bladder becomes visible. This can be recognised by its tenseness and by its muscular fibres. The prevesical space must not be opened up too extensively, only such an area of the bladder being exposed as is sufficient to allow of the further procedures being carried out.

(d) *Opening of the bladder.*—A sharp hook is now taken and its point pushed through the wall of the bladder at the upper extremity of the incision, never above the point of attachment of the urachus to the viscus, but always in front of and below it. The scalpel is forced through the wall of the bladder close to the point of entrance of the sharp hook, and an incision made downwards and towards the pubis, at first not more than 1 in. in length. When the incision in the wall of the bladder has been made, the fluid contents at once flow out and make the aperture apparent. Each margin of this opening is seized with a pair of pressure forceps, which are not too tightly closed. The finger is next passed into the interior of the bladder, and the presence and locality of a foreign body, calculus, or new growth determined. This investigation may be facilitated by the employment of a small electric lamp on a bent holder, which illuminates the interior of the bladder and allows the surgeon to see whatever pathological condition is being dealt with. A bent sound is also very useful in locating calculi or foreign bodies.

(e) *Performance of intravesical manipulations.*—The procedure during this stage of the operation depends

upon the nature of the affection from which the patient is suffering. When a calculus is present it is removed with a lithotomy scoop or forceps, preferably with the latter, since less injury to the adjacent tissues is likely to follow the use of forceps than when either a scoop or the fingers of the surgeon are used. At this stage of the operation some surgeons advise that the rectal bag should be dilated, so as to lift the bladder further into the parietal wound. Usually little difficulty will be experienced in removing calculi from the bladder after the cavity of the viscus has been opened. In old people, however, in whom the calculus is very large and the walls of the bladder have undergone considerable thickening, difficulty may be met with in extracting the stone. Much help is often afforded by an assistant passing his fingers into the rectum and manipulating the stone from below. In all cases great care must be taken not to make a larger incision in the bladder wall than is necessary, or to cause any bruising or laceration of the margins of the incision or the parts of the wall of the bladder which lie in contact with the stone. In the removal of a foreign body, the exact form and size should be ascertained before attempting its extraction, so as to avoid further damage if the body happens to be a sharp one. Usually a foreign body can be readily extracted with the fingers or a fine pair of long-bladed forceps. When the bladder is the seat of an intravesical growth, this is removed either with a curette, a sharp spoon, by twisting with a pair of pressure forceps, or by division of the pedicle with the wire of an electric cautery. In epithelioma of the wall

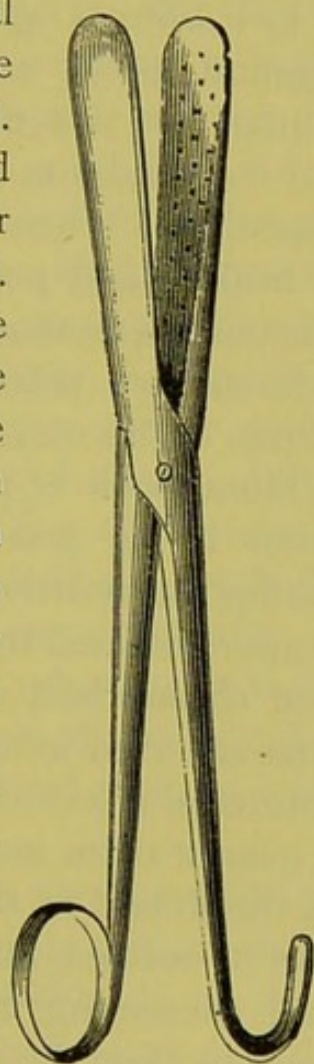


FIG. 127. — Suprapubic cystotomy. Lithotomy forceps.

of the bladder, it may be necessary to resect a portion of the wall of the viscus. Portions of the prostate have been removed by the suprapubic route in cases of chronic enlargement of the gland dependent upon the formation of fibromyomata, but the exact value of this method of procedure has not yet been established.

(f) *Closure of wound in bladder and parietes.*—The question as to whether the vesical wound ought to be sutured or not depends upon the age of the patient and the condition of the bladder walls at the time of the operation. When the muscular tissue of the bladder wall is healthy and possesses its normal contractility, and the mucous membrane is not the seat of ulceration or an inflammatory process, the wound ought to be closed by suture. This may be carried out in the following manner:—A blunt hook is placed in each angle of the incision, and given to an assistant to hold and exert slight traction during the insertion of the sutures; the mucous membrane is approximated by the insertion of a continuous suture of fine chromicised catgut; the cut surfaces of the muscular coat are fixed in apposition by the insertion of a row of fine sutures of silk or chromicised catgut, the sutures being about a quarter of an inch apart; and, finally, the superficial parts of the wound in the muscular coat are further closed by a row of sutures, introduced according to Lembert's method, and alternating in position with those which have been used to close the deeper part of the bladder wound. The parietal incision is now closed in the usual manner, with the exception that about half an inch at the lower angle is left open and a fine drainage tube passed down to the region of the wound in the bladder, so as to allow the escape of urine and any exudation which may occur if the suturing has not been perfect, or the wound does not heal by primary union. When the muscular coats of the bladder are thickened owing to chronic inflammation, or the muscular tissue has lost to a considerable extent its power of con-

tractility, and the mucous membrane is the seat of inflammation (cystitis), or there are ulcerations in the interior of the organ, then suturing of the wound should not be adopted. In all cases of this kind the wound should be left open, a drainage tube inserted, and the area of the operation kept as aseptic as possible. It will usually be found advisable to fix the margins of the incision in the bladder to those of the parietal wound by the insertion of a few points of suture, and if the external wound is large the upper part may also be closed.

After-treatment.—When the wound has been closed, a soft rubber catheter should be passed into the bladder through the urethra and kept there for a few days, so as to allow the escape of urine as it is secreted, and prevent distension of the viscus, which might separate the margins of the wound and allow the urine to escape and so delay healing. When the wound is left open, a catheter or soft rubber drainage tube is passed into the interior of the bladder through the external wound, and a strip of absorbent gauze placed in its lumen, so as to facilitate the escape of urine and prevent accumulation within the bladder. The area of the operation is dusted with iodoform and boracic acid and kept as clean and aseptic as possible.

Lateral lithotomy or cystotomy.—In the operation of lateral lithotomy an oblique incision is made in the perineum, and deepened until the interior of the bladder is reached. It is performed for the extraction of vesical calculi and the removal of foreign bodies from the interior of the male bladder, and also in certain cases of chronic cystitis when it is wished to drain the bladder. The operation, however, has been superseded to a great extent by the suprapubic variety, and the increasing practice of litholapaxy.

Instruments.—Sound, lithotomy knife, curved lithotomy staff with a left lateral groove, lithotomy forceps and scoop, pressure forceps, and perineal drainage tube.

Position.—The patient is placed in the dorsal position at

first while the staff is being passed, and the presence of the stone is being confirmed, and then he is put in the lithotomy position for the remainder of the operation. The surgeon sits opposite the perineum, and an assistant stands on each side.

Operation.—The operation may be subdivided into three stages, namely—(a) Passage of the staff; (b) perineal incision; (c) finding of the stone or foreign body, and its extraction.

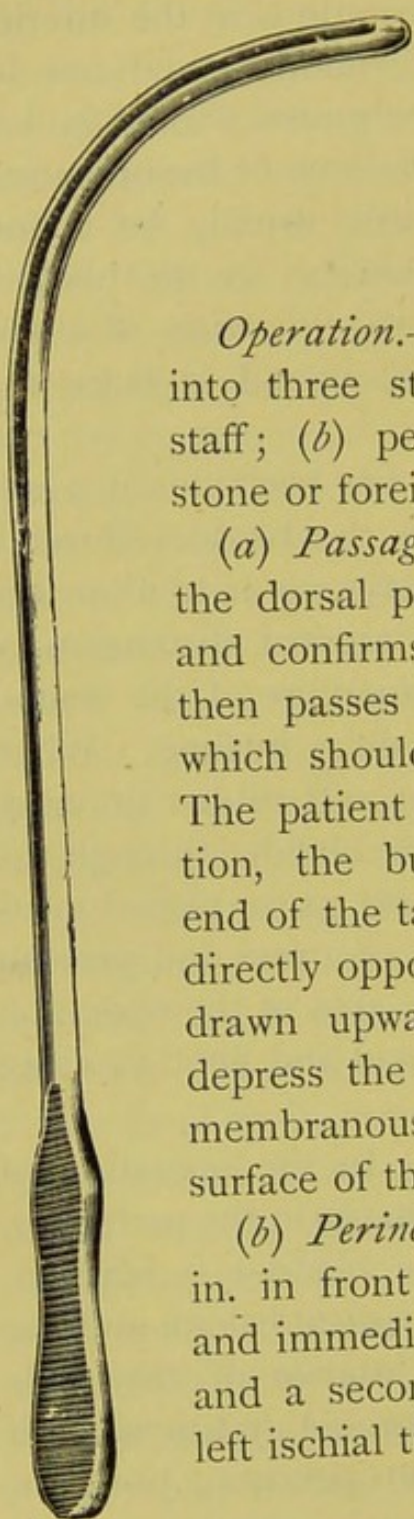
(a) *Passage of staff.*—While the patient lies in the dorsal position the surgeon passes a sound and confirms the presence of the calculus, and then passes the grooved staff into the bladder, which should also be made to strike the stone. The patient is next placed in the perineal position, the buttocks projecting slightly over the end of the table, whilst the surgeon seats himself directly opposite the perineum. The scrotum is drawn upwards, and the assistant directed to depress the handle of the staff so as to lift the membranous portion of the urethra towards the surface of the perineum.

(b) *Perineal incision.*—A point is selected $1\frac{1}{4}$ in. in front of the anterior margin of the anus and immediately to the left of the median raphe, and a second one-third of the distance from the left ischial tuberosity to the lateral margin of the

anus, and then the lithotomy knife is taken and pushed inwards at the first point, until the staff is reached; it is next lateralised

FIG. 126.—Lateral lithotomy.
Staff with left lateral groove.

and made to cut outwards to the second point in the ischio-rectal fossa. The tissues are divided by a kind of sawing movement. The incision made in this manner measures



from 2 to 3 in. in length. The assistant now raises the handle of the staff until it is almost vertical, and at the same time lifts it up against the subpubic arch. The surgeon again introduces the knife, the point being placed in the groove of the staff, and the blade lateralised, and pushes it forwards into the interior of the bladder. The point of the knife must not be allowed to leave the groove in the staff as it is pushed into the bladder, otherwise difficulties may be met with. The forefinger of the left hand is placed on the back of the knife, and follows it into the interior of the bladder, the incision in the neck of the bladder and prostate being made large enough for the finger to pass in easily. The moment when the knife has entered the bladder is recognised owing to a diminution of the resistance to the cutting edge of the knife, and also a gush of fluid from the interior of the

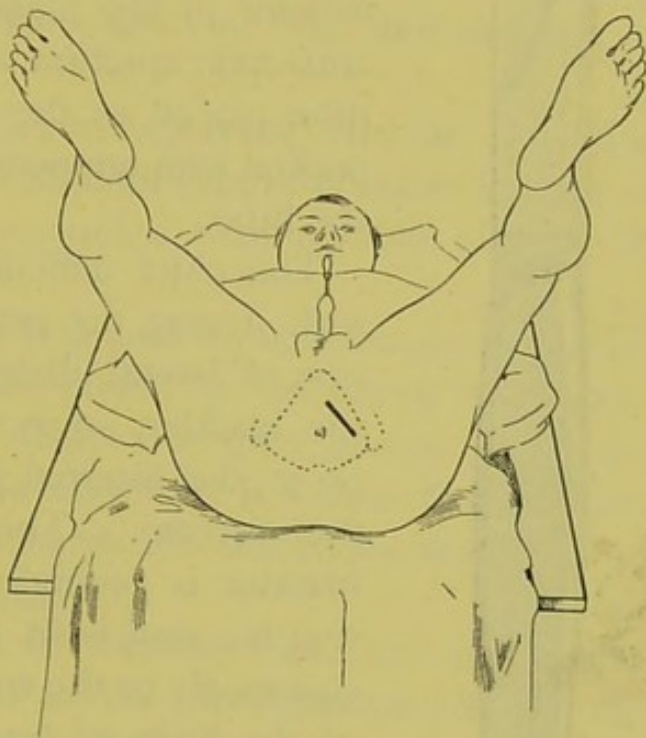


FIG. 129.—Lateral lithotomy. Position of patient and line of perineal incision.

bladder. When the finger is within the bladder; the knife and then the staff are withdrawn, and the calculus felt for.

(c) *Finding and extraction of stone, etc.*—When its position has been made out, the lithotomy forceps are passed into the interior of the bladder along the palmar surface of the finger, and the stone seized with the blades and extracted. If possible the long axis of the stone should be grasped with the forceps, so as to avoid unnecessary laceration of the tissues of the perineum during its extraction. In some cases a scoop will be found more useful than forceps but

usually the calculus can be extracted best and most easily with the forceps. The forefinger can often manipulate the stone between the blades of the forceps and make the long diameter of the calculus correspond to the forceps. Before concluding the operation, the interior of the bladder should be examined for other calculi.

When all calculi have been removed, the interior of the bladder is irrigated with an antiseptic solution and a perineal drainage tube placed in the bladder, and the wound packed with tampons of aseptic gauze around the tube.

The chief difficulties which may be met with during the performance of the operation of lateral lithotomy are inability to find the bladder, injury to the artery to the bulb or to the internal pudic artery, or injury to the rectum. The inability to find the bladder is generally due either to the fact that the staff is in a false passage or more commonly to the surgeon allowing the point of the knife to leave the groove in the staff before the cavity of the bladder has been reached; injury to the artery to the bulb is caused by making the incision too far forward, and injury to the pudic artery by cutting too far outwards towards the ischial tuberosity; whilst damage to the rectum is caused either by cutting too far backwards, or not lateralising the knife sufficiently during the second stage of the operation.



FIG. 130.—Special form of knife for use in lateral lithotomy.

Median lithotomy or cystotomy.—This is an operation which is very rarely performed. An incision is made in the middle line of the perineum a short distance in

front of the anus, and deepened until the membranous portion of the urethra and the interior of the bladder has been reached.

Indications.—The presence of a small foreign body within the cavity of the bladder which cannot be removed through the urethra, the presence of a small vesical calculus which cannot be removed by litholapaxy, or the existence of a condition of the wall of the bladder which necessitates perineal drainage, as in some forms of cystitis, are by some surgeons said to be indications for the performance of median cystotomy.

Instruments.—As for lateral lithotomy, with the exception that a curved staff with a median groove is taken instead of one with a lateral groove, and a long straight bistoury in place of the scalpel.

Position.—The positions of patient, surgeon, and assistant are similar to those recommended for the lateral operation.

Operation.—The staff with a median groove is passed along the urethra until the extremity is within the bladder, the handle is depressed towards the umbilicus, and held in this position by an assistant.

The surgeon passes his left forefinger into the rectum and steadies the staff as it lies in the membranous part of the urethra. The presence of the finger in the rectum enables the surgeon to avoid wounding this structure.

A long straight-bladed and sharp-pointed bistoury is taken and pushed into the tissues of the perineum, the point entering half an inch in front of the anterior margin of the anus. The cutting edge of the knife is turned away from the rectum. The knife is pushed inwards until the point enters the groove in the staff, the staff being now hooked up underneath the pubic symphysis. When the knife has reached the groove in the staff, it is pushed a little further inwards in order to notch the prostate. The knife is now withdrawn, and as this is done the perineal tissues in front

are divided for a distance of an inch or a little more, the aperture being made large enough to allow of the extraction of the calculus or the foreign body. In the case of a calculus it is advisable to make a small incision through which a lithotrite can be introduced, and the stone if large broken up into several fragments before an attempt is made to extract it.

A probe-pointed director is next passed along the groove in the staff into the cavity of the bladder, and the staff withdrawn. The forefinger of the left hand is passed along the director into the vesical cavity, the director is withdrawn, and the lithotomy forceps introduced. The stone or foreign body is now extracted in the usual manner, care being taken to avoid laceration of the perineal tissues.

As a rule no drainage of the perineum is required in cases of calculus or removal of a foreign body. In cases of cystitis a perineal drainage tube is inserted and fixed in position.

External urethrotomy (Wheelhouse's operation).—In this operation the urethral canal is opened from the perineum by a median incision.

Indications.—The performance of this operation is indicated in cases of retention of urine dependent upon an impermeable stricture in the proximal portion of the urethra, and in traumatic rupture of the urethra.

FIG. 131.—Wheelhouse's staff for external urethrotomy.

Instruments.—Clover's crutch, Wheelhouse's staff, scalpel, long straight bistoury, pressure and dissecting forceps, probe-pointed gorget (Teale's), probe-pointed director, fine probes, silver catheters, "railroad" catheter, needles, needle-holder, and ligature silk.



Position.—The patient is placed in the lithotomy position, the legs being held apart by a Clover's crutch. The surgeon seats himself opposite the perineum, and his assistant stands on his left hand.

Operation.—Wheelhouse's staff is passed along the urethra until the extremity comes into contact with the stricture, the groove is turned towards the operator, and it is held in this position by an assistant.

An incision is made in the median raphe of the perineum, about $1\frac{1}{2}$ or 2 in. long, and not extending nearer the anus than the anterior margin of the external sphincter. This is deepened by cutting the fasciæ and the accelerator urinæ muscle, until the groove in the staff is reached. The urethra is then opened in front of the stricture for about 1 in., but care should be taken that the section of the urethral wall does not extend beyond a point one-third of an inch from the stricture. The margins of the urethral incision are picked up with forceps, and a silk

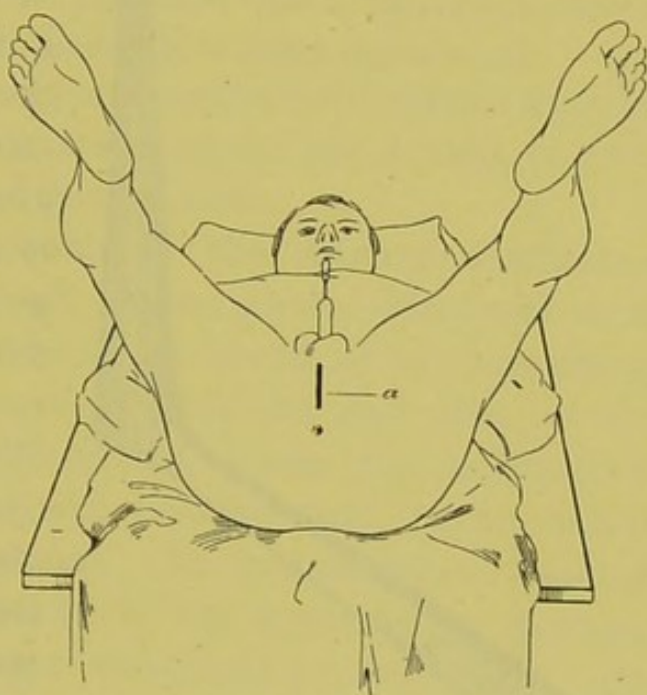


FIG. 132.—External urethrotomy (Wheelhouse's operation). Position of patient and line of external incision.

ligature passed through each side. These ligatures are left long and not tied, the ends being given to assistants to hold; they serve as retractors. Next, the staff is slightly withdrawn and slightly turned round, so that the hook on the tip is brought into the upper angle of the wound. By these means the incision in the urethra is held open at three points—laterally and at the upper extremity. The probe-pointed director is now taken and the proximal portion of the

urethral canal sought for. Often this can easily be seen, but occasionally considerable difficulty is experienced in finding it. In such cases pressure may be made on the bladder from the suprapubic region, in the hope that urine will be expressed, or, failing this, the finger of an assistant should be passed into the rectum, and pressure exerted upon the vesiculæ seminales, and seminal fluid forced onwards.

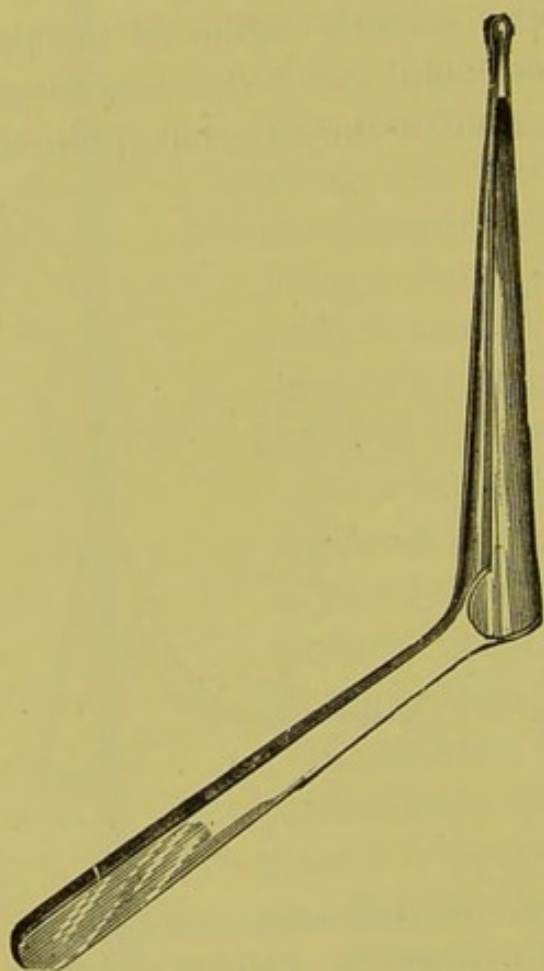


FIG. 133.—Teale's probe-pointed gorget.

The aperture having been found by one of these methods, the probe-pointed director is passed through it into the urethra beyond the stricture and thence into the bladder. The groove of the director is turned towards the surgeon, and the stricture divided with a fine scalpel or a sharp-pointed bistoury. When the stricture has been divided, the groove in the director is turned away from the surgeon, and the probe-pointed gorget passed along this groove until the cavity of the bladder has been reached, which is known by a sudden escape of urine.

The staff is removed, and the part of the urethra in front of the incision examined for fibrous bands, and if any are found, they are divided. Next a full-sized "railroad" gum-elastic catheter (No. 12) is passed along the urethra from the meatus to the perineal incision, and then along the gorget until it passes into the bladder. The gorget is withdrawn, and the catheter tied in the bladder.

The temporary ligatures are removed from the margins of the incision in the urethral canal, and the wound packed with strips of aseptic gauze, and a perineal bandage applied.

A tube should be fastened to the end of the catheter to convey the urine to a receptacle underneath the bed.

After-treatment.—The catheter should be left in for from four days to a week, and the perineal wound dressed daily. In most cases it is wise to change the catheter on the third or fourth day. When the catheter is changed, a long catgut is passed through it into the bladder, and over this the old one is drawn out and the other introduced. Afterwards the catheter is not retained in position, but a full-sized one is passed each day until the external wound has closed.

A catheter ought to be passed regularly for several months, or even longer, after the perineal wound has healed, so as to prevent the recurrence of the stricture.

Treatment of a rupture of the urinary bladder.—

Ruptures of the bladder are of two kinds—intraperitoneal, when the rent causes the establishment of a communication between the cavity of the bladder and that of the peritoneum; and extraperitoneal, when the solution of continuity in the bladder wall involves that portion which is not covered by peritoneum. An intraperitoneal rupture of the bladder is situated on the posterior or posterolateral aspects of the upper two-thirds of the viscus. An extraperitoneal rupture of the bladder is usually situated on the lower part of the anterior aspect, or in the region of the neck, but it may involve any part of the organ which is not covered by peritoneum.

Indications.—All cases of rupture of the bladder in which the diagnosis has been established, and in which the condition of the patient will allow an operation to be performed.

It is important that an operation should be at once performed when the existence of a rupture has been diagnosed. This is especially the case in intraperitoneal rupture.

Instruments.—Scalpel, artery, pressure, and dissecting

forceps, scissors, retractors, blunt hook, sponge-holders, catheter, needles (fine curved), needle-holder (Lane's cleft palate needle-holder will be found to be most useful), and ligature and suture material.

Position.—The patient is placed in the dorsal posture on the operation table, the surgeon stands on the left side of the patient, and the assistant on the opposite side.

Operation (for intraperitoneal rupture).—The operation may be conveniently divided into three stages—(a) Abdominal incision, opening of the peritoneum and finding the rupture; (b) closure of the rupture; and (c) closure of the external wound.

(a) *Abdominal incision, opening peritoneum, and location of rupture.*—The skin of the lower part of the abdomen having been shaved and rendered aseptic, an incision is made, commencing immediately above the pubic eminence and extending upwards for 4 in. towards the umbilicus and in the middle line.

The various strata of the abdominal wall are divided, until the parietal peritoneum and the summit of the bladder are exposed. At this stage it occasionally happens that laceration and ecchymosis of the fundus of the bladder becomes visible; if this is so, the extent of the injury should be made out.

The peritoneum is incised, and usually much fluid, chiefly blood stained urine, will escape. With sponges all urine and other fluid is removed from the peritoneal cavity, and then the visible coils of intestine are pushed upwards and held out of the way by the insertion of one or two large flat aseptic Turkey sponges.

The retropubic region is now carefully examined, in order to find the situation of the rent. When this has been found, its size and extent are ascertained. The interior of the bladder should also be examined, with the finger passed into its interior through the rupture, and should also be sponged dry so as to remove all blood clots

which may be present. A blunt hook is now placed in the upper angle of the rupture and given to an assistant to hold, in order to facilitate the introduction of the sutures.

(b) *Closure of rupture.*—Two tiers of sutures should be inserted for the closure of the rupture; the first consists of several points of catgut suture, which approximate the mucous coat only. A continuous suture may be used for the mucous membrane, but usually it is not so easy to introduce as the preceding one. If silk be used for the mucous membrane, there is a possibility that at a later period salts from the urine may be deposited upon it. If interrupted sutures are used, all should be inserted before any are tied. These should be placed one quarter of an inch apart. When they have been introduced they are tied, the lowermost ones first, and their ends cut short.

The sutures of the second tier are of fine silk. Each suture is introduced after Lembert's method, and transfixes the serous and muscular coats of the bladder wall on each border of the rent. The insertion of these sutures is commenced at the lower angle of the rupture; they are placed at intervals of one-fourth of an inch, or even less if necessary, until the entire aperture has been closed. The sutures should extend a short distance above and below the limits of the rupture. All the sutures are inserted before any are tied, then they are tied and their ends cut short. In cases where the rupture extends towards the lower part of the posterior aspect of the bladder, it will be found convenient to introduce the first suture a short distance above the lower angle, and then to use this suture to lift up the lower part and facilitate the introduction of the lowest sutures. The bladder is now examined in order to ascertain if it is water-tight. Often this can be effected by passing the hand behind the bladder and pressing it forwards against the posterior aspect of the symphysis pubis, when, if urine has collected within the interior of the bladder, it will exude through any deficiency which may exist along the

line of suturing. If the line of suture is perfect the abdominal wound can be closed. When, however, a leakage manifests itself, one or more sutures are inserted at the weak spot. If there is no urine in the bladder at the completion of the suturing, an aseptic fluid (4 oz. of carmine-coloured aseptic fluid) is introduced *per urethram*, and the procedure recommended above repeated.

(c) *Closure of the external wound.*—The region of the rupture is sponged dry, the flat sponges which have been used to keep back the intestines are removed, and the entire exposed part of the peritoneal cavity freed from blood or blood stained urine. Care must be taken not to leave a collection of fluid behind at the bottom of the pelvis.

The parietal wound is then closed in the usual manner by the insertion of two or three tiers of sutures.

If there is peritonitis, or there has been much escape of urine into the peritoneal cavity, it will be advisable to leave open the lower angle of the wound and to pass a glass drainage tube to the bottom of the pelvis. This can be removed in most cases on the following day. It will allow the ready escape of any urine or fluid which has been left behind, or which may be secreted by the peritoneum.

An aseptic soft rubber catheter is passed into the bladder along the urethra and tied in position. Provision is made for the collection of the urine as it trickles away through this catheter as it is secreted. This precaution avoids the distension of the bladder with urine, and hence promotes the quick union of the sutured margins of the rupture. This catheter should be changed daily. It can be permanently removed at the end of a week or ten days. The strictest aseptic precautions must be observed in connection with the passage of the catheter, in order to avoid the occurrence of cystitis.

Operation (for extraperitoneal rupture).—When the anterior aspect of the bladder has been exposed through

an incision similar to the above, the region of the neck and anterior aspect is carefully examined in order to locate the rupture. If this is situated in the exposed area, the interior of the viscus is sponged dry, and then the margins of the rupture are united in the manner described above. When no trace of rupture can be discovered on this aspect, the peritoneum may be incised for a short distance and the peritoneal aspect of the organ laid bare. If no sign of rupture becomes visible, the opening in the peritoneum is closed.

When the symptoms point to unmistakable rupture, and the rent has not become visible by the previous procedure,—a condition which very rarely occurs,—an incision should be made in the anterior aspect of the bladder, as in the manner described in suprapubic cystotomy, and through this opening the base of the bladder and the region of the prostate are examined. If a rupture is discovered, the margins are sponged dry and then united by a series of catgut sutures, introduced from the interior of the bladder. The wound in the anterior aspect of the bladder is closed in the ordinary manner. The abdominal wound is only partially closed in cases of extraperitoneal rupture, the lower part being left open, and through this a glass drainage tube is passed down towards the region of the rupture. This will allow the escape of the extravasated urine.

The further treatment of extraperitoneal rupture is similar to that described in connection with the other form of rupture.

CHAPTER VII.

OPERATIONS UPON THE MALE GENITAL ORGANS.

I. OPERATIONS UPON THE PENIS—

A. Circumcision.

B. Amputation of the penis :

(*a*) Partial.

(*b*) Complete.

2. OPERATIONS UPON THE TESTICLE—

A. Castration.

B. Radical cure of hydrocele.

Circumcision.—Circumcision, or removal of the male prepuce, is necessary in many cases of phimosis, and it is often advisable in patients who have a congenitally long prepuce, which allows the preputial secretion to collect underneath it and become a source of irritation.

Instruments.—Scalpel, scissors, dressing forceps, dissecting and artery forceps, needles, needle-holder, and ligature and suture material.

Position.—The patient is anæsthetised, placed in the dorsal posture, and the genital region well exposed. The surgeon may stand on either side of the patient, and his assistant opposite to him.

Operation.—The prepuce is drawn slightly forward, and then seized with a pair of dressing forceps immediately in front of the corona glandis. The blades are held in a sloping direction, so that more prepuce is beyond the forceps on the dorsal aspect than on the ventral. The blades are closed,

the glans penis slipping backwards, and the part of the prepuce which is distal to the forceps, removed by cutting it away with the scalpel.

The mucous surface of the prepuce is now completely separated from the glans by peeling it backwards with the finger or a probe, and cut away with scissors to within a quarter of an inch of the corona glandis. The skin of the prepuce is next trimmed away with scissors as far as the frenum, care being taken to leave the skin pointed immediately underneath the attachment of the frenum. All bleeding is arrested by ligature, and the free margin of the skin united to that of the mucous membrane just beyond the corona glandis, by the insertion of a series of interrupted sutures of fine silk or catgut. The organ is then washed with an aseptic solution, thoroughly dried, and then the line of incision is covered with a thin strip of gauze and painted with a solution of collodion and iodoform. In children sutures are sometimes unnecessary.

At the expiration of five days to a week, this dressing can be taken off and the stitches removed. A lint dressing with a small quantity of boracic ointment is then applied, and replaced daily until the wound has completely healed.

Amputation of the penis.—Amputation of the penis may be either partial or complete; in the former case, a portion of the dependent organ is removed, and in the latter the entire structure including the crura is taken away.

Indications for operation.—The operation is rendered

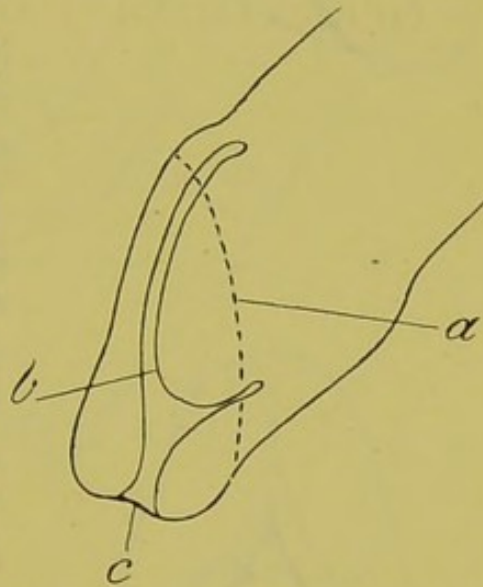
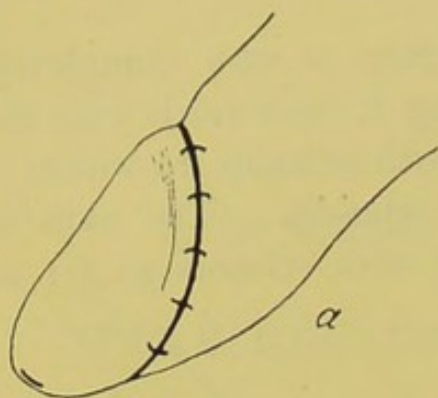


FIG. 134.—Circumcision. Penis showing phimosis.

- a. Line of application of dressing forceps when prepuce has been drawn forward.
- b. Extremity of glans penis.
- c. Aperture of prepuce.

necessary in certain cases of epithelioma of the penis, where it is possible to remove the entire diseased tissue, and occasionally in gangrene of the organ, induced by constriction of rings and other bodies.



Partial amputation of the penis.—The dependent portion of the penis may be amputated at any point between the posterior portion of the glans and the junction of the organ with the scrotum.

Many methods of removing a portion of the penis have been adopted by different surgeons, but one which is easy to perform, and, in addition, gives excellent results, is known as the "flap" operation. This is the one which is now described.

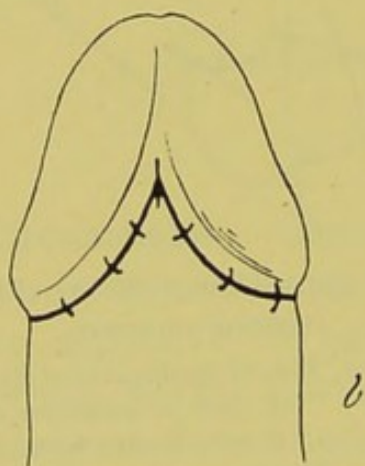


FIG. 135. — Circumcision. Appearance of penis when prepuce has been removed, and margins of incision united with sutures.

a. From lateral aspect.

b. From ventral aspect, showing method of suturing at frenum.

Instruments. — Scalpel, long narrow-bladed knife, pressure, artery, and fine-toothed forceps, dissecting forceps, No. 12 gum-elastic catheter with metal stylet, scissors, sharp hooks, needles (curved and straight), elastic rubber tube, needle-holder, and ligature material.

Position.—The patient lies on his back near the right side of the operation table, with his thighs

slightly separated; the operator stands on the right side, and the assistant opposite to him.

Operation.—An elastic ligature is placed around the root of the penis, so as to avoid hæmorrhage. The plane of the

penis at which it is wished to effect the separation is decided upon, and then a dorsal skin flap is made equal in length and breadth to half the circumference of the organ at the line of section, and dissected back. A ventral flap is then fashioned in a similar manner, but only a quarter of the length of the dorsal, and dissected back as far as the line of section. The gum-elastic catheter with stylet is passed along the urethra, and then the long narrow-bladed scalpel made to transfix the body of the penis between the corpus spongiosum and the corpora cavernosa, immediately anterior to the bases of the skin flaps. The catheter is removed, and the corpus spongiosum with the urethra divided about half an inch in front of the posterior part of the incision. The corpora cavernosa are next divided on a level with the bases of the skin flaps, and all bleeding vessels tied. The arteries which require ligature are—the two dorsal arteries, on the dorsal surface between the two corpora cavernosa; the arteries to the corpora cavernosa in the substance of these structures; and a branch of the artery to the bulb in the walls of

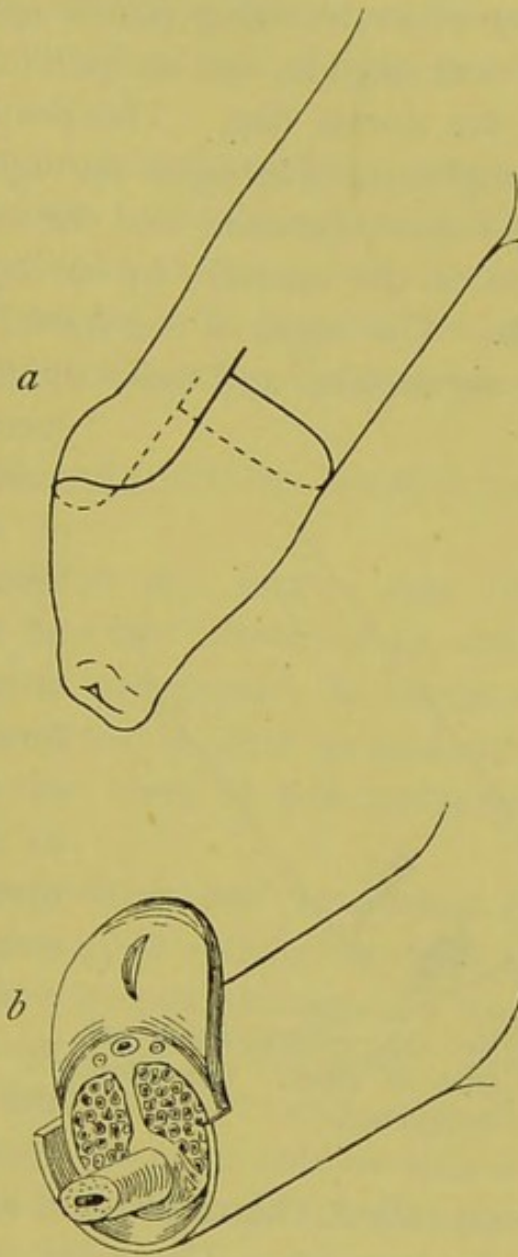


FIG. 136.—Amputation of part of penis.

- a.* Lines of skin incisions in formation of flaps.
- b.* Appearance of stump when part to be amputated has been removed.

the bulbous part of the urethra. The elastic ligature placed around the base of the penis is slightly relaxed, so as to make evident the position of these blood vessels. Any other bleeding points are ligatured, and then a small vertical incision, half an inch in length, is made in the middle of the dorsal flap. The projecting portion of the corpus spongiosum is brought through this aperture, split vertically for a short distance, and the two pieces sutured to the margins of the aperture by curved needles threaded with fine silk. The edges of the dorsal and ventral flaps are brought in apposition, and fixed by the insertion of a row of silk sutures. The operation is now

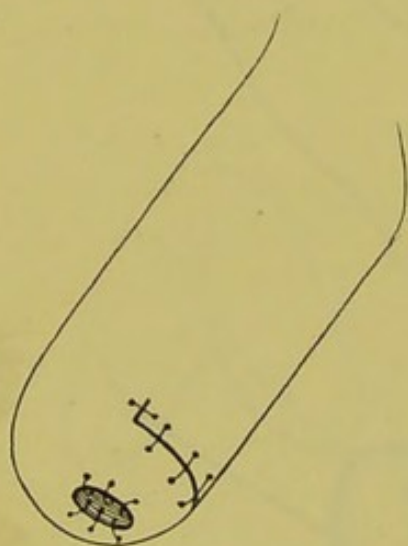


FIG. 137. — Amputation of part of penis. Operation completed.

completed by the application of a collodion dressing to the lines of suture. The retention of a catheter is not necessary after the performance of this form of operation. Contraction of the new meatus is said not to occur so commonly after this method of amputation as after some of the other methods.

Complete amputation of the penis.—This operation comprises the removal of the entire penis together with the crura. It has been called Thiersch's, and also Gould's operation.

Instruments.—These are the same as those required for the previous operation, with the addition of a rugine or a periosteal elevator.

Position.—The patient is placed in the lithotomy position, the buttocks projecting slightly over the end of the operation table; the operator stands between the legs of the patient, and the assistant on his left side.

Operation.—The operation may be divided into the following stages, namely—(a) Skin incision; (b) splitting

the scrotum; (c) division and separation of the bulbous portion of the corpus spongiosum; (d) removal of the remaining portion of the penis including the crura; (e) fixation of the proximal portion of the corpus spongiosum to the posterior angle of the incision, and closure of the remaining part of the external wound.

(a) *Skin incision*.—An incision is made with the scalpel, which commences on the pubic eminence immediately above the dorsal aspect of the root of the penis, extends round the penis to its ventral aspect, and then backwards along the median raphe of the scrotum as far as the anterior part of the perineum.

This incision is racket-shaped, and it divides the skin and fasciæ.

(b) *Splitting the scrotum*.—With the fingers and the scalpel the scrotum is divided into two lateral halves, until the ventral aspect of the corpus spongiosum is reached. The gum-elastic catheter with stylet is next passed into the urethra as far as the anterior layer of the triangular ligament.

(c) *Division of the corpus spongiosum and separation of the proximal portion*.—A long narrow-bladed scalpel is inserted transversely between the corpus spongiosum and the corpora cavernosa, a little in front of the bulb. The catheter is withdrawn, and the knife made to cut outwards and divide the corpus spongiosum not quite half an inch in front of the bulb, a point which is beyond the termination of the ducts of Cowper's glands. When this has been done, the proximal portion of the corpus spongiosum is seized with toothed forceps and dissected free from the crura as far back as the triangular ligament.

(d) *Separation and removal of the remaining portion of the penis*.—The surgeon then grasps the body of the penis with the left hand, and, taking the scalpel in the right hand, he divides the suspensory ligament and other fibrous tissues which fix the organ to the adjacent structures. When the

attachments of the crura to the ischio-pubic rami have been exposed, the scalpel is laid aside and the rugine taken, and with it the crura are separated from their bony attachments, and the organ removed. Four arteries require ligature—the two dorsal arteries of the penis, which will be found immediately underneath the pubic arch, and the arteries to the corpus cavernosa, which come through the triangular ligament close to the attachments of the crura to the bone. These vessels are secured and ligatured together with any other bleeding points which may become apparent.

(e) *Fixation of the proximal portion of the corpus spongiosum, and closure of the external wound.*—The remaining piece of the corpus spongiosum is seized with toothed forceps and slit for half an inch along the dorsal and ventral aspects, and then the flaps so made are united to the margins of the posterior part of the incision by the insertion of fine silk sutures. The anterior part of the incision is well sponged out, the two halves of the scrotum brought together, and the margins closely united with silk sutures, a drainage tube being passed into the deeper part of the wound, if it is thought to be requisite, on account of the oozing of blood which usually goes on for a short time after the operation. It is not necessary to retain a catheter in the urethra.

Castration.—Removal of both testicles is called castration, but either one or both organs may be removed, according to the nature of the affection from which the patient is suffering.

Indications for operation.—Removal of the testis is indicated in certain cases of malignant disease of the organ, in some forms of tubercular and syphilitic affections, and often in cases of “fungus testis.” Removal of both testes has recently been advocated as a method of treatment for chronic enlargement of the prostate, but the advisability of this procedure has not yet been definitely decided.

Instruments.—Scalpel, dissecting and pressure forceps,

clamp forceps (for holding the stump), scissors, retractors, needles, needle-holder, and ligature and suture material.

Position.—The patient lies upon his back with the legs extended and the thighs slightly separated; the surgeon stands on that side of the patient which is to be operated upon, and the assistant on the opposite side.

Operation.—An incision is made which commences, above, a short distance below the external abdominal ring of the affected side, and extends downwards on the lateral aspect of the scrotum to its inferior border. This is made to extend through the tissues of the scrotum until the spermatic cord and the testis with the tunica vaginalis are fully exposed. The spermatic cord is clearly defined, and a clamp placed upon its covering on each side immediately below the external ring; an aneurysm needle is passed through the cord below the level

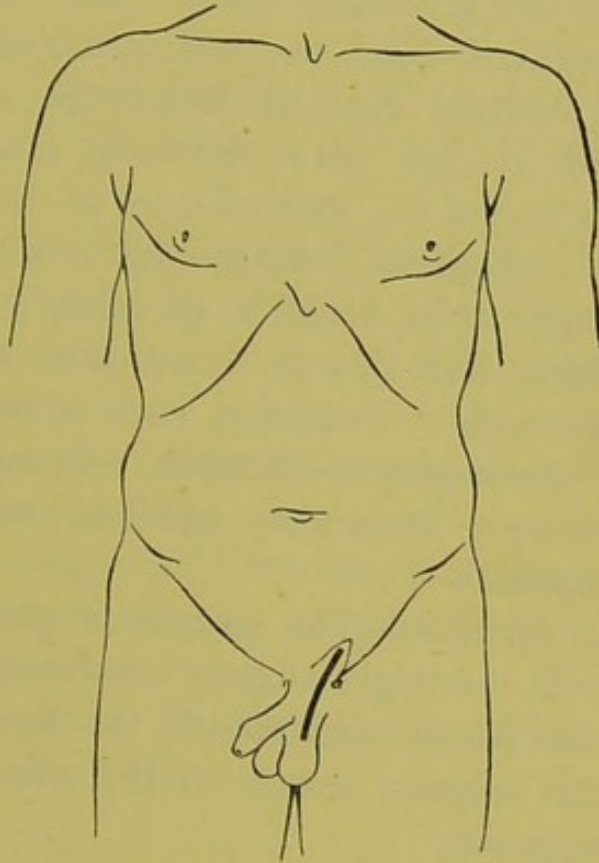


FIG. 138.—Removal of testis.
External incision.

of the clamps, and a double ligature inserted. Each half of the cord is tied separately, and one ligature is made to surround the entire structure. The cord is then divided a short distance below the application of the ligature, and the distal portion of the spermatic cord and the testis and its tunica vaginalis removed. All bleeding points are ligatured, and then the clamps on the spermatic cord are removed, and if any of the arteries bleed they are picked up with artery forceps and tied separately. When all bleed-

ing has been arrested, the stump is pushed into the inguinal canal, and the external wound is closed by the insertion of a series of interrupted sutures. Some surgeons advise that the vessels of the spermatic cord should be tied separately, each one being picked up with artery forceps; this is, however, not usually done.

In the latter method a circular ligature is not placed around the entire cord. The method of transfixion of the spermatic cord, however, is the easier and safer one.

Radical cure of hydrocele.—The operation for the radical cure of a hydrocele involves the removal by dissection of the parietal layer of the tunica vaginalis testis.

Indications.—An attempt at a radical cure of a hydrocele ought to be made in all cases in which the sac wall is very thick, and also in those cases which have resisted milder methods of treatment, such as tapping and injection.

Instruments.—Scalpel, scissors, dissecting and pressure forceps, retractors, needles, needle-holder, and ligature material.

Position.—The patient is placed in the dorsal position, with the thighs slightly separated, and a sandbag of suitable size placed underneath the scrotum in order to raise it; the surgeon stands on the affected side, and his assistant opposite.

Operation.—The scrotum and the skin in the neighbourhood are well shaved, and rendered aseptic by washing with soap and water, ether, and a solution of perchloride of mercury (1 in 500).

The scrotum being made tense by the assistant, an incision is made on the lateral aspect of the affected side. This incision extends the entire length of the swelling caused by the hydrocele. The skin, dartos, and fasciæ are divided, until the surface of the hydrocele is laid bare. All bleeding from the scrotal vessels is arrested, and then an incision, sufficiently large to admit the forefinger, is made into the sac of the hydrocele, care being taken to avoid the region of

the testis. As the contained fluid exudes, the forefinger is introduced into the interior of the sac, and its extent and the exact position of the testis defined. When this has been done, the opening in the sac is enlarged with scissors until the entire length has been incised. Next, the sac walls are seized with pressure forceps, and the parietal portion of the sac separated from its connections with the scrotal tissues. This having been done, the parietal portion is removed by cutting it away with scissors a short distance beyond the junction of the visceral and parietal layers. All bleeding is arrested, and the external wound closed by the insertion of sutures.

Some surgeons advise that the margins of the aperture in the tunica vaginalis testis should be united to those of the scrotal incision, but this is scarcely necessary, and it tends to delay healing of the wound.

All the stages of this operation must be performed under the strictest aseptic precautions; otherwise, if inflammation and suppuration occur, healing will be considerably delayed, and acute orchitis or other unpleasant complications may have to be dealt with.

Varicocele.—The operation for the cure of this affection is described in Chapter XVI., p. 364.

CHAPTER VIII.

OPERATIONS UPON THE FEMALE GENITAL ORGANS.

IN this chapter the following operations will be described, namely—

1. OPERATIONS UPON THE OVARIES AND BROAD LIGAMENTS.

A. Ovariectomy.

B. Salpingo-oöphorectomy, or removal of the uterine appendages.

2. OPERATIONS UPON THE UTERUS.

Hysterectomy.

A. Abdominal { With intraperitoneal treatment of pedicle.
 { With extraperitoneal treatment of pedicle.

B. Vaginal. { Partial.
 { Complete.

3. OPERATIONS UPON THE PERINEUM.

A. Operation for repair of *partial* rupture of the perineum.

B. Operation for repair of *complete* rupture of the perineum.

OPERATIONS UPON THE OVARIES AND BROAD LIGAMENTS.

Ovariectomy.—The term “ovariectomy” includes all those operations which have for their object the removal of a solid or fluid tumour of the ovary, the parovarium, the broad ligament, or the Fallopian tube, and are carried out through an incision in the anterior abdominal wall. The operation is most commonly performed for the removal of a cystic tumour of one or both ovaries.

Instruments.—Scalpel, dissecting, pressure, and artery forceps, large clamp or pedicle forceps, vulsellum forceps, retractors, scissors, ovariectomy trocar and tubing, small trocar,

pedicle needle, straight and curved needles (Hagedorn's), glass and rubber drainage tubes, and ligature and suture material (thick and thin silk, and silk-worm gut). (All instruments should be counted, and a record of their number kept.)

Operation.—The operation may be divided into the following stages, namely—(a) Preparation of the patient; (b) parietal incision; (c) exposure of the cyst or tumour; (d) evacuation of the contents of the tumour, if fluid; (e) division and separation of adhesions, if any are present; (f) transfixion and ligature of the pedicle, and removal of the tumour, and the return of the pedicle into the pelvic cavity; (g) performance of the "peritoneal toilet"; and (h) closure of the abdominal wound, which may be partial or complete, according to whether it is necessary to establish drainage or not.

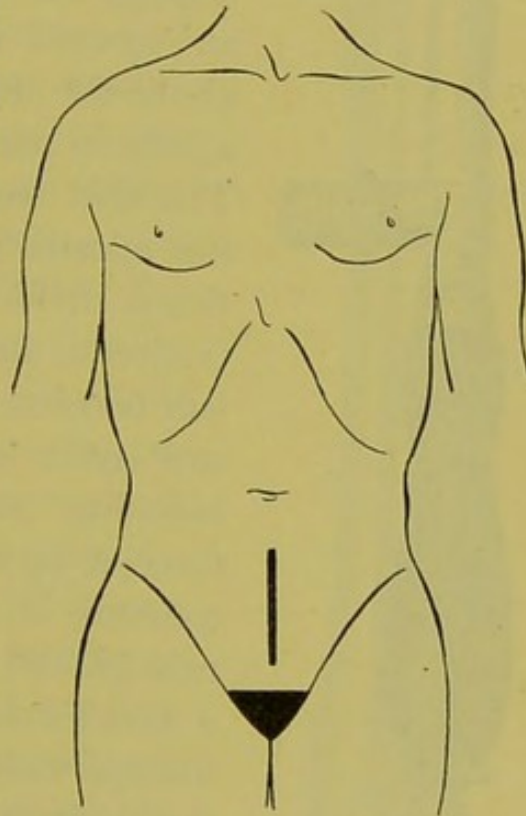


FIG. 139.—Ovariectomy. Parietal incision.

(a) *Preparation of the patient.*—Previous to the operation, the skin of the abdomen is rendered aseptic in the usual manner. The bowels are opened freely by the administration of an aperient the day before, and by a simple enema on the day of the operation. The patient is directed to empty the bladder immediately before going to the operation room, or this may be done by a catheter after the anæsthetic has been administered.

Position.—The patient is placed in the dorsal position on the operating table, and the anterior part of the abdomen is exposed, the rest of the body being clothed with warm woollen materials, and protected by sterilised towels. The

surgeon stands on the right side of the patient, and the chief assistant directly opposite to him.

(b) *Parietal incision.*—An incision 3 in. long is first made, commencing at a point below the umbilicus, and extending downwards in the middle line to a point $1\frac{1}{2}$



FIG. 140.—Trocar
for evacuating
ovarian cyst.

to 2 in. above the upper border of the symphysis pubis. If it is found necessary, in the latter stages of the operation, to enlarge the wound, this is always done in an upward direction, and if it extends above the umbilicus it is better to deviate a little to one side as that point is reached. The skin and fasciæ are first divided, and the aponeurosis of the muscles exposed; this is divided in the interval between the two recti, and then the fascia transversalis will become apparent. This is divided for the entire length of the incision, and all bleeding points are seized with pressure forceps, and ligatures applied. The peritoneum, covered by subperitoneal fat, is now picked up with dissecting forceps, and a notch made into it by cutting on to the forceps with the scalpel. The aperture in the peritoneum is then enlarged, until it is of the same length as the external wound.

(c) *Exposure of the cyst or tumour.*—When the peritoneal cavity has been opened, the cyst or tumour, unless quite small, generally appears in the bottom of the wound. In some cases, however, it is necessary to push aside the lower portion of the great omentum, or a few coils of small intestine, rarely the latter. These structures—omentum and small intestines—are pushed well aside, and kept from protruding by two or three small flat sponges, inserted into the peritoneal cavity around the parietal incision.

(d) *Evacuation of the contents of the tumour, if fluid.*—

The cyst can be evacuated most readily by tapping with a trocar and cannula, the size of the instrument used being dependent upon the size of the cyst. The trocar is pushed into that part of the cyst which appears at the bottom of the wound, and as the fluid escapes, and the cyst becomes flaccid, its walls in the region of the puncture are seized on each side with large cyst forceps, and the entire cyst lifted into the wound. This procedure prevents escape of the fluid contents into the peritoneal cavity. If secondary cysts are met with, they are emptied by pushing the point of the cannula into them from within the cavity of the large cyst. In doing this, care must be taken not to puncture the adjacent viscera by allowing the cannula to pass from the interior of the swelling through the main cyst wall. This can be prevented by passing the forefinger into the peritoneal cavity, and guiding the point of the cannula. When the cyst has been partially brought out of the wound, the secondary cysts may be broken into with the fingers.

(e) *Division and separation of adhesions.*—When the cyst has been emptied, its relations and connections with the surrounding viscera are exactly defined, and if adhesions are found

to exist, they are separated. The slight and recent ones are carefully broken down with sponge pressure, but if distinct fibrous bands are met, it is best to tie them in two places with silk ligatures, and to divide them

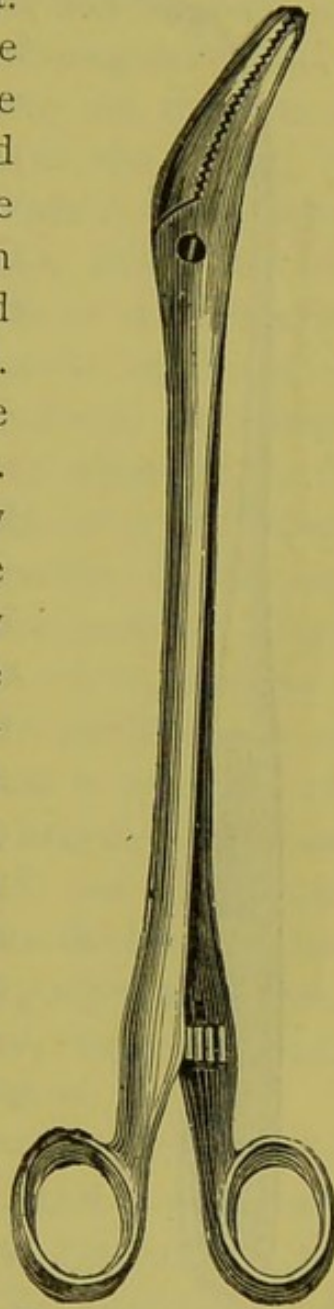


FIG. 141. — Ovariomy. Cyst forceps.

between. When portions of the cyst are firmly fixed to one of the adjacent viscera, and there is no band of tissue which is accessible for the application of a ligature, it is safer to leave the adherent part of the cyst wall behind than to persevere in an attempt to separate the adherent structures, since intestine, which is most commonly involved in these cases, is more easily ruptured than the wall of the cyst.

(f) *Exposure, transfixion, and ligature of the pedicle, removal of the tumour, and return of the stump.*—When all adhesions have been separated, the entire cyst is lifted out of the wound, until its inferior attachment becomes visible in the lower angle of the incision. This is transfixed with the pedicle needle, and then tied in two or more portions, according to its size. The pedicle can be recognised and distinguished from a large adhesion by the presence of the Fallopian tube on its internal and superior aspect. During transfixion, the assistant is directed to lift up the cyst, so as to expose the pedicle fully. The needle is threaded with a piece of strong silk or whip-cord about 3 ft. in length, and then passed through the middle of the pedicle, at a point which is free from large blood vessels, and situated an inch or more, if possible, from the attachment of the

cyst. The ligature is cut into two parts, the two portions are locked by twisting, and one is tied around the Fallopian tube, and the other around the main blood vessels. Each knot should be a true "surgeon's knot," and it is advisable



FIG. 142. — Ovari-
otomy. Pedicle
needle.

finally to tie one ligature around the entire pedicle, since this tends to prevent bleeding from any blood vessel which may have been pierced by the pedicle needle. The cyst is now removed by cutting through the pedicle with scissors, at a point about two-thirds of an inch from the ligature, and on the side near the cyst. The ligatures are cut short, and if there is no bleeding from the surface of the stump, the pedicle is sponged clean, and dropped back into the pelvis.

(g) *The "peritoneal toilet."*—In simple cases of ovariectomy, in which there is no suppuration or inflammation, it is only necessary to thoroughly sponge the region of the pedicle and the margins of the external wound. In complicated cases, however, where there are many adhesions, or the cyst or tumour is the seat of inflammatory processes, careful irrigation of the entire area of the operation is requisite. Various substances have been used for this purpose. Some surgeons use plain sterilised water, others warm solutions of carbolic or boracic acid, and others warm sterilised .75 per cent. salt solution. The last-named fluid is probably the least irritating to the peritoneum. After irrigation has been completed, the pelvis is carefully sponged out with aseptic sponges, so as to remove as much of the fluid as possible. At this stage of the operation all the sponges and instruments should be counted, so as to make sure that none have been left behind in the peritoneal cavity.

(h) *Closure of the abdominal wound.*—In uncomplicated cases the entire wound can be closed, and no drainage is necessary. This is done in the usual manner, by the insertion of three tiers of sutures. The peritoneum is united with a continuous silk suture; next, the aponeurotic and fascial layers are approximated by the insertion of a series of interrupted sutures, the ends of which are cut short; and, finally, the skin and superficial fasciæ are united by a row of sutures of silk-worm gut. The closure of the external incision can be facilitated by an assistant making traction with blunt hooks at the upper and lower angles,

thus bringing the surfaces in exact apposition. When many adhesions have been met with, or the cyst has been the seat of recent inflammation, it is advisable to leave the lower angle of the incision open, and through this portion to pass a strip of aseptic gauze down to the region of the pedicle. This will allow of the escape of all exudations, and usually it can be removed in a few days, and often at the end of twenty-four hours.

When the tumour or cyst of one side has been removed, it is advisable to make it a routine practice to examine the ovary and uterine appendages of the opposite side, since it not uncommonly happens that both ovaries are the seat of cystic degeneration.

Salpingo-oöphorectomy, or removal of the uterine appendages.—In the performance of this operation, the ovary, Fallopian tube, and a portion of the broad ligament of the uterus, are removed on either one or both sides. Removal of the ovary alone, when it is not the seat of cystic degeneration, has been called “oöphorectomy,” and removal of the Fallopian tube “salpingectomy.” In the majority of instances, however, in which removal of the uterine appendages is necessary, it is advisable to remove ovary, Fallopian tube, and adjacent portion of broad ligament.

Indications for operation.—(a) In some cases of disease of the ovary, Fallopian tube, and adjacent parts of the broad ligament, which are not amenable to other forms of treatment, and which are a source of constant inconvenience and annoyance to the patient, or are even a danger to life, such as severe inflammation or suppuration of one or both ovaries or Fallopian tubes; hernia of the ovary, which has become strangulated; tubal pregnancy; and hydro-pyo or hæmato-salpinx. (b) In certain conditions of the uterus, especially fibromyoma; or in complete obstruction to the menstrual flow, which cannot be overcome by other means, such as inoperable atresia of the vagina. (c) In certain mental conditions. Cases of insanity, nymphomania, hys-

tero-catalepsy, and hysteria have been treated in this manner, but the limits of the operation in these affections have not been defined.

Instruments.—Scalpel, pressure, dissecting, artery, and clamp forceps, retractors, pedicle needle, suture needles, needle-holder, and ligature and suture material (thick and thin silk and silk-worm gut).

Position.—The patient is placed in the dorsal position on the operating table, the abdomen exposed and protected as in ovariectomy; the surgeon stands on the right side, and the assistant on the left, directly opposite him.

Operation.—The operation may be divided into three stages, namely—(a) Parietal incision; (b) finding and exposure of the appendages, transfixion of the broad ligament with the pedicle needle, and application of the ligature, followed by the removal of the appendages and return of the stump into the pelvis; (c) performance of the “peritoneal toilet,” and closure of the external wound.

(a) *Parietal incision.*—An incision is made in the middle line of the abdomen, below the umbilicus, about $2\frac{1}{2}$ in. in length, terminating below at a point $1\frac{1}{2}$ in. above the upper border of the symphysis pubis. This incision is deepened in the usual manner, until the peritoneal cavity has been opened.

(b) *Finding of appendages, etc.*—The index and middle fingers of the left hand are passed into the abdomen, towards the pelvis, and the convexity of the fundus of the uterus sought for. When this has been found, the fingers are passed laterally, and made to grasp the broad ligament in the region of the ovary, which can usually be felt as a rounded or oval structure on the posterior aspect of the ligament. The Fallopian tube, broad ligament, and ovary are next drawn into the external wound. If the ovary and Fallopian tube cannot be brought well into the wound with the fingers, the broad ligament and tube are seized with a pair of large bent clamp forceps on the inner side of the ovary, and then lifted well into the wound, so as to fully expose the surface of the broad

ligament. If any adhesions are present which hold down the appendages, they are dealt with in the manner described in connection with "ovariotomy." The broad ligament which forms the pedicle is transfixed by the pedicle needle

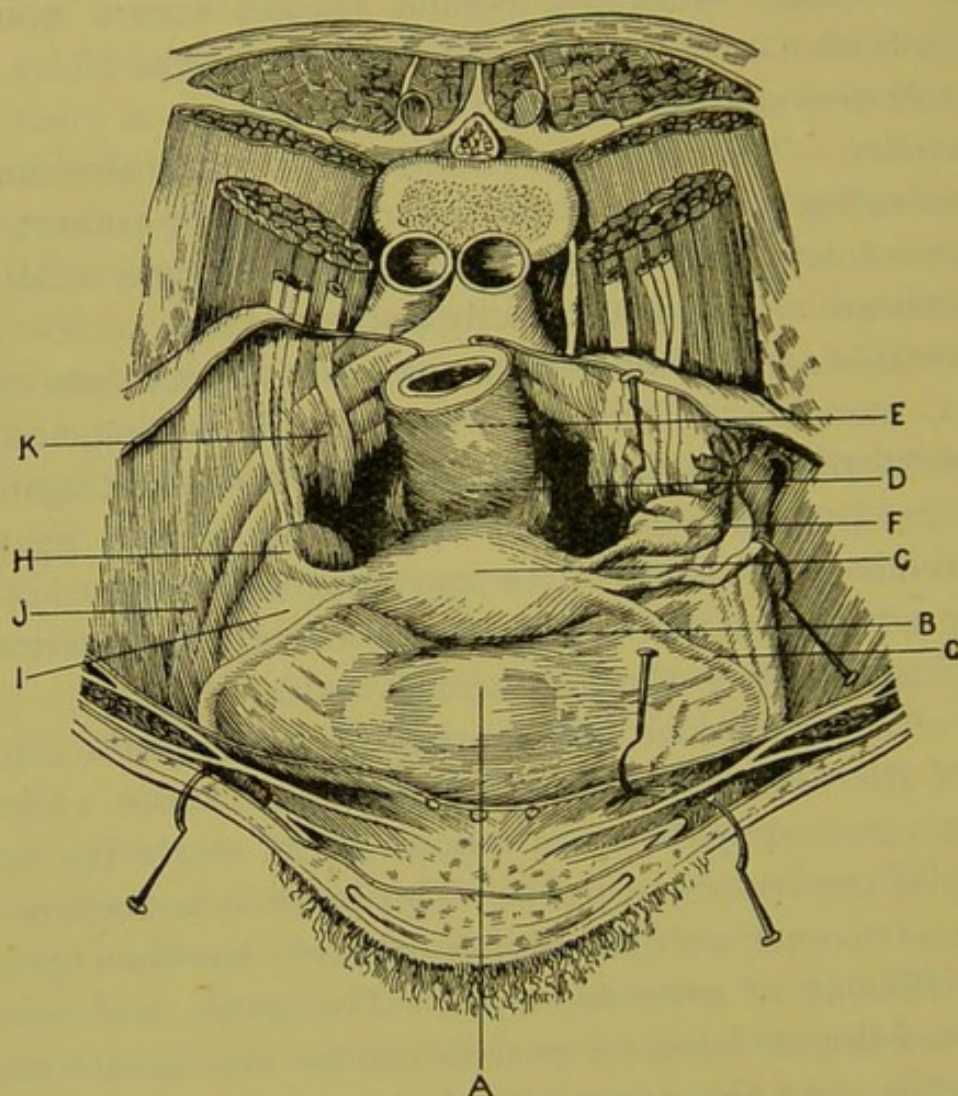


FIG. 143.—The viscera of the female pelvis, as they appear when seen from above and in front.—After TESTUT.

A. Fundus of bladder; B. Utero-vesical pouch; C. Uterus; D. Pouch of Douglas; E. Rectum; F. Ovary; G. Round ligament of uterus; H. Fallopian tube; I. Broad ligament; J. and K. External and internal iliac vessels.

threaded with strong silk, the loop of silk divided, the needle withdrawn, and the two halves tied, one around each portion of the pedicle. The portion of the broad ligament, the Fallopian tube, and the ovary are then removed by cutting through the pedicle about half an inch

on the distal side of the point of application of the ligature. The surface of the divided pedicle is sponged dry, and if no oozing takes place the ligature is cut short, and the stump dropped back into the pelvis. The appendages on the opposite side, if it is deemed necessary, are next removed in a similar manner.

(c) *Performance of the "peritoneal toilet" and closure of the external wound.*—The area of the operation within the pelvis is sponged dry by means of sponges or holders, and the parietal incision closed in the usual manner. When the operation has been performed for the removal of inflamed or suppurating conditions of the ovary or Fallopian tube, irrigation followed by drainage will be necessary, and should be carried out according to the procedure mentioned in the operation of "ovariotomy." The parietal wound is closed in the usual manner.

OPERATIONS UPON THE UTERUS.

Hysterectomy.—Hysterectomy, or removal of the uterus, may be either partial or complete, and it may be carried out either through an incision in the abdominal wall, or through the vagina. The former operation is spoken of as "abdominal or supravaginal hysterectomy," and the latter as "vaginal or perineal hysterectomy."

Indications.—Removal of the uterus has been performed for fibro-myoma of the organ; inversion which cannot be cured by replacement; and cancerous affections which are primary in and limited to the viscus. Cancer of the uterus and very severe cases of inversion are, in nearly all instances, operated upon by the vaginal method, whilst myomata, on the other hand, are almost invariably treated by the abdominal operation.

Abdominal hysterectomy.—Two varieties of this operation are practised at the present time—hysterectomy with "*extraperitoneal*" treatment of the pedicle, and hysterectomy

with "*intraperitoneal*" treatment of the pedicle. The latter operation is the more scientific, and is replacing the former to a considerable extent.

Abdominal hysterectomy, with "*intraperitoneal*" treatment of the pedicle—*Instruments*.—Scalpel, artery, dissecting, and pressure forceps, large clamp forceps, "myoma screws" (Smith's or Tait's), retractors, scissors, pedicle needle, suture needles (straight and curved), needle-holder, elastic rubber tubing, and ligature and suture material (thick and thin silk and silk-worm gut).

Position.—The patient is placed in the dorsal position on the operation table, with the abdomen exposed and prepared in the manner usual for an abdominal operation. (The vagina should be rendered aseptic by irrigation with an antiseptic solution before the operation.) The surgeon stands on the right side of the patient, the chief assistant opposite to him, and a second assistant on his right hand.

Operation.—The different stages of the operation are the following, namely—(a) Parietal incision; (b) exposure and separation of the uterus and the tumours attached to it; (c) ligature of the ovarian and uterine blood vessels, and transfixion of the broad ligaments (if possible); (d) application of an elastic ligature to the pedicle or base of the tumour; (e) removal of the uterus and the attached tumour; (f) closure of the mucous membrane of the uterine canal; (g) closure of the wound left after removal of the uterus; (h) performance of the "*peritoneal toilet*," and closure of the parietal incision.

(a) *Parietal incision*.—An incision is made in the middle line of the anterior abdominal wall, usually about 4 in. in length (at first), and terminating at a point $1\frac{1}{2}$ to 2 in. above the symphysis pubis. This incision may be lengthened later in an upward direction, until it is large enough to allow of the easy delivery of the tumour. The incision is carried through the strata of the abdominal wall between the rectus muscles, until the peritoneal cavity is opened.

(b) *Exposure and separation of the uterus and the tumours in connection with it.*—When the peritoneal cavity has been opened, the tumour, if of moderate or large size, appears in the bottom of the wound. Should the great omentum be adherent to it in any part, the adhesions if recent are separated by gentle manipulation with the fingers, but if of old standing and fibrous in character, they are ligatured in two places and divided between. When the tumour has been fully exposed in this manner, the intestines and omentum are protected with flat sponges, and the mass is delivered as far as possible through the external incision, and lifted up by an assistant. In the case of large tumours the “myoma screws” will be found of much use. If other adhesions become visible as the tumour is lifted up, they are dealt with in the usual manner.




FIG. 144. — Myoma screw.—
TAIT.

(c) *Ligature of the blood vessels and transfixion of the broad ligaments.* — Four arteries require ligature, two on each side—the ovarian artery and the uterine artery. The relative position of these vessels is shown in Fig. 145. The ovarian artery is sought for in the broad ligament, immediately below the pelvic brim, isolated, tied in two places, and then divided between. The broad ligament is then transfixed (if this can be done) and ligatured in two places, and then divided. The division is commenced just internal to the pelvic brim, and extended downwards and inwards to its attachment to the cervix of the uterus. During this part of the operation large veins will be met with, and also the round ligament of the uterus. All these structures are included within the ligatures,

and divided. The uterine artery is now sought for immediately external to the neck of the uterus, and in the base of the broad ligament. When found it is isolated, ligatured in two places, and divided between, care being taken not to

include the ureter, a misfortune which can be avoided by applying the ligature within half an inch of the cervix.

(d) *Application of an elastic ligature to the pedicle or base of the tumour.*—An elastic ligature of red rubber tubing is passed around the lowest portion of the pedicle, and well below the point where it is proposed to effect a separation. This is fastened temporarily by grasping it with a pair of strong pressure forceps. This ligature is only a precautionary measure to control hæmorrhage in case all the large blood vessels have not been included within the ligatures. It is advisable to seize the base of the pedicle on the tumour side of, but close to, the elastic ligature with two pairs of vulsellum forceps, so as to prevent the stump retracting and the elastic ligature slipping off.

(e) *Removal of the uterus and the attached tumours.*—The

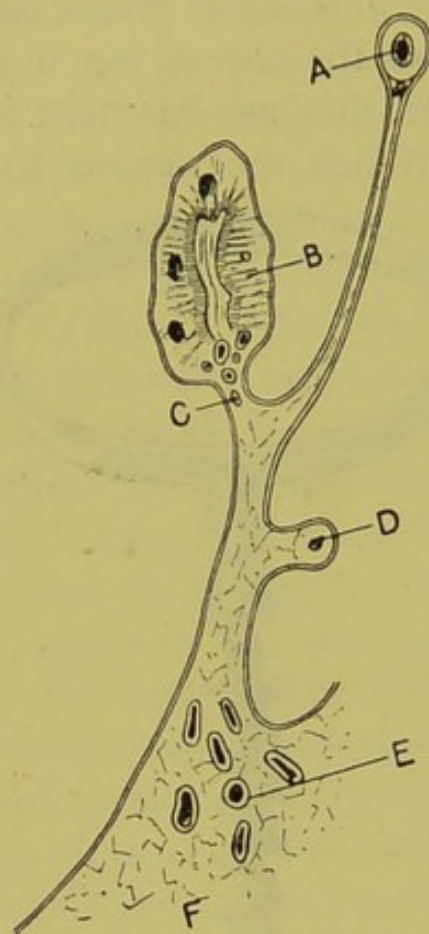


FIG. 145. — Hysterectomy. Relative position of structures in broad ligament, as shown in an antero-posterior section.—After TESTUT.

A. Fallopian tube; B. Ovary; C. Attachment of ovary to broad ligament; D. Round ligament of uterus; E. Uterine artery and veins; F. Position of ureter.

tumour is lifted up by the assistant who has charge of it, and then the surgeon, with a large scalpel, divides the pedicle or base of the tumour by a V or wedge shaped incision, so that the cut surface of the tumour when removed

has the shape of a wedge. If all the blood vessels have been ligatured in the earlier part of the operation, no bleeding takes place from their proximal ends when they are severed. Considerable hæmorrhage, however, often takes place from the tumour itself, on account of its great vascularity. This is avoided by grasping the broad ligaments near the uterus with large pressure forceps. If any bleeding points are seen on the cut surface of the pedicle, they are at once tied.

(f) *Closure of the mucous membrane of the uterine canal.*—If the V-shaped incision has been carefully made, the canal of the cervix will be found in the bottom of the wound and in the middle of the pedicle. The mucous membrane is dissected up for a short distance, well sponged with an antiseptic, and then united with a suture of fine silk.

(g) *Closure of the wound left after removal of the uterus.*—The elastic ligature is carefully relaxed, and if any bleeding points become visible, they are taken up with pressure forceps and tied with fine silk. When all bleeding has been arrested, the surfaces of the V-shaped incision are brought into apposition and fixed, first by buried sutures which bring the muscular surfaces together, and finally by a row of sutures which unite the peritoneum over the surface

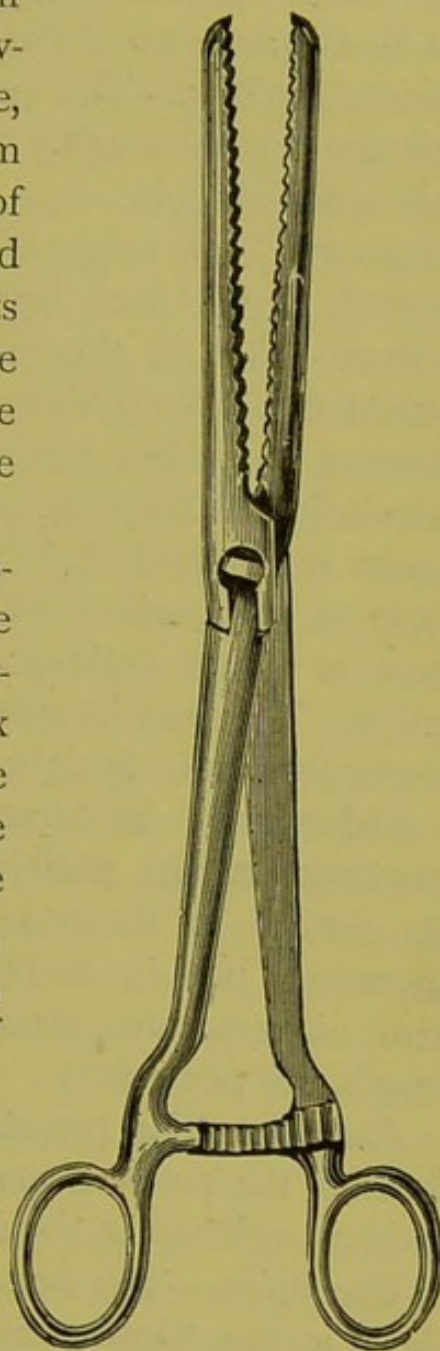


FIG. 146. — Hysterectomy. Large pressure forceps for applying to broad ligament close to uterus to control hæmorrhage.

of the stump. The lines of division of the broad ligaments are also sutured in a similar manner, a covering of peritoneum being fixed over the cut surfaces which are left.

(h) *Performance of the "peritoneal toilet," and closure of parietal incision.*—The pelvic cavity and the area of operation are now thoroughly cleansed from blood clot and fluid, and sponged quite dry. Irrigation may be carried out if necessary. All sponges are removed, and the intestines allowed to fall back into the pelvis. The external wound is then closed in the manner advised in connection with ovariectomy. No drainage tube is as a rule necessary. If, however, there has been much oozing, owing to the great vascularity of the parts, or the tumour has been the seat of recent inflammation, it is advisable to leave the inferior angle of the parietal wound open, and to pass a strip of gauze or a glass drainage tube down into the bottom of the pelvis. This can in most cases be removed at the end of twenty-four or forty-eight hours.

Abdominal hysterectomy with "extraperitoneal" treatment of the pedicle.—*Instruments.*—The instruments are similar to those required for the "intraperitoneal" operation, but in addition a "serre-nœud," piano wire, wire nippers, and strong "guarded" steel pins, 4 in. in length, are necessary.

Position.—The preparation of the patient, and the positions of the patient, operator, and assistants, are similar to those mentioned in the "intraperitoneal" operation.

Operation.—The stages of the operation are the same as those in the "intraperitoneal" method, up to the time of delivery of the tumour. When the uterus and attached tumour have been lifted well up into the abdominal wound, in an almost vertical direction, by an assistant, the operator examines the base of the tumour or the pedicle, and makes out its connections, especially the position of the bladder, the ureters, the internal os uteri, and the uterine appendages. The wire of the "serre-nœud" is then passed

around the pedicle at the level of the internal os uteri if possible, avoiding inclusion of the bladder or ureters, but taking in the ovaries and appendages. If these latter structures are placed so low in the pelvis that they cannot be readily included within the wire ligature, they are tied separately at a later period, when the uterus and attached tumours have been removed. When the wire loop has been placed in position it is gradually tightened so as to firmly grasp the pedicle. The steel "guarded" pins are next passed through the pedicle immediately distal to the wire loop, in a direction at right angles to the parietal wound. The introduction of these pins may be facilitated by pressing down the margins of the abdominal wound with flat wide retractors. The tumours, and that portion of the uterus which is distal to the line of application of the wire and pins, are cut away with a scalpel about three-quarters of an inch beyond them. The wire is then further tightened, and the field of operation completely freed from blood clots and other débris which may be present, and thoroughly cleansed. The stump of the pedicle is fixed in the inferior angle of the parietal wound, and the remainder of the abdominal incision closed by the insertion of sutures in the usual manner. If there are any unnecessary projections from the surface of the pedicle they may be cut away with scissors. Antiseptic dressings are now applied, and the wound treated in the ordinary aseptic manner.

After-treatment.—The divided surface of the pedicle must be carefully looked after, and the wire ought to be tightened daily, or oftener if any oozing appears upon the surface of the stump. No moist form of dressing should be applied to the stump, in order that the formation of a necrosed dry stump may be facilitated. When this has taken place the constricting wire may be removed. The necrosed portion of the stump usually separates in about a fortnight's time, or occasionally a little earlier. The portion of the parietal wound not occupied by the pedicle heals by

first intention in favourable cases, and the part in which the stump of the pedicle is situated at the end of several weeks by a process of granulation.

Vaginal hysterectomy.—Vaginal hysterectomy means the removal of the entire uterus, per vaginam. Supravaginal amputation, or cutting off the cervix uteri at the level of the internal os, is also performed, but for malignant disease removal of the whole uterus is preferable.

Supravaginal amputation of the cervix uteri.—*Instruments.*—Clover's crutch, Sims' speculum, vulsellum forceps, scalpel, scissors, bladder sound, pressure forceps (long and

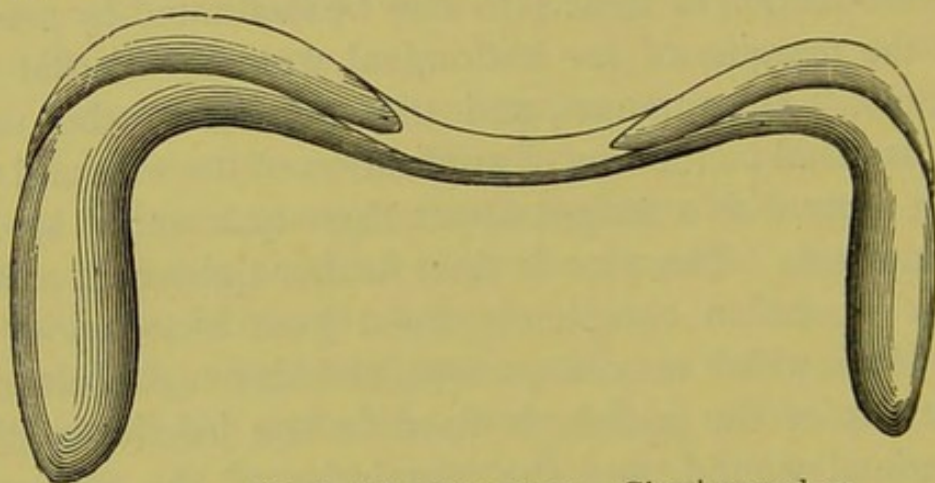


FIG. 147.—Vaginal hysterectomy. Sims' speculum.

short), retractors, pedicle needle, needles, needle-holder, sponge-holder, and ligature material.

Position.—The patient is placed in the lithotomy position, the limbs being separated by Clover's crutch. The surgeon sits facing the perineum, and the assistant stands on his left hand; a second assistant, if available, stands on his right.

Operation.—Careful consideration must be given to the anatomy of the region during the entire operation, otherwise important structures such as the ureters may be wounded.

A large Sims' speculum is passed along the posterior vaginal wall, and the lateral walls of the vagina are held aside with retractors by the assistants. The cervix is seized with vulsellum forceps, and drawn down as far as possible.

An incision is made in front of the cervix as in Fig. 148, *a*,

and a sound passed so as to define the limits of the bladder.

The bladder is now carefully separated from the cervix, partly with the fingers and partly with scissors, and pushed upwards behind the symphysis. This separation is continued until the reflection of the peritoneum is reached, but this is not incised.

The posterior incision is now made, as in Fig. 148, *b*, the speculum is removed, and the cervix pulled forwards and upwards.

The cervix is separated from its posterior attachments, but Douglas's pouch is not opened unless the growth involves a considerable portion of the cervix.

The cervix at this stage is attached laterally to the bases of the broad ligaments, and these attachments require division.

The ends of the anterior and posterior incisions are united by superficial cuts, and the lower portions of the broad ligaments ligatured. This is effected by passing a

strong blunt curved pedicle needle through the base of each ligament, and then tying the ligature carried by the needle, care being taken to avoid the ureter.

The cervix can now be cut away from the ligatured portion of the broad ligament on each side.

When this has been done, the next portion of the broad ligament is treated in a similar manner. By these means the cervix is freed to the level of the internal os uteri; it

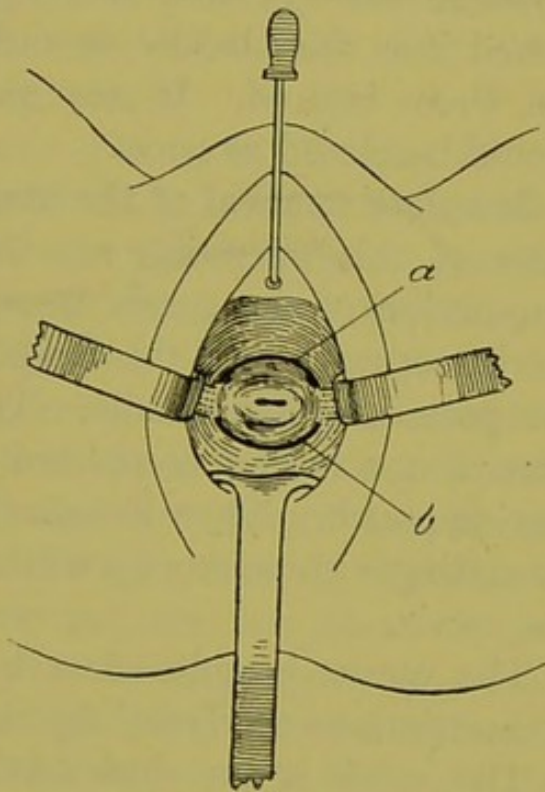


FIG. 148. — Vaginal hysterectomy. Line of anterior and posterior incisions.

a. Anterior. | *b.* Posterior.

can be amputated by cutting across its attached portion transversely.

The margins of the cut vaginal walls can now be united to the stump of the cervix by the insertion of interrupted sutures.

If it is not possible to ligature the broad ligaments, long pressure forceps may be left on as clamps, and removed after twenty-four or forty-eight hours.

Before the operation is completed, the sound should be passed into the bladder, in order to ascertain if this viscus has been injured. If any perforation is discovered, it should be closed at once.

Complete removal of the uterus, per vaginam.—The first steps of this operation are the same as in supravaginal amputation of the cervix uteri, namely, drawing down the cervix, separation of the bladder in front, and incision of the posterior vaginal walls. The separation of the bladder from the cervix is completed by opening up the vesico-uterine pouch. Then Douglas's pouch is opened up behind by cutting with scissors, care being taken to keep close to the cervix.

The uterus is quite clear in front and behind, only its connections to the broad ligaments remain.

The cervix is now drawn well down, first to one side and then to the other, and the broad ligaments on each side ligatured in a series of loops. As each segment of the broad ligament is tied, it is divided close to the uterus. Gradually the cervix is freed on each side, and the uterus may be drawn down lower and lower, till the final ligatures enclose the upper portion of the broad ligament and the Fallopian tube.

The entire uterus is now free and can be removed. If any of the ligatures fail, long clamp forceps may be used to grasp the broad ligament.

The vagina is next thoroughly cleansed by sponging, and its interior packed with strips of aseptic gauze.

Some surgeons advise that the peritoneal cavity should be shut off by uniting the cut margins of the vaginal walls; this does not appear to be necessary, whilst the gauze serves as a drain.

OPERATIONS UPON THE PERINEUM.

Rupture of the female perineum.—Rupture of the female perineum may be either *complete* or *partial*. In the former case the laceration extends into the rectum, and in the latter it falls short of the rectal tissue.

The rupture usually occurs during labour, and in such case the repair should be effected at once. When this is not done, or if the operation fails, the torn tissues granulate and heal, but a laceration is left which may require one of the following operations for its cure.

Operation for partial rupture ("flap-splitting method").

—*Instruments.*—Scalpels, Sims' vaginal speculum, pressure forceps, dissecting forceps, scissors (sharp-pointed and angular), curved needle, needle on a handle, and ligature material (silver wire, silk-worm gut, and fine silk).

Position.—The patient is placed in the lithotomy position, a Clover's crutch being used, and the buttocks allowed to project beyond the end of the table. The surgeon seats himself opposite the perineum of the patient, and an assistant stands upon each side.

Before the operation is commenced, the area of operation should be rendered aseptic by irrigation and washing with an antiseptic solution.

Operation.—An incision is made with the knife or angular scissors, which commences behind at the posterior margin of the rupture, and extends forwards in the direction shown in Fig. 149. By this means a U-shaped flap is made. The surgeon next seizes the lowest portion of this flap with a pair of Spencer Wells' forceps, and with a scalpel or scissors splits up the recto-vaginal septum, so as to

turn up a flap of vaginal mucous membrane to the upper limits of the original incision on each side. The fingers of the left hand may be passed into the rectum during this proceeding, but this should be avoided if possible, on account of the risks of septic contamination of the wound.

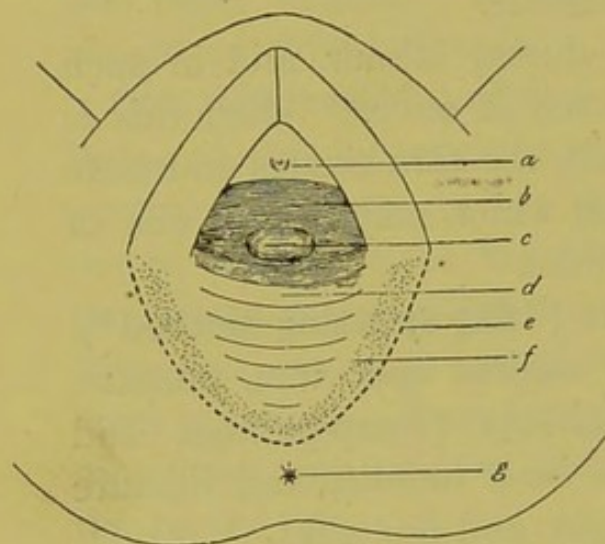


FIG. 149. — Rupture of perineum (partial). Line of first incision.

- a. Vestibule and urethra.
- b. Anterior vaginal wall.
- c. Cervix.
- d. Posterior vaginal wall.
- e. Line for first incision.
- f. Torn surface which has granulated.
- g. Anus.

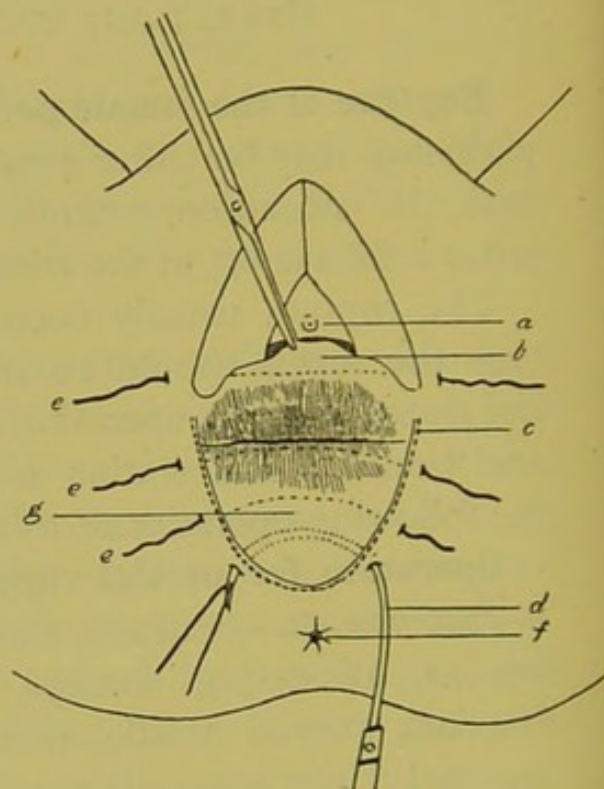


FIG. 150. — Rupture of perineum (partial). Method of introduction of sutures.

- a. Vestibule and urethral orifice.
- b. Anterior or vaginal flap raised.
- c. Line of incision.
- d. Curved needle passed and threaded.
- e. Line of other sutures.
- f. Anus.
- g. Raw surface exposed by raising vaginal flap.

Fig. 150 shows the flap well dissected up. It is advisable to keep this flap fairly thin, in order to avoid wounding the large rectal veins.

All bleeding is now arrested, and the sutures are introduced. For the introduction of the sutures, a curved needle on a handle is the best. The needle is entered on

one side of the incision about one-quarter of an inch outside the margin, then pushed through the tissues in the floor of the wound, care being taken not to allow it to enter the rectum, and brought out an equal distance on the other side. It is threaded with silver wire or silk-worm gut, and

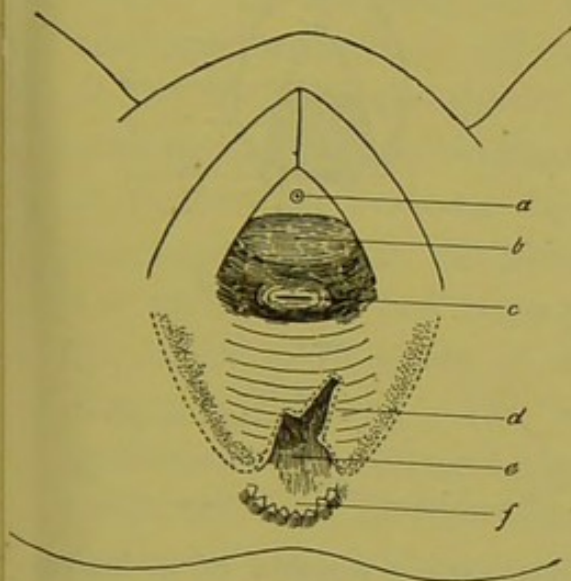


FIG. 151.—Rupture of perineum (complete). Line of first incision.

- a.* Urethral orifice.
- b.* Anterior vaginal wall.
- c.* Cervix.
- d.* Line of incision for raising vaginal flap.
- e.* Mucous membrane of bowel.
- f.* Torn orifice of anus.

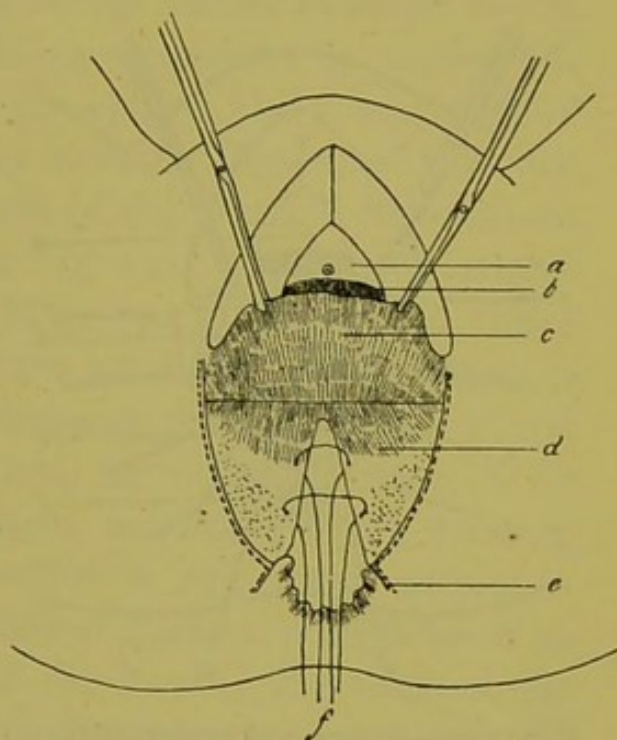


FIG. 152.—Rupture of perineum. Flap dissected up, and sutures closing laceration in rectal wall introduced, but not tied.

- a.* Vestibule.
- b.* Anterior vaginal wall.
- c.* Vaginal flap raised.
- d.* Raw surface made by raising vaginal flap.
- e.* Line of incision prolonged backwards to expose ends of sphincter.
- f.* Rectal sutures passed.

withdrawn. Four or five sutures are requisite, the upper ones taking in the vaginal flap. This method of introducing the sutures is illustrated in Fig. 150.

The sutures are then tied, and the raw surfaces of the lozenge-shaped wound brought into exact apposition from behind forwards. Care must be taken to cleanse the

entire wound from blood, and to bring the edges of the skin close together.

The un-united margins of the vaginal flap are next approximated by the insertion of a few fine silk sutures, and then the operation is completed.

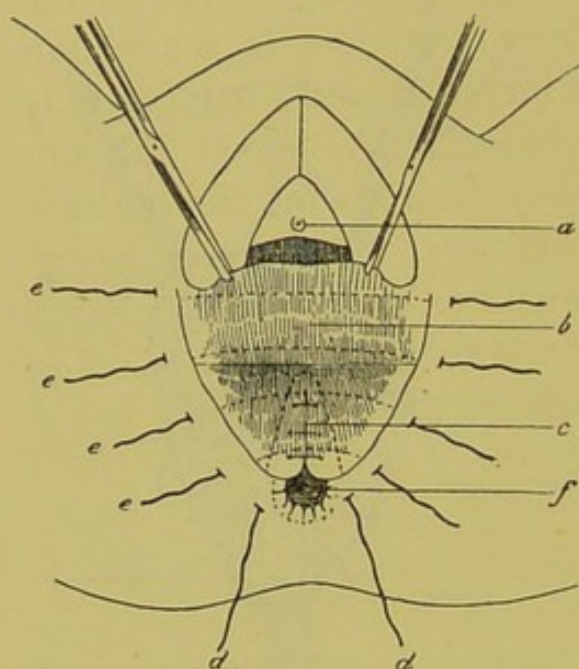


FIG. 153.—Rupture of perineum (complete). Laceration in rectum closed, and second series of sutures introduced.

- a.* Urethral orifice.
- b.* Vaginal flap raised.
- c.* Tear in bowel closed, rectal sutures tied, knots are on bowel surface cut short.
- d.* Purse-string suture passed but not tied.
- e.* Ordinary perineal sutures passed ready for tying.
- f.* Anus restored.

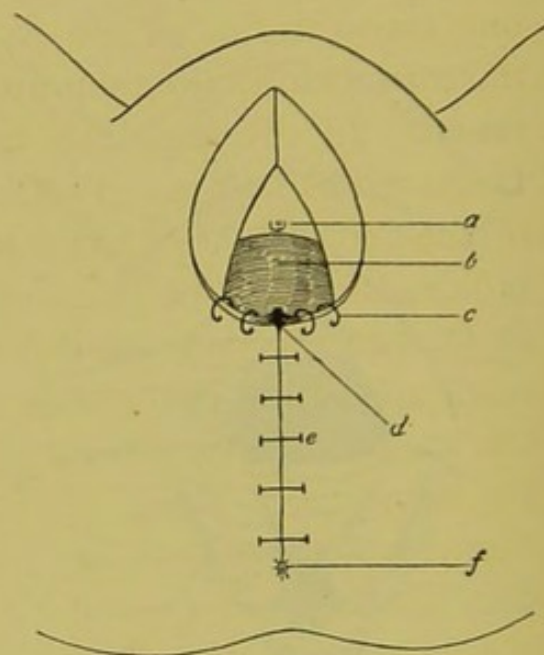


FIG. 154.—Rupture of perineum (complete). Operation completed.

- a.* Vestibule.
- b.* Anterior vaginal wall.
- c.* Vaginal sutures.
- d.* Perineal flaps closed.
- e.* Perineal sutures tied.
- f.* Anus restored.

Operation for complete rupture.—The steps of the operation are practically the same as for partial repair, but in this case the continuity of the external sphincter ani must be restored. In most cases the anus will be seen gaping, with the recto-vaginal septum torn and the mucous membrane of

the bowel exposed and often prolapsed. The ends of the sphincter are torn and widely separated.

Position.—The positions of the patient, the surgeon, and his assistants are similar to those of the preceding operation. The same instruments also are requisite.

Operation.—An incision, which is similar in shape to the one made use of in the previous operation, is made, but the torn recto-vaginal septum is included, and a flap carefully raised. In this case the flap is really W-shaped and not U-shaped as before. The form of the flap and the outlines of the incision are shown in Fig. 151. The lower lateral prolongations of the incision (Fig. 152, *e*) are made in order to freshen the ends of the torn sphincter and to allow of exact apposition in the later stages of the operation. When the vaginal flap has been raised, the rectum is repaired by the insertion of a row of sutures, according to the method shown in Fig. 152. The insertion of this row of sutures is commenced above, and a sufficient number is introduced to close the rent in the wall of the bowel; the ends of the sphincter are approximated, and the anus is reproduced. Catgut or fine silk may be used for the sutures in this stage. In order to further strengthen this union, some surgeons advise that a "purse-string" suture (Fig. 153, *d*) should also be inserted.

The next stage of the operation is similar to that for repair of a partial rupture. The row of sutures of silver wire or silk-worm gut is introduced, after the method shown in Fig. 153; and when these sutures have been tied, the perineum has the appearance shown in Fig. 154.

It occasionally happens that there is much loose flabby skin at the sides of the U-shaped incision, and when this is the case it is advisable to remove the redundant portions, in order that more healthy tissues may be opposed.

After-treatment.—Dry aseptic dressings are applied, and the patient's legs tied together. The bladder should be

evacuated with the catheter for the first few days ; if there is much pain, a morphia suppository may be used. On the fourth day the bowels should be opened with a simple oil enema, or the administration of a mild purgative, or both. The sutures are removed on the eighth day ; but if a "purse-string" suture has been introduced, it will be found necessary to remove this at an earlier period.

When the patient has a prolapse of the uterus, it is advisable to keep her in bed for a week or ten days before the operation is attempted. The uterus is often in these cases much swollen and congested, and the rest in bed helps to restore it somewhat to its normal condition.

CHAPTER IX.

OPERATIONS UPON THE RESPIRATORY SYSTEM.

I. OPERATIONS UPON THE LARYNX.

- A. Laryngotomy.
B. Thyrotomy.
C. Excision of the larynx, (1) complete.
 " " (2) partial.
D. Intubation.

2. OPERATIONS UPON THE TRACHEA.

- A. Tracheotomy. (1) High operation.
 „ (2) Low operation.
 B. Laryngo-tracheotomy.

3. OPERATIONS UPON THE LUNGS.

- A.* Pneumotomy.

4. OPERATIONS UPON THE PLEURÆ.

- A. Paracentesis.
B. Incision of pleura.

OPERATIONS UPON THE LARYNX.

Laryngotomy. — The term "laryngotomy" is used to designate an operation which consists in establishing a communication between the interior of the larynx and the surface of the neck, through an incision dividing the crico-thyroid membrane.

(a) *Indications*.—Sudden impaction of a foreign body, such as a portion of food or a tooth-plate, in the upper aperture of the larynx.

(b) Some forms of disease of the upper part of the

larynx, such as oedema due to swallowing hot fluids, in which the obstruction is only temporary.

Laryngotomy is usually an operation of emergency, since diseases of slow progress are rarely confined to the upper portion of the larynx.

Instruments.—Scalpel, dissecting, pressure, and artery forceps, retractors, blunt hooks, tracheal dilator, laryngotomy tube, needles, and ligature material.

Position.—The patient is placed in the dorsal posture, with a hard pillow underneath the neck, and the head

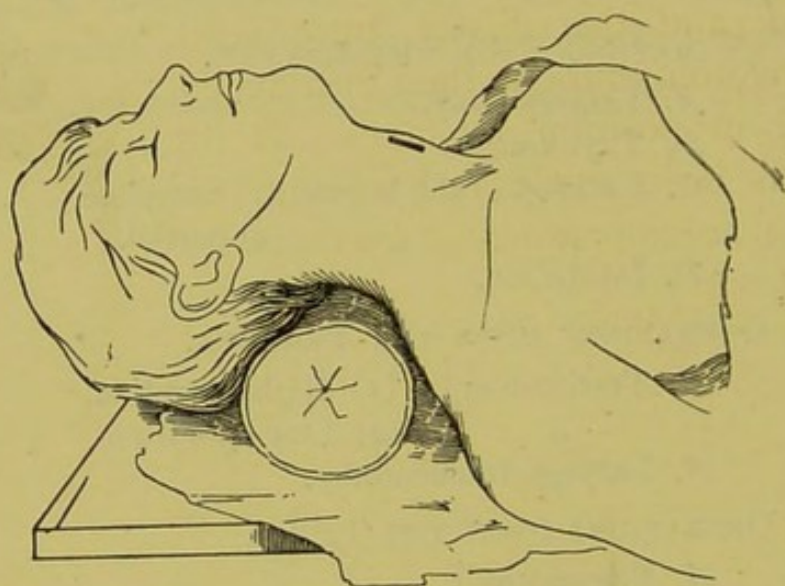


FIG. 155.—Laryngotomy. Position of patient, and line of incision.

projecting slightly over the end of the table; the surgeon stands on the right side of the patient, and his assistant directly opposite to him.

Usually it will not be possible to give the patient anæsthetic, owing to the urgency of the case, and the imperative need for immediate operation.

Operation.—With the finger and thumb of the left hand the surgeon grasps the larynx and holds it firmly, then he makes a vertical incision in the middle line of the neck, about an inch in length, commencing, above, just below the notch of the thyroid cartilage, and extending downwards to the lower border of the cricoid. This incision divides the

skin, superficial and deep fasciæ, and exposes the interval between the two sterno-hyoid muscles. These muscles are held aside with blunt hooks, and the lower border of the thyroid cartilage defined. The anterior surface of the crico-thyroid membrane will then be visible. It is cleared as far as the cricoid, when an incision half an inch in length is made through it and the underlying mucous membrane along the upper border of the cricoid, and at right angles to the direction of the external incision. This having been done, the cavity of the larynx is opened, and the dilator introduced. The laryngotomy tube is then introduced, and fixed in position by tapes. If the wound has been made rather long, the extremities are approximated by the insertion of a few points of suture.

During the course of the operation all bleeding vessels are immediately seized with pressure forceps. The transverse cut in the crico-thyroid membrane is to avoid the anastomosis of the crico-thyroid arteries—branches of the superior thyroid.

Thyrotomy.—The operation of thyrotomy consists in the division of the thyroid cartilage through an incision in the middle line of the neck.

Indications.—(a) Some forms of disease of the larynx in which it is impossible for the surgeon to make an exact diagnosis, such as suspected epithelioma.

(b) The presence of foreign bodies within the sacculus laryngis, or the interior of the larynx, which cannot be extracted by other measures.

(c) Papillomatous growths of the vocal cords, which cannot be satisfactorily removed by the intra-laryngeal method.

(d) Some forms of ulceration of the inter-arytenoid region

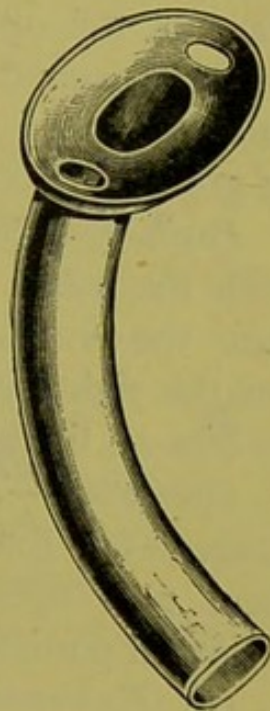


FIG. 156.—Laryngotomy tube.

of the larynx (malignant and tubercular), which are considered suitable for local removal.

Instruments.—Scalpel, dissecting and pressure forceps, sharp hooks, retractors, scissors, Volkmann's spoon, small saw (Hey's), needles, needle-holder, and ligature material (silk and silver wire), and the instruments for tracheotomy.

Preliminary tracheotomy.—Three or four days before the performance of thyrotomy, it is advisable to perform a preliminary tracheotomy, or this can be done as the first stage of the operation. In either case a sponge should be packed around the upper portion of the tracheotomy tube, so as to prevent the passage of blood and particles of growth into the trachea.

Position.—The patient is placed in the dorsal posture, with the neck supported by a sandbag or a pillow, and near the end of the operation table. The operator stands on the right side of the patient, and the assistant opposite to him on the left.

Operation.—The operation may be divided into four stages—(a) External incision; (b) division of thyroid cartilage and opening of laryngeal cavity; (c) removal of diseased portion; and (d) closure of external wound.

(a) *External incision.*—The thyroid cartilage is fixed between the thumb and forefinger of the left hand, and a vertical incision, in the middle line of the neck, is commenced about half an inch below the body of the hyoid bone, and extended downwards to the upper border or the middle of the cricoid cartilage.

This incision divides the skin and fasciæ, and defines the interval between the two sterno-hyoid muscles. These muscles are separated with retractors, and the fascia in front of the thyroid cartilage divided.

(b) *Division of thyroid cartilage and opening of laryngeal cavity.*—If the patient is under 40, it is usually possible to divide the thyroid cartilage with a scalpel along the middle line from the centre of the notch above to the

crico-thyroid membrane below, but in older people this cartilage becomes ossified, and it is necessary to use a small saw for its division. Before the cartilage is divided it is well to pass a silk ligature through both alæ. The cartilage having been cut through, this ligature is pulled out of the larynx and cut across. The two halves of the ligature then serve as retractors to draw aside either half of the cartilage. If a ligature is not used, the two halves are drawn apart with retractors or sharp hooks. The lateral alæ having been separated by one of

the above methods, the mucous membrane which appears at the bottom of the wound is divided so as to open up the interior of the larynx. When this has been done, and the two halves of the thyroid further separated, the interior of the larynx will be fully exposed to view. It is advisable at

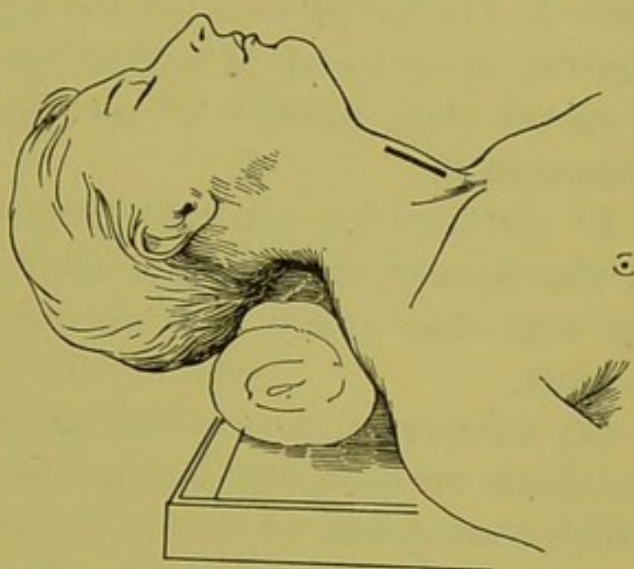


FIG. 157. — Thyrotomy. External incision.

this stage to plug the upper part of the trachea with a small sponge attached to a piece of silk passed downwards between the vocal cords (if it has not already been done). If, however, the rima glottidis is much encroached upon by new growth, this procedure is not possible.

(c) *Removal of diseased tissue, or foreign body, etc.*—If the operation has been performed for the removal of a papillomatous growth, this is removed either by scraping with a Volkmann's spoon, or by careful cutting with a fine pair of scissors or a scalpel; or if for a localised epithelioma, this is dissected away, care being taken to cut through normal tissue well beyond the margins of the affection. In the case of ulceration, in tuberculosis of the larynx,

the affected areas are well scraped, so as to remove all affected tissue. When a foreign body is lodged in the sacculus laryngis, it is extracted, if possible, through the opening of this space into the cavity of the larynx, or, if this cannot be done, the mucous membrane over the most prominent point of the impacted body is incised, and then the extraction is performed.

In order to render the mucous membrane in the interior of the larynx more tolerable to surgical interference, and hence prevent reflex coughing, it is recommended that the entire laryngeal mucous membrane be painted with a 20 per cent. solution of cocaine before the operation is commenced.

If any arteries are cut across during the performance of the intralaryngeal part of the operation, they are picked up with fine artery forceps, and ligatured in the usual manner.

(d) *Closure of the external wound.*—When all bleeding has been arrested, the incision in the mucous membrane, which corresponds to that in the thyroid cartilage, is closed with a continuous silk suture. Next, the two halves of the thyroid cartilage are brought together and fixed in apposition with one or two sutures of silver wire. The holes made by the silk ligature afford a valuable indication in obtaining exact apposition. Finally, the wound in the fasciæ and skin is closed by the insertion of several points of interrupted suture of silk or silk-worm gut.

After-treatment.—The tracheotomy tube is worn for several days after the operation. When the swelling of the mucous membrane of the larynx has subsided, the tube is removed, and the wound allowed to close by granulation. The tracheotomy tube can usually be removed at the end of a week.

Excision of the larynx, or laryngectomy.—Excision of the larynx may be either complete or partial. In the former case the entire organ is removed with all its car-

tilages, and in the latter only the portion involved in the disease, usually a lateral half, is taken away.

Indications.—Removal of the larynx is only carried out for primary malignant disease, which does not involve the adjacent structures to any considerable extent.

Instruments.—Scalpel, scissors, retractors, sharp hooks, periosteal elevator, dissecting, pressure, and artery forceps, sponge-holders, tampon cannula, sponge plugs, needles, needle-holder, and ligature and suture material.

Preliminary tracheotomy.—Before attempting removal of the larynx, complete or partial, ten days or a fortnight previous to the operation a preliminary tracheotomy should be performed. It is advisable to open the trachea below the isthmus of the thyroid gland—low tracheotomy—if possible, so that the tracheotomy tube will not be in the way during the operation, and sufficient room will be allowed for plugging the trachea above the tube.

Position.—The patient is placed lying upon the back near the right edge of the table. The shoulders are slightly raised, and a hard pillow placed underneath the neck. The operator stands on the right side of the patient, and his assistant on the left.

Operation.—Removal of entire larynx.—The positions of the hyoid bone, the thyroid cartilage, and cricoid cartilage are first defined. An incision is then made in the middle line of the neck, commencing at the lower border of the hyoid bone and extending downwards to a short distance below the cricoid. This incision divides the skin and fasciæ, and exposes the surfaces of the cricoid and thyroid cartilages and the crico-thyroid and thyro-hyoid membranes, in the interval between the two sterno-hyoid muscles. A transverse incision is next made along the inferior margin of the body and great cornua of the hyoid bone. When the hyoid bone is exposed, the attachments of the sterno-hyoid, anterior belly of the omo-hyoid, and anterior portion of the thyro-hyoid muscle, are divided,

and the anterior aspect of the thyro-hyoid membrane fully laid bare. If the anterior margins of the sterno-mastoid muscles overlap the lateral portions of the larynx, they are pulled aside with retractors, but not divided.

The thyroid cartilage is split anteriorly, and the interior of the laryngeal cavity examined, and the extent and connections of the disease defined. If the entire organ, including the epiglottis, is found to be diseased, the operation is continued as follows :—

The attachments of the thyro-hyoid and the sterno-thyroid muscles to the external surface of the thyroid cartilage are separated with a periosteal elevator, and all the soft structures on the outside of the larynx peeled back. As the posterior part of the larynx is being reached, the attachment of the inferior constrictor muscle of the pharynx is separated from the cricoid and thyroid cartilages. As this is being done the crico-thyroid branches of the superior thyroid arteries will require ligature, together with any small muscular branches which may be met with. Next, the superior laryngeal branches of the superior thyroid arteries are secured, just before they pass through the thyro-hyoid membrane. Then the thyroid cartilage is pulled forward by an assistant by means of sharp hooks, whilst the surgeon cuts through the median and lateral portion of the thyroid-hyoid membrane, immediately below its attachment to the body and great cornua of the hyoid bone.

The epiglottis can now be hooked forwards, whilst the mucous membrane along its margins is incised, care being taken that the cut is made well beyond the disease. By careful dissection from above downwards, after the mucous membrane above the arytenoid cartilages has been cut through, and by gentle traction, the entire larynx can be pulled forwards, and its separation from the pharynx effected. Care must be taken not to button-hole the œsophageal or pharyngeal wall in the region of the cricoid cartilage. When the separation has been carried

beyond the limits of the disease, the crico-tracheal membrane, or one of the upper rings of the trachea, is cut through transversely and the larynx removed. As this is being done the margins of the trachea must be secured by passing two or more strong silk sutures through its wall; otherwise it may retract downwards towards the thorax.

All bleeding points are ligatured, and the sutures which pass through the tracheal wall tied to the margins of the lower part of the external wound.

The upper portion of the wound is sponged out, and the

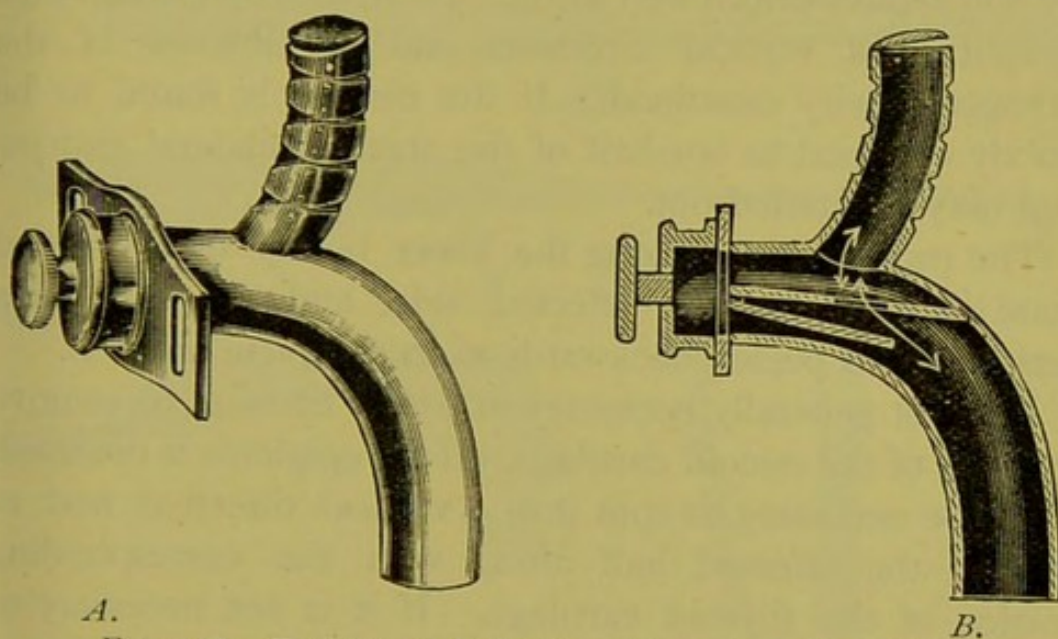


FIG. 158.—Excision of the larynx : Gussenbauer's artificial larynx.

A. External view.

B. Section.

margins of the incision in the pharyngeal wall approximated by the insertion of sutures.

The sponge-plugs are removed from the trachea, the tracheotomy tube taken out, and a cannula passed into the trachea from its upper end.

The entire wound is next packed with tampons of aseptic absorbent gauze. Usually it is advisable to unite the transverse portion of the incision with sutures, but the vertical portion should be allowed to close by granulation.

After-treatment.—The wound is kept as clean as possible

by daily dressing and irrigation, or sponging. The patient is fed by means of an œsophageal tube until the wound has commenced to close up.

When the external wound has sufficiently healed, the patient is fitted up with an artificial larynx, to enable him to articulate. Fig. 158 is a representation of an instrument which is used for this purpose.

Removal of part of the larynx.—The early stages of the operation are similar to those for complete excision.

A vertical incision is made down to the cartilages, and the soft tissues drawn well aside. Next, the thyroid cartilage is split in a vertical direction, and the interior of the laryngeal cavity examined. If the disease is found to be strictly confined to one-half of the organ, unilateral extirpation may be carried out.

The transverse cut along the lower border of the hyoid bone is made on the affected side, and the soft parts detached and peeled backwards as in complete excision.

It is not generally necessary in partial excision to remove any part of the cricoid cartilage. If the epiglottis is diseased, it will be necessary to split it in a vertical direction and to remove the affected half along with the corresponding portion of the thyroid cartilage. If it is not necessary to do this, the line of separation is made along the aryteno-epiglottidean fold of the diseased side.

Intubation of the larynx.—Intubation of the larynx is a bloodless operation, which has been introduced to replace tracheotomy in favourable cases. The operation is carried out by passing a metal tube into the laryngeal canal through the mouth; the enlarged upper end of the tube, when it has been introduced, rests upon the vocal cords, and the lower extremity extends downwards into the trachea.

Indications.—(a) Some forms of œdema of the larynx in which the stenosis is likely to be temporary.

(b) Stenosis of the larynx due to laryngeal croup.

(c) Chronic stenoses of the larynx which are fibrous in character, and due to the contraction of scar tissue formed as the result of previous inflammation and ulceration.

Instruments.—A set of O'Dwyer's tubes, a mouth-gag, a tube introducer or intubator, an extubator, and a long piece of silk of moderate thickness.

Position.—The patient (if a child) is placed in the sitting position on the knee of a nurse, a towel being wrapped around the chest so as to inclose the arms. The assistant

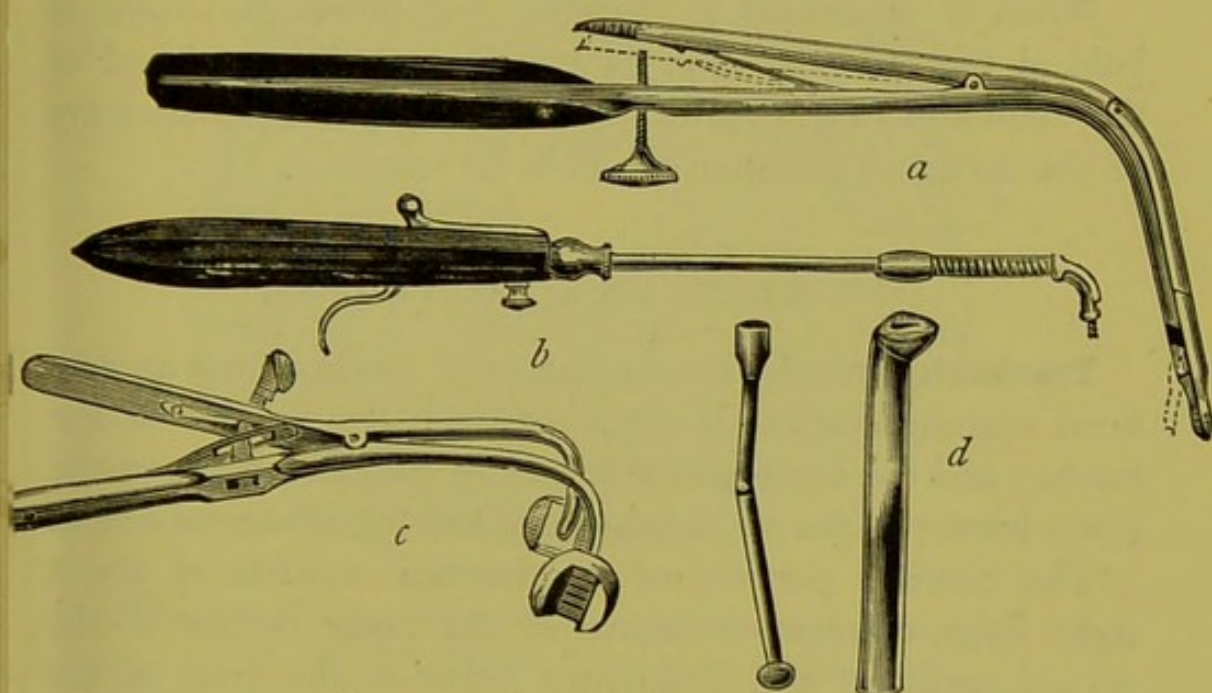


FIG. 159.—Intubation Instruments.

a. Extubator; *b.* Intubator; *c.* Gag; *d.* Intubation tube and pilot.

fixes the head with his hands, and holds the mouth open with the gag. The surgeon stands, or sits, directly in front of the patient.

Operation.—The mouth of the child is held open by the gag (Fig. 159, *c*) which is introduced and held in position by the assistant. A tube of suitable size is selected, the corresponding pilot is fixed on the intubator, the tube itself passed over the pilot, and a piece of silk passed through the aperture in the margin of the flange. Next the surgeon passes his left forefinger into the child's mouth and hooks forwards the epiglottis. The intubator and tube

are taken in the right hand, and the introduction of the tube is accomplished by passing it along the left forefinger until the upper aperture of the larynx is reached. The free extremity of the tube is pushed downwards until the flange at the upper part rests upon the vocal cords and the distal end reaches the upper part of the trachea. The tube is then detached from the intubator and the latter withdrawn. The piece of silk attached to the tube is fixed to the temporal region of the patient with a strip of strapping.

When it is wished to remove the tube, the child is held in the same position as before, and the distal end of the extubator (Fig. 159, *a*) is passed into the upper aperture of the tube. The latter can then be removed.

OPERATIONS UPON THE TRACHEA.

Tracheotomy.—In the operation of tracheotomy an artificial communication is made between the interior of the trachea and the surface of that part of the neck between the lower border of the cricoid cartilage and the episternal notch.

The cervical portion of the trachea consists of about eight rings, commences above at the lower border of the cricoid cartilage, and terminates below at the level of the episternal notch. The relations of the trachea to the surrounding structures are shown in Fig. 160.

The isthmus of the thyroid gland usually crosses the front of the trachea opposite the second and third and occasionally the fourth rings. When the opening into the trachea is made above the isthmus of the thyroid gland, the operation is called “high” tracheotomy; and when below, the “low” operation. The former is the one which is the more commonly performed.

Operation of “high” tracheotomy.—*Indications.*—The operation of tracheotomy may be required in the following clinical conditions, namely—

- (*a*) Certain cases of laryngeal diphtheria.

(*b*) Some forms of chronic ulceration of the larynx, where respiration is dangerously interfered with, or it is wished to give rest to the diseased areas, such as tuberculous, syphilitic, and epitheliomatous ulcerations.

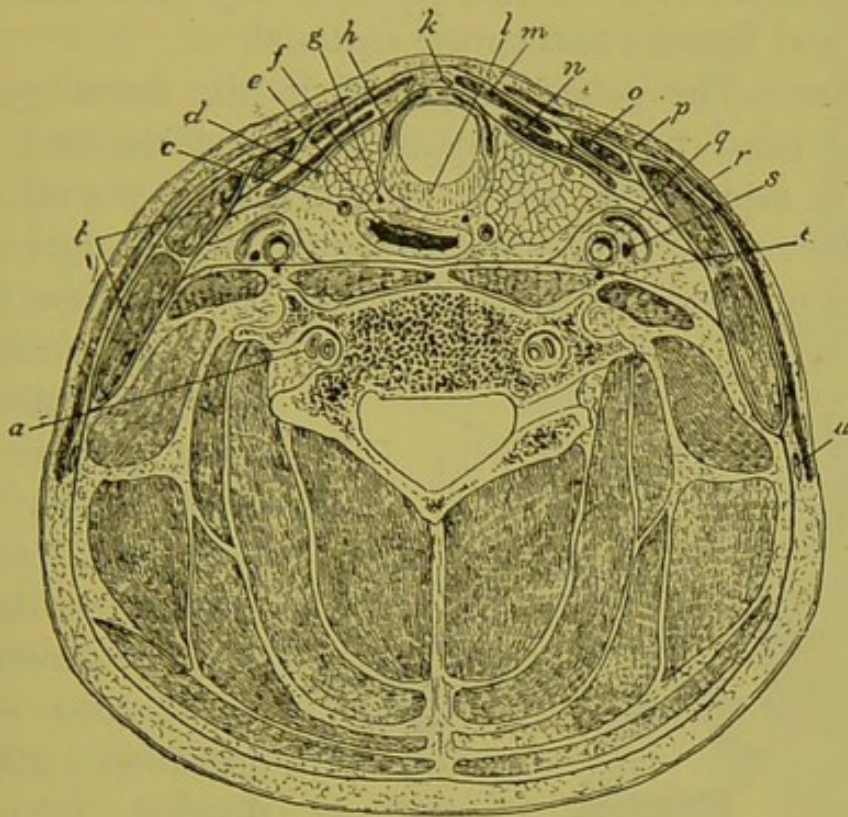


FIG. 160.—Transverse section through the neck, at the level of the lower portion of the cricoid cartilage.

- | | |
|--|----------------------------------|
| <i>a.</i> Vertebral vessels. | <i>l.</i> Cricoid cartilage. |
| <i>b.</i> Sterno-mastoid muscle. | <i>m.</i> Sterno-hyoid muscle. |
| <i>c.</i> Branch of superior thyroid artery. | <i>n.</i> Sterno-thyroid muscle. |
| <i>d.</i> Nerve to infra-hyoid muscles. | <i>o.</i> Omo-hyoid muscle. |
| <i>e.</i> Esophagus. | <i>p.</i> Platysma. |
| <i>f.</i> Lateral lobe of thyroid gland. | <i>q.</i> Common carotid artery. |
| <i>g.</i> Recurrent laryngeal nerve. | <i>r.</i> Internal jugular vein. |
| <i>h.</i> Crico-thyroid muscle. | <i>s.</i> Vagus nerve. |
| <i>k.</i> Inferior thyroid veins. | <i>t.</i> Phrenic nerve. |
| | <i>u.</i> External jugular vein. |

(*c*) Cases of severe stenosis of the larynx dependent upon cicatrisation, or when the interior is filled up with proliferating growths, such as papillomata.

(*d*) For the removal of foreign bodies in the lower portion of the trachea, or the bronchi.

(*e*) As a preliminary to the performance of some severe

operations about the upper part of the pharynx, mouth, or nose.

Instruments.—Scalpel, small retractors, dissecting forceps (two pairs), pressure and artery forceps, blunt hooks, two-bladed tracheotomy dilator, tracheotomy tube and tapes, needle, and ligature and suture material.

Position.—The patient is placed in the dorsal position, with the head projecting slightly beyond the end of the operation table (Fig. 161). A sandbag is placed underneath the neck. The operator stands on the right side of the neck of the patient, the chief assistant opposite to him,

and the anæsthetist (if an anæsthetic is being given) at the head. The anæsthetist will act as a second assistant if occasion demands.

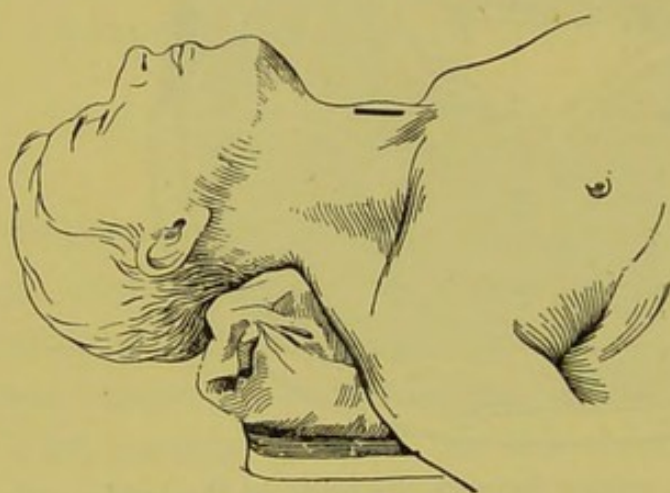


FIG. 161.—Tracheotomy. Position of patient, and line of incision in "high" operation.

Operation. — The operation may be divided into three stages, namely — (a) External incision ; (b) exposure and incision

of the trachea ; and (c) introduction of the tracheotomy tube, and partial closure of external wound.

(a) *External incision.*—The head of the patient is so placed that the symphysis of the lower jaw is exactly in the middle line ; and all through the operation this position of the head is maintained by the anæsthetist. If the head is allowed to deviate to one or other side, the operation is made more difficult, especially in young children. The cricoid cartilage is next defined, and grasped between the thumb and forefinger of the left hand. The central point of the cricoid cartilage is taken, and an incision made vertically downwards from this point for $1\frac{1}{2}$ in., towards

the centre of the episternal notch. In an adult with a fat neck, it is necessary to make the incision longer. With the scalpel the skin, superficial fascia, and anterior layer of the deep fascia, are divided, and the space between the muscles opened. This space is lozenge-shaped, being limited externally by the sterno-hyoid muscles above, and by the sterno-thyroids below. The fascia in this interval is incised, and the muscles drawn aside with retractors or blunt hooks by an assistant. The pre-tracheal layer of the cervical fascia is next divided, and the anterior aspect of the upper rings of the trachea and the isthmus of the thyroid gland laid bare.

(b) *Exposure and incision of the trachea.*—

The isthmus of the thyroid gland is drawn downwards with a blunt hook, so as to fully expose the upper two or three tracheal rings. In order to facilitate this, it is sometimes advisable to divide the fascia transversely, immediately below the lower border of the cricoid. When the surface of the trachea has been thoroughly exposed, an incision is made with the scalpel through its upper three rings, and also through the crico-tracheal membrane, in the middle line and in an upward direction. During all these manipulations the cricoid cartilage and the upper rings of the trachea have been steadied in position by the left forefinger and thumb of the surgeon.

If any blood vessels (usually veins) are divided during the early stages of the operation, they




FIG. 162.—Tracheotomy. Blunt hook for drawing aside margin of wound.

are picked up with artery forceps by the assistant, and ligatured.

(c) *Introduction of the tracheotomy tube, etc.*—When an

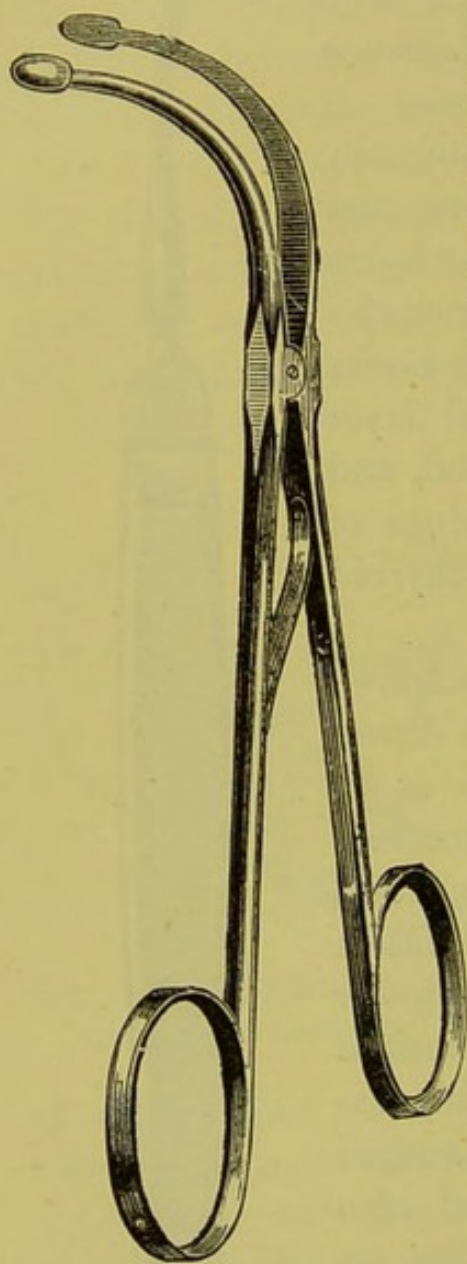


FIG. 163a.—Tracheotomy.
Tracheal dilators.

opening has been made into the cavity of the trachea, its presence is made evident by the rushing sound which is produced by the entrance of air. The margins of the incision in the trachea are held apart by passing into it dilators or a pair of dressing forceps, the blades of which are afterwards separated. All diphtheritic membrane or other loose substance is allowed to be coughed out from the trachea, and then the tube is inserted. The tube is threaded with tapes, and then inserted into the tracheal aperture between the blades of the dilator. The dilator is now withdrawn, and the tube fixed by tying the tapes around the neck.

If the external wound is large, the portions above and below the tube are united by the insertion of one or two points of suture. Aseptic dressings are applied, and the patient sent back to bed.

Operation of "low" tracheotomy.—This operation is occasionally necessary in severe dyspnoea, dependent upon compression of the trachea by an enlarged thyroid gland, or by malignant enlargement of the lymphatic glands of the neck. It is performed as a preliminary operation in laryngectomy, and also for foreign bodies impacted in the bronchi.

The operation only differs from the "high" operation in the position of the external incision, and the greater depth to which the dissection has to be carried. The incision is usually 3 in. in length, or even more; it commences below the cricoid cartilage, and extends to the upper border of the episternal notch. The same muscles are separated, the thyroid isthmus is pulled upwards instead of downwards, whilst the inferior thyroid veins and the thyroidima artery (when present) have to be dealt with.

In young children, if this operation has to be performed, the point of the scalpel must not be allowed to extend into the thorax behind the manubrium sterni, otherwise the innominate artery, the left innominate vein, or the arch of the aorta, may be injured. The upper portion of the thymus gland may cover this part of the trachea and require to be drawn aside.

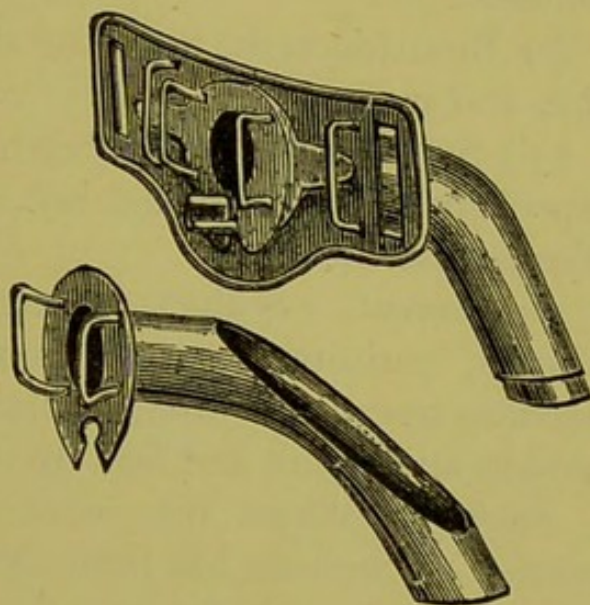


FIG. 163*b*.—Tracheotomy. Tracheotomy tube.—PARKER.

Laryngo-tracheotomy.—

In young children it is often advisable to incise both the cricoid cartilage and the upper rings of the trachea, in order to give sufficient room for the easy introduction of a tracheotomy tube. The operation is similar to the ordinary operation of "high" tracheotomy, with the exception that the incision in the neck extends to a slightly higher level, and the cricoid cartilage is divided at the same time as the upper rings of the trachea. In this operation, one, or at most two, rings of the trachea require division.

OPERATION UPON THE LUNGS.

Pneumotomy.—By the term “pneumotomy” is understood that surgical operation which has for its object the making of an incision into the lung.

Indications.—(a) Localised abscess of the lung.

(b) Gangrene of the lung.

(c) Hydatid cyst of the lung.

(d) Foreign bodies within the lung which are giving rise to symptoms, and are so situated that they are capable of removal.

(e) Bronchiectasis, when the cavities are of considerable size, and increasing.

(f) Some forms of tuberculous cavity of the lung, especially when single, and not associated with tuberculous disease elsewhere.

Instruments.—Scalpel, dissecting, pressure, and artery forceps, periosteal elevator, retractors, scissors, aneurysm needles, trocar and cannula, drainage tube, needles, needle-holder, and suture and ligature material.

Position.—When the exact position of the affected portion of the lung has been defined, the patient is placed lying somewhat on the sound side, and with the affected side near the edge of the operation table. The surgeon stands on the affected side of the patient, and the assistant opposite to him.

Operation.—The area of operation having been carefully rendered aseptic, the position of the abscess, cyst, etc., is made out, an exploring syringe being used if necessary. An incision is made over the middle of the affected area, and so situated that it is parallel with the underlying intercostal space or rib. This incision will usually be from 2 to 3 in. in length. It is deepened until the external intercostal muscle is exposed. If the space laid bare is wide, the intercostal muscles are divided in the line of the original incision, care being taken to keep near the lower

border of the space, so as to avoid injury to the intercostal vessels; the parietal pleura covered by the endothoracic fascia, is then exposed. If the parietal and visceral layers of the pleura are adherent at this point, an incision is made into the lung tissue, until the cavity or cyst is reached. The cavity may be opened by first pushing inwards the needle of the exploring syringe, and then passing the blades of a pair of dressing forceps along the needle.

When the lung is not adherent to the chest wall, the pleural cavity is opened by incising the parietal pleura. Contamination of the pleural cavity must be avoided, either by stitching the lung to the opening in the pleura, or by packing with tampons of aseptic gauze. In some cases it may be advisable to attempt to obliterate the cavity by inducing the formation of adhesions between the visceral and parietal layers of the pleura.

When the intercostal space is small, a portion of one or more ribs should be resected. When removing a portion of rib, the periosteal elevator should be passed underneath it, in order to separate the intercostal vessels from their connection with the groove along the inferior margin. When this has been done, the bone is divided with a saw or bone forceps, preferably the former.

The cavity of the abscess or cyst having been opened, the contents are allowed to exude. In the case of a hydatid cyst, the margins of the incision in the cyst should be stitched to those of the parietal incision, and drainage established; and in the treatment of abscesses or gangrenous cavities, after the contents have been removed, a drainage tube should be inserted. This tube should be of soft rubber, and not too long, otherwise it may cause laceration of the lung tissue forming the boundaries of the cavity, and give rise to hæmorrhage.

OPERATIONS UPON THE PLEURA.

Paracentesis thoracis, or thoracentesis.—This operation has for its object the removal of pus, pleural fluid, or other fluid collection from the interior of the thoracic cavity, usually from within the pleura.

Indications.—(a) Collections of fluid within one or other pleural cavity, which in most instances are either serous or purulent. The diagnosis of these conditions is not always

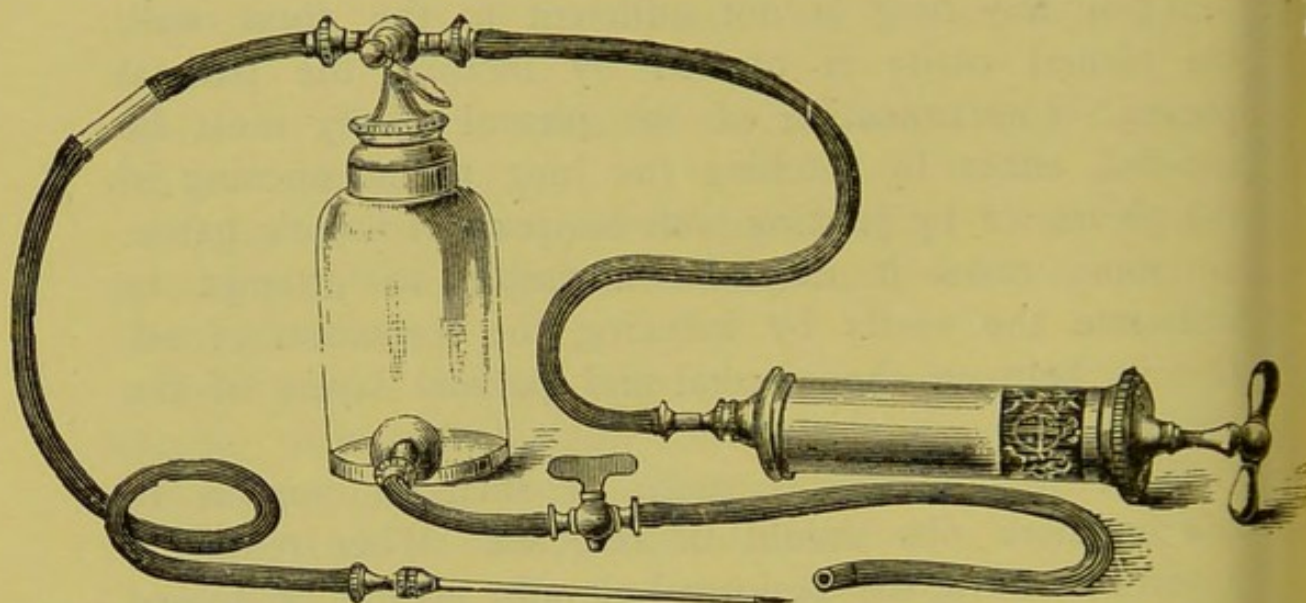


FIG. 164.—Paracentesis thoracis. Aspirator, with vacuum bottle and exhausting syringe.

possible without exploratory puncture with a needle or an aspirating syringe.

(b) Hydatid or other cysts of the lung, and localised abscesses of the lung, as an aid to their diagnosis, and in order to facilitate the performance of a surgical operation.

Instruments.—Scalpel and some form of aspirator or exploring syringe.

Position.—The patient is placed lying somewhat on the sound side, with the affected part of the chest near the edge of the bed. The surgeon seats himself behind the patient, opposite the part of the thoracic wall it is proposed to aspirate.

Operation.—The exact locality of the fluid collection within the chest having been defined, a very small incision is made through the skin over one of the intercostal spaces. It is usual to select a space directly over the central part of the fluid collection. The thumb-nail of the left hand is pressed against the superior margin of the rib which forms the inferior boundary of the selected space, a small notch in the skin is made with the scalpel, and then the exploring needle, or the needle of the aspirator, is pushed inwards until the underlying cavity is reached. Care must be taken to push the needle well into the fluid-containing space, but not beyond this, otherwise either the lungs or some other structure will be damaged. Often the pleura bounding the fluid-containing space is much thickened by the deposition of layers of fibrin, which may be a slight obstacle to the needle passing into the cavity. When the needle has entered the cavity, a condition which can generally be recognised by the sense of diminished resistance at the point of the instrument, it is connected with the aspirator or syringe, which should have been already exhausted.

The fluid collection is allowed to flow out slowly, in order to avoid, if possible, the occurrence of syncope, an accident which may happen.

During the entire procedure the strictest aseptic precautions must be observed, otherwise a non-purulent collection of fluid may be converted into a purulent one, owing to the entrance of septic micro-organisms with the needle.

Serous collections within the pleural cavity can usually be cured by this operation, but when we have to deal with an

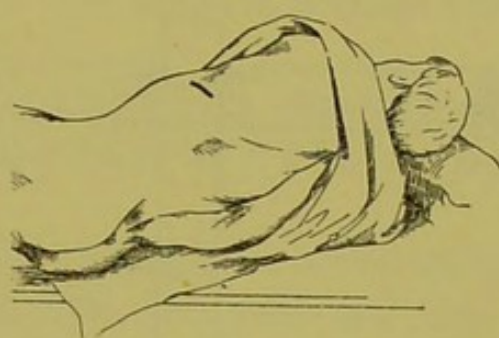


FIG. 165. —Incision of pleura. Position of patient, and line of external incision, in incision of pleura, with resection of a portion of rib.

empyema it is nearly always necessary to provide a freer exit for the pus, and to establish drainage. This is done according to the method described in the next operation.

Incision of the pleura.—An incision is generally made, either through the sixth intercostal space in the mid-axillary line, or through the eighth or ninth intercostal space in the scapular line.

Position.—As for aspiration.

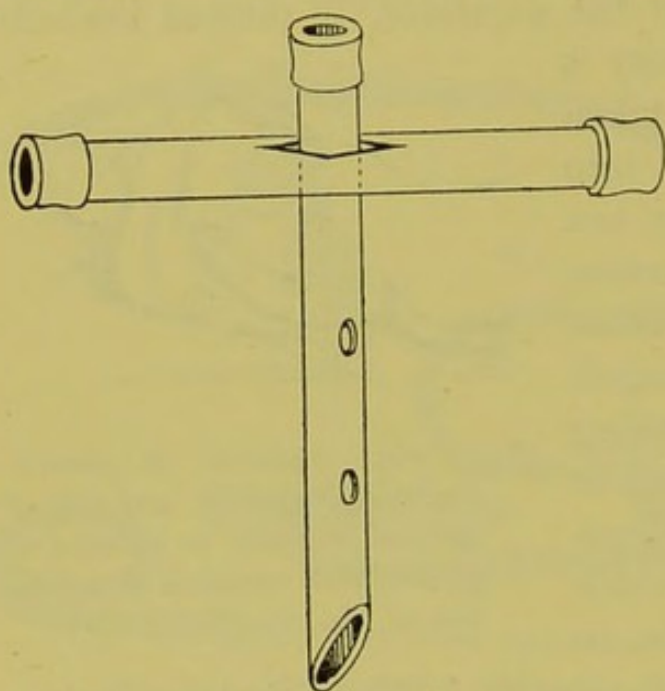


FIG. 166. — T-shaped drainage tube, for drainage of pleura. It is made out of two pieces of rubber tubing, the vertical limb being passed through a slit in the transverse one. The cuff prevents slipping of the tubes.

Instruments.—

Scalpel, pressure and dissecting forceps, dressing or sequestrum forceps, grooved steel director, periosteal elevator, saw or bone forceps, and ligature material.

Operation.—The intercostal space which it is proposed to incise, having been decided upon, an incision is made, $1\frac{1}{2}$ to 2 in. in length, over the middle of the space, and parallel with the rib. The skin, fasciæ, and overlying

muscles are incised until the external intercostal muscle is exposed. The steel director is then pushed inwards through the intercostal muscles and the parietal layer of the pleura, until its point is felt to enter the cavity. Then the blades of a pair of dressing forceps or sequestrum forceps are passed along the groove in the director, and separated, the director being removed when the forceps have been introduced. The pus or fluid will then exude from the opening thus made, and the cavity be emptied.

When all the fluid has been removed, a moderately large drainage tube is inserted and fastened in position, and antiseptic dressings applied.

In children and in patients who have narrow intercostal spaces, it is often necessary to resect a portion of one rib in order to establish satisfactory drainage. When this is the case, an incision is made down to the external surface of the rib, and the periosteum divided for the length of the incision. With a periosteal elevator, the periosteum is separated from the rib, and then the bone is divided with bone forceps or a small saw.

A portion of rib—usually $1\frac{1}{2}$ in. is sufficient—having been removed, the pleural cavity is opened with a director and dressing forceps as above.

After-treatment.—The dressings should be removed daily, and the tube taken out, and, after the first few days, gradually shortened, and replaced by one of smaller calibre.

CHAPTER X.

OPERATIONS UPON THE PERICARDIUM.

A. PARACENTESIS.

B. INCISION.

Paracentesis.—This operation consists in withdrawing, by means of an aspirating trocar and cannula, collections of fluid from the pericardial cavity.

Indications.—(*a*) As a means of diagnosis in some cases of distension of the pericardium.

(*b*) For the withdrawal of serous effusion of the pericardium which is not amenable to ordinary medical treatment, and in which the amount of fluid is increasing.

Instruments.—Scalpel and aspirating trocar and cannula.

Position.—The position of the patient will depend upon his condition; usually it will be more convenient to perform the operation with the patient sitting up. The operator sits on the bed, on the left side of and opposite to the patient.

Operation.—The pericardial area is rendered aseptic by the ordinary methods. A point is selected over the fifth left interspace, either outside the line of the internal mammary artery, that is to say, about 1 in. from the margin of the sternum; or on the inner side of this vessel, close to the lateral margin of the sternum.

A small incision is made in the skin with the scalpel, and the trocar and cannula carefully pushed inwards until the pericardial cavity is reached; this is recognised by the

sense of diminished resistance to their passage. The trocar is withdrawn, and the cannula connected with the vacuum, and the contained fluid evacuated.

When the cavity has been emptied, the cannula is taken out and the aperture covered by a small aseptic dressing.

If the fluid within the pericardium is found to be purulent, aspiration is not sufficient, but incision and drainage must be performed.

Incision.—*Indications.*—Purulent pericarditis, and wounds of the heart.

Instruments.—Scalpel, retractors, pressure forceps, steel director, dressing forceps, drainage tube, and ligature material.

Position.—As for the preceding operation.

Operation.—The skin having been made aseptic, an incision 1 in. to $1\frac{1}{2}$ in. long is made over the fifth left intercostal space, parallel with the costal cartilages, commencing at the outer margin of the sternum.

The skin, fasciæ, pectoralis major, and intercostal muscles are divided, care being taken to avoid the internal mammary artery. This blood vessel lies at right angles to the incision, and at about half an inch from the lateral margin of the sternum. The steel director is then pushed inwards until the pericardial cavity is reached; this may be known by the exit of the pus along its grooved surface. The blades of the dressing forceps are passed along the groove of the director, and separated, the director being removed. By this means free exit is given to the pus.

If the contained pus is very offensive, it may be desirable to irrigate the pericardial cavity.

All the pus having been removed, a soft rubber drainage tube is passed into the cavity, and dressings of aseptic gauze applied.

CHAPTER XI.

OPERATIONS UPON THE THYROID GLAND.

(a) EXCISION OF ONE LOBE.

(b) EXCISION OF THYROID CYSTS AND ADENOMATA.

Excision of one lobe.—Unilateral excision of the thyroid gland is usually carried out through an incision along the anterior border of the sterno-mastoid muscle of the affected side. Kocher employs a transverse or curved incision. The isthmus is generally removed along with the diseased lobe.

Indications.—(a) Bronchoceles which are of large size, or are causing symptoms of pressure upon the trachea or the œsophagus.

(b) Multilocular cyst of one-half of the gland.

(c) Some forms of malignant disease of the thyroid gland, when the surrounding structures are not affected by extension. When the disease has spread to the adjacent tissues, it is not advisable to attempt removal, owing to the important structures which are involved.

Instruments.—Scalpel, dissecting, pressure, and artery forceps, scissors, retractors, steel director, aneurysm needle, sponge-holders, needles, needle-holder, and suture and ligature material.

Cysts of the thyroid gland can in many instances be easily and readily removed after the overlying skin has been painted with a solution of cocaine, and without the use of a general anæsthetic. When the cyst is large this is

a distinct advantage, since the respiration is not so liable to be interfered with or the breathing become embarrassed.

Position.—The patient lies in the dorsal position, with the head turned towards the sound side, the neck being supported by a hard pillow or sandbag. The operator stands on the affected side of the neck, and his assistant directly opposite to him.

Operation.—Removal of one-half of the thyroid gland may be divided into the following stages :—(a) External incision ; (b) exposure of affected lobe of thyroid gland, and division of its capsule ; (c) enucleation of the lobe from its fascial sheath, ligature of thyroid arteries, and division of the isthmus ; (d) removal of the lobe, and closure of external wound.

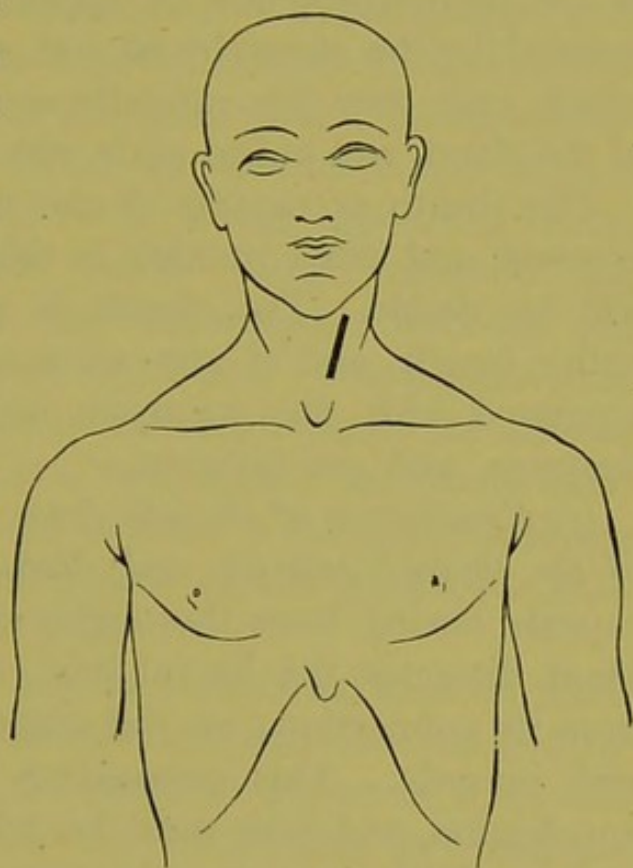


FIG. 167. — Excision of thyroid gland.
Line of first incision for removal of left lobe.

(a) *External incision.*

—An incision from 3 to 5 in. in length, according to the size of the lobe to be removed, is made over the prominent part of the swelling, and in a line from the sternal extremity of the clavicle to the mastoid process. This incision divides the skin, superficial fascia, platysma, and the anterior jugular vein or one of its tributaries. The external jugular vein usually lies near the outer part of the incision, and should be drawn aside. These veins lie underneath the platysma, but in the superficial fascia.

(b) *Exposure of the thyroid gland and division of its capsule.*—The deep fascia which has been laid bare in the first incision is divided for the entire length of the wound, and the anterior border of the sterno-mastoid muscle exposed. This is pulled outwards with retractors, together with the carotid sheath and its contents. Usually the enlarged lobe of the thyroid will now be apparent. It may, however, be covered by the sterno-hyoid and sterno-thyroid muscles, in which case they are carefully separated from the surface of the gland, and pulled aside with retractors.

The sheath or capsule of the thyroid gland will now be exposed, and often running in this sheath numerous veins will be visible. The sheath is carefully incised for the entire length, and if any veins are in the way they are separated with the aneurysm needle, occluded with two ligatures, and cut between.

(c) *Enucleation of the lobe from its fascial sheath, ligature of the thyroid arteries, and division of the isthmus.*—The capsule having been thoroughly divided with a director or blunt dissector, the lateral lobe of the gland is separated from its connections on the outer side, and lifted forwards and inwards. This proceeding is of the nature of an enucleation, and care must be taken to keep close to the surface of the gland, in order to avoid the large veins which generally lie in the fascia forming the sheath.

Any lateral prolongations of the enlarged gland underneath the sterno-mastoid muscle and the carotid sheath are separated during this stage. The middle thyroid veins may require ligature before the lateral lobe can be lifted forwards.

The superior part of the swelling is next dealt with. The superior thyroid artery and the corresponding veins are sought for, as they pass into the apex of the lobe on its anterior aspect. When found they are isolated, ligatured in two places, and divided.

The swelling can be readily separated from its connec-

tions with the lateral portion of the larynx, the operator dissecting from above downwards. The isthmus is now met with, attaching the gland to the anterior aspect of the trachea and the lateral lobe of the opposite side. With the director the isthmus is separated from the trachea, and then transfixed with an aneurysm needle carrying a ligature. The ligature is cut into two, and each half tied around one-half of the isthmus. The isthmus is then divided on the proximal (or tumour) side of the ligatures, and the separation of the tumour continued. When the isthmus is very large, it is better to cut it across and tie the blood vessels separately. Pressure forceps are placed on the blood vessels of the tumour, since there is a free anastomosis between the inferior thyroid arteries of the two sides. The dissection is prolonged downwards until the inferior limits of the tumour are reached; in this stage it is occasionally necessary, when the lateral lobe of the thyroid extends to the upper aperture of the thorax, to expose the dome of the pleura, the subclavian artery, and the large veins.

When the thyroid gland has been separated from all these connections, the inferior thyroid artery and vein will usually be readily found entering the posterior aspect of the lower extremity of the gland, except in those cases in which the enlargement has extended to the thorax, when the vessels will be found on the posterior aspect, on a level with the upper rings of the trachea. The inferior thyroid vessels should be ligatured a short distance from the trachea, in order to avoid including the recurrent laryngeal nerve, which by the side of the trachea lies in very close relation to the artery.

(d) *Removal of the lobe and closure of external wound.*—The inferior thyroid vessels having been ligatured, they are cut, the enlarged lobe is lifted upwards, and any fascial connections which still remain undetached are divided, and the tumour removed. The bottom of the wound is sponged dry, and all bleeding points picked up with artery forceps, and carefully ligatured. Care must be taken in so

doing that too much tissue is not taken up with the blood vessels, otherwise branches of the sympathetic cord, or the recurrent laryngeal nerve itself, may be surrounded by the ligature.

All bleeding having been arrested, the external incision is closed by the insertion of a row of salmon-gut sutures.

The inferior extremity of the wound should be left open, and a drainage tube of soft rubber or a strip of aseptic gauze introduced. This is necessary, on account of the large size and great depth of the wound, and of the difficulty of applying sufficient pressure without causing interference with respiration.

Dry aseptic dressings are applied, and held in position by a bandage and strips of adhesive strapping.

The chief dangers in the removal of thyroid tumours are the occurrence of serious hæmorrhage, and the division or ligature of nerves. These, however, can be avoided by attention to the precautions given above.

If, during the course of the operation, the breathing becomes very much embarrassed, owing to pressure of the tumour on the trachea, it may be necessary to perform tracheotomy. This should, however, be avoided if possible, since, when tracheotomy has been performed, the wound in the neck, in nearly all instances, becomes infected with septic micro-organisms. This usually results in suppuration, which is very prone to extend to the mediastinum, and cause a fatal termination.

Removal of the entire thyroid gland is rarely carried out, on account of the complications which occur after such an operation. The mental condition of the patient is seriously affected, and the patient suffers from a kind of myxœdema or imbecility.

Excision of thyroid cysts and adenomata.—When cysts and adenomatous tumours of the thyroid gland only involve a part of the affected lobe, it is preferable to attempt a local removal in place of extirpation of one-half of the

gland. This method can more commonly be employed in the treatment of cysts than in the case of adenomatous tumours.

Instruments.—As for removal of a lateral lobe.

Position.—As for preceding operation.

Operation.—An incision is made in the lateral aspect of the neck, over the most prominent portion of the swelling, and in the line of the anterior border of the sterno-mastoid muscle if possible. The incision is deepened until the external aspect of the affected portion of the gland is exposed. If any normal gland tissue lie in front of the cyst, this must be divided, and the surface of the cyst or adenoma laid bare. Usually, swellings of this nature have a distinct fibrous tissue capsule, which, when divided, allows the easy enucleation of the cyst or tumour.

The capsule of the cyst or tumour having been divided, and all hæmorrhage from the overlying tissues arrested, the localised swelling is separated from its sheath with a director, and removed. In some cases of cystic swelling, removal will be much facilitated by incision of the cyst wall, and evacuation of the contents. When the cyst or swelling has been removed, any bleeding vessel is picked up with artery forceps, and tied. The external wound is closed by sutures, except at one extremity, where a drainage tube or strip of gauze is brought out.

In some cystic swellings it will be found impossible to effect a local removal, on account of the vascularity of the walls and the absence of a distinct fibrous tissue capsule. Extirpation of one-half of the thyroid gland must then be effected, or, in favourable cases, drainage may be carried out after incision of the cyst wall, evacuation of the contents, and stitching of the margins of the incision in the cyst to those of the parietal wound. Cysts so treated, however, are prone to suppurate, a condition which is to be avoided, if possible.

CHAPTER XII.

OPERATIONS UPON THE ŒSOPHAGUS.

- (a) ŒSOPHAGOTOMY, OR INCISION OF THE ŒSOPHAGUS.
- (b) ŒSOPHAGOSTOMY.
- (c) ŒSOPHAGECTOMY, OR EXCISION OF A PORTION OF THE ŒSOPHAGUS.

Œsophagotomy.—Œsophagotomy, or the making of an incision into the œsophagus, is usually carried out through an incision placed in the inferior part of the left anterior triangle of the neck.

The œsophagus is a continuation downwards of the pharynx. It commences opposite the middle of the cricoid cartilage, at the level of the upper part of the sixth cervical vertebra, or the disc between the fifth and sixth, and terminates immediately below the œsophageal opening in the diaphragm.

The cervical portion of the tube is the part upon which the operation of œsophagotomy is generally performed; but the œsophagus may be exposed as it lies within the thorax, through an incision on the left side of the spinal column, after portions of one or more ribs have been resected.

The cervical operation will be described.

Indications.—(a) Impaction of foreign body, such as a tooth-plate, in the œsophagus; (b) some forms of fibrous stricture occurring high up in the œsophagus, or which cannot be dilated by means of œsophageal bougies passed

through the mouth; (*c*) pedunculated fibrous tumours of the œsophagus, which project internally.

Instruments.—Scalpel, retractors, dissecting and pressure forceps, long-bladed forceps, scissors, œsophageal bougies, needles, needle-holder, and suture and ligature material.

Position.—The patient lies in the dorsal position, with a sandbag underneath the neck. The head is turned towards the right side. The surgeon stands on the left side of the patient's neck, and his assistant on the right.

Operation.—The operation of œsophagotomy may be divided into the following stages, namely—(*a*) External incision; (*b*) exposure of œsophagus; (*c*) incision of œsophageal wall, and removal of foreign body or dilatation of stricture; and (*d*) further treatment of wound.

(*a*) *External incision.*—An incision from 3 to 4 in. in length is made along the anterior border of the left sterno-mastoid muscle, commencing at the sternal extremity of the clavicle, and extending upwards as far as the upper border of the thyroid cartilage. This incision divides the skin, superficial fascia and platysma, and the deep fascia, and exposes the external surface and anterior border of the sterno-mastoid muscle.

(*b*) *Exposure of œsophagus.*—The anterior border of the sterno-mastoid muscle is well defined, and the structure retracted to the outer side, by which means the infra-hyoid group of muscles will be laid bare. The anterior jugular vein will usually be met with at this stage, and should either be drawn aside or ligatured. The deep cervical fascia which lies behind the sterno-mastoid is incised, so as to fully expose the muscles. The intermediate tendon of the omo-hyoid is cut through, and the infra-hyoid group of muscles retracted towards the inner side.

In the floor of the incision, the thyroid gland, covered by fascia, is seen internally, and the carotid sheath with its contents externally. The fascia which covers the thyroid gland is divided; the gland is drawn inwards, and the

carotid sheath outwards. The deep fascia which is exposed at the bottom of the wound, is incised in the line of the original incision, and the above-mentioned structures further retracted. The inferior thyroid artery will now be laid bare in the lower part of the wound. It is surrounded with ligatures in two places, and divided between. In the bottom of the wound the anterior aspect of the longus colli muscle will be seen, and on the inner side the œsophagus, which can be recognised by its red colour.

The recurrent laryngeal nerve of the left side must be carefully avoided; it lies in the chink between the trachea and the œsophagus. It can be pulled to the inner side with a blunt hook.

(c) *Incision of the œsophagus, removal of the foreign body, or dilatation of the stricture.*—When the foreign body is impacted in the exposed portion of the œsophagus, an incision should be made through the wall of the tube in a longitudinal direction, and the obstruction removed with long-bladed forceps. If the impacted body is situated at a lower level, but can be readily felt, an œsophageal bougie is passed, and a cut made on to it in a longitudinal direction. The margins of this incision are held apart with retractors, and long-bladed forceps passed downwards, and an attempt made to extract it.

In the case of fibrous stricture, a bougie is passed downwards until the upper limit of the stricture is reached; a longitudinal cut is made as above, and then the stricture is carefully divided from within by means of a long, narrow-bladed, straight bistoury.

When the operation is being performed for the removal of a pedunculated non-malignant tumour, the location of the swelling is established by palpation. Then a longitudinal incision through the œsophageal wall is made directly over the tumour, and its pedicle is surrounded by a silk ligature, and the tumour removed by cutting across the pedicle distal to the ligature.

(d) *Further treatment of the wound.*—If possible, the aperture in the œsophageal wall should be closed by the insertion of interrupted sutures of fine silk, one tier uniting the mucous membrane, and a second one the muscular wall. If this can be done satisfactorily, the external incision is closed in the usual manner, except at one extremity, where a small drainage tube or a strip of aseptic gauze is introduced, and passed down to the wound in the œsophagus. If the incision in the œsophageal wall cannot be thoroughly closed, or if there has been ulceration, or the tube is in a septic condition, no attempt is made to close the aperture; the entire wound in these cases is packed with pads of aseptic gauze.

Œsophagostomy.—If it is wished to keep open the incision in the neck, the margins of the aperture in the œsophagus are stitched to those of the external wound, a soft rubber tube is passed into the œsophagus, and the remainder of the incision is packed with gauze. The patient is fed through the rubber tube. This operation is generally known as œsophagostomy.

Œsophagectomy.—Œsophagectomy, or removal of a portion of the œsophagus, has been attempted by a number of surgeons. The success, however, which has followed these operations has been very small, and on this account a description of the operation is not given.

CHAPTER XIII.

OPERATIONS UPON THE TONGUE.

1. EXCISION OF THE ENTIRE ORGAN—

(a) Through the mouth.

(b) Through an incision in the submaxillary region (Kocher's operation).

2. REMOVAL OF "WEDGE-SHAPED" PORTION.

Excision.—Removal of the tongue may be carried out either through the oral aperture, or through an incision in the submaxillary region.

Partial removal of the tongue—that is to say, removal of one-half—should be rarely performed, on account of the liability of the disease to recur in the part left behind, and also the comparative uselessness of one-half of the organ.

Indications.—(a) Epithelioma of the tongue, which is not too extensive to prevent the removal of the entire diseased area, and in which there is not extensive lymphatic glandular enlargement.

(b) Sarcoma of the tongue, which admits of local removal and is not associated with internal secondary growths.

The more usual operation is removal of the tongue through the mouth, since this method allows complete removal of the tongue and does not cause a visible scar. When the lymphatic glands in the submaxillary region are extensively involved, and it is thought that they can be entirely extirpated, it is better to carry out the excision through an incision in the neck, the affected gland being removed at the same time. If only a few glands are

enlarged, the tongue should be removed through the mouth, and the lymphatic glands by a second operation in the submaxillary region.

Whitehead's operation of excision of the tongue through the mouth by means of scissors, and Kocher's operation through an incision in the submaxillary region, will be described.

(a) *Excision through the mouth.*

Instruments.—Strong straight blunt-pointed scissors, re-

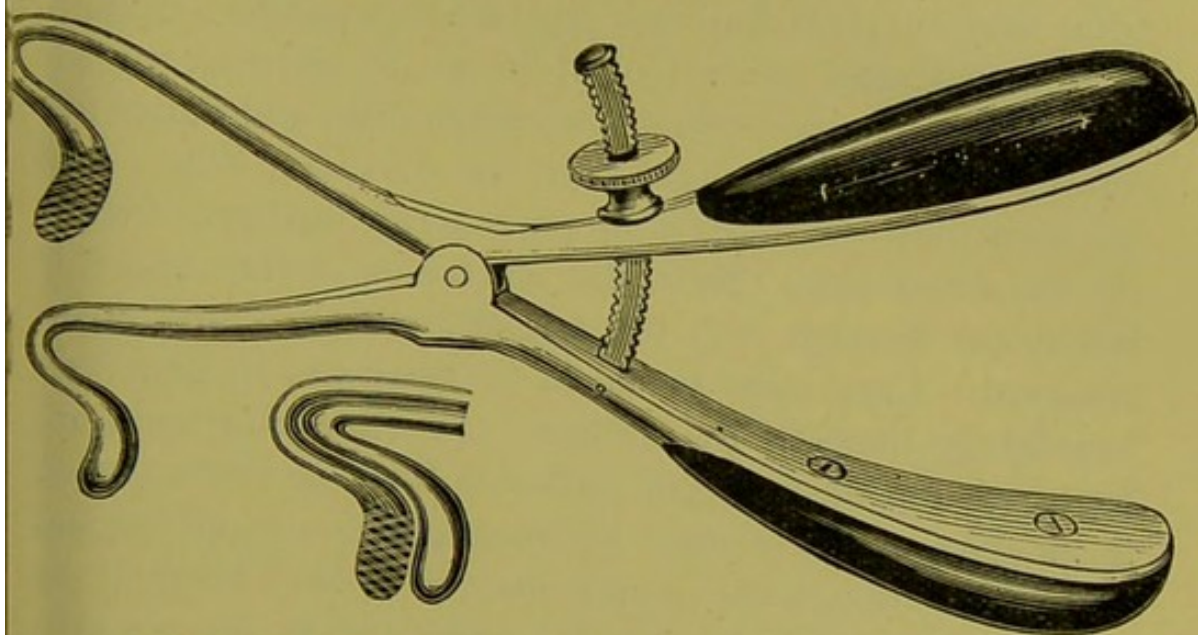


FIG. 168.—Excision of tongue. Gag for keeping the jaws separated.—ACKLAND.

tractors, gag, large needle, pressure forceps, sponge-holders, and ligature material.

Position.—The patient is placed in the dorsal posture, near one edge of the table, with the head turned towards the operator. The surgeon stands on the side of the most affected part of the tongue, one assistant stands at the head of the patient, and a second opposite the surgeon.

Operation.—The gag is introduced on the least affected side, and held firmly open by the assistant at the head. A strong ligature is passed through the anterior portion of the tongue, at the junction of the anterior with the middle third. This is left long, and serves as a retractor to pull the tongue

forwards. The tongue is drawn forwards and upwards towards the roof of the mouth, whilst the mucous membrane of the floor of the mouth and the anterior pillars of the fauces are divided. This will enable the surgeon to pull the greater part of the tongue out of the mouth, and hence give a better view of the parts which are being operated upon.

The soft parts of the tongue are divided, well beyond the limits of the growth, by a series of short snips with the scissors. One or two small arteries will be cut, and when they spurt they are picked up with pressure forceps and ligatured. The lingual arteries are looked for in the anterior part of the incision, on each side of the middle line, and nearer the inferior surface of the organ than the dorsum. When they are seen they are seized with pressure forceps, and divided on the distal side. Next, the remainder of the tongue is boldly cut through with the scissors, and the entire organ removed. Care must be taken to carry the incision well beyond the limits of the disease. The lingual arteries are ligatured, and then the cut surface of the base of the tongue is sponged, and any other bleeding points sought for, and tied. The base of the tongue may be hooked forwards by passing the index finger into the upper part of the pharynx, and exerting forward traction. This proceeding is of considerable value in the temporary arrest of hæmorrhage from the lingual arteries, if they have been divided before being seized with pressure forceps. The vessels are compressed against the posterior aspect of the lower jaw.

When all the hæmorrhage from the base of the tongue and the floor of the mouth has been arrested, the incised surfaces are sponged dry, dusted with iodoform, and the operation is completed.

Before the operation is finished, a loop of strong silk should be passed through the stump of the tongue. This is brought out through the mouth, and fixed to the cheek with a piece of strapping. It will serve to control hæmorrhage if it occur.

(b) *Excision through an incision in the submaxillary region* (Kocher's operation).

Instruments. — Scalpel, scissors, retractors, pressure, dissecting, and artery forceps, mouth gag, aneurysm needle, sponge-holders, needles, needle-holder, and suture and ligature material.

Position.—The patient is placed in the dorsal position, with the head supported by a pillow, and turned to the sound or least affected side. The surgeon stands on the affected side, and his assistant directly opposite to him.

Operation. — The operation can be conveniently divided into three stages, namely—
(a) External incision, exposure and removal of enlarged lymphatic glands and submaxillary salivary gland; (b) division of floor of mouth, isolation and removal of tongue; (c) treatment of external wound.

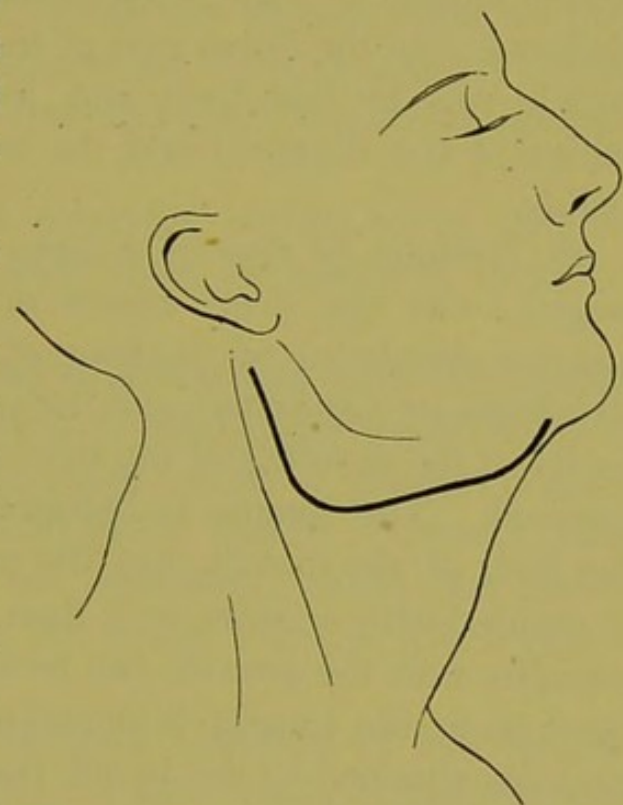


FIG. 169.—Excision of tongue (Kocher).
External incision.

(a) *External incision, exposure and removal of enlarged lymphatic glands and submaxillary salivary gland.*—An incision is made, commencing a short distance below and in front of the apex of the mastoid process, extending downwards and forwards to the upper border of the great cornu of the hyoid bone, then inwards to the middle line of the neck, and finally upwards to the lower part of the symphysis menti. This incision divides the skin, superficial fascia, platysma, superficial veins, and the deep fascia,—all these structures

being reflected upwards in the form of a flap. By this means the superficial portion of the submaxillary salivary gland, and the enlarged anterior cervical and submaxillary lymphatic glands, are exposed; the lymphatic glands are separated and pulled upwards with a retractor, together with the submaxillary salivary gland. The facial artery, as it lies in a deep groove in the gland, is sought for and ligatured in the lower part of the wound. Next, the lingual artery as it passes underneath the hyoglossus muscle, is defined and ligatured. In the upper part of the incision the mylo-hyoid muscle will be laid bare, and in the lower part the two bellies of the digastric and the stylo-hyoid muscles will be visible.

(b) *Division of floor of mouth; isolation and removal of tongue.*—On the deep aspect of the mylo-hyoid is the mucous membrane of the floor of the mouth. Both these structures are perforated, and the aperture enlarged, when the cavity of the mouth and the side of the tongue will be fully exposed. The tongue is brought through the aperture in the floor of the mouth, and the mucous membrane around it divided with scissors, and then almost the entire organ, together with the growth, can be brought out. This having been done, the tongue is detached by cutting through the muscles attached to the hyoid bone. Care must be taken to secure the lingual artery of the opposite side as soon as it is reached.

(c) *Treatment of external wound.*—The tongue having been removed, all bleeding points are ligatured, and part of the external wound closed by the insertion of simple interrupted sutures. The most dependent part is left open. The wound is packed with aseptic gauze, the extremity of the strip being brought out through the external wound.

After-treatment.—The wound is dressed at first twice daily; later, once is sufficient. Feeding is carried out through an œsophageal tube.

This operation in most instances is unnecessarily severe, and is liable to be followed by the development of septic cellulitis of the neck, which may prove fatal.

When there are a number of enlarged lymphatic glands, it is generally better to remove the tongue first through the mouth, and at a later stage remove the enlarged glands by a submaxillary operation.

When, however, there is extensive involvement of the lymphatic glands, and the infiltration extends from the floor of the tongue to the structures in the submaxillary region, Kocher's operation is the only one which can advantageously be performed.

When the disease has extended to the lower jaw, the involved portion of the bone must be removed by partial resection.

Preliminary tracheotomy in operations upon the tongue.

—Some surgeons prefer that a preliminary tracheotomy or laryngotomy should be performed before an attempt is made to remove the tongue through the mouth. Usually, however, this proceeding is not necessary, unless the growth extends far back towards the hyoid bone, in which case it may be advisable.

Removal of a "wedge-shaped" portion of the tongue.

—This operation is necessary in many cases of macroglossia which are not amenable to other means of treatment, and localised innocent new growths.

Operation.—The protuberant portion of the tongue is drawn forwards as far as possible, and a wedge or V-shaped incision made in its substance, the base of the wedge including the protuberant portion. The incision is deepened, the muscular tissues being cut through, until the portion of tongue is removed.

All bleeding vessels are picked up with pressure forceps and ligatured. The incised surfaces are brought into apposition and fixed by the insertion of a number of interrupted sutures. It is advisable to fix the

deeper parts together with a few buried sutures. When the wedge-shaped incision is being made, care must be taken not to leave the lateral portion too thin, otherwise the tongue, when recovery has taken place, will be too pointed.

CHAPTER XIV.

OPERATIONS UPON THE CRANIUM.

I. TREPHINING—

- A.* For fracture of the skull.
- B.* For extra-dural abscess or hæmorrhage.
- C.* For cerebral tumour or cyst.
- D.* For cerebral abscess.
- E.* For cerebellar tumour or cyst.
- F.* For cerebellar abscess.
- G.* Tapping and drainage of the lateral ventricle.
- H.* For the removal of foreign bodies within the skull.
- I.* For epilepsy.

2. TEMPORARY RESECTION OF THE SKULL.

3. CRANIECTOMY, OR LINEAR CRANIOTOMY.

Trephining.—In order to expose any of the cranial contents for the purpose of performing upon them a surgical operation, it is necessary to remove a part of the bony brain-case. This is usually done by the aid of an instrument called a trephine. In some cases, however, a chisel and a mallet will be more useful, and in others, especially in those cases in which it is wished to remove a large piece of the cranial vault, a small circular saw, driven by an electric or other form of motor, will be the most efficient.

The operation of trephining will be considered generally, since the methods of procedure in the different operations upon the cranium which involve the removal of bone are somewhat similar.

Anatomical considerations.—The bony points, depressions, and prominences which can be felt on the surface of the bony cranium are as follows, namely—

(a) *The glabellar fossa.*—A slight depression at the root of the nose, at the junction of the nasal and frontal bones.

(b) *The bregma.*—This is the position of the anterior

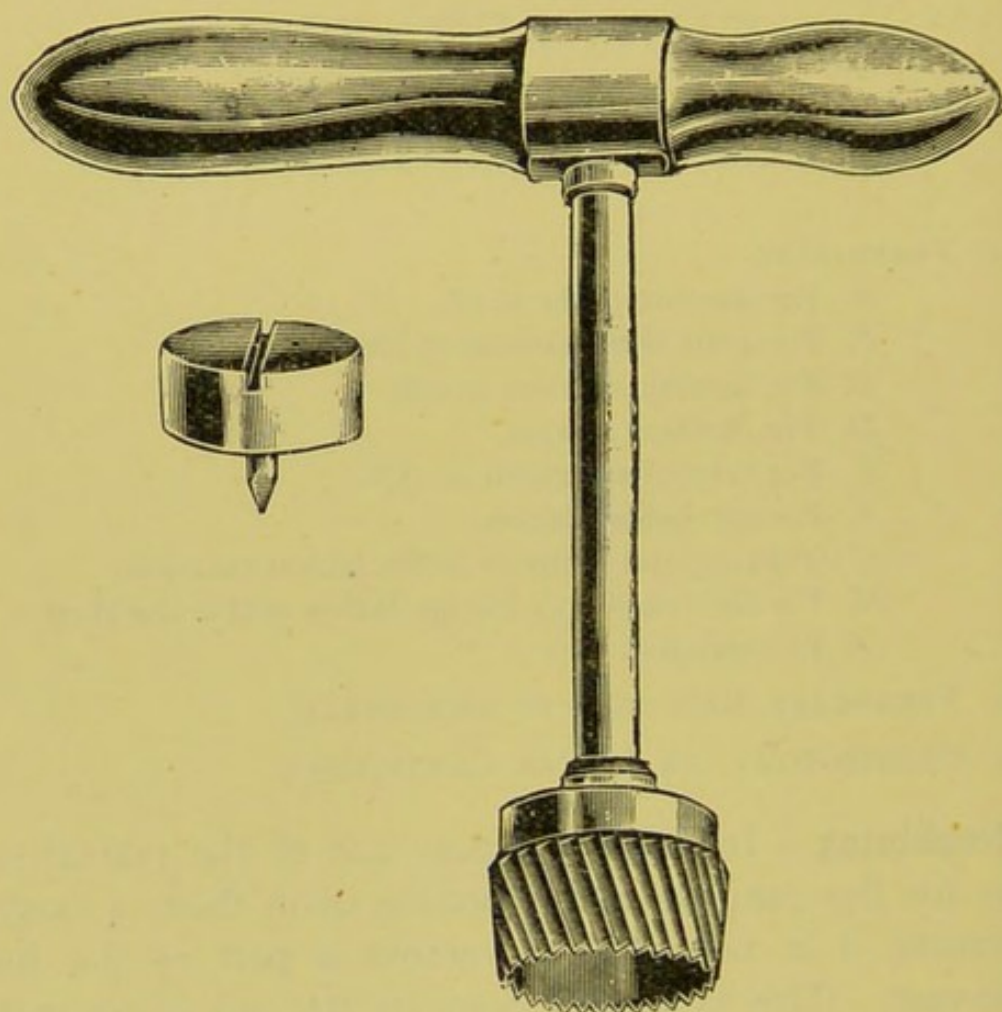


FIG. 170.—Trephining. Conical trephine with central pin fixed on a circular piece of metal, which fits in the interior of the trephine, and is easily removed.

fontanelle of the child. It can often be felt in the adult skull, at the point of union of the sagittal and coronal sutures. It is marked out on the surface by bisecting a line drawn vertically from the anterior margin of one external auditory meatus to a similar spot on the opposite side, and taking a point immediately in front of this.

(c) *The lambda*.—This is the apex of the lambdoid suture; it can usually be felt as a prominence about $2\frac{1}{2}$ in. above and in front of the external occipital protuberance. A line drawn from the bregma to the lambda marks out the sagittal suture, and a line from the bregma to the centre of the zygoma the coronal suture.

(d) *The external occipital protuberance or inion*.—This is a prominence on the occipital bone in the middle line of the neck behind. From this the superior curved line of the occipital bone can be traced outwards and forwards to the base of the mastoid process.

(e) *The mastoid process*.—

This can be felt as a prominence immediately behind the external auditory meatus. The broad base is above and the apex below. It is only very slightly marked in children.

(f) *The zygoma*.—This can be felt as a bar of bone, extending from the anterior border of the external auditory meatus to the external angular process of the frontal bone at the outer angle of the orbit.

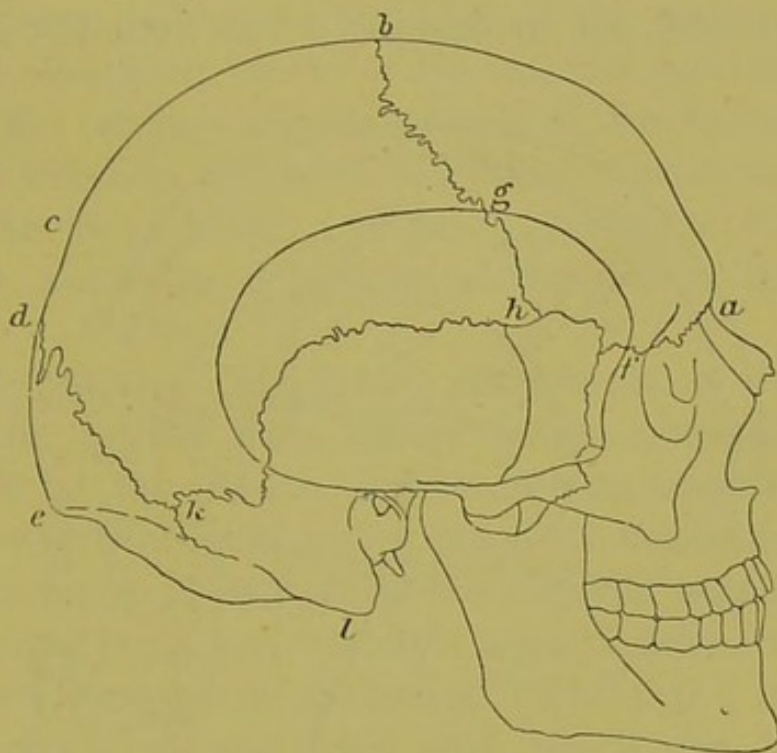


FIG. 171.—Trephining. Skull, showing positions of important bony points, etc.

- | | |
|--|--|
| a. Glabellar fossa. | f. External angular process of frontal bone. |
| b. Bregma. | g. Stephanion. |
| c. Position of parietal foramina. | h. Pterion. |
| d. Lambda. | i. Mastoid process. |
| e. Inion or external occipital protuberance. | k. Asterion. |

(g) *The pterion*.—The pterion is situated half-way between the stephanion (juncture of coronal suture and temporal crest) and the centre of the zygoma, or at a point $1\frac{1}{2}$ in. along a line drawn backwards from the external angular process of the frontal bone and parallel with the zygoma.

Meningeal sinuses.—The superior longitudinal sinus is marked out by drawing a line from the glabellar fossa in

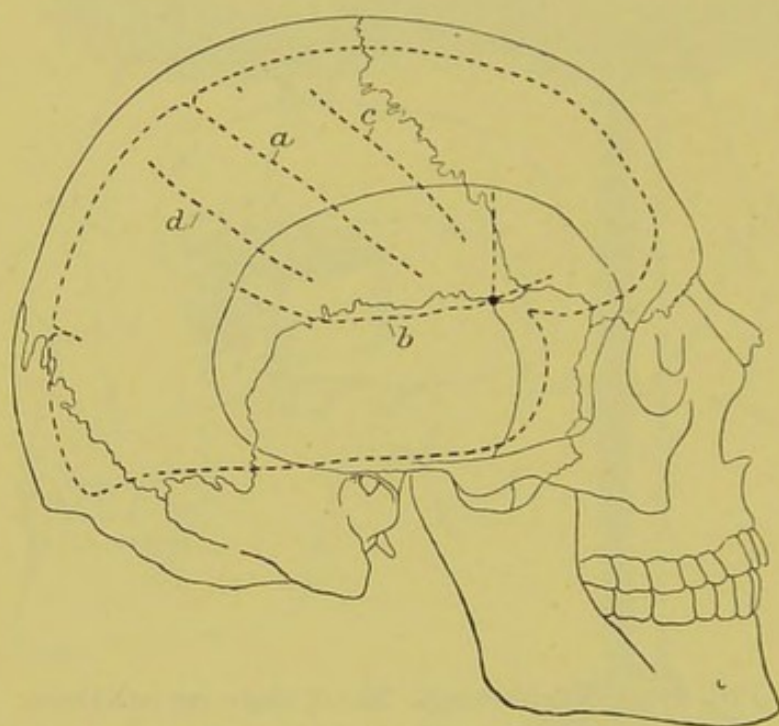


FIG. 172.—Skull showing position of important cerebral fissures.

- | | |
|------------------------|-------------------------|
| a. Fissure of Rolando. | c. Precentral fissure. |
| b. Fissure of Sylvius. | d. Postcentral fissure. |

front to the external occipital protuberance behind; it deviates a little to the right of the median line. The lateral sinus extends from the external occipital protuberance to the base of the mastoid process, and is marked out on the surface by drawing a line from the external occipital pro-

tuberance to the upper border of the external auditory meatus. The last three-quarters of an inch of this line is beyond the sinus, since the latter turns downwards on the deep surface of the mastoid process to reach the jugular foramen.

The line from the root of the nose to the external occipital protuberance marks out the great longitudinal fissure which separates the right and left cerebral hemispheres, the falx cerebri, the inferior longitudinal and straight sinuses. The line from the external occipital protuberance to the mastoid

process also marks out the line of attachment of the tentorium cerebelli, the cerebro-cerebellar fissure, and hence the line of separation of the cerebrum from the cerebellum, the former lying above and the latter below this line.

Cerebrum.—The lower border of the cerebrum is marked out by drawing a line from a point $\frac{1}{4}$ in. above the external occipital protuberance behind, to the base of the mastoid process; thence to the upper border of the external auditory meatus; next to the external angular process of the frontal bone in a curved direction, the convexity being towards the prominence of the malar bone; and finally inwards to the middle line, $\frac{1}{4}$ in. above the depression at the root of the nose.

The fissure of Sylvius.—This fissure commences at the base of the brain, as the main fissure passes outwards and upwards, and at the pterion divides into an anterior horizontal limb, a vertical limb, and a posterior horizontal limb. A point is taken $1\frac{1}{4}$ in. behind the external angular process of the frontal bone, and from this a line is drawn to a point $\frac{3}{4}$ in. below the parietal eminence. The first $\frac{3}{4}$ in. represents that portion of the main limb which can be marked out on the surface, and the remainder the posterior horizontal limb. The anterior horizontal and the vertical limbs commence at a point on the above line 2 in. behind the external angular process, the former passing directly forwards, and the latter vertically upwards for nearly an inch.

If the line of the posterior horizontal limb of the Sylvian fissure be prolonged to the middle line, the last $\frac{3}{4}$ in. will demarcate the external parieto-occipital fissure. This will be about half an inch in front of the lambda.

Fissure of Rolando.—A point is taken $\frac{1}{2}$ in. behind the middle of a line drawn from the external-occipital protuberance to the glabellar fossa, and from this a line is drawn downwards and forwards at an angle of $67^{\circ}5$, or three-quarters of a right angle, to a point immediately above the

posterior horizontal limb of the fissure of Sylvius. This will represent the course of the fissure of Rolando. About the upper third are grouped the centres for the leg and trunk, about the middle third those of the upper extremity, and about the lower third those of the face and head. The exact position of those centres is shown in Figs. 173 and 174.

If a line be drawn from the outer extremity of the

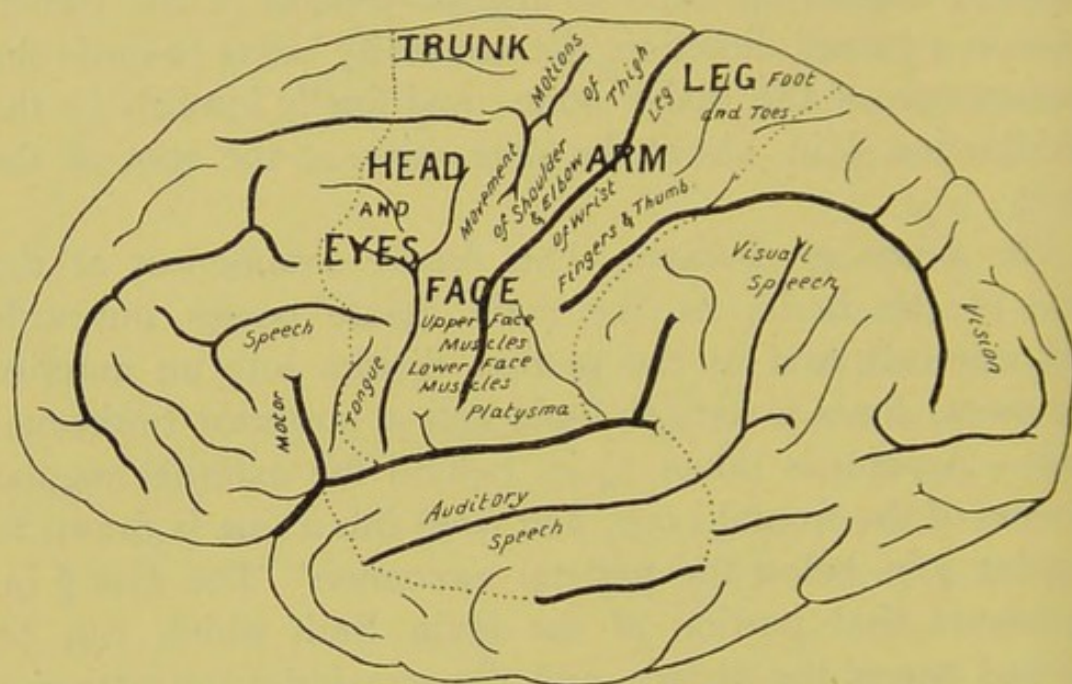


FIG. 173.—Diagram (after EBERSTALLER) of the fissures and convolutions of the convexity of the right hemisphere of the brain. The relative depth of the fissures is indicated by the shading. The extent of the functional areas is indicated by the dotted lines.—ALLEN STARR.

external parieto-occipital fissure downwards to the anterior border of the base of the mastoid process, the different lobes of the brain can be located. The frontal lobe lies external to the great longitudinal fissure above the base line of the cerebrum, and in front of the fissure of Rolando.

The parietal lobe lies external to the great longitudinal fissure, above the fissure of Sylvius (posterior-horizontal limb), behind the fissure of Rolando, and in front of the external parieto-occipital fissure and a line prolonged from this to the base of the mastoid.

The occipital lobe lies external to the great longitudinal fissure, above the cerebro-cerebellar fissure, and behind the external parieto-occipital fissure and a line prolonged from this to the anterior margin of the base of the mastoid process.

The temporo-sphenoidal lobe lies below and behind the fissure of Sylvius (main limb and posterior horizontal limb), above the base line of the cerebrum, and in front of the anterior limit of the occipital lobe.

Instruments.—Scalpel, periosteal elevator (straight and

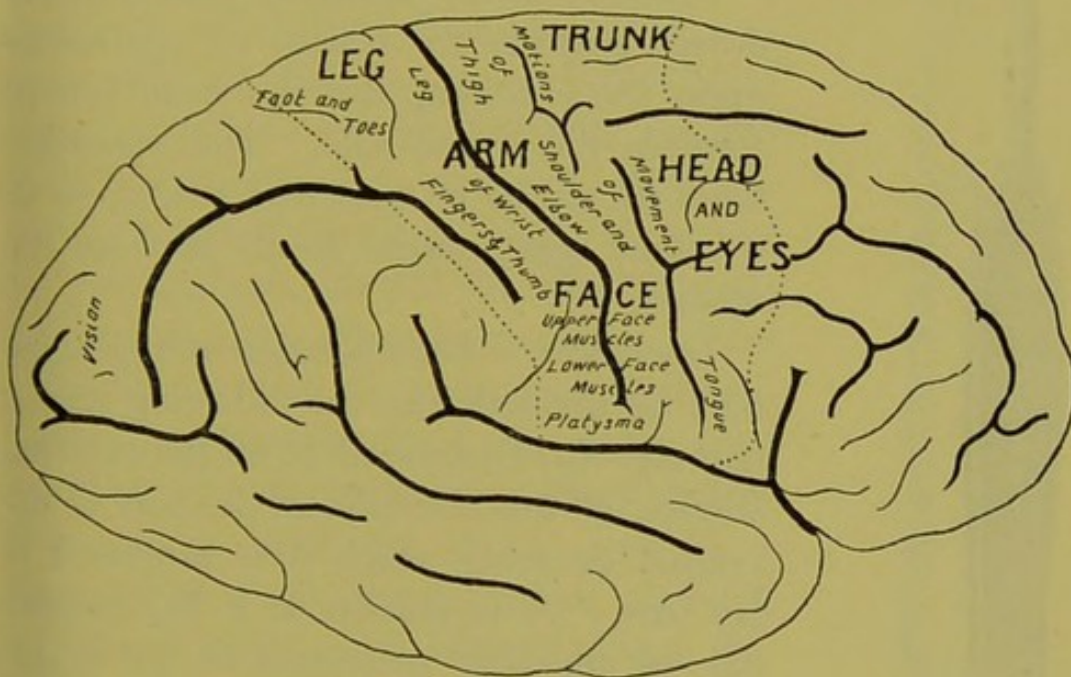


FIG. 174.—Diagrams of the fissures and convolutions of the convexity of the left cerebral hemisphere. The speech area is shown in this hemisphere. The motor area is more extensive than on the right side.—ALLEN STARR.

bent), dissecting, pressure, and artery forceps, bone forceps, gouge forceps, small saw (Hey's), trephine, trephine brush, quill, chisel, and mallet (circular saw driven by a motor, if it is necessary to remove a large piece of bone), fine-toothed forceps, sponge - holders, needles (small curved), needle-holder, and ligature and suture material.

Preliminary preparation of patient.—On the day previous to operation, if the nature of the case will allow, the entire scalp is shaved. The head is next well washed with hot

water and soap, then with ether, and finally with a solution of perchloride of mercury (1 in 500), and an aseptic dressing applied. Just before the commencement of the operation, and after the patient has been anæsthetised, the washing of the head is repeated.

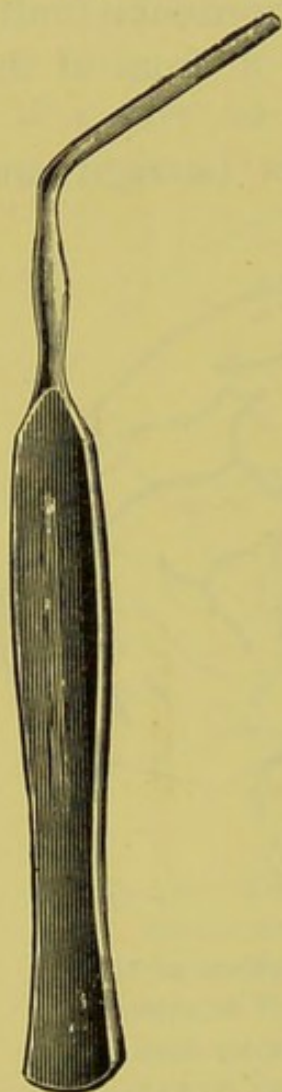


FIG. 175.—Trephining. Periosteal elevator.—HORSLEY.

The strictest aseptic precautions must be observed in connection with all surgical operations upon the cranium or its contents.

Position.—The patient is placed in the dorsal position for nearly all operations upon the cranium, with the head turned towards the sound side. The operation table should be of moderate height, so as to allow ready access to all parts of the wound.

Operation.—The operation of trephining may be divided into the following stages, namely—(a) Demarcation, on the external surface of the cranium, of the part of the cranial contents which it is proposed to lay bare; (b) formation of a flap consisting of the soft structures of the scalp; (c) removal of a portion of the cranial bony vault; (d) incision of the membranes of the brain, and exposure of the brain surface, in those cases, such as cerebral tumour or abscess, in which it is necessary to go beyond the membranes; (e) special treatment of diseased part, such as evacuation of pus from a cerebral abscess, or excision of a cranial tumour; (f) closure, complete or partial, of incision in membranes, and further treatment of wound; (g) after-treatment.

In the operation of trephining, the lines of the meningeal sinuses should be avoided as far as possible, as well as the

region of the bony sutures. It is not always possible, however, to avoid the sutures.

(a) *Demarcation, on the external surface of the cranium, of the part of the cranial contents which it is proposed to lay bare.*—This can be effected by paying attention to the points which have been discussed under anatomical considerations.

(b) *Formation of scalp flap.*—The part to be operated upon having been determined, a semicircular incision is made in the scalp, which comprises this area, and is so situated that the base of the flap is towards the base line of the brain, and the convexity towards the vertex of the skull. The soft structures of the scalp, including the pericranium, should be divided with the scalpel right down to the bone. The periosteal elevator is taken, and the periosteum is detached from the bone, and the flap of soft structures turned down. This flap is held out of the way by a retractor or a silk suture passed through its highest point. All bleeding from the vessels of the scalp is arrested by ligature or pressure forceps.



FIG. 176. — Trephining. Chisel with straight edge.

(c) *Removal of a portion of the bony cranium.*—(1) *By the use of a trephine.*—A trephine is taken of the shape shown in Fig. 170, the centre pin is introduced, and placed on the centre of the piece of bone which it is wished to remove. The pin is thrust into the bone by a pushing and rotatory movement, and then by a series of to-and-from circular movements with the hand, the teeth of the instrument are made to cut a circular groove in the bone. When a definite groove has been made, the trephine is taken out of the wound, the central pin is removed, and the instrument is

again introduced, and the circle of bone gradually sawn through. Care must be taken to avoid using the saw in a



FIG. 177.—Trephining. Chisel grooved.

jerky manner, otherwise much longer time will be taken in removing the circle of bone. From time to time, as the sawing proceeds, the trephine should be taken from the wound, and the bone dust brushed out of the groove in the bone and from the teeth of the instrument. When the bone has been nearly cut through, the crown can be lifted out either by a side-to-side movement with the trephine, or by lifting it up with a periosteal elevator. If the removal of one crown of bone does not give sufficient space, a second or even a third may be removed, and the intervening portions of bone detached with a saw or bone forceps.

(2) *With a chisel and mallet.*—In some forms of injury to the cranial vault, the removal of the portion of bone can be effected most readily by the use of a chisel and mallet. This is especially the case in operations for the relief of a depressed fracture, in opening the frontal sinuses, and also in operations upon the mastoid cells. Figs. 176, 177, 178 are illustrations of instruments which are most useful for this purpose.

(3) *With a circular saw driven by a motor (surgical engine).*—When it is wished to remove a large piece of the bony cranium, as in the removal of a large intracranial tumour, this form of instrument will be found to be the most efficient. No one, however, should attempt to use this instrument in a surgical operation until he has considerable experi-

ence in its use, and knows thoroughly how to manage and control it.

As the portions of bone are removed they are placed in a warm sterilised normal saline solution (.75 per cent. of common salt).

If the object of the operation is evacuation of an extradural collection of pus, ligation of a meningeal artery, or removal of a growth of the bone or a depressed piece of the cranial vault, it will not be necessary to proceed more deeply. These objects can be accomplished through the opening which has already been made.

If the nature of the affection necessitates incision of the membranes, this is now done.

(d) *Incision of the membranes of brain, etc.*—Care must be taken in making an incision through the dura mater not to wound one of the large venous sinuses. The position of these has already been given. The dura mater is best opened by making a semilunar incision in it, the convexity being towards the vertex. The margins of this incision should be a short distance internal to those of the incision in the bone, so as to allow of closure later. When the flap of dura mater so marked out has been turned down, any cyst or abscess in the subdural space may be dealt with. If it is necessary to proceed further, the arachnoid membrane is incised. This is normally a very thin membrane, and lies in close contact with the pia mater. It may, however, be thickened in diseased conditions. The pia




FIG. 178.—Trephining.
Mallet.

mater, a very vascular membrane, is now laid bare, and can be incised if requisite, so as to expose the cortex of the brain in the bottom of the wound.

(e) *Removal of diseased brain tissue, etc.*—In cases of cerebral abscess, cerebral tumour, or foreign body in the brain, or tapping of the lateral ventricle, the cerebral operation proper can now be carried out. Details of these procedures are given under the headings of the separate operations.

(f) *Further treatment of wound.*—In a non-septic case, when the diseased portion or the foreign body has been removed, all bleeding from the surface of the brain is arrested, and the margins of the incision in the membranes are united by the insertion of fine silk sutures. Next, the portions of bone which have been removed are replaced in their original position, and finally the scalp flap is accurately stitched over them and dry aseptic dressings applied. In septic cases drainage must be established. The portions of bone removed are not replaced in cases of this kind. Part of the external wound is left open for the tube, whilst the remainder is closed in the ordinary manner.

(g) *After-treatment.*—The patient must be kept very quiet after the performance of an operation on the brain. In non-septic cases the dressings are left on for a week, and then taken off and the stitches removed. In suppurating cases the dressings must be frequently changed, so as to avoid as far as possible the accumulation of pus or septic fluid within the wound.

A. For fracture of the skull.—*Indications.*—(a) *Punctured fractures of the skull.*—All cases of punctured fracture should be trephined, and an examination made of the extent of the injury, since in this form of fracture the inner table of the skull is very often driven inwards and splintered, whilst the external wound is small and insignificant.

(b) *Compound depressed fractures.*—It is the safest plan

to operate on all cases of this kind, owing to the fact that often particles of dirt which have been carried in at the time of the injury are liable to escape notice and become the cause of suppuration. This is especially the case in bullet wounds.

(c) *Foreign bodies* embedded in the bones of the cranial vault, and possibly extending into the brain substance or penetrating the membranes.

(d) *Simple depressed fractures of the skull*.—In adults it is the best and safest plan of treatment to elevate all depressed fractures; the strictest aseptic precautions being observed. If this is not done, in a certain percentage of cases, although there are no symptoms dependent upon the depressed bone at the time of the injury, they are liable to develop later in the form of focal (or Jacksonian) epilepsy.

In children the bones of the skull are more elastic, and tend readily to resume their original position after a depression; hence many such cases may safely be treated on the expectant plan without operation, if there are no symptoms due to the depressed bone or to cerebral hæmorrhage or abscess.

Instruments.—As for the ordinary operation of trephining.

Position.—The patient is placed in the dorsal position, the head turned to the sound side, and supported by one or two sandbags. The surgeon stands on the affected side of the head, and his assistant opposite to him.

Operation.—If the patient is unconscious as the result of the injury, an anæsthetic is not necessary. If, however, one is required, chloroform is the best.

The head is shaved, and rendered aseptic by washing with soap and water, ether, and a solution of perchloride of mercury (1 in 500), in the usual manner.

An incision, semilunar in shape, if possible, is made which divides everything down to the bone. A flap is turned downwards with the periosteal elevator, or, if muscle has to be detached, as when the injury involves the

temporal fossa, with the scalpel. The flap should be large enough to fully expose the fracture and the adjacent portions of sound bone, the convexity of the flap being towards the vertex of the skull.

The extent and nature of the fracture is now ascertained. If there has been much splintering of bone, it is often possible to elevate or remove the depressed pieces with dressing forceps. If this cannot be done, a crown of bone must be removed with the trephine, which will allow the

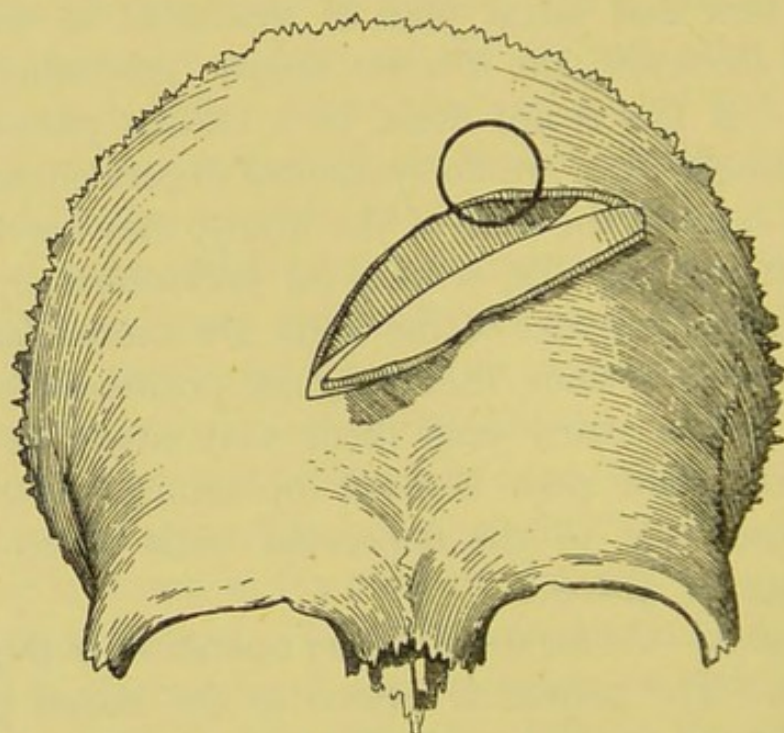


FIG. 179.—Trephining. Depressed fracture of the skull in frontal region, showing place where a trephine should be applied.

elevation of the depressed fragments. A point is selected on one margin of the depressed portion, and the trephine, with the pin protruding, is placed upon it in such a manner that the pin rests upon sound bone. If it is thought that there has been much splintering, and that a sharp fragment has been driven into the brain, the entire circle of the trephine must rest upon sound bone. The area to be trephined having been determined, a crown of bone is removed in the usual manner. The elevator can now be inserted underneath the depressed portion, and elevation

accomplished. The margin of the trephine aperture on the sound bone is used as a fulcrum in lifting up the depressed part.

If hæmorrhage is taking place from the bottom of the wound after the circle of bone has been removed, it may come from a branch of one of the meningeal arteries, usually the middle, from one of the sinuses, or, if the dura mater has been punctured, from the surface of the brain. In each case the site of bleeding must be ascertained, and a ligature applied to the bleeding point, or the wound packed with a strip of gauze.

When all hæmorrhage has been arrested, any tear in the dura mater is closed by the introduction of sutures. Next, the fragments of bone are replaced as far as possible in their original position if they are not contaminated with dirt, care being taken not to allow any sharp edge to project towards the meninges. The margins of the incision in the scalp are brought together and fixed in apposition by sutures. One angle of the wound is left open, and a drain of gauze passed down to the region of the fractured bone. Aseptic dressings are lightly applied, and fixed in position by strapping and a bandage.

After-treatment. — In favourable cases the fragments will unite, and the external wound will heal by first intention. Should suppuration occur, free drainage must be maintained, and fomentations applied.

If a large gap is left in the cranial wall, owing to non-union of the fragments, it may be necessary to provide the patient with a metal plate, which shall accurately cover the aperture in the bony skull, and help to protect it from injury. This metal plate is usually placed external to the skin, but in some cases it has been placed directly upon the bone. The former is the better plan.

B. For extra-dural abscess or hæmorrhage.—*Abscess.*—The formation of an extra-dural abscess is usually preceded by an injury to the cranial bones overlying

the seat of the abscess; the injured bone having become the seat of suppuration which has extended through it to the dura mater, owing to the development of a septic osteitis or osteomyelitis. An extra-dural abscess may also develop as the result of a general pyæmia, but more commonly it is a precursor of this condition.

When an extradural abscess has formed, it usually causes the appearance of symptoms of hemiplegia, but often this condition is not well marked, or is masked by symptoms dependent upon general pyæmia. In every case, however, in which the presence of pus between the bone and dura mater is suspected, or in which the bone is the seat of a septic, infective, or suppurative process, trephining ought at once to be performed, and the diseased bone and the pus removed. Stringent antiseptic treatment is then carried out, with the object of preventing further extension of the suppurative process and the elimination of the diseased tissues.

The actual operation in this case is similar to that described above. Free drainage must be established, and frequent irrigation ordered.

Hæmorrhage.—The operative treatment of this condition is fully considered on p. 312, in connection with ligature of the middle meningeal artery.

C. For cerebral tumour or cyst.—The operations for the removal of tumours or cysts of the cerebrum are essentially similar, and will be considered together. Hale White has investigated the nature of tumours which affect the brain, and found, from an analysis of a hundred cases, that forty-five were tuberculous, twenty-four gliomata, two glio-sarcomata, ten sarcomata, five carcinomata, one lymphoma, one myxoma, four cysts, five gummata, and three doubtful.

Indications.—(a) The presence of a tumour of the cerebrum, which is primary in nature, and is not associated with secondary growths elsewhere. In the case of tuberculous tumours, the absence of a general tuberculosis must be established before an operation is undertaken. In the

case of a gumma, prolonged treatment with potassium iodide must be tried before an operation is performed.

(b) The presence of a cyst of the cerebrum, or of the arachnoid, which is pressing upon the brain and causing symptoms.

(c) The presence of a tumour of the dura mater or of a

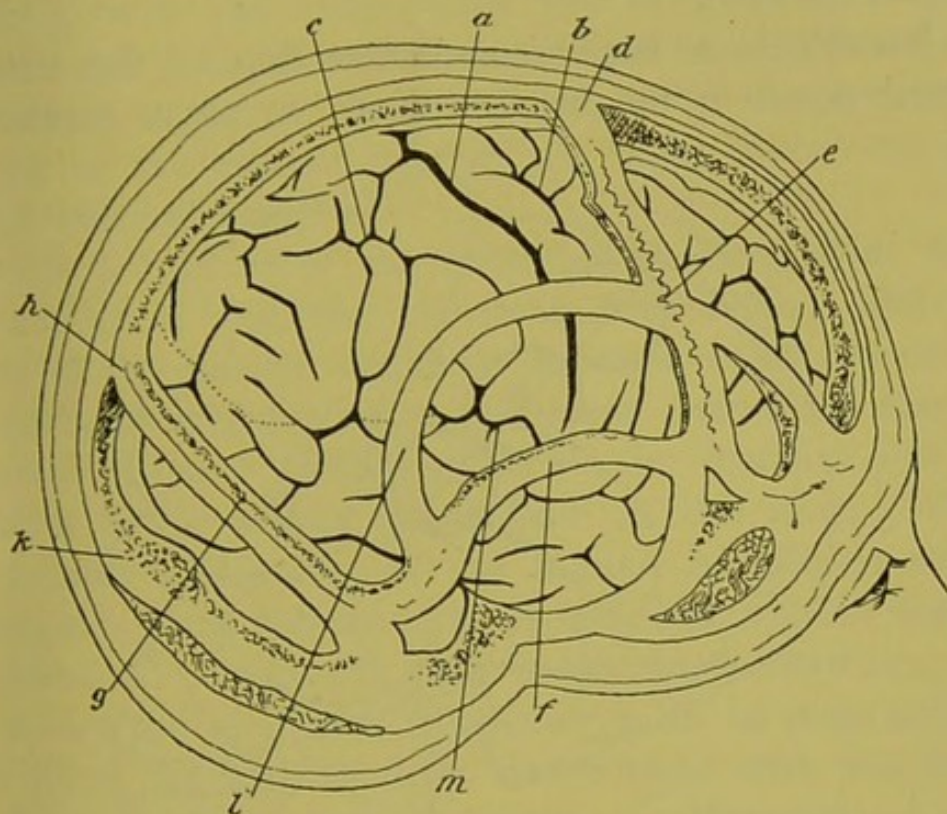


FIG. 180.—The head of an adult female, in which the brain is exposed *in situ*. Bars of bone are left along the lines of the cranial sutures, and also along the line of the temporal ridge.—CUNNINGHAM.

- a.* Fissure of Rolando. *b.* Precentral fissure. *c.* Postcentral fissure. *d.* Bregma. *e.* Coronal suture. *f.* Parieto-temporal suture. *g.* Lambdoid suture. *h.* Lambda. *k.* External occipital protuberance. *l.* Superior temporal crest. *m.* Fissure of Sylvius, posterior limb.

cranial bone, which has extended inwards, and is causing symptoms of irritation, etc., owing to pressure upon the brain matter.

Localisation of tumour or cyst.—Before commencing an operation upon the cerebrum for the removal of a tumour or cyst, its position within the cranial cavity, or at least the

portion of brain which is being pressed upon, is determined from a consideration of the symptoms which have a localising significance.

The probable position of the tumour having been decided upon, the patient is prepared for operation according to the methods mentioned in the earlier part of the chapter (p. 270).

Operation.—A large semicircular flap of the scalp is turned down in the usual manner, so as to expose the

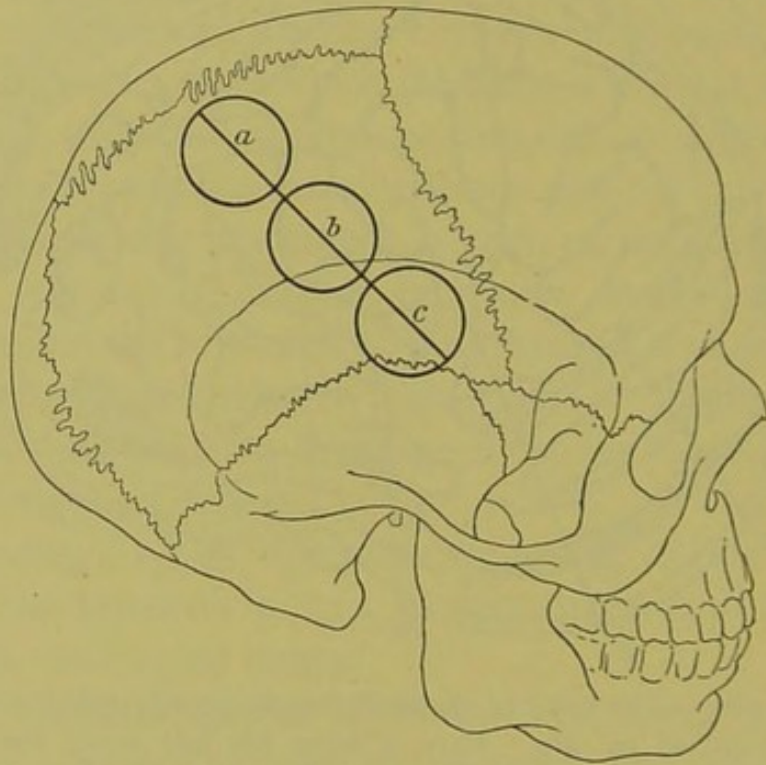


FIG. 181.—Trephining. Skull, showing positions where trephine ought to be first applied in exposing motor centres.

a. Leg. | *b.* Arm.
c. Face and head.

bone overlying the affected portion of the brain. With the trephine, two or more crowns of bone are removed, the intervening bridge of osseous tissue cut through with the chisel, and the dura mater fully exposed. If the growth has sprung from the internal aspect of one of the cranial bones, it will be discovered at this stage, and can be removed. When the underlying portion of the dura mater or the brain has been involved in a growth from

the internal surface of a cranial bone, the infiltrated portions are removed, provided that they are not too extensive. If the bone or the exposed part of the dura mater is not the seat of origin of the tumour, the dura mater is divided in the usual manner, so as to expose the surface of the brain covered by the arachnoid and pia mater. If the growth has arisen from the deep aspect of the dura mater, it is now visible and can be extirpated; or if there is a cyst in the arachnoid, or in the superficial portion of the exposed part of the brain, it can be dissected out and removed.

When a tumour of the cerebrum is being dealt with, the arachnoid and the pia mater are incised, and the limits of the tumour defined. In some cases the cortex of the brain will require to be incised before the tumour becomes visible. Usually, however, its location will be manifest before making an incision of this kind. When the locality and extent of the tumour have been determined, the brain substance is incised with a sharp scalpel all round the tumour, at right angles to the surface. By this means the tumour is freed except on its deep aspect; it is lifted up, and its deep connections with the brain cut through. It can now be removed. Hæmorrhage may take place at this stage, but it can usually be readily arrested by packing the wound with strips of dry aseptic gauze and applying slight pressure.

In many cases it will be found advisable to defer the removal of the cyst until several days after it has been exposed. When the membranes have been incised, an aseptic dressing is applied and the patient sent back to bed. After three or four days the membranes will have become adherent to the margins of the incision, and then removal of the tumour is effected as above.

After the removal of the tumour or cyst, and the arrest of all hæmorrhage, the margins of the incisions in the dura mater are united by sutures, and the external wound closed.

Sarcomatous growths which arise in or involve the cerebrum are very prone to recurrence, but even in these cases some improvement of the patient's condition may be effected, and life be prolonged by the operation.

In the case of non-malignant tumours or of cysts, the prognosis is much more hopeful.

D. For cerebral abscess.—An abscess may involve any portion of the cerebrum, and its locality depends upon the pathological condition which has caused it. Thus in abscess of the brain, dependent upon middle-ear disease, it is usually located either in the posterior portion of the temporo-sphenoidal lobe, or in the anterior and external portion of the lateral lobe of the cerebellum of the corresponding side. When the abscess is due to an injury, such as a perforating wound, it is situated in the injured area, whilst if it is due to pyæmia it may be located in any portion of the brain. In the latter case, multiple abscesses are often met with.

Indications.—(a) *Abscess of the cerebrum, dependent upon a suppurative affection of the middle ear.*—This is usually located in the lower and posterior part of the temporo-sphenoidal lobe of the affected side.

(b) *Abscess of the brain due to an injury.*—If the injury is a perforating one, or the abscess has formed around a foreign body within the brain, the nature of the injury and its point of application will help to determine the locality of the pus. When the abscess is developed in connection with a foreign body, such as a bullet, X-ray photography may help to define the position. In these cases a photograph must be taken in both the antero-posterior and the transverse direction.

(c) *Pyæmic abscess of the cerebrum.*—If there is reason to think that a pyæmic abscess of the brain is single, and there are not pyæmic abscesses elsewhere, it is advisable to operate. If, however, an abscess of the brain is only one of a number of pyæmic abscesses, it is scarcely advis-

able to perform an operation, as good results can scarcely be expected to follow. Each case of pyæmic abscess of the brain must, however, be considered on its merits, and no general rules can be given as to operation.

Operation.—For an abscess of the temporo-sphenoidal lobe.

An abscess of the temporo-sphenoidal lobe, when it is due to extension of a suppurative process from the middle ear, is usually situated, in an adult, underneath a point 1 or $1\frac{1}{4}$ in. above and slightly behind the external auditory meatus.

An incision is made through the scalp in a line corresponding to the free margin of the auricle, and a flap including all the soft

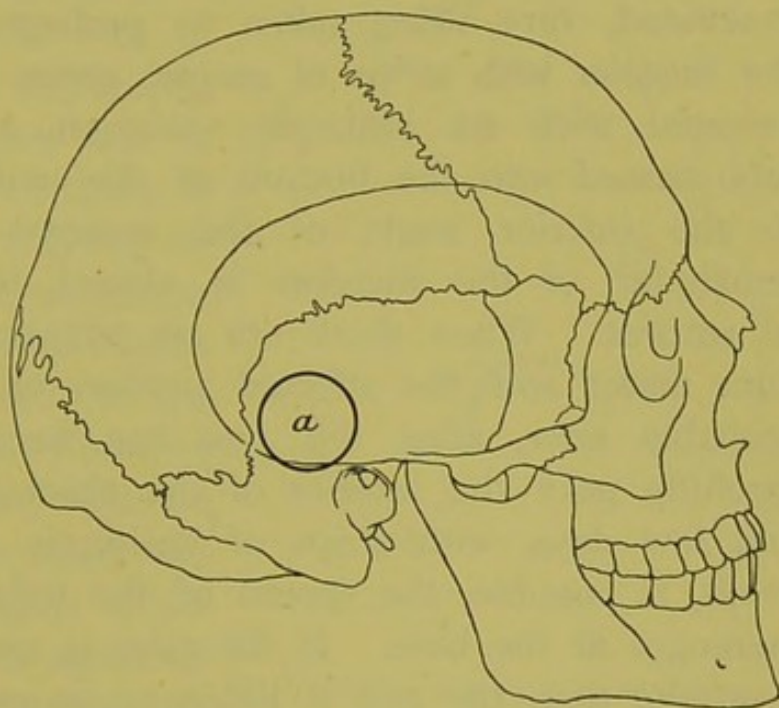


FIG. 182.—Cerebral abscess. Point for applying trephine in abscess of temporo-sphenoidal lobe.

structures turned forwards. In the anterior and upper part of the flap a portion of the temporal muscle will be included. The trephine is then applied in such a manner that the pin is upon a point 1 in. above the external auditory meatus, as shown in Fig. 182. A trephine with a diameter of 1 in. should be used. The crown of bone having been removed, the dura mater is incised, care being taken to avoid the posterior branch of the middle meningeal artery, or if it is in the way it should be ligatured before division. The surface of the brain will now be exposed, and often the subdural

and subarachnoid spaces will be obliterated in the exposed area by inflammatory adhesions. In cases of suppuration, the cerebral substance will protrude into the wound, and the position of the abscess can be seen. If it is not visible from the surface, a trocar and cannula should be carefully pushed inwards so as to find the exact situation of the pus. When this has been done, a grooved director is passed into the abscess cavity along the side of the trocar, an incision is made through the overlying brain substance, and the pus evacuated, care being taken to protect the margins of the incision with strips of aseptic gauze. The cavity is irrigated with an antiseptic solution, a silver drainage tube passed into the bottom of the cavity and stitched to the inferior angle of the external incision. The remainder of the incision is closed by the insertion of sutures. When there are no adhesions between the dura mater and the affected portion of the brain, it is probably safer, after the pus has been evacuated, to carefully pack the interior of the abscess cavity, for the first few days, with strips of antiseptic gauze, so as to avoid, if possible, the spread of the inflammation to the meninges at the base. If the tube is used in these cases from the first, the pus is liable to escape along its side and gravitate towards the base of the brain.

It is not advisable to replace the bone in cases of this kind.

When the locality of the pus is not exposed by the removal of the first trephine crown, a second one should be taken out, or the original opening enlarged with a chisel or with gouge forceps.

E. For cerebellar tumour or cyst.—The diagnosis of tumour or cyst of the cerebellum is difficult, owing to the uncertainty of the symptoms which are produced by growths in this situation. When, however, it is possible to make a diagnosis, with a reasonable amount of certainty, that a tumour or cyst of the cerebellum is present and is

confined to one side, an attempt should be made to remove it by operation.

Position.—The patient is placed in the semiprone position, and lying upon the sound side. The neck is supported by a sandbag. The operator stands behind the patient, and his assistant opposite.

Operation.—An incision, semicircular in shape, is made, commencing at the posterior aspect of the apex of the mastoid process, and extending upwards to the base of the mastoid, and then along the superior curved line of the occipital for two-thirds of the distance towards the external occipital protuberance. This incision is extended down to the bone. In the first part the cut fibres of the sterno-mastoid will be divided, and internally the occipital artery must either be pulled aside or ligatured and divided. It will be found crossing the superior curved line of the occipital bone at the inner part of

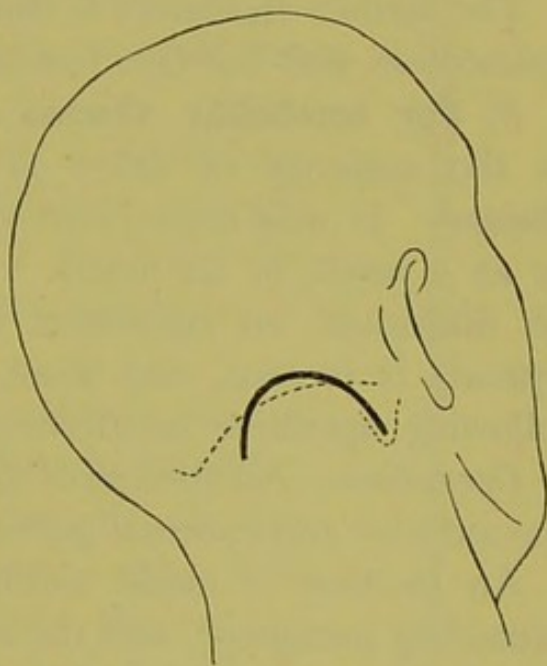


FIG. 183.—Trephining cerebellum. Line of incision in operation for abscess or tumour of lateral lobe of cerebellum.

the incision. With the scalpel and periosteal elevator a flap is turned downwards so as to expose the posterior aspect of the base of the mastoid, and that portion of the occipital bone which lies below the superior curved line. Care must be taken not to separate the soft structures too far inwards, otherwise the spinal canal may be opened, and the medulla injured between the occipital bone and the atlas. When a sufficient area of bone has been exposed, a trephine is applied and a circle of bone removed. In doing this, care must be taken to place

the trephine below the line of the lateral sinus. The bone in this region is often very thin, in which case it can be readily removed with a chisel and mallet. When the bone has been removed, the dura mater is opened by making a semilunar incision in it with the base towards the lateral sinus. The cerebellum is now exposed, and the tumour or cyst sought for, after the manner mentioned in connection with tumours of the cerebrum.

The further treatment is similar to that recommended in connection with cerebral tumours and cysts.

F. For cerebellar abscess.—Cerebellar abscess occurs in the majority of cases as a complication of mastoid disease. It may occur, however, in the course of pyæmia, or as a result of an injury. Whenever its existence can be diagnosed an operation is indicated, unless general pyæmia is present, and there is no hope of good results following operative interference.

Operation.—An abscess of the cerebellum usually involves the anterior and external portion of one lateral lobe.

An incision is made similar to that described in the preceding paragraph, and the abscess exposed. Evacuation and drainage is established as in an abscess of the temporo-sphenoidal lobe of the cerebrum (*q.v.* p. 283).

G. Tapping and drainage of the lateral ventricle.—This operation has been performed for hydrocephalus, but as yet with very poor results.

Operation.—The side of the skull upon which it is proposed to operate having been decided, an aperture is made in the skull $1\frac{1}{4}$ in. above and slightly behind the external auditory meatus, as in trephining for temporo-sphenoidal abscess (Fig. 182). When the dura mater has been turned aside, a trocar is pushed inwards towards a point $2\frac{1}{2}$ in. above the external auditory meatus of the opposite side. After pushing the trocar or needle through a variable thickness of brain matter, diminished resistance is experienced to the passage of the trocar, and fluid escapes. The fluid

is allowed to escape slowly. If it is wished to drain the ventricle, a tube is passed inwards, and fixed in position by stitching it to the margins of the parietal wound. The strictest antiseptic precautions must be observed in the operative and after-treatment of cases of this kind.

H. For the removal of foreign bodies within the skull.—In the treatment of compound depressed or punctured fractures of the skull, it is often necessary to seek for and remove foreign bodies.

In these cases the trephine is applied in the region of the fracture, and an attempt made to trace the course of the bullet or other foreign body from its aperture of entrance.

It occasionally happens, however, that a bullet becomes embedded either in the brain or the membranes, and gives rise to no localising symptoms. In these cases, if it is thought necessary to attempt the extraction of the bullet or foreign body an X-ray photograph should be taken in order to find out where the foreign body has become fixed.

In the first class of cases a light bullet-probe is passed along the wound, the instrument being allowed to find its way more by its own weight than by pressure exerted by the surgeon. If a hard substance is felt, bullet forceps are passed along the probe, and an attempt made to extract the foreign body.

When the missile has passed through the brain, and is located on the opposite side of the skull to the fracture, it is advisable to make a second trephine opening over the foreign body, and remove it through this. Such a method



FIG. 184.—Gun-shot-probe.

of treatment, especially in the case of irregular and angular bodies, entails less injury to the brain substances than when it is removed with long forceps through the aperture of entrance.

When the position of a bullet or foreign body has been located within the cranium by the aid of two X-ray photographs, one taken in an antero-posterior and the other in a transverse direction, it is marked out on the surface of the scalp with an aniline pencil. Next, a semi-lunar flap of the scalp is turned down in the usual manner, and the bone removed with a trephine. The dura mater is incised if necessary, and the brain substance as well when the bullet is underneath the cortex, and by this means the foreign body is laid bare. It is seized by forceps of appropriate shape, and removed. All hæmorrhage from the brain tissue is arrested, the incision in the dura mater is sewn up, the fragments of bone are replaced in their original position, and the scalp wound closed by a series of interrupted sutures.

When the bullet or foreign body has given rise to suppuration, the cavity is treated according to the method described in connection with cerebral abscess.

I. Operative treatment of epilepsy. — *Indications.* — Whenever the fits of epilepsy repeatedly commence by movements in a small and definite group of muscles, it is justifiable to expose that portion of the cortex of the brain in which the cortical centres for these muscles are located. If a tumour of the bone or meninges, or a cyst or tumour of the cerebrum, is found, it is removed, according to one of the methods previously described.

If, however, the exposed part of the cortex of the brain is apparently healthy, and no tumour can be discovered in the subcortical tissue, it does not appear to be justifiable to remove a wedge-shaped portion of brain tissue which shall include the cortical motor centres of the affected group of muscles. If this is done, the corre-

sponding muscles become paralysed and the limb useless. Moreover, the scar which results from the removal of a portion of the brain, will usually contract and affect the adjacent motor centres.

Temporary resection of the skull.—The term “temporary resection of the skull,” or osteoplastic resection, is given to that operation in which a flap of the skull wall is turned back without detaching it; and after an examination has been made of the exposed cranial contents, or an operation has been performed upon them, this flap is replaced in its original position, fixed by the insertion of a few sutures, and then covered by closure of the external wound in the scalp.

Indications.—This operation appears to be indicated in cases in which it is advisable to make an examination of the cranial contents, or in which a large piece of bone must be removed in order to obtain the requisite amount of room for the removal of an intracranial tumour.

Operation.—The head having been shaved and prepared for an operation in the usual manner, an incision, Ω shaped, is made down to the bone with a scalpel. With a surgical engine, or a saw, the bony wall of the cranium is divided for the entire length of the incision. Next, the portion of bone which has been partially detached is forcibly lifted up and turned downwards together with the overlying part of the scalp. In old people, or people with thick cranial bones, it will usually be necessary to partially divide with a chisel the piece of bone in the base of the flap. With a curved or

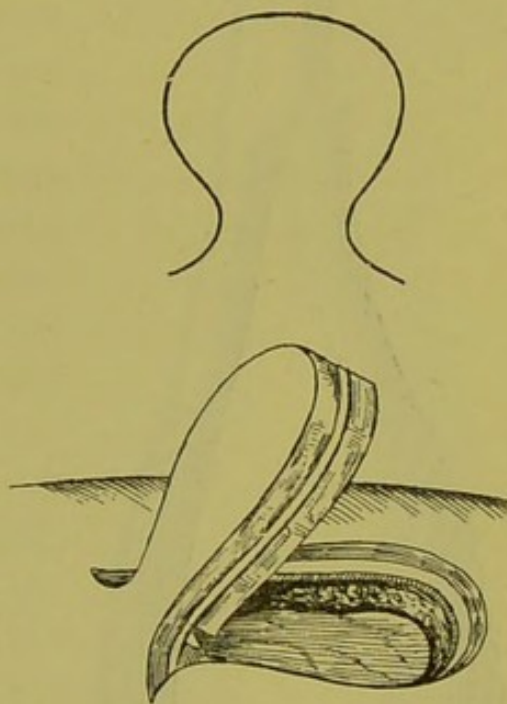


FIG. 185.—Temporary resection of skull. Method of turning down a flap.—After WAGNER.

bent periosteal elevator, the dura mater is detached from the internal surface of the bones of the skull as the flap is turned down.

The examination of the intracranial contents is now made, the dura mater being divided in the line of the original incision, if necessary.

When the intracranial examination, or further operation, has been performed, the margins of the incision in the dura mater are approximated and united with sutures, and the flap of bone and soft tissue of the scalp is turned back into its original position and fixed by the insertion of sutures.

If sufficient tissue is not left at the attached part of the bone flap, the reflected piece of bone is liable to necrose, especially in people who are no longer young.

Craniectomy, or linear craniotomy.—The operation of craniectomy has for its object the removal of a portion of the bony cranium.

Indications.—(a) Some forms of microcephalus, in which there has been premature union along the lines of the sutures.

(b) Cases of early closure of the sutures, dependent upon synostosis of the cranial bones, and necessarily associated with microcephalus, but usually with epilepsy.

Operation.—A linear piece of the parietal bone, parallel to the sagittal suture and a short distance external to it, is

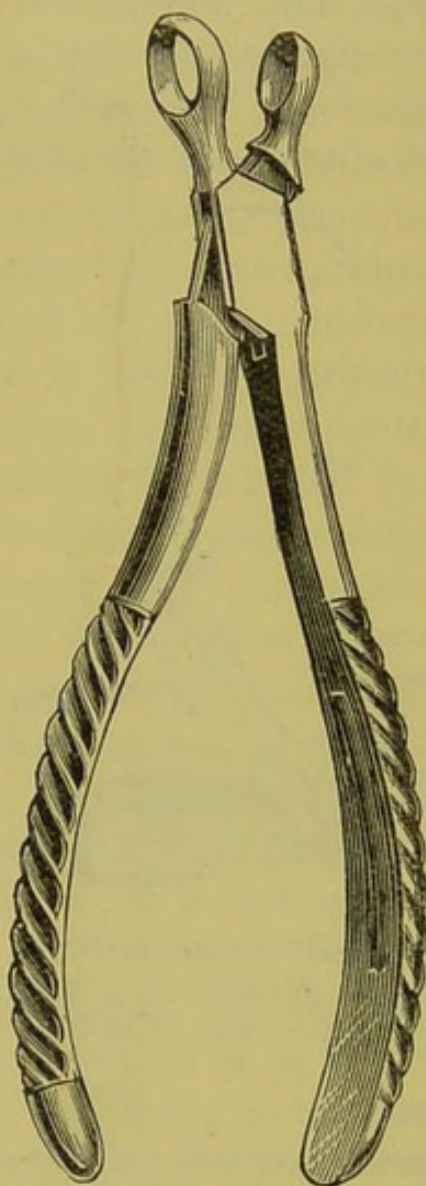


FIG. 186. — Forceps (Hoffman's) for removing portions of cranial bones.

generally removed. Portions of the frontal and occipital bones may be removed as well.

An incision is made parallel with and slightly external to the superior longitudinal sinus, commencing at the lambda and terminating at the bregma or a point more anterior; this divides all the soft tissues of the scalp, including the pericranium. A flap is dissected outwards for a short distance, and then a trephine, half an inch in diameter, is used to remove a crown of bone. Cutting forceps or Hoffman's forceps are then taken, and a strip of bone half an inch in width is removed, for the entire length of the incision, from the exposed portion of the parietal bone, and also from the occipital and frontal bones if it is considered to be requisite. This strip of bone may be removed with a Hey's saw. The pericranium is removed along with the bone. Care must be taken not to injure the dura mater, since in cases which require this operation it is usually closely adherent. When the strip of bone has been removed, all bleeding is arrested, and the external wound closed by sutures.

Usually, it is only necessary to perform the operation upon one side; if, however, the nature of the case necessitates a bilateral operation, a similar portion of bone must be removed from the other side. This is done after the patient has quite recovered from the first operation.

The results which have followed the performance of this operation have as yet not been good. Since, however, the cases are hopeless without operation, it is generally advisable that some surgical measure such as the above should be attempted.

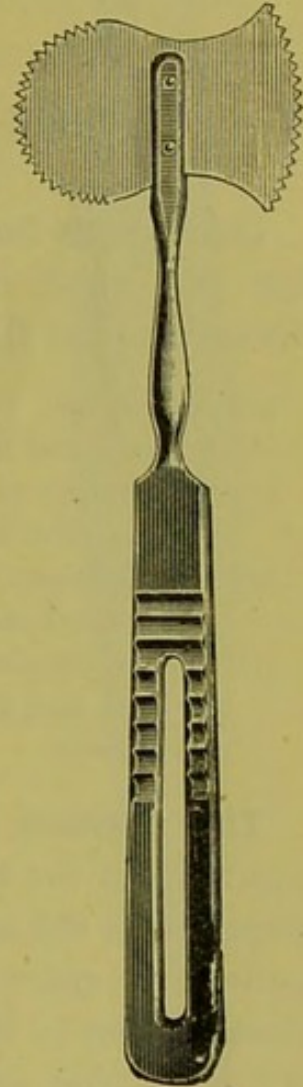


FIG. 187. — Hey's saw.

CHAPTER XV.

THE LIGATURE OF ARTERIES.

Indications for operations upon arteries.—The following are the most important clinical conditions which may necessitate the ligature of an artery :—

- (a) Aneurysm.
- (b) Primary and secondary hæmorrhage.
- (c) Preparatory to the removal of important organs, in order to avoid excessive hæmorrhage.
- (d) Certain cases of pulsating tumours—for example, ligature of the internal carotid for a pulsating tumour of the orbit.
- (e) Certain cases of malignant tumours which have undergone ulceration, and are liable to hæmorrhage, or in order to arrest their growth.

The position of the patient and the operator.—The positions of the patient and the surgeon depend upon the situation of the artery which it is proposed to ligate. The patient is placed in a position which permits the exact demarcation of the blood vessel, and allows of easy access to it; whilst the surgeon stands, in the majority of instances, at that side of the patient which is to be operated upon, his chief assistant being on the opposite side.

Instruments.—The instruments which are required for the ligature of arteries are—

1. *Knife.*—An ordinary scalpel, not too large, is best for the purpose. Some surgeons advise that the skin incision should be made with a large one and the deep dissection with a smaller one; this, however, is not necessary.

2. *Dissecting forceps.*—These should be of medium size,

and not too sharp at the points ; two pairs are requisite. When a deep artery is being ligatured, it may be advisable to have in addition a long pair of forceps with fine serrated points, in order to seize the sheath of the artery while opening it, but this is not usually necessary, as the ordinary dissecting forceps can generally be used for this purpose.

3. *Retractors*.—The kind which is most useful depends upon the artery which is being ligatured. Thus, for the iliac arteries, or whenever there is a deep wound, wide retractors are the best ; while, when the vessel is superficial, blunt hooks serve the purpose. In the case of deep wounds it is better to have both blunt hooks and broad and deep retractors.

4. *Pressure forceps*.—These are for the arrest of hæmorrhage from the margins of the wound. Several pairs are requisite. When operating upon large arteries, it is advisable to have an elastic tourniquet at hand ; this may be found necessary for the control of serious and sudden hæmorrhages.

5. *Aneurysm needle*.—An ordinary curved needle is sufficient in most cases, but for deep-seated arteries, such as the iliacs, a double-curved needle will be the most useful. Two of these should be at hand, one curved to the right and the other to the left.

6. *Ligature and suture material*.—This should be of two thicknesses, one for the vessel itself and the other for the ligation of any small vessels which may be cut during the operation, and for sewing up the wound afterwards. Silk




FIG. 188. — Ligature of arteries. Forceps with fine serrated point, for picking up the sheath of an artery.

is the best ligature material, but many surgeons prefer chromicised catgut. For the external wound salmon-gut will often be found the best.

7. *Needles*.—An ordinary medium-sized half-curved or straight needle is used for sewing up the external wound. When it is necessary to introduce a tier of deep sutures, a fully-curved needle and a needle-holder will be found requisite.

General method of operating.—The operation for the ligature of an artery in its continuity consists of several distinct stages, namely—

(a) *The skin incision*.—The anatomical position of the artery is determined according to the directions which are given in the text-books of anatomy. Great care must be taken in placing the patient in the correct attitude, so as to avoid the possibility of a mistake being made. When this has been done, an incision is made through the skin, usually in the line of the blood vessel, varying in length according to the size of the artery and its depth from the surface of the body.

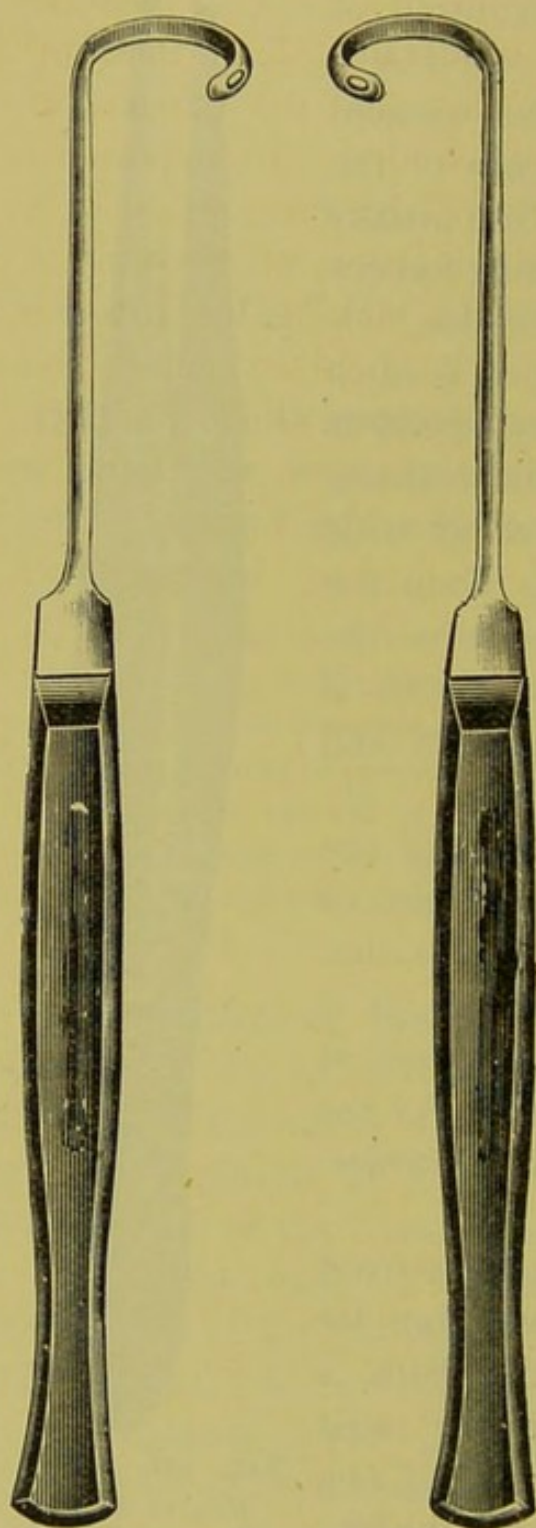


FIG. 189. — Ligature of arteries. Aneurysm needles with a double curve, one to the right and the other to the left.

Thus, in ligature of the radial at the wrist, an incision

of $1\frac{1}{2}$ in. is quite sufficient, whilst for the first portion of the axillary artery it must be 4 in. long. As a general rule, it is advisable to make a moderately long incision, since no harm can be done by this, and the dangers of working in a confined space are avoided. In operations on the face or the exposed parts of the extremities, it is better to avoid making too long an incision, on account of the resulting scar being visible. In making the incision through the skin, the knife may be held in either the "dinner-knife" or the "dissecting" position (Figs. 3 and 5). In the case of small incisions it is advisable to adopt the latter method, and for long incisions the former. The blade of the knife should be sloped whilst making the main part of the wound, and, finally, it should be brought out vertically, so as to avoid "tailing," and to ensure that the wound is of equal depth for its entire extent. Care must be taken to avoid damage

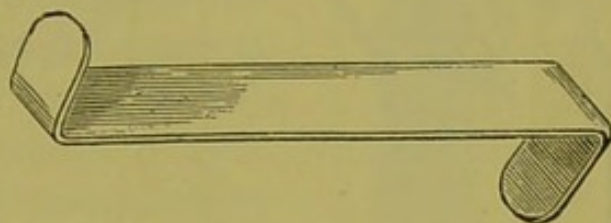


FIG. 190.—Form of retractor suitable for use in exposure of an artery.

to any superficial veins when the skin incision is made, but if one of these structures cannot be easily avoided it must be cut through, and its two extremities tied.

(b) *The division of the deep fascia.*—The deep fascia can, in most parts of the body, be recognised as a thin dense lamina of fibrous tissue immediately underneath the fatty layer. It is divided for the entire extent of the incision, and by this means the muscular strata are exposed. It is important to recognise the deep fascia, especially in fat people or when operating upon the dead body, since all arteries whose ligature may be required lie underneath this layer.

(c) *The separation of the muscles or tendons and exposure of the artery.*—When the deep fascia has been divided, its margins are drawn aside and separated with retractors, so as to fully expose the muscular layer. In most cases, the

space between two particular muscles has to be recognised in order to find the blood vessel. This separation is best effected with the finger or the handle of the scalpel, preferably the former in most cases. The intermuscular septum between two muscles is said to be indicated by a white line, which is caused by a localised thickening of the fascia, but this sign cannot be depended upon. It is better to trust to the finger, and to feel for a slight depression

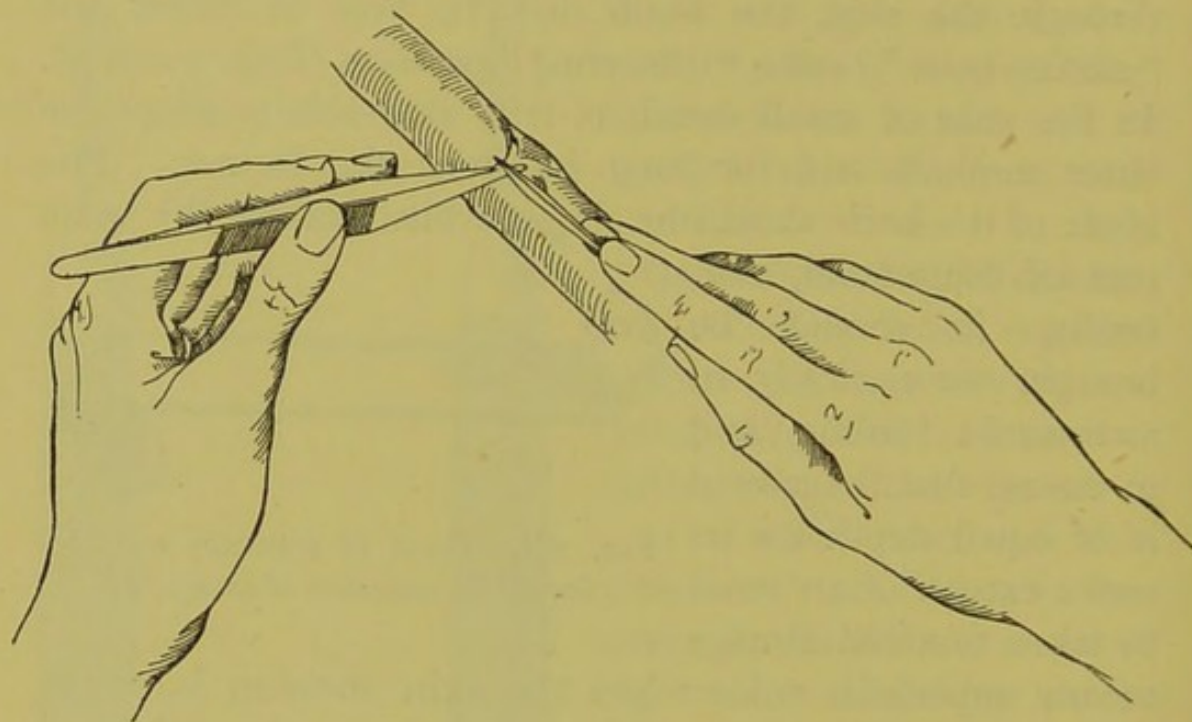


FIG. 191.—Ligature of arteries. Method of opening the sheath of an artery, before an aneurysm needle is passed.

along the line of separation between the two muscles. The muscles are held apart with retractors, and care is taken to make the wound of the same depth throughout. When the muscles have been separated, the artery can usually be recognised lying at the bottom of the wound, and often accompanied or surrounded by its *venæ comites*, or having a nerve in close relation to it. In the living person the artery can usually be distinguished by its pulsations, but care must be taken not to mistake a transmitted pulsation for the true pulsation of the vessel itself.

(d) *The opening of the sheath of the artery and the passage of the needle and ligature.*—When the artery has been exposed, its sheath is opened, so as to permit of the easy passage of the ligature, and to avoid the enclosure of or injury to any important adjacent anatomical structure by the ligature. A small fold of the sheath, transverse to the long axis of the artery, is picked up with fine forceps and incised with a scalpel, an aperture about one-third of an inch in length being made in it. The aperture should lie over the centre of the exposed portion of the vessel, or, when there is only one accompanying vein, somewhat to the side furthest away from that structure. Thus, in the case of the common carotid artery, it is advisable to make the incision into the sheath well on the inner side, so as to avoid wounding the internal jugular vein, which overlaps it to a considerable extent. When the incision into the sheath is being made, the sheath itself should be lifted quite away from the vessel for a distance of about one-third of an inch by means of the aneurysm needle. One margin of the incision in the sheath is seized with the forceps, and then the point of the aneurysm needle is gently insinuated round the artery for half its circumference. Next, the other margin of the sheath is seized and the point of the needle passed round in the opposite direction, until the sheath is separated for the entire circumference. When this has been done, the

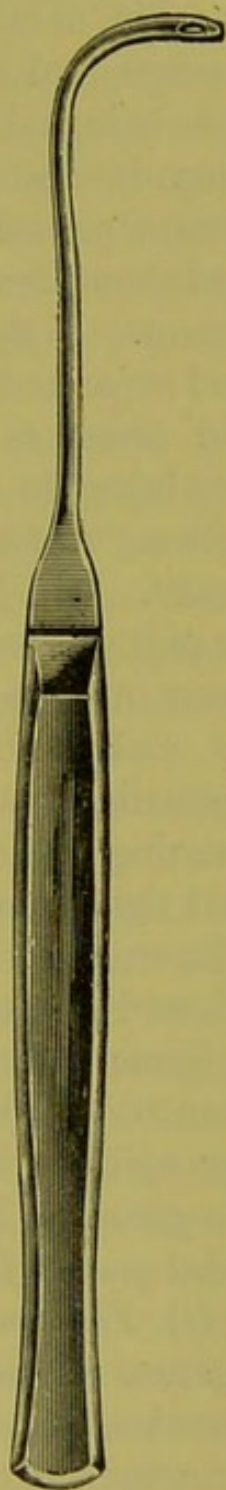


FIG. 192. — Ligature of arteries. Simple curved aneurysm needle.

margin of the sheath which lies adjacent to the accompanying vein, or other important anatomical structure, is held with forceps, and the aneurysm needle passed around the artery, care being taken not to lift up the vessel from its bed more than is absolutely necessary. The aneurysm needle is always passed round an artery in an unthreaded condition, and then threaded with a ligature (usually silk), and withdrawn. If the sheath of the artery has been well opened and separated, and the needle is kept close to the wall of the vessel as it is passed, there is very little risk of doing any injury to neighbouring structures. The ligature is tied with a "reef-knot," at right angles to the long axis of the vessel. The knot is made gradually, and no sudden tension or pull exerted. During the tying of the ligature the artery must not be lifted up in the wound; this is prevented by making the extremities of the two forefingers meet immediately above the artery upon the site of the knot, and exerting tension from the knuckles. The ligature should be tied tightly enough to rupture the inner coats of the vessel. The ends of the ligature are finally cut short, and the knot allowed to retract into the interior of the sheath.

Some surgeons prefer to tie the artery in two places, and then to divide the vessel between the ligatures. This, in my opinion, is not necessary, and in certain regions it is dangerous. This is especially so in connection with the third part of the subclavian.

(e) *The closure of the external wound.*—In most cases of ligature of an artery, it is not necessary to divide any muscles, and hence, when the retractors are removed, the structures resume their normal position; but if it is found requisite to divide a muscle or muscles, or if the deeper parts of the wound do not come into good apposition, it is necessary to unite these with a tier of deep sutures. The margins of the incision in the skin and fasciæ are then united by the insertion of a continuous suture, or an interrupted one if it is preferred, and the ordinary aseptic dressings applied.

EXPOSURE AND LIGATURE OF INDIVIDUAL ARTERIES.

The innominate artery.—The innominate artery is a large branch of the thoracic aorta, given off from the convexity of the arch opposite to a point situated slightly to the right of the middle of the manubrium sterni. From its origin, it passes upwards and to the right to the base of the neck, where it terminates by dividing into the right common carotid and right subclavian arteries.

Its course is represented on the surface of the chest by drawing a line from a point immediately to the right of the central point of the manubrium sterni to the upper border of the sterno-clavicular articulation of the right side. The vessel usually measures about $1\frac{1}{2}$ in. in length, and gives off no branches in its course, though, in exceptional cases, it may give origin to the thyroidea ima.

The innominate artery lies behind the manubrium sterni, the origins of the right sterno-hyoid and sterno-thyroid muscles, and the remains of the thymus gland; whilst at its origin it is crossed by the left innominate vein, and for its entire course it is overlapped from the outer side by the right innominate vein. To the right lie the right innominate vein, the right vagus nerve, and the parietal layer of the right pleura; on the left, the inferior thyroid veins, the remains of the thymus gland, and the commencement of the left common carotid artery; behind, it is in relation with the thoracic portion of the trachea and the right pleural sac. The height at which the vessel divides varies; sometimes it is lower than usual, but only rarely does it divide in the neck above the clavicle.

Position.—The patient is placed in the dorsal position, near the right side of the table, the shoulders are raised, the right arm pulled downwards and fixed in that position, the head extended and rotated towards the left.

The surgeon stands opposite the right shoulder, the chief

assistant opposite to him, and a second assistant on the left side of the head.

Operation.—An angular incision is made, one limb of which extends along the upper border of the inner third of the clavicle, and the other limb along the anterior border of the sterno-mastoid muscle. Each part of the incision is about 3 in. in length. The skin, superficial fascia, and deep cervical fascia are divided along both parts of the incision, and the muscles exposed. The outer and lower portion of the sterno-mastoid and the sterno-hyoid and sterno-thyroid muscles are divided close to their attachments to the clavicle and sternum, and a flap turned upwards and outwards. The deep cervical fascia which lies behind the muscles is now laid bare, and the carotid sheath can be seen in the inner portion of the wound. Care must be taken when turning up the flap not to injure the anterior jugular vein as it passes behind the inner part of the sterno-mastoid. The carotid sheath is opened in the lower part of the incision, and the common carotid artery traced downwards and inwards until the innominate artery is well exposed. When this has been done, it is separated from its sheath as carefully as possible, so as to avoid injury to the veins in the immediate neighbourhood. The right innominate vein may be considerably dilated and overlap the artery; the left innominate vein may cross higher than usual, and appear in front of the vessel in the upper part of its course; and the inferior thyroid veins may be very large and overlap the innominate artery from the inner side. When the artery has been separated from its connections, the aneurysm needle is passed from the outer side, care being taken to avoid puncture of one of the veins, injury to the pleura, or enclosure of the right vagus nerve. A strong silk ligature is probably the best form of material to tie the vessel with. Treves advises that the common carotid and vertebral arteries should be ligatured as well, so as to diminish the risk of secondary hæmorrhage. When this has been done,

the wound is closed and treated aseptically, so as to ensure healing by first intention.

When the innominate artery divides at a moderately high level, or when the patient has a long and thin neck, it will be found that the ligature of the vessel can be effected through an incision along the anterior border of the sternomastoid.

Collateral circulation.—(a) Intercostal branches of aorta with similar branches from the superior intercostal branch of the subclavian; (b) internal mammary, by means of its superior epigastric branch, with the deep epigastric branch of the external iliac, and by means of its musculo-phrenic branch with the lower five or six intercostal branches of the thoracic aorta; (c) the aortic intercostals of the third to the sixth space with thoracic branches of the axillary artery (long thoracic, pectoral branches of acromio-thoracic, and subscapular); (d) communications between various branches of the external and internal carotid arteries on one side, and similar branches on the opposite side.

The common carotid artery.—This vessel on the right side is given off from the innominate artery, and on the left from the arch of the aorta between the innominate and the left subclavian. The thoracic portion of the left artery is not suitable for the application of a ligature. The course of the vessel in the neck is marked out by drawing a line from the sterno-clavicular joint upwards to a point midway between the angle of the jaw and the apex of the mastoid process when the head is turned slightly towards the opposite side. The vessel divides at the upper border of the thyroid cartilage. It is enclosed within a sheath of the deep cervical fascia, and opposite the cricoid cartilage it is crossed by the anterior belly of the omo-hyoid muscle. That portion of the vessel which lies above the omo-hyoid is covered only by the deep cervical fascia, the inner border of the sternomastoid, the superficial fascia, platysma, and skin; whilst that below this muscle has in front of it, in addition to the

above structures, the sterno-hyoid and sterno-thyroid muscles. Within the sheath of the artery lie the internal jugular vein on the outer side, and the vagus nerve behind and between the two. Each structure lies within a special compartment of the sheath. Occasionally, the descendens cervicis nerve

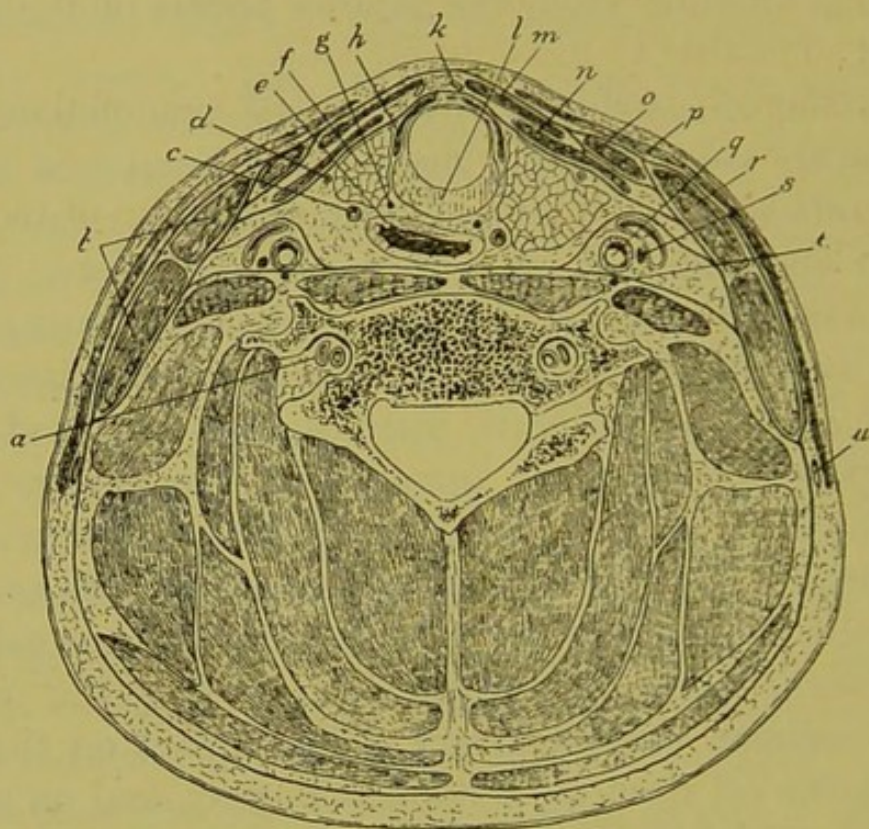


FIG. 193.—Ligature of common carotid artery. Transverse section through the neck at the level of the cricoid cartilage.

- a.* Vertebral vessels.
- b.* Sterno-mastoid muscle.
- c.* Branch of superior thyroid artery.
- d.* Nerve to infra-hyoid muscles.
- e.* Esophagus.
- f.* Lateral lobe of thyroid gland.
- g.* Recurrent laryngeal nerve.
- h.* Crico-thyroid muscle.
- k.* Inferior thyroid veins.

- l.* Cricoid cartilage.
- m.* Sterno-hyoid muscle.
- n.* Sterno-thyroid muscle.
- o.* Omo-hyoid muscle.
- p.* Platysma.
- q.* Common carotid artery.
- r.* Internal jugular vein.
- s.* Vagus nerve.
- t.* Phrenic nerve.
- u.* External jugular vein.

is found in front of the artery within the sheath, but usually it lies outside. The carotid tubercle of the sixth cervical vertebra lies immediately behind the artery. The relative position of the artery to the adjacent structures is shown in Fig. 193.

A ligature may be applied either above or below the omo-hyoid muscle, preferably above in the majority of cases, on account of the superficial situation of the vessel at this level.

Ligature of the common carotid artery above the omo-hyoid.—*Position.*—The patient is placed in the dorsal position, with the shoulders slightly raised, and the head turned somewhat to the opposite side.

The surgeon stands on the affected side of the patient, and the assistant on the opposite side.

Operation.—An incision is made in the line of the artery, 3 in. in length, and so situated that its centre is opposite the upper border of the cricoid cartilage. The skin, the superficial fascia containing branches of the superficial cervical nerves and possibly tributaries of the external jugular vein, and the deep fascia, are divided

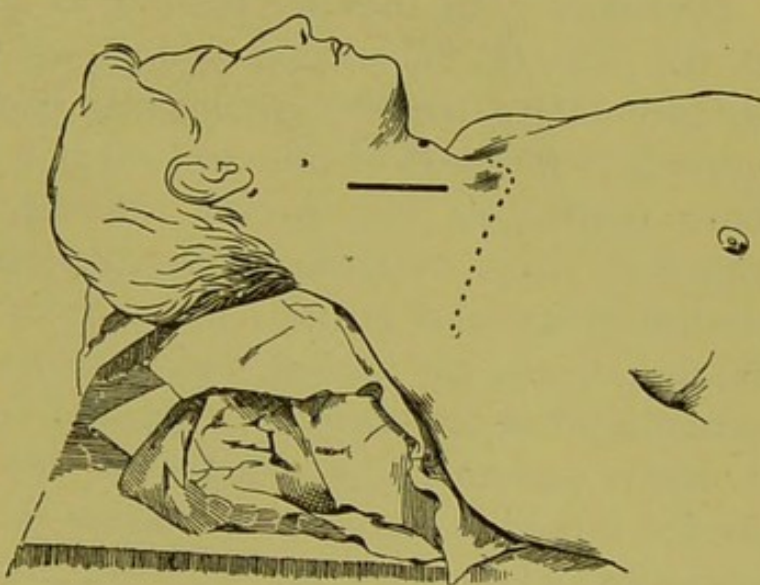


FIG. 194.—Ligature of common carotid artery.
Position of patient and line of external incision.

in the line of the incision. By this means the sterno-mastoid muscle is exposed. The inner border of this is next defined and retracted outwards. The anterior belly of the omo-hyoid will then be seen crossing upwards and inwards. It is pulled downwards with a retractor, and then the carotid sheath will be visible, and lying upon it may be seen in many cases the descendens cervicis nerve. This nerve is pulled outwards, and the sheath opened on the inner side, so as to avoid puncture of the internal jugular vein. The artery is separated from its sheath for a short distance in the usual manner, and the needle is passed from without

inwards, care being taken not to include the vagus nerve or the sympathetic cord which lies immediately behind the sheath. During the passage of the needle and the separation of the sheath, the vessel should not be disturbed more than is necessary. The superior and middle thyroid veins usually cross the front of the carotid sheath, in which case they are drawn upwards, or ligatured in two places and divided between.

Ligature of the common carotid below the omo-hyoid.

—*Position*.—As for ligature of the vessel at a higher level.

Operation.—An incision from 3 to 4 in. long is made in the line of the artery, commencing, below, a short distance above the sterno-clavicular joint, and extending upwards to the level of the crico-thyroid membrane or the lower portion of the thyroid cartilage. The skin, the superficial fascia containing the supra-sternal branch of the cervical plexus and possibly the anterior jugular vein, and the deep fascia, are incised, and the anterior border of the sternal head of the sterno-mastoid laid bare. This muscle is drawn outwards, the attachment to the sternum being divided if requisite, and by this means the sterno-hyoid and sterno-thyroid muscles are exposed, and possibly, in the upper part of the incision, the omo-hyoid. The sterno-hyoid and sterno-thyroid muscles are drawn inwards, their fibres being cut across if necessary, and the omo-hyoid is retracted upwards. One or more inferior thyroid veins may be met with at this stage, and give rise to trouble. If seen they must be drawn inwards, or ligatured in two places and divided between. The carotid sheath, which contains the artery, is now exposed. The sheath is opened on the inner side, and the needle passed from without inwards. On the left side the internal jugular vein lies somewhat anterior to the artery, and may prove a source of trouble.

Collateral circulation.—(a) The superior thyroid with the inferior thyroid; (b) the occipital with the deep cervical and the transverse cervical; (c) the branches of the external

carotid with similar branches from the opposite side; (*d*) branches of the external carotid with branches of the vertebral; (*e*) the various communications at the circle of Willis.

The external carotid artery.—This vessel is one of the terminal branches of the common carotid, and is given off at the level of the upper border of the thyroid cartilage. Its course is approximately marked out by prolonging upwards the line of the common carotid. The artery terminates immediately below and internal to the condyle of the

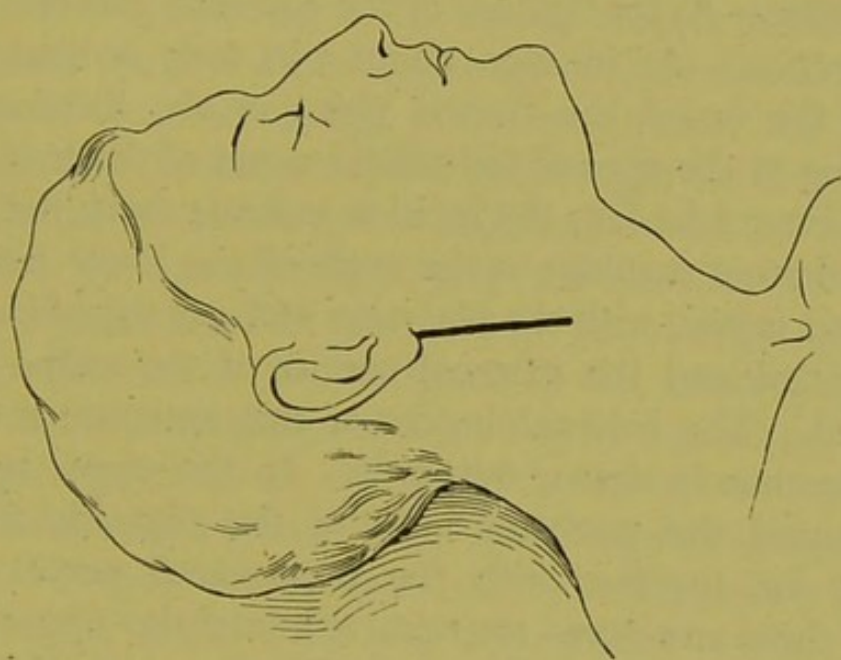


FIG. 195.—Line of incision for ligature of external and internal carotid arteries.

lower jaw, by dividing into the internal maxillary and superficial temporal arteries. In its course it gives origin in front and internally to the superior thyroid, the lingual and the facial arteries; posteriorly it gives off the posterior auricular and occipital arteries, and from its deep aspect the ascending pharyngeal. The superior thyroid is given off immediately above the commencement, the lingual opposite the greater cornu of the hyoid, the occipital and facial at a slightly higher level, and the ascending pharyngeal usually at about the same level. The posterior auricular artery arises a little above the occipital. The superior thyroid may be given

off from the common carotid, whilst the lingual and facial not infrequently arise by a common trunk. The artery at its commencement is somewhat superficial, being covered by the skin and fasciæ and overlapped by the sterno-mastoid. The hypoglossal nerve crosses the vessel about 1 in. beyond its origin, and the posterior belly of the digastric muscle at a slightly higher level. The artery is generally ligatured below the digastric at a point between the origins of the superior thyroid and the lingual arteries.

Position.—As for ligature of the common carotid.

Operation.—An incision about 3 in. long is made in the line of the vessel, the central point of the incision corresponding to the apex of the greater cornu of the hyoid bone. If this cannot be felt, the incision extends from the middle of the thyroid cartilage to the angle of the lower jaw. The skin and fasciæ, with the platysma and any superficial veins, are divided and the external surface of the sterno-mastoid exposed. The internal border of this structure is defined, and the muscle drawn outwards. In the upper section of the wound the posterior belly of the digastric muscle is sought for, together with the hypoglossal nerve. When found these structures are retracted into the upper portion of the incision. The apex of the greater cornu of the hyoid bone is next laid bare, together with that portion of the external carotid artery which lies between the points of origin of the superior thyroid and lingual arteries. This part of the vessel may be surrounded by veins, in which case they are drawn aside and the artery separated from the adjacent structures. The aneurysm needle is then passed from without inwards, care being taken to avoid the superior laryngeal nerve, which lies posterior to the vessel. In some cases it is necessary to ligature the exposed part of the external carotid and the separate branches as well, when they are given off in immediate proximity to the point of application of the main ligature.

Collateral circulation.—This is similar to that given in

connection with ligature of the common carotid, with the exception of the anastomosis between the superior and inferior thyroid arteries.

The superior thyroid artery.—The ligature of this artery is carried out through an incision similar to that described for the external carotid. The external carotid is defined and traced downwards until the superior thyroid is exposed.

The lingual artery.—The lingual artery is a branch of the external carotid, given off opposite the apex of the greater cornu of the hyoid bone. Its course may be divided into three parts, the first extending in an oblique direction from its origin to the outer margin of the hyoglossus ; the second is horizontal in direction and lies underneath the hyoglossus ; whilst the third ascends and is situated beneath the tongue.

The first part is superficial, and has the same coverings as the external carotid ; the second lies deeper upon the middle constrictor of the pharynx and the genio-hyoglossus and behind the hyoglossus, parallel with the upper border of the greater cornu of the hyoid bone, but at a slightly higher level. The cornu of the hyoid bone is the guide to the vessel in this part of its course. The hyoglossus muscle separates the artery from the hypoglossal nerve, which, however, lies at a higher level, and also from the lingual (ranine) vein. The artery may be ligatured in either the first or the second part of its course, usually the latter.

When a ligature is applied to the vessel in the first part of its course, the operation is similar to that for ligature of the external carotid.

Ligature of the lingual artery beneath the hyoglossus.
—*Position.*—The patient lies in the dorsal position near the end of the table, with the shoulders raised, the head turned towards the opposite side, and held in position by an assistant.

The surgeon stands on the side which is to be operated upon, the chief assistant on the opposite side, and a second assistant near the operator. The second assistant holds the

head in position, and retracts the digastric tendon at the proper time.

Operation.—A curved incision is made, commencing half an inch outside and a short distance below the symphysis menti, and extending downwards to the lip of the great cornu of the hyoid bone, and then upwards to a point a little below and in front of the angle of the lower jaw. This incision divides the skin, the superficial fascia with the platysma, and the deep fascia for its entire length. When the deep fascia has been fully divided, the lower margin

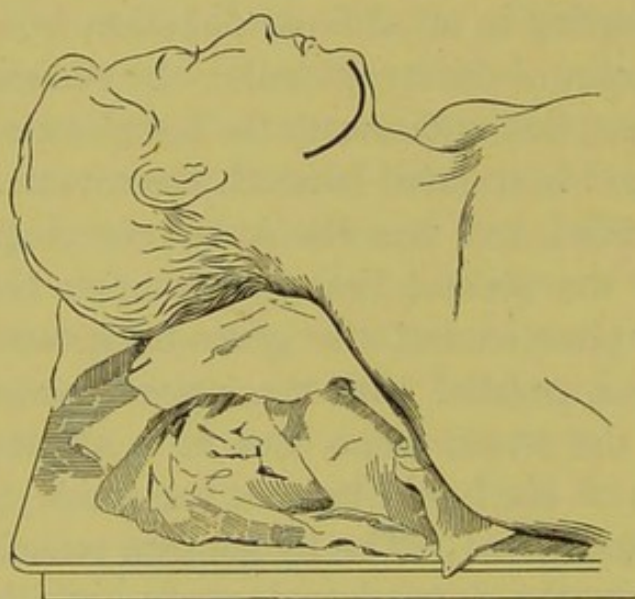


FIG. 196. — Ligature of lingual artery. Position of patient, and line of external incision.

of the submaxillary salivary gland is sought for and hooked upwards with a retractor. Next, the intermediate tendon of the digastric muscle is exposed, as it lies in the lower portion of the wound. When defined it is drawn downwards with a blunt hook, and so held by the second assistant. The fibres of the hyoglossus muscle are now

visible in the angle between the two bellies of the digastric, and in many cases the hypoglossal nerve or the lingual vein is seen lying upon this muscle. If these latter structures are exposed, they are retracted upwards out of the field of operation, and then with the tip of the finger the upper border of the greater cornu of the hyoid bone is felt for. When this has been defined, the fibres of the hyoglossus are cut through about one-third of an inch above the hyoid. A connective tissue or fascial plane will soon be met with when the fibres of the muscle have been divided, and in this tissue will be found the lingual artery. Care

must be taken not to overlook this plane, otherwise the fibres of the middle constrictor may also be divided, and the incision made to communicate with the cavity of the pharynx. When the artery has been exposed, it is separated for a short distance from its surroundings, and the needle passed from above downwards.

The facial artery.—This vessel is a branch of the external carotid, given off a short distance above the apex of the greater cornu of the hyoid bone; or it may be given off along with the lingual by a common trunk. From its origin the artery passes upwards, lying in a deep groove in the submaxillary gland, and then over the horizontal ramus of the lower jaw, about a third of the distance from the angle to the symphysis, and immediately in front of the masseter muscle. Above this point it passes onwards to the tissues of the face. The vessel can be felt pulsating as it passes over the ramus of the jaw, and also just beyond its point of origin in the neck.

In the latter position the operation is similar to that for ligature of the external carotid.

Ligature of the facial artery as it lies upon the lower jaw.—*Position.*—The patient is placed in the dorsal position, with the head resting on a pillow and turned over towards the opposite side. The operator stands on the

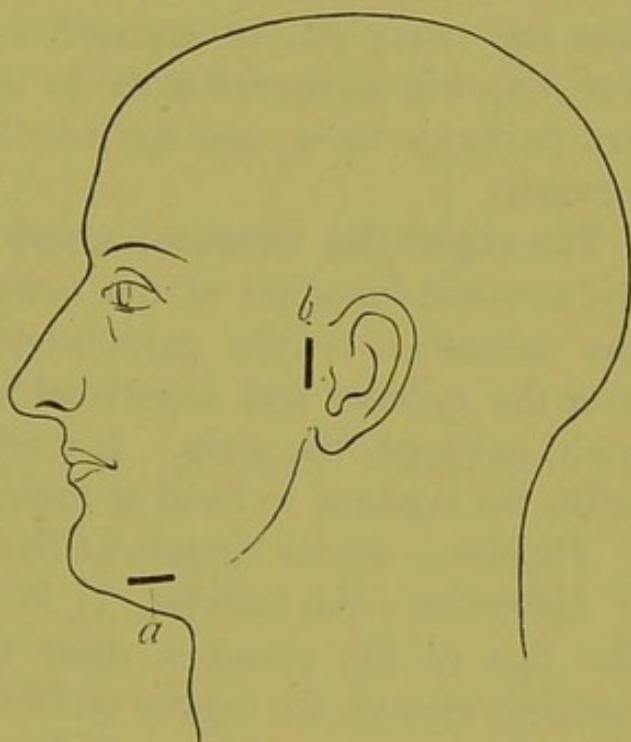


FIG. 197.

- a.* Ligature of facial artery. Line of external incision.
- b.* Ligature of superficial temporal artery. Line of incision.

affected side of the head, and the assistant opposite to him.

Operation.—The anterior border of the masseter and the situation of the vessel on the jaw are first defined; then the skin of the neck and face is drawn upwards, and an incision 1 in. in length is made parallel with the inferior margin of the jaw, and having its central point opposite the vessel. The skin, superficial fascia, and platysma are divided, and then the artery will be exposed as it lies upon the bone. The vessel is separated from its accompanying vein, which lies posterior to it, and the needle is passed from behind forwards.

The superficial temporal artery.—This artery is one of the terminal branches of the external carotid, given off in the substance of the parotid gland. It passes upwards over the zygoma and superficial to the temporo-maxillary joint, to supply the scalp. It may be ligatured where it lies upon the zygoma, in front of the external auditory meatus.

Position.—As for ligature of the facial artery.

Operation.—An incision, $1\frac{1}{2}$ in. in length, is made along the line of the vessel, a short distance in front of the auditory meatus, the central point of the incision corresponding to the zygoma (Fig. 197, *b*). The skin and fasciæ are divided, when the artery will be exposed lying upon the bone, surrounded by its venæ comites, and having the auriculo-temporal nerve immediately behind it. The vessel is carefully separated from the nerve, and from its veins if possible, and the needle passed from behind.

The occipital artery.—This is a branch of the external carotid, arising from this vessel on its posterior aspect and a little above the level of the greater cornu of the hyoid bone. It first passes upwards in the neck and then almost horizontally backwards, between the mastoid process and the lateral mass of the atlas, lying in a groove in the mastoid portion of the temporal bone, and finally ascends vertically to the scalp.

It may be ligatured in the anterior triangle of the neck, or as it lies in relation with the mastoid portion of the temporal bone. In the first case the operation is similar to that for the ligature of the external carotid.

Ligature of the occipital artery as it lies in the mastoid region.—*Position.*—The patient is placed on the sound side, with the head resting on a pillow and turned well towards the opposite side. The surgeon stands on the affected side, and the assistant opposite to him.

Operation.—An incision about 2 in. in length is made, which commences, below, at the posterior border of the mastoid process and immediately above its apex, and extends upwards to a point midway between the mastoid and the external occipital protuberance. The skin, dense fasciæ, the posterior borders of the sternomastoid and the splenius capitis are divided, and the margins of the wound well retracted. The artery will then be exposed, lying in a groove on the internal as-

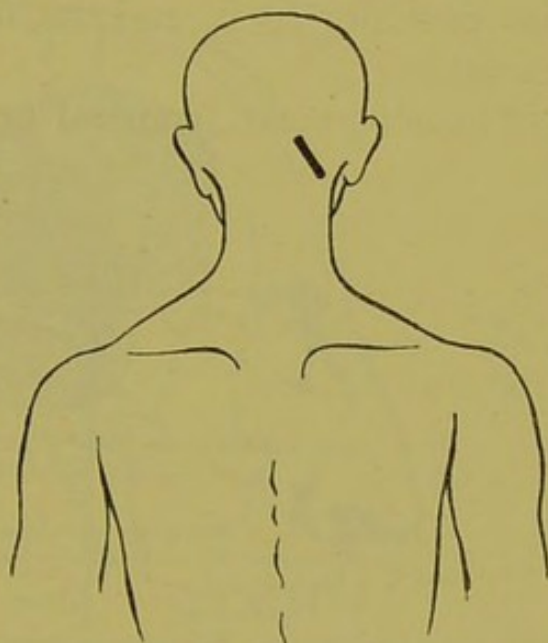


FIG. 198. — Ligature of occipital artery. Position of external incision.

pect of the base of the mastoid process. It is separated from adjacent veins, and the needle passed from either side. Care must be taken not to divide the artery as it lies upon the bone.

The middle meningeal artery.—The middle meningeal artery is a branch of the internal maxillary, given off in the pterygoid region, and passing into the skull through the foramen spinosum. It lies in a groove in the temporal bone, and is partially embedded in the outer layers of the dura mater. The artery divides into anterior and posterior

branches, to either of which a ligature may have to be applied. The anterior branch passes upwards and slightly backwards, and the posterior backwards and upwards, towards the region of the parietal eminence.

Ligature of the anterior branch of the middle meningeal.

—*Position*.—The patient is placed in the dorsal position, with the head raised and turned towards the opposite side. The surgeon stands at the affected side of the head, and the assistant immediately opposite to him.

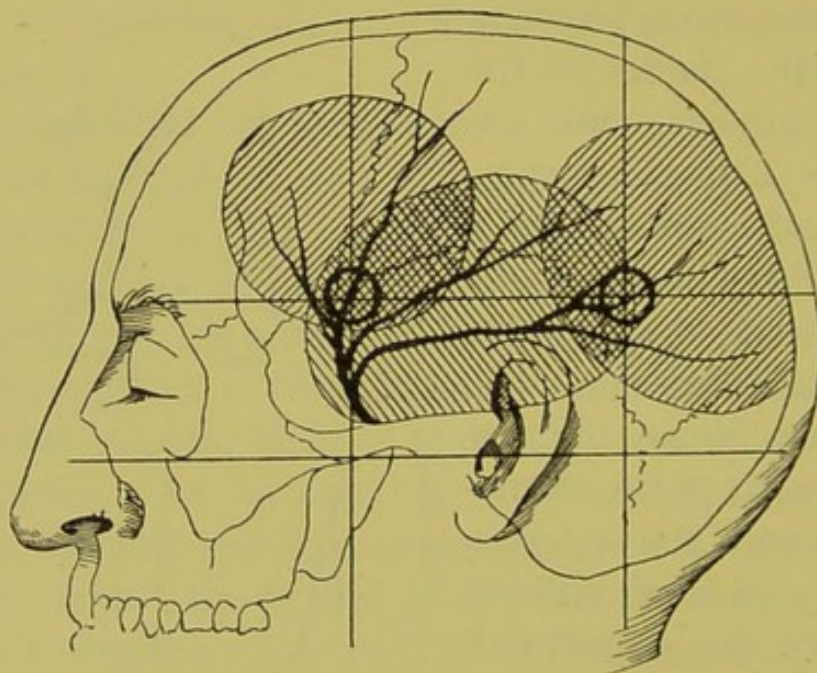


FIG. 199.—Ligature of middle meningeal artery. Position of trephine openings in exposure of anterior and posterior branches.—After KRÖNLEIN.

Instruments.—In addition to the ordinary instruments for the ligature of a blood vessel, those for trephining are also required, and a small fully curved needle.

Operation.—A point is taken $1\frac{1}{2}$ in. behind the external angular process of the orbit, and the same distance above the zygoma, which shall serve for the centre of the field of operation. A flap of the scalp in the form of a semicircle, with a radius of a little more than $1\frac{1}{2}$ in., is reflected, the incision being made with the convexity towards the vertex

of the skull, in order to preserve as far as possible the blood supply of the incised tissues. The scalpel divides everything down to the surface of the bone, including the pericranium, and the flap is reflected with the aid of a periosteal elevator. The middle of the flap turned down should be made to correspond to the position of the artery. When the bone has been exposed, a trephine with a diameter of $1\frac{1}{2}$ in. is applied to the skull, the pin of the instrument being placed over the position of the artery. A

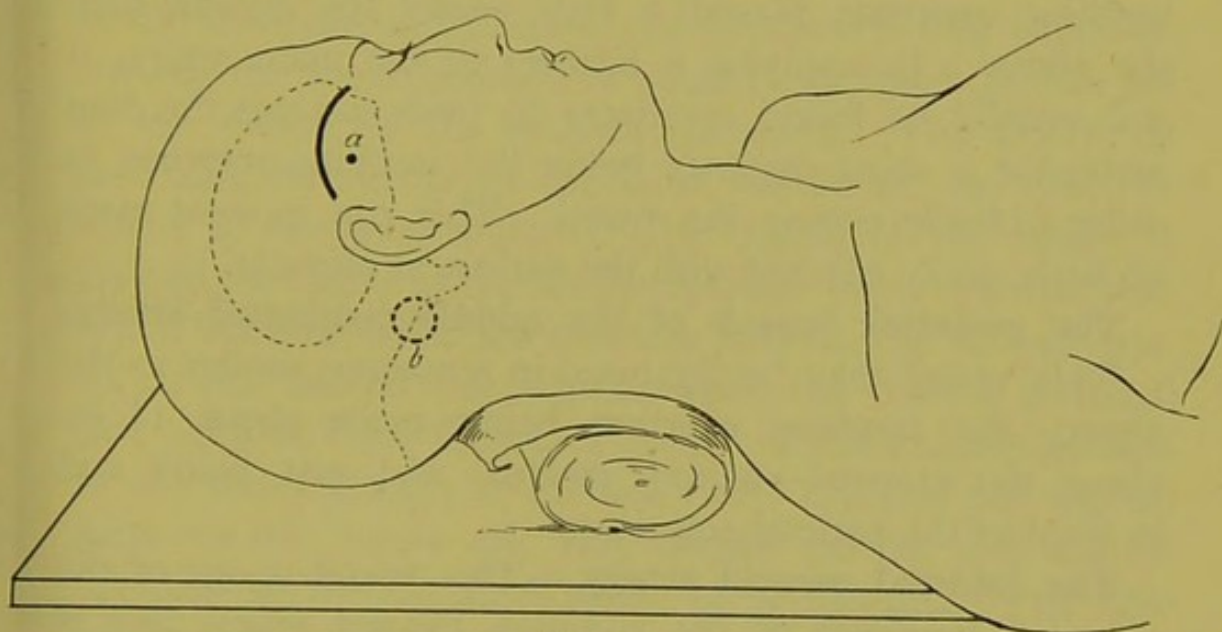


FIG. 200.

- a.* Ligature of middle meningeal artery main branch. Shape of flap, and position of application of trephine.
b. Point for application for trephine, in exposure of lateral sinus.

circle of bone is then removed, care being taken in using the trephine to avoid injury to the dura mater or to the vessel itself. In those cases in which the vessel lies in a canal or a very deep groove in the bone, it is not always possible in the dead subject to avoid injury to the artery; but in the living person, when the operation is done for rupture of the artery, the vessel is usually separated slightly from the bone, and lies out of the way of injury, though this will not be the case if it occupies a canal. When the middle meningeal artery has been exposed in this manner, it will be seen to lie upon the external surface of the dura mater, and to be

accompanied by two small *venæ comites*. The artery is separated from the *dura mater*, and the aneurysm needle passed underneath, and the vessel ligated together with its *venæ comites*. When the artery lies in a canal in the bone, it may be requisite to plug the open mouth of the bony canal with a small piece of wood, in order to arrest hæmorrhage.

The main trunk of the middle meningeal artery within the cranium.—This vessel may be ligatured through a trephine aperture, placed a little nearer the zygoma than the above. In applying a ligature to the main artery, it will usually be found necessary to push inwards the *dura mater* for a short distance below the trephine aperture, in order to freely expose the vessel. This can in most cases be fairly easily effected with the periosteal elevator.

The posterior branch of the middle meningeal artery.—This vessel may be ligatured in a manner similar to the above, the trephine aperture being made about $1\frac{1}{2}$ in. above the external auditory meatus, and just below and in front of the parietal eminence.

The internal carotid artery.—This vessel is one of the terminal branches of the common carotid artery, and is given off at the level of the upper border of the thyroid cartilage. From this point the artery passes upwards to the base of the skull, where it enters the carotid canal in the petrous bone. At its commencement the internal carotid lies a little external and in a plane somewhat posterior to that of the external carotid. As it passes upwards it takes a course behind the digastric, and is very deeply placed. A ligature is only applied to this artery immediately above its commencement.

Operation.—The skin incision and early stages of the operation are similar to those described for the external carotid (Fig. 195), and when this vessel has been exposed it is retracted to the inner side. The sheath of the internal carotid is thus laid bare, and is opened in the usual manner.

The needle is passed from the outer side so as to avoid injury to the internal jugular vein. Care must be taken not to include the vagus or the cervical sympathetic trunk which lies immediately posterior to the artery at this point.

Collateral circulation.—This is established through the communications of the two internal carotids in the circle of Willis within the cranium.

The subclavian artery.—The subclavian artery on the right side arises from the innominate artery behind the sterno-clavicular articulation, and on the left side from the arch of the aorta opposite a point immediately to the left of the centre of the manubrium sterni. The artery on each side terminates at the outer border of the first rib, where it becomes axillary. The course of the vessel is divided into three parts, the first portion being that section which lies internal to the scalenus anticus, the second that which lies behind this muscle, while the third or terminal part extends from the outer border of the scalenus anticus to the outer margin of the first rib. The first and second parts of the vessel are very deeply placed, and almost inaccessible for the application of a ligature. The first part of the artery has been ligatured through an incision similar to that which has been described in the case of the innominate artery.

When the arm lies against the side, the course of the subclavian artery is marked out by drawing a line from the centre of the sterno-clavicular articulation to the central point of the clavicle in such a manner that it describes a curve, the centre of whose convexity is situated about three-quarters of an inch above the clavicle. The thoracic portion of the left subclavian is represented by a line from a point a little to the left of the centre of the manubrium sterni to the left sterno-clavicular articulation.

The third part of the subclavian artery lies somewhat superficial. It is covered in front by a process of the deep cervical fascia, and often overlapped by the lower margin of

the posterior belly of the omo-hyoid muscle, whilst more superficially it has the nerve to the subclavius, the deep fascia, the superficial fascia containing the platysma, the external jugular vein, and the supra-clavicular nerves, and the skin. The dome of the pleura lies below and behind the vessel; the upper surface of the first rib below; the scalenus medius posteriorly; and the cords of the brachial plexus above; the cord formed by the last cervical and first dorsal nerve being situated nearest to the artery. The subclavian vein is anterior, and at a lower level than the artery. The position of the external jugular vein is somewhat variable, but it will usually be met with in the early part of the operation, lying anterior to the artery and at a higher level. No branches are normally given off from this part of the subclavian artery, but occasionally the posterior scapular or the supra-scapular artery arises from the third part of the subclavian.

Ligature of the subclavian artery in the third part of its course.—*Position.*—The patient is placed in the dorsal position, the shoulders raised by a hard pillow, the head turned towards the opposite side, and the arm on the side of the operation drawn well down. The surgeon stands opposite the shoulder on the affected side, and the chief assistant immediately opposite to him.

Operation.—With the left hand the skin is drawn downwards over the middle of the clavicle, and an incision 3 in. in length made, extending to the bone, and dividing the skin, platysma, superficial fascia, and the descending cervical nerves which lie in it. The skin is allowed to retract upwards, and then the deep fascia is incised for the full extent of the incision. In this part of the operation the external jugular vein may be met with, in which case it is pulled upwards out of the field of operation; or, if this cannot be easily effected, two ligatures are passed around it a short distance apart, and tied, and the vein divided between them. Great care

must be taken not to wound the vein before ligatures are applied, since its wall is closely united to the margins of the aperture by which it passes through the deep fascia; and if it be wounded, air is liable to be drawn inward, owing to negative pressure which normally exists in the blood stream in this vessel. If the patient is muscular, the posterior border of the sterno-mastoid and the anterior border of the trapezius will be exposed, and it will be requisite to divide them at the extremities of the incision. When the deep fascia has been fully divided, the posterior belly of the omo-hyoid is sought for immediately above

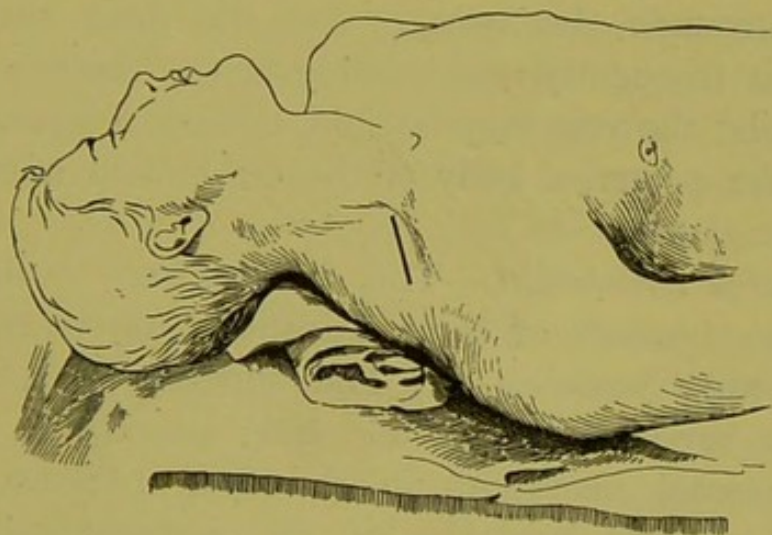

FIG. 201.—Ligature of subclavian artery. Position of patient, and line of skin incision.

the clavicle, and its inferior margin defined, and then the entire structure is drawn upwards. The position of this muscle varies according to the degree to which the arm is drawn downwards. When the omo-hyoid has been distinguished, its lower border is traced inwards, and the fascia which lies behind it incised, the small nerve which passes downwards to the subclavius muscle being generally cut at the same time. When this has been done, the outer border of the scalenus anticus is sought for in the inner part of the wound, and when found it is traced downwards until its insertion into the scalene tubercle on the upper aspect of the first rib can be felt. When this tubercle has

been defined, the fascia immediately above and behind it is carefully divided, when the subclavian artery will be exposed in the third part of its course, lying in a groove on the rib. The sheath of the vessel is opened in the usual manner and separated for a short distance, and the aneurysm needle passed from the nerves, which lie above the artery. Care must be taken not to pierce the vein with the needle. The brachial plexus lies at a higher level in the neck, but if the above stages are not carried out, it occasionally happens that a cord of the plexus is tied instead of the artery, or is included within the ligature which surrounds the vessel. On the dead subject this mistake is frequently made, owing to the absence of pulsation; whilst the vein may be tied, or even a ligature passed around the posterior belly of the omo-hyoid muscle, or a lymphatic gland.

Collateral circulation.—This is very free owing to the numerous channels of communication, and is effected by the following vessels:—(a) The superior thoracic artery, with the superior intercostal and intercostal branches of the internal mammary in the first intercostal space. (b) The pectoral branches of the acromio-thoracic and the long thoracic, with the intercostal branches of the internal mammary and the thoracic aorta in the upper four or five intercostal spaces. (c) The subscapular artery, with the intercostal branches of the thoracic aorta in the second to the sixth spaces, and by means of its dorsalis scapulæ branch with the supra-scapular and posterior scapular branches of the subclavian. (d) Acromial branches of the acromio-thoracic artery, with similar branches from the transverse cervical branch of the thyroid axis.

The inferior thyroid artery.—This artery is one of the branches of the thyroid axis, and supplies the lower portion of the lateral lobe of the thyroid gland. It passes behind the common carotid sheath, about the level of the sixth cervical vertebra. It gives off the ascending cervical

artery, and a ligature is usually applied distal to the origin of this vessel.

Position.—The positions of the patient, surgeon, and assistant are the same as for ligature of the common carotid in the lower part of its course.

Operation.—The incision and the different stages of the operation are similar to those for ligature of the common carotid below the omo-hyoid. When the carotid sheath has been exposed, the fascia on its inner side is divided, and the entire sheath with its contents retracted to the outer side. In the interval on the inner side of the sheath, the carotid tubercle of the sixth cervical vertebra is sought for; and immediately below this, the inferior thyroid artery will be found running inwards from behind the sheath. The vessel is carefully separated from the surrounding structures, and the ligature applied, the needle being passed from below.

The vertebral artery.—The vertebral artery is a branch of the first part of the subclavian artery, and from its point of origin passes upwards to enter the costo-transverse foramen of the sixth cervical vertebra, immediately behind the carotid tubercle.

Operation.—The operation for its ligature is similar to that for the common carotid below the omo-hyoid muscle, or for the inferior thyroid artery. When the carotid tubercle has been defined, the margins of the wound are well retracted, and at the same time the inferior thyroid artery is hooked downwards. In the space immediately below and posterior to the carotid tubercle, the vertebral artery will be discovered, by careful dissection, lying surrounded by its venæ comites. When the artery has been exposed, the vein, if possible, is drawn to the outer side, and the aneurysm needle is passed from without inwards, care being taken not to include any of the branches of the cervical sympathetic which lie in close proximity.

Collateral circulation.—This is established through the

various communications of the two sides in the circle of Willis.

The internal mammary artery.—The internal mammary artery is a large branch given off from the first part of the subclavian. It passes downwards, lying first behind the sterno-clavicular articulation, and then behind the costal cartilages and intercostal spaces, about half an inch outside the lateral margin of the sternum. Opposite the lower border of the sixth costal cartilage it terminates by dividing

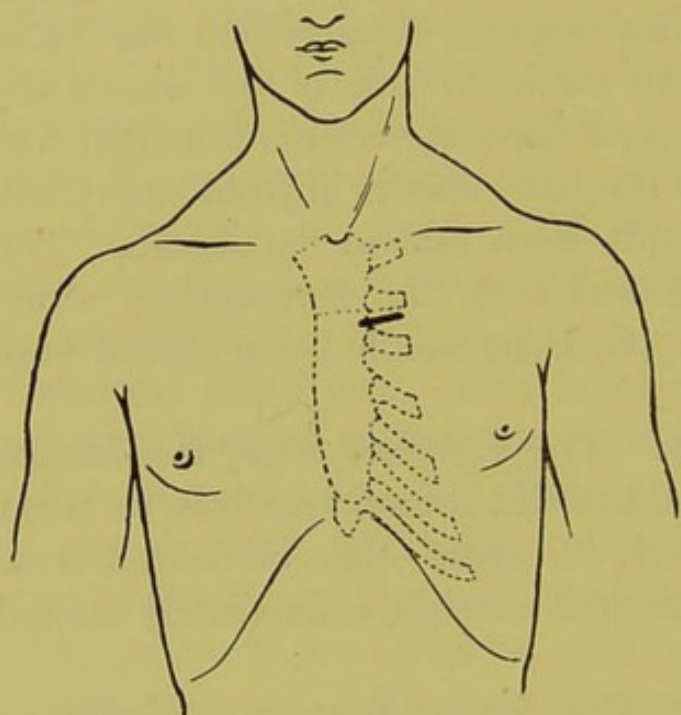


FIG. 202.—Ligature of internal mammary artery. Position of skin incision.

into the superior epigastric and the musculo-phrenic arteries.

The course of the vessel is indicated by drawing a line from the central point of the sterno-clavicular joint downwards to the sixth costal cartilage, or the sixth interspace, about half an inch from the margin of the sternum.

The internal mammary artery lies upon a thin layer of fascia which separates it from the parietal pleura in the upper part of the thorax, and lower down from the triangularis sterni muscle.

Position.—The patient is placed in the dorsal position, the surgeon stands on the affected side, and the assistant on the opposite side.

Operation.—An incision about $1\frac{1}{2}$ in. long is made across the middle of one of the intercostal spaces, preferably the second or third, commencing a short distance from the middle line of the sternum, and extending outwards at right angles to the course of the artery. This incision divides

the skin, superficial fascia, deep fascia, sternal fibres of the pectoralis major muscle, anterior intercostal membrane, and lastly the internal intercostal muscle, when the artery will be exposed lying upon the pleura and having a vein usually on each side. The needle is passed from the vein. In making the incision, great care must be exercised to avoid puncturing the pleura, and notching the underlying lung, or dividing the vessel itself transversely, as it lies on the pleura. It is much more difficult to apply a ligature to the vessel in the lower intercostal spaces, on account of the small distance between the adjacent costal cartilages.

Collateral circulation.—This is established through the anastomoses of the intercostal branches of the internal mammary with similar branches from the superior intercostal or from the thoracic aorta, and through the communication of the superior epigastric artery with the deep epigastric in the region of the umbilicus.

The axillary artery.—The axillary artery is the continuation of the subclavian. It commences at the outer border of the first rib, and terminates at the lower border of the teres major, where this muscle forms the posterior fold of the axilla.

At its commencement the artery lies behind the central part of the clavicle and the subclavius muscle, then behind the costo-coracoid membrane, which separates it from the clavicular portion of the pectoralis major, next behind the pectoralis minor, then behind that part of the pectoralis major which forms the anterior fold of the axilla, and finally behind the deep fascia of the arm as it becomes continuous with the pectoral fascia. That portion of the artery which extends between the outer border of the first rib and the upper border of the pectoralis minor is called the first part, and measures usually a little more than an inch in length; the second part lies behind the pectoralis minor, and measures a little less than an inch; whilst the third part comprises the remainder of the vessel, and extends from the lower

border of the pectoralis minor to the lower margin of the teres major, measuring a little more than 3 in. in length. The first part of the artery lies upon the upper two serrations of the serratus magnus muscle, as they cover the first intercostal space and the second rib, and also behind it are the posterior thoracic nerve and the connective tissue which lies between the serratus magnus and subscapularis; the second portion lies upon the posterior cord of the brachial plexus, and the subscapularis; whilst the third part has the musculospiral and circumflex nerves behind it, and also the lower part of the subscapularis, and the latissimus dorsi and teres major tendons. The axillary vein lies on the inner side of the vessel and on a slightly anterior plane for its entire course, but separated by nerve cords in the lower part. On the outer side, and above the first portion, there is the brachial plexus; the second part of the artery is surrounded by the cords of the plexus; and in the third part of its course the branches of the plexus lie around it. The third part of the artery is often crossed by the external vena comes of the brachial artery, as it passes inwards to join the internal vena comes, and so form the commencement of the axillary vein.

The course of the axillary artery is marked out by placing the limb at right angles to the trunk with the forearm supinated, and drawing a line from the central point of the clavicle to the central point of the antecubital fossa. This line marks out both brachial and axillary arteries, the axillary extending from the clavicle to the lower margin of the posterior fold of the axilla.

The axillary artery may be ligatured in the first or third part of its course, the former operation being the more difficult, and very rarely performed except on the dead body.

Ligature of the first part of the axillary artery.—

Position.—Place the patient upon the back near the edge of the table, with a flat pillow underneath the scapular

region of the affected side, so as to press inwards the scapula towards the spine; the arm lies by the side, but the point of the shoulder is not depressed. The surgeon stands at the outer side of the upper part of the limb when operating on the left side, and opposite the tip of the shoulder when the artery on the right side is to be dealt with. The chief assistant stands directly opposite the operator.

Operation.—An incision about 4 in. long is made, commencing immediately below and two-thirds of an inch outside the sterno-clavicular articulation, and extending to the inner side of the apex of the coracoid process. The skin, superficial fascia containing platysma and supra-clavicular nerves, the deep fascia covering the pectoral muscle, and the clavicular portion of the pectoralis major, are divided in the line of the incision, care being taken to avoid the cephalic vein as it lies in the outer portion of the wound. The pectoralis major may either be detached from the clavicle or its fibres cut through. The margins of the wound are retracted and the costo-coracoid membrane sought for, the subclavius being defined above and the pectoralis minor below. The costo-coracoid membrane is next incised, and the cephalic vein and other structures which pierce it pulled aside, together with the exposed muscles (subclavius and pectoralis minor). The first part of the axillary artery will then be visible, with the vein lying to the inner side and somewhat overlapping it. The sheath is opened in the usual manner, and the needle passed from

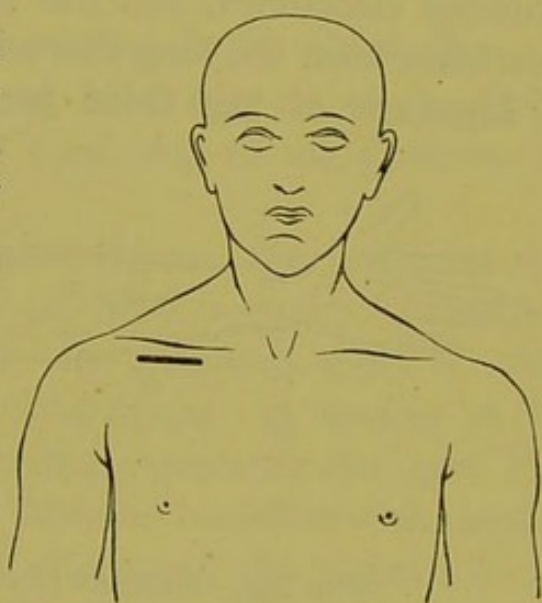


FIG. 203. — Ligature of axillary artery (first part). Line of skin incision.

below so as to avoid damage to the vein. The brachial plexus lies at a higher level, but in the dead body it is possible to apply a ligature to one of the cords instead of the artery. The ligature may be applied to the vessel above or below the origin of the superior thoracic and acromio-thoracic arteries. In the former case, the *collateral circulation* will be the same as after ligature of the third part of the subclavian, and in the latter the humeral branch of the acromio-thoracic will form a communication with the anterior circumflex, and the pectoral branches with similar branches from the long thoracic.

Ligature of the third part of the axillary artery.—

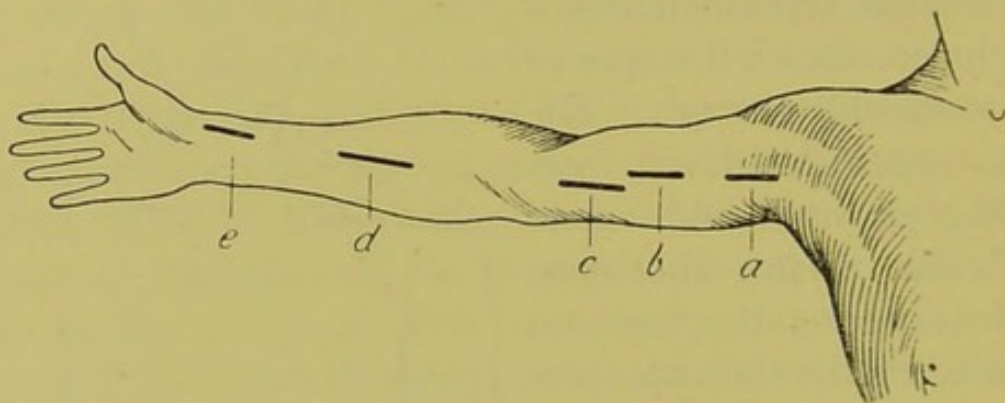


FIG. 204.—Ligature of arteries of upper extremity.

- | | |
|---|--|
| <p><i>a.</i> Incision for third part of the axillary artery.</p> <p><i>b.</i> Incision for brachial at middle of arm.</p> | <p><i>c.</i> Incision for brachial at bend of elbow.</p> <p><i>d.</i> Incision for radial at middle of forearm.</p> <p><i>e.</i> Incision for radial at wrist.</p> |
|---|--|

Position.—The patient is placed in the dorsal position, with the affected limb at right angles to the trunk and supinated. The surgeon stands between the limb and the trunk opposite the axilla, and the chief assistant on the outer side of the upper arm opposite the operator.

Operation.—An incision 3 in. long is made in the line of the artery, commencing above at a point a third of the distance from the anterior to the posterior fold of the axilla. This incision divides the skin, superficial fascia, and deep fascia, and when the margins of the wound are retracted the artery is exposed. The external vena comes of the

brachial artery often crosses it, whilst the median nerve lies in front of it, and the coraco-brachialis overlaps it from the outer side. The median and musculo-cutaneous nerves, together with the coraco-brachialis muscle, are drawn to the outer side, the artery is separated from the adjacent veins—which in the lower part of the axilla may be numerous—and the aneurysm needle passed from the inner side, care being taken not to include the ulnar and internal cutaneous nerves which lie on the inner side, or the musculo-spiral nerve which lies behind.

Collateral circulation.—The channels by which the collateral circulation is established, after ligature of the third portion of the axillary, vary according to the position of the ligature.

When the ligature is applied above the origin of the subscapular artery, they are—(a) The posterior circumflex with acromial branches of the acromio-thoracic and the supra-scapular; (b) the subscapular, by means of its dorsal scapular branch, with the supra-scapular and the posterior scapular, and by its thoracic branches with similar branches from the intercostal arteries of the upper four to six spaces and also from the long thoracic.

When the ligature is applied between the subscapular and the circumflex arteries, the chief channels are the communications between the posterior circumflex and the acromial branches of the acromio-thoracic and supra-scapular arteries.

If the ligature is below the circumflex arteries, the channels are similar to those after ligature of the brachial above the superior profunda, namely, communications between ascending branches of the superior profunda and branches of the circumflex arteries, chiefly the posterior.

The brachial artery.—This vessel commences at the lower border of the teres major, and terminates in the antecubital fossa, anterior and slightly internal to the neck or head of the radius, by dividing into the ulnar and radial arteries.

Its course has been marked out along with that of the axillary artery.

The artery lies upon the musculo-spiral nerve and superior profunda artery, then upon the internal head of the triceps, the insertion of the coraco-brachialis, the brachialis anticus, and at its termination upon the tendon of the biceps. For the greater part of its extent it is superficial, but at the elbow it lies underneath the bicipital fascia and between the supinator longus and pronator radii teres muscles. It is overlapped, especially in muscular subjects, by the biceps, and it is crossed from without inwards (usually

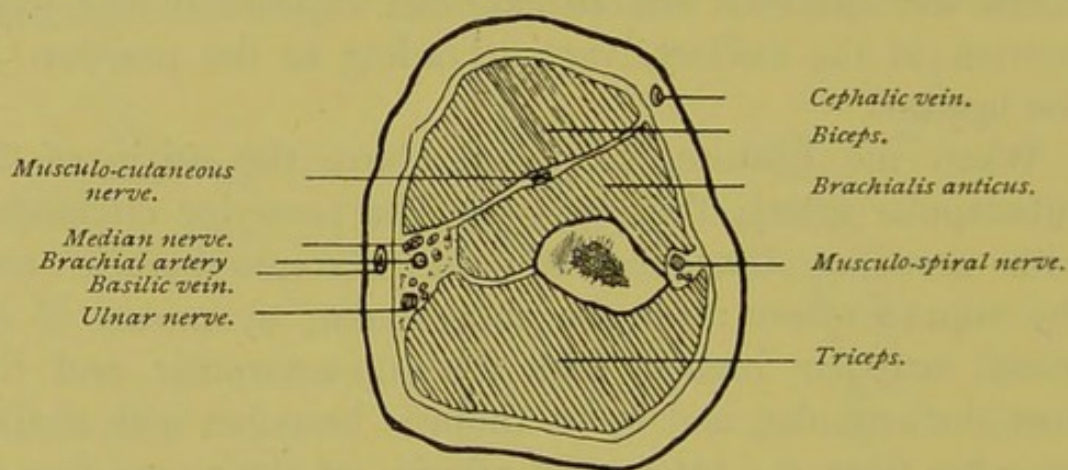


FIG. 205.—Transverse section through the middle of the upper arm, at the level of ligature of the brachial artery.

about the middle of the arm) by the median nerve. The vessel has two venæ comites, one on each side, these structures often being connected by large cross branches.

The artery may be ligatured in the middle of the upper arm, or at the bend of the elbow.

Ligature of the brachial artery at the middle of the upper arm.—*Position.*—The patient is placed on his back near the edge of the table; the arm is abducted to a right angle, and held in the supine position. An assistant should stand on the outer side of the limb and support it at the elbow, or allow the elbow to rest on a small table. The operator stands between the limb and the trunk, and a second assistant opposite him.

Operation.—An incision $2\frac{1}{2}$ in. long is made in the line of the vessel, its central point corresponding to the middle of the upper arm (Fig. 204, *b*). The skin, superficial fascia containing the basilic vein, and the deep fascia are divided, and the inner border of the biceps muscle exposed. Care must be exercised not to mistake the triceps for the biceps, and to avoid injury to the basilic vein. The biceps is retracted outwards, when the artery will be exposed lying upon the triceps, surrounded by its venæ comites, and with the median nerve usually in front. The median nerve is drawn to whichever side is most convenient, the artery separated from its venæ comites, and the needle passed from the nerve. In the dead subject the basilic vein is occasionally ligatured instead of the artery, but this mistake can be easily prevented by taking care that the deep fascia is divided and the biceps exposed.

Collateral circulation.—If the ligature is applied above the origin of the superior profunda, the collateral circulation is established by communications between ascending branches of the superior profunda with branches of the circumflex arteries, especially the posterior. When it is ligatured between the superior and inferior profunda vessels, the principal communications are between the anastomotica magna, the radial recurrent, and the interosseous recurrent, with the terminal branches of the superior profunda.

If below the origin of both profunda arteries, in addition to the above, the anastomotica magna, and the anterior and posterior ulnar recurrent with the inferior profunda.

Ligature of the brachial artery at the bend of the elbow.—*Position.*—Similar to that for ligature of the artery in the middle of the arm, except that the limb may rest on the table.

Operation.—An incision about 2 in. long is made, commencing on the right side immediately above and internal to the central point of the bend of the elbow, and extending upwards and inwards, parallel with the inner

border of the biceps muscle (Fig. 204, *c*). The skin, superficial fascia containing the superficial veins and nerves, and the deep fascia, which is strengthened by the bicipital fascia, are divided, the veins and nerves being retracted as they become visible. The vessel is now exposed, surrounded by its *venæ comites*, and with the median nerve on its inner side and the biceps on the outer side. The vessel is separated from its veins, and the needle passed from the inner side.

Collateral circulation.—This is established along the

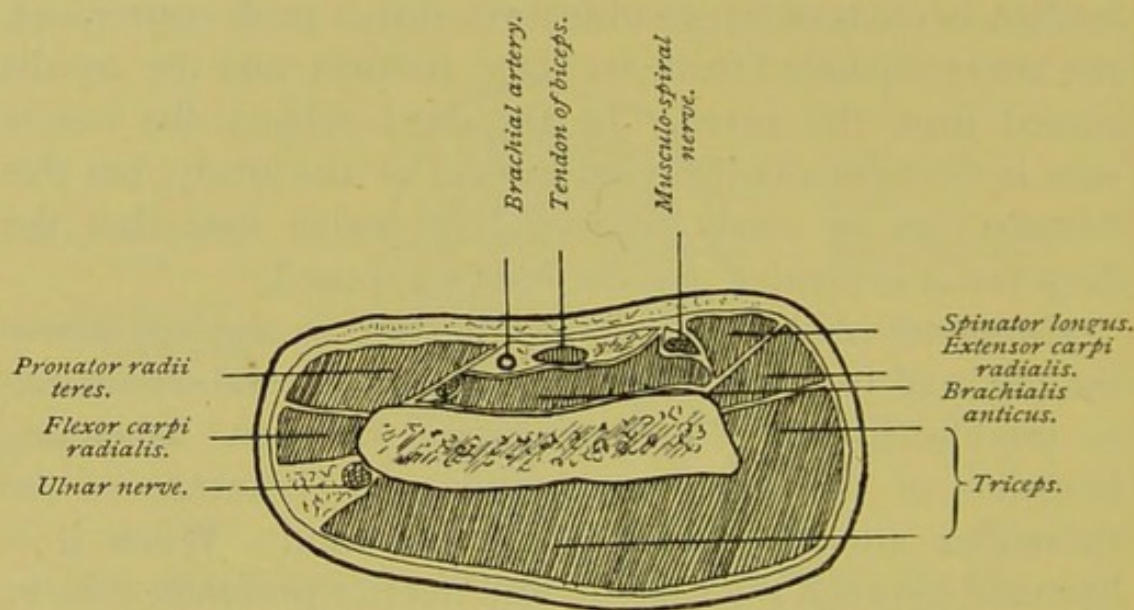


FIG. 206.—Transverse section through upper arm, immediately above the bend of the elbow.

channels which have been enumerated after ligature of the brachial below both profunda arteries.

The ulnar artery.—The ulnar artery is one of the terminal branches of the brachial; it commences in the antecubital fossa, and terminates beyond the pisiform bone by dividing into superficial and deep branches.

In its course downwards it lies upon the insertion of the brachialis anticus, then upon the flexor profundus digitorum, and finally on the anterior annular ligament of the wrist. In the upper part of its course it lies behind some of the flexor group of muscles which come from the internal

condyle; in the next part it is overlapped by the flexor carpi ulnaris, and in the region of the wrist it is covered by fascia and skin only. The ulnar nerve lies on its ulnar side for the lower half of the forearm. The course of the artery is represented in the lower two-thirds of the forearm, by drawing a line from the apex of the internal condyle of the humerus to the radial side of the pisiform bone, and in the upper third by continuing the course of the vessel upwards to the central point of the antecubital fossa.

The artery may be ligatured in the middle or lower third; in the upper third it is very deeply placed.

Ligature of the ulnar artery in the middle third of the

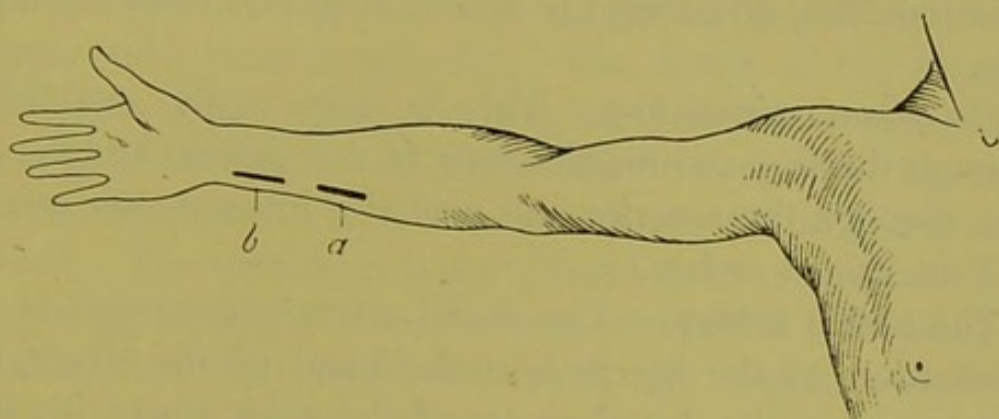


FIG. 207.—Ligation of ulnar artery. Position of skin incisions.

a In middle third of forearm.

b In lower third of forearm.

forearm.—*Position.*—As for the brachial at the bend of the elbow.

Operation.—An incision from $2\frac{1}{2}$ to 3 in. long is made in the line of the vessel, the central point corresponding to the middle of the forearm. The skin, superficial fascia containing the anterior ulnar vein and branches of the internal cutaneous nerve, and the deep fascia are divided, the muscles are exposed, and the interval between the flexor carpi ulnaris and the flexor sublimis digitorum sought for with the finger. When this has been found, the muscles are separated, and the artery will be seen lying upon the flexor profundus digitorum, surrounded by its venæ comites, and with the ulnar nerve on its inner side. The vessel is now

separated from its accompanying veins, and the needle passed from the ulnar side.

Ligature of the ulnar artery in the lower third of the forearm.—*Position.*—As for ligature in the middle third.

Operation.—An incision about 2 in. long is made in the line of the vessel, commencing about 1 in. above the pisiform bone and extending upwards (Fig. 207, *b*). The skin, superficial fascia, and deep fascia are divided, and the artery sought for in the interval between the flexor carpi ulnaris and flexor sublimis digitorum muscles. The artery, when exposed, is separated from the ulnar nerve which lies on the ulnar side, and also, if possible, from the venæ comites, and then the needle is passed from the ulnar side.

Collateral circulation.—This is very easily established through the free communications of the palmar arches, and also through the anterior and posterior interosseous arteries and the carpal arches.

The radial artery.—The radial artery commences at the bifurcation of the brachial, at the bend of the elbow, and terminates on the dorsal aspect of the wrist, where it passes between the two heads of the first dorsal interosseous muscle to enter into the formation of the deep palmar arch.

Its course is represented by a line drawn from the central point of the antecubital fossa to a point about half-way between the tuberosity of the scaphoid and the styloid process of the radius, whence it winds round the lateral aspect of the wrist across the “tabatière” to the base of the first inter-metacarpal space.

It lies upon the tendon of the biceps, the supinator brevis, the pronator radii teres, the radial head of the flexor sublimis digitorum, the flexor longus pollicis, the pronator quadratus, the anterior aspect of the lower end of the radius, the anterior and lateral ligaments of the wrist joint, and finally on the dorsal surface of the trapezium. In the first part of its extent it is covered by the supinator longus, then

it lies superficially, and lastly it passes beneath the extensor muscles of the thumb. It is accompanied by two venæ comites, but the radial nerve lies in contact with the vessel on the radial side for the middle third only of its course.

The radial artery may have a ligature applied to it in the upper, middle, and lower thirds of the forearm, and also as it lies in the "tabatière" on the dorsal aspect of the wrist.

Ligature of the radial artery in the upper third.—

Position.—As for the ulnar artery.

Operation.—An incision, a little over 2 in. in length, is made in the upper third of the forearm, in the line of the vessel. The skin, superficial and deep fasciæ, are divided, and the interval between the supinator longus and the pronator radii teres sought for. The fibres of the former muscle run in a vertical direction, and those of the latter obliquely downwards and outwards. When this interval has been defined, the muscles are separated and the artery exposed. The needle may be passed from either side, the vessel being separated from its venæ comites if possible.

Ligature of the radial artery in the middle third.—

Position.—As in the preceding operation.

Operation.—An incision from 2 to 3 in. long is made in the middle third of the forearm over the line of the artery (Fig. 204, *d*). The skin, the superficial fascia containing the radial vein and branches of the musculo-cutaneous nerve, and the deep fascia are divided, care being taken not to injure the superficial veins or nerves. The ulnar border of the supinator longus, which in this position is muscular above and tendinous below, is defined, and the muscle retracted towards the radial side. The artery is then exposed, lying upon the insertion of the pronator radii teres and surrounded by its venæ comites. These latter structures are separated from the vessel, and the needle passed from whichever side is found to be the more convenient.

Ligature of the radial artery in the lower third.—

Position.—As for ligature of the vessel in the middle third.

Operation.—An incision, about $1\frac{1}{2}$ in. in length, is made, commencing a little above the level of the tuberosity of the scaphoid and extending upwards in the line of the artery (Fig. 204, *e*). The skin and fasciæ are divided, and the interval between the ulnar border of the supinator longus and radial margin of the flexor carpi radialis opened up, care being taken not to injure the superficial veins or to divide the artery longitudinally as it lies in the bottom of the wound. The venæ comites are separated and the needle passed from either side. In many cases it will be found necessary to include the veins in the ligature.

Ligature of the radial artery on the dorsum of the wrist.

—*Position.*—The hand is placed in a position half-way

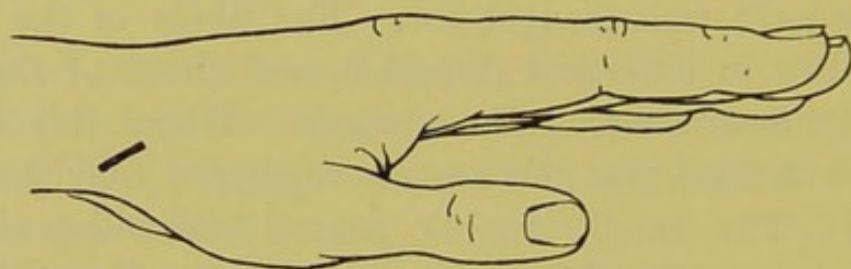

FIG. 208.—Ligature of radial artery on dorsum of wrist.
Position of hand and line of skin incision.

between supination and pronation, resting on its ulnar border, and held by an assistant. The surgeon stands on the outer side of the limb, and the assistant opposite to him.

Operation.—An incision, about 1 in. in length, is made, commencing immediately below the styloid process of the radius, and running across the “tabatière” half-way between the tendon of the extensor primi internodii pollicis and that of the extensor secundi internodii pollicis. The skin and fasciæ are divided, the margins of the incision retracted, and then the artery will be exposed, lying upon the dorsal aspect and radial side of the wrist. The needle is passed from either side. Care must be taken in the performance of this operation to avoid injury to the adjacent tendon sheaths or the underlying joints.

Collateral circulation.—The collateral circulation, after ligature of the radial artery, is established in a manner similar to that which occurs when the ulnar artery is occluded.

Ligature of an intercostal artery.—In each intercostal space intercostal arteries are found, one above and one below, the former being the larger. Each vessel lies in a groove in the rib which forms a boundary of the intercostal space. It is occasionally necessary to apply a ligature to the vessel as it lies in this groove.

Position.—The patient is so placed that the area of the operation is well exposed.

Operation.—An incision, about 2 in. in length, is made over the rib, and in the direction of the blood vessel which it is proposed to ligature. The surface of the rib is exposed, the periosteum separated, and a portion of the rib overlying the vessel removed subperiosteally. When this has been done, the artery is laid bare, and a ligature can easily be applied. In cases of injury it will usually be found requisite to place a ligature on each extremity of the artery as it lies exposed in the bottom of the wound, on account of the free anastomoses between the vessels in each intercostal space.

Abdominal aorta.—The abdominal aorta lies upon the anterior aspect of the posterior abdominal wall, its point of bifurcation being upon the left side of the lower portion of the body of the fourth lumbar vertebra.

This is marked out on the surface of the abdomen by taking a point half an inch to the left of the middle of a line drawn between the highest points of the two iliac crests, or by taking a point which is three-quarters of an inch below and half an inch to the left of the umbilicus. The vessel extends upwards from this point in an almost vertical direction, reaching the middle line of the abdomen above. The inferior vena cava lies to the right of the aorta, and tends to overlap it, whilst it is surrounded

by the aortic plexus of the sympathetic, and has lying in front of it, just above its bifurcation, the inferior mesenteric artery, the parietal peritoneum and the small intestines.

The vessel has only been ligatured a few times ; all the cases have been fatal, usually within a few hours, but one case lived for ten days.

Position.—The patient is placed in the dorsal position ; the surgeon stands upon the right side, and the chief assistant upon the left.

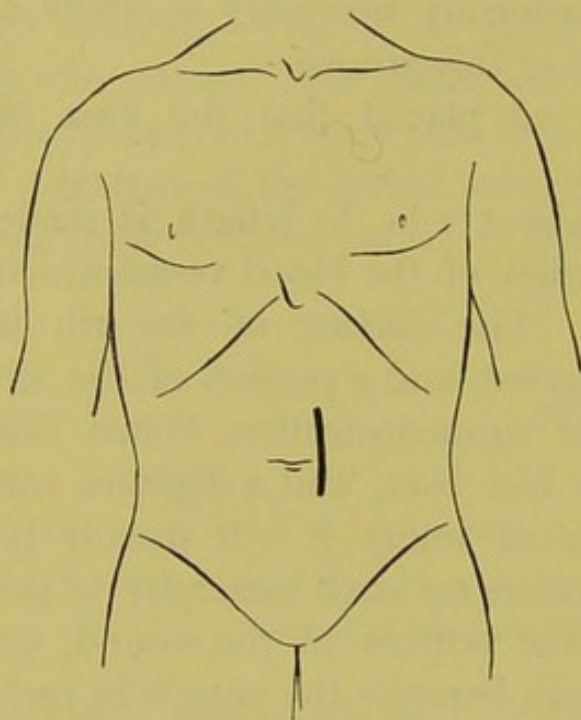


FIG. 209. — Ligature of abdominal aorta. Line of parietal incision.

Operation.—An incision, 3 or 4 in. in length, is made in the linea alba, one-third of the incision being below the point of bifurcation, and two-thirds above. The peritoneum is opened for the entire length of the incision, the small intestines and great omentum are pushed upwards and to the right, and held there by the hands of an assistant

or by large flat sponges, and in this way the anterior aspect of the lower portion of the vessel is exposed, except that it is covered with peritoneum. This peritoneum is divided by a vertical incision, and lifted away from the vessel by the finger. The inferior mesenteric artery is then defined and pushed over to the left, and a point half-way between the origin of this vessel and the bifurcation of the aorta is selected for the application of the ligature. The vessel is then separated from the connective tissue and the plexus of sympathetic nerves which surround it, and a large curved aneurysm needle passed from the right side. This

is threaded with a thick silk ligature, and withdrawn. The ligature is then tied, the ends cut short, and the peritoneum replaced, and, if necessary, united with a continuous silk suture. All sponges are then removed, and the external wound closed.

The above is the *intra-peritoneal* method of operation. An *extra-peritoneal* operation has been performed, but this was made use of chiefly in the pre-aseptic days.

The common iliac artery.—A line drawn from the point of bifurcation of the abdominal aorta to the central point of a line from the anterior superior iliac spine to the symphysis pubis represents the course of the common and external iliac arteries, the upper third corresponding to the common iliac, and the lower two-thirds to the external iliac vessel.

The common iliac artery extends from the lower part of the fourth lumbar vertebra to a point opposite the lumbosacral articulation. It is covered in front by peritoneum, branches of the sympathetic passing to the hypogastric plexus, and at its point of division it is crossed by the ureter. The right common iliac artery is in relation with the commencement of the inferior vena cava and both common iliac veins. Each common iliac vein lies posterior and internal to the corresponding artery at first, but the left vein crosses behind the upper portion of the artery of the right side, and there joins the right vein, which has already passed behind, so as to form the inferior vena cava. The operation of ligature of the common iliac artery may be carried out through the peritoneum, when the procedure is known as *intra-peritoneal*, or it may be performed *extra-peritoneally* through either an anterior or a lateral incision.

Intra-peritoneal operation.—*Position.*—The patient is placed in the dorsal position, with the side which is to be operated upon slightly raised. The surgeon stands on the same side of the patient as the artery, and the chief assistant on the opposite side.

Operation.—An incision about 4 in. long is made in the linea alba or the linea semilunaris, commencing below at a point one-third of the distance from the symphysis pubis to the umbilicus, and extending upwards beyond the umbilicus. The peritoneal cavity is opened, the intestines and great omentum pushed upwards and towards the sound side, and kept out of the field of operation by flat sponges or the hands of an

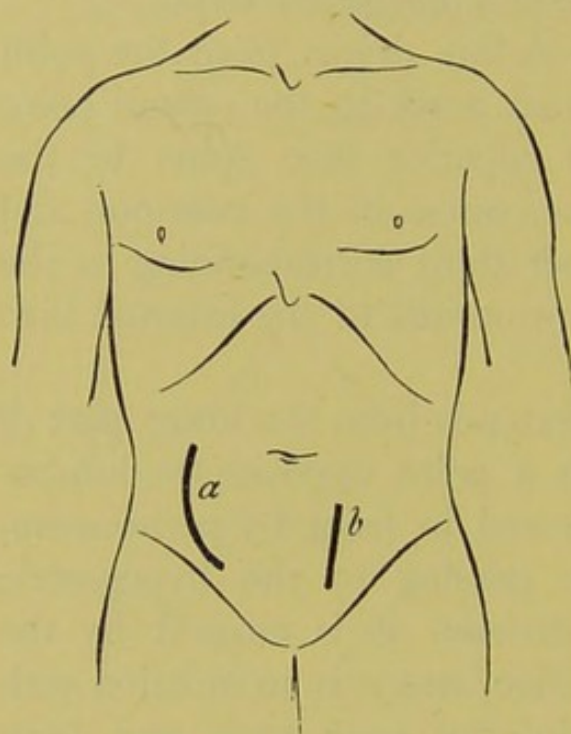


FIG. 210.—Ligature of common iliac artery.

- a.* Incision for extraperitoneal operation on right side.
- b.* Incision for transperitoneal operation on left side.

assistant, and the position of the vessel defined as it lies behind the peritoneum a short distance below the point of bifurcation of the aorta. The peritoneum over the artery is divided for about 1 in. in front of the middle portion, care being taken not to injure the ureter or the branches of the sympathetic. With a long, curved aneurysm needle the artery is separated from its sheath for nearly half an inch, and then the needle is passed from the inner side, threaded, and withdrawn. The ligature is then tied, and the ends cut short. If a long

incision has been made through the peritoneum in front of the artery, the margins may be approximated with one or two points of interrupted suture, but usually this is unnecessary. All sponges are removed, and the parietal wound closed in the usual manner.

Extraperitoneal operation.—(*a*) BY ANTERIOR INCISION.

—*Position.*—As for the preceding.

Operation.—An incision from 5 to 8 in. long is made, commencing $1\frac{1}{2}$ in. above and immediately to the outer

side of the central point of Poupart's ligament, and curving upwards and outwards, first to within $1\frac{1}{2}$ in. of the anterior superior spine of the ilium, then more vertically upwards towards the costal margin, and finally inwards in the direction of the umbilicus. The various strata of the abdominal wall are divided until the layer of extraperitoneal fatty tissue is recognised, when the peritoneal sac is separated by the fingers from the iliac fascia until the external iliac artery is seen. The latter is traced upwards until the common iliac artery is reached, the ureter and the sympathetic nerves are pushed aside, and the common iliac artery cleared. The ligature is passed in a manner similar to that described in the intraperitoneal operation. When the ligature has been applied, the parietal wound is closed by the insertion of two or three tiers of sutures which accurately approximate the different muscular strata and the skin.

(b) BY LATERAL INCISION.—*Position*.—The patient is placed well upon the sound side. The surgeon and assistant stand as in the operation through an anterior incision.

Operation.—A somewhat curved incision, with the concavity towards the umbilicus, is made, commencing above at the tip of the twelfth rib and extending obliquely downwards to just above the iliac crest, and then forwards until a point immediately above the anterior superior spine of the ilium is reached. This incision is deepened until the fascia transversalis has been divided and the extraperitoneal tissue exposed. With the fingers the peritoneal sac is separated from the iliac and psoas fasciæ and lifted forwards, when the common iliac artery is seen exposed in the bottom of the wound. The vessel is then separated from the ureter and the common iliac vein, and a ligature passed, the needle being entered on the inner side of the artery. The ligature is then tied, the ends cut short, the peritoneal sac allowed to fall back into its normal position, and the external wound closed.

Collateral circulation.—(a) Superior epigastric artery and branches from the lower intercostal vessels, with the deep epigastric, a branch of the external iliac. (b) The lower lumbar arteries, branches of the abdominal aorta, with the ilio-lumbar, a branch of the internal iliac, and the deep circumflex iliac, a branch of the external iliac. (c) The middle sacral artery, a branch of the abdominal aorta, with the lateral sacral branches of the internal iliac. (d) The terminal branches of the inferior mesenteric, with rectal branches of the internal iliac. (e) Pubic branches of the obturator, with similar branches from the opposite side. (f) In the female, branches of the internal pudic artery, with similar branches from the opposite side, chiefly in the perineum; (g) Branches of the uterine artery, from the internal iliac, with the ovarian, a branch of the abdominal aorta.

The external iliac artery.—The line of the external iliac artery has already been mentioned in connection with that of the common iliac.

The vessel lies upon the brim of the pelvis to the inner side of the psoas magnus muscle above, but at Poupart's ligament it lies directly in front of this structure, though separated from it by the iliac fascia. The lower coil of the ileum crosses the vessel on the right side, and the sigmoid flexure on the left; whilst on both sides the vessel is covered by peritoneum, and crossed at its lower part in the male by the vas deferens and the spermatic vessels, and in the female by the round ligament of the uterus. A short distance above Poupart's ligament the deep circumflex iliac vein crosses the artery to join the external iliac vein.

Position.—The patient is placed in the dorsal position, with the thigh of the affected side slightly flexed. The operator stands on the same side of the patient as the vessel which is to be ligatured, and the assistant on the opposite side.

Operation.—An incision from $3\frac{1}{2}$ to 4 in. long is made, which commences at a point half an inch above the central point of Poupart's ligament, and extends outwards beyond the anterior superior iliac spine, the main part of the incision being parallel with the ligament, while the last inch is curved slightly upwards. The incision divides the various strata of the anterior abdominal wall until the transversalis fascia is reached. This is carefully picked up with forceps at the inner part of the wound and divided for the entire length of the incision, care being taken not to injure the adjacent portion of the peritoneum. The peritoneum is next peeled upwards with the fingers from the fascia which covers the iliacus and the psoas magnus, until the artery is seen lying upon the internal margin of the muscle, care being taken, especially when performing the operation on the dead body, not to lift up the vessel with the peritoneum, and allow it to be retracted to one side by the assistant. When the vessel has been exposed, a point is selected a little more than an inch above Poupart's ligament for the application of the ligature. The sheath, which at this point is thin, is opened in the usual manner, and the aneurysm needle passed from the inner side, care being taken to avoid the vein. The ligature is tied, the ends cut short, and the

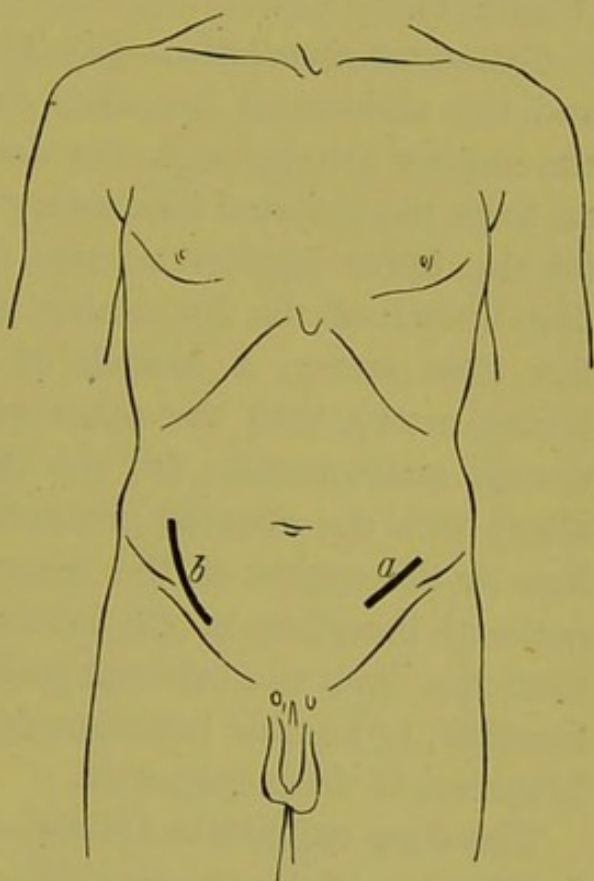


FIG. 211.—Ligature of external iliac artery.

- a.* Incision for Cooper's operation.
b. „ „ Abernethy's „

parietal wound closed. It is advisable in closing the external wound to unite the lower border of the internal oblique muscle to the upper portion of Poupart's ligament.

This operation is a modification of that known as "Cooper's operation." Abernethy employed a more vertical incision, which was also placed at a higher level (Fig. 211).

Collateral circulation.—(a) The superior epigastric artery and the abdominal branches of the lower intercostal and the lumbar arteries with the deep epigastric, which is given off from the external iliac artery below the point of ligature; (b) the lower lumbar arteries (anterior branches) and the iliac branch of the ilio-lumbar artery with the deep circumflex iliac artery, a branch of the external iliac; (c) the sciatic artery, with the other arteries which enter into the crucial anastomosis; (d) the deep branches of the gluteal artery with the external circumflex and the deep circumflex iliac in the region of the anterior superior iliac spine; (e) perineal branches of the internal pudic artery with similar branches from the external pudic, a branch of the common femoral; (f) pubic branches of obturator artery with pubic branches of deep epigastric.

The deep epigastric artery.—The deep epigastric artery is a branch of the external iliac given off immediately above Poupart's ligament.

Its course is marked out by taking a line from the central point of Poupart's ligament to immediately outside the umbilicus.

Position.—As for the external iliac artery.

Operation.—An incision 2 in. long at right angles to the line of the vessel is made, so that the centre of the incision corresponds to the point where the line of the artery crosses the linea semilunaris (Fig. 212, a). The incision is deepened, and the fascial aponeurosis of the external oblique, and the conjoined tendon formed by the union of the internal oblique and the transversalis abdominis, are divided in order, when

the fascia transversalis is exposed. The outer border of the rectus abdominis is then drawn inwards with a retractor, and the fascia transversalis divided in the line of the wound. The deep epigastric artery is then exposed lying upon the peritoneum and in the subperitoneal tissue accompanied by two venæ comites. The artery is separated from its accompanying veins, and a ligature passed from the inner side.

The deep circumflex iliac artery.—This vessel is a branch of the external iliac, given off at about the same level as the deep epigastric artery.

Its course is behind and very slightly above the outer half of Poupart's ligament, where it lies upon the iliac fascia, which separates it from the iliacus muscle. At the anterior superior spine of the ilium it pierces the fascia transversalis, and runs between the abdominal muscles close to their attachments to the crest of the ilium. The external cutaneous nerve lies behind the vessel.

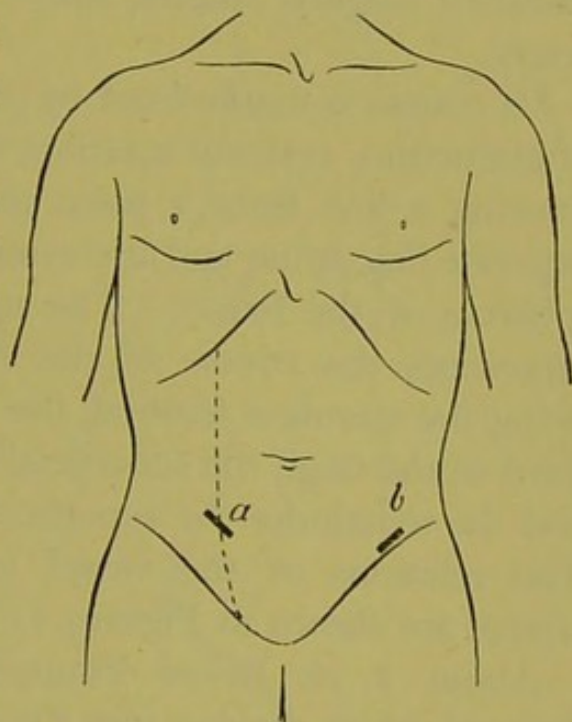


FIG. 212.—Position of skin incision in ligature of

- a.* Deep epigastric artery.
- b.* Deep circumflex iliac artery.

Position.—As for the external iliac artery.

Operation.—An incision 2 in. long is made parallel with and slightly above the external half of Poupart's ligament (Fig. 212, *b*). This divides the fascial layer, the aponeurosis of the external oblique, the lowest fibres of the internal oblique, the transversalis in the outer two-thirds of the wound, and finally the fascia transversalis, when the vessel is exposed lying upon the iliac fascia, and accompanied in this part of its course by two venæ comites. The needle is passed

from either side, care being taken not to include the external cutaneous nerve. A knowledge of the course and relations of the deep circumflex iliac artery is important, as in this region a psoas abscess is often opened.

The femoral artery.—The femoral artery commences opposite Poupart's ligament, where it is continuous with the external iliac, and terminates below at the junction of the middle and lower thirds of the thigh at an aperture in the adductor magnus muscle, where it passes into the popliteal artery.

Its course is marked out by placing the limb in a position of abduction, external rotation, and slight flexion, and then drawing a line from a point midway between the anterior superior iliac spine and the symphysis pubis to the adductor tubercle of the femur. The upper two-thirds of this line represents the course of the vessel, the first $1\frac{1}{2}$ or 2 in. being the common femoral, the part below this in the upper third of the thigh the superficial femoral in Scarpa's triangle, and the remainder the superficial femoral in Hunter's canal. The relations of the vessel in the different parts of its course are shown in Figures 214 and 216.

About 2 in. below Poupart's ligament the common femoral artery divides into the superficial femoral and the deep femoral. The parts of the artery to which a ligature may be applied are the common femoral, the superficial femoral in Scarpa's triangle, the superficial femoral in Hunter's canal, and the deep femoral.

Ligature of the common femoral artery.—This vessel lies immediately under the fascia lata, within the femoral sheath, having the ilio-psoas behind, the common femoral vein on the inner side, and the anterior crural nerve and a few fibres of the psoas muscle on the outer side.

Position.—The patient is placed in the dorsal position, with the thigh slightly flexed, abducted, and rotated outwards. The surgeon stands upon the outer side of the limb, and the chief assistant on the opposite side.

Operation.—An incision, about 2 in. or $2\frac{1}{2}$ in. in length, is made in the line of the artery, commencing, above, immediately below Poupart's ligament. The skin, superficial fascia, and the deep fascia are divided, and the margins of the wound held aside with retractors, when the anterior layer of the femoral sheath will be exposed, the anterior crural nerve lying upon its outer side separated from the artery by a few fibres of the psoas magnus muscle. The crural branch of the genito-crural nerve may be met with, lying upon or within the sheath of the vessel. The artery is situated in the external compartment of the femoral sheath, and lies in close relation with the corresponding vein, which is placed internal to the artery and separated from it by a septum of connective tissue. The sheath is opened somewhat on the outer side, so as to avoid injuring the vein, which may overlap it, and the needle is passed from the inner side. When the ligature has been applied, the wound is closed in the usual manner.

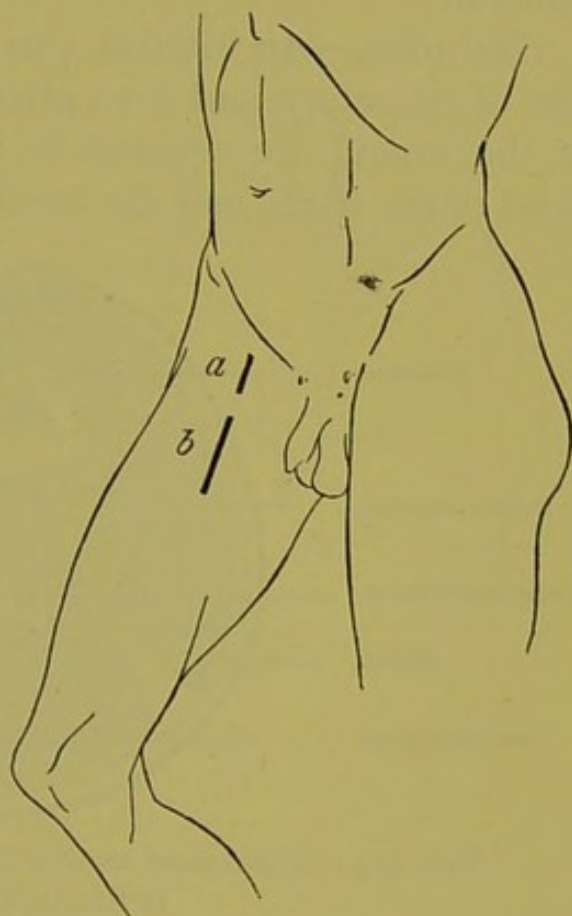


FIG. 213. — Ligature of femoral artery. Position of limb, and lines of external incision.

a. Common femoral.

b. Superficial femoral at apex of Scarpa's triangle.

Collateral circulation.—(*a*) Deep circumflex iliac with the ascending branch of the external circumflex; (*b*) obturator with the internal circumflex; (*c*) sciatic with the other vessels taking part in the crucial anastomosis; (*d*) branches of the internal pudic artery with superficial pudic

branches of the common femoral, when these are given off below the point of application of the ligature.

Ligature of the superficial femoral artery in Scarpa's triangle.—*Position.*—The position of the patient and of the operator is the same as in ligature of the common femoral.

Operation.—An incision 3 to $3\frac{1}{2}$ in. long is made in the line of the artery, and is so placed that the upper two-thirds of the wound are situated in the lower part of the upper third of the thigh, and the lower third of the wound in the

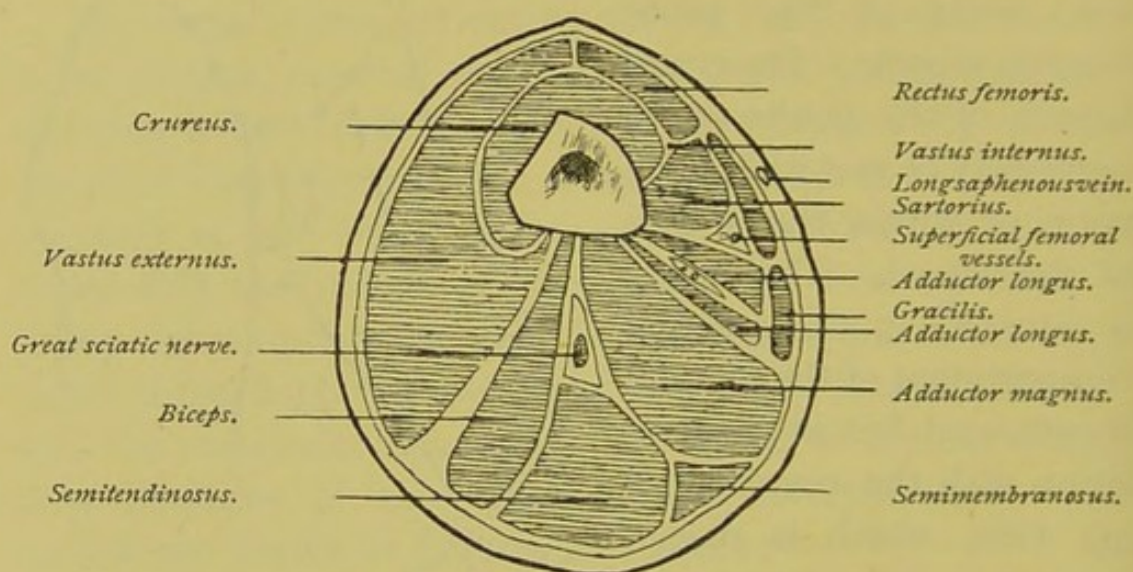


FIG. 214.—Transverse section through the thigh at the apex of Scarpa's triangle.

upper portion of the middle third of the thigh (Fig. 213). The vessel is ligatured at the apex of Scarpa's triangle. The superficial fascia is divided, care being taken to avoid injury to tributaries of the long saphenous vein which may cross the line of the artery in this portion of the thigh; if, however, they cannot be drawn aside, two ligatures are applied, and the vessel divided between them. The deep fascia is then incised, when the sartorius muscle will be visible, its fibres crossing obliquely from above downwards and inwards. The inner border of the muscle is defined, and the entire muscle drawn outwards, by which means the anterior aspect of the sheath is exposed. The vein lies

behind and to the inner side of the artery, whilst the internal cutaneous nerve lies anteriorly, and the long saphenous nerve externally. The sheath of the artery is opened, and the needle passed from the inner side, care being taken to keep the point of the needle against the wall of the vessel, and so avoid enclosure of any of the adjacent structures. When the ligature has been tied, the ends are cut short, the sartorius allowed to return to its former position, and the external wound closed.

Collateral circulation.—

(a) Descending branches of the external circumflex with muscular branches of the superficial femoral, the anastomotica magna, and the superior external articular branches of the popliteal; (b) the perforating branches of the profunda femoris with muscular branches of the superficial femoral, superior muscular branches of the popliteal, and the superior articular branches of the same vessel.

Ligature of the superficial femoral artery in Hunter's canal.—*Position.*—The same as for ligature of the common femoral, the surgeon standing on the outer side of the middle third of the thigh.

Operation.—An incision from 3 to 4 in. long is made in

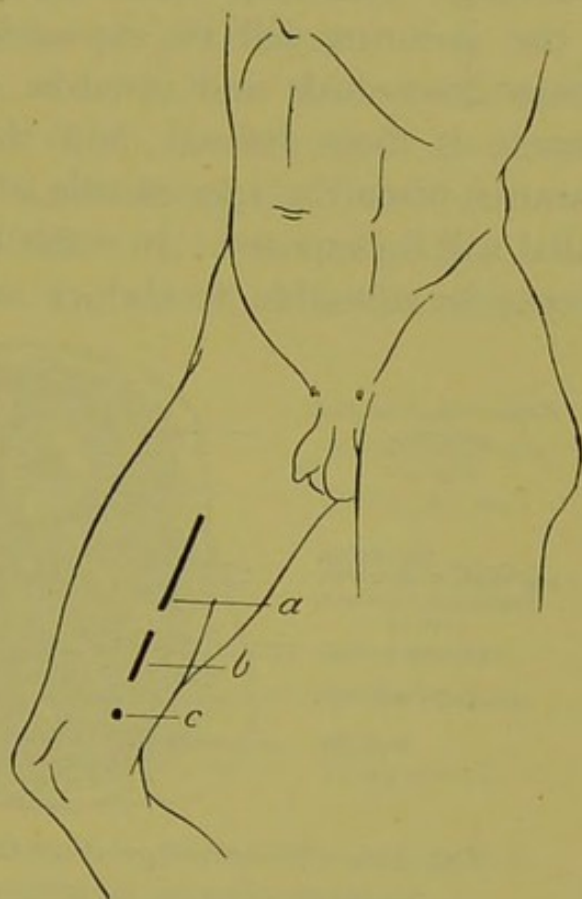


FIG. 215.—Position of limb and lines of incision for ligature of superficial femoral artery in Hunter's canal, and the popliteal artery in the upper portion of the popliteal space.

- a. Incision for superficial femoral artery.
- b. " " popliteal artery.
- c. " " adductor tubercle of femur.

the line of the artery in the middle third of the thigh, the central point of the incision being opposite the mid point of the thigh. The superficial fascia is divided, and if the internal saphenous vein is seen it is drawn inwards with a retractor. The deep fascia is next incised, and underneath it the sartorius will be exposed, the fibres running from above downwards and inwards. The outer border of this muscle is then defined, and the entire structure drawn inwards, when the aponeurosis which forms the roof of the canal will be exposed. In order to make this more distinct, it may be advisable to abduct the thigh more fully. The

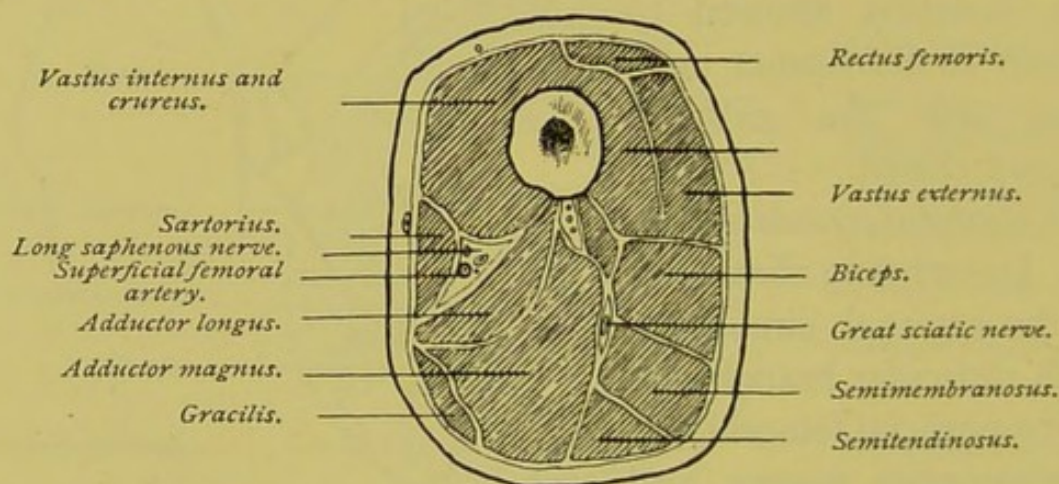


FIG. 216.—Transverse section through the middle third of the thigh, showing the structures in Hunter's canal.

aponeurosis is incised in the line of the incision, and the artery with a thin sheath laid bare. In front of the vessel the long saphenous nerve will be visible, on the outer side the nerve to the vastus internus, and behind the corresponding vein, whilst surrounding the artery are branches of the sympathetic and the deep lymphatic vessels coming up from the popliteal space. The surface of the artery is bared in the usual manner, and the needle passed from either the inner or the outer side, care being taken not to include a nerve in the ligature, or pierce the vein with the needle.

Collateral circulation.—The circulation is re-established along the same channels as have been enumerated in connection with ligature of the artery in Scarpa's triangle.

The popliteal artery.—The popliteal artery commences at the aperture in the adductor magnus, runs at first slightly outwards, but chiefly downwards, to the middle of the space, when it takes a vertical direction to the lower border of the popliteus muscle, at which point it terminates by dividing into the anterior and posterior tibial arteries.

In its course downwards it lies behind the bare triangular area on the posterior aspect of the lower part of the femur, then upon the posterior ligament of the knee-joint, and finally upon the fascia which covers the popliteus. The vein lies in close relation to the artery, at first being on the

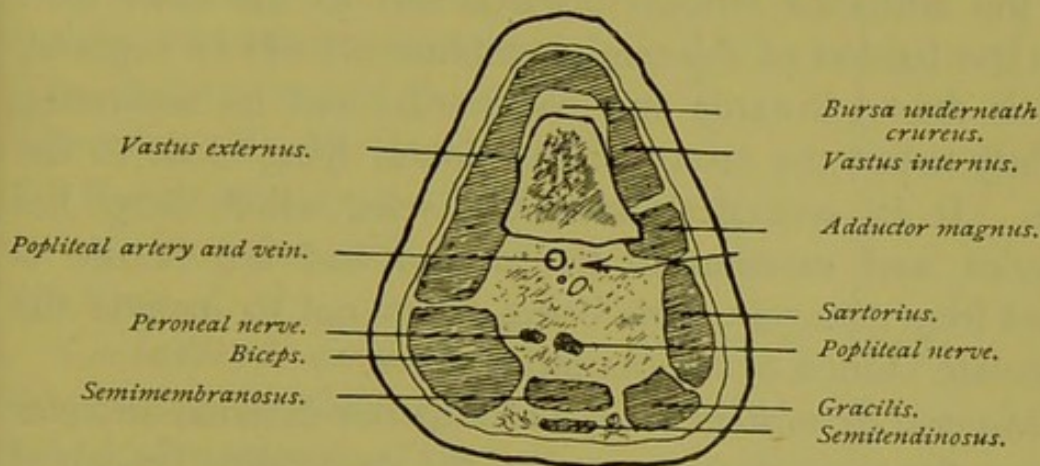


FIG. 217.—Transverse section through the thigh, at the level of the upper part of the popliteal space.

outer side and posterior, then posterior, and finally internal. The popliteal nerve is more superficial, but, like the vein, crosses from the outer to the inner side during its course downwards. That branch of the obturator nerve which goes to the knee-joint lies upon the upper portion of the artery, between it and the vein.

The popliteal artery may be ligatured in the upper part of its course as it lies behind the femur, or in the lower part where it is in relation with the fascia covering the popliteus.

Ligature of the popliteal artery in the upper part of the popliteal space.—*Position.*—The limb is placed in a position similar to that for ligature of the femoral artery, but is more flexed and rotated outwards.

Operation.—The adductor tubercle is defined, and passing upwards from it can be felt the tendon of the adductor magnus. An incision is made, commencing, below, half an inch above the adductor tubercle, and extending upwards for $3\frac{1}{2}$ in. along the posterior border of the tendon (Fig. 215, *b*). The skin, superficial fascia containing branches of the internal cutaneous nerve, and the deep fascia, are divided in the line of the incision; the nerves and the long saphenous vein, if seen, being drawn to one side. The anterior border of the sartorius muscle is then seen, and also the tendon of the adductor magnus. The sartorius is retracted backwards, and the adductor tendon forwards and to the outer side, when the tendon of the semi-membranosus will be exposed. This is drawn inwards and backwards, and on separating the fatty tissue the artery will be found lying close to the bone. It is separated from the vein, which here lies posterior and external to the artery, and the needle is passed from the vein, care being taken not to include the geniculate branch of the obturator nerve.

Collateral circulation.—(*a*) The superior external articular arteries, the anastomotica magna, the descending branch of the external circumflex, and the lowest muscular branches of the profunda femoris, communicate with the inferior articular arteries and the recurrent branches of the anterior tibial; (*b*) the articular branches of the anastomotica magna and external circumflex with the azygos branch of the popliteal.

Ligature of the popliteal artery in the lower part of the popliteal space.—*Position.*—The patient is placed in a semi-prone position, and the limb fully extended. The surgeon stands on the outer side of the limb which is to be operated upon, and the assistant on the opposite side.

Operation.—An incision is made in the middle line of the popliteal space, 3 to 4 in. in length, commencing immediately below the central point of the space, and extending downwards in the line of the artery. The skin is divided,

and then the superficial fascia, in which will be seen the short saphenous vein and the small sciatic nerve. These structures are retracted to the outer side, and then the deep fascia is divided, when the two heads of the gastrocnemius will be exposed. These are separated without injuring the large arteries and nerves which go to them, and the short saphenous vein followed till it joins the popliteal vein. The popliteal nerve is generally seen first, then the vein, and, somewhat to the outer side and at a slightly deeper level, the artery. The popliteal nerve and vein are drawn towards the inner side, and the needle passed from these structures. The performance of the deep dissection may be facilitated by flexing the knee slightly, so as to relax the gastrocnemius.

Collateral circulation.—Similar to that which is established after ligature of the first part of the artery.

The posterior tibial artery.

—The course of the posterior tibial artery is represented by

drawing a line from the central point of the popliteal space to a point half-way between the tip of the internal malleolus and the inner side of the prominence of the heel. The artery commences at a point in the leg on a level with the tubercle of the tibia, and in the first part of its course it lies a little internal to the above line.

The upper part of the artery is deeply placed in the calf, lying underneath the soleus and gastrocnemius muscles, and the deep transverse fascia of the leg which separates the superficial group of muscles from the deep (Fig. 220). In the lower third of the leg it is more superficial, and lies immedi-

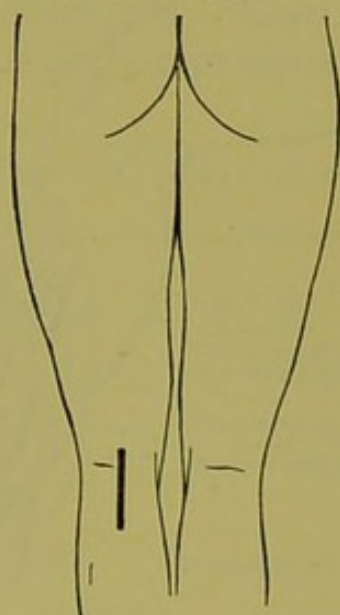

FIG. 218.—Ligature of popliteal artery in lower part of popliteal space. Position of the skin incision.

ately below the deep fascia. In its course downwards it lies upon the tibialis posticus, the flexor longus digitorum, the posterior surface of the tibia, and the ligaments of the ankle joint. The posterior tibial nerve lies on the outer side of the artery, except for a short distance at its commencement. The artery is accompanied by two venæ comites.

A ligature may be applied to the posterior tibial artery in the middle third of the leg, in the lower third of the leg, or at the ankle-joint.

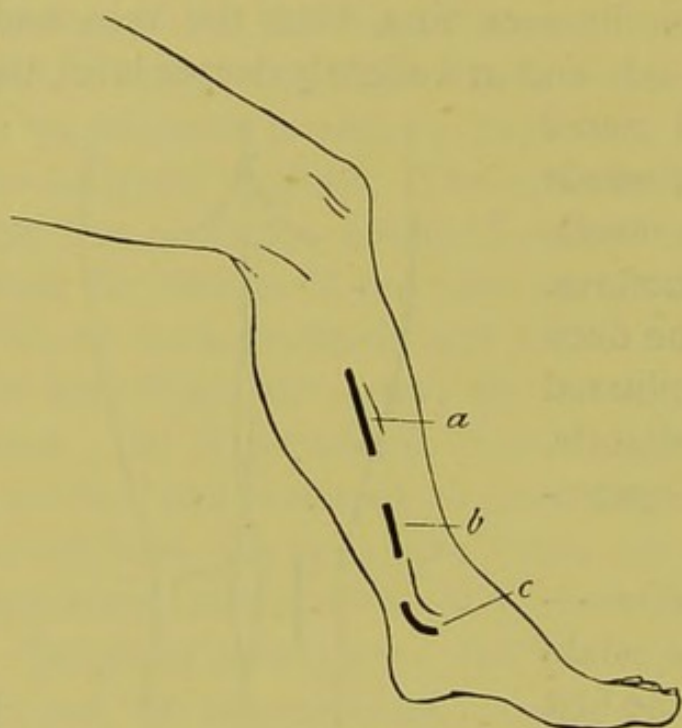


FIG. 219.—Position of limb and lines of incision for exposure of the posterior tibial artery in the middle and lower thirds of the leg, and at the ankle behind the internal malleolus.

Ligature of the posterior tibial artery in the middle third of the leg.—*Position.*—The patient lies in the dorsal position, the limb to be operated upon is flexed at the knee, and the leg lies upon its outer side. The surgeon stands on the outer side of the limb and leans over, the assistant being placed opposite him.

Operation.—The postero-internal border of the tibia is defined, and an incision 3 to 4 in. long made parallel to this border, but about half an inch behind it, in the middle third of the leg. The skin and superficial fascia are divided, and if the internal saphenous nerve and vein are seen they are retracted to the inner side or backwards. The deep fascia is then incised, and underneath it the soleus, where it is attached to the postero-internal border of the tibia, made out. In this part of the operation, in a muscular subject, the edge of the gastrocnemius may become visible,

in which case it is drawn backwards. When the soleus has been bared, it is divided for the entire length of the incision, immediately beyond its attachment to the tibia, and when this has been done, the deep transverse fascia which separates the superficial muscles from the deep is divided in the line of the original incision. On following inwards the deep aspect of this fascia for a short distance, the artery will be seen lying upon its deep surface, between it and the tibialis posticus. On each side of the artery there is a vena comes; the posterior tibial nerve lies on the outer side. Care must be taken not to divide the flexor longus digitorum along with

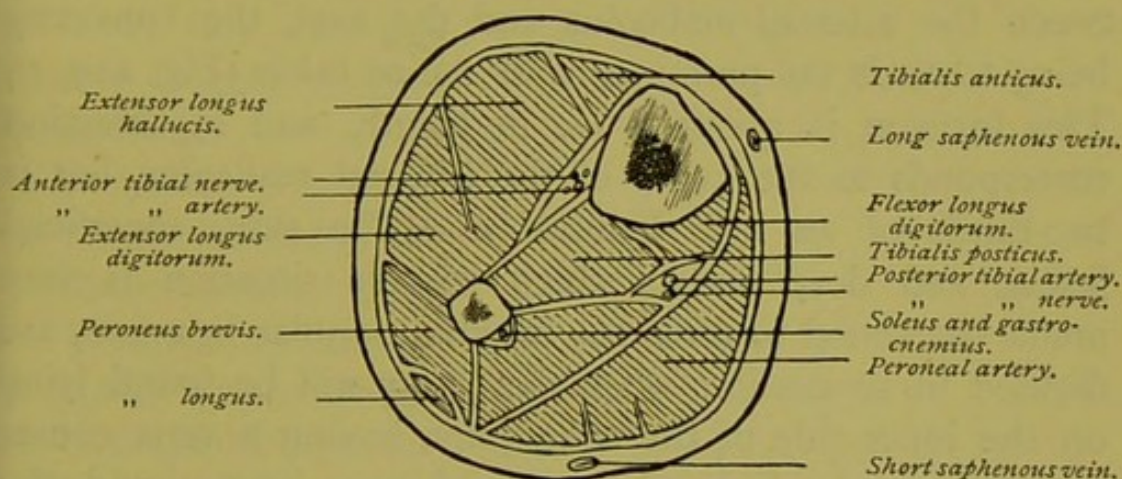


FIG. 220.—Transverse section through middle of leg, at level where posterior tibial artery is ligatured, in the middle third.

the soleus, since if this is done it is possible to mistake the interosseous membrane for the deep transverse fascia, and tie the anterior tibial artery instead of the posterior. The relations of the artery at the point of ligature are shown in Fig. 220.

Ligature of the posterior tibial artery in the lower third of the leg.—*Position.*—The positions of the patient, surgeon, and assistant are similar to those in ligature of the vessel in the middle third.

Operation.—An incision 2 or $2\frac{1}{2}$ in. long is made along the line of the vessel in the lower third of the leg (Fig. 219). This divides the skin, superficial fascia, and the deep fascia, which at the lower part is somewhat thickened, owing to the

transverse fibres being more developed, where it forms the internal annular ligament of the ankle-joint. The incision lies between the postero-internal border of the tibia and the inner margin of the tendo Achillis. Underneath the deep fascia the artery is found lying upon the flexor longus digitorum, surrounded by its venæ comites, and having the nerve on the outer side. The needle is passed from the outer side.

Ligature of the posterior tibial artery behind the internal malleolus.—*Position.*—As for ligature of the vessel in the middle third.

Operation.—A curved incision is made in the space between the internal malleolus and the heel, the convexity being towards the prominence of the os calcis (Fig. 219, *c*). This incision is about 2 in. in length, and in direction corresponds to the curve of the internal malleolus, but is two-thirds of an inch behind it. The skin, superficial fascia, and deep fascia, which in this situation is very much thickened to form the internal annular ligament, are divided in succession, when the artery will be found lying on the inner side of the ankle-joint, having a vena comes on the inner side, and a second vena comes and the posterior tibial nerve on the outer side. The vessel is separated from its venæ comites, and the needle passed from the nerve. If the venæ comites are very closely connected with the vessel, they may be ligatured as well.

Collateral circulation.—When the posterior tibial artery has been ligatured, the following channels become dilated:—(*a*) Branches of the peroneal artery with branches of the posterior tibial which are given off below the point of ligature, and with the external plantar by the calcaneal and malleolar branches; (*b*) internal malleolar branches of the anterior tibial, with similar branches of the posterior tibial; (*c*) the dorsalis pedis artery and its branches, with the internal and external plantar arteries.

The peroneal artery.—This vessel is a branch given off from the posterior tibial, a short distance below its commencement.

It runs downwards, lying behind the fibula, and covered by the flexor longus hallucis muscle. In the lower part of the leg it becomes much smaller, and gives off its malleolar and calcanean branches.

A ligature may be applied to the vessel in the middle of the calf.

Position.—The patient is placed in a semiprone position, lying upon the side which is not to be operated upon. The leg is slightly flexed at the knee, and the limb lies with the external aspect before the operator.

Operation.—The postero-external border of the fibula is defined with the fingers, and an incision 3 in. long made in the middle of the leg over this border of the bone (Fig. 221). When the skin and fasciæ have been divided, the outer border of the soleus muscle will be exposed. This muscle is retracted, and, if neces-

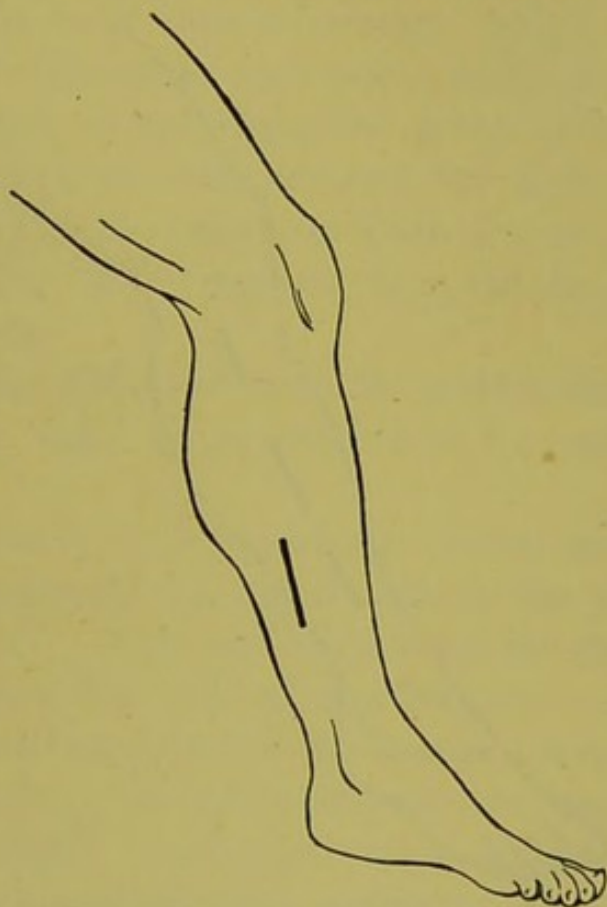


FIG. 221.—Ligature of peroneal artery.
Line of external incision.

sary, its attachment to the fibula in the upper part of the wound cut through. By this means the origin of the flexor longus pollicis from the fibula is laid bare. This is separated from the bone until the artery is exposed, lying in a canal of fibrous tissue between the inner part of the flexor longus hallucis and the tibialis posticus. The needle may be passed from either side.

The anterior tibial artery.—This vessel commences at the lower border of the popliteus muscle, and terminates in

front of the ankle-joint, where it becomes the *dorsalis pedis*.

Its course is marked out by drawing a line from a point which is half-way between the prominent portion of the external tuberosity of the tibia and the head of the fibula, to a point midway between the two malleoli.

In its course downwards it lies upon the interosseous membrane for the

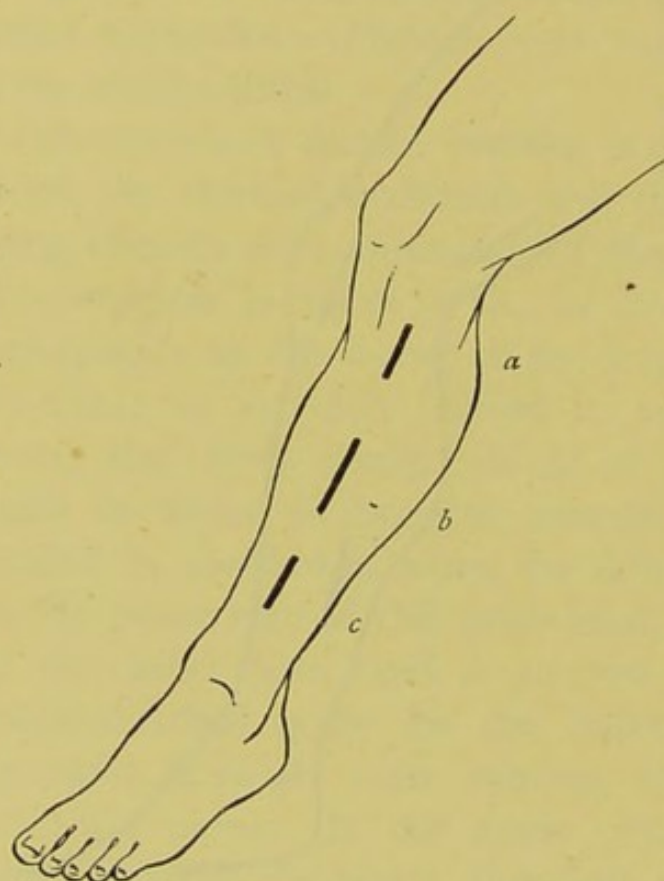


FIG. 222.—Position of limb and lines of skin incisions in ligature of anterior tibial artery.

a. Upper third. | *b.* Middle third.
c. Lower third.

upper two-thirds, and on the tibia and the ankle-joint below this level. It lies in relation with the *tibialis anticus* on the inner side, and on the outer side it has the *extensor longus digitorum* at first, and lower down is separated from this muscle by the *extensor longus hallucis*. The tendon of the latter crosses the artery below. The anterior tibial nerve lies chiefly on the outer side, although, for a short distance, it may

lie in front. The artery is accompanied by two *venæ comites*.

The anterior tibial artery may be ligatured at the upper, middle, or lower thirds of the leg.

Ligature of the anterior tibial artery in the upper third.

—*Position*.—The patient is placed in the dorsal position, the leg being rotated inwards with the foot fully extended. The surgeon stands on the outer side of the limb, and the assistant on the opposite side.

Operation.—An incision 3 or 4 in. long is made in the line of the artery, commencing above at the level of the tubercle of the tibia. The skin, superficial and deep fascia are divided, and the interval between the tibialis anticus and the extensor longus digitorum defined. This interval can usually be felt by the finger as a slight depression in the line of the incision. At this stage the foot is flexed, so as to allow these muscles to be separated with retractors. Upon the anterior surface of the interosseous membrane, and a short distance to the outer side of the tibia, the artery will be found, having a vena comes on each side and the nerve on the outer side. The vessel is separated from the nerve, and, if possible, from the venæ comites, and the needle passed from the outer side.

Ligature of the anterior tibial artery in the middle third.

—*Position.*—This is the same as for ligature in the upper third.

Operation.—An incision 3 in. long, whose central point corresponds to the mid point of the leg, is made in the line of the artery (Fig. 222, *b*). This incision divides the skin, superficial and deep fasciæ, and exposes the muscles. An interval between the tibialis anticus and the extensor longus digitorum is defined (it can generally be felt with the finger, or may appear as a slight depression of a somewhat yellowish tint), and these muscles are separated and retracted. The extensor longus hallucis is next met with, overlapping the vessel from the outer side; it in turn is pulled aside, and the artery will be exposed. In the middle third of the leg the anterior tibial nerve often lies in front of the vessel, in which case it is retracted to the outer side. The needle is passed from the nerve. The venæ comites are usually included within the ligature, owing to the difficulty of separating them from the artery.

Ligature of the anterior tibial artery in the lower third.

—*Position.*—As for ligature of the vessel in the upper third, though the foot is not rotated to the same extent.

Operation.—An incision 2 to $2\frac{1}{2}$ in. long is made in the line of the artery immediately above the ankle (Fig. 222, *c*). This divides the skin, superficial fascia, and deep fascia, which in this situation is considerably thickened to form the transverse portion of the anterior annular ligament of the ankle. Underneath the deep fascia the tendons of the tibialis anticus and the extensor longus hallucis are defined, the former being surrounded with a synovial sheath, and lying in a separate compartment beneath the annular ligament. The tendon of the extensor longus hallucis is drawn to the outer side, when the artery will be exposed as it lies upon the tibia. The nerve lies on the outer side. The nerve is drawn aside, and the needle passed from the outer side.

Collateral circulation.—(*a*) The external malleolar and inferior muscular branches of the anterior tibial, with the external malleolar and calcaneal branches of the peroneal artery; (*b*) the internal malleolar branch of the anterior tibial, with a similar branch from the posterior tibial; (*c*) muscular, tarsal, and metatarsal branches of the dorsalis pedis, with the terminal branches of the anterior peroneal; (*d*) the dorsalis pedis, with the internal and external plantar arteries.

The dorsalis pedis artery.—The dorsalis pedis artery is the continuation of the anterior tibial, and extends from the ankle to the sole, where it joins the external plantar.

Its course is marked out by taking a line from the central point between the two malleoli to the base of the first intermetatarsal space.

It lies upon the dorsal surface of the tarsus, between the tendon of the extensor longus hallucis on the inner side, and that of the extensor longus digitorum on the outer side.

Position.—The patient lies in the dorsal position, with the sole resting upon the table; the surgeon stands on the outer side of the limb. One assistant holds the foot in a

state of complete extension, and the other stands opposite the surgeon and retracts the margins of the wound.

Operation.—An incision from 1 to 2 in. long is made on the dorsum of the foot in the line of the vessel, commencing about 1 in. below the ankle-joint at the lower margin of the inferior portion of the anterior annular ligament. The incision is situated between the tendons of the extensor longus hallucis and the extensor longus digitorum, and divides the skin and superficial and deep fasciæ, when the artery will be exposed lying upon the bone and surrounded by a variable quantity of fatty tissue. The nerve lies externally, and the needle is passed from the outer side.

Collateral circulation.—This is established through the communications of the terminal portion of the vessel with the deep plantar arch.

The internal iliac artery.—The internal iliac trunk extends from the sacro-lumbar articulation almost to the upper border of the great sacro-sciatic foramen. It is one of the two terminal divisions of the common iliac artery.

It lies upon the anterior aspect of the lateral mass of the sacrum, from which it is separated by the lumbo-sacral cord. The corresponding vein lies to the inner side and behind, whilst externally it has the inner margin of the psoas magnus muscle. The ureter lies upon its commencement, and the peritoneum and intestines cover it in front.

Position.—As for ligature of the common iliac artery.

Operation.—An incision about 4 in. long is made in the linea alba, commencing a short distance above the pubic symphysis. The peritoneal cavity is opened, and the intestines and great omentum pushed aside and held

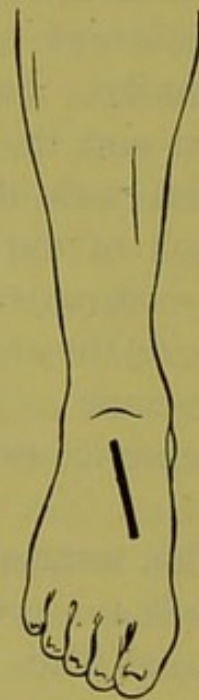

FIG. 223.—Ligature of the dorsalis pedis artery. Position of skin incision.

out of the way by flat sponges and large retractors or by the hands of an assistant. The point of division of the common iliac is defined, and from this the internal iliac artery is traced as it lies upon the front of the sacrum. The peritoneum over it is divided freely, and the vessel separated from the ureter and the sympathetic plexus which surrounds it. The aneurysm needle is passed from the inner side so as to avoid injury to the vein, which is usually of large size.

Collateral circulation.—(a) Ilio-lumbar with the deep circumflex iliac; (b) the lateral sacral with the middle sacral and the lateral sacral of the opposite side; (c) the gluteal with the deep circumflex iliac and the ascending branch of the external circumflex; (d) the internal pudic and obturator arteries, with similar vessels of the opposite side; (e) the obturator artery, with the internal circumflex and the sciatic; (f) the hæmorrhoidal branch of the inferior mesenteric with the hæmorrhoidal branches of the internal iliac.

The sciatic and internal pudic arteries.—Both these vessels are terminal branches of the anterior division of the internal iliac, and are given off from this vessel as it lies upon the anterior surface of the pyriformis muscle, just before the latter leaves the pelvis. They emerge from the pelvis through the great sacro-sciatic foramen at the lower border of the pyriformis. The sciatic artery is more superficial at the point of emergence, whilst the internal pudic lies on the inner side.

The point where these vessels come out from the pelvis is marked on the surface by trisecting a line drawn from the posterior superior iliac spine to the outer part of the ischial tuberosity; the junction of the middle and lower thirds of this line is the point required.

Position.—The patient is placed on the sound side in the semiprone position, with the legs hanging over the end of the table. The surgeon stands on the side to

be operated upon, and the assistant on the opposite side.

Operation.—The point of emergence of the vessels is marked out, and then an incision 4 in. long, whose centre corresponds to the point of emergence, is made in the line of the fibres of the gluteus maximus (Fig. 224, *a*). The skin, superficial and deep fasciæ are divided; then the muscle is incised or its fasciculi separated for the entire length of the wound, and the margins well retracted till the pyriformis is exposed at the bottom of the wound. The lower border of this muscle is defined and traced inwards to the sciatic foramen, when the artery will appear. When dividing the gluteus maximus a large muscular branch of the sciatic artery may be cut across, in which case it will serve as an easy guide to the main vessel, if it is traced inwards. The internal pudic artery lies upon the ischial spine, somewhat internal to the sciatic artery, and at a slightly deeper level. In each case the artery is separated from the adjacent structures, and the needle passed from the inner side. In the case of the internal pudic artery, care must be taken to avoid including within the ligature the pudic nerve, which lies immediately internal to the vessel.

The gluteal artery.—This vessel is the terminal branch of the posterior division of the internal iliac. It passes out from the pelvis through the upper part of the great sacro-sciatic foramen at the upper border of the pyriformis, and is accompanied by two venæ comites and the superior gluteal nerve. Just beyond its point of emergence it subdivides into superficial and deep portions, and on this account it is necessary to apply the ligature close to the margin of the foramen. The gluteal artery emerges from the pelvis at a point corresponding to the junction of the inner and middle thirds of a line joining the posterior superior iliac spine and the top of the great trochanter, the thigh being rotated inwards.

Position.—This is the same as for ligature of the sciatic artery.

Operation.—An incision from $3\frac{1}{2}$ to $4\frac{1}{2}$ in. long is made parallel with the fibres of the gluteus maximus, the centre of the incision corresponding to the point of emergence of the artery from the pelvis (Fig. 224, *b*). The skin, superficial fascia containing a number of cutaneous nerves, and deep fascia are divided, and the gluteus maximus exposed.

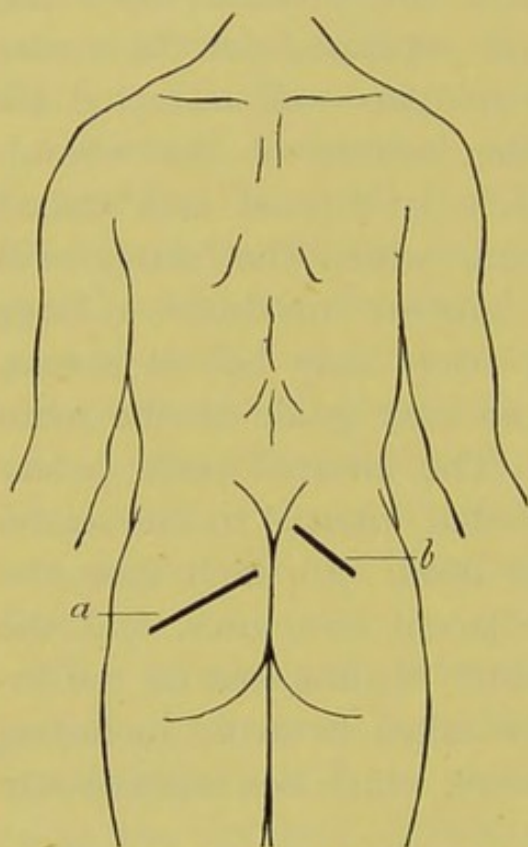


FIG. 224.—Ligature of the gluteal, sciatic, and internal pudic arteries.

a. Incision for sciatic and internal pudic.

b. Incision for gluteal.

The fasciculi of this muscle are separated until the fascia which lies between it and the gluteus medius and piriformis becomes visible. An interval between the two latter muscles is then sought for, and when found the muscles are separated along this line until the sacro-sciatic foramen is reached. The gluteal artery can then be felt against the bony margin of the foramen as a distinct rounded structure.

Whilst separating the fibres of the gluteus maximus, a large muscular branch of the

gluteal artery may become visible, in which case it is traced onwards until it joins the main trunk. When the position of the gluteal artery has been made out, the gluteus medius and piriformis are held well aside with retractors; the artery is separated from the superior gluteal nerve and the venæ comites, and then the needle is passed from the nerve.

CHAPTER XVI.

OPERATIONS UPON THE VEINS.

General considerations.—The remarks which were made under this heading in the previous chapter, in connection with the arteries, apply for the most part to the veins.

The instruments which are necessary are the same as for the ligature of an artery.

The internal jugular vein.—This vein is the chief vessel by which blood is returned from the interior of the cranium to the general circulation. It commences at the base of the skull at the lower border of the jugular foramen, by the union of the inferior petrosal and lateral sinuses as they emerge from the cranial cavity. It passes down the neck, lying in the carotid sheath of the deep cervical fascia, on the outer side of the internal carotid above the level of the thyroid cartilage, and below this level on the outer side of the common carotid. Behind the outer part of the sterno-clavicular articulation it joins the subclavian vein of the corresponding side, the two together forming the innominate vein.

The course of the vein is marked out on the surface, after placing the patient in the dorsal position with the head turned towards the opposite side, by drawing a line from the lower border of the external auditory meatus above to the outer part of the sterno-clavicular articulation below.

Indications.—The internal jugular vein has been ligatured for injuries, on account of involvement in inflammatory and malignant growths, and in cases of thrombosis of the lateral

sinus, the object of the operation in the latter case being to prevent septic material from reaching the general circulation by this route.

Position.—The patient is placed in the dorsal position, with the shoulders raised by a pillow, and the head turned towards the opposite side. The operator stands on the affected side of the patient, and the assistant opposite to him.

Operation.—An incision, 3 in. in length, is made in the line of the vessel, commencing above at the level of the apex of the mastoid process. The skin, superficial fascia containing

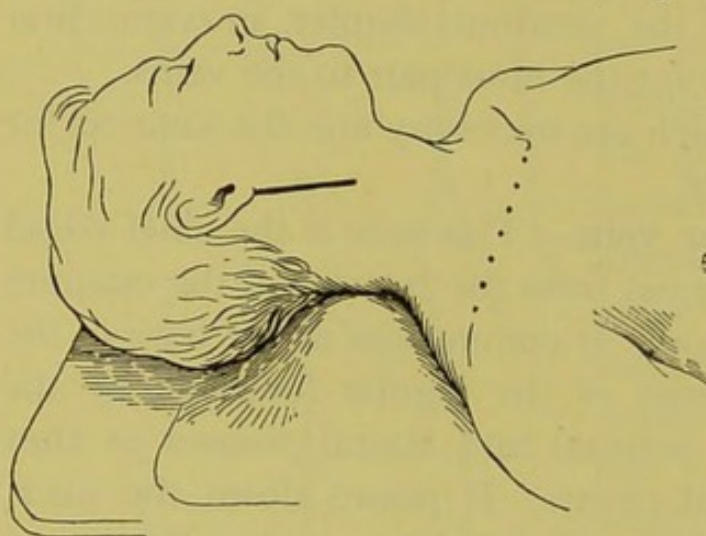


FIG. 225.—Position of patient, and line of incision in exposure of internal jugular vein.

the platysma, external jugular vein, and superficial nerves, and the deep fascia are divided, and the sterno-mastoid muscle exposed along its anterior margin. The sterno-mastoid is retracted outwards, and the fascia which forms its sheath posteriorly

incised, the spinal accessory nerve being avoided. The posterior belly of the digastric muscle will now be seen crossing the bottom of the wound obliquely. This structure is pulled upwards with a retractor, and then a sheath of deep cervical fascia, which encloses the internal jugular vein, will be exposed. This fascial sheath is opened on the outer side, the vein is separated from the sheath for about one-third of an inch, and an aneurysm needle passed unthreaded from the inner side. The vagus nerve lies behind and internal to the vein, and must be avoided in passing the ligature. The hypoglossal nerve or its descendens cervicis branch may be met

with at the lower border of the digastric muscle, in which case the former is drawn upwards and the latter inwards.

Exposure or ligature of the lateral sinus.—The lateral sinus may become the seat of inflammation and thrombosis, owing to the extension of septic affections from the mastoid process, in cases of disease of this portion of the temporal bone. The portion of the sinus which is usually involved is that part which lies in the groove of the mastoid portion of the temporal bone. The course of the sinus is demarcated by drawing a line from the external occipital protuberance to the anterior border of the base of the mastoid, on a level with the external auditory meatus. The sinus is usually exposed as it lies in connection with the mastoid process.

Instruments.—In addition to the ordinary instruments which are requisite for the ligature of a blood vessel, a medium-sized trephine, a periosteal elevator, a chisel and a mallet are necessary.

Position.—The patient is placed in the dorsal position, with the head near the end of the table and turned toward the sound side. The operator stands on the affected side of the head, and the assistant opposite to him.

Operation.—A curved incision, about 2 in. in length, is made parallel to the posterior free border of the external auricle. The incision is somewhat semicircular in shape, the convexity looking backwards, and the central point opposite the line of the sinus (Fig. 199, *b*, p. 312). The first cut divides everything down to the surface of the bone, including the periosteum, and when this has been done a flap is separated with a periosteal elevator. In the upper part of the incision the lower and posterior fibres of the temporal muscle will be divided, and the insertion of the sternomastoid separated from the base of the mastoid process. When this flap has been turned forwards, the posterior margin of the wound is retracted backwards, and then a circle of bone is removed with the trephine. The

pin of the trephine is placed a little above the central point of the base of the mastoid process. Great care is necessary in this stage of the operation, as the bone is usually of varying thicknesses in different parts of the circle, and the sinus is easily opened with the trephine before the bone has been cut through all round. Many surgeons discard the use of the trephine altogether for this operation, and remove the requisite amount of bone with the chisel and mallet. In thrombotic cases, however, injury of the sinus in removal of bone is of no moment, since the lumen of the blood vessel has already been occluded, as the result of the pathological process. When the bone has been removed, the sinus will be visible in the bottom of the wound, and can then be further dealt with as the circumstances of the case demand.

Operation for varicocele.—In this affection the veins of the spermatic cord are abnormally enlarged. The spermatic veins form a plexus, which is called the pampiniform plexus, and this plexiform arrangement extends from the upper border of the testicle to the internal abdominal ring, where the veins join together and form either the spermatic vein or the *venæ comites* of the spermatic artery. The veins lie in front of the vas deferens and the spermatic artery.

Two distinct operations are practised for the cure of a varicose condition of the veins of the spermatic cord. In the first operation the veins are exposed through an open incision, and in the other they are ligatured subcutaneously.

Instruments.—As for ligature of an artery.

(a) *Open method.*—*Position.*—The patient is placed in the dorsal position, with a pillow between the thighs. The surgeon stands on the affected side, and the assistant opposite to him.

Operation.—An incision about 2 in. long is made in the long axis of the scrotum, commencing above over the external abdominal ring and just internal to the pubic spine. The skin and fasciæ are divided and the spermatic cord laid

bare. The dilated veins are next separated from the surrounding structures for a distance of about $1\frac{1}{2}$ to 2 in. or more, according to the length of the scrotum. When this has been done, the vas deferens is held away by the assistant, and two ligatures passed around the separated veins, one at the upper and the other at the lower part of the incision. These ligatures are tied, and the intervening portion of the veins removed. The ligatures are then tied together so as to fix the cut ends of the veins in approximation; the ends are cut short, and the external wound closed in the usual manner.

(b) *Subcutaneous method.*—*Position.*—As in the previous operation.

Instruments.—The only instruments which are necessary for this operation are a small scalpel, a long round needle with a blunt point, and a ligature.

Operation.—The assistant grasps the affected half of the scrotum in such a manner that the veins are held between his fingers and thumbs, whilst the spermatic artery and the vas deferens slip behind out of the way. The surgeon with the left hand defines the exact position of the vas deferens, and then makes a very small incision with the scalpel through the skin. The needle is then entered in such a manner that it passes between the vas deferens and the spermatic veins, and emerges on the opposite part of the affected half

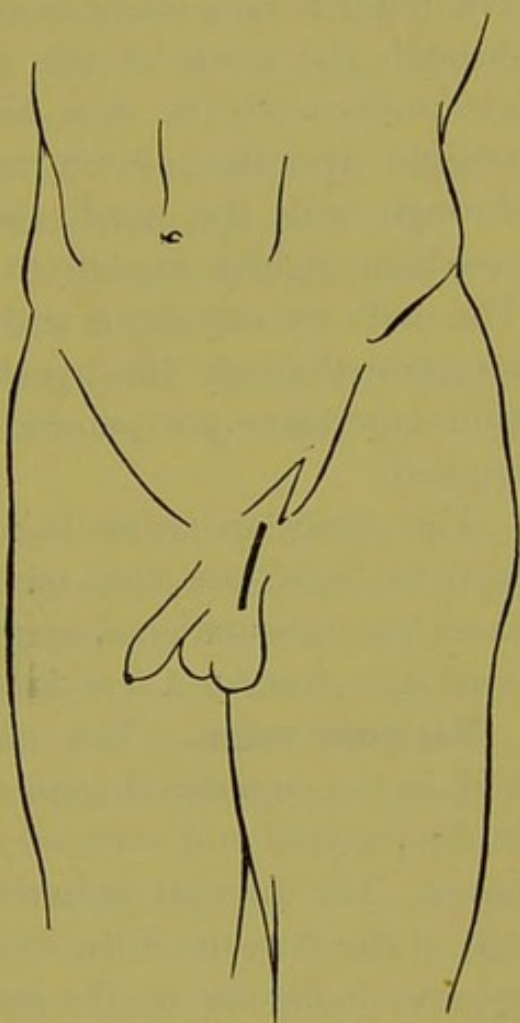


FIG. 226. — Open operation for cure of varicocele. Line of skin incision.

of the scrotum, this being facilitated by making a small cut with the scalpel on to the point of the needle. It is most convenient to make the needle enter posteriorly and emerge anteriorly. The needle, which is already threaded, is drawn right through the scrotum, carrying the ligature with it. The point is now made to enter the aperture of exit, to pass through the tissue of the scrotum superficial to the veins and underneath the skin, and then to emerge through the original aperture of entrance. The ligature is brought through with the needle, and then tied with an ordinary reef knot, tightly enough to occlude all the included veins. The ends are cut short, and the knot made to pass into the scrotum through the aperture of entrance of the needle. Both apertures are painted with collodion and a dressing applied.

The open operation is advisable in all cases where the varicose veins are very numerous and large, but for slight cases the subcutaneous operation is better, since the patient need only rest for a few days.

Varicose veins.—This condition is most frequently met with in the superficial veins of the lower extremity, especially in the internal and external saphenous veins and their tributaries. The internal saphenous vein commences on the inner side of the dorsum of the foot, passes upwards in front of the internal malleolus on the inner side of the leg and the knee, and terminates by passing through the saphenous opening in the fascia lata of the thigh and joining the common femoral vein. The external saphenous vein commences on the outer side of the dorsum of the foot, passes upwards behind the external malleolus, runs along the middle of the calf, and finally perforates the deep fascia in the lower part of the popliteal space, and joins the popliteal vein.

The operation which appears to be the most efficient is the following :—

Operation.—The skin covering the affected portion of the veins is rendered quite aseptic, and then numerous short

incisions are made in succession over the most enlarged parts. The dilated portion of the vein is separated from the surrounding fascia for about 1 in. or more, if the "knot" is very large, and two fine silk ligatures are applied at the extremities of the exposed part. The portion of vein which lies between these ligatures is excised, and the incisions in the skin closed carefully with fine silk sutures, and an aseptic dressing applied.

Venesection.—The operation of venesection or "bleeding" is only occasionally performed at the present day.

According to Mr. Jacobson, the operation is indicated in the following clinical conditions, namely:—

(a) In some cases of pneumonia of traumatic origin, when the patient is a "full-blooded" person, and the affection extends rapidly.

(b) In some cases of chronic bronchitis, when the action of the heart is much impeded, owing to the right side of the organ being much distended and engorged with blood.

(c) In certain cases of impending apoplectic seizures, where a tendency to the occurrence of this condition exists.

(d) In the treatment of some forms of aneurysm, especially when they are intra-thoracic.

When the operation of venesection is considered necessary, from 8 to 10 oz. of blood are removed in the following manner, and in many cases it will be found necessary to repeat the procedure. In the treatment of aneurysms only small quantities are removed, just sufficient to reduce excessive action of the heart.

Instruments.—A small scalpel or a bleeding-lancet, a bandage, a bleeding-bowl, an aseptic pad, and a small narrow bandage.

Position.—The patient is placed in the sitting position, the arm hanging over the side of the chair. The surgeon stands on the outer side of the limb upon which he proposes to operate.

Operation.—A superficial vein is chosen, which is of

moderate size, and can easily be dealt with. In most cases the median basilic or the median cephalic vein of the arm is selected. The vein in this situation is quite superficial, and in addition to receiving the blood from the anterior aspect of the forearm, it has a wide communication with the deep veins in the antecubital fossa, by means of the deep median vein.

The area of skin in the region of the bend of the elbow is rendered aseptic by washing in the usual manner. A bandage is then applied to the middle of the upper arm, and tied sufficiently tightly to stop the circulation in the veins, but to still allow the flow of blood along the arteries. A roll of paper, a bandage, or a piece of wood, is placed in the hand of the patient, and he is told to grasp it during the operation. This serves to divert the attention of the patient, as well as to force the blood of the limb into the superficial veins. The median basilic or the median cephalic vein is then chosen, whichever is the more prominent, care being taken to avoid any abnormal artery which may be given off from the brachial and lie in the superficial fascia at the bend of the elbow.

The thumb of the surgeon's left hand is placed on the selected vein a short distance below the point which is to be punctured, so as to control the flow of blood. A bleeding-lancet or a sharp scalpel is then taken in the right hand, and grasped between the finger and thumb in such a manner that only about half an inch of the blade projects. A small cut, about half an inch in length, is then made with one sweep of the blade, dividing the skin, fascia, and anterior wall of the vein. Care must be taken not to penetrate the posterior wall of the vein, in which case it would be possible to damage one of the adjacent arteries. If the first cut does not extend into the lumen of the vein, a second one is made in a similar manner, but the opening in the skin and in the fascia must be larger than that in the vein.

When the vein has been opened, a bleeding-bowl is placed

beneath the elbow, the left thumb is removed from the surface of the vein below, and the stream of blood allowed to flow until the requisite amount has been removed. During the evacuation of the blood the affected limb should not be moved, so as to avoid entrance of the blood into the surrounding subcutaneous tissue.

The necessary amount of blood having been removed, the left thumb is placed upon the opening in the vein, and the bandage from the upper arm taken off. A small aseptic pad of lint is next placed upon the wound, and fixed in position by the narrow bandage, which is applied in the figure-of-eight fashion.

This dressing is kept on for two or three days, and then discontinued. The limb ought to be kept in a sling for a few days longer.

If the artery is injured at the time of the operation, it may be followed by the formation of an arterio-venous aneurysm, owing to the establishment of a communication between the lumen of the vein and that of the artery.

Injection of saline fluids.—The injection of saline fluids, especially sodium chloride '75 per cent. in sterilised water, has been practised with success in a number of cases. The indications for this proceeding appear to be the following, namely:—

1. Acute anæmia, dependent upon the following causes—

(a) Severe hæmorrhage after an accident, such as the cutting off of a limb in a railway smash, or after attempted suicide or homicide, when a large vessel has been severed, in cases of "cut throat," etc.

(b) Severe loss of blood during a surgical operation.

(c) Severe loss of blood in connection with parturition, as in placenta prævia, adherent placenta, accidental hæmorrhage, and post-partum hæmorrhage.

2. In some cases of shock and collapse, when the action of the heart is very weak, and there is impending dissolution.

It is only in occasional cases of this kind that the injection of a saline fluid can be expected to be of much benefit.

Instruments.—Elastic rubber tube, fine scalpel, fine-pointed dissecting forceps, aneurysm needle, cannula intro-

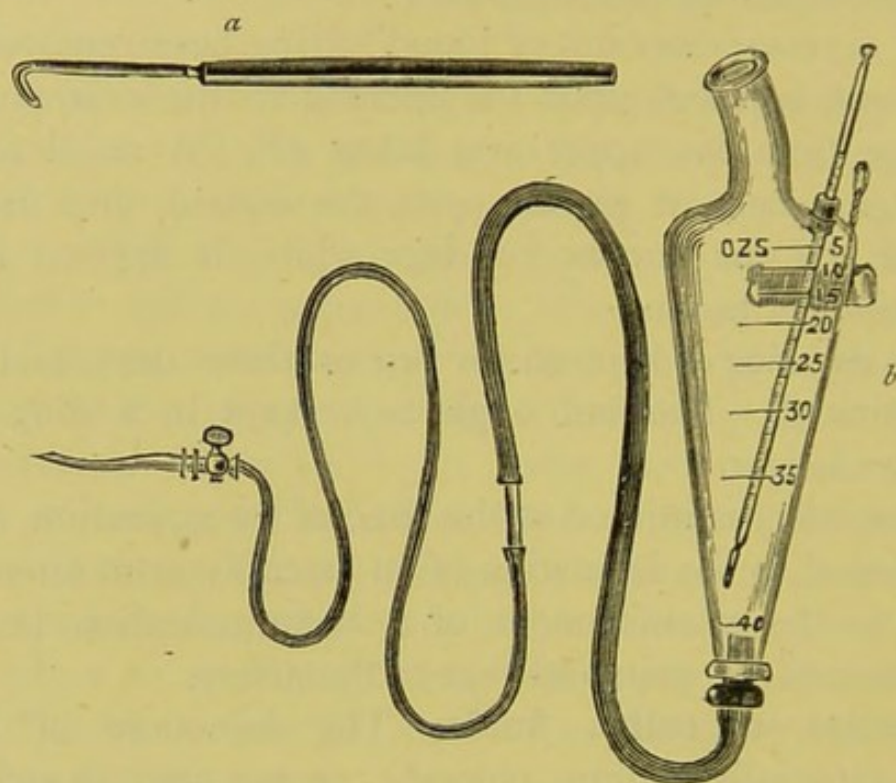


FIG. 227.—Apparatus for the intravenous injection of fluids.

a. Cannula introducer. *b.* Injection apparatus. The cannula is inserted into a vein of the recipient, and the reservoir is filled with the fluid which it is wished to inject. Pressure is obtained by raising the reservoir to a suitable height above the patient. The thermometer is to indicate the temperature of the fluid which is being injected.

ducer (Fig. 227, *a*), injection apparatus with cannula (Fig. 227, *b*), needle, needle-holder, and ligature material.

Preliminary preparations.—The skin over the vein which it is proposed to open is rendered aseptic in the usual manner.

Three to six pints of water are boiled in order to render it sterile. Then a sufficient quantity of sodium chloride is added, to make the solution of a strength of .75 per

cent. (a drachm to a pint is sufficiently approximate for practical purposes).

The solution thus prepared is kept at a temperature of 99° to 100° F.

Immediately before the apparatus is used it is washed out with hot sterilised water, and then filled with the saline fluid.

Operation.—The vein to be opened having been decided upon (the median basilic or the median cephalic, just above the bend of the elbow is most convenient, though in very anæmic persons it may be necessary to expose one of the deep veins of the arm), the elastic rubber tube is wound round the limb on the proximal side of the vein. An incision is made through the skin along the course of the vein, and this structure is dissected free from the surrounding fascia for a distance of an inch. The vein lies in the superficial fascia, and embedded in fatty tissue. A silk ligature is passed with the aneurysm needle underneath the vein at each extremity and in the middle of the incision. The distal ligature is then tied.

The anterior wall of the exposed vein is picked up with the fine forceps, and a small valvular incision made into it with the point of the scalpel. The cannula introducer (Fig. 227, *a*) is now taken and passed into the interior of the vein towards the proximal side. The cannula of the injection apparatus (which has already been filled with fluid) is passed into the vein, on the grooved under aspect of the introducer. The cannula introducer is withdrawn, and the middle silk ligature tied around the neck of the cannula. The elastic rubber tube is now removed. The stopcock of the injection apparatus is turned on, the reservoir gradually raised by an assistant, and a sufficient amount of fluid allowed to flow into the vein. Usually two to four pints will be found to be sufficient.

The upper ligature is now tied above the point of the cannula, and the instrument withdrawn. The incision is

sponged dry and closed by the insertion of one or two points of interrupted silk sutures.

Transfusion.—By this term is understood the transference of blood from one individual to another. It may be accomplished directly by making a connection between the lumen of one of the veins of the “receiver,” and that of one of the “giver.” (The individual who receives the blood is known as the “receiver,” and the individual from

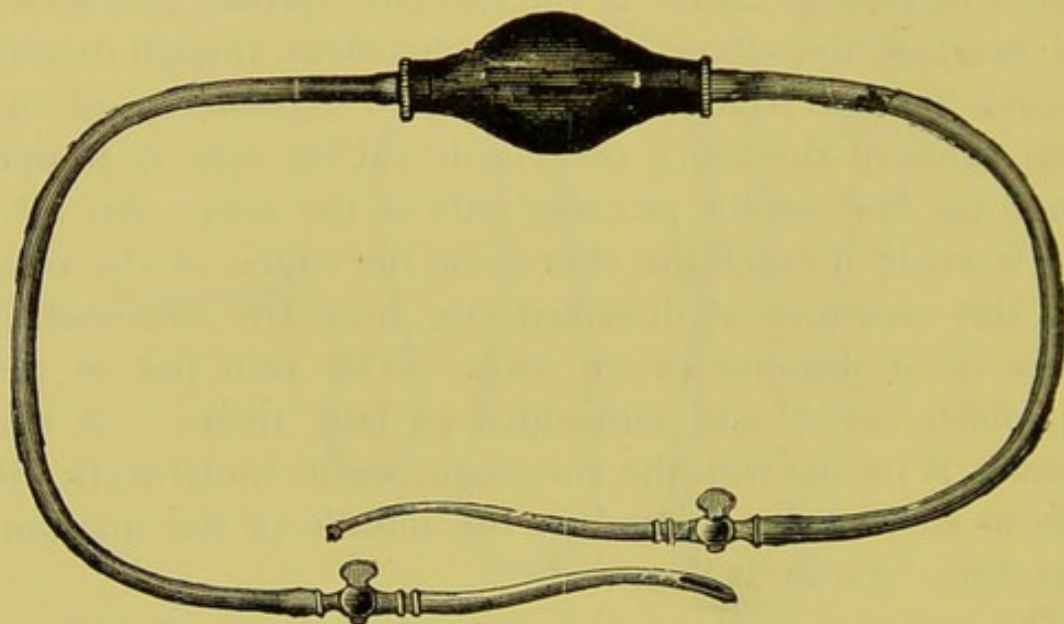


FIG. 228.—Apparatus for direct transfusion. It consists of two glass or metal cannulae with stopcocks, and connected by a rubber tube, in the middle of which is a dilatation which serves as an injection pump.—Aveling.

whom it is taken, the “giver.”) This is called the *direct* method of transfusion: the *indirect* method is, when blood is taken from an individual, defibrinated, and then injected into the vein of the “receiver,” according to the method described in the preceding operation.

Direct transfusion.—For this purpose the instrument illustrated in Fig. 228 will be found most convenient.

The veins of the “giver” and “receiver” are exposed in the manner described above, and a cannula inserted into each. Before inserting the cannulae they should be filled

with a warm solution of sodium chloride. The rubber reservoir is then filled with a similar solution, and the extremities of the tube fixed to the cannulæ. The stop-cocks are turned on, and the tube on the side of the "giver" pinched by an assistant. The rubber reservoir is then compressed so as to drive the fluid in its interior into the vein of the "receiver." Next, the tube on the side of the "receiver" is compressed, that on the side of the "giver" relaxed, and the reservoir allowed to expand, and become filled with blood. The tube on the side of the "giver" is then compressed, that on the side of the "receiver" relaxed, and the reservoir again forcibly compressed.

This proceeding drives the blood within the reservoir into the veins of the "receiver." The reservoir is usually made to contain 2 drms. This alternate compression and relaxation is repeated until a sufficient amount of blood has been transferred from the veins of the "giver" to those of the "receiver."

CHAPTER XVII.

OPERATIONS UPON NERVES.

THE surgical operations which are performed upon the nerve trunks or branches in their continuity may be divided into five groups :—

- (a) Suture of divided nerves, or neurorrhaphy.
- (b) Nerve stretching.
- (c) Division of a nerve, or neurotomy.
- (d) Excision of a portion of a nerve, or neurectomy.
- (e) Excision of ganglia.

In order to perform these different operations, it is necessary, in the first place, to fully expose that portion of the nerve trunk upon which it is proposed to operate. In this chapter the general principles to be observed in performing these operations will be first described, and afterwards the methods of exposing the individual nerve trunks.

General considerations.—Operations upon nerve trunks are generally necessary either on account of an injury to a nerve or to the adjacent tissues, or owing to the formation of a tumour in connection with a nerve, or the involvement of a nerve by the extension of a malignant growth from the neighbourhood. Occasionally it is necessary to divide the sensory nerve supplying an organ which has become the seat of a malignant growth, as in epithelioma of the tongue, in order to relieve the excessive pain from which the patient is suffering. Division or even excision of a portion of a sensory nerve may be required in some cases of intractable

neuralgia. Motor nerves may require division in some cases of severe muscular contraction depending upon an affection of the nerve or of the corresponding centre, as in some forms of wryneck, when it may be necessary to divide the spinal accessory nerve.

Whenever a nerve trunk has been divided by an injury, it is advisable to expose the severed ends and make an attempt to unite them.

Nerve ganglia, such as the Gasserian ganglion, have been excised with the view of curing intractable neuralgias, which have proved non-amenable to less severe forms of treatment.

Primary tumours of nerves are not common, but neuromata, either true or of the nature of fibrous tumours, occur and require treatment.

It occasionally happens that a nerve trunk becomes involved in the callus formed in the repair of a fractured bone, in which case it may be necessary to expose the nerve, in order to free it from the new-formed tissue in which it has become embedded, or by which it has been pressed upon.

Suture of a divided nerve, or neurorrhaphy.—This procedure is rendered necessary when a nerve trunk has been divided by accident or otherwise. If the divided ends of the nerve are united by an operation, performed immediately after the division has occurred, it is called “immediate suture,” while if this is not done until some time afterwards the term “secondary suture” is applied.

Immediate suture.—In union of a nerve by immediate suture, the nerve is sought for in the wound and the two ends freely exposed, and if there has been any laceration or bruising of the divided nerve, the irregular tags are cut away so as to leave two clean ends which can be easily brought into exact apposition. When there has been much laceration, and it is found requisite to remove a portion of the nerve trunk, it may also be necessary to

free each of the divided ends for a short distance so as to facilitate their approximation. The two ends are next fixed in apposition by the introduction of several sutures of fine silk or catgut, the number of sutures varying according to the size of the nerve. A rounded needle or a small Hagedorn's needle is used for the introduction of the sutures. Each suture is passed through the entire nerve substance, about a third of an inch from the cut surface of each extremity, all the sutures being introduced before

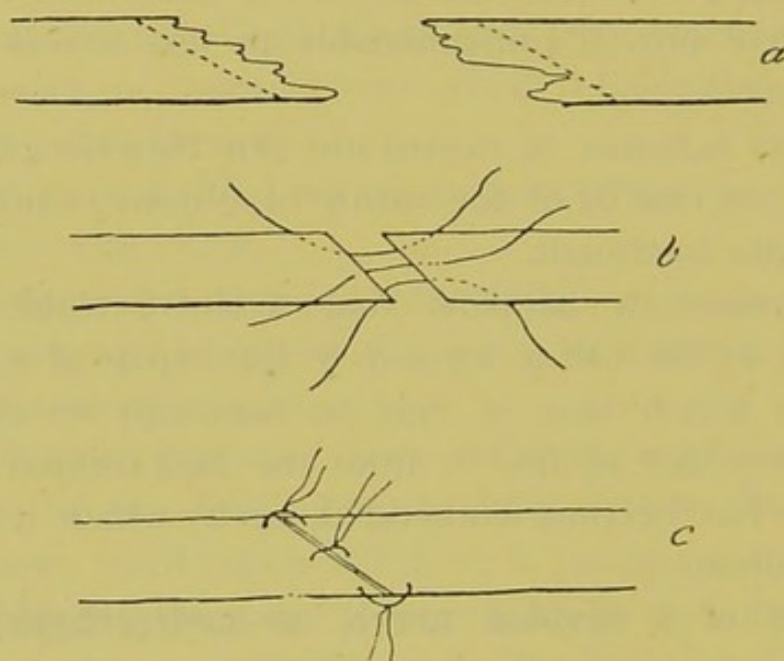


FIG. 229.—Primary suture of a divided nerve.

- a.* Divided nerve with lacerated extremities.
- b.* Extremities pared and sutures inserted ready for tying.
- c.* Ends approximated and sutures tied.

any are tied. When sufficient sutures have been put in, they are carefully tied and the ends cut short. The sutures must not be tied too tightly, or they will cut out; it is sufficient to tie them in such a manner that the cut surfaces are fixed in approximation. When this has been done, it is advisable if possible to put in several fine sutures through the fibrous tissue forming the sheath of the nerve. When the two ends of the nerve have been united in this way, the entire wound is thoroughly cleansed,

and closed with sutures in the usual manner. Care should be taken to approximate the tissues in the deep part of the wound, especially in the neighbourhood of the injured nerve, so as to avoid any undue tension which might tend to separate the sutured nerve-ends. In order to effect this, it will be found advisable in some cases to unite the deep part of the wound with several deep sutures.

Secondary suture.—In the union of a nerve by secondary suture, the divided ends are first exposed by an incision made through the overlying tissues in the long axis of the injured nerve. In many cases it is necessary to make a long incision, owing to the ends of the divided nerve having become separated or extensively involved in scar tissue.

The proximal end of the nerve is usually found to have become enlarged and bulbous, whilst the distal end is atrophied and embedded in the scar tissue. In some cases the distal end is very much shrunken, and appears as a fine thread. When considerable difficulty is experienced in locating the position of the distal end, it is advisable to expose the nerve a short distance beyond the point of division, and then to trace the trunk upwards. When the two ends of the nerve have been fully exposed, they are dissected free from the surrounding scar tissue, and cut across so as to lay bare areas of freshly cut nerve for approximation. The proximal end should be cut across just before the enlarged portion joins the healthy nerve trunk, care being taken that the section exposes healthy nerve bundles. A small portion only of the distal end is excised, generally about one-fourth or one-third of an inch, as in most cases the nerve fibres in this portion have undergone considerable degeneration. When the two ends have been prepared in this manner, they are united according to the method described in connection with "immediate suture." In cases of secondary suture there is more scar and fibrous tissue in the sheath of the nerve, and on this account it is easy to fix the two ends

in apposition. When the ends have retracted and are separated from one another by a short interval, it is necessary to free the nerve both proximally and distally for a short distance, before the two ends can be approximated without exerting undue tension.

When the ends of a divided nerve are embedded in much scar tissue, or the nerve has been extensively lacerated at the time of the injury, it may be impossible

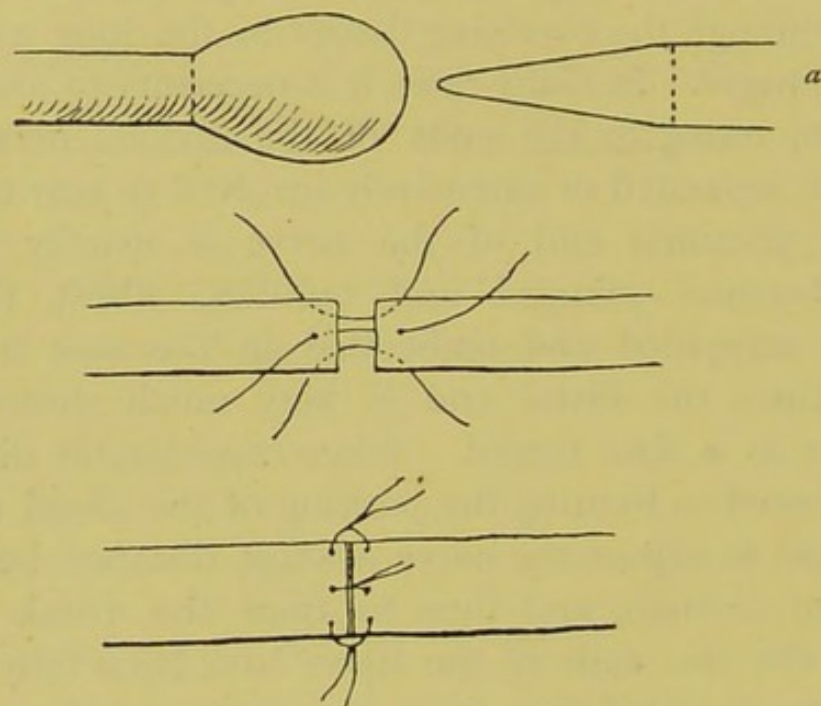


FIG. 230.—Secondary suture of a divided nerve.

- a.* Divided nerve with proximal end enlarged and bulbous, and distal end attenuated.
- b.* Nerve pared and sutures inserted ready for tying.
- c.* Suture completed.

to bring the prepared extremities into apposition by the above procedure.

When this condition is met with, an attempt may be made to approximate the divided extremities by splitting the more healthy segment a short distance from the cut end and turning down a piece of nerve tissue. This piece is fixed to the other end, in the manner described above.

If the loss of nerve substance is so extensive that the

exposed ends cannot be brought together by nerve splitting, an attempt may be made to bring about restoration of the functions of the nerve by introducing into the gap a piece of nerve from an animal, or from the amputated limb of another patient.

Nerve-stretching. — When the nerve trunk which it is desired to stretch has been fully exposed, according to the methods described in connection with individual nerves, it is carefully separated from the surrounding tissue and lifted up in the wound. In the case of the large nerves, such as the great sciatic, the finger and thumb are used for stretching, whilst in the case of small nerves a blunt hook of suitable size will be found most convenient. When the nerve has been seized with the finger and thumb, or a hook has been placed underneath it, steady tension, gradually applied, is exerted, the amount of tension varying with the size of the nerve. Thus, when the large sciatic is being stretched, a force of 30 lbs. may be exerted, while for a small nerve, such as the supratrochlear, not more than half a pound should be employed. The tension is exerted first on the proximal portion for about two to five minutes, and then for a similar period on the distal section. When the nerve has been stretched in this manner, it is replaced in its former position, and the external wound closed.

Division of a nerve, or neurotomy.—

This operation may be performed either through an open incision or subcutaneously. In the great majority of cases



FIG. 231. — Blunt hook, suitable for stretching a small nerve.

it is preferable to adopt the former method. The nerve trunk is exposed in the usual manner, and then cut across either with the scalpel or scissors.

Excision of a portion of a nerve, or neurectomy.—This operation is similar to the preceding, with the exception that a larger portion of the nerve is exposed, and a small piece removed by cutting through the nerve in two places, and taking away the intervening part.

Neurectomy and neurotomy are operations which are performed only on small sensory nerves, such as the supra-orbital; but large branches are divided, in exceptional cases, such as cancer of the tongue and severe intractable neuralgia of the fifth nerve.

In all cases of operations upon nerves, care must be taken not to seize the nerve trunk with forceps or similar instruments, as this always leads to bruising of the nerve fibres.

Excision of nerve ganglia.—Removal of a nerve ganglion, together with the adjacent portions of the nerve trunk with which it is connected, has been practised for the relief of some forms of severe neuralgia, which are not amenable to milder forms of treatment. The Gasserian ganglion and Meckel's ganglion have been removed for intractable neuralgia of the second or third divisions of the fifth cranial nerve. In some cases very good results have followed the performance of the operation, but the comparative value of these procedures has not yet been decided.

EXPOSURE OF INDIVIDUAL NERVES.

The fifth cranial nerve—The supra-orbital nerve.—This nerve is one of the cutaneous branches of the first division of the fifth. It passes out from the orbit through the supra-orbital foramen or notch, which can be felt at the junction of the inner with the middle third of the superior margin of the orbit.

Position.—The patient lies in the dorsal position, with his

head supported by a pillow; the surgeon stands at the head of the patient, and his assistant opposite to him.

Operation.—The eyebrow having been shaved, an incision not quite an inch in length is made along the supra-orbital margin, the centre being opposite to the point of exit of the nerve. The skin, fascia, and fibres of the orbicularis palpebrarum muscle are divided in the line of the incision, and then the nerve will become visible, lying upon

the bone just beyond the notch or foramen, in company with the supra-orbital artery. The nerve may be found to have already divided into two branches at the point where it emerges from the notch or foramen. The nerve is next separated from the vessel, and can then be stretched. Care must be taken in

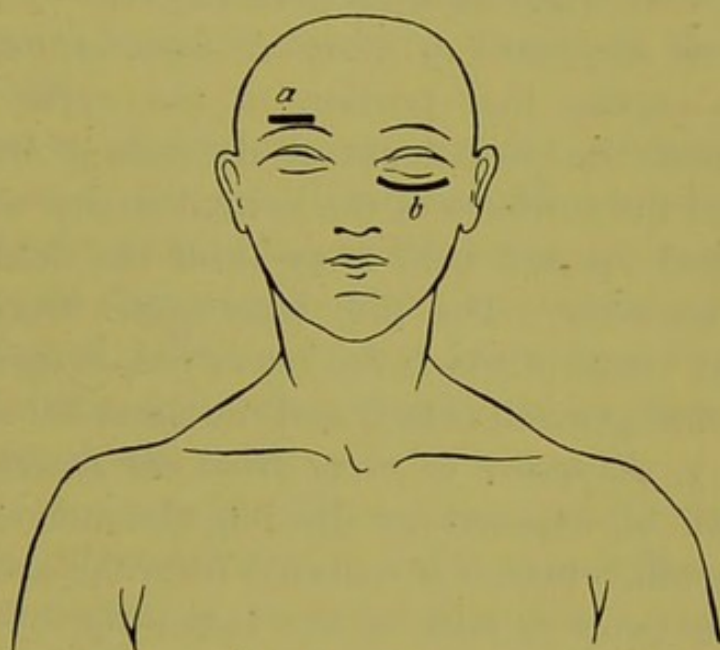


FIG. 232.—Exposure of supra-orbital and infra-orbital nerves.

- a.* Incision for supra-orbital nerve.
- b.* Incision for infra-orbital nerve.

this operation not to divide the nerve as it lies upon the bone.

The infra-orbital nerve.—The infra-orbital nerve emerges through the infra-orbital foramen, which is situated directly below the middle of the lower margin of the orbit. It passes from the speno-maxillary fossa along the floor of the orbit to reach the infra-orbital foramen.

Operation.—1. *Exposure of nerve on face by incision through cheek.*—The patient is placed in the same position as for exposure of the supra-orbital nerve; the surgeon

stands on the affected side of the head, and the assistant opposite to him.

An incision about 1 in. in length is made along the lower margin of the orbit, the centre of the incision being opposite to the foramen (Fig. 232, *b*). The skin, fascia, lower fibres of the orbicularis palpebrarum, and the attachment of the levator labii superioris are divided, and the nerve sought for where it emerges as several branches from the foramen.

2. *Exposure of nerve in infra-orbital canal.*—In order to expose that portion of the nerve which lies in the canal, the periosteum of the floor of the orbit is detached, and the contents of the orbital cavity with the periosteum lifted up and held away from the field of operation with a retractor. The thin bony plate which forms the roof of the canal in which the nerve lies, is carefully removed with a fine grooved chisel, and the nerve lifted up from its bed.

3. *Exposure of nerve from the mouth.*—The nerve may also be exposed by dividing the mucous membrane of the mouth, where it is reflected from the alveolar process on to the inner surface of the upper lip of the affected side. When this has been done, the structures which lie superficially are separated from the bone with a periosteal elevator, until the foramen is reached and the nerve exposed. The advantage of this method of operating is the absence of a visible scar.

Removal of Meckel's ganglion, and division of the second division of the fifth nerve in the spheno-maxillary fossa.—This operation has been carried out—(*a*) Through an incision below the margin of the orbit, and then chiselling a hole through the superior maxilla, opening the antrum, and extending the wound into the spheno-maxillary fossa by removing a portion of the posterior wall of the antrum; and also (*b*) by a deep dissection of the pterygoid region, after the zygoma has been exposed, divided, and turned downwards.

The results which have followed these operations do not appear to have been very favourable, and on this account it is doubtful if they can be said to be justifiable.

The auriculo-temporal nerve.—This nerve is one of the branches of the third division of the fifth. It passes upwards over the root of the zygoma in company with, and immediately behind, the superficial temporal artery.

It can be exposed by an incision similar to that described for the superficial temporal artery (p. 309, Fig. 197, *b*).

The lingual nerve.—This nerve is also a branch of the third division of the fifth.

It can be exposed as it lies underneath the mucous membrane of the floor of the mouth, about half an inch below and behind the last molar tooth of the lower jaw, and also in the upper part of the incision which was described for ligature of the lingual artery. In the latter case the nerve will be found lying upon the hyoglossus, a short distance above the hypoglossal nerve.

Operation (through the mouth).—The patient is placed in the dorsal position, the mouth being held open with a gag, and the tongue drawn to the opposite side. The surgeon stands in front of the open mouth.

The nerve can generally be felt with the finger, as it lies underneath the mucous membrane. An incision, about an inch in length, is made through the mucous membrane on the floor of the mouth in an antero-posterior direction, and situated about half-way between the side of the tongue and the inner surface of the jaw. With a blunt hook the nerve is lifted up from the connective tissue which surrounds it, and may be divided with a pair of scissors, or a small portion may be excised.

The facial (seventh cranial) nerve.—This nerve issues from the cranium through the stylo-mastoid foramen, and then passes downwards and forwards in the substance of the deep part of the parotid gland. It can be exposed immediately beyond its point of emergence.

Position.—The patient lies on the back, with the head turned over towards the unaffected side. The surgeon stands on the affected side of the patient, and his assistant opposite to him.

Operation.—An incision, about $1\frac{1}{2}$ in. in length, is made, commencing above at the anterior margin of the mastoid process and opposite the external auditory meatus, and extending downwards to a point just behind the angle of the lower jaw. The skin, superficial and deep fasciæ are divided, and the anterior border of the sterno-mastoid and the posterior margin of the parotid gland exposed. The former is retracted backwards, and the latter forwards. On dividing the connective tissue between these two structures, the posterior belly of the digastric muscle will become visible. This is drawn downwards, and then the facial nerve will be found in the upper part of the wound. In this position the nerve is surrounded by dense fascia, and careful dissection is necessary to expose it without injury. The posterior auricular artery and vein may be met with, in which case they are drawn aside with a retractor.

The spinal accessory (eleventh cranial) nerve.—The spinal accessory nerve emerges from the cranium through the middle compartment of the jugular foramen in company with the vagus. From this point it passes in a downward and backward direction, crossing the internal jugular vein and the transverse process of the atlas, until it reaches the anterior border of the deep portion of the sterno-mastoid muscle, which it enters at the junction of the upper with the second fourth. It emerges from this muscle a little below the junction of the upper with the middle third, and then crosses the posterior triangle to reach the trapezius, into the deep aspect of which it enters. The nerve can be exposed either before or after it pierces the sterno-mastoid muscle. The operation for exposure of the nerve is usually undertaken for wry-neck, in which case the nerve must be laid bare above the point at which it enters the sterno-mastoid.

Position.—The patient is placed in the dorsal position, with the head and shoulders slightly raised by means of a pillow, and the head turned towards the unaffected side and thrown slightly backwards.

Operation.—An incision about $2\frac{1}{2}$ in. long is made along the anterior border of the sterno-mastoid, commencing above at the apex of the mastoid process. The skin, superficial fascia, and deep fascia are divided for the entire length of the incision, by which means the external surface of the sterno-mastoid is exposed. The anterior border of this muscle is defined, and the head is bent forwards a little so as to allow of retraction of the muscle and exposure of the fascial sheath behind. When this has been done, the posterior part of the sheath is divided in the line of the original incision, and the nerve carefully sought for as it enters the muscle.

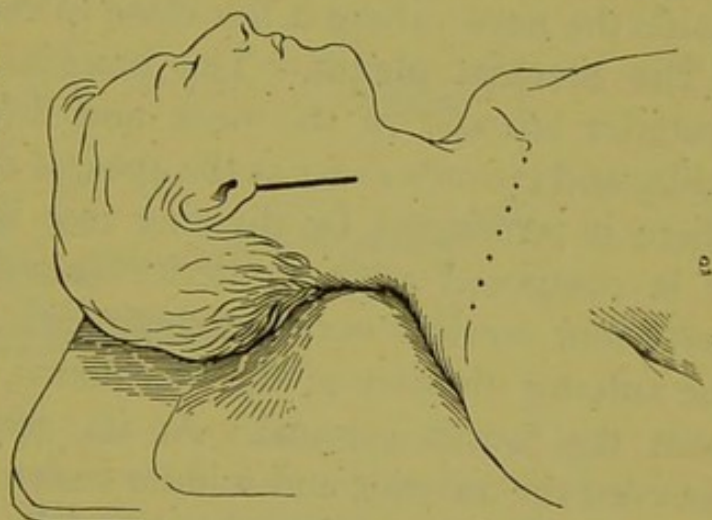


FIG. 233.—Exposure of spinal accessory nerve.
Position of skin incision.

The nerve can often be felt as a rounded cord immediately below and external to the transverse process of the atlas. If the nerve is not readily found, the inferior border of the posterior belly of the digastric muscle should be defined, and the nerve sought for in the space between this muscle and the sterno-mastoid. The fascia in this region is dense, and careful dissection is necessary.

The great occipital nerve.—This nerve is a cutaneous branch of the posterior division of the second cervical, and passes into the scalp through the outer margin of the trapezius muscle where it is attached to the superior curved line of the occipital bone.

Operation.—The patient lies in the same position as for exposure of the spinal accessory nerve, but with the head bent downwards towards the chest.

An incision about $1\frac{1}{2}$ in. long is made parallel with the superior curved line of the occipital bone, commencing a short distance outside the external occipital protuberance. The skin and fasciæ are divided, and then the nerve will become visible lying above and internal to the interval between the sterno-mastoid and trapezius, and on the mesial side of the occipital artery. The surrounding fascia is very dense; on this account care must be taken not to divide the nerve where it lies close to the bone.

The brachial plexus.—The brachial plexus lies in the posterior triangle of the neck and the upper part of the axilla, and extends as far as the apex of the coracoid process, where it terminates by dividing into its various branches. It is composed of the anterior primary divisions of the lower four cervical nerves, together with the greater part of the anterior division of the first dorsal, and a small branch from the fourth cervical. At its commencement it lies between the anterior and middle scalene muscles.

Position.—The patient is placed in the dorsal position, with the shoulders raised, the head turned towards the unaffected side, and the arm drawn well down by the side of the body. The operator stands on the affected side of the patient, and the assistant on the opposite side.

Operation.—An incision, about 3 in. in length, is made, commencing above at the outer margin of the sterno-mastoid, at the level of the notch in the thyroid cartilage, and extending downwards to a point a short distance above the centre of the clavicle. The skin and superficial fascia with the platysma are divided, and the external jugular vein defined. In most cases it is necessary to ligature this vessel in two places, and divide it between, but occasionally it can be drawn aside. The deep fascia is next divided for the entire length of the incision, the supraclavicular nerves

being avoided if possible. In the lower part of the wound the posterior belly of the omo-hyoid muscle will be exposed, and at the inner margin the outer border of the scalenus anticus. The former muscle is drawn downwards, and the fascia carefully separated from the cords of the plexus as they appear at the outer margin of the scalenus anticus. The superficial branch of the transverse cervical artery, and its accompanying vein, lie in front of the plexus in the outer part of the incision.

The musculo-spiral nerve.—This nerve is given off from

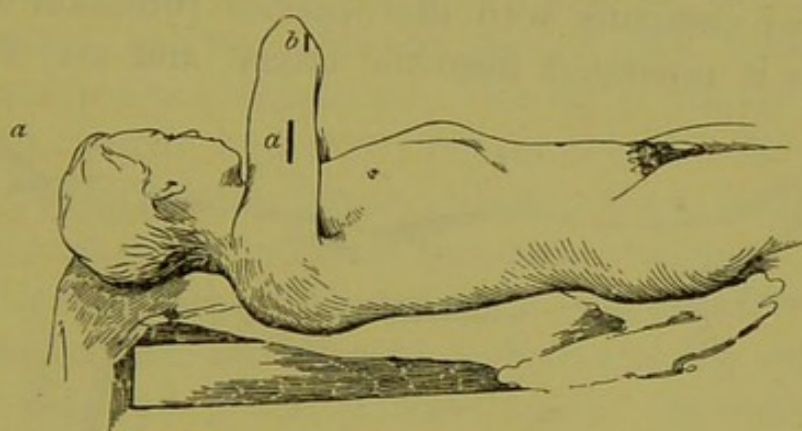


FIG. 234.—Position of patient, and lines of external incisions, in exposure of musculo-spiral nerve in the musculo-spiral groove, and of ulnar nerve behind the internal condyle of the humerus.

a. Musculo-spiral.

b. Ulnar.

the posterior cord of the brachial plexus opposite the coracoid process. From this point it first passes downwards behind the axillary artery, and at the upper part of the arm it begins to wind outwards in the musculo-spiral groove, in company with the superior profunda artery. In the lower third of the arm it pierces the external inter-muscular septum, and lies in front of the brachialis anticus, overlapped by the supinator longus. The nerve may be exposed in the musculo-spiral groove, and also in the lower third of the arm where it lies upon the brachialis anticus.

(*a*) *In the musculo-spiral groove.* — *Position.* — The patient lies in the dorsal position; the upper arm is placed

vertically, the elbow is fully flexed, and an assistant holds the limb in this position (Fig. 234). The operator stands on the affected side, and his assistant at his left hand.

Operation.—An incision, 3 in. in length, is made in the middle third of the posterior aspect of the upper arm, parallel with the long axis of the limb. The skin, superficial fascia, and deep fascia are divided for the whole length of the incision, and the triceps muscle exposed. This structure is divided in a vertical direction until the musculo-spiral groove is reached, when the nerve will be found lying upon the bone in company with the superior profunda vessels. The nerve is separated from the artery, and may then be

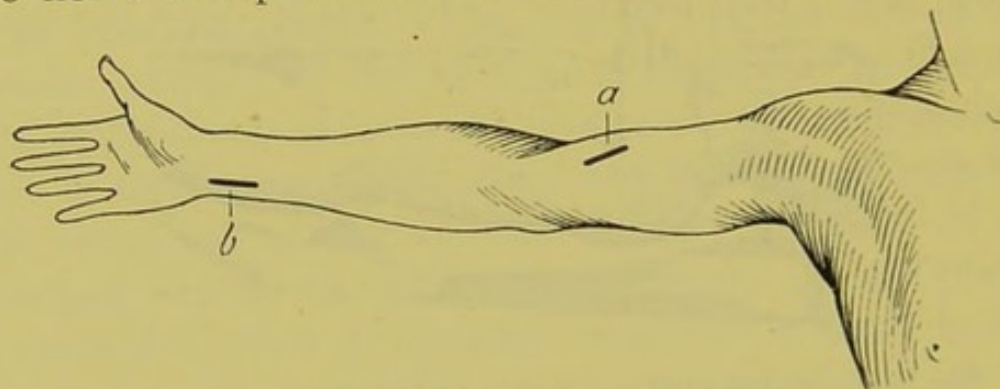


FIG. 235.—Position of limb and lines of external incisions in exposure of musculo-spiral nerve above the bend of the elbow, and ulnar nerve at the wrist.

a. Musculo-spiral. | *b.* Ulnar.

stretched. If care is not taken in the later stages of the operation, the nerve may be divided as it lies upon the bone.

(*b*) *In front of the arm above the bend of the elbow.*—*Position.*—The arm is placed at right angles to the side, supinated, slightly flexed at the elbow, and supported on a table.

Operation.—An incision is made, about 3 in. in length, commencing an inch above a point one-third of the distance from the external to the internal condyle of the humerus, and extending upwards parallel with the outer margin of the biceps (Fig. 235, *a*). The skin and fasciæ are divided, and the fibres of the supinator longus muscle exposed. This muscle is retracted towards the outer side, when the nerve

will become visible lying on the brachialis anticus, a short distance below the point where it has pierced the external inter-muscular septum. The cutaneous portion of the musculo-cutaneous nerve may be met with, in which case it is drawn aside with a retractor.

The ulnar nerve.—This nerve is a branch of the internal cord of the brachial plexus. In the upper part of the upper arm it lies on the inner side of the brachial artery, but separated from it by the internal vena comes and some connective tissue. The course of the nerve in the upper arm is indicated by drawing a line from the coracoid process to a point half-way between the internal condyle of the humerus and the olecranon. The nerve passes behind the internal condyle and down the forearm to the radial side of the pisiform bone, beyond which point it enters the palm and divides into superficial and deep branches. Its course in the forearm is marked out by a line drawn from a point midway between the internal condyle and the olecranon, to the radial side of the pisiform bone. In this part of its course the nerve lies underneath the flexor carpi ulnaris, until it reaches the region of the wrist, where it becomes more superficial.

1. *To expose the nerve in the middle of the upper arm.*—

Position.—The patient is placed in the dorsal position, with the arm at right angles to the side, and supinated. The operator stands between the limb and the trunk, and the assistant on the outer side of the limb.

Operation.—An incision, 2 in. in length, is made in the middle third of the arm, parallel with the line of the brachial artery, and about half an inch to its inner side (Fig. 236, a). The skin, the superficial fascia containing the basilic vein, and the deep fascia are divided, and the nerve exposed as it lies on the inner side of the internal vena comes of the brachial artery.

2. *To expose the nerve at the bend of the elbow.*—*Position.*—The patient is placed in the dorsal position, the affected

arm is semiflexed at the elbow, and drawn across the chest so as to fully expose the posterior aspect of the bend of the elbow (Fig. 234, *b*).

Operation.—An incision, $1\frac{1}{2}$ in. in length, is made over the course of the nerve, the central point being half-way between the internal condyle and the inner margin of the olecranon (Fig. 236, *b*). This incision divides the skin and the superficial and deep fasciæ, and exposes the two heads of origin of the flexor carpi ulnaris muscle. The aponeurosis which connects these two heads is incised, and then the nerve will be found lying in the groove behind the internal condyle and upon the posterior ligament of the elbow-joint. If the incision is deepened too much, the cavity of the elbow-joint will be opened. The ulnar artery is a considerable distance from the nerve in this region.

3. *To expose the nerve in front of the wrist.*—The position of the patient is the same as for exposure of the nerve in the upper arm, the hand being well supinated.

Operation.—An incision, $1\frac{1}{2}$ in. in length, is made over the line of the nerve, commencing below on the radial side of the pisiform bone, and extending upwards on the radial side of the tendon of the flexor carpi ulnaris (Fig. 235, *b*). The skin and fasciæ are divided, and then the nerve will be visible, having the ulnar artery on its radial side.

The median nerve.—This nerve commences opposite the coracoid process by two heads, one from the inner and one from the outer cord of the brachial plexus, and passes downwards in the upper arm, lying first on the outer side of the brachial artery, then in front of it, and finally on its inner side. At the bend of the elbow it is separated from the artery by the internal vena comes. The nerve next sinks between the two heads of the pronator radii teres, and then runs downwards to the middle of the wrist, beyond which point it enters the palm and divides into its terminal branches.

Operation.—1. *In the upper arm.*—The nerve may be

exposed in the upper arm by an incision which is the same as for ligature of the brachial artery (Fig. 204, *b*).

2. *At the bend of the elbow.*—At the bend of the elbow it may be exposed by making an incision, $1\frac{1}{2}$ in. in length, parallel with the long axis of the limb, the centre of the cut corresponding to a point one-third of the distance from the internal to the external condyle of the humerus (Fig. 236, *b*). The skin, superficial and deep fasciæ are divided, care being taken to avoid the superficial veins and the internal cutaneous nerve; the nerve will then be exposed as it lies on the brachialis anticus to the inner

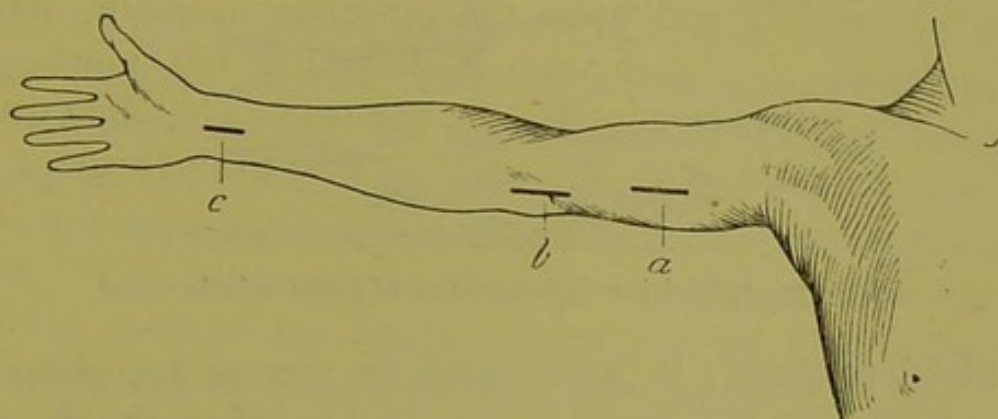


FIG. 236.

- | | |
|----|--|
| a. | Incision to expose ulnar nerve in middle of upper arm. |
| b. | „ „ median nerve at bend of elbow. |
| c. | „ „ median nerve at wrist. |

side of the brachial artery, but separated from this by the internal vena comes. The deep fascia in this region is strengthened by the bicipital fascia from the biceps.

3. *At the wrist.*—The median nerve may also be exposed in front of the wrist.

An incision, $1\frac{1}{2}$ in. in length, is made, commencing below opposite the middle of the anterior aspect of the wrist, and extending upwards on the ulnar side of the tendon of the flexor carpi radialis (Fig. 236, *c*). When the skin and fasciæ and the upper fibres of the anterior annular ligament have been divided, the nerve will appear as a large rounded cord, somewhat pinkish in colour, lying to the ulnar side of the tendon of the flexor carpi radialis and

underneath the palmaris longus tendon when this is present. At this point the nerve is usually enlarged and fusiform in shape.

The great sciatic nerve.—This nerve is the main continuation of the sacral plexus. It emerges from the pelvis below the pyriformis muscle, and extends towards the popliteal space, ending by dividing into its two terminal branches, the peroneal and popliteal nerves. The point

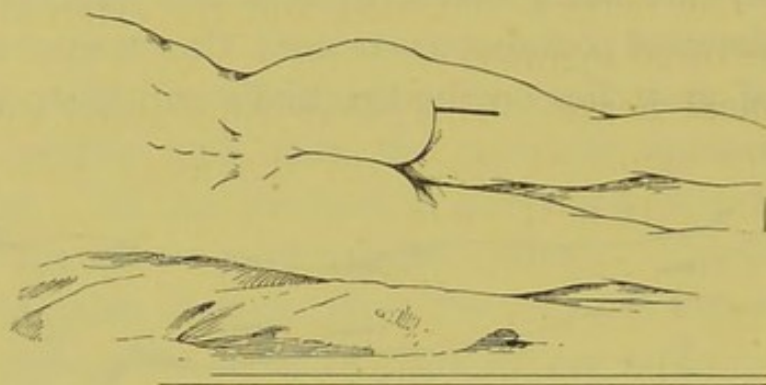


FIG. 237. — Incision for exposure of great sciatic nerve.

of division varies; in some cases the nerves are given off separately from the sacral plexus, and in others the division occurs in the upper part of the popliteal space. The nerve lies upon the short external rotator muscles of the thigh, and lower down upon the posterior aspect of the adductor magnus. The gluteus maximus covers the nerve above, and the hamstrings below. It is usually exposed immediately below the lower margin of the gluteus maximus.

Position.—The patient lies on the sound side, with the affected lower extremity slightly flexed at the hip and knee. The surgeon stands opposite the exposed buttock, and the assistant on his left hand.

Operation.—An incision, $3\frac{1}{2}$ in. in length, is made, commencing above a short distance below the midpoint between the ischial tuberosity and the top of the great trochanter, and extending vertically downwards (Fig. 237); the skin, the superficial fascia in which in the lower part of the incision the small sciatic nerve is contained, and the deep

fascia are divided, when in the upper part of the wound the oblique fibres of the lower portion of the gluteus maximus will be exposed. These are retracted upwards, and then the hamstring muscles will be seen on the inner side of the incision. These structures are retracted inwards, and the bottom of the wound examined with the finger. The great sciatic nerve will then be felt as it lies upon the adductor magnus, and can easily be lifted up in the wound and stretched. The nerve is returned, and the external wound closed in the usual manner.

The peroneal nerve.—This nerve runs along the outer margin of the popliteal space on the inner side of the biceps tendon. It next pierces the postero-external inter-muscular septum, and lies upon the neck of the fibula, underneath the fibres of the peroneus longus muscle, where it divides into the anterior tibial and musculo-cutaneous nerves. The nerve can be felt as a rounded cord lying upon the neck of the fibula, and also to the inner side of the biceps tendon, especially when the knee is extended.

Position.—The patient lies on the sound side, with the affected limb slightly flexed at the hip and knee, so that it rests on the sound one. The surgeon stands behind the limb to be operated upon, and his assistant opposite to him.

Operation.—An incision, 2 in. in length, is made, commencing above at the lower border of the head of the fibula, and extending downwards in the long axis of that bone. This incision divides the skin, superficial fascia, and deep fascia, and exposes the outer surface of the peroneus longus muscle. This muscle is divided for the entire length of the incision, and then the nerve will be exposed as it lies upon the bone. Care must be taken, when dividing the muscle, not to divide the nerve as well.

The anterior tibial nerve.—This can be exposed from the front of the leg by an incision similar to that described for the corresponding artery (p. 354).

The popliteal nerve.—The popliteal nerve can be exposed in the lower part of the popliteal space, through an incision similar to that for ligature of the popliteal artery in this region (p. 349).

The posterior tibial nerve.—This nerve runs down the leg in company with the corresponding artery, and it can be laid bare by operations similar to those described for the artery (p. 350).

The anterior crural nerve.—This nerve passes out from the pelvis through the muscular space beneath Poupart's ligament, lying upon the ilio-psoas muscle half an inch to the outer side of the common femoral artery, from which it is separated by the ilio-pectineal ligament, and a few fibres of the psoas muscle.

Position.—The patient is placed in the same position as for ligature of the common femoral artery.

Operation.—An incision 2 in. long is made half an inch outside the artery, and parallel with it. The incision commences above, at Poupart's ligament. The skin, superficial and deep fasciæ are divided, and then the nerve may be found lying upon the ilio-psoas muscle, surrounded by a variable amount of fatty connective tissue. In many cases it is difficult to distinguish the nerve on account of this fat.

CHAPTER XVIII.

OPERATIONS ON TENDONS, MUSCLES, LIGAMENTS, AND APONEUROSES.

THE division of a tendon by a surgical operation is called tenotomy; that of a muscle, myotomy; of a ligament, syndesmotomy; whilst the term aponeurotomy has been applied to the division of bands of fascia.

These operations may be performed according to two distinct methods of procedure; in the first, the entire operation is carried out subcutaneously through a small skin incision; and in the second, an open wound is made so as to fully expose the structure which it is wished to divide. When an operation is performed according to the first of the above methods, it is said to be done "subcutaneously," and when done according to the second, "by the open method."

The subcutaneous method.—The advantages of this operation are—(a) The small wound which is necessary, and the avoidance of a scar; (b) the small amount of risk of the wound becoming infected with the micro-organisms of suppuration. The disadvantage is, the fact that the surgeon is working somewhat in the dark, on which account important structures in the region of the field of operation may be injured, or the tendon which it is proposed to divide may be missed altogether.

The open method.—When performing an operation by this method, an incision large enough to fully expose the anatomical structure which it is wished to deal with, is

made in the situation required. The advantages of this method of procedure are the free exposure of the tissue which it is intended to operate upon, and the lesser liability to injure the adjacent structures; whilst the disadvantages are the resulting scar and the dangers of sepsis. With the aseptic precautions which ought to be adopted in all surgical operations, the last objection need not be taken into serious consideration. In those cases in which the tendon, muscle, or ligament is deeply placed, or is in close relation with important anatomical structures, it is advisable to adopt the open method; but in cases in which the tendon is easily defined and separated from its surroundings, the subcutaneous method is preferable, and should be made use of.



FIG. 238.—Sharp-pointed tenotome.

Instruments.—When performing an operation by the subcutaneous method, two special knives called tenotomes are requisite, one having a sharp point and the other a blunt one; whilst for the open operation the ordinary instruments for a “cutting operation” are necessary.

Method of operating.—In performing an operation by the subcutaneous method, a point in the course of the tendon is selected, which lies, if possible, above or below any synovial sheath, and on the same side of the tendon as the most important anatomical structure which might be exposed to injury. The sharp tenotome is then pushed inwards so as to pass behind the structure which it is intended to divide, the tendon being slightly stretched so that its position can be defined. The

blade of the tenotome is introduced "on the flat," and the tissues are divided sufficiently to allow the blunt instrument to be easily introduced. The sharp tenotome is withdrawn, and the blunt-pointed one passed in through the original skin puncture with the blade "on the flat." When it has been introduced, the cutting edge is turned towards the tendon, the tendon itself is made tense by the assistant holding the limb, and the structure is divided with a sawing movement, care being taken not to enlarge the skin puncture. The index finger of the surgeon's left hand is held over the tendon where it is being divided, so that the movements of the instrument can be felt and cutting through the skin avoided.

In a few cases, such as the division of bands of contracted fascia which lie near the surface of the skin and away from any important structure, the entire operation can be completed with the sharp tenotome, but in nearly all other cases it is much safer to use the blunt-pointed instrument as well.

SPECIAL OPERATIONS.

Tenotomy of the sterno-mastoid.—The sterno-mastoid muscle is attached by two heads of origin, one—tendinous—to the upper part of the sternum, and the other—muscular—to the upper border of the inner third of the clavicle. It is enclosed within a sheath of deep cervical fascia. Along the inner border of the sternal head lies the anterior jugular vein, and in relation with the clavicular head lies the external



FIG. 239.—Blunt-pointed tenotome.

jugular vein. The carotid sheath with its contents is situated directly behind the muscle, but portions of the sterno-hyoid and sterno-thyroid muscles intervene. The two heads of the muscle are divided separately, through different incisions.

Position.—The patient is placed in the dorsal position, with a pillow underneath the shoulders, and with the head projecting slightly beyond the top of the table. The head is rotated towards the unaffected side by an assistant, who holds it in this position so as to keep the muscle on the stretch.

The surgeon stands upon the affected side of the patient, and the assistant on the opposite side.

Operation.—An incision with the point of a sharp tenotome is made at the inner border of the sternal head of the muscle, about one-third of an inch above the sternum, and deepened until the deep fascia has been divided and the tendon of the muscle exposed. The sharp instrument is then withdrawn, and the blunt one introduced. The tenotome is now carefully pushed behind the tendon, with the blade "on the flat," until it can be felt in the interval between the two heads of the muscle. The cutting edge of the knife is now turned towards the skin, and the muscle divided with a slight sawing movement. The forefinger, during the division of the tendon, is kept over the skin in front of the field of operation. The clavicular head of the muscle is next divided in a similar manner, by entering the tenotome at the outer border of the muscle, about one-third of an inch above the clavicle. Care must be taken in this part of the operation not to injure the external jugular vein.

On account of the close proximity of important structures, some surgeons advise that the sterno-mastoid should only be divided through an open incision.

The adductor longus.—This tendon may be divided a short distance below its attachment to the body of the os pubis.

Position.—The lower extremity is placed in a position of semiflexion, abduction, and external rotation.

The surgeon stands on the outer side of the limb to be operated upon, and the assistant on the opposite side.

Operation.—The outer margin of the tendon is defined about half an inch below the pubic spine, and the sharp tenotome introduced. When an aperture has been made, the blunt instrument is introduced, and the tendon divided by cutting towards the surface. A small branch of the superficial pudic artery may be injured, but usually the tendon is divided below this vessel.

The biceps femoris.—The tendon of the biceps femoris is usually divided a short distance above its insertion into the head of the fibula.

Position.—The patient lies as far as possible on the sound side.

The operator stands behind the patient, and the assistant on the other side.

Operation.—The position of the tendon is defined about an inch above the head of the fibula, along the outer border of the popliteal space. A point is selected on the tibial margin of the tendon, and with the thumb of the surgeon's left hand the peroneal nerve is separated from the tendon. The sharp tenotome is then taken, and a small puncture made which extends down to the surface of the tendon. The sharp tenotome is withdrawn, and the blunt one introduced. The handle of this instrument is depressed, and the blade insinuated underneath the tendon, which is then divided by cutting outwards with a sawing movement. It is possible to mistake the ilio-tibial band of the fascia lata for the tendon of the biceps muscle.

The semitendinosus and semimembranosus.—The tendons of these muscles may be divided by a procedure similar to that for the division of the biceps. They lie on the inner side of the popliteal space, and they are divided about an inch above the knee for the semitendinosus, and

half an inch for the semimembranosus. The tenotome is entered on the fibular side of the tendons. The popliteal nerve lies near the middle of the popliteal space, and is not likely to be injured.

The tendo Achillis.—The tendo Achillis is the tendon of insertion of the soleus and gastrocnemius muscles, and is attached to the prominence of the os calcis. The narrowest portion of the tendon is situated about 1 in. above its insertion, and it is at this point that the tendon is divided.

Position.—The patient is placed in the dorsal position, but lying somewhat on the side of the affected limb; the leg is allowed to project a short distance beyond the end of the table, and is turned on its outer side so as to fully expose its tibial aspect.

The surgeon stands on the outer side of the foot, and the assistant opposite to him, holding the foot with one hand and the leg with the other.

Operation.—The tendon is slightly stretched, so as to render its position definite, and the sharp tenotome entered at its tibial margin about 1 in. above the heel. The tenotome is made to pass in front of the tendon until it can be felt at the fibular margin. The sharp instrument is withdrawn and the blunt one introduced. The cutting edge is turned towards the tendon, and the foot fully flexed by the assistant, so as to make the tendon quite tense. The tendo Achillis is now divided with a slight sawing movement, the forefinger of the surgeon's left hand being held over the portion of the tendon which is being divided, so as to guard against injury of the overlying skin. Care must be taken to divide the entire tendon. It sometimes happens that the tenotome is passed through the tendon itself, in which case only the superficial part will be divided.

The tendon of the tibialis anticus.—This tendon lies in the innermost compartment of the anterior annular ligament of the ankle-joint, and it has a separate synovial sheath, which extends upwards about 1 in. or $1\frac{1}{2}$ in. above the

ankle, and downwards to within 1 in. of the insertion of the muscle into the tibial side of the internal cuneiform and the base of the metatarsal bone of the great toe.

The tendon is usually divided immediately below the synovial sheath, that is to say, not quite 1 in. above the insertion, and as it lies in relation with the scaphoid. It is separated from the dorsalis pedis vessels by the extensor proprius hallucis.

Position.—The surgeon stands on the outer side of the leg, which should project over the end of the table, the patient lying in the dorsal position. The assistant stands opposite, holding the foot with one hand and the leg with the other. The foot is abducted and extended, by which means the tendon is made tense, and can easily be defined.

Operation.—The tenotome is entered on the fibular side of the tendon, a short distance in front of the prominence of the scaphoid, and is made to pass underneath the tendon until it can be felt at the tibial margin. The tendon should be somewhat relaxed as the tenotome is being introduced. When a way has been made for the blunt instrument with the sharp one, the latter is withdrawn and the former introduced. The cutting edge is turned towards the tendon, and the tendon again made tense, and divided from behind forwards, the surgeon's left forefinger being placed over the skin so as to act as a guide and prevent his cutting through to the surface.

The tendon of the tibialis posticus.—The tendon of the tibialis posticus occupies the internal compartment of the internal annular ligament of the ankle-joint, and is surrounded by a synovial sheath, which extends upwards for about 1 in. above the tip of the internal malleolus. The tendon of the flexor longus digitorum lies in the next sheath, and separates it from the posterior tibial vessels and nerve.

The tendon is usually divided above the synovial sheath, that is, immediately above the base of the malleolus.

Position.—The patient lies in the dorsal position, with the foot held in a position of slight flexion and abduction, and placed upon the fibular side. The surgeon stands on the outer side of the limb, and the assistant, opposite to him, holds the foot in the required position.

Operation.—The posterior border of the internal malleolus is defined and traced upwards until the part of the shaft above the base of the malleolus is reached. This point in the adult is about $1\frac{1}{2}$ in. above the tip of the malleolus, but in young children it is not more than two-thirds of an inch above. When this point has been defined and the tendon felt, the foot is relaxed and the postero-internal border of the bone fixed with the thumb of the surgeon's left hand. The sharp tenotome is now passed inwards in a vertical direction between the tendon and the bone, and moved laterally so as to make a passage for the blunt instrument. When this has been done, the blunt tenotome is introduced and the cutting edge turned towards the tendon. The tendon is next made tense, by again flexing and abducting the foot, and divided in the usual manner. As the last fibres of the tendon are being divided, the foot is again relaxed by the assistant. If the tenotome is passed too deeply, it occasionally happens that the posterior tibial vessels are injured. If this accident should occur, pressure by means of a pad and bandage must be applied at once. In many cases the tendon of the flexor longus digitorum is divided as well.

The tendons of the peronei.—These tendons lie behind the external malleolus in a common groove, the peroneus longus being superficial and the peroneus brevis deep. They are surrounded in this position by a common synovial sheath, which extends upwards for about 1 in. above the base of the malleolus, and subdivides below into two portions, one for each tendon. The tendons are generally divided in the leg a short distance above the termination of the synovial sheath.

Position.—The patient lies on the sound side, with a sandbag placed underneath the lower third of the leg, and with the foot flexed and adducted. The foot rests on its tibial aspect, the fibular surface being in front of the surgeon. The operator stands behind the affected limb, and the assistant, opposite to him, holds the leg steady in the position mentioned.

Operation.—The posterior border of the external malleolus is traced upwards, and a point selected about $1\frac{1}{2}$ in. above the apex of the malleolus. The sharp tenotome is entered at this spot (the tendons being relaxed at the time), and made to pass inwards between the bone and the tendons. The sharp instrument is withdrawn, the blunt one introduced, and its edge turned away from the bone. The tendons are then rendered tense, and divided in the usual manner. The short saphenous nerve and vein are behind the tendons at the level of the point of division, and do not run any risk of being wounded if the above directions are adhered to.

The tendon of the extensor proprius hallucis.—This tendon lies in a separate compartment underneath the anterior annular ligament of the ankle-joint, surrounded by a distinct synovial sheath. The tendon is situated on the fibular side of the tibialis anticus and between it and the dorsal vessels of the foot. The tendon is divided a short distance below the bend of the ankle.

Position.—The patient lies in the dorsal position, with the affected foot projecting beyond the end of the table, where it is held in an extended position by the hands of an assistant. The operator stands on the outer side of the foot.

Operation.—A point on the fibular side of the tendon is selected about 1 in. below the bend of the ankle, and with the thumb of the surgeon's left hand the dorsal vessels are held well away from the seat of operation. The tenotome is entered on the fibular side of the tendon, and passed inwards

until its point can be felt between it and the tibialis anticus. The sharp tenotome is then replaced by the blunt one, and the tendon divided in the usual manner. There is no risk of injuring the dorsal vessels if they are protected with the thumb of the left hand.

The tendons of the extensor longus digitorum and peroneus tertius.—These tendons lie in the same compartment of the anterior annular ligament of the ankle-joint, and are surrounded by the same synovial sheath. The dorsalis pedis vessels lie on the tibial side. The tendons are divided 1 in. below the ankle-joint.

Position.—The position of patient and assistant are the same as for the preceding operation, but the surgeon stands on the tibial side of the affected limb.

Operation.—The dorsal vessels are protected with the surgeon's left thumb, and the tenotome entered on the tibial side of the tendons.

Division of the plantar fascia.—The plantar fascia is divided in certain cases of talipes, and in most instances it is the central portion which requires attention. This part is attached posteriorly to the internal tubercle of the calcaneum, while anteriorly it divides into four bands which pass to the four outer toes. The fascia is usually divided in several places, the first point of division being a short distance in front of the calcaneum.

Position.—The patient is placed in the dorsal position, with the affected limb raised by placing a pillow or sand-bag underneath the leg. The surgeon stands on the outer side of the foot, and the assistant opposite him. The foot is grasped by the hands of the assistant and flexed at the ankle, the toes being extended so as to make tense the bands of fascia.

Operation.—A fine sharp-pointed tenotome is taken, and the blade passed between the skin and the contracted band of fascia, from whichever side is the more convenient. The cutting edge is turned towards the sole, and the fascia

divided by cutting inwards. It is better to make several punctures and divisions of the fascia than to completely divide it through one incision.

Division of the palmar fascia (operation for Dupuytren's contraction).—Dupuytren's contraction consists in a pathological shortening of the bands of the palmar fascia passing to the fingers. For the relief of this condition two operations, the *subcutaneous* and the *open*, are practised.

Subcutaneous operation.—The affected hand is placed in a position of supination. A fine sharp-pointed tenotome is used, and passed into the tissues between the skin and the contracted band of fascia. This is then divided by cutting away from the surface. It is necessary to divide the fascia in several places, and when the division is being made the fingers should be stretched by an assistant, so as to render the bands tense and distinct. Care must be taken not to allow the point of the tenotome to pass too near the margin of the finger, otherwise the digital vessels and nerves may be damaged. The points of puncture should be selected where the bands of fascia are not adherent to the overlying skin.

Open operation.—The hand is held in the same position as for the subcutaneous operation. A vertical incision is made through the skin and superficial fascia of the affected finger and the adjacent portion of the palm. This incision commences in the palm above the commencement of the contraction, and extends along the middle line of the affected finger to a point well beyond the contraction. The incision is deepened until the deep fascia is reached, and then the skin and superficial fascia are dissected up on each side. By this means the contracted bands of the palmar fascia are exposed. These are divided transversely, and are then, as far as possible, removed. It is requisite in this operation to have the tissues of the hand rendered bloodless by the application of an Esmarch's bandage. When the contracted bands have been separated, divided, and

removed, the bandage is taken off, and if any bleeding points can be seen they are ligatured. The margins of the skin wound are next brought into exact apposition, and united with fine sutures of horse-hair or salmon-gut. The limb is put up on a splint with the fingers fully extended. Strict aseptic precautions must be adopted in every case, so as to avoid the occurrence of palmar suppuration.

When a case of Dupuytren's contraction is treated by the subcutaneous method, it is necessary to apply splints very carefully, and to see that they are worn for some considerable time, so as to prevent the return of the original condition. The open operation is a more severe one, but if precautions are adopted to avoid the occurrence of septic processes, the duration of treatment is much shorter than with the subcutaneous method, and a recurrence is not so likely to take place.

Division of the astragalo-scaphoid ligaments (syndesmotomy).—In this operation the ligaments which form the connection between the astragalus and scaphoid are divided by a subcutaneous operation.

Position.—The patient lies in the dorsal position, with the foot placed upon its outer side.

The surgeon stands on the tibial side of the foot, with an assistant opposite to him, who holds the foot firmly in position.

Operation.—A point is taken a short distance below and in front of the apex of the internal malleolus, and just behind and above the tuberosity of the scaphoid. The sharp-pointed tenotome is introduced at this point, and pushed forwards and inwards until a point on the tibial side of the dorsal vessels is reached. It is then withdrawn, and a special form of curved tenotome passed in along the tract which has been made. The cutting edge of this instrument is turned towards the bones, the foot is fully extended, so as to render the ligaments and tendons tense, and then the knife is withdrawn; as this is being done

it is made to cut all the structures down to the bone, the tendon of the tibialis posticus being divided just before the point emerges. The foot is then put up in the corrected position.

This operation has been done in a considerable number of cases of congenital talipes varus, and with a fair amount of success.

Suture of divided tendons.—Tendons frequently require to be joined together when they have been partially or completely severed as the result of injury, as after incised wounds in the region of the wrist.

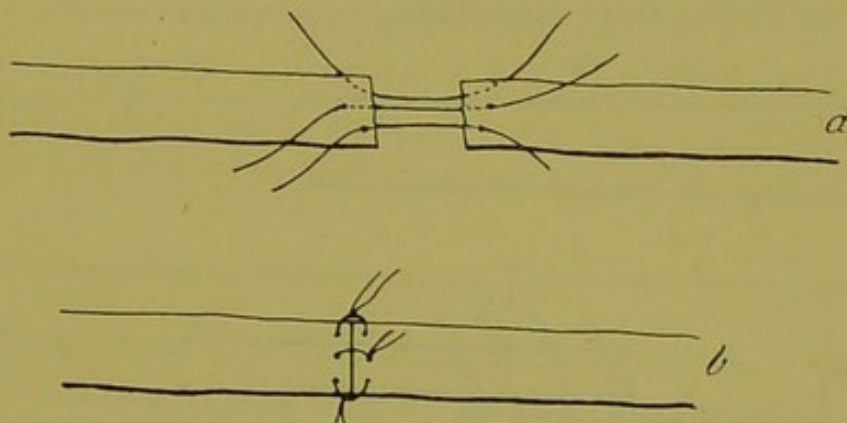


FIG. 240.—Suture of divided tendons.

- a.* Ends pared and sutures inserted.
- b.* Sutures tied.

Instruments.—Scalpel, scissors, fine half-curved needles, needle-holder, and fine silk sutures.

Operation.—The first part of the operation is the free exposure of the divided ends of the tendon. In order to do this it is often necessary to enlarge the wound in a proximal direction, since the muscles may contract and draw the proximal end of the tendon up within the tendon sheath.

The severed ends of the tendon having been exposed, the free extremities, if lacerated, are trimmed with scissors, and brought into apposition.

With a fine needle the tendon is transfixed, as in Fig. 240, and sutures inserted. When all the necessary sutures

have been introduced, each one is tied and the ends cut short. The external wound is then closed in the usual manner.

The limb is placed on a suitable splint, and maintained in a quiescent state until the approximated ends have had time to unite.

When it is found impossible to find the proximal end of the divided tendon, or to bring the two extremities into apposition, the distal end may be implanted on the lateral aspect of one of the adjacent tendons, preferably one of a muscle which has an action similar to the one divided, or an attempt may be made to lengthen the tendon, as in the next operation.

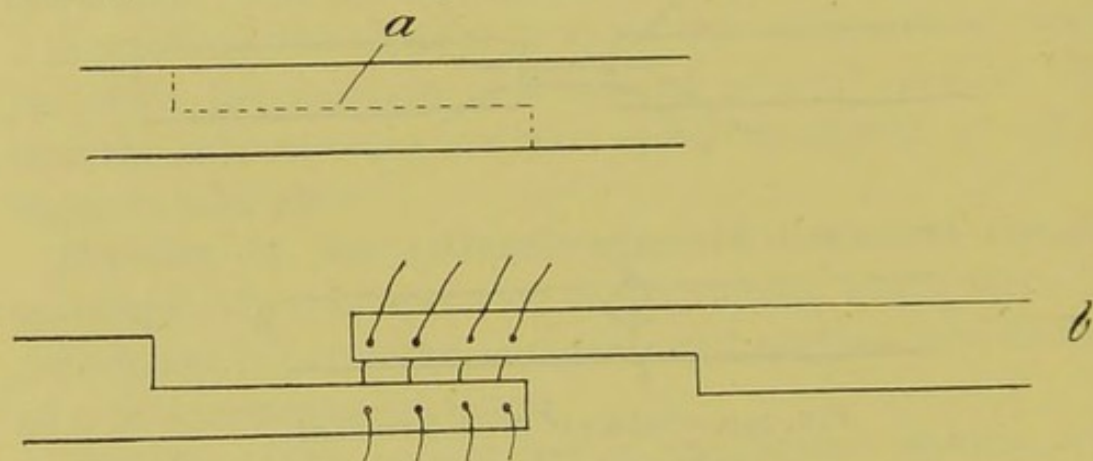


FIG. 241.—Lengthening of tendons. By a vertical incision.

a. Line of incision in tendon.

b. The two portions separated for a distance and sutures inserted.

When implantation is attempted, the lateral aspect of the tendon on which the severed extremity is about to be fixed is refreshed before the insertion of the sutures.

Lengthening of tendons.—Lengthening of one or more tendons may be requisite under the following conditions:—

(*a*) In some cases of severed tendons in which the cut ends cannot be readily approximated.

(*b*) When a portion of tendon is removed, as in the extirpation of a malignant growth, and the ends cannot be brought together.

(*c*) In some cases of congenitally contracted tendons where it is not wished to divide the tendon completely across.

(d) After sloughing of a portion of a tendon.

Operations.—Two methods of lengthening a tendon are practised—

1. *By a vertical incision.*—The tendon which it is wished to lengthen having been exposed, an incision is made in its long axis, as in Fig. 241, *a*. The two portions are separated as in Fig. 241, *b*, and fixed together by the insertion of a number of fine sutures of silk, which transfix both parts of the tendon. The severed ends of the tendon thus lengthened are united, and then it is replaced in its normal position, the fascia sewn over it, and the external

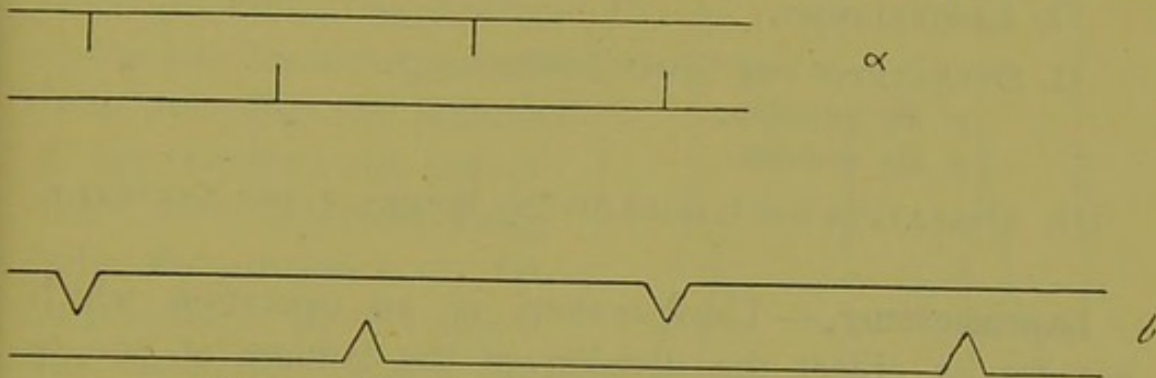


FIG. 242.—Lengthening of tendons. By alternate transverse incisions.

a. Position of alternate incisions.

b. Appearance of a tendon when lengthened, and the margins of the incisions have separated in a V-shaped manner.

wound closed. A splint is applied so as to prevent movement of the affected part of the limb, and kept in position until the parts have become joined. Two or three weeks are usually sufficient for the purpose.

2. *By alternate transverse incisions.*—The tendon having been exposed, a number of transverse incisions placed alternately on each side of the tendon are made, after the method illustrated in Fig. 242, *a*. Each incision ought not to divide more than one-half the thickness of the tendon.

When the incisions have been made and the tendon stretched, the latter has the appearance shown in Fig. 242, *b*. The limb is fixed in the rectified position by a splint, as in the preceding operation.

CHAPTER XIX.

OPERATIONS UPON THE SPINAL COLUMN AND SPINAL CORD.

I. LAMINECTOMY.

II. OPERATIONS FOR SPINA BIFIDA—

1. By injection.
2. By excision.

III. OPERATION FOR CARIES OF THE BODIES OF THE VERTEBRÆ.

Laminectomy.—Laminectomy is an operation which has for its object the division of the laminae of one or more vertebræ.

Indications.—(a) Caries of the spinal column accompanied by the formation of inflammatory products which cause pressure upon the spinal cord.

(b) Fractures of the spinal column in which a piece of bone presses upon the spinal cord or causes intraspinal hæmorrhage.

(c) Intraspinal tumours or cysts which are thought to be capable of removal.

(d) Foreign bodies, such as bullets or pieces of broken knives, within the spinal canal.

Instruments.—Scalpel, resection knife, periosteal elevator, Hey's saw, wide retractors, pressure and dissecting forceps, scissors, bone forceps, fine-toothed forceps and fine scissors, chisel and mallet, needles, needle-holder, and suture and ligature material.

Position.—The patient lies in the semiprone position, close

to one edge of the table. The surgeon stands behind the patient, close to the region of the spine upon which he is going to operate. His assistant stands opposite to him.

Operation.—The region of the spinal column upon which it is proposed to operate having been decided, a vertical incision 4 in. in length is made in the middle line of the back, the centre of the incision being opposite the centre of the affected portion of the spine. With the resection knife, the erector spinæ muscles are separated from the spines and laminae of the vertebræ, the periosteum being detached along with the muscles as far as possible. By this means the posterior aspect of the vertebræ is exposed. A special form of bone forceps (Fig. 244) is now taken, and the smaller blade passed beneath one of the laminae of the lowest vertebra upon which it is proposed to operate, and the lamina divided close to its junction with the transverse process. The laminae may be partially sawn through with a Hey's saw (Fig. 187) before division. This procedure is repeated upon the opposite side. The ligamenta subflava which fix the lower borders of the partially separated laminae to the vertebra below are divided with the scalpel, and then the united laminae and spinous process are raised upwards. The laminae of the

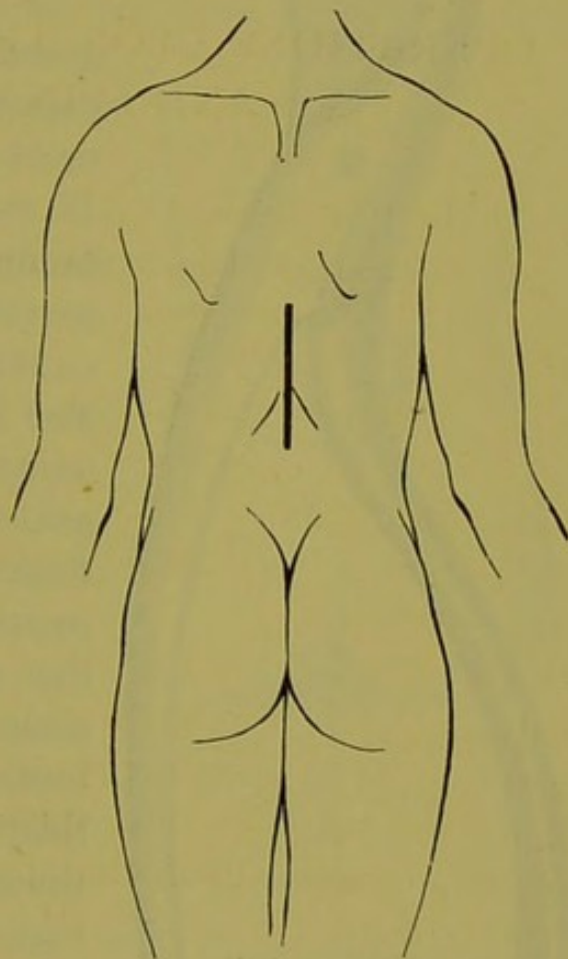


FIG. 243.—Laminectomy. Line of incision for lower dorsal region.

vertebra above are divided in a similar manner, and lifted up along with the first. By this means a bony and ligamentous flap, consisting of the laminae and intervening ligaments of two vertebrae, is partially separated and lifted upwards, and the interior of the spinal column opened.

Any tumour or cyst, projecting spicule of bone, sequestrum, or collection of tuberculous material or blood, can now be dealt with. If more space be required, the laminae of one or more additional vertebrae may be divided.

If it be necessary to expose the spinal cord, the intraspinal veins and fatty tissue are pulled aside and the dorsal aspect of the dura mater exposed. A vertical incision is made through this in the middle line, either with the scalpel or with fine scissors and toothed forceps. The margins of this incision are held apart, and the spinal cord, together with the region of the spinal nerves, laid bare. If hæmorrhage has taken place within the dura mater, the blood is removed.

If it has been found necessary to open the dura mater, the incision is afterwards closed with a series of fine silk sutures.

In those cases in which the operation has been done for fracture of the spinal column, intra-spinal hæmorrhage or tumour, the bony and ligament-

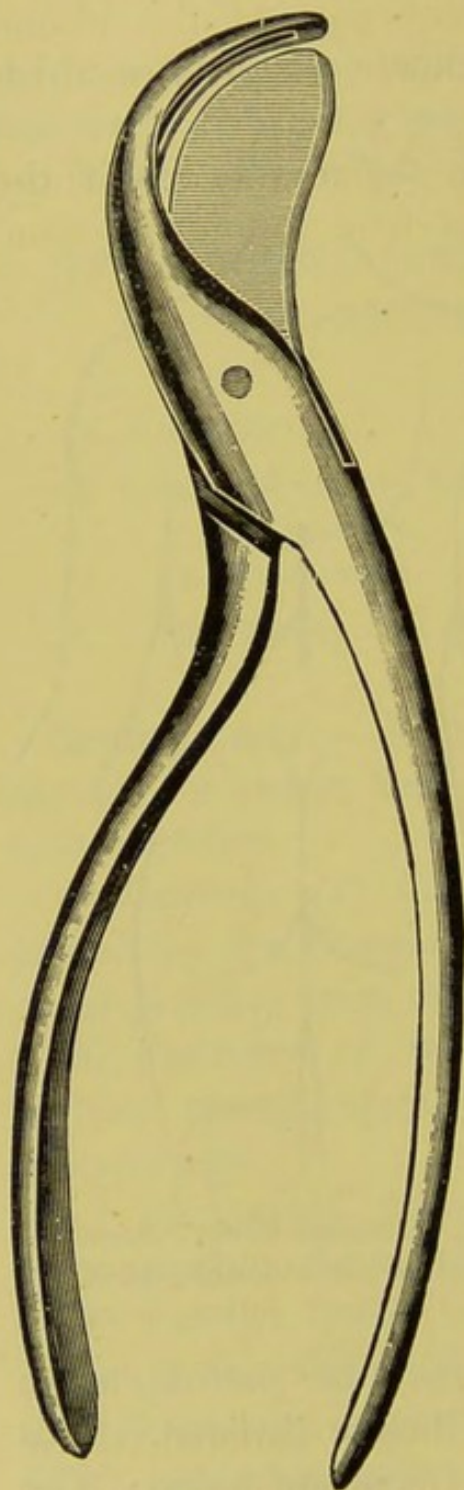


FIG. 244.—Laminectomy forceps.

ous flap is replaced and the wound closed by the insertion of sutures.

In inflammatory or tuberculous cases the laminæ are usually entirely removed; the upper part of the wound is closed with sutures, and the lower part left open for drainage.

II. Operation for spina bifida. — *Indications.* — Those cases of spina bifida which do not tend to undergo spontaneous cure, and in which a fatal result is to be apprehended in the absence of surgical treatment.

Operation. — Two methods of treatment have been made use of, one of which consists in the injection of an irritant fluid into the sac, and the other in complete removal of the sac.

(a) *Injection.* — The fluid which is generally used for this purpose consists of a mixture of iodine, iodide of potassium, and glycerin in the following proportions — Iodine, 10 grs.; potassium iodide, 30 grs.; glycerin, 1 oz. (Morton's fluid).

Injection should be limited to those cases in which the spinal cord does not occupy the interior of the sac.

The skin over the region of the swelling is rendered aseptic in the usual manner. A long fine needle, to which is attached a small syringe, is pushed into the base of the tumour, care being taken that it passes through sound tissue. The fluid is withdrawn from the interior of the swelling, and then 1 or 2 drms. of the injection fluid are introduced.

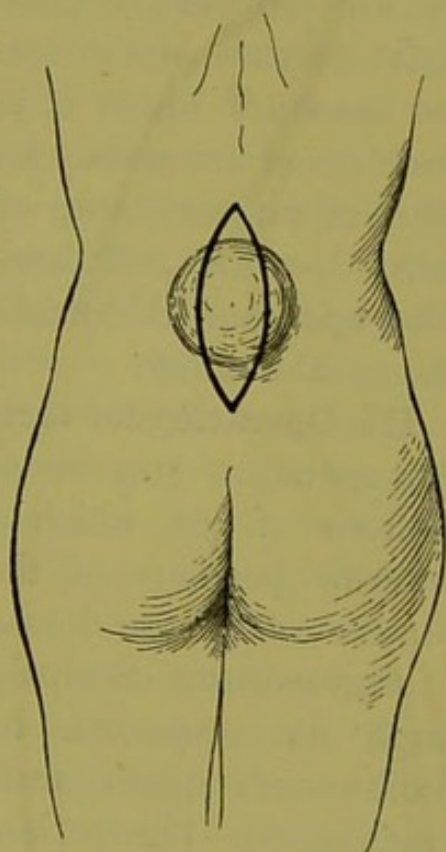


FIG. 245. — Spina bifida. Operation for radical cure. Line of incision through skin over lateral margins of tumour.

This operation generally has to be repeated several times in order to effect a cure.

(b) *Excision*.—An oval-shaped incision is made around the base of the tumour, and the sac dissected from the surrounding tissues until the margins of the deficiency in the wall of the spinal canal have been reached. The sac is now opened, the contained fluid allowed to escape, and any nervous structures which may happen to be within the sac returned, if possible, into the spinal canal. The distal portion of the sac is cut away, and the margins of the aperture which is left carefully approximated by the insertion of numerous fine silk sutures. The erector spinæ muscles on each side of the opening are separated for a short distance, and then united over the stump of the sac. The operation is completed by closing the skin incision in the usual manner.

III. Operation for caries of the bodies of the vertebræ.—

An operation may be performed for the removal of collections of pus, which are dependent upon caries of the anterior portions of the bodies of the vertebræ in the lumbar and in the dorsal region.

Instruments.—Scalpel, dissecting and pressure forceps, large flat retractors, bone forceps, sequestrum forceps, Volkmann's spoon, and drainage tube.

Position.—The patient is placed in the semiprone position, lying upon the sound side, with a pillow beneath the loin. The surgeon stands behind the patient, and the assistant opposite to him.

Operation.—A vertical incision, 3 in. in length, is made in the lumbar region, over the outer part of the erector spinæ muscle, commencing above a short distance below the lower border of the last rib. The skin, fasciæ, and sheath of the erector spinæ muscle are cut through and the vertical fibres of the muscle laid bare. This muscle is strongly drawn inwards, in order to expose the middle layer of the lumbar aponeurosis, which forms the anterior portion of

its sheath. With the left forefinger the surgeon feels for the apices of the transverse processes of the lumbar vertebræ in the floor and inner part of the wound. When these bony prominences can be felt, a vertical incision is made through the anterior layer of the sheath of the erector spinæ immediately external to these processes. The lamina of lumbar aponeurosis thus divided is drawn outward so as to lay bare the posterior aspect of the quadratus lumborum muscle, the fibres of which run in a slightly oblique direction. The fibres of this muscle are detached from the transverse processes, care being taken to avoid the lumbar arteries and their branches. These vessels lie in the intervals between the transverse processes. When the quadratus lumborum has been separated, it is retracted outwards. The posterior aspect of the sheath of the psoas muscle is now exposed. The muscle is detached from the transverse process of one of the vertebræ and an aperture made into the abscess cavity. The surgeon's forefinger is then passed along the anterior aspect of one of the transverse processes until the body of the vertebra is reached.

The aperture in the sheath of the psoas muscle can now be increased to any desired extent, and the contents of the abscess cavity removed. The forefinger should examine the interior of the abscess in order to locate the different pouches and pockets, and also the presence of pieces of necrosed bone.

These latter are removed with sequestrum forceps, and then the interior of the abscess cavity is irrigated with an antiseptic solution, such as perchloride of mercury (1 in 2000).

After irrigation, the wall of the abscess cavity is scraped with the surgeon's forefinger, or some form of blunt instrument, in order to detach as much of the lining membrane as possible.

Careful sponging with small sponges on holders will

often help materially in removing all flakes of tuberculous material. The cavity is again irrigated, then carefully sponged dry, and the external wound closed by the introduction of sutures. Buried sutures should be used for the closure of the deeper parts of the wound.

After-treatment.—The patient is kept in bed at absolute rest until the parts have healed. Often this entails rest in bed for several months.

This form of operation has been proposed by Mr. Treves, and in his hands has been productive of good results.

CHAPTER XX.

OPERATIONS ON THE TONSILS.

I. INCISION OF A TONSILLAR ABSCESS.

II. REMOVAL OF THE TONSIL—

(a) For simple enlargement.

(b) For malignant growth.

(1) Operation through the mouth.

(2) Operation through an incision in the neck.

I. Incision of a tonsillar abscess.—Abscess of one tonsil is a common affection, and frequently the surgeon is called upon to make an incision into it, in order to evacuate the contained pus. This is effected as follows. An ordinary tenotomy knife is taken, and around the blade is wrapped a strip of strapping, in such a manner that only half an inch of the cutting portion, at the point, is left bare (Fig. 246). Next, the surgeon directs the patient to open the mouth, and, by a small stab and cut, makes an opening in the wall of the abscess. The pus is evacuated into the mouth, and is spat out by the patient. The surface of the tonsil may be painted with a 10 per cent. solution of cocaine a short time before the operation, if it is wished to minimise the pain.

After the pus has been evacuated, the pharynx should be frequently washed out with an antiseptic solution.

II. Removal of the tonsil.—(a) For simple enlargement ;
(b) for malignant growths.

(a) *For simple enlargement.*—This is best effected with some form of guillotine. Fig. 247 is an illustration of an instrument which is very suitable for this purpose.



FIG. 246.—Tenotomy knife, "guarded" with a piece of strapping, as used in opening tonsillar abscesses.

The patient is seated in the upright position, whilst an assistant, standing behind, holds the head. When the tonsil is being removed, the assistant is directed to press it inwards by placing his finger immediately behind the angle of the jaw. The guillotine is passed into the mouth, and the tonsil made to protrude through the aperture at its extremity. With a sharp cut it is removed. Both tonsils can be removed simultaneously, by using a guillotine with each hand. This, however, is only necessary in the case of children.

The regions of the tonsils should be painted with a 10 per cent. solution of cocaine a short time before removing them.

(b) *For malignant growths.*—The primary malignant growths which affect the tonsil are epitheliomata and sarcomata, the latter being the more common.

The tonsil, when affected by a malignant growth, may be removed either by an operation carried out through the mouth, or through an incision in the superior and lateral portion of the neck. The former operation is suitable for those cases in which there is not extensive enlargement of the neighbouring lymphatic glands, and the latter for cases in which there is

infiltration of the lymphatic glands in the region of the angle of the jaw. Involvement of the lymphatic glands tends to occur very early in malignant disease of the tonsil. Few, if any, of the cases in which it has taken place have been cured by an operation.

(1) **Operation through the mouth.**—*Instruments.*—Scalpel, retractors, dissecting and pressure forceps, blunt-pointed scissors, gag, vulsellum forceps, laryngotomy tube, needles, needle-holder, and suture and ligature material.

Position.—The patient is placed in the dorsal position, with the head supported by a firm pillow; the surgeon stands on the affected side of the head, and his assistant opposite to him.

Preliminary laryngotomy.—In most cases it is advisable to perform a preliminary laryngotomy, and then to plug the upper aperture of the larynx with a sponge. This will prevent blood passing downwards into the respiratory passages.

Operation.—An incision is made horizontally backwards, from the angle of the mouth, on the affected side, to the anterior border of the masseter muscle. The facial artery is cut across in this procedure, and its two ends must be secured and tied. The flaps of the cheek are held aside, and the tongue drawn forwards. If necessary, a strong silk ligature is passed through the tongue and given to an assistant to hold, in order to exert traction when required.

The soft palate is divided well beyond the limits of the growth with the scissors, and the cut carried backwards into the walls of the pharynx, care being taken to make the incision some distance from the margins of the diseased

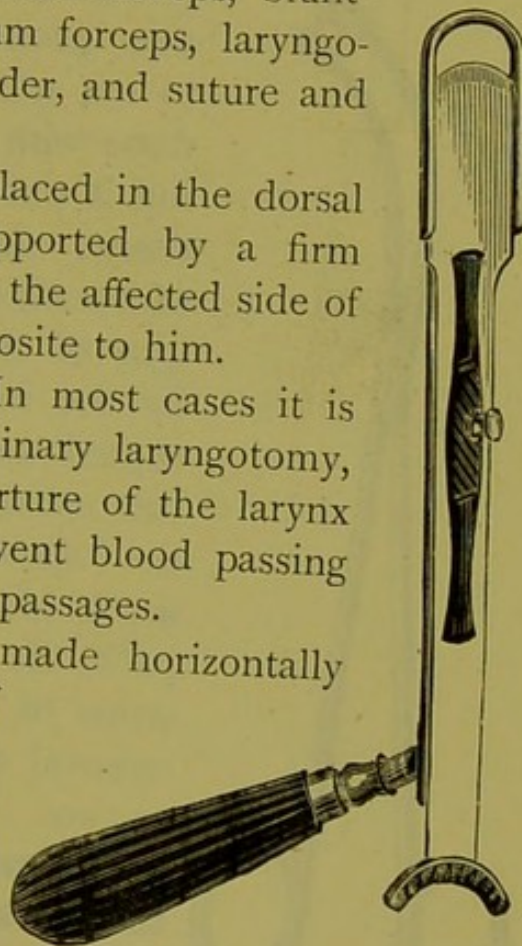


FIG. 247.—Mackenzie's tonsil guillotine.

tissues. The tonsil is next seized with vulsellum forceps, (Fig. 248), and dragged forwards, the tissues which attach it to the wall of the pharynx being cut through with the scissors. By this means the tonsil with the malignant growth is removed. In some cases of sarcomata it will be found that the growth shells out of a sheath. Unfortunately,

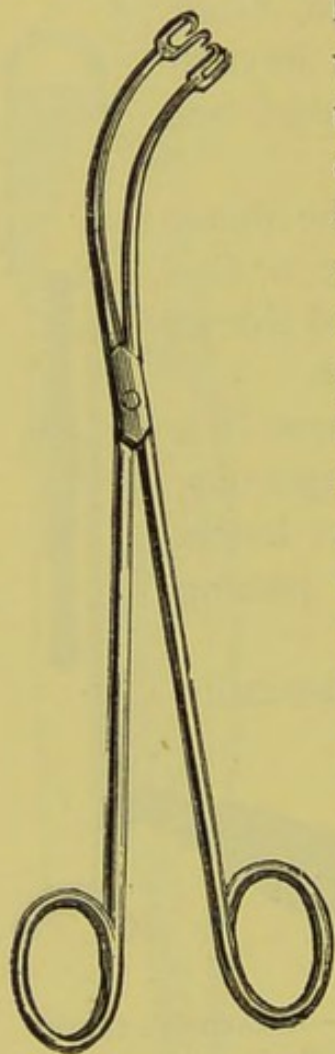


FIG. 248.—Vulsellum forceps.

however, in these cases, recurrence is very prone to occur, and it is better to cut wide of the disease, if it can be done with safety, than to trust to shell-ing it out of the capsule of connective tissue. All hæmorrhage from the area of operation is arrested, and the margins of the incision in the cheek united by the insertion of a series of interrupted sutures. The laryngotomy tube can usually be taken out at the end of the operation. If, however, there is much bleeding, it will be advisable to pack the wound in the pharynx with strips of aseptic gauze and delay the removal of the laryngeal tube for a day or two.

(2) **Operation through an incision in the neck.**—Several varieties of operation by this method have been proposed. The incision is made along the anterior border of the sterno-mas-toid of the affected side, commencing above at the lobule of the ear, and extending downwards to the great cornu of the hyoid bone. In most cases it is necessary to remove a portion of the lower jaw, or at least to saw it through, and turn it aside.

The success which has followed these operations has been very slight, and it may be doubted whether they are justifiable. In those cases with extensive en-

largement of the lymphatic glands it is probably better to remove the primary growth through the mouth, by the method described above, and to deal with the affected lymphatic structures through a second incision in the neck.

CHAPTER XXI.

OPERATIONS UPON THE NOSE AND ITS ACCESSORY CAVITIES.

- I. REMOVAL OF NASAL POLYPI—
 - A. With a snare.
 - B. With forceps.
2. RECTIFICATION OF DEVIATED NASAL SEPTUM.
3. PLUGGING THE ANTERIOR AND POSTERIOR NARES.
4. PASSAGE OF EUSTACHIAN CATHETER.
5. REMOVAL OF NASO-PHARYNGEAL POLYPUS—
 - (a) Through the nose.
 - (b) Through the mouth.
 - (c) After resection of the upper jaw.
6. REMOVAL OF ADENOID GROWTHS FROM THE NASO-PHARYNX.
7. EXPLORATION OF FRONTAL SINUS.
8. EXPLORATION OF ANTRUM OF HIGHMORE.

Removal of nasal polypi.—Mucous polypi of the nose usually grow from the mucous membrane covering the turbinated bones, a fact which must be remembered when an attempt is being made to detach them.

Occasionally, a nasal polypus may be fibrous in character, in which case it will be found to take its origin either from the roof of the nose, or from the periosteum covering one of the bones which enter into the formation of the nasal cavity. In still rarer instances, the polypi may be sarcomata.

Nasal polypi may be removed either with some form of snare or galvanic wire loop, or with forceps. When sar-

comatous polypi have to be removed, it is necessary to perform a more radical operation, and the nasal cavity must be opened up, as in Rouge's operation.

A. Removal by snare or galvanic wire loop.—The interior of the nose may be painted with a 10 per cent. solution of hydrochlorate of cocaine before the operation is commenced.

Instruments.—Wire snare or galvanic wire loop connected with a battery, probe, nasal speculum, lamp, and forehead mirror.

Position.—The patient is seated in a chair of suitable height, with his back towards the source of light, whilst the surgeon sits opposite the patient, and facing the source of light.

Operation.—The nasal speculum (Fig. 249) is introduced into the anterior nasal aperture of the affected side, and the blades separated. The position of the polypus is made out, a probe being used, if requisite, to define its attachment, and then the wire loop of the snare is passed around it (Fig. 250). If the loop of an electric cautery is used, the current is turned on sufficiently to heat the wire to a dull red heat, and the base of the pedicle cut through. If the electric cautery is not available, the base of the polypus is cut through by tightening the wire-loop. The polypus is next removed from the nose through the speculum. Other polypi are sought for, and dealt with in a similar manner, until all have been removed. The nostril of the other side is next examined, and any polypi which are present removed.

Sometimes it is necessary, when the inferior or middle turbinated bones have localised projections or spurs, to remove these, in order to obtain a good view of the upper part of the nose.

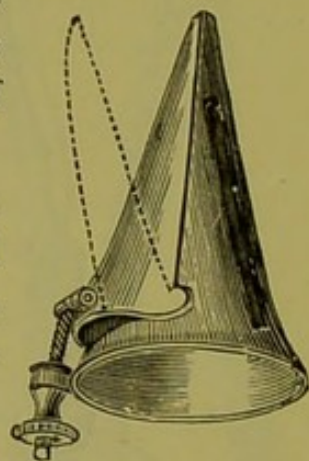


FIG. 249. — Nasal speculum.

It is necessary to keep the nose as free from blood and mucus as possible during the operation, otherwise small polypi will escape removal. These will afterwards increase in size, and necessitate a further operation.

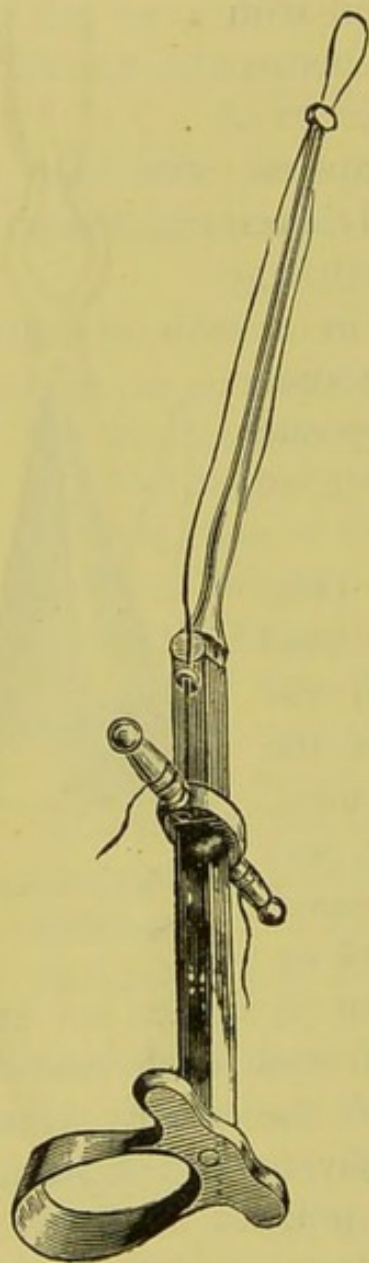


FIG. 250. — Wire snare for removal of nasal polypi.

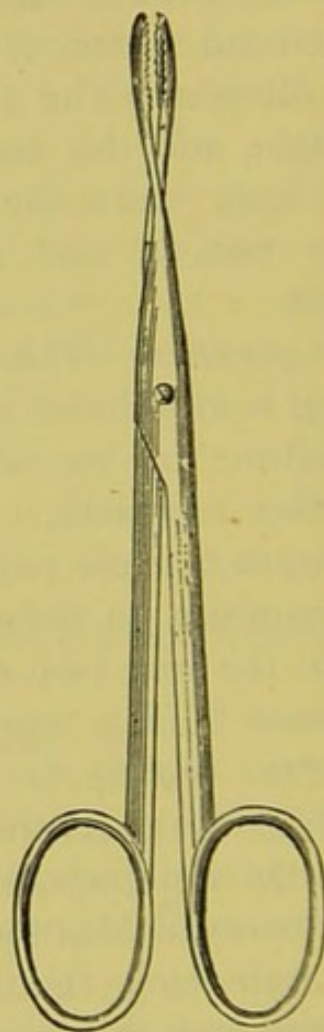


FIG. 251. — Nasal polypus forceps.

The galvanic wire loop is the most convenient to use for the removal of nasal polypi, since it causes very little hæmorrhage.

B. Removal with forceps.—The preparation of the patient,

the instruments, with the exception that the wire snare or loop is replaced by nasal forceps (Fig. 251), and the positions of the patient and operator are the same as in the preceding operation.

Operation.—The nasal speculum having been introduced, the position of the polypi is made out. Next, the blades of the nasal forceps are introduced through the aperture in the speculum, the polypi are seized near their bases, and forcibly avulsed. Usually small portions of the turbinated bones, together with the mucous membrane covering them, are pulled away when the forceps are used. When the polypi are located far back in the region of the naso-pharynx, their removal can be facilitated by passing the forefinger of the left hand behind the soft palate (from the mouth), and pushing the growths between the blades of the forceps, which have been passed backwards along the inferior meatus of the nose.

This method of operation is accompanied by more hæmorrhage than the preceding one.

After-treatment.—Hæmorrhage caused by the removal of non-malignant nasal polypi usually stops spontaneously, shortly after the operation. If it continues, it may be necessary to pack the naso-pharynx, or the nostril, with strips of aseptic gauze. Before this is done, injection of hot water (118° F.) should be tried.

Afterwards, the nose is irrigated twice daily with a dilute antiseptic solution, such as Condyl's fluid or boracic acid. This treatment is continued for a few days, until all discharge from the nose has ceased.

Rectification of deviated nasal septum. — A small

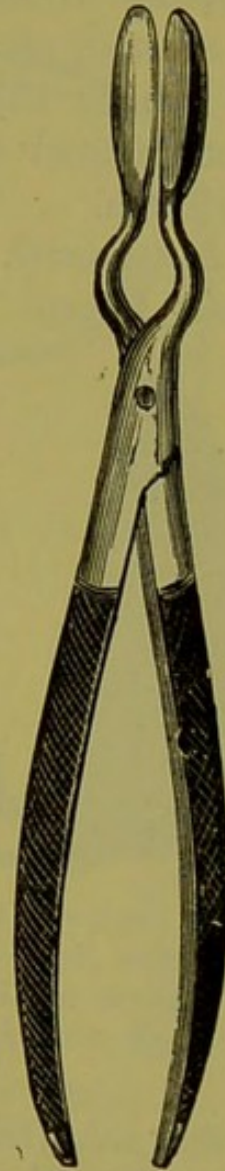


FIG. 252.—Walsham's forceps for rectification of deviated nasal septum.

amount of deviation of the nasal septum to one or other side is commonly met with, but unless it is considerable no inconvenience is caused by it. When, however, the deviation is considerable, and causes practical obliteration of one-half of the nasal passage, it is advisable to attempt to remedy the condition by a surgical operation. The best method of procedure is that recommended by Mr. Walsham.

Instruments.—Nasal speculum and forehead mirror, nasal forceps (Walsham), and nasal plugs. If there is a prominent septal spur, a pair of strong scissors will also be necessary.

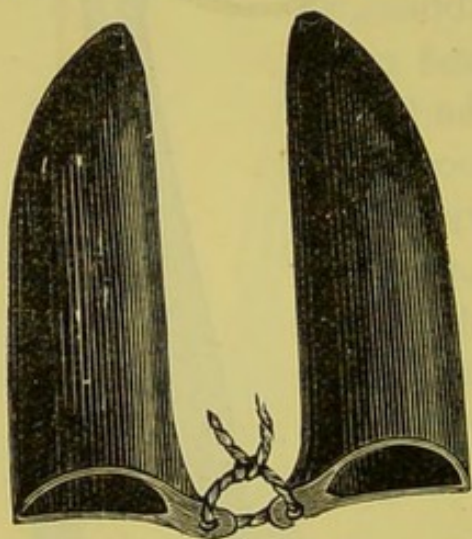


FIG. 253. — Walsham's vulcanite plugs, for use after septum has been straightened with forceps.

Operation.—The patient having been anæsthetised, an examination of the nasal septum is made through the speculum, in order to locate the position of the deviation, and any spur which may happen to be present. With the scissors, the spur, if present, is first cut away. Next, the nasal forceps are introduced, one blade on one side of the septum through one nostril, and the other on the

other side (Fig. 252). The blades are placed over the most prominent portion of the deviation, and then the handles are approximated. This causes a fracture of the bony part of the deviation. When this has been done successfully, the nasal plugs (Fig. 253) are taken and fixed in the nostrils, one on each side of the septum. Vulcanite plugs are best for this purpose, since they can be softened in hot water, and then moulded to the shape of the nose of the case being dealt with. The plugs are fixed in position by a piece of strong strapping.

After-treatment.—The plugs are taken out daily, the

nostrils are irrigated with a dilute antiseptic solution, and then they are replaced. The plugs are worn until the fractured septum has united.

Plugging the anterior and posterior nares.—*Indications.*—Plugging of the posterior nares may be required in the following conditions:—

(a) Severe long-continued bleeding from the nose, which cannot be arrested by simpler measures.

(b) As a preliminary preparation for certain operations on the face and nose, in order to prevent blood from passing into the pharynx.

Instruments.—Bellocq's sound, dissecting forceps, strong ligature silk, antiseptic gauze or wool, and gag.

Position.—The patient should be placed in the dorsal position, with the head slightly raised. The surgeon stands on the right side of the patient.

Operation.—A piece of strong ligature silk is passed through the eye of a Bellocq's sound (Fig. 254); the sound is passed along the inferior meatus of the nose of the affected side, until the naso-pharynx is reached, and the spring is then protruded.

The mouth is opened, and the gag placed between the teeth, and one end of the ligature is drawn out of the mouth with a pair of forceps. The sound is withdrawn from the nose, one end of the ligature being brought out along with it.

An oblong-shaped pad of gauze, usually about 1 in. long and half an inch thick, sufficiently large to plug the posterior nasal aperture of one side, is made, and two pieces of strong silk fastened to it. The free extremities of




FIG. 254.—Bellocq's cannula, with spiral spring, for use in plugging the posterior nares.

one of these are tied to the ligature in the mouth. Traction is now exerted upon the silk thread in the nose, by which means the extremities of the ligature are brought out through the anterior nares. With the left forefinger the plug of gauze is passed behind the soft palate and fitted into the posterior nasal aperture.

A second plug of gauze, half an inch in thickness, is now

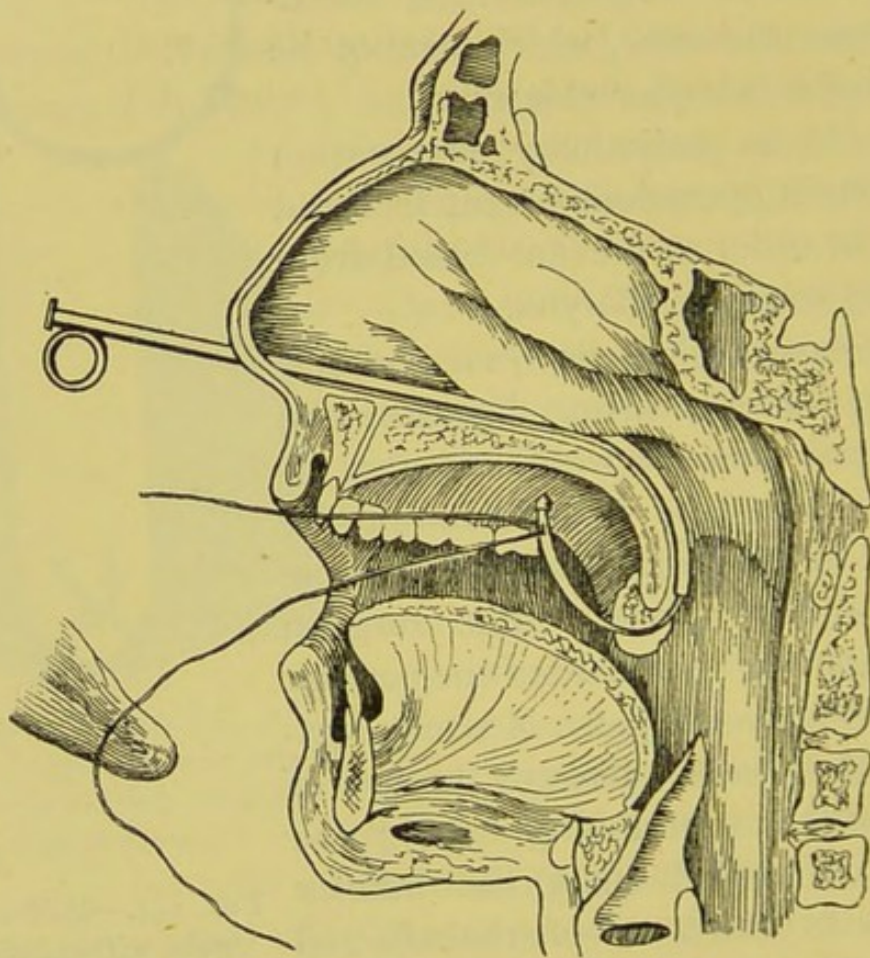


FIG. 255.—Method of plugging the posterior nares with Bellocq's sound.—ESMARCH and KOWALZIG.

taken and placed between the two ends which protrude from the anterior nasal aperture. These are drawn tight, and tied over the pad. The second ligature attached to the plug has one end cut short before the plug is introduced, whilst the other is allowed to hang down into the pharynx. It is used for withdrawing the plug.

If hæmorrhage is taking place from both sides of the nose,

he other posterior nasal aperture may be plugged in a similar manner.

After-treatment.—These plugs should not be allowed to remain in position for more than twenty-four or thirty-six hours without being changed, and the nasal cavity washed out.

Passage of a Eustachian catheter.—

Indications.—As a means of inflating the tympanum—(a) When the ordinary methods, such as politzerisation, have failed; (b) when it is wished to treat one ear alone.

Instruments.—Eustachian catheter, Politzer's bag, rhinoscopic mirror, and forehead mirror.

Position.—The patient is seated with the back to the light; the surgeon stands or sits directly in front of him.

Operation.—The region of the pharyngeal orifice of the Eustachian tube of the affected side is first examined with the rhinoscopic mirror, in order to ascertain whether there is any physical obstruction to the passage of the catheter.

The Eustachian catheter (Fig. 256) is now taken in the right hand, and passed along the inferior meatus of the nose on the affected side, with the point downwards. The handle is at first lowered, but the instrument is brought to the horizontal as it passes onwards. It is passed backwards till the posterior wall of the naso-pharynx is reached, and then drawn forwards until the point is felt to rise over the posterior free margin of the hard palate. Next, the point is rotated towards the affected side for 90° , and the handle pushed towards the median line. This manœuvre generally causes the point of the catheter to enter the Eustachian tube, though it is sometimes necessary




FIG. 256. —
Eustachian
catheter.

to move it a slight distance along the lateral wall of the naso-pharynx.

The point of the catheter having entered the Eustachian tube, the tympanum is inflated with Politzer's bag, or any other procedure which is requisite carried out.

Removal of naso-pharyngeal polypus. — Naso-pharyngeal polypi usually grow from the periosteum of that

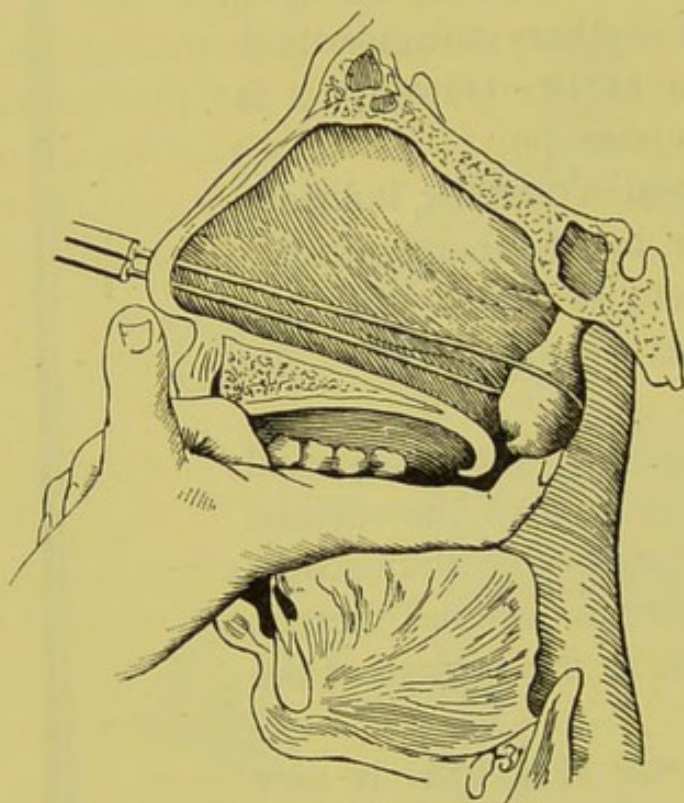


FIG. 257.—Method of surrounding a naso-pharyngeal polypus with a wire before removal.—ESMARCH and KOWALZIG.

portion of the base of the skull which forms the roof of the naso-pharynx; that is to say, the basilar portion of the occipital bone and the base of the sphenoid.

These polypi may be either simple or malignant in character; when simple, they are usually of the nature of fibro-angiomatous or fibrocellular tumours; when malignant, they are always sarcomata.

Care must be taken before commencing an operation on a naso-pharyngeal tumour, that it is not a meningocele which has penetrated through the base of the skull.

Indications.—Simple or malignant polypi growing from the base of the skull that can be completely removed.

Instruments.—Scalpel, scissors, wire snare or electric wire-loop cautery, Paquelin's cautery, gag, nasal speculum, forehead mirror, pressure forceps, dissecting forceps, bone forceps, periosteal elevator, Hey's saw, chisel and mallet,

sponge-holders, needles on handles, ordinary needles, needle-holder, and suture and ligature material.

Position.—The patient is placed in the dorsal posture with a sandbag underneath the head. The surgeon stands on the right side of the patient, the chief assistant on the left.

Operation.—(a) Through the nose; (b) through the mouth; (c) after temporary resection of the upper jaw.

(a) *Through the nose.*—When the growth is small and has a distinct pedicle, it may be removed in the manner described for simple mucous polypi. The wire loop of an electric cautery is passed along the inferior meatus of the nose, and the mouth being held open with a gag, the surgeon with his left forefinger manipulates the loop round the attached portion of the tumour. The loop is tightened until it includes nothing but the pedicle close to its attachment to the bone. The electric current is now turned on sufficiently to heat the wire to a dull red heat, and the base of the pedicle cut through. The tumour can now be removed from the naso-pharynx by the fingers, working through the mouth. If severe hæmorrhage follow the removal of the tumour in this manner, it is advisable to pack the naso-pharynx with long strips of aseptic gauze.

When the tumour cannot be dealt with by the above method, a more severe operation must be carried out for its removal; the best method is the following:—

(b) *Removal through the mouth—Preliminary preparations.*—If the growth is a very large one, and has extensive attachments to the base of the skull, it is often advisable to perform a preliminary laryngotomy and to plug the upper part of the larynx.

Operation.—1. *Division of palate.*—The mouth being widely opened with a gag, an incision is made, commencing behind the uvula and extending forwards in the middle line of the palate as far as may be considered requisite for the extraction of the tumour. Usually it will be found neces-

sary to prolong this incision for the entire length of the palate. The soft palate and the soft structures covering the hard palate having been completely divided, the periosteum and other structures covering the palatal processes of the palate and superior maxillary bones are peeled back as far as the gums with a periosteal elevator. Then with a chisel and mallet the exposed part of the hard palate is removed, together with the necessary part of the bony septum of the nose. The mucous membrane covering the upper surface of the hard palate is now divided, by which means the entire naso-pharynx is opened up.

2. *Removal of tumour.*—With the forefinger the pedicle of the tumour is defined, and it is then divided either with the wire loop of the electric cautery, or with scissors, or with a strong rugine, and the entire tumour removed. This part of the operation must be completed as quickly as possible.

3. *Arrest of hæmorrhage and closure of wound in palate.*—After removal of the tumour the hæmorrhage is arrested, either by ligature or, this failing, by Paquelin's cautery.

The margins of the incision in the soft palate and the soft parts of the hard palate are brought together and fixed in apposition by the insertion of a series of sutures. In the case of vascular tumours it may be necessary to pack the naso-pharynx with tampons of aseptic gauze.

(c) *After temporary resection of the upper jaw.*—The skin incision for this operation is similar to the vertical portion of that for the removal of the upper jaw; that is to say, from the middle of the upper lip to the septum of the nose, outwards along the ala nasi, and upwards along the side of the nose to the inner angle of the orbit. The soft parts, however, are not dissected up from the bone. The bony connections of the upper jaw are divided as if for resection, a second incision, over the malar prominence, being made, to allow of the section through the frontal process of the

malar bone. The upper jaw is then turned aside and the naso-pharyngeal space laid open. The tumour is dealt with as in the preceding operation; when it has been removed and all hæmorrhage arrested, the upper jaw is brought back again to its original position and fixed by the insertion of a number of sutures.

Removal of adenoid growths from the naso-pharynx.

—Adenoid growths of the naso-pharynx may be removed either—(a) through the nose; or (b) through the mouth.

(a) *Through the nose.*

Instruments.—Ring knife or polypus forceps.

Position.—The patient is anæsthetised and placed in the dorsal position, with the head turned to the right side. The surgeon stands at the right-hand side of the patient's head.

Operation.—The mouth being held open with a gag, the curette or polypus forceps is taken in the right hand, and passed along the inferior meatus of the nose into the naso-pharynx. The forefinger of the left hand is hooked round the posterior margin of the palate, and then the growths are either scraped away or avulsed with the forceps, the forefinger being used to guide the instrument to the situation of the growths. In this operation care must be taken to scrape away all small pieces of growth from the region of the Eustachian tubes. Hæmorrhage is somewhat severe, but usually stops after a short time spontaneously.

(b) *Through the mouth.*

Instruments.—Löwenberg's forceps, or some modification of it, or Gottstein's curette.

Position.—As in the previous operation.

Operation.—The mouth being held open with a gag, the forceps or curette is taken in the right hand and passed behind the soft palate into the naso-pharynx. The growths are seized by the forceps and forcibly avulsed, or scraped away with the curette. Care must be taken not to seize or to drag away with the forceps any part of the nasal septum.

This operation is best completed by scraping away with the



FIG. 258.—Ring-shaped knife for removal of adenoid vegetations of naso-pharynx (Meyer).

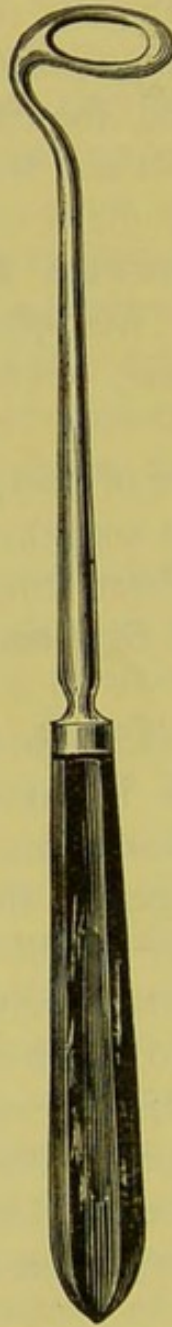

FIG. 259.—Gottstein's curette.

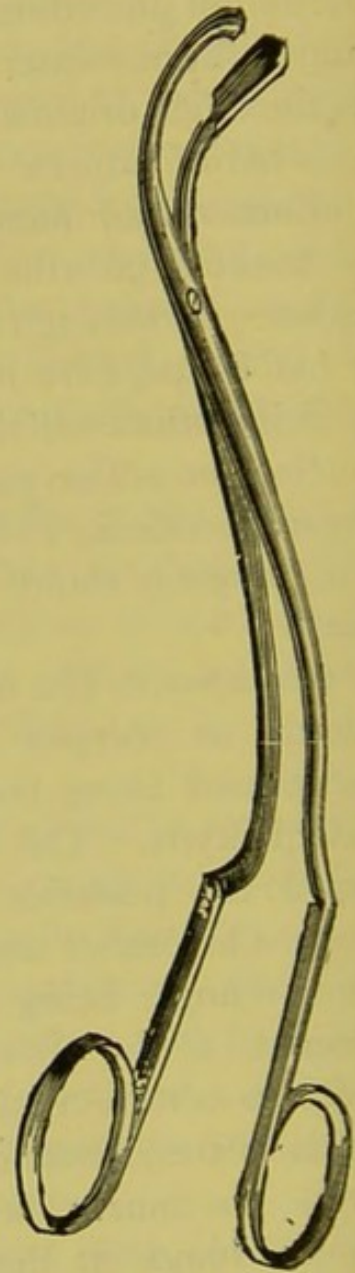


FIG. 260.—Forceps for removal of adenoid vegetations of naso-pharynx. (Walsham).

finger-nail or with an artificial finger-nail whatever portions of the growths have been left behind.

Exploration of the frontal sinuses. — The frontal sinuses are situated between the two tables of the vertical portion of the frontal bone in the region of the superciliary ridges. Their extent varies, often they pass outwards as far as the angle of the orbit.

Indications.—(a) Empyema of the frontal sinus; (b) chronic inflammation of the frontal sinus; (c) foreign body in the frontal sinus; (d) polypoid growths from the mucous membrane of the frontal sinus.

Instruments.—Scalpel, pressure and dissecting forceps, retractors, periosteal elevator, chisel, mallet, bone forceps, sequester forceps, drainage tube, needles and suture and ligature material.

Position.—The patient is placed in the dorsal position. The surgeon stands at the side of the head which

is to be operated upon, and the assistant opposite to him.

Operation.—The eyebrows having been shaved off, an incision is made, 2 in. in length, parallel with the supra-orbital margin and half an inch above it, extending outwards from the middle line. This incision divides all the soft structures down to the bone, including the supra-orbital vessels and nerve and the pericranium.

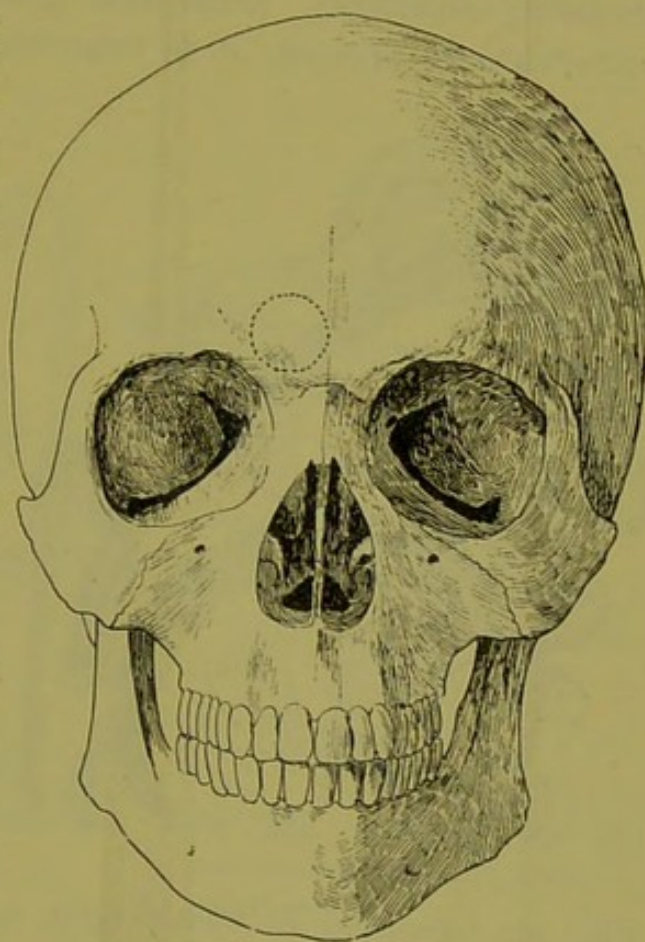


FIG. 261.—Position of incision through the bone, in exploration of the frontal sinus of the right side.

With the periosteal elevator the periosteum is separated from the bone for half an inch at each side of the incision, and then the margins of the wound are held well apart with retractors. The anterior bony wall of the sinus is next removed with the chisel and mallet, and then the mucous membrane forming the wall of the sinus is incised and the cavity opened. If a new growth, foreign body, or sequestrum is present, it is removed. If the operation is

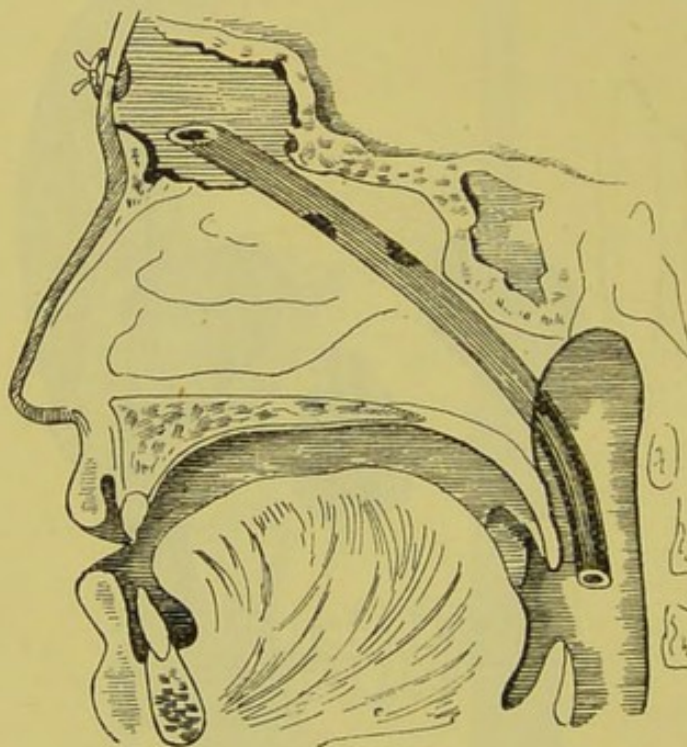


FIG. 262.—Drainage of frontal sinus into pharynx, tube in position. ESMARCH and KOWALZIG.

performed for suppurative inflammation of the sinus, the purulent collection is evacuated. The further treatment of the case depends upon the pathological condition which has been met with; in suppurative conditions it is usually advisable to pass a tube downwards from the sinus through the nose into the pharynx, and to partially close the external wound; in cases of new growth or

foreign body, not associated with suppuration, the external wound is completely closed in the usual manner.

Exploration of the antrum of Highmore.—The antrum of Highmore is situated within the interior of the body of the superior maxilla, and normally communicates by an aperture with the middle meatus of the nose.

Indications.—The interior of the antrum may require exploration for the following conditions:—

(a) Intractable suppuration, not amenable to ordinary treatment.

(b) Necrosis or sequestrum of part of its bony wall.

(c) Empyema of the antrum.

(d) New growths, cystic or polypoid, from the mucous membrane.

Instruments.—Scalpel, retractors, periosteal elevator,

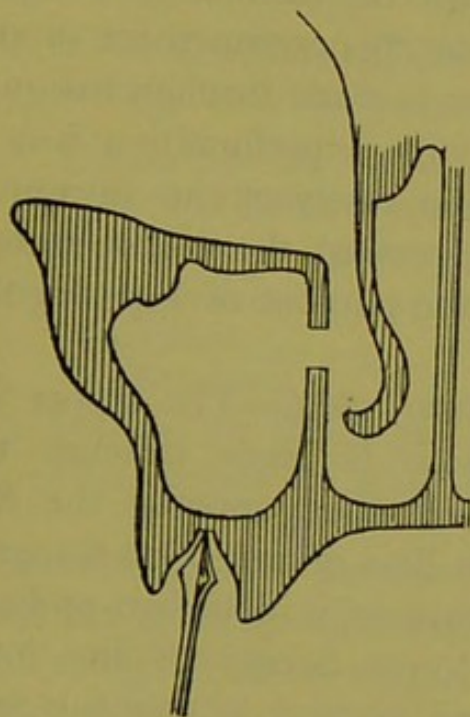


FIG. 263.—Perforation of antrum from socket of a tooth.

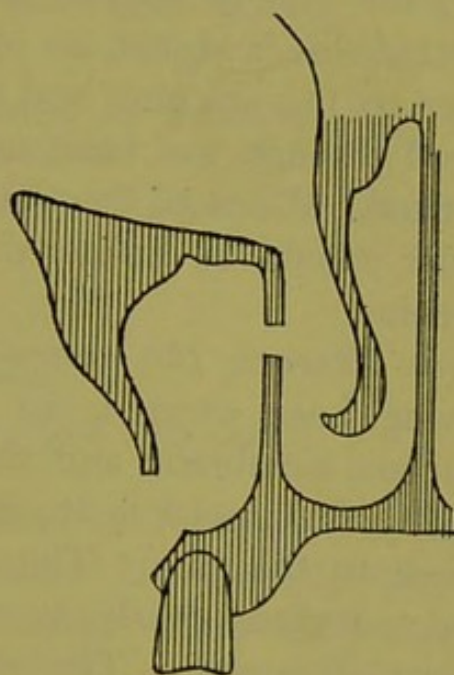


FIG. 264.—Exploration of antrum, through its antero-external wall.

small gouge or perforator, pressure forceps, bone forceps, dental forceps, Volkmann's spoon, drainage tube.

Operation.—The antrum of Highmore may be opened in the following situations:—(1) From the nose; (2) from the mouth—(a) through the alveolus of a tooth; (b) through the antero-external wall above the alveoli.

1. *From the nose.*—Opening of the antrum from the nose is an unsatisfactory operation, since it is impossible in this manner to properly drain the cavity.

The muco-periosteum of the outer wall of the nasal cavity, below the inferior turbinate bone, is divided with

a scalpel ; and then, with a bone perforator, an aperture is made into the cavity of the antrum. If pus is present it is evacuated, and the subsequent discharge passes into the nose and not into the mouth.

The disadvantage of this operation is, that it does not afford free drainage, owing to the fact that the lower part of the antrum is below the level of the aperture.

2. *From the mouth*—(a) *through the alveolus of a tooth*.—If the first or second molar or the canine tooth of the affected side is absent, an incision is made through the gum down to the alveolus, and then with a perforator a hole is bored through the bone until the cavity of the antrum is reached. When all the teeth are present, the first or second molar should be extracted for the purpose of exposing the alveolus.

(b) *Through the antero-external wall*.—The upper lip having been everted, an incision is made through the mucous membrane and the periosteum, opposite the first and second molar teeth, in the line of reflection from the cheek to the gum. The periosteum is detached upwards and outwards nearly to the lower border of the infra-orbital foramen. The exposed portion of bone is now removed with a chisel and mallet, and the cavity of the antrum laid open.

This operation affords free exposure of the cavity, and enables the surgeon to perform any further manipulation which may be requisite, such as removal of a growth or sequestrum.

CHAPTER XXII.

OPERATIONS UPON THE EAR.

1. EXTRACTION OF FOREIGN BODIES, OR RETAINED CERUMEN, FROM THE EXTERNAL AUDITORY MEATUS.
2. REMOVAL OF GROWTHS FROM THE EXTERNAL AUDITORY MEATUS—
 - (a) Polypi.
 - (b) Exostoses.
3. INCISION OF MEMBRANA TYMPANI.
4. EXPLORATION OF MASTOID ANTRUM AND CELLS.

Extraction of foreign bodies, or retained cerumen, from the external auditory meatus.—It frequently happens that foreign bodies require extraction from the external auditory meatus. This is especially the case in young children.

Instruments.—Aural syringe, speculum, forehead mirror, aural scoop, and long thin-bladed forceps.

It is not usually necessary to give an anæsthetic in these cases, except when young and refractory children have a foreign body tightly impacted in the auditory canal. In the latter case the administration of an anæsthetic will facilitate the removal of the impacted substance, and diminish the risk of damaging the adjacent parts of the auditory apparatus during the operation.

Operation.—The patient should be seated in a chair in a good light, or, if artificial light is used, it should be behind the affected ear, the surgeon using a mirror attached to his forehead for illumination.

The position and the nature of the foreign body, or plug of retained cerumen, is first made out by examining the



FIG. 265.—Aural forceps.—CUM-BERBATCH.

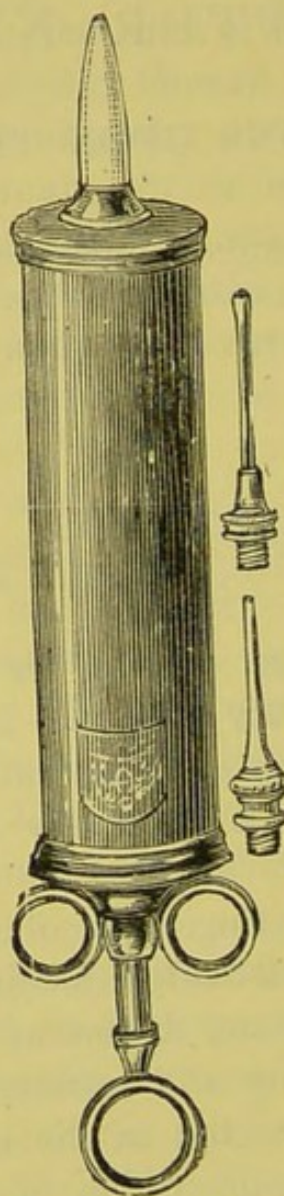


FIG. 266.—Aural syringe. Three forms of nozzle are illustrated.



FIG. 267.—Aural scoop, for removal of foreign bodies from the external auditory meatus.

meatus through a speculum. If the substance is not firmly impacted, it may be possible to seize it with aural

forceps (Fig. 265), and remove it. When it is deeply situated, it is often advisable to syringe out the meatus with warm water, or a solution of boracic acid. The nozzle of the syringe should be directed slightly upwards, so that the stream of fluid may pass in along the upper wall of the meatus and back along the floor. If this is done carefully, it will suffice, in the majority of instances, for the removal of plugs of cerumen, or loosely situated foreign bodies. The object of directing the stream along the roof of the meatus is to ensure the fluid passing internal to the slight prominence which is normally met with on the floor of the canal.

If the foreign body cannot be removed with forceps or by syringing, the auricle should be pulled upwards and backwards, and attempt made to pass the "ring scoop" (Fig. 267) beyond the impacted substance, and to extract it by pulling it outwards. Usually this manœuvre will succeed when the other methods have failed. When the obstruction has been removed, the auditory canal is syringed clean, and a small plug of aseptic wool placed in the meatus.

Removal of growths from the external auditory canal.—(a) *Polypi*.—Polypi situated in the external auditory canal may arise from the walls of the canal, from the membrana tympani, or from the mucous membrane or the periosteum which lines the tympanic cavity. The commonest seats of origin are the external aspect of the membrana tympani and the mucous membrane of the tympanic cavity.

These polypi are usually of the nature of simple fibrous or cellular tumours. Only in very rare instances are they malignant.

Instruments.—As for the preceding operation, with the addition of an aural snare.

Operation.—The external auditory canal should first be syringed out with a dilute antiseptic solution, and then

the nature of the growth and its point of attachment made out. The aural snare (Fig. 268) is next taken, and the wire loop passed around the tumour until its attached portion or pedicle is surrounded. The wire is then

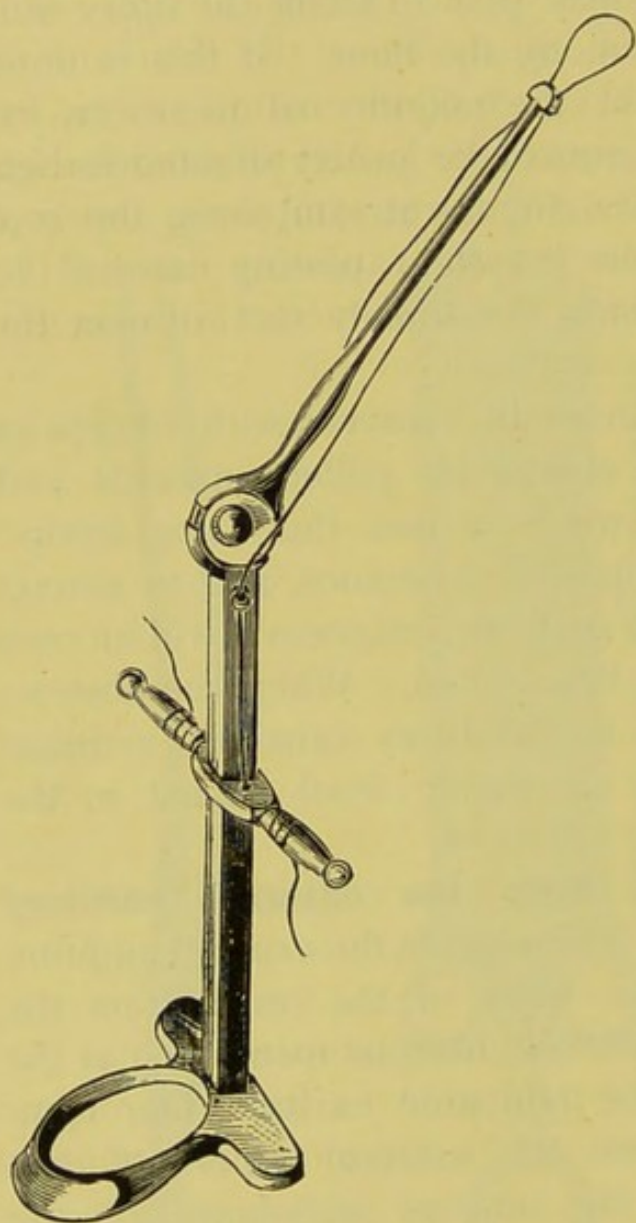


FIG. 268.—Wire snare, for removal of polypi from external auditory meatus or tympanic cavity.

tightened until the pedicle is constricted. If the growth is attached to the wall of the canal, or to the membrana tympani, a sharp pull is made on the snare, by which means the polypus together with its attachment is forcibly pulled away. If, however, it is attached to the mucous membrane of the tympanic cavity, the wire loop should be gradually tightened until the pedicle has been cut through. The polypus is then removed. When the growth has the latter-mentioned attachments, it is not advisable to remove it by forcible avulsion, otherwise one or more of the small bones of the tympanum may be removed along with it.

When the polypus has been removed, the auditory canal is syringed out and then examined through the speculum. If any other growths are discovered, they are removed in a similar manner. In the case of very small polypi, it may not be possible to get hold of them with the

snare. In this case they should be destroyed with the electric cautery, care being taken not to injure the inner wall of the tympanic cavity, on account of the liability of damage to the internal ear.

(b) *Exostoses*.—Exostoses of the external auditory canal occasionally occur. They chiefly affect the floor and the posterior wall. Usually they are of the nature of “ivory” exostoses. No attempt should be made to remove them, unless they are giving rise to severe symptoms, owing to complete blocking of the external auditory canal. If it is decided to remove them, the best method of operation appears to be by the employment of the dental engine or electric surgical engine, the attached base being cut through. The bone at the base is said to be softer than than that at the free extremity. Care must be taken not to splinter the petrous portion of the temporal bone, or damage any of the important anatomical structures in the neighbourhood.

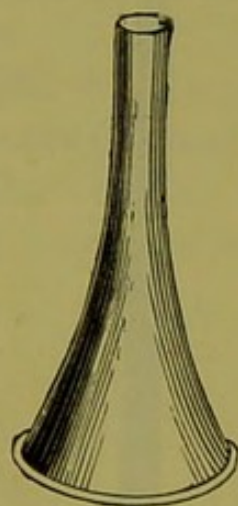


FIG. 269.—Aural speculum.

Incision of the membrana tympani.—*Indications*.—This operation may be necessary in the following conditions:—

- (a) Accumulation of pus within the tympanic cavity.
- (b) The presence of polypoid growths from the mucous membrane of the tympanic cavity, the membrana tympani being intact.
- (c) Necrosis of one or more of the auditory ossicles.

Instruments.—Aural speculum, forehead mirror, special knife, long thin-bladed aural forceps.

Position.—The patient and operator are seated as for the removal of a foreign body.

Operation.—The external auditory canal is syringed out so as to remove all secretion, and then dried with plugs of wool. The speculum is introduced, and the most bulging

portion of the membrane ascertained. The knife (Fig. 270) is passed through the speculum, and an incision made in the bulging portion of the membrane, and if possible at its lower part. If the operation is done for the evacuation of a collection of pus, this will at once exude. If for the removal of a polypus or a sequestrum, the subsequent procedure is similar to that mentioned in the preceding operation.

It is advisable to paint the tympanic membrane with a 10 per cent. solution of cocaine before an incision is made through it.

Exploration of the mastoid antrum and cells.—On account of the close communication which exists between the air-containing spaces within the mastoid process (mastoid antrum and mastoid cells) and the tympanic cavity, and the frequency with which the latter space is the seat of suppurative affections, it often happens that the surgeon is called upon to explore the interior of the mastoid cells, owing to an extension of the suppurative process from the tympanum.

Indications.—(a) Acute suppurative affections of the mastoid process.

(b) Chronic inflammatory affections of the mastoid, associated with the formation of a collection of pus or a sequestrum.

(c) Cholesteatomatous swellings or collections of secretion within the mastoid process, especially in the antrum.

Instruments.—Scalpel, pressure and dissecting forceps, periosteal elevator, grooved chisel, mallet, small Volkmann's



FIG. 270.—Knife for incision of membrane tympani.

spoon, fine sequestrum forceps, drainage tube, needles, needle-holder, and suture and ligature material.

Position.—The patient is placed in the dorsal posture, with a pillow underneath the head, and the head turned towards the sound side. The surgeon stands on the affected side, and his assistant opposite to him.

Operation. — An incision, a little over 2 in. in length, is made parallel with the free border of the auricle, commencing

FIG. 271.—Opening of mastoid antrum and mastoid cells. Position of external incision.

above and terminating near the apex of the mastoid process. This incision divides everything down to the bone, including the periosteum. Some small branches of the posterior auricular artery will usually require ligature. Next, the soft tissues are lifted up from the bone with a periosteal elevator, as far as the posterior

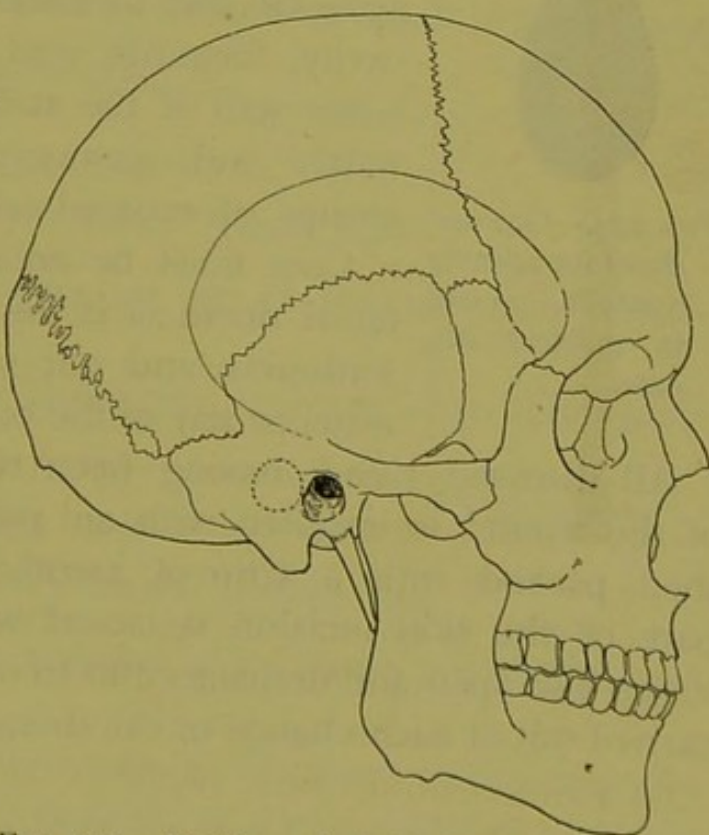


FIG. 272.—Position of the incision through the bone, in exploration of the mastoid antrum and cells.

border of the meatus, and backwards for a short distance if necessary. The assistant pulls the auricle well forwards, and at the same time retracts the margins of the incision. The operator next takes the chisel and mallet, and removes the external table of the mastoid process, the portion of bone removed corresponding to the circle in Fig. 272. By this means the region of the mastoid antrum and the upper mastoid

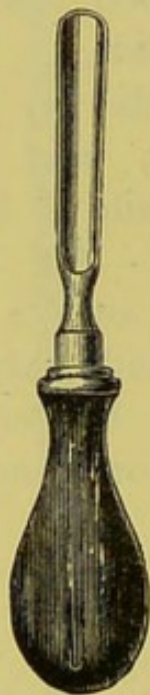

FIG. 273.—Grooved chisel for opening mastoid process in mastoid disease.

cells will be laid bare and can be explored. Any collection of pus, cholesteatomatous material, or sequestrum which may be present, will by this means be partially or entirely exposed. If the former, more bone must be chiselled away in the direction of the diseased part, and then all diseased tissue or abnormal collections can be removed. If necessary, the incision in the bone can be prolonged upwards and forwards into the tympanic cavity, forwards into the outer and posterior wall of the auditory canal, or backwards and downwards into the lower groups of mastoid cells.

Care must be taken not to injure the facial nerve as it lies in the aqueduct of Fallopius, and not to wound the lateral sinus or any of the other cranial contents.

All diseased tissue having been removed, the interior of the wound is irrigated with an antiseptic solution, and then packed with a strip of aseptic gauze. The upper part of the skin incision is closed with sutures, and the lower left open for drainage and to enable irrigation to be carried out at each change of the dressings, if necessary.

CHAPTER XXIII.

OPERATIONS ON THE BONES.

1. OSTEOTOMY.
2. OPERATIONS FOR UNUNITED FRACTURE.
3. EXCISION OF BONES.

Osteotomy.—By the term osteotomy is understood complete division of a bone in its continuity. Two forms of this operation are practised:—

(a) *Linear osteotomy.*—In this procedure a bone is divided transversely, usually through a small skin incision,




FIG. 274.—Chisel. Cutting edge.

the operation being more or less of the nature of a subcutaneous one.

(b) *Wedge-shaped or cuneiform osteotomy.*—In this opera-




FIG. 275.—Osteotome. Cutting edge.

tion, in addition to the division of the bone, a wedge-shaped portion is removed.

The operation of osteotomy is required in the majority of instances for the rectification of a congenital or acquired malformation of one or more bones, or for ankylosis of a joint in a bad position. Usually this condition is the result of

rickets, or of union of a bone in a faulty position after it has been fractured.

Instruments.—Long-bladed narrow scalpel, chisel, osteotomes, wooden mallet, and suture and ligature material.

In certain cases, pressure forceps and retractors may be required, and occasionally some form of saw.

In linear or transverse osteotomies an osteotome is used

for division of the bone; in wedge-shaped osteotomy a chisel will be found more convenient for the purpose. Figs. 274 and 275 show the shape of the cutting edge of a chisel and osteotome respectively.

Osteotomy of the lower extremity of the femur. — *Indications.*

—(a) Those forms of genu valgum dependent upon malformation of the femur, which are not readily amenable to rectification by instruments, splints, or other means.

(b) Some cases of genu varum associated with malformation of the lower end of the femur.

(c) Occasional cases of malformation of the lower end of the femur, resulting from injury.

Different forms of operation.—Several different methods of operation are practised for the rectification of the above forms of malformation of the femur. The three most important ones are—

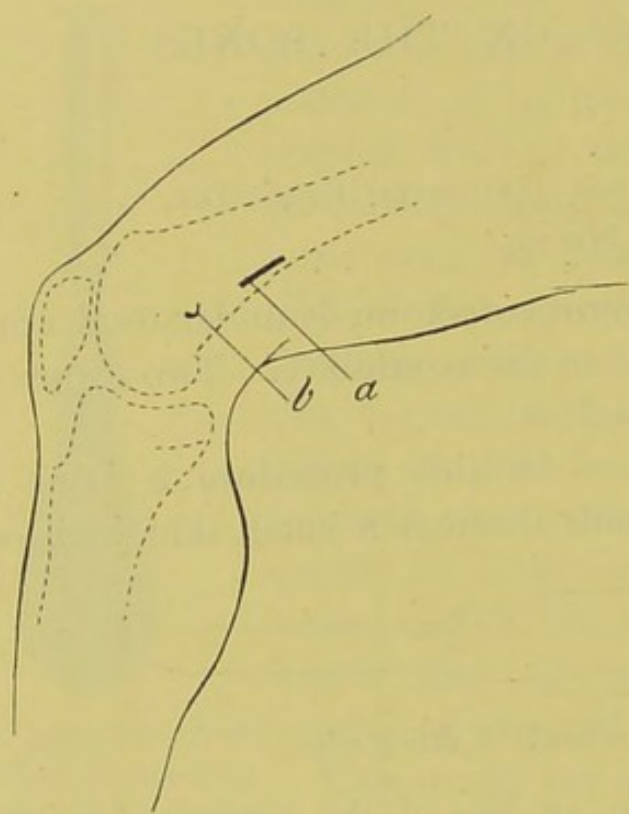


FIG. 276.—Supracondylar osteotomy of femur.—MACEWEN'S.

a. Line of skin incision.

b. Adductor tubercle of femur.

(a) Transverse division of the femur just above the condyles (Macewen's supracondylar operation), through an incision on the inner side.

(b) Transverse division of the femur a short distance above the condyles, through an incision on the outer side.

(c) Detachment of the internal condyle (Ogston's or Reeves' operation).

A. Macewen's operation. —

Position. — The patient is anaesthetised and placed in the dorsal position, with the knee somewhat flexed, and the lower extremity rotated outwards so as to lie upon its outer side. A moderate-sized sandbag is placed beneath the knee of the affected side, so as to support it.

It is advisable in this operation to remove all mattresses and pillows from between the patient and the operating table.

The surgeon stands on the opposite side of the patient to the affected limb, and his assistant opposite to him.

Operation. — The skin of the thigh having been rendered aseptic by the usual methods, a point is taken half an inch above and anterior to the adductor tubercle of the femur. A long-bladed scalpel is pushed inwards to the bone, the incision being parallel to the long axis of the limb. All the

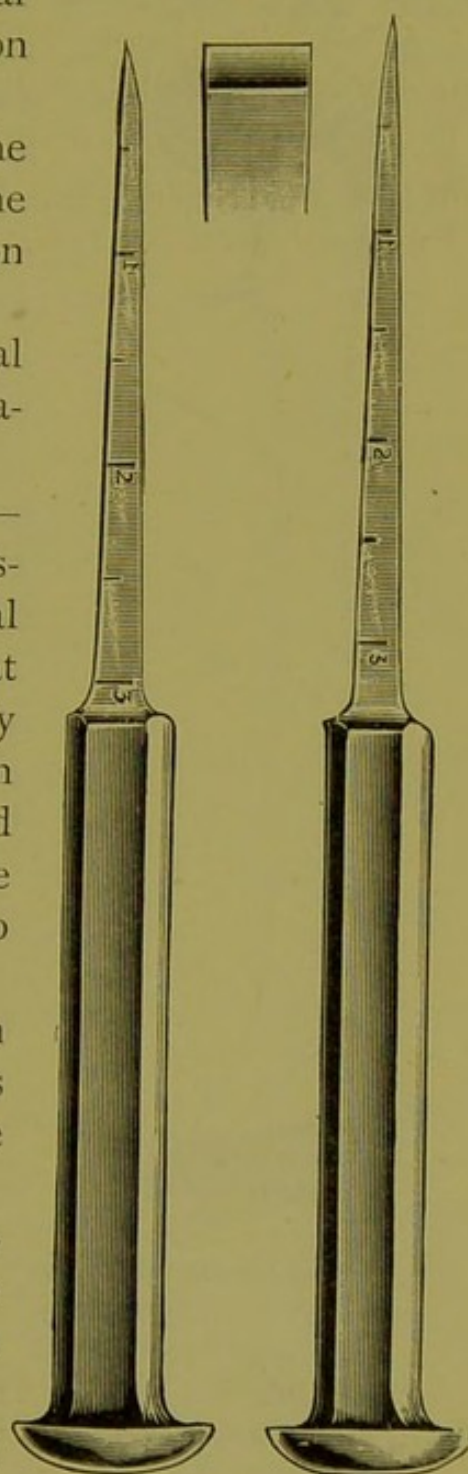


FIG. 277.—Macewen's osteotomes.

soft tissues, including the periosteum, are divided down to the bone for about three-quarters of an inch. The

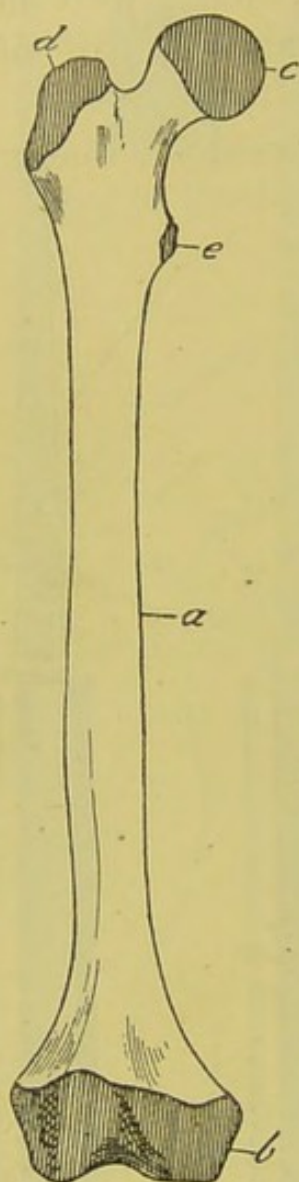


FIG. 278.—Femur, showing parts derived from primary and secondary centres.

- a.* Shaft.
- b.* Lower epiphysis.
- c.* Head.
- d.* Great trochanter.
- e.* Small trochanter.

osteotome is now passed downwards to the bottom of the wound along the blade of the scalpel, which serves as a director. The scalpel is then withdrawn, and the osteotome is turned until its blade is at right angles to the shaft of the femur. A series of short sharp strokes is given with the mallet, so as to drive the cutting part of the osteotome through the femur. The osteotome should be so manipulated that the postero-internal margin of the femur is first divided, and the section then continued forwards and outwards in such a manner that the posterior fourth of the femur is left undivided. The section of the femur should be made at right angles to its shaft; if this is not done, the cut may extend in young people into the epiphyseal cartilage, a complication which ought to be avoided.

After each blow with the mallet the osteotome should be moved to and fro, so as to prevent its becoming impacted in the bone, but any upward and downward movement (with reference to the long axis of the limb) must be avoided. The latter part of the section of the bone may be facilitated by using a smaller osteotome, but this is not usually requisite.

When the section with the osteotome has extended to

the outer part of the bone, the instrument is removed. The thigh is then grasped with the right hand, a short distance above the line of section, and the leg with the left hand, and by forcible flexion the remaining part of the bone is fractured.

The limb is brought into a straight position; one or two points of suture are used to close the skin incision, and aseptic dressings applied.

The limb is fixed in position by the application of a long outside splint, and short back and side splints. After the expiration of from four days to a week the splints may be removed, the stitches taken out, and the limb encased in plaster.

After-treatment.—The plaster case should be kept on for about six weeks from the time of operation. It is then removed, and if union is found to be firm, the patient is allowed to get about on crutches.

B. Transverse division of the femur above the condyles, through an external incision.—In this operation the skin incision is usually made at a somewhat higher level than in the previous operation.

Position.—The patient is placed in the dorsal position; the affected limb is slightly flexed and rotated inwards, a sandbag being placed at its internal aspect to support it.

The surgeon stands at the outer side of the affected limb, and the assistant opposite him.

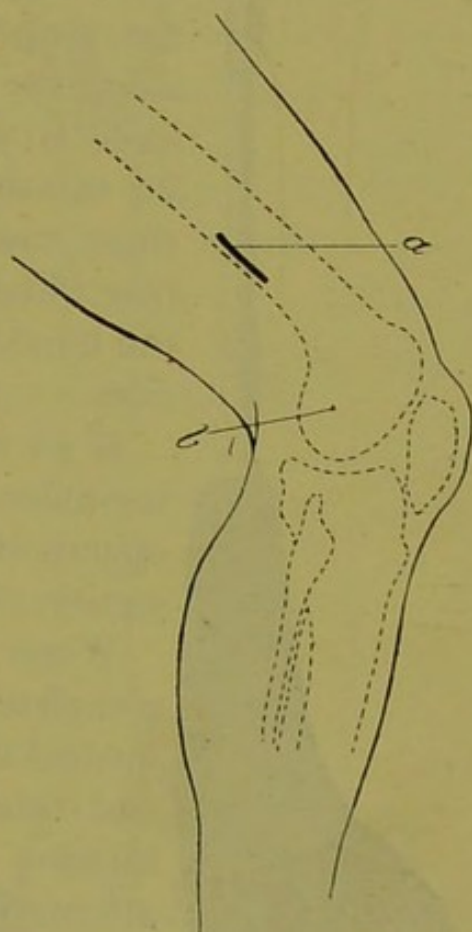


FIG. 279.—Osteotomy of femur. Transverse division through an external incision.

a. Position of incision.

b. Prominence of external condyle.

Operation.—An incision is made, about three-quarters of an inch in length, 3 in. above the external condyle of the femur. This incision divides the skin, fasciæ, vastus externus muscle, and periosteum. Either a saw or an osteotome may be used for the division of the bone.

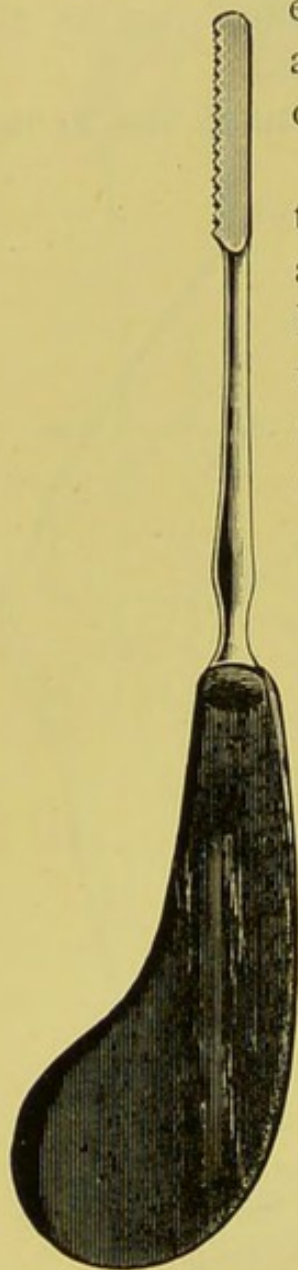

FIG. 280.—Osteotomy saw.—ADAMS.

In the former case an osteotomy saw, of the shape shown in Fig. 280, is passed along the knife down to the bone; the knife is withdrawn, and the bone divided for two-thirds of its extent by a series of short to-and-fro movements. The saw is now withdrawn, and the remaining part of the bone fractured, as in Macewen's operation.

If an osteotome is used, the procedure is similar to that described in the previous operation, with the exception that the section is commenced from the outer side.

When the section of the bone has been completed, the wound in the soft tissues is washed out, so as to remove all bone dust and other foreign material, and the skin incision closed with sutures. Splints are afterwards applied, as in the previous case.

C. Detachment of the internal condyle.

—*Position.*—The positions of the patient, operator, and assistant are similar to those for Macewen's operation.

Operation.—A point is taken about 2 in. above and a little anterior to the adductor tubercle of the femur. A long-bladed knife is pushed through the soft tissues of the thigh at this point in a downward and outward direction, until the anterior intercondylar notch of the femur is reached. Portions of the vastus internus and crureus and synovial membrane

are divided. The skin incision may be slightly enlarged as the knife is withdrawn. Before doing this, however, the blade of an osteotomy saw is passed along the knife into

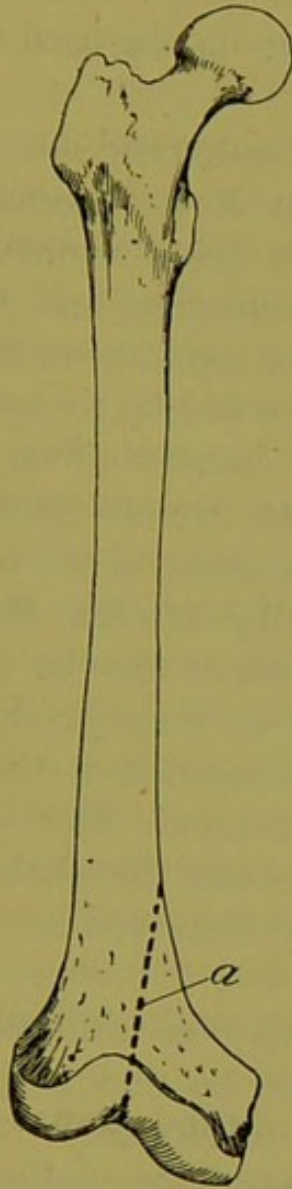


FIG. 281.—Osteotomy of femur. Detachment of internal condyle.—OGSTON.

a. Line of division of bone.

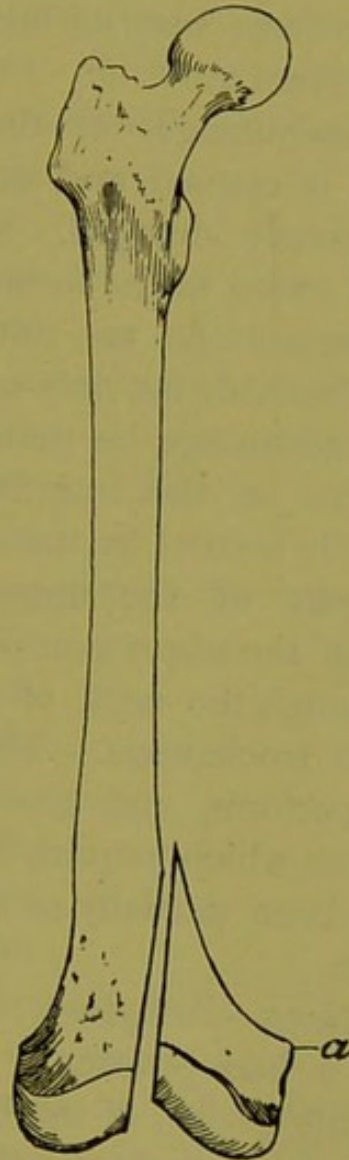


FIG. 282.—Internal condyle detached.—OGSTON.

a. Internal condyle.

the notch. The cutting part of the saw is turned towards the popliteal space, and the bone sawn through for the anterior three-quarters of its thickness. The saw is removed, and the leg bent forcibly inwards, by which means the

internal condyle is completely detached and caused to slide upwards on the inner side of the femur.

The external incision is closed, and antiseptic dressings and splints are now applied.

An osteotome may be used in place of the saw, if the surgeon prefers it.

The disadvantages of the above operation are — The knee-joint is opened and the position of its internal ligaments seriously changed. Stiffness is liable to follow the operation, owing to the formation of adhesions, and if strict aseptic precautions are not observed septic arthritis may follow. Probably the only condition in which the operation may with advantage be performed is in cases of very great enlargement of the internal condyle, which cannot be satisfactorily treated by transverse osteotomy of the bone.

Osteotomy of the upper extremity of the femur.—

Division of the upper portion of the femur may be effected either through the neck of the bone or through the shaft below the trochanters. The latter operation is the more easy to perform, and gives better results. Moreover, in many cases which require this procedure, the neck of the bone has been partially or completely destroyed as a result of disease.

Indications.—Ankylosis of the hip-joint with the limb fixed in a bad position. This may be due to previous tuberculous disease of the hip-joint; to suppurative arthritis of the hip-joint, such as occurs in pyæmia; or to ankylosis after gonorrhœal rheumatism or rheumatoid affections.

Position.—The patient lies somewhat on the sound side, with the outer aspect of the affected hip well exposed. The operator stands on the affected side of the patient, and the assistant directly opposite to him.

Operation.—The skin of the thigh having been rendered aseptic, a point is selected on the outer side of the limb, a short distance below and anterior to the great trochanter of the femur (Fig. 283). A long-bladed scalpel is pushed inwards,

down to the bone at this point, with its blade parallel to the long axis of the limb, and the skin, fasciæ, muscle, and periosteum are divided. The incision should be about three-quarters of an inch in length. The osteotomy saw is pushed along the blade of the knife down to the bone, the latter instrument being now withdrawn. With the saw the femur is divided for the anterior three-fourths of its thickness. The saw is then withdrawn, and the thigh is forcibly straightened, by which means the remaining part of the bone is fractured. The incision in the soft tissues is closed with sutures, an aseptic dressing is applied, and the limb fixed in the rectified position by means of a long outside splint.

After-treatment.—The limb should be kept in this position until firm union has been obtained, usually for about six weeks.

It is not advisable to attempt to create a false joint at the line of section, since very poor results have usually followed such attempts.

Some surgeons, especially Adams, have advocated division of the neck of the femur within the capsule. This is effected through an incision above the great trochanter. In my opinion, however, this operation does not give such good results as the one which has been above described.

Osteotomy of the tibia.—This operation may consist in either simple transverse section of the tibia, or section combined with removal of a wedge-shaped portion.

Indications.—Malformed curved tibiæ, due to rickets, syphilis, osteomalacia, or the result of injury, and certain

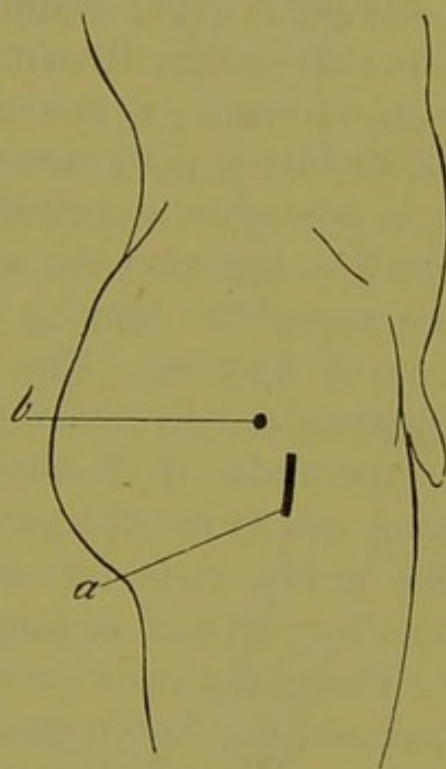


FIG. 283. — Osteotomy of femur. Subtrochanteric operation.

a. Position of skin incision.
b. Top of great trochanter.

cases of ankylosis of the knee-joint in which the limb is in a bad position.

Instruments.—The ordinary instruments for osteotomy.

Position.—The patient is placed in the dorsal position, with the affected limb lying upon its outer side, a sandbag being placed beneath it. The surgeon stands on the outer side of the limb, and the assistant opposite him.

Operation.—(a) *Simple transverse section of the tibia.*—The skin having been rendered aseptic, a vertical incision, 1 in. in length, is made over the most prominent part of the deformed portion of the bone. In making this incision, it is advisable to pull the skin well inwards with the left hand, so that after the section of the bone has been made the superficial opening may be a short distance from the line of fracture. The soft parts—skin, fasciæ, and periosteum—are divided down to the bone. The osteotome is then introduced, its cutting part turned at right angles to the long axis of the tibia, and that bone divided with the aid of the mallet, as in osteotomy of the femur. An osteotomy saw may be used in place of the osteotome, if preferred.

The tibia having been almost completely divided in this manner, the limb is grasped above and below the plane of section and forcibly straightened. In doing this the fibula is fractured at the same time that the undivided portion of the tibia is broken across.

The wound is sponged dry, closed with a few points of suture, and aseptic dressings applied. The limb is fixed in the rectified position by the application of back and side splints.

After-treatment.—Careful attention should be paid to the position of the limb, so as to avoid any displacement. After from five to seven days the splints are taken off, the stitches removed, and the limb put in a plaster or silicate case.

(b) *Transverse osteotomy, with removal of a wedge-shaped portion of bone.*—The first stage of this operation is similar to the above, with the exception that the incision is

made a little longer and the periosteum is detached from the tibia for a short distance, usually 1 in. or $1\frac{1}{2}$ in. The soft parts, including the periosteum, are held aside with retractors, and a wedge-shaped portion of the tibia, the base of the wedge being anterior, removed with a chisel (Fig. 284). Care must be taken to completely divide the bone posteriorly, and if there is any difficulty in getting the limb straight the periosteum on the posterior part of the tibia should be divided also. The wedge-shaped piece of bone having been removed, the limb is forcibly straightened and put up in splints, as in the preceding case.

In certain cases of bony ankylosis of the knee-joint with the limb in a faulty position, it may be necessary, in order to rectify the deformity, either to divide, or to divide and remove a wedge-shaped portion from the upper extremity of the tibia.

This operation is similar to the preceding one, with the exception that the skin incision is made over the upper fourth of the tibia.

Operations for ununited fracture.

— *Indications.* — Those cases of ununited fracture of bone,—usually the femur, tibia, humerus, radius and ulna, patella, or olecranon, which do not unite after treatment by splints,—and some cases of recent fracture, particularly of the patella and olecranon.

Instruments. — Scalpel, dissecting, pressure, and artery forceps, retractors, periosteal elevators, chisel, mallet, osteotomy saw, bradawl, needles, needle-holder, ligature and suture material, and suitable splints.

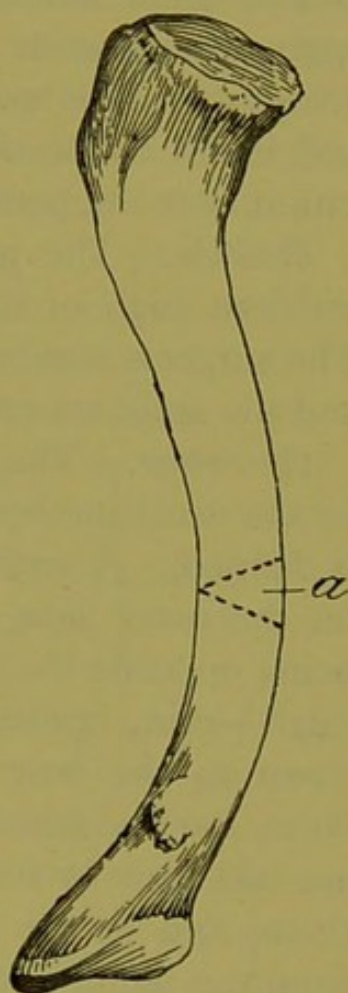


FIG. 284.—Osteotomy of tibia. Removal of wedge-shaped portion.

a. Portion of bone to be removed.

Ununited fracture of the femur.—*Preliminary preparations.*—In those cases of ununited fracture of the femur in which there is considerable shortening owing to malposition of the fragments of bone, it is advisable to keep the patient in bed for a few days previous to the operation, and to apply extension to the affected limb. By this means the deformity will be lessened, the muscles somewhat lengthened, and it will be possible to fashion a suitable splint for application after the performance of the operation.

Position.—The patient is placed in the dorsal position, with the thigh of the affected limb resting upon a sandbag. The surgeon stands upon the affected side of the patient, and the assistant upon the sound side.

Operation.—The skin of the thigh is first rendered aseptic by the usual methods, and then the position of the fracture is defined. A vertical incision, 4 or 5 in. in length, is made on the outer side of the limb, the centre of the incision being opposite the seat of fracture. The soft tissues of the thigh—skin, fasciæ, muscle, and periosteum—are divided down to the bone for the entire length of the incision. Next, the free extremities of the fractured ends of the bone are laid bare by turning aside the soft tissues surrounding them, and at the same time the periosteum is detached from the femur above and below the fracture for a distance of about half an inch. The ends of the bone having been freed in this manner, the limb is bent until one of them projects into the wound. The soft parts are protected with flat retractors, and then with chisel and mallet a portion of the end of the bone, about a quarter of an inch in thickness, is removed. The other extremity is now brought into the wound and treated in a similar manner. In making the section of the bone, care must be taken so to fashion the two free extremities that they may fit one another when brought together. In order to do this satisfactorily, it is better to make one end somewhat convex and the other somewhat grooved or concave. The ends of the bone,

when properly prepared, are brought into apposition, and the external wound closed. Splints are then applied, so as to fix the limb immovably in the position in which it has been placed.

In order to prevent unnecessary movement of the limb after the operation, Mr. Treves suggests that the operation might be performed with the patient lying upon the bed which he is to occupy afterwards.

Some surgeons have advised that the two ends of the bone should be fixed together by sutures of strong silver wire, metal screws, or ivory pegs. In my opinion, however, these methods of fixation of the bone are of little advantage, since, if care be taken to make a free exposure of the fractured ends, to fashion the two extremities so that they fit together, and to apply suitable splints, few, if any, failures will be met with.

Senn has suggested that when the two extremities of the bone have been freed, and the thickened periosteum removed, a bone "ferrule" should be used to hold them in apposition. A sufficient number of cases treated in this manner have not, however, as yet been recorded to justify its inclusion as a recognised surgical operation.

Ununited fractures of the tibia and fibula, radius and ulna, and humerus, are treated in a manner exactly similar to the above.

Ununited fracture of the patella.—*Operation.*—A vertical incision is made over the middle of the anterior aspect of

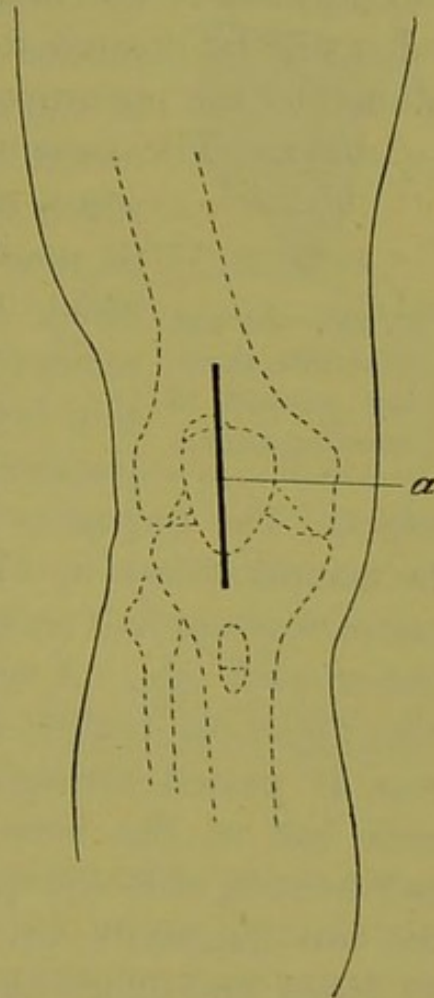


FIG. 285. — Operation for fracture of patella.

α. Position of external incision.

the limb, commencing 1 in. above the lower border of the upper fragment, and terminating 1 in. below the upper border of the lower fragment. The soft

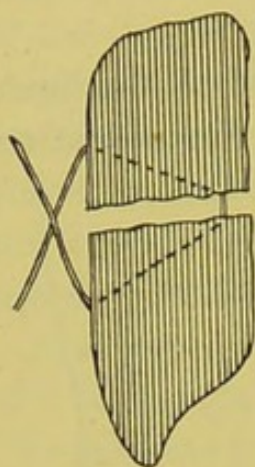


FIG. 286.—Section of patella, showing method of inserting sutures.

parts are divided down to the anterior surface of the bone, and dissected outwards for a short distance, and held aside by retractors. In this way the anterior surface of the two fragments of the patella is exposed, and if the fracture is not a recent one, the intervening fibrous tissue which holds them together. All bleeding is now arrested, and the fibrous tissue which lies between the two fragments is removed. Next, except in recent cases, a thin layer of bone is taken away from the fractured surfaces with the chisel and mallet. The fragments are now pierced with a bradawl, in the manner shown in Fig. 286. It is best to pierce each fragment about half an inch from the middle line on each side. A suture of strong silver wire, about one-twelfth of an inch in thickness, is passed through the perforation in each half of the bone, and by tightening and twisting this the prepared surfaces of the two fragments are fixed in apposition, all blood and débris having been previously sponged away. The ends of the suture are cut short and hammered into the bone, the external wound is closed by the insertion of silkworm-gut sutures, and the limb is fixed in the fully extended position by the application of splints. Passive movements of the knee-joint should be commenced at the end of two weeks from the time of operation. Some surgeons advise that when union is complete the wire suture should be removed through an incision made over it.

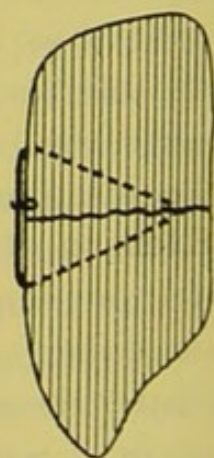


FIG. 287.—Section of bone, showing sutures inserted and fixed.

Ununited fracture of the olecranon.—In ununited fracture of the olecranon process of the ulna, an operation similar to the one described for ununited fracture of the patella may be made use of.

A vertical incision is made in the long axis of the limb, over the posterior aspect of the elbow. The fragments are defined; the fractured surfaces separated from all fibrous tissue and synovial membrane, and freshened by the removal of a plate of bone with the chisel, and then fixed in apposition by the insertion of wire sutures. The limb is put up on an anterior splint, and maintained in position of almost complete extension.

In many cases of widely separated ununited fractures of the patella and olecranon, difficulty is experienced in bringing the freshened surfaces of the fractured portions of the bones together. When this happens, the fibres of the rectus femoris muscle might be divided in the former case, and those of the triceps humeri in the latter, just above their insertion.

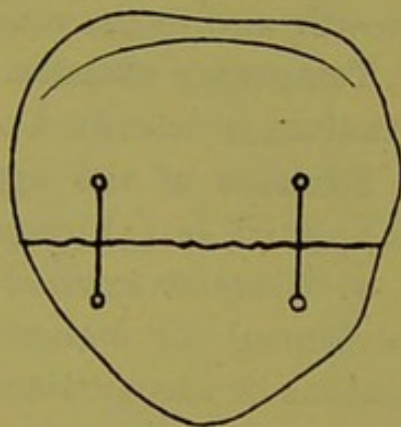


FIG. 288. — Position of sutures on anterior aspect of patella.

Excision of bones.—An excision of a bone may be either partial or complete. In the former case only a part of the bone, either of the shaft or an extremity, is taken away; in the latter the entire bone, including its articular surfaces, is removed. Sometimes a bone is only partially detached, and turned aside, and afterwards replaced and fixed in its original position. This is called "temporary" or osteoplastic resection, and may be performed, for example, in the case of the upper jaw, to allow of the removal of a nasopharyngeal polypus. It is also employed in connection with the cranial vault, in order to obtain a free exposure of portions of the brain or membranes.

Instruments.—The instruments necessary for the resection

of a bone include — scalpel, resection knife, dissecting, pressure, artery, and bone forceps, lion forceps, periosteal elevator, sequestrum forceps, saw, retractors, needles, needle-holder, and ligature and suture material.

Indications. — (a) New growths of bone, especially sarcomata.

(b) Localised inflammatory affections associated with the formation of sequestra or abscesses.

(c) Some forms of malformation, either congenital or acquired, such as inveterate club-foot.

(d) As a temporary measure in some forms of intracranial growth, and in the removal of naso-pharyngeal polypi.

Temporary excision of a portion of the bony wall of the cranium is described on p. 289.

Excision of the upper jaw.—This may be (1) complete, (2) partial, or (3) temporary.

1. *Complete excision of the upper jaw.*—This operation is performed for malignant growths of the upper jaw, sarcomatous or carcinomatous, which have not extended beyond this structure into the adjacent tissues.

Instruments.—In addition to the ordinary instruments for the excision of a bone, a gag and a pair of upper-incisor dental forceps are required. A key-hole saw and a Hey's or other form of small saw are also required.

Position.—The patient is placed in the dorsal position, with the head supported by a pillow, and near the right margin of the operating table. The surgeon stands on the right side of the patient (both for right and left upper jaws), and the assistant stands on the left, directly opposite to him.

Operation.—The operation for the removal of the upper jaw may conveniently be divided into the following stages:—(a) External incision, and dissection back of cheek-flap; (b) division of bony connections, and removal of incisor tooth; (c) division of soft palate, and removal of jaw.

(a) *External incision, and dissection back of cheek-flap.*—

An incision is made, commencing below and a little internal to the internal canthus of the eye of the affected side, extending downwards along the lateral aspect of the nose as far as the ala, then horizontally inwards to the middle line opposite the septum, and finally vertically downwards through the upper lip into the mouth. From the same starting-point a second incision is carried outwards, parallel with the inferior margin of the orbit, as far as the prominence of the malar bone. Both parts of the incision divide skin, fasciæ, and muscle, and a flap is dissected back including all the soft tissues of the cheek except the periosteum. By this means the external surface of the superior maxilla is laid bare. Next, the periosteum along the inferior margin of the orbit is divided, and the orbital contents lifted upwards for a short distance, so as to define the position of the anterior portion of the speno-maxillary fissure and the groove in the lachrymal bone. The cavity of the nose is also opened by detaching the nasal cartilages from their lateral connection with the bone. As the operation proceeds, all blood vessels which are cut across are seized with pressure forceps and ligatured.

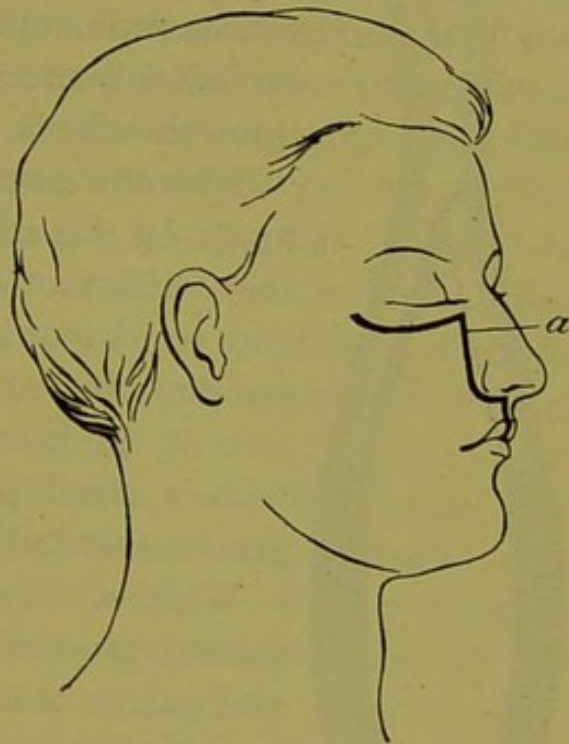


FIG. 289.—Excision of upper jaw.
Position of external incision.

a. Incision.

(b) *Division of bony connections, and removal of incisor tooth.*—With a Hey's saw (Fig. 187) the nasal process of the superior maxilla is divided by a cut which extends from the margin of the bony nasal aperture to the groove in the lachrymal bone. A second saw-cut is made through the

bridge of bone which separates the anterior extremity of the spheno-maxillary fissure from the external surface of the malar bone. Care should be taken in so doing that the malar prominence is left behind, in order to prevent too

great a falling-in of the cheek afterwards. In dividing the nasal process of the superior maxilla, the attachments of the internal orbital ligament must be carefully preserved, otherwise the suspensory ligament of the eyeball will be rendered more or less useless, and the eyeball will afterwards prolapse and come out upon the cheek.

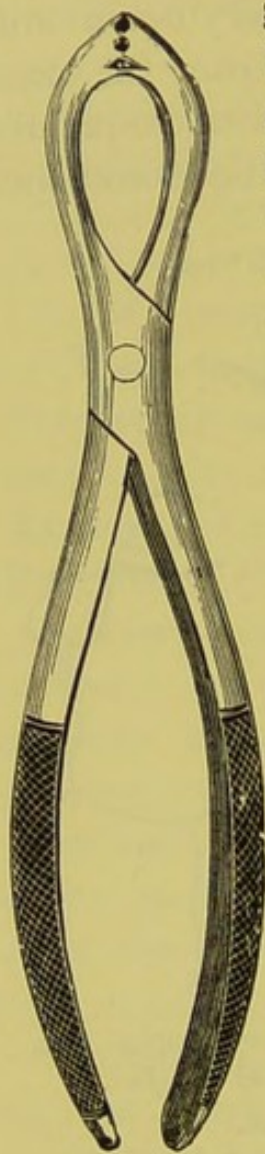
With the dental forceps the central incisor tooth on the affected side is removed, and then with the scalpel the mucous membrane and periosteum along the floor of the nose on the affected side, and on the under surface of the hard palate, are divided, together with a small portion of the soft palate at its junction with the hard.

With a key-hole saw the alveolar and palatal processes of the superior maxillary and palate bones are divided, the saw being passed into the nose for this purpose. In performing this section of bone, care must be taken not to allow the saw to travel too far backwards, otherwise the base of the skull or the naso-pharynx may be injured.

(c) *Division of soft palate, and removal of jaw.*—With the scalpel the soft palate of

FIG. 290.—Excision of upper jaw. Lion-forceps.

the affected side is completely divided in a transverse direction. Next, the lion forceps are taken, one blade placed in the orbit, the other in the mouth, and by a forcible wrenching and screwing movement the entire upper jaw is removed. This part of the operation (incision of the soft palate and removal of the upper jaw) should be



effected as quickly as possible, on account of the severe hæmorrhage which may occur.

The jaw having been removed, the place it occupied is at once packed with sponges, so as to temporarily arrest bleeding. All blood is sponged out of the mouth and pharynx, and any bleeding vessels ligatured. In some cases it may be necessary to make use of a Paquelin's cautery, to arrest hæmorrhage from vessels in the bone. When all hæmorrhage has been arrested, the wound is packed with tampons of aseptic iodoform gauze, and the skin incision closed by the insertion of a series of interrupted sutures of horse-hair or fine salmon-gut. The first of these sutures to be inserted should be the one at the internal canthus, the second the one at the margin of the lip, the third that by the septum of the nose. All the sutures having been tied and cut short, the line of incision is covered with a thin strip of gauze, and painted with a mixture of collodion and iodoform.

After-treatment.—At the end of twenty-four hours the tampons of gauze are removed, the wound syringed out through the mouth, and packed as before. This process of dressing is repeated daily. The sutures are taken out at the end of five days or a week.

If the prominence of the malar bone has been removed, it will usually be found necessary to fit up the patient with an obturator or artificial upper jaw, so as to obliterate the flattening and consequent deformity of the cheek. If, however, the prominence of the malar bone is left, no artificial aid of this kind will usually be required.

2. *Partial excision of the upper jaw.*—Some surgeons have advocated leaving the orbital portion of the superior maxilla in cases of excision of the upper jaw. When, however, excision is undertaken for malignant growths of this bone, whether sarcomata or carcinomata, it is not advisable to leave this part of the bone behind, owing to the great liability to recurrence of the disease in the part left.

Partial excision of the upper jaw may, however, be practised with advantage, under the follow circumstances :—

- (a) In removal of dentigerous cysts.
- (b) In removal of fibrous epulis.
- (c) For drainage of the antrum.
- (d) For removal of Meckel's ganglion.

The precautions to be observed in removal of portions of the upper jaw are described in the different chapters which deal with the individual operations.

In removing a part of the jaw on account of a growth, the teeth in the immediate neighbourhood should first be extracted, and then the entire portion of the bone involved in the growth, together with its periosteum, should be completely removed.

3. *Temporary excision of the upper jaw.*—Temporary or osteoplastic excision of the upper jaw has been practised in a few cases for removal of naso-pharyngeal tumours.

The details of the operation have been described in connection with the removal of naso-pharyngeal polypi (p. 431).

Excision of the lower jaw.—*Indications.*—Sarcoma of the inferior maxilla, carcinoma of the floor of the mouth, extending into the inferior maxilla, and cystic epithelioma of the inferior maxilla.

Instruments.—As for the removal of the upper jaw.

Position.—The patient is placed in the dorsal position, with the head slightly raised by a sandbag. The operator stands on the affected side of the patient, and the assistant on the opposite side.

Operation.—An incision is made through the lower lip, commencing at the junction of the red portion with the skin, and extending downwards to the symphysis menti, then along the horizontal ramus to the angle, and finally upwards as far as the level of the lobule of the ear. This incision extends down to the bone, except in the neighbourhood of the facial artery at the anterior border of the

masseter muscle. The facial artery is isolated, tied in two places, and cut between. Then all the soft tissues of cheek, except the periosteum, are dissected up from the bone. The lower jaw is now sawn through, half an inch external to the symphysis menti, an incisor tooth being first extracted, if requisite. The mucous membrane of the floor of the mouth, and the various muscles which are attached to the internal aspect of the lower jaw, are separated as far back as the angle. The horizontal ramus of the jaw is then grasped by the left hand of the operator, and the bone depressed so as to bring forwards and render evident the coronoid process and temporal muscle. The internal pterygoid is completely detached from the angle and ascending ramus, and the internal lateral ligament cut through where it is fixed to the internal margin of the inferior dental foramen. The inferior dental artery is picked up with pressure

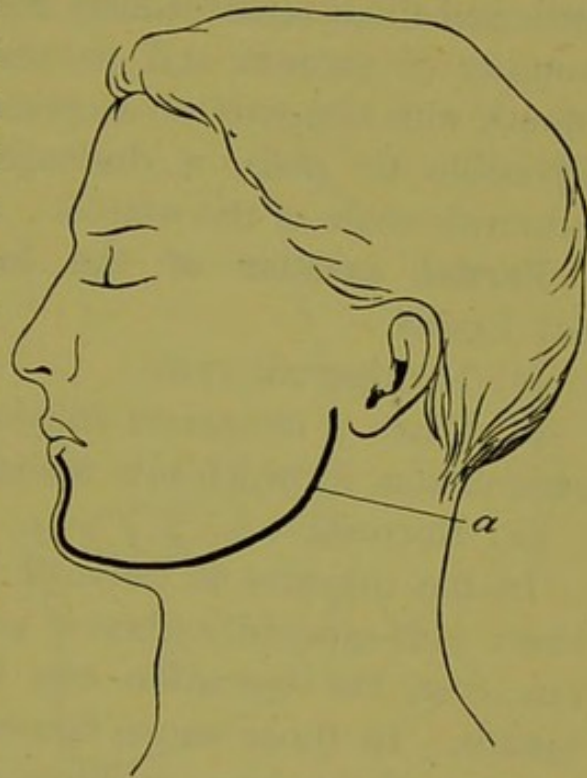


FIG. 291. — Excision of lower jaw.
Position of skin incision.

a. Incision.

forceps, just before it enters the foramen, and cut across, together with the corresponding nerve. The insertion of the temporal muscle into the coronoid process is now detached, and the pterygo-maxillary ligament divided. The ramus of the jaw is then further depressed, so as to render prominent the condyle. The capsular ligament of the temporo-maxillary articulation is opened and then divided all the way round, together with the external pterygoid muscle, which is inserted into the neck of the condyle at its

anterior and internal aspect. When this has been done, the jaw can be completely removed. Care must be taken throughout the operation not to twist the lower jaw upon its axis, otherwise the internal maxillary artery which lies in close relation with the neck of the bone will run great risk of being injured. All through the operation the cutting edge of the knife should be kept close to the bone.

After the removal of the bone, all bleeding vessels are tied, and the external wound is closed by the insertion of a number of sutures, and packed from the interior of the mouth with tampons of aseptic gauze. It is in most cases advisable to place a drainage tube in the lower and posterior angle of the wound.

Partial excision of the lower jaw.—*Indications.*—

(a) Epulis.

(b) Dentigerous cyst.

(c) Cases of inveterate ankylosis of the temporo-maxillary articulation, in which it is wished to make a false joint.

(d) Necrosis.

In the majority of cases of removal of a portion of the lower jaw, especially when it is done for epulis or dentigerous cyst, the operation can be carried out through the mouth. In those cases, however, in which a considerable portion of the bone requires removal, or in which there is any difficulty in performing the operation through the mouth, an incision through the cheek, along the affected portion of the bone, should be made.

Position.—As for the preceding operation.

Operation.—The affected portion of the bone, together with the adjacent part of the floor of the mouth and internal surface of the cheek, are thoroughly exposed, either by opening the mouth with the gag and pulling aside the soft parts with retractors, or by making an incision through the tissues of the cheek overlying the portion of bone involved. Any teeth which may be present in the affected part of the jaw are removed. The mucous membrane and the peri-

osteum are divided with a scalpel a short distance from the margin of the growth, and then with a chisel and mallet the affected portion of the bone is removed. If possible, a bridge of bone should be left along the inferior margin of the jaw, but this must not be done at the risk of leaving any diseased tissue behind.

After the arrest of hæmorrhage the wound is packed with tampons of aseptic gauze.

Removal of a wedge-shaped portion from the horizontal ramus of the lower jaw.—

This operation has been carried out in cases of closure of the lower jaw, dependent upon extensive contraction following burns or cancrum oris.

The wedge-shaped portion of bone is removed from the horizontal ramus, immediately in front of the attachment of the masseter muscle, the apex of the wedge being at the alveolar margin and the base at the lower border.

Fig. 292 shows the portion of bone which is removed in this operation.

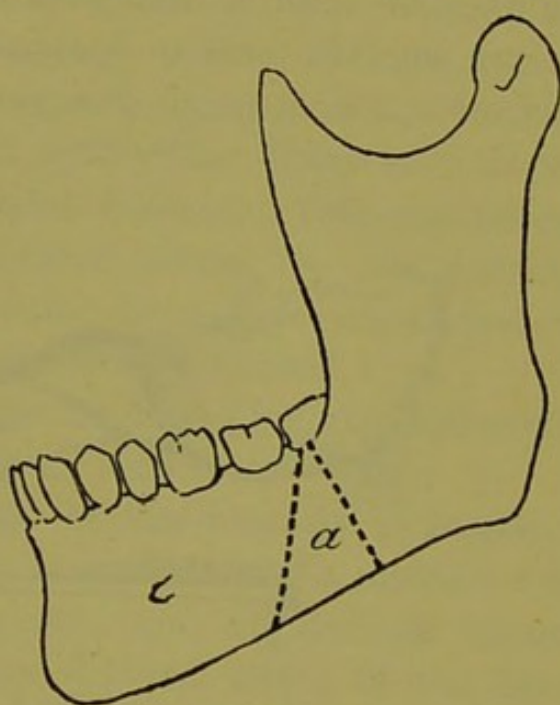


FIG. 292.—Removal of a wedge-shaped piece from lower jaw.

a. Part to be removed.

Operation.—An incision, 2 in. in length, is made parallel with the horizontal portion of the lower jaw, commencing at the anterior border of the masseter, and extending forwards towards the symphysis. The soft parts are divided, the facial artery being pulled downwards, and the external surface of the jaw exposed. The periosteum is now cut through, and the wedge-shaped piece of bone separated with a narrow-bladed saw. When the bone has been sawn through, the attachments of the mylo-hyoid muscle to its

deep surface are cut through, together with the mucous membrane in the floor of the mouth. The separated piece of bone can then be completely removed.

All bleeding is arrested, the interior of the wound packed with tampons of aseptic gauze, and the skin incision closed by the insertion of a series of interrupted sutures.

Good results are said to have followed this operation. Mastication can only be performed on one side.

Excision of the clavicle.—*Indications.*—(a) Sarcoma

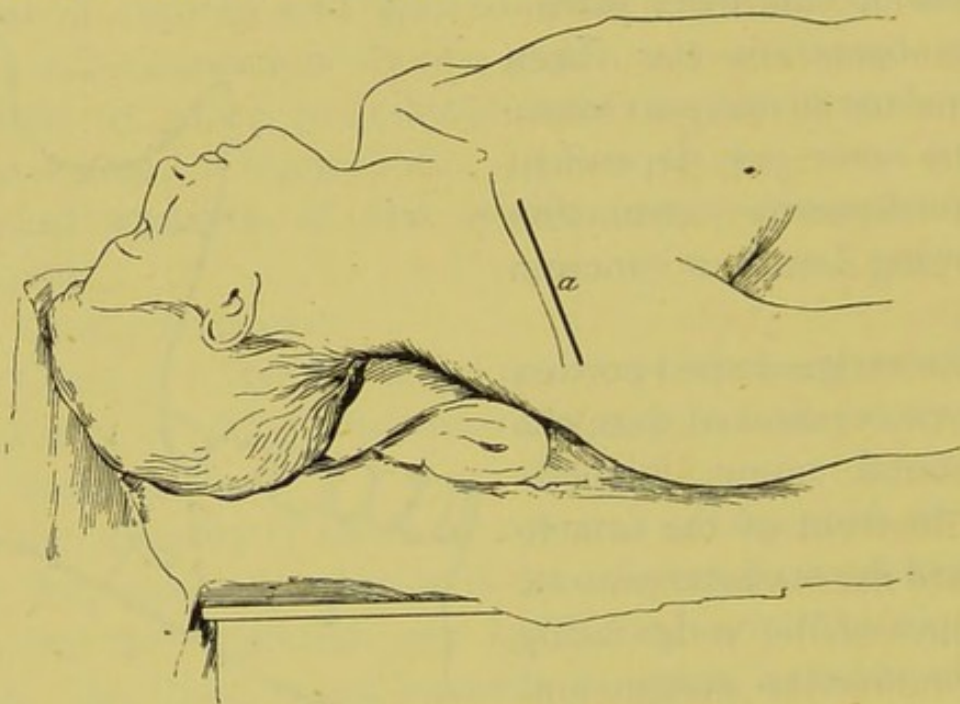


FIG. 293.—Excision of clavicle. *a.* Position of external incision.

of the clavicle; (b) acute necrosis; (c) some cases of backward dislocation of the sternal extremity of the clavicle may require excision of this portion of the bone.

Excision of the entire clavicle.—This is only necessary in cases of malignant growth.

Position.—The patient is placed in the dorsal position, with the shoulder on the affected side slightly raised by a pillow. The operator stands on the affected side, and the assistant opposite to him.

Operation.—An incision is made over the entire length of the bone, commencing internally over the sterno-clavicular

articulation and following the outline of the clavicle to the acromion. This incision divides everything down to the bone except the periosteum, namely, skin, fasciæ, platysma, and supraclavicular nerves. The soft tissues are dissected upwards and downwards, the periosteum being left behind. When the bone has been sufficiently bared, the shaft is sawn through in a convenient situation, usually near the middle, with a Hey's saw, care being taken not to injure the important blood vessels and nerves which lie directly behind it. The sternal extremity is lifted up, the muscles and ligaments attached to its posterior surface divided, and the capsular ligament of the sterno-clavicular joint cut through, after which it can be removed. The outer half of the clavicle is treated in a similar manner. The conoid and trapezoid ligaments are divided close to the coracoid process, the acromio-clavicular joint is opened and its ligaments cut through, and the bone removed.

Any bleeding vessels are ligatured, and the external wound closed by a series of interrupted sutures.

Removal of the diaphysis of the clavicle in cases of acute necrosis.—An incision is made over the middle of the bone parallel with its long axis, and all the soft tissues, including the periosteum, are incised down to the bone. By this means the necrosed portion is laid bare. With a pair of bone forceps the diaphysis is divided transversely, and extracted in two halves with the aid of sequestrum forceps.

The space left by the removal of the diaphysis is thoroughly irrigated with an antiseptic solution, and then packed with strips of aseptic gauze, the extremities of which project from the external wound.

Excision of the sternal extremity of the clavicle.—An incision, usually about 2 in. in length, is made, commencing over the manubrium sterni and extending outwards over the sternal extremity of the clavicle. The soft tissues are divided until the anterior surface of the bone is exposed. The pectoralis major and the clavicular head of the sterno-

mastoid are detached, and with a Hey's saw the shaft of the bone is divided at the outer extremity of the incision. The inner portion of the bone is seized with lion forceps and pulled forwards, and the muscles and ligaments attached to its posterior and inferior aspects cut through. These include the rhomboid ligament, the costo-coracoid membrane, and portions of the subclavius and sternohyoid muscles. Finally, the capsular ligament of the sternoclavicular articulation is cut through with the scalpel, and the separated portion of bone removed. All bleeding is arrested, and the external wound closed.

Excision of the scapula.—*Indication.*—Primary sarcoma of the scapula.

Position.—The patient is placed lying upon the sound side, turned a little more towards the ventral than the dorsal position, so as to fully expose the affected shoulder. The surgeon stands directly behind the patient, and the assistant on the opposite side.

Operation.—An incision is made, commencing over the acromion process of the scapula, and extending along the spine of the bone as far as the vertebral border. This incision divides all the soft tissues down to the bone.

A second incision is then made along the vertebral border of the scapula, commencing at the superior angle and extending downwards to the inferior angle.

Two flaps are then dissected up; they should, if practicable, include all the soft tissues except the periosteum, but care must be taken to avoid leaving any diseased tissue behind. These flaps are dissected outwards until the superior and external margins of the bone are laid bare. Next, the muscles along the superior and vertebral borders are detached; that is to say, the rhomboids, levator, anguli scapulæ, and posterior belly of the omo-hyoid. This having been done, the vertebral border is lifted upwards and outwards, and the serratus magnus and subscapularis muscles separated from the ventral aspect. The

acromion process is sawn through at its junction with the spine, and drawn forwards. By this means the superior aspect of the shoulder-joint is exposed. The capsule of this joint is now divided, together with any of the adjacent muscles or tendons which still remain. The scapula is next pulled downwards and outwards, and the muscles attached to the axillary border and inferior angle cut through (teres major and minor, and long head of triceps). The scapula is now free and can be removed.

It is advisable, if possible, to leave behind the acromion process, together with the attachments of the deltoid and trapezius, but if the disease extends into this part of the bone, these muscles must be cut through and the bone removed at the acromio-clavicular joint.

All bleeding is arrested and the external wound closed in the usual manner.

Partial excision of the scapula.—This procedure may be requisite in cases of necrosis of a part of the bone or for exostoses growing from its surface.

No special directions can be given for this operation, since each case differs according to the position of the exostosis or the sequestrum.

Excision of the radius or of the ulna.—Removal of portions of these bones may be requisite in cases of malignant growth or of localised necrosis.

The operation is usually carried out by making an incision over the most exposed portion of the affected part of the bone, turning the soft tissues aside, and removing as much of the bone as is thought necessary.

The ulna is somewhat more accessible than the radius, on account of its nearness to the surface of the forearm.

Excision of a metacarpal bone.—A metacarpal bone is usually removed through an incision extending the entire length of its dorsal surface. The soft tissues are divided down to the bone, and separated and retracted on each side. The base is first disarticulated, the bone is lifted upwards

and forwards, the muscular and ligamentous attachments on the palmar aspects separated, the head of the bone disarticulated, and the entire bone removed. In making the dorsal incision, care must be taken to avoid injury to any of the digital nerves.

Excision of a phalanx.—In the excision of a phalanx, an incision is made over the lateral aspect of the bone, somewhat nearer the dorsal than the palmar surface. The soft tissues are separated as in the removal of a metacarpal bone, and disarticulation is carried out, the proximal end of the bone being separated first.

Partial excision of a metacarpal bone, or of a phalanx.—In the removal of a portion of a metacarpal bone, or of a phalanx, the external incision is made in the same line as for the removal of the entire bone. The shaft is exposed, sawn through, and the diseased portion removed.

Excision of a rib.—*Indications.*—1. Empyema: (*a*) simple, following pleural effusion; (*b*) tuberculous; (*c*) due to actinomycosis of the base of the lung; (*d*) pyæmic. 2. Caries of a rib. 3. Primary new growth (sarcoma) of a rib. 4. Injury of the chest wall, with perforation of one of the intercostal arteries.

Instruments.—Scalpel, small saw, retractors, periosteal elevator, dissecting forceps, pressure forceps, bone forceps, dressing forceps, probe-pointed director, Volkmann's spoon, aneurysm needle, drainage tube, and ligature and suture material.

Position.—The position of the patient depends upon which rib or ribs have to be excised—usually the patient is turned somewhat on the sound side, so as to expose the lateral aspect of the affected side of the chest. The surgeon stands on the affected side, and the assistant directly opposite to him.

Operation.—The portion of a rib which requires removal is first determined. This having been done, an incision is made over it and parallel with it. This incision should

divide skin, fasciæ, muscles, and periosteum. The margins of the incision are retracted, and the periosteum separated from the internal and external aspects of the rib with a periosteal elevator. The rib itself is divided at each extremity of the incision, either with a pair of bone forceps or with a small saw; usually it is better to employ the saw, for this is less likely to cause splintering. When the portion of rib has been removed, and it is desired to open the pleural cavity, as for the treatment of purulent collections within the chest, a probe-pointed director is pushed inwards through the floor of the space which the rib occupied, and made to pierce the periosteum, the thoracic fascia, and the parietal layer of the pleura. The blades of the dressing forceps are passed along the director, separated, and the opening enlarged. The interior of the chest can now be examined with the finger through this aperture, and any further measures which may be requisite carried out.

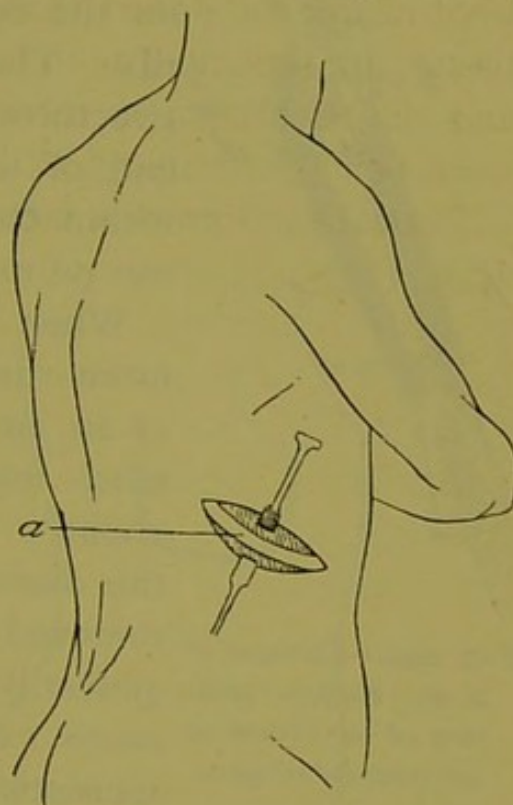


FIG. 294.—Excision of rib.
a Rib to be excised, showing its relation to skin incision.

If the removal of a portion of one rib does not give sufficient access to the interior of the thorax, the margins of the parietal incision are well retracted, so as to expose the adjacent rib, either the one above, or the one below. This is denuded of its periosteum, and a portion removed, as in the previous case. Under these circumstances it will be necessary to ligature the intercostal vessels. This is best effected by means of a curved aneurysm needle, which

carries the ligature behind the vessels. Two ligatures should be applied—one at each extremity of the wound. When this has been done, the incision may be enlarged by cutting transversely across between the ligatures. Care must be taken not to injure the intercostal vessels in the

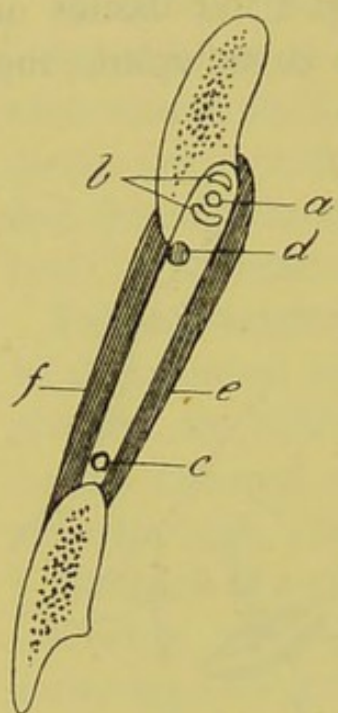


FIG. 295.—Excision of a rib. Relative position of structures in an intercostal space.

- a.* Intercostal artery.
- b.* Venæ comites.
- c.* Branch of intercostal artery.
- d.* Nerve.
- e.* Internal intercostal muscle.
- f.* External intercostal muscle.

process of detaching the periosteum from the bone. They lie in the grooves on the upper and lower aspects of the rib. The relative position of these structures is shown in Fig. 295. If the end of the periosteal elevator is kept within the periosteal sheath, the vessels run no risk of injury.

When partial excision of one or more ribs is required in the treatment of an empyema, it is not necessary in most instances to remove more than about 2 in. of each. In caries of a rib, the diseased portion must be entirely removed. In cases of new growth it is generally necessary to take away much more extensive pieces of bone. The incisions, both through the soft tissues and through the bone, must, in such cases, be carried well wide of the growth.

When it is wished to drain the pleural cavity, after the excision of one or more ribs, the fluid collection is first allowed to escape, and then a guarded indiarubber drainage tube of suitable size is pushed through the opening into the pleura and fixed in position, abundant aseptic absorbent dressings being applied.

Excision of part of the bony wall of an empyema cavity (Estlander's operation).—Removal of a considerable portion of the bony chest wall is necessary in those cases

of long-standing empyema in which the cavity does not spontaneously close.

Operation.—The limits of the cavity which it is proposed to close having been ascertained as far as possible by percussion, auscultation, and examination with probes or sounds, a semilunar flap, comprising all the soft tissues of the chest wall superficial to the ribs, is reflected, the attached base of the flap being in most cases above (Fig. 296). In raising the muscles from the ribs, care must be taken that no periosteum is raised with it. It is safer, in fact, to leave a small portion of the muscle attached to the rib. All bleeding having been arrested by the application of pressure forceps, portions of the exposed ribs are removed. The amount of each which is excised depends entirely on the size of the cavity which it is proposed to close—often it is necessary to remove portions of four, five, or six ribs, pieces from 2 to 5 in. long being taken from each. The longest portions of rib are taken from over the middle of the empyema cavity.

After portions of the ribs have been removed and the cavity thoroughly exposed, it will usually be found advisable to take away the thickened part of the parietal pleura which forms the external boundary of the cavity. In order to do this satisfactorily, it will be necessary to ligature some of the intercostal arteries along the anterior and posterior margins of the exposed space.

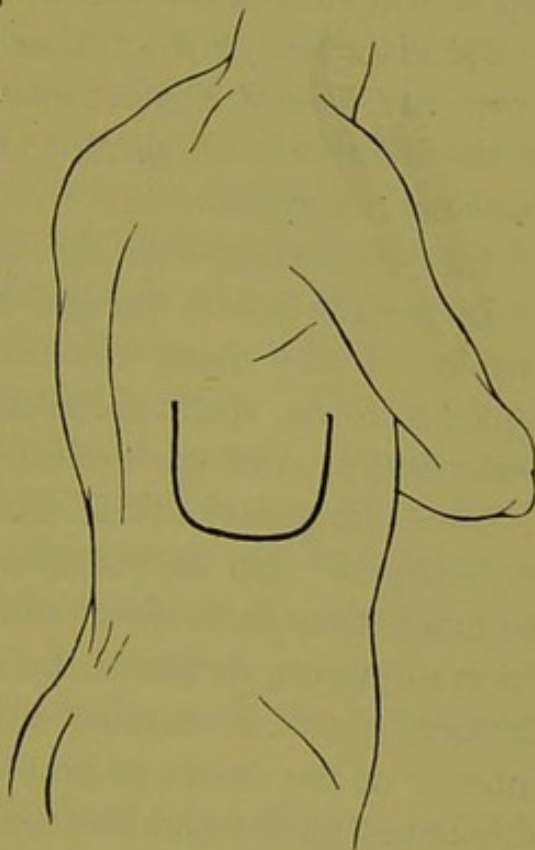


FIG. 296. — Excision of part of chest wall. External incision. — ESTLANDER.

When the cavity has been laid thoroughly open in this manner, its interior is well washed out, all traces of pus and lymph being removed if necessary by scraping with a Volkmann's spoon.

The entire cavity is then packed with strips of iodoform gauze, one extremity of each strip protruding from the lower part of the wound. This having been done, the external flap of soft tissues is replaced and fixed in its former position by the insertion of a number of interrupted sutures. The lower part, however, is left open for the exit of the extremities of the tampons of gauze. Finally, an absorbent aseptic dressing is applied.

After-treatment.—At the expiration of from twenty-four to forty-eight hours, the gauze packing is removed from the interior of the chest, the cavity syringed out with an antiseptic solution, and then packed as before. This is repeated periodically, until the wound is healed.

Some surgeons advise that, instead of making a large "U-shaped" flap of soft tissues, a separate incision should be made over each rib of which a portion is to be removed. In my opinion, however, the above operation is more satisfactory, since it enables a complete examination of the interior of the cavity to be made, and allows the removal of thickened pleura and the layers of fibrous lymph which are usually met with.

Excision of ribs to expose the convex or right lateral surface of the liver by a transthoracic operation.—

Indications.—This operation is requisite in the following clinical conditions :—

(a) Subphrenic hydatid cyst which is not readily accessible through an abdominal incision.

(b) Subphrenic abscess which is not accessible through an abdominal incision.

(c) Abscess of the superior part of the liver which extends upwards towards the thorax.

Position.—The patient is placed lying somewhat on the

left side, so as to fully expose the lateral aspect of the right side of the chest. The surgeon stands on the right side of the patient, and the assistant on the opposite side.

Operation.—A site is selected on that part of the thorax which overlies the most prominent portion of the swelling, and an incision 3 in. long, which may be lengthened if necessary during the later stages of the operation, is made parallel to the ribs. A rib is exposed, the structures attached to it separated, and then a portion of it is excised. The underlying costal layer of the pleura is next divided and the pleural cavity opened, whereupon the air rushes inwards, and the lung on the corresponding side becomes collapsed. The layer of pleura which covers the subjacent portion of the diaphragm is now sought for and brought as far as possible into the wound, and an incision an inch or more in length is made in it. The margins of the incisions in the two layers of pleura (costal and diaphragmatic) are closely approximated and united by numerous fine silk sutures. In this stage of the operation it may in some cases be found necessary to aspirate the hepatic swelling and remove a portion of its fluid contents, so as to relax the diaphragm and the overlying pleura.

The diaphragm in the bottom of the wound is now incised, and sutures are passed through it so as to fix it to the margins of the wound in the thoracic wall. By this means the pleural cavity of the affected (right) side is completely shut off from communication with the external atmosphere, and also from the swelling which is about to be incised.

An incision is now made through the hepatic or other tissue which is exposed at the bottom of the wound, and is deepened until the cavity of the abscess or hydatid cyst is reached. The contents are evacuated, and the cavity is treated in a manner similar to that described when the abdominal operation was under consideration.

The extremities of the incision in the thoracic wall may be closed with sutures if it is thought advisable, and drainage established by a tube.

Excision of the patella.—*Indications.*—This operation may be requisite under the following circumstances:—

(a) Primary new growths in the bone (sarcomata).

(b) Tuberculous affections commencing in and limited to this bone.

(c) As part of the operation of excision of the knee-joint.

Instruments.—Scalpel, retractors, periosteal elevator, pressure and dissecting forceps, needles, needle-holder, and suture and ligature material.

Position.—The patient is placed in the dorsal position, with the affected limb fully extended. The operator stands on the outer side of the knee, and the assistant opposite to him.

Operation.—A vertical incision 3 in. in length is made over the patella, commencing in the middle line about an inch above the upper border of the patella, and extending downwards almost to the tubercle of the tibia. This

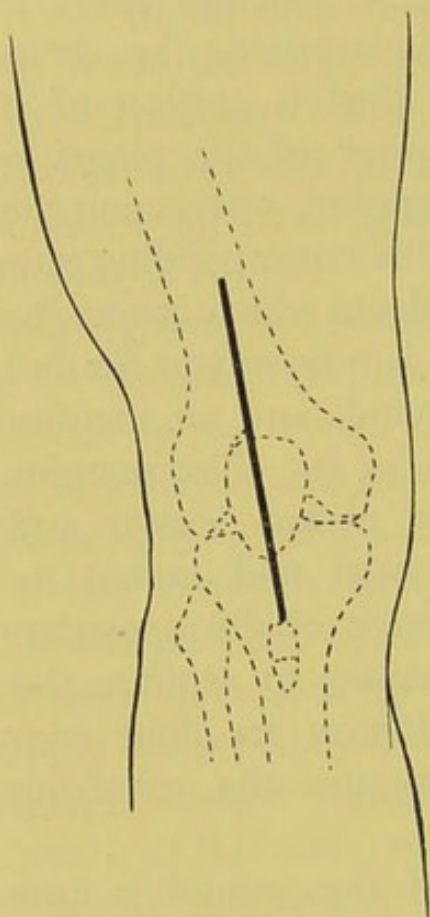


FIG. 297. — Excision of patella. Position of external incision.

incision is deepened until the superficial surface of the bone is reached, the supra-patellar bursa being cut through and turned aside. The soft tissues are then dissected from the anterior aspect of the bone, and held aside with retractors. If the periosteum is not diseased, and the operation is not being performed for a malignant growth, it should be turned aside with the other soft tissues; but when it is the seat of tuberculous processes, or in

cases of sarcoma, it should be removed along with the bone. The margins of the bone are defined, and then the fasciæ, muscular aponeuroses, and ligamentum patellæ are cut through. By these means the patella is separated from its connections with the soft parts, and can be removed. All hæmorrhage is arrested, the part of the knee-joint exposed in the wound sponged clean and dry, and the margins of the incision united by the insertion of a series of sutures. Usually it will be advisable to dissect out the suprapatellar bursa in the early stages of the operation, since if it is left it is liable to impede the healing of the wound.

Aseptic dressings are applied, and the limb firmly fixed in splints.

Partial excision of the tibia.—Removal of a portion of the diaphysis of the tibia is occasionally required in cases of acute necrosis of the bone occurring in connection with acute infective osteomyelitis.

The operation is essentially of the nature of a sequestrotomy, and is usually performed after the expiration of some considerable time from the onset of the disease, when the periosteum has formed a sheath of new bone which encloses the dead portion.

Instruments. — Chisel and mallet, in addition to the ordinary instruments for excision of a bone.

Position.—The patient is placed in the dorsal position, with the affected limb fully extended and lying somewhat upon its outer side. The operator stands on the outer side of the affected limb, and his assistant opposite to him.

Operation.—An incision, usually about 3 in. in length, is made over the middle of the affected portion of the bone. This is generally done by enlarging one of the sinuses which are already present. The soft tissues are divided down to the bone, and then the "involucrum" of new bone which surrounds the dead portion of the diaphysis

is cut through with bone forceps in a vertical direction for the entire length of the incision. The margins of the wound are held apart with retractors, and the enclosed portion of bone extracted with sequestrum forceps. In order to facilitate the removal of the sequestrum, it will usually be found convenient to divide it transversely at the bottom of the incision with a pair of bone forceps, and to remove it in two halves.

The interior of the cavity in the bone from which the sequestrum has been extracted is thoroughly irrigated with an antiseptic solution, and then packed with tampons of iodoform gauze.

In cases where the periosteum does not give rise to the formation of new bone after the sequestrum has been removed, it will be necessary to fill up the cavity either with a portion of bone from a limb amputated from another individual, or with decalcified bone, or with strips of twisted pewter wire. These substances appear to cause increased activity of the periosteum, and to promote the filling up of the cavity with new bone. In those cases where wire is used, it will be necessary to give the patient an anæsthetic in order to extract it after it has become imbedded in the newly-formed tissue.

Excision of the fibula.—*Indications.*—This may be necessary in cases of primary sarcoma of the bone, or more rarely in cases of acute osteomyelitis which has given rise to necrosis of a portion of the bone.

Operation.—A vertical incision is made over the postero-external border of the bone. The muscles are dissected away from their osseous attachments, and the affected part of the fibula exposed and removed.

The entire fibula may be removed without causing serious interference with the use of the limb.

Excision of the os calcis.—*Indications.*—(a) Tuberculous disease of the os calcis which is limited to that bone.

(b) Tuberculous disease of the astragalo-calcaneal articulation involving chiefly the os calcis.

(c) Acute necrosis of the os calcis, the result of acute osteomyelitis.

Position.—The patient is placed in the dorsal position, with the affected foot supported on a sand-bag with its outer surface upwards. The surgeon stands on the outer side of the affected foot, and his assistant opposite to him.

Operation.—An incision is made, commencing at the inner border of the tendo Achillis immediately above its attachment to the os calcis, and extending across the heel and along the outer side of the foot to a point half an inch posterior to the prominence of the fifth metatarsal bone, the tendo Achillis being detached from its point of insertion. This incision divides all the soft tissues down to the os calcis. With a strong scalpel the soft tissues at the posterior and outer margin of the foot and the sole are dissected away from their attachment to the os calcis in the form of a single flap. The posterior portion of the os calcis is now grasped with lion forceps, and the entire bone forcibly pulled downwards, so as to render tense the ligaments of the astragalo-calcaneal joint. This is done by the assistant. The soft tissues at the upper part of the incision are dissected upwards, care being taken not to divide the peronei muscles, which should be held out of the way with retractors. The middle fasciculus of the external lateral ligament of the ankle-joint is cut through, and then the articulation between the inferior aspect of the astragalus and the upper surface of the os calcis is opened from the outer side. The very strong interosseous astragalo-calcaneal ligament is divided, and then the os calcis is pulled further downwards and outwards, and cleared on its inner side. Next, the articulation between the anterior part of the os calcis and the cuboid is opened, by cutting through the ligaments from above. Finally, the calcaneo-scaphoid ligament is divided and the os calcis removed.

If more room is required in order to expose the inner

aspect of the bone, the incision may be prolonged upwards, along the inner margin of the tendo Achillis.

If the synovial membrane which lies between the astragalus and the calcaneum is diseased, it is dissected away.

Hæmorrhage having been arrested, the space previously occupied by the os calcis is packed with aseptic gauze, and the external incision partially closed by the insertion of interrupted sutures.

Excision of the astragalus.—*Indications.*—(a) Some forms of inveterate talipes.

(b) Caries of the astragalus, which is either limited to this bone or does not extensively affect the surrounding tissues.

(c) Some forms of disease of the astragalo-calcaneal joint, in which it is thought from the position of the sinuses that the affection chiefly involves the astragalus and not the os calcis.

(d) Cases of complete dislocation of the astragalus in which the bone cannot be replaced.

(e) Compound dislocation of the astragalus complicated with fracture, in which the bone cannot be satisfactorily replaced and the severity of the injury is not sufficient to justify amputation.

Operation.—An incision, from 2 to 3 in. in length, is made on the external aspect of the ankle. It commences above immediately internal to the anterior border of the external malleolus and half an inch above the level of the ankle-joint, and extends in a downward and forward direction to a point on the dorsal and external surface of the foot over the cuboid bone, about an inch internal to the prominence at the base of the fifth metatarsal bone. This incision is parallel with and posterior to the tendon of the peroneus tertius, and in front of the peroneus brevis. The skin and fasciæ, together

(b) Tuber or annular ligament, are divided until the bones
lation involving the margins of the incision are dissected up

and pulled well aside with retractors. This will expose the outer portion of the astragalus. The anterior fasciculus of the external lateral ligament of the ankle-joint and the anterior ligament of the same joint are divided. The foot is well extended and inverted, and the ligaments which fix the astragalus to the scaphoid on the dorsal aspect of the foot cut through. The astragalus is now seized with lion forceps, pulled strongly outwards, and its ligamentous connections on the inner side of the foot exposed and divided. When this has been done, the bone can be pulled further outwards, and its posterior ligamentous attachments and

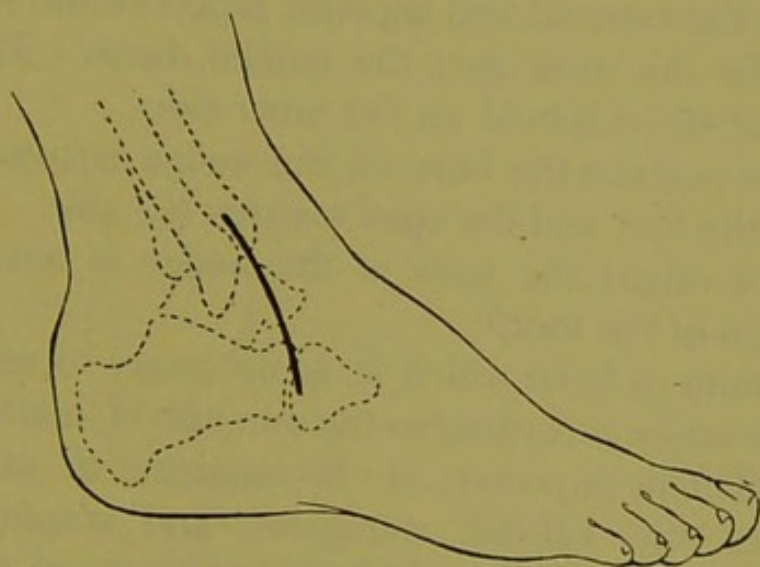


FIG. 298.—Excision of astragalus. Skin incision.

the strong interosseous astragalo-calcaneal ligament cut through. The bone is now free, and can be removed. It should be remembered that no muscles are attached to the astragalus.

The astragalus can usually be removed in this manner in cases of talipes or of dislocation of the bone as a result of injury.

In removal of the bone for disease, however, the above incision does not give a sufficiently free exposure. In such cases a second incision is made on the inner side of the foot, immediately behind the tendon of the *tibialis posticus*.

When the bone has been removed, a gauze drain is placed

in the interior of the wound, and the incision is closed by the insertion of interrupted sutures.

Excision of a wedge-shaped piece from the tarsus (cuneiform tarsectomy).—*Indications.*—An operation of this nature, involving the excision of a wedge-shaped piece from the tarsus, is necessary in certain forms of talipes equino-varus, talipes equinus, and talipes valgus, in which the bones themselves are considerably malformed, and in which other methods of treatment are not productive of a satisfactory result.

In cases of talipes equino-varus the base of the wedge is situated on the external and superior aspect of the foot, and comprises for the most part the cuboid bone. The apex is situated at the scaphoid on the inner side.

In talipes equinus the base of the wedge is towards the dorsum of the foot and the apex towards the sole.

In talipes valgus the base of the wedge is towards the inner margin of the foot.

The amount of bone which it is necessary to remove in these cases varies according to the amount of malformation present. Often, however, it is requisite to take away portions of the cuboid, astragalus, and scaphoid, and occasionally of the other tarsal bones.

Instruments.—Scalpel, dissecting and pressure forceps, retractors, periosteal elevator, chisel and mallet, needles, needle-holder, and ligature and suture material.

Operation.—In the majority of instances removal of a wedge-shaped portion of bone is effected through an incision situated upon the outer side and dorsal aspect of the foot over the most prominent part of the deformity.

An incision is made which commences over the dorsal and external aspect of the astragalo-scaphoid joint, and extends downwards, outwards, and backwards, towards the sole and the prominence of the heel. This incision divides the skin and superficial fasciæ; the cutaneous portion of the musculo-cutaneous nerve is sought for and defined at

the inner angle of the wound and the external saphenous nerve at the outer angle. When these nerves have been defined they are retracted to the inner and outer sides respectively. The deep fascia is then cut through, and the muscles exposed. In the inner angle of the wound the peroneus tertius will be seen; in the outer angle the peroneus brevis and the upper border of the extensor brevis digitorum. These muscles are retracted to the inner and outer sides respectively, and the dorsal aspect of the tarsal bones exposed. The ligaments which fix these bones

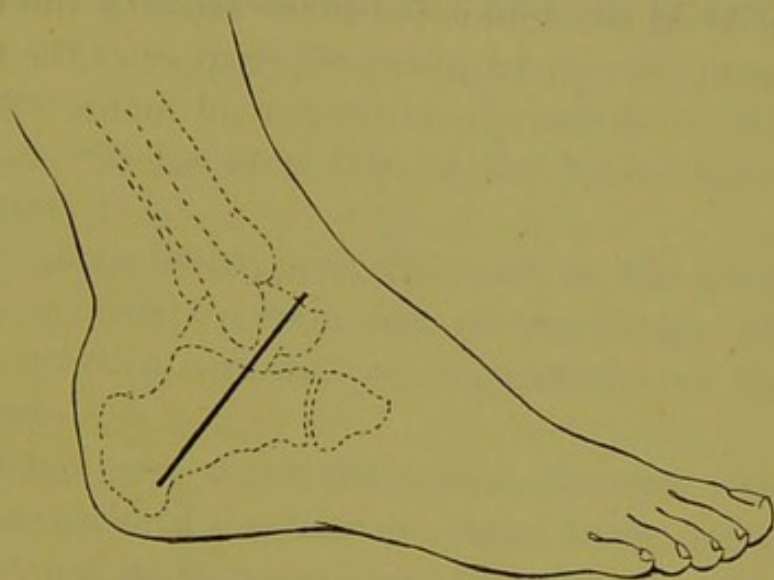


FIG. 299.—Cuneiform tarsectomy. Position and direction of external incision.

together are separated with the periosteal elevator, and the base of the wedge-shaped portion of bone which it is wished to remove exposed. This will usually consist of the greater part of the cuboid, the external and anterior portion of the os calcis, and the head of the astragalus, with possibly a small piece of the scaphoid. When the bones have been sufficiently cleared and freed from their ligamentous connections, the chisel and mallet are taken, and the portions of bone comprising the wedge removed.

Any adventitious bursa which has developed, should, if thick-walled and conveniently reached, be dissected out and removed.

All bleeding having been arrested, the cut surfaces of bone are brought into apposition and the external wound closed in the usual manner. The limb is fixed in the rectified position on a suitable splint. After a few days the dressings are removed, the stitches taken out, and the limb encased in plaster.

Excision of a metatarsal bone, or of a phalanx.—Excision of these bones differs in no essential respect from that of the corresponding bone of the upper extremity. In the case of a metatarsal bone the incision is generally on the dorsal aspect of the foot; in the case of a phalanx, at the side.

CHAPTER XXIV.

EXCISION OF ARTICULATIONS.

By the term "excision of an articulation or joint" is understood the removal from the body, by the performance of a surgical operation, of a part or the whole of the tissues which enter into the formation of the joint which is under consideration.

Thus it generally happens that part or the whole of the ligaments, synovial membranes, interarticular fibro-cartilages, and articular surfaces and extremities of the bones are removed.

When only a part of the anatomical elements which enter into the formation of the joint are taken away, the operation is called a "partial excision," and when all these tissues are removed it is known as a "complete excision." The partial operations are more commonly performed than complete ones, except in the case of tuberculous disease, when it not uncommonly happens that the whole of the joint tissues are excised.

Several distinct methods of performing "the excision of a joint" are practised by surgeons. These are generally known as—

- (a) The open method.
- (b) The subperiosteal subcapsular method.
- (c) The osteoplastic method.

These different methods will now be separately discussed, and afterwards the excisions of the various individual joints will be described.

(a) *The open method.*—In the open method of performing the excision of a joint, an incision is made through the soft tissues overlying the articulation, in order to expose the diseased tissues and enable the surgeon to readily remove them. When the external surface of the capsular ligament has been reached, the soft tissues are turned aside by dissection, and the ligaments together with the articular extremities of the bones laid bare. The periosteum is left attached to the bones. This having been done, the articulation is excised, the ligaments and portions of bone with their periosteum being taken away. This is the method used in extensively diseased joints, in which the disease has extended to all the tissues entering into the formation of the articulation. If only a portion of the joint elements are taken away, the operation is a “partial excision” performed according to the *open* method.

(b) *The subperiosteal subcapsular method.*—In this method of operation the periosteum which covers the extremities of the bones entering into the formation of the joint, and the capsular ligament with its localised thickenings, are turned aside at the same time as the more superficial soft tissues; the diseased synovial membrane and articular surfaces of the bones are removed, and finally the periosteum and the capsular ligament are replaced in their former positions. In order to do this effectively, the first incision is prolonged through the capsular ligament and the periosteum with which it is continuous, and then with a rugine or a periosteal elevator these structures are stripped from their attachments to the bones and turned aside. When this has been done, the interior of the joint cavity is exposed, and all diseased synovial membrane and articular cartilage can be removed. An excision performed according to this method is in reality a partial excision.

This form of operation is applicable to those cases of joint disease in which the synovial membrane and the articular cartilages are alone involved, as in the early stages

of "tuberculous disease of joints," in some forms of joint affection dependent upon traumatic causes, and in some forms of ankylosis. It is not available in cases of extensive disease due to tuberculosis, or in any case of malignant disease of the bone, since in every case of this nature the periosteum must be removed.

(c) *The osteoplastic method.*—In addition to turning aside the periosteum of the articular extremities of bones, and the ligaments, an attempt is made in "osteoplastic excision" to temporarily detach the bony prominences (tubercles, tuberosities, condyles, or trochanters) with the muscles and ligaments still fixed to them. This is effected by exposing the articulation as in the previous method, and then with a chisel and mallet the portions of bone to which the muscles and the ligaments, especially the lateral ones, are attached are chiselled through and turned aside, together with their attached soft tissues. When the diseased tissues from the interior of the joint have been removed, the bony prominences are fixed in their original position by means of bone or ivory pegs, or by sutures of silver wire or strong catgut. This method of performing excision of a joint is of very limited application, and can only be made use of in the earliest stages of tuberculous disease, in some forms of ankylosis, and in traumatic affections.

The term "arthrectomy" is sometimes employed in place of "excision of a joint," complete excisions being known as "complete arthrectomies," and partial operations as "partial arthrectomies."

Arthrotomy is applied to that operation which consists in the incision of a joint, as for the evacuation of a collection of fluid, or the removal of a loose body. Arthrotomy, moreover, is the first stage in all partial or complete excisions.

Indications for excision of joints.—(a) Tuberculous disease of a joint, which is not improving under ordinary palliative measures.

(b) Ankylosis of a joint, which either renders it useless on account of its immobility, or fixes it in a useless position.

(c) Some forms of injury to a joint, when there has been much splintering of bone, or when the fracture into the joint is comminuted, and the fragments cannot be replaced in position.

(d) Ecchondroses or exostoses of the articular extremities of long bones, which extend into the joint cavity, and so make the articulation practically useless.

(e) Some forms of displaced cartilage which cannot be dealt with satisfactorily except by excision.

Arthrotomy is necessary for the removal of loose bodies, foreign bodies, detached portions of articular cartilage, and for the evacuation of fluid collections within the joint cavity which cannot be satisfactorily dealt with in any other manner.

Instruments. — The instruments which are necessary for the excision of a joint are similar in nearly all instances, the chief difference being the form of saw and the size of the knife.

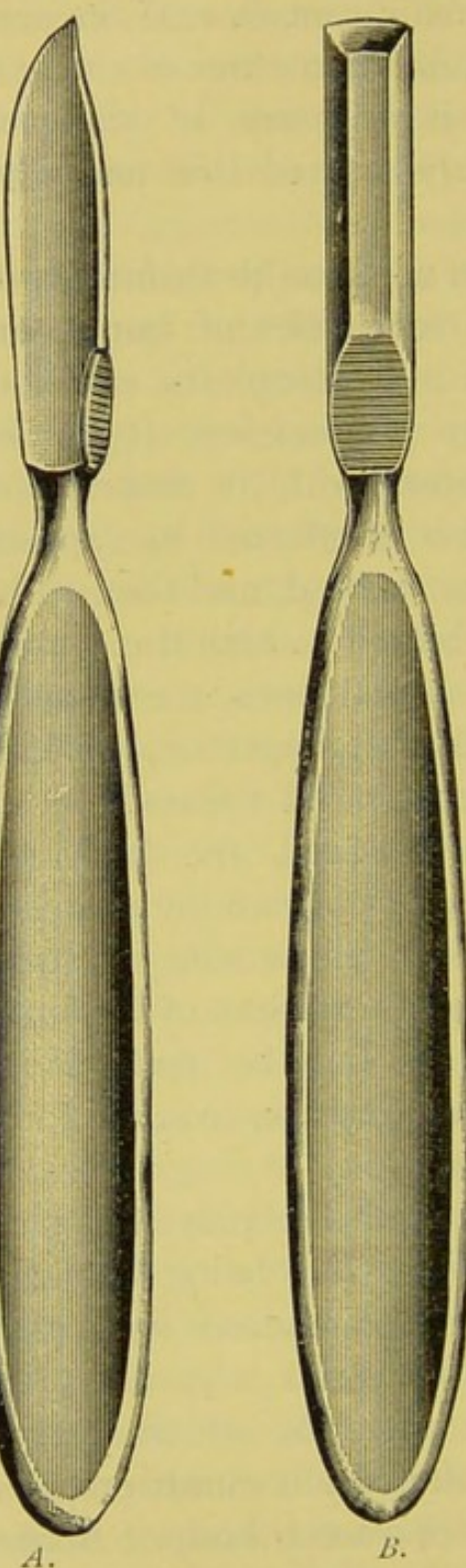


FIG. 300.—Instruments for excision of joints.

A. Resection knife.

B. Periosteal elevator.

The following are requisite:—Scalpel, resection knife,

pressure, artery, and dissecting forceps, lion forceps, retractors, chisel and mallet, periosteal elevators, saw, Volkmann's spoon, needles, needle-holder, and ligature and suture material. Suitable splints are also necessary.

The individual operations for the excision of joints will now be considered *seriatim*.

Excision of shoulder-joint.—The shoulder-joint is the articulation between the glenoid cavity of the scapula and the head of the humerus. In performing an excision of this joint, it may be necessary to remove either a part or the whole of the structures which enter into its formation. Usually, however, the operation is of the nature of a "partial arthrectomy."

Position.—The patient is placed in the dorsal posture, with the affected shoulder somewhat raised and projecting slightly over the margin of the table, and the limb drawn slightly outwards. The surgeon stands on the outer side of the diseased shoulder, the first assistant grasps the limb at the elbow (so as to be able to rotate it as required), and the second assistant takes up a position on the left of the operator.

Operation.—An incision is made which commences at the lower margin of the clavicle opposite the outer border of the coracoid process, and extends downwards in a direction parallel to the long axis of the humerus for a distance of about $3\frac{1}{2}$ or 4 in. This incision lies over the internal fibres of the deltoid muscle. The skin and fasciæ are divided, care being taken to avoid the cephalic vein which lies in

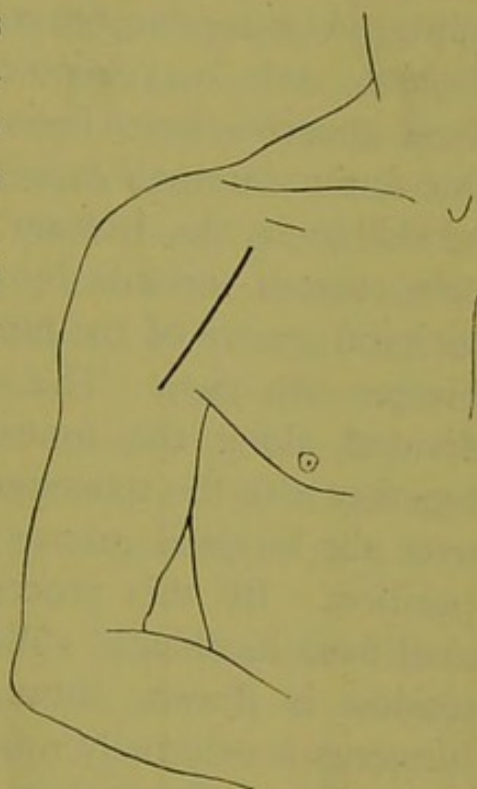


FIG. 301.—Excision of shoulder-joint. External incision.

the groove between the deltoid and pectoralis major muscles. This interval is defined if possible, and the cephalic vein pulled over towards the inner side, or, if the deltoid cannot be easily retracted outwards, its inner fibres are cut through. The pectoralis major is retracted internally, and the deltoid externally, the latter muscle being divided transversely immediately below its origin from the clavicle, if it is found to be necessary, in order to obtain a clear and uninterrupted view of the shoulder-joint. A muscular branch of the acromial portion of the thoracic axis may require ligature at this stage. When these muscles have been well drawn aside by retractors, the antero-internal aspect of the capsular ligament will be visible in the bottom of the wound. The humerus is now rotated inwards by the assistant, so as to bring the bicipital groove of the humerus and the long tendon of the biceps into view. The capsular ligament of the joint is divided along the inner margin of the biceps tendon, together with the transverse humeral ligament which bridges over the bicipital groove and helps to hold the tendon in position. By this procedure the biceps tendon is separated from its sheath. With a retractor or blunt hook this tendon is drawn outwards, and at the same time the humerus is externally rotated by the assistant. This brings forwards the internal or lesser tuberosity of the humerus, together with the insertion of the subscapularis into it. This is separated from the bone either with a scalpel or a periosteal elevator. If the scalpel is used, a series of cuts is made parallel with the bicipital groove. Next, the biceps tendon is drawn towards the inner side, and the humerus is internally rotated by the assistant, so as to fully expose the external or greater tuberosity with its attached muscles. These are the supraspinatus, the infraspinatus, and the teres minor, in this order from above downwards. They are separated from their osseous connections in the same way as the subscapularis, care

being taken not to divide the capsular ligament of the articulation in a transverse direction. In those cases in which the disease is limited to the synovial membrane and the articular extremities of the bone, it may be possible to detach the tuberosities with a chisel, and to turn them aside with their muscles attached to them. When the removal of the affected tissues has been accomplished, the tuberosities can be fixed in their original positions by the insertion of a few sutures. When the head of the humerus, together with as much of the shaft as is requisite, has been exposed, the upper extremity of the bone is forced out of the external wound and sawn across below the diseased area. In some cases it is possible to saw through the anatomical neck, while in others the surgical neck must be cut. When the upper extremity of the bone has been removed, the margins of the cut surface are rounded off so as to make a kind of artificial head to the bone. Next, all traces of diseased synovial membrane are removed, and then the glenoid cavity of the scapula is examined. If this is affected, the diseased portion is removed by bone forceps or a sharp spoon.

The interior of the articulation is now irrigated with an aseptic solution, so as to remove all bone dust or other débris.

A drainage tube is passed into the bottom of the wound, and the external incision is closed.

After-treatment.—The limb is supported in a sling for ten days or a fortnight, and then passive movements are commenced. These must be continued daily until the functions of the joint have become more or less completely restored. It is advisable to commence passive movements of the distal parts of the affected limb a day or two after the operation has been performed.

Some surgeons have made use of a posterior longitudinal incision for excision of the shoulder-joint, and others a U-shaped flap, the deltoid muscle being turned upwards, whilst

others again have made a curved posterior incision and sawn through the acromion. None of these methods seem to be so satisfactory as the one described above, and they cause much more impairment of the functions of the limb.

Excision of the elbow-joint.—Three bones enter into the formation of the elbow-joint—the lower end of the humerus and the upper extremities of the radius and ulna. The superior radio-ulnar joint is usually affected in diseased conditions of the elbow-joint, and requires excision as well.

An excision of the elbow-joint is in most cases complete,

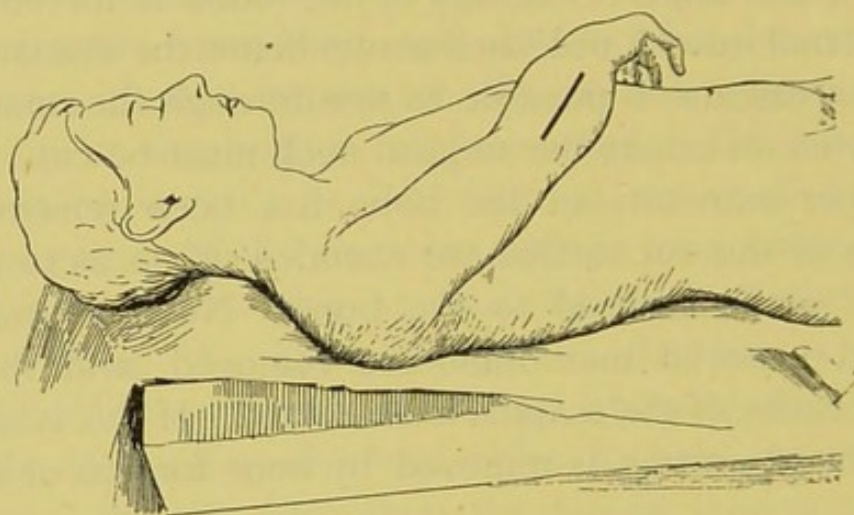


FIG. 302.—Position of patient, and line of external incision in resection of right elbow-joint.

but occasionally it may be advisable to perform a partial operation.

Position.—The patient is placed in the dorsal posture, with the affected arm semiflexed at the elbow and resting upon the trunk. The hand is in a position of partial pronation. The surgeon stands on the outer side of the affected elbow, and his assistant on the opposite side of the patient.

Operation.—An incision, from 3 to 4 in. in length, is made along the posterior aspect of the limb, slightly nearer the ulnar than the radial margin. This incision commences on the dorsal aspect of the forearm, about 2 in. below the elbow-joint, and extends upwards to a similar distance

above. The prominence of the olecranon is situated opposite the middle of the incision. The skin, fasciæ, and muscles are divided down to the posterior aspect of the bones. In the upper half of the incision the triceps is cut through, and in the lower half the fibres of the anconeus near the posterior border of the ulna are exposed. A flap, consisting of skin, fasciæ, and muscles, is now dissected from the bones towards the outer side. In making this flap, the edge of the excision knife, or the periosteal elevator, should be kept close to the bone, and all cuts made parallel with the external incision. This flap consists above of one-half of the triceps, the upper part of the anconeus, and the origins of the extensor muscles which are attached to the external condyle of the humerus, and below of the rest of the anconeus and the continuation downwards of the extensor muscles. If the disease has not extended to the external condyle, this process of bone may be cut through with a chisel, and the attachments of the extensor muscles partially preserved.

Next, a similar flap is turned up from the inner side. In dissecting up this flap, great care must be taken not to injure the ulnar nerve. It lies in the groove between the inner margin of the olecranon process of the ulna and the internal condyle of the humerus. If the edge of the knife is kept close to the bone, and each cut is made in the direction of the course of the nerve, there is little risk of injuring it. The internal condyle is cleared in a manner similar to the external, or in suitable cases it may be cut through and turned aside with the muscles attached.

The joint is flexed by the assistant, and then the posterior part of the capsular ligament is cut through immediately above the olecranon, and the joint cavity opened. The lateral ligaments are usually turned aside along with the muscles. The extremities of the bones are now turned out, and fully exposed. A few slight cuts with the knife will sufficiently free them from the soft

tissues, and then they are ready for the performance of "bone section."

The assistant who has charge of the arm thrusts upwards the forearm, so as to make the upper extremities of the radius and ulna project beyond the lower end of the humerus. The olecranon is then grasped by an assistant with a pair of lion forceps, and steadied whilst the surgeon makes the section with a saw from behind forwards. The olecranon process of the ulna, together with the articular portion of the coronoid, are removed, and also the head of the radius, below the articular surface but above the attachment of the biceps tendon. The lower end of the humerus is now protruded, the trochlear portion grasped with lion forceps, and the section made with the saw along a plane which is above the articular surface. The epiphyseal line is below the level of the section in nearly all cases. When the bones are being divided with the saw, the soft parts should be protected from injury by broad flat retractors held by an assistant.

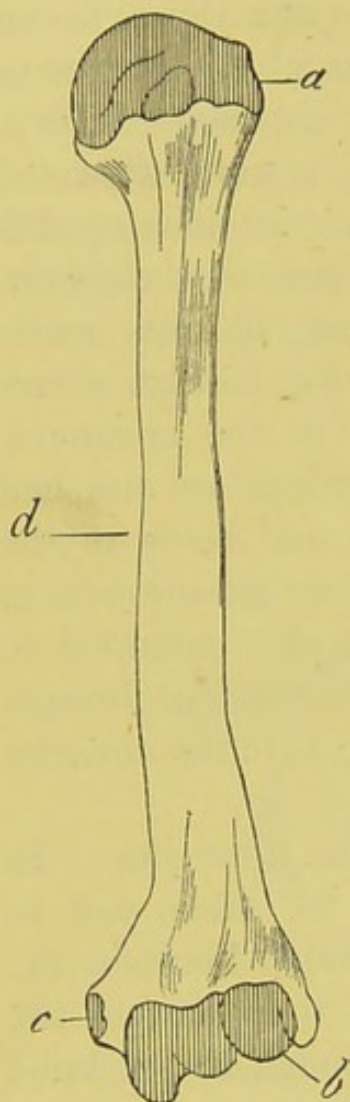


FIG. 303.—Humerus, showing the parts of the bone derived from the several centres of ossification.

- a.* Upper epiphysis.
- b.* Lower epiphysis.
- c.* Centre for internal condyle.
- d.* Shaft.

When the articular ends of the bones have been removed, the space which is exposed is examined for portions of diseased tissue, and if any are found, they are removed by scraping with a sharp spoon.

All bleeding is arrested, and the external wound closed by the insertion of a series of interrupted sutures of silk-worm gut. If a large cavity has been made owing to removal of considerable quantities of tissue, or if

there is much oozing of blood from the incised surfaces, a drainage tube is passed into the bottom of the wound, and the free extremity brought through an angle of the external incision left open for the purpose.

Aseptic dressings are next applied, and the limb placed in a right-angled position and bandaged to a splint; or it may be fixed to a straight splint, and kept in the extended position for the first few days. In all probability the latter method is the better.

After-treatment.—The limb is maintained at rest for two days, and then passive movements of the fingers and the wrist are commenced. At the expiration of about ten days or a fortnight, passive movements at the elbow are commenced, and continued daily until good movements have been restored. It is often necessary, especially in the case of children, to place the patient under an anæsthetic before commencing these movements at the elbow-joint.

There appears to be less risk of producing a "flail-like" joint when the limb is put up in the extended position, than when it is placed on a right-angled splint.

Excision of the elbow-joint through an external, slightly-curved incision.—Kocher recommends that an incision 5 in. in length should be made on the outer

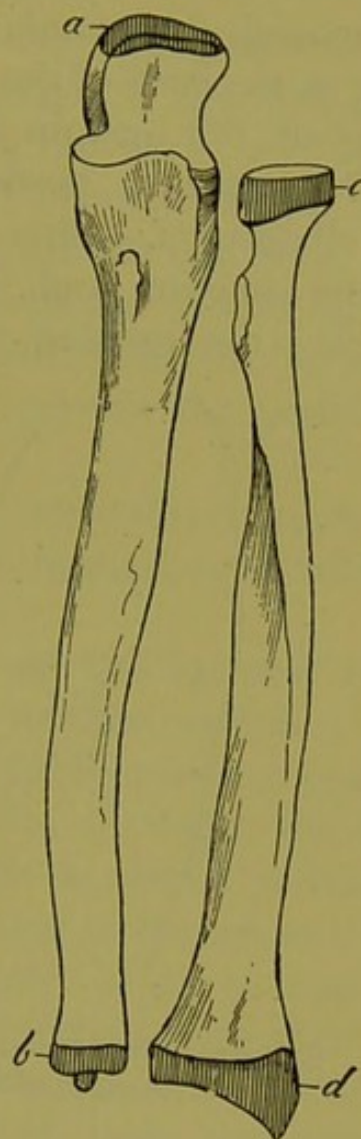

FIG. 304.—Radius and ulna, showing the parts of the bones derived from the several centres of ossification.

- a.* Upper epiphysis of ulna.
- b.* Lower " "
- c.* Upper epiphysis of radius.
- d.* Lower " "

side of the arm. It commences at a point opposite the upper part of the external supracondylar ridge of the humerus, and 2 in. above the level of the articulation, and extends downwards along the outer aspect of the limb as far as the head of the radius; then it crosses the extensor aspect of the forearm in an oblique direction to a point on the posterior border of the ulna about 3 in. below the elbow-joint,—this part of the incision corresponds to the inferior and external margin of the anconeus muscle; the incision terminates by curving inwards for

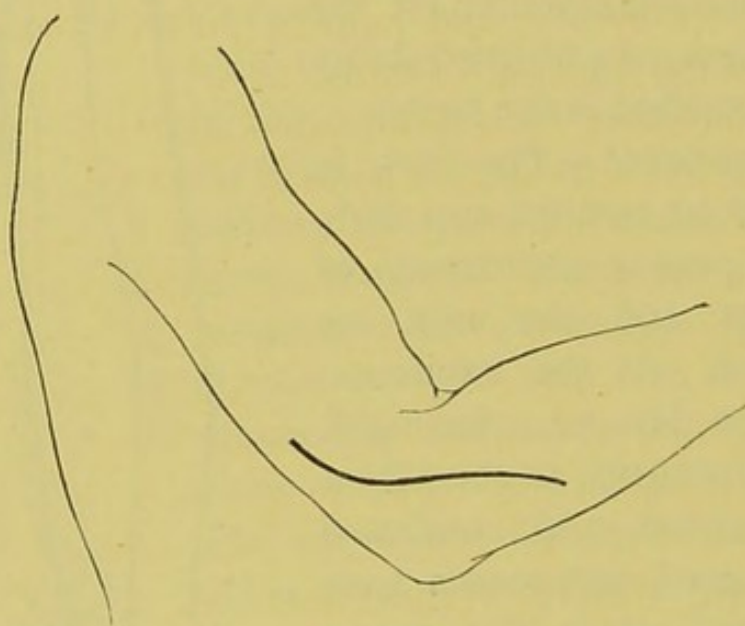


FIG. 305.—Excision of elbow-joint through an external incision.
Position of skin incision.—After KOCHER.

a short distance. The incision is extended to the bones and the external aspect of the elbow-joint. In its upper part it passes between the external head of the triceps posteriorly and the supinator longus and extensor group of muscles anteriorly, and in its lower segment it is situated between the outer margin of the anconeus posteriorly and the extensor carpi ulnaris anteriorly. The external lateral ligament, the outer part of the orbicular ligament, and the adjacent portion of the capsule which is attached to the external condyle, are detached and retracted forwards. The forearm is next forced inwards, so as to dis-

locate the articular surfaces outwards. The internal lateral ligament is next separated, and then the excision of the joint can be readily performed.

The triceps and the anconeus are separated from the bone, the olecranon being cut through, if not too extensively diseased, and drawn towards the ulnar side, in the form of a flap. This gives a good exposure of the joint. The bones are then sawn as in the previous operation.

Kocher recommends that the olecranon should be sawn in a curved direction, so as to preserve a lever for the action of the triceps muscle, and help to prevent the partial dislocation of the forearm forwards.

Other incisions have been advocated for exposing the elbow-joint in excisions, but none of them are so satisfactory as the two above described.

Excision of the radial portion of the superior radio-ulnar joint (excision of the head of the radius).—This operation is occasionally necessary in old-standing cases of dislocation of the head of the radius, in which the bone cannot be replaced and maintained in its normal position.

Operation.—The position of the head of the radius is first defined, and then a vertical incision, 2 in. or more in length, is made over the most projecting portion of the bone, and in a direction parallel with the long axis of the forearm. This incision is deepened until the bone is reached. The orbicular ligament which surrounds the head of the radius is divided, and the soft tissues held aside with retractors. The radius is next cut through at the level of its neck either with a fine saw or bone forceps. The section should be made above the bicipital tuberosity, and care should be taken to avoid injury to the radial and posterior interosseous nerves.

In the after-treatment, passive movements must be commenced immediately the external wound has healed, so as to avoid the formation of adhesions and the limitation of movement.

Excision of the wrist.—The wrist-joint, from a surgical point of view, may be considered to comprise the series of articulations which lie between the distal extremities of the radius and the ulna and the proximal ends of the metacarpal bones. There are in reality three transverse joints included under this term,—the radio-carpal joint, the transverse carpal joint, and the carpo-metacarpal joint,—in addition to the small joints between the individual bones of

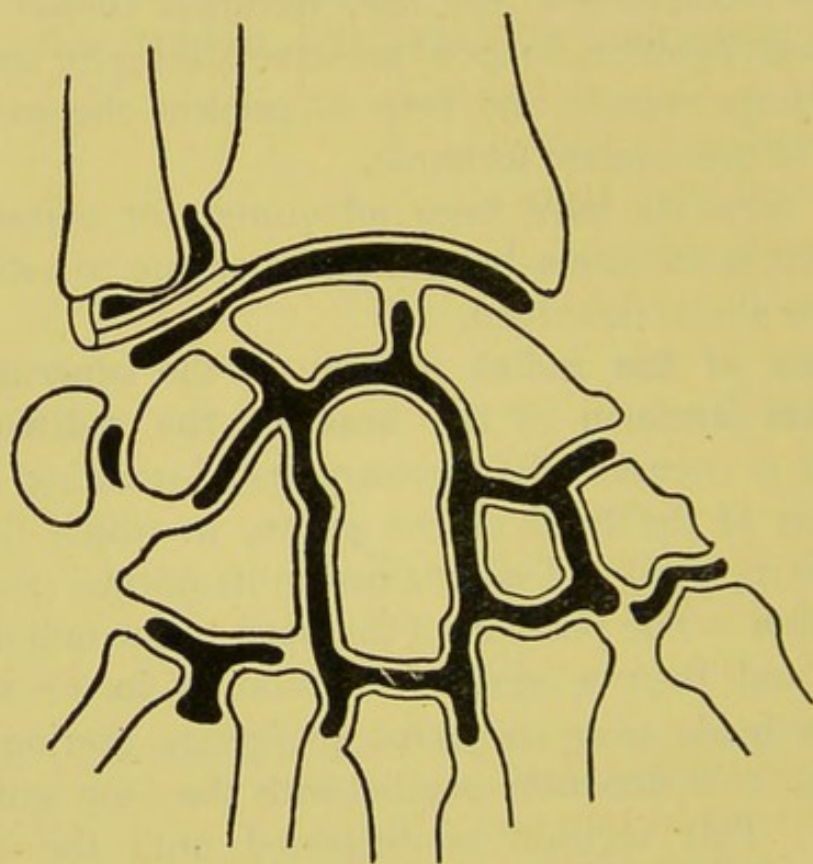


FIG. 306.—Synovial membranes of the carpus.

each row of the carpus. There are six (sometimes only five) separate synovial membranes in connection with these joints, the extent of which is shown in Fig. 306. An excision may be either complete or partial, according to the number of bones removed.

The operation has been performed for tuberculous disease of the wrist, for injuries such as compound fractures and dislocations and gunshot wounds, and in some forms of rheumatic affections of the joint.

Position.—The patient lies on the operation table in the dorsal posture, with the affected limb at right angles to the trunk, and resting upon a second smaller table. The operator seats himself opposite the affected hand, his assistant being opposite him.

Many operations have been practised for excision of the wrist. The best appear to be those which are performed through dorsal incisions, and the most satisfactory of these is the one described by Ollier and recommended by Treves. The following operation is based upon Ollier's method.

Operation.—Excision of the wrist may be divided into the following stages:—(a) Skin incisions, and exposure of the bones; (b) removal of the bones; (c) closure of the external wound.

(a) *Skin incisions.*—Two incisions are made, one on the radial, and the other on the ulnar side of the dorsal aspect of the limb.

The radial incision commences on the dorsal surface of the metacarpal bone of the index finger at a point opposite the middle of the shaft, and extends upwards along the radial margin of the outer tendon of the extensor communis digitorum, to a point situated at the centre of a line joining the styloid processes of the radius and ulna. Beyond this level it is prolonged upwards in a vertical direction for about 1 in. or a little more. This incision

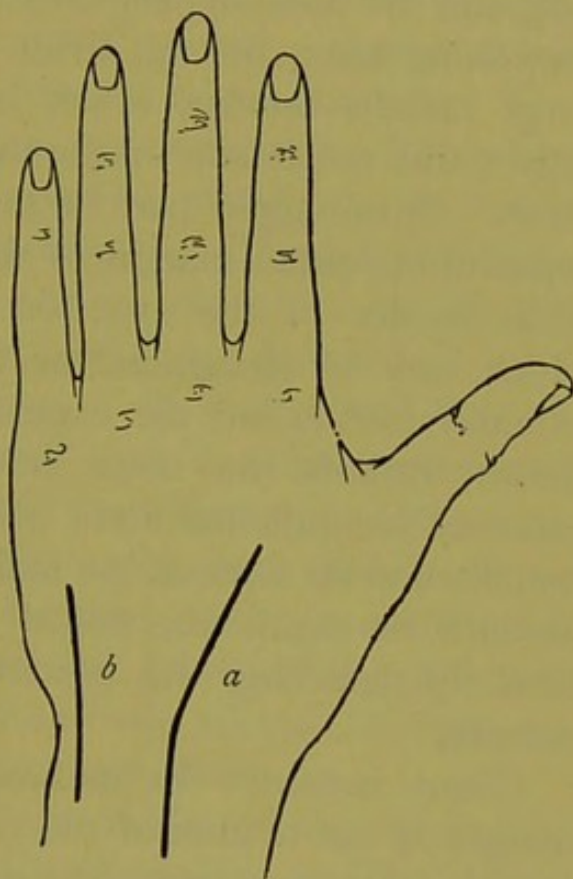


FIG. 307.—Excision of wrist. Skin incisions.

a. Radial incision.
b. Ulnar incision.

measures about 3 or 4 in. in length, one-third being situated above the line joining the two styloid processes, and two-thirds below it. The incision divides the skin and fasciæ with some of the fibres of the posterior annular ligament, and lays bare the radial tendon of the extensor communis digitorum. This muscle is retracted towards the ulnar side, and the incision deepened until the bones are reached, care being taken not to divide the tendon of the extensor carpi radialis brevis, which is inserted into the dorsal aspect and radial side of the base of the third metacarpal bone. In the upper part of the incision, it is necessary to separate the radial margin of the extensor indicis from the ulnar border of the extensor secundi internodii pollicis, which can be recognised by its oblique direction. The extensor indicis and the extensor communis digitorum are drawn towards the ulnar side with retractors, and the extensor secundi internodii pollicis and the extensor carpi radialis brevis towards the radial side. With the periosteal elevator or rugine the dorsal aspect of the bones is laid bare by detaching the posterior ligaments and the periosteum.

Ulnar incision.—An incision is made along the radial margin of the tendon of the extensor carpi ulnaris tendon, commencing at a point opposite the middle of the shaft of the fifth metacarpal bone, and extending upwards to a point about 1 in. or a little more above the prominence of the styloid process of the ulna. The skin and fasciæ are divided, care being taken to avoid the branch of the ulnar nerve to the dorsum of the little finger, and the interval between the extensor carpi ulnaris and the extensor minimi digiti exposed. These muscles are exposed and pulled aside, the former towards the ulnar margin of the limb, and the latter towards the radial. The dorsal aspect of the lower portion of the ulna, the cuneiform, the unciform, and the proximal part of the fifth metacarpal bone, will now be exposed. The ligaments and periosteum are divided with the

scalpel, and then separated from their bony attachments with the rugine.

(b) *Removal of the bones.*—When the carpal bones have been separated from their periosteal and ligamentous connections, each one is seized separately with forceps and removed. It is most convenient to remove the bones from the radial side of the carpus first, and then to remove those on the ulnar side through the ulnar incision. On the radial side the trapezium should be left if it is not diseased. The articulation between this bone and the base of the first metacarpal has a separate synovial membrane, hence it often happens that it can be safely left. The pisiform bone may be disarticulated, and the unciform process of the unciform cut through, and both left if not diseased.

The removal of the extremities of the radius and ulna.—The shafts of these bones are now cleared of their periosteum for about half an inch, or a little more if requisite (according to the extent of the disease process), and then made to protrude through the radial incision. With a narrow saw the ends are removed beyond the limits of the articular surfaces. If they are not extensively affected it may be sufficient to scrape them with a sharp spoon.

Removal of the proximal extremities of the metacarpal bones.—These are protruded through one of the dorsal incisions, usually the ulnar, and the articular ends removed with a fine saw. The section of these bones is generally made just beyond the articular surfaces. The connection of the first metacarpal with the distal surface of the trapezium is not interfered with if possible.

(c) *Closure of the external wound.*—The cavity from which the bones have been removed is sponged dry, freed from all bone débris, and the margins of the skin incisions united by the insertion of a number of interrupted sutures. Part of the ulnar incision is left open, and through this a short drainage tube is passed inwards. Aseptic dressings are then applied.

The limb is fixed in a position of slight dorsiflexion with the fingers gently flexed, by the application of a splint of suitable shape. Fig. 308 is a form of splint which will be found to answer the purpose.




FIG. 308.—Excision of wrist. Splint for use after operation.

The fingers should be passively moved during the time that a splint is worn. In most cases it is necessary for the patient to wear the splint from three to six months.

When the splint has been discarded the patient should wear a leather wristlet.

The results of excision of the wrist-joint have not been good. A certain number of cures have been effected, but often, especially when the operation is performed for tuberculous disease of the carpus, the disease recurs, necessitating a second excision or an amputation.

Excision of a metacarpo-phalangeal joint.—This operation is occasionally performed, most commonly in connection with the metacarpo-phalangeal joint of the thumb or that of the little finger.

Operation.—An incision, from $1\frac{1}{2}$ to 2 in. in length, is made along the lateral aspect of the affected joint, the centre of the incision being opposite the joint. The incision should be situated a little nearer the dorsal than the palmar aspect of the digit. The soft tissues are divided down to the bone, the lateral ligament is divided, and the periosteum and the tendons turned

aside. The ends of the metacarpal bone and the phalanx are protruded through the incision and then removed with a fine saw.

In the case of the thumb the incision is placed on the radial side, in the little finger on the ulnar side, and in the

case of the other metacarpal bones on either the radial or ulnar side, whichever is the more convenient.

The incision is closed with sutures, and the finger fixed to an anterior splint. As soon as the wound has healed passive movements are commenced, usually at the end of a week or ten days.

Excision of an interphalangeal joint.—This operation is similar to the one described for a metacarpo-phalangeal joint. In some cases the operation will be facilitated by making an incision on each side of the joint. Usually, however, one lateral incision will be found sufficient.

Excision of the hip-joint.—The hip-joint is the articulation between the head of the femur and the acetabular cavity of the os innominatum. The capsular ligament of the joint is attached above to the rim of the acetabulum and the transverse ligament which bridges over the cotyloid notch, and below to the anterior inter-trochanteric line in front and the neck of the femur half-way between the margin of the articular surface and the posterior inter-trochanteric line behind. From this it will be understood that the ligamentous attachments and the synovial membrane of the joint extend much farther down the femur anteriorly than posteriorly. The anterior portion of the capsule is much thickened by the ilio-femoral ligament or the Y-shaped ligament of Bigelow. In the interior of the joint there is a ligament fixing the head of the bone to the margins of the cotyloid notch. This is called the ligamentum teres. A large bursa, which is called the psoas bursa, is situated between the anterior aspect of the joint and the deep surface of the ilio-psoas muscle. This often communicates with the cavity of the hip-joint through an aperture in the anterior portion of the capsule.

An excision of the hip-joint is usually only partial, the femoral elements being the parts which are generally removed. The joint requires excision most commonly in tuberculous affections, and also more rarely for ankylosis

in a faulty position, or for inflammatory affections, and in some cases of gunshot wounds. Ankylosis of this joint in a faulty position is usually treated by osteotomy of the femur, as described on p. 455.

Excision of the hip-joint may be carried out (a) through a postero-external incision, or (b) through an anterior incision.

The former is more suitable for extensive operations, and the latter for the less severe ones in which the disease is limited to the upper part of the femur.

A. Excision of the hip-joint through a postero-external incision.—*Position.*—The patient lies upon the sound side, with the diseased hip-joint flexed at half a right angle. The operator stands behind the patient, the chief assistant opposite to him, and a second assistant at the foot of the table holds the affected limb of the patient.

Operation.—The operation may be divided into the following stages:—(a) External incision and exposure of capsule of hip-joint; (b) division of capsule and exposure of the

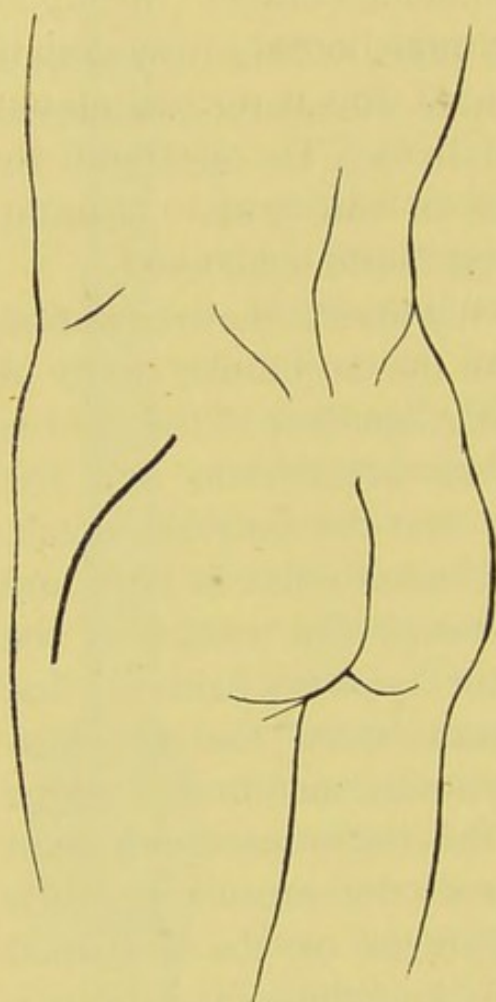


FIG. 309.—Excision of hip, through a postero-external incision.

— Position of incision.

interior of the joint; (c) removal of diseased tissues; and (d) closure of external wound.

(a) *External incision and exposure of capsule.*—An incision, about 4 in. in length, is made, commencing at the lower border of the great trochanter of the femur and extending upwards and backwards towards the posterior superior spine of the ilium. The upper portion of this

incision should be parallel with the direction of the fibres of the gluteus maximus muscle, and may be slightly curved if necessary. The incision divides the skin, fasciæ, and gluteal aponeurosis in the lower half, and the gluteus maximus in the upper. These structures after being divided are held aside with retractors, and the interval between the upper border of the pyriformis and the lower border of the gluteus medius muscle sought. When found, this is opened up and the capsule of the hip-joint laid bare. The assistant who has charge of the limb rotates it outwards, so as to bring the anterior part of the great trochanter into the wound. The surgeon then separates the attachments of the gluteus medius and minimus from the external and anterior aspects of the bone with a rugine. The limb is next rotated inwards, and the pyriformis, obturator internus and two gemelli, and the obturator externus, are separated in a similar manner. The obturator externus is inserted into the bottom of the digital fossa of the femur, and the other muscles to the top of the trochanter.

(b) *Division of capsule and exposure of the interior of the joint.*—The capsular ligament is incised in a direction parallel with the upper border of the pyriformis, and stripped backwards and forwards with the rugine or knife, if requisite. The soft parts are well retracted by the assistant, so as to thoroughly expose the interior of the joint. The head of the femur is dislocated through the opening in the capsule, the ligamentum teres being cut through if necessary.

(c) *Removal of diseased parts.*—The neck of the femur is sawn through beyond the limits of the diseased tissue, any sequestrum which may be present removed, and then all thickened or pulpy synovial membrane taken away by dissection or scraping with a sharp spoon. The interior of the joint is flushed out with sterilised water, and an examination of the acetabulum made. If the disease has involved this part of the joint, all affected portions are scraped away.

(d) *Closure of external wound.*—The interior of the joint

is again washed out, a drainage tube is passed down into the bottom of the cavity, and the external incision closed by the insertion of sutures in the usual manner.

Dressings are applied, and the patient placed on a splint. In the case of a child a double Thomas's hip-splint is the best ; for an adult a Hodgen's or a Bryant's.

After-treatment.—The patient must be kept at rest for five or six weeks, and then he can be allowed to get about, a single splint being substituted for the double one. It will be necessary, however, for the splint to be worn for nine or twelve months. If the splint is left off too early, the ligaments in the region of the hip become elongated and the functions of the limb considerably impaired.

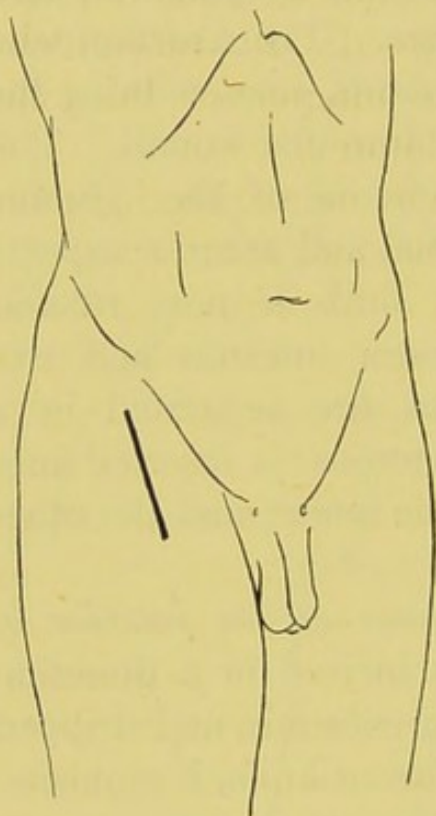


FIG. 310.—Excision of hip-joint through an anterior incision.

— Position of incision.

B. Excision of the hip-joint through an anterior incision—*Position.*—The patient is placed in the dorsal position on the operation table, with the affected hip near the edge. The surgeon stands on the outside of the affected joint, and his assistant on the opposite side.

Operation.—An incision, 3 in. in length, is made on the antero-lateral aspect of the thigh, commencing above about half an inch below the anterior superior spine of the ilium, and extending downwards and slightly inwards. This incision divides skin and fasciæ, and then by dissection the interval between the rectus femoris and sartorius on the inner side, and the tensor fasciæ femoris and gluteus medius and minimus on the outer side, is opened up, and the surface of the capsule of the articulation exposed. The capsule is then incised, and the interior of the joint opened.

Often, one or more abscess cavities are met with, in which case their interior is thoroughly irrigated before proceeding further. When the joint cavity has been opened it is irrigated, and the diseased portion of the femur removed by sawing through the bone *in situ* beyond the limits of the disease. Any other diseased parts of the joint are removed, as in the previous operation; and after washing away all traces of blood, etc., by irrigation, a drainage tube is introduced and the external wound closed. In tuberculous cases it has been advised that the interior of the joint should be filled with emulsion of iodoform.

The further treatment of the case is similar to that after excision through a postero-external incision.

The disadvantages of this operation are said to be the difficulty in obtaining satisfactory drainage, and the limited exposure of the joint during the performance of the operation.

Excision of knee-joint.—The articular surfaces of three bones enter into the formation of the knee-joint. These are the lower extremity of the femur, the posterior aspect of the patella, and the upper end of the tibia. In performing a complete excision all these surfaces are removed.

The object of the surgeon after excision of the knee-joint is to obtain complete ankylosis of the tibia and the femur. The operation is usually performed for tuberculous disease. Ankylosis of the joint in a faulty position, some forms of compound dislocation of the joint, and gunshot wounds may also require this form of treatment.

Partial excision of the knee-joint, or so-called "arthrectomy," is sometimes performed, and in these cases the surgeon aims at producing a movable joint. The operation of complete excision will be described first, and the partial operation afterwards.

A. Excision of the knee-joint (complete). — *Position.*—The patient is placed in the dorsal posture on the operation

table, the affected limb being close to the edge, and the distal half of the leg projecting beyond the end of the table. The surgeon stands on the outer side of the affected limb, and the assistant opposite to him. A second assistant

stands at the end of the table, and holds the limb in the position required.

Operation. — The operation of excision of the knee-joint may be divided into several stages:—(a) External incision; (b) opening of knee-joint, free exposure of articular surfaces, and division of ligaments; (c) section of the bones; (d) coaptation of ends of tibia and femur, and application of a suitable splint; (e) closure of external wound.

(a) *External incision.*—The limb being held slightly flexed at the knee-joint by an assistant, the positions of the internal and external condyles of the femur are exactly defined. An incision is made, commencing in the case of the right leg immediately behind the adductor tubercle, then extending in a curved direction downwards to

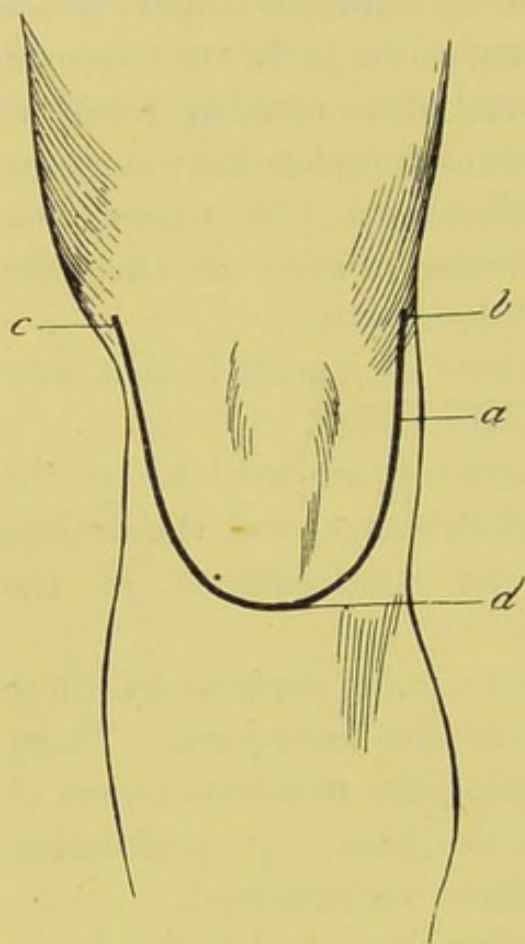


FIG. 311. — Excision of knee-joint. Position and direction of skin incision.

- a. Line of skin incision.
- b. Position of adductor tubercle.
- c. Prominence of external condyle.
- d. Tubercle of tibia.

the upper border of the tubercle of the tibia, and thence upwards to a point immediately behind the prominence of the external condyle. This incision divides the skin, superficial fascia, and deep fascia, which is here thickened on account of expansions of the vasti muscles having been inserted into it, and the flap of soft tissues thus marked

out is dissected upwards until the superior margin of the patella is reached.

(b) *Opening of the knee-joint and free exposure of articular surfaces, and division of ligaments.*—The aponeurosis of the quadriceps extensor muscle is divided along the upper border of the patella until the external surface of the synovial membrane is visible. The synovial membrane, including the large pouch which passes upwards underneath the quadriceps, is dissected away from its connections with the deep aspect of the muscles, and then from the anterior and lateral aspects

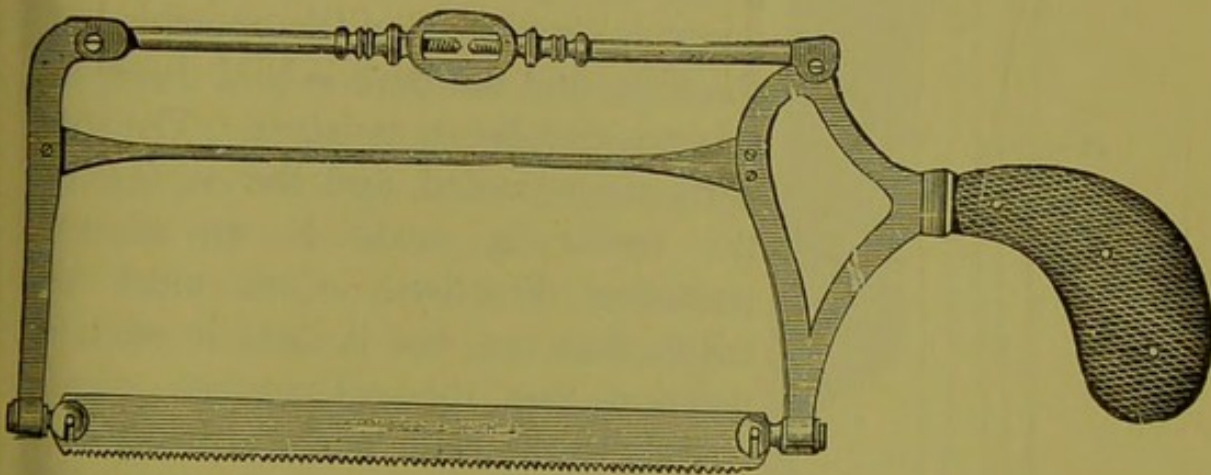


FIG. 312.—Excision of knee-joint. Saw for section of bones.—BUTCHER.

of the femur, until the margin of the articular cartilage is reached. The joint is now opened from above. The incision is extended laterally, and the capsule and the lateral ligaments are divided; the patella is turned downwards, but should not be removed at this stage, as it affords a useful means of steadying the tibia when the bones are being sawn. The large bursa which lies between the ligamentum patellæ and the tibia is dissected away, and the head of the tibia cleared anteriorly as far as the margin of the articular surface. The assistant flexes the knee, so as to more fully expose the interior of the joint. The surgeon detaches the crucial ligaments from their attachments

to the tibia and femur, and removes them together with the interarticular cartilages. The limb is still further flexed, and the posterior and lateral aspects of the femur

and the tibia cleared for a short distance by a series of small strokes with the knife. The bones are now ready for section.

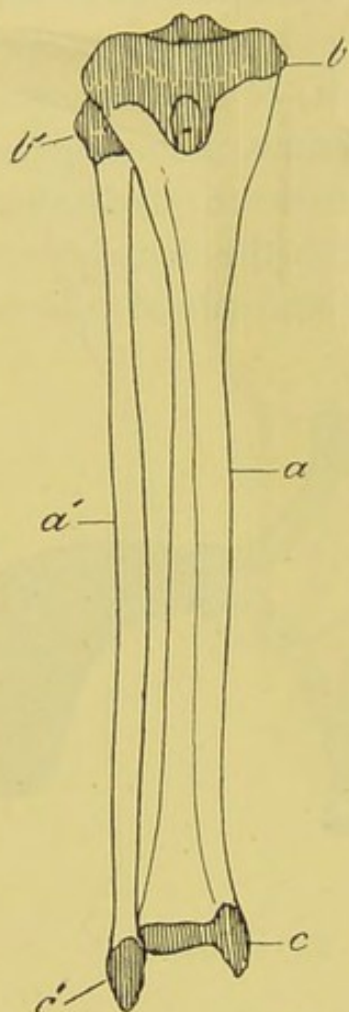


FIG. 313.—Excision of knee-joint. Tibia and fibula, showing the parts of the bones derived from the several centres of ossification. (The femur is illustrated in Fig. 278.)

- a.* Diaphysis of tibia.
- b.* Upper epiphysis of tibia.
- c.* Lower epiphysis of tibia.
- a'.* Diaphysis of fibula.
- b'.* Upper epiphysis of fibula.
- c'.* Lower epiphysis of fibula.

(*c*) *Section of the bones.*—The knee-joint is bent at a right angle, the sole of the foot resting on the table; the posterior aspect of the condyles of the femur is supported on the upper end of the tibia, and the limb is held firmly in this position by an assistant. The soft parts are retracted, and the section of the femur is made in an antero-posterior direction. Care must be taken that the saw is held in such a position that the cut surface corresponds to the plane of the articular surface. An ordinary amputation saw with movable back is the most convenient to employ in most cases, but a Butcher's saw (Fig. 312) is required when one of the bones is to be specially shaped to fit the other. Not more than one inch of the lower end of the femur should be removed, otherwise there is danger of injury to the epiphyseal cartilage, an accident which might be followed by considerable shortening of the limb, if the operation were being performed on a young individual (Fig. 278).

The upper end of the tibia is next made to project beyond the femur, the leg being held in a vertical position with the foot still resting on the table,

and the saw-cut is made in a horizontal plane from behind forwards.

The two sawn surfaces of bone must be at right angles to the long axes of the bones, and in a plane corresponding to that of the articular surfaces which are removed, otherwise when the bones are brought into apposition the limb will be found to be bent at an angle.

The patella with its attached ligamentum patellæ and portions of the capsule and synovial membrane are taken away, the ligamentum patellæ being cut through at its attachment to the tubercle of the tibia.

The posterior portion of the joint is now examined, and any remaining portions of synovial membrane or thickened bursæ removed. The bursa underneath the tendon of the popliteus muscle should be examined, and in nearly all cases it will be advisable to dissect it out, since it invariably communicates with the cavity of the knee-joint. Any other bursæ which are thickened or communicate with the cavity of the knee-joint should be treated in a similar manner.

(d) *Co-aptation of the ends of the femur and tibia, and application of a suitable splint.*—The best splint for use after excision of the knee is the one represented in Fig. 314. This splint is applied, fixed in a position by careful bandaging

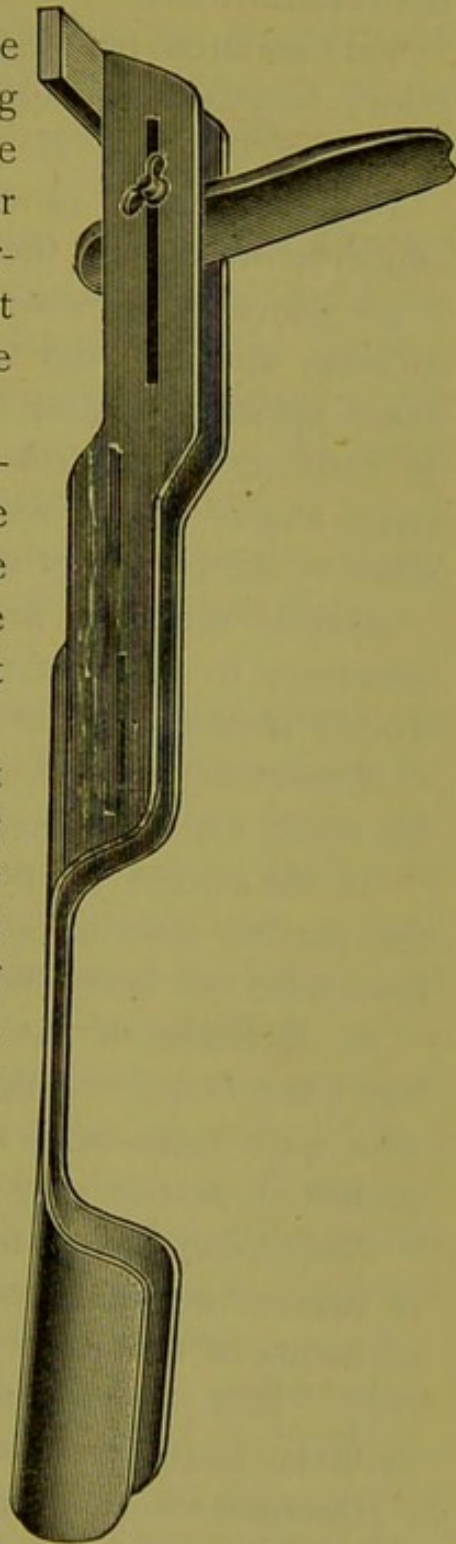


FIG. 314. — Excision of knee. Splint for use after operation.—HOWSE.

and the extremities of the bones brought into exact apposition.

Various methods of pegging or wiring the ends of the bones together have been employed, but they are rarely necessary.

It is advisable in most cases to fix the limb on the splint before closing the external wound with sutures.

(e) *Closure of external wound*.—The margins of the incision through the skin and fasciæ are brought into exact apposition, and fixed by the insertion of a number of interrupted sutures of silk-worm gut. The inner and outer angles of the wound should be left open, so as to allow of the escape of any exudations which may take place.

Aseptic dressings are then applied. It is not usually necessary to introduce a drainage tube if the angles of the wound are left open as above.

After-treatment.—The limb is kept at rest on the splint for about six weeks, until firm union has occurred.

At the end of about three months, in favourable cases, the patient may be allowed to use the limb in which the knee-joint has been excised.

B. Excision of the knee-joint (partial).—This operation has been called "arthrectomy," or "erosion" of the joint. The best term is, I think, *partial excision*; but if it be preferred, *erosion* may be used.

Indications.—The operation is performed in early cases of tuberculous disease in which only a part of the anatomical elements of the joint are involved in the pathological process. It is recommended that it should be done when the synovial membrane alone is involved.

Operation.—A transversely curved incision is made across the front of the knee, as in excision. The ligamentum patellæ is cut through at the lower part of the incision, and the joint cavity opened from below. The ligamentum patellæ, the patella, and the capsule of the joint are lifted upwards, and the interior of the joint

exposed. All thickened or pulpy synovial membrane is then dissected away, or removed by scraping with a Volkmann's spoon, any infiltrated ligaments or interarticular cartilages are cut away, and if the articular ends of the bones are affected, the involved areas are thoroughly scraped, so as to get away all diseased tissue.

When the joint has been freed from all traces of affected tissue, the interior is well irrigated with an aseptic solution. The ligamentum patellæ and the margins of the incision in the capsule are united by the insertion of a series of silk sutures. Next, the external wound is closed in the usual manner, and the limb put up in a suitable splint.

When complete healing has taken place, passive movements are commenced, and an attempt made to get a movable joint.

Kocher recommends that the first incision should be similar to that recommended for "complete excision," and that after the flap of skin and fasciæ has been dissected up, the knee-joint should be opened on each side of the patella, and all necessary manipulations carried out through these incisions. The advantage of this method is that the ligamentum patellæ is not interfered with, and when healing has taken place a much stronger articulation is left. He claims also that a better exposure of the interior of the joint is obtained by this method. Kocher's arguments appear to have considerable weight, and if a partial excision of the knee-joint is to be attempted, it is probable that his operation will lead to a satisfactory result.

Excision of the ankle-joint.—The bones which enter into the formation of the ankle-joint are the inferior articular extremities of the tibia and fibula, and the superior and lateral articular surfaces of the astragalus. The ligaments which hold these articular surfaces together are anterior, posterior, external lateral (with three fasciculi), and internal lateral. There is a single synovial membrane.

Owing to the complicated nature of the joint, excision

has not been followed by such good results as has been the case in other joints.

Indications.—The chief clinical conditions which may necessitate an excision of the ankle-joint are—(a) Tuberculous disease, either originating in the joint, or extending to it from one of the adjacent bones; (b) some cases of compound dislocation of the joint with fracture of one or more of the bones; (c) some forms of suppuration of the joint; (d) some cases of talipes.

Many varieties of operation have been carried out by different surgeons in excising the ankle-joint. The best

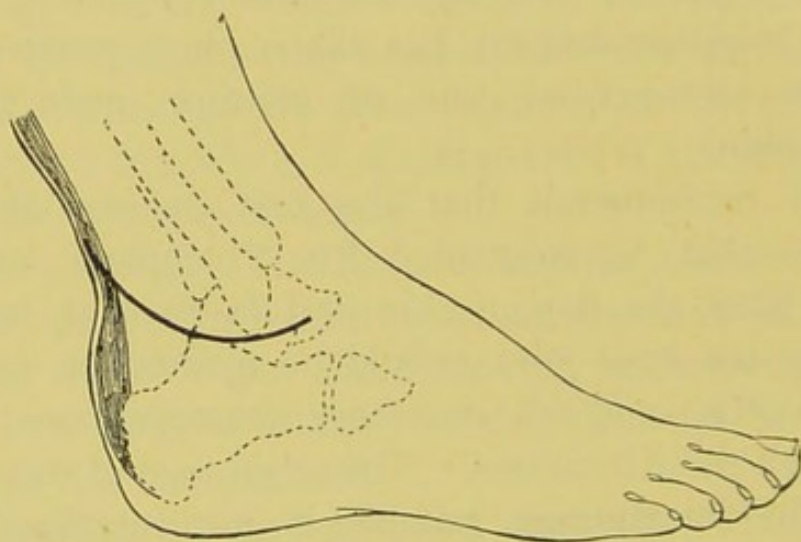


FIG. 315.—Excision of ankle-joint. Position of skin incision.

operation appears to be that which has been recommended by Kocher and Reverdin. In this procedure the joint is excised through a single incision situated on the anterior and external lateral aspects of the foot.

Position.—The patient is placed in the dorsal position on the operation table, with the affected foot lying on its inner side and supported by a sandbag covered with a sterilised towel. The foot should be near the extremity of the table. The operator stands on the outer side of the affected foot, the chief assistant stands opposite to him on the sound side, and a second assistant at the

end of the table. The duty of the second assistant is to hold the foot and manipulate it as required by the surgeon.

Operation.—An incision is made across the dorsal and external lateral aspects of the foot (Fig. 315). It commences at a point half an inch below the centre of the ankle-joint, extends outwards and backwards to the lower margin of the external malleolus, and then upwards and somewhat inwards to the fibular margin of the tendo Achillis. The incision is usually from 3 to $3\frac{1}{2}$ in. in length, and is curved in outline, the concavity looking upwards and towards the tibial margin of the limb.

The skin and fasciæ are divided, the external portion of the musculo-cutaneous nerve sought for in the inner part of the wound, and when found retracted to the tibial side, and the short saphenous nerve and vein in the outer part behind the external malleolus. When the deep fasciæ and the fibres of the anterior and external annular ligaments have been cut through, the tendons of the extensor muscles will be exposed in the anterior part of the wound, and those of the peronei in the posterior part.

With a rugine or periosteal elevator the deep processes of the external annular ligament, and the peronei tendons with their sheaths, are separated from the external aspect of the os calcis and peeled backwards. In very inveterate cases of club-foot, it may be necessary to cut through these tendons, which section must be repaired by suture at the end of the operation. Next, the extensor tendons at the anterior angle of the incision, the processes of the anterior annular ligament, and the anterior ligament of the ankle-joint, are separated with the rugine, and retracted towards the tibial side. The external lateral and the posterior ligaments are then treated in a similar manner, by detaching them from their bony attachments. When these structures have been detached, the joint will be opened on its posterior, internal, and anterior aspects. The internal lateral ligament is left undisturbed.

The foot is now forcibly adducted towards the tibial side, and completely dislocated inwards until the plantar surface lies in contact with the skin on the inner side of the leg. The head of the astragalus and the lower extremities of the tibia and fibula appear in the wound.

A saw of suitable shape is taken, and the diseased portions of the exposed bones removed. All thickened or pulpy synovial membrane and thickened tendon-sheaths are removed by dissection. If the astragalus is extensively involved in the disease, or if the synovial membrane of the astragalo-scaphoid joint is affected, it will be necessary

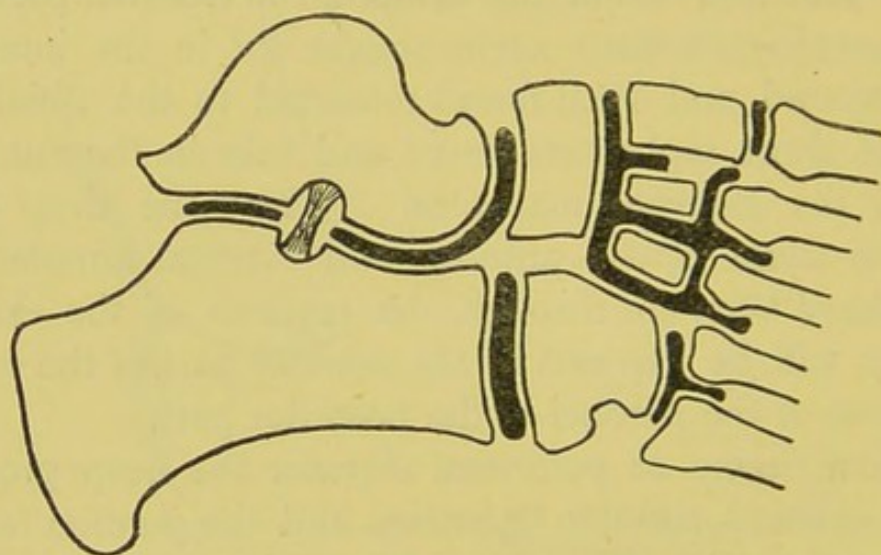


FIG. 316.—Synovial membranes of tarsus and metatarsus.

to remove the entire astragalus along with all other infiltrated and diseased tissues.

All bleeding is now arrested, and the foot brought into its original position. If the peroneal tendons have been divided, the cut ends are sutured together. The ligaments on the external aspect of the joint are united with sutures, if possible, and the external wound closed in the usual manner.

Aseptic dressings are applied, and the limb fixed on a back splint with a foot-piece, side splints being used if considered requisite.

The limb must be kept on the splint until complete healing and union of the divided tissues has taken place.

Excision of the metatarso-phalangeal and interphalangeal joints.—Excision of these joints is performed through a single incision, or through double lateral incisions, placed a little nearer the dorsal than the plantar aspect of the sole. The individual operations differ in no essential respects from the operations on the corresponding digits of the upper extremity (p. 506).

Excision of the temporo-maxillary joint.—The temporo-maxillary joint is formed by the glenoid cavity of the temporal bone and the condyle of the lower jaw.

Important anatomical structures lie in very close relation to the joint. The auriculo-temporal nerve and the super-

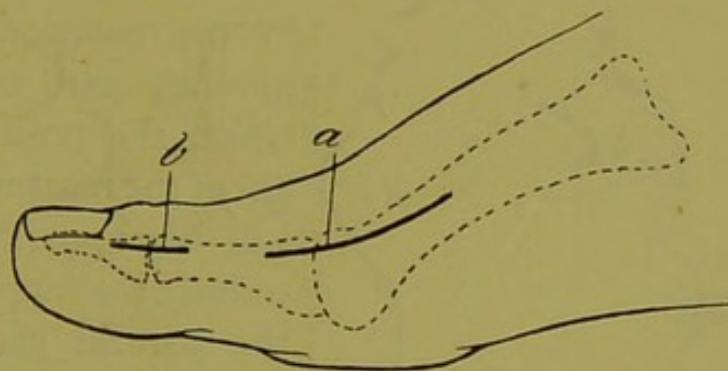


FIG. 317.—Excision of metatarso-phalangeal and interphalangeal joints of great toe.

- a.* Position of skin incision for metatarso-phalangeal joint.
- b.* Position of skin incision for interphalangeal joint.

facial temporal artery lie posterior and external, the internal maxillary artery is below and internal, whilst the glenoid lobe of the parotid gland is situated immediately behind the condyle. The facial nerve lies in the parotid gland at a lower level.

Indications.—Excision of the temporo-maxillary articulation may be necessary in tuberculosis of the joint, in some forms of osteo-arthritis, and in bony ankylosis from any cause.

Position.—The patient is placed in the dorsal posture, with the head turned towards the sound side, and supported by a pillow or sandbag. The surgeon stands on the affected side of the head, and his assistant directly opposite to him.

Operation.—An incision, about $1\frac{1}{2}$ in. in length, is made along the inferior margin of the posterior part of the zygomatic arch, the skin being pulled upwards with the fingers of the left hand before the incision is made.

This incision commences immediately in front of the anterior margin of the external auditory meatus, and extends forwards towards the prominence of the malar bone. The skin, superficial fascia, and the deep fascia are divided,

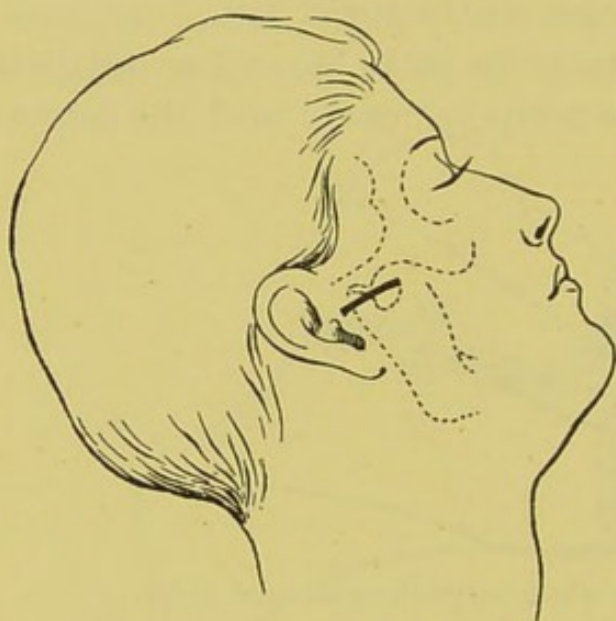


FIG. 318.—Excision of temporo-maxillary articulation. Position of external incision.

vessels being avoided in the posterior angle of the incision, and the temporal branch of the facial nerve in the anterior. In the anterior part of the incision the posterior margin of the masseter muscle will be exposed, and posteriorly the upper part of the parotid gland. The fibres of the masseter are retracted forwards (some of them being divided if requisite) and the parotid gland backwards. The ex-

ternal portion of the capsule of the joint is divided and the cavity opened. The neck of the lower jaw is next freed from the soft tissues, and with a fine saw it is divided from before backwards. The condyle is then seized with a pair of lion forceps, and forcibly pulled outwards. As this is being done, the undivided parts of the capsule are cut through with the scalpel, and the external pterygoid muscle is detached from the anterior and internal aspect of the neck immediately below the articular surface.

The head of the bone can now be removed. The interior of the joint is examined and any diseased tissue removed.

All bleeding is then arrested, and the external wound closed by the insertion of sutures.

Excision of the temporo-maxillary articulation is in most instances a partial excision, the condyle being the only portion of bone which is taken away.

CHAPTER XXV.

AMPUTATIONS.

By the term amputation is understood the detachment and removal of a limb or a part of a limb from the body.

The plane of section of the limb may either pass through the shaft of one of the long bones or through a joint; in the former case the operation is an ordinary amputation, in the latter a disarticulation.

In performing an amputation upon any part of the body, attention ought to be paid to the following important points:—

(a) *The amount of limb to be removed.*—As a general rule it may be stated that as much of a limb should be preserved as possible, for in most cases the value of a stump is greater in proportion to its length.

(b) *The skin.*—Sufficient skin must be retained to form a complete covering for the extremity of the stump without undue tension. The skin-flaps should be so arranged that the resulting scar shall not lie over the end of the stump or in a situation where it is exposed to frequent pressure.

(c) *The covering of the stump.*—The flaps should be so fashioned that plenty of muscle and fascia is left to form a good covering for the bone. In order to effect this, it is often advisable to dissect back the periosteum from the shaft of the bone for a short distance before sawing through the bone, and then to bring down this separated periosteum over the cut extremity and fix it there by the insertion of

sutures. This precaution tends to prevent undue retraction of the muscles.

In the case of a disarticulation, or amputation through a joint, the capsular ligament is divided at the lower part of the articulation, and may be brought over the end of the bone in a manner similar to that recommended above in the case of the periosteum.

(*d*) *The nerves*.—In dividing the soft tissues, an attempt should be made not to cut the nerves in such a manner that their extremities shall be situated where they are liable to undue or frequent pressure.

(*e*) *Aseptic precautions*.—The strictest aseptic or antiseptic precautions should be observed in the performance of every amputation, in order to minimise the risk of the occurrence of suppuration in the wound.

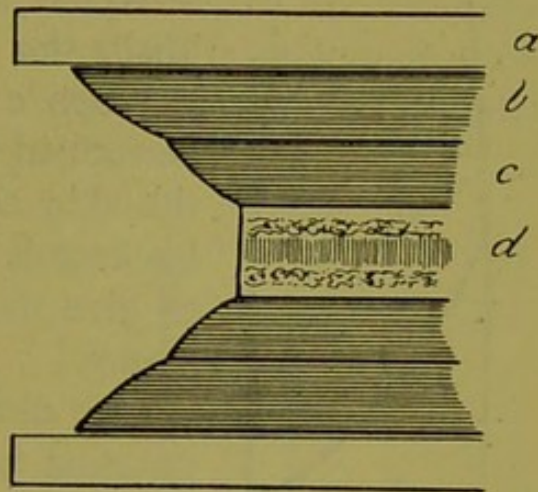


FIG. 319. — Diagrammatic representation of the stump of a limb when a circular amputation has been performed.

- a.* Skin and superficial fascia.
- b.* Deep fascia and superficial muscles.
- c.* Deep muscles.
- d.* Bone.

METHODS OF AMPUTATION.

A considerable number of methods are made use of in the performance of amputations. The most important ones are the following:—

1. **The circular method.**—In this method the tissues of the limb are divided in a circular direction, that is to say, at right angles to the long axis of the limb that is being operated upon. The different tissues, however, are not all divided at the same level, the superficial structures being cut through more distally than the deeper ones. The operation wound in an amputation performed by the circular method has the form of a cone, the edge of the

base of the cone corresponding to the cut margin of the skin and the apex to the bone (Fig. 319).

The skin and superficial fascia are first divided, and then retracted so as to expose the deep fascia at a somewhat higher level. Next, the deep fascia is divided in a similar manner, and retracted. The superficial muscles are now cut through and allowed to retract, and then the deep muscles.

After this the periosteum is incised and dissected back for a short distance, and finally the bone is sawn through.

When a circular amputation is being performed where there are few soft tissues, the skin and superficial fascia are turned backwards in the form of a "cuff," so as to give more cutaneous covering for the stump.

One disadvantage of performing an amputation by the circular method is, that the scar is nearly always situated at the extremity of the stump, and is liable to injurious pressure and to form adhesions to the end of the bone.

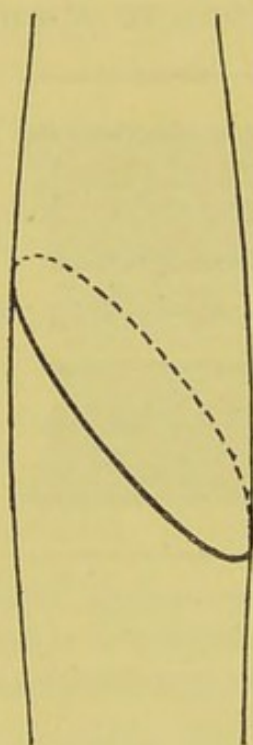


FIG. 320.—Method of making an elliptical or oblique circular incision.

2. The elliptical or oblique circular method.—The skin incision in this operation has the form of an ellipse, one extremity being nearer the proximal portion of the limb than the other. The manner

of division of the different tissues is exactly similar to that adopted in an ordinary circular amputation.

The elliptical method is a very good one, since the resulting scar is situated not over the extremity of the stump, but a short distance proximal to it. A movable cutaneous covering for the stump is thus ensured.

3. The flap method.—In the performance of an amputation by this method, one or more flaps are fashioned from the soft tissues of the limb. These flaps may consist either

of skin and fascia alone, or of skin, fascia, and muscle. In the latter case the skin should always be cut longer than the muscles. It is better, in the majority of instances, that an amputation flap should contain muscle at its base, and not consist throughout of skin and fascia alone.

Varieties of the flap method.—(a) *Single flap.*—The single flap may consist of either skin and fascia, or of skin, fascia, and muscle, and may be formed from the tissues on any aspect of the limb. Its width should be equal to half the circumference of the limb, at the level at which the bone is to be sawn.

(b) *Two flaps.*—When two flaps are formed, they may




FIG. 321.—Forms of amputation flaps.

- a. Single flap.
- b. Equal antero-posterior flaps.
- c. Equal lateral flaps.
- d. Unequal antero-posterior flaps.
- e. Unequal lateral flaps.

either be of equal length, or one may be longer than the other. It is generally preferable that the flaps should be of unequal length, so that the resulting scar may not be situated over the extremity of the stump. The flaps may either be antero-posterior or lateral.

When the flaps have square-cut extremities, they are called "rectangular" flaps; when the angles are rounded off, "U-shaped." The latter (U-shaped flaps) will generally be found more convenient, and will give a better-shaped stump than rectangular ones.

4. The modified circular method.—In the modified circular method of amputation, a circular incision is first

made through the skin and fascia; then one or two lateral incisions are made which extend proximally for a short distance. If two lateral incisions are made, we have two short flaps which may be rectangular in shape or have the corners rounded off. The flaps in all cases are of equal length, and are composed of skin and superficial fascia. The further stages of the operation are similar to those in the circular method (Fig. 322 A).

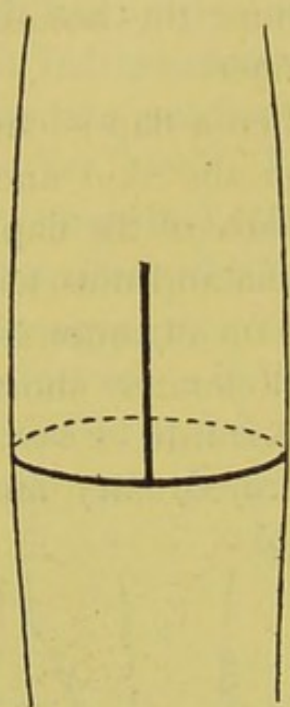


FIG. 322 A.—Modified circular incision.

5. The modified elliptical or "racket-shaped" method.—This form of amputation is a modification of the elliptical method, the incision being prolonged up the limb from the proximal extremity of the ellipse (Fig. 322 B).

MODES OF FASHIONING FLAPS.

Three distinct ways of fashioning amputation flaps are practised—

(a) *By transfixion.*—In this case, a knife whose blade is equal in length to at least half the circumference of the limb, is used. The first incision transfixes the limb from side to side. Thus, in amputation of the forearm by this method, the knife is entered on one side, passes down to the bone, then across the limb in front of the bones until its point emerges on the opposite side, half-way round the limb. By a sawing movement the tissues are divided in a distal direction for the necessary distance. The edge of the knife is then turned towards the surface, and a cut is made

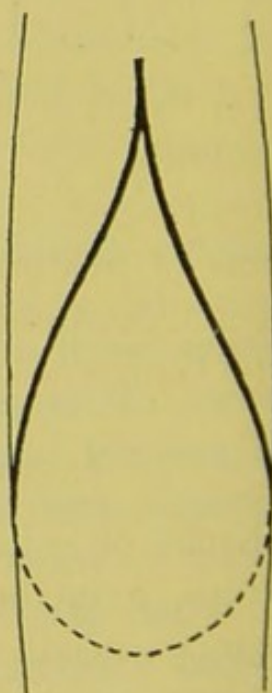


FIG. 322 B. — Modified elliptical or "racket-shaped" incision.

outwards in such a manner that the skin is left longer than the muscles. The knife is then passed behind the bones, and the posterior flap made in a similar manner.

(*b*) *By cutting from without inwards.*—When a flap is cut by this method, an incision is made through the skin and superficial fascia, marking out the shape and size of the flap. These tissues are retracted, and the deep fascia and muscles cut until the bone is reached. For this form of amputation it is advisable to use a knife with a moderately short blade. Fig. 350 illustrates a knife of suitable form.

(*c*) *By dissection.*—This mode of forming an amputation-flap is only occasionally employed. The shape of the flap is first marked out by making an incision in the skin and superficial fascia. These structures are retracted for a short distance, and then the muscles are divided and dissected up from the bone, so that the muscular flap has the shape of the original skin incision.

INDICATIONS FOR AMPUTATION.

(*a*) Injury so severe as to destroy the vitality of a portion of a limb.

(*b*) Disease of a limb which is not amenable to milder forms of treatment, such as malignant disease, extensive tuberculous disease, and some forms of paralysis.

(*c*) Gangrene of a part of a limb from any cause.

INSTRUMENTS FOR AN AMPUTATION.

Knife of suitable size, dissecting, pressure, and artery forceps, retractors, periosteal elevator, saw, bone forceps, scissors, needles, needle-holder, tourniquet or elastic bandage, and ligature and suture material.

AMPUTATIONS IN THE UPPER EXTREMITY.

Amputation of the fingers.—The removal of a digit or part of a digit is generally effected through a joint, and

hence the operation is of the nature of a disarticulation. In a certain number of cases, however, a phalanx or metacarpal bone is sawn through as in an ordinary amputation.

A finger may be amputated through the second interphalangeal joint, the first interphalangeal joint, or the metacarpo-phalangeal joint, or one of the phalanges may be divided, or the entire digit may be taken away together with its metacarpal bone.

Anatomical considerations.—Position of the joints.—When the digits are partially flexed, three prominences are apparent on their dorsal aspect in the neighbourhood of the meta-

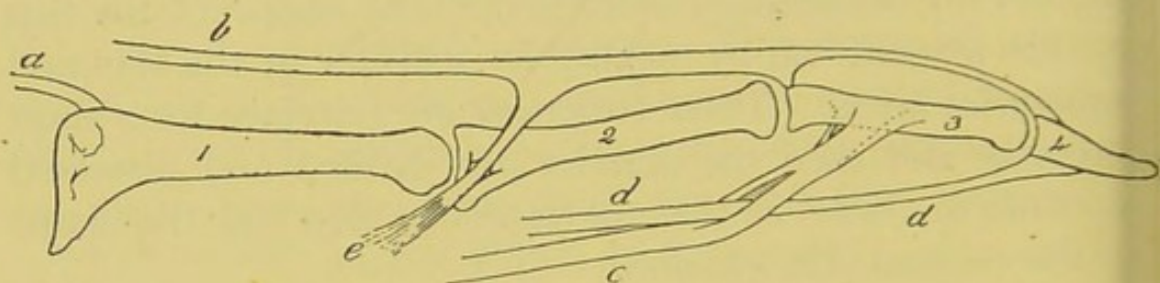


FIG. 323.—Diagrammatic representation of the manner in which the flexor and extensor tendons are inserted into the fingers.

- | | |
|-------------------------------------|------------------------------|
| 1. Metacarpal bone. | b. Extensor communis tendon. |
| 2. First phalanx. | c. Flexor sublimis tendon. |
| 3. Second phalanx. | d. Flexor profundus tendon. |
| 4. Third phalanx. | e. Tendon of a lumbrical or |
| a. Extensor ossis metacarpi tendon. | interosseous muscle. |

carpo-phalangeal and interphalangeal joints. In each case the joint lies distal to the prominence, this being formed by the head of the metacarpal bone or phalanx. The metacarpo-phalangeal joint is situated about one-third of an inch distal to the prominence of the knuckle; the first interphalangeal joint one-fifth or one-sixth of an inch beyond the prominence formed by the distal extremity of the first phalanx, and the second interphalangeal joint about one-tenth of an inch distal to the prominence formed by the head of the second phalanx. On the palmar aspect of the digits three transverse furrows are visible, the proximal one two-thirds of an inch distal to the plane of the metacarpo-phalangeal joint,

the middle one directly opposite the first interphalangeal joint, and the third or distal crease about a quarter of an inch proximal to the line of the corresponding joint.

Ligaments.—The strong ligaments of the metacarpophalangeal and interphalangeal joints are the two lateral ones. The palmar ligament is of medium thickness, whilst on the dorsal aspect the aponeurosis of the extensor tendon takes the place of a ligament.

Insertion of tendons.—The tendons of the flexor profundus digitorum are inserted into the palmar aspect of the bases of the distal phalanges; those of the flexor sublimis digitorum into the lateral aspects of the shafts of the second phalanges;

the slips from the interossei and lumbricales into the lateral aspects of the bases of the first phalanges; and the extensor communis digitorum into the dorsal aspect of the bases of the second and third phalanges (Fig. 323).

Sheath of the flexor tendons.—On the palmar aspect of the first and second phalanges there is a well-marked fibrous

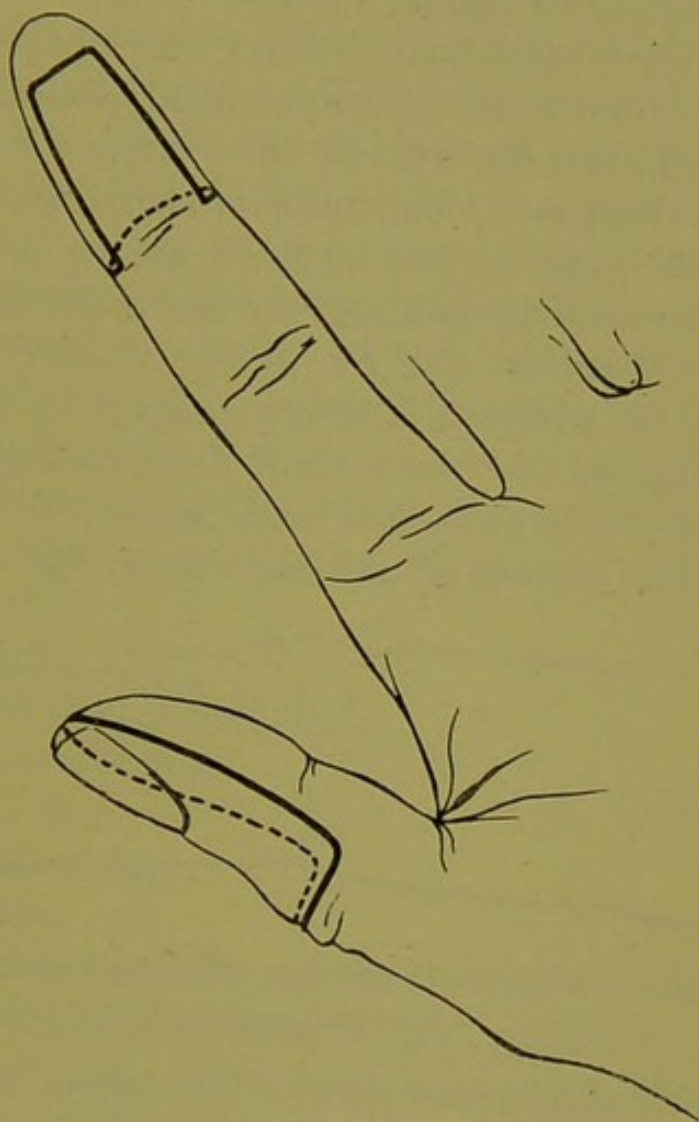


FIG. 324.—Finger and thumb, showing position of skin incisions in amputation of distal phalanx by a long palmar flap.

canal, lined by a synovial sheath, and containing the flexor tendons.

Amputation through the distal interphalangeal joint.—

The following varieties of operation have been made use of :

(a) Long palmar flap.

(b) Long palmar and short dorsal flaps.

Instruments.—Narrow-bladed scalpel and short finger-knife, and the ordinary instruments for an amputation.

Position.—The hand is pronated, and the adjacent fingers held aside by two strips of aseptic gauze by an assistant. The surgeon stands or sits facing the limb.

Operation—(a) *By a long palmar flap.*—The phalanx to be removed is firmly grasped by the left hand of the surgeon, and the second interphalangeal joint flexed. A transverse incision is made across the dorsal aspect of the joint, extending half-way round the digit. This incision

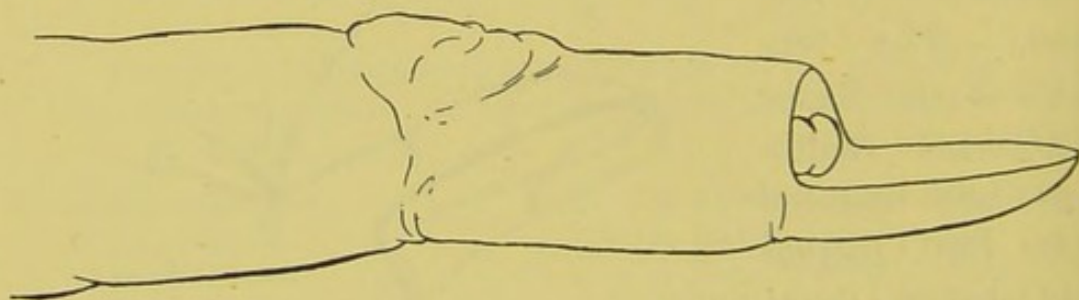


FIG. 325.—Finger from which the terminal phalanx has been removed, showing a long palmar flap.

should open the joint. The lateral ligaments are divided, and the edge of the knife, after cutting through the palmar ligament, is turned towards the tip of the finger, and then, by a slight sawing movement, a flap is cut. Care must be taken to make the extremity of the flap almost square, so as to correspond with the dorsal incision. It usually comprises about two-thirds of the pulp of the finger.

Any bleeding vessels present are ligatured, and then the flap is turned over the free extremity of the second phalanx and stitched to the margins of the dorsal incision.

If a narrow-bladed knife is not available, the palmar

flap may be dissected up first with the scalpel, and disarticulation performed from the dorsal aspect as before.

(b) *By a short dorsal and a long palmar flap.*—In this case a short dorsal flap, one-third the length of the palmar, is dissected up before opening the joint. The other stages of the operation are similar to the preceding, with the exception that the palmar flap is correspondingly shorter.

Amputation through the second phalanx of a finger.—Whenever possible, the amputation should be performed through the distal third of this phalanx, in order to preserve the insertions of the tendon of the flexor sublimis digitorum. When, however, this is not practicable, the divided extremities of the extensor and flexor tendons should be sewn together over the distal extremity of the first phalanx, so as to render movements of the remaining portion of the digit possible.

The amputation may be performed by the following methods:—

- (a) Long palmar flap.
- (b) Short dorsal and long palmar flaps.
- (c) Equal antero-posterior flaps.
- (d) One long lateral flap.
- (e) Two unequal lateral flaps.
- (f) Equal lateral flaps.

The first two of these methods are the best, and should be adopted whenever the condition of the part will allow.

(a) *By a long palmar flap.*—The hand being held as in the previous operation, the operator decides upon the level at which he will divide the bone. An incision is then made round half the circumference of the digit on its dorsal aspect at the level of the proposed plane of section of the bone. The point of the knife is then entered at one extremity of this incision, passed transversely across on the flexor aspect of the phalanx, emerging at the opposite side of the digit. By a series of sawing movements, a palmar flap, two-thirds to three-quarters of an inch in length, is made, and the edge of the knife then turned towards the palmar

surface, and made to cut its way outwards. The soft parts are retracted for a short distance, the periosteum divided, the section of the bone made with a finger saw, and the distal portion of the digit removed.

Hæmorrhage is arrested, and the flap is then turned over the end of the finger and sutured in position.

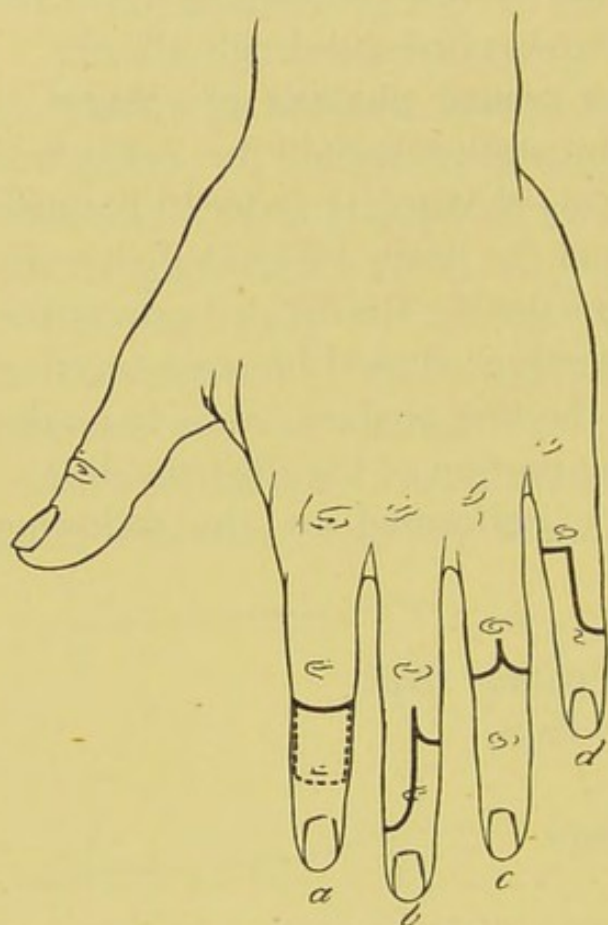


FIG. 326. — Amputation of a finger through second phalanx.

- a.* By long palmar flap.
- b.* By unequal lateral flaps.
- c.* By equal lateral flaps.
- d.* By a single long lateral flap.

(*b*) *By a short dorsal and a long palmar flap.*—A short dorsal flap one-third the length of the palmar one is dissected up, and then the palmar flap is fashioned as in the preceding case, but cut somewhat shorter. The further stages of the operation are similar to the preceding.

(*c*) *By equal antero-posterior flaps.*—The plane of section of the bone having been determined, an incision is made commencing at the lateral aspect of the finger, passing downwards for half or three-quarters of an inch, then transversely across

the dorsum, and upwards on the opposite side. The flap so marked out is dissected upwards, and a similar flap made on the palmar surface. The flaps are retracted, the tendons cut across, the periosteum divided, and the bone sawn through.

Hæmorrhage is arrested, and the margins of the flaps united with sutures.

(d) *By one long lateral flap.*—The plane of section of the bone having been decided upon, a vertical incision is made along the middle line of the dorsal aspect of the finger, commencing at this level and extending downwards for three-quarters of an inch. The incision is carried round to the palmar aspect of the finger, and then upwards along the middle line on the palmar surface to a point opposite that at which it commenced. The flap, consisting of skin and fascia, is dissected up to the plane of section. Then with the scalpel the soft tissues on the opposite side of the finger are divided transversely, together with the flexor and extensor tendons, and the bone sawn through.

Hæmorrhage is arrested, and finally the flap is adjusted over the end of the finger and fixed in position by sutures.

(e) *By two unequal lateral flaps.*—The details of this operation are similar to those of the preceding, with the exception that a short flap is dissected back on one side and a longer one on the other.

(f) *By equal lateral flaps.*—The incision in this operation is similar to that in the preceding, but it is carried for a shorter distance along the dorsal aspect of the finger, and two flaps of equal length are cut.

Amputation through the proximal interphalangeal joint.

—The best operation for this purpose is that in which a long palmar and a short dorsal flap are made.

Operation.—The level of the joint being defined, a short dorsal flap one-third of an inch in length is dissected back. The joint is then opened from above, and the palmar flap, two-thirds of an inch in length, formed by cutting distally behind the phalanx.

Hæmorrhage is arrested, the extensor tendon on the dorsal aspect of the phalanx and the flexor tendons on the palmar aspect brought over the end of the phalanx, and fixed in position with sutures. The palmar flap is then adjusted to the dorsal one, and the margins united in the usual manner.

Amputation of a finger through the metacarpo-phalangeal joint.—This is usually done by means of a “racket-shaped”

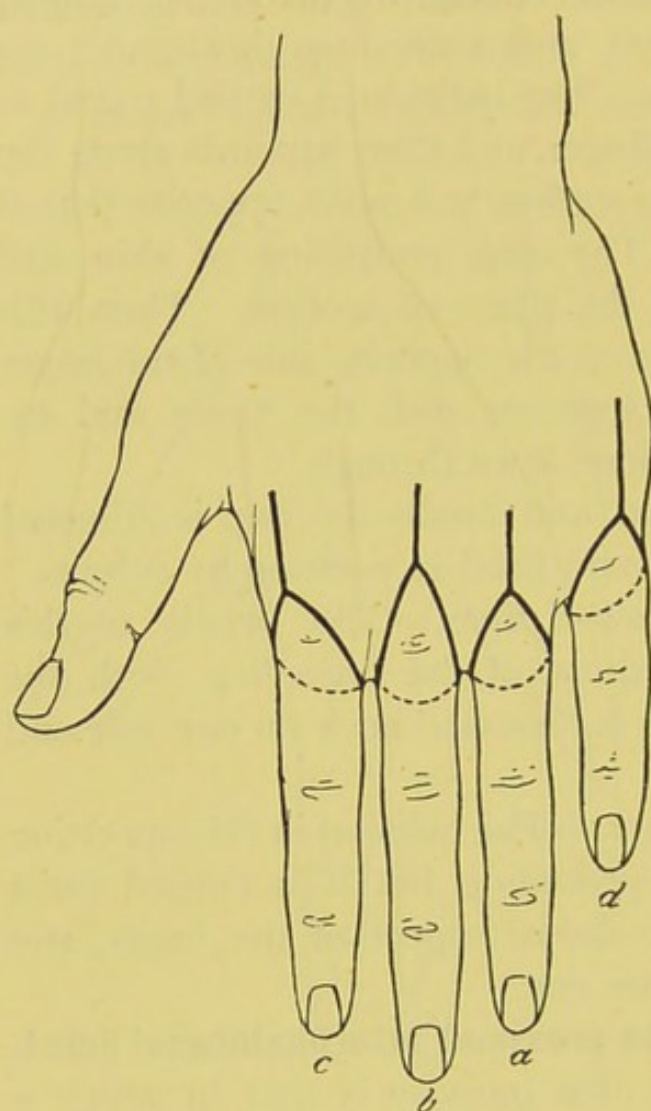


FIG. 327.—Position and shape of incision in amputation of a finger through the metacarpo-phalangeal joint.

- a.* Without removal of head of corresponding metacarpal bone.
- b.* With removal of head of metacarpal bone.
- c.* Index finger.
- d.* Little finger.

incision. The finger which is to be removed being firmly grasped by the left hand of the surgeon, and the adjacent fingers being held aside with strips of aseptic gauze by an assistant, the incision is commenced over the middle line of the dorsal aspect of the corresponding metacarpal bone, two-thirds of an inch from its distal extremity. It is continued downwards to the level of the joint, and then round one side of the finger across the palmar aspect just beyond the web, and up the other side till it reaches the vertical incision again. The flap having been dissected up on each side, the extensor tendon is divided, and disarticulation is performed from

above. Any bleeding digital arteries are ligatured, and the two flaps are brought over the convex extremity of the metacarpal bone and fixed by the insertion of sutures.

If the patient belong to the upper class, and the

appearance of the hand is of more importance than its utility for physical labour, the head of the metacarpal bone should be removed. This is effected by dissecting back the tissues covering it for a short distance, cutting through the transverse metacarpal ligament, and then dividing the shaft with a fine metacarpal saw. Bone forceps should not be used for this purpose, since they are liable to cause splintering of the bone. The later stages of the operation are as before.

Amputation of a finger together with its metacarpal bone.

—The plane of the carpo-metacarpal joint having been determined, an incision is made along the dorsal aspect of the metacarpal bone for its proximal two-thirds, and then round the finger just beyond the

web in an oval manner, as in the preceding operation. The flaps are dissected away from the bone, the dorsal interosseous muscles being detached, and then with the point of the knife the carpo-metacarpal ligaments are cut through. Care must be taken in this part of the operation not to allow the point of the

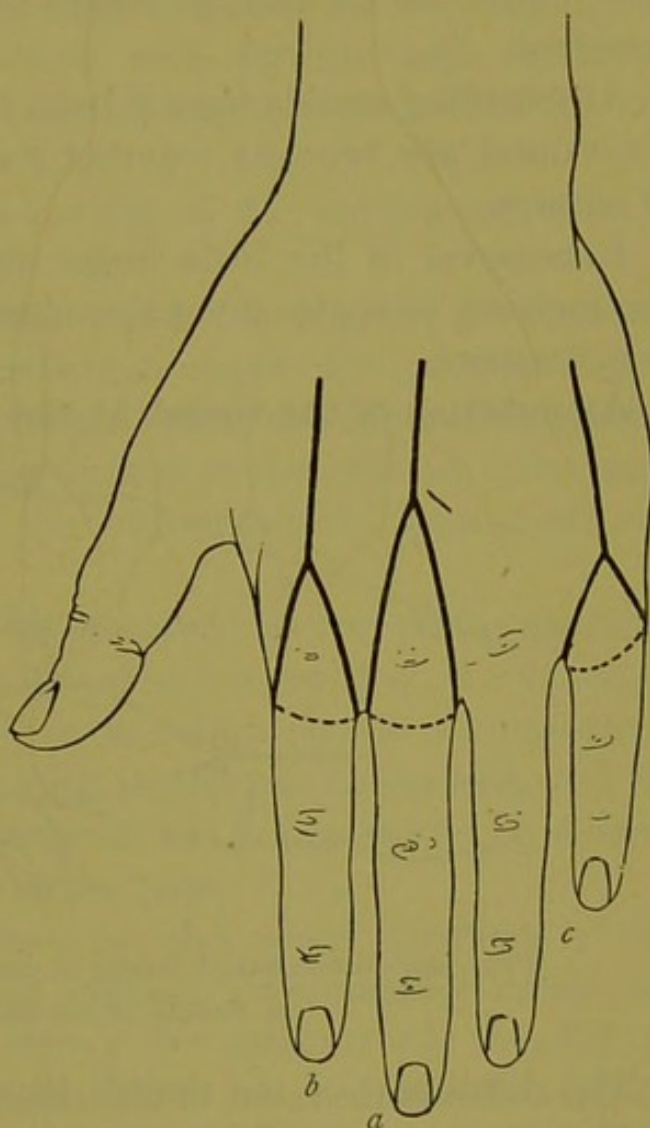


FIG. 328. — Amputation of a finger with the corresponding metacarpal bone.

- a.* Position of incision for third finger.
- b.* For index finger.
- c.* Fifth finger.

knife to travel into the tissues of the palm, in which case severe hæmorrhage might ensue. When disarticulation has been performed, the base of the bone is raised, the soft tissues on its palmar aspect separated, and the digit removed.

All bleeding vessels having been ligatured, the margins of the wound are brought together and fixed by the insertion of sutures.

In removal of the little finger with its metacarpal bone, the incision is made along the ulnar side and not on the dorsal aspect.

Amputation of the thumb at the carpo-metacarpal joint.

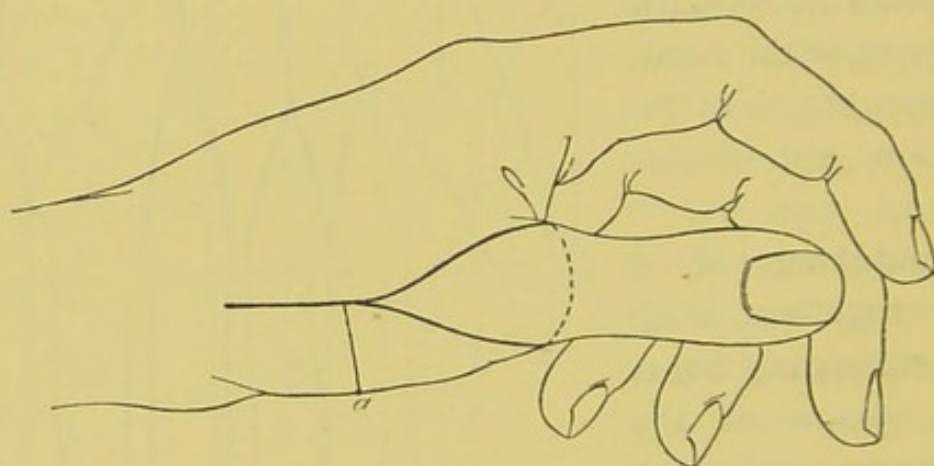


FIG. 329.—Removal of thumb at carpo-metacarpal joint.

a. Position of skin incision.

—The distal part of the thumb being held by the left hand of the surgeon, an incision is made which commences over the base of the metacarpal bone on the radial side. This extends downwards to a point a short distance above the head of the bone, then obliquely round the dorsal and ulnar aspects of the first phalanx until the middle of the palmar aspect is reached. The point of the knife is then pushed through the soft tissues of the palm until it emerges at the commencement of the original incision. By a slight sawing movement the soft tissues of the thenar eminence are divided towards the radial side, and a flap formed. Disarticulation is performed from the dorsal aspect of the joint,

care being taken to avoid the radial artery as it dips in between the two heads of the first dorsal interosseous muscle at the base of the first intermetacarpal space.

When the thumb has been removed in this manner, all bleeding vessels are seized with forceps and ligatured. Finally, the flaps are coapted together and fixed by the insertion of sutures.

Whenever possible a portion of the metacarpal bone of the thumb should be left.

Amputation at the wrist-joint.—During the performance of this operation the strictest aseptic and antiseptic precautions must be observed, since if suppuration occurs adhesions are liable to be formed in the inferior radio-ulnar joint which will limit the movements of pronation and supination.

The general rules to be observed in the performance of an amputation through the neighbourhood of the wrist are, that as much as possible of the limb should be preserved, the inferior radio-ulnar joint should not be opened, and the covering for the extremities of the bones should be derived chiefly from the tissues of the palm.

Indications.—(a) Extensive tuberculous affections of the wrist, together with other chronic inflammatory conditions of the carpus which cannot be satisfactorily treated by excision; (b) severe injuries which cause destruction of the distal part of the hand; (c) occasional cases of contraction of the hand following burns.

The best form of amputation through the wrist-joint is by a long palmar and a short dorsal flap. Other methods are by equal antero-posterior flaps, by a long external lateral flap, and by the circular method.

(a) *By a long palmar and a short dorsal flap.*—*Position.*—The patient is placed in the dorsal position, with the arm at right angles to the side, the forearm supinated, and the hand resting on a small table. The surgeon stands or sits opposite the end of the limb, and the assistant opposite to

him. A second assistant controls the circulation in the brachial artery, either by digital pressure or by applying some form of tourniquet.

Operation.—The surgeon grasps the fingers with his left hand, an assistant abducts the thumb, the wrist is extended,

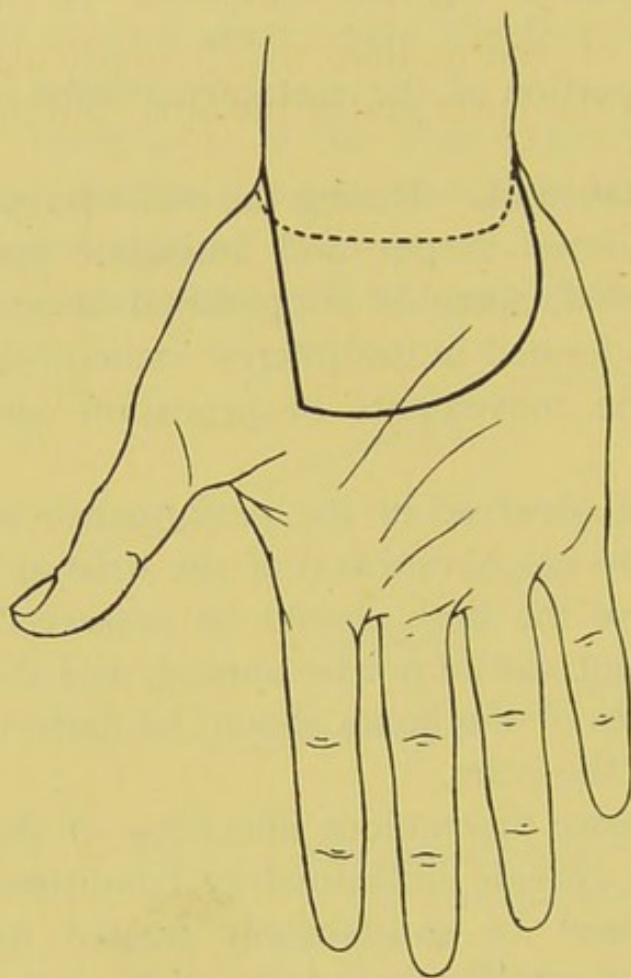


FIG. 330.—Amputation at the wrist by long palmar and short dorsal flaps. The dark line represents the palmar flap, and the dotted line the dorsal one.

and the positions of the styloid processes of the radius and ulna defined. An incision is then made, commencing at the styloid process of the radius, passing vertically downwards over the thenar eminence to the middle of the palm, then transversely across the palm, and upwards over the hypothenar eminence to the styloid process of the ulna. The free extremity of this flap should be slightly convex. The flap is dissected up, and made to include the deep palmar fascia, and if possible the superficial palmar arch as well as in its upper part por-

tions of the muscles of the thenar and hypothenar eminences, so as to preserve a good blood supply to the part (superficialis volæ and superficial branch of the ulnar artery).

The hand is now pronated and strongly flexed at the wrist, and a dorsal incision made from the styloid process of the ulna to that of the radius across the dorsum of the wrist a short distance below the line of the joint. The ex-

tensor tendons being cut through, the wrist is further flexed, and the lateral ligaments of the radio-carpal joint are divided, and then with a few strokes of the knife across the dorsal aspect of the wrist the remaining ligaments are cut through, and the hand finally detached by division of the flexor tendons.

The distal extremity of the radius, the interarticular fibro-cartilage attached to the lower end of the ulna, and the inferior radio-ulnar joint are now examined, and if there are any traces of disease, this is removed by scraping with a sharp spoon, or if the disease is extensive, the articular surfaces of both bones may be sawn off. If this is necessary, however, the movements of pronation and supination are very seriously interfered with.

In all cases the apices of the radial and ulnar styloid processes should be removed.

The compression of the brachial artery is now relaxed, so as to render evident the arteries which have been

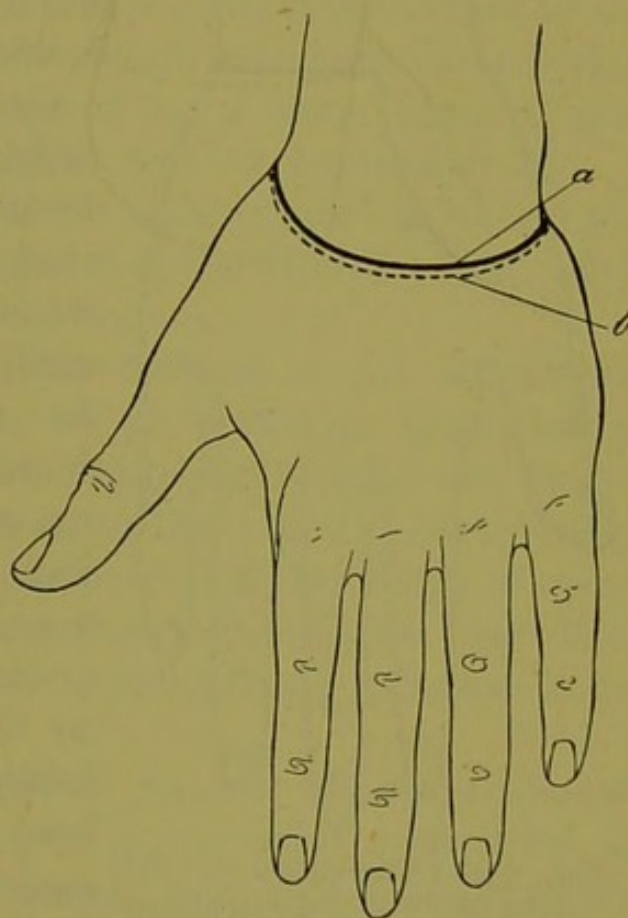


FIG. 331.—Amputation at the wrist by equal dorsi-palmar flaps.

a. Dorsal incision.

b. Palmar incision.

divided. These are picked up with artery forceps and ligatured. The principal vessels requiring ligature are the radial branches of the ulnar, the superficialis volæ, and the terminal branches of the anterior and posterior interosseous.

(*b*) *By equal anterior and posterior flaps.*—This operation may be performed when the condition of the skin of the

palm does not allow of the previous operation being carried out. The details of the operation are similar to the preceding, with the exception that the two flaps are made of equal length (Fig. 331).

(c) *By a long external lateral flap.*—This method of operating should only be made use of when all the tissues

of the ulnar side of the hand are extensively diseased or injured, and the distal part of the thumb is also rendered useless.

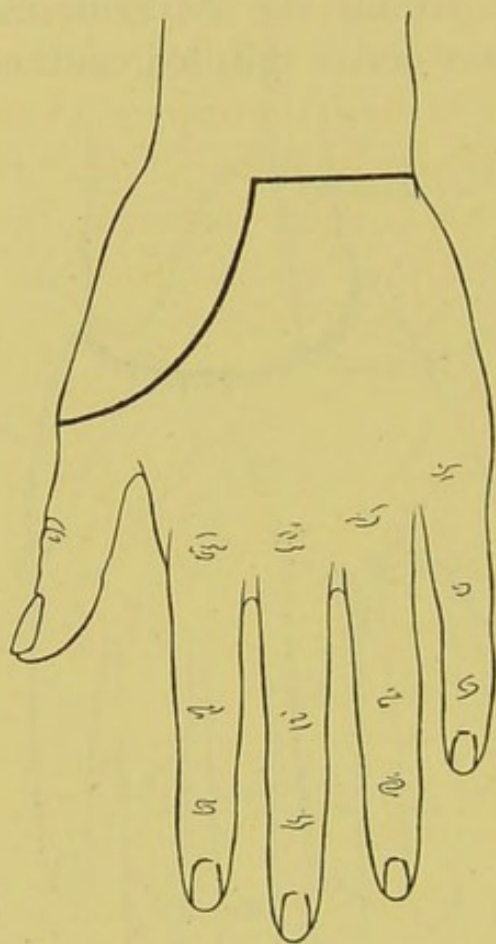


FIG. 332.—Amputation of the wrist by a long external lateral flap. Position of skin incision.

Operation. — An incision is made, which commences on the dorsal aspect of the wrist, somewhat nearer to the radial than the ulnar side, passes first downwards, then outwards, crossing the metacarpal bone of the thumb just below its head, then upwards over the thenar eminence, terminating at a point in front of the wrist corresponding to the point of commencement on the dorsum. A horizontal incision is next made at the level of the wrist-joint, commencing at the dorsal extremity of the first incision, extending round the ulnar side just below

the styloid process of the ulna, and ending at the palmar extremity of the primary incision. The flap which has been outlined on the outer side is dissected up, care being taken to include in it some of the muscles of the thenar eminence. The flap is well retracted, the flexor and extensor tendons divided, and disarticulation performed, the joint being opened from the outer side.

The bones and the bleeding vessels are treated as in the

preceding operation, and finally the flap is brought over the extremities of the radius and ulna, and fixed in position by the insertion of sutures.

(*d*) *By the circular method.*—The skin of the forearm is drawn well upwards by the assistant, and a circular incision made through skin and superficial fascia at the level of the carpo-metacarpal joints. This will include the proximal parts of the thenar and hypothenar eminences. The skin is then further retracted or dissected backwards in the form of a cuff, and the deep fascia and the underlying tendons cut through. These structures are retracted for a short distance, and then the wrist-joint is opened, and the hand removed.

The vessels are secured, the bones treated as before, and then the soft parts are drawn over the extremity of the limb and fixed by the insertion of sutures.

Amputation through the forearm.—An amputation through the forearm may be performed in the following ways:—(*a*) By unequal skin-flaps, longer dorsal and shorter palmar, with circular division of the muscles; (*b*) by lateral flaps; (*c*) by the circular method. This last mode of operation is most suitable for amputation through the lower third of the forearm; it cannot be satisfactorily practised in the upper part.

(*a*) *Amputation through the forearm by antero-posterior flaps.*—The limb is prepared in the usual manner for an amputation by making it aseptic, and an Esmarch's tourniquet is applied to the lower third of the upper arm in order to compress the brachial artery and control hæmorrhage.

Instruments.—The most suitable knife is a small amputating knife, with a blade 3 or 4 in. in length. The saw is the usual amputation saw.

Position.—The affected limb is fully extended with the forearm pronated, and held by an assistant. The surgeon stands on the radial side of the limb in the case of the right arm, and on the ulnar side in the case of the left. His assistant stands opposite to him.

Operation.—The plane of section of the bones having been decided upon, the surgeon grasps the forearm with the left index finger and thumb at this level. With the knife an incision is made which commences at the level of the plane of section and passes vertically downwards for $2\frac{1}{2}$ or $3\frac{1}{2}$ in., according to the size of the limb, and then transversely across the extensor aspect to a point on the ulnar side half-way round the limb, the end of the flap being made slightly convex. The incision is completed by continuing it along the ulnar margin of the limb to the level of the

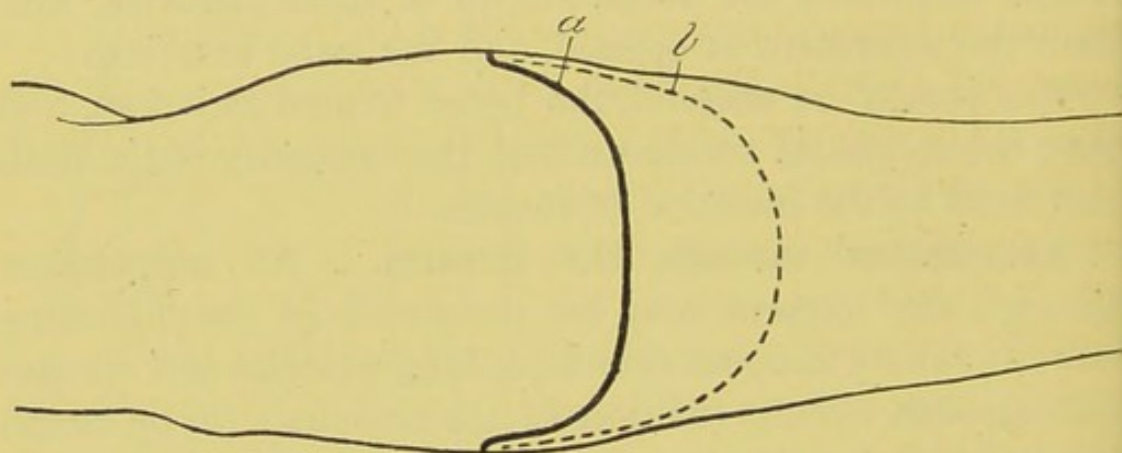


FIG. 333.—Amputation of the forearm by antero-posterior flaps.

- a.* Line of anterior incision.
b. Line of posterior incision.

plane of section of the bones. The flap thus marked out is dissected up by a series of light strokes with the knife; it should consist of skin, superficial and deep fascia, and at its base of some muscle. When the flap has been dissected up, it is retracted by the assistant, and the hand is supinated.

The second flap, which should be from $1\frac{1}{2}$ to $2\frac{1}{2}$ in. in length, is formed on the palmar aspect of the limb by sweeping the knife from the ulnar to the radial side in a slightly curved direction, so as to give its extremity a broadly convex outline. It is dissected up in a manner similar to the preceding, and then both flaps are fully retracted by the assistant.

The muscles are next divided by a series of circular cuts down to the bone, the periosteum is cut through at the level at which the saw is to be applied, and the bones are sawn across. In doing this, care must be taken not to cause splintering. This is avoided by the assistant holding the limb steady, and the surgeon sawing with a series of light sweeps. The forearm should be fully supinated while the bones are being sawn.

The blood vessels, of which there are four main ones,—radial, ulnar, and anterior and posterior interosseous,—are sought for and ligatured. The radial lies under cover of the supinator longus in close proximity to the radius. The ulnar lies beneath the flexor carpi ulnaris, anterior to the ulna. The anterior interosseous lies on the anterior aspect of the interosseous membrane. The posterior interosseous in the upper part of its course lies between the superficial and deep layers of muscles, whilst in the lower third of the forearm it is generally on the interosseous membrane.

Any tags of tendon which may appear on the surface of the wound are cut away, and the flaps brought over the ends of the bones and fixed together by the insertion of sutures.

(b) *By lateral flaps.*—In performing an amputation through the forearm by the lateral flap method, the incisions are made in a vertical direction along the dorsal and palmar aspects of the limb. In other respects the operation is similar to that above described.

The flaps may be formed by transfixion, but this method presents no advantage over the one detailed above, and moreover the flaps cannot be shaped with such great accuracy.

(c) *By the circular method.*—This operation is only suitable for an amputation through the lower third of the forearm.

Position.—The limb is extended and abducted, the forearm supinated, and the hand held by an assistant. The surgeon stands on the radial side when operating upon

the right limb, and on the ulnar side when operating upon the left.

Operation.—The level of the section of the bone having been marked out, the left hand of the surgeon retracts the skin upwards. Then the knife is passed round the limb from below, and a circular incision is made 2 to $2\frac{1}{2}$ in. distal to the plane of section. This incision divides the skin, superficial and deep fasciæ, and then these tissues are dissected upwards as far as the level at which the bones are to be sawn. It is usually convenient to turn them back in the form of a cuff. A second circular incision is now made through all the remaining soft tissues down to the bones, the muscles being allowed to retract, and the periosteum divided at a slightly higher level. The bones are sawn across, the blood vessels ligatured, and the soft parts drawn over the end of the stump and sutured in the usual manner.

Amputation through the elbow-joint.—This may be performed by the following methods:—(a) By antero-posterior flaps; (b) by unequal lateral flaps; (c) by the elliptical method; (d) by the circular method. The best methods of amputating through the elbow-joint are by a long anterior and short posterior flap, and by the elliptical method. Both these operations provide a thick muscular covering, well supplied with blood vessels, for the end of the humerus.

The circular method is easy in its performance, and gives a small wound, but does not afford such a good covering for the end of the bone, while the scar is left in an exposed situation.

The anterior and lateral aspects of the lower extremity of the humerus are well covered with muscles, the posterior aspect being more superficial. The internal condyle is situated at a lower level than the external, and is more prominent. This must be borne in mind when disarticulating.

(a) *By a long anterior and a short posterior flap.*—The

skin is rendered aseptic, and hæmorrhage is controlled by the application of an Esmarch's elastic tourniquet to the middle of the upper arm.

Position.—The limb is somewhat abducted from the side, and held by an assistant in a position of complete supination, with the elbow slightly flexed. The operator stands on the radial side of the right limb, and on the ulnar side of the left limb.

Operation.—The positions of the internal and external condyles of the humerus are determined, and a point selected 1 in. below the internal, and another $1\frac{1}{2}$ in. below the external. With a short amputation knife an incision is made which commences at the first point (in the case of the right limb), extends downwards along the ulnar margin for 3 in., then almost transversely across the front of the forearm, and upwards on the radial side to the point $1\frac{1}{2}$ in. below the external condyle.

The extremity of the flap is cut somewhat convexly, and then dissected upwards. The flap at first consists of the skin and fasciæ, and then of muscle as well.

The margins of the first incision are joined across the posterior aspect of the limb by making a cut from one side to the other in such a manner that a flap, about one-third the length of the anterior, is fashioned. This is dissected back to its base, and then both flaps are well retracted by the assistant. Any remaining muscles or other soft tissues in front of the joint are now divided. The joint is opened on the outer side, the ligaments cut through, and disarticulation completed by cutting out behind. The tendon of the triceps is the last part to be divided. The brachial artery is secured as it lies in front and at the inner side of the stump, the elastic tourniquet is relaxed, and the various small vessels of the arterial anastomosis about the elbow-joint picked up with artery forceps, and ligatured. The flaps are then brought into apposition and fixed by the insertion of sutures.

It is usually advisable to leave open one angle of the wound, so as to provide for the escape of secretion from the remaining part of the synovial membrane of the joint.

(b) *By unequal lateral flaps.*—If this method is employed, the incision is made from the front of the elbow-joint, terminating behind the olecranon. The long flap may be either external or internal, according to the state of the tissues at the time of operation.

(c) *By the elliptical method.*—The proximal extremity of the ellipse should be situated on the extensor aspect of the limb, immediately above the upper border of the olecranon process of the ulna, and the distal extremity on

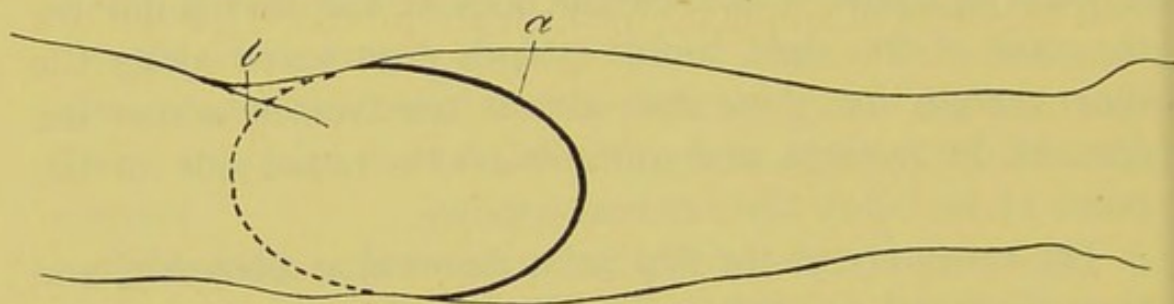


FIG. 334.—Amputation at the elbow-joint. By an elliptical incision.

a. Position of anterior part of incision.

b. Position of posterior part of incision.

the flexor aspect of the forearm, just below the junction of the upper with the middle third.

An incision is made which marks out the ellipse, commencing above and behind, extending downwards to the lowest point in front, and then upwards again to the olecranon behind. As the surgeon makes this incision, the limb, which is held by an assistant, is rotated so as to expose the parts which are being cut. The skin and fasciæ are retracted and dissected up for a short distance, and then the soft tissues in front of the elbow-joint are transfixed with the knife, and a cut is made obliquely outwards, so as to form a muscular anterior flap. This flap is retracted by an assistant, and the remaining soft tissues divided until the anterior aspect of the elbow-joint is laid bare. The

joint is opened from the outer side by dividing the external lateral and the anterior ligaments, and disarticulation is completed as in the preceding operation.

Hæmorrhage is arrested, and the margins of the flap brought together and sutured. The resulting scar is situated on the posterior aspect of the stump.

Amputations through the upper arm.—An amputation may be performed through the upper arm at any point from the tuberosities to the condyles of the humerus. Whenever possible, a part of the humerus should be left behind, in order to provide a stump to which an artificial limb may be attached.

The forms of amputation which are practised for removal

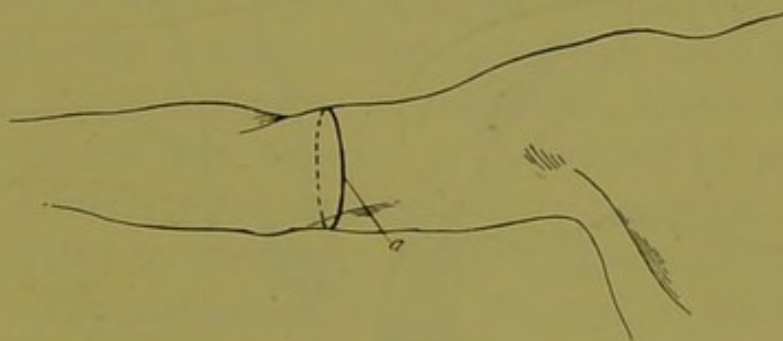


FIG. 335.—Amputation through the upper arm by the circular method.

a. Skin incision.

of the limb, are in the lower third usually the circular method, in the middle and upper thirds either the circular amputation or, more commonly, amputation by antero-posterior flaps with circular division of the muscles.

(*a*) *Amputation by the circular method.*—*Position.*—The patient is placed in the dorsal posture, with the affected limb abducted and held horizontal. One assistant grasps the hand and forearm so as to manipulate the limb during the operation, and the other stands on the right of the operator. The surgeon stands on the radial side of the right limb and the ulnar side of the left.

Operation.—The site of section of the bone being

determined, a circular incision is made through the skin, superficial and deep fasciæ, $2\frac{1}{2}$ to 3 in. distal to the plane of section of the bone.

The divided tissues are dissected upwards, and turned back in the form of a cuff. The superficial muscles are divided and allowed to retract, and then the deeper muscles cut through by making a circular sweep round the limb. Whilst these incisions are being made, the limb is rotated as required by the assistant who has charge of it.

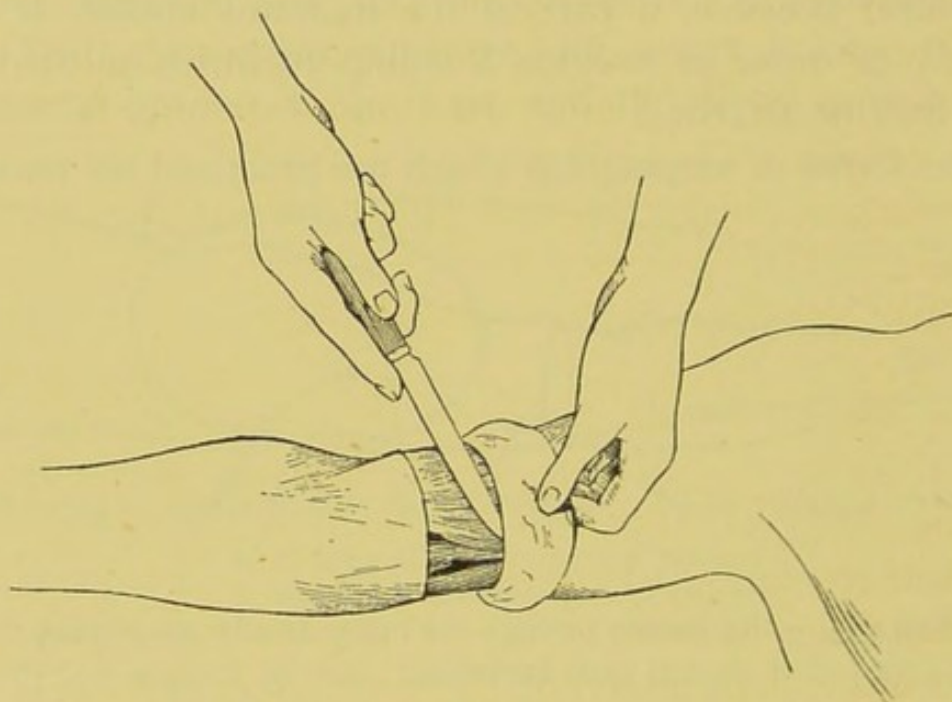


FIG. 336.—Method of dissecting back cuff of skin and fasciæ.

The bone is then freed from its periosteum for a short distance, and sawn through in the usual manner.

The brachial artery is secured in the antero-internal part of the wound, and a ligature applied. The elastic ligature which controls the brachial artery (or the fingers of the assistant, if digital compression has been made use of) is relaxed, and any bleeding vessels tied.

The margins of the wound are brought together in an antero-posterior direction, and united by the insertion of a series of sutures.

(b) *Amputation by skin-flaps with circular division of the*

muscles.—The relative lengths of the anterior and posterior flaps in this operation depend upon the condition of the tissues of the limb.

As much of the limb as possible should be saved, and the skin-flaps taken from the most healthy part.

Position.—The positions of patient, surgeon, and assistant are similar to those of the preceding operation.

Operation.—An incision is made, commencing on one side of the limb, extending downwards for 3 or 4 in., then transversely across to the opposite side, and upwards for an equal distance. The width of this flap ought to be half the circumference of the limb. Its distal extremity is made slightly convex.

The incision divides the skin, superficial and deep fasciæ, and then the flap is dissected up to its base by a series of light cuts. Next, a shorter posterior flap, about one-third of the length of the anterior, is fashioned in a similar manner. Both flaps are retracted by an assistant, and the muscles divided by a circular sweep of the knife down to the bone. The periosteum is cut through, retracted for a short distance, and the bone sawn across.

Hæmorrhage is arrested in the usual manner, and the margins of the flaps united by the insertion of sutures.

In the lower third of the upper arm the brachial artery lies anterior to the shaft of the humerus, in the upper two-thirds it lies away from the bone on its inner side.

In the formation of the flaps some surgeons adopt the "transfixion" method. This presents no advantage, however, over the one above described.

Amputation or disarticulation at the shoulder-joint.—A considerable number of operations have been devised for the removal of the upper extremity at the shoulder-joint. One of the best of these is that by the racket-shaped incision now to be described.

Position.—The patient is placed in the dorsal posture, with the affected shoulder projecting slightly beyond the

edge of the operation table. The surgeon stands on the outer side of the shoulder, one assistant grasps the upper extremity at the elbow and rotates it as required, a second assistant may control hæmorrhage by applying pressure to the subclavian artery, whilst the third assistant helps the operator by retracting the flaps, seizing bleeding vessels, etc.

Operation.—An incision is made, commencing immediately below the clavicle

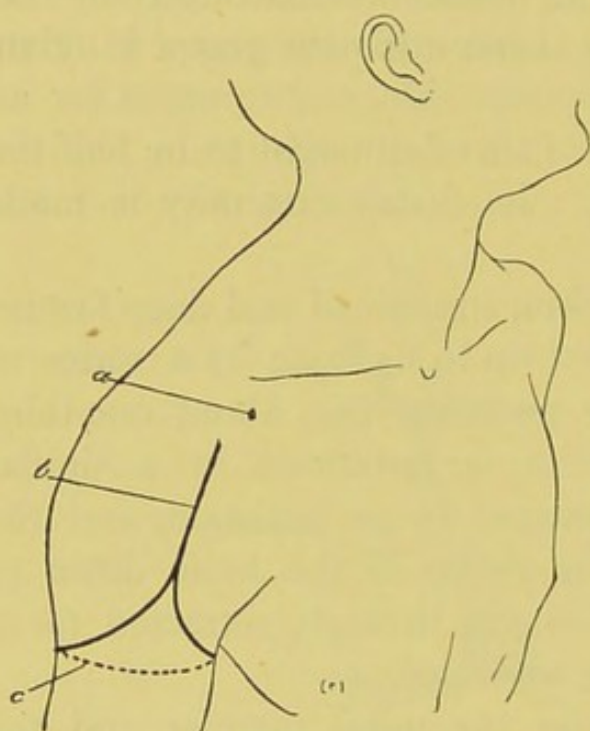


FIG. 337.—Amputation at the shoulder-joint. Position of external incision.

- a. Coracoid process.
- b. Vertical part of incision.
- c. Circular part of incision.

and on the outer side of the coracoid process. It extends downwards for a short distance through the anterior fibres of the deltoid and through the pectoralis major close to its insertion, winds around the outer and posterior aspects of the arm, then across the inner aspect just below the folds of the axilla, and finally upwards until it joins the vertical portion of the first incision. In making the anterior, external, and posterior parts of the incision, the tissues are divided

down to the bone, but on the inner side the skin and fasciæ are alone divided. The vertical part of the incision should open the capsule of the shoulder-joint. The brachial artery may now be sought for at the inner side of the arm, separated from its connections, ligatured, and cut through. A flap is next dissected upwards on the inner side, comprising all the muscles, the subscapularis being detached from the lesser tuberosity of the humerus. The limb is now internally rotated, and an

external flap dissected outwards in a similar manner, the supra- and infra-spinatus and teres minor muscles being detached from the greater tuberosity of the humerus. The remaining part of the capsule is divided behind, and a cut made downwards and outwards behind the bone until the limb is freed from its connections with the trunk.

As the posterior part of the section is being made, the flaps are well retracted, and if the brachial artery has not been ligatured at an earlier stage, it is now grasped by the fingers of an assistant.

The brachial artery is now tied, together with any bleeding points becoming visible as the pressure on the subclavian artery is relaxed.

The entire wound is sponged dry, and the margins of the flaps united by the insertion of sutures.

In some cases it may be advisable, owing to the condition of the tissues in the neighbourhood of the shoulder-joint, to make a U-shaped flap, consisting chiefly of the deltoid muscle and the tissues superficial to it. The preceding operation, however, is generally the more suitable one, and can most often be employed with good results.

Amputation of the upper extremity.—Amputation of the upper extremity comprises removal of the arm, including the scapula and the outer two-thirds of the clavicle. The inner third of the clavicle is usually not removed unless the bone is extensively implicated in the malignant growth.

Indications.—(a) Severe injuries involving destruction of the entire upper extremity, such as gunshot wounds or machinery accidents.

(b) Malignant disease in the region of the shoulder-joint involving the scapula and clavicle, with infiltration of the lymphatic glands in the axilla.

(c) Some cases of extensive tuberculous disease extending from the shoulder-joint into the adjacent tissues.

Instruments.—Scalpel, small amputating knife, artery,

pressure, and dissecting forceps, bone forceps, periosteal elevator, small saw, retractors, scissors, lion forceps, aneurysm needle, ordinary needles, needle holder, and ligature and suture material.

Position.—The position of the patient, operator, and

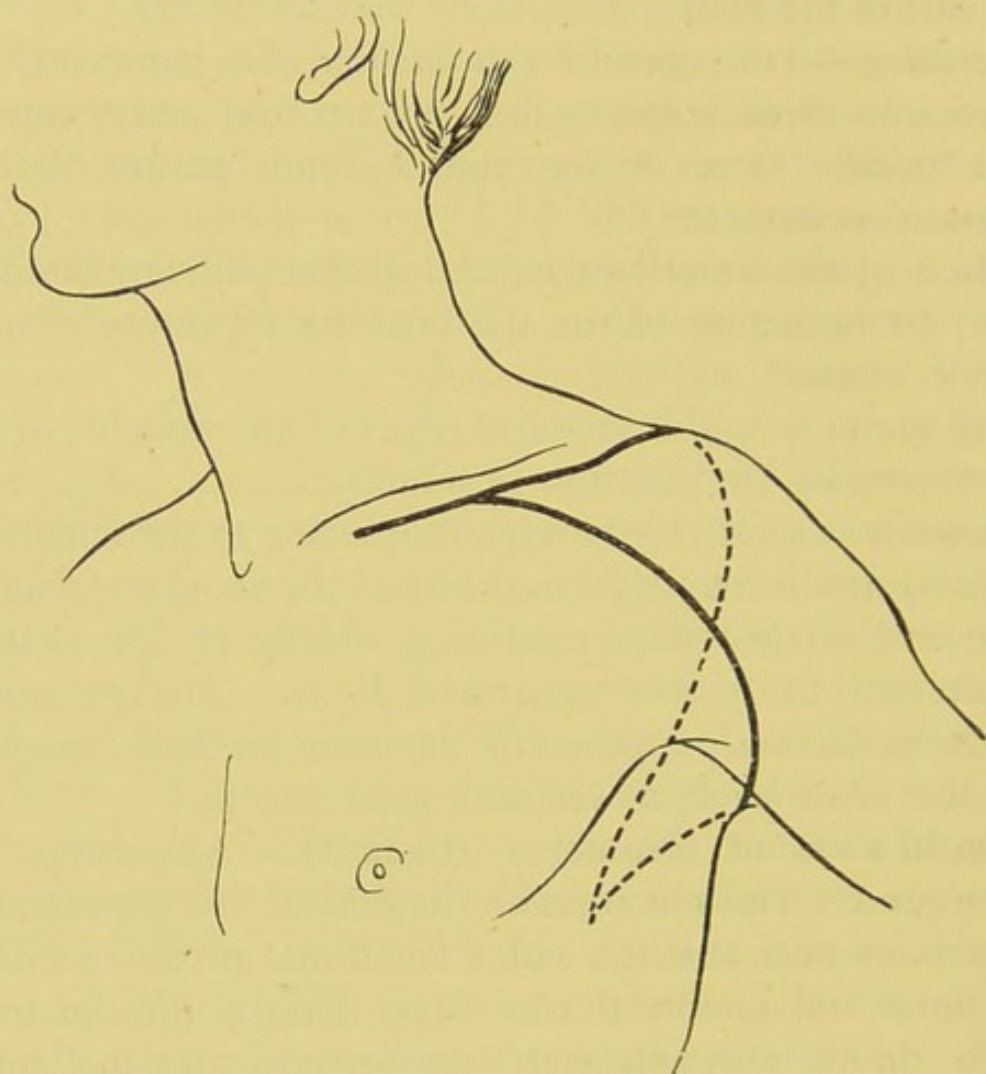


FIG. 338.—Removal of upper extremity, including the scapula. Position of external incisions.

assistants varies during the operation. In the first stage the patient is placed in the dorsal position, with the affected shoulder projecting somewhat beyond the edge of the operation table. A sand-bag is placed between the scapulæ, so as to raise the diseased shoulder. The arm lies by the side. The surgeon stands on the outer side of the affected limb, with an assistant on each side of him.

In the second stage the arm is drawn away from the body, and the surgeon stands between the limb and the trunk.

In the third stage the arm is carried over the chest towards the opposite side, and the surgeon stands on the outer side of the limb.

Operation.—The operation itself may be conveniently divided into three stages:—(a) Incision over and removal of the middle third of the clavicle, and ligature of the subclavian vessels in the third part of their course; (b) formation of the anterior flap, and division of the brachial plexus; (c) formation of the posterior flap, ligature of the posterior scapular and suprascapular arteries, and detachment of the limb.

First stage.—An incision is made commencing over the junction of the inner with the second fourth of the clavicle, and extending along this bone to just beyond the acromio-clavicular articulation. This divides all the soft tissues, including the periosteum, down to the bone. With a periosteal elevator the periosteum is detached from the clavicle, this detachment being aided by its division in a circular manner by the knife at the inner part of the wound. The soft parts are held aside with retractors, and the bone sawn through with a small saw at the junction of its inner and middle thirds. The outer portion of the bone is drawn outwards with lion forceps, and the soft tissues attached to its deep aspect separated. The bone is again sawn through at the junction of the middle and outer thirds, and the separated segment removed. The subclavius muscle will now be seen lying in the bottom of the wound. It is cut through just beyond its attachment to the cartilage of the first rib, and turned aside, thus exposing the subclavian artery and vein. At the outer border of the first rib these structures are separated from their connections with the surrounding tissues, and a double ligature passed around each. These ligatures

are tied so as to leave about three-quarters of an inch of the vessel between them ; the vessels are then divided. The artery is ligatured and cut across before the vein, so that the limb may not remain engorged with blood.

Second stage.—The patient is drawn farther over the edge of the table, the arm pulled away from the side, and the surgeon takes up his position between the limb and the trunk.

A curved incision is then made, which commences at the middle of the clavicle, and extends downwards and outwards to the outer side of the coracoid process, and then over the anterior part of the deltoid muscle to the anterior fold of the axilla. It then crosses the upper arm at its junction with the axilla, to the posterior fold, and finally downwards and backwards to the inferior angle of the scapula. The limb is raised and rotated by an assistant as this incision is being made.

The incision first divides skin and fasciæ, a flap being dissected up and the pectoral muscles cut through. The flap thus separated is retracted to the inner side, so as to expose the brachial plexus, the cords of which are cut through just beyond the outer margin of the first rib. At the lower part of the incision the latissimus dorsi is divided a short distance from its attachment to the humerus.

Third stage.—The limb is drawn across the chest by an assistant, so as to expose the posterior aspect of the scapular region.

An incision is made, commencing over the acromioclavicular articulation at the outer extremity of the first incision, and extending downwards and backwards over the spine of the scapula to the lower extremity of the second incision. This divides skin and fasciæ only. The flap is dissected backwards, the trapezius muscle being cut through just beyond its insertion into the clavicle and scapula, until the superior angle and vertebral border of the scapula are exposed.

The limb is now allowed to hang down by the side, the anterior and posterior flaps are retracted, and then by a series of cuts the muscles which are attached to the vertebral border, the superior angle, and the superior border (rhomboides major and minor, levator angulæ scapulæ, omo-hyoid, and serratus magnus) are cut through, and the arm removed. The suprascapular artery is secured as it passes over the suprascapular notch, and the posterior scapular at the superior angle of the scapula. All bleeding points are picked up with pressure forceps, and ligatures applied.

The margins of the flaps are brought together and fixed in position by the insertion of a series of interrupted sutures. The lower angle of the wound should be left open for drainage.

Aseptic dressings are applied and fixed in position by firm bandaging.

AMPUTATIONS IN THE LOWER EXTREMITY.

Amputation of the toes.—It is advisable as far as possible, in performing an amputation, partial or complete, of any of the toes, that the flaps should be so fashioned that the scar is not placed on the plantar aspect.

An amputation of a toe may be performed either through the terminal interphalangeal or the metatarso-phalangeal joints. Amputations through other parts of the toes are as a general rule not advisable, since the stump which is left is of no practical use, and often becomes a source of irritation.

Amputation of the distal phalanx—(a) Of the great toe.—The best result is obtained by making a large plantar flap.

Operation.—An incision is made, commencing on the tibial aspect of the toe just beyond the line of the articulation, passing downwards nearly to the extremity, then

transversely across the pulp, and up along the fibular side to a point immediately below the line of the joint and opposite its commencement. The toe is fully extended

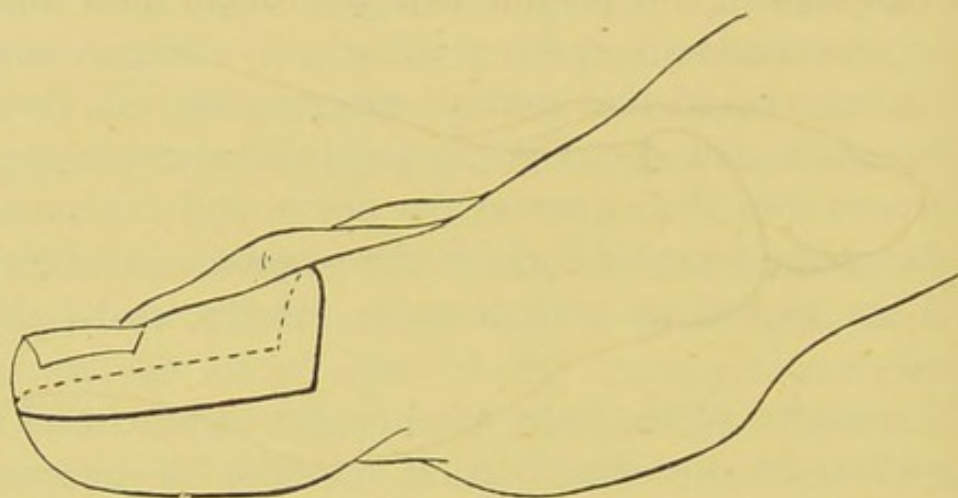


FIG. 339.—Amputation of distal phalanx of great toe.
Skin incision.

by an assistant whilst the surgeon dissects back the flap until the line of the joint is reached, the plantar ligaments being divided at this stage. The surgeon now takes hold

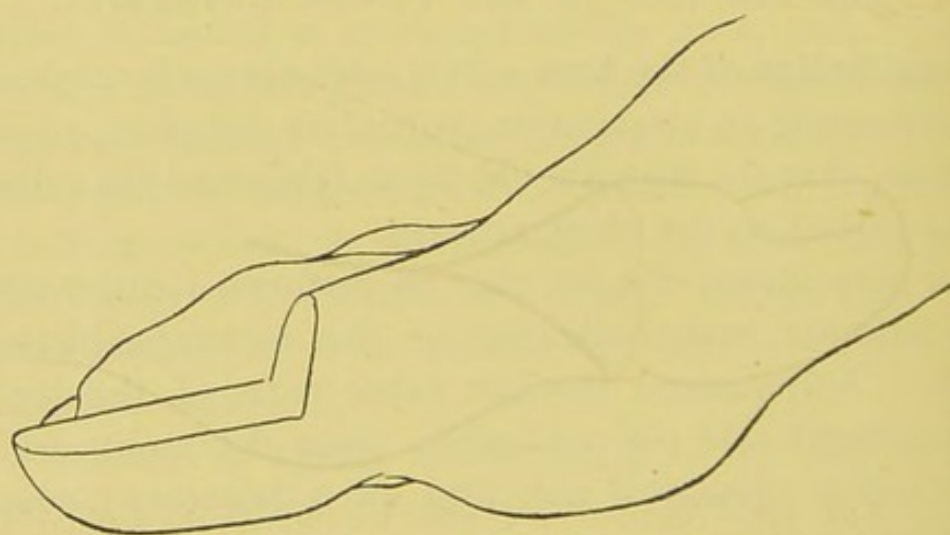


FIG. 340.—Appearance of toe when phalanx has been removed.

of the toe, fully flexes it, and makes an incision across its dorsal aspect. The joint is opened from above, the extensor longus hallucis tendon divided, and the lateral ligaments cut through from without inwards. The toe

is now separated from its connections, and can be removed.

The digital arteries are picked up with pressure forceps and ligatured. The plantar flap is brought over the end

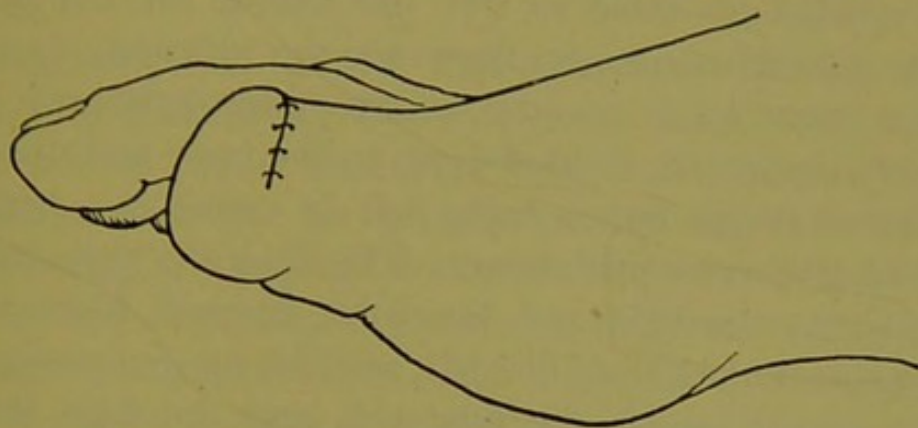


FIG. 341.—Appearance of toe when operation is completed.

of the first phalanx, and the margins of the incision united by the insertion of sutures.

(b) **Of one of the four outer toes.**—This operation differs in no essential respect from the preceding one.

Amputation through a metatarso-phalangeal joint—

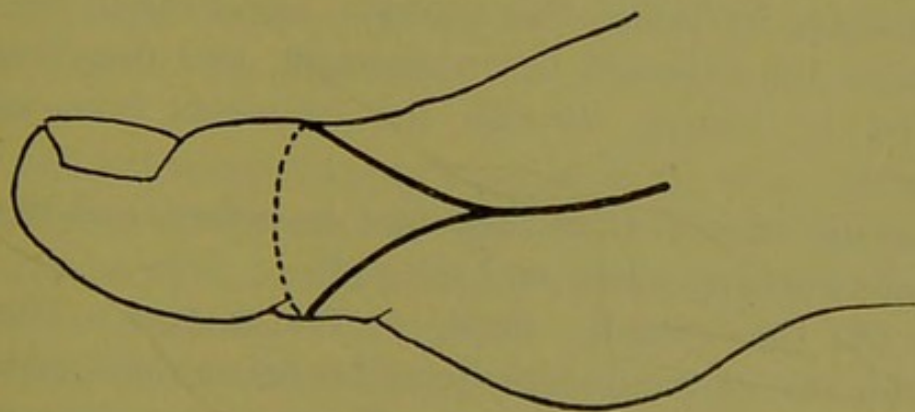


FIG. 342.—Amputation of great toe through the metatarso-phalangeal joint. Skin incision.

(a) **Of the great toe.**—On account of the large size of the head of the metatarsal bone, care must be taken to make the flaps sufficiently large to afford a complete covering for it.

Operation.—An incision is made commencing just above

the head of the first metatarsal bone, extending downwards to below the line of the joint, then around the plantar aspect of the toe, and upwards upon the fibular side and across the dorsum until the vertical incision is reached. It is usually advisable to cut the tissues on the plantar aspect somewhat longer than on the dorsum, and the incision may reach as low as the interphalangeal joint. The soft tissues are divided down to the bone and dissected up, the sesamoid bones being left in connection with the head of the metatarsal bone. The flaps are retracted, the tendons cut through, and the joint opened from above. The ligaments are then divided, and the toe removed.

The digital vessels are ligatured, and the flaps brought together and fixed in apposition by sutures.

(*b*) **Of the little toe.**—An incision is made commencing just above the head of the fifth metatarsal bone, and somewhat nearer the dorsal than the plantar aspect. This passes vertically downwards to a point well below the line of the joint, and then around the toe in an oval-shaped manner until it joins the vertical part of the incision. The soft tissues, including the tendons, are divided, the flaps dissected up, retracted by an assistant, and disarticulation effected by cutting through the ligaments from without inwards.

The digital vessels are ligatured as before, and the flaps brought into apposition and sutured.

(*c*) **Of the second, third, or fourth toes.**—The toes on each side of the one to be removed are held aside with aseptic gauze by an assistant. The surgeon grasps the toe in his left hand, and makes a racket-shaped incision, commencing over the dorsal aspect of the corresponding metatarsal bone, extending downwards to a point just above the metatarso-phalangeal joint, and then around the toe at the level of the web. The flaps so marked out are dissected up, the edge of the knife being kept towards the bone, and the extensor tendons cut through.

The joint is opened from above, disarticulation completed, and the digit removed.

The digital vessels are ligatured, and the margins of the flaps are brought together and fixed in apposition with sutures.

Amputation of a toe together with its metatarsal bone.—(a) **The great toe.**—A point is selected on the tibial side of the internal cuneiform bone somewhat nearer the dorsal than the plantar aspect. An incision is made commencing at this point and extending vertically along the shaft of the metatarsal bone to a point nearly opposite the metatarso-phalangeal joint, and then around the toe in an oval-shaped manner as in disarticulation at the metatarso-phalangeal joint. The soft tissues, including the tendons, are divided down to the bone, and the flaps dissected up. These are held aside by an assistant, and the toe forcibly pulled towards the tibial side by the surgeon, and freed from its connections with the soft tissues by a few strokes of the knife, care being taken to avoid the dorsalis pedis artery as it passes through the proximal part of the first inter-metatarsal space. The joint is then opened from the dorsal aspect, the ligaments cut through, and the toe removed.

The digital vessels on the margins of the flaps are picked up with pressure forceps and ligatured. The margins of the flaps are brought together and fixed in apposition by the insertion of sutures.

(b) **The little toe.**—The prominent base of the fifth metatarsal bone projects backwards for some distance beyond the line of the tarso-metatarsal joint.

The apex of the tuberosity of the fifth metatarsal bone is felt for on the fibular margin of the foot, and an incision made, commencing at this point and extending distally in a vertical direction nearly to the metatarso-phalangeal joint, then round the toe in an oval-shaped manner, as in the preceding operation. The soft tissues are divided

down to the bone, and the flaps dissected up and retracted by an assistant. The toe is then forcibly pulled towards the fibular side, and the connections of the metatarsal bone with the soft tissues cut through. The joint is opened from above, the ligaments divided, and the toe removed.

The digital vessels are ligatured, and the flaps brought together and sutured.

(c) **The second, third, or fourth toe.**—The line of the metatarso-phalangeal joint is defined, and an incision commenced on the dorsal aspect of the base of the metatarsal bone of the toe to be removed. This extends downwards in a vertical direction to a point just above the head of the metatarsal bone, and then round the plantar aspect of the toe in an oval-shaped manner. The soft tissues are divided down to the bone, and the flaps dissected up, care being taken to keep the edge of the knife always turned towards the bone.

The toe is then forcibly extended, whilst the surgeon cuts through the interosseous muscles and other soft structures with which it is connected. The joint is opened from the dorsal surface, the lateral and plantar ligaments cut through, and the toe taken away.

The blood vessels are ligatured, the flaps brought into apposition and sutured.

Amputation through the metatarsus.—This operation is rendered necessary in some cases of severe mutilation of the distal part of the foot. No exact directions can be given for its performance, since the position of the skin incisions depends upon the amount of sound tissue available.

In all cases, however, it is advisable, if possible, to make the plantar flap larger than the dorsal. The metatarsal bones, when exposed after the flaps have been dissected back, are sawn through immediately proximal to the limits of the injury. The various blood vessels are

picked up with artery forceps and ligatured, and the flaps adjusted and fixed in position by the insertion of sutures.

Amputation through the tarso-metatarsal joint.—

Position.—The patient is placed in the dorsal position, with the affected foot projecting beyond the end of the operation table. The surgeon stands on the right side of the foot to be operated upon, facing the sole, and his assistant opposite to him.

Operation.—Two points are defined, one the prominence of the base of the metatarsal bone on the fibular side of the foot, the other opposite the tarso-metatarsal articulation of the great toe. When this cannot readily be felt, a point is taken on the tibial margin of the foot, 1 in. in front of the prominence caused by the tuberosity of the scaphoid.

The foot is grasped by the left hand of the operator, and an incision made in a slightly curved direction, with the convexity towards the toes, across the dorsum, extending between the two selected points. This incision divides all the soft tissues down to the bones. The foot is now fully flexed and held by an assistant whilst the surgeon makes the plantar incision. This commences on the fibular side of the foot at the extremity of the first incision, extends along the outer side as far as the head of the metatarsal bone, then obliquely across the sole and

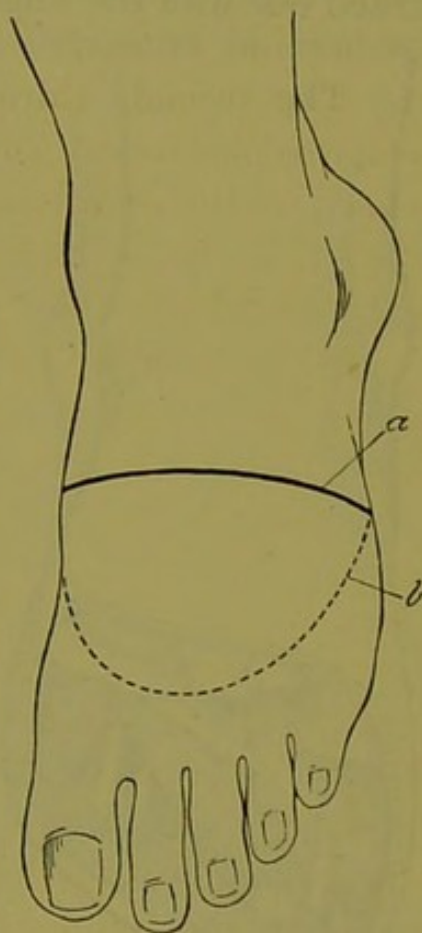


FIG. 343.—Amputation of the foot through the tarso-metatarsal joint. Skin incisions.

- a. Dorsal incision.
- b. Plantar incision.

up the inner side of the foot until the other extremity of the dorsal incision is reached. This incision should be so made that the flap is a little longer on the tibial than on the fibular side, so as to allow a complete covering for the prominent internal cuneiform bone.

The surgeon then takes hold of the edge of the flap thus marked out with the finger and thumb of his left hand, and dissects up the flap, which should comprise all the tissues of the sole down to the bones.

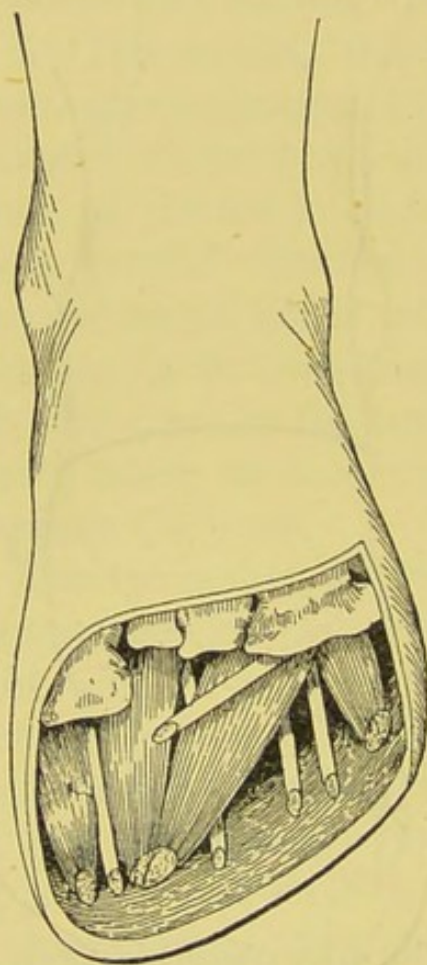


FIG. 344.—Amputation of the foot at the tarso-metatarsal joint. Appearance of foot when distal portion has been removed.

The flap is dissected backwards as far as the line of the tarso-metatarsal articulation. The foot is then forcibly depressed, the structures attached to the base of the fifth metatarsal bone divided, and the three outer metatarsal joints opened from the dorsal aspect.

The articulation between the internal cuneiform and the base of the first metatarsal bone is opened from the inner side, and then the lateral aspects of the base of the second metatarsal are cleared by cutting towards the tarsus.

The joint between the second metatarsal and the middle cuneiform bone is opened from above, the foot further depressed, and

the remaining soft tissues cut through. The foot can now be removed.

The dorsalis pedis artery is secured as it lies in the dorsal and internal portion of the wound, and the external and internal plantar arteries in the outer and inner parts of the

sole flap, together with any other vessels from which hæmorrhage is taking place.

The plantar flap is now brought over the extremity of the stump, and its margins united to those of the dorsal flap by the insertion of a series of interrupted sutures, special care being taken to secure exact apposition on the inner side.

This operation, that is, disarticulation of all the tarso-metatarsal joints, is often known as "Lisfranc's amputation."

Amputation through the tarso-metatarsal joints, with removal of the projecting portion of the internal cuneiform.—

This operation is similar to the preceding, but instead of performing disarticulation through the joint between the base of the metatarsal bone of the great toe and the internal cuneiform, the projecting part of the latter is sawn through. This modification is usually known as "Hey's amputation."

Amputation through the first, third, fourth, and fifth tarso-metatarsal joints, with sawing through of the shaft of the second metatarsal bone below its base.— This operation is similar to the above, with the exception that the shaft of the second metatarsal bone is sawn through in the line of the adjacent articulations. This has been called "Skey's amputation."

Amputation through the transverse or midtarsal

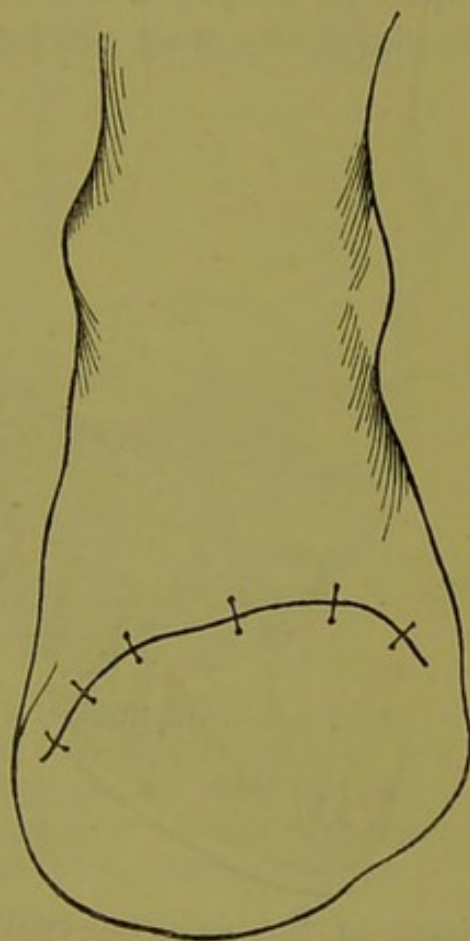


FIG. 345.—Amputation of the foot at the tarso-metatarsal joint. Appearance of foot when flaps have been sutured.

joint.—In this operation, the portion of the foot distal to the midtarsal joint is removed, the only bones of the tarsus left behind being the astragalus and os calcis.

Position.—The positions of patient, surgeon, and assistant are similar to those for amputation through the tarso-metatarsal joint.

Operation.—Two points are defined, one on the tibial aspect of the foot immediately behind the tuberosity of the scaphoid, the other on the fibular side, midway between the

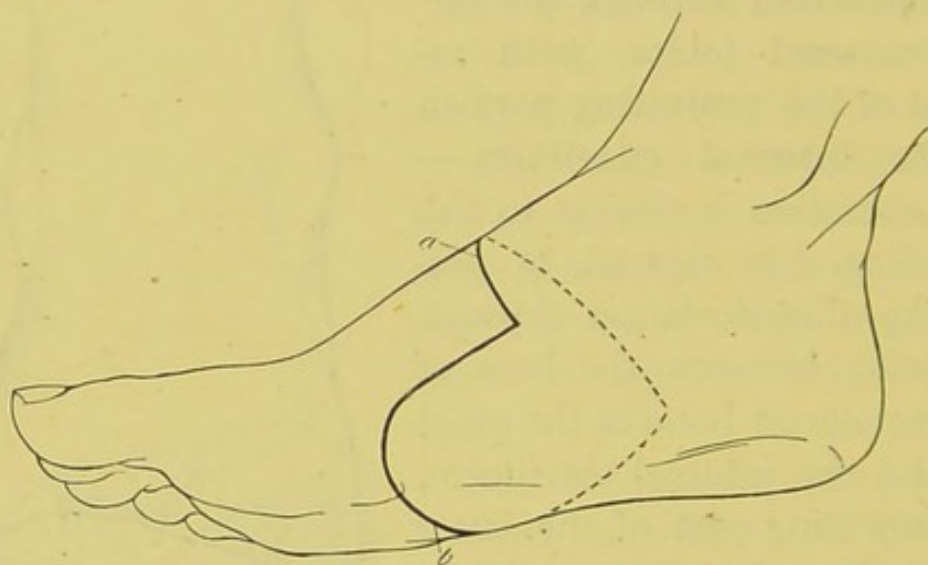


FIG. 346.—Amputation of the foot through the midtarsal joint.
Skin incision.

a. Dorsal part.
b. Plantar part.

apex of the external malleolus and the prominence of the base of the fifth metatarsal bone.

An incision is made which extends between these two points, and crosses the dorsum in a somewhat curved direction, the convexity being towards the toes. This incision crosses the bases of the metatarsal bones just in front of the tarso-metatarsal joints.

The foot is flexed and held in this position by the assistant whilst the operator makes the plantar incision. This commences (in the case of the right foot) at the

fibular extremity of the dorsal incision, and extends along the outer side of the foot as far as the middle of the metatarsal bone of the little toe, then crosses the sole opposite the middle of the other metatarsal bones to the inner side, and then along the tibial margin of the foot to the inner extremity of the dorsal incision.

The plantar flap is dissected up, and made to include all the soft tissues down to the bones, until the transverse tarsal joint is reached. The operator now grasps the distal part of the foot, extends it, and divides the ligaments on the dorsal aspect of the transverse tarsal joint. Care must be taken in this part of the operation not to leave the scaphoid bone behind. This can be avoided by noting the convexity of the head of the astragalus, and the position of the tuberosity of the scaphoid.

The foot is further depressed, the interosseous and plantar ligaments divided, and any other connections severed. It can then be removed.

The dorsalis pedis artery is secured in the dorsal flap, and in the plantar the external and internal plantar arteries. Some branches of the metatarsal artery may also be found in the dorsal flap, and digital arteries in the plantar. These are picked up with artery forceps and ligatured.

All hæmorrhage having been arrested, the plantar flap is brought over the extremity of the stump, and its

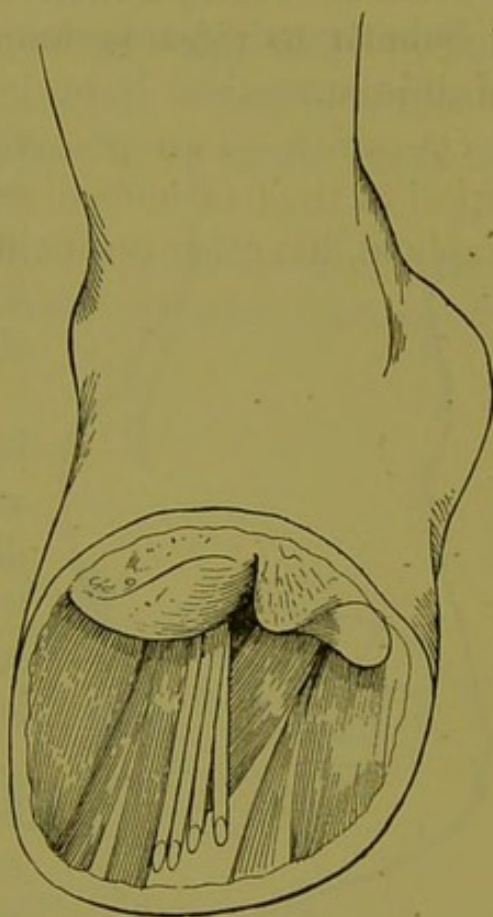


FIG. 347.—Amputation of the foot through the midtarsal joint. Appearance of foot when distal portion has been removed.

margins approximated to those of the dorsal and fixed in position by the insertion of a series of interrupted sutures (Fig. 348).

This amputation through the transverse or midtarsal joint is often known as "Chopart's amputation."

Subastragaloid amputation of the foot.—Several varieties of this operation have been described. The following appears to give rise to the best results and to be moderately easy in its performance. It is in reality a modification of the oval or elliptical method.

Position.—The patient is placed in the dorsal posture, with the affected foot projecting for a short distance beyond the lower end of the operation table. The surgeon stands at the right side of the foot, and his assistant opposite to him.

Operation.—The leg is slightly flexed at the knee, and the foot turned on its tibial side by the assistant. A point is then taken over the upper margin of the external tuberosity of the os calcis at the insertion of the tendo Achillis, and from this an incision is commenced which extends for-

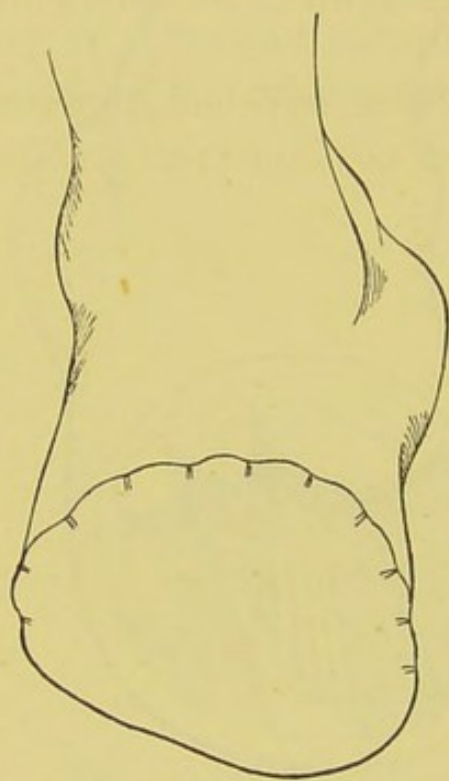


FIG. 348.—Amputation of the foot through the midtarsal joint. Appearance of foot when flaps have been approximated and sutured.

wards to a point a short distance posterior to the prominence of the base of the fifth metatarsal bone. This incision is parallel to the external margin of the foot, and a little more than an inch below the apex of the external malleolus.

It is now carried across the dorsum of the foot in a curved direction, the convexity looking towards the distal and external part of the foot, until the inner side is reached, at a point opposite the middle of the tibial aspect of the

articulation between the internal cuneiform bone and the base of the first metatarsal.

The foot is flexed, and the incision carried across the sole until it joins the first cut opposite the apex of the external malleolus.

The skin and fasciæ are cut through first, and the skin allowed to retract for a short distance. Then by a second sweep of the knife all the soft tissues down to the bones are divided.

The dorsal flap is dissected up for a sufficient distance, the tendo Achillis divided at the posterior part of the

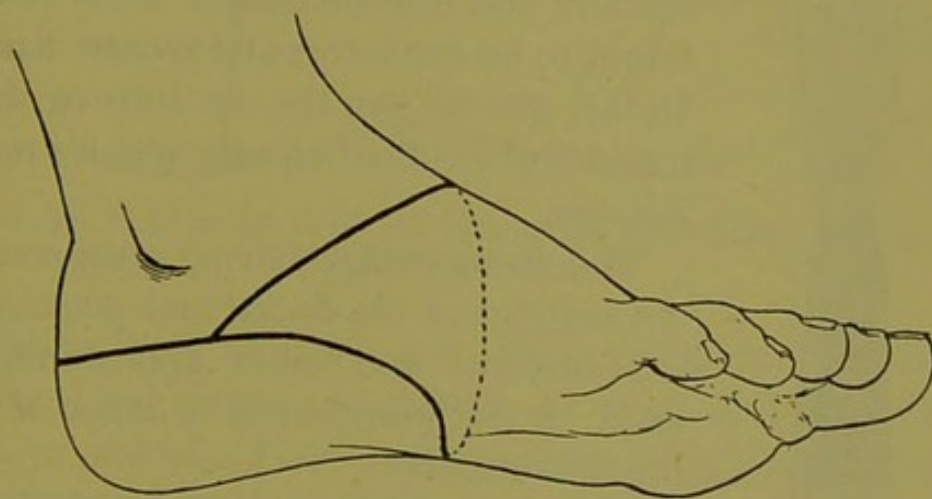


FIG. 349.—Sub-astragaloid amputation of the foot.
Skin incision.

incision just above its insertion into the os calcis, and the posterior part of the astragalo-calcanean joint opened from its external aspect by dividing the ligaments with the knife.

The blade of the knife is carried forwards between the inferior aspect of the astragalus and the superior surface of the os calcis, so as to divide the ligaments which fix the two bones together. The most important of these is the strong interosseous ligament. Any tendons on the outer side which have not been divided at the second sweep of the knife are cut through along with the ligaments.

The foot is firmly twisted inwards, and by a series of short cuts with the knife the internal and inferior aspects

of the os calcis are freed from their connections with the soft tissues. In this dissection the edge of the knife must be kept continually towards the bone, so as to avoid injury to the blood vessels, especially those which lie in the concavity on the internal aspect.

The foot is still more twisted, and the remaining soft structures cut through. The foot can then be removed.

In the dorsal flap, branches of the tarsal and metatarsal arteries, and of the anterior and posterior peroneal arteries, and internally the dorsalis pedis artery, will be found to be cut across and require ligature. In the plantar flap the cut ends of the internal and external plantar arteries require ligature.

The hæmorrhage having been arrested, the margins of the dorsal and plantar flaps are brought into exact apposition, and fixed by the insertion of a series of interrupted sutures.

Amputation of the foot through the ankle-joint by the formation of a heel-flap and removal of the lower extremities of the tibia and fibula ("*Syme's operation*").



FIG. 350.—Amputation of the foot. Short amputation knife.

Instruments.—The ordinary instruments for an amputation (p. 529). The knife should have a blade about 4 in. long.

Position.—The patient is placed in the dorsal position, with the foot which is to be removed projecting beyond the end of the operation table. The surgeon stands opposite to the sole, a little to the tibial side of the left foot and the fibular side of the right. An assistant stands directly opposite to him.

Operation.—Two points are selected, one at the apex of

the external malleolus, and the other a finger's-breadth below the tip of the internal malleolus. With a short

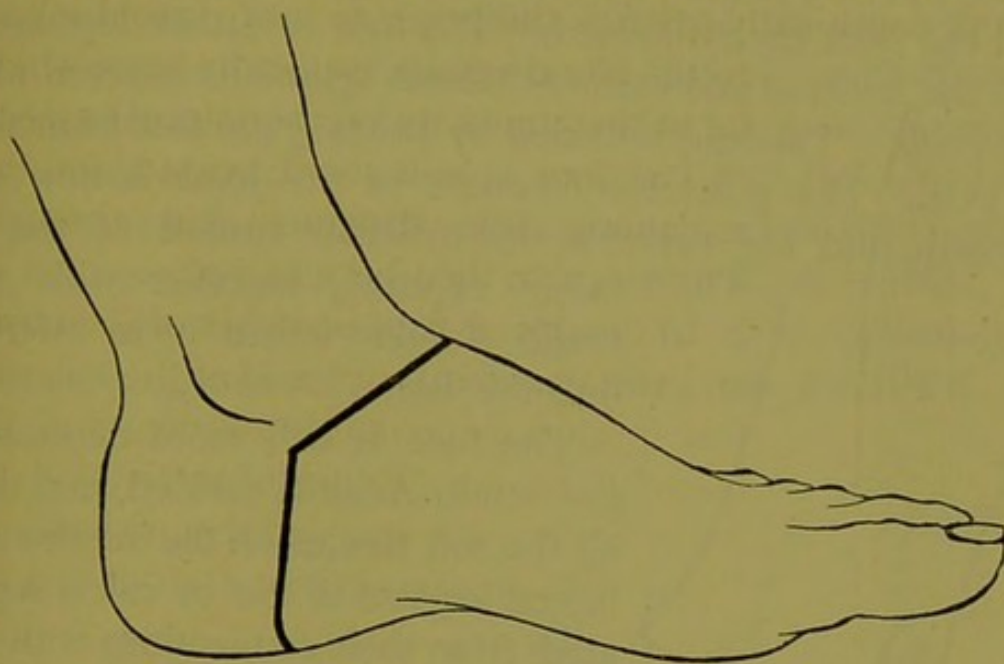


FIG. 351.—Amputation of the foot at the ankle-joint. Incision in "Syme's operation."

amputation knife an incision is made across the sole, which joins these two points and divides all the soft tissues down to the os calcis. This incision crosses the plantar aspect not quite transversely, but sloping a little towards the heel.

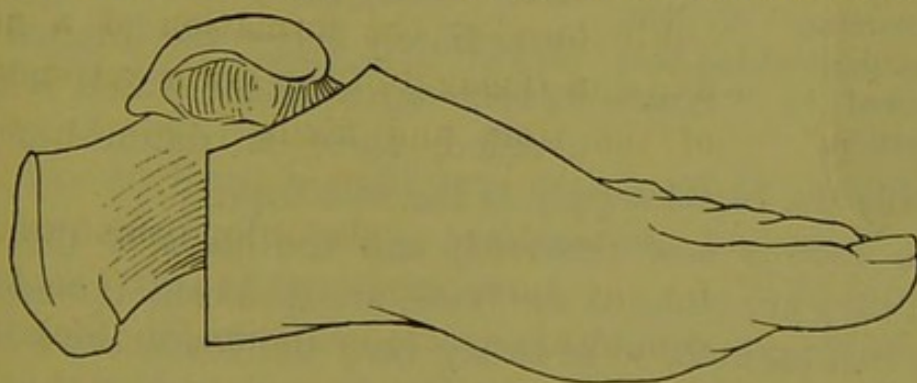


FIG. 352.—Amputation of the foot at the ankle-joint. Foot removed by Syme's method.

The distal part of the foot is grasped by the left hand of the surgeon and depressed, and then a cut is made across the dorsal aspect of the ankle so as to join the extremities of the first incision. This incision divides all the soft tissues

(skin, fasciæ, tendons, and vessels) down to the anterior surface of the joint. The anterior ligament is then divided and the joint cavity opened. The foot is further depressed, and the internal and external lateral ligaments severed with the knife. This can be aided by twisting the foot from side to side. The posterior ligament of the joint is now cut through, and the superior non-articular surface of the os

calcis exposed, together with the tendo Achillis where it is inserted into this bone.

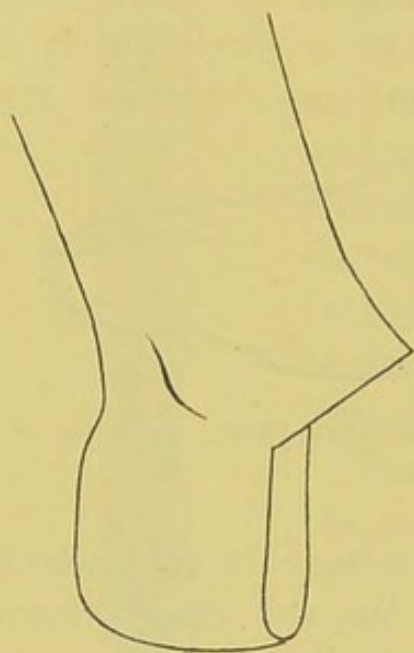


FIG. 353.—Amputation of foot at the ankle-joint. Appearance of limb when the foot has been removed by "Syme's operation."

The foot is still more depressed, the tendo Achillis divided, and then all the soft tissues on the inferior and lateral aspects of the os calcis separated from their connections with the bone by a series of short sweeps with the knife. Care must be taken during the separation of this heel-flap to keep the edge of the knife against the bone, otherwise the flap will be "button-holed," or the posterior tibial artery will be wounded immediately below the internal malleolus,—an accident which is to be avoided, since it diminishes con-

siderably the blood-supply of the sole flap.

The foot is now removed, and the bases of the flaps, where they are close to the bone, are dissected upwards for about half an inch, so as to lay bare the lower ends of the tibia and fibula for a short distance.

A saw is now taken and a thin plate of bone removed in a transverse direction. This piece of bone comprises the two malleoli, the inferior articular surface of the tibia, and a small portion of the cancellous extremities of both bones.

The bones are examined, and any carious or necrotic portions removed by scraping with a sharp spoon.

The anterior tibial artery is secured in the middle of the dorsal flap, and the internal and external plantar arteries at the inner margin of the heel-flap, together with any branches of the peroneal artery which may be causing hæmorrhage.

All hæmorrhage having been arrested, any loose projecting pieces of tendons are cut away, and then the heel-flap is brought over the extremity of the stump, and fixed in position by the insertion of a number of interrupted silk sutures.

The operation described above is a modification of "Syme's operation." The operation, as described and

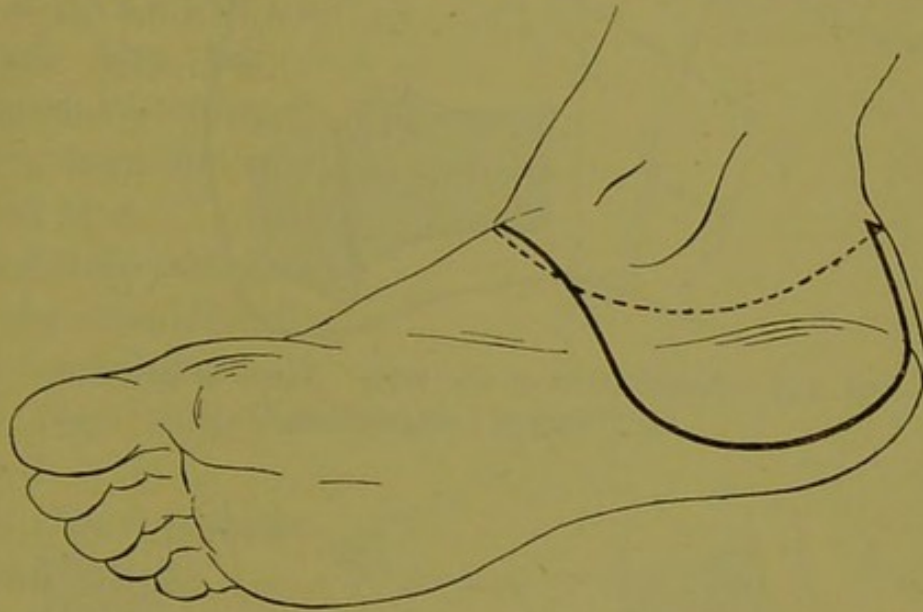


FIG. 354.—Amputation of the foot. Position and shape of internal flap ("Roux' amputation").

practised by Syme himself, was performed by dissecting up the heel-flap from below, and opening the ankle-joint in the later stages of the operation.

The modification as given above will be found to be easier of performance than the original "Syme," and to yield similar results.

When the condition of the tissues in the region of the ankle does not allow of the formation of a heel-flap such as that described above, and there is plenty of sound tissue on the inner side, the amputation may be performed by making a large internal flap, as is shown in Fig. 354.

Amputation at the ankle-joint in which a portion of the os calcis is left behind and fixed to the lower end of the tibia.—There are several modifications of this operation, which depend upon the manner in which the os calcis and the tibia are sawn.

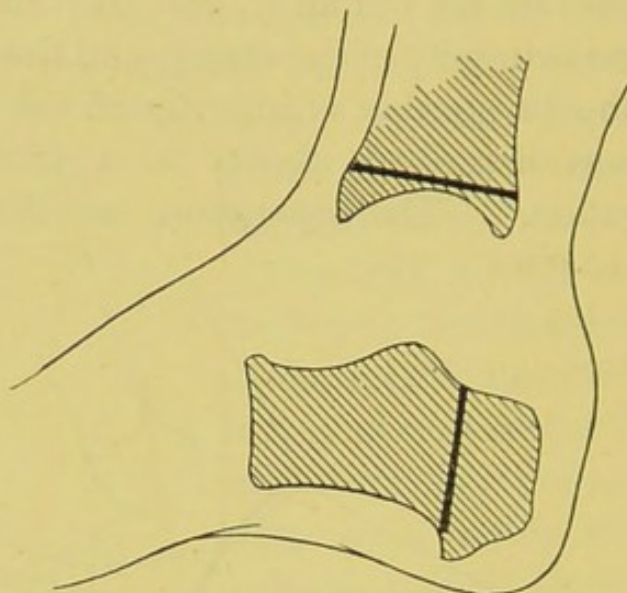


FIG. 355.—Amputation of the foot. Lines of saw-cuts in "Pirogoff's amputation."

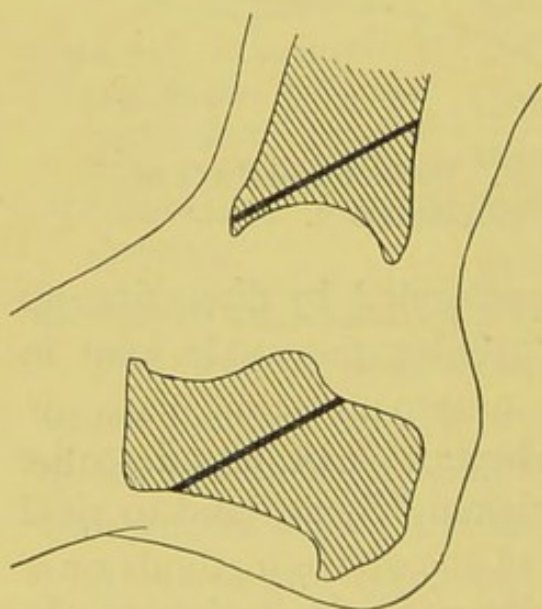


FIG. 356.—Amputation of the foot. Lines of saw-cuts in "Sédillot's operation."

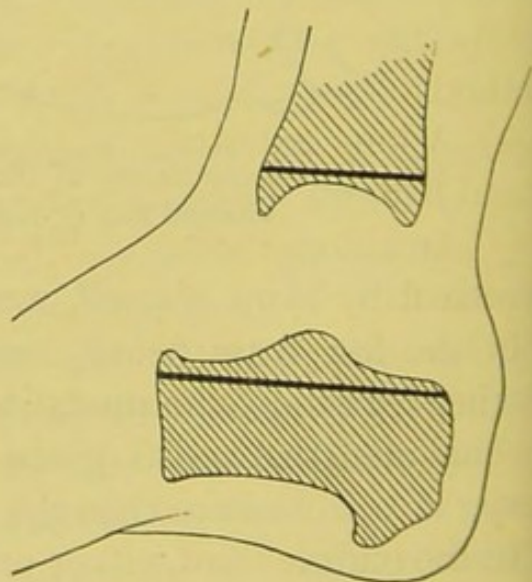


FIG. 357.—Amputation of the foot. Lines of saw-cuts in "Le Fort's operation."

The early stages of the operation are similar to those

described in connection with "Syme's amputation," with the exception that the sole flap is made a little longer, the incision in these cases usually crossing the sole at right angles to the axis of the foot.

Fig. 355 shows the method of sawing the bones in "*Pirogoff's* operation"; Fig. 356 in "*Sédillot* and *Gunther's* method," and Fig. 357 the procedure recommended by *Le Fort*.

Amputations through the leg.—

Amputations through the leg may be performed by—

- (a) Antero-posterior flaps of unequal length.
- (b) Lateral flaps.
- (c) The elliptical method.
- (d) The circular method.
- (e) A long external lateral flap.
- (f) An anterior rectangular flap.

In the lower third of the leg the operations by antero-posterior flaps of unequal length, and by the elliptical method, are the best.

In the middle third, either one of the above methods or a long external lateral muscular flap may be made use of.

In the upper third, lateral skin flaps, with circular division of muscles, or a long external muscular flap, are the most suitable operations.

When an amputation is performed through the junction

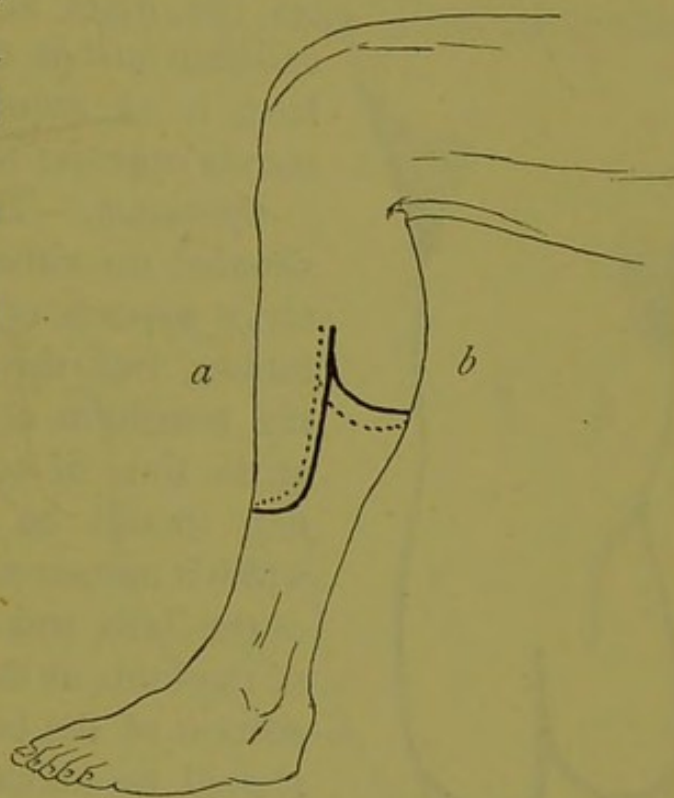


FIG. 358.—Amputation through the leg by a long anterior and a short posterior flap.

a. Anterior incision.

b. Posterior incision

of the upper with the middle third of the leg, it is usually called "amputation at the seat of election."

(a) *By antero-posterior flaps of unequal length.*—

Position.—The patient is placed in the dorsal posture, with the affected limb projecting beyond the end of the table. The surgeon stands on the outer side of the right limb and

on the inner side of the left. One assistant grasps the foot and manipulates it as required, whilst a second stands opposite to the operator.

Operation.—The longer flap may be situated on either the anterior or posterior aspects of the limb, usually the former, but this depends entirely on the condition of the tissues of the leg at the time of operation. The longer flap should be so fashioned that in width it measures half the circumference of the limb, and in length the diameter of the limb, at the level of the plane of section of the bone. The shorter flap should be about one-third the length of the longer one.

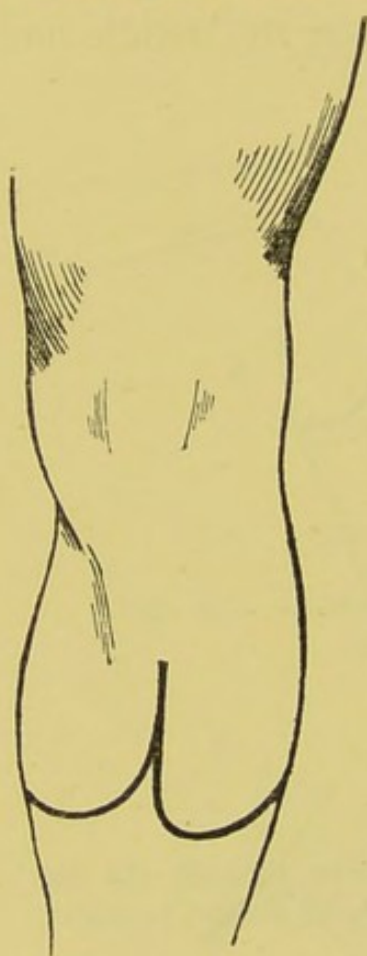


FIG. 359.—Amputation of leg by lateral flaps. Skin incisions.

The incisions are made, and the flaps dissected up. They should at first consist of skin and fasciæ alone, but at their base they should be made to include muscular tissue. Both flaps

being dissected up, they are retracted by an assistant, and the soft tissues divided down to the bone for the entire circumference of the limb.

The periosteum is dissected back for a short distance, and then the bones are sawn across, care being taken to complete the section of the fibula before that of the tibia. The sharp anterior border of the latter may be rounded off, as shown in Fig. 362.

The anterior tibial, posterior tibial, and peroneal arteries are picked up with artery forceps and ligatured. Their relative positions are shown in Fig. 220.

The flaps are now brought over the extremity of the stump, and their margins approximated and fixed by the insertion of sutures.

(b) *By lateral flaps*.—A point is taken in the middle line

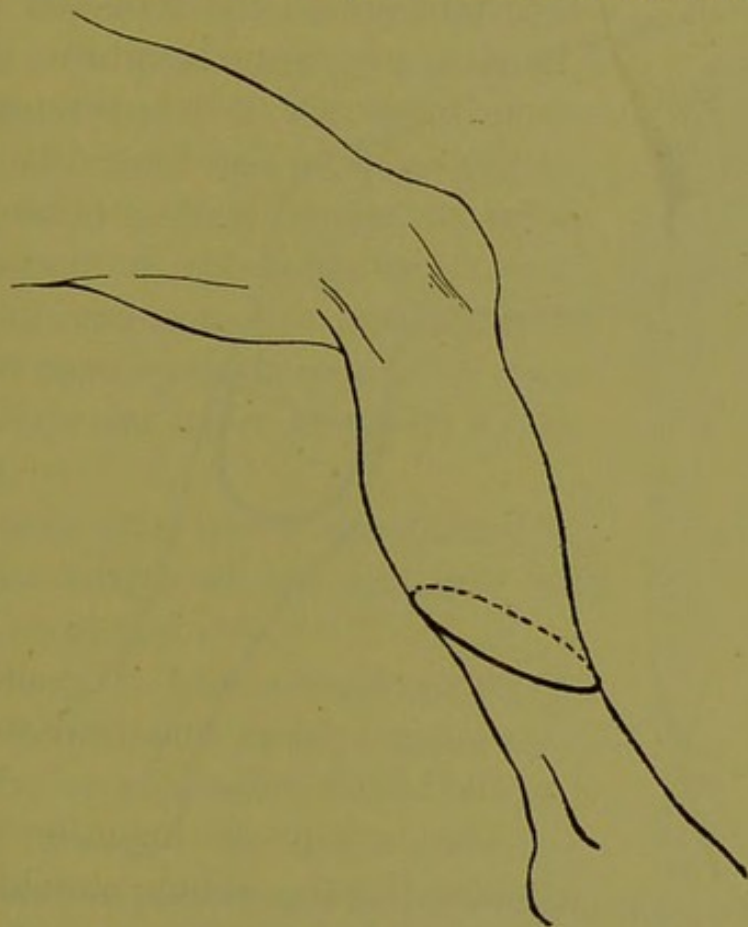

FIG. 360.—Amputation of leg by elliptical method. Position of skin incision.

of the anterior aspect of the limb at the level of the proposed plane of section of the bone, and a vertical incision is made downwards from this point for 3 in. The incision is then carried across the side of the limb in a slightly oblique direction to the middle of the calf behind, and then upwards to the level of the original incision. A similar flap is marked out on the opposite side. The two flaps are dissected up, and should consist only of skin, superficial and deep fascia.

About 1 or $1\frac{1}{2}$ in. below the level at which the bones are to be divided, the muscles are cut through in a circular direction by two or three circular sweeps of the knife. They are then dissected up for a short distance, the periosteum is divided, and the bones sawn as before.

The vessels are picked up and ligatured, and the margins of the flaps united by sutures.

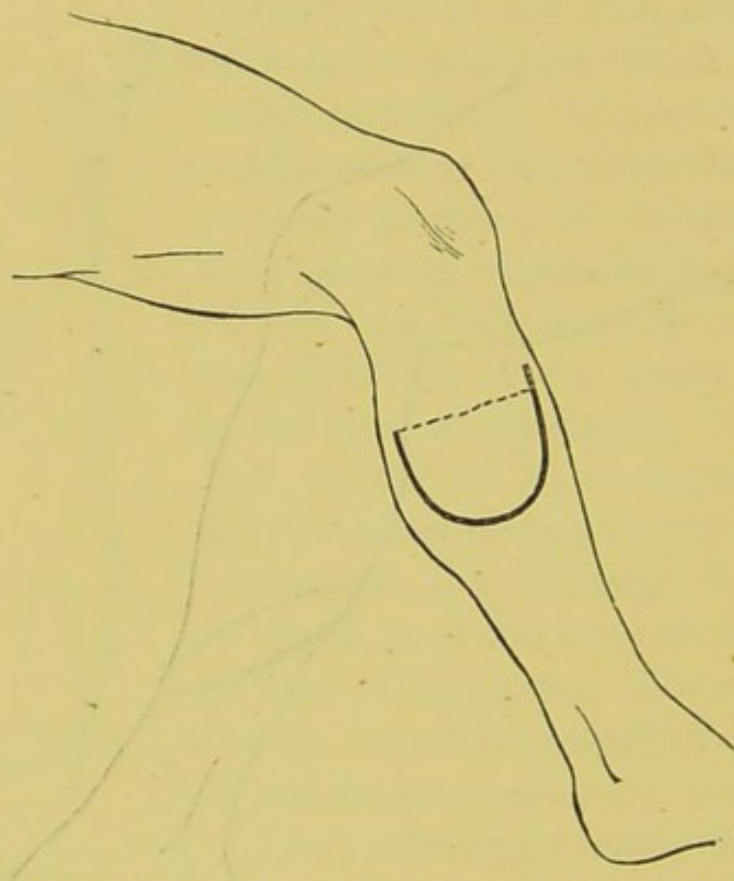


FIG. 361.—Amputation of leg by large external muscular flap ("Farabœuf's operation").

The dark line shows the position of the long external incision; and the dotted line that of the short internal incision.

(c) *By the elliptical method.*—The distal extremity of the ellipse may be situated either on the anterior or the posterior aspect of the limb, usually on the anterior.

The incision first divides skin and fasciæ; these are dissected up, the muscles cut through and dissected back, and the bones sawn across.

(d) *By the circular method.*—The circular method presents no special features.

(e) *By a long external lateral flap.*—This operation is employed in the upper half of the leg, a thick muscular flap being obtained from the external aspect of the limb.

A point is selected in the middle of the anterior aspect of the limb at the level of the proposed plane of section of the bone, and from this an incision is commenced which extends downwards in a vertical direction for a distance equal to one-third of the circumference of the limb at the level at which the bone is to be divided. The incision is then carried round the outer aspect of the limb, in a gently curved direction, to the middle of the calf, and then upwards to a point about 1 in. below the level at which it commenced.

The skin and fasciæ are divided for the entire length of the incision, and allowed to retract.

The limb is now turned outwards, and a second skin incision made from the posterior extremity of the first to a point $1\frac{1}{2}$ in. below the upper extremity of the anterior portion of the same incision. This second incision runs almost horizontally; it should divide skin and fasciæ, which structures are allowed to retract.

The limb is then turned on to its tibial aspect by an assistant, and the surgeon dissects up the large external flap which has been marked out, taking up all the soft tissues down to the bone. Care must be taken not to dissect up the flap too high, otherwise the anterior tibial artery which comes through the upper part of the interosseous membrane may be unintentionally severed. The anterior tibial artery should be

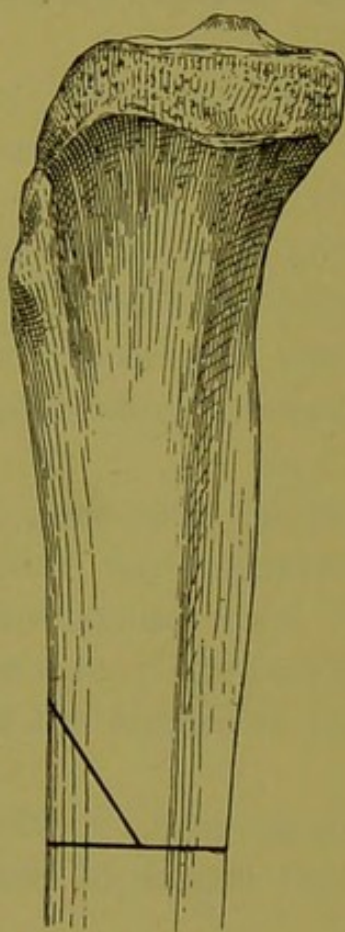


FIG. 362.—Amputation of leg. Method of rounding off anterior border of tibia.

divided at the lower extremity of the external muscular flap.

The muscles of the short internal flap are then divided and the flap dissected up in a manner similar to the preceding.

The periosteum and the interosseous membrane con-

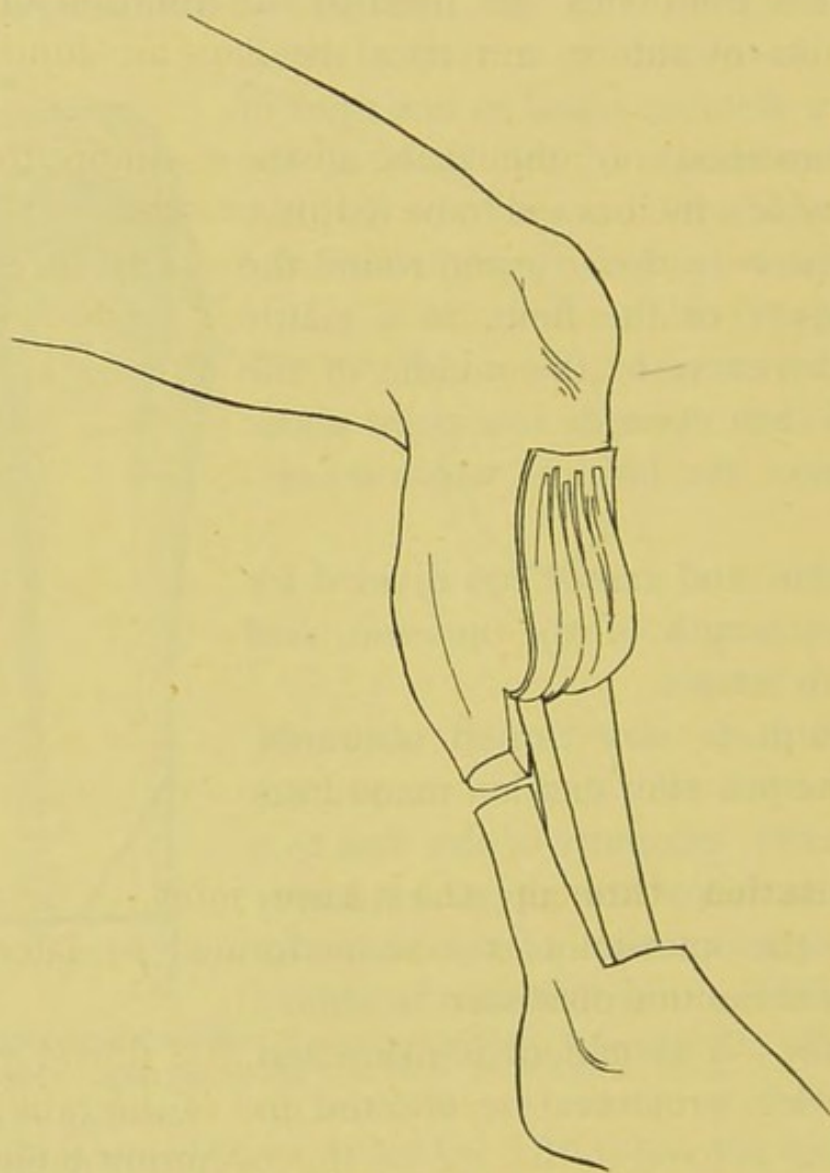


FIG. 363.—Amputation of leg by large anterior rectangular flap ("Teale's operation"). Appearance of parts when flaps have been dissected up.

necting the two bones are then cut through by a circular sweep of the knife, and in favourable cases the periosteum may be separated from the bones for a short distance. All the soft tissues, including the periosteum, are now

retracted, and the bones sawn through. In sawing across the tibia, it is advisable to remove first of all a small segment of the sharp anterior border before making the transverse section. The method of doing this is shown in Fig. 362.

The vessels are ligatured, the periosteum brought over the ends of the bones and fixed by the insertion of one or two points of suture, and then the flaps are adjusted and sewn up.

This method of amputating gives a stump the lower extremity of which is well covered by muscles.

(f) *By an anterior rectangular flap.*—This is generally known as “Teale’s amputation.” It may be doubted, however, whether, with the modern methods of using antiseptics, it is ever advisable to employ this form of operation, since it involves a considerable sacrifice of the healthy tissues of the limb.

The method of marking out and dissecting up the flaps is shown in Fig. 363. The anterior flap measures in length and in breadth one-half the circumference of the limb at the level of the plane of section of the bones, whilst the posterior flap is one quarter of the length of the anterior.

Amputation through the knee-joint.—Amputation through the knee-joint is best performed by lateral flaps (“Stephen Smith’s operation”).

Position.—The patient is placed in the dorsal position, with the legs projecting beyond the end of the table. The sound leg is fixed to the leg of the operation table with a bandage, so as to be kept out of the way. The operator stands on the outer side of the right leg, and on the inner side of the left. One assistant grasps the foot, so as to manipulate the limb as required. A second assistant stands opposite the operator.

Operation.—A point is selected on the anterior border of the tibia an inch below the tubercle. With a short ampu-

tating knife an incision is made, commencing at this point, extending vertically downwards on the anterior aspect of the limb for a distance of 3 to $3\frac{1}{2}$ in., then in a slightly curved direction with the convexity downwards

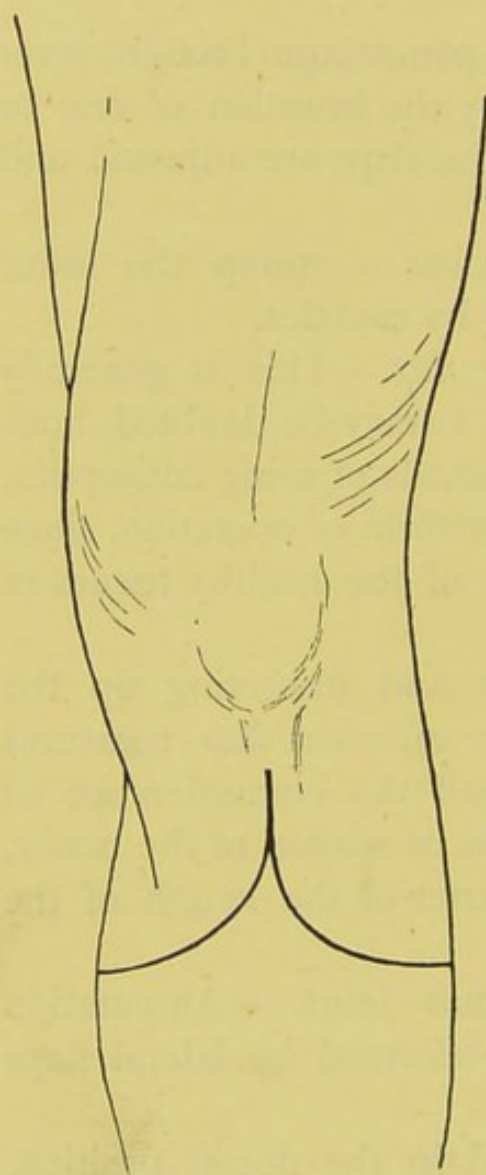


FIG. 364.—Amputation of leg through the knee-joint. Skin incisions. "Stephen Smith's operation."

round the lateral aspect of the limb to the middle line behind, and then upwards to the popliteal space as high as a point opposite the middle of the knee-joint. A similar incision is made on the other side, care being taken to make the internal flap a little longer than the external one.

The incisions divide the skin and fasciæ, and then two flaps are dissected upwards consisting of these tissues. The ligamentum patellæ is divided, and the tissues which lie in front of the head of the tibia separated until the inferior margins of the interarticular fibro-cartilages can be seen. The lateral ligaments and the anterior part of the capsule of the knee-joint are divided, and then by a series of transverse cuts the knife is passed through the knee-joint between the interarticular cartilages and the head of the tibia. The crucial

ligaments are divided close to their attachments to the tibia. The posterior part of the joint being reached, the posterior ligament is exposed and may be cut through, and then with one sweep of the knife all the soft tissues in the popliteal space are divided in a transverse direction backwards.

The popliteal artery and vein are picked up and ligatured, together with any smaller vessels which may have been cut through.

The flaps are adjusted over the extremity of the stump, and fixed in apposition by the insertion of sutures.

When the wound has healed, the line of the scar is situated on the posterior part of the limb between the condyles of the femur, the extremity of the stump being well covered by soft tissues. The advantage of leaving the interarticular cartilages is that the soft parts are kept in their places, and the danger of too great retraction of the flaps is avoided.

Amputations through the knee-joint have also been performed by making a long anterior and a short posterior flap, the main features of such operations being similar to those described in connection with amputations through the leg. The preceding operation, however, should be selected whenever possible, since it gives a very much better stump.

Amputations through the lower fourth of the thigh.—

(a) *By a long anterior flap, with section of the femur immediately above the articular surface and removal of the patella.*—This operation is often known as “Carden’s amputation.”

Position.—The patient is placed in the dorsal position, with the lower extremities, as far as the middle of the thigh, projecting beyond the end of the table. The sound limb is fastened to the leg of the table, so as to be out of the way during the operation. The surgeon stands on the right side of the thigh which is to be operated upon; one assistant takes charge of the limb, and a second stands opposite the operator. An Esmarch’s tourniquet is applied round the upper part of the thigh on the affected side.

Operation.—Two points are selected, one on the outer and the other on the inner side of the thigh, at the level of

the condyles of the femur. An incision is made which commences (in the case of the right limb) at the selected point on the inner side and passes downwards for about 4 in., then across the front of the leg to the outer side, and

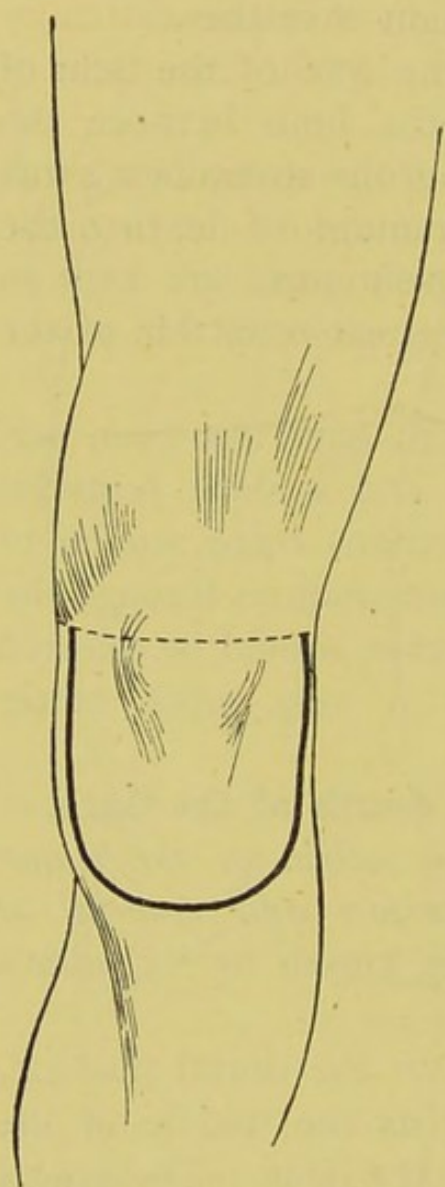


FIG. 365.—Amputation immediately above the knee-joint by a long anterior flap. Skin incision.

then upwards in a vertical direction to the selected point on the outer aspect of the limb. The width of the flap so marked out should be half the circumference of the limb at the plane of section, and the distal extremity should be broadly convex.

The skin and fasciæ are divided for the entire length of the incision, and the flap dissected upwards until the upper border of the patella is reached. The muscles attached to the superior margins and the lateral borders of the patella are cut through, and the knee-joint opened. The muscles are allowed to retract, and the flap dissected upwards to just above the level of the plane of section of the bone.

A long amputation knife is now passed behind the bone from the outer to the inner extremity of the first incision. The cutting edge is turned backwards, and all the soft tissues divided by cutting directly towards the surface.

The soft parts are retracted by the assistant, the femur is cleared for a short distance above the articular surface, and the bone sawn through (Fig. 366, *a*). The limb can now be removed.

The thigh is flexed so as to expose the cut surfaces of the

flaps, and the popliteal artery and vein secured. The tourniquet is removed, and all other bleeding vessels (branches of the anastomosis around the knee-joint) are likewise ligatured.

The broad anterior flap is brought over the extremity of the bone and fixed in position by the insertion of sutures.

In many cases it will be advantageous to make a short posterior flap in addition to the long anterior one, in order to provide an efficient covering for the stump.

(b) *By a long anterior flap, with section of the femur through the condyles and removal of the articular aspect of the patella* ("Gritti's operation").

—This form of operation resembles the preceding, except that the knee-joint is opened below the patella, the ligamentum patellæ and the inferior part of the capsular ligament being cut through, and the patella dissected up in

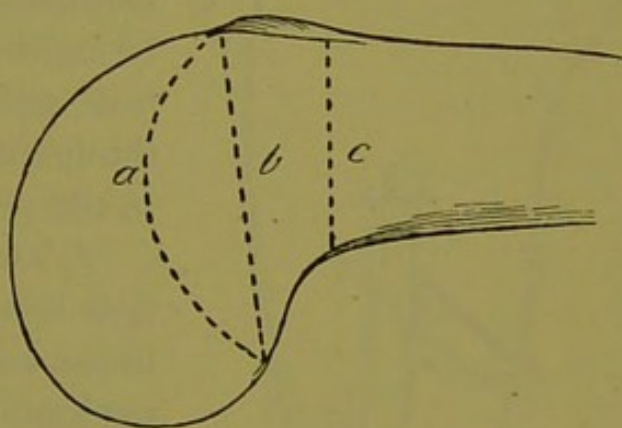


FIG. 366.—Lower end of femur, showing positions of section of bone.

- a. In "Carden's amputation."
- b. In "Gritti's amputation."
- c. In "Stokes's amputation."

the anterior flap. The articular surface of the patella is removed with a fine saw. When the flap is brought into position, the cut surface of the patella should lie in apposition with the sawn extremity of the femur, the two bones becoming firmly united as healing takes place.

Much difficulty is often experienced in keeping the sawn surfaces in apposition, owing to the action of the muscles and the length of the femur. In order to obviate this, the following operation has been proposed, and in many instances gives rise to a better result than the preceding.

(c) *By a long anterior flap, with section of the femur above the condyles and removal of the articular aspect of the patella* ("Stokes's operation").—

This operation resembles the preceding in all essential respects, with the exception that the femur is sawn through at a higher level—through the shaft immediately above the condyles (Fig. 366, c)—and the skin-flaps are commenced at a slightly higher level. The sawn surface of the patella can be brought into and kept in apposition with the sawn surface of the femur much more readily than in the preceding operation.

(d) Ssabanajeff has further modified this operation. He saws the lower end of the femur in a manner similar to Gritti, but leaves the patella intact. A segment of the tibia is fashioned by first sawing the bone in a vertical direction to a point a short distance below the tubercle of the tibia and the attachment of the ligamentum patellæ, and then transversely until the second saw-cut meets the first. By this method a portion of the tibia and the insertion of the quadriceps extensor muscle are separated. The sawn surface of the segment of the tibia and that

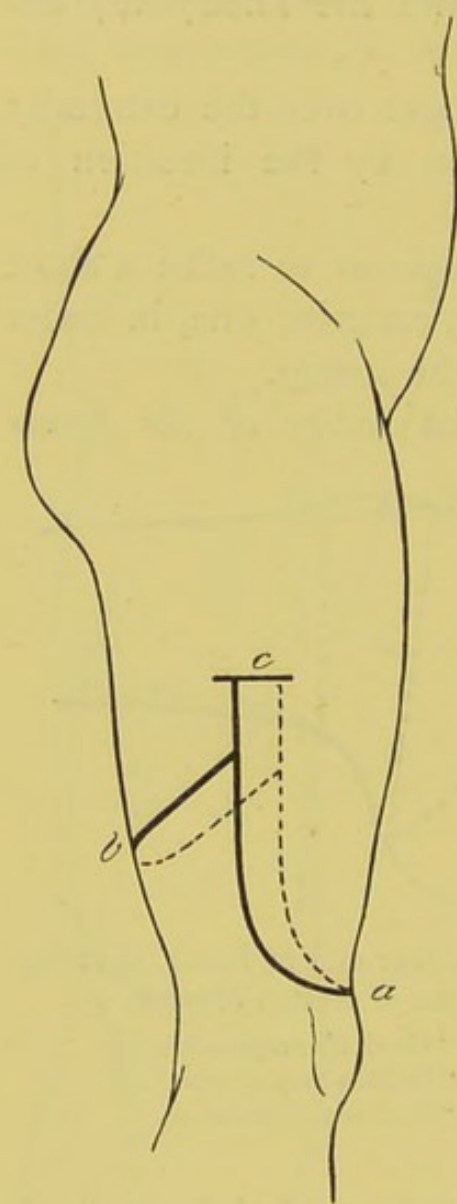


FIG. 367. — Amputation through the thigh. By unequal antero-posterior skin-flaps, with circular division of muscles.

- a. Anterior flap.
- b. Posterior flap.
- c. Section of bone.

of the lower end of the femur are brought into exact apposition, and fixed by the introduction of sutures. The advantages which are claimed for this method are the retention

of the insertion of the quadriceps extensor muscle, the readiness with which the bony surfaces of the tibia and femur unite, and the more satisfactory stump which results. This procedure may be available in cases of injury and in early cases of tuberculous disease, but in advanced cases the state of the bones will not allow of its performance.

In the four preceding forms of amputation the resulting scar will lie on the posterior surface of the limb, and the covering for the end of the stump will be formed from the skin over the patella and the extensor aspect of the knee, which is well fitted to withstand pressure.

Amputations through the middle of the thigh.—Amputations through the middle portion of the thigh may be performed by the following methods:—

(a) By antero-posterior skin-flaps, with circular division of the muscles; (b) by lateral skin-flaps, with circular division of the muscles; (c) by the circular method; (d) by the elliptical method; (e) by a long anterior muscular flap.

Of these forms of operation, those by antero-posterior or lateral skin-flaps, with circular division of muscles, are the best in the majority of instances.

Position.—The positions of the patient, surgeon, and assistants are similar to those in amputation through the

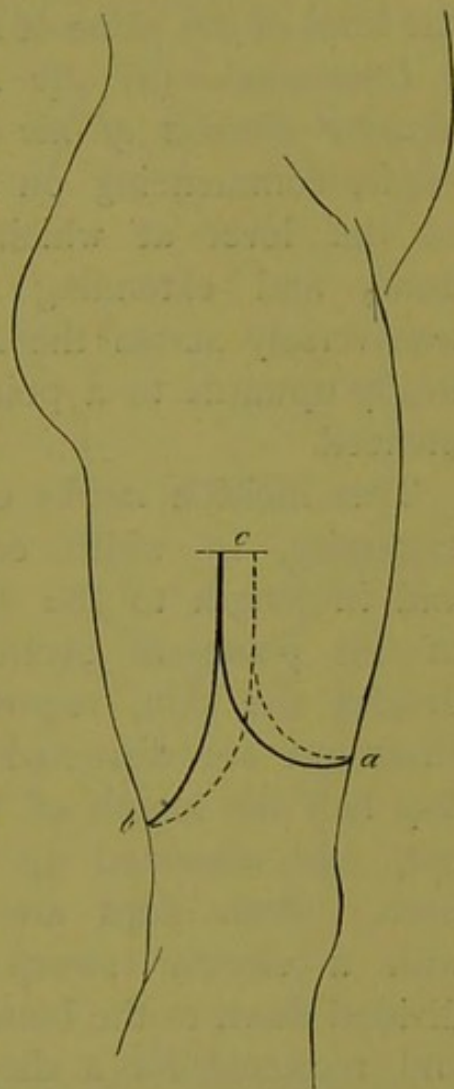


FIG. 368.—By equal antero-posterior skin-flaps, with circular division of muscles.

a. Anterior flap.

b. Posterior flap.

c. Level of section of femur.

lower fourth of the femur, with the exception that the affected limb should project farther beyond the end of the table.

The elastic tourniquet is placed on the thigh well above the level of the plane of section of the bone.

Operation—(a) By antero-posterior skin-flaps, with circular division of the muscles.—A U-shaped incision is made, commencing on the side away from the operator, at the level at which it is proposed to divide the bone, and extending first vertically downwards, then transversely across the front of the limb, and finally vertically upwards to a point opposite that at which it commenced.

This incision marks out a flap with a broadly rounded extremity, in width equal to half the circumference, and in length to the diameter, of the limb at the level of the plane of section of the bone. The incision divides the skin, superficial and deep fasciæ, and these structures are dissected up to form the flap. A similar flap half the length of the anterior one is then marked out, and dissected up on the posterior aspect of the limb. Both flaps are retracted by an assistant, and with a circular sweep of the knife the muscles are divided down to the bone. The periosteum is cut through and retracted for a short distance, and the femur sawn across.

The superficial and deep femoral vessels having been secured, the tourniquet is relaxed, and any bleeding points picked up and ligatured.

The margins of the flaps are then approximated, and united by sutures in the usual manner.

The relative lengths of the flaps may vary according to the condition of the soft tissues. The flaps should be long enough to meet without tension, and to provide a scar which shall not lie immediately over the end of the bone.

(b) *By lateral skin-flaps with circular division of the muscles.*—This operation is similar in many respects to the preceding, but the skin incisions commence and terminate on the anterior and posterior aspects of the limb respectively, two equal lateral flaps being formed (Fig. 369).

(c) *By the circular method.*—A circular incision is made through the skin, superficial and deep fasciæ, 3 to 4 in. below the level at which it is proposed to saw the bone.

The divided tissues are dissected back in the form of a "cuff," and then with a circular sweep of the knife the superficial layers of muscles are cut through; these are allowed to retract, and then the deeper muscles are divided in a similar manner down to the bone. The latter is freed from its periosteum for a short distance, and then sawn through in the usual manner. All hæmorrhage having been arrested, the margins of the wound are brought together and fixed by the insertion of sutures.

(d) *By the elliptical method.*—Amputation by the elliptical method through the middle of the thigh is similar to amputation by the same method in other parts.

The distal extremity of the ellipse may be either anterior or posterior, preferably the former.

(e) *By a long anterior muscular flap.*—When this operation is performed, a long U-shaped flap is dissected up from

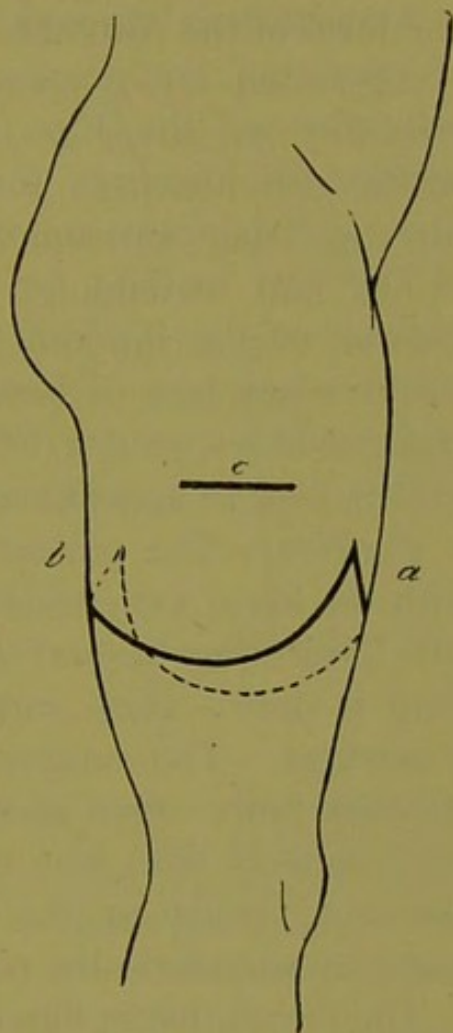


FIG. 369.—By lateral flaps, with circular division of muscles.

- a. External skin-flap.
- b. Internal skin-flap.
- c. Level of section of femur.

the anterior aspect of the limb. At first it consists of skin and fasciæ, and then it includes the muscles.

It is, however, very rarely necessary to employ this form of amputation.

Amputations through the hip-joint.—Several varieties of operation are practised for the removal of the lower extremity at the hip-joint. These are the “racquet” method (of Furneaux Jordan), antero-posterior flaps, lateral flaps, and the formation of flaps by transfixion.

The best method for amputation in cases of extensive disease of the hip-joint is that of Furneaux Jordan. It involves less loss of blood than any of the other methods, and provides a wound the cut surfaces of which can be fairly readily kept in apposition.

Position.—The patient is placed in the dorsal position, with the lower extremities and the buttock of the affected side projecting beyond the edge of the table. The sound limb is drawn aside and fixed to the leg of the table by a bandage. The surgeon stands on the right side of the affected limb. One assistant grasps the lower portion of the diseased limb and rotates it as required, the second assistant stands to the right of the operator. A third assistant attends to the control of the blood vessels.

The circulation is best arrested by passing a strong elastic tourniquet around the junction of the thigh with the pelvis. This tourniquet is passed after the anæsthetic has been administered. The posterior part crosses the ischio-rectal fossa on the inner side of the ischial tuberosity. One end is brought round in front over the inguinal region, and the other round the gluteal region. The two ends meet over the highest part of the iliac crest.

A calico bandage is placed over the middle of Poupart's ligament, and underneath the rubber tube. When the ends of the tourniquet have been tightened, the calico bandage compresses the lower part of the external iliac artery, and the rubber tube the distal portions of the

gluteal and sciatic vessels. A third assistant attends to this tourniquet throughout the operation, and takes care to keep the calico bandage in front of the external iliac artery.

Before the tourniquet is applied, the limb is elevated and the blood allowed to run out of it, in order to minimise the shock which usually follows loss of blood.

Operation.—A circular incision is made through the skin and fasciæ in the middle of the thigh, and the incised tissues dissected upwards for a distance of 2 in. With one or two circular sweeps of the long amputation knife, all the soft tissues, including the blood vessels, are divided down to the bone. The cut ends of the femoral vessels are now sought for in the antero-internal part of the wound and ligatured.

The patient is now turned a little on the sound side, so as to more fully expose the gluteal aspect of the limb.

A vertical incision is made along the outer aspect of the thigh, commencing at a point half-way between the apex of the great trochanter and the iliac crest, and terminating in the circular incision below. This cut is made with a short amputation knife, and all the tissues down to the femur are divided.

Next, the flaps are dissected up on each side, all the soft tissues being included, and the femur cleared from its connections with the muscles. Most difficulty will be experienced in detaching the muscles from the linea aspera. The femur is rotated by the assistant who has charge of the limb as this dissection proceeds.

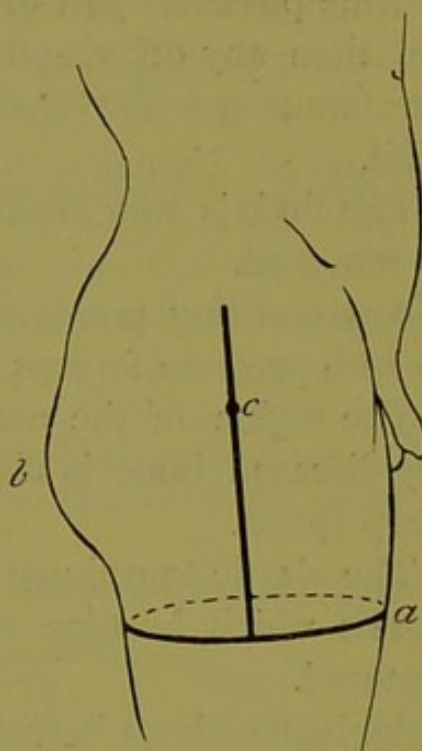


FIG. 370.—Amputation at the hip-joint ("Furneaux Jordan's operation)." Position of skin incision.

- a. Circular portion of incision.
- b. Vertical portion of incision.
- c. Position of top of great trochanter of the femur.

The capsular ligament of the hip-joint is incised above and in front (if it is not already destroyed by disease), the femur is powerfully externally rotated, so as to make the head protrude from the acetabulum, the ligamentum teres and the posterior part of the capsular ligament are divided, and then any other soft tissues which are still attached to the femur are cut through with a few strokes of the knife.

The limb is now separated from its connections, and can be removed.

Any bleeding points which may be apparent are picked up with pressure forceps and ligatured.

The region of the acetabulum is then examined, and if any diseased bone is discovered it is scraped away with a sharp spoon.

The elastic tourniquet is gently relaxed, and any bleeding vessels which become visible are seized with forceps and ligatured.

All hæmorrhage having been arrested, and the tourniquet removed, the cut surfaces of the flaps are brought into apposition and fixed by the insertion of sutures. The angles of the wound may be left open and a drainage tube passed into the depths of the wound, and then the stump is carefully and firmly bandaged.

The main branches of the gluteal artery are not interfered with, and only one of the lowest branches of the sciatic is cut across.

If it is wished to minimise the loss of blood, the femoral vessels should be isolated during the first stage of the operation, ligatured in two places, and cut through.

(*b*) The other methods of amputation through the hip-joint are not so satisfactory in cases of extensive disease as the one above described, but are better adapted for primary amputation after injury.

They resemble in most respects similar amputations in the middle of the thigh.

CHAPTER XXVI.

OPERATIONS UPON THE MAMMARY GLAND.

1. OPERATION FOR MAMMARY ABSCESS.
2. REMOVAL OF LOCALISED NON-MALIGNANT TUMOURS AND CYSTS.
3. AMPUTATION OF THE BREAST—
 - (a) Without removal of the lymphatic glands from the axilla.
 - (b) With removal of the lymphatic glands from the axilla.

THE mammary gland is situated on the antero-lateral aspect of the chest wall, and lies between two layers of the superficial fascia. In front of it lie the skin and the anterior lamina of the superficial fascia, and behind it the deep lamina of the superficial fascia, the deep fascia, and the pectoral muscles covering the surfaces of the ribs and the intercostal spaces.

The gland is divided into a number of lobes, these lobes being separated from one another by processes of fascia.

Fig. 371 is a diagrammatic representation of a horizontal section of the mammary gland.

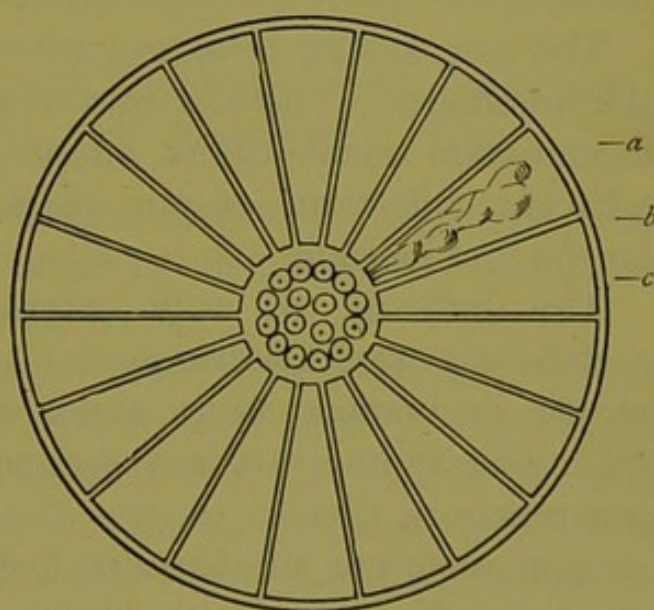


FIG. 371.—Diagrammatic representation of the structure of the mammary gland.

- a. Lobule of gland.
- b. Connective tissue septa which separate the lobules from one another.
- c. Ducts of gland passing to the nipple.

OPERATION FOR MAMMARY ABSCESS.

An operation is indicated in all cases of inflammation of the breast in which the formation of pus has taken place. Before undertaking an operation for the evacuation of the pus, the locality and extent of the abscess should be ascertained as far as possible by careful palpation.

Instruments.—Scalpel, pressure forceps, dressing forceps, director, drainage tube, and ligature material.

Operation.—The position of the abscess having been ascertained, an incision is made over the prominent portion, commencing a short distance outside the nipple, and radiating outwards from this point towards the periphery of the gland. The length of the incision varies according to the extent of the abscess cavity. When the interior of the abscess is reached, the margins of the incision are separated with dressing forceps or the fingers, and the pus allowed to escape.

The pus having been evacuated in the above manner, the forefinger is passed into the abscess cavity and an examination made of its interior, so as to discover any adjacent collections of pus which have not been opened by the first incision.

The majority of acute abscesses of the breast are multilocular, and involve several lobes of the gland. The strong connective tissue septa which separate the lobes from one another are not disintegrated so readily by the inflammatory process as the glandular tissue. If further collections of pus are discovered, the fibrous septa separating them from the cavity of the abscess which has been opened, are completely broken down with the finger, in order to allow the escape of the contents, and to provide free drainage. If it is difficult to establish thorough drainage from a single incision, owing to the size of the abscess, a second and even a third incision may be made. These should radiate from the nipple, and be placed at the lower limits of the abscess cavity.

When free communications have been established between the abscess cavity and the exterior, and all pus has been evacuated, the interior of the abscess is thoroughly swabbed out and irrigated with an antiseptic solution.

Next, drainage tubes are inserted, or the interior may be packed with aseptic gauze, and aseptic dressings applied and fixed in position by firm bandaging.

The arm of the affected side should be fixed in front of the chest, in order to avoid contractions of the pectoral muscles, and so help to maintain the inflamed tissues in a condition of rest.

When the abscess is situated behind the mammary gland, it will be found more convenient to lift up the organ towards the neck, and to make the incision in the sulcus between the gland and the chest wall. No visible scar will result from this procedure.

REMOVAL OF LOCALISED NON-MALIGNANT TUMOURS AND CYSTS FROM THE MAMMARY GLAND.

Adenomata, fibro-adenomata, fibromata, and simple cysts are frequently met with affecting the mammary gland, and when present may require removal.

Operation.—An incision is made over the prominent part of the tumour, in a direction radiating from the nipple. The skin and fasciæ are divided, and the tumour exposed. This is dissected from its surroundings and removed. Hæmorrhage is arrested, and the external wound closed in the usual manner. Dressings are applied, and the limb bandaged to the chest, as in the preceding operation.

When the tumour or cyst is situated in the lower part of the mammary gland, an incision may be made in the sulcus between the organ and the chest wall, the gland incised from its posterior aspect, so as to expose the deep surface of the tumour or cyst, and through this opening the abnormal structure is removed. No visible scar results from the procedure.

AMPUTATION OF THE BREAST.

(a) Amputation of the breast not accompanied by removal of the lymphatic glands of the axilla.

Indications.—(1) Chronic interstitial inflammation of the breast which is not amenable to ordinary palliative measures.

(2) Tuberculous disease of the breast associated with numerous sinuses.

(3) Serocystic disease of the breast, in which the whole or the greater part of the organ is involved.

(4) Very early cases of carcinoma of the breast, in which the disease commences in the internal margin.

(b) Amputation of the breast and removal of the lymphatic glands from the axilla.

Indications.—(1) *Carcinoma of the breast.*—Cases of carcinoma of the breast in which the lymphatic glands are enlarged, or in which the disease commences in the outer two-thirds of the organ.

When the supraclavicular lymphatic glands are enlarged in carcinoma of the breast, the primary disease together with the lymphatic glands may be removed, but it is rarely possible to effect complete removal of the affected glands at the root of the neck. In this case, however, the secondary growths do not always increase in size very quickly, so that it often happens that life is prolonged for a considerable time after the removal of the primary disease.

(2) *Sarcoma of the breast.*—If there are signs or symptoms of the presence of secondary growths in any of the viscera or bones of a patient suffering from malignant disease of the breast, it is not advisable to attempt an operation for the removal of the primary disease.

(3) *Tuberculous disease of the breast* associated with a similar affection of the axillary lymphatic glands.

Instruments.—Large and small scalpels, pressure, artery, and dissecting forceps, retractors, scissors, needles, needle-holder, and ligature and suture material.

Position.—The patient is placed in the dorsal position on the operation table, with the affected side close to the edge. The upper extremity of the diseased side is held at right

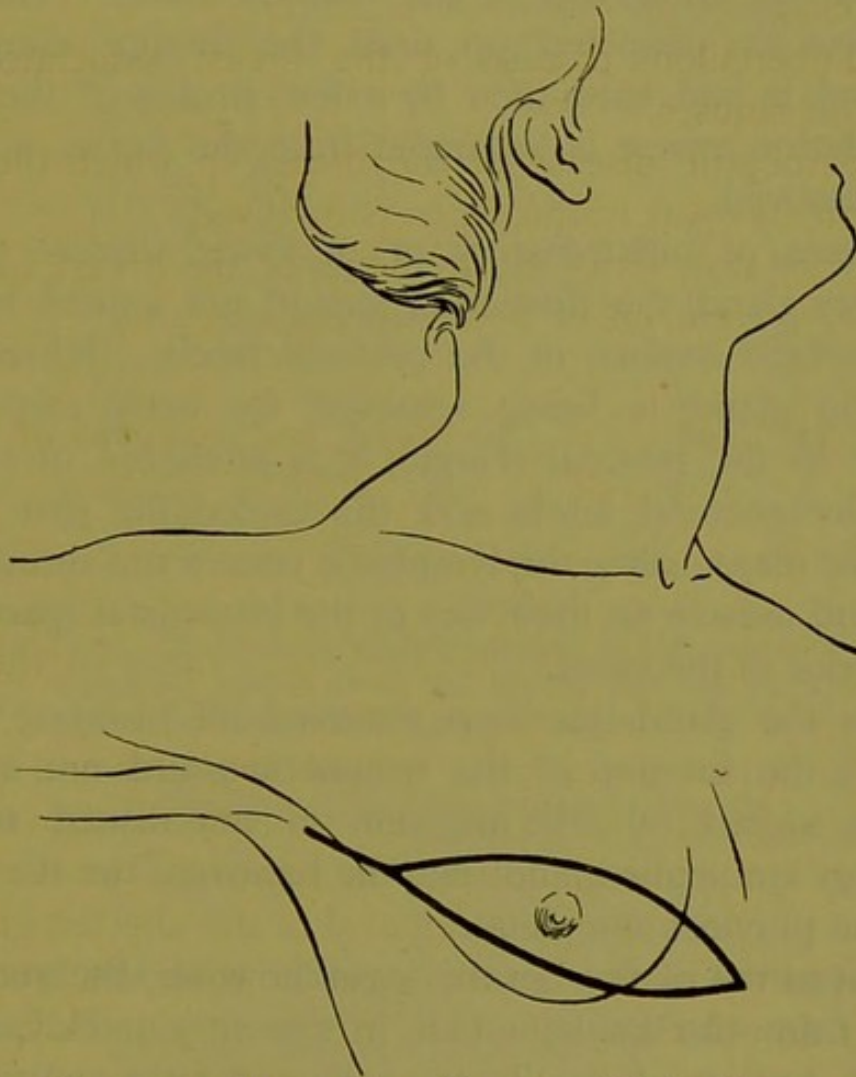


FIG. 372.—Amputation of breast. Skin incision.

angles to the trunk by an assistant. The surgeon stands on the affected side of the patient, and his assistant on the opposite side.

(a) **Removal of the breast (without clearing out of the axilla).**—An oval-shaped incision is made, which includes the nipple and the areola, as shown in Fig. 372. The upper part of this incision is made first, and divides the skin

and superficial fascia, and exposes the anterior aspect of the gland. The skin and fascia are dissected upwards until the superior margin of the mamma is exposed; this is pulled downwards, and the dissection continued on its posterior aspect. When the upper part of the breast has been freed, the organ is retracted upwards by an assistant, and the lower half of the incision made. The skin and fascia are dissected up until the inferior margin of the gland is laid bare, then by a few strokes of the knife the posterior aspect is separated from the fascia, and the gland removed.

In cases of inflammatory or of cystic disease of the mammary gland, the dissection should not extend beyond the superficial surface of the pectoral fascia. When, however, the gland is being removed for early carcinoma, situated in the internal margin, it is advisable to remove freely the pectoral fascia and the underlying part of the pectoralis major, since the lymphatic vessels run through the fascia and muscle on their way to the intercostal spaces and the interior of the chest.

When the gland has been removed, all bleeding vessels are tied, the interior of the wound sponged out, and its margins united by the insertion of interrupted sutures. Dressings are applied, and the arm bandaged to the chest, as in the previous operation.

(*b*) **Removal of the breast, together with the lymphatic glands from the axilla.**—The lymphatic vessels from the external portion of the breast pass outwards and join the lymphatic glands in the axilla, from the upper part they go to those on the costo-coracoid membrane, and from the internal margin to those in the mediastinum. Fig. 373 is a diagrammatic representation of the course of the lymphatic vessels from the mammary gland to the different groups of lymphatic glands to which they go. The majority of the lymphatic vessels from the breast pass into the axilla; a few from its upper margin to the glands on the costo-coracoid

membrane, and those from the internal portion to the glands within the chest.

Operation.—An oval-shaped incision is made, which varies somewhat in size according to the development of the mammary gland, to the position of the carcinomatous swelling, and to the amount of infiltration of the skin. In

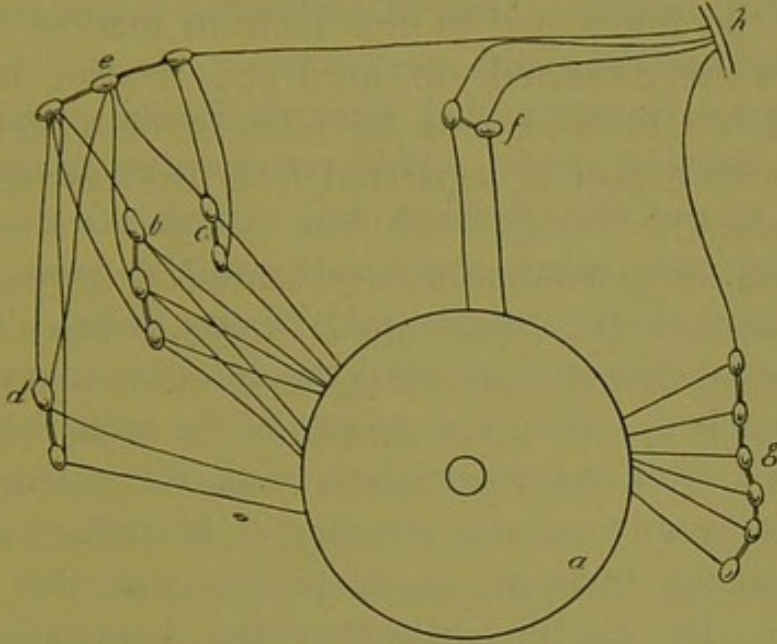


FIG. 373.—Diagrammatic representation of the course of the lymphatic vessels from the breast, and the groups of glands into which they open.

- a.* Mammary gland.
- b.* Lymphatic glands along long thoracic vessels.
- c.* " " between the two pectoral muscles.
- d.* " " in middle of axilla.
- e.* " " along the axillary vein.
- f.* " " upon costo-coracoid membrane.
- g.* " " in anterior and superior mediastina
along the internal mammary vessels.
- h.* Thoracic duct or right lymphatic duct.

every case the skin incision should be carried very wide of the disease, and if the skin is affected the incision should be much wider than that shown in the figure.

The first part of the incision commences at the lateral margin of the sternum on the affected side, some distance below the nipple, and passes upwards across the upper portion of the mammary gland to the anterior fold of the axilla, and thence along the axilla to its outer aspect. This

incision divides skin and fascia. The breast being pulled down by an assistant, the surgeon dissects up a flap of skin and fascia from above until the upper extremity of the gland is reached. This flap is retracted upwards by the assistant, whilst the surgeon seizes the superior margin of the breast, pulls it downwards, and separates its posterior surface from the pectoral fascia. This dissection is prolonged to the lower margin of the gland.

The breast is now pulled upwards by the assistant, and the lower incision made. This commences at the sternal extremity of the first incision, and extends in a somewhat curved direction below the breast until it joins the first incision again at the anterior fold of the axilla. The skin and fascia are dissected up until the inferior margin of the gland is reached. By a few strokes of the knife the mamma is detached from its connections with the pectoral fascia and skin, and only remains attached at its axillary margin.

The axillary incision is deepened and the margins retracted. By careful dissection the lymphatic vessels which pass from the external margin of the mammary gland to the various groups of lymphatic glands in the axilla are removed.

The groups of lymphatic glands which require removal are—

(a) Those which lie adjacent to the long thoracic vessels, immediately underneath the anterior fold of the axilla. One or two glands of this group extend upwards between the two pectoral muscles, and care must be taken that these are dissected out

(b) A mid-axillary group of glands, which receive a few lymphatic vessels from the breast. These usually have connections with the row of glands lying along the sub-scapular vein.

(c) The lymphatic vessels from the above groups of glands join those glands which lie in the outer part of the axilla along the axillary vein.

During the dissection for the exposure and removal of the axillary lymphatic glands, it will be necessary to cut through the intercosto-humeral nerves, but care should be taken to preserve, if possible, the subscapular nerves.

The axillary vein is to be avoided as it lies in the outer part of the axillary space.

When all the lymphatic vessels and glands have been separated from their connections with the structures in the axillary space, the breast with its associated lymphatics can be removed. The pectoral fascia which covers the pectoralis major muscle, and the superficial portion of this muscle, are now removed. All hæmorrhage is arrested, the wound sponged dry, and the margins of the incision brought into apposition and fixed by the insertion of sutures.

In those cases of carcinoma of the breast in which there is extensive involvement of the skin, it will rarely be possible to approximate the margins of the entire wound. Those, however, which can be brought together are fixed by the insertion of sutures, and the surface of the remainder should be covered by several skin grafts according to "Thiersch's method" (see page 627).

In cases in which a portion of the wound cannot be closed by bringing the skin together in the usual manner, it is often possible, by a plastic operation, to cover in the uncovered area by skin from the neighbourhood.

Aseptic dressings are now applied, and the arm bandaged to the chest.

CHAPTER XXVII.

PLASTIC OPERATIONS.

1. HARE LIP.
 - (a) Single.
 - (b) Double.
2. CLEFT PALATE.
 - A. Of both hard and soft palate.
 - B. Of soft palate.
3. OPERATION FOR EXTROVERSION OF THE URINARY BLADDER.
4. OPERATION FOR EPISPADIAS.
5. OPERATION FOR HYPOSPADIAS.
6. SKIN GRAFTING.
 - A. By ordinary method (or Reverdin's).
 - B. By large epidermal strips ("Thiersch's method").

PLASTIC SURGERY.

By the term "plastic surgery" is understood those operative measures which have for their object the repair of malformations or deficiencies which are due to congenital or acquired causes.

The congenital malformations which are most common and which can be repaired by surgical aid, are the different varieties of hare lip and cleft palate, and malformations of the genital organs, such as epispadias, hypospadias, and extroversion of the bladder. Webbed fingers occasionally occur, and can be remedied by surgical treatment.

Acquired malformations may be dependent either upon disease or upon injury. The former class includes loss of part or the whole of the nose by ulceration, and the different forms of contraction which cause de-

formities and are due to the scars of healed ulcers. The deformities or deficiencies which are due to injury may be the result of severe contractions after burns, to the accidental removal of some part, such as the nose, by a sharp instrument, or to the removal of some organ by the surgeon in the treatment of a disease, especially a malignant growth, such as a rodent ulcer.

Skin grafting is so intimately associated with many forms of plastic operations and the repair of defects, that it has been considered advisable to include it in this chapter.

HARE LIP.

A hare lip is a congenital affection which is due to the non-closure or incomplete closure of the original cleft between the central and lateral portions of the upper lip. When it occurs on one side only it is called a *single* hare lip, and when on both sides a *double* hare lip. A *median* hare lip may occur, but it is exceedingly uncommon. When present it is usually due to non-development of the inter-maxillary bone, but cases have been seen in which this bone has been fully formed. In this latter case possibly a lateral cleft has been drawn towards the middle line.

Period of life at which the operation is best performed.—The period of life at which the repair of a hare lip ought to be carried out has varied in the practice of different surgeons. Operation at some date between the termination of the fourth week and that of the fourth month appears to have been followed by the best results, the most favourable time being between the sixth and eighth week.

If the operation is performed after the end of the sixth month, the complications of dentition are liable to interfere with the success of the operation, and before the fourth week an infant is not always strong enough to stand such an operation.

(a) **Single hare lip.**—*Instruments.*—Long-handled fine scalpel or tenotome, scalpel, scissors, fine-toothed long-

handled forceps, half-curved and straight needles, needle-holder, and suture material (fine salmon-gut or horse-hair).

Position.—The patient is placed in the dorsal posture on the operation table, with a sterilised towel wrapped around the chest and arms. The operator stands at the head of the patient, the assistant on the affected side, and the anæsthetist on the opposite side.

Chloroform is the anæsthetic which should be used, and care must be taken that no drops of it fall on the face of the infant, especially in the region of the wound.

Operation.—The operation for the cure of hare lip may be divided into four stages, namely—(a) Incision of the mucous membrane at the reflection between the cheek and the alveolar process, and separation of the two parts of the lip from the external surfaces of the maxillary bones; (b) paring of the margins of the cleft in the lip; (c) fixation of the prepared margins and surfaces in apposition by the insertion of sutures; (d) application of a dressing which shall maintain the parts in position.

(a) *Incision of mucous membrane.*—The margins of the cleft portion of the lip are held apart, and the mucous membrane on the internal surface cut through along its line of reflection from the gums. Next, the lip is dissected upwards for a short distance, so as to allow the easy approximation of the margins of the cleft without the production of tension. In severe cases it may be necessary to effect this separation almost to the infra-orbital foramen on the affected side. The attachment of the ala of the nose to the superior maxilla is also cut through during the separation of the tissues of the cheek. This avoids flattening and malformation of the nostril of the cleft side.

Whilst this separation of the tissues of the cheek is being effected, the edge of the scalpel should be kept turned towards the surface of the maxilla, and away from the cheek.

Any hæmorrhage which occurs can usually be controlled by sponge pressure.

(b) *Paring margins of cleft.*—The methods of paring the edges of the cleft in the lip vary according to the characters of each individual case. The main points to be borne in mind are that the margins of the incision shall correspond, that the line of union of the cleft shall be a little longer

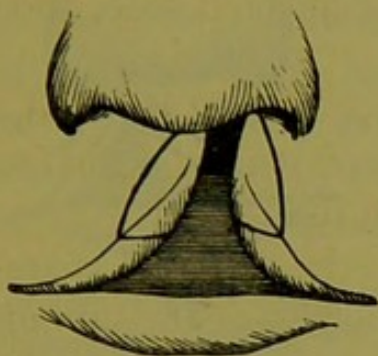


FIG. 374.—Single hare lip. Position of incisions along the margins of the cleft.—W. ROSE.

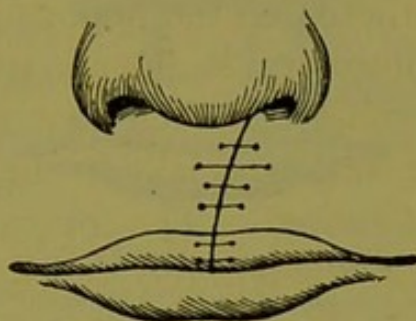


FIG. 375.—Single hare lip. Appearance of the upper lip after the cleft has been closed.—W. ROSE.

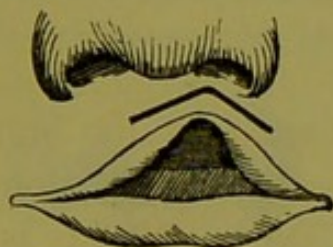

FIG. 376.—Single hare lip. "Nélaton's operation." Position of the incision.

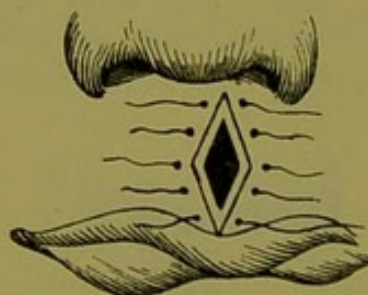


FIG. 377.—"Nélaton's operation." Appearance of parts after the incision has been made, the apex of the cleft drawn downwards, and the sutures inserted.

than is apparently requisite, so as to allow for contraction of the scar tissue along the line of union, and to see that the red line of the lip is quite regular and even.

A thin-bladed scalpel is taken, its point entered at the apex of the cleft or at the nostril (when the malformation is complete), with the cutting edge towards the mouth, and

then a cut is made in a straight or somewhat curved direction as far as the junction of the skin with the mucous membrane, then the blade is turned towards the cleft and a further cut made at an angle of 50° to 70° , according

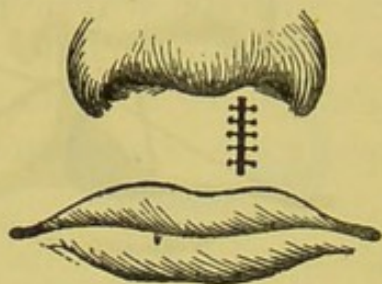


FIG. 378.—“Nélaton's operation.” Appearance of the lip when the sutures have been tied and the operation completed.

It is only in slight and extremely favourable cases that a good result can be obtained by this procedure.

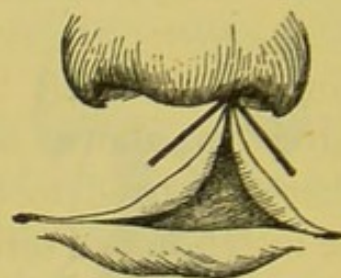


FIG. 379.—Single hare lip. Operation of Malgaigne. Position of incisions at the margins of the cleft.

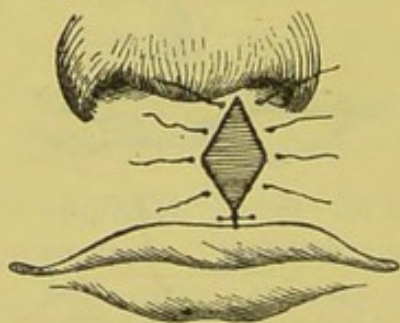


FIG. 380.—Single hare lip. Operation of Malgaigne. Appearance of cleft when the margins have been pared and the sutures inserted.

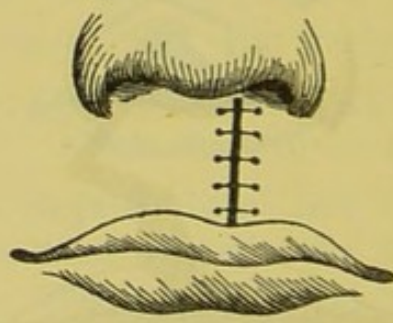


FIG. 381.—Single hare lip. Operation of Malgaigne. Appearance of the lip when the operation is completed.

to the width of the cleft. The manner of making this incision is shown in Fig. 374. This is the operation recommended by Professor Rose. Other methods of making the incisions in the margins of the cleft are shown in Figs. 376–379 and 382.

The other side of the cleft is then treated in a similar manner, the hæmorrhage being controlled by the fingers of the assistant, or by putting on a suitable lip compressor. Usually it will be found more convenient to adopt digital pressure.

(c) *Insertion of sutures.*—The margins of the cleft having been prepared as above, are brought together and fixed in this position by the insertion of a series of simple interrupted sutures.

Fine straight needles are taken, and threaded with fine salmon-gut. The first needle is passed a little above the junction of the skin with the red portion of the lip, its point being entered one-fourth of an inch from the margin, and made to emerge at the junction of the cut surface with the mucous membrane on the internal aspect, and then to pass through the lip on the other side in the reverse

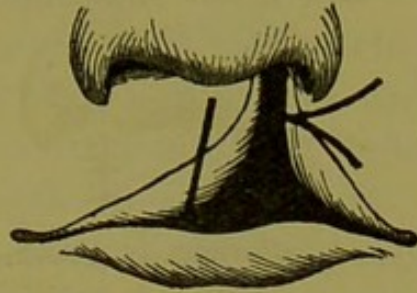


FIG. 382. — Operation of Giralès. Position of incisions at the margins of the cleft.

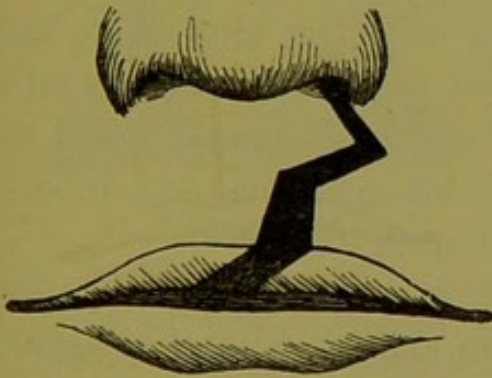


FIG. 383. — Operation of Giralès. Appearance of cleft after the margins have been pared.

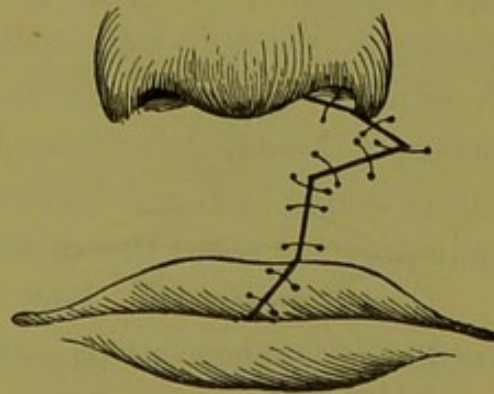


FIG. 384. — Operation of Giralès. Appearance of lip when the operation has been completed.

direction. The second needle is passed in a similar manner at the upper extremity of the cleft, and a third half-way between the two first. Other sutures of fine horse-hair are now passed between the three main sutures, along the other parts of the margins of the cleft, both on the internal and

external surfaces. As these are being introduced, the salmon-gut sutures should be tightened so as to bring the margins of the cleft in exact apposition.

The three salmon-gut sutures are now tied with the first part of the true "surgical knot" (Fig. 22), and the horse-hair sutures in a reef knot in the usual manner. The ends of all the sutures are cut short.

Some surgeons use silver wire in place of the salmon-gut, but quite as good results can be obtained by the use of salmon-gut, and this substance can be removed much more readily and with less bruising of the tissues. A hare-lip pin is generally quite unnecessary.

(d) *Application of dressing.*—The lips and the margins of the united cleft are carefully washed, so as to remove all traces of blood and other débris. Then the lip in the region of the wound is gently sponged with a plug of sterilised wool steeped in absolute alcohol.

The spirit is allowed to evaporate, and then a layer of thin gauze, cut in the shape of an hour-glass, placed on the lip and adjacent parts of the cheeks. The surface of this gauze is painted with collodion, which is allowed to dry. A second sheet of gauze is put on, and collodion applied as before. During the time the dressing is being applied the cheeks are pressed forwards by an assistant, and held in that position until the dressing is quite firm.

After-treatment.—The nurse in charge of the patient should be instructed to pull down the lower lip, if necessary, so as to facilitate respiration through the mouth, since it may be impeded, owing to narrowing of the nasal apertures.

On the fourth or fifth day the dressing should be removed and the salmon-gut sutures taken out. The margins of the wounds are washed and the dressing re-applied. Three or four days later the dressing is again taken off, all the horse-hair sutures taken out, and a dressing applied which is kept in position by a piece of rubber strapping.

The child will usually be able to suck on the seventh or eighth day, that is, when all the sutures have been

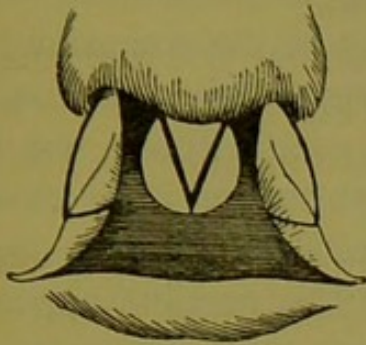


FIG. 385.—Double hare lip. Position of incisions along the margins of the cleft and on the prominence of the premaxilla.—W. ROSE.

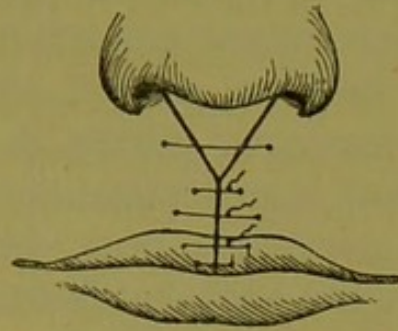


FIG. 386.—Double hare lip. Appearance of the lip when the operation is completed.—W. ROSE.

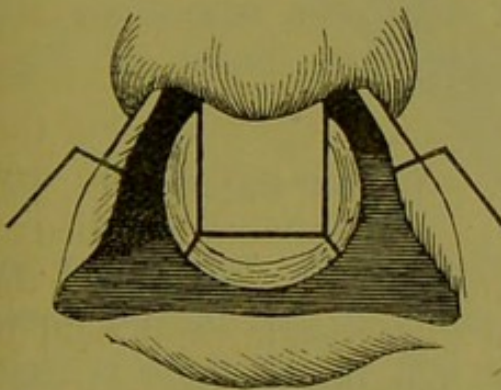


FIG. 387.—Double hare lip (operation of Maas). Position of incisions at margins of the cleft and on the premaxillary prominence.

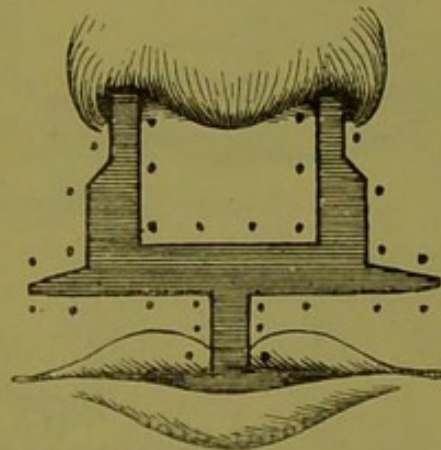


FIG. 388.—Double hare lip (operation of Maas). Appearance of the parts when the margins of the cleft have been pared. The dots represent the points where the sutures are to be inserted.

removed. Up to this time the milk should be given with a spoon.

(b) **Double hare lip.**—In the operation for the radical cure of a double hare lip, the condition of the intermaxillary

bone has much to do with the form of operation and also with the ultimate success. If this bone is very prominent, an attempt may be made to force it backwards, either with or without removal of a portion of the vomerine plate and the nasal septum, after reducing its size by removing the tooth-sacs which it contains. Sometimes the best method is to remove the prominent portion in its entirety, but every case must be considered on its own merits. When the bone has been removed, the maxillæ appear to grow more towards the middle line, until ultimately the space is almost filled up and the cleft in the lip can be readily closed by an operation.

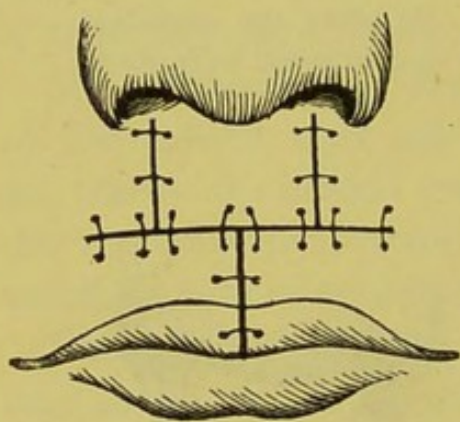


FIG. 389.—Double hare lip (operation of Maas). Appearance of the lip when the operation is completed.

The stages of the operation are similar to those in the single hare lip; the methods of making the incisions, and the appearances presented when the operations are completed, are shown in Figs. 385-389.

CLEFT PALATE.

A cleft in the palate may involve either a part or the whole of the palatal arch. When the soft palate alone is cleft, the uvula may be simply bifid, or the deficiency may extend as far forwards as the posterior margin of the hard palate. When the hard palate is involved, the portion of the arch which is derived from the palate bones may alone be deficient, or the cleft may extend forwards between the superior maxillæ, while in very extensive cases the cleft passes on one or other side of the premaxillary bones to become continuous with a hare lip. It only very rarely happens that a congenital aperture in the hard palate is met with unless associated with a similar condition of the soft palate.

Apertures in the hard or soft palate, usually the latter, may also be dependent upon disease. These usually follow tertiary syphilitic ulcerations of the palatal region. Before attempting to cure an aperture in the palate which has been caused by tertiary syphilis, it is advisable to give the patient a course of antisyphilitic treatment. Apertures in the soft palate may be cured by operation, but only in rare instances can perforations in the hard palate be cured.

Period of life at which the operation ought to be performed

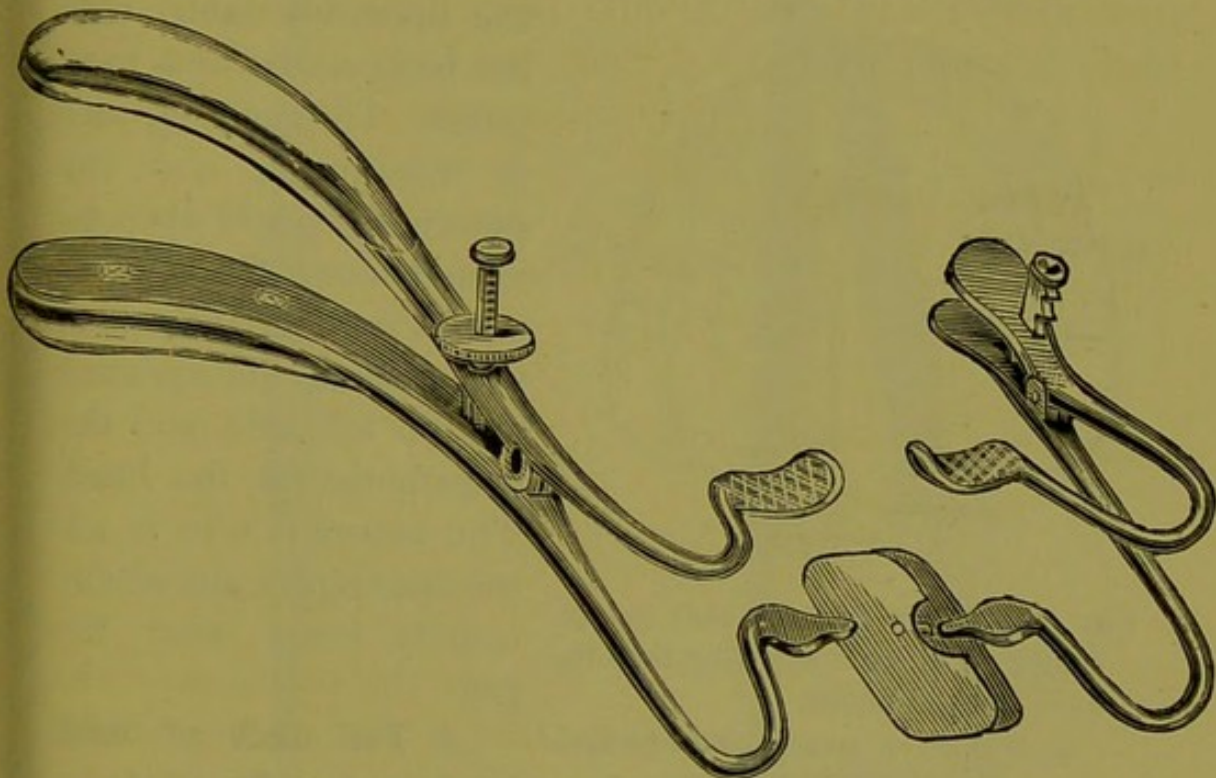


FIG. 390.—Mouth gag for use in operations upon the palate.—SMITH.

in cases of congenital origin.—Some surgeons have advocated operation at an early stage, even during the first few months of life; but, according to the experience of most authorities on the subject, the third or fourth year is now considered to be the most favourable time to operate. If the closure of the cleft in the palate is delayed beyond this period, articulation is liable to be interfered with.

When the cleft involves the tissues of both the soft and the hard palate, it is advisable to ensure union of the hard palate first; and if it is possible, the entire cleft should be

closed at one operation. When this cannot be done, the cleft in the hard palate should be closed first, and that in the soft portion at a later period.

Instruments.—Gag, long-handled tenotome or fine-bladed scalpel, ordinary scalpel, scissors (bent and straight), periosteal elevators, long fine-toothed forceps, palate-hook, needles, needle-holder, suture material (fine silver wire, silk, and horse-hair).

Position.—The patient is placed in the dorsal posture on the operation table, with the head raised by a hard pillow.

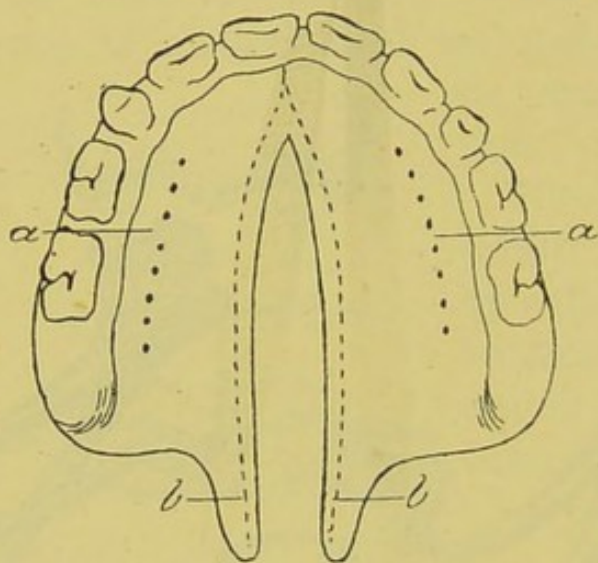


FIG. 391.—Operation for cleft palate, complete; the cleft involving both the hard and soft palate.

- a. Position of lateral incisions for division of muco-periosteum.
- b. Position of incision in paring the margins of the cleft.

the operation table, with the head raised by a hard pillow. The gag (Fig. 390) is introduced, and the mouth thus held open by an assistant. The surgeon stands on the right side of the patient, the assistant on the left side, and the anæsthetist at the head. The assistant who is administering the anæsthetic usually looks after the gag.

A. For cleft of both hard and soft palate.—

Operation.—The operation may be divided into

the following stages, namely—(a) Making of lateral incision, and separation of the muco-periosteal portions of the hard palate; (b) paring of the margins of the cleft; (c) introduction and tying of sutures, and closure of cleft; (d) making of further lateral incisions in order to relieve lateral tension.

(a) *Lateral incision and separation of muco-periosteum.*

—An incision is made through the soft tissues of the palate, commencing at a point internal and opposite to

the last temporary molar tooth, and extending forwards parallel with the alveolar margin as far as the anterior border of the canine tooth, that is to say, just in front of the termination of the cleft, except in those cases in which



FIG. 392. — Periosteal elevator for separation of muco-periosteal flap.

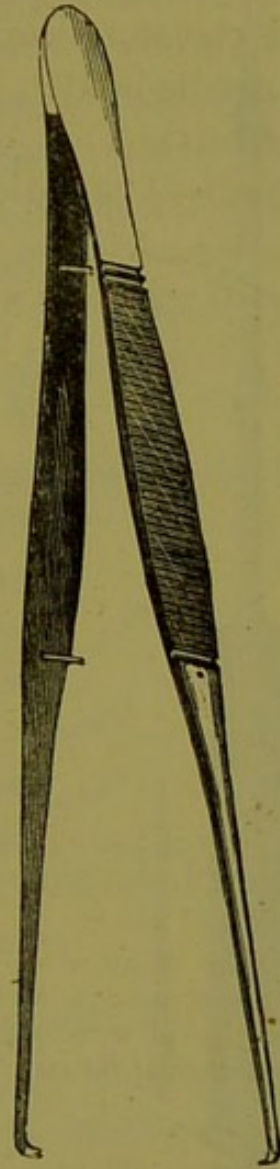


FIG. 393. — Long fine forceps for operations upon palate.

the deficiency extends through the alveolus. The palatal tissues should be incised in a direction perpendicular to the surface, and all bevelling of the margins must be avoided.

Care must be taken to divide everything down to the bone, otherwise one or more of the palatine arteries may be only partially divided, and severe hæmorrhage will ensue, which will be difficult to arrest.

Sponge pressure is applied for a short time, and then the muco-periosteal tissues are separated from their connections with the bony palate with the periosteal elevator (Fig. 392).

The separation of these tissues should be extended until the point of the elevator reaches the margin of the cleft. Great care is necessary in effecting the separation of the soft tissues from the region of the posterior part of the hard palate and the hamular process, owing to their thinness.

The opposite side is treated in a similar manner, and then the second stage can be commenced.

(b) *Paring margins of cleft.*—With the long forceps one margin of the cleft is seized a short distance in front of the base of the uvula. The tenotome is now taken, made to pass through the palatal tissue opposite the forceps with the cutting edge looking towards the front, and then a strip of tissue is removed as far as the anterior margin of the deficiency. The line along which this incision is made is shown in Fig. 391. The forward part of the cut hav-

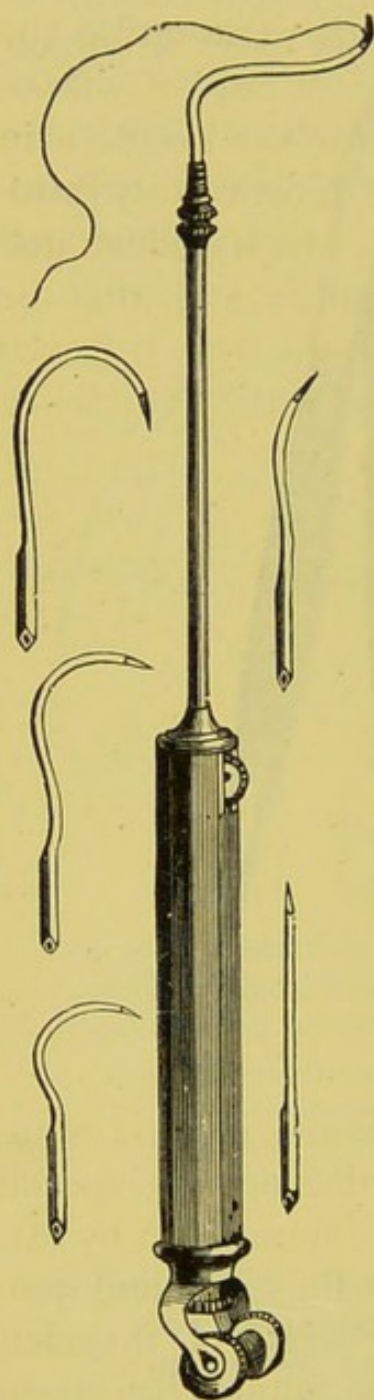
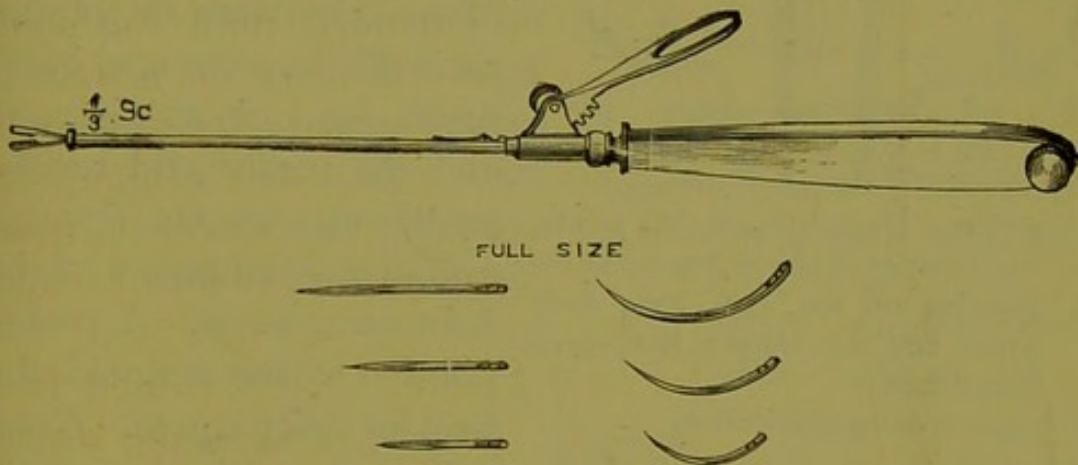


FIG. 394. — Tubular cleft-palate needle.—
T. SMITH.

ing been made, the edge of the knife is turned backwards and the remaining part attached to the uvula cut through. A similar procedure is carried out on the opposite margin of the

cleft. An attempt should be made, if possible, to remove the two strips attached to one another anteriorly, so as to ensure that the entire margins have been thoroughly pared.

(c) *Insertion of sutures.*—Many methods of inserting the sutures have been recommended. The sutures of silk or horse-hair must be introduced by some form of needle with an eye, whilst those of silver wire can be most readily introduced by the needle of Sir Thomas Smith, which is illustrated in Fig. 394. In this needle the stem is hollow, and, after the tissues of the palate have been pierced, the wire is driven through the perforation by turning the reel which is attached



FIGS. 395 and 396.—Needle-holder and small needles for operation upon palate in young children.—ARBUTHNOT LANE.

to the handle. A very useful and expeditious method of introducing the sutures is by the small needles and the special form of needle-holder which have been recommended by Mr. Lane. These instruments are figured in Figs. 395 and 396.

It is best to start from the anterior angle of the cleft in introducing the sutures. When one suture has been inserted, it can be used as a point of support in order to facilitate the insertion of the next one. The sutures which are used to approximate the part of the cleft which corresponds to the hard palate should be of silver wire, and those for the soft palate and the uvula, of horse-hair or fine salmon-gut.

After the sutures have been inserted, the margins of the cleft should be carefully sponged, so as to remove all blood clot, mucus, or other débris. The sutures are now tied and their ends cut short. In the case of the wire sutures

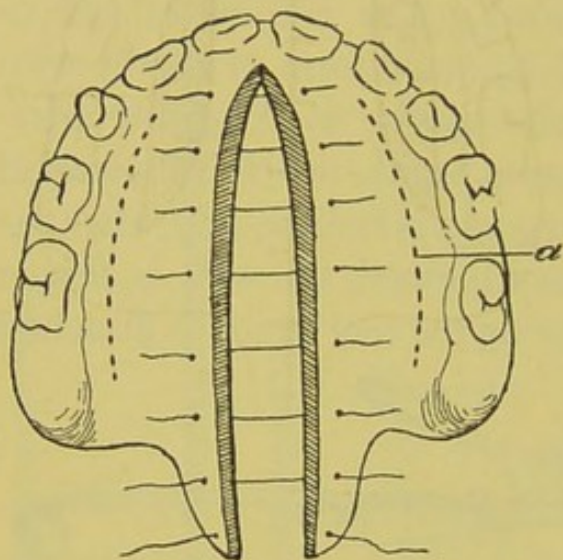


FIG. 397.—Operation for cleft palate. Appearance of the palate when the margins of the cleft have been pared and the sutures have been introduced.

a. Lateral incision.

it is best to twist them with the wire-twister shown in Fig. 398, and then to cut the ends short. The uvula is the last portion of the palate to be closed.

(d) *Relief of lateral tension.*—The lateral incision on each side is prolonged backwards for a short distance, and the tensor and levator palati muscles cut through on the internal aspect of the hamular process. A probe-pointed narrow scalpel is the best for this purpose. When

the incision has been made the wound should be examined, so as to ascertain that the entire muscle has been cut through.

B. For cleft of the soft palate.—The operation for closure of a cleft which involves the soft palate alone is often known as staphylorrhaphy, that for closure of the hard palate being called uranoplasty.

Operation.—The stages of the operation and the manner



FIG. 398.—Wire-twister.

of its performance are very similar to those in the preceding operation.

In this case, however, it is usual to first pare the edges of the cleft, then to introduce the sutures, and afterwards to make the lateral incision. The lateral incision is

placed farther back, and is made to divide the levator palati muscle. The different stages of the operation are illustrated in Figs. 400-402.

After-treatment.—Much of the success of the operations for cleft palate depends upon careful attention to the details of the after-treatment. After the operation has been performed, the patient should be placed in bed with his head low, so that any accumulation of blood, mucus, or exudation may pass into the pharynx, and not collect in the imme-

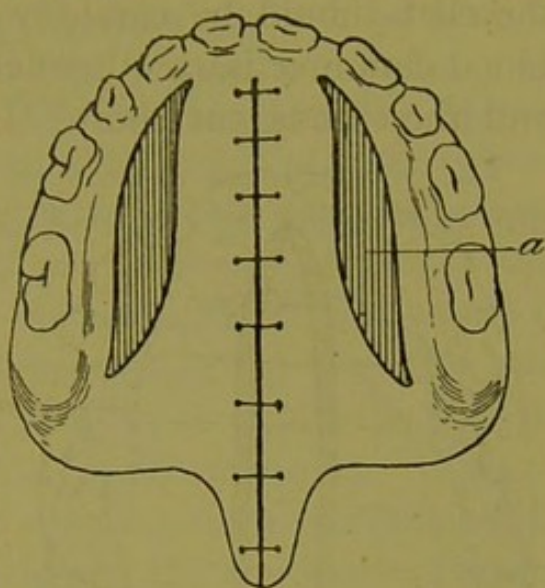


FIG. 399. — Operation for cleft palate. Appearance of the palate when the operation is completed.

a. Space left by separation of margins of lateral incisions.

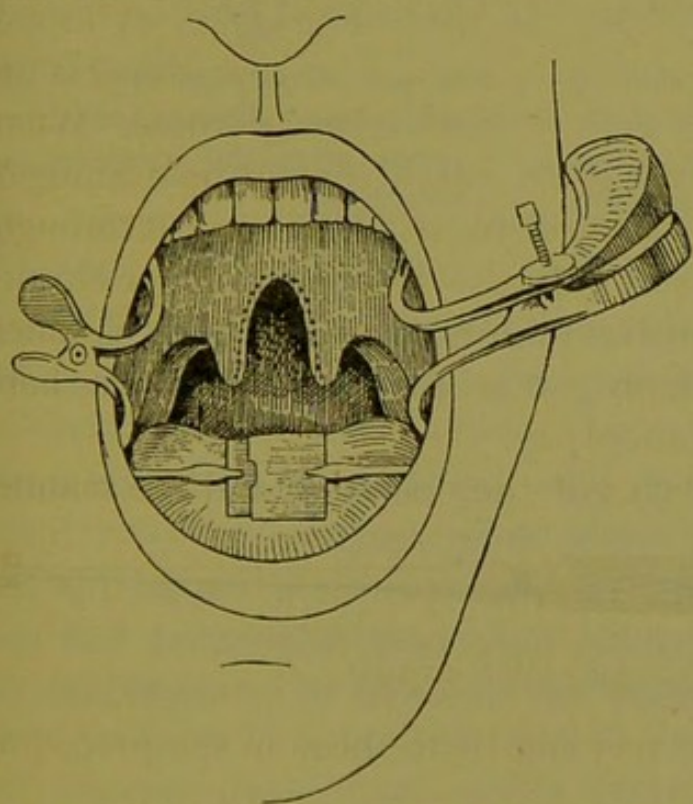


FIG. 400. — Operation for cleft palate. Partial, involving only the soft palate. The dotted line marks the position where the margins of the cleft are pared.

mediate neighbourhood of the wound.

No food should be given for the first five or six hours, and only small quantities of milk, or milk and soda-water, until all danger of vomiting as the result of the anæsthetic has passed off.

After the end of the first day the patient is fed regularly on a fluid diet. The food can be best administered with a spoon or some form of feeder.

After food has been given, the mouth of the patient should be carefully washed out with a dilute antiseptic, such as a solution of boracic acid or Condy's fluid. In refractory children this cannot as a rule be carried out.

The stitches can usually be taken out from the uvula and the soft palate at the end of a week, and those from the

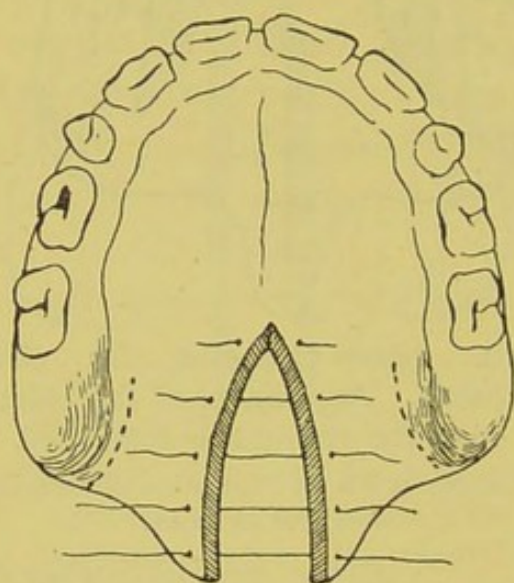


FIG. 401.—Operation for cleft of soft palate. Appearance of the palate when the margins of the cleft have been pared and the sutures introduced.

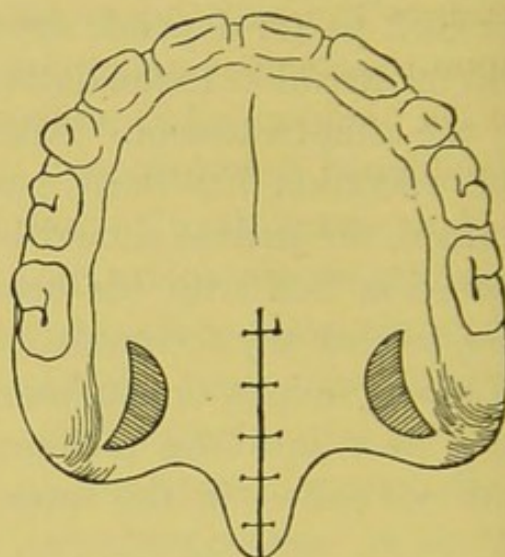


FIG. 402.—Operation for cleft of soft palate. Appearance of the palate when the operation is completed.

hard palate on the tenth or twelfth day. In young children it is generally advisable to give an anæsthetic before removing the stitches.

It is not advisable to give any form of solid food until after the expiration of two to three weeks.

Many modifications of the operation, especially for closure of the hard palate, have been advocated, but the operation above described will be found to be applicable to the majority of cases.

OPERATION FOR EXTROVERSION OF THE URINARY
BLADDER, OR ECTOPIA VESICÆ.

In ectopia of the urinary bladder the anterior wall is deficient, and most commonly this condition is associated with non-approximation of the pubic bones, and epispadias.

The urine as it is secreted passes along the ureters and escapes through the ureteral openings which are situated upon the mucous membrane representing the posterior wall of the bladder. This mucous membrane usually projects as a reddened prominence in the hypogastric region.

The condition of a patient suffering from ectopia vesicæ is a very miserable one, on account of the continuous escape of urine and the difficulty which is experienced in fitting up an apparatus which shall collect it as it passes from the ureteral openings.

Patients, however, who have been the subjects of this condition have lived to old age without an operation being performed.

Two varieties of operation may be performed for the relief of extroversion of the urinary bladder. In one class an attempt is made to form a new anterior wall to the bladder, by turning down and reversing a flap of skin from the umbilical region, the epidermal surface of this umbilical flap becoming the lining membrane of the anterior part of the bladder. Lateral flaps are turned up from the inguinal regions, and used for closing in the cutaneous deficiency. This operation is known as the "flap" operation, or "Wood's operation."

In the second class of operation an attempt is made to bring together the anterior extremities of the pubic bones and fix them in apposition, and at the same time the layer of mucous membrane which represents the wall of the bladder is folded upon itself in front, and the margins united in such a manner that a urinary receptacle is formed, the opening of which is situated below and behind

the united pubic bones. In order to effect this result, it is usually necessary to divide the sacro-iliac synchondroses behind, and then to force the bones apart in order to approximate the pubic bones in front. The surfaces of these latter bones are freshened and fixed together.

A. Flap operations. By a single umbilical flap and two lateral inguinal flaps ("Wood's operation").—A flap of skin and fascia which is pyriform in shape, the narrow portion being above, is reflected from the umbilical region and turned downwards in such a manner that it remains attached by its lower part (Fig. 403, A); the cutaneous aspect is re-

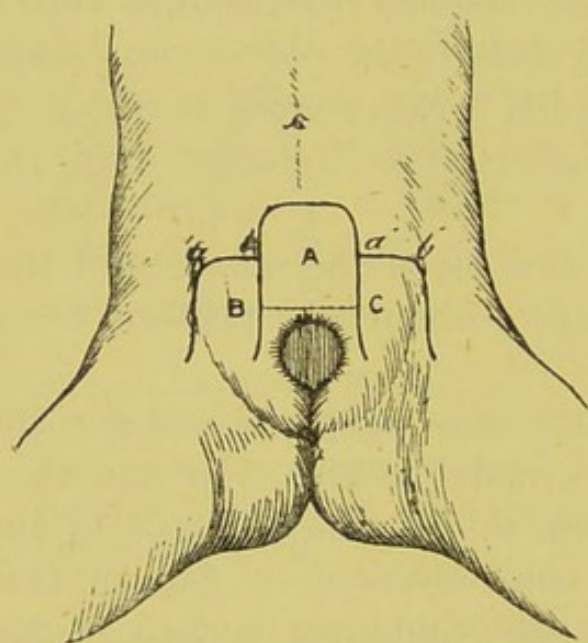


FIG. 403.—Extroversion of the bladder. Formation of skin flaps.—WOOD.

A. Umbilical flap.

B. Right inguinal flap.

C. Left inguinal flap.

a-b and *a'-b'*.—Bases of inguinal flaps which come together.

versed and forms the anterior boundary of the new urinary bladder. The margins of the mucous membrane of the bladder are refreshed and attached to those of the reversed umbilical flap.

A lateral flap is then taken from each inguinal region; this is also pyriform in shape, but the attached portion is the narrower (Fig. 403, B and C).

Each of these flaps should consist of skin and superficial fascia. The free extremities are rotated inwards towards the middle

line until their inner and upper margins meet; these are united to one another by the insertion of numerous interrupted sutures. The raw surfaces thus produced are partially closed by bringing the margins of the denuded surfaces together by sutures, the remainder being allowed to close by granulation.

It is usually necessary to perform a number of operations

before a moderately satisfactory result can be obtained from this form of operation.

The disadvantage of this form of operation is the growth of hair from the cutaneous surface which has been turned inwards.

When this takes place, at puberty or earlier, phosphatic deposits are liable to form, and to give rise to much trouble.

If the mucous membrane which represents the bladder is fairly extensive, an attempt may be made to free the lateral margins, fold them on themselves, and then unite the approximated borders by the insertion of interrupted sutures. If this can be done, a urinary receptacle is formed which is small in size, but its interior is formed entirely of mucous membrane, and the result is likely to be more satisfactory than in the preceding case.

B. Operations with division of the sacro-iliac synchondroses and approximation of the separated portions of the pubic bones ("Trendelenberg's operation").—The first stage in this operation includes the making of two incisions over the sacro-iliac synchondroses, division of the posterior ligaments of these joints, forcible separation of the sacrum and iliac bones behind, and approximation of the pubic bones in front. The surfaces of the pubic bones are freshened with a scalpel before they are fixed together.

In the second stage, which is carried out after the wounds caused by the previous stage have healed, the mucous membrane which represents the urinary bladder is folded upon itself, and its margins united in a manner similar to that described above.

In the third stage an attempt is made to close in the cutaneous deficiency by the formation of skin-flaps from the groin and lateral margins of the cleft. The inner margins of these flaps are united together in the middle line.

The epispadias which is commonly present in these cases is treated at a subsequent operation.

An objection which has been urged against this form of

operation is that the pelvis is so much weakened by the injury to the sacro-iliac joints that progression is seriously interfered with. This in practice, however, has been found not to be true, since the weakening which takes place posteriorly is in part compensated for by the approximation of the pubic bones in front.

The best result, however, which can be expected in a severe case of extroversion of the bladder, is that it is rendered possible to fit up the patient with an artificial urinal which catches in a satisfactory manner the urine as it is evacuated, and avoids the continual soaking of the clothing.

OPERATION FOR EPISPADIAS.

In the condition of epispadias the penis is cleft along the dorsal surface, and the organ is usually turned towards the abdomen and bent upon itself.

Several operations have been practised for the cure of this condition; the best of these is the following, which is generally known as "Thiersch's operation":—

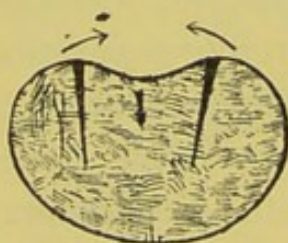


FIG. 404.—Epispadias ("Thiersch's operation"). Incisions into substance of glans penis in formation of the meatus.—ESMARCH and KOWALZIG.

Operation.—The operation is carried out in four stages, the wounds which have been caused in one stage being allowed to heal before the next stage is attempted.

(a) *First stage: Formation of external urinary meatus, and glandular portion of penile urethra.*—Two incisions are made in the glans penis from each dorso-lateral aspect, as in Fig. 404. These incisions should pass through more than half the substance of the glans penis, and should converge towards one another on the ventral aspect.

The margins of the median portion are pared, and then fixed in approximation by the insertion of several points of

interrupted suture. The middle portion, thus separated, and containing a canal in its interior, is depressed and the two lateral portions brought together and united by sutures. An aseptic dressing is applied and the wound allowed to heal, the sutures being removed at the end of a week.

(b) *Second stage: Formation of that portion of the spongy urethra which occupies the body of the penis.*—Incisions are made through the skin and fascia on the dorsal aspect of the penis, as in Fig. 405. The incision on the left side is nearer the cleft than that on the right. The two flaps thus marked out are dissected up, and the flap with the attached base close to the cleft is turned over so as to form the roof of the new urethra, and fixed in position. The other flap is then brought over the first one, and fixed by the insertion of sutures (Fig. 406). A catheter is passed along the new urethra and left in position. Dressings are applied and the parts allowed to heal, the sutures being taken out at the expiration of seven or ten days.

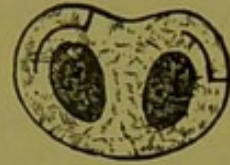

FIG. 405.—Epispadias ("Thiersch's operation"). Incision on dorsum of penis. — ESMARCH and KOWALZIG.

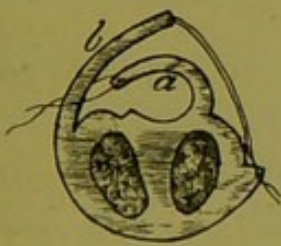

FIG. 406.—Epispadias ("Thiersch's operation"). Method of turning over the skin-flaps. — ESMARCH and KOWALZIG.

(c) *Third stage: Closure of the small interval between the first and second portions of the new urethra.*—The prepuce is brought over the cleft, an incision made through it, and through this the glans penis is passed. The margins of the aperture are freshened, and united to the skin of the prepuce. A sufficient time is allowed for the parts to heal, and then the final stage is undertaken.

(d) *Fourth stage: Closure of the aperture at the base of the penis, between it and the os pubis.*—This is effected by dissecting up two flaps from the adjacent portions of the inguinal regions. One flap is triangular in

shape, and its attached border corresponds to one margin of the orifice which it is wished to close. This flap, after being dissected up, is reversed, and the cutaneous surface made to form the roof of the new urethra. It is fixed in position by the insertion of a number of sutures (Fig. 407). Next, a rectangular-shaped flap is dissected up from the other inguinal region. It is brought over the first flap in such a manner that the two raw surfaces are in approximation. The margins are then united by sutures.

A catheter is passed along the entire urethral canal as thus completed, and allowed to remain until union has taken place.

It is advisable that this catheter should be changed daily after the first twenty-four hours.

In order to obtain a good result from this operation, it is advisable to allow plenty of time to elapse between the individual stages, and if one stage fail, to repeat this before going on to the next.

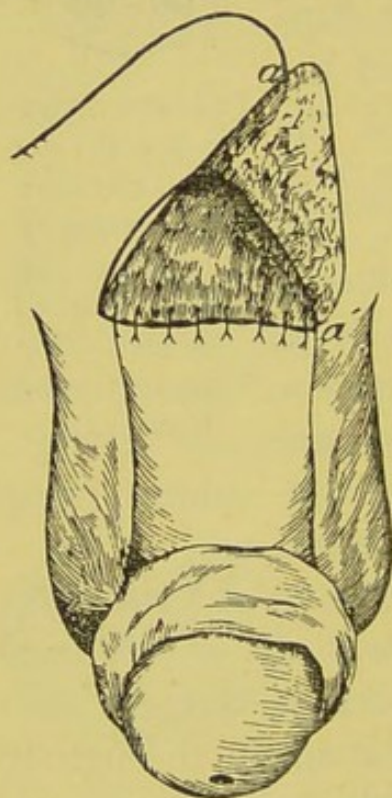


FIG. 407. — Epispadias ("Thiersch's operation"). Closure of fistula between original and newly formed portions of the urethra. — ESMARCH and KOWALZIG.

OPERATION FOR HYPOSPADIAS.

In the condition of hypospadias there is a cleft on the under surface of the penis; this may involve the meatal region alone, or any portion of the spongy portion of the urethra as far back as the perineum.

The slighter malformations of this nature scarcely require surgical treatment, but when the penile part of the urethra is cleft or the scrotum involved, an operation should be attempted for the rectification of the deformity.

Usually the penis is small and deformed, and is bent towards the scrotum, a fibrous band often holding it down.

If an operation is considered advisable, it should be carried out during early childhood, before the fifth or sixth year.

The form of operation which is recommended is that described by Duplay.

Instruments. — Scalpel, dissecting, artery, and pressure forceps, retractors, scissors, catheter, needles, needle-holder, and ligature and suture material.

Position. — The patient is placed in the dorsal position on the operation table, the thighs being separated; or, if the scrotum is involved, in the lithotomy position. The surgeon stands on the right side of the patient, and the assistant on the opposite side.

Operation. — The operation may be divided into the following stages, namely:—(a) Straightening the penis; (b) formation of an external urinary meatus; (c) formation of a urinary canal; and (d) closure of the fistula at the junction of the new-formed canal and the termination of the original urethra.

(a) *Straightening the penis.* — This is effected by making one or more transverse cuts through the fibrous band which fixes the under surface of the penis to the scrotum. It is often necessary to extend these incisions into the substance of the corpora cavernosa.

(b) *Formation of an external meatus.* — An incision parallel with the long axis of the penis is made on each side of the groove which represents the urethral canal on the under surface of the glans penis. A catheter is placed in the groove, and the tissues at the inner margin of each incision are turned inwards over the catheter and fixed thus by the insertion of sutures. Next, the tissues at the outer margins of the incisions are freed for a short distance and brought over the new meatus, and sutured in this position.

The straightening of the penis and the formation of the meatus are performed at the same time. Sufficient time is

allowed for these wounds to heal, and then the next stage is carried out.

(c) *Formation of a urinary canal.*—A catheter is passed through the new meatus and along the groove on the under surface of the penis into the original opening of the urinary canal. An incision parallel with the catheter is then made on each side of the groove and a short distance from it, and a small transverse incision along each extremity of the long one. A small flap is then dissected up for a short distance on each side, and turned over the catheter in such a manner that the cutaneous surface lies in contact with it. It is not necessary that the margins of these two flaps should be in apposition over the catheter. The tissues at the external margin of each longitudinal incision are next dissected up very freely until these margins can be brought into approximation on the ventral aspect of the catheter, which lies in the urethral groove. The approximated borders of the external flaps are fixed in apposition by the insertion of a series of interrupted sutures.

A sufficient time is now allowed to elapse until the flaps thus united have become quite healed.

(d) *Closure of the fistula between the distal extremity of the old urinary canal and the proximal extremity of the new one.*—The margins of the fistulous aperture are pared, and if necessary a flap of skin is dissected up from the adjacent portion of the penis. This is brought over the aperture and fixed by sutures.

SKIN GRAFTING.

This procedure may be requisite in cases of extensive destruction of the skin, the result of a burn or scald, of some form of injury or ulceration, or of a surgical operation carried out for the removal of a malignant growth.

A. Skin grafting by the ordinary method.—The sur-

face upon which the grafts are to be placed is first rendered as aseptic as possible by fomentations or other measures; then, with a pair of fine forceps and scissors, small portions of the skin are removed by sharp snips from a healthy cutaneous surface, and placed upon the prepared surface. Each graft of skin should be about one-sixth of an inch wide, and should include both the epidermis and the superficial part of the dermis.

These grafts are placed at equal distances apart, usually about one-third or one-half an inch from each other. A piece of aseptic oiled silk is then placed over the grafted area, and an aseptic dressing applied. The wound thus treated should not be disturbed for several days, unless there is much exudation from its surface.

When the dressings are removed the surface should be very gently washed, or sponged and dried, and then a similar dressing applied.

B. Skin grafting by "Thiersch's method."—The essential point in this method of skin grafting is the transference of large sheets of epidermal tissue from a healthy part to the surface of the wound which has lost its cutaneous covering.

The strips of epidermis should measure 1 or $1\frac{1}{2}$ in. in width, and from 2 to 3 in. in length. They can be most readily obtained from the internal aspect of the thigh.



FIG. 408.—Skin grafting. Thiersch's knife.

A special instrument, known as Thiersch's knife, is used for the purpose of making these epidermal strips.

The skin of the area from which it is proposed to obtain the epidermal strips is rendered aseptic in the usual manner. Then the blade of the knife is moistened with normal saline solution at the temperature of the body, and a thin shaving made, the blade of the knife being held on the flat. Each strip should consist of the epidermis and the apices of the underlying papillæ; it ought to be not less than half an inch wide, and 2 in. or more long. Care must be taken not to injure the subepidermal tissues in obtaining the epidermal strips.

When a strip of epidermis has been obtained it is placed on the prepared surface, and, when the whole raw surface has been covered, dressings are applied as in the previous case.

When the surface which is to be grafted is granulating, the granulations should be scraped away with a spoon before the epidermal strips are placed upon it. In every case the area to be grafted must be rendered as aseptic as possible before the transference of the grafts is carried out, and hæmorrhage should be completely arrested.

CHAPTER XXVIII.

OPHTHALMIC OPERATIONS.

BY WALTER H. JESSOP, M.B., F.R.C.S.

General considerations. — The main details of the anæsthetic employed, the preparation of the eye, and the position of patient and operator, are, as a rule, the same in all ophthalmic operations, and will be stated here, to prevent repetition under the different operations.

The anæsthetic used is, generally, cocaine, which can be applied easily, and induces sufficient anæsthesia of the cornea, conjunctiva, and even iris, to allow most operations to be performed painlessly with it.

Cocaine is best employed as a 4 per cent. solution, and must be used fresh, owing to its solutions keeping badly. It should be dropped into the eye three or four times before the operation; a good rule to observe is to begin the first instillation ten minutes before the operation, to repeat it again in five minutes, then for the third time just before the speculum is introduced, and for the fourth time after the eye has been washed out. If the iris is to be cut, cocaine should be instilled again immediately after the corneal incision, so that it may be directly applied to the iris. The slight disadvantages of cocaine are—that intra-ocular tension is diminished, the cornea rendered flaccid and more difficult to cut, and from this flaccidity there is a greater difficulty in extrusion of the lens in cataract extraction.

Cocaine is contra-indicated in inflamed eyes, glaucoma, tenotomy in young and nervous patients, and excision.

Of general anæsthetics, chloroform is preferable to ether, but the grave objection to general anæsthetics is their tendency to make patients vomit, and, from the straining thereby induced, intra-ocular hæmorrhage afterwards results.

The operations hereafter described are best performed with the patient lying on his back on a table in a good light, and the operator standing behind his head. The only exception to this rule is tenotomy, when the operator stands in front and on the right side of the patient. If the surgeon be unable to operate with either hand, it is necessary for him, in cases of extraction on the left side, to stand in front and to the left of the patient.

The assistant, when one is required, should stand at the side of the patient.

Owing to the communication of the nasal passage with the conjunctival sac by the canaliculi and puncta, it is impossible to ensure asepsis for more than a short time. It is important, however, that the eye should be well cleansed before the operation. This is best done by carefully washing the lids and eyelashes with boracic acid solution, and then syringing out the conjunctival sac with the same.

When the operation is finished, the eye must be again irrigated before the bandage is applied.

All instruments, except the knife, are to be boiled for twenty minutes. The knife should be dipped into absolute alcohol before being used.

All knives, needles, and scissors should be tested at the time of operation, as to their cutting or perforating powers, on a piece of thin kid leather. A convenient way is to stretch the leather over a small ivory cylinder, thus making a drum.

The following operations are all described as taking place on the right eye, the only change necessary, when operating on the left side, is the transposition of left for right in the description.

Slitting up the canaliculus.—The operation for slitting up the canaliculus is generally performed on the lower canaliculus.

Indications.—The operation is practised for the cure of “watery eye” (epiphora), caused by obstruction or misplacement of the lachrymal drainage system (punctum, canaliculus, and nasal duct).

Instruments.—A probe-pointed canaliculus knife (Weber’s), (Fig. 409), small fixation forceps, and a pair of small scissors.

Operation.—The operator standing behind the patient draws down and outwards the lower lid by means of a finger, so as to expose the punctum. If the latter be very small, it must be dilated by small probes until the probe-point of the knife can be introduced. The probe-point of the canaliculus knife is passed vertically into the punctum, and, the handle being lowered, the point is passed horizontally onwards along the canaliculus until the end of the knife is felt to touch the inner surface of the nasal sac. The knife is then raised forwards and upwards, its handle describing an angle of 90° , till it becomes parallel with the nose; by this means the canaliculus is laid open as far as its entrance to the nasal sac. Any blood is sponged away, and the mucous membrane at the inner or posterior border of the incision is seized with the forceps, and a small strip of it cut off, so as to prevent healing of the wound too soon.



FIG. 409.—Canaliculus knife.
—WEBER’S.

It is usual, after slitting up the canaliculus, to pass a lachrymal probe down the nasal duct, to be sure that there is no obstruction.

Passage of lachrymal probe down the nasal duct.—The probe (Fig. 410) should be introduced into the lower punctum nearly at right angles to the border of the lid; its outer extremity then being depressed, the probe is passed horizontally along the canaliculus till its point is felt to touch the inner mucous surface of the lachrymal sac. The probe is now raised, with its end still touching the mucous membrane of the sac, till it becomes parallel to the nose, and the lower end, which should be now over the entrance to the nasal duct, is pushed downwards and slightly backwards and outwards; it should then glide gently into the duct without the employment of any undue force.



FIG. 410.—Lachrymal probe.

The duct may be dilated quickly at one sitting by passing probes of increasing sizes, or a style may be introduced and left in.

Tenotomy.—Tenotomy in ophthalmic surgery denotes the division of one of the extrinsic ocular muscles. Since convergent and divergent strabismus are the most frequent forms, the internal and external recti are the muscles which generally require division.

Indications.—The presence of squint which is not amenable to other methods of treatment.

Instruments.—Speculum, fixation forceps, blunt-pointed curved scissors, strabismus hook.

Operation.—The operator, standing in front and on the right side, having introduced the speculum (Fig. 413),

fixes the conjunctiva and subconjunctival tissue with the fixation forceps (Fig. 411), at the point of junction of the lower horizontal and inner vertical tangents of the cornea. The fold of conjunctiva thus pinched up is divided in the direction away from the cornea with a pair of blunt-pointed



FIG. 411.—Fixation forceps.

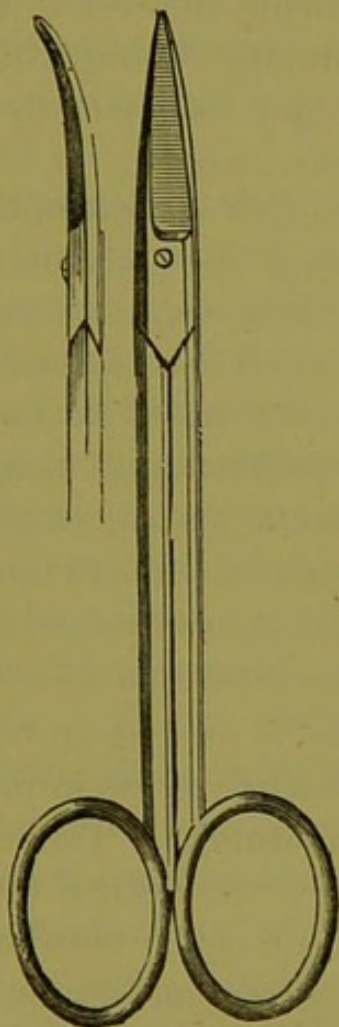


FIG. 412.—Curved scissors.

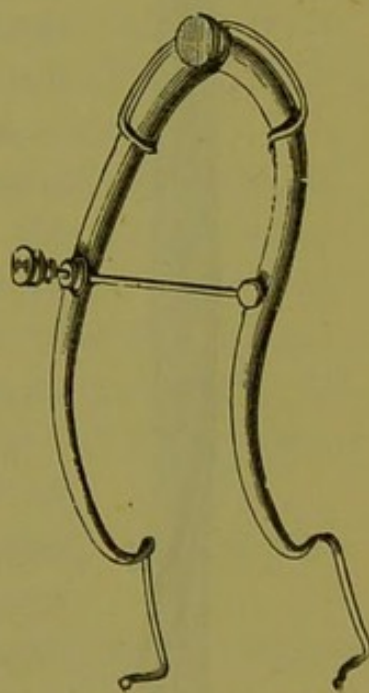


FIG. 413.—Spring speculum.

scissors (Fig. 412) to such an extent as will admit the points of the scissors, which are passed through the opening, and divide the capsule of Tenon beneath the conjunctival incision.

The hook (Fig. 414) is now introduced into the wound with the point directed backwards: the point is then turned upwards between the globe and the tendon until it appears

beneath the conjunctiva at the upper border of the tendon, which is in this way brought forwards. The scissors are now introduced into the wound, and the blades are opened on either side of the tendon, between the hook and the globe, and the tendon is cut through. The hook is removed and again introduced to try if the tendon has been completely divided; if not, the scissors must be again employed.

The eyes should be bandaged up for twelve hours.

The above description applies to the division of the internal rectus; the method of dividing the external rectus is similar, but it must be remembered that the latter tendon is inserted farther back.

Advancement of a muscle.—In cases of strabismus, instead of dividing a tendon, as, for example, the internal rectus for internal squint, the insertion of the opposing muscle, in this case the external rectus, may be advanced.

Indications.—Usually to increase the effect of a tenotomy, especially when there is a marked limitation of the movements of the eye in the direction of the proposed operation.

Instruments.—Speculum, fixation forceps, tenotomy hook, scissors, three needles threaded with thin silk.

Operation.—The operation here described refers to the right external rectus.

The speculum (Fig. 413) being introduced, the operator seizes the conjunctiva with fixation forceps, opposite the middle of the insertion of the external rectus, about $\frac{1}{4}$ in. away from the corneal border, and divides it



FIG. 414.—Strabismus hook.

vertically with a pair of scissors above and below the point of fixation, to the extent of about a quarter of an inch. The subconjunctival tissue and the capsule of Tenon being divided to the same extent, the tenotomy hook (Fig. 414) is passed from below beneath the muscle, and its point brought out at the upper border of the muscle; the tendon by this means is exposed lying on the hook.

A suture is now passed through the tendon on the outer side of the tenotomy hook, and the needle is made to perforate the episcleral tissue and the conjunctiva at the level of the middle of the cornea, in the proposed fresh situation of the attachment of the tendon. This suture may simply be used as a temporary one to give the required direction to the advanced muscle. The muscle is now divided close to its insertion, and, if thought necessary, a piece may be removed from the tendon to shorten it, care being taken not to divide the suture at the same time. The suture is now tied tight. A second suture is introduced into the upper part of the tendon, and this in the same manner is passed through the episcleral tissue and conjunctiva, and should lie above and parallel with the original suture. A third suture is passed through the lower part of the tendon in a similar manner, lying parallel with the preceding ones.

The second and third sutures are now tied, and the first may be removed if desired.

The conjunctival wound is stitched up, and, the speculum being removed, the eye is washed out, and both eyes are bandaged up.

The bandages are kept on for two or three days, and the stitches allowed to work their way out.

Paracentesis.—Paracentesis is the operation of tapping the anterior chamber by puncturing the cornea, and is performed for the purpose of evacuating the contents of the anterior chamber in cases of high tension, hypopyon, and threatening perforation from ulceration or other cause.

Instruments. — Speculum, fixation forceps, keratome or broad bent cutting needle, and curette.




FIG. 415.—Keratome.

FIG. 416.—Curette and cystotome.

Operation. — The operator having introduced the speculum between the lids, steadies the eye by fixation forceps, and passes the keratome (Fig. 415) or the bent needle through the lower part of the periphery of the cornea into the anterior chamber, and thus lets out the aqueous humour. If the aqueous does not escape readily, it may be necessary to press with a curette on the lower lip of the wound to enable it to do so.

After the operation it is very important to be sure that the iris is in place, as otherwise prolapse may result.

Iridectomy.—Iridectomy is the operation for the removal of a portion of the iris.

Indications.—The operation is undertaken—(a) To improve sight in cases of corneal opacity, lamellar cataract, and anterior polar cataract; (b) as a remedial measure in glaucoma, relapsing iritis, complete posterior synechia, and injury; (c) during the operation of

cataract extraction, either at the same time or as a preliminary proceeding.

Instruments. — Speculum, fixation forceps, keratome,

iridectomy forceps, iridectomy scissors, and a curette or spatula.

Operation.—The speculum being introduced between the lids, the operator fixes the conjunctiva gently and firmly, about 1 mm. from the corneal edge opposite the seat of the proposed incision, with a pair of fixation forceps (Fig. 411) in the left hand.

Taking the keratome (Fig. 415) in the right hand, he passes it by pressure through the periphery of the cornea into the anterior chamber parallel to the iris. He now lowers the handle a little until the point of the keratome nearly touches the posterior surface of the cornea, so as to avoid wounding the lens. As soon as the corneal wound is large enough, the keratome is slowly withdrawn and the aqueous escapes often followed by the iris.

The fixation forceps, still attached to the con-



FIG. 417.—Iridectomy forceps.

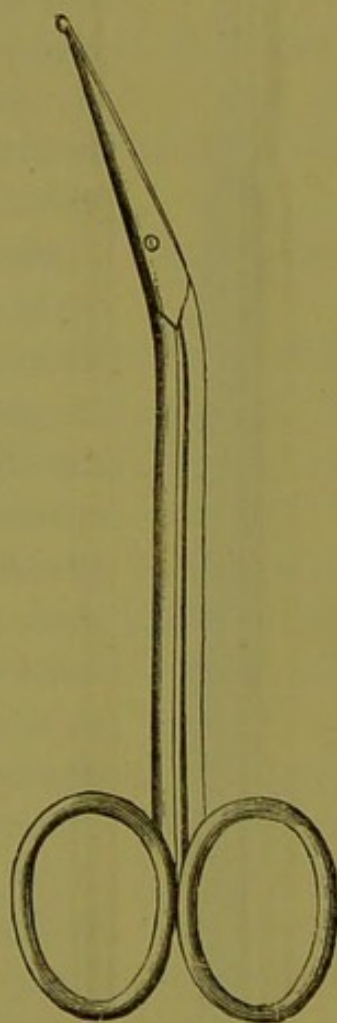


FIG. 418.—Iridectomy scissors.

junctiva, are now given to an assistant to depress the eye, and the operator passes the iridectomy forceps (Fig. 417) through the corneal wound, with their points closed and directed towards the posterior surface of the cornea; the points are then opened and the pupillary border of the iris seized between them; the piece of iris is slowly and carefully drawn out, and cut off with the iridectomy

scissors (Fig. 418). This may be done either parallel to the wound or at right angles to it across the cornea. The edges of the cut iris are carefully returned with a curette (Fig. 416), the operator making sure that the pupillary margin on both sides is in position.

The eye is now bandaged up, and in a simple case of iridectomy the bandage may be discontinued in twenty-four hours, if the anterior chamber is re-formed and the eye not irritable.

Modifications of iridectomy. — (a) The operator may make the corneal section with a Graefe's knife (Fig. 420) instead of the keratome. In such a case he would introduce the knife through the periphery of the cornea, at a point corresponding to one edge of the coloboma which he intends to produce. The knife is then passed across the anterior chamber, and transfixes the cornea at a point corresponding to the other edge of the coloboma. The succeeding steps of the operation are similar to those given above.

(b) In iridectomy for glaucoma, the patient should, as a rule, be under a general anæsthetic. The operation may be done with a keratome, but most surgeons prefer a Graefe's knife. The operator introduces the knife through the sclerotic, about 1 mm. from the apparent corneal margin, and about the junction of the upper one-sixth with the lower five-sixths of the cornea. The knife is then passed across the anterior chamber with great care (so as not to wound the iris), and makes a counter-puncture in the sclerotic at a corresponding point on the opposite side. The knife is then made to cut its way through the sclerotic, producing an arc in this



FIG. 419.—
Stop-needle.

structure parallel to the curve of the cornea. The iris is seized with a pair of iridectomy forceps at one edge of the section, and drawn out; it is then cut with the scissors and torn across to the opposite edge of the wound, where it is again cut by scissors.

Sclerotomy.—By the term “sclerotomy” is understood, division of the sclera beneath the conjunctiva.

Indications.—The operation is performed for the relief of glaucomatous symptoms; it is probably only useful and successful, as a secondary operation, after iridectomy has been performed some time before.

Instruments.—Speculum, fixation forceps, and Graefe's knife.

Operation.—The operator, standing behind the patient, seizes the conjunctiva below the lower margin of the cornea with the fixation forceps held in his left hand. Taking the Graefe's knife (Fig. 420) in the right hand, he enters it at a point in the sclerotic 1 mm. from the corneal margin, as in the operation of iridectomy for glaucoma, and at the junction of the upper one-sixth and lower five-sixths of the cornea.

He now passes the knife across the anterior chamber in a horizontal direction, with its cutting edge upwards, and makes a counter-puncture in the sclera at a point corresponding to the original one on the other side. The knife is made to cut its way upwards, until a small bridge of sclerotic is left above undivided, and is then slowly withdrawn.

A bandage is now placed over the eye and kept on for twenty-four hours.

Extraction.—Extraction is the operation for removal of the lens. The operations for extraction are numerous, so far as details are concerned; the one most often practised now, and described below, is the “three-millimetre corneal flap” operation. It may be performed with or without an iridectomy.

“Three-millimetre corneal flap” operation.—*Instruments.*

—Speculum, fixation forceps, Graefe's knife, iridectomy forceps, iridectomy scissors, cystotome, and curette.

Operation.—The speculum is introduced between the lids, and the operator, holding the fixation forceps in his left hand, fixes the conjunctiva in the middle line below and 1 mm. from the corneal edge. Holding the Graefe's knife lightly between the thumb and first two fingers of the right hand, he introduces the point of the knife on the outer side, just within the corneal margin, at a distance of 3 mm. from the highest point of the cornea. The knife is then passed across the anterior chamber, in front of the iris, to a point within the periphery of the cornea on the nasal side, exactly corresponding to the original puncture, so that the knife on making the counter-puncture lies in a horizontal line with the cutting edge upwards.

The knife is now made to cut its way upwards in the cornea by slow to-and-fro movements, until the upper margin of the cornea is reached and cut through. The aqueous humour has now all escaped, and the whole section will be found to be in the cornea and corresponding to its curve.

Iridectomy stage.—The patient is now directed to gaze at his own hand raised slightly above the level of his body, in order to depress the eyeball; if he cannot be trusted to keep quiet, the conjunctiva must be held by fixation forceps, which are entrusted to an assistant.

The operator, introducing the iridectomy forceps (Fig. 417) through the highest point of the incision, seizes the iris by its pupillary border, and slowly withdraws it through the centre of the wound; he then cuts off the portion withdrawn by means of iridectomy scissors (Fig. 418) held in his right hand.

Next, a cystotome (Fig. 416) is introduced, and by its means the upper part of the lens capsule is gently but freely lacerated. The patient is directed to look downwards, whilst moderate pressure is made by a curette held in

the right hand, below the lower border of the cornea, till the upper edge of the lens presents itself in the wound; this pressure being kept up gradually, the lens is delivered. It assists the process of delivery of the lens, to take a small flat spatula in the left hand and apply it along the upper border of the wound, so that the lens is delivered over the spatula. After delivery of the lens, any débris remaining must be coaxed out by pressure, by the curette from below, until the pupil assumes a black colour. The edges of the iris must now be pushed in by the curette, so as to ensure their not being caught in the wound.

The "three-millimetre corneal flap" operation without iridectomy.—The instructions are the same as above until the corneal incision is made; the description of the iridectomy stage is to be left out, and the details of the operation resumed at the introduction of the cystotome. After the lens has been extruded, it is necessary to return the iris, which has prolapsed, by means of a spatula, and to make sure that the pupil is round and not too large. This is best effected by rubbing the centre of the cornea with the spatula; a drop of eserine will quicken the contraction of the pupil. If, however, the pupil cannot be rendered round, or the iris is caught in the wound, an iridectomy must be performed.

After-treatment.—It is customary to bandage both eyes up so as to procure rest after the operation. The eye which has not been operated upon may be uncovered after the fourth day, but it is usual to keep the operated-on eye covered for at least a week, to ensure firm union of the wound.

Atropine drops are used after two or three days, if the operation has been done without iridectomy; some surgeons always use it after extraction operations.

After two months the vision should be tested for glasses, and if it is good, glasses may be ordered, a weaker pair for distance and a stronger for near objects or reading.

After-cataract.—In many cases, after extraction has been performed, especially without an iridectomy, the capsule left becomes opaque, giving rise to the so-called "after-cataract."

The operation for after-cataract is performed as follows:—

The eye being under the influence of atropine and cocaine, a speculum is introduced by the operator, who fixes the eyeball with forceps, and passes a needle (Fig. 419) through the periphery of the cornea from above, and breaks up the opaque capsule. Sometimes it is necessary to use two needles.

Discission.—This operation consists in the laceration of the anterior capsule and substance of the lens with a needle, so as to allow the aqueous humour access to the lens substance for the purpose of inducing absorption.

Indications.—Discission is performed in some forms of lamellar, congenital, and traumatic cataracts. Lately it has been practised in order to produce absorption of the lens in cases of high myopia.

Instruments.—Speculum, fixation forceps, and a cataract needle.

Operation.—The pupil having been fully dilated beforehand by atropine, the operator introduces the speculum, and fixes the conjunctiva below the lower margin of the cornea with the fixation forceps held in either hand.

The needle (Fig. 419) is then firmly, gently, and slowly pushed through the cornea near its periphery, preferably above, until its point traverses the anterior chamber and reaches the middle of the pupil. The handle of the needle being raised, the point is made to tear through the anterior capsule of the lens near its centre; the needle is now slowly withdrawn.

Atropine is again instilled into the conjunctival sac, and the eye bandaged up for at least twenty-four hours.

This operation has generally to be repeated once or twice.

If the stirred-up lens matter does not tend soon to become absorbed, or, owing to swelling of the lens, glaucomatous symptoms are produced, it is necessary to evacuate the lens débris.

This is done by making a corneal incision, preferably below and on the nasal side, with a keratome (Fig. 415) or bent needle, as described under "Paracentesis" (p. 635). After the aqueous is let out, a curette (Fig. 416) is introduced through the wound, and by manipulating the curette the soft lens matter passes along its groove, and is thus removed.

If afterwards any portion of the capsule remains in the pupil and obstructs vision, the operation for after-cataract (p. 642) must be performed.

Convex glasses are ordered for distance and for reading, after any inflammatory symptoms have subsided.

Excision.—Excision is the operation for complete removal of the eyeball.

Indications.—Rupture of the globe, presence of a foreign body, old painful blind eyes, and malignant growths.

Instruments.—Speculum, fixation forceps, tenotomy hook, and curved blunt-pointed scissors.

Operation.—The operator having introduced the speculum between the lids, fixes the conjunctiva at the inner or outer border with the fixation forceps, and divides the conjunctiva and subconjunctival tissue as close as possible to the corneal margin by means of the scissors (Fig. 412). The hook (Fig. 414) is introduced, and each rectus tendon in succes-



FIG. 420. —
Graefe's
knife.

sion is raised by it, and divided on the ocular side of the hook close to the eyeball, with the exception of the external rectus, which is cut on the orbital side of the hook, and this part of the tendon left attached to the eyeball. It is best, after section of the recti tendons, to sweep the hook round the eyeball, and thus make certain of their division being complete.

The ocular attachment of the external rectus is now seized firmly with the fixation forceps, and the eyeball is rotated inwards and drawn forwards.

The scissors, held in the right hand, are now passed from the outer side with the points closed, and are employed to feel for the optic nerve. When this structure is felt, the scissors are opened and the nerve divided as far back as possible.

The globe is pulled forwards with the fixation forceps, and the attachments of the oblique muscles and a portion of the capsule of Tenon divided, together with vessels and nerves, by the scissors.


The globe is now free from its connections, and can be removed. After the operation, the socket is washed out and a pad and bandage applied.

Hæmorrhage may be profuse, but can always be checked by pressure.

When the bandages are left off, after four or five days, it is advisable to place in the socket every day a pledget of absorbent cotton-wool soaked in oil. This pledget prevents inversion of the lashes, and also prepares the conjunctival sac for the insertion of the artificial eye.

After two to three months an artificial eye may be ordered; it is better that the first eye should be smaller than the permanent one.

INDEX.



I N D E X.

	PAGE		PAGE
Abdominal aorta, ligature of .	333	Amputations, at ankle-joint—Piro-	
„ section	18	„ „ „ goff's method	575
Abernethy's operation for liga-		„ „ „ Roux's me-	
ture of the external iliac		„ „ „ thod	573
artery	340	„ „ „ Sédillot's me-	
Ackland's gag	257	„ „ „ thod	575
Adam's osteotomy saw	452	„ „ „ Syme's me-	
Adductor longus, tenotomy of	398	„ „ „ thod	570
Adenoid growths in naso-		„ „ through arm	549
pharynx, removal of	433	„ „ „ circular me-	
After-treatment of operations.	17	„ „ „ thod	549
Albert's operation for gastros-		„ „ „ skin-flaps	550
tomy	27	„ „ of the breast	596
Amputation in general	524	„ „ of the cervix	
„ „ by circular method	525	„ „ „ uteri	212
„ „ „ „ elliptical me-		„ „ of the fingers	529
thod	526	„ „ „ through distal	
„ „ „ „ flap method	526	„ „ „ interphalan-	
„ „ „ „ modified circu-		„ „ „ geal joint	531
lar method	527	„ „ „ „ second pha-	
„ „ „ „ modified ellip-		„ „ „ „ lanx	533
tical method	528	„ „ „ „ proximal	
„ „ „ „ oblique circu-		„ „ „ „ interphal-	
lar method	526	„ „ „ „ a n g e a l	
„ „ „ „ racket - shaped		„ „ „ „ joint	535
method	529	„ „ „ „ metacarpo-	
„ „ „ „ knife, long	8	„ „ „ „ phalangeal	
„ „ „ „ short	570	„ „ „ „ joint	536
Amputations, special	529	„ „ „ „ carpo-meta-	
„ „ „ at ankle-joint	570	„ „ „ „ carpal joint	537
„ „ „ „ Gunther's me-		„ „ through foot	562
thod	575	„ „ „ „ metatarsus	562
„ „ „ „ Le Fort's me-		„ „ „ „ by Hey's	
thod	575	„ „ „ „ method	565

	PAGE		PAGE
Amputations, through foot—		Amputations, through leg—	
metatarsus—	562	by lateral	
,, ,, by Lis-		flaps .	577
franc's		,, ,, by long	
method	565	external	
,, ,, by Skey's		lateral	
method	565	flap (Fara-	
,, ,, tarso - meta-		bœuf) .	579
tarsal joint	563	,, ,, by anterior	
,, ,, mid tarsal		rectangu-	
joint (Cho-		lar flap	
part) .	565	(Teale) .	581
,, ,, sub-astra-		,, ,, by unequal	
galoid		antero-	
amputa-		posterior	
tion .	568	flaps .	576
,, ,, ankle - joint		,, through metatarsus	562
(see Ampu-		,, of penis .	187
tations at		,, through shoulder-	
Ankle-joint)	570	joint .	552
,, through forearm	543	,, through thigh .	583
,, ,, by antero-		,, ,, lower	
posterior		fourth	583
flaps .	543	,, ,, by Car-	
,, ,, by lateral		den's	
flaps .	545	method	583
,, ,, by circular		,, ,, by Gritti's	
method .	545	method	585
,, through elbow-		,, ,, by Ssa-	
joint .	546	banajeff's	
,, ,, by circular		method	586
method .	546	,, ,, by Stokes'	
,, ,, by elliptical		method	586
method .	548	,, ,, middle .	587
,, ,, by antero-		,, of thumb .	538
posterior		,, of toes .	557
flaps .	546	,, ,, through distal	
,, ,, by unequal		interphal-	
lateral		angeal	
flaps .	548	joint .	557
,, through hip-joint		,, ,, metatarso-	
(Furneaux		phalangeal	
Jordan) .	590	joint .	559
,, through knee-joint		,, ,, tarso-meta-	
(Stephen		tarsal joint	561
Smith) .	581	,, through the upper	
,, through leg .	575	arm (see Am-	
,, ,, by circular		putations of	
method .	578	arm) .	549
,, ,, by elliptical		,, of the entire upper	
method .	578	extremity .	552

	PAGE		PAGE
Amputations, through wrist-joint	539	Aponeuroses, operations upon	395
„ „ by circular method	543	Apparatus for intravenous injection of fluids	370
„ „ by equal antero-posterior flaps	541	Appendix, vermiform, removal of	65
„ „ by long external flap	542	Arm, upper, amputation through	549
„ „ by long palmar flap	539	Arteries, ligature of	292
Anæsthesia, preliminary preparations for	2	„ „ abdominal aorta	333
Anastomosis, intestinal, by bone tube or bobbin	61	„ „ anterior tibial	353
„ „ circular enterorrhaphy	55	„ „ axillary	321
„ „ Maunsell's method	57	„ „ brachial	325
„ „ Murphy's button	59	„ „ common carotid	301
„ „ Senn's plates	62	„ „ „ femoral	342
Anderson's cholecystotomy forceps	130	„ „ „ iliac	335
Ankle-joint, amputation at	570	„ „ deep circumflex iliac	341
„ „ Gunther's method	575	„ „ „ epigastric	340
„ „ Le Fort's method	575	„ „ dorsalis pedis	356
„ „ Pirogoff's method	575	„ „ external carotid	305
„ „ Roux's method	573	„ „ „ iliac	338
„ „ Sédillot's method	575	„ „ facial	309
„ „ Syme's method	570	„ „ femoral	342
„ „ excision of	517	„ „ gluteal	359
Aneurysm needle, doubly curved	294	„ „ inferior thyroid	318
„ „ singly „	297	„ „ innominate	299
Anterior crural nerve, exposure of	394	„ „ intercostal	333
„ tibial artery, ligature of	353	„ „ internal carotid	314
„ tibial nerve, exposure of	393	„ „ „ iliac	357
Antrum of Highmore, exploration of	436	„ „ „ mammary	320
„ mastoid, exploration of	444	„ „ „ pudic	358
Aorta, abdominal, ligature of	333	„ „ lingual	307
		„ „ middle meningeal	311
		„ „ occipital	310
		„ „ peroneal	352
		„ „ popliteal	347
		„ „ posterior tibial	349
		„ „ radial	330
		„ „ sciatic	358
		„ „ subclavian	315
		„ „ superficial femoral	344
		„ „ „ temporal	310
		„ „ superior thyroid	307
		„ „ ulnar	328
		„ „ vertebral	319
		Artery forceps	9
		Arthrectomy	491
		Arthrotomy	491
		Articulations, excision of (<i>see</i> Joints, Excision of)	489
		Asepsis, preliminary preparations for	2

	PAGE		PAGE
Aspiration of pleural cavity . . .	240	Bladder, urinary, operations	
„ of urinary bladder . . .	160	for rup- ture . . .	181
Aspirator	240	„ „ „ supra- pubic cystotomy . . .	166
Aural forceps	440	Bloodless method of operating . . .	9
„ polypus snare	442	Bones, operations upon . . .	447
„ scoop	440	„ „ excision . . .	461
„ syringe	440	„ „ osteotomy . . .	447
Auriculo-temporal nerve, ex- posure of	383	„ „ for un- ited fracture . . .	457
Aveling's transfusion appa- ratus	372	Brachial artery, ligature of . . .	325
Axillary artery, ligature of . . .	321	„ plexus, exposure of . . .	386
Bailey's decalcified bone tube for intestinal anastomosis . . .	61	Brain, operations upon (<i>see</i> Cranium)	263
Bassini's operation for radical cure of inguinal hernia . . .	97	Breast, operations upon (<i>see</i> Mammary gland) . . .	593
Bellocq's cannula	427	Bullet probe	287
Biceps femoris, tenotomy of . . .	399	Butcher's saw	513
Bigelow's evacuator	165		
Biliary system, operations upon . .	128	Cæcum, excision of	69
„ „ cholecystec- tomy	132	Canaliculus knife	631
„ „ cholecysten- dysis	132	„ „ slitting up of . . .	631
„ „ cholecyst- enterostomy	133	Carden's amputation through lower extremity of femur . . .	583
„ „ cholecysto- tomy	128	Carotid artery, common, liga- ture of	301
„ „ choledocho- lithotomy	137	„ „ external, liga- ture of	305
„ „ choledocho- tomy	137	„ „ internal, liga- ture of	314
Bistoury, curved and sharp- pointed	85	Castration	192
Bladder, urinary, operations upon 160, 181		Cerumen, impacted, extrac- tion of	439
„ „ „ aspira- tion	160	Chaput's suture	23
„ „ „ for ex- trover- sion	619	Chisel, grooved	272
„ „ „ lateral litho- tomy	173	„ „ straight-edged . . .	271
„ „ „ lithola- paxy	161	Cholecystectomy	132
„ „ „ median cysto- tomy	176	Cholecystendysis	132
„ „ „ puncture 160		Cholecyst-enterostomy . . .	133
		Cholecystotomy	128
		„ „ forceps	130
		„ „ scoop	131
		Choledocho-lithotomy . . .	137
		Choledochotomy	137
		Chopart's amputation through midtarsal joint	565
		Circumcision	186
		Clamp, intestinal	38

	PAGE		PAGE
Clavicle, excision of . . .	470	Ear, operations upon, extraction	
Cleft palate, operations for . . .	610	of foreign bodies	
,, needle, Smith's . . .	614	from external meatus . . .	439
Closure of wounds . . .	10	,, incision of membrana	
Clover's crutch . . .	82	tympani . . .	443
Colon, resection of . . .	81	,, removal of growths	
Colotomy, inguinal . . .	72	from external meatus . . .	441
,, lumbar . . .	76	Ectopia vesicæ, operations for . . .	619
Common carotid artery, liga-		Elbow-joint, amputation	
ture of . . .	301	through . . .	546
,, femoral artery, liga-		excision of . . .	496
ture of . . .	342	Enterorrhaphy, circular . . .	55
,, iliac artery, ligature		Epispadias, operation for . . .	622
of . . .	335	Erasion of knee-joint . . .	516
Cooper's operation for ligature		Eustachian catheter, passage	
of external iliac artery . . .	339	of . . .	429
Craniectomy . . .	290	Evacuating catheter . . .	164
Craniotomy, linear . . .	290	Evacuator . . .	165
Cranium, operations upon . . .	263	Excision of a bone . . .	461
,, ,, craniectomy . . .	290	,, ,, clavicle . . .	470
,, ,, temporary re-		,, ,, fibula . . .	482
section . . .	289	,, ,, lower jaw . . .	466
,, ,, trephining . . .	263	,, ,, metacarpal	
Cripps' rectal bougie . . .	90	bone . . .	473
Cuneiform tarsectomy . . .	486	,, ,, metatarsal	
Curette, Gottstein's . . .	434	bone . . .	488
Cyst forceps, ovarian . . .	199	,, ,, os calcis . . .	482
Cystotome . . .	636	,, ,, patella . . .	480
Cystotomy, lateral . . .	173	,, ,, phalanx of	
,, median . . .	176	finger . . .	474
,, suprapubic . . .	166	,, ,, ,, toe . . .	488
Czerny's suture . . .	22	,, ,, radius . . .	473
Czerny-Lembert-Wölflersuture	23	,, ,, rib . . .	474
		,, ,, scapula . . .	472
Deep circumflex iliac artery,		,, ,, tibia . . .	481
ligature of . . .	341	,, ,, ulna . . .	473
,, epigastric artery, ligature		,, ,, upper jaw . . .	462
of . . .	340	,, ,, wedge-shaped	
Dilator, tracheal . . .	238	portion of	
Dorsalis pedis artery, ligature		tarsus . . .	486
of . . .	356	Excision of a joint . . .	489
Drainage of wounds . . .	16	,, ,, ankle . . .	517
,, tubes . . .	16	,, ,, elbow . . .	496
Dupuytren's contraction, oper-		,, ,, hip . . .	507
ations for . . .	405	,, ,, interphal-	
		angeal of	
Ear, operations upon . . .	439	finger . . .	507
,, ,, exploration of mas-		,, ,, interphal-	
toid antrum and cells . . .	444	angeal of	
		toe . . .	520
		,, ,, knee . . .	511

	PAGE		PAGE
Excision of a joint, metacarpo-phalangeal	506	Femoral hernia, ligatures for relief of strangulation .	116
„ „ metatarso-phalangeal	520	Femur, osteotomy of .	448
„ „ radio-ulnar (head of radius) .	501	„ „ detachment of internal condyle .	452
„ „ shoulder .	493	„ „ Macewen's operation .	449
„ „ temporo-maxillary .	521	„ „ transverse division above condyles through external incision .	451
„ „ wrist .	502	„ „ at the upper extremity .	454
Excision of the larynx .	226	„ operation for ununited fracture of .	458
„ thyroid gland .	246	Fibula, excision of .	482
„ tongue .	256	Fingers, amputation of .	529
Extensor longus digitorum, tenotomy of .	404	Fistula in ano, operation for .	84
„ proprius hallucis, tenotomy of .	403	Fixation forceps .	633
External carotid artery, ligature of .	305	Foot, amputation of (<i>see</i> Amputations)	
„ iliac artery, ligature of .	338	Forceps, artery .	9
„ urethrotomy .	178	„ aural, Cumberbatch's .	440
Extroversion of urinary bladder	619	„ cholecystotomy, Anderson's .	130
Eye, operations upon .	629	„ dissecting, fine-pointed .	293
„ „ advancement of a muscle .	634	„ dressing .	104
„ „ discission .	642	„ fixation .	633
„ „ excision of eyeball .	643	„ Hoffman's .	290
„ „ extraction of lens .	639	„ iridectomy .	637
„ „ iridectomy .	636	„ laminectomy .	412
„ „ paracentesis of anterior chamber .	635	„ lion .	464
„ „ passage of lachrymal probe .	632	„ lithotomy .	171
„ „ sclerotomy .	639	„ nasal polypus .	424
„ „ slitting up of canalculus .	631	„ „ septum, Walsham's .	425
„ „ tenotomy of ocular muscles .	632	„ ovarian cyst .	199
Facial artery, ligature of .	309	„ post-nasal, Walsham's .	434
„ nerve, exposure of .	383	„ pressure .	9
Farabœuf's amputation through leg .	579	„ renal calculus .	150
Fascia, palmar, division of .	405	„ vulsellum .	420
„ plantar, division of .	404	Forearm, amputation through	545
Femoral arteries, ligature of .	342	Foreign bodies, extraction of, from external auditory meatus .	439
„ hernia, operations on, for radical cure .	108	Fracture, ununited, operations for .	457
		Frank's method of gastrotomy .	27
		Frontal sinuses, exploration of	435

	PAGE		PAGE
Gag, Ackland's	257	Hæmorrhage, arrest of	9
„ Smith's	611	Hæmorrhoids, operations for	81
Ganglion, Meckel's, excision of	382	„ „ „ crushing	83
Gastric ulcer, perforated, operation for	46	„ „ „ excision	83
Gastro-enterostomy	37	„ „ „ ligature	81
Gastrostomy	25	Halstead's quilted or mattress suture	23
Gastrotomy	32	Hare lip, operations for	603
Genital organs, operations upon		„ „ „ single	603
„ „ „ female	196	„ „ „ double	609
„ „ „ „ hysterec-tomy	205	Hepatectomy	122
„ „ „ „ for ruptured perineum	215	Hepatotomy	119
„ „ „ „ ovario-tomy	196	Hernia, operations for	89
„ „ „ „ salpingo-öophorec-tomy	202	„ „ „ for radical cure	95
„ „ „ „ male	186	„ „ „ „ inguinal	95
„ „ „ „ amputa-tion of penis	187	„ „ „ „ femoral	108
„ „ „ „ castration	192	„ „ „ „ umbilical	111
„ „ „ „ circumci-sion	186	„ „ „ „ for relief of strangulation	112
„ „ „ „ epispadias	622	„ „ „ „ inguinal	114
„ „ „ „ hydrocele, radical cure of	194	„ „ „ „ femoral	116
„ „ „ „ hypospa-dias	624	„ „ „ „ umbilical	117
Giraldès' operation for single hare lip	607	„ „ „ „ obturator	117
Glands, lymphatic, removal from axilla	598	„ „ „ „ needle, Macewen's	104
Gluteal artery, ligature of	359	„ „ „ „ knife	116
Gorget, Teale's	180	„ „ „ „ director	115
Gottstein's curette, for removal of adenoid growths	434	Hey's amputation through tarso-metatarsal joint	565
Gould's operation for amputa-tion of penis	190	„ „ „ saw	291
Graefe's knife	638	Hip-joint, amputation through	590
Great occipital nerve, exposure of	385	„ „ „ excision of	507
„ „ „ sciatic nerve, exposure of	392	Hoffman's forceps	290
Gritti's amputation through condyles of femur	585	Horsley's periosteal elevator	270
Gussenbauer's artificial larynx	229	Howse's knee-splint	515
„ „ „ suture	23	Hydrocele, radical cure of	194
		Hypospadias, operation for	624
		Hysterectomy	205
		„ „ „ abdominal	205
		„ „ „ vaginal	212
		Iliac arteries, ligature of	
		„ „ „ common	335
		„ „ „ „ external	338
		„ „ „ „ internal	357
		Inferior maxilla, excision of	466
		Infra-orbital nerve, exposure of	381
		Inguinal colotomy	72
		„ „ „ hernia, operations upon, for radical cure	95
		„ „ „ „ Bassini's operation	97

	PAGE		PAGE
Inguinal hernia, operations upon,		Joints, excision of	489
for radical cure,		" " ankle	517
Kocher's operation	101	" " elbow	496
" " Macewen's operation	105	" " hip	507
" " for relief of strangulation	114	" " interphalangeal, foot	520
Innominate artery, ligature of	299	" " " hand	507
Instruments, selection of	3	" " knee	511
Intercostal arteries, ligature of	333	" " metacarpo-phalan-	
Internal carotid artery, ligature of	314	geal	506
" iliac artery, ligature of	357	" " metatarso-phalan-	
" jugular vein, ligature of	361	geal	520
" mammary artery, ligature of	320	" " radio-ulnar, superior	501
" pudic artery, ligature of	358	" " shoulder	493
Interphalangeal joints, excision of foot	520	" " temporo-maxillary	521
" " " of hand	507	" " wrist	502
Intestinal suture, methods	20	Jordan's, Furneaux, amputation at hip-joint	591
Intestines, operations upon	18	Jugular vein, internal, ligature of	361
" " " large intestine	65	Kidneys, operations upon	145
" " " excision of cæcum	69	" " nephrectomy	152
" " " inguinal colotomy	72	" " nephrolithotomy	145
" " " l u m b a r colotomy	76	" " nephrorrhaphy	158
" " " removal of vermiform appendix	65	" " nephrotomy	151
" " " resection of colon	71	Knee-joint, amputation through	581
" " " small intestine	50	" " excision of	511
" " " closure of perforating wound	50	Knife, amputating, long	8
" " " formation of artificial anus	64	" " short	570
" " " resection	51	" " bistoury	85
Intubation of larynx	230	" " for incision of membrana tympani	444
Irrigation of peritoneal cavity	20	" Graefe's	638
Jaw, lower, excision of	462	" keratome	636
" upper	462	" resection	492
		" ring-shaped, for adenoids	434
		" scalpel	5
		" Thiersch's	627
		" methods of holding	5
		Knots, methods of tying	14
		Kocher's operation for excision of elbow-joint	499
		" " for radical cure of inguinal hernia	101
		" " for removal of tongue	259
		Kraske's operation for excision of rectum	91
		Krönlein, ligature of middle meningeal artery	313

	PAGE		PAGE
Lachrymal probe	632	Liver, operations upon, exposure of upper surface by transthoracic operation	478
Laminectomy	410	Lower jaw, excision of	466
Lane's cleft palate needles and needle-holder	615	Lumbar colotomy	76
Large intestine, operations upon (<i>see</i> Intestines)	65	Lungs, operations upon	238
Laryngectomy	226	„ „ „ pneumotomy	238
Laryngotomy	221	Lymphatic glands, axillary, removal of	598
„ tube	222		
Laryngo-tracheotomy	237	Maas, operation for double hare lip	609
Larynx, artificial	229	Macewen's method of osteotomy of femur	449
„ operations upon	221	„ operation for radical cure of inguinal hernia	105
„ „ intubation of larynx	230	„ hernia needles	104
„ „ laryngectomy	226	„ osteotome	449
„ „ laryngotomy	221	Mackenzie's tonsil guillotine	419
„ „ laryngo - tracheotomy	237	Makin's intestinal clamp	38
„ „ thyrotomy	223	Malgaigne's operation for single hare lip	606
Lateral lithotomy	173	Mallet	273
„ sinus, exposure of	363	Mammary gland, operations upon	593
Le Fort's amputation of foot	574	„ „ „ for mammary abscess	593
Leg, amputation through	575	„ „ „ removal of non-malignant tumours and cysts	595
Lembert's suture	21	„ „ „ amputation of breast	596
Lengthening of tendons	408	Mastoid antrum and cells, exploration of	444
Ligaments, operations upon	395	Mattress suture, Halstead's	23
„ „ division of astragalo-scaphoid ligament	406	Maunsell's method of intestinal anastomosis	57
Ligature of arteries (<i>see</i> Arteries, ligature of)	292	Maxilla, inferior, excision of	466
„ of veins (<i>see</i> Veins, operations upon)	361	„ superior, excision of	462
Lingual artery, ligature of	307	Maydl and Reclus, method of inguinal colotomy	75
„ nerve, exposure of	383	Meckel's ganglion, removal of	382
Lion forceps	464	Median nerve, exposure of	390
Lisfranc's amputation through tarso-metatarsal joint	563	Membrana tympani, incision of	443
Litholapaxy	161	Metacarpal bones, excision of	473
Lithotomy, lateral	173		
„ suprapubic	166		
„ forceps	171		
„ knife	176		
„ staff	174		
Lithotrite	163		
Lithotritry	161		
Liver, operations upon	119		
„ „ hepatectomy	122		
„ „ hepatotomy	119		

	PAGE		PAGE
Metacarpo-phalangeal joints, amputation through .	536	Nerves, operations upon, exposure of special nerves, auriculo-temporal .	383
" " excision of	488	" " brachial plexus	386
Metatarsal bones, excision of .	488	" " facial .	383
Metatarso-phalangeal joints, amputation through .	561	" " great occipital	385
" " excision of	520	" " great sciatic .	392
Metatarsus, amputation through	562	" " infra-orbital .	381
Meyer's ring knife .	434	" " lingual .	383
Middle meningeal artery, ligature of .	321	" " Meckel's ganglion .	382
Murphy's button, for intestinal anastomosis	59	" " median .	390
" " for cholecyst-enterostomy	134	" " musculo-spiral	387
Muscles, operations upon .	395	" " peroneal .	393
Musculo-spiral nerve, exposure of .	387	" " popliteal .	393
Myoma screw, Tait's .	207	" " posterior tibial	394
		" " spinal accessory	384
Nares, plugging of .	427	" " supra-orbital .	380
Nasal plugs, Walsham's .	426	" " ulnar .	389
" polypi, removal of .	422	Nerve-stretching .	379
" septum, deviated, rectification of .	425	Neurectomy .	380
" speculum .	423	Neurorrhaphy .	375
Naso-pharyngeal polypi, removal of .	430	Neurotomy .	380
Needle-holders .	11, 12	Nose, operations upon .	422
Needles .	11	" " adenoid growths of naso-pharynx, removal of .	433
Nélaton's operation for single hare lip .	605	" " deviated nasal septum, rectification of	429
Nephrectomy .	152	" " Eustachian catheter, passage of .	429
" abdominal .	156	" " frontal sinus, exploration of .	435
" lumbar .	152	" " nasal polypi, removal of .	422
Nephrolithotomy .	145	" " naso-pharyngeal polypi, removal of	430
Nephropexy .	158	" " plugging the nares	427
Nephrorrhaphy .	158		
Nephrotomy .	151	Obturator hernia, operation for relief of strangulation of .	117
Nerves, operations upon .	374	Occipital artery, ligature of .	310
" " nerve-stretching .	379	O'Dwyer's tubes .	231
" " neurectomy .	380	Œsophagus, operations upon	252
" " neurorrhaphy .	375	" " œsophagectomy .	255
" " neurotomy .	380	" " œsophagos-tomy .	255
" " exposure of special nerves .	380	" " œsophago-tomy .	252
" " " anterior crural	394		
" " " tibial	393		

	PAGE		PAGE
Ogston's operation for detachment of internal condyle of femur	452	Pirogoff's amputation of foot	574
Olecranon, operation for ununited fracture of	461	Plantar fascia, division of	404
Operations, stages of	5	Plastic operations	602
Operation table	4	„ „ for cleft palate	610
Ophthalmic operations (<i>see</i> Eye, operations on)	629	„ „ for epispadias	622
Os calcis, excision of	482	„ „ for extroversion of the urinary bladder	619
Osteotome, Macewen's	449	„ „ for hare lip	603
Osteotomy	447	„ „ for hypospadias	624
„ of femur	448	„ „ skin grafting	626
„ of tibia	455	Pleura, operations upon	240
Ovariectomy	196	„ „ incision	242
Palmar fascia, division of	405	„ „ paracentesis	240
Paracentesis of anterior chamber of eye	635	Plugging the nares	427
„ of pleura	240	Pneumotomy	238
Parker's tracheotomy tube	237	Polypi, nasal, removal of	422
Patella, excision of	480	„ naso-pharyngeal, removal of	430
„ operation for ununited fracture of	459	Polypus forceps, nasal	424
Pedicle needles	155, 200	Popliteal artery, ligature of	347
Penis, operations upon	186	„ nerve, exposure of	393
„ „ amputation	187	Position of patient, operator and assistant	4
„ „ circumcision	187	Posterior tibial artery, ligature of	349
„ „ epispadias	622	„ „ nerve, exposure of	394
„ „ hypospadias	624	Pressure forceps	9
Pericardium, operations upon	244	Pudic artery, internal, ligature of	358
„ „ incision	245	Pylorotomy	40
„ „ paracentesis	244	Pyloroplasty	35
Perineum, operations upon	215	Quilted suture, Halstead's	23
„ „ for complete rupture	218	Radial artery, ligature of	330
„ „ for partial rupture	215	Radical cure of hernia	95
Periosteal elevator, Horsley's	270	„ „ „ femoral	108
„ „ for excision of joints	492	„ „ „ inguinal	95
Peritoneal cavity, irrigation of	20	„ „ „ umbilical	111
Peroneal artery, ligature of	352	„ „ „ hydrocele	194
„ nerve, exposure of	393	Radius, excision of	473
Peroneus longus and brevis, tenotomy of	404	„ „ head of	501
„ tertius „	404	Reclus and Maydl, method of inguinal colotomy	75
Phalanges, excision of, hand	474	Rectal bag	167
„ „ foot	488	„ bougie	90
Piles, operations for (<i>see</i> Hæmorrhoids)	81	Rectum, operations upon	81
		„ „ excision, perineal method	87


	PAGE		PAGE
Rectum, operations upon, exci-		Sims' speculum	212
sion, sacral		Skey's amputation through	
method	91	tarso-metatarsal joint	565
,, ,, fistula in ano	84	Skin grafting	626
,, ,, hæmorrhoids	81	Skull, operations upon (<i>see</i>	
Resection (<i>see</i> Excision)		Cranium)	263
Resection knife	492	Small intestines, operations upon	50
Respiratory system, operations		,, ,, ,, closure of	
upon	221	perforating	
,, ,, ,, larynx	221	wound	50
,, ,, ,, lungs	238	,, ,, ,, formation	
,, ,, ,, pleuræ	240	of artifi-	
,, ,, ,, trachea	232	cial anus	64
Retractor, abdominal	148	,, ,, ,, resection	51
,, for use in ligature		Smith's cleft palate needle	614
of arteries	295	,, gag	611
Rib, excision of	474	Smith's, Stephen, amputation	
Robson's decalcified bone		through knee-joint	581
bobbin	61	Snare for nasal polypi	424
Rose's operation for single		Speculum, aural	443
hare lip	605	,, lid	633
,, ,, double hare lip	609	,, nasal	423
Roux's amputation of foot	573	,, vaginal	212
Rupture of urinary bladder,		Spina bifida, operations for	413
operation for	181	,, ,, excision	414
		,, ,, injection	413
Saline fluids, injection of, into		Spinal accessory nerve, ex-	
veins	369	posure of	384
Salpingo-oöphorectomy	202	,, column and cord, oper-	
Saw, Adam's	452	ations upon	410
,, Butcher's	513	,, ,, laminectomy	410
,, Hey's	291	,, ,, operations for	
Scapula, excision of	472	spina bifida	413
Sciatic artery, ligature of	348	,, ,, operation for	
,, nerve, great, exposure		vertebral caries	414
of	392	Spleen, operations upon	140
Scissors, curved on the flat	633	,, ,, splenectomy	140
,, iridectomy	637	,, ,, splenotomy	144
Sédillot's amputation of foot	574	Splints for use after excision	
Selection of instruments	3	of knee	
Semimembranosus, tenotomy		(Howse)	515
of	399	,, ,, ,, of wrist	506
Semitendinosus, tenotomy of	399	Ssabanajeff's amputation through	
Senn's plates, for intestinal		femoral condyles	585
anastomosis	62	Staphylorrhaphy	616
Septum, nasal, rectification		Sterno-mastoid, tenotomy of	397
of	425	Stokes' amputation through	
Shoulder - joint, amputation		lower end of femur	586
through	551	Stomach, operations upon	18
,, excision of	493	,, ,, gastro-enterostomy	37
		,, ,, gastrostomy	25

	PAGE		PAGE
Stomach, operations upon,		Suture of intestines, Lembert's	
gastrostomy,		suture . . .	21
Frank's (or		,, ,, simple continuous	
Albert's)		suture . . .	13
method . . .	27	,, ,, simple interrupted	
,, ,, Witzel's me-		suture . . .	12
thod . . .	30	Syme's amputation of foot . . .	570
,, ,, gastrotomy . . .	32	Syndesmotomy . . .	406
,, ,, operation for per-		Synovial membranes of carpus	502
forated gastric		,, ,, ,, tarsus	
ulcer . . .	46	and metatarsus . . .	520
,, ,, pylorotomy . . .	40		
,, ,, pyloroplasty . . .	35	Table, operation . . .	4
Stop-needle . . .	643	Tait's myoma screw . . .	207
Strabismus hook . . .	634	Tarsectomy, cuneiform . . .	486
Strangulated hernia, operations		Tarso-metatarsal joint, ampu-	
for . . .	113	tation through . . .	563
,, ,, femoral . . .	116	Tarsus, amputation through . . .	565
,, ,, inguinal . . .	114	,, excision of wedge-	
,, ,, obturator . . .	117	shaped portion of . . .	486
,, ,, umbilical . . .	117	Teale's method of amputat-	
Subastragaloid amputation of		ing . . .	581
foot . . .	568	,, probe-pointed gorget . . .	180
Subclavian artery, ligature of	315	Temporary resection of part of	
Superficial femoral artery, liga-		cranial wall . . .	289
ture of . . .	344	,, ,, of upper jaw . . .	466
,, temporal artery,		Temporo-maxillary joint, ex-	
ligature of . . .	310	cision of . . .	521
Superior maxilla, excision of . . .	462	Tendo Achillis, tenotomy of . . .	400
,, thyroid artery, liga-		Tendons, operations upon . . .	395
ture of . . .	307	,, ,, lengthening . . .	408
Supra-orbital nerve, exposure		,, ,, suture . . .	407
of . . .	380	,, ,, tenotomy . . .	395
Supravaginal amputation of		Tenotome, blunt-pointed . . .	397
cervix uteri . . .	212	,, sharp-pointed . . .	396
Suture of divided nerve . . .	375	Tenotomy . . .	395
,, ,, tendon . . .	407	,, adductor longus . . .	398
,, of external wound . . .	10	,, biceps femoris . . .	399
,, ,, continuous suture . . .	13	,, extensor longus digi-	
,, ,, interrupted suture . . .	12	torum . . .	404
,, ,, buried suture . . .	15	,, extensor proprius	
of intestines . . .	20	hallucis . . .	403
,, ,, Chaput's suture . . .	23	,, peroneus longus and	
,, ,, Czerny's suture		brevis . . .	402
(Czerny-Lembert) . . .	22	,, peroneus tertius . . .	404
,, ,, Czerny-Lembert-		,, semimembranosus . . .	399
Wölfler suture . . .	23	,, semitendinosus . . .	399
,, ,, Gussenbauer's		,, sterno-mastoid . . .	397
suture . . .	23	,, tendo Achillis . . .	400
,, ,, Halstead's quilted		,, tibialis anticus . . .	400
or mattress suture . . .	23		

	PAGE		PAGE
Tenotomy, tibialis posticus . . .	401	Trephining for extradural hæmorrhage . . .	
Testis, operations upon . . .	192	" " or abscess . . .	277
" " castration . . .	192	" " fractured skull . . .	274
" " hydrocele, radical cure of . . .	194	" " ligature of middle meningeal artery . . .	311
Thiersch's knife . . .	627	" " removal of foreign body . . .	287
" method of skin grafting . . .	626	" " tapping and drainage of lateral ventricle . . .	286
" operation for amputation of penis . . .	190	Treves' operation for vertebral caries . . .	414
Thigh, amputation through . . .	583	Trochar, ovarian . . .	198
" " lower third . . .	583		
" " middle third . . .	587	Ulna, excision of . . .	474
Thoracentesis . . .	240	Ulnar artery, ligature of . . .	328
Thumb, amputation of . . .	538	" nerve, exposure of . . .	389
Thyroid gland, operations upon . . .	246	Umbilical hernia, operations upon, for radical cure . . .	111
Thyrotomy . . .	223	" " for relief of strangulation . . .	117
Tibia, excision of . . .	481	Ununited fracture, operations for . . .	457
" osteotomy of . . .	455	Upper arm, amputation through . . .	549
Tibialis anticus, tenotomy of . . .	400	" jaw, excision of . . .	462
" posticus, " . . .	401	" extremity, entire, amputation of . . .	553
Toes, amputation of . . .	557	Uranoplasty . . .	612
Tongue, operations upon . . .	256	Urethrotomy, external . . .	178
" " excision of wedge-shaped portion . . .	261	Urinary system, operations upon . . .	145
" " excision through mouth . . .	257	" " kidneys . . .	145
" " Kocher's operation . . .	925	" " urethra . . .	178
Tonsil guillotine . . .	419	" " " epispadias . . .	622
Tonsils, operations upon . . .	417	" " " hypospadias . . .	624
Tourniquet . . .	10	" " " urinary bladder . . .	160, 181
Trachea, operations upon . . .	232	" " " ectopia vesicæ . . .	619
" " laryngo-tracheotomy . . .	237	Uterus, operations upon . . .	205
" " tracheotomy . . .	232		
Tracheotomy tube, Parker's . . .	237	Vaginal hysterectomy . . .	212
Transfusion . . .	372	Varicocele, operations for, open . . .	364
Trendelenberg's operation for extroversion of urinary bladder . . .	621	" " subcutaneous . . .	365
Trephine . . .	264	Varicose veins, operation for . . .	366
Trephining for cerebellar abscess . . .	286		
" " " tumour or cyst . . .	284		
" " for cerebral abscess . . .	282		
" " " tumour or cyst . . .	278		
" " epilepsy . . .	288		
" " exposure of lateral sinus . . .	363		

	PAGE		PAGE
Veins, operations upon . . .	361	Walsham's nasal plugs . . .	426
„ „ exposure of lateral sinus . . .	363	„ „ septum for- ceps . . .	425
„ „ ligature of internal jugular . . .	361	Waring's laminectomy forceps . . .	412
„ „ injection of saline fluids . . .	369	„ truss, for use after inguinal colotomy . . .	75
„ „ operations for vari- cocele . . .	364	Weber's canaliculus knife . . .	631
„ „ operations for vari- cose veins . . .	366	Wheelhouse's method of exter- nal urethrotomy . . .	178
„ „ transfusion . . .	367	„ staff . . .	178
Vermiform appendix, removal of . . .	65	Whitehead's operation for piles . . .	83
Vertebral artery, ligature of . . .	319	Wire-twister . . .	616
Vulsellum forceps . . .	420	Wiring of fractured olecranon . . .	461
Wagner's method of temporary resection of skull . . .	289	„ „ patella . . .	459
		Witzel's method of gastros- tomy . . .	30
		Wounds, closure of . . .	10
		Wrist-joint, amputation through . . .	539
		„ „ excision of . . .	502





YOUNG J. PENTLAND'S PUBLICATIONS.

SYSTEM of GYNECOLOGY and OBSTETRICS. By AMERICAN AUTHORS. Edited by MATTHEW D. MANN, A.M., M.D., Professor of Obstetrics and Gynecology in the Medical Department of the University of Buffalo, N.Y.; and BARTON COOKE HIRST, M.D., Associate Professor of Obstetrics in the University of Pennsylvania; Obstetrician to the Philadelphia Maternity Hospital; Gynecologist to the Orthopædic Hospital. In 8 very handsome volumes, Royal 8vo, Cloth, of about 400 pages each, fully Illustrated with Engravings and Coloured Plates. Price 12s. 6d. each, nett. For sale by Subscription only.

TEXT-BOOK of GENERAL BOTANY. By Dr. W. J. BEHRENS. Translation from the Second German Edition. Revised by PATRICK GEDDES, F.R.S.E., Professor of Botany in the University of Dundee. 8vo, Cloth, pp. viii., 374, with 408 Illustrations, finely engraved on Wood, and 4 Analytical Tables, New Edition. Price 5s. (1893.)

THE ELEMENTS OF OPHTHALMOSCOPIC DIAGNOSIS. FOR THE USE OF STUDENTS ATTENDING OPHTHALMIC PRACTICE. By GEORGE A. BERRY, M.B., F.R.C.S.ED., Ophthalmic Surgeon, Edinburgh Royal Infirmary; Lecturer on Ophthalmology, Royal College of Surgeons, Edinburgh. Crown 8vo, Cloth, pp. xii., 83. Price 3s. 6d. (1891.)

DISEASES of the EYE. A PRACTICAL TREATISE FOR STUDENTS OF OPHTHALMOLOGY. By GEORGE A. BERRY, M.B., F.R.C.S.ED., Ophthalmic Surgeon, Edinburgh Royal Infirmary; Senior Surgeon, Edinburgh Eye Dispensary; Lecturer on Ophthalmology, Royal College of Surgeons, Edinburgh. Second Edition revised and enlarged. 8vo, Cloth, gilt top, pp. xvi., 730, Illustrated with many Coloured Plates and Wood Engravings. Price 25s. (1893.)

(Pentland's Medical Series, Volume Second.)

THE NATIONAL MEDICAL DICTIONARY. INCLUDING ENGLISH, FRENCH, GERMAN, ITALIAN, AND LATIN TECHNICAL TERMS USED IN MEDICINE AND THE COLLATERAL SCIENCES, AND

A SERIES OF TABLES OF USEFUL DATA. By JOHN S. BILLINGS, A.M., M.D., LL.D., Harv. and Edin., D.C.L., Oxon., Member of the National Academy of Sciences, Surgeon, U.S.A., &c. With the collaboration of W. O. ATWATER, M.D., FRANK BAKER, M.D., JAMES M. FLINT, M.D., R. LORINI, M.D., S. M. BURNETT, M.D., J. H. KIDDER, M.D., H. C. YARROW, M.D., WILLIAM LEE, M.D., C. S. MINOT, M.D., WASHINGTON MATTHEWS, M.D., W. T. COUNCILMAN, M.D. In Two very handsome Imperial 8vo volumes, containing about 1600 pages. Price 50s. nett. (1890.)

DISEASES of the HEART and THORACIC AORTA. By BYROM BRAMWELL, M.D., F.R.C.P.ED., Lecturer on the Principles and Practice of Medicine, and on Practical Medicine and Medical Diagnosis, in the Extra-Academical School of Medicine, Edinburgh; Assistant Physician, Edinburgh Royal Infirmary. Large 8vo, Cloth, pp. xvi., 783. Illustrated with 226 Wood Engravings, and 68 pages of Lithograph Plates, exhibiting 91 Figures—317 Illustrations in all. Price 25s. (1884.)

INTRACRANIAL TUMOURS. By BYROM BRAMWELL, M.D., F.R.C.P.ED., Lecturer on the Principles and Practice of Medicine in the Extra-Academical School of Medicine, Edinburgh; Assistant Physician to the Edinburgh Royal Infirmary. 8vo, Cloth, pp. xvi., 270, with 116 Illustrations. Price 14s. (1888.)

ILLUSTRATIONS of the NERVE TRACTS in the MID AND HIND BRAIN, AND THE CRANIAL NERVES ARISING THEREFROM. By ALEXANDER BRUCE, M.D., F.R.C.P.ED., Lecturer on Pathology in the School of Medicine, Edinburgh; Assistant Physician (formerly Pathologist), Edinburgh Royal Infirmary; Pathologist to the Royal Hospital for Sick Children. Oblong 4to, Cloth, in a series of 27 Coloured Plates from Original Drawings, with Descriptive Letterpress, and 27 Engravings throughout the Text. Price 50s. nett. (1892.)

DISEASE in CHILDREN: A MANUAL FOR STUDENTS AND PRACTITIONERS. By JAMES CARMICHAEL, M.D., F.R.C.P.ED., Physician, Royal Hospital for Sick Children; University Lecturer on Disease in Children, Edinburgh. Crown 8vo, Cloth, pp. xvi., 520. Illustrated with Charts. Price 10s. 6d. (1892.)

(Pentland's Students' Manuals.

TUBERCULOUS DISEASE of the BONES and JOINTS.

By W. WATSON CHEYNE, M.B., F.R.S., F.R.C.S., Professor of Surgery, King's College, London. 8vo, Cloth, pp. xvi., 374. Illustrated with numerous Wood Engravings throughout the Text. Price 14s. nett. (1895.)

SUPPURATION and SEPTIC DISEASES. THREE LECTURES DELIVERED AT THE ROYAL COLLEGE OF SURGEONS OF ENGLAND. By W. WATSON CHEYNE, M.B., F.R.S., F.R.C.S., Professor of Surgery, King's College, London. 8vo, Cloth, pp. xii., 102, with 4 Illustrations. Price 5s. (1889.)

THE TREATMENT of WOUNDS, ABSCESES, and ULCERS. By W. WATSON CHEYNE, M.B., F.R.S., F.R.C.S., Professor of Surgery, King's College, London. Second Edition. Crown 8vo, Cloth, pp. xvi., 200. Price 3s. 6d. (1897.)

ATLAS of the DISEASES of the SKIN. By H. RADCLIFFE CROCKER, M.D., F.R.C.P., Physician to the Department for Diseases of the Skin, University College Hospital, London. In 16 Fasciculi, containing 96 plates, exhibiting 238 Figures in colours from Original Drawings specially prepared for the work, with Descriptive Letterpress. Price 21s. each nett. Or in Two large handsome Folio Volumes, Half Morocco, gilt tops. Price £18, 18s. nett. (1897.)

* * *Subscribers' Names can be received for the Parts.*

MANUAL OF PRACTICAL ANATOMY. By D. J. CUNNINGHAM, M.D., Professor of Anatomy and Chirurgery, University of Dublin. Second Edition. In two Vols., Crown 8vo, Cloth. Volume First—Upper and Lower Limb; Abdomen. Volume Second—Thorax; Head and Neck. Illustrated with 372 Engravings and 2 full-page Plates. Price 12s. 6d. each. (1896.)

(Pentland's Students' Manuals.

HYGIENE AND DISEASES OF WARM CLIMATES,
IN A SERIES OF ARTICLES BY EMINENT AUTHORITIES. Edited by ANDREW DAVIDSON, M.D., F.R.C.P.ED., late Visiting and Superintending Surgeon, Civil Hospital; Professor of Chemistry, Royal College, Mauritius; Author of "*Geographical Pathology.*" Royal 8vo, Cloth, pp. xvi., 1016. Illustrated with Engravings throughout the Text and full-page Plates. Price 31s. 6d. (1893.)

GEOGRAPHICAL PATHOLOGY. AN INQUIRY INTO THE GEOGRAPHICAL DISTRIBUTION OF INFECTIVE AND CLIMATIC DISEASES. By ANDREW DAVIDSON, M.D., F.R.C.P.ED., late Visiting and Superintending Surgeon, Civil Hospital; Professor of Chemistry, Royal College, Mauritius. Two vols. Large 8vo, Cloth. pp. xvi., 1008. Illustrated with Maps and Charts. Price 31s. 6d. (1891.)

TEXT-BOOK of NERVOUS DISEASES. By AMERICAN AUTHORS. Edited by FRANCIS X. DERCUM, M.D., PH.D., Clinical Professor of Nervous Diseases in the Jefferson Medical College of Philadelphia. Royal 8vo, pp. xvi., 1056, with 341 Engravings in the Text, and 7 Coloured Plates. Price 25s. nett. (1895.)

THE "COMPEND" SERIES.

A Series of Handbooks to assist Students preparing for Examinations.

COMPEND of HUMAN ANATOMY, INCLUDING THE ANATOMY OF THE VISCERA. By SAMUEL O. L. POTTER, M.A., M.D., Cooper Medical College, San Francisco. Fifth Edition, revised and enlarged, Crown 8vo, Cloth, pp. 233, with 117 Engravings and 16 full-page Plates. Price 5s.

COMPEND of the PRACTICE of MEDICINE. By DANIEL E. HUGHES, M.D., late Demonstrator of Clinical Medicine in the Jefferson Medical College of Philadelphia. Fourth Edition, revised and enlarged, Crown 8vo, Cloth, pp. 328. Price 7s. 6d.

COMPEND of OBSTETRICS. By HENRY G. LANDIS, A.M., M.D., late Professor of Obstetrics and Diseases of Women in Starling Medical College. Fourth Edition, thoroughly revised, enlarged, and improved, Crown 8vo, Cloth, pp. 118, with 17 Illustrations. Price 4s. 6d.

COMPEND of SURGERY. By ORVILLE HORWITZ, B.S., M.D., Chief of the Outdoor Surgical Department, Jefferson Medical College Hospital. Fourth Edition, revised, Crown 8vo, Cloth, pp. 272, with 136 Illustrations. Price 5s.

COMPEND of GENERAL PATHOLOGY and MORBID ANATOMY. By H. NEWBERRY HALL, Ph.G., M.D., Professor of Pathology and Medical Chemistry, Post-Graduate Medical School; Surgeon to the Emergency Hospital, &c., Chicago. Crown 8vo, Cloth, pp. 204, with 91 Illustrations. Price 4s. 6d.

COMPEND of DISEASES of CHILDREN. By MARCUS P. HATFIELD, A.M., M.D., Professor of Diseases of Children, Chicago Medical College. Crown 8vo, Cloth, pp. 186, with Coloured Plate. Price 4s. 6d.

COMPEND of DENTAL PATHOLOGY and DENTAL MEDICINE. By GEO. W. WARREN, D.D.S., Clinical Chief, Pennsylvania College of Dental Surgery. Crown 8vo, Cloth, pp. 109, Illustrations. Price 4s. 6d.

CYCLOPÆDIA of the DISEASES of CHILDREN, MEDICAL AND SURGICAL. The Articles written especially for the Work by American, British, and Canadian Authors. Edited by JOHN M. KEATING, M.D. In 8 Vols., Royal 8vo, of about 500 pages each, Illustrated with Wood Engravings in the Text, and numerous full-page Plates. Price 12s. 6d. per Volume nett, Carriage Free.

* * *Detailed Prospectus on application.*

A TREATISE on OBSTETRICS, FOR STUDENTS AND PRACTITIONERS. By EDWARD P. DAVIS, A.M., M.D., Professor of Obstetrics and Diseases of Infancy in the Philadelphia Polyclinic; Clinical Professor of Obstetrics, Jefferson Medical College, Philadelphia. Large 8vo, Cloth, pp. 533, Illustrated with 217 Engravings, and 30 Plates in colours and monochrome. Price 16s. nett. (1897.)

EDINBURGH HOSPITAL REPORTS. PUBLISHED UNDER THE SUPERVISION OF AN EDITORIAL COMMITTEE ELECTED BY THE MEDICAL AND SURGICAL OFFICERS OF THE ROYAL INFIRMARY, ROYAL HOSPITAL FOR SICK CHILDREN, AND ROYAL MATERNITY AND SIMPSON MEMORIAL HOSPITAL. Edited by G. A. GIBSON, M.D., D.Sc., C. W. CATHCART, M.A., M.B., JOHN THOMSON, M.D., and D. BERRY HART, M.D. To be issued annually, 8vo, pp. xvi., 650 or thereby, handsomely printed, illustrated with full-page Plates and Engravings. Price per Volume, 12s. 6d. nett. Carriage free. Volumes I. to V. now ready.

DISEASES of the STOMACH. By DR. C. A. EWALD, Extraordinary Professor of Medicine at the University of Berlin; Director of the Augusta Hospital. Authorised Translation, with Special Additions by the Author, by MORRIS MANGES, A.M., M.D., Attending Physician, Mount Sinai Hospital, New York City, 8vo, Cloth, pp. xvi., 498, with 30 Illustrations. Price 16s. (1892.)

THE EDINBURGH MEDICAL JOURNAL. Edited by G. A. GIBSON, M.D., D.Sc., F.R.C.P.Ed., Assistant Physician, Edinburgh Royal Infirmary. Issued monthly. Price 2s. each part; Subscription 21s. per annum (in advance), post free. For the Colonies and Abroad, 24s. per annum (in advance), post free.

EXAMINATION QUESTIONS, SET FOR THE PROFESSIONAL EXAMINATIONS IN EDINBURGH UNIVERSITY DURING THE PAST TEN YEARS, SELECTED FROM THE CALENDARS. By W. RAMSAY SMITH, M.B., C.M., B.Sc., Formerly Demonstrator of Anatomy, Edinburgh School of Medicine, Minto House; late Senior Assistant to the Professor of Natural History, University of Edinburgh.

NATURAL HISTORY, arranged and annotated. Price 1s.

BOTANY, arranged and annotated. Price 1s. 6d.

CHEMISTRY, answered and annotated. Price 2s.

ANATOMY, answered and annotated. Price 2s.

PHYSIOLOGY, answered and annotated. Price 2s.

MATERIA MEDICA, answered and annotated. Price 2s.

MIDWIFERY AND GYNECOLOGY, answered and annotated.

Price 1s. 6d.

SURGERY, answered and annotated. Price 1s. 6d.

PRACTICE OF PHYSIC, answered and annotated. Price 1s. 6d.

MEDICAL JURISPRUDENCE AND PUBLIC HEALTH, answered and annotated. Price 2s.

THE FUNDUS OCULI, with an OPHTHALMOSCOPIC ATLAS, ILLUSTRATING ITS PHYSIOLOGICAL AND PATHOLOGICAL CONDITIONS. By W. ADAMS FROST, F.R.C.S., Ophthalmic Surgeon, St. George's Hospital; Surgeon to the Royal Westminster Ophthalmic Hospital, London. In one handsome 4to Volume, extra Cloth, gilt top, with 47 Plates, exhibiting 107 beautifully Coloured Figures and numerous Engravings in the Text. Price £3, 3s. nett. (1896.)

PHYSICAL DIAGNOSIS: A GUIDE TO METHODS OF CLINICAL INVESTIGATION. By G. A. GIBSON, M.D., D.Sc., F.R.C.P.Ed., Assistant Physician, Edinburgh Royal Infirmary; Lecturer on the Principles and Practice of Medicine in the Edinburgh Medical School; and WILLIAM RUSSELL, M.D., F.R.C.P.Ed., Assistant Physician, Edinburgh Royal Infirmary. Second Edition, thoroughly revised, Crown 8vo, Cloth, pp. xvi., 383, with 109 Illustrations, some Coloured. Price 10s. 6d. (1893.)

(Pentland's Students' Manuals.

HYDATID DISEASE IN ITS CLINICAL ASPECTS.

By JAMES GRAHAM, M.A., M.D., late Demonstrator of Anatomy, Sydney University; Medical Superintendent, Prince Alfred Hospital, Sydney. 8vo, Cloth, gilt top, pp. xvi., 204, with 34 full-page Coloured Plates. Price 16s. (1891.)

A SYSTEM OF PRACTICAL THERAPEUTICS. By

Various Authors. Edited by HOBART AMORY HARE, M.D., Clinical Professor of Diseases of Children, and Demonstrator of Therapeutics in the University of Pennsylvania; Physician to St. Agnes's Hospital, Philadelphia. 3 Vols., Royal 8vo, of about 1000 pages each. Price per vol. 22s. 6d. *nett*, carriage free.

HANDBOOK OF OBSTETRIC NURSING. By F. W. N.

HAULTAIN, M.D., F.R.C.P.ED., Physician to the Royal Dispensary; late Clinical Assistant to Physician for Diseases of Women, Royal Infirmary, Edinburgh; and J. HAIG FERGUSON, M.D., F.R.C.P.ED., Physician to the New Town Dispensary; late Resident Physician, Royal Maternity Hospital, Edinburgh. Second Edition, Revised and Enlarged, Crown 8vo, Cloth, pp. xvi., 244, with Coloured Plate and 33 Wood Engravings. Price 5s. (1894.)

HUMAN MONSTROSITIES. By BARTON COOKE HIRST, M.D.,

Professor of Obstetrics in the University of Pennsylvania; and GEORGE A. PIERSOL, M.D., Professor of Embryology and Histology in the University of Pennsylvania. In 4 Fasciculi, folio size, Illustrated with Engravings and full-page Photographic Plates from Nature. Price 25s. each Fasciculus. *Sold only by Subscription.*

THE URINE AND THE COMMON POISONS, MEMO-

RANDA, CHEMICAL AND MICROSCÓPICAL, FOR LABORATORY USE. By J. W. HOLLAND, M.D., Professor of Medical Chemistry and Toxicology, Jefferson Medical College, Philadelphia. Second, Edition, Revised and Enlarged, oblong Crown 8vo, Cloth, pp. 65, with 28 Illustrations. Price 4s. (1889.)

DISEASES OF THE SKIN: A MANUAL FOR STUDENTS AND

PRACTITIONERS. By W. ALLAN JAMIESON, M.D., F.R.C.P.ED., Extra Physician for Diseases of the Skin, Edinburgh Royal

Infirmery; Consulting Physician, Edinburgh City Hospital; Lecturer on Diseases of the Skin, School of Medicine, Edinburgh. Fourth Edition, Revised and Enlarged, 8vo, Cloth, pp. xvi., 676, with Coloured Illustrations. Price 21s. (1894.)

(Pentland's Medical Series, Volume First.)

BOTANY: A CONCISE MANUAL FOR STUDENTS OF MEDICINE AND SCIENCE. By ALEXANDER JOHNSTONE, F.G.S., Lecturer on Botany, School of Medicine, Edinburgh. Crown 8vo, Cloth, pp. xvi., 260, with 164 Illustrations and a series of Floral Diagrams. Price 6s. (1891.)

(Pentland's Students' Manuals.)

A NEW PRONOUNCING DICTIONARY of MEDICAL TERMS. By JOHN M. KEATING, M.D., Fellow of the College of Physicians of Philadelphia, Visiting Obstetrician to the Philadelphia Hospital, and Lecturer on Diseases of Women and Children. Handsome 8vo, Cloth, pp. 818. Price 18s. (1892.)

CLINICAL GYNÆCOLOGY, MEDICAL and SURGICAL. By AMERICAN AUTHORS. Edited by JOHN M. KEATING, M.D., LL.D., and HENRY C. COE, M.D., M.R.C.S., Professor of Gynæcology, New York Polyclinic. Two Volumes, Royal 8vo, Cloth, pp. xviii., 994, Illustrated with Full-page Plates and Engravings in the Text. Price 25s. nett. (1895.)

TEXT-BOOK of ABDOMINAL SURGERY: A CLINICAL MANUAL FOR PRACTITIONERS AND STUDENTS. By SKENE KEITH, F.R.C.S.Ed.; assisted by GEORGE E. KEITH, M.B. 8vo, Cloth, gilt top, pp. xvi., 508. Price 16s. (1894.)

(Pentland's Medical Series, Volume Fourth.)

THE ESSENTIALS of MEDICAL ANATOMY. By H. R. KENWOOD, M.B., C.M., L.R.C.P. (Lond.) 12mo, Cloth, pp. 52. Price 2s. (1889.)

THE PARASITES of MAN, AND THE DISEASES WHICH PROCEED FROM THEM. A TEXT-BOOK FOR STUDENTS AND PRACTITIONERS. By RUDOLF LEUCKART, Professor of Zoology and Comparative Anatomy in the University of Leipsic. Translated from the German, with the Co-operation of the Author, by WILLIAM E. HOYLE, M.A. (Oxon.), M.R.C.S., F.R.S.E., Curator of the Museums, Owens College, Manchester. NATURAL HISTORY OF

PARASITES IN GENERAL—SYSTEMATIC ACCOUNT OF THE PARASITES INFESTING MAN—PROTOZOA—CESTODA. Large 8vo, Cloth, pp. xxviii., 772, Illustrated with 404 Engravings. Price 31s. 6d. (1886.)

FIRST AID to the INJURED and MANAGEMENT of the SICK. By E. J. LAWLESS, M.D., Surgeon-Major, 4th V.B., E. Surrey Regiment. Crown 8vo, Cloth, pp. xvi., 262, Illustrated with numerous Wood Engravings. Price 3s. 6d. (1894.)

TRAUMATIC INFECTION. HUNTERIAN LECTURES DELIVERED AT THE ROYAL COLLEGE OF SURGEONS OF ENGLAND. By CHARLES BARRETT LOCKWOOD, F.R.C.S., Hunterian Professor, Royal College of Surgeons of England ; Assistant Surgeon to St. Bartholomew's Hospital ; Surgeon to the Great Northern Central Hospital. Crown 8vo, Cloth, pp. xii., 138, Illustrated with 27 Wood Engravings in the Text. Price 3s. (1896.)

ASEPTIC SURGERY. By CHARLES BARRETT LOCKWOOD, F.R.C.S. Crown 8vo, Cloth, pp. xvi., 233. Price 4s. (1896.)

STUDENTS' POCKET MEDICAL LEXICON, GIVING THE CORRECT PRONUNCIATION AND DEFINITION OF ALL WORDS AND TERMS IN GENERAL USE IN MEDICINE AND THE COLLATERAL SCIENCES. By ELIAS LONGLEY. New Edition, 18mo, Cloth, pp. 303. Price 4s. (1891.)

DISEASES of the THROAT, NOSE, and EAR. By P. M'BRIDE, M.D., F.R.C.P.Ed., Lecturer on the Diseases of the Ear and Throat, Edinburgh School of Medicine ; Aural Surgeon and Laryngologist, Royal Infirmary, Edinburgh ; Surgeon, Edinburgh Ear and Throat Dispensary. Second Edition, thoroughly revised. 8vo, Cloth, pp. xvi., 682, with Coloured Illustrations from Original Drawings. Price 25s. (1894.)

(Pentland's Medical Series, Volume Third.)

REGIONAL ANATOMY IN ITS RELATION TO MEDICINE AND SURGERY. By GEORGE MCCLELLAN, M.D., Lecturer on Descriptive and Regional Anatomy at the Pennsylvania School of Anatomy. In Two Handsome Volumes, large 4to, Illustrated with 100 full-page facsimile Chromo-lithographic Plates, reproduced from Photographs taken by the Author of his own Dissections, expressly designed and prepared for this work, and coloured by him after nature. Price 42s. each nett.

ATLAS of VENEREAL DISEASES. A SERIES OF ILLUSTRATIONS FROM ORIGINAL PAINTINGS, WITH DESCRIPTIONS OF THE VARIED LESIONS, THEIR DIFFERENTIAL DIAGNOSIS AND TREATMENT. By P. H. MACLAREN, M.D., F.R.C.S. ED., Surgeon, Edinburgh Royal Infirmary; Formerly Surgeon in Charge of the Lock Wards, Edinburgh Royal Infirmary; Examiner in the Royal College of Surgeons, Edinburgh. In one handsome Royal 4to Volume, Extra Cloth. Price 63s. nett.

FUNCTIONAL and ORGANIC DISEASES of the STOMACH. By SIDNEY MARTIN, M.D., F.R.S., F.R.C.P., Assistant Physician and Assistant Professor of Clinical Medicine at University College Hospital; Assistant Physician to the Hospital for Consumption and Diseases of the Chest, Brompton. 8vo, Cloth, pp. xvi., 506, Illustrated with numerous Engravings throughout the Text. Price 16s. (1895.)

(Pentland's Medical Series, Volume Fifth.)

A SYSTEM OF GENITO-URINARY DISEASES, SYPHILOLOGY, AND DERMATOLOGY. Edited by PRINCE A. MORROW, M.D. 6 Vols., large 8vo, of about 550 pages each, fully Illustrated. Price per vol. 14s. carriage free.

MANUAL of BACTERIOLOGY. By ROBERT MUIR, M.D., F.R.C.P. ED., Lecturer on Pathological Bacteriology, Edinburgh University; Pathologist to the Royal Infirmary, Edinburgh; and JAMES RITCHIE, M.D., B.Sc., Lecturer in Pathology, University of Oxford. Crown 8vo, Cloth, pp. xvi., 500, with 108 Illustrations in the Text. Price 12s. 6d. [*Pentland's Students' Manuals.*]

PRESCRIBING and TREATMENT IN THE DISEASES OF INFANTS AND CHILDREN. By PHILIP E. MUSKETT, L.R.C.P. & S. ED., late Surgeon to the Sydney Hospital; formerly Senior Resident Medical Officer, Sydney Hospital. Third Edition, Revised and Enlarged, 18mo, pp. xx., 336, in Flexible Leather binding for the pocket. Price 6s. 6d. (1894.)

PRACTICAL TREATISE on MEDICAL DIAGNOSIS. By JOHN H. MUSSER, M.D., Assistant Professor of Clinical Medicine in the University of Pennsylvania; Physician to the Philadelphia and the Presbyterian Hospitals. Royal 8vo, Cloth, pp. viii., 881, Illustrated with 162 Woodcuts and 2 Coloured Plates. Price 24s. (1894.)

MALIGNANT DISEASE of the THROAT and NOSE. By DAVID NEWMAN, M.D., Laryngologist to the Glasgow Royal Infirmary; Assistant Surgeon to the Western Infirmary; Examiner in Pathology in the University of Glasgow. 8vo, pp. xvi., 212, with 3 Illustrations. Price 8s. 6d. (1892.)

TEXT-BOOK of OPHTHALMOLOGY. By W. F. NORRIS, A.M., M.D., and C. A. OLIVER, A.M., M.D. Royal 8vo, pp. viii., 622, Illustrated with 5 Coloured Plates and 357 Woodcuts. Price 25s. (1893.)

LEAD POISONING, ACUTE AND CHRONIC. BEING THE GOULSTONIAN LECTURES DELIVERED AT THE ROYAL COLLEGE OF PHYSICIANS. By THOMAS OLIVER, M.D., F.R.C.P., Physician Royal Infirmary, Newcastle-on-Tyne; Professor of Physiology, University of Durham; Honorary Physician, Newcastle-on-Tyne Dispensary and Industrial Schools. 8vo, Cloth, pp. xii., 121, with Coloured Illustrations. Price 10s. 6d. (1891.)

THE PRINCIPLES and PRACTICE of MEDICINE, Designed for the Use of Practitioners and Students of Medicine. By WILLIAM OSLER, M.D., F.R.C.P., Professor of Medicine in the Johns Hopkins University, and Physician-in-Chief to the Johns Hopkins Hospital, Baltimore. Second Edition, thoroughly Revised and partly Re-written. Large 8vo, Cloth, pp. xvi., 1080, Illustrated with Charts. Price 24s.

LECTURES on ANGINA PECTORIS and ALLIED STATES. By WILLIAM OSLER, M.D., F.R.C.P., Professor of Medicine in the Johns Hopkins University, Baltimore. 8vo, Cloth, pp. viii., 160. Price 6s. *nett.* (1897.)

TREATISE on SURGERY. By AMERICAN AUTHORS. FOR STUDENTS AND PRACTITIONERS OF SURGERY AND MEDICINE. Edited by ROSWELL PARK, A.M., M.D., Professor of the Principles and Practice of Surgery and of Clinical Surgery in the Medical Department of the University of Buffalo, Buffalo, New York; Surgeon to the Buffalo General Hospital, etc. Two Volumes, Large 8vo, Cloth, pp. 1603, with 707 Engravings and 38 full-page Plates in Colours and Monochrome. Price 34s. *nett.* (1897.)

THE SCIENCE and ART of OBSTETRICS. By THEOPHILUS PARVIN, M.D., LL.D., Professor of Obstetrics and Diseases of Women and Children in Jefferson Medical College, Phila-

delphia, and one of the Obstetricians to the Philadelphia Hospital. Third Edition, thoroughly revised, large 8vo, Cloth, pp. 701, with 269 Wood Engravings, and 2 Coloured Plates. Price 18s. (1895.)

BERI BERI : RESEARCHES CONCERNING ITS NATURE AND CAUSE AND THE MEANS OF ITS ARREST. By C. A. PEKELHARING, Professor in the Faculty of Medicine, University of Utrecht ; and C. WINKLER, Lecturer in the University of Utrecht. Translated by JAMES CANTLIE, M.A., M.B., F.R.C.S. 8vo, Cloth, pp. xvi., 160, Illustrated with full-page Coloured Plates from Original Drawings. Price 10s. 6d. nett. (1893.)

REPORTS from the **LABORATORY** of the **ROYAL COLLEGE OF PHYSICIANS, EDINBURGH.** Edited by J. BATTY TUKE, M.D., G. SIMS WOODHEAD, M.D., and D. NOEL PATON, M.D.

VOLUME FIRST, 8vo, Cloth, pp. 212, with 23 full-page Plates, and 19 Engravings. Price 7s. 6d. nett.

VOLUME SECOND, 8vo, Cloth, pp. xiv., 280, with 43 full-page Plates, consisting of Lithographs, Chromo-Lithographs, and Micro-Photographs. Price 10s. 6d. nett.

VOLUME THIRD, 8vo, Cloth, pp. xii., 304, with 11 Plates and Folding Charts. Price 9s. nett.

VOLUME FOURTH, 8vo, Cloth, pp. xii., 254, with 25 Plates and Folding Charts. Price 10s. 6d. nett.

PEDIATRICS : THE HYGIENIC AND MEDICAL TREATMENT OF CHILDREN. By THOMAS MORGAN ROTCH, M.D., Professor of Diseases of Children, Harvard University. Two Vols., large 8vo, pp. 1124, with 450 Illustrations in the Text, and 8 full-page Coloured Plates. Price 25s. nett. (1896.)

TEXT-BOOK of PHYSIOLOGY. By BRITISH PHYSIOLOGISTS. Edited by E. A. SCHAFER, F.R.S., Jodrell Professor of Physiology, University College, London. Two Volumes, Royal 8vo, each pp. xxiv., 950 or thereby, with numerous Illustrations in the Text. *In Press.*

* * The following, among others, will contribute :—Professor BURDON SANDERSON (Oxford), Professor GAMGEE, Dr. GASKELL (Cambridge), Professor GOTCH (Oxford), Professor SHERRINGTON (Liverpool), Professor M'KENDRICK (Glasgow), Professor HALLIBURTON (King's College), Professor HAYCRAFT (Cardiff), Dr.

PEMBREY (Charing Cross), Dr. STARLING (Guy's), Dr. RIVERS (Cambridge), J. N. LANGLEY (Cambridge), the EDITOR, etc. etc.

DISEASES of the MOUTH, THROAT, and NOSE, including RHINOSCOPY AND METHODS OF LOCAL TREATMENT. By PHILIP SCHECH, M.D., Lecturer in the University of Munich. Translated by R. H. BLAIKIE, M.D., F.R.S.E., formerly Surgeon, Edinburgh Ear and Throat Dispensary; late Clinical Assistant, Ear and Throat Department, Royal Infirmary, Edinburgh. 8vo, Cloth, pp. xii., 302, with 5 Wood Engravings. Price 9s. (1886.)

ELEMENTS of PHARMACOLOGY. By Dr. OSWALD SCHMIEDEBERG, Professor of Pharmacology, University of Strasbourg. Translated by THOMAS DIXSON, M.B., Lecturer on Materia Medica in the University of Sydney, N.S.W. 8vo, Cloth, pp. xii. 223, with 7 Illustrations. Price 9s. (1887.)

SURGICAL ANATOMY. A MANUAL FOR STUDENTS. By A. MARMADUKE SHEILD, M.B. (Cantab.), F.R.C.S., Senior Assistant Surgeon, Aural Surgeon and Teacher of Operative Surgery, Charing Cross Hospital. Crown 8vo, Cloth, pp. xvi., 212. Price 6s. (1891.) *(Pentland's Students' Manuals.)*

MEDICAL GYNECOLOGY: A TREATISE ON THE DISEASES OF WOMEN FROM THE STANDPOINT OF THE PHYSICIAN. By ALEXANDER J. C. SKENE, M.D., Professor of Gynecology in the Long Island College Hospital, Brooklyn, New York. 8vo, Cloth, pp. vi., 530, with Illustrations in the Text. Price 21s.

ILLUSTRATIONS of ZOOLOGY, INVERTEBRATES AND VERTEBRATES. By WILLIAM RAMSAY SMITH, B.Sc., and J. STEWART NORWELL, B.Sc. New and Cheaper Edition. Crown 4to, extra Cloth, gilt top, with 70 Plates, exhibiting over 400 Figures. Price 7s. 6d.

EXAMINATION of the EYE. By SIMEON SNELL, F.R.C.S.ED., Ophthalmic Surgeon, Sheffield General Infirmary. Crown 8vo, pp. 150 or thereby, with numerous Illustrations. *In Press.*

DISEASES of the DIGESTIVE ORGANS in INFANTS AND CHILDREN. WITH CHAPTERS ON THE INVESTIGATION OF DISEASE AND ON THE GENERAL MANAGEMENT OF CHILDREN. By LOUIS STARR, M.D., late Clinical Professor of Diseases of Children in the Hospital of the University of Pennsylvania; Physician to

the Children's Hospital, Philadelphia. Second Edition, Post 8vo, Cloth, pp. 396, with Illustrations. Price 10s. (1891.)

EPIDEMIC OPHTHALMIA: ITS SYMPTOMS, DIAGNOSIS, AND MANAGEMENT. By SYDNEY STEPHENSON, F.R.C.S.Ed., Surgeon, Ophthalmic School, Hanwell. 8vo, Cloth, pp. xvi., 278, Illustrated throughout the Text. Price 9s. nett. (1895.)

APPENDICITIS and PERITYPHLITIS. By CHARLES TALAMON, Physician to the Tenon Hospital, Paris. Translated from the French by RICHARD J. A. BERRY, M.B., C.M., late President of the Royal Medical Society, Edinburgh. Crown 8vo, Cloth, pp. viii., 239. Price 6s. (1893.)

THE PATHOLOGY and TREATMENT of VENEREAL DISEASES. By ROBERT W. TAYLOR, M.D., Clinical Professor of Venereal Diseases at the College of Physicians and Surgeons (Columbia College) New York; Surgeon to Bellevue Hospital; and Consulting Surgeon to the City (Charity) Hospital, New York. Royal 8vo, Cloth, pp. 1002, Illustrated with 230 Engravings in the Text, and 7 Coloured Plates. Price 22s. nett. (1896.)

MINOR SURGERY and BANDAGING. INCLUDING THE TREATMENT OF FRACTURES AND DISLOCATIONS, ETC. ETC. By HENRY R. WHARTON, M.D., Demonstrator of Surgery and Lecturer on Surgical Diseases of Children in the University of Pennsylvania. Post 8vo, Cloth, pp. 496, with 403 Engravings. Price 12s. 6d. (1891.)

OUTLINES of ZOOLOGY. By J. ARTHUR THOMSON, M.A., Lecturer on Zoology, School of Medicine, Edinburgh. Second Edition, Revised and Enlarged. Crown 8vo, Cloth, pp. xx., 820, with 266 Illustrations in the Text. Price 15s. (1895.)

(Pentland's Students' Manuals.)

CLINICAL TEXT-BOOK of MEDICAL DIAGNOSIS, BASED ON THE MOST RECENT METHODS OF EXAMINATION. By OSWALD VIERORDT, M.D., Professor of Medicine at the University of Heidelberg. Translated, with additions from the second enlarged German edition, with the Author's permission. By FRANCIS H. STUART, M.D., Member of the Medical Society of the County of Kings, New York. Large 8vo, Cloth, pp. xvi., 700, with 178 fine Engravings, many in Colour. Price 18s. (1891.)

PRACTICAL GUIDE to MEAT INSPECTION. By THOMAS WALLEY, M.R.C.V.S., formerly Principal of the Edinburgh Royal (Dick) Veterinary College ; Professor of Veterinary Medicine and Surgery, &c. Third Edition, thoroughly Revised, pp. xvi., 198, with 44 Figures, mostly in Colours. Price 10s. 6d. (1896.)

DISEASES of the LIVER, GALL BLADDER and BILIARY SYSTEM: THEIR PATHOLOGY, DIAGNOSIS, AND SURGICAL TREATMENT. By H. J. WARING, M.S., B.Sc., F.R.C.S., Demonstrator of Operative Surgery and Senior Demonstrator St. Bartholomew's Hospital ; Senior Assistant Surgeon, Metropolitan Hospital ; Surgeon to the Belgrave Hospital for Children, London. 8vo, Cloth, pp. xvi., 386, with 58 Illustrations. Price 12s. 6d. nett. (1897.)

MANUAL of OPERATIVE SURGERY. By H. J. WARING, M.S., B.Sc., F.R.C.S., Demonstrator of Operative Surgery and Senior Demonstrator of Anatomy, St. Bartholomew's Hospital ; Surgeon, Metropolitan Hospital ; Surgeon to the Belgrave Hospital for Children, London. Crown 8vo, pp. 550 or thereby, with 400 Illustrations in the Text. *In Press.* (*Pentland's Students' Manuals.*

ECTOPIC PREGNANCY. By J. CLARENCE WEBSTER, M.D., F.R.C.P.Ed., Formerly Assistant to the Professor of Midwifery and Diseases of Women and Children in the University of Edinburgh. 8vo, Cloth, pp. xvi., 374, with 22 pages of Plates and Figures throughout the Text. Price 12s. 6d. nett. (1895.)

RESEARCHES in FEMALE PELVIC ANATOMY. By J. CLARENCE WEBSTER, B.A., M.D., M.R.C.P.Ed., Demy 4to, Cloth. Illustrated with 26 full-page Coloured Plates from Original Drawings. Price 30s. nett. (1892.)

TUBO-PERITONEAL ECTOPIC GESTATION. By J. CLARENCE WEBSTER, B.A., M.D., M.R.C.P.Ed. Demy 4to Cloth, Illustrated with 11 full-page Plates, several Coloured, exhibiting numerous Figures. Price 16s. nett. (1892.)

PRACTICAL and OPERATIVE GYNECOLOGY. By J. CLARENCE WEBSTER, M.D., F.R.C.P.Ed., formerly Assistant to the Professor of Midwifery and Diseases of Women, University of Edinburgh. Crown 8vo, Cloth, pp. xvi., 296, with 54 Illustrations. Price 7s. 6d. (1896.) (*Pentland's Students' Manuals.*

MANUAL of DISEASES of WOMEN. By J. CLARENCE WEBSTER, B.A., M.D., F.R.C.P.ED., Demonstrator of Gynecology, McGill University; Assistant Gynecologist, Royal Victoria Hospital, Montreal. Crown 8vo, pp. 650 or thereby, with 300 Illustrations. *In Press.* (*Pentland's Students' Manuals.*)

DIABETES MELLITUS: ITS SYMPTOMS, PATHOLOGY, AND TREATMENT. By RICHARD T. WILLIAMSON, M.D., M.R.C.P., M.R.C.S., Medical Registrar, Manchester Royal Infirmary. 8vo, pp. xvi., 400 or thereby. *In Press.*

TEXT-BOOK of OBSTETRICS, INCLUDING THE PATHOLOGY AND THERAPEUTICS OF THE PUERPERAL STATE. DESIGNED FOR PRACTITIONERS AND STUDENTS OF MEDICINE. By Dr. F. WINCKEL, Professor of Gynæcology and Director of the Royal Hospital for Women. Translated under the supervision of J. CLIFTON EDGAR, A.M., M.D., Adjunct Professor of Obstetrics, University of the City of New York. Royal 8vo, Cloth, pp. 927, Illustrated with 190 Engravings, mostly Original. Price 28s. (1890.)

PRACTICAL PATHOLOGY. A MANUAL FOR STUDENTS AND PRACTITIONERS. By G. SIMS WOODHEAD, M.D., F.R.C.P.ED., Director of the Laboratories of the Royal Colleges of Physicians (London) and Surgeons (England). Third Edition, Revised and Enlarged, 8vo, Cloth, pp. xxiv., 652, with 195 Coloured Illustrations, mostly from Original Drawings. Price 25s. (1892.)

THE JOURNAL of PATHOLOGY and BACTERIOLOGY. Edited, with the collaboration of distinguished British and Foreign Pathologists, by GERMAN SIMS WOODHEAD, M.D., Director of the Laboratories of the Royal Colleges of Physicians (London) and Surgeons (England). Assisted in special departments by SIDNEY MARTIN, M.D., Lond. (*Pathological Chemistry*); G. E. CARTWRIGHT WOOD, M.D., Edin. (*Bacteriology*); C. S. SHERRINGTON, M.D., Cantab. (*Experimental Pathology*); S. G. SHATTOCK, F.R.C.S. (*Morbid Anatomy and Histology*). Issued at Quarterly Intervals. Subscription 21s. per Volume (in advance) post free.

YOUNG J. PENTLAND,

EDINBURGH: 11 TEVIOT PLACE.

LONDON: 38 WEST SMITHFIELD, E.C.

