

**Pathological anatomy of diseases : arranged according to The  
Nomenclature of diseases of the Royal College of Physicians of London /  
by Norman Moore.**

**Contributors**

Moore, Norman, 1847-1922.

**Publication/Creation**

London : J. & A. Churchill, 1889 (London : Ballantyne, Hanson.)

**Persistent URL**

<https://wellcomecollection.org/works/pb3ne7mh>

**License and attribution**

This work has been identified as being free of known restrictions under copyright law, including all related and neighbouring rights and is being made available under the Creative Commons, Public Domain Mark.

You can copy, modify, distribute and perform the work, even for commercial purposes, without asking permission.




Wellcome Collection  
183 Euston Road  
London NW1 2BE UK  
T +44 (0)20 7611 8722  
E [library@wellcomecollection.org](mailto:library@wellcomecollection.org)  
<https://wellcomecollection.org>

STUDENTS

GUIDE SERIES

*Dr. Norman Moore's  
Medical Pathology*





22101613465

9.0  
+  
CQ

**Dr. Geoffrey Evans,  
7, Mansfield Street,  
Portland Place,  
W.I.  
Tel. Langham 1717.**



John D. ...

1872

...

...

*αὐτοψία* non mentis agitatio.—HARVEY.

Dr Matthew Bailey's  
Morbid Anatomy





Digitized by the Internet Archive  
in 2014

<https://archive.org/details/b20408626>

# PATHOLOGICAL ANATOMY OF DISEASES

ARRANGED ACCORDING TO  
THE NOMENCLATURE OF DISEASES OF  
THE ROYAL COLLEGE OF PHYSICIANS  
OF LONDON.

BY  
NORMAN MOORE, M.D.

FELLOW OF THE COLLEGE AND ONE OF THE CURATORS OF ITS MUSEUM  
ASSISTANT PHYSICIAN AND LECTURER ON PATHOLOGICAL  
ANATOMY TO ST. BARTHOLOMEW'S HOSPITAL  
WARDEN OF THE COLLEGE OF ST. BARTHOLOMEW'S HOSPITAL  
ASSESSOR TO THE REGIUS PROFESSOR OF PHYSIC IN  
THE UNIVERSITY OF CAMBRIDGE



LONDON  
J. & A. CHURCHILL  
11 NEW BURLINGTON STREET

1889



95400/29097

-14778467

M15886

WELLCOME INSTITUTE LIBRARY	
Coll.	welMOmec
Call No.	
	QZ4
	1889
	M829
	1

TO  
SIR GEORGE PAGET, K.C.B.,  
FELLOW OF THE ROYAL COLLEGE OF PHYSICIANS  
AND  
REGIUS PROFESSOR OF PHYSIC IN THE UNIVERSITY OF CAMBRIDGE,  
FROM WHOM  
I HAVE RECEIVED CONSTANT ENCOURAGEMENT IN MY  
PROFESSION DURING TWENTY YEARS,

**I Dedicate this Book**

WITH THE WARMEST ADMIRATION  
FOR HIS  
CHARACTER, LEARNING AND SKILL.





## PREFACE.

---

THIS book is based upon observations made for the most part in the post-mortem room of St. Bartholomew's Hospital, where for the last ten years I have taught pathological anatomy, and have myself made two thousand three hundred and sixty post-mortem examinations.

The most learned of bookmen, Dr. Bentley, Master of Trinity College, Cambridge, remarked that in a certain number of years a man might have read all the books worth reading, but whoever has looked into men's bodies knows that there is no such limit in the reading of the characters of disease. Almost every day something never noted before is to be seen in a post-mortem room, and the more time a physician spends there the more is he inclined to feel with Harvey the importance of learning *αὐτοψία*.

To men whose Pathological studies must often terminate with their attendance at a school of medicine it is of no less importance that they should see and



understand as many post-mortem examinations as possible, for thus only can they attain clear notions of disease, sound principles of diagnosis, and accurate views of the right direction of treatment.

In this book I have constantly kept these three objects in mind, and have therefore written most about those subjects which are most likely to be useful to practitioners and students of medicine in the interpretation of their daily clinical observations. I have tried to make clear the anatomical appearances proper to each disease, and to show the direct relation of those appearances to symptoms and to treatment.

I have followed the order of the latest revision of "the Nomenclature of Diseases," issued by the Royal College of Physicians of London, and adopted by the Registrar-General for England as the basis of the registration of deaths.

The morbid anatomy of all the diseases contained in it, which are generally treated by physicians in England, is discussed in these pages.

The chapters of this book correspond to the divisions of the Nomenclature. A few of the terms of the Nomenclature are probably the result of a compromise between conflicting pathological hypotheses, a few others contain reminiscences of obsolete notions of disease, and a few more have become obsolete since the revision of 1885, but as a whole it is worthy of the high authority on which it is



issued, and the more closely it is followed the more useful to science will the registration of disease become.

The table of contents of my book is so arranged that a practitioner wishing to look up the pathological anatomy of a disease mentioned in the Nomenclature will find it in the same order in the table.

In the separate chapters it seemed possible in one or two cases to treat the subject more clearly by adopting another order, this is indicated in the heading of the chapter, while the paging of the table of contents makes it easy to use in relation to the Nomenclature of Diseases.

I should like to have traced the history of the study of pathological anatomy in England, beginning with the numerous observations to be collected from the works of Harvey, many of them made in the very hospital in which this book was written; giving Glisson his due praise as the first English pathologist who wrote a complete monograph on a disease, going on to the discoveries of Willis and Douglas, of Blackall and of Bright, showing how much has been done for the accurate study of medicine through pathological anatomy by Dr. Matthew Baillie, and in our own day by Dr. William Baly, Sir William Jenner, and other great physicians, who have added so much to medicine as the fruit of long days spent in the post-mortem room. This history is worth studying,

because from what has been done in the past it is easy to conclude how much any one may do in the future by the same methods, but with the view of making this book convenient I have left out so much that this must be left out too.

I must not, however, sacrifice to brevity the dues of gratitude. I cannot publish this short treatise without thanking my friend and colleague, Dr. Samuel Gee, from whom I received my first insight into its subject in the post-mortem room of St. Bartholomew's Hospital, as well as Dr. Ormerod, Mr. A. A. Bowlby, Mr. D'Arcy Power, and the numerous students with whom I have been associated in many interesting hours of observation in that room. This book is the fruit of studies in which I owe much to all of them.

THE COLLEGE,  
ST. BARTHOLOMEW'S HOSPITAL,  
ST. LUKE'S DAY, 1889.



# CONTENTS.

---

	PAGE
PREFACE . . . . .	ix

## CHAPTER I.

### METHOD OF OBSERVATION.

Post-mortem examination . . . . .	1
Microscopic examination . . . . .	13
Record . . . . .	16
Certificates of death . . . . .	19

## CHAPTER II.

### MORBID STATES AND PROCESSES.

Hypertrophy . . . . .	24
Atrophy . . . . .	25
Hyperæmia— <i>a.</i> Active ; <i>b.</i> Passive . . . . .	25
Hæmorrhage . . . . .	26
Anæmia . . . . .	26
Dropsy . . . . .	27
Inflammation . . . . .	27
Serous effusion . . . . .	27
Plastic effusion . . . . .	27
Suppuration . . . . .	28
Ulceration . . . . .	28
Gangrene . . . . .	28



	PAGE
Cicatrisation . . . . .	28
Degeneration . . . . .	29
<i>a.</i> Fatty . . . . .	29
<i>b.</i> Calcareous . . . . .	29
<i>c.</i> Fibroid . . . . .	29
<i>d.</i> Mucous . . . . .	29
<i>e.</i> Colloid . . . . .	29
<i>f.</i> Lardaceous . . . . .	29
<i>g.</i> Pigmentary . . . . .	31
New growth . . . . .	31
Cyst-formation . . . . .	45
Tuberculosis . . . . .	46
Mechanical affections . . . . .	46
<i>a.</i> Displacement . . . . .	46
<i>b.</i> Dilatation . . . . .	46
<i>c.</i> Contraction . . . . .	46
<i>d.</i> Stricture . . . . .	48
<i>e.</i> Compression . . . . .	49
<i>f.</i> Plugging (impaction) . . . . .	49
<i>g.</i> Perforation . . . . .	50
<i>h.</i> Laceration . . . . .	50
<i>i.</i> Rupture . . . . .	50
<i>j.</i> Fracture . . . . .	50
Concretion . . . . .	51
Calculus . . . . .	51
Coagulum . . . . .	52
Parasitic invasion . . . . .	52
Errors of development . . . . .	53
Malformation . . . . .	53
Disorders of function ; <i>a.</i> Of excess ; <i>b.</i> Of defect ; <i>c.</i> Of perversion . . . . .	54

## CHAPTER III.

## SPECIFIC FEBRILE DISEASES.

	PAGE
Small-pox . . . . .	56
Cow-pox . . . . .	56
Chicken-pox . . . . .	56
Measles . . . . .	56
Epidemic rose rash (German measles) . . . . .	56
Scarlet fever . . . . .	56
Dengue . . . . .	58
Typhus . . . . .	58
Plague . . . . .	59
Relapsing fever . . . . .	59
Influenza . . . . .	59
Whooping-cough . . . . .	59
Mumps . . . . .	60
Diphtheria . . . . .	61
Cerebro-spinal fever . . . . .	63
Simple continued fever . . . . .	64
Enteric fever . . . . .	64
Yellow fever . . . . .	76
Cholera . . . . .	76
Sporadic cholera . . . . .	77
Epidemic diarrhœa . . . . .	77
Dysentery . . . . .	77
Malarial fever . . . . .	78
Phagedæna . . . . .	80
Erysipelas . . . . .	80
Pyæmia . . . . .	81
Septicæmia . . . . .	83
Syphilis . . . . .	83
Gonorrhœa . . . . .	92
Hydrophobia . . . . .	92
Glanders . . . . .	93
Splenic fever (Wool-sorters' disease) . . . . .	93

## CHAPTER IV.

## DISEASES DEPENDENT ON PARASITES.

	PAGE
Animal parasites . . . . .	94
Vegetable parasites . . . . .	103

## CHAPTER V.

## EFFECTS OF POISONS.

Animal poisons . . . . .	113
Vegetable poisons . . . . .	113
Inorganic poisons . . . . .	113

## CHAPTER VI.

## EFFECTS OF INJURIES AND CLIMATE.

Of the presence of foreign bodies . . . . .	115
Of mechanical injuries . . . . .	114
Of excessive exertion and strain . . . . .	114
Of heat . . . . .	115
Of cold . . . . .	115
Of electricity . . . . .	115
Of chemical agents . . . . .	114
Of climate . . . . .	116

## CHAPTER VII.

## DISEASES PRODUCED BY ERRORS OF DIET.

Surfeit . . . . .	117
Starvation . . . . .	117
Scurvy . . . . .	118
Alcoholism—Delirium tremens . . . . .	118



## CHAPTER VIII.

## DEVELOPMENTAL DISEASES.

	PAGE
Immaturity at birth . . . . .	120
Malformations . . . . .	120
Debility . . . . .	122
Old age . . . . .	124

## CHAPTER IX.

## DISEASES NOT CLASSIFIED.

Rheumatic fever . . . . .	125
Rheumatism . . . . .	127
Gout . . . . .	127
Osteo-arthritis . . . . .	134
Non-malignant new growth . . . . .	134
Malignant new growth . . . . .	134
Tubercle . . . . .	134
Scrofula . . . . .	134
Rickets . . . . .	134
Cretinism . . . . .	137
Myxœdema . . . . .	137
Leprosy . . . . .	139
Purpura . . . . .	139
Anæmia . . . . .	141
Chlorosis . . . . .	142
Idiopathic anæmia . . . . .	142
Leucocythæmia . . . . .	142
Hæmophilia . . . . .	143
Diabetes mellitus . . . . .	143
Glycosuria . . . . .	144

## CHAPTER X.

## DISEASES OF THE NERVOUS SYSTEM.

Hypertrophy . . . . .	146
Atrophy . . . . .	146
Congestion . . . . .	146



	PAGE
Hæmorrhage . . . . .	148
Anæmia . . . . .	152
Chronic hydrocephalus . . . . .	152
Hydrorachis interna . . . . .	153
Meningitis . . . . .	154
Tubercular meningitis . . . . .	156
Syphilitic meningitis . . . . .	162
Encephalitis . . . . .	162
Myelitis . . . . .	163
Anterior polio-myelitis . . . . .	163
Neuritis . . . . .	163
Abscess of the brain . . . . .	163
Softening . . . . .	164
Sclerosis--Insular ; Diffuse ; Miliary . . . . .	165
Progressive muscular atrophy . . . . .	172
Spastic spinal paralysis . . . . .	172
Locomotor ataxy . . . . .	172
Cyst . . . . .	173
Non-malignant new growth . . . . .	173
Malignant new growth . . . . .	174
Tuberculosis . . . . .	174
Syphilitic disease . . . . .	174
Parasitic disease . . . . .	174
Apoplexy . . . . .	175
Paralysis . . . . .	178
Hemiplegia . . . . .	178
Paraplegia . . . . .	179
Local paralysis . . . . .	179
Ophthalmoplegia externa . . . . .	180
Glosso-labio-pharyngeal paralysis . . . . .	180
Acute ascending paralysis . . . . .	180
Diphtheritic paralysis . . . . .	180
Lead palsy . . . . .	180
Pseudo-hypertrophic paralysis . . . . .	180
Infantile convulsions . . . . .	180
Laryngismus stridulus . . . . .	181
Spasm of muscle . . . . .	181

	PAGE
Mercurial tremor . . . . .	181
Paralysis agitans . . . . .	182
Aphasia . . . . .	182
Neuralgia . . . . .	182
Vertigo . . . . .	182
Menière's disease . . . . .	182
Megrim . . . . .	182
Tetanus . . . . .	182
Tetany . . . . .	182
Epilepsy . . . . .	182
Chorea . . . . .	183
Hysteria . . . . .	183
Mental diseases in general . . . . .	184

## CHAPTER XI.

## DISEASES OF THE EYE, EAR, AND NOSE.

## EYE—

Ulcer of cornea . . . . .	185
Tubercle of choroid . . . . .	185
Optic neuritis . . . . .	186
Cataract . . . . .	186
Panophthalmitis . . . . .	186
Squint . . . . .	186
New growth . . . . .	186
Xanthelasma palpebrarum . . . . .	186

## EAR—

Gouty deposit . . . . .	186
Inflammation of middle ear . . . . .	186

## NOSE—

Abscess . . . . .	187
Ozaena . . . . .	187
Necrosis . . . . .	187

## CHAPTER XII.

## DISEASES OF THE CIRCULATORY SYSTEM.

## HEART—

Hæmopericardium . . . . .	192
---------------------------	-----

HEART—*continued.*

PAGE

Hydropericardium . . . . .	192
Pericarditis . . . . .	190
Adherent pericardium . . . . .	191
Endocarditis . . . . .	200
Valvular disease of the heart . . . . .	200
Aneurysm of valves . . . . .	209
Malformation of the heart . . . . .	215
Malignant new growth . . . . .	195
Tubercle . . . . .	193
Syphilitic disease . . . . .	213
Parasitic disease . . . . .	193
Clots in the heart . . . . .	211
Hypertrophy . . . . .	197
Atrophy . . . . .	198
Myocarditis . . . . .	195
Abscess . . . . .	82
Degeneration . . . . .	199
Disease of the coronary arteries . . . . .	215
Dilatation . . . . .	198
Aneurysm of the heart . . . . .	208
Rupture . . . . .	199
Cyanosis . . . . .	223
Angina pectoris . . . . .	214
Syncope . . . . .	214
Palpitation and irregularity of the action of the heart	222

## BLOOD-VESSELS—

## Arteries—

Hypertrophy . . . . .	223
Arteritis . . . . .	223
Degeneration . . . . .	223
Aneurysm . . . . .	224
Rupture of artery . . . . .	224

## Veins—

Phlebitis . . . . .	227
Phlegmasia dolens . . . . .	227



## CHAPTER XIII

## DISEASES OF THE RESPIRATORY SYSTEM.

## NOT STRICTLY LOCAL—

PAGE

Influenza . . . . . 59

Diphtheria . . . . . 61

Whooping-cough . . . . . 59

Croup . . . . . 229

Hay-asthma . . . . . 229

## LARYNX—

Œdema glottidis . . . . . 229

Laryngitis . . . . . 229

Necrosis of cartilages . . . . . 231

Ossification of cartilages . . . . . 231

Non-malignant growth . . . . . 231

Malignant new growth . . . . . 232

Tubercle . . . . . 231

Syphilis . . . . . 231

## TRACHEA AND BRONCHI—

Bronchitis . . . . . 232

Bronchiectasis . . . . . 234

Spasmodic asthma . . . . . 235

## LUNG—

Passive congestion . . . . . 237

Hæmorrhage . . . . . 237

Œdema . . . . . 239

Lobular pneumonia . . . . . 239

Lobar pneumonia . . . . . 240

Abscess . . . . . 244

Vomica . . . . . 246

Pyæmia . . . . . 244

Gangrene . . . . . 243

Cirrhosis (chronic interstitial inflammation) . . . . . 244

Acute pneumonic phthisis . . . . . 244

Chronic pneumonic phthisis . . . . . 244

Aneurysm (of branches of pulmonary artery) . . . . . 248

Malignant new growth . . . . . 248

Tubercle . . . . . 244



LUNG— <i>continued</i> .	PAGE
Emphysema . . . . .	235
Atelectasis . . . . .	250
Collapse . . . . .	250
Embolism . . . . .	250
Parasitic disease . . . . .	252
Mill-stone makers' phthisis . . . . .	252
Grinders' asthma . . . . .	252
Miners' asthma . . . . .	252
PLEURA—	
Hydrothorax . . . . .	252
Pleurisy . . . . .	252
Empyema . . . . .	253
Adhesions, including thickening and calcification . . . . .	252
Malignant new growth . . . . .	254
Tubercle . . . . .	254
Pneumothorax . . . . .	254

## CHAPTER XIV.

### DISEASES OF THE DIGESTIVE SYSTEM.

MOUTH AND FACE—	
Hare lip . . . . .	256
Stomatitis . . . . .	269
Noma . . . . .	269
Malignant new growth . . . . .	269
Syphilis . . . . .	269
Thrush . . . . .	269
JAWS—	
Inflammation of the gums— . . . . .	269
TEETH—	
Syphilitic teeth . . . . .	269
TONGUE—	
Abscess . . . . .	271
Ulcer . . . . .	271
Malignant new growth . . . . .	271
Syphilis . . . . .	271

## PALATE AND FAUCES—

PAGE

Hypertrophy of tonsils . . . . . 271

Quinsy . . . . . 271

Diphtheria . . . . . 61

Malignant new growth . . . . . 271

## SALIVARY GLANDS—

Inflammation—Abscess . . . . . 271

Mumps . . . . . 271

Salivary calculus . . . . . 52

## PHARYNX AND ŒSOPHAGUS—

Post-pharyngeal abscess . . . . . 272

Malignant new growth . . . . . 272

Syphilis . . . . . 272

Dilatation, including diverticula . . . . . 258

Stricture . . . . . 264

Perforation . . . . . 268

Dysphagia . . . . . 272

## STOMACH—

Hæmorrhage . . . . . 275

Gastritis . . . . . 275

Ulceration—Perforating ulcer . . . . . 276

Lardaceous disease . . . . . 284

Non-malignant new growth . . . . . 284

Malignant new growth . . . . . 285

Dilatation . . . . . 290

Contraction . . . . . 291

Stricture . . . . . 264

Hernia . . . . . 291

Perforation . . . . . 291

Dyspepsia . . . . . 291

## INTESTINES—

Hæmorrhage, including Melæna . . . . . 291

Inflammation . . . . . 291

Ulcer . . . . . 291

Lardaceous disease . . . . . 293

Malignant new growth . . . . . 293

Tubercle . . . . . 294

INTESTINES—*continued*.

PAGE

Dilatation—Diverticula . . . . .	258
Stricture . . . . .	264
Intussusception . . . . .	267
Volvulus . . . . .	265
Fistula . . . . .	264
Diarrhœa . . . . .	267

## LIVER—

Hypertrophy . . . . .	307
Atrophy . . . . .	307
Congestion . . . . .	306
Acute yellow atrophy . . . . .	307
Cirrhosis . . . . .	301
Abscess . . . . .	307
Pyæmia . . . . .	307
Fatty liver . . . . .	314
Lardaceous liver . . . . .	305
Cyst . . . . .	46
Malignant new growth . . . . .	315
Tubercle . . . . .	317
Syphilis . . . . .	317
Pylephlebitis . . . . .	318
Hydatid . . . . .	320
Jaundice . . . . .	297

## HEPATIC DUCTS AND GALL-BLADDER—

Inflammation . . . . .	321
Ulceration . . . . .	321
Malignant new growth . . . . .	322
Dilatation of the gall-bladder . . . . .	325
Gallstones . . . . .	299

## PANCREAS—

Abscess . . . . .	329
Cyst . . . . .	327
Malignant new growth . . . . .	333
Obstruction of the duct . . . . .	326
Calculus . . . . .	326



## PERITONÆUM—

PAGE

Ascites . . . . .	337
Peritonitis . . . . .	337
Adhesions . . . . .	339
Hydatid . . . . .	339
Malignant new growth . . . . .	339

## CHAPTER XV.

## DISEASES OF THE LYMPHATIC SYSTEM.

## SPLEEN—

Hypertrophy . . . . .	341
Induration and enlargement from ague . . . . .	341
Leucocythæmia . . . . .	341
Atrophy . . . . .	340
Congestion . . . . .	340
Splenitis . . . . .	343
Abscess . . . . .	343
Lardaceous spleen . . . . .	343
Malignant new growth . . . . .	344
Tubercle . . . . .	343
Embolism . . . . .	344
Parasitic disease . . . . .	345

## LYMPHATICS—

Hypertrophy of lymph-glands . . . . .	346
Atrophy of lymph-glands . . . . .	346
Inflammation of lymph-vessels . . . . .	346
Inflammation of lymph-glands . . . . .	346
Malignant new growth . . . . .	346
Tubercle . . . . .	347
Caseation . . . . .	348
Lymphadenoma (Hodgkin's disease) . . . . .	348

## THYMUS—

Hypertrophy . . . . .	349
Malignant new growth . . . . .	349

## CHAPTER XVI.

## DISEASES OF THE THYROID BODY.

	PAGE
Hypertrophy . . . . .	350
Atrophy (Myxœdema) . . . . .	351
Inflammation . . . . .	351
Goitre . . . . .	351
Malignant new growth . . . . .	353

## CHAPTER XVII.

## DISEASES OF THE SUPRA-RENAL CAPSULES.

Atrophy . . . . .	355
Malignant new growth . . . . .	355
Tubercle . . . . .	355
Addison's disease . . . . .	356

## CHAPTER XVIII.

## DISEASES OF THE URINARY SYSTEM.

## KIDNEY AND DUCTS—

Hypertrophy . . . . .	359
Atrophy . . . . .	361
Passive congestion . . . . .	362
Acute nephritis . . . . .	363
Bright's disease . . . . .	364
Chronic parenchymatous nephritis . . . . .	368
Chronic interstitial nephritis . . . . .	364
Pyelitis . . . . .	370
Abscess . . . . .	371
Lardaceous kidney . . . . .	370
Cysts . . . . .	371
Cystic disease . . . . .	371
Hydronephrosis . . . . .	373
Malignant new growth . . . . .	373
Tubercle . . . . .	375
Syphilis . . . . .	376
Movable kidney . . . . .	376

KIDNEY AND DUCTS— <i>continued</i> .	PAGE
Calculus . . . . .	376
Embolism . . . . .	378
Parasitic disease . . . . .	379
Malformations . . . . .	381
URINARY DISORDERS—	
Diabetes mellitus . . . . .	381
Glycosuria . . . . .	381
Diabetes insipidus . . . . .	381
Suppression of urine . . . . .	382
Hæmaturia . . . . .	382
Intermittent hæmaturia . . . . .	383
Albuminuria . . . . .	383
Chyluria . . . . .	384
Lithuria ; Oxaluria ; Phosphuria . . . . .	384
BLADDER—	
Hypertrophy . . . . .	384
Hæmorrhage . . . . .	384
Inflammation . . . . .	384
Sacculation . . . . .	386
Ulceration and sloughing . . . . .	385
Non-malignant new growths . . . . .	385
Malignant new growths . . . . .	385
Vesico-intestinal fistula . . . . .	386
Recto-vesical fistula . . . . .	387
Vesico-vaginal fistula . . . . .	387
Calculus . . . . .	387

## CHAPTER XIX.

## DISEASES OF THE GENERATIVE SYSTEM.

Diseases of the male organs of generation . . . . .	390
Diseases of the ovary . . . . .	391
Diseases of the Fallopian tube . . . . .	393
Diseases of the uterus and vagina . . . . .	395
Diseases of the breast . . . . .	397
Parturition . . . . .	397



## CHAPTER XX.

## DISEASES OF THE ORGANS OF LOCOMOTION.

BONES (EXCLUSIVE OF THE SPINE)—	PAGE
Osteitis . . . . .	398
Osteitis deformans . . . . .	399
Periostitis . . . . .	399
Necrosis . . . . .	399
Mollities ossium . . . . .	399
New growth . . . . .	399
JOINTS—	
Gout . . . . .	127
Rheumatism . . . . .	127
Gonorrhœal arthritis . . . . .	125
Chronic osteo-arthritis . . . . .	134
SPINE—	
Psoas abscess . . . . .	401
Pott's disease . . . . .	401
DISEASES OF THE MUSCLES . . . . .	402
DISEASES OF TENDONS AND FASCIÆ . . . . .	402

## CHAPTER XXI.

## DISEASES OF THE CONNECTIVE TISSUE AND SKIN.

Hæmorrhage . . . . .	403
Œdema . . . . .	403
Bed-sore . . . . .	404
Malignant new growth . . . . .	404

## LIST OF ILLUSTRATIONS.

FIG.	PAGE
1. COLLOID DEGENERATION . . . . .	30
2. ENDOTHELIOMA . . . . .	33
3. ENDOTHELIOMA . . . . .	34
4. ENDOTHELIOMA . . . . .	34
5. ENDOTHELIOMA . . . . .	35
6. MELANOTIC SARCOMA . . . . .	36
7. LYMPHO-SARCOMA . . . . .	39
8. MELANOTIC SARCOMA . . . . .	40
9. TRANSPOSITION OF VISCERA . . . . .	47
10. DILATATION OF LEFT AURICLE . . . . .	48
11. DILATATION OF ŒSOPHAGUS . . . . .	49
12. PERFORATION IN THE FLOOR OF A SIMPLE ULCER OF THE STOMACH . . . . .	51
13. GALL-STONES IN GALL-BLADDER . . . . .	51
14. HYDATID CYST OF LIVER (FOLDED CYST WALLS) . . . . .	52
15. FOOT WITH SIX TOES . . . . .	53
16. FIRST STAGE OF ENTERIC FEVER . . . . .	65
17. SECOND STAGE OF ENTERIC FEVER . . . . .	66
18. THIRD STAGE OF ENTERIC FEVER . . . . .	67
19. ADULT BILHARZIA HÆMATOBIA . . . . .	95
20. OVA OF BILHARZIA HÆMATOBIA . . . . .	96
21. HYDATID OF LIVER (COMPLETE DAUGHTER CYSTS) . . . . .	98
22. HYDATID OF LUNG . . . . .	100
23. DOCHMIUS DUODENALIS . . . . .	102
24. JAW OF PHOSPHORUS POISONING . . . . .	106
25. LIVER OF TIGHT-LACING . . . . .	115



FIG.	PAGE
26. TRANSPOSITION OF VISCERA . . . . .	121
27. HEART FROM A CASE OF CYANOSIS . . . . .	122
28. MECKEL'S DIVERTICULUM . . . . .	123
29. FOOT WITH SIX TOES . . . . .	124
30. MITRAL STENOSIS . . . . .	126
31. ANCHYLOSIS OF FINGER JOINTS . . . . .	128
32. RIBS OF RICKETS . . . . .	135
33. THYROID OF MYXŒDEMA . . . . .	138
34. HAND WITH CHALK STONES . . . . .	144
35. CEREBRAL HÆMORRHAGE . . . . .	147
36. DILATATION OF CENTRAL CANAL OF SPINAL CORD . . . . .	154
37. CASEOUS TUMOUR OF CEREBELLUM . . . . .	159
38. NERVE OF PERIPHERAL NEURITIS . . . . .	164
39. BRAIN OF DISSEMINATED SCLEROSIS (ADULT) . . . . .	165
40. THREE SECTIONS OF SPINAL CORD OF DISSEMI- NATED SCLEROSIS . . . . .	166
41. POSITION OF LIMBS IN DISSEMINATED SCLEROSIS . . . . .	167
42. BRAIN OF CHILD WITH DISSEMINATED SCLEROSIS (UPPER SURFACE) . . . . .	169
43. BRAIN OF CHILD WITH DISSEMINATED SCLEROSIS (LEFT SIDE) . . . . .	170
43 <i>a</i> . BRAIN OF CHILD WITH DISSEMINATED SCLEROSIS (RIGHT SIDE) . . . . .	171
44. TUMOUR OF CEREBELLUM . . . . .	175
45. PERIPHERAL NEURITIS (NERVE) . . . . .	181
46. ROUND-CELLED SARCOMA (MEDIASTINUM) . . . . .	189
48. ENDOTHELIOMA OF PERICARDIUM . . . . .	193
49. ENDOTHELIOMA IN LUNG . . . . .	194
50. ENDOTHELIOMA ON CLAVICLE . . . . .	190
51. GROWTHS ON MITRAL VALVE . . . . .	202
HEART OF MITRAL REGURGITATION . . . . .	204
53. STENOSIS OF MITRAL VALVE (DILATATION OF AURICLE) . . . . .	205
54. STENOSIS OF MITRAL VALVE . . . . .	206
55. ANEURYSM OF MITRAL VALVE . . . . .	206
56. HÆMORRHAGIC INFARCTION OF SPLEEN . . . . .	211



FIG.	PAGE
57. ANTE-MORTEM GLOBULAR CLOT . . . . .	212
58. MALFORMATION OF HEART . . . . .	215
59. STENOSIS OF PULMONARY VALVE . . . . .	219
60. PATENT SEPTUM VENTRICULORUM . . . . .	222
61. ŒDEMA GLOTTIDIS . . . . .	230
62. SPUTUM OF PLASTIC BRONCHITIS . . . . .	233
63. BRONCHIECTASIS . . . . .	234
64. EMPHYSEMA OF LUNG . . . . .	236
65. ANEURYSM OF PULMONARY ARTERY . . . . .	238
66. TUBERCULOUS ULCERATION OF SMALL INTESTINE	247
67. ENDOTHELIOMA IN LUNG . . . . .	249
68. HYDATID OF LUNG . . . . .	251
69. MECKEL'S DIVERTICULUM . . . . .	257
70. NECROSIS OF JAW . . . . .	270
71. CARCINOMA OF ŒSOPHAGUS . . . . .	273
72. SIMPLE ULCER OF STOMACH . . . . .	277
73. DILATATION OF STOMACH . . . . .	286
74. CARCINOMA OF STOMACH . . . . .	287
75. MICROSCOPIC SECTION OF CARCINOMA OF STOMACH	288
76. PERFORATING ULCER OF STOMACH . . . . .	290
77. ULCER OF DUODENUM . . . . .	292
78. LYMPHO-SARCOMA IN SMALL INTESTINE . . . . .	294
79. GALL-STONES . . . . .	299
80. CIRRHOSIS OF THE LIVER . . . . .	303
80a. CARCINOMA OF LIVER . . . . .	315
81. MELANOTIC SARCOMA OF LIVER . . . . .	316
82. THICKENING OF CAPSULE OF LIVER . . . . .	318
83. HYDATID OF LIVER . . . . .	320
84. OLDER HYDATID OF LIVER . . . . .	321
85. GALL-BLADDER FILLED WITH STONES . . . . .	321
86. CYST IN HEAD OF PANCREAS . . . . .	327
87. INFARCT OF SPLEEN . . . . .	345
88. LYMPHO-SARCOMA OF PEYER'S GLAND . . . . .	347
89. LYMPHO-SARCOMA OF ANTERIOR MEDIASTINUM .	348
90. ATROPHY OF THYROID GLAND . . . . .	350
91. GOITRE . . . . .	351
92. SARCOMA OF SUPRA-RENAL BODY . . . . .	356

FIG.	PAGE
93. HYPERTROPHY OF KIDNEY . . . . .	360
94. ATROPHY OF KIDNEY . . . . .	361
95. CYSTS ON KIDNEY . . . . .	365
96. CYSTIC KIDNEY . . . . .	372
97. RENAL CALCULUS . . . . .	377
98. BILHARZIA IN WALL OF BLADDER . . . . .	379
99. ADULT BILHARZIA . . . . .	380
100. HORSE-SHOE KIDNEY . . . . .	380
101. KIDNEY OF PURPURA HÆMORRHAGICA . . . . .	383
102. CARCINOMA OF BLADDER . . . . .	385
103. SACCULATION OF BLADDER . . . . .	386
104. URIC ACID CALCULUS . . . . .	387
105. OXALATE OF LIME CALCULUS . . . . .	388
106. BILHARZIA IN BLADDER . . . . .	388
107. OVARIAN CYST . . . . .	391
108. DERMOID CYST . . . . .	392
109. MYO-FIBROMA OF UTERUS . . . . .	394
110. CALVARIA SHOWING BOSSES . . . . .	398

All the drawings were made from specimens by Mr. Leonard Mark, L.R.C.P., M.R.C.S., except 2, 3, 4, 5, 6, 12, 13, 14, 16, 18, 21, 26, 41, 42, 43, 48, 49, 50, 54, 64, 67, 76, 79, 83, 89, which were drawn by the late Mr. Thomas Godart; 1 and 75 by Dr. S. K. Alcock; 39, 40, and 73 by myself, and 74 by A. L. Moore; 97, 102, 103, 104, 105 are borrowed from Mr. Bowlby's "Surgical Pathology."

## DIAGRAMS.

- I. NEW GROWTHS IN HEART.
- II. NEW GROWTHS IN LUNGS.
- III. CARCINOMA OF ŒSOPHAGUS.
- IV. CARCINOMA OF STOMACH.
- V. CARCINOMA OF COLON.
- VI. CARCINOMA OF RECTUM.
- VII. CARCINOMA OF GALL BLADDER.
- VIII. CARCINOMA OF PANCREAS.



# PATHOLOGICAL ANATOMY

OF

## DISEASE.

---

### CHAPTER I.

#### POST-MORTEM EXAMINATIONS.

ORDER OF EXAMINATION.	RECORD OF OBSERVATIONS.
MICROSCOPIC EXAMINATION.	DEATH CERTIFICATE.

It is by post-mortem examination, following clinical observation, that the greatest additions have been made to the knowledge of medicine.

Apoplexy was for centuries explained as a confusion or interruption of certain imaginary spirits, till Wepfer by post-mortem examination proved that this state of sudden unconsciousness was generally due to hæmorrhage into the brain.

Enteric fever and typhus fever, which in some cases give rise to the same symptoms, were thought to be varieties of the same disease, till Dr. A. P. Stewart in 1836 observed that their anatomical lesions were distinct.

By the same method Bright demonstrated the constant relation between the large pale kidney of parenchymatous nephritis, dropsy, and albuminuria.



It would be easy to multiply examples which prove how much has been learned in the post-mortem room. Every one who studies medicine soon comes to feel how just was the inclination of Harvey to look upon those facts as best established which were so *αὐτοψία*. He often uses the expression, and was convinced, as every one must be who makes post-mortems, that the soundest knowledge of disease is to be attained by the physician seeing for himself after death the anatomical changes of the disease which had been the subject of his clinical observation.

A post-mortem examination should, in this country, be made about twelve hours after the patient's death. In hospitals, and wherever careful notes are made of the cases during life, leave for a post-mortem examination should, if possible, be obtained in every case. It is important to remember that most valuable additions may be made to pathology by the examination of cases of common diseases, and that it is a mistake only to examine rare cases.

Before making a post-mortem examination of a body, it is advisable to oil the hands all over, or to put on photographer's gloves.

The painful pustules which sometimes appear on the hands of the pathologist are generally due to dead matter getting into a hair follicle, and they may be prevented by wearing gloves or by very careful oiling.

Cuts should be allowed to bleed freely and washed with warm water, or immediately washed and sucked.

If red lines on the arm and swollen lymphatics ensue, the arm should be kept in hot water till they subside.

In the post-mortem examination of a case of pyæmia, if the hands smart it is well to wash them and re-oil them during the examination.

It is advisable to take a meal before making a post-mortem examination.

The necessary inhalation of the gases of decomposition causes a greater feeling of fatigue after making



post-mortem examinations than the physical exertion alone would cause.

The following are the instruments necessary for making a thorough post-mortem examination :—

Saw.	One large knife.
Scissors.	Needle.
Large scissors with hook at the end of one blade, for opening the intestines.	String.
Two or more scalpels.	Blunt chisel with cross handle all of one piece of steel.
	Hammer.

The first point is to examine the whole external surface. Wounds and bruises are, of course, to be sought; but where injuries are known to be absent, careful external examination is nevertheless profitable.

Is the body emaciated, or fat, or jaundiced, or dropsical? Are any traces of rash or of desquamation to be observed? Are there scars of old ulcers or of sores? Is rigor mortis present? Are there any signs of putrefaction?

Purplish tracts of skin in the most dependent parts are generally to be seen in the bodies of well-nourished people.

**Head.**—The external appearances having been noted, it is best to proceed to open the head. A cut must be made through the scalp from ear to ear over the vertex.

The scalp must then be skinned off down to the supra-orbital ridge and below the occipital protuberance.

The skull must next be sawn through. The best plan is to begin to saw in front just above the roof of the orbit, and to continue all round to a point just below the occipital protuberance.

In doing this an angle should be made in the saw line just above the ear instead of sawing level all round, because it is then easier afterwards to fit on the calvaria. It is best not to saw quite through the



inner table of the skull all round, but to raise the bone by a gentle lever action with the chisel.

The dura mater, having been examined, should be cut through and removed. It must be borne in mind that in young children the dura mater is too firmly adherent to the calvaria for the bone to be removed separately.

The convexity of the brain can now be seen, and the condition of its membranes and vessels noted. The veins are generally fuller at the back of the brain than in the front, owing to the body having been lying on its back.

The inner surface of the calvaria must be examined; sometimes great deepening of the meningeal grooves may be noticed, or in children patches of craniotabes.

The cerebral hemispheres may be separated gently, in order to see whether the corpus callosum is flat or arched. Is there any bulging of the hemispheres on either side? The state of the Pacchionian bodies is to be observed. They are often large on each side of the longitudinal fissure and must not be mistaken for the results of disease.

The brain is now to be removed by raising it in front and cutting through the nerves in order and through the tentorium cerebelli. The upper part of the spinal cord can be divided and the brain lifted out. When in the beginning of this proceeding the frontal lobes are raised, note must be made of whether there is any lymph about the optic chiasma, and then of whether there is any fluid in the sub-arachnoid space.

It will be well next to look carefully at the base of the skull, to open the sinuses, and observe the condition of any clots they may contain, and particularly whether these are adherent or non-adherent. The petrous part of the temporal bone should be carefully examined, as it is the most frequent region of necrosis within the skull, and the dura mater should be carefully stripped off from the base of the skull.

The examination of the brain is the next proceeding.



It must be placed convexity downwards. Are the vessels of the circle of Willis natural or degenerate? If degenerate, do they exhibit aneurysm or rupture? Are there any superficial hæmorrhages into the arachnoid or beneath the pia mater? The Sylvian fissures must be looked at. Are their sides adherent? Are their arteries normal, or are they atheromatous or aneurysmal, or does the main artery or do any of its branches contain an embolus?

Are tubercles to be seen in any part of the lymphatic sheaths of the vessels or anywhere in the pia mater?

The pia mater must next be carefully stripped off and the state of the convolutions noted.

A cut made on each side from within the longitudinal fissure outwards at the level of the corpus callosum will lay open the lateral ventricles. Are they dilated? Do they contain blood, or does an abnormal quantity of fluid flow from them? Are their walls softened or torn at any part? Is the foramen of Monro dilated?

The corpus callosum may now be cut through in front and turned back. The third ventricle, middle commissure, and corpora quadrigemina can thus be examined, with the posterior cornua of the lateral ventricles, the choroid plexus, and the pineal gland.

The subsequent examination will necessarily vary with the nature of the case. In cases of hæmorrhage perhaps the best plan is to make slices horizontally in the corpus striatum and optic thalamus, as thus the outer and inner capsule and the lenticular nucleus are best seen.

The brain may now again be turned base upwards, and transverse sections made in the crura cerebri and in the pons Varolii.

The cerebellum is best divided in horizontal layers.

Lastly, transverse sections must be made in the medulla oblongata.

The eye is best examined (in a general medical post-mortem) by breaking through the roof of the orbit



with a chisel from above in the floor of the skull, and then cutting through the sclerotic behind the iris. Thus the lens, choroid, and retina may be examined while the front of the eye remains uninjured. The ear is best examined by sawing out the part of the temporal bone containing it, and then exposing its parts by further sections in the sawn-out piece.

**Spinal Cord.**—The spinal cord may best be removed by turning the body face downwards. A cut must be made down the middle line of the back, and the muscles dissected away from the laminae of the vertebrae.

The spinal canal can then be exposed by sawing on each side and the divided laminae raised with a chisel.

The dura mater may then be divided all down after carefully noting the condition of its surfaces. Cuts through the spinal nerves will then make it possible to take out the cord as a whole. The cord must not be pulled in doing this.

The condition of the central canal must be noted, and transverse sections of the cord made throughout its length.

**Chest.**—The body cavity is next to be opened; a cut must be made through the skin and subcutaneous tissue and muscles from just beneath the chin to the symphysis pubis, guiding the knife to left of the umbilicus, and the flap carefully turned back.

The condition of the cervical vessels, and lymphatic glands—of the thyroid body and of the outer surface of the trachea, may be at once noted, as well as the state of the chest walls.

The costal cartilages must be divided with a knife, or, if calcified, with a saw; the sterno-clavicular joints separated, the front of the diaphragm cut through, and the sternum removed.

At this point in a child the presence or absence of beads on the ribs (due to rickets) should be looked for.

Do the lungs shrink into the pleural cavities, or do they bulge out and cover the pericardium? Does



either pleural sac contain fluid? if any, how much and of what kind?

Before removing the lungs the heart had better be examined. Is it freely movable in the pericardium? Is the outer surface of the pericardium anywhere adherent to the chest wall? Are there any remains of the thymus gland in an adult? What is its condition in a child?

An oblique cut will open the pericardium if not adherent. If adherent it must, if possible, be dissected off. When the pericardial sac is opened, is it dry, or does it contain the normal amount of fluid or more than natural? and if so, what is the nature of the fluid? Are the surfaces of the pericardium smooth or roughened with lymph? has it any milk-spots on it? The heart must be seized in the left hand near the apex and drawn upwards. The great vessels may then be cut through in order—inferior vena cava, superior vena cava, aorta, pulmonary veins, pulmonary artery.

The aortic and pulmonary valves when cleared from clot, if any be present, should at once be tested as to their competence by pouring a stream of water into the cut end of the aorta or pulmonary artery.

The heart is then to be laid upon its front surface with its base and back towards the anatomist, and to be opened in the course of the circulation. The superior and inferior vena cava are to be joined by a cut, and then the appendix of the right auricle to be slit up; a full view of the right auricle will thus be obtained. Are its walls normal? Is the foramen ovale closed? Are there any adherent, probably ante-mortem clots, in the appendix or anywhere else? What is the size of the tricuspid orifice? does it admit three fingers, its normal width, or is it wider, or narrower, than this? Would it have permitted regurgitation or caused obstruction. A scissors cut may now be made down the back of the heart close to the septum to the apex and up the front of the right



ventricle, and keeping close to the septum through the pulmonary artery. If the scissors be kept close to the septum, they will pass between two of the pulmonary valves. The right ventricle is thus laid open. The tricuspid valve may be minutely examined. Is its edge at all thickened? Are any of its cords thickened at their insertion into the valve, where they ought to spread out in a fine web, or in any other part of their length? Are there any clots in the right ventricle? Are they adherent or non-adherent, rough or smooth on the surface, of uniform texture within and without, or firm externally and softened within? What is the state of the pulmonary valves? are they fenestrated or thickened? are they adherent to one another? have they any growths upon them? What is the thickness of the right ventricle?

It ought in an adult to measure about one-eighth of an inch in thickness; does it measure more? Does its cavity look dilated? Is its muscular tissue normal in colour and texture? The left auricle must next be examined by removing the pulmonary veins. Its endocardium is always thicker than that of the right auricle. What is the state of the valve of the coronary sinus? Is the coronary sinus dilated? How many fingers will the mitral orifice admit? In the normal adult heart it commonly admits two.

The ventricle must now be opened down the back and up the front, in both cases by a cut made close to the septum and finally passing through the aortic orifice. The edge and cords of the mitral valve are to be minutely examined. The heart is now to be held up by the apex and the bare spot looked at. Is it aneurysmal or perforate?

All clots must be examined and considered, and the state of the muscular tissue. Its normal thickness at its thickest part is half an inch. Is this exceeded or diminished? The aortic valves having been examined for growths, adhesions, thickenings,



and perforations, the state of the orifices of the coronary arteries and the arteries themselves will be determined. Is the first part of the aorta normal, or does it show any degeneration? The heart should now be weighed. Its normal weight in a man is 10 oz.; in a woman,  $8\frac{1}{2}$  oz. Does it weigh more or less? If either, consider whether the cause has been found in the heart itself, or does it remain to be discovered elsewhere in the body? More precise measurements of the valvular orifices may be made by graduated wooden cones, but it may be doubted whether these measurements are precise indications of the width of the auriculo-ventricular orifices during life.

The pleuræ and their contents must next be examined. Are they smooth or rough, and are there any adhesions? Do they contain little or much fluid, or none? If present, is it clear or purulent, or does lymph float in it, or is it blood-stained?

The lungs may next be removed.

It is sometimes desirable to take them out in one piece, with the trachea and larynx; as, for example, in a case of diphtheria, where it is important to trace the false membrane from the larynx into the bronchi.

Ordinarily, however, it is easier to take the lungs out separately. Each must be drawn out across the middle line, and its root cut through. Adhesions will have to be broken down, and their situation should be noticed. Anything exuding from the bronchus should be noticed as it is cut across.

The lungs should next be weighed. In an adult man a healthy left lung weighs about 21 oz; a right lung, 23 oz. Is this weight exceeded, as in pneumonia, or diminished, as in emphysema? The surface should be examined for recent lymph or organized lymph, for scars, for the bases of recent infarcts, or for specks or nodules of new growth or of tubercle.

The edge of the lung should be thin and even. It ought to be held up to the light to see whether it is



made irregular by emphysematous vesicles. It is sometimes desirable to slit up the pulmonary artery, as in search for an infarct, or the bronchus for false membrane; and the large branches of both should always be so opened. Then a cut should be made laying open the whole lung, and whether the section is normal or solid, œdematous or dry, should be noted. If cavities or caseous masses or calcareous masses are present, their size and position should be noted, as well as the contents of cavities, whether purulent or blood-stained. The bronchial glands should be divided and examined for pigment, tubercle, caseous or calcareous material.

**Neck.**—The sympathetic and pneumogastric nerves should be dissected out before proceeding to the removal of the trachea and œsophagus.

The trachea and larynx are best removed with the œsophagus. A cut having been made on each side into the floor of the mouth and the genio-hyo-glossus muscle on each side having been divided, the tongue should be drawn forward below the symphysis of the jaw, and the part removed by dissecting through the tissue on each side of the neck. When the piece is removed the œsophagus should be slit up with scissors, examined, and then dissected off the back of the trachea; the trachea and larynx should then be opened by a cut made along their posterior aspect. The thyroid body should be divided and the condition of the cervical lymphatics noted.

**Abdomen.**—The contents of the peritoneum are of course looked at when the body is laid open, and any contained fluid examined.

Of the viscera the liver should be first removed. A finger having been passed through the foramen of Winslow, its upper wall should be divided and the suspensory ligaments of the liver cut through in order.

The condition and contents of the gall-bladder and of the bile-ducts and of the glands in the hilum of the liver must be noted.



Cuts must then be made into the several lobes so as thoroughly to examine the interior of the organ, and the main branches of the portal vein ought to be laid open and the liver weighed. Does it weigh more or less than its normal weight in the adult, which is about 50 oz.?

The spleen should next be drawn forward, separated from any adhesions, and taken out of the body by cutting through the gastro-splenic mesentery. Sections of it must be made, and it should be weighed. Its normal weight is about 5 oz.

The stomach and intestines may now be removed.

The most convenient plan is to tie the uppermost part of the jejunum and remove the stomach and duodenum first, with the pancreas, and then the rest of the alimentary canal by cutting through the mesentery, and finally by cutting across the rectum, noting all along any adhesions. The stomach and duodenum should be opened in a large dish by a cut along the greater curvature. The mucous surface and the contents should then be minutely examined and described. The duodenum must also be opened and the condition of the papilla of the bile duct examined. Sections of the pancreas must be made.

The small intestine should be filled with water from a tap, and opened with scissors along its mesenteric side, as ulcers are thus best preserved. The large intestine must also be opened. The whole mucous surface should then be scanned.

The mesentery and mesenteric glands must next be removed and examined.

The aorta and vena cava are now fully exposed, and should be opened and their interior examined.

Before removing the kidney it is desirable to dissect out the semilunar ganglia and examine their condition.

The supra-renal bodies and kidneys and ureters should be removed by cuts made through the peritoneum, and it is often desirable to take out the



bladder (cutting across the urethra) at the same time without separating the ureters. In every case the ureters should before removal be examined throughout their course from the kidney to the bladder.

Each supra-renal must be divided and its appearance on section noted.

Each kidney should be weighed and then opened by a section from the back into the pelvis. The degree of attachment of the capsule to the kidney, and the width of the cortex and the condition of the pelvis, should be noted.

The bladder and ureters should be cut open with a scissors. When the bladder is full, it is desirable to collect a specimen of its contents for chemical examination.

The prostate should be cut across in several places so as to expose abscesses, calculi, or other morbid changes.

It is very important before leaving the abdomen to look at the lumbar and inguinal glands and to make sections of them, and to observe the condition of the vertebræ. The psoas and iliacus muscles should be cut across, as unsuspected abscess may thus be discovered. The terminal portion of the rectum is a frequent seat of unsuspected new growth and must be closely examined.

The abdominal rings, spermatic cords, and testes may be examined by dissection from above, and it is desirable to expose the contents of Scarpa's triangle, and to open the artery and vein.

A catheter ought to be passed down the urethra.

The uterus is to be removed with the ovaries; each ovary is to be drawn forward and its peritoneal attachments divided, and then the vagina cut across.

Sections must be made in the walls of the uterus, and its cavity laid open from behind. A section must be made of each ovary, and the Fallopian tube cut across so that any thickening of its walls or occlusion of its lumen may be observed.



The head, chest, back, and abdomen, having thus been thoroughly examined, it may be desirable to dissect out the great veins of the arms and legs in case of thrombus, the arteries in case of aneurysm, and the nerves in peripheral neuritis.

The metatarso-phalangeal and phalangeal joints of the great-toe should be opened, and any erosion or deposit noted. The knees should also be opened, and the condition of the synovial sac and of its fluid and of the cartilages examined.

A single cut through the integuments is sufficient; the rectus femoris may be divided subcutaneously, and thus the surfaces of femur, patella, and tibia easily examined.

In some diseases, as in gout, hæmophilia, and chronic arthritis, it is desirable to open as many joints as possible.

**Microscopic Examination.**—Small pieces, one-third to one-half inch cube, of the parts to be examined should at once be placed in a 2 per cent. solution of bichromate of potassium. The bottle ought to be carefully labelled. In this solution they are to remain about three weeks, the fluid being changed every four days.

They are then to be put into the same bottle in methylated spirit, and must there remain about a week more, the spirit being changed once during that time.

Some structures harden sooner than others. When distinctly hard the pieces are ready for cutting. Sections are most easily cut with an ether freezing microtome. The piece to be cut must be taken out of spirit, put into water and left there for about twelve hours. It must then be placed in a solution of gum arabic for four hours. It will then freeze easily when placed on the plate of the microtome.

Fine sections cut with the sliding razor are to be placed as soon as cut into warm water. This removes the gum.



They are next put into hæmatoxylin solution, and left to stain for a time varying with the tissue. If by chance too deeply stained, they can be washed in a little distilled water.

The sections are next placed in a watch-glass containing rectified spirit, and finally for a few seconds in absolute alcohol to remove all water from their interstices.

They are then to be put into oil of cloves, and may there await mounting at the observer's leisure.

They are to be lifted by section-lifter from the oil of cloves on to glass slides, and the oil of cloves which flows out is to be removed by small pieces of blotting-paper. When this has been done a thin cover-glass with a drop of Canada-balsam upon it is placed, balsam downwards, on the specimen. The specimen is now complete and may be left to dry.

This general method of preparation is suitable for most structures, and displays well the characters of all inflammations and new growths.

The hæmatoxylin stains the nuclei of all cells and thus makes them distinct.

Old connective tissue and non-cellular structures are but little stained, or not at all.

Picrocarmine may also be used with advantage when contrast makes the structure clearer. It stains epithelial structures yellow, and connective tissue pink.

The student is recommended to proceed upon a uniform method, and not to devote much time to varied processes.

A few special methods are, however, such important helps to investigation, that they ought to be practised.

1. In examination of fatty structures:—The specimen may be frozen fresh and then placed in osmic acid ( $\frac{1}{4}$  per cent. strength), and left to stand in the dark. When subsequently exposed to light the fatty globules are everywhere black, and are thus easily recognized. The liver of phosphorus poisoning and



of fatty infiltration—the heart with fatty degeneration of muscular fibres—are examples, structures of which some sections ought to be stained in osmic acid.

The brain and spinal cord may be hardened, like other tissues, in potassium bichromate solution. They require to remain in it for a longer time, and should never be left long in spirit, and may often be safely cut without going into spirit at all.

Nerves are best placed at once in osmic acid ( $\frac{1}{4}$  per cent. strength), to be cut when hard.

Amyloid degeneration. Organs infiltrated with amyloid material, if stained in logwood show the amyloid material as an opaque partially stained substance contrasting with the well-stained cellular structures.

Methyl violet ( $\frac{1}{4}$  per cent. solution) stains very well fresh sections of organs infiltrated with amyloid material. The amyloid substance is stained of a light pink colour. A needle must not be used in mounting, and the specimen should be mounted in Farrant's solution, a preparation of glycerine, gum and arsenious acid.

Bacilli, micrococci, and other micro-organisms are demonstrated in a tissue or discharge by means of selective stains which remain when the colour has been discharged from the rest of the specimen by another reagent.

Bacteriology has grown to be a special department of study, in the manuals of which, by Klein and others, full details of the several processes will be found.

All microscopic specimens should be examined first with a low power, then with a high. The low power will teach the general relations of the parts of the specimen; the high, the characters of the particular cells. With regard to all new growths, it must be remembered that the microscopic characters alone are often insufficient to determine the nature of the



growth, but that they are one of the observations essential to that determination.

**Record of Observations.**—To complete the value of a post-mortem examination, a careful record of everything observed must be recorded at once.

It saves time to do this on a uniform plan, and the less elaborate any printed scheme for the purpose is made the more generally useful will it be found.

The form on p. 17 is that used at St. Bartholomew's Hospital. Its advantage is that while suggesting the examination of every part, it leaves space for the varying details required in each case.

The conception attained in the dissecting room by most students of human anatomy, is that the fabric of the human body is definite and uniform; that everything has a precise shape and position; that abnormalities now and then occur, but may for general purposes be neglected. This impression is probably due to the fact that the Manual of Dissection occupies so large a share of the student's attention.

In the post-mortem room he soon learns, if he looks at things closely, that apart from disease every human body has its visceral peculiarities, and that a man might be recognized by his heart, or his liver, as well as by his features.

Most of these differences are trivial from a pathological point of view, though as a part of the study of heredity and of variation they deserve careful record and investigation.

Anatomical peculiarities due to age are sometimes mistaken for effects of disease. It should be remembered that, in babies,

1. The dura mater is usually firmly adherent to the calvaria, and that this condition may last up to five years of age.

2. The liver is larger in proportion to the size of the body than in an adult.

3. The Peyer's patches in the small intestines are more prominent than in adults.

Name.	Age.	Date of Admission.	Date of Death.	Under the care of.	Date of Post-mortem.

NATURE OF DISEASE.

*External Appearances* {

HEAD :

Cranial Bones . . .  
 Dura Mater and Sinuses  
 Arachnoid and Pia Mater  
 Arteries . . .  
 Brain . . .  
 Spinal Cord . . .  
 Eye . . .  
 Ear . . .

CHEST :

Œsophagus . . .  
 Glands of Neck . . .  
 Larynx and Trachea  
 Lungs . . . {  
 Heart . . . {  
 Aorta and Vessels . . .

ABDOMEN :

Peritoneum . . .  
 Stomach . . .  
 Intestines . . .  
 Liver . . . {  
 Spleen . . .  
 Pancreas . . .  
 Abdominal Lymphatics  
 Supra-renals . . .  
 Kidneys . . . {  
 Ureters and Bladder . . .  
 Organs of Generation . . .  
 Joints . . .  
 Microscopical Appear-  
 ances . . .



4. The lungs are free from carbon spots, and are of a light pink hue rarely seen in adults.

5. The aortic groove on the left lung is more distinct than it is in adults.

6. The thymus gland is large.

7. Intussusception of the small intestine is common as a condition which occurs just before or soon after death. It may be distinguished from morbid intussusception by the absence of all redness and lymph.

The post-mortem appearances due to putrefaction ought also to be carefully distinguished from those due to disease.

The chief (liable to erroneous interpretation) are :

1. Purplish patches on the skin (a cut into one of these will show it not to be a hæmorrhage).
2. Air in the subcutaneous tissue.
3. Very dark colour of lungs and purplish or pink stains of serous membranes, and of the lining of blood-vessels.
4. Distension of the liver by gases of decomposition, causing what has been described as vacuolation.
5. Blackish appearance of the lower part of the liver, of the lower end of the spleen, and less often of the kidney due to osmosis of faecal gases from the large intestines.
6. Accumulation of blood in the posterior part of the brain.
7. Distension of the heart with gas. Some bubbles in this case usually visible under the endocardium.

The following table may be of use for reference :

*Normal Weights of Organs in Ounces.*

	Male.	Female.		Male.	Female.
Brain . . .	50	44	Liver . . .	50	48
Right Lung .	23	17	Kidney . . .	10	9
Left Lung . .	21	15	Spleen . . .	5	5
Heart . . .	10	8½			



**Death Certificate.**—In relation to post-mortem examinations, every student ought to be fully informed as to the method of filling up certificates of death. It is the duty of every medical man to fill up and sign certificates of death.

The first preliminary to signing a certificate of death on the part of a medical man is to be duly registered.

Care in signing such certificates is well spent, as, if accurate, they form a basis for statistics likely to lead to the most important results.

Every medical man who fills up a certificate of death with precision is adding something to the stock of knowledge of disease.

The law (Births and Deaths Registration Act, 1874, section 20) is that:

“In case of the death of any person who has been attended during his last illness by a registered medical practitioner, that practitioner shall sign and give to some person required by this Act to give information concerning the death a certificate stating to the best of his knowledge and belief the cause of death, and such person shall, upon giving information concerning the death, or giving notice of the death, deliver that certificate to the registrar, and the cause of death as stated in that certificate shall be entered in the register, together with the name of the certifying medical practitioner.”

The form of certificate is given on the next page and the following suggestions as to the filling up of certificates are made by the Registrar-General, and deserve careful perusal:



BIRTHS AND DEATHS REGISTRATION ACT, 1874.

# MEDICAL CERTIFICATE of the CAUSE of DEATH.

To be given by the Medical Attendant to the Person whose duty it is to give it, with information of the Death, to the Registrar of the SUB-DISTRICT in which the DEATH took place, and TO NO OTHER PERSON.

No. of corresponding  
Entry in Register Book  
of Deaths to be inserted  
here by the Registrar :

I HEREBY CERTIFY that I attended \_\_\_\_\_  
during the last illness; that such Person's age was stated to be \_\_\_\_\_; that I last saw h \_\_\_\_\_ on  
the \_\_\_\_\_ day of \_\_\_\_\_ 18\_\_\_\_; that he died \_\_\_\_\_ on  
the \_\_\_\_\_ day of \_\_\_\_\_ 18\_\_\_\_, at \_\_\_\_\_  
and that to the best of my knowledge and belief the Cause of h \_\_\_\_\_ death was as hereunder written.

\* Should the Medical Attendant not feel justified in taking upon himself the responsibility of certifying the fact of Death, he may here insert the words "as I am informed."

† The duration of each form of Disease or Symptom is reckoned from its commencement until death occurs.

Cause of Death.	Duration of Disease in Years, Months, Days, or Hours.†
Primary...	
Secondary.	
.....	

[The Informant  
should read the  
Notice on the back  
of this Form.]

Witness my hand, this \_\_\_\_\_ day of \_\_\_\_\_ 18\_\_\_\_

Signature \_\_\_\_\_

Registered Qualification \_\_\_\_\_

Residence \_\_\_\_\_

N.B.—THIS CERTIFICATE IS INTENDED SOLELY FOR THE USE OF THE REGISTRAR, to whom it should be delivered by the Person giving information to him of the particulars required by law to be registered concerning the Death. *Penalty of £2 for neglect of Informant to deliver this Certificate to Registrar.*

\*\* The Registrar-General cautions all persons against accepting or using this certificate for any purpose whatever except that of delivering it to the Registrar.



1. State the *Causes of Death*, in terms as precise and brief as possible, and use the names adopted in the nomenclature of the Royal College of Physicians, taking the English names in preference to the Latin or other foreign equivalents. Vague terms, such as *Decline*, *Tabes*, *Cachexia*, &c., should be *avoided*. So also *Hæmorrhage* should not be assigned as a Cause of Death without further specification of its *probable origin* and the *organ affected*. *Tetanus* again should be defined as *Idiopathic* or *Traumatic*, and if the latter the *cause and nature of the injury* should be added.

2. Write the Causes of Death, when there are more than one, under each other, *in the order of their appearance*, and not in the presumed order of their importance.

3. Medical Practitioners should not content themselves with assigning, as is too often done, some *prominent symptom* as the Cause of Death; but should state, whenever possible, *the disease to which the symptom was due*. Sometimes, doubtless, it will happen that the nature of the fatal disease cannot be ascertained with certainty; in such cases, and in such alone, a leading symptom should be assigned as the Cause of Death. "Dropsy" should not be returned as the Cause of Death, without stating *whether the Dropsy was due to Heart Disease, or Renal Disease, or the like*; when "Dropsy" alone is returned, it is assumed that the cause of this symptom was not ascertained.

Similarly, when the immediate Cause of Death was dependent upon some general condition, such, for instance, as the Strumous, the Syphilitic, or the Rickety constitution, *this remoter Cause should be stated, as well as the more immediate Cause*.

4. In certifying Deaths from any form of Continued Fever *state the kind of Fever*, and, in so doing, be especially careful to adopt the nomenclature of the College of Physicians. Avoid all such ambiguous terms as Low Fever, Miliary Fever, Brain Fever, Hectic Fever, Febrile Attack, &c. Similarly avoid the term "*Typhoid Pneumonia*," which may mean either Asthenic Pneumonia with typhoid symptoms, or Enteric Fever with secondary Pneumonia.

Do not use the term Infantile Remittent Fever for Enteric Fever in children.

5. When the Cause of Death has been verified by a post-mortem examination, the letters P.M. should be added.

6. State, in fatal cases of Small-pox, whether Vaccination had been performed with effect and when, or whether the deceased was unvaccinated. If possible, state the evidence of Vaccination, *e.g.*, "two bad marks." The term "Vaccinated" should be used in preference to "After vaccination." "Small-pox after Vaccination, 21 days," is ambiguous, be-



cause the question arises whether the period (21 days) refers to the Small-pox or to the Vaccination; the Cause of Death should be certified as "Small-pox 21 days; (vaccinated)."

7. Whenever *Childbirth* has occurred *within one month before death*, this fact should invariably be certified, even though it may be believed that the Childbirth had no connection with the Cause of Death.

8. The *Duration* of primary and secondary diseases in these Certificates will always be considered to mean the time intervening between the first appearance of well-marked characteristic symptoms and Death.

Small-pox, Scarlet Fever, Measles, and other similar febrile diseases should, however, be dated *from the rigors and first symptoms*; not from the later appearance of the eruption.

Ague, Epilepsy, Angina Pectoris, and other maladies that occur in fits or paroxysms, should be dated *from the first attack*, the duration of the last fit being added.

The duration should be stated in minutes or hours, when the disease is fatal in less than 48 hours; in days when the disease is of less than 50 days' duration; in months or years when the disease is of still longer duration.

*Examples:—*

(a) Scarlet Fever	.	.	.	.	30 days
Anasarca	.	.	.	.	7 days

Implies that the earliest symptoms of Scarlet Fever occurred 30 days before death, and that Anasarca was first noticed 7 days before death.

(b) Epilepsy	.	.	.	.	5 years
Last fit	.	.	.	.	6 hours

Implies that the first Epileptic Fit occurred 5 years back, and that the fatal fit lasted 6 hours.

(c) Excessive use of Spirits	.	.	—
Delirium Tremens	.	.	6 days

Implies that the deceased had been for an unknown time given to intemperance, and suffered from Delirium Tremens for 6 days before death.

9. SURGEONS, in all cases of operation, should return (a) the primary disease or injury; (b) the kind of operation; (c) the secondary diseases—such as Erysipelas, Purulent Deposits, &c., and should state also the time from commencement of the primary disease, the time from the operation, and the time from the appearance of secondary disease, *reckoning in each instance to the death.*

*Examples :—*

Femoral Hernia	.	.	.	.	3 years
Strangulated	.	.	.	.	5 days
Operation	.	.	.	.	2 days
Peritonitis	.	.	.	.	45 hours

10. In every Case of Death from violence, or suspected violence, the Medical Practitioner should advise the friends of the deceased to bring the case to the knowledge of the Coroner in order that he may decide as to holding or not holding an Inquest, inasmuch as the Coroner may otherwise feel it his duty, when the case comes to his knowledge, to order the body to be exhumed and inquiry instituted.

N.B.—No Medical Practitioner is justified in giving a Certificate unless he was personally in attendance upon the deceased during the last illness.



## CHAPTER II.

## MORBID STATES AND PROCESSES.

HYPERTROPHY.	GLIOMA.
ATROPHY.	OSTEO-SARCOMA.
HYPERÆMIA :	CHONDRO-SARCOMA.
ACTIVE.	FIBRO-SARCOMA.
PASSIVE.	MELANOTIC SARCOMA.
HÆMORRHAGE.	MYXO-SARCOMA.
ANÆMIA.	GROWTH OF SARCOMA.
DROPSY.	MALIGNANCY AND NON-
INFLAMMATION.	MALIGNANCY.
SEROUS EFFUSION.	OUTGROWTHS :
PLASTIC EFFUSION.	FIBROMATA.
SUPPURATION.	MYXOMATA.
ULCERATION.	LIPOMATA.
GANGRENE.	CHONDROMATA.
CICATRIZATION.	OSTEOMATA.
DEGENERATION :	ANGEIOMATA.
FATTY.	NEUROMA.
CALCAREOUS.	PAPILLOMA.
FIBROID.	ADENOMA.
MUCOUS.	CYST-FORMATION.
COLLOID.	TUBERCULOSIS.
LARDACEOUS.	MECHANICAL AFFECTIONS :
PIGMENTARY.	DISPLACEMENT.
NEW GROWTH :	DILATATION.
CARCINOMA.	CONTRACTION.
ENDOTHELIOMA.	STRICTURE.
SQUAMOUS-CELLED CARCI-	COMPRESSION.
NOMA.	PLUGGING.
RODENT ULCER.	PERFORATION.
SPHEROIDAL-CELLED CAR-	LACERATION.
CINOMA.	RUPTURE.
CYLINDRICAL-CELLED CAR-	FRACTURE.
CINOMA.	CONCRETION.
SARCOMA :	PARASITIC INVASION.
ROUND-CELLED.	MALFORMATION.
SPINDLE-CELLED.	DISORDERS OF FUNCTION.
LYMPHO-SARCOMA.	

**Hypertrophy** is a term applied to a condition in



which any structure receives and uses more nourishment than is necessary to maintain its elements at their normal number and size, and therefore is increased in size. Thus, if one kidney be destroyed by disease, the other may undergo hypertrophy to double its normal weight and thus discharge the function of both kidneys. A heart in which the aortic orifice is obstructed may exhibit an hypertrophy of the left ventricle equal to double the weight of the whole heart. When in its normal state the heart of a man weighs ten ounces, in the state of hypertrophy due to chronic interstitial nephritis it frequently weighs twenty ounces, having thus an addition of ten ounces of muscle-cells to the left ventricle, an addition which may be taken to represent the increased work done by that cavity.

**Atrophy** is a condition of defective nutrition in which the part affected is diminished in size. The extensor muscles of the forearm in cases of lead palsy exhibit atrophy, they are diminished in size, and of shrunken appearance in bulk, while under the microscope each fibre has the same wasted appearance which the whole muscle has.

**Hyperæmia**, the overfilling of a structure with blood, may be due to the too great filling of the arteries of the part, or to the too slow emptying of the veins. Too great filling of the arteries, or **active hyperæmia**, is exhibited in acute nephritis, when the distension of the kidney is shown by its increase in size and by the quantity of blood which drops from it when cut in two.

Too slow emptying of the veins, or **passive hyperæmia**, is exemplified in the nutmeg liver found post-mortem in cases of valvular disease of the heart. The branches of the hepatic vein are intensely engorged, and the liver is in consequence firmer than natural. Some blood drops out on section, and during life much blood passes through the walls of the engorged venous capillaries, stains the liver in several



shades of red and yellow, and may be seen after death in microscopic sections in the lobules round the central minute branch of the hepatic vein.

**Hæmorrhage** is an exudation of blood from large vessels or from capillaries, and when not traumatic occurs in two morbid conditions.

1. From large vessels: arteries and veins never give way to the pressure of blood while their walls are free from disease. A healthy blood-vessel never bursts.

Arterial hæmorrhage is preceded by atheroma and very often by the formation of aneurysm, or by acute changes due to micrococci in the arterial wall.

2. From capillaries:

a. In extreme passive engorgement, as from the gastric mucous membrane in cirrhosis of the liver. The mucous membrane is blood-stained, but no breach of surface is discoverable.

β. In infarction: when capillaries which are no longer receiving nourishment from the artery give way.

γ. In acute engorgement, as in the lung when first invaded by the tubercle bacillus.

**Anæmia** is any condition of bloodlessness, and is of two kinds:

1. Diminished amount of blood, as when an artery is cut across.

2. Supply of defective blood, as in chlorosis, purpura, scurvy; and idiopathic anæmia.

In all varieties, fatty degeneration of muscular tissue, best seen in the heart, follows.

The organs of a person who has bled to death from division of a large artery are so extremely pale as to simulate the appearances of disease. A microscopic section will of course show the several structures to be normal.



**Dropsy** is the exudation of the watery part of the blood, and is associated with—

1. Pressure on veins, or on the venous current, as in thrombosis of the vena cava and valvular disease of the heart.
2. Changes in the nature of the blood, as in renal disease.

The exuded fluid is always highly albuminous, and colourless coagula often float in that found in serous cavities. If lymph be found floating in the fluid, it is proof that serous inflammation and not mere transudation has been present.

**Inflammation** is a general term applied to a series of changes of which active dilatation of vessels is the initial process. Migration from the blood current of leucocytes and their accumulation in the tissues follows, with stasis in the capillaries, exudation of serum, and finally coagulable exudation. The dilatation and engorgement may be the result of

1. Direct injury ;
2. The presence of a micro-organism ;
3. Effects of reduced temperature.

The inflammation is indicated by redness of the inflamed region and by a general rise of temperature. **Effusion of serum** may follow, or a **plastic effusion** which contains fibrin which coagulates immediately. If a serous membrane is affected it loses its gloss and many of its endothelial cells are shed. The migrated leucocytes may degenerate and may be removed in various ways; for example, as sputum in pneumonia; or, if very numerous, they may form pus; or if they remain they become elongated and develop into connective tissue with blood-vessels. Thus adhesions are formed. The connective tissue, after growth ceases, contracts, undergoes slow degeneration, and may calcify.

**Suppuration** is the formation of pus, and is one



of the consequences of inflammation. It is a fluid of a specific gravity of about 1030, of alkaline reaction, and containing in suspension abundant leucocytes, some living and some with degenerate granular contents.

**Ulceration** is destructive inflammation progressing on a free surface, and an abscess is a similar change taking place in an enclosed area. In both cases the formation of pus is in progress.

**Gangrene** is the result of the death of a tissue or region which has ceased to be nourished by the blood.

Direct obstruction of an artery is its most obvious cause, but it may also be due to extreme general malnutrition, and to malnutrition caused by septic or other poison. The commonest form of gangrene seen in medical wards is that of the lung. The patient coughs up a very foetid sputum, containing shreds of lung tissue. Post-mortem, a ragged cavity, without definite wall, and surrounded by sodden, ill-smelling, readily torn lung tissue is discovered. This condition is common when a diabetic patient has acute pneumonia, and sometimes comes on suddenly in pneumonia without diabetes. It is sometimes, but rarely, seen in tuberculosis of the lung.

Frost-bite is gangrene due to complete arrest of the circulation by cold in some part of the outer surface of the body.

The gangrene following the consumption of rye bread containing ergot requires further investigation, and may perhaps, like that of senile degeneration, be due to inelastic atheromatous vessels and general malnutrition.

Gangrene of the limbs, dry and moist, is fully described in surgical treatises.

**Cicatrization** is the formation of fresh connective tissue in a vacant region, as after an ulceration or a wound. The new tissue begins by the elongation of leucocytes, and invariably ends by contracting when its growth is complete.



**Degeneration** is a term somewhat loosely used, but generally applied to the change from a complete and highly nourished to a simpler and less highly nourished structure.

(a) **Fatty Degeneration** occurs when fat granules replace the normal cell-contents of a tissue ; as in the heart, where, in fatty degeneration, fat granules are found replacing the muscular discs of the fibres ; or in the liver of phosphorus poisoning, where the liver cells are filled with fat granules, their nuclei and clear contents having entirely disappeared.

(b) **Calcareous Degeneration** occurs in tissues which have previously undergone fatty degeneration, as in atheroma of arteries ; or in tissues which have been the seat of inflammation, and where dried-up or imperfectly organized products of inflammation remain ; as in lymphatics, which have long been inflamed ; or where a freshly formed tissue has ceased to grow, as sometimes in fibroid tumour of the uterus.

(c) **Fibroid Degeneration** : this form of degeneration is in most cases to be regarded as a slow inflammatory process, due to long-continued irritation, as in chronic interstitial pneumonia, where the lung-tissue is irritated by the continued inhalation of hard dust.

(d) **Mucous Degeneration** is a term used when an increased quantity of mucin is present. It has been described in the skin and mucous membranes, and is to be seen in cases of myxœdema. Other degenerative changes accompany it.

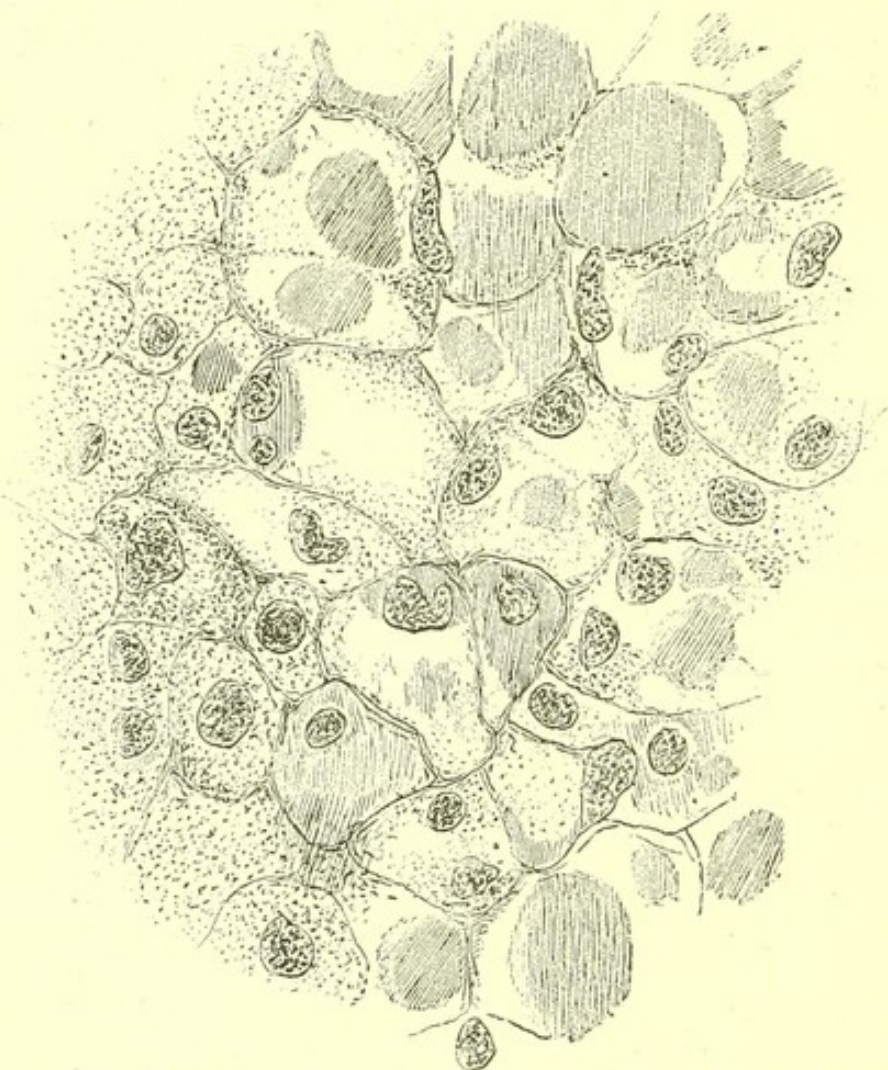(e) **Colloid Degeneration** is a degeneration which epithelial or connective-tissue cells, sometimes normal ones, but more often parts of a new growth, undergo. The contents of the cells become gelatinous. Large tracts of this form of degeneration are often seen in tumours of the ovary and of the thyroid gland ; I have seen it well marked in a case of gastric carcinoma (Fig. 1), and in one of carcinoma of the cæcum.

(f) **Lardaceous or Amyloid Degeneration**



begins in the walls of small arteries, in the muscular coat, and in the walls of capillaries. The change, perhaps, begins as an infiltration, but soon the muscle cell-contents are converted into an albuminoid substance, which is stained a deep brown by iodine, and pink by methyl-violet. It is often formed in such great quantities as to indicate continued infiltration rather

FIG. 1.



*Colloid degeneration in the cells of a Carcinoma of Stomach.*

than degeneration. Thus, while the normal weight of the liver is 50 oz., it may be so greatly infiltrated by amyloid material as to weigh 100 oz. or more. This form of degeneration gives to the organs it affects a firm glistening appearance remotely resembling cut bacon, whence the term lardaceous. On pouring a



solution of iodine on the section, the degenerate parts are stained of a darker brown than the rest of the organ. The organ is always firmer than natural, though not very hard.

The liver, spleen, kidneys, and mucous membrane of the intestines are the commonest seats of amyloid degeneration. It is often confined to one or two of these parts, and though due to a cause affecting the whole body, does not occur uniformly throughout the tissues. When present in one kidney, it is present in the other; but it may occur in the spleen and be absent in the liver, or may be present in the intestines and liver and not in the spleen. It is sometimes discoverable in the pancreas, and sometimes in the walls of the heart.

It occurs in two conditions :

1. After long-continued suppuration, as in chronic disease of bone, empyæma or suppuration in the lungs due to tubercle.
2. As a remote result of syphilis without the presence of suppuration.

**Pigmentary Degeneration** is due to the infiltration of an organ by red blood-cells, which undergo a gradual loss of colour. The best example of it is seen in the pigmentation of the liver, found in cases of valvular disease, when red corpuscles pass into the liver tissue through the walls of the engorged hepatic vein.

The particles of black pigment seen in the scars of old dysenteric ulcers in the large intestine are also examples of pigmentary degeneration, but the black spots to be seen in almost every adult lung are collections of inhaled carbon.

**New Growth** : this term is used somewhat loosely to signify a formation of any cellular structure additional to the normal growth of the body. It is difficult always to use such a term strictly. In this



book it is applied only to cellular growths which owe their origin to normal cells, but continue to grow at an abnormal rate, throughout the patient's life, unless removed by operation. Thus a growth of connective tissue on the capsule of the liver or spleen is not spoken of here as a new growth, since having reached a certain degree of growth it ceases to develop further. It may be called an **outgrowth**.

All carcinomata and sarcomata are new growths, because once begun, they continue to increase by fresh cell-formation as long as cell-growth continues in the body. They are to be regarded as permanent interruptions to what may be called the normal rhythm of cell-growth throughout the body.

**Carcinoma** is a new growth, originating in an epithelium, and may grow from any of the epithelial surfaces developed from the epiblast or the hypoblast. It has many varieties, and these are described further on.

**Sarcoma** is a new growth, originating in a connective tissue, and may begin in any of the many structures which develop from the mesoblast. Its varieties correspond to all the forms of connective tissue.

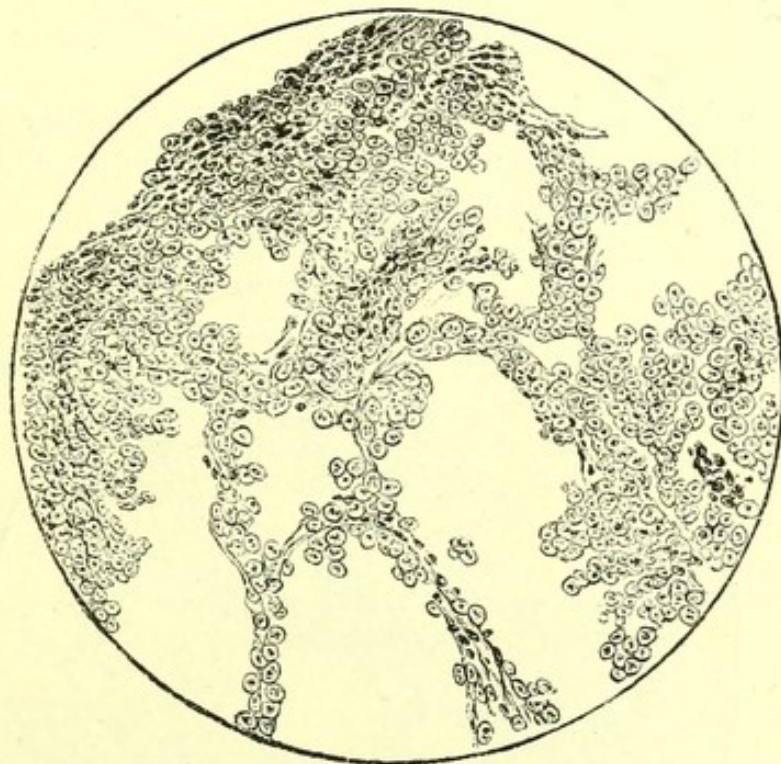
**Endothelioma** is a new growth, beginning in endothelium, and developmentally is a sarcoma, though in microscopic appearance resembling an epithelial new growth, just as epithelium resembles endothelium.

**Origin of New Growths.**—That all new growths derive their character from the region in which their growth begins is proved by the fact that when they appear in several parts of the same body, however remote the parts, the masses of new growth have a common cellular structure, and this structure corresponds to that of the oldest mass, and that to the cellular structure of the region in which it began. A man was admitted into St. Bartholomew's Hospital with a pleural effusion. Signs of pressure



on the rest of the lung led to the belief that he had a new growth in that region. Somewhat later a small tumour grew from the periosteum of the anterior surface of his left clavicle. Post-mortem it was found that at the base of the heart and for one-third downwards on its anterior surface, and two-thirds downwards behind, the visceral layer of the pericardium was infiltrated with a firm, whitish new growth, and this extended over a lesser area of the parietal surface. At the root of the left lung the new growth had invaded the main bronchus for half an inch, and actually formed its wall. At this point it also penetrated the lung substance. There was a small mass of new growth on the sixth left rib, which did not adhere to the lung. The lump on the clavicle

FIG. 2.



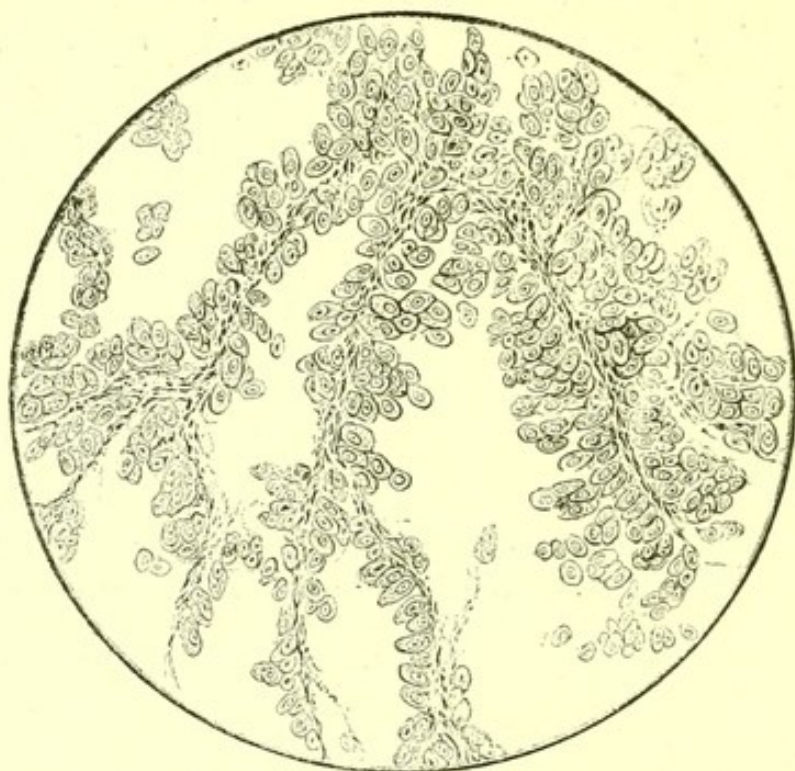
*Endothelioma.* Microscopic section of thickened pericardium, showing the growth consisting of large flattened cells in well-marked alveoli.

was associated with some wasting of the bone, to which and to the periosteum it was firmly adherent. The bronchial glands were infiltrated. Below the diaphragm the new growth was only to be found in the



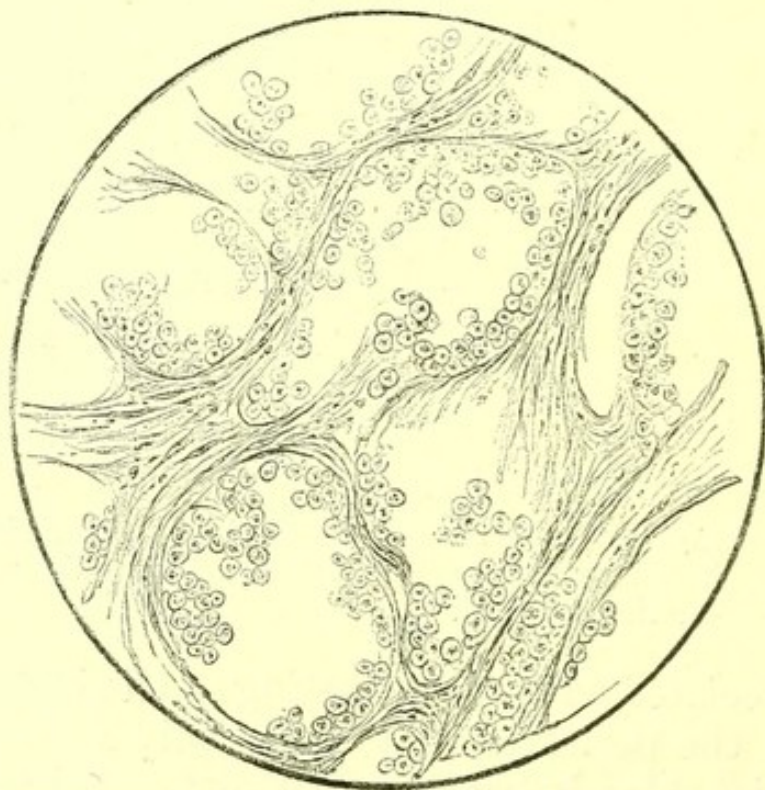
supra-renal bodies, both of which were infiltrated and enlarged.

FIG. 3.



*Endothelioma.* Microscopic section of secondary growth in the lung from the same case, showing the same form of cells as in the pericardium.

FIG. 4.



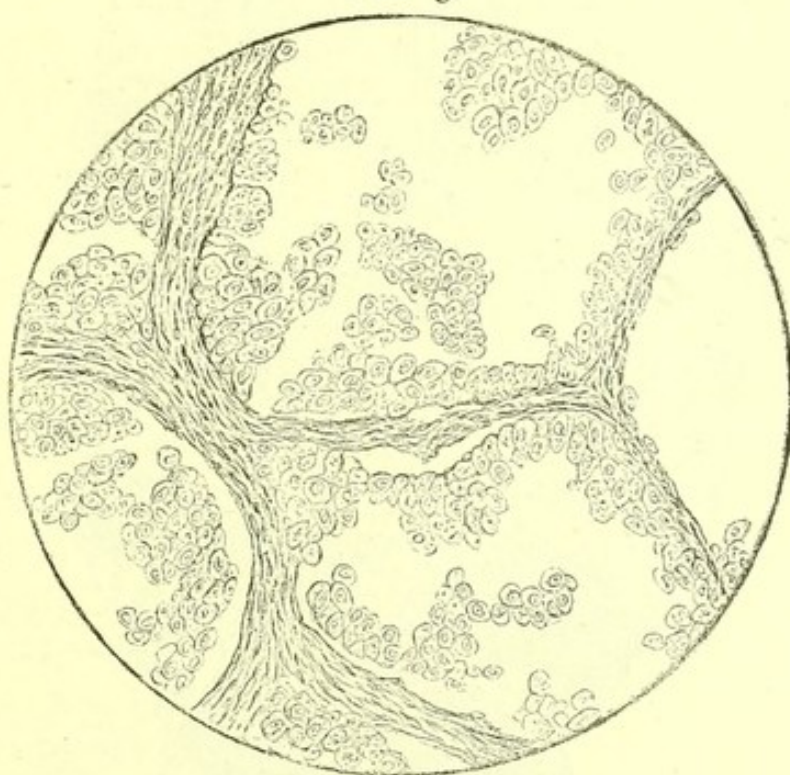
*Endothelioma.* Microscopic section of secondary growth in the supra-renal body, showing the same form of cells as in the pericardium. From the same case.



The new growth was examined microscopically in every part in which it occurred, and its structural characteristics were everywhere identical. It everywhere consisted of abundant large, flattened, nucleated cells of an endothelial type arranged in well-marked alveoli.

Such large flattened nucleated cells form the innermost layer of the pericardium, and do not exist normally in the other regions where this growth occurred. The conclusion is clear that the masses of new growth

FIG. 5.



*Endothelioma.* Microscopic section of secondary growth in the periosteum of the clavicle, showing the same form of cells as in the pericardium. From the same case.

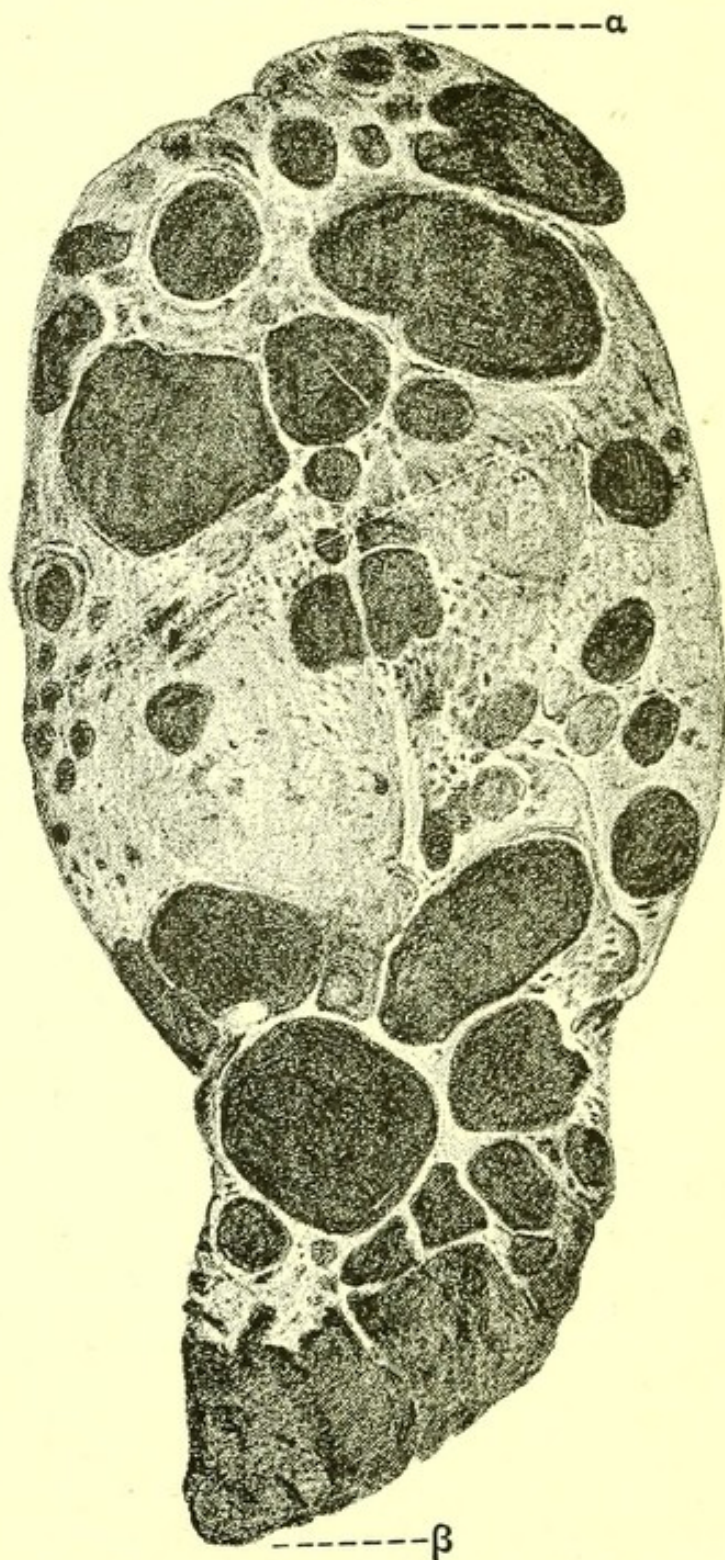
in the clavicle, rib, lung, and supra-renal were the descendants of the new growth from the pericardial endothelium.

Another patient had a sarcoma containing abundant black pigment removed from his right eye. Three years later he died, and post-mortem his liver was found of nearly double the normal weight, the increase being due to masses of melanotic sarcoma. Smaller masses were found in the mesenteric glands,



and two small masses in the skin. All had the same cellular structure as the new growth removed from the eye and there growing in the choroid. They

FIG. 6.



*Melanotic Sarcoma of Liver.* Section through the whole liver. The black patches in the figure represent masses of the melanotic sarcoma, the lighter part is the remaining liver tissue.  $\alpha$ , diaphragmatic surface;  $\beta$ , lower edge of liver.



consisted of imperfectly grown connective tissue cells, most of them round, a few elongated, with much dark pigment among them.

In the case of endothelioma of the pericardium above described, and in this case of melanotic sarcoma of the eye, it was easy, from the unmistakable character of the cells, to be sure of the place of origin of the new growth. It is not always possible to determine post-mortem the place of origin of a new growth, but in most cases it may be ascertained by making the following observations:

1. Of the several parts of the body in which the new growth occurs;
2. Of the free surface, if any, on which it projects;
3. Of its region of greatest density and of the region in which it is most disintegrated or degenerate.
4. Of its cellular structure under the microscope.

From these four observations the primary seat of the new growth is generally determinable, and it is important to consider them all together, and not to rely solely on the characters of a microscopic section; though, as in the examples given above, the microscopic appearances are sometimes in themselves conclusive as to the primary seat of growth.

When the new growth has grown slowly, the place of greatest density indicates roughly the place of longest growth. When it has grown rapidly, degeneration and softening are likely to be most advanced in the oldest and therefore the primary region.

**Carcinoma.**—A carcinoma consists of epithelial cells set in the meshes of a connective-tissue stroma. The more slowly it grows the more connective tissue is present, and the denser does the stroma appear under the microscope. The character of the cells depends upon the region of origin.



**Squamous-celled Carcinoma** is commonest about the two ends of the alimentary canal, and in the skin. The concentric collections of cells commonly called cell-nests, and characteristic of those regions, are always to be found in microscopic sections of this variety of carcinoma. Squamous-celled carcinomata are sometimes called epitheliomata. This term dates from a period when the origin of all carcinomata from epithelium was not recognized, and it ought now to be disused.

**Rodent Ulcer**, a slowly progressing ulcerated surface in the skin, the walls of which contain new growth, is closely allied to squamous-celled carcinoma, but its cells are smaller, and they are probably developed from the gland cells of the skin, and not from the horizontal layers of epithelium.

**Spheroidal-celled Carcinoma** is developed from the epithelium of the alimentary canal and from the epithelium of glands—the character of its cells varying with its region of origin. When it has much stroma and comparatively few cells it is called scirrhus; when many cells and little stroma so that it is like the brain-substance, encephaloid. The term scirrhus was formerly used in medicine for all dense abnormal growths.

Besides carcinoma, dense patches of connective tissue in the pleura and in the pericardium, and the liver of cirrhosis were included in the term scirrhus.

From this wide meaning it came to be restricted to certain tough malignant new growths, but as the density of a new growth depends upon its rate of growth, and not upon its cellular origin, the term scirrhus might with advantage be excluded from pathological writings, even if retained as a clinical term for some forms of malignant disease.

**Colloid Carcinoma** is a term applied to any form of carcinoma in which colloid degeneration has affected the cells, or the cells and stroma.

**Cylindrical-celled Carcinoma** is a carcinoma in

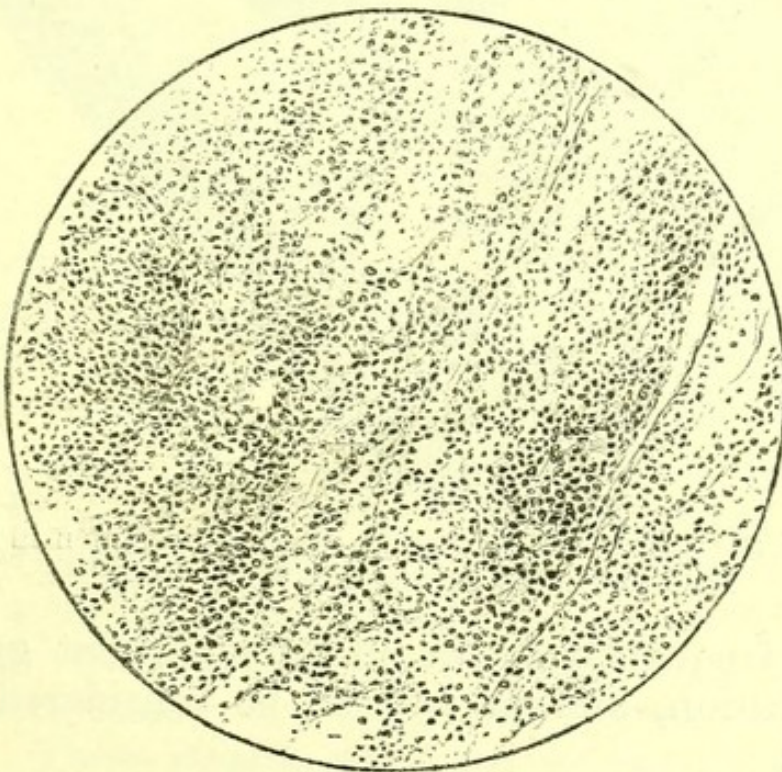


which cylindrical cells are arranged in a stroma so as to form in parts of the growth cavities resembling imperfectly developed glands of the mucous membrane. Cylindrical-celled carcinoma often occurs in the rectum, and less often in the stomach.

**Sarcoma** may be developed from any connective tissue. It consists of numerous cells without stroma, and with blood-vessels running among them. All varieties begin with cells resembling those of embryonic growing connective tissue, small and round or spindle-shaped. In some, one only of these forms is found. In others, both are present. This primary condition may go on to the development of some definite further developed connective tissue, as :

**Lympho-sarcoma** is a variety of sarcoma in which masses of new growth are formed resembling lymphatic glands with groups of small round cells in loculi.

FIG. 7.



*Microscopic section of Lympho-sarcoma growing from glands of anterior mediastinum.*

This condition occurs in the lymphatics of the mediastinum and attains great thickness, penetrating

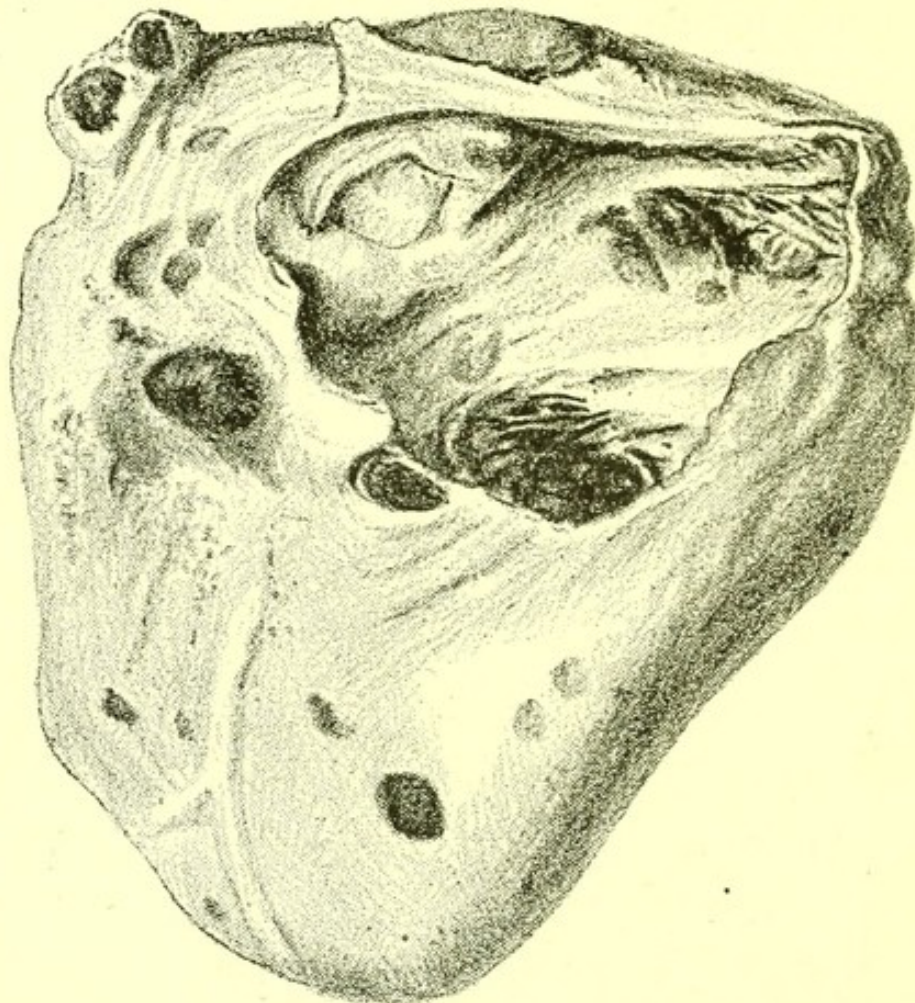


the sternum and making it soft. It is common in the mesenteric glands, and grows from them into the wall of the alimentary canal.

**Glioma** is a sarcoma growing in nerve tissue from the neuroglia, but nerve cells are not formed in it.

**Osteo-sarcoma** is a new growth originating in bone, in which masses of round and spindle cells go on to the development of bone. Simple round-celled

FIG. 8.



*Melanotic Sarcoma of the Heart.* From a specimen in the Museum of St. Bartholomew's Hospital.

sarcoma frequently grows in bone without going on to ossification, and is not to be considered osteo-sarcoma;

**Chondro-sarcoma** is a growth of connective tissue-cells in which cartilage is formed ;

**Fibro-sarcoma** is a growth of connective tissue cells leading to the formation of fibrous tissue.



**Melanotic Sarcoma**, a growth consisting of round and spindle cells in which the cell development is accompanied by development of pigment in the cells and in the matrix. It originates in the connective tissues which contain pigment, as the rete Malpighii of the skin and the choroid of the eye.

**Myxo-sarcoma** is developed in relation to the sub-mucous tissue of a mucous membrane and resembles it in structure.

**Endothelioma**, which is strictly speaking a sarcoma, has already been described.

**Growth of Sarcoma.**—When sarcoma grows rapidly, hæmorrhage generally occurs into its substance here and there. In a child who was a patient in St. Bartholomew's Hospital numerous nodules of round-celled sarcoma in the skin looked during life as if pigmented, owing to extensive hæmorrhages into them, but were proved post-mortem to contain no dark pigment.

When sarcoma grows very slowly, which is a rare occurrence, its progress into an organ may be accompanied by great connective-tissue increase, so that the mass is as tough as any carcinoma, and can only be distinguished from it by microscopic examination. This condition may usually be observed in sarcomata beginning at the root of the lung.

As a rule, the growth of sarcoma is more rapid than that of carcinoma. I examined post-mortem the following case, which is a typical illustration of the rate and method of growth of a round-celled sarcoma. The new growth occurred in a boy, aged a year and a half. In the skull, the frontal bone and anterior part of the parietals, and almost the whole base, were infiltrated with masses of a tough new growth of a reddish colour. These masses projected externally, and also, though to a less degree, into the cranial cavity. Two had pushed the eyes almost out of the orbits, and both corneæ had sloughed away. All the bones of the pelvis were infiltrated in the same way, and there were masses



of sarcoma in the upper third of each femur with general infiltration of the whole shaft of each. The ten upper left ribs and the nine lower right ribs were all infiltrated, and several prominent bosses of new growth on the ribs projected into the chest. In the skull the superior maxilla, palate bones, malar bones, lachrymal bones, nasal bones, and the inferior maxilla were the only bones which were not infiltrated. The basilar part of the occipital bone was infiltrated in continuity with the sphenoid, and there was a small boss on the superior angle, but the rest of the occipital bone was free from new growth. There was no infiltration or softening of the brain, but the pia mater and arachnoid in contact with a boss on the frontal bone were much injected with blood. Several cervical glands were found to be infiltrated with new growth, but the mediastinal glands, pericardium, heart, and lungs contained none. In the abdomen there was no general infiltration of the peritoneum, and the mesenteric glands were not infiltrated, neither were the stomach and intestines, nor the kidneys. All the lumbar glands were infiltrated and enlarged. The right supra-renal body was as large as the child's fist, and was infiltrated and surrounded by new growth. Part of the right lobe of the liver was enlarged, and contained several large projecting masses of new growth. Microscopic examination showed that the new growth had everywhere the same minute structure. It was a sarcoma, consisting entirely of round cells without any intervening tissue. It was possible from the history to estimate the duration of the growth. The boy had been weaned at the age of thirteen months, and was at that time in tolerable health. Three months later he had pain in the right hip, but this pain, with a similar pain in the right arm, passed off in about a fortnight. One month later a swelling appeared over the left eye, and in the course of the next six weeks several other swellings were



discovered in the head. While the child was in the hospital its tumours were observed to grow rapidly. The eyes became more and more compressed, its general cachexia increased, and it died after being in the hospital about six weeks. The temperature was often below normal, and in the fifty-four days during which the child was in the hospital reached  $99^{\circ}$  on the 14th, 28th, 31st, 32nd, and 39th days; while it was above  $99^{\circ}$  on the following days and times of the day:

Day.		Time.		Degrees.
8th	...	Evening	...	99.6
12th	...	Morning	...	99.6
"	...	Evening	...	99.2
19th	...	Evening	...	99.4
20th	...	Evening	...	100.8
23rd	...	Evening	...	99.8
28th	...	Morning	...	101.6
"	...	Evening	...	101.7
36th	...	Morning	...	101.8

From the first symptoms of illness to the time of death five months elapsed, while from the observation of the first swelling on the skull till the day of death was a period of thirteen weeks.

Some observers have suggested that sarcomatous growths give rise to fever, and that carcinomata do not. The temperature depends on the accidents of the growth, and not on its nature. Any rapidly growing structure is more likely to cause serous and other inflammations than one which grows slowly, and therefore to cause fever.

**Malignancy.**—In the "Nomenclature of Diseases" under the section applying to each organ occur the divisions:

**Non-Malignant New Growth: Malignant New Growth.**

The term **malignant** indicates that the new growth is likely to progress till it kills the patient. Such



growths have no definite boundary or wall, and may grow at all parts of their periphery. Under the heading **Non-Malignant New Growth** are included numerous formations, which often exist as projecting swellings or tumours, and which for the most part come into the surgical wards of a hospital.

**Outgrowths or Non-Malignant New Growths.**

**Fibromata** are dense or loose tumours of fibrous tissue. Dense fibromata are common in the walls of the uterus, loose fibromata in the skin.

**Myxomata** consist of mucous tissue. Nasal polypus is perhaps the commonest example. They occur as a rarity in the stomach, and more often in the intestines.

**Lipomata** are tumours consisting of fat enclosed in lobules bounded by a connective-tissue capsule. They most often occur on the surface of the body. They often grow at some seat of irritation, a fact illustrated by the following somewhat uncommon example which occurred in a woman, aged forty-five years, who died of cerebral hæmorrhage :

A renal calculus of hazel-nut size was impacted in the right ureter, and had formed a sort of pouch which was surrounded by a great mass of fat, which had a definite external capsule of connective tissue. The pelvis of the right kidney was dilated, and the ureter on leaving it was thickened till it entered the fat mass, which was as large as a child's head. Beyond the fat mass to the bladder the ureter was but little thickened. Around the pouch projecting from the ureter, and which contained the calculus, there was some fibrous tissue radiating into the fat mass, but microscopic examination showed that there was no new growth in this or in the thickened ureter.

**Chondroma** is an outgrowth forming a tumour of cartilage, **Osteoma** of bone, and **Myoma** of unstriped muscle.

**Fibro-Myoma** is common in the uterus, and is sometimes difficult to distinguish from fibroma under



the microscope. The tumour is generally less dense than a fibroma.

**Angeioma** is a tumour made up of new blood-vessels, arteries, veins or capillaries. Nævus, which is a collection of capillaries, is the commonest variety. It occurs in the skin, and in the tongue, and may often be observed in the liver.

**Neuroma** is a tumour of fresh nerve tubes and cells. It is extremely rare.

**Papilloma** and **Adenoma** are outgrowths of the epithelium.

**Papilloma** is an outgrowth from the papillæ of the skin and mucous membrane, and contains all their structures; epithelium, blood-vessels, lymphatics, and connective tissue.

**Adenoma** is an outgrowth from glands, and contains well-formed gland tubules, often dilated into cysts with intervening tissue.

All these forms of non-malignant new growth might with advantage be spoken of as **Outgrowths**, the term **New Growth** being reserved for malignant growths.

In many cases the clinical facts must be known before it is possible to be quite certain whether a tumour discovered post-mortem was a new growth or an outgrowth.

**Cyst-formation.**—The term cyst is applied to any abnormal non-inflammatory cavity with a definite wall filled with blood or with other fluid. The obstruction of a duct is the most obvious method of formation. The cysts seen on the kidney of chronic interstitial nephritis are thus formed. An ovarian cyst is sometimes a dilated duct of the Wolfian body, and is sometimes due to degenerative change in a rapidly growing new growth.

Cysts in the brain may be cavities of old hæmorrhages, in which case blood crystals are found in the coats or on its walls, or they are vacuities due to parts of the primitive membranous cerebral vesicles being



undeveloped. Small cysts of uncertain origin are sometimes found on the surface of the liver.

Cysts normally occur in the thyroid gland, and may become enormously enlarged. Cysts due to obstructed seminal tubules occur in the testis.

The congenital cysts in the kidney may be due to inflammation in the fœtus obstructing tubules. Large cysts with the cortex of the kidney for a wall are formed by obstruction of the ureter.

**Tuberculosis** is the term applied to that morbid state of the tissues in which the tubercle bacillus can live and multiply in them, giving rise to collections of small cells in the organs affected, which increase in size and rapidly undergo degeneration, passing on into caseation and calcification, or which spread over so large an area or to such situations as rapidly to cause death.

That some hitherto undiscovered anatomical defect in the tissues of the patient is necessary for the development of tuberculosis, is proved by the fact that numbers of medical attendants who certainly inhale the bacillus never acquire tuberculosis.

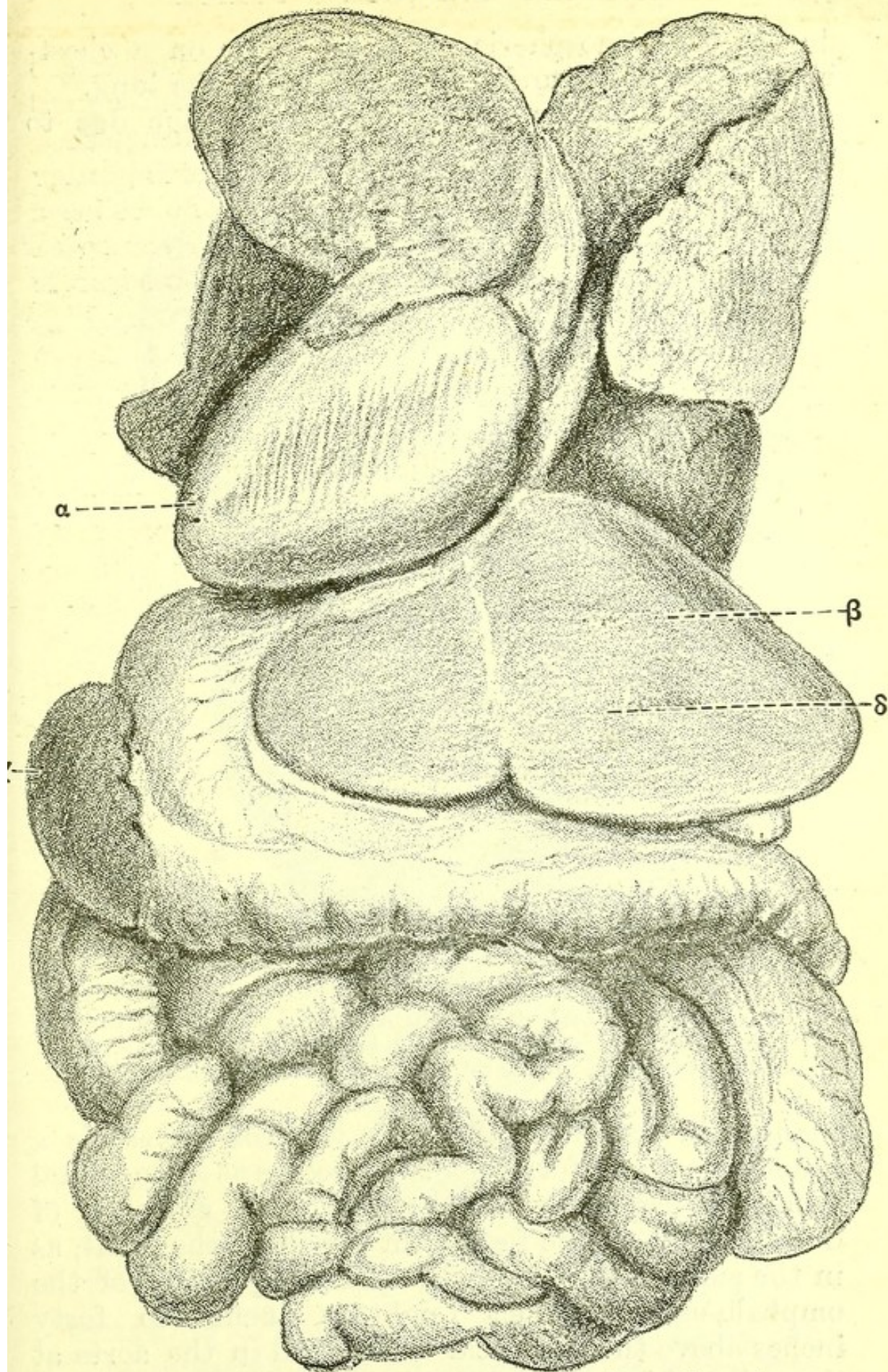
**Mechanical Affections.**—**Displacement** (dislocation) of organs may be due to congenital variety, as in cases of transposition of viscera, when the heart is on the right side, the liver on the left, and the spleen on the right; or to pressure, as when a pleural effusion on the left side pushes the heart beyond the right border of the sternum.

**Dilatation** of the ducts of a gland may arise from obstruction of the common duct, and is always followed by connective-tissue increase in the gland. Dilatation of cavities with muscular walls, if permanent, is generally due to the degeneration of the muscular tissue; if temporary, to malnutrition of it.

**Contraction**, a term which does not include muscular rigidity, is always due to a degeneration of fresh connective tissue. The falling in of the chest in chronic pleurisy is not a true contraction, but is mainly



FIG. 9.



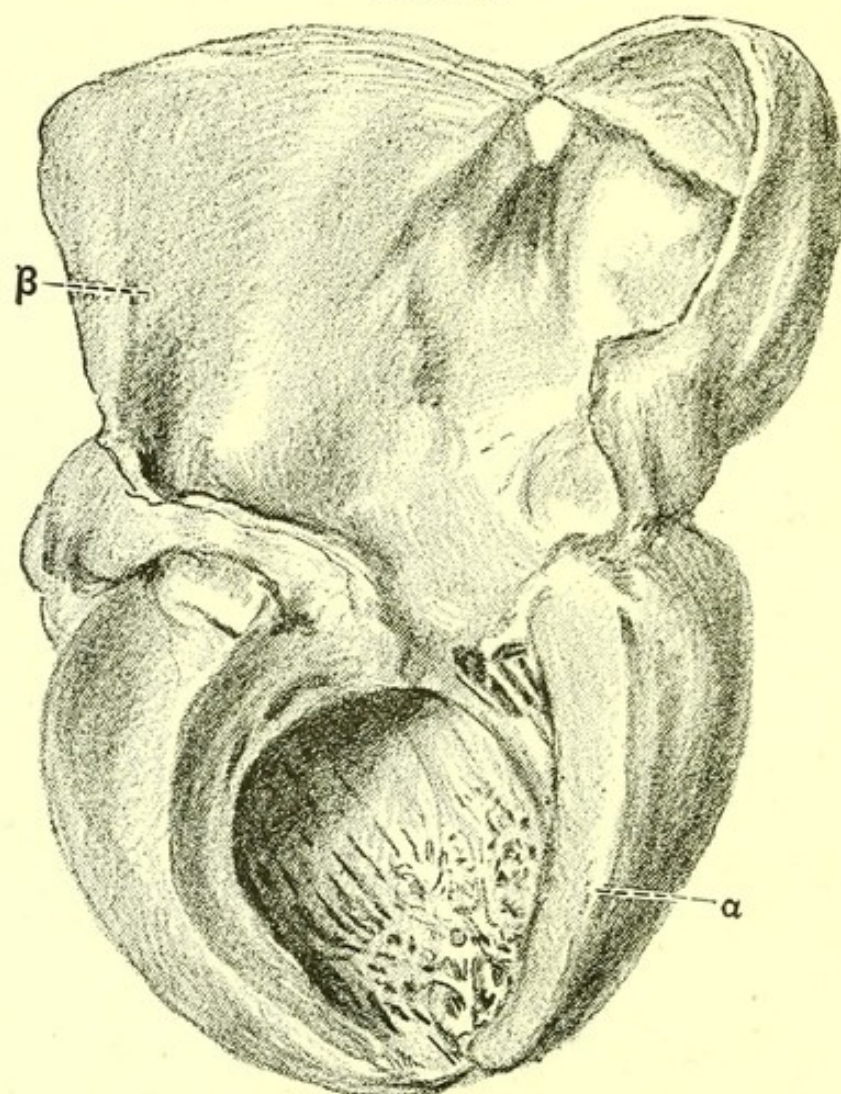
*Transposition of Viscera*, from a case in the post-mortem room of St. Bartholomew's Hospital, showing the heart (α) and the spleen (γ) on the right side, and the liver (β) with the pylorus (δ) on the left side.



due to the atmospheric pressure acting on a chest-wall no longer expanded by air entering the lung.

**Stricture** is any narrowing of a passage due to

FIG. 10.



*Dilatation of Left Auricle*, in a case of stenosis of the mitral valve. *a*, left ventricle; *β*, left auricle. From a specimen in the Museum of St. Bartholomew's Hospital.

changes in its walls, of which the commonest is a connective-tissue formation. It occurs as a congenital condition, especially at the points of entrance of ducts, patent in the fœtus but closed in the adult, as in the small intestines at the point of junction of the omphalo-meseraic duct (eighteen inches to forty inches above the ileo-cæcal valve), and in the aorta at the point of junction of the ductus arteriosus.

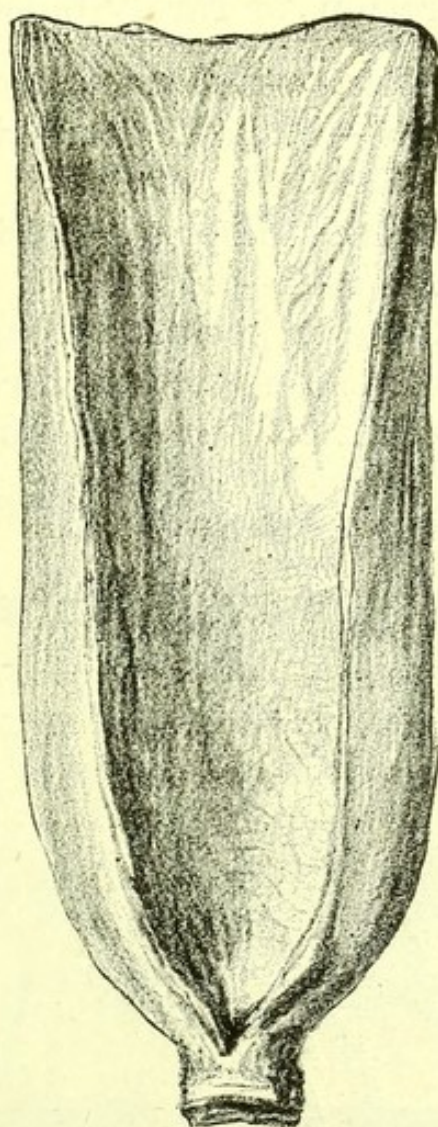
Next to fresh connective-tissue formation encircling



a passage, new growths and patches of scar tissue are the most frequent causes of stricture.

**Compression:** A term which is used in the colloquial sense, leads to atrophy of the tissue compressed. Thus in sarcoma growing from the pelvis of the kidney, the tumour may compress the kidney so that it is found no thicker than a cardboard on the surface of the tumour.

FIG. II.



*Dilatation of the Esophagus due to carcinoma of its lower end. From a specimen in the Museum of St. Bartholomew's Hospital.*

**Plugging.**—The common forms of plugging are :  
*Of Blood-vessels*—a clot formed in situ, or **thrombus** ;  
a fragment of fibrin, of degenerated arterial wall, or  
of new growth projected into the vessel, or **embolus** ;



and, as a very rare circumstance, a new growth growing into a large vein and completely filling its cavity.

*Of the Alimentary Canal*—Fæcal accumulations, and in a few rare cases gigantic gall-stones.

*Of the Bronchi*—In the larger bronchi, foreign bodies, fibrinous exudation in diphtheria ;

In the lesser bronchi, fibrinous exudation in diphtheria and in plastic bronchitis ;

In the smallest bronchi, fibrinous exudation or catarrhal secretion, or rarely blood.

*Of the Urinary Ducts*—Calculi, blood ;

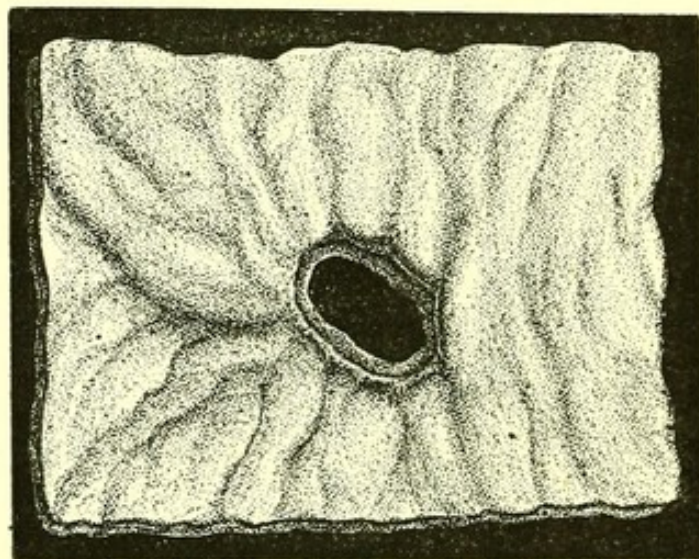
*Of the Bile Duct*—Calculi, products of catarrhal inflammation ;

*Of the Pancreatic and Salivary Ducts*—Calculi.

*Of the Fallopian Tubes*—Blood.

**Perforation** is due to pressure from without, as of an aneurysm on the trachea ; or of a rent in the floor of an ulcer, as in enteric fever and simple ulcer of the stomach.

FIG. 12.



*Perforation in the floor of a Simple Ulcer of Stomach.*  
From a specimen in the Museum of St. Bartholomew's Hospital.

**Laceration, Rupture, and Fracture** are used in the colloquial sense. A healthy organ is never ruptured except by violence.



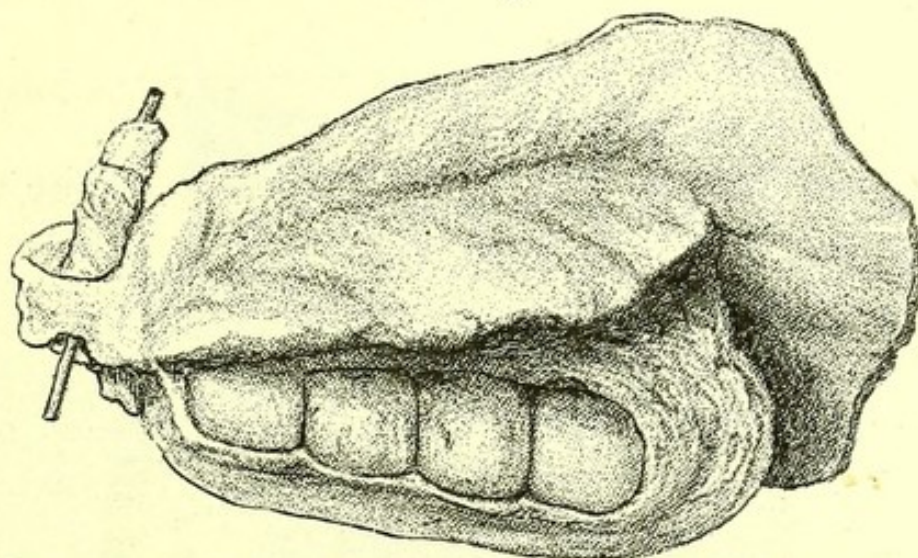
**Concretion:** Calculus is any hard concretion in a duct or cavity. The common calculi are

*Biliary Calculi or Gall-stones*—They consist mainly of cholesterin, and are found either in the gall-bladder or in dilated bile-ducts within the liver. They only occur in adults, and the anatomical changes to which they give rise are:

1. General jaundice by obstruction of the common bile-duct.

2. Distension of the gall-bladder with clear fluid by closing the cystic duct.

FIG. 13.



*Gall-stones in Gall-bladder* surrounded by a dense mass of carcinoma. From a specimen in the Museum of St. Bartholomew's Hospital.

3. General dilatation of bile-ducts and consequent cirrhosis of the liver by long-continued obstruction of the common duct.

4. Abscess of the liver, by ulcerating through the common bile-duct.

5. Carcinoma of common duct of gall-bladder, by long-continued irritation of the mucous surface.

6. Ulceration and tearing of the duodenum at orifice of duct.

*Renal Calculi*—of urine salts, phosphates and oxalates chiefly. They are found in children and adults, and cause:



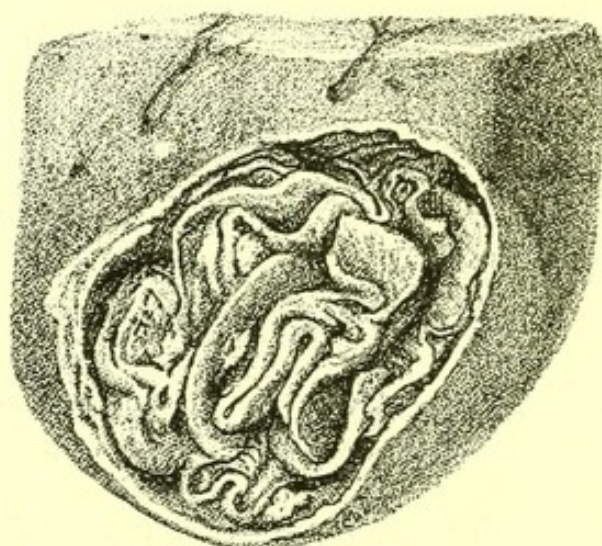
1. Hæmorrhage into the pelvis of the kidney.
2. Atrophy of the kidney.
3. Renal abscess.

*Vesical Calculi*, generally consisting of uric acid, urate of soda and ammonia, oxalate of lime, phosphate of lime and cystic oxide: and

*Prostatic Calculi*, consisting of carbonate of lime, lead to:

1. Hæmorrhage and ulceration of bladder and urethra.
2. Dilatation of both with secondary chronic interstitial nephritis.

FIG. 14.



*Hydatid Cyst of Liver.* The embryo of *Tænia echinococcus*, containing numerous younger embryos developed from its cyst-wall. From a specimen in the Museum of St. Bartholomew's Hospital.

*Pancreatic Calculi*—Whitish in colour and of irregular shape, with numerous projecting processes, consisting of pancreatin, and causing—

1. Abscess,
2. Cysts,
3. General dilatation of ducts,
4. Cirrhosis of pancreas.

*Salivary calculi*—Whitish and of irregular shape, consisting of saliva, salts, and with anatomical results resembling those of pancreatic calculus.

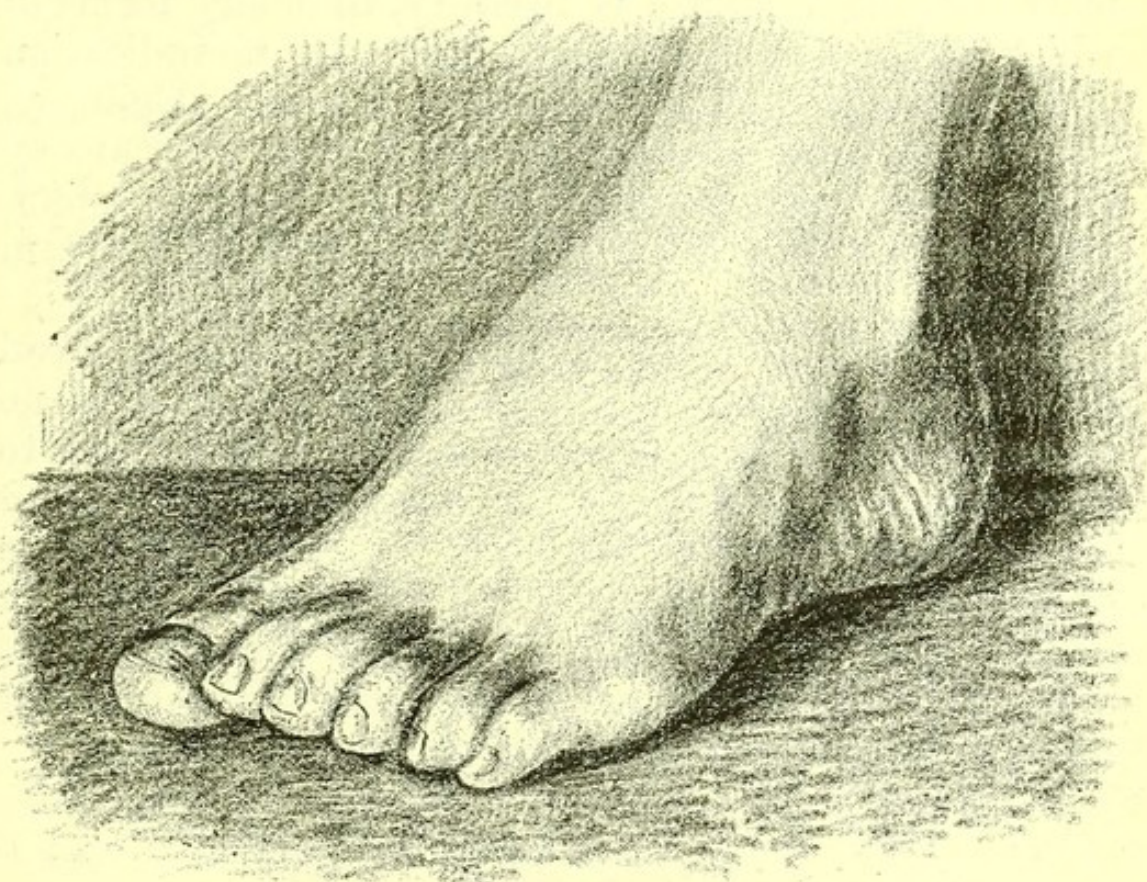**Parasitic invasion** is the inhabitation of the



tissues by living organisms, coming from without and remaining in the body for a longer or shorter time, as of the sexless embryo of *tænia echinococcus* in the liver, or the larval *trichina spiralis* in muscles.

**Errors of Development: Malformation.**—These terms are not of much value, as they include several dissimilar conditions. The writings of Darwin have drawn attention to the fact that varieties in structure are constantly occurring. Any one can see the differ-

FIG. 15.



*Variety in Structure of Foot, six toes being present.*

ence of faces, and the hearts or other viscera of several dead bodies can easily be distinguished by their individual peculiarities. When these variations are extreme, they are sometimes spoken of as malformations. Other peculiarities, also called malformations, are due to the cessation of development at a peculiar stage, sometimes called reversion; others again are the results of foetal disease. Other malformations are due to the partial fusion of two ova.



In the present imperfect state of knowledge of the development of the human ovum and of intra-uterine diseases, full descriptions should be given of all such examples ; and abnormal tissues should be examined microscopically, so as to ascertain whether they have regular layers indicating that they are results of growth, or an irregular disposition of their elements, pointing to their being results of inflammation.

**Disorders of Function** though extreme may be accompanied by no obvious anatomical change. The most striking instance is insanity, in many forms of which the post-mortem appearances give no indication of the state existing in the patient's lifetime. Epilepsy, hydrophobia, and tetanus, accompanied as they are by violent functional derangement of the nervous system, are not yet known by any definite post-mortem changes.

Every year one or two people are brought in dead to St. Bartholomew's Hospital, in whose bodies no anatomical signs of disease, poisoning, or injury are to be found, and in these cases the death must at present be regarded as due to disorder of function. Disorders of function, however, whether disorders of excess, of defect, or of perversion, are probably associated with anatomical changes which later observers with better methods of investigation will some day discover.



## CHAPTER III.

## SPECIFIC FEBRILE DISEASES.

FEVER IN GENERAL.	EPIDEMIC DIARRHŒA.
SMALL-POX.	DYSENTERY.
MEASLES.	MALARIAL FEVER.
EPIDEMIC ROSE RASH.	PHAGEDÆNA.
SCARLET FEVER.	ERYSIPELAS.
DENGUE.	PYÆMIA.
TYPHUS FEVER.	SEPTICÆMIA.
PLAGUE.	SYPHILIS.
RELAPSING FEVER.	GUMMA.
INFLUENZA.	VISCERAL SYPHILIS.
WHOOPING-COUGH.	CONGENITAL SYPHILIS.
MUMPS.	NON-INFECTING SORE.
DIPHTHERIA.	GONORRHŒA.
SIMPLE CONTINUED FEVER.	CEREBRO-SPINAL FEVER.
ENTERIC FEVER.	HYDROPHOBIA.
YELLOW FEVER.	GLANDERS.
CHOLERA.	SPLENIC FEVER.
SPORADIC CHOLERA.	

**Fever in General.**—The following post-mortem appearances are found in all cases of death after a continued rise of temperature :

1. Staining with blood of the intima of the arteries and veins.
2. Swelling of the liver cells and vascular engorgement, causing enlargement of the liver.
3. Enlargement of the spleen, due to arterial engorgement.
4. Swelling of the renal epithelium and enlargement of the kidneys.
5. Increase in the number of white corpuscles in the blood.



The temperature of the body sometimes continues to rise after death, and in a post-mortem examination may be sometimes felt to be higher than that of the anatomist's hand.

**Small-pox.**—The post-mortem examination of fatal cases of small-pox, in addition to the appearances on the skin, observable during life—viz., rash, hæmorrhages and sloughs, shows engorgement of the lungs, a large soft spleen, and some swelling of the liver and kidneys. The bladder may contain blood-stained urine. Pustules may be discovered in the œsophagus. Submeningeal hæmorrhage may be present in the brain. Pericarditis, endocarditis, and pleurisy are occasionally found. Swellings of parts of the bronchial mucous membrane are usually visible.

**Vaccinia.**—The morbid anatomy is confined to the cutaneous appearances.

**Varicella.**—Fatal cases are very rare. Scabs due to the rash are the only characteristic appearances.

**Measles.**—The post-mortem appearances in measles are usually those of the sequelæ of the disease.

The commonest of these is catarrhal pneumonia. General tuberculosis with or without tubercular meningitis, is sometimes discovered, and very rarely necrosis of a long bone.

**Epidemic Rose Rash.**—The internal changes correspond to those of measles.

**Scarlet Fever.**—Death from scarlet fever may occur early in the disease from high temperature, or from gangrenous sore throat, or late in the disease from some of the sequelæ.

When death occurs early from high temperature, there is usually some discoloration of the skin, and decomposition sets in rapidly. Sometimes there are numerous ecchymoses on the skin. All the viscera are soft and engorged. If due to gangrenous sore throat extensive sloughing of the soft palate and fauces is present.



The causes of death later in the disease are :

1. Nephritis ;
2. Abscess of middle ear ;
3. Pericarditis ;
4. Pyæmia.

1. *Nephritis*.—When death has been due to nephritis, the body is dropsical, great general anasarca often being present, with large effusions into the serous sacs.

Small shreds of desquamating epithelium are to be seen on the palms and soles, and more rarely on other parts of the body.

The bladder is empty and contracted. The kidneys are enlarged, and have a pale cortex and dark-coloured pyramids, the structure of the cortex being blurred. Injected stellate veins are visible on the surface. Microscopically, a general swelling of the epithelium of the tubuli, accentuation of the nuclei of the epithelial cells, and several degrees of granular degeneration of the cell contents are visible. The lungs are œdematous. The intestines often contain dark-coloured solid fæces.

2. *Abscess of Middle Ear*.—When death has been due to abscess of the middle ear, the tympanum is often ruptured, and a discharge may be seen issuing from one ear ; but this may be absent, and the first sign of the disease noticed on making the post-mortem examination may be a darkened spot on the roof of the tympanic cavity. This dark spot on pressure with the point of a knife is found to be necrosed, and on opening the cavity of the ear, it is discovered to be full of ill-smelling pus.

Sometimes an abscess of the temporo-sphenoidal lobe of the cerebrum or an abscess of the cerebellum is found in connection with this necrosed piece of bone. The abscess may communicate directly through the necrosed bone with the pus in the middle ear, or



there may be a layer of healthy brain tissue between the abscess and the bone. It is often accompanied by thrombus of one of the cerebral sinuses.

The abscess may have burst during life, so that free pus may be found within the dura mater.

Perforation or destruction of the tympanum is found where an abscess of the middle ear has discharged externally.

3. *Pericarditis*.—In death from pericarditis after scarlet fever the general appearances are indistinguishable from those of rheumatic pericarditis. There is much injection of the minute vessels of the pericardium with abundant deposit of lymph on the surface, explaining the loud friction sound which has usually been heard during life.

4. *Pyæmia* is a frequent cause of death after scarlet fever. Pus in one or more of the joints, and small abscesses in the lungs, are the commonest secondary deposits, while the centre from which the pus is absorbed may be :

1. A deeply ulcerated throat.
2. Abscess of the middle ear.
3. Rarely necrosis of a long bone.

*Remote Anatomical Changes due to Scarlet Fever*.—Chronic parenchymatous nephritis may have originated in the nephritis of scarlet fever.

Chronic interstitial nephritis may be the result of inflammation of the kidney, which began in an attack of scarlet fever.

The kidney resembles the common form of granular kidney. It is small, with narrow cortex, adherent capsule, granular surface and cysts, but instead of being red, it is usually of a white colour.

Pericardial adhesions, though rarely, may be traced to pericarditis following scarlet fever.

**Dengue**.—An epidemic fever of hot climates, is rarely fatal, and its morbid anatomy is unknown.

**Typhus Fever**.—The purplish stains in the skin



due to the slightly faded rash may be present. Rigor mortis is not well marked.

The lungs are engorged, and sometimes show actual pneumonia.

The muscular tissue of the heart is soft, and the endocardium and interior of the great blood-vessels blood-stained.

The spleen is enlarged and very soft.

The liver and kidneys are somewhat enlarged and soft.

**Plague.**—There has been no epidemic of plague in London since 1665. Hæmorrhages into the skin and viscera, enlarged and sometimes suppurating lymphatic glands, swollen parotid glands, pustules as large as a small bean, and true carbuncles, are the anatomical appearances described by Dr. Nathaniel Hodges, who resided in London throughout the last epidemic. From one of the cases he relates, it may be suspected that pericarditis was occasionally present (*De Peste*, p. 116).

**Relapsing Fever.**—The appearances resemble those of typhus, but the spleen is described as larger than in typhus. The rarity of the disease in London is shown by the fact that the records of post-mortems at St. Bartholomew's during the last twenty-two years do not contain a single example.

**Influenza.**—Death is generally due to some pre-existing anatomical defect, and the disease cannot be distinguished anatomically from other forms of catarrhal inflammation affecting the respiratory mucous membrane.

**Whooping-cough.**—Children with whooping-cough do not die at the beginning of the disease, and of its morbid anatomy during the first fortnight nothing is known.

The post-mortem appearances at a later date exhibit the immediate results of the cough or changes due to fatal complications.

*Immediate Results.*—The body is lean and often



livid. General anasarca is sometimes, though rarely, present. Ecchymoses of the conjunctiva are common, ruptured tympanum is somewhat rare. The chest is a pigeon-breast with arched sternum.

The lungs do not collapse when the chest is opened. They are emphysematous, and dilated air-vesicles are easily recognized on their edges. Parts of the lung, most often near the base, may be airless, either simply collapsed or in a condition of catarrhal pneumonia. Great thickening with some dilatation of the small bronchi is sometimes observed, and this is commonest at the bases of the lungs, which present to the naked eye a honeycombed appearance due to the large thickened bronchioles surrounded by lung substance, made denser than normal by a general increase of connective tissue, and with collapsed air vesicles.

Heart: the right ventricle is greatly dilated, and its anterior wall may be observed to arch forwards much more than natural. To this dilatation of the right side of the heart caused by the pulmonary emphysema, the dropsy sometimes present is due. But the dilatation is often present without dropsy. In six weeks great dilatation of the right heart may be produced.

*Complications of Whooping-cough.*—The commonest is general tuberculosis, which often reaches the pia mater. In such cases some caseous bronchial glands are always found, and tubercle may be discovered on every serous membrane and in the substance of the lungs, spleen, kidneys, and liver (mentioned in order of frequency), or tubercular meningitis may be the only other tubercular condition besides the infection of the bronchial glands.

**Mumps.**—Acute engorgement of the parotid gland never going on to suppuration, with more rarely a similar condition of the testis, the ovary, or the breast, are the only anatomical changes noticeable in mumps, a disease which is never seen in the post-mortem room.



**Diphtheria.**—The patient is most often a child, and the body well nourished. Some external swelling of the neck is often the only external morbid appearance in a patient who has died of diphtheria.

The chief internal morbid appearances are :

1. False membrane on the fauces, on the pharynx, or on the larynx.
2. Enlarged cervical glands.
3. Engorgement of the kidneys.

*False Membrane.*—This term is applied to a layer of inflammatory product deposited on a mucous membrane. It consists mainly of masses of leucocytes in several stages of degeneration or development, among which a few epithelial cells are entangled.

The false membrane is whitish in colour, and is easily observed on the red surface of the fauces, pharynx, œsophagus, larynx or trachea. It sometimes extends from the trachea into the large bronchi, and even into the small bronchi and air-vesicles. Much more rarely it extends from the œsophagus into the stomach.

Beneath it the mucous membrane is usually reddened, and where there is submucous tissue, that is sodden and infiltrated with leucocytes. Where the membrane has been stripped off during life, or at its edges, deep destructive ulceration is sometimes present. This is commonest in the fauces, and may extend to the soft palate.

When the false membrane extends to the lung, a whole lobe may be solidified, presenting an appearance exactly resembling, both to the naked eye and under the microscope, the solidification in acute pneumonia.

The quantity of false membrane in the trachea and larynx varies much. Sometimes a few shreds only are to be found, sometimes long strips, and sometimes a complete lining of false membrane. The ventricles of the larynx are often filled with detached fragments.

*Enlarged Cervical Glands.*—Red, soft, enlarged



glands may always be found in the neck, and are of course due to the irritation of the mucous membranes in their neighbourhood.

*Kidneys.*—The kidneys are slightly enlarged, the stellate veins are well marked on their surface, the capsule strips off readily, and on section the striation of the cortex is clouded. Microscopic examination shows a general swelling of the epithelium.

These are the common appearances. Less frequently there are extreme swelling and great engorgement, so that blood drips from the section.

In a good many cases, and chiefly in those in which death has taken place early in the disease, no structural changes are observable in the kidneys.

*Tracheotomy.*—If tracheotomy has been performed, the exact position of the wound and the number of tracheal rings divided should be noticed. Several accidents which follow that operation may be present. Of these the chief are :

1. The posterior wall of the trachea may have been wounded by the knife, or by the tube. In cases in which a tube has been worn for many days, actual ulceration of the posterior wall from the pressure of the tube is occasionally present.

2. Extravasated air in the loose tissue of the neck, or even in the anterior mediastinum, is sometimes an accident of the operation.

3. If death have taken place during the operation, a good deal of blood may be found in the trachea, and may have been the cause of death.

*Cause of Death in Diphtheria.*—Where no operation has been performed, death may be due to an almost complete occlusion of the trachea, and I have seen both chief bronchi with the whole trachea occupied by cylinders of false membrane. After tracheotomy abundant false membrane below the opening in the trachea may have caused death, or shreds of detached false membrane may have fallen into the bronchi, and occluded them, or solidification of the lung due to



continuation into it of the diphtheritic inflammatory process, may be the direct cause of death.

Patients with diphtheria may die, after the acute stage has passed, of sudden asthenia. In such cases the muscular tissue of the heart is found on post-mortem examination to be pale and soft.

Little is known of the anatomical appearance of the nervous system in the form of paralysis which follows diphtheria. No naked-eye appearances are found in the cord or brain.

*Relation of Morbid Appearances to Symptoms.*—The urgent dyspnœa and hoarse brassy inspiratory sound are clearly due to the mechanical obstruction of the trachea and larynx by false membrane. The pale soft condition of the muscular walls of the heart explains the ease with which sitting up induces fainting, in the later period of the disease, or during convalescence.

Where no false membrane can be seen on looking into the mouth, the presence of large cervical glands will help to suggest its presence in the trachea.

The morbid appearances, to which a fatal result may be attributed, point clearly to the fact that when once the medical attendant is satisfied that the obstruction is progressive, all preparations for tracheotomy should be at hand, and that the operation should not be too long delayed.

The accidents of the operation contributing to a fatal result, which are so often to be seen in spite of every care having been taken, show that tracheotomy ought not to be undertaken till it is clear that other methods have failed to dislodge the false membrane.

The soft flabby heart indicates that during a long convalescence caution must be exercised with regard to the patient's getting out of bed, or even sitting up in it.

**Cerebro-spinal Fever** does not differ anatomically from purulent meningitis affecting the meninges of both brain and spinal cord.



**Simple Continued Fever.**—The appearances are those described under the heading Fever in General (p. 55).

Whenever during life a continued fever without obvious cause has been present, a careful search must be made post-mortem for deep-seated suppuration, especially in glands, bones, and muscles ; for a localized empyæma ; for catarrhal pneumonia ; for endocardial ulcers ; for infective infarctions ; and for an adherent softening thrombosis. The discovery of one of these may sometimes explain post-mortem a continued fever of which during life the cause was obscure.

**Enteric Fever.**—The chief circumstance in the morbid anatomy of enteric fever, is the condition of the Peyer's glands in the small intestine. Sir William Jenner established conclusively in 1851 the fact that it is always possible in a post-mortem examination to be certain whether a patient has died with enteric fever. If the Peyer's glands are unaffected, the patient has certainly not perished from enteric fever.

The disease usually begins with rigors, and between these, and the commencement of convalescence, about five weeks commonly elapse. During this period three successive conditions of Peyer's glands are found. In the first stage, which begins before the end of the first week of the disease, they are enlarged ; in the second stage, which lasts during the second and first half of the third week, they have undergone necrosis ; while in the third stage, which begins in the latter part of the third week and lasts for a somewhat indefinite period, into the fourth or even fifth and sixth week, the slough or necrosed part of the Peyer's gland has disappeared, leaving an ulcer with a smooth floor. The healing of this ulcer completes the changes in the small intestine.

Contemporaneously with the enteric changes of the first three weeks, the mesenteric glands and the spleen become enlarged and soft, in the later weeks gradually returning to their normal condition. At the same time the lungs are often engorged and œdematous.



During the latter half of the disease, scattered ulcers or large patches of ulceration may be formed in the large intestine, ulceration may also take place in the larynx and on the epiglottis, and much more rarely on the cornea.

At the same time the muscles of the chest and abdomen show an infiltration into their sarcolemma, and become dark coloured (Zenker's change).

Besides these changes proper to enteric fever, other morbid changes, such as pneumonia and pleurisy, may be found ; or peritonitis, or rarely general septicæmia.

**MORBID ANATOMY IN DETAIL.**—*General condition.*

—The body is usually lean, and the abdomen distended. If the patient has died at a late stage of the disease, there may be anasarca of one or both legs or of an arm, due to thrombosis.

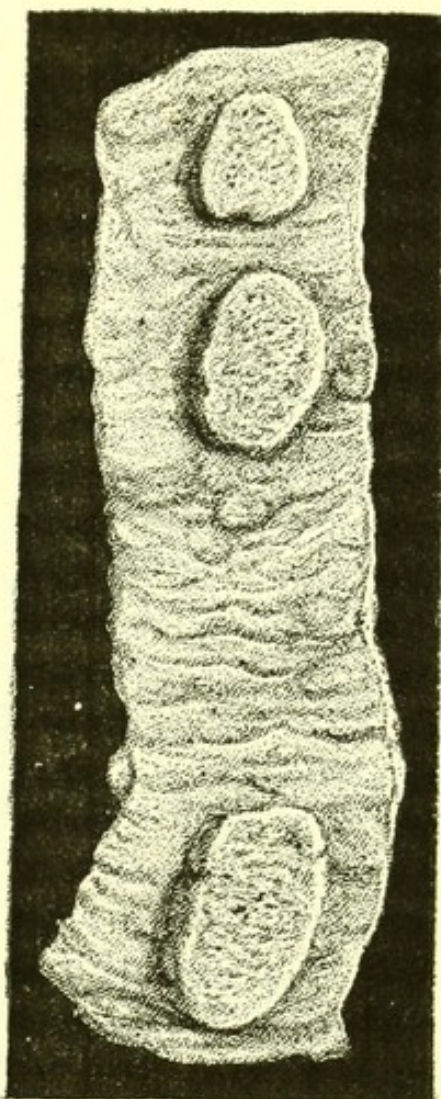
The small rose spots which are the characteristic rash of this fever disappear after death, but sometimes numerous sudamina are to be observed all over the body.

The muscles are often very dark in colour.

*Abdomen.* — On opening the abdomen, some redness may in most cases be noticed on the outside of the lower part of the small intestine, marking the position of the affected Peyer's glands.

*Small Intestine.*—The part of the small intestine invariably affected is that

FIG. 16.



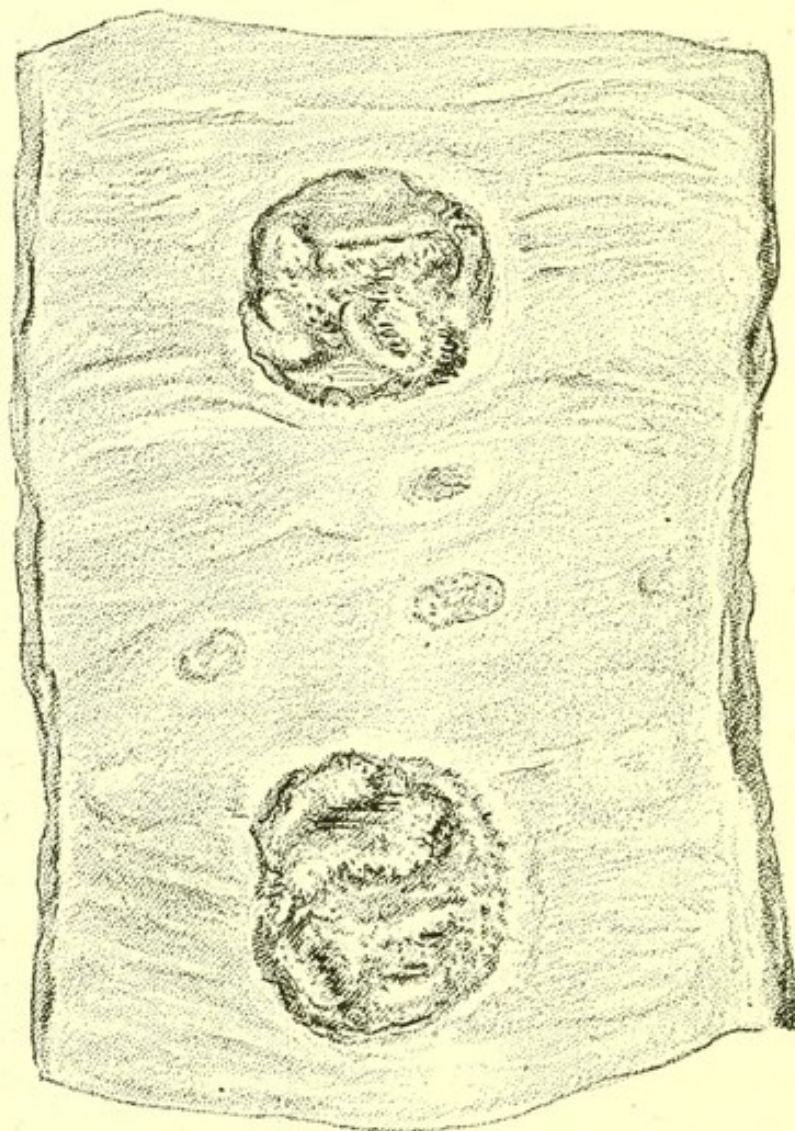
*First Stage of Enteric Fever.* —Part of ileum showing enlarged Peyer's glands from a patient who died about the eighth day.



nearest the ileo-cæcal valve. Sometimes the Peyer's glands throughout several feet are involved, more often only those in the last two feet.

Post-mortems in the first five days of the disease are rare, so that the precise date at which some

FIG. 17.



*Second Stage of Enteric Fever.*—Part of ileum showing ulcers in Peyer's glands, with sloughs from a patient who died about the seventeenth day of the disease.

engorgement of the Peyer's glands is first observable is not precisely known. By the tenth day, and sometimes two days earlier, the enlargement is complete. They stand up like small table-lands from the level of the mucous membrane, having abrupt vertical edges, and on the top a rugose appearance. Microscopic

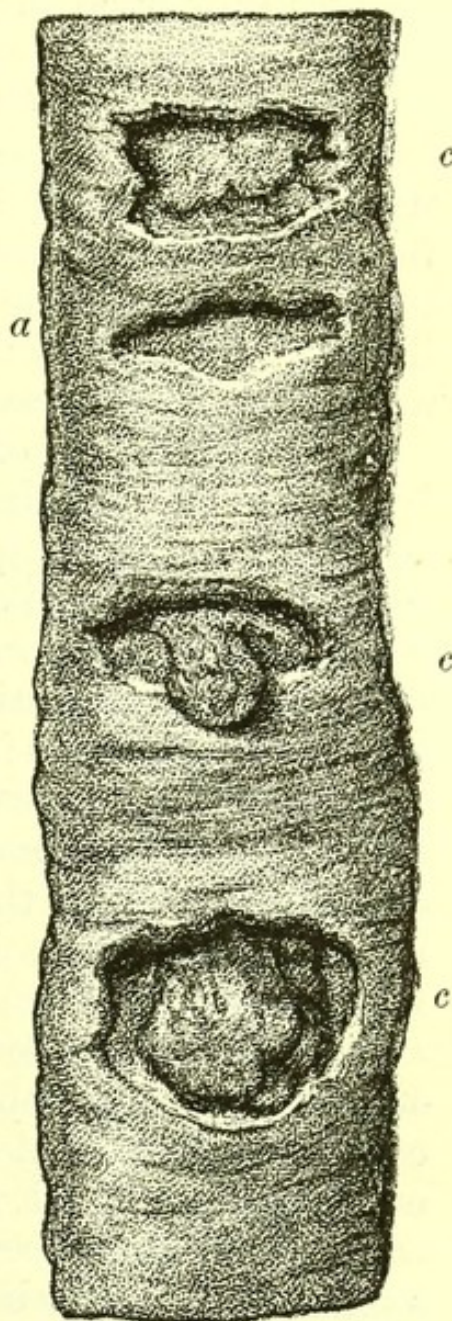


sections show this engorgement to be mainly due to the infiltration of the gland with leucocytes.

Soon after the maximum point of enlargement is reached, ulcers begin to be formed in the swollen glands, and by the end of another week several of the characteristic ulcers of the disease are present. These are formed by the necrosis, complete or partial, of a Peyer's gland, but never extend beyond the area of the gland. The middle is occupied by a slough, the remains of the destroyed gland tissue often stained yellow, and adherent to faecal shreds lying upon it. Where the slough is complete, it is overhung by the edge of the ulcer. If the slough be detached, the muscular coat of the intestine is usually seen beneath it. Microscopic sections show that this is to some extent infiltrated with leucocytes.

The ulcer is of course on the unattached part of the intestine, and as Peyer's glands are arranged with their length continuous with that of the intestine, the ulcers, when they occupy a whole gland, have a longitudinal direction. When they happen to occupy only part of a gland, they may appear transverse, but they never encircle the intestine as tuberculous ulcers sometimes do. Small ulcers of similar character are occasionally to be found in the solitary glands.

FIG. 18.



*Third Stage.*—Small intestine from a case of enteric fever about the twentieth day. *a.* Ulcer with slough detached. *c c c.* Ulcers with a slough remaining.



During the latter part of the third and beginning of the fourth week, the sloughs become detached and leave ulcers with smooth floors and overhanging edges. These thin overhanging edges float when the ulcer is immersed in water, and are thus best demonstrated.

It is common at this period to find that perforation has been the cause of death. The perforation is usually an opening of the size of a pin's-head in the floor of the ulcer. On the peritoneal surface of the intestine round the point of perforation a flaky deposit of lymph is usually present with adhesions to another coil of intestine.

General redness of the peritoneum with abundant lymph glueing the coils together, is often present in such cases. The quantity of faecal matter in the peritoneal cavity is usually small, and it is often confined by adhesions into a closed region near the perforation. Sometimes, and it should always be looked for, a grape-stone or other hard material may be found in or near the perforation, and was its cause. But external as well as internal force may cause a breach in the floor of an ulcer, and cases are recorded in which it was produced by the patient rising from bed.

As the complete necrosis of the Peyer's gland always leaves a considerable thickness of muscular coat, it is clear that a hole in the floor of an ulcer in enteric fever must always be due to force or to a continuance of ulcerative process in the infiltrated subglandular muscular tissue. It may occur while the slough is still attached, but is rare before the end of the third week of the disease. It sometimes occurs much later.

All the Peyer's glands affected are usually in the same or nearly the same condition, but where there has been during life a true relapse with fresh crop of rose spots on the abdomen, a fresh series of glands may become affected, so that many glands simply



enlarged as well as ulcers with sloughs may be found. It seems probable, but is not yet fully established, that a relapse with fresh eruption is to be taken as an external indication that a fresh group of glands has become affected. There is no doubt that some of these as well as primarily enlarged glands do sometimes subside without undergoing necrosis and forming ulcers.

As post-mortems prove that the Peyer's glands first affected are always those nearest the ileo-cæcal valve, the hypothesis that in relapses other Peyer's glands are infected from them is untenable.

*Mesenteric Glands.*—The mesenteric glands become enlarged with the Peyer's glands, and their enlargement continues till after the separation of the sloughs in the ulcers of the small intestine. It is due to a general infiltration, is sometimes very great, and sometimes takes place so rapidly that the glandular tissue breaks down and abscesses are formed.

*Large Intestine.*—Ulcers in the large intestine often occur in long-continued cases of enteric fever, and it was one of the numerous original observations of Dr. Addison, of Guy's Hospital, that obstinate diarrhœa occurring in the later weeks was often due to such ulceration. The ulcers are often formed in the solitary glands, and are very small. At other times they are large and of irregular outline, and have been described by some observers, as by Dr. William Baly, of St. Bartholomew's Hospital, in his Lectures on Dysentery, as due to dysentery complicating enteric fever. In a few cases I have found the whole mucous membrane of the transverse colon reticulated with widespread ulceration. Ulcers have been observed in the vermiform appendix, and have been known to cause death by perforation there. Perforation has also been described as taking place in other parts of the large intestine, but is much rarer than in the ulcers of the small intestine.

*Stomach.*—Is usually without morbid change. I



once found three small shallow catarrhal ulcers near the middle of the greater curve.

*Spleen.*—The spleen begins to enlarge early in enteric fever, and is usually found post-mortem to be large and soft, except in cases where death has taken place after more than the usual number of weeks. Large soft infarcts are sometimes found in it.

*Liver.*—The liver is somewhat soft and slightly swollen, as in all fevers. The gall-bladder is often nearly empty, and if full usually contains pale yellow watery bile.

*Pancreas.*—The pancreas sometimes feels soft and looks swollen to the naked eye, but on microscopical examination no change is found.

*Kidneys.*—Are usually soft, and the cortex commonly shows a slight degree of clouding in its striation, a condition common to all fevers.

*Bladder.*—The mucous surface is often reddened in patches, and sometimes has a dense coating of adherent phosphates.

*Chest.—Larynx and Trachea.*—Shallow ulcers often occur on the edges and at the ends of the vocal cords, and on the surface and at the edges of the epiglottis. In the last position they are sometimes attributable to incautious feeding with a long-spouted feeder.

Extensive necrosis of the arytaenoid cartilages also occurs. In the St. Bartholomew's Museum there is a specimen showing necrosis of both arytaenoid cartilages with a large abscess. The posterior ends of the vocal cords are involved.

*Lungs.*—The lower lobes of the lungs are often engorged and œdematous, but are rarely airless. Sometimes large quantities of frothy sputum fill the bronchi.

*Mouth and Œsophagus.*—The tongue is often coated with hard, dry fur, but later in the disease is abraded and pale.

*Heart.*—The muscular tissue usually looks pale, and is very soft, and in long-continued cases a perceptible loss of weight is observable.



*Vessels.*—Thrombosis of a large vein of leg or arm is sometimes found with anasarca of the limb, and sometimes plugging of lymphatics.

*Nervous System.*—Paraplegia sometimes follows enteric fever, but of the anatomical condition of the brain and cord in such cases nothing is known.

CAUSE OF DEATH.—The chief causes of death in enteric fever demonstrable in the post-mortem room are :

1. Perforation of ileum,
2. Pyrexia,
3. Asthenia,
4. Hæmorrhage,
5. Œdema of glottis,
6. Bronchitis,
7. Perforation of large intestines,
8. Septicæmia,
9. Previous morbid conditions.

*Perforation.*—The commonest cause of death in enteric fever is perforation occurring in the floor of one of the ulcers in the small intestine, and followed by peritonitis.

Other causes are :

*Pyrexia.*—Usually occurring early, and indicated post-mortem by a very large and soft spleen and mesenteric glands, and usually by the affection of a large extent of small intestine.

*Asthenia.*—Occurring late and associated with wasting of the cardiac muscular tissue, and often with thrombosis.

*Hæmorrhage.*—Hæmorrhage occurring early in enteric fever is always a capillary hæmorrhage, and, as in other capillary hæmorrhages, no other evidence than the blood can be found post-mortem. Hæmorrhage occurring late in the disease is more frequently fatal, and in such cases perforation of a small vessel near the ileo-cæcal valve in the floor of an ulcer may usually be discovered.



*Edema Glottidis*, accompanied by urgent dyspnœa, is a frequent cause of death when there is ulceration or necrosis in the larynx.

*Bronchitis*.—Severe bronchial catarrh, usually in patients previously emphysematous, is a not uncommon cause of a fatal termination.

*Perforation of the Large Intestine*.—Is a very rare cause of death. It is of course followed by the same results, as regards the peritoneum, as perforation of the small intestine.

*Septicæmia*.—In a few cases, death seems due to a septicæmia, caused by absorption of septic matter from very large sloughs, and embolic abscesses are found in the lungs and elsewhere.

*Previous Morbid Conditions*.—Old renal disease, interstitial, amyloid, or parenchymatous; may be found in patients who have died of enteric fever, and old valvular disease is sometimes present. I have never met with an instance of a patient with enteric fever who was also in a condition of progressive tuberculosis.

RELATION OF THE SYMPTOMS TO MORBID ANATOMY.—As regards the interpretation of symptoms, the morbid anatomy of enteric fever shows:

1. That a greatly distended abdomen is not necessarily due to perforation, but that where it is not due to perforation, it is often associated with ulceration of the large intestine.

2. That excessive diarrhœa is most often due to a great extent of ulceration, probably including the large intestine.

DETERMINATION OF THE PROGNOSIS FROM THE MORBID ANATOMY.—As regards prognosis, post-mortems demonstrate:

1. That neglect of the rules of treatment is the commonest cause of death.

2. That from an anatomical point of view the cases in which death cannot be prevented are those in which:



- (1) Old renal disease is present ;
- (2) In which a great many Peyer's glands are affected and there is great initial pyrexia ;
- (3) Cases in which extensive ulceration with large sloughs is followed by phenomena closely resembling those of septicæmia.

While cases in which the prognosis is unfavourable, but in which recovery may take place, are :

- (1) Cases in which there is extensive ulceration of the large intestine ;
- (2) In which the lungs are highly emphysematous ;
- (3) In which valvular disease is present.

3. The lesson of post-mortems as to perforation is that it will rarely take place without some neglect of the rules of treatment.

RULES OF TREATMENT INDICATED BY THE MORBID ANATOMY.—As regards treatment, the lessons of the morbid anatomy are :

1. That absolute recumbency is essential to safety ;
2. That the rules as to fluid diet cannot be too strictly enforced ;
3. That where the patient has emphysematous lungs, it is of especial importance to guard against bronchitis.

Bedsore are to be regarded as due to defective treatment—*i.e.*, to bad nursing ; and perforation, where a patient has been under treatment from the beginning, may be looked at in the same light, except in a very few cases.

In every epidemic enteric fever has its particular characteristics. It seems therefore worth while to give a table, showing the anatomical character and cause of death in a severe epidemic, of which the first death took place in St. Bartholomew's Hospital on September 20, 1881. All the deaths took place before the end of 1881.



*Tabular View of the Morbid Anatomy of the Fatal Cases of an Epidemic of Enteric Fever examined post-mortem by the Author, Sept. 20—Dec. 20, 1881.*

No.	Sex.	Age.	Day of Fever	Cause of Fatal Result.	Ulceration of Small Intestine.	Ulceration of Large Intestine.	Spleen.	Larynx.	Morbid Changes independent of those of the Fever.
1	M.	24	15th	Temp. 107.4°. At work for 6 days after 1st day.	7 feet; confluent enlargement; commencing ulceration.	o	26 oz.	—	o
2	F.	23	—	Miscarriage; remains of placenta in uterus.	Confluent enlargement; ulceration just beginning.	Small ulcer of colon.	10 oz.	—	o
3	M.	17	13th	Died suddenly.	4 feet; much enlargement; sloughs; some detached; most adherent in the ulcers.	o	11 oz.	—	o
4	M.	35	15th	Bronchitis.	Ulcers with sloughs.	o	Large.	—	—
5	M.	26	29th	Perforation; peritonitis.	6 inches; perforation of ulcer 3 inches above valve.	Ulcerated throughout.	Very large.	—	o
6	M.	30	35th	Died suddenly.	Ulcers healed.	o	Large.	—	o
7	M.	49	12th	Hæmorrhage.	3 feet.	o	Very large.	—	o
8	F.	46	23rd	Bronchitis.	6 feet.	o	Large.	—	Emphysema.
9	M.	40	21st	A history of drink (a cab-driver).	3 feet; whole of each gland in state of slough; muscular coat exposed in one.	o	18 oz.	Ulcers.	o



10	M.	26	13th	Bronchitis.	6 feet; sloughs in all.	Many small ulcers.	16 oz.	Ulcers.	—
11	F.	15	18th	Bronchitis.	4 feet; sloughs, some detached.	0	10 oz.	Ulceration of epiglottis.	Bronchi much engorged.
12	M.	19	44th	Perforation; peritonitis.	18 inches; 4 shallow ulcers only; 1 perforated.	0	Normal.	0	0
13	M.	16	21st	Perforation; peritonitis.	2 feet; many sloughs detached; 26 ulcers; 2 perforated near valve.	One small ulcer.	6 oz.	1 small ulcer.	0
14	M.	20	43rd	Perforation; peritonitis.	3 ulcers close to valve, almost healed.	Many ulcers; 2 perforated.	Normal.	0	0
15	M.	21	40th	Albuminuria.	5 feet; ulcers healing; no sloughs remaining.	0	Amyloid	0	Amyloid disease; spleen and kidneys (weight, 23 oz.).
16	M.	12	14th	Temp. 106°; much swelling of fauces.	4 feet; sloughs formed in 2 feet, confluent near valve.	A few ulcers.	Enlarged.	Ulceration of epiglottis.	0
17	F.	40	28th	Perforation; peritonitis.	2 ulcers; one 3 feet from valve, with muscular coat exposed; one perforated 1 inch from valve.	0	Large.	0	0
18	M.	16	—	Peritonitis.	2 feet; sloughs detached.	0	20 oz.	0	Amyloid kidneys. Gummata in liver.



The table shows that in these eighteen cases death was attributable to

Perforation . . . . .	in 5 cases
Bronchitis . . . . .	„ 4 „
Previous anatomical changes . . . . .	„ 4 „
Pyrexia . . . . .	„ 2 „
Syncope . . . . .	„ 2 „
Hæmorrhage . . . . .	„ 1 „

There were laryngeal ulcers in five cases. The spleen was enlarged in sixteen out of the eighteen cases.

**Yellow Fever.**—Dr. Greenfield, who had minutely examined one case, and Dr. Wickham Legg, who had read of many cases, differ in some details as to the morbid anatomy of yellow fever, but agree in believing that it is an inflammation of the liver, corresponding to parenchymatous inflammation of the kidney in structural effects, and due to an infective organism.

It seems certain that the liver-cells are always disintegrated, the gall-bladder full of dark bile, and the skin jaundiced, and that the other anatomical appearances are those of high fever.

**Cholera.**—A controversy still continues as to the organism which produces the morbid changes of cholera. It is admitted that a comma-shaped bacillus of a definite species is abundant in the contents of the intestines. Klein maintains that this bacillus is an accident of the disease; Koch that it is its essence.

I have only seen one case of death from cholera, and therefore quote with some abbreviation the report by Dr. Church, of the cases examined by Dr. Andrew and himself at St. Bartholomew's, in the epidemic of 1866 (St. Bartholomew's Hospital Reports, vol. iii. p. 210):—

“Post-mortem rigidity was great in most, and there was the blueness of the finger-nails.

“In sixteen out of seventeen cases examined, the intestinal tract exhibited unnatural appearances in



some portion or other of its length, considerable œdema of the walls of the duodenum and upper part of the jejunum was of common occurrence, the congestion of the mucous membrane being usually greatest in the ileum, and the congestion almost always stopped some six inches above the ileo-cæcal valve, although it was in this position of the gut that the solitary glands were commonly most prominent.

“The peritoneum almost invariably presented traces of increased vascularity, and felt shiny and sticky. In eight cases the kidneys were found congested, in four anæmic, and in four they were natural, or very slightly congested.

“The spleen appeared to be unaffected, as did the liver, which was somewhat congested, and the gall-bladder in every instance contained bile. In nearly every instance the left side of the heart contained blood. The morbid appearances met with in the heart were ecchymoses beneath the endocardium of the left ventricle, and larger ones beneath the visceral layer of the pericardium, especially in the right auriculo-ventricular groove, and on the surfaces of the right auricle and ventricle.”

**Sporadic Cholera and Epidemic Diarrhœa.**—In both these disorders, liquid stools in the intestines, and a pale, empty gall-bladder, are almost the only definite appearances.

In the epidemic diarrhœa of infants, Klein has described an albuminous exudation into the glomeruli of the kidney.

**Dysentery.**—Acute dysentery is rarely seen in London. Large flakes of mucous membrane are separated in the large intestine.

In dysentery as ordinarily seen in the post-mortem room at St. Bartholomew's, deep patches of ulceration are found throughout the large intestine. Some are partly healed, and in their neighbourhood pigment and scar tissue are found in the mucous membrane. A little blood usually lies on the surface of these ulcers.



There are also patches of pigment in the intestine marking the site of former ulcers.

In acute dysentery in India and in West Africa, and in cases thence which die in England, abscess of the liver is frequently found. It is probably due to infection from the large intestine. Some epidemics of dysentery are described as having few or no cases of abscess of the liver. An insufficient number of post-mortem examinations perhaps accounts for this discrepancy. Since the hepatic abscess is pyæmic, it may be expected to occur in some cases of every epidemic of dysentery.

**Malarial Fever.**—Death from malarial fever is now very rare in England, and the few cases in which it occurs are those in which the fever was acquired abroad. In old writings, medical and general, nothing is commoner than to read that a man died of the ague. King James I. is said to have died of it, and Oliver Cromwell.

This difference in frequency is partly due to the fact that deep drainage has made ague of much less common occurrence than in former years, and partly to the successful treatment of patients by quinine. A careful investigation however, shows that the supposed frequency of death from ague in former times was in great part based upon the fact that the thermometer was not used, and that many diseases in which rigors were obvious symptoms were classed as agues, so that the list of deaths from ague was swelled by what are really examples of enteric fever, of pleurisy, of pericarditis, and even of pneumonia.

The characteristic post-mortem appearance in ague is the enlargement of the spleen, which may weigh as much as 80 ounces. The capsule is thickened and opaque, the substance very firm. There is a great increase of connective tissue.

Microscopic sections of such spleens often show considerable extravasation of red corpuscles with different degrees of depigmentation of these corpuscles, in



addition to a large connective-tissue increase into the splenic tissue throughout the gland.

A similar enlargement is sometimes observable in the liver, which may weigh 8 or 9 lb.

The heart is pale, the blood watery and with pale imperfect clots.

Cases in which the results of malarial fever and of leucocythæmia are blended are to be met with, and in such both liver and spleen are usually very large.

In one case which I examined the onset of tuberculosis terminated a case of malarial fever.

The patient was a man aged twenty-one years, who came under my care, in St. Bartholomew's Hospital, November 26, 1885. After some time he left the hospital, was again admitted, and died in one of Dr. Andrew's wards, January 21, 1887. He had worked on a railway in Cape Colony from 1880 till 1884, and in 1883 was laid up for a year with tertian and quotidian ague. He went to Ceylon and had dysentery on the voyage. From 1884 he had noticed his greatly enlarged spleen. After returning to England he had fever again. He never had syphilis. He suffered from an irregular fever; for two months he had a temperature suggesting quotidian ague, then two months of almost normal temperature, then daily fever for a week, then six weeks of normal temperature, then fever again. He improved under very large doses of quinine, thirty-five grains every twenty-four hours, and his spleen was perceptibly reduced in size. The proportion of white blood-corpuscles to red was throughout about one to five; the red corpuscles were normal. Post-mortem the spleen weighed 60 oz., and the liver 120 oz. Naked-eye sections of the spleen showed numerous white specks throughout it, and some larger and caseous masses. None of the masses had any increased vascularity round them. The liver contained many similar white masses. The whole peritoneum was covered with them, some



being caseous. A layer of caseous material a quarter of an inch thick surrounded the upper part of the rectum. In all the lobes of the lungs were scattered masses exactly resembling those of the liver. One caseous abdominal gland had broken down in the middle. Under the microscope the masses in the liver and spleen were seen to consist, some merely of caseous material, others of collections of small cells; some near blood-vessels, others in the midst of the gland tissue. Besides the small round cells a few multinucleated cells could be seen in some of the masses, but no true giant-cells. After several examinations no bacilli were found. The liver showed general connective-tissue increase. The spleen showed collections of cells precisely resembling those in the liver, and also many pigmented patches, a large connective-tissue increase, and a general extravasation of blood-cells. The history of malarial infection and the appearance of the liver and spleen make it certain that their chronic inflammation and connective-tissue increase was due to intermittent fever. The large quantity of caseous material in the glands and the distribution of the white masses over the peritoneum showed that the white masses in the liver and spleen were true tubercles invading viscera already affected by long-lasting changes due to malaria.

**Phagedæna** is a clinical rather than pathological term for rapidly progressing ulceration, passing on into gangrene of large patches of tissue.

**Erysipelas** is an inflammation of the skin and subcutaneous tissue, with exudation of serous fluid, which in places raises the epidermis and causes blisters. Near these some shallow ulcerated patches are sometimes visible. The head and face are frequently the inflamed regions. The condition also occurs near wounds on any part of the body in patients who have been exposed to infection. The cause of death may be fever alone. Of anatomical causes, pericarditis, with scanty deposit of lymph and



very little serum, is common, and a small tract of pneumonic consolidation is often present in one lung. Chronic interstitial nephritis and emphysema of the lungs are generally discovered post-mortem.

Careful search will often reveal caries of bone somewhere in the head, very often of a nasal bone.

**Pyæmia** is said to exist in a patient who has had a region of suppuration, when abscesses appear in distant parts of the body. These abscesses contain foetid pus, and in it abundant micro-organisms. They may often be demonstrated to be due to an infarction of a terminal artery. The embolus is derived through the veins, nearest the region of suppuration. At the same time inflammations of serous membranes appear. These are generally accompanied by turbid effusions, with a small quantity of lymph. Sometimes, however, in the pericarditis of pyæmia there is an abundant deposit of lymph on the heart. When the lymph is scanty, the serous fluid is often brownish or distinctly blood-stained. Pyæmia is not always recognized during life, and as soon as in an autopsy the characteristic abscesses in the lungs are noticed, a careful search must be made for the primary collection of septic material.

An abscess near carious bone in the spinal column, a suppurating joint, an abscess of the middle or inner ear, with necrosis of part of the temporal bone, a suppurating adherent thrombus in a vein, or in a child a necrosed shaft of a long bone, are probable sources of the septic material. Veins near the abscess contain adherent clots. There are generally several abscesses in both lungs. They are not often larger than a hazel-nut, are on the pleural surface, and are more or less conical, with the apex of the cone towards the pulmonary artery and the base on the pleural surface of the lung. The pleura above the abscess has always lost its gloss, and has a scanty deposit of lymph on it. Besides the pleural inflammation over these abscesses, general



pleurisy may be present of the kind already described. A large patch of lobar pneumonia is not uncommon.

Pericarditis is often present, and has already been described. Endocarditis is much rarer. When it appears, small abscesses, generally looking like pale specks or lines in the muscular tissue of the heart, are always present. Pus is often found in the thoracic or cervical lymphatics. Abscesses may occur in any part of the liver, and are sometimes very numerous, though rarely very large. The liver cells look swollen, and the whole organ is softer than natural and increased in weight. The spleen is large and soft, and may have one or more abscesses in it. Large abscesses are not common in the kidneys, but small ones often occur. They are frequently visible as little white lines when the kidney is cut open. Sometimes the kidneys are very much enlarged and very soft.

All the joints ought to be carefully examined, and more than one will probably contain pus.

A pyæmic infarction always contains micro-organisms, and therefore is spoken of as infective. It becomes adherent to a vessel, and need not fill it to produce an abscess.

The conditions of circulation in the liver seem to prevent mere mechanical infarction, but though this is unknown, abscesses in pyæmia due to infective emboli are very common.

PRINCIPLES OF TREATMENT TO BE DEDUCED FROM THE MORBID ANATOMY.—The widespread anatomical effects which may be produced by a suppurating region, point to the extreme importance of tracking out the site of suppuration, when its presence is indicated by symptoms, of draining it effectually, and of excluding by every precaution of cleanliness the introduction of micro-organisms to a focus, from which they may so easily be distributed throughout the body.

*Obscure Pyæmia.*—It should be constantly remembered that obscure and unexplained, but severe,



febrile symptoms during life, are sometimes discovered post-mortem to have been due to pyæmia.

A patient admitted to St. Bartholomew's, with supposed typhus fever, was after death discovered to have pyæmia.

Another patient, supposed to have swallowed poison from his repeated vomiting, proved to have pyæmia. An old (cured) aneurysm of the abdominal aorta lay against the transverse colon. The aneurysm was filled with firmly clotted fibrin. Where the colon lay against the aneurysm, the aneurysm was discoloured, and in the discoloured part the laminated clot had broken down, forming a shallow abscess, containing thin, stinking pus. There were secondary abscesses of the liver and kidney.

**Septicæmia**, or poisoning by septic material from a wound or from an inflamed mucous surface, is recognized by symptoms during life, but cannot be proved conclusively from a post-mortem examination. As in death from other fevers with highly raised temperature the veins and arteries are blood-stained, the lungs are engorged, the liver and spleen and kidneys soft and of swollen appearance. Putrefaction proceeds rapidly. The disorder formerly called puerperal fever is a septicæmia.

**Syphilis** is a morbid condition produced by a specific virus. This virus takes from ten to thirty days to develop after infection and its first manifestation is a local sore. This may occur on any part of the external surface of the body. It consists of a hard, raised, reddened patch of tissue, a region of densely packed inflammation cells. The lymphatics in the neighbourhood become infiltrated and hard. If irritation lead to the ulceration of the sores, they also suppurate.

This is the first lesion observable, but does not correspond to the diseased bone of a case of pyæmia, but rather to the first joint containing pus in such a case. The whole system is infected, and the first



anatomical change due to the infection is this hard sore. For two years or more further changes are demonstrable from time to time, and their consequences may extend for a much longer period. In this syphilis resembles intermittent malarial fever. A patient is cured of malarial fever after suffering from it for several months. Two years pass by without any reappearance of the disease. The patient is placed in unfavourable circumstances, and suddenly his tertian fever returns, though he has clearly had no further infection.

A patient is infected by syphilis, the hard sore appears. For two years he has other slowly succeeding changes, inflammation of the fauces and larynx, and of the iris, palmar psoriasis, rupia, or lichen, ulceration of the tongue, inflammation of a testis. He then has gummata of the bones, blood-vessels, and viscera.

All these conditions leave their mark on the body, and it seems free from further change, when, unfavourable conditions supervening, further changes begin, of which the chief are fresh connective-tissue formation in the nervous system, followed by atrophy of the nerve fibres and cells ;

Posterior sclerosis, causing locomotor ataxy ;  
Lateral sclerosis ;  
Disseminated sclerosis.

The acute inflammations of syphilis are characterized by the large quantity of fibrin exuded.

The chronic inflammations by the density and quantity of connective tissue formed.

A *gumma* is a collection of embryonic connective-tissue cells. To the naked eye it appears when young as a white speck generally surrounded by a red line, and often caseate in the middle.

It has thus to the naked eye a general resemblance to a large tuberculous mass, but the red line at the circumference is never present in tubercle.



Under the microscope, when very young, it is, so far as its cellular structure is concerned, indistinguishable from tubercle. The bacillus tuberculosis is of course not present. When the gumma has ceased to grow, the remaining undegenerate embryonic connective-tissue cells of the gumma elongate, old connective tissue is formed and contracts, leaving a patch of scar tissue.

Gummata may be solitary or thickly sown, and may occur in any tissue. Bone, muscle, nerves, glands, are all common sites. Gummata are commoner in the liver, kidney, and brain than in the spleen and heart. I have never seen one in the thyroid, pancreas, or supra-renal.

**Visceral Syphilis.**—This term is somewhat loosely applied to the manifestations of syphilis in the internal organs of the body.

These manifestations are of two kinds :

- a.* Gummata and their sequelæ;
- β.* Amyloid infiltration.

Most forms of syphilitic ulceration and of connective-tissue increase due to syphilis are commenced by the growth of gummata.

Amyloid infiltration due to syphilis may be present in any vascular region, but is most marked in the liver, spleen, kidneys, and small intestine.

In amyloid infiltration of the liver due to syphilis, there is frequently less ascites than in amyloid infiltration of the liver due to phthisis.

The chief morbid changes due to syphilis in its several stages throughout the body are described in the chapter referring to each region, but those seen in the post-mortem room may be here stated in a summary :

#### IN THE NERVOUS SYSTEM :

1. *Gumma of the brain*, possibly pressing upon an



artery, and thus leading to cerebral softening, and finally to hæmorrhage.

2. *Sclerosis*, occurring in patches throughout the brain as islands of connective tissue.

3. *Multiple gummata of the dura mater*, leading to pachymeningitis, and sometimes to hæmatoma.

4. *Gumma of the spinal cord*, with symptoms due to its particular situation.

5. *Sclerosis of the several regions of the cord* :

Of the posterior columns (locomotor ataxy) ;

Of the lateral columns (lateral sclerosis) ;

Of the anterior columns ;

Of islands of tissue (disseminated sclerosis).

6. *Gummata of the dura mater of the cord*, causing pachymeningitis.

7. *Gummata of particular nerves*, sometimes forming easily perceptible tumours, as on the ulnar nerve.

#### IN THE CIRCULATORY SYSTEM :

8. *Gummata in the wall of the heart*, sometimes of large size.

9. *Chronic endocarditis*, affecting the whole surface, and not only the valves.

10. *Minute gummata in the middle coat of the aorta and large arteries*, leading to the formation of calcified patches, and often of aneurysm.

11. *Chronic arteritis* : this affects the whole calibre of smaller arteries, and is best seen in those of the brain. The inner coat of the vessel is enormously thickened, so that the basilar artery, for example, may become so narrow as but just to admit a common pin.

#### IN THE RESPIRATORY SYSTEM :

12. The epiglottis is the seat of slow deep destructive ulceration, and may be completely destroyed. A similar change affects the vocal cords. This ulceration probably always begins by the formation of gummata.



13. Enormous thickening of the vocal cords, with narrowing of the rima glottidis due to chronic laryngitis, may occur.

14. Minute gummata undoubtedly occur in the lungs, and perhaps are a cause of hæmoptysis. Syphilitic phthisis has, however, no existence as distinct from phthisis in a syphilitic person. In such persons tubercle grows slowly and leads to slow destructive changes, and with great increase of connective tissue. I have never seen a large gumma in the lungs.

15. Soft mucous outgrowths may be present on the vocal cords.

#### IN THE DIGESTIVE SYSTEM :

16. Hard sores, generally with ulceration upon the lips, tongue, internal and external walls of the mouth.

17. Gummata with deep scars on the tongue.

18. Deep destructive ulceration of the tonsils, of the uvula, of the soft palate, and of the hard palate.

19. Ulcers in the small intestine sometimes occur, but are rare. They are due to gummata in the mucous membrane.

20. Ulcers with much connective-tissue formation in the large intestine, sometimes leading to stricture of the transverse colon, and more often to stricture of the rectum.

21. Mucous growths about anus.

22. Amyloid infiltration of the mucous membrane of the stomach and intestine.

23. Isolated gumma of the liver, leading to the formation of a scar.

24. Multiple gummata of the liver, leading to many deep patches of scar tissue, deforming the liver and leading to a condition resembling cirrhosis.

25. Perihepatitis, owing to numbers of minute gummata in the superficial capsule, and sometimes continuing into a condition of general connective-tissue increase throughout the liver.



26. Amyloid infiltration of the liver.
27. Amyloid infiltration of the pancreas may occur, but is extremely rare.

IN THE URINARY SYSTEM :

28. Gumma of the kidney is not uncommon.
  29. Amyloid infiltration of the kidney.
- Chronic interstitial nephritis is common in bodies on which gummata or their scars are found, but cannot be regarded as directly due to syphilis.

IN THE GENERATIVE SYSTEM : besides the specific sore already described,

30. Chronic inflammatory tissue formation in the testis with destruction of its tubules, and sometimes occlusion of the vas deferens.
31. Gumma of testis.
32. Gumma and chronic inflammatory changes in the ovary.
33. The Fallopian tube may be occluded by chronic inflammatory thickening.
34. Gummata in the placenta.

IN THE ORGANS OF LOCOMOTION :

35. Inflammation of the periosteum of any bone leading to a formation of new bone—a hard node.
36. General inflammation of bone usually associated with the formation of gummata in bone. This often causes extensive destruction of bone. It is common in the nasal bones and in the calvaria, and may occur in any bone. When the ulceration of the calvaria is extensive, it may be associated with changes in the dura mater or in the brain as in the case of a man, aged forty-two, who died in St. Bartholomew's Hospital of abscess of the brain. The scalp was entire, but for many months had felt puffy over an extensive area. When raised a quantity of pus was found beneath it, with loose pieces of necrosed bone and much greyish œdematous granulation tissue. The calvaria was



easily cut with a knife, and was ulcerated over its whole outer surface. There were also several patches of necrosis. A lesser degree of the same condition existed on its inner surface. The dura mater was entire, but there was a superficial abscess in the right cerebral hemisphere at its posterior part.

37. Gummata sometimes of large size in muscles of the limbs.

#### DISEASES OF THE LYMPHATIC SYSTEM :

38. Chronic cell infiltration and connective-tissue increase in lymphatic glands.

39. Gumma of the spleen, which may be as large as a hazel-nut. It is rare.

40. Amyloid infiltration of spleen.

#### CUTANEOUS SYSTEM :

41. Palmar psoriasis may be discovered after death.

42. The deep circular scars of rupia may be discovered, most often on the back.

43. Ulceration of finger-nails and of toe-nails, and ulceration between the toes (rhagades).

#### EYE :

44. Adhesion between the lens and iris due to iritis.

45. Destruction of the retina, and white patches of lymph upon it.

#### NOSE :

46. Necrosis of the nasal bones.

47. Necrosis of the turbinated bones, and thickening of the nasal mucous membrane.

The forty-seven morbid changes above mentioned may occur in several combinations. Two examples may be given.

(I.) The patient was a man, aged fifty-six. In November 1881 he had hæmatemesis, and was admitted into St. Bartholomew's Hospital with ascites. He was relieved, but was re-admitted in January 1883, and



died in a few days of general dropsy. There was a distinct history of syphilis. His viscera showed three forms of morbid change attributable to syphilis.

1. A uniform thickening of the whole capsule of the liver and of that of the spleen without any general peritonitis. The spleen weighed 19 oz. Microscopic sections of the liver near the capsule showed in several places minute gummata close beneath the superficial thick layer of fibrous tissue.

The liver was reduced in size, but in the deeper parts of it no increase of connective tissue was present.

2. Amyloid disease of the kidneys.

3. Extensive calcification of the aorta with two aneurysms, one just beyond the arch, the other two inches above the diaphragm.

The hæmatemesis in this case was probably due to engorgement of the gastric capillaries caused by the enclosure of the liver in a thickened capsule.

(II.) The patient was a woman, aged forty-six. The calvaria was very closely adherent to the cranial fascia, and showed a node on its external surface. On the inner side of the right parietal bone was a bare patch, corresponding to which there was a dense local thickening of the dura mater, a partly degenerated gumma. The intestines were distended with fæces, though there was no single obstructed point. In the small intestine were numerous thickened patches, some ulcerated, some showing scar tissue and contraction, and some consisting of fresh connective tissue. The mesenteric glands were not enlarged. The liver was small. It showed many scars and one recent gumma. The kidneys were small and granular, but had no scars. Both Fallopian tubes were greatly thickened and distended with pus. There had clearly been long-continued obstruction at several points in the small intestine, for between the ulcerated places there was a slight general thickening of the intestinal wall. There was no amyloid disease. With regard to this example it may be noted that visceral syphilis,



though a rare cause of obstruction in the upper part of the large intestine, is of rarer occurrence still in the small intestine.

A present external hard sore, recent gummata in the tissues or viscera, or scars of gummata in the liver or kidneys, or elsewhere, are the only conclusive post-mortem evidence of syphilis.

**Congenital Syphilis.**—Syphilis is believed to affect the foetus in utero, causing its death, which is usually followed by its premature discharge from the uterus. Hence the clinical acceptance of numerous stillbirths and miscarriages, without other obvious cause as evidence of the existence of syphilis in the parent. This doctrine, however, seems to require further examination.

Some infants are, however, born alive infected with syphilis already. The following anatomical conditions are present in such cases :

1. Swellings of the nasal mucous membrane and vocal cords, causing snuffling breathing and a peculiar cry.
2. Ulceration about the angles of the mouth and edges of the anus.
3. Catarrhal inflammation of the mucous membrane of the stomach and intestines, in which green faecal material is often found.
4. Catarrh of the common bile duct, with general jaundice. This is comparatively rare.
5. A swollen condition of spleen.
6. Shrivelled skin.

The subjects of congenital syphilis are often without signs of rickets. The proof is not complete that cranio-tabes and the natiform skull are due to syphilis.

7. Thickening and opacity of the cornea.

8. Thickening of the tympanum.

*Syphilis of childhood.*—After the period of infancy, further changes due to congenital syphilis may occur ; as:

1. Thickening and slow inflammation of the periosteum of long bones ;



2. Rapid decay of teeth ;
3. Imperfect development of teeth, the central incisors being small and shaped like the peg of a top.
4. Amyloid infiltration of viscera, and very rarely (5) gummata, as in the following case of a boy, who was under Dr. Gee's care in St. Bartholomew's Hospital from December 1883 to September 1885, with some intervals, and whose most prominent symptoms were emaciation, ascites, and enlarged liver. He had a very sallow skin and well-marked Hutchinsonian teeth. The liver, kidneys, stomach, intestines, and spleen all showed well-marked amyloid change. The liver was very irregular on the surface, and in several places had deep puckered scars. On section, several large yellowish tough masses of irregular outline were found, each surrounded by a red zone of engorged liver-substance.

Microscopic sections showed these masses to be large gummata, and in their vicinity and here and there on the surface were very minute gummata.

**The Non-infecting Sore.**—Another condition, included under the head lues venerea, begins as a pustule, after discharge of the contents of which an ulcer with definite margin, or several such ulcers, remain. The nearest lymphatics become infiltrated with inflammation cells, and frequently suppurate. It is, in fact, an ulcer of the penis, or labium.

**Gonorrhœa.**—An inflammation of the urethra, due to infection by a specific germ, can only be distinguished from non-specific inflammation of the urethra by the fact that the inflammatory exudation is infective. The nearest lymphatics are inflamed or have suppurated. Catarrhal inflammation, and even hæmorrhage into the mucous membrane of the bladder, may be present. The poison may be absorbed into the system, and death from septicæmia occur.

**Hydrophobia.**—The morbid anatomy of this disease has not yet been demonstrated. The scar of a bite sometimes completely and sometimes incompletely



formed may be found. Redness along the edge of the mitral valve has been noticed in some cases. The pathological explanation of the disease is that a virus consisting of developing and multiplying organisms is present in the nervous system inoculated by the bite charged with saliva of a rabid animal. The organism itself and the changes it produces in the brain and spinal cord have yet to be discovered.

**Glanders.**—The post-mortem appearances in the two cases which I have seen were those of pyæmia. Both had suppuration inside the nostrils, and both numerous abscesses in lymphatic glands, and in the lungs.

The disease is due to a definite germ derived by contagion from horses.

**Splenic fever:** is also called anthrax, malignant pustule, and wool-sorters' disease. The first anatomical change observable is a small dark-coloured spot on the skin. If this be removed the disease ceases. If it remain it becomes first vesicular, and then pustular, and a condition resembling septicæmia occurs, and after death similar appearances are seen—stained blood-vessels, soft large dark spleen, soft swollen liver and kidneys.

Rod-shaped bacilli are found in the pustule, in the blood, and sometimes in the tissues of the patient. These bacilli live after the death of the quadruped in which they were bred, and thus the disease is acquired by man from hides and from wool.



## CHAPTER IV.

## DISEASES DEPENDENT ON PARASITES.

FASCIOLA HEPATICA.  
 BILHARZIA HÆMATOBIA.  
 TÆNIA SOLIUM.  
 TÆNIA MEDIOCANELLATA.  
 TÆNIA ECHINOCOCCUS.  
 ASCARIS LUMBRICOIDES.  
 TRICHOCEPHALUS DISPAR.

TRICHINA SPIRALIS.  
 FILARIA MEDINENSIS.  
 FILARIA SANGUINIS HOMI-  
 NIS.  
 DOCHMIUS DUODENALIS.  
 OXYURIS VERMICULARIS.  
 VEGETABLE PARASITES.

THE “Nomenclature of Disease” enumerates one hundred and nineteen animal parasites of man, and nine parasitic vegetable organisms.

The entozoa or worms inhabiting the alimentary canal or the tissues of the body are forty-nine in number, of which the following are the most important:

Of the Trematoda or Flukes:

*Fasciola hepatica.*  
*Bilharzia hæmatobia.*

Of the Cestoda or Tapeworms:

*Tænia solium.*  
*Tænia mediocanellata.*  
*Tænia echinococcus* (larval form).

Of the Nematoda or round worms:

*Ascaris lumbricoides.*  
*Trichocephalus dispar.*  
*Trichina spiralis.*  
*Filaria medinensis.*  
*Filaria sanguinis hominis.*  
*Dochmius duodenalis.*  
*Oxyuris vermicularis.*

***Fasciola hepatica*** (common *Fluke*).—This parasite



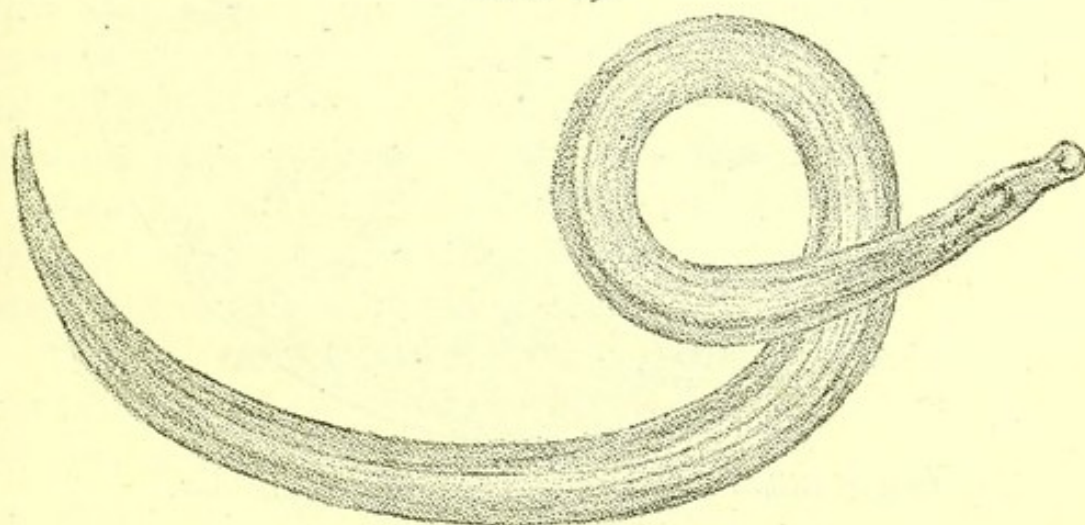
begins life as a free-swimming embryo which finds its way into the tissues of *Lymnæus truncatulus*, a freshwater mollusc. There it passes through two stages, escapes into the water again, and becomes fixed to grass and water plants.

The sheep eats such grass and the fluke develops in its liver into a flat oval entozoon, about an inch long and half as wide, with two suckers. Numbers are found in one liver, blocking the ducts and frequently causing abscesses.

They have been known to occur in the human liver in a few rare cases, and have also been described as present in subcutaneous abscesses in man.

***Bilharzia hæmatobia*.**—This parasite is found in Africa, from the Nile to the Orange River, and in

FIG. 19.



*Adult Bilharzia hæmatobia*, from the portal vein (magnified).

the island of Mauritius. From these regions it is imported to this country, where it only lives in the bodies of patients.

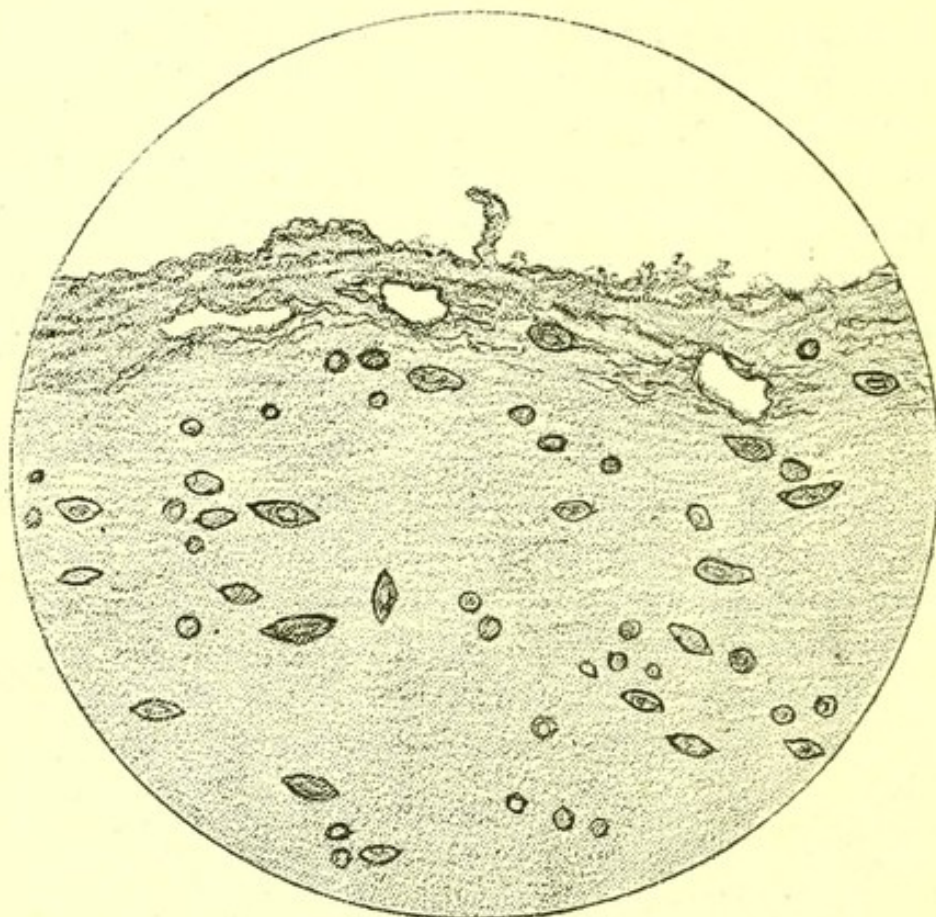
The adult worms, male and female, about one-third of an inch in length, live in the large abdominal veins. In one post-mortem examination, Dr. Mackie found several females in the portal veins.

The ova produced in the veins are oval in shape, with a spine either at one end or near it. They make their way through the tissues to the kidney, where



they cause copious hæmaturia, the discharged blood containing both ova and active ciliated embryos hatched from them. Microscopic sections show these ova in every part of the kidney. They are also to be found in the wall of the ureter and in all the coats of

FIG. 20.



*Ova of Bilharzia hæmatobia, in wall of bladder.*

the bladder, in the layers of the peritoneum, in the omental and mesenteric fat, and in all the coats of the intestine. They also occur in the lung and in the spleen. When they reach the intestinal mucous membrane they cause diarrhœa with hæmorrhage.

The inner surface of the ureters may become roughened, and inflammation with suppuration take place in the pelvis of the kidney. The continued irritation of the ova reaching the surface, in a specimen shown by Mr. A. A. Bowlby at the Pathological Society (1889), had caused a shaggy appearance of the mucous



membrane of the bladder due to inflammatory projections from its surface.

**Tænia solium** and **Tænia mediocanellata**.—Two forms of tapeworm are occasionally found in the small intestine or large intestine post-mortem.

**Tænia mediocanellata** is easily distinguished by the pigmentation of its suckers.

A third form, **Bothriocephalus latus**, occurs in Russians and Swiss, and I have once seen it at St. Bartholomew's Hospital (in a Russian).

The tapeworms are animals with an attached end or head bearing suckers, or suckers and hooks, and followed by small segments, and these by larger and larger segments, a few of which, if the main part of the worm be in the small intestine, may be found detached in the large intestine. The largest segments are sacs filled with fertilized eggs, the smallest segments contain the rudiments of organs, and the middle-sized ones a male and female reproductive system with median egg sac or uterus.

**Tænia solium** occurs in man as a result of eating measly pork—that is, pork which contains the encysted embryos of the **Tænia**.

**Tænia mediocanellata** is due to eating beef containing its encysted embryos. The cyst of these worms is swallowed in underdone pork or beef, and develops in the alimentary canal into the mature tapeworm.

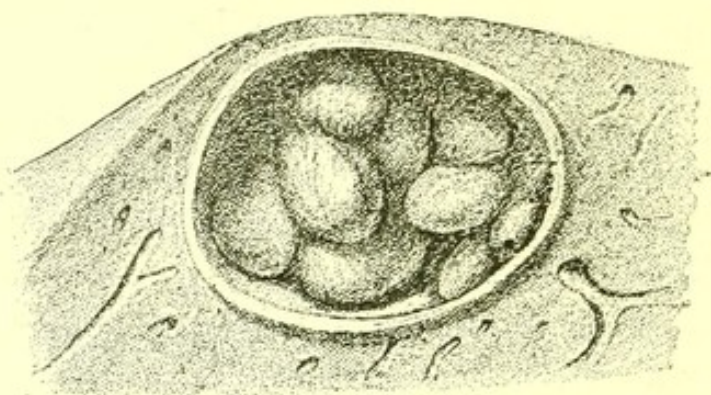
The cystic form of **tænia solium** will live in man as well as in the pig, and is sometimes found in the muscles or skin, either as a membranous or as a small calcified cyst. This is rare, and it is still more uncommon to find a large number of such cysts.

It deserves note that neither the very firmly attached **tænia solium** nor the less well fixed **tænia mediocanellata** leaves any mark visible to the naked eye at its point of attachment to the mucous membrane of the alimentary canal. This is usually situate in the small intestine.



**Tænia echinococcus.**—Hydatid of the liver is the cystic embryo of one of the common tapeworms which inhabit the intestine of the dog and the wolf.

FIG. 21.



*Hydatid of Liver.*—Daughter cysts contained in a large cyst of *Tænia echinococcus*.

The proglottides are deposited on watercress or other vegetable with the fæces of the dog, or are dried and blown about with dust. They are swallowed either as proglottides or as eggs. The egg hatches in the duodenum or small intestine, and a six-hooked embryo pushes its way through the intestinal wall into the liver. Here it rests, and its body wall develops into a cyst, from the interior of which fresh cysts may be formed, and fresh ones again in them—daughter cysts and granddaughter cysts. All contain clear, saline, non-albuminous fluid.

Before the time of Sir Ewen Cameron, who enlarged the long list of heroic exploits associated with the title of Lochiel by slaying the last wolf in Great Britain, the career of a hydatid was continued by the man containing it being devoured by wolves, in whose intestines it grew to be a worm.

Now when it has reached man, the hydatid has seldom an opportunity of developing into its adult form. As the worm is not extinct, it seems probable that as *tænia solium*, though commonly proceeding from pig to man, may develop in man alone; so *tænia echinococcus* may go through all stages in the dog.



The cyst may grow as big as a man's head. Its outer wall becomes very tough, and may calcify, but the liver substance outside it is not in any way infiltrated, and under the microscope usually looks normal.

Sometimes the hydatid suppurates, and is found post-mortem to contain pus. This is generally due to obstruction of a largish bile-duct and consequent inflammation, and seldom begins in the interior of the hydatid cyst.

If the hydatid die before the patient, the fluid contents of the cysts and its daughter and granddaughter cysts become caseous, and ultimately calcareous.

The membranes themselves remain in the caseous material, and their situation is easily recognized even after calcification.

*Situation of Hydatids.*—The commonest situation is the liver, and the cyst may occur in any part of it.

Next to the liver, the lung and the pleural cavity are commonest, and in Australia appear to be very common.

I have once seen a hydatid cyst in the visceral layer of the pericardium : in the spleen, three times : in the peritoneum, just above the bladder, once : and once in the pouch of Douglas : once in the kidney, and once a large cyst in the gastrocnemius muscle.

They have been described in the brain. In the Museum at St. Bartholomew's there is one in the muscular tissue of the heart.

*Rarer Results of Hydatids.*—*In the liver :* they may cause abscess, or by pressing on and permanently occluding the common bile duct, may cause general dilatation of the ducts throughout the liver, intense jaundice, and finally cirrhosis of the liver with ascites.

*In the pleura :* they may produce pleurisy, with effusion of serum and deposit of fibrin.

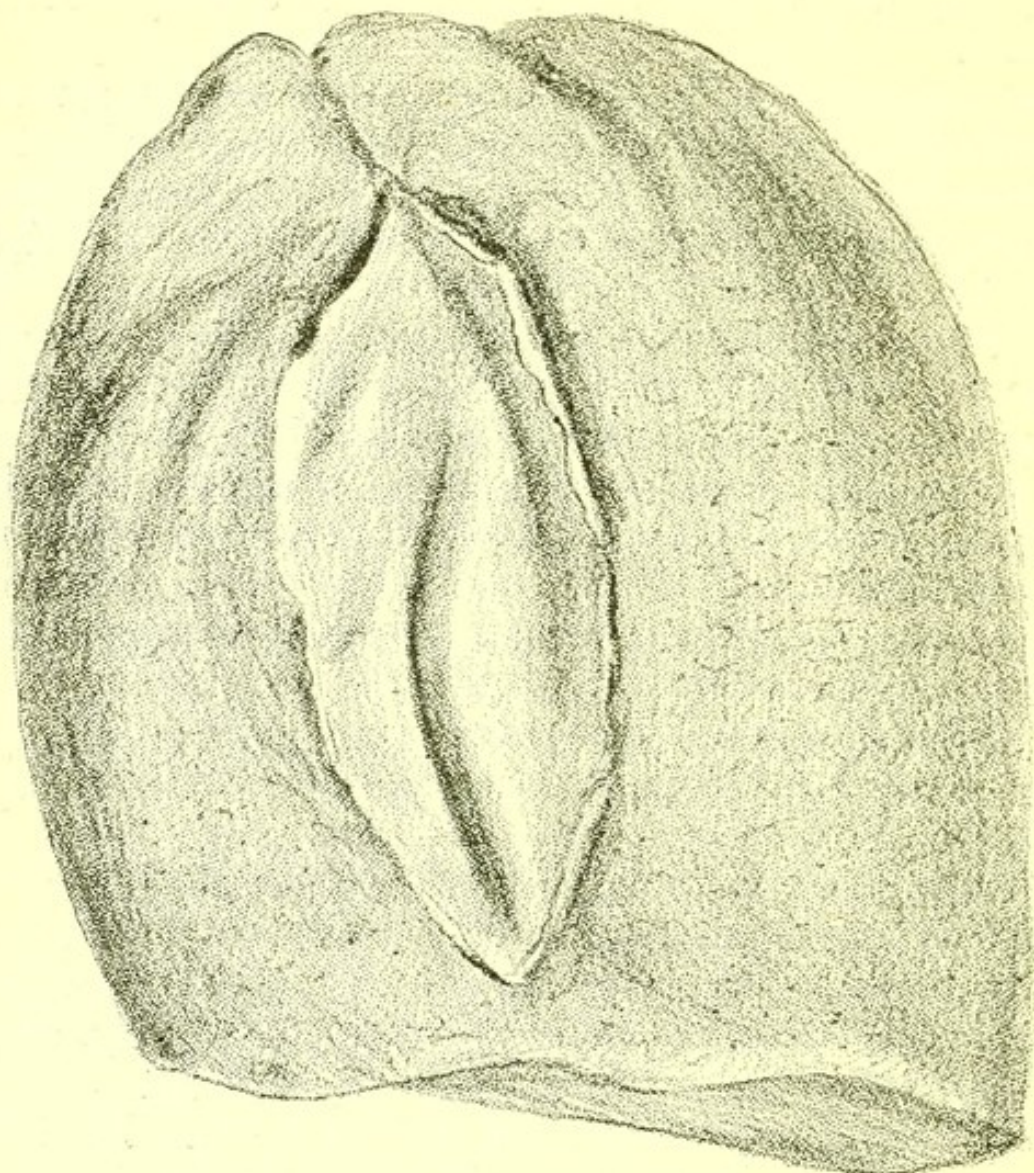
*In the pericardium :* effusion of serum and deposit of fibrin.

*In the peritoneum :* rupture and rapid death from



shock occurred in the two cases I have mentioned. There was no peritonitis.

FIG. 22.



*Hydatid Cyst between the Lobes of a Lung*, from a specimen in the Museum of St. Bartholomew's Hospital. The wall of the cyst is divided, and the daughter cysts have been discharged.

**Ascaris lumbricoides.**—A large round white worm, pointed at both ends, and as large as an earthworm, is sometimes found post-mortem in the duodenum, or lower down in the small intestine or in the stomach.

I have seen two cases in which it caused death. One, a child, in which the worm having got into the œsophagus curved its end over into the rima glottidis, and so choked the child.



The other, in a case of enteric fever in which the moving worm had torn across the floor of an ulcer, and so caused death by perforation.

As a rule, if there is an ascaris in the intestine of a person seized with enteric fever, the worm finds its way into the stomach and is vomited early in the disease.

**Trichocephalus dispar.**—A worm from one to two inches long, easily recognized by being broad at one end and filiform at the other. It lives in the cæcum in large numbers. It is very rare in London.

**Trichina spiralis:** is more often found in the dissecting-room, where it was originally discovered by Sir James Paget in 1835, than in the post-mortem room. It is noticed there owing to the dissecting knife grating against its minute calcified capsule. This capsule is gradually formed round the embryo, which can under the microscope be seen coiled up within it. The best plan for preparation is to stain the muscle in bulk, keep it in glycerine, and tease out bits of fibre for examination under the microscope.

The adults live in the alimentary canal, and there the embryo is hatched and burrows thence through the tissues into the muscles.

Man is generally infected by eating the flesh of pigs containing abundant embryos.

**Filaria medinensis:** a native of India, Persia, Arabia, and Africa; is a long thin worm, sometimes several feet in length, and lives in the subcutaneous tissue. Sometimes its situation is indicated by sloughs. It enters the subcutaneous tissue from the alimentary canal and not from outside. The worm found in man is a female, and contains myriads of living embryos. If the worm is broken during extraction these may escape into the tissues, causing inflammation.

**Filaria sanguinis hominis:** lives in the East and in Egypt, and in this country only in the bodies of travellers from Egypt and the East.



The embryo lives in the blood, and may be found in the urine. The adult inhabits the lymphatic system.

Chyluria and enlargement of the legs and scrotum caused by obstruction of their lymphatics, are the anatomical changes due to this parasite.

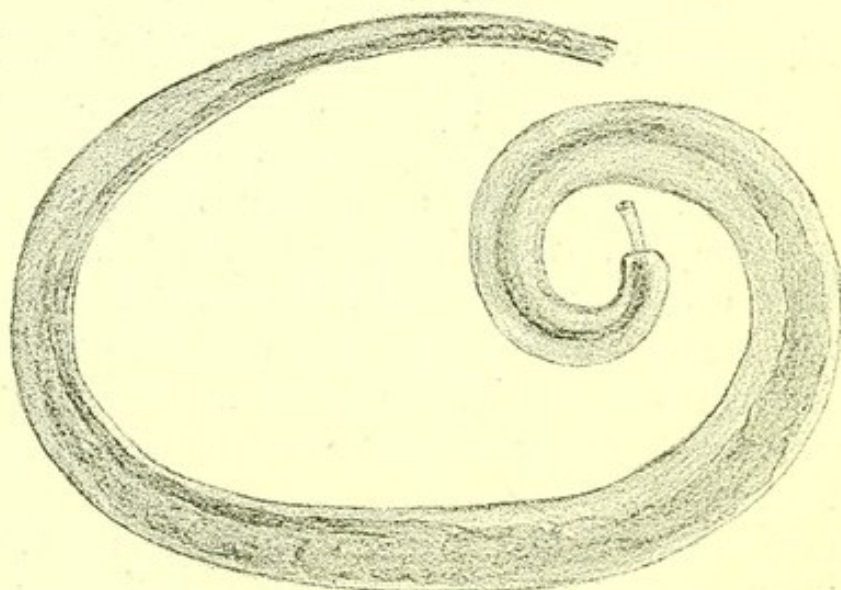
The embryos are only found in blood drawn at night.

They are round at one end, pointed at the other, and about 1-75th of an inch in length.

These embryos get out of the human body by being sucked thence with blood at night by a female mosquito. The mosquito dies after depositing its eggs in water, and the embryos develop in its decaying body and pass thence into the water, where they live as adult worms. They are swallowed by man in the water, and pass from the alimentary canal into the lymphatic system, where they live in the vessels and there discharge living embryos. The adult worm is about  $\frac{1}{100}$  inch wide, and three inches long. Nearly all that is known of this parasite is due to Dr. Patrick Manson, whose writings contain the fullest account of it.

**Dochmius duodenalis** : is found in the duodenum

FIG. 23.



*Dochmius duodenalis*, from a specimen (magnified) in the Museum of St. Bartholomew's Hospital.



as a firmly attached worm about one-third of an inch in length. It is attached by an oval sucker, and draws blood from the duodenum which post-mortem is often found containing some free blood while there is general anæmia of the body. The worm may be seen adhering to the sides of the *valvulæ conniventes*. It is not known to live in England. A specimen in the St. Bartholomew's Museum came from the Mont Cenis Tunnel.

**Oxyuris vermicularis**: is sometimes found post-mortem in the rectum of children. It is a small threadlike worm usually about a quarter of an inch in length.

**Vegetable Parasites.**—The numerous bacteria, vibriones, and bacilli which are believed to be active causes of disease, are best studied as parts of the diseases associated with their development.

The other vegetable parasites do not cause death, though *oidium albicans* occurring as white patches in the mouths of adults indicates its approach. In children it is associated with red patches of the mucous membrane due to oral catarrh. *Sarcinæ ventriculi* are found post-mortem in the contents of dilated stomachs as small square bundle-like spores, often compared to trusses of hay.

The baldness produced by the growth of *trichophyton tonsurans* and the brown patches of *microsporon furfur*, are of course present after death.



## CHAPTER V.

## EFFECTS OF POISONS.

IRRITANT POISONS IN  
 GENERAL.  
 ANTIMONY.  
 ARSENIC.  
 CORROSIVE SUBLIMATE.  
 CAUSTIC ALKALIES.  
 PHOSPHORUS :  
   RAPID.  
   CHRONIC.  
 HYDROCHLORIC ACID.  
 NITRIC ACID.  
 OXALIC ACID.  
 SULPHURIC ACID.

CARBOLIC ACID.  
 CHLOROFORM.  
 HYDROCYANIC ACID.  
 CROTON OIL.  
 STRYCHNIA.  
 OPIUM.  
 CANTHARIDES.  
 SNAKE POISON.  
 CARBONIC ACID AND CAR-  
   BONIC OXIDE.  
 REMOTE EFFECTS OF COR-  
   SIVE POISONS.

**Irritant Poisons.**—Metallic irritants produce inflammation of the alimentary canal, sometimes extensive, sometimes confined to the stomach, the extent of inflammation depending on the quantity of the poison swallowed.

After death due to **antimony**, besides inflammation of the gastric mucous membrane, pustulation of the œsophagus is sometimes found; after death due to **arsenic**, besides patches of inflammation in the mucous membrane, white patches of adherent arsenious acid may sometimes be observed.

After poisoning by **corrosive sublimate**, sloughing of the stomach and intestines is sometimes present. The remote effects of mercury and of lead are described in the chapter on Diseases of the Nervous System.

The **caustic alkalis** produce extravasations of blood



and detachment of epithelium, and in poisoning by ammonia gas there is great redness of the mucous membrane of the larynx, trachea, and bronchi.

**Phosphorus.**—The following were the post-mortem appearances in a man, aged thirty-six years, who died in St. Bartholomew's Hospital about ten days after accidentally taking phosphorus paste which had been spread on bread-and-butter for rats.

There was slight general jaundice with a few very small ecchymoses on the legs.

The brain and its membranes were natural.

There were numerous small hæmorrhages into the tissues of the neck and anterior mediastinum, but the mucous membrane of the œsophagus was normal, and so was that of the trachea.

*Lungs and pleura*: there were numerous hæmorrhages into the mucous membrane of the bronchi and into the substance of both lungs, as well as into both parietal and visceral pleura.

*Heart*: the endocardium and valves were normal, but there were numerous small hæmorrhages into both layers of the pericardium. On microscopic examination, the muscular tissue of the heart was found to be normal.

*Peritoneum*: all over it were numerous small hæmorrhages.

*Stomach and intestines*: the mucous membrane showed no abnormal appearance to the naked eye, but under the microscope sections of the stomach stained with hæmatoxylin and osmic acid showed general fatty degeneration of the gland cells.

*Liver*: of normal size and of a uniform orange-yellow colour, with several small hæmorrhages on its surface, but none in the substance. Firm in texture, but not very dense.

*Gall-bladder*: containing a little greenish bile and very viscid mucus; orifice of common duct into duodenum swollen. For two inches from the papilla towards the gall-bladder the duct was quite white, and



was filled with very viscid mucus firmly adherent to its walls.

Microscopic sections showed complete fatty degeneration of the liver cells. Some large infiltrated fat globules were also present in the lobules.

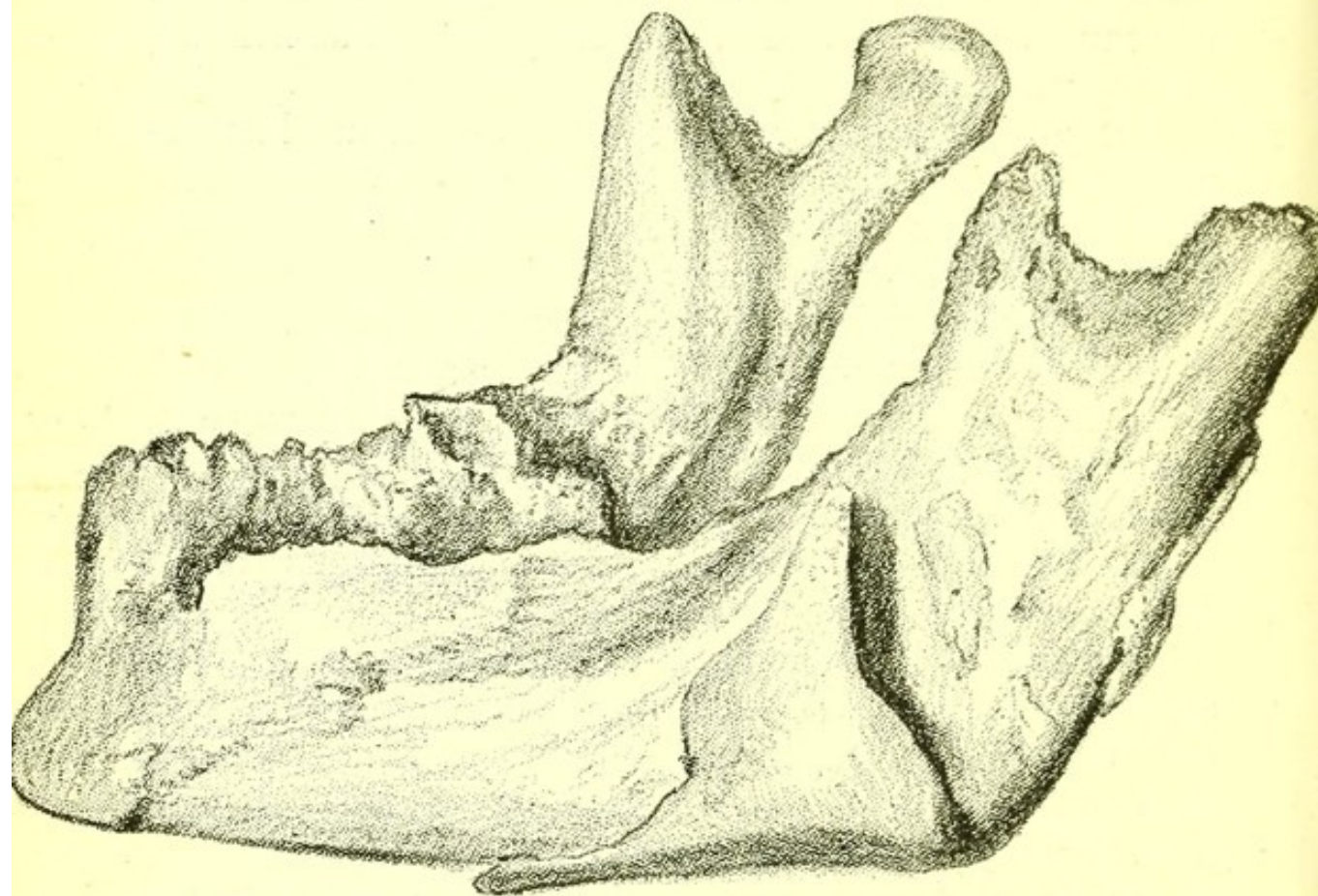
*Spleen* : engorged ; weight, 9 oz.

*Pancreas, abdominal lymphatics, and supra-renals* : normal.

*Kidneys* : some hæmorrhages on the surface of each.

Microscopic sections showed fatty degeneration of the epithelium of the tubules and of the glomeruli.

FIG. 24.



*Inferior Maxilla*, from a case of chronic poisoning by phosphorus, in the Museum of St. Bartholomew's Hospital.

*Ureters and bladder* : normal.

The jaundice in this case of phosphorus poisoning was due to inflammation and closure of the common bile duct, and this is probably the cause in most such cases.



**Chronic Poisoning by Phosphorus.**—The museum of St. Bartholomew's Hospital and most pathological museums contain specimens of necrosis of the inferior maxilla associated with carious teeth from workers in yellow phosphorus (Fig. 24). The necrosis seems always to have begun near the fang of a carious tooth.

**Acids.**—Poisoning by all the mineral acids presents the same general features of discoloration and destruction, with wrinkling of the mucous membrane of the alimentary canal.

Where very large doses have been swallowed, the wall of the stomach may have given way after death, but before the post-mortem examination.

Actual examples best illustrate the appearances produced by the acids of most frequent occurrence.

**Hydrochloric Acid.**—I. A man aged sixty-one years, who died a few hours after poisoning, showed the following appearances: No external stains about mouth; tongue much swollen and of a brownish hue; mucous membrane separated in strips from pharynx, and below it for the first half-inch of the œsophagus. Below this to the stomach the inner surface of the œsophagus was of a blackish colour.

*Larynx and trachea*: not affected.

The back of the heart, near the œsophagus, was slightly blackened.

*Abdomen*: distended, but no peritonitis present, and no perforation of the intestine.

*Stomach*: mucous surface wrinkled with large ridges, the whole mucous surface blackened, except along the lower curvature, where it was of a lighter and brownish colour.

*Intestines*: the duodenum contained much bile, and its mucous membrane was bile-stained. In the part immediately above the papilla of the bile duct, and immediately below it, the mucous membrane was unaltered, but in the first half-inch outside the pylorus the mucous membrane was of a greyish hue,



and so were the last two inches of duodenum, and the following fifteen feet of small intestine. The lower part of the small intestine and the whole of the large intestine were unaltered: solid fæces were present in the large intestine. The small intestine contained much slimy fluid.

II. A woman, aged fifty-two years, who died two and half hours after taking the poison, had no bleeding from the mouth or erosion at the angles of the mouth.

*Œsophagus*: mucous membrane greyish and partially detached in strips: most detached at the lowest part of the œsophagus.

*Stomach*: without perforation, a little changed blood and much mucus in it.

Whole inner surface of a dark brown colour, almost black.

*Intestines*: for six feet from the pylorus, normal; mucous membrane in lower part, greyish.

**Nitric Acid.**—I. A woman, aged fifty-seven years, who died about twenty-four hours after drinking ten ounces of nitric acid.

There were yellow stains on her hands.

*Brain*: normal.

*Alimentary canal*: from the centre of the tongue to the cardiac orifice of the stomach extended a white strip of altered epithelium and coagulated fibrin.

There was some œdema of the epiglottis, but the larynx was natural.

Microscopical sections of the tongue showed that the epithelium was stripped off in parts, and the surface covered with lymph containing abundant leucocytes; the sub-epithelial tissue was infiltrated with leucocytes, but the deeper tissues were unchanged.

Microscopic sections of the œsophagus showed that the epithelium had disappeared, while the muscular tissue was infiltrated with altered blood.

*Heart and pericardium*: normal. A natural quantity of pericardial fluid present.



*Abdomen* : greatly distended. No signs of peritonitis.

*Stomach* : distended, containing much brownish-red fluid. Its whole thickness was discoloured. The mucous membrane showed altered epithelium, and here and there shreds of tissue loosely adherent to the muscular coat.

The mucous membrane of the duodenum was in a similar condition ; the rest of the intestine showed no changes due to the poison.

*Liver* : normal ; gall-bladder empty ; other abdominal viscera normal.

II. Another example illustrates the changes present when death occurs after a longer interval. In a case of suicidal nitric acid poisoning in a man, aged twenty-nine years, who died four days after drinking the acid, the mucous membrane of the œsophagus was grey and partially detached from the pharynx downwards, the fauces being merely œdematous. The epiglottis was much thickened, and the interior of the larynx as far as the vocal cords was greyish in colour ; below the vocal cord, the trachea was redder than natural.

The *pericardium* showed patches of injection, but no lymph.

*Abdomen* : distended. There was a little lymph on the peritoneum, over the anterior surface of the stomach and over the liver, but no general peritonitis.

The *stomach* was contracted, so that the cavity was very small. Its walls felt thick, and internally showed great ridges. The mucous membrane was brownish-black, with a few red streaks.

A similar condition extended about four inches into the duodenum, while to the end of the jejunum the mucous membrane was greyish. Below this the intestine was unaltered.

*Liver, spleen, pancreas, kidneys, bladder* : all normal.

**Oxalic Acid.**—A servant-maid, aged twenty-four, had taken several ounces of oxalic acid, and died in about four hours.



The skin about the mouth was natural; the tongue was whitish; the epiglottis was grey; the fauces and pharynx of a pink and grey tint. The lower part of the œsophagus was grey, and the mucous membrane was detached in parts and everywhere wrinkled. The stomach was distended with dark blood. On washing out the blood no abrasion was found. The mucous membrane generally was of a brownish colour, with darker lines along the course of the vessels. The mucous membrane of the duodenum and jejunum was of a greyish tint, but was not wrinkled. Below the jejunum the mucous membrane of the intestines was not altered, but was covered by an abnormal quantity of mucus. The large intestine contained a quantity of solid fæces. There was no peritonitis. The larynx and trachea were natural.

In a case in which death took place four days after swallowing the poison, the mucous membrane of the stomach and of the whole duodenum was greyish-brown.

The *fauces* and *mouth* were normal.

*Æsophagus*: the mucous membrane was detached in parts.

(II.) In a case in which death took place eight days after poisoning,

*Tongue* was coated with brownish fur.

*Æsophagus*: the mucous membrane was of a greenish-grey throughout. There was no ulceration.

*Larynx*: no erosion.

*Stomach and intestines*: the mucous membrane was of a greenish-grey hue, including the large intestine, but there was no breach of surface anywhere.

**Sulphuric Acid.**—A man, aged twenty-one years, was brought to St. Bartholomew's Hospital on March 3, 1879, who had drunk more than half a pint of the oil of vitriol used for cleaning machinery half an hour before admission, and his death took place an hour and a half after admission.



I made the post-mortem twenty-six hours after his death.

On each side of the mouth was a brownish line running down the chin, and the skin around the umbilicus was of a greyish hue. The inner surface of the rectus abdominis on each side was greyish, and in parts it was almost disintegrated. The upper parts of the external and internal oblique muscles were also affected. The mouth and fauces were dry and whitish, but the mucous membrane did not seem to be greatly injured. The œsophagus was greyish and firmly contracted. Its mucous membrane looked severely burnt, but was not anywhere perforated. Its muscular tissue was infiltrated by the acid, and the posterior wall of the heart exhibited a similar infiltration, being grey and hard for half its thickness. The pericardium was absolutely dry.

The *diaphragm* was entire, but hardened and greyish, and the bases of the lungs showed a hardened tract of a quarter of an inch in depth. There was no breach in the alimentary canal above the diaphragm, but below, the walls ceased, a blackish mass being all that remained to indicate the stomach. The œsophagus ended, in fact, in a fringe of shreds. The intestines were affected right down to the rectum, the parts nearest the stomach being so tender as to fall to pieces when touched.

The *liver, spleen, and kidneys* exhibited various degrees of hardening. The liver and spleen looked outside like leather, and to palpation gave the sensation of bags with tough but partially elastic walls.

The *bladder* was contracted and empty, and also saturated by the acid.

The blood in the aorta and vena cava was changed into hard carbonized masses like pieces of bitumen.

**Carbolic Acid.**—The mouth, œsophagus and stomach of a person who has swallowed strong carbolic acid are whitish and wrinkled, with here and



there patches of engorgement or of hæmorrhage. The stomach may contain some altered blood. The odour of the acid may be noticed on opening the body, and the bladder contains black or blackish urine. Decomposition of the viscera is retarded.

**Chloroform.**—There are no definite post-mortem appearances which prove that a patient has died of chloroform poisoning. When death has taken place during the administration of chloroform the lungs are found to be engorged. The muscular tissue of the heart is pale and flabby, and is often in a state of fatty degeneration.

**Hydrocyanic Acid.**—An odour of the acid on opening the body and general engorgement of the veins, including those of the brain, are the most noticeable circumstances in a post-mortem examination after poisoning by hydrocyanic acid.

**Cyanide of Potassium.**—A man, aged twenty-eight, whose body was examined post-mortem by me, had swallowed about half a tumbler of a saturated solution of cyanide of potassium. He had not vomited, and lay dead in bed as if asleep. The stomach and œsophagus were of a peculiar reddish-brown, and were very much wrinkled; but there was no hæmorrhage, and the mucous membrane was nowhere detached. The intestines showed no morbid change. All the cavities of the heart contained imperfectly clotted blood, and the lungs were engorged. The brain was without morbid change.

**Croton Oil.**—When croton oil has been given to unconscious patients who have died soon after of cerebral hæmorrhage, it is not uncommon to find small patches of inflammation in the mucous membrane of the large intestine, a fact worth remembering in relation to the therapeutic use of the drug.

**Strychnia.**—Traces of opisthotonos, clenched hands and arched feet, with engorgement of the cerebral veins, were the only anatomical appearances suggesting



poison in a case of strychnia poisoning lately examined by me.

**Opium.**—Engorgement of the veins of the head and heavy lungs, full of blood and froth, are to be noticed in cases of opium poisoning.

**Cantharides.**—Engorged patches of mucous membrane are found in the stomach in which fragments of the beetle *Cantharis vesicatorius* may be noticed. The kidneys are engorged, and the pelvis of the kidney as well as the bladder may contain blood.

**Snake-poison.**—The only pathological effects of snake-poison commonly seen in London are, swelling of the limb in which the viper's bite is situate, enlargement of the lymphatics, and rarely abscess.

**Carbonic-acid Gas.**—General engorgement of the venous system and of the abdominal viscera, heavy, dark engorged lungs, and a swollen appearance of face and body, with sometimes superficial hæmorrhages in the brain, are the chief post-mortem appearances observed in poisoning by carbonic acid. All the blood is dark coloured.

In **carbonic-oxide** poisoning the body looks florid, and the blood is of a dark cherry-red colour.

**Corrosive poisons** sometimes produce anatomical changes which cause death after a considerable lapse of time.

These are (1) stricture of the œsophagus, due to the formation of scar-tissue, which contracts; (2) patches of ulceration in the stomach. A man died in St. Bartholomew's Hospital a year after taking a mineral acid. Four shallow irregular ulcers, each as large as a sixpence, with shelving and not abrupt walls, were found in his stomach. In a woman, who had taken hydrochloric acid eighteen months before, great general thickening of the mucous membrane of the stomach was found, but there were no ulcers.



## CHAPTER VI.

**EFFECTS OF INJURIES AND CLIMATE.**

PLEURISY FROM BLOWS.

TIGHT-LACING.

EFFECTS OF EXTERNAL  
PRESSURE.RUPTURE OF MUSCLES IN  
TETANUS.

FROSTBITE.

DEATH FROM COLD.

CLIMATE.

THE effects of mechanical injuries, of the presence of foreign bodies, of strain and of extreme heat, and the external effects of chemical agents, are for the most part to be observed in the surgical wards of a hospital. A few of the effects of injuries in which the result is not observed in direct relation to the injury find their way into the medical wards, and must therefore be mentioned here.

Pleurisy is occasionally discovered post-mortem as a result of a blow on the chest-wall, such as the kick of a horse.

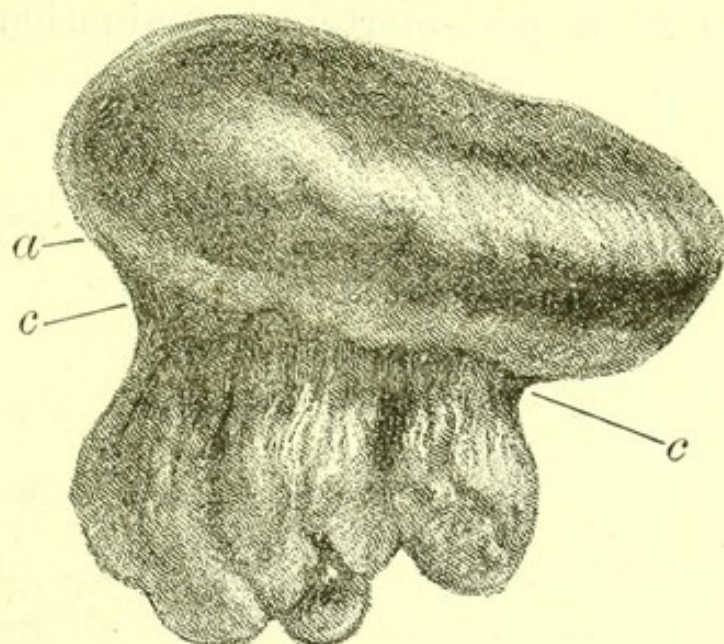
Chairmakers, who usually place the handle of the chisel with which they cut out the mortises of a chair against the first right intercostal space, have an external corn and an internal thickening of the pleura at that spot.

Tight-lacing in women produces a permanent groove in the chest-wall. This is often noticeable post-mortem. In fat women the groove, though invisible externally, is often clear when the skin, subcutaneous fat, and muscle of the chest-wall are turned back. A patch of thickened capsule of the liver often corresponds to this depression, and sometimes a tract of liver-tissue is atrophied, so that a



small isthmus alone connects the lowest part of the right lobe with the rest of the organ.

FIG. 25.



*Liver of Tight Lacing.* From a woman who died in St. Bartholomew's Hospital. *a.* Band of thickening of capsule. *c.* Atrophied liver tissue.

A local thickening of the capsule of the liver is sometimes found in the bodies of shoemakers, due to the pressure of the body against the last.

When death has been due to hæmorrhage from the fauces, it is important to be alive to the possibility of finding post-mortem a foreign body, such as a pipe-end, which may have penetrated an artery.

In cases of tetanus, rupture of parts of the abdominal muscles with hæmorrhage is sometimes found post-mortem.

In addition to frostbite, which has already been mentioned, there is an effect of cold which deserves notice—that in cold weather well-nourished people sometimes die in the streets in whose bodies no other anatomical change than chronic interstitial nephritis can be found.

There are no constant anatomical appearances of death from electricity.



The effects of climate, apart from those of malaria, of endemic diseases, of sunstroke, and of frostbite, while distinct enough on the general condition of the patient, do not produce changes demonstrable in a post-mortem examination of the body.



## CHAPTER VII.

DISEASES PRODUCED BY ERRORS  
OF DIET.

SURFEIT :

RUPTURE OF ŒSOPHA-  
GUS.

STARVATION.

SCURVY.

ALCOHOLISM :

DELIRIUM TREMENS.

MANIA E POTU

**Surfeit.**—A child is sometimes found dead after having had its stomach unduly crammed with food. The brain shows no anatomical change, though a fit has often been the end of life. The thumbs are usually enclosed in the closed fingers of the hand in rigor mortis, and there may be some injection of the capillaries of the stomach.

Surfeit in a healthy adult may be carried far without death ensuing.

I have seen the œsophagus of a man who had gorged for a wager, and then took an emetic. In the violent vomiting which came on his œsophagus was ruptured.

**Starvation.**—A medical man may be called upon to state whether an infant, a child, or a grown-up person has died of starvation.

It is not easy to be positive as to this fact by the post-mortem examination alone.

*Starvation in a baby* is, perhaps, most easy to determine. The most conclusive features of the condition are :

1. Absence of all definite morbid change except wasting.
2. Extreme wasting and deficiency of weight in proportion to age.



3. The absence of all subcutaneous fat, and of fat in the omentum.

4. Dryness of the serous membranes.

5. Dry, wrinkled condition of skin.

*Starvation in a child or adult* : The same conditions are found in the body of a child or of an adult who has died of starvation, but in such cases it is still more important than in examining a baby to bear in mind that signs of malignant new growth, of tubercle and of diabetes must be looked for with minute care.

**Scurvy.**—Death from scurvy was common in the navy two hundred years ago, and even so lately as Lord Anson's voyage round the world, in the years 1740 to 1744, it killed, in the admiral's ship *Centurion*, 380 out of 510 persons. Mr. Clowes, surgeon to St. Bartholomew's in the reign of Elizabeth, saw many cases among the boys of Christ's Hospital, and no doubt witnessed some deaths from this cause in St. Bartholomew's. Such deaths are now very rare indeed.

Subcutaneous hæmorrhages, hæmorrhages into muscles, and large effusions of serum in the pericardium and pleura, with ragged gums, loose teeth, and bleeding from the mouth, are the appearances described by anatomists who lived before the advance of medical knowledge had made the disease rare.

**Alcoholism — Delirium Tremens.**—Symptoms supposed during life to have been due to delirium tremens are sometimes discovered post-mortem to have been associated with acute pneumonia, or with purulent meningitis. In these cases, even if there be a history of drinking, it may remain doubtful whether the patient had true delirium tremens or whether the anatomical change in the lung or brain which undoubtedly caused his death was his whole disease. Autopsies after death terminating an illness which certainly began with true delirium tremens frequently discover one or more of the following changes :

(1) A small ill-defined patch of pneumonic



consolidation in one lung, generally at the base, and sometimes either gangrenous or almost gangrenous ;

(2) Large soft kidneys without the characteristic appearances of chronic interstitial nephritis, or of chronic parenchymatous nephritis ;

(3) A large soft liver ;

(4) A stomach with a soft reddish mucous membrane, sometimes containing small hæmorrhages.

**Mania e potu.**—Delirium tremens comes on after cessation from drinking, and is distinct from the violent mania e potu which may immediately follow deep potation of alcoholic beverages.

After death, with acute mania due to drinking, I have found the pia mater injected all over with lines of purulent effusion in the course of the superficial vessels of the convexity of the brain.



## CHAPTER VIII.

## DEVELOPMENTAL DISEASES.

IMPERFECT DEVELOPMENT :	MECKEL'S DIVERTICULUM.
OF BRAIN.	HYPOSPADIAS AND EPISPA-
OF SPINAL CORD.	DIAS AND ECTOPIA
OF PREMAXILLARY	VESICÆ.
BONE.	IMPERFORATE ANUS.
IMPERFECT CLOSURE OF	CLUB-FOOT.
BRONCHIAL CLEFTS.	SUPERNUMERARY DIGITS.
MALFORMATION OF HEART.	DEBILITY.
IMPERFECT DIAPHRAGM.	OLD AGE.

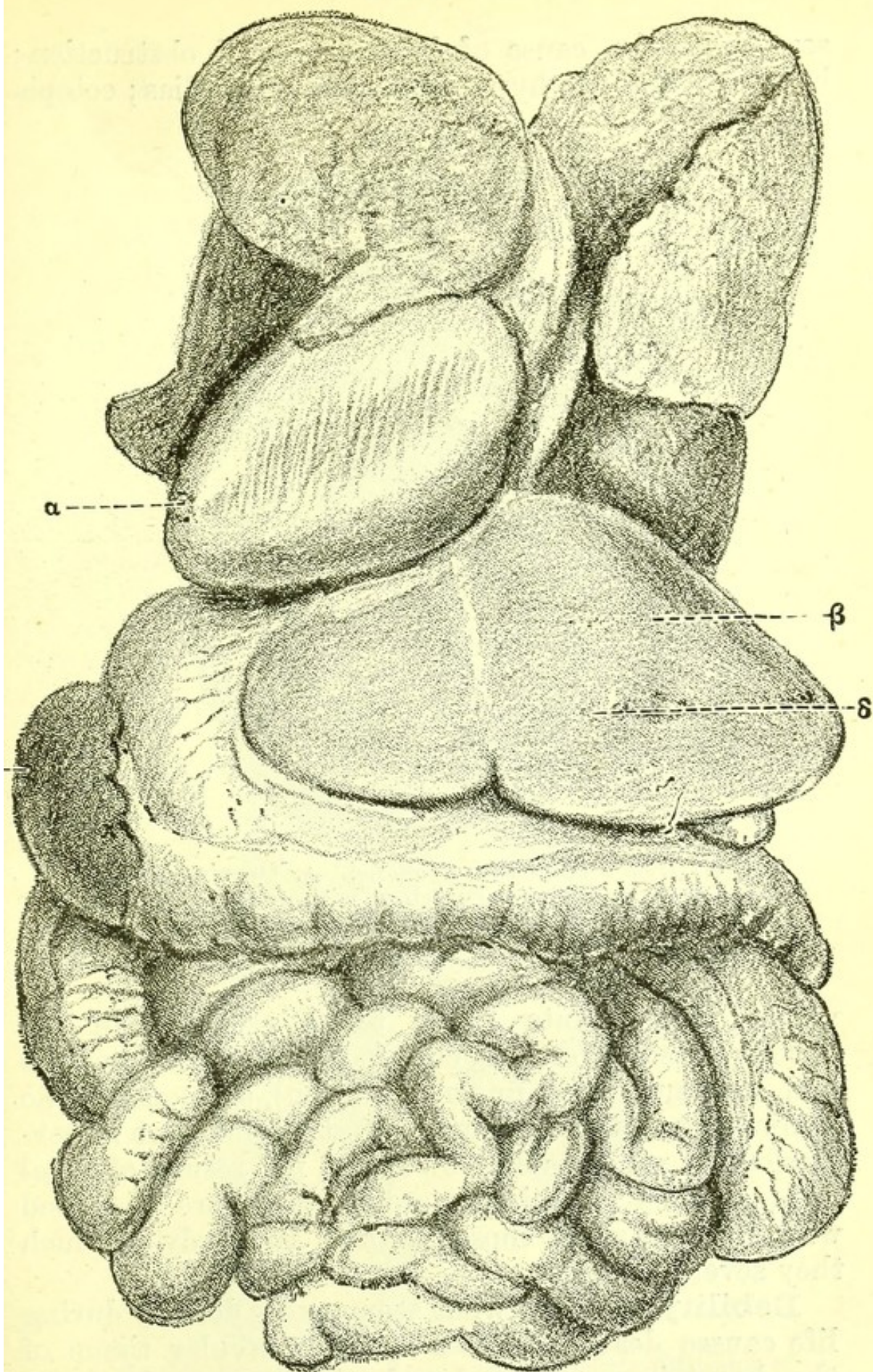
THE subjects of immaturity at birth and of congenital malformations, in part belong to the study of morphology and in part to that difficult and little known subject, the diseases of the fœtus. A more complete knowledge than at present exists of the development of the human fœtus is required before pathological changes taking place in it can be thoroughly understood.

Transposition of viscera (Fig. 26) may perhaps be regarded as a simple variety, comparable to the change in the spiral curve of *Fusus contrarius*. Imperfect development of the brain associated with idiocy, spina bifida, imperfect development of the premaxillary bone producing hare-lip, branchial clefts in the neck, forming imperfectly closed permanent fistulæ, often with little auricles near them, are examples of immaturity at birth.

Some of the forms of malformation of the heart producing cyanosis (Fig. 27); imperfection of the diaphragm, permitting the stomach or colon to pass into the chest and thus sometimes causing strangulation; Meckel's diverticulum from the small intestine (Fig. 28),



FIG. 26.

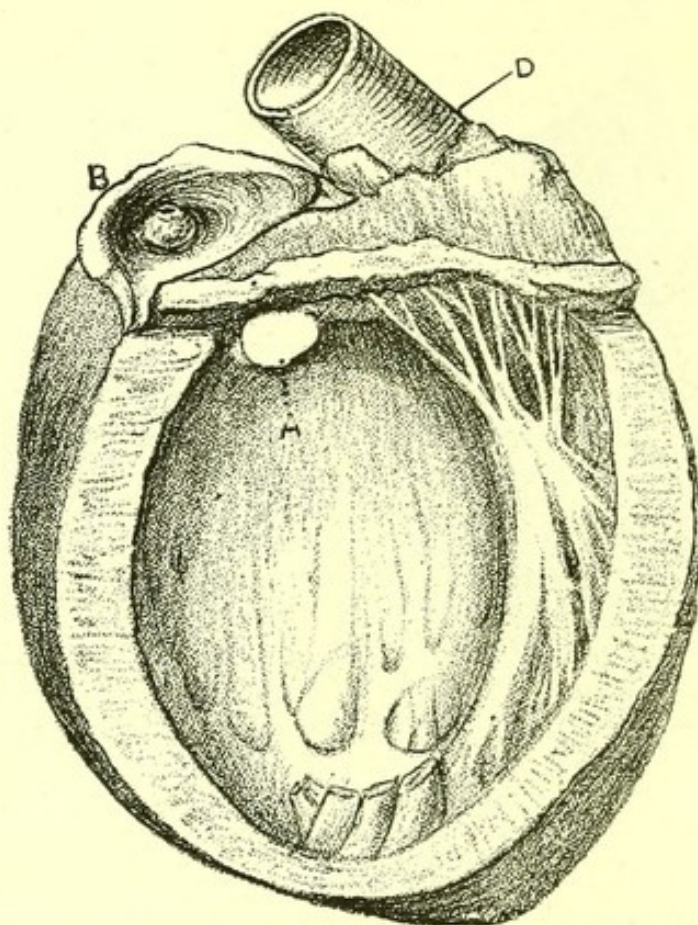


*Transposition of Viscera.* From an example in the post-mortem room of St. Bartholomew's Hospital. The heart and spleen are on the right side, the liver on the left. The right lung has two lobes, and the left three.



sometimes the cause of fatal intestinal obstruction ; horseshoe kidney ; hypospadias and epispadias ; ectopia

FIG. 27.



*Heart from a Child with Cyanosis.* A. Opening between ventricles. B. Pulmonary artery with its lumen reduced to size of a pin. D. Aorta. The cavity of the left ventricle is laid open.

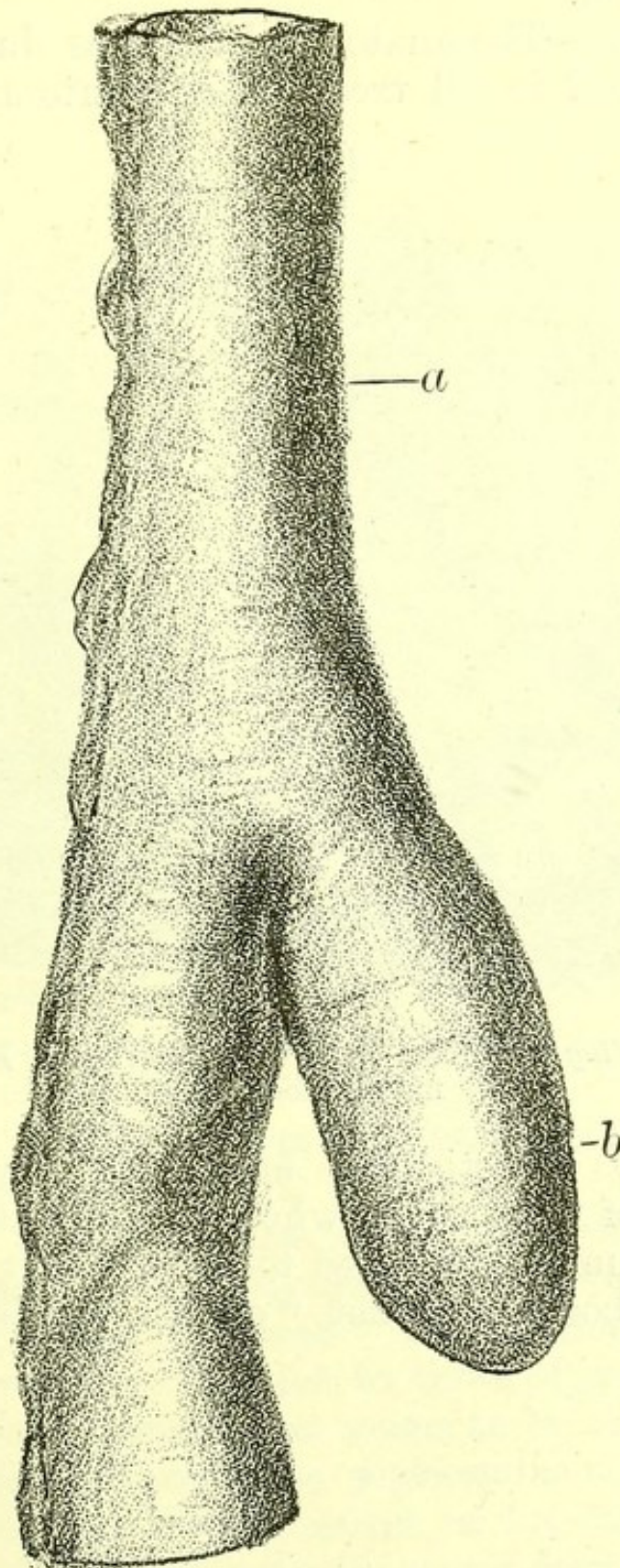
vesicæ ; imperforate anus ; testes retained in the abdomen ; some forms of club-foot, supernumerary toes and supernumerary fingers (Fig. 29), are some of the commonest malformations. Most of them are imperfections or varieties of growth and not results of foetal disease. The most important of these are described with the diseases of those parts of the body in which they severally occur.

**Debility.**—When what seems mere debility during life causes death, paleness of the muscular tissue of the heart is generally found post-mortem, but not always fatty degeneration of its fibres. Extreme de-



bility following mental depression and causing death, often obtains no further explanation by post-mortem

FIG. 28.



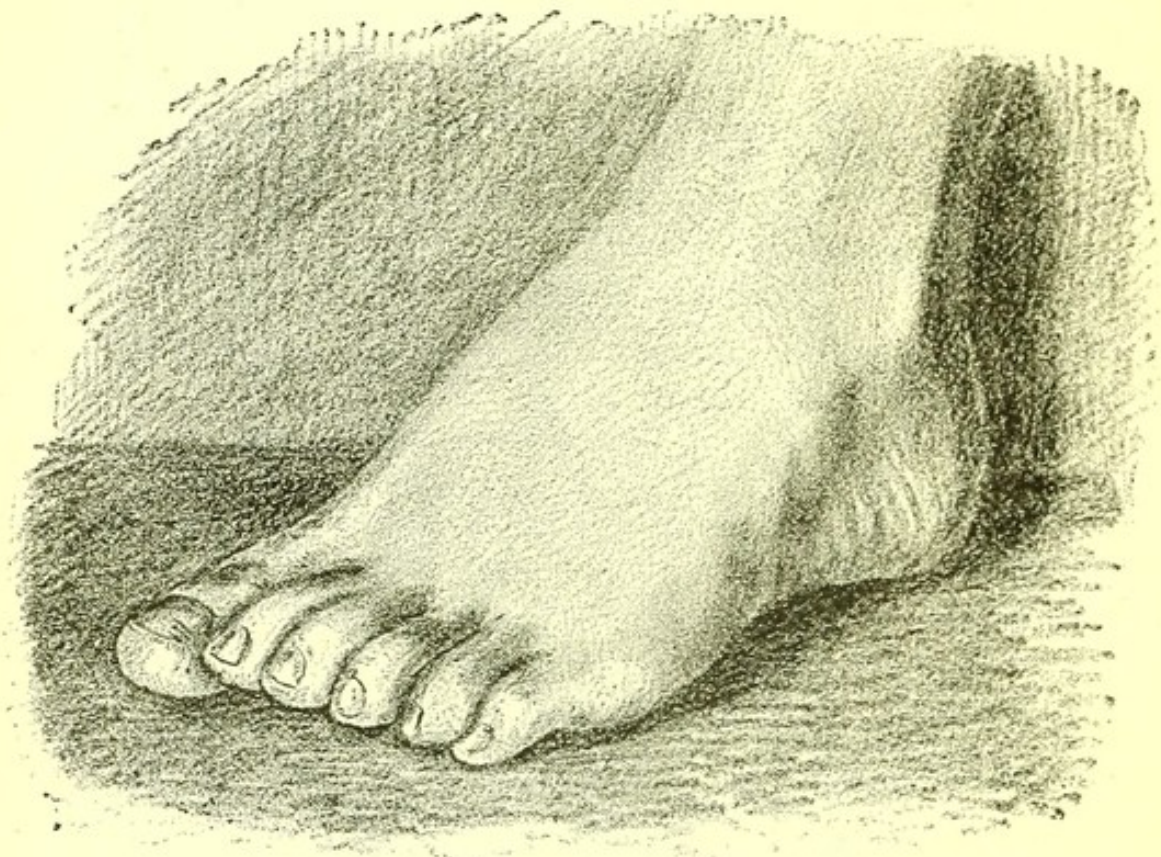
*Meckel's Diverticulum.* From a specimen in the Museum of St. Bartholomew's Hospital. *a.* Small intestine. *b.* Diverticulum.



examination. In such cases the mucous membrane of the stomach and intestines, or of the large intestine only, is generally in a state of slight catarrhal inflammation.

**Old Age.**—The anatomical changes due to old age are described in all treatises on anatomy, and have

FIG. 29.



*Foot showing Six Toes.* From a patient in St. Bartholomew's Hospital.

been lately investigated more fully by Professor Humphry of Cambridge, who points out that death is generally due in the aged to some slight cause, and that their bodies are not "on the whole, prone to disease."



## CHAPTER IX.

## DISEASES NOT CLASSIFIED.

RHEUMATIC FEVER.  
RHEUMATISM.  
GOUT.  
OSTEO-ARTHRITIS.  
SCROFULA.  
RICKETS.  
CRETINISM.  
MYXŒDEMA.  
LEPROSY.

PURPURA.  
SIMPLE ANÆMIA.  
CHLOROSIS.  
PERNICIOUS ANÆMIA.  
LEUCOCYTHÆMIA.  
HÆMOPHILIA.  
DIABETES MELLITUS.  
GLYCOSURIA.

**Rheumatic Fever.**—Patients rarely die of rheumatic fever. When they do, high temperature is the commonest cause, and the post-mortem appearances do not differ from those of any other high fever.

The results of an attack of rheumatic fever are usually demonstrable, and are :

1. The changes in the heart and valves produced by endocarditis.
2. Pericardial adhesions and their consequences.
3. Pleural adhesions.

Permanent changes in the joints are rarely found.

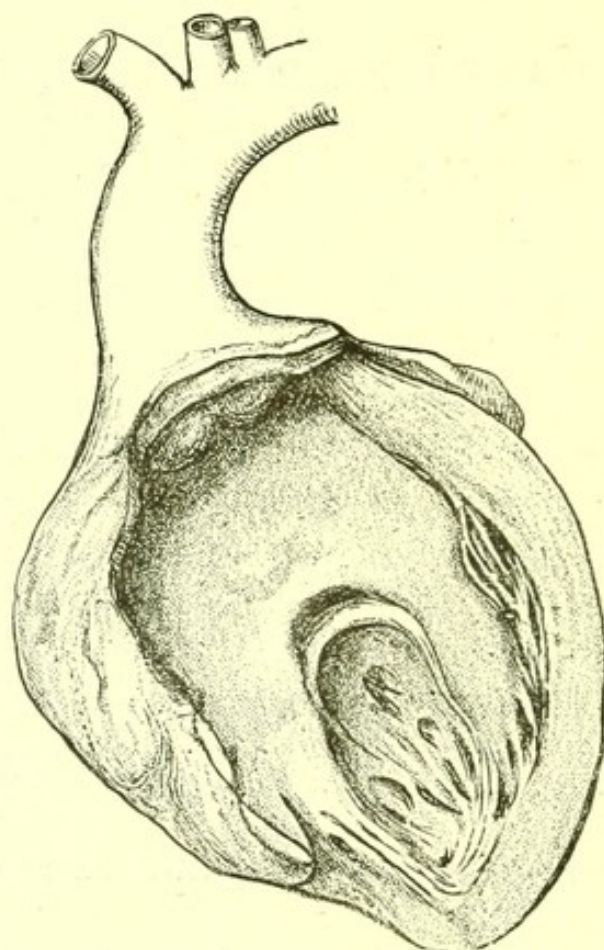
The nature of the pathological condition in rheumatic fever is still uncertain. The phenomena of the disease have a close relation to those of septicæmia.

Gonorrhœal rheumatism seems to be an allied condition, which is nearer to septicæmia than to rheumatic fever. In it the source of infection is clear. The inflamed urethra with its septic discharge infects the body. Pains in the joints, and sometimes endocarditis and pericarditis, follow.



In rheumatic fever, endocarditis is very common. It has certainly no dependence upon the severity of the joint lesion, for in children slight joint affection is often associated with serious endocarditis and its results. The joint affections may probably bear the same relation to the inflamed endocardium that the

FIG. 30.



*Stenosis of Mitral Valve, due to an attack of rheumatic fever.*

suppurating joints do to the primary abscess in pyæmia.

How does the endocardium become a source of infection? Can this be due to a specific organism taken into the body? Rheumatic fever does not run the definite course of typhus, or of small-pox, diseases in which the insemination, growth, florescence and death of a micro-organism so clearly explain the symptoms. Its course rather resembles that of enteric



fever, which has a more or less definite course, but is subject to exacerbations, but the phenomena of which all pathologists now believe are most easily explained by the interposition of a specific germ. The varying numbers and strength of the germ would suffice to explain the series of cases which, with every intermediate gradation, extend from examples with the slightest endocarditis and pains in joints, to those in which there is ulcerative endocarditis, with the distribution of active emboli.

**Rheumatism.**—The anatomy of chronic rheumatic pains in fascia and about joints has yet to be discovered.

When much pain has been felt in joints, gout or osteo-arthritis are generally found post-mortem.

**Gout.**—Gout is a term often used with very indefinite meaning in clinical medicine, but so far as morbid anatomy is concerned, no patient can be said to have gout in whose cartilages urate of soda is not found. Cartilage containing urate of soda is invariably degenerate, and as in gouty persons a profuse deposit of urate of soda is often to be found in some joints, and commencing degeneration without urate of soda in others, it may fairly be asserted that the degeneration of its cartilage precedes the presence of urate of soda in a joint.

*Distribution of Urate of Soda, and of Degeneration of Cartilages.*—The great-toe is the joint most often inflamed in gout during life, and in it after death a deposit is most often found.

The deposit may be in large white patches, or in minute specks all over the cartilage, or a few specks may be observable. It is usually more abundant on the proximal surface of the metatarso-phalangeal joint than on the distal, and the phalangeal surface is often thickly covered. The proximal surface of the phalangeal joint has more often deposit than the distal.

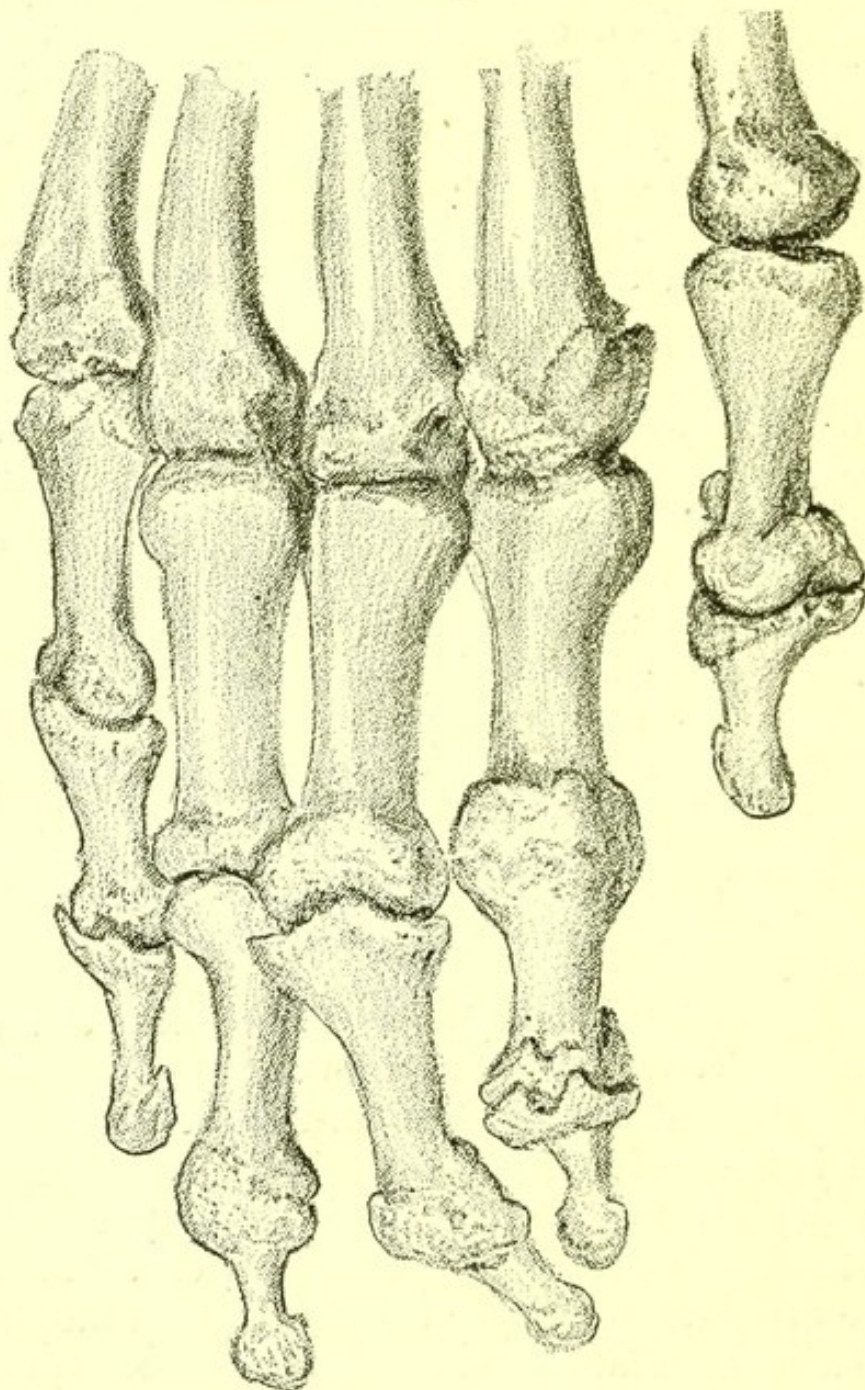
The lesions of the joints in gout have a tendency to symmetry, so that both toes are likely to contain



deposit. Anchylosis of one or more joints is frequently found (Fig. 31).

Deposit is much rarer in the other toes than in the metatarso-phalangeal joint of the great toe, but

FIG. 31.



*Fingers, showing anchylosis in a case of gout.*

may occur at once in all the phalangeal and metatarsal joints, and on all the surfaces of the tarsus. In such cases it will also be found on the tarsal surface



of the tibia, and often in the plantar, and other fascia of the foot.

Next to the metatarso-phalangeal joint of the great-toe, deposit is commonest in the knee-joint, and in the knee is oftenest found in the intercondyloid groove of the femur, and on the corresponding part of the patella. It may, however, cover every part of the joint and the semilunar cartilages, and there may be any variety of distribution, as urate of soda in the intercondyloid groove, and on the outer condyle, and on the ridge of the patella; degeneration over the whole of the rest of the patella, and on the inner condyle, the tibia and semilunar cartilages being free from deposit and from degeneration.

A deposit is rarely found in the hip-joint.

In the hand, the metacarpo-phalangeal joint of the index finger is most often covered with deposit, which may extend to every joint, and is often collected in masses on the sheaths of the tendons and amongst their fibres.

The elbow is less often affected than the knee, but more often than the shoulder-joint, and the cartilage of the olecranon is the part most affected.

The sterno-clavicular joint I have never found affected.

A deposit is very rare on the heads of the ribs and on the vertebral articulations, and on the articulation of the lower jaw, and on the crico-arytenoid articulation.

It is not uncommon in the cartilages of the ear and may occur in those of the eyelids. In mediæval medicine, the study of gems and their supposed virtues often formed part of a physician's knowledge; and masses of urate of soda, projecting from the cartilages of the ears, from their resemblance to the volcanic tophus, which was at the opposite end of the scale of hardness which began with the diamond, were called tophi, and have retained the name long since gems have fallen into disrepute as medicinal agents.



The vertebral fasciæ often contain deposits of urate of soda, and I have seen one in the pia mater on the surface of the brain. Microscopic sections show that the urate of soda is contained in the matrix of cartilage, and also in the cell-walls.

These are the essential lesions of gout.

Granular kidneys with uric acid visible in the tubules, and a heart with hypertrophied left ventricle, are usually, but not always, present. Calcareous degeneration of the aorta, and sometimes of the aortic valves and of smaller arteries, are often found. These patches of degeneration never contain urate of soda.

Emphysema of the lungs is almost invariably present.

Sometimes the synovial fluid in the knees is turbid from floating urate of soda, and any degree of eburnation and of deposit of bone at the edges of the joint may be found.

The fatal result in a case of gout is often found to have been due to pericarditis with a little scanty turbid fluid, to lobar pneumonia, or to cerebral hæmorrhage.

*Relation of Appearances to Symptoms.*—The fact that urate of soda may be found in almost every joint and fascia is proof that the widespread pains often complained of by the gouty are not imaginary, but are the result of definite anatomical change.

The distribution of the characteristic lesion of gout throughout the body is stated in the following rules:

1. That degenerative changes are usually present in the same joint, or in other joints of the same body, or in both, where urate of soda is present even in a single joint.
2. That deposits of urate of soda, like other degenerative changes, are usually more or less symmetrically arranged on both sides of the body.
3. That it is commoner to find a deposit in the joints of the legs than of the arms.
4. That a deposit may be present in nearly all the



joints of the lower limbs, and absent from those of the upper limbs.

5. That a deposit is commoner in the metatarso-phalangeal joint of the great-toe than in the phalangeal joint.

6. That however abundant in and below the knees, a deposit is rare in the hip-joint.

7. That a deposit is often found in the great-toes and knees when absent in the ankles, but not in the ankles when absent in the toes and knees.

8. That when present in the ankles, some deposit may usually be found in the ligaments of the foot.

9. That the elbow-joint has deposit when one is present in the wrist.

10. That the sterno-clavicular joint rarely contains deposit.

11. That the articulations of the larynx rarely contain deposit.

The chief relations of the gouty lesion to other anatomical changes are :

1. That chronic interstitial nephritis is found in a large proportion of those bodies in which urate of soda is to be seen in the joints.

2. That emphysema of the lungs is an equally constant lesion in such cases.

3. That chronic interstitial nephritis (and of course emphysema) are not invariably accompanied by urate of soda in the articular cartilages, though usually accompanied by some traces of degeneration in some of the articular cartilages.

4. That urate of soda is present in the joints of a large proportion of those persons over forty years of age who die of cerebral hæmorrhage.

5. That extensive deposit of urate of soda may exist in the articular cartilages without any external deposit, such as tophi in the ear, and that it is comparatively rare for tophi in the ear to be present in such cases.

6. That in a majority of cases of cirrhosis of



the liver, urate of soda is not to be found in the joints.

7. That the clinical observation that the symptoms of gout are commoner in men than in women corresponds to the post-mortem results as to the presence of urate of soda in the joints.

These general conclusions support the hypothesis that gout with its accompanying changes, acute and chronic, is a condition which never occurs in tissues perfectly normal before its onset, but that it is a disease affecting bodies in which degenerative changes have been already going on for some time.

The following statistics show the relation of gout to renal disease, to cirrhosis of the liver, and to cerebral hæmorrhage:

In 39 cases of chronic interstitial nephritis in men, whose ages ranged from 28 to 76, I found urate of soda in 22; and in 16 cases in women, aged from 34 to 77 years, it was present in 5.

In 9 cases of chronic parenchymatous nephritis in men, urate of soda in the joints was present in 2.

In 14 cases of cirrhosis of the liver in men, aged from 23 to 60 years, urate of soda was present in the joints of 2; and in 9 women, aged from 34 to 67 years, it was absent in all.

In 32 cases of cerebral hæmorrhage in men, aged from 28 to 72 years, urate of soda was present in the joints of 13.

Gout is so often talked of as a joint affection when in fact it ought to be regarded as a condition of general degeneration, that it seems worth while to give in full the post-mortem record of a well-marked case of gout. The patient was a man aged 73 years.

*External Appearance:* Fairly nourished; no anasarca.

*Head.—Cranial Bones:* Calvaria thicker than natural.

*Dura Mater:* Very firmly adherent to the brain along the longitudinal fissure.

*Arteries:* Highly atheromatous.



*Brain:* A large hæmorrhage into the corpus striatum and optic thalamus on the left side; a second smaller hæmorrhage into the pons Varolii.

*Chest.—Larynx and Trachea:* Normal.

*Lungs:* Firm adhesions on both sides; both emphysematous.

*Heart:* Weight 18 oz.; hypertrophy of left ventricle, and some hypertrophy with dilatation of right ventricle present.

*Valves:* Normal.

*Abdomen.—Stomach, Intestines, Liver, Spleen, Pancreas, Abdominal Lymphatics, and Supra-Renals:* Normal.

*Kidneys:* Small; granular on surface; capsules adherent; cortex very narrow; deposit visible in the tubules in the pyramids.

*Ureters and Bladder:* Normal.

*Joints; Right side:* great-toe, metatarso-phalangeal joint, both surfaces thickly coated with urate of soda; phalangeal joint, no deposit. The astragalus, cuboid, scaphoid, and all three cuneiform bones with deposit on every surface. Second toe, metacarpo-phalangeal joint, without deposit. Ankle; tibia, with many streaks of urate of soda. There was much deposit of urate of soda in the fasciæ and ligaments of the foot, and in one mass of fat there was a sprinkling of urate of soda. Knee; femur, tibia, with streaks and patches of urate of soda. Patella thickly coated with urate of soda in parts. On its outer and anterior surface was a nodule of urate of soda as large as half a hazel-nut. This was obvious as a lump, before the skin was reflected. The outer semilunar cartilage had a deposit of urate of soda on its surface and in its substance. Hand; index-finger, metacarpo-phalangeal joint, no deposit. Elbow, humerus, and ulna, both with several streaks and patches of urate of soda. Shoulder joint, no deposit. Sterno-clavicular joint, no deposit. *Left side:* great-toe, metatarso-phalangeal joint, with abundant deposit, but less than on the right side. Knee, a slight erosion, but



no deposit on the patella ; the erosion at its lower edge. A well-marked deposit on the outer condyle of the femur. None on the tibia. Shoulder, sterno-clavicular joint, no deposit. The cervical vertebræ were all more or less anchylosed together, and there were other anchyloses in the column in the dorsal and lumbar region, but no urate of soda was discovered about the vertebræ or the fasciæ in their vicinity. On section, several of the costal cartilages showed a central degeneration, which looked like urate of soda, but which microscopic examination proved not to be.

**Osteo-arthritis**, a disease affecting many joints in the body with degeneration and erosion of cartilage, condensation and eburnation of bone, and bone formation at the edge of the synovial fringe, is, like gout, a constitutional and not merely a local condition. Its bilateral symmetry, and the fact that one of its forms occurs apparently in direct relation to posterior sclerosis of the spinal cord, at present incline some pathologists to the belief that osteo-arthritis may primarily be a disease of the nervous system.

**Scrofula** is a condition in which slow inflammation of lymphatic glands tending to suppuration, but also terminating in caseation, occurs.

The condition is one of hereditary or acquired malnutrition of tissues manifested by varying morbid appearances, all of the type of a sluggish form of inflammation.

**Rickets.**—Rickets is not itself a sufficient cause of death, though from its first mention in the bills of mortality in 1634 to the present day it is often given as such in death certificates.

However much the patient may have been affected by rickets, some other anatomical cause of death is to be sought. The commonest is perhaps pulmonary catarrh.

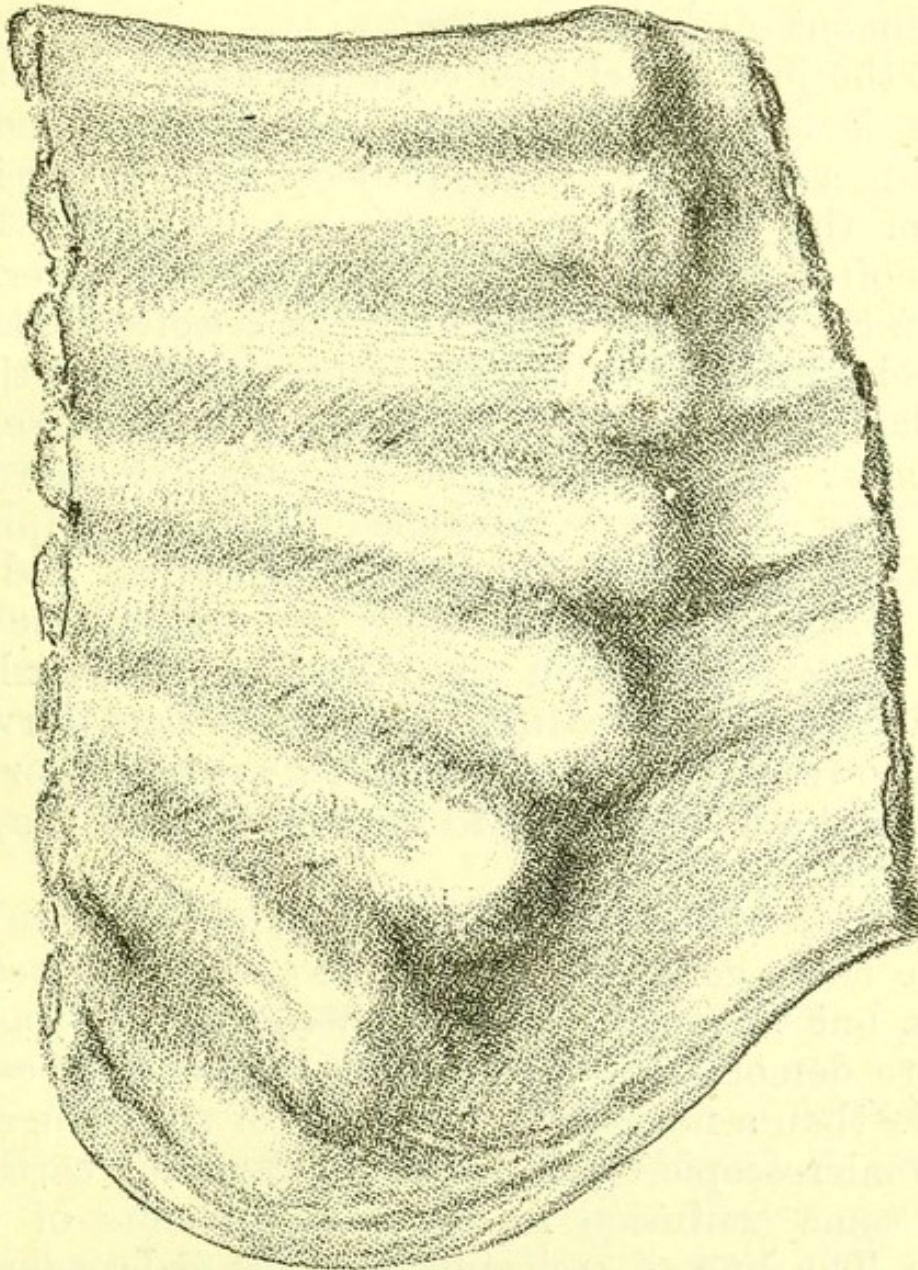
The anatomical appearances of rickets were first exactly described by Glisson, in his famous treatise *De Rachitide*, published in Little Britain in 1650, one of the classical writings of English medicine.



The anatomical appearances are most marked in the skeleton.

*Skull*: the frontal eminences are larger than natural; the edges of the fontanelles, which are larger

FIG. 32.



*Ribs*, showing beads, from a case of rickets. Inner surface.

than proper for the age of the child, are thickened; the periosteum of the jaws is thickened, and the number of teeth is often less than it ought to be in relation to the child's age.

*Chest*: the chest is usually increased in its antero-posterior diameter, so that its proportion, instead of



being of the normal ratio, in which, if the antero-posterior axis be one, the transverse is one and a third, has a transverse diameter of one and a fifth.

There is usually a deep sulcus from above downwards along the line of the ends of the costal cartilages, and a transverse sulcus at the level of the attachment of the diaphragm.

At the junction of each costal cartilage with its rib there is a protuberance of both cartilage and rib, forming a bead. This bead projects more on the inner side of the chest than on the outer, and the lower beads often produce deep depressions on the liver.

*Spine:* The edges of the vertebræ are often enlarged at their junction with the intervertebral cartilage; and lateral curvatures of the spine may be present.

*Limbs:* The pelvis may be distorted and narrowed. The long bones are thickened at their epiphyses, and are often curved, the bones of forearms and shin more often than the humerus and femur, the tibia and fibula most often of all. The tibia exhibits two varieties of twisting. It may be bent forwards so as to resemble the tibia of an armadillo, or forwards and outwards so as to resemble that of the great ant-eater.

The ends of the phalanges are not enlarged.

The bones generally bend more easily than healthy bones, but in several chemical weighings I was not able to demonstrate that they contained less earthy matter than a normal rib of a child of the same age.

On microscopic examination the ossifying cartilages show some confusion in the arrangements of their cells. The line of ossifying cartilage is broader and extends further into the bone, so that islets of cartilage are found enclosed by bone.

*Visceral Changes.*—The intestines often contain fluid fæces, and are often distended with gas. Many authors, including Glisson (*De Rachitide*, 1650) and Sir William Jenner in his excellent Lectures on Rickets (*Medical Times and Gazette*, 1860), describe a



peculiar appearance of the liver and spleen accompanied by enlargement.

In the cases which I have examined post-mortem, I have often found the liver and spleen without morbid change.

*Duration.*—The distorted cranium, bent bones, pigeon-breast, and spinal curvature, may persist throughout life, but the beads grow proportionally less as the chest enlarges, and are rarely to be seen in the chests of adults.

**Cretinism** is a form of idiocy. The skull is ill-developed and the whole skeleton short.

In the form most often seen in London, and known as sporadic cretinism, there are lumps of fat upon the clavicles, and the thyroid gland is often small or atrophied.

**Myxœdema** is a condition the morbid anatomy of which is at present not fully known.

The obvious anatomical changes are: a general fulness of the integuments, particularly of the face, resembling in outward appearance the anasarca of chronic parenchymatous nephritis, but differing from it on section in the fact that very little fluid flows out.

The following were the appearances in a woman, aged fifty-four:

*Face*: full, integuments as if anasarcaous.

*Fingers*: thick and broad.

*Thyroid gland*: very small, left lobe a mere shred, right lobe not more than one-sixth of its natural size.

*Lungs*: some adhesions at both apices, and at each a puckered scar enclosing some calcareous material; general emphysema present, but not extreme.

*Heart*: some hypertrophy of left ventricle, muscular tissue showing traces of brownish degeneration and softer than natural.

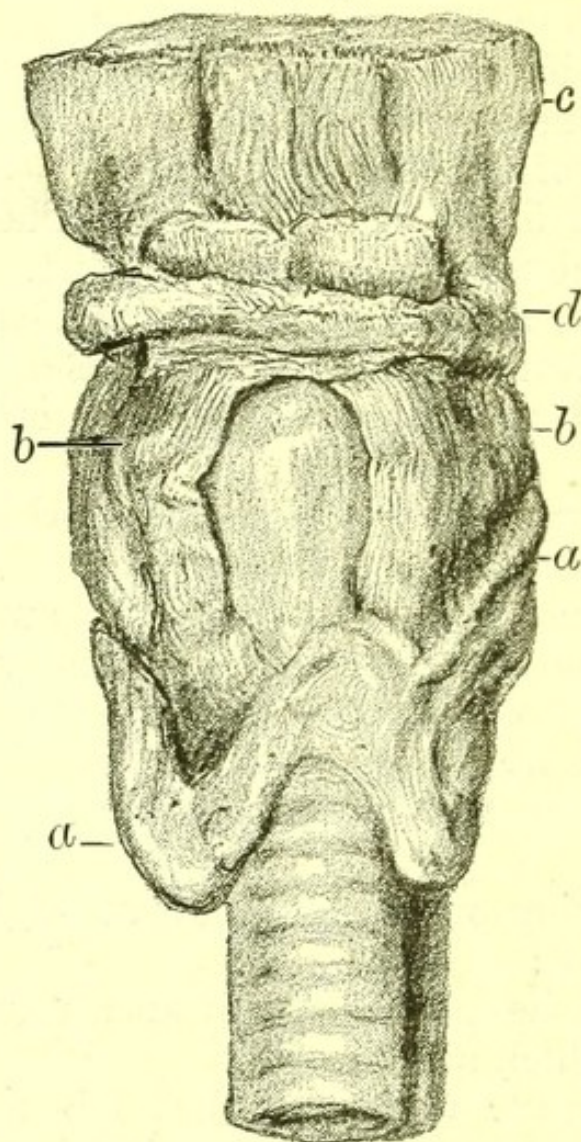
*Peritoneum*: universally thickened, with deep depressions here and there on the glistening white



thickened surface. On stripping off this thickened peritoneum from the liver the capsule is found normal beneath.

*Spleen*: small, of wasted appearance, firmly adherent to the diaphragm.

FIG. 33.



*Thyroid Gland*, from a case of myxœdema. *a. a.* Thyroid gland. *b. b.* Thyro-hyoid muscles. *c.* Root of tongue. *d.* Hyoid bone.

*Stomach*: containing a considerable quantity of blood-stained mucus.

*Mucous surface of intestines*: normal.

*Uterus and ovaries*: normal.

*Kidneys*: capsule thickened, surface rough, with a few small cysts, cortex narrow, all the appearances of chronic interstitial nephritis.



Of these appearances the condition of the skin and of the thyroid gland are most constant.

**Leprosy.**—The anatomical changes found in leprosy are :

Cell-infiltration of the skin in particular regions, forming the “nodules of leprosy,” and leading to an appearance of universal thickening. These perhaps owe their origin to the bacillus lepræ which is found in them. The infiltrated skin is enormously thickened and shows patches of ulceration. Similar nodules are found near the large nerves. Fingers or large parts of the extremities fall off owing to the ulceration.

**Purpura.**—Small hæmorrhages into the skin and subcutaneous tissue occur as a result of extreme venous congestion, as in valvular disease of the heart, in intense jaundice, and in the condition known as purpura simplex. They are also to be seen round the innumerable flea-bites which sometimes cover the skin of ill-cared-for children. The central hole made by the proboscis of the flea may be demonstrated with the aid of a lens, and thus the ecchymosis of flea-bites be distinguished from the spots of **purpura simplex**.

When purpuric spots occur on the surface of the body in valvular disease of the heart, they are usually also found after death on the pericardium, the pleura, the inner surface of the larynx, trachea and bronchi, and the mucous surface of the small intestine, or in some of these regions. The same is true of the purpura of intense jaundice.

Larger hæmorrhages into the skin, sometimes looking like great bruises and sometimes associated with actual destruction of a patch of the epidermis and the sub-epidermic layer, occur in the severer form of purpura—called from its internal hæmorrhages, **purpura hæmorrhagica**—in **scurvy** and in **hæmophilia**. In this series of allied diseases, purpura simplex, purpura hæmorrhagica, scurvy and hæmophilia, it is certain that the capillaries have undergone some morbid



change, and it is generally assumed that in purpura and scurvy the blood is the tissue affected primarily and in hæmophilia the capillary walls. Some observations of Dr. Percy Kidd as to the degeneration of the capillary nuclei in hæmophilia are interesting, because so few observations of any kind have been made on the state of the capillaries, but do not conclusively establish the nature of the disease.

Under the microscope, purpuric hæmorrhages into the skin show an infiltration of the tissues by red blood-cells, some of which are fresh, while others have lost some of their pigment.

Similar hæmorrhages are sometimes to be seen round small but very rapidly formed masses of new growth in the skin of children, and may give the unpigmented new growth as seen through the epidermis the appearance of a melanotic sarcoma.

*Other appearances in purpura hæmorrhagica* : after death from purpura hæmorrhagica, small ecchymoses are found on the pericardium, the muscular tissue of the heart is marked by pale bands which indicate the presence of fatty degeneration, the clots in the heart are very pale, and the blood is paler and more watery than natural. Blood clots in considerable quantity may be found in the stomach, in the small intestine or in the large intestine. No breach of the mucous surface is to be seen, as all the hæmorrhages are from capillaries. A similar hæmorrhage, often very large in quantity, may be found in the substance of one or more muscles or between the muscles of a limb. Common situations for such hæmorrhages are between the muscles of one or both thighs, and into the muscles of the abdominal wall.

A man with purpura hæmorrhagica in St. Bartholomew's Hospital, on getting out of bed felt suddenly faint, lay down again and died in a few minutes. Post-mortem, besides a heart with advanced fatty degeneration of its walls, a large hæmorrhage was found which had begun in the substance of the liver,



extended to the surface near the falciform ligament, stripped off most of the capsule of the left lobe and burst through the capsule and peritoneal covering near the edge of the left lobe, into the cavity of the peritoneum, which contained a large quantity of blood.

Examination of the blood in purpura simplex, and even in purpura hæmorrhagica, often shows no definite change, but sometimes some diminution of red corpuscles may be estimated.

**Simple anæmia** may be due to deficiency in quantity or to altered quality of the blood. The former exists after extensive hæmorrhage, and only requires mention here in order to warn the observer that the very pale kidneys and liver which are sometimes found where death has been due to the division of a large artery, have been mistaken for the kidneys of parenchymatous nephritis and liver of fatty infiltration. Should any doubt exist, a microscopic section will of course settle the question.

Simple anæmia due to a deficiency, generally slight, in the number of red corpuscles is no doubt accompanied by paleness of the viscera, but post-mortem examinations of such cases are of course rare.

Persistent anæmia, for which no obvious cause has been discovered during life, is sometimes demonstrated post-mortem to have been a symptom of deep-seated new growth.

A man in St. Bartholomew's Hospital who had no gastric symptoms, and who was the subject of extreme anæmia, was treated by transfusion after repeated careful examination and after consultation. His anæmia continued, and he was discovered post-mortem to have a large carcinomatous growth in the posterior wall of his stomach.

I have examined one case of fatal anæmia due to prolonged menorrhagia. The woman was aged twenty-two years, and died during a menstrual period. Post-mortem a clot occupied the cavity of the uterus, all



the viscera were pale, and the muscular tissue of the heart was mottled, and under the microscope showed advanced fatty degeneration. There were no hæmorrhages from the mucous surfaces.

**Chlorosis** is a slight form of anæmia the precise anatomy of which is not known.

**Pernicious anæmia.**—This is a clinical term not yet associated with definite post-mortem appearances. An inveterate anæmia without extensive purpura, other obvious hæmorrhage or well-marked blood change, progressing to a fatal termination, will generally be found post-mortem to have been associated with

- (a) deep-seated carcinoma or sarcoma, tuberculosis, or syphilis;
- (β) unnoticed hæmorrhages from the alimentary canal, due to *Bilharzia hæmatobia* in any part of the intestine;
- (γ) *dochmius duodenalis* in the duodenum and jejunum;
- (δ) uterine hæmorrhages.

There are also some cases of fatal anæmia which follow extreme mental depression, and a few cases without obvious cause, and in which no post-mortem appearance explains the disease. Some observers have described active degeneration of red blood-cells and accumulation of detritus in the blood, and believe these to be characteristic of pernicious anæmia.

**Leucocythæmia.**—The condition of the blood is the chief feature in the morbid anatomy of leucocythæmia. The number of white corpuscles is enormously increased. The spleen and the lymphatics, or the spleen only, or the lymphatics only, are enlarged.

The spleen presents under the microscope a great increase of its normal tissue. The same condition prevails in the lymphatics, and no breaking down of structures is discovered.



The liver is often much enlarged, and one of two anatomical conditions may occur in it.

It may be soft though tough in texture, and under the microscope show a general increase of lymphatic tissue among the lobules, or here and there in its substance may be white specks which microscopic examination shows to consist of collections of leucocytes. These groups of cells have neither vascular engorgement around the group nor degeneration of the central cells. (See Chapter XV.)

**Hæmophilia.**—The anatomical appearances described as present in purpura occur in this disease.

In addition, blood is found in the joints. The surface of the articular cartilage is of a dark blood colour owing to hæmorrhage into and under the synovial membrane, and free blood in considerable quantity is present in the synovial sac.

In a specimen in the Museum of St. Bartholomew's Hospital, lipping of the edges of the articular surfaces is to be seen.

**Diabetes Mellitus.**—All the anatomical characters of this disease are not yet known. Post-mortem, the most constant conditions are—

1. A peculiar sweetish odour on opening the body and head, and on section of the liver.

2. A pale pink condition of blood, due to the presence in it of large quantities of fat. Hamilton has described fat emboli in the lungs as in some cases associated with this condition of blood.

In addition, the bladder is generally found with distended urine containing sugar, but it may be quite empty.

The kidneys are generally of a pink colour, large and soft, but they may be granular on the surface, small and hard, or may even be without morbid change.

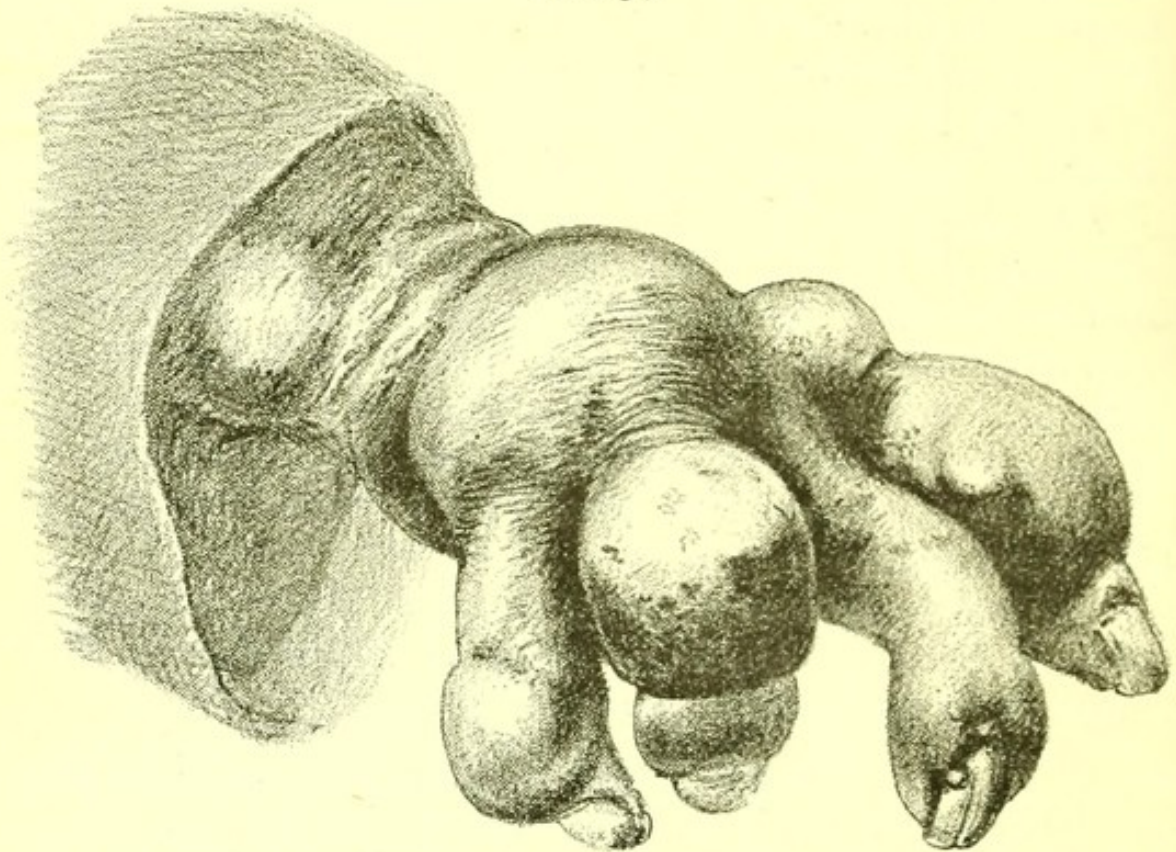
The liver is generally pale and soft.

No changes are discoverable in the brain.



**Glycosuria.**—A morbid condition in which sugar is found in small quantities in the urine without the wasting of tissue almost universal in true diabetes, is not a cause of death, but in cases in which the symptom has existed the anatomical appearances of gout and of chronic interstitial nephritis are frequently discovered.

FIG. 34.



*Hand from a case of Gout, showing ankylosis, projecting deposits of urate of soda, and deformed nails. The man had transient glycosuria.*



## CHAPTER X.

## DISEASES OF THE NERVOUS SYSTEM.

HYPERTROPHY AND ATROPHY.	CEREBRAL TUMOURS :
CONGESTION.	GUMMA.
HÆMATOMA OF DURA MATER.	GLIOMA.
CEREBRAL HÆMORRHAGE.	CARCINOMA.
HÆMORRHAGE INTO SPINAL CORD.	SYPHILITIC DISEASE.
ANÆMIA.	PARASITES.
DROPSY :	APOPLEXY.
CHRONIC HYDROCEPHA- LUS.	PARALYSIS.
HYDRORACHIS INTERNA.	HEMIPLEGIA :
INFLAMMATION :	LEFT.
PURULENT MENINGITIS.	RIGHT.
PYOCEPHALUS.	CROSS.
PACHYMENINGITIS.	WITH DOUBLE CON- TRACTED PUPILS.
TUBERCULAR MENINGITIS.	SQUINT.
SYPHILITIC MENINGITIS.	OPHTHALMOPLÉGIA EX- TERNA.
ENCEPHALITIS.	SUDDEN BLINDNESS.
SPINAL MENINGITIS.	BELL'S PALSY.
MYELITIS.	GLOSSO-LABIO-LARYNGEAL PARALYSIS.
ANTERIOR POLIO-MYELI- TIS.	DIPHTHERITIC PARALYSIS.
ALCOHOLIC NEURITIS.	LEAD PALSY.
ABSCESS OF THE BRAIN.	PSEUDO-HYPERTROPHIC PARALYSIS.
SOFTENING.	INFANTILE CONVULSIONS.
SCLEROSIS :	LARYNGISMUS STRIDULUS.
DISSEMINATED.	CRAMP.
OF THE ANTERIOR COR- NUA OF THE GREY MATTER.	MERCURIAL TREMOR.
OF LATERAL COLUMNS.	PARALYSIS AGITANS.
OF POSTERIOR COLUMNS.	APHASIA.
CYST.	NEURALGIA.
	MENIÈRE'S DISEASE.
	MEGRIM.
	TETANUS.



TETANY.  
EPILEPSY  
CERVICAL OPISTHOTONOS.

CHOREA.  
HYSTERIA.  
MENTAL DISEASES.

IN this chapter the general arrangement of the "Nomenclature of Disease" is followed. Morbid states and processes discoverable post-mortem in the brain, spinal cord and nerves are first described, and then the morbid appearances commonly found after death, when apoplexy, palsy or other symptoms of disease of the nervous system have been observed during life.

**Hypertrophy.**—Increase in size of the brain, spinal cord or nerves never depends upon an actual increase of their nerve elements, so that true hypertrophy of the nervous system does not exist.

**Atrophy.**—Nerves separated from the central nervous system first waste and then undergo more definite degenerative changes. Atrophy of the brain follows too early closure of the fontanelles.

**Congestion.**—Closely set small red specks in the brain-substance indicate post-mortem that during life the brain was congested.

**Hæmatoma.**—A cavity containing altered blood is sometimes found in the substance of the dura mater. The arteries of the brain are at the same time degenerate, and the hæmatoma is generally associated with the presence in the body of chronic interstitial nephritis and general arterial degeneration.

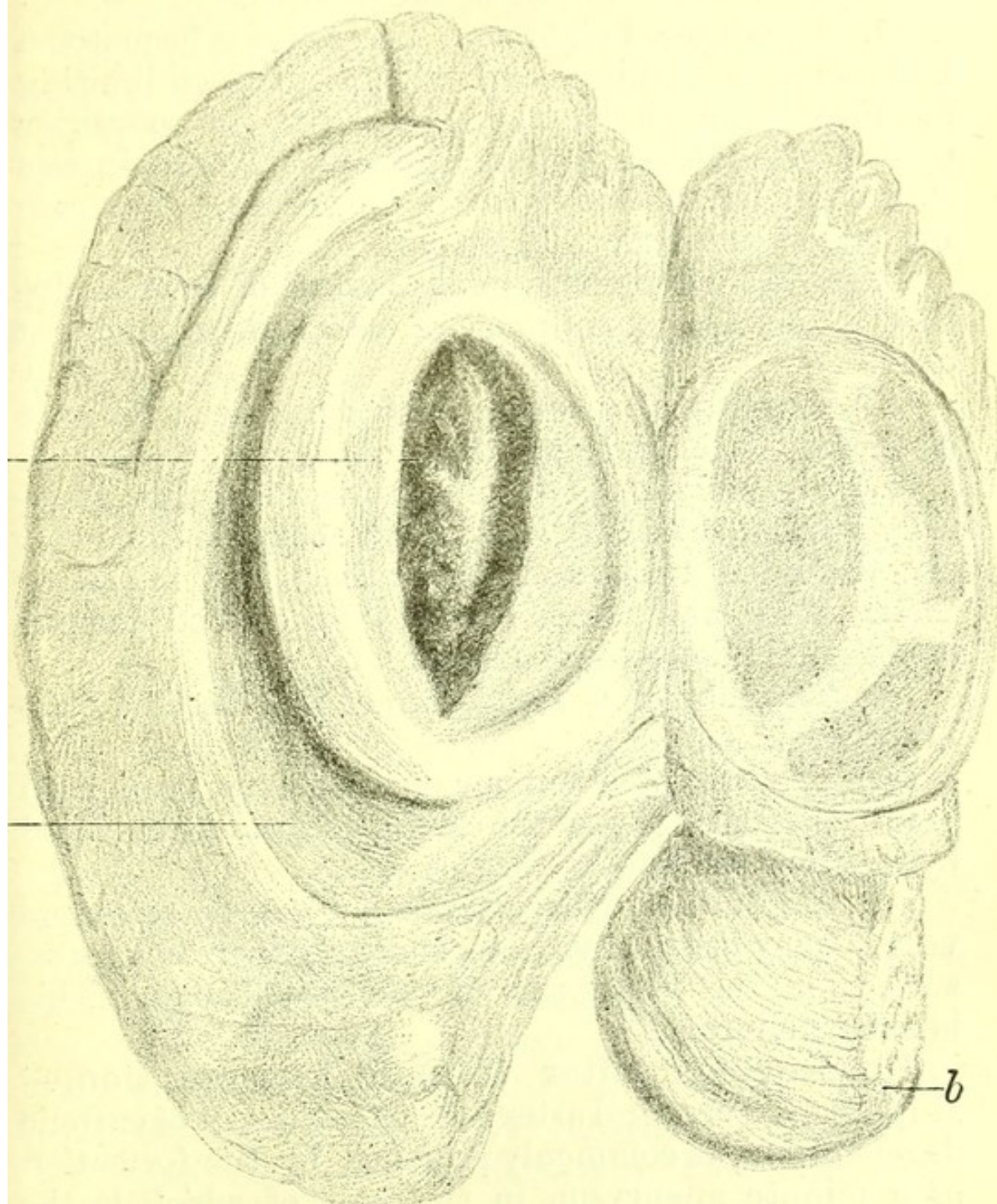
The appearances are those of hæmorrhage, sometimes of one date, and sometimes of successive dates. I have seen a comparatively recent clot in one part of a hæmatoma and yellowish material or partially organized substance in other parts of it.

The brain is of shrunken appearance with prominent Pacchionian bodies and watery fluid in the meshes of the arachnoid and pia mater. Hæmatoma of the dura mater is sometimes found after death from wasting



diseases, as in the following examples, which I examined. In neither of them were any cerebral symptoms observed during life:

FIG. 35.



*Left Cerebral Hemisphere* with a cerebral hæmorrhage due to arterial degeneration. Showing a clot in the internal capsule. *a.* Clot. *b.* Cerebellum. *c.* Lateral ventricle. The hemisphere has been turned back.

I. A woman, aged forty-nine. On removing the skull-cap, the right side of the dura mater was seen



to be very loose and bag-like. On opening it, a sac containing shreds of blood-clot, and with a distinct limiting membrane, was found. The brain-substance was everywhere normal. There was great emaciation, due to cancer of the pylorus.

II. A man, aged eighteen. There was a hæmatoma as large as a shilling, and with a distinct limiting membrane, on the dura mater over the posterior part of the left cerebral hemisphere. The brain was shrunk and the body greatly emaciated. The case was one of saccharine diabetes.

**Cerebral hæmorrhage** is a sequel of several distinct pathological conditions, of which the commonest are—

(1.) Rupture of an artery which has been the seat of chronic degeneration (atheroma).

(2.) The plugging of an artery by an embolus, generally a fragment of an endocardial outgrowth or of a clot deposited upon an outgrowth on the mitral or aortic valves, and thence carried by the blood current into the middle cerebral artery.

(3.) Thrombosis, or a clot formed in a diseased cerebral vessel.

(4.) Pressure of a tumour on an artery leading to gradual degeneration of the cerebral substance supplied by it, often leads to hæmorrhage.

(5.) Rupture of undegenerate but greatly engorged vessels may occur, owing to suddenly increased pressure, as in the paroxysms of whooping-cough. This is extremely rare.

**Hæmorrhage after Chronic Degeneration.**—Rupture of a cerebral artery which is the seat of chronic degeneration, is commonly preceded by the formation of a minute aneurysm, in the wall of which is the actual rupture. In most cases the hæmorrhage is also preceded by degeneration of the brain-substance in the neighbourhood of the vessel. The quantity of blood poured forth and the consequent destruction of brain-tissue vary. The hæmorrhage may be of the



size of a pea or may extend almost throughout a cerebral hemisphere.

The commonest starting-point of hæmorrhage is from the capsular branch of the middle cerebral artery, which supplies the internal capsule.

The age of the hæmorrhage may be determined post-mortem by the character of the blood clot, which, if the hæmorrhage is very recent, is dark-coloured and quite soft; if of some standing, paler in colour and harder.

A very old hæmorrhage is indicated by a cavity with a very pale yellow internal surface, in scrapings of which under the microscope hæmatoidin crystals are to be found.

A very common post-mortem appearance in cases of death from cerebral hæmorrhage is a clot which has burst through the floor of one lateral ventricle and filled it; often extending without further breach of surface through the foramen of Monro into the other lateral ventricle.

It is very rare for a hæmorrhage which fills a lateral ventricle to reach the surface of the brain, but the hæmorrhage is often extended into the white matter of the hemisphere, and when this is the case some flattening of the convolutions and bulging of the outer surface may be observed on the side of the hæmorrhage when the dura mater is removed.

Next to the region of hæmorrhage already described and which is the most frequent, hæmorrhage is commonest in the pons Varolii. Such a hæmorrhage may extend through the iter a tertio ad quartum ventriculum into the third ventricle, or may have proceeded forwards and destroyed the centre of the crus cerebri on one side, or more rarely on both sides.

Hæmorrhages into the cerebellum are rarer, and into the medulla oblongata rarer still.

Hæmorrhages into the anterior cerebral lobes or other outlying parts are frequently found.

Separate hæmorrhages of different dates may be



found in the same brain occasionally, as in the following example, and atheroma of the vessels of the circle of Willis is always present.

The patient was a cabinet-maker, aged fifty-six years. For a week he had had severe headache. On the day of his admission to St. Bartholomew's Hospital he had fallen down insensible while at work. He had never had a fit before; but his friends had for some little time noticed that his manner was odd, and that he sometimes used mistaken names. He died a little more than two months after the seizure, and post-mortem I found:

*Brain:* Four distinct hæmorrhages into the brain—one on the right side (I.), three on the left (II., III., IV.).

(I.) This was the largest. Its seat was the outer and upper wall of the right lateral ventricle. It extended forwards to within one inch of the apex of the anterior cerebral lobe and backwards to within  $1\frac{1}{2}$  inch of the occipital lobe, and had nowhere penetrated the wall of the ventricle. In neither ventricle was there a clot. In the posterior cornu of the right lateral ventricle there was a little reddish serum. A firm, ragged, and partially decolorized clot occupied the rent.

(II.) This was the second in size. It was in the occipital lobe on the left side, and was a cavity without contents but with yellowish walls. This cavity was pear-shaped and from an inch to one-third of an inch in width, the broader part being anterior. Its floor was edged by the external and inferior convolutions of the occipital lobe. At one part it extended into the grey matter.

(III.) A cavity in the centre of the left optic thalamus of the same internal appearance as (II.). It was of pea size.

(IV.) A cavity filled with a fresh well-formed blood clot  $\frac{7}{16}$  inch in length and a quarter of an inch wide in the putamen on the left side. The tissue around



the clot was not extensively softened, but was so in a very narrow tract.

The other parts of the brain were normal.

*Appearances in other parts of the body accompanying cerebral hæmorrhage:* the small red granular kidney of chronic interstitial nephritis, and the hypertrophy of the left ventricle, which accompanies it, are commonly found in the bodies of persons who have died of cerebral hæmorrhage. Emphysema of the lungs is usually present.

Degeneration of some of the articular cartilages is nearly always present, and a deposit of urate of soda in some of the joints is often found.

**Hæmorrhage due to Embolus** presents the same general anatomical appearances as hæmorrhage produced by the ruptured vessel of chronic degeneration. The embolus, if a passive one, is most often found in the left middle cerebral artery or in one of its branches.

An active embolus may be found in any artery.

In either case a small recently formed aneurysmal bulging may usually be discovered at the actual seat of rupture.

A passive embolus is a piece of growth from the mitral or aortic valves, or of blood clot deposited on and washed off such a growth; a piece of calcareous degeneration from the aorta, or a fragment of a clot in an aneurysm of the aorta. In one case which I examined a new growth projected into the aorta, and a fragment of blood clot deposited on its surface was carried into the left middle cerebral artery.

Active emboli proceed from ulcers of the endocardium, or from growths on the mitral and aortic valves in ulcerative endocarditis.

Gummata in the brain-substance by pressing on vessels frequently lead to hæmorrhage, and the same result may be due to other forms of tumour.

Rupture of healthy vessels owing to strain is very rare. The hæmorrhage is often superficial, but sometimes occurs in central parts of the brain.



In purpura and in hæmophilia the capillaries of the brain sometimes give way, producing hæmorrhages which are most often on the surface and are sometimes extensive.

In all cases where blood is found extravasated within the dura mater, it is well to look very carefully for fracture of the cranial bones.

Traumatic hæmorrhage and hæmorrhage due to disease may occur in the same case. A bricklayer fell off a ladder, and fractured his skull. Post-mortem besides the fracture and a superficial hæmorrhage in its neighbourhood, I found a hæmorrhage beginning in the internal capsule and filling the lateral ventricle, and due to rupture of an artery which showed old and advanced degeneration. The cerebral hæmorrhage here probably preceded the fall and caused it.

**Hæmorrhage into the Spinal Cord.**—Hæmorrhage is commonest in the upper part of the cord, and cavities due to it are sometimes found in the brachial enlargement. I have once seen a large fresh hæmorrhage, which caused death in a few hours in the uppermost part of the cord, below the medulla, in a woman aged twenty-one years. In her case a slight convulsive seizure was followed by more severe fits, with a partial opisthotonos which continued till death. Her other viscera were normal, and to the naked eye the cerebral vessels were healthy.

**Anæmia** of the brain is found post-mortem when death has been due to a wound of a great vessel or to rupture of an aneurysm of the aorta. It is also present in death from idiopathic anæmia, and from purpura. The brain-substance looks extremely pale.

**Dropsy: Chronic Hydrocephalus** is a condition which is almost invariably seen in children or in persons in whom it originated in childhood. The head is large, the frontal bones extending obliquely forwards, the roof of the orbits is depressed, both fontanelles are widely open or partly closed by accessory ossifications. On opening the head, the



brain is found to be as much distended as the skull. The convolutions have almost disappeared and the outer surface of the cerebral hemispheres may be no thicker than writing-paper.

The lateral ventricles and the foramen of Monro are dilated, and so are the third ventricle, the iter a tertio ad quartum ventriculum, and sometimes the central canal of the spinal cord.

Some thickening about the membranous roof of the fourth ventricle and near the orifice of the iter may sometimes be found.

In a male child which I examined, aged one year and four months, the brain was enormously dilated and contained in the lateral and the third ventricles more than five pints of fluid. The iter was closed and there was no increase of fluid in the central canal of the cord. Besides widely open fontanelles the skull showed several patches of craniotabes, but there were no signs of rickets in the skeleton.

The original cause of the effusion in chronic hydrocephalus is unknown.

**Hydrorachis Interna.**—Increase of fluid may sometimes be noticed in the central canal of the spinal cord in cases of tubercular meningitis.

Dilatation of the central canal by fluid without signs of acute inflammation may also occur, and is comparable to chronic hydrocephalus.

The only example I have seen was in a married woman, aged twenty-two. Two years before her death she had some loss of power in her left arm, and this became progressively worse. Six months before death her right arm was similarly affected. Some months before death her voice became husky, and she ceased to be able to speak in a loud tone.

From the superior edge of the deltoid upwards she had more or less complete anæsthesia; all her muscles seemed feeble, and on faradization there was hardly any reaction. She had no loss of power in her legs. Her breathing was always accompanied by

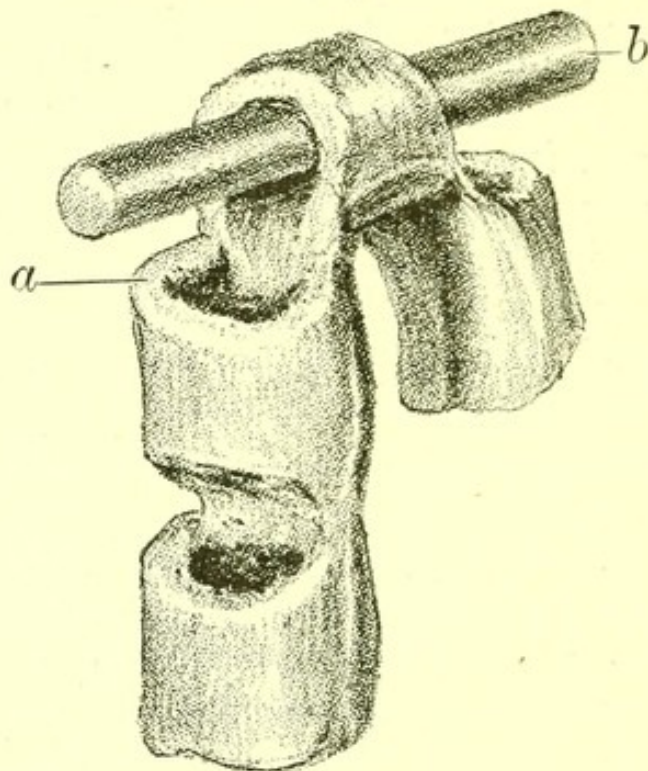


snoring. She had what seemed an epileptic fit and died, having been in St. Bartholomew's Hospital a little over three months.

In the brain the pia mater seemed slightly adherent in parts. The lateral ventricles, iter, and fourth ventricle were distended with clear fluid.

In the cord the meninges were normal, but the cord itself had become a mere tube filled with fluid. The cavity was not due to any breaking down of the cord,

FIG. 36.



*Part of the Spinal Cord* of a woman aged twenty-two, showing dilatation of the central canal due to hydro-rachis interna. *a.* Dilated central canal. *b.* Glass rod passed through dilated canal.

but to dilatation of the central canal. The dilatation extended throughout the cord, but was slightly greater in the upper part. The cavity readily admitted the little finger.

The other viscera were normal.

**Purulent Meningitis.**—When on removing the skull-cap and dura mater the surface of the brain is found covered with purulent fluid, with accumulations of lymph about the base of the brain and origin of the



cerebral nerves, with general injection of the vessels of the pia mater, the following conditions will probably be discovered elsewhere :

1. Pyæmia.
2. Disease of the internal ear, accompanied by necrosis of the roof of the auditory chamber in the temporal bone.

Both may, however, be absent.

**Pyocephalus** is a term used to express the presence of pus in the ventricles of the brain. The condition is common in purulent meningitis.

In a child, aged five months, I found post-mortem both ventricles of the brain distended with pus, an ounce and a half in each. The lining of the ventricle was universally injected and the ventricle much dilated. The central canal of the cord contained pus, and so did the subarachnoid space. There was recent lymph around the roots of the nerves from the back part of the optic chiasma to the medulla, where it was thickest. No tubercle was present in the brain or on pia mater or in the body.

The child had a fit on September 18, and a week later slight cervical opisthotonos came on. It sucked well and seemed no worse till October 8, when it had several fits, the opisthotonos increased, and it died. Its temperature was at first just above normal, but rose to  $101^{\circ}.2$  three days before death and the night before was  $103^{\circ}.4$ .

Purulent meningitis confined to the region of the medulla is frequently found in children who have had cervical opisthotonos for some time before death, as was first pointed out by Dr. Gee and Dr. Barlow (*St. Bartholomew's Hospital Reports*, 1878).

Very careful search must be made for tubercle in all such cases.

**Pachymeningitis.**—The dura mater is thickened owing to the organization of slowly formed tracts of inflammation cells. Patches of calcification may be



found in it. The same condition may follow multiple gumma of the dura mater.

**Tubercular Meningitis.**—Tubercular meningitis is the term used for the acute disease which follows the invasion of the pia mater by tubercle. The anatomical characteristics of the disease are recent tubercle in the pia mater, and an accumulation of fluid in the ventricles of the brain and subarachnoid space. The presence of this fluid is the origin of the term acute hydrocephalus, and in the early days of morbid anatomy led to the idea that this disease had something in common with the accumulation of cerebral fluid, preventing closure of the cerebral sutures, which is now known as chronic hydrocephalus, and popularly as water on the brain. Chronic hydrocephalus is always congenital; acute hydrocephalus always acquired. Almost always tubercle has affected some other part before it attacks the pia mater, so that tubercular material may usually be found in some other region of the body.

Tubercle of the pia mater is almost always a sequel of tubercle in some other part of the body. In fifty cases of tubercular meningitis in children under ten years of age examined by me at St. Bartholomew's Hospital, caseous bronchial glands were discovered in thirty cases. In eighteen of the cases tubercle of the lungs without obvious tubercle of the bronchial glands was found. In one case the chest was free from tubercle but it was present in the abdomen, and in one no tubercle was discovered outside the cranium. In five cases the bronchial glands were the only other seat of tubercle. In forty-six of the cases the tubercle was of widespread distribution.

The subject of tubercular meningitis is commonly a child after weaning, though cases are recorded in which it has affected children under eight months of age, and it occasionally occurs in adults. The commonest cases are those of children who have had measles or whooping-cough, and who, after the measles or whooping-



cough itself has terminated, do not recover strength, but continue ailing, and usually have some cough. Now and then the disease attacks a child previously healthy, and the vomiting which accompanies the cerebral symptoms has occasionally been so sudden as to lead to a suspicion of poisoning. The duration of the disease does not exceed three weeks.

To take first the case of a child in whom tubercular meningitis appears as a sequel of measles :

*General condition* : the body is usually lean and sometimes greatly emaciated, the eyes sunken, and the abdomen retracted.

*Head* : if the great fontanelle has not closed, it may project a little. If it be closed, the head presents no external peculiarity.

On removing the skull-cap it is important to remember that, if the child is under six years of age, the adhesion of the dura mater to the calvaria is a normal and not a morbid appearance, and that on removing the dura mater the Pacchionian bodies are not to be mistaken for tubercles.

The convolutions on both sides are flattened, the hemispheres look full, and on separating them a little, the corpus callosum is seen to be arched.

The whole surface of the pia mater is usually injected, and on the sides of the brain near the vessels small patches of greater injection are observable, and in the middle of these are minute grey tubercles, sometimes not visible without a lens, sometimes easily seen, and occasionally old enough to have become opaque. On raising the brain in front, the optic chiasma is seen to be fringed, before and behind, by lymph, partly opaque and partly semi-transparent. On cutting through the optic nerves and raising the brain further, the subarachnoid space is found full of clear, slightly pearly fluid.

Lymph may also be seen round the origin of the other cerebral nerves, and sometimes over the whole floor of the third ventricle, pons Varolii, and medulla.



On removing the brain by cutting through the cord a quantity of fluid escapes by the infundibulum and from the fourth ventricle, and some flows out of the spinal canal. The canal itself is very rarely dilated.

The sides of the fissures of Sylvius are adherent, and on separating them abundant tubercle with some lymph is usually found along the course of the middle cerebral artery.

It sometimes happens that very few tubercles are to be seen by the naked eye on the upper surface of the brain, or even at the base. When this is the case, they may usually be found on the sides of the hemispheres, and in the Sylvian fissures, or by examining the fresh pia mater of those parts under the microscope.

On opening the brain, in doing which the arched corpus callosum is very easily torn and seems softer than natural, the lateral ventricles are found to be full of clear fluid, and when this has run out, the lining membrane of the distended ventricles often has a finely granular appearance. A few tubercles are commonly found on the choroid plexus.

On removing the back of the eyeball, tubercles are often to be seen in the choroid membrane.

These are the chief points to be observed in the brain, and they are the same whether the disease occurs in a child or in an adult.

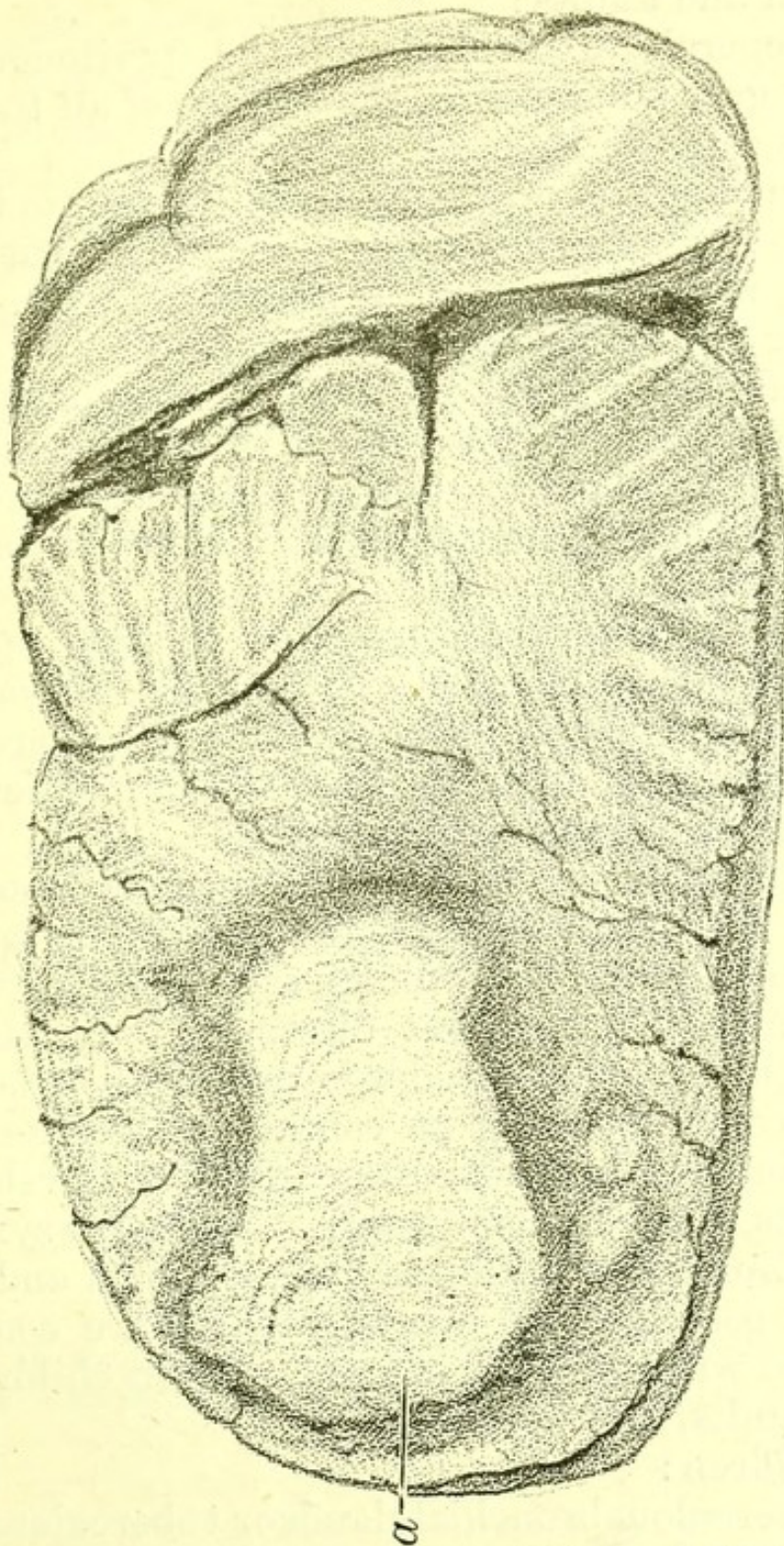
In a few cases a caseous mass is discovered in the brain (in the cerebral hemispheres, or more often in the cerebellum), which may be regarded as the seat of tubercular disease from which the pia mater became infected.

*Chest:* in a child after measles who has died of tubercular meningitis, it is common to find no other morbid condition in the chest than enlarged bronchial glands. Some of these are probably caseous, while others contain tubercle in an earlier stage, either visible to the naked eye or on microscopic examination. The lungs may contain tubercles either scattered throughout them or accumulated into a caseous mass ; or the lungs,



bronchial glands, pleuræ and pericardium may be sown throughout with minute grey tubercles.

FIG. 37.



*Caseous Mass* in the left lobe of the cerebellum.  
a. Caseous mass.

When tubercular meningitis occurs in an adult, pulmonary phthisis with cavities may be present, or the



patient may have died of a general acute tuberculosis.

*Abdomen*: two appearances are common, both in children and adults:

1. General tuberculosis of the peritoneum with minute grey tubercles on the surface of all the organs, and less often in their substance; or,

2. Tuberculosis of the mesenteric glands only. They are often greatly enlarged; some of them may be caseous, while others contain recent tubercle.

Rarer anatomical appearances are—

1. Tubercular disease of the kidney substance;

2. Small tuberculous ulcers of the ileum: they are rare. In the fifty cases of tubercular meningitis in children mentioned above, such ulcers were present in six cases.

*Joints and muscles*: psoas abscess with tubercular disease of the vertebræ; hip-joint disease or tubercular disease of the knee or other joint, are conditions occasionally found in the bodies of patients who have died of tubercular meningitis.

It is usual to regard the oldest manifestation of tubercle as the focus from which the disease spread to the pia mater, and this opinion is justified by the fact that a child with hip-joint disease of long standing, with psoas abscess, with large mesenteric glands, or with a cough pointing to continuous disease in the lung or bronchial glands, often suddenly develops the symptoms of tubercular disease. While the symptoms of preceding tuberculosis may be combined and varied in every possible way, four conditions are commonly associated with tubercular meningitis in children and two in adults, viz.:

In children:

1. Tuberculous bronchial glands or tuberculous lungs;
2. Tuberculous mesenteric glands;
3. Tuberculous disease of a joint;
4. General acute tuberculosis affecting all the serous membranes and viscera in rapid succession.



And in adults :

1. Chronic tuberculous disease of the lungs with cavities ;

2. General acute tuberculosis.

The following is a table of all the cases of tubercular meningitis in persons over twenty years of age, examined by me at St. Bartholomew's Hospital (January 1879-June 1887). It illustrates the fact that in adults, as in children, tubercle of the pia mater is generally part of a rapidly progressing tuberculosis : though in the adult it may sometimes be a rapid development of what has long been progressing slowly.

*Eleven cases of Tubercular Meningitis in adults.*

Sex.	Age.	Lungs.	Bronchial Glands.	Other Organs affected (except Brain).
F.	20	Disseminated tubercle.	Tuberculous.	All abdominal glands tuberculous. Tuberculous ulcers of intestine.
M.	23	Large cavity in right lung.	Tuberculous.	o
M.	24	Cavity left lung. Right full of recent tubercle.	Tuberculous.	o
M.	25	No tubercle.	Tuberculous.	Cervical glands tuberculous.
M.	25	Disseminated tubercle.	Tuberculous.	All the abdominal and thoracic lymphatic glands, spleen, and kidney tuberculous.
M.	25	Old ragged cavities.	Tuberculous.	Peritoneum, mesenteric glands, and kidney tuberculous.



Sex.	Age.	Lungs.	Bronchial Glands.	Other Organs.
F.	25	Calcified tubercle in both lungs.	No tubercle.	One supra-renal body tuberculous.
M.	27	Disseminated tubercle in both.	Tuberculous.	Pericardium tuberculous.
M.	28	Cavity in right lung. Disseminated tubercle in left lung.	No tubercle observed	Tuberculous ulcers in intestine.
M.	36	Old cavity at left apex. Disseminated tubercle in right lung.	No tubercle observed.	Tubercles on surface of liver.
M.	40	Disseminated tubercle in both.	No tubercle observed.	o

Since tubercle is a product not easily (if at all) absorbed, and since old calcareous masses due to tubercle are very rare in the pia mater, the post-mortem evidence leads to the belief that tubercle in the pia mater is invariably followed by a fatal result.

**Syphilitic Meningitis**, due to the presence of gummata in the meninges, is generally confined to some limited area, is always associated with great thickening, and sometimes with hæmorrhage into the meninges.

**Encephalitis** is an acute general inflammation of the brain, indicated during life by violent delirium, and after death by universal engorgement of the pia mater and the presence of red specks in both white and grey matter. This condition is sometimes to be seen after death due to a drinking bout.



Meningitis with purulent effusion is generally present.

**Spinal meningitis.**—Besides the form of inflammation of the membranes of the spinal cord continuous with cerebral meningitis, inflammation of all the membranes may occur after injury, and inflammation of the pia mater frequently accompanies posterior and lateral sclerosis. It is in these cases best seen in microscopic sections. A slight degree of adhesion of the meninges may be detected on the naked-eye examination of the cord.

Injuries to the vertebral column, erosion due to aneurysm, new growths in the membranes and cord, and the suppuration of Pott's disease are all associated with local spinal meningitis.

**Myelitis.**—The most characteristic post-mortem appearance, and sometimes the only one present, is extreme softness of the spinal cord. Microscopic sections show fat granules in the substance of the cord. Some of the ganglion cells are granular, and the axis cylinders of the nerve fibres are of swollen appearance.

**Anterior Polio-myelitis.**—The nerve fibres of the anterior horns of the grey matter, on one or both sides, are atrophied, and the large multipolar cells are absent in part of the cord.

The paralysed muscles contain many fibres in a state of fatty degeneration and show some increase of fibrous tissue. The bones of the limb may also be imperfectly grown or wasted.

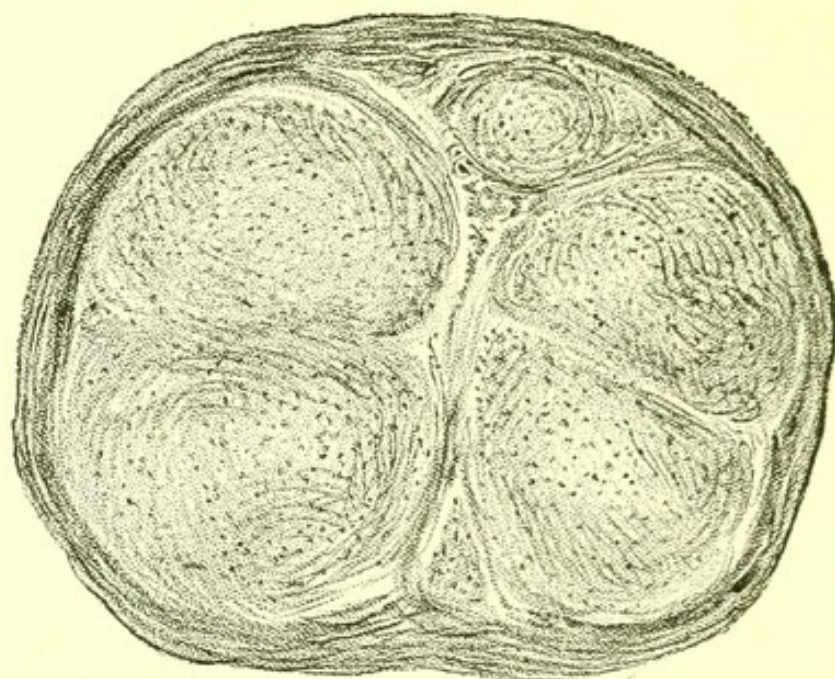
**Neuritis.**—Alcoholic neuritis is the commonest form. It was present in a woman, aged thirty-one years, whom I examined post-mortem. The body was greatly emaciated. Fatty infiltration of the liver was present. The kidneys were normal. The nerves showed fibrous increase and all stages of atrophy of nerve fibres. The nerve endings were degenerate, and the muscular fibres of the tibialis anticus were atrophied.

**Abscess of the brain** may be multiple and due to the active emboli of pyæmia. It may also be due to disease of the calvaria.



It is most often found in the cerebellum or on the posterior cerebral lobe, and it occurs in these regions as a sequence of necrosis of the temporal bone following ear disease.

FIG. 38.



*Microscopic Section of a Nerve.* From a case of *peripheral neuritis*, showing general increase of connective tissue.

It may have reached the surface, in which case general meningitis will be present, or it may be in the brain-substance and only be discovered on making sections. Out of ten cases of abscess of the brain which I examined at St. Bartholomew's Hospital (1879-1886), eight were associated with necrosis of some part of the bony wall of the auditory cavity, and the other two were associated with necrosis of the frontal bone. In four the abscess was in the cerebellum, in one there was one abscess in the cerebellum and another in the posterior cerebral lobe. In the rest the abscess was in the cerebral hemisphere, at the part contiguous to the necrosed bone.

**Softening** is a condition of imperfect or completely defective nutrition of brain-substance, of which the slightest degree is called red softening, the next



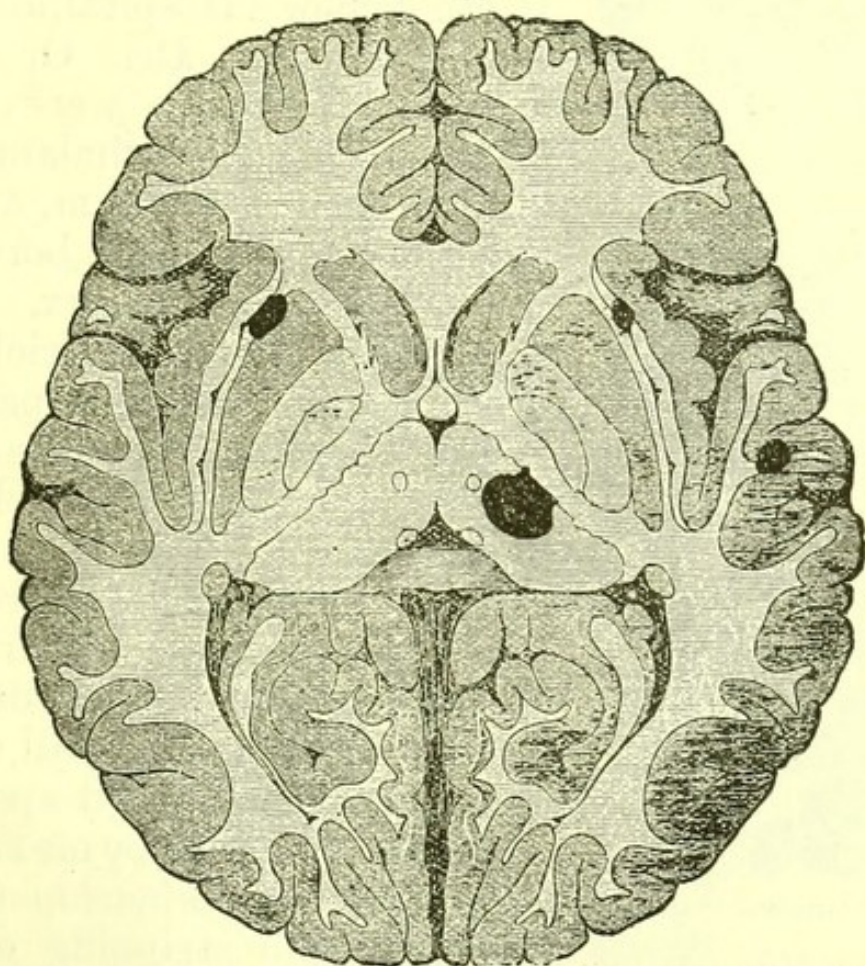
white softening, and the most complete yellow softening.

The colour is of course due to present or absent or altered blood, and under the microscope granular matter and altered blood cells are seen.

Degenerate vessels, or vessels occluded by thrombus or embolus are to be found near a softened patch.

**Sclerosis.**—The term sclerosis is applied to any hardening of the brain or spinal cord which is due to an increase of the neuroglia, followed by subsequent contraction of the fresh tissue with atrophy of the

FIG. 39.



*Horizontal Section: Brain of Disseminated Sclerosis, from an adult. (Cord, Fig. 40.)*

nerve elements. It is usual to speak of the changes as if they took place in this order, by analogy from the process in cirrhosis of the liver, but it should be remembered that in some cases it is at least as probable that the changes in the nervous tissues begin

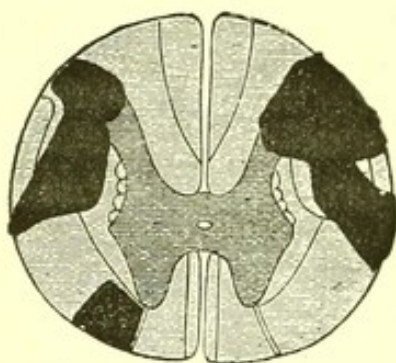


the disease and that the increase of the neuroglia follows them.

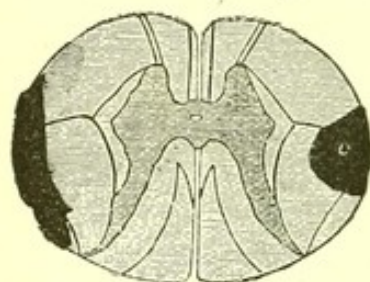
The varieties of sclerosis, so far as is at present known, differ in distribution, not in pathological nature.

**Disseminated sclerosis.**—Under which term

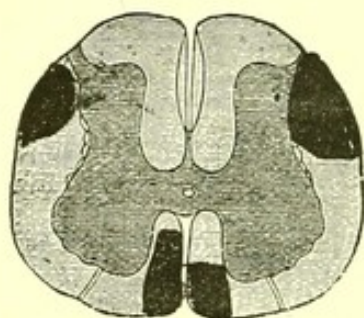
FIG. 40.



Mid-cervical region.



Lower dorsal region.



Upper lumbar region.

*Horizontal Section.*  
Spinal Cord of Disseminated Sclerosis. (From diagrams made by Dr. Ormerod.) The dark patches represent the areas of sclerosis.

insular, diffuse and miliary sclerosis may for general purposes be included, consists in the distribution of sclerosed patches in the brain and cord.

In a man who died in St. Bartholomew's Hospital, and was examined by Dr. Ormerod, patches of sclerosis were found in the right optic thalamus, in the left corpus striatum, and in two situations on the border of the left cerebral cortex. The floor of the fourth ventricle and of the iter showed other patches.

The diagrams show the situations of the patches of sclerosis in the cord. They were most marked in the cervical region. The kidneys were suppurating, the ureters and bladder dilated. The left lung had a small tuberculous cavity at its left apex.

A child examined by me showed still wider dissemination of the sclerosis. On stripping off the pia mater, altered patches were visible on the cortical grey matter. They had well-defined edges, and were denser than the normal brain substance.

When recent, patches of this kind are of a pinkish colour, and their density is not very distinct; when old

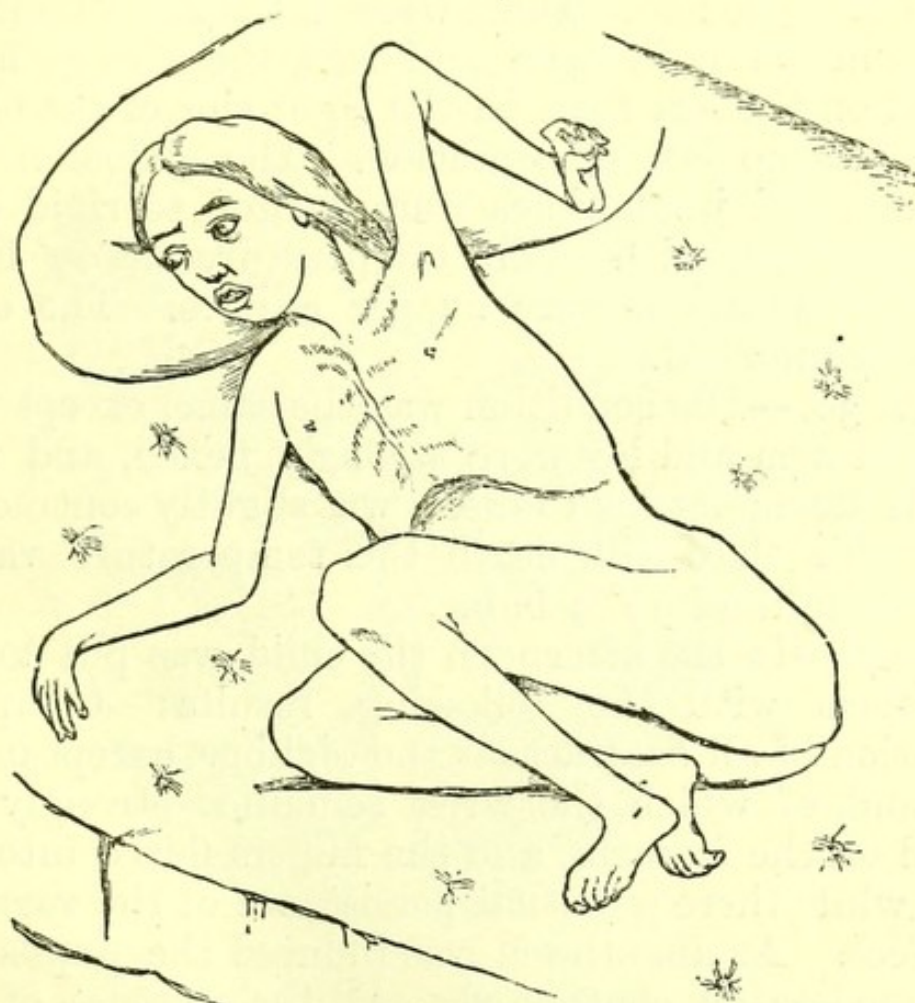

they are yellowish and distinctly tough. These are the appearances found after death, when tremulousness of the limbs and lips and nystagmus were present during life in an adult.

Precisely similar appearances are found in children with athetosis, as in the following example, in which Fig. 41 represents the appearance of the face and limbs during life.

The girl, a patient under care of Dr. Gee, in St.

FIG. 41.



*Child with Disseminated Sclerosis.*

Bartholomew's Hospital, was said to have been healthy till about the middle of March 1879. She died at the end of June in that year.

The first sign of illness was a causeless fall. Twitchings of limbs and face followed a second fall. A few days later she had loss of power in her left arm and leg. Ten days later she became speechless and lost



power in her right arm and leg. Five weeks after the illness began, her left arm and leg began to appear contracted.

In April 1879, six weeks from the beginning of her illness, there was rigid flexion of all the joints of the left arm and leg, except that there was hyper-extension of the carpus and metacarpus on the forearm, with marked flexion of the phalanges.

All the joints of the finger and thumb of the right hand were flexed, but the rest of the right arm showed no abnormal flexion. There were occasional convulsive movements of both arms and legs, these were more marked on the left than on the right side of the body. There was no loss of sensation. The abdomen was retracted, and its muscles were excited to rigid contraction by palpation. The temperature was  $99^{\circ}$  Fah., and the respirations were 24 per minute. The optic discs were normal.

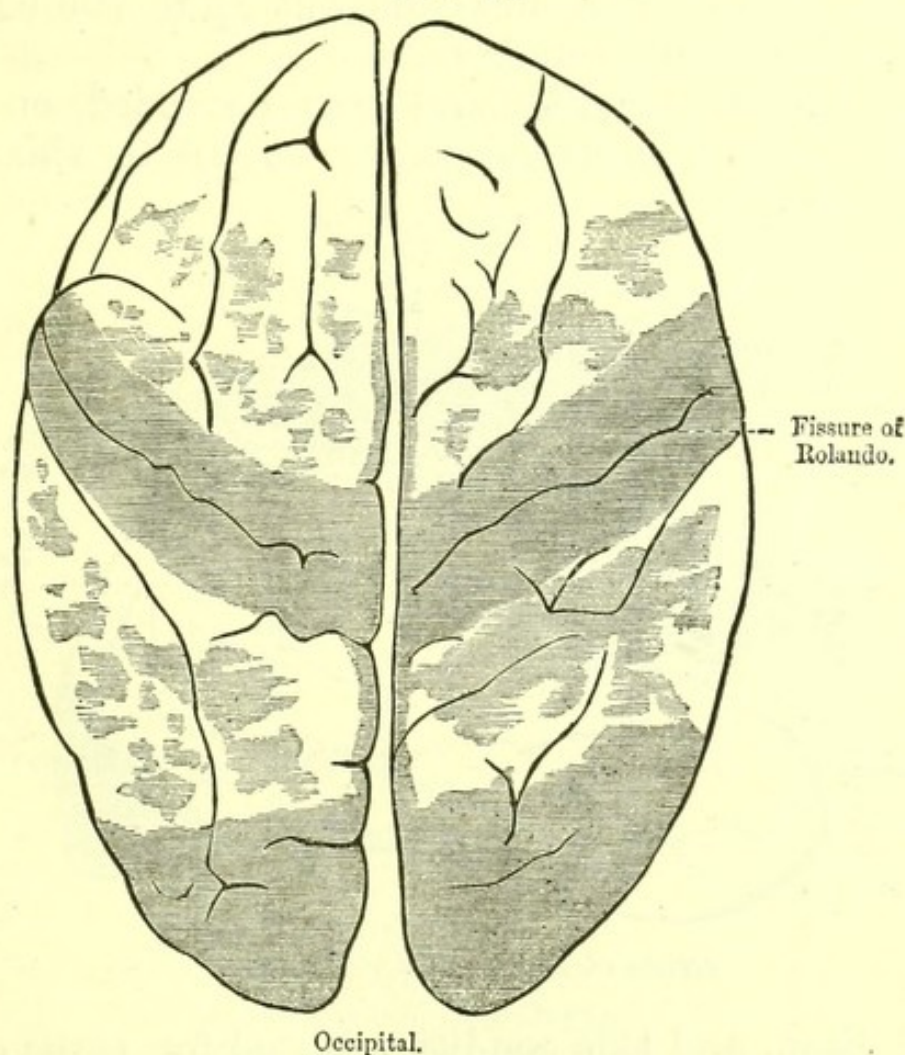
April 30.—The condition was the same, except that the right arm and leg were strongly flexed, and that the left sterno-mastoid muscle was slightly contracted. From this date till death the temperature varied between  $99^{\circ}$  and  $99^{\circ}.4$  Fah.

May 7.—In the afternoon the child was put under chloroform with the following results:—Complete relaxation of all contraction and rigidity, except in the left hand, of which the wrist remained strongly extended on the forearm, and the fingers flexed into the palm, while there was some persistence of the varus of both feet. As anæsthesia was induced the pupils became moderately contracted. All the muscles of the limbs responded readily to faradization of moderate intensity. Faradization of the muscles of the left leg was accompanied by slight movements of pronation of the left hand, with some further extension of that wrist on the forearm. Similar results were not produced by faradization of the right leg or arm. The previous position and posture were resumed as the effect of the chloroform passed off.



May 14.—On this day, at 1 A.M., the child had a fit of epileptic character, lasting for about ten minutes. Her face was drawn to the right, and there were twitchings of the facial muscles on that side. The eye-balls were rolled upwards, the right arm and leg were straightened, but the limbs of the left side remained contracted as usual. The fit was followed by a great

FIG. 42.



UPPER SURFACE OF BRAIN.

*Disseminated Sclerosis, in a child aged five years.*

deal of loud screaming. At 9 A.M. the condition and posture were as they had been before the fit.

May 20.—The child had a similar fit, lasting about twenty minutes, during the night; the tongue was protruded, and after the fit all the limbs appeared more rigid for a while, but by morning had resumed their usual position.



May 23.—Yesterday evening both legs were extended for some time, but in the morning were found flexed in their usual position.

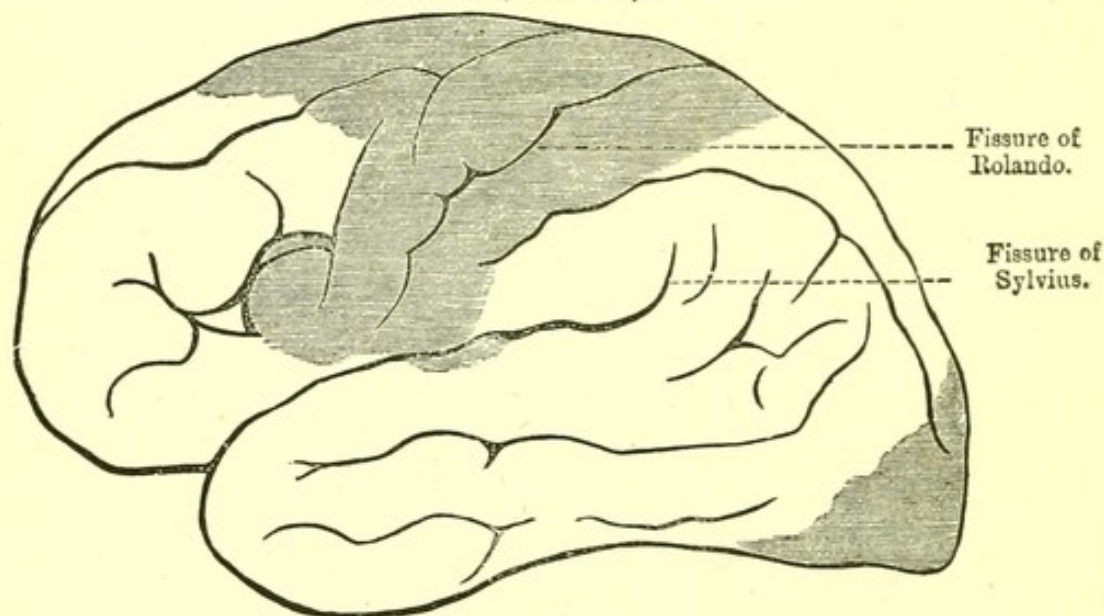
May 31.—On being lifted out of bed the child stretched out its legs quite straight, and arched its trunk strongly backwards three times, each opisthotonic spasm lasting for about three seconds.

June 6.—Some boils appeared this day on the abdomen, and similar ones came out up to the day of death in increasing numbers.

June 7.—The right hand was extended on the forearm, instead of being flexed, as up to this date

FIG. 43.

LEFT SIDE (outer view).



*Brain of same child as Fig. 42.*

it had been, and this condition lasted for three days, when the previous position was resumed. The child would hardly take food, and was weaker and thinner.

June 12.—The legs appeared to possess an equal degree of sensation; the left arm possessed sensation, but below the elbow the right arm did not, and there seemed to be no sensation on the right side of the neck. From this date the child emaciated very rapidly, and the spastic rigidity of the limbs seemed gradually relaxing as from mere weakness.



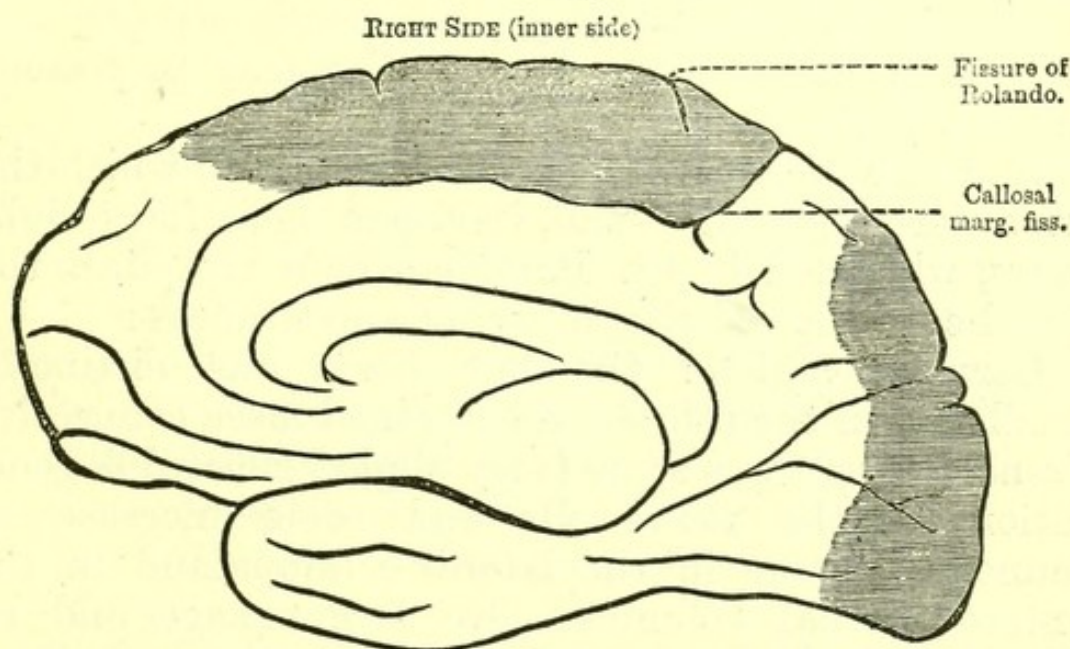
June 24.—The child died at 4.15 A.M., without any convulsions.

While in the hospital the child was never heard to speak, and gave no evidence of being able to see.

I examined the child post-mortem, with the following results.

*Brain*: meninges, normal; convolutions of cerebral hemispheres somewhat flattened. Ventricles containing a much larger quantity of clear fluid than normal. The cortical part of the brain was so soft that it was not possible to remove the arachnoid without tearing the brain substance. The grey matter was altered, and

FIG. 43.



*Brain*, from a case of Disseminated Sclerosis in a child.  
The shaded patches represent the Sclerosis.

of a distinct yellow in several places. This change in some places affected the whole thickness of the grey matter, in others only a superficial layer was yellow and soft, while the grey matter immediately resting on the white was of normal appearance. The size and proportions of every part of the brain were normal, and the white matter, both to the naked eye and under the microscope, was free from morbid change.

The vessels of the base, the origins of the nerves,



the medulla oblongata, and the spinal cord were in every way normal. The white matter of the brain under the microscope showed no morbid change. Microscopic sections of the abnormal cortical substance showed a great increase in the neuroglia and diminution in the number of nerve-cells. Some of the cells looked shrunken and smaller than natural. The increase of connective tissue was great and unmistakable.

The sclerosis was most complete in the fronto-parietal, frontal, and occipital regions.

**Sclerosis of the Anterior Cornua of Grey Matter** (Progressive muscular atrophy).—An increase of connective tissue about the anterior cornua of grey matter is present and the multipolar cells are atrophied.

The wasted muscles may show merely atrophy and anæmia, or actual fatty degeneration may be present in some of the fibres.

In a case of general muscular atrophy in which the arms were especially small, in a man aged forty-eight years, who died in St. Bartholomew's Hospital, the spinal cord showed the following appearances :

Cervical region: the left horn was distinctly smaller than the other and contained more connective tissue. There was some (very slight) general degeneration of the nerve-cells and some increase of connective tissue in the lateral columns and in the antero-internal columns. No hæmorrhage and no thickening of blood-vessels. The corpora amylacea were not very distinct.

Lumbar region: corpora amylacea abundant and distinct; vessels dilated.

The central canal was absent and its position was marked by a stratum of small cubical cells.

**Sclerosis of the Lateral Columns.**—It is probable that this condition rarely occurs without the presence of sclerosis in other regions.

**Sclerosis of Posterior Columns** (Locomotor ataxy).—The posterior, and generally the postero-lateral, columns exhibit sclerosis, and the posterior nerve



roots are diminished in size. Some adhesion of the pia mater is generally present with a zone of cell infiltration beneath it.

The sclerosis does not always extend along the whole cord.

Degenerative changes with bony outgrowths occur in the joints.

Perforating ulcer of the foot is common.

Scars due to gummata may be found in the liver or spleen.

**Cyst:** Besides hydatid, which is very rare, two forms of cyst are found in the brain :

1. Cyst due to an old hæmorrhage, recognizable by the presence of blood crystals within it.
2. Cyst due to imperfect development from the original cerebral vesicles.

These last are commonest in the cerebellum and posterior part of the cerebral hemispheres.

**Cerebral Tumours.**—The dura mater is an occasional seat of sarcoma, and this may be present in large quantity without spreading to the brain.

The commonest tumour of the brain substance is **gumma**, the characters of which do not differ from those it presents in other organs (see p. 84). A gumma frequently causes softening by pressing upon an artery.

Gummata in the cortex are sometimes found in cases of hemiplegia, and are discovered to have been followed by descending degenerative changes.

**Glioma**, next to gumma, the commonest cerebral tumour, has rarely a well-defined margin. It is commonly of a pinkish colour, has never become caseous, but sometimes breaks down easily when touched, or is found to have already broken down in the middle. It belongs to the class sarcoma.

Secondary sarcomatous masses are sometimes found in the brain in cases of widespread sarcoma.

In a case of primary spindle-celled sarcoma of the



thyroid gland, similar masses were found in the brain.

In 60 cases of new growth in different parts of the body, in all of which the brain was examined, I found new growth there in only the four cases given in the following table :—

*Secondary New Growths in Brain.*

Sex.	Age.	Situation of Primary Growth.	Nature of Growth.
M.	27	Right lung . .	Carcinoma.
M.	52	Right lung . .	Sarcoma.
M.	47	Right eye . .	Melanotic sarcoma.
F.	53	Left breast . .	Carcinoma.

**Carcinoma** is rare in the brain. In a woman who died two years after the removal of a carcinoma of the breast, I found several masses of carcinoma of the brain. During life she had loss of power in both legs. There were no masses of new growth in her spinal cord.

Old caseous and calcareous masses found in the brain, and especially the cerebellum, are commonly described as degenerate masses of tuberculous origin. Some are undoubtedly so, as they have been followed by tubercular meningitis. (Fig. 44.)

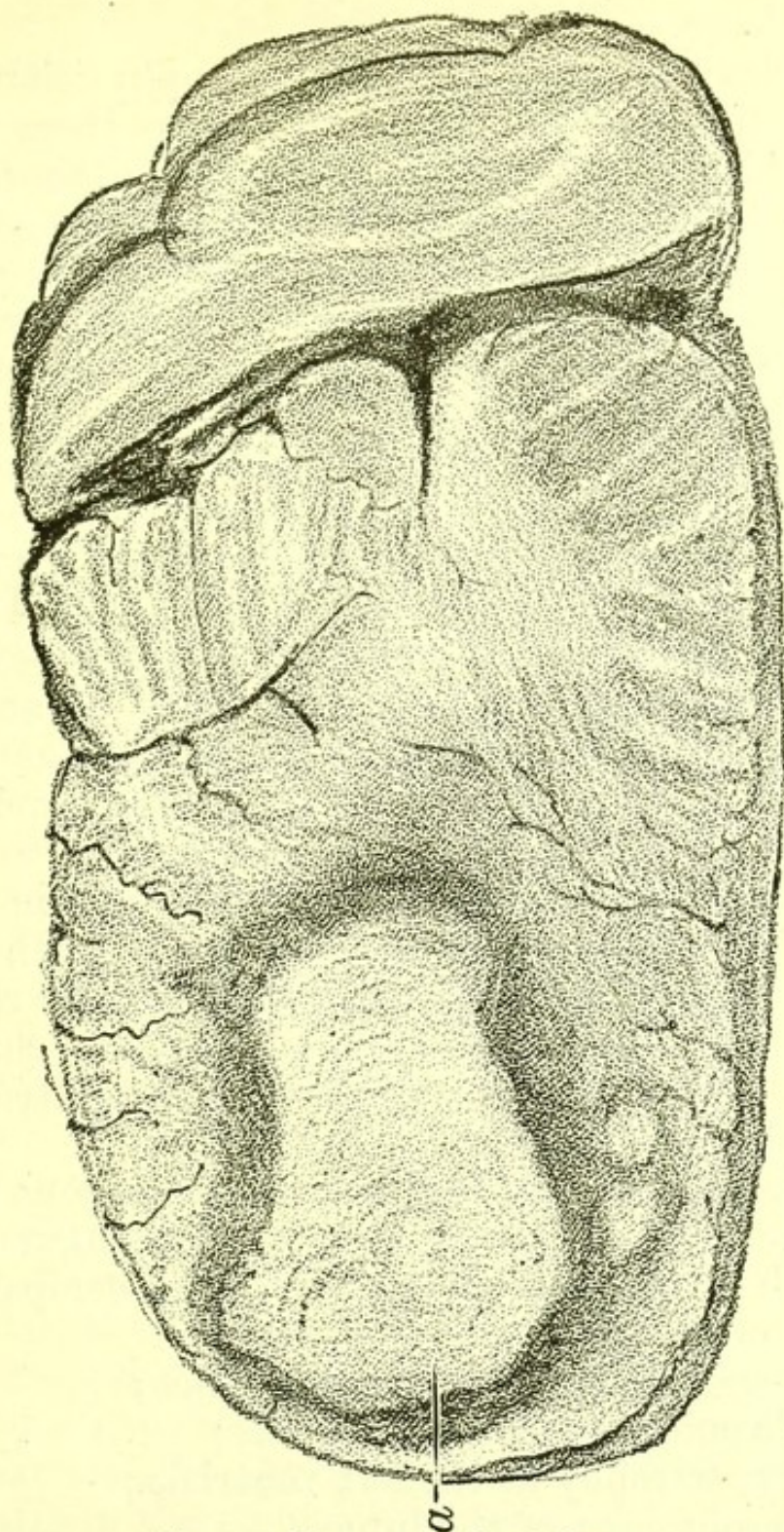
**Syphilitic Disease of the Brain.**—The chief morbid changes are chronic arteritis, with great thickening, gummata in the brain substance or in the meninges, and the results of these, viz. :

1. Aneurysms ;
2. Softening ;
3. Hæmorrhage ;
4. Pachymeningitis.

**Parasites of the Brain**, common in sheep and other animals, are very rare in man, but hydatid cyst sometimes occurs in the human brain.



FIG. 44.

*Caseous Tumour in Cerebellum.*

**Apoplexy.**—When a man falls to the ground as if struck down by an unseen blow, and when raised is found to be insensible, incapable of movement, and breathing stertorously, he is said to have apoplexy. Dr. J. J. Wepfer, of Schaffhausen, was the first to



point out that this condition is often due to cerebral hæmorrhage.

Apoplexy as used by the Greek physicians was a purely clinical term. It conveyed to them no anatomical idea. Since the time of Wepfer (1620-95) it has come to be used as a name for cerebral hæmorrhage, its commonest cause; and so closely has it been associated with effusion of blood that a variety of hæmorrhage into the lung has, by many medical writers, been termed *pulmonary apoplexy*.

This use of the word leads to confusion and ought to be avoided. A man may be said to die of apoplexy who falls down in a fit, shows some signs of paralysis, dies without recovering consciousness, and is not examined post-mortem. If the body is examined post-mortem, the cause of death may be accurately ascertained and should then be stated as *cerebral hæmorrhage*, or as hæmorrhage into such and such a part of the brain.

Death from apoplexy—that is, death without recovery of consciousness, as distinct from death after a longer or shorter period of paralysis—may be related to several anatomical conditions, of which the chief are:

1. A great extent of brain tissue destroyed by hæmorrhage;
2. Hæmorrhage destroying most of the pons Varolii;
3. Hæmorrhage into the medulla oblongata.

Death from apoplexy is generally accompanied by the following anatomical appearances:

1. Degeneration of cerebral arteries;
2. Chronic interstitial nephritis;
3. Hypertrophy of the left ventricle;
4. Emphysema of the lungs.
5. Degeneration of some of the articular cartilages.

The following are examples of the post-mortem appearances in cases of apoplexy:

I. A man, aged forty-one years, who became suddenly comatose while travelling in an omnibus. He never recovered the least consciousness. Both



pupils were extremely contracted. His temperature rose to  $107^{\circ}$  before he died. He died on the day after the seizure.

Post-mortem: *Brain*: Upper surface without any sign of disease. Some hæmorrhage was found under the arachnoid on the under surface of both occipital lobes, and the pons Varolii, instead of being firm, was flattened and bag-like. There was a hæmorrhage of the size of a pea in the posterior part of the occipital lobe of the left cerebral hemisphere. It was a small, soft, dark clot. The whole centre of the pons Varolii was ploughed up by a large hæmorrhage, which extended downwards almost to the surface, upwards to close to the iter (which was, however, intact); backwards into the fourth ventricle, which was occupied by a clot, and forwards into the beginning of each crus cerebri, and on the right side just into the innermost part of the optic thalamus. The medulla oblongata was healthy.

The arteries of the circle of Willis were highly atheromatous.

*Heart*: Weight,  $15\frac{1}{4}$  oz.; valves and pericardium normal.

*Aorta*: Slightly atheromatous.

*Lungs*: Emphysematous.

*Kidneys*: In an advanced stage of chronic interstitial nephritis.

II. A man, aged fifty-one years, who died on the fourth day after the attack of apoplexy.

Post-mortem: *Brain*: The left lateral ventricle contained a large clot, and there was also blood in the third ventricle, in the iter, in the fourth ventricle, and a little in the right lateral ventricle.

In the anterior part of the roof of the left lateral ventricle there was a rent from which the hæmorrhage seemed to have proceeded.

An aneurysm as large as a split pea was found at the anterior origin of the left posterior communicating artery, but it was entire, and there was no effusion of



blood at the base of the brain. The remainder of the brain substance was normal.

*Heart*: Weight, 18 oz.; hypertrophy most obvious in the left ventricle; valves and pericardium normal.

*Lungs*: Emphysematous.

*Kidneys*: In an advanced stage of chronic interstitial nephritis.

III. A man, aged fifty-six years, who died the day after his apoplectic fit.

Post-mortem: *Brain*: In the posterior third of the corpus callosum was a rent occupied by a clot, and each lateral ventricle contained a clot.

The hæmorrhage had begun in the outer and posterior part of the optic thalamus, in which there was a rent, and had extended upwards into the posterior part of the cerebral hemisphere and into the corpus callosum. In the right corpus striatum, within the inner capsule, was a small and evidently old cavity containing a shrunken clot.

Arteries of the circle of Willis highly atheromatous.

*Heart*: Slightly hypertrophied; valves and pericardium normal.

*Aorta*: Very slightly atheromatous.

*Lungs*: Emphysematous.

*Kidneys*: In an advanced stage of chronic interstitial nephritis.

There was a partially healed gastric ulcer at the cardiac end of the stomach, which was adherent to the diaphragm.

**Paralysis.**—A definite morbid change in the brain, cord, or in the nerves supplying the paralyzed region must always be sought in relation to any form of paralysis, and will be found in all cases except a few in which, as in diphtheritic paralysis, the lesion has not yet been clearly isolated.

**Hemiplegia, Left.**—The commonest post-mortem appearance when during life paralysis of the left arm and leg and face has been present, is a hæmorrhage



into the internal capsule. A hæmorrhage of moderate size may here cut across all the fibres coming from the face, arm, and leg centres in the cortex.

Next to hæmorrhage within the internal capsule, the most probable post-mortem appearance in left hemiplegia is embolus of its artery, with consequent softening of the lenticular nucleus.

A third appearance, by no means rare, is hæmorrhage outside the capsule.

Hæmorrhage into the cortex, if extensive enough, may be the anatomical cause of the hemiplegia, or, of course, tumour within the capsule, outside it, or in the cortex.

A hæmorrhage into the pons Varolii may occur with similar effect, but this is a very much rarer cause of hemiplegia.

If before death the arm or leg was rigid, degeneration will be found in the spinal cord, descending through the crus cerebri, pons Varolii, and medulla oblongata.

**Hemiplegia, Right.**—The possible lesions are the same; it is only important to observe that Broca's convolution itself, or the communication with it, will be found injured.

**Paralysis of arm and leg, with facial palsy of the opposite side,** is sometimes called **cross paralysis**. This condition has rarely been elucidated by post-mortem examinations, but the cases on record show that the most probable lesion is a tumour in the pons Varolii.

**Hemiplegia with Double Contracted Pupils.**—The hæmorrhage or tumour will probably be found in the pons Varolii, destroying the centre innervating the fibres of the iris.

**Squint** in its several varieties may be associated with a lesion not demonstrable post-mortem, or with hæmorrhage, embolus, or tumour of the crus cerebri, on either side, with hæmorrhage or new growth in the centres of the oculo-motor nerves, or with pressure on



their external origin by fluid as in tubercular meningitis.

**Ophthalmoplegia Externa.**—A hæmorrhage into the origin of the fourth nerve or a tumour pressing on it are the anatomical changes associated with this lesion.

**Sudden blindness**, when not due to changes within the orbit, may be found post-mortem to have been caused by hæmorrhage into the trunk of the optic nerve or by pressure upon it of tumours or of effusion.

**Bell's Palsy.**—Caries of the aqueductus Fallopii, or hæmorrhage into the origin of the portio dura may be found. In most cases, however, there is only a transitory inflammation of the nerve.

**Glosso-labio-laryngeal paralysis** is closely allied to progressive muscular atrophy.

Degenerative changes and shrinking are found in the roots of the facial and hypoglossal nerves.

The multipolar cells of the medulla have lost their processes and are reduced in size and in number.

**Diphtheritic Paralysis.**—The lesion in this paralysis is at present unknown.

**Lead Palsy.**—Wasting of the muscular fibres with true fatty degeneration in parts may be seen in pieces of muscle removed by the harpoon.

A nerve lesion has not yet been fully demonstrated.

**Pseudo-hypertrophic Paralysis.**—The muscles are large, but contain much fat and many degenerate fibres. They are of a pale pink instead of the proper red hue.

No nerve change has yet been demonstrated.

**Infantile Convulsions.**—After death from infantile convulsions, the brain is often found natural.

Tubercular meningitis, cerebral abscess, or tumour may be present.

A stomach filled with undigested food is often found in those cases in which no lesion is demonstrable in the brain



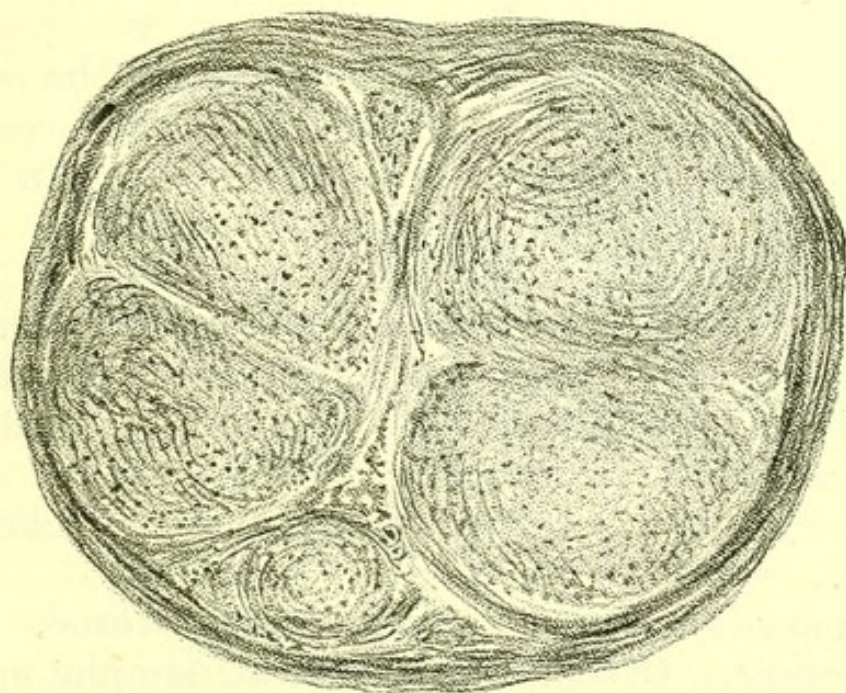
**Laryngismus Stridulus.**—No nerve lesion has been discovered in this disease.

The anatomical appearances of rickets are always present. The disease itself is never fatal, and most of the supposed fatal cases in Dr. Ley's book (1836) are examples in which tubercular meningitis was the cause of death.

**Cramp.**—The morbid anatomy of writer's cramp, wry-neck, stammering, and the other forms of muscular spasm has yet to be discovered.

**Peripheral Neuritis.**—Inflammation of nerve or nerves is a result of pressure, and probably of certain poisons. Degeneration of the axis cylinders and

FIG. 45.



*Magnified Microscopical Section of Nerve, from a case of peripheral neuritis, showing increase of neuroglia.*

increase of neuroglia is found, and sometimes the nerve is flattened and wasted.

**Mercurial Tremor.**—Though this disease was a few years ago common in St. Bartholomew's Hospital and is still occasionally seen there, I have never had the opportunity of examining a patient post-mortem.

Dr. Letulle states that he found a degeneration



(*Brain*, April 1888) of the myeline only of the nerves, the axis cylinders being normal.

**Paralysis Agitans.**—Nothing is yet known of the anatomy of this disease.

**Aphasia.**—In a case in which aphasia has been present, the third left frontal convolution (Broca's convolution), or the fibres leading to it and from it, may be the seat of malnutrition due to embolus, to thrombus, or to hæmorrhage, or it may be the seat of a tumour.

**Neuralgia.**—In every case of prolonged neuralgia the nerves affected should be carefully examined throughout. Sometimes a tumour pressing on the root of the nerve may be found, such as a sarcoma of the dura mater of the cord. More often no demonstrable change will be discovered.

**Menière's Disease.**—Suppuration of the semicircular canals and also of the mastoid cells is present.

I have only seen one case post-mortem in which during life auditory vertigo was observed. There was pus in the mastoid cells.

**Megrim.**—The morbid anatomy is unknown.

**Tetanus.**—The morbid anatomy is unknown.

**Tetany.**—The hands post-mortem are clenched with the thumb inside the fingers.

Beads on the ribs or other signs of rickets are present.

The nerve lesion is at present undiscovered.

**Epilepsy.**—Of the anatomy of simple epilepsy nothing is known. Scars of injuries to the tongue by bites and to the body by falls may be looked for. Death rarely occurs in an epileptic fit, and there are no post-mortem appearances which would make it certain that a patient had died of epilepsy.

**Cervical Opisthotonos.**—A condition of cervical opisthotonos in children lasting for a variable period is explained post-mortem by the discovery of lymph in considerable quantity about the medulla oblongata and pons Varolii, but without signs of inflammation in the



fore-part of the base of the brain. A more general and acute meningitis may terminate the case, as in a child aged five months, which I saw on September 25, 1880. It then had slight cervical opisthotonos. It had had a fit a week before. It sucked well, and seemed no worse till October 8th, when it had several fits, the opisthotonos increased, and it died. Its temperature was at first just above normal, but rose to  $101^{\circ}.2$  three days before death and the night before was  $103^{\circ}.4$ .

Post-mortem I found the lining of the cerebral ventricles universally injected and the ventricles much dilated.

Both ventricles were distended with pus, an ounce and a half in each. The central canal of the cord contained pus, and so did the subarachnoid space. There was recent lymph around the roots of the nerves from the back part of the optic chiasma to the medulla oblongata, where it was thickest. No tubercle was found in the brain or on pia mater or in the body.

**Chorea.**—Emboli have been described by some observers as abundant in the pons Varolii in fatal cases of chorea.

Small growths on the mitral valve are certainly common, and might be a source of embolus, but my own observation does not enable me to support the view that chorea is due to showers of emboli arrested in the vessels of the pons.

**Hysteria.**—Now and then a patient, supposed to be hysterical, to every one's astonishment dies in a fit. I have seen two such cases in young women. One was an example of cerebral tumour, the other of hæmorrhage into the spinal cord and medulla oblongata.

The warning derived from the post-mortem room is that no case should be assumed to be one of hysteria, till after repeated and full physical examination, of which an examination of the optic discs is an essential part.



**Hystero-epilepsy.**—In a few cases of this kind, ovarian disease has been discovered post-mortem.

**Mental Diseases.**—The anatomical changes associated with the several forms of insanity have yet to be discovered.

Tubercle of the lungs, or lobar pneumonia, is frequently the actual cause of death in a case of insanity.

When I asked a distinguished authority what was the most frequent morbid appearance after death from insanity, he replied: "A little softening or a cavity at the apex of one lung."



## CHAPTER XI.

DISEASES OF THE EYE, EAR,  
AND NOSE.

## EYE :

ECCHYMOSIS.

TUBERCLE OF CHOROID.

IN CHRONIC NEPHRITIS.

DESTRUCTION OF GLOBES.

XANTHELASMA PALPE-

BRARUM.

TOPHI.

## EAR :

TOPHI.

## POLYPUS.

PERFORATION OF  
TYMPANUM.NECROSIS OF AQUE-  
DUCTUS FALLOPII.SUPPURATION IN  
MASTOID CELLS.

## NOSE :

NECROSIS OF NASAL  
BONES.

IN a book on general pathology as illustrated in the medical wards of a hospital, a full description of diseases of the eye, ear, and nose would be out of place, and this chapter contains an account of only those morbid appearances in the eye, ear, and nose which are frequently found in association with general diseases.

**Eye.**—*Ecchymosis* is sometimes noticed post-mortem in the eyes of children who have died from whooping-cough, and in the eyes of adults who have died of cerebral hæmorrhage.

*Opacity of the cornea* is to be looked for in children who have died of long-continued tuberculous disease or of congenital syphilis.

*Irregularity of the pupil*, with adhesion, may be seen after death as a result of syphilitic or of rheumatic iritis.

*Tubercle of the choroid* is not infrequently present as a part of general tuberculosis, with tubercular meningitis.



Secondary growths in the viscera following melanotic sarcoma, originating in the choroid and removed by operation, are to be seen in medical post-mortems.

*Chronic Interstitial Nephritis*.—Some cell infiltration and thickening of the vessels of the retina may be observed under the microscope ;

Or white patches of effusion may be visible post-mortem, as they are during life in this disease, or in *chronic parenchymatous nephritis*.

Flame-shaped hæmorrhages may also be discovered.

In cases of sarcoma of the skull in children, it is not uncommon when the orbital plate is affected for there to be destruction of one or both globes due to pressure of the new growth.

*Parasites*.—*Tænia echinococcus* is sometimes found in the aqueous humour.

**Eyelids** : a small yellowish tumour, xanthelasma palpebrarum, may sometimes be noticed on one or both sides of the face, or on an eyelid.

Tophi are very rarely discovered on the cartilages of the eyelids in cases of gout.

Lice may be observed adhering to the eyelashes.

**Ear** : *Tophi*.—Small collections of urate of soda in the cartilage of the external ear are to be carefully looked for. They are present in some cases of gout. Whenever they are present, a deposit of urate of soda and degenerative changes will be found in one or more joints.

*Polypus*.—Small growths consisting of connective tissue with an external layer of epithelial cells are sometimes found in the external auditory meatus.

*Perforation of the Tympanum*.—Perforation will sometimes be discovered and is often associated with the presence of pus in the middle or internal ear.

Post-mortem experience leads to the opinion that every discharge from the ear associated with perforation of the tympanum is to be regarded as a serious disease and may terminate fatally.

Abscess of the middle and internal ear is a common



sequel of scarlet fever. It is often followed by necrosis of the auditory ossicles and of some part of the walls of the aural cavity, and these by abscess of the cerebellum or of the middle cerebral lobe.

When facial palsy has followed a discharge from the ear, which is the common condition of occurrence of facial palsy in children, some necrosis about the aqueductus Fallopii is generally found post-mortem.

*Suppuration in the mastoid cells* is found in some cases of thrombosis of the lateral sinus, sometimes in cases of abscess of the middle ear, and with disease of the semicircular canals in Menière's disease. This last is a condition very rarely verified post-mortem.

**Nose.**—In all cases of facial erysipelas the nasal bones and turbinated bones should be carefully examined, and a small patch of necrosis will frequently be discovered.

The same condition will generally be discovered where the patient has long suffered from ozæna.



## CHAPTER XII.

## HEART.

## PERICARDIUM :

OUTER SURFACE.  
 SARCOMATA.  
 THICKENING.  
 PERICARDITIS.  
 MILK-SPOTS.  
 PASSIVE EFFUSION INTO  
 PERICARDIUM.  
 BLOOD-CLOT IN PERI-  
 CARDIUM.  
 ECCHYMOSES.  
 DRYNESS.  
 TUBERCLE.  
 HYDATID.  
 ENDOTHELIAL NEW  
 GROWTHS.  
 VARIETIES IN STRUC-  
 TURE.

## MUSCULAR TISSUE :

MYOCARDITIS.  
 NEW GROWTHS.  
 SIZE OF THE HEART.  
 HYPERTROPHY.  
 DILATATION.  
 ATROPHY.  
 FATTY DEGENERATION.  
 RUPTURE.

ENDOCARDIUM AND  
VALVES :

GENERAL APPEARANCES.  
 ENDOCARDITIS AND  
 VALVULAR DISEASE.  
 SIMPLE AND ULCERATIVE  
 ENDOCARDITIS.  
 MITRAL INCOMPETENCE.  
 MITRAL STENOSIS.

TRICUSPID STENOSIS.  
 TRICUSPID INCOMPE-  
 TENCE.

AORTIC VALVULAR  
 DISEASE IN GENERAL.  
 AORTIC INCOMPETENCE.  
 AORTIC STENOSIS.  
 PULMONARY VALVULAR  
 DISEASE.

ANEURYSM OF THE  
 HEART.

ANEURYSM OF THE  
 VALVES.

ANATOMICAL APPEAR-  
 ANCES ACCOMPANYING  
 VALVULAR DISEASE.

EMBOLUS.

EFFECTS OF VALVULAR  
 DISEASE ON THE HEART  
 ITSELF.

ANTE-MORTEM AND POST-  
 MORTEM CLOTS.

CHRONIC ENDOCARDITIS.

ENDOCARDIAL CORNS.

ANGINA PECTORIS.

CONGENITAL MALFORMA-  
 TION OF THE HEART.

SYNCOPE.

PALPITATION.

IRREGULAR ACTION OF  
 HEART.

CYANOSIS.

## ARTERIES :

ARTERITIS.

ATHEROMA.

RUPTURE OF AORTA.



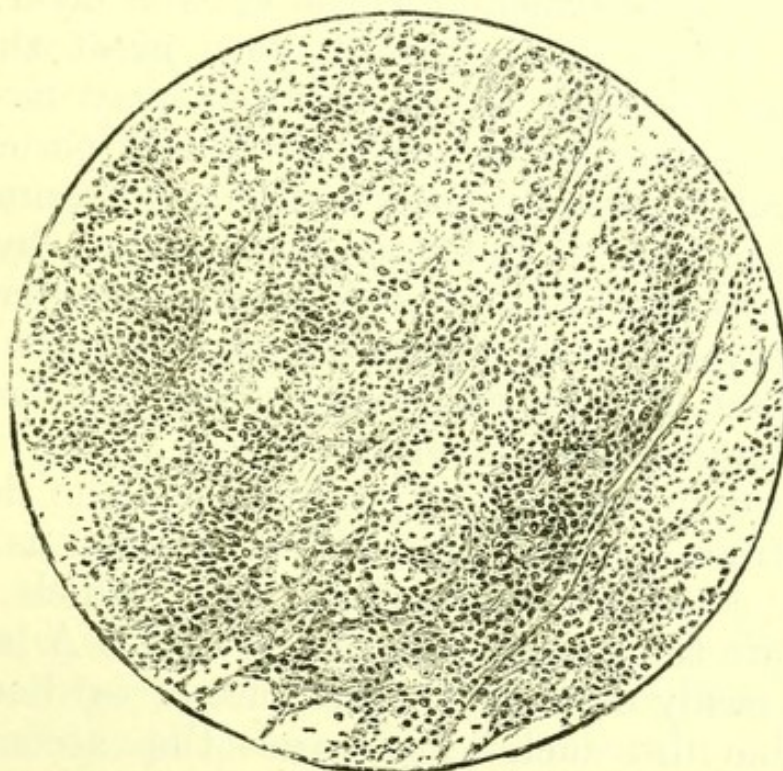
ANEURYSM,  
ANEURYSM OF AORTA.  
OTHER ANEURYSMS.  
CHANGES IN ANEURYSMS  
AFTER TREATMENT.

VEINS :  
PHLEBITIS.  
PHLEGMASIA DOLENS.

### PERICARDIUM.

**Pericardium, outer surface.**—On removing the sternum, the outer surface of the pericardium is visible. It is sometimes adherent to the chest-wall and where retraction of an intercostal space has been observed during life, this adhesion, with a further adhesion of the parietal and visceral surfaces of the pericardial sac, will be found. It is rare, and most apparent retractions of an intercostal space are in reality recessions following the violent impulse of an hypertrophied heart.

FIG. 46.



*Round-celled Sarcoma of anterior mediastinum, involving pericardium and sternum.*

**Sarcomata of Pericardium.**—The small lymphatic glands which lie upon the outer surface of the pericardium are probably the seat of origin of the lympho-



sarcomata which sometimes occupy the anterior mediastinum and are firmly attached to the pericardium. Such sarcomata are whitish and firm, but not intensely hard, and the section has usually the soft, resistant feel of velvet. They are frequently of large size and extend into the neck, involving the cervical glands, and into the pleural cavity, where they sometimes cause a large fluid effusion, by pressing on the root of the lung, and sometimes grow into the lung at the same place. The growth in many cases penetrates the bony tissue of the sternum to such an extent that it is almost replaced by a mass of cells of the sarcoma, and may easily be cut with a knife.

**Thickening.**—The outer wall of the pericardium is sometimes greatly thickened. It may contain calcified pieces or so much fibrous tissue as to cut like cartilage, but both these conditions are rare, so long as it remains unattached to the visceral layer. When the two layers are adherent, very great thickening and large patches of calcification may be present. Such adhesions are one of the results of pericarditis.

**Pericarditis.**—Recently existing inflammation of the pericardium is indicated post-mortem by redness due to injection of the vessels of the inner surface of the sac, by a deposit of lymph with effusion of fluid into the sac, and by easily separable adhesions of the parietal and visceral layers.

The roughened surface produced by the deposit of lymph from the inflammatory exudation is the mechanical cause of the friction sound which indicates during life the presence of pericarditis. A large fluid effusion easily explains the increase of cardiac dulness observable in such cases and the accompanying obscurity of the heart sounds.

Numerous post-mortem observations of cases carefully examined during life will convince the observer that it is sometimes very difficult to distinguish by physical signs between a dilated heart with universally adherent pericardium and a pericardial sac dis-



tended with fluid, and will suggest extreme caution in paracentesis of the pericardium.

Pericarditis seldom occurs as a solitary morbid condition. It is usually a complication of some general acute morbid condition, as of rheumatic fever, scarlet fever, small-pox, or pyæmia; or is itself an acute addition to some general chronic disease, as chronic interstitial nephritis, chronic parenchymatous nephritis, or old valvular disease of the heart; or is an accompaniment of an acute pleurisy.

In rheumatic fever and scarlet fever the effusion is generally copious and contains much lymph. This often forms a uniform ragged covering over the whole heart, to which early morbid anatomists gave the name *cor villosum*. The coat of lymph, instead of being ragged, may be marked by ridges forming a pattern of irregular hexagons; or there may be a finely granular deposit of fibrin, or the lymph may occur in patches and not all over the heart. It is usually more abundant on the visceral than on the parietal surface of the pericardium. When the lymph is stripped off, the pericardium beneath appears to have lost its gloss and shows numerous patches of injection.

In pyæmia the fluid is turbid, irritating to the skin of the observer, and sometimes ill-smelling. There is generally but little deposit of lymph, but in some cases as much lymph may be found as in rheumatic fever.

In chronic interstitial nephritis and chronic parenchymatous nephritis, the effusion is often scanty, and sometimes slightly blood-stained, and it contains long shreds of lymph with patches of very fine granular deposit of lymph here and there, or often in only one spot.

*Results of Pericarditis.*—When organized adhesion has taken place between the two surfaces of the pericardium, great thickening may result and the tissue sometimes attains cartilaginous hardness and sometimes becomes calcified. The heart is often much



dilated, and owes part of its apparent increase in size to dilatation, but on weighing some hypertrophy is usually proved to exist.

**Milk-spots.**—White, thickened, fibrous patches are sometimes found on the visceral pericardium, most commonly over the right ventricle, which are not attributable to any attack of pericarditis.

Much smaller thickenings of the same kind are sometimes visible on the auricles, most often on the appendices.

They look like results of pressure, but it is often difficult to prove that they are so. They are less common on the hearts of children than on those of adults, so that it is improbable that they are congenital. Some of them are probably due to slight local attacks of pericarditis.

**Passive Effusion into the Pericardium.**—In general dropsy a large serous effusion is sometimes found in the pericardium, and a similar effusion is sometimes demonstrated post-mortem to have been due to the pressure of a tumour upon the pericardial veins at the base of the heart. It is also found after death from scurvy.

**Blood-clot in the Pericardium.**—A large blood-clot in the pericardium is usually due to:

1. Rupture of an aneurysm of the arch of the aorta into the pericardium. This most often occurs near the auricles. The aneurysm may be of that part of the arch of the aorta which is within the pericardium, or of the transverse and descending parts when the aneurysm has become adherent to the wall of the sac.

2. Rupture of the heart due to fatty degeneration or to direct injury.

3. Purpura. In this case numerous small ecchymoses will be discovered on the surfaces of the pericardium.

**Ecchymoses.**—In death from purpura, ecchymoses may always be discovered in the pericardium, and they are sometimes found in cases of valvular disease.



**Absence of pericardial moisture**, with a parchment-like condition of pericardium, is found in some cases of death from fever and in death from drinking sulphuric acid in large quantity.

**Tubercle of Pericardium.**—In general tuberculosis a few recent tubercles may often be found in the pericardium. True tuberculous pericarditis with abundant lymph and purulent fluid is a rare condition, but is sometimes discovered, both in children and in adults, as the termination of pulmonary tuberculosis. Some firm adhesions are usually present, indicating that the disease has not a very rapid course.

A layer of caseous material, between the surfaces of the pericardium and covering the whole heart, has occasionally been found.

**Hydatid of the Pericardium.**—In a few rare cases in which during life there were signs of pericardial effusion, a hydatid cyst containing numerous daughter cysts has been found post-mortem in the pericardium.

In a specimen in the St. Bartholomew's Museum, the cyst projects within the pericardial sac from the substance of the heart near the apex.

**New Growths from Endothelium.**—Endothelioma sometimes begins as a primary growth in the pericardium, attains a great thickness and considerable toughness. It extends towards the root of one or both lungs, and grows into the lung.

Microscopically it consists of large flat polygonal nucleated cells with a good deal of connective tissue.

In a case observed in St. Bartholomew's Hospital, secondary growths were found in the lungs, in the left supra-renal body, and in the periosteum of the left clavicle. (Figs. 47, 48, 49.)

Both pericardial and pleural effusion are usually present in such cases.

**Varieties in Structure.**—The method of development of the serous sacs would suggest that the pericardium might sometimes fail to be developed. A



**DIAGRAM I.**  
**Endothelioma in the Pericardium and Heart.**  
**(FIVE CASES.)**

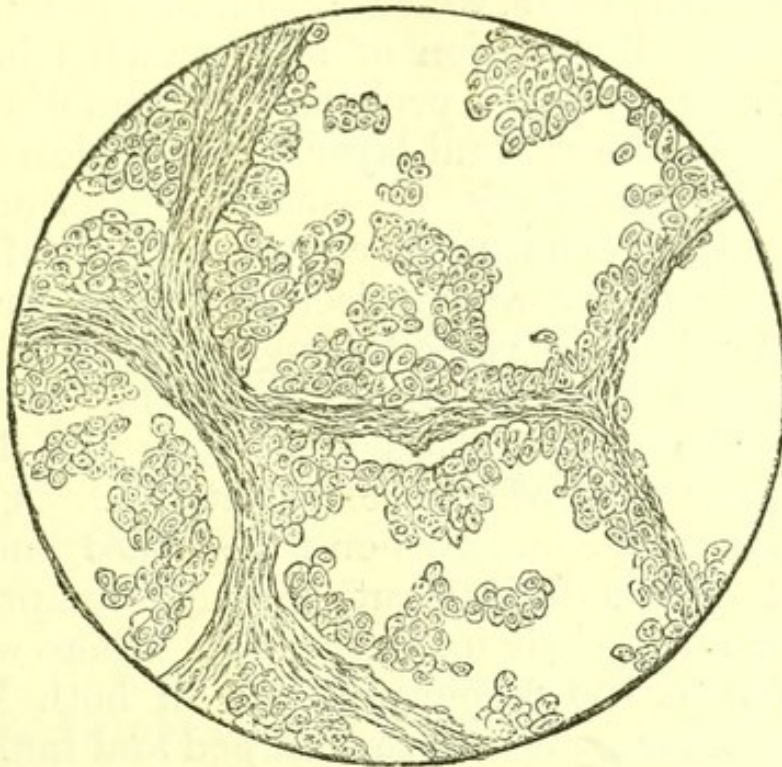
AGE	LYMPHATICS	HEART	LUNGS	THYROID	PERITONEUM	LIVER	PANCREAS	SPLEEN	KIDNEY	ADRENAL	TESTIS	OVARY	UTERUS
37													
41													
XLVI													
LVII													
LXIV													

The black squares indicate the regions of secondary growth. The ages in Arabic figures are those of men, in Roman numerals of women. A microscopic examination was made in each case.



case examined post-mortem by Dr. William Baly shows complete absence of the pericardium. When a part only of the sac is defective it is usually the diaphragmatic surface, and there is at the same time an imperfect development of the midriff, so that the heart rests upon the liver.

FIG. 49.



*Secondary Growth on left Clavicle, from the same case.*

## HEART.

### **Muscular Tissue of the Heart—Myocarditis.—**

In acute pericarditis a dark line may sometimes be observed in the muscular tissue immediately beneath the pericardium, and on microscopic section is seen to be infiltrated with leucocytes showing the presence of a true inflammation of the muscle. A similar condition is less often found beneath the endocardium in acute endocarditis without ulceration, and is of course always present when endocardial ulcers occur on the walls of the heart and before the formation of aneurysm of the heart.

**New Growths.**—Secondary deposits of sarcoma are



not rare in the muscular tissue of the heart, and secondary carcinoma is somewhat rarer.

As a secondary growth after melanotic sarcoma of the eye, numerous masses of dark melanotic sarcoma may be found in all parts of the walls of the heart.

Carcinoma of the heart is sometimes secondary to carcinoma of the œsophagus.

The following cases, which I examined post-mortem, illustrate the distribution of new growths involving the heart. They were probably all endotheliomata originating in the visceral layer of the pericardium :

I. A man, aged forty-one, who died after an illness of five months. The heart contained several masses of a firm whitish growth projecting from the muscular tissue and extending right through it, so as to project both on the endocardial and on the pericardial surface. The largest mass was in the anterior part of the upper wall of the left ventricle. A similar new growth was abundant on the surface and in the substance of the lungs, but did not compress the bronchi or reach their inner surface. There were also masses of it in the diaphragm and in both kidneys, and the lumbar glands were enlarged and infiltrated.

The growth was examined in each situation microscopically, and consisted of abundant polygonal cells in the meshes of a dense stroma.

II. A woman, aged sixty-four, who died after an illness of four months. The heart contained many masses of new growth, and there were some on the parietal as well as on the visceral layer of the pericardium. Nodules of the same new growth existed in the skin, cervical glands, lungs, pleuræ, peritoneum, thoracic and abdominal lymphatic glands, spleen, capsule of liver, and kidneys. Microscopic sections showed that it consisted of polygonal and rounded cells arranged in a dense stroma.

The new growth in both these cases was of less than six months' duration. In both the kidneys as well as the heart contained masses of the new growth.



**Size of the Heart.**—A healthy male heart weighs about ten ounces, and a female heart about nine ounces. The eye should be trained to know the normal relative proportions of the thickness of the walls of the ventricles, and measurements are not valuable for purposes of comparison unless taken with invariable precautions. It is best to determine the bulk of the heart in every case by weighing it after freeing the cavities from clots.

It is important to remember that in putrid bodies the heart is often greatly dilated by gases of putrefaction, and looks large though in no way hypertrophied.

**Hypertrophy.**—When the heart weighs more than natural, one of three sets of conditions will be discovered, viz.:

1. Morbid conditions of the valves ;
2. Adherent pericardium ;
3. Extra-pericardial changes of which the chief are :
  - a. Chronic interstitial nephritis ;
  - β. Emphysema of the lungs.

In emphysema of the lungs, the right ventricle is the part most hypertrophied. In chronic interstitial nephritis the left ventricle is most so, but as emphysema is often a concurrent morbid change, the right ventricle may contribute a little to the increased weight. Precise rules as to the relation of the size of the hypertrophied heart to the degree of increased impulse and of displacement of the apex, cannot be laid down, but it is important to remember that when the apex beat is in the sixth interspace and nipple line the heart is often of double the normal weight. A gigantic heart, the *cor bovinum* of old writers, weighing thirty ounces or more, is always due to one of two causes :

1. Disease of the aortic valves ;
2. Chronic interstitial nephritis.



Incompetence of the mitral valve does not generally increase the weight of the heart beyond sixteen ounces, but in one such case, in which the kidneys were quite free from disease, I found that the heart weighed twenty-two ounces.

In mitral stenosis the weight is not increased unless an adherent pericardium or chronic interstitial nephritis is also present.

When the hypertrophy of the heart seems greater than can be accounted for by the valvular lesion, a minute examination of the kidney will often reveal the presence of chronic interstitial nephritis.

In stenosis of the pulmonary valves, generally a congenital condition, the increase in weight is mainly due to the hypertrophy of the right ventricle. In cases of pericardial adhesions hypertrophy often seems absent, owing to the great accompanying dilatation, but weighing shows that it is in some degree present.

Microscopic examination shows that the additional weight in hypertrophy is due to an increase of well-formed muscular fibres.

Death from syncope sometimes occurs while the muscular tissue of the hypertrophied heart is undegenerate.

If the patient lives, the muscular tissue of every hypertrophied heart sooner or later begins to degenerate, and the degeneration is followed by dilatation.

**Dilatation of the heart** is present,

1. When many of the muscular fibres are in a condition of chronic degeneration.
2. When organized universal adhesion of the pericardium is present.
3. After death from puerperal fever, and less often after death from other fevers.
4. In children after death from whooping-cough.

**Atrophy of the Heart.**—The heart may be of less than its normal weight after death from prolonged wasting disease. This may be observed in cases of



slow growing carcinomata, and less often in chronic pulmonary phthisis. In carcinoma of the stomach in an adult man I have found the heart weigh only seven ounces.

In mitral stenosis the left ventricle often looks smaller than natural, but the whole weight of the heart is rarely diminished.

In cases of chronic interstitial nephritis in which the patient has been ill-fed, wasting of the muscular tissue of the heart is found, and though certainly once hypertrophied it may at the post-mortem weigh less than ten ounces.

In some cases of firmly adherent and greatly thickened pericardium in young children, the growth of the heart appears to have been checked.

**Fatty Degeneration of the Heart.**—Fatty degeneration of the muscular fibres of the heart can only be conclusively demonstrated by microscopic examination. Fat granules are visible within the muscular fibres. This condition may be accompanied by the following naked-eye appearances:

1. Extreme friability of the muscular tissue, which readily breaks down under the pressure of a finger.
2. Paleness of the muscular tissue.
3. A transverse marking with light bands of the musculi papillaries.

The absence of these conditions must not be taken as proof that no fatty degeneration is present, and where it is suspected pieces of muscle from several parts of the heart should always be teased out and examined.

Fatty degeneration is a sequel of all forms of hypertrophy and of dilatation of the heart.

It is also found after death from anæmia, and from purpura hæmorrhagica, and in these cases the whole heart is affected in an extreme degree.

**Rupture of the heart**, apart from injury, never occurs except where there is extensive fatty degeneration. The pericardium is full of blood, and the rup-



ture is generally discovered near the apex of the left ventricle.

**Endocardium and Valves.**—When examining the interior of the heart for pathological changes, it is important to remember that great variety exists in the arrangement of the cords of the valves, but that the termination of the cords in the valves is always in a fine web disappearing on the under surface of the valve. The endocardium of the left auricle is normally more opaque than that of the right. The fossa ovalis is sometimes deep, and sometimes very faintly marked. The foramina Thebesii vary in number and position. The valve of the coronary sinus presents every variety of size, and may be entire or reticulated.

The middle of the base of the septum of the ventricles is always translucent in a normal heart when held up to the light.

It is very common even in young children to find a small opaque patch in that part of the mitral valve which is attached just below the aortic valves.

Small fenestrations are often present in the pulmonary valves, and more rarely in the aortic valves. Their edges are always quite thin, which distinguishes them from openings in the valves due to morbid change. That they do not interfere with the closing of the orifice may easily be proved post-mortem by pouring water into the artery.

**Endocarditis and Valvular Disease.**—Inflammation of the endocardium is commonly acute and very rarely chronic. **Acute endocarditis** is sometimes associated with destruction of part of a valve or of the heart wall, and the formation of an ulcerated surface, bearing micrococci. It is then described as ulcerative endocarditis, a term which indicates a distinct group of clinical phenomena, but which cannot in the post-mortem room be sharply separated from the commoner form of acute endocarditis. In well-marked examples the following distinctions may be made:



*Simple Endocarditis.*

1. Thickening or outgrowth, but no breach of surface is present.
2. No micrococci.
3. Hæmorrhagic infarctions due to emboli are sometimes present in spleen, kidneys or brain, but never break down in the middle.
4. Aneurysms not formed.
5. Spleen frequently of normal size.

*Ulcerative Endocarditis.*

1. A breach of surface of the edge of a valve, or a hole penetrating a valve or a shallow ulcer on the parietal endocardium, is present.
2. Micrococci discoverable in ulcerated surface.
3. Hæmorrhagic infarctions nearly always present in spleen, often in brain or kidneys, and in all places tend to break down in the middle.
4. Aneurysms acutely formed in arteries owing to emboli containing micrococci.
5. Spleen always enlarged and soft.

Bearing in mind these distinctions, ulcerative endocarditis from an anatomical point of view may be described as an extreme form of changes which occur in a less degree in simple endocarditis.

Endocarditis is most often met with as a part of rheumatic fever. Out of 206 cases of rheumatic fever admitted into St. Bartholomew's Hospital in 1885, 128 left the hospital with permanent valvular disease due to endocarditis, while of the remainder a large proportion had some symptoms of endocarditis during their stay in the hospital. Endocarditis sometimes occurs at the end of scarlet fever, and has been described in cases of small-pox and of pyæmia. It may be suspected that the endocarditis found to

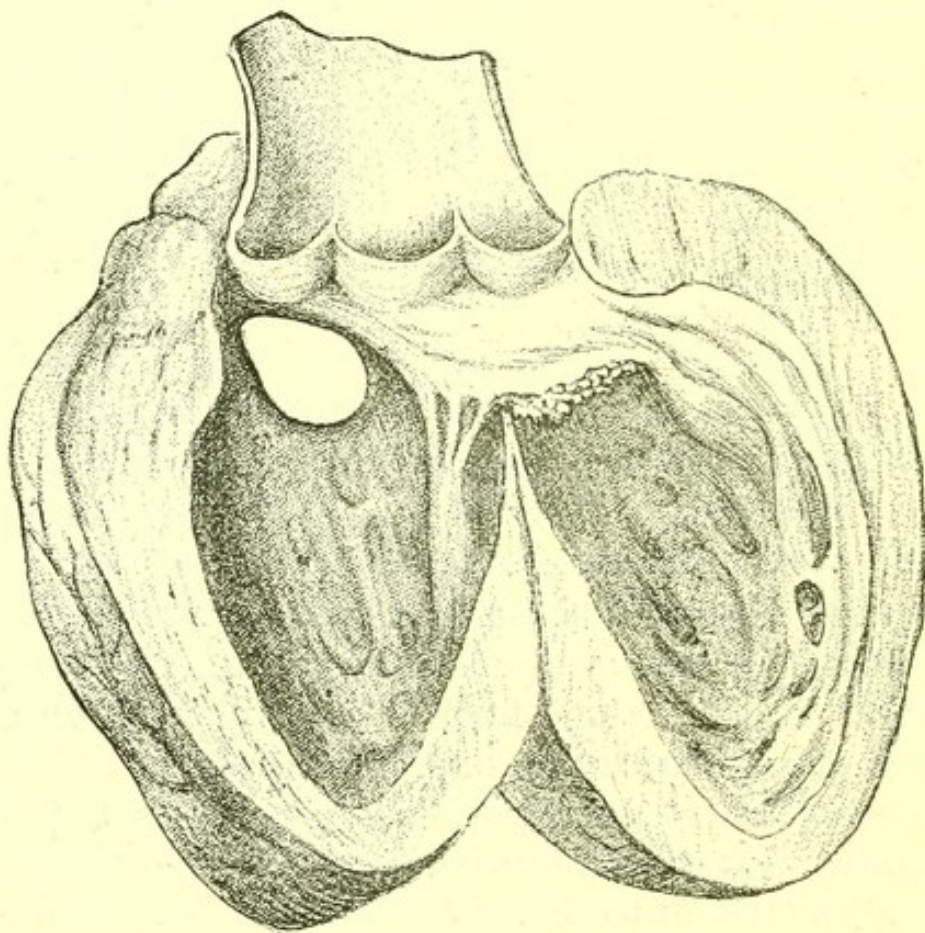


accompany swollen joints after scarlet fever is either due to a true rheumatic fever or to a pyæmic condition. Endocarditis has been found associated with fatal chorea without a distinct history of rheumatic fever.

Dr. Church has observed small raised red prominences on the mitral valve in hydrophobia, and I have seen two such examples. The endocardium was elsewhere quite smooth.

The pathological process in acute endocarditis is a multiplication of the cells of the endocardium with

FIG. 50.



*Growth on Edge of Mitral Valve, due to acute endocarditis. The septum of the ventricles was perforate (a congenital condition).*

infiltration of its layers by abundant leucocytes. This may occur on any part of the endocardium, but is more common on the auricular than on the ventricular surface of the auriculo-ventricular valves, on the



ventricular than on the arterial surface of the semi-lunar valves, on any part of the valves than on the walls of the cavities, and on the left side of the heart than on the right.

The cell multiplication and infiltration result in the protrusion of processes or growths from the surface of the endocardium which may attain considerable size. On their surface fibrin is often deposited from the blood and becomes adherent.

Another result is the thickening of the tendinous cords, especially at their insertion into the valves, and of the edges and general substance of the valves and of the inflammatory adhesion of contiguous parts of valves. These growths, thickenings, and adhesions when examined after the acute stage has passed, show connective tissue arranged in somewhat irregular layers. After a further lapse of time they sometimes undergo calcareous degeneration.

In ulcerative endocarditis the growths are almost invariably soft and numerous and are sometimes branching, and some destruction of surface is always present.

Clinical observation seems to indicate that acute endocarditis may subside without leaving any permanent sign of its former existence on the endocardium. Of permanent indications of past endocarditis the least is a slight thickening of the parietal endocardium. Such thickenings on the internal wall of the heart and without any affection of the valves are sometimes found post-mortem.

Valvular disease in nearly all its varieties may be produced by acute endocarditis. A third and rare result is aneurysm of the heart.

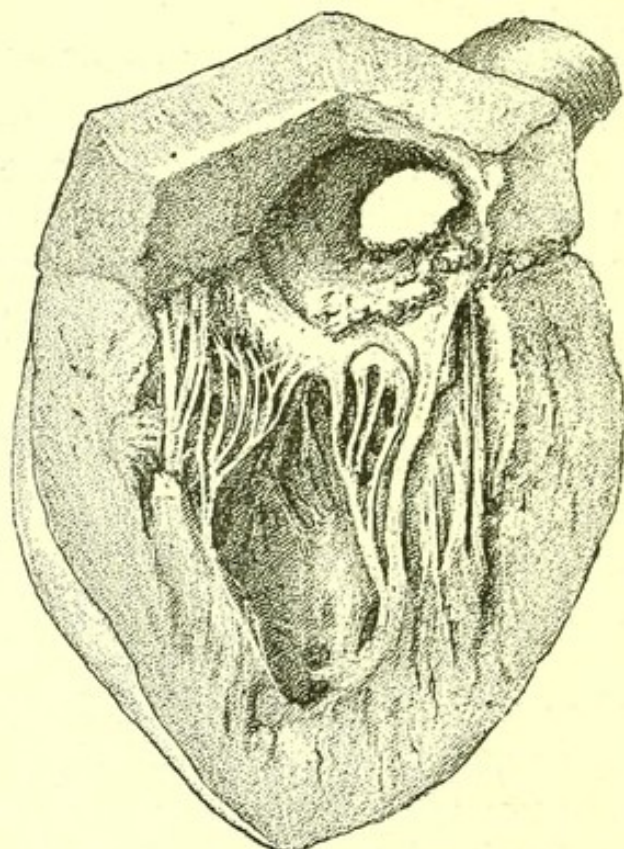
**Mitral Valve: Incompetence.**—The commonest result of the acute endocarditis of rheumatic fever is incompetence of the mitral valve, and this is the commonest valvular disease of the first half of life. The incompetence which during life is indicated by a systolic murmur, loudest at the apex and audible at the



angle of the scapula behind, cannot be proved post-mortem by pouring water into the ventricle because of the relaxation of the muscular walls of the heart, but it is indicated by—

1. The fact that the valvular opening, which when normal admits in the adult but two fingers, will admit three or more ;

FIG. 51.



*Heart of Mitral Regurgitation*, showing elongated cords.  
The aortic valves, also diseased, are visible above.

2. Thickening of the edge of the valve with shortening of the tendinous cords, or with great elongation of the cords.

Growths are often present on the valves. Some hypertrophy of the left ventricle is present.

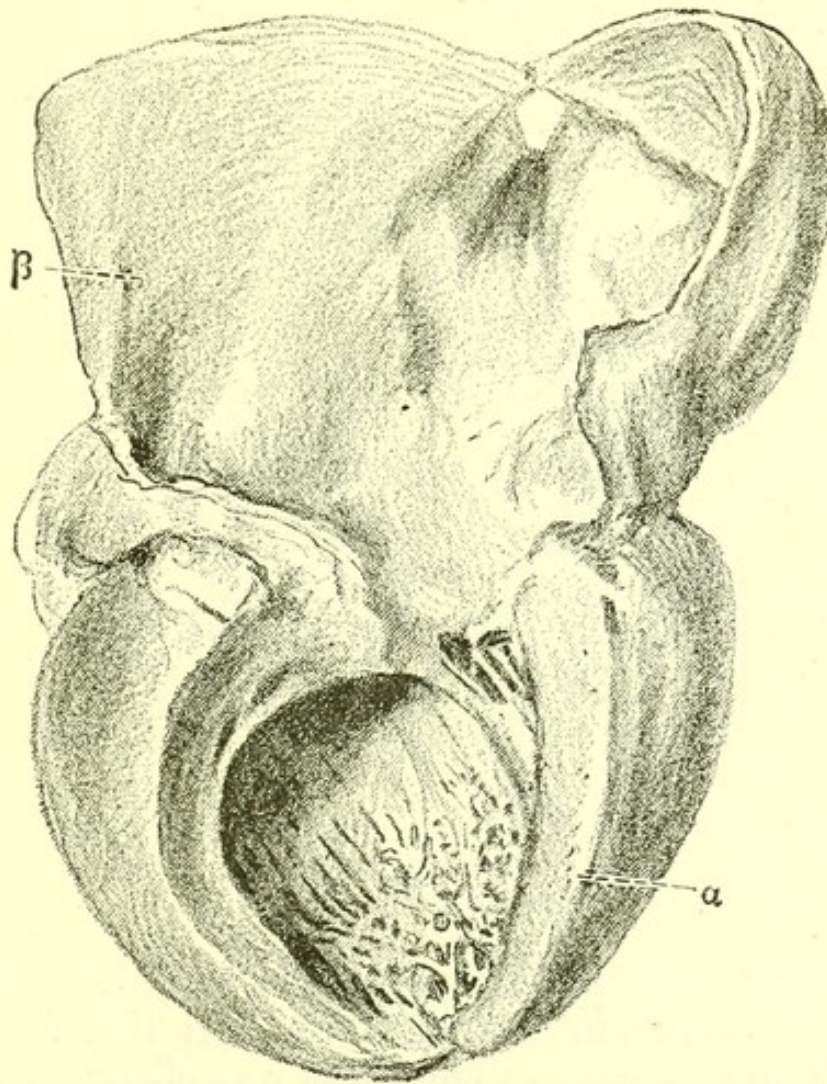
**Mitral Valve: Stenosis.**—Stenosis is less common than simple incompetence. The edge of the valve is thickened, its flaps are adherent, and its cords thickened. The auriculo-ventricular orifice is often very small, barely admitting the tip of the little finger. The left ventricle is never hypertrophied, and may appear



smaller than natural. The left auricle is hypertrophied, and so is the right ventricle. The thickened valve often contains calcified patches. Its extreme rigidity explains the thrill at the apex usually felt during life in this form of disease.

The structure of the thickened valve points to the

FIG. 52.



*Stenosis of Mitral Valve*, showing great hypertrophy of the left auricle. From a specimen in the St. Bartholomew's Hospital Museum.

probability that some regurgitation is often present in these cases, and explains the fact that a systolic as well as a præ systolic murmur is often heard at the apex.

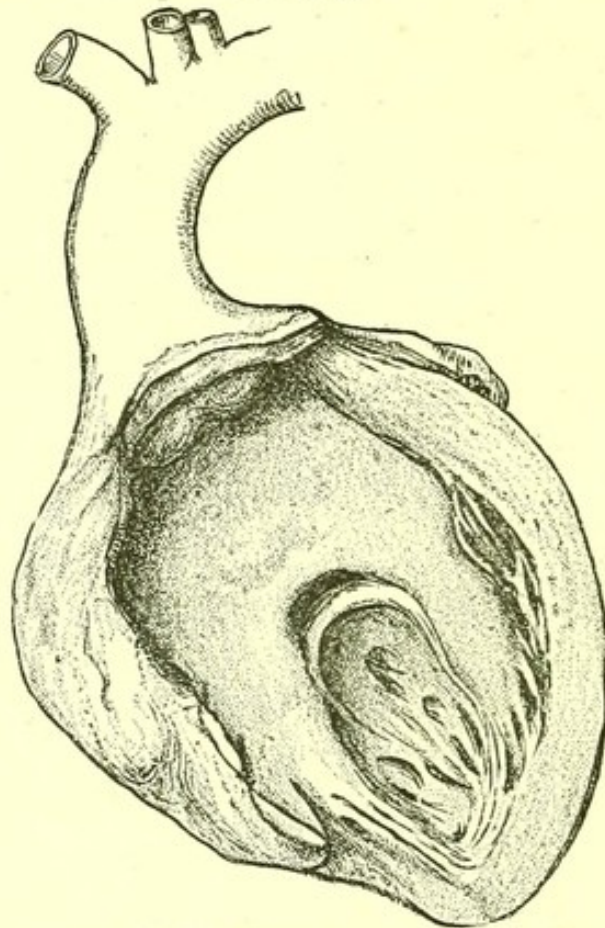
**Tricuspid valve:** stenosis rarely, if ever, occurs alone, but is a somewhat rare accompaniment of mitral



stenosis. The anatomical condition of the valve is the same as in stenosis of the mitral valve.

The following table of cases, taken as they occurred, shows that in twenty cases of tricuspid stenosis the

FIG. 53.



*Mitral Stenosis*, showing extreme thickening of the edge of the valve, and adhesion of all the cords. From a specimen in the St. Bartholomew's Museum.

mitral valve was also diseased in all, both mitral and aortic valves in fourteen, and all the valves in three. The first case in the table was observed by Dr. Church, from the second to the eighth by Dr. Gee, the tenth and twelfth by Dr. Legg, the remainder by myself.



*Twenty Cases of Tricuspid Stenosis at St. Bartholomew's Hospital, 1867-1888.*

Sex.	Age (in Years).	Condition of other Valves.		
		Pulmonary.	Mitral.	Aortic.
F.	35	Thickened	Diseased	Normal
F.	19	Normal	Constricted	Normal
F.	49	"	Constricted	Diseased
F.	48	"	Constricted	Diseased
F.	40	"	Constricted	Diseased
F.	60	"	Constricted	Diseased
F.	53	"	Diseased	Diseased
F.	28	"	Diseased	Diseased
F.	36	"	Constricted	Normal
F.	24	Thickened	Constricted	Diseased
F.	48	Normal	Diseased	Diseased
F.	23	"	Constricted	Diseased
M.	19	"	Diseased	Diseased
M.	16	With growths	Constricted	With growths
M.	30	Normal	Constricted	Diseased
F.	42	"	Constricted	Diseased
M.	13	"	Constricted	Normal
F.	12	"	Constricted	Normal
F.	31	"	Constricted	Normal
M.	36	"	Constricted	Diseased

Some writers have maintained that tricuspid stenosis is invariably congenital. A general and fatal objection to this view seems to me to be the fact that narrowing of the tricuspid valve is invariably associated with signs of endocarditis in other parts of the heart. It is surely far more probable that the tricuspid thickenings and adhesions are due to the affection which produced the precisely similar appearances in the mitral valve than that the tricuspid disease is congenital and the mitral disease acquired.

**Tricuspid valve: incompetence** has the same anatomical characters as mitral regurgitation. It some-



times occurs without mitral disease being present, but in such cases is not a result of endocarditis, but of defect in the muscular parts of the valve.

**Aortic Valves.**—When valvular disease originates early in life it is usually mitral, when in middle or later life it is most often aortic.

The aortic valves are of course frequently damaged in the endocarditis of rheumatic fever, but a large proportion of cases of aortic valvular disease are not due to this cause, but to chronic changes in the endocardium. The cases due to the endocarditis of rheumatic fever are marked by large irregular growths on the valves, while those due to chronic endocardial disease show thickening, opacity, and ultimately calcification of the valve without projecting growths.

This is a mere general distinction and must not be pushed too far, as intermediate cases occur, and there are also numerous examples in which the valves were first affected by rheumatic endocarditis and afterwards by chronic change.

**Aortic valves: incompetence** may be due either to growths or thickening of the valve, or to destruction of a great part of one or all valves. It is always accompanied by hypertrophy of the left ventricle, and of all forms of valvular disease causes the greatest degree of hypertrophy of the left ventricle. The heart often weighs twenty ounces, and may weigh more than thirty.

**Aortic valves: stenosis** is due to growths on the valves and to thickening. Great hypertrophy is present.

**Pulmonary valves** are rarely diseased in adults. Stenosis, due to their adhesion to one another, is usually a congenital condition.

**Aneurysm of the Heart.**—An aneurysmal projection from the cardiac wall always begins in an endocardial ulcer, and is a rare condition. Its commonest seat is on the outer wall near the apex of the left

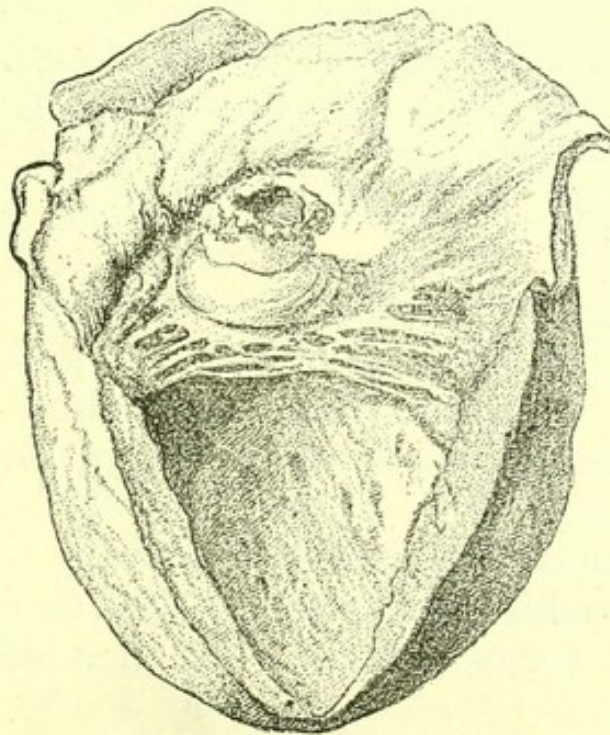


ventricle. Such aneurysms are sometimes very large. I have seen one equal in size to the heart.

Dr. Wickham Legg's Bradshawe Lecture ("Some Account of Cardiac Aneurysms," 1884) mentions more than two hundred accounts of aneurysm of the several parts of the cardiac walls, which illustrates the fact that the condition is so seldom met with that every morbid anatomist who meets with aneurysm of the heart thinks his observation worth publishing.

**Aneurysm of the Valves.**—Aneurysmal projections from the cardiac valves begin in acute endocarditis, or are more rarely a sequence of thickening and degenerative change in a valve. They sometimes attain a considerable size, and are then almost always perforated.

FIG. 54.



*Aneurysm of Mitral Valve, from a specimen in the Museum of St. Bartholomew's Hospital.*

A list of examples, including all the valves, will be found in Dr. Wickham Legg's Bradshawe Lecture.

**Anatomical appearances accompanying Valvular Disease.**—Certain appearances occur in different combinations and degrees in all forms of valvular



disease. They belong to three groups, and are the results—

1. Of arterial emptiness ;
2. Of venous engorgement ;
3. Of local arterial obstruction by embolus.

*The results of arterial emptiness* are chiefly symptomatic, as fainting due to cerebral anæmia, and paleness of complexion.

*The results of venous engorgement* are observable on post-mortem examination :

1. Lividity of the surface, sometimes accompanied by local purpuric hæmorrhages.
2. General infiltration of the tissues by serum (anasarca), and effusion of serum into the peritoneum (ascites), pleuræ, and pericardium.
3. Liver with engorged hepatic veins, from the appearance of its section called nutmeg liver.
4. Hard, engorged kidneys (cardiac kidneys).
5. Engorged, hard, reddish pancreas.
6. Engorged mucous membrane of stomach and intestines with dilated rectal veins (hæmorrhoids).
7. Engorged, hard spleen.

*Results of Embolus.*—The third group of consequences of valvular disease are those of embolus. The embolus carried from the heart into a terminal artery may be—

1. A piece of a growth on a valve.
2. Fibrin which has been deposited on a growth.
3. A clot formed during life in a dilated cardiac cavity.

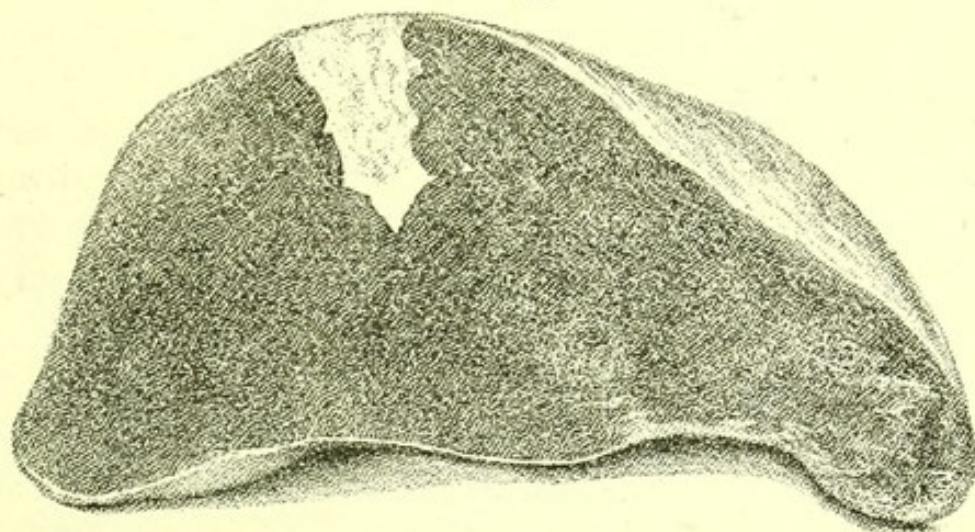
Any of these may be carried in the blood current till it blocks a terminal artery of the spleen, kidney or lung, causing an hæmorrhagic infarction of the organ, or one of the arteries of the circle of Willis causing atrophic changes in the brain substance supplied by the blocked artery.

Soon after the terminal artery is blocked the arterial capillaries become empty, the venous capillaries force



blood into them, and the blood passes through the now imperfectly nourished walls of the arterial capillaries, forming a solid mass, which microscopic examination shows to be the tissue of the organ tightly packed with red and white blood corpuscles. This is an hæmorrhagic infarction. It always has a definite and abrupt edge, is always cone-shaped, the apex of the cone pointing to the main artery of the organ, and the base being always upon the surface of the organ.

FIG. 55.



*Hæmorrhagic Infarction of the Spleen*, from a case of valvular disease in the post-mortem room of St. Bartholomew's Hospital.

When fresh it projects above the surface.

After a time it contracts and sinks below the surface, at the same time gradually losing colour.

Finally, it is marked by a depressed but always slightly conical scar, white in colour.

*The effects of valvular disease on the heart itself are :*

1. Hypertrophy ;
2. Degeneration ;
3. Dilatation ;
4. Ante-mortem clotting.

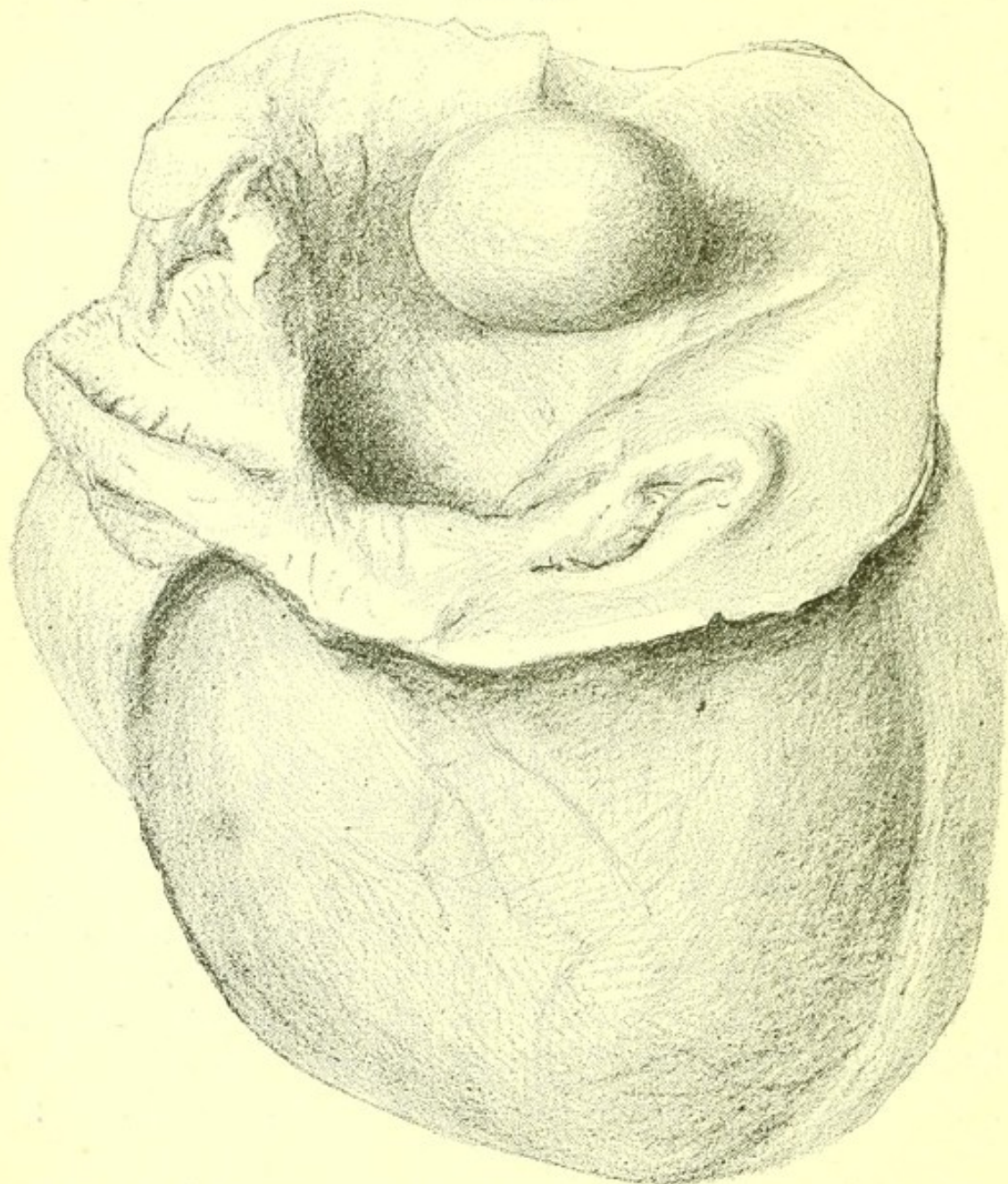
The first three have already been described.

**Ante-mortem Clots.**—Any dilated cavity may have coagula formed in it during life.



The appendices of the auricles and the apices of the ventricles and the deep depressions in the sides of the part of the right ventricle just below the orifice of the pulmonary artery are the commonest places.

FIG. 56.



*Globular Ante-mortem Clot in the Left Auricle, from a specimen in the Museum of St. Bartholomew's Hospital.*

These clots must not be mistaken for the firm clots often found in the heart and formed after death.

The points of distinction are—



<i>Post-mortem Clot.</i>	<i>Ante-mortem Clot.</i>
1. Entangled in the musculi-pectinati, but never truly adherent to the heart wall.	1. Sometimes actually adherent to the wall of the heart.
2. Smooth on the surface.	2. Reticulate or finely granular on the surface.
3. Of one consistence at any given point of transverse section.	3. Softer in the middle than on the surface.

Fragments of such clots are the commonest cause of pulmonary embolism.

Ante-mortem clots in the apices of the ventricles are occasionally globular, and most large museums contain specimens of a rare variety of ante-mortem clot, in which a spherical clot, the size of a walnut, is found in one of the auricles. (Fig. 56.)

Emboli carried from the heart are never found in the liver.

**Chronic endocarditis** is rare except as a sequel of the valvular disease produced by acute endocarditis. The whole endocardium is, however, occasionally much thickened without valvular disease, and the muscular tissue of the heart is at the same time degenerate, and dilatation of the heart present.

This rare condition in one case which I examined post-mortem, and in which the patient had fallen dead while sitting on a bench in an out-patient room, was associated with gummata in the liver, and it seemed possible that the endocardial thickening, which was well marked in both ventricles, but greatest in the left, might have originated in numerous minute gummata of the endocardium, producing a general thickening comparable to that sometimes seen all over the capsule of the liver, and due to a superficial layer of gummata.



In gout and other conditions of general degeneration, chronic thickening of the aortic valves, going on to calcification, is a common occurrence. Chronic fibroid changes sometimes follow acute inflammation of the auriculo-ventricular valves, but I believe this to be rare.

**Endocardial Corns.**—A thickened patch on the septum of the ventricles on the left side is sometimes a result of the rubbing of an old fibroid or calcified growth on the interior surface, or on one of the cords of the mitral valve.

**Angina Pectoris.**—When this symptom has been present during life, some fatty degeneration of the muscular tissue of the heart is always found post-mortem, and in most cases some form of disease of the aortic valves is present.

The following were the post-mortem appearances in a man, aged fifty-six years, who had distinct attacks of angina pectoris during life :

*Body* : Fairly nourished, some anasarca of legs.

*Head.*—*Brain* : normal, arteries of circle of Willis not atheromatous.

*Chest.*—*Lungs* : emphysematous, some pleural effusion of the right side.

*Pericardium* : normal.

*Heart* : aortic valves thickened and incompetent, a small calcareous patch in the middle of each. Orifices of coronary arteries (of which there were two within the middle aortic cusp and one within the posterior aortic cusp) thickened and narrow, but the arteries themselves nowhere calcified.

*Other valves* : normal.

*Muscular tissue of heart* : brownish in colour, showing some degeneration.

*Weight of heart* : twenty-five ounces, all cavities hypertrophied.

*Aorta* : highly atheromatous, with many almost calcareous patches.

*Abdomen.*—*Peritoneum* : no ascites, alimentary canal normal throughout.



*Liver* : of nutmeg appearance on section ; very hard.

*Gall-bladder* : containing a little dark bile.

*Spleen* : small and hard.

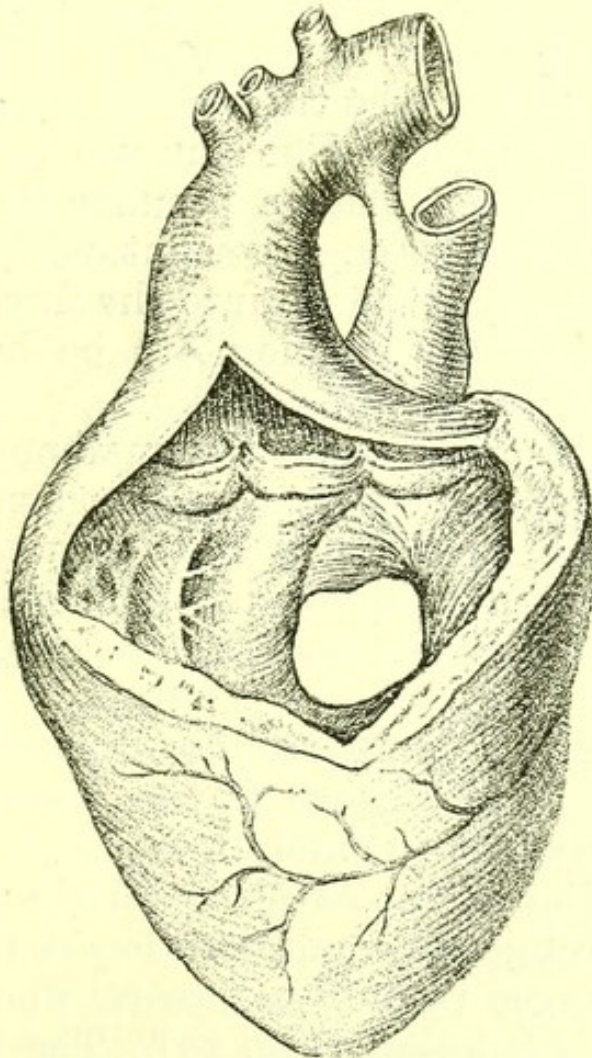
*Kidneys* : very hard, a small cyst on the surface of one ; of normal size ; surface quite smooth.

*Supra-renals* : normal.

*Organs of generation* : a large hydrocele on the left side.

Some degeneration of the coronary arteries is commonly present, and often from the thickening of the aortic valves some obstruction of their orifices.

FIG. 57.



*Congenital Malformation of Heart of a Man*, aged twenty-one years (left side).—A communication between the ventricles is present. For measurements, see Table on p. 218.

**Congenital Malformation of the Heart.**—This is a convenient term which includes several congenital



conditions, the origin of which is obscure. Till more is known about the development of the heart it is impossible to determine what cases are due to variety in growth, and what to intra-uterine endocarditis.

The commonest is :

*Pulmonary stenosis*, with permanent opening in the septum of the ventricles.

The prominent symptom of this condition is *cyanosis*.

In one example which I examined at St. Bartholomew's Hospital, the pulmonary valves were represented by a cone-like projection into the artery, with a small opening at its apex. The right ventricle was hypertrophied, and there was an opening in the septum at its uppermost part in the translucent spot just below the floor of the auricles. The skin was purplish. The fingers, toes, and nose had a peculiar rounded form. This was due to venous engorgement, with a very little fibrous increase ; a cut made into the finger in such a specimen will usually enable it to be brought with pressure into its normal shape.

*Patent ductus arteriosus* is sometimes found and is often accompanied by cyanosis, but not invariably, as in a woman, aged about fifty years, in whom I found post-mortem a patent ductus arteriosus, and no cyanosis. The duct was very narrow and was calcified throughout.

Cyanosis, precisely resembling that of congenital malformation of the heart, is also seen in cases of extreme emphysema in children.

The following examples illustrate the common appearances in congenital malformation of the heart.

I. A man, aged twenty-one years, who died in St. Bartholomew's Hospital (Fig. 57). The layers of the pericardium were adherent and thickened at two points near the apex. The aorta and the pulmonary artery were both somewhat narrow where they were joined by the ductus arteriosus, but at their origins they seemed externally of the normal calibre. The arteries of the



aortic arch were of the usual proportions. The only other external feature requiring remark was a greater degree of roundness at the apex than is usual. On opening the heart its ventricular part was seen to consist of one large cavity, occupying the position of the right ventricle, but extending considerably to left of the middle line, and of a small cavity on the left side, which was little more than an appendix to the large one. The auricles were of the normal proportions and appearance. A well-marked muscular ridge separated the insignificant representative of the left ventricle from the large right ventricle. Below the base of this ridge a transverse section of the heart would include only the right ventricle. The opening between the ventricles was larger than a shilling. Immediately to the left of its upper edge was the orifice of the aorta, and to its right the orifice of the pulmonary artery. The aortic orifice was of the normal size, and had the usual valves. The aorta became considerably reduced in calibre at the point of junction of the ductus arteriosus. The ductus arteriosus was closed throughout. It was to be observed that, while the aorta opened distinctly into the left ventricle, the opening between the ventricles was so situate that the stream of blood may have passed almost without obstruction into the aorta from the right ventricle. The orifice of the pulmonary artery was without valves, and was bounded by a thickened ring in the centre of a small tract of membrane. This was probably the product of the adhesion of the pulmonary valves. Above the orifice the artery was of normal width, but was slightly narrowed at the junction of the ductus arteriosus. Immediately below it, and close to the edge of the opening between the ventricles, the mitral valve opened into the right ventricle. The tricuspid valve opened into the same ventricle, in front of the mitral, and a little above it. The mitral orifice was a very little less wide than normally. Both valves were normal as to their flaps. The vessels on the surface of the heart followed the groove between the



actual right and left ventricle, and did not at the upper part of their course run independently of it.

The lungs of this patient. were excavated by numerous cavities. There was a general dropsy. When alive, the patient was intensely cyanotic. His fingers and toes were clubbed. I mean by this a lateral expansion, and not a mere bending down of the nail. His breath was always very short. The physical signs which I made out when he was in the hospital, were a loud systolic murmur, as loud at the base as at the apex of the heart; a distinct systolic thrill and a somewhat irregular impulse. His history was, that he had always been blue and short of breath, and had always had clubbed fingers. The following table shows the proportions of the several parts of this heart :—

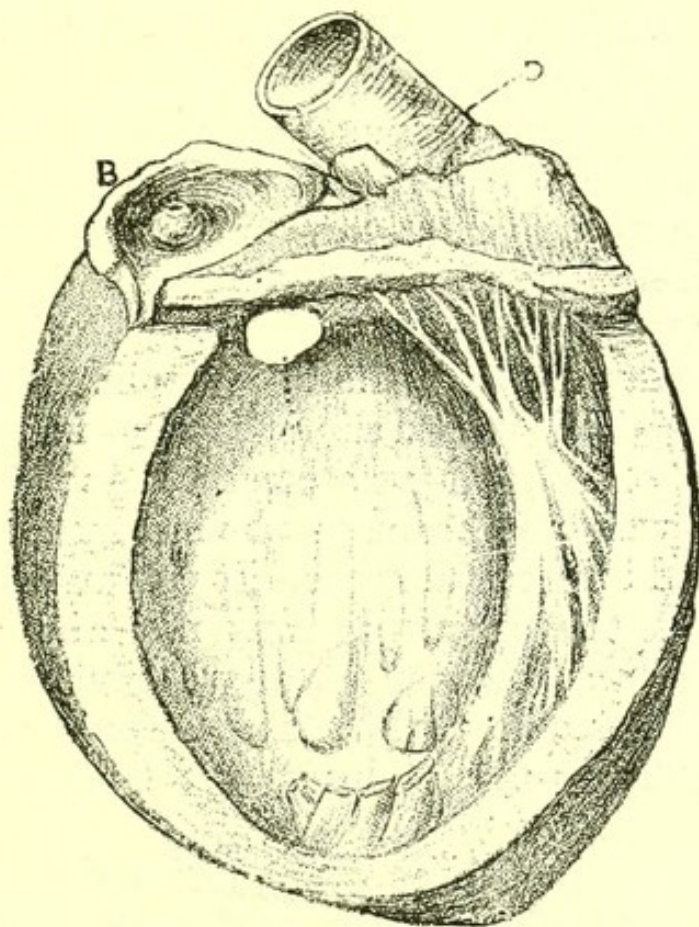
Part measured.	Inches and tenths of an inch.
Length of heart from root of pulmonary artery to apex . . . . .	3.5
Depth of left ventricle from its lowest point to beneath the aortic semilunar valves . . . . .	1.5
Vertical diameter of opening between the ventricles . . . . .	1.1
Transverse diameter of opening between the ventricles . . . . .	1
Width of orifice of pulmonary artery . . . . .	0.25
Width of aorta at origin . . . . .	1.1
Width of aorta at junction of ductus arteriosus . . . . .	0.6

II. A girl, aged eight years (Fig. 58). She was under my care for two years, and I made an examination of her body after death at her home. Her heart was large for her age. It had no external peculiarity. The ductus arteriosus was closed. The auricles were of the usual proportions, and their septum



was complete. The left ventricle occupied its normal position with regard to the apex, but the right ventricle was somewhat more capacious than it usually is, and its walls were a little thicker than those of the left ventricle. The infundibulum of the right ventricle was very narrow above. The pulmonary orifice was less than one-eighth of an inch across.

FIG. 58.



*Congenital Malformation of Heart of a Girl, aged eight years.*—A. Communication between ventricles. B. Pulmonary orifice. D. Aorta.

Externally the base of the pulmonary artery was of the normal width. Looking into the artery from above, the orifice from the heart was seen to be at the apex of a small bulb, which rose from a membranous plane, which occupied what would, in a normal heart, be the position of the pulmonary valves. This bulb was hollow on the ventricular side, and, with the plane, was probably the result of the adhesion of the pulmonary



valves to one another. The edge of the orifice was fimbriated, and was thicker than the rest of the membrane, and in one-third of its circuit was calcified. The septum ventriculorum was not complete. There was a communication between the ventricle at its upper and anterior part. The opening had a muscular edge, and was large enough to admit the little finger. The child died of general dropsy. Her lungs were sound. Her liver, spleen, and kidneys were engorged, but not diseased. During life she was of a cyanotic complexion. This was most marked in the face, feet, and hands, but extended over the whole body. The cyanosis became much deeper on the least exertion. Her nose was clubbed, but her fingers and toes were not so. Her tongue was always of a deep purplish hue. Her feet and hands were always cold. On auscultation of her heart, a harsh systolic murmur was to be heard. This varied slightly from time to time in character of sound, but was constant in position and period. It was best heard on the sternum at the level of the second intercostal space. It was audible, though less loud, at the apex. It was not audible at the angle of the scapula, nor at any other point of the back. There was no thrill. The impulse was somewhat irregular, and not heaving. She was pigeon-breasted.

III. A boy, aged three years, had a very small pulmonary artery and a defective septum of the ventricles. The pulmonary artery was given off at the normal situation; at its root its external measurement was barely a quarter of an inch. Internally its valves were represented by a small cone projecting into the artery, with a perforation at its apex no larger than a medium-sized pin. The aorta was larger than natural, and measured three-quarters of an inch across at its origin (external measurement). Its valves were normal, and its orifice communicated freely with both ventricles exactly over a circular orifice at the top of the ventricular septum. This orifice was three-



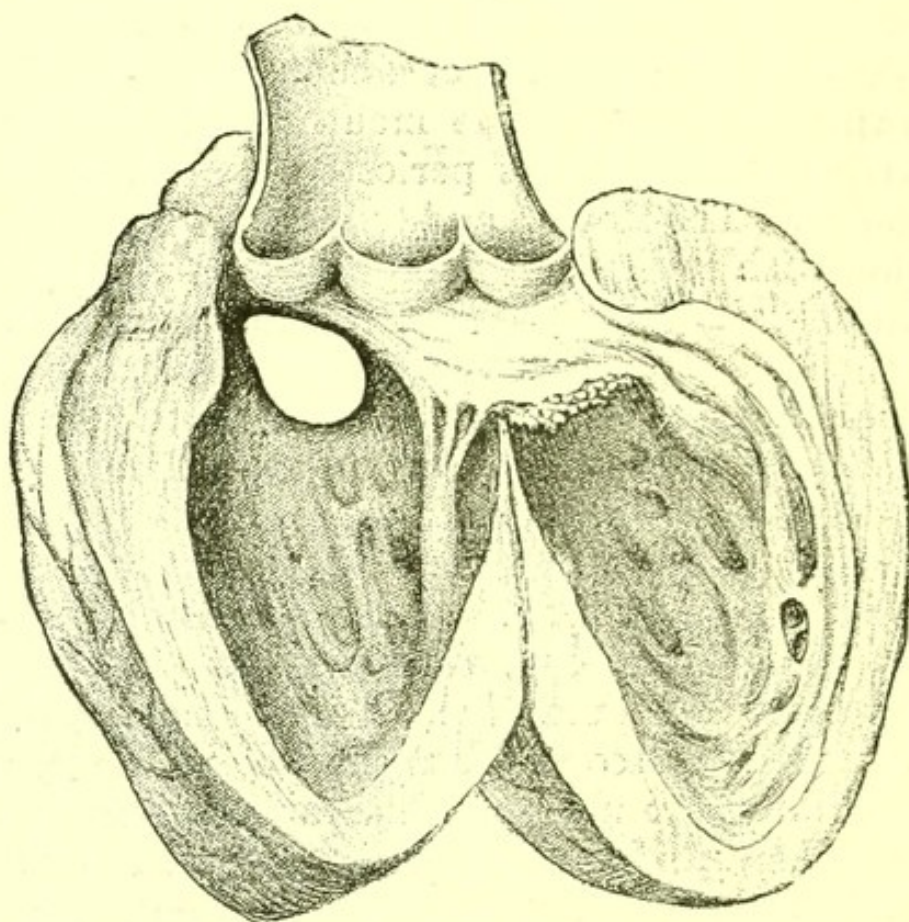
quarters of an inch in diameter. The foramen ovale was also widely open. The ductus arteriosus was closed, and the distribution of the vessels of the aortic arch was normal. The tricuspid and mitral valves were natural. There was great hypertrophy of the right ventricle, but the left was of normal size. At the apex of the cavity of the right ventricle there was a small globular adherent clot, soft within, firm and moulded without, certainly formed during life. The child showed no signs of rickets. It was much emaciated, but not dropsical. On the right side of the face there was a patch of gangrene of about florin size. This included the angle of the mouth, and the superior maxilla was there bare of periosteum, and some teeth were loose. The fingers and toes were very blue post-mortem, with dependent integument at the sides of their extremities where during life there had been clubbing. There were several long ulcerated tracts of irregular shape in the small intestine, and there was a very slight enlargement of the mesenteric glands. There were no other morbid appearances in the chest or abdomen, except one very small caseous mass at the apex of the left lung. A careful search was made for any other anatomical abnormality. The only one found was the presence of small additional lobulations on the under surface of the right lobe of the liver.

The child was under my observation from April 10 to November 4, 1884. It first attracted my attention in the midst of a crowd of out-patients from its extreme blueness and urgent dyspnœa, which seemed to be likely to end its life in a few hours. It ultimately sank owing to the gangrene of its face. When the heart was acting quietly a systolic murmur was audible all over the chest, most distinct at a point midway between the nipple and the sternum. Over the same area a systolic thrill was to be felt. There was no thrill when the heart's action was irregular, and then no murmur was audible. In addition to a deep general cyanosis there was great dilatation of all



superficial veins, those of the eyelids being especially sinuous and distended. The veins of the fundus of the eye were also very tortuous. The fingers, toes, and nose showed well-marked clubbing. On cutting into them at the autopsy the clubbed ends could be reduced by pressure to the normal shape. Microscopic sections of the terminal joint of the second right toe showed that the clubbing, which was chiefly due

FIG. 59.



*Heart with Patent Septum Ventriculorum*, from a woman aged twenty years.

to mere engorgement, was associated with some thickening of the walls of the blood-vessels, but there was not any general increase of connective tissue in the clubbed end.

**Syncope.**—If a patient with valvular disease has died of syncope, disease of the aortic valves will probably be found after death.

**Palpitation** may have been a symptom during



life in cases in which post-mortem no lesion is discoverable in the heart.

Adherent pericardium, pericarditis, dilatation of the heart, hypertrophy of the heart, and all forms of valvular lesion are anatomical changes all of which may have been indicated during life by palpitation.

**Irregularity of action** is not always an indication of demonstrable structural change, but in cases in which it was a symptom pericardial adhesions and thickening of the pericardium, dilatation of the heart, or valvular disease are frequently discovered post-mortem.

**Cyanosis.**—A distinct bluish colour of the skin is an extreme degree of the appearances known in their slighter forms as dus'kiness and lividity. Imperfect aëration of the blood is sufficient to produce dus'kiness and lividity, and may even cause true cyanosis.

In most cases of true cyanosis, however, there is a possibility of a mixture of the venous blood in the right ventricle with the arterial blood in the left ventricle.

## ARTERIES.

**Arteries** are never hypertrophied in all their coats, but the muscular coat may be thickened so as to give the appearance of general increase in size. The muscular coat may undergo fibroid degeneration, and, with the inner part of the middle coat, and ultimately all the coats, may undergo fatty change and finally calcification. A degenerate artery is frequently dilated. Fusiform aneurysm of the aorta is a general dilatation following degeneration.

**Arteritis.**—Acute internal inflammation of an artery is almost invariably due to an infective embolus.

In a young man who died with soft growths on the aortic valves I found growths exactly resembling those on the valves, about one inch and a half above the aortic orifice, projecting from the wall of the aorta.



An aneurysm had formed near them, and they were probably a sequence of the endocarditis.

Slow cell formation in the inner part of the middle coat of arteries, and especially of the aorta, is common. The cell-groups form patches, sometimes raised, sometimes opaque, on the inner surface of the vessel. These patches frequently calcify, and when calcified the patch often has a ragged edge. They are commonest in old people, but occur at all ages after childhood, and may sometimes be discovered even in young children. At all stages they are spoken of as atheroma.

**Rupture of the aorta** sometimes follows extreme degeneration, but apart from aneurysm is extremely rare.

A patient was admitted to St. Bartholomew's Hospital with severe pain in the abdomen, and died next day. The aorta was highly atheromatous, and had ruptured at the end of the arch, the sheath remained entire, and the vessel within the sheath was coated with recent blood from the rupture to just above the bifurcation. The pain seemed due to the great stretching of the sheath of the aorta in the abdomen by blood-clot.

**Aneurysm.**—A bulging of an artery owing to its giving way at some particular point is formed in two ways:

1. When the artery gives way at a degenerate spot.
2. When micrococci from an infective embolus invade the arterial wall at a particular spot, having been carried thither from the heart.

The former is the commoner, and the formation of the aneurysm is slow. It never occurs in childhood.

The latter occurs as a sequel of ulcerative endocarditis, and often leads to multiple aneurysm. It may occur at any age, and such emboli are the cause of all aneurysms (apart from injury) in children.

**Aneurysm of the arch of the aorta** is the form of aneurysm most often seen in the medical wards of a hospital. It may occur at any part of the aorta, but



is most often found in some part of the arch. The sac may attain large dimensions. The aneurysm causes atrophy of the parts on which it presses. When death has been preceded by vomiting or coughing up of blood, erosion of the œsophagus, erosion of the trachea, or erosion of a bronchus is found post-mortem.

The constant pain in the back which frequently occurs in cases of aneurysm of the aorta, and the paraplegia which sometimes follows it, are in some cases explained by the discovery post-mortem of erosion of the bodies of vertebræ and of pressure on the spinal cord.

The recurrent laryngeal nerve may be found flattened by the aneurysm when paralysis of a vocal cord was observed, and a compressed sympathetic nerve when dilatation of the pupil on one side has been observed during life.

Erosion of the sternum is common, but external rupture following it is very rare. In the cases in which it occurs a large laminated fibrinous clot projects from the eroded spot.

Rupture into the pleura is common. The pleural sac is found full of blood and the lung collapsed. The history is that the patient died suddenly or was picked up dead. In one week two men were brought dead to St. Bartholomew's Hospital. In both I found that an aneurysm of the aorta had ruptured into the right pleura, which contained about three pints of blood.

Rupture into the pericardium also occurs, but is rarer.

The following case illustrates another method of termination :—

A man with a large aneurysm of the transverse part of the arch and whose sternum was eroded, the clot being only covered by a thin layer of skin, sat up in bed, became faint, and died. The presumption seemed to be that his aneurysm had burst internally. The post-mortem showed that this was not the case. The aneurysm pressing on the veins at the



root of the left lung had caused a very large passive effusion into the pleura on that side, and the sudden alteration of pressure consequent on his sitting up with this effusion in his left pleura was the cause of death.

**Aneurysm of the thoracic aorta** very frequently causes erosion of the dorsal vertebræ, and sometimes absorption of the head of one or more ribs.

**Aneurysm of the abdominal aorta** has been found with rupture into the peritoneum, and more rarely into the stomach, and with erosion of the lumbar vertebræ. In the only case of aneurysm of the abdominal aorta bursting externally which I have seen, the rupture was in the region of the spleen, so far outwards did the sac extend.

**Aneurysm of the hepatic artery** is very rare. Dr. Osler has described some cases.

**Aneurysm of the pancreatico-duodenalis artery** is frequently found at the base of a gastric ulcer, when in that disease death has been due to hæmatemesis.

**Aneurysms of the arteries of the circle of Willis** may be large or small, and are very often found in cases of death from cerebral hæmorrhage.

**Results of treatment.**—After prolonged treatment by rest and medicines, an aneurysm may fill with laminated clot, become a solid tumour, and give the patient no further trouble. Such cases are sometimes demonstrated, when death occurs long after from some other cause. Less encouraging examples ought also to be mentioned.

A man under my care in St. Bartholomew's Hospital, who for a year adhered to a restricted diet and to absolute rest on his back, sat up in bed the day before that on which he was to have left the hospital. He died in a few moments. Post-mortem it was found that the aneurysm had burst into the right pleura, and that the sac, a large one, did not contain even a single layer of adherent clot.



**VEINS.**

**Phlebitis.**—Inflammation of a vein may follow inflammation in its vicinity, or may be due to irritating elements in the blood, as in gout, or to infective material, as in phlegmasia alba. The inflammation is immediately followed by thrombus, which slowly closes the veins, and which after the inflammation subsides may become organized so that the vein is discovered post-mortem (should death occur from other cause) as a solid cord of fibrous tissue.

The lymphatics in the neighbourhood are always enlarged.

The limb is anasarcaous. Inflammation of a contiguous nerve or of lymphatic vessels may be present.



## CHAPTER XIII.

DISEASES OF THE RESPIRATORY  
SYSTEM.

INFLUENZA, DIPHTHERIA,  
AND WHOOPING-COUGH.  
CROUP.

HAY ASTHMA.

LARYNX AND TRACHEA:

ŒDEMA.

LARYNGITIS.

SYPHILIS.

ULCERATION IN EN-  
TERIC FEVER.

ULCERATION IN SCAR-  
LET FEVER.

OUTGROWTHS.

NEW GROWTHS: CARCI-  
NOMA AND SARCOMA.

BRONCHI:

CATARRHAL BRONCHI-  
TIS.

PLASTIC BRONCHITIS.

ULCERATION.

BRONCHIECTASIS.

BLOOD IN BRONCHI.

ASTHMA.

LUNGS:

EMPHYSEMA.

PASSIVE CONGESTION.

HÆMOPTYSIS.

ŒDEMA.

CATARRHAL PNEU-  
MONIA.

LOBAR PNEUMONIA.

GANGRENE.

ABSCESS.

CHRONIC INTERSTITIAL  
PNEUMONIA.

TUBERCULOSIS: ACUTE.

„ RAPID.

„ CHRONIC.

OBSOLETE TUBERCLE.

NEW GROWTH.

ATELECTASIS AND COL-  
LAPSE.

HÆMORRHAGIC INFARC-  
TION.

THROMBOSIS OF PUL-  
MONARY ARTERY.

HYDATID.

MILLSTONE - MAKER'S  
PHTHISIS, GRINDER'S  
ASTHMA, MINER'S  
ASTHMA.

PLEURÆ:

HYDROTHORAX.

PLEURISY.

PUS IN PLEURA.

AIR IN PLEURA.

BLOOD IN PLEURA.

PARASITES.

NEW GROWTH.

TUBERCLE.

PNEUMOTHORAX.

Influenza, diphtheria, and whooping-cough  
have already been described as specific febrile diseases  
(Chapter III.).



**Croup** is a clinical term, and has no precise pathological meaning. The peculiar respiration and cough in children to which the term is applied may be due to one of three pathological conditions :

1. The nervous condition occurring in rickety children, and known as laryngismus stridulus.
2. Diphtheria affecting the larynx.
3. Acute catarrhal inflammation of the larynx and trachea.

**Simple membranous laryngitis**, analagous to plastic bronchitis in the adult. This condition is extremely rare, and in the absence of the strongest evidence to the contrary, every case of laryngitis in a child in which post-mortem false membrane is found in the larynx or trachea should be assumed to be a case of diphtheria.

**Hay asthma** is not a fatal disease, and beyond the obvious catarrhal condition of the nasal mucous membrane nothing is known of its morbid anatomy.

## LARYNX.

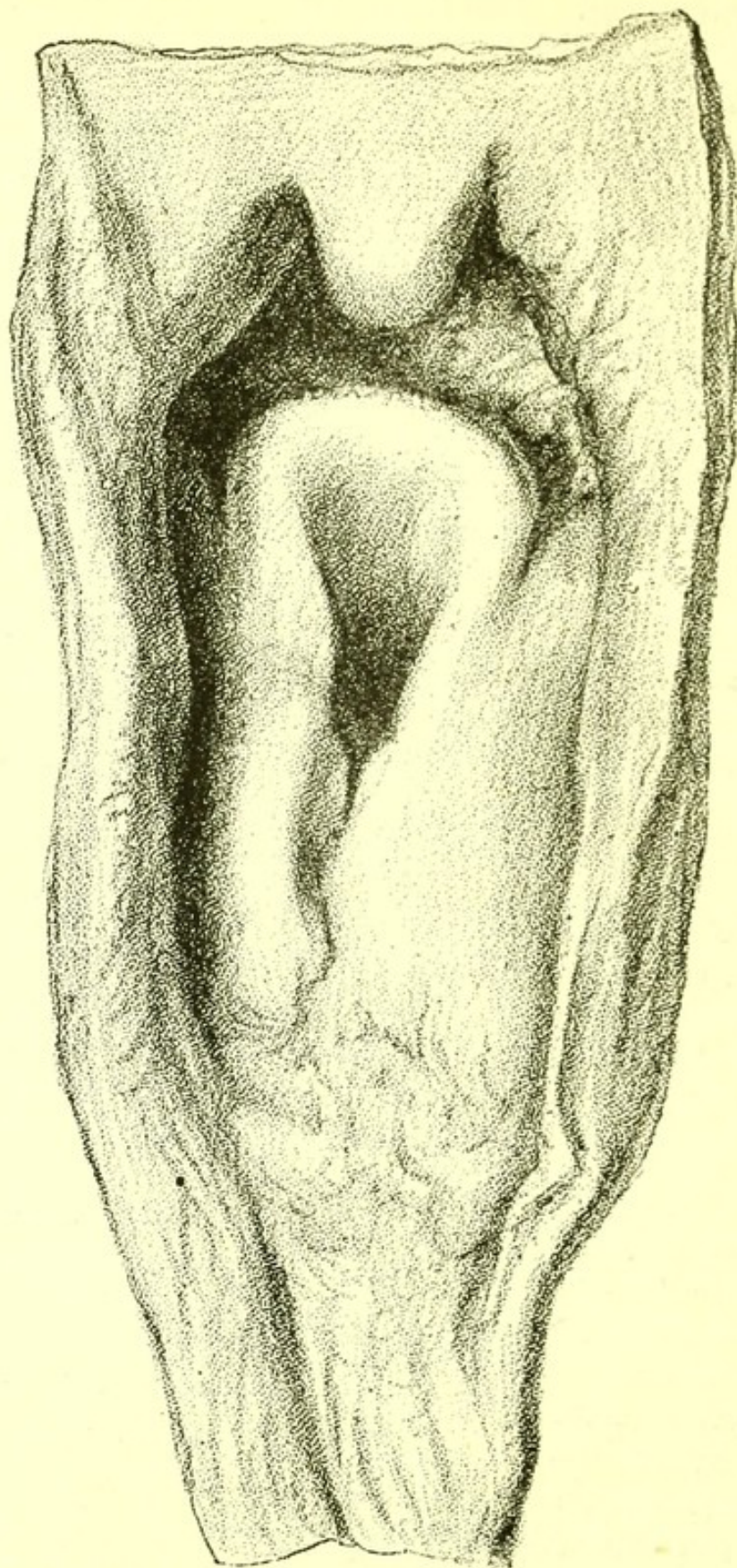
**Œdema glottidis.**—The aryteno-epiglottidean folds are distended with serum, and may completely close the rima glottidis. This condition is a frequent cause of death in both acute and chronic nephritis. It sometimes terminates laryngitis, and sometimes is a result of corrosive poisoning, of inhaling irritating gases, or of inhaling scalding water.

It is very rare in the dropsy of heart disease, but is sometimes found post-mortem to be part of the general dropsy, and may then be regarded as the immediate cause of death.

**Laryngitis.**—Acute catarrhal inflammation of the larynx, except as a result of inhaling an irritating vapour, such as ammonia gas, is rarely seen in the post-mortem room. The mucous membrane in ammonia poisoning shows injected vessels, and catarrhal secretion adheres to it.



FIG. 60.



*Edema Glottidis*, from a specimen in the Museum  
of St. Bartholomew's Hospital.



Chronic inflammation of the larynx is often discovered after death from tuberculosis or from syphilis, and may of course occur without either.

Tubercle of the larynx never occurs without tubercle elsewhere. It is most commonly a sequel of tubercle of the lungs. The vocal cords either have ulcers upon them or have been destroyed by ulceration. Their elastic cartilage has undergone complete or partial necrosis. Very often there is an irregular circular ulcer at the posterior end of each vocal cord. Ulcers are also common at the root of the epiglottis, and small ulcers with recent tubercle near them are often to be found in the trachea. The edge of the epiglottis is sometimes ulcerated, but extensive destruction of it is rare.

Some atrophy and calcification of the thyroid, cricoid, and arytaenoid cartilages are often present. The arytaeno-epiglottidean folds are always thickened.

**Syphilis.**—Great thickening of the vocal cords and destruction of the epiglottis are the characteristic appearances of chronic laryngitis due to syphilis. In congenital syphilis in infants there is much redness and curvature of the edges of the epiglottis.

**Ulceration in enteric fever.**—Ulceration of the vocal cords and of the epiglottis occurs in enteric fever (q.v.), and sometimes is found post-mortem in other specific fevers.

I have seen it in a case of measles in a boy, aged five years, who died of abscess of the brain six weeks after he was first taken ill. The larynx showed simple ulceration of the cords and of the base of the epiglottis.

In a case of scarlet fever, in another boy, aged five years, the ulceration was more extensive. A considerable tract of epithelium was destroyed, but no false membrane could be detected. There was a deep ulceration of the fauces without false membrane.

**Outgrowths.**—Warty outgrowths are not uncommon in the larynx.



**New growths.**—Carcinoma of the larynx is slow-growing. Cell nests are usually visible in microscopic section. The neighbouring lymphatics become infiltrated. Abscess with necrosis of a piece of the thyroid cartilage is frequently found. In one well-marked case of carcinoma of the larynx examined by me post-mortem, an abscess pointing externally just below the lower edge of the thyroid cartilage was the symptom which first led to an accurate diagnosis. Spheroidal and cylinder-celled carcinoma also occur.

**Sarcoma** is not uncommon in the larynx, and is generally a slow-growing variety, but post-mortem secondary growths in other parts of the body are sometimes found.

**Catarrhal Bronchitis.**—After death from acute bronchitis in the adult redness of the trachea and bronchi, and accumulation of frothy sputum in them, are found. All the cavities of the heart usually contain clots, and the right side is often distended by them.

In an infant there are always in addition patches of collapsed vesicles in the lungs.

In chronic bronchitis the appearances of the mucous membrane are similar. Some increase of fibrous tissue in the bronchi is indicated by a thickening of their longitudinal striæ; emphysema is always present, and upon its degree depends the degree of dilatation and hypertrophy of the right side of the heart.

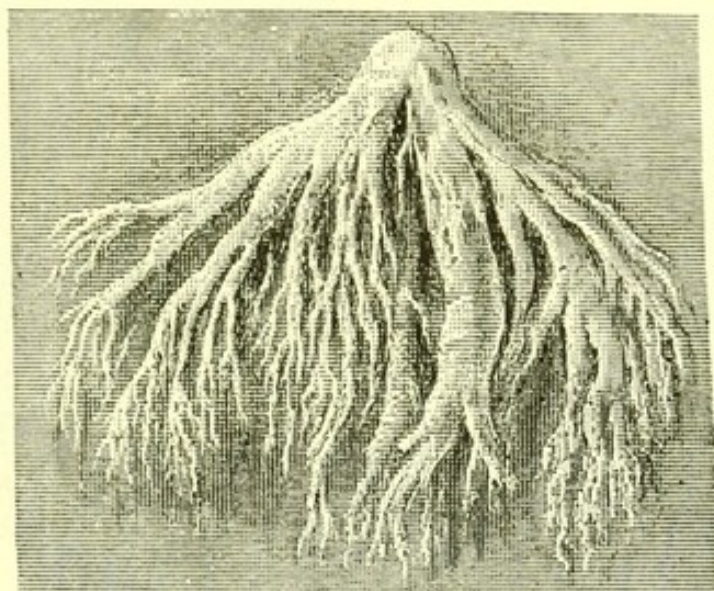Two morbid changes in the lung are traceable to repeated attacks of chronic bronchitis—emphysema and bronchiectasis; emphysema always follows, bronchiectasis rarely.

**Plastic Bronchitis** is a variety in which the exudation into the bronchi contains fibrin, which coagulates so that fibrinous casts of the bronchi are formed and often coughed up. These casts look very like occluded vessels with branches when coughed up, and Van Tulp and other early pathologists mistook



them for vessels. The casts almost invariably have a little blood on their surface when coughed up. The other pathological changes are those of severe and prolonged bronchitis.

FIG. 61.



*Sputum of Plastic Bronchitis* from a specimen in the Museum of St. Bartholomew's Hospital.

**Ulceration of the bronchi** is rare. Shallow ulcers are occasionally found in the large bronchi in cases of tuberculosis, usually when ulcers of the trachea and larynx are also present.

In one case a deep solitary ulcer of a bronchus had caused death by penetrating the pulmonary artery.

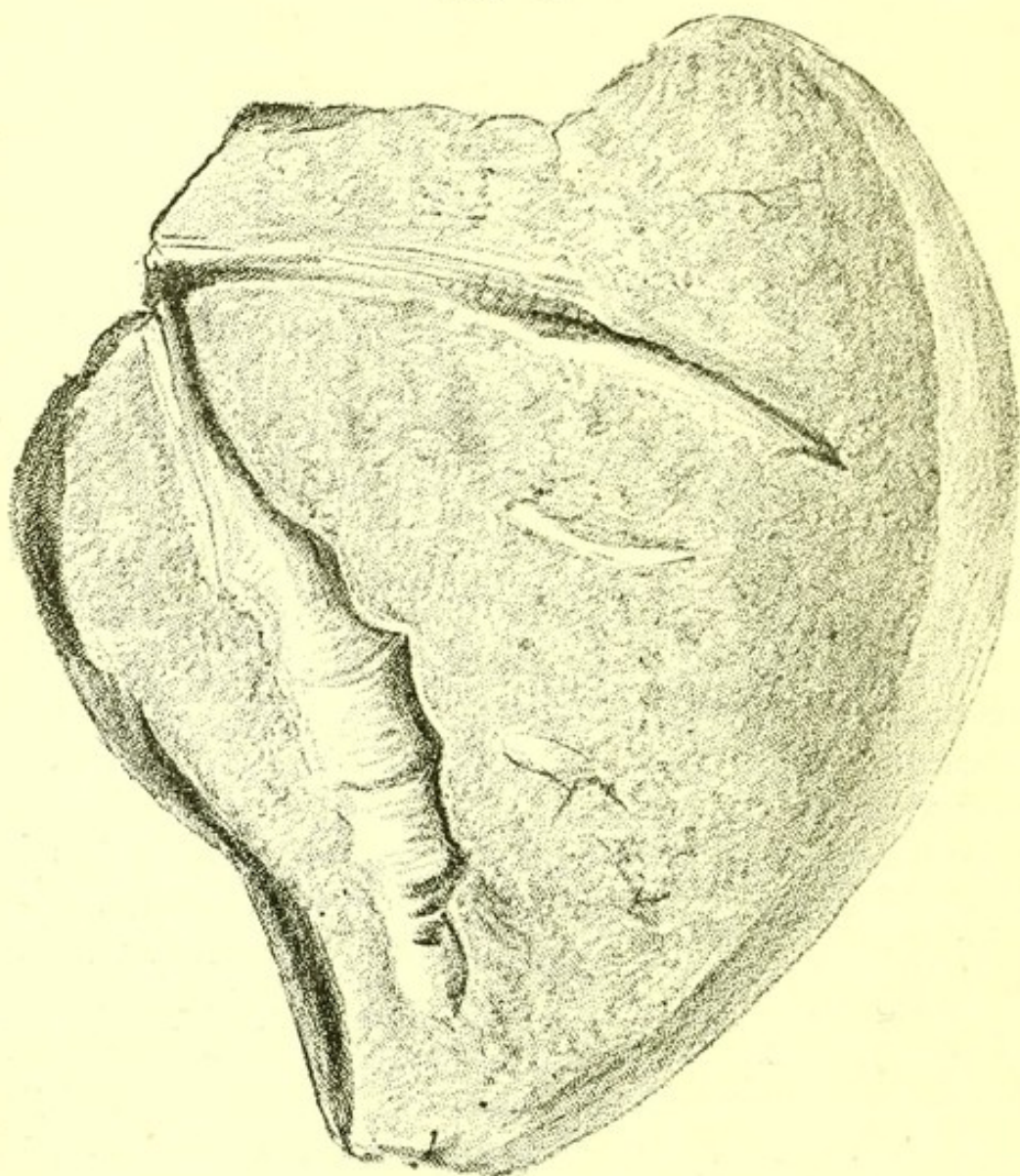
The patient was a man, aged twenty-four, who died of a profuse hæmoptysis. He had copious hæmoptysis on January 1, 1881, followed by febrile symptoms, and on January 9th had a more profuse hæmoptysis, and died. His stomach, as well as his bronchi, was filled with blood. An eroded surface, as large as a shilling, was to be seen in the upper part of the right bronchus. The ulcer had opened into the pulmonary artery. In the centre of the right lung was a cavity of walnut size, and near the apex a small cavity filled with cretaceous matter. Neither communicated with the bronchial ulcer. There was no tubercle of the



larynx, and the unaffected tracheal rings were healthy. A careful search was made for a foreign body, but none was found. The other viscera were healthy.

**Bronchiectasis.**—A bronchiectasis is a smooth walled cavity communicating with a bronchus and produced by its dilatation. It is often difficult to dis-

FIG. 62.



*Bronchiectasis*, from a specimen in the Museum of St. Bartholomew's Hospital.

tinguish from a cavity produced by destruction of lung substance.

The most distinct bronchiectases are those found near the surface of the lung and due to dilatation of a



minute bronchus; the bronchial mucous membrane may be traced into them, and their walls are often quite free from external inflammatory thickening. Their interior is smooth and the entrance into the bronchus likewise smooth, neither thickened nor ragged. They are never crossed by thickened or occluded arteries.

Bronchiectases of this kind are sometimes found in the lungs of children after whooping-cough. The air vesicles near them are often collapsed, which with the dilated bronchi gives a honeycombed appearance to the affected region of lung.

**Blood in the bronchi** may be due to the rupture of an aneurysm into a bronchus, in which case a hole with fibrin partly filling it is found, or to hæmorrhage from the lung tissue. Such hæmorrhage, due to capillary engorgement, often occurs at the onset of tuberculosis. It may accompany ulceration of the lungs in chronic phthisis, or it may be due to the rupture of an aneurysm of a branch of the pulmonary artery in a phthisical cavity. Or it may be due to blood coming from a hæmorrhagic infarction of the lung; or to capillary hæmorrhage caused by direct irritation, as of ammonia gas.

**Asthma.**—No structural change characteristic of spasmodic asthma has yet been discovered. Post-mortem the lungs of most persons who have during life been declared to be asthmatic are found to be highly emphysematous or to contain tubercle.

**Emphysema.**—Emphysema is a progressive degeneration of the walls of the air vesicles of the lungs.

It occurs in infants after violent pulmonary catarrh, and in all subsequent periods of life, some degree of it being always present in the lungs of aged people. The change is generally symmetrical in both lungs. The characteristics of an emphysematous lung are:

1. It contracts very little when the chest is open.
2. It is larger and lighter than a normal lung.
3. All round the edge of the lung enlarged air vesicles are visible, and sometimes, especially at the



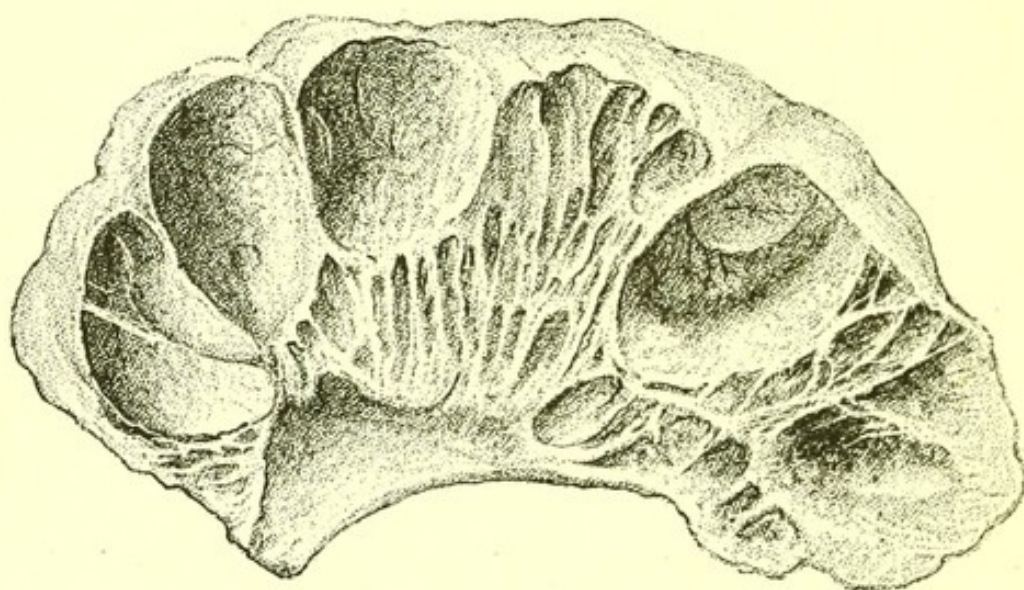
base or at the apex, large bullæ are seen with very thin walls, and which collapse at once when pricked.

4. The pulmonary artery shows small atheromatous patches.

Under the microscope numerous interrupted or abnormally thin septa of air vesicles are visible, though careful preparation is necessary to avoid the error of mistaking torn for atrophied walls.

The right side of the heart is dilated and hypertrophied.

FIG. 63.



*Emphysema of Lung*, from a dried specimen in the Museum of St. Bartholomew's Hospital.

Other degenerative changes are often found in the body, of which the chief are—

1. Chronic interstitial nephritis;
2. Degeneration of articular cartilages and calcification of costal cartilages ;
3. Atheroma of large arteries ;
4. Hæmorrhages into the retina.

In extreme cases of emphysema some anasarca, and often extensive general dropsy, is present.

Bronchitis is the commonest cause of death.

A highly emphysematous right lung weighs from 12 to 15 oz., so that one-third, or even half, of the lung



substance may have been removed by this atrophic change.

The important effect of this diminution of the aërating surface is shown by the fact that pneumonia of one lung is usually fatal in cases where the other is highly emphysematous.

The distension of the lungs in emphysema causes the chest to assume a condition of permanent forced inspiration, the costal angle is obtuse, the sternum arched forwards, especially at the first joint.

Patches of dilated or combined and dilated air vesicles which occur near pleural adhesions or near solidification of long standing, are spoken of as *vicarious emphysema*—the term *local* is a better one, for these large bullæ do less of the work of respiration and not more than a corresponding area of normal vesicles.

Extravasation of air into the lung substance as a result of injury is sometimes spoken of as *interlobular emphysema*; an unfortunate term, all true emphysema produces a gradual junction of several contiguous lobules, but never causes extravasation of air into the lung substance.

**Passive congestion of the lung** is present in disease of the valves of the left side of the heart, and most markedly in mitral stenosis. An increase in weight of the lung is discovered post-mortem.

**Hæmoptysis.**—The commonest post-mortem appearance after hæmoptysis is some form of tubercle.

Copious hæmoptysis may proceed from lungs without cavities, but with local or diffuse tubercle; though in these cases death rarely follows the hæmoptysis immediately.

After profuse hæmoptysis rapidly followed by death, an aneurysm on a branch of the pulmonary artery is almost invariably found, the rupture of which has led to the hæmorrhage. Such aneurysms only occur in tuberculous lungs.

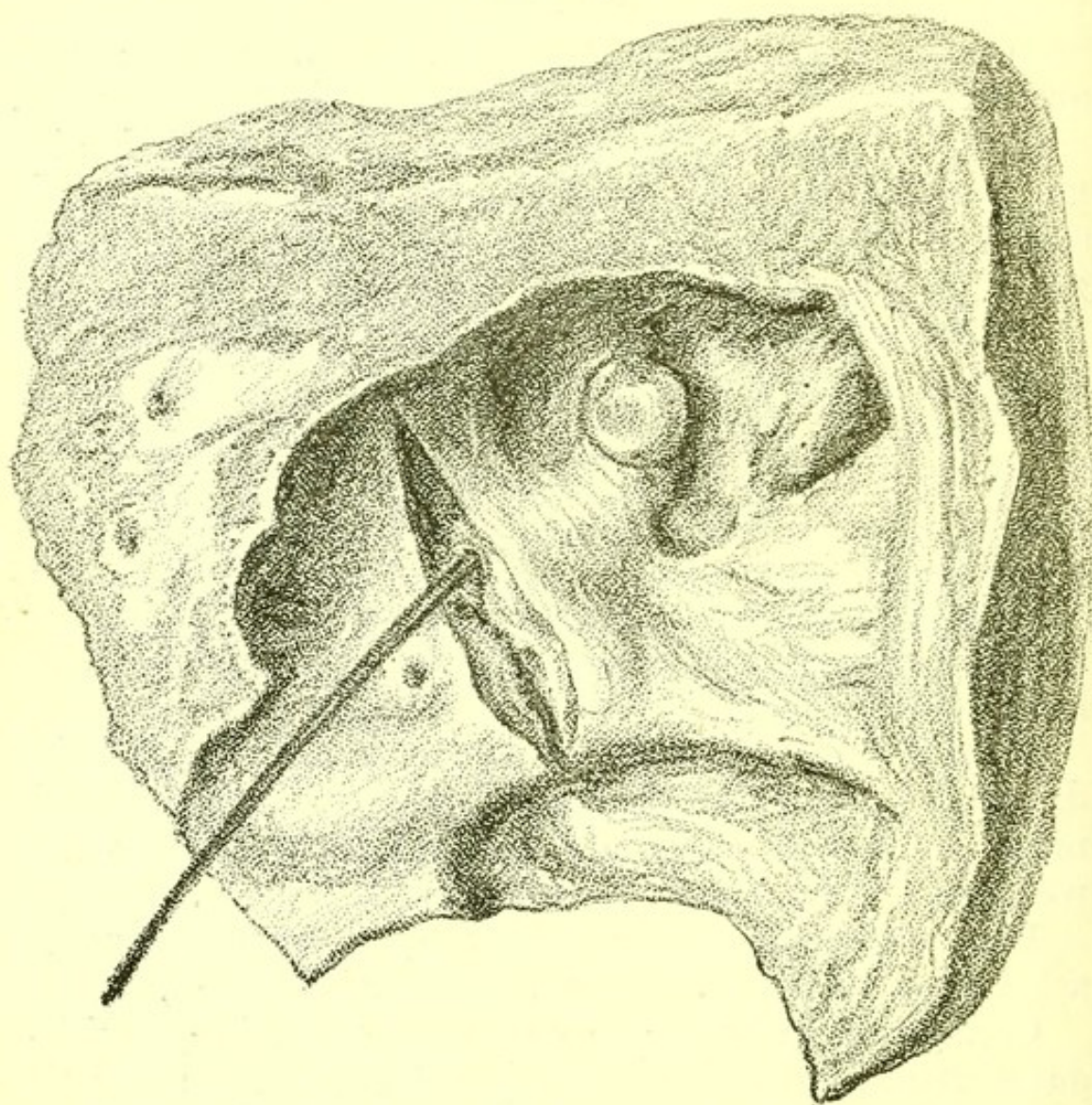
Slight hæmoptysis is sometimes due to scanty



hæmorrhage from the lining membrane of a cavity, or to the engorgement of small bronchi associated with plastic bronchitis.

Hæmoptysis also follows the inhalation of irritating gases such as ammonia, and redness of the mucous membrane of the bronchi is found post-mortem.

FIG. 64.



*Aneurysm of Pulmonary Artery, in a tuberculous cavity.*  
A bristle is passed into the artery which has become aneurysmal.

When hæmoptysis has occurred during valvular disease of the heart, hæmorrhagic infarctions of the lung are discovered post-mortem.

Finally, it must always be remembered that when



hæmoptysis has taken place during life, the hæmorrhage, though in nine cases out of ten coming from the lung, may have been due to an aneurysm opening into the trachea, or even to its penetration by a new growth. Either of these conditions may have existed without any symptom during life which distinctly pointed to the implication of the trachea.

Sometimes an aneurysm of the aorta is a cause of hæmoptysis, either by pressing upon some part of a lung or by bleeding into it.

**Œdema of the lungs** occurs as a part of general dropsy. The lungs are increased in weight and bulk, and pit on pressure. On section, large quantities of frothy fluid can be pressed out, from every part of the lung.

**Catarrhal pneumonia.**—When the inflammatory condition of the mucous membrane which is seen in bronchitis spreads to the minutest bronchi, infundibula and air vesicles, the condition is called catarrhal pneumonia, because the exudation consists of watery material containing epithelial cells shed from the surface as well as some leucocytes. From the fact that whole lobes are not affected, but only small groups of lobules, it is also named lobular pneumonia.

The affected vesicles are not always filled with exudation, and are rarely distended by it, but they are airless, and are easily recognized on the surface of the lung by their collapsed condition. On cutting into the lung they often appear as whitish solid specks, not unlike tubercles in an early stage of degeneration. They may be distinguished from tubercles by the fact that the exudation can with care be squeezed out, while tubercle seated in the actual tissue of the lung may be broken up, but cannot be removed by pressure.

Patches of catarrhal pneumonia are often found in infantile lungs, which in other parts show recently developed tubercle. Before the discovery of the tubercle bacillus, this was considered evidence of the change of catarrhal into tuberculous pneumonia, but it



is now clear that a child's lung which long remains in a state of catarrhal pneumonia affords a good nidus for the multiplication of tubercle bacilli should they reach it, and that catarrhal pneumonia may thus lead to true tuberculosis.

Catarrhal pneumonia may extend from one part of the lung to another, some vesicles clearing up and others becoming affected. Small patches often remain for a very long time at the lower edge of the lung, so that a permanent patch of collapsed lung, which never expands, is formed. This patch, which often extends all round the base of the lung, on section presents a honeycombed appearance, due to the uniform dilatation of numerous minute bronchi with thickening of their walls. An external depression of the chest walls corresponds to this patch of long-continued collapse.

Pleurisy, though not absolutely unknown, is very rare over patches of catarrhal pneumonia.

The presence of lymph on the surface of an airless consolidated patch of lung usually indicates that the pneumonia is not catarrhal, but is true lobar pneumonia with an exudation of leucocytes, completely filling the air vesicles.

The bronchial glands are sometimes enlarged, but to a much less degree than in lobar pneumonia.

Extensive catarrhal pneumonia is rarely seen except in children.

Under the microscope, sections of catarrhal pneumonia show cellular exudation adherent to the walls of air vesicles or partially filling them, the walls having usually fallen in upon the contained exudation, so that the air vesicles are never fully distended with inflammatory exudation as in lobar pneumonia.

**Lobar pneumonia.**—The pathological changes in lobar pneumonia affect the whole, or nearly the whole, of a lobe, sometimes a whole lung, and more rarely parts of both lungs, or the whole of one and part of the other.

Three successive stages may be observed in the



condition of the lung : the *first*, in which the lung is greatly engorged with blood while still permeable to air throughout, is rarely seen in the post-mortem room. In the *second* stage the pneumonic lobe or lung is in a state of deep inspiration. But its air vesicles and minute bronchi, instead of containing air, are filled with the inflammatory exudation of the disease—*i.e.*, with abundant leucocytes imbedded in a fine fibrin mesh-work. The lung feels heavier than natural, and may weigh as much as sixty ounces, but a more common increase in weight is an addition of from fifteen to twenty ounces to the normal weight of the lung. The pleural surface has always lost its gloss in places, and a large deposit of lymph may be present upon it. A fine granular roughening very distinct under a lens, but easily overlooked with the naked eye, is more often present. Every acute lobar pneumonia is a pleuropneumonia. Grooves marking the line of the ribs are occasionally to be seen on the surface of the solidified lung. On section, little or no fluid exudes. The section is pinkish and finely granular.

Under the microscope the walls of the air vesicles are seen to be unbroken ; their cavities are occupied by tightly packed inflammation cells, between which a fine mesh of fibrin may be traced ; a few red blood corpuscles may sometimes be recognized. Any small blood-vessels visible in the section are usually filled with blood corpuscles. The bronchial glands are swollen and soft. The mucous lining of the large bronchi is redder than natural. Where a whole lung or a whole lobe is not solidified, the part of the lung which still contains some air is very œdematous. Some writers have supposed this œdema to be the source of the fine crepitation heard early in pneumonia, and which gradually disappears before steadily increasing bronchial breathing. The bronchial breathing as heard by the stethoscope is clearly due to the conduction of a sound produced in the large bronchi to the surface by the solid lung. A compressed airless lung, on the surface of



which at some point there is a dense layer of fibrin touching both the parietal and the visceral surface, may produce at that spot a similar bronchial breathing ; thus the mere presence of bronchial breathing at a particular spot will not always prove the presence of a pneumonic patch of lung.

The lung in the third stage of pneumonia differs from that in the second in having a smooth instead of a granular surface on section ; the surface is, moreover, pale and bathed with purulent exudation, the result of the degeneration of the fibrin and leucocytes filling the air vesicles. Under the microscope, when the third stage has but just begun leucocytes are to be seen filling the air vesicles, but a fibrin network is no longer recognizable ; a little later complete disorganization of the leucocytes is visible ; the air vesicles are filled with granular material almost unstained by hæmatoxylin.

This exudation is ultimately coughed up, and the lung resumes its natural condition.

*Sputum.*—The frothy sputum of the first stage of pneumonia consists of mucus intimately mixed with air and containing a few epithelial cells. The rusty sputum of the second stage contains abundant red blood-cells, leucocytes, and blood pigment. The opaque sputum of the third stage chiefly consists of leucocytes, the contents of which have become granular.

*Appearance of other viscera :*

The liver is invariably swollen, engorged, and heavier than natural ;

The spleen is enlarged and soft ;

The kidneys are soft and enlarged.

*Cause of death :* pneumonia affecting only one lung is rarely by itself a cause of death. When no other anatomical changes are found, the probability is that the patient was exhausted before the onset of the pneumonia, by want of food or by excessive drinking. In most cases other morbid conditions are found which explain why the patient was unable to resist the



pneumonia. Of these, the commonest is emphysema of the opposite lung; this should be carefully sought for by examining the edge of the lung and by weighing it after squeezing; or, better, allowing the fluid it contains to drain out. Diminution below the natural weight may be taken as a measure of its emphysema. Renal disease in all its forms, and valvular disease of the heart, are also often discoverable as indirect causes of death.

*The Affection of Both Lungs.*—The consolidation of a large part of both lungs is, of course, in itself a sufficient cause of death, and there seems sufficient post-mortem ground for the common opinion that the affection of both apices is the most fatal form of pneumonia. When both lungs are affected, the pneumonic regions may be in the same stage in both, but it is also common to find one lung in a much less advanced stage than the other.

*Gangrene.*—In an ordinary case of pneumonia, however great the exudation into the vesicles, their walls remain uninjured, but sometimes a sudden necrosis takes place and a patch of lung becomes gangrenous. A ragged cavity with broken-down lung-tissue in the middle of it, and foetid sputum in the bronchi, are found.

Tuberculosis (q.v.) may supervene in a lung, the morbid changes of which were first affected by true pneumonia.

**Gangrene of the lung** is sometimes found near a very small patch of pneumonia, or a whole lobe of a pneumonic lung may have become gangrenous, and very rarely a lung which has long contained a tuberculous cavity may become gangrenous. The gangrenous part is of an ashen grey colour, and is either already broken down or breaks down when touched. It has a foetid odour.

Gangrene of the lung is sometimes the terminal lesion in diabetes. It is also a common incident of pneumonia, when it occurs in a lunatic or in a drunkard.



**Abscess.**—Multiple abscess of the lung occurs as part of pyæmia. The abscesses are generally near the pleural surface. They are more or less conical in shape and surrounded by a border of solidified lung, the whole abscess varying in size from a pin's-head to a filbert. The pus is ill-smelling and often blood-stained.

**Chronic Interstitial Pneumonia (Cirrhosis of the Lung, Fibroid Phthisis).**—This form of disease is an increase of connective tissue throughout the lung due to the inhalation of irritating dust, as of steel, porphyry, or coal.

The lungs are wasted but hard, the hardness being due to dense bands of connective tissue radiating from the root throughout the lung. Nodules of connective tissue of large size also occur in some cases. They are very firm, and generally deeply pigmented so as to look like lumps of india-rubber. Microscopic sections show in addition extensive wasting of the walls of the vesicles (emphysema).

The body is emaciated, the right heart is dilated, and the muscular tissue of the heart usually soft, brownish, and easily torn.

**Tuberculosis of the Lung.**—Tubercle was first studied in the lung, and may be defined to be an inflammation beginning in the lymphatic tissue, and due to the penetration of that tissue by a micro-organism, the tubercle bacillus. It is characteristic of the patches of inflammation thus caused, that they have a tendency to caseation of their cell contents, and to subsequent ulceration and slow inflammation of the surrounding tissues.

The term *phthisis* is clinical, and indicates a prominent symptom (the wasting of the body) accompanying tuberculosis of the lung. The word *phthisis* is most useful when regarded as a clinical equivalent of the pathological term *tuberculosis*.

The expressions :

Acute pneumonic phthisis,  
Chronic pneumonic phthisis,



mean tuberculosis with superadded symptoms of inflammation of the lung, so that post-mortem, besides the tubercle, some actual pneumonic consolidation is also discovered. These terms also contain a reminiscence of a pathological view which may now be considered obsolete, and which regarded tuberculosis as a further development of pneumonia.

When tubercle invades the lung, one of four subsequent conditions may occur.

These may be described as :

Acute tuberculosis ;  
 Rapid tuberculosis ;  
 Chronic tuberculosis ;  
 Obsolete tuberculosis.

In each the lung presents certain definite characters, but it must be borne in mind that the first may supervene during the course of any of the other three.

**Acute Tuberculosis.**—Sometimes called miliary tuberculosis. Both lungs are filled with minute grey or whitish tubercles.

There is no caseation, no ulceration, no increase of fibrous tissue in the lung.

The bronchial glands are often caseous.

Tubercle may be found on the pleuræ, pericardium, peritoneum, and pia mater.

The mesenteric glands may be caseous.

The liver, spleen, and kidneys may contain a few tubercles, and very rarely the pancreas also.

The spleen is enlarged and soft.

Sometimes acute pleurisy, and more rarely acute pericarditis, is present.

**Rapid Tuberculosis.**—Tubercle is usually present in both lungs, but more prevalent and advanced in one than in the other.

It has undergone various degrees of degeneration in various parts of the lung, softening, ulceration, and a consequent cavity being present at one or both apices. Such a cavity may be large and ragged, with



thickened irregular walls, and containing much purulent sputum, bacilliferous, and often blood-stained. There are some firm pleural adhesions.

Enlarged caseous bronchial glands are present.

The body is emaciated, and the muscular tissue, including that of the heart, is pale.

The spleen is soft and slightly enlarged.

Tuberculous ulcers may be found in the larynx, and in the ileum and large intestine.

This form of tuberculosis occurs at every age, but is least common in children.

**Chronic Tuberculosis.**—Both lungs are generally affected, often equally, more often unequally. One or more cavities are present. The cavities have thickened walls, and are often crossed by occluded vessels. Patches of tubercle which have undergone caseation, or even calcification, are often found, and throughout the lung there is a great increase of fibrous tissue wherever there is tubercle. In the parts not invaded by tubercle, dilated air vesicles are to be found.

The pleural surface is roughened, the pleura much thickened, and the pleural cavity often obliterated, by firm adhesion of the parietal and visceral layers of the pleura. These adhesions are often of cartilaginous hardness, and are sometimes calcified.

In spite of the loss of tissue in the cavities, the lungs are frequently heavier than natural, the increase of weight being due to the connective-tissue formation, the tuberculous material, and the thickened pleura.

Death may have been due to hæmorrhage, and if so, a small ruptured aneurysm (pin-head to pea size) may usually be discovered by slitting up the branches of the pulmonary artery.

Tuberculous ulcers are usually present in the ileum, and often in the large intestine, very rarely in the stomach.

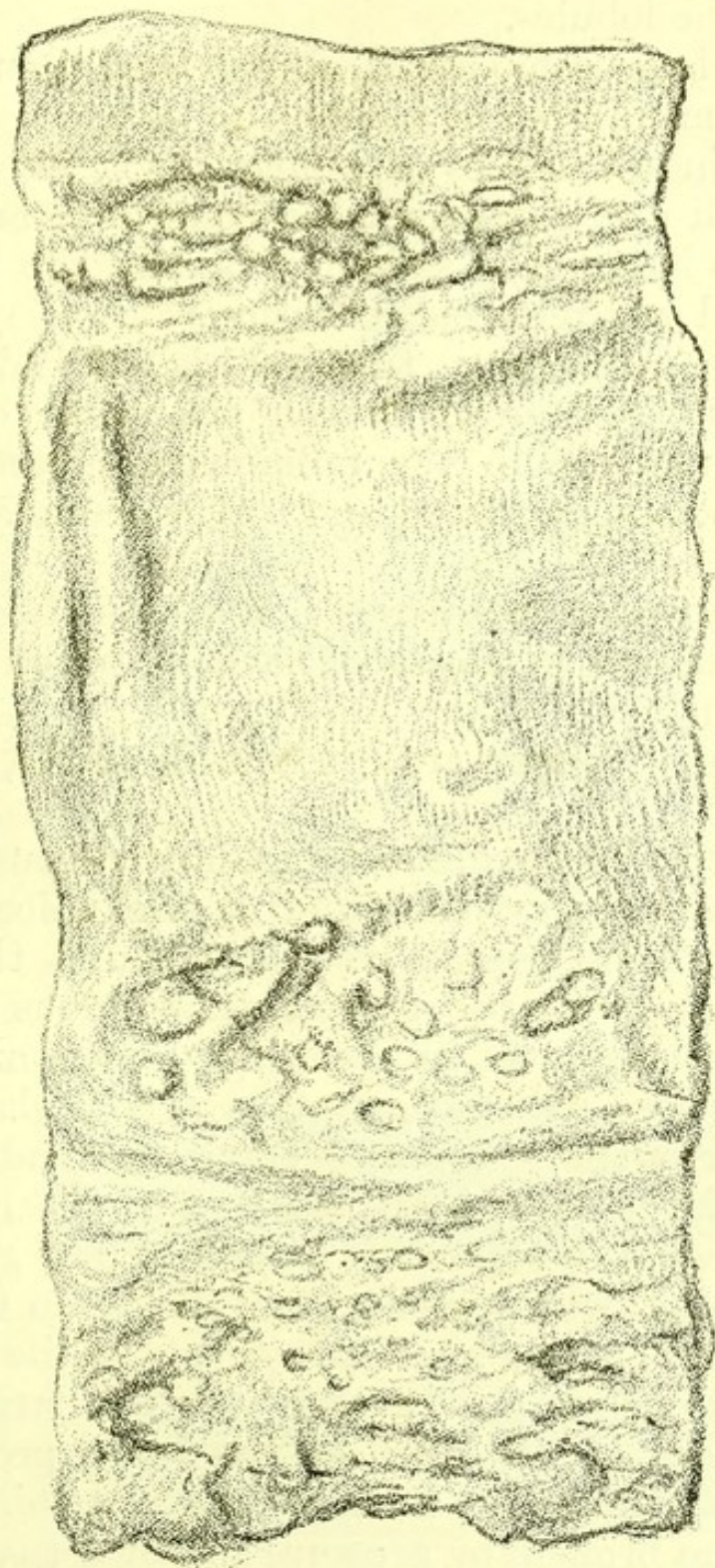
Tuberculous ulceration of the larynx is often present, and less frequently ulceration of the fauces.



The kidneys are rarely affected.


The body is emaciated, most of the subcutaneous fat having disappeared.

FIG. 65.



*Tuberculous Ulceration of Small Intestine.* From a specimen in the Museum of St. Bartholomew's Hospital.







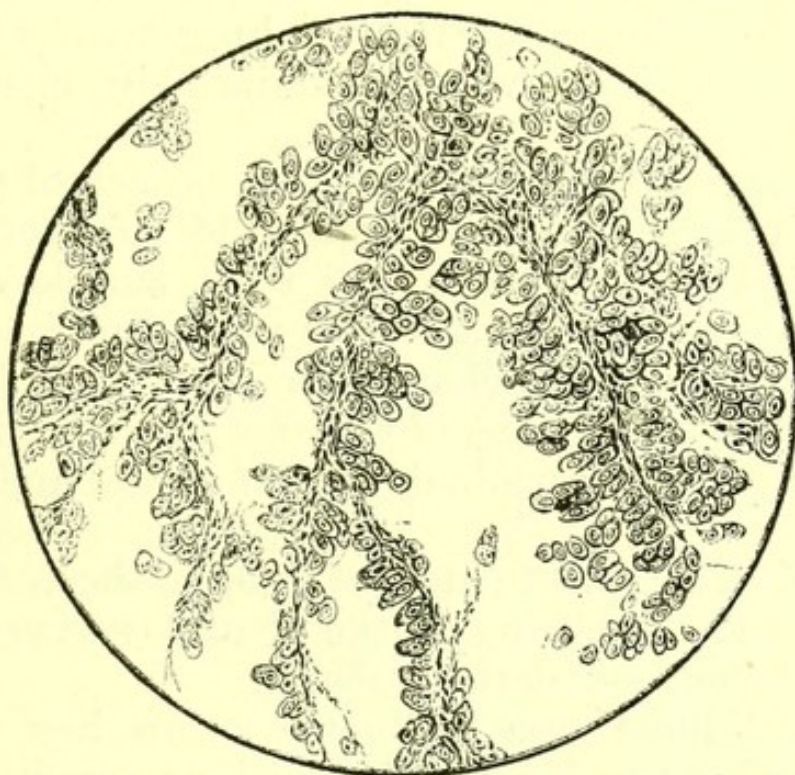
and the new growth has sometimes remote secondary deposits. These sometimes occur in the brain.

Secondary new growth in the lung appears on the pleural surface as thin, whitish-yellow, tallow-like patches, or as nodules of various sizes in the lung substance.

The primary growth is often in the breast, œsophagus or stomach.

Carcinoma of the œsophagus sometimes grows directly into the lung, but a solid patch adherent to a

FIG. 66.



*Microscopic Section of a Nodule of Endothelioma in Lung.*  
(Primary in the pericardium.)

carcinomatous œsophagus must not be assumed to be carcinoma without microscopic examination. It often proves to be merely pneumonic.

**Sarcoma.**—When primary, it occurs in the connective tissue about the root of the lung. It is indistinguishable in its naked-eye appearances from carcinoma, and penetrates the lung in the same way. It is accompanied by the formation of much dense connective tissue outside the small-celled new growth.



Secondary masses of sarcoma, often of large size, are often found in the lungs.

Osteo-sarcoma of the ribs may grow directly into the lung.

Endothelioma of the pericardium is often accompanied by a dense, whitish growth into the lung on one or both sides.

**Atelectasis and Collapse.**—Atelectasis or non-expansion of the lung at birth, when it affects part of a lung only, is recognized post-mortem as a depressed patch of darker colour than the rest of the lung.

In collapse due to pleural effusion, however complete, or of however long duration, the lung usually exhibits normal lung-tissue when examined in microscopic section.

**Hæmorrhagic Infarction.**—A branch of the pulmonary artery is frequently closed by an embolus.

A clot is formed in a dilated right auricle (usually in the appendix), or in a dilated right ventricle (either near the apex or just below the origin of the pulmonary artery), and a fragment of this clot is carried into the lung, plugging a terminal branch of the pulmonary artery.

A conical solidified patch of lung is the result, the base of the cone being on the pleural surface of the lung and the apex at the embolus.

This solidified area is known as an hæmorrhagic infarction of the lung, and the whole condition by a strange confusion of terms is sometimes called pulmonary apoplexy. Such infarctions project as dark spots on the surface of the lung. When the observer's finger is drawn over the surface of the lung the infarct is felt to have an abrupt edge. On the dark raised surface there is often a little lymph. On section from the base to the apex the conical form of the infarct is seen. It is of a dark purple colour.

Microscopic sections show it to consist of air vesicles tightly packed with blood corpuscles, and it may usually be distinguished microscopically from a section



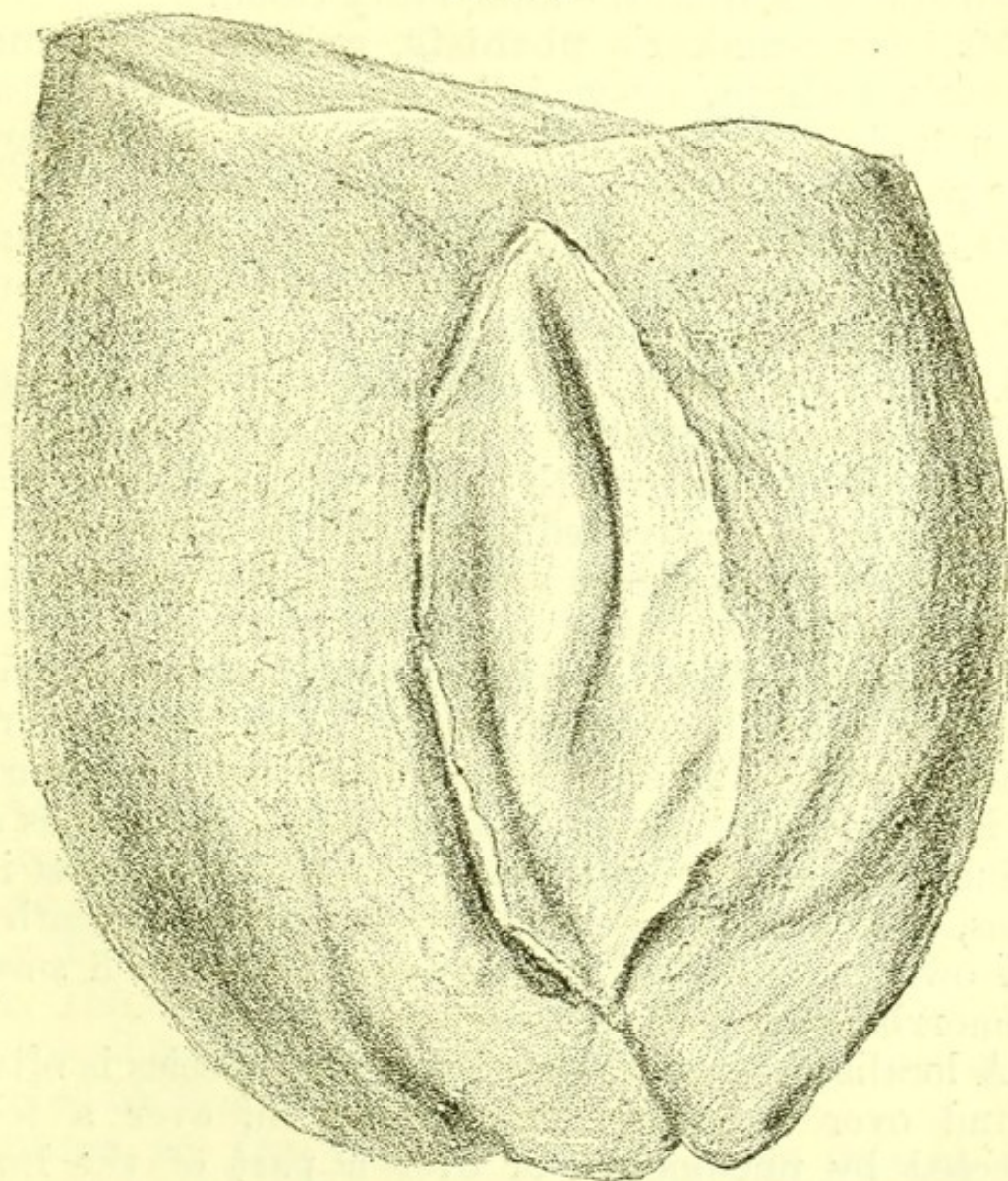
of pneumonia by the large number of red corpuscles visible. It is solid throughout.

Infarctions in later stages are rarely seen in the lung, and infarctions caused by passive emboli do not break down. When an embolus containing micro-organisms is carried into the lung a similar condition is observed, but the infarct rapidly breaks down, forming an abscess.

In cases of pyæmia many such abscesses are found in the lungs.

**Thrombosis of Pulmonary Artery.**—A firmly

FIG. 67.



*Hydatid of Lung.* From a specimen in the Museum of St. Bartholomew's Hospital.



adherent clot is sometimes found in a pulmonary artery or vein, and this condition is sometimes discovered post-mortem, when a patient has complained of sudden pain in the chest shortly before dying.

**Hydatid cysts** are not often found in the lung. They are commonest in the lower lobes, and have the same appearance as hydatids in the liver. Sometimes the sac has opened into a bronchus, in which case daughter cysts have generally been coughed up and may be found post-mortem in the bronchi. (See Fig. 67.)

The situation of the cysts generally suggests that the parasite has made its way into the lung through the diaphragm from the alimentary canal.

**Millstone-maker's phthisis, grinder's asthma, miner's asthma**, are varieties of chronic interstitial pneumonia, the distinction being one of etiology. The pathological change is the same in all.

**Hydrothorax.**—In general dropsy due to renal disease both pleural cavities contain fluid without any inflammatory exudation.

Pressure on the root of the lung due to aneurysm may produce a similar condition of one pleura. Pressure by a new growth on the root of a lung may produce some passive effusion, but is more often a cause of pleural effusion containing some blood and a little lymph.

**Pleurisy.**—When a friction sound accompanying respiration has been heard during life, fibrin is found post-mortem on one or both surfaces of the pleura. It is sometimes present in large flakes, sometimes as a fine granular deposit; near it the pleura has lost its gloss, and when it is stripped off the surface beneath is red owing to injected blood-vessels, near which small hæmorrhages are often to be seen.

A localized patch of pleurisy of this species is often found over a hæmorrhagic infarction, over a lobe affected by pneumonia, or over a part of the lung which is the seat of tubercle or of new growth.

When during life absolute dulness on percussion has



been present, with absence of vocal vibrations, post-mortem the pleural sac is found full of fluid, serous or purulent, while the lung is airless and compressed against its root. On the surface of the lung and on the parietal pleura flakes of lymph and patches of injection are present. If this condition has existed long the lymph has become organized and contains blood-vessels, and the lung in its collapsed state is firmly bound down. Microscopic sections show that even when it has long been thus bound down the collapsed lung contains all its normal structures intact, and is not atrophied.

A fourth variety of pleurisy is where no fluid has been present, but where the two surfaces have slowly been welded together by progressive inflammation and organization of the inflammatory products so that universal adhesion is present. This condition may occur after simple pleurisy, and is common where tubercle has infiltrated the whole lung. The adherent pleura may become very thick and of cartilaginous hardness, and may even contain large calcified patches.

Where an empyema has pointed externally, or a pleural fistula after paracentesis has long existed, necrosis of a rib may be found.

In this condition amyloid infiltration of the liver, spleen, kidneys, or small intestine is sometimes found.

**Pus in the pleural cavity** is generally due to empyema, but may rarely be the result of the rupture of an hepatic abscess through the diaphragm.

**Air in the pleural cavity**, when not due to a wound of the chest-wall or lung, may be discovered post-mortem as a result of:

1. The rupture of a tuberculous cavity in the lung;
2. The rupture of a bronchus; this rarely occurs except when the lung is collapsed against its root and covered by firm adhesions.

**Blood in the pleural cavity**, when present in quantity and not due to a traumatic cause, is a result of rupture of an aneurysm of the aorta, and a suffi-



cient quantity to have caused complete collapse of one lung is often found.

**Parasites.**—Hydatid precisely resembling that in the liver is sometimes found in a pleural cavity.

**New Growths.**—Sarcoma is sometimes, though rarely, primary in the pleura. As a secondary growth it is always present in osteo sarcoma of the ribs, and often in other cases.

Secondary carcinoma of the pleura is common and may be widely distributed in thin patches without penetrating the lung, though it more often occurs when some nodules are also found in the lung (q.v.).

**Tubercle of the pleura** occurs in general acute tuberculosis. In most cases of chronic phthisis, tubercle is found on some part of the surface of the lung with pleural adhesions, which are often extremely dense.

In many cases of phthisis the illness is said to have begun as pleurisy. The post-mortem evidence suggests that in most cases of this kind the inflammation of the pleura was due to the presence of tubercle and did not precede it.

**Pneumothorax.**—When air is found in the pleural cavity post-mortem (apart from injury), it is always associated with some pleural effusion, and its point of exit from the lung into the pleural cavity is usually discovered to be either through a rupture in the wall of a superficial tuberculous cavity or a rent in the bronchus leading into a partially collapsed lung tied up by adhesions.



## CHAPTER XIV.

## DISEASES OF THE DIGESTIVE SYSTEM.

## VARIETIES IN STRUCTURE :

HARE-LIP.  
 DIVERTICULUM OF ŒSOPHAGUS.  
 DIVERTICULUM OF STOMACH.  
 MECKEL'S DIVERTICULUM.  
 MULTIPLE DIVERTICULA.  
 OF VERMIFORM APPENDIX.  
 POINTED CÆCUM.  
 TRANSPOSITION OF CÆCUM.

## ULCERATION :

OF MOUTH AND FAUCES.  
 OF PHARYNX AND ŒSOPHAGUS.  
 OF STOMACH.  
 OF DUODENUM, JEJUNUM, ILEUM.  
 DISTINCTION BETWEEN ULCERS OF TUBERCULOSIS AND THOSE OF ENTERIC FEVER.  
 OF VERMIFORM APPENDIX.  
 OF LARGE INTESTINE.

## NEW GROWTHS :

COMMON SITUATIONS.

## STRICTURE :

SITUATIONS.

## HÆMATEMESIS :

## VOMITING OF PUS :

## FÆCAL VOMITING :

ANATOMICAL CAUSES.

## DIARRHŒA :

ANATOMICAL CAUSES.

## MELÆNA :

ANATOMICAL CAUSES.

## PERFORATION :

OF PHARYNX.  
 OF ŒSOPHAGUS.  
 OF STOMACH  
 OF DUODENUM.  
 OF SMALL INTESTINE.  
 OF VERMIFORM APPENDIX.  
 OF CÆCUM.  
 OF LARGE INTESTINE.

## LIPS :

SYPHILIS.  
 NEW GROWTHS.

## MOUTH :

ULCERATIVE STOMATITIS.  
 NOMA.  
 THRUSH.

## JAWS :

NECROSIS.  
 RICKETS.

## TEETH :

SYPHILITIC.

## TONGUE :

SCARS.  
 GUMMATA.  
 ABSCESS.  
 FUR.

## FAUCES :

HYPERTROPHY OF TONSILS.  
 QUINSY.  
 NEW GROWTH.



## SALIVARY GLANDS :

MUMPS.

## PHARYNX AND ŒSOPHAGUS :

POST-PHARYNGEAL

ABSCCESS.

SYPHILIS.

DYSPHAGIA.

NEW GROWTH.

## STOMACH :

HÆMORRHAGE.

GASTRITIS.

SIMPLE ULCER.

LARDACEOUS DISEASE.

POLYPUS.

CARCINOMA.

DILATATION.

CONTRACTION.

PERFORATION.

HERNIA.

DYSPEPSIA.

## INTESTINES :

HÆMORRHAGE.

CATARRHAL INFLAMMA-  
TION.SIMPLE ULCER OF DUO-  
DENUM.

LYMPHO-SARCOMA.

CARCINOMA.

TYPHLITIS.

COLITIS.

CARCINOMA OF RECTUM.

## LIVER :

JAUNDICE.

ASCITES.

INCREASED RESISTANCE  
IN THE HEPATIC RE-  
GION.

CATARRHAL JAUNDICE.

GALL-STONES.

CIRRHOsis.

LARDACEOUS OR AMY-  
LOID DEGENERA-  
TION.

NUTMEG LIVER.

ACUTE YELLOW

ATROPHY.

SIMPLE ATROPHY.

ABSCCESS.

FATTY LIVER.

CYST.

NEW GROWTHS.

TUBERCLE.

SYPHILIS.

PYLEPHLEBITIS.

HYDATID.

HEPATIC DUCT AND GALL-  
BLADDER :

INFLAMMATION.

ULCERATION.

NEW GROWTHS.

DILATATION OF GALL-  
BLADDER.

OBSTRUCTION.

PARASITES : FLUKE,

HYDATID.

## PANCREAS :

CALCULUS.

CIRRHOsis.

ABSCCESS.

THROMBOSIS.

CARCINOMA.

SARCOMA.

## PERITONEUM :

ASCITES.

## PERITONITIS :

ACUTE.

PYÆMIC.

PUERPERAL.

ADHESIONS.

WITH CLEAR FLUID.

TUBERCULAR.

CHRONIC.

## PARASITES :

HYDATID.

BILHARZIA.

## NEW GROWTHS :

SARCOMA.

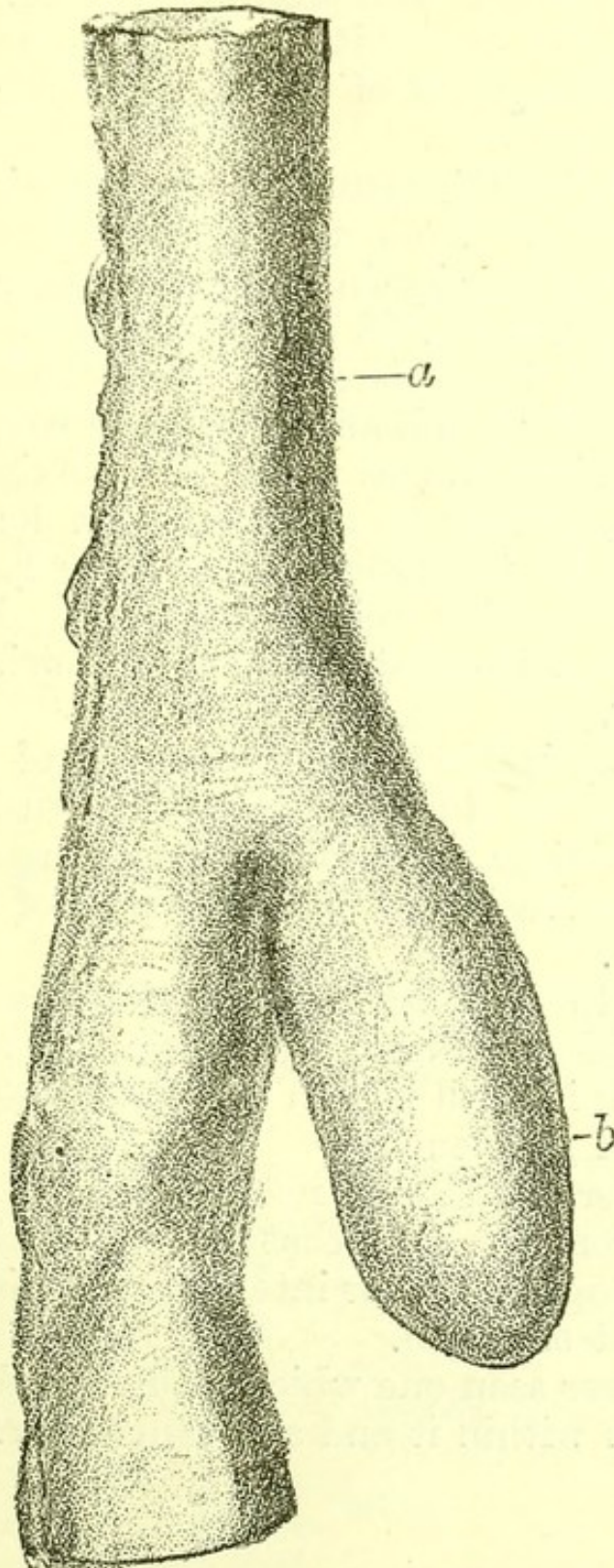
CARCINOMA.

**Hare-lip.**—A defective development, varying in degree, of the premaxillary, maxillary, or palate bones, is treated by surgery only, and is only mentioned



here as the most prominent congenital malformation or defective development of any part of the alimentary canal.

FIG. 68.



*Meckel's Diverticulum.* From a specimen in the Museum of St. Bartholomew's Hospital.



**Diverticula of the œsophagus** are sometimes large, more often of the size of a pea, and are probably the result of abnormal foetal buds from the proesenteron.

**Diverticulum of the stomach** is rare. The only example I have met with was at the cardiac end, closely resembling that of the pig's stomach, but much smaller.

**Meckel's Diverticulum.**—This occurs in the ileum about three feet from the ileo-cæcal valve as an elongated pouch, projecting from the unattached edge of the intestine. (Fig. 68.) It is sometimes as wide as the ileum, sometimes narrower; sometimes it is cone-shaped at the free end, and sometimes has a termination bent at right angles to the main axis. The tip may be free, or may be attached by a long cord of fibrous tissue to the umbilicus, or may have become adherent to another coil of intestine. Rarely the ileum is constricted at the point of origin of the diverticulum.

This variety is due to the persistence of part of the omphalo-mesaraic duct as was first shown by Meckel, before whose time these diverticula were thought to be hernial protrusions of the inner part of the wall of the intestine.

It is easy to demonstrate that the diverticulum is not a hernial protrusion by making a microscopic section, when its wall is seen to contain all the parts of the wall of the ileum.

Such diverticula are not very rare, and are important from the fact that they sometimes cause death by strangulating the intestine, or by obstruction at their point of origin.

I have never seen one which had caused death by accumulation within it and subsequent perforation of its wall.



*Table of Twenty Cases of Meckel's Diverticulum.*

The following Table shows twenty examples, of which two were observed by Dr. Gee and the remainder by myself at St. Bartholomew's:

Sex.	Age.	Position and Size.	Stricture and Adhesions.	Cause of Death.
M.	17	4 ft. 6 in. above valve.	Neither.	Enteric fever.
F.	23	1 ft. 8 in. from ileo-cæcal valve; $2\frac{3}{4}$ in. long, as wide as ileum.	Neither.	Pneumonia.
M.	24	3 ft. above valve, 3 in. long, nearly as wide as the intestine.	Neither.	Valvular disease.
M.	25	3 ft. above valve.	Distinct constricting ring at origin of diverticulum.	Tubercular meningitis.
M.	25	2 ft. 6 in. above valve, 3 in. long.	Tip adherent to dorsal attachment of mesentery.	Obstruction.
M.	29	3 ft. above valve, $1\frac{1}{2}$ in. long.	Neither.	Poison.
M.	29	3 ft. above valve, large.	Neither.	Valvular disease and psoas abscess.
F.	Adt.	1 ft. 6 in. above valve, $1\frac{1}{8}$ in. long.	Neither.	Valvular disease.
M.	32	$3\frac{1}{2}$ ft. above ileo-cæcal valve, $2\frac{1}{4}$ in. long.	Neither.	Pneumonia and mitral stenosis.
F.	34	6 ft. above valve.	No internal stricture. Adherent to omentum.	Obstruction (post-mortem by Dr Gee).
M.	36	3 ft. 6 in. above valve; $1\frac{1}{2}$ in. long, very broad.	Neither.	Phthisis.
F.	39	3 ft. above valve.	No internal stricture. Adherent to omentum.	Obstruction (post-mortem by Dr. Gee).
M.	39	2 ft. 6 in. above valve, $2\frac{3}{4}$ in. long. It was bent upon itself at a right angle, and ended in a small globular cavity.	Neither.	Bronchitis.



Sex.	Age.	Position and Size.	Stricture and Adhesions.	Cause of Death.
F.	40	3 ft. above valve.	No internal stricture. Tip adherent to mesentery.	Mitral disease.
M.	42	4 ft. above valve, 5 in. long; equal in calibre to ileum.	Neither.	Disease of aortic valves.
M.	46	3½ ft. above valve, 1½ in. long.	Neither.	Pneumonia.
M.	46	2 ft. 6 in. from ileo-cæcal valve; 3½ in. long.	Neither.	Hydatid of liver.
M.	50	3 ft. above valve, globular in shape.	Slight internal narrowing of ileum.	Pleurisy.
M.	58	3 ft. above valve, 3½ in. long.	Neither.	Lymphadenoma.
M.	59	4 ft. above valve.	Neither.	Chronic interstitial nephritis.

In three out of the twenty cases the abnormality led to fatal obstruction.

**Other diverticula of the small intestine** are very rare. The following is the only example I have met with:

In a man, aged forty, the intestines showed three diverticula in the first three feet of the small intestine, and a congenital stricture at the commencement of the jejunum. The diverticula were each an inch long and about as much in diameter, and were on the mesenteric side of the intestine. Their walls consisted of all the intestinal coats and they were not mere hernial protrusions. The stricture, which was at the point where the duodenum ends and the jejunum begins, was caused by an internal ring of mucous membrane which would but just admit the little finger. It was obviously a variety in development and not due to any morbid change. Neither peculiarity had given rise to symptoms, and the man died of bronchitis.



The **vermiform appendix** shows considerable variety as regards its length, and precise relation to the cæcum and to its peritoneal covering.

**Pointed Cæcum.**—Sometimes the cæcum is found ending a long narrow point as it does in the Felidæ.

**Transposition of Cæcum.**—The position of the cæcum and of the sigmoid flexure are occasionally reversed without general transposition of the viscera.

**Ulceration of the Alimentary Canal.**—It may be useful to enumerate the several forms of ulceration which occur in the alimentary canal.

*Mouth*: shallow ulcers the sequel of catarrhal inflammation are common, and are often confined to the epithelium. Carcinoma may produce an ulcerated surface. Syphilitic ulcers occur both on the walls and on the tongue. They begin as minute gummata, and as they progress lead to a large formation of fresh connective tissue. The soft palate and uvula, the mucous and bony parts of the hard palate, and tracts of the muscular substance of the tongue are destroyed, and after healing permanent scars always remain.

Later ulceration in contiguity to these scars is also common, and is probably due to imperfect nutrition of the normal tissues near the contracted scar tissue, and not to fresh gummata.

*Fauces and pharynx*: the tonsils are the seat of abscess and of consequent loss of substance, owing to acute infiltration in quinsy, and all parts of the fauces and pharynx may exhibit deep ulceration with hæmorrhage and destruction of the submucous tissue in diphtheria.

*Œsophagus*: the œsophagus (excluding the results of corrosive poisons) is rarely ulcerated, except as a result of carcinoma in its walls.

*Stomach*: two forms of ulceration are common in the stomach—

1. Simple ulcer;
2. Ulceration associated with new growth.



Several months after the swallowing of nitric or oxalic acid the stomach may show numerous ulcerated patches, some shallow, and some reaching the muscular coat. Examples of this kind are rare.

In cases of phthisis one or more tuberculous ulcers may be found in the stomach. They rarely occur and are generally smaller than a silver penny.

*Duodenum*.—Sharply bounded ulcers resembling simple ulcer of the stomach are found, but are much rarer than gastric ulcer.

Ulceration due to a new growth, usually to one which has penetrated from the peritoneal surface, is found.

Ulceration is sometimes to be seen about the orifice of the common bile duct when very large gall-stones have passed.

*Jejunum*.—Simple sharply bounded ulcers occur in the jejunum, but much less often than in the duodenum.

Ulceration from new growth is also rare.

*Ileum*.—The chief forms of ulceration are:

1. Ulcers in Peyer's glands in enteric fever;
2. Tuberculous ulcers;
3. Ulceration near points of obstruction and near new growths.

Ulceration due to new growth may occur, and even lead to perforation of the bladder. A sarcoma penetrating from the peritoneal surface is the commonest variety.

*Distinction between Tuberculous Ulcers and the Ulcers of Enteric Fever*.—The ulcers of enteric fever are always confined to glands, and never spread to the whole surface of the mucous membrane.

They are at first occupied by a slough, and later have thin and often overhanging edges, best seen when the ulcer is placed under water.

The ulcers frequently perforate the peritoneum.

Tuberculous ulcers may occupy the whole surface of



the mucous membrane, sometimes encircling the intestines. Their edges are thick. Tubercle may sometimes be seen in the floor of the ulcer when it is looked at from the peritoneal surface. The process of ulceration is slow, and the ulcers are never occupied by a slough.

The ulcers hardly ever perforate the peritoneum.

*Vermiform Appendix.*—Ulceration, often succeeded by perforation, occurs when a foreign body is lodged in the appendix. The commonest matters found are fruit-stones and small hardened masses of fæces. The ulceration sometimes occurs at the tip, and frequently at some other point in the wall of the appendix.

Perforation into the peritoneum is followed by a copious deposit of lymph, and afterwards by general peritonitis.

Perforation outwards frequently leads to formation of an abscess in the abdominal walls which may open externally.

*Large Intestine.*—The whole large intestine is a common seat of ulceration due to dysentery and to tubercle. In many prolonged cases of enteric fever it contains ulcers.

Dysenteric ulceration occurs in large patches, and in the chronic stages parts of these are found partially healed with much pigmentation and contracted scar tissue.

Tuberculous ulceration in the large intestine does not differ in character from that in the small intestine.

Extensive and diffuse ulceration of the large intestine occurs in prolonged cases of enteric fever: and in death after the fortieth day of the fever it is not a rare post-mortem appearance. The ulcers are very like those of acute dysentery. I have seen one or two cases only of perforation in such examples.

*Cæcum and Ascending Colon.*—These are a seat of carcinoma of a slow-growing variety, and in such cases ulceration is always present over the new growth.

*Transverse and Descending Colon.*—These also are



affected by ulceration due to new growth. They are an occasional seat of ulceration following syphilitic stricture.

*Rectum.*—Ulceration of the rectum is due to—

1. New growth in the wall;
2. Syphilitic stricture;
3. Perforation of the bowel from an external abscess (fistula).

The ulceration when due to new growth may penetrate the bladder or the peritoneum.

**New Growths in the Alimentary Canal.**—The commonest forms of primary new growth found in the alimentary canal are:

*Carcinoma of the Lips and Tongue.*—Generally of the squamous-celled variety with numerous cell nests.

*Carcinoma of Œsophagus.*—Most common at the upper and lower end. Generally of columnar or spheroidal cells.

*Carcinoma of Stomach.*—Most common at the pylorus, next in the whole wall, least often at the cardiac end. Of columnar or spheroidal-celled varieties.

*Lympho-sarcoma of mesenteric glands,* penetrating the wall of the duodenum, jejunum, and ileum, or some of them.

*Carcinoma of cæcum,* often adherent to and growing into the duodenum.

*Carcinoma of descending colon and rectum,* generally columnar-celled. Often accompanied by much thickening and ulceration. Sometimes penetrating the bladder.

**Stricture.**—It is useful to consider seriatim the several points at which stricture of the alimentary canal may be found post-mortem and its nature in each situation.

*Pharynx and Œsophagus.*—Narrowing may occur throughout or at any point when due to formation and contraction of scar tissue after swallowing a corrosive poison.



It may be produced at any point by external pressure of a tumour, or may occur at the site of a carcinoma.

*Stomach*.—An hour-glass stomach is one contracted in the middle, owing to a scar of a healed or partly healed gastric ulcer.

Carcinoma of the pyloric end is the only other frequent cause of stricture.

*Duodenum*.—Stricture is found in the duodenum due to—

1. Congenital narrowing ;
2. Carcinoma ;
3. Very rarely the scar of a simple ulcer.

*Small intestine* may show stricture (*a*) at any point, owing to—

1. Volvulus or external pressure ;
2. New growth ;

(*β*) nearer the ileo-cæcal valve than the jejunum, and generally within three feet of the ileo-cæcal valve at the offset of a Meckel's diverticulum.

*Ileo-cæcal Valve*.—Stricture at this point is rare. I have found it twice due to old inflammation without new growth.

It may of course be also due to new growth.

In one example, the patient was a man, aged forty-seven, who died in St. Bartholomew's Hospital under the care of Dr. Andrew. He had an attack (his first) of obstruction of the bowels on October 18. The bowels not having acted up to November 1, on that day colotomy was performed by Mr. Howard Marsh. At the time there was no relief, but the next day a quantity of fæces came through the wound. The patient died on November 4. The wound showed no unhealthy suppuration. The intestines above and below contained a considerable quantity of soft fluid fæces, but were not greatly distended. The stomach was normal. The small intestine was dilated, œdematous, and reddened ;  $3\frac{1}{2}$  inches above the valve



it showed extensive irregular ulceration, which extended all round. Some of the ulcers seemed healing, and there were many puckerings where healing had been complete. The ridge of the ileo-cæcal valve was very low, and the orifice was so contracted that it would but just admit a large probe. Below the valve for 3 inches there was a less degree of ulceration. The colotomy wound was 2 inches below the valve.

*Large Intestine.*—Stricture due to syphilis and to new growth may also occur in any other part of the large intestine, or it may be caused by the contracted and pigmented scars of old dysenteric ulceration. Stricture is commonest in the rectum owing to

1. The scar tissue of old inflammation ;
2. New growth ;
3. Fresh connective tissue formation due to syphilis.

**Hæmatemesis.**—After copious vomiting of blood, one of several anatomical changes may be found, and the commonest of these, taking all cases without classification, is cirrhosis of the liver, and the next most frequent, simple ulcer of the stomach. The rupture of an aneurysm into the stomach or capillary hæmorrhage in purpura are rarer conditions, and a still less common one is engorgement due to obliteration of the portal vein from pylephlebitis.

Scanty hæmatemesis, in which the blood is partially digested before it is vomited, points to a shallow ulcerated surface, such as is a common accompaniment of carcinoma of the gastric wall.

**Vomiting of Pus.**—When a patient during life has vomited pus, one of the following conditions may be discovered post-mortem :

1. An abscess in one or both tonsils ;
2. An abscess in the fascia in front of the vertebræ bursting in the pharynx, often associated with caries of the cervical vertebræ ;
3. An hepatic abscess bursting into the stomach.

**Vomiting of Fæces.**—After vomiting of fæces one



of the following conditions will probably be discovered post-mortem :

1. Strangulation of some part of the small intestine by hernia, by twisting, by old bands of adhesion, or by a diverticulum ;

2. Intussusception of some part of the small intestine ;

3. Extension of a new growth from the cæcum into the duodenum.

**Diarrhœa.**—The anatomical changes of which diarrhœa is a symptom are :

1. Catarrhal inflammation of any part of the intestine ;

2. Ulcers of choleraic inflammation of the mucous membrane ;

3. Enteric fever ;

4. Tuberculous ulceration ;

5. Ulceration due to new growth in the intestinal wall ;

6. Amyloid disease of the intestine ;

7. Dysenteric ulceration in the large intestine.

**Melæna.**—Blood may be passed from the bowel in small quantities as a result of bleeding from hæmorrhoids. When in larger quantities so as to constitute true melæna, one of the following conditions may be discovered post-mortem :

1. Cirrhosis of the liver ;

2. New growth, in any part of the intestine ;

3. Dysenteric ulceration of large intestine ;

4. Ulcers of enteric fever ;

5. Purpura ;

6. Aneurysm opening into any part of the alimentary canal ;

7. Gastric ulcer, though most of the blood poured out in this condition is vomited, as is also the case in blocking of the portal vein ;

8. Pylephlebitis ;

9. Intussusception, especially in children ;

10. Leucocythæmia ;



11. The presence of a corrosive or irritant poison, a mineral acid, arsenic, phosphorus, or cantharides.

**Parasites.**—The following may be present :

1. *Ascaris lumbricoides* in the duodenum.
2. *Dochmius duodenalis* also in the duodenum.
3. *Tænia solium* and *Tænia medicanellata* in the small and in the large intestine.
4. *Trichocephalus dispar* in the cæcum.
5. *Bilharzia hæmatobia* in any part of the intestinal wall.
6. *Oxyuris vermicularis* in the rectum.

**Perforation** may be found—

1. In the pharynx, most commonly with retro-pharyngeal abscess, with or without disease of the vertebræ.

2. In the œsophagus with carcinoma. It may have taken place into the pericardium, lung, or pleura.

Or it may be found with aneurysm of the aorta which has eroded the œsophagus.

3. In the stomach, often in the floor of a simple ulcer.

Very rarely at the edge of a patch of carcinoma, sometimes with destruction due to a corrosive poison.

Or owing to an hepatic abscess, or an aneurysm bursting into the stomach.

4. In the duodenum with simple ulcer, and very rarely with new growth, or with gall-stone.

5. In the small intestine, commonly in the floor of an ulcer of enteric fever; very rarely in a tuberculous ulcer, sometimes with new growth.

6. In the vermiform appendix, with abscess due to impacted material; more rarely to a small ulcer without impacted material.

7. In the cæcum with new growth, with abscess pointing externally or internally.

8. In the large intestine very rarely, in the ulceration which may occur in enteric fever; also rarely with tubercular ulceration.



With new growth the whole surface of the colon may be fenestrated with holes.

### LIPS.

**Syphilia.**—A syphilitic sore may sometimes be discovered on the lips. I have never seen one in the post-mortem room, but once or twice among out-patients during life.

**New Growth.**—Carcinoma with cell nests, often called epithelioma, is common in the lips, most often in the under-lip. It often exists with secondary growths.

### MOUTH.

**Ulcerative Stomatitis.**—Shallow ulcers on the mucous membrane of the mouth, sometimes accompanied by enlargement of the glands about the lower jaw, are all the observations to be made post-mortem.

**Noma** is a term applied to a gangrenous condition of the walls of the mouth. Post-mortem necrosis of the facial bones is sometimes discovered in association with it.

**Thrush.**—Patches of *oidium albicans* are to be seen during life in the mouths of dying people, and may be sometimes noticed post-mortem.

### JAWS, TEETH, AND GUMS.

**Jaws.**—Necrosis of the inferior maxilla in chronic poisoning by phosphorus, and abscesses in connection with carious teeth, should be looked for.

Some observers have stated that in rickets the periosteum of the jaw is abnormally thick.

**Teeth;** in post-mortems on cases of scurvy, the teeth are loose and the gums infiltrated, and with attached blood-clots.

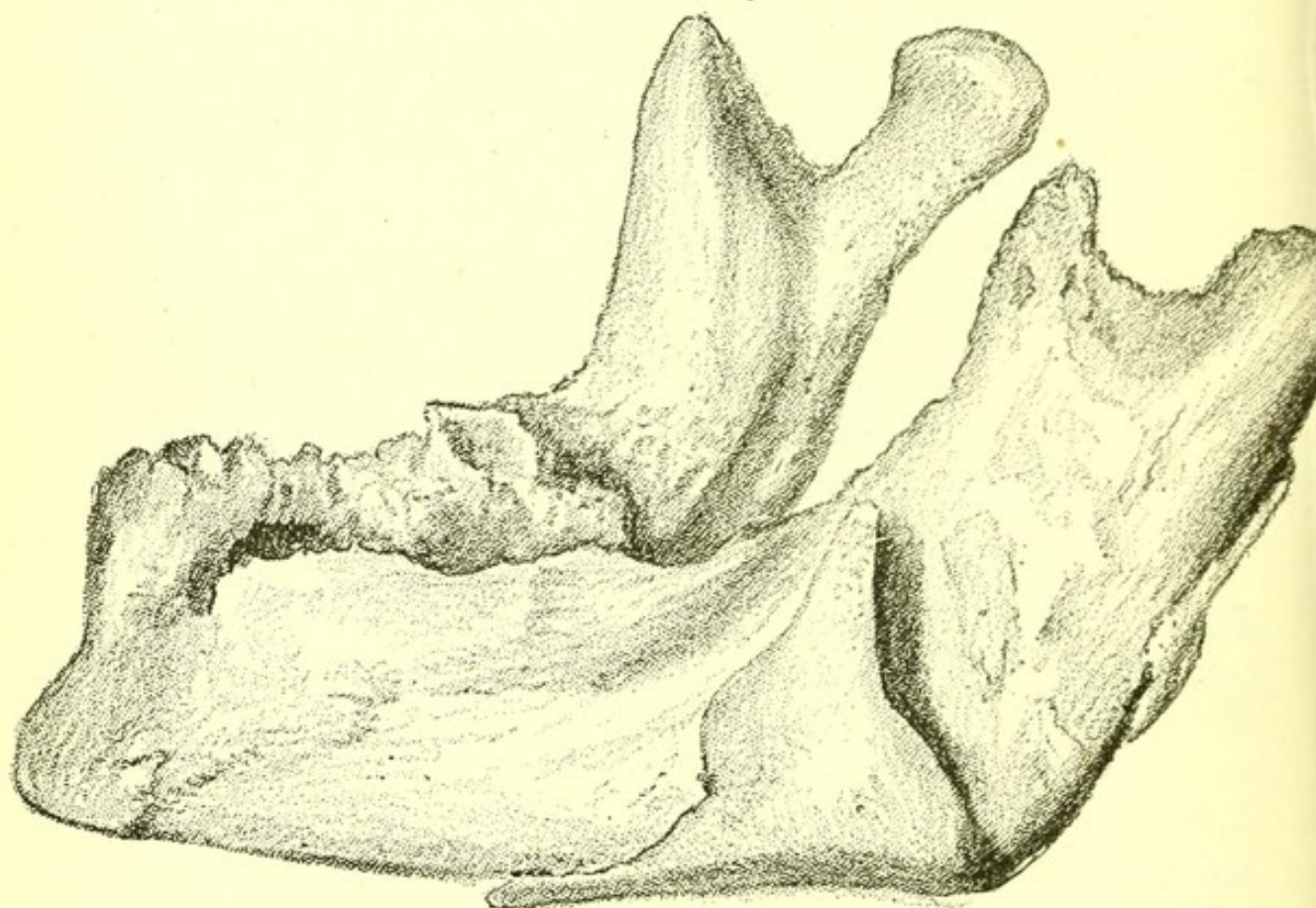
Ill-formed incisors in children accompany anatomical appearances of congenital syphilis, and as they are sometimes spoken of as Hutchinsonian teeth, it may be well to quote the description given by their dis-



coverer, Mr. Jonathan Hutchinson, the present President of the Royal College of Surgeons, to whom several other valuable additions to medical knowledge are due.

“If the upper central incisors are dwarfed, too short and too narrow, and if they display a single central cleft in their free edge, then the diagnosis of syphilis is almost certain. If the cleft is present, and the dwarfing absent, or if the peculiar form of dwarfing be

FIG. 69.



*Necrosis of Jaw*, from a case of chronic poisoning by phosphorus.

present without any conspicuous cleft, the diagnosis may still be made with much confidence. Usually the conditions are symmetrical, but now and then they are notably one-sided.”

### TONGUE.

Morbid conditions of the tongue are not often seen in post-mortem examinations of cases from the medical wards of a hospital.



Scars due to epileptic bites may sometimes be the only post-mortem indication of epilepsy.

Gummata are sometimes discovered, or scars due to syphilitic ulceration.

An absent tongue (removed surgically) may sometimes explain the presence of nodules of carcinoma elsewhere.

Abscess beneath the tongue or in it, calculus in the sublingual duct, or thickened and dilated duct after long obstruction by calculus, or the calculus itself may be found.

The black or brown fur of the febrile condition of course remains after death.

## FAUCES.

**Hypertrophy of Tonsils.**—Continued enlargement of the tonsils is due to repeated attacks of inflammation. They may be so large as almost to meet in the middle line when free from inflammation.

This condition in children is accompanied by a cup-shaped depression in the middle line at the lower part of the sternum due to the collapse of parts of the edge of the lung, and is removed when the inspiratory current of air is increased by removal of the large tonsils.

Microscopic sections show a general hypertrophy of the gland.

**Quinsy.**—An acute inflammatory enlargement, with consequent ulceration of both tonsils. Death is very rare in quinsy, and when it occurs œdema glottidis is to be looked for as the immediate cause.

**New Growths of Tonsils.**—Sarcoma of the tonsil, and less often carcinoma of this part of the mouth, are both known.

## SALIVARY GLANDS.

**Salivary Glands.**—Mumps or acute inflammation of the parotid gland is never fatal. In pyæmia or



with salivary calculus, an abscess is sometimes found in a salivary gland.

### PHARYNX AND ŒSOPHAGUS.

**Post-pharyngeal abscess** is often found compressing the pharynx or opening into it. At the bottom of the abscess a necrosed piece of a body of a vertebra may be found.

**Syphilis of Pharynx.**—Ulceration and contraction of the pharynx due to fresh connective tissue formation occur as results of syphilis.

**Dysphagia.**—When during life dysphagia has been a symptom one of the following appearances is likely to be found post-mortem :

1. Aneurysm or other tumour pressing on the œsophagus.

2. New growth of the œsophagus.

3. Acute pericardial inflammation.

4. Stricture due to scar tissue.

But in some cases of undoubted dysphagia the œsophagus has been found, post-mortem, without obvious lesion.

**New growth in œsophagus** is generally carcinoma with much stroma and flat spheroidal or columnar cells in the meshes of the stroma.

When it becomes adherent to the lung it may grow into it.

More often, however, it allows fragments of food to pass into the lung, producing a patch of pneumonia which usually terminates in gangrene.

The following is a typical example of carcinoma of the œsophagus :

○ The patient was a man, aged fifty-six. His first symptoms of dysphagia were in May, and he died in December, so that the duration of the new growth was about eight months.

The new growth was at the middle third of the œsophagus. It infiltrated the whole wall, and had



DIAGRAM III.—Carcinoma of Oesophagus. (FIFTEEN CASES.)

AGE	Oesophagus	LYMPHATICS	HEART	LUNGS	THYROID	PERITONEUM	LIVER	PANCREAS	SPLEEN	KIDNEY	ADRENAL	TESTIS	OVARY	UTERUS
40														
46														
50														
52														
53														
53														
54														
54														
55														
56														
56														
56														
58														
62														
67														

The black squares show the regions in which the secondary growths were found. All were in men.  
 (All examined microscopically.)

[To face page 272.]



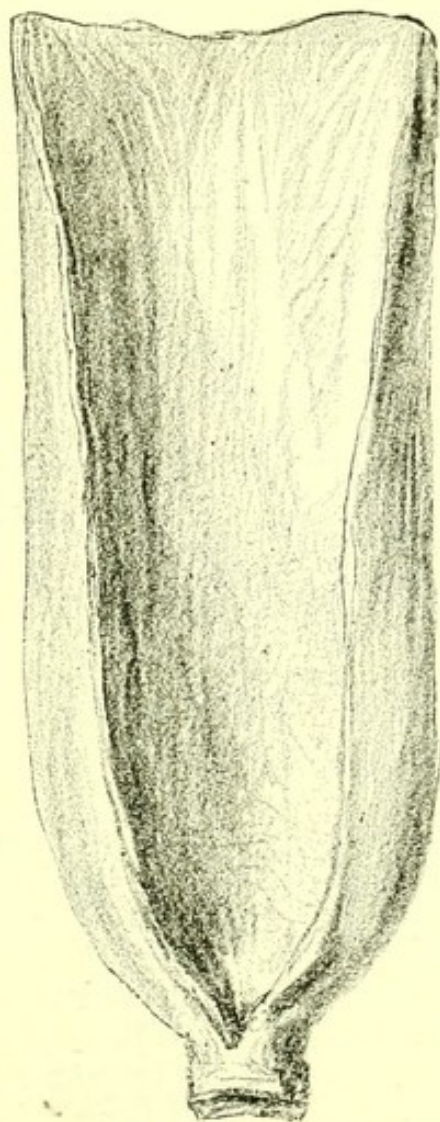



caused a stricture, just admitting a large probe. The œsophagus was adherent to the lung, and at the point of adhesion its wall was perforated. The lung at this point was pneumonic, not gangrenous.

Secondary masses were shown in the small intestine, liver, spleen, mesenteric glands, and both lungs, and there was one nodule in the outer wall of the left

FIG. 70.



*Carcinoma of Lower End of Œsophagus.*

ventricle. All had been examined microscopically, and showed a large-celled epithelial growth with an abundant stroma, exactly similar in character to the primary growth in the œsophagus. All the secondary masses were very firm, and those in the ileum were of the same shape as the new growth in the œsophagus



—that is to say, they encircled the tube and infiltrated all its coats.

The following table of ten cases of carcinoma of the œsophagus, examined post-mortem by me at St. Bartholomew's Hospital, illustrates the situation of the new growth and of its secondary growths. A microscopic examination was made in every case.

*Table of Ten Cases of Carcinoma of Œsophagus.*

Sex.	Age.	Part of Œsophagus.	Adhesion and Growth by direct Infiltration.	Secondary Growths.
M.	52	Lower third	o	o
M.	53	Lower third	o	o
M.	54	Lower third	Bronchial glands	Heart, liver, kidney, supra-renal.
M.	54	Lower third	Right bronchus and bronchial glands	o
M.	56	Lower third	o	Pericardium, pleura, liver.
M.	62	Lowest part	Right lung	Liver, glands in hilum of liver.
M.	55	Middle	Glands of posterior mediastinum	Lumbar glands, heart, lungs, liver, kidney.
M.	56	Middle	Bronchial glands Left bronchus and lung	Left lung.
M.	67	Middle	o	One bronchial gland, and one cervical gland.
M.	40	Whole length	Glands of posterior mediastinum	Cervical glands, lumbar glands, liver.



The duration of the growth, probably owing to its situation causing serious interference with nutrition, is short. It is worthy of note that all the examples are in males. Carcinoma of the œsophagus is very rare in women. A Table showing the distribution of secondary growths in carcinoma of the œsophagus is given at the end of this chapter.

## STOMACH.

**Hæmorrhage.**—Hæmorrhage from the stomach may proceed from the capillaries of the mucous membrane or from a larger vessel, generally from an artery.

The commonest post-mortem condition when capillary hæmorrhage has occurred is cirrhosis of the liver. At the post-mortem the stomach may sometimes be found full of blood. More often there has been hæmatemesis and the stomach contains only a little blood. However much blood there may be in the stomach after death, or may have been vomited during life, no breach of surface of the mucous membrane is discoverable.

Extensive capillary hæmorrhage is also to be found in cases of occlusion of the portal veins due to pylephlebitis.

Smaller capillary hæmorrhages into the mucous membrane are found post-mortem in cases of purpura and of valvular disease of the heart, and they are often present in cases of diabetes.

Hæmorrhage from larger vessels and from capillaries occurs in corrosive poisoning.

Hæmorrhage from larger vessels is often due to rupture of a small aneurysm in the floor of a gastric ulcer. (See Fig. 71.)

The hæmorrhage in carcinoma of the stomach generally comes from the edge of the ulcerated surface.

Aneurysm of a large branch of the aorta, or of the aorta itself, may sometimes be discovered post-mortem to have burst into the stomach.

**Gastritis.**—After acute gastritis hæmorrhages are



often to be found in the mucous membrane of the stomach. The naked-eye changes produced by chronic gastric catarrh, even if the disease has been of long standing, are not well marked.

Dilatation of the stomach is sometimes present.

Any distinct thickening of the gastric wall in such cases should be examined microscopically before the observer can be certain that it is not a thickening due to carcinoma. It will generally prove to be of that nature.

In cirrhosis of the liver, which is very often accompanied during life by symptoms of gastric catarrh, the mucous membrane is often quite natural post-mortem, but in a few cases I have found an increase of connective tissue and atrophy of the gastric glands, the whole wall of the stomach being thinner and not thicker than natural.

**Simple Ulcer of the Stomach.**—Two forms of ulceration of the mucous membrane of the stomach are common. In one the ulceration is associated with the progress of a new growth in the gastric wall, while in the other no new growth or other obvious cause of irritation is present, and it is therefore called simple ulcer of the stomach. This simple ulcer, though described and even figured by earlier writers, was first accurately distinguished from cancerous ulceration by Dupuytren (1778-1835). The first good general treatise upon it was that of Dr. L. Müller (1860)—a work full of information, and still worth reading—"Das Corosive Geschwür im Magen und Darmkanal."

Simple ulcer may occur at any part of the gastric mucous membrane, but is commoner in the pyloric than in the cardiac half of the stomach. A very common situation is on the upper part of the anterior surface of the stomach near the pylorus, and also near the lesser curvature.

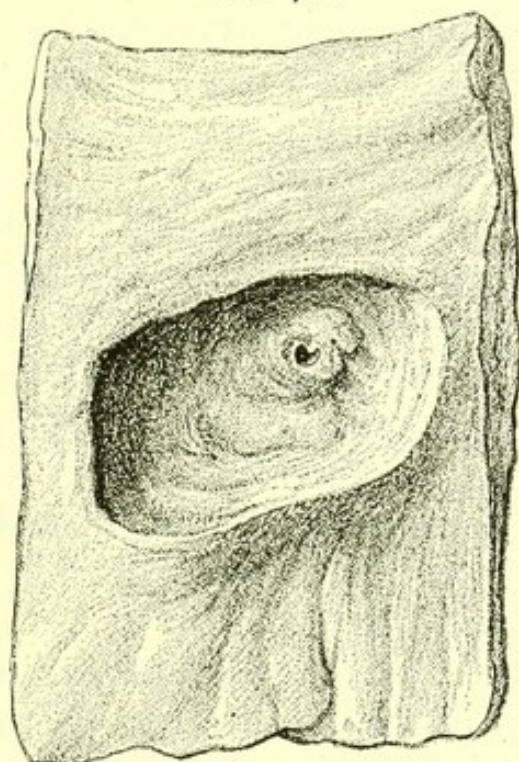
The ulcer is often as large as a shilling, but may be smaller or very much larger. More than one is rarely found. It has abrupt walls, which may either be in



one vertical plane from the upper edge to the base, or in several steps. The ulcer may pass through all the coats of the stomach, so that its floor may be formed by the peritoneum only. This may be perforated, and then of course some of the contents of the stomach are discovered in the peritoneal sac.

In other cases the floor of the ulcer is adherent to the pancreas. It is then common to find a small aneurysm of a branch of the pancreatico-duodenalis artery at its base, which may have burst, and in this

FIG. 71.



*Simple Ulcer of Stomach, with aneurysm at base, in a branch of the pancreatico-duodenalis artery. From a specimen in the Museum of St. Bartholomew's Hospital.*

case the stomach is distended with blood-clot, and death has been due to sudden hæmorrhage. Or the ulcer (and this is common when it is very large) may have formed extensive adhesions, and death may have been due to some slight serous inflammation terminating a prolonged wasting.

Microscopic sections of the ulcer in the state in which it is commonly found post-mortem show nothing more than an infiltration of its walls by leucocytes. In a few examples of gastric ulcer observed at a much



earlier stage, an embolus has been found in the branch of the gastric artery which supplies the area occupied by the ulcer. In other cases advanced degeneration of the same branch of the gastric artery has been found with an occluding thrombus. Examples of this kind, which are probably rare only because death seldom occurs at so early a stage, give one probable explanation of the method of formation of simple ulcer of the stomach. The gastric mucous membrane is not digested by the gastric juice only because it is living. Embolus or thrombus, by blocking a branch of the gastric artery, at once cuts off a part of the mucous membrane from its blood supply. It is immediately acted upon by the gastric juice, and this action is of course precisely limited to the area of distribution of the occluded artery. Hence the abrupt and definite edge of the ulcer.

A punched-out ulcer having thus been formed, the continued irritation of particles of food and of the gastric juice keeps up the ulcerative process, deepening, and to a less degree widening, the ulcer.

That ulcer is sometimes due to a local injury of the stomach by sharp or corrosive ingesta is also probable.

Gastric ulcer is rare before the age of sixteen, but may be found at almost any later age. If post-mortem records are consulted, it seems commonest after forty, while clinical records show it to be most frequent between eighteen and thirty.

It is undoubtedly commoner in the earlier period and most fatal in the later. The accompanying anatomical appearances depend upon the age of the patient and actual determining cause of death.

The appearances of the ulcer itself are the same at all ages. If the patient was young the ulcer was probably due to embolus. The heart may have endocardial growths upon the mitral or upon the aortic valves, a small piece of fibrin carried off from which may have been the embolus plugging the gastric artery and causing the ulcer, or there may be paleness of the muscular tissue of the heart with dilatation of



its cavities, and in the left auricle or left ventricle ante-mortem clots may be found, a fragment of one of which was the embolus carried into the gastric artery and causing the ulcer. Often, however, the actual source of the embolus cannot be demonstrated at the post-mortem examination. In these younger cases the body usually contains a normal quantity of fat, but there is a general anæmia. With this exception the viscera are usually of healthy appearance.

In the cases occurring later in life and in which the formation of the ulcer has probably been due to thrombus, some general degeneration of the aorta and other arteries is present. The lungs are emphysematous, and degenerative changes are observable to a greater or less degree throughout the body.

The following are examples of gastric ulcer associated with general degeneration of the arteries :

I. A man, aged fifty-three years, who was brought dead to St. Bartholomew's Hospital. The ulcer was of circular form, of the size of a sixpence, and situated on the lesser curvature, two inches from the pylorus. In the base of the ulcer were three small adherent clots leading into a branch of the pancreatico-duodenalis artery, a copious hæmorrhage from which was the cause of death. The floor of the ulcer was firmly adherent to the pancreas.

The left ventricle was hypertrophied, and the kidneys were small and granular. The lungs were emphysematous, and the arteries, except those of the circle of Willis, highly atheromatous. Many of the joints showed chronic degeneration of their cartilage.

II. In a patient, aged fifty, who died in St. Bartholomew's Hospital. The ulcer was of oval form and one inch in diameter on the posterior wall of the stomach, two inches from the pylorus. Its edges were remarkably sharply cut; its base showed an opening into a branch of the pancreatico-duodenalis artery, and a hæmorrhage from this was the cause of death. The pancreas was adherent to the stomach at the region of the ulcer.



The kidneys were in an advanced condition of chronic interstitial nephritis. The weight of the heart was 17 ozs., and there was great hypertrophy of the left ventricle.

All the arteries of the body were highly atheromatous. The posterior third of the left cerebral hemisphere was softened, and the cerebral arteries largely calcified. The aorta was atheromatous, and the gastric artery was almost completely calcified.

III. In a woman, aged thirty-four years, who died in St. Bartholomew's of interstitial nephritis associated with atheromatous arteries and abundant gouty deposits in joints and other parts, the ulcer was in the middle of the greater curve of the stomach. The ulcer was bounded by a distinct edge, and its base was in close relation to an adherent clot in an atheromatous gastric vessel.

These three cases are examples of gastric ulcer met with in persons with degenerate arteries. This condition, though rarer than that found in young people, is not infrequent, as the following Table shows.

*Cases in which the Diagnosis of Ulcer of the Stomach was made in the Wards of St. Bartholomew's Hospital.*

Year.	Total number of Cases.	Under 30.	About 40.	Senile Cases.
1882 . . . . .	16	5	5	6
1881 . . . . .	13	8	2	3
1880 . . . . .	6	5	1	0
1879 . . . . .	9	4	3	2
1878 . . . . .	11	7	3	1
1877 . . . . .	12	5	5	2
1876 . . . . .	11	5	1	5
1875 . . . . .	5	2	1	2
1874 . . . . .	14	5	5	4
1873 . . . . .	10	5	2	3
1872 . . . . .	7	5	2	0
Total in 10 years	114	56	30	28



Thus, assuming the diagnosis to have been correct, there were 28 cases with degenerate vessels out of 114. But Case III., given above, shows that some of the cases in period 30-45 may belong to the same group, so that it is probably accurate to state that of cases of ulcer of the stomach not less than one quarter are associated with chronic degeneration of the gastric arteries. The few post-mortems during a somewhat longer period are perhaps insufficient to argue from, but they show that 10 out of 12 cases recorded were in people with degenerate vessels, so great a preponderance as to lead to the belief that ulcer of the stomach associated with degenerate gastric arteries is the most fatal form of the affection.

In both young and old patients gastric ulcer may be present contemporaneously with some other disorder. Phthisis, bronchitis, or cerebral hæmorrhage and death may be due to this disease and not to the ulcer. Putting aside these cases, death in gastric ulcer may usually be demonstrated at a post-mortem examination to have been due to one of three causes :

1. Perforation of the floor of the ulcer, followed by collapse ;
2. Hæmorrhage owing to rupture of an artery in the floor of the ulcer ;
3. Wasting, due to increase in area and long continuance of the ulcer, with the formation of extended adhesions and a slow and gradually extending peritonitis.

When perforation has taken place, a small round hole with thin clean-cut edges is observed on the outer surface of the stomach, and some fragments of food may be found in the peritoneum. At the same time the peritoneum is reddened in parts and its normal glossy appearance dimmed with lymph, but the degree of this acute peritonitis depends upon the length of time which the patient has survived the perforation and the size of the rent in the floor of the ulcer. Where this has been large and death with



extreme collapse very rapid, little or no lymph is found on the peritoneum.

Where death is due to hæmorrhage, blood will probably have been vomited, and in the process of vomiting some may have found its way into the trachea, bronchi, and lungs. More is sure to remain in the stomach, which is often quite filled with a dark blood-clot, and some blood may be found in the small intestine, and even in the large intestine.

On washing away the blood there is usually no difficulty in discovering the ruptured artery. A small aneurysmal dilatation of the artery usually stands up as a little protuberance in the floor, and the adherent clot in the surface from which the hæmorrhage has taken place shows that the hæmorrhage has been preceded by the deposit of fibrin in the aneurysm before its rupture.

The cause of the aneurysm is the weakening of external surface of the wall of the vessel by the progressing ulcer.

The distance from the pylorus to which blood extends in the intestine is some indication of the length of time which the patient survived the hæmorrhage. In cases of this kind the body is as a rule well nourished.

If the hæmorrhage has been large the viscera are of course pale and bloodless.

Where death has been due to wasting, a very large ulcer is usually found with extensive adhesions about its base. In cases of this kind microscopic sections of the walls of the ulcer should always be examined, as without such inspection it is impossible to be certain that carcinoma of the stomach is not present. Cases are not very uncommon in which a patient has for ten or more years had distinct symptoms of simple ulcer of the stomach, and in which, after death in an extremely emaciated condition, a carcinomatous growth has been found in the walls of a large ulcer. As the survival by the patient of a continuous growth of a



carcinoma for so many years is opposed to all other observations as to the duration of malignant disease, it is fair in these cases to believe that the ulcer had long preceded the carcinoma, and that it was a comparatively recent occurrence in the walls of the ulcer.

**Relation of Morbid Appearances to Symptoms.**—In most cases of ulcer of the stomach recovery takes place.

The commonest manifestation of the presence of the ulcer is pain some little time after taking food. This is, of course, due to direct irritation of the ulcer. Pain on pressure is sometimes present, and sometimes localized pain without pressure. In either of these cases some irritation of the peritoneum, and therefore probably some adhesions of the ulcer to a contiguous part, has taken place. This adhesion does not make it certain that perforation will not take place, as a rent has not rarely been found at the edge of such an adhesion.

Vomiting of a large quantity of blood is a common symptom, and sometimes the first one observed. It is a proof that the ulcer has existed for some time and that irritation is causing it to increase in size.

The obvious conclusion as to treatment from the post-mortem appearances is that the stomach should be given complete rest. No food should be given by the mouth, and nutrition is to be maintained by nutrient enemata.

The very thin floor of the ulcer, as often seen post-mortem, is a warning that as long as any symptoms remain, no solid food, and as far as possible no drink should be swallowed.

Scars due to ulcer of the stomach are occasionally to be observed in the gastric mucous membrane as whitish marks of stellate appearance with very little puckering. In large ulcers in part healed a much greater degree of contraction is sometimes seen, and it may be so great as to narrow the cavity of the stomach so as to divide it into two. This is the



only permanent form of *hour-glass contraction* of the stomach. It was formerly confused with the hour-glass appearance of the normal stomach sometimes found after death and due to an unequal spasmodic contraction of the muscular coat.

The following Table illustrates the situation and the cause of death in ten fatal cases of ulcer of the stomach :—

Sex.	Age.	Position of Ulcer.	Description of Ulcer.	Complications.	Cause of Death.
M.	19	Greater curve near pylorus	Shilling size, rounded edges	...	Hæmorrhage.
M.	19	Near pylorus	Shilling size, sharp edges	...	Perforation.
M.	36	Near pylorus	Crown size, clean cut edges	...	Perforation.
M.	40	Near pylorus	Groat size, conical edges thick and rounded	...	Perforation.
M.	41	Pylorus	Large, edges thick	Phthisis	Died of phthisis.
M.	46	Lesser curve, pylorus (2)	Shilling size, edges of both thickened	...	Perforation.
M.	47	Near pylorus	Crown size, edge clean cut	...	Exhaustion.
M.	47	Pylorus	Of crown size, with soft everted edges	...	Died of phthisis.
M.	57	Cardiac end	Size of groat, edges sharp	...	Hæmorrhage.
F.	46	Posterior wall	Shilling size	...	Perforation.

**Lardaceous disease** is sometimes found in examples in which the change is widely distributed, but is not common. The stomach should be well washed and tincture of iodine added, when the capillaries, if affected by amyloid disease, stand out as dark lines.

**Polypus of the stomach** is rare. In one example which I came across it existed as a soft spherical growth from the mucous membrane projecting at the end of the first third of the great curve. It was in a man, aged sixty-eight years, who died of bronchitis, and it had given rise to no symptoms during life. There are three specimens of the kind in the museum of St.







DIAGRAM IV.—Carcinoma of Stomach. (TWENTY-NINE CASES.)

AGE	Stomach	LYMPHATICS	HEART	LUNGS	THYROID	PERITONEUM	LIVER	PANCREAS	SPLEEN	KIDNEY	ADRENAL	TESTIS	OVARY	UTERUS
36														
42														
42														
44														
45														
45														
47														
47														
48														
48														
48														
49														
52														
52														
53														
54														
54														
55														
56														
60														
63														
XIII														
XXXI														
XXXVI														
XXXVIII														
XL														
XL														
LVI														
LVII														

The black squares show the regions in which the secondary growths were found. The ages in Arabic figures are those of men, in Roman numerals of women. (All examined microscopically.)

[To face page 285.



Bartholomew's Hospital, but the infrequency of the growth is shown by the fact that the specimen above described is only the second which has been observed in the last three thousand medical post-mortem examinations at St. Bartholomew's Hospital.

**Carcinoma of the stomach** is generally primary. Three varieties are common, of which the third is far less frequent than the first and second :

1. The new growth is confined to the pylorus ;
2. The whole gastric wall is invaded ;
3. The new growth begins in the walls of an ulcer and spreads from it.

1. When the new growth is confined to the pylorus and its neighbourhood a subglobular mass of considerable size may exist due to infiltration of the gastric wall. This usually stops short at the termination of the stomach and very rarely extends into the duodenum.

There is generally some shallow ulceration of the mucous surface of the stomach at the seat of new growth. The stomach is greatly dilated, sometimes so much so as to extend to the symphysis pubis and over almost the whole of the intestines. (See Fig. 72.)

The dilated stomach and the hard movable tumour are easily made out during life.

2. When the new growth invades the whole gastric wall the stomach is much reduced in size, its cavity is small and its walls thick, and on section glistening. Shallow ulceration may be present, but is rarely extensive. (See Fig. 73.)

In this variety the new growth is less easy to make out during life ; there is no increased area of gastric resonance, and the whole stomach, if felt, is often mistaken for a mass of new growth in some other part.

Intermediate conditions between these two varieties occur.

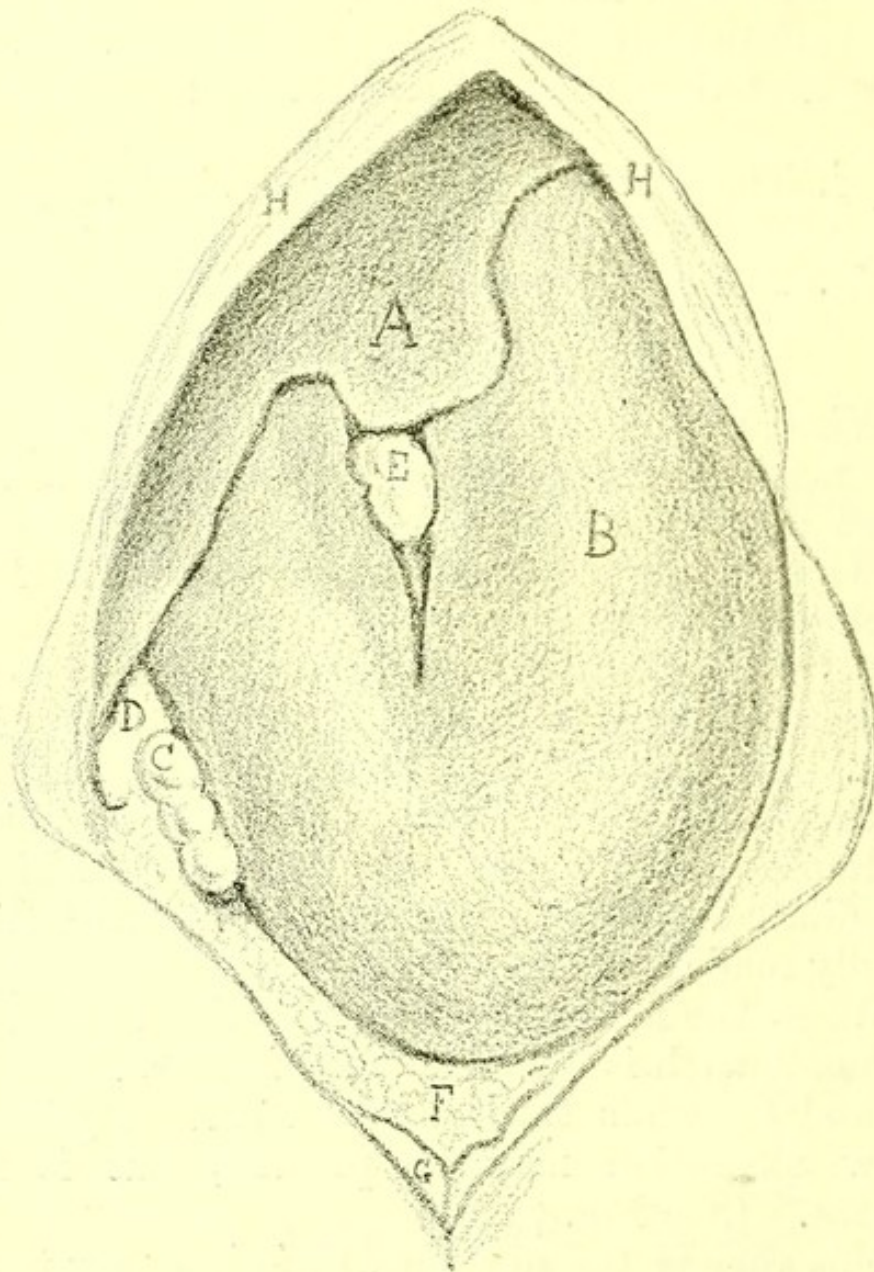
3. Where the new growth begins as a patch in some part of the gastric wall, its origin is sometimes



in the wall of a simple ulcer, or without preceding ulcer it may rapidly give rise to local ulceration.

This is the only form of carcinoma of the stomach in which perforation is often found. The carcinomatous

FIG. 72.



*Diagrammatic Drawing of Dilatation of Stomach, due to new growth near pylorus. B. Stomach. H H. Costal arch. A. Liver. E. Gall-bladder. D. Ascending colon. C. Transverse colon. F. Ileum. G. Poupart's ligament.*

patch becomes adherent to other tissues, and occasionally penetrates the transverse colon. In one case examined by me it had penetrated first the small in-

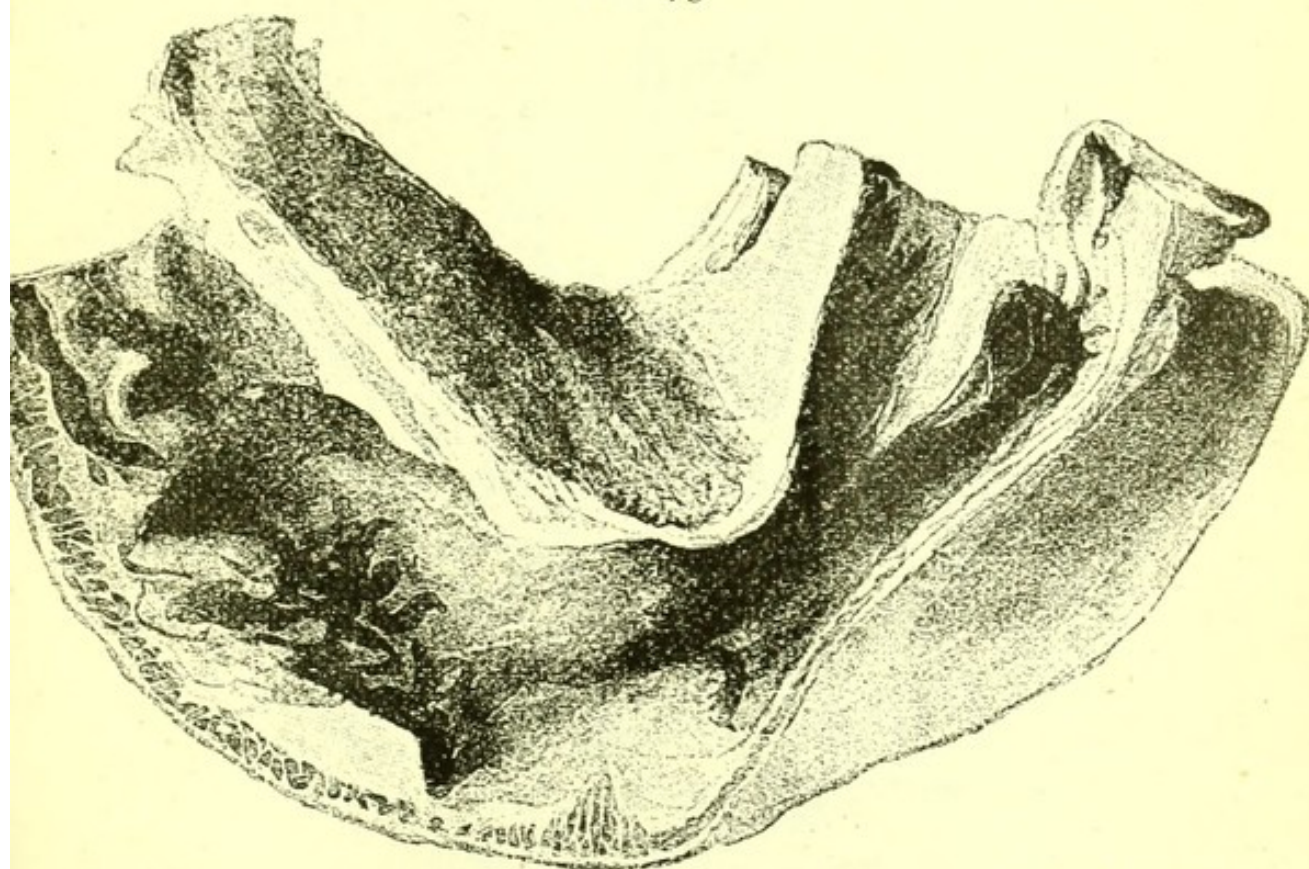


testine, then the descending colon, and finally entered the abdominal wall in the left inguinal region, where it gave rise to an abscess which opened externally.

When perforation into the peritoneum occurs it is found to have taken place near the edge of the carcinomatous patch by a rent between it and the unaffected gastric wall.

The earliest case of carcinoma of the stomach which I have seen was of this kind, and was in a girl, aged thirteen years. She was under my care in St. Bartholo-

FIG. 73.



PYLORUS.

ÆSOPHAGUS.

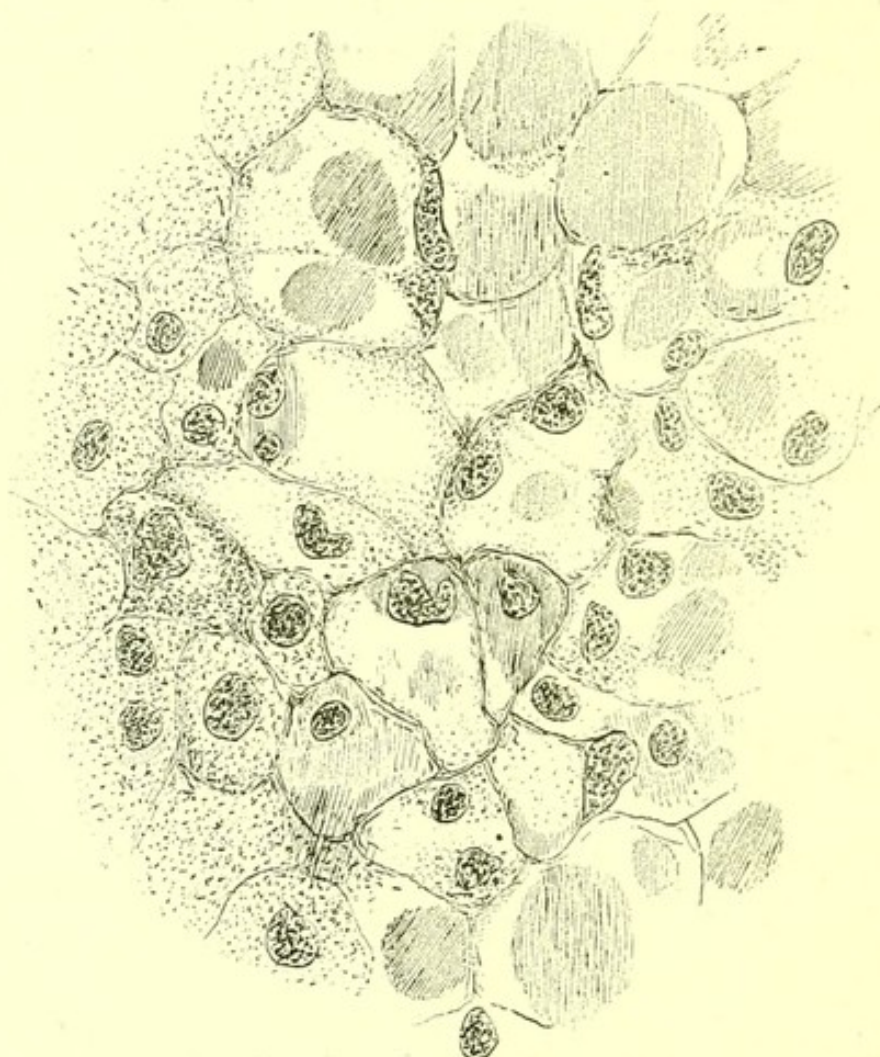
*Carcinoma of Stomach*, invading the whole gastric wall. Two-thirds natural size. The whole organ is much contracted.

mew's Hospital during March and April 1884. She was brought to the hospital in a condition of extreme anæmia, with puffiness of the face and œdema of the legs and arms. She was so short of breath that she could scarcely walk. The heart's action was feeble. There was no albuminuria. She never vomited blood,



but two days before death complained of pain in the abdomen and had several attacks of vomiting. She died five weeks after admission. The autopsy revealed a new growth at the cardiac end of the stomach close to the œsophagus. The mass measured three inches in diameter. The peripheral parts rose from the mucous membrane and were of the same colour,

FIG. 74.



*Carcinoma of Stomach*, in a girl aged thirteen years, showing mucoid degeneration of cells of new growth.

but the central parts were ragged, dark-coloured, and very dense. On section the tumour looked red with pale stripes. The outer part of the growth was adherent to the liver, but did not penetrate it. There were signs of slight recent peritonitis apparently due to a tear near the edge of the new growth. No glands



and no other organs were infiltrated. There was a very old, perhaps congenital, disease of the right hip-joint. The microscopic characters of the new growth were those of a carcinoma, with somewhat wide trabeculae and extensive mucoid degeneration of the cells, and with hæmorrhages into several parts of the growth. Three distinct stages were visible in the growth. In the least degenerated part numerous cells of an epithelial type were collected in large alveoli. In another part advanced mucoid changes were observable in the epithelial cells, and in some cells the nuclei had disappeared. In the most degenerate parts almost all the nuclei had disappeared, leaving a mass of mucoid material intersected by traces of the cell boundaries. (Fig. 74.)

The following Table of cases examined by me post-mortem, illustrates the distribution of secondary deposits in the three varieties of carcinoma of the stomach above mentioned. In each case the nature of the new growth was determined by microscopic examination.

*Table of Twenty Cases of Carcinoma of the Stomach.*

Sex.	Age.	Part of Stomach.	Secondary Growths.
M.	44	Pylorus	Liver, glands in hilum of liver
M.	45	Pyloric third	Liver, lungs, pancreas, supra-renal
M.	45	Pyloric half	Liver, pancreas, lungs
M.	48	Pylorus	o
F.	31	Pyloric half	Liver: one gland near pancreas
F.	40	Pylorus	o
F.	40	Pylorus	o
F.	37	Cardiac end	Liver by direct continuity only
M.	36	Whole	Glands in hilum of liver
M.	42	Whole	o
M.	47	Whole	Peritoneum, lumbar and mesenteric glands
M.	48	$\frac{5}{8}$ of wall	Liver, pancreas, lymphatics near liver and stomach
M.	49	Whole	Glands along edge of stomach
M.	52	Whole	Liver, lungs, kidney



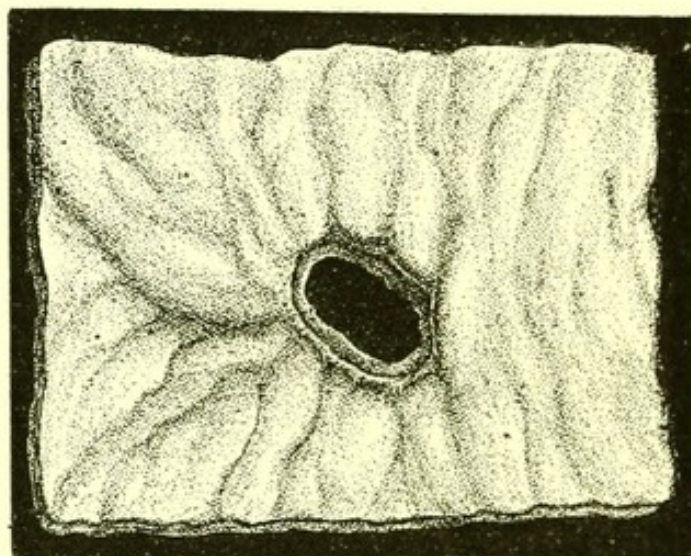
Sex.	Age.	Part of Stomach.	Secondary Growths.
M.	53	Whole	Peritoneum, mesenteric gland, and lumbar
M.	54	Whole	Liver, lumbar glands
M.	60	Whole	o
M.	63	Whole	Liver, lungs, peritoneum, mesenteric glands
F.	56	Large ulcer; whole	o
M.	48	Old ulcer	Lumbar glands, liver, lungs, kidney

**Dilatation of the stomach**, when discovered at an autopsy may sometimes be due to distension by gases of putrefaction.

Dark lines run over and along the situation of the gastric veins, and the pylorus, which is sometimes contracted but never thickened, always occupies its normal position.

Obstruction of the pylorus, commonly due to carci-

FIG. 75.



*Perforation in the Floor of a Simple Ulcer of Stomach.* From a specimen in the Museum of St. Bartholomew's Hospital.

noma, is sometimes associated with very great dilatation of the stomach. It may be so much dilated as



to cover the whole small intestine as well as the transverse and descending colon.

**Contraction.**—Great contraction of the stomach is always due to new growth in its wall or to the formation of scar-tissue after the injury produced by a corrosive poison.

**Perforation of the stomach**, when not due to external injury is commonly due to perforation of a gastric ulcer: and sometimes, though very rarely, to a tear at the edge of a patch of new growth.

**Hernia.**—When the diaphragm has been wounded or is congenitally imperfect, the stomach is sometimes found post-mortem in the pleural cavity.

**Dyspepsia.**—After prolonged dyspepsia the following changes may be discovered in the stomach:—

1. Simple ulcer;
2. New growth;
3. The atrophic changes due to cirrhosis;
4. Amyloid infiltration.

Often no change is discovered. A thorough microscopic examination of pieces removed soon enough after death would probably lead to the more frequent observation of atrophic structural changes in such cases.

Defective blood supply is a probable cause of the dyspepsia of anæmic and of phthisical persons.

## INTESTINES.

**Hæmorrhage** from the several parts of the intestine has already been described.

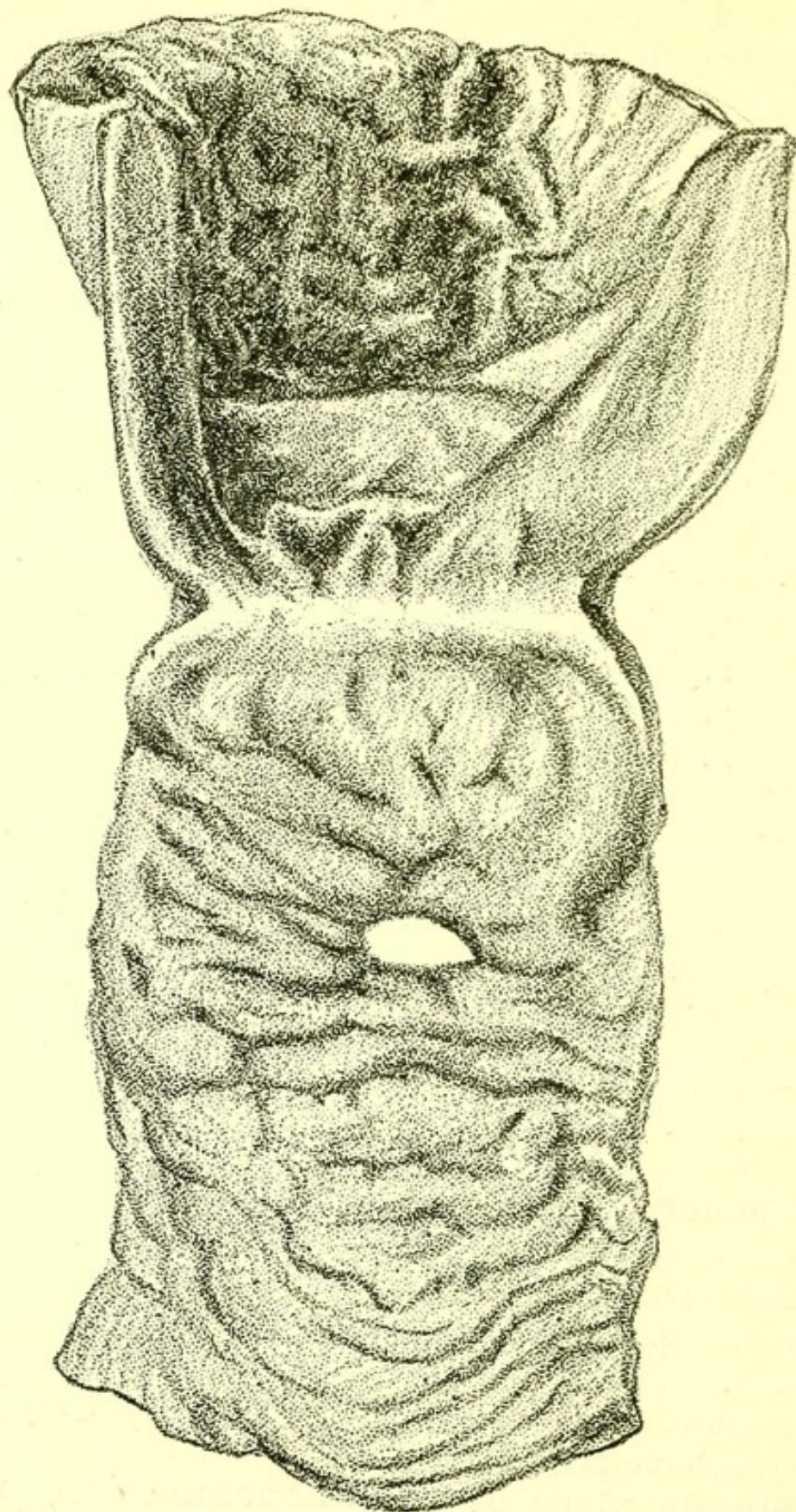
**Catarrhal inflammation** rarely leaves any change recognizable post-mortem, except a slight excess of mucus.

Ulceration in its several varieties and lardaceous disease have been described.

**Simple ulcer of the duodenum** is sometimes found when a patient has regularly had pain two or three hours after a meal.



FIG. 76.



*Simple Ulcer of Duodenum, with Perforation. From a specimen in the Museum of St. Bartholomew's Hospital.*



The following examples illustrate the subject:—

I. A man, aged thirty-four, came to St. Bartholomew's Hospital at 11 P.M. on May 9, 1882. Until that evening he felt quite well, and at 10 P.M. had vomited about a pint of blood. He was admitted into one of Dr. Gee's wards. At 2.30 A.M. on the 10th he vomited a small quantity of blood, and at 6.30 the same morning lost a large quantity per rectum. He became collapsed, and died in an hour and a half.

Post-mortem: All his organs were found much blanched, and the whole intestine was distended with blood; the œsophagus and stomach were normal. In the duodenum close to the pylorus there was an ulcer with clean-cut vertical sides, and about half an inch in diameter. Its base was adherent to the pancreas, and showed two small openings into branches of the pancreatico-duodenalis artery. The pancreas was otherwise normal.

II. A man, aged forty-nine, who died in St. Bartholomew's of bronchitis. He was a bricklayer, and had had repeated attacks of bronchitis. For the three months before his death he had had slight attacks of indigestion, but without distinct or localized pain. His duodenal ulcer was not suspected during life. He was very fat, and died with general anasarca.

Post-mortem: A deep ulcer with abrupt sides was found in the duodenum close to the pylorus. The base of the ulcer was adherent to the pancreas, and there was some puckering of the peritoneum near the adhesion, but no perforation.

The lungs were highly emphysematous, and there was great hypertrophy of the right ventricle.

**New Growth.**—The duodenum is sometimes invaded by lympho-sarcoma, as in a woman, aged forty-one, who died in St. Bartholomew's Hospital.

The lumbar glands were greatly enlarged, and the mesenteric glands to a less degree, by a soft growth, which microscopic examination showed to be a lympho-sarcoma. The duodenal wall was invaded by the



**DIAGRAM V.**  
**Carcinoma of Colon.**  
 (NINE CASES.)

AGE	COLON	LYMPHATICS	HEART	LUNGS	THYROID	PERITONEUM	LIVER	PANCREAS	SPLEEN	KIDNEY	ADRENAL	TESTIS	Ovary	UTERUS
25	■													
35	■													
39	■	■												
40	■													
40	■													
56	■						■							
XLIV	■	■												
XLVI	■													
XLIX	■													

The black squares indicate the regions of secondary growth. The ages in Arabic figures are those of men, in Roman numerals of women. A microscopic examination was made in each case.

[To face page 295.]



The duration of the illness had been eight months. A pulsation in the abdomen was first noticed, then vomiting after food, and the abdominal tumour.

In such cases as in others of new growth invading a large part of the wall of the small intestine, a tumour with muffled resonance on percussion and not absolute dulness may be observed during life.

**Lympho-sarcoma** also occurs in the glandular tissue of the duodenum and of other parts of the small intestine, producing tumours prominent on the mucous surface.

**Carcinoma** rarely extends from the stomach into duodenum. It generally stops abruptly at the pylorus. Primary carcinoma of the duodenum is very rare.

Direct growth of carcinoma from the ascending colon into the duodenum is sometimes observed, but I have not seen a carcinoma which began in the duodenum and extended to the cæcum.

Primary carcinoma of other parts of the small intestine is also rare.

**Cæcum.**—Carcinoma of the cæcum is generally a dense growth, and may grow directly into the duodenum, with an ulcerated passage of communication. Microscopically its cells are generally columnar.

It is often without any secondary deposits.

**Typhlitis.**—In addition to inflammation frequently accompanied by ulceration, and sometimes by abscess outside the cæcum, the only anatomical appearance is the enlargement of lymphatics in the neighbourhood of the cæcum, especially near its inner edge.

**Colitis.**—Inflammation of the colon is sometimes accompanied by ulceration, so as to completely riddle the descending and transverse colon.

This is sometimes found in death after prolonged enteric fever, and sometimes after diarrhœa of no special character.

**Carcinoma of the transverse and descending colon** is usually of a columnar-celled variety. The



surface of the mucous membrane is ulcerated, and the growth sometimes causes an obstruction and thus leads to dilatation of the intestine above it. It becomes adherent and grows in continuity into the stomach or abdominal wall, but is often without secondary growths.

**Carcinoma of the rectum** is discovered, now and then, in cases in which it was not suspected during life. It is usually a columnar-celled carcinoma, and is often without secondary deposits. If present, they are commonly found in the lumbar glands and the liver.

The following Table illustrates the distribution of the secondary growths in carcinoma of the large intestine. All were examined microscopically, and were examples of columnar-celled carcinoma.

*Table of Cases of Cancer of the Rectum and Colon illustrating its Secondary Deposits.*

Sex.	Age.	Part of Intestine.	Secondary Deposits.
<i>Rectum.</i>			
M.	33	Highest part	o
M.	52	Highest part	Liver
M.	53	Highest part	Liver, lumbar glands
M.	58	Upper part	o
F.	37	Upper part	o
F.	65	Uppermost	o
<i>Descending Colon.</i>			
M.	25	Highest part	o
M.	40	Middle part	Ileum in continuity
F.	46	Upper part	Stomach in continuity
<i>Transverse Colon.</i>			
M.	35	Splenic end	o
F.	49	Splenic end	o
<i>Ascending Colon.</i>			
M.	39	Middle part	One lymphatic near cæcum
M.	40	Nearly all	o
M.	56	Upper part	Liver



**DIAGRAM VI.**  
**Carcinoma of Rectum.**  
(EIGHT CASES.)

AGE	Rectum	LYMPHATICS	HEART	LUNGS	THYROID	PERITONEUM	LIVER	PANCREAS	SPLEEN	KIDNEY	ADRENAL	TESTIS	OVARY	UTERUS
24														
33														
52														
53														
58														
XXVII														
L														
LXV														

The black squares show the regions in which secondary growths were found in each case.

The ages in Arabic figures are those of men, in Roman numerals of women. (All examined microscopically.)

[To face page 296.]







Other details as to new growth in the rectum are given earlier in this chapter.

## LIVER.

**Liver.**—The common expression, “the liver out of order,” corresponds to no demonstrable anatomical appearance in the gland. The form of expression is a relic of the Galenic physiology. The external anatomical signs of disease of the liver are—

1. Jaundice ;
2. Ascites ;
3. Increased resistance in the hepatic region.

**Jaundice**, or staining by the bile pigments of all the tissues and secretions of the body, is always due to obstruction of the common bile duct. The commonest obstruction is an acute inflammation of its mucous lining. The walls of the duct are occasionally the seat of carcinoma, the growth of which may occlude the passage. A gall-stone formed in the gall-bladder sometimes obstructs the duct ; its closure may also be produced by pressure from without, and of this the commonest causes are cancerous masses in the liver, hydatid of the liver, cancer of the pancreas, and abscess of the liver. It is certain that a duct not absolutely occluded post-mortem may have been sufficiently obstructed during life to cause retention of a sufficient quantity of the bile to produce jaundice. Even a slight obstruction of the common duct produces jaundice. Permanent obstruction in addition causes dilatation of the minute as well of the large bile ducts, and a general increase of connective tissue throughout the gland.

**Ascites**, or effusion of serum into the peritoneal cavity in relation to the liver, may be produced by any obstruction to the passage of blood through the liver to the heart. The greatest degree of ascites when that change is due to disease of the liver is produced



by cirrhosis. Amyloid disease of the liver is associated with a less degree of ascites, and in this case as well as in the extreme engorgement of the liver, due to valvular disease of the heart (nutmeg liver), the common accompanying affection of the kidneys is a contributory cause of the dropsy.

**Increased resistance in the hepatic region**, in connection with which the lower edge of the liver may often be felt, may be due to a general increase in size of the organ or to the projection of growths at particular points.

A general increase in size is most often due to—

1. Malarial disease of the liver ;
2. General hypertrophy of its connective tissue ;
3. Its engorgement with blood (nutmeg liver) ;
4. Its distension with bile (obstruction of the duct) ;
5. Amyloid infiltration ;
6. Infiltration by fat ;
7. Increase of its lymphatic tissue (leucocythæmia) ;
8. Projections, single or multiple, from the liver, of which the chief are—

- a. Carcinoma ;
- β. Sarcoma ;
- γ. Hydatid cysts ;
- δ. Abscess.

**Catarrhal Jaundice.**—This disease, in its simplest form, is of course never seen uncomplicated in the post-mortem room. Besides the general staining of the tissues of the serous fluid in the arachnoid, pleural, pericardial, and peritoneal sacs, two other conditions may be observed. A plug of mucus occupies the orifice of the common bile duct, and the papilla projects more prominently than natural into the duodenum. The walls of the duct throughout its straight part are swollen, and are pale in colour instead of being yellow. The gall-bladder is distended with dark-coloured bile. The contents of the intestine are pale, and without bile pigment. This condition is



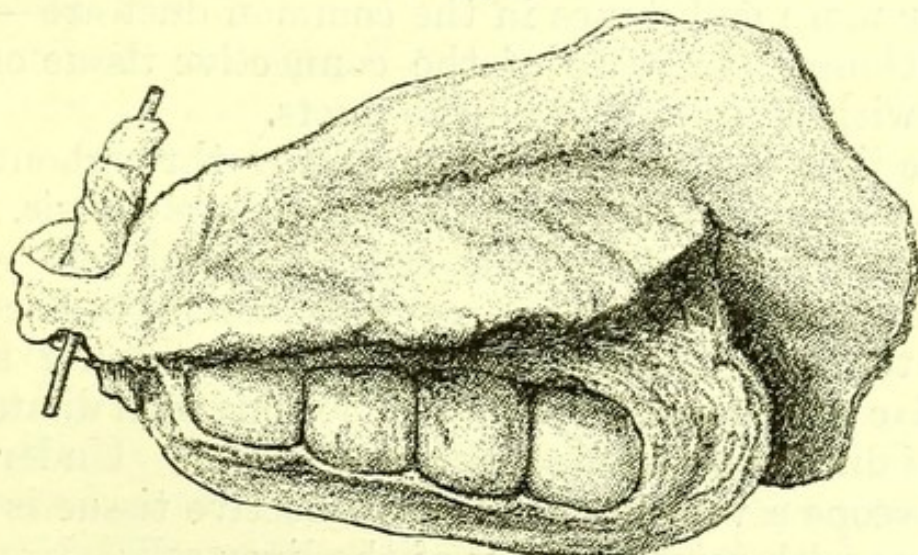
often met with in death from valvular disease of the heart of long standing. It is present in phosphorus poisoning. *Icterus neonatorum* is often a congenital form of catarrh of the bile duct.

When jaundice is present in amyloid disease of the liver, cirrhosis of the liver, and sometimes when it accompanies abscess of the liver, it is due to catarrh of the common duct.

Inflammation of the gastro-intestinal mucous membrane, as evinced by acute diarrhœa, often precedes the onset of catarrhal jaundice, and an engorged condition of the duodenum may sometimes be found in connection with catarrhal jaundice, particularly in cases of irritant poisoning.

**Gall-stones.**—Gall-stones are masses of solid material precipitated from the bile, and are most commonly found in the gall-bladder, in the common duct, or in the intestine, and less often scattered through the liver in the small branches of the bile duct. They are sometimes soft and putty-like, more

FIG. 78.



*Gall-stones in Gall-bladder, surrounded by a dense mass of Carcinoma. From a specimen in the Museum of St. Bartholomew's Hospital.*

often hard but easily broken. Where there is more than one, gall-stones, if occurring in the gall-bladder or common duct, usually have facets, those found in the minuter bile ducts are always angular, and are



sometimes so small as to constitute bile gravel. Gall-stones vary in colour, the commonest colour being dark yellow. Dark green, light yellow, and black gall-stones are of frequent occurrence, while white ones are less common. In size they vary from fine gravel to the size of a hen's egg. Cases have been recorded in which gall-stones, so large as to cause obstruction of the small intestine, have passed into it from the bile duct. They vary in specific gravity, some floating, and some sinking in water. They usually consist chemically of cholestrin and bile pigments, some also contain a small quantity of carbonate of lime. Gall-stones are rarely adherent to the straight part of the common duct, but often adherent to the neck of the gall-bladder; sometimes a single large gall-stone occupies the gall-bladder, the walls of which are firmly adherent to it.

When a gall-stone is fixed in the common duct, the mucous membrane of the duct in front of it is not bile-stained, while that behind it is bile-stained.

Anatomical changes associated with impaction of one or more gall-stones in the common duct are—

1. General increase of the connective tissue of the liver with dilatation of all the ducts.

The liver is of a dark green colour throughout, its surface is often roughened as in simple cirrhosis. Its substance is very tough, its size increased, and wherever cuts are made into it, even at the parts furthest from the gall-bladder, watery bile containing small angular gall-stones flows out. The universal dilatation of the duct is obvious to the naked eye. Under the microscope a vast increase of connective tissue is also obvious with some atrophy of the liver cells.

The same condition is of course found where a sufficiently long lasting closure of the bile duct by external pressure has taken place.

Tumours due to carcinoma, sarcoma, and abscess of the liver usually do not exercise pressure long enough to produce this condition, but it is sometimes found



where the common duct is closed by the external pressure of hydatid of the liver, or of cancer of the pancreas.

2. A gall-stone impacted in the duct sometimes ulcerates through it into the peritoneum or through the papilla, causing a rent in the wall of the duodenum, both conditions being fatal. In a few rare instances the stone ulcerates into the liver substance, forming an abscess. This abscess may obtain a considerable size. Gall-stones mixed with bile and pus are found in its cavity.

3. The permanent fixture of a gall-stone in the cystic duct often causes slow distension of the gall-bladder by its own secretion. This does not of itself cause a fatal result, but is sometimes found in post-mortem examinations. The gall-bladder projects below the edge of the liver, and is pale in colour, its inner surface, instead of being finely reticulated, is smooth.

4. A gall-bladder filled with stones may become adherent to the abdominal wall, and lead to an abscess pointing externally, and from which gall-stones may be discharged.

**Cirrhosis of the Liver.**—Before the use of the microscope a liver tougher than natural was spoken of as a liver invaded by scirrhus. When microscopic observation showed that a roughened and hardened liver, however like a scirrhus carcinoma in texture as felt by the hand, was of altogether different minute structure, the term cirrhosis (derived from the Greek *κίρρος*, tawny) came into use, as these tough livers are most often of a pale canary yellow on section.

Several pathological changes have been included under the term cirrhosis, and parts of the subject are still under dispute.

The commonest form, and that usually known as cirrhosis without any qualifying adjective, is distinct and easily recognized. (Fig. 79.)

In a large majority of cases it is due to spirit-drinking.



The post-mortem appearances are—

*Body*: The face, trunk, arms, and legs are usually emaciated.

*Abdomen*: The abdomen is distended with fluid, and the superficial veins are often distended.

Paracentesis abdominis has often been performed, and the mark due to it is visible on the abdominal wall.

On opening the abdomen a large quantity of fluid escapes.

This is clear, but may (especially if paracentesis has been performed) have some shreds of lymph floating in it or attached near the place of entry of the trocar.

Where tapping has been performed several times there is often considerable thickening of the peritoneum, accompanied by œdema of the wall of the alimentary canal.

*Liver*: The liver is reduced in size, and the left lobe obviously diminished in thickness, the edge being thin, and often having a fibrous fringe. The surface is nodulated, and the investing capsule is unevenly thickened. The wall of the gall-bladder is thickened, and usually contains pale yellow bile. On cutting into the organ the section is yellow, a general increase of connective tissue is obvious, and sometimes islets of liver tissue project between interlacing fibrous bands. Microscopic sections show an increase of Glisson's capsule throughout the liver round each lobule. The amount of new connective tissue varies; where it is great there is considerable atrophy of the hepatic cells. This is the common form of cirrhosis of the liver. The variety produced by permanent obstruction of the bile-ducts has already been mentioned. The liver is green instead of yellow, its surface, though rough, is less definitely nodulated. The dilatation of the minute bile-ducts is obvious. The liver is less reduced in size, being in fact engorged with bile, but there is always extensive atrophy of the hepatic cells.

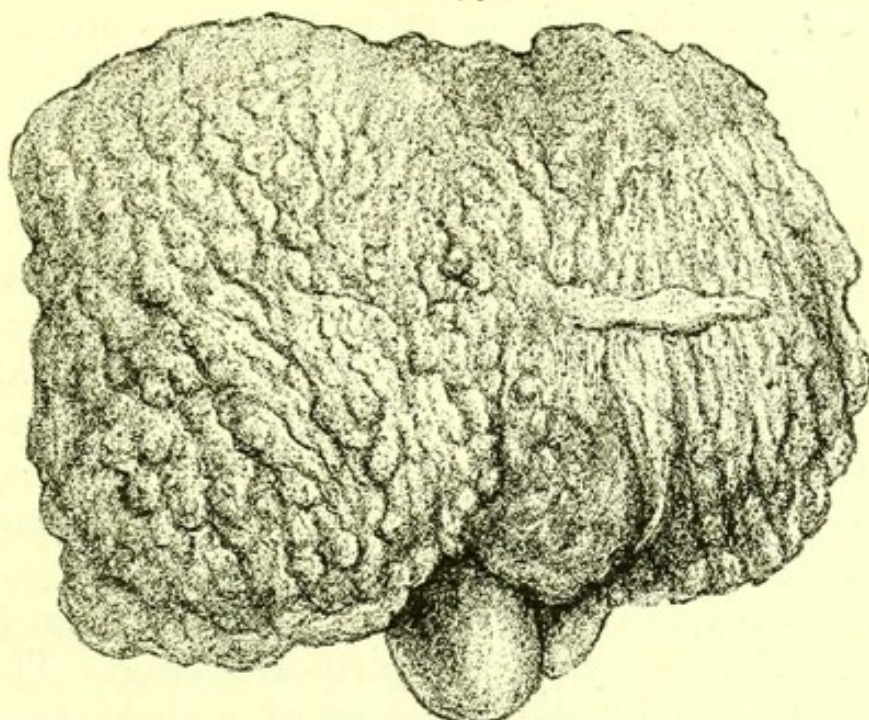
Cirrhosis sometimes begins and progresses in a liver previously infiltrated with fat, and in this case the



reduction in size of the whole organ is less. On microscopic section abundant fat globules are seen in the zone of the portal vein, in each lobule just within the thickened capsule.

Since the reduction in size of the liver in cirrhosis is produced by the scar-like contraction of a quantity of newly-formed connective tissue, it is no doubt the case that at some period in the course of each case of cirrhosis of the liver the gland is to some degree en-

FIG. 79.

*Cirrhosis of the Liver.*

larged. It is not often seen in this condition in the post-mortem room except in cases of a connective-tissue increase in the liver associated with malarial disease. In such cases the liver is very large, often weighing more than a hundred ounces. Its surface is not rough, and although the section is dense, and on microscopic examination shows great connective-tissue increase, it never has the almost cartilaginous consistence of the common form of cirrhosis (see Malarial Disease, p. 78).

*Spleen* : The spleen is most often small and of a wasted appearance. In a good many cases it shows a connective-tissue increase which has undergone con-



traction ; it is sometimes engorged as if from obstruction of the hepatic circulation. In most cases some thickening of its capsule is to be seen.

*Pancreas* : The pancreas is usually healthy.

*Kidneys* : The great connective-tissue increase in the liver is often unaccompanied by any corresponding change in the kidney. Cases in which chronic interstitial nephritis is present are comparatively rare.

*Blood-vessels* : Patches of degeneration, and often of calcification, occur in the aorta.

*Chest* : Scanty serous effusions are often found in the pericardial and pleural sacs.

*Stomach and Intestines* : Capillary hæmorrhage from the mucous membrane of the gastric wall often takes place in cirrhosis. The stomach may be found distended with blood, or more or less digested blood may be found in the intestines. An increase of connective tissue in the gastric wall, with some atrophy of its glands, is comparatively rare. The mucous membrane of the intestine has usually a velvety feel, perhaps due to chronic engorgement. The omentum contains little or no fat.

Cirrhosis of the liver is rare in children, but may be produced at an early age by spirit-drinking. The liver is so easily felt in the abdomen of a child, that it is sometimes possible to learn the time elapsing between enlargement and the contraction of the liver. In a boy, aged five years, with whom his parents shared their potations of spirits, and who in consequence died of cirrhosis of the liver with ascites, the period elapsing between great enlargement of the liver and extreme reduction of its size was five months.

The liver was very large, and its gradual reduction was observed after each paracentesis.

Post-mortem the liver precisely resembled that of an adult who had died of cirrhosis. Its edge was thin, it was diminished in size, and rough all over, and on microscopic examination showed great increase of connective tissue.



In children, tuberculosis of the peritoneum sometimes, originates an inflammation of Glisson's capsule ending in a condition indistinguishable from cirrhosis. Of this variety I have examined two cases. In one the patient was a girl, aged ten years.

The whole liver was dense, with great elastic bands of fibrous tissue in its substance. The surface was rough and nodular. Microscopic sections showed atrophy of the liver-cells with great increase of connective tissue round the lobules.

General tuberculosis of the peritoneum was present, but no tubercle was found in the liver itself, nor upon that part of the peritoneum which covered the liver. The body was emaciated, and there was great ascites.

Some observers maintain that a form of cirrhosis in children and young persons follows acute febrile diseases in which destruction of liver-cells has taken place. I have seen small patches of freshly formed connective cells in the livers of children who had died of scarlet fever.

**Amyloid Liver.**—The liver is a frequent seat of amyloid degeneration, and is sometimes enlarged from this cause to twice its normal weight. The increase is almost entirely due to the amyloid material with which it is infiltrated.

This substance is found in the earlier stages in the walls of the small branches of the hepatic artery, and afterwards outside these arterioles and in their neighbourhood. Later still it is to be discovered within the liver-cells.

To the naked eye its presence is demonstrated by pouring a solution of iodine on the section, when the parts infiltrated with amyloid material are stained of a darker brown than the rest of the liver.

The gland cuts firmly, and has something the appearance of a section of bacon.

The gall-ducts are generally unobstructed. Some ascites is usually present. Amyloid degeneration is



often present in the kidneys, spleen, or intestinal mucous membrane, or in all of these regions.

Palmar psoriasis, scars of gummata in the viscera, suppuration in bone, or chronic tuberculous ulceration of the lungs, is present as a primary disease.

**Nutmeg Liver.**—The term nutmeg liver is given to the condition of chronic engorgement due to venous congestion, of which the commonest cause is valvular disease of the heart.

The liver is slightly enlarged and is harder than natural. Occasionally its surface is somewhat uneven.

The substance of the gland looks reddish-brown and yellow as seen through the semi-transparent capsule, and the section presents a light yellow and reddish-brown appearance.

Microscopic sections show that this is due to a general extravasation of red blood-corpuscles from the engorged hepatic veins. Some of these extravasated corpuscles retain their pigment and are dark red; others, longer extravasated, are of several shades of yellow.

Hence the comparison with the light pericarp and dark carp of the nutmeg.

**Hæmorrhage** into the substance of the liver is rare. It may be due to rupture of a small aneurysm of the hepatic artery. It sometimes occurs in cases of extreme anæmia, as in a man, aged twenty-one years, under Dr. Church's care in St. Bartholomew's Hospital. He was extremely anæmic on admission, with some spots of purpura. On rising from bed one day he felt a sudden pain, became much more anæmic, and died.

Post-mortem I found his liver anæmic and with some fatty infiltration. There was a large rent close to the falciform ligament, with stripping off of the capsule, due to a hæmorrhage into the substance of the liver. The peritoneum contained a large quantity of blood. The heart was in an advanced stage of fatty degenera-



tion. The hæmorrhage resembled those found in the thigh, or other muscular parts, in anæmia.

**Acute Yellow Atrophy.**—The liver is small and shrunken-looking, sometimes almost shrivelled on the surface, but soft and not at all tough.

On section it is of a brownish or yellowish hue. The gall-bladder is distended with bile.

There is a slight degree of general jaundice.

Microscopic sections show granular degeneration and shrinking of the hepatic cells, with hæmorrhages into the centre part of each lobule.

The hepatic cells have lost their nuclei, and are scarcely stained at all by logwood solution.

There is no ascites. The kidneys are soft and the lungs engorged with venous blood. Putrefaction begins early.

**Hypertrophy**, in the sense of functional increase in size, does not occur in the liver.

**Simple atrophy** is often seen in extreme old age, and sometimes in the bodies of persons who have died with wasting due to slowly progressing new growth.

**Abscess of the Liver.**—Acute local inflammation of the liver is followed by abscess. Abscess is also produced by the insemination of the liver with active emboli. This is the cause of the abscess of the liver in dysentery and in pyæmia.

Inflammation of the portal vein and its branches is a third cause of hepatic abscess. Very rarely a hydatid suppurates, and so causes an abscess of the liver; and in three cases I have seen a gall-bladder distended by many calculi, followed by the formation of a large hepatic abscess close to the gall-bladder. This in two cases pointed in the abdominal wall and was opened, with the result of complete recovery; and in the third, burst into the peritoneum and caused death.

The following are examples illustrating the morbid anatomy of abscess of the liver, as observed in London:—



I. In a woman, aged fifty-five years, who had lived in London, and has never been farther from home than Ipswich.

On opening the body the most prominent part of the liver was a whitish mass, which proved to be the wall of an abscess. This abscess extended from the dorsal to the ventral surface of the liver, and contained about eight ounces of thick pus, slightly blood-stained. The gall-bladder itself was compressed, but the ducts were free. In the right lobe deep in the liver substance was a second abscess as large as an orange, and in the same near the diaphragmatic surface was a third abscess of walnut size.

The liver was considerably enlarged, and exhibited amyloid infiltration.

The colon showed several ulcerated patches, all within eight inches of the ileo-cæcal valve. The largest was of the size of a shilling, and the edges of all were somewhat thickened. There was amyloid disease of the small intestine and of the kidneys.

II. The patient was a man, aged twenty-one years, who had been in St. Bartholomew's Hospital under the care of Mr. Marrant Baker, who had amputated his left leg below the knee, for a sinus of long standing. The stump was perfectly healed, and when cut into was found to contain no pus.

The abscess was in the right lobe, and near the diaphragmatic surface of the liver. It consisted of two cavities, and had a thick wall. It contained about an ounce of thin ill-smelling pus. Outside the abscess the liver tissue was rather soft for one-twelfth of an inch, and beyond that was normal.

The intestines were normal. The spleen and kidneys showed amyloid infiltration.

III. The patient was a woman, aged thirty-five years. The abdominal muscles were adherent to the liver, forming the wall of a superficial hepatic abscess.

The abscess was associated with pylephlebitis, for the portal vein at its entrance to the liver was com-



pletely occluded by a firm, closely adherent clot, and along its course in the liver were many small abscesses. The intermediate hepatic tissue was normal. The pylephlebitis probably succeeded, or was the contemporary of an old abdominal inflammation indicated by a much thickened and highly pigmented vermiform appendix.

IV. A man, aged twenty-nine years, who was under the care of Dr. Andrew. He left India in good health on December 6, 1878. Shortly before landing in England he had a violent rigor, and after landing several more rigors. He was admitted at St. Bartholomew's Hospital on March 7, 1879, having then had dysenteric diarrhœa for a month. He had never had dysentery in India. No enlargement of the liver could be felt at the time of his admission, but he had tenderness on pressure in the hepatic region. The pain was continuous, and by April 14 the signs of abscess of the liver were tolerably distinct. On April 19 the abscess was opened, and about four pints of pus let out. He gradually sank, and died on May-day.

The right lobe of the liver was excavated by an abscess as large as a child's head. The abscess was bounded behind by the right kidney and perinephritic tissue, but its cavity did not communicate with the colon. The suppuration had penetrated the capsule, and invaded the cortex of the kidney, but had nowhere reached the pyramids. The hepatic part of the abscess was very uneven, ragged and greyish. It contained a little purulent ill-smelling fluid. Outside the cavity there was a zone of hepatic tissue infiltrated with pus, and the liver contained in every part many similar infiltrated patches, some of which enclosed fluid pus, while others were only partially softened. The gall-bladder and the large ducts were unaffected.

The channel of a trocar wound was visible in the abdominal wall, and in the anterior and lateral wall of the abscess, but the liver was not at the point of puncture adherent to the body-wall. There were the



appearances of general recent peritonitis. The colon was exceedingly thin, and the whole inner surface of the large intestine, except the last three inches of the rectum, was gelatinous in appearance, owing to a layer of faecal matter lying upon and partially adherent to a surface everywhere reticulated by ulceration.

V. The patient was a girl, aged three and a half years, who was under the care of Dr. Andrew, and died in St. Bartholomew's Hospital, and who had never been out of London.

She had been ill ten months with diarrhoea, and for about two months slime and blood were observed in her stools, with general symptoms of dysentery. She was in the hospital for about five weeks, and during that time her temperature occasionally sank to  $99^{\circ}$ , but usually ranged from  $102^{\circ}$  to  $105^{\circ}$ .

The liver showed two abscesses, one in the right lobe as large as a small orange, and one in the left lobe of the size of a filbert, both with very definite boundaries. Microscopic sections of the neighbouring tissue showed healthy liver structure. The whole of the large intestine was extensively ulcerated.

VI. In one example I found abscess of the liver associated with ulceration of the small intestine only, the ulcers being those of enteric fever.

The patient was a woman, aged twenty-seven years.

A soft, organized, and apparently recently formed band reached from the outer part of the small intestine at the ileo-cæcal valve to a point six inches up the bowel, and another adhesion existed between two folds of intestine six inches higher up. At both places the intestine was nipped, and was of a deep blue colour, as if becoming gangrenous, and at the upper place there was a small perforation.

There were typical ulcers of enteric fever in the ileum just above the ileo-cæcal valve, apparently healing, and above the constrictions were others nearly healed.



The large intestine presented no abnormal appearances.

The spleen was large and soft.

There were two abscesses close to each other in the right lobe of the liver, about the size of a walnut and of a pea respectively.

The kidneys were large and soft, with adherent capsule and some swelling of the cortex. The heart and lungs were natural. There were no other abscesses.

Of these cases, in I. and V. the abscess was probably due to an embolus from a large intestine affected by dysentery acquired in England; in IV., to an embolus from a large intestine ulcerated by tropical dysentery; in II., to an embolus from the sinus on the left leg; in III., to pylephlebitis; and in VI., to the ulceration of the small intestine.

Before the doctrine of infection by active embolus containing micrococci was familiar to pathologists, there seemed some mystery in the relation between abscess of the liver and dysentery. It is now clear, and we are no more astonished that abscess of the liver does not occur in all cases of dysentery, than that it is not found in every example of pyæmia, of which the primary source is on the way to the liver.

The following Table shows the relation of abscess of the liver to suppuration elsewhere.

The number of fatal cases of hepatic abscess examined post-mortem at St. Bartholomew's Hospital in the twenty years from October 1867 to October 1887 are shown.



Year.	Sex.	Age.	Seat of Abscess.	Associated Suppuration, &c.
1867	M.	25	Right lobe	Of colon; abscess opening into it; amyloid disease.
1868	M.	24	Right lobe	Extensive ulceration of large intestine.
1869	No case during this year.			
1870	M.	47	Two in right lobe	Extensive ulceration of colon.
1871	F.	34	Right lobe	No other suppuration; this was suspected to be a hydatid.
"	F.	27	Large in left lobe, and small in right lobe	Old abscess of ovary, pericardium, and pleura.
1872	M.	40	Numerous	Scars of old ulcers in cæcum.
1873	M.	30	Right lobe	Extensive ulceration of cæcum.
"	M.	19	Numerous in right lobe	Abscesses about spleen.
1874	M.	37	Right lobe	Extensive ulceration of colon, and many old scars.
"	F.	16	Numerous in left lobe	Ulceration of vermiform appendix and perityphlitic abscess.
"	F.	24	Right lobe	Stone and abscess of right kidney, but no direct communication.
1875	M.	13	Numerous	No other suppuration.
1876	No case during this year.			
1877	M.	27	Four large abscesses, two in each lobe	Ulceration of large intestine.
"	F.	18	An abscess in each lobe	Two ulcers in colon.
1878	M.	41	Right lobe	Numerous ulcers of colon.
"	M.	30	Numerous	Pylephlebitis; ulceration of appendix vermiformis.
1879	F.	55	Three abscesses	Ulceration of colon.
"	M.	21	Right lobe	Sinus in left leg.



Year.	Sex.	Age.	Seat of Abscess.	Associated Suppuration, &c.
1879	F.	35	Numerous	Pylephlebitis; old ulceration of appendix vermiformis.
„	M.	29	Right lobe	Extensive ulceration of large intestine.
1880	F.	3½	Both lobes	Extensive ulceration of large intestine.
1881	No case during this year.			
1882	F.	29	Large abscess in left lobe. Several smaller abscesses in right lobe	No clot in portal vein. No other suppuration.
„	F.	42	Several in right lobe	Firmly adherent thrombus of portal vein.
1883	M.	83	Large in right lobe. Small in left	Abscesses in brain (pyæmia).
„	F.	26	Very large in right lobe	None. No scars or ulcers in large intestine.
1884	No case during this year.			
1885	M.	65	Right lobe	Dysenteric ulceration of large intestine.
„	M.	41	Both lobes	Dysenteric ulceration of large intestine.
„	M.	25	Many	Pyæmia.
„	M.	72	Both lobes	Due to gall-stones.
„	M.	45	Four large abscesses.	Many deep ulcers in large intestine.
1886	M.	22	Many	Pyæmia.
„	M.	18	One abscess in right lobe	Enteric fever. Many ulcers in large intestine.
1887	No case up to October in this year.			

A few of the abscesses, it may be noticed, had clearly begun in the walls of the bile ducts, but the vast majority in the veins.

Since cases of abscess of the liver usually end fatally, this Table, showing but 32 cases out of about 4460



post-mortem examinations, illustrates the rarity of the affection in London.

**Fatty Liver.**—The term fatty liver is applied to two conditions, in both of which Glisson's capsule encloses fat within the liver.

1. Fatty infiltration of the lobules.
2. Fatty degeneration of the cells.

**Fatty Infiltration.**—The liver is larger than natural. It is pale, and pits on pressure. Its edge is rounded, and if the whole organ is taken in the hands it can easily be bent. Once the surface is broken the liver tears easily. On microscopic examination numerous fat cells are found beneath the capsule of each lobe among the ultimate branches of the portal vein.

This form of liver is often found after death from phthisis, where the rest of the body has little fat, and also in persons all whose loose tissues are loaded with fat.

**Fatty Degeneration.**—In cirrhosis of the liver, in fatty infiltration of long standing, and in amyloid infiltration of the liver, some degree of fatty degeneration of the hepatic cells is often to be found under the microscope.

In phosphorus poisoning universal fatty degeneration of the hepatic cells is present. The liver is large and pale, with small hæmorrhages here and there. It yields to pressure and tears easily.

Microscopic sections stained with osmic acid show widespread fatty degeneration of the liver cells.

Fatty degeneration of the kidneys and of the heart are usually present.

This form of degeneration progresses rapidly, and complete fatty degeneration of the liver was found in a man who had taken phosphorus less than a fortnight before his death. (See p. 105.)

The common bile-duct is often closed by catarrhal inflammation, and all the tissues jaundiced.

**Cyst.**—Besides hydatid cysts, small developmental



cysts, rarely larger than a pea, are sometimes found on the surface of the liver.

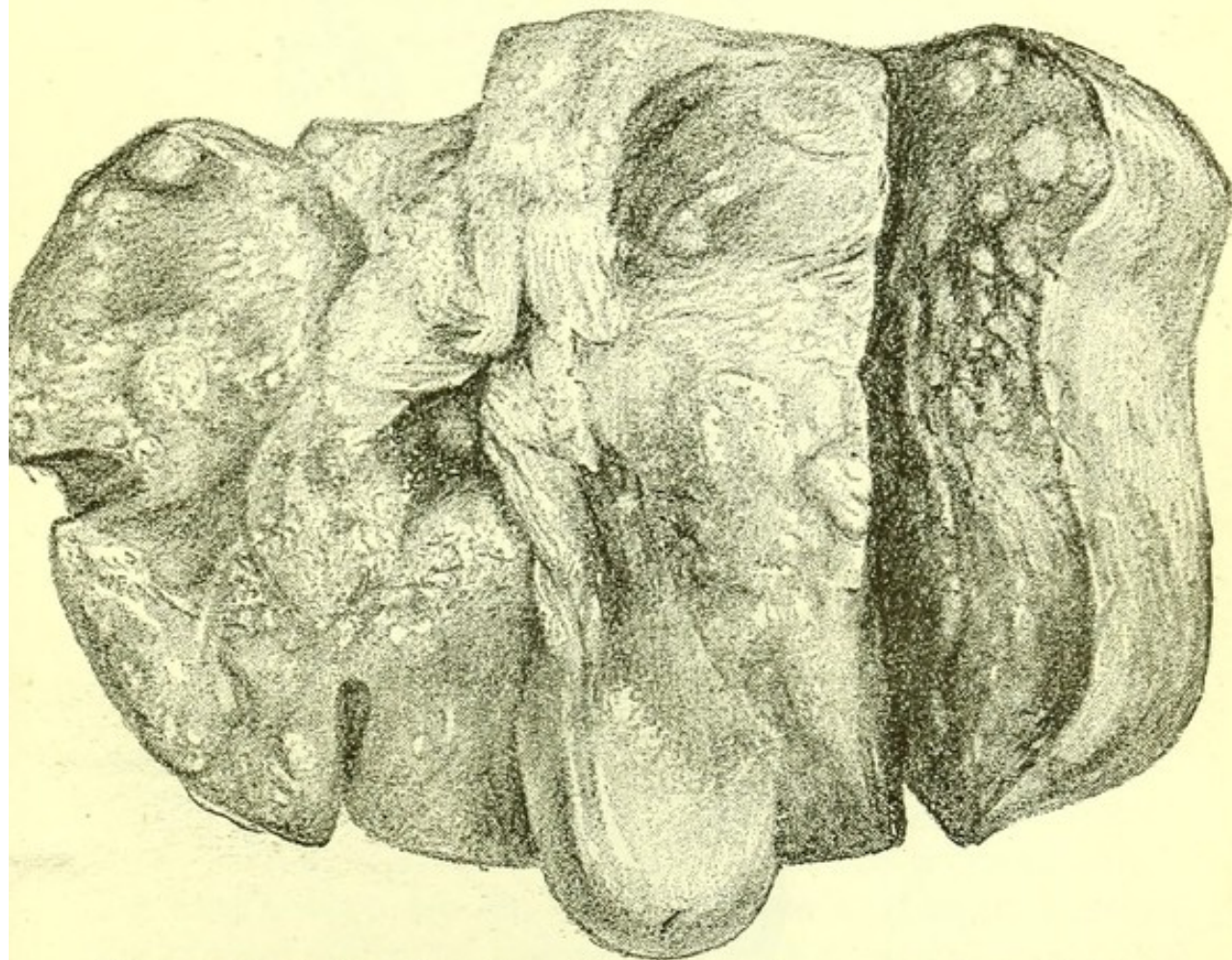
**New Growths in the Liver.**—Primary carcinoma is very rare in the liver substance, and when present has generally grown from the columnar epithelium of the minute ducts, or from the flattened cells near the origin of these.

Two circumstances will indicate that the growth is primary :

1. Its occurrence nowhere but in the liver ;
2. That its nodules are jaundiced while the common duct is free and the body not jaundiced.

Secondary carcinoma of all forms is very common

FIG. 80.



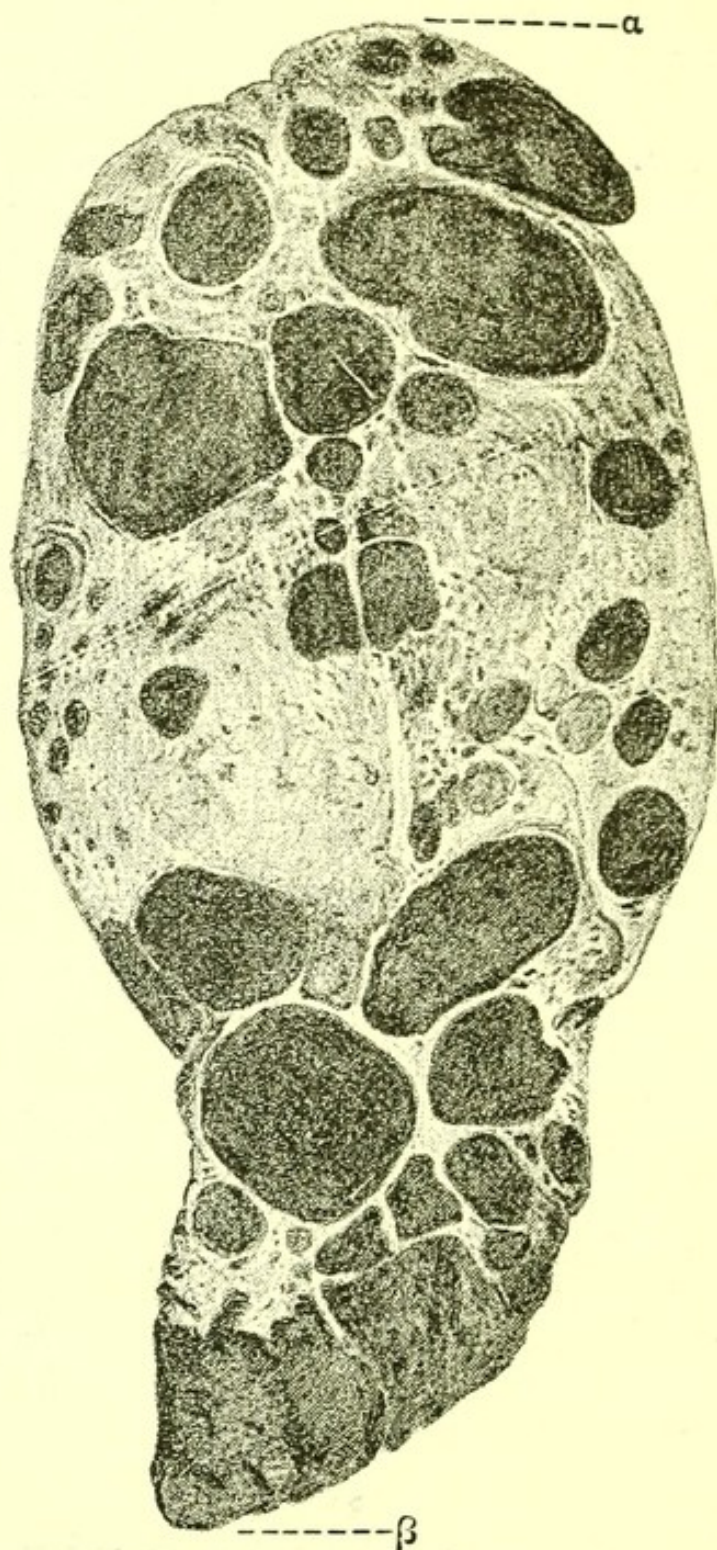
*Liver Infiltrated by Secondary Carcinoma.* From a specimen in the post-mortem room of St. Bartholemew's Hospital.

in the liver—more common than in other organ except the lymphatic glands. When on opening the abdomen



the liver is found enlarged with its surface studded with large and small masses of whitish carcinomatous

FIG. 81.



*Melanotic Sarcoma of Liver.* (The primary growth was in the eye.)

new growth, sometimes umbilicated or depressed in the middle, the probable seat of the primary new growth



is—in a man: the stomach, œsophagus, rectum, pancreas, lung; and in a woman: the breast, uterus, stomach, rectum, pancreas, lung, œsophagus.

In all cases of widely spread sarcoma the liver is a frequent seat of secondary new growth.

The new growth may be so abundant as to leave very little normal liver tissue, and to cause an increase in weight of from fifty to eighty ounces. Secondary melanotic sarcoma is common in the liver.

**Tubercle.**—In acute tuberculosis tubercles are sometimes present in the substance of the liver and very often on its surface.

In tubercular peritonitis the whole liver may be covered by a caseous coat due to degenerate tubercle.

**Syphilis** affects the liver in two ways:

1. By producing amyloid infiltration;
2. By growth of gummata with increase of connective tissue.

The term syphilitic cirrhosis is sometimes applied to a condition in which the shape of the liver is distorted by numerous gummata and their attendant scar tissue.

Perihepatitis is generally due to a uniform superficial layer of such gummata. A depressed scar on the surface of the liver with a line of connective tissue dipping into the liver substance is always due to gumma.

Hæmorrhagic infarction such as is seen in the spleen, kidney, and lung is unknown in the liver.

Gummata, though rare, are certainly an occasional result of congenital syphilis.

The following was an example of this rare condition:—In a boy, aged nine years, who had been under Dr. Gee's care in St. Bartholomew's Hospital from December 1883 to September 1885, with some intervals, and whose most prominent symptoms were emaciation, ascites, and enlarged liver, with a very sallow skin and well-marked Hutchinsonian teeth. I found post-mortem the liver, kidneys, stomach, intes-

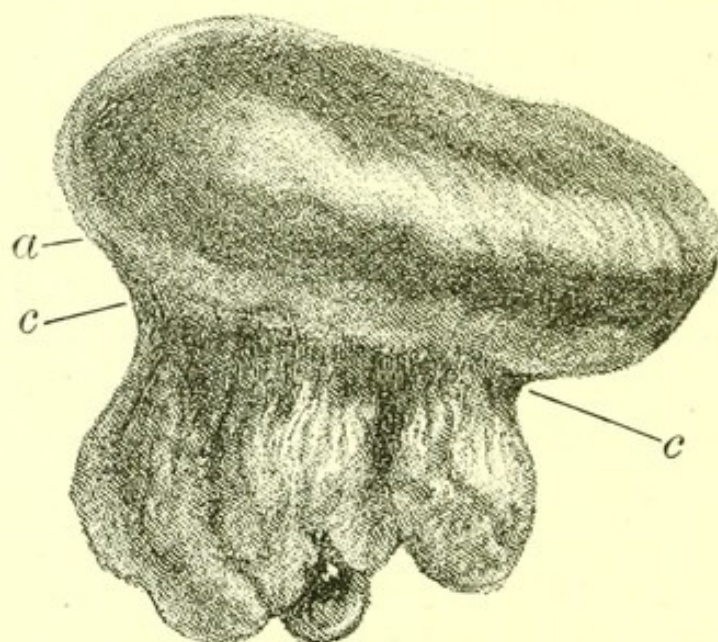


tines, and spleen all showing well-marked amyloid change. The liver was very irregular on the surface and in several places had deep puckered scars. On section, several large yellowish tough masses of irregular outline were found, each surrounded by a red zone of engorged liver substance.

Microscopic sections showed these masses to be large gummata, and in their vicinity and here and there on the surface were minute collections of embryonic connective-tissue cells.

**Other Thickenings of the Capsule.**—All other thickenings of the capsule may be distinguished from gummata by the fact that they do not dip into the substance of the liver, such thickenings are often due to pressure, as in tight-lacing.

FIG. 82.



*Liver*, showing thickening of capsule due to tight-lacing.  
c c. Band of the thickened tissue.

**Pylephlebitis.**—Inflammation of the portal vein, followed by thrombus and sometimes by permanent obliteration of the vein, which is converted into a hard cord, or in which suppuration takes place throughout the liver, sometimes follows inflammation about the uterus.

As in the following examples :—



I. A woman, aged twenty-eight years, who had intermittent fever, diarrhœa, and purulent discharge from the bowel, and albuminuria. She had colic attributed to gall-stone in April. At the end of May she had a miscarriage, and after it a swollen leg. The post-mortem appearances were:

*Body.*—Lean, left leg slightly larger than right. No jaundice. No general dropsy.

*Chest.*—Slight adhesions of both lungs at base. Left lung, on section, normal. Right lung containing two small embolic abscesses.

*Heart.*—Normal, excepting a small valvular opening in the foramen ovale.

*Abdomen.*—The liver and intestines were adherent to the abdominal wall, and the peritoneum contained much lymph and turbid fluid.

The pancreas was thickly covered with lymph, but on section was normal throughout.

The left iliac vein was partly filled with a firmly adherent laminated clot. The vena azygos major was thickened throughout and was filled with sanious purulent fluid, and a thin adherent laminated clot. The lowest part of the vena cava inferior was filled by a firmly adherent clot; higher up a laminated clot lay in the vein, but was not adherent to its walls. The renal vein contained firmly adherent clots. So did the splenic vein. The portal vein in its main trunk contained a large, firmly adherent clot. The liver was enlarged and contained numerous abscesses, all continuous with branches of the portal vein.

The bile-ducts were free, but the gall-bladder contained several small gall-stones with facets. There were no abscesses of the spleen or kidneys. In the left iliac region a peritoneal abscess had perforated the small intestine from without. There was much lymph about the cæcum and vermiform appendix, but they were internally natural.

Three mesenteric glands were caseous. The other viscera were normal.



II. A woman, aged forty-two years.

*Body*.—Slightly jaundiced; slight anasarca of ankles.

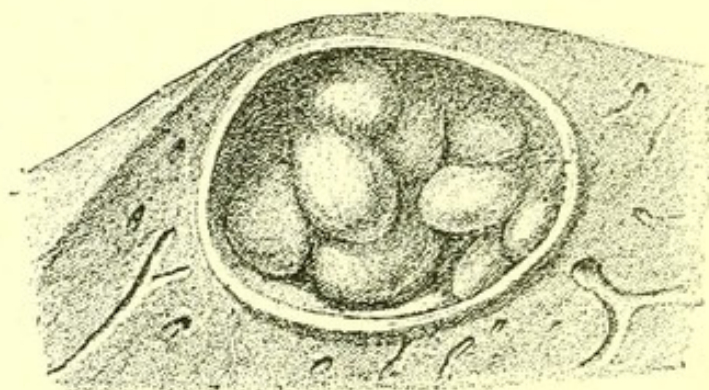
*Head*.—Normal.

*Chest*.—A small gritty mass at the apex of the left lung with a pleural adhesion. Heart, with growths, due to former endocarditis, on the aortic valves.

*Abdomen*.—Portal vein blocked by an adherent clot, which extended into its right branches. Numerous abscesses in the right lobe were traceable to this thrombus. The common duct was not bile-stained. The pancreas, stomach and intestines, were normal. No clots were present in any other abdominal veins. The ovaries contained Graafian follicles distended with blood.

**Hydatid**.—When the larva of *tænia echinococcus* reaches the liver it becomes fixed and its body-wall expands slowly into a cyst containing clear non-albuminous saline fluid, while from the interior of the body-wall numerous smaller cysts develop.

FIG. 83.



*Hydatid of Liver.* Daughter cysts contained in a large cyst of *Tænia echinococcus*. From a specimen in the Museum of St. Bartholomew's Hospital.

The primary cyst may grow as large as a man's head and the daughter cysts increase to any number.

No inflammation is commonly discoverable in the contiguous hepatic tissue. In very rare cases an abscess is formed.

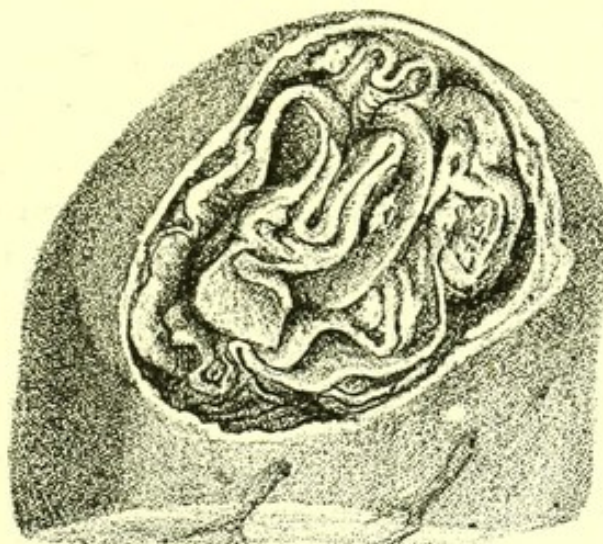It is not rare to find several such cysts in one liver. The cyst may die, and then its contents become first caseous and then calcareous. If it presses on the



common duct, jaundice, followed by dilatation of the bile-ducts throughout the liver and fatal cirrhosis, occurs.

**Inflammation** of the gall-ducts has already been mentioned under the head of catarrhal jaundice.

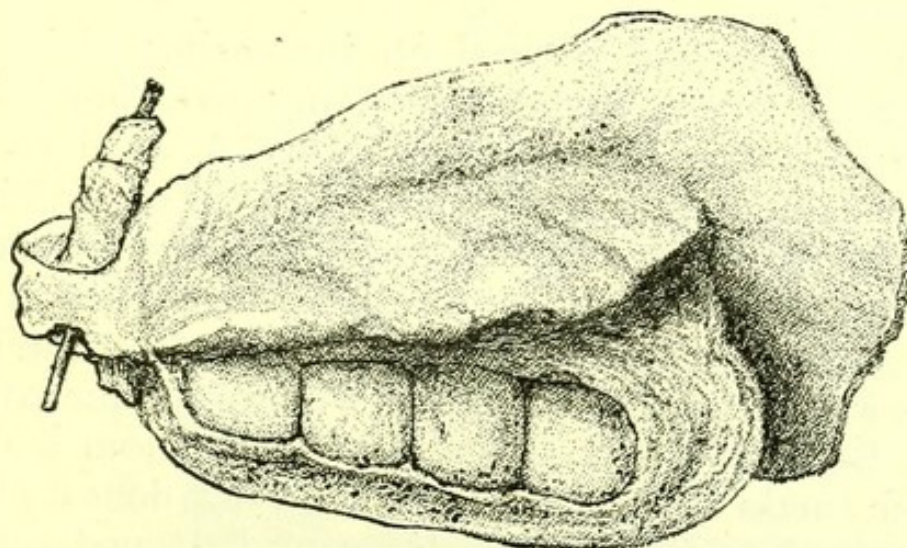
FIG. 84.



*Hydatid of Liver* (with daughter cysts). From a specimen in the Museum of St. Bartholomew's Hospital.

**Ulceration** sometimes, but very rarely, follows the impaction of a gall-stone. In a nurse who died, in St.

FIG. 85.



*Gall-stones* in a Gall-bladder surrounded by a mass of Primary Carcinoma of the Gall-bladder. From a specimen in the Museum of St. Bartholomew's Hospital.

Bartholomew's Hospital, after violent vomiting for



some hours, I found a rupture in an ulcerated patch of the duct near its entrance into the duodenum, and a gall-stone in the peritoneal cavity.

**New Growth.**—**Primary carcinoma of the gall-bladder** is not uncommon. It is sometimes associated with the presence of gall-stones.

In a woman, aged fifty-nine, who was under Dr. Andrew's care in St. Bartholomew's Hospital, I found the gall-bladder infiltrated in every part and surrounded by a mass of soft carcinoma. It contained four large faceted gall-stones, and there were several smaller stones. The growth in and around the gall-bladder was continuous with a mass of infiltrated lumbar glands. The duodenum was compressed and its walls infiltrated by the cancer. The cystic duct was obliterated, the common bile-duct open. The stomach was so dilated as to cover all the abdominal viscera to within an inch of the pubic symphysis. The peritoneum contained a few small nodules, and there were one or two near the gall-bladder on the liver, but none within the liver, and the pancreas was not at all infiltrated. The pylorus was unaffected. There were a few nodules on the pleural surface of both lungs.

The woman had noticed an increasing abdominal swelling for five years, but it had only given her trouble for two months before her death. A hard tumour near the liver was felt during life. The following examples show its duration and method of growth.

**I. Carcinoma of the common bile-duct** is very rare. It may form a large mass surrounding the duct, as in a woman, aged sixty-three, who was under my care in St. Bartholomew's Hospital, and in whom a dense whitish mass of carcinoma, with very dense fibrous stroma and scattered collections of flattened cells of epithelial type, occluded completely the common duct and the cystic duct. The cavity of the duct was discoverable, though its walls were in contact, and the new growth extended from it. The liver was only penetrated in the immediate neighbourhood of the duct.



**DIAGRAM VII.**  
**Carcinoma of the Gall Bladder and Ducts.**  
 (TEN CASES.)

AGE	Gall Bladder	LYMPHATICS	HEART	LUNGS	THYROID	PERITONEUM	LIVER	PANCREAS	SPLEEN	KIDNEY	ADRENAL	TESTIS	OVARY	UTERUS
37														
39														
44														
66														
67														
LXVIII														
LIX														
LXI														
LXIII														
LXIII														

The black squares indicate the regions of secondary growth. In the last three there were no secondary growths. The ages of men are in Arabic figures, of women in Roman numerals. A microscopic examination was made in each case.







The gall-bladder itself was occluded, being adherent to the walls of a small hydatid cyst containing creamy, caseous material, but its fundus contained no new growth. There were no secondary deposits in the liver.

The bile-ducts were dilated throughout the liver, and the organ itself was cirrhotic, and of a dark green colour. There were no secondary growths in any part of the body.

The patient had had pain at intervals in the epigastrium for two years, and after losing flesh for two months became jaundiced, on June 15, 1886.

On her admission, on July 6, she was very deeply jaundiced. The edge of the liver could not be felt. Some weeks later the jaundice was deeper and the gall-bladder (as it afterwards proved to be) was felt as a hard lump at the lower edge of the liver.

She became more and more jaundiced and weaker, and died December 4, 1886.

II. The new growth may be confined to the wall of the duct without extending into the gall-bladder or into the liver substance, as in a man, aged forty-seven, who was under my care in St. Bartholomew's Hospital.

Deep general jaundice was present, and the body was much wasted. There was no dropsy. The brain was normal, and there was no new growth in head or neck. There was no new growth in the chest.

The lungs were firmly adherent at their apices, and both apices contained tubercle.

The heart was normal, and the aorta and large blood-vessels were not anywhere calcified.

The glands of the hilum of the liver contained no new growth, and none were found in any other abdominal lymphatics.

The whole alimentary tract was free from new growth.

The spleen was somewhat enlarged and soft, weighing 10 ozs.



The pancreas was minutely examined, and found to be normal throughout.

The kidneys, supra-renals, ureters, bladder, and urethra were all normal, and contained no trace of new growth.

The cartilages of the knees and great-toe joints on both sides were free from degeneration or deposit.

A microscopic section was made through the wall of the common duct about halfway between its commencement and its terminal orifice. The new growth seemed to grow from the epithelial cells of the duct, and as it extends outwards into the duct wall the cells appear in the meshes of well-developed but not very dense stroma.

Towards the liver the new growth penetrated the hepatic substance at a few isolated points and only for a very short distance. To the naked eye no infiltration of the liver was visible, and there were no secondary deposits in it.

The lumen of the common duct was wider than natural, and the epithelial surface was very faintly bile-stained, almost white. The duct contained a good deal of mucus, but a probe was easily passed down it from the papilla. The gall-bladder was greatly distended with bile. Its walls were not thickened. There was no general dilatation of the ducts in the liver, and no general increase of connective tissue.

The patient's jaundice began on or about June 12, 1886. He had never had jaundice or any serious illness before. The jaundice came on after a few days of pain at the epigastrium after taking food, and without any attack of colic. He stated that he had been losing flesh slightly for two years.

He was very thin when admitted to St. Bartholomew's Hospital on July 22, and deeply jaundiced. His temperature was normal. The edge of the liver was not to be felt, nor was the spleen enlarged.

On August 1 his jaundice was not diminished, but about August 11 it became a little less intense, and



some bile was observed in the stools. On August 18 they were again quite without bile.

On September 10 he was sent to a convalescent hospital. He weighed 9 st. 1 lb. on July 27, and 9 st. 4 lb. on September 7.

On October 13 he was readmitted, obviously much thinner, and weighing 8 st. 4 lb.

He grew steadily weaker, and died November 8.

At the post-mortem, but for the microscopic examination of the duct, the new growth might have been overlooked, and it seems likely that some cases (in which no such examination was made) recorded as examples of chronic catarrh of the bile-duct were really examples of new growth.

The duration of the growth was clearly slow in both cases.

In the man the symptoms extended over two years and six months, and he died five months after the appearance of jaundice.

The woman had symptoms for the same period, and died at about five months after the new growth was advanced enough to cause jaundice.

**Dilatation of Gall-bladder.**—The gall-bladder is sometimes found enormously dilated with clear fluid, a gall-stone being impacted in the cystic duct. The reticulated inner surface has become smooth and the contained fluid is like thin mucus, and not at all bile-stained.

**Obstruction.**—The ducts may be found obstructed by—

1. Catarrhal secretion;
2. Gall-stone;
3. New growth in the wall;
4. The external pressure of a tumour, hydatid, new growth, or aneurysm.

The gall-bladder itself may be filled by one large stone and become firmly adherent to it.

**Parasites.**—*Distoma hepaticum* (the fluke) is occa-



sionally found in the ducts and gall-bladder of the human liver, but is very rare.

In the only case I have seen the parasites were distinctly bile-stained.

*Tænia echinococcus*: I have seen one example of hydatid (calcified) in the outlet of the gall-bladder, and one in the same condition which occupied the fundus.

### PANCREAS.

**Pancreas.**—In the bodies of patients who have died of wasting diseases the pancreas is sometimes very small, and in cases of valvular disease of the heart is abnormally hard and of a reddish colour. In both these conditions its microscopic structure is unaltered. In general acute tuberculosis a few recent tubercles may be found in the substance of the gland, and in cases of amyloid infiltration of other viscera its blood-vessels occasionally exhibit an amyloid deposit. In diabetes it is sometimes found in a state of general fatty degeneration. More important morbid states are—

1. Calculus of duct ;
2. Abscess ;
3. Cysts ;
4. Cirrhosis ;
5. New growths.

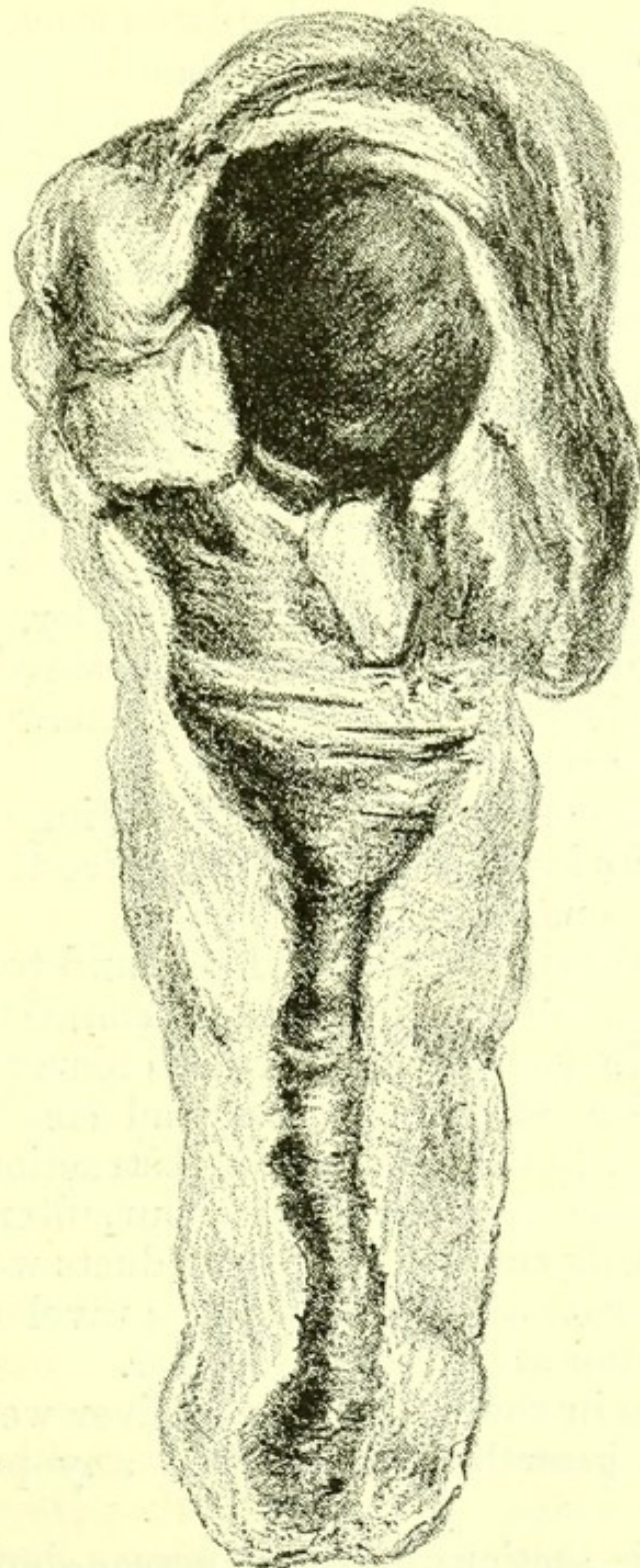**Calculus** is most often whitish in colour with numerous projecting processes, and consists of pancreatin and carbonate of lime. Several are generally found. By blocking the duct, calculi give rise to abscess in the head of the pancreas. Such abscesses may attain a considerable size, and sometimes cause adhesions about the head of the pancreas and the formation of large enclosed abscesses in the pus of which the calculi are discovered. Dilatation of the pancreatic duct with the formation of a large cyst may also follow.

All the branch ducts may be dilated.



In this case a true *cirrhosis of the pancreas* occurs.

FIG. 86.



*Cyst in Head of Pancreas*, with dilatation of the duct due to calculi. From a specimen in the Museum of St. Bartholomew's Hospital.

Fresh connective tissue is formed, the acini atrophy and the whole gland becomes hard.



The following examples illustrate the appearances associated with calculus of the pancreas :—

I. The pancreas had a much dilated duct, containing numerous irregular calculi of carbonate of lime. The duct was most dilated near the head, but was nowhere completely closed by the calculi.

The patient was a man, aged forty, who died in St. Bartholomew's Hospital of diabetes. The bile-duct was pervious, and there was never any jaundice.

II. The pancreas had a slightly dilated duct, and contained a calculus of irregular shape, around which was a large abscess in the head. This abscess pressed upon the orifice of the bile-duct, but did not cause complete obstruction, though sufficient to have produced great distension of the gall-bladder.

The patient was a man, aged forty-three, who died in St. Bartholomew's Hospital of an attack of pleurisy following one of gout.

III. The pancreas had great dilatation of the duct throughout its length. Near the orifice the duct was blocked by a small irregular calculus.

The whole gland was very hard, and to the naked eye showed an obvious increase of connective tissue. The papilla in the duodenum was enlarged, and the hardened tissue of the pancreas had constricted the bile-duct so as to cause complete obstruction.

The liver was of a deep green colour, intensely hard, nodulated on its surface, and all its ducts were dilated. On section watery bile and bile gravel exuded in abundance from all parts of the liver.

The glands in the hilum of the liver were normal, and no new growth was found in any part of the body.

Microscopic sections of the pancreas showed an extensive increase of connective tissue. Many bands of oldish growth traversed the gland, and here and there were abundant nuclei of patches of more recent connective-tissue growth. Some normal gland-cells were to be seen, but many acini showed several



degrees of atrophy. There were no signs of carcinomatous growth. The condition was of the same kind as that found in the liver of cirrhosis.

Dr. Wickham Legg has shown that dilatation of the hepatic ducts will produce a general connective-tissue increase throughout the liver, and in this pancreas a general dilatation of its ducts, due to the occlusion of the main duct by the calculus, seems to have been the cause of the new connective-tissue growth throughout the gland.

The man in whom this condition occurred was aged sixty-four years, and died in St. Bartholomew's Hospital after an illness of five months, during three of which he was jaundiced. His liver did not seem enlarged when he was admitted, but steadily increased in size. During his illness he had many attacks of vomiting, but never had colic.

It is worthy of note that attacks of vomiting occurred in all three cases of calculus, jaundice in only one, while colic was not a symptom in any of the three.

**Abscess of the pancreas** sometimes occurs as a part of a general pyæmia. In former times it was observed to be common after operations on the spermatic cord. It also follows thrombosis of the veins of the pancreas associated with pylephlebitis, and may occur as a sequel of calculus. The following example shows its relation to pylephlebitis:—

I. The patient was a man, aged twenty-four years, who died in St. Bartholomew's Hospital.

The pancreas showed several small collections of pus and a large abscess in the duodenal end. The main veins were filled with firmly adherent clots. It is important to state the post-mortem appearances at length.

*Body.*—Lean; slightly jaundiced, no dropsy, no scars.

*Chest.*—Fauces and œsophagus, larynx, and trachea normal.



Lungs, heart, bronchial glands normal.

*Abdomen.*—There were patches of lymph over the whole surface of the peritoneum, including the under surface of the diaphragm.

*Stomach.*—Normal.

*Small Intestine.*—Mucous surface normal; near the valve the Peyer's glands were more pigmented than is usual, but were not raised, and showed no sign of ulceration.

*Large Intestines.*—In the cæcum, about two inches from the end was a small opening, apparently of an almost healed ulcer. This led into a large abscess cavity behind the cæcum. The abscess had in one or two places penetrated the uppermost part of the iliacus muscle, but nowhere the psoas.

On further dissection I found that the appendix vermiformis was firmly adherent to the cæcum, and was much thickened in every part. It led into the abscess described as behind the cæcum, and the tip was ulcerated away. It was clear that the abscess had pointed into the cæcum, for the mucous membrane on minute examination showed no trace of ulceration or loss of tissue (except at the pinhole-sized opening), and the ridges were perfect. The contiguous bones were not diseased.

The bladder, ureters, and kidneys were normal.

*Liver.*—A firmly adherent thrombus, partially softened, filled the vena portæ, and, following this on its hepatic branches, numerous small abscesses were found in every part of the liver.

In the vena cava inferior, below the liver, there was no thrombus, but just below the diaphragm there was a firmly adherent but small thrombus, about three-quarters of an inch long, lying in the long axis of the vessel, and adherent throughout its whole length.

In the following example I did not discover the cause of the abscess:—

II. The patient was a man, aged seventy-four years.



*Pancreas*.—The head partially broken down and forming one wall of an abscess, elsewhere bounded by peritoneal adhesions. Duct unaffected. Papilla in duodenum prominent, a probe readily passed into it.

*Liver*.—With old adhesions to diaphragm. Ducts free and structure normal. A little gritty material in the gall-bladder. In the vena portæ some firmly adherent clots.

There was pneumonia of the right lung. The other viscera were normal.

In a third the state of the common bile-duct seemed to indicate that the inflammation which caused the abscess had been due to a gall-stone.

III. The patient was a man, aged thirty-five. There was slight general jaundice.

*Liver* of a deep green colour, with general hardening, increase of connective tissue, and dilatation of the ducts. No gall-stones were found.

*Gall-bladder* thickened and œdematous, but with no new growth in its walls.

The common duct led into a large cavity containing broken-down tissue and blood, and bounded by the pancreas, duodenum, and under surface of stomach. Into this cavity, at the other end, led the duct from the duodenum. It was patulous and readily admitted the little finger. Near the head of the pancreas there was an opening from the abscess into the peritoneum.

The abscess had eroded a part of the main trunk of the pancreatico-duodenalis artery, and had destroyed a large part of the head of the pancreas.

The stomach and intestines were elsewhere normal.

The thoracic viscera were normal.

**Thrombosis** of the pancreatic vein, while frequently associated with abscess of the pancreas, may exist without it, just as the results of pylephlebitis may last long and yet not terminate in suppuration within the liver.

This was shown in the body of a woman, aged



twenty-seven years, who died in St. Bartholomew's Hospital.

*Body.*—Lean ; no dropsy, no jaundice.


*Chest.*—All organs normal. All veins above the diaphragm normal.

*Abdomen.*—Two feet two inches from the pylorus the small intestine was very red and almost gangrenous for ten inches. The mesentery attached to this piece of bowel was swollen, and the neighbouring peritoneum was rough. There were also soft adhesions to other coils of intestine. At the time of the post-mortem there was no obvious cause for this condition of the bowel, but the mesentery was unusually long, and by a slight twist could be made to constrict the bowel, at the commencement of the above-mentioned redness. It was clear that during life there had been some obstruction, afterwards overcome. The mesenteric veins in the mesentery attached to the inflamed piece of bowel were filled with firm, partly decolorized, clots which were adherent to the inner coat of the vein. The splenic vein in its whole course was occupied by a similar adherent clot, and so were the gastric veins. The pancreatic veins were also blocked by decolorized and adherent thrombi.

The portal vein was represented by a firm imperious cord. Lying upon it, in the anterior wall of the foramen of Winslow, were four small veins passing into the liver, and all filled with adherent clots. The vena azygos minor was filled in the lowest three inches of its course by a similar adherent clot, but all the other abdominal veins were free. It was clear that the portal vein had at some remote time been the seat of inflammation, and that, after its obliteration, the four small veins above mentioned had been enlarged, and had carried blood into the liver till they had themselves become the seat of a comparatively recent thrombosis.

The spleen was large and firm, and the liver, except







**DIAGRAM VIII.**  
**Carcinoma of Pancreas.**  
 (ELEVEN CASES.)

AGE	LYMPHATICS	HEART	LUNGS	THYROID	PERITONEUM	LIVER	PANCREAS	SPLEEN	KIDNEY	ADRENAL	TESTIS	OVARY	UTERUS	DUCTS
45														
54														
55														
57														
64														
70														
XXXVIII														
XLIV														
XLVI														
LIII														
LVI														

The black squares show the regions in which secondary growths were found. The ages in Arabic figures are those of men, in Roman numerals of women. (All examined microscopically.)

[To face page 333.]



that it was somewhat pale, was natural. It had no abscess, nor sign of a healed abscess.

The vena cava inferior, with all its branches, was quite free. In a former case a similar, but smaller, thrombus in the pancreatic vein was continuous with an abscess.

Thrombosis of the veins of the pancreas is not necessarily present in thrombosis of the portal vein, even if that be of long standing. It is not recorded in any other of the cases of pylephlebitis which are in the post-mortem records of St. Bartholomew's (1867-1889).

**Carcinoma** is sometimes primary in the pancreas. It originates in the epithelium of the minute ducts, most commonly in the head. The growth compresses the orifice of the bile-duct and thus causes jaundice.

Secondary growths occur in the glands in the hilum of the liver, and less often in the liver itself.

**Sarcoma.**—Primary sarcoma is very rare in the pancreas.

Secondary growths of lympho-sarcoma and of melanotic sarcoma occur in the pancreas.

Secondary deposits of new growth are not common in the pancreas, and it is often found surrounded by a mass of sarcoma or of carcinoma, but nowhere penetrated by it.

Jaundice is nearly always present in cases of primary new growth in the pancreas; in secondary new growth it is present in about a quarter of the cases. In some of the cases of primary new growth in the head of the pancreas, cirrhosis of the liver is as a result of the obstruction of the common duct.

The following Table shows the distribution of the growth in eleven cases of primary carcinoma of pancreas:—



## PANCREAS.

Sex.	Age.	Primary Organ.	Microscopic Appearances.	Growth in continuity.	Lymphatics.	Heart.	Lungs.	Thyroid.	Liver.	Pancreas.	Spleen.	Kidney.	Supra-renal.	Uterus.	Ovary or Testis.	Brain.
M.	64	<i>Pancreas</i> : head much enlarged (cirrhosis of liver, due to dilatation of ducts from pressure of new growth).	<i>Carcinoma</i> columnar celled epithelium in moderate amount of stroma.	—	—	—	—	—	—	Infiltrated.	—	—	—	—	—	—
F.	44	<i>Pancreas</i> : dense mass.	<i>Carcinoma</i> columnar and spheroidal epithelium very dense stroma.	—	—	—	—	—	—	Dense mass.	—	—	—	—	—	—
M.	70	<i>Pancreas</i> : large mass in head.	<i>Carcinoma</i> columnar celled.	—	—	—	—	—	—	Mass in head.	—	—	—	—	—	—
M.	54	<i>Pancreas</i> : head, dense mass.	<i>Carcinoma</i> cells large flattened, traces of tubular arrangement.	—	Mesenteric glands. Gland in abdominal wall.	One small nodule.	Some small nodules in both.	—	Some small nodules.	Whole head.	—	Nodules, a few small.	—	—	—	—



F.	38	<i>Pancreas</i> : large mass in head. Primary here: bile ducts normal, and no jaundice present.	—	Lymphatics in hilum of liver.	—	—	—	—	—	Filled with soft new growth.	Large mass in head.	—	—	—	—	—	—
F.	46	<i>Pancreas</i> : growth through-out; head large and white mass.	Into cavity of duodenum.	Lumbar glands.	—	—	—	—	—	Many white masses.	Large mass in head, general infiltration	—	—	—	—	—	—
M.	45	<i>Pancreas</i> : dense white growth.	—	Lumbar glands. Glands in hilum of liver.	—	Right lower lobe small masses.	—	—	—	Weight 160 ozs., many masses of dense growth.	Dense white new growth.	—	—	—	—	—	—
F.	56	<i>Pancreas</i> : whole gland.	Lymphatics in portal fissure.	In portal fissure.	—	—	—	—	—	Numerous nodules of growth.	Infiltrated through-out.	—	—	—	—	—	—







## PERITONEUM.

**Ascites**, or non-inflammatory effusion of fluid into the peritoneum, occurs post-mortem as part of a general dropsy due to

- a.* Renal disease ;
- β.* Valvular disease of the heart ;
- γ.* Dilatation of the heart.

Or without dropsy elsewhere, and owing to

- δ.* Cirrhosis of the liver ;
- ε.* Pressure on the vena porta.

Or with dropsy of the legs, and owing to

- ζ.* Pressure on the vena cava inferior.

The fluid often contains a few pale coagula and is highly albuminous.

**Peritonitis**.—Small patches of redness, of soft lymph or of organized lymph, are often found post-mortem in some part of the peritoneum. The commonest regions of their occurrence are the surface of the liver and of the spleen, and the neighbourhood of the ovaries.

They indicate local inflammation of the peritoneum.

When the base of the left lung is firmly adherent to the diaphragm, the peritoneum near the spleen is almost always thickened and the spleen adherent to the diaphragm.

After the performance of paracentesis abdominis for ascites in cirrhosis, a small patch of lymph is always found near the point of puncture.

These are the slightest degrees of peritonitis.

**Acute peritonitis**, affecting the whole peritoneum, is found associated with—

1. Pyæmia ;
2. Rupture of some part of the alimentary canal ;
3. Intestinal obstruction by intussusception, volvulus, or hernia ;
4. Tubercle ;
5. New growth.



Peritonitis, with much lymph glueing the intestines together, is common in pyæmia, and in that form of it formerly called puerperal fever.

The peritoneum covering the intestines is reddened, and the coils are bound together by soft flakes of lymph. The free fluid is slightly turbid and makes the hands smart.

A similar form of peritonitis is found with perforation of the intestine or with volvulus.

Long thin bands of adhesion, the results of past peritonitis, are frequently found extending from one part of the peritoneum to another. They are sometimes very tough, and may cause death by strangulation of the intestine. This is sometimes the case even when they have been recently formed, as in the following example in a woman, aged twenty-six years, who was under my care in St. Bartholomew's Hospital with enteric fever. Death took place about the fiftieth day.

A soft, organized, and apparently recently formed band reached from the outer part of the small intestine at the ileo-cæcal valve to a point six inches up the bowel, and another adhesion existed between two folds of intestines six inches higher up. At both places the intestine was nipped, and was of a deep blue colour, as if becoming gangrenous, and at the upper place there was a small perforation. There were partially healed ulcers in the ileum close to the ileo-cæcal valve, and above the constrictions were others nearly healed. The adhesions corresponded to the floors of two ulcers.

**Peritonitis with clear fluid**, in which a few shreds of lymph only are floating, sometimes occurs acutely in a way comparable to that in which similar pleurisy occurs.

**Tubercular Peritonitis.**—The whole peritoneum is dotted with tubercles, in the neighbourhood of which are numerous hæmorrhages. The mesenteric glands are enlarged and generally caseous, and the effusion is either purulent or blood-stained.



Sometimes patches of caseous material between adhesions are found on the surface of the liver or between the intestines.

Tubercular peritonitis is sometimes discovered post-mortem without tubercle in any of the viscera.

**Chronic Peritonitis.**—The whole peritoneum is dull and often much thickened. On the liver pits generally remain, which probably mark the orifices of lymph spaces. The coils of intestine are often firmly adherent to one another. The walls of the intestine are thick and œdematous, and when the intestine is separate from the mesentery it often seems to have lost several feet in length and to be very short.

There is always some fluid in the peritoneal cavity, which may be either clear or turbid.

**Parasites.**—**Hydatid.**—Hydatid occurs, though rarely, in the peritoneum itself. The two examples I have seen were both within the pelvis.

*Bilharzia hæmatobia* may be found in any part of the peritoneum.

**New Growth of Peritoneum.**—Sarcoma originating in the peritoneum is not uncommon, and either forms large tumours which invade the intestinal wall, or are scattered in small masses over the peritoneum.

Lympho-sarcomata generally originate in the abdominal lymphatics and grow from them into the peritoneum.

Carcinoma of the viscera often extends to the peritoneum, or may have large secondary growths within the peritoneal cavity.

All these conditions are associated with fluid in the peritoneal cavity, and the fluid is frequently blood-stained.



## CHAPTER XV.

## DISEASES OF THE LYMPHATIC SYSTEM.

## SPLEEN :

SPLENUNCULUS.  
 ATROPHY.  
 ADHESIONS.  
 ENLARGEMENT.  
 HYPERTROPHY.  
 INDURATION AND EN-  
 LARGEMENT FROM AGUE.  
 LEUCOCYTHÆMIA.  
 ABSCESS.  
 LARDACEOUS SPLEEN.  
 TUBERCLE.  
 GUMMA.  
 NEW GROWTHS.  
 HÆMORRHAGIC INFARC-  
 TION.  
 HYDATID.

## LYMPHATICS :

HYPERTROPHY.  
 ATROPHY.  
 INFLAMMATION AND SUP-  
 PURATION OF LYMPH  
 VESSELS.  
 INFLAMMATION AND SUP-  
 PURATION OF LYMPHA-  
 TIC GLANDS.  
 NEW GROWTHS.  
 TUBERCLE.  
 PIGMENT IN LYMPHA-  
 TICS.  
 LYMPHADENOMA.  
 THYMUS :  
 DELAYED INVOLUTION.  
 NEW GROWTH.

**Spleen.**—The normal weight of the spleen is about five ounces. A small supplementary spleen or splenunculus is often present, and sometimes more than one.

**Atrophy.**—In old people, and after wasting diseases not associated with rise of temperature, the spleen is often reduced in size, and is of brownish colour instead of its proper red hue.

**Adhesions.**—Without being enlarged the spleen is often firmly adherent to the diaphragm. This condition is almost always present when long-lasting pleurisy has existed at the base of the left lung. It also occurs as a result of inflammation beginning in the peritoneum itself.

**Enlargement.**—In cases of death during all forms of fever the spleen is enlarged and soft, weighing from 8 to 15 ozs.

This condition is due to arterial engorgement.



Obstruction of the outflow of blood, as in valvular disease of the heart, or in an early stage of cirrhosis of the liver, or in pylephlebitis, also causes its enlargement. This is a venous engorgement, and the spleen is hard and brittle and of a darker colour than natural.

It may be enlarged owing to some local irritation within it, as an embolus whether active or passive, an abscess, a gumma, or a hydatid.

In general tuberculosis it may contain a great many small tubercles, and is almost always somewhat enlarged.

New growth in it is rare, but when present causes some enlargement. When the spleen is enormously enlarged so as to fill a great part of the abdominal cavity, the enlargement is usually due to one of three causes—

1. Malarial disease ;
2. Leucocythæmia ;
3. Amyloid infiltration.

Whenever the spleen is enlarged the splenunculus, if one be present, is enlarged also.

After chronic peritonitis the capsule of the spleen is universally thickened. It is also common to find thickened and sometimes calcified patches in the capsule, the results of local inflammation. In such cases some neighbouring peritoneal adhesions are generally to be found.

**Hypertrophy.**—True hypertrophy of the spleen perhaps exists in ague and in leucocythæmia.

**Spleen of Malarial Disease.**—The spleen is always enlarged after prolonged malarial disease, and may weigh as much as thirty pounds.

The capsule is thickened and opaque.

The spleen contains more connective tissue than natural, and an enormous infiltration with blood cells.

Under the microscope this infiltration with red blood cells in every stage of alteration of colour is observable, and there is also some increase of connective tissue.

**Leucocythæmia.**—The spleen often attains a very



large size in this disease. The section has a velvety feel. Microscopic sections show that the increased weight is due to a multiplication of the small cells of which the spleen is in great part composed.

A microscopic section of a spleen from a case of leucocythæmia does not exhibit the infiltration with altered red blood cells which is always to be seen in the enlarged spleen of ague.

The following were the post-mortem appearances in a well-marked case of leucocythæmia. They show the chief anatomical changes commonly discovered in this disease.

The patient was a man, aged thirty-seven years, who died in one of Dr. Andrew's wards in St. Bartholomew's Hospital.

*Body.*—Wasted, the legs anasarcaous. Left thigh much larger than the right, being distended by an extravasation of half a pint of blood into the vastus externus.

*Chest.*—Left lung containing a white mass of hazelnut size, not caseous and not a tubercle. Right lower lobe coated with recent lymph.

*Heart.*—Dilated, muscular tissue showing fatty degeneration. Valves, normal.

*Abdomen.*—A little more than the normal quantity of fluid in the peritoneum.

*Liver.*—Greatly enlarged, weight 169 ozs., texture soft, a few small white specks to be seen in it here and there.

*Gall-bladder.*—Containing a little normal bile.

*Spleen.*—Weight 145 ozs., adherent at its upper part to the diaphragm. Section of a pale red colour, feeling like velvet when touched.

*Kidneys.*—Large and soft, capsule detached with difficulty. On the surface of the section several white specks.

*Inguinal Glands.*—Somewhat hard, but not enlarged.

*Other Abdominal Viscera.*—Normal.

*Marrow of Right Tibia.*—Of normal appearance.



*Blood.*—Everywhere imperfectly clotted and pale. The clots in the auricles were altogether colourless.

**Abscess of the spleen** sometimes occurs in cases of general pyæmia. An infarction of the spleen in ulcerative endocarditis may sometimes be found broken down in the middle.

In enteric fever I have twice seen a large tract of the spleen just beginning to break down.

A condition of splenitis of course precedes the formation of abscess, but is rarely seen post-mortem.

**Amyloid Disease of Spleen.**—The spleen is perhaps the organ most often affected by amyloid infiltration.

The infiltration is sometimes distinct, though the spleen be but little enlarged, or the infiltration may produce an increase in weight to ten times the normal weight of the organ. The amyloid material is most often present in the Malpighian bodies, and where iodine is poured over the cut surface these stand out like dark spots. Without the addition of iodine they sometimes stand out from the section obviously altered and with a glistening appearance. Hence the spleen of amyloid infiltration is sometimes spoken of as "*sago spleen*."

In a very large amyloid spleen the intervening tissue as well as the Malpighian corpuscles is infiltrated by the amyloid material.

Whenever the spleen is much enlarged in amyloid infiltration the capsule is thickened.

The spleen only may be infiltrated or the amyloid change may be found in other organs.

**Tubercle.**—The spleen is never affected by tubercle except as part of a general tuberculosis. Tubercles are most often found upon its surface, but also occur in its substance.

Both conditions are often found in children who have died of tubercular meningitis. Tubercle in the substance of the spleen is rarer than tubercle in the kidney in adults who have died of chronic phthisis.



**Gumma of the spleen** is rare. Out of about 2500 post-mortem examinations I have seen it but twice. It occurs as a white patch, degenerate in the middle and with a deep red zone round it. The common affection of the spleen in syphilis is amyloid infiltration.

**New Growths in the Spleen.**—Primary new growth in the spleen is very rare. It is not often the seat of secondary new growth, for out of 122 cases of new growth I only found secondary growth in the spleen in eight cases.

The only case which I have seen was that of a man, aged forty-nine years, who was under my care in St. Bartholomew's Hospital.

He was much emaciated. His spleen was felt during life as a prominent tumour, and its rapid growth was easily perceptible. Post-mortem the spleen was found to be as large as a man's head, being converted in a single mass of mixed-celled sarcoma, round cells predominating. The new growth extended in direct continuity into the outer part of the gastric wall and into the diaphragm. The abdominal lymphatics were the only seat of secondary deposit. A small pleural effusion on the left side was the only other morbid appearance.

**Hæmorrhagic Infarction of the Spleen.**—The spleen is one of the commonest seats of hæmorrhagic infarction.

When recent the infarction is dark-coloured and bulges out on the surface of the spleen. When older it is pale and level with the surface.

When very old it is depressed below the surface and appears in the section as a patch of scar tissue.

In all its stages it is conical, the base of the cone towards the surface.

When the embolus causing it has been an active one, as in ulcerative endocarditis, it may have begun to soften.

The method of its formation may be thus explained.

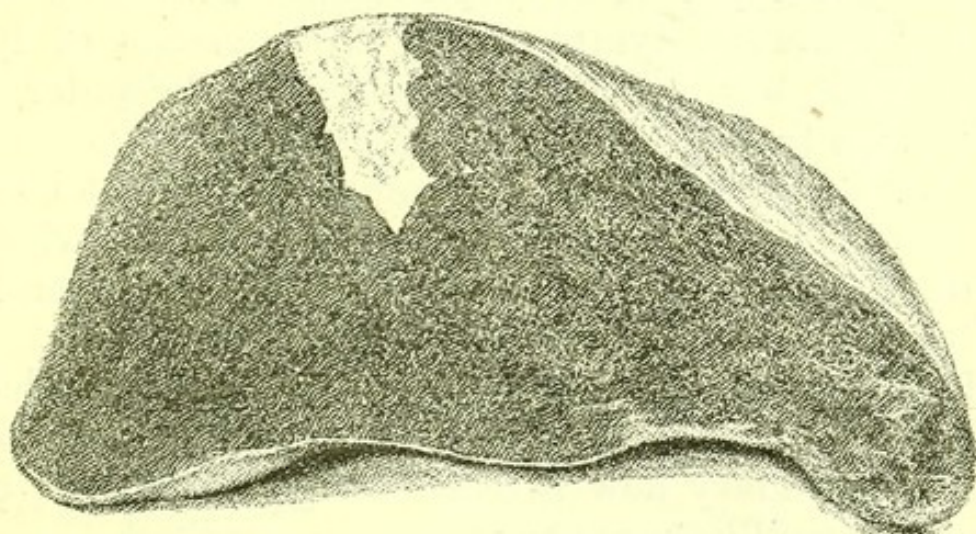


An embolus carried in the blood-stream fills a terminal artery. The capillaries of that artery become empty and cease to be nourished. The rest of the blood-flow in the organ goes on. The empty arterial capillaries are in communication with empty venous capillaries. These are nevertheless in communication with a full vein further on. Thus the empty capillaries, venous and arterial, form a sort of back water into which there is nothing to prevent a flow of blood. This takes place: the unnourished capillary walls let the corpuscles through, more take their place, and thus a solid mass is formed, till the packing has reached the tightest possible, and the direction of least pressure, is no longer towards the plugged artery.

The infarct, dark with tightly packed red blood-cells, sticks out on the surface of the spleen.

The irritation then sets up connective-tissue increase.

FIG 87.



*Hæmorrhagic Infarct of Spleen.* From a photograph of a fresh specimen taken in the Post-mortem Room of St. Bartholomew's Hospital.

The new tissue contracts. The pigment of the extravasated blood-cells is absorbed, and the infarct becomes a depressed white scar.

**Hydatid of the spleen** is commoner than gumma. Perhaps the considerable daily variations in size of the spleen are inimical to the growth of a hydatid, for most



of the hydatids which I have seen in the spleen have been dead and partly calcified.

### LYMPHATICS.

**Hypertrophy.**—Indefinite enlargements of lymphatics are generally of the nature of a slow inflammation. Microscopic sections show increased area of cellular structure not different from the normal tissue of the gland.

**Atrophy** is common in aged and emaciated persons.

**Inflammation of lymph vessels** occurs when septic poison has been absorbed from a wound or from other septic source, such as a suppurating thrombus or a morbid uterine membrane. Red lines marking the lymphatics are observable on the skin, and the whole limb is swollen, and in long-standing cases remains hard, long after it has ceased to be red. Abscess sometimes forms.

**Inflammation of Lymphatics.**—A section of a slightly enlarged lymphatic shows increase of lymphatic cells, and is often indistinguishable under the microscope from a bit of normal gland.

After a long period of inflammation without breaking down a connective-tissue increase becomes visible.

The lymphatics near a vein occluded by thrombus are invariably enlarged.

**New Growths in Lymphatics.**—Lymphatic glands are of all parts of the body the most common seat of secondary new growth of every variety, carcinoma as well as sarcoma.

During life a secondary growth in a lymphatic is often the first proof of the presence of new growth in the body.

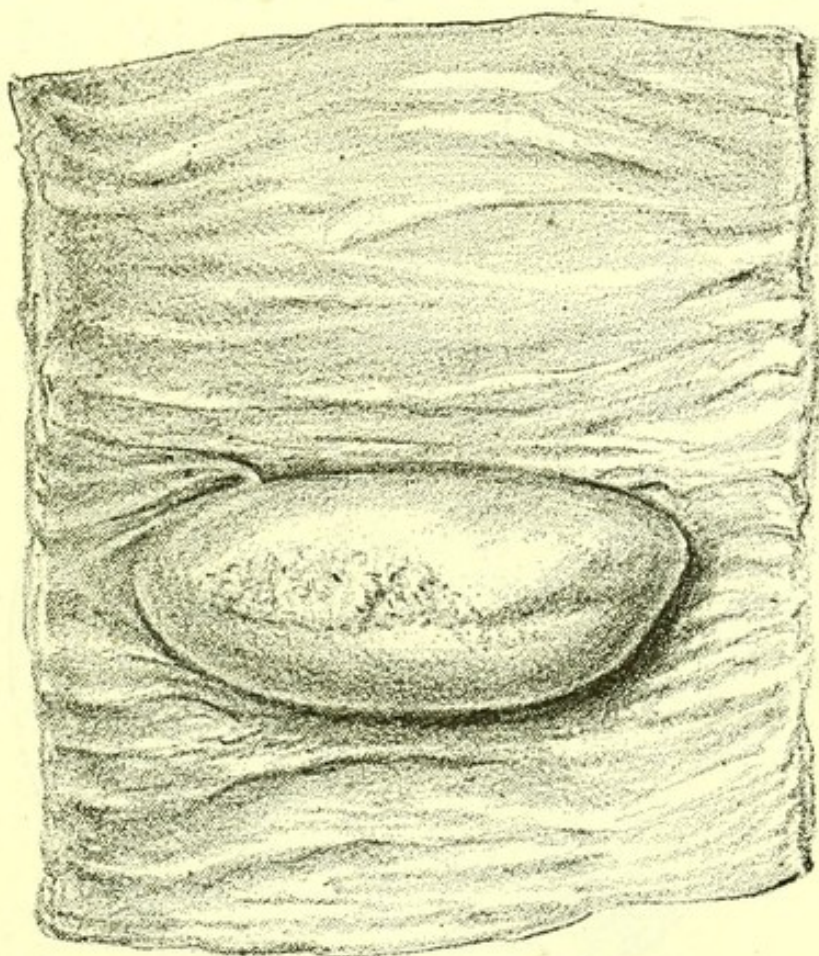
Primary sarcoma, usually called lympho-sarcoma, of the lymphatics is also common. The regions in which it oftenest occurs are the mediastinum and the mesentery. Lympho-sarcoma of the mesentery sometimes grows into the whole wall of the small intestine, con-



verting it into a tube, the walls of which are composed of a thick layer of new growth. Such growths have a peculiar firm velvety feel, and under the microscope show abundant small round-celled growths, with the cells enclosed in well-developed trabeculæ resembling those of a normal lymphatic gland. When this growth reaches a free surface ulceration takes place.

Lympho-sarcoma also begins in the lymphatic tissue of the intestine itself, producing great enlargement of the Peyer's glands, which may become so much en-

FIG. 88.



*Lympho-sarcoma of Peyer's Gland.* From a specimen in the Museum of St. Bartholomew's Hospital.

larged as to stand out half an inch from the surface of the intestine.

In the stomach large polypoid masses of the same kind occur.

**Tubercle in Lymphatics.**—Tubercle in all stages



of growth is found in lymphatics. In general tuberculosis the bronchial glands contain recent tubercle.

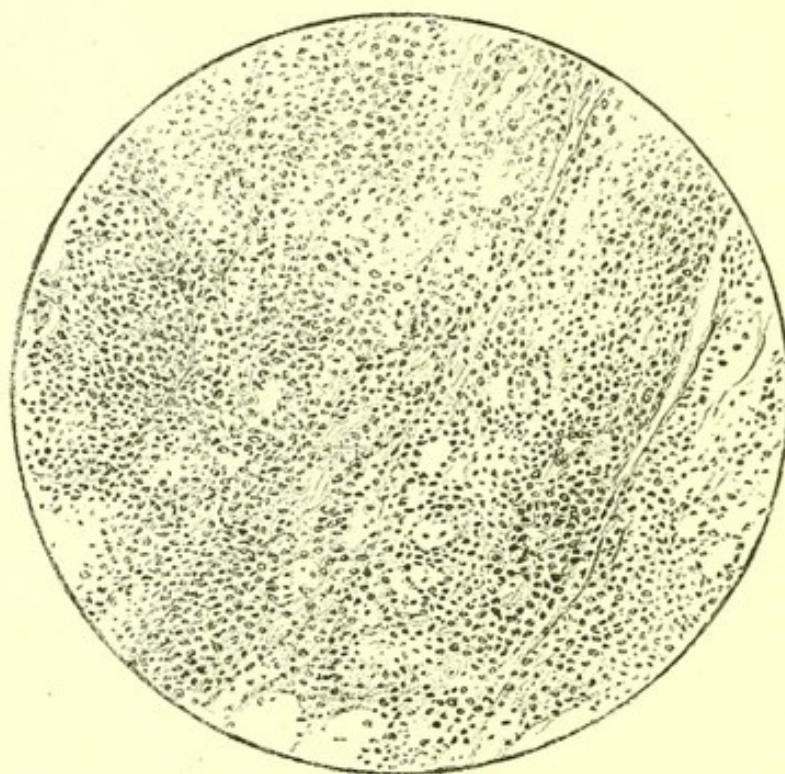
In old tubercle of the lungs, and sometimes (as a pre-existing condition) in acute tuberculosis, they contain caseous material, the product of the degeneration of tubercle.

They are also frequently calcified.

Bacilli are easily shown to be present in fresh sections from tuberculous lymphatics.

**Pigment in Lymphatics.**—The bronchial glands generally contain carbon pigment when much is present in the lungs. This is the case in most adult inhabitants of towns. Dark pigment is found in lymphatics near tattoo marks made with Indian ink or indigo, and red near those made with cinnabar.

FIG. 89.



*Lympho-sarcoma of Anterior Mediastinum.*

**Lymphadenoma**, also called from Dr. Hodgkin, of Guy's Hospital, its first describer, **Hodgkin's disease**, consists in a general increase of lymphatic tissue throughout the body, in all the lymphatics as well as in the liver and spleen.



The blood remains unaltered, by which the disease is distinguished from leucocythæmia.

The enlarged lymphatics do not contain pus, and thus Hodgkin's disease is distinguished from simple chronic inflammatory changes in the lymphatics.

### THYMUS GLAND.

**Delayed Involution.**—The thymus gland occasionally remains of the same proportions in an adult as in a child, but this condition is rare. I have once seen it in a case of exophthalmic goitre in a woman.

**New Growth.**—Lympho-sarcoma growing in the anterior mediastinum may be suspected sometimes to originate in the remains of the thymus. A full description of this kind of growth is given in Chapter XII.



## CHAPTER XVI.

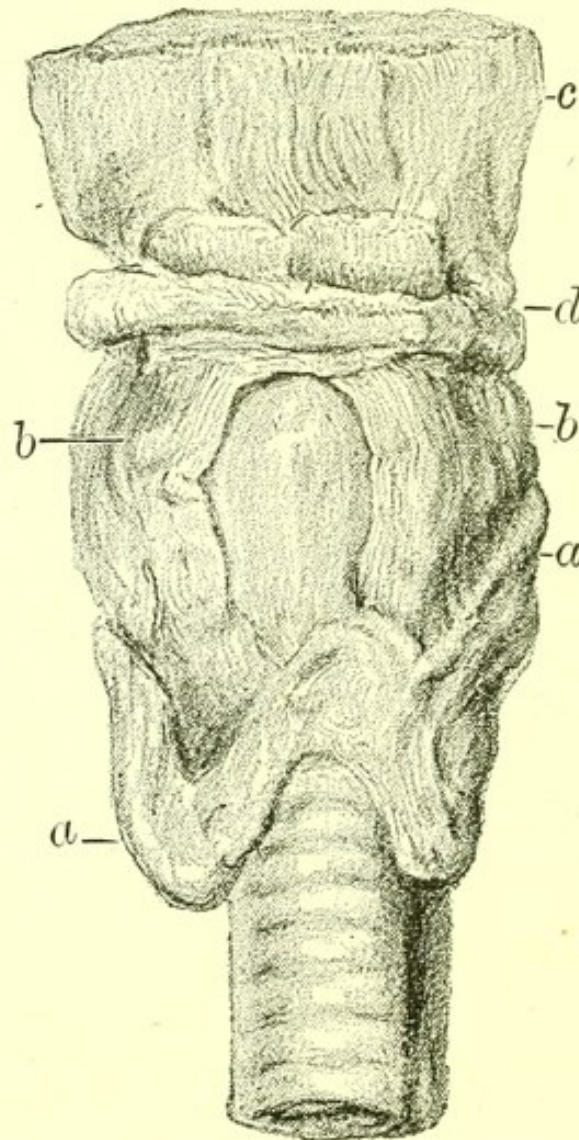
## DISEASES OF THE THYROID GLAND.

HYPERTROPHY AND  
ATROPHY.  
INFLAMMATION AND  
ABSCESS.  
GOITRE :  
SIMPLE CYSTIC.

GOITRE—*continued*.  
VASCULAR.  
EXOPHTHALMIC.  
CARCINOMA.  
SARCOMA.

**Hypertrophy** of the thyroid gland sometimes occurs in one half when the other has been removed by operation.

FIG. 90.



*Atrophy of Thyroid Gland in a case of Myxædema. a a.* Thyroid gland. *b b.* Thyro-hyoid muscles. *c.* Root of tongue. *d.* Hyoid bone. From a specimen in the Museum of St. Bartholomew's Hospital.

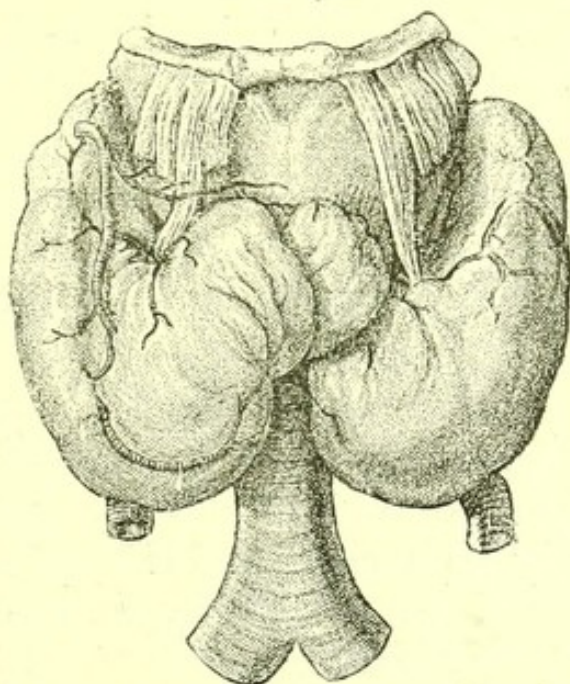


**Atrophy** of the whole gland is present in myx-  
œdema. (*See* p. 137.)

**Inflammation** and **abscess** of the gland are generally associated with new growth.

**Goitre** is a term applied with propriety to all enlargements of the thyroid body.

FIG. 91.



*Goitre*: which caused death by narrowing the trachea.  
From a specimen in the Museum of St. Bartholomew's  
Hospital.

A simple goitre, a term which may be used to include parenchymatous, fibrous, and gelatinous goitre, consists in an increase of the loculi and of their contents, with a general increase of connective tissue throughout the gland. The goitre may attain a very large size, and the older it is the more connective tissue does it contain.

The enlargement is not always symmetrical.

**Cystic goitre** is an enlargement of the thyroid, in which extensive cyst formation, in part due to the enlargement of the natural cavities, goes on throughout the gland. One or two large and many small cysts may be formed, and may contain cholesterin, serum, or blood.

**Vascular goitre** I have never seen, nor even an



enlarged thyroid from which much blood dripped on cutting into it post-mortem.

When the thyroid seems to pulsate it will be found post-mortem to have owed its apparent pulsation to a neighbouring artery, and this appearance is not uncommon where thyroid enlargement and disease of the aortic valves happen to coexist.

**Exophthalmic Goitre.**—The exophthalmos of this disease, plain enough during life, has not been observable post-mortem in those cases which I have examined. Nor were the contents of the orbit in any way abnormal.

The thyroid body is enlarged symmetrically.

It is not very hard on section, although quite as firm as natural. Its arteries are normal.

Microscopic sections show that the normal cavities of the gland are filled with a small-celled growth which to a slight extent infiltrates the gland itself.

The heart may be normal, and if hypertrophied, one of the recognized causes of hypertrophy, valvular disease, adherent pericardium, or interstitial nephritis, is present.

Valvular disease (aortic or mitral, or both) is present in a large proportion of cases.

In the following case of exophthalmic goitre which I examined post-mortem the immediate cause of death was pleurisy.

The patient was a girl, aged sixteen years, who was in one of Dr. Gee's wards in St. Bartholomew's Hospital.

*Body* : Wasted, very little subcutaneous fat being present.

*Head* : Eyes sunken in their sockets, not in the least prominent.

*Neck* : Thyroid gland very firm. Both lobes were enlarged.

The right lobe was a little the larger, and extended higher and further round the larynx than the left. The gland contained no cysts, and no hæmorrhages,



and was of uniform texture throughout. No blood exuded on cutting into it.

*Carotid and thyroid* arteries not larger than natural. The distribution of the vessels from the arch of the aorta was normal.

*Sympathetic Ganglia and Pneumogastric Nerves* : Normal.

*Larynx and Trachea* : Normal.

*Chest* : On opening the chest the large size of the thymus gland was noticeable. It was three inches long by one inch and a half wide.

In the left pleural cavity was an effusion of half a pint of serum, and the lower lobe of the lung was coated with flakes of soft lymph and was compressed and airless.

*Right Lung* : Normal

*Bronchial Glands* : Normal.

*Heart* : Normal.

*Abdomen* : All organs normal except one mesenteric gland which contained caseous material, and the spleen which was very soft and of twice its normal size.

**Malignant New Growth.**—Primary sarcoma and primary carcinoma both occur in the thyroid gland. The carcinoma originates in the epithelium lining the cavities.

Secondary carcinoma sometimes occurs in the thyroid in cases of cancer of the œsophagus, and secondary sarcoma is found there in some cases of widely distributed sarcoma.

A woman, aged forty-six, who was under my care in St. Bartholomew's Hospital, had a primary sarcoma of the thyroid gland. The growth formed a huge mass which had ulcerated through the skin and into the larynx, and also through the upper wall of the aortic arch, but without causing hæmorrhage. It completely compressed one recurrent laryngeal nerve and pressed on both carotid arteries. Secondary masses were found in the kidneys, on one rib, and in the brain. The duration of the growth was about four months.



On the patient's admission to the hospital a large cyst projected from the right lobe, and from this blood-stained fluid was let out but rapidly returned. After a month the tumour burst through the skin and appeared as a fungating mass. There was some dysphagia and partial aphonia, but never urgent dyspnœa.

Microscopically the growth showed a great variety of structure in different parts. There were a few collections of large epithelial cells like those of the loculi of the thyroid gland, and there was some general increase of the structures of the gland itself, but the main part of the growth showed abundant spindle-cells without any definite stroma, and proved it to be a spindle-celled sarcoma.

Some parts of the growth had undergone hyaline transformation.

The smaller growths in the kidney and brain showed precisely the same microscopic structure.



## CHAPTER XVII.

DISEASES OF THE SUPRA-RENAL  
CAPSULES.

NEW GROWTHS. | ADDISON'S DISEASE.

**New Growths.**—The supra-renal capsules are sometimes the seat of secondary new growths: sarcoma or carcinoma.

They are sometimes found in an atrophied condition, and are sometimes the seat of recent tubercle. All these changes may be present without any special symptoms.

In 123 cases of new growth (102 carcinoma, 21 sarcoma) I found secondary growths in the supra-renal capsules in only eight.

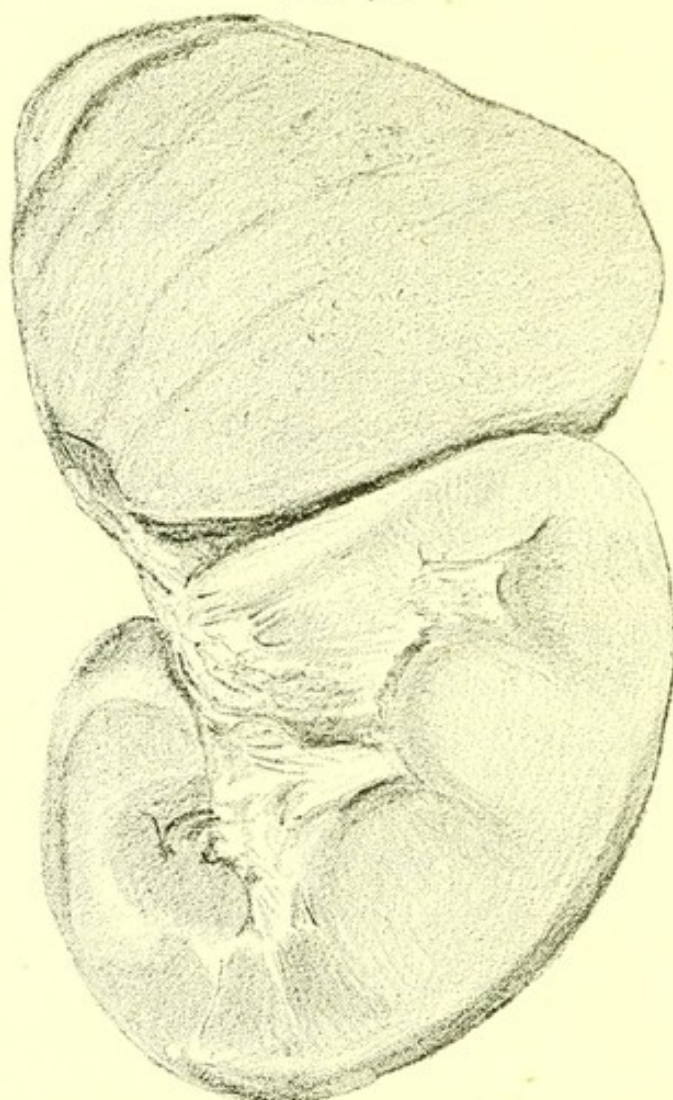
Sex.	Age.	Primary Site.	Nature of Growth.
M.	50	Œsophagus.	Carcinoma.
M.	45	Stomach.	Carcinoma.
M.	46	Lungs.	Sarcoma.
M.	60	Lungs.	Sarcoma.
F.	46	Heart.	Endothelioma.
F.	64	Heart.	Endothelioma.
M.	60	Brain.	Sarcoma.
F.	48	Kidney.	Carcinoma.

The above is a Table of these eight cases of new



growth, in which a secondary growth was found in one or both supra-renal capsules. A microscopic examination was made in each case.

FIG. 92.



*Sarcoma of Supra-renal Body.* Secondary to a round-celled sarcoma of the lung. From a specimen in the Museum of St. Bartholomew's Hospital. The supra-renal body is nearly equal in size to the kidney which is below it.

**Addison's Disease.**—The anatomical changes accompanying the group of symptoms known from its first describer as Addison's disease are caseous degeneration or simple atrophy of the supra-renal bodies, accompanied by pigmentation of the skin in patches, with sometimes pigmentation of the mucous membrane of the mouth. The pathological relations of these appearances must remain uncertain while the function of the



supra-renal bodies continues unknown. Some pathologists have supposed that symptoms only occur when the semilunar ganglia are involved, but well-marked cases of Addison's disease have been described in which the semilunar ganglia were carefully examined microscopically, and were found to be without morbid change.

In some undoubted cases they contain no caseous material, though it is commonly present. What seems essential to the production of the general debility, pigmentation of the skin and vomiting, which are the group of symptoms constituting Addison's disease is, that the supra-renal capsules should be in part destroyed.

The following examples examined by me post-mortem illustrate the two chief varieties of anatomical appearance in well-marked cases of Addison's disease :

I. The patient was a man, aged thirty-nine years.

*Body* lean. Hands and forearms dark, as if sun-burnt. Slight pigmentation about nipples. Spots of brownish-black pigment at root of tongue and on roof of mouth, and lesser ones on gums.

*Head* : Brain and spinal cord normal.

*Chest* : Œsophagus, cervical glands, larynx, and trachea without signs of disease.

*Lungs* : Some old and slight pleural adhesions of both ; some general emphysema.

*Heart* : Slight hypertrophy of left ventricle. Muscular tissue otherwise normal.

*Aorta and great vessels* without morbid change.

*Abdomen* : Peritoneum, stomach, intestines, pancreas, liver and abdominal lymphatics without morbid change.

*Spleen* : Soft and slightly enlarged.

*Supra-renals* : Each of walnut size and shape, with some calcareous patches, but otherwise changed into a soft caseous material, all structure having disappeared.



*Splanchnic Nerves and Semilunar Ganglia* : Normal.

*Kidneys* : Capsule somewhat adherent, surface slightly granular. No cysts.

*Pelvic Organs* : Normal.

Microscopic sections showed that the pigment in the skin was deposited in irregular patches of small size in the deeper layers.

II. The patient was a woman, aged 26 years.

*Body* : Lean. There were scattered patches of brownish pigment on the face, forearms, and abdomen. There were also patches on the knees, and on the ball of the great toe, but none on the dorsum of the foot or on the ankle. There was no pigment on the shoulders.

*Chest* : All organs free from morbid change.

*Abdomen* :

Liver, normal.

Spleen, weight 7 ozs., somewhat soft.

Pancreas and lymphatics without morbid change.

Supra-renal bodies, both atrophied, remaining as mere shreds. Semilunar ganglia unaltered, prominent, and firm.

Kidneys, ureters, bladder, uterus, and ovaries without morbid change.



## CHAPTER XVIII.

## DISEASES OF THE URINARY SYSTEM.

## KIDNEY :

HYPERTROPHY.  
 ATROPHY.  
 ALBUMINURIA.  
 ARTERIAL ENGORGEMENT.  
 VENOUS ENGORGEMENT.  
 ACUTE NEPHRITIS.  
 SCARLATINAL NEPHRITIS.  
 CHRONIC NEPHRITIS :  
   INTERSTITIAL.  
   PARENCHYMATOUS.  
   AMYLOID.  
 ACUTE SUPPURATIVE NE-  
   PHRITIS : PYELITIS.  
 ABSCESS OF KIDNEY.  
 CYSTS.  
 CYSTIC DISEASE.  
 HYDRONEPHROSIS.  
 CONNECTIVE TISSUE NO-  
   DULES.  
 NEW GROWTHS :  
   SARCOMA.  
   CARCINOMA.  
 TUBERCLE.  
 SYPHILIS.  
 MOVABLE KIDNEY.  
 RENAL CALCULUS.  
 PERINEPHRITIC ABSCESS.  
 HÆMORRHAGIC INFARC-  
   TION.  
 PARASITES :  
   HYDATID.  
   BILHARZIA.  
 VARIETIES IN STRUCTURE :  
   HORSESHOE KIDNEY.

## URINARY DISORDERS :

DIABETES MELLITUS.  
 GLYCOSURIA.  
 DIABETES INSIPIDUS.  
 SUPPRESSION OF URINE.  
 HÆMATURIA.  
 INTERMITTENT HÆMA-  
   TURIA.  
 ALBUMINURIA.  
 CHYLURIA.  
 LITHURIA.  
 OXALURIA.  
 PHOSPHURIA.

## BLADDER :

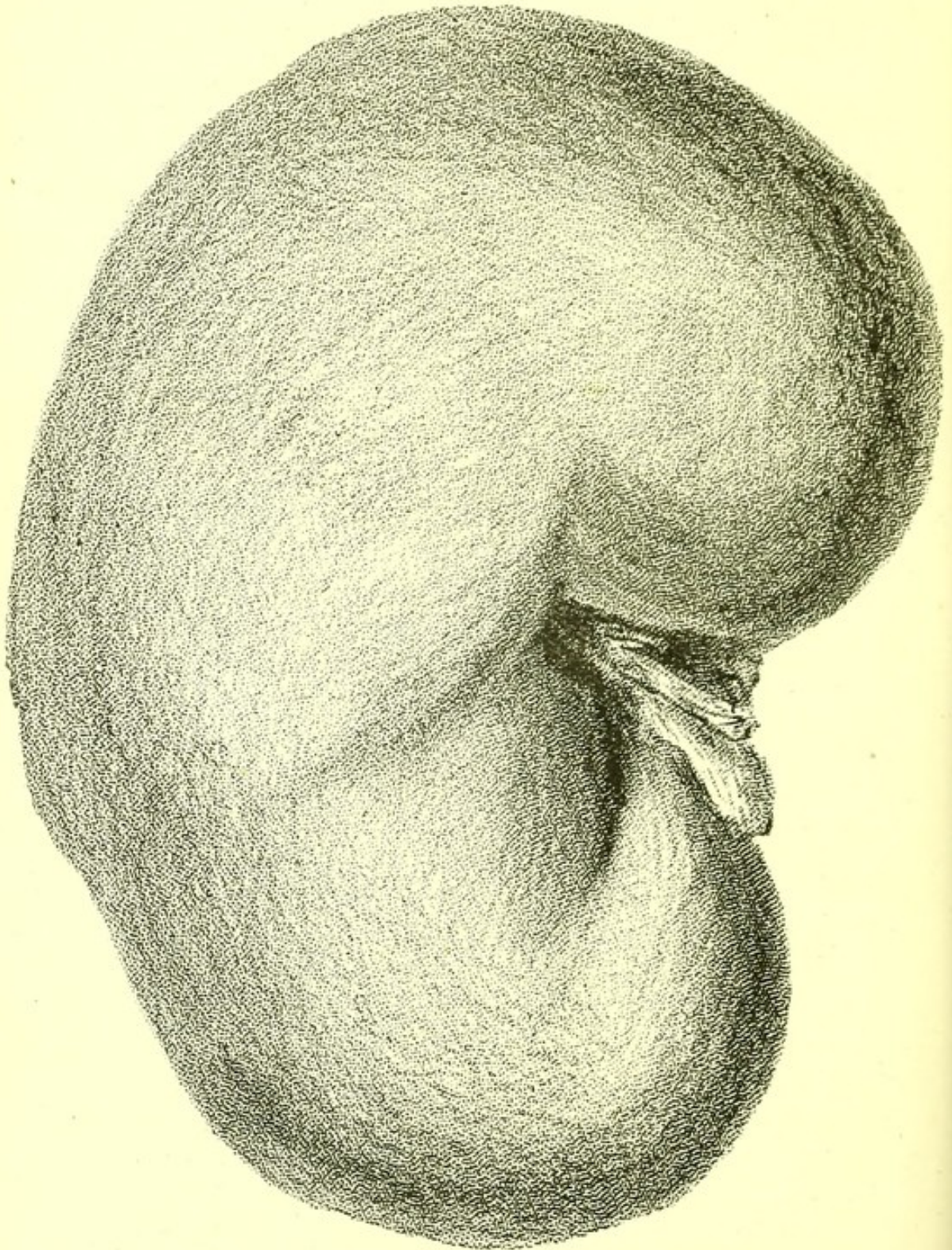
HYPERTROPHY.  
 HÆMORRHAGE.  
 INFLAMMATION, ULCERA-  
   TION AND SLOUGHING.  
 OUTGROWTHS :  
   PAPILLOMA.  
   POLYPUS.  
 NEW GROWTHS :  
   SARCOMA.  
   CARCINOMA.  
 SACCULATION.  
 VESICO-INTESTINAL FIS-  
   TULA.  
 RECTO-VESICAL FISTULA.  
 VESICO-VAGINAL FIS-  
   TULA.  
 CALCULUS.  
 PARASITIC DISEASE.  
 MALFORMATIONS.

**Hypertrophy of Kidney.**—When one kidney is imperfectly developed, or rendered functionally use-



less, the other hypertrophies and may attain double its normal size and weight, the structure remaining healthy. The commonest condition in which one

FIG. 93.

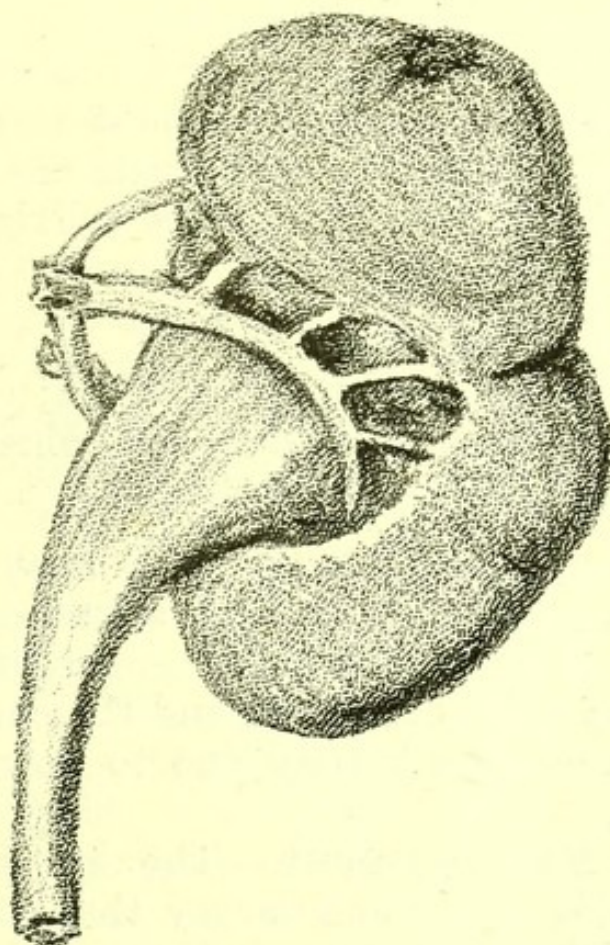


*Hypertrophy of Kidney, due to Atrophy of the other Kidney, which is depicted in Fig. 94. From a specimen in the Museum of St. Bartholomew's Hospital.*



hypertrophied kidney is found during life is where the other has been rendered useless by a calculus in childhood.

FIG. 94.



*Atrophy of Kidney.* From a specimen in the Museum of St. Bartholomew's Hospital.

The kidneys in diabetes mellitus are often found to be both larger and heavier than natural. This may sometimes be due to true hypertrophy, but in most cases (though not in all) which I have examined microscopically some degeneration of epithelium was discoverable, and in all the kidney was less firm than in health.

**Atrophy of Kidney.**—Atrophy of one kidney is found as a congenital condition. It may occur early in life owing to inflammatory closure of the ureter without the presence of calculus, and may be produced at any period by calculus.

Atrophy of both kidneys, in which the pelvis is



much increased in size and the area of tubular structure reduced to a narrow strip, is an occasional consequence of stricture of the urethra, and is invariably accompanied by chronic interstitial changes in the remaining renal substance.

**Albuminuria.**—The presence of albumen in the urine may be associated with almost any change in the kidney, but its commonest causes are the diseases often loosely included under the term Bright's disease.

These are :

1. Acute nephritis ;
2. Chronic interstitial nephritis ;
3. Chronic parenchymatous nephritis ;
4. Amyloid disease of the kidney.

Tubercle, parasitic disease, and new growth are occasional anatomical causes of albuminuria, and it accompanies the acute arterial engorgement of the kidney which occurs in fever, and the chronic venous engorgement of the kidney due to valvular disease of the heart.

**Arterial Engorgement.**—The kidney of raised temperature is softer and larger than natural, with the superficial veins somewhat more distinct than natural, and with some obscurity in the linear structure of the cortex, but blood does not exude much on section of it. Microscopically, some increase in prominence of the nuclei, with swelling of the epithelial cells of the tubules, is visible.

**Venous Engorgement.**—The kidney of valvular disease of the heart with prolonged venous engorgement is heavier and a little larger than natural, exceedingly hard, and so brittle that one-half, after median section has been made, can easily be broken in two by the hands. The surface, if the engorgement has lasted long, is somewhat roughened when the capsule is detached. In the cortex the glomeruli are dark-coloured, and easily visible to the naked eye.

Microscopic sections show some slight increase of



connective tissue with extravasated red blood cells in varying quantity in the intertubular tissue.

A swollen enlarged condition of kidney, in which it is soft, easily bent, and pale in colour, is often found after death within a fortnight of delivery, and may be attributed to the raised temperature of septicæmia.

It is to be distinguished from the true parenchymatous nephritis, sometimes found in cases of death from puerperal convulsions.

**Acute Nephritis.**—*Kidney.*—The kidneys are greatly enlarged, often weighing together twenty ounces. On cutting into the kidney the capsule retracts and strips off very easily. The surface is red, with prominent minute veins. Blood drops freely from the section. The cortex is increased in width and its structure is confused. The bladder is either empty or contains a very small quantity of blood-stained urine.

*Appearances in other parts of the Body.*—There is general anasarca. The serous cavities contain accumulations of fluid. The lungs are œdematous, and death has been caused by œdema of the lungs, or œdema glottidis, or by uræmic poisoning with suppression of urine.

Microscopic sections of the kidney show swollen epithelium, with enlarged nuclei throughout the tubuli and glomeruli. Many tubuli are blocked with casts of epithelium or of blood, and in the interstitial tissue groups of extravasated red blood-corpuscles are seen.

Acute nephritis is often attributable to exposure to cold, the renal epithelium being the selected site, so to speak, of the disease.

**Scarlatinal Nephritis.**—A variety of acute nephritis associated with scarlatina has been described by Dr. Klein. The naked-eye appearances are those of acute nephritis. Microscopically, there is a peculiar albuminous exudation into the glomeruli.

In scarlatinal nephritis the disease is an aggrava-



tion of the condition of kidney, existing for some hours in every case of scarlet fever, as indicated by the presence of albumen, and attributable with reasonable probability to the development and growth of the scarlatinal germ.

**Chronic Nephritis.**—The origin of each of the two commonest forms of chronic nephritis is often obscure.

Chronic interstitial nephritis is sometimes regarded as a result of spirit-drinking, chronic parenchymatous nephritis of beer-drinking. Both, however, occur in temperate people, and each may be the descendant or ultimate result of nephritis, beginning in an attack of scarlet fever, or of acute nephritis without scarlet fever, and both, though the interstitial form more often than the parenchymatous may be discovered in an advanced state without a definite clinical history of a period of commencement.

The relative frequency in London of the varieties of chronic nephritis is shown by the fact that, out of 255 cases of chronic nephritis examined at St. Bartholomew's Hospital during seven years, the numbers of the seven forms were—

Chronic interstitial nephritis . . . . .	159
Chronic parenchymatous nephritis . . . . .	75
Amyloid disease . . . . .	21

**Chronic Interstitial Nephritis.**—The characteristic morbid appearances are small kidneys, rough on the surface, and hypertrophy of the left ventricle. Patches of degeneration in the large arteries, emphysema of the lungs, and degeneration of some articular cartilages are almost invariably present.

The kidneys are smaller than natural and of firmer texture, the change being symmetrical.

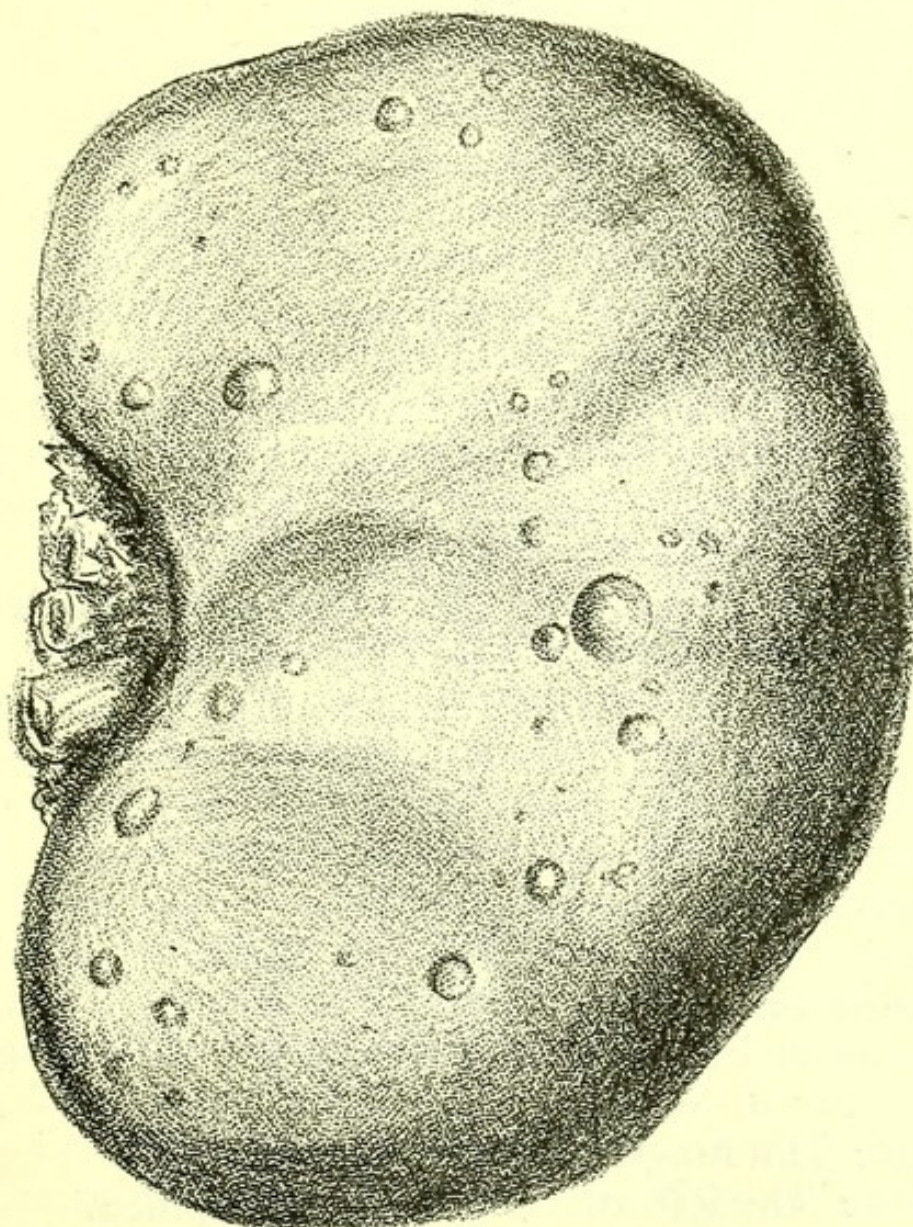
They may be so small as not to weigh more than 3 ozs., and have usually lost 2 or 3 ozs. of weight, the normal weight being about 10 ozs.

The capsule is detached with difficulty, and often



tears off some of the kidney substance. When it is removed the surface is seen to be rough, and it has usually several cysts upon it. These may be minute or as large as a walnut. They contain urine, or rarely cholesterin, are smooth internally, collapse when punctured, and structurally are dilated tubules.

FIG. 95.



*Kidney of Chronic Interstitial Nephritis, showing numerous cysts on the surfaces. From a specimen in the Museum of St. Bartholomew's Hospital.*

On section the kidney substance is found to be firmer than natural, the cortex is narrow, and the pyramids present a frayed-out appearance.

The organ is usually of a uniform red colour. It



is spoken of as a *granular kidney*, from the appearance of the surface; as a *contracted kidney*, from the hypothesis that it was once large, and has contracted; as a *cirrhotic kidney*, because it has a general resemblance to the pathological condition of the liver in cirrhosis. The degree of former largeness may be uncertain, but as the increased hardness is due to additional connective tissue, there can be no doubt that the organ has contracted. Sometimes kidneys larger than natural are accompanied by the other anatomical changes of chronic interstitial nephritis, and are microscopically found to have a great increase of intertubular connective tissue.

Microscopically, a great increase of connective tissue between the tubules is obvious; the tubules have usually lost most of their epithelium, the glomeruli look shrunken, their capsules are thickened, and their contents more or less degenerate. The small arteries are much thickened.

*Other Morbid Appearances.*—Externally, slight anasarca of the ankles is usually discoverable.

*Head :* Degeneration of some of the arteries of the circle of Willis is usually present, and may be accompanied by cerebral softening, by recent hæmorrhage, or by a small yellowish cavity containing blood crystals and indicating old hæmorrhage.

*Retina :* Degenerative spots, and hæmorrhages and patches of thickening may be present, with degenerative changes in the retinal arteries resembling those in the circle of Willis.

*Chest :* The lungs are emphysematous.

*Heart :* The left ventricle is hypertrophied.

In twenty cases of well-marked chronic interstitial nephritis without pericardial adhesion, valvular disease, or other cause of hypertrophy of the left ventricle, the average weight of the heart was a little over 18 ozs. The greatest weight was 23 ozs., the least 14 ozs.; eight hearts weighed from 20 to 23 ozs., nine from 17 to 20 ozs., two 15 ozs. and one 14 ozs.



In relation to this disease it should be remembered that an apex beat (during life) in the fifth interspace in the nipple line may be associated with a left ventricle so much hypertrophied that the heart weighs 20 ozs.

*Aorta*: Is usually more or less atheromatous.

*Abdomen*: The other abdominal viscera are often free from morbid change.

*Joints*: Some degeneration of the cartilages is present. Sometimes only slight fibrillation, sometimes fibrillation and erosion, sometimes all the changes of chronic arthritis, and frequently a deposit of urate of soda.

*Cause of Death*.—The common causes of death are: cerebral hæmorrhage, pneumonia, pericarditis, and pleurisy, a sudden œdema generally affecting both glottis and lungs, or uræmic poisoning.

*Pericarditis*: a small quantity of turbid serum and a few shreds of lymph are usually found, more rarely a copious deposit of lymph. The serum is often slightly blood-stained.

*Cerebral hæmorrhage*: a minute aneurysm, or an atheromatous cerebral vessel has burst.

*Pneumonia*: a lobe, or often only part of a lobe, is solidified, and it is usually in the second or beginning of the third stage of pneumonia.

*Pleurisy*: the quantity of serum and lymph are usually both small.

Fatal "gout in the stomach" usually means chronic interstitial nephritis terminated by pericarditis, with pain in the epigastrium.

Out of twenty-five cases of simple chronic interstitial nephritis taken consecutively, in sixteen death was due to cerebral hæmorrhage, in three to pleurisy, in three to œdema of glottis and lungs, in two to pericarditis, and in one to pneumonia.

Sometimes, however, death occurs after exposure to cold without any other anatomical change than the renal one.

*Varieties*: Besides the above described form, three



varieties of kidney all due to chronic interstitial nephritis are met with :

1. Small white granular kidney.
2. Gouty kidney.
3. Granular kidney following stricture of the urethra.

1. *Small White Granular Kidney*.—Chronic interstitial nephritis is sometimes found in children, and less rarely in patients under thirty years of age. In these cases it may sometimes be the ultimate condition of a kidney, the disease of which began in an acute nephritis at the termination of scarlet fever. In such examples, it is often white or pale instead of red, but in other particulars precisely resembles the typical kidney of chronic interstitial nephritis.

2. *Gouty Kidney*.—This term is correctly applied to a granular kidney, when uric-acid crystals are visible post-mortem in the tubules. It does not differ from the common form, and is, in reality, a diseased kidney examined while the patient is in an acute gouty state.

3. *Granular Kidney following Stricture of the Urethra*.—This form occurs in both males and females. It differs from the common variety merely in the dilated condition of the pelvis of the kidney, but is of extreme interest from its bearing on the question of the causation of the hypertrophied left ventricle.

The vessels of the body may be healthy in these cases, but the left ventricle is hypertrophied, a circumstance which points to interference with the renal circulation as a sufficient cause of the hypertrophy.

Sometimes extensive anasarca is present in chronic interstitial nephritis. When this is the case, it is usually associated with a great degree of emphysema, and consequent dilatation of the right side of the heart.

**Chronic Parenchymatous Nephritis**.—General œdema and enlarged pale kidneys are the chief morbid appearances.



The kidneys are symmetrically affected. They are larger than natural, the two together weighing from 18 to 20 ozs. in an adult.

The capsule is easily detached. The surface is smooth, and white or pink and white in colour.

On section, the cortex, which is white, is seen to be broader than natural, and its regular linear structure is confused, while the pyramids are pink.

Microscopically, the epithelium of the tubules is universally degenerate, the nuclei being swollen and the cell contents opaque and granular. Great numbers of epithelial cells in a state of fatty degeneration are found in the tubules. The term *large pale kidney* is appropriate, and this is the variety which Dr. Bright described in 1827, in the memoir which has led to the general application of the term Bright's disease to all forms of albuminuria.

*Appearances throughout the Body.*—Great general dropsy is present with well-marked anasarca of the face and legs.

The lungs are œdematous, and large collections of clear fluid are found in the pleural cavities and pericardium. The heart is not hypertrophied. If the larynx be examined before the lungs are removed œdema of the aryteno-epiglottidean folds is often found.

The peritoneum contains fluid. The intestinal walls are œdematous.

In the arachnoid there is often a good deal of fluid.

Pleurisy, pericarditis, and pneumonia are often the cause of death, but it is most frequently due to œdema of the lungs or to uræmic poisoning. There are no post-mortem appearances which prove the presence during life of uræmic poisoning, and even after the most violent uræmic convulsions no post-mortem indications are found in the brain.

Small hæmorrhages on the pericardium and pleuræ are often present.

White atrophic patches are sometimes discoverable in the optic disc.



**Amyloid Disease of the Kidney.**—The kidneys are symmetrically affected. They are larger and firmer than natural, and the two together often weigh 18 ozs. The capsule is easily detached and the surface is smooth. The cortex on section is seen to be wide and is pale, though of a less uniform white than in chronic parenchymatous nephritis.

On pouring an iodine solution on to it, the glomeruli are stained of a blackish colour.

Microscopically, the reactions of amyloid infiltration are seen in the glomeruli and in the walls of the small arteries.

The epithelium is degenerate, the cells swollen or detached. There is usually some increase of inter-tubular connective tissue.

*Other Anatomical Appearances.*—Amyloid degeneration of the liver, the spleen, or the intestines is often present.

When the left ventricle is hypertrophied, interstitial change in the kidney, secondary to the amyloid infiltration, is always present.

Anasarca, though less of it than in chronic parenchymatous nephritis, is present.

Some source of suppuration, either tuberculous cavities in the lung, caries of the vertebræ or of other bones, is present in most cases; but sometimes amyloid kidneys are found with palmar or plantar psoriasis, gummata in the liver or other anatomical signs of syphilis, and without active suppuration.

**Acute Suppurative Nephritis.**—Acute inflammation of the kidney with suppuration is due to the spreading of inflammation from some other part of the urinary tract, and is therefore usually secondary to inflammation of the bladder.

The kidneys are symmetrically enlarged, often very greatly, the capsule strips off readily, leaving a smooth and engorged surface, the cortex is confused in structure and increased in width. The pelvis of the kidney and the ureter contain pus, and have obvious engorgement of their vessels.



Some suppuration at the edges of the calices is often present.

Microscopically the appearances are, in the cortex, those of simple acute nephritis, and in the pyramids abundant collections of leucocytes are also to be found with exuded red blood-corpuscles, and groups of micrococci are discoverable near the patches of suppuration.

**Abscess of the kidney**, when single, may be a result of acute suppurative nephritis leading to rapid breaking-down of the kidney structure. When a renal calculus is present, suppuration may occur and the kidney be converted into a pus sac.

Multiple abscess of the kidney occurs in pyæmia.

A local abscess, always including part of the cortex, may be due to an infective infarct in ulcerative endocarditis.

An infarction due to passive embolus never leads to abscess.

Abscess in the kidney may lead to pus formation outside it, and the formation of perinephritic abscess.

**Cysts.**—Renal cysts, instead of being filled with clear fluid, may contain cholesterin and sometimes a kidney is converted into a huge mass of soft brownish mud which is chiefly cholesterin.

In a man, aged sixty-one years, who died in St. Bartholomew's Hospital, I found the right kidney to be considerably larger than a man's head. It had no adhesions, and was slightly elastic on pressure. On section it was found to consist of a soft, brownish, mud-like mass, with numerous glittering particles.

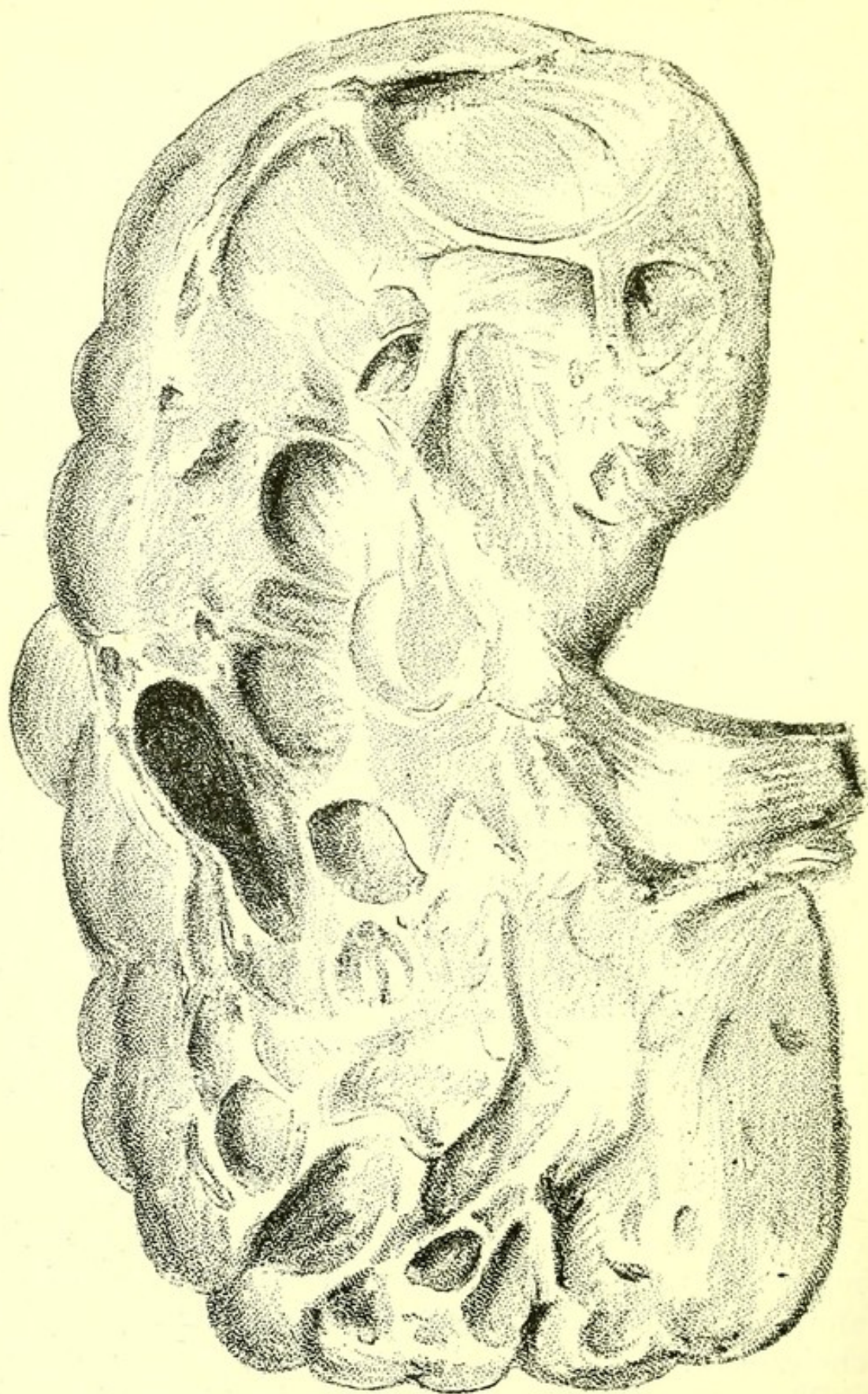
Here and there were small traces of the septa, and of what seemed (it was very putrid) to be a small mass of new growth. Microscopical examination showed that the main part of the tumour was simply cholesterin.

There was a mass of cholesterin of pea size in the left kidney.

**Cystic Degeneration of Kidneys.**—The cysts



FIG. 96.



*Cystic Kidney.* From a specimen in the Museum of  
St. Bartholomew's Hospital.



found on the kidneys of chronic interstitial nephritis may be single or numerous, but are always scattered and with wide non-cystic intervals; but kidneys are sometimes found, post-mortem, the surface of which is a mass of cysts, and on section many more are visible in the cortex. The kidneys are larger than natural and two forms occur, one in which the intervening tissue shows the changes of chronic interstitial nephritis, and one in which healthy glomeruli and tubules are found in the intervals.

The second form is the commoner, and must be regarded as a condition due to imperfect development of the tubules. In such cases the left ventricle is not hypertrophied.

A kidney may be converted into one huge cyst, with very few or no traces of tubules, by an early or congenital occlusion of the ureter.

A cyst may also be formed owing to an injury of the kidney by a blow on the abdomen.

Urine is excreted under a detached piece of capsule, and a very large cyst is formed which may even project in the front of the abdomen.

**Hydronephrosis.**—When the kidney is converted into a single large sac containing fluid it is called a hydronephrosis. This condition is frequently associated with a congenital obstruction of the ureter. The sac may consist wholly of connective tissue representing the fibrous capsule of the kidney, all tubular structure being absent.

**Connective-tissue Nodules.**—Small round nodules of connective tissue are occasionally seen in the pyramids. They are probably developmental.

**New Growths.—Sarcoma.**—Large sarcomatous growths, usually originating in the capsule or in the connective tissue of the pelvis of the kidney, occur in children as well as in adults. The growth occasionally contains striped muscular fibre as well as abundant small round cells.

Sarcoma in the kidney as a secondary growth in small



nodules is tolerably common in cases of widespread sarcoma.

**Carcinoma**, as a secondary growth, is found in the kidney, though not very often. It occurs sometimes in cases of carcinoma of the œsophagus.

Primary carcinoma of the kidney originating in the epithelium of the renal tubules or of the pelvis is very rare. Some of the cases recorded were associated with renal calculus. In one which I examined post-mortem at St. Bartholomew's Hospital, in a man, aged twenty-five years, the left kidney was greatly enlarged, and formed a large firm tumour with a thick external wall. The cortex and pyramids were infiltrated in every part with a new growth, and the pyramids were ulcerated at their edges, while, besides a calculus, weighing several ounces, the pelvis of the kidney contained a large quantity of purulent fluid. The ureter was greatly thickened, and the lowest two inches of it were completely filled by a cylindrical calculus, which was consistent but very friable. This stone rested on the bladder, and on the inner surface of the bladder, around the orifice of the left ureter, there was a shallow patch of ulceration, but the bladder and ureter contained no new growth. The right kidney weighed  $6\frac{1}{2}$  ozs., and was normal in structure.

Around the cancerous kidney there was much thickened tissue and some pus, and part of this thickened tissue pressed on the skin near the eleventh rib, and produced a small, firm tumour, felt externally. No other organ contained any new growth, and the peritoneum was quite free from any.

One lumbar vertebra was partly eroded and carious from pressure of the renal tumour.

The body was greatly emaciated, and no dropsy was present.

Microscopic sections showed the new growth to be a cancer originating in the epithelium of the renal tubules. Numerous tubules or pseudo-tubules were seen in longitudinal and in transverse section, with



processes or chains of cells extending from them into the stroma.

**Tuberculosis of Kidney.**—Tubercle occurs in the kidney in two conditions:

1. Disseminated in small patches.
2. In large tracts causing ulceration.

Scattered tubercle is associated with acute tuberculosis and general dissemination of tubercle throughout the body. Sometimes little red rings of engorgement surround these fresh tubercles, which are commonest on the surface and in the cortex, but may also be found in the pyramids.

In tuberculous disease, both kidneys may be affected, but the disease is rarely precisely symmetrical, and one kidney may be quite free while the other is deeply ulcerated.

A tuberculous kidney may, in rare cases, become converted into a sac containing caseous or calcified tubercle, without further spread of tubercle throughout the body.

Tuberculosis of the kidney may occur with chronic phthisis, though this is rare, or it may be the chief tuberculous lesion of the body.

Tubercle in large patches always leads to ulceration of the calices, and this ulceration is often found to have destroyed a large part of the kidney, and may be associated with tubercle in process of breaking down, and deep in the substance of the pyramids or in the cortex.

Some cases have been described, in which tuberculous ulceration of the bladder has spread up the ureter, the ureter being much thickened.

The following example illustrates the post-mortem appearances in a case of tuberculosis of the kidney and bladder. The patient was a woman, aged thirty-five years, who died in St. Bartholomew's Hospital, and whom I examined post-mortem.

*Body* : Much emaciated. No anasarca present.

*Chest* : Scattered tubercles were present in both lungs, but without any cavities or pleural adhesions.

*Heart* : Normal.



*Peritoneum* : Studded all over with tubercle.

*Abdomen* : Distended.

*Intestine* : Coils matted together, no ulcers present on the mucous surface.

*Liver* : Some fatty infiltration ; no tubercle present.

*Spleen* : Soft, slightly enlarged.

*Kidneys, Left* : Much enlarged, with deep ulceration round the edges of the calices and caseous material below the ulcerated surface. *Right* : Slight ulceration of one calyx.

*Ureters and Bladder* : Distended with purulent fluid, the left dilated to the size of my index finger. Shallow ulceration of posterior part of bladder and of the fundus present.

*Uterus* : Imbedded in adhesions.

**Syphilis.**—Amyloid infiltration of the kidney is a common form of visceral syphilis.

Gumma occurs in the kidney with the same characters as in other solid viscera, but is not common.

A depressed patch of scar tissue on the surface, but dipping into the substance of the kidney, may sometimes be due to a gumma, but is far more often the mark of a long past hæmorrhagic infarction.

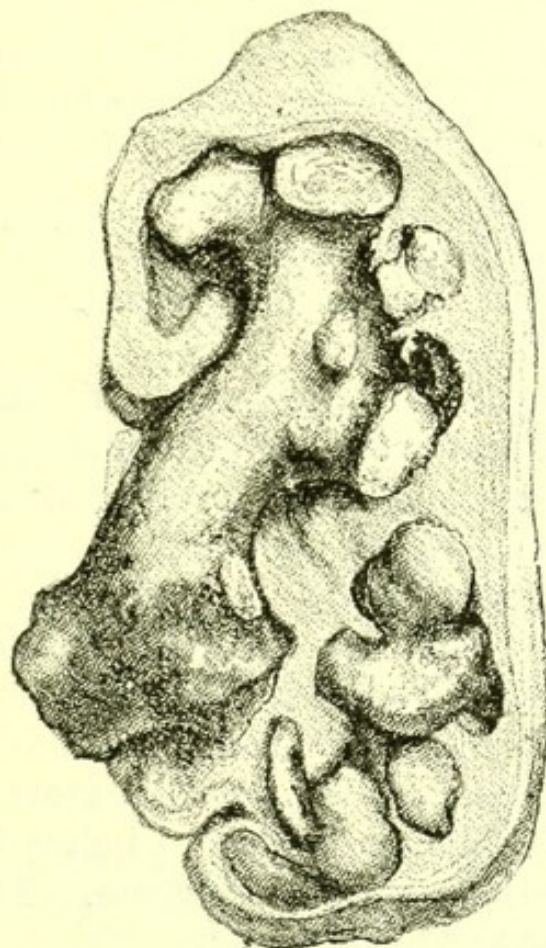
**Movable Kidney.**—One kidney, instead of being fixed behind the peritoneum, may be attached by a mesentery, hanging more or less freely in the abdominal cavity, where it may be felt during life. More floating kidneys are felt in the wards and out-patient room than are seen in the post-mortem room, where the condition is rare.

**Renal Calculus.**—The calculus may consist of uric acid, oxalate and phosphate of lime, and may be single, smooth and round, or may fill the whole pelvis with branches between the calices, forming a sort of cast of the renal cavity. It may grow to any size, and a cast-like large one may be accompanied by any number of small ones. A single calculus may from time to time obstruct the orifice of the ureter, or obstruct it occasionally only. In either case it leads to dilatation of the pelvis, which may be followed by



destruction of the kidney. Large calculi lead to renal abscess, converting the kidney into a pus sac with thickened walls, and causing atrophy of the secreting structures.

FIG. 97.



*Renal Calculus*, filling the Pelvis of the Kidney. From a specimen in the Museum of St. Bartholomew's Hospital.

Very large and very numerous calculi may exist in one or both kidneys for a long time. In the Museum of St. Bartholomew's Hospital are the kidneys, with calculi, of a watchmaker, who had been at work till a few weeks before he died. The right kidney showed some remains of structure, and contained a calculus composed of phosphate of magnesia and ammonia, weighing  $36\frac{1}{4}$  ozs., and about one thousand smaller calculi, besides a large quantity of calcareous dust. The left kidney contained a branched calculus weighing  $9\frac{3}{4}$  ozs.

*Other Morbid Appearances.*—The commonest are—

1. Calculus in the other kidney ;
2. Hypertrophy of the other kidney.



Chronic interstitial nephritis may be present. Urates of soda is often found in the articular cartilages of adults with renal calculus. Chronic pleurisy, with adhesions or with old empyema, is sometimes accompanied by renal calculus.

**Perinephritic Abscess.**—As a sequence of calculus an abscess may form outside the kidney above, below, in front or behind the pelvis, touching it, but often excluded from the kidney.

Such abscesses are sometimes found when a dilated pelvis and ureter remain as evidence of the calculus which has itself passed on.

**Hæmorrhagic Infarction of Kidney.**—The plugging of an end-artery in the kidney by a passive embolus leads to results resembling those seen in the lung and spleen.

A conical area, with base on the surface and tightly packed with red blood-corpuscles, is formed. At first it is dark red and projects from the surface, but in its later stages is first yellowish and finally white, first level with the general external surface of the kidney and finally depressed below it, ultimately becoming a mere line of scar tissue. The capsule is not adherent over the infarct.

In the earliest stage of hæmorrhagic infarction of the kidney, blood-stained or albuminous urine may be found in the bladder.

Such infarctions are commonest in valvular disease of the left side of the heart with dilatation.

They are never broken down.

Active emboli may also become fixed in the kidney.

In ulcerative endocarditis these usually completely fill some small end-artery, and give rise to the same anatomical appearance as a passive embolus, with this difference, that some softening may have taken place in the centre of the infarct.

Active emboli are also lodged in the kidney in cases of pyæmia. These are usually small, and their results do not always reach the surface, but are seen in



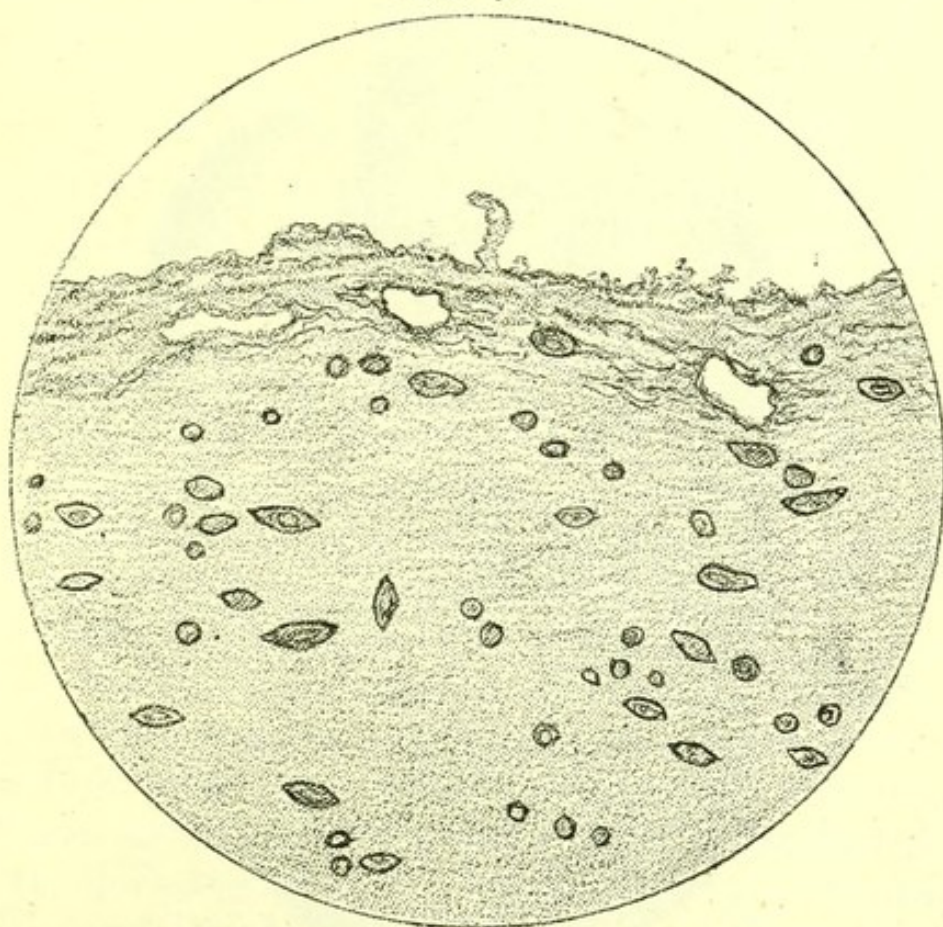
the cortex and pyramids as numerous minute abscesses; those that reach the surface conical, and those which do not cylindrical, in shape.

In cases of supposed but uncertain specific fever the kidney should be carefully scrutinized for these, as they are sometimes the first indications that a centre of infection has existed and that the case has really been one of pyæmia.

Urine containing pus cells and probably traces of blood may be found in the bladder.

**Parasites of the Kidney.**—Hydatid (*Tæniaechinococcus*) occurs very rarely in the kidney, but if present may attain a considerable size, and even penetrate the diaphragm, extend into the lung, and ultimately rupture through a bronchus, making the true nature of the tumour known by daughter-cysts being coughed up.

FIG. 98.

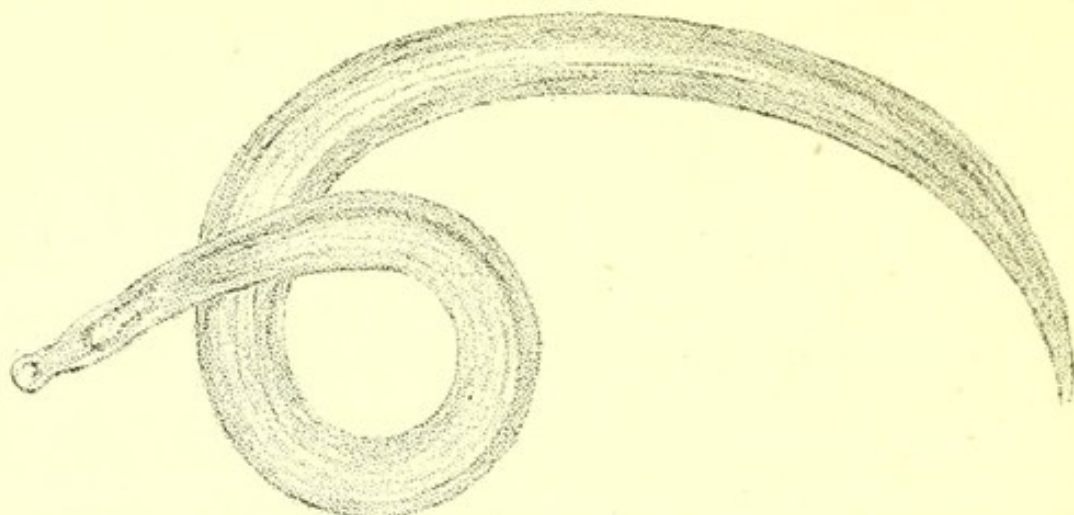


*Bilharzia Embryos in Wall of Bladder.*

**Bilharzia Hæmatobia.**—This parasite may be found in great numbers in the kidney.

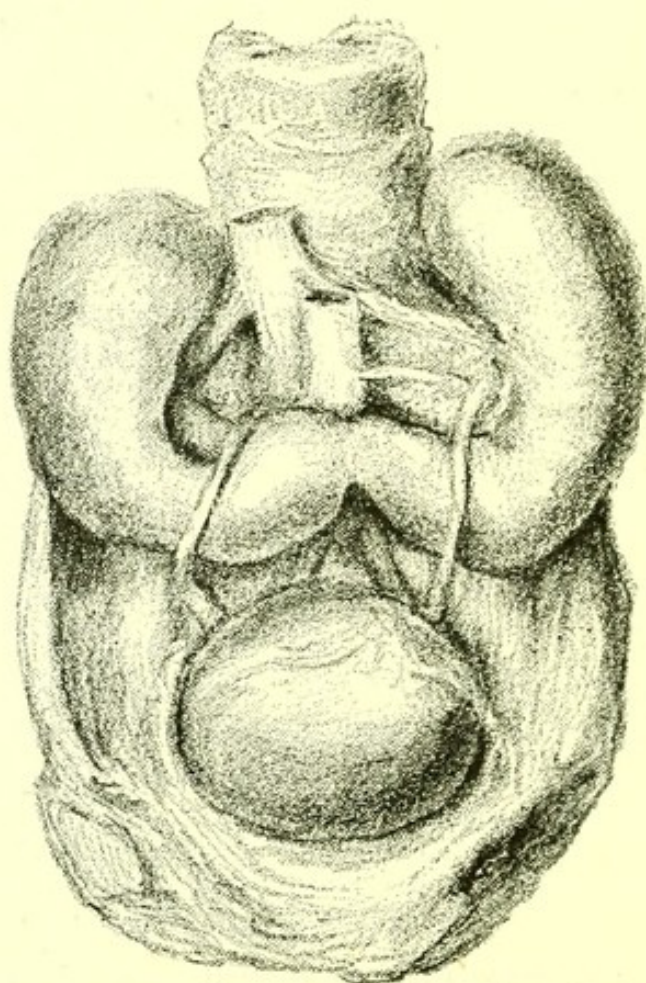


FIG. 99.

*Adult Bilharzia Haematobia. (Magnified.)*

Acute nephritis may accompany it. Microscopic sections show abundant ova in all parts of the kidney and in the walls of both ureter and bladder. (See Chap. IV.)

FIG. 100.



*Horseshoe Kidney.* From a specimen in the Museum of St. Bartholomew's Hospital. The ureters are seen crossing the kidney substance.



**Varieties in Structure.—Kidney.**—Two or more ureters sometimes proceed from one kidney.

The lobulation well marked in the foetus may persist in the adult.

**Horseshoe Kidney.**—The kidneys are united by a band of tissue resting on the lumbar vertebræ. This band may be of renal tissue, continuous with the kidney, or may be merely fibrous. The ureters cross over it in their descent. (See Fig. 100.)

No functional disturbance occurs.

**Abnormalities in Position.**—Besides movable kidney, the organ may be found in some abnormal position.

In a man, aged sixty-three years, I found the left kidney between the common iliac arteries and under the promontory of the sacrum. Its artery came off between the common iliac arteries. The right kidney was normal in position and the bladder normal.

## URINARY DISORDERS.

**Diabetes Mellitus.**—Any form of renal disease may coexist with diabetes. The kidneys may both be without morbid change. The commonest post-mortem appearance is a somewhat pale, large, flabby kidney. The paleness is not at all like that of chronic parenchymatous nephritis, for the cortex and pyramids in the soft kidney of diabetes are of a uniform pale pink.

**Glycosuria.**—Chronic interstitial nephritis is the affection of the kidney most often present.

**Diabetes Insipidus.**—The term diabetes in early medical writers includes conditions in which an excessive flow of urine was observed. Dr. Thomas Willis (1621-1675) showed that in some of these cases sugar was present in the urine, and thus excluded saccharine diabetes. Dr. John Blackall (1771-1860), Dr. Richard Bright (1789-1858), and other observers showed that an excessive flow of urine was, in a large proportion of cases, associated with actual disease of



the kidney, and thus excluded these from the general term diabetes.

A residuum of cases in which there is an excessive flow of urine, and of which no satisfactory anatomical explanation has been given, are now described as cases of diabetes insipidus.

It should be remembered that several cases of supposed diabetes insipidus in children, in which large quantities of non-albuminous urine were passed during life, have proved post-mortem to be examples of chronic interstitial nephritis.

**Suppression of Urine.**—When this symptom has existed during life—

Acute nephritis, or some form of chronic nephritis, will generally be found post-mortem.

It occasionally occurs as the terminal symptom of diabetes mellitus, without actual renal disease.

The bladder should be carefully examined, and will be found empty. This is important, as scanty excretion, or obstruction of a sufficient excretion, is occasionally mistaken during life for true suppression.

**Hæmaturia.**—A large quantity of pure blood flowing suddenly in the urine, is in London generally due to injury of the kidney, by a ragged calculus contained in its pelvis.

New growth in the kidney may cause a copious flow of blood.

Cantharides and turpentine do the same.

Copious hæmorrhage from the kidney also occurs in purpura and in scurvy.

In purpura the whole pelvis of the kidney and the ureter may be found, post-mortem, filled with a dark blood-clot.

In acute nephritis, altered blood is at some time during the disease present in the urine, and in all forms of chronic nephritis it may occasionally be present.

In acute suppurative nephritis, blood as well as pus and urine may be found post-mortem in the pelvis of the kidney.

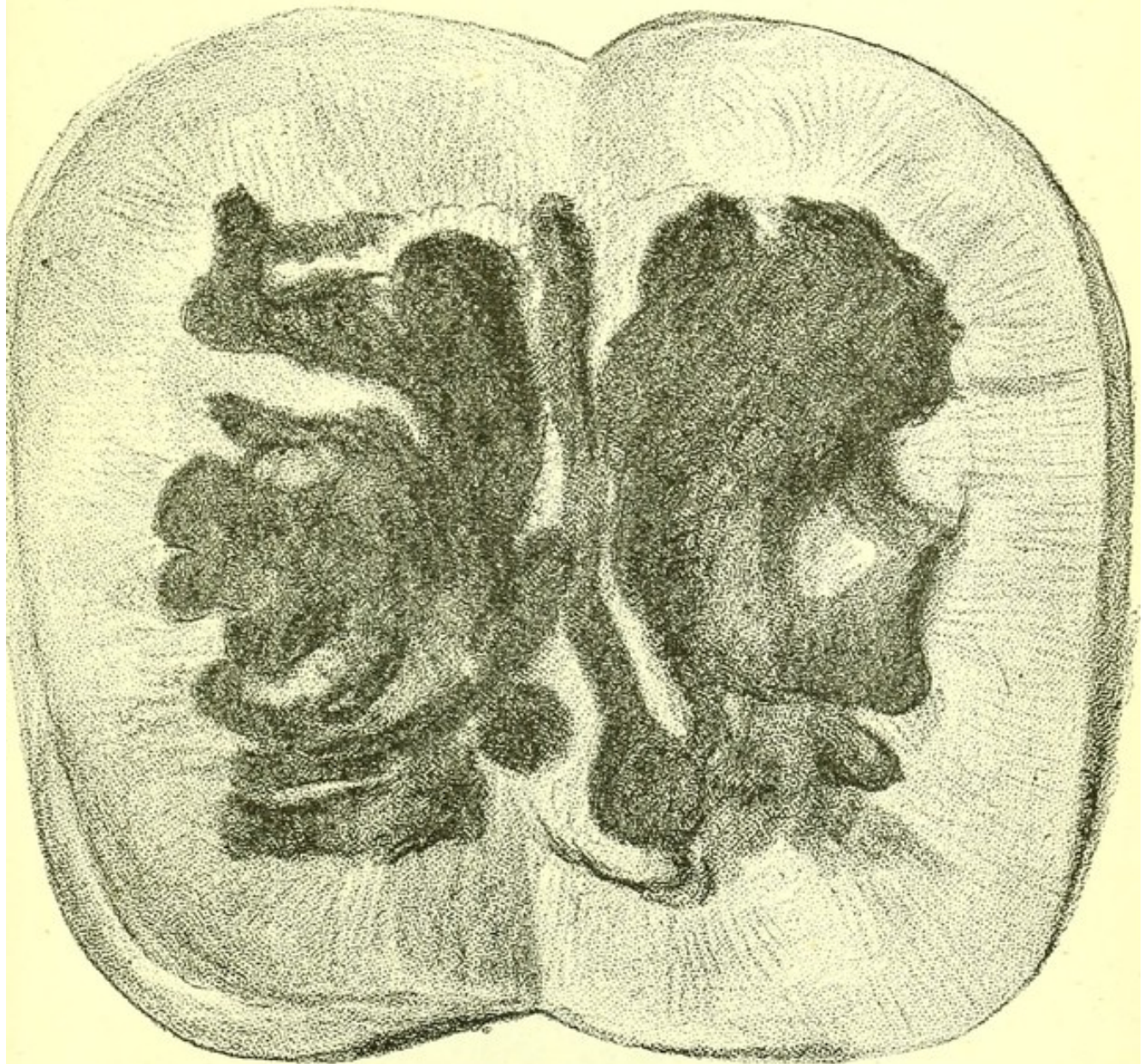


The dark colour in the urine of the subjects of carbolic-acid poisoning is not a condition of hæmaturia.

**Intermittent hæmaturia** is often discovered post-mortem to have been due to calculus in the kidney.

In persons who have been abroad, ova of *Bilharzia hæmatobia* may be found in the kidney.

FIG. 101.



*Kidney from a case of Purpura Hæmorrhagia. The Pelvis is filled with Blood Clo'ts.*

**Albuminuria :** The anatomical changes associated with albuminuria have already been fully described.



**Chyluria.**—In this disease, due to communication, according to Dr. Patrick Manson (Pathological Society: Transactions, London, 1882), between the urinary tract and the lymphatic vessels, produced by a parasite, the *Filaria sanguinis hominis*, the bladder may be found post-mortem filled with chylous urine. Ova are found in microscopic sections of lymphatics. Elephantiasis arabum may be present.

**Lithuria, oxaluria, and phosphuria** may be recognized post-mortem by the deposits characteristic of each being discovered in the pelvis of the kidney, or in the bladder.

Phosphates are sometimes visible in the uriniferous tubules of stillborn children.

Uric acid with phosphates is occasionally present post-mortem in the tubules of the kidney of gouty people.

### BLADDER.

**Hypertrophy.**—In all cases of long-standing obstruction of the urethra, whether due to enlarged prostate or to stricture, the bladder is thickened, the thickening being a functional hypertrophy of its wall.

Post-mortem, a contracted empty bladder, unless it is stretched, by pouring water into it, may easily be mistaken for a bladder with hypertrophied walls.

**Hæmorrhage.**—When during life there has been hæmorrhage from the bladder, one of the following conditions will probably be found post-mortem—

1. Enlarged prostate ;
2. Inflammation of the whole bladder, or of some part of it ;
3. New growth ;
4. Stone.

**Inflammation** is found in all the conditions just mentioned, and is frequently a sequence of simple inflammation of the urethra, or of gonorrhœa.

After death from enteric fever, the mucous membrane of the bladder is sometimes found to be red,



owing to engorgement of its blood-vessels, due to the irritation of large quantities of phosphates, and these salts are found adhering to the mucous surface of the bladder.

**Ulceration and sloughing** may both follow inflammation of the bladder.

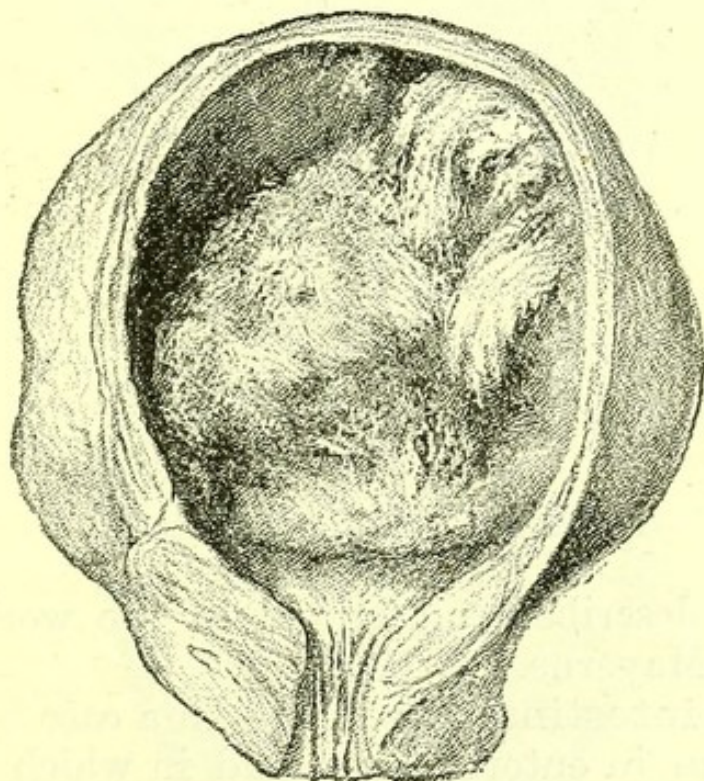
**Outgrowths.**—Of these papillomata are the commonest, and are often of large size.

Simple mucous polypi also occur.

Both are fully described in surgical treatises.

**New Growths.**—Carcinoma of the bladder is not uncommon, and often projects as a large growth into the cavity. It is squamous-celled or spheroidal-celled, and tends if it spreads through the wall of the bladder to grow continuously into contiguous parts, thus sometimes opening into the intestine and producing a recto-vesical fistula.

FIG. 102.



*Carcinoma of the Bladder.*

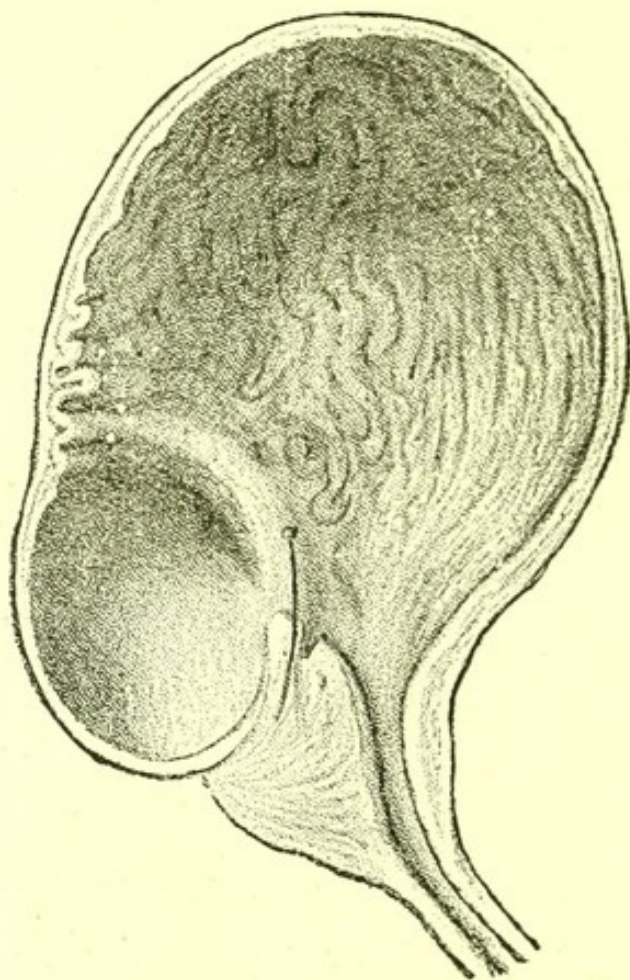
This, however, is a more frequent result of growth from the rectum into the bladder.

Sarcoma originating in pelvic fascia may grow into the bladder from the outside.



**Sacculation** of the bladder is due to its wall yielding between thickened bands of tissue. The sacculi may be numerous and large. Their openings into the bladder are usually of much less diameter than the sacculus. Calculi are sometimes found in them, as in the case of Isaac Casaubon, the famous scholar, whose

FIG. 103.

*Sacculation of the Bladder.*

bladder is described and figured in the works of Sir Theodore Mayerne.

**Vesico-intestinal Fistula.**—In a case believed to have begun in enteric fever, and in which there was an ulcer of the ileum, the floor of which had become adherent to the bladder, I found a communication between the two, one plum-stone in the bladder and others in the intestine. It deserves remark that some part of the last twelve inches of the ileum, a region



always affected in enteric fever, generally lies in contact with the bladder, if the bladder is distended.

**Recto-vesical fistula** is formed in four ways—

1. Perforation of the bladder by a carcinoma of the rectum.

2. Perforation of the bladder due to a perforating wound of the rectum, such as a fish-bone may make, with subsequent abscess.

3. Perforation of the rectum by a carcinoma of the bladder.

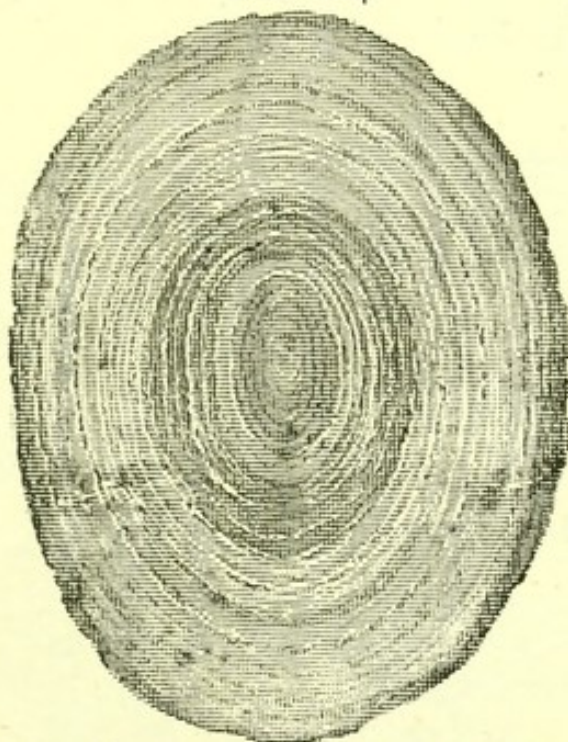
4. Perforation of both rectum and bladder by a sarcoma originating in the intervening tissue.

**Vesico-vaginal fistula** may be formed in the first, third, and fourth ways.

**Calculus.**—A calculus is formed in the bladder by accretion of urinary salts surrounding some nucleus.

In countries where *Bilharzia hæmatobia* flourishes collections of its ova may form such a nucleus. I have seen one such example in St. Bartholomew's Hospital, in a soldier who had served in Natal.

FIG. 104.



*Uric Acid Calculus*, bisected so as to show its Concentric Layers.

Calculi are commonly composed of—

Uric acid, urates, xanthin, cystine, oxalate of



calcium, phosphate of calcium, triple phosphate, carbonate of calcium. Very large calculi are usually of

FIG. 105.

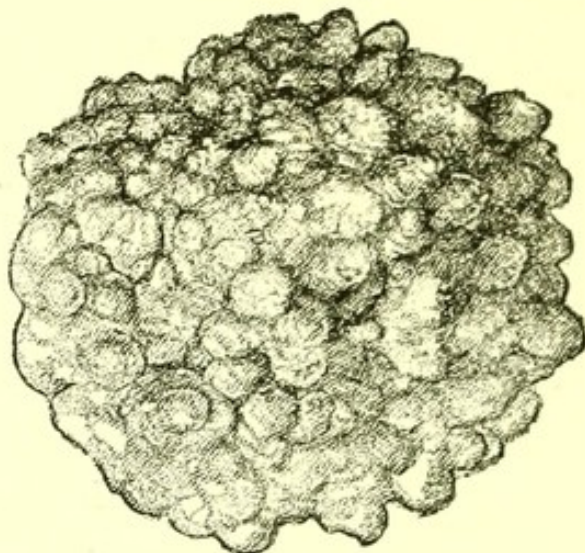
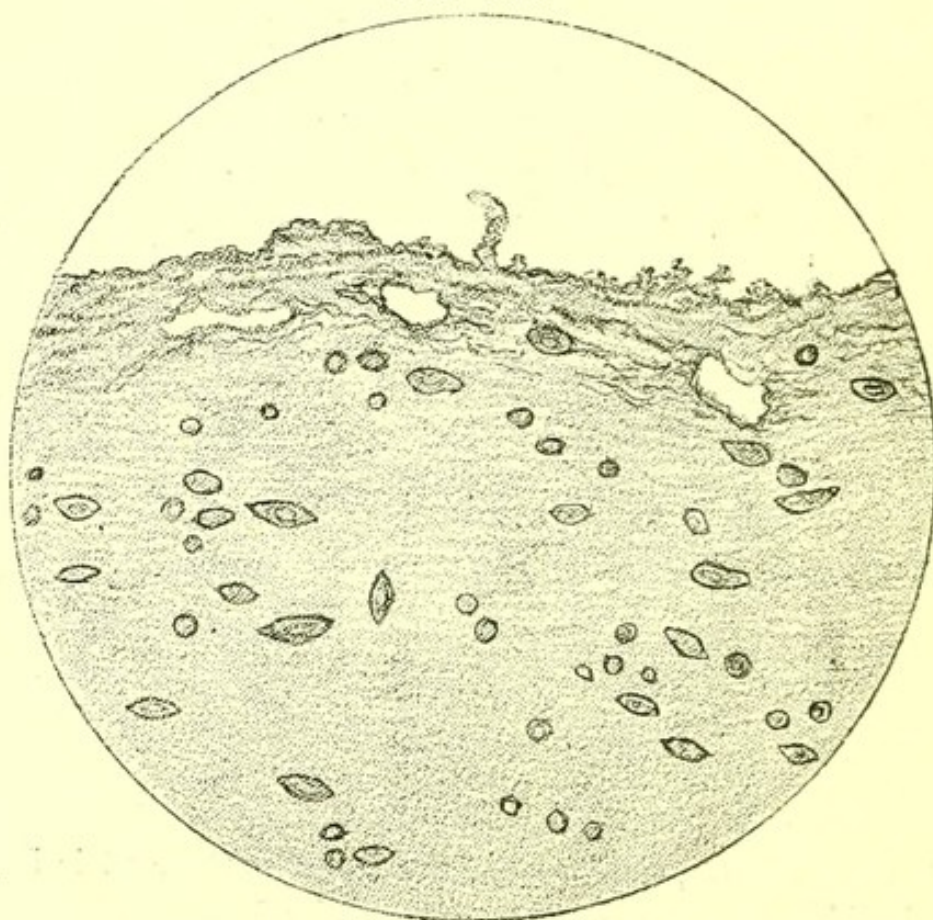
*Oxalate of Lime Calculus.*

FIG. 106.

*Ova of Bilharzia Hæmatobia, in Wall of Bladder.*



uric acid, very corrugated ones of oxalate of calcium. The laminae of uric calculi are oval, those of oxalate of calcium calculi are crenulated or wavy.

On post-mortem examination a calculus, if found in the bladder, may be disguised by a thick coating of firm dark blood-clot.

**Parasitic Disease.**—The ova of *Bilharzia hæmatobia* may be found free in the bladder, and may also exist in numbers in all parts of the walls of the bladder, and in the peritoneum lying on the fundus of the bladder.

This deserves attention, as proving that injections into the bladder can be of little service in the treatment of this disease.

**Epispadias.**—The anterior wall of the bladder may be absent with defective development of the body wall in front of it.

The ureters then open on an exposed mucous surface. The upper wall of the urethra is undeveloped, and the pubic symphysis is also imperfect.

**Hypospadias.**—The floor of the urethra is undeveloped, owing to imperfect closure of the genito-urinary cleft, so that a groove instead of a canal is formed.



## CHAPTER XIX.

DISEASES OF THE GENERATIVE  
SYSTEM.

MALE ORGANS:	HYDROSALPINX.
GONORRHŒA.	PYOSALPINX.
STRICTURE OF THE URE-	HÆMATOSALPINX.
THRA.	UTERUS:
ŒDEMA.	INFLAMMATION.
FEMALE ORGANS:	FLEXIONS AND VERSIONS.
OVARY: HYPERTROPHY	OUTGROWTH.
AND ATROPHY.	POLYPUS.
HÆMORRHAGE.	NEW GROWTH.
INFLAMMATION AND AB-	RUPTURE.
SCCESS.	CRIMINAL ABORTION.
CYSTS.	VAGINA:
OUTGROWTH.	NEW GROWTH.
NEW GROWTH.	MENORRHAGIA.
HYDATID.	PARTURITION.
DISPLACEMENT.	FEMALE BREAST:
FALLOPIAN TUBE:	NEW GROWTH.
TUBERCLE.	

## MALE ORGANS OF GENERATION.

THE male generative organs when diseased generally come under the care of a surgeon, and their morbid conditions are fully described in surgical treatises.

**Gonorrhœa** deserves mention from a medical point of view, as sometimes the sole cause discovered post-mortem for a fatal septicæmia.

**Stricture of the urethra** consequent on gonorrhœa sometimes leads to dilatation of the ureters, and of the pelvis of the kidney, and thus to chronic interstitial nephritis with hypertrophy of the left ventricle.

**Œdema.**—Extreme œdema of the penis and



scrotum is always present in chronic parenchymatous nephritis, and sometimes in dropsy associated with valvular disease of the heart.

## FEMALE ORGANS OF GENERATION.

### OVARY.

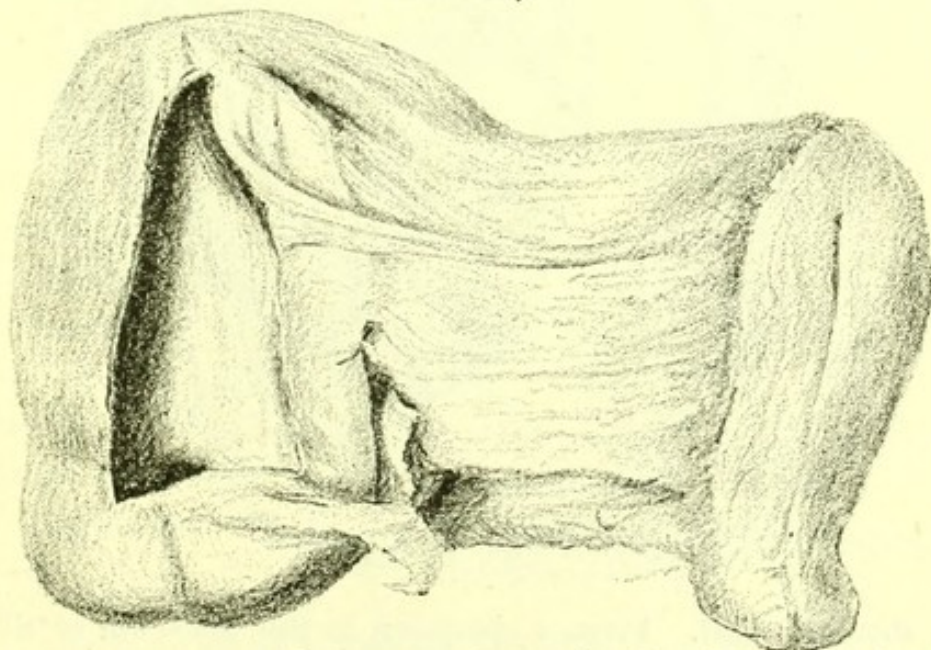
**Hypertrophy.**—Uniform increase in size of the ovaries is sometimes discovered, and on microscopic section an increase of the stroma is seen, but never a proportionate increase of Graafian follicles.

**Atrophy** is common after the menopause. The ovaries are small, hard, and puckered on the surface.

**Hæmorrhage.**—Besides the normal hæmorrhages into corpora lutea, hæmorrhage into cysts in the ovary is of common occurrence.

**Inflammation and abscess** are sometimes found after parturition. Abscesses sometimes burst into the peritoneum, as in a woman, aged twenty-nine years, who died in St. Bartholomew's Hospital. The left ovary contained numerous small abscesses, one of which had burst into Douglas's pouch.

FIG. 107.



*Ovarian Cyst.* From a specimen in the Museum of St. Bartholomew's Hospital. The broad ligament has been cut away on one side.



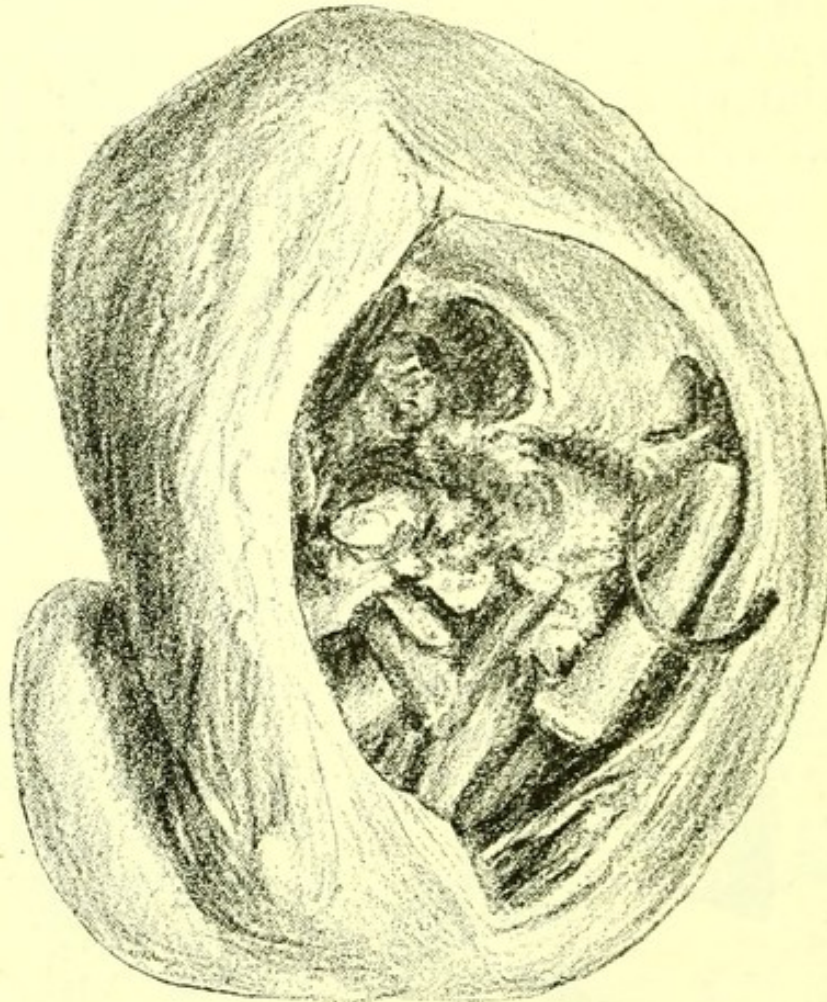
General peritonitis was present. The right ovary was normal.

**Cysts.**—Several varieties of cyst are common in the ovary, the parovarium, and the broad ligament.

**Simple cystic tumour** is generally of small size, and is sometimes a Graafian follicle which has undergone dilatation. (Fig. 107.) Parovarian cysts are formed by occlusion of tubules in the Wolffian body.

**Multiple cystic tumour** is generally large, multilocular, and containing much fluid. All new growths of the ovary, and especially sarcomata, tend to develop cysts, which often contain blood. Villous growths often project into these.

FIG. 103.



*Dermoid Cyst.* From a specimen in the Museum of St. Bartholomew's Hospital. A rib projects across an imperfectly formed tibia on the right of the specimen.

**Dermoid cysts** are cysts containing imperfectly



developed epiblastic or mesoblastic structures, such as hair, teeth, nerves, bones, and muscles.

**Outgrowth.**—Fibroid tumours consisting of ovarian connective tissue are to be found in the ovary, and are sometimes calcified.

**New Growth.**—Sarcoma is the commonest new growth of the ovary, and parts or the whole of the tumour often undergo colloid degeneration.

Sometimes such growths exhibit degeneration of nearly all their cells, so that nothing but a stroma of connective tissue and numerous cystic cavities are left as in a woman, aged sixty-three years, who died in St. Bartholomew's Hospital, and whose right ovary weighed 118 ozs.

Another woman, aged thirty-five years, showed a large mass of small round celled sarcoma growing in and around the right ovary and which was adherent to the uterus.

Secondary growths were found in the liver and the lung.

The lumbar glands and the liver are the commonest seats of secondary growths.

These tumours often cause dilatation of one or both ureters by pressure, and sometimes dilatation of the pelvis of the kidney.

**Parasitic Disease.**—Hydatid (*Tænia echinococcus*) has been observed in the ovary.

**Displacement.**—The ovary may be found prolapsed into Douglas's pouch, or may be adherent to the posterior surface of the uterus or to a tumour of the opposite ovary.

It may become adherent to the omentum, and even completely detached from its ligament.

It is sometimes found adherent in the abdominal ring.

#### FALLOPIAN TUBE.

The Fallopian tube is sometimes found thickened and even occluded, a result of old inflammation.



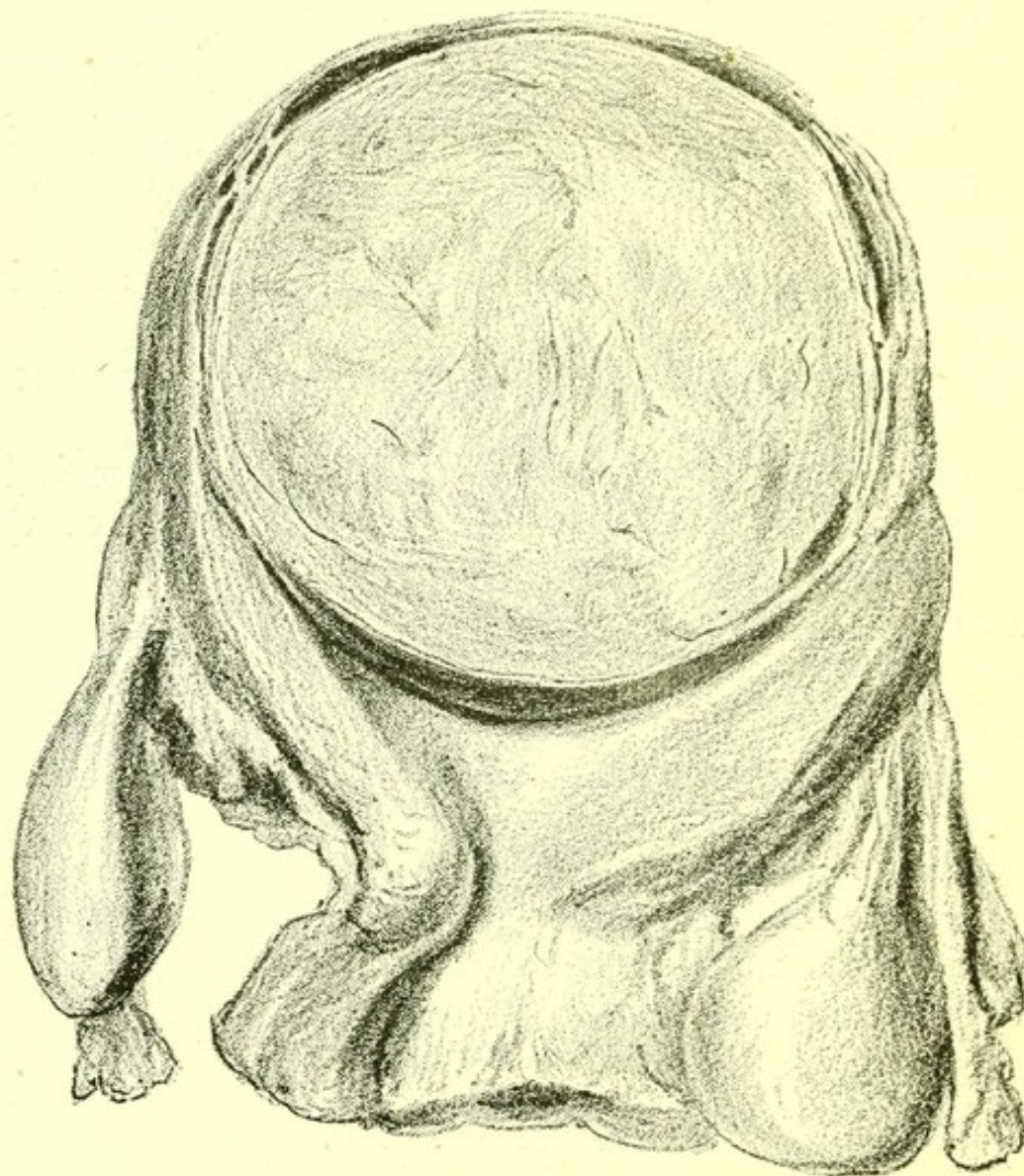
Tubercle may occur in its walls, and this sometimes leads to its whole inner surface being caseous.

It may be greatly distended with clear fluid, a condition called **hydrosalpinx**; or with pus, **pyosalpinx**; or with blood, **hæmatosalpinx**. This is sometimes due to hæmorrhage from its own walls.

These conditions may be unilateral or bilateral.

Its walls are sometimes the seat of new growth, which may sometimes be a primary carcinoma of the tube, but is more often part of a new growth of one ovary, of the uterus, or of the peritoneum.

FIG. 109.



*Myo-fibroma of Uterus.* From a specimen in the Museum of St. Bartholomew's Hospital.



## UTERUS.

**Inflammation.** — Small fissures and ulcerated patches are occasionally found at the os uteri, post-mortem.

After death soon after parturition a foetid slough may occupy the placental site, and the uterus itself be subinvolute. In cases of new growth a gangrenous condition of the upper part of the vagina is sometimes found.

**Flexions and Versions.** — Conditions of the uterus in which it is bent forwards and backwards on itself, or is inclined as a whole in any direction, are discovered post-mortem to be due to heavy growths, generally fibroid tumours, in some part of its wall, or to adhesion of the uterus to some neighbouring structure, as to the intestines in chronic peritonitis, to new growths or outgrowths of the ovary, to carcinoma of the rectum, or to collections of fluid in the pelvis.

**Outgrowth.** — Two forms of non-malignant growth are frequently discovered in the uterus post-mortem — myo-fibroma and polypus.

**Myo-fibroma.** — This forms a dense mass, when small, embedded in the uterine wall; when large, projecting from it either beneath the peritoneum or into the uterine cavity or into the vagina. Its density is the chief naked-eye character of the tumour. Under the microscope it is found to consist of cellular elements precisely like those of the uterine wall. Such tumours occasionally become wholly or in part calcified, or may become cystic and be calcified on the surface only.

**Polypus** is generally a soft projection from the uterine cavity and consists structurally of its components. Sometimes such outgrowths are dense and contain a large proportion of connective tissue.

**New Growth.** — **Carcinoma** of the uterus is common and is a primary new growth.

It is usually made up of spheroidal-cells, arranged



in a stroma of varying thickness. It extends into the uterine wall, and also forms a projecting and sometimes ulcerated surface in the cavity.

Squamous-celled carcinoma is found on the vaginal aspect of the cervix, and grows downwards into the vagina and never into the uterine cavity.

It sometimes grows slowly and sometimes quickly, frequently invading the upper part of the vagina, and commonly reappears in secondary growths in the peritoneum and the liver.

**Rupture of the uterus** is occasionally found after parturition. Lymph is generally present on the neighbouring peritoneum.

**Criminal Abortion.**—It may in some obscure cases be well to keep this possibility before the mind while making a post-mortem examination. Local peritonitis and a wound of the uterine wall, and possibly also of the vagina and os uteri, may be discovered.

**Vagina.**—Outgrowths and most morbid changes in the vagina are described in surgical treatises.

New growth is not uncommonly primary in the vagina, as in a woman, aged forty-five years, in whom I found post-mortem a firm carcinomatous growth occupying the upper and anterior wall of the vagina, and involving the posterior wall of the bladder, perforating it.

**Menorrhagia** sometimes causes death. I have examined post-mortem one young woman who died of it. She died during menstruation, and the cavity of her uterus was occupied by a very pale blood clot. All her organs were much blanched, and the muscular tissue of her heart was in a state of fatty degeneration.

**Parturition.**—Of more remote morbid changes due to parturition, abscesses within the connective tissue of the pelvis and thrombus in the veins of the legs, are the only ones of common occurrence in medical post-mortem examinations.

Septicæmia and pyæmia following parturition have



no special character. Peritonitis is generally present.

When death has occurred soon after parturition from some quite separate condition, the liver is always somewhat larger than natural, and is infiltrated to a slight degree with fat.

The kidneys are somewhat larger and softer than natural. These conditions may be found for a fortnight or three weeks after parturition.

### BREAST.

Diseases of the female breast are rarely seen in the medical wards of a hospital, but it is worth pointing out that very widespread new growth may follow the removal of a breast for carcinoma.

In a woman, aged thirty-five years, whose right breast contained a thickened scar of operation for scirrhus, I found, post-mortem, nodules of carcinoma, consisting of large squamous epithelial cells in the meshes of an abundant stroma, in the lungs, the heart, the liver, the peritoneum, the lumbar glands, the spleen, and both kidneys.

Another patient, aged fifty-three years, was admitted into St. Bartholomew's Hospital with paralytic symptoms.

Her left breast was found to contain a hardened scar, and the glands of the left axilla were enlarged.

She had had a scirrhus removed about a year before. After death I found two large masses of carcinoma in the brain, and none elsewhere.



## CHAPTER XX.

DISEASES OF THE ORGANS OF  
LOCOMOTION.

## BONES :

OSTEITIS.  
OSTEITIS DEFORMANS.  
ACUTE NECROSIS.  
MOLLITIES OSSIIUM.  
OSSIFICATION OF THE CAR-  
TILAGES OF THE RIBS.  
GOUTY DEPOSIT.  
NEW GROWTH.

## JOINTS.

## SPINE :

PSOAS ABSCESS.  
POTT'S DISEASE.  
EROSION BY ANEURYSM.

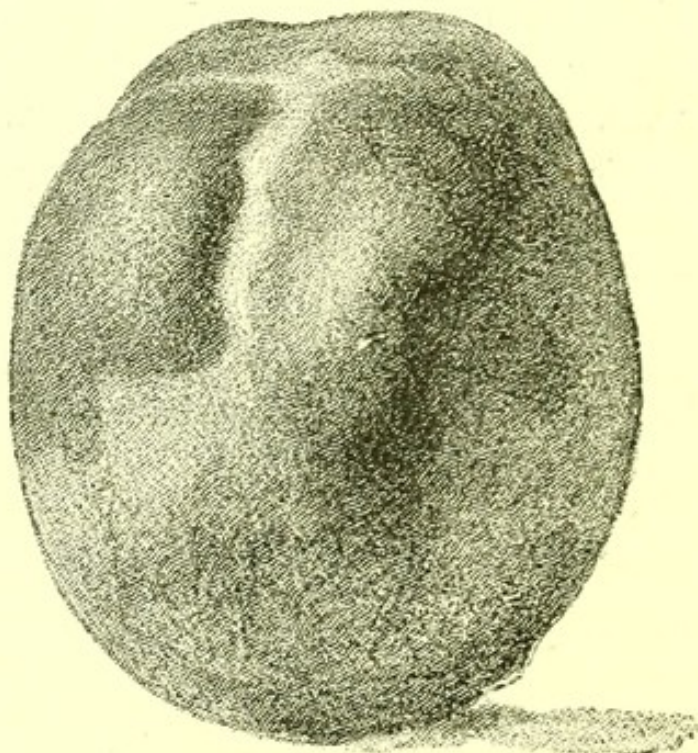
## MUSCLES :

NEW GROWTH.  
TRICHINOSIS.  
HÆMORRHAGE.

TENDONS AND FASCLE AND  
BURSÆ.

**Osteitis.**—Inflammation of bone with cell infiltra-  
tion and outgrowth, occurs in the skull of children,  
producing bosses and forming the natiform skull

FIG. 110.



*Skull, showing the Bosses of Parrot. From a specimen in  
the Museum of St. Bartholomew's Hospital.*



described by the late Dr. Jules Parrot. He and other good authorities believe the change to be due to syphilis. The bosses when fresh are red, and project at the four extremities of the calvaria, and also at other parts.

**Osteitis Deformans.**—In this disease of elderly people, which was first described by Sir James Paget, new bone is formed at the periphery, from the periosteum. Processes are thus reduced in prominence or abolished. The bone becomes softer and bends, so that the patient grows shorter. The skull and spine, as well as the long bones, are affected.

**Acute necrosis** is described in surgical textbooks, and only requires notice here because the shaft of a long bone lying loose in its periosteum is sometimes found post-mortem in a case of pericarditis or pleurisy in a child.

Death in such a case has generally been caused by pyæmia, and pus is to be found in some of the joints.

**Mollities ossium** affects the pelvis or the whole skeleton.

The bone loses its mineral constituents and becomes very soft, while the marrow is increased in quantity.

The origin of the change is unknown.

**Ossification of the cartilages of the ribs** is generally found in aged people. It is present sometimes in young people who have died of phthisis. It is always present in the bodies of adults with extensive emphysema of the lungs.

**Gouty Deposit.**—Urate of soda is sometimes found in the substance of the articular end, and even of part of the shaft of a long bone, generally of the femur. In such examples the articular surface has always a similar deposit.

**New Growth.**—Most new growths of bone are treated surgically. Diffuse sarcoma of the bones, sometimes itself ossifying, is not very rare, and is seen in medical practice in children as well as in adults.

**Sarcoma of Skeleton.**—A condition best de-



scribed by this term occurs in children and in young adults. A boy, aged one year and a half, who died in St. Bartholomew's Hospital and whom I examined post-mortem, was an example of it, and his case is a typical example of the distribution and duration of this form of sarcoma. In his skull the frontal bone and the anterior part of the parietals, and almost the whole base, were infiltrated with masses of a tough reddish new growth. These masses projected externally and also, though to a less degree, into the cranial cavity. Two had pushed the eyes almost out of the orbits and the cornea had sloughed away. All the bones of the pelvis were infiltrated in the same way and there were masses in both femora, with general infiltration of the whole shaft of each. The ten upper left ribs and the nine lower right ribs were all infiltrated, and several of the prominent bosses on the ribs projected into the chest. In the skull the superior maxillæ, palate bones, malar bones, lachrymal bones, nasals, and inferior maxilla were the only bones not infiltrated. The basilar part of the occipital bone was infiltrated in continuity with the sphenoid, and there was a small boss on the superior angle, but the rest of the occipital bone was free from new growth. There was no infiltration or softening of the brain, but the pia mater and arachnoid in contact with a boss on the frontal bone were much injected with blood. Several cervical glands were found to be infiltrated with new growth, but the mediastinal glands, pericardium, heart, and lungs contained no new growth. In the abdomen there was no general infiltration of the peritoneum, and the mesenteric glands were not infiltrated, neither were the stomach and intestines, nor the kidneys. All the lumbar glands were infiltrated and enlarged. The right supra-renal body was as large as the child's fist and was infiltrated and surrounded by new growth. Part of the right lobe of the liver was enlarged and contained several large projecting masses of new growth. Microscopic examination showed that the new growth had everywhere the same minute



structure. It was a sarcoma consisting entirely of round cells without any intervening tissue. It was possible from the history to estimate the duration of the growth. The boy had been weaned at the age of thirteen months and was at that time in tolerable health. Three months later he had pain in the right hip, but this pain, with a similar pain in the right arm, passed off in about a fortnight. One month later a swelling appeared over the left eye, and in the course of the next six weeks several other swellings were discovered on the head. While the child was in the hospital its tumours were observed to grow rapidly. Its eyes became more and more compressed, its general cachexia increased, and it died after being in the hospital about six weeks.

From the first symptoms of illness to the time of death five months elapsed, while from the observation of the first swelling on the skull till death was a period of thirteen weeks.

**Joints.**—In persons who have had rheumatic fever, permanent joint changes traceable to it are very rare. A general account of the diseases in which joint changes take place is given in the Chapter on Diseases not Classified, where also the subject of rickets is treated.

**Spine.—Psoas Abscess.**—Abscess in the psoas muscles associated with caries of the lumbar vertebræ is sometimes found post-mortem in children who have suddenly been attacked with tubercular meningitis.

**Pott's Disease.**—Percival Pott, who was surgeon to St. Bartholomew's Hospital (1750-1784), and whose admirable portrait by Sir Joshua Reynolds hangs in the Committee-room of that Hospital, first accurately described the results of caries of the bodies of the dorsal vertebræ.

From a medical point of view the degenerative changes observable in the cord are the most important features.

In a man, aged thirty-two years, who died in St.



Bartholomew's Hospital, and in whom the left arches and left half of the bodies of the third, fourth, fifth, and sixth dorsal vertebræ were carious, the cord though pressed upon showed no change to the naked eye.

Microscopic sections showed in the upper dorsal region degeneration of the columns of Goll with numerous gaps and atrophied medullary sheaths. In the lower dorsal region only neuroglia remained. Below, the cells of the grey matter, especially of the anterior horns, had lost their processes.

**Erosion by Aneurysm.**—Erosion of the spine due to aneurysm of the aorta is common. The bodies of several vertebræ are often eroded, the heads of the ribs are sometimes also eroded, and in rare cases the spinal cord is compressed.

**Muscles.**—**Gummata** are sometimes found in the substance of muscles.

**Sarcoma.**—Extensive invasion of muscular tissue by sarcoma sometimes occurs.

**Trichinosis** is described in the Chapter on Parasites.

**Hæmorrhage into Muscles.**—Large hæmorrhages into and between the muscles of the thigh are sometimes found in cases of purpura and of extreme anæmia. Fatty degeneration of the heart is always present.

**Tendons and fasciæ and bursæ** are occasional seats of a deposit of urate of soda in cases of gout. The bursa so common at the elbow in gouty people often contains a deposit of urate of soda.

The precise changes in tendons and fasciæ accompanying the pains of chronic rheumatism are unknown. Sometimes thickenings due to inflammation are discovered post-mortem.



## CHAPTER XXI.

DISEASES OF THE CONNECTIVE  
TISSUE AND SKIN.

CONNECTIVE TISSUE :

HÆMORRHAGE.

ŒDEMA.

INFLAMMATION.

SKIN :

EXANTHEMATA.

TATTOO MARKS.

NEW GROWTH.

BED-SORE.

HÆMORRHAGE.

**Connective Tissue.**—**Hæmorrhage** into the connective tissue is found in cases of purpura and of scurvy, and large hæmorrhages are sometimes present in cases of death from anæmia, with fatty degeneration of the heart.

**Œdema** is an exudation into the connective tissue of the serum of the blood. It may be due to a passive cause, such as—

1. Retardation of the venous blood-stream, by valvular disease of the heart.

2. Obstruction of the venous blood-stream, as in cases of thrombus, or of pressure upon a vein.

3. Blood changes, as in renal disease.

Or to an active cause, as exudation from capillaries near an inflammation, as in an eyelid after an insect's sting, or of the connective tissue near a gouty joint.

On cutting into an œdematous spot watery fluid exudes in quantity, and the meshes of the connective tissue seem distended by fluid.

**Inflammation.**—Long tracts of inflammation are frequently found in connective tissue post-mortem.

The condition known as angina Ludovici is a good example.



In a man, aged nineteen years, in whom death was due to pneumonia of the apex of the left lung, I found all the cervical glands enlarged, while round the lower part of the trachea and behind the œsophagus, extending up to the floor of the mouth and down to the anterior mediastinum, was a collection of pus in the meshes of the connective tissue, with some hæmorrhages here and there into the swollen tissues. There were no adherent clots in the cervical veins.

**Skin.**—The exanthemata, except those which are pustular, and the blotches of typhus fever disappear after death, and all skin diseases dependent on colour are altered or effaced.

Tattoo marks, of course, remain, and the glands near them often contain traces of the pigment used in the tattooing.

Primary squamous-celled carcinoma and melanotic sarcoma may be discovered post-mortem in the skin, and it deserves notice that extensive melanotic sarcoma of viscera may be present when the primary nodules in the skin are but small.

**Bedsore** should always be noted in a post-mortem examination.

Very large patches of necrosed connective tissue and skin are sometimes found in cases of disease of the spinal cord, and have been supposed to be due to direct injury of the nerves, and thus to be unavoidable.

The better opinion is that while some spinal lesions interfere with sensation so as to make it less easy to obtain notice of the onset of necrosis in the skin,—all bedsores are due to continued pressure and interference through it, with the circulation, and can therefore be prevented by careful nursing.

**Hæmorrhage** into the skin is found post-mortem in purpura, scurvy, and hæmophilia, and sometimes in the neighbourhood nodules of sarcoma which have grown rapidly.



# INDEX.

- ABNORMALITIES in position of  
    kidney, 381  
*See Displacement*
- Abortion, criminal, 396
- Abscess : brain, 163  
    kidney, 371  
    liver, 307  
        table of cases, 312  
    lung, 243  
    middle ear in scarlet fever,  
        57  
    ovaries, 391  
    pancreas, 329  
    perinephritic, 378  
    post-pharyngeal, 272  
    psoas, 401  
    spleen, 343  
    thyroid gland, 351
- Acids (poisons), 107
- Addison, Dr., 69, 356
- Addison's disease, 356
- Adenoma, 45
- Adhesions : spleen, 340
- Ages, anatomical peculiarities  
    of, 16
- Albuminuria, 383
- Alcoholism, 118
- Alimentary canal. *See New  
    Growth, Parasites, Perfora-  
    tion, Stricture, Ulceration*
- Alkalies, caustic (poisons), 104
- Amyloid disease : kidney, 370  
    spleen, 343
- Amyloid liver, 305
- Anatomical appearances in post-  
    mortem sometimes mistaken  
    for disease, 56
- Anæmia, 26  
    brain, 152  
    pernicious, 142  
    simple, 141
- Andrew, Dr. J.  
    on cholera, 76  
    case of intestinal obstruc-  
        tion, 265  
    cases of abscess of liver, 309  
    cancer of gall-bladder, 322
- Aneurysm : abdominal aorta,  
    226  
    arch of aorta, 224  
    arteries, 224  
        of the circle of  
            Willis, 226  
    heart, 208  
    hepatic artery, 226  
    pancreatico-duodenalis ar-  
        tery, 226  
    thoracic artery, 226  
    results of treatment, 226  
    valves, 209
- Angeioma, 45
- Angina pectoris, 214
- Anson's voyage, 118
- Anthrax, 93
- Antimony (poison), 104
- Aortic valves : incompetence,  
    208  
    stenosis, 208



Aphasia, 182  
 Apoplexy, 175  
 Arteries, 223  
     *See* Aneurysm  
 Ascaris lumbricoides, 100  
 Ascites, 297, 337  
 Asthma, 235  
     hay, 229  
 Atelectasis, 250  
 Atrophy, 25  
     heart, 198  
     kidney, 361  
     liver, acute yellow, 307  
         simple, 307  
     lymphatics, 346  
     nerves, 146  
     ovaries, 391  
     spleen, 340  
     thyroid gland, 137, 351

BAILLIE, M., xi.  
 Baker, Mr. Morrant, 308  
 Baly, W., xi., 69, 195  
 Barlow, Dr. Thomas, 155  
 Bedsore, 73, 404  
 Bell's palsy, 180  
 Bentley, on books, ix.  
 Bilharzia hæmatobia, 95  
     in kidney, 379  
     as a cause of calculus, 387  
 Biliary calculi, 51  
 Blackall, xi., 381  
 Bladder, diseases of, 384  
 Bladder. *See* Calculus, Fistula, Hæmorrhage, Hypertrophy, Inflammation, New Growth, Outgrowths, Parasitic Disease, Sacculation, Ulceration  
 Blindness, sudden, 180  
 Blood. *See* Pleural Cavity  
 Blood-clot in pericardium, 192  
 Bone. *See* Gouty Deposit, New Growths  
 Bothriocephalus latus, 97  
 Bowlby, Mr. A. A., xii.  
     on Bilharzia, 96

Brain : atrophy, 146  
     congestion, 146  
     hypertrophy, 146  
     hæmorrhage into, 148  
     secondary new growths in, 174  
 Breast (female), diseases of, 397  
 Bright, Dr. R., xi., 1, 369, 381  
 Bronchi, blood in, 235  
 Bronchiectasis, 234  
 Bronchitis, catarrhal, 232  
     plastic, 232  
 CÆCUM : pointed, 261  
     transposition of, 261  
     *See* Carcinoma  
 Calcareous degeneration, 29  
 Calculi : biliary, 51  
     pancreatic, 52  
     prostatic, 52  
     renal, 51  
     salivary, 52  
     vesical, 51  
 Calculus : bladder, 387  
     pancreas, 326  
     renal, 376  
 Cameron, Sir Ewen, of Lochiel, 98  
 Cantharides (poison), 113  
 Carbonic acid gas (poison), 113  
 Carbonic oxide (poison), 113  
 Carcinoma, 32, 37  
     brain, 174  
     cæcum, 295  
     colon, 295  
     cylindrical-celled, 38  
     intestines, 295  
     kidney, 373  
     oesophagus, 274  
     pancreas, 329  
     primary, of gall-bladder, 322  
     rectum, 296  
     spheroidal-celled, 38  
     squamous-celled, 38  
     stomach, 285



- Carcinoma, uterus, 395  
 Catarrhal bronchitis, 113  
     inflammation, 291  
     pneumonia, 291  
 Cerebral hæmorrhage, 148, 176  
     tumours, 173  
 Cerebro-spinal fever, 63  
 Cervical opisthotonos, 182  
 Cestoda, 94  
 Chairmakers, corn on chest, 114  
 Chloroform (poison), 112  
 Chlorosis, 142  
 Cholera, 76  
     sporadic and epidemic, 77  
 Chondroma, 44  
 Chondro-sarcoma, 40  
 Chorea, 183  
 Church, Dr. W. S., on cholera, 76  
     on hydrophobia, 202  
     case of anæmia, 306  
 Chyluria, 384  
 Cicatrization, 28  
 Circulatory system, syphilis in, 86  
 Cirrhosis : liver, 301  
     lung, 244  
 Climate, effects of, 116  
 Clots, distinction of ante mortem from post-mortem, 212  
 Clowes, Mr., on scurvy, 118  
 Colitis, 295  
 Collapse of lung, 237  
 Colloid degeneration, 29  
 Colon. *See* Carcinoma  
 Compression, 49  
 Concretion, 51  
 Congenital malformation, 120  
     of heart, 215  
     syphilis, 91  
 Congestion, 146  
     passive, of lung, 237  
 Connective-tissue, diseases of, ch. xxi. p. 403  
     hæmorrhage into, 403  
     nodules, 373  
 Continued fever, simple, 64  
 Contraction, 46  
 Contraction of stomach, 291  
 Corrosive poisons, 113  
     sublimite (poison), 104  
 Cramp, 181  
 Cretinism, 137  
 Cromwell, Oliver, 78  
 Cross paralysis, 179  
 Croton oil (poison), 112  
 Croup, 229  
 Cutaneous system, syphilis in, 89  
 Cyanosis, 216, 223  
 Cyst : brain, 173  
     dermoid, 392  
     hydatid, in lung, 252  
     kidney, 371  
     liver, 314  
     ovaries, 392  
 Cyst-formation, 45  
 Cystic tumour, simple, 392  
     multiple, 392  
  
 DARWIN, effect of his writings, 53  
 Death, cause of, without demonstrable cause, 54  
     in diphtheria, 62  
     enteric fever, 71  
 Death certificate, 19  
 Debility, 123  
 Degeneration : calcareous, 29  
     colloid, 29  
     cystic, of kidney, 371  
     fatty, 29  
     fatty, of heart, 198  
     fatty, of liver, 314  
     fibroid, 29  
     lardaceous or amyloid, 29  
     mucous, 29  
     pigmentary, 31  
 Delirium tremens, 118  
 Dengue, 58  
 Dermoid cysts, 392  
 Developmental diseases, ch. iii p. 120  
 Diabetes insipidus, 381  
     mellitus, 143



- Diarrhœa, 267  
 Diet, diseases produced by  
     errors of, ch. vii. p. 117  
 Digestive system, diseases of,  
     ch. xiv. p. 255  
     syphilis in, 87  
 Dilatation, 46  
     gall-bladder, 325  
     heart, 198  
     stomach, 290  
 Diphtheria, 61, 228  
 Diseases not classified, ch. ix.  
     p. 125  
 Disorders of function, 53  
 Displacement, 46  
     ovary, 393  
     *See* Position, Abnormalities of  
 Disseminated sclerosis, 166  
 Diverticula: œsophagus, 258  
     small intestine, 260  
 Diverticulum, Meckel's, 258  
     stomach, 258  
     table of cases of, 259  
 Dochmius duodenalis, 102  
 Douglas, Dr. James, xi.  
 Dropsy, 27, 152  
 Dupuytren, 276  
 Dysentery, 77  
 Dysphagia, 272  
 Dyspepsia, 291  
  
 EAR, perforation of tympanum,  
     186  
     polypus, 186  
     suppuration in mastoid  
         cells, 187  
     tophi, 186  
 Ecchymosis: pericardium, 192  
 Effusion, passive into pericar-  
     dium, 192  
     plastic, 27  
     of serum, 27  
 Embolus, 49  
 Emphysema, 235  
 Encephalitis, 162  
 Endocardial corns, 214  
 Endocarditis, 200  
  
 Endocarditis, acute, 200  
     chronic, 213  
     simple, 201  
     ulcerative, 201  
 Endothelioma, 32  
 Engorgement, arterial and  
     venous, of kidney, 362  
 Enlarged cervical glands in  
     diphtheria, 61  
 Enlargement of spleen, 340  
 Enteric fever, 64  
 Epidemic rose rash, 56  
     of enteric fever, table  
         of, 74  
 Epilepsy, 182  
     hystero-, 184  
 Epispadias, 389  
 Errors of development, 53  
 Erosion of spine due to  
     aneurysm, 402  
 Erysipelas, 80  
 Exanthemata, 404  
 Eye, ear, and nose diseases,  
     ch. xi. p. 185  
 Eye: chronic interstitial neph-  
     ritis, 186  
     ecchymosis, 185  
     irregularity of pupil, 185  
     opacity of cornea, 185  
     parasites, 186  
     tubercle of choroid, 185  
     in syphilis, 89  
 Eyelids, tumours of, 186  
  
 FÆCES. *See* Vomiting  
 Fallopian tube, diseases of, 393  
 False membrane in diphtheria,  
     61  
 Fasciola hepatica, 94  
 Fatty degeneration, 29  
     heart, 198  
     infiltration of liver, 314  
     liver, 314  
 Fauces, diseases of, 271  
 Female organs of generation,  
     391  
 Fever, in general, 55



- Fever, cerebro-spinal, 63  
   enteric, 164  
   malarial, 78  
   relapsing, 59  
   rheumatic, 93  
   scarlet, 125  
   splenic, 56  
   typhus, 58  
   yellow, 76  
 Fibroid degeneration, 29  
   phthisis, 244  
 Fibromata, 44  
 Fibro-myomata, 44  
 Fibro-sarcoma, 40  
 Filaria medinensis, 101  
   sanguinis hominis, 101  
 Fistula. *See* Recto-Vesical,  
   Vesico-Intestinal, Vesico-Va-  
   ginal  
 Flexions of uterus, 395  
 Floating kidney, 376  
 Fracture, 50  
  
 GALL-BLADDER, ulceration of,  
   321  
 Gall-ducts, inflammation of, 321  
 Gall-stones, 51, 299  
 Gangrene, 28  
   of lung, 243  
 Gastritis, 275  
 Gee, Dr., xii., 155, 167, 293, 317  
 Generative system, diseases of,  
   ch. xix. p. 390  
   syphilis in, 88  
 Glanders, 93  
 Glioma, 40  
   of brain, 173  
 Glisson, xi., 134, 136  
 Glosso-labio-pharyngeal par-  
   alysis, 180  
 Glycosuria, 144, 381  
 Goitre, 351  
   cystic, 351  
   exophthalmic, 352  
   malignant, 353  
   vascular, 351  
 Gonorrhœa, 92, 390  
  
 Gout, 127  
 Gouty deposit in bone, 399  
 Greek writers on apoplexy, 176  
 Greenfield, Dr., 76  
 Gumma, 84  
   brain, 173  
   muscles, 402  
 Gums, diseases of, 269  
  
 HÆMATEMESIS, 266  
 Hæmatoma, 146  
 Hæmatosalpinx, 394  
 Hæmaturia, 382  
   intermittent, 383  
 Hæmophilia, 143  
 Hæmoptysis, 237  
 Hæmorrhage, 26  
   cerebral, 148, 176  
   after chronic degenera-  
   tion, 148  
   into connective tissue,  
   403  
   due to embolus, 151  
   from intestines, 291  
   into muscles 402  
   of ovaries, 391  
   into skin, 404  
   into spinal cord, 152  
   from stomach, 275  
   venous, arterial and  
   capillary, 26  
 Hæmorrhagic infarction. *See*  
   Infarction  
 Hamilton: on fat in blood, 143  
 Hare-lip, 256  
 Harvey, 2  
 Hay asthma, 229  
 Heart, diseases of, ch. xii.  
   p. 189  
   atrophy of, 198  
   dilatation of, 198  
   fatty degeneration of, 196  
   hypertrophy of, 197  
   rupture of, 199  
   size of, 197  
   congenital malformation,  
   215



- Hemiplegia, left, 178  
     right, 179  
     with double contracted pupils, 179  
 Hepatic artery, aneurysm of, 226  
     region, increased resistance in, 298  
 Hernia of stomach, 291  
 Hodges, Dr. N., 59  
 Hodgkin's disease, 348  
 Horseshoe kidney, 381  
 Humphry, Professor, 124  
 Hydatids : liver, 99, 320  
     lung, 252  
     pericardium, 194  
     spleen, 345  
 Hydrocephalus, chronic, 152  
 Hydrochloric acid (poison), 107  
 Hydrocyanic acid, 112  
 Hydronephrosis, 373  
 Hydrophobia, 92  
 Hydiorachis interna, 153  
 Hydrosalpinx, 394  
 Hyperæmia, active and passive, 25  
 Hypertrophy, 24  
     bladder, 384  
     heart, 25, 197  
     kidney, 359  
     lymphatics, 346  
     ovaries, 391  
     spleen, 341  
     thyroid gland, 350  
     tonsils, 271  
 Hypospadias, 389  
 Hysteria, 183  
 Hystero-epilepsy, 184  
  
 IMMATURITY at birth, 120  
 Infantile convulsions, 180  
 Infarction, hæmorrhagic : kidney, 378  
     lung, 250  
     spleen, 344  
 Infiltration, fatty, of liver, 314  
  
 Inflammation, 27  
     catarrhal, 291  
     of gall-ducts, 321  
     of lymphatics, 346  
     of lymph-vessels, 346  
     of ovaries, 391  
     of uterus, 395  
 Influenza, 59, 228  
 Intestines, diseases of, 291  
     *See* Lympho-Sarcoma, New Growths  
 Involution, delayed, of thymus gland, 349  
 Irregularity of action of heart, 223  
 Irritant poisons, 104  
  
 JAMES I., King, 78  
 Jaundice, 297  
     catarrhal, 298  
 Jaws, diseases of, 269  
 Jenner, Sir W., xi., 64, 136  
 Joints, changes in, 401  
  
 KIDD, Dr. P., 140  
 Kidney. *See* Abscess, Amyloid, Atrophy, Calculus, Carcinoma, Cyst, Degeneration, Engorgement, Hypertrophy, Movable, Syphilis, Tuberculosis  
 Kidneys in diphtheria, 62  
 Klein on cholera, 76  
     on epidemic diarrhœa, 77  
     on nephritis, 363  
 Koch on cholera, 76  
  
 LACERATION, 50  
 Lardaceous degeneration, 29  
 Large intestine, ulceration of, in enteric fever, 69  
 Laryngismus stridulus, 181  
 Laryngitis, 229  
     *See* New Growths, Sarcoma  
 Larynx, diseases of, 229  
 Lead palsy, 180



- Legg, Dr. Wickham, on yellow fever, 76  
     on aneurysm of heart, 209  
     on cirrhosis, 329
- Leprosy, 139
- Letulle, Dr., 181
- Leucocythæmia, 77, 142, 344
- Lipomata, 44
- Lips, diseases of, 269
- Lithuria, 384
- Little Britain, famous publication in, 134
- Liver, diseases of, 297  
     *See* Abscess, Amyloid, Atrophy, Cirrhosis, Cyst, Degeneration, Fatty, Gallstones, Hypertrophy, New Growths, Nutmeg.
- Lobar pneumonia, 240
- Locomotion, organs of, diseases in, chap. xx. p. 398  
     syphilis in, 88
- Locomotor ataxy, 172
- London: varieties of nephritis in, 364
- Lung. *See* Abscess, Cirrhosis, Collapse, Congestion, Gangrene, New Growths, Edema, Parasites, Sarcoma, Tuberculosis
- Lymphadenoma, 348
- Lymphatics, diseases of, 346  
     *See* Atrophy, Hypertrophy, Influenza, New Growths, Pigment, Tubercle
- Lymphatic system, diseases of, chap. xv. p. 340  
     syphilis in, 89
- Lympho-sarcoma, 394  
     of intestines, 293
- MACKIE, Dr., on Bilharzia, 95
- Malarial fever, 78, 341
- Male organs of generation, diseases of, 390
- Malformation, 53  
     *See* Congenital
- Malignant new growth, 43
- Mania e potu, 119
- Manson, Dr. P., on chyluria, 384
- Marsh, Mr. Howard, 265
- Mastoid cells, suppuration in, 187
- Measles, 56
- Mechanical affections, 46
- Meckel, 258
- Megrim, 182
- Melæna, 267
- Melanotic sarcoma, 41
- Menière's disease, 182
- Meningitis. *See* Pachymeningitis, Purulent, Spinal, Syphilitic, Tubercular
- Menorrhagia, 396
- Mental diseases, 184
- Mercurial fever, 181
- Microsporon furfur, 103
- Milk spots, 192
- Mitral valve, incompetence, 203  
     stenosis, 204
- Mollities ossium, 399
- Morbid anatomy of enteric fever, 65  
     of valvular disease, 209
- Morbid appearances, relation to symptoms in diphtheria, 63  
     in gout, 130  
     in ulcer of stomach, 283
- Morbid state and processes, 24
- Mouth, diseases of, 269
- Movable kidney, 375
- Mucous degeneration, 29
- Müller, Dr. L., 276
- Mumps, 60
- Myelitis, 163  
     *See* Pyomyelitis
- Myocarditis, 195
- Myo-fibroma, 395
- Myoma, 44
- Myxædema, 137
- Myxomata, 44
- Myxo-sarcoma, 41



- NECROSIS, acute, 399  
 Nematoda, 94  
 Nephritis, acute, 363  
     acute suppurative, 370  
     chronic, 364  
         interstitial, 364  
         parenchymatous, 368  
     scarlatinal, 57, 363  
 Nervous system, diseases of, ch. x. p. 145  
     syphilis in, 86  
 Neuralgia, 182  
 Neuritis, 163  
     *See* Peripheral  
 Neuroma, 45  
 New growth, malignant, 43  
 New growths : origin of, 32  
     alimentary canal, 264  
     bladder, 385  
     gall-bladder, 322  
     intestines, 293  
     kidney, 373  
     larynx, 232  
     lips, 269  
     liver, 315  
     lung, 248  
     lymphatics, 346  
     muscular tissue of heart, 195  
     oesophagus, 272  
     origin of, 32  
     ovaries, 393  
     pericardium, 194  
     peritoneum, 339  
     pleura, 254  
     spleen, 344  
     supra-renal capsules, 355  
     thymus gland, 349  
     thyroid gland (malignant), 353  
     tonsils, 271  
     uterus, 395  
     vagina, 396  
 Nitric acid (poison), 108  
 Noma, 269  
 Nose, 187  
 Nutmeg liver, 307  
 OBSTRUCTION of gall-ducts, 325  
 Œdema : connective tissue, 403  
     glottidis, 229  
     lungs, 239  
     penis and scrotum, 391  
 Œsophagus, diseases of, 272  
     *See* New Growths  
 Oidium albicans, 103  
 Old age, 124  
 Ophthalmoplegia externa, 180  
 Opisthotonos, cervical, 182  
 Opium (poison), 113  
 Ormerod, Dr., xii., 166  
 Ossification of cartilages of ribs, 399  
 Osteitis, 399  
     deformans, 399  
 Osteo-arthritis, 134  
 Osteoma, 44  
 Osteo-sarcoma, 40  
 Outgrowths, or non-malignant  
     new growths, 44, 45  
     connective tissue, 32  
     larynx, 231  
     ovaries, 393  
     uterus, 395  
     vagina, 396  
 Ovary, diseases of, 391  
 Oxalic acid (poison), 109  
 Oxaluria, 384  
 Oxyuris vermicularis, 103  
  
 PACHYMENINGITIS, 155  
 Paget, Sir James, 106, 399  
 Palsy. *See* Bell's Palsy  
 Pancreas, diseases of, 326  
     *See* Abscess, Calculus, Carcinoma, Sarcoma  
 Pancreatico-duodenalis artery  
     aneurysm of, 226  
 Papilloma, 45  
 Paralysis, 178  
     agitans, 182  
     of arm and leg, with palsy of opposite side, 179  
     *See* Glosso-labio-pharyngeal, Pseudo-hypertrophic



- Parasites: alimentary canal,  
268  
bladder, 389  
brain, 174  
gall-bladder, 326  
kidney, 379  
ovaries, 393  
peritoneum, 339  
pleura, 254  
vegetable, 103  
diseases dependent on, ch.  
iv. p. 95  
Parasitic invasion, 53  
Parturition, 396  
Perforation, 50  
alimentary canal, 268  
stomach, 291  
Pericardial moisture, absence  
of, 193  
Pericarditis, 190  
in scarlet fever, 58  
Pericardium, 189  
hydatid of, 193  
tubercle of, 193  
varieties in structure,  
194  
Peripheral neuritis, 181  
Peritonitis, 337  
Peritoneum, hydatid of, 339  
new growths, 339  
Pernicious anæmia, 142  
Phagedæna, 80  
Pharynx, diseases of, 272  
*See Syphilis*  
Phlebitis, 227  
Phosphorus (poison), 105  
Phthisis, fibroid, 244  
Pigmentary degeneration, 29  
Plague, 59  
Plastic bronchitis, 232  
effusion, 217  
Pleura. *See New Growths,*  
Parasites, Tubercle  
Pleural cavity, air in, 253  
blood in, 253  
pus in, 253  
Pleurisy, 252  
Plugging, sites of, 49  
Poisons, effects of, ch. v. p. 104  
*See Irritant*  
Polypus, ear, 186  
stomach, 284  
uterus, 395  
Pneumonia, catarrhal, 239  
chronic interstitial, 244  
lobar, 240  
Pneumothorax, 254  
Poliomyelitis, anterior, 163  
Post-mortem examination, when  
to be made, 2  
appearances due to putre-  
faction in, 18  
of abdomen, 10  
of alimentary canal, 1  
of brain, 4  
of chest, 6  
of head, 3  
of heart, 7  
instruments necessary in, 3  
microscopic examination  
in, 13  
record of observations in  
16  
of spinal cord, 5  
Post-pharyngeal abscess, 272  
Pott, P., 401  
Power, Mr. D'A., xii.  
Prognosis of enteric fever from  
the morbid anatomy, 72  
Pseudo-hypertrophic paralysis,  
180  
Pulmonary apoplexy, 176  
artery  
*See Thrombosis*  
valves, 208  
Purpura, 139  
hæmorrhagic, 139  
simplex, 139  
Purulent meningitis, 154  
Pus, vomiting of, 266  
*See Pleural Cavity*  
Pustules, due to post mortem  
work 2  
Putrefaction, appearances due  
to, in post-mortem, 18  
Pyæmia, 81



Pyæmia in scarlet fever, 58  
 Pylephlebitis, 318  
 Pyocephalus, 155

QUINSY, 271

RECTO-VESICAL fistula, 387  
 Relapsing fever, 59  
 Renal calculus, 376  
 Respiratory system, diseases of,  
     ch. xiii. p. 228  
     syphilis in, 86  
 Rheumatic fever, 125  
 Rheumatism, 127  
 Ribs, cartilages of. *See* Ossification  
 Rickets, 134  
 Rodent ulcer, 38  
 Rupture, 50  
     of heart, 199  
     of uterus, 396

SACCULATION of bladder, 386  
 Salivary glands, diseases of,  
     271

Sarcinæ ventriculi, 103

Sarcoma, 32, 39, 41  
     chondro-, 40  
     fibro-, 40  
     lympho-, 39  
     melanotic, 35, 41  
     myxo-, 41  
     osteo-, 40

Sarcoma of kidney, 373  
     larynx, 232  
     lung, 249  
     muscles, 402  
     pancreas, 329  
     pericardium, 189  
     skeleton, 399

Savage, Dr., on anatomy of  
     insanity, 184

Scarlet fever, 56

Sclerosis of anterior cornua of  
     grey matter, 172  
     of brain and spinal cord, 165

Sclerosis, disseminated, of ditto,  
     165  
     of lateral columns, 172  
     of posterior columns, 172

Scrofula, 134

Scurvy, 118

Septicæmia, 83

Simple continued fever, 64

Skin, diseases of, ch. xxi.  
     p. 403

    exanthemata, 404

    tattoo-marks, 404

Sloughing of bladder, 385

Small-pox, 56

Snake-poison, 113

Softening of brain, 164

Sore, the non-infecting, 92

Specific febrile diseases, ch. iii.  
     p. 55

Spinal meningitis, 113

Spleen, 340

    malarial disease, 341

Spleen. *See* Abscess, Adhe-  
     sions, Amyloid Enlargement,  
     Gumma, Hypertrophy, In-  
     farction, Leucocythæmia,  
     Malarial Disease, New  
     Growths, Tubercle

Splenic fever, 93

Splenunculus, 340

Squint, 179

Starvation, 117

Stewart, Dr. A. P., 1

Stomach, diseases of, 275

*See* Carcinoma, Contraction,  
     Dilatation, Hæmorrhage,  
     Hernia, Lardaceous Dis-  
     ease, Perforation, Polypus

Stomatitis, ulcerative, 269

Stricture, 48

    of alimentary canal, 264

    of urethra, 398

Strychnia (poison), 112

Sulphuric acid (poison), 110

Supra-renal capsules, diseases  
     of, ch. xiii. p. 355  
     table of new growths in,  
     355



- Suppression of urine, 382  
 Suppuration, 28  
 Surfeit, 117  
 Syncope, 222  
 Syphilis, 260  
 Syphilis, 83  
     congenital, 91  
     kidney, 276  
     larynx, 231  
     pharynx, 272  
     visceral, 85  
 Syphilitic disease of brain, 174  
     meningitis, 162  
  
 TABLE of cases, of cancer, of  
     rectum and colon, 296  
     of carcinoma of stomach,  
         289  
     of carcinoma of œso-  
         phagus, 274  
     of carcinoma (primary) of  
         pancreas, 334  
     of enteric fever (fatal), 74  
     of hepatic abscess, 312  
     of Meckel's diverticulum,  
         259  
     of new growths in brain,  
         174  
     in supra-renal capsules,  
         355  
     of tricuspid stenosis, 207  
     of tubercular meningitis,  
         161  
     of ulcer of stomach, 280,  
         284  
 Tænia echinococcus, 98  
     mediocanellata, 97  
     solium, 97  
 Tattoo-marks on skin, 404  
 Teeth, diseases of, 269  
 Tendons, fasciæ, and bursæ,  
     urate of soda in, 402  
 Tetanus, 182  
 Tetany, 182  
 Thickening of capsule of liver,  
     318  
     of pericardium, 190  
  
 Thrombosis of pulmonary  
     artery, 251  
 Thrombus, 49  
 Thrush, 269  
 Thymus gland, diseases of, 349  
     *See* Involution, New Growth  
 Thyroid gland, diseases of,  
     350  
     *See* Atrophy, Hypertrophy,  
         Inflammation  
 Tight-lacing, anatomical effects  
     of, 114  
 Tongue, diseases of, 270  
 Tonsils. *See* Hypertrophy  
 Tophi, 186  
 Tracheotomy in diphtheria, 62  
 Transposition of viscera, 120  
 Treatment of aneurysm, results  
     of, 226  
     indicated by the morbid  
         anatomy of enteric fever,  
         73  
     of pyæmia, 82  
 Trematoda, 94  
 Tremor, mercurial, 181  
 Trichina spiralis, 101  
 Trichinosis, 402  
 Trichocephalus dispar, 101  
 Trichophyton tonsurans, 103  
 Tricuspid valves, incompet-  
     ence, 207  
     stenosis, 205  
         table of cases of  
         207  
 Tubercle of lymphatics, 347  
     of pleura, 254  
     of spleen, 343  
 Tubercular meningitis, 156  
     in adults, 161  
 Tuberculosis, 46  
     of kidney, 375  
     of lung, acute, 245  
         chronic, 246  
         obsolete, 248  
         rapid, 245  
     of lymphatics, 347  
     of pleura, 254  
     of spleen, 343



- Tulpius, on plastic bronchitis, 232  
 Tympanum, perforation of, 186  
 Typhlitis, 294  
 Typhus fever, 58
- ULCERATION, 28  
   of alimentary canal, 261  
   of bladder, 385  
   of bronchi, 233  
   of gall bladder, 321  
   of larynx in enteric fever, 231  
   (simple) of stomach, 276  
   tables of statistics of, 280, 284
- Ulcerative stomatitis, 269  
 Ulcers, distinction between tuberculous and those of enteric fever, 262  
 Urinary disorders, 381  
   system, diseases of, ch. xviii. p. 359  
 Uterus, diseases of, 395  
   *See* Flexions and Versions of, Inflammation, New Growths, Outgrowths, Polypus, Rupture
- VACCINIA, 56  
 Vagina, outgrowth of, 396  
 Valves of heart, 200  
   *See* Aortic, Mitral, Pulmonary, Tricuspid  
 Valvular disease, 200  
 Varicella, 56  
 Varieties of structure in kidney, 381  
 Vermiform appendix, 261  
 Versions of uterus, 395  
 Vesico-intestinal fistula, 386  
 Vesico-vaginal fistula, 387  
 Visceral syphilis, 85  
 Vomiting of blood, 266  
   fæces, 266  
   pus, 266
- WEPFER, I, 175, 176  
 Whooping cough, 59, 228  
 Willis, Dr. T., 381  
 Wolf slain by Lochiel, 98
- YELLOW fever, 76
- ZENKER's change, 65





J. & A. CHURCHILL'S  
MEDICAL CLASS BOOKS.

---

ANATOMY.

*BRAUNE*.—An Atlas of Topographical Anatomy, after Plane Sections of Frozen Bodies. By WILHELM BRAUNE, Professor of Anatomy in the University of Leipzig. Translated by EDWARD BELLAMY, F.R.C.S., Surgeon to Charing Cross Hospital, and Lecturer on Surgery in its School. With 34 Photo-lithographic Plates and 46 Woodcuts. Large Imp. 8vo, 40s.

*FLOWER*.—Diagrams of the Nerves of the Human Body, exhibiting their Origin, Divisions, and Connexions, with their Distribution to the various Regions of the Cutaneous Surface, and to all the Muscles. By WILLIAM H. FLOWER, C.B., F.R.C.S., F.R.S. Third Edition, containing 6 Plates. Royal 4to, 12s.

*GODLEE*.—An Atlas of Human Anatomy: illustrating most of the ordinary Dissections and many not usually practised by the Student. By RICKMAN J. GODLEE, M.S., F.R.C.S., Surgeon to University College Hospital; Teacher of Operative Surgery, and Assistant Professor of Clinical Surgery in University College; With 48 Imp. 4to Coloured Plates, containing 112 Figures, and a Volume of Explanatory Text, with many Engravings. 8vo, £4 14s. 6d.

*HEATH*.—Practical Anatomy: a Manual of Dissections. By CHRISTOPHER HEATH, F.R.C.S., Holme Professor of Clinical Surgery in University College and Surgeon to the Hospital. Seventh Edition, revised by RICKMAN J. GODLEE, M.S. Lond., F.R.C.S., Teacher of Operative Surgery, and Assistant Professor of Clinical Surgery in University College, and Surgeon to the Hospital. With 24 Coloured Plates and 278 Engravings. Crown 8vo, 15s.



**ANATOMY—continued.**

**HOLDEN.**—**A Manual of the Dissection of the Human Body.** By LUTHER HOLDEN, F.R.C.S., Consulting-Surgeon to St. Bartholomew's Hospital. Fifth Edition, by JOHN LANGTON, F.R.C.S., Surgeon to, and Lecturer on Anatomy at, St. Bartholomew's Hospital. With 208 Engravings. 8vo, 20s.

*By the same Author.*

**Human Osteology: comprising a Description of the Bones, with Delineations of the Attachments of the Muscles, the General and Microscopical Structure of Bone and its Development.** Seventh Edition, edited by CHARLES STEWART, Conservator of the Museum and Hunterian Professor of Comparative Anatomy and Physiology, R.C.S., and R. W. REID, M.D., F.R.C.S., Lecturer on Anatomy at St. Thomas's Hospital, Examiner in Osteology to the Conjoint Examining Board, R.C.P. Lond. and R.C.S. Eng. With 59 Lithographic Plates and 75 Engravings. Royal 8vo, 16s.

ALSO,

**Landmarks, Medical and Surgical.** Fourth Edition. 8vo, 3s. 6d.

**MORRIS.**—**The Anatomy of the Joints of Man.** By HENRY MORRIS, M.A., F.R.C.S., Surgeon to, and Lecturer on Anatomy and Practical Surgery at, the Middlesex Hospital. With 44 Plates (19 Coloured) and Engravings. 8vo, 16s.

**The Anatomical Remembrancer; or, Complete Pocket Anatomist.** Eighth Edition. 32mo, 3s. 6d.

**WAGSTAFFE.**—**The Student's Guide to Human Osteology.** By WM. WARWICK WAGSTAFFE, F.R.C.S., late Assistant-Surgeon to, and Lecturer on Anatomy at, St. Thomas's Hospital. With 23 Plates and 66 Engravings. Fcap. 8vo, 10s. 6d.

**WILSON — BUCHANAN — CLARK.** — **Wilson's Anatomist's Vade-Mecum: a System of Human Anatomy.** Tenth Edition, by GEORGE BUCHANAN, Professor of Clinical Surgery in the University of Glasgow, and HENRY E. CLARK, M.R.C.S., Lecturer on Anatomy in the Glasgow Royal Infirmary School of Medicine. With 450 Engravings, including 26 Coloured Plates. Crown 8vo, 18s.

---

11, NEW BURLINGTON STREET.



**BOTANY.**

**BENTLEY AND TRIMEN.—Medicinal Plants:**

being descriptions, with original Figures, of the Principal Plants employed in Medicine, and an account of their Properties and Uses. By ROBERT BENTLEY, F.L.S., and HENRY TRIMEN, M.B., F.R.S., F.L.S. In 4 Vols., large 8vo, with 306 Coloured Plates, bound in half morocco, gilt edges, £11 11s.

**BENTLEY.—A Manual of Botany. By Robert**

BENTLEY, F.L.S., M.R.C.S., late Professor of Botany in King's College and to the Pharmaceutical Society. With nearly 1178 Engravings. Fifth Edition. Crown 8vo, 15s.

*By the same Author.*

**The Student's Guide to Structural,**  
Morphological, and Physiological Botany. With 660 Engravings. Fcap. 8vo, 7s. 6d.

ALSO,

**The Student's Guide to Systematic**  
Botany, including the Classification of Plants and Descriptive Botany. With 357 Engravings. Fcap. 8vo, 3s. 6d.

---

**CHEMISTRY.**

**BERNAYS.—Notes on Analytical Chemistry**

for Students in Medicine. By ALBERT J. BERNAYS, Ph.D., F.C.S., F.I.C., Professor of Chemistry, &c., at St. Thomas's Hospital Medical School. Third Edition. Crown 8vo, 4s. 6d.

**BLOXAM.—Chemistry, Inorganic and Organic ;**

with Experiments. By CHARLES L. BLOXAM, late Professor of Chemistry in King's College. Sixth Edition. With 288 Illustrations. 8vo, 18s.

*By the same Author.*

**Laboratory Teaching; or, Progressive**  
Exercises in Practical Chemistry. Fifth Edition. With 89 Engravings. Crown 8vo, 5s. 6d.

**BOWMAN AND BLOXAM.—Practical Chemistry,**

including Analysis. By JOHN E. BOWMAN, and CHARLES L. BLOXAM, late Professor of Chemistry in King's College. Eighth Edition. With 90 Engravings. Fcap. 8vo, 5s. 6d.



**CHEMISTRY**—*continued.*

**CLOWES.**—**Practical Chemistry and Qualitative Inorganic Analysis.** Adapted for use in the Laboratories of Schools and Colleges. By FRANK CLOWES, D.Sc. Lond., Professor of Chemistry in University College, Nottingham. Fourth Edition. With Engravings. Post 8vo, 7s. 6d.

**COOK.**—**Introductory Inorganic Analysis.** A First Course of Chemical Testing. By ERNEST H. COOK, D.Sc. Lond., F.C.S., Physical Science Master, Merchant Venturers' School, Bristol. Crown 8vo, 1s. 6d.

**FOWNES.**—**Manual of Chemistry.**—*See WATTS.*

**FRANKLAND AND JAPP.**—**Inorganic Chemistry.** By EDWARD FRANKLAND, Ph.D., D.C.L., F.R.S., and F. R. JAPP, M.A., Ph.D., F.I.C. With 2 Lithographic Plates and numerous Wood Engravings. 8vo, 24s.

**JOHNSON.**—**The Analyst's Laboratory Companion.** By ALFRED E. JOHNSON, Assoc. R.C.Sc.I., F.I.C., F.C.S., First Prizeman in Chemistry, Physics, and Mathematics of R.C.Sc.I. Crown 8vo, 5s.

**MORLEY.**—**Outlines of Organic Chemistry.** By H. FORSTER MORLEY, M.A., D.Sc., Joint Editor of "Watts' Dictionary of Chemistry." Crown 8vo, 7s. 6d.

**VACHER.**—**A Primer of Chemistry, including Analysis.** By ARTHUR VACHER. 18mo, 1s.

**VALENTIN.**—**Chemical Tables for the Lecture-room and Laboratory.** By WILLIAM G. VALENTIN, F.C.S. In Five large Sheets, 5s. 6d.

**VALENTIN AND HODGKINSON.**—**A Course of Qualitative Chemical Analysis.** By the late W. G. VALENTIN, F.C.S. Seventh Edition by Dr. W. R. HODGKINSON, F.R.S.E., Professor of Chemistry and Physics in the Royal Artillery College, and Royal Military Academy, Woolwich; assisted by H. CHAPMAN-JONES, F.C.S., Demonstrator in the Royal School of Mines, and F. E. MATTHEWS, Ph.D., of Cooper's Hill College. With Engravings and Map of Spectra. 8vo, 8s. 6d.

**The Tables for the Qualitative Analysis of Simple and Compound Substances, with Map of Spectra, printed separately.** 8vo, 2s. 6d.



**CHEMISTRY**—*continued.*

**WATTS.**—Physical and Inorganic Chemistry.

By HENRY WATTS, B.A., F.R.S. (being Vol. I. of the Thirteenth Edition of Fownes' Manual of Chemistry). With 150 Wood Engravings, and Coloured Plate of Spectra. Crown 8vo, 9s.

*By the same Author.*

**Chemistry of Carbon - Compounds, or**

Organic Chemistry (being Vol. II. of the Thirteenth Edition of Fownes' Manual of Chemistry). Edited by WM. A. TILDEN, D.Sc., F.R.S. With Engravings. Crown 8vo, 10s.

---

**CHILDREN, DISEASES OF.**

**DAY.**—A Manual of the Diseases of Children.

By WILLIAM H. DAY, M.D., Physician to the Samaritan Hospital for Women and Children. Second Edition. Crown 8vo, 12s. 6d.

**ELLIS.**—A Practical Manual of the Diseases

of Children. By EDWARD ELLIS, M.D., late Senior Physician to the Victoria Hospital for Sick Children. With a Formulary. Fifth Edition. Crown 8vo, 10s.

**GOODHART.**—The Student's Guide to Diseases

of Children. By JAMES FREDERIC GOODHART, M.D., F.R.C.P., Physician to Guy's Hospital and Lecturer on Pathology in its Medical School; Physician to the Evelina Hospital for Sick Children. Third Edition. Fcap. 8vo, 10s. 6d.

**SMITH.**—On the Wasting Diseases of Infants

and Children. By EUSTACE SMITH, M.D., F.R.C.P., Physician to H.M. the King of the Belgians, and to the East London Hospital for Children. Fifth Edition. Post 8vo, 8s. 6d.

*By the same Author.*

**A Practical Treatise on Disease in Chil-**

dren. 8vo, 22s.

*Also,*

**Clinical Studies of Disease in Children.**

Second Edition. Post 8vo, 7s. 6d.

**STEINER.**—Compendium of Children's Dis-

eases; a Handbook for Practitioners and Students. By JOHANN STEINER, M.D. Translated by LAWSON TAIT, F.R.C.S., Surgeon to the Birmingham Hospital for Women, &c. 8vo, 12s. 6d.

---



**DENTISTRY.**

**HARRIS.**—*The Principles and Practice of Dentistry*; including Anatomy, Physiology, Pathology, Therapeutics, Dental Surgery, and Mechanism. By CHAPIN A. HARRIS, M.D., D.D.S. Twelfth Edition, revised and edited by FERDINAND J. S. GORGAS, A.M., M.D., D.D.S. With over 1,000 Illustrations. 8vo, 33s.

**SEWILL.**—*The Student's Guide to Dental Anatomy and Surgery.* By HENRY E. SEWILL, M.R.C.S., L.D.S. Second Edition. With 78 Engravings. Fcap. 8vo, 5s. 6d.

**STOCKEN.**—*Elements of Dental Materia Medica and Therapeutics, with Pharmacopœia.* By JAMES STOCKEN, L.D.S.R.C.S., late Lecturer on Dental Materia Medica and Therapeutics and Dental Surgeon to the National Dental Hospital; assisted by THOMAS GADDES, L.D.S. Eng. and Edin. Third Edition. Fcap. 8vo, 7s. 6d.

**TOMES (C. S.).**—*Manual of Dental Anatomy, Human and Comparative.* By CHARLES S. TOMES, M.A., F.R.S. Third Edition. With 200 Engravings. Crown 8vo. (*In the Press.*)

**TOMES (J. and C. S.).**—*A System of Dental Surgery.* By Sir JOHN TOMES, F.R.S., and CHARLES S. TOMES, M.A., M.R.C.S., F.R.S.; late Lecturer on Anatomy and Physiology to the Dental Hospital of London. Third Edition. With 292 Engravings. Crown 8vo, 15s.

---

**EAR, DISEASES OF.**

**BURNETT.**—*The Ear: its Anatomy, Physiology, and Diseases. A Practical Treatise for the Use of Medical Students and Practitioners.* By CHARLES H. BURNETT, M.D., Aural Surgeon to the Presbyterian Hospital, Philadelphia. Second Edition. With 107 Engravings. 8vo, 18s.

**DALBY.**—*On Diseases and Injuries of the Ear.* By SIR WILLIAM B. DALBY, F.R.C.S., Aural Surgeon to, and Lecturer on Aural Surgery at, St. George's Hospital. Third Edition. With Engravings. Crown 8vo. 7s. 6d.

---

11, NEW BURLINGTON STREET.



**EAR, DISEASES OF**—*continued.*

**JONES.**—Practitioner's Handbook of Diseases of the Ear and Naso-Pharynx. By H. MACNAUGHTON JONES, M.D., M.Ch.; Examiner, and late Professor in the Queen's University; and Surgeon to the Cork Ophthalmic and Aural Hospital. Third Edition of "Aural Surgery." With 128 Engravings, and 2 Coloured Plates (16 Figures). Royal 8vo, 6s.

*By the same Author.*

**Atlas of the Diseases of the Membrana Tympani.** In Coloured Plates, containing 59 Figures. With Explanatory Text. Crown 4to, 21s.

---

**FORENSIC MEDICINE.**

**ABERCROMBIE.**—The Student's Guide to Medical Jurisprudence. By JOHN ABERCROMBIE, M.D., F.R.C.P. Senior Assistant Physician to, and Lecturer on Forensic Medicine at, Charing Cross Hospital. Fcap. 8vo, 7s. 6d.

**OGSTON.**—Lectures on Medical Jurisprudence. By FRANCIS OGSTON, M.D., late Professor of Medical Jurisprudence and Medical Logic in the University of Aberdeen. Edited by FRANCIS OGSTON, Jun., M.D., late Lecturer on Practical Toxicology in the University of Aberdeen. With 12 Plates. 8vo, 18s.

**TAYLOR.**—The Principles and Practice of Medical Jurisprudence. By ALFRED S. TAYLOR, M.D., F.R.S. Third Edition, revised by THOMAS STEVENSON, M.D., F.R.C.P., Lecturer on Chemistry and Medical Jurisprudence at Guy's Hospital; Examiner in Chemistry at the Royal College of Physicians; Official Analyst to the Home Office. With 188 Engravings. 2 Vols. 8vo, 31s. 6d.

*By the same Author.*

**A Manual of Medical Jurisprudence.** Eleventh Edition, revised by THOMAS STEVENSON, M.D., F.R.C.P. With 56 Engravings. Crown 8vo, 14s.

ALSO,

**On Poisons, in relation to Medical Jurisprudence and Medicine.** Third Edition. With 104 Engravings. Crown 8vo, 16s.

**TIDY AND WOODMAN.**—A Handy-Book of Forensic Medicine and Toxicology. By C. MEYMOTT TIDY, M.B.; and W. BATHURST WOODMAN, M.D., F.R.C.P. With 8 Lithographic Plates and 116 Wood Engravings. 8vo, 31s. 6d.

---



**HYGIENE.**

**PARKES.**—A Manual of Practical Hygiene.

By EDMUND A. PARKES, M.D., F.R.S. Seventh Edition by F. DE CHAUMONT, M.D., F.R.S., late Professor of Military Hygiene in the Army Medical School. With 9 Plates and 101 Engravings. 8vo, 18s.

**WILSON.**—A Handbook of Hygiene and Sanitary Science.

By GEORGE WILSON, M.A., M.D., F.R.S.E., Medical Officer of Health for Mid Warwickshire. Sixth Edition. With Engravings. Crown 8vo, 10s. 6d.

---

**MATERIA MEDICA AND THERAPEUTICS.**

**LESCHER.**—Recent Materia Medica. Notes

on their Origin and Therapeutics. By F. HARWOOD LESCHER, F.C.S., Pereira Medallist. Third Edition. 8vo, 2s. 6d.

**OWEN.**—A Manual of Materia Medica; in-

corporating the Author's "Tables of Materia Medica." By ISAMBARD OWEN, M.D., F.R.C.P., Lecturer on Materia Medica and Therapeutics to St. George's Hospital. Second Edition. Crown 8vo, 6s. 6d.

**ROYLE AND HARLEY.**—A Manual of Materia

Medica and Therapeutics. By J. FORBES ROYLE, M.D., F.R.S., and JOHN HARLEY, M.D., F.R.C.P., Physician to, and Joint Lecturer on Clinical Medicine at, St. Thomas's Hospital. Sixth Edition, including addition and alterations in the B.P. 1885. With 139 Engravings. Crown 8vo, 15s.

**SOUTHALL.**—The Organic Materia Medica of

the British Pharmacopœia, Systematically Arranged. By W. SOUTHALL, F.L.S. Fourth Edition. Crown 8vo, 5s.

**THOROWGOOD.**—The Student's Guide to

Materia Medica and Therapeutics. By JOHN C. THOROWGOOD, M.D., F.R.C.P., Lecturer on Materia Medica at the Middlesex Hospital. Second Edition. With Engravings. Fcap. 8vo, 7s.

**WARING.**—A Manual of Practical Therapeu-

tics. By EDWARD J. WARING, C.I.E., M.D., F.R.C.P. Fourth Edition, revised by the Author and DUDLEY W. BUXTON, M.D., M.R.C.P. Crown 8vo, 14s.

---



**MEDICINE.**

**BARCLAY.—A Manual of Medical Diagnosis.**

By A. WHYTE BARCLAY, M.D., F.R.C.P., late Physician to, and Lecturer on Medicine at, St. George's Hospital. Third Edition. Fcap. 8vo, 10s. 6d.

**CHARTERIS.—The Student's Guide to the**

Practice of Medicine. By M. CHARTERIS, M.D., Professor of Therapeutics and Materia Medica, University of Glasgow. With Engravings on Copper and Wood. Fifth Edition. Fcap. 8vo, 9s.

**FAGGE.—The Principles and Practice of Medi-**

cine. By the late C. HILTON FAGGE, M.D., F.R.C.P., Edited by PHILIP H. PYE-SMITH, M.D., F.R.S., F.R.C.P., Physician to, and Lecturer on Medicine in, Guy's Hospital. Second Edition. 2 Vols. 8vo. Cloth, 38s., leather, 44s.

**FENWICK.—The Student's Guide to Medical**

Diagnosis. By SAMUEL FENWICK, M.D., F.R.C.P., Physician to the London Hospital. Sixth Edition. With 114 Engravings. Fcap. 8vo, 7s.

*By the same Author.*

**The Student's Outlines of Medical Treat-**

ment. Second Edition. Fcap. 8vo, 7s.

**HARRIS.—The Student's Guide to Diseases**

of the Chest. By VINCENT D. HARRIS, M.D., F.R.C.P., Physician to the Victoria Park Hospital for Diseases of the Chest. With 55 Engravings, plain and Coloured. Fcap. 8vo, 7s. 6d.

**WARNER.—The Student's Guide to Clinical**

Medicine and Case-Taking. By FRANCIS WARNER, M.D., F.R.C.P., Physician to the London Hospital. Second Edition. Fcap. 8vo, 5s.

**WEST.—How to Examine the Chest: being a**

Practical Guide for the Use of Students. By SAMUEL WEST, M.D., F.R.C.P., Assistant Physician to St. Bartholomew's Hospital, Physician to the City of London Hospital for Diseases of the Chest, &c. With 42 Engravings. Fcap. 8vo, 5s.

**WHITTAKER.—Student's Primer on the Urine.**

By J. TRAVIS WHITTAKER, M.D., Clinical Demonstrator at the Royal Infirmary, Glasgow. With Illustrations, and 16 Plates etched on Copper. Post 8vo, 4s. 6d.



**MIDWIFERY.**

**BARNES.**—**Lectures on Obstetric Operations,** including the Treatment of Hæmorrhage, and forming a Guide to the Management of Difficult Labour. By ROBERT BARNES, M.D., F.R.C.P., Consulting Obstetric Physician to St. George's Hospital. Fourth Edition. With 121 Engravings. 8vo, 12s. 6d.

**BURTON.**—**Handbook of Midwifery for Midwives.** By JOHN E. BURTON, M.R.C.S., L.R.C.P., Surgeon to the Liverpool Hospital for Women. Second Edition. With Engravings. Fcap 8vo, 6s.

**GALABIN.**—**A Manual of Midwifery.** By Alfred LEWIS GALABIN, M.A., M.D., F.R.C.P., Obstetric Physician and Lecturer on Midwifery, &c., to Guy's Hospital, Examiner in Midwifery to the Conjoint Examining Board for England. With 227 Engravings. Crown 8vo, 15s.

**RAMSBOTHAM.**—**The Principles and Practice of Obstetric Medicine and Surgery.** By FRANCIS H. RAMSBOTHAM, M.D., formerly Obstetric Physician to the London Hospital. Fifth Edition. With 120 Plates, forming one thick handsome volume. 8vo, 22s.

**REYNOLDS.**—**Notes on Midwifery: specially designed to assist the Student in preparing for Examination.** By J. J. REYNOLDS, L.R.C.P., M.R.C.S. Second Edition. With 15 Engravings. Fcap. 8vo, 4s.

**ROBERTS.**—**The Student's Guide to the Practice of Midwifery.** By D. LLOYD ROBERTS, M.D., F.R.C.P., Lecturer on Clinical Midwifery and Diseases of Women at Owen's College, Physician to St. Mary's Hospital, Manchester. Third Edition. With 2 Coloured Plates and 127 Engravings. Fcap. 8vo, 7s. 6d.

**SCHROEDER.**—**A Manual of Midwifery; including the Pathology of Pregnancy and the Puerperal State.** By KARL SCHROEDER, M.D., Professor of Midwifery in the University of Erlangen. Translated by C. H. CARTER, M.D. With Engravings. 8vo, 12s. 6d.

**SWAYNE.**—**Obstetric Aphorisms for the Use of Students commencing Midwifery Practice.** By JOSEPH G. SWAYNE, M.D., Lecturer on Obstetric Medicine at the Bristol Medical School. Ninth Edition. With 17 Engravings. Fcap. 8vo, 3s. 6d.



**MICROSCOPY.**

**CARPENTER.**—The Microscope and its Revelations. By WILLIAM B. CARPENTER, C.B., M.D., F.R.S. Seventh Edition. With about 600 Engravings. Crown 8vo. (*Preparing.*)

**LEE.** — The Microtometist's Vade-Mecum; a Handbook of the Methods of Microscopic Anatomy. By ARTHUR BOLLES LEE. Crown 8vo, 8s. 6d.

**MARSH.** — Microscopical Section-Cutting: a Practical Guide to the Preparation and Mounting of Sections for the Microscope. By Dr. SYLVESTER MARSH. Second Edition. With 17 Engravings. Fcap. 8vo, 3s. 6d.

---

**OPHTHALMOLOGY.**

**HARTRIDGE.**—The Refraction of the Eye. By GUSTAVUS HARTRIDGE, F.R.C.S., Surgeon to the Royal Westminster Ophthalmic Hospital. Third Edition. With 96 Illustrations, Test Types, &c. Crown 8vo, 5s. 6d.

**HIGGENS.**—Hints on Ophthalmic Out-Patient Practice. By CHARLES HIGGENS, F.R.C.S., Ophthalmic Surgeon to, and Lecture on Ophthalmology at, Guy's Hospital. Third Edition. Fcap. 8vo, 3s.

**MACNAMARA.**—A Manual of the Diseases of the Eye. By CHARLES MACNAMARA, F.R.C.S., Surgeon to, and Lecturer on Surgery at, the Westminster Hospital. Fourth Edition. With 4 Coloured Plates and 66 Engravings. Crown 8vo, 10s. 6d.

**NETTLESHIP.**—The Student's Guide to Diseases of the Eye. By EDWARD NETTLESHIP, F.R.C.S., Ophthalmic Surgeon to, and Lecturer on Ophthalmic Surgery at, St. Thomas's Hospital. Fourth Edition. With 164 Engravings, and a Set of Coloured Papers illustrating Colour-blindness. Fcap. 8vo, 7s. 6d.

**POLLOCK.**—The Normal and Pathological Histology of the Human Eye and Eyelids. By C. FRED. POLLOCK, M.D., F.R.C.S.E., and F.R.S.E., Surgeon for Diseases of the Eye, Anderson's College Dispensary, Glasgow. With 100 Plates, containing 230 Original Drawings by the Author, Lithographed in black and colours. Crown 8vo, 15s.

---



**OPHTHALMOLOGY—continued.**

**WOLFE.**—**On Diseases and Injuries of the Eye :**  
a Course of Systematic and Clinical Lectures to Students and Medical Practitioners. By J. R. WOLFE, M.D., F.R.C.S.E., Senior Surgeon to the Glasgow Ophthalmic Institution, Lecturer on Ophthalmic Medicine and Surgery in Anderson's College. With 10 Coloured Plates, and 120 Wood Engravings, 8vo, 21s.

---

**PATHOLOGY.**

**BOWLBY.**—**The Student's Guide to Surgical Pathology and Morbid Anatomy.** By ANTHONY A. BOWLBY, F.R.C.S., Surgical Registrar and Demonstrator of Surgical Pathology at St. Bartholomew's Hospital. With 135 Engravings. Fcap. 8vo, 9s.

**JONES AND SIEVEKING.**—**A Manual of Pathological Anatomy.** By C. HANDFIELD JONES, M.B., F.R.S., and EDWARD H. SIEVEKING M.D., F.R.C.P. Second Edition. Edited, with considerable enlargement, by J. F. PAYNE, M.B., Assistant-Physician and Lecturer on General Pathology at St. Thomas's Hospital. With 195 Engravings. Crown 8vo, 16s.

**LANCEREAUX.**—**Atlas of Pathological Anatomy.** By Dr. LANCEREAUX. Translated by W. S. GREENFIELD, M.D., Professor of Pathology in the University of Edinburgh. With 70 Coloured Plates. Imperial 8vo, £5 5s.

**SUTTON.** — **An Introduction to General Pathology.** By JOHN BLAND SUTTON, F.R.C.S., Sir E. WILSON Lecturer on Pathology, R.C.S. ; Assistant Surgeon to, and Lecturer on Anatomy at, Middlesex Hospital. With 149 Engravings. 8vo, 14s.

**VIRCHOW.**—**Post-Mortem Examinations: a Description and Explanation of the Method of Performing them, with especial reference to Medico-Legal Practice.** By Professor RUDOLPH VIRCHOW, Berlin Charité Hospital. Translated by Dr. T. P. SMITH. Second Edition, with 4 Plates. Fcap. 8vo, 3s. 6d.

---

**PHYSICS.**

**DRAPER.**—**A Text Book of Medical Physics,**  
for the use of Students and Practitioners of Medicine By JOHN C. DRAPER, M.D., LL.D., Professor of Chemistry and Physics in the University of New York. With 377 Engravings. 8vo, 18s.

---

11, NEW BURLINGTON STREET.



**PHYSIOLOGY.**

**CARPENTER.**—**Principles of Human Physiology.** By WILLIAM B. CARPENTER, C.B., M.D., F.R.S. Ninth Edition. Edited by Henry Power, M.B., F.R.C.S. With 3 Steel Plates and 377 Wood Engravings. 8vo, 31s. 6d.

**DALTON.**—**A Treatise on Human Physiology :** designed for the use of Students and Practitioners of Medicine. By JOHN C. DALTON, M.D., Professor of Physiology and Hygiene in the College of Physicians and Surgeons, New York. Seventh Edition. With 252 Engravings. Royal 8vo, 20s.

**FREY.**—**The Histology and Histo-Chemistry of Man.** A Treatise on the Elements of Composition and Structure of the Human Body. By HEINRICH FREY, Professor of Medicine in Zurich. Translated by ARTHUR E. BARKER, Assistant-Surgeon to the University College Hospital. With 608 Engravings. 8vo, 21s.

**SANDERSON.**—**Handbook for the Physiological Laboratory :** containing an Exposition of the fundamental facts of the Science, with explicit Directions for their demonstration. By J. BURDON SANDERSON, M.D., F.R.S.; E. KLEIN, M.D., F.R.S.; MICHAEL FOSTER, M.D., F.R.S., and T. LAUDER BRUNTON, M.D., F.R.S. 2 Vols., with 123 Plates. 8vo, 24s.

**SHORE.**—**Elementary Practical Biology. Vegetable.** By THOMAS W. SHORE, M.D., B.Sc. Lond., Lecturer on Comparative Anatomy at St. Bartholomew's Hospital. 8vo, 6s.

**YEO.**—**A Manual of Physiology for the Use of Junior Students of Medicine.** By GERALD F. YEO, M.D., F.R.C.S., F.R.S., Professor of Physiology in King's College, London. Second Edition. With 318 Engravings (many figures). Crown 8vo, 14s.

---

**PSYCHOLOGY.**

**BUCKNILL AND TUKE.**—**A Manual of Psychological Medicine :** containing the Lunacy Laws, Nosology, Ætiology, Statistics, Description, Diagnosis, Pathology, and Treatment of Insanity, with an Appendix of Cases. By JOHN C. BUCKNILL, M.D. F.R.S., and D. HACK TUKE, M.D., F.R.C.P. Fourth Edition with 12 Plates (30 Figures). 8vo, 25s.

**CLOUSTON.**—**Clinical Lectures on Mental Diseases.** By THOMAS S. CLOUSTON, M.D., and F.R.C.P. Edin.; Lecturer on Mental Diseases in the University of Edinburgh. Second Edition. With 8 Plates (6 Coloured). Crown 8vo, 12s. 6d.



**SURGERY.**

**BELLAMY.**—*The Student's Guide to Surgical Anatomy; an Introduction to Operative Surgery.* By EDWARD BELLAMY, F.R.C.S., Surgeon to, and Lecturer on Surgery at, Charing Cross Hospital. Third Edition. With 80 Engravings. Fcap. 8vo, 7s. 6d.

**BRYANT.**—*A Manual for the Practice of Surgery.* By THOMAS BRYANT, F.R.C.S., Consulting Surgeon to Guy's Hospital. Fourth Edition. With 750 Illustrations (many being coloured), and including 6 Chromo-Lithographic Plates. 2 Vols. Crown 8vo, 32s.

**DRUITT AND BOYD.**—*Druitt's Surgeon's Vade-Mecum; a Manual of Modern Surgery.* Edited by STANLEY BOYD, M.B., B.S. Lond., F.R.C.S., Assistant Surgeon and Pathologist to the Charing Cross Hospital. Twelfth Edition. With 373 Engravings. Crown 8vo, 16s.

**HEATH.**—*A Manual of Minor Surgery and Bandaging.* By CHRISTOPHER HEATH, F.R.C.S., Holme Professor of Clinical Surgery in University College and Surgeon to the Hospital. Eighth Edition. With 142 Engravings. Fcap. 8vo, 6s.

*By the same Author.*

**A Course of Operative Surgery: with**  
Twenty Plates (containing many figures) drawn from Nature by M. LÉVEILLÉ, and Coloured. Second Edition. Large 8vo, 30s.

ALSO,

**The Student's Guide to Surgical Diagnosis.** Second Edition. Fcap. 8vo, 6s. 6d.

**JACOBSON.**—*The Operations of Surgery: intended especially for the use of those recently appointed on a Hospital Staff, and for those preparing for the Higher Examinations.* By W. H. A. JACOBSON, M.A., M.B., M.Ch. Oxon., F.R.C.S., Assistant Surgeon to Guy's Hospital, Teacher of Operative Surgery and Joint Teacher of Practical Surgery in the Medical School. With 199 Engravings. 8vo, 30s.

---

11, NEW BURLINGTON STREET.



**SURGERY—continued.**

**SOUTHAM.**—Regional Surgery: including Surgical Diagnosis. A Manual for the use of Students. BY FREDERICK A. SOUTHAM, M.A., M.B. Oxon., F.R.C.S., Assistant-Surgeon to the Royal Infirmary, and Assistant-Lecturer on Surgery in the Owen's College School of Medicine, Manchester. Vol. 2. The Upper Extremity and Thorax. Crown 8vo, 7s. 6d. Vol. 3. The Abdomen and Lower Extremity. Crown 8vo, 7s.

**WALSHAM.**—Surgery: its Theory and Practice (Student's Guide Series). By WILLIAM J. WALSHAM, F.R.C.S., Assistant Surgeon to St. Bartholomew's Hospital. Second Edition. With 294 Engravings. Fcap. 8vo, 10s. 6d.

---

**TERMINOLOGY.**

**DUNGLISON.**—Medical Lexicon: a Dictionary of Medical Science, containing a concise Explanation of its various Subjects and Terms, with Accentuation, Etymology, Synonyms, &c. New Edition, thoroughly revised by RICHARD J. DUNGLISON, M.D. Royal 8vo, 28s.

**MAYNE.**—A Medical Vocabulary: being an Explanation of all Terms and Phrases used in the various Departments of Medical Science and Practice, giving their Derivation, Meaning, Application, and Pronunciation. By R. G. MAYNE, M.D., LL.D. Sixth Edition, by W. W. WAGSTAFFE, B.A., F.R.C.S. Crown 8vo, 10s. 6d.

---

**WOMEN, DISEASES OF.**

**BARNES.**—A Clinical History of the Medical and Surgical Diseases of Women. By ROBERT BARNES, M.D., F.R.C.P., Obstetric Physician to, and Lecturer on Diseases of Women, &c., at, St. George's Hospital. Second Edition. With 181 Engravings. 8vo, 28s.

**BYFORD.**—The Practice of Medicine and Surgery applied to the Diseases and Accidents incident to Women. By W. H. BYFORD, A.M., M.D., Professor of Gynæcology in Rush Medical College, and of Obstetrics in the Woman's Medical College, and HENRY T. BYFORD, M.D., Surgeon to the Woman's Hospital, Chicago. Fourth Edition. With 306 Engravings. Royal 8vo, 25s.

**DUNCAN.**—Clinical Lectures on the Diseases of Women. By J. MATTHEWS DUNCAN, M.D., F.R.C.P., F.R.S., Obstetric Physician to St. Bartholomew's Hospital. Third Edition 8vo, 16s.

---



**WOMEN, DISEASES OF—continued.**

**GALABIN.**—*The Student's Guide to the Diseases of Women.* By ALFRED L. GALABIN, M.D., F.R.C.P., Obstetric Physician to Guy's Hospital, Examiner in Obstetric Medicine to the University of Cambridge, and to the R. C. P. Lond. Fourth Edition. With 94 Engravings. Fcap. 8vo, 7s. 6d.

**REYNOLDS.**—*Notes on Diseases of Women.* Specially designed to assist the Student in preparing for Examination. By J. J. REYNOLDS, L.R.C.P., M.R.C.S. Third Edition. Fcap. 8vo, 2s. 6d.

**SAVAGE.**—*The Surgery of the Female Pelvic Organs.* By HENRY SAVAGE, M.D., Lond., F.R.C.S., one of the Consulting Medical Officers of the Samaritan Hospital for Women. Fifth Edition, with 17 Lithographic Plates (15 Coloured), and 52 Woodcuts. Royal 4to, 35s.

**WEST AND DUNCAN.**—*Lectures on the Diseases of Women.* By CHARLES WEST, M.D., F.R.C.P. Fourth Edition. Revised and in part re-written by the Author, with numerous additions by J. MATTHEWS DUNCAN, M.D., F.R.C.P., F.R.S., Obstetric Physician to St. Bartholomew's Hospital. 8vo, 16s.

---

**ZOOLOGY.**

**CHAUVEAU AND FLEMING.**—*The Comparative Anatomy of the Domesticated Animals.* By A. CHAUVEAU, Professor at the Lyons Veterinary School; and GEORGE FLEMING, Principal Veterinary Surgeon of the Army. With 450 Engravings. 31s. 6d.

**HUXLEY.**—*Manual of the Anatomy of Invertebrated Animals.* By THOMAS H. HUXLEY, LL.D., F.R.S. With 156 Engravings. Post 8vo, 16s.

*By the same Author.*

**Manual of the Anatomy of Vertebrated Animals.** With 110 Engravings. Post 8vo, 12s.

**WILSON.**—*The Student's Guide to Zoology: a Manual of the Principles of Zoological Science.* By ANDREW WILSON, Lecturer on Natural History, Edinburgh. With Engravings. Fcap. 8vo, 6s. 6d.


---

11, NEW BURLINGTON STREET.











8/6



