

Ligaments : their nature and morphology / by J. Bland Sutton.

Contributors

Bland-Sutton, John, Sir, 1855-1936.

Publication/Creation

London : H.K. Lewis, 1897.

Persistent URL

<https://wellcomecollection.org/works/khw8eegx>

License and attribution

This work has been identified as being free of known restrictions under copyright law, including all related and neighbouring rights and is being made available under the Creative Commons, Public Domain Mark.

You can copy, modify, distribute and perform the work, even for commercial purposes, without asking permission.



Wellcome Collection
183 Euston Road
London NW1 2BE UK
T +44 (0)20 7611 8722
E library@wellcomecollection.org
<https://wellcomecollection.org>

M18172

D. iv d.

W. G. Ball

4 / 11 / 07.

LIGAMENTS



Digitized by the Internet Archive
in 2014

<https://archive.org/details/b20408286>

LIGAMENTS

THEIR

NATURE AND MORPHOLOGY

BY

J. BLAND SUTTON

SECOND EDITION

LONDON

H. K. LEWIS, 136 GOWER STREET

1897

180

94366

PRINTED BY
H. K. LEWIS, 136 GOWER STREET,
LONDON, W.C.



14782 893

M18172

WELLCOME INSTITUTE LIBRARY	
Coll.	welMomec
Class	
No:	WE 300
	1897
	B64d


PREFACE.

SOME anatomical teachers, whose judgment I value, assured me that students find this work useful and recommend me to keep it in print.

In this edition I have re-arranged the matter and added a chapter on the Ligaments of the Larynx.

J. BLAND SUTTON,

January, 1897.



CONTENTS.

CHAP.	PAGE
I. THE NATURE OF TENDONS AND LIGAMENTS	I
II. ANOMALOUS MUSCLES IN RELATION TO LIGAMENTS	10
III. THE MORPHOLOGY OF APONEUROSES AND FASCIA	17
IV. MIGRATION OF MUSCLES IN RELATION TO LIGAMENTS	25
V. THE LIGAMENTS OF THE KNEE JOINT	32
VI. THE ANTERIOR ANNULAR LIGAMENTS OF THE ANKLE	39
VII. THE LIGAMENTS OF THE PECTORAL GIRDLE	49
VIII. THE LIGAMENTS OF THE PECTORAL GIRDLE (continued)	57
IX. THE LIGAMENTS OF THE HIP JOINT AND PELVIS	67
X. THE LIGAMENTS OF THE LARYNX	79
XI. THE LIGAMENTS OF THE VERTEBRAL COLUMN	86
XII. THE LIGAMENTS OF THE VERTEBRAL COLUMN (continued)	95
XIII. EXAMPLES OF METAMORPHOSIS AND REGRESSION OF MUSCLES FROM THE LOWER VERTEBRATES	102

LIST OF ILLUSTRATIONS.

FIG.	PAGE
1. The supra-condyloid process of the humerus	5
2. Transverse humeral ligament of a gibbon	7
3. The biceps-foramen of <i>Moschus</i>	7
4. The scapula of a sloth	7
5. The epitrochleo-anconeus of man	II
6. The epitrochleo-anconeus of an opossum	II
7. The coraco-brachialis	15
8. The femoro-caudal of Iguana	34
9. Section through the knee-joint of a human fœtus	37
10. The annular ligament of the ankle-joint	39
11. The ligaments of the ankle of a fowl	41
12. Leg of an embryo chick	42
13. Leg of an embryo chick	43
14. The distal end of the tibio-tarsus of an ostrich	44
15. The clavicular ligaments	50
16. The shoulder girdle of an ostrich chick	51
17. Shoulder girdle of ornithorhynchus	54
18. The gleno-humeral ligament of the beaver	58
19. The subclavius of a bird	59
20. The ligamentum teres of an ostrich	69
21. The gluteus quartus	71
22. The ilio-femoral band	73
23. Pelvis of a kangaroo	75
24. Pelvis of a sloth	78
25. The epiglottis and its ligaments	80
26. The larynx of a porpoise	81
27. The epiglottis of the great ant-eater	82
28. The hyoid and hyo-epiglottideus	84
29. The intervertebral disc of a seal	88
30. The conjugal ligament of a fœtus	88
31. An adult intervertebral disc	89
32. The interneural plate of a skate	91
33. Axis showing the first intervertebral disc	97
34. Wing of a vulture dissected	105
35. Muscles of a bird's thigh	107
36. The bicipital loop of an emu	108
37. The inter-mandibular ligament of the kangaroo	III

LIGAMENTS :

THEIR NATURE AND MORPHOLOGY.

CHAPTER I.

THE NATURE OF TENDONS AND LIGAMENTS.

JOINTS and ligaments have long been a dry study with students, but the following pages will serve to shew that some of the most important processes of evolution may be inculcated by an earnest study of these apparently uninteresting bands. The more important ligaments of the body are derived from the metamorphosis and regression of muscles ; others are due to the degeneration of osseous and cartilaginous tissues.

Morphological problems of the greatest interest may centre around a band of fibrous tissue, whilst in the immediate neighbourhood, ligaments abound of functional value, but of no interest to the morphologist.

To sort out from among the enormous heap of structures known as ligaments, those which can boast a noble descent, and trace the history of their downfall, is the object of the present treatise. Attention will also be devoted to those tracts of fibrous and tendinous tissues known as aponeuroses.

Metamorphosis of Muscle.—Anyone dissecting an amphibian or reptile for the first time, will be impressed

with the small amount of tendon entering into the composition of the muscles. This becomes more marked when the muscular system of an amphibian is compared with that of a high mammal. Muscle and tendon have too long been regarded as distinct tissues; the arrangement of the fibres in tendon strongly recalls those of the fasciculi in the belly of a muscle. It is very difficult to determine how the muscle and tendon are joined, or by what means the union is brought about, for the parts become insensibly blended. The formation of tendon from muscle may be traced in the psoas magnus, for in the infant it is almost devoid of tendon. Ledwich pointed out that the omohyoid has no intermediate tendon until the twentieth year.

The position of tendons has an important bearing on this question:—As a rule they are situated at the extremities of muscles where contractile tissue has little opportunity of exerting itself advantageously, *e.g.*, the long tendon of the biceps at the shoulder, the elongated tendons of the flexors and extensors of the fingers and toes. When a tendon develops in the centre of a muscle, as in the digastric of man, it is usually in a situation where muscular tissue would be of little avail. When a muscle is so situated that its contractile power can be brought into play throughout its whole length, it may remain muscular in structure from origin to termination, as in the case of the intrinsic and extrinsic muscles of the tongue. If one or both extremities of a muscle fail to act to full advantage, the reason for the existence of such a tissue fades, and the ends degenerate into tendons to play an important part nevertheless as passive agents. Physiologists agree that voluntary muscle fibre is to be regarded as one of the master-tissues of the animal body. To maintain such highly specialised structure in good condition the frequent exercise of its function is necessary. Parts frequently used are, as a rule, abundantly supplied with blood, for healthy performance of function depends on the organ being ade-

quately nourished. If these premisses be correct then the conclusions which must necessarily follow are these:—The ends of certain muscles are badly situated to exert their full contractile power, or, on account of modification in the creature's habits, portions of, and in some cases whole muscles become rarely used or rendered inoperative. Loss of function leads to diminished blood supply, decrease in the amount of nutrition ends in degradation of tissue. The converse of this leads to hypertrophy. The ends of muscles, when compared with the central portions, are passive; they need little blood supply, and become in consequence, *metamorphosed into tendon*. The active central parts are often called into play, are well nourished and increase in size and quality. A very good illustration of this presents itself in the biceps flexor cubiti.

If the muscle to which the tendon belongs is one frequently exercised as in the case of the gastrocnemius and soleus, the attached tendon contains a very large amount of elastic tissue. Whole muscles may be replaced by tendon, *e.g.*, the *flexor sublimis muscle* in the mole is represented by an enormous tendon, thicker than the ulna: the auriculo-ventricular valves are muscular in the embryo, but later metamorphose into tendinous tissue. The right ventricle of the bird's heart contains a muscular valve, and in a mammal, the echidna, the same condition prevails. Ogle observed a patch of muscular tissue in the anterior segment of the mitral valve of a man's heart. This patch was about a centimetre in diameter and resembled under the microscope the natural tissue of the heart.

Regression of Muscle.—When a muscle degenerates either from morphological or pathological causes, the amount of contractile tissue is diminished, and the parts take on the character of fibrous tissue and become ligament. This change may conveniently be referred to as *regression*.

These two processes *metamorphosis* and *regression* assisted

by a singular change of position in muscles known as *migration*, which will be considered in detail later, have been most active in providing ligaments in the limbs.

The view that tendon results from the metamorphosis of muscle receives great support from the fact that nerves terminate in them by end-organs something like those of muscle. These curious terminations have been especially studied by Golgi. They seem to be most numerous near the muscular insertion. They may form peculiar reticulated plates of primitive fibrillæ, or end in structures recalling the end-bulbs found in the conjunctiva.

The question of the relation of muscles, tendons, ligaments and nerves has a practical bearing, inasmuch as it affords an anatomical explanation of the knee-jerk phenomenon so familiar to school-boys, which when used by the physician becomes an example of "philosophy in sport made science in earnest."

It also serves to account for the intense pain caused by tension of a joint or the accumulation of pus under dense fascia. The curious and intractable contractions of palmar and plantar fasciæ and other aponeurotic structures are more comprehensible if we regard them as arising from the metamorphosis and regression of muscles.

Degeneration of osseous and cartilaginous tissues.—Ligaments arising by this method occur with greatest frequency in the axial skeleton and pectoral girdle. As a very large portion of what is to follow in the succeeding chapters is devoted to the consideration of this question, it will be unnecessary to give many illustrations in this chapter, but it may be mentioned as a further inducement to those who are inclined to prosecute the further study of this question, that the inquiry will carry the investigator into some of the most fascinating regions of morphological science, and convince them that "morphology is the very soul of anatomy."

As examples of ligaments arising from the degeneration

of bone or cartilage, the following are furnished by the human skeleton :—

- (1). The supra-condyloid foramen.
 - (2). The supra-trochlear foramen.
 - (3). The biceps-foramen.
 - (4). The supra-scapular notch.
 - (5). The stylo-hyoid ligament.
 - (6). The speno-mandibular ligament.
- (1). *The Supra-Condylloid Foramen.*—In many carnivora, rodents, lemurs, &c., there exists above the internal condyle (epitrochlea) of the humerus, a bony tunnel known as the supra-condyloid foramen. This transmits as a rule, the median nerve and the brachial artery.

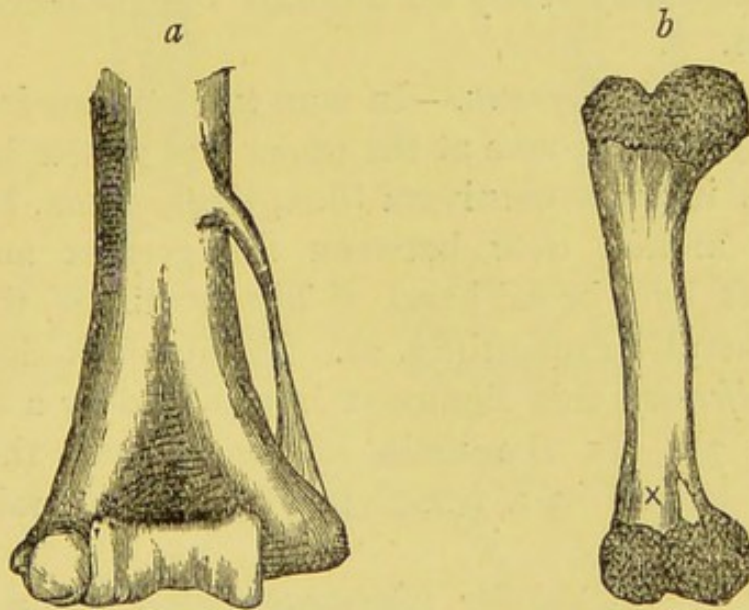


FIG. 1.—*a*. The supra-condyloid process and ligament of the humerus. *b*. The humerus of a lion at birth ; *x*, the supra-condyloid foramen.

In the young lion at birth as in the fœtal cat, the foramen is in part formed by an outgrowth from the diaphysis, as well as by an upgrowth from the epiphysis, as in fig. 1 *b*. In man the most frequent condition of this foramen when existing, is to have the upper part of the ring formed by an osseous outgrowth from the humeral shaft, named the supra-condyloid process; the lower

part of the ring is completed by a band of fibrous tissue extending to the internal condyle. From this ligament the uppermost fibres of the *pronator radii teres* muscle arise (fig. 1 a).

(2). *The Supra-Trochlear Foramen.*—The olecranon and coronoid fossæ of the humerus are usually separated from each other by a thin translucent septum of bone. Not infrequently this septum presents a central circular perforation in macerated specimens. This hole is known as the supra-trochlear foramen. When the parts are studied in unmacerated specimens, the foramen is filled with a firm fibrous diaphragm. As the supra-trochlear foramen is constant in many mammals, *e.g.*, the dog, the student can easily verify for himself the presence of this diaphragm.

(3). *The Biceps-Foramen.*—In man the long tendon of the biceps plays in a groove at the upper end of the humerus; in him, as in some carnivora (lion, tiger, puma, bear) this groove is arched over between the greater and lesser tuberosities by a broad band of fibrous tissue, the transverse humeral ligament (fig. 2). In the musk deer (*Moschus moschiferous*) this ligament is replaced by a bridge of bone (fig. 3). In the mole (*Talpa europæa*) the biceps tendon is lodged in a completely osseous tunnel (Austin Freeman).*

(4). *The Supra-Scapular (Coraco-Scapular) Foramen.*—The notch in the upper border of the scapula which transmits the supra-scapular nerve and occasionally the artery, is usually converted into a foramen by a band of fibrous tissue known as the transverse ligament of the scapula. This band is frequently replaced by bone, a condition characteristic of sloths (fig. 4).

I have been able to study the formation of the complete bony foramen in the young ant-eater (*Myrmecophaga jubata*).

* *Journal of Anatomy and Physiology*, vol. xx., p. 206.

In this mammal the foramen is composed in part by the body of the scapula and completed by the coracoid process, thus affording an example in the limbs of the formation of a nerve-foramen by two centres of ossification, a condition of things almost constant in the skull. There-

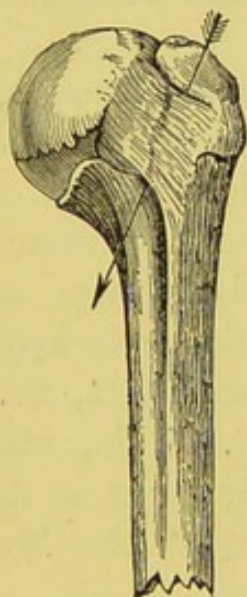

FIG. 2.—Upper end of the humerus of a Gibbon shewing the biceps-foramen (Brodie).

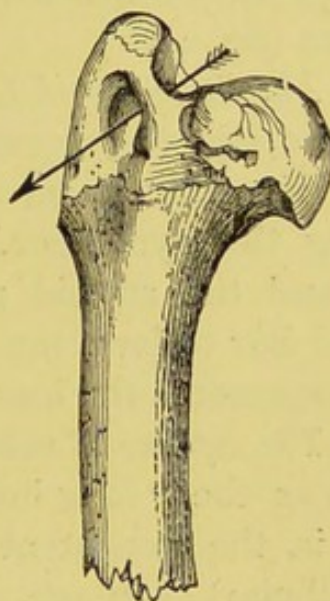

FIG. 3.—Upper end of the humerus of *Moschus* shewing the biceps-foramen (Brodie).

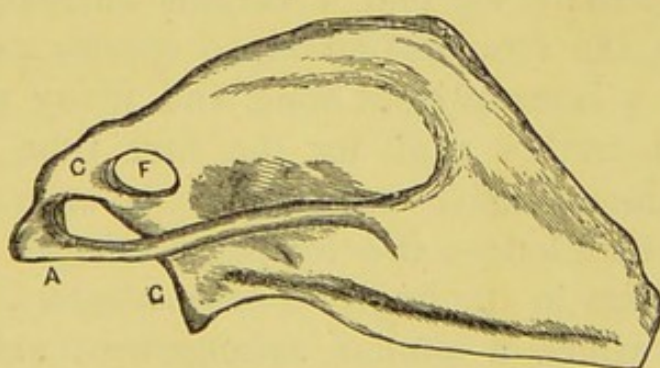


FIG. 4.—The scapula of a sloth, showing F, the osseous coraco-scapular (supra-scapular) foramen; C, coracoid; A, acromion; G, glenoid fossa.

fore I am disposed to the view that the transverse ligament in man is the fibrous representative of this bony bridge constant in sloths, and that the occasional occur-

rence of a complete osseous foramen in this situation is not to be regarded as an ossification of the transverse ligament, but as reversion to a former condition.

As the supra-scapular notch is formed in part by the scapula and coracoid process in man and other mammals, it would be far more convenient to refer to it by the name it bears in comparative anatomy—the coraco-scapular foramen (fig. 4).

(5). *The Stylo-Hyoid Ligament.*—This structure stretches from the styloid process to the lesser cornu of the hyoid bone: it results from the degeneration of the cartilage forming the hyoid bar. The proximal end becomes the incus and the styloid process, the distal fuses with the thyroid bar to form the basi-hyal. The stylo-hyoid ligament represents the long epi-hyal of ruminants, &c.

(6). *The Spheno-Mandibular Ligament.*—This, commonly known as the “long internal lateral ligament of the lower jaw” is the persistent representative of the Meckelian (mandibular) cartilage.

The morphological identity of tracts of fibrous tissue in one vertebrate with bone in another may be illustrated by the following examples:—

Among reptilians we find a curious anomaly, for some turtles have the temporal fascia, so conspicuous in man, replaced by a layer of stout bone, and many students on examining a turtle's skull for the first time have been puzzled by the extensive compartment on each side of the true skull, which lodges the temporal muscle. A similar condition exists in the frog (*Pelobates cultripes*). The only mammal in which a similar arrangement exists, is the singular African rodent (*Lophiomys*).

In man, bones which are, as a rule, well formed, may be replaced by fibrous bands. Several examples have been reported in which the fibula has been in part (and in some entirely) replaced by a stout ligament from which muscles took origin. Many specimens have been observed in

which the shaft of the first rib was replaced by a fibrous band extending from near the neck of the rib to the sternum.

II. RIBS.

The ribs are divided into true ribs, false ribs, and floating ribs. The true ribs are the first ten ribs, which are connected to the sternum by costal cartilages. The false ribs are the eleventh and twelfth ribs, which are not connected to the sternum. The floating ribs are the eleventh and twelfth ribs, which are not connected to the sternum. The ribs are attached to the vertebrae by costal facets. The costal facets are formed by the heads of the ribs, which articulate with the vertebral bodies and the transverse processes of the vertebrae. The ribs are also attached to the sternum by costal cartilages. The costal cartilages are composed of hyaline cartilage. The first rib is attached to the sternum by a fibrous band. The second rib is attached to the sternum by a costal cartilage. The third to tenth ribs are attached to the sternum by costal cartilages. The eleventh and twelfth ribs are not attached to the sternum. The ribs are also attached to the vertebrae by costal facets. The costal facets are formed by the heads of the ribs, which articulate with the vertebral bodies and the transverse processes of the vertebrae. The ribs are also attached to the sternum by costal cartilages. The costal cartilages are composed of hyaline cartilage. The first rib is attached to the sternum by a fibrous band. The second rib is attached to the sternum by a costal cartilage. The third to tenth ribs are attached to the sternum by costal cartilages. The eleventh and twelfth ribs are not attached to the sternum. The ribs are also attached to the vertebrae by costal facets. The costal facets are formed by the heads of the ribs, which articulate with the vertebral bodies and the transverse processes of the vertebrae.

CHAPTER II.

ANOMALOUS MUSCLES IN RELATION TO LIGAMENTS.

THE study of anomalous muscles has occupied the attention of many able anatomists, and the enormous number of recorded observations may be arranged in two groups :—

I. Supernumerary muscles.

II. Morphological variations in existing muscles.

I. **Supernumerary Muscles.**—These are occasionally represented by bands of fibrous tissue. Of these the more easily observed examples are :—

- (1). The epitrochleo-anconeus.
- (2). The muscles of the coccyx.
- (3). The abductor of the fifth metatarsal.
- (4). The azygos pharyngis.
- (5). Flexor carpi radialis brevis.

In determining whether or no a given band of fibrous tissue represents a degenerate muscle it is necessary to satisfy the following rules :—

1. It must correspond with its presumed representative in origin and insertion.
2. The muscle should occasionally reappear as an anomaly in the human subject and replace the fibrous tissue.
3. Failing Rule 2, the muscle should assume a functional importance in other animals.

If Rules 1 and 2 be satisfied, the assumption that a given fibrous band represents the muscle is reasonable; if the third rule be sustained, the evidence is then very strong, and becomes almost a certainty.

When Rules 1 and 2 are not satisfied, the notion of representation should be entertained with caution.

(1). *The Epitrochleo-Anconeus.*—This muscle well illustrates these rules. It is an occasional muscle in man; arising from the back part of the internal condyle of the humerus; it is inserted into the inner side of the olecranon process, and completes the tunnel for the ulnar nerve (figs. 5 and 6). When not represented by muscle a piece

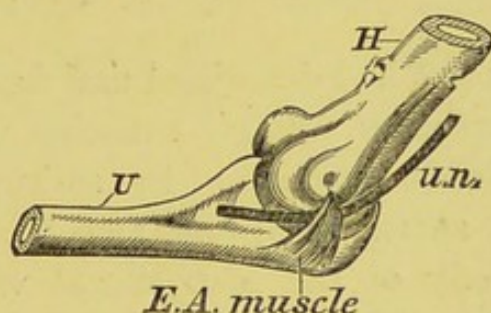


FIG. 5.—The epitrochleo-anconeus muscle of man. H. Humerus. U. Ulna. u. n. Ulnar Nerve.

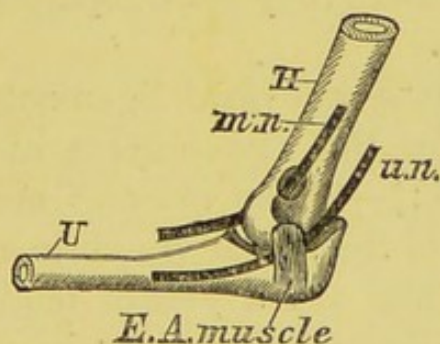


FIG. 6.—The epitrochleo-anconeus muscle of a Virginian opossum. H. Humerus. U. Ulna. m. n. Median nerve. u. n. Ulnar nerve.

of fascia occupies its place. Gruber has described the *epitrochleo-anconeus* as being the most frequent muscular abnormality in the body.

The *epitrochleo-anconeus* is present in very many mammals from marsupials upwards.*

(2). *The Muscles of the Coccyx.*—The horse in common

* J. C. Galton, *Journal of Anatomy and Physiology*, vol. ix., p. 169.

with other mammals possessing a flexible tail, is furnished with muscles enabling it to raise and depress the tail, as well as muscles to move it from side to side. Such muscles are useless when the caudal vertebræ are reduced to the vestigial condition characteristic of man and the tailless apes: nevertheless the positions of these muscles are well represented in man by the bands known as the sacro-coccygeal ligaments. It is also well-established that two at least of these ligaments are occasionally replaced by muscle.

Morrison Watson* has described and figured the occurrence of the *Curvatores coccygis* muscles in man. They arose from the anterior surface of the sacrum between the third and fourth sacral foramina, also from the anterior surface of the body of the fifth sacral vertebra. They were inserted into the front surface of the body of the second, third and fourth coccygeal vertebræ. Watson relates that Albinus† had noted the muscles in three subjects, but that in others they were replaced by ligamentous or tendinous fibres.

The posterior sacro-coccygeal ligaments are sometimes replaced by muscles the attachments of which are thus described by Hyrtl:‡—"The muscles are found between the hinder surface of the sacral vertebræ and the last piece of the coccyx. They are a pair of tendinous muscles—repetitions of muscles which appear in most mammals—*sacro-coccygeus posticus seu extensor coccygis*."

(3). *The Abductor of the Fifth Metatarsal Bone*.—This is often known as Wood's muscle (*abductor ossis metatarsi quinti*). It arises from the outer tubercle of the calcaneum and the plantar fascia, and is inserted into the prominence at the base of the fifth metatarsal bone. In my dissections it

* *Journal of Anatomy and Physiology*, vol. xiv., p. 407.

† *Historiæ Musculorum*, 1734, p. 336.

‡ *Lehrbuch der Anatomie*. 14th auflage, 487.

was so frequently present that I am in the habit of teaching that the first layer of the sole consists of four muscles, thus regarding Wood's muscle as of normal occurrence. When no muscular fibres represent it, a stout fibrous band invariably occupies its place. Flower and Murie* found this fibrous band in the Bushwoman dissected by them. The muscle was present in the feet of two chimpanzees I dissected; and it exists in many monkeys.

(4). *The Azygos Pharyngis*.—This muscle arises from the pharyngeal tubercle on the under surface of the basi-occipital. It is inserted into the median raphe of the pharynx superficial to the insertion of the superior and middle constrictors of the pharynx. It is a rare muscle in man, but is often represented by a firm fibrous band. The muscle is present in the pharynx of several mammals.

(5). *The Flexor Carpi radialis brevis*.—This muscle arises from the anterior surface of the radius above the *pronator quadratus*, to the outer side of, and below the *flexor longus pollicis*. Its insertion is variable: when the muscle is well-developed the tendon passes under the anterior annular ligament of the wrist to be inserted into the base of the middle metacarpal bone: sometimes it spreads out and blends with the fibrous tissues covering the carpal bones, or it may end in the anterior annular ligament.

The upper part of this muscle is often represented by a firm fibrous band. Gruber and Testut† have each detected a fasciculus of tendinous fibres occupying the position of this muscle which they name the *radio-carpal*.

Normal muscles are occasionally replaced by fibrous and tendinous bands. Bruce Young found the subclavius muscle entirely replaced by fibrous tissue. Professor Sir William Turner in one case could not find the *extensor carpi ulnaris*, but on careful dissection a narrow band could

* *Journal of Anatomy and Physiology*, vol. i., p. 204.

† *Anomalies Musculaire*, p. 501.

be detected in the deep surface of the aponeurosis of the forearm, somewhat stronger and more opaque than the rest, extending longitudinally down the limb, parallel with the ulna. Above the styloid process the band became isolated from the fascia, and entered the groove on the back of the ulna in which the tendon of the *extensor carpi ulnaris* ought to have been lodged; finally it became attached to the base of the fifth metacarpal bone.

Turner regards this as an example of the conversion of a muscle into fibrous tissue, and refers to a similar case recorded by Gruber.*

The interest of the case is this: when a muscle is found wanting in a subject in which normally it exists, search should be made for its fibrous representative. Doubtless many instances of muscular variations and absence of muscles receive explanation in this way.

This view is supported by our knowledge of a small muscle belonging to the thenar group known as the *interosseous primus volaris* (Henle). This muscle arises from the palmar aspect of the base of the first metacarpal, and is inserted into the ulnar sesamoid, blending with the inner head of the *flexor brevis pollicis*. It is frequently represented by firm band of fibrous tissue.

II. Morphological Variations in existing Muscles.—This subject is well illustrated by the *coracobrachialis*. The morphology of this muscle was carefully investigated by Wood,† who demonstrated its triple constitution. The muscle arises from the tip of the coracoid process of the scapula in company with the short head of the biceps, with which it is united for some distance, and is inserted into the inner border of the humerus near its middle. Some of the higher fibres are attached to a fibrous loop extending from the coracoid process to the

* Virchow's *Archiv*, bd. xcix., s. 478.

† *Journal of Anatomy and Physiology*, 1867, vol. i., p. 44.

lesser tuberosity of the humerus. The muscle is usually pierced near its insertion by the musculo-cutaneous nerve.

The variations of this muscle observed in man and the information furnished by comparative myology enable us to describe its three parts thus:—

1. The portion represented by the fibrous band (fig. 7 *c'*) sometimes develops as a distinct muscle which is known as the *Rotator humeri*.

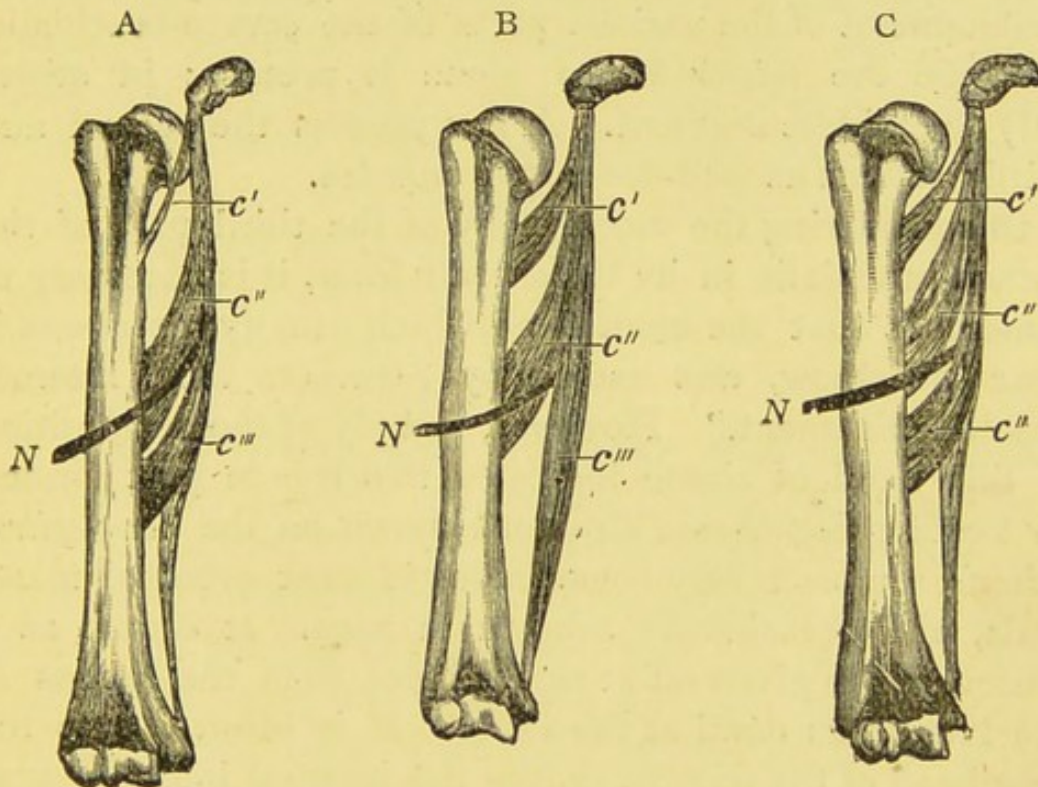


FIG. 7.—Three drawings exhibiting the chief variations of the coraco-brachialis muscle of man.

c' Coraco-brachialis brevis. *c''* Coraco-brachialis medius. *c'''* Coraco-brachialis longus. *N* The musculo-cutaneous nerve.

2. The middle portion is the coraco-brachialis of human anatomy (fig. 7 *c''*).

3. The third piece (fig. 7 *c'''*) may exist as a muscular belly extending from the common tendon to the internal condyle: this, however, is rare, but its position is usually indicated by a thin tendon attached to the internal con-

dyle. When a supra-condyloid process is present this portion of the muscle is inserted into it.

The three parts of the muscle are sometimes named coraco-brachialis brevis, medius and longus, the musculo-cutaneous nerve indicating the line of separation between the medius and longus. The disposition of this muscle recalls in a striking manner the adductor brevis, longus and magnus muscles in the thigh.

Many variations exist among mammals in regard to the development of the various parts of the coraco-brachialis. In some the *rotator humeri* alone is present; in others only the middle segment. A few possess the second and third portions as well-developed muscles.

In considering the morphology of the third part of the coraco-brachialis in its degenerate form, it is necessary to remember that the stout band which usually represents it near the elbow, was named by Struthers the "internal brachial ligament." However, a study of the composition of this band of tissue indicates that it is in part formed by another degenerate structure known as the *dorso-epitrochlearis*, a muscle very conspicuous in most arboreal mammals, and occasionally present in man. It occurs as a muscular slip given off at right angles from the tendon of the latissimus dorsi at the axilla. It is inserted into the long head of the triceps, or into the internal intermuscular septum. Rarely it extends as far as the internal condyle.

The dorso-epitrochlearis is a conspicuous muscle in apes. Often in man the axillary section of the muscle is represented by a very definite rounded tendon, which I have many times easily followed in the internal intermuscular septum to the epitrochlea.*

* For good figures of this muscle in man, see Perrin, *Journal of Anatomy and Physiology*, vol. v., plate x. Also Champneys, "Anatomy of the Chimpanzee," *Journal of Anatomy and Physiology*, vol. vi., foot-note on p. 180.

CHAPTER III.

THE MORPHOLOGY OF APONEUROSES AND FASCIA.

IN the last chapter examples were given of tendinous and fibrous bands replacing muscles. Evidence will now be offered of the formation of extensive membranes and aponeuroses as a result of the metamorphosis and regression of muscles: it will be considered in relation with:—

1. The palmar and plantar fasciæ.
2. The interosseous membranes.
3. The deep fascia of the limbs.
4. The lumbar aponeurosis.

1. **The Palmar and Plantar Fasciæ.**— These structures are so well known to the student of human anatomy that it would be tedious even to recapitulate the details relating to their anatomy. It is sufficient for the purposes of morphology to remember that the palmar fascia is connected superiorly with the anterior annular ligament, whilst the middle, strongest portion of the fascia, is directly continuous with the tendon of the *palmaris longus*. This muscle may be absent without in the least impairing the utility of the limb. Usually it consists of a definite belly with a rounded tendon, occasionally two bellies are present with a tendinous intersection; the muscle may end in the fascia of the forearm, or may be wholly represented by ligament.

In many animals, *e.g.*, the armadillo and the cape ant-bear (*Orycteropus*),* the *palmaris longus* is large and important, muscular throughout its whole extent, sending

* Galton, *Trans. Linnean Society*, vol. xxvi., p. 567.

slips to all the digits, and serving as one of the chief agents in flexing them.

That the palmar fascia arises from the degeneration of the distal end of the palmaris longus muscle, admits of no doubt, for it occasionally happens that portions of the fascia reassume their lost character and present themselves as slips of muscle. This occurs most frequently in connection with the strips of fascia going to the thumb. There is good reason to believe that the abductor pollicis and abductor minimi digiti are derived from the distal end of this once extensive muscular sheet, of which the sole representatives, in a muscular form beside them, are the palmaris longus and the palmaris brevis muscles.

The Plantar Fascia.—The disposition of this fibrous sheet in the sole of the foot exactly repeats that seen in the hand, and the same arguments will be used to show that in this case the fascia results from the regression of the *plantaris*. This muscle, like the palmaris longus, is vestigial in man, and like such structures in general is liable to all kinds of variations. Normally it is inserted into the inner side of the tendo Achillis, but it may join the deep fascia, the internal annular ligament, or the plantar fascia; occasionally it is absent.

These vagaries alone are sufficient to indicate that the muscle has an interesting ancestry. Turning to lower forms we find that in the armadillo the plantaris muscle instead of being, as in man and many mammals, chiefly represented by a long, thin, and straggling tendon, is larger than the gastrocnemius. The muscle arises as usual from the back part of the external condyle of the femur, it then expands into a large fleshy belly extending the whole length of the calf; at the heel it forms a tendon which glides in a well-formed groove on the back of the calcaneum, and spreads out as the plantar fascia, slips of which pass to the hallux, second, and third toes, extending even to the terminal phalanges.

As many of the short muscles belonging to the thumb and fifth digit may have arisen from portions of the original palmaris longus, so may some of the short muscles in the first layer of the sole be considered as detached portions of the plantaris. An exception must be made in the case of the abductor hallucis, which is probably a migratory muscle.

2. The Interosseous Membrane of the Forearm and Leg.—Passing between the radius and ulna is a flat fibrous membrane, known as the interosseous membrane of the forearm. Its fibres are directed for the most part obliquely downwards from the radius to the ulna, the membrane commences a little below the bicipital tubercle. On the posterior aspect small bundles of fibrous tissue intersect the direction of the main fasciculi at right angles. Lying on the membrane are the anterior interosseous nerve and artery. Careful dissection shows that small bands of tissue, intimately connected with the membrane, arch over and thus enclose the nerve and artery in a fibrous tunnel. In the leg a similar interosseous membrane exists, the fibres of which pass more or less horizontally from the fibula to the tibia and are intersected by fibres passing obliquely between the two bones in different directions. The anterior tibial nerve and artery bear the same relation to the membrane as is the case in the forelimb.

In the iguana, gecko, menopoma, sphenodon, chameleon, and the like, a muscle exists, the fibres of which arise from the fibula to be inserted into the tibia, thus occupying the position of the interosseous membrane so common among mammals. The muscle in question has been named the peroneo-tibial and it exists in a well-developed form in the hind leg of the wombat. The anatomical relations of the muscle may be studied most completely among the lizards.

If the interosseous membrane in the leg of man were not originally derived from a peroneo-tibial muscle, it is at

least the morphological representative of that structure. As the muscle occurs within the mammalian circle, it is not unreasonable to regard the membrane as a degenerated muscle. If this view be accepted for the forearm, then the anterior interosseous artery and nerve are to be regarded as originally ministering to this remarkable muscle. The fibrous tunnel in which they lie is formed as a consequence of the degeneration of the muscle.

It is quite possible that the popliteus is a remnant of the original peroneo-tibial muscle; also the rotator fibulæ of the gibbon.

3. The Deep Fascia of the Limbs.—On comparing the limbs of a lizard or a bird with that of man or any of the higher mammals, we shall be struck with the fact that in the latter forms the muscles are invested by strong aponeuroses known as the deep fasciæ, and separated one from the other by fibrous intermuscular septa. Not so in the Sauropsida (birds, lizards, crocodiles).

Careful inquiry, by means of dissection will force an impartial worker in the end to the conclusion, that the deep fasciæ and the intermuscular septa are in reality the result of the metamorphosis and regression of muscular tissue, at least so far as the fore- and hind-limbs of most mammals are concerned.

An attempt is made in Chapter XIII. to show that there is good ground for believing that the broad band of fascia continuous with the biceps femoris tendon, and extending thence to the external annular ligament of the ankle, may be traced to a large and functional muscle in lizards, crocodiles, and birds.

It is commonly recognised that the thickening of the fascia lata known as the ilio-tibial band is the degenerate representative of that portion of the tensor fasciæ femoris muscle which in some animals extends to the knee.

There can be little doubt that the larger portion of the fascia lata on the posterior aspect of the limb is derived

from degeneration of the distal portion of the gluteus maximus muscle. This muscle in man consists of a superficial part inserted into the fascia lata, and a deep part inserted into the gluteal ridge: thus his gluteus maximus is a compound of two muscles. When the gluteal ridge is well marked it is called the gluteal (or third) trochanter.

The gluteal muscles in birds are very numerous, as many as four are present in some species. In others, some of these muscles are entirely represented by tracts of fibrous tissue or fascia.

If the dissector wishes to find the external cutaneous nerve in the thigh he has to seek it in a tunnel formed in the fascia lata. When dealing with the interosseous membrane of the forearm it was shown that the artery and nerve were enclosed in a tunnel in consequence of the degeneration of the muscle to which they originally ministered. Comparative anatomy supports the view that the external cutaneous nerve of man lies in a tunnel in consequence of the muscle which it supplied, having undergone regression, and burying the nerve and artery in fibrous tissue.

The same line of argument applies to the deep fascia of the arm. I have seen an instance in which the bicipital expansion was replaced on both sides by a thin sheet of muscular tissue, much broader than the fan-shaped arrangement of fibrous tissue which it replaced.

4. **The Lumbar Aponeurosis.**—Under this name human anatomists have found it convenient to describe three stout layers of fascia ensheathing the erector spinæ and quadratus lumborum muscles.

The *posterior layer* springs from the spines of the lumbar vertebræ and the posterior part of the iliac crest. After closely investing the erector spinæ, it joins with the middle layer of the aponeurosis at the outer border of that muscle.

The *middle layer* springs, by strong fibrous bundles, from the tips of the transverse processes of the lumbar vertebræ ;

and, passing between the erector spinæ and quadratus lumborum muscles, blends with the posterior layer, as already described, and forms a strong tendon of origin for the transversalis abdominis muscle.

The *anterior layer* of the lumbar aponeurosis is attached to the front of the transverse processes of the lumbar vertebræ, covers the anterior surface of the quadratus lumborum muscle, and blends with the middle layer of fascia. Thus the anterior blends with the middle layer at the outer border of the quadratus lumborum, whereas the posterior and middle layers of the aponeurosis blend at the outer border of the erector spinæ muscle.

The *posterior layer*. This probably arises from the metamorphosis of the lower fibres of the *latissimus dorsi* muscle, for in many animals this fascia is wholly replaced by muscle-fibres continuous with the latissimus dorsi.

The *middle layer*. When the structures in the ilio-costal space are removed down to the quadratus lumborum care being taken not to injure its investing fascia, there will be seen arising from the tips of the transverse processes of the three upper lumbar vertebræ a fan-shaped arrangement of fine fasciculi composed of fibrous tissue, but more elastic in character than the rest of the aponeurosis, and strongly recalling in appearance the nacreous-looking fibres of origin of the serratus posticus inferior muscle. These fan-shaped masses have a direction downwards and outwards, the apices being attached to the tip of the transverse process exactly like a *levator costæ*, and there can be little doubt that the thickenings in the middle layer of the lumbar fascia are the degenerate remains of a set of muscles in continuation of the levatores costarum. These fan-shaped collections of tissue in the middle layer of the transversalis aponeurosis may be demonstrated in any dissecting-room subject.

In bodies possessing a lumbar rib, however small, the fan-shaped ligament attached to the twelfth thoracic vertebra is replaced by a functional muscle.

The *anterior layer*. This is in all probability derived from the regression of that portion of the transversalis muscle lying nearest the spine.

An examination of the cœlom (pleuro-peritoneal cavity) of lizards leads me to believe that in a typical condition the abdominal and thoracic parietes may be conceived as possessing in their lateral and ventral aspects three muscular strata.

1. The external oblique sheet intersected in a part of its course by the ribs, giving rise to the external intercostal muscles.

2. An internal oblique stratum, also partially interrupted by the ribs forming the internal intercostal muscles.

3. The transversalis sheet immediately subjacent to the serous lining of the pleuro-peritoneal cavity.

Mammals are distinguished from lower vertebrata in the possession of a complete diaphragm. This singular structure probably represents that portion of the transversalis sheet which covers, in lizards, the inner aspect of the ribs. The thickenings known as the *ligamentum arcuatum internum* and *externum*, are to be regarded as tendinous intersections between its thoracic and abdominal segments.

The original extension of this muscular stratum into the thorax is indicated by the occurrence of the sub- or infracostal muscles which are found most frequently near the angles of the ribs on their inner aspect, and the *triangularis sterni* which is directly continuous with the transversalis.

The origin of three layers of the lumbar aponeurosis may be briefly stated thus.

- (a) The *posterior* layer results from the metamorphosis of the lower fasciculi of the *latissimus dorsi* muscle.
- (b) The *middle layer* contains vestiges of the lower representatives of the *levatores costarum* muscles.
- (c) The *anterior* layer is the result of the metamorphosis of the vertebral portion of the transversalis muscle.

In that man possesses in the posterior and anterior regions of the trunk (for there can be little doubt that the aponeuroses of the obliqui and transversalis muscles are the result of the metamorphosis of the fasciculi of these muscles), large sheets of tissue composed of minute glistening tendons, he contrasts markedly with amphibians, lizards, and ophidians, in whom these aponeurotic tracts are represented by sheets of well developed muscular tissue.

CHAPTER IV.

MIGRATION OF MUSCLES IN RELATION TO LIGAMENTS.

MIGRATION of a muscle may be defined as the changing of its situation by alteration of its attachments.

The following examples from the limbs will be considered in this chapter.

1. The peroneus longus.
2. The adductor magnus.
3. The extensor longus digitorum.
4. The extensor brevis digitorum.
5. The deep extensors of the forearm.
6. The gastrocnemius.
7. The interossei.

1. **The Peroneus Longus.**—Every student engaged in dissecting a knee joint must have had his attention arrested by the beautiful, rounded, cord-like condition of the external lateral ligament. The notion of it being, or rather that at some time it had been, the tendon of a muscle seems irresistible, and this suspicion is strengthened on occasionally finding in young subjects, a synovial sheath investing it. The ligament really represents a former origin of the peroneus longus muscle from the femur. In the opossum, and the ox, the fibres of this muscle arise directly from the ligament; even in man the muscle fibres of the peroneus longus often have a considerable origin from it. In the gibbon (*Hylobates leuciscus*) I found the tendon of the peroneus longus arising from the external condyle of the femur, and replacing the ligament; the tendon having no attachment to the head of the fibula.

2. **The Adductor Magnus.**—The tendon of this muscle terminates at a tubercle on the internal condyle of the femur. In young subjects the fibres of the tendon may be traced into the internal lateral ligament of the knee joint. In two young orangs which I dissected the adductor magnus muscle was directly continuous with the ligament.

A broad study of the relations of this muscle to the internal lateral ligament indicates that the adductor magnus muscle was originally inserted into the head of the tibia.

3. **The Extensor Longus Digitorum.**—This muscle in man arises from the fibula, and its upper fibres takes origin from the external tuberosity of the tibia; in many mammals it arises from the external condyle of the femur, *e.g.*, hyrax, pig, horse, hare, and the orang. In the ostrich it arises from the condyle by a very thick tendon.

4. **The Extensor Brevis Digitorum.**—The history of this muscle has been unravelled by Ruge.* He has shewn that in the Monotremata it belongs to the peroneal group, and arises entirely from the fibula. Ascending the scale of mammalian forms we find the muscle passing down tendon by tendon until it reaches the condition presented in the foot of man.

The koala (or native bear as it is called in New Zealand) presents an intermediate condition, for we find two tendons on the dorsum of the foot, whilst the remainder still retain an attachment to the fibula.

In very many mammals and even quadrumana we find two muscles arising from the fibula, and gaining the dorsum of the foot by passing behind the external malleolus. They are known as the peroneus quartus and peroneus quinti digiti muscles. They are really the representatives of the slips from the *ex. brevis digitorum* muscle to the fourth toe and the peroneus tertius muscle.

* *Morph. Jahrbuch*, 1878.

The peroneus tertius muscle is regarded as a muscle exclusively human, but it is simply the most external slip of the short extensor of the digits, which has failed to migrate when its companions passed downwards from the leg to the dorsum of the foot.

5. **The Deep Extensors of the Forearm.**—The posterior interosseous nerve, after supplying twigs to the deep layer of muscles on the extensor aspect of the forearm, terminates in a collection of fibrous tissue on the dorsum of the carpus. An inquiry into this singular mode of termination has had the effect of throwing some light on the nature of the tissue in which the nerve ends.

When the extensor muscles of man's forearm are compared with those of the majority of *Quadrumana*, we at once observe that man is distinguished from them in the absence of a second extensor for the medius and annularis, whereas most monkeys possess a complete double set of extensors. We may distinguish the muscles in question by the name of the finger to which each belongs, thus:—

MAN.	MONKEYS.
Ex. secundus.	Ex. secundus.
„ indicis.	„ indicis.
	„ medius.
	„ annularis.
„ minimus.	„ minimus.

The deep extensors originally arose as a common muscle from the external condyle of the humerus and adjacent parts of the olecranon, its discrete tendons joining those of the common extensor; each part of this second extensor muscle had a small belly but a long tendon, and received the nerve supply near its origin, the posterior surface of the ulna being practically unoccupied. This primitive condition, which may be studied in kangaroos

and phalangers, became disturbed by the migration of the *ext. sec. internod. pollicis* from the condyle to the ulna ; gradually the *indicis* followed, and acquired a new attachment to the ulna below the *secundus* ; in the same way the *medius* and *annularis* migrated from the external condyle to the ulna below the *indicis* ; the *annularis* acquiring an attachment below the *medius*. As far as I can ascertain, the *minimus* retains its old attachment to the humeral condyle in all forms.

In man the *medius* and *annularis* are not normally represented, but when they appear as anomalous muscles they are in most cases attached to the lower end of the ulna. When these two muscles are not functional a band of fibrous tissue may be often detected containing numerous strands of tendon, arising from the lower third of the dorsal surface of the ulna below the *extensor indicis*, and becoming lost on the carpus. In one case I could trace the tendon in the fascia until it was lost in the belly of the *extensor minimus*. This fibrous tissue is probably the degraded representative of the *medius* and *annularis* muscles ; and what is equally significant, the posterior interosseous nerve ends in this tissue.

If man be descended from ancestors normally supplied with an *extensor medius* and an *extensor annularis*, we ought to find these muscles very frequently in a functional condition, and more so, as these two muscles are so constantly represented in the group of mammals zoologically so closely allied to man as the Anthropomorpha. This is actually the case, for the *medius* and *annularis* muscles are recognised as common muscular anomalies in anatomical textbooks. In some cases these muscles are only represented in part, usually the distal portion. It is not unusual to find the anomalous muscle designated *extensor brevis digitorum manus*.

More briefly summarised, the matter stands thus :—

1. The *extensor secundus*, *indicis*, and *minimus* are the

remnants of a second long extensor, which originally arose from the external condyle of the humerus and corresponding surface of the olecranon.

2. The *ext. minimus* maintains its old attachments, the remaining slips having migrated down the ulna.

3. The *ext. medius* and *annularis* slips have regressed into fibrous tissue, but not infrequently they reappear as functional muscles.

4. As these muscles *migrated* from the neighbourhood of the elbow, they carried with them the branch of the musculo-spiral nerve which supplied them; this subsequently became the posterior interosseous nerve. Its apparently meaningless termination on the back of the carpus is probably due to its being involved in the regression of the *medius* and *annularis* muscles.

5. The *ext. primi internodii pollicis* may be regarded as a segment of the long extensor, which has been *supplanted* by the *ext. secundus*.

The translocation of nerves in consequence of the migration of a muscle, or part of a muscle, is a fact of considerable interest, and one concerning which we know very little. Indeed, the only case known to me, beside that of the posterior interosseous nerve, is the instance described by Dr. St. John Brooks,* in which he seeks to explain in a measure those not infrequent cases in which the ulnar nerve supplies the radial head of the flexor brevis pollicis muscle.

6. **The Gastrocnemius.**—In the hind limb of the horse, a strong ligament passing from the posterior surface of the calcaneum to the cuboid and head of the rudimentary external metatarsal bone may be readily dissected. This fibrous band is known as the calcaneo-metatarsal ligament. Near the origin of this ligament from the calcaneum, the tendo Achillis or combined insertion of the gastrocnemius

* *Journal of Anatomy and Physiology*, vol. xx., p. 641.

and soleus muscles is attached. In the foetal horse and foetal deer, the tendo Achillis and the calcaneo-metatarsal ligament form a continuous structure. It would be most illogical to urge that because the tendon and ligament were one structure in a limb so peculiarly modified as that of the horse, the same source of the ligament could be maintained for the long and short plantar ligaments of man's foot, unless other evidence exists. If a human foetus even as late as the sixth month of intra-uterine life be examined by a vertical section carried through the tendo Achillis, calcaneum and cuboid, the ligament and tendon will be seen to form a continuous band, and the attachment of the tendon to the under surface of the calcaneum is of the loosest kind. After the seventh month of intra-uterine life the tendon is gradually divided by extra growth occurring at the posterior extremity of the calcaneum, the inferior portion becoming the long and short plantar ligaments, the other gaining a permanent attachment to the lower border of the calcaneum. If in the adult, the origin of the muscles composing the third layer of the sole of the foot be dissected, they will be found, with the exception of the transversus pedis, to be thoroughly incorporated with the plantar ligaments. When the corresponding parts are dissected in the foot of a seal the anatomist will quickly come to the conclusion that the adductor hallucis, flexor brevis hallucis, flexor minimi digiti, long plantar ligaments, tendo Achillis, gastrocnemius, and soleus muscles, have been derived from a muscular layer which in lower primitive forms was a continuous muscular stratum.

The conclusion is inevitable, that the long and short plantar ligaments are degenerated muscular tissue.

7. **The Dorsal Interossei.**—Ruge has made some admirable observations on the remarkable change of position which these muscles undergo in the foot.

In the early embryo the dorsal interossei are plantar in position and the metatarsals are in contact with each

other, gradually the metatarsals separate and the interossei make their way between them eventually appearing on the dorsum of the foot. In their earliest stage these muscles possess one head, it is only in their new position that they become bipenniform.

It is also important to remember that the varying positions these muscles pass through, indicate stages which are permanent in lower vertebrates. Thus, the first stage is characteristic of the majority of mammals and may be conveniently studied in the dog. In others, the second stage is represented; whilst the third stage is probably never so completely attained in any mammal as in man.

CHAPTER V.

THE LIGAMENTS OF THE KNEE JOINT.

THE general relations of the fibro-cartilages of the knee joint in man are familiar to every student of human anatomy. It must sound somewhat startling to him, however, to learn that they are metamorphosed muscles and tendons. The history of the mode by which they have acquired so remarkable a position is replete with interest.

The Interarticular Fibro-Cartilages.—If one of the tailed batrachians be examined, and *Menobranchus lateralis* will serve as an excellent example, we shall find the knee joint deficient in crucial ligaments and interarticular fibro-cartilages, so that this animal forms a very good starting point.

On looking closely into the myology of these amphibians, a curious fact at once becomes evident; in mammals, and in man especially, the muscles destined for the pes take origin, with very few exceptions, from the tibia and fibula; in amphibians they arise almost exclusively from the femur. This is significant, and clearly indicates that it is in the forms filling up the gap between Urodele batrachians and the lowest mammals that we must seek for an explanation of the change.

In our first ascensive step we are encountered by the frogs, who startle us with the richness of the musculature of their limbs, for in many respects myological differentiation in them surpasses that of man.

On examining the knee joint of a frog, it will be found to possess interarticular fibro-cartilages and crucial liga-

ments, but these structures differ in a very important manner from those of mammals.

In the first place, the interarticular fibro-cartilages are directly continuous with the tendons of muscles. The inner cartilage is in direct continuity with a muscular mass corresponding to the semi-membranosus; this muscle is usually described as being inserted into the back of the tibia, but the main mass will be found inseparably associated with the cartilage. The external fibro-cartilage is not well formed, and seems rather to be a continuation of the inner one than as representing a discrete element of the knee joint, such as we find in higher forms.

The question at once suggests itself—Why should so much difference prevail in the anatomy of this joint in animals so closely related as the tailed and tailless batrachians?

Gadow* explains matters thus:—"We must remember that the change of an aquatic animal, which used its limbs simply like paddles, into a semi-aquatic and partly terrestrial, and therefore crawling, creeping and running creature, involved a complete change of its muscles, and at a later period of bony framework. In swimming animals, such as *ceratodus* and *menobranchus*, the longitudinal axis of the whole limb is nearly straight, whilst a terrestrial life necessitates the bending of a limb at several angles, and the development of more or less complicated joints."

It is this flexion which explains how tendons outside the joints in animals whose limbs are nearly straight, get drawn into them when the limbs are acutely bent.

When the leg is extended, the anterior surfaces of the femur and tibia are in the same plane; when the leg is flexed, the broad upper extremity of the tibia is brought into contact with the distal part of the posterior surface of

* *Journal of Anatomy and Physiology*, vol xvi., p. 501.

the femoral shaft, and immediately in relation with the tendons of origin of the muscles destined for the foot, and in many cases with muscular tissue.

Therefore in menobranchus, the axis of whose hind limb is nearly straight, the tendons are excluded from the joint, and arise from the femur. In the frogs, whose limbs are flexed, the tendons of origin of many of the leg muscles intruding upon the joint get drawn between the opposed

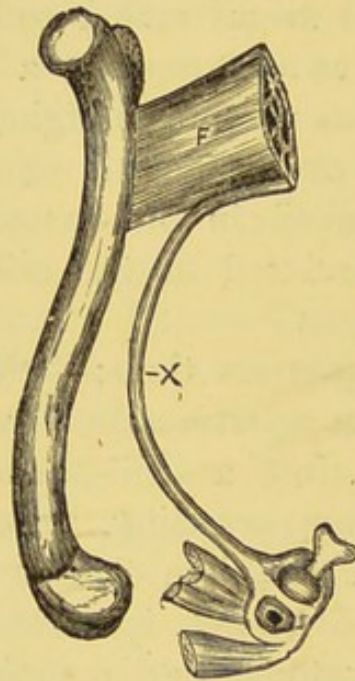


FIG. 8.—The femur, with the femoro-caudal muscle, F., of an iguana. Its long tendon X passes downwards to the interarticular cartilage of the knee joint. The cut ends of the muscles are those of the biceps, semi-membranosus, &c.

surfaces of the tibia and femur, constituting fibro-cartilages, crucial or lateral ligaments, as the case may be.

The lizards furnish the strongest possible evidence that the interarticular fibro-cartilages arise in this way. The iguana may be selected as a type.

In the thigh we find a very remarkable muscle known as the femoro-caudal (fig. 8). It is exceedingly large and arises from the infero-lateral aspect of the caudal ver-

tebræ : it is inserted by a large, broad, and strong tendon into the base of the trochanter on its extensor aspect. A little space before its insertion the muscle gives off, at right angles to its lower border, a long, thin, and delicate tendon, which passes down the thigh, on the inner side of the great sciatic nerve, to the popliteal region, where it passes between the fibula and tibia to blend with the outer part of the interarticular fibro-cartilage of the knee joint.

This would seem to shew that in lizards, at least, the interarticular cartilages are the modified tendons of muscles which have become interarticular, during the modifications the joint has passed through in its evolution. For further information concerning the morphology of this extraordinary muscle, consult this reference.*

An extended survey of the relation of these parts in animals from the lizards onward to man, leaves little doubt that the fibro-cartilages in the human knee joint are survivals of the distal termination of the femoro-caudal and associated muscles.

The Crucial Ligaments.—It is fairly conclusive that the muscles in the region of the knee joint have been affected by very considerable disturbance. For example, in primitive forms, like lepidosiren, the muscular layers pass from the trunk and invest the limbs without any transverse segmentation occurring. In frogs, lizards, and crocodiles, a gap occurs in the muscular sheet, the proximal segments attaching themselves to the tibia, the distal muscles arising from the lower end of the femur. In this way the quadriceps extensor, sartorius, gracilis, the hamstring group, and the adductor magnus, become inserted into the tibia; whilst the extensors and flexors of the digits, the peroneal group, gastrocnemius, plantaris, tibialis anticus and posticus, arise from the femur.

* *Journal of Anatomy and Physiology*, vol. xx., p. 39.

Many of the muscles have shifted their insertion from the tibia and formed new attachments to the femur, *e.g.*, the adductor magnus. On the other hand, many have left their acquired origin from the femur and descended to new attachments on the tibia and fibula (migration). Hence, it is necessary to decide whether a given ligament of the knee joint, had its origin from one of the thigh muscles shifting its insertion, or a leg muscle migrating to the tibia or fibula from the femur.

Both these processes have been in operation, and in Chapter IV. evidence was adduced to support the view that the external lateral ligament was originally the tendon of the peroneus longus, which muscle migrated from the femur to the fibula; whilst the internal lateral ligament results from the adductor magnus muscle withdrawing its point of insertion from the tibia to the femur.

The Synovial Membranes.—In the beaver the arrangement of the synovial membranes of the knee joint is after this fashion. There is a distinct synovial pouch for the patella and the patellar surface of the femur. The cavity for the articular surfaces of the femur and tibia is divided into two parts by the crucial ligaments and septum of connective tissue, thus making three synovial membranes in all: one for the patella, and one for each femoral condyle and the corresponding articular surface on the head of the tibia.

In man, however, this septum disappears, save a few strong fibres in the middle line, which pass from the lower border of the patella to the intercondyloid notch immediately below the patellar facet. This band of tissue, with its lateral fringes, adipose and fibrous in structure, is denominated in human anatomy the *ligamentum mucosum* and the *ligamenta alaria*. In reality they are simply vestiges of the sac-wall of the bursa, originally developed between the patella and the femoral condyles.

Examine a human foetus at the third month, by dividing

the knee joint vertically (fig. 9), the synovial membrane will be found arranged as follows:—The proper cavity ends on a level with the upper border of the articular cartilage of the femur. Immediately above this, and lying behind the quadriceps extensor muscle, is a large bursa, whose sac communicates with that of the knee joint proper by a small opening in its lower part. After birth, however, the diaphragm between the two cavities quickly disappears; the synovial membrane of the joint and the bursa blend to form one common cavity. Thus it follows that

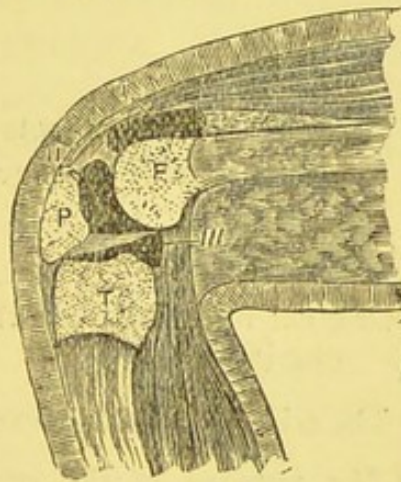

FIG. 9.—Vertical section through the knee joint of a human foetus at the third month. F. Femur. P. Patella. T. Tibia. I. Quadriceps bursa. II. Patella bursa. III. Knee joint proper.

the large cul-de-sac of synovial membrane extending under the extensor muscles of the thigh is due to secondary causes; it has also been shown that this has occurred in connection with the patella, so that the knee joint, as seen in man, is made up of its own synovial membrane reinforced by two very considerable bursæ.

Viewed in full light, the evolution of the structures concerned in man's knee joint may be considered as resulting from the changes produced by the metamorphosis, regression and migration of muscles to provide it with ligaments and interarticular fibro-cartilages; and, lastly, the annexa-

tion of bursæ to extend the dimensions of its synovial territory.

For convenience, the origin of the various structures of the knee-joint are arranged in a tabular form :—

Lateral Ligaments.

Internal	Tendon of the adductor magnus muscle.
External	Tendon of the peroneus longus.

Fibro-Cartilages.

Internal—External .	.	.	{ Modifications of the femoro-caudal, biceps and semi-membranous muscles.
---------------------	---	---	---

Crucials.

Anterior and Posterior	.	.	{ There are no certain facts as to which muscles they originally belonged.
------------------------	---	---	--

Synovial Membrane.

The great cul-de-sac .	.	.	{ Original bursa between the quadriceps extensor and the femur.
Middle portion	The original patellar bursa.
Lig. mucosum and alaria	{ The remains of the sac-wall of the patellar bursa.

CHAPTER VI.

THE ANTERIOR ANNULAR LIGAMENTS OF THE ANKLE.

THE structures included under the above title are two in number, one is placed at the lower end of the leg, and is simply a transverse band of fibrous tissue passing from the tibia to the fibula and serving to retain the vertical portion of the extensor tendons. Although it is a structure very general, from amphibians to man, it has apparently no morphological significance. The other ligament arranged

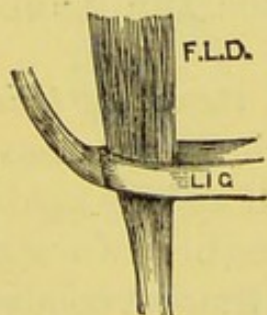


FIG. 10.—The inferior anterior annular ligament of the ankle joint of a monkey. F.L.D., extensor longus digitorum muscle.

in the form of a loop, is attached to the calcaneum at the outer end of the deep groove which lodges the interosseous ligament; the contiguous fibres of these two ligaments blend. The loop of this ligament is traversed by the tendons of the extensor longus digitorum and peroneus tertius muscles. From the inner limb of the pulley a fibrous cord passes beneath the extensor proprius hallucis and tibialis anticus muscles to be attached to the internal malleolus.

By studying the relations of this structure in a large number of mammalian forms, it turns out that the loop

which encircles the extensor longus digitorum is the essential portion of the ligament (fig. 10), but the fibrous cord passing to the internal malleolus is entirely secondary, and exhibits an extreme vagary in the way it disports itself with regard to the extensor hallucis and tibialis anticus muscles.

It is impossible to deal satisfactorily with the annular ligament of the ankle joint without taking into consideration the condition these ligaments present in birds, and as the inquiry has led me deeply into the subject of the development of the tarsus in the feathered tribe, it will be necessary to go systematically into the matter.

THE AVIAN TARSUS AND ANNULAR LIGAMENTS.

The tibia, or more correctly *tibio-tarsus*, of birds is a bone very characteristic of the class. It is a cylindrical bone, usually about half as long again as the femur. The proximal extremity presents two somewhat concave articular surfaces for the femoral condyles; in front it is produced into a prominent cnemial crest or process, which in a few cases (struthio and rhea) is ossified as an epiphysis. The distal end of the bone is terminated by a trochlear, or pulley-like, articular surface. Not unfrequently there is an oblique bar of bone on the anterior face, just above the trochlea; this osseous loop transmits some of the extensor tendons (fig. 11). The true composition of this bone will be considered when dealing with its development. The fibula of birds is usually imperfect, and presents itself as a slender osseous rod attached to the outer side of the tibio-tarsus. Its proximal end articulates with the outer condyle of the femur, being received in the fibular fossa; the distal end gradually thins and fuses with the tibio-tarsus. Although as a rule the fibula is shorter in the adult bird

than the tibia, yet it may be of the same length as in some of the penguins.

The segment beyond the tibio-tarsus is a compound of certain bones of the tarsus and metatarsus, hence it may be correctly referred to as the tarso-metatarsus; the various metatarsals which compose it, fuse to form a single bone.

As the proximal part of the tarsus becomes confluent with the tibia, and the distal portion fuses with the metatarsus, it thus comes about that the joint between the tibio-tarsus and the tarso-metatarsus is in fact a meso-

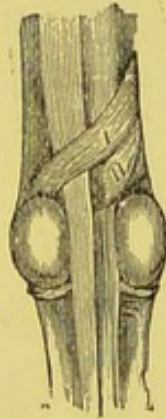

FIG. 11.—The ligaments of the ankle-joint of a fowl. I. The superficial. II. The deep ligament.

tarsal articulation, really corresponding with the medio-tarsal joint of man, which exists between the calcaneum and astragalus as its proximal elements, and the navicular and cuboid as the distal bones.

The above statements are warranted by an appeal to the development of the parts. Gegenbaur proved that the distal end of the tibia, which in the young bird is separated from the main bone by a suture, is not an epiphysis, for the cartilage in which it ossifies is separate; this individuality in the cartilaginous state distinguishes it as an element, *an epiphysis being a distinct ossification in a continuous cartilage.*

In order that the true nature of the parts shall be correctly comprehended, it will be safer to give in brief outline the development of the bird's leg, which has been worked out by Gegenbaur, Rosenberg, Baur, and Miss Johnson.*

In the limb of a chick, five days old, the tissue is condensed axially into a single mass, and the skeleton of the

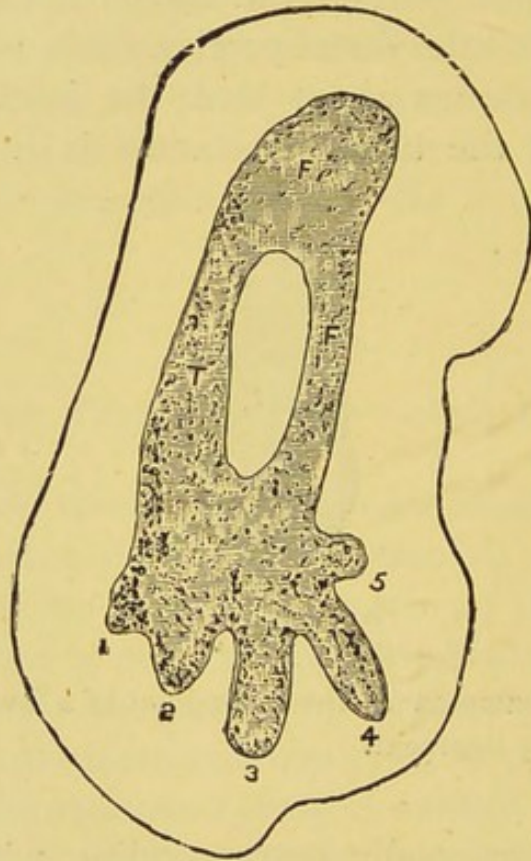


FIG. 12.—Leg of a chick at the fifth day of incubation (after Miss Johnson). Fe. Femur; T. Tibia; F. Fibula. The numerals refer to the digits.

limb is produced by the subsequent elongation and segmentation of the mass.

At this stage the limb presents the condition represented in figure 12. All the chief elements may be recognised, though they are completely continuous. The tarsus is

* "Development of the Pelvic Girdle in the Chick," *Quar. Jour. Mic. Science*, vol. xxiii. (This paper contains numerous references of value).

continuous with the tibia and fibula above and with the metatarsals below. Five metatarsals are present.

At the eighth day all the elements of the tarsus are at

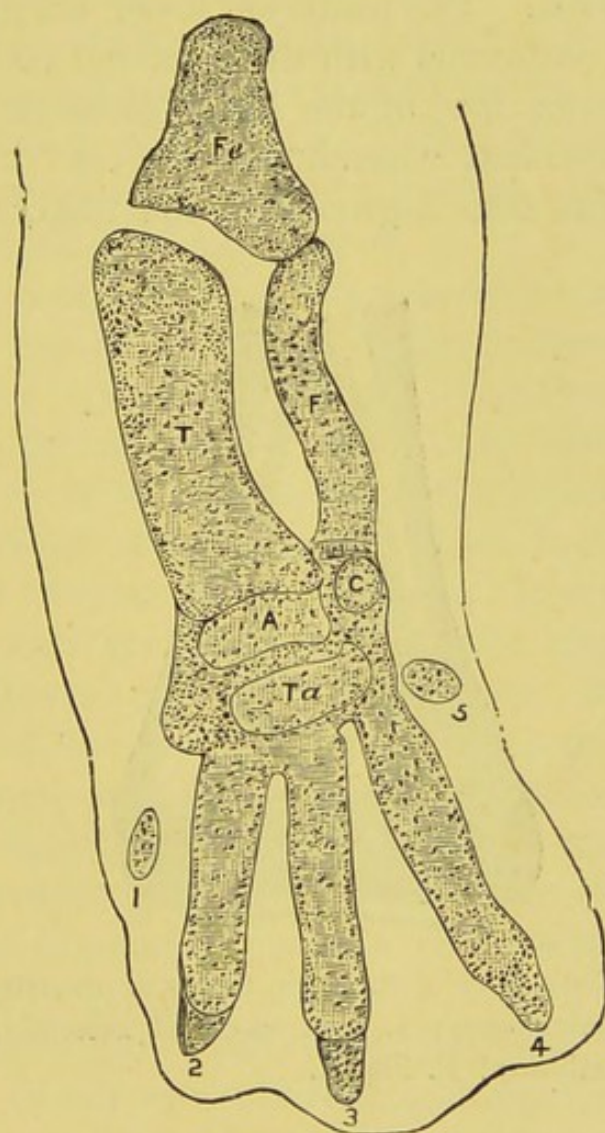


FIG. 13.—The leg of a chick at the eighth day of incubation (after Johnson). Fe. Femur; T. Tibia; F. Fibula; A. Astragalus (tibiale); C. Calcaneum (fibulare); Ta. Tarsalia. The numerals refer to the digits.

their most distinct and independent stage, though they are still united with one another, as well as with the tibia, fibula, and the metatarsals, by the condensed tissue of the groundwork of the tarsus (fig. 13).

Later, the distal and proximal parts of the tarsus become separated, and the two proximal elements fuse together. Next, the proximal parts fuse with the tibia, which has grown more than the fibula, so that the latter no longer reaches the tarsus. The posterior lower edge of the tibia first becomes continuous with the proximal tarsal cartilage while the anterior face of the latter gives off an upward process, the so-called "ascending process" of the astragalus, which fits into a groove in the tibia, and remains

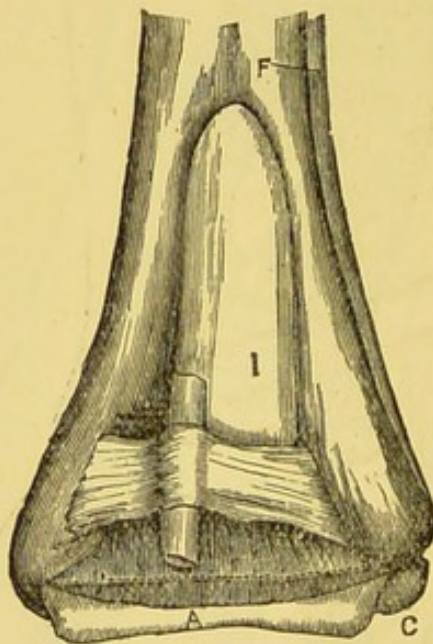


FIG. 14.—The distal end of the tibio-tarsus of an ostrich chick. A. Astragalus; C. Calcaneum; I. The so-called ascending spike of the astragalus (intermedium); F. Fibula.

for a long time separate from it. At about the same time the distal part of the tarsus fuses with the metatarsals, first with the second, next with the fourth, and lastly with the third. All these processes take place while the tarsus is still cartilaginous. In the chick two ossific nuclei later make their appearance in the proximal piece of cartilage, the inner one representing the astragalus, the outer and smaller piece the calcaneum. The distal piece of cartilage represents the tarsalia.

In the majority of birds the astragalus sends up a long osseous "spike," which fits into a groove on the anterior surface of the tibia, as shown in figure 14, and is commonly referred to as the ascending process of the astragalus. This spike has been shown by Morse* to have an independent ossific centre, and he considers it to correspond with the intermedium of the typical tarsus. The question is one so full of interest, and as I wish to give an account of some observations of my own on the subject, it is well to refer in detail to Morse's paper.

It appears that Professor Wyman sent a note to Morse, to the effect that he had found in the tarsus of an embryo heron, a long style-shaped bone, broadest at its distal extremity, lying in front of and at the distal end of the tibia, which he believed to represent the so-called ascending process of the astragalus, but which had an independent centre of ossification, and remained free from the other tarsal bones until the young had left the egg. Morse had previously shown that as the proximal series of bones become united, the fibula diminishes in size proportionally with the rapid increase of the tibia, becoming finally a splint-like bone with its attenuated distal end far removed from the tarsus; the tibia, on the contrary, enlarges, so that its distal extremity equals in transverse diameter the two proximal tarsal bones.

The intermedium, while occupying its proper position between the tibiale and fibulare, and finally uniting with them, becomes displaced, so to speak, by standing in front of the tibia. As proving the correctness of this assumption, it may be mentioned that the bone may be found occupying its true position in the tarsal series, and between the distal extremity of the tibia and fibula in the embryos of those birds in whom it is represented.

* *Anniversary Memoirs of the Boston Society of Natural History*, 1880, Morse, *On the Identity of the so-called Ascending Process of the Astragalus with the Intermedium.*

An examination of the tarsus in the embryos of the Tern (*Sterna hirundo*), Petrel (*Procellaria pelagica*), Sea Pigeon (*Uria grylle*), Eider Duck (*Somateria mollissima*), Herring Gull (*Larus argentatus*), and in the Great Auk (*Aptenodytes pennanti*), showed that in these birds the intermedium is present as a separate bone. It lies at first in a line with the proximal row of tarsal bones, opposite the space between the tibia and fibula. As the tibiale and fibulare coalesce the intermedium is crowded upwards and outwards so as to occupy a position in front of the tibia. It is the last bone to unite with the confluent tibiale and fibulare.

Since reading Morse's paper, I have had an opportunity of investigating the condition of the ascending process of the astragalus in a cygnet of *Cygnus mutis*, and in an ostrich and an emu chick. In the cygnet the "bony spike" was present as a separate ossification, exactly as Morse figures it. In the case of *Struthio* and *Dromæus* the process was just in the act of uniting with the astragalus; on making a longitudinal section through the lower end of the tibio-tarsus the line of separation was clearly visible. These three specimens have convinced me that the ascending process of the astragalus is an independent element.

I felt it was necessary to enter minutely into the details of the ossification of the bird's tarsus for two reasons:— (1) To show that the bony bridge on the lower edge of the tibio-tarsus is an "adventitious" ossification, and (2) to prove its relationship with the tarsus.

In order to show that a great deal of misconception prevails as to the nature of this oblique bar of bone, I will make the following extract from Mr. Parker's paper, "On the Osteology of *Balaniceps rex*" (*Trans. Zool. Soc.*, vol. iv.):—"The inferior or distal end of the tibia is developed from a distinct osseous centre in young birds, which piece forms all the articular parts and sends upwards a wedge-

shaped process in front, the seat of the ossification which makes the large, wide, oblique, tendon-like bridge."

Morse finds that this oblique tendon-like bridge in the heron and many other birds has no relation with the intermedium, and I am convinced, from the examination of a very large number of birds, that the pulley in question is really the homologue of the loop which in mammals binds down the tendon of the extensor longus digitorum, and has its main attachment to the proximal row of tarsal bones. It is, therefore, an adventitious ossification and not an intrinsic element of the bird's tarsus.

So far as the anterior annular ligaments of the bird's leg are concerned, it must be clear to any one who has followed the preceding account that the two structures differ very considerably in their mode of origin and in their relation to each other. It must also be very evident that the upper ligament, which involves all the extensor tendons, is the homologue of the superior ligament of the mammalian ankle joint, but the deep or inferior band, ossified in some birds, which transmits the extensor longus digitorum tendon, is the avian representative of the loop attached to the calcaneum in most mammals, including man. It may perhaps be advisable to state that the fact of it often undergoing ossification in birds is no objection to it being considered as the homologue of a purely fibrous structure, (and, so far as one knows, always so in mammals) for in the West African Lemur (*Perodicticus potto*) the anterior annular ligament of the wrist joint (which arises as the result of regression of certain portions of the short muscles of the hand) contains an osseous nodule, thus completing a bony tunnel for the flexor tendons, comparable in a certain measure to the osseous loop at the lower end of the bird's tibio-tarsus.

Admitting then that the ligaments in the legs of birds and mammals are homologous, it necessarily follows that the question be asked:—How do these structures arise, and what is their nature?

A full discussion of the mode of evolution of these two ligaments, would lead us far beyond the scope and intention of this little work, the enthusiastic student is referred to the author's original paper dealing with this particular question. The principles involved are of great interest.*

Briefly the ancestry of the anterior annular ligaments may be stated thus:—

1. The upper or vertical band arises from thickening of fibrous tissue, the result of long continued strain.

2. The lower one represents an old attachment of the extensor longus digitorum muscle as seen in the iguana and Parson's chameleon. As far as my dissections have extended, this is a structure peculiar to birds and mammals.

* *Journal of Anatomy and Physiology*, vol. xx., "Nature of Ligaments," part iv. Consult also Mivart, "Myology of Parson's Chameleon," *Proceedings of the Zoological Society*, 1870.

CHAPTER VII.

THE LIGAMENTS OF THE PECTORAL GIRDLE.

THE term pectoral girdle is applied to those elements of the skeleton which serve the purpose of attaching the upper limbs to the trunk. The component parts of this arch or girdle in the adult, consist of the clavicles and scapulæ with their connecting ligaments. It will be necessary to briefly recapitulate the leading characters of the ligaments, in order that we may fully understand their significance when dealing with the development of the parts and their morphology.

1. THE LIGAMENTS AT THE STERNAL (VENTRAL) END OF THE CLAVICLE.

(a) *The interclavicular.* This is a T-shaped band of dense fascia uniting the clavicles across the median line and sending a vertical slip downwards to be attached to the top of the sternum.

(b) *Capsular ligaments.*

(c) *An interarticular fibro-cartilage*, interposed between the sternum and the clavicle. Occasionally a cartilaginous, or an osseous nodule may be found in the lower end of these ligaments, named the epi-sternal bone.

2. THE LIGAMENTS AT THE ACROMIAL END OF THE CLAVICLE.

(a) *The capsular*, an insignificant structure.

(b) *An interarticular cartilage*, this is occasionally absent.

3. The clavicle is connected with the costal cartilage of the first rib by the *rhomboid* ligament, and with the coracoid process of the scapula by means of the *conoid* and *trapezoid* ligaments.

4. Closely connected with the preceding group are two ligaments passing from the scapula to the humerus; one the *coraco-humeral* lying *outside* the capsule of the shoulder joint, the other the *gleno-humeral* which may be *inside* the joint, but in man is usually situated *between* the capsule and the synovial membrane.

5. The *coraco-acromial* ligament; a very strong band of fascia passing from the outer side of the coracoid to the acromion process.

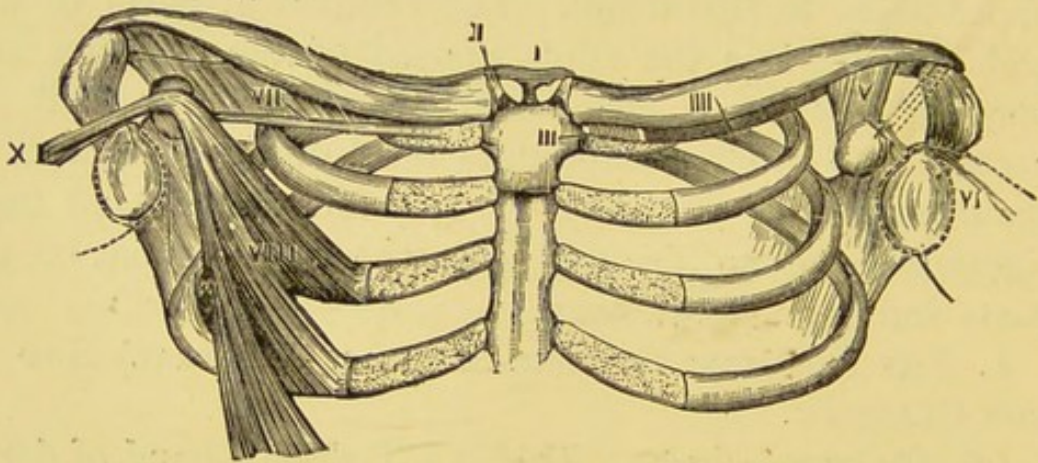


FIG. 15.—A general view of the clavicular ligaments and associated structures. I. The interclavicular ligament; II. Interarticular fibrocartilage; III. Rhomboid ligament; IIII. The subclavius muscle; V. The conoid and trapezoid; VI. The gleno-humeral ligament; VII. The costo-coracoid membrane and ligament; VIII. The minor pectoral muscle; X. Its tendon as the coraco-humeral band. The dotted line indicates the situation of the coraco-acromial ligament.

6. The *costo-coracoid ligament*; a dense band of tissue marking the limit of the costo-coracoid membrane and running from the tip of the coracoid to the costal cartilage of the first rib, and thence to the sternum. Frequently it contains cartilage nodules. It is stronger and more pronounced in many of the quadrumana than in man, but in him it is frequently very conspicuous.

The ligaments of the girdle when considered morphologically readily fall into two groups:—

- (I.) Those derived from its intrinsic elements.
 (II.) Those arising from the regression of muscles.
 Group I includes the following ligaments:—

1. The interclavicular.
2. The interarticular fibro-cartilages.
3. The coraco-acromial.
4. The costo-coracoid.
5. The coraco-scapular (transverse) ligament (p. 6).

The origin of these ligaments is so involved in the ontogeny of the various bones and their cartilaginous precursors, that the development of the clavicle and scapula must be detailed. Before doing so, however, it will be advisable to give an account of what may be

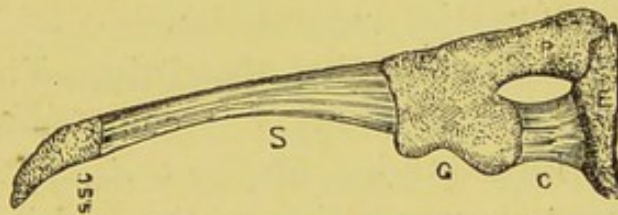


FIG. 16.—The shoulder-girdle of an ostrich chick. S. Scapula; SSC. Supra-scapular cartilage; C. Coracoid; P. Precoracoid; E. Epicoracoid; G. Glenoid fossa.

considered the typical or generalised form of the cartilaginous girdle.

This consists essentially of a bar of cartilage which may be divided into three parts:—1. A dorsal segment representing the scapula. 2. A ventral bar, the coracoid, forming with the scapula a socket for the reception of the proximal bone of the limb. 3. A rod or bar situated anteriorly to the coracoid, and named in consequence the precoracoid. These two segments agree in the circumstance that they meet the sternum ventrally and the scapula dorsally; but the precoracoid is, as a rule, excluded from the glenoid fossa (fig. 16). The bar of cartilage which unites the ventral ends of the coracoid and precoracoid is termed the epicoracoid.

From such a shoulder-girdle as this, we may derive any form, from chelonians onwards to man, by the two processes of addition and suppression, the suppressed parts being usually represented by fibrous tissue.

This type form is also valuable, when we wish to compare homologous parts of the pectoral with the pelvic girdle, for although in the adult the differences are considerable, yet in the cartilaginous state they are very similar.

From the type-form, man's primitive pectoral arch differs only in this particular;—the continuity of the coracoid and precoracoid bars is interrupted. This defect in the precoracoid is due to the intrusion of the clavicle as a secondary element in the arch. In the case of the coracoid it is a consequence of partial suppression.

The ossification of the clavicle.—This bone is the first in the skeleton to ossify. It commences about the sixth week of intra-uterine life by a deposition of ossific matter at a spot corresponding to the middle of the shaft of the clavicle; it may be detected before the formation of the precoracoid cartilage, consequently it must be regarded as a membrane bone. Later, the extremities of the clavicle invade the cartilage and serve as an example of a bone originally arising in membrane becoming secondarily engrafted on cartilage and assuming a composite character.

The clavicle is completed by an additional ossification at the sternal end. The nucleus is usually detected about the eighteenth year, and unites with the shaft at twenty-two.

The interarticular fibro-cartilages at the sternal and acromial ends of the clavicle, arise from the regression of the inner and outer extremities respectively of the cartilaginous precoracoid. The nodule of bone known as epi-sternal, is developed in this remnant of the precoracoid bar.

Carwardine* has investigated the epi-sternal bones in man, and detected a band which he names the supra-sternal ligament passing from the sternal end of the clavicle to the top of the sternum. He regards this ligament as a remnant of the precoracoid, and the epi-sternal bone as an ossification in the ligament. The epi-sternal bones are sometimes represented by tubercles at the top of the sternum.

The ossification of the scapula.—This bone is preformed in cartilage. The primary centre appears about the third month of intra-uterine life near the base of the spine, and quickly extends itself throughout the cartilage, so that at birth we only find a thin strip of cartilage, along the vertebral border; the glenoid fossa, the coracoid and acromion processes are yet unossified. In the first year after birth a nucleus appears for the coracoid, and from this centre ossific matter extends into the glenoid fossa and as far backwards as the notch in the upper border of the scapula; ossification only extends a short way into the coracoid bar, the chief portion being represented by the costo-coracoid ligament. At the fifteenth year the coracoid becomes ankylosed to the scapula and ossific nuclei appear for the acromion; the supra-scapular cartilage ossifies from two centres, one opposite the spine, the other at the inferior angle. A thin lamina is added later to the glenoid fossa, and by the twenty-fifth year the ossification of the scapula is complete.

The most remarkable feature in the development of this bone is the early appearance of the coracoid centre, and the long persistence of the strip of cartilage at the vertebral border. With regard to the coracoid, many look upon its nucleus as a primary one; even then it differs from the usual course of events, for its appearance is late, so that considering it from either point of view its de-

* *Journal of Anatomy and Physiology*, vol. xxvii.

velopment is anomalous and suggestive. This opinion is confirmed when the part is studied morphologically.*

On comparing the scapula of a human foetus at the seventh month with the type-form, we shall at once see that the strip of cartilage along its vertebral border is homologous with the supra-scapular cartilage, which in batrachians persists throughout life, merely becoming impregnated with lime-salts. There is substantial agreement in that the glenoid fossa is formed by the confluence of the coracoid and the body of the scapula. The coracoid differs

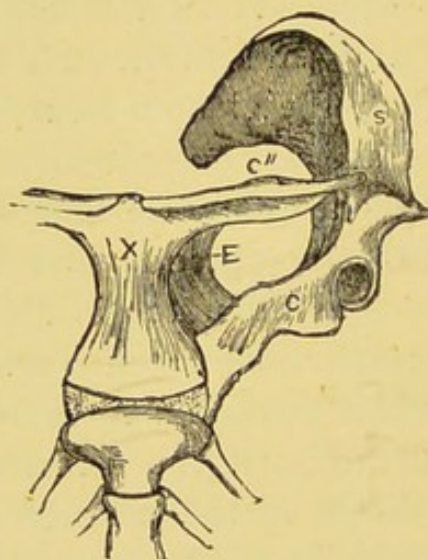


FIG. 17.—The shoulder girdle of *Ornithorhynchus*. S. Scapula. C. Coracoid. C''. Clavicle. E. Epicoracoid. X. The interclavicle.

from the type-form, in the fact that it is represented by bone in only the scapular third, the sternal portion being replaced by fibrous tissue.

The Interclavicular Ligament.—In order to elucidate the nature of this ligament, we must study the pectoral girdle of *Ornithorhynchus*.

The complex pectoral arch of this low mammal is shown in figure 17, where S represents the scapula, tipped with

* Howes, "On the Coracoid of Terrestrial Vertebrata," *Proc. Zool. Soc.*, June, 1893.

its thin streak of supra-scapular cartilage, C is the coracoid, which in no group of mammals other than the monotremata is prolonged as bone to the sternum. The precoracoid is represented by an osseous nodule resting on the sternum anterior to the coracoid, and as it articulates with the latter it contains also the epi-coracoid element. The clavicles, C", are supported at their inner extremities by a large T-shaped bone, of membranous origin, the inter-clavicle. It is certainly remarkable that in order to find a similar skeletal element we must descend to lizards.

A general survey of the pectoral girdle teaches us that fundamentally it consists of a dorsally placed scapula and two ventral segments, coracoid and precoracoid. The scapula and coracoid together form a glenoid fossa. The scapula is in relation with coracoid and precoracoid, whilst the two latter are united ventrally by a bar of cartilage, the epi-coracoid. In the majority of types the precoracoid becomes divided in its centre by the clavicle, and its extremities are invaded by the growing bone. Its median extremity is in man represented by the interarticular fibro-cartilage between the clavicle and sternum, occasionally a little cartilage or osseous nodule is present in them (the epi-sternal bones of Breschet). The scapular remnant of the precoracoid finds a representative in the interarticular fibro-cartilage between the acromion and clavicle (Parker's confusing mesoscapular segment). The coracoid in man is a stunted process, which early fuses with the scapula, but its prolonged condition in frogs, birds and monotremes, is represented by the **costo-coracoid ligament** running in the free border of the membrane of that name, and presenting chondral particles at its sternal attachment. The interclavicular ligament is the fibrous representative of the bone of that name in lizards and in monotremes.

The Coraco-acromial Ligament.—This structure

is triangular, its apex being attached to the tip of the acromian process and its base extending along the outer border of the coracoid process. The ligament consists of three parts:—An anterior broad band (some of its marginal fibres can be traced into the short head of the biceps muscle); a posterior narrower band reaching to the base of the coracoid, and a thin stratum of fibrous tissue bridging the interval between the two diverging limbs. When the pectoralis minor is inserted into the capsule of the shoulder joint instead of into the coracoid process, its tendon passes between the two limbs of the coraco-acromial ligament (Gordon Brodie).*

In the scapula of the two-toed sloth the acromion process sends a long hook-like piece of bone to meet the coracoid. In the foramen triosseum of very many birds the scapula joins the coracoid above as well as below the foramen, hence it would seem probable that the anterior limb of the coraco-acromial ligament represented this osseous element. Brodie has carefully investigated the morphology of this ligament and thinks it probable that it is derived from the short head of the biceps.

* *Journal of Anatomy and Physiology*, vol. xxiv., p. 247.

CHAPTER VIII.

THE LIGAMENTS OF THE PECTORAL GIRDLE (*Continued*).

WE have now to consider those ligaments arising from the regression of muscles, namely:—

1. The costo-clavicular (rhomboid).
2. The coraco-clavicular.
3. The gleno-humeral.
4. The coraco-humeral.

The rhomboid ligament.—The costo-clavicular or rhomboid ligament is attached to the cartilage of the first rib near the sternal end, and passes obliquely upwards, backwards and outwards to a rough impression on the under surface of the clavicle near its inner extremity.

The coraco-clavicular ligament.—This ligament consists of two parts, an inner fasciculus termed the conoid, and an outer the trapezoid ligament. The conoid fasciculus is attached by its base to the conoid tubercle of the clavicle, whilst the apex is inserted into the root of the coracoid process. The trapezoid portion passes from the upper surface of the coracoid to a ridge on the under aspect of the outer extremity of the clavicle. Between the two ligaments a bursa may frequently be detected.

The gleno-humeral ligament.—This ligament is usually described as an accessory band, springing from the edge of the glenoid fossa at the root of the coracoid process, and passing downwards to the lesser tuberosity of the humerus. It runs more or less parallel with the long tendon of the biceps, and may be identified in the usual conditions of the parts as a bulging into the joint, separated from the synovial cavity by the thin serous membrane only.

Occasionally the ligament is completely surrounded by synovial membrane and is as prominent a structure in the joint as the biceps tendon; indeed it then exists as a veritable *ligamentum teres*. This condition is far more frequent in the foetus than in the adult. It also exists as a strong and well defined ligament normally in a very large number of mammals. We shall return to this subsequently, the general character of the ligament is shewn in figure 18, from the Beaver, *Castor canadensis*.

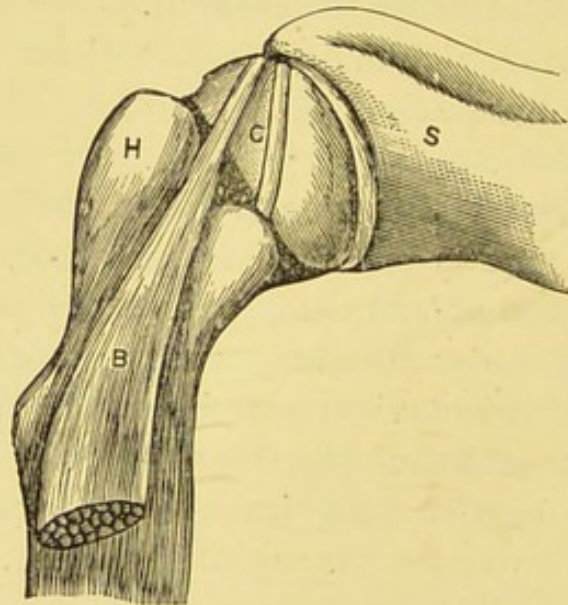


FIG. 18.—The shoulder joint of a Beaver (*Castor canadensis*), to show the large size of G. The gleno-humeral ligament; S. Scapula; H. Humerus; B. Biceps.

The coraco-humeral ligament.—This is a strong wide band passing from the root and outer border of the coracoid process to the neck of the humerus above the great tuberosity, it is intimately associated with the capsule of the joint.

The morphology of the subclavius muscle.—In man the subclavius muscle arises from the first costal arch at the junction of the rib with its costal cartilage, close to the costo-clavicular (rhomboid) ligament. The fibres pass

outwards and upwards arranged in a prismatic manner to be inserted in a groove on the under surface of the clavicle extending as far as the interval between the conoid and trapezoid ligaments lying beneath the costo-coracoid membrane.

Its most important variations are the following:—1. It may be inserted into the root of the coracoid process instead of the clavicle. 2. The muscle may divide its insertion, one part passing to the clavicle, the other ending in the root of the coracoid process. In some instances a few fibres are inserted into the conoid ligament. 3. Occasionally it is attached to the coracoid process, and a bursa

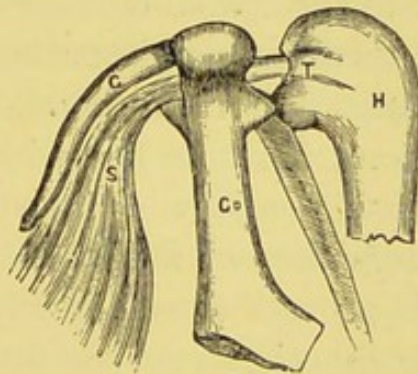


FIG. 19.—The subclavius of a bird. H. Humerus. S. Subclavius. T. Its tendon. C. Clavicle. Co. Coracoid.

exists between the tendon and the coracoid, whilst a prolongation may pass from this tendon to the humerus. Other variations are described, but these three are alone of importance at present.

Leaving man for the present and descending to the amphibia we shall find that the interesting form *Menobranchus lateralis* presents about the shoulder a very distinct muscle, having the following attachments:—

It arises from the ventral surface of the long precoracoid cartilage and passes backwards to be inserted into the head of the humerus, between the deltoid, pectoralis major and supraspinatus muscles.

St. George Mivart in his paper on the myology of this creature, identifies the muscle as the *subclavius*. Whether it deserves this name or that of *epicoraco-humeral* is a matter of little moment, but its situation and points of attachments are, for the purpose of the argument, of great importance. It is probable that this muscle is the ancestor of the *subclavius* of human myology.

If the shoulder joint of a carinate bird be dissected, a muscle will be found arising from the keel and median portions of the body of the sternum, as a broad flat sheet, which passing forward ends as a strong tendon, in order to traverse the foramen formed by the union of scapula, coracoid and clavicle (fig. 19); emerging from the osseous ring it is inserted into the dorsal surface of the head of the humerus, in the immediate neighbourhood of the attachment of the *pectoralis major* muscle. The tendon after threading the foramen triosseum lies within the capsule of the joint. This muscle enjoys a variety of names, *e.g.*, *pectoralis secundus*, *levator humeri*, and *subclavius*.

Prof. Rolleston* proved most conclusively that this muscle, whose main function consists in raising the wing, is homologous with the mammalian *subclavius* and not with the *pectoralis minor*.

Having discussed the morphology of this muscle, an attempt will now be made to render it responsible for the rhomboid, coraco-clavicular and gleno-humeral ligaments. In many mammals the *subclavius* arises from the sides of the sternum and the costal cartilage of the first rib, replacing the rhomboid ligament, and it is reasonable to regard the rhomboid ligament as arising from the regression of the sternal fibres of the *subclavius*.

We must now consider the relation of the *subclavius* muscle to the coraco-clavicular ligaments. When describing the variations to which that muscle was liable, we

* *Linnean Soc. Trans.*, vol. xxvi., 1868.

noted that it may be inserted into the coracoid process, or partly into the coracoid and clavicle, and in some instances into the fibres of the conoid ligament; under these conditions it seems the most probable explanation that these ligaments arise from regression of a portion of the subclavius. If their relation to the gleno-humeral be examined, it will be found that the two sets come into relation at the base of the coracoid process. Seeing that the gleno-humeral ligament is closely associated with the coraco-clavicular set, and these are intimately connected with the subclavius muscle, the inference would be that *the gleno-humeral ligament is the divorced tendon of that muscle.* This is further supported by a case reported by Walsham* in which the subclavius was inserted into the coracoid process, and a tendinous expansion passed thence to the capsule of the shoulder joint. Between the tendon and the coracoid a bursa existed.

Previously the only gleno-humeral known, besides that of man, was the structure so commonly referred to as "the ligamentum teres in the shoulder joint of the frog." If the view which would regard the gleno-humeral band as originally belonging to the subclavius is correct, a gleno-humeral ligament ought to be present with tolerable frequency, especially as the subclavius is so constant in mammals, and in other forms above fishes. The examination of a very large number of mammals has shown that a gleno-humeral, as well-developed as that represented in fig. 18, is present very frequently, in many instances it is as thick as the tendon of the biceps. In this condition it exists in many Quadrumana, Lemuridæ, and Insectivora, in all Rodentia, and many of the Marsupialia.

It is curious that those mammals which have no ligamentum teres in the hip joint have not a gleno-humeral ligament in the shoulder:—The seal, elephant, rhinoceros,

* *St. Bartholomew's Hospital Reports*, vol. xvi.

walrus, ornithorhynchus, echidna, sea-otter, sloth, orang, *hyrax* and *pangolin*.

1. Every mammal in whom I have up to the present time found a gleno-humeral ligament, likewise possesses a ligamentum teres in the hip.
2. Those mammals in whom a ligamentum teres is absent, also lack a gleno-humeral band.
3. In those forms in whom the gleno-humeral is well developed, the ligamentum teres of the hip is also very thick and strong.

The reason for regarding the gleno-humeral ligament (or gleno-humeral band when it merely appears as a thickening in the capsule) as the divorced tendon of the subclavius muscle, may be briefly enumerated.

1. All amphibians which possess the equivalent of the subclavius—the *epicoraco-humeral* of Mivart—in a well-developed form, lack the gleno-humeral ligament.
2. In birds the subclavius muscle (under the name of *levator humeri*) reaches its maximum of development, and passes through the shoulder joint as a tendon to be inserted into the humerus; no gleno-humeral ligament is present.
3. In mammals the subclavius is a very constant muscle and a gleno-humeral ligament is present in a very large number of them; when not represented as a free ligament it may often be detected blended with the capsule of the shoulder joint, lying *between* it and the synovial membrane.

Viewed in the full bearings of this speculation the history of the subclavius is very instructive. Commencing with menobranchus we see it as a muscle arising from the precoracoid, and at its insertion enveloping the outer aspect of the head of the humerus, being muscular throughout.

Next we see it luxuriating in full perfection in flying birds, its distal end metamorphosed into tendon, per-

forming the laborious and important function of raising the wing.

Lastly, in man it becomes reduced to almost insignificant proportions lying as a second rate muscle under the clavicle and representing in its retirement the middle portion only of the bird's *levator humeri*, its proximal end degenerated into a uniting band to connect the clavicle with the first costal arch, whilst its outer end is represented by the coraco-clavicular ligaments, and the small insignificant band, so far as function is concerned, known as the gleno-humeral ligament. In some cases in man the muscle may be represented entirely by the fibrous tissue.

The coraco-humeral must now be discussed. In man it is usual for the pectoralis minor muscle to be inserted into the upper surface of the coracoid process near its outer border; a bursa frequently intervening between the tendon and the coracoid. Frequently it happens that the tendon glides over the coracoid process and gains an insertion into the great tuberosity of the humerus. In very many monkeys this is the normal condition. This induced some anatomists to believe that the gleno-humeral ligament was the tendon of the pectoralis minor muscle. Their view of the matter is invalidated on two points. 1. The tendon of the pectoralis minor when it takes this course lies outside the capsule, whereas the gleno-humeral ligament is situated between the capsule and the synovial membrane. 2. The tendon of the *levator humeri* is inside the capsule, and this muscle of the bird is homologous with the subclavius. Lastly the relation of the pectoralis minor to the capsule in certain cases occurring in man and monkeys, induces me to believe that the coraco-humeral ligament is the tendon of that muscle transformed into a fibrous band.

The ancestry of the various ligaments of the pectoral arch may be arranged in two categories:—Those representing skeletal elements and those derived from muscles.

1st Group.

The ventral end of precoracoid	The interarticular fibro-cartilage between clavicle and sternum and the so-called episternals.
The scapular end of precoracoid	Acromial interarticular fibro-cartilage.
Coracoid	Coracoid and costo-coracoid ligament.
Coraco-scapular bridge (sloth, etc.)	Coraco-scapular ligament.
Interclavicular bone (lizards and monotremes).	Interclavicular ligament.

2nd Group.

Sternal end of subclavius	Rhomboid ligament.
Humeral end of subclavius	Conoid, trapezoid and gleno-humeral ligaments.
Humeral end of pectoralis minor	Coraco-humeral ligament.
Short head of biceps	Portion of coraco-acromial ligament (Brodie).

A list of mammals which have been examined to determine the presence or absence of the gleno-humeral ligament.

In all the mammals enumerated in the accompanying list, the ligament was present and as well developed as represented in the beaver on page 58. The numeral refers to the number of each species specially examined.

QUADRUMANA.—*Cercopithecus cynosurus*, 8; *C. lalandii*, 7; *C. callitrichus*, 2; *C. mona*; *C. erxlebeni*; *C. campbelli*; *C. nictitans*; *C. albigena*. *Macacus sinicus*, 20; *M. cynomologus*, 10; *M. cyclopis*; *M. nemestrinus*, 6. *Theropithecus gelada*. *Cynocephalus hamadryas*; *Cyn. anubis*, 2. *Chrysothrix sciurea*, 5. *Cebus*

fatuellus; *Ceb. capucinus*, 3; *Ceb. albifrons*. *Ateles paniscus*; *A. ater*, 2. *Hapale jacchus*, 4; *H. penicillata*, 2. *Cercocebus albigena* (in this species the ligament is thin). *Semnopithecus leucoprymnus*; *Nyctipithecus vociferans*, 2. *Brachyurus rubicundus*.

LEMURIDÆ.—*Lemur catta*, 3. *Galago alleni*, 3; *G. maholi*, 2. *Perodicticus potto*, 2. *Chirogaleus coquereli*. *Microcebus smithi*. *Hapalemur griseus*. In *Chromys madagascariensis* it was present but very thin.

INSECTIVORA.—*Talpa europæa*, 3. *Erinaceus europæus*. *Tupaia peguana*, 2. *Centetes madagascariensis*. *Microgale longicauda*. *Sorex vulgaris*.

RODENTIA.—*Pteromys magnificus*. *Arctomys monax*. *Cynomys ludovicianus*, 3. *Castor canadensis*, 8. *Myoxus glis*; *M. dryas*. *Fiber zibethicus*. *Dipus ægyptius*; *D. hirtipes*. *Myopotamus coypus*, 6. *Hystrix cristata*. *Erithrizon dorsatus*. *Sphingurus prehensilis*. *Cælogenys paca*. *Dasyprocta aguti*. *Sciurus maximus*. *Sciurus hypopyrrhus*. *Xerus getulus*. *Sciuropterus fimbriatus*. *Gerbillus indicus*. *Cricetomys gambianus*. *Mus barbarus*. *Rhizomys badius*. *Octodon cumingi*. *Cerodon rupestris*. *Arvicola amphibius*. *Mus musculus*; *Mus decumanus*. *Lepus cuniculus*.

In some rodents the ligament is very large, and occupies a groove in the cartilage covering the head of the humerus.

MARSUPIALIA.—*Belideus breviceps*. *Didelphys cancrivora*; *D. virginiana*, 2; *D. opossum*; *D. philander*, 2; *D. viverrina*. *Phalangista vulpina*, 3. *Hypsiprymnus gaimardi*. *Phascalomys wombat*. *Cuscus maculatus*, 2.

EDENTATA.—*Chlamydophorus truncatus*.

The gleno-humeral ligament is *absent* in the mammals mentioned in the lists which follow, but in many a thickened band was detected in the capsule which may have represented it.

QUADRUMANA.—Gorilla, Chimpanzee (*Anthropopithecus troglodytes*), 3. Orang-outang (*Simia satyrus*), 2. Gibbon (*Hylobates leuciscus*), 2. *Macacus inuus* (in this form a thick band may be seen in the capsule).

CHIROPTERA.—*Pteropus poliocephalus*. *Desmodus rufus*.
Plecotus auritus.

HYRACES.—*Hyrax capensis*, 2.

UNGULATA.—*Rhinoceros (Rhinoceros sumatrensis)*. *Tapirus americanus*. *Cariacus virginianus*; *C. rufus*. *Pudua humulis*. *Tragulus meminna*. *Equus*. *Bos taurus*; *B. indicus*. *Oreas canna*. *Llama huanacos*; *L. peruana*. *Sus scrofa*. *Porcula salvania*. *Babirussa alfurus*. *Strepsiceros kudu*. *Capra hircus*. *Ovis aries*; *O. blandfordi*; *O. burrhel*. *Moschus moschiferus*. *Tragulus*, species incerta. *Hydropotes inermis*. *Muntjac sclateri*. *Hippopotamus amphibius*. *Oryx beisa*. *Cephalophus mergens*; *C. pygmæus*.

CETACEA.—*Phocæna communis*.

CARNIVORA.—*Felis leo*; *F. tigris*. *Canis familiaris*. *Herpestes ichneumon*; *H. griseus*. *Lycaon pictus*. *Lutra vulgaris*. *Nasua rufa*. *N. narica*. *Phoca vitulina*. *Enhydra marina*, 2. The common cat. *Felis javanensis*, 2. *Paradoxurus typus*. *P. trivirgatus*. *Ursus syriacus*. *Ursus maritimus*.

Very many other species of Carnivora and Ungulata have been examined with a negative result, but at first I did not make note of these cases, therefore, the species cannot be indicated individually.

Although in most of the Carnivora the gleno-humeral ligament is absent, yet it turns up in that singular form the Two-spotted Paradoxure* (*Nandinia binotata*); it is also present in the Himalayan Bear (*Ursus tibetanus*).

EDENTATA.—*Bradypus tridactylus*, 3. *Tatusia peba*; *T. hybrida*; *T. sexcinctus*. *Dasypus villosus*. *Myrmecophaga jubata*, 2. *Tamandua tetradactyla*, 2. *Manis didactyla*, 2. *Orycteropus capensis*.

MARSUPIALIA.—*Perameles lagotis*. *Phascolarctus cinereus*, 3. *Macropus rufus*; *M. giganteus*; *M. melanops*. *Halmaturus bennettii*; *H. ualabatus*; *H. derbianus*.

MONOTREMATA.—*Echidna hystrix*. *Ornithorhynchus paradoxus*.

* It was absent in a specimen subsequently dissected.

CHAPTER IX.

THE LIGAMENTS OF THE HIP JOINT AND PELVIS.

As in the case of the shoulder girdle, so with regard to the pelvis, a study of the hard parts is not sufficient to enable us to comprehend, in its fulness, their morphology. The various ligaments in connection therewith must be considered; for this purpose the ancestry of the following structures will be detailed.

1. The pectineus and the ligamentum teres.
2. The gluteus quartus and the ilio-femoral band.
3. The pyramidalis and the marsupial bone.
4. The biceps and the great sacro-sciatic ligament.
5. The coccygeus and the lesser sacro-sciatic ligament.

1. **The Pectineus and the Ligamentum Teres.**

—The round ligament of the hip joint has long been an anatomical puzzle and many opinions have been held concerning it. Arguments will be raised here to shew that in all probability it belonged to the pectineus but has become separated from it in consequence of skeletal modifications. The ligament is fairly constant in mammal, but it is absent in the seal, elephant, rhinoceros, walrus, ornithorhynchus, echidna, sea-otter, sloth, orang, hyrax and pangolin.

In birds the ligament is said to be present with only one exception—the cassowary,—but in a specimen of *Casuarus appendiculatus* dissected by me, the ligamentum teres was present in both hip joints.

In reptiles possessing limbs, and in amphibians, a band representing the round ligament is universally present.

It is in the horse that we first get the glimpse of the true nature of the ligament, for in this animal it consists of two parts, one hidden within the joint termed the cotyloid portion, the other passes out of the cavity to join the linea alba at its junction with the pubes, hence it is termed the pubio-femoral portion. From this band the pectineus takes origin.

In the ostrich the ligamentum teres has a true tendinous structure. It is dense and strong, contains a large quantity of yellow elastic tissue arranged in fasciculi as in the tendon of a muscle. In this bird it may measure 2 cm. in transverse section.

Many birds possess in their thigh a very extraordinary muscle known as the ambiens, full of interest on account of its remarkable course, variability, and relations. When fully developed it has the following attachments. It arises from the tip of the short anteriorly directed spine which is situated just above the anterior border of the acetabulum and runs along the inner side of the thigh to the inner side of the knee, where it is covered by the sartorius, which is above it in the former part of its course. Its thin tendon then crosses the knee, in front of the patella, to join the fibres of origin of the flexor perforatus digitorum.

In the adult ostrich a section carried through the acetabulum so as to divide the ambiens at its point of origin, and the ligamentum teres, will show that the two latter are connected by fibrous tissue.

In the winter of 1883, I was fortunate enough to obtain an ostrich chick, and a dissection of its hip joint showed clearly enough the ligament and a small muscular slip, parallel with the ambiens, in direct continuity, as shown in figure 20. The actual specimen is preserved in the museum of Middlesex Hospital. The ambiens and the muscular slips mentioned above, are the representatives in birds of the mammalian pectineus.

The hip-joint of a sphenodon was then examined. In

this very curious lizard, as in lacertilia generally, the hip-joint is of very simple character, and the muscle corresponding to the ambiens of birds and the pectineus of mammals arises by two heads, one from the lateral spine of the pubes, the other lies inside the capsule and gains an attachment to the head of the femur, thus corresponding in its relation with the joint, to the ligamentum teres of mammals and birds.

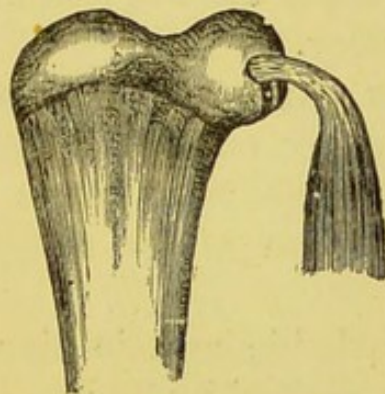


FIG. 20.—The femur of an ostrich chick with the pectineus muscle and ligamentum teres in continuity.

The varying relation of muscle and ligament may be arranged in a tabular form thus:—

<i>Sphenodon</i>	{ Tendon of ambiens* (pectineus) passes inside the capsule to the head of the femur.
<i>Struthio</i> .	{ Ligamentum teres and ambiens muscle directly continuous.
<i>Equus</i> .	{ Ligament in two parts, one continuous with the pectineus outside the joint.
<i>Homo</i> .	{ Ligamentum teres, a fibrous band carrying blood vessels to the head of the femur.

* For all that relates to this strange muscle consult Garrod's remarkable paper in *Proc. Zool. Soc.*, 1873, p. 626. "On certain Muscles in the Thigh of Birds, etc."

There is no ligament in the body which can boast such an extensive literature, or has exercised more the ingenuity of physiologists and surgeons than the one we have been considering.

Teleologists like Paley* have been enraptured with this structure, and anatomists have ascribed to it wonderful mechanical resistance and uses. Alas! in this, as in so many like cases, morphology demands for it a low level and determines it to be a vestigial and practically useless ligament. In this sense teleology is as poetry, but morphology as plain history.

2. **The Gluteus Quartus (scansorius).**—In 1818 Dr. Traill,† in a paper entitled “Observations on the Anatomy of the Chimpanzee,” makes the following remarks in his description of the myology of this mammal:—

“The most remarkable muscle about the top of the thigh has not been noticed by Tyson, Camper, Cuvier, or the older anatomists. It is a flat triangular muscle arising from the whole anterior edge of the ilium to within half an inch of the acetabulum, and is inserted to just below the fore part of the great trochanter, between the head of the cruralis and the vastus externus, a little below the origin of the former; it is thin and fleshy throughout its whole extent, except where it is inserted by a very short, flattened tendon. At its upper part it is united by cellular substance to the iliacus internus. The action of the muscle, which appears to be peculiar to this animal, is to draw the thigh upwards towards the body; and it seems especially intended to assist in climbing. On this account we propose to call it the *scandens* or *musculus scansorius*, and we are disposed to regard this as one of the principal peculiarities of the muscle.”

* See especially his *Natural Theology*.

† *Wernerian Transactions*, vol. iii. It was really an Orang.

Gruber* under the name of *Gluteus quartus* has described two occurrences of the *scansorius* in man.

The muscle arose from the ilium near the anterior superior spine, in close relation with the gluteus minimus, but was quite distinct from it, and passed to the outer surface of the great trochanter, slightly posterior to the tendon of insertion of the gluteus minimus (fig. 21). In both cases Gruber states precisely that it was an independent muscle, and not a detached portion of the gluteus minimus or

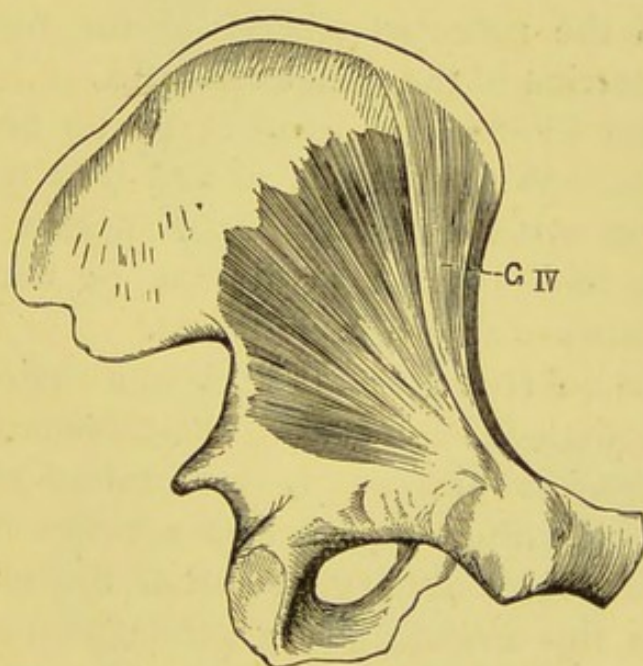


FIG. 21.—The Gluteus quartus (*scansorius*) in man (after Gruber).

medius. Gruber further refers to his examination of some fifty mammals, with regard to the existence, degree of development, and homology of this muscle.

A comparison of the hip-joint in man and *Quadrumana* brings out one point very strongly. The various bands known as accessory ligaments of the capsule seem to be peculiarly human, and the reflected tendon of the rectus

* Virchow's *Archiv*, Bd. cvii., S. 480. See also Testut, *Les Anomalies musculaire*.

which, in man, lies between the layers of the capsule, in mammals is quite outside this structure.

In mammals possessing a gluteus quartus, the muscle fibres, which arise from the ilium near the anterior inferior spine, overlap the reflected tendon of the rectus femoris, and bear precisely the same relation to it as the fibrous expansion in the capsule of man's hip-joint. The limb of the ilio-femoral band, which is associated with the great trochanter and anterior inferior spine of the ilium, corresponds in its attachments and relations to the gluteus minimus and the reflected tendon of the rectus, to the origin and insertion of the gluteus quartus.

Further, the ilio-femoral band is by no means a constant structure. When fully developed it is rounded and tendon-like, at other times it simply appears as a slight thickening in the capsule; or it may be unrepresented. Its attachments are shown in figure 22.

The gluteus quartus presents itself in a variety of forms. In many mammals it lies between the gluteus medius and minimus. In others the muscle is in actual contact with the capsule of the hip-joint. It also appears to be correlated with the degree of development of the gluteus minimus. When this muscle is large, the gluteus quartus is merely a narrow muscular slip. In some cases, when the gluteus minimus is relatively small, the gluteus quartus may nearly equal it in size. In all cases in which I have been able to determine the nerve supply, it was derived from the superior gluteal.

In *Cercocebus collaris* I found the gluteus quartus absent, but its place was occupied by a well-developed band of ligamentous tissue resting upon the capsule of the joint, covering the reflected tendon of the rectus femoris, and attached below to the great trochanter.

A full consideration of these facts induces me to venture the opinion that *the outer limb of the ilio-femoral band is the fibrous representative of the gluteus quartus (scansorius) muscle.*

The argument may be arranged in a convenient form :—

1. The ilio-femoral ligament corresponds in its attachments to the gluteus quartus muscle.

2. The relation of the ligament to the reflected tendon of the rectus femoris muscle is precisely that exhibited by the gluteus quartus in most mammals.

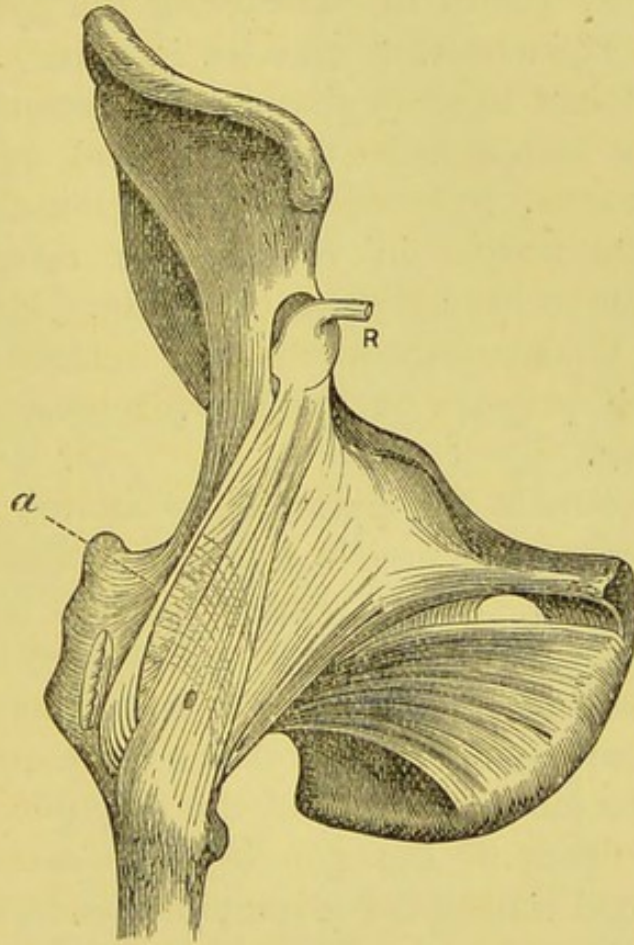


FIG. 22.—The Hip-joint of Man, showing (a) the ilio-femoral band. R. Tendon of the rectus. (After Henry Morris).

3. In at least one monkey, *Cercocebus collaris*, the ilio-femoral band is present, but no gluteus quartus.

4. In other monkeys possessing a functional gluteus quartus, the ilio-femoral band is unrepresented.

3. **The Pyramidalis Muscle.**—No scientific anatomist will deny that the pyramidalis is a vestigial muscle.

When developed to its fullest condition in man, it may reach to the umbilicus ; this is, however, very exceptional. Usually it is a small muscle, in front of the lower part of the rectus. It arises from the front of the pubes and the ligaments of the symphysis ; assuming a pointed shape, it passes upwards to be inserted into the linea alba, midway between the symphysis and umbilicus. Most anatomists will agree with Testut in considering the pyramidalis as one of the most inconstant muscles in man. This inconstancy is sufficient to show that it is of secondary importance. One or both muscles may be absent, or represented by fibrous tissue. Occasionally the muscles may be scarcely a centimetre in length. In rare cases two pyramidales have been seen on each side. Malkmus* has endeavoured to demonstrate that the retractor and protractor of the prepuce in the sheep represents the pyramidalis in man.

Among mammals the pyramidalis attains its greatest proportions among Marsupials, it is exceptionally developed in *Ornithorhynchus*. In the kangaroos this muscle arises from the ventral aspect of the symphysis pubis, and from the contiguous surface of the pubic ramus as far outward as the pectineal process ; it also has a large and important origin from the median border of the epipubic (marsupial) bones. The fibres of the muscle are closely connected with the ventral wall of the marsupium, and pass forwards immediately in contact with the rectus muscle, to be inserted into dense tissue over the costal cartilages of the most posterior ribs and the xiphi-sternum. On its way along the abdomen we find it blending with its fellow, to form with the rectus the linea alba.

If the connections of the epipubic bones be closely examined, it will be seen that each bone is firmly bound to the horizontal ramus of the pubes by a very strong and

* *Archiv für Theirheilkunde*, Bd. xiv., 1888.

dense fascia (fig 23). This fascia is attached to the iliopectineal line, and closely associated with Poupart's ligament, whilst above it is inserted to the whole length of the outer border of the epipubic bone.

If we compare the corresponding parts of man's pubic

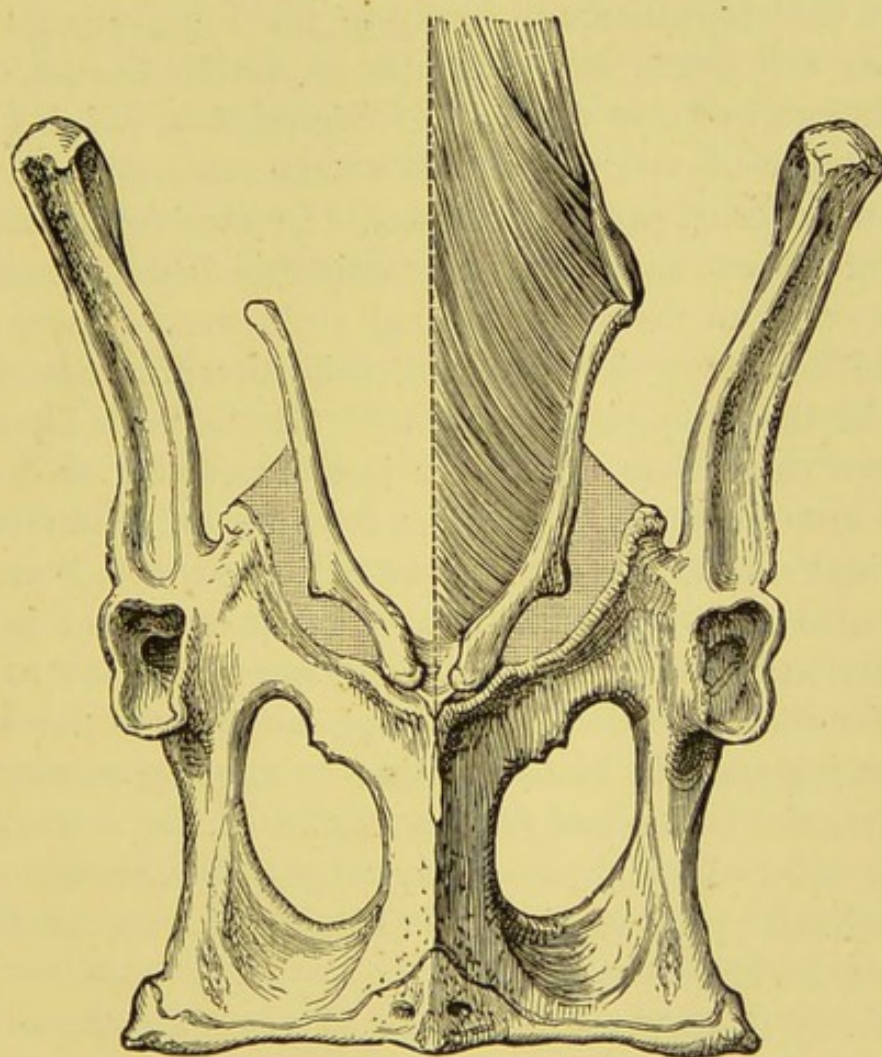


FIG. 23.—Pelvis of *Macropus rufus*. Ventral view to show the pyramidalis arising from the epipubic bone.

region with that of the kangaroo, we find the internal pillar of the external abdominal ring representing the epipubic bone, and two well-marked fibrous structures known as *Gimbernat's ligament* and *the triangular fascia*. These two structures are not only directly continuous with

each other, but are intimately related to the internal pillar of the abdominal ring. Some careful dissections of these fasciæ, compared with dissections of the corresponding parts in the marsupials, make me bold enough to state that Gimbernat's ligament and the triangular fascia are remnants of the very stout ligament which, in marsupials, anchors the epipubic bone firmly to the ilio-pectineal line. Whether this fascia was muscular or not in the ancestors of the kangaroos it is difficult to decide, but, judging from the anatomy of the superficial rectus abdominis in the salamander, most probably it was. In *Ornithorhynchus* the ligament is very small, and the epipubic bone extends as far outward as the ilio-pectineal eminence. There need be little hesitation in accepting this interpretation of the nature of the triangular fascia and Gimbernat's ligament, when we remember that there is a consensus of opinion among anatomists in regarding the internal pillar of the abdominal ring as the homologue of the epipubic bone.

It is also a point of considerable interest to find in man this relation of fascia, ligament, and internal pillar to each other, for the regression of the large metatherial pyramidalis muscle stands in close relation to the degeneration of the marsupial bones and disappearance of the marsupium. Neither must the comparatively large development of the ilio-pectineal process in the kangaroos, especially in embryos, be forgotten.

To many it may seem strange to associate these parts of most mammals with those of marsupials now practically confined to the Australian continent. But we must remember that, in former periods of this planet's history, our own island was inhabited by marsupial forms of large size and in goodly numbers, judging from the fossil remains which from time to time have come to light. Their former wide dissemination is a point not to be forgotten.

4. **The Biceps and the Great Sacro-sciatic Ligament.**—When the tendons of origin of the ham-

string muscles are traced to the tuberosity of the ischium, they may by a very little dissection be seen to pass onwards into the great sacro-sciatic ligament, and by pulling on the muscles the ligament is tightened. When traction is made on the biceps the coccyx can be made to move on the sacrum. In fact the ligament may not unfairly be described as a tendinous expansion of these muscles. This relation of the ligament to the hamstring muscles was first pointed out by Mr. Morris* and the relation of the parts are shewn in a figure. Among the Ruminantia this ligament is replaced by a broad, strong tendon.

The conclusion is irresistible that the great sacro-sciatic ligament is the divorced tendon of the biceps muscle.

5. The Coccygeus and the Lesser Sacro-sciatic Ligament.—The coccygeus is in man a vestigial muscle, and a superficial examination is sufficient to show that it contains a large amount of fibrous tissue, and a study of the comparative anatomy of the muscle demonstrates satisfactorily that the lesser sacro-sciatic ligament results from the regression of a large tract of the coccygeus. The anatomy of the coccygeus and levator ani muscles has been investigated by Kollmann in "Tailed and Tailless Monkeys," and he carefully describes the very great degenerate changes which the loss of the caudal appendage entails on the muscles of the pelvis. It seems clear that the stout and complicated pelvic fascia of man arises from the regression of the levator ani group of muscles due to the suppression of the caudal vertebræ.

In the first edition of this book I regarded the lesser sacro-sciatic ligament as the fibrous representative of the long ischial spine which in armadillos, sloths, and other edentata, recent and extinct, reaches to the sides of the pseudo-sacral vertebræ. The view that the coccygeus is

* *Anatomy of the Joints of Man*, 1879.

reponsible for it is simpler and more probable. There are other fibrous structures about the pelvis, such as the sub-pubic and triangular ligaments whose morphology

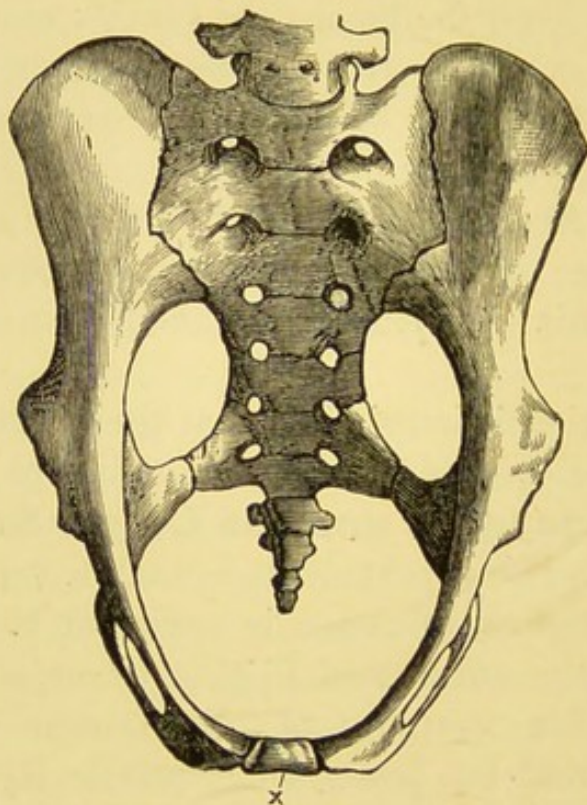


FIG. 24.—The pelvis of a sloth to show the pubic ossicle \times and the long ischial spines reaching to the sides of the pseudo-sacral vertebræ (after Albrecht).

would well repay investigation, and especially the nature of the pubic ossicle in the pelvis of sloths, armadillos, and other mammals (see fig. 24 \times).

CHAPTER X.

THE LIGAMENTS OF THE LARYNX.

AN extraordinary feature of specialised organs is the abundance of vestigial structures directly and indirectly associated with them: the organs of sight and hearing, the brain, and the reproductive organs afford many striking examples. It is the object of this chapter to show that the organ of speech—the larynx—is no exception.

In order to study in their full meaning the vestigial and specialised parts of the vocal organs it is convenient to compare the larynx of man with that of a whale.

The False Vocal Cords.—These are described in Quain's *Anatomy* thus:—

The superior thyro-arytenoid ligaments consist of a few slight fibrous fasciculi, contained within the folds of mucous membrane forming the false vocal cords, and are fixed in front to the angle between the alæ of the thyroid cartilage, somewhat above its middle, and close to the attachment of the epiglottis; behind they are connected to the tubercles on the rough anterior surface of the arytenoid cartilages.

Critical dissections of these ligaments show that, instead of being attached exclusively to the thyroid cartilage, they become connected with the pedicle or base of the epiglottis; embedded in these ligaments we find the cuneiform cartilages (Wrisberg's), and on tracing them backwards the fibrous bands will be found to send, from their points of attachment to the arytenoids, accessory slips to the cornicula laryngis (Santorini's) (fig. 25).

When the corresponding parts are examined in a foeta

porpoise (fig. 26) the epiglottis is easily recognised, whilst the long cartilages parallel with it are as Howes'* pointed out; enormously elongated cornicula laryngis. The epiglottis in the young as in the adult porpoise is azygous. The cornicula remain separate throughout life, but are united by means of dense fibrous tissue. The extremities of the epiglottis and the cornicula are swollen so as to enable the larynx to be "buttoned" into the soft palate, thus allowing it to project into the posterior nasal orifice.

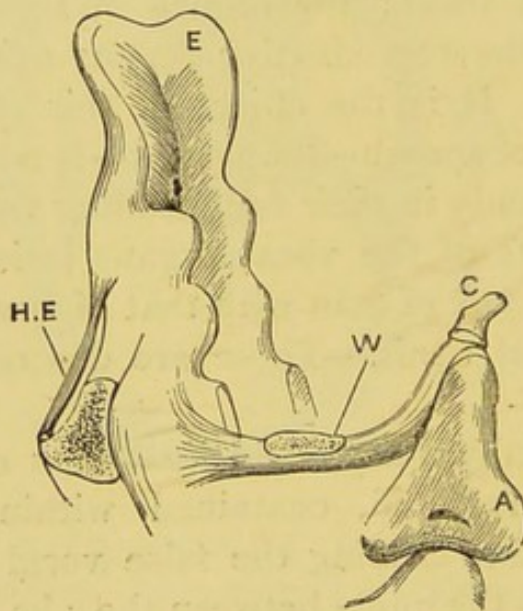


FIG. 25.—The human epiglottis, E; the false cord with Wrisberg's cartilage, W; the corniculum, C; arytenoid cartilage, A; the hyoepiglottideus, HE (diagrammatic).

The cornicula are separated from the cricoid by means of cartilages representing the arytenoids. On examining the base of each corniculum a style-like process projects between the arytenoid and epiglottis to become connected by means of fibrous tissue with a piece of cartilage projecting from the base of the epiglottis. Some nodules of cartilage lie in this fibrous tissue.

* *Journal of Anatomy and Physiology*, vol. xiv., p. 467.

The larynx of the great ant-eater, *Myrmecophaga jubata*, has a well-marked intra-narial epiglottis; from each side of the base of the epiglottis a rounded piece of cartilage passes backwards and terminates in a pointed extremity overtopping the arytenoid cartilage (fig. 27). These parallel cartilaginous bars cause projections of the mucous membrane and constitute the false vocal cords, the rods

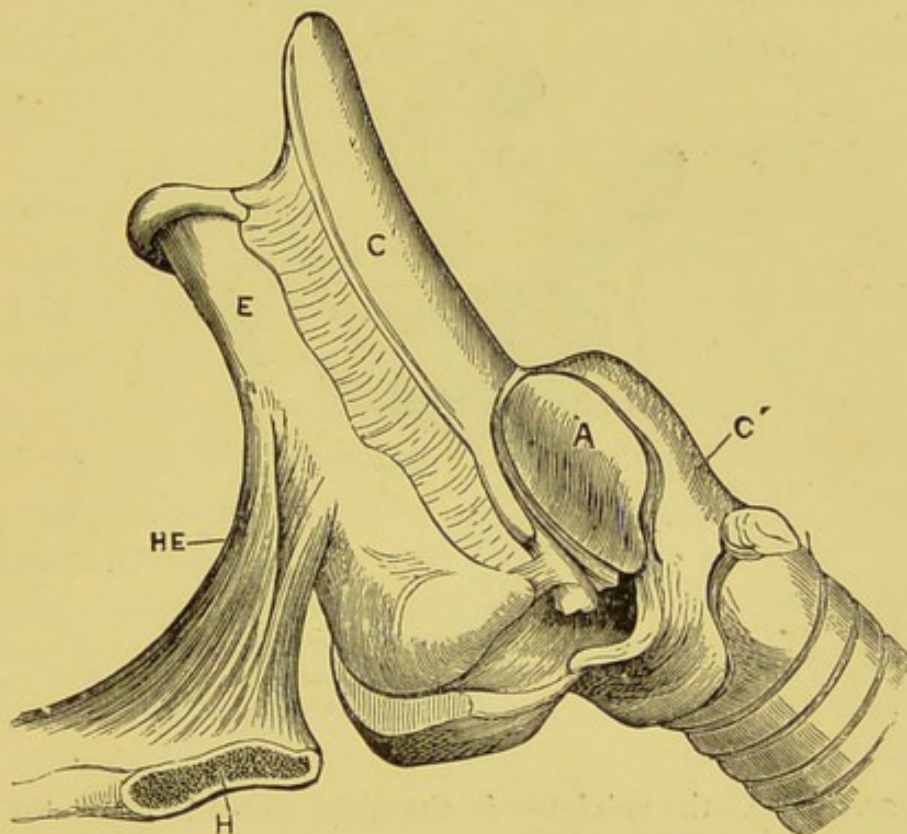


FIG. 26.—The larynx of a porpoise. E, epiglottis; C, corniculum; A, arytenoid; C', cricoid; HE, hyo-epiglottideus muscle; H, hyoid bone in section.

of cartilage representing in man the thyro-arytenoid ligaments, the cuneiform cartilages and the cornicula laryngis.

In the horse the base of the epiglottis is furnished with a pair of processes which project into the false vocal cords.

Then, so far as Man is concerned, *the false vocal cords, with the cuneiform cartilages, are the degenerate representatives of the bar of cartilage by means of which the epiglottis and cornicula*

were originally united, and with the cornicula laryngis must be regarded as vestigial structures.

The True Vocal Cords.—These, often called the inferior thyro-arytenoid ligaments, consist of closely arranged elastic fibres attached anteriorly to the middle of the receding angle of the thyroid cartilage, and behind to the base of the arytenoid cartilages. On close dissection they will be found intimately connected with the thyro-

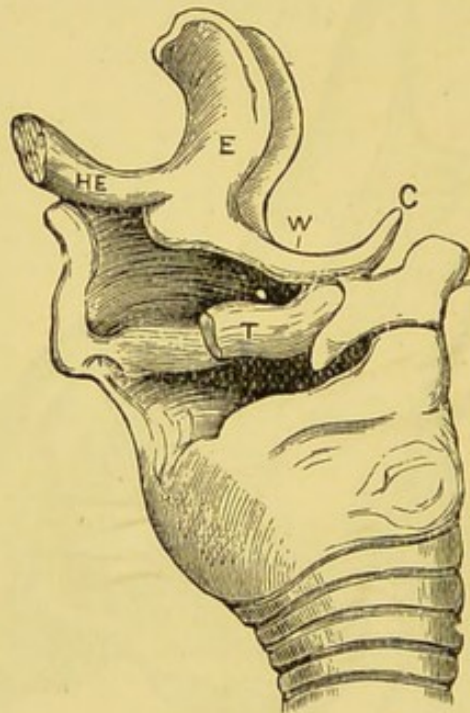


FIG. 27.—EWC, the epiglottis in the great ant-eater, with the cartilage representing the false cord, Wrisberg's cartilage, and the corniculum: HE, the hyo-epiglottic muscle; T, the thyro-arytenoideus muscle.

arytenoid muscle; indeed, many fibres of this muscle are directly continuous with the cords. This relation suggests, that the cords have been derived from the thyro-arytenoid muscles, the more so as the true vocal cords are structurally tendon. This view is confirmed by an examination of the larynx in *Myrmecophaga*. In this mammal the cords are broad bands, lacking the sharp definite edges seen in *Primates*; the thyro-arytenoid muscle

too is round and compact in appearance; when this muscle is dissected away the true cords also disappear. The muscle is absolutely devoid of tendon, except that aspect of it which is immediately subjacent to the laryngeal mucous membrane; here the surface of the muscle presents a glistening tract of fine, thin, delicate tendons, constituting the true vocal cord.

In the horse a similar disposition of muscle may be seen, and after dissecting away the thyro-arytenoideus and examining the vocal cords, we shall find them to contain tracts of muscular tissue.

These facts indicate that the true vocal cords *arise from the tendinous metamorphosis of those fibres of the thyro-arytenoideus muscle subjacent to the laryngeal mucous membrane.*

It has been urged as unlikely that muscle tissue should metamorphose into such highly elastic tissue as that composing the vocal cords. A parallel example is the *tensor patagii* in the wings of birds, which is occasionally entirely replaced by exceedingly elastic tendon, perhaps even more elastic than the vocal cords of man.

The Hyo-epiglottidean Muscle.—In the horse this muscle is situated beneath the mucous membrane which constitutes the glosso-epiglottic fold. The muscle fibres, somewhat pale, are embedded in the fatty tissue at the root of the tongue, immediately adjacent to the base of the epiglottis. The muscle is fusiform in shape, and arises from the lingual aspect of the epiglottis, and passes to an insertion in the hollow of the glosso-hyal; near its insertion the muscle sends off two lateral portions to be attached to the cerato-hyal (lesser cornu of man) on each side.

In the porpoise the hyo-epiglottideus arises from the dorsal aspect of the basi-hyal as two distinct muscles, but they soon fuse into a single mass of some size, and gain an insertion into the median ridge on the lingual aspect of the epiglottis by means of a distinct tendon. In some Cetaceans (*Globiocephalus*) it has been seen double.

In man, a stout band of fibrous tissue passes from the lingual aspect of the epiglottis, and is attached to the upper and anterior aspect of the basi-hyal (fig. 28), this, the hyo-epiglottic ligament, is the degenerate representative of the muscle of that name, as seen in the whale and horse; it is well developed in *Myrmecophaga*, in *Ateles*, and very many mammals. In man the hyo-epiglottic ligament is occasionally replaced by muscular tissue.

In the horse a stout process projects from the middle of the basi-hyal, and is known as the glosso-hyal; it is into this process that the hyo-epiglottideus is inserted, as well

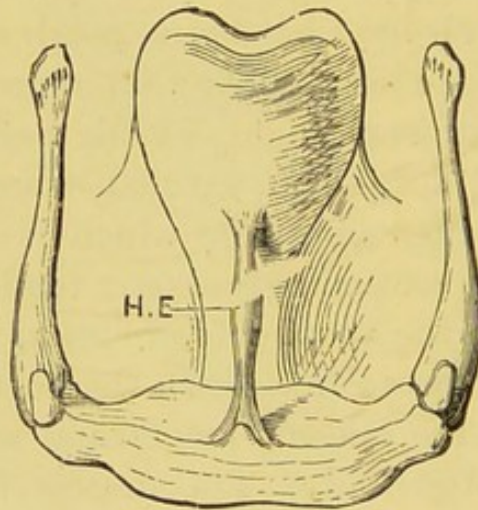


FIG. 28.—The hyoid bone and epiglottis of man, showing the hyo-epiglottideus muscle, H.E. Semi-diagrammatic.

as into the basi-hyal. In man the glosso-hyal is indicated by a small tubercle in the centre of the basi-hyal. There is in the Museum of the Royal College of Surgeons a hyoid bone in which the glosso-hyal is indicated by a rounded process of bone two millimetres in length.

The subjects discussed in this chapter may be summarised thus:—

1. The true vocal cords, or the inferior thyro-arytenoid ligaments, arise from the tendinous metamorphosis of

those fibres of the thyro-arytenoid muscle subjacent to the laryngeal mucous membrane.

2. The false vocal cords, or the superior thyro-arytenoid ligaments, represent, with the cuneiform cartilages, an old communication between the epiglottis and the cornicula laryngis; the cornicula are vestigial structures in most mammals.

3. The hyo-epiglottidean ligament in the human subject is the fibrous representative of a well-formed muscle in many mammals.

The student interested in the hyo-epiglottic muscle would do well to consult Professor Howes' papers on "The Intra-narial Epiglottis," *Journal of Anatomy and Physiology*, vol. xxiii., pp. 263 and 587.

CHAPTER XI.

THE LIGAMENTS OF THE VERTEBRAL COLUMN.

THE ligaments which bind the vertebræ together may be arranged in two groups:—

- I. *Ligaments common to all vertebræ.*
 1. The anterior common ligament.
 2. The posterior common ligament.
 3. The supra-spinous ligament.
- II. *Ligaments confined to two vertebræ.*
 1. The intervertebral discs.
 2. The conjugal ligaments.
 3. The interspinous ligaments.
 4. The intertransverse ligaments.
 5. The ligamenta subflava.

GROUP I.—**The Anterior Common Ligament.**—

This consists of a longitudinal band of dense fibres placed on the anterior aspect (ventral) of the vertebral column, extending from the under surface of the basi-occipital bone, with a slight break at the atlas, to near the middle of the sacrum; here it becomes scarcely distinguishable from the periosteum, but as it nears the coccygeal vertebræ it again becomes prominent, and ends at the tip of the coccyx. The superficial fibres extend over several vertebræ (four or five), the intermediate ones pass over two, whilst the deepest fibres only connect adjacent vertebræ.

The Posterior Common Ligament.—Lying on the dorsal surfaces of the centra of the vertebræ, and extending from the upper surface of the basi-occipital bone to the lower end of the sacrum, is a fairly broad fibrous band. The upper part of the ligament, that which lies

between the occipital bone and the axis, is often designated the posterior occipito-axoid ligament. The more important features of the posterior common ligament are these:—In the neck it extends quite across the bodies of the vertebræ, in the thoracic and lumbar regions it is broader opposite the intervertebral discs than at the middle of the bodies of the vertebræ; between these narrower portions and the vertebral centra there is loose connective tissue containing a venous plexus; the ligament is only connected with the spine at the intervertebral discs and the corresponding margins of the vertebræ, presenting throughout its course a series of attached and unattached segments.

The Supra-spinous Ligament.—This consists of bundles of longitudinal fibres which form a continuous cord from the seventh cervical vertebra to the sacrum. It serves to connect the tips of the spinous processes together.

GROUP II.—**The Intervertebral Discs.**—These are plates composed of fibrous tissue arranged in laminæ externally, with a pulpy nucleus internally. They are situated between the centra of the vertebræ beginning at the axis and ending in the adult at the sacrum, but in the young child they extend even to the coccyx. The outer or circumferential portion of each disc is composed of laminæ of white fibro-cartilage arranged concentrically, which run obliquely between the vertebræ and are firmly attached to both. The centre of the disc is made up of pulpy substance which when examined microscopically is seen to be composed of fine fibrous tissue containing cells. The anterior edge of each disc is firmly attached to the anterior common, and the posterior edge to the posterior common ligament. In many animals notably the seal, a very strong rounded band glides across the dorsal aspect of the disc, as shewn in figure 29. This serves to connect the heads of the corresponding ribs, and the ligament is pro-

vided with a synovial membrane. A band also passes along the anterior face of the disc, and may be named the anterior conjugal ligament. In the human foetus similar bands can be dissected from the dorsal and ventral aspect

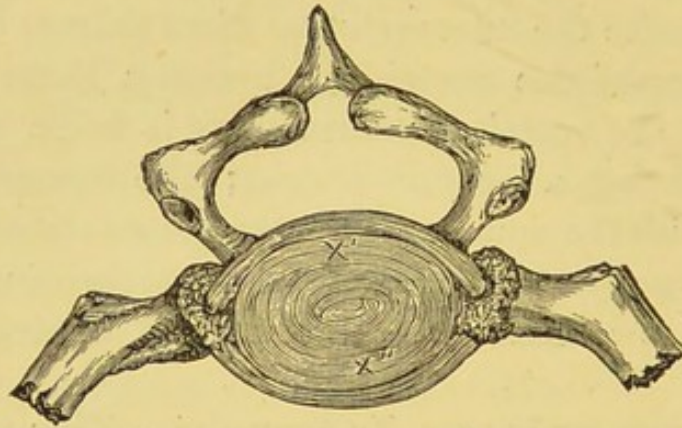


FIG. 29.—The intervertebral disc of a seal with the anterior and posterior conjugal ligaments. X' and X''.

of the discs. The posterior band is continuous with the interosseous ligament of the rib-head, whilst the anterior becomes later the middle fasciculus of the well-known stellate ligament of the costo-vertebral articulation. After

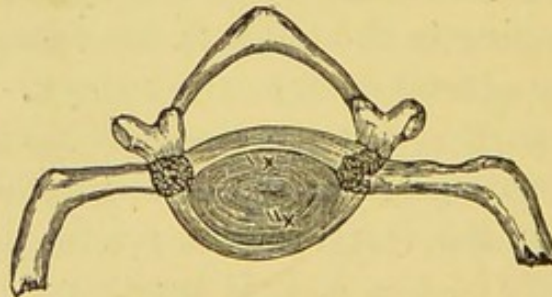


FIG. 30.—The anterior and posterior conjugal ligaments of a foetus at the seventh month.

birth the intermediate portion of these ligaments become incorporated with the intervertebral discs. The accompanying figures represent the ligaments in a foetus at the seventh month and their fate in the adult (figs. 30 and 31).

The ligamentum conjugale costarum was first described by Mayer* of Bonn, in 1834, in various mammals. It has escaped the attention of most anatomists. Prof. Humphry in his well known work on the skeleton merely refers to Mayer's observation in a foot note; Cleland unaware of Mayer's paper described the ligament in a seal in the *Edinburgh New Philosophical Journal*, 1858. These re-

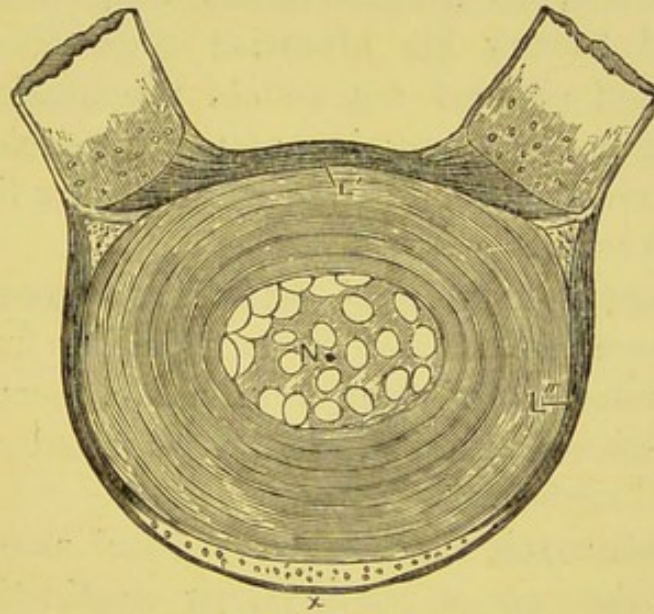


FIG. 31.—An intervertebral disc of an adult shewing the posterior conjugal ligament *L'* incorporated with the disc. Its ends as the interosseous ligament of the ribs. The anterior conjugal ligament *L''* is represented by the middle fasciculus of the stellate ligament; *N.* remains of the notocord.

searches were unknown to me, when in 1882 I noticed the ligament whilst dissecting a seal. Mr. Henry Morris then drew my attention to Cleland's papers. Later I examined the condition of this structure in a large number of mammals, including the horse, lion, otter, fox, dog, weasel, squirrel, rabbit, calf, sheep, badger, pig, ape, &c.

The ligament is best developed in that part of the tho-

* Meckel's *Archiv.*

racic region of the spine where the ribs articulate with two vertebral centra.*

The credit of drawing attention to the existence of this ligament in man rests with me, if we exclude the transverse ligament of the atlas, to be considered in the succeeding pages. It is very remarkable, but Hunter knew of this conjugal ligament. Mr. Henry Morris requested the admirable assistant at the College of Surgeons, William Pearson, to prepare some dissections of this structure and having his attention thus drawn to the matter, Pearson shewed me an old preparation labelled *Hunterian*. It is the dissection of two thoracic vertebræ of a horse so arranged as to shew the posterior ligamentum conjugale costarum.

The Interspinous and Intertransverse Ligaments.—These are fibrous cords resulting from the regression of muscles of the same name, occupying the spaces their names indicate, but best studied as muscles in the cervical region.

The Ligamenta Subflava.—Called also ligamenta intercruralia, they are plates of yellow elastic tissue alternating with the laminæ of the vertebræ from the axis to the middle of the sacrum.

A great deal of light seems to be shed on the nature of the ligamenta subflava by studying the vertebral column of a cartilaginous fish. In the skate these ligaments are represented by pieces of cartilage hexagonal in shape, known as the interneural plates (fig. 32). The laminæ are represented by a cartilaginous pedicle known as the neural processes, these only exceptionally join the neural spines.

In the skate the ventral root of a spinal nerve leaves by a foramen in the neural process, whilst the dorsal root traverses the interneural plate.

* For further details the student may consult the *Journal of Anatomy and Physiology*, vol. xviii., p. 225.

The elementary nature of the present book prevents me pursuing the argument to the fullest extent, but it may be mentioned that in man we have no alternation of the roots of the spinal nerves as in some of the cartilaginous fishes, nevertheless, as in them, man's spine consists of segments composite in character, thus:—

A centrum, with pedicles, laminæ and a spinous process, succeeded by a disc composed of notochordal remains, and two plates of yellow elastic cartilage—the ligamenta subflava.

The researches of American paleontologists, especially Cope's, go to support the view that the intervertebral disc

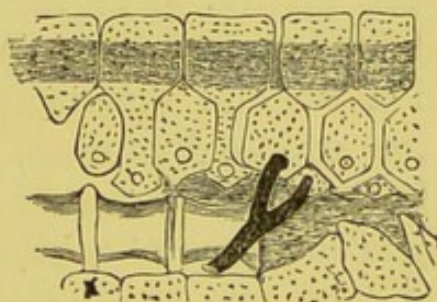


FIG. 32.—A portion of the vertebral column of a skate shewing the interneural plates.

may with good reason be regarded as representing a suppressed segment. In many of the remarkable batrachian forms, now extinct, unearthed in the Permian formation of Texas, the vertebral column possessed intercentra rivalling in size the true vertebral centra, and helping to form part of the bony boundaries of the neural canal.

The first real attempt to attach a morphological value to a spinal ligament was that of Rathke, in his famous *Entwicklung der Schildkröten*, 1848, where, in a masterly piece of anatomical reasoning, he shews most conclusively that the os odontoideum of the turtle is really the representative of the body of the atlas, and that the ligamentum suspensorium, a thin fibrous band passing from that pro-

cess to the margin of the foramen magnum, is the remains of the notochordal sheath.

Rathke had previously promulgated this doctrine in his *Entwicklungsgeschichte der Natter*, so far as the odontoid process is concerned. Cuvier, in his *Recherches sur les ossémens fossiles*, had previously identified the true homology of this bone by a study of its condition in the turtle and in the Matamata terrapin. Bergmann confirmed the statements of Rathke, and now the matter rests beyond dispute, after the investigations made into the subject as regards mammals, by J. Müller, Robin, and Hasse. Then, the fact that the nucleus pulposus in the middle of the intervertebral discs is the remains, in part, of the notochord, lends additional interest to the matter. For this last satisfactory advance we are indebted to Luschka. Although in adult mammals, we find a definite ligamentum suspensorium attached only to the odontoid process, yet in birds, as Jäger* has shown in *Das Wirbelkörpergelenk der Vögel*, we find a suspensory ligament in many other parts of the column. In its most typical form the arrangement may be thus described:—

Between the centra of contiguous vertebræ is a fibrocartilaginous ring, which is continued inwards in the form of a disc which has free anterior and posterior faces, this portion is called the meniscus; this thins towards the centre, which is always perforated. The meniscus, when perfect, divides the space between the centra of the opposed vertebra into two synovial cavities. The central perforation in the meniscus is traversed by a ligament, which in the chick contains the remains of the intervertebral portion of the notochord. In some instances the meniscus is reduced to a mere rudiment, in other cases it is united with the vertebral bodies, whilst in the caudal region, in its relation to the bodies of the vertebræ, it resembles an ordinary intervertebral disc.

* *Sitzungsberichte der Wiener Akademie*, 1858.

There seems to be no rule by which one could predict the presence or absence of this disc. In two specimens of Rhea (*Rhea Americana*) dissected by me, the discs and suspensory ligaments were absent, the vertebral centra coming into direct apposition. In the emu the meniscus is alone represented, whilst in the pigeon, fowl, and similar birds the meniscus and suspensory ligaments are present in a perfect condition; when carefully dissected, the cervical vertebræ and the discs, alternating and threaded as it were by the suspensory ligaments, present a striking appearance.

If the cervical vertebræ of a child be macerated until the intervertebral discs drop away, it will be found that the vertebral bodies will in many cases remain attached to each other by the thickened sheath surrounding the remains of the notochord; in this way it strikingly resembles the avian suspensory ligament.

In the skeleton of a modern bird not the least among the peculiarities of its bones is the shape of the articular surfaces of the pre-sacral vertebræ. Choosing a typical one from the middle of the cervical series, we find that the anterior articular surface of the centrum is slightly excavated from above downwards and convex from side to side: the posterior is the reverse of this, being convex from above downwards and concave from side to side. The anterior aspect resembles the curious surface on the trapezium for the metacarpal bone of man's pollex.

The origin of this curious mode of articulation among the vertebræ of birds has long been a mystery, especially as whole series of extinct avian forms from the tertiary deposits present the same peculiarity.

Prof. O. C. Marsh* has, however, described a remarkable small Cretaceous bird named *Ichthyornis*, which pro-

* "The Vertebræ of Recent Birds." *The American Journal of Science and Arts*, vol. xvii., p. 266.

bably had great powers of flight and bi-concave vertebræ as in fish, amphibians and a few reptiles. The third cervical vertebra of *Ichthyornis* when viewed in vertical section is, in its anterior articulation moderately convex, transversely it is strongly concave, thus presenting a near approach to the saddle-like articulation.

No other vertebræ in *Ichthyornis* present this character. The specialisation occurs at the bend of the neck and greatly facilitates motion in the vertical plane. This is the dominant movement in the neck of the modern bird; anything that facilitates this motion would itself tend directly to produce the modification.

Such modification of the vertebræ would naturally appear first where the neck had most motion, viz., in the anterior cervical region and would gradually extend down the neck, and so on to the sacrum if the flexion continued.

In modern birds behind the axis we find no exception to the saddle-shaped articulation in the whole cervical series. In a few birds especially that remarkable parrot, *Stringops*, the penguins, the terns, and a few others, one or more vertebræ are opisthocælian, or imperfectly bi-concave. In the caudal series of recent birds the vertebræ preserve their original bi-concave structure.

Thus BI-CONCAVE VERTEBRÆ are the rule in fish and amphibians. From this form we derive:—The PLANE VERTEBRÆ of mammals. The CUP-AND-BALL variety of reptiles which are *Procæalous* in serpents and *Opisthocæalous* in Dinosaurs and *Saddle-shaped* in birds.

CHAPTER XII.

THE LIGAMENTS OF THE VERTEBRAL COLUMN (*continued*).

THE ATLAS AND AXIS.

THE ligaments in connection with the first two cervical vertebræ are of sufficient importance to demand separate mention, especially as they require to be taken into consideration in questions connected with the morphology of these two extraordinary elements of the vertebral column.

The ligaments to be studied are:—

1. The transverse.
2. The check ligaments.
3. The suspensory ligament.
4. The lateral occipito-atlantal ligaments.
5. The intervertebral disc between the odontoid process and the body of the atlas.

It will also be necessary to extend the discussion to the anterior arch of the atlas, for an endeavour will be made to demonstrate that this part of the atlas may be considered as an ossified anterior conjugal ligament, and is in its nature comparable to the inter-centrum of batrachians and reptilians.

The Transverse and Check Ligaments.—The transverse ligament divides the ring of the atlas into two unequal parts. The anterior space lodges the odontoid process, whilst the posterior serves for the transmission of the spinal cord. The ligament which is dense and strong derives firm attachments from the tubercle on the inner aspect of each lateral mass of the atlas. Where it glides

around the constricted portion of the neck of the odontoid process it has a synovial covering.

The check ligaments arise from the tubercles on the inner margin of the ex-occipitals, and passing transversely, meet together at the tip of the odontoid process into which they are inserted. Many text-books of anatomy figure them as though passing obliquely to the odontoid process from above downwards, but they maintain a direction strictly parallel with that of the transverse ligament. In two instances I have seen the check ligaments form a continuous band so that it seemed as if there were two transverse ligaments.

There can be little doubt that these two bands are repetitions of the posterior conjugal ligament. This view of the matter also occurred to Cleland. To enter into a full discussion of the relationship would be to enter step by step into the question of the morphology of the atlas and axis, and is beyond the scope of this treatise.

The Suspensory Ligament.—This passes from the summit of the odontoid process and joins, at the margin of the foramen magnum, the basi-occipital bone. Its true nature was detected by Rathke when he showed that it was derived from the sheath of the notochord as it passed onwards to the base of the skull.

The Lateral Occipital-atlantal Ligaments are bands of fibrous tissue passing from the lateral mass of the atlas to the jugular process of the occipital bone. Each runs parallel with the corresponding rectus capitis lateralis muscle: this muscle is simply a continuation of the inter-transversales series, and the lateral occipito-atlantal ligament results from the conversion of a posterior rectus capitis lateralis muscle into fibrous tissue, thus becoming homologous with an inter-transverse ligament.

The Intervertebral Disc between the odontoid process and the body of the Axis.—Cunningham has shewn that if, in the adult, an axis be bisected, a

lenticular disc of cartilage of the shape and situation shewn in fig. 33 will be exposed. It is on all sides surrounded by bone so as only to be brought into view by means of sections. It is best marked in young subjects and gradually becomes smaller as life advances, disappearing in extreme old age.

The Odontoid Process.—The discussion of the morphology of the atlo-axoid and occipito-axoid ligaments would be incomplete without a summary of the facts supporting the view that the odontoid process is the dissociated body of the atlas.

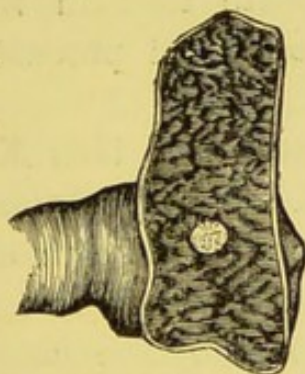

FIG. 33.—Transverse section of the body of the axis of a youth, to shew the intervertebral disc between the odontoid process and the body of the axis.

This evidence may be arranged in a table for convenience.

1. The notochord passes through the process on its way from the axis to the base of the skull.
2. Between the odontoid process and axis there is a "swelling" of the notochord in the early embryo as in other intervertebral regions.
3. This "swelling" is latter indicated by an intervertebral disc hidden in the bone.
4. The odontoid process has independent centres.
5. It persists as an independent ossicle in chelonians, lizards, and crocodiles. In *Ornithorhynchus* it remains distinct for a very long time.

6. An epiphysial plate develops between it and the body of the axis in man and many mammals.
7. The neck of the odontoid process is embraced by a "conjugal" ligament—the transverse.

The bilateral ossific nuclei for the main portion of the mammalian odontoid process has given rise to a great deal of speculation among morphologists. Cope* has found, in an extinct batrachian exhumed from the Permian formation of Texas, the vertebral bodies composed of two lateral pieces. The skeleton belonged to an animal named *Eryops megaloccephala* of the order *Ganocephala*. This seems to indicate that in the possession of two lateral nuclei, the odontoid process retains a primitive character.

The anterior arch of the Atlas.—In the seal, as represented in figure 29, the rib-heads of opposite sides are united by a ligament passing round the dorsal aspect of the intervertebral disc, known as the posterior conjugal ligament. In addition they are united by a fibrous band passing round the anterior aspect of the disc, known as the anterior conjugal ligament. The fate of these ligaments has been fully described on page 88, and evidence has also been adduced to prove that the transverse ligament of the atlas, represents the posterior conjugal ligament of the ribs. I shall now attempt to show the anterior conjugal band has, in the case of the atlas, become ossified.

In the first place it is necessary to mention that the anterior part of the lateral mass of the atlas agrees in its nature with the corresponding part of the transverse processes of the remaining cervical vertebræ, and is a rudimentary rib. The most conclusive arguments on this head are furnished by Macalister.†

* *Proc. American Philosoph. Soc.*, vol. xix., p. 51, 1880-82.

† *Journal of Anatomy and Physiology*, vol. iii., p. 54.

Lying between the vertebræ in the lumber region of a mole on the ventral aspect, are some small ossicles known as hypapophyses, or sub-vertebral wedge-bones. In the remarkable lizard, sphenodon, these ossicles, or intercentra, form a continuous chain in the cervical, thoracic and lumbar regions of the spine. A careful examination of these bones in the mole, convinced me that they must be regarded as ossifications of the anterior conjugal ligament. According to this view, the anterior arch of the atlas is really an intercentrum fused with the two rudimentary ribs, which constitute the anterior boundary of the lateral mass of the atlas of man.*

The Subnotochordal Rod.—In all Ichthyopsida (fish and amphibians), at a period slightly subsequent to the formation of the notochord, there appears a rod-like thickening, split off from the dorsal wall of the alimentary canal. This singular body is known to embryologists as the subnotochordal rod. Its situation and appearance are drawn by Gœtte, in sections of *Bombinator igneus*. The rod lies between the notochord and alimentary canal, and is of almost the same longitudinal extent as these two structures.

It was first detected by Gœtte, who gave an account of it in Schultze's *Archiv. fur Mik. Anat.*, 1869. In his elaborate account of the *Entwicklungsgeschichte der Unke (Bombinator igneus)*, 1875, he refers to it under the name of *der Axenstrang des Darmblattes*, and suggests that later it becomes a lymphatic trunk (page 775). The subnotochordal rod had been observed independently by Prof. Semper, and Balfour has given a description of it in his account of the development of Elasmobranch fishes.

It is known to be present in the embryos of Elasmobranchs, Ganoids, the Teleostei, Dipnoi, and in the

* Mivart, *Elementary Anatomy*, p. 217. Humphry, *The Human Skeleton*

Amphibia, in all of whom it develops fundamentally in the same way.

Although it has not yet been found in a fully developed form in any amniotic vertebrate, nevertheless a structure, which in all probability is a rudiment of the subnotochordal rod, was detected by Balfour and Marshall as a thickening of the hypoblast in the neck of chicks.

Salensky has further shown that in the sturgeon the subnotochordal rod becomes, in the adult, the subvertebral ligament an observation which, according to Balfour, confirms an earlier suggestion made by Bridge.

This point is important, and it will be interesting to endeavour to extend this view to vertebrata in general, and show that the *anterior common ligament of the spine results, in some forms at least, from the degeneration of the subnotochordal rod*, in the same way that ligamentous tissue in various parts of the adult column is the vestige of the embryonic notochord. I have made a series of observations on tadpoles of the common frog (*Rana temporaria*), and have been able to satisfy myself that in them, after the disappearance of the subnotochordal rod, a band of tissue can be seen in the sections replacing that structure. Further, as chondrification proceeds in the tissue lying between the notochord and the subnotochordal rod, the latter can be seen to flatten out over the bodies of the future vertebræ and finally assumes a fibrous appearance, to become in the adult, the subvertebral ligament.

It may be argued that, even admitting this to be true, so far as amphibians or fish are concerned, yet it cannot apply to vertebrate forms above that group, in whom, with the exception of the chick, a subnotochordal rod has not yet been demonstrated. However, its existence in fish and amphibia is indisputable, therefore we may assume, unless later on its presence may be detected in higher forms, that the process has suffered abbreviation, and that the anterior ligament appears in these forms in obedience

to the great principle heredity. In support of the notion that this anterior common ligament may represent the subnotochordal rod of Sauropsida, without actually existing in the peculiar condition it presents in this class, I would draw attention to the fact that although Comparative Anatomy shows incontestibly that the various structures about the knee joint—ligaments and fibro-cartilages—are in reality the disguised remnants of the tendons of muscles, yet during the development of the human embryo, as Barth has shown in an interesting article (“Die Entwicklungsgeschichte der Menschen,” *Morph. Fahr.*, Bd. iv., s. 403, 1878), the various ligamentous elements of the joint arise as thickenings of the connective tissue. In this case, as in so many others, embryological testimony will not always satisfy our demands when we ask for ancestral history, because the process has become abbreviated; hence we are driven to Comparative Anatomy.

CHAPTER XIII.

EXAMPLES OF METAMORPHOSIS AND REGRESSION OF
MUSCLES FROM LOWER VERTEBRATES.

INSTANCES of the transformation of muscles into ligaments are almost as frequent in the lower vertebrates as in man. It may not be uninteresting to devote a chapter to the consideration of some striking examples chosen from the horse, whales, and birds.

William Percivall in his excellent work on the *Anatomy of the Horse*, 1858, adds a footnote to his account of the suspensory ligament of the fetlock, stating that Bourgelat regarded it as a tendon, but Girard as a muscle.

Percivall describes it thus :—"The suspensory ligament, so-called, I imagine, because the sesamoid bones seem to be *suspended* by it) is, perhaps, the strongest in the whole body, and is remarkable for its high degree of elastic property. It takes root, superiorly, in a projection at the upper and back part of the cannon, whence it passes, enclosed within a cellular sheath, between the splint bones, filling up their interspace. Opposite to about the terminations of these small bones, it splits into two divisions, which, diverging in their descent, become implanted into the lateral and posterior parts of the sesamoid bones, and into the fibro-cartilaginous substance uniting them. From the places of implantation, two lateral slips are continued from it downward and forward to join the extensor tendon. Between the suspensory ligament and the joint, enveloped in adipose membrane, are some large *bursæ mucosæ*. In composition and texture, this *ligament* possesses peculiari-

ties; it has a sanguineous tinge interiorly, which is not perceptible in other ligaments or in tendons; and its fibres, which are very coarse, are disposed in layers. But its chief peculiarity consists in its exhibiting an intertexture of delicate, pinky fleshy fibres which appear to be the uniting medium of the ligamentous fasciculi."

Cunningham* has studied the development of this ligament in the horse, ox, roe-deer, and sambre-deer and conclusively proved that it is formed in the horse by the metamorphosis of the short flexor muscle of the middle digit into fibrous tissue. The corresponding structure in the ox, sheep and camel arises from the coalescence and fibrous regression of the short flexor muscles of the middle and fourth digits.

The Muscles of the Fore-limbs of Whales.—

Cetaceans abound in vestigial structures, and the fore-limbs of these huge mammals which are used as fins, possess representatives of the various long flexors and extensors of the fingers, but in the majority of whales they are mainly ligamentous, and in some species the muscles are ligamentous throughout. The fore-limbs of the porpoise are easily obtainable and furnish good examples of the extreme regression these muscles have undergone. Professor Struthers gives a detailed account, with exquisite drawings, of the finger-muscles in whales, as well as a summary of the literature of the subject, in his *Memoir of the Anatomy of the Humpback Whale*, Edinburgh, 1889, p. 46.

THE WING OF A BIRD.

A bird's wing abounds in examples of the conversion of muscular tissue into tendon. In this place we cannot do more than notice a few of the more important ones.

* *Journal of Anatomy and Physiology*, vol xviii., p. 1.

In most birds the flexor carpi ulnaris is a fairly well developed muscle, but in the vulture and in the rail, *Rallus aquaticus*, razor bill, *Alca torda*, and others, this muscle is replaced by a strong thick and elastic tendon.

Mr. D'Arcy Thompson,* in a paper "On the Nature and Action of Certain Ligaments," which is worthy of careful perusal, points out that ligaments of this kind, though degenerate muscles, continue to perform the function of the muscle they represent. Tendons of this kind are developed from muscles which pass over two joints and which have a more or less ligamentous action.† This is well seen in the case of the bird's flexor carpi ulnaris, for when the elbow is flexed the tendon serves automatically to flex the wrist joint. Mr. Thompson writes that he "knows of no case in which the muscles have become purely ligamentous, it is indisputable that the stronger the wing the weaker these muscles, and the longer are their tendons in proportion to the fleshy bellies."

As a matter of fact the flexor carpi ulnaris is purely ligamentous in many birds (fig. 34).

Every student of human anatomy must have experienced a certain amount of curiosity when he dissected for the first time the plantaris muscle; this strange structure sinks into insignificance when compared with the celebrated ambiens of the bird's leg, or the tendon of the femoro-caudal in the lacertilia. Of all strange muscles, the one known as the *expansor secundariorum* (Garrod) in the bird's wing stands pre-eminent. It is a small triangular muscle arising from the quills of the last few secondary remiges at the elbow. Its remarkably long and slender tendon, which frequently traverses a fibrous pulley on the axillary margin of the *teres* muscle, runs up the arm side by side with the axillary vessels and nerves, to be inserted

* *Journal of Anatomy and Physiology*, vol. xviii., p. 406.

† See especially Cleland, *Ibid.*, vol. i., p. 85.

in the thorax into the middle of a tendon which runs from the inner side of the middle of the scapular element of the scapulo-coracoid articulation, to near the middle of the thoracic border of the sterno-coracoid articulation, at right angles to it when the fore-limb is extended (fig. 34).

In the ducks and geese, among the Anseres, the tendons

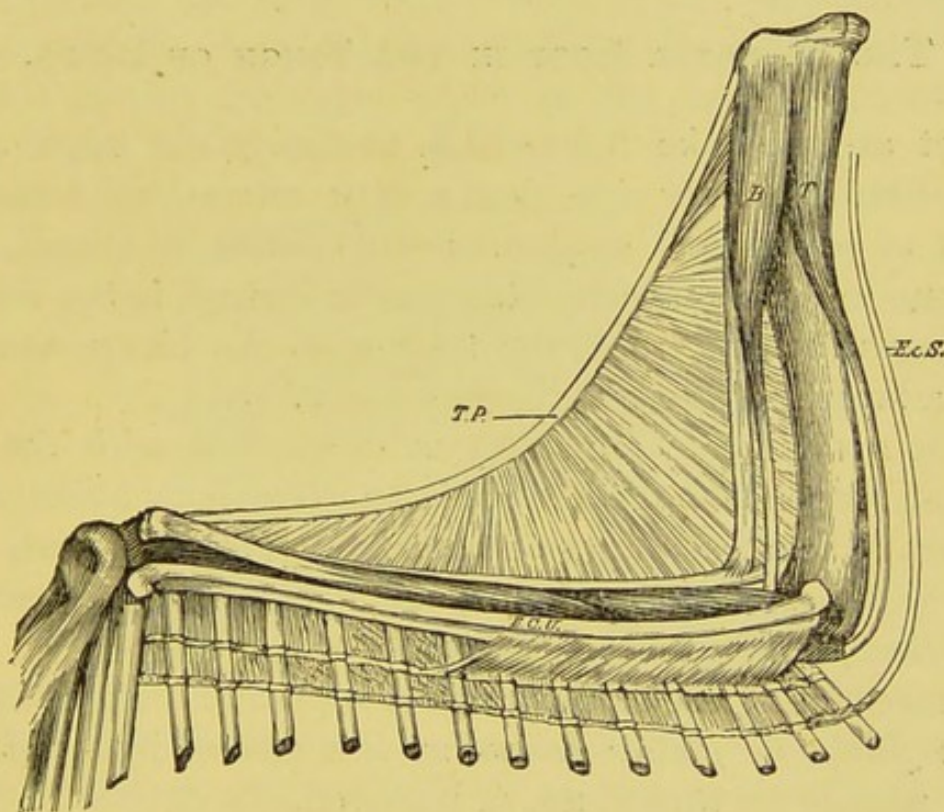


FIG. 34.—Wing of a vulture dissected to shew the insertion of the expansor secundariorum and the ligamentous flexor carpi ulnaris. T.P. Tensor patagii. B. Biceps. T. Triceps. F.C.U. Flexor carpi ulnaris. Ex.S. Expansor secundariorum.

under consideration, when they enter the thorax, run towards one another and join (after having expanded out) in the middle line in front of the œsophagus, and behind the trachea.

The Penguin's Wing.—I know of no more instructive exercise in comparative anatomy than the dissection of the wing of a pigeon and the wing of a penguin, and the

comparison of the muscles, tendons and ligaments in each. The transformation of a wing into a paddle is accompanied by very striking modifications of muscles. The wing of the penguin among bird's limbs resembles, so far as vestigial muscles are concerned, the paddle of whales among mammalian limbs.*

THE BICIPITAL LOOP IN THE THIGH OF BIRDS.

Let anyone take the trouble to dissect the thigh of a fowl from the outer side, then a most interesting arrangement of myological structures will reward his labour, but the one to which especial attention is invited, is the singular loop which transmits the tendon of the biceps muscle and a branch of the great sciatic nerve.

The great point of interest in connection with the bicipital loop is the fact that it is an exclusively avian character, at least so far as recent forms are concerned, and that with very few exceptions, among them a steganopod (*Phaethon*), no known bird lacks this sling.

On reflecting the skin, the most superficial muscle is the *tensor fasciæ* or *gluteus primus* as it is termed by some. If this muscle be turned up, or removed, the deep structures will be exposed; the most conspicuous is the biceps, which has the following attachments:—It arises from the upper three-fourths of the post-acetabular ridge (a slight bony elevation which separates the post-acetabular area from the external lateral surface of the ischium). Just in front of the tensor fasciæ the fibres converge to form a rounded tendon, which on the outer side of the popliteal region is bent sharply downwards by passing through a tendinous sling or loop; it is inserted nearly half way down the

* Watson, "Report on the Spheniscidæ," *Zoology of the Voyage of H.M.S. "Challenger"*; and Smith, The Owens College "Reports," vol. i., 239.

fibula to a bony prominence on its outer side. The loop in question is attached to the lower end of the femur; the outer limb is slightly connected with the head of the gastrocnemius, which is situated to its outer side. A nerve to the leg and foot, derived from the great sciatic, accompanies the tendon through this sling (fig. 35). This tendinous loop, studied in the fowl and similar birds, is curious and puzzling, and evidence will be adduced in support of the view, that it is derived from the metamorphosis of the muscular fibres of the outer head of the

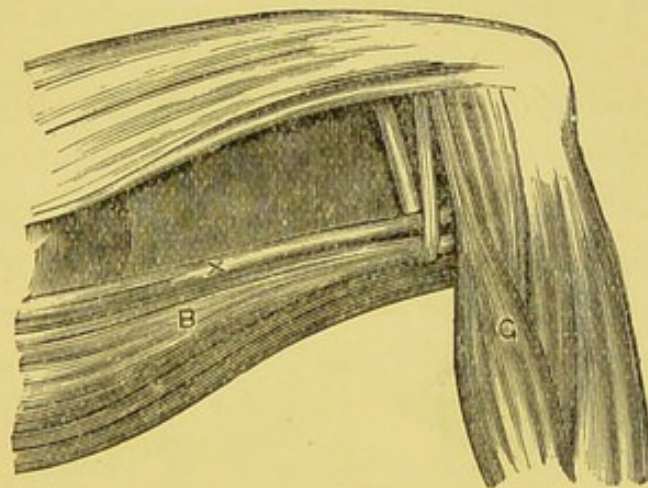


FIG. 35.—Thigh of a bird (Tinamou) dissected from the outer side to show the tendinous loop which transmits the tendon of the biceps and a nerve, the latter is represented by X. B. Biceps. G. Gastrocnemius.

gastrocnemius muscle. Before doing so, however, it will be necessary to state that the muscle, here termed biceps, has not the same anatomical relationship as the muscle so named in the leg of mammals, indeed, to my mind it is certainly not homologous with that structure, and there is little utility in discussing the morphology of muscles in so highly specialised a form as that of the fowl as compared with man. In the thigh of the rhea (*Rhea Americana*), the emu (*Dromæus Novæ-hollandiæ*), *Ramphastos loco*, and many other avian forms, the loop through which the biceps ten-

don passes is modified in this way:—The inner limb is a tendon of great strength and of considerable thickness, but the outer limb of the loop is constituted by the muscular and tendinous fibres of that head of the gastrocnemius muscle which is attached to the external femoral condyle; hence one half of the loop is tendinous, the other muscular (fig. 36). This arrangement clearly affords the clue by which we may seek to interpret the origin of so singular a pulley, *for clearly it is the result of the metamorphosis of muscle fibres.*

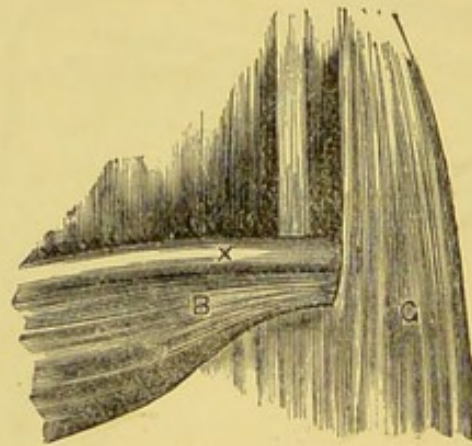


FIG. 36.—The bicipital loop in the thigh of an emu. One half is formed by the gastrocnemius, the other half is tendinous, the nerve is represented by \times . B. The biceps.

In the lizard, *Iguana tuberculata*, if the dissection be commenced from the outer side, as in the bird, a prominent muscle, referred to by Mivart as the *ilio-peroneal*, is easily recognised. It has the following attachments and relations:—It arises from the posterior part of the outer side of the ilium, covered by the posterior portion of the tendinous origin of the gluteus maximus, and even a little overlapped by the gluteus medius. It is inserted by a strong tendon, which dips between a muscle called *peroneus primus* by Mivart, and the external head of the

gastrocnemius, into the outer side of the fibula near its summit.*

It will be necessary, before discussing the ilio-peroneal muscle, to take into consideration the muscles named *peroneus primus* and the gastrocnemius. The first muscle arises by a strong tendon from the summit of the outer side of the external condyle of the femur. It becomes tendinous below the outer malleolus; a portion of this expansion gains an insertion into the peroneal border of the fifth metatarsal bone, a little above its middle. On the posterior aspect of the ankle-joint it forms a broad aponeurosis, and joins with the expansion of the gastrocnemius.

The gastrocnemius consists of two distinct parts; one arises from the internal condyle of the femur, with a slight attachment to the head of the tibia near the insertion of the semi-membranosus and semi-tendinosus. Passing downwards it becomes aponeurotic near the ankle-joint, and blends with a broad tract of tissue—the plantar fascia. The second portion arises from the femur, just above the external condyle; passing down the leg it becomes aponeurotic near the ankle-joint, and blends with the plantar fascia.

In very many birds the gastrocnemius arises by three heads, an inner one from the tendon of the rectus, and cnemial crest of the tibia; the middle head from between the condyles of the femur, and an outer one arising from the external condyle of that bone. Between these two heads—the middle and the external—passes the biceps tendon.

On comparing the fowl's leg muscles with those of the iguana, it becomes evident that the muscle marked *peroneus primus* in the iguana is really the equivalent of

* Mivart's admirable account of the "Myology of *Iguana tuberculata*" (*Proc. Zool. Soc.*, 1867), has been to me of the utmost utility in my dissections.

the outer head of the fowl's gastrocnemius, and that the bird's biceps cruris is really the representative of the ilio-peroneal of the iguana; they agree in position and especially in their relation to the great sciatic nerve.

Admitting this to be so, it will give us the steps or stages by which the bicipital sling has become fashioned. They may be briefly summarised as follows:—

1. In its original condition the so-called biceps passed between two muscles; one the third head of gastrocnemius or peroneus primus, and the other the outer head of the gastrocnemius.
2. The two muscles tend to fuse near the knee-joint, and enclose the distal end of the biceps.
3. The leg becomes bent at a more or less acute angle with the thigh; this leads the biceps to drag on the muscle-fibres of the gastrocnemius through which it passes. The muscular tissue in relation with the tendon of the biceps thus plays a passive part, and becomes metamorphosed into tendon.
4. The inner limb first separates from the parent muscle; the outer head may do so and form a complete tendinous sling; differentiation may not proceed so far, the outer head remaining in many birds permanently attached to the outer portion of the gastrocnemius.

The question at once arises, Have the facts any bearings on the myology of the mammalian limb? My answer is this. If the biceps femoris in man be carefully traced, the insertion is not by any means confined to the head of the fibula, but its fibres spread into a broad aponeurotic expansion covering the outer side of the leg. The relative size of the biceps in man, as Mivart points out, is much inferior to its possible development. In some forms, *e.g.*, the Agouti (*Dasyprocta Aguti*), the muscle combines with the tensor fasciæ and gluteus maximus to form an almost continuous sheet of muscle, extending from the pelvis over

the outer side of the leg to the ankle-joint. I was very much interested in the biceps of a rhinoceros, in whom the muscle, after being inserted into the fibula, was prolonged by means of an enormously thick and broad tendon to the ankle-joint. This and similar facts induce me to venture the following explanation. The muscle in iguana called peroneus primus, that in birds known as outer or third

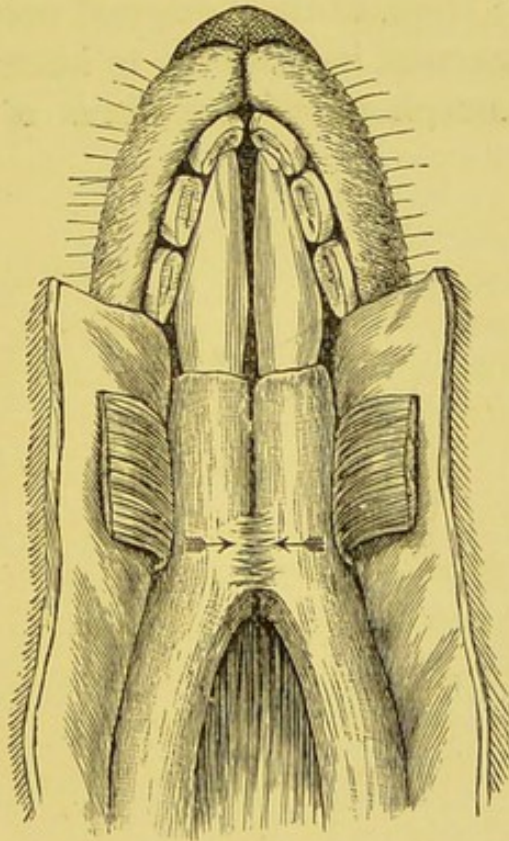


FIG. 37.—The under surface of the mandible of the kangaroo, shewing the inter-mandibular ligament.

head of gastrocnemius, the broad muscular expansion in the Agouti, the enormous tendon of the biceps femoris in the rhinoceros, and its broad fibrous expansion in man, are morphologically identical.

The nerve which originally supplied this muscle, lies in part of its course beneath the fascia, and in part superficial to it, and is named musculo-cutaneous.

The Intermandibular Ligament of the Kan-

garoo.—The mandible of *Macropus* differs from that of Eutherians in the fact that the halves of the mandible remain movable in the situation of the symphysis throughout life. Immediately in the angle formed by the opposition of the two bones there is a well-marked transverse highly elastic ligament (fig. 37). When the mandible is deprived of soft parts with the exception of this ligament, and the rami of the mandible are separated, its elasticity is sufficient to restore them to their original position. A careful study of the ligament induces me to believe that it arises from the metamorphosis of the fibres of the mylo-hyoid muscle.

INDEX.

Bones.

- Atlas, 98
- Axis, 96
- Clavicle, 52
- Epipubes, 74
- Episternal, 52
- Fibula, 42
- Intermedium, 44
- Marsupial, 74
- Odontoid, 97
- Scapula, 53
- Subvertebral, 99
- Tibia, 42
- Tibio-tarsus, 40
- Vertebræ, 93

Fascia.

- Lata, 20
- Lumbar, 21
- Palmar, 17
- Plantar, 17
- Temporal, 8

Ligaments.

- Alar, 36
- Annular of ankle, 39
 - wrist, 47
- Anterior, of spine, 86
- Atlantai, 95
- Calcaneo-cuboid, 30
- Check, 95
- Conjugal, 88

Ligaments (continued)]

- Coraco-acromial, 55
- Coraco-clavicular, 57
- Coraco-humeral, 58, 63
- Costo-coracoid, 55
- Crucial, 35
- Gleno-humeral, 57
- Hyo-epiglottic, 84
- Ilio-femoral, 72
- Inter-articular of knee, 32
- Inter-clavicular, 49, 54
- Inter-mandibular, 112
- Internal brachial, 16
- Interspinous, 90
- Intertransverse, 90
- Intervertebral, 87
- Lateral, of knee, 25
- Mucous, of knee, 36
- Occipito-atlantal, 96
- Plantar, 30
- Posterior, spinal, 86
- Rhomboid, 57
- Sacro-sciatic (great), 76
- Sacro-sciatic (small), 77
- Spheno-mandibular, 8
- Stylo-hyoid, 7
- Spinal, 86
- Subflava, 90
- Supra-spinous, 87
- Supra-sternal, 53
- Suspensory of axis, 96
 - fetlock, 102

Ligaments (*continued*).

- Teres, 67
 Thyro-arytenoid (inferior), 82
 Thyro-arytenoid (superior), 79
 Transverse (atlas), 95
 (scapular), 6
 (humeral), 6


Muscles.

- Adductor magnus, 26
 metatarsi, 12
 Ambiens, 68
 Azygos pharyngis, 13
 Biceps of birds, 106
 man, 76
 Coccygeus, 77
 Coraco-brachialis, 14
 Curvator coccygis, 12
 Dorso-epitrochlearis, 16
 Epicoraco-humeral, 60
 Epitrochleo-anconeus, 11
 Expansor secundariorum, 104
 Extensor annularis, 28
 carpi ulnaris, 13
 coccygis, 12
 digitorum (brevis), 26
 digitorum (longus), 26
 indicis, 28
 minimus, 28
 secundus, 28
 Femoro-caudal, 34
 Flexor brevis pollicis, 14

Muscles (*continued*).

- Flexor carpi radialis brevis, 13
 ulnaris (birds), 104
 Gastrocnemius, 29
 Gluteus maximus, 21
 quartus, 70
 Hyo-epiglottideus, 83
 Ilio-peroneal, 108
 Interossei, 30
 Interosseus primus volaris, 14
 Latissimus dorsi, 22
 Levator costæ, 22
 Levator humeri, 60
 Palmaris longus, 17
 Pectineus, 67
 Pectoralis minor, 63
 Peroneus longus, 25
 primus, 109
 quartus, 26
 quintus, 26
 tertius, 27
 Peroneo-tibialis, 19
 Plantaris, 18
 Pyramidalis, 73
 Radio-carpal, 13
 Rotator-humeri, 15
 Scansorius, 70
 Subclavius, 58
 Tensor fascia femoris, 20
 Thyro-arytenoideus, 82
 Transversalis, 23
 Triangularis sterni, 23







SELECTED LIST
OF
NEW AND RECENT WORKS
PUBLISHED BY
H. K. LEWIS,
136 GOWER STREET, LONDON, W.C.
(ESTABLISHED 1844).

* * * *For full list of works in Medicine and Surgery published by H. K. Lewis see complete Catalogue sent post free on application.*

HENRY R. SWANZY, A.M., M.B., F.R.C.S.I.
Surgeon to the Royal Victoria Eye and Ear Hospital, and Ophthalmic
Surgeon to the Adelaide Hospital, Dublin.

A HANDBOOK OF DISEASES OF THE EYE AND
THEIR TREATMENT. Seventh Edition, Illustrated
with Wood Engravings, Colour Tests, etc., large post 8vo, 12s. 6d.
[Now ready.]

DUDLEY W. BUXTON, M.D., B.S., M.R.C.P.
Administrator of Anæsthetics and Lecturer in University College Hospital;
Consulting Anæsthetist to the National Hospital for Paralysis and
Epilepsy, Queen's Square, &c.

A NÆSTHETICS: their Uses and Administration. Third
Edition, with Illustrations, crown 8vo, 6s. [Now ready.]

H. LEWIS JONES, M.A., M.D., F.R.C.P.
Medical Officer in Charge of the Electrical Department in St. Bartholomew's
Hospital.

MEDICAL ELECTRICITY. A Practical Handbook for
Students and Practitioners. Third Edition, with Illus-
trations, crown 8vo, 10s. 6d. [Just published.]

SIR RICHARD DOUGLAS POWELL, BART., M.D. LOND., F.R.C.P.
Physician in Ordinary to H.M. the Queen; Physician to the
Middlesex Hospital, &c.

THE LUMLEIAN LECTURES ON THE PRIN-
CIPLES WHICH GOVERN TREATMENT IN
DISEASES AND DISORDERS OF THE HEART. Coloured
Diagrams, demy 8vo, 6s.

By the same Author.

DISEASES OF THE LUNGS AND PLEURÆ IN-
CLUDING CONSUMPTION. Fourth Edition, with
coloured plates and wood-engravings, 8vo, 18s.

2 New and Recent Works published by

A. C. ABBOTT, M.D.

Professor of Hygiene and Bacteriology, University of Pennsylvania.

THE PRINCIPLES OF BACTERIOLOGY: A Practical Manual for Students and Physicians. Fifth Edition, with 106 Illustrations, 26 being coloured, post 8vo, 12s. 6d. *nett.*

H. ALDERSMITH, M.B. LOND., F.R.C.S.

Medical Officer, Christ's Hospital, London.

RINGWORM AND ALOPECIA AREATA: Their Pathology, Diagnosis, and Treatment. Fourth Edition, enlarged, with new Illustrations, demy 8vo, 10s. 6d.

IZETT ANDERSON, M.D. EDIN.

YELLOW FEVER IN THE WEST INDIES.
Crown 8vo, 3s. 6d.

JAMES ANDERSON, M.D., F.R.C.P.

Late Assistant Physician to the London Hospital, &c.

NOTES ON MEDICAL NURSING; from the Lectures given to the Probationers at the London Hospital. Edited by E. F. LAMPORT. Third Edition, crown 8vo, 2s. 6d.

FANCOURT BARNES, M.D., M.R.C.P.

Physician to the Chelsea Hospital; Obstetric Physician to the Great Northern Hospital, &c.

A GERMAN-ENGLISH DICTIONARY OF WORDS AND TERMS USED IN MEDICINE AND ITS COGNATE SCIENCES. Square 12mo, Roxburgh binding, 9s.

H. CHARLTON BASTIAN, M.A., M.D., F.R.S.

Emeritus Professor of the Principles and Practice of Medicine in University College London, etc.

I.
A TREATISE ON APHASIA AND OTHER SPEECH DEFECTS. With Illustrations, med. 8vo, 15s.

II.
PARALYSES: CEREBRAL, BULBAR, AND SPINAL. A Manual of Diagnosis for Students and Practitioners. With numerous Illustrations, 8vo, 12s. 6d.

III.
VARIOUS FORMS OF HYSTERICAL OR FUNCTIONAL PARALYSIS Demy 8vo, 7s. 6d.

RUBERT BOYCE, M.B., M.R.C.S.

Professor of Pathology in University College, Liverpool.

A TEXTBOOK OF MORBID HISTOLOGY FOR STUDENTS AND PRACTITIONERS. With 130 coloured figures, royal 8vo, 31s. 6d.

A. BROCA, M.D.

Chirurgien des Hôpitaux des Paris, &c.

AND

F. LUBET-BARBON, M.D.

Ancien Interne des Hôpitaux de Paris.

MASTOID ABSCESSSES AND THEIR TREATMENT. Translated and edited by HENRY J. CURTIS, B.S. and M.D. (Lond.), F.R.C.S. (Eng.), Assistant to the Professor of Pathology, University College, London, &c. With coloured Illustrations, cr. 8vo, 6s.

CHARLES H. BURNETT, A.M., M.D.

Clinical Professor of Otology in the Woman's Medical College of Pennsylvania; Aural Surgeon to the Presbyterian Hospital, Philadelphia.

SYSTEM OF DISEASES OF THE EAR, NOSE AND THROAT. By 45 Eminent American, British, Canadian and Spanish Authors. Edited by CHARLES H. BURNETT. With Illustrations, in two imperial 8vo vols., 48s. *nett*.

HARRY CAMPBELL, M.D., B.S. LOND., F.R.C.P.

Physician to the North-West London Hospital.

I.

THE CAUSATION OF DISEASE. An exposition of the ultimate factors which induce it. Demy 8vo, 12s. 6d.

II.

FLUSHING AND MORBID BLUSHING, THEIR PATHOLOGY AND TREATMENT. With plates and wood engravings, royal 8vo, 10s. 6d.

III.

DIFFERENCES IN THE NERVOUS ORGANISATION OF MAN AND WOMAN, PHYSIOLOGICAL AND PATHOLOGICAL. Royal 8vo, 15s.

IV.

HEADACHE AND OTHER MORBID CEPHALIC SENSATIONS. Royal 8vo, 12s. 6d.

4 **New and Recent Works published by**

ALFRED H. CARTER, M.D. LOND., F.R.C.P.
Senior Physician to the Queen's Hospital; Professor of Medicine,
Mason College, Birmingham, &c.
ELEMENTS OF PRACTICAL MEDICINE.
Seventh Edition, crown 8vo, 10s.

FRANCIS HENRY CHAMPNEYS, M.A., M.B. OXON., F.R.C.P.
Physician-Accoucheur and Lecturer on Obstetric Medicine at St. Bartho-
mew's Hospital, &c.
LECTURES ON PAINFUL MENSTRUATION.
Royal 8vo, 7s. 6d.

E. TREACHER COLLINS, F.R.C.S.
Assistant Surgeon to the Royal London Ophthalmic Hospital, Moorfields;
Hunterian Professor, Royal College of Surgeons, England, 1893-94
**RESEARCHES INTO THE ANATOMY AND PA-
THOLOGY OF THE EYE.** With 10 Plates and 28
Figures in the text, demy 8vo, 6s.

WALTER S. COLMAN, M.D., F.R.C.P.
Assistant Physician to the National Hospital for the Paralysed and Epileptic,
&c.
SECTION CUTTING AND STAINING: A Practical
Introduction to Histological Methods for Students and
Practitioners. Second Edition, with Illustrations, crown 8vo,
3s. 6d.

W. H. CORFIELD, M.A., M.D. OXON., F.R.C.P. LOND.
Professor of Hygiene and Public Health in University College, London.
I.
DWELLING HOUSES: their Sanitary Construction and
Arrangements. Fourth Edition, with Illustrations, crown
8vo. 3s. 6d.
II.
DISEASE AND DEFECTIVE HOUSE SANITATION.
With Illustrations, crown 8vo, 2s.

SIDNEY COUPLAND, M.D., F.R.C.P.
Physician to the Middlesex Hospital, and Lecturer on Practical Medicine in the
Medical School, etc.
NOTES ON THE CLINICAL EXAMINATION OF
THE BLOOD AND EXCRETA. Third Edition, 12mo,
1s. 6d.

H. RADCLIFFE CROCKER, M.D. LOND., B.S., F.R.C.P.
Physician for Diseases of the Skin in University College Hospital.
DISEASES OF THE SKIN: THEIR DESCRIPTION,
PATHOLOGY, DIAGNOSIS, AND TREATMENT.
Second Edition, with Illustrations, 8vo, 24s.

EDGAR M. CROOKSHANK, M.B.

Professor of Comparative Pathology and Bacteriology, King's College,
London.

I.

A TEXT-BOOK OF BACTERIOLOGY: Including the
Etiology and Prevention of Infective Diseases, and a
short account of Yeasts and Moulds, Hæmatozoa, and Psoro-
sperms. Fourth Edition, illustrated with 22 coloured plates and
273 illustrations in the text, med. 8vo, 21s. *nett.*

II.

HISTORY AND PATHOLOGY OF VACCINATION.
2 vols., royal 8vo, coloured plates, 20s. *nett.*

HERBERT DAVIES, M.D., F.R.C.P.

Late Consulting Physician to the London Hospital, etc.

THE MECHANISM OF THE CIRCULATION OF
THE BLOOD THROUGH ORGANICALLY DIS-
EASED HEARTS. Edited by ARTHUR TEMPLER DAVIES, B.A.,
M.D. Cantab., M.R.C.P. Crown 8vo, 3s. 6d.

ROBERT W. DOYNE, F.R.C.S.

Surgeon to the Oxford Eye Hospital; Ophthalmic Surgeon to St. John's
Hospital, Cowley, etc.

NOTES ON THE MORE COMMON DISEASES OF
THE EYE. With test types, crown 8vo, 2s.

DR. A. DÜHRSSSEN.

Professor of Gynæcology, University of Berlin.

I.

A MANUAL OF GYNÆCOLOGICAL PRACTICE FOR
STUDENTS AND PRACTITIONERS. Second Edition,
translated and edited from the sixth German edition, by JOHN
W. TAYLOR, F.R.C.S., Professor of Gynæcology, Mason College,
Birmingham; and FREDERICK EDGE, M.D. LOND., F.R.C.S.,
Surgeon to the Women's Hospital, Wolverhampton. With 125
Illustrations, cr. 8vo, 6s. [Now ready.]

II.

A MANUAL OF OBSTETRIC PRACTICE FOR
STUDENTS AND PRACTITIONERS. Translated
and edited from the sixth German edition by JOHN W. TAYLOR
and FREDERICK EDGE. With Illustrations, cr. 8vo, 6s.

W. ELDER, M.D., F.R.C.P. EDIN.

Physician to Leith Hospital.

APHASIA AND THE CEREBRAL SPEECH ME-
CHANISM. With Illustrations, demy 8vo, 10s. 6d.

6 New and Recent Works published by

W. SOLTAU FENWICK, M.D., B.S. LOND., M.R.C.P.
Physician to Out-patients at the Evelina Hospital for Sick Children, &c.

I.
THE DYSPEPSIA OF PHTHISIS: Its Varieties and
Treatment, including a Description of Certain Forms of
Dyspepsia associated with the Tubercular Diathesis. Demy 8vo,
6s.

II.
DISORDERS OF DIGESTION IN INFANCY AND
CHILDHOOD. With illustrations, demy 8vo, 10s. 6d.
[Now ready.]

J. MILNER FOTHERGILL, M.D.

I.
INDIGESTION AND BILIOUSNESS. Second Edition,
post 8vo, 7s. 6d.

II.
GOUT IN ITS PROTEAN ASPECTS.
Post 8vo, 7s. 6d.

III.
THE TOWN DWELLER: HIS NEEDS AND HIS
WANTS. Post 8vo, 3s. 6d.

DR. ERNEST FUCHS.

Professor of Ophthalmology in the University of Vienna.

TEXTBOOK OF OPHTHALMOLOGY. Second Edition,
translated from the Seventh German Edition by A. DUANE,
M.D., Assistant Surgeon, Ophthalmic and Aural Institute, New
York. With 277 Illustrations, large 8vo, 21s. [Now ready.]

PROFESSOR DR. PAUL FÜRBRINGER.

Director of the Friedrichshain Hospital, Berlin, &c.

TEXTBOOK OF DISEASES OF THE KIDNEYS
AND GENITO-URINARY ORGANS. Translated by
W. H. GILBERT, M.D., Physician in Baden-Baden, &c. Vol. I.,
demy 8vo, 7s. 6d. Vol. II., demy 8vo, 10s. 6d.

SIR DOUGLAS GALTON, K.C.B., HON. D.C.L., LL.D., F.R.S.
Formerly Secretary Railway Department Board of Trade; Assistant Inspector-
General of Fortifications, &c.

HEALTHY HOSPITALS. OBSERVATIONS OF
SOME POINTS CONNECTED WITH HOSPITAL
CONSTRUCTION. With Illustrations, 8vo, 10s. 6d.

JOHN HENRY GARRETT, M.D.

Licentiate in Sanitary Science and Diplomate in Public Health, Universities of Durham and Cambridge, &c.

THE ACTION OF WATER ON LEAD: being an inquiry into the cause and mode of the action and its prevention. Crown 8vo, 4s. 6d.

E. W. GOODALL, M.D. LOND.

Medical Superintendent of the Eastern Hospital of the Metropolitan Asylums Board; Formerly Medical Registrar to Guy's Hospital;

AND

J. W. WASHBOURN, M.D. LOND., F.R.C.P.

Physician to the London Fever Hospital; Assistant Physician to Guy's Hospital, and Lecturer in the Medical School.

A MANUAL OF INFECTIOUS DISEASES.
Illustrated with Plates, Diagrams, and Charts, 8vo, 15s.

JAMES F. GOODHART, M.D. ABERD., F.R.C.P.

Physician to Guy's Hospital, and Consulting Physician to the Evelina Hospital for Sick Children.

ON COMMON NEUROSES; OR THE NEUROTIC ELEMENT IN DISEASE AND ITS RATIONAL TREATMENT. Second Edition, crown 8vo, 3s. 6d.

JOHN GORHAM, M.R.C.S.

TOOOTH EXTRACTION: A manual on the proper mode of extracting teeth. Fourth edition, fcap. 8vo, 1s. 6d.

GEORGE M. GOULD, A.M., M.D.

I.

THE STUDENT'S MEDICAL DICTIONARY: Including all the words and phrases generally used in Medicine, with their proper pronunciation and definitions. Eleventh Edition, with numerous Illustrations, 8vo, 14s. *nett*.

II.

A POCKET MEDICAL DICTIONARY, giving the Pronunciation and Definition of the Principal Words used in Medicine and the Collateral Sciences. Fourth edition, containing 30,000 words, 32mo, 5s. *nett*.

LANDON C. GRAY, M.D.

Professor of Nervous and Mental Diseases in the New York Polyclinic, &c.

A TREATISE ON NERVOUS AND MENTAL DISEASES FOR STUDENTS AND PRACTITIONERS OF MEDICINE. With 168 Illustrations, 8vo, 21s.

DR. JOSEF GRUBER.

Professor of Otology in the University of Vienna, &c.

A TEXT-BOOK OF THE DISEASES OF THE EAR.
Translated from the German, and Edited by EDWARD LAW, M.D., C.M. EDIN., M.R.C.S. ENG., Surgeon to the London Throat Hospital for Diseases of the Throat, Nose and Ear; and COLEMAN JEWELL, M.B. LOND., M.R.C.S. ENG. Second edition, with 165 Illustrations, and 70 coloured figures, royal 8vo, 28s.

DRS. HARVEY AND DAVIDSON.

SYLLABUS OF MATERIA MEDICA. Revised in accordance with the "British Pharmacopœia" 1898, by WILLIAM MARTINDALE, F.L.S., F.C.S. Tenth edition, fcap. 16mo, 1s. *nett.*

W. S. HEDLEY, M.D.

Medical Officer in charge of the Electro-Therapeutic Department of the London Hospital.

I.
THE HYDRO-ELECTRIC METHODS IN MEDICINE. Second Edition, with Illustrations, demy 8vo, 4s. 6d.

II.
CURRENT FROM THE MAIN: The Medical Employment of Electric Lighting Currents. With Illustrations, demy 8vo, 2s. 6d.

III.
PRACTICAL MUSCLE-TESTING; AND THE TREATMENT OF MUSCULAR ATROPHIES. With Illustrations, demy 8vo, 3s. 6d. [*Now ready.*]

BERKELEY HILL, M.B. LOND., F.R.C.S.

Professor of Clinical Surgery in University College,

AND

ARTHUR COOPER, L.R.C.P., M.R.C.S.

Surgeon to the Westminster General Dispensary, &c.

SYPHILIS AND LOCAL CONTAGIOUS DISORDERS. Second Edition, entirely re-written, royal 8vo, 18s.

NORMAN KERR, M.D., F.L.S.

President of the Society for the Study of Inebriety; Consulting Physician, Dalrymple Home for Inebriates, etc.

INEBRIETY: ITS ETIOLOGY, PATHOLOGY, TREATMENT, AND JURISPRUDENCE. Third Edition, 8vo, 21s.

LEWIS'S PRACTICAL SERIES.

In Crown 8vo Volumes, with Illustrations.

- DISEASES OF THE NERVOUS SYSTEM. A Handbook** for Students and Practitioners. By C. E. BEEVOR, M.D. Lond., F.R.C.P., Physician to the National Hospital for the Paralysed and Epileptic. 10s. 6d.
- THE TREATMENT OF PULMONARY CONSUMPTION.** By VINCENT D. HARRIS, M.D. Lond., F.R.C.P., and E. CLIFFORD BEALE, M.A., M.B., Cantab., F.R.C.P., Physicians to the City of London Hospital for Diseases of the Chest, &c. 10s. 6d.
- THE SURGICAL DISEASES OF CHILDREN AND THEIR TREATMENT BY MODERN METHODS.** By D'ARCY POWER, F.R.C.S. Eng., Assistant Surgeon to St. Bartholomew's Hospital. 10s. 6d.
- DISEASES OF THE NOSE AND THROAT.** By F. de HAVILLAND HALL, M.D., F.R.C.P. Lond., Physician to the Westminster Hospital, and HERBERT TILLEY, M.D., B.S. Lond., F.R.C.S. Eng., Surgeon to the Hospital for Diseases of the Throat, Golden Square. Second Edition, 10s. 6d. *[Just published.]*
- PUBLIC HEALTH LABORATORY WORK.** By H. R. KENWOOD, M.B., D.P.H., F.C.S., Assistant Professor of Public Health, University College, &c. Second Edition, 10s. 6d.
- MEDICAL MICROSCOPY.** By FRANK J. WETHERED, M.D., M.R.C.P., Medical Registrar to the Middlesex Hospital. 9s.
- MEDICAL ELECTRICITY.** By H. LEWIS JONES, M.A., M.D., F.R.C.P., Medical Officer, Electrical Department, St. Bartholomew's Hospital. Third Edition, 10s. 6d. *[Now ready.]*
- HYGIENE AND PUBLIC HEALTH.** By LOUIS C. PARKES, M.D., D.P.H. Lond. Univ., Lecturer on Public Health at St. George's Hospital, and H. R. KENWOOD, M.B., D.P.H., F.C.S., Assistant Professor of Public Health at University College, London. 12s. *[Now ready.]*
- MANUAL OF OPHTHALMIC PRACTICE,** By C. HIGGENS, F.R.C.S., Lecturer on Ophthalmology at Guy's Hospital Medical School, &c. 6s.
- A PRACTICAL TEXTBOOK OF THE DISEASES OF WOMEN.** By ARTHUR H. N. LEWERS, M.D. Lond., Obstetric Physician to the London Hospital. Fifth Edition, 10s. 6d.
- ANÆSTHETICS: their Uses and Administration.** By DUDLEY W. BUXTON, M.D., B.S., M.R.C.P., Administrator of Anæsthetics at University College Hospital, &c. Third Edition, 6s. *[Now ready.]*
- ON FEVERS: their History, Etiology, Diagnosis, Prognosis and Treatment.** By A. COLLIE, M.D. 8s. 6d.
- HANDBOOK OF DISEASES OF THE EAR.** By URBAN PRITCHARD, M.D. (Edin.), F.R.C.S., Professor of Aural Surgery at King's College, London, &c. Third Edition, 6s.
- A PRACTICAL TREATISE ON DISEASES OF THE KIDNEYS AND URINARY DERANGEMENTS.** By C. H. RALFE, M.A., M.D. Cantab., F.R.C.P., Physician to the London Hospital. 10s. 6d.
- DENTAL SURGERY FOR MEDICAL PRACTITIONERS AND STUDENTS OF MEDICINE.** By ASHLEY W. BARRETT, M.B. Lond., M.R.C.S., L.D.S., Consulting Dental Surgeon to the London Hospital. Third Edition, 3s. 6d.
- BODILY DEFORMITIES AND THEIR TREATMENT.** By H. A. REEVES, F.R.C.S. Ed., Senior Assistant Surgeon and Teacher of Practical Surgery at the London Hospital. 8s. 6d.

F. CHARLES LARKIN, F.R.C.S. ENG.

Surgeon to the Stanley Hospital,

AND

RANDLE LEIGH, M.B., B.SC. LOND.

Senior Demonstrator of Physiology in University College, Liverpool.

OUTLINES OF PRACTICAL PHYSIOLOGICAL CHEMISTRY. Second Edition, with Illustrations, crown 8vo, 2s. 6d. *nett.*

J. WICKHAM LEGG, F.R.C.P.

Formerly Assistant Physician to Saint Bartholomew's Hospital.

A GUIDE TO THE EXAMINATION OF THE URINE. Seventh Edition, edited and revised by H. LEWIS JONES, M.D., Medical Officer in charge of the Electrical Department in St. Bartholomew's Hospital. With Illustrations, fcap. 8vo, 3s. 6d.

LEWIS'S POCKET MEDICAL VOCABULARY. Second Edition, 32mo, limp roan, 3s. 6d.

WILLIAM THOMPSON LUSK, A.M., M.D.

Professor of Obstetrics in the Bellevue Hospital Medical College, &c.

THE SCIENCE AND ART OF MIDWIFERY. Fourth Edition, rewritten, with numerous Illustrations, 8vo, 18s.

WILLIAM A. M'KEOWN, M.D., M.CH.

Surgeon to the Ulster Eye, Ear and Throat Hospital, Belfast; Lecturer on Ophthalmology and Otology, Queen's College, Belfast.

A TREATISE ON "UNRIPE" CATARACT. With Illustrations, roy. 8vo, 12s. 6d. *nett.* [Now ready.]

JEFFERY A. MARSTON, M.D., C.B., F.R.C.S., M.R.C.P. LOND.

Surgeon General Medical Staff (Retired).

NOTES ON TYPHOID FEVER: Tropical Life its Sequelæ. Crown 8vo, 3s. 6d.

WILLIAM MARTINDALE, F.L.S., F.C.S.

AND

W. WYNN WESTCOTT, M.B. LOND.

THE EXTRA PHARMACOPŒIA, revised in accordance with the "British Pharmacopœia," 1898, with Seropathy, Organotherapy, Medical References, and a Therapeutic Index. Ninth Edition, limp roan, med. 24mo, 10s. 6d.

A. STANFORD MORTON, M.B., F.R.C.S. ENG.

Surgeon to the Moorfields Ophthalmic Hospital, &c.

REFRACTION OF THE EYE: Its Diagnosis, and the Correction of its Errors. Sixth Edition, small 8vo, 3s. 6d.

C. W. MANSELL MOULLIN, M.A., M.D. OXON., F.R.C.S. ENG.

Surgeon and Lecturer on Physiology at the London Hospital, &c.

I.
INFLAMMATION OF THE BLADDER AND URINARY FEVER. 8vo, 5s.

II.
ENLARGEMENT OF THE PROSTATE: its Treatment and Radical Cure. Second Edition, 8vo, 6s.

III.
SPRAINS; THEIR CONSEQUENCES AND TREATMENT. Second Edition, crown 8vo, 4s. 6d.

WILLIAM MURRAY, M.D., F.R.C.P. LOND.

I.
ROUGH NOTES ON REMEDIES. Third Edition, enlarged, crown 8vo, 3s. 6d.

II.
ILLUSTRATIONS OF THE INDUCTIVE METHOD IN MEDICINE. Crown 8vo, 3s. 6d.

WILLIAM MURRELL, M.D., F.R.C.P.

Physician to Westminster Hospital.

WHAT TO DO IN CASES OF POISONING. Ninth Edition, royal 32mo, 3s. 6d.

G. OLIVER, M.D., F.R.C.P.

I.
PULSE-GAUGING: A Clinical Study of Radial Measurement and Pulse Pressure. Illustrations, fcap. 8vo, 3s. 6d.

II.
ON BEDSIDE URINE TESTING: a Clinical Guide to the Observation of Urine in the course of Work. Fourth Edition, fcap. 8vo, 3s. 6d.

III.
HARROGATE AND ITS WATERS: Notes on the Climate of Harrogate, and on the Chemistry of the Mineral Spring. Crown 8vo, with Map of the Wells, 2s. 6d.

DR. A. ONODI.

Lecturer on Rhino-Laryngology in the University of Budapest.

THE ANATOMY OF THE NASAL CAVITY, AND ITS ACCESSORY SINUSES. An Atlas for Practitioners and Students, translated by ST CLAIR THOMSON, M.D. LOND., F.R.C.S. ENG., M.R.C.P. LOND. Plates, small 4to, 6s. *nett.*

WILLIAM OSLER, M.D., F.R.C.P. LOND.

Professor of Medicine, Johns Hopkins University, &c.

ON CHOREA AND CHOREIFORM AFFECTIONS. Large 8vo, 5s.

LOUIS C. PARKES, M.D. LOND., D.P.H.

Lecturer on Public Health at St. George's Hospital, &c.

INFECTIOUS DISEASES, NOTIFICATION AND PREVENTION. Fcap. 8vo, cloth, 2s. 6d., roan, 4s. 6d.

DR. THEODOR PUSCHMANN.

Public Professor in Ordinary at the University of Vienna.

HISTORY OF MEDICAL EDUCATION FROM THE MOST REMOTE TO THE MOST RECENT TIMES. Translated by EVAN H. HARE, M.A. (OXON.), F.R.C.S. (ENG.), F.S.A. Demy 8vo, 21s.

SAMUEL RIDEAL, D.SC. (LOND.), F.I.C., F.C.S.

Fellow of University College, London.

I.
PRACTICAL ORGANIC CHEMISTRY. The detection and properties of some of the more important Organic Compounds. Second Edition, 12mo, 2s. 6d.

II.
PRACTICAL CHEMISTRY FOR MEDICAL STUDENTS, Required at the First Examination of the Conjoint Examining Board in England. Fcap. 8vo, 2s.

J. JAMES RIDGE, M.D., B.S., B.A., B.SC. LOND.

Medical Officer of Health, Enfield.

ALCOHOL AND PUBLIC HEALTH. Second Edition, Crown 8vo, 2s.

SYDNEY RINGER, M.D., F.R.S.

Holme Professor of Clinical Medicine in University College; Physician to University College Hospital,

AND

HARRINGTON SAINSBURY, M.D., F.R.C.P.

Physician to the Royal Free Hospital and the City of London Hospital for Diseases of the Chest, Victoria Park.

A HANDBOOK OF THERAPEUTICS. Thirteenth Edition, 8vo, 16s.

FREDERICK T. ROBERTS, M.D., B.SC., F.R.C.P.

Professor of the Principles and Practice of Medicine in University College
Physician to University College Hospital, &c.

THE THEORY AND PRACTICE OF MEDICINE.
Ninth Edition, with Illustrations, large 8vo, 21s.

H. D. ROLLESTON, M.D., F.R.C.P.

Fellow of St. John's College, Cambridge; Assistant Physician and Lecturer
on Pathology, St. George's Hospital, London;

AND

A. A. KANTHACK, M.D., M.R.C.P.

Lecturer on Pathology, St. Bartholomew's Hospital, London.

PRACTICAL MORBID ANATOMY. Crown 8vo, 6s.
[CAMBRIDGE NATURAL SCIENCE MANUALS.]

WILLIAM ROSE, B.S., M.B. LOND., F.R.C.S.

Professor of Surgery in King's College, London, and Surgeon to King's
College Hospital, &c.

ON HARELIP AND CLEFT PALATE. Demy 8vo,
with Illustrations, 6s.

BERNARD ROTH, F.R.C.S.

Orthopædic Surgeon to the Royal Alexandra Hospital for Sick Children,
Brighton, &c.

**THE TREATMENT OF LATERAL CURVATURE
OF THE SPINE.** Second Edition, with Photographic
and other Illustrations, roy. 8vo, 10s. 6d.

DR. C. SCHIMMELBUSCH.

Privat-docent and Assistant Surgeon in Prof. v. Bergmann's University Clinic
at Berlin.

THE ASEPTIC TREATMENT OF WOUNDS.
Translated from the Second German Edition by A. T. RAKE,
M.B., B.S. LOND., F.R.C.S. ENG. With Illustrations, crown
8vo, 5s.

G. E. SHUTTLEWORTH, B.A., M.D.

Medical Examiner of Defective Children, School Board for London; late
Medical Superintendent, Royal Albert Asylum for Idiots and Imbeciles
of the Northern Counties, Lancaster, &c.

MENTALLY-DEFICIENT CHILDREN: their Treat-
ment and Training. Second Edition, with Illustrations,
crown 8vo, 5s. *nett.* [Now ready.]

ALEXANDER J. C. SKENE, M.D.

Professor of Gynæcology in the Long Island College Hospital, Brooklyn.

TREATISE ON THE DISEASES OF WOMEN.
Third Edition, with 290 engravings and 4 chromo-litho-
graphs, medium 8vo, 28s.

J. LEWIS SMITH, M.D.

Physician to the New York Foundling Asylum; Clinical Professor of Diseases of Children in Bellevue Hospital Medical College.

A TREATISE ON THE MEDICAL AND SURGICAL DISEASES OF INFANCY AND CHILDHOOD. Eighth Edition, with Illustrations, large 8vo, 21s. [Now ready.]

E. HUGH SNELL, M.D., B.SC., LOND.

Diplomate in Public Health of the University of Cambridge; London County Council Medical Officer to the Blackwall Tunnel.

COMPRESSED AIR ILLNESS, OR SO-CALLED CAISSON DISEASE. Demy 8vo, 10s. 6d. [Now ready.]

JOHN KENT SPENDER, M.D. LOND.

Physician to the Royal Mineral Water Hospital, Bath.

THE EARLY SYMPTOMS AND THE EARLY TREATMENT OF OSTEO-ARTHRITIS, commonly called Rheumatoid Arthritis. With special reference to the Bath Thermal Waters. Small 8vo, 2s. 6d.

LEWIS A. STIMSON, B.A., M.D.

Surgeon to the New York, Bellevue, and Hudson Street Hospitals; Professor of Surgery in the University of the City of New York, &c.

AND

JOHN ROGERS, JUN., B.A., M.D.

Assistant Demonstrator in the College of Physicians and Surgeons, New York, &c.

A MANUAL OF OPERATIVE SURGERY. Third Edition, with numerous Illustrations, post 8vo, 12s. 6d. *nett.* [Now ready.]

JAMES STOCKEN, L.D.S. ENG.

Pereira Prizeman for Materia Medica; Late Dental Surgeon to the National Dental Hospital.

DENTAL MATERIA MEDICA AND THERAPEUTICS. Fourth edition, revised by LESLIE M. STOCKEN, L.R.C.P., M.R.C.S., L.D.S.; and J. O. BUTCHER, L.D.S. ENG., Assistant Dental Surgeon to Guy's Hospital. Fcap. 8vo, 4s.

C. W. SUCKLING, M.D. LOND., M.R.C.P.

Professor of Materia Medica and Therapeutics at the Queen's College, Physician to the Queen's Hospital, Birmingham, etc.

I.

ON THE DIAGNOSIS OF DISEASES OF THE BRAIN, SPINAL CORD, AND NERVES. With Illustrations, crown 8vo, 8s. 6d.

II.

ON THE TREATMENT OF DISEASES OF THE NERVOUS SYSTEM. Crown 8vo, 7s. 6d.

J. BLAND SUTTON, F.R.C.S.

Assistant Surgeon to the Middlesex Hospital.

LIGAMENTS: THEIR NATURE AND MORPHOLOGY. Second Edition, wood engravings, post 8vo, 4s. 6d.

ALBERT TAYLOR.

Associate Sanitary Institute; Chief Sanitary Inspector to the Vestry of St George, Hanover Square, etc.

THE SANITARY INSPECTOR'S HANDBOOK. Second Edition, with Illustrations, cr. 8vo, 5s.

E. G. WHITTLE, M.D. LOND., F.R.C.S. ENG.

Senior Surgeon to the Royal Alexandra Hospital for Sick Children, Brighton.

CONGESTIVE NEURASTHENIA, OR INSOMNIA AND NERVE DEPRESSION. Crown 8vo, 3s. 6d.

SIR JOHN WILLIAMS, M.D., F.R.C.P.

Professor of Midwifery in University College, London, &c.

CANCER OF THE UTERUS: BEING THE HARVEIAN LECTURES FOR 1886. Illustrated with Lithographic Plates, royal 8vo, 10s. 6d.

E. T. WILSON, M.B. OXON., F.R.C.P. LOND.

Physician to the Cheltenham General Hospital, &c.

DISINFECTANTS AND ANTISEPTICS: HOW TO USE THEM. In Packets of one doz. price 1s., by post 1s. 1d. [*Thoroughly revised.*]

BERTRAM C. A. WINDLE, D.SC., M.D., M.A. DUBL.

Professor of Anatomy in Mason College, Birmingham, &c.

A HANDBOOK OF SURFACE ANATOMY AND LANDMARKS. Second Edition, revised with the collaboration of T. MANNERS-SMITH, M.A., M.R.C.S., Lecturer on Osteology, Mason College, Birmingham. With illustrations, post 8vo, 3s. 6d. [*Now ready.*]

EDWARD WOAKES, M.D. LOND.

Senior Aural Surgeon, London Hospital; Lecturer on Diseases of the Ear, London Hospital Medical College.

ON DEAFNESS, GIDDINESS, AND NOISES IN THE HEAD. Fourth Edition, Part I., with Illustrations, 8vo, 10s. 6d. [*Now ready.*]

OSWALD ZIEMSEN, M.D.

Knight of the Iron Cross, and of the Prussian Order of the Crown.

THE TREATMENT OF CONSTITUTIONAL SYPHILIS. Post 8vo, 3s. 6d.

LEWIS'S DIET CHARTS. A Suggestive set of Diet Tables for the use of Physicians, for handing to Patients after Consultation, modified to suit Individual Requirements; for Albuminuria, Anæmia and Debility, Constipation, Diabetes, Diarrhœa, Dyspepsia, Eczema, Fevers, Gall Stones, Gout and Gravel, Heart Disease (chronic), Nervous Diseases, Obesity, Phthisis, Rheumatism (chronic); and Blank Chart for other diseases. 5s. per packet of 100 charts, post free. A special leaflet on the Diet and Management of Infants is sold separately. 12, 1s.; 100, 7s. 6d., post free.

LEWIS'S FOUR-HOUR TEMPERATURE CHART. Meets the requirements of a chart on which the temperature and other observations can be recorded at intervals of four hours. Each chart will last a week. 20, 1s.; 50, 2s.; 100, 3s. 6d.; 500, 14s.; 1000, 25s.

CHART FOR RECORDING THE EXAMINATION OF URINE. Designed for the use of medical men, analysts and others making examinations of the urine of patients, affording a convenient method of recording the results of the examination. 10, 1s.; 100, 7s. 6d.; 250, 15s.; 500, 25s.; 1000, 40s.

CLINICAL CHARTS FOR TEMPERATURE OBSERVATIONS, ETC. Arranged by W. RIGDEN, M.R.C.S. 12, 1s.; 100, 7s.; 250, 15s.; 500, 28s.; 1000, 50s.
Each Chart is arranged for four weeks, and is ruled at the back for making notes of cases; they are convenient in size, and are suitable both for hospital and private cases.

LEWIS'S CLINICAL CHART, SPECIALLY DESIGNED FOR USE WITH THE VISITING LIST. This Temperature Chart is arranged for four weeks, and measures 6 × 3 inches. 12, 6d.; 25, 1s.; 100, 3s. 6d.; 500, 16s. 6d.; 1000, 30s.

LEWIS'S NURSING CHART. Printed on both sides. 20, 1s.; 50, 2s.; 100, 3s. 6d.; 500, 14s.; 1000, 25s.

* * MR. LEWIS is in constant communication with the leading publishing firms in America and has transactions with them for the sale of his publications in that country. Advantageous arrangements are made in the interests of Authors for the publishing of their works in the United States.

MR. LEWIS'S publications can be procured of any Bookseller in any part of the world.

Complete Catalogue of Publications post free on application.

Printed by H. K. Lewis, Gower Street, London, W.C.

