

An essay on the malformations and congenital diseases of the organs of sight / by W.R. Wilde.

Contributors

Wilde, W. R. 1815-1876.

Publication/Creation

London : John Churchill, 1862 (Dublin : University Press.)

Persistent URL

<https://wellcomecollection.org/works/abnpjddp>

License and attribution

This work has been identified as being free of known restrictions under copyright law, including all related and neighbouring rights and is being made available under the Creative Commons, Public Domain Mark.

You can copy, modify, distribute and perform the work, even for commercial purposes, without asking permission.




Wellcome Collection
183 Euston Road
London NW1 2BE UK
T +44 (0)20 7611 8722
E library@wellcomecollection.org
<https://wellcomecollection.org>

M20356



22300004601





J. Daniel

875.07.

with the author's regards.

AN ESSAY

J. Tweedy

ON THE

MALFORMATIONS AND CONGENITAL DISEASES

OF THE

ORGANS OF SIGHT.

BY

W. R. WILDE, M.D., F.R.C.S.,

SURGEON OCULIST IN ORDINARY IN IRELAND TO THE QUEEN;
VICE-PRESIDENT OF THE ROYAL IRISH ACADEMY;
SURGEON TO ST. MARK'S OPHTHALMIC HOSPITAL;
HONORARY MEMBER OF THE ROYAL ACADEMY OF SCIENCE OF UPSALA;
CORRESPONDING MEMBER OF THE MEDICAL SOCIETIES OF STOCKHOLM AND DRESDEN,
OF THE SCIENTIFIC AND NATURAL HISTORY SOCIETY OF ATHENS,
AND THE STATISTICAL AND GEOGRAPHICAL SOCIETIES OF BERLIN AND FRANKFORT;
ETC. ETC.

With Sixty Illustrations.

LONDON:

JOHN CHURCHILL, PRINCESS-STREET, SOHO.

DUBLIN: FANNIN & CO., GRAFTON-STREET.

1862.

21547

19764536

DUBLIN:
Printed at the University Press,
BY M. H. GILL.

M20356

WELLCOME INSTITUTE LIBRARY	
Coll.	weIMOmec
Call	
No.	WW100
	1802
	W67c

TO

JAMES DIXON, F.R.C.S.,

SURGEON TO THE ROYAL LONDON OPHTHALMIC HOSPITAL, MOORFIELDS,

This Tract

IS DEDICATED,

AS A MARK OF THE ADMIRATION AND ESTEEM

OF

HIS FRIEND,

THE AUTHOR.

THE HISTORY OF THE

REIGN OF KING CHARLES THE FIRST

IN

THE YEAR 1649

BY JOHN BURNET

AND

JOHN BURNET

THE SECOND

P R E F A C E.

THE history of this *brochure* is as follows:—In the winter of 1844–5, I delivered an Address to the Dublin Obstetrical Society on the subject of congenital malformations. That Address contained the skeleton of this tract, portions of which were published in the Bimonthly Dublin Journal, in 1845, and in the quarterly volumes of that periodical in 1848, 1861, and 1862. From the worked-off sheets of these papers the following pages have been supplied. Conceiving that, for reference, they would be acceptable to my brethren engaged in the practice of ophthalmic medicine, and as no other work of the kind has been published in English, I present them just as they originally appeared.

DUBLIN, 1, MERRION-SQUARE, NORTH,
January, 1862.

TABLE

The history of the American people is a story of the struggle for freedom and justice. It is a story of the people who have fought for the rights of the oppressed and the weak. It is a story of the people who have fought for the rights of the poor and the ignorant. It is a story of the people who have fought for the rights of the colored people. It is a story of the people who have fought for the rights of the women. It is a story of the people who have fought for the rights of the children. It is a story of the people who have fought for the rights of the old. It is a story of the people who have fought for the rights of the young. It is a story of the people who have fought for the rights of the whole people. It is a story of the people who have fought for the rights of the future. It is a story of the people who have fought for the rights of the present. It is a story of the people who have fought for the rights of the past. It is a story of the people who have fought for the rights of the future. It is a story of the people who have fought for the rights of the present. It is a story of the people who have fought for the rights of the past.

1

Copyright, 1911, by the American People
New York, N. Y.

CONTENTS.

	PAGE.
Introduction,	1
Malformations and Congenital Diseases of the Defences of the Eye and Ocular	
Appendages,	8
— Epicanthus,	8
— Ptosis,	10
— Ectropium,	11
— Entropium and Trichiasis,	12
— Symblepharon,	13
— Phimosis Palpebrarum,	17
— Lagophthalmus,	20
— Coloboma Palpebræ,	20
— Blepharobyschorea and Nævi,	21
Malformations of the Lachrymal Organs,	24
— Angiectasia,	25
— Absence of the Lachrymal Gland,	25
— Atresia Puncti Lachrymalis,	25
— Fistula Lachrymalis,	26
Alterations in the size, form, structure, and position of the Globe,	29
— Microphthalmus,	29
— Megalophthalmus,	32
— Anophthalmus,	33
— Nystagmus,	38
— Luscitas,	41
Malformations of the Conjunctiva,	43
— Alterations in Colour,	43
— Morbid Growths,	43
— Xeroma,	46
Alterations in the structure, size, and shape of the Cornea,	48
— Opacities,	58
— Annulus Juvenilis,	51
— Microcornea,	60
— Cornea Conica,	63
— Cylindrical Cornea,	67

	PAGE.
Alterations in the structure, size, and shape of the Cornea,— <i>continued.</i>	
— Plurality of Cornea,	67
— Deficiency of Cornea,	67
Malformations of the Iris and Choroid,	71
— Development of the Human Eye,	71
— Varieties of Colour.—Albinos,	78
— Heterophthalmus,	83
— Korestenoma,	86
— Malformations of Pupil,	87
— Myosis or Microcorea,	87
— Coroptosia,	88
— Mydriasis,	90
— Dyscoria or Coremetamorphosis,	90
— Polycorea,	92
— Atresia pupillæ,	94
— Tremulous Iris,	94
— Coloboma Iridis,	95
— Iriderimia,	103
Malformations of the Choroid,	107
— Peculiarities of Colour,	107
— Deficiency of Pigment,	107
— Coloboma Choroideæ,	108
— Deficiency of Choroid,	108
— Absence of Anterior Chamber,	109
Malformations of the Lens and Capsule,	110
— Development of the Lens,	111
— Absence of Lens,	116
— Double Lenses,	116
— Myopia,	116
— Malposition of Lens,	117
— Entozoa within the Capsule,	117
— Congenital Synechia Posterior,	117
— Congenital Cataract,	118
— Complete Lenticular Cataract,	123
— Cataracta Lactea,	124
— Central Lenticular Cataract,	125
— Posterior Lenticular Cataract,	131
— Capsular Cataract,	133
— Pyramidal Cataract,	134
— Capsulo-lenticular Cataract,	137
Malformations of the Vitreous Body, Retina, and Optic Nerve,	139
— Cyclops and Monoculus,	140
— Plurality of Eyes,	142

AN ESSAY
UPON THE
MALFORMATIONS AND CONGENITAL DISEASES
OF THE
ORGANS OF SIGHT.

IN what way the new-born infant differs in its anatomical construction from the full-grown, well-formed adult, in the relative proportions of their bodies, or the comparative sizes and development of individual organs, is still a question propounded in the schools. Thus the proportion, compared with the rest of the body, of the head, the liver, and the abdomen, generally; the cavity of the thorax, the structure of the lung, the condition of the larynx, or the other organs of sense; as well as the proportions of the extremities, the construction of the bones, and the size, peculiarities, and functions of particular structures and tissues, are all dwelt upon, and the causes of their greater or less development explained, or attempted to be done so.

Now as we follow up this analogy and this comparison, through the organs of sense in particular, a wide and interesting field for anatomical observation, and physiological

speculation, opens to us. The condition of the organs of sight, touch, hearing, speaking, or smelling, as they naturally present some peculiarities at birth, which they do not afford in after life, when their peculiar powers have been called into action, and, if I may so say, educated, demands not only the attention of the anatomist and the physiologist, the surgeon and physician, but of the well-educated midwifery practitioner also; for, so long as the hand of man is with us at our birth, so long will the first days of our infantile existence, with all the diseases of intra or extra-uterine life, congenital, or subsequently acquired, medical or surgical, as well as all the peculiarities of the new-born babe, fall under the eye, or require the skill of the attendant accoucheur. We are all aware of the necessity of being well acquainted with the usual natural appearances which the child presents at birth; as, for instance, the peculiar colour of the skin; the character of the first alvine discharges; the mucus which lines the meatus auditorius; or even the occasional existence of milk in the mammæ; or a remnant of the membrana pupillaris remaining in the eye, &c. &c.; together with numerous other infantile conditions, generally specified in the books, and which are of such common occurrence as not to require specific notice here.

But there are other abnormal conditions,—aberrations from the general laws that appear to regulate the formation of the internal organization, or the external contour of living bodies, both in man and the lower animals—*lusus naturæ*,—deviations from the original type, as, in accordance with modern phraseology, and extended scientific research, they are now styled; and which are usually denominated monstrosities, or congenital deformities,—that every practitioner, but in particular the accoucheur, from his being in all cases the first opinion asked, should be well informed upon. Thus, the supernumerary organs, as additional fingers and toes, or the defi-

ciency of these, or of any such parts, singly or collectively; the various solutions of continuity, known as hare-lip, cleft palate, or spina bifida, and recognized either as the result of morbid action or irregularity in the growth of the fœtus; or again, when parts become displaced, as in the viscera, or, are altogether wanting, as in acardiac or acephalous fœtuses; together with closure of the anus, the ear, the urethra; or in fine, any of those curious appearances, such as Siamese twins, or fœtuses joined together after various fashions; it is our duty to be informed upon.

Heretofore such curiosities were termed freaks of nature, but they are all now classed according to some more definite rules, which in those days of transcendental anatomy, have been styled laws of analogy, by which every deformity or monstrosity is referred to some arrest of development, while the young animal is "passing," as it is called, "through some of the transitions" from reptile to fish, fish to fowl, and fowl to mammalia.

I have often thought that it would form a very interesting, and not altogether uninteresting essay, if some careful and laborious investigator in this country would draw up an outline, or brief *resumé*, of all the known congenital deformities to which the human subject is liable. After all, essays and papers of that description are of great value, although men have seldom awarded them the meed of praise they deserve, for the labour and industry expended in their compilation. The materials of such essays are generally scattered throughout a great number of works, or are to be found in detached notices, in monographs, and periodicals, and when such are carefully and skilfully arranged, their authors are as deserving of praise, as the bee who collects from every opening flower, upon the wide expanse of the landscape, the sweets, that when brought home to the cell, form delicious food; but which, if uncollected, or left in the honeybags of their native

flowers, we would never know anything about. Such compositions act like modern reviews; they put men in possession of the current modern literature of the day, without obliging them to read the works themselves. And although the practical experience of the compiler may not be very extensive, still one great object may be achieved: inquiry may be elicited and discussion provoked. For such a task I have neither ability nor inclination, there are, however, certain congenital abnormal appearances of the organs of sight, either the result of arrest of development at some period of their growth, or, as is much more frequently the case, of disease and morbid action going forward during uterine life, which are occasionally met in ophthalmic practice, and which I shall now endeavour to lay before my readers.

From the researches of Wagner, Burdach, Bischoff, and other recent observers in the field of embryology, we have been made acquainted, in a great measure, with the progress, growth, and development of the human fœtus, progressively, and step by step, from the earliest period of its existence, when its parts can be only distinguished in the field of the microscope, to the epoch of its uterine expulsion, and individual and independent life. We are aware also, that not only are the various parts and organs of the growing animal superadded and developed, one by one, according to a regular scale of formation, but that the various structures, which enter into the composition of each of these parts or organs, are also added, day by day, till they make an individual and perfect whole, and the sum of these organs goes to constitute the living animal, complete in all its parts, and fitted to occupy the precise position, and to fulfil the exact objects, for which it was intended by an allwise and overruling Providence.

We know that even after organs have received their definite and particular shape, various remarkable changes still

take place in the structures which enter into their composition; some that were originally highly vascular, presenting at birth, and in after life, no traces of such peculiarity; whole parts that performed important offices in uterine, and the early portions of infantile life, after a short time, withering, becoming absorbed, and completely removed, as the suprarenal capsules, and the thymus gland, &c.; parts that were before opaque, now becoming transparent, and those that were originally translucent or diaphanous, losing such characters, and becoming white, thickened, and increased in strength and power of resistance: we know how cartilage becomes bone, apertures close up, and the very stream of life turns into a new and before unoccupied current. All these various stages of development, collectively and individually, together with numerous others, which it is unnecessary to enumerate, are now tolerably well established.

The organs of sense form no exception to these rules; and, as in the adult normal eye, we have from its transparency, and the peculiarity of its structures, a better opportunity of observing some of the peculiar phenomena of life, than elsewhere; and in the diseased state, the very best field for the observation and study of disease, its progress and result; so, from like peculiarities of structure, has the embryologist in it a favourable opportunity for noting its origin, growth, and progress of development. The eye does not become a perfect whole at one and the same instant, nor is its perfection as an optical instrument completed till the last month of uterine existence, and perhaps not even then. The original membranous envelope, which, in the early days of foetal life, forms the general investment to the organ of vision, as a homogeneous semiopaque structure, afterwards becomes divided into cornea and sclerotic, possessing all the peculiarities and remarkable distinctions which these two different materials present in adult life; the choroid, the iris, and the lens, are

superadded in their turn, the pigment is deposited, and the membrana pupillaris is absorbed, all according to definite laws, and at tolerably regular and precise periods.

Did space permit, it would form no indifferent preface to this paper to sketch the progress and growth of this individual organ, from the researches of the best recent observers, but as that cannot, in an essay of this description, be fully accomplished, my readers must concede the anatomical description of its development, as we proceed to inquire into those vices of conformation, the result of arrests of development in its growth, its colour, its consistency, transparency, and vascular arrangement, as well as those diseases, the result of inflammation, morbid growth, injury, or irregular action, which present at birth, under the general head of congenital defects.

On this subject very little has yet appeared in medical literature. In England I know of no special work, or even essay, upon the vices of conformation, or congenital deformities of the organs of sense; and Mr. Lawrence, in his article on monstrosities, in the *Medico-Chirurgical Transactions*, in the year 1814, sums up the defects of the organs of sense, in a paragraph of less than a dozen lines! Since then, however, several dissections of monstrosities have been recorded in the various periodicals of this country, in which some passing note has been afforded us, of the anatomical condition or malformation of the eye, and in the same class of literature, we find here and there, few and far between, facts related upon the same subject specially; and works upon ophthalmology, more particularly, occasionally allude to congenital diseases of the organs of sight.

In France, as far I have been able to have access to its literature, the same defect is even more apparent than in this country; the works of Geoffroy St. Hillaire, Malliard, and Cruveilhier, have afforded me but little information.

To Germany, the library of the civilized world, and the centre of every thing that concerns the eye in particular, we naturally look for information upon this curious subject;—here, in the land of the Sömmerrings, and Meckels, the Arnolds and Webers, of Treviranus, Walther, and Rosenmüller, who have all contributed so much to the normal anatomy of the eye, we turn to its literature, and not in vain, for some light to cheer us in this dark, and hitherto unexplored path. But until very lately, the knowledge of the Germans themselves, upon the congenital defects of the eye, was, like that of the English, scattered through the periodicals of the last forty years. At the commencement of this century, Kieser published a small commentary, "*De Anamorphosi Oculi*," at Göttingen. In 1833, the venerable Seiler, Professor of Anatomy at Dresden, published some observations upon the congenital faults of the eye, but these were mostly confined to, or grounded upon the examination of monocoli. To this kind, good man, not only in his writings, but personally, I am indebted for much valuable information, and for an opportunity of examining the preparations of congenitally morbid eyes, in his splendid collection in the Surgical Academy, at Dresden.

Since then, the magnificent work of Friedrich Von Ammon, the *Klinische Darstellungen der Krankheiten des menschlichen Auges*, has appeared, and one fasciculus of it is devoted to the congenital diseases and malformations of the human eye. The *Ophthalmologische Bibliothek* is likewise rich in cases of this description, and *Graefe und Walther's Journal*, together with the new edition of *Himly's Augenhelkundie*, afford many interesting examples.

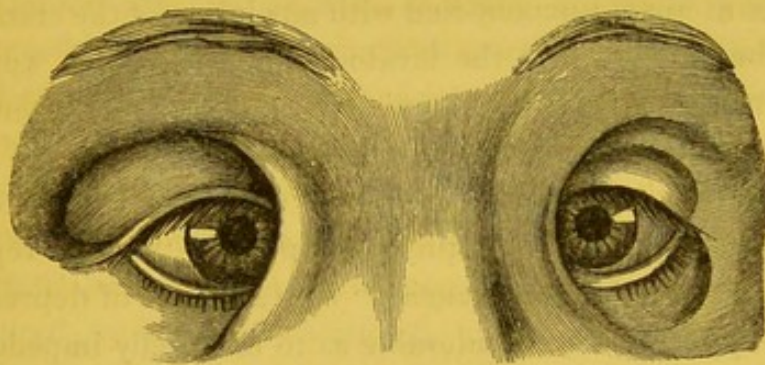
Messrs. Ware and Wardrop, Lawrence, Mackenzie, Middlemore, Travers, and Walker, have added a few cases, and I myself have made a small collection, some of which are made use of in this paper. With this material, and some unique

cases, furnished me by a Russian oculist, Professor Vanzetti of Scharkoff, and other friends, I have endeavoured to arrange a classification of congenital affections of the eye, according to the structures engaged. Thus, we will begin with the defences of the eye, and ocular appendages, the brow, the lids, the ciliæ, and lachrymatory organs, then proceed to the affections of the globe itself, in figure, size, position, and colour; in its various tunics, the conjunctiva, the cornea and sclerotic; next follow up this inquiry with regard to the parts subsidiary to the perfection of the eye as an optical instrument, as the iris and the pigmentum nigrum. Afterwards we shall take up the specially sensitive parts, as the optic nerve and the retina; this will lead us to the consideration of the malformations and the diseases of the dioptric or refractive media, the vitreous body and the crystalline lens, the affections of which are so common in this country; and conclude with a few general observations upon the condition of the eye or eyes, taken as a whole, found in those monstrosities denominated monocoli.

MALFORMATIONS AND CONGENITAL DISEASES OF THE DEFENCES
OF THE EYE AND OCULAR APPENDAGES.

The first malformation of the ocular appendages which I shall enumerate, is that peculiar affection denominated EPICANTHUS, which consists in a general superfluity of skin over the root of the nose, which, falling outwards on either side, forms a crescentic fold, covering over the inner canthus of the eye, completely hiding the caruncula, and, in some instances, advancing over the inner margin of the cornea, so as to give the appearance of strabismus. This disease was first remarked by Dr. Von Ammon of Dresden, but originally described by Schön; and it appears to have been by no means an uncommon affection in Germany. I have seen but two well-marked cases of it in this country; in one of these,

a little girl seven years old, there was a great flattening of the nasal bones, which, added to the peculiar condition of the integument, gave the child a very Chinese or Kalmuk appearance. Indeed I am inclined to think, from what I have observed of the Mongolian race, and from the examination of a great number of their crania, that the epicanthus, which we look upon as an irregularity, or congenital malformation in the European and the Caucasian race generally, is the natural or stereotyped condition of those nations to which I have just alluded. Epicanthus may occur in one or both eyes together ; generally, however, in the latter form.



The accompanying sketch, from a drawing by Dr. Adelman, of Würzburg, expresses, better than words, the peculiarities of this remarkable conformation. At first sight this defect has so much the appearance of strabismus, that both the cases which occurred in my own practice, were brought to me under the supposition, that the operation for the removal of that disease would have remedied the epicanthus. Carron Du Villards has likewise described seven instances, which he likens (not very aptly, however) to the appearance which dropsy of the lachrymal sac presents.*

* Schön,—*Handbuch der Pathol. Ant. d. Auges*, s. 60.

Von Ammon,—*Zeitschrift für die Ophthalmologie*. Bd. 1. 533.

Carron du Villards,—*Bulletin de Therapie*. Tom. xv. 1838.

In the notes to this essay I do not pretend to give all the authorities, nor any portion of the authorities on each subject ; but as far as I can I give the ori-

PTOSIS, or falling of the upper eyelid, is so frequently observed in new-born infants, the result either of accident, disease, or congenital malformation, that there are few practitioners who have not witnessed it, and therefore it is unnecessary to enter, at any length, upon the appearance it presents; my object not being to dwell upon the description of any of the well-known affections which one meets in the daily walk of practice, but to remark upon or delineate such rare vices of conformation as are not generally known or understood.

In ptosis in one or both eyes, in the atrophic form which appears at birth, unconnected with any injury of the cranium, it has been found that the levator palpebræ muscle was either entirely deficient, or existed in a mere rudimentary state.* The Germans say that in congenital ptosis, the rima palpebrarum is generally too small; and in their far-fetched analogies they liken it to phymosis penis. "I have repeatedly met," says Dr. Mackenzie, "with a degree of depression of the upper lid, so considerable as to materially impede the function of vision, and which had existed from birth; in some of these cases the lid was the reverse of being swollen; it rather appeared atrophic, as if the levator muscle had either been originally deficient, or had wasted from disease." A case of this latter form is now under my care. I remember, however, when a pupil in the Lying-in Hospital, distinctly recognizing two forms of ptosis, one with a swollen lid, when


ginal ones; and where I have not had access to such, or am not acquainted with them, then I have endeavoured to supply their places by the best and latest authorities I could procure. Thus, for example, in the disease under consideration, Epicanthus—Schön, Von Ammon, and Carron du Villards, were the three original describers—but since their publications we find descriptions in Von Ammon's great work, *Klinische Darstellung der Angeborenen Krankheiten*, and in the late editions of Mackenzie, Himly, and Walker.

* In some nations, particularly Orientals, I have observed a much greater development of the upper lid, and also a greater droop in it, as a natural peculiarity, than in the European.

it generally appeared to arise from some undue pressure, exercised on the head while passing through the pelvis; and the other, the atrophic condition, seemed to be an original want of nervous energy in the part.

Jüngken thinks congenital ptosis is sometimes hereditary. In a case of this description mentioned by Mr. Lawrence, "the lids could not be opened on either side by voluntary effort to more than one-third of the usual extent; and when this was accomplished, the upper palpebra was quite smooth, without any fold between it and the eyebrow." The most remarkable case of congenital ptosis is one recorded by Seiler, and figured by Von Ammon, in which the upper lid was so extremely long as to overhang the margin of the lower.

ECTROPIUM is a very rare congenital malformation. Two German writers, however, Loschge and Schütte, have figured cases of the turning out of the tarsal margin, as existing at birth. In appearance, the congenital form of the affection presents nearly the same characters as that subsequently acquired by disease in after life. In Loschge's case there likewise existed lagophthalmus, and the palpebral fissure was partially closed, while in a case submitted by Von Ammon the



contrary appearance was presented, for there was imperfect development of the globe or microphthalmus, and strong divarication of the lids, together with great eversion, as shewn in the preceding wood cut.*

* Loschge.—See *Isenflamm's und Rosenmüller's Beiträge, z. Zergliederungsk.* Bd. 1.

Schütte.—*Gräfe und Walther's Journal.* Bd. 9.

Von Ammon.—*Klin Darstell Angeborenen Krankheiten.*

ENTROPIUM and TRICHIASIS in new-born infants, I have myself observed, and in the Number of the *Dublin Journal* for March, 1844, I published a case of this description, for which I was indebted to Dr. Nixon. I may here remark, that as far as my own observation extends, and as far as I have been able to gather from the writings of others, it would appear that the foetus *in utero* is liable to a great number of the inflammatory diseases of the eye. We know that entropium is most frequently the result of chronic inflammation, thickening and contraction of the conjunctiva lining the palpebræ, and this may take place within, as well as without the womb.

The following observation accords with the fact which I have described, though, strange to say, its learned author, in the latter part of the sentence, denies the possibility of this being a congenital affection:—"Die Augenlidränder sind in einer späten Periode des Fötuslebens stark nach innen gewendet; dauert dieser Zustand über die Norm an, so kann eine schwache Spur von Entropion congenitum die Folge sein; wahres Entropion kommt aber nicht angeboren vor."*

Cases of inordinate length and strength of the ciliæ have been noted by some accurate observers; and great varieties of colour have from time to time presented themselves, both in the brow and in the eye-lashes. Instances of pye-bald men as well as animals have occurred. I myself witnessed a very remarkable case of this description in an adult female in the west of Ireland, in whom the eyes and the hair generally were of a dark colour; one brow, however, was perfectly white, the other was half white and half dark brown, and the ciliæ were long, soft, thick-set, and perfectly white. The general contour of the brow, however, depends so much either on national peculiarity or upon the bony structure of the orbit, the superciliary ridge, the muscles of the forehead, and those

* *Die Krankheiten und Missbildungen des Menschlichen Auges*, of the distinguished Dr. Karl Himly, of Göttingen, now editing by his son, Dr. E. A. W. Himly, and coming out in monthly parts.—Berlin, verlag von August. Hirschwald, 1843, u. 4.

immediately presiding over expression, that the congenital peculiarities of the eyebrow become the consideration of the student of Lavater or Prichard more than the pathologist or morbid anatomist.

Two peculiarities of the eye must have struck even the most superficial observer, viz., that in which the brows are scanty, light-coloured, and set widely apart—and that when they are dark, full, and bushy, and meet over the root of the nose. These, though occasionally seen among all races of men, and even in the same family, are in some races so marked and frequent, as to become national peculiarities. Dr. T. S. Sömmerring, in his splendid engravings of the eye, represents the eye of an Albino as a type of the former, and the latter is certainly more common among the Tartar, Persian, and Jewish races than any other. A remarkable instance of the total deficiency of eyebrows is mentioned by an old German writer.* Maderosis or complete baldness of the brow and ciliary margins has been likewise observed by oculists as a congenital deformity.

I have not been able to find more than one notice of adhesion of the eyelids to the eyeball, commonly called *SYMBLEPHARON*: it is that lately observed by Rognetta (*Cours d'Opthalmologie*), in which the conjunctiva of both lids adhered intimately to the globe, and covered over most of the cornea, which also presented an opaque, muco-secreting surface in the interval between the tarsal margins, which were from two to three lines apart. A small channel at the outer angle formed an outlet for the tears.

Instances of *ANCHYLOBLEPHARON*, or concretion of the tarsal margins to one another, were remarked upwards of one hundred years ago by Banister, Heister, and others. "I have seen," says Mr. Middlemore, "three cases in which the tarsal margins have been coherent from birth. The defect has

* Friderici.—*Monstrum human rariss in tabula exhibit.* Lips. 1737, p. 10.

occurred in both eyes; *the eyelashes have not been formed*, and in the situation of the intertarsal slit there was a narrow sulcus, lined by a delicate vascular portion of skin, which admitted of extension but not of absolute separation. In one of these cases the eyeball appeared to be very imperfectly developed, for the lids were scarcely at all convex externally, neither was there any proper globe to be felt through them. In two other examples of this malformation, the eyeball appeared to be adequately developed, but to be firmly adherent to the globe,* inasmuch as the very limited movements of which it was susceptible, occasioned an evident dragging of the eyelid." Beer mentions his having operated on cases of congenital anchyloblepharon, but it seems more than probable, that in at least one of the cases recorded by Mr. Middlemore, there were no globes at all.

Mr. Travers says he saw a remarkable instance of co-adhesion of the tarsi "in a full-grown boy, whose eye was found perfect after the division, though he had been thus blind from his infancy. It is similar to the co-adhesion of the nymphæ or labia pudendi, and the closed anus in new-born infants;" from which it would appear that he considered it congenital. St. Yves, Benedict, Wenzel, and many others, mention congenital anchyloblepharon; and record cases that occurred in their practice. I have never, however, met an instance myself. Dr. Hocken of London narrates a curious and unique case of partial anchyloblepharon in an infant, then about three months old, in which a small filamentary portion of integument, occupying the site of the junction of the outer with the middle third of the left eyelids, produced this unnatural adhesion of their edges. It was not thicker than a common sewing thread, and in all other respects the eyes were perfectly healthy and normal.

Himly thinks this concretion or adhesion of the margin of the lids arises, as he says, "from too great sharpness of the

* A misprint, we presume, for *palpebra*.

liquor amnii ;" but any inflammation in the edges of the lids occurring during their closed condition in the uterus, would very easily explain the cause of their adhesion.*

Here, however, a very interesting anatomical investigation presents itself as to the mode of growth in the embryo, and the precise condition of the eyelids in the fœtus. Among the most distinguished anatomists and embryologists of modern times, opinions are at variance; and too much stress has, perhaps, been laid on observations made on the lower animals. The analogies of these have, however, led to many interesting hypotheses, while the accurate observations (often conducted under the field of the microscope) of J. F. Meckel, Von Walther, Weber, Arnold, Burdach, Von Ammon, and Serres, upon the human subject, enable us to explain many, heretofore unaccountable congenital pathological phenomena. Many of the feline tribe, we know, do not separate the lids till some days after birth. The younger Himly tells us in his recent publication, that this union of the tarsal margins is sustained by a continuity of the palpebral conjunctiva; and that there is an intimate vascular connexion he was convinced by a happy injection which he made in the eye of a new-born tree martin. This normal condition is, in all those animals which keep the lids shut from the ninth to the fourteenth day after birth, removed by absorption; perhaps, in like manner, with

* Middlemore,—*Treatise on Diseases of the Eye*, vol. ii. p. 842.

Banister,—*Chirurgical Works*. London.

Beer,—*Das Auge*. S. 37.

Seiler,—*Bildungsfehler d. Augen*. S. 34.

Travers,—*Synopsis of Diseases of the Eye*, p. 104.

Wenzel,—*Manuel de l'Oculiste*, tom. ii. p. 155; who says, "*cet accedent est un vice de conformation.*"

Hocken,—*Lancet*, vol. ii. 1840-41, p. 919.

Œhne,—*De Morbis neonatorum Chirurgicis*. Lips. 1773.

Himly,—*Augenkrankheiten*, 1844. Various other authorities are quoted in this latter.

the membrana pupillaris. It was believed by Meckel and Von Walther, that such was the natural condition of the human eyelids at an early period of foetal life—closed by a vascular and membranous connexion;—any arrest of developement, therefore, at this very early period, will readily account for the existence, at birth, of anchyloblepharon. That the human eyelids stick together, or are adherent at their edges, even to the fifth month of uterine existence, all observers agree, but whether their connexion is owing to internal vascular continuity, external continuity of the skin, or mere mucous adhesion, is still a disputed point. Vicq d' Azyr, Sprengel, and others, assert, that originally the skin is entire and without cleft or fissure over the eyeball, and without any sign or mark of either tarsus, ciliæ, or glands; and such, it is remarkable, was the condition of a case of anchyloblepharon operated on and recorded by Mr. Middlemore.

Burdach's observations lead him to believe, that up to the eighth week of foetal life the general skin of the body covers, without interruption, the organs of vision; that then, two fine lines are perceived traversing the horizontal diameter of the globe of the eye, and these, in the eleventh week, become well-marked lines of demarcation of the upper and under eyelids. In the fourth month the lids are bound together by the cuticle; in the fifth month the epidermis gives way, and by the end of this month their separation is determined. In another place he asserts, that in the eleventh week they stick together by their borders through the adhesion of the meibomian secretion, and the continuity of the epidermis.*

Von Ammon believes, that in the eighth month they are closed by a process similar to that observed in the pupil, and that by a condition of absorption like that which takes place in the membrane of the iris, the lids are opened, or at least

* S. Burdach,—*Physiologie*, Bd. 2. Leipz. 1828. S. 376. bis. 397.

cease to be closed by either membrane or any glueing material. The writer of the article *Développement de l'Œil*, in the recently published volume of the *Encyclopédie Anatomique*, states, that the lids are free till the beginning of the third month; that then, the skin passes smoothly and completely over them, at first assuming the characters of conjunctiva, and that at the end of the tenth week, the eyelids commence by folds, which by the end of the fourth month cover over the globe, and are glued together by meibomian secretion (Arnold), but that in the inferior animals they completely adhere. The lachrymal gland appears, according to the same authority, about the second half of the fourth month. After this period the eyelids separate, and in the sixth month the ciliæ are visible.

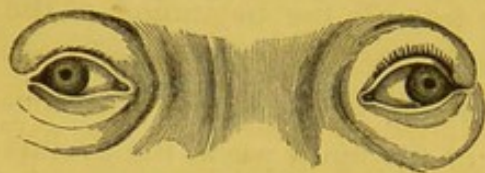
PHIMOSIS PALPEBRARUM, is a term applied by Kirnberger, Von Ammon, Himly, and others;* to a natural defect of the eyelids, in which the palpebral aperture is evidently too small. It has been found in connexion with microphthalmus and atrophy of the bulb, in which case the lids are much sunken, and the rima palpebrarum is very narrow, or it may exist together with a naturally formed globe, in which case the affection is too evident to be mistaken. Some difficulty may arise in recognizing this defect from partial congenital anchyloblepharon, but the want of a definite line to mark the edges of the original eyelids, will assist in distinguishing it from that disease. Chelius of Heidelberg has recorded three well-marked instances of this affection, which is not to be confounded with another somewhat similar, but differing from Blepharophimosis, in being merely a semilunar fold of the conjunctiva, joining both the lids, and occupying the external angle of the

* Kirnberger,—*Abhandlung über Phimosi Palpebrarum*. Mainz, 1830.

Von Ammon,—in *dessen Zeitschrift*, Bd. 2, s. 140, and in *Hecker's Literar. Annalen*, Bd. 13, s. 83.

Chelius,—*Handbuch der Augenheilkunde*, Bd. 2, s. 26.

eye, as the valvula semilunaris does the internal, but its free margin is quite unattached to the globe. This disease, of which the accompanying woodcut affords a good example,



is described by Von Ammon in his *Angeborene chirurgische Krankheiten des Menschen*.


Himly asserts that Blepharophimosis is the normal condition of certain families of the human race, and specifies the Mongolian; yet from what I have observed of this extensive people, the only nations of that family, in whom I am aware that this peculiarity exists, are the Samoides of the extreme north of Europe, on the Siberian coast. In general, the true Mongolian people have remarkably long, narrow, palpebral apertures, the external angles of which turn upwards, much more so than the rest of mankind, as is well exhibited in the present Chinese and Japanese. The ancient Egyptians too, as may be seen in the numberless representations still handed down of that people, possessed a similar remarkable peculiarity, and even increased it by prolonging the angle of the



aperture with a line of dark paint, as represented by the accompanying wood-cut, from a sketch of the eye of Sesostris, taken from one of the Egyptian tombs; while even

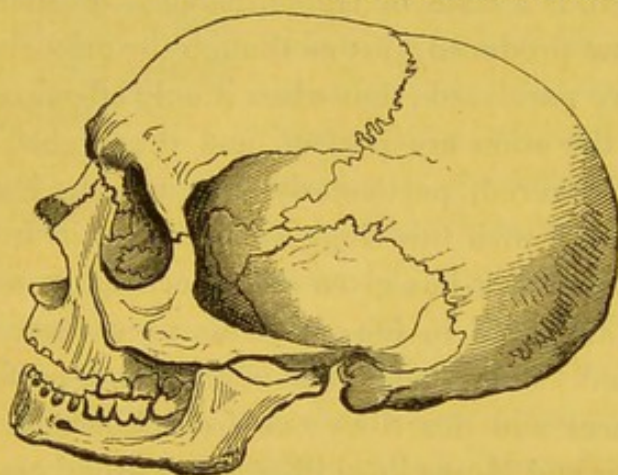
the modern Egyptians retain a portion of the same custom, as we see by the annexed engraving.

There is, however, scarcely an abnormal condition of the form and position of the brow, the lids, and the globe, which is not to be observed as the stereotyped character of particular races, either living or extinct; in the almond-shaped eye of the Copt and Abyssinian, the long, linear, elliptical pal-



pebral fissure of the Chinese, the small sunken eye of the American Indian, and the large, full, blue eye of the unmixed Celt.*

* I am inclined to believe that the ante-Celtic aborigines of the British Isles, and Ireland in particular, had dark hair and complexions, and in all probability, dark eyes also. The most ancient Irish MSS. tend to confirm this view, which is likewise held by Molbeih, Eschricht and Retzius, the most distinguished northern antiquaries of the present day. Certain it is, the crania of undoubted Irish origin, as for instance, those found in ancient tombs and barrows, have remarkably high, well-marked superciliary ridges, with exceeding development of the attachments of the occipito-frontalis muscle, as exhibited in this sketch from one of the ancient skulls in the museum of the Royal Irish Academy. From this



bony contour, and from the expressions in the MSS., as well as some existing remains of our early people, I am induced to believe that they had full, bushy, dark, arched brows—probably meeting in the centre. The orbit in those ancient Irish heads that have come to light is very Mongolian in shape; and I am not quite clear, but that the present Samoide people, still inhabiting the northern shores of Europe, are the existing remnants of the first or earliest inhabitants of the British Isles, who, driven northward by the following (perhaps Celtic) wave of population, passed over from this country through Denmark, Norway, and Sweden (where they also rested and left many remains), to their present locality. This however, is but conjecture; time, the examination of the monuments, antiquities and crania of both people, and above all the exploration of our magnificent collection of MSS. in the Academy Library, will, I feel convinced, decide this question. *Eochaidh Abhadh-ruaidh*, or Eochaidh of the red eyebrows, an ancient Celtic king of Leinster, is thus designated in the MSS.; as also *Eibhlin-na-Suile-Gleoir*, or Ellen of the black eye, and the blue eye—a peculiarity often observed in the present day.

LAGOPHTHALMUS, or such shortening of the upper lid, as to render the complete covering of the globe impossible, has been several times remarked in new-born infants, but the pathological anatomy of the affection: whether the result of disease, or arrest of development, has not been explained. Mr. Middlemore and B. W. Seiler have both observed this affection; the former says: "I have several times witnessed a rigid and contracted state of the eyelid, independently of the existence of a cicatrix, or of inflammation, or of any injury to the part. Sometimes it has affected only one, and in other instances, both the palpebræ. When it affects both eyelids, there is a state of lagophthalmos, or shortening of the palpebræ produced, just as though the orbicularis palpebrarum were paralysed; but when it only affects one lid, the motions of the other are perfect, and the eyeball is pretty completely covered, particularly if merely the lower palpebra be affected with this singular rigidity of its integument. In a few instances it has given rise to ectropium as the individual has advanced in life; but this occurrence is a very unusual one." Von Ammon has never seen a perfect case of it, but figures and describes one from Loschge. Thomas Sömmerring and Rosas have likewise recorded cases.*

Complete absence of the eyelids has also been observed, but in connexion with so many other faults and malformations of the globe, orbit, and head generally as not to require or deserve notice as a special congenital affection.

COLOBOMA PALPEBRÆ, or cleft eyelid, though a very rare affection, was mentioned by the old English surgeon, Banister, near a century ago, who says that this part is sometimes cleft in the centre in a perpendicular direction, as occurs in hare-lip. Several cases of this description, but in a much minor

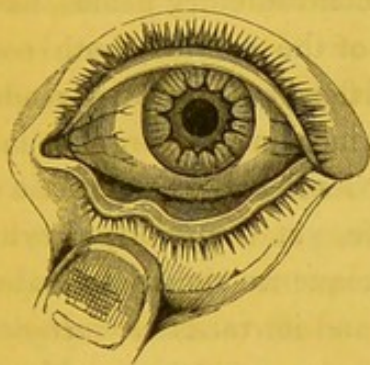
* Middlemore,—*Treatise on the Diseases of the Eye*. Vol. ii., p. 841.

Seiler,—*Beobachtung. ursprüngl. Bildungsfehler*.

Loschge,—In *Isenflamm und Rosenmüllers, Beitr. z. Zergliederungsk.*—Bd. 1, s. 318.

degree, have been figured by continental authors since then. It has only been observed in one eye at a time, and is frequently to be found in connexion with hare-lip, and similar vices of conformation of a light character.

As in hare-lip, so in cleft eyelid, it is chiefly and generally confined to the upper. Heyfelder found it in conjunction with hare-lip and coloboma iridis. St. Yves and Beer have noticed instances of cleft eye-lid, and the sketch beneath is copied from Von Ammon's great work, who, how-



ever, asserts that coloboma palpebræ occurs as well in the upper as in the lower lid, and states this remarkable similarity to hare-lip, that as in it the mucous membrane turns outward along its margin, in the same manner that it does in the red border of the normal lip, so the ciliæ, and other

peculiarities of the tarsal margin, dip into and border the unnatural cleft, as well as the rest of the natural tarsus.

Blasius of Halle, has described a malformation under the name of *ECTOPIA TARSI*, consisting of a fold or reduplication of the conjunctiva of the upper lid, which, extending from canthus to canthus, and falling like a curtain over the front of the globe below the margin of the upper lid, obscured the greater portion of the cornea. As the learned Professor had never seen the person (a woman, aged 37), during life, it is very doubtful whether it ought to be recorded as a congenital deformity or not. From his own description it appeared to me not unlike an old *ptyregium crassum*. No account could be obtained from the friends of the person who was the subject of this disease.*

Alterations in the colour of the eyelids, styled *BLEPHAROBYSCHOREA*, are not uncommon affections: they are generally the result of *NÆVI*, the well-known disease of the cutis,

* Von Ammon.—*Zeitschrift für Ophthalmologie*.—Bd. 4, 1834, p. 160.

and may, as when they occur on other parts of the body, be divided into the erectile and the non-erectile, the passive and the active, or the cutaneous and sub-cutaneous. They may occur on any part of the external surface of the eyelids, varying in extent, colour, and elevation, from that of a small spot, of a purple hue, occupying the border of the tarsus, to a tumour the size of a walnut, but in shape and colour resembling a ripe mulberry, and engaging the entire lid, or even proceeding from and often filling up a portion of the orbit. So many, and often such contradictory names, have been applied to *nævus maternus* of the eyelids, both congenital and acquired, that the superficial or inattentive reader is liable to fall into error, not only in nomenclature, but in a practical and diagnostic point of view; and in a disease of this nature, often endangering life, yet frequently proving innoxious, it is of the utmost consequence rightly to understand its peculiar nature, its seat, and its varieties. *Angiektasia*, *Telangiektasia*, *Tumor fungosus sanguineus*, *Morum congenitum palpebrarum*, *Gefäss-Erweiterung*, and *Balggeschwulste*, are applied to this disease by the Germans—the *Tumeur erectile* of the French, but Maunoir distinctly calls it *Fungus hæmatodes*; while among English and American surgeons it is known as the *Aneurism by anastomosis* of John Bell, its original describer, *nævus maternus*, *aneurisma racemosum*, and *varicose aneurism*, &c. Mr. Middlemore, as would appear from his work, considers *nævus* and *varicose aneurism* as distinct from *aneurism by anastomosis*. Much of this confusion of names appears to arise from the peculiarity of the seat, the active or passive character, the colour, and the predominating vascularity of the tumour, as whether it is venous or arterial.

This congenital disease often appears as a small, irregular, slightly-raised, pale red mark on the lids, but increasing somewhat in size, and particularly in depth of colour (frequently assuming a bright scarlet), on the infant crying or making any exertion;—or, it may be raised, and of the shape

and colour of a ripe raspberry, or even a bunch of red currants, to which it is often likened, from the usual superstition with which, as a "mother's mark," it is regarded by the unprofessional. In this latter case it is generally active, of an erectile nature, with arterial vascularity predominating, having a firm pulsatory feel, and attended by increased temperature, and, generally, rapid growth. In others, the venous capillaries are chiefly the vessels of which it is composed, and their purple hue has caused it not inaptly to be likened to a mulberry (the *morum* or *maulbeerförmige Geschwulst* of the Germans); it is cold, of a sponge-like doughy consistence, and easily emptied of its blood by pressure: it seldom enlarges, or if it does so, it is very slowly. But it is not alone the external surface of the lids which is the seat of this peculiar vascular arrangement; besides those parts already enumerated, the conjunctiva and the globe itself are liable to its seizure, where it may appear in a congenital as well as an acquired form; and in a case related by Dr. Mackenzie, "the tumour was most prominent on the conjunctival surface of the lid." When in the orbit it is naturally more formidable. It is unnecessary to cite individual cases of this disease, as English medical literature is particularly rich in them, and to Englishmen our continental neighbours are indebted for the very best descriptions of it. Messrs. Wardrop, Abernethy, Hodgson, Bell, Travers, Dalrymple, Lawrence, and Brodie, as also Drs. Warren and Mussey, of America, have all afforded cases sufficient for a complete description of the disease. Among the cases of Dyschorea may be mentioned a remarkable one, figured by Von Ammon, of a congenital discoloration of the skin, of a diamond shape, and a bright yellow colour, occupying exactly the same position on both sides, and situated just over the upper puncta. Another is that of a bright-coloured nævus, which spotted over both lids, but without being raised above the surface; another, in which a dark brown colour, like that which is observed on a *mole*, occupied patches of the lid and brow

(*Nævus Lipomatodes*). From the drawing, and his own descriptions this appears to have been more of a *mole* than an aneurismal tumour, and the hairs of the brow were continued down on the lid, nearly to the ciliary border; the brown colour likewise advanced over the tarsal margin to the conjunctiva. But by far the most curious case figured by this writer is one which came under his own observation, in which all the non-transparent tissues of the eye, as well as the lids, both within and without, were stained of a deep blue, much deeper than that exhibited in the general morbus cæruleus, and proceeding, in all likelihood, from some disease in the orbital veins.

MALFORMATIONS OF THE LACHRYMAL ORGANS.

Malformations and congenital diseases of the secreting and excreting lachrymatory apparatus are of exceeding rare occurrence, except in those instances in which there is some well-marked arrested development in those parts of the organs of sight to which they are subservient. *Trichiasis carunculæ lachrymalis*, or the growth of hairs from the caruncle, is reported by authors as a congenital defect; but the anatomical fact of several small light-coloured cilia, growing from the surface of this conglomerate mucous gland, is so well established at present that few writers will fall into this mistake for the future, or apply the term disease or malformation to what is evidently a natural and regular occurrence. "Each duct," says Mr. Dalrymple, in his admirable treatise on the anatomy of the human eye, "is garnished with a minute hair planted close to its orifice." That these hairs do, occasionally, in after life, assume an irregular and morbid growth, so as to excite considerable uneasiness in the inner canthus of the eye, is a well-established disease, though one of exceeding rarity, and to this the term *Trichiasis Carunculæ* may with justice be applied; but certainly not to the ordinary, though minute growth of hair, which may always be found, by accurate observation, covering the second lachrymal gland, as in olden times it was denominated.

ANGIEKTASIA, or NÆVUS, has likewise been mentioned in works as affecting the caruncle, in very young children (I believe, at birth), forming a purple, mulberry-shaped swelling, and instances have been adduced by Malacarne and Seiler of the affection called *Rhyas*, arising from deficiency of the caruncle at birth: but in both the cases recorded by these writers there were other co-existing faults of the lachrymal organs. Plenck considers it a very rare congenital defect.*

ABSENCE OF THE LACHRYMAL GLAND.—The lachrymal gland, which, according to the writer of the article *Développement de l'Œil*, in the *Encyclopédie Anatomique*, is first recognizable in the first half of the fourth month of uterine existence, has been found wanting at birth; and a total deficiency of this organ is on record as far back as the year 1721, when Botin, in the Memoirs of the Academy of Sciences of Paris, related a case of this arrest of development, but in connexion with deficiency of the globe and congenital anchyloblepharon. Himly adduces the authority of Lycosthenes, Thomas Bartholinus, Storch, Spielenberg, and Hoffmann, in support of the fact of anophthalmous children being also deficient in lachrymal secreting apparatus.† And J. Adam Schmidt, in his valuable work on the *Thränenorgans*, considered *Dacryops*, or mucocoele of the lachrymal sac, as frequently arising from congenital disease.

ATRESIA PUNCTI LACHRYMALIS, or complete occlusion of both ducts and puncti has occurred in a congenital as well as an acquired form. Morgagni, in his *Epistolæ* (Ep. 13, na. 27), relates a case in which all four puncti were closed. Mr. Travers says: "I have seen a congenital deficiency of the puncti, but the case is very rare: obliteration is much less so."‡ Otto, Anel and Jurine likewise establish the fact.

* Plenck.—*Doctrina de Morbis Oculorum*.—Vienna, 1777.

Malacarne.—*I sistemi del Corpo umano*, &c.

† Himly.—*Lo. cit.* Bd. 1, s. 275.

‡ Travers.—*Synopsis of the Diseases of the Eye*, p. 238.

While these pages have been passing through the press, Dr. Marks, of this city, showed me the case of a young girl, with the upper punctum, on the left side absent, and the papilla in which it is usually situated, also deficient.

FISTULA LACHRYMALIS.—In Blasius' Zeitschrift, for 1837, we find a very remarkable case of *fistula canaliculi lachrymalis*, set forth by Dr. Behr, of Bernberg, in which a small fistulous opening, of a size sufficient to admit a hog's bristle, and through which a drop of fluid continually distilled, existed in the inferior lachrymal canal at birth: this is, I believe, a unique case.

Dupuytren once observed a congenital imperforate condition of the nasal duct; and in Walker's cases of congenital deficiency of both eyes, noticed at page 35 of this Essay, he says, "when the children cry, copious lachrymation takes place, proving the existence of a lachrymal gland, but the tears always roll down the cheeks in consequence of the non-existence of the *puncta lachrymalia*." Although his inference of the tears rolling down the cheeks during the act of weeping, does not bear upon the point in question, still his statement of the fact of the non-existence of puncta, is sufficient evidence.

Before we enter upon the consideration of the vices of conformation, the result of arrests of development in the globe of the eye, it may not be amiss to inquire what the embryologists say as to its precise mode of growth, and the order in which its various structures and tunics are created, as well as the metamorphoses they subsequently undergo.*

Two hypotheses are at present held by the learned, those of Baer and Huschke. According to the former, the visual

* For the latest and best article on this subject, I must refer the reader to the work of that able ovologist and profound anatomist, Professor Bischoff,—*Entwicklungsgeschichte der Säugethiere und des Menschen*—Leipzig, 1842, 8vo. 575 pages; or to the eighth volume of the *Encyclopédie Anatomique*, containing the researches of Bischoff, Henle, Wagner, Valentin, Vogel, and other distinguished German anatomists, and translated by M. Jourdan, Paris, 1843.

organs in man and quadrupeds appear first as two small excrescences on the floor of the first cerebral cellule—the future optic tracts; from these spring two conical projections, which bury themselves on each side of the embryo head; of these the anterior portion becomes the optic bulb, and the posterior the nerve. With this early conformation results the analogies of the dura mater with the sclerotic and cornea; the lamina fusca and the membrane of Descemet with the arachnoid; the choroid with the pia mater; and finally, the retina with the actual cerebral substance.

The opinion of Huschke, on the contrary, is more complex; it is, that both eyes spring from one simple primary rudiment, that is, from a depression formed by the original dorsal nervous laminae, separating, before their dilatation in front (the primary cerebral cellule), and again uniting so as to form a small cavity. This cavity or vesicle is closed by a very fine thin membrane, but a posterior foramen keeps up a free communication between it and the original cerebral cellule. The ocular vesicle separating from the cerebral, and increasing in size, the latter presses on the posterior margin of the former (the ocular), and gradually divides it into two portions, which becoming more and more distinct, and the canal, or communication between them, also separating by the pressure of the cerebral cellule, the two parts or organs are ultimately and completely divided from each other on the development of the supra and infra-maxillary bones. The eyes, according to this observer, are not, then, as Baer supposes, prolongations of the original medullary tube, but are, like it, produced by the development of the dorsal plates themselves (Bischoff). The visual organs thus once formed, these two authors are nearly agreed as to their subsequent development. According to Huschke the rudimentary eyes become apparent before the end of the first day, and as Baer perceived them at the 36th hour, it is possible the observation of the former may be correct, and that of the latter be owing to the later period of his observation,

when, probably, the separation "*deux espèces d'excroissances*" had been completed by the pressure of the cerebral vesicle. The phenomenon of cyclops is decidedly opposed to the theory of Baer, and in support of that of Huschke. Valentin and Seiler's researches accord with this latter also. Arnold says the eyes are not to be discerned at all in an embryo a line and a half in length; and Bischoff, in his minute examination of the embryo of the dog and rabbit, asserts that the eyes are distinct from the very first; he says that at the period of the very first perception of the cerebral vesicle, two prominences can be observed upon it, which, in a future stage, presents a heart-shaped projection, the apex of which is turned toward the dorsal portion of the rudimentary nervous axis, and the anterior, shoulder-like extremities of which become eyes. As these protuberances are prolonged from the original medullary tube and cellule, their anterior, closed, bulbous extremities become globes, and their posterior, narrow stalks, which are also at first tubular, solidifying, become optic nerves; no distinct envelope or sclerotic can, however, be discerned in the human embryo till the fifth week, at which period there is no distinction into transparent cornea and opaque sclerotic, but the two are confounded together, and present a blueish translucent appearance till the beginning of the sixth week, at which time the cornea begins to be more convex and transparent.

A line of separation marks the difference between those two membranes, according to Ammon, in the second month, but in the opinion of Valentin not till the fourth; and it is remarkable, that the proportional curvature of the cornea is greater in the fœtus of twelve weeks than at any subsequent period of either intra or extra-uterine life (Gescheidt and Wimmer). The proportional thickness also is inversely as the age, which Meckel attributes to the accumulation of a reddish fluid between its laminae, whereas the sclerotic is much thinner during embryotic life than afterwards, hence its early bluish tinge, owing to the subjacent pigment. At

this period is also seen most manifestly the "*protuberantia scleroticalis*" of Ammon, caused, it is thought, by the inclination of the globular axis toward the optic nerve, and, therefore, producing a bulging of the sclerotic toward the external side of the entrance of the nerve. This appearance, however, gradually diminishes with the increased development.

According to the observations of Valentin, both sclerotic and cornea are formed from cellules metamorphosing themselves into fibres, which afterwards interlace, and assume in their subsequent appearance all the characters which these membranes present at birth.

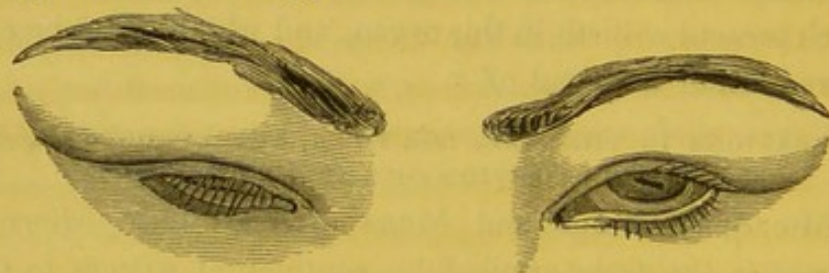
Having thus far briefly noted the earliest formation and subsequent growth of the optic bulbs, we are now in a position fully to understand those arrests and congenital defects which present at birth in this organ, and which are to be considered under the head of

ALTERATIONS IN THE SIZE, THE FORM, THE STRUCTURE, AND
THE POSITION OF THE GLOBE.

MICROPHTHALMUS and MEGALOPHTHALMUS. *Microphthalmus* is the term applied by continental writers to that peculiar condition of the eye, when there appears to be an arrest of development of this organ at some particular period of its growth, without either atrophy or disease, but when at birth, although the eye may appear natural in all its parts, and, perhaps, perfect as an optical instrument, it does not bear the usual proportion which that organ does to the rest of the body. Three varieties of this affection have been enumerated by the best writer upon this subject, (Gescheidt), first, where the arrest took place at an early period of embryo existence, when the iris was just forming, and therefore in all such cases the iris is generally wanting; the second occurs at a more advanced period, when the iris has been formed, but not completely closed, and, therefore, with this condition of microphthalmus, we generally find coloboma iridis, or cat's-pupil. The third is where all the parts are natural, but there is frequently a false or irregular position of the pu-

pil, and also faults of the colour and structure of the iris generally. In microphthalmus the posterior segment of the bulb is smaller than natural, and the eye is preternaturally lengthened in the longitudinal diameter. Seiler, and Otto of Breslau, have shewn, that with this peculiar conformation of eye, there is likewise a vice, or malformation in the bones of the upper portion of the face, which is preternaturally small, and the bones of the orbit smaller than usual, irregularly placed, and undeveloped. In one dissection, the levator palpebræ was wanting, and the lachrymal canals have also been found closed, or but rudimentary, in such cases.

In the annexed representation we have a very good example of the appearances and peculiarities of this affection, in a girl 12 years of age.



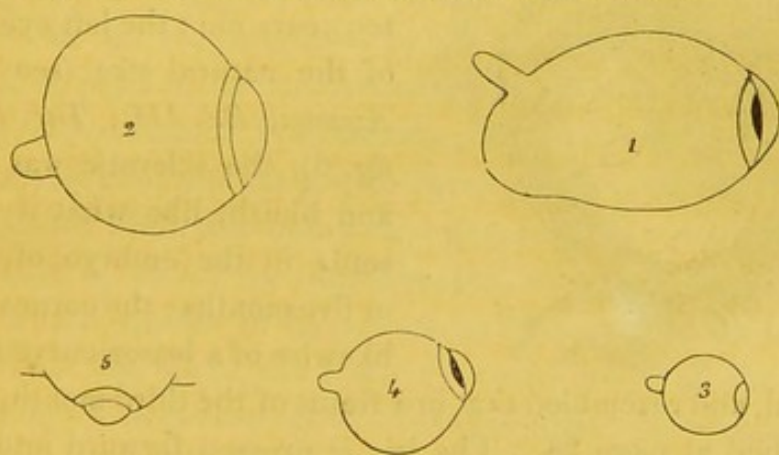
Here there is considerable irregularity of the orbits themselves; both globes are preternaturally small, the right being by far the lesser of the two; both upper lids are affected with Blepharoptosis, probably from the want of sufficient support from the bulbs they cover. In the right, this is so marked that the globe is completely obscured, and in the left the cornea is more than one-half covered: the palpebral fissures are likewise very irregular, their external angles inclining upwards much more than natural. In both eyes there existed irregularity of the pupil, in form as well as in position, that in the right being triangular, and that in the left transversely oval.

Von Ammon relates a case of a brother and sister born with microphthalmus; Pœnitz, that of a four-week old child, with the left eye one-half larger than the right. The cases of two brothers are likewise recorded by Himly.

The German periodicals of the last fifteen years abound in such cases, recorded by Schoen, Fischer, Weller, and others. In most of these cases the little bulb lay deep in the socket, and in several the rima palpebrarum was too small.

Besides the general diminution of the bulb, there is often connected with it irregularity in the growth or development of particular parts, and also in their relative proportions to one another; thus, the cornea has, in cases of microphthalmus, been found, in proportion to the sclerotica, too large, and in others too small. The elder Himly has related several such cases.*

Independent of arrests of development, we find congenital microphthalmus, arising from disease *in utero*, and presenting one or both bulbs diminished from atrophy or synchysis; here, however, the case is manifest; there is generally hard cataract, of a flake-white colour, with discoloured, irregular, and often immoveable iris, with choroid disease, and other evident marks of disorganising inflammation having gone on in the eyes while the child was still in the womb.



The drawing above exhibits profile views of the five most remarkable forms which the human eye has presented

* Gescheidt, — *Angeborne Krankheit der Augen in Zeitschrift für. Ophthalmologie*, Bd. 2, Heft. 2, s. 257.

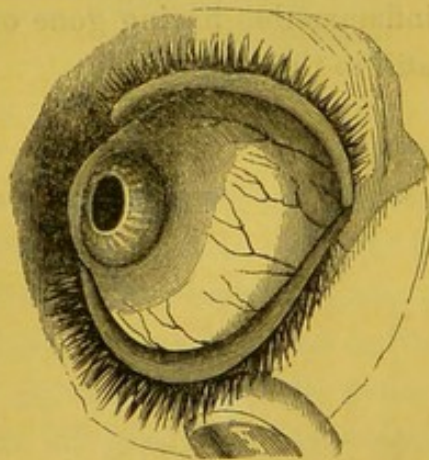
Weller, — in *Meckel's Arch.* 1830. H. 2, 3, s. 179.

Von Ammon, — *Darstell. der Angeb. Krank.*

Himly, — *Krankh. u. Missbild. d. Mens. Auges*, Bd. 1, s. 528.

at birth, as deviations from the normal condition of that organ. Figures 3 and 4, however, are those most applicable to this division of the subject.

MEGALOPHTHALMUS, or BUPHTHALMIA, is applied to that congenital condition of the globe when it appears too large in comparison with other parts of the body, and the head especially. It is a rarer affection than that of the over small eye; it differs from it in being more frequently found singly or in one eye at a time, and in being not an arrest of development, but a congenital pathological appearance, the result of disease of the bulb alone, as in hydrophthalmia, or connected with hydrocephalus, or other diseases of the brain. The peculiar goggle-eyed appearance of this disease, and its also occurring in adult life, renders any minute description of the characters which it presents unnecessary, particularly as this engraving affords a very tolerable idea of the most usual appearance of the affection.



The person from whom this drawing was taken was a boy ten years old; the left eye was of the natural size (see *Von Ammon, Bd. III., Taf. III., fig. 6*), the sclerotic was thin and bluish, like what it presents in the embryo of four or five months; the cornea was likewise of a lesser curve than

natural, and resembled that in a foetus of the third month, as I described at page 28. The iris is pressed forward into the anterior chamber. This disease is reputed to be hereditary. Mr. Laurence says, "I have seen the chambers unusually large, with the cornea transparent or slightly nebulous, as a congenital malformation in children otherwise healthy. Jüngken says he knew a Swedish family in which seven brothers were affected with congenital dropsy of the anterior chamber, while the parents and two sisters have no defect in their

eyes." The pathology of HYDROMAGELOPHTHALMUS, or that form of eye-dropsy connected with water on the brain, is explained by Huschke by the fact, that where this disease was present, he found (as in the early stages of fœtal life), a small tube or canal leading from the ventricle to the interior of the eye, by which means the fluid of the former communicated with, or gravitated into the latter, as I have explained at page 27.

This form of disease has been described by Demours and Von Ammon; in both it, and the preceding, vision is generally very much impaired, but more so in the former; yet a young friend of mine, in this city, who is affected with a preter-development of one eye, sees best with that. Acephalous fœti, owing to the want of the supra-orbital ridges and anterior portion of the cranial bones, generally present the characters of megalophthalmus, as do also hydrocephalic children, in whom I have generally observed that the eyes are turned downwards.

In most instances of megalophthalmus the curvature of the globe is irregular, presenting a bulging at one or two points, as we see exhibited in the profile sketches, Nos. 1 and 2, at page 31, in the first of which we have the *protuberantia sclerotalis* of Von Ammon, so well marked that we may reasonably conclude the preter-development occurred about that period when this embryotic appearance is most observable, that is, about the fourth month, whereas microphthalmus would appear to be an arrest of growth at an earlier epoch; in the latter, the relative proportions of all the parts of the organ are preserved, while in the former—the megalophthalmus, (which is evidently a pathological appearance), the greatest disproportion of parts prevails.

Some instances of the complete absence of both eyes, ANOPHTHALMUS, have been recorded by British surgeons. In 1831 Mr. Walker communicated to the *Lancet* the cases of two children (sisters), the one five years of age, the other four months, in whom both eyes were completely wanting,

the orbits being filled up with condensed cellular tissue ; the lids were normal and well-formed, but naturally collapsed for want of the support of the globe ; the lachrymal glands were present, but there were no lachrymal passages. Four years afterwards a case very similar is recorded by Mr. Davy, and death occurring a few months subsequently, we are indebted to this gentleman for the following interesting autopsy :

There was but one olfactory nerve present, "the optic commissure was placed more posteriorly than natural ; the sella turcica being much anterior to it. From its forepart and in the median line, the rudiment of a nerve was continued ; it was of a loose texture, and a scarlet hue, as if from injection of its vessels. It proceeded into the substance of the pituitary gland, where it was lost. Several small blood-vessels pressed through the foramen opticum ; the fissura lacera transmitted, both into and out of the orbit, the ordinary nerves and the ophthalmic vein. Nothing else of interest presented itself within the cavity of the cranium.

"The orbital roofs were then removed, and disclosed the presence only of condensed cellular tissue, which, when cautiously dissected away, exposed the several small muscles which naturally belong to the organs of vision, supplied with their respective nerves ; the periosteum and cellular substance, lining the internal parietes of the orbit, afforded the muscular attachments, in place of the tunica sclerotica. It is particularly worthy of notice that on neither side was the levator palpebræ superioris present. As we were compelled to avoid disfiguring the face, it could not be ascertained whether or not the orbicularis palpebrarum and the corrugator supercilii muscles existed. No further examination took place."

My esteemed friend, Mr. Estlin, of Bristol, has just communicated to me a similar case. He writes:—"A few years ago a child was brought to me, born without eyes, and with hardly any thing else but cellular membrane, apparently, within the orbits."

Those conversant with medical literature will recollect

many early notices of this deformity, which is by no means a very uncommon occurrence. Cases are related in the *Monstrorum Historia*, published at Frankfort in 1609; in the lesser works of Haller; in Thomas Bartholinus's Natural History of Rareties; in Hufeland's Journal (1818); in the Memoirs of the Royal Academy of Paris; in Malacarne's book *I sistemi del Corpo umano* (1803), from which I have already quoted; by Rudolphi in the Transactions of the Royal Academy of Berlin (1826);—and in most of the anatomical and pathological museums on the Continent, specimens of eyeless children will be found. Vicq. d'Azyr remarked a case of anophthalmus, in which, not only were both eyes deficient, but the foramen opticum was imperforate, the orbits were preternaturally small, and the mouth very much less than usual. V. Walther has described two cases, in one of which there was also congenital anchyloblepharon. Otto mentions a case in the collection of Breslau, in which there was also congenital malformation both of the mouth, and the upper and lower extremities. Biermayer in his description of the anatomico-pathological collection of the Viennese University, describes two instances of anophthalmous children; in one of them there likewise existed hydrocephalus, and it had neither mouth nor nose: the other had cleft palate. On examining the authorities on this subject, I find congenital deformities of the mouth a very frequent concomitant, with deficiency of the optic bulbs. In a dissection made by Schön of Hamburgh, in 1828, of an anophthalmus, the brain was normal, as were also the 3rd, 4th, 5th and 6th pairs of nerves, but the optic nerve was wanting; the orbits were completely filled with fat and cellular membrane, and in this cellular membrane appeared all the motive apparatus; the muscles were all distinctly recognizable, but in a very thin, attenuated condition. The frequent occurrence of closed eyelids in connexion with absence of eyes, may explain, in some measure, the mode in which these appendages are originally

opened—viz., by the pressure of the globes against the tarsal edges, causing absorption of their lining membrane.

Anophthalmus of one eye (not monocus) is a much rarer vice of conformation; yet a case of this nature was described by Klinkosch a Bohemian surgeon, in 1766, and three others have been since recorded by Rudolphi, V. Walther and Peringer. In all these there was manifest defect of the orbital parietes on that side.*

In the museum of the College of Surgeons, in this city, there is a preparation (D. b. 250) of "two pieces of chalky matter—the only remains of the eyes of a Guinea pig which had been born blind."—(*Houston's Catalogue*).

Some physiological speculations have been put forward, by continental writers, to account for this arrest of development, which, as well as the faults (*Fehler*), or defects of the orbit, will be considered under the head of monocoli, and the malformations of the muscles under that of strabismus.

The globe of the eye may be congenitally altered in form and position by nævus maternus or aneurism by anastomosis attacking its tunics, or by fungus hæmatodes enlarging and protruding it, but as the former presents all the particularities which have been considered when describing that affection occurring on the lids (see page 22), it is unnecessary here to particularize it: and as the latter has not, that I am aware of, been so far advanced at birth as to cause any manifest alteration in the size, or form, or position of the globe, it appears to me more in accordance with the classification laid

* Walker,—*The Lancet*, vol. ii. 1831–2, p. 169.

Davey,—*The Lancet*, vol. ii. 1835–6, pp. 52 and 293.

Botin,—*Memoire de l'Acad. d. Sciences*. Paris, 1721.

Vicq. d'Azyr,—*Memoire de l'Acad. d. Sciences*. Paris, 1776.

Beer,—*Das Auge* Wien, 813, s. 57.

Biermayer,—*Mus. Ana. Path. Nosocomi Universat Vendobonensis*, 1816.

Seiler,—*Beobachtungen ursprunglicher Bildungsfehler*. Dresden, 1833.

Himly,—*Krankh. u. Missbild. d. Mens. Auges*, 1843.

Rau,—In Von Ammon's *Monatsschrift*, Bd. 3, H. S. 50.

down and endeavoured to be pursued in this Essay, to consider it under the head of diseases of the retina—in all probability, its primary seat. We therefore advance to the abnormal peculiarities which the MOTIVE APPARATUS of the globe presents at birth.

I cannot find an instance of the complete absence of all the muscles which move the globe, in an eye otherwise healthy and natural; for even in cases of the total deficiency of the visual organs, rudimentary muscles have been observed. One of the few records bearing on this point will be found in Dr. Houston's Catalogue (G. a, 23): it is that of a preparation in the Museum of the Dublin College of Surgeons, of an ancephalous human foetus, in which "the entire of the calvarium and brain was absent, and the top of the head looked like the surface of a recently cicatrized ulcer. The spinal marrow and nerves were well-formed; the eyes were large and prominent, and the vessels of the conjunctiva very turgid with blood; the eyelids were perfect, the superior constituting the highest point in the head; the eyeballs were also perfect; *but most of the muscles*, and the upper part of the orbits, were absent,"* &c. &c. This interesting preparation affords additional proof of the position put forward by Huschke and Baer, as I have explained at page 27, of the optic bulbs being derived from the original dorsal laminæ of nervous matter, at the top of which we find the primary cerebral vesicle, and therefore the globes of the eyes may be perfect in form without any remnant of brain, whereas the nerves that supply the motive apparatus being, as a necessary consequence with the want of brain, deficient, the muscles which they govern are likewise absent; so that we have many instances on record of the muscles being present in children born with brains, although the globes into which they would have been attached

* Descriptive Catalogue of the Preparations in the Museum of the Royal College of Surgeons in Ireland. Dublin, 1834, vol. i. p. 149.

were totally absent. Had a recent examination of the eyes of this foetus, which is supposed to have been at about the seventh month of gestation, been made, it would have been of considerable value in reference to the growth and development of this organ, and the iris, in particular, which from want of the ciliary nerves, we would predict would have exhibited some arrest of developement.

Since the adoption of the operation for strabismus, much attention has been paid to the pathological condition of the muscles in the orbit; but few of the abnormal appearances described by authors appear to have been original, and not acquired defects after birth. And those attachments of one to another; or the blending of two muscles into one, as the levator palpebræ with the superior rectus, the trochleator with the internal rectus, and the trochleator itself with the trochlea, &c. appear to be also acquired pathological conditions (Morgagni and Wrisberg); but instances have recently been recorded, by good authorities, of decided false insertion, and also bifurcation of the internal rectus at its sclerotic extremity (Dieffenbach); of the external rectus being *double* (Zagorsky), and also the superior oblique (Albinus); while Caldani saw, more than once, an additional muscle, which, from its insertion and use, he has denominated *M. detractor palpebræ inferioris*; and both recti and both obliques have been found wanting, in cases of monstrosities, by Seiler and Colomb.*

NYSTAGMUS, or oscillatory motion of the eye,† is a con-

* Olbers,—*Disser. de Mutationibus oculi internis*.—Göttengen, 1781.

† I know not why two of the most distinguished writers on ophthalmic subjects in Great Britain, have considered and described this disease under two separate and distinct heads, as constituting two different kinds of motion. Doctor Mackenzie in his late edition says:—"In Oscillation the eyeball is affected with an almost perpetual *rotatory* motion round its antero-posterior axis, and seems to be produced by the antagonising action of the oblique, the recti having lost, in a great measure, their control over the eye." (p. 291). And under the section Nystagmus, he writes; "this term is used to signify an involuntary motion of the eyeball from side to side." Surely the pendulum-like or "oscillatory" motion,

stant and well-marked symptom in those born blind. It is an attendant upon congenital amaurosis, but the disease with which it is most frequently connected is congenital cataract, in which the eyes roll from side to side in a uniform and synchronous manner, as if seeking light around. Generally speaking, this is the most commonly observed character of the motion, but I lately witnessed, in a case of congenital fungus hæmatodes of both eyes, a very peculiar condition of the muscular apparatus, in which the globes were principally rolled upwards, instead of from side to side. So well marked was this affection, that it attracted my attention among a large number of persons sitting in the waiting-room of a dispensary. I have lately seen a similar form of

is more applicable to this affection than to the former, which is not, in fact, an oscillatory, or swinging, but a positive rotatory action; both however, are frequently combined, but the motion from side is not only the most obvious, but in congenital cataract is often the only one present. Mr. Middlemore likewise notices them under two separate sections, and describes Nystagmus as an affection, "wherein the eye-ball is not rolled to and fro in the way I have just pointed out (oscillation), but is pulled from side to side by the action of the recti muscles:" (vol ii. p. 570.) Mr. Lawrence appears to take the clearest view of this affection, for, under the class of irregular motions, he says, "an irregular movement of the eyes from side to side, of involuntary character, seen in those born blind—unsteady or involuntary movements,—&c., either oscillatory or of irregular character—have been designated by the term *nystagmus*" (p. 770). In fact the exceeding latitude allowed to the word (which is derived from *νυσταζω*, to wink), would, according to the definition of Kuhn, permit of its being applied to constant or irregular movements of either eyelids, globe, or iris.

I have been led into this lengthened explanation lest it might be supposed I had confounded the two terms. That a slight rotatory motion does exist, in connexion with marked oscillation, in some cases, I am fully aware; and in the trembling or shaking eye, in which it looks like an artificial eye placed at the end of a fine spiral wire spring, it is really as difficult to say what is the exact motion, or set of motions, as it would be to define those of the object I have used as a simile. In the most confirmed and violent involuntary action of the eye-ball, there are three apparent motions—the full sweep from side to side, or Nystagmus; the lesser quick vibratory action from time to time; and also with this, the semirotatory.

Nystagmus in a child affected with hydrophthalmia and opaque cornea. In this case the mother asserts that when the child was born its eyes were in a healthy condition ; but this statement I am very unwilling to receive, as there is evident malformation in several other organs, and the head in particular. The child, which is resident in North King-street, in this city, though upwards of six years old, and hearing tolerably well, has not yet attempted to speak, and has only now commenced walking by assisting herself with the furniture of the room. A friend of mine possesses a small King Charles's dog, in which, from the effects of a scald, both lids of one eye have grown together by their tarsal margins, and are also united with the anterior surface of the globe. In fact, it has got both symblepharon and anchyloblepharon, and in this case the nystagmus, or rolling of the eye underneath the skin of the eyelids, is very perceptible, although the other eye is perfectly natural, and unaffected by any such spasmodic or tetanic affection.

In albinos, in the human subject, the oscillatory motion is nearly always present in a greater or less degree, increasing, however, with the intensity of the disease, and being less when any portion of colouring matter is developed. In some instances, where there is a total absence of all colouring matter, and the eyes are of a brilliant pink, the motions are so quick that we can scarcely follow them with the eye ; in others, the eyes roll inwards and outwards leisurely two or three times, the corneæ making a complete sweep of the palpebral aperture, and then rapidly move eight or ten times in a lesser circle, and also in a semirotatory manner.

I know not whether the remark be original, but it has struck me as curious, that in albinism in the lower animals, particularly the ferret and rabbit, where the colourless iris and choroid are just as apparent, and the vascularity just as intense, there is neither nictitation nor oscillatory motion of the globe.

LUSCITAS, or fixing of the globe in one particular position, although recorded as a family defect, has not been described, that I am aware of, as existing at birth.

Various abnormal and pathological conditions of the recti and oblique muscles, such as atrophy, paralysis, hypertrophy, shortening, lengthening, tonic contractility, irregular insertion, an over-tendinous or over-fleshy condition, and so forth, have lately been dwelt on, by the writers on Strabismus, as if they were congenital defects; but where these effects have not been observed at birth, it is scarcely fair to attribute their subsequent condition to any intra-uterine malformation or disease.

A young wild-duck, as I have often seen, will run about as briskly, avoid objects, pick up food, and exhibit all the effect of perfect vision, a few minutes after emerging from the shell, as the parent bird; so will several other animals; but it is very doubtful whether the human infant can discern objects distinctly until a considerable time after birth, and therefore, so long as this imperfect vision remains, so long as this indistinctness of perception continues (which period it is impossible accurately to determine), we have a constant want of parallelism of the globes, or a tendency to slight strabism or irregular action in one or both eyes. I remember, when a pupil at the Lying-in Hospital, several years ago, observing this in the new-born infants, who were generally laid down opposite the fire before they were dressed and given to their mothers. Hence this irregular action, from the inability of the child to fix the eyes steadily on any object, producing strabismus of various kinds, divergent and convergent, double or single, but, in general, the convergent kind prevails. This disposition to irregular action of the eye or eyes wears off with the power which the eye acquires of being fixed on particular objects, and also with the experience gained by the young animal.

One of the most frequent and popular errors (and it is one

common even among the Profession), is that the great majority of cases of squinting are congenital; yet I believe a rarer form of congenital disease scarcely exists—and where it does prevail at birth, it is generally the result of some diseased condition of the sensorium, such as congenital hydrocephalus, and then, most likely, it would affect both globes—Von Ammon has figured a case of this nature, (Bd. iii. Taf. xv. Fig. ii.) where the choroid and sclerotic were likewise affected, and there also existed nystagmus. I have never heard of an authentic case of *strabismus divergens congenitus*, nor do I think it likely to occur, from what I have observed of the condition of the eye, and the causes producing this variety of squinting in the adult.

The varieties of functional disease, such as one retina being weaker than another, seldom present, at least we are not cognizant of their existence, till after the infantile period, and the varieties of adapting power of the eye which might produce strabism, are mostly all acquired subsequent to birth or infancy.

Most mothers, particularly those in the lower ranks of life, when they bring their children for operation, affirm that they “had it always,” or that they “never remember them without it;” yet when questioned closely, admit that it appeared suddenly in a convulsive fit—or during dentition; or when something went wrong with the digestive organs; or on the appearance of worms, &c. &c.

Having considered the varieties in size, form, and position of the globe as a whole, we now arrive at the examination of the changes of structure and the malformations of its various tunics.

The principal deformities of the conjunctiva palpebrarum have been already disposed of under the head of the eye-lids and lachrymal appendages; and those of that which invests the globe now claim our attention: but so intimately is this delicate membrane connected with the structure on which it

rests, and such is the extreme tenuity of its corneal portion, that it would not be possible, even were it advantageous, to separate all its diseases, and those morbid growths which it sometimes presents at birth, from the same affections occurring in the cornea and the sclerotic coat beneath it.

MALFORMATIONS OF THE CONJUNCTIVA.

ALTERATIONS IN COLOUR.—The *conjunctiva bulbi* presents many preternatural appearances at birth, in colour and vascularity, in structural alteration, and in growths of various kinds. Nævi, unconnected with either the sclerotic or the eyelids, have been observed to have their seat in the conjunctiva covering the globe. A rare case of this form of *Telangiectasie* has been recorded by Von Ammon in his *Zeitschrift für Ophthalmologie* (Bd. v. p. 84), and also in his great work, the *Klinische Darstellungen* (Bd. iii. taf. vi. fig. vii.), occurring on the inner side of the right eye in a girl whose father and mother were both born with a similar peculiarity, but in a much less degree. It presented the characters of a simple ecchymosis in the centre, and of a vascular network round its margin.

This membrane assumes different hues in the various races of mankind; from light pearl colour to dark yellow, and even orange, as in some of the dark varieties; and among ourselves of the Caucasian family it is susceptible of various colours, the result of disease, or the application of chemical agents, such as the salts of silver, &c. &c. But there are instances on record in which the conjunctiva has been observed of a deep blue tint in the white races; and Professor Vanzetti has furnished me with the particulars of a very remarkable case, seen by him at Scharkoff, in which this tunic, both lining the lids and on the globe, was of a dark *black* colour. In this man, who was a native of the north of Russia, the iris was also dark, but vision was quite perfect.

MORBID GROWTHS.—Tumours of various kinds, fatty and

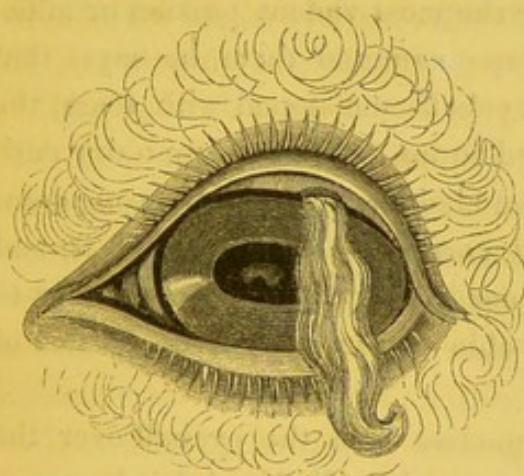sarcomatous, with and without hairs growing from their surface, have been found upon the conjunctiva bulbi, both of cornea and sclerotic, at birth; and from the days of Mr. Wardrop to the present, instances have been multiplied of locks of hair growing from the surface of the eye itself. In the remarkable case of *Lipoma crinosum*, related by this eminent authority, "the patient was upwards of 50 years old, and the tumour had been observed from birth. It was about the bulk of a horse bean, and only a small portion of it adhered, and seemed to grow from the cornea; the other part was situated on the white of the eye, next the temporal edge of the orbit. But the singularity in this case was, that a considerable number of very long and strong hairs, upwards of twelve in number, grew from the middle part of it, passed through the eyelids, and hung over the cheek. The patient remarked that these hairs did not appear until he advanced to his 16th year, at which time also his beard grew."* Sir Philip Crampton, in his valuable "Essay on the Entropeon," records an instance of "a tuft of very strong hairs proceeding from the sclerotica."† Cases of a single hair growing from the conjunctiva, covering the tunica albuginea, and unaccompanied by any tumour, have also been met with. Excrescences have been seen on all parts of the globe; but the true *Lipoma crinosum* most frequently occurs over the junction of the cornea and sclerotic; and in some of the cases related in the Journals, it was remarked that although the eyelashes were fine, thin, and light-coloured, the abnormal hair, or hairs, were thick, strong, and of a dark colour. Dr. Monteath mentions a case of one strong hair, which grew from the conjunctiva lining the lower lid; and Mr. Guthrie removed three hairs which were attached to the external angle of the conjunctiva of a new-born infant.

* Wardrop,—*Essays on the morbid Anatomy of the human Eye*. Edinburgh, 1808. *Lancet* for 1834-5, vol. i. November 29, p. 344.

† Crampton,—*Essay on the Entropeon*. London, 1805.

Dr. Mackenzie, who extirpated one of these tumours, says :
 "it was so incorporated with the sclerotic that its root was left, but died away under the use of nitrate of silver solution."*

These congenital morbid growths are not confined to the human species, they have been frequently observed in the lower animals. The first volume of Wardrop's "Essays on the Morbid Anatomy of the Human Eye," published in 1808 (p. 33), contains the description of the eye of an ox, in which a "thick tuft of black hair" grew from and covered about one-third of the cornea, and which appeared to be congenital. Dr. Prinz, in Von Ammon's *Zeitschrift*, affords us an instance of a pencil of hairs growing from the outer side of the conjunctiva and sclerotic in a pointer dog; and the accompanying illustration is copied from an original afforded by the same author, and figured by Von Ammon. It represents the eye



of a sheep, from the junction of the cornea and sclerotic of which a long silky lock of wool† depended. Ryba of Prague instances another case of the growth of hair from the eye of an ox.‡

Mr. W. Cooper has laid before the Profession the case of a fibrous

corneal tumour, about the size of a pea, triangular in shape, and covered by the conjunctiva, which was there of a pale pink colour, and studded over with minute hairs that grew from the junction of cornea and sclerotic on the outer

* Mackenzie,—*A Practical Treatise, &c.*, third edition, p. 236. London, 1840.

† Prinz,—Von Ammon's *Zeitschrift*. Bd. ii. s. 114, taf. i. fig. 3 und 4.

‡ Ryba,—*Dusensy Schrift über die Krankheiten der Cornea*. Prag. 1830.

side of the left eye in a lad of nineteen years of age. A similar growth, and also congenital, but of a smaller size, occupied a like position on the inner side of the same eye; and a small one of the same character was situated on the right eye: they are figured in the *London Medical Gazette* (vol. xxix. p. 278). Ryba has described a case precisely similar in Von Ammon's *Monatsschrift* (Bd. i. s. 657.) Middlemore likewise details some cases of this description (vol. i. p. 540, and vol. ii. p. 510), but those I have related are sufficient for the present purpose.

XEROMA.—In 1834 Mr. Wardrop published an account of "A remarkable Lusus of the Lachrymal Organs and Conjunctiva" in a female, then in her twentieth year. "About three days after birth, it was observed that her eyes had not the usual lustre of those of other infants, and that they looked opaque and dry, being completely deprived of tears, even when the child was labouring under the most violent passion or affliction." When Mr. Wardrop examined them, he says, that "instead of finding the eyeballs moistened with tears, the whole conjunctiva appeared to be converted into a dry cuticle, resembling a thin, dried bladder, sufficiently transparent to permit the sclerotic and cornea to shine through it, and to be distinguished from one another, but so opaque as to destroy vision, as she was able to see merely the outline of large objects.

"On tracing the conjunctiva from the eyeball over the palpebræ, it presented the same shrivelled and dried appearance, but instead of extending posteriorly, as in the natural eye, there was a deficiency in the prolongation of the membrane, so that the eyelids adhered to the globe, and neither could be separated far from it, nor could the edges of the eyelids be brought sufficiently together to cover the eyeball. She was observed always to sleep with her eyelids open, and when she attempted to shut them, she experienced a good deal of uneasiness, while the frequent endeavours to do so

produced a tendency to entropium of the upper eyelid. The natural sensibility of the corneal and sclerotic conjunctiva was so much diminished, that the surface of the eye, when touched, gave but very slight uneasiness. The lachrymal punctæ of each eye were open, and I could squeeze through them, from the lachrymal sac, a small quantity of a sebaceous fluid."

These congenital peculiarities would appear to be the result of some adhesive inflammatory action between the lids and globe going on *in utero*, and producing partial symblepharon at the same time that it obliterated the openings of the lachrymal gland.

"Both eyeballs appeared of the natural form, and to have that rolling motion which is so common in the eyes of persons born blind. The sense of smell was sufficiently acute, but though the application of stimulants produced the usual effect on the olfactory nerve, they had not the least influence in moistening the conjunctiva of either of the eyes."

This very curious, and, I believe, unique case of congenital *xeroma*, or cuticular conjunctiva, is one of exceeding interest, not only on account of the peculiarity of the affection itself, as illustrating in a very remarkable manner the functions of the tears, and affording a beautiful demonstration of the extension of the conjunctiva over the cornea, but also from the result of an operation which Mr. Wardrop performed for its relief, by making an artificial opening into the lachrymal gland from the point of junction of the conjunctiva bulbi and that lining the lids, when a most remarkable change took place "between the lachrymal gland and those organs which are supplied with nerves from the third branch of the fifth pair. Stimulating substances, when applied to the nostrils, and which formerly acted alone on the Schneiderian membrane, on the evening of the operation gave her severe pain in the site of the lachrymal gland and adjacent part of the head, followed by convulsive coughing.

The repetition of the use of vapour of ammonia on the day following seemed to occasion great distress; besides, she also complained of a severe pain in the right ear, which was much increased when smelling the ammonia."

ALTERATIONS IN THE STRUCTURE, SIZE, AND SHAPE OF THE CORNEA.

The cornea alone may be altered in transparency, thickness, size, form, and curvature; but morbid conditions, or malformations of this portion of the visual apparatus seldom occur singly, but are generally in connexion with microphthalmus, and often with defects of the iris and pupil; yet the congenital, abnormal characters of this part resemble more those that occur as the result of accidental disease in after life, than those of any other structure in the eye.

OPACITIES, partial or total, varying in intensity from that seen in keratite or of mere nebulae, to that resembling the characters which a leucoma or an albugo present, have not unfrequently been observed at birth. They have almost invariably been found occupying the periphery of this membrane, making it look as if the sclerotic had partially grown over and dimmed its surface. A reference to the mode of growth of this structure, as I have explained it at page 28 of this Essay, will easily account for its congenital opacities; and the knowledge that its transparency commences at its central part, and proceeds gradually to its sclerotic border, tells us why the arrest occupies the situation it usually does. To this form of disease, the *Hornhauttrübung* of the Germans, Keiser has given the name of *Sclerophthalmus*.

Writers have divided this abnormal condition into partial and total, according to the extent of surface occupied by the opacity. Independent of this arbitrary division, it would appear that two forms of corneal opacity have presented at birth, not distinguishable according to their intensity, but

differing in their appearance from the difference of their causes. One is the true congenital opacity, the result of an arrest of development at that period (probably from the third to the fourth month), when the cornea has not yet become transparent, but looks like muffed glass, and has a pearl-coloured aspect. This appearance it sometimes retains in whole or in part at birth, frequently to such an extent as to intercept our view of the pupil, and gives an idea of a general muddiness of the aqueous chamber. In such cases (the form and size of the cornea being natural), the opacity appears to arise from an interstitial deposit in the laminated portion of this membrane, and which is usually absorbed after birth, leaving the front of the eye clear, and the organ unimpaired: and this form of malformation the practitioner should be well acquainted with, as in such a case his diagnosis may in general be favourable. And here I may remark, that, exclusive of the originality of some of the cases detailed, and quite independent of all literary interest in an essay of this description, a practical benefit, of no mean importance, is at least intended, if not carried out, by summing up and collecting together the present state of knowledge on a subject on which all who practise medicine in any shape may be called on to give an opinion.

In illustration of this, the true malformation, the result of some impediment in the absorbent vascularity of the cornea, I quote the following satisfactorily recorded case, out of many with which I am acquainted, which has been published during the present year by Surgeon Maclagan, of the Canadian Rifle Corps. His narrative informs us that he was called to see a female infant, said to be born blind, on the 7th of October, 1844. It was the fourth child, and the three others, "all girls, bore evident marks of a dropsical constitution, but at the same time were healthy, good-looking children. The state of the eyes at this time, i. e. about fourteen

hours after its birth, was as follows: on neither was there the slightest trace of vascularity or purulent discharge; the left cornea was completely opaque; the right was in the same condition on its inferior two-thirds, but the upper third was clear, the opacity terminating by a tolerably defined edge. At first I thought that I could perceive this edge to change its position as the child's head was inclined to one side or the other, which led me to suppose the opacity resided in the aqueous humour, but this I found to be a mistake. Never having seen such a case, and not being able to hear of one, I was led to form an unfavourable prognosis, but in this I was agreeably disappointed; for in a few weeks the edge of the opacity on the right cornea began to thin off, to become less defined, and at length to recede, so that a part of the pupil could be seen on looking straight at the eye, while at first it could only be observed by looking from above. It was long before any change could be perceived on the left eye, but about the beginning of January, i. e. three months after birth, it too began to improve, the opacity at the upper part of the cornea becoming more diluted-looking, and by degrees disappearing."

Mr. Maclagan was removed from the locality where this case occurred, in March, 1845, when he says: "The improvement was gradually progressing. There is now only a small portion of the right cornea opaque, and the upper half of the left is tolerably clear, so that the child directs the eyes forwards, and not, as formerly, downwards; and I have great hopes that the opacity may disappear entirely, or at least so far as to leave vision unimpeded."*

Sometimes an opaque ring, exactly resembling the *arcus senilis*, is observed at birth. I have lately seen an instance of this peculiarity in a young gentleman from the Isle of

* Maclagan,—*The London and Edinburgh Monthly Journal of Medical Science*, No. LV. July, 1845, p. 493. Edinburgh.

Man; in one eye the opacity completely encircled the cornea, in the other it was interrupted. It may be recognized from *microcornea* by the remains of the general congenital opacity; and from the overlapping of the sclerotic which we sometimes meet with at birth, by its defined edge, and by a diaphanous ring external to the opaque one; and in general, it is more complete than the *arcus senilis*. This malformation, to which we may with propriety apply the term of *annulus juvenilis*, was noticed, though not accurately described, by Wardrop, in 1808.* I do not find it alluded to as frequently as other congenital appearances in the writings of the Germans. Sybil, however, alludes to this *Macula Arcuata*;† but it has yet to be determined whether in the annulus of youth, as in that of old age, a similar opaque ring encircles the margin of the lens.‡

Von Ammon's observations would lead us to the conclusion that these corneal defects are, to a certain extent, hereditary: he says he knew them to occur in several of the same family in both eyes, and also in a single eye. Sometimes malformation of the lids, and frequently nystagmus, have accompanied these congenital deformities.

Of the total darkening of the cornea, not the result of evident inflammatory action and disease *in utero*, I find many well-authenticated instances in English literature; for instance, that of the left eye in Mr. MacLagan's case; one or two mentioned by Mr. Walker, and some by the late Mr. Ware. Two very remarkable cases of it recorded by Von Ammon, whose work is very explicit on this subject; but the originality of the discovery of this disease is due to an English surgeon, Mr. Samuel Farar, of Deptford, who on

* Wardrop,—*Essays on the Morbid Eye*, vol. i. p. 85. London, 1808.

† Sybil.—*Dissertatio formæ aberrationibus a Statu normali*. Halna, 1799.

‡ Von Ammon,—*Gräfe und Walther's Journal der Chirurgie und Augenheilkunde*, bd. xiii. p. 114. Berlin, 1829.

the 2nd of March, 1790, detailed to the London Society for promoting Medical Knowledge "an Account of a very uncommon Blindness in the Eyes of newly-born Children."

In one of the cases related by Von Ammon the entire cornea, both periphery and centre, were opaque, and of a whitish pearl colour, polished like a mirror (*Spiegelglatt*); very much vaulted, apparently hypertrophied, and approaching a staphylomatous metamorphose;—giving the entire bulb a more globular form than it presents naturally, such, for instance, as is represented in figure 2, page 31, of this essay. The cornea was so much larger than natural, that when the lids were drawn asunder it completely filled the rima palpebrarum;—its insertion into the sclerotic was not marked by a defined line, but was irregular and zig-zag; and between the cornea and sclerotic there was a band of deeper colour than the rest; the eyes were turned upwards, and rolled constantly from side to side, and at first it was not possible to distinguish the pupils. Ammon had an opportunity of accurately observing the case from the second week to the end of the fourth year, and has noted all the changes it underwent during that period with the greatest care. He has moreover increased the value of this contribution to science, by illustrating his remarks by eight coloured engravings, shewing the process of clearing which took place in the eyes of this child during the period of his observations.* A few weeks after birth the pupils could be faintly distinguished, shewing through the clearing cornea, of a small size, and situated in the upper portion of the iris, as in the right eye of the case of Peter Curry, which I have represented further on under the head of malformations of the iris and pupil. In this case of Ammon's, the right cornea cleared entirely, but in the left a remarkable dark bluish opacity of a somewhat crescentic form

* Ammon,—*Klinische Darstell. d. Angeborenen Krankh.*, p. 10, taf. vii.

and accurately defined margin, permanently remained, situated transversely, and nearly in the centre, but consequently below the lower edge of the pupil.

Dr. F. Battersby has just assured me that he knows a lady in the country who has a *central* opacity of the cornea, which was congenital, and states that one of her children was born with a similar defect. Mr. Farar has related three cases of this peculiar malformation, which, as they are so very apposite, as he was the original describer of the affection, and as his views have been lately called in question, I here quote at length, as they are perspicuously, though briefly, detailed in the "Medical Communications."

"About nine years since, I was desired to see a child, who was about a month old, and apparently blind, having the corneæ of both eyes opaque, so that not the least of the iris was to be seen. My opinion was, that nothing could be done in this case, and that the child would for ever be blind.

"About a month afterwards the parents informed me there was some alteration in the child's eyes, and requested I would examine them again. I then perceived the opacity to be so much lessened, that I could faintly discern the iris. In two months more the child could perceive light, and from that period, the sight progressively increased; and before it was ten months old the recovery was complete.

"About three years after, another child was born of the same parents, with exactly the same appearance. Having seen the progress of the first case, I concluded that in this the event would be nearly the same, and indeed so it happened, in much about the same space of time.

"The manner in which the cornea acquired its transparency was, in these cases, remarkably curious: the external edge, first growing thin, soon after became clear and transparent; and after this manner the whole surface of the cornea brightened up, the centre being the last spot that recovered its transparency.

"Two years ago the same persons had a third child born with the same appearances, except that the opaque part seemed thicker, and that a short, round ligament, about three-eighths of an inch long, and of the thickness of a probe, arose from the inner part of the upper eyelid, was attached to the inferior edge of the cornea, and when the eyelid lifted up, acted in some measure like an additional muscle, by partly raising the globe of the eye. This ligament soon began to waste, and in about three weeks quite vanished.*

"From having seen the two preceding instances of sight restored, and from the disappearance of this ligament, I thought the opacity of the cornea in this child, too, would soon begin to give way, but in this I was deceived, a whole year having elapsed before the smallest alteration took place. At the end of a year the child seemed to be much diverted by passing its hand perpetually with the fingers extended before its eyes; and this has been its constant amusement from that time. The opacity has slowly diminished, but much of it yet remains. The child is now two years of age, but as it can find its way about the house, and distinguishes colours and different objects, by holding its head in a particular direction, I think in time the opacity will entirely disappear."†

In 1835 this Essay was quoted by Mr. Middlemore in his elaborate Treatise on Diseases of the Eyes, as a "very curious blunder;"—this learned author conceiving these cases to have been the result of *ophthalmia neonatorum*. In 1840 Mr. Crompton of Manchester, when publishing in the Medical Gazette some cases of congenital opacity of the cornea, to which I shall presently allude, took occasion to criticise the "curious blunder" of Mr. Middlemore, and entered into a lengthened refutation of his views. His notice, however,

* Here it would appear that there was a congenital pterygium;—a disease of which I have not in any other work met an instance as being present at birth.

† Farar,—*Medical Communications*, vol. ii. p. 463. London, 1790.

savours somewhat more of special pleading and hypercriticism than we think the occasion demanded. The investigations of the last ten years have added many new facts to this section of ocular pathology, and we are sure that Mr. Middlemore will, in the subsequent editions of his work, agree with the opinions of Mr. Farar, who must have been a most accurate observer of eye diseases.

Most modern authors, with the exception of Mr. Laurence, have overlooked the valuable observations of Mr. James Ware on this subject, originally communicated to the London Medical Society in May, 1810, and afterwards reprinted from their Transactions and published by his son in his "Tracts on the Eye" in 1818. This authority says he had "seen several instances, three of which happened in the same family." Three of these children who were affected with congenital opacity of the cornea, accompanied by unusual enlargement and prominence of the eyes, were those originally described by Farar; but of this Mr. Laurence, who is generally so accurate, does not seem to be aware. They were all short-sighted, and had very prominent corneæ; and, adds Mr. Ware, who, it would appear, had frequently examined them, "Mr. Farar does not mention any particular prominence in the eyes of these children; but, having seen two of them shortly after the time when Mr. Farar drew up the account of the cases, I find, by a minute I then made, that the corneæ appeared to me remarkably prominent." In a fourth case, mentioned by Mr. Ware as occurring in his own practice, where the corneæ were large, prominent, and completely opaque, one cornea cleared in three years, the other became transparent at its circumference, like that spoken of by Von Ammon, but remained clouded in the centre. The same work details a fifth case of a like nature, and attended by like results. In Mr. Ware's two cases there was likewise prominence and enlargement of the corneæ; but, he continues, "in all these instances, the enlargement of the eye

was not sufficient to be of serious consequence, independent of the opacity of the cornea; and, when this opacity was dissipated, the power of vision was restored. But when, on the contrary, the enlargement is not confined to the cornea, but extends to the sclerotica, and is so considerable that the eyelids cannot be closed without difficulty, the patient being not only blind, but unable to sleep without the aid of opiates; the prospect of restoring sight is wholly lost, and the only question is, in what way ease may be obtained, and deformity obviated.* Mr. Laurence himself says: "I have seen two or three similar cases, in which the corneal opacity has diminished after birth; but the progress has been very slow, and I have not known the ultimate result."†

I have seen some years ago, in the west of Ireland, a congenital opacity of both corneæ, but although the corneæ cleared, vision was totally deficient, apparently however from other causes; there was, besides, manifest megalophthalmus, and dropsy of the eyes. I understood lately from the child's father, that the globes had very much increased in size, and had become irregular in form, probably from general staphyloma. In Von Ammon's case the iris was drawn inwards, like an inverted funnel; the person was in after-life shortsighted, squinted outwards, and had nystagmus. It would not be possible by woodcuts to represent accurately any of these malformations. Mr. Walker, in his Lectures, writes: "Some few years ago I saw a child, then only two or three days old, the cornea of each of whose eyes was opaque throughout, and unusually large and prominent, so that very little of the sclerotic was discernible. The opacity was of a

* Ware.—*Observations on the treatment of the Epiphora or Watery Eye, and on the Fistula Lacrymalis, &c. &c.*, generally styled "Ware's Tracts on the Eye," London, 1818. See the article "Staphyloma Hydrophthalmia and Carcinoma of the Eye." Mr. Crompton does not appear to have been aware of these observations when writing his article in the Medical Gazette.

† Laurence,—*A Treatise on Diseases of the Eye*, p. 361. London, 1841.

bluish white colour ; there was scarcely any irritation about either eye ; nothing like inflammation. This child, however, when about two years old, was again brought to me on account of some slight inflammatory condition of the eyes, and I was surprised to find that they had assumed a perfectly healthy appearance, the cornea having become quite transparent and of the normal size."*

The second form of congenital opacity to which I alluded at page 48 is that where it is obviously caused by disease *in utero*, in which the same process of inflammation, ulceration, lymph deposits, sloughing, prolapsus iridis, synechia, and staphyloma, may and does take place as in ordinary extra-uterine ophthalmia. An instance of this kind has been related by Mr. Walker, who saw the child six months after, and the mother, a very intelligent person, informed him that the eyes exhibited the same appearance at birth as they did when he examined them. "The disease," he says, "had run through its entire course previously to birth, for, according to her account, there was no puriform discharge, inflammation, or intolerance of light, noticed at any time subsequently. The cornea of one eye had completely sloughed, the eye-ball had sunk, and, of course, not the slightest vision existed. More than one-half of the cornea of the other eye was opaque ; through the remaining transparent portion a part of the pupil could be discerned, and the iris and cornea appeared almost in contact. The transparency gradually extended, and more of the pupil became accessible to light ; hence, though vision was very imperfect when I last saw the child, yet it appeared to be gradually improving."† The elder Himly mentions having seen a case of *synechia anterior*, in a new born infant, in which the anterior chamber was completely

* Walker,—*The Lancet*, July 8th, 1840, p. 713.

† Walker,—*The Lancet*, July 8th, 1840, p. 713.

obliterated owing to the iris being in close contact with the corneæ; and the same authority relates a similar instance occurring in a microphthalmus.*

Mr. Crompton relates the case of "two brothers in Manchester who are commonly supposed to have been born with opaque corneæ. The elder boy is eighteen years old; the younger three; and they are the second and tenth of a family of ten children of the same parents: the eyes of the rest being perfect." The youngest of these boys is, we find, the person referred to by Mr. Walker in the case just quoted.

"The right eyes of both brothers are staphylomatous; the staphyloma being much more prominent in the eldest boy. Their left eyes agree in the following particulars: They are very small, and soft to the touch; the line of union of the sclerotica and cornea is irregular, and less distinct than is natural. The irides are blue, and very convex. The eye-balls are wanting in plumpness and rotundity, and look unfinished. In the younger boy's left eye, an opacity of the cornea keeps a part of the pupil out of sight; and, at the "upper part, there is an irregularity in the outline of as much of it as is visible. But the elder boy has a regular pupil, and the whole of his cornea is quite transparent, saving a small portion of the lower part of it at its junction with the sclerotica, and I am not sure whether this opacity is not from an encroachment of the sclerotica at this point, and a result of the irregular line of union of the cornea and sclerotica, of which I have already spoken."

The mother "states that on the day after he was born, she discovered that the eyes of the elder of these two boys were 'not right.' She was led to examine them by observing, when he was asleep, a prominence of the upper eyelid of the right eye. On looking at this eyeball, she discovered

* Himley's, — *Augenheilkunde*, Bd. ii. p. 100. Berlin, 1843.

that it was far from being as it ought to be. It projected at that time as it does now, but not so far. The front of the left eye was partly covered by a 'pearl.' This opacity grew thin first of all at the outer edge of the cornea; that portion of it which was at the nasal margin of the cornea, being the last to gain its transparency."*

Mr. Braithwaite, when quoting these cases in his valuable *Retrospect*, says most judiciously: "We give these two cases because it may happen, at some time or other, for any practitioner to meet with similar ones which he may not be able to account for; and if he were not able to refer to well-marked cases of congenital disease, it would be at once supposed that the disease producing the opacity had been progressing after the birth of the child, while he had neglected to notice it."†

In the same communication, Mr. Crompton says, Mr. Barton pointed out to him "a case from Ripon, in Yorkshire, in which there was a like imperfect formation of the eye-balls: in this case the cornea was transparent, but the lens opaque. The eyes were particularly small, and it was said that the child was born with these appearances." It is to be regretted that no further particulars of this case were recorded. Beer observed cases of congenital leucoma, and considered them the result of too great sharpness of the liquor amnii.

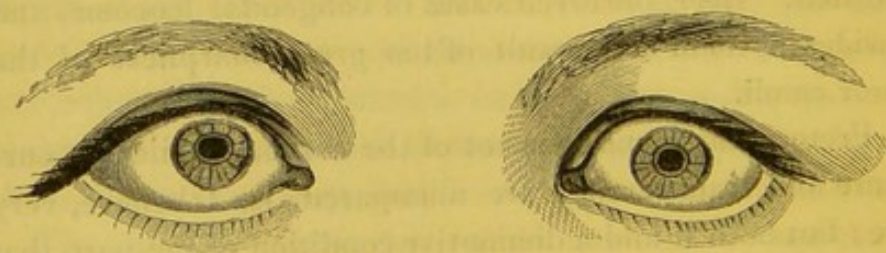
Preternatural enlargement of the cornea, while its curvature and transparency are unimpaired, is, I believe, very rare; but both it and a diminutive condition of the part, that is, in proportion to the other structures of the eye, have been frequently observed, and have been recounted among the cases of megalophthalmus and microphthalmus, detailed by

* Crompton,—*Medical Gazette*, December 11, 1840, p. 432.

† Braithwaite,—*Retrospect of Medicine and Surgery*, vol. iii. p. 128. 1841. London.

authors, some of which I have related when discussing that division of the subject, as well as the one we have just been engaged on. In all the cases that I have heard or read of, when the other parts were normal, and the cornea too large, its setting on to the sclerotic was circular and well-defined, while in all the instances of *microcornea*, its edge was irregular, ill-defined, puckered, and looked as if it had been overlapped by the sclerotic.

MICROCORNEA.—As instances of *microcornea*, or diminution of this portion of the external tunics, with a natural-sized globe, and unaccompanied by any other malformation, are exceeding scarce, I am glad to have an opportunity of presenting my readers with one of which this engraving gives a tolerably correct idea. It represents the eyes of Mary Anne Warren, of this city, aged 11 in January last, when the original drawing was made. On first seeing this child one is at once struck with the wide staring look of the eyes; this, however, proceeds from the diminutive size of the corneæ allowing the white sclerotic to appear above and below their circumferences; whereas, in an ordinary, natural eye, the upper lid overhangs the superior edge of the cornea, and the lower slightly overlaps its inferior margin.



The rest of this girl's family are perfectly healthy, and undeformed: she herself is, however, a *seventh month child*, but in every other respect is well developed. The irides are very peculiar; in colour they are very brilliant, the orange hue of the inner circle predominating much more than is usual, and the substance of each iris has a plaited

appearance, as if compressed towards its pupillary margin by the diminutive size of the cornea and the encroachment of the sclerotic: it is likewise rather funnel-shaped, the pupil, which is slightly irregular, being drawn backwards toward the lens. There is very severe myopia in this case, though the corneæ are unusually flat. At present the girl cannot read, except with the print within six inches of the eyes; and reading, or looking at any minute object for fifteen minutes at a time, causes pain, particularly in the right eye, which squints very slightly inwards.

In most cases of this peculiarity the cornea is either oval or of an irregular shape, and has a zig-zag margin, looking as if the sclerotic grew into or over it. The reader will always bear in mind, that it is only in the third month the distinction between the cornea and sclerotic is completed.

Mr. Middlemore says: "When the cornea is small from birth, it usually happens that the other parts of the eye exist in a corresponding diminished size; but I have lately seen two instances in which the cornea was scarcely at all developed, the other parts of the eye being apparently perfectly well-formed; I have also seen two examples of undue development of the cornea."

Seiler, of Dresden, recites a number of cases of both *microcornea* and *megalacornea*. On the former subject Mohrenheim and Kieser are quoted as authorities by the German writers, particularly Himly, and as far as my researches have led me, all their observations tend to confirm the idea of these affections being family peculiarities, and likewise hereditary. The former oculist mentions a case of peripheral opacity of the cornea in a child whose mother had a remarkable development of the *arcus senilis* in corresponding segments of the cornea. To this peculiarity Keiser has given the name of *Klarophthalmos*.

The cases of Ware, Von Ammon, and Walker, previously

quoted, afford us examples of MEGALACORNEA ; to which may be added that in which there is a preternatural development of this structure presenting at birth, and unattended by opacity. To this the term CORNEA GLOBOSA has been applied. Here the insertion of the cornea into the sclerotic is round and defined ; but the cornea itself is larger, and more vaulted than natural, giving to the eye that peculiar glancing, metallic appearance observed in the *staphyloma pellucida*, a disease with which it has been frequently confounded. In this case, however, the cornea retains its spherical form, and possesses neither the conical shape nor the central opacity so often seen in the hyperkeratosis. The iris is also drawn backwards, so that the anterior chamber is very much increased in magnitude, and the eyes appear to be affected with dropsy of this cavity, though the sclerotic is unaffected, and there is no general hydrophthalmus. Weller was, I think, one of the first to figure this disease.* Since the day in which he wrote, many cases have been recorded. There can be no doubt of its being sometimes a congenital deformity, though it is frequently an effect of disease in after life : as, for instance, in pannus and keratite, where the cornea clears, it often assumes this enlarged form by becoming a portion of a smaller sphere than in the healthy normal state, and in certain forms of choroid disease I have likewise observed it. Sometimes it would appear to be caused by gradual and general distention from increase of the aqueous fluid, and here the eye feels to the touch hard and unyielding. In one case of congenital *cornea globosa* which I have seen, the pupil, which is generally drawn toward the interior of the eye, was abnormal, being small, immovable, and situated upward and outward in the iris ; and a case precisely similar has been figured by Von Ammon (Taf. vii. fig. xiii. and xv.) In all cases of this affection, vision is

* C. H. Weller,—*Die Krankheiten der Menschlichen Auges*, &c. &c. (Taf. ii. fig. 9.) Berlin, 1819.

more or less impaired, and extreme short-sightedness is always a consequence.

CORNEA CONICA, known under the different appellations of *Hyperkeratosis*, *Ochlodes*, *Staphyloma Pellucida*, *Conical Cornea*, &c. &c. This disease, consisting of a conical projection of the cornea, in whole or in part, generally in the centre, but sometimes at one side, while its transparency remains unaffected, is now tolerably well known to the Profession, and although it usually occurs after birth, and often as the result of other diseases, it is at times, and, I believe, more frequently than is suspected, a congenital affection. I have had many instances of this peculiarity under my care, three of which, I have every reason to suppose, were congenital, and one was undoubtedly so; two of these were in females. In every instance that I have heard of, where the conical condition of the cornea existed at birth, it increased subsequently.

Levéillé is said to be the original describer of this disease, but John Taylor mentions it in his *Nova Nosographica Ophthalmia*, printed at Leipsic, in 1766; Von Ammon was, however, the first to state that it is ever congenital, and he has published an account of its appearance in three sisters, of the same family. Seiler and Gescheidt witnessed this peculiarity in a child of two months old. During the last thirty years this affection has received a good deal of attention both from physiologists and practical oculists. Ware, Wardrop, Lyall, Adams, and Demours, as well as all the modern writers on ophthalmology, have described it accurately; and the present state of knowledge on this subject has been lately summed up by Dr. Pickford, in a very learned and elaborate essay published in this Journal about eighteen months ago, to which I may confidently refer the reader, as containing the best information on Conical Cornea. This latter authority describes its appearance so graphically, that

I here transcribe his words. "In the disease under consideration the normal convexity of the cornea is lost; a transparent conical structure, apparently differing in no particular from the natural texture of the cornea, unprecedented and unattended by pain or inflammation, supplies its place; the cornea is prolonged forwards, and presents to the observer a peculiar dazzling, sparkling point of brilliancy, a dew-drop or gem-like radiance, as though a piece of solid crystal were embedded in its centre."*

The true pathology of this affection has, however, been explained by Mr. Middlemore and Professor Jaeger, of Erlangen, who, from actual dissection after death, shewed that the circumference of the cornea remains in its natural healthy state, but that the apex has become thinned; and to me it always appeared as if the laminated cornea had gradually given way, allowing the elastic cornea to bulge out through its layers. In some cases there is also an opacity at the apex, supposed by writers to be caused by its rubbing against the upper lid. The iris is generally flat, and in every respect natural; and on the surface of the cornea Sir D. Brewster discovered a number of small spherical elevations and depressions: but of these minute details, and their effects on vision, it is not my province, in the present essay, to deal, it being sufficient to shew that at times it appears at birth. With this peculiar formation of cornea, exceedingly defective and myopic vision must be the consequence.

Drs. Wimmer and Ammon, the former of whom has written an ingenious little work on the subject, have taken up the idea that when this malady is congenital it is accompanied with a peculiar sugar-loaf form of head (*Spitzkopf*). In connexion with this view of the case, I may re-

* Pickford,—*The Dublin Journal of Medical Science*, vol. xxiv., p. 357, January, 1844.

mark, that on looking over the last "Report of the Medical Missionary Society in China," where the heads of the inhabitants partake very much of this character,* I was particularly struck with the great number of cases of conical cornea, recorded among the affections of the eyes treated at Chusan, Ningpo, and Shanghai. In the two former places, among nine hundred and fifty cases of diseases of the eye, there occurred eight cases of conical cornea; and at the latter nineteen in 2366, or altogether, about one in every 122, in round numbers, which is a very much greater proportion than has ever been noticed among a similar number in Europe. The Germans think that the English and French people have a greater predisposition to this peculiarity than themselves, and Radius conceived that the greatest proportion of persons so affected were to be met with in England. The two Demours say they saw one hundred cases in France.

The only disease with which this is likely to be confounded is the preceding, but in the Cornea Globosa the conical form is absent, and there is no central opacity, such as is sometimes seen in this affection; besides, in this globular form the cornea is said to be peculiarly thickened throughout; but at all events its thickness is equal at all parts, whereas in the conical it is more prone to thin at its apex than elsewhere. I am inclined to believe that when it is congenital, the axis of the cone is seldom in the middle of the cornea, but is either above or below the centre, or to one side. In the case which, from the history, I am most certain of its congenital nature, this was so, and likewise in two of the patients mentioned and figured by Von Ammon. Moreover, when congenital, both eyes are usually affected, whereas when it occurs in after life it is very frequently in but one.

* These peculiarly formed crania, which are much more common in Germany than with us, are well represented in the collection of Dr. Tiedemann, of Heidelberg.

I have two cases of boys who have conical corneæ now under my care. One, who, I have every reason to believe, was born with the affection, has a sharp, crystal-like projection in both corneæ, the other, where it is evidently the result of recent disease, and is less conical, has it in but one eye, and has an opacity on the apex of the cone.

In cases of Cornea Globosa, and Conica Cornea also, where they occur as the sequel to inflammatory action, the sclerotic is often implicated in the disease. In such instances the abnormal curvature commences in the sclerotic, about the place of insertion of the four straight muscles, and then the front of the globe very much resembles that of some birds (the raptores), where the peculiarity is formed by a circle of bony plates; while in the true congenital globular, or conical-shaped cornea, the curvature of the sclerotic is unaffected. This appearance has not been sufficiently noticed by writers on the pathology of these diseases.

I am strongly disposed to believe, both from the hereditary nature and the early development of some cases of MYOPIA which I have seen, that the peculiarity of the cornea which produces this defect is occasionally congenital, but the short-sightedness may be induced or warded off by the treatment and occupation of the person so affected. Too great thickness, as well as an over-convexity of the cornea, are allowed to be causes of short-sightedness, and these may, and, I believe, often do, the former particularly, present at birth; but until it is decided how far myopia depends on unnatural conditions of the cornea alone, and what part the peculiarities of curvature of the crystalline lens, &c. play in the affection, it would be foreign to the subject to enter upon these vices of refraction.

For other peculiarities of vision and irregularities of refraction, apparently the result of congenital deformation of the cornea, I refer the reader to the interesting case of Professor Airy, of Cambridge, published some years ago in the *Trans-*

actions of the Cambridge Philosophical Society, and since quoted into the various Cyclopædias and works on both optics and ophthalmic medicine. It is known that the cornea is not a correct surface of revolution, but that the curvature of its horizontal plane is less than that of its vertical. When this exceeds the usual extent, it gives rise to irregular refraction, causing a circle to appear an oval, a point a line, &c. ; in fact, lengthening out an object in one direction, and compressing it in another. To this malformation Mr. W. Jones has applied the term "cylindrical eye;"* perhaps it would be better to call it CYLINDRICAL CORNEA.

Instances are on record of PLURALITY OF CORNEÆ, and also a total DEFICIENCY OF CORNEA ; thus it is sometimes double, as occurs in *monoculi*, under which head that deformity will be considered ; and two instances have been recorded of the complete absence of all vestiges of this structure. One of these fell under the observation of the elder Himly, in a case of *microphthalmus* with a very small palpebral aperture. The bluish sclerotic passed over the place of the cornea, in the same form and curvature as the rest of the globe, and did not there partake of the shape which that membrane presents, a proof, according to Rudolphi and himself, that it was true sclerotic, and not opaque cornea.† A somewhat similar instance is related by Klinkosch.‡

The malformations of the sclerotic itself are, I believe, exceedingly rare ; and those congenital peculiarities and diseases which have not been already disposed of under the head of *Megalophthalmus* and *Microphthalmus*, will be considered under that of *Monoculi*.

In addition to those cases of *microphthalmia* which I

* Wharton Jones,—*Cyclopædia of Practical Surgery*, article "Cornea," p. 832.

† Rudolphi,—*Grundriss d. Physiologie*, Bd. ii. s. 174.

‡ Klinkosch,—*Progr. quo anatomen partus capite monstroso proponit*. Prag. 1766.

detailed in the former portion of this Essay, I may mention some others which have since been recorded in the foreign periodicals.* M. Stœber, of Strasbourg, has lately laid before the Medical Society of Lyons the particulars of some most interesting facts relative to this congenital deformity, which, as well as the cases which I have already alluded to, lead us to incline to the idea of its being at times an hereditary transmission of defect. A man living in the neighbourhood of Saverne lost his right eye by accident. His daughter was born with microphthalmus of the left eye. She had two sons; the eldest was born with this vice of conformation in both eyes, and the younger in but one only,—the right. In the mother, at the period of her examination by M. Stœber, in her thirty-eighth year, the palpebral aperture was very much less than natural; the cornea was flat; the anterior chamber almost entirely wanting; the iris was of a grey colour, non-contractile, and incomplete at its inferior part, so as to produce coloboma iridis. She stated that the vision had decreased of late years in that eye, yet she was still able to distinguish objects of a large size pretty clearly.

In the case of the elder boy, the globes were both very much less than natural, and affected with the oscillatory motion of those born blind, yet the sight was tolerably good; the lids were greatly depressed, the cornea flattened, and, according to the account of the mother, were so small at birth as to resemble two minute black spots in the centre of the eyes, but that subsequently they increased in magnitude, apparently by the clearing of the sclerotic coat; and the reporter of the case says, that even then, when the boy was seven years old, the cornea passed off irregularly and im-

* Petrequin,—*Annales d'Occulistique, publiees par le Dr. F. Cunier*, tome xiii., Janvier, 1845. Bruxelles.

perceptibly into the sclerotic; this transparent tunic first becoming opaline, then opalescent, and finally opaque. The irides were of a grey colour, like the mother's, and deficient in their lower and outer parts, causing coloboma in both organs. The pupils were non-contractile. The particulars of the younger boy are not given in the report.* In two of the cases related by Gescheit, it would appear that a similar coincidence with that of the grandfather of these children existed. This state of parts, to which I have already alluded, together with the increase of transparency of the cornea after birth, is confirmatory of the doctrine of development insisted on by the anatomists.

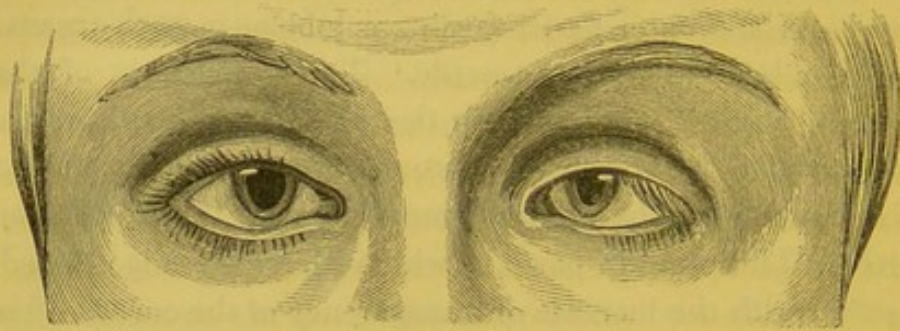M. Cunier, of Brussels, in the January Number of the *Annales d'Oculistique* for this year, has afforded us some most interesting information on the subject of the hereditary nature of microphthalmia and deaf dumbness. In the instances recorded by this oculist, we find that a woman whose eyes were quite perfect, but whose mother had microphthalmus, married a man whose grandmother was deaf and dumb. The product of this union was five children, three boys and two girls. The girls were both affected with microphthalmia, one of them was deaf and dumb, and had moreover complete absence of the iris in one eye; the other, who is now married, has had a child who is deaf and dumb, has microphthalmus, and coloboma iridis.†

While these pages were passing through the Press, I met with one of the most remarkable cases of microphthalmia, attended with coloboma iridis, convergent strabismus, and nystagmus, that has yet been recorded, and of which the accompanying woodcut, from a drawing by our distinguished artist, Mr. Connolly, affords a faithful representation.

* Stœber, — *Gazette Médicale de Strasbourg*, 20 Decembre, 1844.

† Cunier, — *Microphthalmie et Surdi-mutité héréditaires*. — *Annales d'Oculistique*, Janvier, 1845.

This little girl, Ellen Sullivan, æt. 10, at present an inmate of the South Union Workhouse of this city, is well



formed in every other respect, and states that none of her family were affected with any peculiarity of vision or visual apparatus; but having been placed in this establishment some years ago, and knowing little about her family, this latter statement must be received with caution.

The first view of this child impresses one with the idea that the globes have collapsed from injury, so small are they, and so much drawn within the palpebræ. The left eye, which is the most affected, is little more than half the natural size, but the right is somewhat larger, though very much smaller than a well-formed globe. There is convergent strabismus in both eyes, slightly developed in the right, but well marked in the left, so that when she steadies the right eye on any object, the cornea of the left is partly hidden by the caruncle. The oscillatory motion consists in a general

My friend, Mr. Dalrymple, writes to me :

"In addition to the cases mentioned in the *Gazette Medicale* I have seen two cases, one of Microphthalmia in both eyes, with vertical coloboma of the iris, and one in one eye, also with coloboma. In the double case it was complicated with cataract. One was a man of forty-five or fifty years of age, intelligent, and capable of making observations. He was obliged to use the highest powers of double convex lenses I ever saw, which was not a microscope;—it was a sort of doublet made up like an opera glass. No ordinary lens would do. In the single case both corneæ were small and vertically oval; the coloboma was only complete in one eye, but the fissure was marked in the other."

sweep of the globes from canthus to canthus, and in addition a quick rotatory and tremulous action of the eyes on their antero-posterior axes. The corneæ themselves are somewhat flattened, though circular in their margins, and notwithstanding that they are diminutive in size, they are not disproportioned to the other parts of the globe. The irides are brown, and remarkable for the want of those prominent lines, and diversity in shades of colour, as well as the complete absence of the pupillary rings, which characterize these membranes. Both irides are deficient at their lower borders, leaving a much larger pupil than in any other instance of coloboma that I have met. Her vision is weak, and she is, as might be expected, very short-sighted, but still she can read good-sized print with either eye. It is more than probable that the strabismus was congenital.

The endeavour to keep the eyes open while the drawing was taking, has given an appearance of greater magnitude of the globes than in reality they possess, and has also caused the peculiar elevated position of the brows.

MALFORMATIONS OF THE IRIS AND CHOROID.

We now approach the most interesting portion of our subject, the congenital peculiarities and diseases of the iris and choroid, which, on account of their intimate anatomical relation, and the manner of their early development, we must consider under the same head.

In the foetal eye, the choroid is developed long antecedent to the iris. This membrane, supposed by Le Cat and Arnold to be the analogue of the pia mater, is said to be apparent so early as the end of the first month, but Valentin could not find any trace of it till the eighth week. The researches of this very accurate observer enabled him at this period to detect two vascular laminae, enclosing between them a pigmentous layer, and a layer of the proper substance of the choroid (*une couche de substance*), four in all, and developed in the following

order: the substantial layer first, then the two vascular envelopes, and finally, the pigment. On a microscopical examination, this pigment is found to consist, at first, of clear globules, which by compression subsequently assume the form of hexagonal or pentagonal cellules. In these the dark or pigmentary matter is developed, at first at the periphery, but subsequently it penetrates the entire cellule. The choroid commences to be formed at its anterior or corneal margin, a circumstance which has given rise to so many errors with regard to the development of the iris.

In vertebrate animals, embryologists have discovered a thin colourless line in the choroid, running from within outwards, and ending at the anterior and inferior angle of the eye; this is considered to be a rent (*feute*) of the choroid, and in very early life it is believed to extend to both sclerotic, retina, and vitreous humour; and in the former of these membranes (the choroid) a trace of it can be subsequently recognized by the thinness and tenuity of the structure, as well as the absence of pigment along its course. In some rare instances, this obliterating or fusing process is arrested, and then this curious condition presents at birth, under the form of *coloboma choroideæ*. To account for its appearance many ingenious theories have been put forward, and many vague hypotheses broached.

Walther and others have attributed it to the union of the double primary element at this point; if so, however, the line or cicatrix should be mesial and vertical. Huschke considers it a trace of the original separation of the germ into two parts, as explained at page 27; while Beer denies the existence of the fissure in *toto*; yet he acknowledges that in birds there is in this situation a fold of retina in very early embryonic life, into which the choroid, devoid of pigment, subsequently insinuates itself to form the pecten or marsupium, with which every anatomist is acquainted. In some of the cartilaginous fishes (the sturgeon, for instance) I have detected more than one fissure of the choroid.

In this fish there is a very remarkable thick, cartilaginous sclerotic, of an irregular shape, particularly upon the internal surface, as is well shown in the drawings to the accompanying notes, which I had made from the eyes of the sturgeon of the Danube, many years ago, in Vienna(a); and the choroid is tucked into each of those angles. Baer asserts that the fissure of the choroid which remains permanent in some animals is to be found at a certain period of the embryonic state in man. The ciliary ligament has been found by Valentin so early as the middle of the third month; and the formation of the ciliary body commences, according to Arnold, during the fifth week, by a number of small folds (the ciliary processes), at the anterior border of the choroid, where it encircles the margin of the

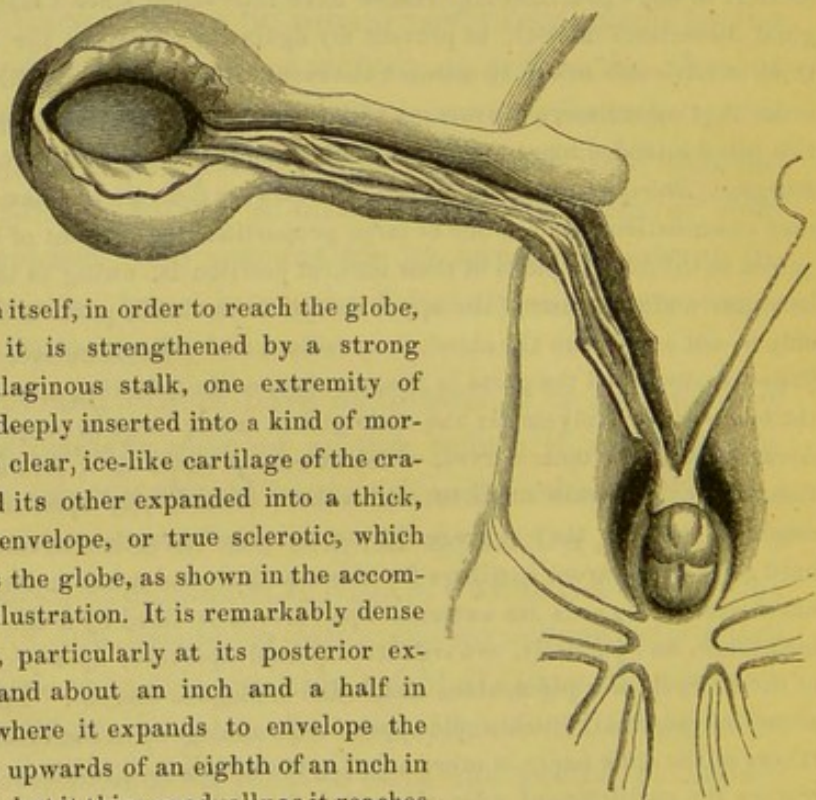
(a) It was my original intention to have written an anatomical paper upon the peculiarities of the visual apparatus in this class of fishes; but as matters of more practical importance have intervened since I made the original dissections in 1841, to prevent my again investigating the subject, I think it advisable briefly to mention the result of my inquiries in this place, in order that others more conversant with such matters may take it up; this notice being intended more to elicit investigation than to satisfy inquiry. In a sturgeon (*Sturio accipenser*) of small size it is very difficult to make the necessary examinations, and in one of large proportions the amount of labour required to exhibit the parts in their natural position is, owing to the intense hardness and thickness of the upper section of the head, parts of which can only be cut away with the chisel, very tedious and difficult indeed. Having, however, displayed the parts *in situ*, we observe the following appearance:—the brain remarkably small; the optic globes rather large in proportion; no decussation of the optic nerves, which at once proceed in a forward direction, and at an acute angle to each other; immediately upon leaving the cerebral chamber they traverse in an outward direction a canal in the hard semi-transparent cartilage for about an inch and a half in length; this canal widens towards its external aperture, it is lined by a thick fibrous membrane, and partially, towards its external aperture, by a prolongation of the choroid, or a pigmentous membrane analogous thereto. This fibrous sheath of the canal, which would appear to be analogous to the ordinary neurilemma of the optic nerve in other animals, is continued on to where the nerve pierces the cartilaginous sclerotic, which, in a large specimen of the *Sturio accipenser*, is upwards of three inches in length. Immediately upon the nerve leaving the cranial cavity it begins to break down into a thin membranous

crystalline. Von Ammon, however, has not been able to detect the ciliary processes till the fourth month.

Some slight difference of opinion exists among embryologists as to the precise periods at which the iris can first be seen; Arnold having stated that he could observe it in the seventh week, while Valentin, to whose opinions great deference should be paid, was unable to perceive it till the end of the third or the beginning of the fourth month. All, however, agree that it is formed subsequently to the choroid. It at first appears in the form of a narrow transparent ring, which gradually extends inwards from the anterior margin of the choroid, in which the pigment is afterwards deposited on its posterior surface. According to some anatomists it consists of a mem-

expansion, which enlarges into a flat, tape-like body, folded upon itself, as shown in the accompanying wood-cut. Having advanced to the edge of the cartilaginous plate of the skull, this optic tube turns at an acute

angle with itself, in order to reach the globe, and here it is strengthened by a strong fibro-cartilaginous stalk, one extremity of which is deeply inserted into a kind of mortice in the clear, ice-like cartilage of the cranium, and its other expanded into a thick, fibrinous envelope, or true sclerotic, which surrounds the globe, as shown in the accompanying illustration. It is remarkably dense and thick, particularly at its posterior extremity, and about an inch and a half in length; where it expands to envelope the globe it is upwards of an eighth of an inch in thickness, but it thins gradually as it reaches the cornea; it differs from the well-known cartilaginous stalk which attaches the globe to the cranium in some of the osseous fishes by thus surrounding



braniform expansion of the long ciliary arteries, as the choroid is supposed to be developed from the reticulation of the posterior ciliary vessels. At first the iris is a complete ring without any slit or aperture in it. A contrary opinion, however, was held by many of the most distinguished anatomists, from Malpighi and Haller down to the days of J. Müller; but Bishoff considers that their error arose from observations made upon the anterior border of the choroid (where a natural division may be seen in very early life), and not on the actual iris. A vice of conformation, however (*coloboma iridis*), occasionally takes place, to which we shall presently refer, in which a slit in the iris is found at birth, which rather lent support to the

and forming a sheath for the expansion of the optic nerve, which latter, as I have already shown, appears to be resolved into a substance resembling retina in many respects, immediately after leaving the cerebral cavity. Within the external fibrous sclerotic we find a thick, dense, cartilaginous envelope, scarcely susceptible of alteration in its form by pressure between the fingers, a posterior view of which is represented by figure 1, and an anterior view of a transverse section of which is shown by figure 2 in the accompanying wood-cut. The optic nerve, having pierced this cartilaginous body by means of the ovoid aperture shown in

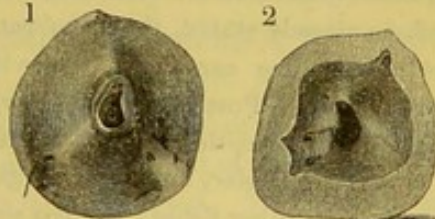
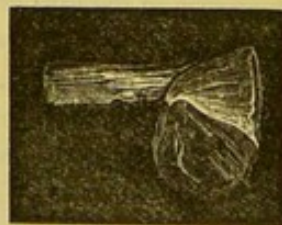


figure 2, does not expand into a hemispherical cup, like that in other animals, but traverses a deep sulcus in the cartilage, and pierces the choroid by a line or fissure of about half an inch in extent, from which it expands into the ordinary cup-shaped retina, as shown in the accompanying drawing made from a specimen in which the nerve was completely removed from the surrounding parts. I have not had an opportunity of examining the nerve microscopically; but I may remark that, while in the canal between the brain and the globe, it possesses all the physical characters of the retina, being a thin, greyish, semi-transparent lamina, easily breaking down under the fingers or a forceps, and only to be examined effectually by manipulating with a fine camel-hair pencil while the parts are under water, or by hardening the nervous substance by the addition of a little alcohol or alum. In the first specimen that I examined I was under the impression that this



observations of the early anatomists, and to explain which the ingenious hypothesis of Walter—of the eye being formed from the fusion of two lateral and symmetrical portions—was invented. The capsulo-pupillary sac, and the membrana pupillaris, discovered by Wachendorff and Haller, being united by their vessels, must be considered together as one membrano-vascular expansion; the former passing from the surface of the crystalline capsule, traverses the superficies of the posterior chamber to the edge of the pupil, where the anterior layer of the serous membrane of Descemet, uniting with the fine ramification of these vessels derived from the long ciliary arteries already described, and passing across the pupil, forms the mem-

portion of the nerve was tubular, but I have not been able by subsequent observations to satisfy myself upon that point. Where it passes through the fissure in the choroid it is remarkably thin and attenuated, as if constricted or deprived of one or other of its coats at this point; but having fairly entered the eye it becomes more consistent. The choroid is dark brown towards the cartilaginous sclerotic, through which it receives several fine vessels, the trajets of which are seen in the views already given of that structure. The inner surface of the choroid is of a beautiful silvery grey, and, as already stated, this membrane enters deeply into the sinuosities of the surrounding cartilages, where it is intimately united to it by means of those vessels. Posteriorly the external layer of the choroid sends a prolongation into the optic canal, where its black pigment is easily recognised. The lens is globular, but rather larger in proportion to the size of the organ than in most other fishes; the iris presents the tapetum-like appearance of the choroid; the pupil is slightly oval; the cornea flat. A horizontal section of the eye, from the cornea to the optic nerve, gives very much the appearance seen in the eyes of cetaceæ,—the external coats being much thickened posteriorly, and the cavity in the interior bearing no proportion to the size of the globe externally. In a volume of Rheil's Archives (I think for 1825), some notice is taken of this internal cartilaginous sclerotic, but, with this exception, I am not aware of the subject having been investigated by any anatomist; and this was the opinion of Professor Müller of Berlin, to whom I showed the drawings and preparations in 1841. Without a series of expensive, highly-coloured illustrations it would not be possible faithfully to represent the anatomical peculiarities in the eyes of the sturgeon. The foregoing observations, with the accompanying wood-cuts, may, however, serve to draw the attention of future observers to this interesting subject.

brana pupillaris. Generally speaking, this membrane and its vessels disappear shortly before birth, but sometimes it remains permanent for a length of time, constituting a congenital disease which occasionally engages the attention of the surgeon. Embryologists have not discovered any trace of pigment in the eye of the human embryo up to the fourth or fifth week, as already stated; and in the fourth or beginning of the fifth month the iris is said to be invariably found of an uniform blue colour, perfectly smooth upon its surface, and without any of the network which gives that peculiar marking to the front of the iris with which we are all familiar, and which, in all probability, subsequently becomes muscular.

This brief review of the most generally received opinions and most faithful observations, as regards the formative process in the parts now under consideration, will considerably assist our subsequent investigations, by explaining, in many instances, how those arrests of development occur which present such marked peculiarities in after life(a). This subject is not one of mere speculative interest or unpractical importance, but is well deserving the attention not only of the special ophthalmic practitioner, but the general surgeon also; for, without

(a) Since the publication of the foregoing portion of this essay, some additional information has been elicited on the subject of the malformations of those structures which have already been discussed. This I have embodied, together with some additional cases, which occurred in my own practice, in the Ophthalmic Reports for 1846 and 1847, which appeared in the fifth and tenth Numbers of the present series of the Dublin Quartely Journal.

The malformations of the visual organs in the lower animals shall only be considered so far as they in any way explain or illustrate these peculiarities in the human species.

In this and the foregoing portions of this essay, I have, in the descriptions of the anatomical developments, referred chiefly to the eighth volume of the *Encyclopédie Anatomique*, Paris, 1843, already referred to at page 26, in which the opinions of the most celebrated German observers are set forth, and where the various authorities and works quoted are specified and set out in full.

some knowledge of it, any one who undertakes the treatment of diseases of the eye may find himself led into serious errors in diagnosis.

The congenital defects and peculiarities of the iris may be classified into three great divisions:—irregularity of colour; deficiency of parenchymatous structure; and abnormal conditions in the size, shape, and position, of the pupil.

Under the first head might be considered, did our space permit, those national peculiarities which distinguish the various races of mankind. This, however, is too wide a field for any minute investigation here; the subject is well set forth in various works upon the physical history of man, and is also touched upon in most modern books of travel.

VARIETIES OF COLOUR.—*Albinos* are frequently found, and indeed were first remarked and described by the Portuguese, among the dark Negro races. We have, however, but few opportunities of examining such curiosities in this country. Furnari, in his Medical Voyage in Africa, informs us that albinism or *Leucosis* is very frequent among the Jews of the northern part of that continent; and that, besides the ordinary appearances which albinos usually present, there is in these persons the remarkable peculiarity superadded, of the ciliæ, as well as the skin of the eye-lids, being covered with minute reddish spots. He also states that glaucoma is a very frequent affection among this race; and some pathologists are of opinion that in this disease there is a deficiency of colouring matter in the eye. It has been asserted that dampness and unwholesome air or food assist to induce this disease, and in proof of this assertion it is stated that the Isthmus of Darien, one of the dampest countries in the world, possesses the greatest number of albinos. There can be little doubt but this peculiarity is hereditary; at the same time it is frequently seen among several brothers and sisters of the same family, whose parents or forefathers never exhibited any symptoms of the defect. The general appearance of albinos

is too well known to require any minute description(*a*). They are generally below the middle size; the skin all over the body is remarkably fair and fine in texture; the hair of the head is long, of a fine silky texture, and rather inclined to curl, and that upon the brow is generally thick-set and often bushy; the skin of the eye-lids is particularly delicate; the upper lid usually droops somewhat; and the palpebræ are, from the intolerance of light, generally contracted, like those of a person labouring under photophobia. The ciliæ are, like the rest of the hair, long, fine, and silky, and usually more curved than in those persons in whom colouring matter is developed. The globes are in constant oscillatory motion (nystagmus), such as has been already described in the former part of this essay, and there is often slight strabismus; the conjunctiva is pale, except towards the caruncle, where it contains some fine pinkish-red vessels; the sclerotic is generally somewhat thinner than natural; the cornea presents no well-marked peculiarities that I am aware of; but the iris and choroid are of a brilliant pink colour, owing to the total absence of all pigmentous matter permitting the vascular arrangement of these membranes to be seen and thus present this peculiarity(*b*). Several of the writers who have described the eyes of human albinos mention irregularities in the position and form of the pupil; but these I believe to be accidental or exceptional peculiarities, not the

(*a*) The general description of the albino will be found at length in all the cyclopædias. See in particular the articles under this head in the *Encyclopædia Britannica*, *Encyclopædia Metropolitana*, Dr. Bostock's article in *Todd's Cyclopædia of Anatomy and Physiology*, and Dr. Prichard's notices of leucosis and the xanthous varieties of the human race, in his *Physical History of Man*; see also Herr Sach's work on the subject: both this author and his sister were Albinos. See also Söemmerring's and Seiler's great works already referred to.

(*b*) Blumenbach, in October, 1784, first advanced this theory, and before the end of that year Signor Buzzi verified it by actual dissection. Mr. T. W. Jones has shown that the membrane of the pigment or choroidal epithelium is present in albinos, though devoid of colouring matter.

ordinary condition in such cases. The iris is peculiarly brilliant, and in all instances which I have examined, it differs in colour from the deep pink hue of the pupil by having a slight trace of white and blue colour mixed through it, the former being caused by well-marked development of the internal circle and the radiating fibres which appear upon its surface. I lately dilated the pupils of an albino, and observed that as the irides expanded their bluish hue increased in intensity, and contrasted the more forcibly with the brilliant pink tint seen through the enlarged pupil. The pupils, which are remarkably sensitive, are, it is said, usually drawn upwards, and in some instances a minute line of dark-coloured pigment may be observed on the margin of the extreme edge of the iris: this peculiarity I have only observed in horses. Buzzi, who has written an interesting anatomical memoir on the albino eye, has found the iris white in the dead subject, without any trace whatever of uvea; the choroid fine in texture and light red; the retina normal, but whiter and finer than usual; the macula lutea close to the origin of the retina, and somewhat higher in colour than natural: this latter peculiarity, however, has not been confirmed by the observations of others^(a).

From the absolute albino, where there is a total deficiency of colouring matter, to the normal state of the dark-eyed races, we find numerous varieties of imperfect and incomplete leucosis, presenting more or less the general characteristics in the hair, intolerance of light, trembling condition of the globe, &c., &c. In the xanthian variety the iris is of a lilac tinge, and the hair presents a greenish hue; whereas in some forms of leucosis a violet or purplish tint of the eyes predominates, from the admixture of the blue and rose-red colours.

All such persons, as well as true albinos, are weak-sighted,

(a) A question here suggests itself, whether the yellow colour seen round the foramen of Söemmerring, and which is supposed to be a ganglionic appearance, is really a pigment.

and what is generally styled purblind, seeing best in a modified light, or in the dusk. Although I have seen the hairs on the brow and the eye-lashes perfectly white on one side and dark on the other, I have never heard of an instance in which one eye was affected with leucosis and the other not. In a case related by Seiler the eye-lashes were white, the irides of a bluish red, but the hair on the brows and over the head generally was dark. Partial leucosis has, however, been observed in animals in a wild as well as those in a domestic state, particularly those denominated piebald; but I feel assured that, in many instances, these spots upon the iris are not colourless, but arise from a peculiar *white* deposit, similar to that which is denominated a "wall-eye," so frequently seen in mottled dogs and cream-coloured horses.

In the human embryo observers have not found any pigmentous deposit until the fourth or fifth week, so that it is probable that an arrest of development has been the cause of this peculiarity. Cases of leucosis are recorded in which it would appear that some colouring matter was deposited after birth. Dr. Graves has related a very remarkable instance of this, in which, in a born albino, the "eyes had changed from violet-red to grey, and his hair from white to light-brown, and that the susceptibility of the eyes to the light had greatly diminished"(a). I do not believe, however, that any of the cases in which the eyes darkened in after life, presented at birth the highest degree of complete leucosis. I have myself had an opportunity of examining a case of this description in the person of Master D——, aged about three years, when I first saw him, in 1843, along with Dr. Brereton. His irides at that time were a light lilac blue, and his pupils a violet-red colour; there was partial oscillation of the globes, which were somewhat enlarged, and the corneæ were more prominent than natural: the hair of the head, as well as that upon the brows and

(a) See Prichard's *Natural History of Man*, second edition, 1845, p. 79.

eye-lids, was then of a dirty cream colour. His parents and attendants stated that he was born an albino, the hair being then much whiter, and the eyes of a bright pink. I have frequently seen this child since; both eyes and hair have become considerably darker, so that at present the latter are what would be termed light blue. The boy is, however, very weakly, and the vision (apparently owing to some enlargement of the globes) has not improved with the development of colouring matter. Sybel relates a case in which the outer ring of both irides was, at its upper part, of a rose-red colour till the eighth day after birth when it became a dark brown. Meyer and Aschersohn have observed similar instances where colouring matter appears to have been developed after birth: the first in a child born with violet-coloured eyes, which at the end of the third year were changed to blue, and the white hair to light brown; the second where a very light blue-grey iris, with red pupil, altered at the end of the seventh year to a cherry brown. Fermin relates cases in which a peculiar light appears to have been emitted in the dark from the eyes of albinos(a).

It still remains questionable whether treatment can in any way promote the deposit of colouring matter, the deficiency of which is the cause of leucosis.

The natural colours of the iris are different shades of brown and hazel, yellowish, light and dark blue, and blue grey. The term true black can scarcely be applied to any condition of the iris, although I have seen instances, even in Europeans, in which it was not possible, without a very close examination, to discover any difference between the colour of the pupil and iris. According to some observations made by M. Petrequin upon the inhabitants of France and the adjoining countries, it appears that the grey eyes predominate among males and the brown among females, and that in both, the light-coloured eyes predominate over the dark considerably. With the intention of drawing

(a) *Description de Surinam*. Paris, 1769.

up some statistical tables with respect to the diseases which prevail among individuals with different coloured irides, I have had the colour of the eyes noted in my hospital registry for the last eighteen months, and find the result to be as follows:

Of 2776 individuals, 1884 had light eyes, consisting of 752 blue, and 1132 grey, in the proportions of 992 males to 892 females; 288 hazel, and 604 dark eyes, varying in shade from light brown to what is denominated black; the proportion of males to females in this latter class (amounting altogether to 892), being 470 males to 422 females. From this series of observations it follows, that, in the Irish population in and about Dublin, the proportion of light to dark eyes is nearly three to one, speaking in round numbers.

There are, however, particular localities in Ireland in which dark eyes predominate, as in certain parts of Galway, Kerry, and Londonderry, but not to any great extent. In these places I have observed that the females possessed the dark eye in the greatest numbers. The true orange-brown eye, found in connexion with auburn hair, is very rare in Ireland; but a yellow-orange, with wiry reddish-chesnut hair and densely freckled skin, is by no means uncommon here. The very light blue eye, with dark hair, brows, and eye-lashes, still obtains in many parts west of the Shannon.

The most frequent peculiarity of the iris consists in partial varieties of colour, denominated by the ancients *Heterophthalmus*, of which we have frequent examples among the light-eyed Celtic inhabitants of these countries. One of the most remarkable examples of these irregularities of colour consists in one iris being light blue or grey, and the other dark brown, of which I have seen several instances. Another example of this peculiarity consists in a portion of the iris, frequently the lower or outer half, being brown or hazel, the remainder blue or grey, and the iris upon the opposite side being also light-coloured. Spots and patches of a dark colour, varying from the deepest shade of brown to that of light cinnamon colour, and even to

a yellowish hue, are frequently observed in light eyes; and it behoves the practitioner to be well acquainted with these circumstances, as such blemishes might possibly be mistaken for the result of disease; and in cases in which a surgeon is called upon for the first time to visit a patient labouring under ophthalmia, in whom such peculiarities exist, it is possible that a serious error might be committed. I have never seen congenital maculæ or discoloration of the iris in very dark eyes, and I have never known these defects to influence vision one way or the other.

One of the most remarkable instances of mottled irides which has yet been recorded is that related by Professor Osborne, in the seventh volume of the former series of this Journal, page 33, and which also proves that these peculiarities are sometimes hereditary. In this case the irides were of a "dusky, light yellowish ground, and a number of dark, reddish brown spots were sprinkled on them in an irregular manner, but in greatest number towards the internal angle of each eye. The spots on the back of a tortoise-shell cat afford the best resemblance." The person who was the subject of this peculiarity had fifteen brothers and five sisters, who all possessed the same peculiarity, which was derived from his mother, whose three sisters and one brother had the same, which was in her again derived from the mother's side. This peculiarity, which was well known and recognised in that part of the country (county Waterford) from which this patient came, had always been believed to be transmissible by intermarriage or descent.

Sometimes the adventitious colour occupies the whole breadth of the iris; in other cases it appears in isolated patches. I lately published an account of a very peculiar and until then undescribed form of discoloration. In this case,

"On examining the eyes at about two feet distance, the edge of each pupil appeared remarkably ragged and irregular, so as to look like a case of synechia posterior, the result of iritis, in which the attachment of the iris to the lens had been

put upon the stretch by the action of belladonna. Upon a closer view the appearance turned out, however, to be the result of an irregular circle of remarkably black pigment (darker even than that which is usually found upon the uvea) which occupied the inner fifth of the circle of the iris, and was apparently raised above the surface of that membrane. It was with some difficulty that the pupillary margin (which was perfectly normal) could be distinguished at the distance of even twelve inches. The outer edge of this deposit, though most irregular, was very sharply defined. Either the pigmentary membrane turned round the pupillary margin and spread over the anterior surface of the iris, or the parenchymatous structure of the iris was congenitally deficient at this point, and allowed the uvea to be seen anteriorly. The circles and radiating lines were not well marked in this person's irides"(a).

It is unnecessary to adduce more instances of varieties of colour in the iris, the result of congenital defect. The lower animals, dogs in particular, frequently present these peculiarities.

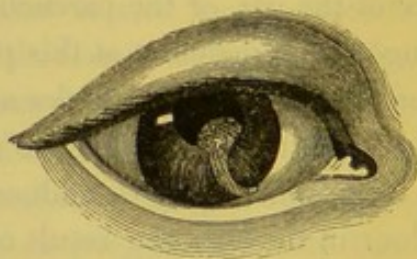
The development or deficiency of the peculiar striæ, loops, and rings upon the surface of the iris gives rise to certain well-known appearances, which it is unnecessary to detail. Some years ago a child was exhibited on whose irides it is said the words "Napoleon Empereur" were written. This phenomenon, which attracted much attention at the time, appears to have been produced by an unusual arrangement of those loops, bands, and striæ,—similar to the fleshy pillars and tendinous cords of the heart,—which mark the surface of the ocular diaphragm, and which a stretch of the imagination amplified into the letters forming the name of the Emperor(b).

(a) See the Author's Report on the Progress of Ophthalmic Surgery for the Year 1846, in Dublin Quarterly Journal for February, 1847.

(b) I possess a very good lithograph of "Josephine Louis, the French child born with the words "Napoleon Empereur" in its eyes." Upon the lower section of the right iris the marks resemble the capital letters in the

Between the varieties of colour and the deficiencies in the structure of the iris may be placed the defect denominated *Korestenoma*, in which there is not only a difference in colour, but also an unnatural projection of the substance of the iris within the circle of the pupil in any one part. This congenital peculiarity, which is one of the very rarest forms of malformation, is faithfully represented by the accompanying wood-cut, copied from Dr. Szokalski's paper on the subject, which I lately re-published from the Prague Medical Journal.

“ The subject of this malformation was a girl of scrofulous constitution, born with hare-lip, and said to be affected with syphilis. The irides were light blue, and in each iris was observed a light yellow stroke of a conical shape; it arose broad from the border of the pupil, and extended obliquely downwards and inwards to the ciliary margin. In the right eye, however, its upper edge formed a rounded, wart-like protuberance, which projected into the pupil, and occupied about half the size of that aperture in its moderately dilated state, and also extended into the anterior chamber. It was said to be covered with minute hairs. The other parts of the eye were normal. While the ordinary discoloration of the iris, which this resembles, has been accounted for on the belief that it is an early cicatrix of this membrane, no plausible hypothesis has yet been advanced which will explain this peculiar fault in the formation of the ocular diaphragm. A case similar to this is reported to have occurred in the practice of the venerable Walther of Munich”(a).



Although the Russian physician has, and perhaps correctly,

word “Empereur,” and the word “Napoleon” occupies somewhat the same position on the left iris.

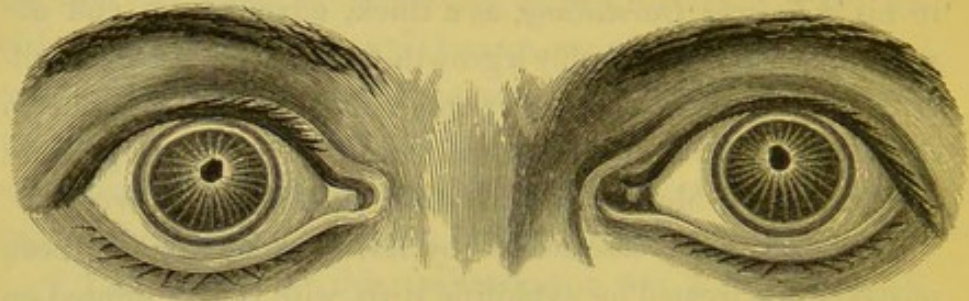(a) *Vierteljahrschrift für die praktische Heilkunde* III., Jahrgang, 1846. *Vierter Band*. Prag. See Dublin Quarterly Journal for May, 1848, p. 472.

placed this peculiarity under the head of *Korestenoma*, yet it differs in many respects from the affection to which Ammon first applied this name, and which he has described and figured in his *Klinische Darstellung*, as a thick, adventitious, and abnormal substance, probably a growth from the persisting pupillary membrane, filling up the pupil, except a small aperture in the centre. Borthwick mentions a case of this description in the Edinburgh Medical and Physical Commentaries, vol. i.

The fact of the case related by Dr. Szokalski having been mistaken and treated for syphilitic iritis, with lymph effused on the surface and border of the iris, is in itself a sufficient proof of the necessity of the profession being made acquainted with all these vices of conformation.

MALFORMATION OF THE PUPIL.—The varieties in the position, form, and size of the pupil, next engage our attention. The two most remarkable of these are the over-contraction and the over-dilatation, compared either with the average magnitude of this aperture in the human eye generally, or with the eye upon the opposite side in the same person, supposing it to be normal. To the former, or the state of contraction, is applied the term *Myosis* or *Microcoria*, and to the latter or preternatural dilatation, *Mydriasis*. Both these conditions, however, are occasionally induced by disease, and certain poisons, such as opium, belladonna, &c.; and the former sometimes exists quite independent of any mechanical hinderance, such as attachment to the capsule of the lens, &c. It would, however, be out of place in this essay to enter upon either the accidental varieties or the causes which induce these affections in after life. The accompanying drawing very faithfully represents one of the most remarkable instances of *Congenital Myosis*, joined with *Corectopia*, or displacement of the pupil, and other peculiarities both in the colour and structure of the iris, that I have yet met or read of. In this case the iris is of a greyish slate colour, with a number of whitish lines radiating from the pupil upon all sides, and there

is a total deficiency of those looped or transverse bands which assist to form the ordinary circles of the membrane, which is also slightly oscillatory. The pupils, which are placed in the junc-

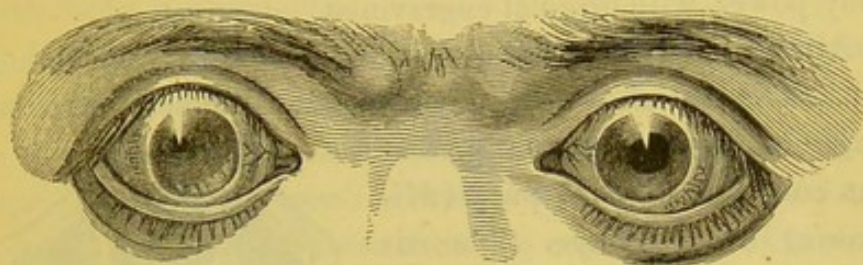


tion between the upper and middle thirds of the iris, are not more than the size of large pins' heads, but susceptible of dilatation by modification of light,—that upon the right side ovoid, that on the left somewhat quadrangular; at first view, however, the edges of both appear to be irregular and fringed, but this, by careful examination with a lens, we find to arise from the turning over of the pigment round the pupillary edge, as in the case described at page 85. There is a very broad, well-marked corneal ring, resembling the arcus senilis; but in this case it was congenital. The eyes are almost exactly alike upon both sides. The subject of this peculiarity never suffered from disease of the eyes of any description, and none of his family have been similarly affected. Although at present rather near-sighted, he has been able to shoot snipe, and to follow his profession, that of an officer, without any inconvenience(*a*).

Sometimes but one eye is affected with eccentric pupil. To the irregular or abnormal position of the pupil the terms *Corectopia* and *Parastrophe* are applied. Here is an example which serves also to illustrate the displacement as well as the preternatural contraction of the pupil, which is here situated in the upper and outer side of the iris in the right eye. The sub-

(*a*) I cannot allow this opportunity to pass without expressing to Captain O—— my sense of the obligation under which he has placed me by permitting the drawing of his eyes, from which the accompanying wood-cut was made, to be taken.

ject of this defect, who is a labouring man, has also very weak and uncertain sight with both eyes, but particularly the right.



When I first saw this person he was under treatment for what was believed to be syphilitic iritis, with irregular pupil. In his case we have another instance of the necessity of being acquainted with these malformations. I lately extracted a cataract from an old lady in whom congenital myosis presented considerable opposition to the exit of the lens.

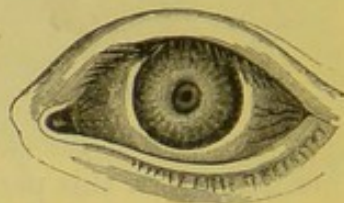During the past year I operated upon a case of acquired cataract in a young gentleman from the north of Ireland, whose elder brother, then about twenty, presented the following appearances. The right eye was perfectly normal, and of a bluish grey colour; the left, on the contrary, was yellowish brown, the iris tremulous, the pupil placed in the upper and outer third of it, not larger than a good-sized pin's head, and totally incapable of motion. Although he had vision with this eye sufficient to find his way, it was totally useless in reading or for examining minute objects.

Demours has accurately figured the eccentric pupil(*a*). Schwartz believed it to be at times hereditary: he saw two sisters in whose left eyes the pupils occupied the inferior ciliary edge of the irides, and in whose right eyes they were placed superiorly; in the brother of these girls the pupils were placed superiorly in both eyes(*b*). Similar remarkable cases have been related by Ritter, Baer, and others; these, however, are sufficient to explain this portion of the subject, my object being to present the profession with types of the various mal-

(*a*) *Maladies des Yeux*, plate 64, fig. 1. (*b*) Quoted by Rau, vol. ii. p. 167.

formations, without entering immediately into the description of each different variety, and to illustrate this essay, as far as in my power, with original engravings.

Almost similar in appearance to the instances mentioned at p. 88 is that shown by this illustration, which represents a high degree of congenital permanent contraction of the pupil (*Microcoria*) in the left eye. The iris was greyish at the circumference, but light cinnamon-coloured towards the pupillary margin. This person was remarkably near-sighted.



I have seen cases of *Mydriasis* in which it was stated that the enlargement of the pupil was observed so shortly after birth as to make me believe that they were congenital; very little disturbance of vision was experienced in after life. In congenital amaurosis we have sometimes well-marked dilatation.

Dyscoria or *Coremetamorphosis*.—The three forms of pupil figured here, which are copied from Ammon's great work,



together with those upon the opposite page, may be taken as types of the varieties which this aperture presents. The variety of form, however, which the pupil presents, independent of loss of parenchymatous structure, is infinite,—triangular, comet-shaped, oval, heart-shaped, fringed, irregular, linear, and even square. Here is a specimen of well-marked irregularity of the pupillary edge of

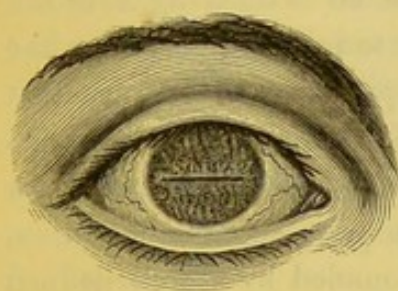


of the pupillary edge of the iris, in connexion with central opacity of the capsule of the lens, where the aperture is stellated, apparently caused by persistence of portions of the pupillary membrane.

Sometimes we find a sort of fringe projecting into the pupil at one point, as is the natural condition in several fishes, the ray,

for example; and again, in other cases, we observe a single knob or projection jutting into and distorting the pupillary circle, as in korestenoma.

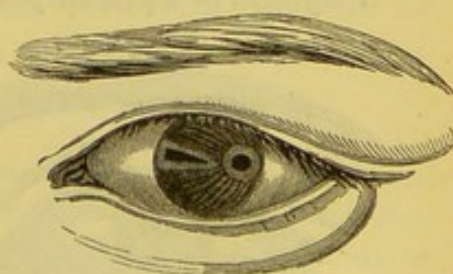
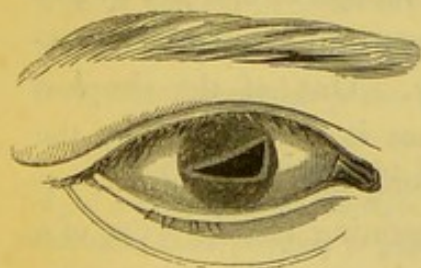
Himly observed a case where the pupillary opening was not circular, but indented to the depth of a line. In one eye he saw several such indentations, so that the margin of the pupil formed seven small semicircles(*a*). The idea is forced upon us that several of these abnormal conditions are the result of disease *in utero*. One of the most remarkable forms of pupil



which I have yet met with is shown by this figure, for the drawing of which I am indebted to my friend Mr. W. W. Cooper. It represents the right eye in a female infant, none of whose progenitors ever had any peculiarity of the visual organs.

The eyes were similar on both sides; the irides were a mottled brown or hazel, and each pupil in its contracted state presented a fine transverse line extending nearly across the entire breadth of the iris, but dilating into an elliptical aperture in a modified light, or under the influence of belladonna. The vision was perfect, and there was no hereditary tendency to malformation of the eyes.

While passing through the wards of Steevens' Hospital a few years ago, my attention was attracted by a young man then

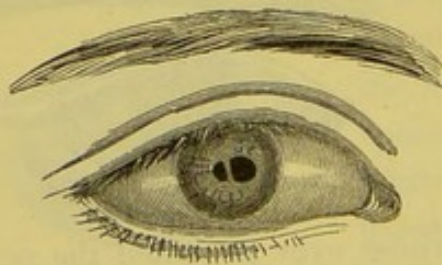


labouring under an accident, whose eyes presented the very extraordinary and unique peculiarities shown by the accom-

(*a*) Wardrop, vol. ii. p. 38.

panying engraving. The palpebral apertures were rather narrow and elliptical; the globes and cornæ natural; the irides were dark brown. Upon the right side there existed a large triangular pupil, extending right across the iris (which was of a homogeneous dark brown), its edges slightly curved, and its entire margin bordered by a narrow band of a bluish tint. In the left iris, which was lighter in colour and its striæ more developed, there were two pupils, the internal one triangular and extending from about the centre of the membrane to its ciliary attachment; its edges bordered with a light brown margin paler in colour and more dense in appearance than the surrounding iris. The external pupil, situated between that just described and the outer edge of the iris, was perfectly circular, and in its medium state of the size here represented, for it alone of the three pupils seemed to be susceptible of motion, at least to any extent. It was surrounded by a well defined broad band or circle of slate-coloured blue, about half a line in breadth. The radiating lines of the iris all appeared to tend to this pupil. The person who was the subject of this malformation was rather dull of comprehension, and totally uneducated; he stated that he followed his occupation, that of attending a lime kiln, without inconvenience; but it was manifest that his vision was not good. In this case we have a complication of irregularity, malposition, deformities, and plurality of pupils, as well as a form of coloboma.

Polycoria or a plurality of pupils, though rare, is not by any means an unknown irregularity. One of the simplest forms is that shown by the accompanying wood-cut, representing the right eye of a gentleman of my acquaintance, where a simple band,



probably a remnant of the membrane of Wachendorff, crosses the normal opening and produces an hour-glass or figure of 8

pupil, both sections of which are obedient to light. In this case the other eye is perfectly natural, and this gentleman sees equally well with both eyes. Another case is that in which there is a normal pupil both in size, form, and situation, with a deficiency upon one side of the iris, which, however, is separated from the true pupil by a narrow band of the free edge of the iris, which separates it from the latter, thus causing a second aperture. But for this band the case would be one of coloboma iridis, a peculiarity to be described further on. An instance has been recorded of three pupils, the lower one being circular and natural, although misplaced, and the two upper mere elliptical apertures(*a*). In all the instances of polycoria which I have met with or seen described, except that figured on the opposite page, the second pupil was irregular in form. None of the cases of plurality of pupils that I have met with had double vision.

Himly relates a case in which the normal and abnormal pupils alternately contracted and dilated. Wardrop says that "sometimes a double pupil is met with in one eye when other parts are single; and sometimes both lens and pupil have been found double"(*b*). I have never known an instance of double pupil in both eyes, nor have I ever heard of such. Polloplasis pupillæ, as this deformity is styled by some recent German authors, is occasionally observed among the lower animals, thus Sybel saw it in the eye of a calf; and a preparation of this nature is shown in Mickel's celebrated anatomical collection at Halle. This deformity will again come under our consideration when describing the eye in the cyclops monster.

(*a*) This case is figured by Von Ammon, vol. iii. plate ix. fig. 24. In one of our ancient Irish manuscripts we read that Chucullan, the celebrated Irish chieftain, had a plurality of pupils in one of his eyes; and also of Ingil, son of the King of the Britons, who had an eye as large as an ox. Many instances of this nature might be adduced from our early Irish chronicles. See the Author's Introductory Address, in the *Lancet* for April 19, 1845.

(*b*) *Morbid Anatomy of the Human Eye*, vol. ii. p. 40. In this case he refers to "*Voigtel's Handbuch*."

Atresia Pupillæ, or Sinizesis Congenita.—The closure of the iridial aperture produced by persistence of the pupillary membrane, is, in all probability, a much more frequent disease at birth than we are aware of; but as it seldom remains permanent for any length of time, and very rarely engages the attention of the surgeon, it has been to a certain degree overlooked. Cases have been recorded by Wrisberg, Wenzel, Cheselden, Von Ammon, Paolo Bernard(a), and others. I gave the history of Dr. Bernard's case (which was mistaken for opacity of the crystalline capsule), in my last Ophthalmic Report (p. 499). "When it is not observed after birth, it appears," says Wardrop, "in the form of an opaque web, which is easily distinguished from cataract by its being vascular, from the size of the pupil being unaltered, and from its being on the same plane with the iris." It is probable that persistence of the membrane may be owing to some iritic inflammation *in utero*. Occasionally small spurs of dark coloured membrane may be seen in adult life, jutting out from the place of attachment of the pupillary membrane on its anterior margin.

I have remarked that, in most of these cases of malformed irides and pupils, the colours differed materially from the normal hues in healthy eyes. There is a want of brilliancy upon the surface of the membrane; the general colour is, as it were, dirty; the greenish and slate-coloured tints sometimes produced by disease in after life predominate towards the ciliary margin; and the pupillary circle, in the great majority of instances, is of a light cinnamon or yellow colour.

Tremulous Iris.—There can, I think, be little doubt but that tremulous iris is occasionally a congenital defect. In this disease a portion of the iris at some particular spot waves backwards and forwards upon the slightest motion of the eye or head. When

(a) *Gazetta Medica di Milano*, for 26th Dec. 1846, quoted in the May Number of this Journal for 1848; see also M. J. Cloquet's *Memoire sur la Membrane Pupillaire*, Paris, 1818; and Dr. Jacob's valuable paper on its anatomy in the twelfth volume of the Medico-Chirurgical Transactions.

the whole iris oscillates, as sometimes happens after the removal of the lens, or from the effects of concussion, it is believed to result from a want of support caused by fluidity of the vitreous humour. This hypothesis, however, will not explain the phenomenon of partial oscillation of the iris, which appears to result from paralysis of some of the radiating or dilating fibres of the iris. I have occasionally seen cases of paralysis of a portion of the circular or contracting fibres of the iris, causing distortion of the pupil at that particular point. If the iris be carefully examined in these cases, particularly in its contracted state, it will be seen that the usual plaits, or folding in as if by a running string, of the free edge of the iris, are deficient at this point, the surface of the membrane being there quite plane and smooth and the colour less intense. Should we not reckon among the congenital peculiarities the voluntary power of contracting and enlarging the pupil which it is said some persons are endowed with?

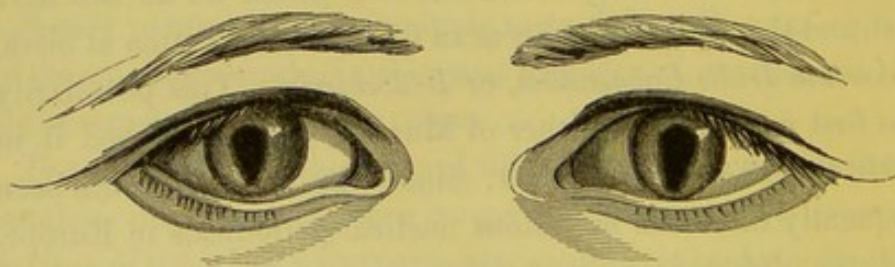
COLOBOMA IRIDIS.—This term has been applied by ophthalmic pathologists to a deficiency of the parenchymatous structure of the iris at some particular point, generally in the lower segment, by which the pupil presents the pear-like or key-hole appearance shown by some of the accompanying illustrations. Two forms of this disease have been enumerated by writers: that caused by accident, with which we do not here deal, and that which presents as an unnatural formation at birth, *Coloboma Iridis Congenitum*, or *Iridochisma*. This peculiarity was first named by Walther of Munich, who described it in 1810, and afterwards in 1821. Since then the subject has been frequently discussed in various medical periodicals in Europe, and the defect is now usually enumerated in ophthalmic works under the head of the congenital diseases of the iris. This author was not, however, altogether original in his discovery of coloboma, or split iris, for it is manifest that some of the very early writers were acquainted with it. Thus

Thomas Bartholinus not only mentioned but figured it so early as 1672. The pupil figured by Bartholinus is of the true key-hole shape; his description of it is, "huic pupilla sinistri oculi non rotunda, ad oblonga est hac forma sine detrimento aut mutatione visus"(a). But in those days congenital peculiarities, which were usually denominated freaks of nature, received but little attention from pathologists. Block, Meckel, and other writers of those times, also noticed it.

Mr. Wardrop, although he did not name this "malconformation," was perfectly well aware of its occasional existence, when he published the second volume of his *Morbid Anatomy of the Human Eye*, in 1818; and, under the head "of alterations in the form of the pupil," quotes most of the authorities then known on the subject of coloboma.

I myself have seen ten, and had drawings made of seven cases of coloboma, and a sufficient number of instances have been enumerated and figured by others to enable modern writers to classify and arrange the different varieties under certain heads.

The most common form consists in a prolongation of the natural pupil downwards and slightly inwards, as shown by the annexed engraving of the eyes of a boy aged eight years, the cat's pupil appearance of whose eyes attracted my attention

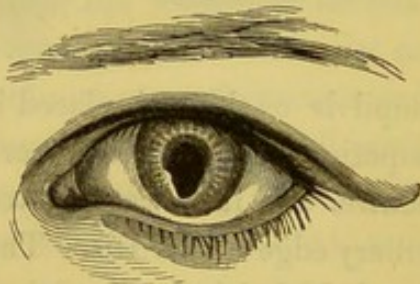


when visiting one of our workhouses a few years ago. This is the simplest form of complete double cleft iris. The irides

(a) *Acta Medica et Philosophica Hafniensia*, Hafniæ, 1673, p. 62.

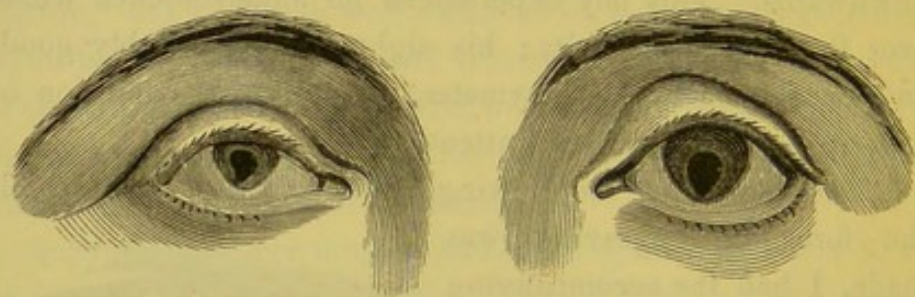were blue-grey and somewhat deficient, particularly round the lower edge of the prolonged pupil, in those loops and arches which form the marks and circles upon these membranes in a well-developed natural state. The pupils were susceptible of light, and contracted partially, but the upper normal portion much more so than the cleft or prolongation; they did not quite reach to the ciliary edge of the iris. In this, as well as in all the cases of coloboma in both eyes which I have seen, the prolonged pupils slightly converged inwards as well as downwards. This boy experienced no inconvenience whatever from this peculiarity; his sight was remarkably good, and, except among his playmates, the unnatural condition of his pupils had not attracted attention.

Two years after the drawing had been taken, from which the foregoing engraving was made, I had the accompanying illustration of the minute structure of the left iris painted, which shows the whitish radiating fibres round the upper margin of the pupil, ending in a circular light-coloured band immediately surrounding the pupillary edge, but which are wanting in the lower or cleft portion. This drawing also shows the shoulder which usually exists in such cases at the junction of the cleft and the normal pupil.



As regards position, coloboma may occur in any part of the iris: most frequently, however, it is observed in the inferior section, next to that internally, then outwards, and, rarest of all, it may appear in the upper segment of the iris. It much more frequently exists in both eyes than in one. It may be present, as in the case just figured, without any other peculiarity or defect; but it is often found in connexion with other ophthalmic malformations, particularly micophthalmia, coloboma palpebræ, irregular-shaped lens, split choroid and vitreous humour, and

also with cleft palate and hare lip. At page 70 of the former portion of this essay, I described and figured a case of iridochisma connected with microphthalmus and strabismus, &c. Here again is an illustration of a somewhat similar case in Mary Craig, a young woman aged 22, a native of the County Wicklow, of whom I gave an account in February, 1847^(a). Both eyes are remarkably sunken, the globe of the left is somewhat less than the natural size; the cornea irregular in shape; the iris is a deep brown colour, and wanting its circles and radiating lines; the

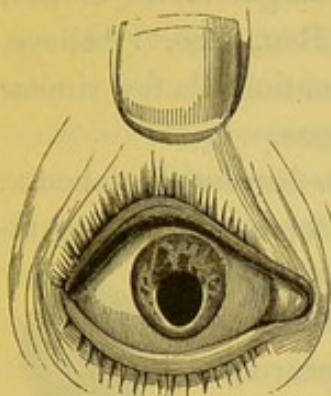


pupil is ovoid and placed in the inferior half of the iris; the superior edges of its upper great extremity being about the centre, and its lower pointed end running down almost to the ciliary edge of the iris. The globe of the right eye is scarcely one-half the size even of the left, and the palpebral aperture, which is a very narrow ellipse, is about a third less than the left; the sclerotic is thin and bluish, and the cornea disproportionately small and irregular. The iris has a homogeneous brown colour, somewhat lighter than that on the left side; the pupil occupies more than one-half its perpendicular diameter, and is somewhat more triangular than that upon the opposite side. There is slight nystagmus of both eyes; her sight is very defective, and has become much worse during the last few years.

The amount of deficiency of the iris in both these cases,—that now related, and the one figured in the previous part of this paper,—resembles more partial iriderimia than true coloboma,

^(a) See Ophthalmic Report in Dublin Quarterly Journal for Feb., 1847.

in which there is generally some distinction between the segment of the true pupil and the cleft or prolongation.



Although the striæ and circles which mark the well-developed iris were wanting in several of the cases which I have observed, there was in the case of Ellen Sullivan—described and figured at page 70, of the former portion of this essay—a peculiar whitish mottling on the upper segment of the blue iris, as shown by the accompanying cut.

Coloboma has been divided into complete and incomplete. The former degree, in which there is a thorough division of the iris, is sufficiently shown by the foregoing illustrations. The latter, or more penetrating form, consists in an apparent attempt at fissure, the external parenchymatous and coloured substance of the iris being deficient, thus allowing the dark pigment of the uvea to appear anteriorly through the thin transparent membrane of the aqueous humour(*a*), as is



well exemplified in the accompanying illustration, which has been kindly placed at my disposal by my friend Mr. Dalrymple, of London. In this we find a perfect iridochisma of the right eye in a young man aged 22, with very light hazel irides,

(*a*) It is possible that the solution of continuity which originally existed in the embryonic state in this case may have subsequently healed *in utero*. I am acquainted with a child who was born with a well-marked cicatrix a little to the right of the mesian line of the upper lip, and bearing all the characters of a united hare-lip.

whose globes were also somewhat smaller than natural. Upon the left side the pupil is circular, but an irregular dark space, extending downwards from it to the margin of the cornea, marks the partial cleft of the iris. Dr. Rau, who, I believe, first called attention to this form, has mentioned a few similar cases(*a*). Helling has also seen the disease.

Gescheit enumerates three varieties or degrees of coloboma: first, that with parallel edges, of which the accompanying representation affords a good idea. Second, with convergent legs, which is the most common, and of which the foregoing examples of pear-form pupils are sufficiently characteristic. And, third, that in which the base of the coloboma is below or placed next to the ciliary edge. The last is the rarest form. The third engraving, under the head of dyscorea, at page 90, as also the pupils figured at page 92, are illustrations of it, Ammon has given but two cases of this variety.

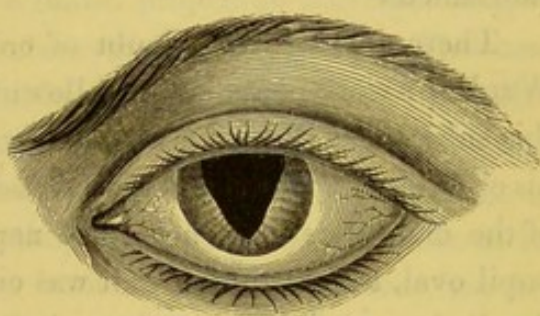


The edges of the cleft are seldom linear, they are usually slightly curved, sometimes irregular, usually thin, and occasionally deficient of pigment, and there is very seldom a perfect correspondence or a similarity between the fissures upon both sides; and in the best marked cases there is a sort of shoulder defining the limit of the original pupil. As already stated, the internal or pupillary circle of the iris does not surround the cleft, but is either altogether wanting in the iris, or, existing round the upper circular portion of the pupil, it gradually shades off towards the part where the cleft commences. In some cases, as in that of Mary Craig, whose eyes are figured at page 98, the coloboma is nearly circular in the right eye, and egg-shaped as in the left.

In addition to the forms already specified, I may add the accompanying very rare peculiarity, for the drawing of which I am indebted to Dr. Butcher, who was good enough to pro-

(*a*) *Die Krankheiten und Bildungsfehler der Regenbogenhaut.* Bern, 1845.

cure it for me from Dr. M'Evers of Cork. Although not drawn very artistically, it is, I believe, a faithful representation of this very singular variety of malformation. It shows the left eye of a young man aged about 20, with auburn hair and bluish grey eyes. In this case the globe was normal, but the pupils occupied the greater portion of the iris, and were completely triangular, the inferior point almost touching the ciliary circle. They were nearly symmetrical, that on the right side, however, was somewhat narrower than that upon the left; their lateral edges were straighter and sharper than is usually the case, but the internal edge was slightly irregular upon both sides; and the



superior one was somewhat curved. I have not been able to learn more of the history of this case. Dr. Mess of Leyden has recorded a similar case of V-shaped pupil(a). Rau saw double coloboma, in which two small narrow splits, placed close beside each other, existed in the same iris.

As I already stated, there is frequently very little defect of vision in cases of simple coloboma uncombined with other malformations. From the variety of opinions which have been expressed with regard to the influence of belladonna, it is manifest that great variety must exist with regard to its effects, depending, no doubt, upon the amount, degree, and position of the cleft, and the perfection or deficiency of other parts of the organ. Dr. Mackenzie, in describing a case of coloboma in 1831, says, "both the natural pupil and the cleft proceeding from it contracted on sudden exposure to light, but the cleft slowly, and not so as to close, at least in a modified light"(b).

(a) *Annales d'Occulistique*, tom. vii. p. 179.

(b) *London Medical Gazette*, vol. ix. p. 738, 1842; see also the article

Mr. Middlemore, in describing cleft iris, under the title of "Cordiform Pupil," says, "The prolongation of the pupil possesses the power (though not in a very active degree) of contraction, so that when the eye is suddenly subjected to the influence of a vivid light, the cleft in the iris is nearly closed, and the defect in the form of the pupil is scarcely visible." Such, however, has not been my experience. I have never seen a case in which the cleft "nearly closed" under any circumstances.

There can be little doubt of coloboma being hereditary. Wardrop's work contains the following facts and authorities on this subject: "Block knew a family in whom the father, with his children, nephews, and nieces, had long-shaped pupils. One of the daughters and one of the nephews had in one eye the pupil oval, and in the other it was circular. Conradi mentions that he knew a father, daughter, and grand-daughter, in whom the under margin of the pupil was, as it were, cut out; the pupil consequently was not round but oval, and run oblong to a point at the lower part. Hagström saw a whole family, in which each member had such a large oval-shaped pupil that the under edge of the iris had quite vanished. Acrell saw a similar deformity, which was hereditary."

Rau assents to the same opinion, and adduces many instances in support of it. Himly records the fact of three

Coloboma, by Mr. T. Wharton Jones, in the *Cyclopædia of Practical Surgery*, part viii., and also his *Manual of Ophthalmic Medicine and Surgery*, page 319; see also Middlemore's *Treatise on the Diseases of the Eye*, vol. ii. p. 761; Seiler's *Beobachtungen Urspruenglicher Bildungsfehler und Gaenzlichen Mangels der Augen Bei Menschen und Thieren*, fol. Dresden, 1833.

Since the first portion of this essay was published, M. Desmarres of Paris published his *Traite Theorique et Pratique des Maladies des Yeux* (1847), in which he includes the congenital malformations. This portion of the Parisian oculist's book possesses little originality, and is very defective in reference to cases published in Great Britain. The latest and best work upon the subject is *Die Krankheiten und Bildungsfehler der Regenbogenhaut*, von Dr. Wilhelm Rau.

children in one family, and the father and son in another, being affected with it.

Several hypotheses have been put forward to account for coloboma iridis. By most authors it is believed to be an arrest of development at a very early period of uterine life, when a cleft naturally exists, it is said, in the choroid, which occasionally runs on into the iris. In a case dissected by Ammon, not only was the iris cleft, but also the choroid, retina, and the ciliary processes; and externally a bluish projection corresponding to the line of the fissure was observed in the sclerotic. This case bears out the theory of Walther, already referred to; but Rudolphi and Udgin, who had likewise opportunities of dissecting cases of coloboma, were unable to confirm the observations of the Dresden author; but they found the lens deficient at its lower part and the vitreous humour fluid. Moreover, we frequently find coloboma existing in situations where no fissure of the choroid has ever been observed, as on the upper and outer sides. Comparative anatomy, it is true, rather confirms the views of Walther and Ammon, for in several fish and some molluscs we find both the sclerotic and retina cleft. In birds, and also in some amphibians, there is a cleft in the choroid and sclerotic, and, it is said, in the iris of the sheep foetus also. Irregularity of the cornea, protuberance of the sclerotic along the line of the cleft, and congenital cataract, are often found in connexion with coloboma. According to Gescheit the iridochisma is owing to the non-closure of the choroid split. Seiler believed it to be caused by a want of perfect anastomosis, or accidental obliteration of the iris vessels. Baer believed that it was owing to the too rapid absorption or over absorption of the pupillary membrane. In some instances the ciliary body is distorted and prolonged, or bent backwards behind the end of the split, but not interrupted.

IRIDERIMIA.—The iris has been found altogether absent, or only partially present. To the total deficiency of the iris the term *complete iriderimia* has been applied; and when there

is only a rudimentary portion of the membrane existing at birth, the word *partial*, or incomplete, is used. So many instances of this peculiarity have now been observed, that it is only necessary to make a selection of the most remarkable and characteristic cases. Without coloured engravings it would not be possible to convey, by means of illustrations, anything like an adequate idea of this malformation.

A very interesting case, of total loss of the iris, occurred in England in the year 1826, in a girl, in whom, shortly after birth, her mother remarked a peculiar general blackness of the eyes,—the usual characteristic of this affection. Upon examination it was found that both irides were deficient; the corneæ were more prominent than usual; and there was great intolerance of light, as well as irregular motion or trembling of the globe. When the child was two years old the eyes became more steady, and the light was more tolerated, but vision was very defective. She saw better in the evening or in a modified light,—nay, as the observations were extended, and the child became more sensible, it is reported that she could distinguish objects even in complete darkness, or at least what would be considered so by any other person. She liked to look at the most brilliant colours, such as scarlet and yellow; and when examining objects she always placed them very near the eyes, and somewhat below the usual axis of vision. If placed in a darkened room, and the rays of light were made to fall upon the eyes, “they assumed,” says the narrator, “a sort of reddish phosphorescence, like rubies, or burning coals.”(a) The other senses were all natural.

Another case of congenital deficiency of the irides, both total and partial, is related by M. Cazentree, of Bordeaux, in a man aged 46. In this case there was no vestige of iris in the right eye, and the left presented merely a slight crescent-shaped

(a) A question here suggests itself as to whether the brilliancy of the cat's eye in the dark is not owing to the complete expansion of the iris, and not to any tapetum structure.

slip of this membrane. Both corneæ were a little convex, and somewhat smaller than natural; the ciliary ligament is said to have projected inwards, and performed somewhat the office of an iris. At first this case was considered to be one of total blindness, but as the child advanced in years the eye became less sensible to the over stimulus of light, and at the period when examined by M. Cazentree, although there was great disturbance of vision, the subject of the malformation could distinguish objects placed near him. Great photophobia still existed; the lids were usually kept closed during the bright part of the day, and he experienced great pain in the orbits when his eyes were exposed to strong sun-light. By candle-light all objects appeared to him as if enveloped in a thick fog, but it is said that he was able to read in a degree of darkness where it would have been quite impossible for any one else to have done so.

Shortly after this case was recorded, Mr. Willisford published a somewhat similar one of *partial iriderimia*, in which the corneæ were natural. On the outer and lower side of each eye a small section of a greyish membrane, the rudimentary iris, still existed; there was great vacillation, which was a good deal increased by excitement. It was observed that, while nursing, "the child would keep its eyes fixed on the sun for several minutes together, without showing any uneasiness;" and yet, in the subsequent history of the case, we are told that when the child was four years of age it could pick up a pin from the ground. In this instance the head was somewhat deformed, and hydrocephalus existed in the family.

Von Ammon mentions three sisters, born without irides, and the father of these girls had only a rudiment of the iris at the lower margin of the cornea.

Gutbier, who has written an inaugural dissertation on this defect, mentions the following curious circumstance with regard to its hereditary transmission. Christian Keal, the youngest of eight brothers, each of whose eyes were normal, had this defect.

He had eight children, of whom three boys inherited the malformation of the father. The eldest of these had four sons, in whom the irides were absent in all except the second, who possessed it but only in a rudimentary form. The second son of the original Christian Keal had a daughter, in whose eyes the irides were deficient; and the third had two children, a daughter, with deficiency of the irides, and a male child with eyes well-formed. These cases are quoted by Mr. Lawrence.

In *partial iriderimia* there is generally but a small segment of the lower or inner edge of the iris existing, as I have explained in some of the previous cases; but Demours has given a drawing and description of a congenital deficiency of about a third of the inferior or inner edge of the iris, which I believe is the only instance of the kind recorded. In most cases the segment of the iris forms a slight crescentic projection: but in Demours' case the edge of the iris was nearly straight; the iris itself was brown, and there was no pupil. These remarks are chiefly founded on the drawing, as his description is very defective.

In both the complete and incomplete varieties cataract has frequently been observed; and even in cases where at birth the lens was perfectly clear, either it or its capsule became subsequently opaque, probably owing to the constant over-exposure to light; therefore, in such cases, means should be taken either by coloured glasses, or some mechanical contrivance analogous to the pupil, to obviate, if possible, the occurrence of this accident. Carron du Villers has recorded some cases of iriderimia connected with tremulous cataract and nystagmus. The least degree of partial iriderimia is, perhaps, but an aggravated form of coloboma, of which the drawings of the eyes of Craig and Sullivan (pp. 98, 99) afford examples. Ammon has figured a case in which two distinct half-moon-shaped segments of the iris existed at the lower part. Lusardi has recorded a case of total absence of the iris in one eye, and in the other of the same patient a remnant of the iris, a line broad, existed.

Henschel observed a rudimentary iris in a man whose children had no irides at all. Willis, Helling, and Rau, have observed cases where there was considerable deficiency of the anterior layer of the iris, resembling somewhat the form of partial coloboma already described. In looking over the records of cases of defect of iris it appears that females are much more frequently the subject of it than males, but Forchon observed it in three generations of the same family in males only. The partial form of the disease is much less frequent than the complete. In the *Annales d'Oculistique* will be found several instances of both these defects. Many years ago Morrison observed this peculiarity in London. Mr. Middlemore has given, in the first volume of his Treatise on Diseases of the Eye, a most accurate description of two cases which he had an opportunity of observing; and Mr. France has also given, in Guy's Hospital Reports, the history of a very interesting case which is particularly valuable, from his observations having been continued for a great length of time. It would not, however, increase the value of this essay to multiply instances beyond those which I have now afforded.

MALFORMATIONS OF THE CHOROID.

Peculiarities of Colour.—The abnormal conditions discovered in the choroid membrane at birth are comparatively rare, and, owing to the scarcity of dissections, as well as to the concealed position of this structure during life, very few cases have as yet been observed or described. In the foregoing observations upon the congenital defects of the iris most of the remarkable peculiarities of the choroid have been detailed, especially under the head of leucosis, where there is either a *partial or total deficiency of its pigment*. And again, in connexion with certain cases of coloboma iridis, the split or fissure of the choroid has been found existing in later life, and extending backwards through the entire length of its inferior portion. This, however, is but an arrest of development, like that which occurs in other congenital fissures, for, as has already been shown,

in considering the anatomy of this part, a cleft exists as a normal condition in the early embryonic state.

Instances of partial deficiency of pigment, in which the inner surface of the membrane presented a greyish mottled appearance, have been observed, of which Ammon gives some examples: one in particular, where the iris exhibited the same speckled appearance. In cases of glaucoma it has been observed that the colouring matter of the choroid assumes a lighter tint; and specimens of this peculiarity have likewise been observed at birth, both in man and some ruminating animals. Dr. Prinz, of Dresden, has described a form of congenital glaucoma, which he has several times seen in lambs where this peculiarity existed. The choroid has also been observed of a reddish brown or fawn-colour, particularly at its fundus.

The converse state to leucosis, that of preternatural development of the pigmentary matter, has been remarked in certain cases of congenital hydrophthalmia and amaurosis, as well as in cyanosis. I have, however, seen a case of congenital amaurosis in which there was a well-formed blue iris, where a light coloured, tapetum-like appearance presented at the bottom of the eye, very different, however, from the condition presented in malignant disease, and too deep to have its seat either in the posterior capsule of the lens or in the vitreous humour surrounding it.

Deficiency of Choroid.—Coloboma choroideæ has been already described. An instance has been recorded by Von Ammon of a partial transverse fissure of the choroid immediately behind the ciliary body, the two portions being joined by a kind of net-work(*a*). I can find but one well-marked instance of total absence of the choroid; it is that related by Klinkosch, of Prague, in 1766(*b*). In the case in which this peculiarity ex-

(*a*) *Klinische Darstellungen der angeborenen Krankheiten*, tab. xv. figs. 7, 8.

(*b*) I have not seen Klinkosch's work. It is thus quoted by Seiler: "Programma quo anat. partus capite monst. proponit." Prag. 1766, p. 7. It is referred to by Himly, Ammon, and all the German writers upon the subject.

isted, the eyes were in other respects remarkably malformed, and more resembled, it is said, hydatids than true visual organs. There is no mention made of the state of the iris in this case; but Seiler, in quoting it, says the ciliary body was partially present.

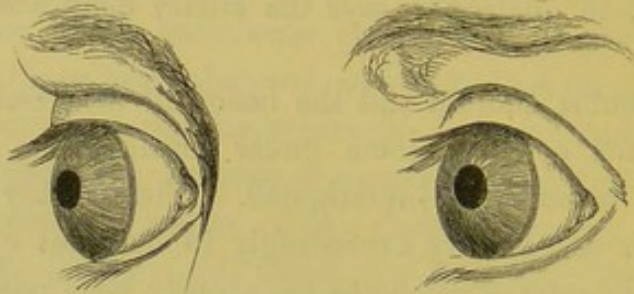The double choroid and the fusion of the vascular membrane of the eye will come under consideration when the subject of monocoli is investigated. The number of ciliary processes is said to vary exceedingly in different eyes; their distortion in cases of coloboma has already been remarked.

According to the plan adopted in the arrangement of this essay, we now come to the consideration of the congenital diseases and malformations of the dioptric media. The abnormal conditions of the fluid filling the aqueous chamber, irrespective of general disease of the organ, such as hydrophthalmus, must be very rare in the human eye. I am not aware of any well-authenticated instance mentioned by the various authors whom I have consulted, of its being in greater quantity than natural, except that related by Benedict and Demours. Von Ammon mentions the instance of a calf, in which the anterior chamber was filled with a dirty red, gelatinous mass, and there was also a thickening of the membrane of aqueous humour; and Professor Prinz afforded Seiler the particulars of the case of a dog, in which, at birth, a movable body, with a polished surface and a sooty appearance, was found in the anterior chamber; but, as the author himself observes, it was, probably, an opaque lens, marked by the pigment of the uvea, which had started through the pupil^a.

Dr. France, of London, has recorded a case of congenital deficiency of the aqueous humour, and has been good enough to furnish me with a drawing of the patient, from which the

^a Seiler's *Beobachtungen ursprünglicher Bildungsfehler und gänzlichen Mangels der Augen*. Dresden, 1833, s. 61.

accompanying illustration has been made. The corneæ were slightly convex, the irides bluish, and lay in contact with the



corneæ. There was no anterior chamber, and no aqueous humour; the irides were active, and free from adhesions; the pupils blue, clear, and circular. The subsequent history of this case, forwarded to me in 1850, is unknown*.

MALFORMATIONS OF THE LENS AND CAPSULE.

The best authorities upon embryology, and more especially upon the formative process of the human eye, state that the lens becomes apparent in the human fœtus about the commencement of the sixth week. Minute anatomists differ as to whether the capsule, with its contents, is a portion of the original internal or medullary tube, continued on into the ocular vesicle destined to form the future visual organ, or a reflexion of the external tegumentary envelope, drawn inwards so as to form the lens-capsule, and afterwards nipped off by the action of the iris and choroid.

It would not tend to elucidate the more immediate object of this essay, were I to enter into a discussion of the various and rival theories which have been promulgated during the last twenty-five years upon this subject. As already stated in the former portions of this essay, the *Encyclopédie Anatomique*—especially vol viii., containing Bischoff's *Entwicklungsges-*

* London Medical Gazette, vol. x., p. 11.

chichte der Saeugethiere und des Menschen, translated from the German by Jourdan, published in 1842—really contains the great bulk of all the authorities which could be quoted upon the subject. Some anatomists include the vitreous substance with the original formative process of the lens; and others define it as a mere mechanical recipient of that body. The former, however, seems the most plausible theory, and one justified by the subsequent intimate relation of these two structures. Huschke, one of the earliest and most accurate observers, while he believes in the connexion of the vitreous body with the primary medullary tube, holds that the lens is formed by a reduplication, or tucking-in of the tegumentary membrane. Those who assert that the lens-capsule is formed from without, produce, in proof thereof, the fact of the original want of chambers in the eye, and also, that at an early period of embryo existence the anterior section of the capsule is in immediate contact with the iris, and, so far as the *membrana pupillaris* admits, with the cornea also. It is even asserted that an opening exists (in the chick, for example, at the end of the third day) in the middle of the future cornea; but this has been denied by others. The substance of the lens is believed to be formed by, or secreted from, the inner layer of the capsule; and in the early period of foetal life is composed of a mass of granules and globules of a much softer consistence than it subsequently assumes, when these globules, uniting in compressed lines or bands, form the fibres of which the future lens is composed. In consistence it is then soft, compared with all its future stages from birth to old age, and is of a reddish hue; but whether derived from the amount of surrounding vascularity (as from the capsule and the reddish vitreous body, &c.), or by any deposit of colouring matter within its substance, has not been clearly defined by writers. Some say that the lens is originally opaque, while others assert that it is transparent. These are questions of much interest in investigating the causes

of those peculiar appearances which present at birth, and form the more immediate subjects for description in this essay.

During the first months of foetal life the lens is globular, like that in fishes, and larger in proportion to the size of the globe of the eye than in extra-uterine life. According to Arnold, the process of becoming transparent begins in the circumference, and proceeds towards the centre; and this is an opinion in which, from my own observations upon congenital cataract, I can fully concur. The late venerable Von Walther of Munich also maintained the original opacity of the lens, and asserted that cataract was an arrest of development while it was passing into the normal transparent stage; while Von Ammon of Dresden, of whose observations I have so largely availed myself in the foregoing portions of this essay, maintains that it is a pathological change in an originally transparent structure. About the period of birth the lens becomes relatively smaller, and less spherical, than in the foetus.

The capsule, resembling in structure the elastic lamina of the cornea,—a description of transparent fibro-cartilage,—may be said to be that which gives form to the lens, as well as produces from its inner secreting surface the proper substance of that body. It also supplies it, in early life, with its proper vascular support, by means of the ramifications of the arteria centralis retinae upon its posterior surface, and a venous connexion anteriorly with the membrana pupillaris; while upon its periphery, and for some distance over its anterior edge, a minute and intimate vascular connexion is maintained with the edges of the ciliary process. Judging from analogy, we may well suppose that the membrane of aqueous humour, which passes over the front of the capsule, affords a general vascular connexion to all those structures, both in the anterior and posterior chambers, with which it maintains anatomical relations. Intimate as these connexions of the lens with the surrounding parts of the eye appear to be in embryonic and foetal life, they

cease to be demonstrable after the full period of intra-uterine existence; so that, except by the fact of an adhesion of the lens to its capsule, when the latter is fully opened, we have no anatomical proof, either by injection or by the aid of the microscope, of any union between these two parts.

"As the crystalline lens in the healthy eye of an adult," says Dalrymple, in his "*Anatomy of the Human Eye*," "is perfectly transparent, and void of colour, it follows, of course, that it contains within its substance no vessel carrying red particles of the blood; and inasmuch as in earlier periods of the science the art of making anatomical injections was unknown, it is anything but surprising that the existence of bloodvessels in this part of the eye was denied by Galen and the old anatomists. Haller, in his description of the arteries of the eye, quotes an Englishman of the name of Allen Moulin as the first observer, and in fact the discoverer, of these long-denied vessels." These vessels were, however, subsequently acknowledged by Ruysch, and demonstrated by Winslow. The "Englishman" alluded to in the foregoing paragraph was Allen Moulin, or Mullen, an Irish anatomist, and one of the original members of the Dublin Philosophical Society in 1684^a.

Ancillary to the foregoing observations may be considered the question of the restoration or regeneration of the eye, in whole or in part, as related by authors. The experiments and observations which have been made on the lower animals tend to prove that the contents of the capsule may be repaired after its removal or absorption. So early as 1781, C. Bonnet appears to have made experiments which proved that the eye of the newt, or salamander, could be restored, if the globe, as far only as the entrance of the optic nerve was removed^b. Blumenbach made some observations upon the same subject sub-

^a See the Author's Preface on the History of Medical Literature, in the first volume of the Dublin Quarterly Journal of Medical Science, 1846.

^b *Œuvres d'Hist. Nat. de Philos.* Liv. xi., 1781.

sequently^a. In 1801, G. Vrolik, of Amsterdam, observed that a depressed lens had been imperfectly replaced, after ten years, by an irregular ring of lenticular substance, open in the centre, and which he thought arose from a new secretion of lenticular substance, owing to the incompletely-destroyed vessels of the capsule^b. Twenty-six years later, Leroy D'Etiolles, whose experiments were chiefly made upon rabbits, cats, and dogs, and who was, perhaps, unaware of the foregoing discoveries of Bonnet and Vrolik, stated that the restored part was either a crumbly mass, a diminutive, lenticular body, or even a full-sized lens. Mayer's experiments demonstrated that in rabbits, eight days after the destruction of the lens, a small ring of soft lenticular substance had formed; and that this went on increasing in quantity until the middle of the fifth month after the operation, when a new lens, open in the centre, but normal in the circumference, was formed; but although it is not so stated, these so-called lenses were, I presume, opaque. When the periphery of the capsule was destroyed, there was no reproduction.

In the details of all these experiments, the original mode of destroying the lens is not clearly expressed. The subject has been much discussed among the German physiologists; but the results of their inquiries and experiments have not tended to advance practical science—in this country, at least. William Soemmering's and Werneck's experience confirm the opinion of Vrolik, and show that after reclinication, or depression, a crystalline mass is sometimes formed in process of time within the capsule, the posterior segment of which is alone open.

As, however, almost all these experiments and observations have been recorded by anatomists not practically engaged in operative ophthalmic surgery, and consequently not very fa-

^a *Kleine Schriften*. Leipzig, 1804.

^b See Müller's *Physiology*, translated by Baly; and also Magendie's *Journal* for 1827.

miliar with pathological products in the human eye, I think I am warranted in asserting that we require satisfactory evidence as to the reproduction of the lens, in whole or in part, in man, under any circumstances. Those who have had much experience in operating know full well that, owing to the cortical substance of the lens being softer than the nucleus, especially towards its circumference, a portion of it often remains within the capsule, even after the operation of extraction. Unless anatomists are also experienced operators, their mode of treating the eye in the lower animals for the purpose of these experiments, may, I think, with justice, be questioned by those who well know the great difficulties which surround this branch of practical surgery. Even acknowledging to the fullest extent the most favourable results of these experiments, observations, and assertions, no practical good is ever likely to accrue therefrom, no more than from the asserted transplantation of the cornea, or, as stated, the reading with the pit of the stomach, as some years ago was gravely stated to me by an eminent dignitary of the Irish Church*.

Deviations from the normal condition in this part of the organ of vision may be divided into:—the absence of lens; the fusion of two lenses together, as in monocoli; a double lens in one eye; malpositions of the lens, and alterations in the size, form, structure, consistency, and transparency of the lens and its capsule, as well as organic changes, such as absorption of the lens, and adhesions between the iris and the anterior cap-

* Vagaries of this description, so repugnant to common sense, irrespective of science, and so subversive of the cause of true religion, might be laughed at in the ignorant, and despised in the charlatan; but when they are upheld by the exalted in station and influential in position, they become truly dangerous; and when they bias a mind, by nature "open as day to melting charity," so far as to withdraw from the public charities of a large city, which supply shelter, food, care, and all the appliances which science and humanity have devised for the amelioration of human suffering, because mesmerism and homœopathy are not practised in such institutions, then there can be no hesitation in asserting that such conduct becomes not only deplorable, but reprehensible.

sule, from intra-uterine accident, or disease; and, finally, entozoa within the capsule, &c.

Absence of Lens.—Rosas quotes Morgagni, Von Walther, and Arnemann, as authorities for cases of deficiency of the lens^a; and Haller records the case of a child with but one orbit, containing, however, two globes, but not fused, as in monocoli. One globe was perfectly normal; in the other, however, the lens was absent^b. Seiler has recorded a case of deficiency of the lens in a microphthalmus. A similar case is recorded by Von Ammon; but it is probable that in both instances the deficiency was the result of the general disease, or arrest of development in the whole organ at a very early period of foetal life. In case of deficiency of lens, one would expect fluctuation and unsteadiness of the iris.

Double Lenses.—Supernumerary lenses have been observed by Vallisnieri and Fritsch; but the particulars are not specified in the works to which I have had access; and it is possible that these cases may have been instances of cyclopia, in which two eyes were fused together. Wardrop says—"The crystalline lens is sometimes entirely wanting; in which cases the pupil is also double"^c. But he does not cite his authority, nor more particularly describe the cases. He adds, however, that Heister "found it [the lens] divided into different portions," or fused lenses. See *Monocoli*.

Myopia, arising from abnormal curvatures of the anterior or posterior capsule of the lens, must frequently be the natural or born condition of these parts, although not remarkable until the child has arrived at that period of life when its short-sightedness attracts attention. Authors state that congenital cataract has been confounded with, and occasionally mistaken for, myopia. I have more than once seen

^a *Handbuch der theoretischen und praktischen Augenheilkunde von Anton Rosas.* Wien, 1830, I. Band Seite, 284.

^b *Hist. de l'Acad. de Science*, 1751, p. 49.

^c *Essays upon the Morbid Anatomy of the Eye*, by James Wardrop, vol. ii. p. 76.

such a case. Porterfield says the lens has been, in some rare instances, unusually flat; and hence the patient was congenitally presbyopic, or long-sighted. And Foigtel states that it has been found of a triangular shape.

Malposition of Lens.—Klinkosch asserts that he saw a lens behind the vitreous body, and lying on the optic nerve. Such a case is not by any means improbable, when we consider how easily it might occur in case of fluidity of the vitreous humour. Although anterior dislocation of the lens, observed at birth, has not been related by authors, it is an accident so likely to happen, that one rather wonders at the absence of it than otherwise.

Mr. Dixon, in the last edition of his "Guide to the Practical Study of Diseases of the Eye," records the circumstance of the "abnormal position of the lens occurring in four members of the same family," in which the lenses appeared to have had one edge tilted forwards, and the other backwards, either from side to side, or from above downwards. In one instance, however, the twist of the lens took an oblique direction^a.

Entozoa within the Capsule at birth have been observed and described by several authors. Von Ammon has figured two forms of *Distoma*, and also a *Filaria oculi humani*, found in connexion with congenital cataract; but does not state the particulars. Nordmann found entozoa between the lens and capsule in the embryo of fishes. The same author, Gescheidt, and other observers, have related many cases of entozoa within the capsule after operations performed for non-congenital cataract^b.

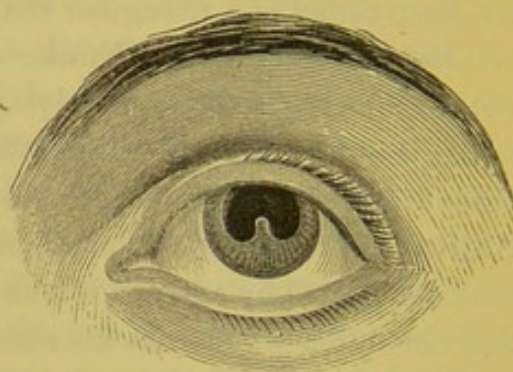
The lens has been found absorbed, and the capsule shrivelled up, apparently from defective nutrition, during embryo life.

Congenital Synechia Posterior, the result of intra-uterine iritis, occasionally occurs, as I have shown in the previous por-

^a See Appendix to the Second Edition, p. 401.

^b Upon this subject see *Zeitschrift für Ophthalmologie*, band III. heft 4; and article "Entozoa," in the *Cyclopædia of Anatomy and Physiology*, by Professor Owen; also *Archiv für Ophthalmologie*, Bd. i., iv., vii.

tion of this essay. It is a pathological condition which I have myself observed so soon after birth, that it could only be attributed to inflammatory, and probably specific action going forward in utero. The case illustrated by the accompanying woodcut is, however, of a different character from those instances of syphilitic intra-uterine iritis which are usually met with. The pupil, here represented under the influence of belladonna, is horse-shoe-shaped, owing to attachment of a small portion of the free edge of the iris to almost the centre of the lens-capsule; this appearance existed at birth. Vision was quite perfect when I had this drawing made, in 1849, from a young woman then aged 23.



Congenital Cataract may be divided into capsular, lenticular, and capsulo-lenticular, according to the structures affected,—partial or complete, according to the amount of opacity present; fluid, or of the normal consistence of the lens; and single or double, as one or both organs are affected; in all of which this disease is analogous to those forms observed in after life. But there are two descriptions of cataract which are solely the result either of intra-uterine *disease*, or that occurring immediately after birth; these are the central and the pyramidal.

Until the days of Saunders, English surgeons do not appear to have paid much attention to congenital cataract, neither had it been well described by Continental authors. To Saunders is also due the introduction of the early anterior operation for this affection, or what he properly terms the operation on the capsule. Since then, German writers have been very minute in their definitions of congenital cataract; thus, Himly describes *Cataracta capsularis totalis, anterior, posterior, et centralis; C. lenticularis dura, caseosa, lactea, et centralis; and C. capsulo-*

lenticularis dura, centralis, et pyramidata. Among the forms of cataract described by Von Ammon, including all the foregoing, he enumerates those connected with the malformations of the iris, club-foot, umbilical hernia, and elongated crania, &c.

The most frequently attending symptom of congenital cataract is nystagmus, which is more or less decided, according to the density of the opacity, or the space it occupies behind the pupil, and occasionally aggravated by amaurosis. The two forms of motion of the globes may, however, be distinguished by a careful and experienced observer. Where the irregular motion of the eyeball has been caused or aggravated by nervous disease, there is generally a staring look in the eye, and the motions partake more of the rotatory form than those more side to side; while in the uncomplicated cataract, with a healthy brain and retina, the movements consist of a "peering" upturn of the eye, at the same time that the features of the face are brought into what may be termed a seeing or listening attitude; occasionally, the globes take sudden transverse sweeps within the palpebral aperture, as if seeking light, while the head is usually turned a little to one side. According to my observation of congenital cataract, it is very rarely connected with any other malformation. In two instances, however, both in men past middle life, and affected with double congenital central cataract, each consisting of a dense, white spot, about the size of a large pin's-head, there was a remarkably high formation of skull,—what the Germans would call "Spitzkopf," and not unlike some of those malformed heads figured by Von Ammon, in his tables of *Cæcitas Congenita*.

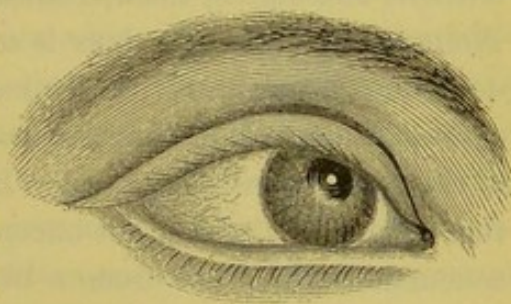
I lately witnessed a case of congenital cataract, with deficiency of the iris on both sides; but as the girl had been operated on prior to my seeing her, I cannot state what was the original condition of her lens and capsule. She had intense nystagmus, and great intolerance of light. I am inclined to think such cases should not be interfered with. Tremulous iris

occasionally coexists with the born cataract, and the lens itself is occasionally shakey.

The causes of congenital cataract may be divided into the proximate and remote. The latter is more frequently induced by hereditary predisposition than any other affection of the eye with which I am acquainted. I also believe that it may, like muteism, be induced by the consanguinity of parents; but we require more extended observations to confirm this opinion. All authors, however, agree with respect to the hereditary character of the disease. I saw three generations affected with it, and I operated upon members of two of them. All the older authors, from the days of Maitre Jean and Woolhouse, were well aware of the hereditary nature of this disease. The journals and works upon ophthalmology record many curious instances, illustrative thereof. I have several times seen three of a family affected with it; and I know an instance in which the father and his six children were born blind from this cause. The father had been operated on by the late Dr. Little, of Sligo; the three children whom I examined had all malformed eyes, in addition to the opacity of the lens; two were totally amaurotic, and the third had a microphthalmus on one side. The form of cataract, whether central, lenticular, or diffused, &c., is generally persistent in the different members of the family, although I have seen exceptions thereto. Saunders relates the following remarkable case, showing the identity of the disease in the same family:—"Two brothers, twins, became blind with cataracts at the age of twenty-one months, each within a few days of the other. It is remarkable that the four cataracts had precisely the same character." In these instances, however, it is more likely that the children were born with cataracts.

Before I come to discuss the proximate cause of the diseases, I wish to dispose of one form of non-congenital cataract, with which it is often confounded. Under the head of congenital cataract, authors have described central capsular cataract, caused

by ophthalmia neonatorum; but they have not explained the mode in which this occurs. Infants become affected with purulent ophthalmia a day or two after birth; in many cases the cornea opens in the centre, thereby differing in some respects from the violent ophthalmia of adults, in which that structure most frequently gives way near its circumference. Possibly, the cornea is weaker in the centre at birth than subsequently. The rent having taken place, either by slough, ulceration, or what might really be styled a crack or burst, the aqueous fluid is evacuated, and the iris and lens fall forward against the cornea, where the capsule, by simple apposition with an ulcerated, or otherwise diseased surface, becomes, in my opinion, inflamed and opaque by mere contiguity of parts. The rent in the cornea closing, by lymph-deposit on its edge, or becoming plugged up with a portion of protruded iris (in which case there is permanent synechia anterior), and the fluid re-accumulating, the chambers are re-formed, and the lens is restored to its normal position, but with the central opacity remaining permanent. It is always in one eye only, and is often connected with the anterior synechia, as shown in the accompanying illustration, taken from a man then aged 25, and with whose history I am acquainted.



The proximate causes of opacity of the lens may be stated as arrest of development, during the clearing process, supposing the lens to have been originally opaque—interstitial deposit of opaque matter occurring in utero as in after life—inflammation producing opacity especially of the capsule; and morbid growth, as in the case of anterior pyramidal cataract. According to Arnold, the lens-substance is originally a thick milky fluid, which subsequently acquires the consistence of albumen,

then becomes more solid, and finally begins to clear at the circumference, leaving the central nucleus opaque, as in the fifth week in the foetal calf, and does not altogether become transparent till the eighth week.

Werneck found the human lens opaque up to the eleventh, and in some instances to the fourteenth week. Thus, an arrest of development at the very earliest stage of embryonic life would afford at birth the milky cataract; and, at a little later period, that of the general homogeneous opacity which is a common form of congenital cataract; although, I believe, it may also be the result of inflammatory action, or congestion. The vices of formation receive more distinctive proof from that form of cataract which Dr Mackenzie calls *cataracta cum zonula*, in which there is a central nucleus of opaque matter surrounded by an envelope of transparent lens, through which occasionally run spiculæ, or needle-shaped opacities. Other authors, and among them, Haller, Zin, Petit, Seiler, and Von Ammon, hold that the lens is originally clear, and that the deviations from the normal formative process are owing to disease in the capsule or lens, and more particularly to obliteration of the arteria centralis retina. This is susceptible of explanation by analogy with a not uncommon accident in after-life—concussion of the lens from a blow on the eye, the brow, or the temple, when the surrounding vascular connexions of the crystalline being destroyed, it becomes, in an incredibly short space of time, opaque. But although this explanation may account for the diffused form of lenticular cataract at birth, it does not elucidate the circumscribed and partial opacities of congenital cataract. Scrofula is also charged with this congenital defect; but in what way it acts has not been explained by the supporters of that doctrine. In an inquiry of this nature, nothing very certain or exact can be affirmed: and, even if it were, it could exercise but little practical effect. The forms, however, which the disease presents are of far greater importance to the ophthalmic surgeon.

It is asserted by Wardrop and other writers, that although congenital cataract commonly affects both eyes in the same way, that sometimes the lens of the one and the capsule of the other is affected; but this is contrary to my experience; for where the cataract was truly congenital, I have always observed a marvellous amount of symmetry between the eyes. It is true, a slight speck on the anterior capsule may be observed in connexion with lenticular cataract in one eye, and not in the other; but it is not sufficiently extensive to be denominated capsular cataract, according to the sense in which it has been applied by Wardrop. Having paid a great deal of attention to this subject many years ago, I had a very extensive collection of drawings illustrative of the different forms of the disease (many of which are not figured in books), made by Mr. Connolly and the late Mr. Neilan; but without coloured engravings, it is very difficult to represent their special peculiarities.

Distinguished from all other forms of cataract, the congenital, which is the result of some vice of formation, almost invariably presents a definite, distinct, well-defined figure, not shading off gradually into the surrounding clear portion of the lens, as in the opacity of age, nor mottling the lens irregularly, like that of middle life, but presenting a sharp line of demarcation between the opaque nucleus and the surrounding normal transparent structure.

Lenticular congenital cataract may be divided into the complete and partial.

Complete Lenticular Cataract not uncommonly presents at birth, in which the capsule is unaffected, and the entire substance of the lens is of a uniform, skim-milk colour, homogeneous, and retaining, so far as we can judge, something about its normal consistence, perhaps a little softer. I have seen this transmitted more than any other form, although it may occasionally appear accidentally in one member of a family. Owing to the great occlusion of light, there is always nystagmus in such cases; and they are those which usually require early

operation. Von Ammon relates the case of a hard lenticular cataract in one eye, and a soft lens, with partial opacity of the capsule, in the other. I have seen one instance (to be described hereafter) in which the lens was yellowish, and apparently hard in one eye. In two cases of congenital cataract, also recorded by Von Ammon, the yellow spot on the retina was wanting—as shown, I suppose, by dissection.

Cataracta Lactea, in which I presume the lens has either remained in its original fluid and opaque condition, as already stated, or, having become solid and opaque, has degenerated into the milky substance observed at birth, like the softening process which the cortical substance of the lens undergoes in what is termed Morgagnian Cataract, is rather rare. In all the cases of this kind which I have seen, the lens appeared unusually large; there was great nystagmus, and a certain amount of amaurosis, with dilatation of the pupil, present; the capsule is frequently mottled with greyish-white spots. This form may be distinguished from the foregoing variety by its less apparent density; and, when the capsule is mottled, by the greater amount of relief with which such opacities are thrown forward. But it requires a very practised eye to make an accurate diagnosis of the amount of fluidity in certain cases of cataract. One of the most remarkable circumstances attending this pathological condition is, that while the colouring matter of this milky substance remains either well mixed or suspended in the fluid, so long as the capsule is intact, when it is opened, as by the needle in operating, and that the whitish substance mixes with the contents of the aqueous chambers, it gradually, but within a few minutes, deposits in the form of a greyish-white powder, leaving the pupil perfectly clear; as if the admixture of the aqueous humour had chemically acted upon it, and thrown down the precipitate referred to. Occasionally the substance which is deposited in the bottom of the anterior and posterior chambers produces, like that observed in Morgagnian Cataract, great constitutional

ance, with irritability of stomach, and inflammation of the eye.

Neither of these two forms of cataract could be exhibited effectively in a woodcut.

Central Lenticular Cataract.—I have been for many years acquainted with a peculiar form of congenital cataract, to which this appellation is applicable; and I presume it is that known to some of the older writers as the *cataracta cum zonula*, but which name Dr. Mackenzie applies to that form of siliquose capsulo-lenticular cataract, in which the lens and capsule, “not having grown in proportion to the rest of the body, but remaining nearly of the size they were at birth, on dilating the pupil, a black zone—formed exteriorly by the ciliary processes, and interiorly by the space between them and the circumference of the capsule—is brought into view, surrounding the cataract.” The disease, however, of which I speak, is purely lenticular, and unattended with any alteration in the form or deficiency of size in the crystalline. It is so frequently met with in this country, that having a large collection of drawings of both eyes (in 13 cases), made of it many years ago, and representing all its varieties, I have long ceased to illustrate such cases when they present. The only author who has presented us with anything like a faithful representation of the disease is Sichel, in his *Iconographie Ophthalmique*, pl. xviii. figures 1 & 2. In Dalrymple’s *Pathology of the Human Eye*, Plate xxvi, figures 4 and 5 would appear from the drawing to be of this nature; but the author, no doubt looking upon the central opacity as including the entire substance of the lens, believed that the crystalline was “manifestly smaller than the natural structure”—an opinion to which Sichel also leans.

The accompanying woodcuts serve, as well as such illustrations possibly can, to illustrate this form of the disease, but they fall very far short of giving anything like a characteristic expression of the appearances. On looking into an eye so

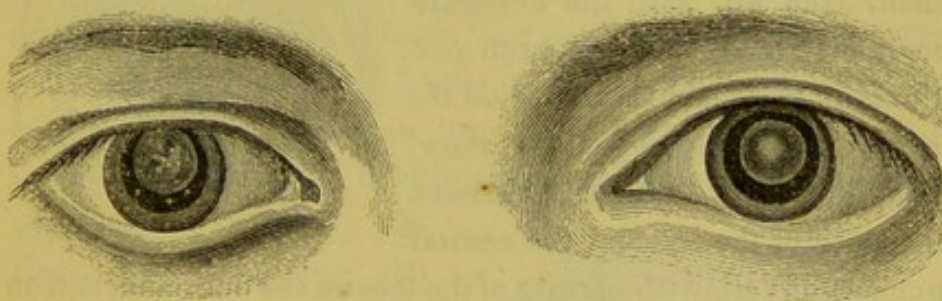affected, we observe an opacity, more or less dense and whitish, behind the pupils; but at such a distance, and with so much shadow thrown from the pupillary edge of the iris, as to show a practised eye that a considerable clear space intervenes between the level of the pupil and the surface of the opacity. On dilating the pupil, we then observe a clear, sharp, well-defined, and always circular edge to this opacity, round which there is a perfectly clear, and consequently black zone, varying in size according to the magnitude of the central opacity, which usually occupies about three-fifths of the transverse diameter of the normal lens—the entire cortical substance of the lens, both in its antero-posterior and transverse diameter, together with the capsule, remaining perfectly clear. To an eye long accustomed to such examinations, this piece of opaque matter presents somewhat the appearance of the coloured enamel seen in the centre of some of the specimens of old Venetian glass, an art latterly revived in our globular paper-weights. The patient always experiences considerable improvement from the dilatation of the pupil; and it is a description of cataract which, when in a mild form, is so frequently mistaken for myopia, that it is often first observed in adults, having been in early life attributed to that affection^a.

In the early cases of this disease which I met with, I na-

^a Several years ago I operated upon two ladies and a gentleman in one family, all upwards of twenty years of age, where the disease had not been discovered until the time I saw them. Their defect of vision was attributed to hereditary shortsightedness—their mother having very defective sight. Not long since, while examining a lady's eyes, I was struck by the peculiar moping gait and peering look of her daughter, a girl of seventeen or eighteen years of age, who was in the room; and, on inspection, I found she had congenital cataract in both eyes. On asking the parents about her, I received the following answer: "Oh yes, indeed, poor thing, it is a great pity; she's very blind, and we have gone to a great deal of expense in trying to get her proper glasses." The poor girl herself complained bitterly of the treatment she received at school, on account of her "stupid blindness." Neither the school-mistress nor the parents had ever thought of having her examined by any competent authority. She has since continued to use atropine, and derives so much comfort from it, that she is unwilling to risk an operation.

turally experienced some difficulty in diagnosis, but the first on which I operated, proved the correctness of the opinion I had formed; for as soon as the capsule and anterior layer of the lens were well incised with the cutting edge of the needle, the latter became, in a very short time, opaque throughout, as in ordinary cases of traumatic cataract.^a

This form of cataract is often complicated with opacity of the capsule; and the disease itself, in its uncomplicated form, presents many varieties. The opaque nucleus is seldom uniform in colour and density throughout, although I have seen it occasionally so. The edge is sometimes whiter, and apparently denser than the portion immediately within it, and occasionally presents a very remarkable whitish ring. With this form, as shown in some of these illustrations, there is a central spot denser than the portion between itself and the ring; and occasionally this part assumes a very regular figure, as seen in the right eye of William Nightingale, a boy aged 18, from whom I had this drawing taken, prior to operation, in 1847.^b

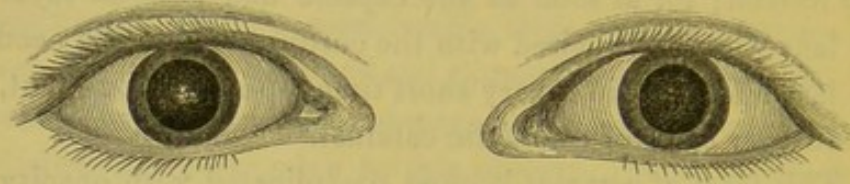

Sometimes, instead of the appearances there presented, we may observe a little nucleus of white dots, each about the size of a small pin's-head, and which may be distinguished from the surrounding skim-milk colour of the opaque portion of the

^a Persons about to submit to an operation for this form of cataract should be informed previously of the result of the first necessary step towards solution.

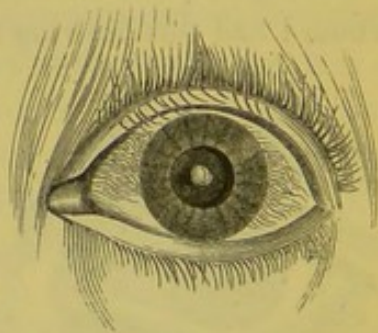
^b These blocks, as originally engraved, being too wide for the page, have been cut in the middle.

lens, as shown in the accompanying illustration of Mr. K's eyes. In one instance the spot was so small, white, and central,



as to resemble the cataracta centralis, which has its seat in the anterior capsule of the lens; and it was only by examining the eye in partial profile, that the difference could be distinguished. In two cases, I have seen lenticular cataract of a straw-coloured yellow, with a central anterior knob of dense white, like chalk. Both instances were adults, and the lenses were possibly hard; but the defined form of the opacity luted into the centre of the clear lens in each left no doubt as to its congenital origin.

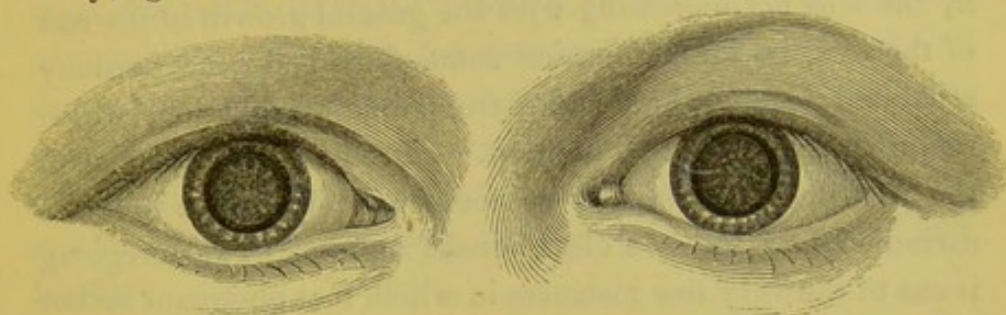
In the accompanying illustration drawn from Bridget Danass, a woman, aged 46, both the draughtsman and engraver have been particularly fortunate in hitting off the aspect of the disease, and in showing the spaces that exist between the edge of the iris and the central



nucleus of yellowish opacity of the lens on the one hand, and on the other the chalky-white anterior central cataract within the capsule, which throws its shadow upon the yellow opacity behind it. In the remainder of the lens, the interspace between the capsule and the congenital cataract was clear. The upper lid was affected with trichiasis, as shown in the illustration. It was for the latter disease the patient came under my observation.

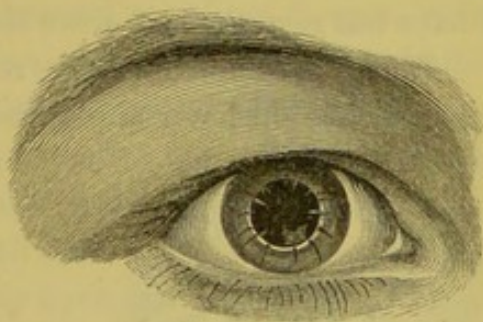
Not an uncommon variety of this form of partial lenticular cataract consists in white striæ, radiating from a central spot with

extreme regularity, as shown here in the eyes of Louisa Pen-
tony, aged 12, who was operated on in 1849. I may here men-



tion, that regularity of formation affords, in most of these cases
of congenital cataract, a very ostensible differential diagnosis.

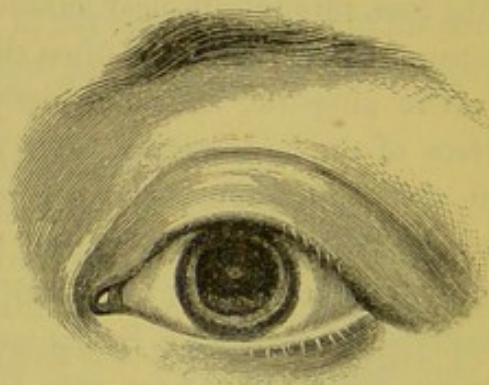
Starting from the edge of the opacity, we occasionally per-
ceive a number of white lines passing out to the circumference
of the lens, through its clear annulus, not unlike those spiculæ
of opaque matter which are often the first manifestations of ca-
taract in after-life, and are chiefly situated on the posterior
surface of the lens, having their base at the extreme edge,
with their apices pointing to the centre. Like these, the ra-
diating lines in the pheriphery of the lens in congenital cata-
ract, chiefly occupy its lower half, although a few are occa-
sionally seen all round. Sometimes the radiating lines of the
cataract are continued on into those peripheral ones; and
in the accompanying drawing we see, in addition thereto,
three opaque spots very dis-
tinct, and occupying the
clear peripheral space in the
normal lens. In his descrip-
tion of Plate xxvi, figure 4,
already alluded to, Dal-
rymple has given a figure of
what would appear to be a



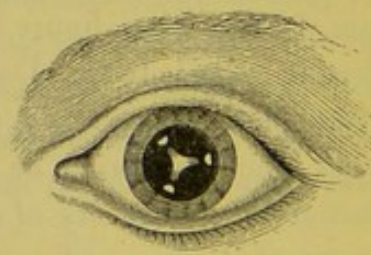
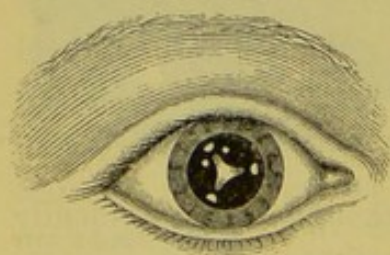
partial central opacity of the lens, although he was evidently
aware of its surrounding normal investiture. In that repre-
sentation, we observe two of those radiating lines, upon which
he observes—"Sometimes we see a little opaque tag or fibre,

which seems to attach the capsule to the vitreous body, or, more probably, to the anterior layer of the zone of Zinn; as if, the lens not increasing with the general growth of the rest of the eye, its former natural connexions had been partially separated, leaving, here and there, points of adhesion, which retain it in its central position." From our knowledge of the pathology of the eye, we could scarcely expect to find a dwindled lens within a clear normal capsule. The foregoing is one of the very few instances in which that observant author failed to detect the true character of any appearance within the human eye.

In connexion with central lenticular cataract in the left eye of Anne Duffy, aged 13, the appearance shown in the accompanying cut was observed when the pupil was artificially dilated. It resembled a curtain, with a fringed upright edge, stretched across and behind the iris. It was neither a development of the ciliary process nor a persistence of the membrana pupillaris. In colour it was light brown below, and whitish at the fimbriated margin. I have not seen the case since the drawing was made, in 1846.



When I commenced the revision of this portion of my essay, I thought I was acquainted with every form which con-

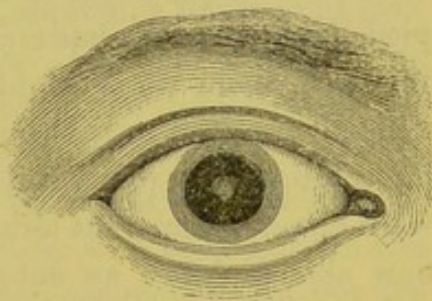


genital cataract could assume; yet here is the appearance in the eyes of a child, aged 4 years, who was brought to me last

week, and which, so far as I know, has never been observed previously. In the centre of each lens there is a whitish cruciform mass, the outline of which presents an extraordinary amount of regularity. Towards the extremity of each limb of this figure, and somewhat deeper in the clear substance of the lens, may be seen small triangular pin-head opacities, and near the upper and outer limb on the right side, there are three white specks. Vision is imperfect, but the child is well-formed and healthy.

Very rarely, indeed, do we observe a small circular opacity in the centre of the lens; and when we do, it is very difficult to give it the proper expression.

The accompanying drawing is the nearest approach to it which an illustration in wood can effect. Seiler says, that although the central cataract is usually white throughout, he has seen

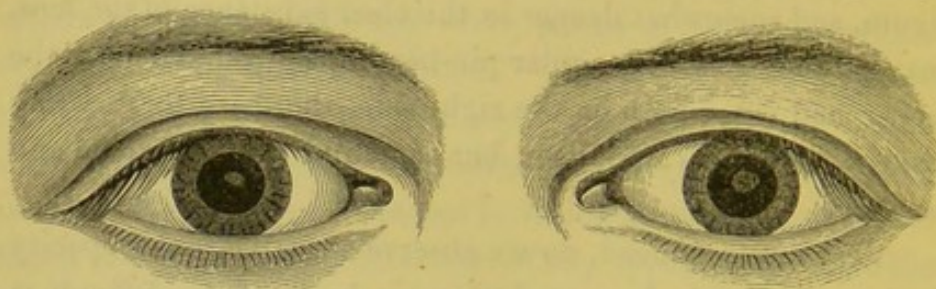


it annular, with a transparent spot in the middle; and he has figured this appearance in the plate attached to his work already referred to, see figure xi.

Posterior Lenticular Cataract.—Opacities upon the posterior capsule of the lens, if not often seen by some of the older authors, were at least believed to be of frequent occurrence. Many years ago, I observed a yellowish spot, with a few radiating fibres, very deep, in each lens, in a middle-aged man. I had a very careful drawing made of the appearance which the eyes then presented. In the course of about three years, the entire body of each lens became opaque. I extracted them, and demonstrated to those present upon each occasion, the opacity upon the apex of the posterior surface of the lens; and, when the section of the cornea had healed, showed that there was not the slightest opacity remaining upon the capsule. The man worked many years subsequently as a shoemaker. Since then I have seen many such

cases, and never failed to recognise them as diseases of the posterior surface of the lens.

M. H., aged 15, with impaired vision from birth, presented the following appearance:—A dense brownish-yellow opacity,



circular in shape, larger in the left eye than the right, occupied the apex of the posterior surface of the lens. Surrounding each, there was a slight nebulous condition, with a well-defined edge not easy to represent on wood. The operation for solution was performed in both eyes, without any untoward circumstance; but although he is greatly improved, and now able to follow an out-door occupation, he is not able to read, and has derived less assistance from glasses than any case of congenital cataract I have ever met with.

A very natural suggestion here presents itself, and one which is sure to be asked by the partially blind from congenital cataract, or their friends—Will the disease increase, either in density or extent, unaided by any adventitious or accidental causes—such as congestion, inflammation, age, &c.? I believe not. I have never seen, nor have I read of, a well-authenticated instance of congenital opacity of the lens, or its capsule, increasing in after-life. Dr. Mackenzie, in the last edition of his great national work on the diseases of the eye, at page 769, when discussing the question of operating early in cases of congenital cataract, says—"If the operation is delayed, the capsule becomes opaque and tough, and, therefore, much more difficult to remove, &c." This opinion is contrary to my observation and experience of the disease. I never saw a capsule, unaffected at birth, become spontaneously

diseased subsequently ; nor, as already stated, have I ever seen a congenital opacity of the lens spread or increase in after-life ; and in this respect the congenital differs from all other forms of cataract, either lenticular or capsular, except that which is the result of ophthalmia neonatorum.^a There are, in many cases, cogent reasons for operating early, such as nystagmus, and total defect of vision, &c. ; but the danger of thickening, and opacity of the capsule, does not, so far as I have seen, come under this category.

Capsular Cataract.—I have never seen the capsule so completely opaque at birth, as to obscure the view of the lens beyond ; neither have I ever seen, through a transparent lens, an opacity on the posterior capsule. The most frequent form of this disease is a small white speck in the middle of the anterior capsule, and generally known as *Cataracta Centralis*. As already stated, it may exist in two forms, with or without lenticular opacity. When seen alone, it is often but the size of the smallest pin's-head ; and when congenital, and not the result of infantile ophthalmia, it almost invariably presents a very regular circular form, with a sharp, well-defined edge. The spot is always of a dull flake-white, but is occasionally surrounded with a greyish-white border, evidently of thinner material. This annulus is often so very narrow, as only to be observed with a good glass.^b When the disease is the result of ophthalmia, this nebular ring is not seen, and the edge of the opacity is generally irregular. Many years ago, I observed that several of these central cataracts were nail-shaped, the

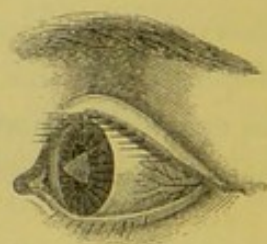
^a I think it possible that the greyish-white nucleated cataract might, in after-life become both yellowish in colour and hard in substance, although I have no authority for so stating. Besides those cases related at page 65, the only instance presenting such an appearance I ever saw was in Thomas Cartmill, aged 36, where the substance of the opacity was a straw-coloured yellow, with a whitish annulus, and a chalky-white central nucleus ; yet it is possible that these may have been the appearances at birth.

^b By far the best glass I have ever used is the little compound instrument made by Hawes, of Leadenhall-street, London.

head presenting anteriorly, and the tang—sometimes about a line in length, and tapering off to a point—passing into the clear substance of the lens, in which it could be well observed when the eye was viewed in partial profile. Upon examining some modern German publications, I find that this appearance has been denominated posterior pyramidal cataract.

With this species of cataract there is usually a good amount of vision, but varying according to the light; therefore persons so affected are improved by the application of belladonna. The disease has long been recognised by oculists, and was known even in the days of Taylor and St. Yves. Von Ammon is of opinion, that it may be caused by adhesion of the pupillary membrane and anterior wall of the capsule at that point. True congenital central opacity of the capsule is usually double.

Pyramidal Cataract is a large central opacity of the capsule, which bulges out beyond the level of the lens, and through the pupil into the anterior chamber. It is always conical, with a circular base, and presents a chalk-white appearance. Fourteen years ago, the late Mr. Hocken, of Manchester, was good enough to forward me a drawing, from which the accompanying illustration was made. Although not very artistic, it affords a good idea of the appearance, viewed in partial profile. Upon the card containing the drawing is the following, in Mr. Hocken's handwriting:—"Congenital Disease:—Conical opaque growth from the crystalline capsule, projecting through the pupil into the anterior chamber." He had promised to afford me the history of the case, when, unhappily for the cause of science, he died. Von Ammon who has paid a good deal of attention to the subject, accounts for this disease by a patency of the presumed aperture in the anterior capsule in very early life, through which, he thinks, the substance of the lens bulges.



He has also given drawings of the *post-mortem* appearance in an eye affected with this peculiar malformation; but the preparation appears to have been much altered by the spirit when the drawing was made. Wardrop figured and described a case of it, and said that Wenzel related a similar one, but where I have not been able to discover.

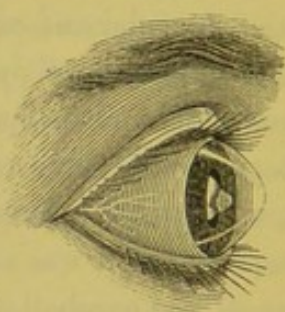
The latest record of pyramidal cataract in this country is that afforded by my assistant, Dr. Wilson, who says:—

“Pyramidal cataract, of which there appear to be two varieties, capsular and capsulo-lenticular, is characterized by an opaque-white cone or pyramid, its base being in or on the lens or its capsule, and its apex projecting into the pupil, and passing beyond the plane of the iris into the anterior chamber. Beer, who was, I believe, the first author to describe this form of cataract, said it was always the product of very acute inflammation of the eye-ball attacking principally the capsule, lens, and iris, and that it was always adherent to the pupil, which was immobile and irregular^a. Beer gives no opinion as to its being congenital, but says it is formed not only by increase in volume of the anterior capsule, but also by a deposition on it of fibro-albumen, which can readily be separated from the capsule; and in this he is borne out by more modern writers, as Mackenzie and Dixon, two of the few English authors who mention this description of cataract. Some writers affirm that it occurs during the progress of ophthalmia neonatorum, when the cornea is swollen, and its posterior surface nearly in contact with the lens; this opinion is held also by Sichel, who gives an illustration of it in the 24th plate of his *Iconographie*; he admits, however, never having seen it follow the ophthalmia of infants, or found any opacity, &c., of the cornea.

“M. F., aged 17, a delicate-looking girl, seemingly much younger than she states, is small in stature, being only four and a half feet high; the head is flattened at top, forehead massive in proportion to face; hair dark brown; lashes very

^a Lehre von den Augenkrankheiten, 1817, bd. ii.

long and black; irides differing in colour. On examination, the following appearances in the right eye are seen. The cornea is altered in shape, being conical, and perfectly transparent; iris of a light-brown colour, having a washed-out appearance, rings of iris very faintly marked; the pupil is circular, and dilates and contracts naturally; no adhesions apparent; it is occupied by an opaque lens, which, viewed in profile, presents the remarkable appearance I have delineated in the accompanying cut. The cataract involves the whole of the lens, and in front assumes, with the opaque capsule, a pyramidal shape, and protrudes into the anterior chamber; it is composed of several masses differing in colour and consistency; the apex of the pyramid is formed of a soft-looking substance of a blue-white colour; there is a sulcus between it and the base, which latter is apparently firmer; a mass of small opaque-white earthy-looking bodies projects from the temporal side of this latter portion. These are the conical bodies mentioned by writers as easily detached; in the present instance, however, they are situate posterior to the plane of the iris. On the nasal side there is what appears to be a membrane extending from the margin of the opaque lens, to which it is attached, towards the ora serrata; this is, undoubtedly, a portion of the ciliary processes.

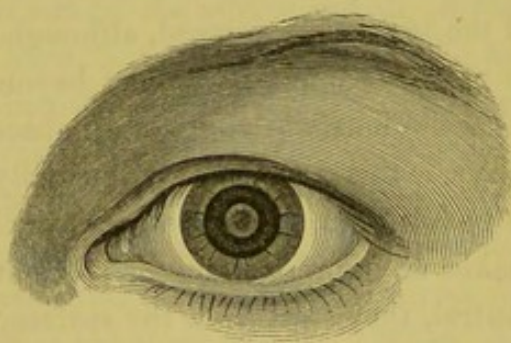


"I could not perceive, on ophthalmoscopic examination, any light reflected from the choroid. The girl has merely perception of light with this eye. There is also present in both eyes a symptom which is generally seen in congenital affections of the eye, nystagmus, or oscillation of the globe, an affection which has been made the subject of a book by Dr. Boehm,* who has proposed to cure it by cutting the internal rectus; a proceeding which will not, I believe, be undertaken

* *Der Nystagmus und dessen Heilung*, von Dr. L. Boehm, 1857.

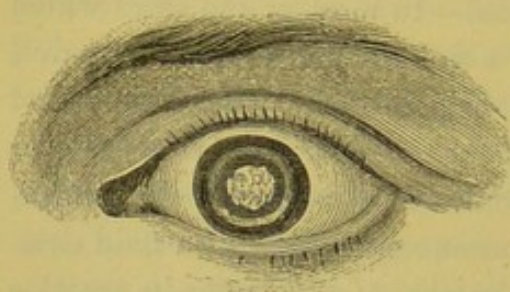
by many practitioners. Conical cornea is, according to Von Ammon, frequently congenital, and often found combined with cataract"^a.

Capsulo-Lenticular Cataract.—In most of the cases which I have seen, there was either a central flake, of a dense dull white, and sometimes greyish, or yellowish-drab-coloured, and irregular in form, occupying about a sixth of the central or lower portion of the capsule, and contrasting well with the bluish-white lens behind; in other instances, especially in fluid cataracts, there were several small patches of white upon its anterior surface. In neither of these cases is it possible to discover the precise condition of the posterior segment of the capsule. In the former, that of a single patch of dull greyish-white substance occupying the centre of the anterior capsule, I have found, in operating, that, when touched with the needle, it chipped off like a piece of eggshell; and in one case, that of J. Mooney, here figured, the scale fell into the anterior chamber, and remained there, innoxious, for more than a year, during which time the boy was under my observation, I have observed that there is less regularity between the appearances of the right and left eye, when the capsule is affected, than the crystalline. In the uncomplicated capsular cataract, the opacity, whether merely central or pyramidal, is always regular both as to shape and position; while in the capsulo-lenticular, such opacity, or opacities, are irregular, both as regards their situation, shape, and colour, and would appear to be more the result of intra-uterine inflammation, than the consequence of any interference with the formative process. In the accompanying illustration of the eyes of Richard Lynn, a boy



^a Dublin Hospital Gazette for December, 1860, vol. vii. p. 372.

twelve years of age, made from a drawing taken when the pupils were dilated with belladonna, we have a good representation of one of the most frequent forms of congenital cap-



sulo-lenticular cataract. In the original, the dull flake-white, irregularly-edged, and uneven surface of the large patch of opaque capsule contrasts well with the greyish-white substance of

the lens beyond and behind it. In this, as well as other instances that I have met with, the capsular opacity resembled that siliquose condition which follows upon accidents in which, the capsule being ruptured, the substance of the lens is absorbed, and the two hemispheres, thickened and rendered opaque by inflammatory action, adhere, and present the appearance so well known, not merely to the oculist, but to the general hospital surgeon. In Lynn's case, however, the volume of the lens was preserved, although the opaque capsule, viewed in profile, seemed to project beyond its surface; and finally, after the lens was completely absorbed subsequently by keratonyxis, this opaque body, partially obscuring the pupil, had to be removed, through an opening in the cornea. The needle makes no impression on such formations; if they are small and central, they start from the surface, as in the case of Mooney, already alluded to; but if they occupy so large a portion of the capsule as in the case of Lynn, the cutting side of the needle should be passed round the edge, so as to bring the lens into contact with the aqueous fluid; and, subsequently, if they cannot be displaced from the field of vision, they should be extracted.

MALFORMATIONS OF THE VITREOUS BODY, RETINA, AND OPTIC NERVE.

Having already, at page 26, described the formative process in the human eye, it is unnecessary to enter at any length upon

the peculiarities in the mode of growth in the retina. Within the last two years V. Ammon published a memoir on the Embryology of the Eye, in the *Archiv für Ophthalmologie*^a, in which he says the retina appears, in the fourth or fifth week, as a white downy membrane in contact with the lens, open behind and on one side. In some very rare cases of development this retinal fissure remains permanent, an instance of which is given by that author in his previously published work, the *Klinische Darstellungen der Angeborenen Krankheiten*, Bd. iii., Taf. xi., Fig. xv. From the middle of the third to the middle of the fourth month, the retina resembles brain—white and thick, and filling up the space between the choroid membrane and vitreous body. About that period a ridge or projection, like the pecten in birds, passes in through the slit in the retina to a sulcus in the vitreous structure; but this in time is absorbed. During the fourth and fifth month, convolutions like those seen on the surface of the brain are observed on the retina, and are not altogether lost till the eighth month. A few of these folds may, in some cases, be seen in the site of the fissure, even up to the ninth month; and V. Ammon says that the persistence of this embryotic condition, in the slightest degree, impairs vision. In the second month, nerve-cells and granules are recognisable, and in the third and beginning of the fourth the ora serrata is discernible; but the optic nerves do not appear till about the end of the third month. When the brain and eye-cells, originally in contact and communication, become separated by the orbital plate of the frontal bone, the optic nerve is developed in the form of a fissure or gutter, which is afterwards closed along its length, and filled with nerve matter. The retina and optic nerve are joined towards the end of the third month; and in the fifth, the arteria centralis, which had been formed very early in foetal life, dwindles. Any in-

^a See review thereof in the Dublin Quarterly Journal of Medical Science for August, 1861, vol. xxxii. p. 127.

terference with the foregoing process must result in malformation, or congenital disease.

Besides the cases mentioned above, dissections have been given of club-shaped retinae, each of which presented a pyriform mass, lying between the ocular end of the optic nerve and the lens. In other instances, it is said that there was over-constriction of the optic nerve at the cribiform plate.

In cases of microphthalmos, and other manifest alterations and arrests of development in the eye, there is generally evidence of deficiency of formation in the vitreous body or retina, but careful dissections of such have been rarely recorded.

CYCLOPIA.

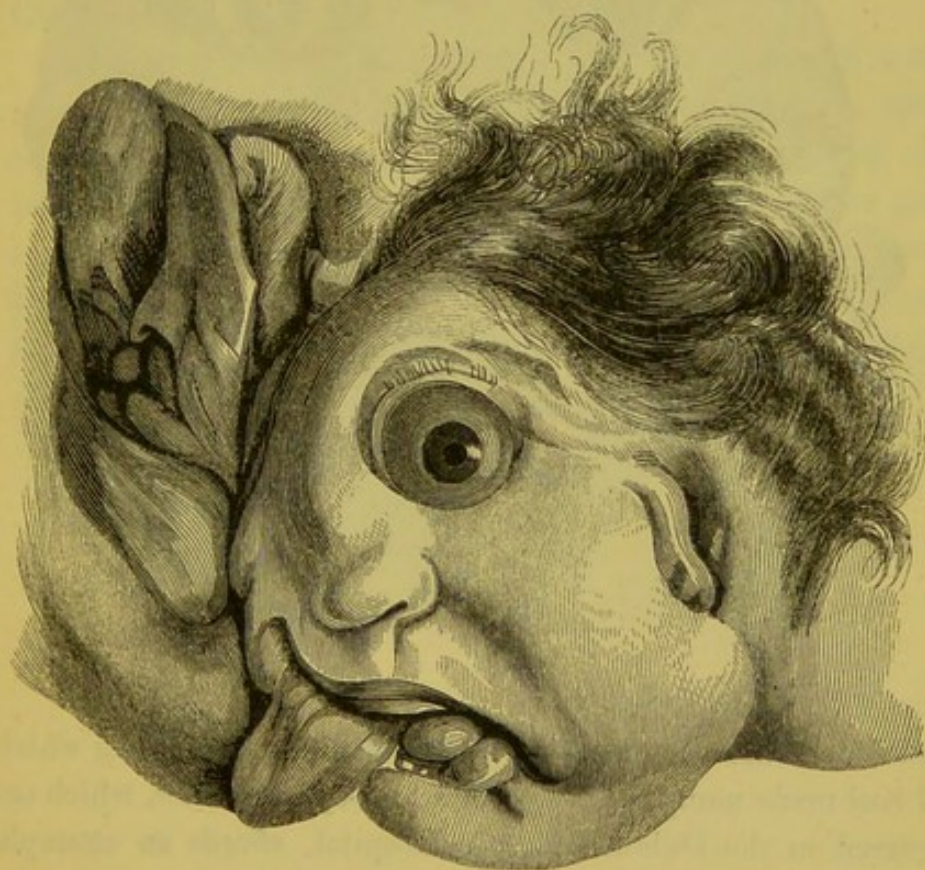Monstrosities in which there is but one apparent eye are not unusual in the human subject, and are also seen in the lower animals, especially lambs, kittens and calves. In nearly every instance the foetus is acephalous. Where only one eye exists, but retains its natural position, the case may be termed monocus; and where the eye is misplaced, it may be called a cyclops. In this latter condition, although there is apparently but one eye, it consists of two globes fused together, and there are either three or four eyelids.

From Dr. Mayne's able article on the Optic Nerves, in Todd's *Cylopædia of Anatomy and Physiology* I extract the following passages:—

“ A single eye placed in the middle line of the forehead, and in general a trunk or proboscis growing immediately above this solitary organ of vision, constitute the most striking apparent anomalies in monsters of this class. The fundamental defect in these monstrous foetuses consists in the total absence of the organ of smell, in consequence of which deficiency the symmetrical organs at either side become united in the middle line, and actually engrafted upon each other: the two eyes are conjoined so as to form but a single organ of vision, and the very same metamorphosis occurs in the two orbits, the two optic

foramina, the two optic nerves, &c. That this is the rationale can scarcely admit of a doubt, since in some parts of the organs the fusion remains incomplete ; thus two crystalline lenses still exist in the interior of the solitary eye-ball ; a double set of muscles, with their corresponding nerves, are provided for the globe of the eye ; and four eye-lids protect the organ in front, causing the aperture of the lids to assume a quadrangular form."

One of the most remarkable instances of monocus, or a single eye in its normal position, occurred in the Dublin Lying-in Hospital, about fifteen years ago, and from the recent spe-

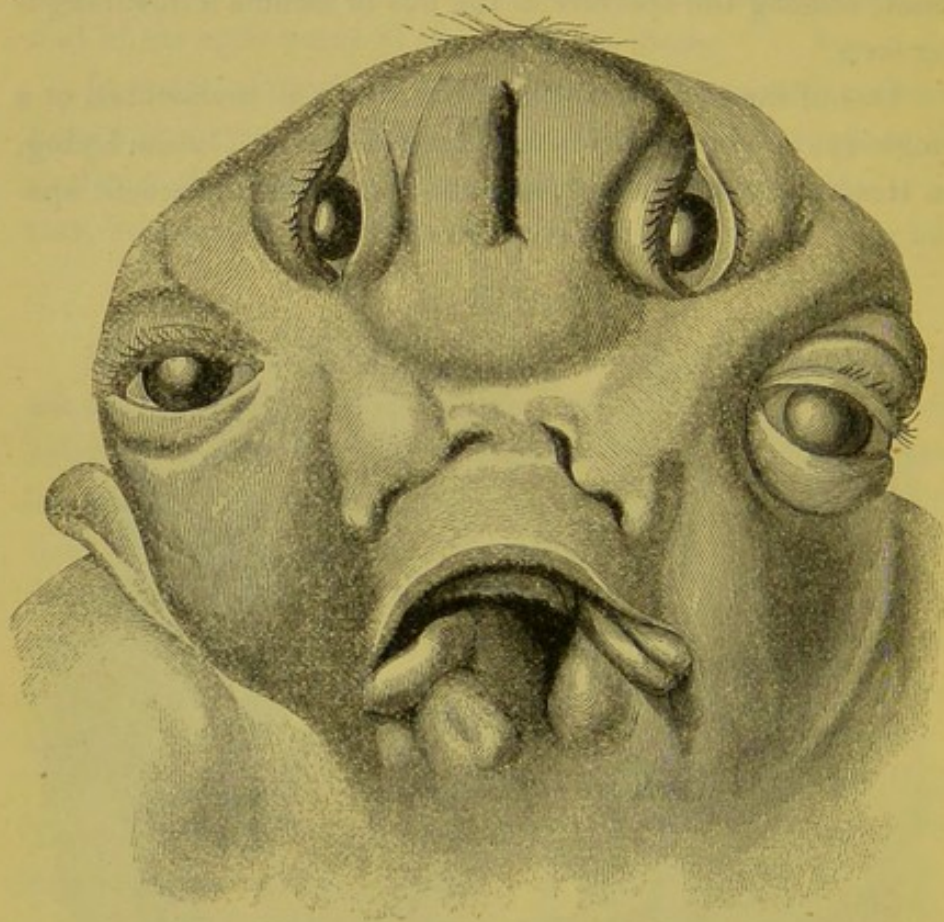


cimen of which case I had the accompanying illustration made. The foetus had nearly arrived at the full period ; one side of the head and a large portion of the face were deficient, and the parts were there attached to the shoulder, as shown in the

engraving. The preparation still exists in the Museum of the Lying-in Hospital.

PLURALITY OF EYES.

This peculiar form of malformation, to which may be given the name of polyoculi has not heretofore been mentioned by



authors. The accompanying illustration, from a drawing which I had made many years ago, of a four-eyed monster, which occurred in the Dublin Lying-in-Hospital, affords an example of this very rare malformation. This child was in other respects well formed; but the upper portion of the head and face was double, all the part below the nostrils being fused into one.

Vrolik, of Amsterdam, who paid much attention to the sub-

ject of Cyclopia, in 1834 and 1836, has divided this form of congenital malformation into five varieties:—1. Where the eye or eyes are not visible externally; in which there is a single orbit, with a slit between some folds of skin, marking the site of the eyelids; the orbital portion of the frontal bone generally absent, and no optic nerves. 2. A single eye, visible externally. 3. A single sclerotic, containing one or more of the internal parts in duplicate. With this variety there is generally a snout-like nose. 4. The division into two globes is more distinct than in the former case. 5. The eyes are double, partially or completely, but divided by a septum, and there is a proboscis-like nose.

The state of the eye-lids from a mere slit to that of a triangle, and finally a lozenge-shaped opening, depends upon the foregoing condition of the globe. It is manifest that the fusion of the eyes in cyclopia is a pathological condition consequent on an arrest of development in other and adjacent parts; and the state of the choroid and other internal structures depends on the greater or less amount of fusion of the corneæ and sclerotics.

FINIS.







