

**A monograph on diseases of the breast : their pathology and treatment,  
with special reference to cancer / by W. Roger Williams.**

**Contributors**

Williams, W. Roger

**Publication/Creation**

London : John Bale, 1894.

**Persistent URL**

<https://wellcomecollection.org/works/cmuyh8zh>

**License and attribution**


This work has been identified as being free of known restrictions under copyright law, including all related and neighbouring rights and is being made available under the Creative Commons, Public Domain Mark.

You can copy, modify, distribute and perform the work, even for commercial purposes, without asking permission.



Wellcome Collection  
183 Euston Road  
London NW1 2BE UK  
T +44 (0)20 7611 8722  
E [library@wellcomecollection.org](mailto:library@wellcomecollection.org)  
<https://wellcomecollection.org>










22101777788













A MONOGRAPH  
ON  
DISEASES OF THE BREAST

*THEIR PATHOLOGY AND TREATMENT*

With Special Reference to Cancer

BY

W. ROGER WILLIAMS, F.R.C.S.

LATE

*Surgeon Western General Dispensary, and Surgical Registrar Middlesex  
Hospital*

WITH 76 FIGURES

London

JOHN BALE & SONS

87-89, GREAT TITCHFIELD STREET, OXFORD STREET, W.

1894

[All rights reserved.]



	PAGE
mary Structures: mostly due to sequestration, rarely of atavistic origin—The Axillary Mammary Processes—True Axillary Polymastia extremely Rare—Axillary Galactoceles—Supernumerary Mammary Structures in the Vicinity of the Axilla—Paramammary Neoplasms arising from supernumerary Mammary Structures—The Frequency of such Cases demonstrated—Axillary Mammary Neoplasms—Important Bearing on Cohnheim's Theory—Cases of Fibroadenoma and Cancer thus arising—Schultze's Observations on the Development of the Mammaræ in Pigs, Rats, and other Multi-mastic Animals—The Mammary Ridges, &c. ... ..	43

## CHAPTER V.

## HYPERTROPHY.

Diffuse and Circumscribed Forms—Infantile Hypertrophy: usually associated with precocious Sexual Development—Diffuse Hypertrophy of Adults: illustrative cases of the types, correlated with puberty, pregnancy, &c.—Pathology, Etiology, Progress and Treatment—Partial Hypertrophy—Gynæcomastia ( <i>a</i> ) with healthy sexual organs; ( <i>b</i> ) with impaired development, disease or injury of the testes—In Male Animals—The Effects of Castration ... ..	82
---	----

## CHAPTER VI.

## HISTOLOGY AND NEOPLASTIC PATHOGENY.

Histology of the Mamma—Histological Metamorphoses of Lactation—Neoplastic Processes ... ..	113
--	-----

## CHAPTER VII.

## THE VARIETIES OF MAMMARY NEOPLASMS AND THEIR RELATIVE FREQUENCY.

Analysis of 13,824 Primary Neoplasms, showing their chief Seats in both Sexes—The great Frequency with which in Females the Reproductive Organs are attacked—The Majority of Mammary Neoplasms arise in the Seats of greatest Post-embryonic Developmental Activity, where Cells capable of Growth and Development most abound—The Relative Frequency of the Different Varieties of Mammary Neoplasms: analysis of 2,432 consecutive cases—Table showing the relative Frequency of Neoplasms in general, and of Female Breast Neoplasms—The Liability of the Breast to Cancer much above the average for the body in general—The great Frequency of Mammary Cancer; at least 10,000 women now suffering from it in England and Wales—The Influence of Sex in the Liability to Neoplasms; 99 per cent. of all mammary neoplasms occur in females—Functionless, obsolete Structures, like the Male Mammaræ, very rarely take on Neoplastic Action ... ..	127
--	-----

## CHAPTER VIII.

## THE PATHOGENESIS OF CANCER AND OTHER NEOPLASMS, WITH SPECIAL REFERENCE TO THE MICROBE THEORY.

Historical Review—Galen, Boerhaave, Hunter, Broussais, Müller, Virchow, and Cohnheim—The Author's Views—The Cell Theory and the Microbe Theory—The Microbe Theory, and the Broussaisian Doctrine of Irritation and Chronic Inflammation—Volkmann's Data controverted—Critical Examination of the Microbe Theory— <i>à priori</i> Reasons for regarding the Microbe Theory as Improbable	
---	--



# Synopsis of Contents.

V.

PAGE

—The Argument <i>à posteriori</i> —The Search for a Specific Cancer Microbe—Negative Results; Psorospermosis and Cancer; Inoculation Experiments; the Question of Infection and Epidemiology; Auto-inoculability; Traumatic Dissemination; Conclusion ...	132
---	-----

## CHAPTER IX.

### THE MORPHOLOGY OF MAMMARY CANCER.

Definition of the Term "Cancer"—Influence of Locality—Two Varieties of Mammary Cancer: the <i>tubular</i> and <i>acinous</i> —The Term "Encephaloid" discarded—Clinical Sketch of Acinous Cancer—Its General Morphology—The Primary Neoplasm—Histology—Karyokinesis and other Nuclear Phenomena—Pseudo-parasitic Endocytes—The Non-Specific Pathogenic Microbes of Cancer—Leucocytes—The Stroma—Ossifying, Chondrifying, and Calcifying Varieties—The Blood Vessels and Lymphatics of Cancer—The Absence of Nerves—Chemical Analysis—The Concomitant Hyperplasia and its Significance—The Nitric Acid Method of Examination—Local Dissemination—The Lymphatics of the Breast—Lymph gland Dissemination—General Dissemination—Cachexia—Recurrence—Inflammation, Gangrene, Ulceration, Degenerative Metamorphoses, the Question of Spontaneous Cure, &c. ...	151
--	-----

## CHAPTER X.

### THE GENERAL PATHOLOGY OF MAMMARY CANCER.

The Influence of Sex—Age—Complexion, Race, Geographical Distribution and Topography—Family History: (a) heredity, (b) correlated hereditary proclivities—The Prevalence of Cancer and its Increase—The General Health of Cancer Patients—Traumata, Chronic Irritation, and Cancer—Multiple Primary Cancer and the Association of Cancer with other Neoplasms—The Question of the Origin of Malignant from non-Malignant Neoplasms ...	233
---	-----

## CHAPTER XI.

### THE VARIETIES OF ACINOUS CANCER.

The Acute, Chronic, and Melanotic Types— <i>En cuirasse</i> —Atrophic and Colloid Varieties—Carcinoma Myxomatodes ...	318
---	-----

## CHAPTER XII.

### THE CLINICAL FEATURES OF MAMMARY CANCER.

Symptomatology: pain, retraction of the nipple, dimpling of the skin, discharge from the nipple—Differential Diagnosis: <i>induratio benigna</i> , chronic mastitis, tubercle, cold abscess, &c....	336
---	-----

## CHAPTER XIII.

### THE TREATMENT OF ACINOUS CANCER.

Operative—Inadequate Operations—Anatomico-pathological Memorabilia—The Essentials of a thorough Operation—The Necessity for Extirpating the whole Disease, as well as the whole Breast, and for Clearing the Axilla—The <i>Pectoralis Major</i> Muscle—Description of the Author's Operation—Antiseptic Precautions—Skin Grafting—The Mortality and Causes of Death after Operation—The Question of Radical Cure—Is Life Prolonged thereby?—Caustic Treatment—Palliatives ...	344
---	-----



## CHAPTER XIV.

## THE SO-CALLED VILLOUS DUCT CANCERS.

PAGE

The Prevalent Confusion as to the Nature of these Growths—Two Distinct Kinds of Neoplasms have hitherto been included under this Heading: the non-malignant <i>villous papilloma</i> and the malignant <i>tubular cancer</i> —Villous Papilloma, its Pathology and Treatment—Tubular Cancer, its Pathology and Treatment— <i>Épithéliôme tubulé...</i>	372
--	-----

## CHAPTER XV.

## CANCER OF THE MAMMARY INTEGUMENT.

Chronic Inflammatory Conditions of the Nipple and Areola preceding Cancer (Paget's Disease, &c.)—Butlin, Thin, and Duhring's Histological Researches—Darier, Wickham, and others on its Association with Psorospermia—Critical Review and Conclusion—Illustrative Cases—Treatment ... ..	393
--	-----

## CHAPTER XVI.

## CANCER OF THE MALE BREAST.

Analytical Summary of 100 Cases: (a) acinous, (b) tubular—Pathology and Treatment—Secondary Growths in the Bones—Cutaneous Epithelioma ... ..	403
---	-----

## CHAPTER XVII.

## SARCOMA OF THE BREAST.

Classification—Statistical Summaries—Adeno-sarcoma—Pure Sarcoma—The So-called Alveolar Sarcoma—Myxoma—Keloid and its Allies—Sarcoma of the Male Breast ... ..	417
---	-----

## CHAPTER XVIII.

## FIBROMA AND FIBRO-ADENOMA.

Pure Fibroma—"True Adenoma"—Fibro-Adenoma; its General Morphology, Pathology, Diagnosis and Treatment; Instances of Recurrence	458
--	-----

## CHAPTER XIX.

LIPOMA, CHONDROMA, OSTEOMA, ANGIOMA, PAPILLOMA, &c. ... ..	483
--	-----

## CHAPTER XX.

## CYSTIC DISEASE AND CYSTS.

Pathogenesis—Mucoid Cysts—Lacteal Cysts (galactoceles)—General Cystic Disease—Lymphatic Cysts—Hydatids—Sebaceous and Dermoid Cysts ... ..	492
---	-----

## CHAPTER XXI.

## NON-MALIGNANT NEOPLASMS AND CYSTS OF THE MALE BREAST.

Fibroma and Fibro-Adenoma—Villous Duct Papilloma—Lipoma—Chondroma and Osteoma—Angioma—Cysts ... ..	509
--	-----

# *Synopsis of Contents.*

vii.

## CHAPTER XXII.

### AXILLARY TUMOURS.

PAGE

Cutaneous Neoplasms—Moles, Nævi, Sebaceous Cysts, Molluscum, Papilloma, Melanoma, Sarcoma and Epithelioma—Axillary Mammary Neoplasms—Galactoceles—Angiomata—Cystic Tumours—Lymph-angiomata—Lipomata—Sarcoma and Myxoma—Fibrous, Cartilaginous and Osseous Tumours—Lympho-sarcoma—Lymph Glandular Tumours, &c. ... ..	516
--	-----

## CHAPTER XXIII.

### INFLAMMATORY AND SUPPURATIVE DISEASES.


Mastitis and Microbes—Chronic Mastitis—Diffuse, Periductal and Circumscribed—Chronic Abscess—Inflammatory Diseases of the Nipple and Areola—Acute Inflammation and Suppuration—Erysipelas ...	525
---	-----

## CHAPTER XXIV.

TUBERCLE, SYPHILIS, DIPHTHERIA, &c. ... ..	554
--	-----

## CHAPTER XXV.

TRAUMATA, NEUROSES, MINOR SURGERY ... ..	564
--	-----







# DISEASES OF THE BREAST.

---

## CHAPTER I.

### THE ONTOGENY AND PHYLOGENY OF THE BREAST.

---

#### § I.—Introductory.

THE extra-uterine continuation of the nutrition of the fœtus is effected through the mammæ—glandular organs destined to secrete milk for the nourishment of the young immediately after birth. Correlated with these important organs are other structural peculiarities, so that, since the time of Linnæus, morphologists have classified all animals having them in the same order under the name of "mammalia." All such animals are viviparous; their young are brought forth naked, without any fœtal envelopes or stored-up nourishment. Hence they usually depend for very existence upon the ability of the mother to nourish and protect them. The origin<sup>1</sup> of the mammæ is intimately connected with this helpless condition of the young.

---

<sup>1</sup> Mammalian animals are among the most highly organised and latest evolved. It was formerly thought that they came into existence at the commencement of the tertiary period; but it is now known that the leading types, as at present existing, were even then differentiated; and mammalian remains have since been found throughout almost the whole of the secondary or mesozoic rocks. As at present known mammals are completely isolated from all other groups of animals. Huxley believes we must go straight down to the amphibia for their nearest progenitors. According to Darwin, the descent of man from the lowest mammalia is through the ancient Monotremata to the ancient Marsupials, and from these to the early pro-



Both sexes of human beings, like all other mammalian animals, possess mammae; but in males they are usually small and functionless. It is only in females that they develop into true milk-secreting organs. In this their perfect state, the mammae must therefore be regarded as appertaining essentially to the female organisation. It is, however, certain that it was not always so. We must remember that the earliest and most primitive sexual relation was hermaphroditism; and that the separation of the sexes, as they at present exist, was only secondarily effected, by division of labour, in the gradual progress of evolution. Hence in every male we still find rudiments of female reproductive structures, and *vice versâ*. But it is chiefly in consequence of sexual selection that male animals differ so widely from their females, and that they tend to vary anatomically and pathologically in a different manner. Thus were developed the so-called "secondary sexual characters;"

---

genitors of the placental Mammals. Thence to the Lemuridae and through these to the Simiadae. The latter then branched off into two great stems: from the catarrhine or old-world division, of which—after they had diverged from the new-world division—man, at a late period, proceeded. The time at which this took place is still a matter of controversy. It is, however, much more remote than historians and chronologists have led us to believe. The oldest of such records prove that civilised communities and large states flourished in Egypt and some parts of Asia prior to 4000 B.C. In these countries, therefore, man must have had far higher antiquity than this. In Europe his presence can be traced in this way only to about 2000 to 3000 B.C. Geologists have, however, proved his existence at much more remote periods. Geikie says ("Prehistoric Europe," p. 2, *et seq.*): "We know now that many long centuries before the advent of the Romans our islands were occupied by a people whose knives and swords were fashioned of bronze; we know further that this people was preceded by a race or races ignorant of the use of metals, who lived during several considerable changes of climate and oscillations of the sea level; and we have also learned that at a still more remote period our country and the neighbouring parts of Europe were tenanted by tribes of yet ruder barbarians, during whose occupancy several extensive geological mutations occurred." On this subject Prestwich remarks ("Antiquity of Man," vol. ii., 1888, p. 534): "If we can be allowed to form a rough approximate estimate—on data as yet very insufficient and subject to correction—we may give to paleolithic man no greater antiquity than perhaps about 20,000 to 30,000 years; while should he be restricted to the so-called post-glacial period, this antiquity need not go further back than from 10,000 to 15,000 years before the time of neolithic man. The extreme antiquity of even 80,000 years (not to speak of 150,000 to 200,000 years) assigned to man, seems to me based on very inappreciable evidence."



that is, those differences between individuals of opposite sexes which appear, not in the sexual organs themselves, but in other parts of the body, such as the beard of man and the breast of woman. It is certainly very remarkable that in every female all the secondary male characters, and in every male all the secondary female characters, exist in a latent state, ready to be evolved under certain conditions. Thus in men and male mammals the breasts occasionally attain a large size and secrete milk. To account for the existence of male *mammæ* Darwin<sup>2</sup> suggests, that long after the progenitors of the whole mammalian order had ceased to be androgynous, both sexes yielded milk, and that the males aided the females in suckling their offspring; but that afterwards, from some cause (as from the production of a smaller number of young), the males ceased to give this aid; disuse of the organs during maturity would lead to their becoming inactive, and this state would be transmitted to the males at the corresponding age. Curiously enough, the male *mammæ* are much less completely aborted than are the other female reproductive structures rudimentary in man. Having no use, their persistence is remarkable, and indicates high antiquity.

## § II.—Ontogeny of the Gland.

The human breasts (*mammæ*), like those of all other *mammalia*, are generally regarded as greatly enlarged and modified cutaneous sebaceous glands. The observations of Champneys<sup>3</sup> on the development of mammary functions by the axillary sebaceous glands of women during lactation; as well as those of Duval<sup>4</sup> on the nature of the secretion of the acinous glands of the areola under like conditions, show that the difference between sebum and milk is only one of degree. In all this it

<sup>2</sup> "Descent of Man," 1879, p. 163.

<sup>3</sup> *Med. Chir. Trans.*, vol. lxix., 1886, p. 419.

<sup>4</sup> "Du Mamélon et de son Auréole," Thèse de Paris, 1861, p. 43.



appears to me there is nothing to countenance the extraordinary view recently advanced, that in human beings highly specialised organs like mammæ and teeth, which have taken immense ages to attain their present degrees of perfection, can be suddenly evolved, as "sports" from ordinary sebaceous glands and cutaneous epithelial processes respectively. I must protest against this assumption, which is a contravention of the fundamental principle of heredity; and as I have elsewhere shown,<sup>5</sup> the evidence on which it is based is altogether delusive.

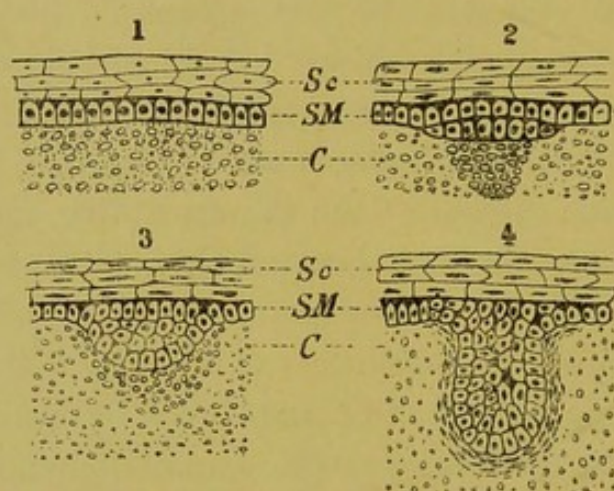


FIG. 1.—DIAGRAM SHOWING EARLY STAGES IN THE DEVELOPMENT OF THE BREAST.

Sc. Horny stratum. SM. Malpighian stratum. C. Derma (*Wiedersheim*).

The question has arisen whether the mamma is the homologue of a single sebaceous gland or of an aggregation of such glands. It appears to me that here we have but one reliable guide—viz., the ontogeny of the organ. Inasmuch as all observers are now agreed that the mamma is developed from but a single epithelial ingrowth, and that the form ultimately attained—in which the gland discharges by numerous ducts on the summit of the nipple—is due to secondary modification (kenogenesis), I am decidedly of the opinion that we must

<sup>5</sup> *Journal of Anatomy*, vol. xxv., 1891, p. 225.



regard it as the homologue of but a single specialised sebaceous gland.

Like all other glands opening on the free surface of the body, the mamma is developed from the deep cells of the epidermis by a process of continuously progressive ingrowing gemmation with differentiation (fig. 1). The process begins at about the third or fourth month of intra-uterine life by certain of the columnar cells of the Malpighian stratum in the site of the future organ, proliferating more rapidly than those adjacent (*SM.*). A solid, knob-shaped mass of proliferous epithelial

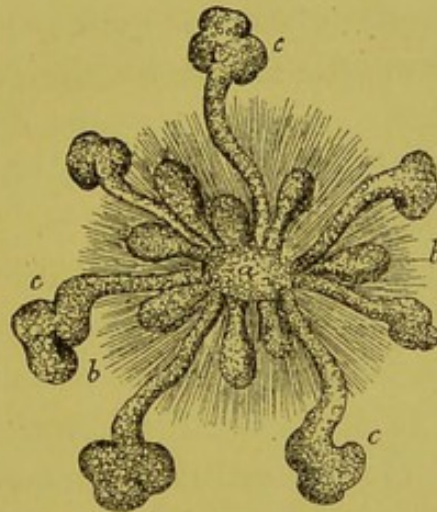


FIG. 2.—THE MAMMARY GLAND OF A MATURE FÆTUS.

(*a*) Primary ingrowth, with (*c*) secondary and (*b*) tertiary offshoots (*Langer*).

cells ingrowing into the subjacent derma is the result (primary epithelial deposit). About this knob the small, round-celled embryonic parablasic tissue aggregates and forms a zone from which the nipple is subsequently developed (nipple zone). A few weeks later, by repetition of the initial process, secondary buds arise from the primary ingrowth, and likewise grow into the adjacent structures as solid cellular plugs (secondary epithelial deposit). These form the first rudiments of the ducts and lobes, and it is only subsequently that they become excavated.

At this stage the nascent gland consists of a single branching system of proliferous epithelial cells ingrowing into the



surrounding tissues. In the derma, beneath the nipple zone, there now becomes differentiated a fresh zone of embryonic parablastic tissue, from which the stroma of the gland is developed (stroma zone).

In the next stage the primary epithelial ingrowth undergoes retrogressive metamorphosis, often with a certain amount of cornification, and these changes eventually lead to its complete disappearance. At the same time the secondary epithelial ingrowths undergo further development; they become hollowed out and give off numerous club-shaped buds at their extremities—the rudimentary lobules. In connexion with these, small aggregations of irregularly shaped epithelial cells subsequently appear, which constitute the matrix for the development of the true secreting glandular parenchyma—the acini. Towards the end of intra-uterine life each lobe has developed a single external opening or duct.

At birth the organ consists of from fifteen to twenty lobes, the excretory ducts of which are excavated and lined with a single layer of small cubical cells, the rest of the organ being still solid (fig. 2). “In newly-born children,” says Langer,<sup>6</sup> “we rarely find anything more than the principal ducts, with some indications of ramification in the form of two or three club-shaped processes; and even if these be somewhat more developed, the terminal vesicles are always absent, even in those cases where fluid is secreted.” This description has hitherto been generally accepted, but it is now known to be true only for stillborn children and for those who have died immediately after birth. De Sinéty<sup>7</sup> has found that during the first ten days of extra-uterine life considerable formative changes take place in the gland; so that if it be examined at the end of this period some acinous tissue can always be found, resembling that of the adult female mamma during lactation, and capable under certain conditions of secreting milk. These changes occur in both

<sup>6</sup> “Stricker’s Histology,” *Sydenham Society’s Transl.*, vol. ii., p. 281, 1873.

<sup>7</sup> “Recherches sur la Mamelle des Enfants Nouveau-nés,” *Archives de Physiologie*, p. 293, 1875.



sexes, and they are described by Variot<sup>8</sup> as attaining their maximum between the eighth and fifteenth days after birth. Similar observations have been made by Kölliker.<sup>9</sup> Whence it follows that the secretion of milk is natural in the newly born of both sexes. The male mammæ being functionally inactive continue in this imperfectly evolved condition throughout life, although they generally manifest some temporary disturbance at puberty.

At this period in females remarkable structural changes set in, but it is not until after conception that the organ attains its full development. Before puberty the female breast consists chiefly of excretory ducts, but as this period approaches the true secreting structure arises by the abundant new formation of glandular acini. This wonderful post-embryonic transformation is brought about by progressive gemmation, with subsequent differentiation, in the same way as the initial embryonic development, of which it is but a superinduced repetition. Thus we see that between embryonic and post-embryonic developmental processes there are no differences other than those of degree. In the words of Paget—"It is one and the same power which, being maintained continuously from the germ to the latest period of life, determines all organic formation." The commencement of this mammary rejuvenescence usually precedes the first catamenial period, and at every subsequent period more or less temporary sympathetic reaction is excited. But the most important changes are those induced by the stimulus of conception, which converts the previously functionless structure into an active milk-secreting gland. During this period the acini attain their highest degree of structural perfection. This, however, is but a transitory condition which ceases after a time, when the stimulus is withdrawn, and is again renewed on its repetition. During the intervals between

<sup>8</sup> *Gazette Médicale de Paris*, Oct. 4, 1890. "Remarques sur la Sécrétion Lactée chez les Nouveau-nés."

<sup>9</sup> "Brustdrüsen der Neugeborenen," *Verhandl. d. phys. med. Ges. zu Würzburg*, N.F., Bd. xiv., 1880, s. 144.



these periods the breast remains in a functionless resting state. These and many other similar facts show that normal tissues may remain quiescent for long periods, and then suddenly take on new phases of growth and development. In this way, then, the whole organ is gradually evolved from the columnar cells of the epidermis.

A gland in its simplest form is merely a modification of a single epithelial cell; and, according to Goodsir,<sup>10</sup> each acinus of the more complex glands consists at first of but a single epithelial cell. It seems not improbable that the initial germ of the mammary gland itself may be of this simple nature.

This account of its ontogeny is chiefly after Rein,<sup>11</sup> Hüss,<sup>12</sup> Kölliker<sup>13</sup> and Langer.<sup>14</sup> Creighton<sup>15</sup> has given a very different description of the process. According to him the development of the mammary acini is step for step the same as that of the fat lobules, and the ducts arise from the same parablasic matrix; therefore, the homologue of the mamma is not a cutaneous gland, but a "fat body." These heterodox views have not been confirmed by subsequent observers—*e.g.*, Rein and Bowlby.<sup>16</sup>

### § III.—Ontogeny and Phylogeny of the Nipple.

The nipples (*mammillæ*)—papilla-like outgrowths adapted for being sucked—do not develop until after the glandular elements have been formed, and sometimes they never arise. These ontogenetical phenomena are of great interest from the standpoint of phylogeny, because the lowest mammals—the monotremata—have no nipples. In them the milk simply emerges by numerous ducts through a sieve-like perforated

<sup>10</sup> "Anatomical Memoirs," vol. ii., p. 422, 1868.

<sup>11</sup> *Arch. f. mik. Anat.*, Bd. xx., 1882, s. 431; also Bd. xxi., s. 678.

<sup>12</sup> *Jenaische Zeitschr.*, Bd. vii., 1873, s. 176.

<sup>13</sup> *Entwicklungsgeschichte des Menschen*, 1878, s. 799.

<sup>14</sup> *Denkschriften der Wiener Akad. der Wissenschaften*, Bd. iii., Lief 2.

<sup>15</sup> *Journal of Anatomy*, vol. xi., p. 1; also "Physiology and Pathology of the Breast," p. 83, 1878.

<sup>16</sup> *Brit. Med. Journal*, 1882, vol. ii., p. 1143.



patch of the abdominal skin, from which the young animals have to lick it. These ducts open either on a flat surface (*ornithorynchus*) or into a pouch of the integument (*echidna*). From this it may be inferred—inasmuch as the ontogeny of organs generally represents and accords with their phylogeny—that our mammalian progenitors had no nipples, though they had the glands. The marsupials differ from the monotremata

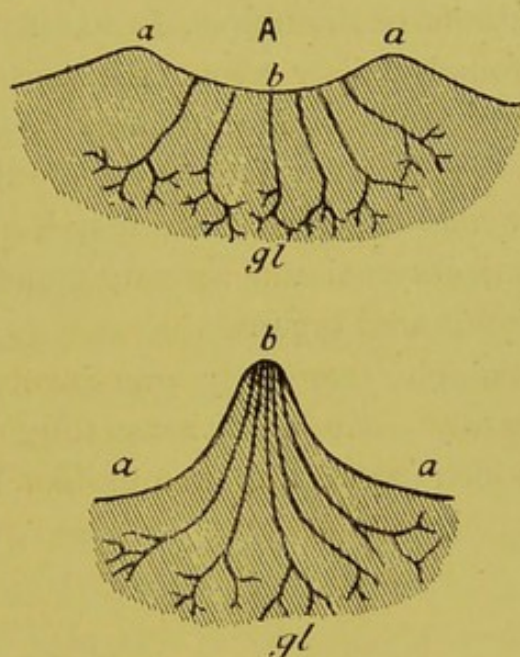


FIG. 3.—DIAGRAM OF THE DEVELOPMENT OF THE NIPPLE.

A. Indifferent stage: glandular area depressed. B. Elevation of the glandular area with the nipple.

(a) Periphery of glandular area. (b) Glandular area. (gl.) Glandular elements (*Gegenbaur*).

in possessing nipples. According to Darwin, these structures were first acquired by marsupials after they had diverged from and risen above the monotremata, and were by them transmitted to the placental mammals. In human beings at an early stage of development the site where the nipple will subsequently appear is marked by a depression, towards the bottom of which the ducts of the gland converge (fig. 3, A *b*). Owing to arrest of development at an early stage this rudimentary state may persist throughout life; and such malformations are met with

both in the normally placed and in the supernumerary nipples. They remind us of the mammary pouch of *Echidna*. The further development of the nipple is effected by the area of skin, perforated by the ducts, being raised up into the form of a papilla, above the level of the rest of the integument (fig. 3, Bb). When the whole of the cutaneous area perforated by the ducts of the nascent gland is not integrated with the developing nipple, then such of the ducts as are left behind, instead of opening on the summit of the nipple, do so on the areola, where they are to be found chiefly about the base of the nipple. Thus the so-called glands of Montgomery (*glandulæ lactiferæ aberrantes*) arise. From the frequency of these and other somewhat similar malformations, we may conclude that the mammæ, like the lachrymal and salivary glands, are normally very imperfectly integrated organs.

At birth the nipples are fairly prominent in both sexes. Their ducts generally contain disintegrating epithelial cells which sometimes deliquesce into a milk-like fluid.



## CHAPTER II.

## MORPHOLOGY, SECRETORY ANOMALIES, ETC.

## § I.—Post-embryonic Variations.

THE size and shape of the breasts present many variations, according to the influence of sex, age, function, idiosyncrasy; genital, racial and climatic conditions. Some of the most important of these changes have been briefly sketched in the preceding chapter. A few supplemental remarks are now necessary.

At puberty the female breast attains its typical form, which is due even more to overgrowth of its fibro-fatty envelope than to the glandular ectasia. At this period, and at all subsequent stages of female organisation, the correlation between the mammary development and that of the internal sexual organs is a marked feature. Hence derangements of the latter often determine abnormal activity in the former. The development of the breasts at puberty is almost invariably symmetrical; but it is occasionally delayed in one of the glands, even for several years, and this although the catamenia have been normally established.<sup>1</sup> Sometimes developmental retardation affects both breasts. Premature mammary development is occasionally met with, mostly in association with precocious sexual evolution.

The changes that take place in the breasts during pregnancy are briefly as follows. At about the second month they get

---

<sup>1</sup> For cases *vide Gaz. des Hôpitaux*, No. 24, 1881, p. 1074; and *New York Medical Record*, Oct. 10, 1891, p. 448.



tender and begin to enlarge. As the process advances this enlargement becomes more obvious ; at the same time they get harder, and bluish veins become visible in the skin, especially around the areola. This increase in size is almost entirely due to physiological overgrowth of the glandular parenchyma—lobes, lobules and acini ; and it is accompanied by absorption of the interlobular fat, so that the fully evolved mamma, like the pancreas and other actively secreting glands, consists almost entirely of parenchymatous tissue, and this causes the organs to feel nodulated. But the most characteristic signs of pregnancy are those associated with the nipples and areolæ. These parts deepen in colour and become turgid. The nipples become covered with minute branny scales, from desiccation of escaped colostrum-like fluid, which even as early as the third month can generally be squeezed from them. The areolæ get moist ; and a number of small tubercles (tubercles of Montgomery) develop in them, forming a circle around the nipple. As pregnancy advances they become still more prominent. These signs are more reliable in primiparæ than in multiparæ. The first flow of milk usually sets in about the second or third day after delivery, and it is generally accompanied with some constitutional disturbance. Its normal duration is from twelve to eighteen months, and while it lasts the catamenia are usually in abeyance. In those who do not suckle it usually ceases in from two to three weeks. After premature births, and even after abortion at the second or third month, the lacteal secretion is established, as in women who have gone to their full term. After lactation the breasts gradually revert to the state of passive maturity. The involution process is characterised by extensive atrophy of the glandular tissue, with re-formation of fat in the stroma ; but the gland never quite recovers its virginal condition. An excess of lax fibro-fatty tissue remains, and its peripheral processes have become elongated and widely diffused. The skin covering the virginal breast is thin, smooth, supple and of great delicacy. After its distension in association with pregnancy or other causes, it often becomes marked by fine



white striæ (*lineæ atrophicæ*). Marks of this kind have very exceptionally been met with in nulliparæ.

With the decline of reproductive activity at the climacteric period, retrogressive changes set in and the glandular parenchyma begins to disappear, and the breasts diminish in size. As age creeps on, these changes become more marked, and the peripheral processes waste away. At length, of the once active gland there remains nothing but the ducts, with here and there a few isolated acini that have survived the general dissolution. These fragments are embedded in a stroma of dense fibrous tissue, interspersed with fat. Degenerative changes in connection with them not unfrequently originate small, multiple cysts—the so-called involution cysts. The peculiar hardness of cancer arising at this period is due to the density of this fibrous stroma, in which the rapidly increasing cellular elements of the disease are confined. In obese women the fibrous tissue is largely replaced by fat.

## § II.—Secretory Anomalies.

In connection with the functional activity of the breast the following anomalies may be met with :—

(1) *Agalactia*, or complete failure of the lacteal secretion is a rare phenomenon. In cases of this kind the breasts undergo no change during pregnancy, nor after *accouchement*. There is usually no obvious mammary defect, the subject appearing to be in all respects normal. Several instances of its hereditary occurrence have been recorded.<sup>3</sup> Puech<sup>4</sup> mentions the case of a woman, the mother of thirteen children, whose breasts had never yielded a drop of milk, although they were of normal configuration. Her mother gave birth to twenty-three children, but like her daughter, her breasts never yielded any milk.

<sup>3</sup> Capron, "Anomalies de la sécrétion mammaire," Thèse de Paris, 1877.

<sup>4</sup> "Les Mamelles et leurs Anomalies," Paris, 1876.



When this anomaly is met with, both breasts are usually affected, but sometimes only one.

Various degrees of defective lacteal secretion, short of agalactia, are of common occurrence. Both breasts are usually affected. The quantity may be unduly small, it may be of poor quality, or it may cease before its proper time. These conditions are generally associated with ill-health, in which anæmia is a prominent factor.\* In their *treatment* good feeding, rest—mental and bodily—appropriate tonic medicines, frequent and regular *suction* of the nipples, either by mouth or with a special apparatus, together with electricity and massage applied to the breasts, ovarian and spinal regions, are the means most to be relied on. Coffee, jaborandi and tasi have been recommended as galactagogues.

(2) *Galactorrhœa* is the term applied to excessive lacteal secretion. This excess may manifest itself in the great quantity produced within a given time, or in undue prolongation of the lactation period. It has been estimated that lactating women in the prime of life normally yield about 1,300 grammes of milk in twenty-four hours. Puech refers to a case of galactorrhœa in which the patient lost a litre of milk every six hours, and in a case by Mussy, seven litres were secreted daily. Excessive hypersecretion is a serious disease, leading to loss of appetite, emaciation, anæmia, and hectic symptoms. The lactation period may be unduly prolonged for a few months, or for several years—even for twelve years and upwards. In this connection one naturally recalls the persistent lacteal secretion of cows. A writer in an old edition of the "Encyclopædia Britannica"<sup>5</sup> expresses himself on this subject as follows:—"In Europe the constant practice of milking cows has enlarged the udder greatly beyond its natural size, and so changed the secretion, that the supply does not cease when the calf is removed. In Columbia, where circumstances are entirely different, nature

---

\* *Vide* also chapter iii., § 4.

<sup>5</sup> Seventh edition, vol. ii., p. 653.



shows a strong tendency to assume her original type; a cow there gives milk only while the calf is with her." As in agalactia, both breasts are usually affected, but sometimes only one, and instances of its heredity have been reported.

In the *treatment* of galactorrhœa suckling should be abandoned, and endeavours should be made to re-establish the catamenia. Of local applications the mixture of belladonna and iodide of lead is the most likely to be useful, cocaine and mint are also said to have antigalactogogic effects; with these compression may be combined. Internally, iodide of potassium with bromide of potassium are indicated; and in the event of these failing antipyrin<sup>6</sup> may be tried.

(3) *Heterochronous Lactation*.—It has been proved by De Sinéty and others, that the secretion of a small quantity of milk shortly after birth is of normal occurrence in children of both sexes. When milk is secreted at any other period, except in connection with pregnancy, it is heterochronous. Heterochronic lactation has been very seldom met with before puberty; but Baudelocque mentions the case of a girl, eight years old, whose breasts secreted milk after she had allowed a child to suck them for some time. In young girls at puberty a few drops of mucoid or lactescent fluid are often secreted, and also at the catamenial periods. Similar conditions have been observed in association with mammary tumours and certain chronic diseases of the uterus and ovaries. Independently of such conditions, however, heterochronous lactation has been observed in non-pregnant women, and in those who have never experienced sexual intercourse. Cases of this kind have been recorded by Beigel, Capron, Duval, Montgomery, Puech, Johnston, Engström\* and others. There can be no doubt but that mechanical irritation of the nipples, &c., is a powerful excitant of lactation; and most of the recorded cases are attributable to this cause. Similar instances have been met with in various animals. In some few

<sup>6</sup> For two cases of Suppression of Lacteal Secretion by Antipyrin, *vide Arch. de Toc. et de Gyn.*, juin, 1892.

\* *Ann. de Gyn.*, t. 31, 1889, p. 283.



cases lactation is said to have been established in women even long after the climacteric (Heister, Beigel, &c.).

Engström reports the following case :—

A Jewess, aged 36, in whom the catamenia first appeared at 17, and subsequently remained regular, although there was pain at each period. She had never been pregnant. After recovery from the removal by laparotomy of a large dermoid cyst of the left ovary of eight years' obvious duration, she experienced a great desire to have a child. A few months afterwards the *mammæ* enlarged, and milk began to flow freely from both breasts, although menstruation continued regularly. She thought herself pregnant, but it was not so. The discharge continued for two years.

Instances of the establishment of lactation in man and male animals have also been recorded (*q. v. ch. v., § 6*).

### § III.—The Morphology of the Gland.

In well-developed females after puberty but before pregnancy, the breasts present as hemispherical swellings at the front of the upper part of the chest on each side. The extreme limits of their external configuration extend in the vertical direction, from about the third rib above to the seventh below; and laterally, from near the edge of the sternum to the anterior border of the axilla, but peripheral processes of the *corpus mammæ* reach beyond these limits. Their external configuration depends mainly upon the amount of adipose tissue present; hence the largest seldom give the most milk. Pressure on the breast causes a feeling of nausea, and when extreme may even excite vomiting. Well-marked fibrous trabeculæ—the so-called suspensory ligaments of Astley Cooper<sup>7</sup>—unite the gland to the overlying skin (fig. 4 *x.*); and according to Giralès<sup>8</sup>, through the superficial fascia it is connected with the clavicle.

In healthy young women the breasts stand out from the chest wall by virtue of their own resiliency; but after pregnancy

<sup>7</sup> "The Anatomy of the Breast," p. 49.

<sup>8</sup> *Mém. de la Soc. de Chir. de Paris*, 1851, t. ii., p. 198.



they are generally lax and pendent. The artists of ancient Greece regarded no breasts as truly beautiful that could not be covered by the hand. The women of tropical countries usually have much larger and more pendent mammæ than their European sisters ; and residence in tropical climates tends to produce this condition, even in the latter. In certain of the lower races, *e.g.*, negresses, Hottentots,<sup>9</sup> &c., the breasts are often very large and lax, reaching even as low as the groins, so that the mother can suckle her child when carrying it on her back by throwing the breast over her shoulder.

Most authors are agreed that the *left* mamma is rather larger and heavier than the right, that its association with the pelvic sexual organs is the more intimate, and that it is the more prone to hypertrophy, and to originate cancer and other neoplasms. This difference in size is probably due to the fact that most mothers, being right-handed, suckle chiefly with the left breast. Hennig<sup>10</sup> and Puech<sup>11</sup> are among the few who controvert these statements. I can confirm the last of them from my own experience.<sup>12</sup>

The average weight of the mamma, according to Hennig, is from 160 to 556 grammes.

From the summit of the breast, near its centre, projects the nipple, surrounded by the areola. In women, other than young virgins, its position is inconstant ; but in the latter, as in men, it is usually placed over the fifth rib,<sup>13</sup> at about three-fourths of an inch external to the junction of the rib with its cartilage.

<sup>9</sup> For an account of the celebrated "Hottentot Venus," with an excellent coloured drawing, see Art., "Femme de Race Boschismanne," St. Hilaire, and Cuvier's *Nat. Hist. des Mammifères*, t. i. (1824), p. 1.

<sup>10</sup> *Arch. f. Gyn.*, Bd. ii. (1871), s. 331.

<sup>11</sup> "Les Mamelles et leurs Anomalies," Paris, 1876, p. 17.

<sup>12</sup> *Vide Middlesex Hospital Surgical Reports*, 1888, p. 87, and 1889, p. 81.

<sup>13</sup> In nearly all English text books the male nipple is said to be placed between the fourth and fifth ribs. This subject has been very carefully investigated by Wenzel Grüber (*Mém. de l'Acad. imp. de St. Petersbourg*, vii., 1866, série t. x., No. 10), with the following results:—Of 100 individuals the nipple was found, in 12 over the fourth rib ; in 31 over the fourth intercostal space ; in 43 over the fifth rib, and in



The mammary gland proper (*corpus mammæ* of Henle) is embedded in fibro-fatty tissue. Freed from these surroundings it is usually described as an irregularly circular flattened mass, thicker at the centre than at the circumference; but this description is very inadequate, as I shall presently have occasion to show. Its axillary and inferior segments are much more bulky than the rest. Connected with the summit of its anterior convex surface are the excretory ducts, one for each lobe, which converge towards the nipple. This surface is separated from the skin by a thick fatty layer (fig. 4, *c.c.*), except beneath the

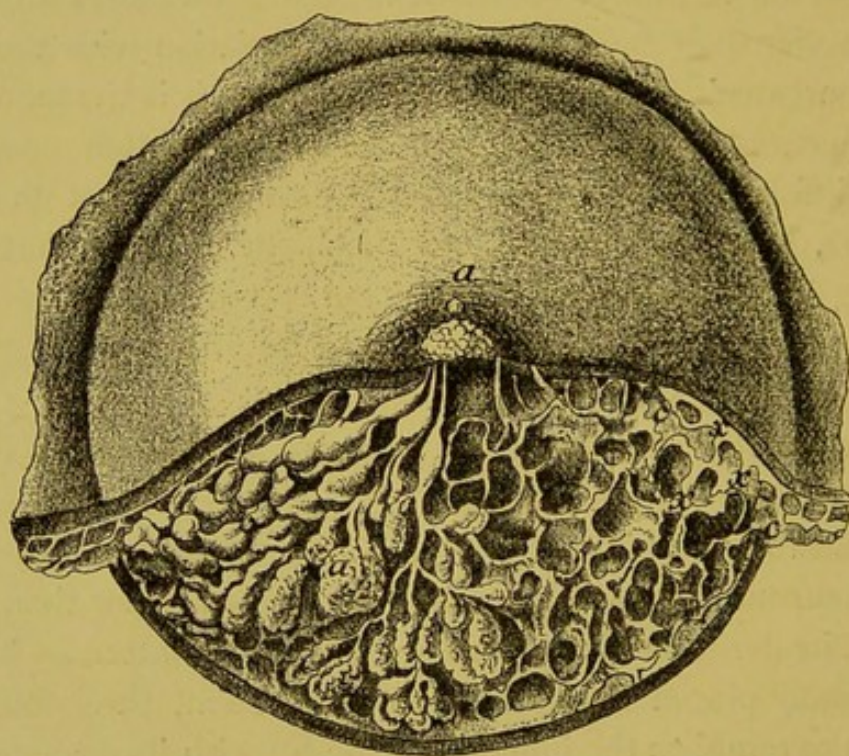


FIG. 4.—MAMMARY GLAND OF A LACTATING WOMAN.

(*a*) Orifice of glandula aberrans; (*b*) Sinus lacteus; (*c*) Fatty layer; (*d*) Lobule of the gland; (*x*) Fibrous septum connected with the cutis (*Luschka*).

nipple and areola, where there is no fat. Posteriorly, its slightly concave base rests for the most part upon the thin sheath of the pectoralis major muscle, from which it is separated only by loose areolar tissue, in which numerous outlying glandular pro-

---

9 over the fifth space. On the other hand, of 60 persons examined, *Luschka* (*Anatomie*, Bd. i.) found that the nipple was situated, in 6 over the third rib; in 8 over the fourth rib, in 44 over the fourth space, and in 2 over the fifth space.



cesses may usually be found. According to Stiles, about one-third of the whole gland lies below and external to the axillary border of the pectoralis major. Behind the gland the fatty envelope is scanty or imperfect, and the glandular lobules come into close relationship with the muscle (Heidenhain). It is important to remember this when removing malignant tumours of the breast. Sometimes a serous bursa is met with here.

Very misleading are the accounts of the gland that describe it simply as a flattened circular mass. The truth is, as Hennig<sup>14</sup> has so well shown, the fully developed female mamma has normally a tricuspid form, two of the cusps project towards the axilla—an upper and a lower one—and the other towards the sternum. The upper of these two axillary mammary extensions is frequently prolonged round the border of the pectoralis major muscle right into the axilla; and the same occasionally happens with the lower one. The sternal process sometimes reaches as far as the edge of the sternum, which it occasionally overlaps. In the ordinary operation of amputation of the breast these processes are almost invariably cut off and left behind. Though commonest in the axillary and sternal regions, similar smaller processes spring from other parts of the surface of the gland, and radiate in the paramammary fatty tissue. On this subject, Astley Cooper<sup>15</sup> remarks: "The margins of the breast do not form a regular disc, but the secreting structure often projects into the surrounding fibrous and adipose tissues so as to produce radii from the nipple of very unequal lengths, hence, a circular sweep of the knife cuts off many of its projections, spoils the breast for dissection, and, in surgical operations, leaves much of the disease unremoved." Stiles<sup>16</sup> describes glandular processes of this kind springing from the anterior surface of the gland, as being contained within the so-called ligaments of Cooper, which bring them into close proximity with the corium. Whence

---

<sup>14</sup> "Ein Beitrag zur Morph. des weib. Milch-drüse," *Arch. f. Gyn.*, Bd. ii., 1871, s. 331.

<sup>15</sup> "The Anatomy of the Breast," 1840, p. 13.

<sup>16</sup> "Surgical Anatomy of the Breast," *Edin. Med. Journ.*, June, 1892, p. 1105.



it follows that to completely extirpate a cancerous gland, the over-lying skin must be freely sacrificed. These peripheral processes are longer and more attenuated in multiparous than in nulliparous glands. From all of this, it will be gathered that the female mamma is naturally—like the salivary and lachrymal glands—a very imperfectly integrated organ, for its constituent lobules, instead of being compacted together in a small space, are generally widely diffused, and some of them are completely sequestered. From these isolated supernumerary mammary structures, as I shall elsewhere show, neoplasms frequently arise.

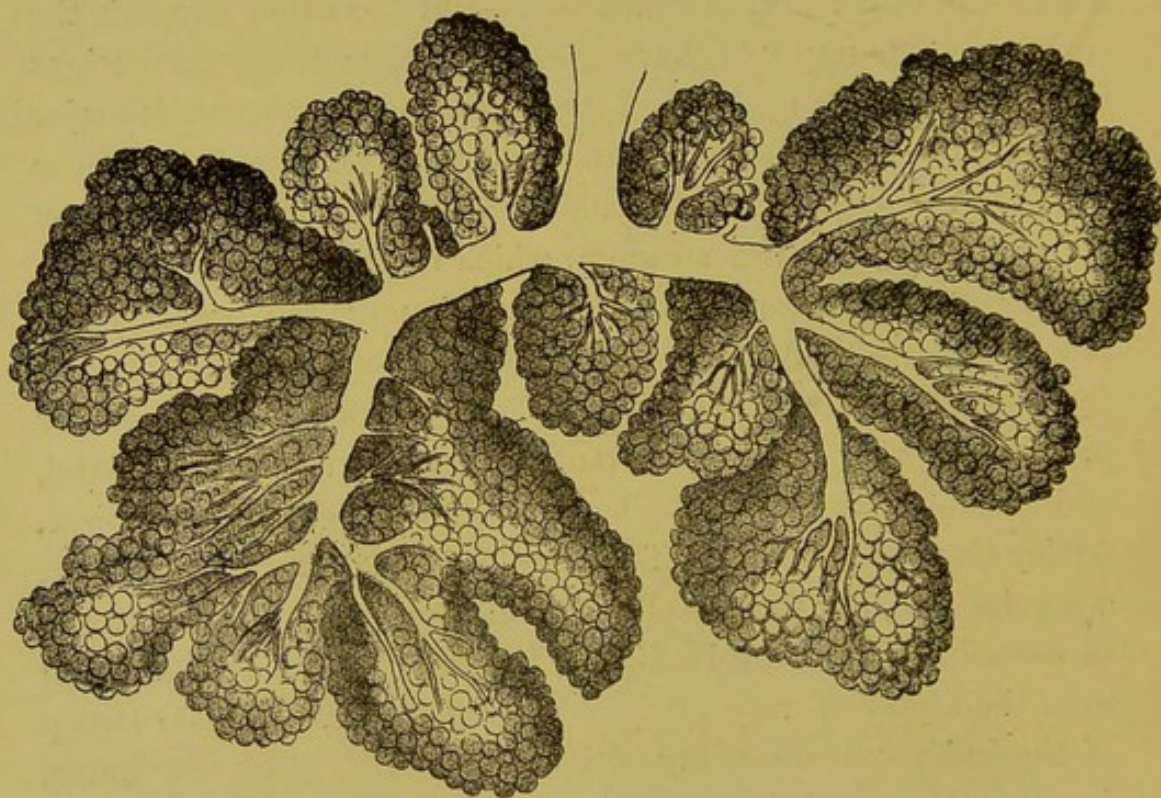


FIG. 5.—Injected lobule of the mammary gland in lactation,  $\times 70$  (*Langer*).

The mamma is a gland of the compound racemose order, and, like all such, it is composed of excretory duct *tubes*, and of secreting *acini* (fig. 5). The secreting part is made up of from fifteen to twenty distinct lobes, each of which consists of numerous lobules, of which the acini or dilated terminations of the ducts are the proximate constituents. Each lobe has its own excretory (*galactophorous*) duct, which opens separately on



the summit of the nipple; and, as a rule, there is no communication between adjacent ducts. As these converge towards the base of the nipple, where they lie beneath the areola, each duct presents a fusiform dilatation (*sinus lacteus*, fig. 4), which acts as a reservoir for the milk. In many animals (*e.g.*, cow, mare, ewe, goat, &c.) these sinuses attain great size. In the cow they are often capable of retaining more than a quart of milk. Velpeau has met with instances in which the walls

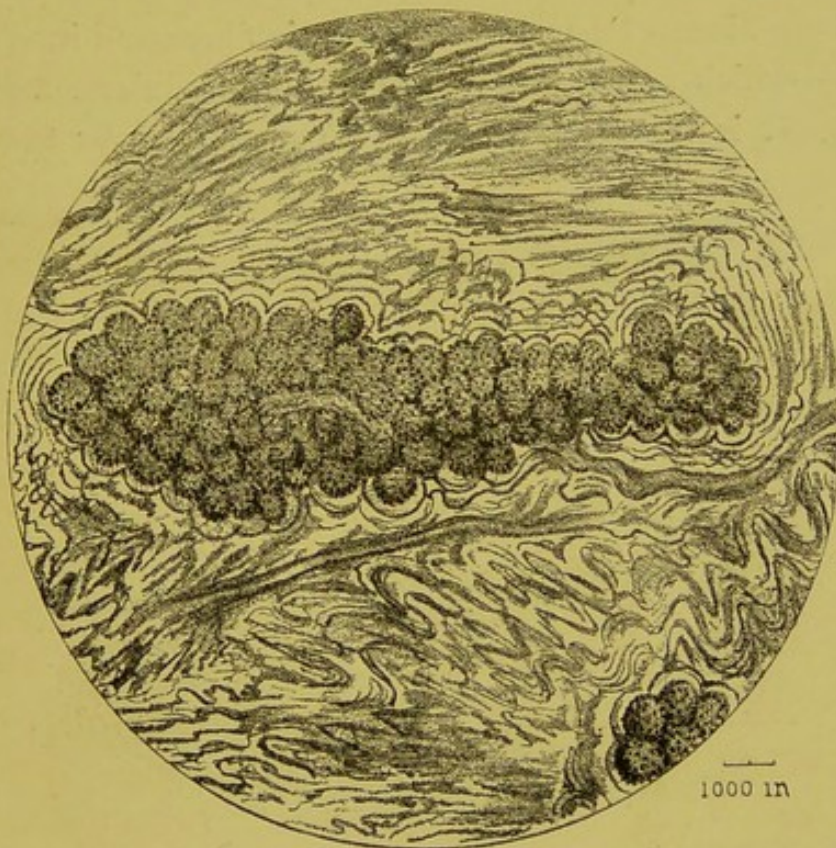


FIG. 6.—Section of normal mammary gland, showing a lobule and its duct, and the abundance of the fibrous stroma (*Nunn*).

of the mammary ducts were calcified. In their course through the nipple the ducts maintain a uniform calibre, but their external orifices are markedly contracted. As seen in transverse sections, they present a corrugated appearance, owing to their wall falling into numerous folds when not distended. According to Sappey, each duct has a well-developed coat of longitudinal organic muscle, in addition to a connective tissue sheath, rich in elastic fibres. Outside the latter the ducts are



surrounded by numerous irregular bands of organic muscles, most of which are horizontal. These increase in size and number during pregnancy and lactation. It is owing to their contraction, under the influence of slight frictions, voluptuous ideas, &c., that the nipples harden and become more prominent (*thelothism*).

A fibrous membrane envelops each of the constituent parts of the gland, but there is no capsule in the ordinary sense. These are invested and firmly held together by abundant dense fibrous tissue—rich in elastic fibres and interspersed with fat—which penetrates between the glandular subdivisions (fig. 6). It is to the presence of so much fibrous tissue that

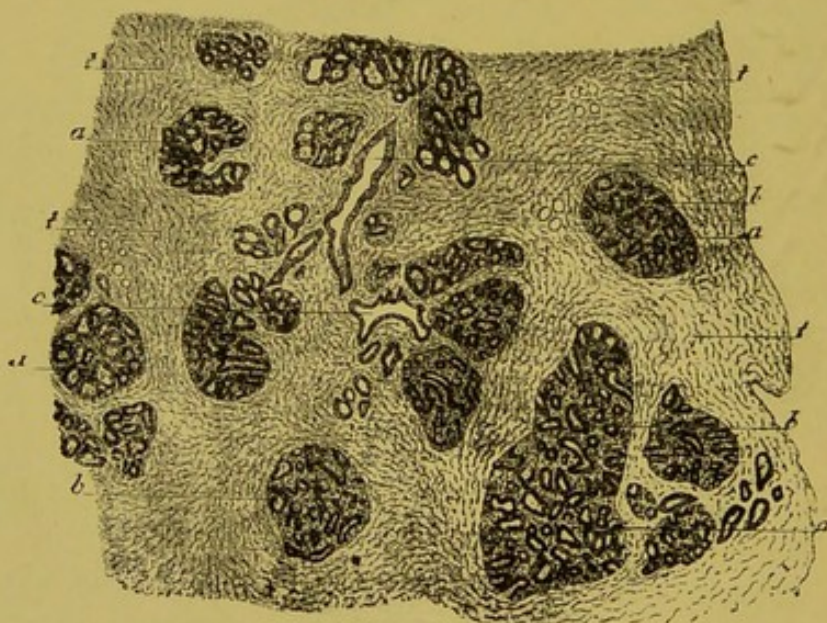


FIG. 7.—SECTION OF THE GLAND DURING LACTATION.

(a) Lobules ; (b) Acini ; (c) Ducts ; (t) Fibrous stroma (20 dia.). (*De Sinéty.*)

the gland owes its characteristic hardness and toughness. Calcareous and cartilaginous nodules are occasionally found in the stroma; and in old women, very exceptionally, it has been found completely calcified, as in cases recorded by Bryk,<sup>17</sup> Bérard,<sup>18</sup> Bonnet, and Morgagni.

<sup>17</sup> "Eine petrificirte Brustdruse," *Arch. f. klin. Chir.*, Bd. xxv., 1881, s. 808.

<sup>18</sup> Velpeau, "Maladies du Sein," Paris, 1854, p. 295.



## § IV.—The Nipple and Areola.

The nipple is the somewhat conical, dusky outgrowth that projects from the summit of the breast. As already mentioned, it contains the excretory ducts of the gland, which converge to its apex, where they open separately, in minute depressions, between the rugæ of the cutis. In shape, length, size, &c., the nipple is extremely variable. In many cases it is so short as to render suckling difficult; and not infrequently it is retracted to such a degree as to incapacitate the mother for this important duty.

The deeply-coloured circular area surrounding the nipple is the areola. Like the nipple it varies much in size and in other respects. Its usual diameter is from one to two inches. In the "Hottentot Venus" the areolæ attained the great size of four inches in diameter.

The skin of the nipple and areola differs strikingly, in several respects, from the general integument. Owing to the presence of pigment in the cells of the Malpighian layer, it is of a darker colour than any other part of the external skin. In young virgins it is pale brown or pinkish, but after pregnancy it permanently acquires a much darker shade. Other variations in colour occur in connection with complexion, race, and sexual conditions. The skin of these parts is extremely thin, and intimately blended with the subjacent connective tissue, without the interposition of the usual fatty layer. Its rugose condition is mainly due to connections with numerous irregularly disposed bands of organic muscle, which are really derived from the normal skin muscles. In the nipples horizontal fibres usually predominate; but sometimes longitudinal fibres are in excess. According to Sappey and De Sinéty,<sup>19</sup> most cases of retracted nipples, not of congenital origin nor due to organic disease, must be ascribed to overaction of

---

<sup>19</sup> "Des causes anatomiques de la rétraction du mamélon." *C. R. de la Soc. de Biologie*, 1876.



the latter. Beneath the areola, intimately blended with the overlying skin, is a well marked layer of organic muscle, consisting of irregularly disposed concentric rings. The mammillary and areolar integument is thickly studded with papillæ, those of the nipple being exceedingly large and numerous, many of them being compound. In connection with the latter, Duval and De Sinéty have occasionally found tactile corpuscles. It is also very abundantly furnished with lobulated sebaceous glands, opening by minute orifices in the depressions between the papillæ which they serve to lubricate, and protect from secretions of the child's mouth. According to Sappey neither hairs nor sweat glands are found in the skin of the nipple. In addition to the foregoing, the nipple is well supplied with connective tissue, blood-vessels, lymphatics and nerves; but it is quite devoid of fat. In the *Hunterian Museum*<sup>20</sup> are some preparations by Astley Cooper, showing calcareous degeneration of the nipple arteries.

The surface of the areola is studded with numerous slight projections (*tubercles of Montgomery*), which during pregnancy and lactation become very prominent. These correspond to the orifices of subjacent glands—of which there are several varieties. Most of them are of the sebaceous type, all grades being represented from a simple follicle to a multilobular racemose gland. During lactation they secrete a milk-like fluid. Around the periphery of the areola, there exists a circle of these tubercles. In connection with each of them is a minute hair, which may be readily detected on careful examination with a magnifying glass. These glands are of the same nature as those found at the base of hairs in other parts of the body, only they are somewhat larger. In some women this circle of rudimentary hairs is occasionally well developed.

Sappey describes two kinds of sweat glands as occurring in the areola; those of the ordinary small cutaneous type, and others much larger and more deeply placed. Like the other

---

<sup>20</sup> Nos. 4822 and 3. *Path. Series.*



areolar glands these also hypertrophy during pregnancy and lactation.

Around the base of the nipple are the orifices of yet another variety of gland—the *glandulæ lactiferæ aberrantes*. Their number is variable, but several always exist. These really are the ducts of detached lobes of the mammary gland, which open here instead of on the summit of the nipple. Each duct usually presents a well marked *sinus lacteus*. They are much more deeply situated than any other of the areolar glands; and their minute structure is precisely similar to that of the normal mamma. They secrete milk under the same condition as the latter. Their existence has long been a subject of debate between anatomists; but the careful researches of Sappey, Duval, De Sinéty<sup>21</sup> and others, have now placed the matter beyond dispute. According to Sappey the main mammary ducts occasionally give off a branch that opens directly on the areola.

#### § V.—The Axilla.

The mammary gland, its blood-vessel, lymphatics, and nerves have such intimate relations with the *axilla*, that I must here introduce a few remarks about its anatomy.

The skin of this part of the body is pigmented and firmly connected with the subjacent fascia. It contains numerous large sebaceous glands, long hairs and dense lymphatic net works. Under the influence of pregnancy these glands often enlarge and secrete a milk-like fluid, thus originating the “axillary lumps” of Champneys. Beneath the skin, over the top of the axilla, where the adhesions with the fascia lata are especially well marked, a brownish, lobulated, roundish *plâque*—about the size of a florin—may usually be seen. This structure was first investigated by Sappey,<sup>22</sup> who found it comprised numerous large, tubular, coiled glands, like sweat glands, but penetrating

<sup>21</sup> *Bull. de la Soc. Anat.*, t. lii., p. 460. He has found that about four of these glands exist in fourteen out of every fifteen women.

<sup>22</sup> *Traité d'Anatomie Descriptive*, t. iii. (1871), p. 546.



more deeply. Sometimes these glands are irregularly scattered about the axilla, instead of being aggregated into a distinct layer, and they are occasionally scanty or altogether wanting. Similar structures have been found in connection with the skin of various mammals and batrachians. It has been suggested that the axillary odour, which characterises certain individuals of both sexes, is associated with their marked development. Creighton<sup>23</sup> has seen neoplasms originate from them in dogs; and he thinks that in human beings certain axillary tumours may spring from this source. Ordinary sweat glands also abound in the axillary skin. Between these various glandular structures and the overlying skin, bands of unstriped muscle fibres are distributed.

The outer wall of the axilla is a region that the operating surgeon will avoid as much as possible, because here lie the axillary vessels and nerves, the artery being between the nerve cords, with the vein on its inner side. The general tend of their branches is inwards, towards the thorax, but the veins of course proceed in the converse direction. When the arm is raised above the shoulder, the head of the humerus projects into the axilla, and displaces the large vessels downwards and towards the chest; this should be borne in mind when operating in this locality.

The posterior wall of the axilla is also an undesirable region to trench upon during operations, for here are the sub-scapular blood-vessels and nerves (to *teres major* and *latissimus dorsi*).

There are fewest obstacles to surgical proceedings in the vicinity of the inner wall of the axilla. Here the only important structure likely to be injured is the long thoracic nerve, which proceeds almost vertically downwards, on the serratus magnus muscle, to which it is distributed.

The breasts are well supplied with blood-vessels, which are, however, very variable in their origin and course.

---

<sup>23</sup> *Med. Chir. Trans.* vol. lxx. (1882), p. 53.



The *arteries* come chiefly from the axillary and the internal mammary (br. of the subclavian)—each of these giving two or three branches.

The axillary supplies the following:—

(1) The *long thoracic*, which arises beneath the pectoralis minor and courses along the lower border of that muscle to the chest, where it gives branches to the external and inferior segments of the breast.

(2) The *external mammary*, which arises from the axillary, below the foregoing, and is distributed to the lower part of the gland. It not infrequently takes origin from the long thoracic. Both of the foregoing send branches to the nipple.

(3) The thoracic branch of the *acromio-thoracic*, which arises from the axillary above the pectoralis minor, also sends branches to the upper part of the mamma, after perforating the pectoralis major.

The internal mammary gives off *direct* branches, which perforate the second and third intercostal spaces, and are distributed to the sternal part of the gland; and through its *intercostal* branches—of the second, third, fourth and fifth spaces—it also sends numerous twigs *indirectly* to this part of the breast. The *aortic intercostals* also send numerous small branches to its deep surface. Through its anastomosis with the internal mammary artery, the *deep epigastric* (br. of ext. iliac) also contributes to the mammary circulation.

With regard to the *veins*, the deep ones for the most part accompany the arteries; but the superficial ones, which are numerous, take different courses. Some of them join to form a venous circle round the areola—the *circulus venosus areolæ* of Haller—others enter the cephalic; and many pass over the clavicle, to unite with the external jugular and subclavian veins.

The *nerves* of the breast and the skin covering it, come from the second, third, fourth, fifth and sixth intercostals; from the thoracic branches of the brachial plexus; and from descending branches of the cervical plexus. Communications take place between the intercostal branches and filaments supplying the



skin of axilla, inner side of arm, shoulder and scapula. These nervous intercommunications explain the wide-spread pain sometimes experienced in certain mammary affections. Branches from the sympathetic accompany the mammary blood-vessels.

The anatomy of the mammary and axillary *lymphatic system* has such important practical bearings in connection with cancer, that it will be more convenient to describe it when treating of this subject, rather than here (*q. v.* ch. ix., § 5).



### CHAPTER III.

#### MAMMARY VARIATIONS PER DEFECTUM.

---

##### § I.—*Amazia.*

THE development of the breast may fail at any stage of its evolution—from early embryonic life up to the climacteric period. When the morbid process sets in before the second or third month of intra-uterine life, there results complete suppression of the organ—*amazia*.

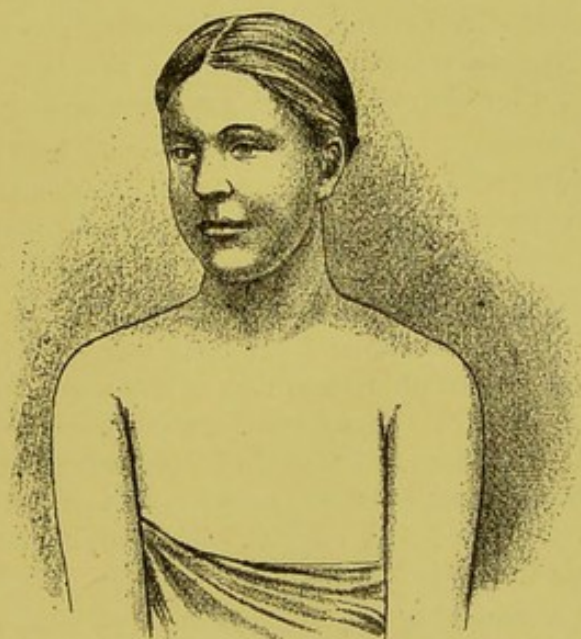

FIG. 8.—Complete absence of both mammæ and nipples (*Wylie*).

In animals having normally a large number of mammæ, some of them are often aborted in this way, and the males of such animals often have fewer than their females; but in human beings and other bimastic animals, *amazia* is a very rare affection—much rarer, for instance, than *polymazia*. Most of the cases hitherto recorded, in which the sex has been well marked, have been in females.

The deformity is frequently, but by no means invariably,



associated with grave malformations *per defectum* of the adjacent chest or of the sexual organs. One or both breasts may be affected.

Complete absence of *both* mammæ is one of the very rarest congenital deformities. Most cases have been met with in acephalous monsters, associated with deficient development of the thorax.

I know of only four instances unaccompanied by such conditions.

CASE I.<sup>1</sup>—A single woman, aged 21, who, when examined three months after giving birth to a healthy male child, was found to present no trace whatever of mammæ, areolæ, or nipples (Fig. 8). Not a drop of milk had been secreted, so that she was unable to suckle. Menstruation set in at 15, and she had since been regular. But for the mammary deformity she was well made, and her health had been good. In answer to a letter of inquiry, Dr. Wylie, her medical attendant, kindly informed me that there was no deficiency of the pectoral muscles or ribs, and that the external genitals, the teeth, hair, and other dermal appendages, were well developed.

CASE II.<sup>2</sup>—A woman, who one week previously had been prematurely delivered of a living child, presented no trace of mammæ or nipples; but in the position of each of the latter was a pigmented patch of skin, the size of a sixpence.

CASE III.<sup>3</sup>—In this case the patient was a boy 3½ years old, in whom complete absence of both mammæ from birth was associated with similar absence of hair, and an atrophic condition of the whole integument and its appendages, except that of the external genitals. The latter were well developed, except for phimosis; and presented a remarkably plump appearance, as compared with the shrivelled aspect of the rest of the body. The testes were well placed and normal. The boy's mother had suffered from *alopecia areata* from the age of 16.

CASE IV.<sup>4</sup>—The subject of this observation was a so-called hermaphrodite, aged 65, who had always passed for a female. On examination of the body after death, its general appearance was that of a male, and there was a tremendous beard. Both mammæ were completely absent. Menstruation had never occurred, nor was there any history of sexual desire. Further examination was limited to the genital organs. The clitoris was very large—quite as large as in many competent males. The corpora cavernosa were large; there was a bulb to the urethra, a rudimentary prostate, and rudi-

<sup>1</sup> Wylie, W., *Brit. Med. Jour.*, 1888, vol. ii., p. 235.

<sup>2</sup> Batchelor, H. T., *Brit. Med. Jour.*, 1888, vol. ii., p. 876.

<sup>3</sup> Hutchinson, J., *Med. Chir. Trans.*, vol. lxix. (1886), p. 473.

<sup>4</sup> Pilcher, *Lancet*, vol. i. (1838), p. 915.



mentary ejaculatores seminis. In addition there was a rudimentary uterus and vagina—the latter ending in the urethra. Nothing is said about ovaries or testes.

Complete absence of *one* breast is only a little less rare than that of both. Several authors have stated that the right breast is the one more frequently affected. I am unable to support this statement; for, as will be seen below, in most of the cases collected by me the deformity was on the left side. It is alleged sometimes to occur independently of any other deformity. Birkett<sup>5</sup> cites a case (Marandel's) of this kind; but, on looking up his reference,<sup>6</sup> I found the record so meagre and unsatisfactory, that I was unable to determine whether there was associated deficiency of the pectoral muscles or not.

In the following cases unilateral amazia was correlated with malformation of the adjacent chest wall:—

CASE I.<sup>7</sup>—In a woman aged 30, who died of peritonitis eight days after her confinement, there was found in place of the right breast a shallow depression; but no trace of the nipple, areola, or gland. Beneath the skin there was nothing but a thin layer of adipose tissue. The left breast was well developed and full of milk. The anterior parts of the third and fourth ribs were absent, together with the corresponding intercostal muscles, the sternal part of the pectoralis major muscle, the whole of the pectoralis minor and portions of the serratus magnus. The gap was closed in by tough aponeurosis. The pleura and lung were normal.

CASE II.<sup>8</sup>—Here the patient was a healthy-looking girl, 5 years old, whose parents also were healthy and free from any deformity. Of the right mamma, nipple, and areola there was no trace; the skin over this region was like that of the rest of the body. The pectoralis major and minor muscles were deficient, as well as the anterior part of the fourth rib and the adjacent intercostal muscles. At this spot, during respiratory movements, hernial protrusion of the pleura took place, the overlying skin being in close contact with the latter. The six upper ribs, except the first, were markedly bent and arched forwards on both sides, causing considerable deformity of the thorax. The left mamma was normal.

CASE III.<sup>9</sup>—In this case complete absence of the left breast was associated with absence of the left upper limb, which was represented only by a small

<sup>5</sup> "Diseases of the Breast," 1850, p. 23.

<sup>6</sup> *Dict. des Sci. Méd.*, t. xxx., p. 378.

<sup>7</sup> Froriep, *Neue Notizen*, Bd. x., 1839, s. 9.

<sup>8</sup> Reid, *Froriep's Neue Notizen*, No. 500, Bd. xxiii., 1842, s. 254.

<sup>9</sup> Förster, A., *Die Missbild. des Mensch.*, 1861, s. 105, in atlas, Taf. xi. f. 16.



conical stump at the shoulder. There was also large deficiency of the thoracic wall on this side, through which the thoracic and abdominal viscera protruded, covered only by a membranous envelope.

CASE IV.<sup>10</sup>—A girl, aged 10, with complete absence of the left mamma, areola, and nipple. The sternal part of the pectoralis major also wanting. The other breast normal. No heredity. The mother attributed the disease to fright during pregnancy, from having seen a woman's chest after amputation of the breast.

CASE V.<sup>11</sup>—In a healthy married woman, aged 22, shortly after her first confinement, complete absence of the left breast was noticed by the medical attendant. The nipple was represented by a small pimple. The pectoral muscles of the affected side were imperfectly developed. The woman's mother first noticed the deformity three weeks after the patient's birth. She attributed it to having been frightened when pregnant by a woman who called at her house and exposed her chest, showing marks from amputation of her breast for cancer.

CASE VI.<sup>12</sup>—A single woman, aged 21, with complete left amazia. The pectoralis major imperfect. The patient otherwise well formed. No heredity.

CASE VII.<sup>13</sup>—In a *man* seen by Birkett, left amazia was associated with deficiency of the lower fibres of the pectoralis major muscle.

CASE VIII.<sup>14</sup>—Young has reported an instance of absence of the sternal portion of the *pectoralis major* muscle in a man, whose nipple also was stunted, and no trace of mammary structure could be detected.

Other cases have been recorded by Lousier<sup>15</sup> and Schlözer.<sup>16</sup>

Referring to the former of these cases, St. Hilaire<sup>17</sup> says:—"Le Dr. Lousier fait mention d'une dame qui privée d'une mamelle, transmet à sa fille le vice de conformation dont elle était elle-même affectée." In accordance with this, almost all subsequent authors have referred to the case as an example of hereditary transmission; but, according to Puech,<sup>18</sup> Lousier never asserted this. All he said was, "J'ai connu une dame et une demoiselle chez les quelles la glande mammaire manquait complètement d'un côté.

In the two following cases congenital amazia was associated with total absence of the corresponding ovary. Both are re-

<sup>10</sup> King, *Med. Times and Gaz.*, 1858, vol. i., p. 527.

<sup>11</sup> Paull, *Lancet*, 1862, vol. i., p. 648.

<sup>12</sup> Widmer, *Corresp. Blatt. f. schw. Aerzte*, 1888, s. 472.

<sup>13</sup> Holmes' "System of Surgery," vol. iii., 1883, p. 460.

<sup>14</sup> *Lancet*, vol. i., 1894, p. 313.

<sup>15</sup> "Dissert. Anat. et Physiol. sur la sécrétion du lait," Thèse de Paris, An. x., No. 53, p. 15.

<sup>16</sup> "Ueber die angeborenen Missbild. der gesam. weibl. Genitalien. I.D., Erlangen," 1842.

"Histoire des Anomalies," t. i., p. 710.

"Les mamelles et leurs anomalies," p. 63.



ported by Scanzoni,<sup>19</sup> and I know of no others precisely similar, although, as I shall presently mention, there are on record many cases of micromazia associated with deficient ovarian development.

The first patient was a beggar woman, who died, aged 64, of tubercle. There was complete absence of the left mamma, nipple, and areola, and at the necropsy no trace could be found of the left ovary. She had been subject to amenorrhœa since the age of 27, but she had previously menstruated regularly.

The second patient was a girl, aged 18, who died of typhoid fever. In this case right amazia was associated with complete absence of the right ovary. She had menstruated regularly.

Absence of the breast may occasionally be caused by inflammation and injuries in the newly born.

Puech<sup>20</sup> relates the case of a girl, aged 17, of whose left breast there was hardly a trace, although the right was well developed. This resulted from acute inflammation of the part at birth, followed by suppuration and the formation of a large abscess, which had to be incised.

## § II.—Micromazia.

When the defect is less complete than in the above cases, we get a very small imperfectly-developed gland, like the normal male breast, or smaller—*micromazia*. This condition, though rare, is of more frequent occurrence than any of the foregoing. The rudimentary organs are useless for lactation. Both *mammæ* may be affected, or only one.

The deformity occurs independently, or associated with malformations of the adjacent chest or of the sexual organs.

The three following instances of micromazia of independent origin are related by Puech:<sup>21</sup>—

In a single woman, aged 24, there was complete absence of the projection of the bosom on both sides, while the nipples and areolæ were small and stunted. Menstruation set in at 15, but the catamenia were not regular until two years later. Her mother and sisters had well-developed breasts.

In another case it was noticed that both the breasts of a woman about

<sup>19</sup> Kiwisch, *Klin. Vorträge über spec. Path. u. Therap. d. Krank. des weib. Gesch.*, Bd. iii. (1855), s. 47.

<sup>20</sup> *Op. cit.*, p. 90.

<sup>21</sup> *Op. cit.*, p. 89.



to be confined were rudimentary, and they remained so after delivery, only a few drops of colostrum being secreted. Her mother had a similar deformity.

In the next case only one breast was affected. The patient was a young woman who married early, and was the mother of three children. At puberty the asymmetrical condition of the mammæ was first noticed, for while the right attained its full size the left remained undeveloped. After each pregnancy the right gave plenty of milk, but the left none.

McGillicuddy<sup>22</sup> relates the case of a delicate hysterical woman, aged 26, the condition of whose mammæ resembled that of a man, and no glandular structure could be detected.

As examples of micromazia associated with malformation of the adjacent chest wall, I can cite the following:—

In a single woman, aged 21, seen by Engeström,<sup>23</sup> all that existed of the left breast was a small stunted papilla, and under it “un petit amas de graisse, mais si insignifiant qu’il ne forme même pas une éminence.” The sternal part of the left *pectoralis major* muscle was completely absent. She was otherwise well developed.

In another case by the same author, the patient was an emaciated phthisical woman, aged 27, who had recently been delivered of her second child. The left breast was well formed, and full of milk, but the right was very small, although its nipple and areola were normal, and only a few drops of milky fluid could be expressed from it. This secretion ceased shortly afterwards. Most of the sternal part of the corresponding *pectoralis major* muscle was absent. No history of any malformation in others of her family.

In a similar case, seen by Ebstein,<sup>24</sup> the right breast was not larger than a hemp-seed. The sternal part of the *pectoralis major*, and the whole of the *pectoralis minor*, muscles were wanting.

Grüber<sup>25</sup> saw a young lady, aged 18, in whom nearly all of the costosternal part of the right *pectoralis major* muscle was wanting, and whose right breast was represented only by a malformed nipple, surrounded by a large areola, beneath which a thin glandular *plaque* could be felt. Menstruation set in at 15, but the right mamma never developed, although the left attained a large size. She was otherwise well formed, but thin and phthisical.

A less degree of the same condition is shown in fig. 9. The patient was a very anæmic woman, aged 26, the mother of several children.<sup>26</sup> The left breast was so ill-developed as to be less than half the size of the right. During lactation it gave but a scant supply of milk. The left pectoral region was very flat, and the subjacent muscles appear wasted.

<sup>22</sup> *N. Y. Medical Record*, Oct. 10, 1891, p. 448.

<sup>23</sup> *Ann. de Gyn.*, t. xxxi. (1889), p. 84.

<sup>24</sup> *Deutsch. Arch. f. klin. Med.*, vi., s. 283.

<sup>25</sup> *Arch. f. path. Anat.*, cvi., 1886, s. 501.

<sup>26</sup> McGillicuddy, *N. Y. Medical Record*, Oct. 10, 1891, p. 446.



The following cases illustrate the connection between micromazia and defective development of the generative organs. In many of the individuals thus affected the secondary sexual characters are imperfectly evolved, and there is often manifest an approach to the male type of organisation.

In a woman, aged 26, seen by De Sinéty,<sup>27</sup> both breasts were like those of a girl before puberty; they had no areolæ, and their nipples were hardly perceptible. The uterus and vagina were of an equally stunted, infantile type.

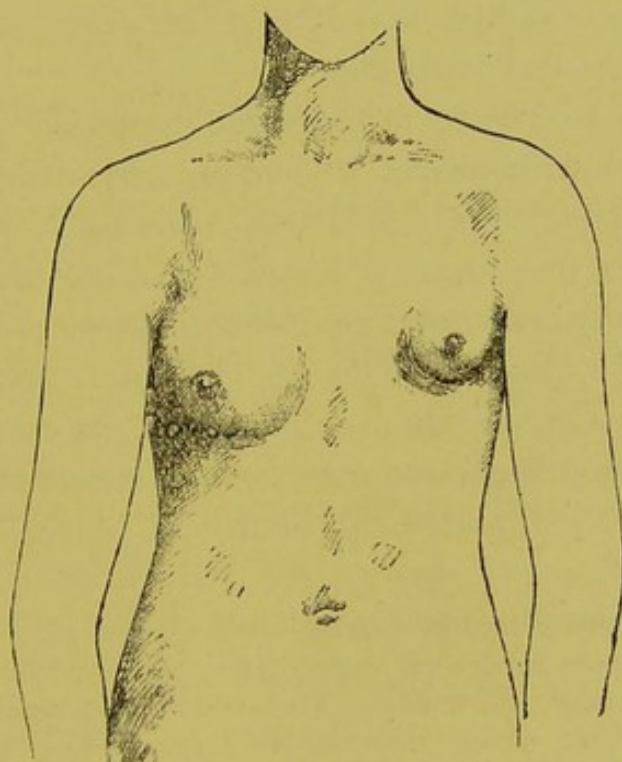


FIG. 9.—Defective development of the left breast and pectoral region (*McGillicuddy*).

In a case recorded by Greenhow<sup>28</sup> the patient was an unmarried servant girl, aged 22, who was very flat in the mammary regions, and on careful manipulation no trace of either gland could be felt, although she had a small stunted nipple and areola in the usual position on each side. She was of spare, girlish aspect, and had never menstruated. The pelvis and hips were small, as was also the mons veneris, on which there were but a very few hairs. The vagina was small and narrow, with a well-marked hymen. The os and cervix uteri were absent, but on rectal examination a small hard lump was detected in the position of the body of the uterus. The ovaries could not be felt. In addition, she had bifid sternum, associated with con-

<sup>27</sup> *Traité de Gyn.*, 1884, p. 947.

<sup>28</sup> *Med. Chir. Trans.*, vol. xlvii., 1864, p. 195.



genital malformation of the heart, the exact nature of which could not be determined. She suffered much from palpitation of the heart, cough, and dyspnœa.

Pears<sup>29</sup> has related the case of a dwarfed woman, aged 29, who was only four feet six inches high. Her breasts and nipples were like those of a male. She had never menstruated. There was no hair on the pubes, nor any other signs of puberty. "She always expressed an aversion to young men who were too familiar with her." She had been subject to violent fits of coughing and convulsions for several years, and in one of these she died. At the necropsy the uterus was of the infantile type. "The ovaria were so indistinct as rather to show the rudiments which ought to have formed them than any part of their natural structure.

Analogous instances have been recorded by Baynham,<sup>30</sup> Caillot,<sup>31</sup> Rénauldin,<sup>32</sup> and others.

According to Puech, the infantile condition of uterus, that generally goes with absent or rudimentary ovaries, is nearly always correlated with defective mammary development,<sup>33</sup> when, however, the uterus is really absent, the mammæ are, as a rule, unusually well developed, and in these cases the ovaries are generally normal.<sup>34</sup> This is just the converse of what happens in males, in whom absence of the testes is usually associated with exaggerated mammary development.

A case lately reported by Beuttner<sup>35</sup> well illustrates these remarks.

The patient was a healthy-looking woman, aged 18, with rudimentary *uterus bicornis* and absence of vagina; but both ovaries existed, though they were rather large and tender. The mammæ and pubic hair were well developed. She had never menstruated. Both ovaries, tubes and uterine horns were removed by abdominal section. The ovaries contained normal follicles, follicular cysts with serous or blood-stained fluid contents, and numerous cicatrices of old cysts, &c., so that ovulation had evidently gone on. The tubes were patent, but the uterine cornua presented no lumina.

It follows from what has been stated, that the mammary development is dependent upon *ovarian* rather than uterine

<sup>29</sup> *Philosophical Trans. R. S., Lond.*, 1805, p. 225.

<sup>30</sup> *London Medical Gazette*, vol. iii., 1829, p. 72.

<sup>31</sup> *Mém. de la Soc. Méd. d'Emulation*, Paris, t. ii. (1798), p. 270, *et seq.*

<sup>32</sup> *Séances de l'Acad. Roy. de Méd.*, 28 fév., 1826.

<sup>33</sup> For two well recorded cases confirmatory of this view, *vide* Warren, "Surgical Observations," Boston, 1867, p. 305.

<sup>34</sup> "Les ovaries et leurs anomalies," Paris, 1873; see also *Op. cit.*, p. 91.

<sup>35</sup> *Cent. f. Gynäk.*, No. 49, 1893.



integrity. According as the ovaries are well or ill developed so will the mammæ be.

### § III.—*Athelia*.

Congenital absence of the nipple—*athelia*—is much commoner than any of the foregoing anomalies.

Inasmuch as this structure is formed by upheaval of the area of skin perforated by the ducts of the nascent gland, it follows that in true *athelia* none of the nipple structures—skin, connective tissue, vessels, nerves, ducts, &c.—are really wanting, as Duval erroneously supposed; but we have to do simply with failure of the normal mamillary outgrowth. This condition is usually unaccompanied by any other malformation, and it generally affects both breasts.

I lately saw a healthy young lady, aged 18, with marked defect of this kind, associated with eczema of the malformed parts. Her breasts were large, and otherwise well developed; but their nipples were completely absent, and in the place of each was a small transverse groove, surrounded by a diminutive, stunted areola. The affection dated from birth. There was no family history of any similar deformity. Menstruation was normal.

Analogous cases have been seen by Cruveilhier,<sup>36</sup> Davis,<sup>37</sup> and many others. Persons thus affected usually have plenty of milk during lactation, but they are nevertheless unable to suckle their children.

Like other forms of defective mammary development, *athelia* is sometimes found associated with imperfect development of the genital organs, as in the following remarkable case, related by Chambers.<sup>38</sup>

The patient, aged 24, had the general appearance and external sexual organs of a female, including the well developed female bust. She had always passed as a female, having been engaged as a housemaid. Both nipples were completely absent, and the place of each was occupied by a small rose-coloured spot, representing the areola. There was no hair in the pubic region. The mons veneris was ill developed. The vagina was

<sup>36</sup> "Traité d'Anatomie Descript., éd. 1874, t. 2<sup>me</sup>, p. 525.

<sup>37</sup> *Medical Times*, vol. i., 1852, p. 250.

<sup>38</sup> *Trans. Obstet. Soc. Lond.*, vol. xxi. (1879), p. 256.



small, and ended in a *cul-de-sac*, and there was no trace of uterus or ovaries. Menstruation had never taken place nor had molimina ever been experienced. In each inguinal region there was an irreducible congenital hernial tumour, each of which contained a firm circumscribed body, thought to be an ovary. These bodies were excised, but on microscopical examination after removal they proved to be *testes*.

In such cases as the foregoing we evidently have to do with defective nipple evolution almost *ab initio*. In consequence, we often see persistence of the depression which, in the normal course of development, marks the site where the nipple will subsequently arise.

When the morbid process supervenes at a somewhat later period, then we get some of the various minor degrees of congenital mamillary imperfection which are of such frequent occurrence: thus the nipple may be small, stunted, flattened, short, depressed, umbilicated, or quite invaginated, or otherwise malformed. Such conditions are fruitful sources of trouble during lactation; they are, indeed, one of the chief causes of the acute inflammations and abscesses so common at that period. According to Birkett,<sup>39</sup> out of 97 cases of acute mammary abscess, there was imperfect mamillary development in 48, or in half the total number. Congenital imperfection of the nipple is often found in association with neoplasms (*q. v.* ch. xii., § I). The alleged examples of *imperforate nipples* of congenital origin are by no means convincing; if this condition really exist it has yet to be demonstrated. Absence or defect of the nipple is not infrequently caused by traumatism or diseases in the newly born, such as bites, burns, wounds, abscesses, ulcers, &c.

When the nipple is deficient, the areola is often stunted or absent; but it is rare to find the areola absent when the nipple is well formed, as in the following case by O'Flynn.<sup>40</sup>

A healthy-looking woman, aged 30, the mother of seven children, who, when she came under observation, was pregnant for the eighth time. Her breasts were small and flaccid like those of a girl at puberty, and

<sup>39</sup> Art. "Diseases of the Breast," Holmes' "System of Surgery," vol. iii. (1883), p. 435.

<sup>40</sup> *Dublin Medical Press*, vol. liv. (1865), p. 312.



during her previous pregnancies they had never enlarged nor given any milk. The nipples were prominent, but neither of them had an areola. Her mother's breasts were rudimentary, and though she had eleven children, no milk was ever secreted.

Anomalies of this kind are, however, fairly common in connection with supernumerary mammillary structures.

#### § IV.—Involution atrophy, &c.

At the climacteric period the breasts normally undergo atrophic changes, which usually affect the fibro-fatty as well as the glandular elements. The degree to which this involution takes place, and the age in which it sets in, are variable. Occasionally these changes begin at a very early period of life, and proceed to such a degree as to constitute veritable disease.

A well-marked instance of this affection lately came under my notice in the person of a young widow, aged 30, both of whose breasts were small and flaccid, like those of a thin old woman. Before the death of her husband, two years previously, she had a well-formed bust; but since then the breasts had gradually wasted away. Her general health was good, but she was less plump than formerly. The catamenia were scanty, but regular. Shortly after the death of her husband she lost her only child. Here grief, and suppression of the sexual function, seem to have been the determining causes.

Another somewhat similar case<sup>41</sup> is that of a married lady, aged 24, who had noticed her breasts wasting away for four months. They were formerly well developed, and she knew of no cause for their atrophy. The general health was good, there was no organic disease, and menstruation was normal. On examination the mammae were found very atrophied. She had been married for two years, and one year after marriage gave birth to a child, which died a few weeks afterwards of bronchitis.

In sterile women, and in those who have neglected to suckle their offspring, the mammae often shrink to quite small proportions.

Reynolds<sup>42</sup> has given an account of a woman, aged 21, who, having suckled her first child only for a few weeks, soon afterwards saw both her breasts completely disappear, so that not a vestige of them could be felt. Yet when she became pregnant again, they both enlarged to a fair size and

<sup>41</sup> *Lancet*, vol. i., 1884, p. 782.

<sup>42</sup> *Ibid.*, p. 331.



gave milk ; but, as she neglected to suckle, the glands soon wasted away as before—and so after each pregnancy.

There can be no doubt that the habit of weaning children does in the long run tend to defective mammary development. Disuse leads to atrophy and the result is inherited. De Sinéty<sup>43</sup> says he has seen examples of this in the women of families whose children have been weaned for several generations ; and in two instances, although very prolific, they were unable to suckle, through failure of lacteal secretion. In an interesting essay on this subject Altmann<sup>44</sup> tells us that very few of the peasant women of the table-lands of Bavaria and Swabia have sufficient milk for suckling their children. Among them the custom of rearing by hand is almost universal ; consequently their infant mortality is very high. He examined the mammæ of thirty of these women, and compared them with the mammæ of Silesian peasant women, who always suckle their infants. He found that the former set of glands were much the smaller. In only eight of the Bavarian specimens did the weight of the gland exceed 100 grammes ; the normal weight, according to Hennig, being from 160 to 556 grammes. On histological examination of sections from the two sets of specimens marked differences were noticeable. In the Bavarian glands the acini and small ducts were scanty and ill developed, and the fibrous stroma was unduly abundant ; whereas in the Silesian glands acini and tubuli were well developed, and the stroma was less abundant and dense. Altmann does not hesitate to ascribe this atrophic condition of the Bavarian mammæ to hereditary influence, owing to the custom of weaning having prevailed for many years. Reinhold<sup>45</sup> has also ably investigated this interesting subject with similar results.

Atrophy of the ovaries, and morbid conditions interfering with their integrity, at comparatively early periods of life induce somewhat similar conditions.

---

<sup>43</sup> *Traité de Gyn.*, p. 918.

<sup>44</sup> *Arch. f. path. Anat.*, Bd. cxi., 1888, s. 318.

<sup>45</sup> *Arch. f. path. Anat.*, Bd. cxi., Hft. 2.



Thus in Potts<sup>46</sup> well-known case, the catamenia became suppressed, the mammae wasted, and the body got thinner in a healthy and plump young woman, aged 23, each of whose ovaries presented as a hernial swelling at the inguinal rings; and were excised in consequence of their incapacitating the patient from work.

According to most oöphorectomists,<sup>47</sup> extirpation of the ovaries in adult human females is seldom followed by marked mammary atrophy, or the loss of feminine qualities, other than those of menstruation and procreation. Keppler,<sup>48</sup> however, distinctly states that in most of his castrated patients, the breasts subsequently wasted, and tended to revert to the male type. The truth seems to be, that when the essential sexual organs are removed early in life, before the secondary sexual characters have become thoroughly well established, the latter subsequently abort; whereas when the removal of these organs is deferred until the secondary sexual characters have become well established, then the latter generally persist, provided that the patient is still in the prime of sexual life. Under these circumstances Schwinzinger's<sup>49</sup> suggestion that castration should be practised to bring about atrophy of the mammae in order to prevent the development of cancer, or its recurrence after operation, can hardly be taken seriously.

Several cases have been recorded showing that mammary atrophy may sometimes be due to hereditary syphilis. The patients thus affected are generally otherwise defective in sexual and general development. Claude,<sup>50</sup> Fournier<sup>51</sup> and Rivington<sup>52</sup> have especially directed attention to this subject.

Other alleged causes of mammary atrophy are prolonged and excessive suckling, exhaustive illnesses, and the frequent internal administration of iodide of potassium in large doses.

In the *treatment* of mammary atrophy, frequent and regular

<sup>46</sup> "Surgical Works," vol. iii., p. 329.

<sup>47</sup> Battey, R., *Am. Syst. Gyn.*, vol. ii., 1888, p. 849.

<sup>48</sup> *Ann. de Gyn.*, Oct., 1890.

<sup>49</sup> Report Berlin Congress, April 25, 1889.

<sup>50</sup> Thèse de Paris, 1886.

<sup>51</sup> "Leçons sur la syphilis héréditaire tardive," 1886.

<sup>52</sup> *Med. Times and Gaz.*, Oct. 19, 1872, p. 433.



suction of the nipples, by mouth or with an apparatus, is the most likely means of succeeding ; together with massage of the breasts, ovarian and spinal regions. Suction of the nipples, as previously mentioned, is a most powerful stimulus to mammary activity, for it is known to have induced lactation in non-pregnant multiparæ, and even in virgins. The internal administration of mild stimulating tonics, and aphrodisiacs should be combined with the local treatment. When syphilis is suspected the local application of mercurial ointment, with iodide of potassium internally, is recommended, together with good feeding.



## CHAPTER IV.

POLYMASTIA, WITH SPECIAL REFERENCE TO "MAMMÆ ER-RATICÆ," AND THE DEVELOPMENT OF NEOPLASMS FROM SUPERNUMERARY MAMMARY STRUCTURES.

---

§ I.—Phylogenetical.

HUMAN beings usually have but a single pair of mammary glands, which are situated on the ventral aspect of the thorax (*pectoral*), as in apes, bats, elephants, and a few other mammals. This is the smallest number normally met with throughout the group. Most mammals have several pairs of such glands, situated at various points of the ventral surface of the trunk; and, as a rule, there is a certain relation between their number and the number of young brought forth at a birth, the former being twice as numerous as the latter. In the insectivorous order, which yields the largest number, there may be as many as eleven pairs, and there are seldom fewer than seven. In these cases the glands extend along the whole length of the ventral surface, in two nearly parallel rows, from the axillary to the inguinal regions. I said *nearly* parallel, because the two rows converge towards the inguinal regions. In the lowest mammalians (monotremes, marsupials, &c.)—which represent the primitive type—the mammæ are as a rule exclusively inguinal; in the highest class they are almost invariably pectoral; whilst animals with abdominal mammæ occupy an intermediate position.

In human beings any diminution of the normal number is very exceptional; but it is by no means uncommon to find their number increased. When this does occur, it is a significant fact that the additional mammary structures do not develop just anywhere; but they appear only in certain definite positions, which



almost invariably correspond with those occupied normally by the glands of polymastic animals. Such facts warrant us in attributing their origin to reversion ; and they imply the existence in the past of a polymastic *atavus*, accustomed to produce several young at a birth. The transition from polymastism to bimastism may now be seen going on in the Lemurs, whose inguinal and abdominal mammæ are aborting, so that only a single pair of pectoral ones tends to be well developed ; and this change has been correlated with diminution of the number of young brought forth at a birth. Similarly in many marsupials it has been observed that more nipples are found in the foetal than in the adult state : some of these structures atrophy, whilst others develop. "On the whole," says Darwin,<sup>1</sup> "we may doubt if additional mammæ would ever have been developed in both sexes of mankind, had not man's early progenitors been provided with more than a single pair."

I think it would conduce much to a more complete understanding of the subject if I could give a sketch of the mammary arrangement of these early progenitors. According to Meckel von Hemsbach, human beings originally had five mammæ : a pair corresponding to the normal pectoral ones, one in each axilla, and a median one just below the sternum. I suppose the author must have based this idea of his on some cases he had seen, in which the glands really had this distribution ; but I have been unable to find the record of any such case. Modern investigations have discredited this conception of Meckel's. In the numerous well-recorded cases of supernumerary mammary structures now available, there are ample materials for reconstructing the mammary arrangement or the ideal human *atavus* on a really scientific basis. From this source it may be gathered that our early progenitors had at least seven pairs of mammæ on the ventral aspect of the trunk ; of these only the present pectoral pair have survived. Of the six lost pairs three were situated above and external to the present normal pair, and three below and internal to them (fig. 10).

---

<sup>1</sup> "Descent of Man" (1879), p. 37.



On careful consideration of all the facts known to me relative to the distribution of mammæ in human beings and animals under normal and abnormal conditions, it seems probable that the mammæ were originally *segmental organs*—a pair being developed on the ventral aspect of each *somite*. In confirmation of this view the following cases may be cited :—

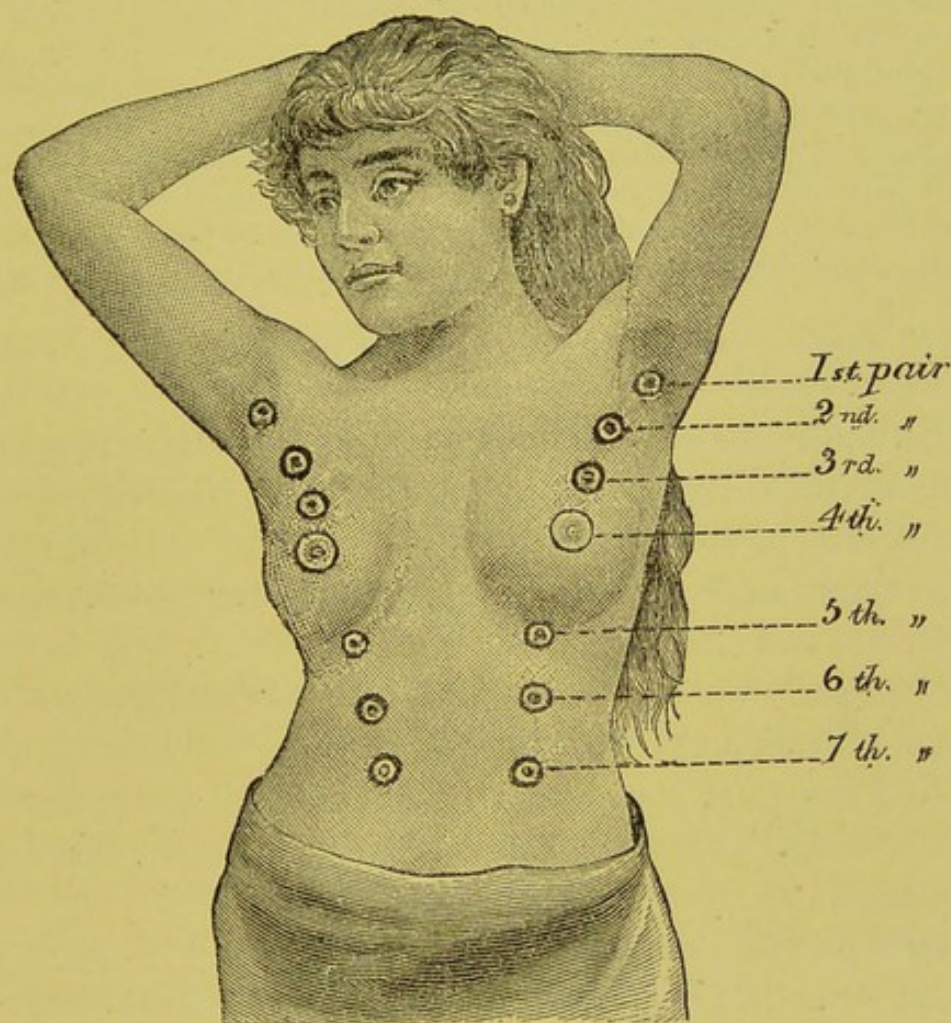


FIG. 10.—Diagram showing the mammary arrangement of man's early progenitors.

In *Neugebauer's*, with eight supernumerary nipples, the largest number yet observed in any human being, three pairs were situated above the normal mammæ, in positions identical with those figured in my diagram. The other two nipples were situated below, and internal to the normal pair; that on the right side was placed immediately below the bosom, that on the left side was some inches *lower down*. These unsymmetrical nipples must *not* be regarded as a pair; the upper one evidently represents the right nipple of the fifth pair of my diagram, and the lower one the left nipple of my sixth pair.



In *Ammon's* case there were three pairs of supernumary mammary structures. One pair was situated above the normal nipples and external to them, over the middle of the anterior axillary border, in a position corresponding to the second pair of my diagram. The other two pairs were placed below, and rather internal to the normal ones. Of these, the lowest pair was situated close to the costal margin, in the position of the sixth pair in my diagram; the other pair was situated midway between these and the normal ones, corresponding in position with the fifth pair of my diagram.

In *Fitzgibbon's* case, two pairs of supernumerary nipples were present; one pair above the normal mammæ corresponds to the third pair of my diagram; and the other pair, below the normal, answers to my fifth pair.

In *Mortillet's* case, two pairs of supernumerary nipples were also present, but both were situated below the normal breasts; the lower pair occupied the upper part of the *abdomen*, in a position which corresponds with the seventh pair of my diagram; the upper pair was situated between the normal mammæ and the abdominal pair, probably in the position of the fifth pair of my diagram, but as to this the author's description lacks definition.

In *Alexander's* case, there were also two redundant pairs of nipples, below the normal pair, in similar situations to Mortillet's.

The other cases of supernumerary mammary structures occupying positions corresponding to those figured in my diagram, may be classed as follows:—

*First pair* (axillary). Cases by Leichtenstern, D'Outrepont, Perreymond and Godfrain.

*Second pair* (middle of anterior axillary border). Cases by Quinquad, Bruce and Charpentier.

*Third pair* (just above and slightly external to the normal female bosom). Cases by Shannon (fig. 14), Lee, Gardiner, and Champneys.

*Fourth pair* (the normal mammæ).

*Fifth pair* (just below and slightly internal to the normal female bosom). More than three-fourths of all instances of supernumerary mammary structures have been found in this position. Typical examples of the development of this pair of mammæ in women have been recorded by Leichtenstern (fig. 13), Whitford, Chatard, and many others; and in men by Max Bartels, Handyside and myself (fig. 12).

*Sixth pair* (below and slightly internal to the preceding, near the costal margin). Cases in men by Ammon, Leichtenstern and Hamy, and in women by Rapin, De Sinéty, &c.



*Seventh pair*<sup>2</sup> (below and slightly internal to the preceding, on the upper part of the *abdomen*). Cases by Tarnier, Bartholin, Bruce and Alexander.

Further on details will be given of most of the cases above referred to. Supernumerary mammæ appearing in any of the above positions must, for the reasons before mentioned, undoubtedly be regarded as true reversions.

## § II.—Mammæ Erraticæ.

It is an exceedingly rare thing for redundant mammary structures to be found in any other part of the body. Of 166 cases collected by Leichtenstern<sup>3</sup> and Bruce,<sup>4</sup> there were only four instances of the kind (*mammæ erraticæ*), and they are certainly rarer even than this.

I now propose to examine these cases, and other similar ones since recorded, with a view to determining their real significance. Considering the great similarity between the condition resulting from chronic fistula in connection with sebaceous and dermoid cysts that have undergone suppuration, which extends even to the production of a milk-like fluid, and several of the alleged cases of *mammæ erraticæ*, I think the latter ought to be very critically examined before they are definitely accepted as such.

These remarks are especially applicable to the two cases of so-called *dorsal mammæ*, of which the records are ancient and very imperfect. For instance, all the information we have of the case mentioned by Paulinus,<sup>5</sup> is as follows:—

<sup>2</sup> McGillicuddy's case (*N. Y. Med. Record*, Oct. 10, 1891) with a pair of rudimentary abdominal mammary structures at about the level of the umbilicus—in a man aged 35—seems to indicate that the *atavus* had a *second* pair of abdominal mammæ, lower down than the seventh pair of my diagram. It accords with this that there is in St. Bartholomew's Hospital Museum (series xxxviii., No. 32 A) a drawing of the body of a man with a single redundant abdominal nipple and some subjacent swelling, at about the level of the umbilicus and external to it.

<sup>3</sup> *Arch. f. path. Anat.*, Bd. lxxiii. (1878), s. 222.

<sup>4</sup> *Journal of Anatomy*, vol. xiii. (1879), p. 425.

<sup>5</sup> "Obs. med.-phys. select," in the *Miscel. Curios. Acad. med. phys. nat. curios.*, an. iv., p. 203, in the appendix.



"Rustica fœmina e comitatu Winzemborch præter duas in loco ordinario adhuc duas alias ejusdem quantitatis et qualitatis mammas lacte fœcundas, habuit e regione in tergo. Jam tertia vice peperat gemellos, qui ante retroque suxerunt."

The account of Helbig's<sup>6</sup> case is still more unsatisfactory.

"B. Salewsky, nobilis Polonus, vir fide dignus in insula Macassar (veteribus celebes) mulierum vidit quæ mammas duas in dorso habens, eas sub axillis protractas infanti debat et firmiter asserebat integro con-sanguinearum suarum numero hanc monstrositatem esse propriam."

It is very well for such cases to be in the mind of the scientist; but until confirmed by modern observation they ought not to be regarded as an integral part of our science.

In this connection it may be well to recall the fact that in a few animals the mammaræ normally have a dorsal position; e.g., *Myopotamus coypus*<sup>7</sup> (near the dorsal spine), *Capromys fournieri*<sup>8</sup> (behind each axilla), and *Lagostomus trichodactylus* (dorso-lateral aspect of thorax).

Barth<sup>9</sup> has recorded a very remarkable case of alleged "*mamma erratica*" on the face.

The patient was a slender blonde, aged 20, who had, just in front of the lower part of her right ear, a peculiar wart-like growth surrounded by a pigment and a few hairs. It was erectile, and looked very like a nipple. The patient said it generally enlarged during menstruation, and that it had existed as long as she could remember. She had a somewhat similar growth, which also enlarged during menstruation, above her nose; and several pigment spots on various parts of the face, as well as a large one at the lower edge of the right breast. The nipple-like growth on the face was excised. On *microscopic examination* it was found to consist chiefly of sebaceous gland tissue, which was *not* embedded in the subcutaneous fat. In several of the sections small epithelial pearls were seen, and cellular collections like small sebaceous cysts; as well as irregularly arranged groups of sweat glands, and bundles of unstriated muscle fibres. A few ducts were observed, but none could be traced to the nipple-like process. Waldeyer, who examined the histological preparations, advised giving no positive opinion as to the real nature of the disease; and the title of Barth's essay, "*Eine eigenthümliche Warze nahe der Ohrmuschel*," suggests that the author himself was in doubt.

I have several times seen similar histological appearances in

<sup>6</sup> *Op. cit.*, an. ix. and x., p. 456.

<sup>7</sup> *Proc. Zool. Soc.* (Christy), 1835, p. 182.

<sup>8</sup> Cuvier, G., *Leçons d'Anat. Comp.*, t. viii., p. 606 (leçon 38e).

<sup>9</sup> *Arch. f. path. Anat.*, Bd. cxii. (1888), s. 569.



connection with congenital malformations of the skin of the face (warty moles); and I am inclined to regard the case as belonging to this category, rather than to that of "*mamma erratica*."

The case of accessory mamma *near the acromion*, recorded by Klob,<sup>10</sup> may be regarded as an unusual form of reversion; for, as Beddard<sup>11</sup> has shown, in *Haplemur griseus*, mammæ are of normal occurrence in this locality; as they are also in certain pachystomatous Cheiroptera.<sup>12</sup> In one of Champney's<sup>13</sup> cases, a lying-in woman had a supernumerary mammary structure in each axilla, the size of a pigeon's egg, which opened by a single pore at the middle of the anterior axillary fold. From the glandular body in the right axilla *a tail was prolonged down the arm for nearly an inch*.

Klob's patient was a man, and the supernumerary gland presented as a conical swelling, the size of a walnut, just below the left acromion, over the convexity of the deltoid muscle. It had a rudimentary nipple, but no areola. *Microscopic examination* revealed acinous gland tissue like that of the normal mamma.

Puech<sup>14</sup> refers to a case by Scalzi, from an Italian source, in which an aged woman, who was admitted into hospital for a scalp wound, was found to have a rudimentary supernumerary mamma on the right shoulder, near the axilla, and another below the left breast. Her daughter had a supernumerary milk-giving mamma.

An analogous case, in the lower limb, has been recorded by Robert of Marseilles.

The patient was a woman, aged 50, with a supernumerary milk-giving mamma on *the outer side of the upper part of the left thigh*, 4 inches below the great trochanter. The case was examined and reported upon by Magendie,<sup>15</sup> for the French Academy of Science. The real nature of the supernumerary gland was only discovered after her first confinement, when

<sup>10</sup> *Zeitschr. d. K. K. Gesellsch. d. Aerzte z. Wien* (1858), N.F.I., No. 52, s. 815.

<sup>11</sup> *Proc. Zool. Soc.*, 1884, p. 394. Although the specimen to which the description relates is a male, well-developed mammary glands were found to exist. The apertures of these glands were upon the upper part of the arm; and, on removing the skin, the glands themselves were found to be attached by membrane to the *pectoralis major*, the *biceps*, and part of the *deltoid* muscles.

<sup>12</sup> Milne-Edwards, H., *Leçons sur l'Anat. Comp.*, &c., t. ix. (1870), p. 132.

<sup>13</sup> *Med. Chir. Trans.*, vol. lxxix. (1886), p. 434.

<sup>14</sup> Puech, "Les mamelles et leurs anomalies," Paris, 1876, pp. 72 and 117.

<sup>15</sup> *Four. Gén. de Méd.*, t. c. (1827), p. 57.



it attained the size of half a lemon, and secreted milk. She had previously noticed in this situation, "un petit corps arrondi qui a toujours été le siège de douleurs et de démangeaisons, comme les seins mêmes aux époques de ses règles." The gland had a nipple, like the normal ones, so that she could suckle her children as well with it as with them. Strange to relate, this woman's mother had a supernumerary pectoral mamma on the right side.

The position of the redundant gland in this case reminds us of the so-called *glandula femoralis* of the male *Ornithorhynchus*; of *Capromys furnieri*, which has, in addition to a mamma behind each axilla, two others "en avant des cuisses, tout à fait sur le côté et plus près du dos que du ventre;"<sup>16</sup> and of the *Mare*<sup>17</sup> and *Ass*, which have the mammæ in the groins, far in front of the vulva.

Here also it seems tolerably certain that we have to do with an aberrant form of reversion.

Roberts' case has often been erroneously cited as an example of *inguinal* mamma—a condition which, according to Leichtenstern, has never been observed in any human being.

Testut<sup>18</sup> has, however, lately published the history of a woman in whom, soon after her confinement at the Bordeaux Lying-in Hospital, he noticed a true supernumerary mamma, on the antero-internal aspect of the right thigh, 65 mm. below the fold of the groin, and in a vertical line with the pubic spine. It presented as a rather small, irregular, bossy swelling, immediately beneath the skin, and it felt just like the normal gland. Its summit was surmounted by a conical nipple, in the vicinity of which were several small pigmentary *tâches*. The patient was 41 years old, and otherwise well formed. The pectoral mammæ were normal, the right being rather the larger. She first noticed the crural structure when about 20 years old, on account of it becoming painful during menstruation. At each of her five confinements it increased in size, so that she could hardly walk, on account of its rubbing against her other thigh. She never noticed that milk escaped from it during lactation, and when she was seen by Testut, several months after her last *accouchement*, lactation had ceased and no discharge from the crural structure was noticeable.

As previously mentioned mammæ exclusively inguinal are typical of the lowest mammalian orders. Among the highest

<sup>16</sup> Milne-Edwards, *Op. cit.*, p. 132.

<sup>17</sup> Naturalists were long at a loss to discover the glands of the horse in the male, until at last they were found by Buffon, in connection with the sheath of the penis.

<sup>18</sup> *Bull. de la Soc. d'Anthropologie*, ser. iv. ; t. ii., 1891, p. 757.



orders, rudimentary inguinal mammæ are occasionally present as in the *Rhinolophidæ*, although all other Cheiroptera have long since lost all trace of their inguinal mammæ. In some Lemurs, in the Aye-Aye, and in many other animals, mammæ are of normal occurrence in the inguinal regions. The above case seems to indicate that in human beings reversion may occasionally reproduce this very ancient ancestral mammary arrangement.

Hartung's<sup>19</sup> case is evidently nearly allied to the foregoing. Here a supernumerary mamma was situated in the *left labium majus*.

The patient, a woman aged 30, who was suckling her child, had a pedunculated tumour, the size of a large goose's egg, attached to the lower and inner part of the *left labium majus*. It was covered over with skin, and its pedicle was the size of a man's thumb. In front, at its upper part, there was an eroded ovoid patch, from which milk-like fluid escaped. The patient said she had noticed the tumour for several years; and that it had lately got much larger. It was freely excised with the pedicle, and during the operation a considerable quantity of milky fluid escaped. On examination after removal, a flattened rounded prominence, like a retracted nipple, could be made out in the centre of the eroded area; and surrounding this was a shallow depression. At the summit of this prominence were several small orifices, some of which admitted a probe; they were ducts which radiated into the tumour substance. It was obviously a rudimentary malformed nipple, with its areola. The rest of the tumour consisted of two gland-like masses, the smaller one about the size of a walnut; on *microscopic examination* these were seen to be composed of acinous glandular structure, lined with sub-cylindrical epithelium, just like that of the normal mamma. In the region of the rudimentary nipple were numerous ducts lined with cubical epithelium. The pedicle consisted of fibro-fatty tissue and vessels. From the careful description given of this case it seems impossible to doubt that we here have to do with a true supernumerary mamma.

In most *Cetaceans* the mammæ normally occupy a somewhat similar position; and a little insectivorous animal (*Sorex crassicaudatus*), in addition to two pairs in the groins, has a third pair under the base of the tail, at the level of the anus.<sup>20</sup>

<sup>19</sup> "Ueber einen fall von Mamma Accessoria," *Inaug. Diss. Erlangen*, 1875.

<sup>20</sup> Cuvier, *Op. cit.*, p. 606.



In a very few cases supernumerary mammary structures have been found in the *median* line of the front of the body.

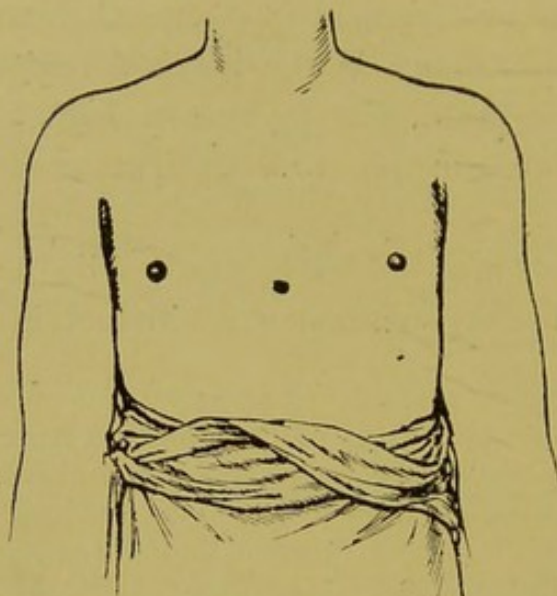


FIG. 11.—Median nipple.

I lately saw a man (fig. 11) aged 67, with recurrent epithelioma of the lower lip, who had a well marked supernumerary mammary structure, the size of a shilling, over the lower part of the sternum, at two inches below the level of the normal nipples. The central part of this structure presented a conical elevation, just like a nipple, of dark brown colour, and *devoid of hair*; around this was a pinkish brown, tuberculated areola, whence numerous long hairs grew. No subjacent gland could be felt. The normal mammæ were large and movable, like those of a middle-aged woman (*gynæcomastia*). At about four inches below the left nipple and rather internal to it, was a small supernumerary nipple surrounded by a few hairs, but devoid of areola. The patient was under the care of Dr. Purcell.

In a case mentioned by McGillicuddy,<sup>21</sup> a female child 7 weeks old, is said to have had a supernumerary mammary structure, over the sternum, rather above the level of the normal glands. Sutton<sup>22</sup> appears to have met with a somewhat similar condition. The mammary glandular nature of the structures in these two cases appears to me doubtful.

Gorré<sup>23</sup> refers to a Wallachian *vivandière*, the mother of two children, who died shortly after the birth of her second child from the effects of exposure and privation. On examining her body after death Gorré was surprised to find a well-developed pair of supernumerary milk-giving

<sup>21</sup> *New York Medical Record*, October 10, 1891, p. 448.

<sup>22</sup> *Illustrated Medical News*, February 1, 1890, p. 99.

<sup>23</sup> *Dict. des Sci. Méd.* (1819), t. xxxiv., p. 529.



mammæ, situated below and internal to the normal ones ; and between these a rudimentary median one, five inches above the umbilicus.

Max Bartels<sup>24</sup> alludes to an instance of similar malformation in a man.

In another case<sup>25</sup> an exceedingly beautiful lady, the mother of five well-formed children, had a small rudimentary median mamma rather below the level of the normal glands.

Median mammæ are very rare in the animal world ; but instances occur in the Virginian Opossum (*Didelphys virginiana*), and in a few other marsupials.

From the foregoing remarks it will be gathered that I regard the so-called *mammæ erraticæ* as due to reversion to ancestral arrangements much more ancient than those reproduced in ordinary cases of polymastia. There is no evidence whatever that such structures can arise just anywhere, as "sports," from ordinary sebaceous follicles ; on the contrary, I have shown that they only arise in positions corresponding with those occupied normally by the glands of polymastic animals. My investigations prove that highly specialised structures like the mammary gland, with its nipple and appendages, never develop suddenly in any human being, except in response to ancestral hereditary influence. Were it otherwise, human beings would have even more mammæ than Diana of Ephesus. We know that supernumerary teeth, like supernumerary mammæ, are occasionally met with in mankind. But these redundant teeth do not occur just anywhere on the general cutaneous surface, but only in certain regions of the mouth, &c., hereditarily predisposed to produce them. Supernumerary mammæ are frequently found on the general cutaneous surface of the front of the trunk, but teeth never. What is the reason of this ? The answer is, that our remote ancestors were accustomed to have mammæ developed there, but not teeth. It will be advanced as an objection to this reasoning that *supernumerary mammæ and teeth*

<sup>24</sup> Reichert and Du Bois Reymond, *Arch. für Anat., &c.*, 1872, s. 306.

<sup>25</sup> Percy, "Mém. sur les femmes multimammæ," *Jour. de Méd. de Corvisart*, An. xiii., t. ix., p. 381.



have been found *in the walls of ovarian dermoid cysts*.<sup>26</sup> I willingly answer this objection, as it will afford me an opportunity of refuting the erroneous interpretation that has lately sprung up as to the origin of these remarkable anomalies.

The current view, that ascribes the origin of most ovarian dermoid cysts to sequestration of a portion of the cutaneous matrix, at an early stage of development, enables us to understand the presence of hairs, sebaceous follicles, sweat glands, and other normal dermal structures in the walls of such cysts. Since it may very well happen, during the process of sequestration, that portions of the matrix of adjacent structures may also be involved, we can understand on this hypothesis how it is that connective and fatty tissues may be found in connection with such cysts, and even pieces of bone and cartilage.

But when in the walls of congenital ovarian cysts we find highly specialised structures, like mammæ and teeth, which are never produced in the normal ontogeny by any portion of skin likely to be thus sequestered, this hypothesis is, I maintain, no longer tenable. In these cases, I believe, we have to do with very imperfect parasitic foetuses *per inclusionem*, in which only the mammæ or teeth of the parasite have survived.<sup>27</sup> Many examples<sup>28</sup> of this kind of monstrosity have been recorded, in which only a single part or organ of the parasite has developed; in a case lately published by Kümmel<sup>29</sup> there was only a rudimentary eye. The cases of cows with udders on the back and supernumerary extremities also belong to this category.<sup>30</sup>

<sup>26</sup> Corradi, A., *Dell Ostetrica in Italia*, Bologna, 1874, p. 1459; Haffter, E., *Arch. f. Heilk.* 1875, s. 56; *Arch. f. path. Anat.* (Velitz), Bd. cvii., s. 505; *Trans. Path. Soc. Lond.* (Sutton and Shattock), vol. xxxiv., pp. 437, 442.

<sup>27</sup> It is no objection to this explanation that several hundred teeth have been found in a single cyst; because under such abnormal conditions the dental germs may multiply almost indefinitely by gemmation, as has been often observed in dentigerous cysts of the jaws.

<sup>28</sup> Lannelongue, *Traité des Kystes Congénitaux*, 1886, pp. 236-256. I have lately seen an account of a congenital cyst in the vicinity of the orbit, from the wall of which a tooth had developed.

<sup>29</sup> *Arch. f. path. Anat.*, Bd. cxviii., Heft 1.

<sup>30</sup> Bugnion has recently described, in the *Revue Méd. de la Suisse Romande* (1889, p. 334), the case of a woman with a parasitic monstrosity, consisting of pelvis and lower extremities, which was attached by its rudimentary pelvis to her pubic region.



§ III.—The General Pathology of Supernumerary Mammary Structures.

Mammary anomalies *per excessum* were formerly regarded as great rarities, because the old observers noticed only very marked examples, to which their attention was usually drawn by the escape of milk from the tumour. Hence most of their cases were in women—pregnant or recently confined.

According to Bruce,<sup>31</sup> of 315 individuals of both sexes, taken indiscriminately, 7·6 per cent. presented the malformation; of 207 males, it was present in 9·1 per cent.; and of 104 females, in 4·8 per cent. It is therefore nearly twice as frequent in males as in females. Herein it resembles most other congenital malformations, which, as I have elsewhere shown,<sup>32</sup> are much commoner in the male than in the female sex. In this connection it is interesting to recall the observations of Darwin,<sup>33</sup> as to the great proneness of secondary sexual characters to vary, especially in males.

Supernumerary mammary structures very rarely attain the structural and functional completeness of the normal glands; as in the case of a woman described by Tarnier,<sup>34</sup> who had an extra pair of abdominal mammæ, which equalled the normal ones in every respect. It is usual to find the supernumerary organ represented only by a nipple—with or without its areola. In other instances there is neither nipple nor areola, but simply a subcutaneous mass of glandular tissue, which may communicate with the surface of the body by one or several pores, or be altogether cut off from it. Between these varying structural grades all kinds of intermediate conditions are met with.

In its least degree, the malformation *per excessum* is represented by the bifid nipple.

---

In each groin she had a nipple-like process, surrounded by a pigmented area, which represented the mammæ of the *parasite*. The woman herself was otherwise well formed.

<sup>31</sup> *Journal of Anatomy*, vol. xiii., p. 423.

<sup>32</sup> "The Influence of Sex in Disease," Churchill (1882), p. 4.

<sup>33</sup> "Descent of Man" (1879), p. 223, *et seq.*

<sup>34</sup> *Traité de l'art des Accouch.*, par Cazeaux, 8me éd. (1870), p. 86.



Duval<sup>35</sup> says, "I have seen a young woman, 25 years old, who had the nipple of each breast divided nearly to its base into two equal parts. She said her nipples had been thus from birth. The deformity did not interfere with lactation."

Slight exaggeration here leads to the formation of two nipples on one areola (intra-areolar polythelia), as in a case described and figured by Tiedemann.<sup>36</sup>

In this case the drawing was made from the body of a girl in the dissecting room, on each of whose otherwise well-formed breasts two nipples were found within one areola—one nipple perpendicularly below the other.

In other cases one or more supernumerary nipples, each with its own areola, have been met with, in various positions, on a single breast (intra-mammary polythelia<sup>37</sup>).

Percy and Laurent<sup>38</sup> in their clever essay, have related a remarkable instance of this kind. The patient was a woman who had two large pectoral mammae in the normal position, of which the left was furnished with five nipples, each with its own areola, and the right with two nipples, also with distinct areolæ.

Prackel<sup>39</sup> saw a Scotch woman with three nipples on each breast, arranged so that they corresponded to the angles of an equilateral triangle, the two additional ones being below the normal nipple. Each of them gave milk. The woman had given birth to twins several times.

De Sinéty<sup>40</sup> and Tarnier<sup>41</sup> have each related a case of intra-mammary polythelia in women whose mothers had identical malformations.

A most remarkable instance of the inheritance of redundant nipples has been recorded by Blanchard.<sup>42</sup>

A man, the father of thirteen children—seven males and six females—had a supernumerary nipple with a rudimentary areola on each breast, a few cm. below each normal nipple. All his seven sons had the like deformity, but none of his daughters. The youngest of the sons became the father of five children—four boys and one girl. All the boys had supernumerary nipples like their father, grandfather, and six uncles.

<sup>35</sup> Duval, *Du Mamelon et de son auréole*, Paris (1861), p. 90.

<sup>36</sup> Tiedeman and Treviranus, *Untersuchung über die Nat. der Mensch*, &c. (1831), Bd. v., s. 110, taf. i., fig. 3.

<sup>37</sup> Duval, *Op. cit.*, p. 83 *et. seq.*; Engeström, O., *Arch. de Gynéc.*, t. 31, p. 282; Chowne, *Lancet*, vol. ii., 1842, p. 465; Puech, *Op. cit.*, p. 84.

<sup>38</sup> *Dict. des Sci. Méd* (1819), t. 34, p. 525.

<sup>39</sup> *Miscell. Curios., &c.*, Dec. ii. Ann. v., *App. Obs.* 67, p. 40.

<sup>40</sup> *Gaz. Méd. de Paris* (1887), p. 317.

<sup>41</sup> Cazeaux, *Traité de l'art des Accouch.*, 8<sup>e</sup> ed. (1870), p. 86.

<sup>42</sup> *Bull. de la Soc. d'Anthropologie*, t. ix. (1886), p. 485.



These anomalies arise from excessive growth of the rudiment of the gland and nipple, after the developmental process has made a certain amount of progress; consequently the causes which determine them must be referred to a much later stage of embryonic development than those which determine atavistic supernumerary mammæ. That is to say, the causes of these malformations are of the same nature as those which originate *discontinuous growth* in general.

From such conditions, which are relatively rare, I will now pass to those much commoner ones, in which the supernumerary mammary structures are quite independent of the normal breasts.

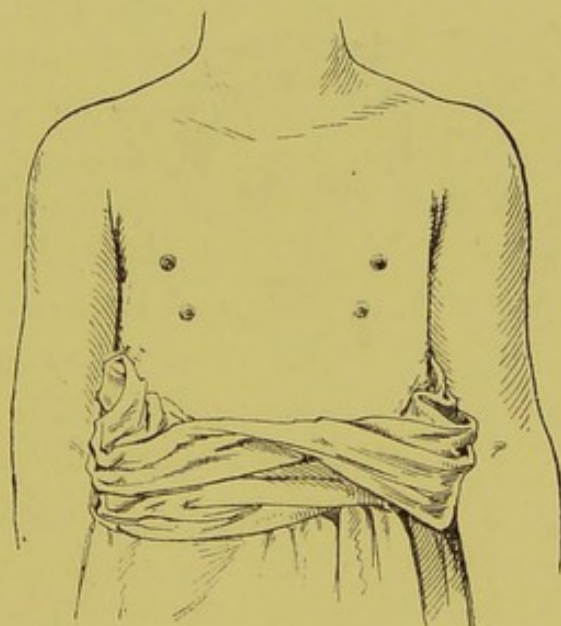

FIG. 12.—A pair of supernumerary mammary structures in a boy.

The above figure represents a boy, 11 years old, with a pair of supernumerary nipples, etc., two inches below and slightly internal to the normal ones, which they nearly equalled in every respect. The patient was under treatment for tubercular lymphadenitis of the neck of three years' duration. The figure is from a photograph, for which I am indebted to Mr. Jesset.

The number of these supernumerary parts may vary from one to eight, but more than two are very exceptional. Of Leichtenstern and Bruce's 166 cases, in 112, or two-thirds, there was only a *single* extra structure. Such single redundant mammary structures are almost invariably situated a little below and internal to the corresponding normal



mammæ, in the position of the fifth pair of my diagram (fig. 10), and in females they are much more frequently seen on the left than on the right side.<sup>43</sup> I have not found the same disproportion in males; for, on separating the sexes in Bruce's list: of 42 males, the deformity occurred on the left side in 22, and on the right in 20.

A small proportion of these single extra mammary structures are met with lower down than the above, in a position corresponding to that occupied by the sixth pair of my diagram. Both Leichtenstern and Bruce have recorded several such cases.

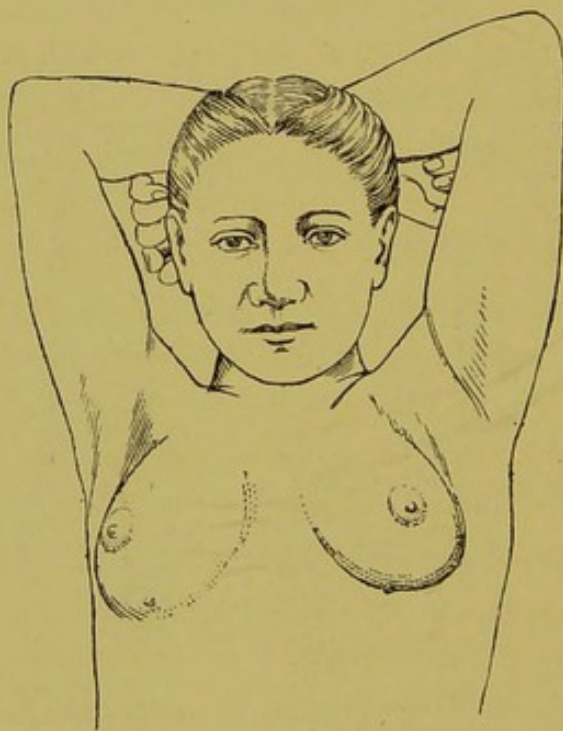


FIG 13.—A pair of supernumerary mammary structures in a young woman (*Leichtenstern*).

In the great majority of the remaining cases there was present a pair of supernumerary mammary structures, situated a little below and internal to the normal glands, in the position of the fifth pair of my diagram (fig. 10). Typical instances of

---

<sup>43</sup> Of 101 single cases in Leichtenstern and Bruce's lists, 64 were on the left side, and only 37 on the right.



this kind in males have been recorded by Max Bartels,<sup>45</sup> Handy-side,<sup>46</sup> &c. ; and in females by Leichtenstern,<sup>47</sup> Whitford,<sup>48</sup> Chatard,<sup>49</sup> and others.

In Leichtenstern's case (fig. 13) the patient was a healthy young woman with a redundant pair of small, erectile, symmetrical nipples, each surrounded by a pigmented areola, situated just below and internal to the normal mammæ.

In more than three-fourths of all cases, supernumerary mammary structures have been found in this situation, on one or both sides ; and it is significant that elsewhere such conditions are most exceptional. We may conclude from this, that our progenitors had a redundant pair of thoracic mammæ here, long after they had lost all their other supernumerary glands. In some *Lemurs* a similarly placed second pair of pectoral mammæ is still of normal occurrence.

In a certain number of cases a supernumerary *pair* of mammæ has been found below and internal to the above, in the position of the sixth pair of my diagram (fig. 10). Typical instances of this kind in men have been recorded by Leichtenstern<sup>50</sup> and Hamy,<sup>51</sup> and in women by Rapin,<sup>52</sup> De Sinéty,<sup>53</sup> &c.

Abdominal mammæ in human beings are very rare. I know only of the following cases :—

The most remarkable is Tarnier's<sup>54</sup>—

He says, "I have myself seen a woman with four breasts, who died in the Maternity Hospital. Two breasts of the usual size occupied the normal position ; while two others, as fully developed, were situated on the upper and lateral parts of the abdomen, nearly in the vertical line with the thoracic ones. At the necropsy I found abundance of glandular tissue in all four breasts, which also contained milk."

<sup>45</sup> Reichert and Du Bois Reymond, *Arch. f. Anat.* (1872), s. 304.

<sup>46</sup> *Journal of Anatomy* (1872), p. 56.

<sup>47</sup> *Arch. f. path. Anat.*, Bd. lxxiii., s. 252, No. 87, taf. iv., fig. 4.

<sup>48</sup> *Chicago Med. Jour. and Examiner* (1884), p. 528.

<sup>49</sup> *Journal de Méd. de Bordeaux*, Sept., 1861.

<sup>50</sup> *Op. cit.*, s. 251 (No. 85), taf. iv., fig. 2.

<sup>51</sup> *Bull. de la Soc. d'Anthropologie*, t. viii. (1885), p. 229.

<sup>52</sup> *Rev. Méd. de la Suisse Romande* (1882), p. 472.

<sup>53</sup> *Gaz. Méd. de Paris* (1887), p. 317.

<sup>54</sup> Cazeaux, *Op. cit.*, p. 86.



Bartholin<sup>55</sup> has seen a woman with a pair of supernumerary mammæ in the same situations, each the size of the normal male breast.

Bruce<sup>56</sup> has described and figured a redundant nipple in this situation in a man, and says he has seen several other instances of the kind.

In Mortillet's and Alexander's cases, already alluded to, a pair of supernumerary mammary structures were present in this situation, nearly as perfect as the normal ones.

A case recorded by McGillicuddy<sup>57</sup> differs from all the foregoing, in that the supernumerary structures were much lower down. The anomaly occurred in a man, aged 35, who had a pair of rudimentary mammæ at about the *level of the umbilicus*, three to four inches from it. These yielded a milk-like fluid, which contained numerous colostrum corpuscles.

It seldom happens (12 out of 166 cases) that supernumerary mammary structures are met with *above* the normal glands. When this is the case, it is interesting to note that the redundant structures are always found *external* to the normal ones, as in polymastic animals. Cases of this kind will be cited in the section on axillary mammæ.

Probably all races of men are subject to these malformations; instances have been met with in nearly all European nations, and, in addition, in a Mongol, West Indian, Malayan, in a Mulatto from the United States, and in a Mulattress from the Cape, a Moorish woman, and a Negress.

With regard to their occurrence in animals, Owen says<sup>58</sup>:—"In the Orang-utan (*Pithecius satyrus*), I have observed an accessory nipple on the left side, below the normal one, and of smaller size."

Our domestic cows have normally four well-formed, and often two rudimentary teats. I have several times seen the latter well developed, and they occasionally yield milk. The supernumerary teats are always placed behind the normal ones. Of the two normal pairs the anterior one is generally obviously longer and larger than the other. I have seen a cow with all

<sup>55</sup> *Epist. Med.*, cent. iv., No. 38, p. 218.

<sup>56</sup> *Journal of Anatomy*, vol. xiii. (1879), p. 446.

<sup>57</sup> *N. Y. Med. Rec.*, Oct. 10, 1891, p. 447.

<sup>58</sup> *Comp. Anat.*, vol. iii., p. 780.



these three pairs of teats well developed, and with, in addition, a fourth rudimentary pair behind the last of the three well-developed ones. I have also seen a cow with *five* teats, an anterior pair corresponding to the normal one, a posterior pair corresponding to the ordinary supernumerary one, and between these a single long, thin, flabby teat, corresponding to the left one of the normal posterior pair, its fellow having completely aborted. Variations in the number and degree of development of the teats of cows are of common occurrence.

In sheep, which are also prone to this anomaly, the additional teats are, according to Sanson,<sup>59</sup> always found in front of the normal ones. Daubenton<sup>60</sup> has described a goat with double teats on each udder, and instances of redundant mammary structures have been met with in various monkeys, cows, and other animals. It may be inferred, with tolerable certainty, that all animals having normally but a few mammæ are liable occasionally to have additional ones developed.

The question has been raised whether polymastic women are more liable than others to beget more than a single child at a birth. Of seventy polymastic women in Leichtenstern's list, three had given birth to twins, or 4·3 per cent. This proportion is much above the average, which for Great Britain is only about 1 per cent.

In this connection, Marie's<sup>61</sup> recently recorded case, in which a marked hereditary anomaly of this kind was associated with frequent twinning and very large families, is of interest.

The patient was a young girl with a supernumerary nipple below her left breast, in whose family this anomaly had been traced for four generations. In all of those affected but two, the supernumerary nipple was, as in the patient. Of her eleven brothers and sisters four were twins; and of her father's fifteen brothers and sisters six were twins; all these six had supernumerary nipples, while in none of the nine remaining children did the anomaly exist. Marie points out that the faculty of bearing twins in women is not less certain than the faculty of begetting twins that is observed in men. The father of the girl in this case was a twin, he begat two pairs of

---

<sup>59</sup> *Bull. de la Soc. d'Anthropologie*, t. ix. (1886), p. 511.

<sup>60</sup> Fourcroy's "*Méd. éclairée*," t. v., tab. 12.

<sup>61</sup> *Bull. de la Soc. Méd. des Hôp.*, t. x. (1893), p. 457.



twins, and one of his brothers, also a twin, became the father of at least one pair.

In polymastia the normal pectoral pair of mammæ are invariably present in their proper position, and well developed.

It is very unusual to find these anomalies associated with other congenital malformations, as in cases of amazia.

Bryant,<sup>62</sup> however, has seen a girl, aged 6, with a supernumerary nipple on the left side, below the normal one, in whom the vagina was absent, and she had a clitoris as large as a boy's penis.

Voltaire<sup>63</sup> also relates having seen at a fair a woman with a pair of redundant mammæ, "qui portait de plus au croupion une sorte d'excroissance convertie de peau et de poils, la quelle ressemblait à une queue de vache."

It is alleged that in the beautiful Anne Boleyn, polymastism was associated with polydactylism.

Supernumerary mammary structures are often hereditary as in the previously mentioned cases of Blanchard and Marie. In seven out of ninety-two cases (7.6 per cent.) collected by Leichtenstern there was history of similar malformation in near relatives.

In Petrequin's case,<sup>64</sup> the father, his three sons and two daughters, each had a single supernumerary pectoral mamma.

Handyside<sup>65</sup> has seen two brothers, each with a supernumerary pair of pectoral nipples below the normal ones.

In a case related by Edwards,<sup>66</sup> a man had a single additional nipple with areola below the right normal one, and his sister had a similar deformity of the left side. Edwards had the opportunity of examining both persons. Bathurst Woodman<sup>67</sup> has recorded the case of a woman with a supernumerary nipple below the left breast, whose daughter had the like deformity. Roberts' case has been already mentioned. Other instances of hereditary polymastism by Bartholinus, Tiedemann, and Scalzi have also been previously referred to.

Anomalies of this kind are often overlooked for the want

<sup>62</sup> "Diseases of the Breast" (1887), p. 9.

<sup>63</sup> *Dict. Philosophique*, art. "Monstres."

<sup>64</sup> *Gaz. Médicale*, av. 1837, p. 195.

<sup>65</sup> *Journal of Anatomy*, vol. vii. (1872), p. 56.

<sup>66</sup> *Phil. Med. News*, 1886, p. 264.

<sup>67</sup> *Obstet. Soc. Trans.* (London), vol. ix. (1867), p. 50.



of knowing what to expect. Those who know *where to look* and *what to look for* are not likely to have much difficulty in making a diagnosis. In minor degrees of this deformity, instead of a redundant nipple, only a depression may be found (*athelia*). Hairs are never seen on normal nipples; but the supernumerary ones occasionally have them.<sup>71</sup> In many instances supernumerary mammary structures have been mistaken for moles, *nævi*, lipomata, and cold abscesses. Morbid growths in connection with the nipple sometimes simulate supernumerary malformations. I lately saw a middle-aged married woman with a small *molluscum fibrosum* near the nipple, which it closely resembled. I have already alluded to the resemblance between some cases of supernumerary *mammæ* and the condition resulting from chronic fistula, in connection with sebaceous and dermoid cysts that have undergone suppuration. Very little help is to be got from the metropolitan museums in this matter; altogether they contain but a single specimen! This *rara avis* is to be found in the museum of the London Hospital—a single supernumerary nipple from a man. As a rule, supernumerary mammary structures, being small and rudimentary, hardly attract the notice even of those who bear them. Sometimes, however, especially in women during lactation, the overflow of milk from them causes considerable annoyance.

There can be no doubt as to the propriety of excising such redundant parts for those who desire to be relieved of the deformity, and the procedure is free from danger.

#### § IV.—Axillary Supernumerary Mammary Structures.

The subject of supernumerary mammary structures in the axilla and its vicinity is of such importance, that I propose to devote a special section to its consideration.

Two varieties of this condition may be met with; a commoner one due to *sequestration*, and a rarer one of *atavistic* origin.

---

<sup>71</sup> Bruce, *Op. cit.*



Several anatomists have recognised the fact, that in females a process of the mammary gland is not infrequently prolonged round the border of the *pectoralis major* muscle right into the axilla. According to Hennig<sup>72</sup> the fully developed female mamma has normally a tricuspid form, two of the cusps projecting towards the axilla—an upper and a lower one—and the other towards the sternum. It is the upper of these two axillary mammary extensions that so often extends right into

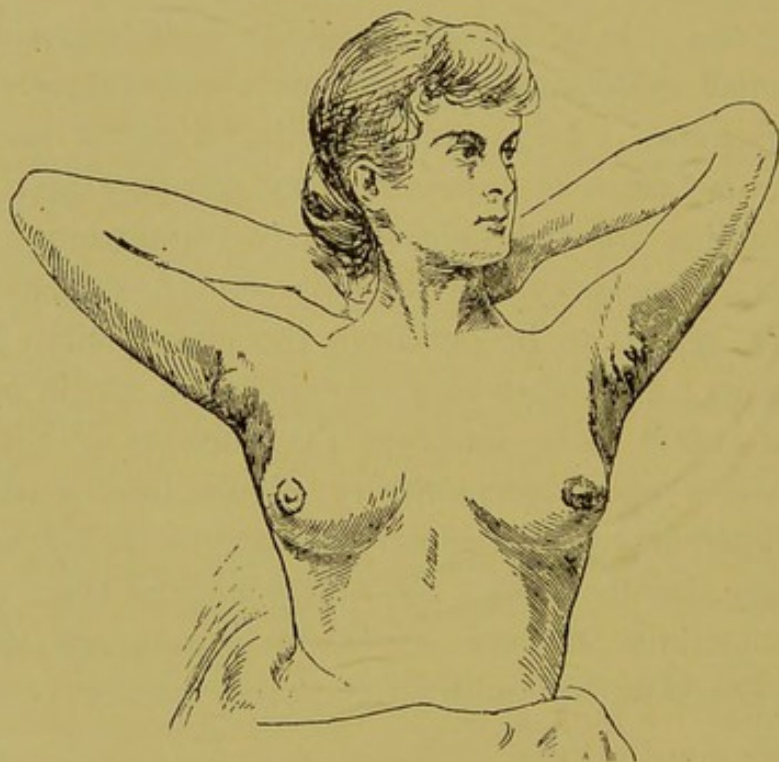


FIG. 14.—A pair of enlarged milk-secreting axillary sequestrations in a puerperal woman (McGillicuddy).

the axilla. Though commonest in the axillary region, similar glandular offshoots project from other parts of the mamma. The connection of these outlying processes with the *corpus mammae* is often reduced to a narrow pedicle; and not infrequently by its rupture they become completely sequestered.

I have found on record numerous instances of so-called *axillary mammae*; but when one comes to examine these cases

<sup>72</sup> *Arch. f. Gyn.*, Bd. ii., 1871, s. 331.



critically only a very few of them can be definitely accepted as such; most of them are of the nature of axillary mammary extensions or sequestrations. I have not met with a single instance of the kind in a male. Subjoined are abstracts of some typical cases.

I.<sup>73</sup>—The patient (fig. 14,) was a well developed, healthy, married woman, aged 24, who during her second pregnancy first noticed a swelling in each axilla. Soon after her confinement these increased in size; and milk escaped through minute pores in the overlying skin, causing her much discomfort through keeping her clothes constantly wet.

II.<sup>74</sup>—Puech has reported the case of a woman, aged 19, who the day after her first confinement, noticed a swelling—the size of half a hen's egg—in her left axilla, immediately beneath its anterior border. The superjacent skin was not adherent, nor pigmented, nor otherwise discoloured; and no trace of a nipple existed. On pressing the swelling a few drops of milk oozed from the skin. The corresponding breast was full of milk, which freely issued from its healthy nipple. The tumour felt as though composed of mammary glandular tissue; and a distinct cord could be traced from its inner aspect to the left breast. On exploring the right axilla a similar swelling was found. It was slightly smaller than its fellow, but in other respects precisely similar. There was no nipple and no visible external orifice, but milk exuded from the skin on pressure, and there was a cord running to the right breast. Shortly afterwards the patient went out as a wet nurse. The breasts were full of milk but none issued from the skin over the swellings, which soon diminished in size; and in the course of a fortnight they had almost disappeared. The axillary swellings in this case were evidently nothing but pedunculated axillary mammary extensions.

III.<sup>75</sup>—Bué attended a woman in her third confinement, which occurred at term. Two days later a swelling developed in the anterior part of each axilla, especially on the right side. The normal breasts were full of milk. The swelling on the right side was situated on the border of the pectoralis major and on the thoracic wall in the adjacent part of the axilla. It measured  $2\frac{1}{4}$  inches in diameter and over 6 in circumference, and was separated by a groove from the normal gland. When the child was put to the right breast a distinct diminution in the size of the axillary swelling was observed. Afterwards it again enlarged. There was no trace of any nipple. The left axillary swelling lay in the same position as the right, but was much smaller. On the day after its appearance it vanished. Its fellow on the right side remained stationary all the time that the patient suckled.

IV.—Champneys<sup>76</sup> has related the three following striking

<sup>73</sup> *N. Y. Med. Record*, Oct. 10, 1891, p. 447. McGillicuddy's case.

<sup>74</sup> *Arch. de Toc. et de Gyn.*, May, 1892.

<sup>75</sup> *Ibid.*, June, 1893.

<sup>76</sup> *Med. Chir. Trans.*, vol. lxi., 1886, p. 429.



examples of this condition in lying-in women. In all of these cases, as in Bué's, no secretion escaped externally.

(1) On the third day after admission a mammary extension, two inches broad, was noticed in each axilla, to the apex of which it reached. These extensions joined the outer border of the mammary gland at a tangent; they felt nodular, and in all respects like the mamma itself.

(2) On the sixth day after admission a mammary extension was felt on the inner wall of each axilla. These extensions were obviously connected with the breasts, and they felt just like them.

(3) On the second day after admission there was noticed a nodular prolongation from the outer side of each mamma along the inner wall of the axilla, nearly to the apex.

V.—Charcot and Legendre<sup>77</sup> have recorded two instances in which supernumerary nipples—in one case with and in the other without an areola—were met with in connection with axillary mammary extensions.

In each there was but a single supernumerary nipple, which was situated just above and external to the normal one—in one case on the left side and in the other on the right. In both these cases the connection between the supernumerary nipples and the mammary extensions was verified by *post-mortem* examination.

VI.—In Notta's<sup>78</sup> case there was a tumour the size of a walnut over the middle of the left anterior axillary border, which was connected with the breast by a narrow pedicle. On pressure milk escaped through a single small pore in the overlying skin. There was no sign of nipple or areola, and the other axilla was normal. The patient was a woman, aged 26, who was suckling her fourth child. No escape of milk in the axilla had taken place during previous lactations. To account for this Notta has made the feasible suggestion, that on these occasions the secretion from the tumour was carried off by the normal nipple through the pedicle, which subsequently, for some reason or other, became occluded; when the accumulating secretion made its exit by the axilla. In order to determine the precise nature of this condition Notta dissected the mammæ of a number of women. In one, aged 26, who died in child-bed, he found an axillary mammary extension, which presented as—"Une sorte de cordon qui, suivant le bord externe du grand pectoral, remontait vers le milieu du deuxième espace intercostal."

VII.—Champneys<sup>79</sup> has seen two similar cases in lying-in women. In both there was supernumerary gland substance in each axilla, which dis-

<sup>77</sup> *Gaz. Méd. de Paris*, 1859, p. 773.

<sup>78</sup> *Arch. de Toc. et de Gyn.*, 1882, p. 108.

<sup>79</sup> *Op. cit.*, pp. 430, 431.



charged externally by a single pore at the middle of the anterior axillary borders. In another of Champneys' cases,<sup>80</sup> a lying-in woman had a supernumerary mammary swelling in each axilla, connected with the normal gland by a narrow pedicle. On pressure milk escaped from each of them, through a small pore in the overlying skin.

VIII.—Precisely similar cases, without any communication with the cutaneous surface, have been met with by Polden,<sup>81</sup> Godfrain,<sup>82</sup> Maschat,<sup>83</sup> and Auvard.<sup>84</sup>

Conditions of this kind may easily be mistaken for enlarged axillary glands, tumours, hypertrophied cutaneous sebaceous glands ("axillary lumps" of Champneys), abscess, &c.

Numerous examples of axillary mammary *sequestrations* have, from time to time, been recorded. In what follows reference is made to the most important of these.

I.—Meyer<sup>85</sup> has reported the case of a woman, aged 27, who shortly after her third confinement, first noticed a lobulated tumour in her left axilla, unconnected with the breast, and not in communication with the cutaneous surface. A little later, above and external to the left breast, she noticed another tumour. As the patient feared she had cancer, having lost a relative from this disease, the axillary tumour was dissected out. It proved to be a mammary gland tumour, containing milk, and having no connection with the breast; this was verified by microscopical examination. The other tumour subsequently disappeared spontaneously.

II.—Martin,<sup>86</sup> Siebold,<sup>87</sup> Champion,<sup>88</sup> Harris,<sup>89</sup> Dixon,<sup>90</sup> and Moore,<sup>91</sup> have each of them seen a lying-in woman with a tumour the size of a hen's egg in both axillæ, whence milk exuded on pressure through several small pores in the overlying skin. No nipple was present in either of these cases; nor is mention made of any connection between the axillary tumours and the normal mammæ.

<sup>80</sup> *Op. cit.*, p. 423.

<sup>81</sup> *Indian Med. Gaz.*, vol. xxii., 1887, p. 241.

<sup>82</sup> *Thèse de Paris*, 1877, p. 35. "Sur les mamelles surnuméraires."

<sup>83</sup> *Thèse de Paris*, 1883, No. 184. "Anomalies de la mamelle."

<sup>84</sup> *Arch. de Toc. et de Gyn.*, t. xv., 1888, p. 622.

<sup>85</sup> *N. Y. Med. Record*, 1886, vol. i., p. 455.

<sup>86</sup> *Annal. d'Ophtalm. et de Gyn.*, t. i., liv. 8.

<sup>87</sup> *Med. Ztg. v. e. Verein f. Heilk.*, in *Pr.*, 1838, No.

<sup>88</sup> *Dict. des Sci. Méd.*, t. xxx., p. 377.

<sup>89</sup> *Med. Times and Gaz.*, 1861, vol. i., p. 397.

<sup>90</sup> *Lancet*, 1843, vol. ii., p. 844.

<sup>91</sup> *Lancet*, 1838, p. 786.



III.—In a case seen by Cameron,<sup>92</sup> a woman aged 33, in her sixth lactation, had a tumour the size of a hen's egg in the left axilla, from which milk escaped on pressure through a single small pore. She first noticed the swelling after having over-exerted herself in extinguishing a fire when she was pregnant with her sixth child. In all her previous confinements she was free from any axillary trouble. It seems probable here, as in Notta's case, that the tumour was formerly connected with the normal gland by a pedicle, which carried off its secretion *per vias naturales*.

Cohn<sup>93</sup> has recorded a precisely similar case, also on the left side.

IV.—Matthews Duncan<sup>94</sup> has published an account of a woman, aged 26, who, in the ninth month of her pregnancy, complained of constant wetness in the right axilla. Four days after her confinement a tumour the size of a walnut was found in this situation, which, on pressure, emitted milk through a single small pore in the overlying skin. The tumour had no obvious connection with the normal mamma.

Turney,<sup>95</sup> Auvard,<sup>96</sup> and Hare<sup>97</sup> have met with precisely similar conditions in women, also on the right side.

In the cases of Harris and Hare, milk cysts formed in the axilla.

V.—Johnson<sup>98</sup> has described a curious condition, in which there formed in the right axilla of a woman, during her third pregnancy, a pear-shaped, pendulous, lobulated tumour, like the male scrotum. Its size was greatest just before *accouchement* and shortly afterwards, when it measured nine inches in circumference. On squeezing it milk exuded through several small pores, over its lower part. It was evidently an axillary galactoceles. She had also a small tumour in the left axilla. During her previous pregnancies nothing abnormal had been noticed in either axilla.

VI.—Neve<sup>99</sup> has reported a similar case :—

The patient was a Kashmiri woman, aged 25, who came under his notice, with a tumour the size of a hen's egg in her left axilla. It felt lobulated, and the overlying skin, which was much pitted, was adherent to it. The tumour formed during her first pregnancy five years ago. It was excised, and proved to be circumscribed, and unconnected with any important adjacent structures. On section, after removal, it consisted of congeries of convoluted tubes, the thickness of a crow-quill, which contained thick, yellowish substance, resembling inspissated milk. It was evidently an old axillary galactocoele, that had originated from an axillary mammary sequestration.

<sup>92</sup> *Journal of Anatomy*, vol. xiii., 1879, p. 149.

<sup>93</sup> *Berlin klin. Woch.*, 1885, S. 291.

<sup>94</sup> *Obstetrical Journal*, 1873, vol. i., p. 516.

<sup>95</sup> *Phil. Med. News*, 1886, p. 264.

<sup>96</sup> *Arch. de Toc. et de Gyn.*, 1888, p. 622.

<sup>97</sup> *Lancet*, 1860, vol. ii., p. 405.

<sup>98</sup> *Boston Med. and Surg. Journal*, 1886, vol. ii., p. 547.

<sup>99</sup> *Lancet*, 1894, vol. i., p. 801.



We can now proceed to study the various much rarer forms of atavistic supernumerary mammary structures met with in the axilla and its vicinity.

First of all, with regard to those found in the *vicinity* of the axilla. Several cases are on record of supernumerary mammæ occupying a position corresponding to the third pair of my diagram (fig. 10) *i.e.*, just above and a little external to the swell of the bosom. Subjoined are abstracts of four cases of this kind.

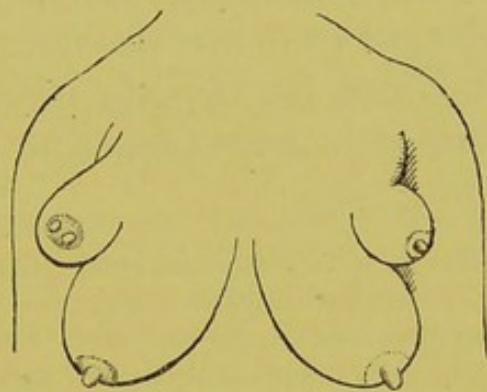


FIG. 15.—A pair of supernumerary mammæ above the normal ones (*Shannon*).

(1) In Shannon's case<sup>100</sup> the patient was a woman, aged 34, who came under observation soon after her sixth confinement, when it was noticed that she had a pair of supernumerary breasts just above and external to the normal ones (fig. 15). Each of the redundant organs was the size of a large goose's egg. Curiously enough, the right supernumerary gland was furnished with two nipples, and the left with a single one; each nipple had its own well-developed areola, and during lactation milk flowed freely from them all, especially when the normal ones were being sucked. A mole-like body on the right supernumerary breast gave the appearance of a third nipple. The patient said she first noticed the supernumerary glands at about the time of puberty, and that they had always enlarged and given milk under the same conditions as the normal mammæ. She had never brought forth more than one child at a birth. The generative organs were normal. There was no history of any similar deformity among her relations.

(2) Lee's patient<sup>101</sup> was a woman, aged 35, in whom a pair of supernumerary mammæ were noticed shortly after her premature delivery of a still-born child. The redundant glands were situated just above and external to the normal ones; each had a single, small, flat nipple which yielded milk. She first noticed the deformity shortly after her first confinement ten years

<sup>100</sup> *Dublin Med. Journal*, vol. v., 1848, p. 266.

<sup>101</sup> *Med. Chir. Trans.*, vol. xxi., p. 266.



previously. She subsequently had several single children; and at 30 she had twins. The generative organs were normal.

(3) In Gardiner's case<sup>102</sup> the patient was a mulattress from the Cape, aged 29, healthy and well developed, except that she had a pair of supernumerary mammæ a little above and external to the normal ones. The redundant mammæ were smaller than the normal ones—about the size of those of a girl at puberty. After child-birth these glands enlarged and gave milk.

(4) Champneys<sup>103</sup> has observed in a lying-in woman a rudimentary nipple in the like situation just above the right breast. This woman had also an extra pectoral pair of nipples below and internal to the normal ones.

As examples of supernumerary mammary structures in a position above and external to that described in the foregoing cases; yet not in the axilla, but over the middle of its anterior border, corresponding to the second pair of my diagram (fig. 10), I can cite the following cases:—

(1) Quinquad's<sup>104</sup> patient was a woman, aged 24, who, in addition to a large pair of normal mammæ, had another smaller pair situated above them, over the middle of each anterior axillary border. Each was the size of a small orange, and was furnished with well-formed nipple and areola. During lactation these glands gave milk. She had suffered from right internal strabismus since the age of two. There was no history of any malformations among her relatives. The areolæ of the normal mammæ were very large. Directly I saw her photograph this particular recalled to mind Cuvier's celebrated drawing of the Hottentot Venus<sup>105</sup> whose areolæ were over four inches in diameter.

(2) Bruce<sup>106</sup> has seen a man with a pair of rudimentary supernumerary nipples in the like position, who had also an extra nipple on the left side below the normal one.

(3) A woman observed by Charpentier<sup>107</sup> with a pair of well-formed supernumerary mammæ situated over the middle of the anterior border of each axilla. The additional mammæ differed only from the normal ones in that they were smaller; they had well formed nipples, whence milk escaped on pressure. The description is accompanied by a good figure.

The connection between pectoral and axillary mammæ

<sup>102</sup> Cited by Percy in his "Mém. sur les femmes multimammæ," *Journal de Méd., &c., de Corvisart.*, ann. xiii., t. ix., p. 383.

<sup>103</sup> *Op. cit.*, p. 434.

<sup>104</sup> "Femme Tétramaze." *Rev. photo. des Hôp.*, 1870, p. 16.

<sup>105</sup> "Femme de race boschismanne." *Hist. nat. des mammifères*, St. Hilaire et Cuvier, t. i., 1824, p. 1.

<sup>106</sup> *Op. cit.*, p. 425.

<sup>107</sup> *Traité pratique des Accouchements*, t. i., 1889, p. 69.



is admirably illustrated by the five following rare cases of multiple mammæ:<sup>108</sup>—

(1) Fitzgibbon's<sup>109</sup> patient was a man, aged 24, a native of Jamaica, who had four supernumerary mammæ: a well-formed pair below and internal to the normal ones; and another rudimentary pair just above and slightly external to the normal ones.

(2) In Mortillet's<sup>110</sup> case, two pairs of supernumerary mammæ were also present, but both were situated below and internal to the normal ones. The lowest pair was placed on the upper part of the abdominal wall, in the position of the seventh pair of my diagram (fig. 10); the other pair was situated between the foregoing and the normal pair, probably in the position of the fifth pair of my diagram, but as to this the description is not very precise. The patient was a healthy young conscript, and there was no history of any hereditary malformation in his family. The supernumerary mammæ were only a little less perfect than the normal ones. The lowest pair was the smallest.

(3) Alexander's patient<sup>111</sup> was a tall, stout mulatto from the United States. He was admitted into hospital at St. Helena, with self-inflicted flesh wounds of the chest, done to avoid going to sea with his ship. On examination it was noticed that he had six nipples, in two vertical lines, three on each side, the distance between them from above downwards being about four inches. The uppermost pair were in the normal position; the second pair corresponded to the fifth of my diagram (fig. 10), and the third pair to the seventh of the diagram. He was discharged a few days later, but returned shortly afterwards, having deliberately broken his forearm to avoid going on board his ship. Beyond this mutilating tendency and a rather ferocious aspect, he seemed otherwise normally constituted. His mother had four supernumerary mammæ in similar positions to his own, and two of them secreted milk. Of his several brothers and one sister, all (except one brother) had the like malformation.

(4) Ammon's<sup>112</sup> patient, with three pairs of supernumerary mammary structures, was a soldier, 22½ years old, in a Baden infantry regiment. The positions occupied by these anomalous structures have already been sufficiently described (*q. v.* p. 46). The highest and the lowest pairs were the least perfect.

(5) Neugebauer's<sup>113</sup> case is remarkable for the large number of supernumerary structures present, viz., eight, the largest number yet seen in any

<sup>108</sup> Petrone (*Prog. Med. Napoli.*, iii., 1889, 516) has recorded another case of six nipples in a male, but, as I have been unable to get access to the original memoir, I am unable to state the precise distribution of the redundant nipples.

<sup>109</sup> *Dublin Quarterly Journal Med. Sci.*, vol. xxix., 1860, p. 109.

<sup>110</sup> *Bull. de la Soc. d'Anthropologie*, t. vi., 1883, p. 458.

<sup>111</sup> *Medical Times and Gazette*, vol. ii., 1855, p. 70.

<sup>112</sup> Cited by Bonnet, in Merkel and Bonnet's *Ergebnisse der Anat. u. Entwicklungsgeschichte*, Bd. ii., 1893, S. 604.

<sup>113</sup> *Cent. f. Gynäk.*, 1886, S. 729.



human being. This anomaly was met with in the person of a single woman of Warsaw, a domestic servant, who was admitted into the lying-in hospital for her second confinement. Her normal mammæ were large and well formed, and during lactation they gave an abundant supply of milk. Soon after her confinement, when suckling, she noticed an uncomfortable wetness in each axilla. On examination as to its cause, a supernumerary nipple without areola was found in each axilla, from which milk flowed freely when the child sucked either of the normal breasts. At the same time two other pairs of nipples, each with its own areola, were found above the normal ones. The upper pair was situated over the middle of each anterior axillary border; and the lower pair, just above the periphery of each bosom, and slightly external to the normal nipples. Shortly afterwards, on raising the pendent mammæ, two other unsymmetrical redundant nipples were found below and internal to the normal ones; that on the right side was immediately below the bosom, that on the left was some inches *lower down*. Neugebauer has spoken of these two unsymmetrical nipples as a *pair*, but it is quite clear to me that this is a mistake; the upper one evidently represents the right nipple of the fifth pair of my diagram, and the lower one the left nipple of my sixth pair (fig. 10). On pressure, milk escaped from all these redundant nipples. It is a curious fact that after her first confinement—seven years previously—she never noticed any abnormality about the chest, other than the presence there of several brown spots, which she took for moles. The patient was exhibited at a meeting of the Warsaw Medical Society. A woodcut, from a photograph, which accompanies the record of this case, makes it very complete.

Of true atavistic supernumerary mammary structures *in the axilla*, I am only able to cite the four following cases, to which Neugebauer's must be added. This shows that the anomaly is of extreme rarity in this situation.

(1) In a case observed and figured by Leichtenstern<sup>114</sup> there was a nipple the size of a split pea, without areola, at the top of the left axilla; and connected with it was a mass of gland substance the size of a walnut. The patient was a woman recently delivered of her first child. When suckling, milk escaped from this nipple, as well as from another supernumerary nipple just below and internal to the left breast, though no gland substance could be felt beneath the latter.

(2) A similar case has been recorded by D'Outrepont.<sup>115</sup> The patient was a pregnant woman with a tumour the size of a hen's egg in the left axilla, connected with which was a nipple, whence colostrum escaped.

(3) Perrymond<sup>116</sup> has related the case of a woman, aged 27, who shortly after her second confinement noticed a tumour the size of a pigeon's egg in

<sup>114</sup> *Arch. f. path. Anat.*, &c., Bd. lxxiii., p. 245, No. 38, taf. iv., fig. 1.

<sup>115</sup> *Neue Zeit. f. Geburtsh.*, &c., Hersang von Busch, &c., Bd. ix., 1840, S. 40.

<sup>116</sup> *L'Union Méd.*, 1874, t. xviii., p. 864.



the right axilla. It was movable, and not connected with the breast. Over it was a small nipple surrounded by an areola. On pressure, milk escaped. The tumour was first noticed about the time of puberty at the age of 14. At her first confinement it was taken for an abscess. Six weeks after delivery the secretion ceased, and the tumour diminished in size.

(4) In Godfrain's<sup>117</sup> case the patient was a lying-in woman, aged 25, who a few days after her second confinement, noticed a tumour, the size of a fowl's egg, in each axilla. Each tumour appeared to be connected with the main gland by a pedicle, and over each there was a rudimentary nipple and areola.

In animals axillary mammæ are most exceptional, but they are met with in the *pteropi* (fruit bats) and in the flying lemur (*galeopithecus*).

#### § V.—On Paramammary Neoplasms arising from Supernumerary Mammary Structures.

It has been maintained by Cohnheim, that in the development of every part of the body, portions of the matrix become sequestered and remain disseminated in the adjacent tissues. He ascribes the origin of all neoplasms to belated rudiments of this kind. To Cohnheim's theory it has been objected, that no evidence of such an amount of developmental irregularity as it presupposes, has ever been demonstrated. At one time I thought there was some force in this objection, but a more thorough examination of the subject, in the light of modern research, has convinced me that it is not so; for sequestered fragments of the kind alleged have now been shown to exist in every part of the body, that has been specially examined for them.

Hitherto the breast has seemed to be an exception to this rule, but from the facts set forth in the preceding section, and from such as I will now proceed to mention, it is obvious that paramammary sequestrations are of common occurrence; and that from them neoplasms—identical in structure with mammary neoplasms—frequently arise.

Considering the importance of this subject, it is astonishing

<sup>117</sup> *Thèse de Paris*, 1877, p. 35.



how little attention it has hitherto received. Ollier, of Lyons, was one of the first who specially directed attention to the occurrence in the vicinity of the mammary gland of isolated encapsuled masses of mammary glandular tissue arising in this way. The enlargement of such rudiments, consequent on inflammatory or neoplastic action, gives rise to the various paramammary tumours, as in the following cases.

A patient of Ollier's<sup>118</sup> a single woman, aged 20, had a hard, nodulated, mobile tumour, the size of a walnut, above and external to the left bosom, and quite independent of the mamma. It was excised, when it was found to be encapsuled, and unconnected with the adjacent parts. On *microscopical examination* it consisted chiefly of fibrous tissue, in which mammary gland structures (ducts and acini) were embedded. The tumour was of one and a-half year's duration, and it was first noticed six months after a blow.

In a similar case by Labbé and Coyne,<sup>119</sup> the patient, a woman, aged 40, had a hard, nodulated, mobile tumour, the size of a pigeon's egg, to the axillary side of the right breast, and so close to the axilla that it was at first mistaken for an enlarged axillary lymphatic gland. It had no connection whatever with the mamma. This was verified when the tumour was dissected out; it was completely encapsuled, and histologically consisted of dilated tubular and acinous mammary glandular structures embedded in hyperplastic fibrous stroma.

In dissecting a breast, Eve<sup>120</sup> found a firm nodule, about the size of a hazel nut, lying near its axillary border, but completely detached from it. Microscopical examination revealed large ducts, lined with short columnar epithelium, in places greatly dilated. There were also present other smaller ducts, which ended in acini. These structures were embedded in fibrous stroma. The tumour was in all respects just like an accessory mammary glandule. The patient was a woman, aged 59, who died of bronchitis, after removal of an epulis of the lower jaw. In addition to this tumour she had at the upper and inner part of each breast a small ordinary adenoma.

Lücke<sup>121</sup> has seen cases of the same kind.

Forbes<sup>122</sup> mentions an instance of cystic adeno-sarcoma, that sprang from one of these sequestrations.

Cameron<sup>123</sup> has related the two following examples :—

In the first the patient was a single woman, aged 30, who, five years previously, had noticed a lump the size of a walnut in her right axilla.

<sup>118</sup> *Gaz. Méd. de Lyon*, 1855, p. 144.

<sup>119</sup> *Traité des Tumeurs Bénignes du Sein.*, Paris, 1876, p. 131.

<sup>120</sup> *Brit. Med. Journal*, vol. i., 1883, p. 298.

<sup>121</sup> *Pith.-Billr. Hdb.*, Bd. ii., S. 281.

<sup>122</sup> *Phil. Medical News*, March 5, 1892.

<sup>123</sup> *Journal of Anatomy*, vol. xiii., 1879, p. 150.



On examination, there was found in this situation an ovoid, elastic tumour, the size of a large cricket ball. It had been rather painful for the last two years. The tumour was excised. There was no difficulty in the operation, because it was encapsuled, and readily shelled out. On section, after removal, it looked like a fibro-lipoma; but on *microscopic examination* it proved to be an ordinary fibro-adenoma.

In the second case the patient was also a single woman, aged 33. She had a tumour, "the size of the fist, in the axilla." It had not increased in size since puberty. No operation was done.

In the Museum of University College I have found an interesting specimen of this condition, which is thus described in the Catalogue.<sup>124</sup>

"A large tumour removed from the mammary region. It is rounded in form, and measures five inches in its long diameter. Its surface is slightly lobulated, and it is enclosed in a loose capsule of areolar tissue. The section shows the tumour to be composed of closely packed lobules, bound together by a moderately abundant fibrous stroma. The resemblance to a section of the pancreas is almost perfect. There is one cyst, about half an inch in diameter, seen in the section. It has some fine papillary intra-cystic growths projecting into it. The tumour was removed by Quain from a lady, aged 26, the mother of several children. It was first noticed eighteen months before operation; and during the last six months it had increased continuously. At the time of the operation the lady was six months pregnant. The tumour was on the left side, and did not implicate the mamma, which was quite free from it. After removal it weighed four pounds. On *microscopic examination* the tumour was seen to be composed of a structure closely resembling that of the normal mamma. Groups of acini were present, lined with abundant epithelium, which in some places quite filled them up. Here and there small ducts were seen which communicated with the acini; but no large ducts were seen which received the smaller ones. The inter-acinous tissue was very abundant, and consisted of mature fibrous tissue. No fat was found in any part of the specimen."

Beyond the foregoing scattered facts, which are now for the first time brought together, very little has been recorded as to the development of neoplasms from supernumerary mammary structures.

Having made this subject the object of special investigation during several years, I have arrived at the following results:—

Of fifty cases of *Fibro-adenoma* of the mammary region consecutively under my observation, I found that seven (14 per

---

<sup>124</sup> Vol. ii., 1887, p. 445, No. 1960.



cent.) had originated in supernumerary mammary structures, quite outside the normal mammae. I append brief abstracts of these cases:—

(1) A well-formed, healthy, single woman, aged 36, a cook, had a hard, circumscribed, ovoid tumour, the size of a bantam's egg just above and external to the right bosom. There was no connection between the tumour and the mammary gland; and it was free from adhesions with the adjacent structures. The nipple and axillary lymph glands were normal. The patient said she first noticed a small lump in the site of the present tumour six months previously. There was no history of previous injury or disease of the part. Her mother died of cancer of the left breast. The catamenia had always been regular. During the last few years she had been subject to bilious dyspeptic attacks; but otherwise her previous health had been very good.

The tumour was dissected out. It was encapsuled and solid, and unconnected with the mamma. It presented to the naked eye the ordinary appearance of fibro-adenoma.

On *microscopic examination* acini and ducts were seen embedded in fibrofatty tissue. The acini were arranged in grape-like clusters, as in the normal mamma; but most of their cells were in granular degeneration, and in some places small cysts had formed. The ducts were seldom excavated, and their cells were also in granular degeneration.

(2) A well-nourished single woman, aged 38, with a hard, movable, circumscribed tumour, the size of a large walnut, just above the right bosom. No enlargement of the adjacent lymph glands. Slight congenital retraction of both nipples. The tumour was first noticed three weeks previously. No injury or known cause for it. Catamenia always regular. Previous health good. Her father died, aged 69, of cancer of the stomach; and she has lost a sister with cancer of the breast.

The tumour was dissected out. It proved to be a typical, solid fibro-adenoma, unconnected with the breast.

(3) A pale, fair woman, aged 26, with two small, hard, nodular tumours above the left bosom, and entirely unconnected with the gland. The nipple and adjacent lymph glands normal. The tumours of three months' duration. The patient had been twice married. By her first husband she had one child and two miscarriages. Her previous health had been good. She lost her mother of "internal tumour."

The tumours were dissected out. Each had the appearance of ordinary fibro-adenoma. On *microscopic examination* glandular acini in the resting stage were seen, surrounded by nucleated fibrous tissue, which contained a few spindle cells.

(4) A healthy-looking woman, aged 43, who had on the axillary side of the left breast, and unconnected with it, a smooth, hard, movable tumour, the size of a walnut. No enlargement of the adjacent lymph glands. It was first noticed two months previously. Both nipples were congenitally retracted. Catamenia regular. The tumour was excised—a typical solid, encapsuled fibro-adenoma.



(5) A healthy woman, aged 40, with a hard, racemose tumour, the size of a walnut, over the edge of the sternum, on the left side, quite outside the mamma. It was first noticed three years previously. The patient had married at 21, and had cohabited with her husband ever since, but she had never been pregnant. On examination of the tumour after removal, it was found to be an encapsuled, loculated fibro-adenoma. The loculi were full of papillary ingrowths. On *microscopic examination* fibro-adenoma—the intra-locular growths consisted of fibrous processes lined with cubical epithelium.

(6) A single woman, aged 27, a dressmaker, with a circumscribed tumour, the size of a hazel nut, over the edge of the sternum on the right side, and unconnected with the mamma. It was first noticed nine months previously. The tumour was dissected out, and it proved to be a solid ordinary fibro-adenoma.

(7) A single woman, aged 32, who had a firm nodular tumour, the size of a walnut, just below and quite outside the left bosom. It was first noticed two years previously. Her sister had a similar mammary tumour. It was dissected out, and proved to be an ordinary solid, encapsuled fibro-adenoma, unconnected with the mamma.

With regard to the development of *Cancer* from supernumerary mammary structures, I have the following observations to record :—

Of 132 cases of cancer of the mammary region in women, consecutively under observation, I found that thirteen (9·8 per cent.), had originated in supernumerary mammary structures, quite outside the normal mammæ.

Subjoined are brief abstracts of these cases :—

(1) Single, aged 50. Six months previously she first noticed a lump in the sternal side of left breast. On examination, a hard, nodular, cancerous tumour, the size of a walnut, in this situation, quite outside the mamma. The overlying skin adherent ; no obvious affection of the adjacent lymph glands. Amputation of the breast, and removal of the tumour with it. No history of tumour or cancer in the family.

(2) Single, aged 71. Seven years previously a hard nodule first noticed at the upper part of the chest, some distance above the left bosom. Six years ago the breast amputated, and the tumour removed. Recurrence at the primary seat five years later. No history of tumour or cancer.

(3) Single, aged 29. Two years previously first noticed a hard lump, the size of a pea, above the left bosom and unconnected with the gland. In the course of four months it increased to the size of a marble. It was then excised ; but the breast was left. Recurrence at the primary seat six weeks later ; this again excised. Nine months later further recurrence in the same locality. On examination, a hard lump, the size of a brazil nut, above the left breast over the second intercostal space. The breast still quite free. Several small hard glands above and below clavicle. Just below the tumour



are the scars of the former operations. Axillary glands free. The recurrent disease again freely excised. She was convalescent twenty-four days later, and I have not seen her since. No history of cancer or tumour in the family.

(4) Single, aged 45. Quite below the left breast, on its axillary side, is a hard, fixed, nodular tumour, with the overlying skin infiltrated and ulcerated. The disease was first noticed a year previously, when it presented as a lump the size of a hazel nut. The axillary glands enlarged. No history of cancer or tumour. Breast amputated, the tumour and axillary glands removed.

(5) Aged 54, married at 42, never pregnant. At the lower and axillary side of the right breast, quite outside the gland, is a hard, knobby, rounded tumour, the size of a small orange. Nipple normal; overlying skin adherent. Axillary glands enlarged. The tumour was first noticed one year previously. No history of cancer or tumour. Amputation of breast; removal of tumour and axillary glands.

(6) Single, aged 46. Above the left breast, and on its inner side, is a hard, nodular tumour the size of a bantam's egg, quite outside the mamma. Nipple normal; overlying skin adherent; axillary glands slightly enlarged. First noticed four months previously. Amputation of breast with the tumour and removal of axillary glands. No family history of cancer or tumour.

(7) Married, mother of three children, aged 51. Above the right bosom, over the middle of the anterior axillary fold, is a hard, nodular tumour, the size of a hen's egg, quite outside the mamma. The overlying skin adherent; the axillary lymph glands enlarged. Duration of tumour eighteen months. Removal of breast, tumour and axillary glands. No family history of tumour or cancer.

(8) Married, four children and one miscarriage, age 67. Three years ago first noticed a hard tumour at the sternal side of left bosom, unconnected with the gland. Three months later it was excised, but the breast was not removed. Recurrence set in at the primary seat six weeks ago. On examination over the edge of sternum, on the left side, quite outside the mamma, is a tumour, the size of a walnut, in the old scar. Nipple normal; no enlargement of axillary glands. Amputation of breast and removal of tumour.

(9) Single, aged 64. Over the edge of the sternum, on the left side, is a hard, rounded tumour, the size of an orange, firmly adherent to the adjacent structures. The lymph glands of left axilla enlarged. The patient says the disease began as a lump, quite outside the breast, eighteen months ago. No family history of cancer or tumour. No operation.

(10) Single, aged 49. Four and a-half years ago a hard lump first noticed quite outside the left bosom, near the axilla. A fortnight later breast amputated and tumour removed. Recurrence at primary seat and in axilla two years later. Her sister died of cancer of the breast.

(11) Married, six children, aged 47. Above the left breast, over the edge of the sternum, is a hard tumour the size of a walnut, quite outside the bosom. It is adherent to the adjacent parts. Nipple retracted; axillary glands full. The patient says she first noticed a lump in site of present



disease, outside the breast, two years ago. Amputation of breast and removal of tumour; axilla not touched. No family history of cancer or tumour.

(12) Single, aged 62. Over the right edge of sternum, opposite the middle of the breast, but unconnected with it, is a hard tumour the size of an orange. The overlying skin is infiltrated, and the axillary glands are enlarged. The disease was first noticed two years ago as a tumour the size of a hazel nut, over the edge of the sternum. Congenital contraction of the nipple. No family history of cancer or tumour. Breast amputated, tumour removed and axilla cleared.

(13) Single, aged 69. Pale and weak. Just beyond the periphery of the axillary part of the right bosom is a hard, nodular tumour, the size of a small orange. The overlying skin adherent; axillary lymph glands enlarged. Duration five years. Breast amputated, tumour removed and axilla cleared.

Among these 132 cases there were a few others, in which it seemed almost certain that the disease originated quite outside the mamma, but as I could not be quite sure of it I have omitted them.

With regard to the literature of the subject:—

Foerster<sup>125</sup> has cited a case by Busch, in which cancer developed in a supernumerary mammary structure in the neighbourhood of the axilla. The breast was amputated and the axillary cancer was dissected out. On examination after removal, the mammary gland was found to be unconnected with the axillary tumour, and free from the disease. In connection with the cancerous tumour, some of the supernumerary axillary mammary tissue still remained uninvaded by the disease. On *microscopic examination* this was seen to consist of glandular tissue, just like that of the normal mamma.

Gluck<sup>126</sup> has recorded an interesting case of the kind. The patient was a woman who for twenty-eight years had been affected with a hard freely movable tumour, quite above the mamma. This swelling, after remaining stationary for many years, subsequently increased much, and presented all the appearances of cancer. The tumour was then excised, and it was evidently cancerous, as it recurred two years later. Here we have an enlarged supernumerary mammary structure, from which cancer subsequently originated.

In the Hunterian Museum<sup>127</sup> is half a cancerous tumour, removed from the axilla of a lady, aged 35. The breast and the skin over it were normal. It was easily detached. *Microscopical examination* revealed alveolar cancer. This is evidently a case of the kind we have been considering.

<sup>125</sup> *Die Missbild. der Mensch.*, 1861, S. 49.

<sup>126</sup> *Berlin klin. Woch.*, 1885, S. 292.

<sup>127</sup> *Path. Catalogue*, vol. iv., p. 292, No. 4811 A.



Since the above was written I have seen a specimen of Willett's,<sup>128</sup> in which a cancerous tumour, the size of a walnut, of four or five years growth, was excised from just below the right clavicle. It was quite separate from the breast, which was normal. Histologically its structure was that of acinous mammary cancer. The patient was an elderly lady.

Most of the alleged cases of primary cancer of the axillary lymph glands belong to this category. The following case by Nunn<sup>129</sup> is a typical instance :—

A woman, aged 60, seven months previously noticed a hard lump, the size of a hazel nut, in her left axilla. A month later the breast became hard. Three months ago the arm began to swell, and in the left axilla a hard, cancerous mass had formed. Numerous hard, cancerous tubercles had disseminated in the skin over the tumour.

The two examples of primary scirrhus of the axilla in men figured by Erichsen<sup>130</sup> also belong here.

Quite recently Martin<sup>131</sup> has published an account, with interesting remarks, of a *fibro-adenoma* developed from an atavistic supernumerary mammary rudiment, situated below the normal left mamma.

Billroth<sup>132</sup> mentions having seen acinous cancer develop in a breast with two nipples.

The *treatment* of neoplasms thus arising must be conducted in accordance with the same principles that guide us in dealing with corresponding neoplasms in the breast itself.

Much valuable information on the subject of polymastism will be found in recent publications by Schultze,<sup>133</sup> Klaatsch,<sup>134</sup> Wiedersheim,<sup>135</sup> Bardeleben,<sup>136</sup> Bonnet<sup>137</sup> and Hennig.<sup>138</sup>

<sup>128</sup> *Trans. Path. Socy. Lond.*, vol. xlii., 1891, p. 319.

<sup>129</sup> *Cancer of the Breast*, 1882, p. 95.

<sup>130</sup> *Science and Art of Surgery*, vol. ii., 1872, p. 50, *et seq.*

<sup>131</sup> *Arch. f. klin. Chir.*, Bd. xlv., 1893, S. 880.

<sup>132</sup> *Deutsche Chir.*, Lief 41, S. 10.

<sup>133</sup> *Anat. Anzeiger*, 1892; also *Verhandl. d. Phys.-med. Gesellsch. z. Würzburg*, 1893.

<sup>134</sup> *Morph. Jahrb.*, 1892 and 1893.

<sup>135</sup> *Der Bau des Menschen*, &c., Freiburg, 1893.

<sup>136</sup> *Anat. Anzeiger*, Bd. vi., 1891, S. 247; also 1892, No. 3, S. 87. *Verhandl. d. Anat. Ges. Wien.*, 1892, S. 199; also 1893, S. 191. He found supernumerary mammary structures present in 9 per cent. of all men, and in 4 per cent. of all women, examined.

<sup>137</sup> Merkel and Bonnet's *Ergebnisse der Anat. u. Entwicklungsgeschichte*, Bd. ii., 1893.

<sup>138</sup> *Arch. f. Anthropol.*, Bd. xix., Heft 3, 1890.



Schultze's account of the development of the mammæ in the cat, fox, rabbit, rat, pig and other multimastic animals is particularly interesting, as it enables us better to understand many of the previously mentioned anomalies. He finds that in these animals the first mammary rudiment presents as a linear thickening of the epidermis, extending on each side from the base of the evolving anterior extremity to the inguinal region, and lying nearer the dorsal than the ventral surface. This is the "mammary ridge," or common rudiment of the mammary glands. Soon spindle-shaped thickenings appear in the course of the line, corresponding in number with the mammæ of the adult form. After a time the connecting strands usually disappear, and only the lenticular thickenings are left. This dorsal position of the mammary rudiments is not long retained, for migration soon takes place towards the ventral surface. Probably it will eventually be found that all mammals, in an early stage of development, present "mammary ridges," or traces of them.



## CHAPTER V.

### HYPERTROPHY.

---

#### § I.—Introductory.

THE term hypertrophy is commonly used in a very loose manner, especially as applied to the breast. Of this affection in general, two forms may be recognised: in one the increase of bulk is due to increase of function—physiological hypertrophy; in the other no such causal relation exists—pathological hypertrophy. The former condition is practically unknown as a disease in the breast; it is solely with the latter that we now have to do.

From the ontogenetical standpoint the breast is one of the most remarkable organs in the body, for most of its essential morphological features are evolved, *not* in the embryo, but at various successive periods of post-embryonic life. Thus at different epochs its structure varies. These metamorphoses are especially noticeable at puberty and after conception; while at the climacteric period equally striking retrogressive changes set in. It is in connection with these biological processes that the phenomena of mammary hypertrophy may be most profitably studied.

Two varieties of the disease are met with—the *diffuse* and the *circumscribed*; in the former the whole breast is affected, in the latter only certain of its constituent divisions. The *diffuse* form is certainly very rare, for while 2,422 cases of mammary neoplasms came consecutively under treatment at Middlesex, University College, Bartholomew's and Thomas' Hospitals during a period of from sixteen to twenty-one years, only six cases of diffuse hypertrophy were seen in the same period.



Both sexes are liable to it ; but in males the enlargement hardly ever surpasses the size of the normal female mamma, and the condition is not of grave import.

The following remarks apply exclusively to the disease as it affects females.

## § II.—Infantile Hypertrophy.

Most cases begin in early adult life ; yet there are on record a few instances in which mammary hypertrophy is said to have been *congenital*, and in others it has originated in *early infancy*. In most of these we evidently have to do with exaggeration of the formative processes natural to the mammæ during the first week or two of extra-uterine life. Cases of this kind differ essentially from those of the adult type, for, as in gynæcomostism, the breasts having attained a certain size then cease to increase.

Such a case is Howitt's,<sup>1</sup> in which considerable hypertrophy of both mammæ was noticed one week after birth, and this increased in the following week, without any sign of inflammation or abscess, the child being in other respects normal.

In a similar case related by Hahn,<sup>2</sup> the left breast was affected, and both hands were hypertrophied.

In a girl, 3½ years old, Grout<sup>3</sup> saw both mammæ developed like those of a fully grown woman, although in other respects she resembled children of her own age.

Most cases of infantile hypertrophy have, however, been met with in association with *precocious sexual development*. In studying these it must be borne in mind that in the tropics girls attain puberty at a very early age, often at 8 years or even earlier. The following cases are of this kind :—

In a child, 3 years old, Jacobovitch<sup>4</sup> found the mammæ as large as hen's eggs, and discharging a considerable quantity of lactescent fluid. She was also subject to sanious vaginal discharge. The genitals were normal. When next seen three years later, menstruation, with the usual molimina,

<sup>1</sup> *Lancet*, 1837, vol i., p. 537.

<sup>2</sup> *Schmidt's Jahresbericht*, Bd. v., S. 138.

<sup>3</sup> *Arch. Gén. de Méd.*, 1854, t. i., p. 758.

<sup>4</sup> *Nouv. Arch. d'Obstét. et de Gyn.*, Sup., June, 1893.



had become of frequent occurrence, and her breasts were as large as small oranges. The labia minora and clitoris were somewhat enlarged.

In a child born at New Orleans, U.S., of poor white parents, Lebeau<sup>5</sup> found both breasts largely developed and the mons veneris covered with hairs. The catamenia appeared when she was 3 years old, and subsequently continued regularly. Each breast was the size of a large orange.

In the south of France Comarmond<sup>6</sup> met with an infant 3 months old, who had breasts like those of a woman at puberty, hairs on the pubes, and the catamenia regularly established.

Ramon de la Sagra<sup>7</sup> has related the case of an infant negress, who had very large breasts from birth, and some months afterwards sanious discharge from the genitals. This recurred several times during the first year, and from the second it took on the regular periodicity of the catamenial flow. When only 32 months old, she had all the signs of puberty as in a woman of 16.

In Mallet's case,<sup>8</sup> some days after birth, the mammæ attained the size of large fowl's eggs, and colostrum-like fluid could be expressed from them. The external genitals were unusually well developed, and there was sanious vaginal discharge.

Wilson's<sup>9</sup> case is very similar to the foregoing. At birth the breasts were the size of fowl's eggs. In the course of the next five months they increased to the size of those of a young woman at puberty. At this time the catamenia first appeared. When 6 years old she was fat, with breasts like those of an adult woman, and the pubes was covered with hairs.

Mandelsloot<sup>10</sup> mentions having seen an infant, 2 years old, with breasts larger than those of an adult woman, in whom menstruation set in at the age of three years.

I have given prominent attention to these cases because they have generally been overlooked by those who have previously written on this subject.

The following case furnishes a connecting link between such cases as the foregoing, and those that follow in the next section.

A small, ill-nourished girl, only 12 years old, exhibited by Sinclair<sup>11</sup> at the North of England Obstetrical Society. Both breasts were so enormously hypertrophied, that each was estimated to weigh about ten or twelve pounds.

<sup>5</sup> *Gaz. Méd. de Paris*, 1832, p. 681.

<sup>6</sup> *Ibid.*

<sup>7</sup> *Comptes Rendus de l'Acad. des Sci.*, t. 61, p. 570.

<sup>8</sup> *Gaz. Méd. de Paris*, 1832, p. 620.

<sup>9</sup> *Gaz. des Hôp.*, 1854, p. 315.

<sup>10</sup> *Weitenweber*, "Über die Hyp. der Brüste," in *Vierteljahr-schrift, f. d. prakt. Heilk. Prag.*, 1847, Bd. xiii., s. 80.

<sup>11</sup> *Liverpool Med. Chir. Journal*, Jan., 1892, p. 138.



§ III.—Cases Illustrative of the Chief Types of Diffuse Hypertrophy in Adults.

Before entering on the description of this disease in general terms, it will be advantageous to relate some of the most notable examples of each of its chief types.

A.—Most cases arise about the time of *puberty*, when the breasts are in the transition state. In the resulting enlarge-

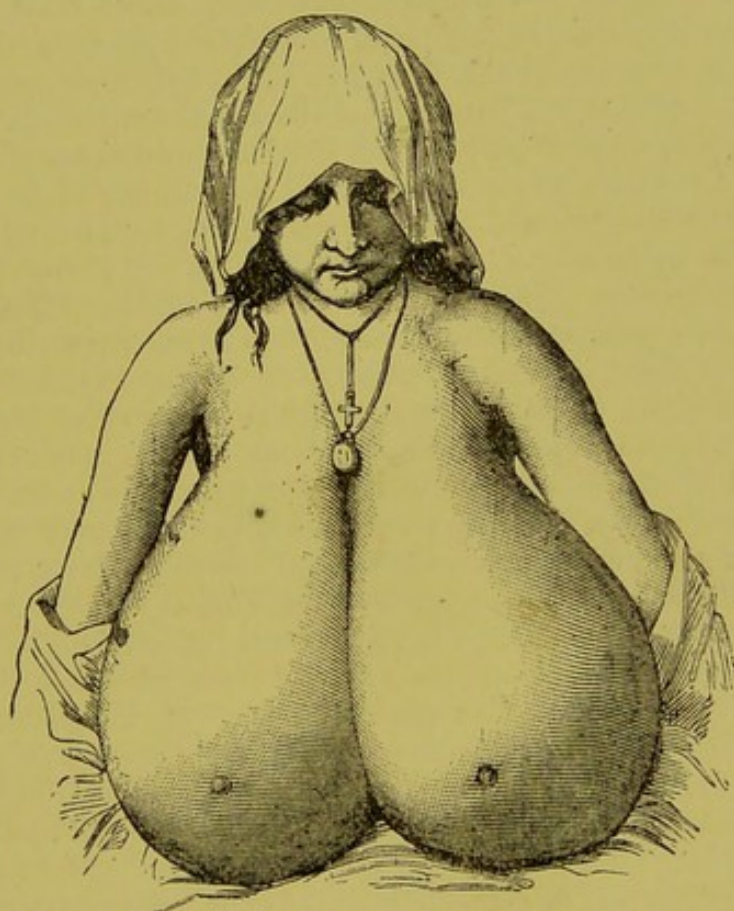

FIG. 16.—Hypertrophy of both breasts in a nun (*Manec*).

ments stroma structures predominate, chiefly of the fibrous kind, although a considerable quantity of glandular tissue is always present as well.

CASE I.—*Manec's*<sup>12</sup> patient was a nun aged 17, whose breasts presented as two enormous pendent, pedunculated masses covering the whole of the front of the abdomen, as far down as the pubes (Fig. 16). The greatest circumference of the left was 75 centimetres ; and of the right 72 centimetres.

<sup>12</sup> *Gaz. des Hôp.*, No. 18, 1859, p. 45.



The left was estimated to weigh 7 kilogrammes, and the right  $6\frac{1}{2}$ . The skin was not obviously altered, but the galactophorous ducts were enormously dilated. By successive operations both breasts were ablated, and the patient was thus cured.

CASE II.—Crofford<sup>13</sup> reports the case of a girl, aged 15, who commenced to menstruate about a year previously. Before this, her mammæ were perfectly normal. Shortly after the establishment of the catamenia, she noticed that her breasts had become unusually large, and the deformity rapidly increased. On examination both breasts were of enormous size. The left in its largest circumference measured  $35\frac{1}{2}$  inches; the right  $32\frac{1}{2}$  inches. The adjacent lymph glands were unaffected. Compression and all other available means having failed to arrest the progress of the disease, both breasts were amputated by lateral flaps, the left being removed sixteen days after the right. When last heard of about nine months after the second operation she was in good health; and free from any return of the disease. The weight of the right breast after removal was 14, and of the left  $11\frac{1}{2}$  lbs. At the time of the operations, the diseased organs were noticed to be very vascular. The subcutaneous fatty layer over each breast had disappeared, being replaced by the rapidly growing diseased organ. On section each presented a pale yellowish-white, doughy, nodulated aspect, with vascular areas here and there, some parts being quite hard and quasi-fibrous, while others were soft, the whole exuding a juice that contained granular cells. On *histological examination* the bulk of the growth consisted of fibrous tissue, devoid of fat, with glandular structures sparsely embedded in it—in some places of normal appearance, in others evidently degenerating. Some of these glandular structures were filled with hyperplastic cell elements. Every part of the growth was pervaded by fibrous tissue, containing but few nuclei, but numerous large lymph channels. Even with osmic acid no fat could be detected in this stroma. Near the base of one of the enlarged organs was a circumscribed fibro-adenomatous nodule the size of a walnut.

CASE III.—In a case by Labbé,<sup>14</sup> the patient was a well formed and healthy looking girl, aged 14. Both breasts were exceedingly hypertrophied, and by their weight they caused her great inconvenience. Both were amputated: after removal the left weighed nearly 9 lbs. and the right nearly 8 lbs. The disease was of eight months' duration. Menstruation began at 12. *Histological examination* showed that the increase in size was chiefly due to overgrowth of the fibrous tissue of the organ.

CASE IV.—Le Double<sup>15</sup> has recorded the case of a healthy-looking servant girl, aged 15, living in Paris, but not a virgin. Menstruation began at the age of 14, and continued normally for six months, when it suddenly ceased without any known cause. Almost at the same time both breasts began to enlarge. A month later the catamenia reappeared, and subsequently continued regularly, although excessive in quantity. The breasts, however, continued to enlarge. When she was first seen by Le Double, six months

<sup>13</sup> *American Journal of Obstetrical Science*, vol. xxiv., 1891, p. 695.

<sup>14</sup> *Bull. Acad. de Méd.*, 28 juillet, 1891.

<sup>15</sup> *Bull. de la Soc. Anat.*, 1875, t. x., p. 185.



after the onset of the disease, both breasts were of great size and pendulous, the right being the larger. They felt firm, elastic and lobulated. The nipple was flattened and the areola distended. The skin was marbled with large veins, and that over the lower part of the right breast was congested. There was no pain, but much trouble was experienced from the great size and weight of the hypertrophied parts, which made walking and breathing difficult. She was treated by the internal administration of twenty drops of tincture of iodine daily, and subsequently compression by bandaging was tried. As there was no obvious improvement after some months of this treatment, and as the patient's general health was failing, it was decided to amputate the right breast. This was accordingly done—the operation being commenced with the galvano-cautery and completed with the bistoury. The wound healed rapidly; the general health improved, and soon afterwards the left breast diminished markedly in size. The part removed weighed 1,987 grammes (4·3 lbs.). On examination after removal the overlying skin was normal, and glided freely over the subjacent fatty layer. The galactophorous ducts were dilated. Section showed a lobulated structure of varied aspect. Most of the lobes were about the size of walnuts. In some parts were whitish areas, studded with small, soft, yellowish granular areas, which were hypertrophied glandular *cul-de-sacs*. In other parts, especially at the periphery, there was a dense fibrous structure of nacreous aspect. Between the lobes were several small cystic cavities containing serous fluid. Fatty tissue was found chiefly under the skin, and more sparingly between the lobes; its total amount was inconsiderable. *Microscopic examination* of sections of the lobulated masses showed them to be composed mainly of white fibrous tissue, infiltrated here and there with small round cells. A considerable quantity of glandular structures—acini and ducts—were embedded in this stroma; these were more abundant in some parts than in others, and they were filled with cubical epithelial cells. The overgrowth was thus composed of both connective and epithelial elements, the former preponderating. A considerable number of blood vessels were met with in the stroma.

CASE V.—Desenne's patient<sup>16</sup> was a healthy-looking mulattress of Mauritius, aged 15, an illegitimate child of Creole-Indian extraction. The left breast began to enlarge one year previously, after an attack of malarial fever, in the course of which the part became swollen and painful. Four months later the right breast also increased in size, and an abscess formed in its lower part. The catamenia were entirely absent, and no sign of them had ever appeared. She admitted having first had sexual intercourse at the age of 11, and of having continued it almost every day for the next two and a-half years. During this time the mammae were inconspicuous, and there were none of the other signs of puberty. It was only a few months before the onset of the present disease, that the breasts began to develop, and that hairs appeared on the pubes. When she came under observation, one year after the onset of the disease, both breasts were large and pendulous, reach-

<sup>16</sup> *Le Progres Méd.*, 1886, p. 492.



ing below the level of the umbilicus—the left being the larger. The left breast was now amputated, and the patient soon recovered from the operation. Two and a-half months later she was seen again, when it was found that in the interval the right breast had considerably enlarged. About this time the catamenia appeared for the first time, and subsequently recurred regularly. Shortly afterwards the right breast was amputated, and, as after the previous operation, she soon made a good recovery. She was last heard of three years later, when she had been safely confined of a healthy male child. The left breast after removal weighed nearly 4½ lbs. On section it consisted mainly of dense, lardaceous tissue, containing a few cysts with mucoid contents. *Microscopical examination* showed numerous hypertrophied glandular acini distended with mucoid fluid, embedded in white fibrous tissue, whose cells were in active proliferation.

CASE VI.—In Benôit and Monteil's<sup>17</sup> case, the disease began at 14½. At 16 both mammae were of great size, and remained so until 24, when she married. After marriage they diminished; and the retrogression became still more marked after pregnancy. In this respect the case is unique.

CASE VII.—A typical specimen of this kind of hypertrophy may be seen in the Museum of the Royal College of Surgeons of London (No. 4739 of the Path. Series). It was removed by Fergusson, from a single woman, aged 19, both of whose breasts had been enlarging for a year and a half. The hypertrophied part after removal measured a foot in diameter, and its weight was 13 lbs. Its structure resembled that of the normal mamma except for the great increase in size. The blood vessels were enlarged. *Microscopic examination* showed overgrowth of the glandular parenchyma, as well as of the fibro-fatty structures. The other breast was amputated three months later.

Similar cases have been recorded by Humbert,<sup>18</sup> Kaufmann,<sup>19</sup> Marjolin,<sup>20</sup> MacSwiney,<sup>21</sup> Grähs,<sup>22</sup> Birkett,<sup>23</sup> Malgaigne,<sup>24</sup> Fingerhuth,<sup>25</sup> Hey,<sup>26</sup> Aitken,<sup>27</sup> and others.

As a good example of mammary hypertrophy in which the stress of the disease fell on the fatty tissue, Robert and Amussat's<sup>28</sup> case may be cited.

<sup>17</sup> *Montpellier Méd.*, t. xxxviii., 1877, p. 481.

<sup>18</sup> *Gaz. des Hôp.*, 1885, p. 433.

<sup>19</sup> *Corr. Bl. f. Schweiz, Aerzte*, No. 13, 1882.

<sup>20</sup> *Gaz des Hôp.*, 1868, No. 131, p. 519.

<sup>21</sup> *Dublin Quarterly Journal of Med. Sci.*, vol. xlviii., 1869, p. 500.

<sup>22</sup> *Schmidt's Jahrbucher*, Bd. 118, 1863, S. 44.

<sup>23</sup> "Diseases of the Breast," 1850, p. 108.

<sup>24</sup> *Gaz. des Hôp.*, 1844, p. 599.

<sup>25</sup> *Zeitschrift f. die gesammte Medicin*, 1837.

<sup>26</sup> "Practical Observations in Surgery," 1810, p. 500.

<sup>27</sup> *Med. Times and Gaz.*, vol. ii., 1878, p. 608; also vol. i., 1857, p. 360.

<sup>28</sup> *L'Union Méd.*, 1851, p. 219.



CASE VIII.—The patient was a healthy looking woman, in whom the catamenia first appeared at 18. Four months later they ceased without any known cause. The breasts, till then small, became painful and swollen, the left first and then the right. In the course of a year they attained a large size and became pendulous. When seen two years later, she was emaciated, but otherwise in fairly good health.

The front of the abdomen was entirely covered by her immense breasts, which reached to the knees. On account of their great weight she had been obliged to maintain the recumbent position for the last two years. The left breast was now amputated. Its blood vessels were very large; in the course of the operation she lost about two pints of blood; however, she soon recovered. Twenty-six days after this operation the right breast was removed. Again she made a speedy recovery. Two months later her general condition had much improved. After removal the left breast weighed  $30\frac{1}{2}$  lbs., and the right  $20\frac{1}{2}$ . The patient's weight after their removal was 101 lbs.; the weight of the two tumours was therefore more than half that of the whole body. The enlarged breasts consisted chiefly of fatty tissue, embedded in which were excessively hypertrophied glandular lobules. It is not improbable that this may really have been an instance of diffuse lipoma; at any rate in hypertrophy such great overgrowth of the fatty tissue is very unusual. A. Cooper<sup>29</sup> has recorded a somewhat similar case.

The three following cases illustrate the more acute form of this type of hypertrophy.

CASE IX.—A healthy-looking servant girl, aged 16, *virgo intacta*, came under Billroth's<sup>30</sup> observation, with both breasts immensely hypertrophied, so that they reached below the umbilicus, the left being the larger (fig. 17). She said they had attained this great size in the course of two and a half months. Menstruation began at the age of 15. She declined operative treatment, and when last heard of, one year later, the breasts were said to be a little smaller.

CASE X.—The subject of the disease in this case was a young and active negro girl, of medium size, engaged in domestic service at Philadelphia, U.S.<sup>31</sup> Changes indicative of puberty set in at 14; but she menstruated only once, and the discharge was very scanty. About this time the left breast began to surpass its proper size; and soon afterwards the right. Subsequently both increased rapidly. At the age of 16, she was admitted into hospital, on account of a large slough having formed at the dependent part of the left breast, after a contusion. Both breasts were pendulous and of great size, the left being the larger; they reached below the level of the umbilicus. The nipples were embedded; and the left breast was very painful. The general health was greatly impaired; and there was fever of

<sup>29</sup> "Diseases of the Breast," 1828, p. 66.

<sup>30</sup> *Krankheiten der Brustdrüsen. Deutsche Chirurgie*, Lief 41, 1880, S. 69.

<sup>31</sup> Huston, *Am. Journal Med. Sci.*, No. xxviii., 1834, p. 374.



the hectic type. In the course of a few days, unmistakable signs of gangrene of the whole of the left breast set in, together with delirium and

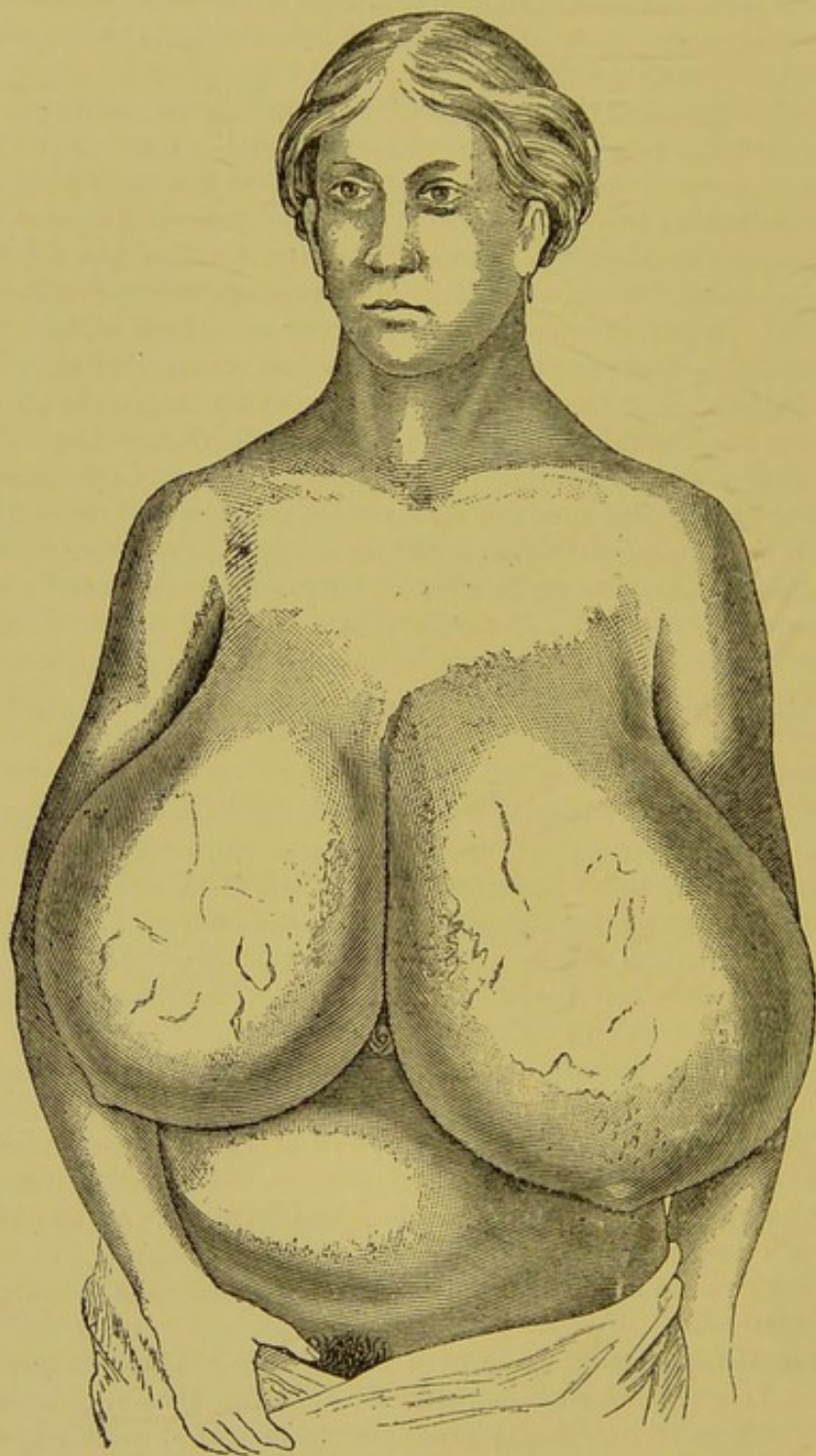


FIG. 17.—Hypertrophy of both breasts in a virgin, aged 16 (*Billroth*).

exhaustion. She died thus on the eighth day after admission. After death the right breast weighed 12 lbs. ; and the left 20. On examination of the



right breast after removal, it was found that the disease consisted of simple overgrowth of the whole organ ; in which the adipose and fibrous tissues, as well as the glandular parenchyma, had participated. The ovaries were diseased and larger than normal ; and the interior of the body of the uterus was lined with a layer of coagulable lymph.

CASE XI.—This case<sup>32</sup> is remarkable for the suddenness of the onset of the disease, for the rapidity of its progress, and for the colossal size attained by the breasts ; in all of which respects it is unparalleled. It occurred in the person of a short, fair-complexioned woman, between 23 and 24 years of age. She was in rather poor circumstances, but of good constitution, and a native of Plymouth. On July 3, she went to bed in her usual health and slept well. "In the morning when she awakened and attempted to turn herself in bed, she was not able to do so, finding her breasts so swelled." For six months before the onset of the disease she had suffered from complete suppression of the catamenia. When she first came under observation, shortly afterwards, both breasts were greatly enlarged ; and it was estimated that the left breast, which was the larger, weighed 25 lbs. On this account she was obliged to keep her bed, which she never afterwards left. During the ensuing months, the breasts increased rapidly in size ; and then ulcers formed at their lower parts. Loss of appetite with progressive emaciation set in ; and she died of exhaustion on October 21. The total duration of the disease was thus under four months. After death the left breast was removed, when it was found to weigh 64 lbs. ; the right breast was estimated to weigh 40 lbs. On section, the structure of the diseased part resembled that of the normal female breast, from which it differed only in its great size.

B.—The five following cases are instances of the disease arising at a *later period of life*, unconnected with pregnancy, when the breasts are in the state of passive maturity.

CASE I.—An unmarried woman, aged 41, both of whose breasts had been slowly enlarging for eleven years.<sup>33</sup> No history of injury or other known cause. Her aunt died of cancer of the breast. Old scarring of both sides of the face from lupus. Both breasts large, pendulous and painful. On manipulation they felt firm and nodular. The injection of arsenic and elastic compression were tried ; but as no improvement followed, both breasts were amputated at one operation. The patient made a good recovery. After removal the breasts weighed 27 and 22 oz. respectively. On section they presented a dense fibroid appearance.

CASE II.—In a healthy-looking, married woman, aged 43, who had always menstruated regularly. The left breast began to enlarge a year ago, without any known cause. When first seen by Velpeau,<sup>34</sup> the left breast was

<sup>32</sup> Durston, W., *Phil. Trans. R. S. Lond.*, vol. iv., 1669, p. 1047, and p. 1068.

<sup>33</sup> Boyd, *Univ. Coll. Hosp. Rep.*, 1881, p. 40.

<sup>34</sup> "Traité des Maladies du Sein," 1854, p. 239.



very voluminous, heavy and pendent. Its superficial veins were enlarged. The whole mamma felt bossy and of variable consistence. She was the mother of two children ; both of whom she had suckled. The enlarged breast was amputated ; and the patient was quite well a month after the operation. On examination of the part after removal, the skin was thin and non-adherent ; the subcutaneous fatty layer had disappeared ; the bulk of the tumour was made up of a lobulated structure, and between the lobes was loose connective tissue ; each lobe consisted of dense fibrous tissue in which was embedded softish granular material.

On *microscopic examination* of sections of these lobes they all showed glandular structures, surrounded by white fibrous tissue.

CASE III.—Lihotzky<sup>35</sup> exhibited before the Vienna Obstetrical Society in February, 1892, a hypertrophied breast removed from a single woman, aged 26. When fresh it weighed nearly 10 lbs. There was uniform increase in the interglandular connective tissue with development of glandular acini in abundance.

Proctor,<sup>36</sup> Burton<sup>37</sup> and Demarquez<sup>38</sup> have recorded similar cases.

Proctor's patient was a negress, aged 40, in whom the disease was of twelve years' duration ; in Burton's case the progress was more rapid, both breasts having attained great size in the course of less than a year. The woman was 40 years old, and the disease followed the removal of an ovary and tube for an inflammatory affection.

C.—Many cases of mammary hypertrophy arise in connection with *pregnancy*, when the glandular parenchyma is chiefly affected, as in the following examples :—

CASE I.—Porter<sup>39</sup> gives the history of a woman, aged 37, who three years previously first noticed swelling of the right breast, which gradually increased. Three months after the onset of this enlargement, the left breast also increased in size. They steadily attained such great dimensions, that at last she was hardly able to stand ; but there was no pain. On examination the greatest circumference of the right measured 38, and of left 28 inches. The overlying skin was œdematous and thickened. In both breasts numerous hard irregular nodules could be felt. The left breast was first amputated, and three weeks afterwards the right. She soon recovered from the last operation, but before long she developed erysipelas in the right mammary region. As this was fading away, she suddenly aborted of a six months' foetus, and died a few hours afterwards of collapse. Pregnancy

<sup>35</sup> *Cent. f. Gynäk.*, No. 10, 1892.

<sup>36</sup> *British Medical Journal*, 1883, vol. ii., p. 456.

<sup>37</sup> *Liverpool Med. Chir. Journal*, Jan., 1892, p. 138.

<sup>38</sup> *Gaz. Méd. de Paris*, 1859, p. 818.

<sup>39</sup> *Boston Med. and Surg. Journal*, March 3, 1892.



was not suspected until she was convalescent from the second operation. Histologically examined, the predominant structure was œdematous fibrous tissue, rich in cells, embedded in which were acinous and tubular glandular structures. There were numerous intra-canalicular fibromatous growths.

CASE II.—An anæmic woman<sup>40</sup>—aged 26, subject to amenorrhœa, who married at 21, and was the mother of five children—noticed that during her first pregnancy the right breast became unduly enlarged and painful; but after accouchement its size diminished, although it never regained its normal bulk. During each of the four succeeding pregnancies, these phenomena were repeated; the breast after each confinement being left larger than before. When she first came under observation, at the end of her fifth pregnancy, the right breast reached to the iliac crest, and it was estimated to weigh 20 lbs. It was of varying consistence, and several firm lobulated masses could be felt in it. The left breast was normal, and gave a plentiful supply of milk during the lactation period; but none was ever secreted by the right. She refused operative treatment.

CASE III.—In this case<sup>41</sup> the patient was a domestic servant of good physique, who when 19 years old first noticed marked enlargement of both breasts. During the next two years and a half they continued slowly to increase, without causing her pain or any other special inconvenience. Her previous health had been good. Menstruation began at 15, and continued regularly until she was 21½ years old, when it suddenly ceased. From this time the size of the mammæ increased with great rapidity, and she was soon unable to follow her avocation. When she was first seen by Billroth the disease was of three years' duration. Both mammæ had then attained a great size, reaching to the navel; and the patient was obliged to maintain the recumbent position on account of their great weight. The nipples were effaced, the areolæ enlarged, and the skin was marbled with large veins. On examination she was found to be five months pregnant. Compression with elastic bandages was resorted to, but the pressure caused excoriations. In connection with these erysipelas set in. On the following day abortion took place; and she died, collapsed, the day after. Examination of the breasts after death showed diffuse overgrowth of the glandular and connective constituents; and each organ presented numerous circumscribed, lobulated, fibro-adenomatous masses, which contained colostrum-like fluid, as also did their ducts. *Microscopic examination* of the parenchymatous new formation, showed large, closely packed, and irregularly formed acini, with comparatively little intervening connective tissue. The appearance presented by some of the sections somewhat resembled glandular carcinoma.

CASE IV.—Both breasts of a healthy woman,<sup>42</sup> aged 26, began to enlarge shortly after the rather sudden suppression of the catamenia. In the course of five months they attained a great size, and became tender and painful. Two months later it was discovered that the patient was in an advanced

<sup>40</sup> Speth, *Aerztl. Int. Bl.*, München, 1885, Bd. xxxii., S. 479, 501 and 559.

<sup>41</sup> Billroth, *Die Krank. der Brustdrüsen*, *Deutsche Chir.*, Lief. 41, 1880, S. 71.

<sup>42</sup> Skuhersky in *Weitenweber's neue Beiträge z. Chir.*, 1841, S. 42.



stage of pregnancy, which she had before denied. The breasts were now larger than ever; the nipples and areolæ had become embedded in their mass; and the superficial veins were unduly prominent. The general health was impaired. About two months later, after a lingering labour of four days, she was delivered at term of a pale, emaciated and feeble male child. Soon afterwards the mammæ diminished rapidly, and the general health improved. No milk was ever secreted. Two months later her health was quite restored; and the breasts were still further diminished in size. She was treated with iodine internally, and iodide of potassium ointment was rubbed into the breasts, but these never regained their proper size. Some months later she was able to resume her avocation as a domestic servant, and menstruation was regularly re-established. More than two years later, she again came under observation, with cessation of the catamenia of four months' duration, and rapidly progressing enlargement of the breasts. Fresh pregnancy was recognised. As this went on the breasts got larger and larger until they reached the pubes, when on account of their great weight, she was obliged to maintain the recumbent position. At term she was delivered of a well-formed, still-born, female child. Each breast was then estimated to weigh about 20 lbs. No milk was secreted. Shortly after the confinement, both breasts became red, painful and œdematous; large vesicles formed over their lower parts, followed by ulceration and gangrene. At the same time fever set in, with rapid progressive emaciation, diarrhœa, dyspnœa and cough. She died thus of exhaustion on the fourteenth day after her confinement.

At the necropsy, twenty-four hours after death, there was extensive gangrene of both breasts. After ablation the right weighed 18 lbs.; and the left 19 lbs. Both were very œdematous, and contained numerous small cysts. There was great excess of the interlobular fibrous tissue, and the galactophorous ducts were dilated. There were tubercular lesions of both lungs.

CASE V.—Lotzbeck<sup>43</sup> has reported a case of unilateral hypertrophy that began about puberty. During the second pregnancy the breast attained immense size. However she suckled with it, as with the other. Subsequently uncontrollable galactorrhœa set in, which only ceased when the breast was amputated. This is one of the very few cases in which the lacteal secretion has become established in a hypertrophied breast.

CASE VI.—The following case by Warren<sup>44</sup> is of interest, as in it the *fatty envelope* of the gland was the part chiefly involved.

A married lady, aged 28, had for some months noticed rapidly increasing enlargement of her left breast. On examination Warren found the breast uniformly enlarged; the skin rather red and hot, but otherwise normal. The axillary glands also were normal. As treatment failed to avert the progress of the disease, the breast was amputated. After removal it

<sup>43</sup> *Schmidt's Jahrb.*, Bd. cvi., 1861, S. 51.

<sup>44</sup> "Surgical Observations on Tumours," Boston, 1837, p. 228.



weighed 8 lbs. The only change noticeable was overgrowth of its fatty capsule. Subsequently the other breast underwent similar enlargement.

Other cases of hypertrophy associated with pregnancy have been recorded by Esterle,<sup>45</sup> Rousseau,<sup>46</sup> Jördens,<sup>47</sup> Iverg,<sup>48</sup> &c.

#### § IV.—Progress, Etiology and Treatment.

Although in favourable cases of mammary hypertrophy the morbid process ceases to progress, and ends by leaving nothing worse than deformity, yet in many instances the disease runs a most dangerous course. It usually begins insidiously and

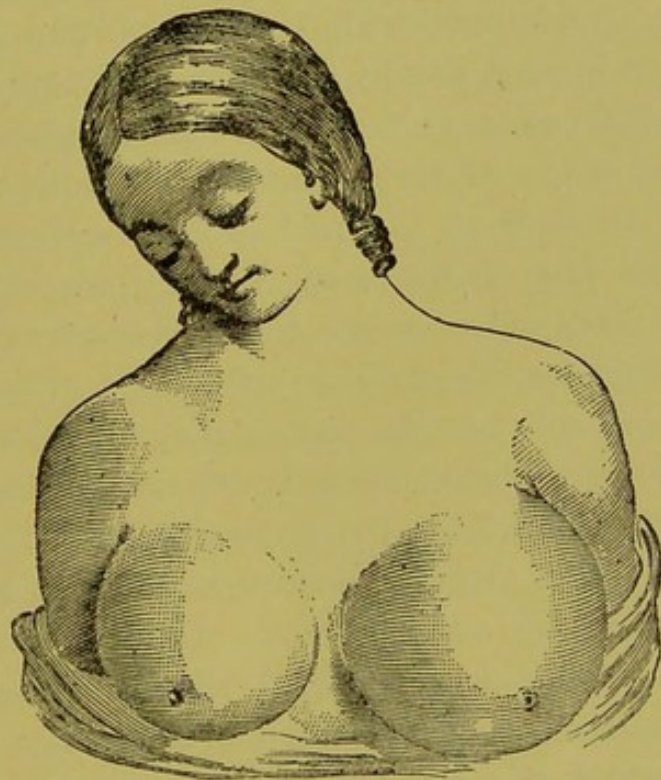


FIG. 18.—Hypertrophy of the breasts. Early stage (*Birkett*).

progresses gradually, without pain or tenderness. The first thing to attract attention is the increasing size of the breasts.

At this early stage the mammæ are firm and elastic, stand-

<sup>45</sup> *Gaz. Méd. de Paris*, 1858, p. 678.

<sup>46</sup> *Revue Méd. Chir.*, t. iv., 1856, p. 596.

<sup>47</sup> *Hufeland's Journal d. prakt. Heilk.*, Berlin, 1801, Bd. xii., S. 28.

<sup>48</sup> *Ibid.*, Bd. xiii.



ing well out from the chest by virtue of their own resiliency like the ideal busts of the great sculptors (fig. 18). Later on they become flaccid, pendent and pedunculated. The nipples are not affected by the disease, except that they tend to get effaced from distension; the areolæ enlarge; and both are sometimes embedded in the growing mass.

Large veins become visible through the distended integument, which usually remains otherwise unaltered, and does not adhere to the subjacent parts as in diffuse mastitis. On manipulation, the diseased part feels of varied consistence—bossy, nodulated masses being interspersed with soft or fluctuating areas. Tenderness, with lancinating, burning or aching pains may set in; but usually the disease is painless.

In the advanced stage the breasts sometimes attain colossal size, reaching as low as the patient's thighs or knees; and their weight may be such as to equal or even surpass that of the whole of the rest of the body. (Durstons's case, &c.) In instances of this kind progression is impossible; even the erect attitude cannot be maintained; bowed down by the weight of their enormous breasts such patients are compelled to maintain the recumbent position. Great respiratory embarrassment often arises from the same cause. With all this the adjacent lymphatic glands remain unaffected, so long as there are no inflammatory complications. These, however, are very apt to arise. They usually begin with redness and œdema at the lower part of the enlarged breast; then blebs form, which break and give rise to ulcers; and these may be succeeded by sloughing or even by gangrene of the whole breast. (Huston, Skuhersky, &c.)

In other cases inflammation leads to the formation of abscesses and fistulæ. Very slight injuries suffice to bring about such lesions; or they may arise spontaneously. In advanced progressive cases the general health becomes impaired, the appetite fails; there is restlessness, with loss of sleep, weakness and emaciation; hectic symptoms supervene, and finally death from exhaustion may ensue. (Durstons.)



It generally requires several years for the breasts to attain this great size; but sometimes only a few months. As a rule the most acute cases are those that arise in association with pregnancy; and in these the danger to the life of the patient is the greatest. (Porter, Speth, Billroth, &c.)

The children of such women, if born alive, are generally weak and stunted; abortions and still-births are not uncommon. Even during the lactation period hypertrophied breasts seldom secrete milk, although a little colostrum-like fluid may generally be expressed from them. However, in Lotzbeck's case there was galactorrhœa, and in one of Billroth's cases the diseased part contained milk. When unassociated with pregnancy, the progress is much slower; and life is seldom endangered. In one case the disease is known to have lasted for eighteen years. It usually begins in both breasts at about the same time, but not unfrequently only one is at first involved, and subsequently the other becomes affected, or the disease may be unilateral from beginning to end. When both are affected, the left almost invariably surpasses the right in size and weight, and when only one is involved, it is generally the left.

In the *causation* of this disease, it seems to me that the chief factors are certain states of the pelvic genitalia, which—through correlation with the *mammæ*—determine in the latter exaggerated formative activity. In this connection the influence of *age* is a striking feature, for three-quarters of all cases begin between the years of 14 and 30 (the majority being under 20), that is to say, during the high tide of sexual activity, when the breasts receive from the sexual organs an immense stimulus. Only very rarely does the disease begin after 40, and I know of only one instance in which it set in after the climacteric.

Most cases arise in association with *menstrual deficiencies* and *pregnancy*. The particular menstrual defects usually met with are failure of the function to be established at its proper time, and its sudden suppression after it has been properly established. These two conditions—amenorrhœa and mammary hypertrophy—are frequently associated. The influence



of pregnancy as a determining cause is of the most marked kind (*vide* the foregoing cases under section B.); but after delivery the swelling generally lessens, although the normal size of the part is never regained. Other alleged factors in its causation are repeated manipulations of the breast, masturbation, excessive coitus, prolonged suckling and traumas. In three cases it has been found associated with ovarian disease, but in two there appeared to be no causal connection between the two conditions.

Heredity has been noted in only a single instance (Rousseau's case). The patient was one of several sisters, all of whom had very large breasts, and of these one became the subject of hypertrophy, under the influence of pregnancy. Racial and climatic conditions are important ætiological factors, for the disease is much commoner in tropical countries than in Europe, and most cases have been met with in negresses, creoles and mulattresses. In the females of some families, and of some races of animals, we constantly see the *mammæ* largely developed without there being any disease. We can only account for this by reference to constitutional peculiarity, and so it is with some cases of diffuse hypertrophy.

The *mammæ* occasionally become enlarged in association with uterine hypertrophy due to tumours or retained menstrual secretion.

Ribbert<sup>49</sup> has shown that after extirpation of one mamma, its fellow becomes hypertrophied, and this in adults as well as in the young. He attributes the enlargement mainly to increased development of the glandular structures, the result of increased blood supply owing to collateral fluxion. As he points out, all paired organs are liable to this vicarious or compensatory hypertrophy, after destruction of one of the pair.

It must be admitted, as Herbert Spencer has pointed out, that the growth and development of every part of the body is

---

<sup>49</sup> 'Ueber die compensatorische Hypertrophie des Geschlechtsdrüsen,' *Arch. f. path. Anat.*, Bd. cxx., 1890, S. 260.



regulated by a certain restraining or integrative force, which causes its cells to develop in a regular and orderly manner, in accordance with the specific hereditary tendency of the whole. So long as the growing cells are subject to this normal restraining influence—which has nothing to do with nerves or blood vessels, themselves integrated structures—the proper proportions of the body are maintained. But when this influence is weakened or withdrawn, the potential powers of the cells may then become actual, and various structural abnormalities may be produced. It appears to me that the phenomena of mammary hypertrophy are ultimately attributable to post-embryonic developmental aberrations of this kind. In the disease, as in the physiological overgrowths, both the glandular and fibro-fatty structures participate, though in varying proportional degrees, according to the developmental stage of the breast at the time when the morbid process sets in. The pathological conditions met with in the various types of hypertrophy have their counterparts in the normal physiological processes. In both alike the essential feature is, not mere enlargement of pre-existing elements, but excessive new formation of mammary tissues. With regard to the pathological anatomy of the disease, a sufficiently full description has already been given in connection with the foregoing typical cases.

Probably some instances of acute diffuse malignant disease of the breasts are an outcome of this form of hypertrophy (*e.g.*, cases by Aitken, Klotz, Billroth, &c.).

The *diagnosis* of hypertrophy of the breast is seldom attended with much difficulty, but it is well to bear in mind that large cyst-adenomas, cysto-sarcomas and lipomas, occasionally present appearances resembling it. In the early stage it may be confounded with some forms of chronic diffuse interstitial mastitis with multiple cyst formation, but in the latter affection the skin generally gets adherent and thickened. From acute diffuse malignant disease, it may be distinguished by the skin and lymphatic glands being unaffected.

In the *treatment* of cases unassociated with pregnancy, attention should first of all be directed to the menstrual function;



and endeavours should be made to rectify any derangement. In the event of the catamenia being retarded or suppressed, *pil. aloes et ferri* or *pil. aloes et myrrhæ* may be prescribed; and when molimina are felt, the hot pediluvium with mustard at night may be serviceable, or the spinal ice bag may be tried.

All forms of sexual excitement increase the morbid tendency, and must therefore be avoided. With this object anaphrodisiac medicines, bromides and unstimulating regimen are indicated, together with saline aperients. Inasmuch as the influence of pregnancy on the progress of the disease is almost invariably highly prejudicial, marriage should be avoided. Iodine and its compounds have been more frequently employed than any other remedy both externally and internally. In the early stage of the disease *compression* is the best local treatment. A convenient way of effecting this is to cover the breast with a thin film of absorbent wool, and then to paint iodized collodion<sup>50</sup> freely and rapidly over it. Compression by bandaging, whether with ordinary calico bandages or elastic webbed ones, generally proves too irksome to be kept up, on account of its interference with the respiratory movements, and the same objection applies to strapping. To overcome this difficulty special forms of breast compressors have been devised, of which the best are Arnott's and Duke's.<sup>51</sup>

When the disease is associated with pregnancy, it has been recommended by Fingerhuth, that attempts should be made to excite lactation artificially by repeated suction of the nipples, &c. I am not aware that the favourable results thus obtained by him have been endorsed by others. In Monod's<sup>52</sup> case it was ineffective.

If after trial of these remedies, the disease continues to progress, and the enlarged part becomes troublesome from its

---

<sup>50</sup> Iodine, pot. iod. āā, gr. xx.; collodion, ʒj.

<sup>51</sup> For description of these *vide* Ch. xxv.

<sup>52</sup> *Bull et Mém. de la Soc. de Chir.*, 1891, p. 738.



size and weight, amputation must be resorted to; but it is desirable to avoid proceeding to this extremity during the puerperal state. When both breasts are affected the larger one should be amputated first, and several months may be allowed to elapse before repeating the operation on the other; as in some cases after removal of one breast, its fellow has diminished spontaneously. The operation should be done with antiseptic precautions, by making a semilunar incision through the skin and subcutaneous fatty tissue on each side of the base of the pedicle, and then dividing the latter. Care must be taken to avoid unnecessary loss of blood, by quickly securing the severed vessels, as these patients being weakened by the disease bear hæmorrhage badly. To this end an efficient plan is that of transfixing the base of the tumour with two large knitting needles, and behind these firmly applying a temporary elastic ligature to the pedicle.

Considering the great size often attained by the diseased part, the results of the operation are very good. Thus of twenty-two such amputations, of which I have collected notes, done on sixteen patients, there was only one death (4·5 per cent.); this patient died twenty-two hours after the operation of collapse, from excessive hæmorrhage during the proceeding.

#### § V.—Partial Hypertrophy.

In the *partial* form of mammary hypertrophy, the disease may be limited to a single lobule, or several may be affected. In some instances large areas of the gland are thus involved, indicating transition to the diffuse form, as in the following cases.

(1) A woman, aged 33, under the care of Richet,<sup>53</sup> with a slowly progressive swelling at the upper and outer part of the left breast of five years duration. She knew of no injury or other cause for it. Her only child

---

<sup>53</sup> *Gaz. des Hôp.*, 1881, p. 322.



was born thirteen years ago, when both breasts were normal and gave plenty of milk. On examination the left breast was found to be nearly four times its proper size, and its surface was marbled with large veins. A firm, nodular swelling occupied its outer segment, and displaced the nipple towards the sternum: to this the increased size of the part was due. On palpation the swelling was composed of about a dozen quasi-lobular masses to a large extent separable from one another. There was no pain or tenderness. The treatment adopted was compression by elastic bandage. While under treatment she had several floodings due to uterine fibroids.

(2) In the Hunterian Museum<sup>55</sup> is a specimen of a right mammary gland, similarly affected, presented by T. Smith. It was removed from a young lady, aged 21, who had noticed increasing enlargement of both breasts for three years. After removal it weighed 3 lbs.; her left breast was estimated to weigh 5 lbs. The enlargement was almost entirely due to hypertrophy of the lobules of the axillary and inferior segments of the gland, which formed a lobulated mass readily detached from the rest of the organ. On *microscopical examination*, this consisted of white fibrous tissue, studded with glandular structures, the former being in excess.

(3) In a case described and figured by Billroth<sup>56</sup> the whole breast was affected except its lower segment. The diseased part was composed of nodulated lobules held together by loose fibro-fatty tissue. *Histological examination* showed that the lobules consisted of dilated acinous and tubular structures embedded in fibro-cellular tissue, which was much more abundant than in the normal gland. Billroth was unable to decide whether the parenchymatous structures were of neoplastic formation or not. He gives no clinical details.

In most cases of partial hypertrophy there can be felt in the breast one or more firm, circumscribed, bossy, mobile nodules, which are obviously connected with the rest of the gland. These tumours are generally of irregularly elongated shape, radially disposed, and they usually occupy a peripheral position. Their size is seldom great, varying in this respect from an almond to a date.

They never contract adhesions with the adjacent skin, nor do they cause retraction of the nipple. Their development is slow, often extending over many years, and it is seldom attended with pain, but sometimes, in neurotic individuals, pain is a prominent symptom (*nodosités névromatiques* of Velpeau). Serous or mucoid discharge from the nipple is not uncommon.

---

<sup>55</sup> No 4739A, *Path. Catalogue*, Appendix ii., 1888, p. 38.

<sup>56</sup> *Deutsche Chir.*, Lief. 41, S. 77.



One or both breasts may be affected. On examination of such a tumour after removal, it will be found to consist of a dense whitish, circumscribed fibroid structure, in which small yellowish spots may be recognised (glandular elements). In connection with the latter small cysts may often be found. By means of its pedicle the ducts of the tumour are in direct communication with those of the rest of the gland.

The diagnosis of partial hypertrophy from ordinary fibro-adenoma, cold abscess, and chronic mastitis often presents much difficulty. The chief points in favour of partial hypertrophy are, the presence of a pedicle, multiple nodules, and freedom of the skin from adhesions.

In examples of this disease seen by me, the patients have been pale, delicate women, in whom the disease has appeared to have resulted from imperfect involution after lactation. With this exception it is commoner in young adult, unmarried women in feeble health, and in those who though married are sterile, than in other women. It is often associated with menstrual irregularities, of which amenorrhœa is the commonest, and sometimes with uterine fibroids and other forms of chronic uterine and ovarian disease.

By many pathologists cases of this kind are ascribed to chronic mastitis, but the evidence of inflammation is seldom appreciable.

The general principles of treatment here are the same as for diffuse hypertrophy. Catamenial irregularities must be corrected. For local treatment it is sufficient in slight cases to apply *emplast. ammoniaci cum hydrargyro* or *emplast. belladonnæ*, so as to exert compression, or, as I prefer, to paint the breast with iodized collodion. In obstinate cases Arnott's breast compressor will be serviceable. When these means fail the tumour should be excised. This is done as follows: the tumour is made to project beneath the skin, by pinching up the parts behind it with the forefinger and thumb of the left hand, in such a way that its long axis radiates from the nipple, an incision is then made through the overlying skin, &c., in this



direction, and as the tumour projects it is transfixed with a sharp hoop and pulled upwards until by a little dissection it is completely separated. This operation may be done under cocaine, by first painting the skin with 10 per cent. solution, and then injecting a few minims of 5 per cent. solution, at various points of the periphery of the tumour. In several cases treated in this way, after removal of one tumour I have known others to form. When the disease is extensive cuneiform amputation may be necessary.

### § VI.—Gynæcomastia.

Among the ancient Greeks, as mentioned by Paul of Egina, undue development of the male mammæ was a well recognised affection. At the present time it seems to be rare, for, according to French military statistics (Puech), it is met with in the proportion of only one in 13,000 conscripts.

The enlargement of gynæcomastia differs from the diffuse hypertrophy of females, in that it has no tendency to indefinite increase; having attained a certain size, which never exceeds that of the normal female mamma, the overgrowth ceases spontaneously. At any rate, I am not aware of a single instance, in the records of modern science, in which this limit has been surpassed. In ancient literature, however, mention is made by Pétrequin<sup>57</sup> of a man at Pavia with mammæ 18 inches long, and so heavy that they had to be amputated.

With regard to the histological structure of the enlarged organs, from such scanty data as science has hitherto furnished, it is evident that they present great variations in accordance with the age of the individual bearing them. In old persons, as pointed out by Grüber<sup>58</sup> and others, the enlargement consists almost entirely of fatty tissue. In adults Baillet<sup>59</sup> and

<sup>57</sup> *Anat. Med. Chir.*, p. 231.

<sup>58</sup> "Über die Gynæcomastie," *Mém. de l'Acad. des Sci. de St. Petersburg*, 7th ser., t. x., 1866.

<sup>59</sup> *Bull. de la Soc. Anat.*, 1890, p. 532.



Rémy,<sup>60</sup> have found that it was mainly due to increase of the fibrous stroma, in which a few glandular *cul-de-sacs* were embedded. On the other hand, De Sinéty<sup>61</sup> reports having examined a specimen in which the galactophorous ducts were as well developed as in a puerperal woman, and lined by two layers of cylindrical epithelium. In this instance the glandular *cul-de-sacs* contained fatty globules, and there were well developed acini, lined by a single layer of cubical epithelium. The latter structures, however, were not very numerous. A considerable quantity of fatty tissue was contained in the stroma. In two cases Gaillet<sup>62</sup> also found an abundance of well formed glandular structures. Thus may be explained the occasional secretion of lactescent fluid, &c., by these hypertrophied mammæ.

The chief interest in this affection centres in its etiology. It was formerly believed that gynæcomastism invariably implied testicular atrophy, loss of virility, and the *cachet* of femininism. This ancient opinion, although not without some foundation, can no longer be maintained; for it is now known that gynæcomastism often co-exists with absolute integrity of the sexual organs, with unimpaired virility and without any of the characteristics of femininism. In accordance with the foregoing two types of gynæcomastism may be discriminated.

A.—In the *first* the sexual organs are well developed and function normally, and all the attributes and appearances of virility are usually present. Cases of this kind are probably due to reversion to the condition prevalent, when the males aided the females in suckling their young. Although such breasts usually yield no secretion, yet they have occasionally been known to secrete colostrum-like fluid and even true milk.

Hunter<sup>63</sup> refers to the case of a gynæcomast, aged 50, whose breasts gave such an abundant supply of milk, that he shared equally with his wife in suckling their eight children.

<sup>60</sup> *Thèse de Paris*, 1880.

<sup>61</sup> *Traité de Gyn.*, 1884, p. 953.

<sup>62</sup> *C. R. de la Soc. de Biol.*, fév., 1850.

<sup>63</sup> "Essays and Observations," by Owen, vol. i., p. 238.



Even in the absence of obvious gynæcomastism, it appears that repeated suction may sometimes determine enlargement of the gland, secretion of colostrum-like fluid, and even of true milk, as in cases reported by Robert<sup>64</sup> and Humbolt.<sup>65</sup> Similar instances have been observed in various male animals, *e.g.*, goat, dog, ox, cat, hare, &c.

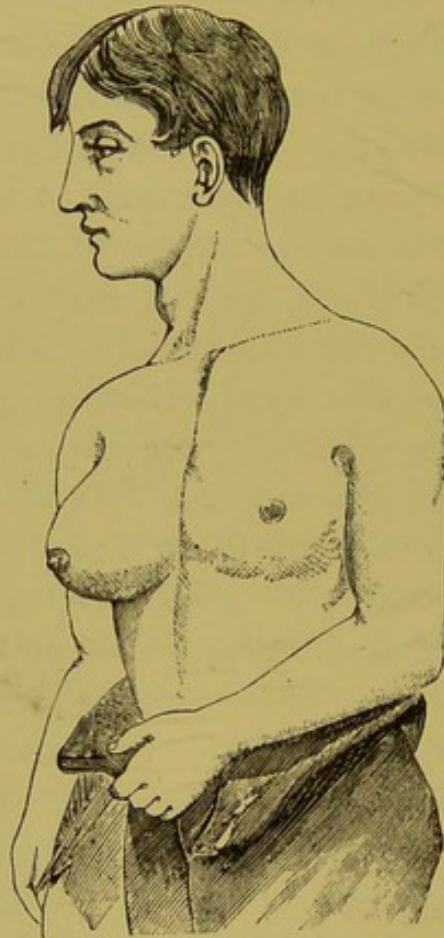


FIG. 19.—Hypertrophy of the right breast in a seaman aged 21 (*Morgan*).

Aristotle refers to the yield of milk by male goats. An instance of this has been published by Blumenbach<sup>66</sup> in which the animal had to be milked every other day for a year. I. G. St. Hilaire<sup>67</sup> kept for many years in the *Jardin-des-Plantes* at Paris, a large-uddered he-goat that freely gave milk.

Most hypertrophies of this kind arise at about puberty, owing to the formative processes natural to the male breasts at

<sup>64</sup> *Phil. Trans.*, Lond., No. 461, p. 813, "On a man who gave suck to a child."

<sup>65</sup> "Travels in Equinoxial Regions," &c.

<sup>66</sup> *Comp. Anat.*, 1827, p. 365.

<sup>67</sup> "Sur un bouc lactifère," *C. R. de l'Acad. des Sci.*, 1845 and 1852, p. 386.



this period, instead of being arrested as usual after a short time, continuing to progress, as in the normal female development. There are, however, on record a considerable number of cases in which the affection has originated at much earlier periods. In the cases seen by me both breasts have been enlarged; but the majority of the recorded cases have been unilateral, the left breast being the one usually affected.

Subjoined are abstracts of some illustrative cases:—

(1) In the person of an ordinary seaman, aged 21, Morgan<sup>68</sup> found the right breast, in size and configuration, just like that of a well developed, adult female (fig. 19). The left breast was normal. The enlargement began when he was 16½ years old, and gradually increased to its present size. No secretion had ever escaped from the nipple. The man was in other respects well formed, his testes and genitalia being normal. For his age he was of rather youthful and effeminate appearance, and he had no facial hair.

(2) In a man, aged about 25, Foot<sup>69</sup> found both breasts as large as those of the adult virgin female. From the nipple of one of them, thin serous discharge occasionally escaped. He was otherwise well developed, with plenty of facial hair, and presented nothing feminine in his appearance or disposition.

(3) In another case by the same author, the left mamma of a boy, 14 years old, exactly resembled that of a pubescent female. It was conical, dependent, and felt of firm glandular consistence. He was in other respects normally developed.

(4) In a soldier seen by Tufnell<sup>70</sup> the left breast in form and size was like that of the female at puberty. It began to be large at 12. The male secondary sexual characters were well developed.

(5) Montgomery<sup>71</sup> mentions the case of a man, aged 45, with well-developed genitalia, who had mammæ like those of an adult woman. He never married, and died of phthisis.

Similar cases have been reported by Schnitt,<sup>72</sup> Peters,<sup>73</sup> Hunter,<sup>74</sup> and others.

As instances of the onset of the affection prior to puberty in

<sup>68</sup> *Lancet*, vol. ii., 1875, p. 767.

<sup>69</sup> *Dublin Journal of Med. Sci.*, vol. xli., p. 417.

<sup>70</sup> *Ibid.*, vol. xix., p. 230.

<sup>71</sup> "Signs and Symptoms of Pregnancy," p. 125.

<sup>72</sup> *Rec. de Mém. de Méd., &c., Milit.*, Paris, 1881, 3 sér., t. xxxvii., p. 690.

<sup>73</sup> *N. Y. Med. Times*, 1863, p. 196.

<sup>74</sup> *Op. cit.*



young boys, children, and infants, the following rare cases are noteworthy.

(1) A young man, aged 22, was exhibited at the *Société de Chir.*, of Paris, by Labbé,<sup>75</sup> in 1870, whose right breast was then just like that of a well-developed adult female. At birth the part was unduly large; and by the time he was 5 years old, it had attained a considerable size. In the course of the next few years it increased to the size of a fowl's egg. With the advent of puberty, at the age of 15, its maximum dimensions were attained. When about 12 years old, a yellowish discharge was noticed from the nipple, which continued until 17. The other mamma was normal. His genitalia were well developed.

(2) In a case cited by Olphan,<sup>76</sup> both breasts began to enlarge in a boy only 4 years old.

(3) Krieger<sup>77</sup> met with an instance in an otherwise healthy and well-developed lad only 7 years old. He had noticed swelling of the breasts and fluid discharge from the nipples for some time previously. When first seen his mammae were like those of a well-developed female at puberty. His skin was thin and delicate, and devoid of hairs. In both breasts several small hard nodules could be felt. On pressing the enlarged organs, milky fluid escaped from the nipples, which were seldom free from some discharge. This fluid was alkaline in reaction, and contained colostrum, granular, and large epithelial cells in fatty degeneration.

(4) Belcher's patient<sup>78</sup> was a delicate looking boy, 12 years old, whose left breast had been gradually enlarging, without pain or tenderness, for five months. Its size then equalled that of the female breast at puberty. The right breast was normal, and so were the external genitals. In answer to a letter of inquiry, Dr. Belcher has kindly informed me that the boy, who then was 13½ years old, presented no signs of puberty, and was backward in sexual development. The testes and penis were of normal size, but there were no hairs on the face, nor on the pubes. The left breast had enlarged a little during the last year, but the right still remained normal.

A somewhat similar case came under observation at the London Hospital in 1860.<sup>79</sup>

(5) The patient was a delicate-looking boy, 13 years old, whose right breast was hypertrophied to the size of his fist.

The enlargement began, without any known cause, six months previously. The left breast was normal. He looked younger than his age, and manifested no signs of puberty.

<sup>75</sup> *Gaz. des Hôp.*, 1870, p. 46.

<sup>76</sup> *Thèse de Paris*, 1880, "Sur la Gynécomastie."

<sup>77</sup> *London Med. Rec.*, 1879, p. 404.

<sup>78</sup> *Brit. Med. Journal*, 1890, vol. i, p. 364.

<sup>79</sup> *Medical Times and Gaz.*, 1860, vol. i., p. 11.



It is most exceptional for congenital malformations, other than those of the sexual organs, to be associated with gynæcomastism; but in a case reported by Wagner,<sup>80</sup> hypertrophy of the right breast co-existed with hypertrophy of the right upper extremity, and of the hand and finger.

Very few instances of disease of the hypertrophied mamma have been recorded.

(1) Bryant<sup>81</sup> has seen a gynæcomast, aged 45, in whose breast a fibro-adenoma had developed.

(2) In a boy, aged 16, whose left breast was hypertrophied, Foot<sup>82</sup> found a cystic tumour, the size of a gooseberry, at the base of the nipple, superficial to the hypertrophied gland. The tumour was of one year's duration. He was otherwise well formed and healthy.

(3) I have had under my care a stout, gouty clergyman, aged about 50, both of whose breasts had been hypertrophied since youth, with painful nodular induration of the right breast, which I attributed to subacute gouty mastitis. Under appropriate treatment the pain and nodular thickening disappeared. A few years previously similar nodular induration had been dissected out of his left breast, under the belief that it was a tumour. He was the father of several children, and the facial hair was moderately developed.

In the preceding chapter (p. 52) I have related an instance in which gynæcomastism was associated with supernumerary mammary structures, and epithelioma of the lower lip.

B.—The *second* type of gynæcomastism is invariably associated with some morbid testicular condition interfering with their integrity; consequently, loss of virility and of the secondary male characters usually go with the mammary deformity. The morbid conditions referred to are of very variable nature; but they may, for the most part, be grouped under one or other of the following heads:—

(1) Congenital malformations of the sexual organs, with defective testicular development, *e.g.*, hermaphroditism, anorchism, hypospadias, epispadias, &c. In male hermaphrodites (*hermaphroditismus transversus virilis*) the mammae are almost invariably hypertrophied, as in the following instances:—

<sup>80</sup> CEsterr, *Med. Jahrb.*, Bd. xix., S. 3.

<sup>81</sup> *Lancet*, vol. i, 1868, p. 285.

<sup>82</sup> *Dublin Med. Jour.*, vol. xli, p. 457.



Polaillon<sup>83</sup> met with a person, aged 27, with large, well developed mammæ of the female type. The beardless face, soft skin, voice, sexual instincts and general tastes were all suggestive of femininity; however, menstruation had never supervened. On examination the vulva, clitoris and meatus were normal. The vagina was represented by a shallow depression. No trace of a uterus could be felt on recto-abdominal palpation. In each inguinal canal there was a firm, tender body. This person afterwards led an irregular life; and constant attempts at coitus deepened the rudimentary vagina. She subsequently died from albuminuria. After death the sexual organs were carefully dissected. A recto-vesical pouch of the male type was discovered. Below its reflection, just in front of the blind end of the vagina, in the middle line, was a mass of unstriped muscle tissue the size of a haricot bean, which might have represented either uterus or prostate. Two cords proceeded from this mass to the bodies in the inguinal canal, which proved to be testes, but the epithelial lining of the tubuli seminiferi were atrophied. In all other respects, except in the absence of uterus, tubes and catamenial phenomena, the person was female.

Kochenburger<sup>84</sup> has reported a similar case. The patient was 33, and had never menstruated. She had been married for ten years, but coitus was difficult, and she never felt any desire. She was large in frame, but feminine in form, with well developed breasts and mons veneris. The vagina formed a blind sac, about two inches deep. An elastic body the size of a broad bean, lying rather to the right, appeared to represent the uterus. In each labium majus was a firm, ovoid, but very tender body. These were excised. Histologically examined they proved to be *testes*, containing tubuli seminiferi, and not Graffian follicles.

I have given an abstract of an almost identical case by Chambers, in a preceding chapter.<sup>85</sup>

Ledentu<sup>86</sup> has seen an instance of *ectropia testis* associated with hypertrophy of the corresponding breast.

(2) Certain diseases that entail destruction of the testicular substance, such as syphilitic orchitis, traumatic orchitis, the orchitis of mumps, &c., are after a time apt to be followed by hypertrophy of the breasts. This sequence is of commoner occurrence after the orchitis of mumps, which so often causes atrophy, than after any other form of the disease.

In a case by Lereboullet,<sup>87</sup> a robust young man, aged 22, presenting all the characters of virility, was attacked with mumps. The disease seemed

<sup>83</sup> *Bull. de l'Acad. de Méd.*, 7 av., 1891.

<sup>84</sup> *Zeitschr. f. Geburtsh. u. Gynäk.*, Bd. xxvi., 1893, S. 73.

<sup>85</sup> Chapter iii., p. 37.

<sup>86</sup> *Thèse de Paris*, 1869. "Anomalies du Testicule."

<sup>87</sup> *Gaz. hebdomadaire de Méd. et de Chir.*, 1877, pp. 533 and 542.



mild, but on the fourth day, though the parotitis had not disappeared, double orchitis came on. Rapidly progressive testicular atrophy soon afterwards set in, with failure of sexual power and desire, and hypertrophy of both mammæ.

Similar instances have been reported by Charcot<sup>88</sup> and others. Tubercular and gonorrhœal affections seem seldom to cause this result, probably because in these diseases the morbid process centres in the epididymis rather than in the testicle itself. Galliet<sup>89</sup> has, however, reported two cases of gynæcomastism coincident with diseases of the epididymis.

In another class of cases, atrophy of the testes and consequent gynæcomastism, are but the expressions of general constitutional debility and degeneration; such individuals present signs of femininism, and they often become tubercular.

(3) Lastly come the cases in which gynæcomastism has resulted from traumatic destruction of the testes, or from their surgical removal.

Of the former condition, the case of two soldiers, mutilated by the explosion of a shell, as recorded by Martin,<sup>90</sup> is a typical example. Soon after the loss of their testes, the breasts began to enlarge. Gorham<sup>91</sup> long ago reported a similar case.

Much light may be thrown on the interpretation of the foregoing phenomena, by studying the effects of castration. When this operation is practised prior to puberty, gynæcomastism hardly ever ensues; hence oriental eunuchs, who are castrated at a very early age, are never affected in this way. Similarly, castration of adults over 30 years of age, is hardly ever followed by mammary hypertrophy. It is only when testicular destruction supervenes during the heyday of sexual life, that gynæcomastism subsequently ensues. As previously mentioned,<sup>92</sup> in women, the effect of removal of the ovaries, under similar conditions, is to determine mammary atrophy.

<sup>88</sup> *Soc. de Chir.*, 11 mars, 1891.

<sup>89</sup> *C. R. de la Soc. de Biologie*, fév., 1850.

<sup>90</sup> *Gaz. hebdomadaire de Méd. et de Chir.*, 1877, p. 591.

<sup>91</sup> *London Med. Gaz.*, vol. ii., 1839-40, p. 659.

<sup>92</sup> Chapter iii., p 41.



How can we explain these remarkable and apparently contradictory phenomena? I think they may be rendered intelligible, if we bear in mind the principle of correlated variability and the doctrine of the latent hermaphroditism of every human being. It is a very remarkable fact that in every female all the secondary male characters, and in every male all the secondary female characters, exist in a latent state, ready to be evolved under certain conditions. It seems perfectly warrantable to assume that the normal condition of the mammæ in each sex is determined by correlation with the essential sexual organs. When the latter are destroyed the correlated integrating force determining mammary development also fails, so that the latent tendency to develop the opposite secondary sexual characters then becomes manifest.

Gynæcomastism entails no ill consequences; but for those who desire to be relieved of the deformity the following operation may be done. A curved incision is made along the lower part of the periphery of the enlarged organ, and through this the gland is removed, together with its fibro-fatty envelope. The nipple, areola and overlying skin are preserved, as well as sufficient of the subcutaneous fat to ensure the vitality of these parts.



## CHAPTER VI.

## HISTOLOGY AND NEOPLASTIC PATHOGENY.

## § I.—Histology.

INASMUCH as the mammary *epithelium* is derived by descent from the columnar cells of the epidermis, it is not surprising that throughout the whole gland these cells partake more or less of the columnar type. The flattened cells that cover the surface of the nipple penetrate but a very short distance into the galactophorous ducts. The latter are lined by a layer of columnar

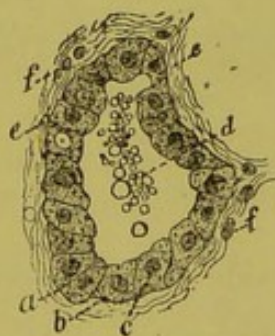

FIG. 20.—HISTOLOGICAL SECTION OF A FULLY DEVELOPED MAMMARY ACINUS DURING LACTATION (*De Sinéty*).

(a) Epithelial cell; (b) Nucleus; (c) Nucleolus; (d) Milk globules; (e) Fibrous stroma; (f) Connective tissue cells ( $\times 300$  dia.).

cells, which is often double; but throughout the rest of the gland the epithelium is single-layered. As the ducts get smaller and approach the acini, their epithelium gets shorter and more cubical; while in the smallest ducts, and in the acini themselves, the cells are of the flattened cubical or even polygonal type.

In the structure of a fully developed acinus, according to



De Sinéty, five distinct layers may be recognised from within outwards.

(1) A single layer of flattened cubical epithelial cells, each with its nucleus and nucleolus.

(2) An endothelial layer situated between the epithelial cells and the *membrana propria*, which is rendered visible by staining with nitrate of silver.

(3) The *membrana propria* a thin, pellucid layer, difficult to demonstrate in the physiological state; but easily seen under certain pathological conditions. It appears to be a myxomatous modification of the peri-acinous connective tissue, consisting of a network of flattened branching cells, embedded in hyaline matrix. Processes of the surrounding peri-acinous fibrous tissue often project into it.

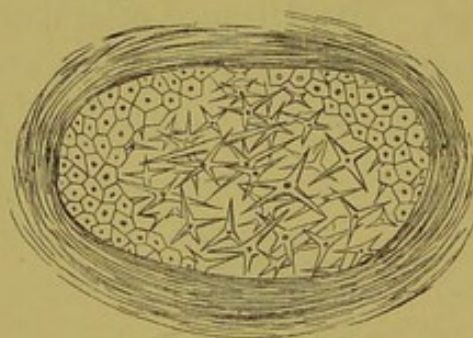


FIG. 21.—An expanded acinus with the epithelial lining partially removed, so as to show the *membrana propria* (Moullin).

(4) Immediately outside the *membrana propria* and continuous with it, Labbé and Cöyne<sup>1</sup> have pointed out that a thin transparent layer of modified connective tissue, devoid of lymphatics, exists, in which few or no formed elements can be seen.

(5) A much thicker layer, external to the foregoing, consisting of ordinary fibrous tissue, rich in elastic fibres and cells, the latter arranged concentrically around the acini. It blends externally with the adjacent inter-lobular fibrous stroma. In this layer numerous *lymphatic capillaries* and *lacunæ* are met with. These completely surround the acini; but they are not directly

<sup>1</sup> *Traité des Tumeurs Bénignes du Sein*, Paris, 1876, p. 87.



in contact with them, owing to the intervention of the above-mentioned clear zone. This it is that prevents the lymphatic system from being invaded in the earliest stage of mammary cancer.

Each acinus is immediately surrounded by a dense network of capillary *blood vessels*, which form a system for the different lobules. The exact distribution of the *terminal nerve filaments* is unknown; but from the fact that nerve filaments have been traced to secretory cells of the salivary glands, it is inferred that they may be similarly connected with the cells of the mammary acini. The structure of the *smallest ducts* is similar to that of the acini; and it is probable that these parts are also identical in function.

In the interlobular fibrous stroma islets of fatty tissue are interspersed, which atrophy during lactation.

From this account of the histology of the gland it will be gathered that its *archiblastic* (epithelial) and *parablastic* (connective tissue) elements, are very intimately blended.

## § II.—Histological Metamorphoses of Lactation.

By the stimulus of conception the previously functionless gland is gradually converted into an active milk-secreting organ. This wonderful transformation is brought about by a process of progressive ingrowing gemmation of the glandular elements, with differentiation; which is essentially of the same nature as that of the embryonic development, of which it is—like the changes at puberty—but a superinduced repetition. During this period the pre-existing, as well as the newly formed glandular structures, attain their highest degree of morphological perfection.

The *secretion* of the breast is elaborated after the same type as that of a sebaceous gland, of which the following is a brief description. Within the *membrana propria* of its secretory part, we find a stratum of small, irregularly-shaped, epithelial cells, each with a large nucleus (fig. 22, *b*). The cells of this



region are constantly proliferating, and as the products of the process gradually shift towards the duct, they become changed and gradually form the secretion. The steps of the process are as follows:—The cells next the marginal cells (fig. 22, *b*) increase in size and their nuclei dwindle. As they approach the centre of the acinus their nuclei disappear, and the cells become distended with granules and oil globules. Finally they burst and their *débris* forms the secretion, which is discharged. These changes may be compared with the analogous transformations of the cells of the epidermis which eventuate in desquamation.

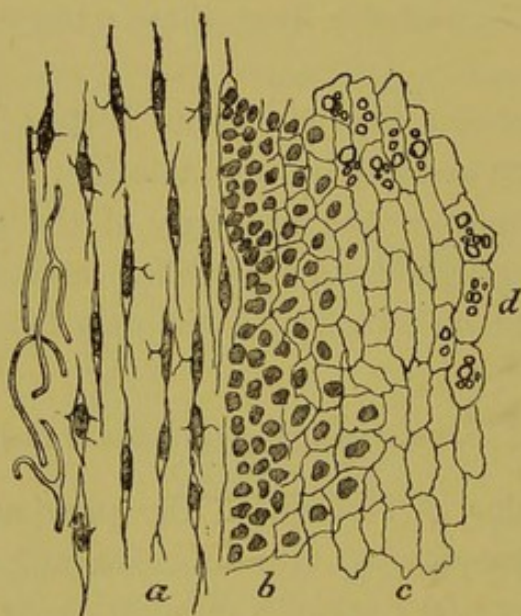


FIG. 22.—HISTOLOGICAL SECTION OF THE WALL OF A SEBACEOUS CYST  
(Cornil and Ranvier).

(*a*) Fibrous stratum with embedded connective tissue corpuscles ; (*b*) The marginal stratum ; (*c*) Hornifying cells ; (*d*) Sebaceous cells.

Lactation is the outcome of a similar process. Milk must therefore be regarded as the product of the deliquescence of successive generations of epithelial cells, which are destroyed in the process, and replaced by relays of new cells, derived by division from other still active epithelial cells of the part. Thus we see that growth, development and secretion, are but slightly varied manifestations of cellular activity finding expression in different ways. When in a sebaceous gland the metamorphoses



of the cells are, from any cause unduly delayed, the constant proliferation going on in the marginal stratum causes great accumulation of imperfectly changed cells to arise, instead of the proper secretion (fig. 22). It is under such conditions that sebaceous cysts originate. Here, the formative activity of the glandular cells predominates over their secretory activity. Abnormal processes of this kind, going on in the mammary acini, play an important part in the origination of neoplasms.

The complete degree of mammary function that eventuates in lactation is only attained periodically, and the process is always gradual. The following is a brief account of Creighton's

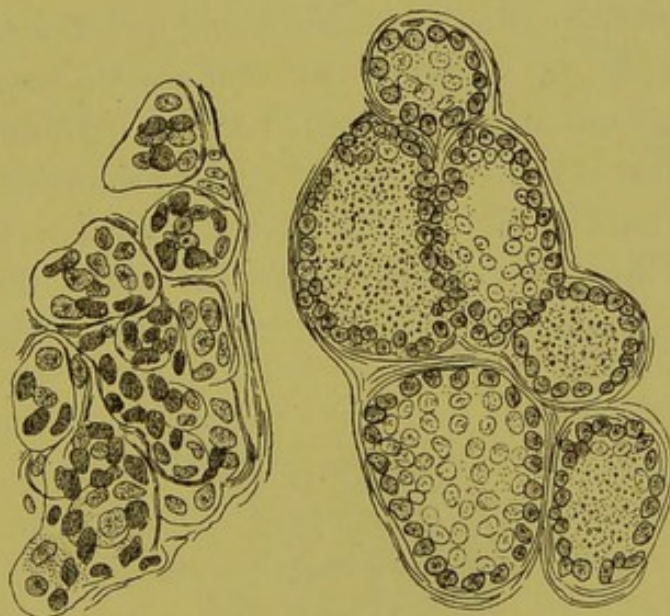


FIG. 23.—Mammary lobule near the resting stage (*Creighton*).

FIG. 24.—Mammary lobule of rising function (*Creighton*).

description of it. Subsidence of function goes hand in hand with undoing of structure, and revival of the function with the building up of structure. Variations of intensity in the secretory force are measured by its products, which correspond to changing aspects of the secreting acini. The beginning of the rising function coincides with the beginning of pregnancy, and the process occupies the entire period of gestation. During the intervals between its periods of functional activity the breast remains in a quiescent functionless state—the *resting stage*.



In this condition the gland is shrunken and surrounded by a considerable quantity of fibro-fatty tissue. The acini are shrivelled up. On microscopical examination of sections of the gland in this stage (fig. 23), each acinus appears as an alveolar space bounded by a thin layer of fibrous tissue, denuded of epithelium. Its contents are irregularly-arranged, polymorphic, epithelial cells, with large nuclei and scanty surrounding protoplasm. This is the structure that is mimicked in most cases of mammary cancer.

During the *rising* function the size of the acini gradually increases from that of the resting stage. The cells increase in number and size, and acquire more protoplasm. They gradually arrange themselves so as to form a lining membrane for the wall of the acinus (fig. 24) which, as lactation approaches, is converted into a regular mosaic. The cells become granular, irregularly shaped, excavated and vacuolated, secreting granular and mucous fluids. The milk of the first few days is always somewhat crude, containing colostrum cells, which are the last of the long series of secretory products thrown off during the period of rising function.

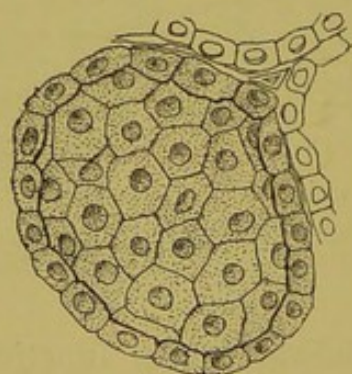


FIG. 25.—Fully expanded mammary acinus, showing the epithelial mosaic (*Creighton*).

The *fully expanded acinus* (fig. 25) in a state of active secretion, is at least four times as large as that of the resting stage. Its contained cells are much more numerous than at any other period, and they form a perfect mosaic, lining the *membrana propria*. Each cell is flattened and of polyhedric shape, and has a large nucleus surrounded by a broad zone of protoplasm.



During the period of *subsiding function* the organ gradually reverts to the resting stage through the converse series of changes. In this process the cells pass through a succession of transformations, from the forms characteristic of the perfect mosaic of lactation to those peculiar to the various stages of the subsiding process. These changes are accompanied by constant destruction and renewal of the participating cells.

It will be gathered from this description, that the changes which take place in the mammary acini during the periods of functional activity are but a slightly modified, sustained repetition of those of the ontological development. The embryonic cells, in order to become secreting cells of the mammary acini, go through a cycle of changes; and the changes that they undergo are precisely those that the cells of the mature organ undergo in producing the periodical secretion.

This account of the changes in the gland during its periods of functional activity refers almost exclusively to its archiblastic elements; but its parablastic elements are somewhat similarly affected, although in a less degree.

With regard to the influence of the *nervous system* on the mammary secretion, most of those who have studied the subject are agreed that the secretion of milk is not directly under its control. Laffont,<sup>2</sup> however, maintains that the mammæ possess vaso-dilator nerves, which, when stimulated, cause augmentation of the quantity of milk secreted; but De Sinéty,<sup>3</sup> who has repeated his experiments, is unable to accept his conclusions.

### § III.—Neoplastic Processes.

It now remains for me to show that the *pathological neoplastic processes* of the breast are explicable as aberrant repetitions of these normal developmental processes.

In my work on the "Principles of Cancer and Tumour For-

---

<sup>2</sup> *Comptes Rendus de l'Acad. des Sci.*, 1879, t. lxxxix., p. 649.

<sup>3</sup> *Mém de la Soc. de Biol.*, t. i., 1879, p. 301.



mation," I have pointed out: that since the origin and development of neoplasms follows a course homologous with that of the tissues in which they originate, we may classify these growths, like the normal tissues in association with which they develop, accordingly as they originate from cell derivatives of the one or the other of the germinal layers. That is to say, they are either of *archiblastic* (epithelial) or *parablastic* (connective tissue) origin. As in the normal development the cell derivatives of the blastodermic layers are never transformed into each other, so, under pathological conditions, no such metamorphoses ever occur.

In what follows—for the sake of clearness—each of these classes of neoplasms will be treated separately; although in reality elements from *both* tissue-systems are almost invariably concerned in every mammary neoplasm. This is due to the fact, that nearly all such neoplasms originate in connection with the acini or small ducts, where archiblastic and parablastic structures are normally very intimately blended.

With regard to the origin of the *archiblastic* neoplasms, it should be observed that during the period of rising and subsiding function, the secretory metamorphosis of the gland cells is incomplete; so that instead of milk, only *cellular* products result. Creighton has done excellent service in pointing out how such cells become the germs, whence cancer and other epithelial neoplasms originate. He says:—"Taking the breast at the resting state, it cannot under any circumstances reach the perfection of its function without going through the somewhat slow series of unfolding changes. When the evolution that is set up is of a spurious kind, or in other words, when the gland is disturbed from its resting state by some cause other than pregnancy, the steps of its unfolding are less orderly than in the normal evolution; and the fatality of the morbid process consists in this, that the spurious excitation never carries the gland to the end of its unfolding, or to the perfect function. The products of the gland never get beyond the crude condition; and it is the crude cellular kind of secretory product that makes the tumour."



Cells that should have passed out of the gland as waste products, remain at their place of origin, where they proliferate and aggregate more or less independently. It is upon such deviations from the physiological track that the origin of most archiblastic mammary neoplasms depends. Neoplasms of this kind generally arise at a time when the breast is undergoing the retrograde changes of the climacteric period, which finally eventuate in the effacement of its secretory mechanism, and the withdrawal of its secretory force. Fragments of structure with correlated functional force, surviving the general obsolescence, are the sources to which we must look for the origin of the post-climacteric neoplasms. It makes no difference in this respect

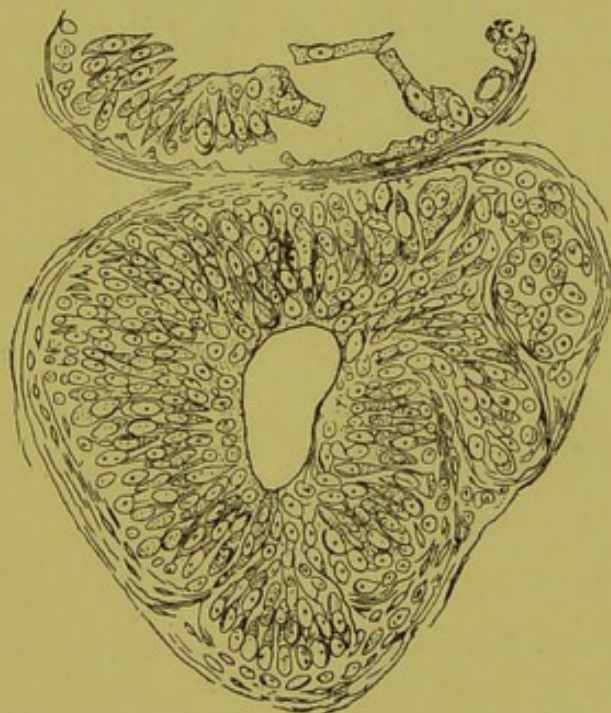


FIG. 26.—A pathological acinus. The epithelium massed in several layers (*Creighton*).

whether the glandular elements that originate the disease form part of the gland itself, or whether they exist as supernumerary structures separated by sequestration from the true gland. According to *Creighton*, the kind of cell most commonly found in such mammary tumours is the large nucleated cell, with scanty surrounding protoplasm. Measured on the physiological scale,



these cells belong to the intermediate stage of the unfolding process; they stand for a half-roused physiological stimulus. The morbid force delays at this intermediate stage. The result is the accumulation of cellular waste products instead of true secretion (fig. 26). The formative activity of the cells predominates over their secretory activity. This accumulation within the acini causes them to become greatly enlarged. Solid bud-

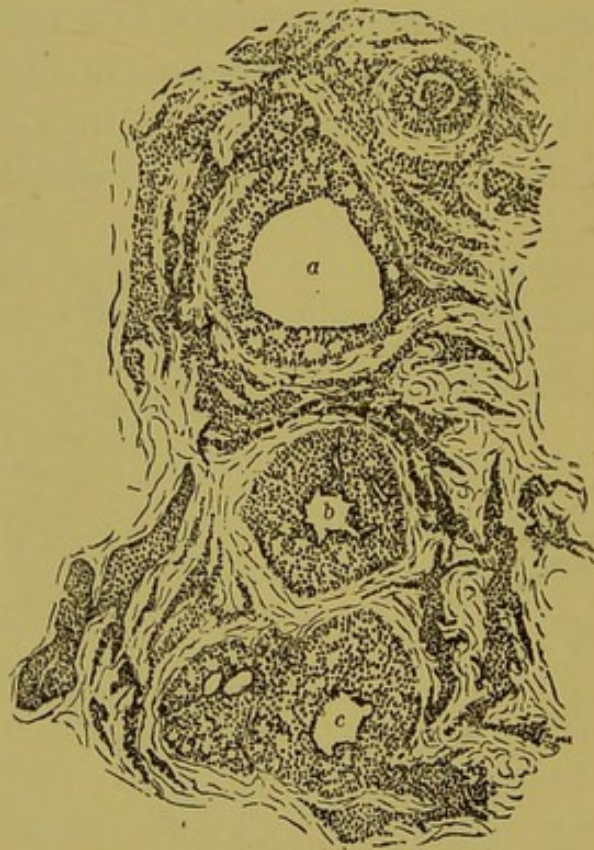


FIG. 27.—HISTOLOGICAL SECTION, SHOWING THE PATHOGENESIS OF CANCER (*Gross*).

(*a b c*) Enlarged acini packed with polymorphic cells of which the peripheral layer is columnar. At *a* and *c* the epithelial cells are invading the stroma. Only the stained nuclei of the cells are delineated ( $\times 180$  dia.).

like cellular processes arise from their walls, which grow and ramify in the adjacent tissues (fig. 27).

In the case of *cancer*, the process seldom advances much beyond this low grade of organisation; but, by a kind of continuously progressive gemmation, which is merely a superinduced repetition of the initial process, this crude formation grows and



reproduces itself indefinitely. The morbid product, however, always has a certain likeness to the parent tissues. Hence two forms of mammary cancer can be recognised—the *acinous* and the *tubular*. In the former—which is much the commoner—large lobulated nodules are developed, having an alveolar structure roughly resembling acini of the resting-stage; in the latter we find instead, thin branching columns of epithelial cells, growing into the connective tissue stroma, and presenting an appearance not unlike that of ductal structures. All such neoplasms are more or less malignant. The development of mammary cancer is sometimes accompanied by imperfect secretion, as shown by the escape of fluid from the nipple, and cysts occasionally arise from the same cause. This is the nearest approach to normal function that the pathological structure ever attains.

In the *adenomata* a much higher grade of organisation is reached. The newly-formed gland tissue tends to be very like the normal, although it falls short of this high standard. The cells of such a pathological acinus are generally massed in several layers; and intra-acinous papillary projections are often met with. The lumen, as a rule, is absent, or more or less occluded, and it has no connection with the excretory duct. These glandular new formations are invariably associated with considerable overgrowth of the peri-glandular connective tissue. Fibro-adenomata are incapable of producing normal secretion, but they are very prone to form serous and mucous fluids which originate cysts.<sup>1</sup> Such neoplasms never manifest malignant properties.

I will now refer briefly to the origin of the *parablastic* or connective tissue neoplasms.

At an early period of embryonic life those parts of the breast where connective substances will subsequently arise, are composed solely of closely aggregated parablastic cells. These cells are

---

<sup>1</sup> For some remarks on the real nature of alleged instances of milk-secreting fibro-adenomata (*vide* ch. xviii., § 2).



nothing but small rounded masses of nucleated protoplasm. Such is the embryonic parablasic tissue, whence any kind of connective substance may subsequently develop. The first step in the evolution of the mature connective tissues, from the cellular embryonic structure, is that the cells become separated from one another by the differentiation of intercellular substance from their protoplasm. A distinction thus arises between the cells that form, and the intercellular substance that is formed. As development progresses most of the cells are used up and converted into special tissues. Usually, however, a considerable number persist, embedded in the intercellular substance, and are still capable of active growth and development. Such cells are especially numerous in the vicinity of the acini and small ducts. Under ordinary circumstances these cells simply concern themselves in maintaining the normal structures; but under certain pathological conditions they become the germs whence the various parablasic neoplasms originate.

When the embryonic parablasic new formation, formed by the proliferation of these cells, shows little or no tendency to advance beyond this low grade of organisation, the various kinds of *sarcomata* arise. These neoplasms consist chiefly of rounded or spindle-shaped cells, interspersed with fibrous tissue; and with these elements altered glandular structures are usually associated. The degree of malignancy of such tumours will be found to vary, according to the grade of organisation attained by the parablasic new formation.

In addition to the cellular embryonic form of connective tissue, gelatinous, fibrous, calcareous, fatty, cartilaginous and osseous varieties may be recognised. These differences depend upon the character of the constituent cells, the relation they bear to the intercellular substance, and the physico-chemical constitution of the latter. Modifications *inter se* cause transformations to occur between the different connective substances (*metaplasia*).

The formation of gelatinous tissue from the embryonic tissue takes place by the differentiation of soft, hyaline, intercellular



substance containing mucin. In this the cells are sparsely embedded; they may be of rounded shape, when they are generally isolated, or stellate, when they usually communicate by fine protoplasmic processes. In its grade of organisation, gelatinous tissue occupies an intermediate position, between the embryonic parablasic formation on the one hand, and the highly developed fibrous and fatty tissues on the other.

As I have previously mentioned, in the normal condition, the mammary acini and small ducts are immediately surrounded by a thin layer of this tissue. Pathological new formations thus constituted are the *myxomata*. They arise from the parablasic cells of the part, in just the same way as the sarcomata; from which they differ only in being a degree higher in organisation. They represent immature tissue, and are comparatively lowly organised, hence after removal they often recur locally, and occasionally give rise to metastases. Gelatinous tissue in neoplasms is often derived by metaplasia from fibrous and fatty tissues; under these circumstances its presence is not of such serious import.

Fibrous tissue may be regarded as a further development of gelatinous tissue. In its evolution the diffuent, mucin-bearing, intercellular substance, gradually solidifies and fibrillates, and is converted into gelatine. Some histogenists describe fibrous tissue as originating without a gelatinous transformation, by the developing cells (fibroblasts) arranging themselves into compact masses and their protoplasm fibrillating. In the developmental process, the cellular elements are gradually used up, and many disappear. However, a considerable number remain embedded in the fibrillar intercellular substance. It is to abnormal proliferation of these cells that the *fibromata* owe their origin. The embryonic tissue thus formed, passes into fibrous tissue as in the normal development. Neoplasms of this nature are highly organised and of innocent nature. Strange to say, they are of very rare occurrence in the breast. Fibrous tissue readily passes by metaplasia into gelatinous, calcareous or ossiform states.



Fatty tissue is but a modification of ordinary areolar tissue, owing to the deposition of fat within its cells. The *panniculus adiposus*, whence the mammary fatty envelope is derived, is in the foetus, a gelatinous tissue. In its evolution fatty tissue passes through the cellular and gelatinous stages; but while fibrillation is still incomplete, the cells form groups and fat accumulates within them. The accumulation of fat within the cell causes its nucleus, with the little remaining protoplasm, to be pressed against the cell wall. These cells, however, are still capable, under pathological conditions, of taking on fresh activity. Embryonic parablasic tissue is thus formed, which finally develops into fatty tissue as in the normal evolution. Thus the *lipomata* arise from normal fatty tissue.



## CHAPTER VII.

THE VARIETIES OF MAMMARY NEOPLASMS AND THEIR  
RELATIVE FREQUENCY.

IN no part of the body, except the uterus, do neoplasms arise so frequently as in the mammæ.

On making an analysis of 13,824 primary neoplasms of all parts, consecutively under treatment at Middlesex, University College, St. Thomas', and St. Bartholomew's hospitals during the 16 to 21 years preceding 1889, I have found that 2,422 (17·5 per cent.) originated in the breast (males 25, females 2397).

The following tables, based on these 13,824 cases, show the relative frequency of the neoplastic process in its chief seats:—

TABLE I.

A. *Showing the Relative Frequency of the Neoplastic Process in its Chief Seats in both Sexes (based on 13,824 cases).*

	Per cent.
Uterus ... ..	19·2
Mammæ ... ..	17·5
Skin ... ..	9·4
Connective tissue (general) ... ..	7·7
Tongue and mouth ... ..	6·3
Ovaries... ..	5·8
External genitalia ... ..	5·1
Bones ( <i>ex. maxillæ</i> ) ... ..	4·0
Rectum ... ..	3·3
Maxillæ ... ..	2·9
Stomach ... ..	2·6
Lower lip ... ..	2·6
All other localities ... ..	13·6
	<hr/>
	100·0



B. *Showing the Relative Frequency of the Neoplastic Process in its Chief Seats in Males (based on 4,597 cases).*

	Per cent.
Skin ... ..	16.4
Tongue and mouth ... ..	15.9
Connective tissue (general) ... ..	9.4
Lips ... ..	7.3
External genitalia ... ..	6.1
Bones ( <i>ex. maxillæ</i> ) ... ..	6.1
Rectum ... ..	5.0
Stomach ... ..	4.8
Maxillæ ... ..	3.9
Brain ... ..	3.4
Œsophagus ... ..	3.1
Testes ... ..	2.0
Mammæ ... ..	0.5
Prostate ... ..	0.2
All other localities ... ..	15.9
	<hr/> 100.0

C. *Showing the Relative Frequency of the Neoplastic Process in its Chief Seats in Females (based on 9,227 cases).*

	Per cent.
Uterus ... ..	28.7
Mammæ ... ..	26.0
Ovaries ... ..	8.7
Connective tissue (general) ... ..	6.9
Skin ... ..	5.9
External genitalia ... ..	4.6
Bones ( <i>ex. maxillæ</i> ) ... ..	2.9
Rectum ... ..	2.5
Maxillæ ... ..	2.4
Tongue and mouth ... ..	1.6
Brain ... ..	1.4
Stomach ... ..	1.4
Liver ... ..	1.2
All other localities ... ..	5.8
	<hr/> 100.0

A noteworthy feature in connection with these analyses is the great frequency with which, in females, the reproductive organs—uterus, mammæ, ovaries, &c.—are attacked; in fact, nearly 70 per cent. of all neoplasms in women arise from these organs.



The very great frequency with which the uterus and mammae are affected is particularly striking. From the fact that both of these parts are subject to remarkable post-embryonic developmental changes, it may be inferred that they are normally rich in cells, which still retain much of their embryonic capabilities for growth and development. It is probably owing to this peculiarity that they are so much more prone to originate neoplasms than other parts of the body.

The following considerations tell in favour of this view:—It may be said of neoplasms in general, that they arise from archiblastic (epithelial) structures, much more frequently than they do from parablastic (connective tissue) ones. Thus, of these 13,824 primary neoplasms, 72 per cent. originated from the archiblast, and only 28 per cent. from the parablast. In the breast archiblastic neoplasms predominate to a still greater degree, for I have found that no less than 95·74 per cent. of all such neoplasms have this origin, whereas only 4·26 per cent. arise from the parablast. Now, of all the tissues of the body, the archiblastic ones have on the whole departed less from the primordial type than any others, hence their cells still retain their primitive powers of growth and reproduction in a higher degree than others. It is to this that I attribute the greater proneness of archiblastic tissues to originate neoplasms under pathological conditions.

Again, the liability of the tissue systems of the various organs to originate neoplasms is not diffused equally throughout their whole extent, but it is much greater in certain parts than in others. In the breast, for instance, most neoplasms originate in the immediate vicinity of the acini and small ducts; whereas it is very rare for such growths to arise from the skin of the mammary region, the areola, the nipple, the large ducts, or the para-mammary fibro-fatty tissue. That is to say, the majority of mammary neoplasms arise in the seats of greatest post-embryonic developmental activity, where it may be inferred that cells still capable of growth and development most abound.

The relative frequency of the occurrence of the different



varieties of mammary neoplasms is shown in the subjoined table, which I have compiled from the 2,422 consecutive cases of primary breast neoplasms previously mentioned.

TABLE II.

*Analysis of 2,422 Consecutive Cases of Primary Mammary Neoplasms.*

				Males.		Females		Total.
Cancer	...	...	...	16	...	1,863	...	1,879
Sarcoma	...	...	...	3	...	92	...	95
Myxoma	...	...	...	2	...	2	...	4
Fibro-adenoma	...	...	...	1	...	372	...	373
Papilloma	...	...	...	—	...	3	...	3
Fibroma	...	...	...	—	...	1	...	1
Lipoma	...	...	...	1	...	—	...	1
Chondroma	...	...	...	—	...	1	...	1
Angioma	...	...	...	1	...	—	...	1
Cystoma	...	...	...	1	...	63	...	64
				—		—		—
Total	...	...	...	25	...	2,397	...	2,422

Throughout the body malignant neoplasms occur with greater relative frequency than non-malignant ones; I have found the ratio to be 64 per cent. of the former to 36 per cent. of the latter. In the breast the relative preponderance of malignant neoplasms is still greater, for, as the above table shows, 81·7 per cent. of all its neoplasms are of this nature, and only 18·3 per cent. are non-malignant.

While 54·5 per cent. of malignant neoplasms in general spring from the archiblast, and 9·5 per cent. from the parablast, in the breast 77·6 per cent. of its neoplasms are of archiblastic, and only 4·1 per cent. of parablastic, origin.

Of non-malignant neoplasms in general, 17·5 per cent. (including cysts) are derived from the archiblast, and 18·5 per cent. from the parablast; whereas, in the breast, 18·14 per cent. of its non-malignant neoplasms are of archiblastic, and only 0·16 per cent. of parablastic origin.

Or the facts may be stated thus:—



TABLE III.

*Showing the Relative Frequency of Neoplasms in General and of Female Breast Neoplasms.*

Neoplasms in General.						Breast Neoplasms.	
Per cent.						Per cent.	
Cancers	...	...	...	54'5	...	...	77'7
Sarcomas	...	...	...	9'4	...	...	3'9
Non-malignant neoplasms				24'7	...	...	15'7
Cysts	...	...	...	11'4	...	...	2'7
<hr/>						<hr/>	
100'0						100'0	

This shows that the relative liability of the female breast to cancers is very much above the average; while its liability to simple cysts, non-malignant neoplasms, and sarcomas is below the average.

Some idea of the great frequency of mammary cancer may be gathered from an estimate I have made, according to which there cannot be fewer than 10,000 women now suffering from this disease in England and Wales. In arriving at this result I have taken the average duration of cancerous disease in general at two years, which is probably under rather than over the mark. If we estimate it at a higher figure, then the number of breast cancer cases must be still more numerous.

The influence of sex in the development of neoplasms is very great. In general, females are about twice as liable as males, the percentage proportion, according to my estimate, being 67 females to 33 males. In the breast, however, nearly 99 per cent. of all its neoplasms occur in females, and only about 1 per cent. in males. This is a good illustration of the law—of which many other instances might be cited—that functionless, obsolete structures have but little tendency to take on the neoplastic process. Herein is further evidence in favour of the view I have advanced, that neoplasms are most prone to arise in the sites of greatest post-embryonic developmental activity.



## CHAPTER VIII.

THE PATHOGENY OF CANCER AND OTHER NEOPLASMS,  
WITH SPECIAL REFERENCE TO THE MICROBE THEORY.

## § I.—Historical Review.

AT the present time one of the most absorbing pathological controversies that have ever arisen, centres round the pathogeny of neoplasms.

Before entering on this discussion, it will be profitable briefly to review the leading opinions prevalent in former times on this subject. The ancients divided tumours into three great classes:—" *Tumores secundum naturam, supra naturam, præter naturam.*" Physiological enlargements were included in the first group, the second comprised swellings due to displacements of natural parts; while the third embraced all other swellings—a very miscellaneous assemblage, comprising all that we now include under the term "tumour," and many other conditions besides.

By Galen<sup>1</sup> and his followers the tumours "*præter naturam*," were believed to result from the accumulation of one or other of the four *humours*, each of which generated its corresponding kind of tumour. Of these humoral tumours, those of the group called "*scirrhus*"—which embraced cancer, and nearly corresponded with what we now understand by the word "tumour"—were believed to arise from the accumulation of *atrabile*. It was several centuries before the doctrine of the four humours was overturned by the discovery of the circulation of the blood and the lymph (Harvey, Malpighi, &c.). But even these discoveries did not at once destroy the humoral pathology, the essential

<sup>1</sup> "De tumoribus præter naturam."



ideas of which, in slightly modified form, continued to prevail until the eighteenth century, and even now it would be rash to pronounce them altogether extinct. In place of the humours, the blood came gradually to be regarded as the centre of disease. To the newly-discovered lymph—a derivative of the blood—the Cartesians, with Boerhaave at their head, ascribed the origin of all tumours. The different properties of the latter they attributed to its varying degrees of crudity, density, acridity, fermentation, &c. Cancer they regarded as the outcome of vitiated, depraved or degenerated lymph. It is interesting to note the precise form given to these views by the rank and file of the profession of that age. Happening, not long ago, to meet with a well-written essay “On the General Method of Treating Cancerous Tumours,” dated 1753, when these doctrines were in full swing—by one William Norford, “Surgeon and Man-midwife,” evidently a very up-to-date practitioner—I read as follows:—

“Messieurs Du Fouart and Faget, in the ‘Memoirs of the Royal Academy of Surgery,’ at Paris, have by several curious Experiments discovered that cancerous Tumours are formed by stagnant, inspissated lymphatic and gelatinous juices; which by a putrid dissolution, are thought to be converted into a malignant and corrosive *Sanies*, that soon ulcerates the Flesh, &c.”

Doctrines of this kind continued to hold the field until the time of Hunter.<sup>2</sup> With his advent, towards the end of the eighteenth century, observation was substituted for vain theorising, and we begin to discern the first rudiments of modern conceptions emerging from the ancient chaos. The merit of Hunter’s work with regard to tumours is, that by studying their structure he recognised their affinities with the normal tissues, from which he maintained they arose by modification of the formative process. This was an immense advance on previous ideas. In Hunter’s time it was believed that the development of the various tissues, &c., commenced by the secretion of a plastic fluid, derived from the blood, which after its effusion became the centre of the subsequent developmental changes. To this sub-

---

<sup>2</sup> “Hunter’s Works,” Palmer’s edition.



stance Hunter gave the name of *coagulable lymph*; and to its effusion he traced the origin of all tumours, whose diverse morphological and dynamical properties did not escape his notice. He thus laid the foundations of the anatomico-pathological study of tumours; which were subsequently further strengthened by Bichât, Laënnec, Abernethy, Cruveilhier, &c.

At this juncture the current of thought was suddenly completely changed, by the appearance on the scene of the celebrated Broussais.<sup>3</sup> His doctrine was that all tumours, including cancer, were but forms of chronic inflammation, consequent on organic irritation. The extreme simplicity, comprehensiveness, and positiveness of this brilliant generalisation—suddenly sprung on a scientific world, hesitating between the old humoral doctrines and the nascent anatomico-pathological tentatives—captivated everyone; and the Broussaisian system, in an incredibly short time, became supreme. But its supremacy was short-lived.

What more than anything else contributed to its downfall was the application of the microscope to the study of new growths. This instrument, invented towards the end of the sixteenth century, at about the period to which our history refers, underwent important improvements, of which naturalists quickly availed themselves, with the result that the cellular structure of organised bodies was ere long discovered. For the famous *Cell Theory*, which must be ranked among the most important steps by which the science of biology has ever been advanced, we are indebted to the vegetable morphologist Schleiden;<sup>4</sup> and shortly afterwards Schwann<sup>5</sup> demonstrated the applicability of his generalisations to the animal world. In the very same year the publication of Müller's important work,<sup>6</sup> established the cellular nature of cancer and other neoplasms. At this period the cells themselves

<sup>3</sup> "Traité des Phlegmasies Chroniques," 1808; and "Examen des Doctrines Médicales," 1821.

<sup>4</sup> *Beiträge zur Phytogenesis*, 1838.

<sup>5</sup> *Mikroskop. Untersuchungen über die Uebereinstimmung in der Structur und dem Wachsthum der Thiere und Pflanzen*, 1838.

<sup>6</sup> *Ueber der feineren Bau und die Formen der krankhaften Geschwülste*, 1838.



were believed to originate from a formative fluid exuded from the blood (*blastema* or *cytoblastema*), which was nothing but the "coagulable lymph" of Hunter under another name. The origin of cancer and other neoplasms, and their variations *inter se*, were ascribed to aberrations of the force inherent to this primordial substance, causing the resulting cells to deviate from their usual evolution. Like Hunter, Müller strongly insisted on the correspondence between the development from the embryo and the pathological neoplastic process. Pathological cells, he maintained, differed from physiological cells only in respect to the degree of evolution ultimately attained. Laënnec's division<sup>7</sup> of neoplasms into two great classes, according as their structure resembled the normal tissues (*homologous*) or differed from them (*heterologous*), Müller completely rejected. "It is evident," he says, "that no division of pathological structures into homologous and heterologous can be established. Such a classification is formed without any knowledge of the structure of morbid growths, and is founded on blind gratuitous hypothesis. The most innocent growths do not differ in their minute elements, nor in their origin, from the most malignant ones."

The establishment of the cell theory gave an immense impetus to pathological histology, and a vast mass of new data soon accumulated. Virchow,<sup>8</sup> twenty years later, pounced upon these; and, with wonderful insight, skill and energy, elaborated them together with independent observations, into a kind of new cell theory, which still prevails. Virchow's influence on modern times has been so great that it will be of interest to trace the genetic relationship of his ideas with those of his predecessors. It may be said that he adopted the cell theory in its entirety, as laid down by Müller, with the single important exception that he completely exorcised the blastemal origin of cells. It was just this omission that chiefly constituted the novelty of his system. Instead of a hypothetical blastema he substituted the

---

<sup>7</sup> "Essai sur l'Anat. Path.," 1808.

<sup>8</sup> "Cellular Pathologie," 1859.



famous formula "*Omnis cellula è cellula*." "Where a cell arises there a cell must have previously existed, just as an animal can spring only from an animal, and a plant only from a plant." Whence it follows that all normal and pathological structures are evolved from cells by a process of *continuous development*. Another important respect in which Virchow's cellular pathology of tumours differs from that of his predecessors, is in the addition to it of the whilom extinct Broussaisian doctrine of irritation and chronic inflammation. "Irritation," he considers to be the fundamental cause of all true neoplastic action.<sup>9</sup> Nowhere in his works have I met with any attempt to explain the compatibility of this view, with the doctrine he has also adopted of the correspondence between the embryonic and neoplastic developmental processes. In my opinion these views are absolutely incompatible, and this incompatibility constitutes a serious flaw in Virchow's neoplastic pathology.

Of late, owing to a variety of causes, Virchow's doctrines have undoubtedly lost ground. For this lapse Virchow himself is to a large extent responsible, because he has gone out of his way, in a really extraordinary manner, to prevent his followers from assimilating the new facts and principles brought to light by modern biological progress in connection with the doctrine of evolution. Hence, while the rest of biology has been completely revolutionised, the cellular pathology has remained stationary. So far as the pathology of neoplasms is concerned, in my work on "The Principles of Cancer and Tumour Formation" (1888), I endeavoured to repair Virchow's error by laying the foundations of a modified cellular pathology, in harmony with modern biology; and I confidently look forward to the time when these views will be generally accepted, as the only really scientific basis for explaining the phenomena of pathological neoplasia. To this end nothing will be more conducive than the wider spread of biological knowledge among pathologists. There is profound truth in this saying of Savory's: "Before we shall ever be able to answer the question, why or how do

---

<sup>9</sup> *Die krankhaften Geschwülste*, Bd. i., 1863.



tumours form? we must be able to solve the problem of normal growth and development, and to answer the question, why or how it is that these continue up to a certain point and then suddenly cease?"

Another circumstance that has tended to weaken Virchow's authority is the large measure of success accorded to a modification of the cellular theory, propounded by Cohnheim,<sup>10</sup> according to which the *only* cells of the body capable of originating neoplasms are those contained within detached fragments of the various organs, &c., sequestered during embryonic life. That a considerable proportion of malignant and non-malignant mammary tumours actually do arise in connection with such belated sequestrations I have elsewhere demonstrated,<sup>11</sup> but it seems to me in the highest degree improbable that these are the *only* cells capable of originating such growths. On the contrary, as I have elsewhere pointed out,<sup>12</sup> there are good reasons for believing that neoplasms may arise wherever undifferentiated cells are present, and that they are most prone to originate where such cells most abound.

But what more than any other recent occurrence has undermined the authority of the cellular neoplastic pathology, is the widespread belief that neoplasms will eventually turn out to be of *microbic origin*. In short, it is now evident, that out of the confusion of a transition period, but two conceptions as to the origin of neoplasms have emerged; the one based on the cell theory, and the other on the germ theory, and henceforth the struggle must be between these two.

## § II.—The Present Controversy.

Briefly stated, the question now is—do cancers and other neoplasms arise, as John Hunter and Johannes Müller maintained, through a modification of the formative process; or, are

<sup>10</sup> "Lectures on General Pathology," *Syd. Socy. Transl.*, vol. ii., 1889, p. 746.

<sup>11</sup> Ch. iv., § 5.

<sup>12</sup> *Annals of Surgery*, Oct., 1891. "The Initial Seats of Neoplasms and their Relative Frequency." See also Ch. vii.



they the outcome of the inflammatory process, owing to the presence of micro-organisms, or some other sources of irritation? In other words, are neoplasms, from first to last, merely the result of the abnormal play of forces arising within the body; or are they, directly or indirectly, due to the intrusion of some irritant *ab extra*? I incline to the former alternative; and I think the future will see decided reaction in this direction. As I have elsewhere<sup>13</sup> fully set forth my views on this subject, I need only briefly allude to them here.

In the genesis of neoplasms, as in the genesis of other organic structures, I believe that we must take into consideration two factors—the *cells* whence they originate, and the *force* that regulates the cellular activities.

With regard to the *cells*, although each is largely dependent upon others, yet, at the same time, each manifests a certain independence or autonomy. In the special changes underlying pathological new formations the autonomy of the cells plays a very important part. Herbert Spencer<sup>14</sup> has shown that we are justified in assuming, that every component cell of the multicellular organisms has the inherent power, under favourable conditions, of developing itself into the form of the parental organism; so that each cell may be regarded as potentially the whole organism. This doctrine has lately been strenuously attacked by Weismann,<sup>15</sup> who has founded his theory of heredity on the assumption that the reproductive properties of somatic and germ cells are fundamentally different. In my opinion, the validity of Spencer's view remains unimpaired. At any rate, it is quite certain that somatic cells are possessed of much greater reproductive powers than they ever ordinarily manifest; evidence of this is seen in the process of repair, and in a variety of other pathological processes. Strange to relate, this wonderful reproductive capacity, which enables us to understand

---

<sup>13</sup> "The Principles of Cancer and Tumour Formation," London, 1888.

<sup>14</sup> "Principles of Biology." 1884.

<sup>15</sup> "The Germ Plasm." 1893.



how a single cell may originate the largest neoplasm extant, has received but scant attention from pathologists in explaining the neoplastic process. That the reproductive activity actually manifested by somatic cells usually falls so far short of their potentiality, is believed by Spencer to be due to the restraining and modifying influence exerted by the whole organism on their protoplasm; which is thus compelled to the performance of other comparatively subordinate, modified functions. In the performance of these special duties most of their protoplasm is metamorphosed and used up. Hence, in proportion as the cells are highly specialised, their reproductive function is either greatly reduced or altogether lost. But in the higher organisms certain cells never attain a high degree of development, they remain in a lowly organised condition, and serve, according as they are more or less unspecialised, either as germs for reproducing the entire individual, or for forming and maintaining the various tissues and organs. Cells of this kind abound in all parts growing and capable of growth; they are, I maintain, *the only real cancer and tumour germs*.

With regard to the *force* that regulates the cellular activities, first a few words as to its reality. In the ordinary course of organic evolution, the processes of cell growth and multiplication go on, until the amount of structure proper to the organism has been produced; then they are restricted within certain limits. In the healthy organism this state of balanced equilibrium is maintained throughout the whole life of the individual. Herein we have evidence of the most conclusive kind, of a force regulating the growth and development of the tissues and organs in relation to each other, and to the organism as a whole. As long as the growing cells are subject to this normal restraining influence—which has nothing to do with nerves and blood vessels, themselves integrated structures—they develop in a regular and orderly manner, in accordance with the specific hereditary tendency of the whole. Spencer's investigations have led him to conclude that the natural tendency of every completely emancipated, lowly organised cell or cellular group, when placed in fit



conditions, is to form a new individual by agamogenesis. But in the higher organisms the component cells are never wholly undifferentiated, and their emancipation is always more or less incomplete, so that in them, under favourable conditions, instead of new individuals, various structural modifications result, such as new tissues and neoplasms. Thus the essence of the neoplastic process is, that certain cells of the affected part grow and multiply more rapidly than their congeners. I explain this rejuvenescence as due to failure of the integrative force, that normally restrains their activities within proper limits. Under these circumstances, whenever there is a sufficient supply of nutritive materials, capable of being utilised for growth by the cells of the part, there a neoplasm will arise; that is to say, the abnormally emancipated cells will there grow and multiply more or less independently, regardless of the requirements of the adjacent tissues, and of the organism as a whole. Thus the process by which cancers and other neoplasms arise may be regarded as a kind of abnormal gemmation, the tumour being the result of this modified, superinduced repetition of the developmental process; and its qualities the result of the grade of organisation attained. Mitchell's<sup>16</sup> conception of the disease, as arising by what he calls "histogenic dissolution" is, I think, fundamentally similar to mine. It follows from the foregoing, that the genesis of cancer and other neoplasms, is a phenomenon of the same order as discontinuous growth in general.

Before setting aside these views in favour of the theory of irritants *ab extra*, I think strong evidence ought to be forthcoming as to the probability of the latter hypothesis furnishing as complete an explanation of the phenomena of the disease. Let us see whether this is the case.

Those who believe that neoplasms are caused by external irritants may be divided into two classes: the Broussaisians pure and simple, such as Hutchinson<sup>17</sup> and Boyce,<sup>18</sup> who consider that

<sup>16</sup> "The Philosophy of Tumour Disease," London, 1890.

<sup>17</sup> *Archives of Surgery*, October, 1890, p. 138.

<sup>18</sup> *British Medical Journal*, vol. i., 1894, p. 219; also vol. ii., 1892, p. 678.



any form of chronic irritation may originate the disease, whether of microbic origin or otherwise; and the exclusive supporters of the germ theory, such as Soudakewitch, Ruffer, Pfeiffer, Wickham, &c., who maintain that only microbic irritants are effectual.

The only evidence of any scientific value, hitherto adduced in favour of the Broussaisian doctrine, is Volkmann's.<sup>19</sup> He collected, from many and various sources, records of 223 cases of primary cutaneous cancer of the extremities; and on analysing these he found, that in no less than 88 per cent. the cancerous disease had originated in connection with some pre-existing lesion of the part; in only 12 per cent. did it appear to have sprung up spontaneously. If the state of things revealed by this analysis could be proved to be really representative of the ordinary mode of development of cancer, these data would be conclusive evidence in favour of the influence of irritation. But I maintain that it is not so. The cases analysed by Volkmann were *not* consecutive cases, but most of them had been recorded at various times by different observers, with the special object of showing the association between cancer and pre-existing disease, as to the occasional occurrence of which there is no doubt. The fallacy of accepting these data, as typical of what takes place in the ordinary development of cutaneous cancer, is well seen by comparing Volkmann's results with the following analysis of forty *consecutive* cases of primary cutaneous cancer recorded by myself,<sup>20</sup> in which special attention was directed to the question of pre-existing disease of the part. Of these 40 cases, only 11, or 27·5 per cent., were associated with pre-existing lesions—viz., old scars in four cases, congenital lesions in two, suppurating sebaceous cyst, soot wart, wart of eighteen years duration, recent wound and chronic sinus, each in one case. In other words, the most careful examination, directed expressly to this end, failed to reveal the presence of any pre-existing local disease in 72·5 per cent. of

---

<sup>19</sup> *Samml. klin. Vorträge*, Nos. 334-335, 1889.

<sup>20</sup> *Middlesex Hosp. Surg. Reps.*, 1882-89.



all cases. In the breast,<sup>21</sup> uterus, and most of the other chief seats of cancer, the evidence as to the association of the disease with pre-existing lesions of the part is of similar tenour—the proportion of cases in which such association is traceable very much smaller. It is evident, therefore, that chronic inflammatory lesions cannot be regarded as the necessary antecedents of cancer. In the great majority of cases the outbreak of this disease appears to be entirely spontaneous; that is to say, it cannot be attributed to the immediate action of any appreciable extrinsic cause whatever. It has, however, been clearly shown, that repeated irritations of long duration and moderate intensity are, in a certain proportion of cases, the precursors of neoplasia. Further, I think we are justified in believing, that parts thus chronically irritated, may thereby be rendered more apt to take on neoplastic action than they otherwise would have been. Thus may we account for the great relative frequency with which certain cutaneous cancers are met with, such as those to which chimney sweeps, workers in tar, paraffin, and other irritant substances are subject. But this is a totally different thing from admitting that chronic inflammatory lesions are the *necessary* antecedents of cancer, the doctrine against which I protest.

Perhaps the most striking feature about cancerous growths is the wide morphological differences that obtain between them according to the localities whence they originate. Herein they differ completely from the inflammatory pseudo-plasms, which always have the same indifferent structure, no matter in what part of the body they arise. What, for instance, can be more divergent in this respect than the appearances presented on microscopical examination by sections of cancers from such different parts as the breast, rectum, and skin. We learn from such examinations, that cancerous growths are sufficiently organised to present unmistakable histological resemblance to the structures whence they originate. Another

---

<sup>21</sup> *Q. v.*, Ch. x., § 7.



remarkable property of all cancers is their power of autonomous growth and development (individuality), upon which their so-called parasitism depends. It is by virtue of this property that cancers tend to persist and increase indefinitely.

Nothing in the least degree comparable to this is seen in connection with any of the inflammatory pseudo-plasms, which tend to disappear. The great resemblance always noticeable between primary and secondary cancerous growths is a phenomenon of similar import, which is absolutely unaccountable on the basis of inflammation and micro-organisms. It is impossible to conceive a valid explanation of such conditions, without the presence of epithelial cells, capable of growth, multiplication, and organisation, these phenomena clearly imply that the disease centres in the epithelial cells themselves. Thus there are strong *à priori* reasons for regarding the microbe theory of cancer as improbable.

Now let us turn to the *à posteriori* side of the question. Before a disease can properly be called parasitic, the parasite must be found, isolated, and the disease it is alleged to cause must be reproduced by its inoculation. How far has the hypothetical cancer microbe fulfilled these conditions? Of the numerous researches undertaken of late with a view to finding it, all have proved abortive. One after another the alleged discoveries of this recalcitrant organism have ended only in disappointment. Where, now, are the specific cancer microbes of Rappin, Freire, Scheurlen, Schill, Francke, Lampiàzi-Rubino, Sanarelli, Kübasoff, Russell and others? Scheurlen's<sup>22</sup> cancer bacillus was no sooner announced than it was shown by Senger<sup>23</sup> and others to be nothing but a potato bacillus—one of the several kinds of organisms that grow readily on slices of potato. The "fuchsine bodies" described by Russell<sup>24</sup> as "the characteristic organism of cancer," and regarded by him as vegetable parasites of the

---

<sup>22</sup> *Deutsche med. Woch.*, No. 48, 1887, S. 1033.

<sup>23</sup> *Berlin klin. Woch.*, No. 10, 1888, S. 185.

<sup>24</sup> *Brit. Med. Journ.*, vol. ii., 1890, p. 1356; vol. i., 1891, pp. 112 and 568.



same order as the yeast plant, have since been met with in a great variety of conditions; and they are now generally regarded as nothing but proteid coagula.\* It seems certain that the attempt now being made to attribute cancer to psorospermiosis will prove equally abortive.<sup>25</sup> In any event it is evident that the protozoön infesting the liver and intestines of rabbits, cannot be the cause of cancer, for in these animals the hepatic lesions are not really cancerous; they consist merely of dilated bile ducts containing papillary ingrowths. If the animals recover, as usually happens, the tumours disappear and the lesions completely heal. Moreover, in the undoubted instances of psorospermiosis in human beings observed by Albarran, Eve, Silcock, &c., the induced lesions had no resemblance whatever to cancer.

Of the many special researches for the cancer microbe that have yielded only negative results it will suffice to mention those of Shattock and Ballance,<sup>26</sup> Senger,<sup>27</sup> Makara<sup>28</sup> and Brazzole. Hitherto the net result of all this bacteriological pathology has been to demonstrate that, although under certain conditions various micro-organisms may find a suitable habitat in cancerous growths, yet these have nothing whatever to do with the causation of the disease. In spite of repeated failures, however, the germ pathologists seem now to be more confident than ever that there *must* be a specific cancer microbe.<sup>29</sup> I should like to know why? since we can so well account for all of the phenomena of the disease without it. It appears to me that the agency of micro-organisms is no more *necessary* to account for the genesis of cancer than it is to account for the genesis of a tooth or a hair. The microbe of cancer has not yet been discovered, because in all probability it does not exist.

---

\* *Arch. f. path. Anat.*, Bd. cxxxii., Heft 3, 1893, &c.

<sup>25</sup> *Q. v.*, Chapter ix., § 3; also Chapter xv.

<sup>26</sup> *Trans. Path. Soc. Lond.*, vol. xxxviii., 1887, p. 413.

<sup>27</sup> *Op. cit.*

<sup>28</sup> *Deutsche med. Woch.*, 1888.

<sup>29</sup> *Brit. Med. Jour.*, vol. i., 1891, p. 565.



## § III.—The Question of Contagion.

Of the many attempts that have been made to transmit cancer experimentally from human beings to the lower animals, the results have almost invariably been negative (Senger, Senn, Billroth, Duplay, Shattock, Klebs, Maas, &c.). The alleged successes of Langenbeck, Follin, Goujon, and others, were never rigorously proved. Recently Mayet<sup>30</sup> claims to have succeeded in artificially producing the disease in a white rat by the subcutaneous injection of a *filtered* glycerine extract of human cancer. At the *post-mortem* examination, eleven months after the injection, two cancerous nodules, each the size of a pea, were found in the animal's kidney. These may very well have been due to the spontaneous development of the disease. Francke and De Rechter's<sup>31</sup> alleged successful transmission of human cancer to the white mouse probably belongs to the same category. Dupuytren fed dogs and other animals for considerable periods with human cancers, but they did not acquire the disease. The dogs that Alibert caused to swallow the discharge from cancerous ulcers, &c., experienced similar immunity.

It seems reasonable to suppose that such experiments would have a better chance of success if confined to animals of the same species. The attempts made in this direction by Jeannel, Bert, Senn, Weber, Köster, Erbre, Doutrelepon, and many others, have, however, all proved abortive.

Hanau<sup>32</sup> (rat to rat), Wehr<sup>33</sup> (dog to dog), and Morau<sup>34</sup> (mouse to mouse), now allege that, after numerous failures, they have at length succeeded. It is difficult to determine the validity of these claims, especially when the numerous sources of fallacy are borne in mind. There can be no doubt that dogs, rats and mice in confinement (especially the white varieties),

<sup>30</sup> *L'Union Méd.*, No. 20, 19 août, 1893.

<sup>31</sup> *Bull. Acad. de Méd. Belgique*, t. x., 1892, p. 999.

<sup>32</sup> *Corresp. Bl. f. schw. Aerzte*, No. 11, 1889, S. 334.

<sup>33</sup> *Arch. f. klin. Chir.*, Bd. xxxix., 1889, S. 226.

<sup>34</sup> *C. R. Soc. de Biol.*, 1891, p. 289.



are very prone to develop cancer spontaneously, and in these animals tubercle is a common disease easily mistaken for cancer. Having in view the fact that so many previous experiments of the same kind have ended only in failure, it seems prudent for the present to accept these alleged successes only in a tentative sense. Even if definitively accepted they would not prove the contagiousness of cancer, but merely the possibility of successfully transplanting the morbid tissue.

With regard to human beings, there is no proof that cancer has ever been communicated from one individual to another.<sup>35</sup> The attempts made by Alibert and others to inoculate themselves and their pupils with the disease were uniformly unsuccessful. There is not a single case on record of a surgeon having acquired cancer during the performance of operations for its removal, notwithstanding the frequency of exposure to infection under such circumstances. Of the thousands of persons habitually engaged in attendance upon the victims of this disease, how few have ever become similarly affected. Notwithstanding that many men have had sexual intercourse with women the subjects of uterine cancer, there is not a single well-authenticated case on record of cancer of the penis acquired in this way. The number of cases in which cancerous disease of the uterus and penis have co-existed in husband and wife is so small as to deprive them of all value as evidence of contagion. Of 134 men with cancer of the penis tabulated by Demarpray, only one had a wife with uterine cancer. Thus there is every reason to believe, that cancer is not inoculable; and it seems to be out of the question that a *virus* in any way comparable to that of tubercle or syphilis plays any part in its genesis. Here, again, the hypothetical cancer microbe fails to make good its entity.

Lately the attempt has been made to utilise the irregularities invariably met with in the topographical distribution of cancer,

---

<sup>35</sup> For a series of alleged cases to the contrary *vide The Lancet*, vol ii., 1887, pp. 727, 888, 919, 986, 1091, 1145, &c. I regard these simply as highly exceptional coincidences.



as evidence of the *infectious* nature of the disease. Arnaudet<sup>36</sup> was the first to formulate these ideas. In certain remote rural districts in Normandy he found that cancer was two or three times more prevalent than in Paris. He also adduced instances of cancers co-existing in various organs of persons living in certain houses or in their vicinity. Hence he concluded that the locality where a cancer patient had lived was contaminated; and he thought it probable that contagion was propagated chiefly through cider, water, &c. Similar views have since been advocated by Sorel,<sup>37</sup> Rebulet,<sup>38</sup> Guelliot,<sup>39</sup> Fabre,<sup>40</sup> Fiessinger,<sup>41</sup> Webb,<sup>42</sup> Power,<sup>43</sup> and others. As an example of the alleged epidemic occurrence of cancer Fiessinger cites the following group of cases.

In a small village a woman died of cancer of the breast, and within a comparatively short space of time, two other women lodging in the house died of the same disease—one of the rectum and the other of the vulva; and, after a certain time, two neighbours also died—one of cancer of the stomach, and the other of sarcoma of the leg.

On the strength of some exceptional coincidences of this kind, without any other requisite data, the exaggerated conclusion has been drawn that cancer is an epidemic disease, and such groups of cases have been styled cancer epidemics! If the alleged epidemiology of cancer has no surer foundation than this to rest on, the less said about it the better. It will be time enough to entertain such surmises when the cancer microbe has been discovered. What to my mind completely negatives these assertions is the significant fact; that in the crowded cancer wards of the Middlesex Hospital, during the last 20 years, not a

<sup>36</sup> "Le cancer dans une commune de Normandie," *L'Union Méd.*, 25 av., 1889, *Normandie Méd.*, 1 and 15 av., 1890, also 15 fév., 1891. "Nouveaux faits à l'appui de la nature infectieux du cancer."

<sup>37</sup> *Normandie Méd.*, dec., 1890.

<sup>38</sup> *Normandie Méd.*, 1 sept., 1891.

<sup>39</sup> *Gaz. des Hôp.*, No. 139, 1892.

<sup>40</sup> *Thèse de Lyon*, juillet, 1892. "De la Contagion du Cancer."

<sup>41</sup> *Rev. de Méd.*, jan., 1893.

<sup>42</sup> *Birmingham Med. Rev.*, 1892.

<sup>43</sup> *Brit. Med. Journal*, vol. i., 1894, also p. 1240 and p. 1302.



single instance is known in which a sister, probationer, nurse, ward-servant, surgeon, student or anyone engaged in attendance on the cancer patients, has ever subsequently developed the disease. The question of the prevalence of cancer in Normandy has lately been investigated by a committee of 35 local practitioners,<sup>44</sup> and their conclusion is; that although the disease is undoubtedly unduly prevalent in certain remote hamlets—probably in consequence of heredity—yet, when the whole of Normandy is taken into consideration, cancer is no more prevalent there than elsewhere in France. In this connection it should be borne in mind that other diseases besides cancer—deaf mutism, for instance—manifest similar topographical variations.

I have found very few experiments on record as to the *auto-inoculability* of cancer in the lower animals. Senn's attempts on a dog failed.<sup>45</sup> In human beings Hahn<sup>46</sup> claims to have succeeded in transplanting several small grafts of cancerous skin from one side of a woman's chest to healthy skin on the other side; and Cornil<sup>47</sup> has related a similar case. This amounts to the artificial production of metastasis. Senn failed in an attempt to transplant a fragment of cutaneous epithelioma from a man's leg into the connective tissue of the part. The chief evidence as to the auto-inoculability of cancer is, however, derived from clinical observation. This, if not quite conclusive, is certainly weighty. In a considerable number of cases it has been observed, that when cancerous growths have remained for some time in contact with apparently healthy epithelial surfaces, the latter have at length become cancerous, as if by direct implantation.

Cripps<sup>48</sup> has related the case of a woman with extensive cancerous ulceration of the left mammary region, who, being unable to put on any

---

<sup>44</sup> Brunon Raoul, "Enquête sur le Cancer en Normandie," &c., Rouen, 1893.

<sup>45</sup> "Surgical Bacteriology," 1889, p. 261.

<sup>46</sup> *Berlin klin. Woch.*, No. 21, 1888, S. 413.

<sup>47</sup> *Le Progrès Méd.*, No. 26, 1891, p. 522; and No. 27, p. 5.

<sup>48</sup> *Trans. Path. Soc., London*, vol. xxxii., 1881, p. 111.



dress, had kept her arm—bent at a right angle—in constant contact with the disease for several months. In consequence of this the skin in the vicinity of the elbow became the seat of a cancerous ulcer several inches in diameter.

A somewhat similar case had been previously recorded by De Morgan.<sup>49</sup>

He says, "My colleague, Mr. Shaw, attended a woman whose pendulous breast—the seat at its most dependent part of ulcerated cancer—rubbed against the skin of the thorax. At the point of contact a circular patch of cancerous ulceration (the size of a florin) took place, the intervening skin between this and the fold of the mamma remaining healthy."

Many facts of similar import have been noticed in various other parts of the body. Klebs<sup>50</sup> has seen instances in which primary cancer of one part of the alimentary tract has been followed by the development of cancerous nodules of *similar structure* at other parts lower down, as if by direct implantation of fragments detached from the primary growth. Cases in which the disease has spread by direct implantation, from one lip to another, from one vocal cord to the other, from the tongue to the buccal mucous membrane, from visceral to parietal pleura and peritoneum, &c., have been recorded by Bergmann,<sup>51</sup> Kraske,<sup>52</sup> Lücke,<sup>53</sup> and many others.

I have myself seen several instances of the kind, especially in the mouth and bladder, in which it appeared to me almost certain that cancerous growths had originated in this way.

Several cases have been recorded which go to show that eroded surfaces may become infected through constant contact with the discharge from cancerous ulcers; and some surgeons (Hahn, Donitz, Sabatier, &c.) believe in the traumatic dissemination of the disease through infection of wounds by the escape of "cancer juice" during operations.

In all the foregoing instances the phenomena met with more

<sup>49</sup> "On the Origin of Cancer," London, 1872.

<sup>50</sup> *Handb. der path. Anat.*, Bd. i., S. 190.

<sup>51</sup> *Berlin klin. Woch.*, No. 47, 1887, S. 891.

<sup>52</sup> *Cent. f. Chir.*, No. 48, 1884, S. 801.

<sup>53</sup> *Billroth und Pitha's Handb.*, Bd. ii., S. 50.



closely resemble those of tissue grafting, than they do those resulting from the inoculation of infectious disease. It may be inferred that the morbid epithelial cells are themselves the infecting agents, and that cancer auto-inoculability is a phenomenon of the same order as cancer metastasis. The evidence here, as before, is against the existence of a specific cancer microbe.



## CHAPTER IX.

## THE MORPHOLOGY OF MAMMARY CANCER.

## § I.—Introductory.

THE term "cancer," after having in the past undergone repeated changes of meaning, is now used in such different senses, that it is necessary for those who employ it to state precisely what they mean by it. In the popular sense every malignant neoplasm is a cancer. In medical science, however, the term is usually restricted to certain malignant neoplasms, which as Waldeyer,<sup>1</sup> Thiersch,<sup>2</sup> and others have shown, are of *epithelial* origin. This is the sense in which I employ it.

Every part of the body is liable to its own peculiar forms of cancerous growth, and the diverse characters manifested by each variety, according to its seat of origin, show that the influence of locality in determining the structure and progress of the disease is very great.

In the breast two types may be recognised—the *tubular* and the *acinous*. These terms, as applied to mammary cancers, originated with Billroth ; but they are used by him in a different sense to what I employ them. According to my views the great majority of breast cancers—about 94 per cent.—consist entirely, or almost entirely, of structures of the acinous type, the tubular form being a comparative rarity. I regard the ordinary scirrhus

<sup>1</sup> *Arch. f. path. Anat.*, Bd. xli., S. 470, "Die Entwicklung der Carcinome."

<sup>2</sup> "Der epithelial Krebs namentlich der Haut," 1865.



or alveolar cancer as morphologically of the former type, the alveoli and their contents roughly representing acini in the resting stage. The latter term I restrict to certain cancers—histologically often very duct-like in appearance—the true duct cancers. These are usually associated with cysts and intracystic papillary growths, structures hardly ever seen in connection with acinous cancers. The former spring from the mammary ducts, the latter from the acini. This classification enables me to dispense with the term “encephaloid,” as applied to mammary cancers; for when the villous papillomata, tubular cancers, myxomata, *carcinomata myxomatodes*, and sarcomata—hitherto generally confounded under this head—have been assigned to their proper groups, nothing remains to which this obsolete term can properly be applied.

As I have elsewhere<sup>3</sup> fully described the chief pathological and clinical features of the tubular variety of mammary cancer, what I now have to say refers exclusively to the acinous form.

Acinous cancer of the breast usually begins as a small, hard, solitary nodule, which, though movable, is connected with the mammary parenchyma. It increases slowly and painlessly, but without remission. A tumour is thus formed which, however, seldom attains very large size. As the disease progresses it causes retraction of the nipple, and dimpling of the overlying skin. The latter soon becomes adherent to the tumour, which eventually ulcerates. In consequence a hard, crateriform ulcer forms, which spreads slowly but never heals. In like manner the other adjacent structures are gradually invaded—pectoral muscles, ribs, pleura, the thoracic viscera, and sometimes even the opposite breast.

At a comparatively early stage, before ulceration sets in, the axillary lymph glands become enlarged, and secondary cancerous growths eventually develop in them, which behave just like the primary one. Finally, similar growths arise in

---

<sup>3</sup> Ch. xiv.



various remote parts of the body, such as the liver, lungs, bones, &c. As the disease progresses the patient's health becomes much impaired, and at length death ensues from exhaustion. The average duration of the disease from beginning to end, according to my calculation, is from four to five years.<sup>4</sup>

## § II.—General Morphology.

The initial lesion of mammary cancer is almost invariably a solitary nodule; the occasional origin of the disease from more than a single primary focus, I have elsewhere discussed.<sup>5</sup> In very rare instances its first obvious manifestation is not a nodule, but a diffuse infiltration of the whole of one or both glands. Cancer may also supervene in connection with chronic eczematous conditions of the nipple and areola (Paget's disease). According to Gross this happens only in 1·31 per cent. of all cases. The question of the origin of mammary cancer from non-malignant neoplasms I have fully entered into elsewhere.<sup>6</sup>

Nearly all statistics show that in women the *left* breast is more frequently affected than the right. In 151 consecutive cases under my observation, the left breast was the seat of the disease in 56 per cent., and the right in 44 per cent. Of the numerous cases collected by Gross, 869 were of the left breast, and 793 of the right; and in Billroth's practice the proportion was 301 of the left to 279 of the right. In women all other mammary neoplasms manifest the same predilection for the *left* breast, but I have not found a similar disproportion in males.<sup>7</sup>

<sup>4</sup> 44·8 months for the non-operated and 60·8 months for the operated; *q. v.* Ch. xiii. § 1, sub-section (*f*).

<sup>5</sup> Ch. x., § 9.

<sup>6</sup> Ch. x., § 10.

<sup>7</sup> "Cancer of the Male Breast, based on the records of 100 Cases," *Lancet*, vol. ii., 1889, p. 262. Right side, 38 or 53 per cent.; left, 33 or 47 per cent.



A very rare form of initial outbreak is the simultaneous appearance of the disease in *both* breasts. Two instances of this occurred in the 1,664 cases of mammary cancer collected by Gross.

Cancerous tumours are more prone to develop in some parts of the gland than in others. Its periphery, for instance, is a much commoner seat of the disease than its central part. Of 132 cases under my observation, in ninety (68 per cent.) the tumour was *peripheral*, and in forty-two (32 per cent.) *central*. This accords with what I have elsewhere pointed out;<sup>8</sup> that the majority of mammary neoplasms arise in the seats of the greatest post-embryonic developmental activity, where cells still capable of growth and development most abound; that is to say, in the immediate vicinity of the acini, which are much more numerous in the peripheral than in the central part of the gland.

Most of the peripheral tumours are met with in the *upper* and *axillary* mammary segments. Thus in ninety cases under my observation the disease was situated in the *upper* segment in forty-six, in the *axillary* in twenty, in the *lower* in twenty, and in the *sternal* in three. This coincides with the results arrived at by Winiwarter and Gross: the latter's analysis of 256 cases gives ninety for the *upper*, eighty-three for the *axillary*, fifty-one for the *lower*, and thirty-two for the *sternal* segment.

A considerable number of these peripheral cancers are situated *quite outside the mammary gland*, where, as I have shown, they originate from outlying sequestered mammary structures. This happened in thirteen (9·8 per cent.) out of 132 consecutive breast-cancer cases under my observation. Of twenty-nine neoplasms that originated in this way, fifteen were in situation *axillary*, eight *sternal*, and six were found *above* the breast. As I have elsewhere<sup>9</sup> treated this important subject at some length, I need not further allude to it here.

---

<sup>8</sup> *British Medical Journal*, Sept. 10, 1892; also Ch. vii.

<sup>9</sup> *Journal of Anatomy*, vol. xxv., p. 253; also Ch. iv., § 5.



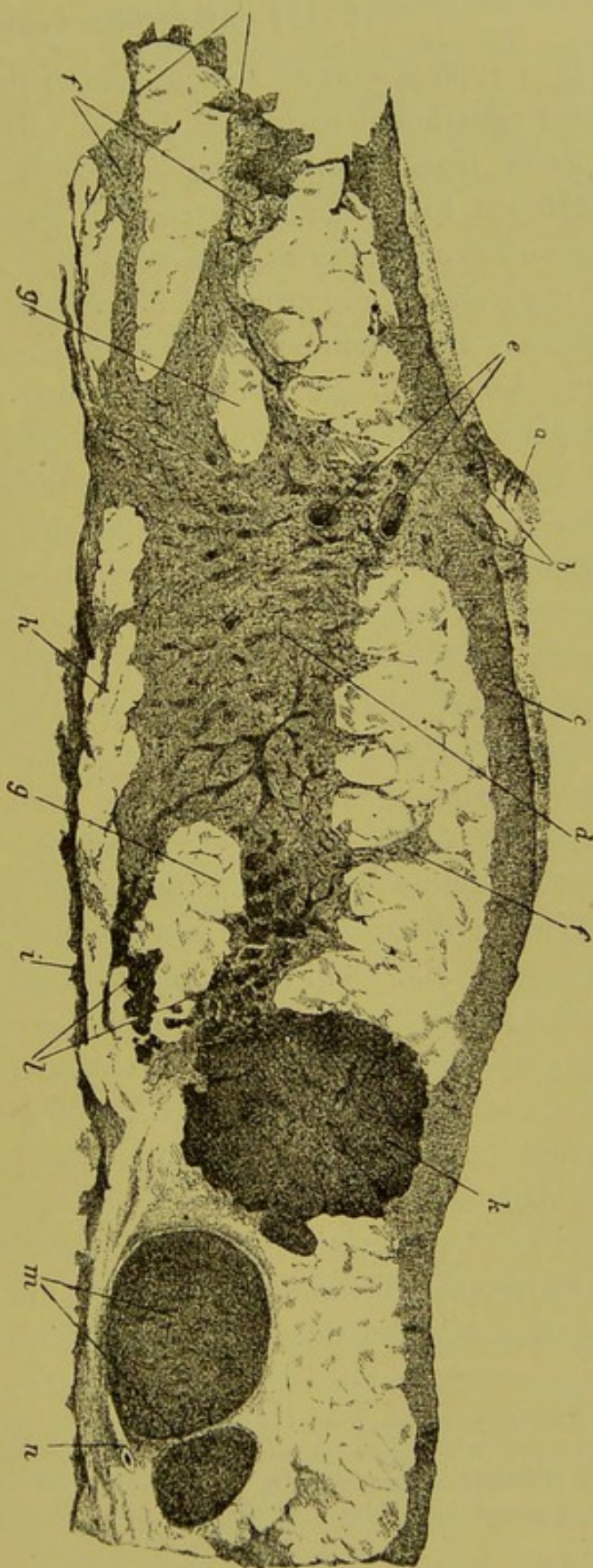


FIG. 28.—SECTION THROUGH A CANCEROUS BREAST (*Stiles*).

The growth occupied the peripheral part of the lower and outer quadrant; close to it were some cancerous axillary glands.

(*a*) Nipple; (*b*) Areolar glands; (*c*) Cutis; (*d*) *Corpus mammae*; (*e*) Dilated ducts; (*f*) Peripheral processes of the *corpus mammae*; (*g*) Intra-mammary fatty tissue; (*h*) Retro-mammary fat; (*i*) Pectoral fascia; (*j*) The cancerous tumour, to which the overlying skin is adherent; (*l*) Cancerous infiltration of adjacent tissues; (*m*) Cancerous axillary glands; (*o*) Surgeon's cut surface, showing sternal peripheral glandular processes cut across.



## § III.—The Primary Neoplasm.

In a typical case of acinous cancer the disease presents as a hard (scirrhus)<sup>10</sup> nodulated, heavy, solid tumour. Although we know from histology the infiltrating character of such a growth, yet to the unaided senses it generally seems to be a more or less circumscribed mass (fig. 28 *k*).

On careful examination of its periphery no capsule can be made out; and it will be seen that the passage from the diseased to the healthy tissue is by no means sharply defined—the irregularly growing edge of the cancer is, so to speak, dovetailed into the surrounding pre-existing tissues. On this subject Astley Cooper remarks:<sup>11</sup> “I would observe that the scirrhus tumour is not all of the disease, there are roots which extend to a considerable distance, and those who gave the disease the name of cancer probably knew more of its nature than we are disposed to give them credit for. It is supposed by some that this name was given on account of the appearance of the surrounding veins. I should rather say it was from the appearances on dissection than from anything without. When you dissect a scirrhus tumour you see a number of roots proceeding to a considerable distance, and if you remove the tumour only, and not the roots, there will be little advantage from the operation” (fig. 28 *o* and fig. 29). This admirable *resumé* of the subject is entirely in accord with the results of modern research.

If we examine the growing edge of a mammary cancer we shall find that one way in which the disease progresses is by the continuous centrifugal extension of ingrowing epithelial processes (fig. 29). These spread most rapidly in the directions of least resistance, which are usually along the adjacent lymphatics and perivascular sheaths. Köster has found these structures dis-

<sup>10</sup> This term was used by Galen (σκήρσις, from σκίρος, a piece of marble) as synonymous with σκληρώμα—hardness. It was applied by him and his successors to all hard tumours; subsequently its application was limited to indurations having a special tendency to terminate in intractable ulceration, and so eventually to hard cancer.

<sup>11</sup> “Lectures on Surgery,” 1839, p. 386.



tended with cancer cells. Fine, elongated, cord-like processes of cancerous growth thus arise, which often extend from the parent tumour far into the surrounding tissues, especially posteriorly. In this connection nodular growths often develop, which, to the naked eye, may appear to have no connection with the primary tumour. In addition to these there are frequently found in the vicinity of the latter really discontinuous nodules, which are the first signs of regional dissemination. Besides the foregoing,

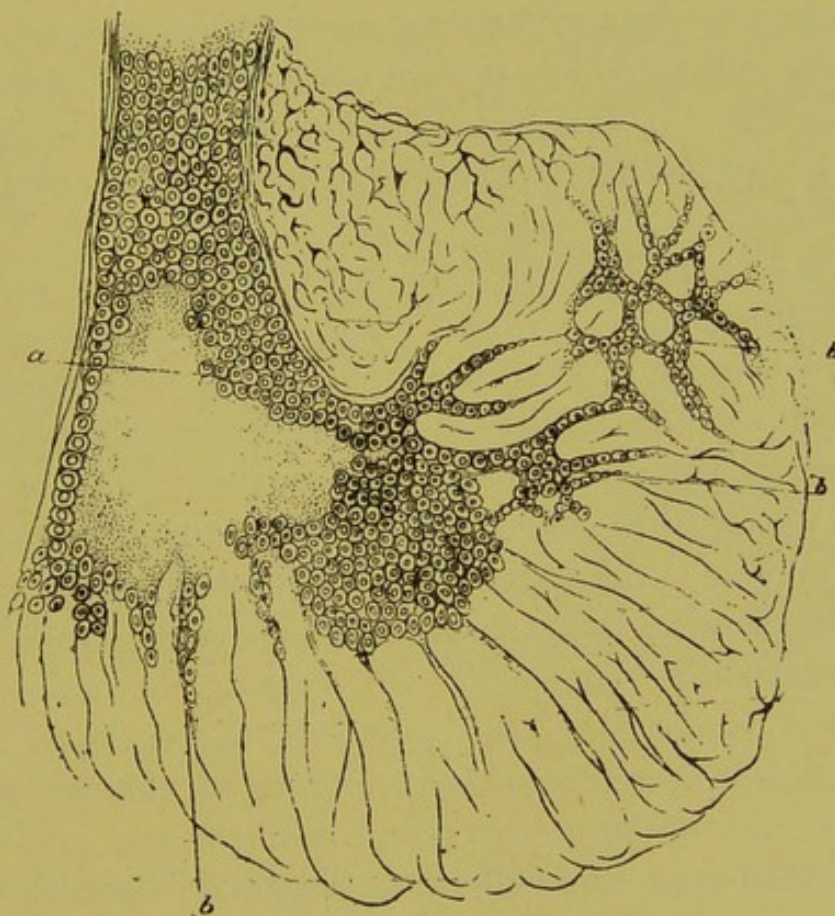


FIG. 29.—HISTOLOGICAL SECTION OF CANCER, SHOWING THE ROOTS (*Waldeyer*).

(a) Epithelial proliferation; (b) Invasion of stroma by the proliferating epithelial cells.

small, discontinuous, satellite nodules are occasionally found in the vicinity of the main tumour, which probably arise as spontaneous outbreaks of the disease in outlying proliferating acini. These indicate that the tendency to cancer formation extends beyond the immediate limits of the initial lesion; and from their presence we may infer *regional* as well as *structural* proclivity.



It will thus be gathered that the integration of cancerous growths is very inferior to that of normal parts. New centres of development are constantly arising among their constituent proliferating cells, so that before the initial growth has made much progress numerous subsidiary centres of morbid activity have arisen in it. In this sense, as Virchow<sup>12</sup> has pointed out, every cancerous tumour is a conglomerate mass made up of a number of small foci, every one of which, like the initial tumour itself, may be referred to a single, or but a few parent cells. Yet, owing to their infiltrating mode of increase, sections of mammary cancers seldom present obvious signs of lobulation.

The effect of cancerous growths on the tissues in the midst of which they develop is to cause their destruction by pressure atrophy.

A crisp, creaking sensation is experienced on making a section through such a growth, and the cut surface "cups," presenting a glistening, whitish, fibroid aspect, interspersed with small, yellowish, opaque spots. Its appearance has not inaptly been compared to that of a section of unripe pear (*apinoid*).

The yellowish, opaque, granular areas—most abundant at the central part of the growth—are due to degenerative changes in the cancer cells. Consequent shrinkage of the stroma causes the characteristic "cupping." On scraping the cut surface a milky fluid is obtained—the so-called "cancer juice," which consists of polymorphic epithelial cells in an albuminous fluid. Irregular tracts of fatty tissue can generally be seen interspersed in the morbid mass, especially at its periphery, a peculiarity not met with in any other kind of mammary neoplasm. The more recently formed external parts of cancerous neoplasms often present a semi-translucent appearance.

Under the microscope sections of the growth are seen to consist of ovoid or irregularly rounded masses of epithelial cells, enclosed in corresponding alveolar spaces, bounded by thick walls of fibrous tissue (fig. 30).

---

<sup>12</sup> "Cellular Pathology," Chance's Translation, 1860, p. 457.



In their entirety these cells form solid, branching, racemose masses, ingrowing into the surrounding fibrous stroma (fig. 31) Such tumours increase in size by the continuously progressive ingrowing of these budding epithelial masses. Altogether the pathological appearances present striking resemblance to those observed during certain stages of the normal ontogeny of the organ, of which they may be regarded as a modified superinduced repetition.

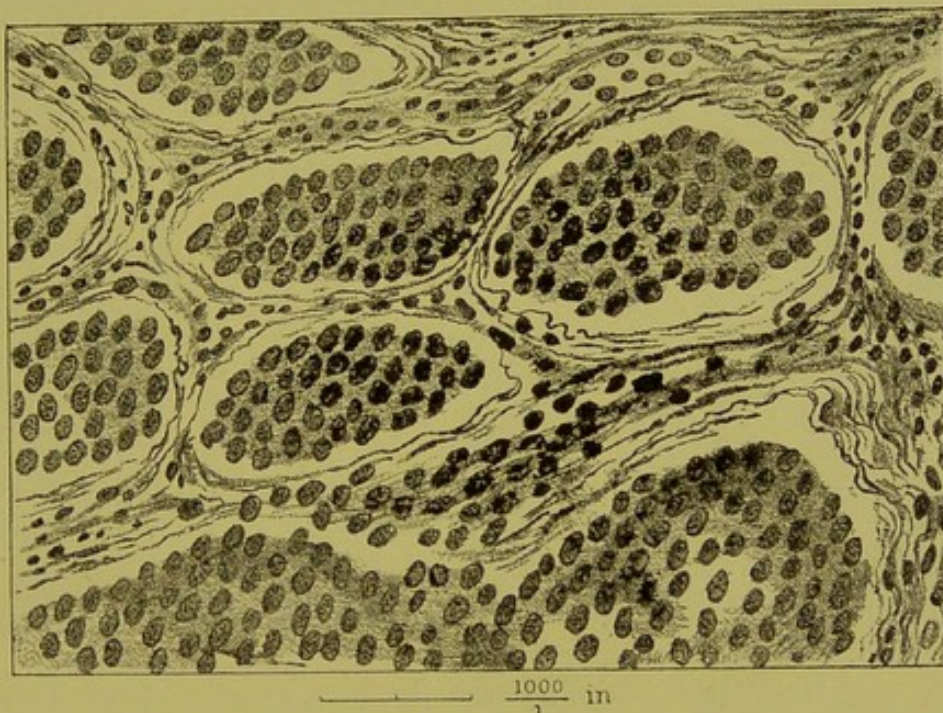


FIG. 30.—Histological section of hard mammary cancer showing the acinous grouping of the cells and the alveolar disposition of the stroma (*Nunn*).

The factor underlying the progressive gemmation of these cell masses is the continuous growth and proliferation of their constituent epithelial elements. These vary much in size ( $\cdot 010$  to  $\cdot 050$  mm. and upwards in diameter) and shape; yet the varieties met with are not unparalleled by what is seen in the cells of the normal acini during the various phases of physiological evolution. The cells of the cancer alveoli are evidently but the slightly altered descendants of the secretory cells of the gland; hence their tendency to revert to the parental type, which is always obvious. The polymorphism of the cells of



acinous cancer of the breast, when not thus accountable, is simply a pressure effect, owing to the rapidly increasing cells being cramped by the density of the surrounding stroma; hence it is seldom seen, to the same extent, in cancers of other parts.

The pathological cells multiply, like their physiological prototypes, chiefly by indirect nuclear division; and the similarity extends even to the details of karyokinesis—equatorial plates,

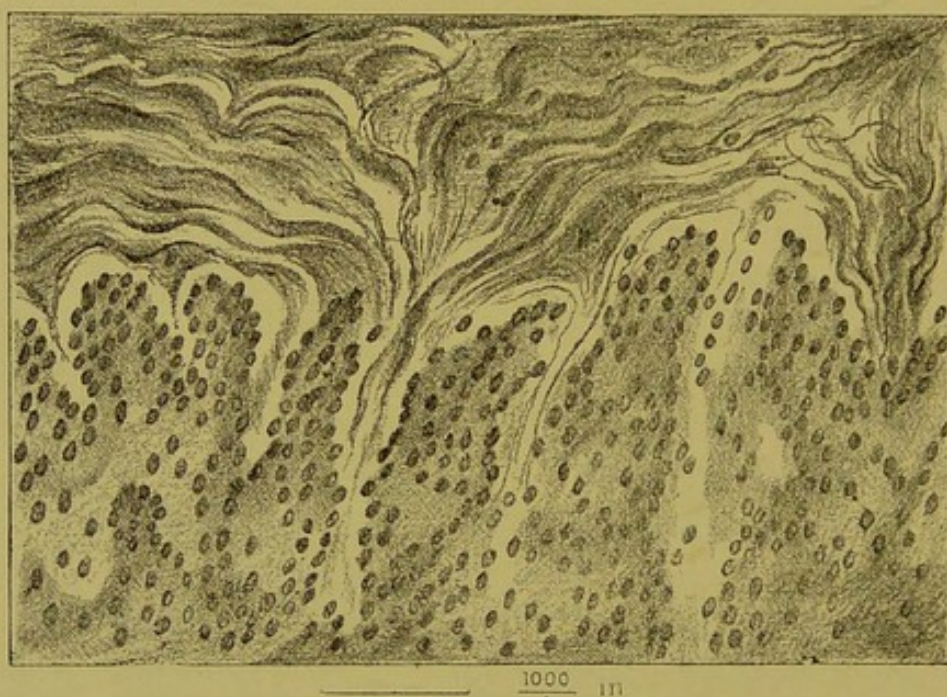


FIG. 31.—Histological section through the growing edge of the foregoing (Nunn).

achromatic spindles, &c. (fig. 32). Cattle<sup>13</sup> and others think, considering the comparatively sparse occurrence of nuclear figures in some actively growing cancers, that direct division of cells is extremely common. Thus the component cells of a cancerous tumour are the direct descendants of the primary neoplastic cells. It has been stated that the latter, by a kind of spermatic influence, infect adjacent cells, and so excite in them morbid action similar to their own. This conception appears to

<sup>13</sup> "Obs. on the Histology of Carcinomata and the Parasite-like Bodies found in them," *Journal of Pathology*, Feb., 1894.



me to be based upon complete misunderstanding as to the true nature of spermatic influence; and the appearances actually observed afford it no support, especially the comparative rarity of karyokinetic figures in the cells of the parablast in the vicinity of active cancer growth.

The nuclei of cancer cells are almost invariably much larger than those of the normal secretory cells of the gland; they are richer in chromatin, and they more frequently originate karyo-

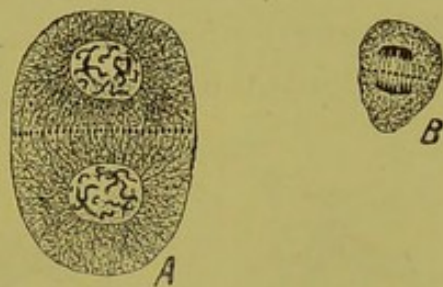


FIG 32.—HIGHLY MAGNIFIED CANCER CELLS SHOWING KARYOKINESIS (*Ide*).

(A) Large, (B) small cell. The "*plaque cellulaire*," reticular filaments, &c., are well shown.

kinetic figures than the latter. A special characteristic of cancer cells, according to Hansemann<sup>14</sup> is, that they divide by asymmetrical mitoses. Moreover, the pathological cells, oftener than their physiological prototypes, contain more than a single nucleus; and, as pointed out by Martin,<sup>15</sup> Cornil,<sup>16</sup> and others, multipolar nuclear division is of more frequent occurrence in them than in the normal cells. Fabre-Domergue† maintains that in proliferating cancer cells the axis of cellular division becomes displaced from its normal plane. Another peculiarity of cancer cells, noticed by Shattock and Ballance,<sup>17</sup> is the prone-

<sup>14</sup> Ueber path., Mitosen., *Arch. f. path. Anat.*, Bd. cxxiii., Heft. 2, 1891; see also Ueber asym. Zelltheilung, &c., *Ibid.*, Bd. cxix., Heft 2, 1890.

<sup>15</sup> *Arch. f. path. Anat.*, Bd. lxxxvi., S. 56.

<sup>16</sup> "Sur le procédé de division indirecte des noyaux, &c., dans les tumeurs," *Arch. de Physiol.*, 1886, t. viii., p. 310.

† *C. R. Acad. des Sci.*, 26 mai, 1893.

<sup>17</sup> "Note on the Histology of Sterile, Incubated, Cancerous and Healthy Tissues," *Trans. Path. Soc. Lond.*, vol. xlix., 1888, p. 409.



ness of their nuclei to shed their chromatin into the cell body, &c., as a sort of preliminary to division. Thus the so-called giant cells of cancer arise. Nuclear fragments detached during mitotic changes probably originate the chromatin bodies (*corps colorables*) described by Foà and others.

Taken in their entirety these deviations from the normal are but the morphological expressions of a high degree of reproductive activity, which is the essential characteristic of cancer cells. This phenomenon seems to me to be of the same nature—in exaggerated degree—as the accelerated proliferation of epithelial cells noticeable in the process of repair of wounded epithelial surfaces. Just as this exceeds the physiological rate of increase

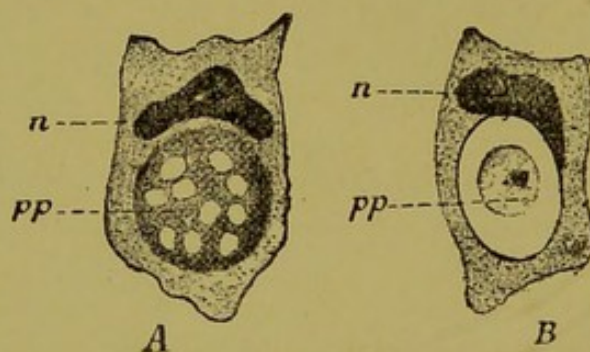


FIG. 33.—MAMMARY CANCER CELLS SHOWING PSEUDO-PARASITIC ENDOCYTES (*Soudakewitch*).

*A* and *B*, two separate cells; *pp*, Pseudo parasitic bodies; *n*, Nucleus (Hartnack Obj. and Oc. No. 3).

requisite to maintain the normal *status*, so the former exceeds the latter; but I believe all these manifestations belong to the same order of events. The wonderful reproductive activity of cancer cells enables us to understand how a single such cell may be the germ of a large tumour—even the largest. Only in what relates to this, do cancer cells differ from normal epithelial cells. In their young state as Klebs, Waldeyer and others have observed, both possess contractile and locomotive properties.

In addition to nuclear structures and their derivatives, cancer cells often contain certain rounded homogeneous, hyaline, spore-like bodies (figs. 33 and 34), which microscopists now are—and



for some time have been—exceedingly busy in investigating. These were first described more than half-a-century ago by Hake, as parasitic protozoa; and subsequently by Virchow, who regarded them as the outcome of endogenous cell-formation and degenerative changes. Now that the subject has been revived the contro-

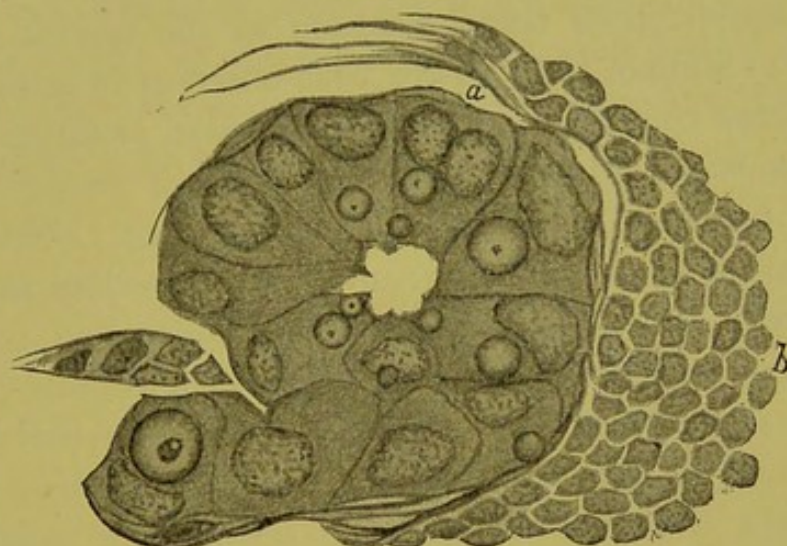


FIG. 34.\*—A HIGHLY MAGNIFIED CANCER ALVEOLUS SHOWING ENDOCYTES (Cattle).

The lining cells contain numerous parasite-like bodies. At *a* is a dividing nucleus. In the large cell at the left hand corner *n* indicates the nucleus and *c* the pseudo-parasite, *b* small round cell infiltration ( $\frac{1}{12}$  in. Obj. Oc. No. 2).

versy still rages round these rival views. Among recent workers Virchow,<sup>18</sup> Noeggerath,<sup>19</sup> Delépine,<sup>20</sup> Edington,<sup>21</sup> Kanthack,<sup>22</sup> Gibbes,<sup>†</sup> Klebs, Ribbert, Cornil, Stroëbe and others maintain the former view; while Metschnikoff,<sup>23</sup> Soudakewitch,<sup>24</sup> Ruffer,<sup>25</sup>

\* For this fine figure I am indebted to Dr. Cattle, of Nottingham, to whom I here tender my thanks for the loan of his block.

<sup>18</sup> "Bemerkungen über die Carcinom-zellen Einschlüsse," *Arch. f. path. Anat.*, Bd. cxxvii., 1892, S. 188.

<sup>19</sup> *Beiträge zur Struktur und Entwicklung des Carcinoms*, Wiesbaden, 1892.

<sup>20</sup> "Protozoa and Carcinoma," *British Medical Journal*, vol. ii., 1892, p. 974.

<sup>21</sup> "On a Form of Hyaline Degeneration," *Ibid.*, vol. i., 1891, p. 112.

<sup>22</sup> *Ibid.*, vol. i., 1891, p. 579.

<sup>†</sup> *Am. J. Med. Sci.*, July, 1893.

<sup>23</sup> "Carcinomata and Coccidia," *Brit. Med. Journal*, vol. ii., 1892, p. 1273.

<sup>24</sup> "Des Parasites Intra-Cellulaires des Néoplasmes Cancéreuses," *Ann. de l'Inst. Pasteur*, 25 mars, 1892, p. 145; also *Ibid.*, 25 août, 1892, p. 545.

<sup>25</sup> *British Medical Journal*, vol. ii., 1892, p. 113; also *Ibid.*, vol. ii., 1893, p. 825.



Foà,<sup>26</sup> Pfeiffer,<sup>27</sup> Cattle, Sjöbring, Galloway, Heukelom and others uphold the latter. These bodies are usually most abundant where there is greatest evidence of cellular activity. Recently abortive attempts have been made to isolate them and cultivate them outside the body.<sup>28</sup>

The following considerations—*inter alia*—appear to me to militate against their being regarded as the specific cause of cancer: (1) Similar bodies have been observed in many various *non-cancerous* conditions, *e.g.*, Darier's disease, molluscum contagiosum, delhi-boil, rhinoscleroma, elephantiasis arabum, leprosy, mycosis fungoides, chronic ulceration, herpes, acute yellow atrophy of the liver, non-malignant cysts and villous papillomas of the breast, villous papilloma of the bladder, &c. (2) In undoubted cases of human psorospermosis, such as those described by Albarran, Eve and Silcock—with lesions in internal organs—these proved to be cystic formations, similar to those found in the rabbit's liver, which have no resemblance whatever to cancer. (3) Before a disease can properly be called parasitic, the parasite must be found, isolated, and the disease it is alleged to cause must be reproduced by its inoculation. It cannot positively be affirmed that any of these postulates have been fulfilled by the alleged cancer microbe. Although the bodies under discussion often look very like parasites, no evidence has yet been produced that they really are such; and, as for the other proofs required, they are conspicuous only by their absence.

The presence of various, *non-specific, pathogenic microbes* in cancerous growths, has been demonstrated by Verneuil, Zahn, Hauser, Schiel, Nepveu, Schutz, and others. Verneuil<sup>29</sup> having

<sup>26</sup> *Gaz. degli Ospitali*, Feb. 2, 1892. *Lancet*, vol. i., 1894, p. 958. *Gaz. Med. di Torino*, 1891.

<sup>27</sup> "Die Protozoen als Krankheitserreger," Jena, 1891; see also his recent work "Untersuchungen über den Krebs," Jena, 1893.

<sup>28</sup> *Lancet*, vol. i., 1894, p. 1232.

<sup>29</sup> *Rev. de Chir.*, t. ix., 10 oct., 1889. "Propriétés pathogènes des microbes, renfermés dans les tumeurs malignes."



noticed the frequent septic infection of operation wounds after the removal of cancerous tumours, was led to examine the latter for bacteria; and in the softened areas he found various kinds of bacilli and micrococci in abundance. Zahn,<sup>30</sup> by cultivation experiments, has shown that microbes abound in cancer metastases, even when the latter are not in direct communication with the surface of the body. To account for this, Hauser<sup>31</sup> supposes that they were carried there along with cancer cells detached from the primary focus.

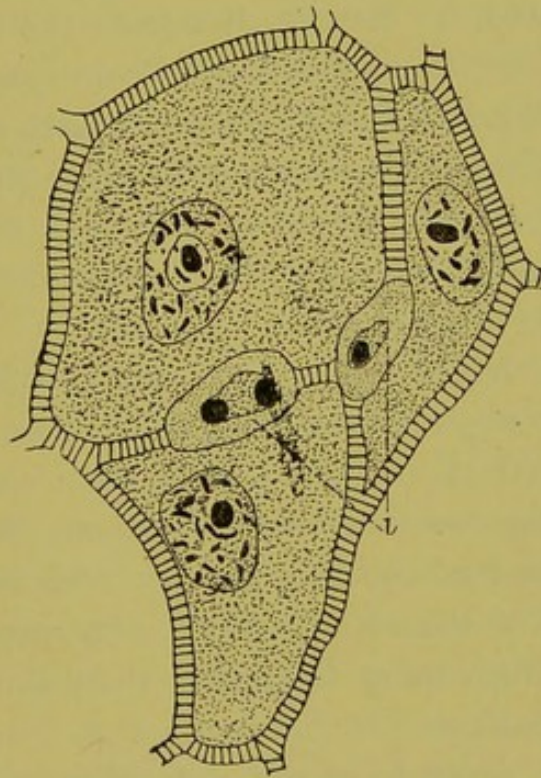


FIG. 35.—A GROUP OF CANCER CELLS HIGHLY MAGNIFIED (*Ide*).

Showing the "*ponts intercellulaires*," and leucocytes (*L*) which have penetrated into the intercellular spaces.

*Leucocytes* and red blood corpuscles have often been detected between closely approximated cancer cells (fig. 35), and even within them. It is easy to mistake cells of this kind for parasites, especially when they have undergone degenerative changes.

<sup>30</sup> *Arch. f. path. Anat.*, Bd. cxvii., 1889, S. 37, and S. 209.

<sup>31</sup> "*Das cylinder Epitheliom des Magens*," &c., Jena, 1890.



The presence of leucocytes between and within cancer cells is most noticeable in inflamed areas. Stroëbe<sup>32</sup> maintains that this indicates a kind of phagocytosis; others think it has sexual significance, and they ascribe the abnormal proliferative activity of cancer cells to the effect of the conjugation. In the vicinity of actively growing cancer the stroma is invariably infiltrated with small, round, nucleated cells.

It has been demonstrated by Ide<sup>33</sup> and others, that the cells of the normal epidermis and those of cutaneous epitheliomas, possess a finely reticulated cell membrane. Instead of being completely isolated, as hitherto believed, Ide has shown that both the physiological and pathological cells communicate freely with their neighbours by small bridges—*ponts intercellulaires*—in which both cell membrane and protoplasm are involved, and sometimes even nuclear filaments (fig. 35). The cells of the mammary epithelium, being derivatives of the epidermis, are probably similarly related.

In cancer of the breast, however, the constituent epithelial cells usually hold together much less firmly than do those of the normal gland; in fact, they frequently seem to be completely detached, and immersed in the albuminous fluid within the alveoli. This want of cohesion between their constituent cells, is probably one of the chief reasons why mammary cancers disseminate so much more frequently than similar neoplasms in most other localities.

A remarkable property of the cells of mammary cancers is their proneness to *granulo-fatty degeneration*. Vacuolation is also of common occurrence. In these respects they remind us of the similar metamorphoses that the cells of the normal gland undergo during lactation; and, like the latter, they often end in complete disintegration, with the occasional formation of small cysts and cholesterine crystals from the *débris*. Similarly

---

<sup>32</sup> *Ueber Kerntheilung und Riesenzellenbildung in Geschwülste, &c.*, Jena, 1892.

<sup>33</sup> "Nouvelles observations sur les cellules épithéliales," *La Cellule*, t. v., 1889, p. 321.



mucoid secretion is sometimes produced, which may escape from the nipple, or accumulate within the tumour, and so form cysts. This is the nearest approach to normal secretion that the pathological structure ever produces. Very rarely the cells undergo colloid metamorphosis, as in the true colloid cancers and still more rarely they calcify, forming the so-called sand grains (sand-körner<sup>34</sup>).

It is chiefly on account of the greatly increased numbers of the cells, and their disorderly grouping, that cancer alveoli differ from normal acini. To this may be ascribed the absence of lumina and ducts, and the great increase of size. It is, however, a striking fact, that the peripheral cells of newly formed cancer alveoli, present well marked resemblance in shape and arrangement to the cells of normal acini. This condition, as Morton has pointed out,<sup>35</sup> occasionally persists; and even distinct lumina may be formed. Another point of resemblance is in the distribution of the blood vessels and nerves, neither of which are found within cancer alveoli, any more than they are within normal acini. The relations of both to the lymphatic system are also very similar; for, as De Sinéty has shown, within the *membrana propria* of the normal acini, there exists an imperfect lining of endothelial cells, which is probably a derivative of the lymphatic system; and Cornil and Ranvier—by injection of Prussian blue and nitrate of silver staining—have demonstrated that the cancer alveoli are in direct communication with the lymphatic radicles (fig. 36). It is noteworthy that the endothelial cells of the latter take no part in the cancerous process.

From the foregoing we learn that there is nothing specific about cancer cells and structures, as was formerly believed;

---

<sup>34</sup> Q.v. Ackermann, *Arch. f. path. Anat.*, Bd. 45, S. 60. Creighton, "Physiology and Pathology of the Breast," p. 169. Eve, *Trans. Path. Soc. Lond.*, vol. xxxvii., 1886, p. 493.

<sup>35</sup> "Some Histological Conditions observed in Carcinoma of the Breast," *British Medical Journal*, vol. ii., 1892, p. 676.



there is departure from the normal type of development, but no foreign structures are produced.

The *stroma* of mammary cancers forms the fibrous alveolar system, in the meshes of which the proliferating epithelial cells are confined (figs. 30 and 31). Alveolar disposition of the stroma was formerly regarded as the histological criterion of cancer; but it is now known to be merely a local peculiarity. In most acute mammary cancers alveolar arrangement is

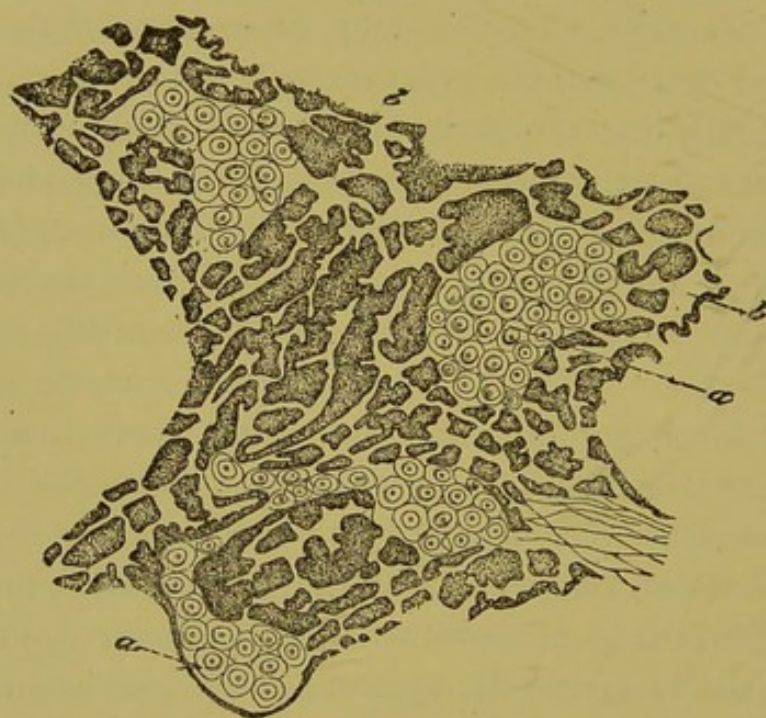

FIG. 36.—CANCER ALVEOLI AND THE LYMPHATIC RADICLES  
(Cornil and Ranvier).

Histological section of mammary cancer stained with nitrate of silver; (a) Cancer alveoli with their contained cells; (b) Stromal tissue showing the deeply stained cell spaces. To the right the endothelial lining cells of a lymphatic radicle are similarly displayed ( $\times 150$  dia.).

wanting, the cells being diffused, often in single rows, between the fibrils of the stroma. In its minute structure and general characters, the cancer stroma closely resembles the stroma of the normal gland, of which it is evidently a derivative. It consists of thick bands of dense white fibrous tissue, containing elastic fibres, and anastomosing connective tissue cells, which are especially numerous at the meeting points of the diverging



bands. The characteristic *hardness* of mammary cancers is due to its abundance and density. The question has been much discussed whether the cancer stroma is of new formation, or simply the modified pre-existing structure. It seems almost certain, from its great abundance, and from other considerations, that it is largely of new formation. Coincidentally with the initial proliferation of the cells within the pathological acinus, there appears an infiltration of the periacinous connective tissue with small round cells. It is from this embryonic parablasic tissue that the newly-formed cancer stroma is chiefly developed. The constant presence of these cells in the stroma of mammary cancers is an important factor. By some pathologists they are regarded merely as leucocytes, derived from the blood vessels of the stroma, as the result of chronic inflammation; but from their periacinous grouping it is more probable that most of them arise as the outcome of the developmental rather than of the inflammatory process. They consist mainly of nuclear substance. Their presence in the cancer stroma indicates that the latter is an imperfect formation. An extreme degree of the same condition is seen when the stroma does not evolve beyond the myxomatous stage, as in the rare variety of the disease called *carcinoma myxomatodes*. In like manner, the presence of spindle cells in the stroma may be explained. Hansemann,<sup>36</sup> who has lately made special study of the cells in the cancer stroma, describes four different kinds: (1) Fusiform and stellate cells, the ordinary connective tissue cells. (2) Flattened epitheloid cells arranged around the walls of the lymphatic canaliculi. (3) Cells with large deeply staining nuclei and little protoplasm—*lymphocytes*. (4) Cells with lobulated or budding nuclei—*leucocytes*—emigrant white blood corpuscles. He has often met with mitotic figures in connection with the multiplication of these cells.

Inasmuch as there may occasionally be found in the stroma of the otherwise normal gland, small cartilaginous, calcareous,

---

<sup>36</sup> *Arch. f. path. Anat.*, Bd. cxxxiii., 1893, S. 147.



and even truly osseous nodules, it need not surprise us that now and then similar conditions are found associated with cancers,<sup>37</sup> and other mammary neoplasms.<sup>38</sup> In the *Hunterian Museum*,<sup>39</sup> there are some specimens by Astley Cooper, showing calcareous deposits—chiefly periductal—in cancerous breasts.

The following case by Heurtaux is remarkable:—

A woman, aged 52, eight months previously received a slight blow on the left breast; two months afterwards she noticed a small, hard tumour in the organ, which gradually increased. On examination, there presented in the left breast a tumour the size of a small orange. It was circumscribed, mobile, nodulated, and very hard; no retraction of the nipple, but slight adhesions with the deep part of the overlying skin; the overlying cutaneous veins distended; no enlargement of the axillary glands. Amputation of the breast. On attempting to make a section of the tumour, it seemed to be composed of a substance like cancellous bone. Closer examination revealed a lardaceous, scirrhous structure with osteoid areas. On histological examination, the scirrhous structure consisted of ordinary alveolar cancer with which were intermixed *small areas of cartilaginous tissue*. The osteoid areas, although not presenting all the characters of fully formed bone, seemed to have resulted from imperfect ossification of the cartilaginous dépôts. Three months after operation, two extremely hard tumours appeared in the axilla, and increased very rapidly, and other nodules sprang up. These were of stony hardness, just like the primary tumour. Health rapidly deteriorated, and symptoms developed as of secondary growths in the lungs. She died thus of asthenia eight months after the first appearance of the recurrent disease.

Within the cancer stroma numerous small *arteries, veins*, and *capillaries* ramify, most of which are derivatives of the pre-existing vessels. They have been injected by Thiersch, Billroth, and others, and found to form networks of similar form to the alveoli. They are generally larger and less regular in their calibre and arrangement than the corresponding normal blood-vessels, tortuous dilatations and small saculations being of frequent occurrence. According to Quénu, their walls are often thickened, and their lumina occluded, in consequence of chronic

<sup>37</sup> Coen, *Condro-osteo-carcinoma della Mammella Muliebre*, Bologna, 1891. Heurtaux "Cancer ostéοide du Sein," *Mém de la Soc. de Chir.*, t. vii., p. 1., Hacker, *Arch. f. klin. Chir.*, Bd. xxvii., S. 614, Warren, "Surg. Obs. on Tumours," Boston, p. 213.

<sup>38</sup> Billroth, *Die Krankheiten der Brustdrüsen*, 1880, S. 48, &c.

<sup>39</sup> *Path. Catalogue*, Nos. 4747 A, B, and C.



endarteritis. These lesions are occasionally so marked as to produce a telangeiectatic condition. While the vascular system of cancers can be readily injected by the arteries—even the smallest—it is generally difficult to do so by the veins, the substance injected then finding its way into the circumferential venous system, instead of into that of the neoplasm. This is probably due to the frequent blocking of the veins by the growth of the neoplasm, by thrombi, &c. Thus may be explained the venous engorgement—often obvious through the overlying skin—that is almost invariably associated with mammary cancer.

Accompanying the stromal blood vessels are numerous *lymphatics*, which have been injected, and their distribution studied by Schröder van der Kolk, Krause, Rindfleisch, and others. Their radicles, as previously mentioned, are in direct communication with the cancer alveoli. This explains the great frequency of dissemination in the lymphatic glands.

Cancers are generally regarded as *nerveless*, but vaso-motor filaments probably accompany the stromal blood vessels, although this is denied by Verneuil and Nepveu. Our knowledge of this subject is singularly inadequate, and there is here great need of further investigation.

The *chemical analysis* of cancerous growths—much neglected of late—has hitherto failed to reveal the presence of any specific morbid substance.<sup>40</sup> Albuminous constituents predominate. Beneke has found an abundance of myeline and cholesterine. According to Freund, sugar and glycogen are invariably present. The reaction of the juice of fresh mammary cancers has been in dispute for the last half century, and the statements of different observers now are just as conflicting as they ever were. According to the latest experiments,<sup>41</sup> the juice

---

<sup>40</sup> Adamkiewicz (*Untersuchungen über den Krebs*, &c., Vien., 1893) alleges that he has discovered such a substance, which he calls "cancroin"; and he claims to have cured many cancers by injecting it subcutaneously. According to A. the constituent cells of cancers are not epithelial cells, but parasitic organisms (*coccidium sarcolytus*).

<sup>41</sup> *Lancet*, vol. i., 1894, p. 1232.



of perfectly fresh mammary cancer is of alkaline or neutral reaction; whereas within a few hours after death the reaction has become acid. Waring<sup>42</sup> has lately demonstrated the highly important fact that the constituent cells of cancers of the pancreas and stomach produce the same ferments—trypsin, pepsin, &c.—as the normal secretory cells and these organs. Since the above was written I have seen a report of some recent investigations by Hewlett\* whence he concludes; that the cells in cancer, sarcoma, and adenoma contain about the same amount of phosphorus as those of the normal tissues; that there is no special distribution of iron in these tumours, their cells being neither richer nor poorer in this respect than the ordinary tissue cells; and that the proteids of cancer, like those of other cellular organs, consist chiefly of neucleo-albumin. As to the presence of albumoses in cancerous tissue and their alleged tendency to accumulate in the spleen, these questions are still *sub judice*.

In many parts of the body, such as the buccal cavity, the outbreak of cancer is commonly preceded by obvious hyperplastic changes (ichthyosis) in the surface epithelia. Moreover, it is noticeable that these lesions are seldom limited to the precise starting-point of the cancerous disease. This clearly implies that the abnormal activity, which at a given spot culminates in cancer, affects in a less degree the adjacent epithelia of the region for a considerable extent. The question arises whether all parts of the body, in which cancers arise, are not similarly circumstanced. The indications at present forthcoming are decidedly in favour of an affirmative answer; the admirable researches of Heidenhain<sup>43</sup> have, at any rate, answered the question in this sense for the female breast. He has conclusively shown that every mamma containing a

---

<sup>42</sup> *Journal of Anatomy*, Oct., 1893, p. 142. "The Physiological Characters of Carcinomata."

\* *Brit. Med. Journal*, vol. ii., 1894, p. 190.

<sup>43</sup> *Arch. f. klin. Chir.*, Bd., xxxix., 1889, S. 97. Heidenhain's results have been fully confirmed by the observations of Messrs. Johnson and Beadles. *Trans. Path. Soc., Lond.*, 1892.



cancerous tumour is diseased throughout. Its secretory cells are unduly numerous, and they everywhere show signs of excessive reproductive activity; while the periacinous connective tissue is much increased, its nuclei are unduly abundant and it is infiltrated with small round cells. It is a legitimate inference, that parts in such a condition are more prone to originate cancer than perfectly normal structures. Heidenhain is no doubt right in maintaining that proliferating acini of this kind, left behind at the primary operation, are the germs whence most *late* recurrences arise.

He has also shown that the loose areolar tissue intervening between the mammary gland and the *pectoralis major* muscle, contains numerous glandular offshoots and lymphatics, which in cancer cases are nearly always diseased. Some of these not only adhere to the fascia over the muscle, but often penetrate it, and even become embedded in the muscle itself. In the ordinary operation of amputation of the breast, these structures are almost invariably cut off and left behind. On careful examination after removal, Heidenhain found that the disease had not been completely extirpated from this situation in twelve out of eighteen breasts consecutively amputated for cancer, and he predicted recurrences, which soon followed. To obviate this he recommends that the fascia over the *pectoralis major* muscle, and a layer of the subjacent muscular substance, should be removed in every case, together with the diseased breast; and I certainly think this recommendation ought to be regarded as an essential feature of the operation.

Stiles<sup>44</sup> has lately devised a method for determining, without microscopical examination, whether the whole of the cancerous growth and glandular tissue have been removed or not. The breast is first freed from blood by immersion in running water; it is then submerged (whole or sliced) for about ten minutes in a quart of five per. cent aqueous solution of *acidum nitricum*, B.P.,

---

<sup>44</sup> "Contribution to the Surgical Anatomy of the Breast," *Edinburgh Medical Journal*, June, 1892.



and then washed again for a few minutes, after which it is placed in undiluted methylated spirit. By this method the highly albuminous epithelial cells are converted into a dull, greyish-white opaque substance, which can be readily distinguished from the more translucent stroma. From the arrangement of the opaque epithelial areas their cancerous or non-cancerous nature can generally be determined. In this way the relations of the neoplasm to the gland, its exact limits, and the mode and extent of its infiltrations can be definitely ascertained.

As the result of the extensive application of this method, Stiles, like Heidenhain, has found that the disease is very seldom completely extirpated by the ordinary operative proceedings hitherto in vogue. He has especially pointed out the facility with which the skin over cancerous growths becomes affected, owing to its connection with the *ligamenta suspensoria* of Cooper, and their contained glandular processes, lymphatics, &c., along which the disease readily spreads] (fig. 28).

#### § IV.—Local Dissemination.

Waldeyer, from the histological standpoint, has defined cancer as "a-typical, epithelial proliferation;" but the researches of Wyss,<sup>45</sup> Friedländer<sup>46</sup> and others, have shown that this definition does not suffice. They have found atypical epithelial ingrowths common enough in many chronic inflammatory processes, affecting epithelial-covered surfaces. One of the best examples is furnished by the so-called "erosions" of the *os uteri*; in this condition newly-formed structures abound exactly like cancer structures. To the above definition, therefore, it must be added, that the proliferation is of a *malignant* nature, and this is its essential feature. In accepting this definition we abandon the field of histology, for histological analysis cannot furnish a criterion of malignancy. I have observed that much confusion

---

<sup>45</sup> *Arch. f. path. Anat.*, Bd. lxi., S. 24.

<sup>46</sup> *Ueber Epithelwucherung und Krebs*, Strassburg, 1877.



exists as to the precise meaning of this term—*malignancy*. It is commonly used as synonymous with *disseminative*, whereas these two properties of certain neoplasms, although they usually go together, are in reality quite distinct. The term malignancy is by me applied to the remarkable inherent power possessed by certain neoplasms of *continuous undue increase*, owing to the *indefinitely sustained*, excessive proliferative activity of their constituent cells. In this sense all cancers are malignant. The disseminativeness of certain neoplasms, on the other hand, is largely of the nature of an accidental occurrence ; that is to say, it is chiefly dependent upon local structural peculiarities, which render it easy for the constituent proliferous cells to get access to and to be transported by the adjacent lymphatics and blood-vessels. This explains the great variability in the degree of disseminativeness that is so frequently witnessed. Cancers are usually disseminative as well as malignant ; yet, when the local conditions are unfavourable, as in rodent ulcer and some tubular cancers of the breast, we get malignancy without dissemination.

That mammary cancers are so very commonly disseminative is mainly due to the great abundance of the lymphatics and blood-vessels of the breast, and to the close relationship obtaining between these—especially the lymphatics—and the cancer cells, as well as to the feeble cohesion existing between the latter.

As previously mentioned, at an early stage of the disease, there may frequently be found in the vicinity of the primary neoplasm, really discontinuous satellite nodules, which are the first signs of regional dissemination.<sup>47</sup> These arise, as Langhans, Waldeyer and others have shown, from cellular elements detached from the primary tumour, and conveyed to their new destination by the lymphatics or veins, or by their own spontaneous movements.

In mammary cancer the tendency to local dissemination is

---

<sup>47</sup> Q.v. Leopold, *Arch. f. Gyn.*, Bd. v., S. 405.



very marked. Török and Wittelshöfer,<sup>48</sup> basing their observations on 366 *post-mortem* examinations, met with it in about 52 per cent. of all cases. They found nodules in the skin in 10 per cent., in the para-mammary fatty tissue in 8 per cent., in the pectoral muscles in 16 per cent., in the intercostals in 6 per cent., in the ribs in 8 per cent., in the sternum in 5 per cent., in the clavicle in 8 per cent., in the pleura and lungs in 6·8 per cent., in the pericardium in 54 per cent., and in the opposite breast in 9 per cent.

With regard to the last named condition, it is not so very rare for cancer of one breast to be followed after a time by outbreak of the disease in the other. This occurred in eight of the forty-four necropsies in my list, or in 18·1 per cent. According to Gross it is a late symptom, not supervening on the average until 29·8 months after the onset of the primary disease. Of nine such cases under my observation four were due to lymphatic dissemination, three to direct extension, one to metastasis and one to multiple origin.

Subjoined is a short account of the cases due to *lymphatic dissemination*.

(1) A widow, aged 76, twenty years ago noticed a small hard cancerous nodule in her *left* breast, beneath the nipple. Ten months ago she found a similar lump in the upper part of her *right* breast. No operation had ever been done. When I first saw her she was pale, sallow and emaciated. The breasts were small and wasted. A hard, irregular, cancerous ulcer rather larger than the palm of the hand, occupied the left mammary region; and was fixed to the subjacent tissues. There was a smaller cancerous ulcer of similar nature at the upper part of the right breast. The glands of the left axilla and those above the left clavicle were obviously affected.

(2) A single woman, aged 65, six years ago noticed a small, hard, cancerous tumour at the lower and outer part of her *right* breast. Four years later the diseased part was amputated. One year later there was recurrence in the chest and axilla. Six months later a hard lump was first noticed at the inner part of the *left* breast and in the left axilla. When I first saw her she was emaciated and sallow. Across the right mammary region, in the seat of the operation scar, was a hard, elongated, cancerous ulcer; and at the inner edge of the left breast a hard, nodular, cancerous growth, the size

<sup>48</sup> *Arch. f. klin. Chir.*, Bd. xxv., 1881, S. 873.



of a hazel nut. The glands of both axillæ were enlarged and hard. She died of asthenia fifty days later. At the *necropsy* the ulcerated cancerous growth in the right mammary region was found to have penetrated the entire thickness of the pectoral muscle and to have infiltrated the sixth rib. The spleen contained eight small secondary nodules on its surface. There was double emphysema and bronchitis, with old pleural adhesions. Liver and heart fatty. Double chronic interstitial nephritis. Left femoral hernial sac, containing omentum.

(3) A multipara, aged 46, in the middle of whose *right* breast a cancerous tumour, the size of a walnut, first appeared three and a-half years ago. One year later the part was amputated. Six months ago the disease returned *in situ*, and soon afterwards she noticed a lump the size of a walnut in the middle of her *left* breast. When I saw her she was pale and rather sallow. Surrounding the puckered operation scar were numerous small, hard, recurrent nodules, many of them eroded. In the left breast was a hard lump, the size of a hen's egg, adherent to the overlying nipple, which was retracted, but mobile on the chest wall. The glands of both axillæ enlarged, as well as some of those above the right clavicle. A year later this patient again came under my notice, when I found the skin of the whole of the front of the chest and the upper half of the abdomen thickly studded with small, flat discs of hard cancer—mostly discrete, but here and there confluent. Many of them were eroded. On the right side of the chest this condition extended back as far as the scapula. The right upper limb was much swollen from œdema. In addition to the glands previously mentioned as affected, those of both groins were also invaded. She died of asthenia nineteen days later. At the *necropsy* the right side the chest wall was deeply invaded over a wide area by dense, white, fibroid new growth. The right pleura was infiltrated by direct extension. At its lower part was a localised suppurative focus. No other internal cancerous lesions. Extreme stenosis of the mitral and tricuspid orifices. Atheroma of aortic arch. Liver fatty. Double chronic interstitial nephritis. Numerous small uric acid calculi in pelvis of left kidney, and similar gravel in pelvis of right kidney.

(4) A sterile married woman, aged 50, six months ago noticed ill-defined hardness at the middle of her *right* breast. When seen by me she was stout and healthy looking. The right mammary region was occupied by a hard, projecting mass of new growth, the size of the foetal head at birth. This mass was movable on the subjacent parts, but adherent to the overlying skin. The nipple was retracted, and there was an enlarged gland in the right axilla. No operation was done. She died of asthenia two and a-half months later. At the *necropsy* the body was pale, emaciated, and sallow. Each breast was occupied by a large mass of hard, cancerous growth, to which the overlying skin was adherent and ulcerated. On the right side the muscles and bones of the chest wall were infiltrated. The skin of the front of the chest was thickly studded with small, hard nodules, some of them eroded. The axillary glands of both sides were infiltrated. The liver contained several firm, whitish, cancerous nodules.



The three following cases illustrate the invasion of the opposite breast by *direct extension*.

(1) Three years ago a multipara, aged 45, first noticed a cancerous lump in her *right* breast above the nipple, and an enlarged gland in the axilla. No operation. On examination I found several hard, cancerous nodules in the right breast, and the skin of the right pectoral, axillary, and left mammary regions infiltrated "*en cuirasse*." The right axillary glands were infiltrated, and the upper limb of this side was œdematous. She died of pulmonary complications, &c., forty-two days later. At the *necropsy* a mass of hard cancer, the size of an orange, occupied the right mammary region. There was extensive cuirassed infiltration of the skin of the front of the chest on both sides. The glands in both axillæ were cancerous. Both lungs and bronchial glands contained secondary cancerous growths.

(2) A woman, aged 38, the mother of three children, seven years ago noticed a lump the size of a hazel nut in the upper part of the periphery of her *left* breast. Four and half years later she also noticed a lump in the axilla. Six months later the breast was amputated, and the axilla cleared. One year afterwards a recurrent nodule appeared at the middle of the mammary scar. When I saw her the whole of the space between this scar and the clavicle and the parts for a few inches below the scar, were invaded by hard, nodular, cancerous growth, which was firmly fixed to the chest wall. The overlying skin was adherent, infiltrated and purplish. The infiltration had crossed the median line of the body, and had begun to encroach on the *right* breast. The left axilla was invaded by cancerous infiltration, as also were the glands at the root of the neck. The upper limb on this side was œdematous. In the right axilla was a cancerous lump the size of a walnut. She died of hydrothorax and pulmonary collapse, eighty-one days later. At the *necropsy* the entire thickness of tissues of the left pectoral region invaded by dense cancerous growth, which had perforated them and spread to the lung and anterior mediastinum, and thence to the root of the left lung, where, by compressing the pulmonary veins, it had caused extreme hydrothorax and collapse of the lung; five pints of clear serous fluid were removed from this pleura. The left axillary vein had been compressed by a mass of cancerous glands there. Secondary cancerous growths in the left supra-renal body, both kidneys and the left ovary.

(3) The primary disease in the *left* breast was first noticed two years ago. Three months later the breast was amputated and the axilla cleared. Six months afterwards recurrence in the chest and axilla set in. On examination I found the whole of the tissues of the upper part of the chest on the left side, the shoulder and the arm, infiltrated by hard, cuirassed cancer, which in the subsequent progress of the disease crossed the middle of the body and invaded the opposite breast. Both axillary glands were infiltrated. She died from invasion of the left lung and pericardium by direct extension of the disease through the chest wall. The ribs were infiltrated, and there were secondary growths in the liver and peritoneum.

In certain rare cases of irregular lymphatic dissemination



the disease may be conveyed to the large nerve cords of the axilla,<sup>49</sup> to the upper end of the humerus,<sup>50</sup> to the retro-sternal tissues, &c.

Local dissemination has an important bearing when the question of operation is under consideration, for it appears from the following considerations, that the spread of the disease to the lymphatic glands and to the system generally, is greatly favoured by local dissemination. Thus, of 192 cases with local dissemination, Török and Wittelshöfer found the lymphatic glands invaded in 52·6 per cent., and metastases in 72·9 per cent.; whereas of 174 cases free from local dissemination, the lymphatic glands were affected only in 42·5 per cent., and there were metastases in but 45·4 per cent.

In structure, these local disseminative nodules are identical with the primary tumour whence they originate; and they constitute fresh centres of the disease, which progress precisely as the latter.

#### § V.—Lymph Gland Dissemination.

One of the earliest consequences of the development of a cancerous tumour in the breast is that the adjacent axillary lymph glands become enlarged. This condition may be only transitory, as in the glandular enlargements occasionally seen in the course of most infectious diseases, in association with non-malignant mammary tumours, and in the axillary glands left behind after amputation of the breast. Such enlargements are usually ascribed to "irritation" or "chronic inflammation." Histological examination reveals nothing more than undue increase in number and size of the lymphoid cells, together with thickening of the fibrous reticulum, and proliferation of its nuclei, as well as hyperplasia of the endothelia. These changes cause obstruction of the lymph sinuses; and consequent clogging of the circulation through the gland.

<sup>49</sup> Pilliet, *Bull. de la Soc. Anat.*, 1892, p. 137.

<sup>50</sup> Snow, *Brit. Med. Jour.*, vol. i., 1892, p. 549.



When associated with mammary cancer, this glandular enlargement is usually followed, after a time, by the development in the affected glands of cancerous growths precisely similar in character and structure to the primary neoplasm. This indicates that the secondary growths are derivatives of the primary one. Yet it is exceptional to find any direct continuity between the two. Wherein, then, does the connection consist? We have seen that the lymph radicles communicate directly with the cancer alveoli. Hence, detached cellular elements from the neoplasm may easily enter the lymphatics, and be carried by the lymph stream into the adjacent glands, just as happens with particles of colouring matter after tattooing. From the smallness of the lymph radicles it may be inferred that such transported fragments must be exceedingly minute—probably a single cell or a small cellular group in most cases. That epithelial cells thus dis-severed from their normal connections may still grow and multiply, we know from the familiar process of skin grafting. Probably all mammary cancer cells are capable of dissemination; but all are not capable of growing when disseminated. There are good grounds for believing that the majority of these “cancer emboli” perish and are absorbed, owing to the metabolic activity (phagocytosis) of the cells of the glands; and that only those with sufficient vitality to overcome this resistance originate dissemination tumours. Hence the lymph glands form a temporary barrier to the spread of the disease; and do not themselves usually become affected until a considerable time after its primary outbreak.

Gussenbauer's<sup>51</sup> histological researches confirm this. He found traces of cancer cells disseminated in the glands of the neck, secondary to primary disease of the lip, in twenty-nine out of thirty-two consecutive cases, and doubtful evidence of it in the other three. Yet clinical experience proves that when the primary disease is extirpated without removal of the adjacent

---

<sup>51</sup> *Zeitschrift f. Heilk.*, 1881, Bd. ii., S. 17.



glands, in a large proportion of cases the latter do not originate recurrences. Similarly of Küster's,<sup>52</sup> 117 breast cancer extirpations, in which the excised axillary glands were microscopically examined, in only two instances were they found perfectly free from any signs of cancerous dissemination; and of six cases of the same disease, with no enlargement of the axillary glands clinically appreciable, Gussenbauer nevertheless found—on histological examination after removal—evidence of dissemination in these glands in every case. But we know from clinical experience that after extirpation of cancerous breasts, without opening the axilla, recurrences in the axillary glands are proportionately much less frequent than this.

We have thus arrived at the important conclusion, that the outbreak of the disease in the lymphatic glands is due to grafts from the primary neoplasm, arrested there, which subsequently develop in accordance with their inherent tendencies. This explains the great resemblance always noticeable between the primary and secondary growths, the significance of which it is impossible to ignore. Moxon has sagely insisted upon this. He says<sup>53</sup>: "The first cancer which appears has a likeness to the part in which it appears, and the secondary cancers arising from it have the likeness of that first cancer; and those who doubt that they came from that first cancer must show us why they have that likeness." In this connection, Waring's experiments<sup>54</sup> are of interest; they show that the cellular elements of the secondary, as well as of the primary growths, in cancer of the pancreas and stomach, produce the same ferments, &c., as the normal secretory cells of these parts.

On examination of affected glands removed at an early stage of the disease it can generally be made out, that the new growth consists of but a few small, circumscribed foci, situated in the peri-follicular lymph sinuses of the cortex, or in their

---

<sup>52</sup> *Verhand. der deutsche Gesellschaft f. Chir.*, Bd. xii., S. 288.

<sup>53</sup> "Debate on Cancer," *Trans. Path. Society, Lond.*, 1874.

<sup>54</sup> *Journal of Anatomy*, Oct., 1893, p. 142.



immediate vicinity, that is to say, in the course of the normal afferent lymph stream. In a case of melanotic cancer of the breast with secondary lesions in the axillary glands, the dark colour of the cells enabled Billroth<sup>55</sup> to follow the extension of the dissemination along the lymph sinuses; and his observations have since been confirmed and amplified by Zehnder.<sup>56</sup> The latter describes the initial foci as increasing in size by continuous proliferation of their constituent cells, which soon assume the alveolar arrangement, just as in the development of the primary tumour in the breast. These cells are very rich in karyokinetic figures; and they can easily be distinguished from the cells (lymphoid) of the parenchyma of the gland, which show no signs of reproductive activity, and appear not to participate in the spread of the disease. Petrick<sup>57</sup> has arrived at similar conclusions. Finally, by multiple staining, Gibbes<sup>58</sup> has conclusively demonstrated the correctness of this interpretation. Large multi-nucleated cells, the so-called "giant cells of cancer," are also of frequent occurrence. As the cancerous grafts increase in size, the parenchymatous cells of the gland suffer atrophy from pressure; the blood-vessels of the stroma enlarge, and their endothelial and muscular coats thicken. The endothelial cells of the lymph vessels and glands show no visible alterations, and they evidently take no active part in the process. In its subsequent course the disease progresses precisely as the primary outbreak.

Although the lymphatics connecting the cancerous breast with the affected glands are usually free from disease, it occasionally happens (one in twenty according to Broca) that they are found distended with cancer cells. The so-called lymph cord, often to be felt passing from the mammary tumour to the axillary glands, is usually nothing more than the pedicle of the

---

<sup>55</sup> *Arch. f. path. Anat.*, Bd. 21, S. 441.

<sup>56</sup> "Ueber Krebsentwicklung in Lymphdrüsen." *Arch. f. path. Anat.*, Bd. cxix. Heft 2, 1890, S. 261.

<sup>57</sup> *Deutsche Zeitschr. f. Chir.*, 1891, Bd. xxxii., S. 530.

<sup>58</sup> *International Journal of Medical Science*, August, 1889, p. 145.



axillary tail of the mamma itself. The glands first affected are those that receive their lymph directly from the part of the organ involved by the primary neoplasm; and the subsequent spread of the disease from gland to gland corresponds to the course of the lymph stream; but it must be borne in mind that each infected gland constitutes a new centre of dissemination. In cancer we never meet with any general infection of the lymphatic system, such as is often observed in tubercle, syphilis, and other infective diseases. This important fact, taken with the foregoing considerations, is an indication against the fancied resemblance, traced by some pathologists, between these diseases and cancer. Here it may be mentioned that *only* malignant neoplasms have the property of reproducing their like by dissemination in the adjacent lymph glands. The few instances in which it is alleged that non-malignant neoplasms have manifested similar properties, are capable of being otherwise explained.

About a dozen lymphatic glands are normally to be found in the axilla; but in cases of cancer this number is often greatly exceeded. In a patient operated on by Gross<sup>59</sup> fifty diseased glands were removed, which varied in size from a small shot to a large nut. I have seen several instances in which the number was nearly as great. This condition is no doubt due to morbid enlargement of the numerous small lymph-glandular structures normally present in the axillary fat, although ordinarily invisible to the naked eye. The number of glands usually affected is of course much less than this, but half-a-dozen or more are often obviously diseased; yet the resulting tumours seldom attain large size. When, however, only a few glands are involved, or but a single one, tumours larger than usual often ensue. Cancerous axillary glands generally remain discrete; but sometimes they blend together, forming a single, hard irregular, nodular mass.

In most of our standard text-books the *axillary glands* are

---

<sup>59</sup> *Ibid.*, March, 1888, p. 232.



described as lying along the inner side of the axillary vessels. I need hardly remind any practical surgeon that it is useless to seek for enlarged glands, secondary to disease of the breast, in this position. The axillary glands that, as a rule, first receive the lymphatics from the breast are those situated on the chest wall at the lower part of the inner side of the axilla, under the border of the *pectoralis major* muscle (*pectoral*). These are the first to be invaded in cases of cancer. It is well to remember that the axillary tail of the mamma lies close by them, and under certain circumstances it may easily be mistaken for an enlarged gland.

The remaining axillary glands are grouped as follows: (a) Those along the inner side of the large vessels, which receive the lymphatics from the upper limb and are in free communication with the foregoing (*brachial*). (b) Those of the posterior part of the axilla, along the course of the subscapular vessels, which receive lymphatics from the back (*subscapular*). (c) A few small glands immediately below the clavicle (*infraclavicular*), between the *pectoralis major* and *deltoid* muscles, which receive branches from the arm and shoulder, and communicate above with the inferior cervical and below with the pectoral glands. (d) There can be no doubt—as pointed out by Hyrtl and Reiffel<sup>60</sup>—that some lymphatics from the mamma reach the glands at the upper part of the axilla, through Mohrenheim's space, without entering the pectoral group. These pass between the pectoral muscles and enter the axilla above the *pectoralis minor*, where they have often been found infiltrated in cases of mammary cancer.

These various groups of glands communicate—directly or indirectly—with one another, so that all may eventually become diseased from a single morbid focus. Their efferent vessels ascend with the subclavian vein, and having formed one or more trunks terminate, on the left side in the thoracic duct,

<sup>60</sup> "De quelques points relatif aux récidives et aux généralisations des cancers du sein chez la femme," *Thèse de Paris*, 1890.



and on the right side in the right lymphatic duct or subclavian vein. Next to the pectoral glands, those in the vicinity of the large blood vessels and nerves are the ones chiefly affected in cancer of the breast—as far upwards as the clavicle, and sometimes even above this level.

When these glands are extensively involved œdema of the upper extremity, from pressure on the axillary vein, may ensue; and at the same time there often is great pain from compression of the large nerve trunks. Should this condition pass on to

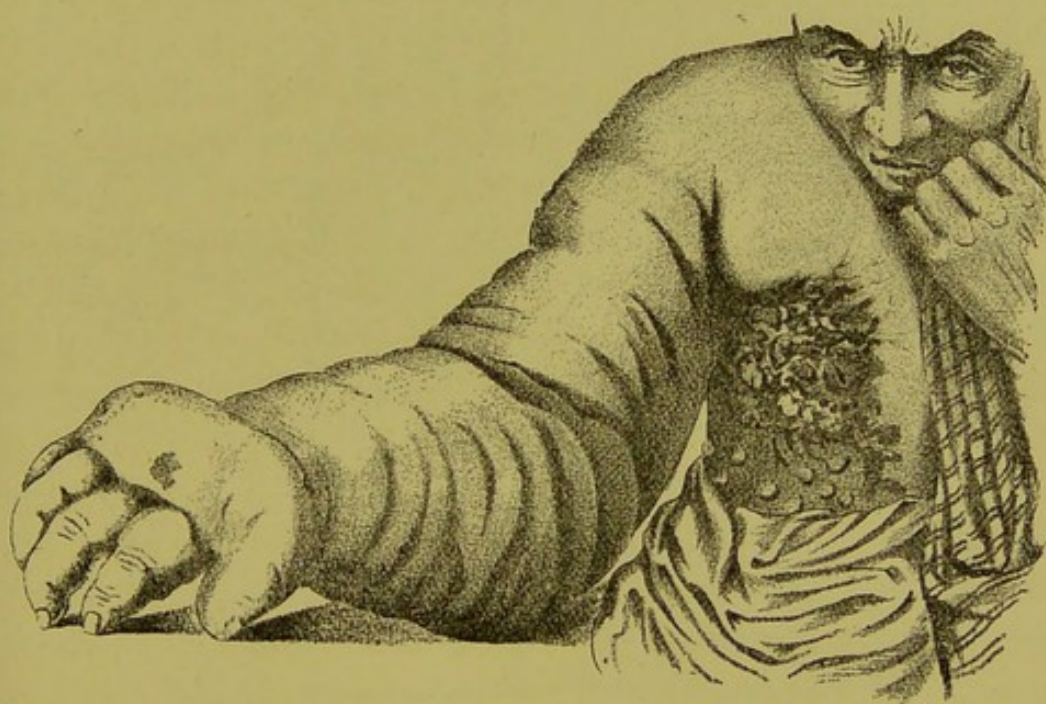


FIG. 37.—œdema of the upper limb, with impending gangrene, from compression of the axillary vein by cancerous glands (*Billroth*).

gangrene the suffering of the patient will be very great, for death is then approaching in one of its most horrible forms (fig. 37). It is for the relief of such cases that German surgeons have resorted to amputation at the shoulder-joint, &c.

The *lymphatics* of the breast are extremely abundant. No other gland can compare with the mamma in this respect. Moreover, its lymphatics are relatively much more numerous than its blood-vessels, and their intercommunications are very free. Inasmuch as the spread of cancer and other diseases is



effected mainly through their agency, accurate knowledge of their disposition is a matter of great practical importance. They chiefly consist of two sets: superficial ones derived from the

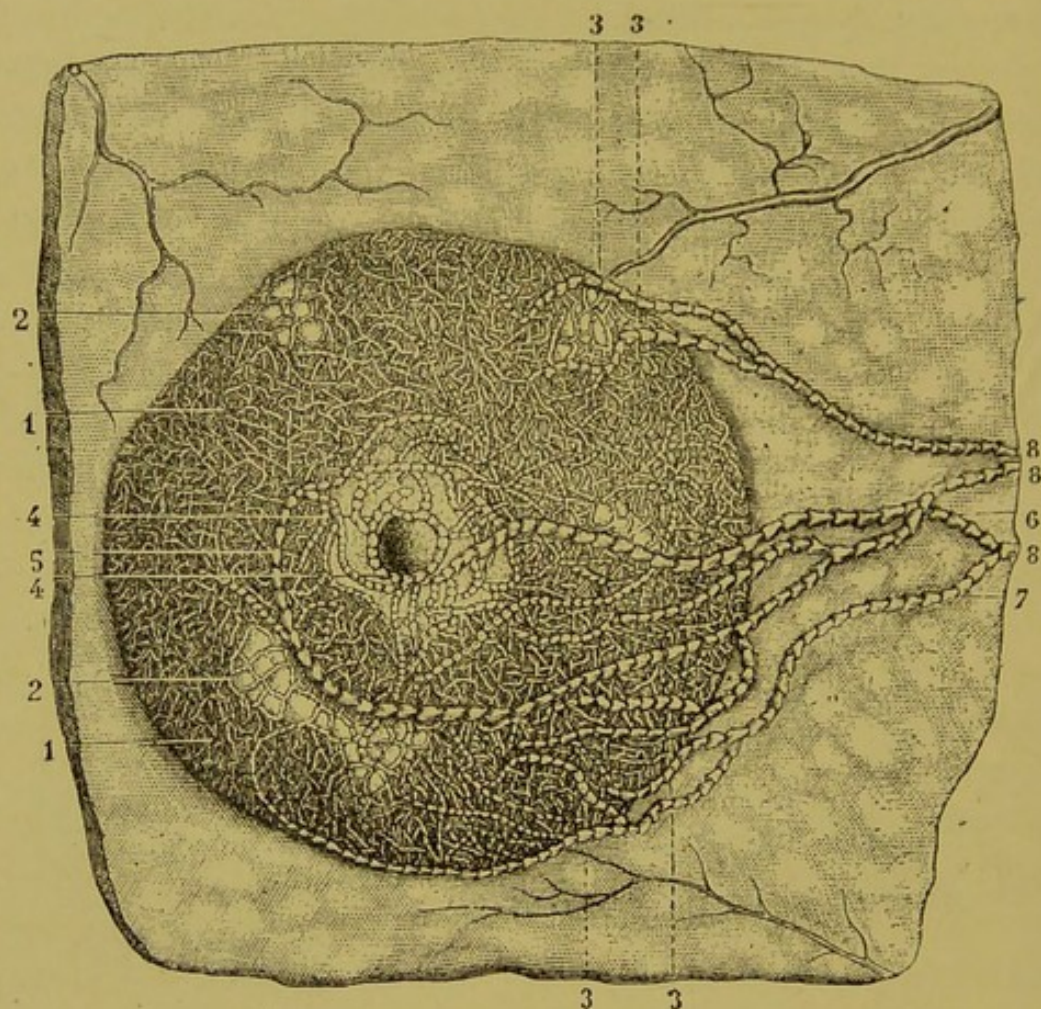


FIG. 38.—THE LYMPHATICS OF THE BREAST (*Sappey*).

(1) Lymphatic network of the anterior surface of the gland. (2) Glandular lobules whose peripheral network has not been injected, so as to allow the circumlobular lymphatics to be seen. (3) Lymphatic trunks from the superior and inferior segments of the gland. (4) Subareolar lymphatic plexus. (5) Lymphatic vessel arising from inner part of this plexus, and the proceeding by curved course towards the axilla. (6) Another vessel arising from outer part of plexus, and passing directly outwards. (7) Vessel arising from inferior part of the gland eventually uniting with preceding. (8) Vessels arising from outer part of sub-areolar plexus, and from upper part of gland proceeding to the axilla.

*skin*, and deep ones from the *gland*. The superficial lymphatics are most abundant in the nipple and areola, where they form fine networks. From these a variable number of branches arise



which join the subareolar lymphatic plexus, towards which the deep lymphatics from the gland itself also converge. The lymphatics of the mammary gland are unequally distributed on its two surfaces, the anterior set being the larger and more numerous. Most of the large trunks that go to the axilla arise from these vessels. Each acinus, lobule and lobe, is surrounded by intercommunicating lymphatic anastomoses. The branches from these various sources converge towards the areola beneath which their large trunks communicate freely, forming the subareolar plexus of Sappey. This plexus is the meeting point of the chief mammary lymphatics. Hence cancerous neoplasms originating in this part of the gland are particularly apt to be attended by widespread acute local diffusion.

From this plexus two main trunks arise—one from its outer and one from its inner side—which course in the subcutaneous fat to the axilla (fig. 38). Each receives one or more branches from the upper and lower peripheral parts of the gland. Sometimes these peripheral branches join the axillary glands independently. In the axilla it is rare to find more than two or three large lymphatic trunks. The above description is mainly after Sappey;<sup>61</sup> but I think this distinguished anatomist is in error in maintaining that all the lymph from the breast necessarily passes through the subareolar plexus. There are other lymphatics proceeding from the breast, besides those described by him. Some accompany the bloodvessels (perivascular). These consist merely of a layer of endothelial cells, lining the connective sheaths of the vessels they accompany. Numerous other efferent branches, as Langhans<sup>62</sup> has shown, pass from the posterior part of the breast into the loose retro-mammary connective tissue, whence they proceed to the axilla, without ever entering the subareolar plexus. Through these branches cancer frequently disseminates. Some lymphatics, from the deep aspect of the breast, also enter the

---

<sup>61</sup> "Des vaisseaux lymphatiques," Paris, 1885, p. 48 *et seq.*

<sup>62</sup> "Die Lymphgefäße der Brustdrüse und ihre Beziehungen zum Krebse," *Arch. f. Gyn.*, Bd. viii. 1873, S. 184.



chest through the pectoral and intercostal muscles, and so come into close relationship with the pleura.<sup>63</sup> Branches from its upper part sometimes pass directly to the subclavicular and inferior cervical glands. Others from its sternal part pass through the second, third, fourth, and fifth intercostal spaces to the anterior mediastinal (retro-sternal) glands, where they communicate with the anterior intercostal, internal and external mammary branches. It is strange that cancerous dissemination does not affect these glands more frequently than it appears to do. Török and Wittelshöfer found them diseased only in 6·5 per cent. of all their necropsies. In this connection it is of interest to recall the previously mentioned fact, that cancer originates in the sternal segment of the gland, much less frequently than in any other part.

The para-mammary lymphatics communicate on the one hand with circumferential mammary branches—from both the superficial and deep aspects of the gland—and on the other with the subcutaneous thoracic lymphatics. Through these channels the lymph systems of both breasts communicate indirectly. Thus may be explained those rare instances in which cancer of one breast has caused disease of the glands in *both* axillæ (Scarpa, Cooper, Moore, &c.), and others in which cancer of the sternal segment of one breast has induced secondary disease in the glands of the *opposite* axilla (Volkmann). In a case mentioned by Moore,<sup>64</sup> cancer of the left breast disseminated not only in the glands of the left axilla and *groin*, but also in those of the opposite breast.

It is a matter of considerable practical importance to determine how soon after detection of the primary neoplasm the axillary lymph glands become diseased. According to Fink<sup>65</sup>

---

<sup>63</sup> Through the medium of numerous arterial, venous, and lymphatic vessels, the pleuræ and mammæ are closely related. Hence the frequent association of pleurisy and pleural effusions, with cancerous and other affections of the mammæ; hence also in certain intra-thoracic diseases the mammæ may be secondarily involved.

<sup>64</sup> *Med. Chir. Trans.*, vol. xii., p. 272.

<sup>65</sup> *Zeitschr. f. Heilkunde*, 1888, Bd. ix., S. 453.



this happens as early as from the sixth to the twelfth month; and after the thirteenth month they are invariably invaded. Winiwarter estimated the period at from fourteen to eighteen months. Gross gives the average as 17·7 months. These are but clinical data, which, of course, do not enable us to affirm that the glands are free from disease for the whole period of apparent immunity. In forty-three of Küster's cases, with no clinically appreciable disease of the glands, signs of cancerous dissemination were, nevertheless, found in them on histological examination after removal. In some very rare instances glandular implication is so rapid that it appears to coincide with or even to antedate the primary disease. In others it may be delayed for several years—for ten years, or even more, or it may never occur at all. Certain scirrhus cancers may undoubtedly run their entire course, causing systemic dissemination and death, without the adjacent lymph glands ever being implicated. Hence the absence of lymph gland disease is no absolute guarantee against general systemic dissemination, which in these cases evidently takes place through the blood vessels. According to my experience, such occurrences are most exceptional. I have met with but a single instance of the kind in forty-four consecutive necropsies on patients who had died of mammary cancer, there being metastases in twenty-eight.

In this case the patient was a healthy looking woman, aged 58, with a hard cancerous tumour, the size of a hen's egg, at the upper part of her left breast. The nipple was normal; but the overlying skin was adherent to the tumour, which was, however, movable on the subjacent chest wall. The disease was of three months duration. No enlarged glands could be detected in the axilla or elsewhere. The diseased breast was extirpated, without interfering with the axilla. The patient made a good recovery from the operation; but she died five months later of asthenia, without any sign of recurrence. At the *necropsy* the operation scar and the adjacent parts of the chest were found to be healthy and quite free from cancerous disease. The axillary and other adjacent lymph glands were also quite free from disease. There were a few firm, white, cancerous nodules, about the size of peas, on the surface of each lung; and throughout the liver numerous cancerous growths, varying in size from a pea to a hazel nut.

According to Gross, metastases occur without any antecedent lymph gland dissemination in about one in seven of all cases.



This estimate appears to me too high, probably because many operation cases have been included. Török and Wittelshöfer's figures, which are much higher still, err also from this cause.

An idea of the frequency of lymph gland dissemination may be gathered from the following figures:—

Of 118 cases of primary cancer of the breast consecutively under my observation there was obvious glandular disease—when the patients were first seen—in 86, or in 73 per cent. In all of these cases the *axillary* glands of the same side as the disease were affected; with the *supra-clavicular* as well in five cases, the *infra-clavicular* in two, and the glands of the opposite axilla in two—*both* breasts being involved in these cases. Gross gives the proportion of cases of lymph gland dissemination, under like circumstances, as 68 per cent., those of the axilla being diseased in all, the supra-clavicular in 5·4 per cent., and the infra-clavicular in 1·3 per cent.

Turning now to the *post-mortem* evidence, what I have found in the cases under my observation is, that of forty-four consecutive necropsies, there was lymph gland dissemination in forty, or in 90·9 per cent.: the *axillary* glands were affected in all, with both the *supra* and *infra-clavicular* ones in five cases, the *supra-clavicular* alone in two, the *infra-clavicular* alone in four, and those of the *opposite* axilla in ten cases (in seven of these *both* breasts were cancerous). In three of the four cases in my list free from lymph gland disease, cancerous axillary glands had just previously been removed by operation.

From this it follows that dissemination in the adjacent axillary glands is, sooner or later, an almost invariable concomitant of acinous (scirrhus) cancer of the breast; the cases that run their course without it are of the greatest rarity. Should anyone oppose to this conclusion Török and Wittelshöfer's analysis of 366 necropsies, in which the axillary glands were found invaded only in 175 or 48 per cent.; my answer is, that these statistics are useless for determining the point under consideration, because of the large number of operation cases they include, in which the affected lymph glands had recently been removed.



It is commonly stated that the progress of the disease is much slower, and the total duration of life much longer, in cases where lymph gland dissemination is long delayed, than in those where the glands are attacked at an early period of the disease. I am not aware of any statistical evidence that can be adduced in support of this belief; but my impression is that it is well founded.

It is, however, clearly shown by statistics, that lymph gland affection is an important factor in determining the results attained by operations for the removal of the disease.

Thus, according to Winiwarter, after amputation of the breast for the primary disease, *with* removal of affected axillary glands, the subsequent duration of life averaged 13 months, the total duration being 29 months; whereas in cases where the breast was amputated, *without* removal of axillary glands—none being obviously affected—the subsequent duration of life averaged 22 months, the total duration being 50 months.

Gross' statistics are equally conclusive. Thus of 136 cases of extirpation of the breast, in 93 diseased glands were removed; the total duration of life averaged 39·3 months, and local recurrence ensued on the average in 1·9 months; whereas in 43 cases free from obvious gland dissemination, the average duration of life was 52·7 months, and the average period of recurrence was 8 months. The latter, therefore, lived 13·4 months longer than the former; and when recurrence followed, it appeared 6·1 months later.

The same author has shown that the proportion of cures after operation is 5·10 per cent. greater when the axillary glands are free from disease, than it is when they are obviously affected.

## § VI.—General Dissemination.

The appearance of cancerous growths in various parts of the body, remote from the primary disease and its derivatives (so-called *metastases*), to which allusion has already been made, is one of the most striking features of the disease. It is remark-



able that the cancers of every locality have their own special modes of dissemination, and even the various forms of the disease in particular organs manifest differences in this respect.

The female breast is one of those parts of the body in which the tendency to dissemination is very great. Growths of this kind are met with in considerably more than one half (61 per cent.) of all fatal cases of breast cancer.

Of 44 consecutive necropsies under my observation, systemic dissemination growths were found in 28, or in 63.1 per cent. Of 102 necropsies tabulated by Nunn<sup>66</sup> they were present in 74, or in 58.8 per cent.; and of Török and Wittelshöfer's 366 necropsies they were met with in 215, or in 58 per cent. The percentage figures would be much higher, but for the fact that in all the foregoing estimates a large proportion of cases, fatal shortly after operation, have been included. Ten of the 44 necropsies in my list were of this nature. Of the remaining 34 necropsies, in which death ensued in the natural course of the disease, there were metastases in 25, or in 73.5 per cent.

Statements vary as to the precise date of onset of general dissemination; but there is universal agreement that it is not until a comparatively late period of the disease—generally some two or three years after the initial outbreak, and about 15 months after invasion of the lymphatic glands. Winiwarter, Sprengel, and Fink estimate it at 25 months, Henry at 30, and Oldekop at 38 months. As a rule, the slower the progress of the primary disease, the later metastases appear. Occasionally they form during the first few months; and at other times not until after the lapse of several years—even 10 years or more. According to Gross, out of 100 cases with metastases, 24 form within the first year, 3 in from 13 to 18 months, 18 in from 19 to 24 months, 27 in from 25 to 36 months, and 28 after three years. The average duration of life after the first appearance of metastases is, according to my estimate, about two years. Growths of this kind may exist for a long time in important

---

<sup>66</sup> "Cancer of the Breast," p. 130.



organs such as the liver, lungs, brain, &c., without causing any obvious functional disturbance.

In the *ensemble* of their characters—histological and otherwise—metastatic cancers closely resemble the primary mammary neoplasm. They differ from the latter, however, in that they are usually multiple, and spring up in several different localities. Occasionally the number of metastases is very small, and in rare instances there may be only a single one. In soft, vascular organs like the liver, these growths often attain immense size;<sup>67</sup> but in other parts they are commonly of moderate dimensions. Usually they present as small, hard, nodular flattened, or discoidal masses, which soon become cupped or umbilicated, owing to contraction of the older parts of the growths; but they sometimes take the form of diffuse infiltrations, especially in the pleura and bones.

The sequence of their development, and the combinations of organs invaded are difficult to explain. The deep parts of the body are much more frequently invaded than the superficial; but the order of eruption in most individual internal organs is just the converse of this.

I have seen it stated by good authorities, that metastases invariably effect *both* of paired organs; but I have convinced myself by repeated observations, that it not so: both are usually affected, but often only one.

Sometimes these growths are exceedingly numerous and widely spread throughout the body, as in Velpeau's<sup>68</sup> remarkable case of mammary cancer in which hundreds of them were found distributed throughout the general connective tissue, lungs, liver, bones, muscles, heart, stomach, duodenum, small intestine, pancreas, kidneys, gall bladder, vena cava, peritoneum, dura mater, and thyroid gland.

---

<sup>67</sup> A good example of the acceleration of the growth of cancer owing to *increased blood supply*. In like manner the cock's spur, transplanted to the comb, grows much in excess of its natural size.

<sup>68</sup> "Traité des Maladies du Sein," &c., Paris, 1854.



An excellent example of this widespread dissemination was lately brought before the Edinburgh Medico-Chirurgical Society by Bramwell;<sup>69</sup> and Kautorowicz\* has reported a similar case.

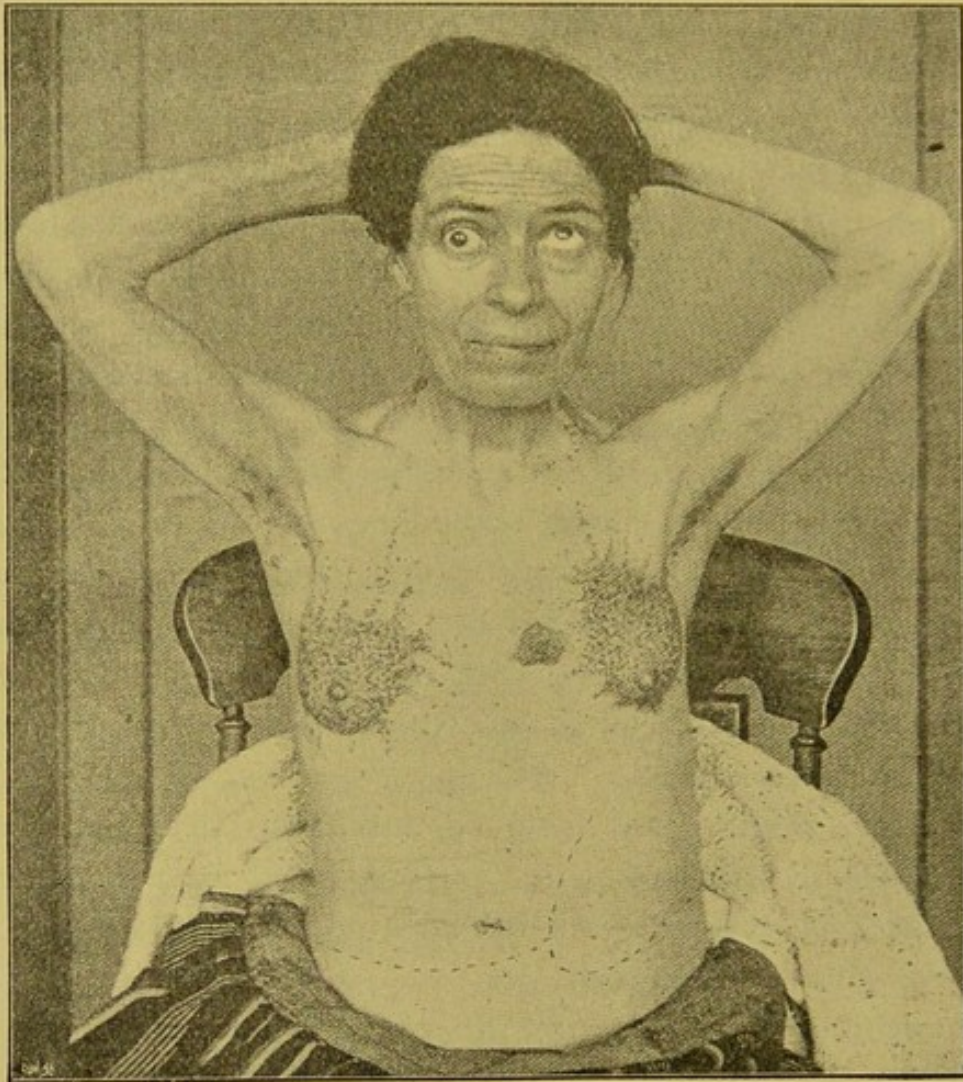

FIG. 39.—CANCER OF BOTH BREASTS; LYMPHATIC DISSEMINATION; WIDE-SPREAD SYSTEMIC DISSEMINATION (*Bramwell*).

The dark patch on the inner side of the left breast represents the spot where a cancerous nodule was excised for diagnostic purposes. The dotted lines show the size of the liver and spleen. The photograph was taken with the patient looking up at the ceiling; it shows the immobility of the right eye.

A single woman, aged 40, came under observation with numerous small hard, cancerous nodules in both breasts, and in the adjacent structures. Numbers of these nodules ran out as beaded chains under the surrounding skin, in all directions. Below the nipple of the left breast was a hard, cir-

<sup>69</sup> *Edinburgh Med. Journal*, July and Aug., 1894.

\* *Cert. f. allg. Path., &c.*, No. 20, 1893.



cumscribed tumour the size of a walnut. The axillary glands of both sides were enlarged and hard. She had diplopia and was blind in her right eye. Her first intimation of any mammary disease was the discovery—about three years ago—of a hard tumour, of no great size, below the nipple of her left breast. This never increased, but two and a half years later, without any obvious cause, numerous nodules began to develop in both breasts and in the adjacent integument. These continuously increased until she died of asthenia about half a year after their first appearance. The progress of the disease was marked by great debility and emaciation, and shortly before death she became unable to stand owing to painful swelling at the upper part of her left femur. No family history of cancer or tubercle. At the necropsy numerous small hard secondary growths were found in both mammae, the adjacent lymph glands, the subcutaneous cellular tissue of the thorax, abdomen and back, mesentery, peritoneum, liver, spleen, ovaries, kidneys, suprarenals, pancreas, vagina, uterus, sciatic nerves, stomach, pericardium, pleurae, dura mater, spinal meninges, the left femur, and in the periosteum of the ribs. Strange to relate, the lungs and brain were unaffected; and so was the thyroid gland. The liver and spleen were converted into large, fibroid, cancerous masses of stony hardness. The histological characters of the disease were those of acinous cancer. The tumour first noticed in the left breast proved to be an ordinary fibro-adenoma. The local dissemination seemed to have taken place through the lymphatics.

The following analyses give a good idea of the relative frequency with which the various parts are affected.

Of forty-four consecutive necropsies, many of them made by myself, the seats of metastases were:—

Liver	...	...	...	...	...	...	in 20 cases
Lungs (B. 5, L. 2, R. 1)	...	...	...	...	...	8	"
Pleura (B. 5, L. 1)...	...	...	...	...	...	6	"
Femur (B. 2, R. 1, L. 1)	...	...	...	...	...	4	"
Retroperitoneal glands	...	...	...	...	...	3	"
Bronchial glands	...	...	...	...	...	2	"
Humerus (R. 1, L. 1)	...	...	...	...	...	2	"
Kidneys (B. 2)	...	...	...	...	...	2	"
Supra-renals (B. 1, L. 1)	...	...	...	...	...	2	"
Pancreas	...	...	...	...	...	2	"
Vertebrae (lower dorsal and upper lumbar)	...	...	...	...	...	1	case
Mesenteric and omental glands	...	...	...	...	...	1	"
Gastro-hepatic omental glands	...	...	...	...	...	1	"
Peritoneum	...	...	...	...	...	1	"
Uterus	...	...	...	...	...	1	"
Ovary (L.)	...	...	...	...	...	1	"
Tibia (R.)	...	...	...	...	...	1	"
Ribs (B.)	...	...	...	...	...	1	"
Spleen	...	...	...	...	...	1	"
Duodenum	...	...	...	...	...	1	"



By massing Török and Wittelshöfer's numerous necropsies with those of several other European observers, Gross has brought together 423 necropsies on persons dead of breast cancer, with the result that metastases were distributed as follows :—

	Per cent.
Pleura ... ..	in 50·9
Lung ... ..	49·9
Liver ... ..	48·6
Bones ... ..	20·5
Brain ... ..	9·4
Ovary ... ..	8
Mamma (of opposite side)...	7·8
Dura mater ... ..	5·9
Kidney ... ..	5·7
Retroperitoneal glands ... ..	5·4
Uterus ... ..	5·2
Peritoneum ... ..	4·7
Spleen ... ..	4·7
Stomach ... ..	4·7
Pericardium ... ..	4·4
Bronchial glands ... ..	3·5
Mesenteric glands ... ..	3·3
Thyroid gland ... ..	1·8
Intestines ... ..	1·8
Suprarenal ... ..	1·8
Pancreas ... ..	1·6
Omentum ... ..	1·2
Heart ... ..	·9
Venous system ... ..	·9
Mediastinal glands ... ..	·9
Fallopian tubes ... ..	·9
Bladder ... ..	·7
Muscles ... ..	·7
Vagina ... ..	·4
Spinal cord ... ..	·2
Œsophagus ... ..	·2
Ureter ... ..	·2

The above analyses show that metastases are of much more frequent occurrence in some parts of the body than in others.

The liver, lungs, pleuræ and bones are their seats of predilection ; while they are very rarely found in the lips, tongue, mouth, pharynx, œsophagus, small intestine, skin, mucous mem-



brane, ligaments, tendons, prostate, urethra, bladder, pelvis, clitoris, vagina, lachrymal gland, parotid, and other salivary glands, eye, ear, nose, thyroid, vermiform appendix, spinal cord, heart, muscles, stomach, uterus, mamma, &c. The only parts really quite exempt are avascular structures like cartilage, cornea, &c.

Careful examination of the facts show, that, strictly speaking the mutual local exclusiveness between primary and secondary cancers, announced by Virchow,<sup>70</sup> does not exist; nevertheless it is undoubtedly true, that parts specially prone to originate the disease, *i.e.*, tongue, lip, skin, mouth, œsophagus, uterus, breast, stomach, &c., are seldom the seats of secondary outbreaks.

Most pathologists are agreed, contrary to what is shown in Gross' table, that the *liver* is the organ most frequently affected with metastases in mammary cancer. My analysis of forty-four necropsies shows this in a striking manner; but it would have been otherwise had I not carefully separated the true pulmonary metastases from those cases (twelve in all), in which the lungs were invaded by *direct extension* of the primary disease, or by its *local dissemination*. The discrepancy between Gross' analysis and mine is evidently due to this cause. The same criticism applies also to the *pleura*.

The ribs, sternum, and occasionally the clavicle, as I have previously mentioned, not unfrequently become cancerous through direct extension of the primary disease or through its local dissemination.

In addition to this, however, as shown by the subjoined analyses, certain *bones* are very prone to metastases. Thus—

*Of Török and Wittelshöfer's 336 P.M.'s*

Cranial bones were invaded	...	...	...	in	33	cases
Vertebræ	...	...	...	"	9	"
Innominate	...	...	...	"	9	"
Humerus	...	...	...	"	5	"
Femur	...	...	...	"	3	"

<sup>70</sup> "Path. des Tumeurs," 1867, t. i., p. 67.



*Of Nunn's 123 P.M.'s*

Cranial bones were invaded	...	...	...	in	3 cases
Ribs	...	...	...	"	3 "
Vertebræ	...	...	...	"	1 case
Femur	...	...	...	"	1 "
Humerus	...	...	...	"	1 "
Not stated	...	...	...	"	1 "

*Of the Author's 44 P.M.'s*

Femur was invaded	...	...	...	in	4 cases
Humerus	...	...	...	"	2 "
Vertebræ	...	...	...	"	1 case
Ribs	...	...	...	"	1 "
Tibia	...	...	...	"	1 "

By massing the above we get 533 *necropsies* with metastases in the cranial bones in thirty-six, vertebræ in eleven, innominate in nine, femur in eight, humerus in eight, ribs in four, tibia in one, and not stated one.

The exalted position of the *cranial* bones in this list is entirely due to Török and Wittelshöfer's analysis, in which these bones were cancerous in 9 per cent. of all necropsies; whereas in the other two estimates they were affected only in 1·8 per cent. In the latter series, however, the cranium was only opened when signs of its disease had been noticed during life, whereas in the former the cranium was opened as a matter of routine in nearly every case. The apparent discrepancy may be accounted for by the fact that most metastases in the cranial bones start in the *diplœ*, and progress more rapidly inwards than outwards, owing to the greater thickness and density of the outer table. Probably also in many of Török and Whittelshöfer's cases the cranial bones were affected from *within*. It accords with this that they met with intra-cranial metastases in forty cases (10·9 per cent.); whereas in the other series metastases were found here only in seven cases (4·2 per cent.). It may be inferred from the above that intra-cranial metastases frequently exist without giving rise to any obvious symptoms. The seats of the tumours in Török and Wittelshöfer's forty intra-cranial cases were :—Dura mater in twenty-five, cerebrum in twenty-two, cerebellum in thirteen, pia mater in three, and pineal body in two.



Metastases in the *vertebræ*<sup>71</sup> almost invariably originate in the bodies; usually several adjacent bones are affected, and in most cases the disease is situated in the lower dorsal or upper lumbar regions. As the growths progress they often cause excruciating pain, and eventually kyphosis or even angular curvature, and sometimes paraplegia.

The following instance of this kind came under my observation:—

A woman, aged 43, first noticed a hard lump—about the size of a marble—in her left breast four years ago. As the disease increased the breast was amputated, rather less than two years ago. One year later recurrent nodules were excised from the same region. Since this time she has suffered from excruciating pain in the right lower limb—like sciatica; also from abdominal pain, chiefly in the hepatic region. A few months after the last operation a fresh outbreak of the disease was noticed in the vicinity of the old scar. When I first saw her—some months later—she had several hard, cancerous nodules in this situation; and she was suffering much from sciatica. The axillary glands (left) were enlarged and hard. She died about sixteen months later, and three weeks before death paraplegia supervened. Nearly the whole of this time she was bed-ridden, and suffered much pain in the right lower limb, and subsequently in the lower part of the back. At the *necropsy* the body was greatly emaciated. There was a hard, nodulated, adherent mass of scirrhus cancer, the size of an orange, in the scar of the left mammary region. The axillary glands of this side were enlarged and cancerous. The bodies of the lower dorsal and upper lumbar *vertebræ* were soft and infiltrated with cancerous growth. Opposite the bodies of the sixth and eighth dorsal *vertebræ* projections from this growth compressed the spinal cord—which was here narrowed and diffuent—but neither the cord nor its membranes were infiltrated. The upper part of the left pleura contained several small cancerous nodules, probably the result of local dissemination. In the upper part of each lung were old tubercular lesions, together with pleural adhesions. Recent miliary tubercles were scattered throughout the right lower lobe. There were no other noteworthy lesions.

As an example of metastases in the *innominate* and *pelvic* bones, I will cite the two following remarkable cases:—

The patient, aged 60, under the care of Arnott,<sup>72</sup> died with ulcerated scirrhus of the breast, of eight and a half years duration, for which no operation had ever been done. During the last two years of her life she complained much of pains in the back, pelvis, and thighs. Three months

<sup>71</sup> For further details *vide* Delorme. “Etude sur le cancer de la colonne vertébrale consécutif au cancer du sein,” *Thèse de Paris*, 1876.

<sup>72</sup> *Trans. Path. Socy., Lond.*, vol. xix., p. 356.



before death, complete paraplegia supervened, which had been preceded first by numbness of the left lower limb (with the formation of a slough over the metatarsus), and subsequently by hyperæsthesia. At the *necropsy* the glands of both axillæ and inguinal regions were found infiltrated with cancer, but there were no deposits in any of the viscera. The bodies of the four lower lumbar vertebræ were infiltrated with cancer, much flattened, and so soft that they could easily be cut with a knife; their spinous and transverse processes were similarly affected. A globular cancerous tumour, four inches in diameter, occupied the posterior part of the left innominate bone above the sciatic notch, and the adjacent part of the sacrum was extensively invaded by it. Projecting into the pelvis from the right innominate bone, over the region by the acetabulum, was a tumour the size of half an orange, at the base of which the cancerous disease extended through the entire thickness of the bone, and projected from its external surface—below and behind the acetabulum—as a pear-shaped mass. The ischial tuberosity was thickened and infiltrated. Numerous small cancerous nodules were found throughout other parts of both innominate bones and the sacrum; and these bones were in places quite soft. The head of the right femur, though not changed in form, was infiltrated with cancer and quite soft.

The case of an old woman, related by Cruveilhier,<sup>73</sup> who some time previously had undergone amputation of the breast for cancer, which had not returned, is very similar to the above. She was seized with severe pains in the pelvis, and inability to stand; but there was no obvious deformity. She subsequently died of exhaustion; and on examination after death it was found that the whole of both innominate bones were carnified by diffuse cancerous infiltration, but the periosteum was uninvaded.

When cancer disseminates in the bones, several are usually involved, but quite exceptionally only one. Moreover it is rare for disseminative lesions to be limited solely to the osseous system, as in the above cases, and the following ones by Walther,<sup>74</sup> &c.

A woman, aged 60, died with ulcerated scirrhus cancer of the lower and outer part of the left breast, and numerous small, hard nodules disseminated in its vicinity, no deep infiltration of the subjacent parts. On *post-mortem* examination, secondary growths were found in the cranial bones, the upper part of the left femur, and in the bodies of the sixth and seventh dorsal vertebræ, but none elsewhere.

In a case of which there is a plaster cast in St. Thomas' Hospital Museum (fig. 40), the secondary deposits in the bones were diffuse. The patient died after amputation of her right breast for cancer. The scar in the mammary region appeared quite healthy; and the only obvious lesions were confined to the osseous system. At the necropsy the skeleton was greatly

<sup>73</sup> *Anat. Path.*, liv. 20, p. 2.

<sup>74</sup> *Bull. de la Soc. Anat.*, 1890, p. 423.



distorted. The thorax had flattened transversely; the sternum and ribs having sunk in, so that the former almost touched the spinal column. The pelvis exhibited somewhat similar deformity. The right humerus and both femora had undergone spontaneous fractures at their upper parts; and the fragments had united in very faulty positions. There was diffuse cancerous infiltration of the medulla of the fractured bones; and on microscopical examination, the new growth was found to consist of alveolar cancer, very like the ordinary scirrhus of the breast.

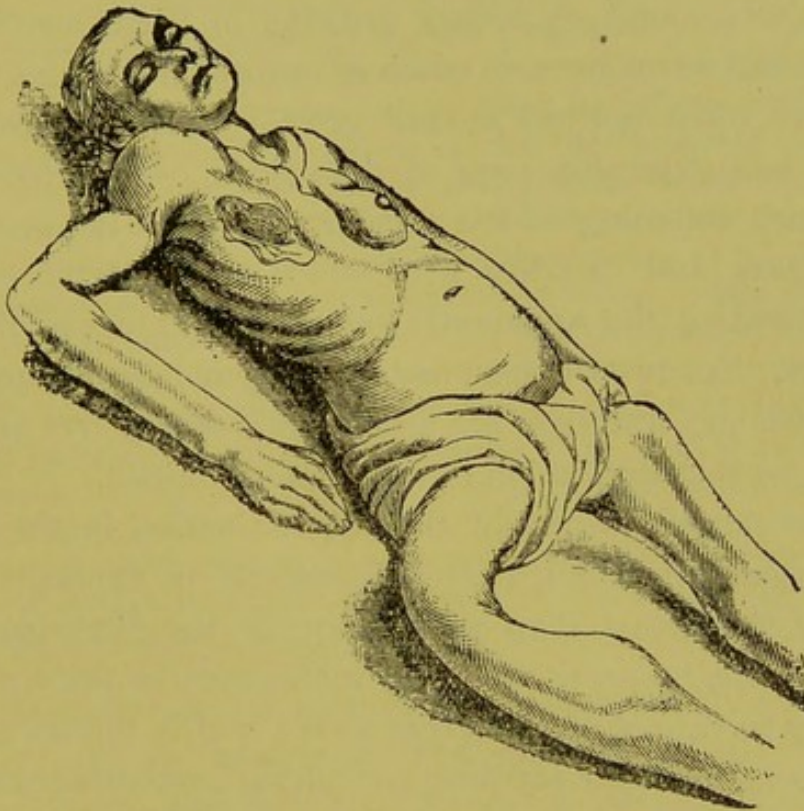


FIG. 40.—Multiple spontaneous fractures from dissemination in the bones (*Snow*).

Of the long bones metastases are commonest in the *femur* and *humerus*; both sides are generally affected, but often only one.

As an instance of wide-spread dissemination of this kind, mention may be made of a case I once saw, in which, several years after amputation of the left breast for primary cancer, recurrence took place in the mammary region; and metastases subsequently formed in the liver, spleen, retro-peritoneal glands; as well as in the following bones (all of which fractured spontaneously)—both humeri, right clavicle, third, fourth, and fifth right metacarpals, and the left femur. In this case the osseous growths were circumscribed.



In the femur metastases generally originate in the medulla at about the middle of its upper half; and in the humerus at the junction of its upper and middle thirds. As the growths increase, they cause "pressure atrophy" of the cortex, and so eventually spontaneous fractures. Until this happens, osseous metastases seldom give rise to symptoms—other than quasi-rheumatic pains. In making *post-mortem* examinations I have several times found secondary growths in these bones, whose presence had never been so much as suspected during life.

I have often noticed around growing endosteal cancers, a more or less extensive zone of decalcified osseous tissue; this preparatory softening of the adjacent bone no doubt accounts for the ease and rapidity with which the growths progress, notwithstanding the apparently unyielding nature of their surroundings. Fractures due to metastases generally excite a great deal of swelling, and they are usually followed by free formation of callus, so that firm union is sometimes attained.

There can be no doubt that dissemination in the osseous system occurs very much more frequently in connection with cancer of the breast, than with cancer of any other part of the body. I have, however, met with metastases in the right tibia, secondary to cancer of the *cervix uteri*; and in the seventh and eighth dorsal vertebræ (causing paraplegia), secondary to cancer of the lower part of the *rectum*: moreover, I know of several other similar cases.<sup>75</sup>

Of these, the University College case presents so many remarkable features that I subjoin a brief account of it:—

---

<sup>75</sup> *Q. v. Bart's Hosp. Rep.*, 1888, p. 389. "Cancer of *cervix uteri* with dissemination in the left *femur*."

*Univ. Coll. Hosp. Rep.*, 1888, p. 92 and p. 142. "Cancer of *cervix uteri* with dissemination in upper part of right *humerus*."

*Middlesex Hosp. Museum Catalogue*, p. 69, No. 600. "Cancer of *cervix uteri* with dissemination in the *ribs*."

*Trans. Path. Soc., Lond.*, 1891. "Cylinder-celled epithelioma of *rectum* with dissemination in right *humerus*."

Cruveilhier's *Anat. Path.*, liv. 20, p. 5. "Cancer of *stomach* with dissemination in right *humerus*."



The patient, aged 52, came to the hospital on account of painful swelling at the upper part of her right arm, of two months duration. She complained also of considerable loss of power in the part, which began to weaken about a year ago. On examination there was found great enlargement of the upper end of the humerus, which extended as far down as the insertion of the deltoid. The overlying skin was reddened, and the subcutaneous veins were much enlarged. There was great loss of power in the limb, and constant "gnawing" pain was experienced, which extended down to the elbow. Passive movements at the shoulder joint could be effected, but they caused much pain. There was family history of phthisis; and a sister had died of internal cancer. Her previous health had never been good. The swelling was aspirated, but only some blood and fatty matter came away. Under these circumstances it was resolved to amputate at the shoulder joint. During manipulation, prior to operation, the bone fractured through the surgical neck. The part was removed by cutting the deltoid flap by dissection, and the internal flap by transfixion, with antiseptic precautions. The upper part of the humerus, as far down as the insertion of the deltoid, was found to be involved by a cancerous growth; but the cartilage of the head was intact. The wound healed quickly; but the patient's health, nevertheless, progressively deteriorated, and she died about seven months after the operation. Some time prior to this it was discovered that she was suffering from ulcerated cancer of the *cervix uteri*, to which the cancerous tumour of the humerus was evidently *secondary*. Histologically examined, the latter growth consisted of fibrous stroma containing numerous small spaces, for the most part lined by but a single layer of short columnar cells, but some of the spaces were filled with cells of a more flattened type. The appearances were similar to those met with in cancer of the *cervix uteri*.

I have seen several instances in which elderly women with mammary cancer have sustained—in consequence of some trivial accident—spontaneous fracture of the upper part of the femur. Usually such cases have been mistaken for ordinary senile intra-capsular fracture; until, after a time, the presence of mammary cancer has been discovered. *Spontaneous fractures of the upper part of the femur in emaciated, sallow, elderly women should always be regarded as suspicious of mammary cancer.* The two following cases illustrate this:—

(1) A pale, sallow and emaciated woman, aged 49, came under treatment on account of having recently fractured her left femur when turning in bed. On examination there was found great swelling at the upper third of the thigh, and the bone was obviously fractured at this situation. Some time afterwards there was accidentally discovered a nodular tumour of extreme hardness, the size of a bantam's egg, in the upper and axillary segment of her right breast. The nipple was retracted, and the overlying skin adherent; but the tumour was movable over the subjacent parts. At the junction of



the first and second pieces of the sternum, there was a hard flattened swelling as from a cancerous growth. The axillary glands were enlarged and hard. When questioned, the patient said she first noticed a lump in her right breast three months before breaking her femur. She had suffered much from rheumatic pains for a year, and on this account she had been confined to her bed for four months. She died of asthenia about three months later, when, in addition to cancerous growths in the femur and sternum, both pleuræ, the liver, and the axillary glands contained secondary growths, all of them, like the primary disease, of the atrophic type.

(2) This patient, aged 60, also came under treatment on account of having recently sustained a spontaneous fracture of the upper extremity of her right femur, at the junction of the shaft and great trochanter. She was emaciated and sallow. It was subsequently discovered that she had in the central part of each breast a hard nodular cancerous tumour, the size of half a small orange. The overlying skin on both sides was adherent, and over the right tumour the skin was eroded. The adhesions with the subjacent parts were but slight. Both tumours were exceedingly hard. A tumour in the right breast was first noticed one year ago. The axillary and infra-clavicular glands of both sides were enlarged and hard. She died of asthenia about a month later. At the necropsy there was found to be a fracture of the right femur in the position above indicated. At this spot there was a large mass of whitish cancerous growth with calcareous deposit in it. The medulla of the upper part of the shaft was infiltrated and the cortex atrophied. The adjacent soft parts and the glands of the groin were invaded. On sawing open the left femur, which presented externally no obvious sign of disease, I found a cancerous growth the size of a walnut, in the medulla, at the junction of the shaft with the great trochanter. Here the cortex of the bone had been eaten away by contact with the cancerous nodule, and it was almost perforated. There were secondary cancerous growths in the third, fourth, and fifth ribs of the right side on the antero-lateral aspect of the chest; and a similar growth in the fifth left rib. In these positions the bones were fractured. The liver, mesenteric and omental glands, with the pleuræ, as well as the glands of both axillary and infra-clavicular regions, were also the seats of secondary growths.

On *à priori* grounds there seems to be no reason why cancer of one breast should not cause, by systemic dissemination, secondary disease in the *opposite breast*, and of this condition the last recorded case seems to be an example. Metastases in the breast, secondary to cancer elsewhere than in the mamma, are by no means unknown. I have seen instances of this kind in which the primary disease was in the uterus, ovary, rectum and peritoneum. Of the first of these I will give a brief abstract.



The patient was a married woman, aged 49, the mother of one child. One and three-quarter years ago, she first became subject to sanious vaginal discharge, and shortly afterwards flooding set in. She had since been subject to return of the latter condition every two or three months. Eight months ago the cancerous cervix was amputated. She was relieved for two months, when the old symptoms returned. Four months ago she first noticed a lump in her left breast, the size of a hazel nut; and two months later a small nodule in the skin over the upper part of the sternum. When first seen by me she had profuse sanio-puriform vaginal discharge; and the *portio vaginalis uteri* was replaced by a hard, nodular, ulcerated surface, with infiltration of the adjacent parts of the bladder, vagina and rectum. She complained of pain in the sacral and genital regions, and of difficult and painful defæcation. At the lower and axillary part of her left breast was a hard, flattened nodule, the size of half a walnut, adherent to the overlying skin, but movable on the subjacent parts; the nipple normal; and the axillary glands not obviously affected. In the skin over the left edge of the sternum, level with the second costal cartilage, was a hard nodule the size of a pea. She died of asthenia six months later; and there was no necropsy.

The massed statistics of Gross show dissemination in the *uterus* in 5·2 per cent. of all breast cancer necropsies. In Nunn's 123 necropsies it was met with in four; and in my forty-four necropsies in one; or in about 3 per cent. of these 167 necropsies. Uterine metastases almost invariably affect the *body* of the organ, generally its peritoneal surface. In a case under my observation several nodules were found in this situation, as well as in both pleuræ, the right femur, and the right humerus. In very exceptional cases, however, we do find dissemination in the *cervix uteri* secondary to mammary cancer; under these circumstances the uterine lesion debuts as a *nodule*.<sup>76</sup>

Bryant<sup>77</sup> has put on record a case of this kind. His patient, aged 50, came under observation with infiltrating cancer of the breast, of two years duration. The axillary glands were not affected. The breast was amputated without interfering with the axilla. Four years later, being quite free from any return of the cancerous disease, melanotic sarcoma developed in a mole of the skin of the left armpit. In the course of six months it increased to the size of a hazel nut. It was then excised, and there was no return of this disease. Eight years after amputation of the breast the left arm became œdematous and swollen, and a painful swelling developed at the upper part of the left femur. About the same time she had "flooding," and a cancerous

<sup>76</sup> For instances of the independent outbreak of cancer in the breast and uterus *vide*, ch. x., § 9.

<sup>77</sup> "Diseases of the Breast," p. 340.



*nodule*—the size of a hazel nut—was found in the *cervix uteri*. Six months later recurrent cancerous nodules were for the first time noticed in the left mammary region in the vicinity of the old operation scar ; and when turning in bed she fractured her left femur at the seat of the painful swelling. She died a few months later—nine years after extirpation of the primary disease. There was no necropsy. Here, I think, we evidently have a case of recurrence in the mammary region—at first unnoticed—followed by dissemination in the *cervix uteri*, femur, &c. .

Brodie<sup>78</sup> mentions an instance of cancer *en cuirasse* of the female breast, with metastases in the liver and *cervix uteri*.

In Nunn's<sup>79</sup> case of associated cancer of the *cervix uteri*, both breasts and liver, the disease probably originated in the uterus, and disseminated in the other organs.

Gross' statistics show metastases in the *ovaries* in 8 per cent. of all breast cancer necropsies. Of Nunn's and my 167 necropsies, ovarian dissemination was met with in eight cases, or in 4·8 per cent. In four of these cases *both* ovaries were affected, and in four only *one*. Coupland<sup>80</sup> has met with a case in which *both breasts and ovaries* were cancerous.

The patient was a stout, healthy-looking Irish *brunette*, only 24 years old, who came under observation with a very hard subglobular tumour—about three inches in diameter—in the sternal segment of her right breast, and a second small nodule in its upper part, as well as an enlarged gland in the axilla. The whole breast was extirpated, and the axilla cleared. Five months later two small recurrent nodules were excised from the mammary region. Two months afterwards there was sudden and rapid eruption of recurrent nodules, beginning in the right mammary region and spreading to the left ; and soon afterwards the whole of the upper part of the front of the chest on both sides was invaded by cuirassed cancer, together with the glands of both axillæ and those at the root of the neck. As the disease progressed, cyanosis supervened, with dyspnœa and asphyxia, of which she died a fortnight after the onset of the acute cancerous outbreak. At the *necropsy*, in addition to the above mentioned lesions, the surface of the heart was the seat of diffuse cancerous dissemination, as well as both ovaries. Histologically, the breast cancer was of the ordinary acinous type, and that of the ovaries is described as medullary. There was effusion of fluid into the left pleura ; the other organs were normal.

This case has lately been cited as an example of primary multiplicity, as it appears to me, without adequate reason, for

<sup>78</sup> "Lectures on Path. and Surgery," 1846, p. 209.

<sup>79</sup> "Cancer of the Breast," p. 106.

<sup>80</sup> *Trans. Path. Soc., Lond.*, vol. xxvii., p. 26.



had the ovarian outbreaks been of independent origin, the pelvic lymph glands, &c., would have been invaded.

By far the most feasible explanation known to me of the phenomena of systemic dissemination is that furnished by the "embolic theory." This implies that the germs whence metastases arise are proliferous cells, detached from the primary neoplasm or its derivatives, and carried off by the *blood stream*. These, by their continuous proliferation, directly originate the secondary growths; so that the first cancer is the parent of all that form after it. The conception of metastases, as due to specific virus (blastema, &c.) dissolved in the blood, belongs to old humoral pathology, and now finds no support,<sup>81</sup> except with those who would revive the old doctrine in connection with the microbe theory. It has been proved by many observers that cancer cells enter the blood stream directly through the blood vessels—especially the small veins—as well as indirectly through the lymphatics. In the latter instance, cancer cells taken up by the mammary lymphatics, and not arrested by the glands, are carried on with the lymph stream into the large veins at the root of the neck. Astley Cooper, Andral and others have found free "cancer emboli" in the thoracic duct and in the large lymphatic trunks of this locality; and these vessels have often been found plugged with cancerous growth.

The occurrence of general dissemination, without any lymph gland affection, shows, however, that cancer cells may enter the blood otherwise than through the lymphatics; and my own belief is that metastases frequently originate in this way, just as they do in sarcoma. Hardly ever can a mammary cancer be examined without finding the veins of the tumour and its vicinity invaded by the disease. In the earliest stage the venous wall becomes adherent to the neoplasm; then it gets infiltrated,

---

<sup>81</sup> Friedreich's case (*Arch. f. path. Anat.*, Bd. xxxvi., S. 465) of cancerous metastases in the left knee of a foetus, whose mother died of cancer of the liver with metastases during the pregnancy, much relied upon by the advocates of infection by the fluids as supporting their theory, can easily be accounted for by the embolic theory.



and its external coat perforated. In the next stage the new growth projects more and more into the vein, covered only by the intima of the latter. This soon yields, and the neoplasm—in the form of a small fungus—then projects into its lumen; whence the growth may be detached *en masse*, or in minute fragments. Cancer emboli of this kind have frequently been found free in the blood between the primary seat of disease and its derivatives, and the right side of the heart, and even in the latter and in the pulmonary artery. Several trustworthy observers—Lücke among others<sup>82</sup>—maintain that they have found cancer cells free in the blood. That cancer emboli may develop into cancerous neoplasms, the well-known facts as to the auto-inoculability of the disease conclusively prove (Hahn's experiments, &c.).

We have now to enquire what it is that determines the development of metastatic tumours in certain localities rather than in others. There can be no doubt that the dissemination of cancer emboli is regulated by the same mechanical conditions that determine the distribution of ordinary emboli: from the veins at the root of the neck they pass to the right side of the heart, thence to the lungs; whence those small enough pass through the pulmonary capillaries, and so into the left side of the heart, and thence into the aortic system. It seems to follow from this—since the pulmonary capillaries are considerably smaller (·007 to ·008 mm.) than most cancer cells (·010 to ·050 mm. and upwards)—that the latter must almost invariably be arrested first of all in the lungs; and consequently that metastases must originate there, and that other organs can only be attacked through dissemination thence. But such conclusions are not in conformity with the results of actual observation, which show that the liver is more frequently the seat of metastases than the lungs; and that the latter often escape, when other organs are invaded, whose capillaries are larger than

---

<sup>82</sup> *Handb. d. allg. u. spec. Chir.*, 1876.



those of the lungs.<sup>83</sup> These and other phenomena of similar import, indicate that the formation of metastases is conditioned by other considerations besides those of mere mechanical distribution.

The experiments of Maas and Cohnheim<sup>84</sup> have shown that though fragments of post-embryonic tissues, displaced from their normal surroundings and introduced into the bodies of other animals, grew at first; yet, after a time, they were invariably absorbed, and completely disappeared. The reason for this evidently is that the foreign structures were ultimately unable to withstand the metabolism of the healthy tissues. In like manner I suspect most cancer emboli perish; but because some organs are less active in this respect than others, therefore they are more frequently affected with metastases. How otherwise can we explain the great frequency with which the liver is affected, and the remarkable relative immunity of the spleen, both organs being equally exposed to the incidence of cancer emboli? That cancer emboli frequently survive and develop into secondary tumours, in spite of the resistance of the tissues, evidently must be due either to their abnormal inherent activity, or to falling off in the physiological capacity for resistance of the tissues. According to Cohnheim, it is wholly and solely due to the latter. In this I cannot concur. The experiments of Zahn<sup>85</sup> and Leopold<sup>86</sup> appear to me to point the other way. They have shown that transplanted grafts of *embryonic* tissues survive in spite of the physiological resistance, even to the extent of increasing 200 or 300 times in size. This is clearly due to the inherent activity of their constituent cells; and, as I have previously shown, it is with embryonic

---

<sup>83</sup> The passage of cancer emboli through the lungs, in spite of the above-mentioned difficulties, becomes intelligible when we consider the velocity of the flow, the distensibility of the capillaries, and the smallness of *young* cancer cells, which often measure considerably less than the figures given above.

<sup>84</sup> *Arch. f. path. Anat.*, Bd. lxx., S. 161.

<sup>85</sup> Sur le sort des tissus implantés dans l'organisme, *Cong. méd. internat. de Genève*, 1878.

<sup>86</sup> *Arch. f. path. Anat.*, Bd. lxxxv., S. 283.



rather than with post-embryonic tissues, that actively growing cancer structures are comparable.

From the foregoing it will be gathered that the ultimate fate of a cancer embolus—its complete absorption or its development into a secondary cancerous growth—depends mainly upon whether the inherent vital activity of its constituent cells, is strong enough to resist successfully the phagocytic action of the part of the body in which it has lodged, or not.

### § VII.—Cachexia.

Consideration of the phenomena of cachexia naturally follows that of dissemination, because, as I shall proceed to show, just as the latter depend upon the entry of living cancer cells into the circulation, so the former likewise depend upon the entry into the circulation of the products resulting from their disintegration.

After a cancerous growth has existed in the breast for a variable time, which is generally rather long, the patient's health begins to suffer—even in the absence of ulceration, hæmorrhage, &c. Pallor, weakness, emaciation and loss of appetite, are among the most obvious manifestations. These, as the disease progresses, become greatly aggravated—the pallor taking on a peculiar earthy or straw-coloured tint—while other indications of profound disturbance of the general nutrition arise; which, when the malady runs its natural course, eventually determine death from asthenia.

The condition thus briefly sketched is that generally known as the cancerous cachexia. As a rule it is more typically developed in connection with breast cancers, than with those of most other parts of the body; yet in the tubular and colloid varieties of mammary cancer it is seldom seen. Sarcomatous tumours very rarely cause it, and non-malignant ones—even the largest—never. Hence the condition evidently cannot be attributed to the mere abstraction of nutritive materials from the blood, as some have suggested.

It is a noteworthy fact that cachectic symptoms never pre-



cede the outbreak of the primary disease; from this we may infer that they are a consequence of its local progress. Certain it is that after removal of the disease by operation the cachectic symptoms often disappear, and in the absence of recurrence, patients may retain their healthy appearance for several years, as in cases I have observed. The degree of cachexia is, however, by no means always proportionate to the mere extent of the local malady, for I have seen well-marked cachectic symptoms supervene acutely, at an early stage, when the primary disease has been quite small. Neither can it be maintained that cachexia is dependent upon dissemination, for it may be absent when the latter is very marked, and *vice versa*. In certain exceptional cases cancer of the breast may even run its entire course without ever causing any cachexia, or other very obvious disturbance of the general nutrition, the patients being able to follow their usual avocations almost to the last. The date at which cachectic symptoms supervene, their sequence, and degree of development are so exceedingly variable, that nothing definite can be stated in respect to them.

We may, I think, best interpret these symptoms as the result of a general toxæmia, the explanation of which must be sought in the remarkable proneness of the constituent cells of breast cancers to undergo granulo-fatty degeneration, which is often so extreme as to lead to their complete destruction by disintegration. When such excrementitious products find their way—by nutritive absorption or otherwise—into the general circulation, in quantities too great to be quickly eliminated and destroyed, they poison the fluids of the body, and so, by a kind of auto-intoxication, similar to that by which the system is infected from an inflammatory focus, they originate the phenomena of the cancerous cachexia. Hence these symptoms are much more frequently met with in association with cancers, whose cells are especially prone to degenerative disintegration, than with those whose cellular elements are more stable. It seems probable, from the experiments of Adamkiewicz,<sup>87</sup> that the excrementitious

---

<sup>87</sup> *Untersuchungen über den Krebs*, &c., Vien, 1893.



products thus produced contain toxines, analogous to the virulent substances secreted by microbes.

Through these agencies the *blood* of cancer patients gets profoundly modified both morphologically and chemically. Hayem<sup>88</sup> and others have found marked leucocytosis, the number of white corpuscles being increased, according to Hayem, from 6,000 per cubic millimetre—the normal standard—to 11,400 in breast cancer patients. Its poverty in hæmoglobin has been demonstrated by Quinquad:<sup>89</sup> 1,000 grammes of blood normally contain about 125 grammes of this substance, whereas in cancer patients the amount often does not exceed 25 grammes. Nothing comparable to this is met with in cases of sarcoma and non-malignant neoplasms. Laker<sup>90</sup> maintains that the difference between cancerous and non-cancerous blood in this respect is so marked and constant, that it may be relied on for the purpose of differential diagnosis. Andral and Simon long ago showed that in cancer patients the relative number of red corpuscles is diminished—even in the absence of ulceration and hæmorrhage—and these results have been confirmed by Ardle and others. The quantity of albumen dissolved in the serum is also less than normal. To these causes may be attributed the diminished specific gravity of the blood. Hence also the tendency in advanced cachexia to passive serous effusions—hydrothorax anasarca, &c.—as well as to venous thromboses. According to Freund<sup>91</sup> an excess of sugar in the blood is of constant occurrence in cancer.

Not only are the morphological and chemical constituents of the blood thus altered, but the experiments of Louis<sup>92</sup> show that its total quantity is notably diminished. This affords a ready explanation of the smallness of the heart and aorta, observed

<sup>88</sup> *C. R. de la Soc. de Biol.*, 1887, t. iv., p. 270; see also his work, “*Du Sang*,” Paris, 1889.

<sup>89</sup> *Chimie pathologique*.

<sup>90</sup> *Cent. f. d. med. Wissenschaft*, 1887, S. 405.

<sup>91</sup> “*Zur Diagnose des Carcinoms*,” *Wiener med. Blätter*, No. 9, 1885.

<sup>92</sup> “*Researches on Phthisis*,” Walshe’s transl., 1846, pp. 52, 54.



*post-mortem*, in most cancer cases that have run their natural course; although, as Beneke<sup>93</sup> has shown, prior to the outbreak of the disease, cancer patients have large hearts and blood vessels. Similar changes occur in the course of other chronic wasting diseases, especially in phthisis.

One of the most obvious manifestations of this depraved state of the blood is *pallor* of the skin, which, as the disease progresses, often assumes a waxy, puffy aspect, together with the peculiar straw-coloured tint, so characteristic of the cancerous cachexia. A somewhat similar condition may arise in certain stages of chlorosis and pernicious anæmia. From jaundice it differs in that it affects chiefly the skin—the mucous and synovial membranes and urine escaping. To the same cause may be attributed the hæmic murmurs so often audible over the heart and large vessels. A later developed manifestation is *emaciation*, which, when it has once set in, is steadily progressive, so that the wasting is often extreme. This, like most of the other individual symptoms of the cancerous cachexia, may, however, occasionally be absent.

*Gastro-intestinal* disturbance is commonly experienced. Loss of appetite, dyspepsia, anorexia, together with thirst, are often prominent symptoms. Nausea and vomiting are also of frequent occurrence, even in the absence of visceral dissemination; and slight jaundice is not uncommon. Constipation oftener exists than diarrhœa.

*Quasi-rheumatic pains* in various parts of the body, remote from the primary seat of disease, such as the loins, hips, lower limbs, &c., are often complained of. When these coincide with subacute febrile disturbance, as occasionally happens, the condition may easily be mistaken for subacute rheumatism, of which I have seen several instances. Often pains of a neuralgic character are experienced, as well as numbness and tingling of the hands, feet, &c.

Those who have examined cancer patients for *peripheral*

<sup>93</sup> "Constitution und constitutionelles Kranksein des Menschen," Marburg, 1887.



*neuritis* have generally found it—*e.g.*, Gombault, Klippel, Arthaud, Auché,<sup>94</sup> Isch-Wall,<sup>95</sup> &c. Other observers (Cuffer, Riehl, &c.) have described various visceral vaso-motor disturbances, which they attribute to inflammation of the sympathetic nerves.

In a few cases, after the disease has existed for a considerable time, cancer patients become *insane*; the form of mental derangement I have most frequently seen is that of dementia. Pinel<sup>96</sup> mentions a case of this kind in which the insanity was cured by removal of the cancerous disease.

Alterations in the blood that involve considerable reduction in its hæmoglobin, as in phthisis, chlorosis, anæmia, &c., are usually associated with widespread *fatty degeneration*, the result of impaired oxidation from diminished supply of oxygen. The cancerous cachexia is no exception to this rule; but it is not until emaciation has made marked progress that these changes set in. The parts most obviously affected—to the naked eye—in breast cancer, are the liver, kidneys, aortic arch, blood vessels, heart, &c.; but histological examination shows that these changes are not limited to the above-mentioned localities—they affect most parts of the body, especially the gastric mucous membrane.

A remarkable fact that may be mentioned here, is the rarity of *amyloid degeneration* in association with cancer; there was not a single instance of it in the forty-four necropsies on breast cancer patients analysed by me.

From the general malnutrition consequent on the cancerous toxæmia, the *bones* suffer as well as the other structures. Great interest attaches to these little studied changes, which require to be carefully discriminated from the lesions produced by cancerous dissemination, with which most pathologists have confounded them. According to my experience the bones most frequently

<sup>94</sup> *Revue de Méd.*, 1890, p. 785. "Des névrites pérphériques chez les cancéreuses."

<sup>95</sup> "Cancer et Arthritisme," *Thèse de Paris*, No. 147, 1890, p. 119.

<sup>96</sup> "Traité de Path. Cérébrale," p. 224.



thus affected in a marked degree are the *ribs*, *sternum*, *femur*, *humerus*, and *vertebræ*. These when affected still retain their normal size and shape; but they are lighter and more fragile than they should be, so that they are easily fractured. There is thinning of the cortex, with increased size of the medullary canal, and relative deficiency of inorganic salts. The Haversian canals and cancelli are much enlarged, and filled with diffuent fatty matter, hence the undue porosity. There is, however, no softening from decalcification as in osteo-malacia. Altogether the indications point to defective deposition of new bone, to replace the normal loss by absorption, as the proximate cause of the disease. The condition seems to have many analogies with the bone degeneration of the insane and of the senile. Owing to this fragility of the bones, so-called *spontaneous fractures* are easily determined, as in the following cases:—

(1) A pale woman, aged 53, came under my observation with recurrent scirrhus cancer of the right mammary region. Between the amputation, scar and the outer third of the clavicle was a hard, fixed, nodular mass, adherent to the overlying skin. The right upper limb was œdematous and useless, and the axillary glands were extensively involved. There was an ununited fracture of the upper part of the right femur, accompanied by great swelling, which resulted from spontaneous fracture three months previously. Five years ago the primary disease began as a small hard lump in the upper segment of the right breast. Three years later the diseased part was amputated, and one year ago the present recurrence set in. No further operation was done, and the patient died of pulmonary complications some nine months later. At the *necropsy* an old ununited fracture of the upper third of the right femur was found, with angular displacement of the fragments, the ends of which were embedded in a large mass of partially ossified callus; there was a similar fracture of the left femur. In moving the body the right humerus fractured just above the elbow joint. The ribs and sternum were very brittle. Longitudinal sections were made of all these bones and of several others; but no sign of cancerous growth could be found in connection with any of them. The cortex of each was very thin; the medullary cavity greatly enlarged was full of diffuent fatty substance. The cancerous growths in the mammary region and axilla were of a hard, crisp, scirrhus nature. The former had penetrated the chest wall and invaded the upper part of the right pleura; this had caused hydrothorax and collapse of the right lung. The œdema of the right upper limb was caused by the pressure of cancerous glands upon the axillary vein. The liver contained several cancerous nodules.



(2) A woman, aged 47, with atrophic scirrhus of the left breast, and infiltration of the axillary and supra-clavicular glands. At the necropsy a secondary nodule was found in the right kidney. There were double spontaneous fractures of four ribs on the right side ; and two similar rib fractures on the left side—one double and the other single. There were no secondary cancerous growths at the seats of fractures. The right ventricle of the heart was in advanced fatty degeneration. The lungs were emphysematous and congested.

(3) In the museum of University College, London, there is a specimen of this disease, which is described in the catalogue as follows :<sup>97</sup> "Longitudinal section of humerus, the shaft of which was fractured a short distance below its middle, by the patient turning in bed. A ring of porous osseous tissue has been formed around and unites the end of the fragments, the compact walls of which are coarsely reticulated from inflammation accompanying the reparative process. A second fracture had occurred about one and a half inches below the preceding, and had firmly united, the medullary canal being still filled with osseous substance. The osseous tissue has throughout a friable chalky appearance, and towards its upper end the bone is considerably atrophied. From a woman who was extensively affected with cancer. There is no appearance of the humerus itself having been the seat of, or invaded by any morbid growth."

De Morgan<sup>98</sup> mentions a similar case in which the bodies of several vertebræ completely disappeared.

Török and Wittelshöfer<sup>99</sup> met with the like osseous lesions in eight of their 366 necropsies on patients dead of breast cancer. Rokitansky, Lücke, Billroth, and others have also described cases of this kind.

When *ulceration* sets in, and the wound gets invaded by microbes, the ordinary symptoms of septic infection are super-added to those of the cancerous cachexia. Consequent suppuration and hæmorrhage further weaken the patient. At length, if not cut off by some intercurrent disease, death results from *asthenia*, as happened in twenty-four out of forty cases that ran their natural course under my observation.

<sup>97</sup> "Catalogue of Surgical Pathology," part i., 1881, p. 5.

<sup>98</sup> "On the Origin of Cancer," 1872.

<sup>99</sup> "Zur Statistik des mamma Carcinoms," *Arch. f. klin. Chir.*, Bd. xxv., S. 873, 1881.



## § VIII.—Recurrence.

No feature of cancer has attracted more attention than that which is known as "recurrence." It certainly does seem extraordinary, after everything has been done to ensure its destruction—whether by the knife, by fire or by caustics—that the disease should, nevertheless, so frequently spring up again. Before attempting to explain this remarkable phenomenon, I propose briefly to set forth the chief known facts relating to it.

In the great majority of these cases the recurrent disease makes its first appearance in the *locality* occupied by the primary disease, less frequently in the adjacent lymph glands, and—rarest of all—in remote parts of the body.

Thus of forty-seven recurrent mammary cancers under my observation, the disease first reappeared in the primarily affected mammary region in twenty-one cases; in the mammary region and in the axillary glands, at about the same time, in eighteen cases; and in the axilla alone in eight cases.

According to Gross,<sup>102</sup> of 496 local recurrences—

294 or 59·27	per cent.	were in the mammary region alone.
117 or 23·59	" "	mammary region and the adjacent lymph glands.
77 or 15·50	" "	adjacent lymph glands alone.
8 or 1·61	" "	opposite breast.

Thus of these 543 recurrent cases the disease was situated in the mammary region in about 83 per cent.; and in the axilla alone in about 15 per cent.

Recurrences in the mammary region, when first noticed, usually present as small nodules—from three to six or more in number; their initial situation being either in the operation scar or its immediate vicinity, or in the subjacent muscle—rarely elsewhere.

Reappearance of the disease in parts of the body not directly connected with the primary neoplasm or its derivatives (so-

<sup>102</sup> *Am. Syst. Gyn.*, vol. ii., p. 301.



called metastatic recurrence), was found by Gross to have taken place in 178 out of 1,036 cases, or in 17 per cent.; but in 129 of these cases there was local or lymph gland recurrence as well.

The *period* at which recurrences first present is exceedingly variable; and the numerical results obtained by different investigators are often divergent. Of forty-seven consecutive cases under my observation, the average interval between the operation and the first obvious recurrence was twenty-six months, the maximum 130 months, the minimum a few weeks. These results are more favourable than those arrived at by my predecessors. According to Gross, the average period of immunity only amounts to 9·4 months.

I have compiled the following table, based on 599 cases, to show the periods at which recurrence may be expected.

Interval between <i>operation</i> and <i>first obvious recurrence</i> .	Author's 47 cases.	Paget's 74 cases.	Gross' 478 cases.	Total 599 cases.	Per cent.
Under 3 months .....	4	23	211	238	39·7
3 to 6 months .....	8	22	87	117	19·5
6 to 12 months .....	9	14	106	129	21·5
12 to 24 months .....	10	7	47	64	10·8
2 to 3 years .....	6	3	16	25	4·2
Over 3 years .....	10	5	11	26	4·3

From this we learn that nearly 60 per cent. of all recurrences take place within the first six months after operation; and of these 40 per cent. originate within the first three months. According to Gross, 22 per cent. occur within the first month, and 8·9 per cent. within the first fifteen days. The proportion of recurrences attributed by Winiwarter to the first month is even higher than this. On the other hand, only 4·3 per cent. of all recurrences originate after three years.

Occasionally recurrence sets in *immediately* after operation, as in the following case:—

A stout, healthy-looking woman, aged 68, with very large mammæ, came under my observation with a movable tumour—of three months growth—the size of a turnip, in the middle of her right breast. There was no obvious affection of the axillary lymph glands. The breast was amputated without opening the axilla. Immediately afterwards acute diffuse recurrence



set in, which involved the whole wound. The skin, pectoral and intercostal muscles, ribs and pleura, were quickly infiltrated. Six weeks after operation, death ensued from hydrothorax and collapse of the right lung, owing to direct extension of the disease through the chest wall. At the necropsy the right parietal pleura was found to be studded throughout with cancerous nodules; and it showed signs of recent acute inflammation. The diaphragm and liver contained numerous secondary growths, but none were present in either of the lungs, nor in the left pleura. It was a case of *acute traumatic malignancy* after operation.

At other times recurrence is delayed for many years—even for from twenty to thirty years. According to Nunn,<sup>103</sup> on the average one in thirteen of all operated cases remains free from recurrence for from ten to twenty years. Of the forty-seven recurrent cases in my list there were, however, only two instances in which the period of immunity had extended to ten years. A striking example of tardy recurrence is afforded by members of the family, whose history Sibley<sup>104</sup> has recorded, in which the mother and her five daughters all had cancer of the left breast. Two of these sisters passed eleven and twelve years respectively, after removal of the primary disease, without recurrence; and upon its return at those dates and repetition of the operation, each remained free from its return for seven years more, and they were still free when last heard of.

The two following cases of late recurrence have come under my own observation.

CASE I.—An emaciated woman, aged 62, with a large hard mass of ulcerated recurrent cancer in the right mammary region, and cancerous glands in the axilla and lower part of the neck. About twelve years ago she first noticed a lump in her right breast, which was amputated soon afterwards. Ten years subsequently several small recurrent nodules appeared in the vicinity of the scar and in the axilla. Two years ago these were excised. Six months later the present recurrence set in. No further operation was done. She died of pulmonary complications, apparently due to invasion of the chest by the local disease, some two and a half months later.

CASE II.—A well-nourished, healthy-looking woman, aged 58, with a nodule of atrophic recurrent cancer—the size of a hazel nut—at about the middle of the old scar in the left mammary region; and no obvious enlarge-

<sup>103</sup> "Cancer of the Breast," 1882, p. 45.

<sup>104</sup> *Med. Chir. Trans.*, vol. xlii., p. 111.



ment of the axillary glands. Twenty years ago she first noticed a small hard lump in the middle of her left breast. It slowly increased. Ten years later the breast was amputated. She remained quite free from any return of the disease until six months ago, when the present recurrence was first noticed. It was excised, and the wound had healed a fortnight later.

The following highly remarkable instances of this kind have been reported by others.

Bryant<sup>105</sup> has related the history of a woman, about the age of 38, who underwent amputation of the breast for primary cancer of five years' duration; and subsequently remained free from recurrence for twenty-five years, when there was return of the disease in the scar, &c. A daughter of hers died, aged 50, of acute mammary cancer of only six months' duration. In another case by the same surgeon, the patient, aged 44, remained free from recurrence for twenty-three years after extirpation of the primary disease, when recurrence appeared in the vicinity of the old scar.

In a patient of Nunn's,<sup>106</sup> aged 37, there was immunity from return for sixteen years, when the disease reappeared in the scar.

The longest period of immunity hitherto recorded is in a case by Verneuil,<sup>107</sup> in which the disease recurred *in situ* thirty years after amputation of the breast for the primary cancer. Both the primary and secondary growths were submitted to careful histological examination, and the appearances they presented were those of ordinary scirrhus cancer.

The foregoing cases admirably illustrate the extraordinary differences that obtain in relative malignancy, between cancers of the same variety—morphologically indistinguishable—in the same locality, and apparently under similar conditions.

Careful examination of recurrent growths reveals the important fact, that in both their morphological and pathological characters they precisely resemble the primary neoplasm. From this we may infer either that recurrences originate from the primary neoplasm or its derivatives, or that both spring from the same source—the mammary gland itself. These are in fact the sole sources of recurrent growths. Very significant is it that the great majority of recurrences are situated in the mammary region, either in, or in the immediate vicinity of the operation wound. The histological researches of Heidenhain and others have conclusively demonstrated, that fragments of the

---

<sup>105</sup> "Diseases of the Breast," p. 158.

<sup>106</sup> *Op. cit.*

<sup>107</sup> *La Semaine médicale*, 1888, p. 112.



original disease are almost invariably left behind after operations undertaken for its removal, as hitherto usually practised. Taken altogether the foregoing considerations point to these morbid fragments as the germs whence most recurrent growths originate. Thus may be explained the *initial multiplicity* of most recurrences, wherein they differ so markedly from independent spontaneous outbreaks which are almost invariably solitary.

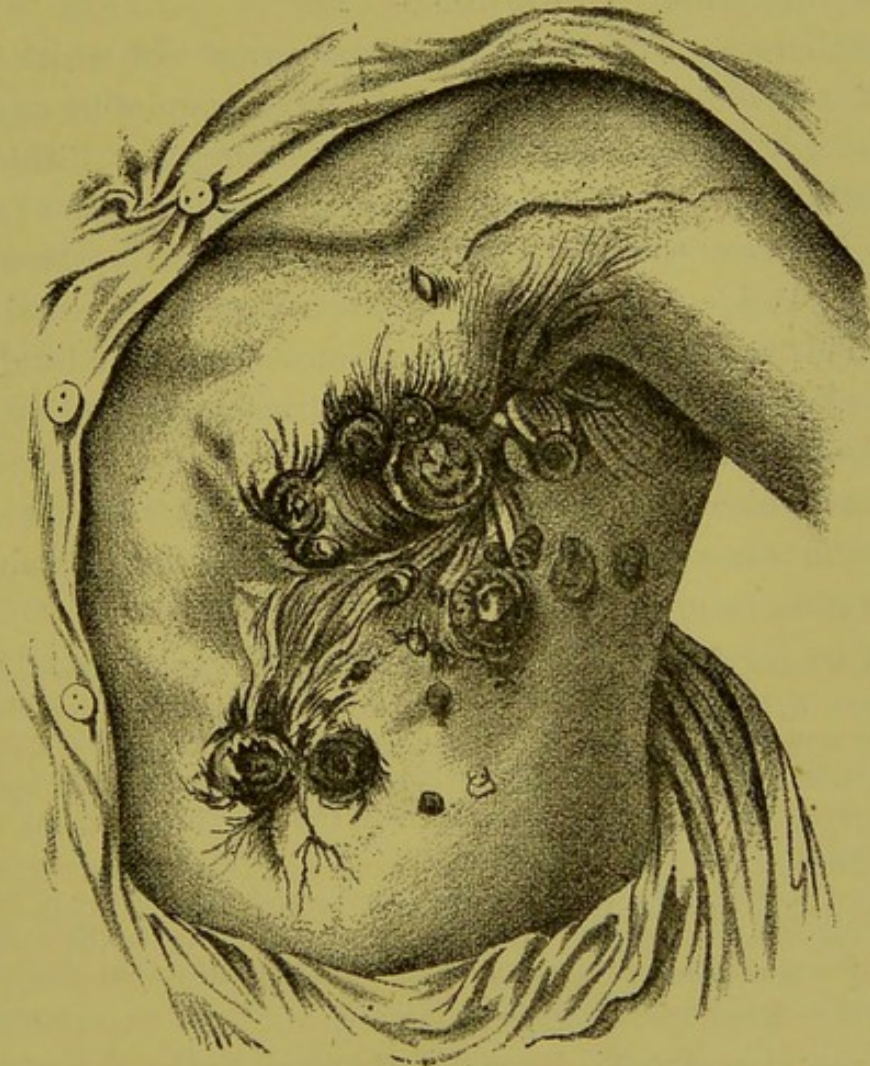


FIG. 41.—Recurrent mammary cancer (*Hutchinson*).

The great frequency of recurrences soon after operations points in the same direction. Hence we may conclude that the immense majority of local recurrences are due to incomplete ablation of the primary growth. In these cases there is indeed



no real reproduction of the disease, but merely continuation of it in the surviving unextirpated fragments (*continuation recurrence*). Similarly, when after operation the disease recurs in adjacent lymph glands, or in remote parts of the body—apparently unaffected before—we may infer that its recrudescence in these situations is generally due to the dissemination there of fragments of the primary disease, prior to the operation for its removal, which have subsequently developed as in the formation of other disseminative growths.

Yet there are some *late* local recurrences—of which several instances have been described above—that cannot be explained in this way. These cases, which are rare, are I think undoubtedly due to independent outbreaks of the disease (*repullulation*) in unextirpated remains of the mammary gland itself, which, as Heidenhain has shown, are never in a normal condition. This last fact explains the almost invariable localisation of these late recurrences in the affected mammary region rather than elsewhere.<sup>108</sup>

I have also met with certain cases of *late* return of the disease *in the axilla*, which I think cannot be explained as continuation recurrences, *e.g.*—

(1) A woman, aged 59, first noticed a cancerous tumour in her left breast nine years ago. Seven years ago the part was amputated, but the axilla was not touched. She remained quite free from any return of the disease until two months ago, when a hard cancerous lump formed at the upper and inner part of the left axilla; the scar in the mammary region and its vicinity being quite free.

(2) In a patient, aged 48, four years after amputation of her right breast for hard cancer, the disease reappeared in the right axilla, the scar in the mammary region and its vicinity being quite healthy. At the primary operation the axilla was not touched.

I have elsewhere<sup>100</sup> directed attention to the almost invariable occurrence of extensions of the mammary gland into the axilla, which are often completely sequestered; and to the frequency with which neoplasms originate from these axillary

<sup>108</sup> For some additional cases, *vide* Ch. x., § 9.

<sup>100</sup> *Journal of Anatomy*, vol. xxv., p. 253; also Ch. iv., § v.



mammary sequestrations. In the foregoing cases I think we have to do with independent outbreaks of the disease in such outlying extensions or sequestrations left behind at the time of operation. In like manner *primary* axillary cancers arise. It is probable that certain cases of late recurrence in the mammary region, arising at some distance from the operation scar, have also a similar origin.

*Second* recurrences are fairly common. I have met with them in eight out of forty-three recurrent cases; the earliest appeared a few weeks after the operation; the latest 130 months, and the average interval was 23.2 months. In these same eight cases the period of onset of the first recurrence averaged 41.5 months. This supports Thiersch's dictum, that the interval between operation and recidivity tends to shorten with each successive operation.

*Third* recurrences are rare; there was only one instance of the kind among the forty-three recurrent cases of my list.

Lastly, it seems not improbable that local recurrences are sometimes due to wound infection from the dissemination of cancerous fragments, &c., detached by the surgeon's knife during operation. To avoid this Donitz<sup>101</sup> recommends that care should be taken not to cut into such neoplasms during their removal.

§ IX.—Inflammation, Gangrene, Ulceration, Degenerative Metamorphoses, Retrogression, the Question of Spontaneous Cure, &c.

Cancerous neoplasms once formed live and are nourished like normal parts of the body; yet they, in return for the nutriment thus supplied, contribute nothing serviceable. Nerveless, functionless, and redundant, their relationship to the rest of the organism differs but little from that of parasitism.

The biology of cancers, like that of normal parts, is conditioned mainly by the inherent properties of their constituent cells, and, in a less degree, by their blood supply. Hence the same elementary pathological disturbances may be witnessed in



them as in the breast itself—*e.g.*, congestion, inflammation, suppuration, gangrene, ulceration, and the degenerative metamorphoses. That long-continued augmentation of the blood supply may accelerate the growth of cancers, and diminished blood supply retard it, is, I think, indisputable. The marked exacerbation of mammary cancers, consequent on pregnancy, traumata, and various irritants are examples of the former effect; while many chronic forms of the disease are probably largely dependent upon the latter. I am, however, far from believing that most of the striking irregularities in the rate of growth of cancers can be accounted for by circulatory disturbances. The inherent properties of the neoplastic cells themselves here play the leading part.

The most frequent anatomical cause of *congestion* and *inflammation* of cancers is obstruction of their venous circulation, which, as I have previously mentioned, so often happens during the process of their growth. Cancers are, however, less frequently subject to acute inflammation than might *à priori* be expected. When this does occur, not only the neoplasm itself, but also its immediate surroundings may be affected. Such attacks, which are mostly of septic origin, often greatly accelerate the progress of the disease. Subacute inflammations are commoner than the acute ones. Cohnheim believes that inflammatory conditions of the surrounding tissues weaken their capacity for resistance, and so favour the spread of the disease. Inflammation of cancer may terminate in resolution, suppuration, or gangrene. *Suppuration* is rare, but it undoubtedly does occur.

Habermaas<sup>109</sup> relates a curious case, in which the breast was amputated for a tumour—accompanied by enlarged axillary glands—which was believed to be tubercular. On examination of the part after removal this diagnosis appeared to be correct, for there was revealed a pus-containing cavity, surrounded by caseous looking masses. However, histologically examined, these proved not to be tubercular, but cancerous.

Gross<sup>110</sup> mentions the case of a woman whose breast he amputated for a cancerous tumour the size of a hen's egg. On section of the growth after removal, he found in it an abscess full of greenish pus.

<sup>109</sup> *Beitrage z. klin. Chir.*, 1886, Bd. ii., S. 44.

<sup>101</sup> *Am. Syst. Gyn.*, vol. ii.



A more frequent ending than suppuration is *gangrene*. This is generally only partial (necrosis), but exceptionally the whole neoplasm may fall into a state of slough, as in cases recorded by Nunn,<sup>111</sup> Broca,<sup>112</sup> and Warren.<sup>113</sup> Ulcerated cancers are more prone to gangrene than others. Sometimes the sphacelus is determined by injury; but usually there is no obvious cause. Obliteration of the veins is its chief determining factor; hence it is generally of the moist kind, but the dry form is not unknown. Gangrene is always a harmful complication; severe local inflammation and pain attend it, together with profuse foetid discharge, pyrexia, and much constitutional disturbance; and the danger from sepsis is very great. Gangrene may be followed by almost complete cicatrization; but, as the disease is never entirely destroyed, recurrence is inevitable—at any rate, I cannot cite a single instance of cure by gangrene.

Like their physiological prototypes of the mamma, sebaceous glands and epidermis, the cells of breast cancers are short lived. Hardly ever can one examine a cancerous tumour without discovering some of its cells in *fatty degeneration*, and this eventually ends in their complete disintegration. Such conditions have little or nothing to do with circulatory disturbances; they occur as regular stages in the evolution of the disease, owing to molecular changes inherent to the cells themselves. To this cause we must attribute the tendency of mammary cancers to spontaneous *ulceration*, at a certain stage of their development; which may begin, as Hunter pointed out, either superficially or deeply. In the former circumstance the growing tumour becomes adherent to the overlying skin, which gets thinned and excoriated and eventually yields, leaving the surface of the neoplasm exposed, and this consequently ulcerates; in the latter, the changes leading to ulceration begin in the substance of the neoplasm, and open outwards. Ulceration once started usually

---

<sup>111</sup> "Cancer of the Breast," 1882, p. 53.

<sup>112</sup> "Traité des Tumeurs," t. i., ch. x.

<sup>113</sup> "Surgical Observations on Tumours," p. 274.



tends to spread indefinitely ; yet a cancerous neoplasm is never completely destroyed in this way, for the disease progresses faster than the ulcerative process.

The *typical ulcer* of mammary cancer presents as an irregularly rounded, excavated, crater-like cavity, with hard, raised, swollen, craggy edges, which are usually everted ; and to these edges the surrounding skin is always adherent (fig. 42). Dirty yellowish, sloughy shreds cover its surface ; beneath which are undulating projections of the underlying denuded neoplasm,

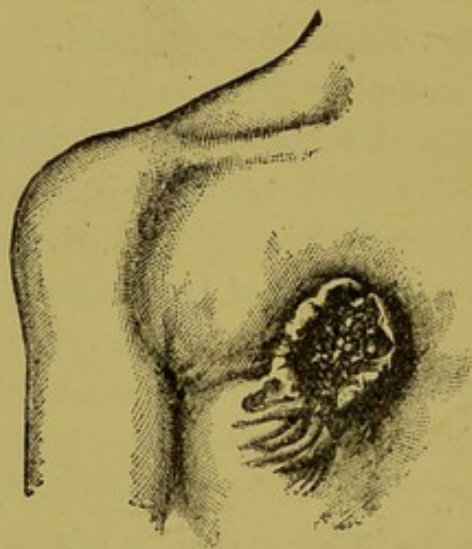


FIG. 42.—Ulcerated Cancer of the Breast (*Bryant*).

covered here and there with areas of ill-formed granulations. The ulcer is obviously scooped out of the subjacent cancerous growth, hence its hardness ; hence also its intimate adhesions with adjacent structures. From the ulcer there exudes, thin acrid, dirty yellowish ichor, which is often blood stained ; it has a peculiar penetrating and most disagreeable, fœtid odour. Its contact with the surrounding skin often causes inflammation and even excoriation. In these respects it differs from true pus ; it differs also in its composition, which, among other things, comprises necrotic shreds of the growth, degenerated neoplastic cells, leucocytes, altered blood corpuscles, oil globules, granular *débris* and various micro-organisms.



Cancerous ulcers of long standing often present quite a different aspect to the foregoing: they are shallow, with slightly raised and sinuous edges, the base comparatively smooth, and covered with small granulations, which in places have a florid and almost healthy appearance. A thin parchment-like layer of indurated cancerous tissue underlies the whole affected area, and binds it to the subjacent structures. Such ulcers not unfrequently cicatrise more or less extensively, especially at those spots where the progress of ulceration has destroyed the subjacent morbid growth; and they may even remain for long periods in a non-progressive, quiescent state. The conditions underlying these favourable changes are closely allied to those that determine the so-called atrophic form of the disease.

Cancerous ulcers of the breast are liable to bleed; but they seldom bleed freely, and the hæmorrhage is easily arrested, if it does not cease spontaneously as is usually the case. The only really dangerous kind of hæmorrhage to which they are liable is that due to perforation of small arteries, and this is, fortunately, the rarest of all.

Various forms of abnormal *fat formation* in cancerous tumours arise in connection with circulatory disturbances, influencing the metabolism of their cells. Thus, parts where growth is exceedingly active sometimes exhibit a kind of local *embonpoint*; that is to say, fat globules are separated and deposited, which would have been oxidised and removed, but for the local supply of nutritive materials being in excess of metabolism.

Localised fatty degenerations, due to deficient blood supply through venous congestion, inflammation, thrombosis, arteritis, &c., are of frequent occurrence. When the arteries are seriously interfered with, considerable areas of the neoplasm may be affected in this way. In such cases, not only the cells, but the stroma also may degenerate—as in the so-called *lipomatous cancers*.

In like manner the areas of caseous softening, sometimes seem irregularly scattered throughout cancerous tumours arise



as in the so-called "*caseating cancers*."<sup>114</sup> The ultimate fate of such lesions is chiefly dependent upon the subsequent cellular changes; if these go on to complete disintegration, the resulting products may be absorbed and completely disappear, or they may liquefy and form cysts, or caseate and eventually even cretify.

In connection with circulatory defects, mention must be made of the diffuse overgrowth of the fatty capsule of the mamma (*capsular lipoma*), which occasionally accompanies cancer of this organ, when the peripheral circulation is interfered with in the progress of the disease.<sup>115</sup>

*Ecchymoses* and *hæmorrhages* into the substance of mammary cancers are not very common. Blood thus effused may be completely absorbed; or, this being incomplete, the residue may cretify or originate a cyst.

*Cysts* thus arising can generally be distinguished by their yellowish lining membrane, and straw-coloured fluid contents. Other cysts arise in connection with mammary cancers owing to dilatation of terminal gland structures, through proliferation of their epithelia with subsequent mucoid or fatty degeneration. Simple involution cysts may also co-exist with acinous cancer. Intra-cystic papillary growths are hardly ever met with in this variety of the disease. The so-called "*hæmorrhagic cancers*"<sup>116</sup> are not of the acinous variety; they are either tubular duct cancers or villous papillomas: the pseud-alveolar appearances often noticeable on histological examination, when closely studied, are very different from the alveoli of acinous cancer.

*Calcification* and *ossification* of the stroma, as previously mentioned, is of very rare occurrence.

The changes produced in mammary cancers by the *colloid*, *myxomatous* and *atrophic* metamorphoses, constitute special varieties of the disease (*q. v.*, ch. xi.).

<sup>114</sup> For cases by Masterman, *vide Bart.'s Hosp. Rep.*, vol. xxvii., 1891.

<sup>115</sup> See Virchow's *Path. des Tumeurs*, t. i., p. 372, with figure.

<sup>116</sup> For some cases by Masterman, *vide Bart.'s Hosp. Rep.*, vol. xxvii., 1891, p. 193.



I have before mentioned, that the characteristic feature of cancer is its tendency to persist indefinitely, and to increase continuously. Yet indications are not wanting of occasional spontaneous *arrest* of the disease, and even of its *retrogression*; but I cannot cite a single instance of its complete spontaneous cure. Nevertheless, in face of the following facts, I think it would be rash altogether to deny the possibility of such a fortunate occurrence. The extreme chronicity of certain cases of acinous mammary cancer shows, that the increase of the disease may sometimes be so exceedingly slow, as hardly to be appreciable. Instances of this kind are of more frequent occurrence than is generally believed; and, what is still less appreciated is, that the great majority of such cases are *morphologically indistinguishable from ordinary acinous cancer (scirrhus)*, being neither of the atrophic nor of the colloid variety, although both atrophic and colloid cancers exhibit in a high degree the tendency to chronicity.<sup>117</sup>

Several examples have also been recorded of actively progressive scirrhus cancers—even when ulcerated—having subsequently subsided into quiescent, non-progressive states, with eventual great diminution in size. Nutritive failure leading to degenerative changes in the constituent cells of the neoplasm, and so eventually to their complete destruction by disintegration, seems to be a factor in many cases; but it is probably seldom the chief one. The following are some of the best examples of this *healing tendency* known to me:—

CASE I.<sup>118</sup>—A lady, the whole of whose right mammary region was occupied by a thin, smooth, parchment-like, glossy scar, which extended backwards beyond the mid-axillary line; its edge was slightly elevated, hard and sinuous, like that of rodent ulcer. Near this large scar-like area, were several small, isolated patches of similar appearance. The left mammary region was affected in the same way. Near the anterior border of the left axilla was a subcutaneous nodule, the size of a hazel-nut. This was the only situation in which the growth had any thickness. Nowhere was there even a trace of ulceration. There were a few hard glands in each axilla,

<sup>117</sup> For cases *vide* Ch. xi., § 2.

<sup>118</sup> Hutchinson's *Archives of Surgery*, vol. ii., No. 8, April, 1891, p. 354.



none of them larger than horse-beans. The disease began as a hard tumour in the right breast thirteen years ago, and it only subsequently invaded the left breast. Never at any stage had it ulcerated. She consulted Mr. Hutchinson on account of pulmonary complication of recent development, which was thought to be due to fluid in the right pleura. After the chest had been tapped several times without any fluid being discovered, it became evident that the dulness was due to intra-thoracic solid growth. The patient died about two months later from this cause; but there was no necropsy.

CASE 2.<sup>119</sup>—A healthy-looking, childless, married woman, aged 33, with an ulcerated cancerous tumour of the right breast, of stony hardness, and firmly fixed to the pectoral muscle. The tumour was first noticed six years ago; and ulceration began four years ago. The ulcer was the size of the palm of the hand, its edges nodular and crumbly. The axillary glands enlarged and hard. Operative interference was declined. Fifteen months later the tumour was obviously smaller and harder; and several pieces—the size of nuts—had shed from its edge. Six months later it had still further diminished, and much of the original tumour had crumbled away. Some discrete cancerous tubercles now appeared in the adjacent skin over the sternum. In the course of the next year the tumour continued to contract, and to throw off pieces. The cutaneous tubercles notably diminished, and the axillary glands got smaller and harder. Two years later the ulcer had almost completely cicatrised—a puckered linear scar was all that remained, in which were a few small hard nodules. The tubercles in the adjacent skin had completely disappeared. A year later all that remained of the original disease was a single nodule, the size of a hazel-nut, in the scar. The axillary glands were hardly perceptible. The patient's general health was unimpaired. One and a half years later she again came under observation; during this interval several fresh tubercles had appeared in the skin near the cicatrix, and had subsequently disappeared, so that only two small ones now remained. The patient considered herself quite well. She died five and a half years later of some pulmonary complications, without any obvious increase of the local disease having taken place. Altogether the disease had lasted for nearly nineteen years.

The two following somewhat similar cases, by Broca,<sup>120</sup> are also of much interest.

CASE 3.—A woman, aged 69, who died in hospital with secondary cancer of the liver. She was admitted with extensive chronic ulceration of the mammary region, which had supervened on hard cancer of the breast of many years' duration. The ulcer was shallow; its edges but slightly raised, and it had commenced to cicatrise in several places. On microscopical examination of the part after death it was found that the whole of the cancerous growth had been destroyed by ulceration, except a single nodule—the size of a hazel-nut—near the centre of the ulcer.

<sup>119</sup> Bryant, T., "Diseases of the Breast," 1887, p. 142.

<sup>120</sup> *Traité des Tumeurs*, t. i., 1866, p. 240.



CASE 4.—A lady, who when first seen had an irregular scar in the mammary region, in connection with which there was a small hard cancerous nodule of some months' growth. She said that fifteen years previously she first noticed a tumour in her breast, which subsequently ulcerated, and after a time healed up without any operation ever having been done. Some time afterwards, however, a fresh growth appeared in the cicatrix, which later on ulcerated, but again the ulcer healed spontaneously, after which the present recurrence set in. She refused operative treatment. The disease subsequently progressed so rapidly, that she died of it a few months later.

Some instances of retrogression of the local disease, as in the two following cases, coincide with its outbreak in remote parts of the body. These seem greatly to have impressed the old surgeons, who erroneously regarded them as true metastases, which term they henceforth applied to all systemic disseminations.

CASE 5.<sup>121</sup>—A woman, aged 40, with an infiltrating cancerous tumour of the left breast, the size of an apple, who refused operation. One year later she again came under treatment with paraplegia due to dissemination of the disease in the vertebræ. The former tumour with its surrounding infiltration had completely disappeared; in its place nothing remained but a flat, indurated superficial scar, which was slightly excoriated.

CASE 6.<sup>122</sup>—A very cachectic woman, with non-ulcerated hard cancer of the breast of two years' duration, was seized with violent cephalalgia, followed by apoplectic symptoms with hemiplegia. At about the time of this attack the mammary tumour notably diminished; and when she died, ten weeks later, it had almost completely disappeared. The *necropsy* revealed a cancerous tumour, the size of a nut, in the brain.

In the next case I have to relate, subsidence of the cancerous disease coincided with the active progress of pulmonary tubercle.

CASE 7.<sup>123</sup>—The patient was only 25 years old, yet she had a large hard cancerous tumour of the breast. The disease had progressed very rapidly, its total duration being only three months. The overlying skin and nipple were invaded. The axillary glands were enlarged and hard. The breast was amputated, when the swelling of the axillary glands subsided. Six months after this operation there was recurrence in the mammary region and in the axilla. In the former situation the disease made rapid progress; numerous tubercles formed in its vicinity, which coalesced, and eventually ulcerated. Thus it progressed for a year, when the ulcer began to cicatrise, and in the course of six months it had almost completely healed.

<sup>121</sup> Billroth, Th., *Deutsche. Chir., Lief.* 41, 1880, S. 106.

<sup>122</sup> Walshe, W. H., "The Nature and Treatment of Cancer," 1846, p. 110.

<sup>123</sup> Paget, J., "Lectures on Surg. Pathology," vol. ii., 1853, page 337.



The axillary disease also subsided, one hard lump alone remaining of what had been a large cluster of hard glands. Meanwhile, however, the patient had emaciated and lost strength, and she died about two years after the operation, and six months after the cancer had so nearly healed, of tuberculosis of both lungs. On careful examination of the mammary region after death, a thin, flattened, nodular *plaque* of extremely hard and dense cancer, was found beneath the old scar, binding it to the pectoral muscle. In the axilla was a single hard cancerous gland; and the liver contained several equally hard growths.

Sigg<sup>124</sup> and others have met with similar cases.

Lastly, it remains for me to mention that in the penultimate stage of cancerous cachexia and other exhaustive illnesses,<sup>125</sup> cancerous growths often become stationary, and even appear to wither and dry up, shortly before death.

Probably most of the alleged curative results of erysipelas inoculations for cancer should be included under this heading.<sup>126</sup>

---

<sup>124</sup> *Corresp.-blatt. f. sch. Aertz*, 15 av., 1891.

<sup>125</sup> For a case of retrogression of mammary cancer, after an operation for goitre, followed by much suppuration, *vide* Perrion. *Rev. méd. de la Suisse Romande*, x1 mars p. 195.

<sup>126</sup> As in Janicke and Neisser's case, *Cent. f. Chir.*, 1884, &c.



## CHAPTER X.

## THE GENERAL PATHOLOGY OF MAMMARY CANCER.

## § I.—The Influence of Sex.

THE influence of sex in the development of cancer is very marked. Not being aware of any comprehensive statistics on this subject embracing a sufficiently large number of cases to be thoroughly reliable, I have made an analysis of 14,480 primary neoplasms of all kinds, consecutively under treatment in the medical and surgical wards of four large metropolitan hospitals during the sixteen to twenty years preceding 1888.<sup>1</sup> This list comprises 7,878 consecutive cases of cancer—2,861 males and 5,017 females, or the proportion is 1 male to 1·7 females. The mortality returns of the Registrar-General for the twenty-five years 1872-48, which include all kinds of malignant disease, give a proportion of 1 male to 2·29 females. One male died of cancer to every 100 male deaths from all causes, and one female died of this disease to every 41 female deaths.<sup>2</sup> Of late this distinction has diminished, owing to the increasing cancer mortality falling unduly on males. For instance, during the period 1881-84, the death rates were—males, 3·79; females, 6·92; ratio, 1 to 1·8. For the year 1890 they were—males, 5·12; females, 8·30; ratio, 1 to 1·6. Thus

<sup>1</sup> "The Initial Seats of Neoplasms and their Relative Frequency," *Annals of Surgery*, October, 1891.

<sup>2</sup> Total mortality, 10,512,146; males, 5,419,865; females, 5,082,281. Total cancer mortality, 177,300; males, 53,867; females, 123,433. Thus the cancer mortality = 1 in 59 of all deaths.



the female liability to cancer now is considerably less than twice that of males.<sup>3</sup> The relative liability of females to non-malignant neoplasms and cysts is even greater than it is to cancer. This arises from the great frequency with which in women the reproductive organs—uterus, mammae, and ovaries are attacked, the corresponding male organs seldom being affected. The *localisation* of neoplasms is, indeed, singularly influenced by sex, and this is especially true of cancerous neoplasms.

To illustrate this I have compiled the following tables based on the analysis of 7,297 cases of primary cancer—2,669 males and 4,628 females—consecutively under treatment in the medical and surgical wards of four large metropolitan hospitals.

FEMALES (4,628 Cases).				MALES (2,669 Cases).			
			Per cent.				Per cent.
Breast	...	...	40·3	Tongue and mouth	...	...	26·3
Uterus	...	...	34·0	Skin	...	...	14·3
Rectum	...	...	4·3	Lip	...	...	12·2
Skin	...	...	4·1	Stomach	...	...	8·3
External genitalia	...	...	3·4	Rectum	...	...	7·5
Stomach	...	...	2·8	External genitalia	...	...	6·8
Liver	...	...	2·5	Œsophagus	...	...	5·3
Tongue and mouth	...	...	2·18	Liver	...	...	4·4
Intestines	...	...	1·06	Intestines	...	...	1·9
Œsophagus	...	...	0·70	Breast	...	...	0·6
Lip	...	...	0·06	Prostate	...	...	0·3
All other localities	...	...	4·60	All other localities	...	...	12·1
			100·00				100·0

This shows that 40·3 per cent. of all cancers in females are of the mammae, and 34 per cent. of the uterus; whereas in males only 0·6 per cent. of all their cancers attack the mammae, and only about 0·3 per cent. the prostate. On the other hand, 26·3 per cent. of all cancers in males affect the tongue and mouth, 14·3 per cent. the skin, and 12·2 per cent. the lower lip;

<sup>3</sup> I am indebted to Dr. Macdonald, of Dunedin, for calling my attention to the remarkable sex distinction of cancer in New Zealand. During the years 1879-89, 1,772 deaths from cancer took place there, and of these 893 were *males* and only 879 females. Of 233 cancer patients under treatment at the Dunedin Hospital during the same period, 140 were *males*, and only 93 females. This is the only country in the world known to me in which cancer is more prevalent among males than among females.



whereas in females only 2·18 per cent. of all their cancers attack the tongue and mouth, 4·1 per cent. the skin, and 0·06 the lower lip.

The same subject, from another standpoint, is further illustrated by the following table:—

	MALES.	FEMALES.	TOTAL.
Breast ... ..	16	1,863	1,879
Uterus and Prostate ...	7	1,571	1,578
Tongue and Mouth ...	703	101	804
Skin ... ..	381	190	571
Rectum ... ..	199	202	401
Stomach... ..	222	130	352
External Genitalia ...	182	158	340
Lip (Lower) ... ..	326	3	329
Liver ... ..	115	113	228
Œsophagus ... ..	144	35	179
Intestines ... ..	49	49	98
Superior Maxilla ...	42	28	70
Bladder ... ..	43	16	59
Testis and Ovary ...	27	27	54
Larynx ... ..	34	4	38
Anus ... ..	17	10	27
All other localities ...	162	128	290
Total.....	2,669	4,628	7,297

This shows that of 1,879 consecutive cases of mammary cancer in both sexes, only 16 were of the male breast, or 1 in 117. According to Paget, 98 cases out of every 100 occur in women. The like peculiarity is noticeable with regard to uterine cancer, for it is met with 224 times oftener than prostatic cancer. In almost all other localities—except the sexual glands, liver, rectum, and intestines, where both sexes are equally liable—the male proclivity to cancer greatly exceeds that of the female. In the lower lip it is 108 times as great, in the tongue and mouth 7 times, in the œsophagus 1·7 times, and in the external genitals 1·2 times.

Curiously enough *sarcomas*, which manifest no very marked tendency to attack the female reproductive organs, are nearly equally distributed between the sexes.

From the foregoing facts we may draw this conclusion: that



the greater liability of females to cancer is not the outcome of any general constitutional condition correlated with sex, but that it is due to biological peculiarities inherent to the reproductive organs themselves. In the breast, for instance, most neoplasms originate in the immediate vicinity of the *acini* and *small ducts*; whereas it is very rare for such growths to arise from the *skin* of the mammary region, the *areola*, the *nipple*, the *large ducts* or the *para-mammary fibro-fatty tissue*. That is to say, mammary neoplasms are most prone to arise in the sites of greatest post-embryonic developmental activity, where cells still capable of growth and development most abound. The like is true of the other organs.

Since the foregoing was written, I have had the opportunity of studying the localisation and sex distribution of the disease, as shown by the chief *mortality* returns. From these I have compiled the subjoined tables, showing the localities affected per 100 deaths from cancer in each sex.

Thus treated, the English reports, which are based on returns for the years 1868 and 1888, yield the following results:—

FEMALES.				MALES.			
			Per cent.				Per cent.
Uterus (ovaries, vagina, and vulva) ... ..	...	...	34'7	Stomach ... ..	...	...	29'6
Breast ... ..	...	...	21'2	Liver ... ..	...	...	13'4
Stomach ... ..	...	...	10'9	Rectum ... ..	...	...	8'3
Liver ... ..	...	...	9'5	Tongue and mouth... ..	...	...	7'6
Rectum ... ..	...	...	4'2	Intestines ... ..	...	...	5'3
Intestines ... ..	...	...	3'7	Face ... ..	...	...	4'7
Face ... ..	...	...	1'3	Œsophagus ... ..	...	...	3'3
Tongue and mouth... ..	...	...	1'1	Bladder ... ..	...	...	2'6
Œsophagus ... ..	...	...	1'0	Lip ... ..	...	...	2'4
Pharynx, fauces, tonsils, &c.	...	...	0'8	Jaw ... ..	...	...	2'3
Bladder ... ..	...	...	0'7	Pharynx, fauces, tonsils, &c.	...	...	2'2
Jaw ... ..	...	...	0'6	Prostate ... ..	...	...	0'3
All other localities ... ..	...	...	10'3	Breast ... ..	...	...	0'1
			100'0	All other localities ... ..	...	...	17'9
							100'0

With this the following table, based on data derived from the Irish reports for the years 1887, 1888, and 1889, may be compared; thus:—



FEMALES.				MALES.			
			Per cent.				Per cent.
Stomach	...	...	22'4	Stomach	...	...	34'3
Breast	...	...	21'5	Liver ...	...	...	7'7
Uterus	...	...	14'1	Lip ...	...	...	6'4
Liver ...	...	...	8'8	Face ...	...	...	6'3
Face ...	...	...	4'2	Tongue	...	...	4'6
Intestines	...	...	3'0	Throat	...	...	4'6
Rectum	...	...	2'7	Rectum	...	...	3'6
Leg ...	...	...	2'4	Jaws ...	...	...	3'4
Throat	...	...	1'6	Neck ...	...	...	3'3
Neck ...	...	...	1'4	Leg ...	...	...	3'2
Lip ...	...	...	1'0	Intestines	...	...	2'9
Jaws ...	...	...	1'0	Hand...	...	...	1'0
Eye ...	...	...	0'8	Head...	...	...	0'8
Hand...	...	...	0'7	Eye ...	...	...	0'7
Foot ...	...	...	0'7	Foot ...	...	...	0'7
Tongue	...	...	0'6	Breast	...	...	0'3
Head...	...	...	0'5	All other localities	...	...	12'5
All other localities	...	...	12'5				
			100'0				100'0

Analysis of the Frankfort-on-Main Cancer Mortality Returns<sup>4</sup> for the thirty years, 1860-89, gives the following results :—

FEMALES.				MALES.			
			Per cent.				Per cent.
Uterus ...	...	...	27'5	Stomach	...	...	29'2
Stomach	...	...	18'3	Liver ...	...	...	18'6
Liver ...	...	...	12'6	Intestines	...	...	11'6
Breast ...	...	...	11'3	Œsophagus and pharynx	...	...	6'5
Intestines	...	...	8'8	Bladder, penis, &c.	...	...	4'0
Ovaries	...	...	3'7	Peritoneum, &c.	...	...	3'0
Peritoneum, &c.	...	...	3'6	Nervous system	...	...	2'6
Nervous system	...	...	1'2	Tongue	...	...	2'0
Œsophagus	...	...	1'1	Respiratory system	...	...	2'0
Vagina ...	...	...	0'9	Kidneys	...	...	2'0
Bladder	...	...	0'8	All others	...	...	18'5
Kidneys	...	...	0'4				
Tongue	...	...	0'3				
All others	...	...	9'5				
			100'0				100'0

<sup>4</sup> Cited by King and Newsholme, *Proceedings Roy. Soc.*, vol. liv., No. 327, p. 239.



It will be seen that these *mortality* estimates differ from the *clinical* data gathered by me, chiefly in that they show much greater frequency of the disease in the stomach, liver, and intestines; and its less frequency in the female breast, skin, tongue and mouth, lips, &c. The ponderous data from which they have been compiled are confessedly not altogether reliable; and it is highly probable that the deaths attributed to cancer of the stomach, liver, and intestines have been exaggerated owing to diagnostic errors. At the same time I must state, that these figures are in accord with most continental estimates (Sallé, D'Espine, Virchow, &c.), all of which place the stomach at the head of their lists; but these are also based on mortality returns.

## § II.—The Influence of Age.

The first four quinquennia of life are completely exempt from mammary cancer; at least I know of no well authenticated case that can be cited as having occurred within this period. Alleged examples of it by Lyford (at 8 years), Carmichael (at 12), Cooper (at 13), Home (at 15), &c., have never been histologically verified. Henry's<sup>5</sup> is the earliest credible case known to me; and in his patient the disease was first noticed at the age of 21. In a case under my own observation the disease began at 24. Its occurrence before 25 is, however, a great rarity. In the third decennium, mammary cancers are met with more frequently, but their number is still small. Subsequently they occur with increasing frequency until the quinquennium, 45 to 50, when they attain their maximum. After 70 the disease is rare, and it is very rare after 80. The oldest patient with mammary cancer seen by me was 84 when the disease commenced; but Bryant<sup>6</sup> has met with an instance in which it began at the phenomenal age of 96. The oldest

<sup>5</sup> "Statist. Mittheil. über den Brustkrebs," Breslau, 1879.

<sup>6</sup> "Diseases of the Breast," 1887, p. 149.



cancer patient I have ever heard of is the lady attended by Coker<sup>7</sup> of Chicago, who died, aged 106, of cancer of the tongue.

According to my estimate, the average age of women at the onset of mammary cancer is 48 years; whereas for uterine cancer it is 44; for cancer of the tongue and mouth, 50; and for rectal cancer, 53 years. The foregoing statement is based on the subjoined analysis of 500 consecutive cases of breast cancer; and for the sake of comparison I have appended similar analyses of cases of uterine cancer, and of cancer of the tongue and mouth in women—all of them reduced to the percentage basis.

Age Periods.				Breast. Per cent.	Uterus. <sup>8</sup> Per cent.	Tongue and Mouth. <sup>9</sup> Per cent.
20 to 25 years	...	...	...	0'6	0'2	3
25 " 30 "	...	...	...	4'0	7'0	5
30 " 35 "	...	...	...	6'0	11'0	7
35 " 40 "	...	...	...	14'0	20'0	4
40 " 45 "	...	...	...	16'0	17'0	10
45 " 50 "	...	...	...	20'0	16'0	17
50 " 55 "	...	...	...	15'0	13'0	22
55 " 60 "	...	...	...	10'0	9'0	10
60 " 65 "	...	...	...	9'0	5'0	9
65 " 70 "	...	...	...	3'2	1'0	6
Over 70 "	...	...	...	2'2	0'8	7
				100'0	100'0	100'0
Mean age	...	...	...	48	44	50
Earliest age	...	...	...	24	22'25	24
Latest age	...	...	...	84	83	77'5

Statistics by Gross, Bryant, Winiwarter, Paget, and others give very similar results.

We learn from them the absolute frequency of the disease at the various age periods; but they tell us nothing as to the relative tendency to it at different ages—*i.e.*, of the influence of age in its evolution. In order to ascertain this we must compare these figures with the total number of females living

<sup>7</sup> *British Medical Journal*, March 5, 1887, "Additional Report on Centenarians."

<sup>8</sup> Calculated on 500 cases.

<sup>9</sup> Calculated on 90 cases.



at the corresponding age periods. Calculations made in this way for malignant disease in general show that the relative liability to it increases with each successive decade until the seventy-fifth year. The following table from the Registrar-General's Report for 1884<sup>10</sup> illustrates this :

				Males.		Females.	
20 to 25 years	...	...	...	29	...	...	34
25 " 35 "	...	...	...	70	...	...	176
35 " 45 "	...	...	...	270	...	...	849
45 " 55 "	...	...	...	894	...	...	1,953
55 " 65 "	...	...	...	2,002	...	...	3,146
65 " 75 "	...	...	...	3,305	...	...	4,132
Over 75 "	...	...	...	3,449	...	...	4,135
All ages	...	...	...	379	...	...	692

In reference to these results Dr. Ogle remarks : " In simply saying that the liability to death from cancer increases with age, no more is said than may be stated with equal truth of liability to death generally. The question is, does the annual liability to death from cancer increase more rapidly than the annual liability to death of all kinds ? " To answer this question he has compiled the following table, showing the ratio of total deaths to deaths from cancer during the decennium 1871-80, at successive age periods :

#### TOTAL DEATHS TO ONE FROM CANCER.

Age Periods.				Males.		Females.		Persons.
20 to 25 years	...	...	...	262	...	248	...	255
25 " 35 "	...	...	...	131	...	49	...	71
35 " 45 "	...	...	...	57	...	15	...	24
45 " 55 "	...	...	...	28	...	9	...	14
55 " 65 "	...	...	...	22	...	10	...	14
65 " 75 "	...	...	...	27	...	17	...	21
75 and upwards	...	...	...	56	...	44	...	48

It will be gathered from the foregoing, that the characteristic feature of cancer mortality is not its increase with advance of years, but its disproportionate increase in the post-meridian periods. This table also shows very well the relative

<sup>10</sup> Showing the mean annual mortality of males and females from cancer per million living at successive age periods.



liability of the sexes at different ages. It will be noticed that the relative liability of females increases until the period 45-55, after which it lessens at each decade in a marked degree.

With regard to cancer of the female breast, statistics compiled on this basis by Paget<sup>11</sup> and Nunn<sup>12</sup> show that the period of its greatest relative, as well as absolute frequency, is between the fortieth and fiftieth years. Nunn's table, which was compiled for him by an actuary, is as follows:—

Age Periods.							Per cent.
25 to 30 years...	...	...	...	...	...	...	·831
30 " 35 " ...	...	...	...	...	...	...	3'933
35 " 40 " ...	...	...	...	...	...	...	8'783
40 " 45 " ...	...	...	...	...	...	...	12'311
45 " 50 " ...	...	...	...	...	...	...	18'006
50 " 55 " ...	...	...	...	...	...	...	16'161
55 " 60 " ...	...	...	...	...	...	...	8'368
60 " 65 " ...	...	...	...	...	...	...	9'696
65 " 70 " ...	...	...	...	...	...	...	9'181
70 " 75 " ...	...	...	...	...	...	...	4'983
75 " 80 " ...	...	...	...	...	...	...	3'923
80 " 85 " ...	...	...	...	...	...	...	3'824
							100'000

This shows that the relative liability of females to mammary cancer lessens progressively in a marked degree at each age period after 55.

Considerations of this kind induced me to investigate the mortality from cancer of centenarians and aged persons of 80 years upwards. The information thus obtained shows that these aged persons are relatively much less prone to the disease than their juniors. Cancer seldom originates in extreme old age. Of 797 centenarians of whom the causes of death are tabulated in the Registrar-General's Reports for the ten years 1876-85, and for the year 1873, only 5 died of cancer, or 1 in 159. Of 208 males, 2 died of cancer, or 1 in 104; and of 589 females, 3 died of it, or 1 in 196.

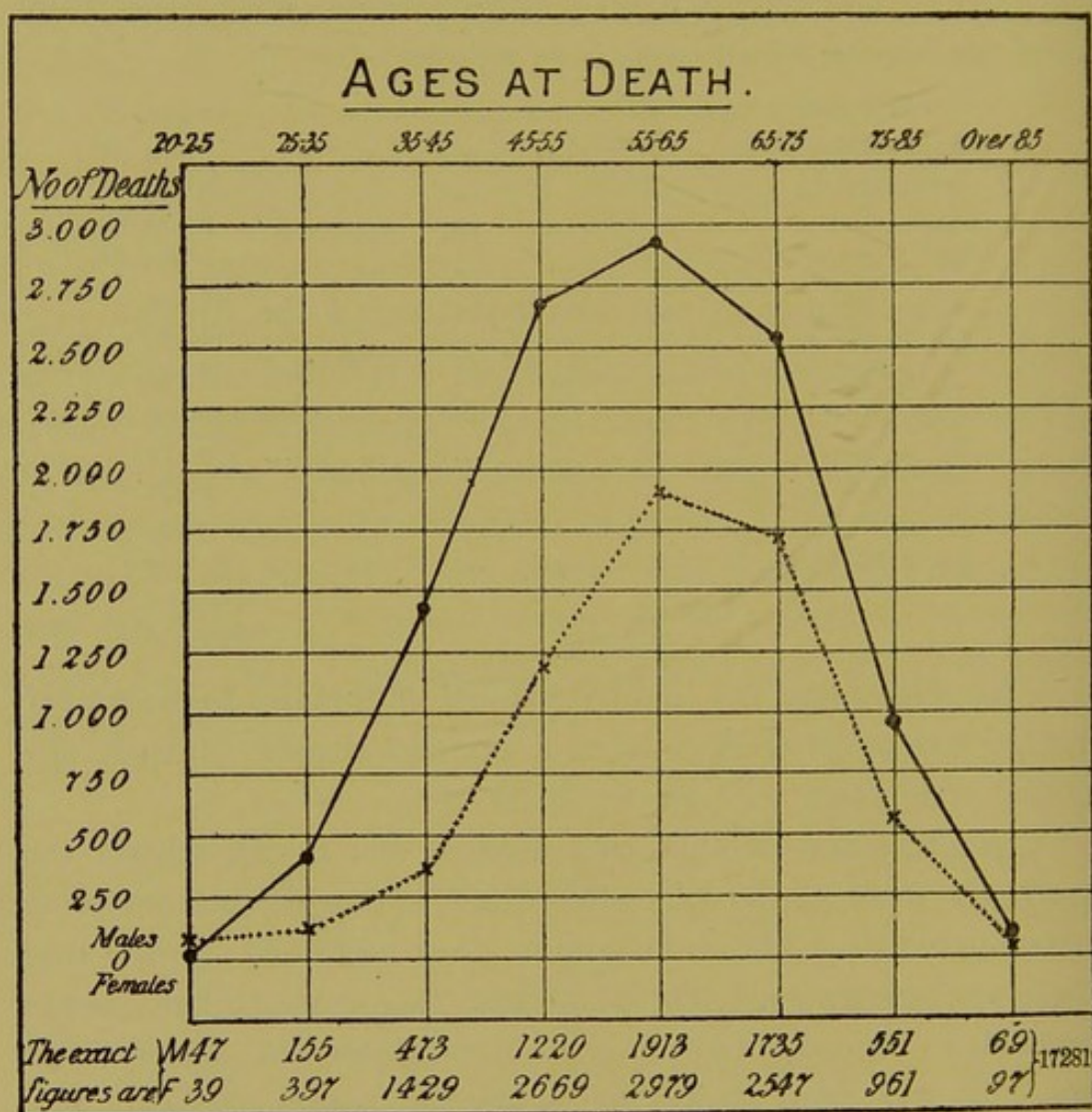
<sup>11</sup> "Lect. on Surg. Path.," vol. ii., 1853, p. 326.

<sup>12</sup> "Cancer of the Breast," 1882, p. 161.



Humphry's report<sup>13</sup> on the maladies of old people is of similar import. Among 202 persons—males 92, females 110—90 years of age and upwards, there was not a single instance of

I.—DIAGRAM SHOWING THE MORTALITY FROM CANCER AT DIFFERENT AGES IN EACH SEX.<sup>14</sup>



malignant disease ; and of 622 persons—males 340, females 282, between 80 and 90 years old, there were only 14 instances of it.

<sup>13</sup> *Brit. Med. Journal*, July 30, 1887.

<sup>14</sup> The figures on which this diagram is based are from the Registrar-General's Report for the year 1888



Thus of these 824 aged persons, malignant disease was met with only in 1·7 per cent., or in the ratio of 1 to 58·8. Of 432 males 7 were affected, or 1 in 61·7; and of 392 females 7, or 1 in 56. Of the males, the lip was the seat of the disease in 3 cases; the penis, ear, finger, and shoulder each in 1 case. Of the females, in 5 the breast was affected, and in 2 the face.

These facts clearly show that cancer is *not* a senile disease, and that senility *per se* plays no essential part in its development. The contrary belief is a mere myth, that by dint of continual repetition has gained wide-spread credence, without there being a particle of truth in it.

In order to show plainly the differential influence of sex at the various age periods, I have constructed the two following diagrams.

The first of these (No. 1.) exhibits the absolute mortality from all kinds of malignant disease at different ages, for the year 1888. From this it is obvious that at the period, 20 to 25 years, the mortality is nearly equal in both sexes. After this the female mortality increases much more rapidly than does the male; but both reach their maximum at the period 55 to 65, and then both decline rapidly. Further, it will be seen that the female mortality greatly exceeds the male mortality at all age periods when the disease is most prevalent, *i.e.*, between the end of the thirty-fifth and seventy-fifth years, and the difference is greatest at the period of maximum prevalency between 55 and 65 years. In other respects the similarity in the general outlines of the tracings for each sex is very noteworthy.

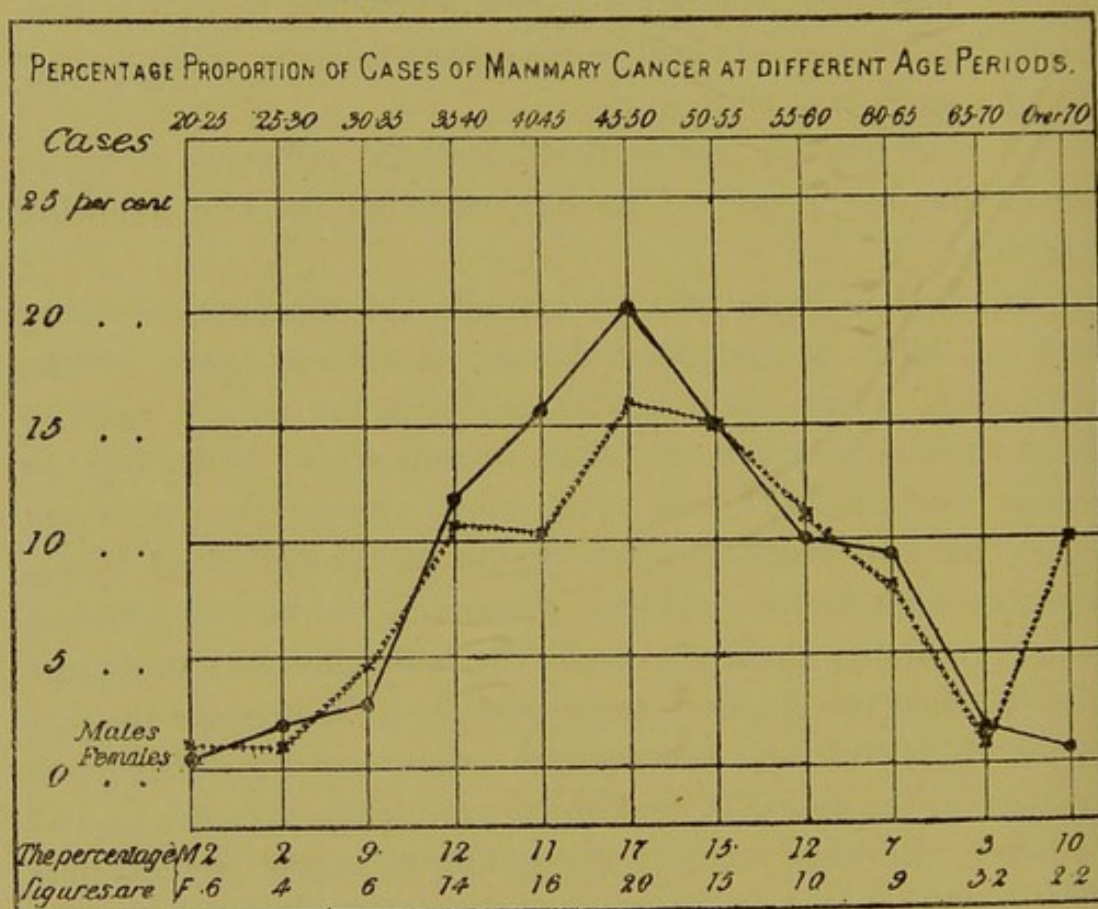
The second diagram shows the absolute frequency with which mammary cancer originates at different ages in each sex. The striking feature about the diagram is the great similarity of the age tracings in the two sexes, both of which attain their maximum at the period 45-50 years. Another noteworthy feature is the large number of male cases that originate after 70. This it is that causes the average age at onset of mammary cancer in males (50 years) to exceed that in females (48 years). The difference in the age tracings of the two



diagrams should also be noticed, showing as it does, that mammary cancers are most prevalent at an earlier age than malignant disease in general.

It seems only natural to seek an explanation of the great frequency of cancer of the female breast in the changes normally incidental to the correlated pelvic reproductive organs at this

II.—DIAGRAM SHOWING THE FREQUENCY OF MAMMARY CANCER AT DIFFERENT AGES IN EACH SEX.<sup>15</sup>



period. In this connection I have ascertained the following facts:—

Of eighty-seven females with mammary cancer the disease was first noticed:

Before the cessation of menstruation .....in 35  
 At about the time of the menopause, ..... „ 10  
 After the cessation of menstruation ..... „ 42

<sup>15</sup> Based on the author's analysis of 500 cases of cancer of the female breast and 90 of the male breast.



The only catamenial abnormalities noticed in these patients were, profuseness in six, irregularity and scantiness in four. Sixty-two per cent. of the patients investigated by Gross were menstruating at the onset of the disease, but in only 8.45 per cent. of these was there any catamenial irregularity. The average age in eighty breast cancer patients, at which the catamenial function was first established, I have found to be 14.5 years; that for English women in general being usually computed at 15 years. The average age at the cessation of menstruation in forty-three breast cancer patients under my observation was 46.3 years—over a year later than the period usually assigned as the date of the normal climacteric. The following table, from Paget,<sup>18</sup> shows the ages at which menstruation ceased in 400 women, and the ages at which cancer of the breast was first detected in an equal number:—

Ages.	Cessation of Menstruation.			Onset of Cancer.		
Below 35 ...	...	...	9	...	...	36
35 to 40 ...	...	...	51	...	...	62
40 " 45 ...	...	...	140	...	...	78
45 " 50 ...	...	...	159	...	...	101
Above 50 ...	...	...	41	...	...	123
			400			400

These facts suffice to show that the development of cancer in the female breast has no causal connection with the catamenial function. A glance at Diagram II., which shows that the age distribution of mammary cancer is nearly identical in both sexes, confirms this conclusion.

To sum up:—We learn from the foregoing that while the forces of growth, development, and reproduction are in greatest activity—during the periods of intra-uterine life, infancy, childhood, adolescence, and adult age—the tendency to cancer is exceedingly small. In both sexes the disease begins to be frequent as soon as the period of perfection has been attained, *i.e.*, after the 35th year; during middle age and the decline of

<sup>18</sup> "Lect. Surg. Path.," vol. ii., 1853, p. 327.



life the liability to it increases, until about the 55th year; after which period it becomes markedly less frequent, and increasingly so as age advances. The principles that govern the age distribution of cancer in general, apply also to its various local manifestations in both sexes. That some parts of the body—such as the uterus and mamma—are attacked at an earlier age than others, is due to the fact that the former attain maturity earlier than the latter and *vice versâ*. The general rule for the breast and all organs is, that their liability to cancer begins with the decline of their functional activity, and increases while this is progressing. Thus the liability to cancer waxes as the developmental and reproductive activities wane. The antagonism between the forces of genesis, growth, development and expenditure, is the same in pathology as in physiology. It is owing to the varied interactions of forces thus called into existence, that the constitution is so different at different periods of life; and that each period has its special morbid proclivities. In this we have an illustration of the universal biological law that growth varies according to the surplus of nutrition over expenditure. So long as the surplus exists—that is to say, while nutrition is relatively high—simple *continuous* growth is maintained; but when nutrition is relatively low—that is to say, when it is nearly equalled by expenditure—new centres of development are apt to arise, and growth tends to become *discontinuous*. Changes of nutrition determine the transition from the one to the other mode of growth. To the operation of such causes, as I have elsewhere maintained,<sup>17</sup> the origin of cancers and other neoplasms must ultimately be ascribed.

### § III.—Complexion, Race, Geographical Distribution, and Topography.

The fact is well established that when a number of individuals are exposed to the influence of similar conditions of life, all are not identically affected; and it is evident that the

<sup>17</sup> "The Principles of Cancer and Tumour Formation," London, 1888.



different effects thus induced depend upon inherent constitutional differences. In human beings well-marked constitutional peculiarities are correlated with *complexion* and *race*. I now propose to inquire whether the development of cancer is influenced by these. To this end I have noted the *complexion* of 384 cancer patients under my observation. In doing this I have relied chiefly on the colour of the hair and eyes, as in white people, these are its most permanent and easily recognisable factors.

MALES (128 Cases).				FEMALES (256 Cases).			
	Dark.	Fair.	Total.		Dark.	Fair.	Total.
Tongue and mouth	30	28	58	Uterus	70	37	107
Rectum	12	12	24	Breast	44	42	86
Lower lip	9	11	20	Rectum	12	5	17
Skin	6	5	10	Rodent	5	7	12
Tonsil	1	3	4	Tongue and mouth	4	4	8
Ext. genitalia	1	3	4	Ovary	4	2	6
Rodent ulcer	3	—	3	Ext. genitalia	2	3	5
Anus	3	—	3	Vagina	3	1	4
Œsophagus	2	—	2	Œsophagus	1	2	3
				Other localities	6	5	11
	66	62	128		150	106	256

The numerical results thus obtained show that the majority of cancer patients (56 per cent.) are of the dark type; and it is to the female sex that this preponderance is almost exclusively due. In order to appreciate the significance of these results, we must first know the proportional frequency of the dark and fair types in the general population. Dr. Beddoe<sup>18</sup> has most kindly furnished me with information as to this. His estimate shows that among the London lower classes 43 per cent. are of the dark, and 57 per cent. of the fair type. Hence it follows that cancer is relatively much more frequent among dark than among fair-complexioned persons, the proportion being, according to my estimate, 69 per cent. of the former to 31 per cent. of the latter. Beddoe's analysis nearly accords with this. He has also found that individuals of the rufus type are relatively less exempt than other fair-complexioned persons.

<sup>18</sup> See also his monograph on "The Races of Britain," 1885.



As to the influence of *race* in the liability to cancer, we have singularly little reliable information.

The United States statisticians (Billings, Barker, Chisholm) are, however, agreed that the disease is relatively more than twice as frequent among the whites as among the blacks. According to Billings<sup>19</sup> of 23,000,000 whites, 6,321 died of cancer; and of 9,000,000 blacks, only 790. That is to say, the deaths from cancer per 100,000 whites and blacks living, were 27·96 and 12·17 respectively; for whites the male death-rate was 20·5, and the female death-rate 35·4; for blacks it was for males 5·8, and for females 19·3. This accords with the almost unanimous testimony of the United States gynæcologists, who have frequently called attention to the comparative immunity of negroes from uterine and mammary cancer, although they are very prone to uterine fibroids. We learn from numerous observers that this comparative immunity of the negro race from cancer is even more noticeable in their African homes. Whether this is due to racial influence or to savage ancestry is not easy to decide. Those who have travelled among savage people are, however, unanimous in asserting that cancerous diseases are almost or quite unknown among them. This immunity applies alike to meat-eating and vegetarian savages. It should, however, be borne in mind that most uncivilised people get comparatively little animal food; or, at any rate, they often have to abstain from it for long periods.

On the other hand, it is certain that cancerous diseases are very prevalent in all highly civilised communities. Among the whites in the United States, Billings found that those of Irish and German extraction were the most prone to cancer. It has been asserted that the Jews are seldom affected, but in this, Richardson—who has had considerable experience among them—does not agree; Billroth's experience coincides with this; moreover, Billings' report shows that in the United States their

---

<sup>19</sup> "Report on 10th U.S. Census," vols. xi., xii., 1880.



death rate from cancer is almost the same as that of the rest of the white population.

Notwithstanding the interest lately manifested in the *geographical distribution* of cancer, of accurate scientific information there is rather a dearth. Statistical records have been kept only in Europe, the United States, and some of our colonies. These show the much greater prevalency of the disease in Europe. According to the "Report of the 10th United States Census" (1880), already referred to, the cancer mortality for the whole country then amounted to 2.22 per 10,000 living, or 17 per 1,000 (1 in 59) of the total deaths.

For the chief *European countries* the death rates per 10,000 living are :—Sweden (1886-7), 9.5 ; Saxony (1876-85), 6.9 ; Netherlands (1884-88), 6.5 ; Italy (1881-83), 6.1 ; England and Wales (1881-85), 5.47 ; Norway (1862-66), 5.2 ; Austria (1885-87), 4.8 ; Ireland (1885), 3.9 ; Prussia<sup>20</sup> (1876-85), 3.4. I have been unable to meet with any recent statistics showing the mortality from cancer in France. Writing in 1880, Lombard<sup>21</sup> says it is much in excess of the English mortality. In Scandinavian countries cancer is very prevalent.

With regard to the chief large towns the cancer mortality of New York (1885) was 5.2 ; Philadelphia (1872-76), 4.4 ; of 50 U.S. large cities (1880), males 2.8, females 5.1 ; and for the State of Massachusetts (1876-86), 4.6.

For some of the chief European towns the numbers are as follows :—Edinburgh (1889), 10.4 ; Paris<sup>22</sup> (1886-91), 10.4 ; Bremen (1875-78), 8.1 ; Hamburg (1871-83), 7.6 ; Aberdeen (1889) 7.3 ; London (1884), 6.5 ; Glasgow (1889), 6.1 ; Berlin (1870-82), 5.7 ; Bergen (1886-87), 5.4 ; Christiania (1886-87), 5 ; Utrecht (1870), 4.9 ; Brussels (1874-8), 4.2. According to Lombard,

<sup>20</sup> The Prussian cancer mortality for the thirteen years 1875-87 was 1.24 per 100 deaths; the sex ratio 147 females to 100 males. The tubercle mortality was 12.4 per 100 deaths. *Vierteljahres f. gericht. Med. und öff. Sanit.*, 3rd. ser., I., 314. Ap. 1891.

<sup>21</sup> *Traité de Climatologie Méd.*, t. iv., p. 520.

<sup>22</sup> According to Bertillon the Paris cancer mortality for 1889 was 4.15 per 100 of the total deaths.



cancer is more prevalent in Geneva than in any other European town. Of German towns, Frankfort<sup>23</sup> and Breslau furnish the most cases. The St. Petersburg cancer mortality is less than that of Berlin.

The disease is said by Panum to be unknown in the Faröe Islands, and to be very rare in Iceland, Greenland, Turkey and Greece—these results need confirming. Eventually it will probably be found that no place is really exempt.

Continental statistics indicate much greater frequency of the disease in the stomach, intestines and liver, than British ones. Chimney sweep's cancer, rare in England, is hardly ever met with elsewhere.

Of Asiatic countries it is generally agreed that cancer is most prevalent in *China*; and, according to Hobson, the female breast is frequently affected. Desiring to obtain some recent information on this subject, I lately wrote to Dr. Cantlie, of Hong-Kong, who very kindly furnished me with the following details, for which I now thank him. Referring to the prevalency of the disease he says: "I do not think I have been without a case of malignant disease under my care ever since I came to China six years ago." Of 3,608 consecutive Chinese hospital in-patients under his care, 114 had cancer, or 3·1 per cent. This proportion is almost identical with that met with in large London general hospitals, like St. Bartholomew's, where 3·5 per cent. of the in-patients have cancer. Of Cantlie's 114 Chinese cancer patients, the primary seats of the disease were as follows: female breast, 38; upper jaw, 25; lower jaw, 14; penis, 9; uterus, 8; parotid, 5; hip, 5; tongue, 4; lip, 3; and thigh, 3. At Dr. Kerr's hospital in Canton, during the year 1887, 30 cases of malignant disease were operated on, including 11 amputations of the female breast. Strange to relate, Cantlie has never met with cancer of the stomach among the Chinese.

---

<sup>23</sup> The cancer mortality for 1888-89 per million living aged 25 and upwards, was males, 2,313, females, 3,515; for England (1889) the corresponding figures were: males, 1,393, females 2,038. King and Newsholme, *Proc. Roy. Society*, vol. xiv., No. 327, p. 242.



With regard to their diet he says: "All Chinamen eat fish and pork at morning and evening meals. Fowls and ducks are always on the table of all but the most humble of the coolie class; and they do not have them because they cannot afford them. I hope this will be a sufficient answer to those who maintain that Chinamen live on rice. It is not nearly so true as that the Scotch live on porridge."

In *India* cancer is said to be rare; but neither the rice-eating Hindoos, nor the flesh-eating Mohammedans are exempt. In support of the alleged rarity of cancer in India, Davidson<sup>24</sup> mentions that of 2,657 operations performed at the Afzulung Hospital at Hyderabad in 1886, only two were for cancer; while in Bombay only 1 per 1,000 of the total deaths were ascribed to it. On the other hand, McLeod<sup>25</sup> states that malignant neoplasms (cancer and sarcoma) are common among the natives of Bengal, both in hospital and private practice; in females the breast being chiefly affected, and in males the cutaneous system, oral cavity and especially the penis. Hendley's<sup>26</sup> experience at the Jeypore Hospital seems to accord with this, for during the period 1880-88, when the hospital was under his charge, 102 major operations were undertaken for the treatment of malignant disease. As, in the face of these conflicting statements, further information seemed desirable, I wrote to Surg. Lieut-Col. Lawrie, of Hyderabad, who kindly favoured me with the following reply, "My experience of cancer is, that it is as frequent in India as in Calcutta, Lahore and Hyderabad. The Afzulung Hospital England; and I have formed this opinion from observation in was under my charge in 1886, and that year was no exception to the rule. The small number of operations for cancer shows nothing, except that the people are averse to operation for most diseases, other than stone and cataract."

---

<sup>24</sup> "Geographical Pathology," 1892.

<sup>25</sup> "Operative Surgery in Calcutta," 1885, p. 102.

<sup>26</sup> *British Medical Journal*, July 7, 1888.



In Cashmere, Orissa, Madras, Anam and Cochin, cancer is said to be more prevalent than in adjacent communities.

In Syria, Persia and Arabia, according to Lombard, the disease is very rare; and generally speaking it is not common within the tropics.

No part of the world is said to enjoy such relative immunity from cancer as *Africa*; this applies to nearly all parts of the continent, but especially to its northern part—Egypt, Tunis, Algiers, &c. In order to ascertain the present state of things in *Egypt*, I lately wrote to Dr. Engel Bey, of Cairo, who very obligingly sent me the following data. Of 19,529 deaths among natives in Cairo during 1891, only nineteen were returned as due to cancer (females 10, males 9), or one in 1,028; in England during the same year, the proportion of cancer deaths was 1 in 29. Of 12,950 patients in the Kasr-el-Aini Hospital during the years 1889-91, 77 were affected with cancer, or '6 per cent.; whereas in Metropolitan General Hospitals I have ascertained that the proportion of cancer cases is about 3'5 per cent. From these data it appears that the reputation of Egypt for comparative immunity from cancer is well founded. With regard to the prevalence of cancerous diseases in Morocco, I am indebted to Mr. Ernest Hart for the following valuable information. In answer to my letter of inquiry, he very kindly wrote to Dr. Terry, of Tangiers, who replied as follows: "Cancers, sarcomas, &c., do not seem to be very prevalent; at any rate the number of cases met with, as compared with other diseases, shows that they are of less frequent occurrence than in England. Among the inhabitants, who are of mixed Arab and native blood, I have seen cancers of the female breast, uterus and tongue; as well as sarcomatous growths in various parts of the body." At the Cape, cancer is common among the whites, but very rare among the natives. Livingstone<sup>27</sup> speaks of cancer as being absent from the Barotze Valley and among the Bakwains, although the latter are prone

<sup>27</sup> "Missionary Travels in South Africa," pp. 127 and 504.



to fatty and fibrous tumours. In Abyssinia cancer is said to be commoner than in any other part of Africa.

Cancer has been notified in Brazil, Mexico, Montevideo, Ecuador and Peru; but as to its relative frequency in *South American* countries we have hardly any definite information. According to Jourdanet it is almost unknown in the hot regions of Mexico, while in the high cool regions it is as frequent as in Europe. At Rio-de-Janeiro cancer is comparatively rare and tubercle very common. Of 13,725 deaths in 1890, 123 were due to cancer, or 1 in 111; and 2,200 to tubercle.<sup>28</sup> In British Guiana the cancer mortality in 1888 amounted to 3 per cent. of the total deaths. It is rare in Jamaica (1·19 per 10,000 living in 1888) and Mauritius (·6 per 10,000 living in 1889).

In our *Australian Colonies* cancer is common, especially in Tasmania, but less so than in England. The following are some of the chief ascertained death rates per 10,000 living:—Tasmania (1882-6), 4·8; Victoria (1882-6), 4·7; New Zealand (1888), 4·3; W. Australia (1882-6), 3·8; S. Australia (1882-6), 3·2; New S. Wales (1882-6), 2·8; Queensland (1882-6), 2·4.

Among whites cancer is fairly common in all parts of *British North America*.

In every part of the world the distribution of cancer presents many *topographical variations*.<sup>29</sup> Moore<sup>30</sup> was one of the first to study these for England and Wales. He showed that the disease was more prevalent in London and the adjacent southern and eastern counties than elsewhere; and that it was least prevalent in Wales and in the north-western (Lancashire) and northern counties. If, he says, the country be divided by a

<sup>28</sup> Havelburg, "Beitrag. z. Trophenhygiene," *Berlin klin. Woch.*, No. 14, 1892, S. 336.

<sup>29</sup> In the United States cancer is much more prevalent in the Northern than in the Southern States. It is especially frequent in New England, the Southern part of the Pacific coast, New York, Pennsylvania and Ohio. In Prussia it is commonest in Schleswig. Lately a great deal of attention has been directed to its prevalence in certain Normandy villages, St. Sylvestre de Corneilles, St. Leones, Ardeuse, &c., (*q. v.* 147.)

<sup>30</sup> "Antecedents of Cancer," 1865, p. 42.



line from Bristol to Peterborough—which practically separates the industrial from the agricultural communities—the mortality from cancer in the southern divisions is considerably in excess of that on the north of the line. In the year 1861, for instance, one of every thirty deaths of females in the south-eastern (agricultural) division was due to cancer; while the deaths of females from cancer in the north-western (industrial) division were only about half as many, or one in fifty-nine of the total female mortality.

Moore gives the following table in illustration of his observations, based on the Registrar-General's returns for the ten years 1851-61.

	One death from cancer in female population between ages of 35 and 64.			One death from cancer in total female mor- tality between ages of 35 and 64.		
England and Wales (average)	...	91	...	...	15	
London	...	67	...	...	12	
South-Eastern Division	...	83	...	...	12	
South-Midland	...	89	...	...	13	
Eastern	...	84	...	...	12	
South-Western	...	100	...	...	14	
West-Midland	...	90	...	...	14	
North-Midland	...	97	...	...	14	
North-Western	...	103	...	...	20	
York	...	100	...	...	16	
Northern	...	102	...	...	16	
Wales	...	137	...	...	20	

In the Forty-Seventh Annual Report of the Registrar-General (1886), this subject has been further investigated.

The subjoined table, from this source, shows the cancer mortality in the registration divisions during the 30 years 1851-80:—

MEAN ANNUAL MORTALITY PER STANDARD MILLION, AGED 25 AND UPWARDS.

	Males.		Females.		Persons.	
England and Wales (average)	...	561	...	1,144	...	867
London	...	736	...	1,463	...	1,117
South-Eastern	...	557	...	1,207	...	898
South-Midland	...	597	...	1,148	...	886
Eastern	...	502	...	1,175	...	855



			Males.	Females.	Persons.
West-Midland	...	...	519	1,133	841
Yorkshire	...	...	511	1,114	827
Northern	...	...	565	1,041	815
South-Western	...	...	555	1,043	811
North-Western	...	...	523	1,055	802
North-Midland	...	...	496	1,074	799
Wales...	...	...	538	841	697

It will be seen that the results brought out by these two tables are practically identical.

The counties with the highest cancer mortality<sup>31</sup> are :—

London, Cambridgeshire, Northamptonshire, Huntingdonshire, Sussex, Warwickshire, Beds, Surrey, Middlesex, Berks, Devon, Norfolk, Hants, Notts, Lincolnshire, &c.

Those with the lowest are :—

Derbyshire, South Wales, Bucks, Herts, Durham, Cornwall, Monmouthshire, Dorsetshire, North Wales, Lancashire, &c.

Haviland<sup>32</sup> gives the following tables showing the places having the *highest death rates* from cancer ; and it will be seen how persistent these are :

A. PLACES WITH THE HIGHEST DEATH RATE FROM CANCER AMONG FEMALES.

	1851-60.	1861-70.
Richmond (Surrey)	7'30	6'61
Pickering (Yorks)	8'05	8'39
Shrewsbury	7'17	7'35
Stafford	7'47	6'81
Stratford-on-Avon	6'79	6'37
Downham	6'70	6'98
King's Lynn	7'09	9'15
Yarmouth	7'64	6'32
Wangford	6'74	8'15
Cambridge	7'38	8'09
Bury-St.-Edmunds	7'53	7'70
Witham	6'56	6'10
Tilbury	7'30	3'55
Marlborough	6'66	4'62
Reading	8'68	8'73
Droxford	6'87	5'73
Chichester	6'65	8'23
Ticehurst	6'73	5'50
Brighton	6'69	7'71
Romney Marsh	6'61	3'88
Plymton-St.-Mary	6'20	6'74
Plymouth	6'50	7'23
Mean at all ages	6'87	6'81
Mean above 35 years of age	10'82	10'97
Mean at all ages (England and Wales)	4'34	5'23
Mean above 35 (England and Wales)	12'98	15'64

<sup>31</sup> Corrected for age and sex distribution.

<sup>32</sup> *Lancet*, vol. i., 1888, p. 366.



## B. PLACES WITH HIGHEST DEATH RATE FROM CANCER AMONG MALES.

	1851-60.	1861-70.
Thakeham .. .. .	4'40	3'82
Ringwood .. .. .	4'00	3'69
Wellingborough .. .. .	3'70	4'26
Huntingdon .. .. .	3'70	6'71
St. Ives .. .. .	3'90	8'78
St. Neots .. .. .	3'80	4'50
Cambridge .. .. .	3'80	4'22
South Molton .. .. .	3'70	4'00
Bristol .. .. .	3'80	3'38
Shrewsbury .. .. .	4'20	4'07
Uttoxeter .. .. .	3'90	4'08
Nuneaton .. .. .	3'80	4'79
Solihull .. .. .	3'80	4'03
Reeth .. .. .	3'70	3'77
West Ward .. .. .	3'60	4'07
Machynlleth .. .. .	4'00	4'70
Mean .. .. .	3'86	4'21
Above 35 .. .. .	11'25	13'16
Mean at all ages (England and Wales) .. .. .	1'93	2'44
Above 35 (England and Wales) .. .. .	5'87	7'52

I have been informed, by a Jersey practitioner, that cancer is very prevalent there, as well as in Guernsey. In order to ascertain the extent of the mortality, I wrote to the gentleman who furnishes the mortality statistics for Jersey, to the Registrar-General; but no information has been forthcoming.

The foregoing observations refer exclusively to the *death* places of cancer patients. In order to ascertain whether similar relations hold for their *birth* places, I have noted where 352 consecutive cancer patients were born, with the following results:—

Of 242 females (breast 91, uterus 129), 70 were born in London, 54 in other towns, and 118 in the country.

Of the *town-born*, 41 were from England:—Birmingham (3), Stowmarket (3), Norwich (2), Newmarket (2), Rotherhithe (2), and 1 each as follows—Hungerford, Aylesbury, Southampton, Yeovil, Honiton, Epping, Shields, St. Albans, Bristol, Scarborough, Liverpool, Hull, Manchester, Ely, Worcester, Southsea, Portsmouth, Woolwich, Plymouth, Maidstone, Devonport, Wells, York, Hemel-Hempstead, Yarmouth, Oxford, Ipswich, Harwich, and Cheltenham. Seven were from Irish towns—Dublin (4), Cork (2), Limerick (1). Two from Wales—Bangor (1), Haverfordwest (1). Two from Scotland—Edinburgh (1), Leith (1). The other two were of foreign birth—the Hague (1), Warsaw (1).

Of the 118 *country-born* patients, 98 were of English birth:—Berks (8), Devon (8), Herts (8), Surrey (7), Essex (6), Suffolk (6), Norfolk (6), Lincolnshire (5), Bucks (5), Gloucestershire (5), Kent (5), Hants (5), Northampton-



shire (4), Wilts (4), Cambridgeshire (3), Somersetshire (3), Beds (3), Cheshire (2), Oxon (2), Middlesex (2), Cumberland (2), and 1 each as follows:—Cornwall, Leicestershire, Notts, Warwickshire, Sussex, Northumberland, and Derbyshire. One was of Welsh birth—from Glamorganshire. Nine were Irish—Cork (3), Limerick (2), Kerry (1), North (2), and South (1). Three were Scotch—1 each from Roxburgh, Dumbarton, and Dumfries.

Of 110 male cancer patients 36 were born in London, 24 in other towns, and 50 in the country.

The *town-born* patients were, from Liverpool (2), Bristol (2), and 1 each as follows:—Guildford, Bath, Maidstone, Lewes, Devonport, Manchester, Deal, Ipswich, Buckingham, Woolwich, Sandhurst, Cheltenham, Tewkesbury, Reading, Windsor, Winchester, Cork, and Aberdeen.

The *country-born* patients came from Cambridgeshire (6), Essex (4), Herts (3), Kent (2), Lincolnshire (2), Devon (2), Berks (2), Norfolk (2), Bucks (2), Dorset (2), Glamorganshire (2), Carmarthenshire (2), and 1 each as follows:—Gloucestershire, Beds, Sussex, Somerset, Hants, Wilts, Northamptonshire, Leicestershire, Warwickshire, Huntingdonshire, Cornwall, Isle of Wight, Isle of Man, Pembrokeshire, Cardiganshire, Renfrewshire, Co. Limerick, near Carlow, and near Skibbereen.

Of 1,030 consecutive cases tabulated by Nunn,<sup>33</sup> 335 were born in London, 588 in various English counties, 20 in Wales, 13 in Scotland, 53 in Ireland, and 21 abroad. The English counties that furnished most of the cases were Kent, Essex, Sussex, Berks, Hants, Herts, Middlesex, Norfolk, Suffolk, Devon, Somerset, Bucks, and Wilts; while those that furnished fewest were Isle of Wight, Rutland, Westmorland, Huntingdonshire, Worcestershire, and Leicestershire.

It will be gathered from these analyses that the localities of greatest cancer mortality are also its most frequent birthplaces.

These remarkable topographical variations are regarded by Haviland<sup>34</sup> as entirely due to geological configuration and its consequences. He maintains that the regions of highest cancer mortality are low-lying districts, traversed by, or contiguous to, rivers that seasonally flood the adjacent riparial lands; whereas the lowest cancer mortality is found in high and dry sites, where

<sup>33</sup> "Cancer of the Breast," 1882, p. 165.

<sup>34</sup> "Geographical Distribution of Heart Disease, Cancer, and Phthisis in England and Wales," London, 1892.



floods do not occur, and where the subsoil consists of hard, non-retentive rocks (*e.g.*, English lake district); or of absorbent substances like chalk and oölite. In support of these views, he instances the Thames and its tributaries, which run through a vast cancer-field, and he points to the only localities in the lower Thames valley—the Orsett and Dartford districts—where there is a low cancer mortality, as being just those spots where the chalk crops out.

In favour of the opinion that in this country cancer is specially prevalent in flat, low-lying, fenny districts, there is, I think, much to be said. The forty-seventh report of the Registrar-General shows that Cambridgeshire and the adjacent counties of Northamptonshire, Huntingdonshire and Bedfordshire, all have very high cancer mortality. Lincolnshire and Essex figure less prominently in this report; but my analyses show that the number of cancer patients born in these localities is exceedingly high. Nevertheless, I am unable to accept Haviland's views as a sufficient explanation of the topographical variations in the distribution of cancer. All low-lying and seasonally flooded districts have not a high cancer mortality; the very large area drained by the Severn and its tributaries, for instance, has throughout a low average mortality from this disease.<sup>35</sup>

It appears to me that the explanation of these variations must be sought in the conditions of life peculiar to the respective populations.

Generally speaking the cancer mortality is lowest where the struggle for existence is hardest, the density of population greatest, the tubercle mortality highest, the average duration of life shortest, the general mortality highest, and where sanitation is least perfect—in short, among the industrial classes; whereas, among the wealthy and well-to-do—where the standard of health is at its best and life is easiest—and among the agricultural community, there the cancer mortality is highest. Other

<sup>35</sup> “Registrar-General's Forty-Seventh Report, Table J., p. 21.



things being equal, there are, in my opinion, no more potent factors in the causation of cancer than high feeding and easy living. Hence it is that the cancer mortality of mining and industrial centres like South Wales, Lancashire, Durham, Cornwall, West Riding, &c., is so low; and that it contrasts so favourably with the cancer mortality of the generality of agricultural districts. Although the ratio of pauperism in the rural districts is quite double that of the industrial ones, I have no hesitation in saying, as the result of my own observation of life under both conditions, that so far as food and comfort are concerned, the agricultural labourer is much better off than his more highly paid *confrère* of the industrial army.

On the other hand, in London and the home counties, where the wealth of the nation is clotted, there the cancer mortality is highest; and it is a significant fact that this mortality is highest of all in those parts of the metropolis where the well-to-do most abound.

According to the Registrar-General's Report for 1884, the cancer mortality of the chief metropolitan districts was as follows:—

*West*.—Chelsea, 1 in 647; Marylebone, 1 in 890; St. George's, Hanover Square, 1 in 1,109; Kensington, 1 in 1,251; Fulham, 1 in 1,292; Westminster, 1 in 1,369. *East*.—Whitechapel, 1 in 839; Mile End, 1 in 2,200; Poplar, 1 in 2,173; St. George's-in-the-East, 1 in 2,245; Stepney, 1 in 2,341; Shoreditch, 1 in 2,482; Bethnal Green, 1 in 2,885. *Average for all London*, 1 in 1,465; *average for England and Wales*, 1 in 1,786.

Cripps,\* taking an average of ten years, found the cancer mortality of *West* London, double that of the *East*.

Of 69 London-born cancer patients interrogated by me at the Middlesex Hospital, 23 were born in the *West*, 15 in the *East*, 14 in the *North*, 7 in the *South*, 3 in the *City*, and 7 in districts not stated.

Of 476 patients from London under treatment at the Brompton Cancer Hospital in 1889, 154 came from the *South-West* district, 93 from the *West*, 89 from the *South-East*, 54 from the *East*, 40 from the *North*, 30 from the *North-West*, and 3 from the *West Central*.

For some of our large towns the cancer death rates are as follows:—Manchester, 1 in 1,566; Salford, 1 in 1,994; Liverpool, 1 in 1,604; Preston, 1 in 1,926; Bradford, 1 in 1,822; Leeds, 1 in 1,413; Birmingham, 1 in 1,520;

---

\* *British Medical Journal*, April 22, 1884.



Norwich, 1 in 1,440; Newcastle, 1 in 1,855; Durham, 1 in 2,573; Nottingham, 1 in 1,488.

What a contrast with these is well-to-do, easy-going Richmond, with a cancer mortality of 1 in 960!

#### § IV.—Family History.

##### (a) *The Heredity of Cancer.*

Very conflicting are the views now prevalent as to the *heredity* of cancer. On the one hand are those who regard this as an impossibility; and on the other those who cannot conceive an explanation of the disease without it. These contradictory opinions are no doubt largely attributable to Weismann's teaching, which has wrought such confusion in the fundamental conceptions of heredity. I cannot here enter on the burning question of Weismannism *versus* Darwinism: suffice it to say that I regard Weismann's doctrine of the non-heredity of acquired variations as improbable.<sup>36</sup> The first principles being in this unsettled state, it will be best to pass at once to the facts.

An analysis of the records of 136 consecutive cases of cancer of the female breast, from data collected by myself, gives the following results.

There was a history of cancer in 33 families, or in 24·2 per cent.<sup>37</sup>

The relatives thus affected and the seats of the disease were as follows :—

<sup>36</sup> The distinction between *somatic* and *germ* cells, on which Weismann's theory is based, appears to me to be entirely artificial. I believe that the reproductive properties manifested by somatic and germ cells are the same in kind and that they differ only in *degree*.

<sup>37</sup> From whatever point of view the subject is regarded, this is a very high percentage. Many anomalies, well known to be hereditary, yield on inquiry a much lower proportion; for instance, of 92 cases of supernumerary mammary structures analysed by Leichtenstern, there was history of heredity only in 7, or in 7·6 per cent.



Father's father (in 2 families)	...	{	Nose.
		{	Œsophagus.
Father's mother (in 2 families)	...	{	Breast.
		{	Breast.
First cousin of father's mother (in 1 family).	1	{	Œsophagus.
Father (in 5 families)	...	{	Breast.
		{	Lip.
		{	Hand.
		{	Internal.
		{	Liver.
Father's sister (in 10 families)	...	{	Breast (5).
		{	Mouth.
		{	Face.
		{	Scalp.
		{	Liver.
		{	Internal.
Mother's mother (in 3 families)	...	{	Breast.
		{	Uterus.
		{	Locality not stated.
Sister of mother's father (in 1 family)			Breast.
Mother (in 7 families)	...	{	Uterus (2).
		{	Stomach.
		{	Breast.
		{	Tongue.
		{	Internal (2).
Mother's sister (in 6 families)	...	{	Breast (4).
		{	Internal.
		{	Tongue.
Mother's brother (in 1 family)	...		Groin.
Female cousin on mother's side (in 2 families).	2	{	Breast.
		{	Locality not stated.
Patient's sister (in 5 families)	...	{	Breast (3).
		{	Uterus.
		{	Locality not stated.
Patient's brother (in two families)...		{	Throat.
		{	Back.
Patient's daughter (1 family)	...		Internal.

These 48 seats of hereditary disease may be grouped thus :  
breast 19, internal 6, uterus 4, liver 2, œsophagus 2, all others 15.

In 8 cases *more than a single relative was affected*, thus :



(1) Father's father, aged 60, and first cousin of father's mother, both died of cancer of œsophagus ; the patient was 47 years old.

(2) Father, aged 71, mother, and mother's sister, all died of internal cancer ; the patient was 45 years old.

(3) Father died, aged 42, of cancer of the breast ; father's two sisters—one of the breast, age 52, the other of the liver ; and two of patient's sisters, both of the breast ; and patient's brother died of tumour of the back, aged 30 ; the patient was 37 years old.

(4) Father's sister and daughter of mother's sister both died of cancer of the breast ; the patient was 59 years old.

(5) Father's sister (aged 75), of the scalp ; mother (aged 54) and patient's sister (aged 59), both internal ; the patient was 46 years old.

(6) Mother died of cancer (locality not stated), and mother's brother died of cancer of groin ; the patient was 60 years old.

(7) Father's mother and patient's sister (aged 48) both died of cancer of breast ; the patient was 51 years old.

(8) Father's sister died (aged 40) of cancer of mouth, and another of his sisters died, at about the same age, of cancer of the eyelid ; the patient was 47 years old.

In four cases there was history of cancer in the families of *both* parents.

(1) Father, of the liver, and mother, of the breast.

(2) Father, mother, and mother's sister, all internal.

(3) Father's sister and mother's sister, both of breast.

(4) Father's sister, of scalp ; mother and patient's sister, both internal.

From this we learn that while in some families cancer had never before been known to have occurred, in others several of the members had been affected in successive generations, and in half of the latter cases the affected relatives were all on one side.

Let us now turn our attention to these cases of multiple family cancer, for they will well repay careful study.

In addition to those above mentioned, I will cite five other remarkable instances of this kind :—

(1) A woman, aged 53,<sup>38</sup> came under my observation with uterine cancer, whose maternal grandmother, mother (aged 45), mother's sister, and the patient's two sisters (aged 32 and 36), had all died of cancer of the *uterus*.

(2) In a case recorded by Sibley, a mother and her five daughters all died of cancer of the *left breast*.

<sup>38</sup> She was one of a family of eleven ; of her brothers and sisters, three died in infancy, and five were still alive and well.



(3) Of the celebrated Bonaparte family, Napoleon I., his father, his brother Lucien, and two of his sisters, all died of cancer of the *stomach*.

(4) The following case, recorded by Broca,<sup>39</sup> is the most complete of its kind that has ever been published; and this is mainly due to the fact that the family included an eminent physician among its members, who furnished the particulars as under:—

*First Generation.*—Madame Z. died of cancer of the breast (1788), aged 60. She left four daughters—A, B, C and D.

*Second Generation.*—The four daughters of Madame Z.—

(1) Madame A. died of cancer of liver, aged 62 (1820).

(2) „ B. „ „ „ „ 43 (1805).

(3) „ C. „ „ breast „ 51 (1814).

(4) „ D. „ „ „ „ 54 (1827).

*Third Generation.*—Madame A. had three unmarried daughters, who are still alive and well, aged 68, 72 and 78 years.

Madame B. had five daughters and two sons. First son died—not cancerous—at the age of 28, and without issue. Second son died of cancer of stomach, aged 54, and without issue.

First daughter died of cancer of breast, aged 35	} All unmarried, and without issue.
Second „ „ „ „ „ 35—45	
Third „ „ „ „ „ 35—45	
Fourth „ „ „ liver, „ 35—45	
Fifth „ „ not cancerous, aged 60, married, but no issue.	

Madame C. had five daughters and two sons:—

First son died in the army, without issue.

Second son alive and well, aged 72.	} He had a son who died paralytic, aged 18; and an only daughter, who is now alive and well, aged 24, unmarried.

First daughter died of cancer of the breast, aged 37, leaving two sons and three daughters.	} First son, aged 58, alive and well. He has three sons alive and well—the oldest 30. Second son died young, abroad, without issue. First daughter died in child-bed, about 28. Second daughter died of cancer of the breast, aged 49. She left two daughters; both are alive and well; the elder is now 22. Third daughter died of phthisis, aged 41.	

<sup>39</sup> *Traité des Tumeurs*, t. i., 1866, p. 151.



Second daughter died, aged 40, of cancer of breast. { She left an only son, who is still alive and well.

Third daughter died, aged 47, of cancer of uterus. { Unmarried.

Fourth daughter died, aged 55, of cancer of the breast. { She left two sons, who are alive and well.

Fifth daughter died, aged 61, of cancer of liver. { Unmarried.

Madame D. had an only son, who is alive and well, aged 70.

(5) In a case recorded by Warren,<sup>40</sup> the father had cancer of the *lower lip*, his son and two daughters each had cancer of the *breast*; in the succeeding generation a daughter of this son, and a daughter of one of his sisters, each had cancer of the *breast*.

These cases of multiple family cancer in successive generations—which are not so rare as is generally believed, for I have found them in nearly 6 per cent. of all cases—prove conclusively the heritability of cancer.<sup>41</sup> They indicate that the cause of the disease must be sought in intrinsic rather than in extrinsic conditions.

In studying this subject it must be borne in mind that morbid conditions, like other recently acquired characters, are never reproduced in the offspring with the same constancy and regularity that normal conditions are. In the long run the tendency always is to normality rather than to abnormality. Hence cancer and all diseases tend to die out in the course of transmission. So great is the preponderating influence of the previous ancestral balance, that even in families where hereditary tendency is strongest, most of the members usually escape. Hence my analysis shows only about 8 per cent. of inheritance directly from parents.

As an example of this prophylactic power of heredity—now-a-days generally overlooked—reference may be made to

<sup>40</sup> "Surgical Observations on Tumours," p. 281.

<sup>41</sup> Virchow cites some remarkable instances of the hereditary transmission of melanomata in horses. In one of these a young white stallion, with melanosis of the anus, transmitted this disease to all its *white* descendants, while those of darker colour escaped. From horses thus bred the disease became widely spread throughout the neighbouring country side. (*Path. des Tumeurs*, t. ii., p. 236.)



the transmission of deaf-mutism. Buxton's researches show that of 303 marriages in which *both* of the contracting parties were deaf and dumb, only one in twenty of the offspring were similarly affected; and that of 310 deaf mutes married to hearing people, the proportion of deaf and dumb among the offspring amounted only to one in 135.

It is difficult to apply this kind of treatment to the family histories of cancer cases because *both* parents are very rarely thus affected; moreover, cancer being a disease of adult life, the liability to it of those of the offspring who die young, and of those who are still living, are disturbing factors. Nevertheless, in spite of these sources of fallacy, I think the following analyses have some utility. Of 136 family histories of breast cancer patients investigated by me, in only two instances were *both* parents cancerous. These marriages produced seven children, of whom two had died of cancer, or one in 3.5. Seven marriages in which only *one* parent was cancerous, produced sixty-two children, of whom ten, or one in 6.2 had become cancerous. Six marriages in which although neither parent was cancerous, the disease existed in their *collaterals*, produced forty-one children, of whom eight, or one in 5.1, had become cancerous. Here, as in the case of deaf-mutism, the tendency of the disease liability to diminish in transmission is well seen.

In physiological heredity it is a generally accepted rule that the descendants of an individual in whom a new variation has appeared, are—other things being equal—more likely to vary again in a similar way, than are persons whose ancestors have never manifested such variation. That the same tendency, in a less degree, holds also for cancer heredity, I have not the slightest doubt, although attempts have been made to prove the contrary by ingenious statistical computations.<sup>42</sup>

---

<sup>42</sup> In his report for 1889 the Registrar-General writes as follows: "Seeing that one of twenty-one males and one of twelve women, who reach the age of 35, die eventually of cancer, it follows by the law of probabilities that on an average in one of three either a parent or grandparent will have died of such an affection, supposing such parents or grandparents to have died after 35; and the proportion will be still



This opinion, in addition to the above-mentioned data, is based upon the following evidence :—

(1) That derived from the study of multiple family cancers. Thus, in Broca's celebrated case, of the twenty-six descendants of Madame Z. who attained or exceeded the age of 30, fifteen died of cancer; whereas the cancer mortality for the same number of persons of the general population, at the corresponding period of life, is considerably less than one; that is to say, the liability to the disease was increased more than fifteen times by the influence of heredity.

(2) That derived from comparing the proportion of cases with family history of cancer among the cancerous and the non-cancerous. Thus, of my 136 cases of cancer of the female breast, there was history of cancer in thirty-three families, or in 24.2 per cent.; whereas of ninety-five cases of non-malignant tumours and cysts in women there was history of cancer only in fourteen families, or in 14.7 per cent.<sup>43</sup> Hence in these cases the liability to the disease was increased nearly 10 per cent. by the influence of heredity. The above data were collected by myself, and the inquiries were equally carefully carried out in both sets of cases.\*

The phenomena of inheritance teach us that the actual product of a fertilised germ never represents the full measure

---

higher if the circle of relatives is extended so as to include not only these direct progenitors, but collateral relatives such as uncles and aunts." The appositeness of this seductive chain of reasoning is, of course, entirely dependent upon the absolute correctness of the premisses on which it is based; and of this we have no guarantee. The results arrived at are so completely at variance with the very plain facts cited by me, whose accuracy hardly admits of dispute, that I confidently conclude some error has crept in. Just so is it with Cripp's calculation (*St. Bartholomew's Hospital Reports*, vol. xiv., p. 287) in which he has attempted to prove that cancer in the parent in no way increases the liability of the offspring to suffer from the same disease.

<sup>43</sup> Fibro-adenoma of breast thirty-eight cases, with family history of cancer in five; lipoma thirty-six cases, with family history of cancer in six; ovarian cysts twenty-one cases, with family history of cancer in three.

\* Of 147 cases of non-malignant neoplasms, whose family history was analysed by Paget (*Medical Times and Gazette*, August 22, 1857, p. 191), only 6.8 per cent. were aware of having had cancerous relatives.



of its potentiality. Only a portion of the many varying tendencies inherited by the reproductive cells from their long line of ancestors are actually evolved in each generation. Hence, in normal heredity, we constantly see transmitted besides developed structures, certain tendencies and predispositions. Thus the male and female secondary sexual characters are transmitted through each sex, though usually developed in one alone. Similarly, tendencies are transmitted through the earlier years of life that are only subsequently developed. In like manner we often see qualities transmitted in a latent state through one or more generations, and then suddenly developed, as in the wonderful phenomena included under the term reversion. By virtue of these considerations it has been truly said, that to know a man well we must know his relations—grandparents, parents, uncles, aunts, cousins, brothers, sisters, children—in them we shall often see developed his own latent tendencies. For this reason those who neglect collaterals in studying heredity are greatly in error. Such are the physiological conditions that must be borne in mind when studying the inheritance of cancer.<sup>44</sup>

It will generally be found that the birth of the subjects of direct cancer heredity dates from a period long anterior to that at which the disease appeared in their parents. Thus, in Broca's case, the four daughters of Madame Z., who all died cancerous, were born fifteen, twenty-five, twenty-six, and thirty years respectively before the period when their mother died of the disease: that which was latent in the parent was transmitted potentially to the offspring.

It frequently happens that such latent tendency to the disease in ancestors, although it never becomes effective in

---

<sup>44</sup> According to Darwin's hypothesis of pangenesis every cell of the body throws off gemmules or undeveloped atoms, which are transmitted to the offspring of both sexes, and are multiplied by self-division. They may remain undeveloped during the early years of life or during successive generations; and their development into cells like those from which they were derived, depends on their affinity for, and union with, other cells previously developed in the due order of growth.



them, nevertheless does so in their descendants. Thus cases occur in which cancerous grandparents transmit the disease to their grandchildren, while their own offspring escape (*atavism*). This happened in seven of the 136 cases of cancer of the female breast analysed by me, or in 5·1 per cent. In three of these cases the disease was inherited from the maternal grandmother, in two from the paternal grandmother, and in two from the paternal grandfather. In three cases the locality affected in the grandparents, as in the grandchildren, was the breast; in the other four cases the localisation of the disease in the grandparents differed from that in the grandchildren. Whether cancer is ever transmitted by reversion, after skipping more than a single generation—as often happens in physiological heredity—I am unable to state, and I know of no facts bearing on this point.

Much commoner than true atavism, or than heredity by direct descent from parents, is a form of inheritance in which the disease is transmitted through parents, &c., who themselves never manifest it, although their sisters, brothers, or other relatives do. On reference to my analysis it will be seen that the inherited disease manifested itself, in this way, in the father's sisters in ten families, the breast being the organ affected in five; and in six families in the mother's sisters, the breast being affected in four.

It will be gathered from the foregoing that what is transmitted in cancer heredity is not the disease itself, but a tendency or predisposition to the production of those conditions that may finally eventuate in it. It is a legitimate inference from what has been stated, that the special tendency to cancer is of gradual evolution; and that without this antecedent preparation the disease can never be developed under ordinary circumstances.

A remarkable feature about many cases of inherited cancer is that the disease, like normal structure, is homotopic in its transmission; that is, it attacks the corresponding organ in each of the related individuals. This is especially noticeable in Sibley's case, where the mother and her five daughters all had



cancer of the *left* breast. Although this form of transmission often defaults, it is nevertheless noteworthy that, on the average—taking all the seats of inherited cancer into consideration—homotopic transmission preponderates. Thus, of the forty-eight seats of inherited cancer in my analysis of the family history of 136 cases of mammary cancer in women, the breast was the organ affected in nineteen; similarly, of the fifteen seats of the disease inherited from Madame Z., who had mammary cancer, in nine the breast was affected. The tendency to homotopic transmission may thus be taken as the established rule, although the number of cases in which heterotopic transmission occurs is by no means inconsiderable. I can discover no ground for the dictum that homotopic transmission is especially apt to prevail among near relatives and heterotopic transmission among distant ones. In ten instances of mammary cancer inherited directly from one or both parents, in only two was the breast the locality affected in the ascendants. From the foregoing facts it may be inferred, that the molecular protoplasmic disturbance which eventuates in inherited cancer, affects the whole of the archiblastic tissues of the body; but that its influence is most felt in that part which corresponds to the seat of the disease in the ancestor.

Inherited cancer manifests itself much more frequently in the female than in the male relatives, although the disease is as often derived from the father's as from the mother's side of the family. My analysis shows this very well; thus of forty-seven affected individuals, there were ten males to thirty-seven females. In cases of multiple family cancer this tendency of the inherited disease to repeat itself unduly in the female sex is especially noticeable. Thus, in Broca's case, all the persons attacked but one were females. Of the nineteen daughters and granddaughters of Madame Z., who attained the age of 30, fourteen became cancerous; but out of seven males only one was thus affected.

As in normal heredity—but with less constancy—cancer tends to appear in the offspring at about the same age that it



appeared in the ancestor. Hence, like gout, cataract, phthisis, insanity, and some other heritable conditions, the disease usually does not manifest itself until an advanced period of post-embryonic life.

It has been suggested that during the course of its transmission by inheritance, cancer may be *transmuted* into sarcoma or some form of non-malignant neoplasm. On *à priori* grounds, I have no objection to offer to this suggestion; but the facts collected by me show that the existence of such a coincidence in the family history of cancer patients is very exceptional. Of the 136 family histories of women with breast cancer there were only two undoubted instances of non-malignant neoplasms in relatives; in one case the patient's mother, who was still alive and well, aged 75, had a "tumour" removed from her thigh when she was 50 years old, which never recurred; in the other, the patient's father, who was still alive and well, had a lipoma of the back. Two other instances of so-called "tumour," one "internal" and the other "abdominal," were also reported, one in a patient's mother and the other in a mother's sister; but as both of these ended fatally, the disease was probably really malignant. This experience is by no means exceptional, for I have found equally few instances of non-malignant neoplasms in the relatives of patients with cancer of other parts of the body, although I inquired just as carefully after the former as after the latter.<sup>45</sup>

(b) *Hereditary proclivities correlated with cancer.*

The remarks I have to make on this subject are based upon the subjoined analysis of the family history of 134 women with cancer of the breast. This analysis shows:—

(1) That pulmonary *tubercle* is by far the most prevalent disease among the relatives of cancerous persons. Such a result is only what might have been expected *à priori*, considering the frequency of tubercular disease in the community at large; but

<sup>45</sup> For some further remarks on this subject the reader is referred to chap. xviii.



a great mistake has been made in taking it for granted, on this account, that the relatives of cancerous persons have no special proclivity to tubercle. On the contrary, as I shall proceed to show, such persons are very much more prone to it than the rest of the community; indeed, their liability to phthisis is so considerable, as even to equal that of the phthisical themselves.

No statistics show a greater amount of heredity in phthisis than Dr. R. Thompson's,<sup>46</sup> because he has included in his list only those cases in which the family history had been very completely recorded. He obtained history of heredity in 44 per cent. of 5,000 consecutive phthisical cases—58 per cent. in females and 36 per cent. in males. Now, my analysis of the family history of 134 women with mammary cancer shows a history of phthisis in 55 per cent., which is almost as high a proportion as Thompson's. The amount of hereditary phthisis among the rest of the community is very much less than this; it has been estimated by Dovey,<sup>47</sup> from analysis of the family history of 409 non-consumptive life-policy holders, at 10·8 per cent. Nothing, therefore, can be plainer than that the relatives of cancerous patients are very much more prone to tubercle than the rest of the community. This is borne out by the results deducible from my analysis of the causes of death of the brothers and sisters of patients with mammary cancer in 88 families. These averaged 8·8 members each, in all 774 individuals. Now, one or more deaths from phthisis took place in 40 of these families. Supposing only a single death to have occurred in each of them, this would be equivalent to one death from phthisis in 19 members, whereas the mortality from phthisis in the general population in 1885 amounted to 1 in 570. Similarly among 83 fathers of mammary cancer patients, who had died of various causes, the mortality from phthisis was 22, or 1 in 3·8; among 71 mothers, it was 18, or 1 in 3·9, or among these 154 parents, it was 40, or 1 in 3·8; whereas the ratio of deaths from phthisis to the total

---

<sup>46</sup> "Family Phthisis," London, 1885.

<sup>47</sup> Quoted by Thompson, *Op. cit.*, p. 16.



mortality in the general community, in 1885, amounted only to 1 in 11. Long study of the family history of cancer patients has convinced me, that a large proportion of the latter are the *surviving members of tubercular families*; and the facts just cited confirm this belief. On the same ground I conclude, that no hereditary condition is more favourable to the development of cancer than that which predisposes to and accompanies tubercle.

The much greater frequency with which obsolete tubercle is found in association with cancer than with most other diseases, is also an argument in favour of this view. Thus, of 136 consecutive necropsies on women under my observation, who died of cancer (uterus 79, breast 44, rectum 13), obsolete pulmonary tubercle was found in 17, or in 12·5 per cent;<sup>48</sup> whereas of 16,562 consecutive necropsies, tabulated by Heitler,<sup>49</sup> on persons who had died of various causes—which included but 110 cases of cancer (0·6 per cent.)—obsolete tubercle was met with only in 789 cases, or in 4·7 per cent.

Although cancer and tubercle are thus intimately connected, it is very rare to find both diseases in active progress in the same individual. I have met with this conjunction only twice out of 136 cancer necropsies.<sup>50</sup> In the other cases it was evident that arrest of the tubercular disease had long preceded the outbreak of cancer. The combination of both phthisis and cancer in the same family's history was noted by me in 18 out of 134 cases, or in 13·4 per cent. Another consideration which accords with the foregoing views is, that in families where cancer prevails, according to Moore,<sup>51</sup> the elder members are more prone to become cancerous than the younger ones, the first-born being the most liable. Whereas, with regard to phthisis, it has been shown by Thompson that the younger members are the more

<sup>48</sup> Of 130 breast cancer patients, five were aware of having had previous phthisical disease, or 3·8 per cent.

<sup>49</sup> *Wiener Klinik*, 1879, S. 269.

<sup>50</sup> Of 173 cancer necropsies analysed by Sibley, in 11 active tuberculosis was present, *Med. Chir. Trans.*, vol. xlii.

<sup>51</sup> "Antecedents of Cancer," p. 35.



liable—the greatest liability being with the last born. I have dwelt at some length on this subject, because it appears to me to have an important bearing on the ætiology of cancer; and so far as I know, it has never before been set forth in its true light.

(2) If similar investigations were set on foot with regard to other diseases, I believe it would be found that the tubercular predisposition gives proclivity to many of them, as, for instance, it certainly does to *insanity*. Thus Clouston<sup>52</sup> found tubercular deposits twice as often in the bodies of those who died insane as in the bodies of those who died sane; and he has proved that hereditary predisposition to insanity is much greater among the tubercular than among the non-tubercular. In this connection it is worthy of note that the relatives of cancerous persons are more prone to insanity than are the relatives of the non-cancerous; at least this is the conclusion I draw from the fact that 51 female cancer patients under my observation gave a family history of insanity in 7 cases, or in 13·7 per cent.; whereas 29 women with non-malignant neoplasms knew of insane relatives only in 3 instances, or in 10·4 per cent.; and the latter is probably a higher percentage than would be met with in the general community.

The liability of insane persons and idiots to cancer is decidedly below the average.<sup>53</sup> Of 5,373 lunatics who died while under treatment at the Hanwell and Hitchen Asylums (1870-91) only 125 died of cancer, or 1 in 39. Of 2,741 females, 101 died cancerous, or 1 in 27, and of 2,623 males 34, or 1 in 77.

(3) Many authors regard *apoplexy* as a manifestation of the same neurotic disposition, of which insanity is also an outcome; and my analysis shows that this disease is unduly prevalent among the relatives of cancerous persons. Thus of 154 parents of women with mammary cancer, who died of various causes, 17 died of apoplexy, or one in nine; whereas the ratio of deaths

<sup>52</sup> Cited by Maudsley, "Pathology of Mind," p. 112.

<sup>53</sup> Snow, *Journal Mental Sci.*, Oct., 1891, p. 548.



from apoplexy to the total mortality of the general population in 1884, was only one to 36. Similar undue frequency of this disease is noticeable among the brothers and sisters of these cancer patients; for, while one in 258 of the latter died of apoplexy, the mortality from it in the general community in 1884 amounted only to one in 1,841.

(4) There is reason to believe that the members of cancer families are also unduly prone to *arthritic manifestations*, as was the case, for instance, in the Bonaparte family, Prince Pierre having died of heart disease, consequent on rheumatic fever, and Napoleon III. of stone in the bladder.<sup>54</sup> My analysis shows twelve deaths from heart disease among 154 parents of breast cancer patients, or one in 12·8; whereas in the general community the corresponding ratio in 1884 was one to 79. From rheumatic fever my analysis shows one death in 154 parents; whereas the rate for the community at large, in 1884, was one in 195. Of 160 cases analysed by Nunn, gout and rheumatism were traced in 15. There is also evidence of a considerable amount of heart disease and rheumatic fever among the patient's brothers and sisters; and of 130 breast cancer patients under my observation, 11 had previously suffered from rheumatic fever and 6 from rheumatism.

There still remain to be considered two other proclivities to which the members of cancer families are remarkably subject, viz., longevity and great reproductive fecundity.

(5) The evidence furnished by my analysis as to the *longevity* of the parents of cancer patients is of the most striking and conclusive kind. To prove this it will suffice to mention only a few of the leading facts.

Of 112 dead fathers 14 attained the age of 80, which is equivalent to 1,250 per 10,000, whereas in the general population only 463 males live to this age out of 10,000.

---

<sup>54</sup> Two other members of this family—King Jérôme and his son, Prince Napoleon—were subject to diabetes. This—which is a rare disease—is associated with insanity and tubercle: my analysis shows an undue amount of it (two deaths in 154) among the relatives of cancer patients.



Of 103 dead mothers 17 attained the age of 80, which is equivalent to 1,650 per 10,000, whereas in the general population only 682 females live to this age out of 10,000.

Of these 215 dead parents two attained the age of 95, which is equivalent to 93 per 10,000, whereas in the general population only 21 per 10,000 live to this age.

At first sight this result appears to be in contradiction with the conclusion previously arrived at, that the relatives of cancer patients are especially liable to pulmonary tubercle, but it must be borne in mind that these cancer families are generally exceedingly numerous. Striking confirmatory evidence is furnished by inquiring into the family history of centenarians and aged persons, whence it appears that a large proportion of these—20 per cent. in the case of females—are the surviving members of phthisical families. It is evident, therefore, that the constitutional peculiarity, which is associated with tubercle, is by no means incompatible with longevity.<sup>55</sup>

(6) Equally conclusive is the evidence as to the great *fecundity* of cancer families.

Thus, 110 of these families included in my analysis, averaged 8·8 members in each family, or 968 members in all; whereas, according to Farr,<sup>56</sup> in the general community the average number to a family is 4·6, so that an equal number of families would include only 506 members.

The foregoing conclusions, although based solely upon facts derived from the study of the family history of women with cancer of the breast, are nevertheless, as I have ascertained, equally valid for cancer of all parts of the body.

*Analysis of the family history of 134 women with cancer of the breast:—*

*The Fathers.*—Of 129 cases in which inquiries were made with regard to the fathers, in 117 they were *dead*, and in twelve still *alive*. The *causes of death* were known in 83 cases, as follows:—Phthisis in 22 cases; heart

<sup>55</sup> "Old age and the changes incidental to it," *British Medical Journal*, May 9, 1885.

<sup>56</sup> "Vital Statistics," 1885, p. 98.



disease, 11 ; apoplexy, 9 ; bronchitis, 8 ; cancer, 5 ; dropsy, 5 ; old age, 4 ; accident, 3 ; cholera, 2 ; strangulated hernia, 2 ; renal disease, diabetes, fever, diarrhoea, white swelling of knee, sunstroke, erysipelas, typhoid fever, ulcer of leg (hæmorrhage), suicide (alcoholism), insanity and cerebral softening, each one case.

Of those who had died of *phthisis*, in 7 cases other members of the family had also died of this disease. Twelve of these fathers who had died of causes other than *phthisis* were, however, of *phthisical* families. Thus of these 83 fathers, 34 (40·9 per cent.) were of *phthisical* families.

There were among them 5 deaths from *cancer* (6 per cent.) ; the localities affected being the breast, lip, hand, liver, and "internal." Seven fathers who had died of causes other than cancer were, however, of cancerous families.

The relatives thus affected and the seats of the disease were as follows :—

(1) Father died, aged 57, of heart disease ; his father died, aged 60, of cancer of the œsophagus ; and his mother's first cousin died of cancer of the œsophagus.

(2) Father died, aged 55, of *phthisis* ; his mother died of cancer of the breast.

(3) Father died, aged 69, insane ; his sister died of cancer of the breast.

(4) Father died, aged 64, of apoplexy ; his father died, aged 76, of cancer of the nose.

(5) Father died, aged 80, of apoplexy ; his sister died, aged 75, of cancer of the scalp.

(6) Father died, aged 62, of apoplexy ; his sister died of internal cancer.

(7) Father died, aged 73, of heart disease ; his mother died of cancer of the breast.

Thus of these 83 fathers, 12 (14·4 per cent.) were of cancerous families.

The average *age of the fathers at death*, in 112 cases, was 62·4 years ; the oldest 96 (14 having attained or exceeded 80 years), the youngest 30.

Of the 12 *fathers still alive*, two were subject to heart disease and dropsy, and one to chronic rheumatism, one to chronic bronchitis, and one had a lipoma of the back. The others were in good health.

The average *age* (in the nine cases in which it is stated) was 72·4 years ; the oldest 83 (two attained or exceeded 80), the youngest 60.

Two of these 12 fathers were of *phthisical* families, each having lost a sister from this disease, as well as from cancer.

Four of them were of *cancerous* families, the relatives affected and the seats of the disease being as follows :—

(1) Sister died, aged 40, of cancer of the mouth, and another sister died, at about the same age, of cancer of the face.

(2—4) In two cases a sister died of cancer of the breast ; and in one case, a sister was suffering from cancer of the breast.

*The Mothers.*—Of 125 cases in which inquiries were made with regard to the mothers, in 105 they were dead, and in 20 still alive. The causes of death were known in 71 cases, as follows :—*Phthisis*, 18 cases ; apoplexy, 8 ; dropsy, 8 ; cancer, 7 ; bronchitis, 6 ; liver disease, 3 ; pneumonia, 3 ; cholera, 3 ; childbed, 2 ; old age, 2. Abdominal tumour, chest disease,



rheumatic fever, diabetes, jaundice, peritonitis, quinsy, typhoid fever, heart disease, strangulated hernia, and sudden death in bed, each one case.

Of those who had died of phthisis, in three cases other members of their families had also died of this disease. Six of these mothers, who had died of causes other than phthisis, were, however, of phthisical families. Thus, of these 71 mothers 24 (33·9 per cent.) were of phthisical families.

There were among them seven deaths from cancer (9·8 per cent.), the localities affected being the uterus (2), internal (2), breast, stomach, and tongue, each one. Six of these mothers who had died of causes other than cancer were, however, of cancerous families. The relatives thus affected, and the seats of the disease were as follows :—

(1) Mother died, aged 70, of phthisis ; a relative of hers died of cancer of breast.

(2) Mother died, aged 82, suddenly in bed ; her sister died of cancer of breast.

(3) Mother died, aged 68, of apoplexy ; her sister died of cancer of tongue.

(4) Mother died, aged 70, of apoplexy ; her cousin died of cancer—locality not stated.

(5) Mother died, aged 66, of bronchitis ; her mother died of cancer of uterus.

(6) Mother died of phthisis ; her sister died of cancer of breast.

Thus, of these 71 mothers, 13 (18·3 per cent.) were of cancerous families. The average age of the mothers at death, in 103 cases, was 62 years ; the oldest within a few months of 100 (17 having attained or exceeded 80 years), the youngest 25.

Of the 20 mothers still alive, all save 2 (bronchitis 1, and spinal disease 1), were well. Their average age (in 16 cases) amounted to 71·5 years ; the oldest 84 (3 had attained or exceeded 80), the youngest 60. Of these 20 mothers 5 were of phthisical and 2 of cancerous families.

*Consanguinity in the Parents.*—As to this, inquiries were made in 33 cases, with the result that in 2 instances the parents were blood relations.

In one case they were first cousins ; the father died of heart disease, aged 66, and his father died insane ; the mother died, aged 78, of dropsy. There were 5 children of the marriage ; 2 died in infancy, and 2 sisters were still alive and well. There was no history of cancer, tumour, or phthisis in either family. In the other case the parents were third or fourth cousins. The father died, aged 55, of phthisis, and his mother died of cancer of the breast. The mother died, aged 80, of old age.

*The Patient's Brothers and Sisters.*—In 88 families the following causes of death were noted among the adults :—Phthisis (one or more deaths) in 40 families ; heart disease, 8 ; dropsy, 6 ; cancer, 5 ; childbed, 5 ; rheumatic fever, 3 ; apoplexy, 3 ; bronchitis, 3 ; typhoid fever, 3 ; traumatism, 3 ; fever, 2 ; smallpox, 2 ; cholera, 2 ; peritonitis, 2 ; and hepatic disease, 2 families. Cerebral disease, scarlet fever, yellow fever, insanity, delirium tremens, tubercular abscesses, pleurisy, diabetes, pneumonia, tuberculosis of the bowels, pyæmia, jaundice, tubercular arthritis, and strangulated hernia, each one case.



Of the families in which *phthisis* prevailed, in 15 more than a single member had died of this disease.

Of 110 families, the *number of members in each family* was noted, with the result that the smallest family consisted of one (two instances), the largest of 19 (two of 17), the average of 8·8

*The Occurrence of Phthisis.*—Of 134 families, among the adults, one or more relatives had died of or were subject to phthisis, in 74 or 55·2 per cent.

In 37 of these families more than a single individual had died of this disease.

The relatives thus affected may be conveniently arranged as follows :—

Both paternal grandparents in	...	...	...	1 family.
Paternal grandmother in	...	...	...	1 „
Both parents	...	...	...	5 „
Fathers	...	...	...	16 „
Father's brothers and sisters	...	...	...	18 „
Mothers	...	...	...	13 „
Mother's brothers and sisters	...	...	...	8 „
Patient's brothers and sisters	...	...	...	37 „

*The Combination of Phthisis and Cancer.*—Of 134 cases, in 18 there was history of both phthisis and cancer in the same family. Thus :—

Phthisis on	{	Father's side nine families.
	{	Mother's side in one family.
	{	Patient's brothers and sisters in four families.
Cancer on	{	Father's side in two families.
	{	Mother's side in twelve families.
	{	Patient's brothers and sisters in two families.
Cancer and Phthisis on	{	Father's side in three families.
	{	Mother's side in three families.

*The Occurrence of Insanity.*—As to this enquiries were made in 18 families : in three there was history of insanity, the patient's paternal grandfather, father, and sister being the relatives respectively affected.

## § V.—The Prevalence of Cancer and its Increase.

In the course of organic evolution some types of disease—like species—have diminished and become extinct ; while others have increased and become more prevalent. In comparatively recent times, plague, typhus, leprosy, ague, and dysentery have almost or quite disappeared from this country, and smallpox has greatly diminished, while phthisis and other forms of tubercular disease are now decidedly on the wane. On the other hand cancer—a disease known to have existed in its present form



from the most remote times of which we have any record—has steadily increased during the last half century, and is still increasing, and this in spite of diminution in the general death-rate. Insanity also is on the increase.<sup>57</sup>

Prior to 1837, when the Registration Act came into operation, we have no reliable information as to the prevalence of cancer. In 1840, it caused 2,786 deaths, the proportion being one in 5,646 of the total population, one in 129 of the total mortality, or 177 per million living; in 1890, the deaths due to it numbered 19,433, being one in 1,480 of the total population, one in twenty-eight of total mortality, or 676 per million living. Thus the proportionate mortality from cancer now is about four times greater than it was half a century ago. Among women of 35 years of age and upwards, it has increased from one in ninety-one for the decennial period, 1851-60, to one in twelve for the period 1887-89. From the extent of the mortality and the average duration of the disease,<sup>58</sup> there cannot be fewer than 40,000 persons now suffering from cancer in England and Wales; whereas, in 1840, the number was only about 5,500.

In this respect its position is unique; no other disease can show anything like such an immense increase. It seems certain, that if unchecked, cancer will ere long become one of the commonest diseases of modern communities.

In illustration of this subject I have compiled the following table, which shows the increase in England and Wales since 1840:—

---

<sup>57</sup> In 1871 the proportion of insane persons in England and Wales was 3,034 per million living, or 1 in 329; in 1881 it had increased to 3,252 per million, or 1 in 307; and in 1891 the numbers were 3,360 per million, or 1 in 297. Thus the increase during 1871-81 was 7.04 per cent., and during 1881-91, 3.23 per cent. Most of the increase has taken place in persons above 45 years of age, and females have been affected more than males. Suicides have also increased from 65.2 per million living in 1861-65, to 79.4 in 1886-90.

<sup>58</sup> Taken at the low estimate of two years.



TABLE SHOWING THE PREVALENCE OF CANCER AND ITS INCREASE IN ENGLAND AND WALES.

Year.	Total Population.	Total Deaths.	Cancer Deaths.	Cancer Death-Rate per Million Living.	Proportion to Population.	Proportion to Total Deaths.
1840	15,730,813	359,687	2,786	177	1 to 5,646	1 to 129
1850	17,773,324	368,995	4,966	279	1 „ 3,579	1 „ 74
1855	18,829,000	426,646	6,016	319	1 „ 3,129	1 „ 70
1860	19,902,713	422,721	6,827	343	1 „ 2,915	1 „ 62
1865	21,145,151	490,909	7,922	372	1 „ 2,670	1 „ 62
1870	22,501,316	515,329	9,530	424	1 „ 2,361	1 „ 54
1875	24,045,385	546,453	11,336	471	1 „ 2,121	1 „ 48
1880	25,714,288	528,624	13,210	502	1 „ 1,946	1 „ 40
1881	25,974,439	491,937	13,542	520	1 „ 1,918	1 „ 36
1882	26,413,861	516,654	14,057	532	1 „ 1,879	1 „ 36
1883	26,770,744	522,997	14,614	546	1 „ 1,763	1 „ 35
1884	27,132,449	530,828	15,192	559	1 „ 1,786	1 „ 35
1885	27,499,041	522,750	15,560	566	1 „ 1,767	1 „ 33
1886	27,870,586	537,276	16,243	583	1 „ 1,715	1 „ 33
1887	28,247,151	530,758	17,113	606	1 „ 1,650	1 „ 31
1888	28,628,804	510,971	17,506	610	1 „ 1,635	1 „ 29
1889 <sup>59</sup>	29,015,613	518,353	18,654	643	1 „ 1,555	1 „ 27
1890 <sup>60</sup>	28,762,287	562,248	19,433	676	1 „ 1,480	1 „ 28
1891	29,081,047	587,925	20,117	692	1 „ 1,445	1 „ 29

Mere increase of population will not account for this continuously progressive augmentation of the cancer death-rate, as

<sup>59</sup> Estimated on the 1881 Census.

<sup>60</sup> Estimated on the 1891 Census.



is evident from the fact that its rate of increase has proportionally been much in excess of this; and there is far too much uniformity in the variations of the increments of increase in the long succession of years, to warrant its being ascribed to improved diagnosis or other casual error. Moreover, the increase has not been confined to one or a few parts of the body; but it has involved them all—on the whole without any considerable disturbance of the normal proportionate localisation ratios.<sup>61</sup>

Again, as I have previously indicated,<sup>62</sup> the increase has been diffused over the whole country, instead of being limited to certain areas only; so that those parts that formerly had the highest, lowest, and average cancer death rates, still preserve their distinction in these respects, although the cancer mortality has everywhere augmented. There can, therefore, be no doubt as to its reality.<sup>64</sup>

The returns for Scotland exhibit a similar state of things, as is shown by the following figures:—

						Cancer death rate per million living.
1861 to 65	...	...	...	...	...	404
1866 „ 70	...	...	...	...	...	428
1871 „ 75	...	...	...	...	...	468
1876 „ 80	...	...	...	...	...	504
1881 „ 85	...	...	...	...	...	540

<sup>61</sup> The Registrar-General's report for England, based on the mortality returns for the years 1868 and 1888, show that all the seats of the disease participated in the increase, although it affected the commoner ones to a less degree than the others. It was least in the uterus, female breast and stomach; and in males, in the tongue and mouth, face, penis, &c.; and greatest—for both sexes—in the intestines, liver, rectum, cesophagus, bladder, &c. The Registrar-General's report for Ireland for the five years 1887-91, also show that all the seats of the disease participated in the increase, and that without any considerable disturbance of the normal localisation ratios. For further details *vide* a communication by the author in the *British Med. Journ.*, vol. i., 1893, p. 547.

<sup>62</sup> § III., pp. 254-6.

<sup>64</sup> In a recent publication (*Proceedings of the Royal Society*, No. 327, vol. liv.) Dr. Newsholme has maintained the contrary thesis, attempting to account for the increase as the result of improved diagnosis. For his discussion of this question with the author *vide Brit. Med. Journ.*, Dec. 30, 1893, and early numbers of 1894.



Year.	Total Popu- lation.	Total Deaths.	Cancer Deaths.	Cancer Death- Rate per Mil- lion Living.	Proportion to Population.	Proportion to Total Deaths.
1884	3,829,772	75,168	2,110	550	1 to 1,815	1 to 35
1885	3,859,234	74,607	2,173	560	1 „ 1,776	1 „ 34
1886	3,888,922	73,640	2,313	590	1 „ 1,681	1 „ 31
1887	3,918,841	74,546	2,373	600	1 „ 1,652	1 „ 31
1888	3,948,989	71,174	2,450	610	1 „ 1,612	1 „ 29
1889	3,979,406	73,238	2,643	670	1 „ 1,505	1 „ 27
1890	4,003,132	79,004	2,428	610	1 „ 1,643	1 „ 32

In most civilised countries where statistical records have been kept similar increases have been observed. In Norway the cancer deaths increased from 32 per 1,000 of the total mortality in 1877 to 60 per 1,000 in 1886-87. In the Netherlands the increase was from 4·9 per 10,000 living in 1867-79 to 6·5 in 1884-88, and in Prussia from 3·1 in 1881 to 3·8 in 1887. Brussels is credited with an increase from 3·9 in 1864-73 to 4·2 in 1874-78; and in New York the rise was from 4 in 1875 to 5·3 in 1885. In Australia and New Zealand similar phenomena have been recorded; thus the Victoria cancer mortality, which was 3·7 in 1871-80, rose to 4·7 in 1882-86, and in New Zealand the rise was from 2·6 in 1879 to 4·3 in 1888.

In all the above instances the augmented cancer mortality has coincided with progressive population, increased national wealth, and marked improvement in the general well-being. It seems to me impossible to regard these coincidences otherwise than as the result of cause and effect.

It accords with this view that in Ireland—where less favourable material conditions have prevailed—the cancer death-rate has been much lower than in either of the sister countries; and for many years it has shown no such marked increase as in the latter, as is shown by the subjoined figures:—



						Per Million Living.
1870	...	...	...	...	...	330
1873	...	...	...	...	...	330
1875	...	...	...	...	...	330
1877	...	...	...	...	...	350
1878	...	...	...	...	...	360
1879	...	...	...	...	...	340
1880	...	...	...	...	...	340

Year.	Total Population.	Total Deaths.	Cancer Deaths.	Cancer Death- Rate per Mil- lion Living.	Proportion to Population.	Proportion to Total Deaths.
1881	5,144,983	90,035	1,909	371	1 to 2,695	1 in 47
1882	5,097,853	88,500	1,882	369	1 „ 2,708	1 „ 47
1883	5,015,281	96,228	1,995	398	1 „ 2,514	1 „ 48
1884	4,962,693	87,154	1,947	392	1 „ 2,548	1 „ 44
1885	4,924,342	90,712	1,925	391	1 „ 2,558	1 „ 47
1886	4,889,498	87,292	2,029	415	1 „ 2,409	1 „ 43
1887	4,837,313	88,585	2,067	427	1 „ 2,340	1 „ 42
1888	4,777,534	85,892	2,003	419	1 „ 2,358	1 „ 42
1889	4,730,566	82,908	2,134	451	1 „ 2,212	1 „ 38
1890	4,688,462	85,850	2,145	458	1 „ 2,185	1 „ 40

A curious fact about the increasing cancer mortality of Great Britain is, that it has affected males to a much greater extent than females. Thus, from 1851 to 1890 the increase for males was 167 per cent. ; whereas for females it only amounted to 91 per cent. The following figures illustrate this more fully :—

	Male Cancer Death- Rate per Million Living.		Female Cancer Death- Rate per Million Living.		Ratios.	
1851 to 1860	...	195	...	434	...	1 to 2'2
1861 „ 1870	...	244	...	523	...	1 „ 2'1
1871 „ 1880	...	315	...	622	...	1 „ 1'9
1885	...	411	...	713	...	1 „ 1'7
1890	...	512	...	830	...	1 „ 1'6



It seems to me probable that this undue incidence of the increasing cancer mortality on males, may be ascribed to the fact that of late, as the result of urbanisation, the conditions of life for men have come to resemble more closely those for women than heretofore. Excess of food, with want of proper exercise, and changed surroundings, are, I think, its chief causative agents. In this connection the remarkable sex distribution of cancer in New Zealand, to which I have previously referred, should be borne in mind. Here more men are affected than women; and this is attributed locally chiefly to their gluttonous habits with regard to meat eating. It is worthy of note that for both sexes the percentage of cancer deaths above 55 is greater than it used to be; and a far larger proportion of the male deaths occur after 65 than of the female deaths.

The attempt to explain the increasing cancer mortality as due to the average age of the population having advanced and the consequent liability of greater numbers, will not bear critical examination; for the saving of life in modern times has been mainly confined to early years. The death rates of males over 35, and of females over 45, have actually increased; while the numbers that attain old age have decreased.<sup>65</sup> This increased mortality at post-meridian ages is no doubt largely due to the survival in augmented numbers of weakly lives artificially prolonged by improved conditions of existence; but, according to Newsholme, not more than  $\frac{1}{40}$  of the increased cancer mortality can be thus accounted for. Besides, it is a mistake to assume that increased cancer mortality, is a necessary corollary of the survival of augmented numbers to the cancer age. The average age of the Irish population is very much higher than that of either England or Scotland, owing to the large number of elderly people left behind after the younger ones have emigrated; yet the cancer mortality of Ireland is much less than that of either England or Scotland. Hence it is doubtful whether the higher age of the agricultural, as compared with

<sup>65</sup> Longstaff, "Studies in Statistics," p. 256



the industrial population, in any way explains the greater proneness of the former to cancer.

In conclusion I must direct attention to the remarkable decline in the death rate from phthisis and other tubercular diseases that has coincided with the great increase in the cancer mortality. The following data from the fifty-second report of the Registrar-General indicate its extent.

TABLE SHOWING THE ANNUAL MORTALITY PER MILLION LIVING FROM CANCER, PHTHISIS, AND OTHER TUBERCULAR DISEASES IN GROUPS OF YEARS FROM 1861-1889.

	1861-65.	1866-70.	1871-75.	1881-85.	1886-89.
Cancer ... ..	376	403	415	544	610
Phthisis ... ..	2526	2447	2218	1820	1598
Other tubercular diseases	784	752	722	706	674

I regard this decline in the prevalence of tubercular disease, as the outcome of improved hygienic conditions, due to that augmented prosperity, which I have endeavoured to show, by its action in another direction, is also responsible for the increased cancer mortality.

It seems to me exceedingly probable, from considerations derived from the study of the family history of cancer patients, that a large proportion of those thus saved from tubercle eventually perish of cancer and insanity; and I think the increase in the latter diseases has largely been brought about in this way.

## § VI.—The General Health of Cancer Patients.

Long continued observation of cancer patients in the early stage of the disease has convinced me, that most of those affected are large, robust, well-nourished, florid persons, who appear to be overflowing with health and vitality; and they often present a considerable amount of *embonpoint*. Mr. and Mrs. John Bull, as so frequently depicted in the pages of *Punch*, are the physical types of the majority of cancer patients. Such types are indicative of general hyper-nutrition.



At first there seems to be some difficulty in reconciling this appearance of rude health with the conclusion previously arrived at, that most cancer patients are the surviving members of tubercular families; but in reality there is here no contradiction, for it commonly happens that the surviving members of tubercular families, although they never develop cancer, are remarkable for their robust and vigorous constitutions. The famous Astley Cooper was a striking example of this; yet he was of a very tubercular family, having lost five near relatives of this disease; moreover, in his youth he had hæmoptysis, which was rightly supposed to be due to pulmonary tubercle, for when in accordance with his last instructions his body was submitted to *post-mortem* examination, a healed tubercular lesion was found at the apex of his lung. According to my views he was a very likely subject for cancer, and although he escaped, it would be interesting to know whether his descendants have been equally fortunate.

Beneke<sup>66</sup> describes cancer patients as having large hearts and wide arteries, with small lungs, large livers, and long, large capacious intestines. This quite accords with what I have myself observed, that cancer patients usually are of a coarse physical type. Those recently attacked never present a cachectic appearance. The small, pale, ill-nourished, and over-worked women of the type so familiar in Lancashire and other large industrial centres, are seldom the victims of this disease.

It is remarkable how little the *general nutrition* of breast cancer patients often appears to suffer—in the absence of ulceration—even when the disease has lasted for a considerable time.

Of 75 consecutive cases of this kind, when they first came under my observation, 4 were markedly cachectic or sallow (primary 3, recurrent 1), 8 were emaciated (primary 6, recurrent 2), and 14 pale (primary 10, recurrent 4); the remaining 57 (primary 47, recurrent 10) were well nourished and healthy-looking, 7 of them being obese.

---

<sup>66</sup> "Constitution und constitutionelles Kranksein des Menschen." Marburg, 1887.



It accords with the foregoing that the natural functions of cancer patients are almost invariably performed with ease and regularity. In women with cancer of the breast, as I have previously mentioned,<sup>67</sup> the *catamenial function* is seldom disturbed. That it is established earlier and ceases later than in the generality of women is also a sign of vigorous health. Just so is it with regard to *marriage*; for a greater proportion of the subjects of mammary cancer marry than of the female population of corresponding age. According to Gross,<sup>68</sup> of 1,545 women with mammary cancer, 85.5 per cent. had married, and 14.5 per cent. were single,<sup>69</sup> whereas in the general population only 79 per cent. of women over 24 ever marry.<sup>70</sup> Such facts have induced some pathologists to regard marriage as *per se* a cause of cancer, but, as it seems to me, without sufficient reason.

The amount of *sterility* among married cancerous women is almost identical with that existing in the general community. Of 98 married women with breast cancer, under my observation, 12 were absolutely sterile (never pregnant), but two of these had not married until over 40. Of 1,034 similar cases analysed by Gross, 127, or 12.2 per cent., were barren. Among married women in the general community, the amount of sterility has been estimated by Simpson at 11.6 per cent. Modern statistics afford no support to Astley Cooper's<sup>71</sup> *dictum*, "that married women who bear no children, and single women, are more subject to this complaint than those who have had large families."

Fourteen of the above mentioned 98 women produced only a *single child*, that is, about 1 in 6 of the fertile: the ratio of one-child sterility for fertile married women of the general

---

<sup>67</sup> p. 245.

<sup>68</sup> *International Jour. Med. Sciences*, March, 1888, p. 220.

<sup>69</sup> Of 154 consecutive cases of mammary cancer under my observation, 80 were married, 30 widowed, and 44 were single.

<sup>70</sup> Farr, "Vital Statistics," p. 20.

<sup>71</sup> "Lectures on Surgery," 1839, p. 378.



population, according to Ansell, is 1 in 13—but 5 of the patients in my list had not married until between the ages of 32 and 42. Gross has estimated the amount of one-child sterility among fertile breast cancer patients at 1 in 10.

The remaining 68 of these married cancer patients all had more than a single child, the maximum offspring being 16 children; the average 4·8 children each.

Of 74 of these *fruitful* cancerous women, 34 had miscarried—the maximum number of times being 13, the minimum 1—of which there were 20 instances; the average number 1·4 each.

To sum up, 98 married cancer patients had between them 340 children and 112 miscarriages; which gives an average of 3·4 children and 1·1 miscarriages each. This amount of fertility probably about equals the average in the general community (4·6 children per marriage); when allowance has been made for the fact, that a certain proportion of cancerous women die before the completion of their reproductive life.

The average age of these patients at their first marriage was 24·9 years, and the average age at which they commenced child-bearing 26·2 years. These figures differ but little from the corresponding averages for married women of the general community. It is evident from the above facts, that the fertility of cancer patients of itself has nothing whatever to do with the causation of their disease.

With regard to *lactation*, Gross' statistics show that of 416 breast cancer patients, 316, or 76 per cent., had suckled; while 100, or 24 per cent, had not. Of 110 cases tabulated by Velpeau, 60 had suckled, or 54·54 per cent.; and 50, or 45·46 per cent., had not. Winiwarter analysed 102 cases, with the result that 65 had suckled, or 63·8 per cent.; and 37 had not, or 36·2 per cent. These data afford no proof that suckling predisposes to cancer; and I am at a loss to find any justification for the assertion that the breasts of married women, and of those in whom the gland has been active, are more liable to cancer on this account, than are the breasts of single and sterile women. Mammary cancer is a disease not of the active breast, but of



the breast becoming obsolete. Of 71 prolific women with mammary cancer, I have found that in no less than 55 (77·4 per cent.), the disease did not commence until after child-bearing had ceased. Rarely does it arise during pregnancy or lactation. Of 71 prolific women the subjects of breast cancer, interrogated by me, in 3 the onset of the disease coincided with childbirth, and in 2 with miscarriage, and in 4 it occurred during the lactation period. In none of these cases was the subsequent progress of the disease in any way different from the ordinary. In several cases women with cancer already developed subsequently became pregnant, and in due time gave birth to children, without any interference with the ordinary course of the disease. It is evident, therefore, that the acute cancers sometimes met with during pregnancy and lactation are highly exceptional.

From the foregoing it will be gathered that the due discharge of natural functions in no way predisposes to cancer.

In the present imperfect state of our knowledge it is very difficult adequately to estimate the influence of *alimentation* in the causation of cancer. This difficulty is singularly increased by the consideration, that the effects of diet in this direction probably only become appreciable after more than a single generation of individuals has been exposed to them. Hence the failure of the praiseworthy attempt of the British Medical Association's Collective Investigation Committee to solve this problem.<sup>72</sup> From returns collected by this committee it appears that of 194 cancer patients, 123 had been moderate eaters, 59 small eaters, and 12 large eaters. With regard to meat, 99 had been moderate, 78 small, and 16 large eaters. There was not a single strict vegetarian among them; and only a few had been great eaters of vegetables.

That cancer is much less prevalent in vegetarian than in flesh-eating communities is generally believed; and the following considerations are favourable to this view. In Ireland, where

---

<sup>72</sup> *British Medical Journal*, February 26, 1887.



a large proportion of the population live chiefly on vegetable diet, the prevalence of cancer, as I have previously pointed out, is much less than in either of the sister countries; and Beneke's statistics,<sup>73</sup> show that cancer is very rare in prisons, where but little animal food is allowed, and hard work is exacted. The remarkable fact that in New Zealand men are more liable to cancer than women is probably due, as MacDonald reports,<sup>74</sup> to their gluttonous habits in respect to meat eating. "Meat for breakfast, lunch, dinner, tea and supper, just like the porridge pot in Scotland." The greater prevalence of cancer in rural than in urban districts,<sup>75</sup> and, in the latter, its greater prevalence in those localities where the well-to-do and easy-going reside, rather than among the poor and working classes, point to the same conclusion.<sup>76</sup> It is certain, however, that vegetarians are not exempt from cancer; for of 102 cancer patients operated on at the Jeypore Hospital during the period of 1880-88, 61 were strict vegetarians and 41 meat eaters.<sup>77</sup> Meat-eating communities are, as a rule, also *alcohol* consuming. There is, however, no evidence that the habitual consumption of alcoholic liquors *per se* in any way predisposes to cancer. The British Medical Association's inquiry indicates that the effect of this habit has rather the opposite tendency.<sup>78</sup> The

<sup>73</sup> *Op. cit.*

<sup>74</sup> "Cancer Statistics of New Zealand," *New Zealand Medical Journal*, February, 1890.

<sup>75</sup> This was long ago demonstrated by Walshe ("Nature and Treatment of Cancer," 1846, p. 16, *et seq.*) Subsequent investigations have fully confirmed Walshe's conclusion, especially those of the late Registrar-General, *q. v.*, 47th Annual Report, Table J, p. xxi.

<sup>76</sup> § III. The facts there cited prove conclusively the greater frequency of cancer among the well-to-do than among the poor and working people. Hofmeier (*Zeitschr. f. Geburts., &c.*, Bd. x., S. 270), states that of 16,800 patients at the Berlin Polyclinic, 603, or 3.6 per cent., suffered from uterine cancer; whereas in Schroeder's private practice, of 9,400 patients, 299, or 2.18 per cent., were similarly affected. I have often seen these data quoted as evidence of the greater prevalence of cancer among the poor than the rich; but this is a conclusion that cannot fairly be drawn from them.

<sup>77</sup> Hendley, *British Medical Journal*, July 7, 1888.

<sup>78</sup> *British Medical Journal*, January 23, 1888. Dr. Owen's Report.



exemption of savages from cancer, and its great prevalence in civilised communities is probably largely attributable to the influence of diet. At any rate, it is certain that savages are, as a rule, less well fed than are the members of modern communities.

According to Rommelacre,<sup>79</sup> the amount of urea and phosphates in the urine of cancer patients is markedly below the normal, independently of alimentation; and Schöpp<sup>80</sup> has lately published an account of some experiments as to the alleged diminished elimination of chlorides in their urine.

The *ensemble* of the facts relating to the life history of mammary cancer patients shows, that they have almost invariably led regular, sober, and industrious lives. Persons of drunken and dissolute habits are comparatively seldom affected. Of 165 female breast cancer patients consecutively under my observation, not a single one had ever been addicted to *prostitution*, so far as I could ascertain; and, what is still more remarkable, there was not among them a single individual who presented undoubted signs of having had *syphilis*. In this connection the almost complete immunity of mammary cancer patients from *chronic ulcer of the leg* is well worth noting. Of 165 patients consecutively under my observation, there was not a single instance of it. There is, however, no absolute incompatibility between the two diseases, for on analysing 597 consecutive cases of breast cancer, I have found that two patients had as well, chronic ulcer of the leg. The great rarity of the coincidence of these two diseases—each of itself so common in women over middle age—is certainly very remarkable. I have seen it stated that the subjects of *osteitis deformans* are specially prone to malignant disease. With regard to this I can only say that of over 1,000 cases of malignant disease investigated by me, and of which I now have written records, not a single one was complicated by

---

<sup>79</sup> *Journal de Méd. de Bruxelles*, 1883-84.

<sup>80</sup> *Deutsche med. Woch.*, No. 46, S. 1155, 1893.



this disease; 170 cases of breast cancer in women are included in this list.

The *occupation* usually followed by these patients was noted in 144 cases, as follows:—

Of 80, married—housewife, 66; governess, 2; laundress, 2; nurse, 2; and one each as follows: straw hat factory, needlework, boot factory, cook, mantle-maker, tailor, servant, charwoman. Of 20, widowed—housework, 8; laundry, 3; cook, 2; monthly nurse, 2; and one each as follows: dress-maker, paper-factory, factory, midwife, lady's maid. Of 44, single—cook, 9; servant, 9; dressmaker, 5; at home, 4; governess, 2; school teacher, 2; and one each as follows: staymaker, nursery, lady's companion, monthly nurse, upholstress.

Some authors, following the example of Astley Cooper,<sup>81</sup> have attached great importance to grief, anxiety, and mental distress as causes of cancer; and they have adduced statistics in support of their belief. I am unable to confirm this. The majority of cancer patients whose life history I have investigated, appeared to me to have been less exposed to depressing influences of this kind than most women of corresponding age in the general population.

I have often noticed on the face, chest, and upper limbs of breast cancer patients minute, pink telangiectases; but these are also commonly seen on the non-cancerous of corresponding age. The small outgrowths of warty or dermoid structures, said by De Morgan to coincide with or follow the development of cancer, I have very rarely seen in association with breast cancer; nor have I noticed that eczema, psoriasis, or other dermatoses often appear in the course of this disease, as Bazin and Hardy allege.

In conclusion, I must here express entire concurrence with Moore's statement: "that cancer is eminently a disease of persons whose previous life has been healthy, and whose nutritive vigour gives them otherwise a prospect of long life."

Some idea of the *non-cancerous morbid conditions* to which women with cancer of the breast are liable may be gathered from the subjoined analytical statements.

---

<sup>81</sup> He says ("Lectures on Surgery," 1839, p. 383), "Fully three-fourths of these cases arise from grief and anxiety of mind."



(1) In 165 consecutive patients the following associated lesions, &c., were noticed when they *first came under observation*:—

Arcus senilis in 5, pains in the limbs (chiefly thighs) in 4, scanty beard and moustache in 3, old corneal leucomata in 2, lipoma in 2, molluscum fibrosum (large and pendulous) in 2, scars of old abscesses of neck, &c., in 2, varicoid capillaries of cheeks in 2, extreme deafness in 2, spontaneous fracture of femur in 2, and each in one case—whitlow, lobular hypertrophy of opposite breast and scars of old abscesses, general tubercular enlargement of lymphatic glands and scars of old abscesses, old ankylosis of knees after suppurative white swelling, jaundice, nausea and vomiting, bronchitis, pneumonia, erythema, pasty swollen face from renal disease, chronic alcoholism, bronzed complexion, freckled complexion, smallpox pitted, internal strabismus (R.), enlarged thyroid, enlarged lymph gland of sub-maxillary region, cataract and posterior synechiæ.

(2) Of 130 breast cancer patients, whose *previous health* was investigated, 100 stated that it had been habitually good (with no serious illness since youth in 52), 19 that it had been indifferent, and 11 that it had been bad.

The following *previous diseases* were noted as having occurred among these patients since childhood:—

Bronchitis in 17 cases, rheumatic fever in 11, typhoid fever in 11, chronic rheumatism in 6, phthisis in 5, ulceration of uterus in 4, small-pox in 4, erysipelas in 4, dyspepsia in 3, alcoholism in 3, scarlet fever in 3, hæmorrhoids in 2, migraine in 2, varicose veins of legs in 2, peritonitis in 2, and each in one case—extreme myopia, glaucoma, iritis, neuralgia, disorganised eyeball, corneal ulcers, femoral hernia, enlarged cervical glands, quinsy, fistula-in-ano, suppurative white swelling of knee, measles, otorrhœa, ulcerated sore throat, heart disease, laryngitis, cholera, phlegmasia dolens, small fibro-adenoma of breast (35 years' duration), jaundice and gallstones, diphtheria, cystitis, nervous debility, intermittent fever, syncopal attacks, hypertrophied tonsils.

(3) *Post-mortem examination* of the bodies of 44 women, the subjects of breast cancer, revealed the presence of the following non-cancerous lesions, &c.:—

The general condition of the body was noted in 40 cases—

It was emaciated in 18; well-nourished, 11 (obese, 5)—of these 8 (obese 2) had died shortly after operation—moderately nourished, 7 (of these 2 had died shortly after operation); sallow, 2; icteric, 2; bronzed and mottled, 1.

*Lungs*.—Old pleural adhesions in 24 cases (general in 16—both lungs in 13, one lung in 3—in 8 cases adhesions confined to one or both upper lobes); emphysema in 12; acute pleurisy with effusion in 11 (6 of these of septic



origin, 4 due to invasion of thorax by direct extension of the primary disease, and 1 secondary to tubercular pneumonia); collapse of lung in 7 (in 5 cases secondary to acute pleural effusion and in 2 to invasion of thorax by cancer); congestion in 6; phthisis in 6 (the phthisical lesions in 4 cases were in the form of old scarring and pigmentation at each apex associated with old pleural adhesions, and in 1 of these cases with a cavity and in another with caseous old nodules as well; in the other 2 cases the disease was in active progress; in 1 there was a large cavity surrounded by tubercular consolidation, and in the other almost the whole of both lungs were consolidated by caseous tubercle, with cavities and softening in places); bronchitis in 5; hydro-thorax in 3; each in 1 case—recent pleural adhesions, old dried-up empyema with partial collapse, hypostatic pneumonia. In not a single instance were both lungs normal.

*Heart.*—Small and atrophied in 5 cases; atheroma of aortic arch in 5; atheroma and thickening of mitral valve in 4; atheroma and thickening of tricuspid valve, &c., in 3; atheroma of aortic valves in 2; large aneurism of aortic arch in 2; walls of heart soft and flabby in 2; milk-white patch on anterior surface of ventricles in 2; acute pericarditis (septic, 1; secondary to invasion by cancer, 1) in 2; and each in 1 case—mitral stenosis, atheroma of pulmonary valves and aorta, general hypertrophy, excess of fat on surface, deeply stained endocardium. In 25 cases the heart was normal.

*Liver.*—Fatty in 17 cases; gall-stones in 7 (or in 16 per cent. of these 44 cancer necropsies);<sup>82</sup> nutmeg, 3; cirrhosis, 3; congestion, 3; small, 2; cloudy swelling, 1; and multiple angioma in 1 case. In only a single case was the liver normal.

---

<sup>82</sup> This percentage of gall-stones is twice as high as that which is stated to hold for women who have died of causes other than cancer. According to Schroeder, gall-stones are met with in from 5 to 12 per cent. of all necropsies—females 20.6 and males 4.4 per cent. This is a German estimate. In England gall-stones are probably not so common. Of 777 necropsies, mostly on adults, at the Manchester Infirmary, gall-stones were found in 34, or only in 4.4 per cent; of 228 necropsies on females, they were met with in 18, or 7.9 per cent.; and of 542 necropsies on males in 16, or in 2.9 per cent. (Brockbank, *Med. Chronicle*, Dec., 1893). Of 281 necropsies for *surgical cancer* analysed by me, gall-stones were found in 18, or in 6.4 per cent.; 181 were females with gall-stones in 14, or in 7.7 per cent.; 100 were males, with gall-stones in 4. Of the foregoing, 79 necropsies were for *uterine cancer*, with gall-stones in 5, or in 6.3 per cent.; and 52 for cancer of the *tongue and mouth in males*, with gall-stones only in a single case. It has been stated that gall-stones are more frequently found associated with cancer of the stomach and liver than with any other forms of cancer. I have not tested this statement, and no cancers of these localities are included in my analysis, which shows that gall-stones are more frequently found in association with *breast cancer* than with any other surgical form of the disease. Gall-stones are frequently found in the bodies of those who die insane. Snell's analysis gives the percentage as 19.4 for females and 9.2 for males (*Neurol. Centralbl.*, June 1, 1893). In the female insane Beadles met with gall-stones in 36 per cent. Gall-stones are also of very frequent occurrence in the tubercular (*Journal Mental Sci.*, July, 1892).



*Spleen.*—Large and congested in 5, very small in 2, and normal in 35 cases.

*Kidneys.*—Chronic interstitial nephritis (small and granular kidneys) in 16 cases; fatty in 5; renal calculi (uric acid, 2; phosphatic, 1) in 3; congestion, 2; acute pyelitis (associated with acute cystitis) in 1 case; cloudy swelling in 1; very small in 1 case. In 18 cases the kidneys were normal.

*Gastro-Intestinal Tract.*—Acute peritonitis in 2 cases (1 due to perforation, 1 to secondary cancer); gastric catarrh in 1 case; femoral omental hernia in 1; ascites in 1; fistula between gall-bladder and duodenum (owing to blocking of common bile duct by cancerous growth in head of pancreas) in 1 case. In 38 cases the gastro-intestinal tract was normal.

*Other Lesions.*—Uterine fibro-myomata in 5 cases; soft polypi of uterus in 3 cases; and each in 1 case—dermoid cyst of ovary, small parovarian cysts, small multilocular ovarian cystomata, pyometria and pyo-salpinx (owing to occlusion of the os uteri), old un-united fracture of neck of femur, spontaneous fracture of both femora (part of general fragilitas ossium un-associated with secondary growth), cold abscess in axilla (on side opposite to the cancerous breast).

## § VII.—Traumata, Chronic Inflammation and Cancer.

Those who maintain that cancers are caused by traumata, must explain how it is that men, who suffer nearly three times as often from traumata as women, are nevertheless only about half as liable to cancers.

Thus, of 9,229 consecutive cases of traumata under treatment at four large Metropolitan hospitals, I have found that 6,856 were males, and 2,373 females, or 2·89 males to 1 female. Similarly, of 240,063 deaths from traumata, tabulated by the Registrar-General for the twenty-five years, 1872-48, 178,005 were males and 62,058 females, or 2·8 males to 1 female.

On the other hand, of 7,878 consecutive cases of cancer under treatment at the above-mentioned hospitals, 2,861 were males and 5,017 females, or 1 male to 1·7 females. Similarly, of the 19,433 cancer deaths in England and Wales during 1890, 7,137 were males and 12,296 females, or 1 male to 1·7 females.

Evidently either these facts must be refuted, or the theory of the traumatic causation of cancer must be given up.

Still more cogent is reasoning of this kind when applied to cancer of the breast; for whereas men are quite three times as



liable to traumata of this part as women, yet they suffer from mammary cancer only in the proportion of 16 to 1,863, or of 1 male to 116 females. Moreover, were mammary cancers thus caused, the *nipple*, *areola* and *skin* would be more frequently affected than other parts of the breast; but the actual proportion of cancers that arise from the nipple only amounts to 1.31 per cent., while the areola and skin of this region enjoy still more remarkable immunity. This completely negatives the alleged causation of mammary cancer by pressure of the corset, injury of the nipples in suckling, &c., &c.

Again, the initial lesion of cancer is almost invariably *solitary*; whereas if the disease were of traumatic origin it would often be multiple. It is a curious circumstance that the advocates of the traumatic theory of cancer should have overlooked these obvious facts.

They base their belief in it on statements made by the patients themselves as to the antecedent occurrence of traumata. Of 137 women with mammary cancer interrogated by me, 35 gave a history of antecedent traumata, or 25.5 per cent.; in other words, the most careful investigation directed expressly to this point, failed to elicit any previous history of trauma in 74.5 per cent. of all cases. Many of the above affirmations appeared to me to be the outcome of imagination, rather than of any real causal relationship; and in no case was there evidence that the disease had developed out of induration or other obvious lesion thus induced. Injury was often merely the means of directing the patient's attention to the previously existing disease, of which she had been until then unconscious. Of 1,000 cases of cancer consecutively under my observation, there was but a single instance in which the disease immediately followed an injury, and this was a case of so-called acute traumatic malignancy. Yet if traumata were the efficient causes of cancer, such occurrences would be quite common, instead of being so infinitely rare. Moreover, we cannot produce cancer by any kind of traumatism, even in those who are already subject to the disease, and their wounds heal just as do those of the non-



cancerous. Again, if the traumatic theory of cancer were true, those parts of the body most subject to injuries, such as the upper and lower extremities, the head, face and neck, would be the commonest seats of the disease, but its actual localisation is totally different.

Though a blow, wound, or other injury may sometimes precipitate the formation of a cancer, yet it appears to me, from the foregoing considerations, that such stimuli are of themselves inadequate to originate the disease; the final outbreak in these cases is but the explosion of a long train of antecedent preparation. I regard the relation of trauma to cancer—to borrow a Darwinian simile—as resembling that of a spark in contact with combustible matter, the result depending upon the nature of the latter, rather than upon the spark itself.

It is often asserted that cancers of the breast are due to antecedent attacks of inflammation or abscess of the affected part, yet no conclusive evidence of this has ever been adduced. Equally destitute of support is the constantly reiterated assertion, that the latter lesions are of more frequent occurrence in the cancerous than in the non-cancerous. The following facts are conclusive in this respect.

Winckel<sup>83</sup> has estimated that after 1000 consecutive *accouchements* mastitis developed in 6 per cent. This of course refers only to its frequency after single deliveries in a succession of women; and not to the frequency of its occurrence in regard to the total pregnancies of each woman during her entire puerperal life. To obtain the latter datum Winckel's percentage must be multiplied by 4·6, this being the average number of *accouchements* of each married woman. Reckoned in this way it will be found, that 27·6 per cent of all fertile married women have suffered, at some period or other of their puerperal life, from inflammatory disease of the breast. In order to ascertain what proportion of mammary cancer patients suffer from similar affections I made special inquiries on this subject in 137 cases. Of these only 24, or 17·5 per cent., gave a history of some previous disease of the breast—abscess in 15, sore nipple in 8, and inflammation in 1; and in 6 of these cases the nipples were congenitally malformed.<sup>84</sup>

---

<sup>83</sup> *Path. u. Therap. des Wochenb.* 1878.

<sup>84</sup> In thirteen other cases, unassociated with any previous inflammatory lesion, the nipples were also congenitally malformed.



The above facts prove that the only basis for this alleged causation is, that in a certain proportion of cancer cases, inflammatory lesions have pre-existed. Moreover, against the assumed etiological importance of previous inflammatory disease is the fact, that in most of the cases the interval between the antecedent disease and the subsequent outbreak of cancer extended over many years, and during this period the breast appeared to be free from any lesion. Of like import is the consideration that cancer of the breast is relatively almost as frequent in the single and sterile as in the married, although the former are much less prone to inflammatory affections of the breast than the latter. On *à priori* grounds, no inflammatory lesion seems more likely to be the precursor of cancer than chronic mastitis; and since this disease gives rise to circumscribed induration, its presence can hardly be overlooked. Yet how rarely does mammary cancer ever appear to start in connection with such indurations. I have met with this conjunction only twice in 137 cases; hence it seems to me improbable that chronic mastitis plays an important part in the genesis of mammary cancer.<sup>85</sup>

The outcome of all this is; that intrinsic causes are much more important factors in the origination of cancer than extrinsic ones, which are by no means its necessary antecedents. In the vast majority of cases the outbreak of this disease appears to be entirely spontaneous; that is to say, it cannot be attributed to the immediate action of any appreciable extrinsic cause whatever.

### § VIII.—The Biological Distribution of Cancer, &c.

In studying the etiology of malignant<sup>86</sup> and other neoplasms,

<sup>85</sup> According to Gross, cancer of the breast appeared to develop out of chronic inflammatory induration in 49 out of 907 cases, or in 5·4 percent.—*Internat. Journal Med. Sci.*, Mar., 1888, p. 222.

<sup>86</sup> As I have elsewhere pointed out ("The Principles of Cancer and Tumour Formation," London, 1888, p. 140), the essential feature of malignancy is not auto-infectiveness—as most pathologists assume—but the indefinitely sustained power of certain cells to grow and multiply in excess of the normal requirements.



it is important to recollect that they are not peculiar to mankind, nor even to animals. It seems probable, under certain conditions, that such growths may arise from any multicellular animal or vegetable being.

In a state of nature these abnormalities hardly ever occur. It is exclusively among domesticated varieties, or those that have been kept long in confinement that they are met with. Even under such circumstances, malignant epithelial neoplasms are of very rare occurrence in the animal world, as compared with mankind; however, cases have been met with in most of our domesticated animals, especially in horses,<sup>87</sup> dogs and cats, also rats and mice in confinement. The mammary glands of many female animals are liable to be thus affected.

Much commoner and more widely diffused are the sarcomas which have been met with in nearly all classes of animals, from fish upwards; but they oftenest occur among ordinary domesticated animals, *e.g.*, dog, horse, cat, cow, common fowl, &c. Male dogs, horses, asses, and pigs are particularly liable to sarcoma of the testis. Horses—especially those of white or grey colour—are remarkable for their proneness to melanotic sarcoma, the region of the anus or tail being the part usually affected. Other situations in which melanotic growths have been observed in these animals are the vulva, scapular region, skin, axilla and lungs. In the *Hunterian Museum*<sup>89</sup> is a specimen of melanoma of a white cow's udder. Horses are also subject to psammomas of the brain.

According to Rayer, carnivorous animals are more prone to malignant disease than herbivorous ones,<sup>90</sup> whereas, with regard to tubercle, the relative liability is just the converse. In this connection it is noteworthy that monkeys manifest very little tendency to neoplasms, malignant or otherwise; and they are seldom the victims of tubercle.<sup>91</sup>

---

<sup>87</sup> For a histologically verified case of epithelioma of the penis of a horse, by Patterson, *vide Illus. Med. News*, Dec., 1888, p. 220.

<sup>89</sup> No. 469, Path. Series.

<sup>90</sup> For cases of cancer in herbivora by Burke, *vide Veterinarian*, Feb., 1890, p. 63.

<sup>91</sup> Sutton, *Lancet*, Aug., 1883.



Fibromas, enchondromas, and osteomas are as common and as widely diffused as sarcomas.

Fatty tumours are occasionally seen in domesticated animals, such as the ox, horse, sheep, and fowl.

Mammary fibro-adenomas of female dogs, cats, &c., are fairly common, and enchondromatous mammary growths are much oftener met with in these animals than in mankind.

Cysts occur frequently in most domesticated animals, their commonest situation being in the ovaries.

That trees are liable to be affected by malignant and non-malignant neoplasms, I have elsewhere shown.<sup>92</sup>

#### § IX.—Multiple Primary Cancers, and the Association of Cancer with other Neoplasms.

It is now generally recognised that cancer may originate primarily from more than a single focus. Pathologists have been aware of this for some time,<sup>93</sup> although it is only recently that the subject has attracted special attention. Such cases are, however, exceedingly rare. The wonder is that they do not occur more frequently, especially if, as alleged, cancer be a parasitic disease.

The breast is no exception to this rule, for the initial lesion of mammary cancer is almost invariably solitary. According to Gross two or more nodules are met with as its first obvious manifestation in about 3 per cent. of all cases. Leopold,<sup>94</sup> examining cancerous breasts removed at early stages of the disease, when the lesions were quite small, almost invariably found local dissemination. Most of these multiple nodules no doubt arise in this way. In rare instances they may be due to the co-existence of one or more small fibro-adenomatous, or other non-malignant nodules, with the cancerous tumour, of which examples have been recorded.

<sup>92</sup> "The Principles of Cancer and Tumour Formation," 1888, chap. iii.

<sup>93</sup> *Q.v.* Virchow, "La Pathologie des Tumeurs; Broca, "Traité des Tumeurs," &c.

<sup>94</sup> *Arch. f. Gyn.*, Bd. v., 1873, S. 405.



The hyperplastic condition of the glandular epithelia that accompanies the outbreak of mammary cancer may be regarded as analogous to the ichthyotic changes in the buccal mucous membrane, that so often co-exist with cancer of the tongue, mouth, &c. In connection with these ichthyotic areas of the buccal region, independent outbreaks of cancer have often been observed; and it is highly probable that hyperplastic glandular elements in the breast may occasionally originate multiple cancerous growths in like manner; although, owing to the impossibility of certainly excluding disseminative lesions, this mode of origin does not here admit of absolute demonstration. Nearly allied to these independent outbreaks are those cases in which, after operation, with freedom from recurrence for long periods, the disease at length returns in the vicinity of the primary lesion, owing to fresh outbreaks arising, as Heidenhaim believes, from proliferating glandular elements, left behind at the primary operation.

In no part of the body does the initial outbreak of cancer so frequently manifest itself in the form of multiple foci, as in the *skin*—especially the skin of the face. In these cases hyperplastic changes of the adjacent integument almost invariably co-exist. The persons thus affected usually are workers in tar, paraffin, &c., as in cases reported by Volkmann, Tillmann, Schimmelbusch, &c. In chimney sweeps I have seen the scrotal integument similarly affected. Tillmann<sup>95</sup> has met with an instance of epithelioma of the integument of the *forearm* and of the *scrotum*, in a paraffin worker. In old persons, multiple cutaneous cancers sometimes arise in connection with chronic seborrhœa. Primary multiplicity is also often seen in cases of rodent ulcer, especially in aged subjects. It will be noticed that in most of the cases just mentioned, the outbreak of the disease appears to have arisen in connection with some form of chronic irritation.

Cancer may also spring up as a primary disease in more than one part or tissue of the body, although such coincidences are of the greatest rarity.

In certain cases of acute diffuse mammary cancer, *both* breasts may be simultaneously invaded, of which examples

---

<sup>95</sup> *Deutsche Zeitschr. f. Chir.*, Bd. xiii., 1880.



have been recorded by Billroth,<sup>96</sup> Aitken,<sup>97</sup> Klotz,<sup>98</sup> Volkmann,<sup>99</sup> and others.

A similar state of things is occasionally met with in other paired organs, such as the testes and ovaries; and Mandry<sup>100</sup> has recorded an instance of symmetrical cancer of both legs, and another of both ears. Of 263 cases of primary cancer of the extremities, analysed by Michael, two were symmetrical.

It is by no means rare to see cancer of one breast followed, after a time, by outbreak of the disease in the other. The great majority of these cases are, however, due to direct extension of the primary disease, or to its dissemination. Yet it occasionally springs up independently in the opposite breast, as in the following case.

(1) An unmarried woman, aged 60, twenty-one months before I saw her, first noticed a hard lump, the size of a Brazil nut, in the middle of her left breast; four months later a similar lump was discovered in the middle of her right breast. When she came under my observation the central part of each breast was occupied by a large hard tumour, to which the overlying purplish skin was adherent, and both nipples were retracted, and the glands in both axillæ enlarged. Her face had a peculiar pinched expression, and she was very emaciated, but not sallow. She died of asthenia ninety-nine days later, without having undergone any operative treatment. At the *necropsy*, the cancerous growths in each breast were found to have increased somewhat in size, but neither had ulcerated. Both were extensively adherent to the overlying skin and to the subjacent structures. The glands in both axillæ were cancerous, and the liver contained a cancerous nodule the size of a pea, and four small angiomatous growths.

The three subjoined cases evidently belong also to the same category.

(1) A patient seen by Bucher,<sup>101</sup> having remained free from any return of the disease for six years, after amputation of one breast for cancer, then found the disease spring up in the other breast.

(2) <sup>102</sup> A woman, aged 48, under Bryant's care with cancer of the right breast, without obvious disease of the axillary glands. Ten years previously her left breast had been amputated for similar disease. The right breast

<sup>96</sup> *Deutsche Chir.*, Lief 41, S. 128.

<sup>97</sup> *Med. Times and Gaz.*, 1859, vol. i., p. 357.

<sup>98</sup> "Ueber Mastitis Carcinomatosa," &c., I. D. Halle, 1869.

<sup>99</sup> *Beitr. z. klin. Chir.*, 1875, S. 310.

<sup>100</sup> *Beitr. z. klin. Chir.*, 1892.

<sup>101</sup> *Zeigler's Beitr. z. path Anat.*, Bd. xiv., S. 74.

<sup>102</sup> "Diseases of the Breast," 1887, pp. 213 and 221.



was now amputated. Three years later, when last heard of, the patient was well and free from any return of the disease.

(3) The patient, aged 60, when first seen by Bryant had scirrhus cancer of her *right* breast of eight months' duration, there being no disease of the axillary glands. Two years and a-half previously her *left* breast had been amputated for ulcerated cancer of several years' duration, but which had not affected the axillary glands. The right breast was now amputated, without opening the axilla. She soon recovered, and was free from recurrence when last heard of eighteen months later.

Nunn,<sup>103</sup> has recorded an instance of *tubular* cancer (with cysts) of the left breast, co-existent with atrophic *acinous* cancer of the right breast.

The patient was a lady, aged 57, in whose *left* breast—near the nipple—a small tumour was first noticed six years previously. This gradually increased to a large size, and was associated with occasional sanious discharge from the nipple. There was no enlargement of the axillary glands. The affected breast was amputated. The tumour consisted chiefly of one large thin-walled cyst, with a few nodules the size of hemp seeds projecting into the cavity. These, on microscopical examination, presented the appearance of tubular cancer. She remained well after the operation for three years, when her health began to fail, without any obvious cause. In the course of medical examination of the chest, atrophic acinous cancer of the *right* breast—which she had hitherto carefully concealed—was accidentally discovered. She died of this disease a few months later. There was no necropsy.

The following somewhat similar case by Mandry,<sup>104</sup> is of interest.

A multipara, aged 43, in whose *right* breast was a cancerous tumour—the size of an apple—of four months' duration. It was adherent to the pectoral muscle, and the axillary glands were enlarged. The breast was extirpated, together with the pectoral muscle and the axillary glands. Histologically the tumour proved to be ordinary *acinous* (scirrhus) cancer. Three months and a-half later, recurrence was first noticed in the old cicatrix. A fortnight previously a nodule had been noticed in the *left* breast. The latter soon increased, and the glands in the left axilla enlarged. The local recurrence was then excised, the *left* breast extirpated, and the left axilla cleared. On histological examination of the tumour in the *left* breast, it proved to be *tubular* cancer.

Multiple cancers situated in different parts of the body can only be regarded as primary, when each has developed from the

<sup>103</sup> *Trans. Path. Soc. Lond.*, vol. xli., 1890, p. 224.

<sup>104</sup> *Beitr. z. klin. Chir.*, 1892.



epithelium of its own locality ; and consequently when each has usually different histological structure.

In the following case, under my observation, a patient who had suffered for many years from *rodent ulcer of the face*, at length developed *mammary cancer*.

She was a widow, aged 77, who, nine years previously, first noticed a small rodent ulcer at the inner angle of the left orbit. The disease progressed but slowly. After it had lasted for seven years, hard cancer developed in the left breast. The latter disease progressed rapidly, and she died from it rather more than two years after its first appearance. No operation was ever done for either cancer. At the necropsy the left mammary region was occupied by an adherent mass of hard, ulcerated cancer, and the adjacent soft parts were extensively infiltrated. The axillary glands were invaded, and there were several cancerous nodules in the skin of the left arm. The rodent ulcer was still of no great size. The left lung was collapsed, and its apex was bound to the chest wall by old adhesions. There was about a pint of blood-stained watery fluid in the pleural cavity. The right lung was emphysematous. The liver was atrophied, and the gall bladder full of calculi. The right kidney was also atrophied, and its pelvis contained a large calculus. Several fibro-myomatous tumours were connected with the uterus, one—the size of a duck's egg—was calcified.

Hutchinson<sup>105</sup> says he has several times seen similar coincidences, but he gives hardly any details.

In one case, the patient, who had suffered long from Paget's disease of the nipple and *cancer of the breast*, had also a *rodent ulcer of the left eyebrow*.

The three following somewhat similar coincidences were observed by Bryant :<sup>106</sup>—

(1) A widow, aged 74, had atrophic cancer of the *right breast* of twenty-six years' duration, that had been ulcerated for thirteen years. Epithelioma of the *nose* then supervened, the breast cancer having remained nearly stationary for many years.

(2) A childless, married woman, aged 63, had epithelial cancer of her *nose* excised. Five years later she came under observation again, with hard cancer of her right *breast* of eight months' duration, of which she died two years later. There was no return of the nasal cancer.

(3) A thin, feeble woman, aged 60, with an ulcerated scirrhus cancer of the central part of the left *breast* of eight or nine years' duration. During the last five years there had been increasing difficulty in swallowing, and for some months she had only been able to take fluids. Stricture of the

<sup>105</sup> "Archives of Surgery," vol. iii., No. 9, p. 47.

<sup>106</sup> "Diseases of the Breast," 1887, p. 340.



*œsophagus* was discovered—passable only by the smallest bougie—which had every appearance of being cancerous.

Panas<sup>107</sup> mentions having seen cancer of the *breast in a man*, aged 65, from whom Velpeau had excised an epithelioma of the lip, fifteen years previously; and Graviller<sup>108</sup> has met with a case of cancer of the *male breast* associated with epithelial cancer of the *lip*.

Dobson<sup>109</sup> had a patient with a primary cancer of the breast, who remained well and free from any return of the disease for six years after its amputation, when epithelial cancer of the tongue supervened, of which she soon died.

In a woman rather over 60, Michelshon<sup>110</sup> met with hard cancer of the right *breast* and cutaneous epithelioma of the *right ala nasi*.

The following cases illustrate the independent outbreak of the disease in the *breast* and *uterus*.

Broca<sup>111</sup> has recorded an instance in which, after *mammary cancer* had existed for two and a-half years, the *cervix uteri* became cancerous. Six months later no sign of cancer had appeared elsewhere. The uterine disease here presented every indication of being of independent origin.

Mercanton<sup>112</sup> reports the three following examples:—

(1) A woman, aged 48, with hard cancer of the right *breast* and secondary disease of the axillary glands. The diseased breast was extirpated, and the axilla cleared. About nine weeks later cancer of the *cervix uteri* was discovered and excised. About eight months after the mammary extirpation, the disease had recurred *in situ* and in the axilla; it was again removed from these situations. Six months later she came under treatment again with further recurrence in the right mammary region, and in the left breast. These were removed by operation, and a month later secondarily diseased glands were removed from the left axilla. About this time there was noticed free discharge from the vagina; on examination the uterus was found to be fixed, and the cervix infiltrated with hard cancerous growth. Six months after the last mammary operation there was extensive recurrence in both pectoral regions, and in both axillæ.

(2) In a patient 48 years of age, there was a hard cancerous tumour in the left *breast* of two years' growth. It was adherent to the overlying skin, and the axillary glands were invaded. The *portio vaginalis uteri* was replaced by a large, fungating, hæmorrhagic cancerous outgrowth.

(3) A woman, aged 51, in 1889, became subject to pain in defæcation. In the summer of 1890 induration in the left *breast* was noticed. In

<sup>107</sup> Cited by Poirier, "Tumeurs du Sein chez l'homme," Paris, 1883, p. 98.

<sup>108</sup> *Canada Medical and Surgical Journal*, Montreal, 1873, i., p. 271.

<sup>109</sup> *Bristol Med. Chir. Journal*, Dec., 1889.

<sup>110</sup> "Zur Multiplicität der primären Carcinomen," I.D., Berlin, 1889.

<sup>111</sup> "Traité des Tumeurs," t. i., 1866, p. 284.

<sup>112</sup> "Des Carcinomes primaires multiples," *Rev. Méd. de la Suisse Romande*, No. 3, 1893, p. 173.



November of the same year she was found, on examination, to have cancer of the breast, and cancer of the *corpus uteri*.

As instances of associated *mammary* and *ovarian* cancer, in which each neoplasm probably originated independently, the following cases are interesting.

(1) <sup>113</sup>The patient, aged 53, the mother of two children, came under observation on account of a left ovarian tumour, with symptoms of one year's duration. During this period she had been tapped nine times. A multilocular cystic cancer of the *left ovary* was removed by laparotomy. She made a good recovery. About nine months later she again came under treatment with a cancerous neoplasm of a year's growth in her *left breast*, and enlarged axillary glands. For twenty-one years she had been aware of the existence in the diseased breast of a hard, indolent, stationary tumour, the size of a hazel nut, and the present tumour seemed to grow in connection with this. The breast was extirpated, and the axillary glands removed. Recurrence in the mammary region soon afterwards set in, and was extirpated. Seven months later there were further recurrences in the pectoral region, and ascites developed, with nodular masses disseminated in the abdomen. Finally, double pleural effusion supervened, of which she died. There was no necropsy.

(2) In Mercanton's case the patient was an unmarried peasant, aged 47, who had suffered from uterine prolapse for four years. Not the least interesting feature in her case is the extraordinary series of operations she underwent in the course of a few years, which must, I should think, be unique, even in continental experience. For the prolapse the following operations were done:—anterior kolporrhaphy with perinæo-plasty, Alexander's operation, excision of the *portio*, and extirpation of the vaginal mucous membrane. Prolapse of the anus having supervened twelve months after the first of these operations, the actual cautery was applied to the recto-anal region. While this lesion was healing, fourteen months after admission, a hard nodule, the size of a nut, was noticed in the inferior and axillary region of the *left breast*, with enlarged axillary glands. For this the breast was extirpated and the axilla cleared, sixteen months after her admission into hospital. On histological examination the tumour proved to be acinous cancer. The uterine prolapse having returned, a further operation, hysteroplexy, was done for it. She soon recovered, and left the hospital in good health a month later. She returned three months afterwards with a *left ovarian tumour*. For this laparotomy was done, and *both* ovaries being found affected with soft cystic cancer, they were removed. A few months later she left the hospital convalescent. Two and a-half years later she again came under treatment with an intra-abdominal tumour of the left sacro-iliac region. Laparotomy was again performed, when the sigmoid and rectum were found embedded in a hard mass of cancerous growth, and the peritoneum was infiltrated. Under these circumstances an

<sup>113</sup> Poupinel, *Ann. de Gyn.*, Jan., 1890.



artificial anus was established at the abdominal wound. From the operation this poor peasant woman again recovered, but subsequently she succumbed to the disease.

Primitively multiple cancerous growths have been met with in a variety of situations, other than those associated with breast cancer, as in the following typical examples :—

Several instances of *uterine* and *ovarian* cancer thus arising have been reported by Reichel and others.

In a woman, aged 53, Mercanton found the disease affecting the *uterus* and *vulva*.

In a man, aged 74, Beck met with cancer of the pyloric part of the *stomach* developed from the mucous glands, and colloid cancer of the *cæcum*, developed from Lieberkühn's follicles.

Abesser has reported an instance of squamous epithelioma of the *tongue*, with colloid, cylinder-celled cancer of the *jejunum*.

Bard has seen squamous epithelioma of the *uterus*, associated in the same person with cylinder-celled cancer of the head of the *pancreas*; and Beck found the same variety of uterine cancer co-existing with cylinder-celled cancer of the *sigmoid* flexure of the colon.

Kaufmann excised a squamous epithelioma of the *upper eyelid*, from a man who died six months later of cylinder-celled cancer of the *rectum*.

Squamous epithelioma of the *vulva*, and cylinder-celled cancer of the *colon*, co-existed in Chiari's patient; and cancer of *bladder* and *stomach* in Szumann's.

Schimmelbusch mentions having met with a case in which squamous epithelioma of the *ear* was associated with similar disease of the *lower lip*; and a man was under Billroth's care with cancer of the *stomach*, whose *ear* had previously been excised for epithelial cancer.

As examples of the co-existence of mammary cancer with *sarcoma*, I can cite the following cases :—

(1) A married woman,<sup>114</sup> aged 55, the mother of seven children, six years ago first noticed a small lump in the *left* breast, which made little progress until four months ago, since when it had rapidly increased. When she came under treatment this breast was occupied by a mobile, elastic, nodular tumour, 11 by 10 inches; but there was no enlargement of the axillary glands. At the same time the *right* breast was the seat of a typical scirrhus cancer of one and a-half year's growth, the nipple being retracted and the axillary glands enlarged. The left breast was amputated, and the patient made a good recovery without recurrence; but she died two and a-half years later from the cancerous affection of the right breast. On histological examination, the excised mammary tumour proved to be a small round and spindle-celled *adeno-sarcoma*.

<sup>114</sup> De Morgan, *Trans. Path. Soc. Lond.*, vol. xix., p. 394.



(2) Billroth<sup>115</sup> has reported a remarkable instance of *cystic sarcoma* of the left breast—locally recurrent after amputation, the axillary glands being unaffected—in which, a little later, *cancer* of the right breast supervened, with secondary affection of the axillary glands, and death from internal dissemination.

(3) Some time ago a case was brought before the *Clinical Society* by Kesteven,<sup>116</sup> in which six years after extirpation of *recurrent mammary cancer*, without any local return of the disease, the patient developed *cancer of the rectum* and *sarcoma of the femur*, of which she subsequently died.

(4) A healthy-looking woman, aged 64, consulted Bryant<sup>117</sup> for a smooth, ovoid, elastic tumour, the size of a cocoanut, which occupied the right mammary region. It was of eight months' growth. In the left breast was an *atrophic scirrhus* which had existed for sixteen years. Over the left hip was a *fatty tumour*, the size of the fist, of twenty-five years' duration. The right breast was amputated, and upon examination after removal the growth proved to be a mixed-celled *sarcoma*, in which spindle cells predominated. Recurrence at the primary seat soon set in, and after another operation there was likewise speedy recurrence, and so on for the next four and a-half years, during which time sixteen operations were performed. She was then still in good health, and the cancer of the left breast continued unprogressive.

(5) A multipara, aged 50, whose left breast was amputated by the same surgeon for *cancer* of two years' duration, four years later had *melanotic sarcoma* develop in a mole of the skin of the left axilla. In the course of six months this increased to the size of a hazel nut, when it was excised and never returned. There was no recurrence of the original cancerous disease until more than eight years after the operation, when it reappeared in the mammary region and elsewhere, and caused the patient's death some months later.

(6) In another case, also under the same surgeon, a single woman aged 40, had an ulcerating *melanotic sarcoma*, the size of an orange, in the right axilla. It originated there, in a cutaneous mole, two years previously. The patient remained well for nearly four years after its excision, when the breast of the same side began to enlarge. Six months later a *cancerous growth* was found there. The scar of the old operation was sound, and free from recurrence. The breast was amputated; and eight years later the patient was in good health and free from any return of either disease.

(7) Two years after amputation of the breast for primary *cancer*—of which there was no return—a patient of Dobson's<sup>118</sup> developed small round-celled *sarcoma* of the tonsil.

Guende<sup>119</sup> has met with *sarcoma of the choroid* developed in a woman the subject of *mammary cancer*.

<sup>115</sup> *Chir. Klin. Wien.*, 1868, S. 66.

<sup>116</sup> *Lancet*, vol. i., 1876, p. 315; *Clin. Soc. Trans.*, vol. vi. and ix.

<sup>117</sup> "Diseases of the Breast," p. 335.

<sup>118</sup> *Bristol Med. Chir. Journal*, Dec., 1889.

<sup>119</sup> *Marseille Méd.*, No. 7, 1890, p. 422.



As examples of cancer and sarcoma co-existing in the same person, elsewhere than in the breast, the following cases will suffice.

An elderly lady, one of whose *eyes* had been excised by Hutchinson<sup>120</sup> for *melanotic sarcoma*, died, free from any return of the original disease ten years afterwards, of *cancer of the uterus*.

A man, aged 52, under treatment at the Middlesex Hospital for *rodent cancer of the face*, had sixteen years previously undergone excision of *epithelioma of the lower lip*, of which there had been no return.

Langton<sup>121</sup> reports the case of a man, aged 46, with *rodent ulcer* of twelve years' duration, just below the lower eyelid, which was first excised two years after its appearance, but recurred six years later, when it was again removed. Two years later it re-appeared for the third time, and again recurred a few months after removal. About this time signs of a growth within the antrum became obvious. The superior maxilla was excised, together with the overlying skin and the rodent ulcer. The patient left the hospital free from any return of the disease, after rapid convalescence. The growth within the antrum proved to be *sarcomatous*.

Cutler<sup>122</sup> has met with *sarcoma of the ovary* co-existing with *cancer of various thoracic and abdominal organs*.

Following the example of Virchow,<sup>123</sup> some pathologists admit the existence of *mixed malignant neoplasms*, forms in which the sarcomatous and carcinomatous processes go on simultaneously. The histological characters of certain rare new growths seem to countenance this view; but never have transitions from one species of malignant new formation to another been verified.

Of the various non-malignant neoplasms—not of the breast—met with in patients having mammary cancer, I have found *uterine fibro-myomas* and soft polypi by far the commonest. Of 44 consecutive necropsies, the former were present in 5, and in 3 of these cases there were soft polypi as well.<sup>124</sup>

Next in frequency to these *ovarian cystomata* come, of which there were three examples in the 44 necropsies, one each as follows—dermoid, parovarian and ovarian.

<sup>120</sup> *Archives of Surgery*, vol. iii., No. 9, p. 48.

<sup>121</sup> *St. Bart.'s Hosp. Rep.*, vol. xxiv., 1888, p. 284.

<sup>122</sup> *Boston Medical Journal*, Oct. 6, 1892.

<sup>123</sup> *Path. des Tumeurs*, t. ii., 1869, p. 178.

<sup>124</sup> Of 123 similar necropsies tabulated by Nunn, uterine fibro-myomas were present in 20.3 per cent.



In this connection the following case is of interest :—

A single woman, aged 56, came under my observation with scirrhus cancer of the right breast, and a few enlarged axillary glands. In the left iliac region there was also an ovarian tumour, the size of a man's fist. The breast was amputated and the axilla cleared. She was soon convalescent. Shortly afterwards a multilocular cystoma of the left ovary was removed by laparotomy. There was no sign of malignant disease in connection with it. She had completely recovered six weeks later.<sup>125</sup>

Of 86 consecutive cases of mammary cancer, I found *fatty tumours* present in two, as under :—

(1) A spare woman, aged 85, with ulcerated hard cancer of the right breast of one year's duration. She had also a subcutaneous lipoma (3 in. by 2 in.) over the right deltoid muscle, and at the upper and outer part of the right thigh a pendulous *molluscum fibrosum*, the size of a bantam's egg, and several smaller ones at the back of the neck. After death she was found to have also a *dermoid cyst of the left ovary*, and a *soft polypus of the cervix uteri*.

(2) An obese woman, aged 55, with large pendulous mammæ. The right one contains a cancerous tumour, the size of a turnip, of one year's duration. At the upper part of the left thigh, on its inner side, is a subcutaneous lipoma of fourteen years' growth, the size of a man's hand.

Hutchinson<sup>126</sup> mentions the case of a woman who, having suffered for many years from *morphœa* of the side of the trunk and neck, at length developed hard cancer of the breast, for which she had undergone several operations. When last seen most of the *morphœa* patches had disappeared.

In the *Hunterian Museum*<sup>127</sup> is a specimen of hard cancer of the breast associated with *warty excrescences* of the overlying skin.

#### § X.—The Question of the Origin of Malignant from Non-Malignant Neoplasms.

Important practical issues are involved in the solution of the question as to the alleged liability of non-malignant neoplasms to become malignant. If any such tendency really exist, then these neoplasms ought to be extirpated as soon as possible.

<sup>125</sup> A similar case is reported in *St. Bart's Hosp. Reps.*, vol. xxvii., 1891, p. 62; and another in *Ann. de Gyn.*, t. xxxiii., 1890, p. 35.

<sup>126</sup> *Archives of Surgery*, July, 1891, p. 43.

<sup>127</sup> No. 4819 of the Pathological Series, *q.v.* *Pathological Catalogue*, vol. iv.



Widely divergent opinions have been expressed on this subject. It was formerly believed that every chronic tumour of the breast either was malignant or tended to become so. After the non-malignant neoplasms had been clearly differentiated from the malignant ones by Astley Cooper, the partisans of the old belief still maintained that the latter commonly developed from the former. Cooper himself admitted the possibility of such an occurrence. He says,<sup>128</sup> "I believe that if a person has a tumour of the breast which is not malignant, and that it remains so till the change of life takes place, that then an undue action may be excited in the part, and the tumour become scirrhus."

Since innocent neoplasms may inflame, suppurate, ulcerate, necrose and degenerate just like physiological parts of the body, it seems not unreasonable to suppose, on *à priori* grounds, that they may also become the seats of malignant disease. The occasional co-existence in the same breast of benign and malignant neoplasms favours this view. Such are the chief reasons which have given rise to the common belief, that innocent tumours are peculiarly apt to become malignant.

On critical examination of the subject two considerations have much impressed me. The first is the extreme rarity with which these two kinds of neoplasms co-exist in the same breast. Of 254 consecutive cases of mammary cancer, of which I have made a detailed examination, the disease was associated with fibro-adenoma in only two. In other words, for every case of cancer, that had originated under circumstances suggestive of the possibility of its having sprung from a fibro-adenoma, there were 126 cases that had evidently originated otherwise. But the relative frequency with which fibro-adenomatous and cancerous neoplasms arise in the female breast is, as I have elsewhere shown,<sup>129</sup> as 372 to 1863, or the proportion is 1 to 5. Hence, even if we admit that malignant transformation takes place in

<sup>128</sup> "Lectures on Surgery," 1839, p. 378.

<sup>129</sup> "The Initial Seats of Neoplasms and their Relative Frequency."—*Annals of Surgery*, October, 1891; also ch. vii., p. 130.



all such associated neoplasms, the event must be one of extreme rarity ; very much rarer than it would be if fibro-adenomatous neoplasms were especially prone to become cancerous. The second consideration is, the inconclusiveness of the evidence as to the malignant growths in most of these cases, having sprung from their non-malignant associates. In many instances it is perfectly evident that the association is a mere coincidence, each neoplasm having originated from the gland independently.

Paget<sup>130</sup> refers to an example of this kind, in which there was found in the breast excised from a woman, aged 32, a small fibro-adenoma that had existed for four years, and far apart from it a hard cancer of four months' duration.

In a case under Bryant's<sup>131</sup> care, a scirrhus tumour occupied the lower and axillary part of the right breast, while upon the surface of the gland, between the cancerous tumour and the nipple, there was a quite separate encapsuled fibro-adenoma. The patient was a single woman, 49 years old.

Richet<sup>132</sup> has recorded an instance of two fibro-adenomata of twenty-two years' duration in the lower segment, and cancer of recent growth in the upper segment of the same breast.

Gross,<sup>133</sup> having enucleated three fibro-adenomata from the right breast and amputated the left for cancer, found that the latter also contained three fibro-adenomata.

Waldeyer<sup>134</sup> met with a cancerous tumour associated in the same breast with eight fibro-adenomata.

In other cases the co-existing neoplasms are more closely associated ; but even in these the appearance of the non-malignant neoplasms is often such as hardly to countenance the belief that the malignant disease had sprung from them.

The two following cases have come under my observation:—

(1) A well-nourished, married woman, aged 63, had a small, stationary fibro-adenomatous tumour in the upper part of her breast for thirty-five years. During the last two months a hard cancerous growth, the size of a Tangerine orange, has developed in connection with it. She died a few weeks later of syncope from aneurism of the aortic arch. On examination of the breast after death, it contained a small circumscribed encapsuled fibro-adenoma, partially embedded in scirrhus cancer.

<sup>130</sup> "Lectures on Surgical Pathology," vol. ii., 1853, p. 259.

<sup>131</sup> "Diseases of the Breast," 1887, p. 339.

<sup>132</sup> *Le Practicien*, No. 14, 1879, p. 163.

<sup>133</sup> "Am. Syst. Gyn.," vol. ii., p. 207.

<sup>134</sup> *Arch. f. path. Anat.*, Bd. lv., S. 124.



(2) A large, obese, sterile, married woman, aged 54, thirty-four years ago noticed a tumour in the upper part of her right breast, which slowly increased to the size of a hen's egg and then became stationary. So it remained until three months before I first saw her, when, without injury or other known cause, the tumour began to increase. In this short time it attained the size of the foetal head at birth. On examination I found a circumscribed bossy tumour, adherent to the overlying skin, which was reddened in places, but movable over the subjacent structures. Some of the bosses were soft and fluctuating, while others were hard. The nipple was retracted. The axillary glands were slightly enlarged, as well as those below the clavicle. There was no history of cancer in the family. The breast was amputated, and the axillary glands removed. On examination of the tumour after removal, the whole of it was distinctly encapsuled. In many parts of the capsule there were extensive calcareous deposits. On section, the bulk of it was seen to consist of large cysts, containing brown serous fluid, and there were also numerous small cysts in the adjacent parts; in addition to the fluid many of the cysts contained villous papillary growths. At the sternal side of the main tumour was a solid, yellowish, encapsuled mass, the size of a Tangerine orange, which appeared to be of more recent formation than the rest. Microscopical examination of a portion of this revealed duct-like structures, which often contained papillary ingrowths. Examination of the excised axillary glands revealed only inflammatory changes. It was evidently a case of tubular cancer that had developed in connection with cystic villous papilloma of old standing. Two and a-half months later recurrence was noticed in the mammary region. Seven months later the skin over the whole of the front of the thorax and upper part of the abdomen contained numerous small, hard, cancerous nodules. In the right mammary region these were confluent and ulcerated. The right axilla was infiltrated, and the upper limb oedematous. She died of right hydrothorax, with collapse of the lung, nearly seventeen months after the operation. At the necropsy the local disease was found to have spread by direct extension through the thoracic wall to the right pleura and lung, both of which contained numerous cancerous nodules. The pleural sac contained 70 ounces of fluid, and the lung was collapsed. There were two caseating tubercular deposits in the upper lobe of the left lung. The heart was small and fatty. The peritoneum was thickly studded with cancerous nodules. The liver was large and fatty, and the gall bladder contained three facettled calculi. The spleen and both kidneys were congested. The uterus was small, and presented several pedunculated fibroids at its fundus.

Of cases observed by others the following will suffice :—

(1) <sup>135</sup> A lady, aged 49, under Haward's care, with a firm, lobulated, non-progressive tumour—the size of a bantam's egg—in the upper part of her right breast. After it had remained in this condition for nine years, a hard nodule formed between the tumour and the overlying skin, which presented

<sup>135</sup> *Lancet*, vol. i., 1894, p. 245.



all the signs of cancer. The axillary glands were unaffected. On histological examination after extirpation, the old tumour proved to be a typical fibro-adenoma. In the overlying skin was a button-like nodule of hard cancer, which adhered to the adjacent adenoma, but had only superficially invaded it. Eleven months after this operation two small recurrent nodules appeared in the vicinity of the scar.

(2) <sup>136</sup> In an unmarried woman, aged 61, White found a single fibro-adenoma in the *left* breast, and three similar tumours in the *right* breast. In close association with one of the latter an acinous cancerous growth had sprung up.

(3) <sup>137</sup> A woman, aged 44, had noticed from girlhood a stationary tumour the size of a cherry, beneath the skin of her left breast. Two years before she came under observation hard cancer started in the vicinity of this tumour. When first seen she had a cancerous mass there, adherent to the overlying skin. This was excised, and some affected axillary glands were removed. On examination of the part after removal, a rounded fibro-adenomatous tumour was found, completely embedded in scirrhus cancer, which surrounded it to the extent of from 1 to 1½ inches. On microscopical examination it was found that the cancerous disease had invaded the structure of the adenoma; but the author is doubtful whether this implies that it really commenced in the tissue of the first tumour.

(4) <sup>138</sup> The patient, 50 years old, had a hard, painless, quiescent, filbert-sized tumour in her left breast for 22 years; when she was found to be suffering from an abdominal tumour, which was removed by laparotomy, and proved to be an adenoma of the ovary. Three months after convalescence the mammary tumour became painful and commenced to increase progressively. A year later it was excised, when it proved to be cancerous, and recurred twice within the two following years.

(5) <sup>139</sup> A single woman, aged 65, whose mother, sister, and other relations had died of cancer. Seven years ago she first noticed a swelling at the upper part of her right breast, which subsequently increased slowly, until three years ago, when it began to progress more rapidly. When first seen the right breast was occupied by a cystic tumour the size of the foetal head at birth; at its upper part a hard lump could be felt. Examination of the breast after removal revealed a large unilocular cyst containing a brownish fluid, with a cancerous tumour (2in. by 2in.) in the upper part of the cyst wall. The central part of this cancer had undergone calcareous degeneration; that part of its surface which bulged into the cyst cavity presented several polypoid growths.

(6) <sup>140</sup> A farmer's wife, aged 42, married for fifteen years, but childless, came under treatment with a tumour the size of a walnut in the upper part

<sup>136</sup> *Trans. Path. Soc. Lond.*, 1892, p. 120.

<sup>137</sup> J. Hutchinson, jun., *Trans. Path. Soc. Lond.*, vol. xxxix., 1888, p. 315.

<sup>138</sup> G. Ponpinel, *Annales de Gyn.*, xxxiii., 1890, p. 35.

<sup>139</sup> T. Smith, *Trans. Path. Soc. of Lond.*, vol. xxii., p. 267.

<sup>140</sup> R. Parker, *Ibid.*, vol. xxxii., p. 233.



of her left breast, the nipple and the axillary glands being normal. There was some doubt as to its nature, so an exploratory incision was made into it, when, as it looked just like cancer, the whole breast was removed. On examination of the part after removal the breast was found separated from the fascia pectoralis by a bursa, into the anterior wall of which a nodular tumour projected, having all the gross characters of ordinary fibro-adenoma. It was enveloped in a thick fibrous capsule, with the superficial aspect of which the cancerous growth that had been incised at the exploratory operation, was connected. Histological examination showed that the former tumour consisted of wavy fibrous tissue, enclosing acinous and tubular structures, and the latter presented the appearance of ordinary acinous (scirrhus) cancer.

(7) <sup>141</sup> A healthy widow, aged 30, with one child 10 years old, came under observation having a nodular, elastic, painless swelling in the clavicular part of her left breast. It was somewhat pear-shaped, with the narrow end near the nipple, and of seven months' duration. Pressure caused a viscid fluid to exude from the nipple, which was otherwise normal. There was no enlargement of the axillary glands. The tumour was excised, together with the adjacent parts of the breast. On examination, after removal, most of the tumour was formed of a *cyst* that communicated with a duct near the nipple, and contained serous fluid. The surrounding tissues contained numerous small cysts, with intra-cystic villous growths. The patient remained free from any return of the disease for eleven and a-half years after the operation, when scirrhus cancer developed in the old cicatrix, with enlargement of the axillary glands. For this the breast was amputated and the axilla cleared; the patient making a good recovery.

Paget<sup>142</sup> refers to a specimen in the museum of St. Bartholomew's Hospital (Series xxxiv., No. 16) which shows a hard cancer and a *proliferous cyst* in the breast of a woman who died some time after its removal, with recurrence of the cancer. In this instance the two neoplasms, although co-existing in the same breast, were nevertheless quite distinct.

Poulsen<sup>143</sup> has related the history of a man in whom mammary cancer developed in connection with a *nævus*.

Many instances of the development of *sarcoma* in association with mammary fibro-adenoma have also been recorded. Labbé and Coÿne<sup>144</sup> believe that most sarcomata of the breast originate thus, rather than from the tissues of the gland itself. In support of this they instance the following case, in which an adeno-cystic sarcoma arose in close connection with an old adeno-fibroma.

<sup>141</sup> Bryant, *Op. cit.*, p. 161.

<sup>142</sup> "Lect. Surg. Path.," vol. ii., 1853, p. 259.

<sup>143</sup> *Arch. f. klin. Chir.*, xlii., 1891, S. 593.

<sup>144</sup> "Traité des Tumeurs bénignes du Sein," pp. 290 and 363.



In the left breast of a woman, aged 44, a hard tumour, the size and shape of a walnut, had existed without alteration for ten years ; when, without any known cause, it began to enlarge, and in the course of two years increased to the size of a newly-born child's head. It was then removed, together with the breast, and on microscopical examination it proved to be a spindle-celled myx-adenosarcoma.

Of eight mammary sarcomata examined by these authors, no less than 4 had a similar history—whence their conclusion. I have not met with such cases in anything like so large a proportion. Of 30 sarcomata of the breast analysed by me there was only one instance of this kind.<sup>145</sup>

In this case the patient, aged 43, first noticed a small hard lump in her right breast six years before she came under my observation. This lump having remained stationary for over five years, then began to enlarge during pregnancy, and in nine months' time it attained the size of a large orange. On histological examination after removal, it proved to be a round and spindle-celled adeno-cystic sarcoma.

Probably many cases of this kind really are sarcomatous from the first.

Under these circumstances I feel bound to reject Labbé and Coÿne's conclusion, which appears to be based upon too narrow an experience. In a certain proportion of their cases, the initial tumours were probably nothing more than overgrown supernumerary mammary sequestrations. In other instances the initial slowness of growth was probably due to the comparative paucity of the incorporated cellular elements, which subsequently become more numerous, and may be, even changed their nature. As examples of similar conditions by other observers, the following cases are of interest :—

Poulsen<sup>146</sup> gives the history of a girl 16 years old, who—after a blow—noticed a tumour, the size of a walnut, in her breast, at the inner side of the nipple. This remained stationary for nearly thirty-six years, and then in the course of a few years it attained the size of an orange, when it was removed.

Manignac<sup>147</sup> relates an analogous case in which a tumour, the size of a

<sup>145</sup> Billroth mentions having met with two such instances, out of 19 cases. *Deutsche Chir.*, Lief xli., S. 67.

<sup>146</sup> *Arch. f. klin. Chir.*, xlii., 1891, S. 593.

<sup>147</sup> *Bull. de la Soc. Anat.*, t. lii., p. 428.



walnut, after having remained quiescent for fifteen years, then increased so rapidly as to attain the size of a double fist, in the course of three months.

In a case by Tillaux<sup>148</sup> a tumour, the size of an egg, that had been quiescent for eighteen years, in the course of a few months attained the size of an adult head.

Gross<sup>149</sup> extirpated the breast of a lady, aged 65, for a small spindle-celled sarcoma of four years' growth, that originated in connection with a tumour, the size of a chestnut, of thirty-six years' duration. When removed the tumour was larger than the foetal head at birth, and it had doubled its volume in the course of the previous year. A recurrent nodule required removal from the pectoral muscle seven months later.

It follows from what has been stated that the possibility of benign neoplasms taking on malignant characters later in life, must be admitted; but this is a very different thing from admitting that such neoplasms are specially prone to develop malignant disease. This is disproved by the extreme rarity of the coincidence. My investigations show that non-malignant mammary neoplasms are less liable to originate cancer, than are the glandular elements of the breast itself.

---

<sup>148</sup> Cordier, *Thèse de Paris*, No. 494, 1880.

<sup>149</sup> "Am. Syst. Gyn.," vol. ii., p. 206.



## CHAPTER XI.

## THE VARIETIES OF ACINOUS CANCER.

## § I.—The Acute Type.

ALTHOUGH cancer of the breast is usually a chronic disease, yet certain cases occasionally run an acute course. Of these the following types may be recognised :—

(i.) A very rare diffuse form—denominated by the French *cancer d'emblée*, *squirrhe ligueux en masse* by Velpeau, and *mastitis carcinomatosa* by Klotz—in which the whole of one or both breasts may be at once involved. It arises suddenly, progresses rapidly, and is often accompanied by inflammatory phenomena. No special tumour is formed, but the whole breast becomes enlarged and hard, the skin reddened, œdematous and adherent, and the subcutaneous veins unduly visible. Verneuil and Estlander found the temperature of the affected skin from  $\frac{1}{2}$  to  $2^{\circ}$  above the normal, and the former has demonstrated in some cases a veritable cancerous fever. The adjacent lymph glands are usually soon invaded, and there is general dissemination of the disease, with death from acute cachexia. Its total duration seldom exceeds a few months. Most cases—but not all—arise in connection with pregnancy or lactation.

As examples of this form of the disease the two following cases will suffice :—

(a)<sup>1</sup> A thin, pale woman, aged 36, the mother of seven children, was

<sup>1</sup> Billroth, Th., *Deutsche Chir.*, Lief xli., S. 128.



admitted into hospital when near the full term for her eighth confinement, with both breasts larger than a child's head, hard, and firmly adherent to the chest wall and to the over-lying skin. The latter was tense, shiny, congested and marbled by bluish veins. The breasts gave no milk or colostrum. There was no obvious disease of the axillary glands. The history she gave was, that five weeks previously hardness set in at the periphery of both breasts, which rapidly spread with increase of size. A week after admission labour was artificially induced, and she gave birth to a healthy child; but herself died shortly afterwards of collapse. At the *necropsy* both mammary glands were found invaded by a softish, lobulated, reddish growth, from which milky fluid exuded on section. Histological examination revealed epithelial cylinders and alveolar gland-like formations, such as are found in ordinary breast cancers, embedded in a fibrous stroma densely infiltrated with small, round cells. Secondary nodules were disseminated in the thyroid gland, pericardium, liver, peritoneum and kidneys, but not in the axillary glands. The total duration of the disease was only six weeks.

(b) In the following case by Aitken<sup>2</sup> the progress was even more rapid.

A cook, aged 30, with both breasts enlarged to double their natural size, of a dusky red colour, hot and tender; they adhere firmly to the adjacent parts, and feel firm, lobulated and elastic. On puncture free hæmorrhage ensued. There was pyrexia and dyspnœa. She was thought to be pregnant. The onset of the disease dated only from ten days previously, and she attributed it to a chill. Eighteen days later there was obvious loss of strength, with typhoid symptoms, and she died a week later, almost hemiplegic. The total duration of the disease was only thirty-eight days. After death the right breast was rather larger than the left. On section each presented a lobulated appearance, and weighed six pounds fourteen ounces. There were cancerous glands in each axilla, as well as in the liver and both ovaries. Microscopical examination of the diseased breasts showed proliferating acinous structures, as in ordinary cancer.

Similar cases have been recorded by Klotz,<sup>3</sup> Volkmann,<sup>4</sup> Terrillon,<sup>5</sup> Monod<sup>6</sup> and others.

(ii.) Although I do not regard the *squirrhe tégumentaire* of Velpeau as a distinct variety, but merely as a peculiar form of cutaneous dissemination of ordinary acinous cancer, yet it will be convenient to describe it here. Acinous cancers that ori-

<sup>2</sup> *Medical Times and Gazette*, vol. i., 1857, p. 357.

<sup>3</sup> "Ueber Mastitis carcinomatosa gravidarum et lactantium," I. D. Halle, 1869.

<sup>4</sup> *Beitr. z. Chirurgie*, Leipzig, 1875, S. 310.

<sup>5</sup> *Bull. Gén. de Thérap.*, 13 mai, 1891, p. 385.

<sup>6</sup> *Gaz. Méd. de Paris*, 1886, pp. 1, 17, 37 and 48.



ginate beneath the nipple and areola are specially prone to be followed by acute dissemination in the skin, owing to early implication of the subareolar lymphatic plexus, and rapid diffusion of cancer cells through its communicating cutaneous branches. Lesions thus induced assume the form either of small tubercles (*squirrhe disséminé, acute miliary carcinosis*), of irregularly shaped discs (*en plaques*), or of diffuse infiltrations (*en cuirasse*). Velpeau, who first clearly differentiated these conditions, thought that some cases were from first to last limited entirely to the skin, but most pathologists are now agreed that the cutaneous infiltration is invariably secondary to primary disease of the breast. Cases of this type run a rapid course, and are exceedingly malignant. According to Estlander, the average duration of life seldom exceeds from five to twelve months. This estimate is no doubt true for those cases in which the skin is implicated at an early stage of the disease; but I have seen instances in which cutaneous dissemination did not supervene until several years after the onset of the primary disease in the breast.

Of 170 cases of mammary cancer consecutively under my observation, there were only two instances of *squirrhe disséminé*. The following is a typical example.

A pale, weak, emaciated woman, aged 32, the mother of five children, with a small, hard tumour in the left breast, of one month's duration. The overlying skin is adherent, and it contains an immense number of small cancerous nodules, varying in size from a pea to a pin's head, which are in some places confluent. The skin of the parts adjacent to the left breast is similarly affected, as well as that of the left axilla, where the lymph glands are enlarged. In the course of the next few months the opposite breast and the whole of the integument of the front of the chest was similarly invaded. No operation was done. She died thus of asthenia, with symptoms of intrathoracic dissemination, seven and a-half months after the disease was first noticed. She was of a very tubercular family, both her parents and three of her brothers and sisters having died of phthisis; but there was no family history of cancer.

In the *diffuse* form the onset is generally insidious and painless, like that of ordinary cancer. Too often nothing wrong is noticed until the disease has made considerable progress. The



first thing to attract attention often is the presence in the mammary skin of one or more dusky red, erysipelatous-looking, hard *plaques*. These may be accompanied by a feeling of heat and burning, together with a vague sense of discomfort, sleeplessness and loss of appetite. As the disease progresses, these indurated areas increase and coalesce, thus converting the skin into a hard, coriaceous structure of dusky red colour, and fixing it firmly to the subjacent parts. This leather-like transformation often extends far beyond the region of the originally affected breast. It may even involve the skin of the whole trunk, transforming it into a constrictive *cuirasse*, as in one of Velpeau's<sup>7</sup> cases, which he describes as follows :—

“Toute la poitrine, depuis les flancs jusqu'au cou, depuis l'ombilic jusqu'au larynx, depuis les lombes jusqu'à l'occiput, avait subi la transformation ligneuse et qu'était en outre criblée d'ulcères squirreux, avec une foule de bosselures cancéreuses, jusque dans les aisselles et sur les épaules. Cette pauvre femme, dont les deux bras étaient triplés de volume et dur comme du marbre, avait la respiration si petite, si courte, qu'elle ressemblait à une personne qu'on étrangle, ou dont la poitrine est violemment prise dans un étau ; ne pouvant remuer ni les bras, ni la tête, éprouvant des douleurs atroces à tout instant, elle offrait, quand je la vis, le spectacle le plus navrant qui se puisse imaginer,” &c.

Soon death ensues, which is generally due either to acute cachexia, to extension of the disease to the thorax causing hydrothorax, &c., or to constrictive dyspnœa, owing to mechanical interference with the respiratory movements.

Histological examination of the thickened skin shows that the corium is infiltrated with cancerous new formation, consisting of irregular aggregations of polyhedric or variously shaped epithelial cells, closely packed, without definite arrangement, in the irregularly shaped meshes of a fibrous reticulum. These meshes appear to be dilated lymph spaces. There is seldom any definite alveolar formation, and sometimes the spaces contain only a single file of cells. The epidermis is unaffected. I have seen two examples of similar disease in the neck, which

---

<sup>7</sup> *Traité des Maladies du Sein*, Paris, 1854, p. 429.



probably originated in connection with epithelial remains of the branchial clefts.<sup>8</sup>

Of 170 cases of mammary cancer consecutively under my observation, there were only three instances of this cuirassed form of the disease. According to Gross it is met with once in every twenty-two cases. The following are two typical examples:—

(a) A pale, dark-complexioned woman, aged 45, the mother of five children. When I first saw her the skin of the whole of the right pectoral and axillary regions, and part of that of the left pectoral region, was infiltrated with cancer *en cuirasse*, firmly adherent to the subjacent parts. Several hard cancerous nodules could be felt besides in the right breast. The glands of the right axilla were invaded, and the right upper limb was œdematous. The disease began three years previously, when she first noticed a hard lump beneath the skin of the right breast, just above the nipple. No operation had been performed. She died asthenic a month and a-half later, with dissemination of the disease in both lungs, and in the glands of both axillæ.

(b) <sup>9</sup> A childless married woman, aged 52, six months ago first noticed a painless enlargement of her right breast, which increased rapidly. At the end of this period the breast was amputated, but recurrence set in before the wound had healed. The whole of the adjacent part of the chest was quickly infiltrated, together with the axilla and shoulder. The upper limb became œdematous and useless. The skin of the affected part was bound to the subjacent tissues and thickened. It was of reddish coriaceous character, and the papillary structures seemed hypertrophied. The infiltration soon involved the skin of the scapular region, of the lateral and anterior parts of the chest, and spread across the middle line to the left breast, which enlarged to more than double its natural size and became hard and fixed. Itching and sharp shooting pains were complained of. The patient's general health was soon affected; her appetite failed and she could not sleep; she rapidly lost flesh and strength; and the breathing became hurried. On waking, after a quiet night, she died suddenly, eight months after the onset of the disease. At the *necropsy* there was serous effusion into the pericardium and the right pleura; but *no metastases*. The other organs were healthy.

(iii.) I here propose to call attention to certain cases of mammary cancer, which—although they in no way differ morphologically from ordinary acinous cancers—nevertheless run a very acute course. I have met with six such cases out of

<sup>8</sup> *Medical Press and Circular*, Oct. 29, 1884. "Two Cases of Acute Diffuse Strangulating Cancer of the Neck."

<sup>9</sup> Nunnely, *Trans. Path. Soc. Lond.*, vol. xiii., p. 47.



sixty-four consecutively fatal breast cancers. The following is a typical example :—

A moderately nourished, single woman, aged 30, five months ago first noticed a hard lump, the size of a bantam's egg, in the axillary segment of her right breast. On examination, I found in this situation a hard mass of new growth, the size of half an orange, adherent to the chest wall and to the overlying skin. The glands of the right axilla were extensively infiltrated and matted together. Family history good. No operation. She died of asthenia about five and a-half months later. At the *necropsy* the body was greatly emaciated. A large ulcerated cancerous growth occupied the right breast, and the adjacent soft parts were infiltrated. It was of firm, whitish scirrhus structure. The sternum and adjacent pleura were infiltrated with similar growth. The liver contained numerous secondary nodules.<sup>10</sup>

### § II.—The Chronic Type.

Mammary cancers that take more than five years to run their entire course I reckon as of the chronic variety. Such cases are much commoner than is generally supposed, and what is still less appreciated is, that the great majority of them are *morphologically indistinguishable from ordinary acinous cancer (scirrhus)*.

(i.) Of 170 consecutive women with mammary cancer under my observation, no less than 31 (18·2 per cent.) were of the chronic type; and of these, *all but six* were morphologically of the ordinary acinous kind. The duration of the disease in these 25 *chronic acinous cancers* had already lasted as follows :—

5	to	10	years	...	...	in 14 cases.
10	"	15	"	...	...	" 6 "
15	"	20	"	...	...	" 2 "
20	"	25	"	...	...	" 1 case.
Over 25	"		"	...	...	" 1 "

Similarly of 64 consecutive *fatal* cases, that had run their natural course, in 17, or 26·5 per cent., the disease had lasted upwards of five years; and of these all but 3 were of the ordinary scirrhus type. The total duration of life in these 14 chronic scirrhus cases was as follows :—

<sup>10</sup> For abstracts of similar cases *vide* pp. 177 (No. 4), 189, 194, and 218.



5	to	10 years	...	...	in	8 cases.
10	"	15	"	...	"	5 "
		Over 20	"	...	"	1 case.

The 3 subjoined cases, that have come under my own observation, suffice to illustrate the chief features of this form of chronic cancer.

CASE 1.—A large, well nourished, healthy looking, dark complexioned woman, aged 55, the mother of four children. In the middle of her left breast is a hard nodular lump, the size of a small orange. It is adherent to the overlying skin, but movable on the chest wall. The nipple is stunted and retracted, and the axillary glands are full. *Twenty-eight years* previously, shortly before the birth of her first child, she noticed a lump the size of a hazel nut in the middle of her left breast, beneath the nipple. It remained nearly stationary until ten years ago, but ever since that time it has continued gradually to increase. Her father died of cancer of the lip. The breast was amputated, and the tumour proved to be ordinary scirrhus. She was convalescent about a month later, and I know nothing of her subsequent history.

CASE 2.—As in the preceding instance, this patient was large, well nourished, and of dark complexion, a cook by occupation, aged 69. She had recurrent cancer of the left pectoral region, in the shape of a hard, knobby mass, the size of an orange, near the axillary extremity of the scar resulting from amputation of the breast. The growth adhered to the overlying skin and to the subjacent chest wall. In the left axilla was a hard nodulated lump the size of a hen's egg, adherent to the overlying skin. The disease began twenty-three years ago, when she first noticed a hard lump, the size of a pigeon's egg, in the lower segment of her left breast. In the course of four years it attained the size of a man's fist, and the overlying skin having ulcerated, the breast was amputated. Four years after this a recurrent growth in the scar, the size of a hen's egg, was excised. For eight years she then remained free from any return of the disease. At the end of this time, about five years ago, the present recurrent disease was first noticed in the pectoral region, and subsequently in the axilla. Her mother died of phthisis. The patient married at twenty-five, and in the next few years had one still-born child and one miscarriage. No further operation was done. She died about a year later of asthenia, the pectoral growth having previously ulcerated. The total duration of the disease was nearly *twenty-four years*. At the *necropsy* the chest wall and axilla were found to be extensively infiltrated by hard, dense white, nodular cancerous growths. There were no other secondary lesions. Both lungs were emphysematous and congested. There were old fibrous adhesions over the upper part of the left lung. The heart presented an excessive amount of subpericardial fat. The liver was congested. The kidneys were small and granular, the cortex of each much wasted, containing a few small cysts. The uterus was small, and at its fundus were two calcified pendulous fibroids. The brain was normal.



CASE 3.—A large, fleshy, dark-complexioned, sallow woman, aged 57, with an ulcerated mass of hard cancerous growth, about the size of a man's hand, occupying the left pectoral region, in the situation of the mamma. The surrounding skin and other structures are infiltrated. The mass is firmly adherent to the subjacent chest wall. The discharge from the ulcer is abundant and fœtid. The left axillary glands are enlarged. The disease began sixteen years ago, when she first noticed a lump, the size of a hazel nut, at the lower peripheral part of the left breast; this slowly increased for about twelve years, and then began to ulcerate. In consequence the breast was amputated about a year later, and the axillary glands were removed. Ten months later a recurrent growth in the pectoral region was excised; shortly afterwards the present recurrence began there. She was married at 17, and is the mother of two children. Both her parents died young of phthisis. No further operation. She was last seen about seven months later, when her strength was failing and cachectic symptoms were well marked. The disease then had already lasted nearly *seventeen years*.

In point of chronicity it would be difficult to surpass such cases, even among the atrophic and colloid varieties of the disease, which are generally supposed to have a monopoly in this respect.<sup>11</sup>

(ii.) The form of cancer I now have to describe is rare, for of 170 consecutive mammary cancers, I met with only six instances of it, or 3·5 per cent. According to Gross, *atrophic varieties* constitute about 7·9 per cent. of all breast cancers.

The characteristic feature of this type is the continuous, gradual shrinking of the new formation, and the consequent irregular contraction of the breast, which is often thereby diminished rather than increased in size. The deformity produced is apt to resemble that met with in "chronic cirrhusing mastitis." These atrophic, cicatrising or cirrhusing cancers usually begin with obscure hardness, which progresses slowly, forming at length ill-defined, flattened or irregular nodulated thickening, with numerous "roots" stretching far into the adjacent parts. Such growths consist of very dense, whitish, dry, fibroid substance, and on account of their extreme hardness, they have not inappropriately been designated "stone cancers."

Histologically the fibrous stroma preponderates, while epithelial elements are very scanty, or altogether wanting (fig. 43).

<sup>11</sup> For other instances of extreme chronicity, *vide* chap. ix., pp. 219 and 220.



This stroma consists of irregularly disposed bundles of fibrous tissue, rich in elastic fibres, but poor in cellular elements. It contains variously shaped small spaces—atrophied alveoli—in which are a few degenerate epithelial cells, or merely cellular *débris* and fatty granules. The constituent cells of cancers of this kind are very short lived, for no sooner have they formed than they thus degenerate; only at their extreme periphery are proliferous epithelial cells to be found. A notable feature of atrophic cancer is the marked deformity of the breast, caused by the shrinkage of the neoplasm; at first only the

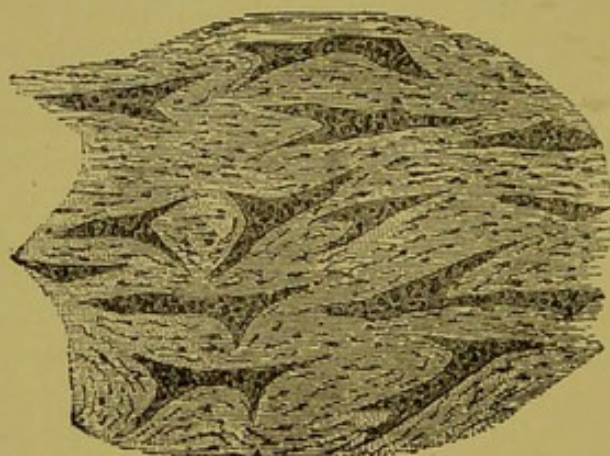


FIG. 43.—Histological Section of atrophic Mammary Cancer (*Billroth*).

nipple and skin are retracted, but finally the latter is thrown into obvious plications. The subcutaneous veins are seldom seen distended, as in ordinary cancers. Usually the disease runs an extremely chronic course, most cases lasting for from ten to fifteen years or more; but spontaneous cures are, nevertheless, unknown. Here I may as well mention, that I have met with several examples of atrophic cancer, that have run their entire course in less than a year.<sup>12</sup>

The general health of women with atrophic cancer usually remains unimpaired for a long time; but at length cachectic symptoms supervene. Shallow indolent ulcerations often result,

---

<sup>12</sup> I have reported two typical cases of this kind in chap. ix., p. 203.



which occasionally partially cicatrise. Old women are said to be particularly liable to atrophic cancer; but this is only partially true. Most cases supervene at a more advanced period of life than ordinary scirrhus; but, as Gross has pointed out, quite 55 per cent. originate before the age of 50.

Atrophic cancers are specially prone to invade extensively the adjacent tissues by direct extension, and in a less degree by local dissemination. Lymph glandular and general dissemination, although often long delayed, are seldom absent; and recurrence after operation is of frequent occurrence. The secondary growths reproduce the atrophic characteristics of the primary one.

Subjoined are abstracts of some typical cases, that have come under my observation.<sup>13</sup>

(a) A pale, sallow, and thin woman, aged 76, with both mammae small and wasted. The greater part of the left breast is occupied by an irregular ulcer rather larger than the palm of the hand. Its base is fixed to the subjacent chest wall. The nipple and areola are quite destroyed. Its edges are raised and hard. The left axillary glands and those above the clavicle on this side are enlarged. At the upper part of the right breast there is a smaller cancerous ulcer. Twenty years previously she first noticed a small nodule in the left breast near the nipple. It has since slowly attained its present condition. Ten months ago a similar nodule was first noticed in the upper part of her right breast. No operation has ever been done. Her maternal grandmother died of cancer of the breast, and her father of phthisis.

(b) A well nourished but sallow woman of dark complexion, aged 52, with a linear scar across the right mammary region, at the middle of which is a hard recurrent nodule the size of an almond. A single enlarged gland in the right axilla. Five days ago, when out walking, she suddenly felt a pain in her right thigh, which caused her to fall, when it was found that she had fractured her femur at the junction of its upper and middle thirds. The patient said she first noticed a hard lump, the size of a pea, at the upper part of the periphery of her right breast, ten years ago. After it had slowly increased for six years, the breast was amputated. The present recurrent nodule was only recently noticed. No further operation was done. She died of asthenia nineteen months later. At the *necropsy*, both pectoral regions were found infiltrated with hard cancerous growths, which had invaded the muscles and ribs, and had spread by direct extension to the anterior mediastinum and to both pleuræ. The glands in both axillæ were infiltrated. A cancerous nodule in the pancreas had invaded and

<sup>13</sup> For other cases *vide* ch. ix., pp. 229 and 230.



blocked the common bile duct, at its entrance into the duodenum. The gall bladder was dilated and contained several calculi. A fistulous communication had established itself between the gall bladder and duodenum. The liver was atrophic and of brownish tint. The heart and lungs were small. Both kidneys were small, and the pelvis of each contained numerous miliary calculi. The whole of the right femur was infiltrated with cancerous growth; and it was fractured in several places. The head of the right tibia was similarly invaded. The left femur was fractured just below the small trochanter; and here there was a mass of cancerous growth the size of an orange. The whole of the left humerus, except the articular extremities, was converted into a mass of cancerous growth. The growth in the left femur was of a whitish colour and india-rubber-like consistency; and on histological examination proved to be typical acinous (alveolar) cancer.

(c) A rather pale, emaciated and sallow woman, aged 46, with a hard flattened mass near the middle of her right breast, over which the skin is plicated and adherent, and the nipple deeply retracted. The axillary glands are enlarged and hard. The disease began as a small nodule at the lower and inner part of the breast, five years ago. No operation had been done.

(d) <sup>14</sup> A lady, who died aged 75, twenty-four years previously, after having borne a numerous healthy family, first noticed a small hard tender lump in her left breast, with retraction of the nipple. She would not submit to operation. In the course of several years the breast got much harder and smaller, and the skin became puckered; until at length the gland seemed to have almost completely disappeared. During the last eight years of her life the disease seemed stationary; and it caused her hardly any pain or inconvenience. When first seen two years before her death, the whole breast appeared to have shrivelled up and wasted away. The prominence of the bosom had quite disappeared; in its place was a flat surface, contrasting markedly with the opposite side, where there was a full bust. The nipple was deeply retracted and sunk in a fossa, whence radiated grooves and fissures. Beneath it there was a small hard infiltrated area, with a few hard tubercles adjacent. The patient came under treatment for senile cataract of both eyes, which had made her quite blind. Notwithstanding the cancerous disease she was operated on successfully and made an excellent recovery. There was no *post-mortem* examination.

(iii.) *Colloid* cancer of the breast is certainly very rare, since of 170 consecutive cancers of this part I have not met with a single instance of it. Gross estimates that 1.34 per cent. of all breast cancers are of this variety; and Brindejone<sup>15</sup> reports eight examples of it in 326 cases.

The disease owes its peculiar features to the proneness of its constituent cells to undergo colloid metamorphosis.

<sup>14</sup> E. Hart, *Trans. Path. Soc.*, vol. xiii., p. 225.

<sup>15</sup> "Étude sur quelques carcinômes colloïdes de la Mamelle," *Thèse de Paris*, No. 373, 1891.



Sections of such growths reveal small, translucent masses of glutinous fluid, embedded in the fibrous stroma, in place of the usual opaque cellular aggregations (fig. 44). It comparatively seldom happens, however, that the whole neoplasm is thus affected, for some parts nearly always retain their ordinary scirrhus character.

The process begins with the formation within the cells of clear colloid globules. As these increase the cells perish; the freed globules then coalesce and so form the larger colloid

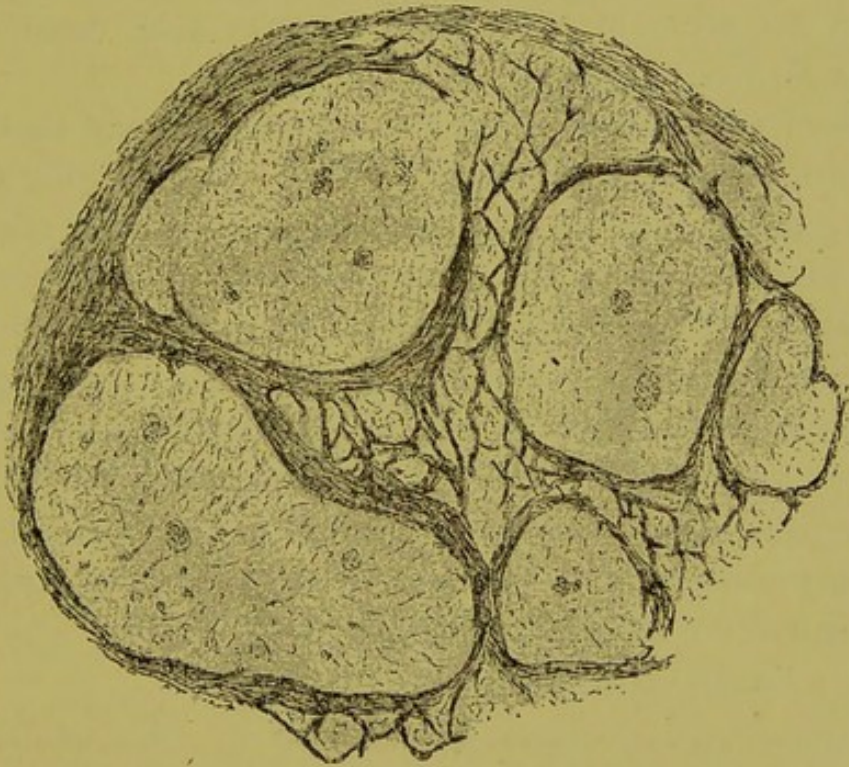


FIG. 44.—Histological Section of Colloid Cancer of the Breast (*Cazin*).

masses. Thus all the cancer cells of a wide area may perish; so that the stroma is the only formed constituent left. In other parts of the same growth regions may be found in which the cells are merely fringed with colloid change; and in yet other localities no colloid change may be noticeable. As the disease progresses the fibrous stroma often becomes œdematous, and much of it may eventually disappear, leading sometimes to cyst formation. Histological sections show large, thin-walled



alveoli, distended with colloid fluid containing granular *débris*, in which only a few degenerated cells, or perhaps none at all, can be made out (fig. 44). Owing to these changes in the cells their growth is retarded and the malignancy of the disease is thereby diminished; hence colloid cancers run a very chronic course, the average duration of life being about twelve years; and they are more tardily, and less frequently, followed by local, glandular and general dissemination, than any other form of mammary cancer. Moreover, in this variety of the disease cachectic symptoms seldom supervene. When secondary growths do arise, in their main features they resemble the primary ones.

Colloid cancer usually begins as a small, lumpy swelling in the breast, which increases very slowly. The resulting tumour seldom exceeds the size of a hen's egg, and it may take from ten to fifteen years to attain this size. It generally feels firm and elastic, with projecting bosses. As these growths do not shrink, the nipple and overlying skin are much less frequently retracted than in ordinary scirrhus. Ulceration occasionally ensues at an advanced stage of the disease. Recurrences are less frequent than after the removal of any other form of mammary cancer. The average age at onset is 47 years; and in about half the cases the disease begins after 50.

The following is an illustrative case.<sup>16</sup>

A healthy, married, childless woman, aged 65, with a lobulated livid tumour—of seven years' growth—the size of a man's fist, occupying her right breast. The lobulations feel soft and fluctuating; in one of them is an opening, whence thick, glairy fluid escapes. On section after removal the lobular structure was well marked. Each lobulation was composed of reddish jelly-like material with caseating areas in it. Histological examination revealed delicate fibrous alveolar stroma, containing glutinous fluid in which were large granulation-like cells. There was no recurrence of the disease in this breast; but seven years afterwards she developed cancer (colloid?) in the opposite breast. Six years later this had but slightly increased; and she was still in good health.

<sup>16</sup> Bryant, *Op. cit.*, p. 201. For other cases *vide*—*Trans. Path. Soc.*, xxx. (Godlee), p. 416; xxix. (Watson), p. 218; xxvii. (Butlin), p. 233. *Arch. f. klin. Chir.* (Doutrelepon), Bd. xii., S. 551. *Thèse de Paris* (Brindejone), No. 373, 1891, &c.



(iv.) Many cases of so-called colloid cancer of the breast are really examples of *carcinoma myxomatodes*, the variety now to be described. The gelatinous transformation is here due to myxomatous metaplasia of the fibrous tissue of the stroma; and in extreme cases to its cellular elements as well. Very exceptionally, it may even happen that the cancer cells themselves thus degenerate. In this connection it should be borne in mind that a layer of mucoid connective tissue is normally present immediately around the ducts and acini. Eve<sup>17</sup> has recorded the two following typical examples:—

(a) A lady, aged about 80, with a rather soft, bossy, circumscribed tumour, at the lower part of her breast, of three years' growth. Her general health was unimpaired; and there was no obvious enlargement of the adjacent lymph glands. On examination after removal, a pale, soft growth was revealed, which contained much thick gelatinous material. Histologically it was composed of narrow columns of spheroidal epithelial cells, supported by myxomatous connective tissue. The latter contained numerous nucleated round and spindle cells, as well as some curious yellow, botryoidal masses—so-called colloid bodies—which appeared to have originated from mucoid degeneration of small groups of connective tissue cells. The cancer cells themselves were exceedingly well preserved, and appeared to be unaffected by these degenerative changes.

(b) In this case the breast was removed from a woman, aged 35, for a so-called colloid cancer of four years' growth. Its section showed mucoid material embedded in a wide meshed connective tissue reticulum. Microscopical examination revealed a granular mucoid stroma, enclosing rounded columns of closely packed, but ill-defined epithelial cells.

A subvariety of this form arises—to which the term *cylindroma* has been applied—when the mucoid stroma grows into the epithelial masses, and becomes more or less enclosed in them, of which a few instances have been recorded.

### § III.—The Melanotic Type.

Any form of melanotic neoplasia of the breast is of extreme rarity. My table of 2,397 consecutive primary neoplasms of the female breast does not contain a single instance. It appears, however, to be rather less exceptional in the male

<sup>17</sup> *Trans. Path. Soc. Lond.*, vol. xxxvii., 1886, p. 493.



breast, for of 100 primary cancers of this part collected by me,<sup>18</sup> three were of the melanotic variety. The greatest diversity of opinion exists among pathologists, as to the classification of melanotic neoplasms. Billroth and others maintain that they are always sarcomatous; but this exclusive view as to their origin cannot be any longer maintained, for many well-authenticated cases of pigmented epithelial cancer have lately been recorded. Unna<sup>19</sup> now holds that melanomata are invariably carcinomatous. Under these circumstances it seems desirable to bring together in this section the chief cases of mammary melanoma, hitherto recorded, whether of sarcomatous or carcinomatous nature.

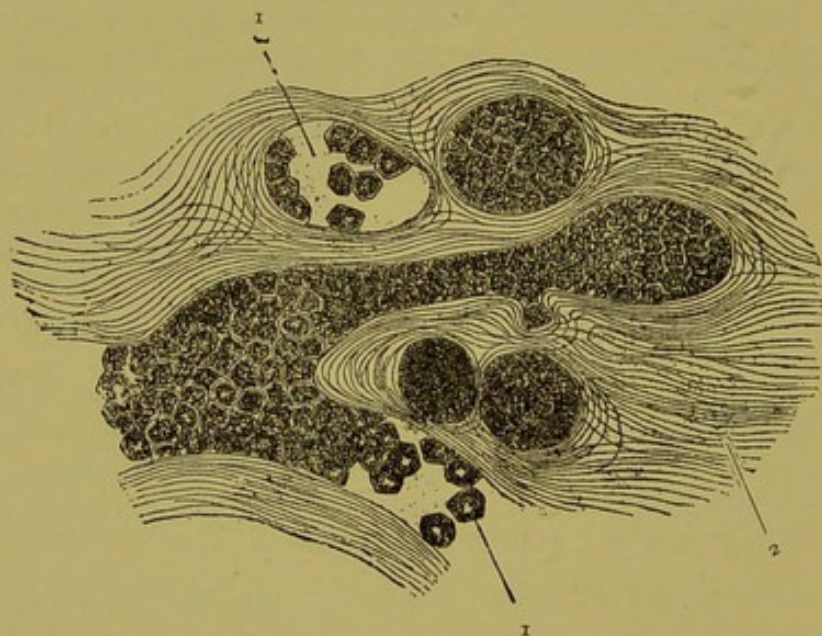


FIG. 45.—HISTOLOGICAL SECTION OF MELANOTIC CANCER OF THE BREAST.  
(Cornil and Ranvier.)

(1) Glandular cells infiltrated with Pigment. (2) Stroma.

The two subjoined examples of melanoma of the *female mammary gland* itself, are the only cases of the kind known to me.

(1)<sup>20</sup> A thin, pale woman, aged 68, the mother of ten children, first noticed a lump in the outer and lower part of her right breast three years

<sup>18</sup> Ch. xvi.

<sup>19</sup> *Berlin klin. Woch.*, No. 1, 1894.

<sup>20</sup> Billroth, Th., *Deutsche Chir.*, Lief. xli., S. 56.



ago. When she came under treatment the breast was larger than a child's head, owing to the presence of a hard, nodular tumour, to which the overlying skin was adherent. The whole mass was movable on the chest wall; and the axillary glands were enlarged. The patient also presented two small congenital cutaneous moles; one beneath the right eye, and the other in the region of the supra-spinous fossa. The diseased part was freely amputated and the axilla cleared. On examination after removal, it proved to be a circumscribed melanotic growth. Its histological diagnosis appears to have much exercised Billroth; for while in his "Clinical Surgery" he describes it as on the whole of carcinomatous nature, in his essay in the *Deutsche Chirurgie*, he classes it as an alveolar sarcoma, and then speaks of it as a "combination of sarcoma with carcinoma." It will suffice for us to know that a well marked fibrous alveolar stroma was present, the meshes of which were filled with dense masses of large, ovoid, nucleated quasi-epithelial cells, and the pigment was mostly in the stroma. Before the wound had healed, a fresh melanotic growth formed in the skin of the back; and she died about a year later of marasmus, but without recurrence in the chest or axilla. I must refer those who desire further details of this interesting case, to the original article in the *Deutsche Chirurgie*, where its microscopical and macroscopical features are fully detailed and figured.

(2) In an instance mentioned by Cornil and Ranvier<sup>21</sup> the gland presented black spots, visible to the naked eye, and the melanotic substance was contained, not in the connective tissue, but in the epithelial cells of the glandular acini (fig. 45). Here the pigment had evidently been secreted by the cells themselves. Such cases soon disseminate widely and cause death. This being so, I cannot agree with Cornil and Ranvier that there is no real neoplastic action. It seems to me that it would be just as unreasonable to deny the existence of neoplasia in atrophic and colloid cancers, as in these melanotic ones.

The three following instances of similar disease in the *male* breast have also been recorded:—

(1) An Italian, aged 53, seen by Lawrence,<sup>22</sup> with a large, hard, fungating tumour of the right breast of one year's duration. The skin and other adjacent soft parts extensively invaded by hard cancerous nodules. The right clavicular, and the axillary glands of both sides, also infiltrated. Œdema of the right upper limb, and great dyspnoea. Palliative treatment; followed by death from asthenia three months later. At the *necropsy* the whole of the soft parts of the front of the right side of the chest infiltrated by very hard quasi-fibrous growth of bright yellowish green colour. The thoracic muscles, anterior mediastinal glands, right pleura and diaphragm were invaded by growths of similar nature, evidently by direct extension. There was right hydrothorax, with collapse of the lung. There were metas-

<sup>21</sup> *Manual d'Hist. Path.*, t. i., 331.

<sup>22</sup> *Med. Chir. Trans.*, vol. iii., p. 72.



tatic nodules of bright coloured, hard growth, like the primary disease, in the pancreas, both kidneys and the base of the bladder. This is evidently a case of *chloroma*.<sup>23</sup>

(2) Langenbeck<sup>24</sup> mentions having met with an instance of recurrent melanotic alveolar cancer of the male mamma.

(3)<sup>25</sup> The only details I have been able to obtain of this case are as follows:—The patient had ulcerated scirrhus cancer of the breast of two years' duration. The disease followed a blow. The axillary glands were infiltrated. On histological examination of the growth after removal, it proved to be fibrous alveolar cancer, both the cells and stroma being pigmented.

The *Hunterian Museum* contains a specimen of melanoma of the cow's udder (No. 469 of the Pathological Series). It is thus described in the catalogue: "A portion of the udder of an almost white cow. It contains a tumour three inches long and uniformly black. The skin of the udder is marbled by numerous pigmented blotches."

As examples of melanoma of the mammary integument I can cite the following cases:—

(1) Nunn<sup>26</sup> mentions, without giving histological details, the case of a woman, aged 73, with a group of melanotic warts of the skin of her right breast towards its lower border. The axillary glands were enlarged from malignant infiltration, and the upper limb was œdematous. She had also some hard, rounded warts on either side of her forehead. About five months later she died of hemiplegia.

(2) Wacker<sup>27</sup> has reported an example of multiple melanotic neoplasms of both breasts, with dissemination in the left axillary glands, spleen, brain and mesenteric glands. He thought the disease originated in the mammary integument. It is described as "alveolar sarcoma."

(3) Velpeau<sup>28</sup> has seen two instances of melanoma of the mammary integument, one of the areola, the other of the breast. In both of these cases there were numerous melanotic growths elsewhere, and it is doubtful whether in either of them the disease originated in the mamma.

<sup>23</sup> For an account of this rare disease the reader is referred to Lang's "Monographie du Chloroma," *Arch. Gén. de Méd.*, dec., 1893; also jan., fév. and mars, 1894. Among the instances there cited the above case is not included; nor is any example given of this disease in the breast.

<sup>24</sup> *Med. Centralzeitung*, Bd. xviii., 3, cited by Schuchardt.

<sup>25</sup> Marciano's case, cited in Poirier's "Tumeurs du Sein chez l'Homme," Paris, 1883, p. 51.

<sup>26</sup> "Cancer of the Breast," 1882, p. 105, No. 48.

<sup>27</sup> *Inaug. Dissert.*, Rostock, 1884.

<sup>28</sup> "Traité des Maladies du Sein," p. 456.



(4) In the museums of Guy's and St. Bartholomew's hospitals<sup>29</sup> are specimens showing similar secondary melanotic growths in the breasts.

(5) I have seen a reference to a case of primary melanotic sarcoma in the breast of an infant, by Vieregge,<sup>30</sup> but, as I have been unable to consult the original report, I cannot give details.

Bryant<sup>31</sup> reports the two following instances of secondary melanotic sarcoma of the breast :—

(1) A married woman, the mother of one child, came under observation with her right breast covered and filled with melanotic lumps the size of nuts. There were also similar growths on the skin over the sternum, abdomen and back. The axillary glands were much enlarged. Ten months previously a black tumour, the size of a walnut, of a year's duration, had been removed from her left forearm, where it originated from a mole.

(2) A sterile married woman, aged 55, four months before she came under treatment, had a melanotic tumour—the size of a duck's egg—removed from the skin over the sternum, where it had originated from a mole. On examination many melanotic growths were found disseminated over the sternum, both breasts and the abdomen. The glands in both axillæ were enlarged.

---

<sup>29</sup> *Vide* the respective Pathological Catalogues.

<sup>30</sup> *North Western Lancet*, St. Paul, U.S.A., 1891, xi., p. 28.

<sup>31</sup> "Diseases of the Breast," p. 231.



## CHAPTER XII.

## THE CLINICAL FEATURES OF MAMMARY CANCER.

## § I.—Symptomatology.

IN the three preceding chapters several of the clinical features of breast cancer have been described ; but besides these there are some others that must now be briefly noticed.

*Pain.*—It is a popular belief, in which many practitioners share, that pain is one of the cardinal symptoms of mammary cancer. To hear some people talk, one would think that the absence of pain precludes the possibility of cancer. Such ideas are most erroneous. There is, as a rule, no pain in the early stages of cancer of the breast. It is not until the disease has existed for a considerable time that pain supervenes, and many cases run their entire course without causing much suffering. Hence cancerous growths in the breast generally escape notice until they have attained a certain size ; and it is often only by some trivial accidental occurrence that the patient's attention is first directed to the disease.

On the other hand, benign tumours, and especially chronic inflammatory swellings, are often attended with a considerable amount of variable pain and tenderness ; and in the absence of any appreciable lesion whatever, pain may be experienced.

Nothing, therefore, can be more fallacious than to attempt to estimate the gravity of mammary tumours by the amount of pain present.

Generally speaking, cancers do not cause severe pain until



the near approach of ulceration. Then the pain is usually described as of a dull aching, burning, stabbing or lancinating character, and it often manifests intermittent or quasi-neuralgic features.

The formation of secondary growths in the axilla may cause pain, owing to pressure on the nerves. Pain thus induced is generally referred, at first, to the inner side of the arm near the elbow.

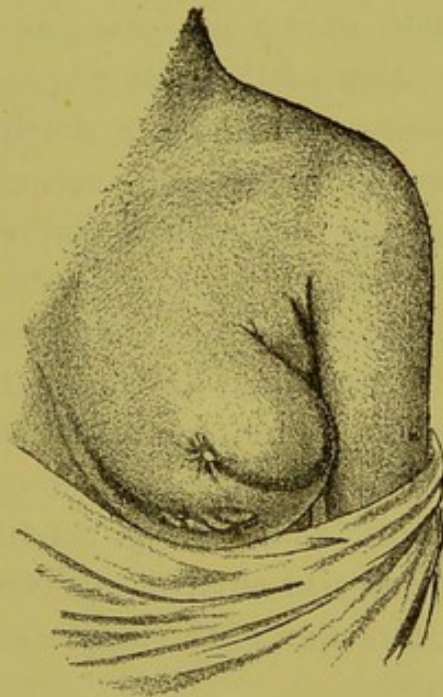


FIG. 46.—Cancer of the Breast, showing Retraction of the Nipple and Puckering of the Skin (*Bryant*).

*Retraction of the Nipple.*—When associated with other signs of cancer, retraction of the nipple is a valuable diagnostic aid, but of itself it has no special significance. There is nothing about it pathognomonic of cancer. Hence care should be taken to avoid jumping at the conclusion, that a neoplasm is necessarily cancerous, because it is associated with a retracted nipple. Of 207 cancer cases, Gross noticed retraction of the nipple in 108, or in 52 per cent. It is more frequently seen in association with central, than with peripheral, neoplasms. Its proximate cause in these cases no doubt is shrinkage of the older parts of



the growth, and consequent pulling on the lacteal ducts. Hence in cancer the nipple is generally not only retracted, but it is also drawn out of its proper position in the direction of the neoplasm. The whole gland is sometimes displaced in this way.

Congenital imperfection of the nipple is often found in association with neoplasms. Of 137 consecutive cases of cancer of the female breast, I found congenital malformation of the nipple in 19, or in 13·8 per cent.; and of 42 cases of fibro-adenoma, there was similar mamillary imperfection in 10, or in 23·8 per cent. Gross' estimate of 5·2 per cent., as the proportion of cases in which retraction of the nipple is associated with non-cancerous neoplasms, appears to me much below the mark. Although these growths seldom *cause* retraction of the nipple, they are not unfrequently found in association with it.

In addition to the foregoing, it must be remembered that retraction of the nipple may also result from injury or disease during infancy or childhood, and during adult life it often supervenes as an acquired condition, in the absence of any tumour, owing to over-action of the longitudinal organic muscle fibres. Finally, certain chronic inflammatory conditions of the breast—that in other respects also often closely simulate cancer—not unfrequently cause retraction of the nipple, *e.g.*, chronic mastitis, tubercle and cold abscess.

*Dimpling of the Skin.*—Dimpling of the skin over cancerous growths is one of the earliest phenomena of cancer; and it is seldom or never wanting at some stage or other. It occurs long before any adhesion has taken place between the skin and the growth. Contraction of the neoplasm, drawing on the surrounding parts, especially—through the *ligamenta suspensoria*—on the corium, is evidently its cause. At first the skin is merely slightly dragged upon, so that dimpling is only appreciable on pinching of a cutaneous fold; subsequently a permanent dimple is produced, and later on puckering. This condition is of much greater diagnostic value than retraction of the nipple; since but few morbid conditions, other than cancer, produce it. Many surgeons regard it as an infallible sign of



cancer. Velpeau especially insists upon this. Herein I am convinced they are mistaken; for I have seen several marked instances of it in association with chronic mastitis; and it has also been noticed in cases of chronic abscess.

*Discharge from the Nipple.*—Discharge from the nipple is met with under a great variety of conditions; but it is not of common occurrence in connection with cancer. Gross estimates that it is present only in about 7 per cent. of all cancer cases. When it does occur, it is often the earliest symptom of the disease, attracting attention even before the cancerous growth itself. Under these circumstances the discharge is never abundant—seldom does it amount to more than a few drops. The fluid may be straw-coloured, sanious or of watery aspect; but occasionally it presents a mucoid or lactescent appearance.

Its formation is due to a kind of pseudo-secretion, associated with hyperplasia of the glandular epithelia, together with the congestion and increased vascularity that always accompany cancer. Discharge from the nipple is also met with in connection with other neoplasms besides cancer; and it not unfrequently occurs in the absence of any mammary neoplasm whatever. With the ordinary solid tumours, such as sarcoma and fibro-adenoma, it occurs about as often as with cancer. No form of mammary disease more frequently induces it than the cystic, and it is especially apt to occur when intra-cystic villous growths are present. Under these circumstances the discharge is usually blood-stained. Colostrum-like fluid is also often discharged from the nipple in connection with unhealthy states of the gland, correlated with disease of the pelvic organs, and sometimes in connection with menstruation. Abnormal stimuli to the gland, especially such as are protracted and of low intensity, are apt to excite secretory activity.

## § II.—Differential Diagnosis.

The differential diagnosis of mammary cancer is one of the most important questions that a surgeon can have to decide; and it is often a question of the greatest difficulty, requiring for



its solution skill and knowledge of the highest order. It must be recollected that nearly all the difficulties to be encountered appertain to the early stages of the disease. No conditions, likely to be confounded with cancer, are more difficult to discriminate from it, than certain chronic inflammatory swellings (the *induratio benigna* of the old surgeons) and cold abscesses. Two sources of error are here possible; either of these affections may be mistaken for cancer, or *vice versâ*. Fortunately such conditions are rather uncommon, although not so rare, that the possibility of their occurrence, in a given case, can ever safely be forgotten; for their clinical features sometimes so closely resemble those of cancer, that the most skilful surgeons have been deceived. In making the differential diagnosis I attach considerable importance to the presence or absence of pain and *tenderness on manipulation*, for cancers at this stage hardly ever cause pain, nor are they tender; whereas both of these symptoms are nearly always associated, in greater or lesser degree, with chronic inflammatory lesions. On the other hand, dimpling of the skin, although it cannot be relied on as an absolute criterion of cancer, is nevertheless much more frequently associated with the latter than with chronic inflammatory conditions. The margins of cancers are generally more nodular, and feel better defined, than those of most inflammatory tumours. The latter seldom attain the extreme hardness of the former. Enlarged veins visible through the overlying integument are suggestive of cancer; but the presence of a similar swelling in the opposite breast is against it. The presence of slight œdematous swelling of the skin over the tumour points strongly to inflammation. Another fact of great importance to remember in making the differential diagnosis is, that neoplasms very rarely take origin in connection with lactation, whereas most inflammatory tumours do. In doubtful cases an exploratory incision into the tumour may be made; but even then the naked eye appearances sometimes mislead, so that when necessary the microscope must also be invoked.

The conditions I have seen most frequently mistaken for



cancer are *chronic mastitis*, *chronic tubercular mastitis* and *cold abscess*. Of each of these I will give a typical instance.

(1) A large, obese, healthy looking woman, aged 57, the mother of two children, with a lump in her left breast of seven years' duration. There was no history of any previous injury or disease of the part. Her previous health had been very good; there was no family history of cancer or tubercle. On examination I found, near the periphery of the axillary segment of her left breast, a very hard nodulated mass, the size of a tangerine orange. The breasts were voluminous, and the tumour was covered by a thick layer of fat. The overlying skin was adherent and dimpled, but the tumour was movable on the subjacent parts, and the nipple was normal. There was no pain or tenderness. Several of the axillary glands were enlarged. In this case all the indications of mammary cancer were present, with the exception of retraction of the nipple, which was hardly to be expected, considering the peripheral situation of the neoplasm. Before proceeding to amputation and clearance of the axilla, I made an exploratory incision into the tumour, which presented a dense, whitish, fibroid aspect, just like that of ordinary scirrhus. On examination after removal, the diseased area looked very like cancer; but on section it seemed rather less hard and crisp than scirrhus usually is; moreover, it did not cup, and it was juiceless. The enlarged axillary glands presented no signs of cancer. These indications induced me to submit the tumour to careful microscopical examination, the result of which was, that it was seen to be composed mainly of dense, white fibrous tissue, containing numerous nuclei, in which a few acinous and tubular gland structures were here and there embedded. When last seen, about three years after the operation, the patient was in excellent health, and free from any return of the disease. It was a clear case of simple chronic mastitis. Here the unusual absence of pain and tenderness, together with the presence of dimpling of the skin, and all the usual symptoms of cancer, prevented the recognition of the real nature of the disease.

(2) I was requested by a medical friend to see an unmarried lady, aged 40, with a swelling in her breast of some months' duration, which she attributed to an accidental blow from a child's elbow. On examination I found, near the periphery of the axillary part of her left breast, a nodular lump, the size of a marble, surrounded by irregular, ill-defined thickening and induration. Although the lump was hard, yet the degree of induration seemed to me to fall short of that usually associated with scirrhus cancer. The tumour was painful, and on manipulation decidedly tender. The nipple was stunted and transversely grooved, but both were alike in these respects, and neither was retracted. The skin over the tumour was decidedly drawn upon, so that when a cutaneous fold was pinched up it dimpled; but the tumour was movable on the subjacent parts. The adjacent axillary glands were enlarged. I also detected slight lobular thickening in the opposite breast. The patient had chronic cough, with a small amount of muco-purulent expectoration, and moist *râles* could be heard over the upper lobe of her left lung. In early adult life she had hæmoptysis, and subsequently for many years active phthisical disease. Some years ago, however, the disease became quiescent,



and her general health subsequently greatly improved. Three of her sisters had died of phthisis. Under these circumstances—relying mainly on the pain and tenderness of the swelling, the comparative rapidity of its formation, its ill-defined margins and moderate hardness, as well as the slight lesions in the opposite breast—I was able to assure the patient that the tumour was almost certainly not cancerous. Moreover, relying on the presence of tubercular disease in the lungs, and the history of it in her family, I expressed the opinion that in all probability it was also of tubercular origin, and recommended local and general anti-tubercular treatment. I was then for the first time informed that the lady had previously consulted a medical man elsewhere, who had pronounced her disease to be cancerous, and had made every arrangement for amputating the breast the following week. I consequently sent this gentleman a polite note, stating the circumstances, and what I had recommended. He wrote a huffy letter to the patient's friends, making light of my diagnosis and suggestions for treatment; recommending that the operation should nevertheless be proceeded with as arranged, and deprecating the painful predicament in which they were placed. Fortunately this advice was *not* followed, and after a few months' treatment the disease entirely disappeared.

(3) I witnessed the following instructive case at the Pitié Hospital in Paris in 1879.

A healthy-looking multipara, aged 30, applied to Verneuil on account of a mammary tumour of six months' duration, which she first noticed about a month after her last confinement. There was no history of cancer in her family. On examination there was found, deeply seated in her left breast, an exceedingly hard, irregularly shaped mass, about the size of an orange. At one spot the tumour was softer than elsewhere, and gave indications of indistinct fluctuation. The adjacent axillary glands were enlarged. The nipple was not retracted, nor was the overlying skin dimpled; and there was only slight pain and tenderness. Basing his remarks on this case, the learned professor gave to the large assembled class an eloquent address on the differential diagnosis of mammary cancer, with special reference to its discrimination from cold abscess. He concluded from the extreme hardness of the tumour and the enlargement of the axillary glands, that the case before them was an undoubted example of scirrhus, although several of the usual clinical features were wanting. In accordance with this view, he proceeded, before the whole class, to amputate the breast with the thermo-cautery knife. In the middle of the operation a large abscess cavity was opened, out of which quite a considerable quantity of thick yellow pus gushed out. The professor looked grave and puzzled. He proceeded with his operation, however, including removal of the axillary glands. The patient made a complete and rapid recovery. Microscopical examination of the indurated cyst wall revealed only signs of inflammation—viz., abundant fibrous tissue densely infiltrated with small round cells, &c.

It would be easy to multiply cases like the foregoing; and illustrative specimens may be found in most pathological



museums. They show that, under certain circumstances, even the most experienced may sometimes be mistaken.

Indurations of the breast, resembling cancer, due to interstitial mastitis, are sometimes caused by syphilis; these disappear under appropriate treatment.

Certain cysts, especially when tense, deeply seated and unilocular, occasionally acquire stony hardness, and may otherwise simulate cancer; some other forms of cystic disease may also now and then be met with that much resemble cancer. It is hardly possible for anyone who has made himself familiar with the cardinal features of sarcoma, fibro-adenoma, tubular cancer, villous papilloma, lobular hypertrophy and the ordinary forms of cystic disease, to mistake these conditions for scirrhus; at any rate, nothing special need here be said as to the differential diagnosis in such cases.



## CHAPTER XIII.

## THE TREATMENT OF ACINOUS CANCER.

## § I.—Operative.

PATHOLOGICAL doctrine points so emphatically to the possibility of cancer being curable by sufficiently thorough operations, that no one, now-a-days, doubts the propriety of such proceedings. Instead of discussing this question, modern surgeons have concentrated their attention almost exclusively upon devising better methods for completely eradicating the disease. Earlier and more thorough operations than have hitherto been customary are now the order of the day.

In the operative treatment of mammary cancer from this standpoint, I think it must be admitted that British surgery has not taken the leading position to which it was entitled. This is the more to be regretted, because the modern thorough operation is unquestionably of English origin. All its fundamental essentials were clearly set forth, with illustrative cases, in a paper—remarkable for its keen insight and sound judgment—communicated to the London Medico-Chirurgical Society by Charles Moore in 1867.<sup>1</sup> Strange to relate, notwithstanding its completeness, the influence of this remarkable communication on contemporary surgical practice was almost *nil*—so difficult is it, in the hurly-burly of intellectual strife, to discrimi-

<sup>1</sup> "On the Influence of Inadequate Operations on the Theory of Cancer," *Med. Chir. Trans.*, vol. i., p. 245.



nate real merit. In spite of it, British surgeons continued, as heretofore, to be satisfied with partial operations, in which the axillary glands were seldom removed. Fortunately the seed that failed here, germinated elsewhere. The excellent results obtained in Germany by Moore's method, at length compelled reconsideration of the subject. Its reintroduction into this country dates from the publication of Banks' experience in 1882;<sup>2</sup> while in the United States the practice of Gross has tended to the same end.<sup>3</sup>

(a) *Anatomico-Pathological Memorabilia.*

The requisites of a satisfactory thorough operation for mammary cancer comprise complete removal of the local disease, and of the entire breast, as well as of the axillary glands.

At first sight complete extirpation seems to be a very simple affair; yet, nothing is more certain, than that in the great majority of such operations, even as done by experienced surgeons, this result is not obtained—fragments of the disease and of the breast are almost invariably left behind. Of course, operations, thus conducted, can never be really curative. Hence the supreme importance of paying attention to certain anatomico-pathological facts—now generally neglected—without knowledge of which it is impossible to perform the operation effectually. The enumeration of these will necessitate some repetitions, for which, on account of the importance of the subject, I beg to be excused. They are briefly as follows:—

(1) In operating for cancer the cardinal consideration to be borne in mind is, that the *whole disease* must be removed, since the smallest fragment left behind will suffice to originate a new growth. To do this effectually, accurate knowledge of the disposition of the local disease is essential. On careful exami-

<sup>2</sup> "Some Results of the Operative Treatment of Cancer of the Breast," Edin., 1882.

<sup>3</sup> *International Journal of Medical Sciences*, April, 1888.



nation of the periphery of the primary neoplasm it will be found, that the passage from the diseased to the healthy tissues is by no means sharply defined; the irregularly growing edge of the cancer is, so to speak, dovetailed into the surrounding pre-existing structures. On this subject Astley Cooper remarks: "I would observe that the scirrhus tumour is not all of the disease; there are roots which extend to a considerable distance, and those who gave this disease the name of cancer probably knew more of its nature than we are disposed to give them credit for. It is supposed by some that this name was given on account of the appearance of the surrounding veins. I should say that it was from the appearances on dissection rather than from anything without. When you dissect a scirrhus tumour, you see a number of roots proceeding to a considerable distance; and if you remove the tumour only, and not the roots, there will be little advantage from the operation." This admirable *résumé* of the subject is entirely in accord with the results of modern research. If we examine the growing edge of a mammary cancer we shall find that one way in which the disease progresses is by the continuous centrifugal extension of epithelial ingrowing processes. These spread most rapidly in the directions of least resistance, which are usually along the adjacent lymphatics and perivascular sheaths. These Köster has found distended with cancer cells. Fine, elongated, cord-like processes of cancerous growth thus arise, which often extend from the tumour far into the surrounding tissues. In connection with these, nodular growths often develop, which to the naked eye may appear to have no connection with the primary tumour. In addition, there are frequently found in the vicinity of the latter, really discontinuous nodules, which are the first signs of regional dissemination. These arise from cellular elements detached from the primary tumour, and conveyed thence by the lymphatics or veins, or by their own spontaneous movements. Such is the great abundance of the mammary lymphatics, and the freedom of their anastomoses; that from a single primary focus the disease soon spreads.



Hence the paramammary adipose tissue, the skin overlying the vicinity of the tumour, and the sheath of the pectoral muscle are quickly invaded, and must in every case be carefully extirpated. With regard to the paramammary fibro-fatty tissue, it should be noted that it forms a thick layer anteriorly, while posteriorly it is generally defective. The channels along which the disease most readily spreads into the anterior paramammary fat and thence to the skin, are the lymphatics accompanying the peripheral processes of the gland; these, with their accompanying lymphatics, ultimately come into close relationship with the skin, through the *ligamenta suspensoria* of Cooper, *within* which they are contained. Hence the attempt to save the integument overlying cancerous tumours is a pernicious error; in every case it should be freely excised. Posteriorly, all that intervenes between the concave base of the gland and the subjacent pectoral fascia, is some loose areolar tissue. In this peripheral processes of the gland, with their accompanying lymphatics, &c., are always to be found; which not only adhere to the subjacent muscular fascia, but often penetrate it, and even become embedded in the muscle itself. In cases of mammary cancer these structures are nearly always diseased; and at ordinary operations they are almost invariably left behind. Hence recurrences soon follow. To obviate this Heidenhain recommends that the fascia over the pectoral muscle, together with a layer of the subjacent muscular substance, should be excised in every case; and his recommendation certainly ought to be regarded as an essential feature of the operation. When the muscle itself is obviously diseased, Heidenhain recommends that the *whole* of it should be extirpated. This I think is unnecessary. It is nearly always the sternal part alone that is invaded; and it is then sufficient to excise this, without interfering with the clavicular part. This is justified on anatomical grounds; because, as I have repeatedly convinced myself by dissection, these two parts of the muscle are usually quite separate, except at their insertion into the humerus. Excision of the sternal part of the muscle causes very little deformity, and no appreciable loss of power.



(2) In cases of mammary cancer the *whole gland* is diseased, and must therefore be removed. Its secretory cells are unduly numerous, and they everywhere show signs of excessive proliferative activity; while the peri-acinous connective tissue is much increased and infiltrated with small round cells. This clearly implies that the abnormal cellular activity, which at a given spot culminates in cancer, affects in a less degree the adjacent epithelia of the part for a considerable extent. It is impossible to doubt that parts in such a condition are more prone to originate cancers, than perfectly normal structures. Heidenhain is, I believe, right in maintaining that proliferating acini of this kind, left behind at the primary operation, are the germs whence most *late* recurrences arise. In order to effect the removal of the entire gland, certain facts, that I will now proceed to mention, must be kept steadily in view. The female breast is normally a very imperfectly integrated organ; like the lachrymal and salivary glands, its constituent lobules, instead of being compacted together in a small space, are generally widely diffused; and often some of them are completely sequestered. On this subject Astley Cooper remarks: "The margins of the breast do not form a regular disc, but the secreting structure often projects into the surrounding fibrous and adipose tissue, so as to produce radii from the nipple of very unequal lengths; hence a circular sweep of the knife cuts off many of its projections, spoils the breast for dissection, and, in surgical operations, leaves much of the disease unremoved."

The ordinary anatomical description of the breast, as a flattened circular mass, is certainly very misleading. The truth is, as Hennig has so well shown, the fully developed female mamma has normally a tricuspid form; two of the cusps project toward the axilla—an upper and a lower one—and the other towards the sternum. The upper of these two axillary mammary extensions is usually prolonged round the border of the *pectoralis major* muscle, right into the axilla; and the same occasionally happens with the lower one. The sternal prolongation reaches nearly as far as the edge of the



sternum—at the level of the fourth cartilage—and even occasionally overlaps it. In the ordinary operation of amputation of the breast, these processes are almost invariably cut off and left behind. Though commonest in the axillary and sternal regions, similar smaller peripheral processes spring from other parts of the surface of the gland, and radiate in the paramammary tissues. It has been previously mentioned that those arising from the anterior surface of the gland come into close relationship with the skin; while those that originate from its posterior surface come into contact with the pectoral muscle and its fascia. Their precise limits are ill defined and vary in different individuals; as a rule, however, they do not extend higher up than the second, nor lower down than the sixth interspace.

(3) In the mammary region completely isolated supernumerary mammary structures are of frequent occurrence. I have elsewhere shown that these redundant structures are very prone to originate neoplasms—14 per cent. of all so-called adenomas of the breast, and 9·8 per cent. of all its cancers, arise in this way. Two varieties of the condition may be recognised—a commoner one, which is simply the result of sequestration; and a rarer one of atavistic origin—true polymastia. Structures of this kind, left behind after operation, sometimes originate recurrences. In order to be able to remove them effectually, their distribution must be studied. This is best done by noting the positions of the neoplasms that have sprung from them. Of 29 such cases, in 15 the tumours were *axillary*, in 8 they were *sternal*, and in 6 they were situated *above* the breast.

In this connection it may be mentioned that cancerous tumours are more prone to develop in some parts of the gland than in others. The periphery, for instance, is a much commoner seat of the disease than its central part. Of 132 cases under my observation, in 90 (68 per cent.) the tumour was peripheral, and in 42 (32 per cent.) central. Most of the peripheral tumours are met with at this *upper* and *axillary* parts of the gland.

(4) Such is the great tenacity of life, and the wonderful pro-



liferative power, of even the most diminutive fragments of cancer, that care should be taken to avoid the dissemination of such elements in the wound during the operation, lest they constitute fresh centres of disease. Hence, in doing the operation, no actually morbid texture should be exposed; and it is desirable not only to avoid any incision into the tumour, but even the very sight of it. Where these precautions are, unfortunately, of no avail, the wound must be well washed out with a strong solution of chloride of zinc (40 gr. to 1 oz.), so that any fragments of the disease, disseminated there, may be destroyed.<sup>4</sup>

(5) In extirpating mammary cancer, it was formerly customary for surgeons to open and clear out the axilla only when its glands were obviously diseased. The result of this practice was, that in many cases the disease reappeared after operation in the axilla alone, while the mammary region remained free. As previously mentioned, it happened thus in 17 per cent. of the cases under my observation. Moreover, Gross<sup>5</sup> has shown that glandular recurrences are more frequent, by 27 per cent., when the breast alone is removed, than when it is extirpated together with the axillary contents. To obviate this, the practice of clearing out the axilla in every case destined for operation—whether the glands were obviously affected or not—was inaugurated. Gussenbauer and Küster on the Continent (1881), and Banks in this country (1882), were the pioneers of this improvement, which now constitutes an essential part of every thorough operation. The necessity of clearing the axilla is further shown by the fact, that in the immense majority of cases in which the axillary glands have been histologically examined after removal, they have been found to be invaded by the disease, and this, although in many cases careful clinical examination, before operation, had failed to detect their morbid condition.

---

<sup>4</sup> A further reason for these precautions has been furnished by Verneuil (*Rév. de Chir.*, t. ix., Oct. 10, 1889), who has shown that the wounds resulting from the removal of malignant tumours are frequently infected by pathogenic microbes derived from these tumours.

<sup>5</sup> *Internat. Jour. Med. Sci.*, April, 1888, p. 347.



In clearing the axilla, the glands should be removed as far as possible *en masse*, together with the fatty tissue, &c., in which they are embedded, and it is important *not* to sever the bridge of tissue intervening between this part and the breast, as it contains the axillary process of the mamma, together with the chief mammary lymphatics and some blood-vessels, all of which it is desirable to remove *en masse* with the rest of the implicated mammary structures.

It is in the vicinity of the inner axillary wall that the fewest obstacles to surgical proceedings are encountered. Here the only important structure likely to be injured, is the long thoracic nerve, which courses nearly vertically downwards, on the serratus magnus muscle, which it supplies. Fortunately it is in this region that the glands first affected in mammary cancer are usually to be found; they lie on the chest wall, at the lower part of the inner axillary boundary. The axillary tail of the mamma is close by, and may be mistaken for them. The thickened cord that can sometimes be felt passing from this part of the axilla to the breast is hardly ever due to cancerous lymphatics, but to the pedicle of the axillary mammary process.

In the neighbourhood of the outer axillary wall are the axillary blood-vessels and nerves—the artery between the nerve cords, with the vein on its inner side, where it is joined by several large branches. These are often severed when removing the glands, and unless care is taken they may be cut so short as to render the application of ligatures impossible. In such an event the axillary vein must be ligatured above and below the point at which the severed branch joins it, and divided between the ligatures, just as if the vein itself had been wounded. I have seen this done several times, without any other ill result than slight transient œdema of the hand. In close relationship with the inner side of the axillary vein is a group of glands, which are usually affected soon after the above-mentioned group with which they freely communicate. They may extend as high up as the clavicle, or even higher. In this connection it should



be remembered, that when the upper limb is raised from the side, as usually happens in the course of this operation, the head of the humerus is apt to project and displace the large vessels downwards towards the chest wall.

At the extreme summit of the axilla—in the space identified in Germany with the name of Mohrenheim—between the clavicle and the upper border of the *pectoralis minor* muscle, a few lymphatic glands are placed, which receive branches directly from the breast. These sometimes require extirpation, which can best be done after removal of the sternal part of the *pectoralis major* muscle. In the interval between the *pectoralis major* and deltoid muscles, just below the clavicle, a few diseased glands may also be met with. These regions should always be explored.

In clearing out the axilla it is desirable to avoid trenching on the posterior wall as much as possible, especially at its lower and outer parts, as here the large subscapular blood vessels and nerves (to the *teres major* and *latissimus dorsi*) lie.

#### (b) *The Operation.*

The following *operation* is designed to fulfil the above indications. So far as I know, it is not exactly like any other; but most modern thorough operations have much in common. Supposing the breast to be of medium size, the tumour compact and central, the incision is commenced in the median line over the sternum, at the level of the fourth costal cartilage, along which it passes outwards to the nearest part of the periphery of the cutaneous area, overlying the disease, which it is desired to remove. This is generally a circular area, several inches in diameter, which includes the nipple and areola. Thence the incision is continued along the lower half of the periphery of this area to its axillary side, whence it passes over the anterior axillary border to the top of the axilla. The next step is to separate the skin from the subjacent fatty tissue, by careful dissection, throughout the whole length of the thoracic part of



the lower lip of this incision—to the extent of an inch or more. The more thoroughly this is done the better, short of impairing the vitality of the skin. The cutaneous area to be removed with the diseased breast should now be completely separated from the adjacent integument, by carrying the knife round its unsevered upper periphery. The upper lip of the thoracic part of the incision must next be separated from the subcutaneous fatty tissue to near the axilla, just as was done with the lower lip.

The periphery of the part to be removed being thus defined, its separation may be commenced by raising its upper and inner margins. The knife should then be sunk slightly into the subjacent pectoral muscle, and by dissection the whole mass must be turned outwards towards the axilla, until it remains united with the latter only by an intervening bridge of tissues, which should on no account be severed.

Thus the whole diseased breast—embedded in its fatty capsule, together with the overlying skin and underlying pectoral fascia—is detached from its bed. This concludes the first stage of the operation.

The second stage comprises the removal *en masse* of the axillary glands, lymphatics, &c., together with the fatty tissue in which these are embedded. On no account should these structures be torn away piecemeal. To effect this, the *fascia lata* having been divided, the upper flap should be raised and freely separated from the subjacent structures; but there is seldom occasion for any such free separation of the lower flap in this situation. However, should this be requisite, a counter opening must be made for drainage. It is well to commence the detachment below, and to work upwards along the chest wall to the apex of the axilla; then detach from the great vessels, and finally from the posterior axillary wall. In doing this any blood-vessels requiring division should be included between two ligatures, and cut through between them. If absolutely necessary, even the axillary vein and artery may be treated



in this way, often without ill effect, provided that the occlusion is below the level of the circumflex and subscapular branches.<sup>6</sup>

Much more extensive operations than the foregoing have been undertaken by German surgeons, who have not hesitated to extirpate, in addition, one or both pectoral muscles, the outer part of the clavicle, and even in certain cases, they have removed as well the entire upper limb, together with the scapula. When the large nerve cords are involved, as well as the blood vessels, amputation is the only resort.

The only *contra-indications to operation* are such wide-spread local or lymph gland dissemination as would render impossible the removal of the entire disease, as in cases of cancer *en cuirasse* and some other forms of diffuse cancer ; and of course operation is contra-indicated when there is reason to suspect dissemination of the disease in internal organs.

The treatment of *recurrent cancer* should be conducted in accordance with the same principles as for the primary disease.

With regard to the *technique* of the operation the following are the chief points:—The axilla having been shaved, the patient is placed on her back, and the shoulders are well raised. The surgeon stands on the same side as the breast to be removed. Opposite to him is his first assistant. His second assistant stands at the patient's shoulder on the same side as the disease ; he has charge of the patient's upper limb, and during the operation he must keep it raised and manipulate it as required. For the pectoral part of the operation a large stout scalpel should be employed ; but for the axillary part blunt-pointed scissors and the fingers usually suffice. Bleeding vessels should be seized with torsi-pressure forceps as they present, and subsequently ligatured if necessary. On approximation of the flaps, after removal of the diseased mass, it will

---

<sup>6</sup> For cases in which both the axillary artery and vein were divided, without any subsequent ill effects, during the removal of axillary tumours, *vide* McLeod's "Operative Surgery in Calcutta," 1885, p. 152. Also Holmes' "Syst. Surgery," vol. iii., 1883, article "Axilla," p. 887.



generally be found that they come well together, notwithstanding the free removal of skin. In certain cases, where the flaps are large and bulky and tend to fall apart, tension may be relieved by the use of *button sutures*. The most convenient of these are thin leaden discs having a central perforation, and two small wings laterally. The silver wire joining two buttons passes through these central apertures, and by twisting is secured to the wings.

When, owing to the free removal of skin, a large gap remains, after laying down the flaps, this may be repaired by *skin grafting*, after the method of Ollier<sup>7</sup> and Thiersch, either at the time of the operation, or a few weeks afterwards. The surface to be grafted must be quite free from hæmorrhage. Grafts may be furnished by the skin of any part of the body, but they are usually taken from that of the thigh or arm. The integument of the selected locality having been sterilised, is put on the stretch with one hand, while with the other, a broad razor or microscopic-section knife is applied flat-wise, and by a series of to-and-fro movements, long cutaneous strips—about an inch broad, embracing the entire thickness of the epidermis and about half that of the dermis—are excised. The operation is facilitated by keeping the knife flooded with normal salt solution (3 per cent.). By means of this solution, each graft, as soon as cut, is at once floated on to the sterilised wound surface to which it is to be applied. In effecting the transfer, a camel's hair brush and a mounted needle will be found useful. The grafts should lie close together until they completely cover the wound. Finally they are covered by protective, outside which a sterilised dressing, moistened with salt solution, and having waterproof material over it, is lightly bound.

Inasmuch as over 60 per cent. of all deaths after extirpation of the breast for cancer are due to *septic diseases*, it is obviously a matter of vital importance to utilise the best means for counteracting these baneful influences that modern science has revealed. To this end the importance of good hygienic con-

---

<sup>7</sup> "Des Greffes Autoplastiques," Cong. fr. de Chir., *Rev. de Chir.*, 1889, p. 910.



ditions—such as plenty of cubic space, efficient ventilation and drainage, cleanliness, good feeding, the segregation of those with open wounds, and prompt isolation of infective cases—cannot be too strongly insisted upon. But, unfortunately, these powerful adjuncts against the origin and spread of septic diseases—under the actual conditions—of themselves seldom suffice to entirely prevent their outbreak. In the resources of modern *antiseptic surgery*, we have, however, more direct means for combating them.

It has been shown by Lister and others that the septic diseases, which so frequently arise in connection with wounds, are due to infection of the latter by microbes *ab extra*. By means of various agents, capable of destroying such organisms, without acting injuriously upon the tissues, it is claimed that these wound-infection diseases may be entirely prevented. The substances that have hitherto been chiefly employed with this object, are carbolic acid, corrosive sublimate, double cyanide of mercury and zinc, salicylic acid, iodoform, boric acid, &c. Of these, carbolic acid<sup>8</sup> has proved to be the most generally useful and reliable. It is employed as follows:—The cutaneous area of the field of operation—which teems with pathogenic microbes—is first of all thoroughly purified, by sponging it for some minutes with 1 in 20 watery solution of the acid. The instruments to be used during the operation are kept immersed in similar solution. The surgeon and his assistants wash their hands in 1 to 40 solution before commencing the operation, and a special supply of this must be provided for their subsequent use. A towel, wrung out with 1 in 20 solution, and having under it waterproof sheeting, is arranged so as to border the lower part of the field of operation. A basis is thus formed on which instruments, &c., in use during the operation, may be temporarily placed, without fear of con-

---

<sup>8</sup> Only the purest forms should be used, as these are more soluble and less irritating than impure kinds. The absolute phenol, manufactured by Bowdler and Bickerdyke, of Church, near Manchester, is recommended by Lister as one of the best forms for surgical purposes.



tamination. It is well to have handy a large piece of lint, wrung out with 1 in 40 solution, for temporarily covering the thoracic wound while the axilla is being cleared. Sponges used during the operation should have been soaked for twenty-four hours previously in 1 in 20 solution; this renders them aseptic, no matter how dirty they may otherwise be. The difficulty in satisfactorily cleansing sponges after operations, has led some surgeons to abandon their use altogether. Instead, they employ pads of various antiseptic materials, which after use are burnt; but such substitutes are much less efficient than sponges.<sup>9</sup> For ligatures the materials employed are asepticised chromic gut and silk (Chinese twist), the latter being reserved for securing the largest vessels; they should be steeped in 1 in 20 solution before use. Of the various substances available for sutures, horsehair and silkworm gut are the best; they are fit for use after having been immersed for some time in 1 in 20 solution. When horsehair is employed, double threads must be used, as the single threads are not strong enough. The use of the spray is now generally abandoned, consequently before closing the wound, at the conclusion of the operation, it must be washed out with 1 in 40 solution. This, of course, irritates the wound, and causes free discharge. Hence the necessity for drainage. For this purpose red rubber tubes, with fenestræ cut in them, are employed; and to keep them from slipping carbolic silk threads are attached to their external orifices. These are kept ready for use in 1 in 20 solution. The wound having been closed is covered by a piece of protective, that has been dipped in 1 in 40 solution. Outside this several layers of carbolic gauze, wrung out with 1 in 40 solution, are applied, and the various adjacent inequalities, especially about the axilla, are packed with dry gauze. Over all this is placed a large specially prepared carbolic gauze dressing—consisting of eight superim-

---

<sup>9</sup> To get rid of the fibrin, &c., adhering to sponges after operations, Lister macerates them for some days in water. This causes putrefaction of the fibrin, after which they are well washed, and placed in 1 in 20 solution until required for further use. Sponges are spoilt by boiling.



posed layers, with a thin sheet of pink mackintosh cloth interposed under the outermost layer. This must be long enough to reach in front from the opposite nipple across the field of operation to the spine behind, and wide enough to extend from below the elbow to above the top of the shoulder. At the level of the axilla a deep vertical notch is cut in the upper border of the dressing, which is drawn well up between the axilla and the arm, and its anterior and posterior parts are pinned together over the top of the shoulder. The whole dressing is then secured in its place by gauze bandages. The arm is thus left outside the dressing, but some surgeons so arrange the latter that the whole arm is included within it. As this dressing is very apt to slip, especially at its edges, these are secured by applying an elastic bandage around them, and safety pins are freely employed ; but care must be taken that these do not perforate the mackintosh sheeting.

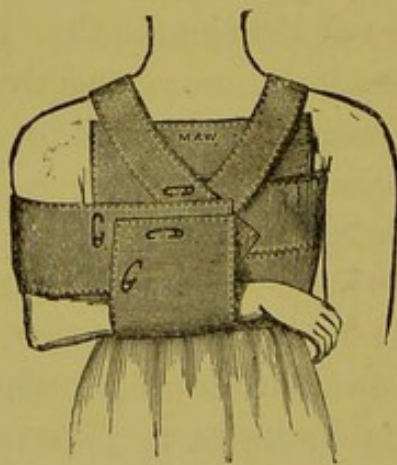


FIG. 47.—Jessel's bandage for use after operations on the breast.

A very efficient substitute for this outside gauze dressing, and one that more readily keeps its place, is a similarly shaped thick layer of alembroth (ammonio-mercuric chloride) wool, which, to distinguish it from ordinary wool, is stained blue.<sup>10</sup> Many surgeons also employ corrosive sublimate solutions (1 in 1,000 to 1 in 2,000), instead of the carbolic acid ones.

<sup>10</sup> These and other antiseptic dressings of a reliable kind are manufactured and supplied by John Milne, of Ladywell, London, S.E.



In order to secure perfect rest, the arm—with the elbow bent at a right angle—is bound gently to the trunk by a broad calico binder, or an ordinary towel. A pillow should be placed under the elbow to support it. Jesset has devised a special form of bandage for use after these operations, which is certainly convenient<sup>11</sup> (fig. 47).

The dressing should be changed for the first time on the day after the operation, for the next few days daily, and subsequently every two or three days. After the first few dressings, provided all is going on well and the drainage tubes have been removed, only the outer dressing need be changed.

When carbolic acid is brought very freely into contact with wounds and maintained there, it is apt to be absorbed and to cause symptoms of carbolic acid poisoning. Hence, subject to attaining the object in view, the acid should be brought as little as possible into contact with the wound itself. On no account should wounds be forcibly injected with carbolic acid solutions; as by thus forcing the acid into the interstices of the tissues, it is sure to be absorbed and to produce injurious results, as in cases I have seen. The symptoms of this accident are loss of appetite, nausea and vomiting, with excessive secretion of frothy saliva. The urine diminishes in quantity and becomes of a dark olive green colour. Finally, in severe cases, stertor with symptoms of collapse may supervene. With ordinary care dangerous symptoms hardly ever occur. The careless use of corrosive sublimate lotions may also sometimes cause symptoms of mercurial poisoning.

With regard to the *choice of an anæsthetic* there is nothing special to be said, except that the safest is the best. The following figures show how it stands in this respect with the agents in ordinary use: <sup>12</sup>—

Ether preceded by gas, 12,941 consecutive administrations with 1 death, or 1 in 12,941.

---

<sup>11</sup> It is supplied by Maw, Son & Thompson.

<sup>12</sup> For details see a paper by the author on "The Relative Safety of Ether and Chloroform," *Med. Chronicle*, December, 1892, p. 150.



Ether alone, 8,391 consecutive administrations with 3 deaths, or 1 in 2,797.

Chloroform alone, 19,526 consecutive administrations with 13 deaths, or 1 in 1,502.

(c) *The Mortality and Causes of Death after Operation.*

Critical inquiry into the comparative results of extirpation of the breast for cancer shows that modern operations—notwithstanding their increased severity—are attended by a smaller mortality than was formerly experienced, when far less extensive operations were done. That this gratifying result is attributable to the improved methods of wound treatment, which have come into use since the introduction of Listerism, the following figures prove:—

Of 167 hospital extirpations done by Velpeau<sup>13</sup> prior to 1854 the mortality was 19 per cent.; of 305 similar operations done by Billroth<sup>14</sup> prior to 1877, the mortality was 15·7 per cent. Thus in these 472 *non-antiseptic* operations the mortality was over 17 per cent.

The results obtained by the earliest antiseptic operations are much more favourable than this.

After 53 mammary extirpations by Lister<sup>15</sup> (1871-80), in the majority of which the axilla was also cleared, 4 patients died, or 7·5 per cent. After 110 similar operations by Volkmann<sup>16</sup> (1874-77), in 75 of which the axilla also was cleared, 6 died, or 5·4 per cent. After 68 antiseptic extirpations by Billroth<sup>17</sup> (1877-79), in many of which the axilla also was cleared, 4 died, or 5·8 per cent. Thus in these 231 strictly *antiseptic* breast extirpations the mortality was only 6 per cent.

The *causes of death* in the 14 fatal cases were as follows:

<sup>13</sup> "Traité des Maladies du Sein," p. 151, Paris, 1854.

<sup>14</sup> *Deutsche Chirurgie*, Lief xli., S. 155.

<sup>15</sup> W. Cheyne, "Antiseptic Surgery," 1882, pp. 373 and 382.

<sup>16</sup> *Ibid.*, p. 388.

<sup>17</sup> *Op. cit.*, S. 155.



Septicæmiæ in 4; erysipelas, 3; shock, 3; exhaustion, 2; hæmorrhage, 1; and anthrax, 1.

Recent operators have had still better results, for Gross' latest mortality is only 3·7 per cent.; Gussenbauer's 2·8; and Küster's, 2·5. Referring to such progressively favourable results Billroth says: "I should not be surprised if an experienced operator were to succeed in doing 100 consecutive extirpations with but a single death."

The superiority of strict Listerism over other less carefully devised antiseptic methods, is shown by the following data; which I have compiled from the registrar's reports of four large metropolitan hospitals.

At the Middlesex Hospital during the years 1882-89 the breast was extirpated 100 times for primary cancer, with 10 deaths. At St. Bartholomew's Hospital during the years 1886-90, 157 similar extirpations were done, with 15 deaths, or 9·5 per cent. At University College Hospital during the years 1884-89, 94 extirpations were done, with 9 deaths, or 9·5 per cent. At St. Thomas' Hospital during the years 1886-90, 138 operations were done, with 12 deaths, or 8·7 per cent.

Thus at these four hospitals 489 mammary extirpations were performed for cancer, with 46 deaths, being a mortality of 9·4 per cent. In nearly all these cases some form of antiseptic treatment was employed, other than strict Listerism. The figures show the marked superiority of the results thus obtained over those of pre-antiseptic methods; and at the same time they demonstrate the superiority of Listerism over other forms of antiseptic treatment.

Butlin<sup>18</sup> is averse to clearing the axilla in every case of mammary cancer destined for operation because of the greater mortality thus entailed, which, he says, is much more than twice as great as when the axilla is not opened. I think he has over-estimated the danger of this proceeding, for of the

---

<sup>18</sup> "Operative Surgery of Malignant Disease," 1887, p. 371.



above 489 hospital operations, in 332 the axilla was cleared as well, with 36 deaths, being a mortality of 10·8 per cent.; while of the other 157 cases operated upon—in which the diseased breast alone was removed—10 died, or 6·3 per cent.

An analysis of the *causes of death* in the above 46 fatal cases gives the following results: Septicæmia, 14 cases; erysipelas, 9; pyæmia, 6; pleurisy, 2; pneumonia, 2; bronchitis, 2; shock, 2; and 1 each as follows: traumatic delirium, syncope, supuration in the anterior mediastinum, secondary hæmorrhage, acute recurrence, peritonitis (perforation), exhaustion, mania and renal disease. Thus, of these 46 deaths 29, or 63 per cent., were indubitably due to septic disease. In most of the above cases the disease began as erysipelas.

Velpeau<sup>19</sup> relates that after his 235 breast extirpations for cancer 54 patients were subsequently attacked by erysipelas, or 23 per cent.; whereas after 395 of the above hospital operations only 40 were subsequently thus attacked, or 10 per cent. This shows that the liability to septic disease has been much diminished by modern methods. The supervention of erysipelas after mammary extirpation is an exceedingly grave complication, for of 40 cases thus attacked I have found that 20 ended fatally.

It will be gathered from the foregoing that although septic diseases have been abated, they have as yet by no means been abolished.

As might be expected from their comparative triviality, operations for *recurrent cancer* are attended with but a slight mortality. Of 96 such operations under my observation there was only a single death, which was due to erysipelas, followed by septicæmia.

Among the rarer complications that occasionally follow extirpation of the breast for cancer, mention must be made of *tetanus*. The two following cases are typical examples:—

CASE I.—The patient was a lady from whom Butlin<sup>20</sup> had removed the breast and cleared out the axilla. By the third day the temperature had

<sup>19</sup> *Op. cit.*, p. 652.

<sup>20</sup> "The Operative Surgery of Malignant Disease," 1889, p. 370.



fallen to normal. Subsequently all went well for nearly a week. At the end of this time the wound was quite healed, except where a small drainage tube had been inserted into the axilla, whence a few drops of clear fluid still oozed. On the eleventh day after the operation the patient was allowed to get up. Next day she presented slight symptoms of tetanus, which soon became acute, and she died thus four days later.

CASE II.—Pritchard, of Clifton,<sup>21</sup> reports that after amputation of a cancerous breast the wound healed quickly by first intention, and there was promise of speedy convalescence, when one day the patient complained of having taken cold, and of pain in her face. Next day the muscles of the face were stiff and hard, and there was unmistakable "*risus sardonicus*," and pain in the abdominal muscles. These symptoms developed rapidly into tetanus of the most violent kind, with opisthotonos, and death soon followed.

It has occasionally happened after extirpation of the breast for cancer, as after other operations, that insanity has supervened.

(d) *The Question of Cure by Operation.*

Left to itself, mammary cancer inevitably ends in death. Volumes would be necessary merely to mention the remedies that have been tried for its cure; but in spite of all that has been done, no medicine or surgical application has ever yet been discovered capable of arresting the progress of the disease. Hence the question of questions is—Can it be cured by operation?

The views of our predecessors on this important subject may be briefly summarised as follows:—Paget<sup>22</sup> says: "I will not say that such a thing is impossible, but it is so highly improbable that a hope of its occurring in any single case cannot be reasonably entertained." According to De Morgan,<sup>23</sup> "Entire and permanent immunity after operation does occur; but it is undoubtedly rare." Velpeau,<sup>24</sup> whose clinical experience was unrivalled, alone seems to have grasped the truth. He says: "Des observations tirées de ma propre pratique démontrent, sans contestation possible, l'existence de guérisons radicales par

<sup>21</sup> *Bristol Med. Chir. Journal*, Sept., 1888, p. 169.

<sup>22</sup> "Lectures on Surgical Pathology," vol. ii., 1853, p. 351.

<sup>23</sup> "On the Origin of Cancer," 1872.

<sup>24</sup> "Traité des Maladies du Sein," Paris, 1854, p. 598.



l'operation." In support of this he gives details of twenty cases in which freedom from recurrence had ranged from seven to twenty-seven years.

In their definition of the term "cure," the older surgeons were more exacting than we are. They would not admit its applicability to cases, other than those that had remained free from the disease for at least ten years after operation ; but even this severe test is fulfilled in a considerable proportion of cases—in nearly 11 per cent. of those analysed by Gross.

It is now generally recognised that the longer the period of immunity lasts, the rarer recurrences become. By modern surgeons the term "radical cure" is applied to cases that have remained free from recurrence for at least three years after operation. Volkmann's law is now almost universally accepted. "When," he says, "after operation a whole year has elapsed without recurrence, radical cure may be hoped for ; after two years it is probable ; and at the end of three years it is almost certain."

It has been clearly proved by modern statistical investigations, not only that radical cures after operation do occur, but also that they are of much greater frequency than has hitherto been generally believed. They have increased *pari passu* with the thoroughness of operating. Of recent operators, those who have done the most thorough operations have obtained the best results. Of 1,234 operated cases of mammary cancer collected by Gross, 146 (11·83 per cent.) resulted in radical cure ; while Kœnig, Küster, Gross, Banks, Estlander and Gussenbauer estimate the cures in their latest series of similar operations respectively at 22·5, 21·5, 21, 20·35, 20 and 16·7 per cent.

The immense superiority of these results over those formerly attained, may be gauged by Alexander Monro's experience.<sup>25</sup> Writing about 1750, this distinguished surgeon says, that of sixty cancers he had seen extirpated, in only four instances had the patients remained free from return of the disease for upwards of two years.

---

<sup>25</sup> "Medical Essays," p. 7.



Hence it is well within the limit to expect complete cures after thorough operations for cancer of the breast, in at least 15 per cent. of all cases. There is therefore fair prospect of saving the patient by operation. No other mode of treatment has yielded anything like the same amount of success. These results, so encouraging alike for patient and surgeon, ought to be more widely known and acted upon than they are at present.

Nunn\* found that one in 13 of his cases remained free from recurrence after operation for from ten to twenty years; and of 250 patients operated on by Velpeau,† 20 remained free from recurrence for periods of from five to twenty-seven years.

(e) *Is life prolonged by operation?*

Considerable discrepancies are apparent in the results arrived at by different investigators, as to the duration of life in cancer of the breast. Astley Cooper says,<sup>26</sup> "The progress of this complaint is in some persons extremely slow. In general, however, it destroys life in about four years from its commencement." According to Paget,<sup>27</sup> "The average duration of life, from the patient's first observation of the disease, is a little more than four years." Bryant's<sup>28</sup> experience agrees with this. Sibley<sup>29</sup> found the duration of life in cases *operated* on 53·2 months; and in those *not* operated on 32·25 months. Of Marrant Baker's<sup>30</sup> 84 cases, for the *non-operated* the average was 43 months; and for the *operated* 56·5 months. Gross,<sup>31</sup> the latest worker in this field, gives 38·5 months as the duration of life for *operated* cases; and 28·6 months for the *non-operated*.

\* "Cancer of the Breast," p. 45.

† *Op. cit.*, p. 598.

<sup>26</sup> "Lectures on Surgery," 1839, p. 379.

<sup>27</sup> "Lectures on Surgical Pathology," 1853, vol. ii., p. 344. The average duration of life of 66 *non-operated* cases was rather over 48 months, of 47 *operated* cases the average duration of life was a little over 49 months.

<sup>28</sup> "Diseases of the Breast," 1887, p. 151.

<sup>29</sup> *Trans. Med. Chir. Socy., Lond.*, vol. xlii.

<sup>30</sup> *Med. Chir. Trans.*, vol. xlv.

<sup>31</sup> *Internat. Jour. Med. Sci.*, March, 1888.



I have tabulated all the fatal cases of breast cancer that came under my observation at the Middlesex Hospital during a period of six years, with the result that the average duration of life—dating from the time when the disease was *first noticed*—is 60·8 months for those who underwent operation; and 44·8 months for those in whom the disease ran its natural course.

Gross' statistics are derived from massing the results of more than a dozen different surgeons, chiefly German. He has not expressly stated that in all his cases the duration of life is dated from the time when the disease was *first noticed* by the patient. It appears to me, whether from this cause or some other, that his figures considerably under-estimate the total duration of life in this disease. I believe the experience of English surgeons will be found to be more in accord with my figures.

In further illustration of this subject I have compiled the following tables:—

TABLE I.

Duration of life in periods of 6 months.	Under 6 months.	6 to 12	12 to 18	18 to 24	24 to 30	30 to 36	36 to 42	42 to 48	48 to 54	54 to 60	60 to 66	66 to 72	72 to 78	78 to 84	84 to 90	Over 102 months.	Shortest duration in months.	Longest duration in months.	Average duration in months.
Thirty cases in which the breast was amputated <sup>32</sup> ..	1	3	3	..	3	2	4	1	..	2	1	1	1	2	2	4	5'5	297	60'8
Thirty-four cases in which no operation was done ..	3	3	5	3	3	1	6	1	2	..	..	..	..	1	2	4	2'7	194'7	44'8

This shows that the number of women *operated* upon, who died before the end of the third year, was 40 per cent.; whereas of the *non-operated* the number who died before this period was 53 per cent.

Moreover, the *average duration of life* for the *operated* cases was 16 months more than for the *non-operated*.

Of the 4 cases of the first group in which the duration of the disease exceeded 102 months, it lasted 137·6, 149·8, 159, and

<sup>32</sup> The immediate risks of the operation are not here included; as the data were derived from patients who had survived the proceeding.



297 months respectively. Of the 4 cases of the second group in which the duration of the disease exceeded 102 months, it lasted 116.6, 130, 157 and 194.7 months respectively.

TABLE II.

Showing the duration of life after amputation of the breast for the primary disease.	Under 1 month.	1 to 6	6 to 12	12 to 18	18 to 24	24 to 30	30 to 36	36 to 49	49 to 56	56 to 62	62 to 68	68 to 74	74 to 111.5 months.	111.5 to 159 months.	159 to 259 months.
In twenty-five cases <sup>33</sup> ..	7	1	2	1	3	2	2	2	1	1	1	1	1	1	1

In these 25 cases the *average* duration of life, after extirpation of the primary disease, was 40.3 months; the shortest duration 7 days, the longest 259 months.

TABLE III.

Showing the interval between the first operation and the first obvious recurrence in monthly periods.	Under 3 months.	3 to 4	4 to 5	5 to 6	6 to 7	7 to 8	8 to 9	9 to 10	10 to 11	11 to 12	12 to 13	13 to 15	15 to 17	17 to 23	23 to 25	25 to 33	33 to 36	36 to 44	44 to 52 months and upwards.
In forty-seven cases of recurrent breast cancer .. .. .	4	3	1	4	1	1	3	1	3	6	1	1	1	2	5	1	1	1	8

In these 47 cases the *average interval between the first operation and the first obvious recurrence* was 26 months, the maximum 130 months, the minimum 2.5 months. The duration of the interval between the first operation and the first obvious recurrence in the 8 cases of from 52 months and upwards was as follows; 52 months (2 cases), 58, 62, 89, 91, 124, and 130 months respectively.

I think the facts revealed by the above analyses justify us in taking a more hopeful view of breast cancer than is customary. We must not forget that cancer is a disease less malignant in some parts than in others. The prognosis is certainly much better in breast cancer, as regards duration of life, than it is when this disease affects the tongue (when the total duration of life amounts to 18 months), the uterus (24 months), or the

<sup>33</sup> Those who died of the immediate risks of the operation are here included.



rectum (27 months). In this respect cancer of the breast is on a par with cancer of the lower lip, in which the average duration of life is 60·7 months.

Had Hippocrates been aware of the foregoing facts, he would certainly have written his celebrated aphorism,<sup>34</sup> relating to the operative treatment of mammary cancer, very differently.

## § II.—Caustic Treatment.

As a curative means the treatment of mammary cancer by caustics is in every way inferior to the knife. It is a blind agency, the limits of whose action we cannot precisely determine. Since, however, there are always to be found some patients with such an exaggerated dread of cutting operations, that they cannot be persuaded to submit to them, it may, under such circumstances, sometimes be desirable—in the absence of any obvious implication of the axillary glands—to destroy the disease by caustics.

It would be superfluous to enumerate the many various substances that have from time to time been employed for this purpose. One of the most efficient is *chloride of zinc*—a powerful tissue coagulant, which for use is made into a paste with flour. It is a painful application, but it has the advantage of not being absorbed and of being easily handled. On the healthy skin this caustic produces comparatively little effect, hence, before using it, when the skin is unbroken, the latter has to be first of all destroyed by the application of some other caustic, such as nitric acid. The mode of preparing the paste and its application, best adapted for ordinary use, is that known as “Fell’s process,” of which the details are as follows:—Take of chloride of zinc, 16 oz.; opium in powder, 1½ oz.; hydrochloric acid, 6 drachms; boiling water, to 1 pint. Macerate the opium in 12 ounces of the boiling water for twelve hours, add the acid and filter; then dissolve the chloride of zinc in the filtered liquid, and add

---

<sup>34</sup> *Aphor.*, vi., 38.



distilled water up to 20 ounces. The paste is prepared by adding sufficient wheatened flour to this fluid to render it of proper consistence; thus:—of the above solution, 1 oz.; flour, 120 grs. Mix and heat in a water bath until of proper consistence.

By the application of fuming nitric acid the skin over the field of operation is destroyed. This is effected by swabs of lint or cotton wool mounted on pieces of wood, or by the use of a glass rod or brush. The parts adjacent to the field of operation are protected from its action by being first smeared over with benzoated lard. Plenty of blotting paper and alkaline solution should also be at hand to dispose of any accidental excess of acid; and care should be taken that the swabs, &c., used, are not over-charged with the acid. The application is painful, and some surgeons employ general anæsthesia. The necessity for this may be avoided by painting the skin of the part with a 10 per cent. solution of hydro-chlorate of cocaine, and by subcutaneous injections of a few drops of 5 per cent. solution of the same drug at various points in the field of operation. By the next day the skin, thus treated, will be found to be converted into a hard parchment-like substance. Into this multiple incisions are made with a short knife, at about half an inch distance from one another, and into these, narrow strips of linen impregnated with the paste are inserted. The part is then covered with dry, loose, carbolic gauze, and over this a layer of alembroth wool. In a day or two the strips of caustic linen should be removed, and if necessary, fresh incisions made, into which fresh strips of caustic linen are inserted, and so on until the requisite amount of tissues have been destroyed.

The chief difficulty in using this method, is to know when the caustic has penetrated deeply enough. It not unfrequently happens that its action is much more extensive than was intended.

In a case under my observation, when the slough separated, it was found that not only the disease, but also the entire thickness of both pectoral muscles had been destroyed, as well as the costal cartilages, and the



adjacent parts of the 2nd, 3rd, 4th, 5th and 6th ribs, thus laying bare a large extent of pleura and pericardium, through which the movements of the heart and lungs were plainly visible. In this condition the patient lived for several months—apparently not much the worse for it—until she died of acute pyelitis. At the necropsy it was found that the exposed pleura was adherent to the adjacent part of the lung; but the heart and pericardial sac were normal. With the exception of a cancerous nodule the size of a walnut, near the anterior axillary border, the disease had been completely destroyed.

### § III.—Palliative Treatment.

It is desirable for cancer patients to live on high and dry ground, in a warm, dry climate, where there is plenty of sunshine; and exercise in the open air, not pushed to the extent of fatigue, is likely to be beneficial. Whatever tends to divert the patient's attention from her malady, and to promote cheerfulness, is desirable; hence the good effects of participating in musical and other social entertainments. With regard to diet, the chief object should be to reduce the consumption of butcher's meat to a minimum. The moderate use of stimulants is to be commended; of wines, port, sherry and burgundy are the most suitable, and of spirits, brandy and whisky. Soda, potash, lithia or seltzer waters may be freely taken.

I have found no drug so useful in the treatment of cancer as *bromide of potassium*. In small doses it has a very soothing effect, and in larger ones it suffices to induce sleep, except when there is acute pain. In ordinary cases I generally employ it in combination with Fowler's solution. As a hypnotic the dose is from 30 grains upwards. In cases attended with much pain, if the bromide fail to give relief, resort must be had to opium and its derivatives.

As a tonic I have found *ferri et quininæ citras* and *quininæ valerianas* useful.

As local applications for mitigating pain, *belladonna* (equal parts of the extract and glycerine) and *stramonium* (ung.), are chiefly relied on. *Cold* is also an excellent local anæsthetic. It is applied in various forms. When a freezing mixture (two



parts of pounded ice to one of salt) is used, the application should not last longer than five or ten minutes. By this time the breast will be frozen through. To prevent too violent reaction after its removal, Leiter's iced water coil may be applied for a quarter of an hour, and after this cold compresses. If instead of the freezing mixture a bladder of ice is employed, it should be kept on for at least an hour.

Hot applications should be avoided, as they only serve to increase the congestion that is always associated with mammary cancer.

*Ulcerated* cancer is best treated by washing the eroded surface once or twice daily with hyd. perchol. solution (1 in 1,500), and then dressing the sore with carbolic gauze wrung out in 1 in 20 carbolic acid solution, and over this a pad of dry gauze or of sal alembroth wool of adequate size and thickness, kept in place by strapping. In this way even the foulest ulcers may soon be rendered quite free from smell.

I should much like, did time and space permit, to give here a sketch of the various remedies that have from time to time been employed for the cure of cancer, from orchitic fluid, cancröin, cultivations of the streptococci of erysipelas, &c., &c., to raw lizards' flesh and pounded snails; but as it is, I must instead refer those who wish to pursue these studies to the works of the classical writers, &c., and for the latest achievements—which are exceedingly numerous—to the *Index Medicus*, and other such compilations.



## CHAPTER XIV.

## THE SO-CALLED VILLOUS DUCT CANCERS.

NO chapter in the history of mammary neoplasms is more obscure than that which refers to the so-called villous duct cancers. This is strikingly exemplified by the many designations applied to them by different observers. It may be worth while to reproduce some of these, since they doubtlessly indicate, however imperfectly, varied aspects of the morbid process.

By Brodie,<sup>1</sup> who first clearly differentiated them, they are described as "sero-cystic tumours." It is impossible not to be struck with admiration at the singularly clear and penetrating insight into this obscure disease which this distinguished man had attained, and that without the microscope and other modern aids. Billroth<sup>2</sup> calls them "tubular cyst adenomas," Gross "true adenomas," Labbé and Cöyne<sup>3</sup> "epithelioma intra-canaliculaire," Rindfleisch "glandular cancroids," Cornil and Ranvier<sup>4</sup> "carcinôme vilieux," while others have given them such names as "duct papilloma," "papillary endo-canalicular fibroma," "cystic adenoma," "blood cyst," "épithéliôme cylindrique," "épithéliôme dendritique," "épithéliôme kystique," "villous duct epithelioma," "hæmorrhagic carcinoma," "duct cancer," "tubular carcinoma," &c. What confusion all this implies! Yet there is no lack of

<sup>1</sup> "Lectures on Pathology and Surgery," 1846, p. 137.

<sup>2</sup> *Deutsche Chir.*, Lief. xli., S. 79.

<sup>3</sup> "Traité des Tumeurs Bénignes du Sein," Paris, 1876, pp. 206, 212, and 264.

<sup>4</sup> "Manuel d'Hist. Path," t. iii., 1876, p. 1167.



facts, the problem is rather to set these in order and to interpret them aright.

To this end I think the first and most important step is the recognition of the fact that under this term "villous cancer," as hitherto commonly employed, at least two perfectly distinct kinds of neoplasm are included—viz., the *non-malignant villous papilloma* and the *malignant tubular cancer*.

I will now proceed to sketch briefly the salient features of each of these diseases, basing my remarks upon the study of thirty-six cases, several of which have come under my own observation.

### § I.—Villous Papilloma.

Villous papillomata of the breast may be either *single* or *multiple*. They may arise from any part of the mammary duct system, but hardly ever from the acini. The galactophorous

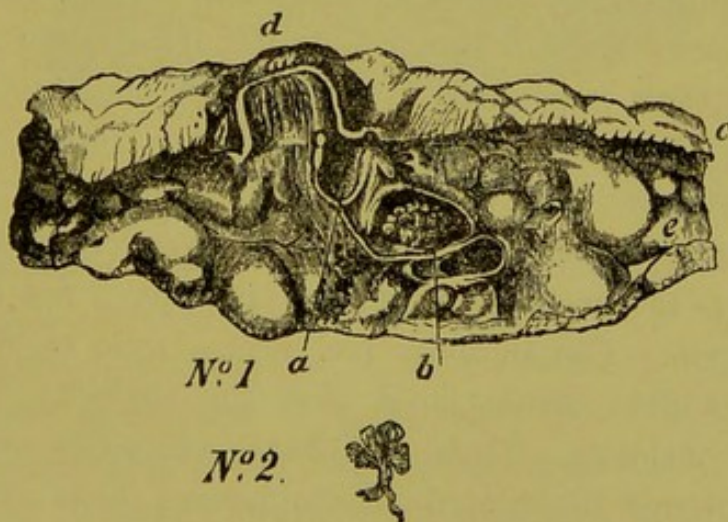


FIG. 48.—SOLITARY VILLOUS PAPILLOMA (*Barker*).

No. 1 Section through centre of nipple of right breast, showing dilated ducts and a duct papilloma projecting into one of them. (a) Dilated duct. (b) Papilloma. (c) Skin. (d) Nipple. (e) Breast tissue.—No. 2. Vertical section through the raspberry-like papilloma of No. 1. It is seen to be made up of four main lobes, each of them divisible into smaller leaflets.

ducts are their favourite seats, especially the lacteal sinuses (fig. 48). In its simplest form the disease presents as a soft,



granulated or shaggy, pea-sized, solitary outgrowth of reddish or purplish colour, connected by a slender stalk with the wall of the duct whence it originates, as in cases by Barker, Bryant, Billroth, Pollard, and others. When such a growth is floated in water, its branching, arborescent structure at once becomes apparent. Its delicate villousities, which are often of extreme complexity, are, of course, easily lacerated; and as they contain large capillary blood vessels, ecchymoses and hæmorrhages frequently result. Their prevalent dark colouration is ascribable to this, and it has often caused them to be mistaken for blood clots, and even for melanosis. On careful dissection it is easily determined that the cavity within which the papilloma is contained is the dilated duct itself, and the fluid contents are derived from its lining membrane. These may be either serous, mucoid, or pultaceous, and they are often blood-stained; they may contain epithelial cells in granulo-fatty degeneration, corpuscles of Glüge, leucocytes, granular *débris*, cholesterine scales, blood corpuscles, &c., as well as dissolved albumen. These neoplasms present as circumscribed tumours of ovoid or conoid shape, with their long axes parallel to the main ducts. They are usually centrally situated beneath the nipple or areola. Though connected with the breast itself, they seldom adhere to other adjacent structures. They cause retraction neither of the nipple nor of the overlying skin; but these parts are sometimes dragged upon. The tumours feel firm, elastic or fluctuating, but they seldom attain large size, the majority being like filberts or walnuts. Their peripheral villousities occasionally protrude through the dilated galactophorous ducts at the summit of the nipple, where they form red granular excrescences.

More common than the solitary papillomata are the multiple ones of which cases have been recorded by Billroth, Pollard, Labbé, Morton, and others (fig. 49). These may be confined to the ducts of several adjacent lobules, or to those of an entire lobe, or they may be scattered irregularly throughout the ducts of the whole gland. Thus firm, irregular, nodular tumours are produced, which often attain considerable size. On section



numerous small cystic cavities are noticeable, within which the villous growths are contained; when the latter grow freely they sometimes cause absorption of the intervening cyst walls, the result being a softish mass of coalesced villous growths, which, on section, presents a spongoid appearance, its meshes containing pultaceous or mucoid fluid, derived from the cells lining the closely packed villousities. In these cases there is often no distinct capsule, and the bulging intra-canalicular growths sometimes seeming to infiltrate the surrounding fibro-fatty structures.

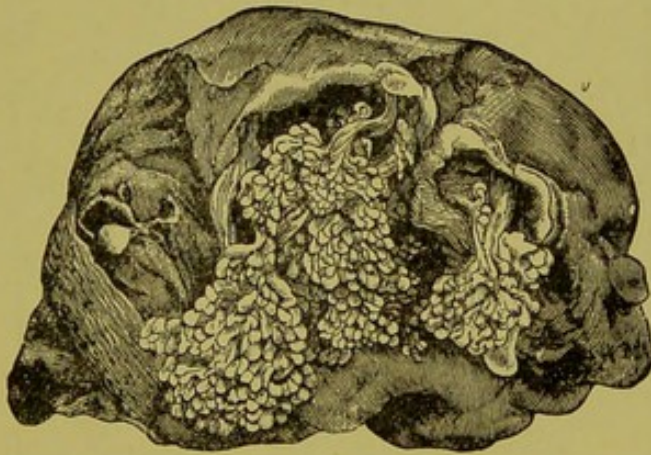

FIG. 49.—Multiple Villous Papilloma (*Gross*).

Microscopical examination of mammary papillomata shows them to be composed of a slender framework of fibrous connective tissue, lined by one or more layers of columnar or sub-columnar epithelium (figs. 51 and 52). In this fibrous framework very few, if any, cellular elements can be detected. It serves the purpose of supporting the capillary blood vessels. In some instances the epithelial investment is exceedingly thick; upwards of twenty layers of cells have been counted. Under these circumstances the more superficial cells lose their columnar form and undergo granulo-fatty changes. Cells similar to those that cover the free surface of the neoplasm line also the wall of its containing cyst. In their microscopic appearances such growths occasionally present some resemblance



to alveolar cancer, for certain sections show ovoid spaces containing epithelial cells surrounded by scanty fibrous stroma. These cells, however, differ from the cells of acinous cancer, in that they are of the columnar type; and instead of being irregularly massed within the alveolar spaces, they are regularly arranged round their walls. The alveolar appearance is produced by cross sections of the epithelial lined, interpapillary depressions, between the closely packed ramifications of the neoplasm. In certain cases, when the villousities are lined with

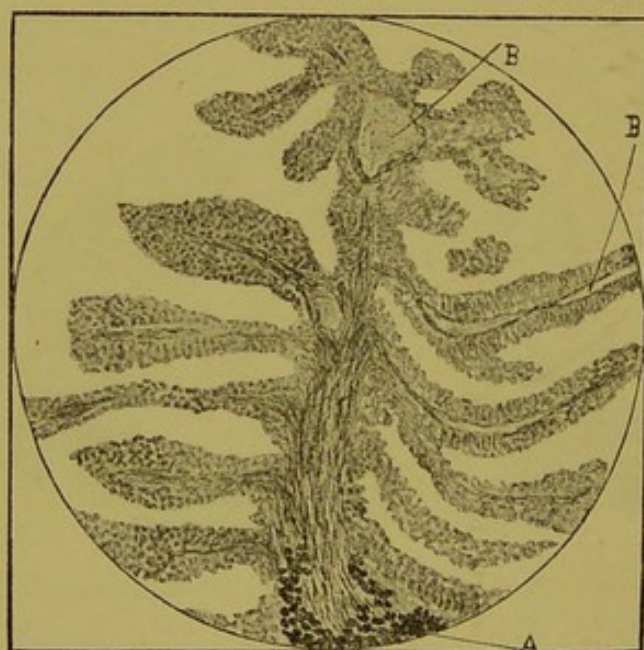


FIG. 50.—VILLOUS PROCESS OF DUCT PAPILLOMA UNDER A LOW POWER (*Morton*).<sup>\*</sup>  
(A) Pigment, probably of hæmorrhagic origin; (B) Blood vessels.

but a single layer of epithelium, a tubular appearance is thus produced.

In the initial stage of their development villous growths present as simple conical or forked outgrowths of the lining membrane of the duct. In this condition such growths are occasionally met with in the ducts in the vicinity of the fully developed growths. Further proof of their origin from this source is to be found in the fact that the cells lining their free surfaces are invariably of the same columnar type as those of the

<sup>\*</sup> Mr. Morton, of Clifton, very obligingly lent me the block for this figure.



originating ducts. Labbe and Coÿne<sup>5</sup> have recorded a case of multiple villous papillomata in which the free surfaces of the neoplasms and of the containing cyst walls were lined throughout with flattened epithelium. Here the disease was probably of intra-acinous origin. This is the only case of the kind with which I am acquainted.

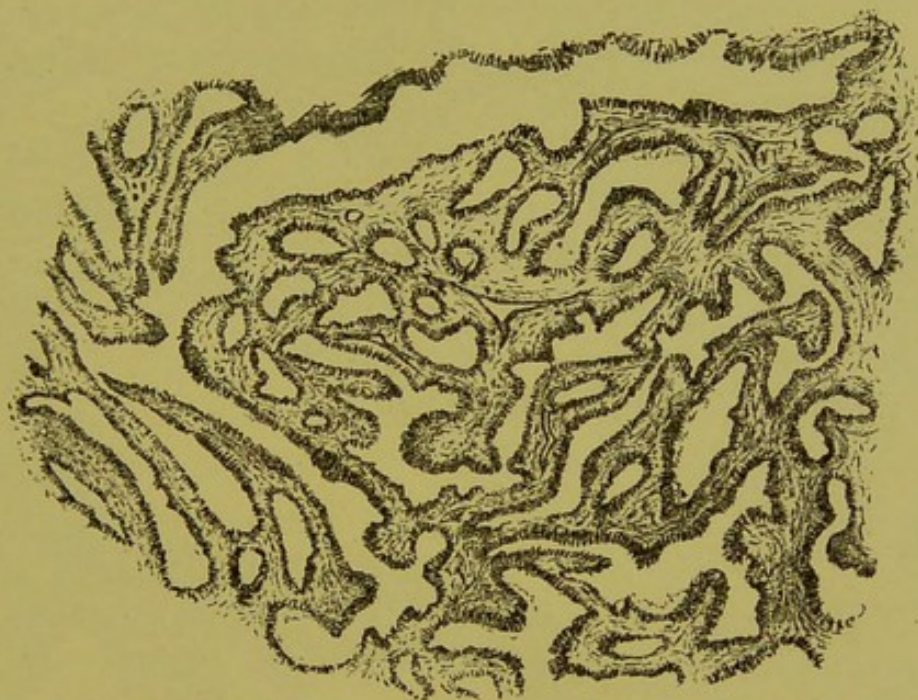


FIG. 51.—Villous Papilloma of Breast under a low power (*Pollard*).

It will be gathered from the foregoing description that these growths are of a perfectly innocent nature; though often multiple, they have no tendency to local infection, nor do they ever disseminate in the adjacent lymphatic glands, nor in the system at large; and when completely removed they do not recur. Of the patients in my list one was known to be alive and well 14 years after operation, and others,  $7\frac{1}{4}$ , 7,  $3\frac{1}{2}$  and 3 years (two cases). In a few instances growths of this kind have been found associated with ordinary fibro-adenomata.

As an example of recurrence probably due to incomplete ablation of the primary disease, the following case by Morton\* is of interest.

<sup>5</sup> "Traité des Tumeurs Bénignes du Sein," 1876, p. 163.

\* *Bristol Med. Chir. Journal*, March, 1894.



A woman, aged 53, with an irregularly bossed recurrent tumour, the size of a cocoanut, pendent from the mammary region near the axilla. Just above it was the scar of the old operation, to which the tumour was adherent. There were no adhesions with the subjacent structures. The axillary glands were normal. The tumour felt firm and elastic. Three years ago the breast was amputated for a tumour, four and a-half by three inches. The present

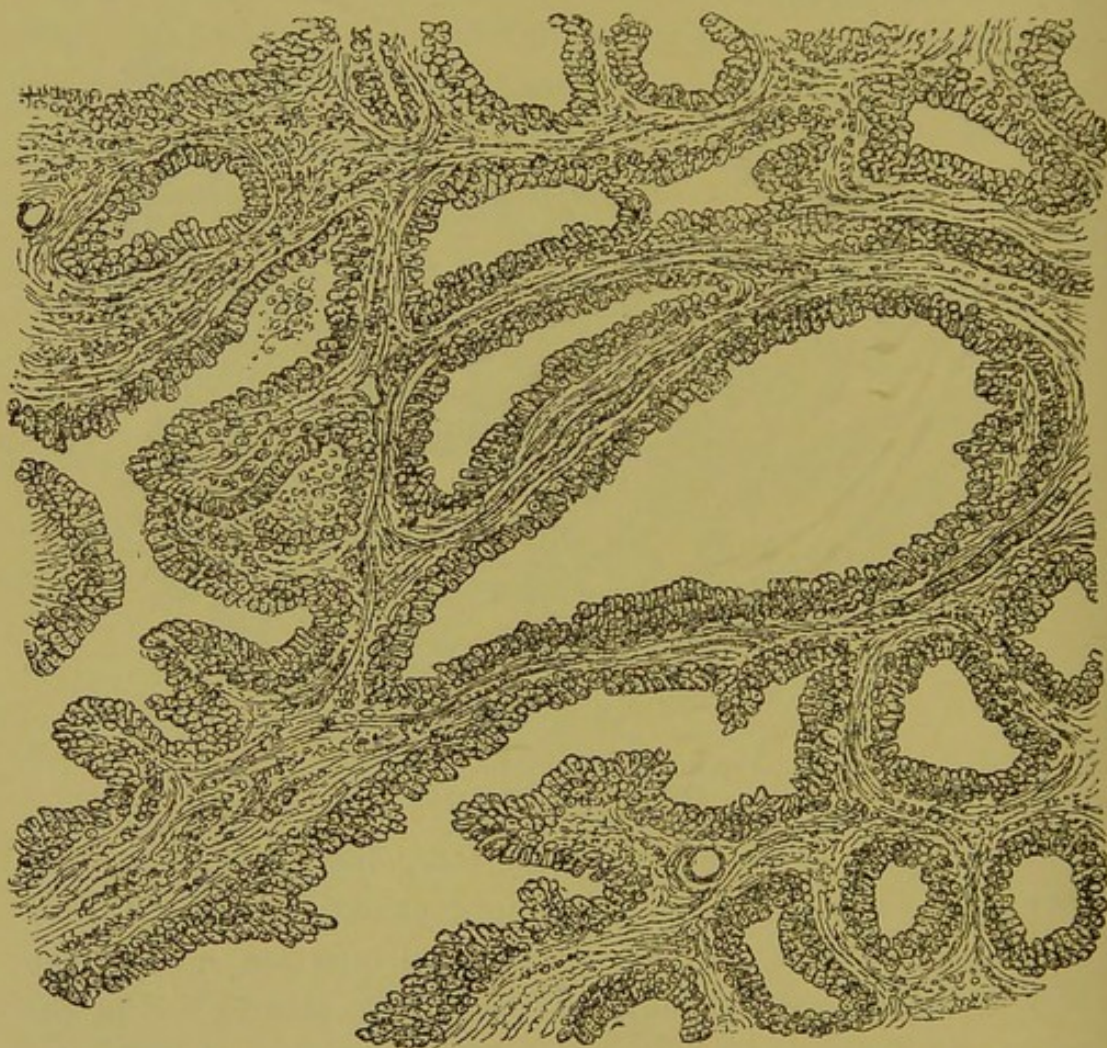


FIG. 52.—Villous papilloma of breast under a high power (*Billroth*).

recurrence first made its appearance two years later. After removal the recurrent growth measured five and a-half by four inches. On section it at first appeared to be a soft solid growth, enclosed in a fibrous capsule. Closer examination showed that it was composed of a number of small cysts containing velvet-like papillary ingrowths and blood clots. There was no solid growth between the cysts. Where the skin was adherent there was no infiltration. Histologically examined the contents of one of the smaller cysts consisted of an arborescent mass of papillary excrescences, the structure of which is shown in fig. 50. In the hospital museum Morton was



fortunate enough to find the primary tumour, which upon examination proved to be identical in all respects with the recurrent one.

Usually the first symptom of villous papilloma to attract attention is the presence of a fluid discharge from the nipple, which persists, and after a time becomes sanious. Even when this is not the initial symptom it generally appears at an early date, and remains throughout a salient feature. In other cases a small pea-sized tumour is the thing first noticed. The presence of a tumour is, however, often overlooked by the patient, as it seldom causes pain or other inconvenience. The disease progresses slowly and almost imperceptibly, so that a surgeon is seldom consulted until it has existed for several years. Of the eighteen cases in my list it was known to have existed for periods of twelve, ten, four and three years (two cases) before advice was sought. Having maintained this slow rate of increase for some years, these tumours not unfrequently get larger rather rapidly, owing to increase in the fluid contents of the cysts. In two out of my eighteen cases there was history of previous injury; in one the nipple had been severely bitten twenty-two years previously; in the other the disease was first noticed four months after a blow. The patients affected are generally prolific married women, and the right breast is as often the seat of the disease as the left. The average age at onset was 43 years; the youngest in my list 23, the oldest 55. The numbers for each quinquennial period were as follows:—

20 to 25 years	...	...	...	...	in 1 case
25 „ 30 „	...	...	...	...	„ 1 „
30 „ 35 „	...	...	...	...	„ 1 „
35 „ 40 „	...	...	...	...	„ 5 cases
40 „ 45 „	...	...	...	...	„ 3 „
45 „ 50 „	...	...	...	...	„ 2 „
50 „ 55 „	...	...	...	...	„ 2 „

Villous papillomata therefore develop at a much later period than fibro-adenomata—of which the average age at onset is 30·4 years; but they arise somewhat earlier than cancers, of which the average age at onset is 48 years.

The disease I have just sketched has hitherto almost in-



variably been confounded with cancer, or sarcoma, and treated like these affections by amputation of the breast, and in several cases the axillary glands have been removed as well. It is clearly a mistake to resort to such severe measures when we have to do merely with a solitary villous growth, or even with several such growths confined to a limited area of the gland. In these cases the disease should be excised, together with the containing cyst wall. Several cases illustrate the futility of cutting into these tumours, and of destroying the overlying skin by caustics. The only result of such treatment is to cause them to fungate and to increase rapidly. When the disease is diffuse the whole gland must be extirpated; but even then the overlying skin, including the nipple and areola, may usually be preserved.

The following typical cases illustrate the leading features of this disease.

(1)<sup>6</sup> A recently married woman, aged 24, came under observation with a tumour in the right breast, of one year's duration. It was the size of a hen's egg, firm, fixed, and lobulated. No mention is made as to the condition of the axillary glands; presumably, therefore, they were not obviously diseased. The breast was amputated. When last heard of, fourteen years afterwards, the patient was in good health, and free from any return of the disease. On examination of the tumour after removal, it was found to be blended with the surrounding glandular substance. On section, a scanty fibroid stroma was revealed, studded with small cysts, varying in size from a pea to a millet seed. These contained pultaceous, yellowish substance, which on microscopical examination proved to be papillary villous growths, bathed in mucoid fluid, and contained within dilated acini.<sup>7</sup> In cross sections these growths presented the appearance of plexiform glandular tubuli, lined by two or more layers of subcolumnar epithelial cells, and supported by a scanty fibrous stroma (fig. 52). Nowhere did these structures appear to have overpassed the limits of the containing cyst wall. The growth is designated by Billroth "*tubular cyst-adenoma*."

(2)<sup>8</sup> A married lady, aged 44, the mother of six children, of whom the last was born fourteen years ago. Four years before she came under observation first noticed, in the upper and outer part of her right breast, a

<sup>6</sup> *Deutsche Chirurgie.*, Lief. xli., 1880, S. 79.

<sup>7</sup> These so-called "acini" are figured as lined with columnar epithelium; and they are evidently *not* acini, but small ducts.

<sup>8</sup> Labbé et Coÿne, "*Traité des Tumeurs Bénignes du Sein*," 1876, p. 264.



swelling the size of a nut. Her attention was directed to it by the super-vention of pain there. In the course of about two years it increased to the size of a hen's egg, and the pain also got worse. She then underwent caustic treatment; but in reality only the overlying skin and subcutaneous tissues were thereby destroyed. Consequently after cicatrisation of the resulting large ulcer, the tumour continued to increase. Two years later she applied to Labbé on this account, and he freely excised the growth. When last heard of, nearly three and three-quarter years after the operation, she was in good health, and free from any return of the disease. On examination of the part after removal, a completely encapsuled tumour, the size of a large egg, was found, which on section was of moist, shiny, greyish-white aspect, and quasi-lobular structure. This lobular appearance was due to the presence of numerous cystic cavities—varying in size from a grain of maize to an almond—completely filled with papillary ingrowths. The capsule of the tumour and the walls of the cysts consisted of very dense fibrous tissue. The intracystic growths adhered to the containing cyst walls, each by a narrow pedicle, which could only be demonstrated after freely opening the containing cyst, and turning out its contents. The various cystic cavities communicated with one another. Often two or more of these growths sprang from the wall of a single cyst. The slender pedicle of each consisted of old sclerosed connective tissue—without any obvious cellular elements—as also did its main branches; but its more peripheral extensions contained numerous flattened and rounded cells. The much ramified free surface of these vegetations was lined by a single layer of cylindrical or cubical epithelium, which at the level of the pedicle was directly continuous with the similar cells lining the containing cyst. The deep and narrow depressions which separated the various divisions and sub-divisions of the branching growth, seen in section, presented appearances that simulated glandular *culs-de-sac*, for the cylindrical epithelium everywhere lined these depressions. It was only by examining large sections of the growths that their true nature could be determined; they were then seen to be simply epithelial-lined inter-foliate depressions. Nowhere was there any extension of the growth beyond the cyst walls. This neoplasm is classed by Labbé and Coÿne as "*Fibrome intra-canaliculaire avec végétations foliacées intra-kystiques.*"

(3)<sup>9</sup> A vigorous, healthy woman, aged 49, the mother of four children. She still menstruates regularly. Ten years ago she first noticed a small tumour in her right breast, just external to the nipple. When she pressed the tumour sanious fluid escaped from the nipple. Two and a-half years ago it began to increase more rapidly than formerly, and became fluctuating. About this time it was incised, and a considerable quantity of reddish viscid fluid escaped. A fistula resulted at the seat of puncture, from which large quantities of sanious fluid have since discharged. When she came under observation the right breast, beneath the nipple, was occupied by a large, soft, flabby tumour, presenting rounded fluctuating bosses and soft depressions, as

---

<sup>9</sup> Labbé et Coÿne, "Traité des Tumeurs Bénignes du Sein," 1876, p. 206.



from empty cystic pouches. External to and below the nipple is an eroded outgrowth, surrounding the orifice of a fistula, whence blood-stained fluid freely escapes. The skin is not invaded, although it is adherent to the structures around the fistulous orifice, and the tumour is freely movable on the subjacent parts. There is no enlargement of the axillary glands. The tumour was freely excised. It was found to be easily enucleable, although rather adherent in some places. The bulk of it consisted of three large cystic pouches filled with dark-coloured blood. The walls of these cysts were of fibrous tissue. At numerous points on their inner surface, large, fleshy outgrowths were attached, which projected into the cystic cavities. Numerous small cysts, containing intra-cystic growths and a little fluid, were found in the vicinity of the large cysts. The intra-cystic vegetations were formed of much ramified papillary outgrowths, lined with cylindrical epithelium. In section these inter-papillary epithelial spaces often simulated glandular structures. The pedicle of each outgrowth and its main branches consisted of fibrous tissue. Vertical section entirely through one of these vegetations showed a mass of branching papillary structures, disposed after the manner of the cerebellar *arbor vitæ*. In the fibrous framework of the more recent vegetations vascular loops were visible. The growth is described as "*Fibrome endo-canaliculaire papillaire*."

(4) A woman, aged 35, who six years ago had a miscarriage and seven years before this a stillborn child. Two years ago she first noticed a tumour the size of a nut in the middle of her left breast. This she attributed to a blow there, four months previously. After the tumour had existed for a few months she noticed that on pressing it a yellowish fluid escaped from the nipple. When she came under observation there was at the upper and inner part of her left breast a soft conoid tumour, the size of a pigeon's egg, with its long diameter parallel with the main ducts. It narrowed as it approached the nipple, beneath which its apex disappeared; its base was directed towards the periphery. The disposition of the swelling suggested that it might be due to a distended galactophorous duct. There were no adhesions with the skin, nor with any of the other adjacent parts. The axillary glands were normal. The tumour was excised by Verneuil. On examination after removal there was found, projecting into a greatly dilated galactophorous duct, at 2 cm. from the nipple, an arborescent polypoid outgrowth, behind which the duct was greatly pouched, and contained some clear fluid. The neoplasm was histologically examined by Nepveu, who described it as "*un épithélioma à cellules cylindriques*," that had originated from the lining membrane of a galactophorous duct.

(5)<sup>10</sup> A spare but healthy looking married lady, aged 52, three years ago first noticed serous discharge from the right nipple, which became sanious a week ago. On examination the mammae were found small and wasted. Just above and to the inner side of the base of the right nipple, was a hard nodule the size of a filbert, and another in the substance of the breast close to it. Manipulation of these caused sanious fluid to escape from the nipple.

<sup>10</sup> Barker, A. E., *Brit. Med. Journ.*, vol. i., 1890, p. 590.



The tumours were neither painful nor tender. There was some induration and puckering at the base of the nipple, which the patient ascribed to an accident twenty-two years ago, when the nipple was nearly bitten off while suckling. The axillary glands felt knotty. The breast was amputated, and the axillary glands removed.

On examination of the specimen it was seen that the disease was due to the presence of a single, bright red, raspberry-like, papillary growth, the size of a pea, which occupied the interior of a dilated galactophorous duct, at about an inch from the nipple. Several of the adjacent ducts were also dilated, one of them to a marked degree. This growth was connected with the wall of the containing duct by a slender pedicle. Its structure was arborescent, consisting of four primary divisions spreading from the parent stem, each of which was divisible into secondary lobes, and these again into tertiary ones, and so on (fig. 48). Histological examination showed that all of these divisions were of essentially the same structure; they comprised a central strand of fibrous tissue—containing very few nuclei—enclosing capillary blood vessels, and lined externally by one or more layers of cuboid or columnar epithelium. Sections through their main lobes showed a number of ovoid spaces lined for the most part by epithelium similar to that covering the free surface. These spaces were separated from one another by fibrous stroma, and into the largest of them papillomatous growths projected. Some of the sections were so broken up by these spaces as to present quite an alveolar appearance. This the author attributed to depressions of the surface lining membrane between approximated villousities, seen in cross sections. In the parts of the breast subjacent to this papilloma nothing abnormal could be discovered either with the naked eye or with the microscope. In answer to a recent letter of inquiry Mr. Barker has kindly informed me that the patient is now—four and a-quarter years after the operation—well, and free from any return of the disease; also that the removed axillary glands were not affected. The author is undecided as to the precise nature of the disease, which he describes as a “so-called duct cancer.”

(6)<sup>11</sup> A woman, aged 36, the mother of five children. Sixteen months ago she had a miscarriage. Eleven months ago she first noticed a small lump in her right breast, and a month afterwards discharge from the nipple. When she came under observation there was found, just beneath the right nipple, an elastic tumour the size of a hazel nut. On pressing it sanious fluid escaped from the nipple and the tumour diminished in size. No mention is made as to the condition of the axillary glands, so presumably they were not obviously diseased. The tumour was excised, together with some of the surrounding breast structure. On examination after removal, in the cavity of a dilated galactophorous duct, there was found a red, pedunculated, papillomatous growth, resembling a ripe raspberry. Several other small growths, none of them larger than a pin's head, sprang from other parts of the cyst wall. When last heard of, six years later,<sup>12</sup> the patient was well and free from any return of the disease. The growth is classed by the author as a “villous carcinoma.”

<sup>11</sup> Bowlby, A., *St. Bart.'s Hosp. Rep.*, vol. xxiv., p. 263. Case 1.

<sup>12</sup> *Lancet*, vol. i., 1893, p. 1371.



(7)<sup>13</sup> A married woman, aged 50, the mother of six children. Twelve years ago, when about six months pregnant with her last child, she first noticed sanious discharge from her left nipple, which continued for three years, when a soft, warty growth, the size of a pea, protruded from the nipple. This was then ligatured and cut off, but it soon grew again. It was then burnt off, but soon returned. Three and a-half years ago it was repeatedly destroyed with caustics, but each time it grew again. When the patient first came under observation, about two and a-half years ago, there was a hard lump in the breast beneath the nipple, which extended outwards for about two inches. The axillary glands were not obviously affected. Eight months ago the breast was amputated, without opening the axilla. Examination of the part after removal revealed a very friable growth of dark red colour, enclosed in a distinct fibrous capsule. Histological examination showed closely packed tubules separated from one another by scanty fibrous tissue. These tubular spaces were lined with two or three layers of cubical epithelial cells, some of which contained secondary papillary growths (fig. 51). This appearance seemed to be due to cross sections of closely appressed arborescent papillary structures, of which the bulk of the growth was composed. A smaller portion of the growth was of more solid structure, and under the microscope the fibrous stroma was much more abundant here than elsewhere. The growth is described as a "*duct papilloma*."

The Hunterian Museum<sup>14</sup> contains numerous specimens of growths of this kind, although details are generally wanting.

## § II.—Tubular Cancer.

As previously mentioned, the term "tubular cancer" is applied by me to certain cancers, originating from the mammary ducts, that histologically are very duct-like in appearance. They are also called by some "duct cancers." Cysts and intra-cystic growths, seldom found in association with acinous (scirrhous) cancer,<sup>15</sup> frequently arise in connection with the tubular variety.

The concurrent testimony of recent observers is against Cornil and Ranvier's statement, that villous cancer is merely a form of scirrhus accompanied by intra-cystic villous growths. This form of breast cancer is undoubtedly a distinct variety.

<sup>13</sup> Pollard, B., *Trans. Path. Soc., Lond.*, vol. xxxvii., 1886, p. 483.

<sup>14</sup> Nos. 280 to 290, also 4757 to 4769, *q.v.* *Path. Catalogue*, vol. i., 1882, also vol. iv.

<sup>15</sup> In very exceptional cases villous papilloma and acinous cancer may coexist as independent growths in the same mamma. See Bowlby's paper (No. 2), *St. Bart.'s Hosp. Reports*, xxiv., 1888, p. 265; and Hutchinson's *Archives of Surgery*, vol. ii., No. 6, Oct., 1890, plate xxv., fig 2.



Histologically it is characterised by the presence of elongated, inter-communicating, cellular processes, growing into the surrounding connective tissue (figs. 53 and 54). These processes have the form either of hollow tubes lined with one or several

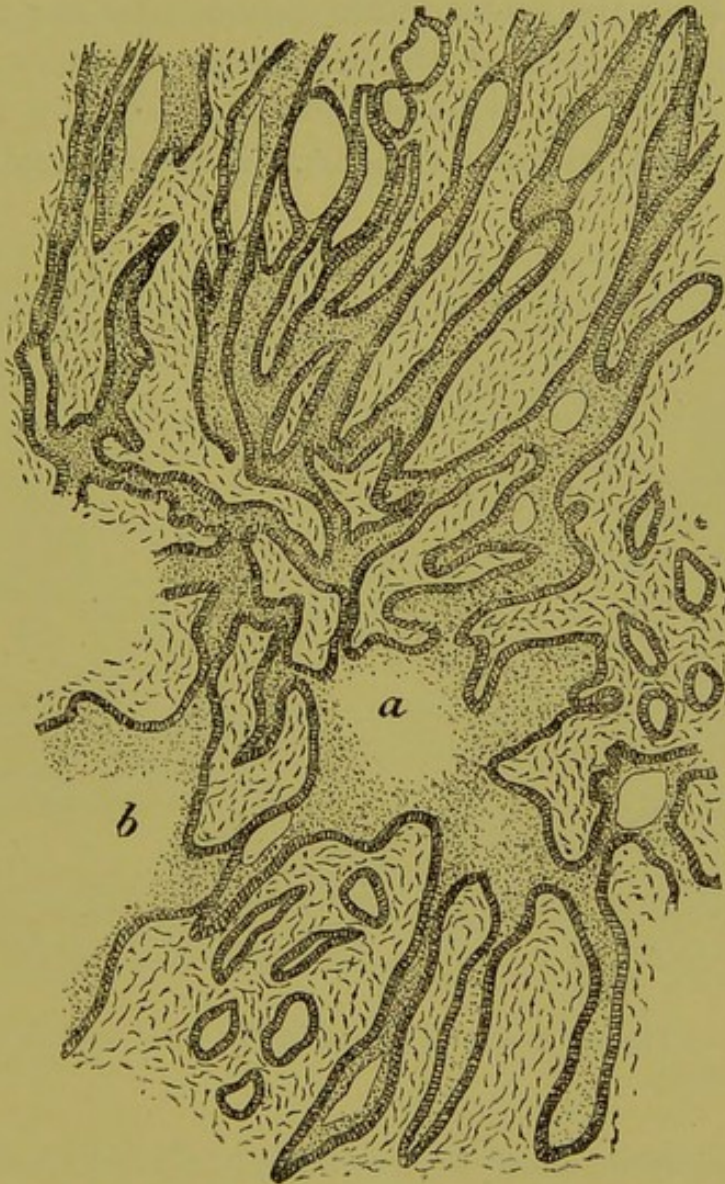

FIG. 53.—TUBULAR CANCER OF THE BREAST (HOLLOW FORM) IN LONGITUDINAL SECTION.

(a) Dilated duct giving off nine prolongations in the form of tubes lined by columnar epithelium, which anastomose with one another and with similar offshoots from other ducts. (b) Intertubular connective tissue scanty.  $\times 100$ . (*Gross.*)

layers of columnar epithelium; or of solid cellular cylinders of which at least the peripheral cells are of the columnar type.



The appearances seen in cross sections are well shown in figs. 55, 56 and 57. In connection with these structures, numerous small cysts frequently arise, through granulo-fatty disintegration of their cells; and within the cysts papillary growths often spring up. From the columnar type of their cells, and from the tubular form assumed by the in-growths, it may be inferred that the neoplasms originate from the mammary ducts. Growths of this kind generally present as hard, nodulated, irregular tumours, which are usually circum-

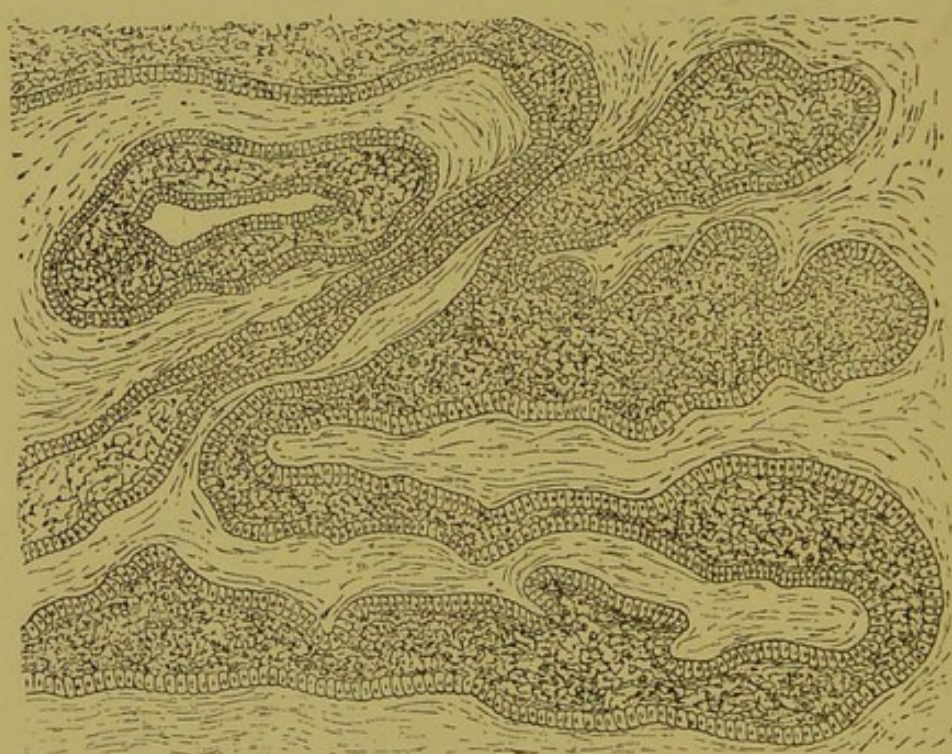

FIG. 54. — Tubular Cancer of Breast (solid form) in longitudinal section (*Labbé and Coÿne*).

scribed, and often more or less completely encapsuled. They vary in size from a hazel nut to a newly born child's head, and commonly they are as large as a hen's egg. They are generally mobile, and very seldom do they cause retraction of the nipple, or of the overlying skin. On section we find them composed of firm, whitish—or, in places, pale pinkish—solid substance, formed by the ingrowing epithelial processes, with here and there yellowish areas out of which pultaceous sub-



stance—consisting of epithelial cells in granulo-fatty degeneration—may be squeezed. Embedded in this solid substance are numerous minute cysts. Sometimes the latter are so numerous as to convert the tumour into soft reticular substance. These cysts, some of which occasionally attain rather large size, contain mucoid or pultaceous fluid, and not unfrequently intra-cystic papillary growths. In this connection ecchymoses and hæmorrhages may arise.

Their clinical history is a matter of great interest. The chief

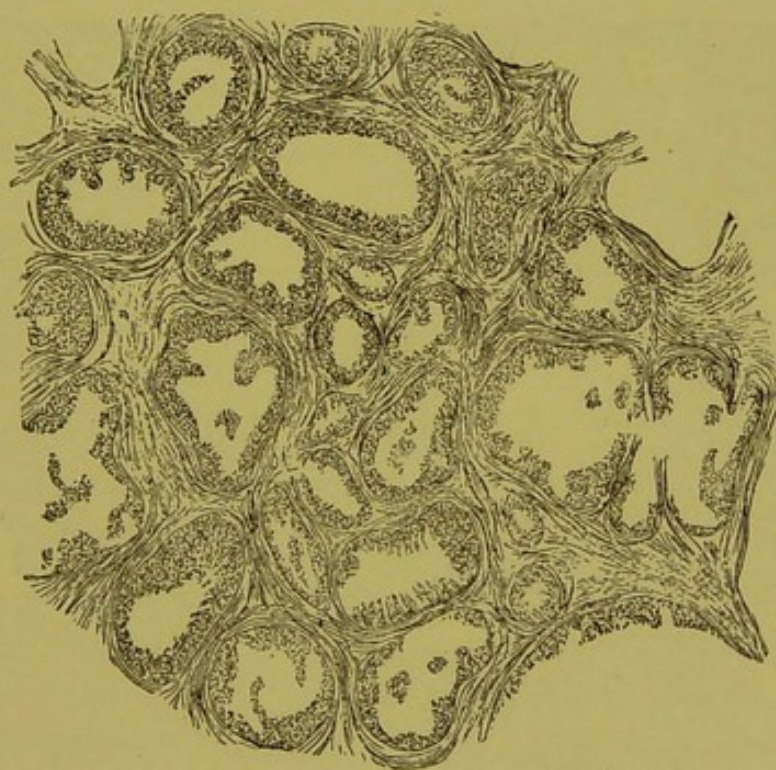


FIG. 55.—Tubular Cancer of Breast (hollow form) in transverse section, under a low power (*Bryant*).

points are as follows:—They occasionally disseminate in the adjacent structures. In a case recorded by Shattock<sup>16</sup> nodules of this kind were found adherent to the two upper ribs in a woman aged 60, who died a few weeks after amputation of the breast for the primary disease. They have been found frequently to recur locally after removal. This is known to

---

<sup>16</sup> *Trans. Path. Soc. Lond.*, 1888, p. 324.



have happened in eight out of the eighteen cases in my list. The most striking of these is Butlin's.<sup>17</sup>

His patient was a married woman, aged 64, the mother of several children. Six months before coming under treatment she first noticed a lump the size of a hazel nut in her left breast. When seen she had a tumour the size of a bantam's egg, below and external to the left nipple. It was firm, irregular, and not adherent to the overlying skin, neither did it cause retraction of the nipple. The axillary glands were normal. The breast was extirpated, together with the tumour, which was circumscribed and invested with a thin capsule. It was of brownish-black colour and friable consistence. Two years later she returned with a recurrent tumour,

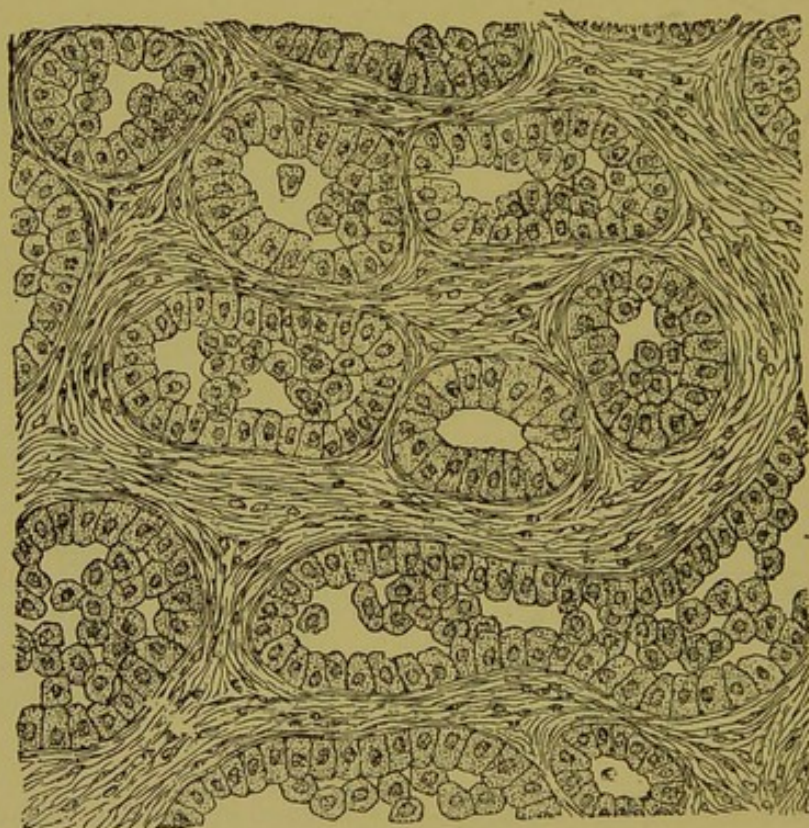

FIG. 56.—Tubular Cancer (hollow form), in transverse section, under a high power (*Formad*).

the size of a walnut, at the axillary end of the scar. It was freely excised, and presented the same appearance as the primary disease. One year and a-half later she came under observation again, with several recurrent nodules in the same situation. They were of a year's growth. These were freely excised, together with the surrounding tissues. They presented the same circumscribed outline and brownish-black colour as the former tumours. Two years and nine months later two fresh recurrent tumours, of some

<sup>17</sup> *Trans. Path. Soc.*, vol. xxxviii., p. 343.



months' duration, were excised from beneath the old scar. Their structure precisely resembled that of their predecessors. The axillary glands were never affected, nor was there any sign of dissemination of the disease in any part of the body. The general health remained unimpaired.<sup>18</sup>

The adjacent axillary lymph glands are occasionally infected by these neoplasms. This occurred in five out of my eighteen cases. Godlee's is a typical instance.<sup>19</sup>

His patient was a childless widow, aged 63, who when first seen had a mammary tumour of four months' duration. It was destroyed by caustic. Three or four months later it recurred in the scar. A year later a small lump was first noticed in the axilla, which in the course of another year had grown into a hard rounded tumour two inches in diameter, and the overlying skin was adherent and red. The breast was amputated, and the axillary tumour was dissected out. On dissection, the mammary tumour was found to be enclosed in a dense fibrous capsule, which contained a considerable quantity of solid dark brown substance, like modified blood-clot, and about two drachms of dark treacle-like blood. The axillary tumour was of similar nature, only it contained less blood. It was described as "an anomalous form of blood cyst." On placing the tumour in water, it was seen to consist of a number of tortuous processes. After hardening it was very friable, and difficult to cut in sections, as these tended to fall to powder. On microscopical examination, there was revealed a scanty fibrillar tissue uniting together a number of tubules, lined by several layers of hexagonal epithelium.

To account for the comparative rarity of lymph gland dissemination, Labbé and Coÿne have pointed out that between the proliferating epithelial zone and the nearest lymphatic lacunæ, a barrier of thick fibrous tissue exists (fig. 57), which must be overcome before the cancer cells can gain entrance into the lymphatics. The slowness with which this is effected indicates, I take it, rather the low degree of malignancy of the new growth, than the strength of the intervening barrier. These neoplasms sometimes cause general systemic dissemination; my list comprises two cases of this kind.

The following example came under my notice a few years ago.

---

<sup>18</sup> In answer to a letter of inquiry, Mr. Butlin has kindly informed me that he last saw this patient in June, 1889, two years and a-half after the last operation. "She then had a small dark tumour below the scar, towards the axilla, and one or two hard enlarged glands in the axilla."

<sup>19</sup> *Trans. Path. Soc. Lond.*, vol. xxvii., 1876.



A healthy-looking multipara, aged 45, thirteen months ago first noticed a lump, the size of a hazel nut, in her left breast. No history of any previous injury or disease of the part. On examination I found an ovoid tumour, the size of a turkey's egg, embedded in the upper and outer part of her large breast. The overlying skin was adherent, and perforated by several sinuses. The tumour was also adherent to the subjacent structures. It was of elastic consistence. No enlargement of the axillary glands. Amputation of the breast and clearance of the axilla. Erysipelas supervened on the seventh day after operation, and soon afterwards acute left pleurisy with effusion, and collapse of the lung, of which she died a few days later. At the necropsy the local disease appeared to have been completely

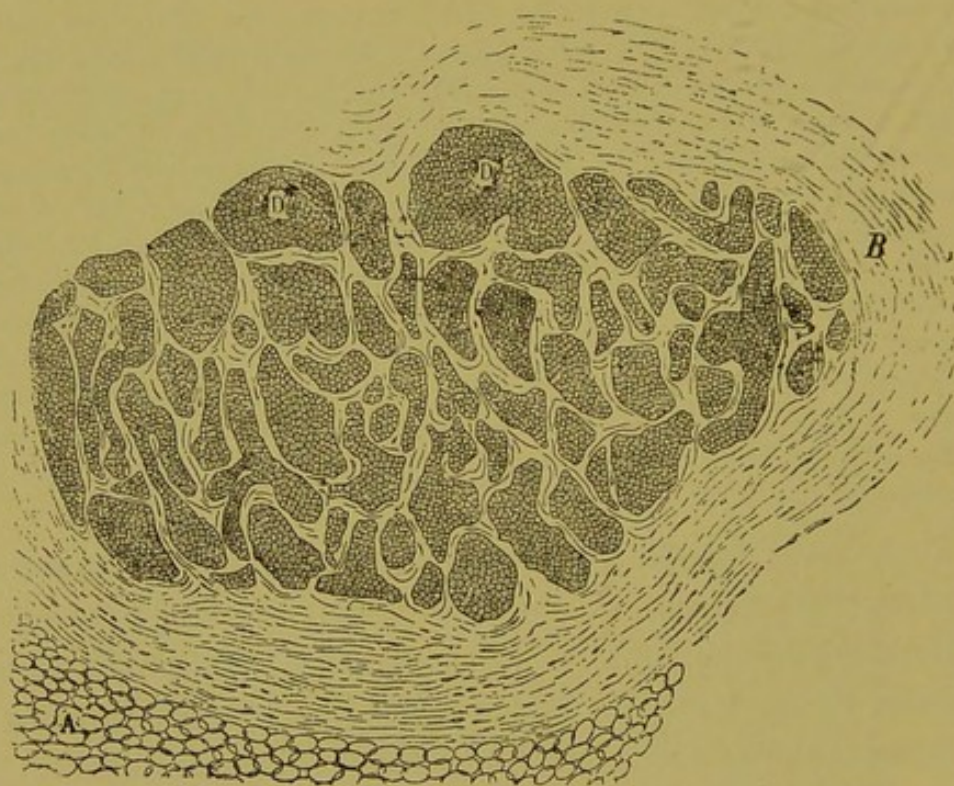

FIG. 57.—TUBULAR CANCER (SOLID FORM) IN TRANSVERSE SECTION.

(a) Fatty tissue. (b) Fibrous capsule. (d) Epithelial cylinders. (*Labbé and Coÿne.*)

removed; but there was a cancerous nodule the size of a walnut in the lower lobe of the right lung. Histological examination of the breast tumour revealed tubular carcinoma.

The first symptom of tubular cancer usually is the presence of a small tumour in the central part of the breast, beneath the nipple or areola. Discharge from the nipple is seldom experienced. Tubular cancers increase much more rapidly than villous papillomas; in less than a year they commonly attain



the size of a hen's egg. Occasionally they burst through the overlying skin, and fungate. In my list there are four cases of this form of cancer in which tumours had been present for long periods, viz., thirty-six, eighteen, fifteen, and seven years respectively. In each of these cases a small tumour had existed for most of the time—whose increase was almost imperceptible—and then during the last few years it had rapidly attained large size. There are several facts about the history of these cases that make me think we here have to do with tubular cancer supervening on villous papilloma of many years' standing, of which I have previously reported a typical instance.<sup>21</sup> The following is a similar case by Labbé and Coÿne.<sup>22</sup>

A well-nourished, healthy-looking woman, aged 67, four years after her only confinement, which was forty years ago, first noticed a small movable tumour in the inner part of her left breast. She had at this time and for two years subsequently sero-sanious discharge from the nipple, which then ceased spontaneously. After this the tumour got larger, then it remained nearly stationary for thirty-three years. At the end of this time it was the size of a small egg. Soon afterwards, without any obvious cause, it began to increase rapidly, and quickly invaded the whole breast. In the course of three years a hard nodulated tumour, the size of a man's two fists, had developed. The nipple was buried in the growth, but not retracted; nor was the overlying skin adherent. Some of the bosses fluctuated. Nothing is said about the condition of the axillary glands. The diseased part was amputated. On examination after removal, the tumour was found to be encapsuled. In addition to the large lobulations and bosses, its surface was thickly studded with small rounded projections. On section its central part consisted of whitish compact lobular structure, and its periphery was occupied by numerous small cysts containing papillary growths and brownish fluid. Microscopical examination of the solid basis of the tumour showed numerous elongated, tortuous, anastomosing cylinders of epithelial cells growing in scanty fibrous stroma. The peripheral cells of these ingrowing processes were regularly arranged and columnar, those within were of irregular shape, and in various stages of granulo-fatty degeneration (fig. 54.).

Tubular cancer supervenes at a much later period of life than villous papilloma, and even than acinous (alveolar) cancer.

<sup>21</sup> *Ch. x.*, § 9, p. 313.

<sup>22</sup> "Traité des Tumeurs Bénignes du Sein," Paris, 1876, p. 343; for the other cases *vide op. cit.*, p. 352; also Gross, "Amer. Syst. Gyn.," vol. ii., 1888, p. 262.



The average age of my cases at the onset of the disease was 53·5 years; the oldest 65·5, the youngest 40. The numbers for each quinquennial period were as follows:—

40 to 45 years	...	...	...	...	in 4 cases
45 „ 50 „	...	...	...	...	„ 3 „
50 „ 55 „	...	...	...	...	in 2 cases.
55 „ 60 „	...	...	...	...	„ 4 „
60 „ 65 „	...	...	...	...	„ 5 „
65 „ 70 „	...	...	...	...	„ 1 case

The only *treatment* of any avail is free extirpation of the affected part, as for acinous cancer.

### § III.—“*Épithéliôme Tubulé.*”

Under this heading French pathologists have described a neoplasm with a fibrous stroma in which are embedded tubular structures full of *flattened*, denticulated, epithelial cells, presenting no signs of epidermic evolution, although they sometimes disintegrate and give rise to cysts.

According to Cornil and Ranvier,<sup>23</sup> growths of this kind are occasionally found in the female breast. They describe them as of slow growth, liable to disseminate in the glands, and as being sometimes recurrent after ablation.

Pean<sup>24</sup> has recorded an instance of a mammary neoplasm answering to this description, which appeared to have arisen from epithelial elements connected with the areola, rather than from the mammary parenchyma itself.

In a similar case by Oppenheimer,<sup>25</sup> the patient, aged 63, had in the upper and axillary segment of her breast a circumscribed tumour, the size of a small tangerine orange. The nipple was retracted, and the overlying skin adherent; but there was no obvious affection of the axillary lymph glands. The tumour had grown very slowly.

<sup>23</sup> “Manuel d’Hist. Path.” t. i., 1869, p. 279.

<sup>24</sup> “Leçons de Clin. Chir.,” 1892, p. 960.

<sup>25</sup> *Bull. de Soc. Anat.*, 1888, p. 744.



## CHAPTER XV.

CANCER OF THE MAMMARY INTEGUMENT.

---

ONE of the most remarkable features about cancer of this part of the breast is its extreme rarity. Notwithstanding the exposed position of the mammary integument, and the frequency with which it is attacked by inflammatory and other lesions, cancers, nevertheless, originate from it much more rarely than from any other part of the organ. Of 1307 cases of mammary cancer brought together by Delbet, in only eleven ( $\cdot 84$  per cent.) did the disease start in this connection; and of the numerous cases tabulated by Gross, only 1.31 per cent. were of like origin. When the disease does spring up in this part, it is almost invariably the nipple and areola that are affected. Cancer arising from any other part of the mammary integument is so exceedingly rare that neither Velpeau nor Billroth, with their large clinical experience, ever met with a single instance, and the number of such cases even now on record may be counted on the fingers of one hand.

Attention was first prominently directed to this subject by Paget's<sup>1</sup> well-known essay, "On Disease of the Mammary Areola preceding Cancer of the Mammary Gland," which was published in 1874. He describes the disease as beginning with an eruption on the nipple and areola, which, in most cases, presents the appearance of a florid, intensely red, finely granulated, raw surface, like that of acute eczema or acute balanitis. It yields

---

<sup>1</sup> *St. Bart.'s Hosp. Reps.*, vol. x., p. 87.



copious, clear yellowish, viscid discharge, and is accompanied by tingling, itching, and burning sensations. In other cases the eruption resembles chronic eczema, with minute vesications, succeeded by soft, moist, yellowish scabs or scales, and accompanied by viscid exudation. Sometimes it is dry, like psoriasis, with a few whitish scabs slowly desquamating. The persons affected were middle aged and elderly women. It will be gathered from this description—so far as gross characteristics go—that the disease in question exactly resembles certain previously well recognised affections of the part usually denominated eczematous. If the reader will compare the account given by Velpeau<sup>2</sup> of these affections—twenty years previously—he cannot fail to be struck with the almost absolute identity in every respect of these two clinical sketches. But the extraordinary feature of Paget's cases is, that after the cutaneous disease had existed for a year or two, it was "very often" succeeded by the formation of scirrhus cancer in the substance of the gland, without there being any obvious connection between the two diseases. So frequently was this sequence observed, that Paget concluded the cancer was probably a consequence of the cutaneous disease, the suggestion being, that the latter induced changes in the subjacent structures, which made them apt to develop cancer. Paget, however, admits that the cutaneous disease may often be cured without any ill consequences ensuing; and this accords with Velpeau's experience, who cured many similar cases with white precipitate ointment. It seems certain, from the rarity with which—as modern statistical observations have shown—mammary cancer is preceded by eczematous disease of the nipple, that Paget has greatly overestimated the frequency with which the latter disease is followed by the former.

One of the earliest to investigate the histology of this affection was Butlin. In his first two cases the areolar disease was

---

<sup>2</sup> "Traité des Maladies du Sein," Paris, 1854.



unaccompanied by cancer of the gland.<sup>3</sup> He found the mucous layer of the epidermis much thickened from hyperplasia, the corium and adjacent subcutaneous tissues infiltrated with small round cells; the galactophorous ducts dilated, and full of epithelial cells, which for the most part were of the flattened instead of the usual subcolumnar, type. The periductal tissues were infiltrated with small round cells. These conditions extended for more than an inch into the subareolar part of the breast. In his next two cases the areolar disease had been succeeded by the formation of cancer.<sup>4</sup> In these the areolar, ductal and periductal changes were of the same nature as in the non-cancerous cases. In one of the latter he was able to trace these changes along the larger ducts to the smaller ones, and so eventually to the acini, which were dilated and filled with proliferating epithelial cells, as in commencing cancer. It will be gathered from this description that Butlin regards the areolar disease and its downward extension, as of non-malignant inflammatory nature.

Thin's<sup>5</sup> account of the histology of four specimens, ascribes the origin of the disease to cancerous change in the epithelium of the galactophorous ducts near their orifices. The disease remains limited to this position for some time, before extending over the surface of the nipple; the areolar affection he regards as a secondary complication, due to the irritant action of the fluid which escapes from the cancerous ducts.

Duhring<sup>6</sup> considers the lesion to be a peculiar disease with a malignant tendency, which starts as abnormal cell proliferation of *rete Malpighii*, and spreads thence by continuity to the lining membrane of the lactiferous ducts, which he found filled with epithelial cells. He describes the middle and lower layers

---

<sup>3</sup> "On the Minute Anatomy of two Breasts, the Areolæ of which had been the seat of long-standing Eczema," *Trans. Med. Chir. Soc., Lond.*, vol. lix.

<sup>4</sup> "On the Minute Anatomy of two Cases of Cancer of the Breast preceded by Eczema of the Nipple," *Op. cit.*, vol. lx.

<sup>5</sup> *Trans. Med. Chir. Soc. Lond.*, vol. lxiv.

<sup>6</sup> *American Jour. Med. Sci.*, July, 1884.



of the corium as infiltrated with epithelial cells, arranged in alveoli, like "atrophic scirrhus." Both of these latter observers describe the areolar disease as having a sharply-defined, slightly raised, hard, sinuous margin, with parchment-like induration of the base, so that the whole, when seized, feels not unlike a penny piece.

From what has been stated it is evident that the condition described by Thin and Duhring is quite different from that investigated by Paget and Butlin. It is specially stated by Paget that in all of his cases but one, the cancerous disease did not start in connection with the mamillary or areolar lesions, nor was induration ever observed in connection with the latter affections. Moreover, in nearly all the cases reported by Paget and Butlin the associated mammary cancer was of the ordinary acinous type, whereas in Thin's cases it was of the tubular type. In one of Butlin's cases<sup>7</sup> the areolar disease was found to present the characters of cutaneous epithelioma—ingrowing interpapillary processes with "nests," &c.; and Paget<sup>8</sup> speaks of the lesions in one of his cases as having assumed—after a time—the appearance of rodent ulcer. Numerous other instances of cutaneous epithelioma originating in this way have since been recorded.

It is evident, therefore, that several varieties of cancer may originate in association with what has been called "Paget's disease," for while some spring from the mammary parenchyma, others take origin from the ducts, and others from the mamillary or areolar structures. Thus the variable progress of the disease may be accounted for.<sup>9</sup> In the presence of these facts we may well ask, with Kaposi, if we have not here to do with certain obstinate cases of eczema of the nipple and areola,

---

<sup>7</sup> *Trans. Med. Chir. Soc. Lond.*, vol. lx.

<sup>8</sup> *Op. cit.*

<sup>9</sup> In some cases the cancer has appeared nearly at the same time as the cutaneous disease; in others not until one, two, three, four, five, six, or ten years afterwards; and in others the cutaneous disease is known to have lasted seven, eight, eleven, twelve, and even twenty years, without cancer ever having developed.



complicated with one or other of the various forms of cancer, rather than with a special, mysterious, morbid entity.

The announcement in 1889, that Darier<sup>10</sup> had discovered parasitic protozoa-like bodies in connection with the epithelial cells in this disease marked a new epoch in its history; and the affection soon became the cynosure of pathological eyes, for the problem of the origin of cancer seemed to concentrate in it. These bodies he describes as amœba-like protoplasmic cells, becoming after a time nucleated and encysted, and looking very

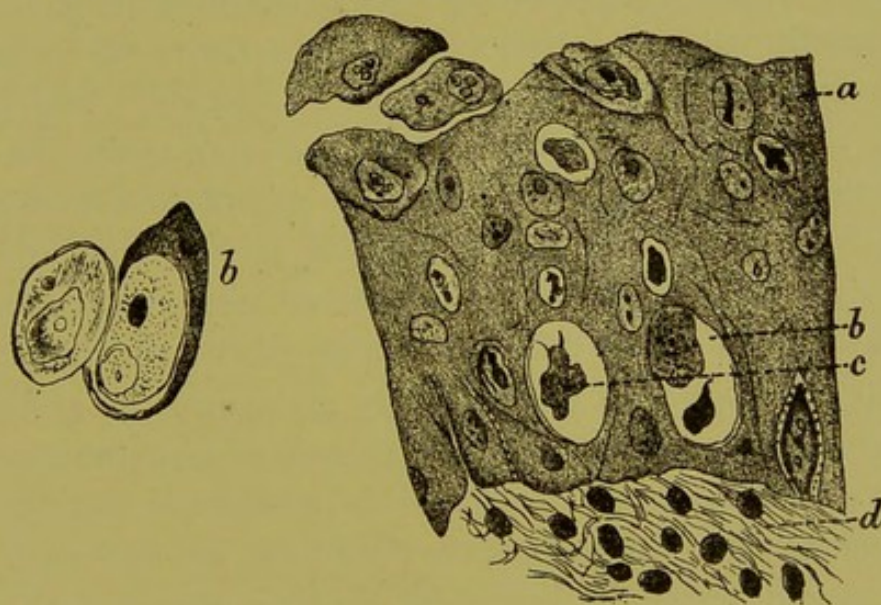


FIG. 58.—PSEUDO-PARASITIC BODIES IN CONNECTION WITH "PAGET'S DISEASE"  
(Hutchinson, jun.).

(a) Hyperplastic epidermic cells. (b) Coccidia-like bodies with their contained psorospermia (c) embedded in the *rete*. (d) The subjacent corium with leucocytes.

like psorospermia. They were found mostly within the epithelial cells of the affected part, chiefly in connection with those of the *rete Malpighii* and of the lacteal ducts. To their presence Darier attributed both the areolar disease and the associated cancer. Wickham,<sup>11</sup> Hutchinson,<sup>12</sup> Bowlby,<sup>13</sup> and others soon followed in the same strain.

<sup>10</sup> "Sur une nouvelle forme de psorospermose cutanée, &c.," *Comptes Rendus de la Soc. de Biol.*, 13 av., 1889.

<sup>11</sup> *Arch. de Méd. exp.*, No. 1, 1890, p. 46.

<sup>12</sup> *Trans. Path. Soc. Lond.*, vol. xli., 1890, p. 214.

<sup>13</sup> *Trans. Med. Chir. Soc. Lond.*, 1891.



One of the first to repudiate Darier's conclusions was Borrel.<sup>14</sup> The so-called psorosperms he regarded as the products of degenerative changes and of endogenous cell proliferation. As to their etiological significance, he points out that they have been found in association with various non-malignant affections, such as papillomata, *psorospermiosis follicularis vegetans*, and in the thickened edges of tubercular ulceration, and that in typical instances of Paget's disease they are sometimes absent. Moreover, as all attempts at cultivations and inoculations have hitherto failed, Borrel explicitly denies the parasitic nature of these bodies. In this view he is supported by Thin,<sup>15</sup> Fabre-Domergue,<sup>16</sup> Delépine,<sup>17</sup> and others. It will thus be seen that we here have over again, the same battle that has raged so fiercely with regard to the origin of cancer in general; and the conclusion now arrived at is the same, viz., that the evidence hitherto adduced as to the existence of specific cancer microbes is altogether inconclusive.

This being so, it would be a very grave error to proceed to the extirpation of every breast affected with chronic erosive disease of the nipple and areola, in the absence of distinct signs of cancer, as some surgeons have done; for, as previously mentioned, recent statistical investigations have shown that only a small minority of these cases are ever complicated with the outbreak of cancer. Of course, when there is evidence of the latter disease having developed, the same treatment must be adopted as for cancer of the gland. Otherwise the appropriate treatment is, first of all to wash the diseased part with an antiseptic lotion, such as carbolic acid (1 in 20), hyd. perchlor. (1 in 1,500), or zinc. chloride (gr. xx. ad ʒj.) and then to keep constantly applied, boric acid, salicylic acid, or ammoniated

---

<sup>14</sup> "Sur la signification des figures décrites comme coccides dans les épithéliomes," *Arch. de Méd. exp.*, t. ii., 1890, p. 786.

<sup>15</sup> *Brit. Med. Jour.*, May 16, 1891.

<sup>16</sup> *Sem. Méd.*, 11 av., 1891.

<sup>17</sup> "Cultivation of Psorospermia," *Trans. Path. Soc. Lond.*, vol. xlii., 1891, p. 371.



mercury ointment, to either of which 5 per cent. of resorcin may be advantageously added.

As examples of cancer originating in association with chronic erosive disease of the nipple and areola, the following cases are instructive :—

(1)<sup>18</sup> A woman, aged 46, who for four years had suffered from chronic eczematous disease of the left areola and the adjacent parts. The eroded area was four inches in diameter, of pinkish red colour, with numerous smooth, pale, shining spots ("îlots épidermisés") scattered over it. The nipple was retracted. A few months before the patient first came under observation there was noticed in the breast, some distance below the eroded areola, a hard cancerous lump. The axillary glands soon became implicated, and the tumour increased in size. The whole breast was then extirpated, and the axilla cleared. After hardening in the usual manner, sections of the skin were made perpendicularly to the surface and stained with hæmatoxylin, picro-carmin, carmine, &c., and then examined especially for alleged psorospermia, numbers of which were found (fig. 58). The best way of estimating their number was by soaking surface scrapings in *liquor potassæ* for half an hour, and then mounting in Farrant's solution. The breast tumour was, for the most part, of the usual acinous type of cancer, and there was dissemination of the disease in the axillary lymphatic glands. The coccidia were found oftenest in the deepest cells of the *rete Malpighii*. The opposite breast was normal. No one has yet succeeded in finding a distinctive stain for these pseudo-parasitic bodies.

(2)<sup>19</sup> A married woman, aged 54, the mother of eight children, the youngest of whom was born twelve years ago. Fifteen years ago, when suckling her seventh child, she had sore nipples and her breasts were inflamed. With this exception, she never had anything the matter with her breasts until the present disease began, three years before she first came under observation, when the right nipple became tender, inflamed, and eroded, exuding a watery discharge. When first seen she complained of severe pain in the right breast, which was eroded for two inches around the nipple. The base of the ulcer was smooth and red, slightly lower than the surrounding skin, and there exuded from it copious discharge, which stiffened linen. There was no family history of cancer. The application of oxide of zinc, &c., failed to cure the disease. Three years later the ulcerated area extended for three inches round the nipple, and it was acutely painful, and discharged freely. A few months previously a hard mass was first noticed in the middle of the breast, beneath the nipple, and soon afterwards the axillary glands were noticed to be enlarged. She was advised to have the disease extirpated, but could not make up her mind to it until about four months later. The breast was then removed and the axilla cleared. About seven and a-half months

<sup>18</sup> J. Hutchinson, jr., *Trans. Path. Soc. Lond.*, vol. xli., 1890, p. 214.

<sup>19</sup> H. O'Neill, *Brit. Med. Journal*, Ap. 8, 1891, p. 846.



later several small, hard nodules of recurrent cancer were felt in the skin of the right axilla, just below the cicatrix; also in the skin over the external condyle of the right humerus. She complained of pain in the hepatic region, and the liver felt enlarged and nodulated. The right supra-clavicular gland, soon afterwards became enlarged. She died exhausted about six weeks later. There was no necropsy. Histological examination of the surface disease showed the usual appearances met with in such cases, the small, round-celled infiltration being particularly abundant. Double contoured coccidia-like bodies in great numbers were found in connection with the epidermic cells; but none could be detected in connection with the cancerous disease of the breast, which was of the ordinary acinous type. The sections were stained with Neelson's fluid, picro-carmin, safranin, and logwood. In scrapings treated with *liquor potassæ*, fewer quasi-parasitic bodies were found than in the preceding case.

(3)<sup>20</sup> A lady, aged 58, with intractable eczematous affection of the left nipple and a hard nodule in her breast; the former lesion of six months' duration. The areola was not involved. The nipple was abraded, and covered at its base with thick, sticky substance. From its base there was prolonged downwards into the substance of the breast for about one and a-half inches, a hard cord, which ended in an indurated nodule, the size of a horse bean. The overlying skin was mobile, and free from puckering, and the axillary glands were not obviously enlarged. A month later the middle third of the breast, including the diseased parts, was excised. On section, the small tumour presented a firm, yellowish-white, cupped appearance just like ordinary scirrhus. Twenty months later the patient was well, and free from any return of the disease. Histological examination showed that the horny layer of the epidermis had almost completely disappeared from the nipple; the *rete* was here much thickened; both it and the subjacent corium were densely infiltrated with small, round cells; the sebaceous glands of the part were hyperplastic, the galactophorous ducts were distended with epithelium of a subcolumnar type, and often multi-nucleated. The deeper ductal and peri-ductal structures were similarly affected. The subjacent tumour was ordinary acinous, spheroidal-celled cancer. Nothing is said as to the presence of pseudo-parasitic bodies.

So exceedingly rare is it for cancer of the mammary integument to arise in any other connection, that I can cite only the following instances:—

Czerny's<sup>21</sup> patient was 53 years old, and she suffered from hereditary tuberculosis. She was the mother of four healthy children, all of whom she suckled. In February, 1885, superficial swelling of the left areola was first noticed, which in April began to ulcerate. In December the left mamma

<sup>20</sup> G. Barling, *Trans. Path. Soc. Lond.* vol xli., 1890, p. 219.

<sup>21</sup> *Cent. f. Chir.*, No. 24, 1886, S. 28, in the Supplement.



appeared full, and the nipple projecting; the skin of the areola was replaced by a hard, shallow, epitheliomatous ulcer, the edges of which were hard and irregular; its base, uneven and hard, secreted a yellowish-red watery discharge. The subjacent mammary gland was hypertrophied, but not involved in the disease. There was no obvious infiltration of the axillary glands, but several of those above the clavicle were enlarged and hard. For the purpose of diagnosis a portion of the disease was scraped away with a sharp scoop. On microscopical examination of these fragments the disease proved to be squamous-celled epithelioma, which had probably originated from the interpapillary processes of the *rete*. The breast was amputated shortly afterwards, and the infiltrated lymph glands were removed. The glandular tissue of the mamma was found, on microscopical examination, to be quite free from cancerous change; but the lymphatic glands were distinctly cancerous. The patient made a good recovery, but she returned three months and a-half later with a recurrent ulcer the size of a florin at the outer end of the scar in the chest. This was destroyed with the thermo-cautery. Czerny points out that the condition he has here described is quite different from that known as Paget's disease.

Bryant mentions having seen epithelioma of the areola arise from a suppurating, sebaceous cyst in a middle-aged woman; just as similar disease sometimes supervenes in connection with suppurating "wens" of the scalp.

On this subject, Brodie<sup>22</sup> long ago published the following original observations:—

"A scirrhus tumour may occur in the nipple, and I believe that this may properly be distinguished from a scirrhus tumour of the breast itself, and that there is a greater chance of a permanent cure from an operation, where the disease originates in the nipple than where it originates in the breast. There was a lady who has had such a tumour of the nipple. She consulted several surgeons about it, and as the disease was in a quiet state, it was recommended that it should be let alone. After some time she came to London, and was under the care of the late Mr. Rose, and I saw her with him. The tumour was still confined to the nipple, and had been going on for some years without coming to any harm, but it was now making progress. The result of the consultation was that Mr. Rose removed the breast, which appeared sound, the disease being confined to the nipple and its immediate vicinity. She recovered, and I have reason to believe that the cure was permanent.

"Another lady consulted me concerning a scirrhus tumour of the nipple, for so I call it, as it was of stony hardness, and presented the usual characters of that disease. The tumour was in a state of ulceration. She was a stout, elderly lady, with an enormous breast, and a great deal of adeps over it." In this case the disease was destroyed with chloride of zinc paste and caustic potash. She was free from any return three or four years after the operation.

---

<sup>22</sup> "Lectures on Pathology and Surgery," 1846, p. 201.



In the same lecture<sup>23</sup> Brodie also refers to some instances of disease which he believes to have been cancer of the mammary integument as follows:—

“A hard tumour sometimes forms on the surface of the breast, which feels like scirrhus, and on cutting into it, it looks like it, so that I can give the disease no other name. It appears to be unconnected with the breast, but when you remove it you find that it is attached to the surface of the gland just at one narrow corner. I have removed three tumours of this kind, leaving the breast untouched, except where I separated the tumour from it; and in each of these three cases I learned that the patient continued well a considerable time afterwards. Indeed, I do not know that in any one of them there has been a return of the disease.”

In the *Hunterian Museum* are two specimens of epithelioma of the nipple, but of neither of them are the histological details quite satisfactory.

(1) No. 4,820.—Breast with a discoidal, thin-edged excrescence projecting from the nipple. It has in parts a warty aspect. Beneath this is a soft neoplasm, and deeper still diseased breast tissue and dilated ducts. From a sterile married lady, aged 58. The nipple first became enlarged and tender six months previously. The breast was amputated, but she died with recurrence *in situ* subsequently.

(2) No. 4,821.—The nipple is occupied by a small nodular tumour, composed of numerous small papillæ, and surrounded at its base by a slightly raised fold of skin. The papillæ are lined by squamous epithelium in various stages of evolution. The deeper structures are infiltrated by epithelial ingrowths. The patient was a single woman, aged 25, and the disease was of six months' duration. It was excised, but recurred. The recurrent disease was treated by repeated applications of acid nitrate of mercury, and at length it completely disappeared. When last heard of five years later she was free from any return of the disease.

A few instances of cutaneous epithelioma have been observed in connection with *intertrigo* of the thoracico-mammary groove. Richet<sup>24</sup> and Winiwarter<sup>25</sup> have each recorded a case of this kind. Mayor and Quénu<sup>26</sup> have met with similar disease developed from the cicatrix of a burn.

<sup>23</sup> *Op. cit.*, p. 200.

<sup>24</sup> *Gaz. des Hôp.*, No. 122, 1883.

<sup>25</sup> “Beiträge z. Statistik der Carcinome,” Stuttgart, 1878.

<sup>26</sup> *Rév. de Chir.*, 1881, av. 4, p. 990.



## CHAPTER XVI.

## CANCER OF THE MALE BREAST.

MOST treatises on diseases of the breast dismiss this subject in a few lines. Considering the large number of well-recorded cases now available for study, such a state of things is extremely unsatisfactory. That fuller information about cancer of the male breast is desirable, both on its own account, and because of the value of such knowledge as a factor in the solution of many problems relating to cancerous disease in general, I have not the slightest doubt. Therefore, I have undertaken the present investigation, which is based on the records of one hundred cases, collected from various sources, and on information otherwise derived.

With regard to the *relative frequency* with which mammary neoplasms originate in the two sexes, as I have previously mentioned (chap. vii.), nearly 99 per cent. occur in females, and only about 1 per cent. in males. Similarly, of 1,879 mammary cancers only sixteen, or one in 117, were males. This is a good illustration of the law that obsolete structures have but little tendency to take on cancerous or other neoplastic action. Of the twenty-five neoplasms of the male breast in my list, sixteen were cancers, three sarcomas, two myxomas, and one case each of fibro-adenoma, angioma, lipoma, and cystoma. Of 269 similar cases collected by Schuchardt,<sup>1</sup> 244

---

<sup>1</sup> *Arch. f. klin. Chir.*, Bd. xxxi., 1885, S. 57.



were cancers, three sarcomas, three fibromas, two fibro-adenomas, fifteen cysts, one enchondroma, and one myoma.

A predisposing cause to cancer and other tumours of the male breast may be, as Creighton suggests, the undue persistence in certain cases of an unusual amount of glandular parenchyma, together with corresponding impulses to imperfect functional activity.

Cancer of the male breast, like that of the female, may originate either from the acini, the ducts, or the integument. Of my 100 cases 91 were of the acinous variety (melanotic two), six of the tubular (cylinder-celled duct cancers), and three were squamous-celled epitheliomas (melanotic one). It appears from this that the male breast is relatively more liable to the tubular variety of cancer (which originates from the ducts) than the female. This is only what one might have expected *à priori*, because in the normal condition of the male breast ducts predominate, and acini are but imperfectly developed. It will also be gathered that cancer of the mammary integument is of much more frequent occurrence in males than in females. This accords with the distribution of integumentary cancer in general, which is met with much oftener in males than in females. Another fact worth noting, is the comparatively frequent occurrence of melanotic cancer in the male breast (3 per cent.). Growths of this kind in general, arise much more frequently in connection with structures of integumentary origin than with any others. In the male breast we have to do with a structure of this kind, which, having lost most of its special characters, is in process of reversion to the primordial cutaneous condition, out of which it formerly evolved. Herein we may find an explanation of its comparative proneness to melanosis.

Of the ninety-one acinous cancers three were described as "encephaloid," but as in all these cases the histological examination was wanting, nothing special need be said about them. I will only remark, that of the numerous mammary cancers examined by me, I have never met with a single instance of encephaloid acinous cancer; all the supposed examples of this



kind, on histological examination, proved to be either *carcinoma myxomatodes*, tubular cancer, sarcoma, myxoma, or villous papilloma.

I will now set forth the results of an analytical summary of the remaining eighty-eight *acinous* cancers, leaving the others for separate treatment.

*Age.*—The earliest age at which the disease was first noticed (in eighty-eight cases) was 20 years, the latest 82 years, the mean age 50 years. In the subjoined table the numbers for each quinquennial period are given, calculated on the percentage basis, and for comparison I have appended the corresponding numbers in cancer of the female breast :—

Sex.				Total number of cases.	20 to 25 yrs.	25 to 30 yrs.	30 to 35 yrs.	35 to 40 yrs.	40 to 45 yrs.	45 to 50 yrs.	50 to 55 yrs.	55 to 60 yrs.	60 to 65 yrs.	65 to 70 yrs.	Over 70 yrs.	Mean age.	Earliest age.	Latest age.
Males	..	..	..	88	2	2	9	12	11	17	15	12	7	3	10	50	20	82
Females	..	..	..	500	0.6	4	6	14	16	20	15	10	9	3.2	2.2	48	22	84

It will be seen from this table that the average age at which the disease originates in males is two years later than in females. It is further noticeable that a relatively large number of the male cases begin over 70. In most other respects there is remarkable similarity as to the age distribution in the two sexes. Not a single case originated in either sex under the age of 20.

*Total Duration of Life.*—In eighteen fatal cases the total duration of life, dating from the time when the disease was first noticed, averaged sixty-one months, which is about eight months longer than the average duration of the disease in the opposite sex. Of the above cases, 5 had undergone amputation of the breast, &c.; in these the duration of life averaged about 124 months, or 20.5, 27, 117, 182, and 273 months each. In the other 13 cases no operation had ever been performed; in these the duration of life averaged 38 months, the shortest period 11 months, the longest 85 months.

*Duration of Life subsequently to Amputation for the primary Disease.*—This was noted in 6 cases, it averaged nearly 60



months. The exact duration in each case was as follows: 26 days, 1 month, 5, 13, 78, and 260 months. In 25 similar cases of the female breast I found the average period was about 40 months, the longest 259 months.

*Interval between first Operation and first obvious Recurrence.*

—In 14 cases this averaged 9·7 months, the maximum 32·5, the minimum 1·5 months. In females, according to my observations, the average interval is 26 months. The following figures further illustrate this subject:—

3 months and under ...	...	...	...	...	in 3 cases
3 to 4 months ...	...	...	...	...	" 5 "
8 months ...	...	...	...	...	" 1 case
10 " ...	...	...	...	...	" 1 "
13 " ...	...	...	...	...	" 1 "
19·5 " ...	...	...	...	...	" 1 "
26·0 " ...	...	...	...	...	" 1 "
32·5 " ...	...	...	...	...	" 1 "

*Civil state.*—Of 12 cases, 7 were married, 2 widowers, and 3 single. Particulars with regard to offspring are given in 3 cases: one was the father of 6 and another of 15 children, the other had no offspring. In 38 cases the occupation had been as follows: butcher, gentleman, and carpenter each in 3 cases; sailor, compositor, merchant, teacher and clerk, each in 2 cases; soldier, brass-finisher, 'bus conductor, piano factory, chimney-sweep, clergyman, blacksmith, locksmith, publican, labourer, waggoner, hospital attendant, plasterer, peasant, bootmaker, carrier, coachman, stone sawyer, and hall porter, each in 1 case.

*The Side affected.*—Right side in 38 cases, or 53 per cent.; left in 33 cases, or 47 per cent. In females the left breast is always the more frequently affected. In 4 of the above 88 cancers of the male breast both breasts were affected on admission, but in no instance were both breasts primarily affected. Similarly of 151 cases in females, in 7 both breasts were involved on admission.

*Seat of initial Lesion.*—This was noted in 14 cases; in 8 the disease was central, being situated underneath the nipple; in 3 it was near the nipple; in 1 below the nipple and to its axillary side; in 1 below and to its sternal side; and in 1 above the nipple and to its axillary side.



*Character of initial Lesion.*—In 42 cases this was as follows :—Small nodule or lump (varying in size from a pea to a hazelnut) in 30 cases ; enlargement and induration of gland in 5 ; redness, soreness, or induration of nipple or areola (Paget's disease) in 7.

*Discharge from the Nipple.*—This was noticed during the course of the disease in 7 out of 88 cases ; it was sanious in 4, puriform in 2, and lactiform in 1. According to Gross, females are liable to similar discharges in 15 out of 207 cases.

*Previous Injury or Disease of Breast.*—Of 30 cases there was a history of previous injury or disease in 16, or 53 per cent., as compared with 43 per cent. in females. The injuries are described as contusions in 10 cases, recurrent pressure at work in 2, and strain in 2. The only previous diseases noted were two cases of long-standing eczema of the nipple and areola.

*Previous Health.*—This was stated in 13 cases. It had been good in 11 (with no serious illness since youth in 3), and bad in 2 cases. The following previous diseases were noted as having occurred since childhood :—Pneumonia and migraine each in 2 cases ; tubercular arthritis of knee, hæmorrhoids, eczema, erysipelas of face, herpes zoster, chancre, gonorrhœa, epilepsy, and dyspepsia each in 1 case. With regard to the patient's habits, 3 are said to have been temperate and 3 intemperate. As to syphilis, inquiries were made in 7 cases, but there was evidence of this disease only in 1.

*Family History.*—Of 29 cases in which inquiries were made, there was history of cancer in 7 families, or in 24 per cent. The relatives thus affected and the seats of the disease may be shown as follows :—

Father's mother (one family)	...	...	Locality not stated.
Father's sister (one family)	...	...	Breast.
Fathers (four families)	...	...	<div> <div>Neck.</div> <div>Liver.</div> <div>Breast.</div> <div>Locality not stated.</div> </div>



Mothers (three families)	...	...	...	...	...	{ Tongue. Lip. Locality not stated.
Patient's sisters (two families)	...	...	...	...	...	{ Breast. Locality not stated.

Thus of the 7 cases in which the seats of hereditary disease are stated, the breast was affected in 3. In 3 cases there was history of cancer in more than a single relative:—(1) Father died of cancer of neck, and mother died of cancer of tongue; (2) father died of cancer (locality not stated), and 2 of patient's sisters (1 of breast, the other locality not stated); (3) father's mother and patient's mother both died of cancer (locality not stated).

*Duration of the Disease from the time it was first noticed until the patient came under observation.*—In 86 primary cases this averaged 29·5 months; in 119 primary cancers of the female breast the average was 26·5 months. The following statement further illustrates this subject:—

Under 6 months	...	...	...	...	...	in 7 cases
6 to 12 "	...	...	...	...	...	" 15 "
12 " 18 "	...	...	...	...	...	" 14 "
18 " 24 "	...	...	...	...	...	" 7 "
24 " 30 "	...	...	...	...	...	" 12 "
36 " 42 "	...	...	...	...	...	" 11 "
42 " 48 "	...	...	...	...	...	" 1 case
48 " 54 "	...	...	...	...	...	" 10 cases
60 " 66 "	...	...	...	...	...	" 2 "
78 " 84 "	...	...	...	...	...	" 3 "
104 "	...	...	...	...	...	" 4 "

In 10 recurrent cases the duration of the disease when the patient first came under observation had averaged 62 months, as compared with 75 months in 39 cases of recurrent cancer of the female breast. In 2 cases the duration of the disease had exceeded 102 months—viz., 129 and 130 months respectively.

*State on Admission.*—Of 26 primary cases, 20 were well nourished (obese 4, sallow 1); of these, 9 were ulcerated and 11 non-ulcerated. The other 6 cases were weak and emaciated (sallow 2); of these, 5 were ulcerated and 1 non-ulcerated. In



14 of the above cases retraction of the nipple was noted. In 2 cases the primary disease had assumed the atrophic form, in 2 cases the diffuse discrete form, and in 1 case the *en cuirasse* form; in the others it presented as a more or less circumscribed mass. Of 3 recurrent cases, 2 were non-ulcerated (1 well nourished, 1 weak and emaciated); 1 was ulcerated, the patient being weak, emaciated, and sallow.

*The Axillary Glands, &c.*—Of 68 primary cases, there was obvious enlargement of the axillary glands in 43, or in 63 per cent. In 2 cases the glands near the clavicle were affected as well; both of these were ulcerated. Of the 43 cases in which the axillary glands were affected, 26 were non-ulcerated and 17 ulcerated. Of 25 cases in which there was no obvious affection of the axillary glands, 20 were non-ulcerated and 5 ulcerated. Of 12 recurrent cases, there was obvious enlargement of the axillary glands in 4 (clavicular glands as well in 1 non-ulcerated case); of the latter, 2 were ulcerated and 2 non-ulcerated. The other 8 cases, in which there was no glandular affection, were all non-ulcerated.

*Treatment and Result.*—The treatment of cancer of the male breast should be conducted in accordance with the same principles as cancer of the female breast; free extirpation of the *pectoralis major* muscle being even more imperative in males than in females. Of 56 amputations of the breast for primary cancer there were only 2 deaths—a mortality of 3·6 per cent. In 20 of these cases the axillary glands were removed as well; the 2 fatal cases belong to this category. Both of them died of septicæmia about a month after the operation. With regard to the other cases, the ultimate result is stated only in 3; in all there was recurrence: (1) in the axilla two years and three-quarters after the operation, with subsequent invasion of the thorax by direct extension; (2) in the chest three months after the operation, and death twelve months later, with metastatic deposits in liver and bones; (3) in the chest a few months after the operation; this was destroyed with caustic several times, but it returned and increased rapidly. The average period of convalescence in 8 of the above cases was thirty days.



In the other 36 cases the axillary glands were not touched. All of these recovered. The average period of convalescence in 6 cases was eighteen days. The ultimate result is mentioned in 14 cases as follows:—One was well eleven years after the operation, and quite free from recurrence; another died six years after of apoplexy, without any recurrence. In the other 12 cases there was recurrence—in the chest in 9, opposite breast in 2, and the axilla in 1. In 6 of these the recurrent disease was extirpated; all recovered from the operation. The ultimate result was as follows:—(1) Four months after amputation of the breast for the primary disease there was recurrence in the opposite breast; this was amputated. There was no further recurrence in either chest or axilla; but  $2\frac{1}{4}$  years after the last operation a recurrent nodule formed in the skin of the hand, which was successfully excised. (2) At the primary operation both breasts were amputated. There was recurrence a year later in the left axilla. This was excised. The disease recurred six years later in the left chest and axilla. Two years later he was reported dying from invasion of the thorax by direct extension. (3) Soon after amputation of the left breast for primary cancer, recurrence was noticed in the chest. In the course of ten years it increased to the size of an orange, and several discrete hard nodules developed at the axillary end of the scar, but there was no obvious affection of the axillary glands. At the end of this time the recurrent disease was excised. There was no subsequent return of the disease in the chest or axilla, but eleven years afterwards the patient died with cancerous growths in the liver and in the cardiac part of the stomach. (4) There was recurrence in the chest seven months after amputation of the breast for the primary disease. This was excised, but there was further recurrence soon afterwards. (5) The disease recurred in the opposite breast a month and a-half after amputation of its fellow for the primary disease. This breast was also amputated; he was convalescent ten days later. (6) Recurrence in the chest eight months after amputation of the breast for the primary disease.



Four months later this was excised; but the disease subsequently recurred in the chest.

*Initial Seat of the Recurrent Disease.*—This was noted in 14 cases:—In 10 the disease was seated in the mammary region. (No glands were removed at the primary operation in 4, glands were removed at the primary operation in 2, not stated in 4.) In 2 it was situated in the opposite breast. (No glands in either case were removed at the primary operation.) In 2 it occupied the axillary glands. (At the primary operation the glands were removed in 1, and not touched in 1.)

*Causes of Death.*—In 18 fatal cases the causes of death were as follows: asthenia, with metastatic growths, in 7 cases; invasion of thorax by direct extension in 6 cases, not stated in 2 cases, septicæmia (after operation) in 2 cases, apoplexy (without any recurrence) in 1 case.

*The Necropsies.*—Of these only 10 were recorded. There were metastatic deposits in 7 cases, or in 70 per cent. In two other cases the thorax, lungs, &c., were invaded by direct extension. In these 7 cases the metastatic deposits were situated as follows: in the liver in 3 cases, lungs and pleura (both 2, right 1) in 3, and bones in 3; kidneys (both) in 1 case; bladder in 1; peritoneum in 1; stomach (cardiac part) in 1; and pancreas in 1. The following were the bones affected: both clavicles and tibiæ, the vertebræ and other bones, the sphenoid and base of skull, each in one case. Thus of these 10 necropsies there were metastatic deposits in the bones in 30 per cent.

*Secondary Deposits in the Bones.*—Of 88 cases secondary deposits in the bones were noticed in 5. Subjoined are brief abstracts of these cases:—

(1) The patient, aged 42, had a mass of hard cancer, the size of a hen's egg, occupying his right breast, which infiltrated the overlying skin and the axillary glands. It was of eight years' duration. The breast was amputated and the axilla cleared out. On microscopical examination alveolar fibrous cancer was found. Three months later there was recurrence of the disease in the chest. Shortly afterwards, in raising his arm, spontaneous fracture of the right clavicle occurred, and at the seat of fracture a cancerous tumour



soon formed. Subsequently cancerous growths developed in both tibiae. He died of asthenia a year after the operation for the primary disease. At the necropsy the whole of the soft parts of the right mammary region were extensively infiltrated by a dense fibroid cancerous growth, which had invaded the subjacent ribs and the sternum by direct extension. There were secondary deposits in both clavicles and tibiae, as well as in the liver.

(2) The patient, aged 40, came under observation with ulcerated scirrhus of the breast, and extensive nodular infiltration of the skin and adjacent soft parts and axillary glands. The disease was of five years' duration. He died shortly afterwards with secondary deposits in the sphenoid and base of skull.

(3) This man, aged 45, had a hard nodular cancer of the right breast, with infiltration of the overlying skin and axillary glands. No operative treatment was undertaken. He died with extensive cancerous growths in the vertebrae and other bones. The total duration of the disease was thirteen months.

(4) The disease began as a hard nodule, the size of a marble, in the right breast, a year before the patient came under observation. It soon increased to the size of a walnut, and the axillary glands became enlarged. The patient, whose age was 45, was emaciated; and, after he had been under treatment but a short time, he sustained spontaneous fracture of the right humerus at its lower third when turning in bed. About this time he complained of pain in all the limbs; and he died shortly afterwards with symptoms of secondary disease of the lungs.

(5) This patient, aged 48, had ulcerated scirrhus cancer of the left breast of four months' duration, and a cancerous growth of the left clavicle.

I will now conclude with brief abstracts of some cases of cutaneous epithelioma, and tubular cancer.

*Cutaneous Epithelioma of the Male Mamma.*—Of this there were in my list the three following cases:—

(1)<sup>2</sup> The patient, aged 63, came under treatment with a hard cancerous ulcer of the mammary region the size of a walnut. It was of a year's duration, and ulceration began after the disease had existed for six months. He had experienced several hæmorrhages from it. The disease was extirpated. The histological examination was made by Cornil, who described it as an example of "*épithéliôme pavimenteux lobulé*," which probably originated in the skin of the areola.

(2)<sup>3</sup> The age of the patient was 47. He came under treatment with a hard cancerous ulcer of the breast and infiltration of the axillary glands. The disease was first noticed five years previously as a hard lump at the left nipple. Ulceration began eighteen months ago. On microscopical examination it proved to be "squamous-celled carcinoma."

<sup>2</sup> Bernadet's case, quoted by Horteloup.

<sup>3</sup> Barling's case, *Brit. Med. Journ.*, vol. i., 1887, p. 883.



(3)<sup>4</sup> A tall, thin, dark, neurotic man, aged 41, came under observation with epitheliomatous ulceration of the areola, in the midst of which the nipple was still visible. The disease seemed to consist of indurated *plaques* in the skin, which were movable over the subjacent soft parts. In the edges and base of the ulcer a blackish tint was obvious. The axillary glands were enlarged. He stated that the disease began five years previously as a small wart in the skin of the areola; ulceration set in six months ago. His mother died, aged 60, of "cancer of the bowels." His previous health had been good, although he had suffered from dyspepsia and emphysema. He had led a regular life under favourable conditions. The breast was amputated, and the axillary glands removed. On microscopical examination it proved to be a case of melanotic cancer of the skin of the areola, and the axillary glands were similarly affected. The patient recovered from the operation, but recurrence set in before complete healing of the wound. This was destroyed by Vienna paste; but it rapidly recurred in the chest and axilla. One year after the first operation he was in a moribund condition, with extensive recurrent disease invading the thorax and secondary disease of the liver.\*

Le Dentu<sup>5</sup> has met with an interesting case of "*Epithéliôme pavimenteux lobulé, corné, d'apparence calcifiée*" of the areola in a man aged 44; and Robinson<sup>6</sup> has lately recorded an instance of *rodent ulcer* of the male nipple.

The following example of "*Paget's disease*" of the male nipple is by Forrest.<sup>7</sup>

The patient, 72 years old, nine months ago first noticed that a lactescent secretion escaped from his right nipple. This dried and formed a scab, on removing which, the subjacent skin was found red and eroded, and fresh scabs soon formed. Three months later retraction of the nipple set in; and shortly afterwards enlarged glands were noticed in the axilla. On examination six months later scirrhus cancer was found to have developed in the breast.

Nunn<sup>8</sup> has seen a case of ulcerated cancer *over the sternum* in a man aged 62; the disease was first noticed ten years previously, when it appeared as "a small scaly patch."

*Tubular Cancer of the Male Mamma.*—As examples of this condition, abstracts of the following cases will suffice:—

(1) This patient came under my own observation. He was a well-nourished, dark complexioned, sallow man, aged 64, a joiner by trade. One

<sup>4</sup> Chênét's case, quoted by Poirier, p. 50.

\* For other examples of melanosis of the male breast *vide* p. 333.

<sup>5</sup> *Bull. et. Mém. de Soc. de la Chir.*, 1885, t. ix., p. 1887.

<sup>6</sup> *Trans. Path. Soc.*, 1893.

<sup>7</sup> *Glas. Med. Journ.*, vol. xiv., p. 457.

<sup>8</sup> "Cancer of Breast," p. 118.



and a-half years previously he first noticed a hard lump, the size of a marble, beneath the right nipple. There had been no previous injury or disease of the part. His previous health had been very good, with the exception of a severe attack of eczema—fourteen years ago—which involved almost the whole body. He continued to be subject, more or less, to this affection, until the present disease began. There was no history of cancer or phthisis in the family. On examination I found that the right nipple and areola had completely disappeared: in their place was a cancerous ulcer,  $2\frac{1}{2}$  by  $1\frac{1}{2}$  inches. Its edges and base were hard, and the former raised and knobby. Beneath this ulcer was a mass of hard growth, slightly adherent to the subjacent parts. A mass of cancerous glands occupied the right axilla. About various parts of the body, but especially at the back of the lower part of the neck, were numerous small warty, fibromatous and varicoid outgrowths. The diseased breast was extirpated, together with a large portion of the pectoral muscle; and the axilla was cleared out. Erysipelas supervened on the twelfth day after the operation, followed by acute double septic pleurisy, and collapse of the lungs, of which he died. At the necropsy the body was fairly nourished. The partially healed operation wound occupied the right thoracic region and the axilla. The right upper limb was œdematous. On careful dissection this proved to be due to thrombosis, which had extended from the subscapular vein; starting from the point at which it had been ligatured during the operation, the thrombosis had spread to the axillary vein, and thence to all its tributaries of the upper limb as far as the wrist. At the extreme apex of the axilla a few cancerous glands were found; and also beneath the pectoralis minor. Recent double acute pleurisy with effusion, and collapse of the lower lobes of both lungs. The liver large and fatty. Double chronic interstitial nephritis. On microscopical examination, the mammary growth proved to be tubular cancer the tubular structures being hollow and lined with but a single layer of sub-columnar epithelium.

(2) This and the following case are by Courtade.<sup>9</sup> The patient was a locksmith, aged 56. Four months ago he felt pain in his right breast, and soon afterwards he noticed a tumour there, the size of a hazel-nut. There was no history of syphilis. His family history was free from any cancerous taint. On examination, a small, hard tumour was found beneath the right nipple, which was retracted. There was no enlargement of the axillary glands. The diseased breast was amputated. The patient was convalescent in fourteen days. On histological examination of the mammary tumour, it was found to consist of duct-like structures, lined with a single layer of cubical epithelium.

(3) Here the patient was a stone sawyer, aged 46, who five months previously first noticed a small area of induration in his right breast. He attributed it to pressure of the saw at his work. There was no family history of cancer. His previous health had been good. On examination a rounded tumour, the size of a walnut, was found beneath the nipple of his

<sup>9</sup> *L'Union Médicale*, 1885, t. xl., p. 1070.



right breast, but the nipple was not retracted. There was no obvious enlargement of the axillary glands. The diseased breast was amputated, and he was convalescent in 18 days. He returned 1½ months later with a tumour the size of a hazel-nut in his left breast, which he first noticed a fortnight ago. It was intimately connected with the nipple. This breast also was amputated, and he left convalescent 10 days later. On histological examination the growth consisted of duct-like structures, lined by cells of columnar type.

(4)<sup>10</sup> In this case the disease presented as a bossy tumour, adherent to the overlying skin, but movable over the subjacent pectoral muscle. Histologically it was composed of fibrous stroma, in which were embedded duct-like structures, lined peripherally with cells of columnar type, within which were flattened cells. It is described by the author as "épithéliôme cylindrique à tubes allongés."

(5)<sup>11</sup> A "conciérge," aged 60, three years ago first noticed a small tumour beneath the areola of his left breast; two years later it began to ulcerate. His previous health had been good, but seven years ago he had an attack of "shingles" in the left side, at about the level of the mamma, and he had for many years been subject to migraine. There was no history of cancer in his family. When first seen he was well nourished, and in good health. A hard, nodular, circumscribed tumour (12 by 8 cm.) occupied the left mammary region. Its central projecting part was eroded, over an area the size of a crown piece. The overlying skin was adherent, but the tumour was movable on the subjacent parts. The axillary glands were not obviously affected. The diseased part was amputated. Recovery was delayed by slowness of cicatrisation. Eight months later two small recurrent nodules had appeared in the scar, but the axillary glands were free. Four months later this recurrent disease was excised. Several recurrences subsequently took place at the primary seat, and finally in the axillary glands. Histologically the primary disease was tubular cancer, but some of the recurrent growths were of quasi-acinous type.

(6)<sup>12</sup> A coachman, aged 56, nine months ago noticed sanious discharge from his right nipple, and a small hard nodule beneath this part. Six weeks ago the tumour had attained the size of two fists. It was then tapped, and a large quantity of blood-stained fluid was evacuated. No previous injury or disease of the part. When he came under observation the right breast was occupied by a tumour, the size of a tangerine orange, situated beneath the nipple, which was retracted. The tumour was of ovoid shape, fluctuating in parts, and lobulated. It was adherent to the overlying skin, but movable over the subjacent parts. There were several enlarged hard glands in the axilla. The breast was amputated, and the axilla cleared. He was convalescent 15 days later. The mammary tumour contained numerous cysts. Histologically, it consisted of cylinder-celled duct-like structures, "Epithéliôme intra-canaliculaire."

<sup>10</sup> Marcowitz, *Bull. de la Soc. Anat.*, 1860, p. 134.

<sup>11</sup> Thorens, *L'Union Médicale*, 1881, No. 7, p. 74.

<sup>12</sup> *Bull. de la Soc. Anat.*, 1892, p. 780.



(7)<sup>13</sup> This patient, aged 57, three years previously first noticed yellowish discharge from his nipple, and a lump beneath. On examination a circumscribed spheroidal tumour (2.5 by 1.5 cm.) presented beneath the nipple, with which it was closely related. On examination after removal it was found to be enclosed in a fibrous capsule, which adhered closely to the surrounding tissues. On section it was of firm consistence, and quasi-alveolar structure. Histological examination revealed a mass of hollow tubular structures, lined by a single layer of columnar cells. Nothing is said about the condition of the axillary glands.

Similar cases have been recorded by Hermann and Tourneux,<sup>14</sup> Gross,<sup>15</sup> Baccialli,<sup>16</sup> Robinson<sup>17</sup> and others.

For further information about neoplasms of the male breast reference should be made to the publications of Schuchardt,<sup>18</sup> Poirier,<sup>19</sup> Horteloup,<sup>20</sup> Wagstaffe,<sup>21</sup> and Pemberton.<sup>22</sup>

<sup>13</sup> Shattock, *Trans. Path. Soc.*, 1892, p. 119.

<sup>14</sup> *Journal de l'Anat. et de la Physiol.*, 1876, xii., p. 607.

<sup>15</sup> "Carcinoma recurring in the Axillary Glands after excision of a Tubular Cancer of the Male Mamma," *Phil. Med. News*, 1880, x., p. 261.

<sup>16</sup> *Revisita Clinica de Bologna*, Dec., 1887, p. 833.

<sup>17</sup> *Trans. Path. Soc.*, 1890, p. 227. This patient had also squamous epithelioma of the tongue.

<sup>18</sup> *Arch. f. klin. Chir.*, Bd. xli., 1891, S. 64; Bd. xxxii., Heft 2, 1885; and Bd. xxxi., Heft 1, 1884.

<sup>19</sup> "Tumeurs du sein chez l'homme," Paris, 1883.

<sup>20</sup> "Des tumeurs du sein chez l'homme," Paris, 1872.

<sup>21</sup> *Trans. Path. Soc.*, vol. xxvii., p. 234.

<sup>22</sup> "Clinical Illust. of Cancer," p. 14, &c.



## CHAPTER XVII.

## SARCOMA OF THE BREAST.

SARCOMA of the breast is a rather rare disease. Of 13,824 primary neoplasms analysed by me (males, 4,593; females, 9,227), 1,081 were sarcomata (males, 559; females, 552); and of the latter, only 99 were of the breast (males, 5; females, 94).

The account I have to give of this disease is mainly based upon the study of 30 cases, 7 of which are of my own recording,<sup>1</sup> supplemented by reference to the analyses of Schuoler,<sup>2</sup> Gross,<sup>3</sup> Poulsen,<sup>4</sup> and Schmidt.<sup>5</sup>

As I have elsewhere pointed out,<sup>6</sup> the relative liability of the female breast to sarcomatous growths is much below the average for the body in general; 9·4 per cent. of the body neoplasms being sarcomatous, whereas only 3·9 per cent. of female breast neoplasms are of this nature.

The feature that, more than any other, especially attracts attention in connection with this disease is the great rarity of its occurrence, as compared with cancer. Of 2,397 consecutive

---

<sup>1</sup> Of the others, 10 are from the *University College Hospital Reports* (1884-89), 7 from the *Middlesex Hospital Reports* (1875-81), and 6 are from Bryant's work on "Diseases of the Breast," p. 124, *et seq.*

<sup>2</sup> "Beiträge z. klin. Bilde des Brustdrüsensarcoms," *Corresp.-Bl. f. schw. Ärzte*, 1890, S. 283.

<sup>3</sup> "American Syst. Gyn.," vol. ii., p. 226.

<sup>4</sup> *Arch. f. klin. Chir.*, xlii., 1891, S. 593.

<sup>5</sup> *Beiträge z. klin. Chir.*, iv., S. 40, 1888-9.

<sup>6</sup> "The Varieties of Mammary Neoplasms and their Relative Frequency," *British Medical Journal*, September 10, 1892.



neoplasms of the female breast analysed by me, 1,863, or 77·7 per cent. were cancers; while only 94, or 3·9 per cent., were sarcomata. This shows the much greater stability of the parablasic as compared with the archiblastic elements of the gland.

The great majority of mammary sarcomata arise in the immediate vicinity of the small ducts (adeno-sarcomata); only rarely do they originate elsewhere (pure sarcomata). This is the more remarkable when we recollect the great abundance of fibro-adipose tissue that goes to make up the breast, which elsewhere is such a favourite starting-point for these growths. Moreover, the mammary integument enjoys even more complete exemption from sarcoma than it does from carcinoma; for with the exception of a few rare cases of keloid, I know of hardly any other instances of sarcoma originating from it. The matrix tissue of the initial proliferative changes, usually is the layer of hyaline substance immediately surrounding the epithelial investment of the small ducts, which is but a myxomatous modification of the adjacent connective tissue, consisting of a network of flattened, branching, nucleated cells, embedded in hyaline stroma. Owing to the intimate genetic relationship thus subsisting between the morbid growth and the glandular structures, the latter are usually involved in sarcomatous neoplasms. This close association of the disease with the glandular elements seems to indicate, that it is in some way an outcome of functional aberration.

The question has been much discussed whether the glandular structures met with under these circumstances are of neoplastic origin, or whether they are merely the outcome of the mechanical distortion of pre-existing structures. From the fact that they have often been found within intra-cystic growths several inches long, it seems to me that their ectasic origin—in such cases at least—must be admitted. Nevertheless, it seems certain, from considerations presently to be mentioned, that these proliferous glandular structures do not form an essential element of the disease. The term adeno-sarcoma, given by Billroth to growths thus constituted, is, however, a good one; and it ought to be



retained. Some idea of the relative frequency of the occurrence of adeno-sarcoma and pure sarcoma, and of their structural peculiarities, may be gathered from the subjoined analysis of the 30 cases comprised in my list.

In 21 of these cases the disease was primary, and in 9 recurrent.

Of the primary group, 17 were adeno-sarcomata, and 4 contained no glandular elements.

Of the adeno-sarcomata, in 10 there were cysts with intra-cystic growths, and in 7 no cysts were obvious to the naked eye.

Of the cystic cases, in 3 the sarcomatous disease presented as round and spindle-celled tissue, in 2 it was round-celled, in 1 round-celled and myxomatous, in 1 spindle-celled, and in 3 cases its exact characters were not specified.

Of the non-cystic cases, in 4 spindle cells, in 2 spindle and round cells, and in 1 round cells alone, predominated.

It will be gathered from this that in the cystic adeno-sarcomata round cells predominate, whereas in the non-cystic forms spindle cells are of more frequent occurrence.

Of the 4 primary sarcomata in which no glandular elements were found, 2 were mainly composed of round and spindle cells, 1 of round cells, and 1 was an alveolar sarcoma.

Of the recurrent group, in 2 cases the neoplasms contained gland elements, and in 7 none could be found. Of the latter cases, in 5 the new growth was round-celled, in 1 spindle-celled, and in 1 alveolar. Of the former cases, in 1 the sarcomatous tissue was round-celled, and in the other its exact character was not stated.

### § I.—Statistical Summaries.

An analytical summary of my 12 cases of *cystic* adeno-sarcoma gives the following results:—

*Age.*—The earliest age at which the disease was first noticed was 23·5 years; the latest, 59·2 years; the mean age, 44·8 years. The numbers for each quinquennial period were as follows:—

20 to 25 years	...	...	...	...	...	...	in 1 case.
30 " 35 "	...	...	...	...	...	...	" 1 "
35 " 40 "	...	...	...	...	...	...	" 1 "
40 " 45 "	...	...	...	...	...	...	" 2 cases.
45 " 50 "	...	...	...	...	...	...	" 1 case.
50 " 55 "	...	...	...	...	...	...	" 3 cases.
55 " 60 "	...	...	...	...	...	...	" 2 "

*Duration.*—Of 9 primary cases, the duration of the disease



from the time it was first noticed until the patient came under treatment, was as follows :—The shortest period, 1 month ; the longest, 6 years ; the mean duration, 31·4 months. In the two fatal cases the total duration of life was 68·8 months (large round-celled sarcoma), and 28·5 months.

*Civil State.*—Married, 6 ; widowed, 2 ; single, 3.

*Occupation.*—Of 4 married, all were housewives ; of 2 widows, 1 was a nurse, the other a housekeeper ; of the 3 single, 1 was a cook, 1 a servant, and 1 a governess.

*Pregnancy, &c.*—Of 7 who had lived in wedlock, 2 were barren (never pregnant) ; 1 of these had not married until the age of 42, and she only cohabited with her husband nine months. Of the others 1 had only 2 miscarriages (she had cohabited with her husband for many years) ; all the other 4 were prolific : 1 had 12 children and 4 miscarriages, another 8 children, another 4, and another 3.

*Catamenia.*—Of 5 cases in which inquiries were made, all had been regular (profuse, 2). Puberty supervened (in 2 cases) at 15 and 16 ; and the climacteric (in 3 cases) at 47·5, 49, and 51.

*The Side Affected.*—The right breast in 7 cases, the left in 5.

*The Original Site of the Disease.*—In the central part of the breast in 5 cases ; and in the peripheral parts in 5 (lower and axillary 3, upper 1, lower, 1). In one case when the disease was first noticed it consisted of two separate nodules ; in all the other cases the initial manifestation was a solitary nodule.

*Previous Injury or Disease of the Breast.*—Of 8 cases in which inquiries were made there was history of previous injury or disease in 2. In one of these cases the nipple was congenitally retracted, and there had been an induration of the breast for 20 years, which supervened after a milk abscess. In this case the disease was first noticed a month after a contusion of the part in moving an iron bedstead. In the other case the onset of the disease was attributed to a strain in lifting. In one case a small tumour that had existed in the breast for over five years, attained a large size in the course of several months,



under the influence of pregnancy. This was the only case in which pregnancy appeared to have played an important part in the evolution of the disease.

*Previous Health.*—Of 7 cases the previous health had been good in all; but one of these patients had suffered from three attacks of rheumatic fever, from typhoid fever, and from smallpox. Another of them had suffered from smallpox and bronchitis; the others had been free from any serious disease since childhood.

*Family History.*—*The Fathers.* Of 10 cases in which inquiries were made, in 8 the fathers were *dead*, and in 2 they were still *alive* and well (1 aged 77).

The causes of death were:—Phthisis, 1; typhoid fever, 1; accident, 1; old age, 1; and unknown, 4. The ages at death were 44, 52, 64, 65, 72, 76, and 81.

*The Mothers.*—Of 10 mothers 9 were *dead*, and 1 was still *alive* and well. The causes of death were: malignant disease of the breast, 1; phthisis, 1; childbed, 1; bronchitis, 1; old age, 1; unknown, 2. The ages at death were—under 30, 40, 60, 64, 70, and 79.

*Consanguinity in the Parents.*—As to this, inquiries were made in three cases with negative results.

*The Patients' Brothers and Sisters.*—In eight families the following causes of death were noted among the adults:—Phthisis (1 or more deaths) in four families, apoplexy in one family, and in one family the patient's brother died of tumour of the liver. The number of members in each family were as follows:—2, 4, 7 (3 instances), 12, and 14.

*The Occurrence of Malignant Disease.*—Of 11 families, there was history of malignant disease in 3. In one case the sister of patient's mother died of malignant disease of the breast; in another case the patient's mother died, aged 33, of malignant disease of the breast; in the other case the patient's maternal grandfather died of cancer of the chin. In one case the patient's brother died of tumour of the liver, of nature unknown. In the two families in which relatives had died of malignant disease of the breast, there was history of phthisis as well.

*The Occurrence of Phthisis.*—Of 10 families, one or more of the adults had died of phthisis in 4; in one family the father and 2 of the patient's brothers died of phthisis (the



patient's mother died of malignant disease of the breast); in another family the father's mother and several of his brothers and sisters, as well as the patient's brother, all died of this disease.

*The Occurrence of Insanity.*—Inquiries were made in 2 cases with negative results.

*State on Examination.*—Of 6 primary cases, 4 were well nourished and healthy-looking (obese 1), and 2 were moderately nourished.

The complexion was noted in 4 cases—2 were dark and 2 fair. Of 9 primary cases, in 5 the overlying skin was adherent and reddened, and in 1 of them it was ulcerated and invaded by the disease. The superficial cutaneous veins were markedly enlarged in 4 cases. In one case the nipple was congenitally stunted, and in another it was obliterated by stretching; but in no case was it retracted, as in cancer. The tumours were generally of large size—mostly as large as a good-sized turnip; the smallest was the size of a walnut, the largest of a man's head. They were generally circumscribed and of irregularly rounded shape, lobulated and nodular. In not a single instance did the tumour adhere to the subjacent pectoral muscle.

With regard to the axillary glands, in the 10 primary cases, these were slightly enlarged in 2, and normal in 8; of the 2 recurrent cases, in one the glands were invaded, and in the other they were free.

*Treatment and Result.*—Of 10 primary cases, in 9 the breast was freely removed, together with the overlying adherent skin in 5 cases, and in one case slightly enlarged axillary glands were also removed. All these patients recovered from the operation, the periods of convalescence being 13, 16, 19, 25, 37, 47, 70, and 90 days. The subsequent history of 2 of them is recorded :—

(1) In this case the patient, aged 52, came under treatment with a large lobulated cystic sarcoma of the left breast, of ten months' duration, the axillary glands being unaffected. The diseased breast was freely removed.



After a tedious convalescence of seventy days, the patient passed from observation before the wound had quite healed. Soon afterwards recurrence set in. Six weeks later, the whole of the left pectoral region was found to be infiltrated with recurrent disease, which in some places had ulcerated. The axillary and other adjacent glands were unaffected. No further operation was done. She died of asthenia about a month later. At the necropsy no secondary growths were found.

(2) The patient, aged 50, came under observation with a large nodulated elastic tumour of the right breast, of three years' duration. The overlying skin was adherent, but the mass was movable on the subjacent pectoral muscle. The axillary glands were normal. The breast was amputated with the tumour; and the overlying skin, together with a portion of the sheath of the pectoralis major muscle, was also removed. The axilla was not touched. The tumour was a large round-celled adeno-cystic sarcoma, imperfectly encapsuled. The patient passed from under treatment sixteen days later. She was next seen nine months later, when there was recurrence of the disease at the primary seat, the axilla being normal. The recurrent disease was then excised, and the patient went away convalescent twenty days afterwards. One year later she again came under observation, with a recurrent tumour, the size of an orange, in the right axilla, of two months duration, the pectoral region being quite free from disease. The axillary growth was freely dissected out. It was encapsuled, and otherwise of similar structure with the primary growth. The patient went away convalescent fourteen days after the operation. Five months later she again came under observation, with extensive recurrence in the axilla, the pectoral region still being quite free. No further operation was done. She died of asthenia ninety-eight days later. At the necropsy the axillary glands and adjacent structures were found to be extensively infiltrated by the disease, as well as the lower cervical glands. The subclavian artery was compressed by the growth, with consequent dry gangrene of the whole upper limb, as far upwards as two inches above the elbow. The axillary part of the thoracic wall was invaded by direct extension, and the adjacent pleura infiltrated. There were no metastases. The pectoral region was quite free from recurrent disease.

In only one of the primary cases was the growth excised without removing the breast.

The patient was a woman, aged 36, whose left breast was occupied by a large adeno-cystic sarcoma, which extended chiefly downwards and outwards towards the axilla, where an enlarged gland could be felt. The tumour, which after removal weighed 2lbs. 4oz., was excised without the breast, and the enlarged axillary gland was also dissected out. She remained free from any return of the disease for two years, and in the interval had a child, which she was suckling with this breast, when she first noticed a small lump, just above the nipple and the old cicatrix. In the course of a year this developed into a large lobulated recurrent growth. It was then excised together with the whole of the breast. In its gross characters the recurrent tumour resembled



the primary one. When last heard of, two years later, she was quite well and free from any return of the disease.

The history of the two cases that came under treatment with recurrent disease is briefly as follows:—

(a) Three months after excision of the primary disease, which was of five months' duration, without removal of the breast, recurrence took place at the primary seat. A few months later the whole breast was removed, together with the recurrent disease. A month later there was rapidly growing recurrence in the axilla. The disease was soon afterwards freely dissected out from this region, and as the scar in the mammary region appeared somewhat thickened, it was also excised. The recurrent disease was small round-celled sarcoma. The patient went away convalescent fifty-three days later, and nothing further was heard of her.

(b) Two years after amputation of the left breast for the primary disease, which was of one and a-half years' duration, recurrence took place in the mammary region. Half a year later this was freely excised. The axillary glands were normal. She went away convalescent thirty days later, and has not since been heard of. The recurrent disease was a small, round-celled, adeno-cystic sarcoma.

An analytical summary of my seven cases of *non-cystic* adeno-sarcoma gives the following results:

*Age.*—The earliest age at which the disease was first noticed was 22 years; the latest 49·8 years; the mean age 36·4 years.

The numbers for each quinquennial period were as follows:—

20 to 25 years	...	...	...	...	in 2 cases
30 „ 35 „	...	...	...	...	„ 2 „
45 „ 50 „	...	...	...	...	„ 3 „

*Duration.*—The duration of the disease from the time it was first noticed until the patient came under treatment was as follows:—The shortest period, 6 weeks; the longest, 4 years; the average, 14·2 months.

*Civil State, &c.*—Married, 4; single, 3. Of the married all were fertile. One had 1 child, one 3 children, one 3 children and 4 miscarriages, and one 5 children.

*The Side Affected.*—The right in 5, the left in 2.

*The Original Site of the Disease.*—It was central in 4, and peripheral in 3 (upper and axillary segment in 2, upper in 1). In all, the first obvious manifestation of the disease was a solitary nodule.

*Previous Injury or Disease of the Breast.*—None in any case.



In one case the outbreak of the disease took place during pregnancy.

*Family History.*—Of 7 cases there was family history of cancer in 1, the patient's aunt having died of malignant disease of the breast.

*State on Examination.*—The size of the tumour in most cases did not exceed that of a hen's egg, the smallest was the size of a haricot bean, the largest of a man's head. In all cases the tumours were mobile; there was no instance of adhesion either to the overlying skin or to the subjacent pectoral muscle. The nipple was obliterated by stretching in one case and normal in the other six. Most of the tumours were of globular shape, lobulated, and encapsuled. In two cases the superficial veins were much enlarged. The lymph glands of the axilla were unaffected in every case.

*Treatment and Result.*—Of seven primary cases, in five the breast was removed, together with the tumour, all the patients soon recovered; in two cases the tumour alone was removed, both recovered. The period of convalescence was from seven to fourteen days. In no instance was the axilla touched.

The subsequent history of four of the above cases was as follows :—

(1) The patient, aged 49, had a fibro-spindled-celled, adeno-sarcomatous tumour of the right breast of large size and of two years' growth. The axillary glands were unaffected. The breast was removed, together with the tumour, which was found to have grown from the posterior part of the gland. When last seen, six years later, this patient was well, and free from recurrence.

(2) The patient, aged 50, had a sarcomatous tumour, the size of a hen's egg, in the upper and axillary part of her right breast. The axillary glands were normal. The tumour was excised. It possessed a distinct capsule. When last heard of two and a-half years later she was free from any return of the disease.

(3) A single woman, aged 33, with a spindle-celled sarcomatous tumour at the upper and outer part of her left breast, of eight months' duration. The axillary glands normal. The breast was extirpated together with the tumour. Two years afterwards the patient again came under observation, with a somewhat similar tumour in her right breast of one year's duration. This breast was, therefore, removed together with the tumour. The latter proved to be of the same structure as the original one in the left breast. When last



heard of two years later she was well, and free from any return of the disease.

(4) In this case the patient was a married woman, aged 24, with a round-celled sarcomatous tumour of large size in her right breast. It was first noticed twelve months previously, during the latter part of her first pregnancy. The overlying skin and the axillary glands were normal. The tumour was removed, as well as the breast. Four months later a growth of a similar nature had formed in her left breast, and the axillary glands were slightly enlarged. This breast with the tumour and the axillary glands was now removed. When last heard of two years after the second operation, she was in good health, and without any return of the disease.

## § II.—Adeno-Sarcoma

Bearing in mind the foregoing facts, I now propose to pass in review the chief features of mammary sarcomata. At the outset I may as well state that the usual varieties of sarcomatous growths, met with in other parts of the body, are also found in the breast. The immense majority of these neoplasms consist mainly of round or spindle-celled structures; and, according to my observations, it is commoner to find a mixture of these two forms than either of them separately. Thus, of 19 consecutive primary cases, in 7 round and spindle cells predominated, in 6 round cells (with myxomatous tissue in 1), in 5 spindle cells, and 1 was so-called alveolar sarcoma. In the cases analysed by Gross, spindle-celled forms were by far the most numerous; he estimates the percentage proportions as—spindle-celled 68, round-celled 27, and myeloid 5.

What gives a certain peculiarity to sarcomata of the breast is the frequency with which glandular elements are incorporated in their structure. Although there is every reason to believe that this admixture makes no essential difference in the nature of the disease, yet it often causes the form assumed by the neoplasm to be strangely modified, through the development of cysts and intra-cystic growths.

It is generally agreed that adeno-sarcomata of the breast are of much commoner occurrence than pure sarcomata, but no one, so far as I know, has furnished precise data. According to my



investigations, the proportion is about 80 per cent. of the former to 20 per cent. of the latter. This indicates a much larger proportion of pure sarcomata than has hitherto been generally believed. Leaving the latter for subsequent consideration, in what follows I propose to confine my remarks to the adeno-sarcomata.

As in mammary cancer, the initial lesion in these growths generally is a small, hard, solitary nodule. Of the 17 primary cases in my list, in only one did the first obvious manifestation consist of two distinct nodules. Of 156 cases, Gross found multiple nodules in 7; in one of these there were 4 nodules in one breast, and 1 in the other. The question of the origin of mammary sarcomata from non-malignant neoplasms I have elsewhere discussed.\*

In women, cancer and non-malignant neoplasms arise more frequently from the left than from the right breast. According to Schuoler, this is also the case with sarcoma, for of 35 cases, 21 were of the left and 14 of the right side. Of my 19 cases, 12 were of the right gland and only 7 of the left. Both breasts are occasionally simultaneously affected: this happened in 3 out of Gross' 156 cases, and of Schuoler's 40 cases, 4 were double. In a case reported by Delbarre<sup>7</sup>, small round-celled mammary sarcoma was associated with similar ovarian disease.

As compared with cancer, it appears that sarcomata arise less frequently from the peripheral parts of the gland; for of 17 cases in my list, 9 were of central and 8 of peripheral origin; of the latter, 3 sprang from the axillary and lower segment of the gland, 2 from its axillary and upper segment, 2 from its upper and one from its lower segment. Forbes<sup>8</sup> mentions a case in which the disease originated from a supernumerary mammary sequestration.

At an early stage of the disease the initial proliferating

---

\* Pp. 315-317.

<sup>7</sup> *Bull de la Soc. Anat.*, 1870, p. 337.

<sup>8</sup> *Phil. Med. News*, March 5, 1892.



cellular aggregate, together with its contained glandular elements, that constitutes the germ of the future tumour becomes separated from the surrounding structures by the differentiation of a fibrous capsule, which soon completely isolates it. By the continuous proliferation and differentiation of these cells and their descendants, as in the normal development, the tumour increases in size. This being so, there must, of course, be new formation of glandular, as well as of connective tissue elements. Another consequence of this mode of development is, that fatty tissue is never found in the midst of the morbid mass, as in cancer, in which a capsule does not form. As the tumour increases in size, it pushes aside the

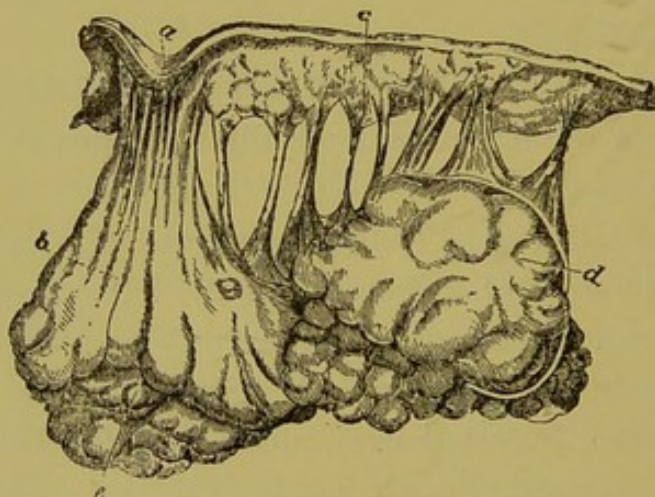


FIG. 59.—ADENO-SARCOMA (*Birkett*).

Breast and tumour dissected to show their mutual relations. (a) Site of nipple; (b) Mamma; (c) *Ligamenta suspensoria*; (d) Tumour and its capsule; (e) Small cysts.

surrounding parts; and where these hinder its progress, they are destroyed by pressure atrophy. The form ultimately assumed by the new growth depends much upon the evolution of its glandular elements. When these remain comparatively unaltered, non-cystic solid tumours of no great size result; but when they dilate and form cysts, large tumours, complicated with intra-cystic growths, commonly ensue. According to my observations, the majority of mammary adeno-sarcomata are of the cystic kind, the proportion being 59 per cent. of the former to 41 per cent. of the latter.



These tumours are abundantly supplied with blood-vessels, which are often not only unduly numerous, but also unduly large and otherwise malformed. Most of them may be regarded as imperfect capillaries, but veins are also numerous and arteries exist. They are derived by ectasis from the pre-existing vessels. In soft, cellular tumours, the vascular walls being very thin and ill-supported, readily dilate and even rupture; whereas in the hard, fibroid kinds, these structures play a much less prominent part. Sarcomata are believed to be devoid of nerves and lymphatics.

The *non-cystic* growths usually present as lobulated encapsuled solid tumours, of ovoid or globular shape, varying in size from a walnut to a hen's egg (fig. 59). On section their appearance is whitish, fibroid, or fleshy-looking. They are generally

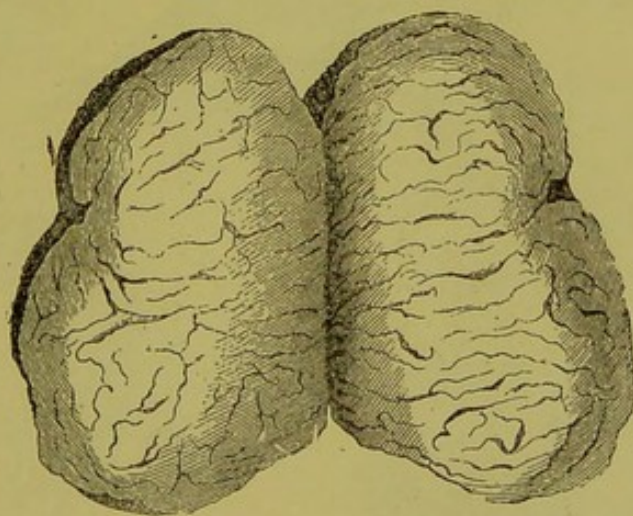


FIG. 60.—Non-cystic adeno-sarcoma in section. Natural size (*Astley Cooper*).

of firm and elastic consistence, rather than hard. In the tougher varieties fibrous tissue predominates; in the softer kinds cellular elements. Interspersed throughout their substance numerous small branched, cleft-like slits can be seen (fig. 60); these are the included glandular structures, in connection with which minute cysts may be noticeable.

Histological examination shows that such tumours consist mainly of fibro-cellular tissue in which, according to my observations, spindle cells usually predominate. The slit-like clefts



embedded in this tissue are the elongated and otherwise altered ductal structures, lined by one or several layers of sub-columnar cells. Sometimes the lumina of these structures are distended by degenerating cells, and fluid accumulations. Hardly ever does one see glandular structures of this kind lined by flattened cells similar to those of the normal acini.




FIG. 61.—Adeno-cystic Sarcoma. Clinical view, from a photograph.

In the *cystic* form of the disease large, irregular, globular tumours are met with, which sometimes attain immense size (figs. 61 and 64). They are markedly lobulated, and their various sub-divisions are irregularly nodular. Occasionally they acquire



a pedunculated form. A capsule can generally be made out, but in tumours of large size it is often thin and incomplete.

The appearances on section vary much, according as the solid or cystic constituents predominate. As a rule there is revealed a multilocular structure, with which is associated a variable amount of irregularly distributed, moist, whitish-grey fleshy solid substance. The loculi are usually distended with polypoid ingrowths and a variable amount of fluid. Of the

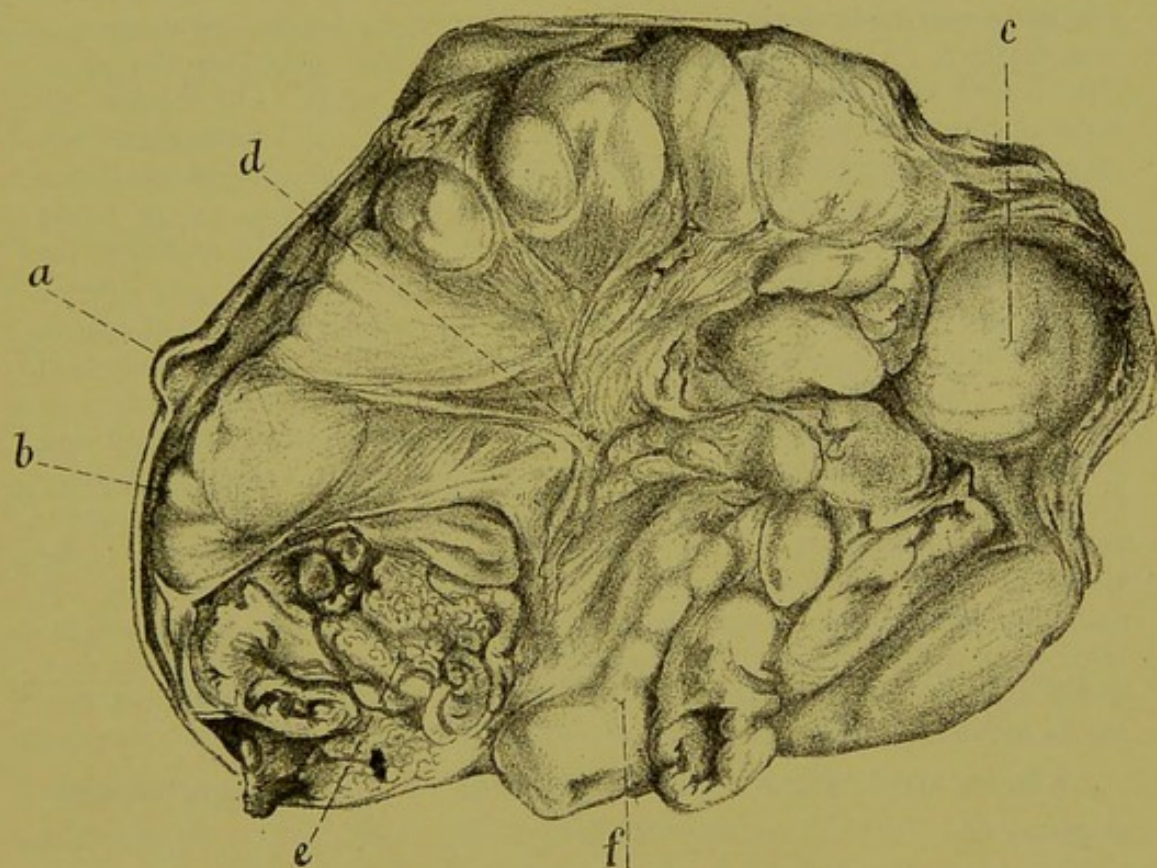


FIG. 62.—THE FOREGOING TUMOUR IN SECTION.

(a) Nipple. (b) Capsule. (c) One of the several solid sarcomatous masses comprising the peripheral part of the tumour. (d) The central fibroid part. (e) Its cystic portion, with intra-cystic growths. (f) Remains of the mammary gland.

cases under my own observation, one of the smallest tumours presented on section quite a solid appearance. It was only after careful examination, that it was seen to consist of numerous loculi tightly distended with solid polypoid ingrowths, without any associated fluid whatever. The sarcomatous new formation in this case was small, round and spindle-celled tissue.



The following is an account of the largest tumour of the kind that has come under my notice :—

The specimen was removed from the right breast of a married woman aged 57, who, two years previously, after a strain in lifting, first noticed two lumps the size of hazel nuts in the lower part of the breast. One year later a single tumour had formed there, the size of an orange. When I first saw her the breast was occupied by a projecting irregularly ovoid tumour, nearly as large as a man's head (fig. 61). The overlying skin was adherent, purplish, and marbled by large veins; but the tumour was freely movable on the subjacent parts. Its surface presented numerous rounded, lobular projections, which were nodulated. The nipple was not retracted. Most of the mass was of firm elastic consistence, but at its lower part fluctuation was distinct. There was a single slightly enlarged gland in the axilla. The breast was amputated without opening the axilla. On section, the bulk of the tumour was seen to be composed of solid substance, contained within a thick fibrous capsule (fig. 62). Its peripheral part consisted of numerous large, whitish, fleshy-looking nodules, except below the nipple, where there was an encapsulated multi-locular structure the size of a hen's egg, the loculi of which were full of softish, gelatiniform, club-shaped ingrowths. The central part of the growth consisted of coarse, dense, fibroid tissue, from the meshes of which pale, dirty yellowish fluid exuded. On histological examination of the peripheral lobules, which comprised the bulk of the tumour, these were composed of small round and ovoid celled sarcomatous tissue; the central fibroid part consisted of white fibrous tissue, with nuclei unduly numerous. No glandular structures were met with in this part of the tumour. The intralocular growths consisted of loose œdematous fibrous tissue, with many nuclei; while the epithelial lining had completely disappeared, as the result of disintegration. The patient completely recovered from the operation, and when last heard of a month afterwards she was in good health, and free from any return of the disease.

I have lately seen a similar tumour of much larger dimensions.

It occurred in the person of a widow, aged 55, the mother of several healthy children. A huge, rounded, bossy mass, hung from the right mammary region, reaching as low as the iliac crest. Most of it was of firm, elastic consistence, with here and there small fluctuating areas, evidently due to cysts. It was freely movable over the subjacent parts, and none of the adjacent lymph glands were enlarged. The overlying skin was adherent, marbled with large veins, and purplish. An area the size of a crown piece, over the lowest part of the tumour, was in a state of slough; and extensive gangrene here seemed imminent. The tumour was of fifteen years' growth, but until sloughing set in a few weeks ago, it had not caused her much pain. I estimated its weight as about 20 lbs. As gangrene was evidently impending, I advised its immediate ablation. This the patient declined, as she was persuaded by a quack, who had treated her for some years, that the tumour was



coming away by its roots. Extensive gangrene soon set in, and after having endured horrible sufferings for some months, she died exhausted. This is a case that by operation might have been completely cured, but unfortunately nothing could shake this poor woman's faith in the ignorant man into whose hands she had fallen. Such a combination of obstinacy and ignorance is fortunately rare.

Among the constituent elements of the neoplastic tissue, round cells generally predominate; frequently these are associated with spindle cells, and occasionally the latter predominate. Myeloid cells are now and then met with. Within sarcoma cells Paulowsky,<sup>9</sup> Clarke,<sup>10</sup> and others have met with rounded, spore-like bodies, which they regard as parasitic protozoa.

The following is the only example of rhabdo-myo-sarcoma of the breast known to me:—

In an ill-developed, chlorotic girl, aged 16, with a large adeno-cystic sarcoma in the middle of the left breast, of nine months' duration, Billroth<sup>11</sup> found, on histological examination of the tumour after removal, in addition to small round-celled sarcomatous tissue, numerous spindle-like, transversely-striated muscle cells. To account for this unique phenomenon, he thinks either that we must admit the origin of these cells from the sarcoma cells, or that we must ascribe their origin to germs of transversely-striated muscle tissue sequestered during an early stage of development.

In addition to the foregoing, there is generally found a variable—but considerable—amount of fibrous intercellular substance, which is often aggregated into irregular strands. It is said to differ from the fibrous stroma of the normal and cancerous glands in that it is devoid of elastic fibres. Irregular gelatinous metaplasia is not uncommon; and in this connection pseudo-cysts sometimes arise. Both cells and intercellular substance are prone to fatty degeneration, which may be so extensive as to retard the progress of the disease and cause partial regression. Both of these degenerative changes give

---

<sup>9</sup> *Arch. f. path. Anat.*, Bd. cxxxiii., S. 464. "Ueber parasitäre Zellen-schlüsse in sarcomatösen Geweben."

<sup>10</sup> "Cancer, Sarcoma, and other Morbid Growths in Relation to the Sporozoa," 1893.

<sup>11</sup> *Deutsche Chir.*, Lief lxi., S. 53.



rise to yellowish discolouration, and sometimes to caseation. Hyaline metamorphosis of the stroma has also been noticed. Small calcereous deposits may be met with, but it is rare to find large areas thus affected, as in cases recorded by Dubar,<sup>12</sup> Clarke,<sup>13</sup> and others. Very exceptionally osseous and cartilaginous tissues have also been found in the stroma, as in cases recorded by Hacker,<sup>14</sup> Wagner,<sup>15</sup> Bowlby,<sup>16</sup> Coats,<sup>17</sup> Battle,<sup>18</sup> Pilliet,<sup>19</sup> &c. Unduly numerous, enlarged, and irregularly formed blood vessels are not very rare, and in the telangiectasic variety they predominate. These various changes have little or no influence on the course of the disease. Inflammation and suppuration may also occur.

With regard to the included glandular structures, at an early stage their cells by proliferation become unduly numerous, and as the result of their morbid activity fluids are secreted, which distend their lumina, and so finally convert them into cysts. In the next stage irregular processes of the proliferating periductal sarcomatous tissue project into the cysts, and finally form intra-cystic growths. These generally take the form of nodular club-shaped masses (fig. 63) which sometimes attain great size; but quite exceptionally papillary structures are produced.<sup>20</sup> Cysts of all shapes and sizes are met with. Epithelial cells of columnar type line their walls and the surface of the intra-cystic growths. This indicates that their origin is from the small ducts rather than from the acini. These lining cells sometimes completely disappear during the growth of the tumour as the result of degenerative changes (fig. 63); at other times they undergo a kind of corneous transformation, forming

<sup>12</sup> *Thèse de Paris*, 1888.

<sup>13</sup> *Lancet*, 1890, vol i., p. 1,179.

<sup>14</sup> *Archiv. f. klin. Chir.*, 1882, S. 614.

<sup>15</sup> *Arch. f. Heilkunde*, 1861, S. 275.

<sup>16</sup> *Trans. Path. Soc. Lond.*, 1882, p. 306.

<sup>17</sup> "Manual of Pathology."

<sup>18</sup> *Trans. Path. Soc. Lond.*, 1886, p. 473.

<sup>19</sup> *Bull. de la Soc. Anat.*, 1890, p. 552.

<sup>20</sup> Pilliet, "Cysto-sarcome papillaire du sein," *Bull. de la Soc. Anat.*, 1893.



little pearls, as in cases signalised by Borchmeyer and Schmidt.<sup>21</sup> In addition to the solid ingrowths, the cysts usually contain a highly albuminous, pale, yellowish fluid, in which histological

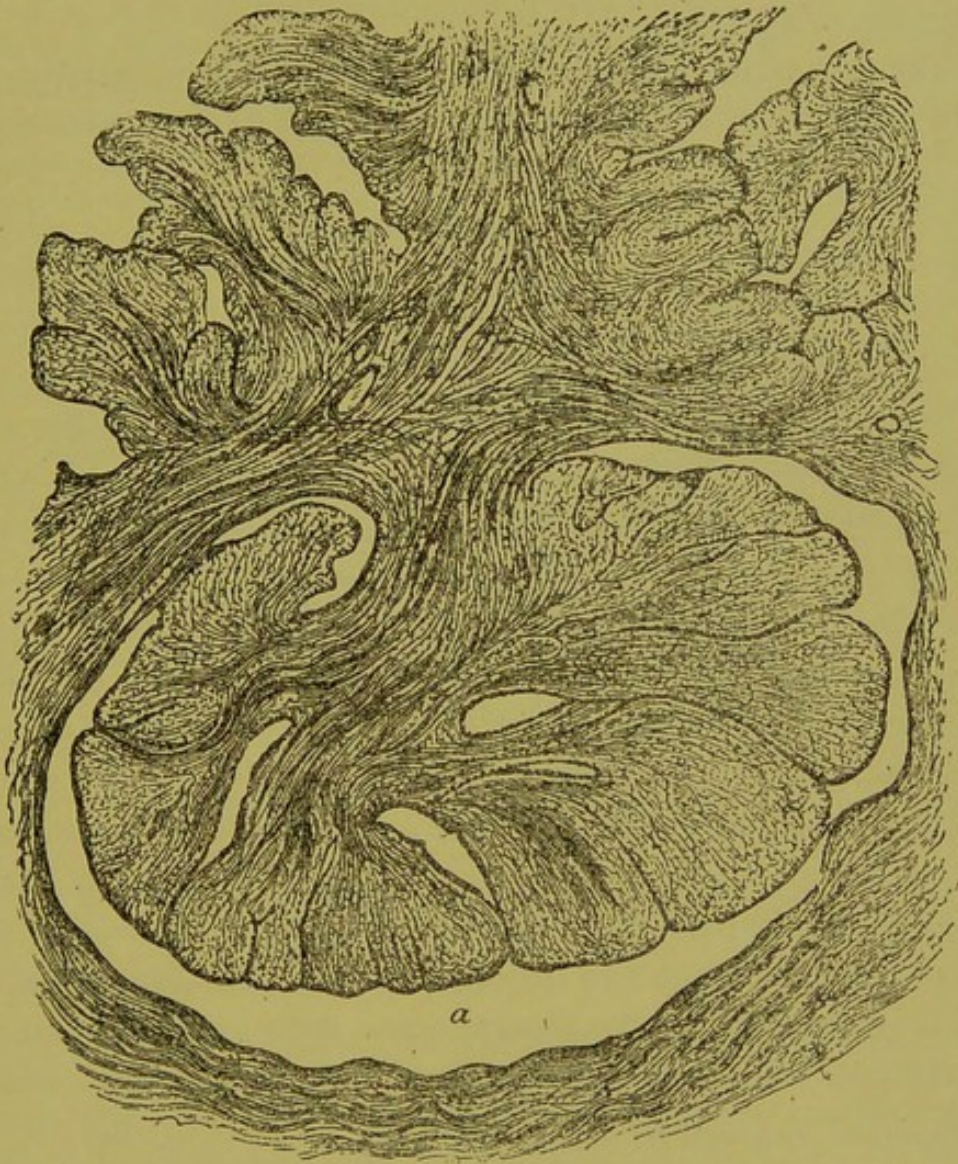


FIG. 63.—HISTOLOGICAL SECTION OF ADENO-CYSTIC SARCOMA, SHOWING INTRA-CYSTIC GROWTHS (*Billroth*).

(a) Cystic cavity nearly filled by a large ingrowth, but denuded of its epithelial investment.

examination reveals numerous, degenerating epithelial cells, corpuscles of Glüge, leucocytes, &c. Sometimes the contents form a granulo-fatty magma, like cheese or butter, as in the "tumeurs

<sup>21</sup> *Arch. f. Gyn.*, Bd. xxiii., 1884, S. 93.



butyreuses," described by Velpeau.<sup>22</sup> In a specimen of this disease, removed during lactation, Billroth<sup>23</sup> found milk in the dilated glandular structures. Occasionally there is complete absence of any fluid contents, the solid ingrowths completely filling the cysts.

The rate of increase of these neoplasms is very variable, and their progress is often irregular. It happens in a certain pro-

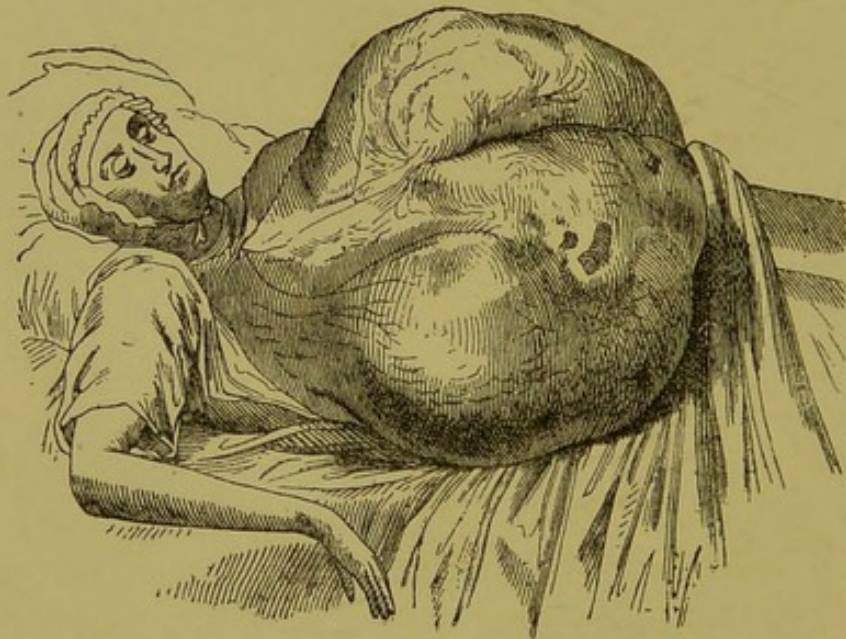


FIG. 64.—An enormous adeno-cystic sarcoma (*Velpeau*).

portion of cases that the original tumour remains small and almost stationary for a long period, and then suddenly increases rapidly without any obvious cause. The round-celled varieties are believed to progress the most rapidly, but as to this the evidence is by no means definitive. Marked local elevation of temperature not unfrequently accompanies this rapid increase, and occasionally pyrexia (Steinberger). The size attained by growths of this kind is often very considerable—in fact, cystic adeno-sarcomata are among the most bulky of mammary neoplasms. Specimens weighing 7, 12, 13, 14, 22, 26 pounds

<sup>22</sup> "Traité des Maladies du Sein," p. 301 *et seq.*

<sup>23</sup> *Arch. f. path. Anat.*, Bd. xviii., S. 68.



and upwards have been met with. In the following remarkable instance by Velpeau,<sup>24</sup> the tumour was of truly colossal proportions :—

Mrs. A., aged 54, four years ago first noticed a tumour in her right breast which in the course of three years attained the size of a man's two fists, and then increased rapidly to its present gigantic size. An enormous lobulated tumour is connected with the right breast, the overlying skin being congested and eroded in places inferiorly, and marbled by numerous large veins (fig. 64.) Some parts of it feel solid, others cystic. Its largest circumference, 120 cm. (over 44 inches); its diameters, 36 cm. (14½ inches) by 30 cm. (over 12 inches). On tapping it two litres (over 1¾ quarts) of fluid were evacuated. The patient was weak and emaciated, and refused to have it removed. She only ceased to menstruate at 52. Death subsequently supervened from marasmus. After death the tumour weighed 20 kilos. (over 44 lbs.). Nothing is said as to the state of the axillary glands, nor as to dissemination.

In cases of this sort the nipple may be more or less effaced by stretching, but it is hardly ever retracted. The superficial veins are enlarged. It often happens, when the tumours project much, that the overlying skin becomes congested and adherent; ulceration may then supervene, followed by fungation of the growth (*fungus hæmatodes*). In the event of the exposed capsule rupturing, the intra-cystic growths may also fungate. Even under these circumstances the skin is not often invaded by the disease.

I witnessed the following instance of this kind in 1879 at the Hôpital Necker, Paris, in the practice of Broca :—

A rather ill-nourished, but otherwise healthy-looking woman, aged 55, the mother of several healthy children, was admitted with a purplish, fungoid outgrowth, the size of a hen's egg, growing from the central part of the right breast, rather below and internal to the nipple. It was of firm and elastic consistence, its centre somewhat depressed, its borders swollen and everted, and its surface granular, discharging thin, sanious, puriform fluid. The nipple was displaced but not retracted. The tumour was mobile on the subjacent parts, but slightly adherent to the overlying skin in the immediate vicinity of the fungus. There was no pain, and the adjacent glands were normal. The patient said she first noticed a lump in her breast eighteen years previously, soon after having suckled her first child. It remained stationary for eight years, when, having increased quickly, it burst and discharged some fluid, after which the fungus formed. She cut it off, but it

<sup>24</sup> *Op. cit.*



soon formed afresh. The breast was excised together with the tumour. On examination after removal the latter was of denser structure than anticipated. Section revealed a glistening, whitish-yellow, fibroid surface, divided into lobes by irregular fissures. Numerous small cystic cavities were seen filled with intra-cystic growths. Histologically, the latter consisted of loose, fibro-cellular tissue, well supplied with dilated blood vessels. The solid part of the tumour presented numerous elongated, irregular, anfractuous cavities, lined by cubical epithelium, mostly in a single layer. The cysts were surrounded by abundant fibro-spindle-celled tissue.

Obvious local disseminative lesions are met with in this disease very much less frequently than in cancer, and the pectoral muscles are rarely invaded. Nevertheless, it is a mistake to regard the presence of a capsule as an infallible sign of benignancy, for, as these growths increase, they often overpass the limits of their capsules and invade the adjacent parts. Even when the capsule remains intact, and there is no obvious invasion of the surrounding structures, careful histological examination, nevertheless, often reveals tumour elements spreading out far from the main tumour. This insidious advance of the disease takes place along the walls of the blood vessels—arteries and veins—and their adventitia, which may often be found infiltrated with sarcomatous tissue. As Virchow,<sup>25</sup> with his usual perspicacity has pointed out, growths of this kind are surrounded by a zone of latent infection which usually extends far beyond their immediate limits.

The opinions that have been entertained by competent observers, during the last half century, as to the benignancy or malignancy of mammary adeno-sarcomata, have been very varied. It is now, however, generally recognised that all neoplasms of this kind are of a more or less malignant nature. The comparative rarity of dissemination in the axillary glands is one of their most striking clinical features, in which they differ markedly from cancer. I am, however, inclined to think that this relative immunity from lymph gland dissemination has been overestimated, for of 24 adeno-sarcomata in my list, there were two instances of it. For abstracts of these cases I must refer the

---

<sup>25</sup> *La Pathologie des Tumeurs*, t. ii., p. 261.



reader to the foregoing analytical summaries. It is, however, only the round-celled variety of the disease that thus occasionally disseminates in the glands. In two other instances the glandular enlargement noticeable was only hyperplastic.

As to whether these growths originate general disseminative lesions, very different opinions have been held. Virchow<sup>26</sup> was the first who showed conclusively that most varieties have this power. He instanced a case in which the liver, lungs, mediastina, ribs, vertebræ, pelvic bones, dura mater and sphenoid were thus implicated. The correctness of Virchow's observations has been fully borne out by subsequent investigations. Of 91 cases tabulated by Gross,<sup>27</sup> there were metastases in 17, or in 18·68 per cent.; and Schuoler met with metastases in 12·4 per cent. In Gross' cases the secondary lesions were situated as follows:—Lungs in 10 cases, liver in 4, brain in 3, and one each in the dura mater, retro-peritoneal glands, mediastinum, pleura, heart, kidney, muscles and bones. Gross believes that metastases are really of more frequent occurrence than the above figures indicate.

Since these lesions arise in the absence of secondary affection of the lymph system, their germs evidently enter the blood directly, in the vicinity of the primary disease, whence they are transported by the circulation to the localities where they finally develop into fresh tumours. The secondary growths differ from the primary ones in being devoid of glandular elements, which are thus shown not to be an essential part of the disease. Metastases have not been signalised in connection with the myeloid form, and only exceptionally does this variety cause dissemination in the axillary glands.

All the varieties of mammary adeno-sarcomata frequently recur locally after removal. Under these circumstances the recurrent growths usually contain no glandular elements. This was the case in 7 of the 9 recurrences in my list. When glandular elements are present in the latter, it means either

---

<sup>26</sup> *Op. cit.*, t. ii., p. 360.

<sup>27</sup> "Am. Syst. Gyn.," vol. ii., p. 247.



that the primary disease has been imperfectly extirpated, or that fragments of the gland have been left behind, which have subsequently taken on the same form of morbid activity.

Of 14 primary adeno-sarcomata in my list in which the breast had been removed together with the disease, in 3 local recurrence was known to have occurred, or in 21·4 per cent. Schuoler met with it in 25 per cent. of his cases, and Gross in 58 per cent. In one of the above-mentioned cases in my list the patient was well and free from any return of the disease six years after the operation. In another case the patient was well and free from recurrence two and a-half years after excision of the first local recurrent growth. In 3 other of my cases the sarcomatous tumour was simply excised, without removing the breast; in one of these there was local recurrence two years later, and in the other the patient was free from any return of the disease when last heard of, two and a-half years after the operation. In the 3 locally recurrent cases of my list, the disease reappeared three months, nine months, and two years respectively after the last operation.

According to Gross, more than half of the local recurrences (57·5 per cent.) take place during the first six months after the operation; while after the first year only 28·8 per cent. of recurrences arise, and after the first two years but 8·8 per cent. Hence the longer the period of immunity after operation the more favourable the prognosis. In his cases the average date of local recurrence was 10·5 months after operation; the latest date was four years. Return of the disease locally after operation is, however, sometimes met with at a much later period than this. Péan<sup>28</sup> has recorded an instance in which, twenty-five years after amputation of the breast for adeno-cystic fibro-sarcoma, a large tumour of similar nature formed at the primary seat, in a woman aged 62. The number of recurrences is sometimes very great; as many as 4, 5, 6, 7, 12 and upwards have been witnessed. In the following remarkable case by Gross, the patient underwent

---

<sup>28</sup> *Leçons de Clin. Chir.*, 1892, p. 960.



22 operations, and 54 recurrent tumours were removed in the short space of four years :—

A single woman, aged 44, with a small tumour in her left breast of about seven months' duration. It was excised, and found to be a small, spindle-celled sarcoma. During the next sixteen months two similar operations were done ; and then a fourth recurrence, together with the entire breast, was extirpated. Three and a-half months later further recurrent disease was excised, and soon afterwards several other operations were required. During the last two years sixteen similar operations were performed, and large portions of the pectoral and intercostal muscles were excised. The recurrent growths varied in size from an almond to a hen's egg ; they appeared at or near the cicatrices and quickly assumed a fungating aspect. There was no enlargement of the adjacent lymph glands, and the patient's general health throughout was good. When last heard of, ten years and nine months after the last operation, she was in perfect health, and free from any return of the disease.

According to the same author, the period of immunity from recurrence is longer for spindle than for round-celled forms, and it is longest of all for the myeloid variety. The recurrence of adeno-cystic growths sets in, as a rule, about eight months after operation, whereas the period for the non-cystic form is about thirteen months.

Of 91 primary operated mammary sarcomata in Gross' list, 32 were found to have survived and to be free from recurrence for periods ranging from 1 month to 10 years and 9 months, the average period being rather over 49 months. The mean duration of the life of these patients, since the onset of the disease, had been nearly 10 years. The freedom from recurrence had lasted—

From 1 to 12 months ...	...	...	...	in 4 cases
„ 1 „ 2 years ...	...	...	...	„ 4 „
„ 2 „ 3 „ ...	...	...	...	„ 7 „
„ 3 „ 4 „ ...	...	...	...	„ 5 „
„ 4 „ 5 „ ...	...	...	...	„ 5 „
„ 7 „ 10 „ ...	...	...	...	„ 4 „
„ 10 „ 10 „ and 9 months	...	...	...	„ 3 „

The total duration of life, in operated cases, Gross has found to be 81 months ; 90 months for spindle-celled forms, 54 for round-celled ones, and 108 months for the myeloid kind.

In 2 of the cases in my list it will be observed that, after



removal of the primarily affected breast, there was recrudescence of the disease in the opposite breast, and none at the primary seat. In both of these cases the second attack appeared to be of spontaneous origin, rather than the result of local dissemination or metastasis. For further details of these cases the reader is referred to the foregoing analyses.

With regard to the data relating to the influence of sex, age, civil state, occupation, pregnancy, catamenial function, previous injury or disease of the breast, previous health, family history, &c., little need be added to what has been set forth in my analyses.

According to Gross, the disease may supervene as early as 9 years, and as late as 75, the average age of his cases being 40.6. Only 2.7 per cent. of them supervened before the sixteenth year, while 52 per cent supervened after the fortieth year. The average age at onset for the spindle-celled forms was 36, for the myeloid 47, and for the round-celled 48 years. Twelve per cent. of the spindle-celled cases commenced before 16.

The data relating to family history and heredity are on the whole similar to those ascertained by me to hold for cancer, and similar inferences may be drawn from them.<sup>29</sup> There is in the Middlesex Hospital Museum<sup>30</sup> a specimen of sarcoma of the breast, removed from a lady whose two sisters had similar disease, also of the breast; and Paget<sup>31</sup> cites the case of a lady, the victim of hard cancer of the breast (other members of her family were believed also to have died of cancer), whose three daughters all developed adeno-sarcoma of the breast.

Just so is it with regard to the etiological significance of previous local injury or disease, civil state, pregnancy, &c.; the conclusion from the data being, that in the vast majority of cases the outbreak of the disease is entirely spontaneous, and not traceable to the immediate action of any appreciable extrinsic cause whatever.

---

<sup>29</sup> *Q.v.* Ch. x., § iv.

<sup>30</sup> Nos. 2,079 and 2,093, Path. Catalogue, pp. 257 and 259.

<sup>31</sup> "Lectures on Surgical Pathology," vol. ii., 1854, p. 260.



In making the differential diagnosis the following are some of the chief *clinical features* to be borne in mind :—

The disease usually presents as a rather large, rounded or ovoid, lobulated, bossy tumour. It feels firm and elastic, except where cysts prevail. It is distinctly circumscribed, and freely movable over the subjacent parts and under the overlying skin. Occasionally, however, the latter becomes adherent, discoloured, and ulcerated, and the tumour may fungate. The subcutaneous veins are generally obviously enlarged. The nipple may be flattened by stretching, but its retraction is never caused by the disease. Serous or sero-sanious discharge from the nipple is exceptionally seen—1 in 9·5 cases, according to Gross. There is no enlargement of the adjacent lymph glands. Satellite secondary nodules in the parts adjacent to the main tumour are but rarely met with. A certain amount of pain and tenderness is experienced in many cases, but these sensations present no special characteristics. The disease generally runs a chronic course.

With regard to the *treatment*, it follows from what has been stated, that the whole breast, together with the tumour and the overlying skin, should be freely removed in every case at the earliest possible date. Unless the tumour is situated altogether on the anterior aspect of the gland, the fibrous sheath of the pectoral muscle should also be removed with it. Simple enucleation of the tumour must be condemned as an unscientific procedure. After extirpation of the diseased part it is a good practice to wash the wound with strong solution of chloride of zinc (20 to 40 gr. ad. 1 oz.). In doing the operation care must be taken to completely remove the axillary mammary processes. When enlarged lymph glands are present the axilla should be cleared, just as is done for cancer.

As to the mortality after the operation, of the 14 primary extirpations in my list (the axilla having been cleared in one) all recovered.

With regard to the after results but little need be added to what has already been stated. From this it will be gathered



that recurrences rarely supervene later than four years after the primary operation. Those, therefore, who survive free from return of the disease after this period may be regarded as cured. Of Gross' 91 operated cases, 12 fulfilled this requirement, or 13·18 per cent. Recurrent growths, when operable, should be freely excised as soon as noticed. This practice not only prolongs life, but in many cases, after repeated operations, it has at length resulted in permanent cure.

### § III.—Pure Sarcoma.

In the absence of the requisite data, it is impossible to write the history of the pure sarcomata of the breast; but from such information as is forthcoming, it may with tolerable certainty be inferred, that the main features of this disease are very similar to those met with in the corresponding varieties of adenosarcoma. Pure sarcomata seldom originate such large tumours as the adenoid variety, moreover, the former are generally less lobulated and bossy than the latter. Both varieties are usually encapsuled; and very rarely does either disseminate in the adjacent lymph glands. Stilling<sup>32</sup> has met with a pure sarcoma that contained cartilaginous and osseous nodules. As examples of the ordinary varieties of pure sarcoma, the following cases are instructive:—

(1) <sup>33</sup> An emaciated woman, aged 50, came under Morton's notice, with a tumour the size of a child's head occupying her left breast. She said it began nine months previously, one month after having had a blow on the breast. The tumour was of firm consistence and bossed. On its axillary aspect were two nodules, one of them firm and the other quasi-fluid. The tumour was freely movable over the pectoral muscle. The skin over its most dependent part was red, œdematous, and sloughing, and the superficial veins were greatly enlarged. The nipple was retracted. In the axilla was a smooth tumour the size of a duck's egg. The breast was amputated and the axilla cleared. On section, a uniformly whitish, solid, succulent structure was exposed, devoid of cysts and clefts. The axillary glands were invaded by similar growth. Histologically, it proved to be a small, *round-celled*

<sup>32</sup> *Deutsche Zeitschr. f. Chir.*, Bd. xv., 1881, S. 247.

<sup>33</sup> *Trans. Path. Soc. Lond.*, 1893, p. 126.



sarcoma, with some spindle cells and fibrous tissue intermixed, but no glandular structures. Death occurred a month after the operation, from an acute outbreak of the disease in the glands at the root of the neck, &c. On *post-mortem* examination there were no metastases.

(2) <sup>34</sup> A multipara, aged 44, ten years ago first noticed a tumour the size of a pea in the right breast, just above and external to the nipple. During the first eight years of its existence it made hardly any perceptible progress. Since then it has increased rapidly. On examination, Mouchet found the breast occupied by a tumour the size of an orange, over which the skin was reddish, and at one place eroded. It was freely movable over the subjacent parts, and the nipple was normal. Her general health was good. There were no enlarged axillary glands. The breast was extirpated, and the axilla cleared. On section, a firm, solid tumour, of uniform texture and whitish-grey colour; no juice exuded. Histologically, *fibro-spindle-celled sarcoma* with complete absence of glandular structures.

(3) <sup>35</sup> A childless widow, aged 53, two or three months before coming under observation, first noticed a small lump in her left breast. Her general health was excellent, but a sister had died of cancer of the breast. On examination, in the sternal segment of the gland, on a level with the nipple, was a rounded, well-defined, slightly nodular tumour, one and a-half inches in diameter. It felt moderately firm, was mobile under the overlying skin, and over the subjacent pectoral muscle, and the nipple was not retracted. There was a single, slightly enlarged gland in the axilla. An exploratory incision was made into the tumour, when some soft pinkish-white granulation-like tissue extruded. This was found to consist of round and spindle cells, so that the whole breast was extirpated, together with the overlying skin. The patient made a quick recovery. On examination of the tumour after removal, its superficial part was surrounded by a dense fibrous capsule, which, at its deep aspect, was incomplete. The neoplastic tissue consisted of *rounded and ovoid cells*, with a few small spindle cells, embedded in a granular matrix. The spindle cells were in places arranged in irregular fasciculi. The tumour contained numerous blood vessels, surrounded by spindle cells. It was solid throughout. The sarcoma cells contained large nuclei, and often more than a simple nucleolus. No glandular structures could be found in any part of the tumour. Numerous minute cysts were found in the breast, which was otherwise normal.

(4) A plethoric multipara, aged 53, about eight years ago noticed a small, hard lump in her right breast, which, during the last two years, had caused her much pain. On examination the right breast was found to be occupied by a rounded tumour, five inches in diameter. It felt firm and elastic, except over its most projecting part, where it was softer and quasi-fluctuating. Over this area the skin was purplish, but not adherent. The superficial veins were enlarged. The nipple was flattened by stretching, but not retracted. The tumour was mobile under the skin and over the sub-

<sup>34</sup> Mouchet, *Bull. de la Soc. Anat.*, No. 21, 1893, p. 545.

<sup>35</sup> This and the following case are from the *Univ. Coll. Hosp. Rep.* for 1889.



jacent parts. There was no enlargement of the axillary glands. The whole breast was excised, and she left, convalescent, twenty days later. When last heard of, ten months later, she was well and free from recurrence. The tumour was found to be lobulated and encapsuled, but in some parts the capsule was thin and ill-defined. On section it presented a pinkish-white aspect, and was solid throughout. Its peripheral part was of soft, succulent nature, while more centrally a firmer structure prevailed, in which there was a small calcareous deposit. Histologically, the growth consisted of *small round and spindle cells* embedded in an abundant fibrillar matrix, which contained numerous small blood vessels. No glandular structures were present.

(5) Chrétien<sup>36</sup> has published an account of a pure *spindle-celled* sarcoma, that developed with great rapidity in the breast of a woman during lactation, and in the course of seven months attained the weight of over two pounds.

The following remarkable case of acute sarcoma of *both breasts* is from Billroth's<sup>37</sup> practice :—

An artisan's wife, aged 31, the mother of two children, when about three months gone in her third pregnancy, noticed a rapidly increasing swelling in her left breast. There was some slight oozing from the nipple, but no pain. As the swelling increased, the patient got progressively weaker and more emaciated. When Billroth first saw her, a few months later, the left mamma was occupied by a tumour the size of a man's head, which felt firm and elastic. The overlying skin was œdematous, but the mass was freely movable on the subjacent parts. There was no enlargement of the adjacent lymph glands. In the right breast several hard nodules could be felt. Thinking the spread of the disease might be checked if delivery were accomplished, abortion was induced, and a living seven months' child was born, which died soon afterwards, but presented nothing abnormal. Pyrexia followed, with cough, anorexia and marasmus ; and she died thus one month after delivery, no milk secretion having taken place. There was no necropsy. The right breast had in the meantime grown as big as the left, which, in its general features, it resembled. An incision was made into each breast, and pieces were removed for histological examination. The tumour, on section, presented a whitish-yellow, succulent aspect, exuding a milky fluid on pressure. Histological examination revealed a small, round-celled, lympho-sarcomatous structure, which contained no glandular elements.

#### § IV.—So-Called Alveolar Sarcoma.

Under the name of alveolar sarcoma, plexiform angio-sarcoma, endothelioma, &c., certain rare forms of mammary neoplastic disease have been described, in which the glandular

<sup>36</sup> *Bull. de la Soc. Anat.*, 1891, p. 367.

<sup>37</sup> *Deutsche Chir.*, Lief. xli., S. 27.



elements do not participate. According to recent investigations these growths arise from the endothelial cells of the adventitia, or of the lymph spaces. If we accept this view of their origin, they should be classed with the cancers, for embryological researches have shown, that the endothelium is a derivative of the archiblast and not of the parablast, to which its origin has hitherto generally been ascribed.

There are many facts in the morphology and clinical history of the disease, that are best explained from this standpoint. Schmidt<sup>38</sup> has studied these neoplasms as they occur in the breast. He describes their gross morphological features as being very similar to those of the adeno-sarcomata. They differ from the latter, however, in that the overlying skin is more frequently adherent; moreover, they much more frequently disseminate in the adjacent lymph glands and in the system generally. In these respects they resemble the cancers; but unlike the latter, they generally have a pseudo-capsule, they do not cause retraction of the nipple, neither do they entail cachectic symptoms.

With regard to the relative frequency of lymph gland dissemination, Gross says it is met with in over 66 per cent. of all cases; whereas Schmidt describes it as being rare. Both are, however, agreed as to the frequency of metastases. These have been found in the liver, lungs, bones, spleen, kidneys and omentum. Local recurrences after removal are of rapid formation, and of very frequent occurrence.

On section a reddish-yellow structure is displayed, in which imperfect alveolation can often be made out with the naked eye, certain of the septa generally being perfectly obvious. Histological examination reveals an alveolar formation, the walls of which consist of strands of sarcoma cells grouped around fine capillary blood vessels. Within the alveoli are large ovoid or rounded, nucleated, epitheloid cells, which are derived by proliferation from the cells lining the dilated lymph spaces within

---

<sup>38</sup> *Arch. f. klin. Chir.*, Bd. xxxvi., 1887, S. 421.



which they lie (fig. 65). As the intra-alveolar cells increase, they often cause by their pressure obliteration of the surrounding blood vessels, and so hyaline or myxomatous degeneration of the corresponding part of the neoplasm, which sometimes results in cystic formation.

Inasmuch as these growths are highly malignant, they should be freely extirpated, as soon as possible, together with the breast and overlying skin ; and the axilla should be cleared as well in every case. The following is a good example from the *University College Hospital Reports*.<sup>39</sup>

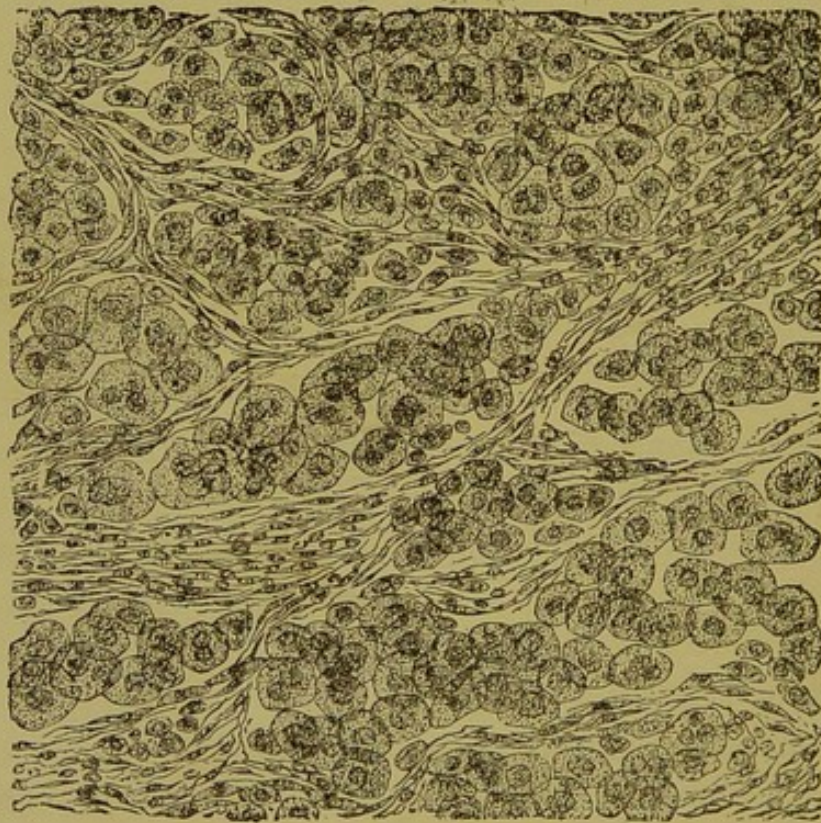


FIG. 65.—Histological section of alveolar sarcoma.  $\times 400$ . (*Formad.*)

A multipara, aged 55, with a tumour in her left breast the size and shape of a fowl's egg. It was of five months' duration. A single enlarged gland could be felt in the axilla. The tumour was mobile, and neither the skin nor the adjacent structures were obviously invaded. The breast was ampu-

<sup>39</sup> For 1885, p. 124 ; and for 1887, p. 184.



tated and the axilla cleared. She was convalescent about a month later. The tumour was firm in consistence, its cut surface was intersected by fibroid bands, and in its substance were embedded numerous minute cysts. On histological examination the tumour structures were found to be much degenerated, but at its periphery the alveolar arrangement was clearly manifest. The alveolar walls consisted of embryonic round and spindle-celled tissue, including ovoid spaces containing epithelioid cells. Similar disease had invaded the enlarged axillary gland. About two years later this patient again came under observation with recurrence in the mammary region and axilla; and she died soon afterwards with metastases in the vault of the skull (which had perforated the bones), brain, right femur, left humerus, sternum, both lungs, liver, and both kidneys.

Billroth<sup>40</sup> has reported the following instance of a rare variety of the disease—*myeloid alveolar sarcoma*.

A multipara, aged 42, with a tumour the size of a fist—of a few months' duration—in her right breast. It was nodular, circumscribed, mobile and felt tough. The axillary glands were unaffected. On examination, after extirpation of the breast, the tumour was found to be encapsuled. On section it presented a greyish-red, lobulated aspect, and on pressure pulpy substance exuded from its quasi-alveolar structure. Histologically there was revealed an alveolar arrangement, with here and there small areas of cystoid softening. The alveolar structure consisted of fibro-spindle-celled tissue, and its meshes were packed with numerous large cells, many of them containing from five to ten nuclei. About three months later she again came under treatment with development of the disease in the axilla. This was dissected out, and it exactly resembled the primary neoplasm. Two months later there was recurrence in the mammary scar. This was also excised. Four months later she again came under treatment with recurrence in the axilla. This was again excised, but she died shortly afterwards of septic disease supervening on erysipelas. The necropsy revealed no metastases.

Under the name of *myeloid carcinoma* similar cases have been recorded by Snow<sup>41</sup> and Farmakowsky.<sup>42</sup>

It seems to me, that Phillips<sup>43</sup> remarkable case of "multiple epithelioma," of which an abstract is subjoined, properly belongs to this category.

The patient was a single woman, aged 34, who two years previously first noticed a small subcutaneous tumour in her right breast; and about two months afterwards, over a dozen similar tumours appeared beneath the skin

<sup>40</sup> *Deutsche Chir.*, Lief. xli., S. 58.

<sup>41</sup> *Brit. Med. Journal*, vol. i., p. 62, 1894—"Breast Carcinoma with Myeloids."

<sup>42</sup> "Ueber Carcinoma Mammæ mit Riesenzellen," Bern, 1890.

<sup>43</sup> *N. Y. Med. Record*, June 10, 1893, p. 639.



of various parts of the trunk. The original tumour in the breast steadily increased in size. There was no obvious affection of the adjacent lymph glands. Seven months later sixty-four of these small tumours were counted. They were pretty evenly, and somewhat symmetrically distributed over the scalp, face, neck, trunk, and thighs, but only a few very small ones formed in the forearms and legs. There was no family history of neoplasia. When a child she had rheumatic fever, and she was choreic at 11; and until a few years ago she suffered much from rheumatic pains, especially in the knees and ankles. A year later, as the tumours continued to increase in size and numbers, seven of the largest were excised; and ten days later fifteen more. Most of these soon recurred with renewed vigour. During the next few months 113 more were excised; the wounds healed rapidly and in many instances there was no subsequent recurrence. The largest tumour removed was the original one in the right breast; it weighed 10 ounces. In spite of this heroic treatment new growths continually formed, so that 2½ years after the appearance of the original tumour, over 600 were enumerated, and many flattened clusters and very small isolated ones could not be counted. At this time anasarca had supervened. She died paralytic two months later, having for some time previously experienced intense aching pains all over. There was no necropsy. Histological examination of the excised tumours revealed solid branching columns of epithelial-like cells embedded in fibrous stroma; the cells were of flattened, ovoid, rounded or irregular shape, large, nucleated, and presented no signs of epidermic evolution.

### § V.—Myxoma.

This is a rare form of mammary neoplasm, since of my 2,397 female cases there were only two examples of it.

In their main features myxomata of the breast closely resemble sarcomata, of which they are evidently but a sub-variety. The chief pathological consequences of the histological diversity, subsisting between these two forms of the disease are, that the myxomata rarely originate metastases; and that they recur locally after removal much less frequently than other sarcomata. Like the latter, most myxomata originate in the immediate vicinity of the small ducts, hence they usually contain glandular structures, whence cysts with intra-cystic growths frequently evolve, as in the adeno-cystic sarcomata. Myxomata are also met with devoid of any glandular structures; these originate from the fibro-fatty tissue of the organ remote from



the ducts, and their structure often comprises a considerable amount of fatty tissue.<sup>44</sup>

Mammary myxomata generally present as ovoid, circumscribed, lobulated tumours, of elastic consistence, and about the size of hen's eggs. They are enclosed in a thin fibrous capsule, which isolates them from the surrounding parts. In most cases they are mobile, but not infrequently they adhere to the overlying skin, which may ulcerate, and so the growth may fungate. They do not cause retraction of the nipple, and dissemination in the axillary glands is very exceptional.

On section the myxomatous tissue seldom presents the clear, glassy appearance of pure mucous tissue, such as is typically seen in the jelly-fish; instead there is revealed a translucent, yellowish, or greyish gelatinous substance—which exudes a viscid fluid—with various opaque or semi-opaque areas irregularly scattered throughout it, due to fatty changes, &c. Histologically this tissue consists of stellate and spindle cells, which communicate by means of numerous fine processes, and the meshes of the network thus formed are filled with mucous substance. Numerous capillary blood vessels pervade the tissue, and not infrequently round and ovoid cells are also present. Billroth found a number of lentil-like, osseous nodules in a mammary myxo-sarcoma. In some varieties the mucous element predominates, in others the cellular, and in yet others the fibrous, fatty, or vascular elements. When the neoplastic cells themselves degenerate pseudo-cysts often result. The complications arising from the cystic evolution of the included glandular structures are identical with those met with in the adeno-cystic sarcomata, and need not be further alluded to.

Mammary myxomata require to be treated in accordance with the same principles as mammary sarcomata. The prognosis is, however, more favourable than for the latter; for,

---

<sup>44</sup> In the midst of a myxomatous tumour of six years' growth, removed from the breast of a multipara, aged 35, Moore found a distinct lipoma. *Dub. Journ. Med. Sci.*, vol. lxiii., p. 489.



according to Gross,<sup>45</sup> local recurrences after removal are met with only in 16·6 per cent. of all cases.

The period of life at which the disease supervenes is much the same as that for sarcoma. Ashby and Wright have figured an instance of *congenital* myxo-lipoma of the breast in their treatise on the diseases of children, but they give no history of the case.

As an example of the malignant form of the disease the following case by Morris<sup>46</sup> is of interest :—

A widow, aged 38, in delicate health, with a tumour four inches in diameter in her left breast. About six months previously she first noticed two lumps in the breast; these subsequently fused, and from them the tumour grew. There was no enlargement of the axillary glands. The breast was amputated, and the patient was convalescent in about six weeks. A month later she again came under treatment with local recurrence, which was excised; but shortly afterwards the disease recurred again and was again excised. On section after removal the primary tumour presented to the naked eye several spaces filled with gelatinous fluid; the rest of it consisted of soft solid substance of greyish colour, mottled with plum-coloured streaks. It was enclosed in a thin capsule. Histological examination revealed fibrous tissue, spindle cells, and irregularly shaped branching cells, communicating with one another, and forming a network, in the meshes of which mucoid fluid was contained. A year after the last operation, the patient again came under treatment, complaining of great pain in the right side of her chest and hacking cough; there was dulness as high as the fourth rib. She died of exhaustion a month later. At the necropsy the mammary region and axilla were found to be quite free from the disease. From the posterior part of the right lobe of the liver there projected upwards a mass of new growth, the size of the foetal head, which had compressed the right lung and displaced it upwards. There were some secondary growths in the left lung. Histologically, the secondary growths were of similar structure to the primary one in the mamma, only they contained rather more spindle cells.

## § VI.—Keloid and its Allies.

One of the favourite seats of origin of keloid is the skin over the sternum, but occasionally it originates from the mammary integument. The disease is decidedly rare. As to the precise

<sup>45</sup> "Am. Syst. Gyn.," vol. ii., p. 259.

<sup>46</sup> *Trans. Path. Soc. Lond.*, vol. xxiii., p. 274, &c.



morbid conditions to which the term keloid is applicable although there is much diversity of opinion, two distinct types may be recognised.

(1) In the commoner form, the disease usually presents as an oblong, flattened outgrowth from the derma, of smooth, purplish-red aspect, much resembling an overgrown and irritated scar. Indeed, it is from cicatricial tissue that such growths usually arise. Hence Virchow has described them as *sarcomata of scars*. Occasionally, however, they evolve spontaneously. This is the type of the disease denominated by Alibert *kelis* (κηλὶς = blemish). Growths of this kind resemble sarcomata, in that they recur locally again and again, even after very free removal. A notable peculiarity about these recurrences is, that they sometimes occur not only in the extirpation scars, but also in any little scars that happen to have been made in the vicinity by the use of sutures, needles, leeches, &c. In such cases it is impossible to avoid the inference that the morbid tendency thus manifested appertains to the locality, as well as to the structure. They also resemble sarcomata in that they do not disseminate in the adjacent lymph glands; but, unlike most sarcomata, these growths are not encapsuled, and they never cause metastases. Histologically they consist of immature fibrous tissue, containing numerous nuclei, with generally some round and spindle cells intermixed. When the question of treatment is under consideration, it is well to remember that, having attained a certain size, the disease often ceases to increase. Moreover, under the influence of soothing applications, it sometimes manifests a tendency to spontaneous resolution. Consequently, operative interference, caustic and irritant applications should be sedulously avoided. The best treatment is to cover up the lesion with belladonna, salicylic acid, or ammoniacum cum hydrargyro plaster.

The following example of this disease in the breast has come under my notice:—

---

\* *Path. des Tumeurs*, t. ii., p. 239.



A well-nourished, fair complexioned, healthy looking woman, aged 51, the mother of five children, with a hard red nodule, the size of a pea, projecting slightly from the skin at the upper part of the periphery of the left bosom. Fourteen years ago she had a boil in this situation, which, when it healed, left a small scar; the present disease has sprung from this scar during the last six months. No enlargement of the adjacent lymph glands. Previous health good. No family history of cancer or tumour. The growth was excised, together with a rim of the surrounding integument. On examination, after removal, it presented as a thickening of the derma. Its section presented a dense, whitish-yellow fibroid aspect. On microscopical examination a fibrous felt-work was seen rich in nuclei, with a few small round and spindle cells embedded in it. She was soon convalescent, and I have since seen nothing more of her.

Velpeau<sup>47</sup> has recorded the subjoined instructive case:—

A young lady of great beauty consulted him for a small reddish growth, projecting from the integument of the inner side of the left bosom. It caused her no pain, but its presence was a source of great annoyance. She got a surgeon to excise it, but six months later a fresh tumour had formed in the scar bigger than the first. A second operation soon afterwards was followed by a similar result. When Velpeau first saw her, some months after the second operation, there was a projecting smooth, reddish *plaque* in the scar (3 cm.  $\times$  2½ cm.). The deformity worried her very much, and she shrank from no risk to be rid of it. Velpeau therefore excised it for the third time; but although the wound united by first intention, recurrence soon afterwards took place. Then the lady in despair gave up all attempts at cure, and subsequently the tumour diminished spontaneously.

In a case reported by Bryant,<sup>48</sup> eight years after excision of a fibro-adenoma of six months' duration, from the left breast of an unmarried lady, aged 34, a typical keloid growth developed in the old scar. This was subsequently excised, and there was return of the disease five years afterwards.

The following case of lupus-keloid is by Hutchinson:<sup>49</sup>—

A widow lady, aged 50, came under observation with a purplish-red, slightly raised, indurated, horse-shoe-shaped patch—rather larger than a crown piece—on the inner side of her right bosom. Unlike ordinary keloid, it had a shelving edge that merged gradually into the surrounding integument; moreover, instead of its surface being smooth and glossy, as in ordinary keloid, it was rough, showing the orifices of hair follicles. The disease began about twenty years ago, and it has ever since been spreading very slowly, but there has never been the least ulceration. It had been diagnosed some years previously by a skin specialist as *lupus erythematosus*.

<sup>47</sup> "Traité des Maladies du Sein," &c., 1854, p. 467.

<sup>48</sup> "Diseases of the Breast," p. 111.

<sup>49</sup> *Archives of Surgery*, Oct., 1891, p. 129.



She had a scar on the left side of her nose, which resulted from the cure of a patch of *lupus erythematosus*, after repeated applications of the galvanic cautery, &c., five years ago. With regard to the treatment of the patch on the breast, she was advised to leave it alone.

(2) The rarer form of the disease is characterised by the formation in the derma of whitish, ivory-like, slightly elevated, indurated areas, which feel firm and elastic, each being surrounded by a faint, lilac-coloured vascular areola. It seems in reality to be a localised sclero-derma. From it numerous fibroid processes often extend far into the surrounding structures; and, in connection with these, satellite nodules may develop. This is the form termed by Addison *cheloid* ( $\chi\eta\lambda\eta$  = crab's claw). The disease begins with proliferative changes in the fibro-cellular tissue surrounding the *adventitia* of the small arteries of the derma, and by its spread along similar channels, the outlying processes arise. The result is considerable overgrowth of the fibrous tissues in the parts affected. If left alone it generally progresses, but very slowly; and after a time retrogressive changes sometimes supervene spontaneously.

The following interesting cases—in which the breast was involved—are by Hutchinson:<sup>50</sup>—

(a) A comely married woman, aged 40, with extensive, irregular thickening, sclerosis, and fixation of the skin over the left pectoral region, shoulder, deltoid region, front of the arm, and the radial border of the forearm, thumb, and finger. In some of the affected parts there are groups of ivory-like, lardaceous, shining patches, which send out spurs; but the appearance of most of the thickened integument resembles that of kelis, and in some places it looks very like cancerous infiltration *en cuirasse*. In consequence of this fixed and tightened condition of the skin, the movements of the limb are much impaired. Numerous small subcutaneous tubercles, not larger than hazel nuts, are present in the diseased parts. Some similar reddish indurated patches, occur in the skin of the front and outer parts of the left leg and the second toe. This curious disease began with the development of a single morphœa-like node in the skin, above the left breast, six or seven years previously. It remained without obvious change until about a year ago, when there was sudden outbreak of the disease on all the four extremities, but chiefly on the left side. The lesions of the right side subsequently almost entirely disappeared. Three and a-half years later she again came under observation. Her general health then was very good. The skin of the left

<sup>50</sup> *Archives of Surgery*, July, 1891, pp. 30 and 34; also July, 1890, p. 32.



pectoral region, from the clavicle to the nipple, was occupied by a dusky-brown thickened induration, by which it was bound firmly to the subjacent parts. Nothing but knowledge of the previous history of the case, and examination of the similar lesions in other parts of the body, could have prevented the diagnosis of cancer *en cuirasse*. In the deltoid region there were a few ivory-like *plaques* and atrophic patches, where the disease seemed to have receded. There were also atrophic areas along the course of the upper limb where the nodules had been most marked; and both hands were considerably affected with diffuse scleroderma.

(b) A single lady, aged 23, with lardaceous thickening and tightening of the skin of both mammary regions, the face, and both upper and lower extremities, due to diffuse scleroderma. She said the disease came on gradually three years previously, owing to grief at the death of her mother. Symptoms of Raynaud's disease subsequently developed, and when next seen three years later, both forefingers were necrotic.

(c) A widow lady, aged 45, apparently in excellent health, applied under the belief that she was suffering from cutaneous cancer of the breast. About eight months previously she first noticed a patch of indurated skin just in front of the left axilla. At a consultation a fortnight later two patches were noticed there, each about the size of a florin. They seemed to consist of firm, leathery, cutaneous induration, and they were of mottled pinkish-yellow tint. Two subcutaneous nodules could be felt in their vicinity. No known cicatrix had previously existed, so far as the patient knew, in the site of either patch. The axilla felt normal. It was evidently an instance of ivory-like morphea patches, and not cancer.

## § VII.—Sarcoma of the Male Breast.

From such instances of sarcomatous disease of the male breast as have hitherto been recorded, it may be inferred that all the above described varieties met with in the female breast may also be found in it, although, of course, such occurrences are of great rarity.\* Most of the recorded cases known to me have been pure sarcomata, as in the four following examples:—

(1)<sup>51</sup> A man, aged 43, a week previously first noticed a small, hard lump in his left breast, just above and internal to the nipple. No previous injury or other known cause. His father died of "cerebral tumour." It increased rapidly. On examination, a hard, elastic, elongated nodular tumour was found there, which was freely movable under the skin and over the pectoral muscle. There was no retraction of the nipple, and the axillary glands were normal. A fortnight later the breast was amputated. The tumour was enclosed in a thick capsule, and on section it was composed of solid sub-

\* For table showing its relative frequency *vide* p. 130.

<sup>51</sup> Haslam, *Birmingham Medical Review*, vol. xxv., 1889, p. 286.



stance, containing a few small cysts. Histologically, the solid substance consisted almost entirely of small round cells, with the characteristic grouping of *lympho-sarcoma*. He was convalescent about three weeks later.

(2) <sup>52</sup> A labourer, aged 37, strong and healthy-looking, came under observation with a large fungating and eroded tumour of the right breast of seven years' duration. It was hard, lobulated, circumscribed, and freely movable on the subjacent parts. Its circumference measured 27 inches. There was profuse foetid discharge from it. No enlargement of the adjacent lymph-glands. The patient ascribed the origin of the disease to the effect of a blow from a heavy piece of iron. His mother's sister died of a malignant tumour of the breast, which recurred twice after removal. The diseased part was amputated. The tumour weighed 2lbs. after removal. It was a *spindle-celled sarcoma*. He was convalescent soon after.

(3) <sup>53</sup> A soldier, 40 years old, with a nodular tumour, the size of a walnut, projecting from the right mammary region. The overlying skin was purplish, and marked with dilated veins. It was situated above and external to the nipple. It felt firm and elastic. About 22 years ago the patient first noticed a small nodule in the site of the present tumour. Its increase was hardly perceptible until about five years ago. Amputation of the diseased part. On examination after removal, the tumour was found to consist of three nodules, united by dense fibroid tissue. The smaller one was obviously connected with the mammary gland, but not so the other two. On section the tumour presented a convex, nacreous, fibroid aspect. Histologically, *fibro-spindle-celled sarcoma*.

(4) <sup>54</sup> A man, aged 21, eight months previously first noticed a mobile lump, the size of a horse bean, external to the left nipple over the edge of the pectoralis major muscle. This subsequently increased in size and the axillary glands became enlarged. The diseased part was excised and the axilla cleared. Five months later he again came under observation with recurrence high up in the axilla and in the glands at the root of the neck, and in the mammary region. The disease spread with terrible rapidity. In attempting to clear the axilla a mass of soft new growth was found to have completely surrounded the large blood vessels, &c., and it could only be partly removed. He died six weeks later, and at the necropsy secondary growths were found in both lungs. Histologically the disease was *round-celled sarcoma*.

Instances of *adeno-cystic sarcoma* have been recorded by Birkett,<sup>55</sup> Amado,<sup>56</sup> and others; while Rothmann<sup>57</sup> has met with an example of *alveolar sarcoma*, and Obolensky<sup>58</sup> with an *adeno-myxoma*.

<sup>52</sup> Morton, *Glasgow Medical Journal*, vol. xiv., 1880, p. 157.

<sup>53</sup> Ward, *Trans. Path. Soc. London*, vol. xi., 1860, p. 268.

<sup>54</sup> Banks, "Clinical Notes," 1884, p. 69.

<sup>55</sup> "Diseases of the Breast," 1850, p. 257.

<sup>56</sup> *Correio Med. de Lisboa*, 1871-2, vol. i., p. 210.

<sup>57</sup> "Ein Fall von cystische Endotheliom der männlich Brust." Wurzb., 1891.

<sup>58</sup> Cited in Labbé and Coÿne's *Traité des Tumeurs Bénignes du Sein*, p. 553.



## CHAPTER XVIII.

## FIBROMA AND FIBRO-ADENOMA.

## § I.—Pure Fibroma.

ACCORDING to Billroth<sup>1</sup> and Schimmelbusch,<sup>2</sup> mammary fibromata always contain glandular structures. This is too sweeping a statement, for pure fibromata of the breast are undoubtedly occasionally met with. Among the 2,397 cases of mammary neoplasms in women analysed by me, there was one instance of this kind. It is difficult to account for their great rarity, considering the abundance of the fibrous tissue of the part. In their general characters such growths precisely resemble the ordinary fibrous tumours of the subcutaneous tissue, &c.

Lancereaux<sup>3</sup> figures a good specimen from Péan's collection, showing two rather large tumours of this kind, situated over the front of the gland, immediately beneath the skin.

In the *Hunterian Museum* there are three somewhat similar specimens, which in the catalogue<sup>4</sup> are described as follows:—

(1) No. 4,775A. A tumour, one inch in diameter, of fibrous appearance, from the surface of the mammary gland. Histological examination showed only fibrous tissue, without any trace of glandular elements. From a woman aged 44.

(2) No. 4,776. An encapsuled fibroma, of eighteen months' duration, from the right breast of a married multipara, aged 53. Histologically it was composed of fibrous tissue, containing but few nuclei.

<sup>1</sup> *Deutsche Chir.*, Lief. xli., S. 43.

<sup>2</sup> *Arch. f. klin. Chir.*, Bd. xlv., 1892, S. 102.

<sup>3</sup> "Traité d'Anat. Path.," t. i., 1875, p. 377.

<sup>4</sup> "Path. Catalogue," vol. iv., 1885, p. 477.



In another specimen of this kind the tumour weighed seven pounds, and was of thirteen years' growth. The patient was a middle-aged woman. The tumour was situated behind the gland.

Broca<sup>5</sup> mentions having met with two instances of fibroma in the mammary region. In one the tumour was situated beneath the gland, between it and the pectoralis major muscle; in the other it was situated under this muscle. In neither case had the tumour any connection with the gland itself.

Some of the polypoid growths met with within the large ducts, are occasionally purely fibromatous in structure ("*fibrome intra-canaliculaire*").

Paget<sup>6</sup> has recorded the following remarkable case of *malignant fibroma*, which is of great interest, from whatever point of view we regard it.

A poor widow, aged 47, crippled from chronic rheumatism, came under observation with a mobile tumour in her right breast, which had increased but very slowly until seven weeks previously; when, after an injury, it augmented rapidly and became very painful. A spherical tumour, two to three inches in diameter, soon formed, which was so exceedingly hard as to resemble cancer. The whole breast was extirpated. On examination after removal, the tumour was circumscribed, encapsuled and solid. Its cut surface precisely resembled that of an ordinary fibroma. The most careful histological examination, often repeated, revealed nothing but well-formed fibrous tissue, with embedded elongated nuclei; on boiling it yielded gelatine. Three months after this operation further growth appeared under the scar, which grew very quickly, forming a tumour very like the primary one. Two months later the overlying tissues began to ulcerate, and soon afterwards the whole growth separated by sloughing. This tumour also presented the characters—histological and otherwise—of simple fibroma. The walls of the large sloughing cavity, left after the separation of the tumour, soon presented hard knots of recurrent disease, and finally they were invaded throughout by firm, nodular, whitish, new growth. After death numerous secondary growths of similar appearance were found in both lungs, which, histologically and otherwise, seemed identical with unmixed fibrous tissue.

One is, of course, naturally inclined to regard such growths as of fibro-sarcomatous nature; but it is strange, after repeated examinations directed specially to this end, that no sarcomatous elements could be detected. Having myself met with several similar instances, in which the prognosis—based upon micro-

---

<sup>5</sup> "Traité des Tumeurs," t. ii., p. 454.

<sup>6</sup> "Lectures on Surgical Pathology," vol. ii., 1853, p. 151.



scopical examination, &c.—was equally at fault, I have been much impressed by the circumstance.<sup>7</sup>

Small, pedunculated, fibrous outgrowths (*molluscum fibrosum*) from the skin of the areola and nipple, are occasionally seen.

In a healthy, young adult woman, I met with a growth of this kind, close to the nipple, that looked at first sight very like a redundant nipple. Bryant<sup>8</sup> mentions a somewhat similar case, and he also refers to an instance in which a fibrous growth sprang from the apex of the nipple. MacSwiney<sup>9</sup> has reported an example of pendulous fibroma of this part, in which the tumour attained a large size, its pedicle being about seven inches long, and at its largest circumference the tumour measured six inches.

## § II.—Fibro-Adenoma.

At the beginning of the present century it was customary to regard all mammary tumours as of a malignant nature. To Astley Cooper—the *beau ideal* of an English surgeon—belongs the credit of having been the first to discriminate the non-malignant forms. These he called “*chronic mammary tumours*.” His knowledge of the subject was so advanced, that had the microscope then been available, it is evident he would have left very little for his successors to discover. His description of these tumours is as follows:<sup>10</sup>—

“This disease is not of a malignant character, and by no means dangerous to life; it is generally very young people who are attacked by it, and we seldom see it in persons above 30 years of age. I will try to describe, in a familiar manner, the mode in which this disease will be exhibited to you. A young person between the age of 15 and 30, will be brought to you by her parents, on account of a swelling in her breast; when you look at her, you see that she has a perfectly healthy appearance, and, in all probability, is much younger than those who are usually attacked by scirrhus tubercle. Her parents being naturally anxious for their child’s safety, express their fears of the disease being cancerous; at this you smile, and tell them that cancer does not attack persons so young; upon examining the breast you find an exceedingly movable tumour—the size of which is generally from that of a filbert or walnut to that of a billiard ball—having a lobulated feel, being divided into distinct apartments by septa,

<sup>7</sup> *Medical Press and Circular*, Nov. 28, 1888.

<sup>8</sup> “*Diseases of the Breast*,” pp. 333 and 334.

<sup>9</sup> *Dublin Journal of Medical Science*, 1875, p. 484.

<sup>10</sup> “*Lectures on Surgery*,” 1839, p. 392.



producing the same kind of sensation to the fingers as fatty tumours. You have here (delivering a preparation to a student) an opportunity of seeing this kind of tumour, and upon carefully examining it, you will find that the account which I have given you of it is correct. Well, then, the age and healthy appearance of the person, and the lobulated feel of the tumour, will at once point out to you that the disease is not cancerous; which, gentlemen, you may inform the person's parents, and likewise tell them that the disease will never become cancerous. I can assure you that this disease is not in the slightest degree of a malignant character, neither is it attended with the least danger."

Cooper's views were soon accepted in England; but elsewhere they penetrated very slowly. Thus in France, shortly afterwards (1839), we find Velpeau describing these same tumours as "*tumeurs fibrineuses*," for he thought they were nothing but deposits of inspissated fibrine, left behind after localised extravasations of blood. Some years later (1844), the celebrated Cruveilhier communicated to the Royal Academy of Medicine his much-discussed *Mémoire*, in which he maintained that these tumours were veritable fibromata, "*corps fibreux*," as he called them. The next step forward was by Lebert, who some years later, with the aid of the microscope, first clearly demonstrated the presence of glandular structures; whence he described them as "*hypertrophies partielles*" of the gland. Soon afterwards Velpeau, having convinced himself of the accuracy of Lebert's observations, rechristened them "*tumeurs adénoïdes*." The identity of these variously named tumours with one another, and with the "chronic mammary tumours" of Cooper, then, at length, became generally recognised.

These investigations having demonstrated that the tumours consist of both *fibrous* and *glandular* structures, the question then arose, as to which was the essential constituent. It cannot be said that this has even yet been definitely settled; in fact, being at bottom essentially a genetic question, its solution must perhaps ever be mainly a matter of inference. Accordingly we need not be surprised to meet with divergent interpretations. Thus, while Virchow and most German pathologists, together with Labbé and Coÿne, Cornil and Ranvier, and Gross, regard these growths as *fibromata*; Broca, Verneuil, Cadiat, Delbet and others, consider them as essentially of



glandular origin, or *adenomata*. Since physiological impulses in the breast manifest themselves mainly through its glandular elements; it seems only reasonable to suppose that the stress of its pathological impulses will fall, also, chiefly on these. Believing, as I do, that the immense majority of these growths arise from portions of the breast, where both the glandular and fibrous elements are intimately blended, that is to say, from the small ducts and their immediate vicinity; it seems to me highly probable that both factors participate in the origin of the disease; which may, therefore, with propriety be designated *fibro-adenoma*.

Unfortunately, instead of restricting the term "*adenoma*" exclusively to such growths as the foregoing, many pathologists have given it a much wider application. Hence, so many different kinds of neoplasm have come to be included under this heading, that hardly any two pathologists now employ the term in the same sense. By Gross it is applied to "tubular cancers" and "villous duct papillomata"; the latter are also thus designated by Billroth, who, under this heading, includes as well "the partial glandular hypertrophies," and it is in the latter sense that the term is used by Cornil and Ranvier.

"True adenoma" is the name given by some pathologists to tumours structurally exactly like a segment of the breast itself, only not united to the gland by its main duct. Tumours of this kind undoubtedly occur; and it is such as these that have occasionally been observed to secrete milk. A thorough examination of this subject, in connection with my investigations relating to supernumerary mammary sequestrations, has convinced me; that in these cases we have to do with overgrown supernumerary mammary sequestrations, rather than with true neoplasms. Such I believe to be the nature of Birkett's two remarkable cases,<sup>11</sup> of which an epitome is subjoined:

(1) Soon after marriage, a healthy young woman, aged 21, first noticed a small lump in the axillary region of her left breast. Her first child was born

---

<sup>11</sup> *Guy's Hosp. Rep.*, 1855.



within a year, and she suckled it for nearly ten months, becoming pregnant again while doing so. She came under observation when about six months gone in this second pregnancy. The left breast then was about double the size of the right, owing to the presence of ill-defined, quasi-fluctuating swelling in its axillary segment. The nipple was displaced inwards, but it was not retracted. After parturition in due course, a definite tumour was for the first time distinctly made out. Whilst suckling this child milk abscesses formed in her left breast. Some months later she became pregnant again, and in due course a third child was born, which she suckled for a month, when it died. At this time a circumscribed, lobular, mobile, solid tumour, quite isolated from the breast, could be made out. About a year later the tumour having continued to increase, was excised. In the course of the dissection, it was found to be encapsuled and isolated from the mammary gland, which was not injured by its removal. The tumour weighed three pounds. Its structure closely resembled that of the normal mamma, consisting of loosely connected lobes, each composed of lobules, and these again of aggregates of acini. The smaller ducts from these sources united to form larger ones; the distal ends of which terminated on the surface of the mass. In this vicinity there was a large, thin-walled cyst, as if due to a dilated main duct, which was distended with soft, solid substance resembling thick cream, and on chemical examination its composition was found to be very cream-like. Not far distant from this cyst was a smaller one, filled with cretaceous material.

(2) A healthy, unmarried woman, aged 23, three and a-half years ago first noticed a lump in her left breast. The catamenia did not appear until 19, when they ceased for nearly a year, and at about the time they re-appeared the breast tumour began to enlarge. On examination a well defined lobulated tumour could be felt, which seemed to be situated behind the sterno-clavicular segment of the mamma. It was excised some months later, without the breast sustaining any injury. On examination after removal it proved to be an exceedingly firm, dense, lobulated tumour—structurally, very like the normal mamma—consisting of numerous, closely-packed, small lobes and lobules, many of whose chief ducts were distended with a substance exactly resembling cream. It seemed probable that this person was a virgin.

The following case of so-called true adenoma, by D'Arcy Power,<sup>12</sup> is evidently of similar nature.

A lady, four months pregnant, five months ago first noticed a tumour in her breast, which subsequently was excised. It was encapsuled, lobulated and nodular; four and a-half inches by two inches in diameter. In section it was of pearly white appearance, like freshly cut mammary gland. Histologically it consisted of fibrous stroma in which were embedded lobular and acinous structures, like those of the normal mamma, but less regularly arranged.

<sup>12</sup> *Trans. Path. Soc. Lond.*, vol. xxxvi., 1885, p. 411.



I have previously cited many other examples of tumours and tumour-like swellings thus arising.<sup>13</sup>

With regard to the *general morphology* of this disease it may be mentioned that although fibro-adenomata are usually solitary, yet more than a single tumour is occasionally met with. Of forty-six cases consecutively under my observation, forty-four were solitary; of the other two cases, in one several small tumours were present in *both* breasts, and in the other there were two small tumours in the affected breast. These multiple tumours usually evolve successively at different periods. I have never met with an instance in which the disease developed simultaneously in both breasts. In this connection it may be mentioned, that after the removal of one tumour another has been known to form in the same vicinity, or in a different part of the same breast, or even in the opposite breast.

According to my experience the *left* breast is more frequently affected than the right, in the proportion of 33 to 19. Of Velpeau's 54 cases, 27 were of the left breast, 22 of the right, and in 5 both breasts were affected. As a rule, these tumours are superficially situated, but they may be found in any part of the gland or its vicinity. Very rarely they are placed altogether beneath it; and instances have been met with, in which the tumour has been embedded in the pectoral muscle. Of much greater frequency is their occurrence in the peripheral than in the central part of the gland; more than three-fourths of the tumours under my observation were thus located. More than half of these peripheral tumours were found in the upper segment of the breast, and of the others, as many occupied its sternal as its axillary segment; while the fewest were met with in its lower segment.<sup>14</sup>

---

<sup>13</sup> Ch. iv., §§ iv. and v.

<sup>14</sup> Of 42 cases *central* 8, *peripheral* 34. Of the *peripheral* tumours in the *upper* part 16, *upper and sternal* 3, *lower* 3, *lower and axillary* 3, *lower* 2, *axillary* 4, *sternal* 3. I have found that 14 per cent. of all fibro-adenomata of the mammary region, originate from sequestered supernumerary mammary structures, having no connection with the adjacent gland. (For cases *vide* pp. 73-76).



In 5 out of 50 cases I noticed that fibro-adenomata were associated with *lobular hypertrophy*; in two of these cases both breasts were thus affected; in 2 the lobular enlargement was of the same breast as the tumour, and in one case it was of the opposite breast.

Here reference must be made to the important observations of Labbé and Coÿne,<sup>15</sup> who, as the result of histological examination, have shown that the glandular structures in the vicinity of fibro-adenomata frequently exhibit hyperplastic changes, which indicate that the morbid process that has culminated in the neoplasm, has affected also the adjacent structures of the gland in a less degree, just as in the case of cancer. It seems impossible to doubt but that these hyperplastic structures are the source whence recurrences occasionally arise.

In their gross structural outlines fibro-adenomata much resemble fibro-sarcomata. They are invariably encapsuled. The capsule generally consists of an external dense layer of fibrous tissue, and an internal loose one. The laxity of the latter is sometimes so considerable, that bursa-like pseudocysts may develop in connection with it. On this peculiarity Paget's theory<sup>16</sup> is based, according to which fibro-adenomata are essentially of cystic origin, the solid growths arising secondarily from the walls of the cysts into which they grow, and so eventually completely filling them to the exclusion of their fluid contents. I cannot accept this view, because cysts of this kind are of very rare occurrence, and they are not found in association with fibro-adenomata of small size. Moreover, histological examination of the capsule of these tumours, fails to reveal any trace of an endothelial lining membrane.

Owing to the laxity with which fibro-adenomata lie within their capsule, and to their complete detachment from the surrounding parts, they are exceedingly mobile, and when pressed upon by the finger they slip freely about; hence also, after

---

<sup>15</sup> "Traité des Tumeurs Bénignes du Sein," p. 549.

<sup>16</sup> "Lectures on Surgical Pathology," vol. ii., 1853, p. 70; *vide* also Goodhart, *Ed. Med. Jour.*, 1872, p. 1015.



opening the capsule, they can be enucleated with great facility. Both cystic and non-cystic forms of the disease are met with, but cysts are relatively of much rarer occurrence in fibro-adenomata, than in fibro-sarcomata.

The *non-cystic* varieties usually present as small, ovoid or rounded, lobular tumours, which are irregularly bossed. On section the cut surface assumes a convex shape, and there is revealed a whitish fibroid structure, in which are embedded some small, branched, cleft-like slits, which indicate the glandular

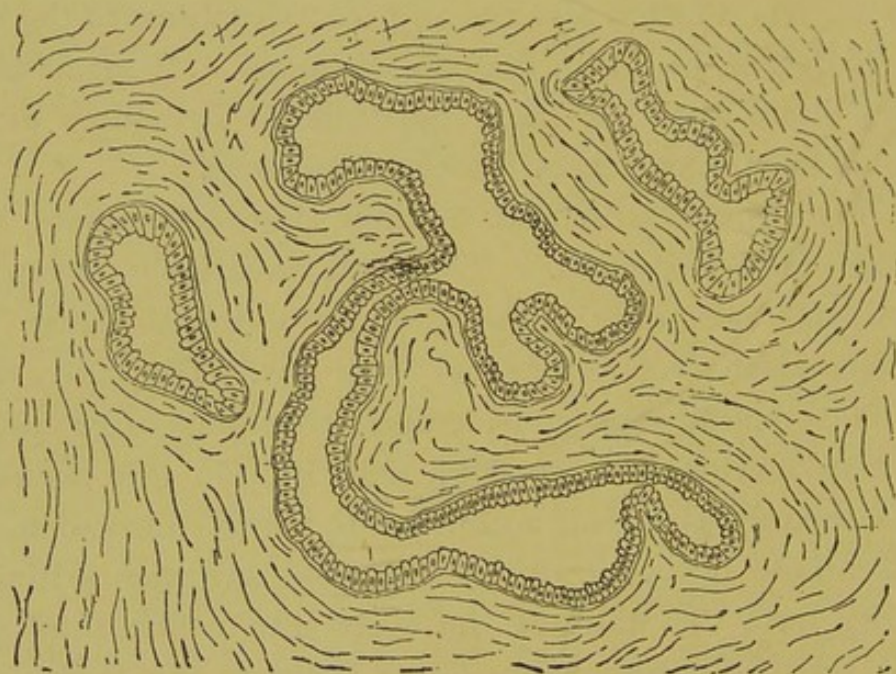


FIG. 66.—Histological section of fibro-adenoma, showing incipient intra-cystic vegetations (*Labbé and Coyne*).

structures (fig. 60). In solid tumours the fibrous stroma invariably predominates; but in some specimens the glandular elements are more abundant than in others. The latter consist of duct-like structures which are invariably lined with cells of columnar type (fig. 66); they must therefore be regarded as representing small ducts, and not acini as usually stated. In some specimens the stroma consists of dense, wavy, mature fibrous tissue, containing hardly any nuclei; the corresponding tumours then feel extremely hard, and on section they look dry



and nacreous ; in other specimens the stroma is looser and contains numerous nuclei : these forms are more succulent looking and of elastic consistence.

*Cysts* and *intra-cystic growths* evolve in connection with the glandular structures of fibro-adenomata, just in the same way as they do in connection with the fibro-sarcomata (figs. 67 and

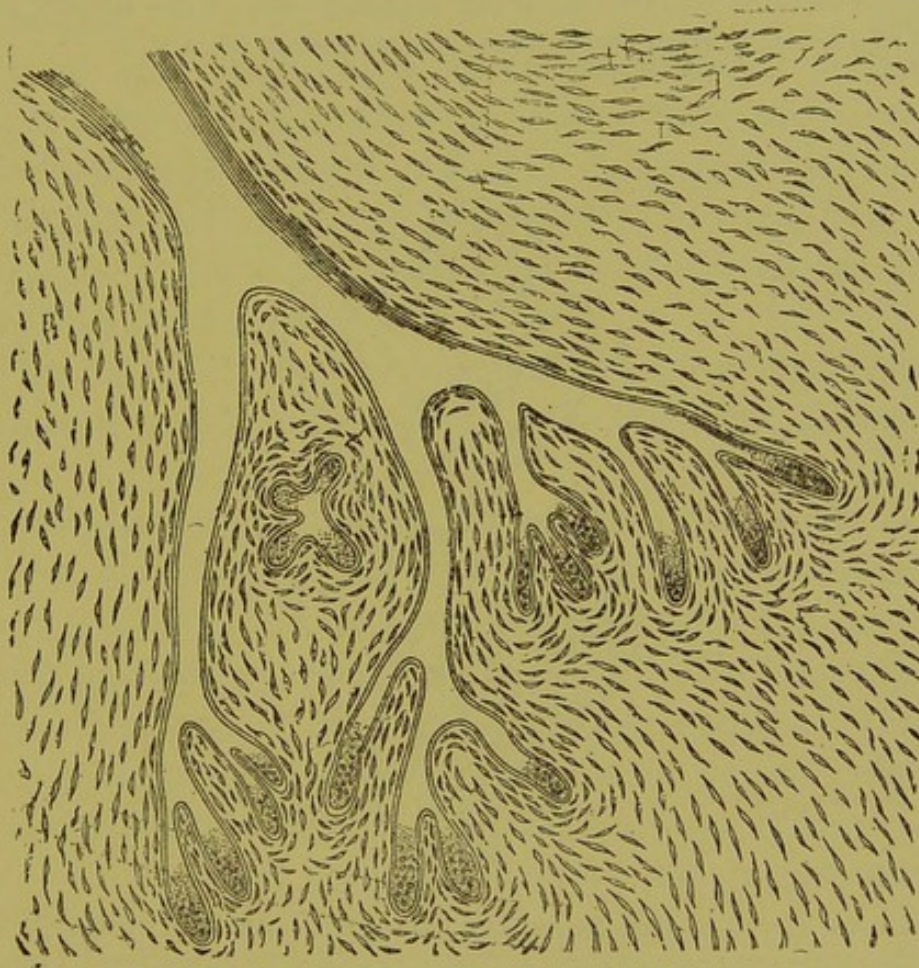


FIG. 67.—Histological section of fibro-adenoma, showing well-developed intra-cystic ingrowths, within the largest of which glandular structures are included (*Labbé and Cojné*).

68). Of 50 fibro-adenomata consecutively under my observation, 13 were cystic ; in every case but one the cysts were multilocular, and contained both solid and fluid contents, the former predominating in 5 instances. The gross characters of these tumours resemble those of the cystic sarcomata, although they seldom attain such a large size.



Fibro-adenomata occasionally undergo fatty, myxomatous, telangiectasic and calcareous changes. Gross<sup>17</sup> mentions an instance in which a tumour of this kind became partially ossified:—

The patient was a lady, aged 74; and she was free from any return of the disease when last heard of, eight years after its removal. The tumour was  $3\frac{1}{2}$  cm. in diameter, encapsuled, very hard, rounded and nodular. The histological sections showed numerous myeloid cells in the stroma, in the vicinity of the ossification, but nothing characteristic of cancer.

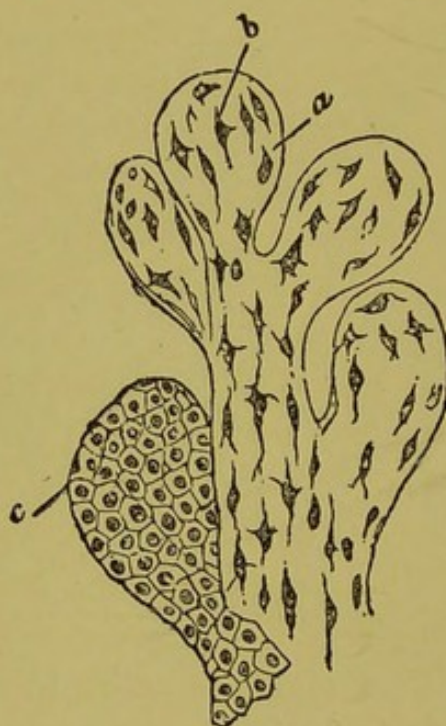


FIG. 68.—AN INTRA-CYSTIC INGROWTH, SHOWING THE EPITHELIAL LINING; AND THE SUB-JACENT CONNECTIVE TISSUE FRAMEWORK (*Cornil and Ranvier*).

(a) Fibrous stroma. (b) Connective tissue corpuscles. These ingrowths have been denuded of their epithelial investment. (c) An ingrowth with its epithelial investment entire.  $\times 300$  dia.

They may also inflame, and Jahoda<sup>18</sup> has reported an instance of elimination by suppuration.

The *rate of increase* of the solid forms is generally exceedingly slow; often after having attained a certain—not very

<sup>17</sup> "Am. Syst. Gyn.," vol. ii., p. 205.

<sup>18</sup> *Wien. med. Woch.*, No. 49, 1892.



large—size, they remain almost stationary for long periods. Of 52 cases consecutively under my observation, 6 had been in existence for periods varying from 6 to 34 years. The cystic forms often increase more rapidly and irregularly. Rapid increase has also occasionally been noticed to supervene in connection with pregnancy and lactation; but such a sequence is exceptional.

It has been alleged by some pathologists that fibro-adenomata occasionally altogether disappear spontaneously. The evidence hitherto adduced as to this is, however, far from convincing. Probably most of the cases alluded to, were really examples of lobular hypertrophy or of localised chronic mastitis (*induratio benigna*).

The important question as to the liability of these tumours to originate cancer and sarcoma, I have elsewhere discussed (p. 310).

Fibro-adenomata occasionally project considerably beyond the level of the skin; and so eventually assume a pendulous form. Under these circumstances the overlying skin may become purplish, adherent, and eventually ulcerate, so that the tumour may fungate, but this very rarely happens. In a case related by Labbé and Coÿne,<sup>19</sup> a tumour of 34 years' duration, was almost completely eliminated in this way. I have seen a chronic fistula result from the bursting of an inflamed cyst in a tumour of this kind.

In 5 out of 50 cases under my observation there was decided "irritative" enlargement of the adjacent axillary glands.

The patients who bear these tumours generally appear to be in good health. Of 35 cases under my observation, 30 were well nourished (obese 1), 4 moderately nourished, and 1 was emaciated. Eleven of them were pale and 1 was sallow. Eighteen were of dark, and 15 of fair, complexion. Of 53 consecutive fibro-adenomata, only 2 were associated with disease of other parts of the body; of these 1 patient was subject

---

<sup>19</sup> "Traité des Tumeurs Bénignes du Sein," p. 275.



to retroversion of the uterus and hysteria, and the other had *ovarian cystoma*. Of the latter case I append a brief abstract, a remarkable feature being, that in both situations the disease was on the same side.

A sterile married woman, aged 49, moderately nourished and with a pronounced moustache. Eight months ago she first noticed a swelling in the *left* iliac region, and three months later œdema of the left foot and leg; five months ago a tumour was noticed in her *left* breast. Her mother died, aged 55, of cancer of the breast. On examination I found a large ovarian tumour in the left iliac region and adjacent parts; and in the upper and axillary segment of the *left* breast, near its periphery, was a hard, circumscribed, mobile tumour, the size of half a Tangerine orange. Nipple normal. No enlargement of axillary glands. Median laparotomy, a thick-walled multilocular cyst of left ovary, universal adhesions and matting together of parts, to such an extent as to prevent tumour being removed. Cysts perforated, evacuated, and drained; edges of cyst wall stitched to the external wound. Subsequent recovery with great diminution of the tumour.

With regard to the *previous health*, inquiries were made in 38 cases; it had been good in 31 (with no serious illness since childhood in 18), and indifferent in 7. The following previous diseases had been experienced:—

Leucorrhœa in 3 cases; typhoid fever in 3 cases; pelvic cellulitis (after parturition), in 2 cases; scarlet fever, pleurisy, and phthisis, each in 2 cases; and 1 case each as follows: ulceration of the *os uteri*, hysteria, axillary abscess, hemiplegia, bronchitis, pneumonia and rheumatic fever.

Fibro-adenomata never cause *retraction of the nipple*; but it must be borne in mind that in a considerable proportion of these cases the nipple is retracted or otherwise malformed, owing to congenital defect. It happened thus in 10 out of 42 cases consecutively under my observation.

*Discharge from the nipple* is occasionally associated with these tumours, especially with the cystic forms. It is usually serous, and when intra-cystic vegetations are present it may be blood-stained.

As a rule their presence causes little or no *pain*, but occasionally, uneasy sensations are experienced at the menstrual periods. Sometimes, however, they are associated with paroxysmal attacks of quasi-neuralgic pain, out of all proportion to



the size of the lesion, as in the so-called "irritable tumours" of the breast, some of which are fibro-adenomata, while others are subcutaneous fibromata. A similar state of things occasionally supervenes in cancer and other mammary diseases. In this connection it is well to recollect, that the breast may become the seat of quasi-neuralgic attacks of pain, even in the absence of any appreciable lesion whatever.

The *general pathology* of the fibro-adenomata presents many points of interest.

The influence of *sex* is very marked, for of 373 consecutive tumours of this kind analysed by me, there was only one instance of the disease in a male.

*Age* is also an important factor, for in the majority of cases the disease begins in young adults, before 30; but it not infrequently starts much later in life. Of 52 cases in which I specially inquired with regard to this factor, the earliest age at which the disease first appeared was 15 years, the latest 63 years; and the mean age was 30·4 years. The numbers for each quinquennial period were as follows :—

15 to 20 years	...	...	...	...	in 11 cases
20 „ 25 „	...	...	...	...	„ 11 „
25 „ 30 „	...	...	...	...	„ 6 „
30 „ 35 „	...	...	...	...	„ 5 „
35 „ 40 „	...	...	...	...	„ 9 „
40 „ 45 „	...	...	...	...	„ 6 „
45 „ 50 „	...	...	...	...	„ 1 case
50 „ 55 „	...	...	...	...	„ 1 „
55 „ 60 „	...	...	...	...	„ 1 „
60 „ 65 „	...	...	...	...	„ 1 „

From this it will be gathered that fibro-adenomata hardly ever occur before puberty, as in the following cases :—

Bryant<sup>20</sup> mentions having seen an instance in a male child 10 months old; but inasmuch as fatty, as well as fibrous tissue, formed part of this tumour, it was most probably a case of "*induratio benigna*," due to chronic mastitis, for fatty tissue never enters into the formation of fibro-adenomata. Hopkins<sup>21</sup> having removed a fibro-adenoma the size of a

<sup>20</sup> "Diseases of the Breast," p. 90.

<sup>21</sup> *Boston Med. and Surgical Journal*, March 26, 1885, p. 290.



chestnut, from the right breast of a girl 7 years old, noticed that a similar tumour soon afterwards formed in her *left* breast, which in two and a-half years' time attained nearly as large a size as the one removed from her right breast. Histologically these tumours consisted of wavy fibrous tissue, containing a few tubular glandular structures.

Velpeau<sup>22</sup> met with a similar tumour in the breast of a girl 8 years old.

Patteson<sup>23</sup> has recorded two instances of this disease in childhood. In one case there was a tumour, the size of an almond, in the left breast of a girl 13 years old, of ten months' duration; and in the other case the right breast of a girl, 12 $\frac{3}{4}$  years old, contained a similar tumour of three months' duration. Both these tumours were encapsuled; and the fibro-adenomatous nature of the disease was determined by histological examination.

Velpeau mentions having seen a fibro-adenoma that developed as late as the 85th year; and Gross as late as the 74th.

*Civil State.*—Single, married, fruitful and barren women are none of them exempt from the formation of these tumours; nevertheless, as the subjoined figures show, they are of more frequent occurrence in the single, and in the sterile married, than in others.

Of 17 women thus affected, who had lived in wedlock many years, I found that 4 were barren (never pregnant); of 33 similar cases, analysed by Gross, 6 were barren. Thus of these 50 married women, 10 were barren, or 20 per cent.; whereas in the general community the amount of absolute sterility amounts to only about 11 per cent.

Three of the 13 fruitful women in my list produced only a single child, or 1 in 4.3; whereas the ratio of one-child sterility for fertile married women of the general population, is only about 1 in 13.

Of 52 women with these tumours, under my observation, 20 were married, 3 widowed, and 29 were single.

*Catamenia.*—It has often been pointed out that the development of fibro-adenomata is not infrequently associated with catamenial irregularities, &c. The following data seem to support this view; they also show that catamenial irregularities are much more frequently associated with these tumours, than they are with cancers.

Of 37 cases the catamenia were stated to have been *regular* in 31 (scanty 4, profuse 2); and *irregular* in 6 (scanty 4, profuse 2).

<sup>22</sup> "Traité des Maladies du Sein, &c.," 1854.

<sup>23</sup> *Journal of Anatomy*, vol. xxvi., 1892, p. 509.



The earliest age at which the catamenial discharge first appeared, was 12 years (there was also a case at 12·5); the latest 20; and the mean age was 15·4 years.

The *occupations* followed by 49 of the patients in my list were as follows:—

Of 19 *married*—housewives 16, boot factory 1, dressmaker 1, and tailoress 1. Of 2 *widowed*—governess 1 and needlework 1. Of 28 *single*—domestic service 7, needlework 6, nurse (sick) 3, at home 3, laundry 2, governess 2, shop assistant 2, and 1 each as follows:—schoolmistress, nursery, milliner.

Their *birth places* were noted in 17 cases, thus:—

Nine were *town* born (London 6, Newmarket, Luton and Chatham each 1). Eight were *country* born (Norfolk 2, Northamptonshire, Lincolnshire, Suffolk, Middlesex, Essex and near Edinburgh, each 1).

As to the influence of *previous injury or disease of the breast*, in the causation of these tumours, it will be gathered from the subjoined data, that history of such antecedent occurrences was much less frequently obtained than in the cancer cases. As in the latter these factors were shown to play only a secondary part in the causation of that disease, so, *à fortiori*, it follows that in the causation of fibro-adenomata their influence is also only subsidiary. The data alluded to are as follows:—

Of 46 cases I obtained history of previous *injury* in 7 (blow 6, pressure of stays 1). Of the same number of cases, there was history of *previous disease* in 4 (sore nipple 3, discharge from nipple 1).

*Heredity*.—That the tendency to mammary fibro-adenomata may be transmitted by inheritance, the following cases prove.

(1) In this case a lady and her three daughters all had fibro-adenoma of the breast. The patient, aged 50, consulted Broca,<sup>24</sup> on account of a large fibro-adenoma of twenty-nine years' duration, in her left breast. During this long time its increase had been continuous, but very gradual. When she came under observation the tumour had attained the size of a man's head and was pendulous and pedunculated. The skin over its most dependent part was congested and eroded. There was no enlargement of the adjacent lymph glands. The patient declined operation; sloughing of the growth subsequently supervened, of which she died exhausted, without any signs of malignant disease being manifest. Broca's father, who had practised medicine for many years in the locality where this lady lived, informed

<sup>24</sup> "Traité des Tumeurs," t. i., p. 156.



him, that three other members of this family had been under his treatment for similar tumours. The eldest sister of the patient had a tumour form in her breast at the age of 25, which in the course of some years attained the size of a big walnut, and subsequently remained stationary. Her younger sister had a similar tumour form in her breast at the age of 20. Finally, the mother of these three ladies died at an advanced age, having in her breast a tumour the size of a fowl's egg, which first formed when she was quite a young woman. This lady had no other children. It is remarkable that all the three, at about the same age, became subject to the same disease.

(2) In a case by Puls,<sup>25</sup> a woman and her daughter, each had *two* cystic fibro-adenomata, in the *left* breast.

Instances of the hereditary transmission of mammary fibro-adenomata are, however, relatively of much less frequent occurrence than the hereditary transmission of cancer.

Thus of 38 cases of fibro-adenoma in my list, there was history of similar disease in but three families, or in 7·9 per cent. ; whereas there was history of similar disease in 24·2 per cent. of the cancer families. Similarly if we restrict the inquiry only to *direct* inheritance, it appears that of 38 patients with fibro-adenoma, there was only one instance of direct transmission of the *disease* from mother to daughter, or 2·6 per cent. ; whereas in the cancer cases there was history of direct transmission in about 8 per cent.

On the other hand, among the relatives of patients with mammary fibro-adenoma, I have found a greater proportion of *other* non-malignant neoplasms to exist, than among the relatives of the cancer patients.

Thus of 38 patients with fibro-adenoma, two knew of instances of the occurrence among their relatives of other non-malignant neoplasms, or 5·2 per cent. ; whereas of the breast cancer patients, only 1·5 per cent. knew of the occurrence of non-malignant neoplasms in their families.

Another point to which I wish to call attention is, that of 38 patients with fibro-adenoma, there was family history of cancer in 5, or in 13·1 per cent., and in 2 of the cases the breast was the seat of the disease.

Hutchinson<sup>26</sup> has recorded an instance of mammary fibro-adenoma hereditary in three generations, complicated with scirrhus cancer in one of them.

<sup>25</sup> *Arch. f. path. Anat.*, Bd. xciv., S. 455.

<sup>26</sup> *Archives of Surgery*, January, 1891, p. 261, Plate xxiv.



Twenty years ago Mrs. H——'s breast was removed for a rather large fibro-adenoma. She then was 50 years old. She is still alive and well. Lately one of her daughters, aged 40, came under Hutchinson's care for what seemed to be scirrhus cancer of the breast. She had noticed a small tumour in her breast ever since childhood. On examination of the part after removal, it was found to contain an encapsuled fibro-adenoma, the size of a marble, beneath which there was an ill-defined area of hard cancer. The fibro-adenoma was not itself infiltrated. There was subsequent recurrence in the axillary glands. One of this woman's daughters now has fibro-adenoma of the breast.

It will be gathered from the foregoing, that although in the transmission of neoplasms by heredity, the original morbid type is usually preserved, yet instances do occur in which in the course of transmission the type is changed, malignant neoplasms being transmuted into non-malignant ones and *vice versa*; and cases are even met with in which varieties of these types are transmuted *inter se*. Such considerations seem to support Verneuil's theory, according to which the different kinds of neoplasms are but varied manifestations of a certain general predisposition, the so-called *neoplastic diathesis*, as to the nature of which he leaves us in doubt. That a pre-disposition to cancer does exist I have elsewhere shown (ch. x. § iv.); and I have there indicated that it is closely allied to the tubercular predisposition, of which it is probably but a diluted form. The subjoined analysis of the family history of patients with fibro-adenoma, shows that to this disease, a similar predisposition also exists.

In further illustration of the subject I append the following *Analysis of the Family History* of 38 patients with mammary fibro-adenoma.

*The fathers* :—Of 27 cases in which inquiries were made, in 16 the fathers were *dead*, and in 11 still *alive*.

The *causes of death* were as follows :—

Phthisis	...	...	...	...	...	in 3 cases
Bronchitis	...	...	...	...	...	" 2 "
Accident	...	...	...	...	...	" 2 "
Pneumonia	...	...	...	...	...	" 1 case
Cancer of stomach	...	...	...	...	...	" 1 "
Alcoholism	...	...	...	...	...	" 1 "



Apoplexy	...	...	...	...	in 1 case
Small-pox	...	...	...	...	" 1 "
Carbuncle (back of neck)	...	...	...	...	" 1 "
Total					13 cases

In 3 cases the *causes of death were unknown*.

The average *age of the fathers at death*, in 16 cases, was 55·4 years ; the oldest 75, the youngest 27.

Of the 11 fathers still *alive*, 1 was hemiplegic, 1 bronchitic, and 1 subject to gravel ; the others were in good health.

Their average *age* 62·3 years ; the oldest 75, the youngest 50.

The *mothers* :—Of 30 cases in which inquiries were made, in 20 the mothers were *dead*, and in 10 still *alive* and well.

The *causes of death* were as follows :—

Phthisis	...	...	...	...	in 4 cases
Apoplexy	...	...	...	...	" 3 "
Heart disease	...	...	...	...	" 3 "
Cancer (breast 1, uterus 1)	...	...	...	...	" 2 "
Childbed	...	...	...	...	" 2 "
Insanity	...	...	...	...	" 1 case
Accident	...	...	...	...	" 1 "
Internal tumour	...	...	...	...	" 1 "
Bronchitis	...	...	...	...	" 1 "
Small-pox	...	...	...	...	" 1 "
Total					19 cases

In 1 case the *cause of death was unknown*.

The average *age of the mothers at death* (in 19 cases) was 45·2 years ; the oldest 68 ; the youngest 24.

The average *age of the mothers still alive* (in 6 cases) was 57 years ; the oldest 64 ; the youngest 45.

*Consanguinity in the Parents* :—As to this, inquiries were made in 19 cases with negative results.

*The Patient's Brothers and Sisters* :—In 12 families the following causes of death were noted among the adults :—

Phthisis (1 or more deaths)	...	...	...	in 5 families
Insanity	...	...	...	" 2 "
Bronchitis	...	...	...	" 2 "
Alcoholism	...	...	...	" 1 family
Heart disease	...	...	...	" 1 "
Fever	...	...	...	" 1 "
Childbed	...	...	...	" 1 "
Peritonitis	...	...	...	" 1 "
Typhoid Fever	...	...	...	" 1 "

The *number of members in each family* was noted in 27 cases. The smallest family consisted of 2 ; the largest of 16 ; the average of 7·2.

*The Occurrence of Tumour* :—Of 38 cases, there was history of *tumour*



in 7 families (18.4 per cent.). The relatives affected, the seats of the disease, &c., were as follows :—

- (1 and 2) Sister with *adenoma* of *breast* (in 2 families).
- (3) Mother with *adenoma* of *breast* (in 1 family).
- (4) Maternal grandmother with *lipoma* of *abdominal wall* (in 1 family).
- (5) Female cousin on father's side with *lipoma* of *shoulder* (in 1 family).
- (6) Maternal grandmother with *sebaceous cysts* of *scalp* (in 1 family). In this case the patient's mother died of cancer of the breast.
- (7) Mother died of *internal tumour* (in 1 family).

*The Occurrence of Cancer*:—Of 38 cases, there was history of *cancer* in 5 families (13.1 per cent.).

The relatives thus affected, and the seats of the disease, were as follows :—

- (1) Father died of cancer of *stomach*, and his sister of cancer of *breast*.
- (2) Mother died of cancer of *breast* (her mother had sebaceous cysts of scalp).
- (3) Mother died of cancer of *uterus*.
- (4) Maternal grandmother died of cancer of *breast*.
- (5) Maternal grandmother died of *internal cancer*.

*The Occurrence of Phthisis*:—Of 25 families, in 10 (40 per cent.) one or more relatives had died of phthisis; in 6 of these families more than a single member had thus succumbed.

The relatives affected may be classed as follows :—

Fathers	...	...	...	...	...	in 3 families
Father's brothers	...	...	...	...	...	" 2 "
Mothers	...	...	...	...	...	" 3 "
Mother's brothers and sisters	...	...	...	...	...	" 4 "
Mother's father	...	...	...	...	...	" 1 family
Patient's brothers and sisters	...	...	...	...	...	" 5 families

*The Combination of Phthisis and Cancer*:—Of 38 families, this was noted in 2. Thus—

- (1) Mother died of cancer of *uterus*; and her father died of phthisis.
- (2) Maternal grandmother died of *internal cancer*; and patient's father died of phthisis.

*The Combination of Phthisis and Tumour*:—Of 38 families, this was noted in 2.

- (1) Female cousin on father's side had *lipoma* of *shoulder*; patient's father and 2 of his brothers and sisters died of phthisis.

- (2) Mother had *adenoma* of *breast*; her sister and patient's sister were phthisical.

*The Occurrence of Insanity*:—Of 10 families, there was history of insanity in 2; in 1 of these the patient's mother and her brother died insane, and in the other the patient's mother died insane.

The *diagnosis* of fibro-adenomata, as a rule, is not a difficult matter.

In their general features certain *sarcomata* much resemble



them; but these tumours are seldom so mobile as the adenomata; their increase is more rapid, and they generally occur in older subjects. From *villous papillomata* they may be differentiated by having regard to the fact, that the tumours produced by these growths usually fluctuate and are central in position, being disposed in a radiating manner from the nipple; moreover they are generally accompanied by a blood-stained serous discharge from the nipple. From *tubular cancers* without lymph gland enlargement, they may be known by the irregularity in the shape of the tumours in these cases, by the frequent presence of small nodular cysts, and by the comparatively advanced age of the patients thus affected. Certain *hard cancers*, when small, circumscribed and unaccompanied by lymph gland enlargement, occasionally resemble fibro-adenomata; on careful examination they will be found to be more incorporated with the gland, and above all, to be less mobile, and they generally occur in persons of more advanced age than those who bear fibro-adenomata. Some forms of *lobular hypertrophy* may also mimic fibro-adenomata, but in these cases the tumours are obviously connected with the gland; they are less circumscribed than fibro-adenomata, and moreover, they are often multiple. *Chronic inflammatory swellings* ("induratio benigna") may simulate these growths, but they are seldom so circumscribed and mobile. The same applies to certain localised tubercular and syphilitic lesions occasionally met with in the breast. The only other lesions likely to be mistaken for fibro-adenoma are small tense *cysts* and *chronic abscesses*, as to the differential diagnosis of which nothing further need be said.

Under the name of *diffuse fibroma* Virchow<sup>27</sup> has described diseases of the breast which are really examples of the fibrous form of hypertrophy, and of diffuse chronic mastitis, rather than of true neoplastic action. It is evident also that the so-called "*plexiform fibroma*"<sup>28</sup> (*maladie noueuse*) is a periductal

<sup>27</sup> "Path. des Tumeurs," t. i., pp. 318 and 325.

<sup>28</sup> Nordmann, *Arch. f. path. Anat.*, Bd. cxxvii., S. 338.



inflammatory sclerosis, and not a form of true neoplasia. In this connection mention may be made of the attempt made by Delbet<sup>29</sup> to account for fibro-adenomata, as localised periductal scleroses, consequent on chronic inflammation, in support of which I think there is very little to be said.

*Treatment.*—The only treatment that I can recommend for mammary fibro-adenomata, is their complete removal by operation; and the sooner this is done the better. It is a vain delusion to expect their resolution either spontaneously, or as the result of local applications or internal medicaments. Compression, electrolysis, &c., are equally futile. Removal by caustics is out of the question on account of the deformity thus produced. Nothing, therefore, remains,<sup>30</sup> but the knife. For small, mobile, chronic tumours, *enucleation* is the procedure usually adopted. The patient being anæsthetised, the part of the breast in which the tumour lies is seized between the fingers and thumb of the left hand, so as to make the tumour project, with the skin tightly stretched over it. An incision, radiating from the nipple, is then made through the skin, &c., over the tumour, right down to the latter, which—on division of its capsule—at once projects from the wound, when it is seized by an assistant with vulsellum forceps, and removed with a few touches of the knife. As a rule there is no hæmorrhage worth mentioning, but a vessel or two may require ligation. The wound is then irrigated with carbolic lotion, closed with deep and superficial sutures, and dressed with anti-septic appliances. The upper limb should for a time be kept in a sling. This operation is not, as a rule, attended by any danger; the wound generally closes by first intention, and the only mark eventually left is a small linear scar.

Of 39 consecutive hospital operations of this kind under my observation, not a single one was attended with any subsequent untoward event; there was no instance of the supervention of erysipelas or other septic disease. This immunity from septic

<sup>29</sup> Duplay and Reclus' "Traité de Chirurgie," t. vi., p. 259, &c.



disease contrasts very favourably with the results obtained before antiseptics came in vogue; for of 60 hospital operations of this kind done by Velpeau,<sup>30</sup> in 10 the wounds were subsequently attacked by erysipelas, in 2 by hospital gangrene, and in several by diffuse suppuration.

An ingenious proceeding has been devised by Gaillard Thomas,<sup>31</sup> with the object of concealing the scar resulting from the operation. It is a modification of the ancient operation for gynæcomastia. He makes his incision along the fold uniting the lower hemisphere of the bosom with the thorax, and having separated the base of the gland from the pectoral muscle, he removes the tumour by incision through the under surface of the gland. Jamieson,<sup>32</sup> Hayward<sup>33</sup> and others, have obtained satisfactory results from this operation.

In the great majority of cases the simple enucleation of fibro-adenomata suffices for their permanent cure. Occasionally, however, after a certain time, there is return of the disease, either locally, in some other part of the same breast, or in the opposite breast. Of 39 consecutive enucleations under my observation, there was only a single instance of local recurrence; but, according to Gross, recurrence is met with on the average once in 25 cases. As to the explanation of such local recurrences, the very complete encapsulation of fibro-adenomata quite precludes the possibility of their being ascribed to portions of the primary tumour left behind at the operation. It seems certain that most cases are veritable *repullulations*, due to fresh outbreaks of the disease in adjacent hyperplastic glandular structures. In some instances it may be, that at the time of the first operation a second tumour already existed, which, after removal of the main one, has subsequently grown into prominence.

The following example of recurrence has come under my notice.

---

<sup>30</sup> "Traité des Maladies du Sein," &c., 1854, p. 420.

<sup>31</sup> *New York Medical Journal*, April, 1882, p. 337.

<sup>32</sup> *British Medical Journal*, vol. i., 1888, p. 1216, also vol. ii., 1893.

<sup>33</sup> *British Medical Journal*, vol. i., 1889, p. 410.



A healthy looking, single woman, aged 22, who was a schoolmistress, with a firm, elastic, freely movable nodule—the size of a large filbert—in her left breast, close to a small scar, resulting from the enucleation of a similar tumour, eighteen months previously. It was first noticed, as a pea-sized tumour, fifteen months ago. The axillary glands were normal. The tumour was dissected out. Microscopically and macroscopically examined, it presented the appearance of ordinary fibro-adenoma. The wound completely healed in the course of a few days. Three and a-half months later she again came under observation with a similar tumour in the same situation, which was again excised.

Rosenstirn<sup>34</sup> has reported the following:—

From the *left* breast of a multipara, aged 45, a fibro-adenoma of one year's duration was enucleated. Five years later, a similar tumour of six months' duration was enucleated from the *right* breast. A year after the last operation, a fresh tumour having formed in the *left* breast, was excised. Eighteen months later, another tumour was excised from the same breast, yet another four years later; and finally still another three years later. From the *right* breast a second tumour was removed about two years after the first operation; and another seven years later. All these tumours were in their histological and other characters just like the ordinary fibro-adenoma. Velpeau<sup>35</sup> relates that a lady from whose breast he had removed a fibro-adenoma ten years previously, then applied to him with another similar tumour in the same situation, which he also excised.

Considerations of this kind have induced many surgeons to doubt the efficacy of the ordinary enucleation, as a means for removing these tumours. Instead, they recommend that the disease should be got rid of by partial amputation of the breast, the tumour and its capsule, together with a wedge-shaped zone of the surrounding tissues, being removed *en masse*. Where æsthetic considerations are not of paramount importance, this operation is clearly indicated, especially for tumours that have attained a larger size than a walnut. For tumours of still larger dimensions, bigger than a hen's egg, for instance, total amputation of the breast is the preferable operation; since these large tumours, oftener than others, eventually prove to be of a sarcomatous nature.

A few instances have been recorded in which within a comparatively short time after the removal of fibro-adenoma,

<sup>34</sup> *Arch. f. path. Anat.*, Bd. lvii., S. 166.

<sup>35</sup> "Traité des Maladies du Sein," p. 350.



the same breast has become the seat of cancer;<sup>36</sup> and Pick<sup>37</sup> has related a case in which after removal of such a tumour from the breast, cancer developed in the axilla.

In the event of operative treatment being refused, the best thing is to cover the tumour with a *belladonna* plaster; or to paint the part with extract of belladonna in glycerine (to which an equal part of *ung. plumbi iodidi* may be added), and cover it with cotton wool, kept in place by strapping.

---

<sup>36</sup> Erichsen, *Lancet*, February 14, 1852.

<sup>37</sup> *Trans. Path. Soc. Lond.*, vol. xx., p. 347.



## CHAPTER XIX.

LIPOMA, CHONDROMA, OSTEOMA, ANGIOMA, PAPILLOMA, &amp;C.

## § I.—Lipoma.

I HAVE previously called attention to the remarkable immunity from neoplasia of the fibrous tissue of the breast, other than that in the immediate vicinity of the small ducts ; its fatty tissue, which is never found in close proximity to these structures, is still more rarely affected in this way. Of 2,397 consecutive neoplasms of the female breast analysed by me, there was not a single instance in which the disease originated from its fatty tissue. Circumscribed lipomata do, however, occasionally arise in the breast and its vicinity ; and very exceptionally the whole of the fatty envelope of the gland becomes overgrown (so-called *diffuse lipoma*). Some of these cases are probably instances of hypertrophy, in which the stress of the disease has fallen on the fatty capsule.<sup>1</sup> In other instances overgrowth of the fatty envelope of the gland is associated with circulatory disturbances due to cancer, or chronic mastitis<sup>2</sup> (so-called *capsular lipoma*). In this category I think Roper's<sup>3</sup> case of mammary lipomatosis ought to be included.

Here there was a large pendulous tumour of 58 years' duration. The woman who bore it died at the age of 87. During her lifetime it had been taken for fibro-adenoma ; but upon cutting into the tumour after death, it

<sup>1</sup> For cases, see pp. 89 and 94.

<sup>2</sup> See p. 228.

<sup>3</sup> Birkett in Holmes' "System of Surgery," vol. iii., 1883, p. 449.



was found to consist of a mass of fatty tissue, enclosing an irregularly shaped piece of bone at its centre. I should interpret these appearances as the result of "quiet necrosis," with lipomatosis of the congested and chronically inflamed surrounding tissues.

Here also the case mentioned by Brodie<sup>4</sup> of "chronic mammary tumour" surrounded by a large mass of fat situated behind the breast probably belongs; as also the so-called multiple mammary lipomata signalled by Reclus.<sup>5</sup>

When they do occur mammary lipomata almost invariably arise from the para-mammary fatty tissue; I know of only three recorded examples of intra-mammary lipoma.

In Kœhler's<sup>6</sup> case, a large fibro-lipoma was removed from within the gland. A similar case has been reported by Bégouin.<sup>7</sup> The other case is by Astley Cooper;<sup>8</sup> he describes processes of the tumour as being interspersed between the glandular lobes.

The majority of para-mammary lipomata arise in the sub-cutaneous fatty tissue over the front of the breast; in this situation they seldom attain a large size; on the other hand, the tumours of retro-mammary origin often attain immense proportions. The following are some good examples of this form of fatty tumour.

(1) A multipara, aged 34, came under Billroth's<sup>9</sup> observation with colossal enlargement of the right breast, which reached as low down as the pelvis. Its greatest length was 43 cm. The nipple and areola were situated at the lowest part of the swelling; and in this situation the skin was of a dark purple colour from congestion. The diseased part felt soft and elastic, with here and there firmer knots and lobulations. The superficial veins were unduly obvious. There was no enlargement of the axillary glands; the patient was moderately nourished and in fairly good health. She said she first noticed some enlargement at the upper part of the breast six years ago, which subsequently gradually increased. Her last child was born nearly two years ago. The left breast was normal. It was thought to be a case of hypertrophy or cysto-sarcoma. After amputation of the part it proved to be a gigantic retro-mammary lipoma. The mammary gland flattened from pressure was found in the vicinity of the nipple. Unfortunately the tumour was not weighed. The patient was soon convalescent.

<sup>4</sup> "Lectures on Pathology and Surgery," p. 281.

<sup>5</sup> *Clin. Chir.*, p. 414.

<sup>6</sup> *Charité Annalen*, Bd. xiii., 1888, S. 531.

<sup>7</sup> *Journal de Méd. de Bordeaux*, Feb. 25, 1892.

<sup>8</sup> "Illustrations of Diseases of the Breast," p. 68.

<sup>9</sup> *Deutsche Chir.*, Lief. xli., S. 45.



(2) In a case by Bryk<sup>10</sup> a large fibro-lipoma, weighing 12 lbs., was removed from behind the right breast of a woman aged 49, who shortly afterwards died of septicæmia. At the *necropsy* she was found also to have a lipoma of the cæcum.

(3) In a similar case by Brodie,<sup>11</sup> a lady came under treatment for what appeared to be a tumour of the breast. She was the wife of a medical practitioner; and she had the opinions of three or four of the leading surgeons of the day on her case; but they could not agree as to its nature. It was decided to cut down on the tumour, and on this being done, it was found to be a large lipoma, situated behind the breast; which, being of large size, had been lifted up by the tumour, and seemed itself to be enlarged.

(4) A delicate young woman, under Velpeau,<sup>12</sup> had a very large pendulous tumour of this kind, growing from her right breast. When she stood up it reached as low down as the iliac crest. It was of three and a-half years' duration, and its situation was behind the breast. After removal it weighed 4½ lbs.; and it was composed only of adipose tissue.

As examples of subcutaneous lipoma the following cases will suffice:—

(1) An unmarried servant, aged 30, came under my observation with a fatty tumour—the size and shape of a lady's watch—at the upper and outer part of the periphery of the left breast. It was of two years' duration. She was soon convalescent, after its excision.

(2) In a case under Bryant's care<sup>13</sup> a lobulated fatty tumour the size of half an orange was removed from over the upper part of the left breast of a multipara, aged 50. It was of five years' growth.

(3) A dressmaker, aged 45, the mother of five children, came to Velpeau<sup>14</sup> on account of tumour of several years' duration of her left breast. On examination there was found a large, irregularly-shaped, lobular tumour, the size of two fists, over which the skin was reddened. Some parts of it felt quite soft, others rather hard. It was dissected out; and proved to be a lobulated fatty tumour, which appeared to have been situated over the front of the breast.

(4) In another case by the same surgeon, a stout, healthy-looking woman, aged 30, had a tumour the size of a hen's egg, in the lower and outer part of her left breast. It was of several years' duration. It felt soft, bossy, and subcutaneous. Velpeau took it for a cyst, believing fluctuation certain. It was punctured, but no fluid escaped. On exploration with the knife, a lobulated fatty tumour was exposed and removed.

<sup>10</sup> *Arch. f. klin. Chir.*, Bd. xvii., S. 576.

<sup>11</sup> "Lectures on Pathology and Surgery," 1846, p. 271.

<sup>12</sup> "Traité des Maladies du Sein, &c.," p. 250.

<sup>13</sup> "Diseases of the Breast," p. 348.

<sup>14</sup> "Traité des Maladies du Sein, &c.," Paris, 1854, p. 248.



## § II.—Chondroma, Osteoma, &amp;c.

It has been pointed out by several observers (Hacker,<sup>15</sup> Rindfleisch,<sup>16</sup> &c.), that in the stroma of the otherwise normal breast, small cartilaginous and even truly osseous nodules may occasionally be found. The most feasible explanation of the presence of these heterotopic structures in this situation, is that which ascribes their origin to sequestrations of small portions of the matrix of the evolving thoracic skeleton, at an early stage of development. The cartilaginous and osseous structures occasionally found associated with cancerous and sarcomatous neoplasms doubtlessly spring from this source. It seems certain that the various cartilaginous and ossifying growths we now have to study, which are great rarities, have a similar origin. In the mammæ of bitches, as pointed out by Virchow and Creighton, tumours containing cartilage are of frequent occurrence. Although several cases of innocent cartilaginous ossifying tumours of the breast have been recorded, most pathologists still hesitate to admit the existence of true enchondroma and osteoma of this part. Subjoined are brief abstracts of the chief cases of this kind hitherto recorded.

(1) According to Wacker,<sup>17</sup> there is in the Pathological Institute of Rostock a specimen of true mammary chondroma, the size of a hen's egg, composed of hyaline and fibrous cartilage, interspersed with calcareous deposits.

(2) Lange<sup>18</sup> removed from the breast of a woman, aged 51, a tumour composed of a number of rounded lobular masses, united together by strong bands of fibrous tissue. Histologically these consisted mainly of hyaline cartilage, partially ossified.

(3) Cruveilhier<sup>19</sup> says: "I have seen in the substance, and on the surface of the mammary gland, enchondromas which presented all the clinical characters of fibroid masses, and all the pathological characters of cartilaginous tissue." He then refers to a cartilaginous tumour that had been removed from the breast by Nélaton, which he says was firm and resistant, and had all the characters—macroscopical and microscopical—of cartilage.

<sup>15</sup> *Arch. f. klin. Chir.*, t. xxvii., S. 614.

<sup>16</sup> *Path. Anat.*, § 601.

<sup>17</sup> "Inaug. Diss.," Rostock, 1884, cited by Gross.

<sup>18</sup> *Medical Record*, vol. ii., 1881, p. 161.

<sup>19</sup> "Traité d'Anat. Path.," t. iii., p. 824.



(4) In Astley Cooper's case,<sup>20</sup> a hard, lobulated tumour—the size of a duck's egg—of fourteen years' duration, was removed from the breast of a woman aged 32. Her general health was good, and the axillary glands were normal. On examination of the tumour, "the larger part of it had the appearance of that cartilage which supplies the place of bone in the young subject; the remaining part was ossified."

(5) Among instances of this kind in ancient literature, reference may be made to one by Morgagni,<sup>21</sup> in which there was, at the lower part of the breast, an irregularly-shaped bossy tumour, of thirty years' duration. On one of these bosses being incised, an irregular osseous tumour—the size of a walnut—was exposed.

Numerous instances have now been recorded of the association of cartilaginous and osseous structures with malignant disease. Reference has already been made to several of these; in further illustration of the subject, the following cases will suffice:—

(1) In one reported by Battle,<sup>22</sup> a woman, aged 73, presented with a hard circumscribed tumour—the size of a large orange—at the inner part of the right breast. It consisted of two chief bosses, an inner one—the size of a walnut—very hard and rounded, of long duration; and an outer one—much larger and more elastic—of comparatively recent formation. The skin over the inner part of the tumour was adherent and red, and the nipple was retracted. Otherwise it was freely mobile. There was a single, enlarged, hard gland in the axilla. The patient said she first noticed a hard lump—the size of a pea—in the inner segment of the breast, six years previously. For the next two years there was no appreciable increase, but since then it had been progressive. On examination of the tumour, after amputation of the breast, it was found to consist chiefly of soft, vascular substance, which presented signs of numerous ecchymoses, and of a smaller very hard portion which resembled bone. Histologically the soft part consisted of round and spindle-celled sarcoma tissue, and the hard part of ossifying cartilage. The enlarged gland was lost before it had been examined. When last seen, about nine months after the operation, the patient was well, and free from return of the disease.

(2) In Bowlby's case<sup>23</sup> the patient was a single woman, aged 42, who had a tumour in her right breast of one year's duration. On examination there was found, occupying the outer segment of the gland, an ovoid tumour the size of an orange. The overlying skin was somewhat reddened, but not adherent, and the superficial veins were enlarged. The tumour was freely mobile; it felt hard and uneven; there was marked tenderness on pressure;

<sup>20</sup> "Illustrations of the Diseases of the Breast," p. 47.

<sup>21</sup> "De sedibus et causis Morborum," &c. Ep. l., § 41.

<sup>22</sup> *Trans. Path. Soc. Lond.*, vol. xxxvii., 1886, p. 473.

<sup>23</sup> *Trans. Path. Soc. Lond.*, vol. xxxiii., 1882, p. 306.



the adjacent lymph glands were normal. The tumour was removed, together with the whole breast. It was encapsuled, and in its general features resembled cystic sarcoma with intra-cystic growths. Its periphery was soft and succulent in appearance ; somewhat deeper, a more fibroid structure prevailed, interspersed with small, smooth, glistening islets of cartilage. The central part of the tumour presented signs of mucoid softening, and in various parts small ecchymoses were visible. On cutting into the tumour calcareous particles were encountered. Histological examination showed that its peripheral part consisted of small, round and ovoid cells, embedded

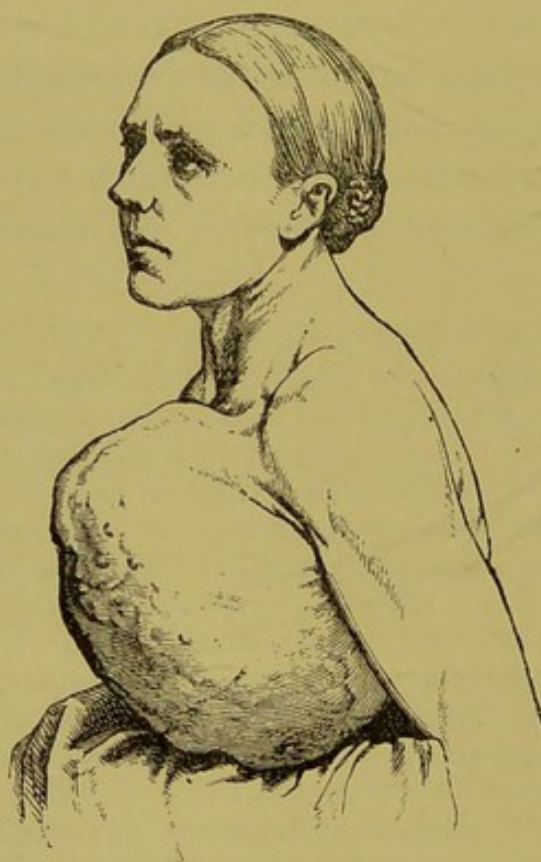


FIG. 69.—Large osteo-chondroma growing from the ribs in the mammary region  
(Kolaczek).

in homogeneous or fibrillar matrix, which also contained cystic glandular structure. In the deeper parts of the tumour fibrous tissue was more abundant, and the cells were spindle-shaped. The glistening islets embedded in this part of the tumour consisted of hyaline or fibro-cartilage, many of which had undergone calcareous changes in some places, and mucoid changes in others. The patient succumbed six months later with recurrent disease, but as there was no necropsy it is impossible to say whether there was dissemination.

In this connection it may be mentioned, that from the ribs and adjacent structures of this part of the thorax, there



occasionally arise innocent and malignant cartilage-containing tumours, in many respects similar to the foregoing, as in the following cases:—

(1) Kolaczek<sup>24</sup> reports an instance of a large osteo-chondroma of the mammary region that originated from the fourth rib. The patient, a woman aged 48, first noticed a tumour in this region four years previously. On examination, a very large tumour, fixed to the subjacent chest wall, projected from the antero-lateral part of the left side of the thorax. It extended from the clavicle above to the costal margin below (fig. 69). In removing it large portions of the fourth, fifth, sixth and seventh ribs, together with the subjacent adherent pleura, had to be excised. Through the large opening thus left the lung, pericardium and diaphragm could be plainly seen. The pleural cavity was irrigated with salicylic acid solution and drained. In a month's time the whole wound had soundly healed. There remained in the chest wall a large depression (five by four and a-half inches) through which the heart's movements could be plainly seen, even to the pulsation of the coronary arteries. On examination, the tumour was found to consist mainly of hyaline cartilage, interspersed with osseous deposits.

(2) Soulier<sup>25</sup> has reported an instance of an osteo-chondromatous tumour that originated in the mammary region, and disseminated in the superior maxilla and scapula.

### § III.—Angioma, Papilloma, &c.

Angiomata of the breast are certainly rare. In the few cases that have been recorded the disease has generally affected the skin or the subcutaneous tissues. Alibert<sup>26</sup> mentions having met with a tumour of this kind, situated over the *pectoralis major* muscle, in the vicinity of the breast of a female child, 13 months old. There is a specimen of subcutaneous mammary angioma in the *Hunterian Museum*, No. 409, of the pathological series. It is thus described in the catalogue.<sup>27</sup>

“A flattened, lobulated, oval erectile tumour or nævus, removed from under the skin of the left side of the breast of a child 9 months old. A small portion of the overlying skin is involved in the disease. The tumour consists of lobules of fibrous tissue and fat, with numerous large vessels coursing through it.”

<sup>24</sup> *Arch. f. klin. Chir.*, Bd. xxiv.

<sup>25</sup> *Dauphine Méd.*, Grenoble, 1891, xv., p. 261.

<sup>26</sup> “*Nosol. Nat.*,” p. 337.

<sup>27</sup> “*Path. Catalogue*,” vol. i.



Bryant,<sup>28</sup> Snow,<sup>29</sup> Image and Hake,<sup>30</sup> and Langenbeck,<sup>31</sup> have also recorded instances of mammary angiomata.

In Bryant's case the tumour was the size of half a small orange, and it occurred in a female child 15 months old. It felt spongy, and was readily emptied on pressure, but at once filled again when this was withdrawn. The whole of the breast was involved as well as the overlying skin.

In Image and Hake's case the disease supervened in a woman aged 21, as the result of a blow. At first she noticed a red patch on the skin above the nipple, which in the course of two years developed into a very large pulsatile swelling. On examination after excision, all the veins in the vicinity of the tumour were dilated, and the chief of them presented monili-form enlargements, the intermediate narrow parts being markedly thickened. These veins terminated in alveolar spaces, which involved the whole breast.

Langenbeck's cases much resembled the foregoing. The patients were women 18 and 20 years old.

A girl, aged 7, under the care of Lannelongue,<sup>32</sup> with a disc-shaped tumour the size of a crown piece, in the upper part of the right mammary region, above the nipple, and apparently not connected with the rudimentary mamma. Its periphery lobulated. The tumour freely mobile under skin and over subjacent parts; although over its central part the skin is slightly adherent. Here the skin has a bluish, purplish colouration, and presents some small epidermic *plaques*. The tumour was first noticed three months previously. On examination, after extirpation, it appeared to be composed of about half-a-dozen communicating small cystic pouches, with a larger one in the centre. These spaces contained turbid, brownish fluid, with fatty matters. Evidently it was a degenerated subcutaneous nævus.

Sendler<sup>33</sup> has reported an instance in which a cavernous angioma of the nipple presented as a small pendulous, pedunculated tumour.

In the treatment of these tumours, by excision or otherwise, care must be taken to avoid injuring the galactophorous ducts.

Notwithstanding the great abundance of the mammary lymphatics, I cannot cite a single case of mammary *lymph-angioma*; although, as will be mentioned when treating of axillary tumours, there are on record several cases of lymph-angioma in the vicinity of the axilla.

<sup>28</sup> "Diseases of the Breast," p. 346.

<sup>29</sup> *Lancet*, vol. i., 1890, p. 240.

<sup>30</sup> *Med. Chir. Trans.*, vol. xxx., p. 109.

<sup>31</sup> "Nosol. u. med. Therap. der chir. Krankh.," Bd. v., S. 83.

<sup>32</sup> "Traité des Kystes Congenitaux," 1886, p. 391.

<sup>33</sup> *Cent. f. Chir.*, No. 29, 1889, S. 52.



Two cases of *a-myelinic neuromata* of the mamma have been recorded by Tripier.<sup>34</sup>

*Papillomata* of the tegumentary system of the female breast are occasionally met with. My analysis of 2,397 mammary neoplasms includes three instances of this kind. They are oftener found growing from the nipple or areola than elsewhere.

There is a specimen of a pedunculated papilloma in the *Hunterian Museum* (No. 4,819 A), that was removed from the nipple of a married woman, aged 38.

Bryant<sup>35</sup> has described and figured a papillomatous growth, the size of a nut, which grew from the extremity of the nipple of a woman aged 48. It was of twenty-six years' duration. She was the mother of ten children, all of whom she had suckled.

In this connection it is well to remember that villous duct papillomata sometimes project from the nipple.

A case of *leio-myoma* of the right nipple has been put on record by Sokolow.<sup>36</sup> *Moles* are also met with in connection with the mammary integument.

---

<sup>34</sup> "Dict. Encycl. des Sci. Méd., 'art. "Mamelle."

<sup>35</sup> "Diseases of the Breast," p. 333.

<sup>36</sup> *Arch. f. path. Anat.*, Bd. lviii., 1873, 316.



## CHAPTER XX.

CYSTIC DISEASE AND CYSTS.

---

THE varieties of cystic disease that arise in connection with neoplasms, have been sufficiently described in the preceding chapters. There now remain for consideration those rarer forms that originate independently of neoplasia. Instances of this kind are not very common. Of 2,397 consecutive mammary tumours, analysed by me, only 63 were cysts, or 2·6 per cent.

The pathogeny of mammary cysts is still a subject of much obscurity, and requires to be thoroughly re-investigated. The cardinal fact hitherto revealed is, that the great majority of these cysts originate in connection with the *glandular* structures of the part. Moreover, it appears that it is from the ducts, rather than the acini, that they spring, the small ducts (*conduits aciniens*) being more frequently involved than the larger ones. The tumours thus formed seldom have closed sacs, detachable from the surrounding parts; but they present as pouched protrusions or dilatations of the pre-existing structures. Recent investigations point to the probability of these changes being due to the presence of some source of irritation within the affected ducts, probably of microbic origin.

Of the cysts that arise in connection with the larger ducts, two varieties may be recognised, according to the nature of their contents—the mucoid and the lacteal.



## § I.—Mucoid Cysts.

These cysts are so named because their contents are secreted by the glandular structures whence they originate ; hence their contents more or less resemble the pseudo-secretions found in dilated ducts. When of some size, the fluid they contain is usually of a pale yellowish, quasi-serous or opalescent aspect ; the contents of smaller cysts often present a viscid, greasy, or mucoid appearance, and their colour may be dirty brown, greenish or reddish. Histologically, epithelial cells in granulo-fatty degeneration, corpuscles of Glüge, oil globules and granulo-fatty *débris* are generally to be found in the fluid ; and sometimes cholesterine scales and hæmatin crystals. No matter what appearance the fluid presents, it always contains more or less albumen. The cyst wall is generally thin, and blended with the surrounding parts. Externally it consists of fibrous tissue, and internally it is lined by a layer of cubical epithelium. Cysts of this kind are usually single, and they are of commoner occurrence in the vicinity of the nipple and areola than elsewhere. Not unfrequently more than a single cyst is present. Both breasts are seldom affected. They generally present as smooth, rounded, or ovoid tumours—of slow growth—varying in size from a walnut to a goose's egg. They are often so tense that fluctuation may be difficult to make out. A valuable diagnostic sign is that on pressure fluid may often be made to escape from the nipple. The tumour has no adhesions with the overlying skin, or other adjacent parts. The nipple is not retracted, nor are the axillary glands usually enlarged. It is usually a painless affection, and there is no tenderness on pressure. The persons who most commonly bear these cysts are young adult and middle-aged women ; hardly ever are they met with before puberty. When unassociated with neoplastic action, these cysts are of a perfectly innocent nature. In cases of doubtful diagnosis, the tumour should be aspirated. Similar cysts may rarely arise in connection with the *glandulæ lactiferæ aberrantes*. Velpeau<sup>1</sup> mentions the case of a young girl with a tumour of

---

<sup>1</sup> "Traité des Maladies du Sein," &c., p. 251.



this kind, who could express fluid through a pore near the base of the nipple.

The most effectual and satisfactory mode of treatment is that of dissecting them out ; or they may be incised and stuffed with a strip of lint soaked in tincture of iodine. In some cases cure has been effected simply by evacuation—either by pressing the contents out through the nipple or by puncture ; in either case combined with subsequent compression.

The two following instances have come under my notice :—

(1) A well nourished and healthy looking, dark complexioned, unmarried woman, aged 47, by occupation a dressmaker, presented herself with a rounded tumour, the size of a small walnut, immediately beneath the right nipple. It was freely movable. The axillary glands and the nipple were normal, and so was the opposite breast. Three weeks previously she first noticed a lump in the site of the present disease. No history of any previous injury or disease of the part. Catamenia ceased at 42. Her previous health had been indifferent, and she had generally been weak and nervous. She had rheumatic fever at 17, and typhoid fever at 37. Her father's sister died of cancer of the breast, three of her brothers and sisters had died of phthisis. The tumour was dissected out—a thin-walled cyst containing clear, pale yellowish fluid.

(2) An ill nourished, single woman, aged 67, subsisting by needlework. At the centre of her left breast is a globular, fluctuating tumour, the size of a Tangerine orange. About its periphery some ill-defined, rather hard nodules can be felt, as of lobular hypertrophy. The overlying skin is slightly reddened and adherent. There is no enlargement of the axillary glands ; but the nipple is retracted, the latter condition being of congenital origin. Tumour of the breast was first noticed fourteen months ago, and she thought it due to a blow. She had rheumatic fever at 19, and has since been subject to rheumatism. Her mother died of "tumour of the brain." The tumour was incised, when clear fluid escaped, and drained. Three weeks later the opening had almost completely closed.

## § II.—Lacteal Cysts (Galactoceles).

Galactoceles are cysts containing milk, or some of the various substances resulting from its modification. In other respects galactoceles much resemble the cysts last described, and like them they are of rare occurrence. Most galactoceles contain pure milk, but fairly often their contents are butter-like, creamy, caseous or cheesy. They generally present as solitary, tense,



ovoid or rounded tumours, of no great size, situated beneath the nipple or areola. In exceptional instances cysts of this kind may be very large, containing many pints of fluid. In a case treated by Scarpa<sup>2</sup> the tumour measured thirty-two inches in circumference, and reached the patient's thigh. Galactoceles develop painlessly and without inflammatory symptoms. They contract no adhesions with the overlying skin, nor with subjacent parts. The nipple is not retracted, nor are the axillary glands enlarged. When the cysts contain milk, fluctuation may be detected ; when cheesy matters, they pit on pressure. In the former instances, on pressing the tumour, milk may be made to escape from the nipple, but this sign is not of much diagnostic importance, except in the absence of lactation. Galactoceles almost invariably arise during lactation. The development of a tumour in the breast, at or about the lactation period, should always excite the suspicion of galactocoele. It does, however, very exceptionally happen, that cysts of this kind develop independently of lactation, as in Bouchacourt's<sup>3</sup> remarkable case, in which a large milk-containing cyst formed in the breast of a woman, aged 51, twenty-four years after her last pregnancy. In an instance reported by Altee<sup>4</sup> a similar tumour developed sixteen months before childbirth. Galactoceles are chronic formations. With the subsidence of lactation they generally diminish in size, but hardly ever do they disappear spontaneously. At each fresh pregnancy there is apt to be fresh enlargement. They may inflame, suppurate or ulcerate ; and there are good reasons for believing that a certain proportion of mammary abscesses—both of the acute and chronic type—originate in this way. In cases of doubtful diagnosis an exploratory puncture or incision should be made. Some pathologists believe that in certain cases the cyst formation is the result of ductal rupture and extravasation ; however this may be, a considerable proportion of

---

<sup>2</sup> Cited by Forget, *Bull. de Thérapeutique*, 1844, t. xxvii., p. 356.

<sup>3</sup> Cited by Richelot, "Des Tumeurs kystiques de la Mamelle," 1878, p. 18.

<sup>4</sup> *Am. J. Med. Sci.*, April, 1874, p. 419.



those who bear these tumours, attribute them to the effect of injury.

In the treatment of galactoceles the first thing is to suspend suckling and to arrest lactation, by the local application of belladonna and glycerine, to which *ung. plumbi iodidi* may be advantageously added; and these measures may be supplemented, if necessary, by the use of the breast pump. For the cure of the tumour, incision with evacuation of its contents, and the insertion into the empty cyst of a strip of lint steeped in *tr. iodi.*, usually suffices. A more radical method is to dissect out the cyst wall, the wound being treated antiseptically, and closed by deep and superficial sutures, so as to ensure union by first intention. Puncture with injection has also been resorted to, but I cannot recommend it. Small galactoceles have occasionally been cured simply by expressing their contents through the nipple; and then applying pressure, and some discutient ointment.

The two following illustrative cases are from the *University College Hospital Reports*.<sup>5</sup>

(1) A married woman, aged 42, six months previously noticed a small, painful lump in her left breast. No injury or other known cause. On examination a hard, nodular, mobile tumour—the size of a Barcelona nut—presents at the inner part of the breast. The nipple normal; and no enlargement of the axillary glands. It was excised through an incision radiating from the nipple. The wound soon healed. Examination of the tumour revealed a smooth-walled cyst, one-third of an inch in diameter, surrounded by indurated fibro-fatty tissue, which contained soft cheesy substance, evidently inspissated lacteal secretion.

(2) A woman, aged 43, three months after a miscarriage, first noticed a hard tumour in her left breast. On examination a very hard, mobile circumscribed swelling—the size of a walnut—was found there. The nipple was not retracted, neither were the adjacent glands enlarged. It was incised, and inspissated milk evacuated. The wound subsequently healed by granulation from the bottom.

Illustrative cases have been recorded by Bryant,<sup>6</sup> Klotz,<sup>7</sup>

---

<sup>5</sup> *Q.v.* Report for 1888, p. 761, and for 1884, p. 51.

<sup>6</sup> "Diseases of the Breast," 1887, p. 311, *et seq.*

<sup>7</sup> *Arch. f. klin. Chir.*, 1880, Bd. xxv., S. 47.



Gould,<sup>8</sup> Gillette,<sup>9</sup> Jobert,<sup>10</sup> Puech,<sup>11</sup> Birkett,<sup>12</sup> Velpeau,<sup>13</sup> Forget,<sup>14</sup> Astley Cooper,<sup>15</sup> and others. I have elsewhere<sup>16</sup> related some remarkable instances of axillary galactoceles.

### § III.—General Cystic Disease.

Among the moderns, Astley Cooper was the first who clearly recognised the occurrence in the breast of a general cystic disease, chiefly affecting the small ducts; and, following his lead, Brodie was the first who published a comprehensive description of this malady. Strange to relate, notwithstanding their completeness, the observations of these distinguished surgeons gradually lapsed into oblivion; so that when in 1883 Reclus<sup>17</sup> published a fresh account of the disease, almost every one, even in England, hailed his observations as a new discovery, and the disease has since been generally known as "*la Maladie kystique de Reclus*."

Nevertheless, almost every particular noted by Reclus, and some that escaped his observation, had previously been described by Brodie; if, therefore, the personal element is to be introduced into the nomenclature of this affection, "Brodie's disease" would be a much more appropriate term for it than "Reclus' disease." His neglected account of the malady, as far as it goes, is still the best extant, so I propose to give it *in extenso*. He says:<sup>18</sup>—

<sup>8</sup> *Lancet*, vol. ii., 1880, p. 850.

<sup>9</sup> *L'Union Méd.*, t. xxv., 1878, pp. 945, 957 and 993.

<sup>10</sup> *Gaz. des Hôp.*, 1863, p. 525.

<sup>11</sup> *Monit. des Sci. Méd.*, &c., 1860, p. 4.

<sup>12</sup> "Holmes' System of Surgery," vol. iii., 1883, p. 448; also "Diseases of the Breast," 1850, p. 201.

<sup>13</sup> "Traité des Maladies du Sein," &c., 1854, p. 297.

<sup>14</sup> *Bull. gén. de Thérapeutique*, 1844, t. xxvii., p. 355.

<sup>15</sup> "Illustrations of the Diseases of the Breast," 1829.

<sup>16</sup> Ch. iv., § iv.

<sup>17</sup> *Rév. de Chir.*, 1883, p. 761.

<sup>18</sup> "Lectures on Pathology and Surgery," 1846, p. 137.



"The disease of which I propose to treat on the present occasion, is an affection of the female breast. It is one of great interest in various ways, and among others in this : that in its more advanced stages, although it is not really of a malignant nature, it is liable to be confounded with carcinoma. I have not met with any description of it in books corresponding to what I have myself observed of its actual progress. You will presently see that this is easily to be explained by the disease assuming a wholly new character as it proceeds, so that if you were to look at two cases of it, one in an early, and the other in a more advanced stage, without having witnessed the intermediate changes which have taken place, you would be scarcely able to recognise their identity. Let me not, however, be misunderstood as representing that no notice whatever has been taken of this disease by surgical writers. The account which Sir Astley Cooper has given of the hydatid breast has been taken principally from cases of this kind, and there are also some allusions to it in the 'Treatise on Diseases of the Breast,' lately published by M. Velpeau.

"The first perceptible indication of the disease is a globular tumour embedded in the glandular structure of the breast, and to a certain extent movable underneath the skin. Sometimes there is only one such tumour ; at other times there are two or three, or many more. The examination of the breast in the living person does not enable you to determine the exact number which exist, as it is only where they have attained a certain magnitude that they are perceptible through the skin. In most instances the disease is confined to one breast, though it is by no means very uncommon for both breasts to be similarly affected.

"The globular form which the tumour invariably assumes in the first instance, is a sufficient proof that it is formed of fluid collected in a cyst, and of course pressing equally in every direction. If you puncture the tumour with a grooved needle, the fluid may be evacuated so as completely to empty the cyst, and the perfect subsidence of it afterwards proves how little space the cyst itself occupies. The fluid is always serous. When the tumour is small it seems to be serum, unmixed with anything else. In a more advanced stage of the disease, some colouring matter is generally blended with it, and it may be green, or brown, or so dark-coloured as to be almost black. The quantity of fluid of course varies. In dissection, I have sometimes found the cyst to be so small as to contain scarcely a single drop. But in a more advanced stage it is capable of containing several ounces. In two cases, in each of which I had the opportunity of dissecting a breast affected with this disease, I found small cysts, composed of a thin membrane, and containing serum, pervading the whole of the glandular structure, the intermediate parts of the breast presenting a perfectly healthy and natural appearance ; and I could discover nothing more. There seems to be little doubt that the cysts are originally formed by a dilatation of the lactiferous tubes. In one of the preparations now on the table, you will perceive a bristle introduced into the orifice of one of these tubes opening on the nipple, which has passed into a cyst immediately below ; and it is not uncommon to find that by pressure on the tumour the fluid may be made to escape by the nipple, so that you may even expel the whole of it.



"To complete the history of the disease, as it first shows itself, I may add that the general health is unaffected, and that the patient complains of no pain, unless it be that, in some instances, there are those disagreeable nervous sensations that are apt to arise whenever the attention is anxiously directed to any one part of the body. I have never known the disease to occur previously to the age of puberty; it is rare after the middle period of life, and I am inclined to believe it is more common in single than in married women."

It is clear from the above that Brodie was perfectly familiar with every phase of this disease, and the following quotation proves that he knew also how to discriminate it from *cystic tubular cancer*—a disease that, in its clinical features, is very like it. On this subject he thus expresses himself<sup>19</sup> :—

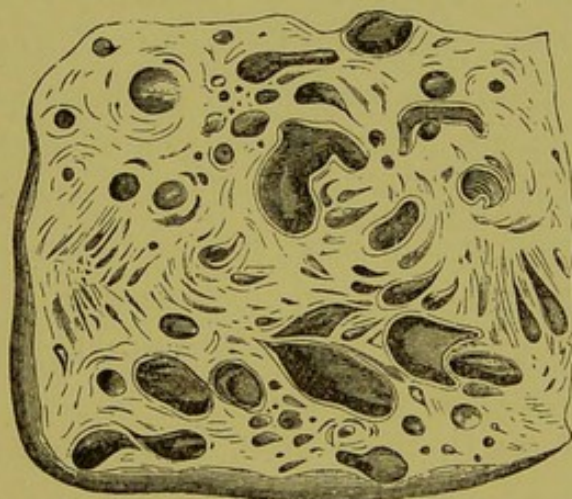


FIG. 70.—Multiple cystic disease (*Gross*).

"There are not a few cases in which no morbid changes take place beyond those that I have already described; the cyst remaining unaltered, or only slowly increasing in size during the remainder of the patient's life. But in other cases the tumours lose their globular form, and a *solid substance is deposited in the breast, connecting different cysts with each other in one large mass of disease*. This process may be going on for many successive years without inducing pain or much inconvenience, except what belongs to the bulk of the tumour. But the period at last arrives when other changes take place, the disease assuming a more formidable and dangerous character. The skin, being in some one part more tense and thin than elsewhere, becomes inflamed and ulcerates, and an intractable and bleeding ulcer is the consequence, &c."

<sup>19</sup> *Op. cit.*, p. 140.



Elsewhere he also recognises the existence of a form of non-malignant cystic disease associated with intra-cystic villous growths.

In his description of the malady Reclus<sup>20</sup> lays stress on the frequency with which both breasts are affected, each gland being riddled throughout with small cysts, so that hundreds may be visible to the naked eye, of which denser aggregations are met with at the periphery and posterior surface of the gland than elsewhere. In these cases it usually happens that one or more cysts in the vicinity of the nipple increase in excess of the others so as to form an obvious tumour, varying in size from a cherry to a walnut. It is the discovery of such a tumour that usually constitutes the patient's first intimation of there being anything wrong with the breast. On examination the surgeon finds in this situation one or more smooth, rounded or ovoid tumours, feeling it may be very hard, so that fluctuation is not readily elicited, while on careful palpation of the rest of the gland numerous small, hard, shot-like nodules may be felt disseminated through it. On examination of the opposite breast the larger central tumours are usually absent, but the small, shot-like bodies can generally be felt. The other symptoms are of the negative kind. The nipple and skin are normal, there are no adhesions between the breast and adjacent parts; and the axillary glands are not affected except when irritative conditions co-exist. The great hardness sometimes manifested by these tumours has occasionally caused them to be mistaken for hard cancer, from which they may be readily distinguished by exploratory puncture. Most cases are met with between the ages of 30 and 40 years.

Since Reclus' publication numerous *brochures*--mostly by French writers--have appeared, dealing with the morphological aspects of this disease. Nearly all agree in describing the cysts as lined by epithelium of the columnar type; when more than a single layer of lining cells is present the columnar type is well

---

<sup>20</sup> *Op. cit.*



marked in the peripheral cells, although it may be lost in the more central ones. This was the condition present in all the specimens that I have myself examined. It clearly points to the origin of the cysts from the small ducts, yet nearly all the authors referred to state that they are of acinous origin. I have never seen any structure having the least resemblance to an acinus, in specimens of general cystic disease of the breast. The cysts arise as solid cellular buds from the small ducts. Lately histologists have concentrated their attention on the stromal tissues in the immediate vicinity of the small cysts. In a considerable proportion of the specimens examined, signs of chronic inflammatory lesions have been met with here; this has induced Delbet<sup>21</sup> and others to maintain, that cystic disease of the breast is always a deuteropathic phenomenon. I have, however, in some specimens been unable to discover any trace of past or present inflammatory action. This is especially the case with that form of the disease, which arises in association with atrophic changes of the glandular structures, such as normally ensue during the involution period.

The *diagnosis* of general cystic disease from cystic tubular cancer, and multiple papilloma of the diffuse kind, is often very difficult. An important point of difference is that in the two latter affections the disease involves only one breast; moreover, the papillomata frequently cause sanious discharge from the nipple, and the tubular cancers occasionally disseminate in the axillary glands. Except when large cysts form in the vicinity of the nipple, general cystic disease rarely presents as a distinct tumour; whereas in the other two affections well-marked tumours usually form. The differential diagnosis from chronic mastitis will be considered when treating of the latter subject.

When this disease causes no great deformity, and is not otherwise intolerable to the patient, it is not necessary to resort

---

<sup>21</sup> "Maladie Kystique et Mammite Chronique," *Bull. de la Soc. Anat.*, 2 jan., 1893.



to heroic treatment. In the absence of large cysts, it will suffice to apply to the breast an application consisting of equal parts of belladonna in glycerine, with iodide of lead ointment; together with moderate compression by bandaging, strapping or by special apparatus. When one or more large cysts exist these may be incised, evacuated and plugged with a pledget of lint, steeped in tincture of iodine. When such treatment does not suffice, the breast should be removed by Thomas' operation, the overlying skin, nipple and areola being carefully preserved, so as to minimise the subsequent deformity. In doing this care must be taken completely to remove the glandular elements, for if these are left behind they may become the germs of fresh cystic disease, as in a case of much interest reported by R. Johnson,<sup>22</sup> of which the following is an abstract.

Miss —, aged 33, came under treatment with general cystic disease of the left breast, for which it was extirpated. Several of the larger cysts contained villous ingrowths. Four years later the right breast was extirpated for similar disease. Twelve years after the first operation, the patient again came under observation with a mobile rounded tumour just above the middle of the scar, resulting from extirpation of the left breast. It had been slowly growing for two years. On examination after removal it was found to consist of two cysts of some size, containing villous ingrowths, surrounded by numerous minute cystic glandular formations. In this case recurrence was probably due to some of the peripheral mammary processes having been left behind at the first operation.

For further information as to this disease reference may be made to publications by Besancon and Broca,<sup>23</sup> Brissaud,<sup>24</sup> Moullin,<sup>25</sup> Sicre,<sup>26</sup> Pilliet,<sup>27</sup> Verchère,<sup>28</sup> Sourice,<sup>29</sup> Schimmelbusch,<sup>30</sup> &c.

---

<sup>22</sup> *Trans. Path. Soc. Lond.*, 1892.

<sup>23</sup> *Le Prog. Méd.*, mars, 1886.

<sup>24</sup> *Arch. de Phys.*, 1884, p. 98.

<sup>25</sup> *Journal of Anatomy*, vol. xv., p. 346.

<sup>26</sup> *Thèse de Paris*, No. 77, 1890.

<sup>27</sup> *Bull. de la Soc. Anat.*, 9 jan., 1891.

<sup>28</sup> *Ibid.*, 4 juillet, 1890.

<sup>29</sup> *Thèse de Paris*, 1887.

<sup>30</sup> *Arch. f. path. Anat.*, Bd. xlv., S. 117.



## § IV.—Lymphatic Cysts.

It has been demonstrated by Labbé and Coÿne,<sup>31</sup> that the stroma of the mamma, and the connective tissue in its vicinity, contain numerous large lymphatic lacunæ, which are lined by a single layer of flattened endothelial cells, exhibiting the characteristic reaction when stained with nitrate of silver. In the breast cysts are occasionally met with lined by similar cells. Such cysts no doubt arise from the distension of these lymphatic lacunæ, owing to the undue accumulation of fluid within them. They may be either single or multiple. They differ from the foregoing in that each forms a perfectly closed sac, having no communication with the glandular structures. Villous intracystic growths have not been found in these cases. They usually contain a clear, pale yellowish or brown, mucoid fluid. In size they seldom exceed a pigeon's egg. Being deeply seated and surrounded by unyielding structures, these cysts often feel very tense and hard; and as fluctuation can seldom be detected, they have often been mistaken for hard cancer. However, unless associated with inflammatory changes, as not unfrequently happens, they never cause dimpling of the overlying skin, retraction of the nipple, nor enlargement of the axillary glands. Most examples have been met with in patients over 40 years of age. In the cases hitherto recorded the affection has invariably been unilateral. The so-called bursa of Chassaignac, occasionally found between the breast and the sheath of the pectoralis major muscle, is likewise generally regarded as originating from cystic lymphatic lacunæ. The same means of treatment are suitable for these cases as for the previously described varieties of mammary cysts; they may be incised and evacuated, &c., or dissected out. The following illustrative case is by Pollard.<sup>32</sup>

The patient, aged 44, two months previously accidentally noticed a lump in her breast. There was no known cause for it. On examination a tumour the size of a marble was found in the midst of an indurated lobule.

<sup>31</sup> "Traité des Tumeurs Bénignes du Sein," p. 90.

<sup>32</sup> *Univ. Coll. Hosp. Rep.*, 1885, pp. 76 and 148.



The axillary glands were normal. It was dissected out together with some of the adjacent indurated tissues ; and the wound soon afterwards healed up. On examination it proved to be a tense cyst, containing clear, straw-coloured fluid. The cyst wall was shown by staining with nitrate of silver to be lined with a single layer of flat epithelioid cells, some of which had wavy margins.

Cases histologically verified have also been recorded by Butlin,<sup>33</sup> Gadsby,<sup>34</sup> and others.

### § V.—Hydatid Cysts.

Although a considerable number of well recorded examples of mammary hydatids have been published, yet it is a very rare disease. The tænia embryo finds its way to the breast and develops there into the hydatid cyst, just as it does in other organs. The mother vesicle, surrounded by the condensed fibrous tissue of the part, increases slowly—several months passing before it attains the size of a nut. In most cases the disease then presents as a single cyst, containing clear, non-albuminous fluid of low specific gravity, in which, on histological examination, the pathognomonic hooklets may be found ; while, adhering to its germinal membrane or floating in its contained fluid, are numerous scolices. At a later stage several daughter cysts may be present within the parent cyst. In the breast hydatid cysts seldom attain the immense size they do in other parts ; however, Astley Cooper<sup>35</sup> and Warren<sup>36</sup> have met with specimens that weighed from twelve to fourteen pounds, and contained an immense number of daughter cysts. Mammary hydatids usually present as smooth, rounded, mobile, painless, chronic tumours about the size of a small apple, which either fluctuate or are of elastic consistency. They occasionally become inflamed and suppurate, and then they may give rise to adhesions with adjacent structures and enlargement of the axillary glands. According to Haussmann<sup>37</sup> hydatids may develop in any part of

<sup>33</sup> *Lancet*, vol. i., 1884, p. 748.

<sup>34</sup> *Lancet*, vol. i., 1878, p. 234.

<sup>35</sup> "Lectures on Surgery," 1839, p. 371.

<sup>36</sup> "Surgical Observations on Tumours," p. 206.

<sup>37</sup> "Die Parasiten der Brustdrüse," Berlin, 1874.



the breast, except the nipple and its immediate vicinity. They are invariably unilateral. The great majority arise between the ages of 20 and 50. Similar cysts, arising from structures in the vicinity of the breast, may also present in the mammary region. In a case reported by Gardener<sup>38</sup> the tumour sprang from the pectoralis major muscle; in Graefe's<sup>39</sup> case it was situated beneath this muscle; while Schnepf<sup>40</sup> and Landau<sup>41</sup> have met with instances in which cysts thus presenting were of intra-thoracic origin. In cases of doubtful diagnosis exploratory puncture should be resorted to. The treatment consists in incision and evacuation of the laminated cyst-wall, the empty cavity being dressed from the bottom with lint steeped in tincture of iodine. Partial amputation of the breast, together with the cyst, may in certain cases be necessary, when the latter is of large size—the wound being closed by deep and superficial sutures, so as to secure immediate union.

The following recently recorded examples illustrate the chief features of the disease:—

(1) A patient of Dubrueil's,<sup>42</sup> aged 44, had suffered for two years from an indolent tumour of the breast, which, two months before she came under his observation, became painful and increased rapidly. On making an exploratory incision into it purulent fluid, with hydatid membrane, escaped. The resulting cavity was irrigated with boric acid lotion, and then with nitrate of silver solution. Two months later it had completely healed.

(2)<sup>43</sup> A multipara, aged 30, two years ago first noticed a tumour in her right breast. On examination a rounded, fluctuating, circumscribed tumour, three inches in diameter, was found in the upper part of the breast. It was freely movable, but the skin over it near the nipple was inflamed. When punctured, pale, watery fluid escaped, which soon became slightly opalescent, but contained no hooklets. Through a vertical incision the whole tumour was dissected out. A little pus was found in the tissue over it near the nipple. On examination after removal, the tumour was found to consist of a thick capsule of chronically inflamed, sclerosed connective tissue, within which was the hydatid membrane. There were no secondary cysts.

---

<sup>38</sup> *Lancet*, vol. i, 1878, p. 851.

<sup>39</sup> *Arch. Gén. de Méd.*, t. xvi., p. 593.

<sup>40</sup> *Cent. f. Chir.*, 1876.

<sup>41</sup> *Arch. f. Gyn.*, Bd. viii., S. 350.

<sup>42</sup> *Rév. de Chir.*, May, 1890.

<sup>43</sup> Symonds, *Trans. Path. Soc. Lond.*, vol. xxxviii., 1887, p. 448.



Cases have also been reported by Bryant,<sup>44</sup> Guermonprez,<sup>45</sup> Fischer,<sup>46</sup> Henry,<sup>47</sup> Birkett,<sup>48</sup> and others.

Various inert foreign bodies embedded in the breast, such as pins, needles, bits of glass, altered blood, inspissated tubercle, and small sequestra from the ribs, that have separated by quiet necrosis, &c., are occasionally found inside pseudo-cystic spaces.

### § VI.—Sebaceous Cysts.

These are great rarities, arising chiefly in connection with the areola, but exceptionally also from other parts of the mammary integument.

Billroth<sup>49</sup> mentions the case of a very obese married woman, aged 46, the mother of several children, who died in hospital after laparo-hysterectomy for uterine myo-fibroma. Before operation it was noticed that she had in her right breast a circumscribed, mobile, painless tumour, the size of a duck's egg, of many years' duration; and stationary of late. On examination of the part after death, an encapsuled tumour was found immediately beneath the integument, which on section contained a large quantity of imbricated, cholesteatomatous scales, and within this some pulpy magma. Billroth thought it probably originated from a deep cutaneous sebaceous gland.

He also mentions having seen another case, in which a sebaceous cyst, the size of a pigeon's egg, existed in the left breast, whose contents could be expelled by squeezing them through a fine opening in the overlying skin.

Cruveilhier<sup>50</sup> has reported two similar cases; both in the persons of adult females; in connection with each of which the orifice of the diseased sebaceous gland was plainly visible.

Lebert<sup>51</sup> also refers to a case of this kind; and Bryant<sup>52</sup> instances several examples arising from the sebaceous glands of the areola, one of which was pedunculated; while another, having ulcerated, subsequently became the seat of cancer.

Cysts of this kind should be dissected out *en masse*; in default of this they may be incised, evacuated and dressed from the bottom.

<sup>44</sup> "Diseases of the Breast," 1887, p. 317.

<sup>45</sup> *Arch. de Tocologie*, 1884, p. 14.

<sup>46</sup> *Deutsche Zeitschr. f. Chir.*, Bd. xiv., S. 366.

<sup>47</sup> *Lancet*, vol. ii., 1861, p. 497.

<sup>48</sup> "Holmes' System of Surgery," vol. iii., 1883, p. 450.

<sup>49</sup> *Deutsche Chir.*, Lief xli., S. 90.

<sup>50</sup> *Traité d'Anat. Path.*, t. iii., p. 338.

<sup>51</sup> *Bull. de la Soc. Anat.*, 1852, p. 42.

<sup>52</sup> "Diseases of the Breast," 1887, p. 332.



In this connection mention may be made of the occasional occurrence on the breast of *molluscum contagiosum*. The commonest seat for its development is the child's face, and thence it may be communicated to the mother's breast. It presents as sessile, pearly-looking rounded tumours, umbilicated at the centre, and varying in size from a pin's head to a pea. These arise in the sebaceous glands, and their contents are sebaceous cells and their products. They should be treated by incision, their contents being squeezed or scraped out.

### § VII.—Dermoid Cysts.

There are on record several examples of dermoid cysts situated in the median line, in the region of the sternum, especially at about the level of the junction of its first and second segments.<sup>53</sup> Of these Clutton's<sup>54</sup> case is one of the most instructive.

A married woman, aged 38, came under observation with a large pendulous tumour, hanging from the centre of the sternum, between her two breasts. Its circumference measured thirteen inches. It felt soft and fluctuating. The overlying skin was freely mobile, but its central part showed atrophic changes, such as are not unfrequently seen in the skin over dermoid cysts. When only six weeks old, a median pea-sized body is said to have been noticed in the site of the present tumour. At 19 years of age this had increased to the size of a hen's egg. The cyst was dissected out. It had no connection with the sternum, which was normal. Its thin wall was lined internally with epidermic flakes, within which were eleven ounces of thick fluid, containing epidermic scales, fatty matter, cholesterine, &c., but no hairs. Histological examination of the cyst wall revealed the ordinary structure of *cutis vera*, but the papillæ were small and scanty, and neither glandular structures nor hair follicles were visible.

Cases have also been published by Bramann,<sup>55</sup> Cahen,<sup>56</sup> Lannelongue,<sup>57</sup> Fontaine, Landrieux and others.

Lannelongue's patient was 16 years old when the cyst was removed. It was situated in the middle line, in front of the upper part of the sternum. It contained numerous hairs.

<sup>53</sup> In this situation there may occasionally be seen a median congenital depression—the sternal dimple.

<sup>54</sup> *Trans. Path. Soc. Lond.*, vol. xxxviii., 1887, p. 393.

<sup>55</sup> *Arch. f. klin. Chir.*, Bd. xl.

<sup>56</sup> *Zeitschr. f. Chir.*, Bd. xxxi., S. 370.

<sup>57</sup> "Traité des Kystes Congénitaux," 1886, p. 27, also p. 195.



Dermoids of the breast itself are of much rarer occurrence than the foregoing; the following are some of the chief examples hitherto recorded:—

(1) In the lower half of the right breast of a woman, aged 66, who died of emphysema of the lungs, Hermann<sup>58</sup> found a globular tumour bigger than a man's fist. The skin over its most projecting part was ulcerated, and on squeezing the tumour caseous matter, together with large epidermic flakes, escaped through the ulcer. No satisfactory history of the disease could be obtained. Hermann suggests that the cyst originated as a sequestration from the epiblastic ingrowth of the developing gland.

(2) Reverdin and Mayor<sup>59</sup> relate the case of a woman, aged 47, with a tumour of the left breast, the size of a child's head. The overlying skin mobile, purplish and marked by enlarged veins; the nipple normal. The main tumour seemed distinctly to fluctuate, but adjacent to it several hard nodules could be felt. The history the patient gave was, that twenty-eight years ago, after having suckled for fifteen months her first child, she noticed several hard nodules in her left breast. During the last two years most of the present large tumour has developed. After ablation the main tumour was found to be a dermoid cyst, and the surrounding hard nodules were fibro-adenomata.

(3) In a case by Albers,<sup>60</sup> the cyst contained hairs in the midst of a quasi-sebaceous magma.

(4) In the lower and outer part of the left breast of a healthy multipara, aged 42, Velpeau<sup>61</sup> found a circumscribed, mobile tumour, the size of a fowl's egg. It was soft, fluctuating and tender. The axillary glands and nipple were normal. When punctured, quasi-serous fluid containing grumous flakes escaped. Fifteen years ago, a small lump was first noticed in the site of the present tumour; it remained almost stationary until about eighteen months ago, since when it has rapidly increased, and this increase has been attended with pain and tenderness. Velpeau dissected the tumour out. During the operation it proved to be completely embedded in the tissues of the part; a thick layer of fat separating it from the overlying skin. On examination after removal, it consisted of a fibrous capsule, blended with the surrounding parts, within which were whitish imbricated epidermic lamellæ, forming a kind of second cyst wall, which contained whitish-yellow pulp, consisting of degenerating epithelial cells, fatty globules, cholesterine crystals, &c. The complete way in which this tumour was embedded in the breast and the absence of any external orifice, are, I think, sufficient reasons for regarding it as a dermoid, rather than as a sebaceous cyst.

(5) Erichsen<sup>62</sup> says: "In some rare cases, tumours containing foetal remains have been met with in the breast." However, he gives no instances, and I know of none.

<sup>58</sup> *Prager med. Woch.*, No. 44, 1890.

<sup>59</sup> *Rev. Méd. de la Suisse romande*, 1887, p. 96.

<sup>60</sup> *Erläuterungen*, Bd. iii., S. 589.

<sup>61</sup> "Traité des Maladies du Sein," p. 314.

<sup>62</sup> "Science and Art of Surgery," vol. ii., 1872, p. 406.



## CHAPTER XXI.

NON-MALIGNANT NEOPLASMS AND CYSTS OF THE MALE  
BREAST.

THE present state of our knowledge of this subject warrants us in believing, that every variety of neoplastic disease met with in the female breast, has also its counterpart in the male breast; although in the latter these morbid manifestations are of great rarity. The following cases suffice to illustrate the truth of this statement, so far as non-malignant neoplastic diseases are concerned.

## § I.—Fibroma and Fibro-Adenoma.

As examples of pure *fibroma* I know only of the two subjoined cases.

(1)<sup>1</sup> A man, aged 34, with a hard tumour, the size of a walnut, situated at the outer side of the nipple of his left breast. It was of four months' duration, and arose without any injury or other known cause. During the operation for its removal, it was found to be partially embedded in the *pectoralis major* muscle, and it had evidently originated from the posterior aspect of the gland. On section it appeared to consist of dense, whitish, fibrous tissue, which centrally presented a hyaline appearance. Histologically it was composed of white, fibrous tissue, in which at the periphery nuclei were abundant. It contained no glandular structures.

(2)<sup>2</sup> In this case a hard tumour, two and a-half inches in diameter, was removed from the breast of a young man aged 18. Histologically it consisted solely of dense, white, fibrous tissue.

<sup>1</sup> Beadles, *Trans. Path. Soc. Lond.*, 1893, p. 124.

<sup>2</sup> Virchow, "Path. des Tumeurs," t. i., p. 329.



Some cases of so-called diffuse fibroma have been described, but they are really examples of chronic mastitis.<sup>3</sup>

*Fibro-adenoma* is much commoner than fibroma, although the number of cases hitherto recorded is by no means large.

Monro<sup>4</sup> has reported the case of a labourer, aged 27, beneath the nipple of whose right breast, a small tumour was first noticed six months ago, which followed a kick there six months previously. On examination a hard circumscribed, rounded, lobular tumour, the size of a Tangerine orange, presented beneath the nipple. It was freely mobile, except that it appeared slightly held in the vicinity of the nipple. There was no pain or tenderness associated with it. It was extirpated together with the overlying skin. The patient was soon afterwards convalescent. Histologically it consisted of dense fibrous tissue, in which were scattered a few tubular glandular structures, lined by a single layer of columnar epithelium.

Paget<sup>5</sup> mentions a case of this kind, which occurred in the person of a countryman, 25 years old, in whose breast it had been growing for five years. After removal the tumour presented as an encapsuled, discoidal, slightly lobulated mass, three and a-half inches in diameter. Histologically it was a typical fibro-adenoma.

Velpeau<sup>6</sup> has reported an interesting example, in which a large lobulated cystic tumour of this kind caused ulceration of the overlying skin, through which it projected. The patient was a retired army surgeon, aged 85. The tumour was of fifteen years' duration, and ulceration began three years previously. It was removed by ligation, and he was free from any return of the disease, when he died of some other cause four years later.

Cases have also been recorded by Röder,<sup>7</sup> Le Dentu,<sup>8</sup> Parona,<sup>9</sup> Cruveilhier,<sup>10</sup> and others.<sup>11</sup>

## § II.—Villous Papilloma.

As examples of this disease of the male breast, I can cite the following cases:—

(1) In the *Hunterian Museum* (No. 4752 A., Path. Series), is a specimen

<sup>3</sup> *Bull. de la Soc. Anat.*, 1888, p. 42.

<sup>4</sup> *Lancet*, vol. ii., 1892, p. 368.

<sup>5</sup> "Surgical Pathology," vol. ii., 1853, p. 258.

<sup>6</sup> "Traité des Maladies du Sein," p. 717.

<sup>7</sup> "Beitrag z. Stat. d. Neubildungen der männlichen Brustdrüse," I. D., Würzburg, 1889, S. 28.

<sup>8</sup> *Bull. et Mém. de la Soc. de Chir. de Paris*, t. xi., 1885, p. 900.

<sup>9</sup> *Gaz. Med. Ital.-Lomb.*, Milano, 1868, No. 31, p. 258.

<sup>10</sup> *Traité d'Anat. Path.*, t. iii., p. 54.

<sup>11</sup> *Rev. Méd.-phot. des Hôp. de Paris*, 1874, t. vi., p. 137, &c.



which is described in the catalogue<sup>12</sup> as follows : "A male breast showing two oval cysts beneath the nipple and areola, separated by a thin fibrous septum, the larger one measures an inch in its longest diameter. Each cyst is filled with blood clot. The specimen was removed from the left mammary region of a man aged 49, who, fifteen years previously, first noticed a few drops of brownish discharge escaping from his left nipple. This continued for many years. About four years before operation, the discharge ceased, and the tumour then appeared."

(2)<sup>13</sup> An unmarried man, aged 30, three years ago noticed some slight irritation about his left nipple, in connection with which shortly afterwards, he found a tumour, the size of a hazel-nut. Six months ago it was only half its present size. On examination, a large, rounded, elastic tumour—twelve inches in circumference—occupied his left mammary region. The nipple had almost disappeared through stretching. The skin over the most prominent part of the tumour was purplish and slightly adherent, otherwise the tumour was freely mobile. There was no enlargement of the axillary glands. On exploratory puncture a large quantity of "coffee-ground" fluid escaped. The breast was amputated. On examination after removal the tumour consisted of one large cyst and several smaller ones, which all contained "coffee-ground" fluid, and soft reddish pulp.

(3)<sup>14</sup> A married man, aged 55, with a cystic tumour, the size of an orange, in his left breast, of two years' duration. On examination after removal, a large thin-walled cyst, filled with fluid and intra-cystic villous ingrowths.

### § III.—Lipoma.

A case of *diffuse lipoma* of both mammary regions in a man aged 29, has been reported by Baker and Bowlby.<sup>15</sup> The disease was of one year's duration. He had also symmetrical fatty masses on each side of the front of the abdomen, especially in the supra-pubic region, in each scrotum, and at the upper and inner part of each upper limb. He was a great drinker of gin and beer.

In some forms of gynæcomazia, the enlargement is often mainly due to overgrowth of the fatty tissue (ch. iii.).

An example of a large fatty tumour of the male mammary region was reported by Queirel at the French Surgical Congress in 1889.<sup>16</sup>

I have met with a lipoma, the size of a lady's watch, situated two inches below the left nipple of a man, aged 33.

S. Paget<sup>17</sup> has seen a large fatty tumour beneath the lower part of the breast, in a man aged 35, which pushed the breast forward and made it seem to be enlarged.

<sup>12</sup> "Path. Catalogue," Appendix v., 1891.

<sup>13</sup> De Morgan, *Brit. Med. Journal*, vol. ii., 1873, p. 542.

<sup>14</sup> Hewett, *Lancet*, vol. ii., 1863, p. 482.

<sup>15</sup> *Med. Chir. Trans.*, vol. lxix., 1886, p. 41.

<sup>16</sup> "Proc. verb.," 1890, t. v., p. 671.

<sup>17</sup> *Lancet*, vol. i., 1894, p. 1173.



## § IV.—Chondroma.

The following examples have been recorded :—

(1) In Foucher's<sup>18</sup> case a large tumour, fixed to the pectoral muscle, occupied the mammary region of a man, aged 35. It was removed, together with a portion of the fifth rib, from which it seemed probable that the tumour really sprang. The patient died soon afterwards of acute suppurative pleurisy.

(2) Seydel's<sup>19</sup> case is an example of osteo-chondro-sarcoma. The patient, a young man, aged 22, having a year previously sustained an injury from a fall, and subsequently from a blow on the same spot, soon afterwards noticed a swelling over the antero-lateral part of the eighth right rib. In the course of a few months this swelling greatly increased. When he came under observation, a large rounded tumour projected from the antero-lateral aspect of the right side of the thorax. It reached from the seventh rib above to the tenth below, and laterally it extended from the mid-axillary to the mammary line. An attempt at excision had to be abandoned, after removal of its superficial part and the adjacent ribs, as the deep part of the tumour was found to have involved the liver. Consequently it soon grew up again, and secondary growths appeared in several of the ribs higher up. About six months after the operation the patient died, the disease having involved the whole of this part of thorax from the sternum to the scapula, and from the nipple to near the iliac crest. There were secondary growths in both lungs, and the main tumour had spread by direct extension to the right lung and liver. The peripheral parts of the primary tumour consisted of sarcomatous tissue ; while more centrally only newly formed cartilaginous and osteoid tissues were found. The secondary growths in the lungs and liver appeared to consist only of osteo-chondromatous structures.

(3) In a case by Virchow<sup>20</sup> an osteo-chondromatous tumour the size of two fists, grew from the thoracic wall of an old man, and disseminated in the pleura and lungs. Remarkable features of this growth are, that Virchow could detect no sarcomatous tissue in it, and that the tumour had no immediate connection with any of the adjacent ribs ; but it appeared to have sprung from the soft parts of an adjacent intercostal space, having probably originated from some belated skeletal sequestration.

## § V.—Angioma.

(1) A labourer, aged 17, came under my observation<sup>21</sup> with a considerable swelling of the right mammary region, of congenital origin. On examination, I found a softish, discoidal, lobulated tumour, three and a-half inches in

<sup>18</sup> *L'Union Méd.*, 1859, No. 103, p. 403.

<sup>19</sup> *Central. f. Chir.*, No. 56, 1890.

<sup>20</sup> "Path. des Tumeurs," t. i., p. 533.

<sup>21</sup> This account of the case is from my own notes, which were published in the "Middlesex Hospital Surgical Report," for 1887. Sutton, I believe, subsequently published an account of it somewhere or other



diameter, involving the whole of the mammary region. The overlying nipple was stunted, and the areola ill developed. The skin above the areola presented a purplish nævoid area. Here the tumour seemed adherent to the overlying skin, elsewhere it was freely mobile. About three inches below the nipple, and one inch to its inner side is a circumscribed satellite tumour, of similar character to the main one, and about the size of a hazelnut. An ill-defined hard cord seems to connect the two tumours. The glands in both axillæ slightly enlarged. The patient otherwise well formed. He said that soon after birth a lump, the size of a walnut, was noticed beneath his right nipple. It subsequently became red, and increased in size. It has since slowly increased. The nævoid condition of the overlying skin has been noticeable as long as the patient can remember, but his mother says it was not noticeable at birth. No family history of moles, nævi, congenital deformity, tumour, or cancer. Breast amputated together with the whole tumour and the overlying skin. Free hæmorrhage. On examination after removal, a cystic, cavernous nævoid structure. Histological examination revealed vascular structures mixed with fatty tissue, and in the neighbourhood of the nipple mammary glandular tissue was found. The satellite nodule was composed of nævoid tissue, with a small cyst, containing serous fluid, embedded in it. He was convalescent a month later.

I have seen a very similar tumour also in a man, that developed in connection with a congenital nævus, situated over the lower antero-lateral part of the thorax on the right side.

(2) Virchow<sup>22</sup> cites a case of a large angioma, occupying the left pectoral region of a male child, 2 years old.

(3) The following case has also come under my observation: A male child, aged 7 years, with a discoidal swelling, the size of half-a-crown, situated an inch above the right nipple and rather internal to it. It was first noticed five months previously. It lies nearly over the intercostal space, and is adherent to the surrounding parts. Nipple and areola well formed. The tumour of congenital origin. It was dissected out; a thin-walled cyst containing grumous, yellowish brown fluid, internally smooth, externally blended with adjacent structures. Beneath it the intercostal muscles deficient; a process of the cyst seemed to have projected in this direction towards the pleura; but apparently did not join it. The cyst appeared to have originated from a degenerate angioma.<sup>23</sup>

## § VI.—Cysts.

There are on record a larger number of examples of cystic tumours of the male breast, than of any other sexcept cancer. The following case was observed by my brother, the late Dr. J. A. Williams, and the account of it is from his notes.

<sup>22</sup> "Path. des Tumeurs," t. iv., p. 56.

<sup>23</sup> For reference to a case of cancer developed from a nævus of the male breast, *vide* p. 315.



An army pensioner, aged 72, came under his observation with a rounded, slightly lobulated tumour, the size of a small orange, beneath his left nipple. It was circumscribed, freely mobile, translucent and fluctuating. The nipple was not retracted, nor were the axillary glands enlarged. On pressure, yellowish fluid escaped from the nipple, which under the microscope showed cholesterine scales, epithelial cells, granular cells and *débris*. The swelling in the breast was first noticed eighteen months ago, after a blow. No family history of cancer or tumour. The tumour was excised together with the overlying skin. On examination after removal a single thin-walled cyst, containing blood-stained thin fluid; its interior smooth and shiny. The wound soon healed. The cyst had evidently originated from one of the larger ducts.

Velpeau<sup>24</sup> mentions having met with a similar cyst—the size of an infant's head—in the breast of a boy 15 years old.

I was consulted a short time ago by a gouty, middle-aged gentleman, whose right breast, some years previously, had been partially removed for cystic disease; he now came to me with an enlargement of his left breast. On examination I found the whole organ enlarged, unduly hard and tender, and presenting numerous small nodules, as if due to multiple cysts. The nipple, overlying skin and axillary glands were normal. The uneasiness and tenderness in connection with it subsided under the influence of the extract of belladonna and iodide of lead ointment. It was probably a case of general cystic disease of both breasts with some subacute gouty mastitis.

Velpeau has reported an instance of a large cystic tumour of the breast of a man, 75 years old. It was of nine years' duration, and contained lactescent fluid. By Velpeau it was regarded as a veritable *galactocoele*, the only case of the kind ever signalled in the male sex.

An instance of *sebaceous cyst* of the areola, on the verge of ulceration, in a man has been seen by Birkett;<sup>25</sup> it was dissected out with a favourable result. A somewhat similar case has been met with by Burggræve.<sup>26</sup>

A man, aged 39, under Billroth's<sup>27</sup> care, had a hard, lobulated swelling, the size of a walnut, under his right nipple. It was first noticed six months ago. On examination after removal a multi-locular, encapsuled tumour, containing dryish, mortar-like substance. Billroth thinks it probably arose from a sebaceous gland of the areola. It appears to me to bear more resemblance to a degenerated angioma.

In the *Hunterian Museum* (No. 235, Path. Series) is a specimen of a *dermoid cyst* of the male breast, with the following description by Hunter himself:<sup>28</sup> "An encysted tumour taken from the breast of Mr. Waters, filled with a flaky substance, which seemed to be a succession of cuticles, being the same with that which lines it."

<sup>24</sup> "Traité des Maladies du Sein," p. 717.

<sup>25</sup> "Holmes' System of Surgery," vol. iii., 1883, p. 460.

<sup>26</sup> *Bull. de la Soc. de Méd. de Gand.*, 1857, t. xxiv., p. 160.

<sup>27</sup> *Deutsche, Chir.*, Lief. xli., S. 161.

<sup>28</sup> "Path. Cat.," vol. i., 1882, p. 94.



Another specimen of a *dermoid cyst* of the male mamma has since been added to the Museum,<sup>29</sup> of which the following is an account.

No. 256 B., of the Pathological Series. A dermoid cyst, measuring three inches in its long diameter, and flattened from side to side. It contains fatty matter, and its walls are formed of skin. The specimen was removed from the mammary region of a man, aged 40, where it was situated just above the left nipple. He had noticed a swelling there for fifteen years. At the same time that this cyst was removed, a smaller one of similar nature was also extirpated from the right infrascapular region. About ten years previously other similar cysts, first noticed at the ages of 16 and 20, had been removed, one from over the *vertebra prominens* and another from the scalp.

---

<sup>29</sup> "Path. Catalogue," Appendix i., 1887, p. 5.



## CHAPTER XXII.

## AXILLARY TUMOURS.

As a sequel to the preceding description of mammary neoplasms, it seems desirable to say a few words about the chief tumours met with in the axilla.

In connection with the axillary integument, *moles*, *nævi*, *sebaceous cysts*, *molluscum*, *papilloma* and *epithelioma* may arise.

Bryant mentions two instances in which *melanotic sarcoma* developed from moles of the axillary skin.<sup>1</sup>

The following example of dissemination of melanotic sarcoma in the axillary glands, by Carless,<sup>2</sup> is of interest as showing the course of lymphatic infection.

A woman, aged 54, with "melanotic sarcoma" of the skin of the abdominal wall of two years' growth. The tumour was situated midway between the xiphoid appendix and the umbilicus, and a little to the left of the median line. In the left axilla could be felt two enlarged glands, the size of pigeon's eggs. Below and to the inner side of the left mamma were several small melanotic deposits, evidently due to lymphatic dissemination. The primary growth was excised, together with the strip of skin and subcutaneous tissues extending from it to the axilla, including the small cutaneous nodules below the breast; and the axilla was cleared. She rapidly recovered from the effects of the operation.

A case of supposed sarcoma of the skin of this part was lately brought before the Clinical Society by Bristowe.<sup>3</sup>

An emaciated, hectic young man, aged 22, with the skin of the right axilla and adjacent parts of the chest and neck extensively invaded by

<sup>1</sup> *Q.v.* ch. x., § ix., p. 308.

<sup>2</sup> *Medical Press and Circular*, vol. i., 1894, p. 469.

<sup>3</sup> *Clin. Soc. Trans.*, 1893.



numerous slightly projecting nodules, from a-half to one and a-half inches in diameter. In connection with some of these nodes deep ulcers had formed. The disease, in some respects, resembled *granuloma fungoides*. Some of those who saw the lesions thought they were tubercular. The patient died a month later of miliary tuberculosis of the lungs. On histological examination of the axillary nodes after death, they presented a sarcomatous structure. The total duration of his illness was about six months. I should certainly hesitate to accept this as an example of sarcoma, for the indications seem to me to point strongly to tubercle. It is highly exceptional to find active tubercle associated with any form of malignant disease.

In pregnant women tumour-like swellings ("the axillary lumps" of Champney's) not unfrequently form in connection with hypertrophy of the axillary sebaceous glands, especially during the lactation period, when they often furnish lactescent fluid. Chronic inflammatory conditions ("blind boils," &c.) arising in connection with these glands, also sometimes give rise to tumour-like swellings.

Notwithstanding the great number of sebaceous glands connected with the axillary integument, *sebaceous cysts* are of remarkably rare occurrence. Of forty-five consecutive cases of these cysts in females analysed by me, not one was axillary; and of fifty-five cases in males, there was only a single instance of sebaceous cyst of this part.

In the case referred to the patient was a married man, aged 30, by occupation a painter. He had noticed a lump in the skin of his left axilla for seven years. When I first saw him he had a suppurating sebaceous cyst there. It was dissected out, and he was well a few days later.

Another rare affection of the axillary skin is *epithelioma*. Of 571 consecutive cases of primary skin cancer analysed by me—males 381, females 190—only three were axillary, two males and one female.

Subjoined is an instance of this condition :—

A widow, aged 79, in an ill-nourished and demented condition. On examination I found, at about the middle of the inner wall of her left axilla, a circular sloughy ulcer, about three inches in diameter. Its edges were raised and hard, its base depressed, hard, and covered with dirty sloughs. Surrounding the ulcer is an indurated zone about a-quarter of an inch in width. This indurated mass was non-adherent to the chest wall. The axillary glands were markedly enlarged. The only history I could gather



was that there had been some disease in the site of the present ulcer for fifteen years. She died about nine weeks later of acute pericarditis. At the *necropsy* the condition of the ulcerated mass was much as at admission. On section it presented as a dense fibroid growth, about half an inch thick. The axillary glands were infiltrated with similar disease. No other secondary growths. Old healed tubercular lesions at the apex of each lung. Visceral and parietal layers of pericardium greatly thickened and shaggy from recent lymph formation. Old thickening of auriculo-ventricular valves. Extensive atheroma of aorta. Sloughs at back of both heels.

In studying axillary tumours it is important to bear in mind that the mammary gland sends extensions into the axilla, which not unfrequently are completely sequestered. These, under the influence of pregnancy, or from simple inflammation, often enlarge; and so form tumours, which, during lactation, may discharge milk through one or more pores. In this connection cysts may arise, containing either thin mucoid fluid or milk, either pure or variously altered. Fibro-adenomatous, sarcomatous and cancerous axillary neoplasms also take origin from this source.<sup>4</sup>

A great deal of interest attaches to axillary *angiomata*, not only on their own account, but also because it seems probable that most congenital axillary cysts arise from their degeneration.

A good example of a large tumour of this kind has been reported by Osburne.<sup>5</sup>

An ill-nourished, puny, female child, aged 10 months, came under his notice with a rapidly growing angioma of the left axilla. It had previously been treated by passing pins under it; after which it increased faster than ever. On examination an angioma, four by two and a-half inches, was found occupying the whole axilla, and extending backwards towards the scapula. It was dissected out. Several large vessels connected with it had to be ligatured. The wound was dressed antiseptically, and it soon healed.

McLeod<sup>6</sup> has recorded the history of a male Hindu, aged 45, who came under his care for a rapidly increasing axillary tumour of two months' duration. On examination the left axilla was found to be filled by a large, tense, globular swelling. This was dissected out. It was found to communicate

<sup>4</sup> For further details and cases *vide* chap. iv., § iv. and v.

<sup>5</sup> *Lancet*, vol. ii., 1890, p. 668.

<sup>6</sup> "Operative Surgery in Calcutta," 1885, p. 154.



by numerous branches with the axillary vein, which had to be ligatured and severed. It was a typical angioma.

A healthy woman, aged 60, came under Ormerod's<sup>7</sup> notice with a pedunculated, pendulous tumour, the size of the fist, hanging from the lower and inner part of the left axilla. It was of dark purplish aspect, hard, knotty, and distinctly pulsatile. It had existed for many years, but of late its increase had been unduly rapid. The pedicle was ligatured and it was cut off. On examination after the removal, the tumour was gorged with blood. It consisted of a mass of small blood vessels, irregularly arranged and of varied sizes; supported by a small quantity of fibrous tissue.

Busch<sup>8</sup> has described the case of a woman, aged 30, with a non-pulsatile axillary angioma, the size of a pigeon's egg, that was first noticed when she was 16 years old.

As examples of *cystic tumours derived from degenerate angiomata*, the following cases are instructive.

(1)<sup>9</sup> A male Hindu, aged 23, eight months before coming under observation, had a small inflammatory swelling form in his left axilla, which after bursting, left an ulcer that healed slowly. During the last two months a rapidly increasing swelling had supervened in this axilla. On examination, McLeod found a circumscribed soft, doughy, mobile tumour there, which extended from the scapular region to six and a-half inches above the nipple. It was rather tender on manipulation. In attempting its removal by dissection, the tumour proved to be intimately connected with numerous adjacent veins, and it had no capsule. The patient died of exhaustion on the third day after the operation. On examination of the part after death, a multilocular cystic structure was revealed, composed of a fibro-elastic felt-work, lined with flattened epithelial cells. The loculi, for the most part, varied in size, from a sparrow's egg to a walnut. They contained a glutinous fluid, in which were found mucous corpuscles, degenerated epithelial cells, and blood corpuscles. In some parts the walls of the loculi were thick and solid looking; in others quite thin. On section the growth presented a honeycomb appearance.

(2) In the *Hunterian Museum* (No. 298 of the Pathological Series) is a specimen of this kind, which is thus described in the catalogue.<sup>10</sup> "A tumour composed of a collection of cysts freely mobile under the skin, and over the deeper parts that filled the hollow of the axilla. Its walls were fibrous; and its contents a granular pulpy magma."

Other cases have been recorded by Hawkins, Guersant, Birkett, Trendelenburg, Lücke, &c.

<sup>7</sup> Cited by Paget, "Lectures on Surgical Pathology," vol. ii., 1854, p. 276.

<sup>8</sup> "Chir. Beobachtungen," S. 213.

<sup>9</sup> McLeod's "Operative Surgery in Calcutta," Pl. 88, p. 149.

<sup>10</sup> "General Pathology Catalogue," vol. i., 1882, p. 11.



Hawkins<sup>11</sup> was one of the first who clearly pointed out the origin of these cystic tumours from degenerate nævi. In one of his cases, a congenital axillary tumour of this kind sent prolongations into the neck and arm.

In Guersant's<sup>12</sup> case, a boy, 3 years old, came under treatment for a congenital tumour at about the middle of the anterior border of the axilla. It was extirpated. On examination after removal, the tumour looked like a cardiac auricular appendix. On section it consisted of several cysts containing sanio-serous fluid.

Of Birkett's<sup>13</sup> cases, the first was a man, aged 28, from whose axilla a congenital cystic tumour of this kind was successfully extirpated. His second was a male child, 7 years old, who had a cyst of this kind that occupied the right axillary and subscapular regions; and was first noticed six years previously. In the third case the patient was a man, aged 20, in the lower part of whose neck, on the right side, a cystic swelling was first noticed soon after birth, which gradually extended into the axilla. When only 3 years old it was tapped, and several ounces of quasi-serous fluid were withdrawn; but it soon refilled. An immense cystic tumour subsequently developed, which now occupied the whole axilla and the lower part of the neck. It was repeatedly tapped, and in all 181 ounces of dark brown fluid were withdrawn, but it soon filled again.

In Trendelenberg's<sup>14</sup> case, a boy, one day old, had a large cystic tumour of the neck, which sent a prolongation into the axilla. It was cured after three iodine injections.

Lücke's<sup>15</sup> patient, a boy aged 7 weeks, with a congenital tumour of the right axilla, which extended also over the adjacent part of the thoracic wall. The overlying skin presented some telangiectatic *taches*. On section after removal, it presented a multilocular structure, in vascular communication with the subclavian vein.

The case I am about to relate is a good example of a congenital multilocular axillary cyst of nævoid origin.

A female child, aged 8 weeks, otherwise well formed and healthy, came under the observation of my brother, the late Dr. J. A. Williams, with a large soft, lobulated tumour in the right axilla. The mother said she had noticed a swelling in the child's axilla ever since birth. It was then about the size of a walnut. It had increased very rapidly during the last few weeks. No injury or other known cause. The mother has had twelve other children, none of whom had similar tumours, or were otherwise deformed; four of them are now alive and well, the others have died of various infantile

<sup>11</sup> *Med. Chir. Trans.*, vol. xxii., p. 231. "On a peculiar form of Congenital Tumour of the Neck."

<sup>12</sup> *Gaz. Hebd. de Méd.*, 1855, p. 398. "Sur les Kystes développés dans les tumeurs érectiles veineuses enflammées."

<sup>13</sup> *Med. Chir. Trans.*, 1868, p. 185, "A Contribution to the Surgical Pathology of Sero-sanguineous Cysts in the Neck and Axilla."

<sup>14</sup> *Arch. f. klin. Chir.*, 1871, Bd. xiii., S. 404.

<sup>15</sup> Pitha and Billroth's "Handb. d. alleg. u. spec. Chir.," Bd. ii., S. 284.



diseases. She has also had one miscarriage. The birth of the patient was easy and natural. On examination the child's right axilla is occupied by a large, bossy, pyramidal tumour, which measures about five and a-half inches in its long diameter (fig. 71). It fluctuates and is translucent. Several unduly enlarged subcutaneous veins can be seen coursing over the tumour. It was tapped in several places, and about six ounces of pale yellow fluid were evacuated. On standing this clotted, and after a time separated into gelatinous clot, and pale serous fluid. The fluid coming from the cyst contained so much albumen that it solidified on boiling ; it contained no sugar.

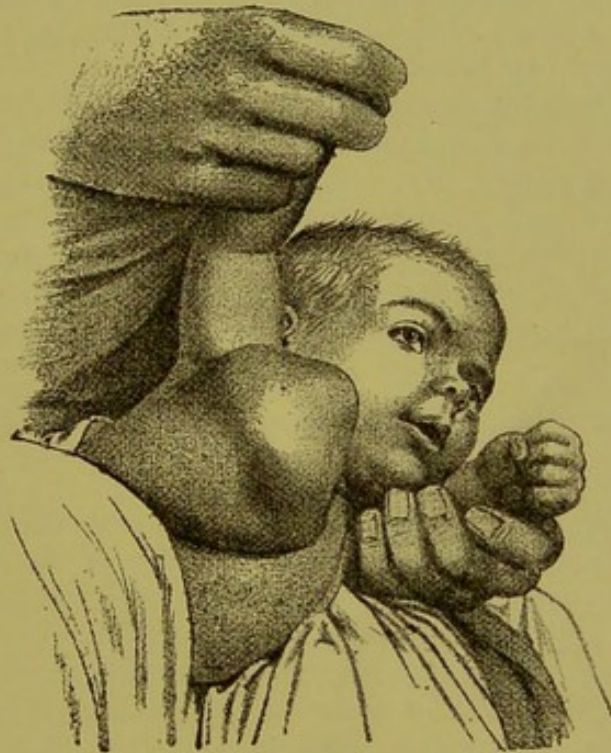

FIG. 71.—A congenital multi-locular cystoma of the axilla.

The fluid that remained after clotting was also highly albuminous. This fluid was contained in distinct loculi, so that a considerable quantity of it could only be obtained by numerous tapplings in different places. Even after this the tumour did not entirely disappear. A fortnight later it was as large as ever again. It was again tapped in several different places, and this time the fluid that escaped was blood stained. A month later the cysts had again refilled, and were evacuated again. Three weeks later the tumour was larger than ever. Setons were now passed through it, which excited free suppuration. A month later—the tumour having shrunk to the size of a walnut—the patient died, apparently from exhaustion. At the *necropsy* the tumour was quite small, and contained only about a drachm of pus. It had no communication with the chest wall, pleura or neck. The various internal organs were healthy.

It occasionally happens that degenerate nævoid tumours give rise to unilocular cysts, as in the two following cases :—



(1)<sup>16</sup> A woman, aged 26, eighteen months ago, first noticed a swelling—the size of a walnut—in her right axilla. In the course of a year it attained the size of an orange, when it was twice aspirated. Three months later she was confined; and the cyst rapidly increased to the size of a cocoa-nut, the skin over it becoming red, and the subcutaneous veins much distended. It was then tapped, and thirty-two ounces of brownish fluid were evacuated. This was twice repeated at intervals of about a week, thirty and sixteen ounces of fluid being drawn off on these occasions. Each time the fluid thus obtained was more blood-stained. About a fortnight after the last tapping, the cyst having filled again, the whole mass was dissected out. It was found to be a single, thin-walled cyst, firmly fixed to the subcutaneous tissues at the upper part of the axilla.

(2) In the *Hunterian Museum*<sup>17</sup> (No. 297 of the Pathological Series) is a specimen of a large cyst from the axilla of a man, aged 35, which contained three and a-quarter pints of turbid yellowish, highly albuminous fluid, in which was much granular matter and cholesterine. Its wall is of fibrous tissue, lined internally by a layer of smooth granulations.

The resemblance between such cases as the foregoing, and the large axillary cysts described by T. Smith,<sup>18</sup> is so close as to suggest similarity of origin.

A few examples of *lymph-angioma* of the axilla and its vicinity have been recorded.

In a boy, 4 years old, Pinner<sup>19</sup> met with a case of this kind. There was a congenital multilocular tumour at the lower part of the left axilla, which contained fluid of varied nature. It was cured after two tappings, followed by injection with 3 per cent. solution of zinc chloride.

Müller<sup>20</sup> has reported a case of congenital cystic lymph-angioma of the right axilla, that extended also down the right side of the trunk, in a male child, one year old. Extirpation was followed by rapidly fatal collapse.

Wegner<sup>21</sup> has successfully extirpated a congenital cystic lymph-angioma from the right side of the thorax of a boy, nine months old.

Godlee<sup>22</sup> has related a curious case, in which a suppurating intra-thoracic dermoid cyst pointed in the axilla, where it was opened. It discharged pus and hairs; and its wall resembled *cutis vera*. The patient was a woman, aged 30, with symptoms of pulmonary abscess.

The axilla is an occasional seat for the development of *lipo-*

<sup>16</sup> *St. Bart's. Hosp. Reports*, vol. xxiv., 1888, p. 304.

<sup>17</sup> "General Pathology Catalogue," vol. i., 1882, p. 111.

<sup>18</sup> *Clin. Soc. Trans.*, vol. xiii., p. 197.

<sup>19</sup> "Ein Fall von Lymph-angioma cystoides," &c., *Cent. f. Chir.*, 1880, Bd. ix., S. 177.

<sup>20</sup> "Zur Casuistik der Lymph-angiome," *Cent. f. Chir.*, 1885, S. 356.

<sup>21</sup> "Ueber Lymph-angiome," *Arch. f. klin. Chir.*, Bd. xx., S. 641.

<sup>22</sup> *Med. Chir. Trans.*, 1889.



*mata.* Of 190 consecutive lipomata analysed by me, males 59, females 131, 10 were situated in the axilla, males 3, females 7. In this situation lipomata sometimes assume the polypoid form. The following cases have come under my notice :—

(1) A well-nourished, dark-complexioned servant girl, aged 19, with a lobulated, soft subcutaneous tumour, the size of half an orange, just within the posterior fold of the right axilla, at its lower part. The breast and nipple normal. A swelling in this situation was first noticed two years ago. No injury or other known cause. Catamenia first at 13, and since regular. She was born in London. Previous health good ; no serious illness, except rheumatic fever at 14. Her mother's sister died of internal cancer. The tumour was dissected out, and it proved to be a typical lipoma. The wound healed slowly, and nineteen days after the operation a small sinus still remained. As this did not close of itself, it was scraped ten days later. About a fortnight afterwards the sinus had quite healed.

(2) A well-nourished, healthy looking married woman, aged 33, with a pedunculated subcutaneous tumour, hanging from the middle of the anterior fold of the right axilla. She had noticed it for three years. It was excised, and proved to be an ordinary encapsuled lipoma. The wound soon healed.

(3) A widow, aged 41, engaged in the nursery. Married at 21, and the mother of two children, widowed at 26. An obese, dark-complexioned woman. Three years ago she first noticed a small swelling in the site of present disease. On examination I found, over the middle of the anterior fold of the right axilla, a rounded, projecting, lobulated, soft tumour, the size of a large walnut. No injury or other known cause. No family history of tumour, cancer, or tubercle. Her previous health had been good. It was dissected out. An ordinary subcutaneous lipoma. In about a fortnight's time the wound had quite healed.

(4) A dark-complexioned, obese multipara, aged 46. Seven years ago she first noticed a swelling in site of present disease. It came without injury or other known cause. Previous health good. No family history of tumour, cancer or tubercle. At the upper part of the anterior border of the left axilla is a soft, lobulated, circumscribed, mobile swelling. Breast and nipple normal. Dissected out. A typical subcutaneous lipoma. The wound had quite healed in three weeks' time.

(5) A well-nourished, healthy looking married woman, aged 31, with a rather firm, lobulated, elastic, freely mobile tumour, situated immediately under the skin, over the anterior fold of the right axilla. Her brother has a lipoma of his back. Her mother died of cancer of the breast. No injury or other known cause. Previous health good ; typhoid fever six years ago. A lump was first noticed in the site of the present tumour two years ago. It was dissected out, and proved to be a fibro-lipoma. The wound was quite healed two weeks later.

(6) A healthy multipara, aged 32, with a subcutaneous tumour, over the middle of the posterior fold of her right axilla. It was soft, lobulated and freely mobile. She attributed it to a strain in lifting a heavy weight, two years ago. No family history of tumour, cancer or tubercle. It was



dissected out. An ordinary lipoma. The wound had healed a fortnight later.

Fatty tumours that originate in the neck and other adjacent parts sometimes extend into the axilla.

*Sarcomatous*, *myxomatous* and *fibromatous* tumours also arise from the axillary connective tissue; but they are very rare.

Erichsen<sup>23</sup> figures an example of fibro-sarcoma of the right axilla of a woman, that presented as a large, smooth, rounded tumour, of very slow growth. It originated beneath the *serratus magnus* muscle.

*Chondromatous* and *ossiform* tumours of the axilla generally spring either from the upper end of the humerus, or from the coracoid process (Dolbeau). They are great rarities.

The majority of axillary tumour-like swellings are due to enlarged *lymph glands*. Most of these are either the outcome of chronic inflammatory conditions, associated with tubercle, or they are secondary to some lesion of the upper extremity or adjacent parts within the zone of the axillary lymphatics. Under these circumstances several glands are usually affected. In other instances one or more glands enlarge without any obvious cause—simple lymphoma. Such enlargements may be strictly local, or they may form part of a general lymphadenosis, with or without leucocythæmia and splenic affection. Winiwarter maintains that there is a sharp distinction between hyperplastic lymphatic tumours of this kind, and *primary sarcoma starting from lymph glands*, which may be either of the round or spindle celled variety. After a short time lympho-sarcomata generally infiltrate the surrounding structures; and they often disseminate in the lungs, liver and spleen. They tend to run a rapidly fatal course. All kinds of lymph-glandular tumours may come into close relationship with the large vessels and nerve cords. They are known by their smooth, ovoid shape, and their elastic consistence; but chiefly by reason of their position in the localities where glands normally exist.

Other sources of axillary tumour-like swellings are *chronic abscesses* (mostly of lymph-glandular origin), *aneurism*, and *ruptured blood vessels*.

<sup>23</sup> "Science and Art of Surgery," vol. ii., 1872, p. 503.



## CHAPTER XXIII.

## INFLAMMATION AND SUPPURATION.

## § I.—Mastitis and Microbes.

BEFORE entering on the study of inflammatory diseases of the breast, it seems desirable briefly to set forth the chief facts relating to the rather recently established conclusions, as to the connection between these diseases and micro-organisms. By modern pathologists inflammation is regarded as a reaction of the organism, provoked by the presence of microbes in the tissues, which it is destined to neutralise or destroy. According to the old ideas, the acute inflammations of the breast associated with lactation, were attributed to engorgement of the glandular structures with stagnant milk. But recent experiments have shown, that when—in suckling animals—the out-flow of milk is artificially prevented, no inflammation follows unless the milk contain an abundance of microbes.

Numerous investigations point to the conclusion, that nearly all forms of mammary inflammation are consequent on the presence within the ducts, &c., of irritant substances of microbic origin. Hence the morbid process almost invariably first manifests itself in the immediate vicinity of these structures. The possible exception to this rule is in the case of cutaneous erysipelas, secondarily spreading to the breast, when the microbes are believed to enter the organ by way of the lymphatics. But even in a case of this kind Billroth and



Ehrlich<sup>1</sup> found the ducts, &c., distended with micrococci. This may, however, have been due to mixed infection.

That pathogenic microbes may exist in the healthy body without necessarily exciting disease, is now generally believed. To this rule the breast is no exception. Palleske<sup>2</sup> has demonstrated that milk fresh from the breasts of healthy women, frequently contains pathogenic microbes, chiefly *staphylococcus pyogenes albus*. This enables us to understand the occasional temporary occurrence of foetid milk in the mammæ, of which Jorissenne<sup>3</sup> has recorded the following instance :—

A woman of rather tubercular aspect, though in good health, having freely suckled her child for about three months, was then one day absent from it for seven and a-half hours. During this time she was walking for five and a-half hours, driving for another hour, and only one hour was allowed for rest and refreshment. On her return home the milk was so foetid, that when she commenced suckling her friends could hardly remain in the same room with her. The child nevertheless sucked greedily, although it was sick afterwards. Next day her milk was quite sweet again, and there was no sign of inflammation of the breast, nor of any disturbance of the general health. The patient said that on several previous occasions, under similar circumstances, she had noticed transitory foetidity of her milk.

It is an important matter to determine how microbes enter the breast. Most pathologists believe that they pass into it from the cutaneous surface, through the galactophorous ducts, and they point to the frequency with which inflammations and abscesses arise in the lower segment of the gland, as evidence in favour of this view. Under these circumstances the pathogenic germs are probably derived from the child's mouth, or from the hands, &c., of the mother—contaminated with lochial discharges. The number of micro-organisms—many of them pathogenic—that find a suitable *habitat* in the mouth is immense.

It has been proved that microbes having entered the blood, are often eliminated by the secretions, especially by the urine.

---

<sup>1</sup> *Arch. f. klin. Chir.*, Bd. xx., S. 418.

<sup>2</sup> *Arch. f. path. Anat.*, Bd. cxxx., 1892, S. 185.

<sup>3</sup> *Arch. de Toc. et de Gyn.*, fev., 1891.



In like manner, Escherich<sup>4</sup> believes that microbes associated with puerperal septic conditions, which enter the blood through lesions connected with the genital tracts, often find their way into the milk. Hence the necessity of keeping the genital passages thoroughly aseptic, in order to avoid this source of infection.

In 1884, Bumm<sup>5</sup> demonstrated the presence of microbes in the milk of women suffering from puerperal mastitis. From a case of this kind he cultivated a *diplococcus*, much like the gonococcus; and the culture, when injected under his own skin, produced an abscess. In women suffering from this affection, Escherich found that the milk invariably contained numerous specimens of *staphylococcus pyogenes aureus* or *albus*. In continuation of his previous investigations Bumm<sup>6</sup> also found in cases of this kind, that the glandular structures teemed with *staphylococci*, which made their way thence into the surrounding tissues. By studying numerous sections removed at different stages of the disease, he was able to give the following account of the morbid process:—The rapid proliferation of the microbes within the glandular structures, causes the milk to ferment, its sugar being transformed into lactic and butyric acids, while its casein coagulates. Thus the glandular structures become filled with coagula, teeming with bacteria. Inflammatory changes soon manifest themselves in the peri-glandular tissues, which become infiltrated with leucocytes and microbes. Meanwhile the epithelial cells lining the glandular structures swell, desquamate and disappear. Purulent miliary foci soon form in great numbers, adjacent foci unite, and so irregular purulent cavities are formed, traversed by shreds of the partially destroyed tissues. In the walls of these suppurating cavities leucocytes accumulate, which stop the progress of the microbes, and thus the further spread of the disease is prevented.

---

<sup>4</sup> *Fortschritte der Medecin*, Bd. iii., 1885, S. 231.

<sup>5</sup> *Arch. f. Gyn.*, Bd. xxiv., 1884, S. 262.

<sup>6</sup> *Sammlung klin. Vorträge*, No. 282, 1886.



In a case of puerperal mastitis, followed by fatal pyæmia, in which the breast was riddled with abscesses, Grosse<sup>7</sup> found *staphylococcus pyogenes aureus* and *albus* present in great abundance. Brieger, Rosenbach, Pawlowsky and others believe that these cocci, considered by some pathologists to be comparatively harmless, may—under certain conditions—induce pyæmia. According to Monnier,<sup>8</sup> most post-puerperal abscesses of the breast are due to the presence of *staphylococci*, either alone or associated with other microbes, such as *micrococcus tetragenus*, *streptococcus* or *micrococcus subflavus*.

It will be gathered from the foregoing that in human beings there is no specific microbe of mastitis, for several different pathogenic organisms have the power of inducing the disease.

It appears to be otherwise in some animals, for Nocard and Mollereau<sup>9</sup> have shown that the contagious forms of mastitis of milch cows and sheep, are due to specific organisms. These observers have proved that in cows the disease is due to the presence of a *streptococcus* within the glandular structures, which it never leaves. Consequently the resulting inflammatory reaction is limited to the peri-glandular tissues, so that multiple nodulations are formed. The lesions thus produced in many respects resemble those met with in certain forms of diffuse, peri-ductal chronic mastitis in human beings. On the other hand, in sheep the disease assumes the form of an acute diffuse suppurative inflammation, which often quickly leads to gangrene and death. In these cases Nocard found very minute *micrococci* both in the milk and in the fluid of the œdematous adjacent tissues. These, he believes, enter the gland by the ducts, and rapidly penetrate into the surrounding parts. The condition thus produced much resembles the acute diffuse suppurative mastitis of puerperal women.

---

<sup>7</sup> *Cent. f. Gyn.*, No. 34, 1892.

<sup>8</sup> *Thèse de Paris*, 1891.

<sup>9</sup> "Annales de l'Institut Pasteur," 1887, p. 109 and p. 417.



## § II.—Chronic Mastitis.

Chronic inflammation of the breast may involve the whole organ (*diffuse*); it may be limited to the vicinity of the glandular structures (*peri-ductal*); or only a small segment of the organ may be affected (*circumscribed*). This classification is clinically useful, but it must be remembered that all sorts of intermediate and mixed forms may be met with. In all these cases the probable cause of the disease is the presence of microbes, or of irritant substances of microbic origin, within the glandular structures. Consequently the morbid process almost invariably originates in their immediate vicinity.

A. The *diffuse form of chronic mastitis* was first clearly described by Wernher,<sup>10</sup> over forty years ago. He recognised the initial painful enlargement, the subsequent induration, and the final irregular atrophy. On account of the likeness of the disease to cirrhosis of the liver, he called it *cirrhosis mammae*. Cruveilhier<sup>11</sup> also was familiar with the disease, and he was well aware that in its atrophic stage it is often difficult to distinguish it from cancer, a feature to which Phocas<sup>12</sup> and others have lately called attention. By Velpeau<sup>13</sup> it was briefly described under the title of *induration chronique en masse*. In his great work on tumours, Virchow<sup>14</sup> has given an excellent account of the disease, which he calls "*diffuse fibroma*," or "*hard elephantiasis*."

Chronic mastitis has lately attracted a great deal of attention in connection with its bearing on the question of the inflammatory origin of general cystic disease, and even of fibro-adenomata. The tendency of modern pathologists to resurrectionise the doctrine of Broussais in connection with the microbe theory, is one of the signs of the times; and it invariably crops up

<sup>10</sup> *Zeitschr. f. rat. Medicin.*, 1851, Bd. x., S. 153.

<sup>11</sup> "*Traité d'Anat. path.*," t. iii., p. 605.

<sup>12</sup> *Gaz. des Hôpitaux*, 19 août, 1890.

<sup>13</sup> *Traité des Maladies du Sein*, &c., p. 255.

<sup>14</sup> "*Path. des Tumeurs*," t. i., p. 325



whenever any question relating to neoplastic pathogeny is under consideration.

The initial symptoms of the disease are those of subacute inflammation. At first there is tenderness and swelling, which may begin by involving the whole gland, or it may start from a

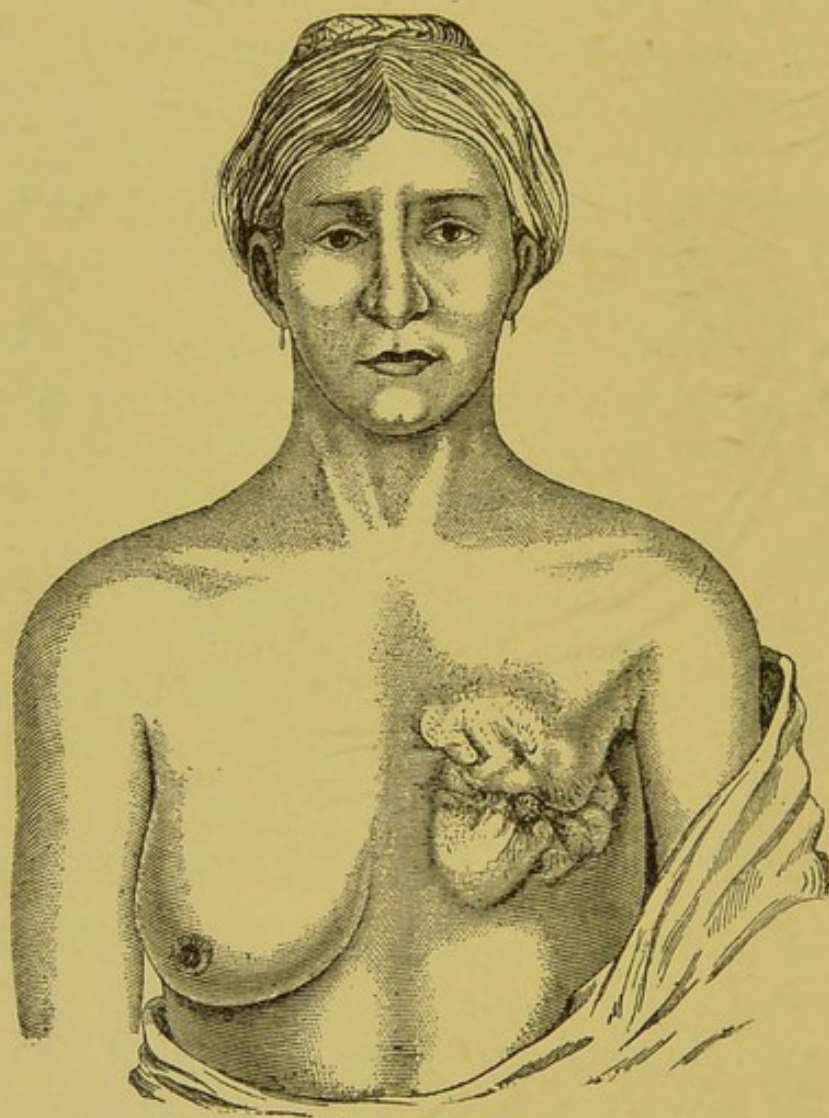


FIG. 72.—Chronic cirrhosing mastitis (*Billroth*).

circumscribed focus and subsequently spread to the rest of the organ. After a time the affected part becomes hard and painful, but there are no febrile symptoms. The morbid process often involves not only the whole gland, but also the paramammary fatty tissue, the overlying skin and even the nipple. Where the



skin is affected it seems adherent, thickened and rough looking—what the French call *peau d'orange*. By-and-bye the inflammatory tissue contracts, the swollen part diminishes in size and increases in density. As the contraction is irregular a nodulated tumour results, while the nipple and overlying skin become drawn in. The axillary glands may also enlarge, and there may be watery discharge from the nipple. Eventually all that remains of the once hypertrophied organ is a small, hard, shrivelled nodule, which is often much smaller than the healthy breast (fig. 72).

The progress of the disease is generally irregular, stationary periods alternating with periods of regression and active progress. It runs a chronic course. In the inflammatory stage there is great increase of the stroma, which is infiltrated with leucocytes, and its nuclei are unduly numerous. These changes are most marked in the vicinity of the glandular structures. As the disease spreads the fatty tissue entirely disappears, and is replaced by an œdematous fibroid tissue. Parts thus affected present an opaque, whitish, lardaceous aspect. During this stage the epithelial lining of the glandular structures proliferates, and the cells increase in number. Subsequently they atrophy and disintegrate. As the contractile stage sets in, the stromal leucocytes and nuclei diminish, and they are replaced by marked sclerosis, especially in the vicinity of the glandular structures. These are consequently irregularly compressed and distorted. Great numbers of acini and small ducts completely disappear. These atrophic changes often coincide with a certain amount of glandular ectasia. In connection with the latter, and with the remains of the pre-existing glandular structures, numerous small cysts sometimes form. When this cyst formation takes place in the absence of marked induration, the appearances met with are indistinguishable from those of general cystic disease. Indeed, it is not improbable, as Delbet has ably argued, that the latter disease, like the former, is also the outcome of chronic inflammation. Diffuse chronic mastitis has been confounded by



some pathologists with the fibrous form of hypertrophy; but in reality the two diseases are totally distinct. The fibrous overgrowth in hypertrophy is progressive, and as it is not the outcome of inflammation, there is no subsequent contractility.

This form of mastitis is commonest at about the climacteric, but it may arise at any period from puberty upwards. It not unfrequently originates as a post-puerperal *sequela*. Generally only one breast is affected, but not unfrequently both—either simultaneously or consecutively, usually the latter.

In most cases the disease eventually terminates in resolution, the gland remaining permanently diminished in size. Very exceptionally the diseased part may calcify, as in cases by Bryk, Bérard, and others.

I have found belladonna and glycerine, mixed with an equal part of iodide of lead or compound mercury ointment, spread on lint, a very effectual application, especially when combined with compression by strapping, &c., or by a special compressor.<sup>15</sup> This local treatment should be associated with the internal administration of iodide of potassium. When persistent painful swelling remains in spite of treatment, it may be concluded that cysts are present. Under these circumstances, especially if there are indications of the tumour increasing in size, the breast should be removed by Thomas' subcutaneous method, leaving the skin, nipple and areola intact.

As an example of the cirrhusing form of the disease, the following case by Billroth<sup>16</sup> is of interest. Referring to it he says: "I was inclined to doubt the existence of a chronic mastitis, ending in scirrhus contraction, until I met with this case."

A healthy-looking peasant woman, aged 45, the mother of nine children, the last of whom was born two and a-half years ago, came under observation with her left breast in the condition represented in fig. 72. In the place of the mamma could be felt a hard, irregularly nodulated swelling, which was adherent to the overlying skin, but not to the subjacent muscle. The

---

<sup>15</sup> *Vide* chapter xxv.

<sup>16</sup> *Deutsche Chir.*, Lief. xli., S. 33.



nipple was markedly retracted; and so was the overlying adherent skin, which was thrown thereby into irregular folds. There was no pain, nor had there ever been any. The axillary glands were not obviously affected. The patient said she had been accustomed to suckle each of her children for about sixteen months. She had never had any previous injury or disease of the breast. About two years ago, when suckling her last child, she noticed a hard lump, the size of a hazel-nut, in her left breast above the nipple. This slowly but steadily increased, and gradually the whole gland became deformed. Her right breast was perfectly normal. The catamenia still continued regularly. Billroth advised palliative treatment.

Labbé and Coÿne<sup>17</sup> have reported a somewhat similar case, in which the atrophic changes had not yet supervened.

A woman, aged 40, after a normal *accouchement* began to suckle her child. Having done so for two or three months, she was obliged to desist, because of the supervention of pain and swelling in her left breast. In the course of the next year the breast enlarged considerably, and she occasionally suffered from intermittent febrile attacks. On examination, at the end of this time, the left breast was twice as large as its fellow; the whole gland was hard and bossy, and adherent to the overlying skin, which was thickened and in the condition known as "*peau d'orange*." The subcutaneous veins were greatly enlarged; but there was no obvious affection of the axillary glands. The diseased part was extirpated; and the wound soon healed. On examination the whole breast and the overlying skin appeared to be affected with chronic inflammation; the augmented size being due to the great increase in the fibrous tissue. In the axillary and upper part of the affected breast there was an encapsuled, puriform collection, the size of an almond. Histological examination showed hyperplasia of the stroma, which was everywhere infiltrated with numerous small round cells.

Two good specimens of this disease are to be found in the *University College Museum* (Nos. 1950-1 of the Pathological Series). No. 1950 is described as follows in the catalogue:—

A thin, flattened breast, affected with general chronic mastitis. There is scarcely any fat over it. Its substance presents an opaque appearance intersected with dense, fibroid bands. In this numerous small cysts are embedded, many of which are so minute as to be only just visible to the naked eye. They are lined by a smooth membrane. From a spinster, aged 40, whose right breast had been amputated, for what she calls cancer—but which was probably chronic mastitis—some time previously. Soon after this operation her left breast became painful. On examination the left breast was obviously unduly enlarged, tender, indurated and bossy. It was removed by amputation.

<sup>17</sup> "Traité des Tumeurs Bénignes du Sein," p. 243.



In the *Hunterian Museum* (No. 4819B of the Pathological Series) there is an interesting specimen of diffuse chronic mastitis, which shows the atrophic stage of the disease in the breast itself, while the nipple is greatly enlarged from more recent inflammatory hyperplasia.

It is described in the catalogue<sup>18</sup> as an extremely atrophied breast, of which the nipple is greatly enlarged from overgrowth of its fibrous tissue. Histological examination revealed great increase of mamillary fibrous tissue with atrophic ducts; the adjacent parts of the breast were similarly affected. It was removed by Bryant from an elderly lady. Cases of this kind are sometimes erroneously cited as examples of hypertrophy of the nipple.

It seems to me certain that Bryk's<sup>19</sup> remarkable case of calcified mamma belongs to this category. At any rate we know that chronically inflamed structures are more prone to calcify than healthy ones, and the history of this case points to previous rheumatic inflammation.

The patient was a childless, married woman, aged 62, who had all her life been subject to rheumatism. About eleven months before coming under observation, severe pain supervened suddenly in her left breast, which she attributed to rheumatism, and a tumour subsequently formed. On examination, a hard tumour, the size of a fowl's egg, was felt there. The breast was amputated. It was then found that the tumour consisted of a solid calcareous mass, surrounded by fibro-fatty tissue. The calcification had invaded the whole of the mammary stroma, and so had caused atrophy of the parenchymatous structures.

I have met with an instance of chronic diffuse mastitis in the *male* breast.<sup>20</sup> Anderson,<sup>21</sup> Tuffier,<sup>22</sup> and others have recorded similar cases; and there is a specimen of this kind in the *University College Museum* (No. 1952 of the Pathological Series).

Anderson's patient was a man, aged 45, with enlargement and induration of the whole of the breast, of six months' duration. Histologically there was seen great increase of the fibrous tissue in which a few glandular elements

---

<sup>18</sup> Vol. iv., 1885, p. 477.

<sup>19</sup> *Arch. f. klin. Chir.*, Bd. xxv., 1881, S. 808.

<sup>20</sup> *Q.v. ch.* xxi., § iv.

<sup>21</sup> *Trans. Path. Soc. Lond.*, 1893.

<sup>22</sup> *Bull. de la Soc. Anat.*, 1888, p. 42.



were embedded, and in their vicinity there was a considerable amount of small round-celled infiltration.

In Tuffier's case, a man, aged 27, presented with an induration of his left breast of six months' duration, which supervened after pleurisy. The nipple and skin were intact, but the axillary glands were slightly enlarged. The breast was extirpated. Histological examination after removal revealed chronic mastitis.

In another case the patient was a vigorous man, aged 42, who after a fall five months ago, first noticed swelling of his right breast. On examination, the whole breast felt indurated, bossy and finely nodular, forming a hard *plaque* 5 cm. in diameter and 2 cm. thick. The overlying skin was unaffected and mobile. The diseased part was extirpated. Histologically examined it consisted of dense fibrous tissue with here and there a few glandular structures interspersed.

A curious form of subacute transitory inflammation of the breast, chiefly affecting men, has been observed by Leudet,<sup>23</sup> Allot,<sup>24</sup> and others, in association with phthisis. It is accompanied by pain and swelling. Its onset appears to coincide with the development of tubercle in the lung of the corresponding side; but according to Klippel,<sup>25</sup> the affection itself is not tubercular. I have elsewhere\* recorded an example of a similar affection of the female breast.

B. The *periductal form of chronic mastitis* was long ago recognised by Velpeau, Virchow and Billroth, although it has only recently been made the object of special study. Kœnig<sup>26</sup> and Phocas<sup>27</sup> were among the first to publish a satisfactory account of this disease. By the latter it was designated "*maladie noueuse*;" and Nordmann<sup>28</sup> has lately studied the same condition under the name of "*plexiform fibroma*." The disease is essentially a peri-canalicular chronic inflammation, limited to the vicinity of the glandular structures; and as the inflammatory lesions subside they are followed by sclerosing fibrosis. In

<sup>23</sup> *Arch. Gén. de Méd.*, Jan., 1886.

<sup>24</sup> *Thèse de Paris*, 1887.

<sup>25</sup> *Bull. de la Soc. Anat.*, 1887, p. 246.

\* P. 342, case (2).

<sup>26</sup> *Cent. f. Chir.*, 1893, No. 3, S. 49.

<sup>27</sup> *Thèse de Paris*, 1886.

<sup>28</sup> "Ueber das plexiforme Fibrome der Mamma," *Arch. f. path. Anat.*, Bd. cxxvii., S. 338.



a breast thus affected, multiple hard nodules, freely mobile, although obviously connected with the mamma itself, can be felt. The largest of these seldom exceeds the size of a hazelnut or walnut, and sometimes it is no bigger than a pea. In addition to these, on careful palpation, there can often be felt throughout the gland, an immense number of minute hard bodies, not larger than pins' heads. The tumours are generally tender on pressure; they seldom cause mamillary retraction. The onset is insidious, it is often only by some accident that the existence of the disease is discovered, as it causes but little deformity. Sometimes pain or tenderness is the revealing symptom. Usually only one breast is affected, but exceptionally both. The axillary glands occasionally enlarge. It runs a chronic, irregular, oscillating course. Some nodules diminish, others increase, and new ones form. It is commonest in middle-aged women, near the climacteric. In some cases its origin is post-puerperal; in others it appears to be connected with catamenial derangements; and in certain cases it has been attributed to local injury. The disease usually eventually terminates in resolution.

In many cases, however, periductal sclerosis persists; and Delbet<sup>29</sup> has very ably argued, that general cystic disease often originates in connection with these residual lesions.

The *treatment* to be adopted in this form of mastitis is similar to that for the diffuse variety.

C. The account I have to give of *chronic circumscribed mastitis* is based on the study of about a dozen cases. The disease usually presents as a circumscribed tumour of ovoid or rounded shape, and the size of a walnut. Not unfrequently, instead of a rounded tumour, an indurated *plaque* is met with. In any event the diseased part feels hard, and finely nodular, but on careful palpation less circumscribed than it at first appeared. The tumour is found to be intimately blended with the gland. There is usually tenderness on pressure and some-

---

<sup>29</sup> "Maladie Kystique et Mammite chronique," *Bull. de la Soc. Anat.*, jan., 1893.



times pain is complained of. The mass, as a rule, is freely mobile, but occasionally the overlying skin becomes adherent. The nipple generally remains normal, but sometimes it is retracted. Enlargement of the axillary glands is only occasionally met with. Histologically examined, the tumour is seen to consist of a few glandular structures—ducts and acini—embedded in a relatively excessive amount of fibrous stroma, presenting, in variable degree, the usual signs of chronic inflammation. The small ducts and acini are often more widely separated and irregularly arranged than in the normal state; they are also generally unduly large, from proliferation of their lining cells, and sometimes deliquescence of the latter leads to the formation of small cysts. It occasionally happens that the glandular structures are destroyed by atrophy, so that they almost entirely disappear from the morbid mass; but this is decidedly rare. Exceptionally, more than a single tumour is met with in one breast, and—still more exceptionally—both may be affected. Contrary to what is generally stated, I have found the disease to be as common in single as in married women. In the latter it generally originates as a post-puerperal affection; in the former, a blow or injury is usually assigned as its cause. Indurations of this kind sometimes undoubtedly arise from the pressure of the corset. Foreign bodies embedded in the breast (pins, needles, bits of glass, &c.) are also exceptional causes. Of fourteen patients on my list, the oldest was 66 at the onset of the disease, and the youngest 16; but most cases originated between 35 and 50. A small lump in the breast is generally the first thing noticed, and this is occasionally painful or tender. Its increase is slow, so that in the absence of pain, a surgeon is seldom consulted until it has existed for one or more years. It is sometimes exceedingly difficult to diagnose tumours of this kind from hard cancer. For an account of a typical case of this kind, and for some remarks on the differential diagnosis, I must refer the reader to a previous chapter.\*

---

\* Ch. xii., p. 341.



A considerable proportion of these cases, especially when properly treated, eventually terminate in resolution. Velpeau<sup>30</sup> has recorded several instances of this, of which the following is a good example :—

A short, stout, married lady, aged 48, one year ago first noticed a lump in her breast. On examination there was found, in the lower and outer part of her right breast, a hard tumour the size of a fowl's egg. It was intimately blended with the surrounding structures, and its margins were ill defined. The overlying skin was adherent, depressed and indurated. It was painful, and had been so for the last few months. Her general health was good, and menstruation still continued. She was treated with iodide of potassium internally, and the inunction of iodide of lead ointment into the breast. The tumour soon afterwards began to decrease ; in a few months' time it was markedly smaller. At the end of eight months it had quite disappeared. When last seen, ten years later, the breast was quite normal.

In others after a time chronic abscess supervenes. In yet others, the indurated nodule persists indefinitely. Influenced by the prevalent desire to extend the microbe theory, Delbet and others have argued, that the ordinary fibro-adenomata are eventually evolved out of these chronic inflammatory indurations. This seems to me to be a purely gratuitous assumption. Very exceptionally tumours of this kind calcify, as appears to have happened in the following remarkable case by Heudoupe.<sup>31</sup>

A woman, aged 35, with great inflammatory swelling of her left breast, over the upper part of which was a large irregularly ulcerated cavity, whence pus freely escaped ; at the bottom of this, with a probe, a hard, porous mass was felt. Under ether spray, a calcareous mass, the size of a fowl's egg, was extracted from the abscess cavity in which it lay. The antecedent history was as follows :—Twenty years ago she hurt her breast by a fall. Soon afterwards a lump—the size of a nut—formed at the seat of injury. She married, and had two children, whom she suckled. Four years ago, after another injury, an abscess formed in connection with the old lump ; it was incised, and a pus-discharging fistula subsequently remained, in connection with which the present ulceration, &c., had since developed.

I have seen several instances in which the breast has been amputated for chronic inflammatory indurations mistaken for cancer, one of which has been previously related.\*

<sup>30</sup> " *Traité des Maladies du Sein*," &c., p. 582.

<sup>31</sup> *Gaz. des Hôp.*, 25 août, 1887, p. 841. " *Obs. de tumeur calcaire de la mamelle.*"

\* Ch. xii., § ii., p. 341.



There is a specimen of this kind in *University College Museum* (No. 1952 of the Pathological Series). It is described as follows in the catalogue:<sup>32</sup>—

Breast extirpated for cancer, containing a hard tumour three-quarters of an inch in diameter, which was situated immediately beneath the skin, to which it slightly adhered. The tumour occupied the peripheral part of the gland near the axilla. Its limits were well defined. The adjacent lymph glands were slightly enlarged and hard. On examination after removal the tumour looked like an indurated segment of the gland. Histologically it consisted of dense fibrous tissue, containing a few glandular structures, in connection with which some small cysts had developed.

In the treatment of this disease compression and the remedies recommended for the other forms of chronic mastitis should first be tried. These failing, if the patient experience any annoyance from the persistent induration, it should be excised, the wound being closed by deep and superficial sutures, so as to secure immediate union; or the tumour may be removed by Thomas' method.

In the *male* breast similar lesions are occasionally met with of which the following is an example:<sup>33</sup>—

A man, aged 27, eight months ago first noticed a lump in his right breast below the nipple. It increased slowly and became rather tender. On examination a lobulated, semi-lunar, indurated mass could be felt at the lower part of the breast. The adjacent axillary glands were enlarged. The left breast was sound. The diseased breast was excised, the nipple being left. On histological examination of the indurated area, the ordinary signs of chronic mastitis were found—great increase of the inter-acinous fibrous tissue, and infiltration of the stroma with small round cells, which were especially numerous in the immediate vicinity of the glandular structures.

For further information on this subject, reference may be made to the thesis of Moizard.<sup>34</sup>

### § III.—Cold Abscess.

Great interest attaches to cold abscess of the breast, not only *per se*, but also because of the ætiological connection with

<sup>32</sup> "Path. Catalogue," part ii., 1887, p. 439.

<sup>33</sup> *Univ. Coll. Hosp. Rep.*, 1881, p. 40.

<sup>34</sup> "Contrib. à l'étude de la Mammite chez l'Homme," *Thèse de Paris*, No. 414, 1881.



tubercle, and the close clinical resemblance of many cases to cancer and other neoplasms. Only a few years ago, surgeons never thought of associating cold abscesses with tubercle; lately, however, many cases have been proved to be due to this cause, and now we have pathologists who assert that all cold abscesses are of tubercular origin. The truth seems to lie between these extremes, for many cold abscesses in the breast undoubtedly occur independently of tubercle. These I now propose to describe, leaving the tubercular ones for subsequent discussion. My remarks will be based chiefly on the study of twenty-five cases.

The immense majority of simple chronic abscesses are *intra-glandular*, that is to say, they originate in the *corpus mammae*; thus of twenty-two cases the abscess was centrally situated in sixteen, and peripheral only in six. Of the latter four were in the axillary segment and two in the upper. It is only very rarely that chronic abscesses originate in the subcutaneous or retro-mammary tissues. Cold abscesses have occasionally been met with in the mammary region or its vicinity, which have originated, not from the breast itself, but from adjacent parts, such as the ribs, sternum, or even the intra-thoracic structures.

With regard to the influence of sex, only three of the twenty-five cases in my list were males. The affected breast usually contains only a single abscess; this was the condition in twenty out of twenty-two cases. In two of these instances a fistula had formed from bursting of the abscess. Both breasts are equally liable; but in no instance was more than a single one affected. In several cases, in addition to the abscess tumour, the whole breast was indurated and sclerosed from diffuse mastitis. Most of the patients were married women, but many single ones were also affected—the proportion being fifteen married to six single. Of the married, in only eight cases was the super-vention of the disease associated with pregnancy or lactation. The history of most of these cases justifies the belief that they were of galactoceles origin. Only three were associated with previous injury or disease of the breast—sore nipples 2, blow 1.



The following is a typical instance<sup>35</sup> of abscess thus originating :—

A married woman, aged 34, the mother of two children, one month after the birth of her last child eighteen months ago—while still suckling—first noticed at the upper part of the axillary border of her right breast a hard lump. When she came under treatment there was in this situation a nodule, the size of a marble, of firm, elastic consistency, to which the overlying skin was slightly adherent. The axillary glands were normal—as also was the nipple. The tumour was dissected out. It contained puriform substance of cream cheese appearance. There was no family history of tubercle.

In but very few of these cases does suppuration appear to have supervened on chronic mastitis, as in the following case.<sup>36</sup>

A man, aged 47, two years ago first noticed some enlargement of his breast, which after a time diminished. Five weeks ago the breast increased in size and became painful. It was then incised, and half an ounce of pus was evacuated. When he came under observation a hard swelling occupied the centre of the breast, extending for about three-quarters of an inch beyond the areola, in all directions. The overlying skin was mobile, and the swelling itself had no adhesion with the subjacent structures. There were no enlarged glands in the axilla. An exploratory incision was made into the tumour, which, proving to be of inflammatory nature, was excised. He was convalescent a fortnight later.

Of the seven married women in whom the disease originated independently of lactation, in two it was attributed to a blow, and in two to sore and retracted nipple. Of the six cases in unmarried women, in one the disease followed a blow, and in one it was associated with a congenitally retracted nipple. Thus in most cases there was no obvious cause for it.

Generally its duration had been so comparatively short, as hardly to warrant the application of the term "chronic;" for in half the total cases it had lasted under six months, and in only five did it exceed one year, the longest term being twelve years.

The disease usually presented as a firm, nodular tumour, situated in the middle of the breast, varying in size from a hazel-nut to a cocoa-nut, the average size being between that of a walnut and Tangerine orange. Retraction of the nipple was

<sup>35</sup> *Univ. Coll. Hosp. Rep.*, 1889, p. 98.

<sup>36</sup> *Ibid.*, 1885, p. 74.



the symptom most frequently met with, for this occurred in thirteen out of twenty-two cases. In eight cases the overlying skin was adherent; in six there was some pain or tenderness; in five the axillary glands were enlarged; in five there was an indistinct sense of fluctuation; and in two puriform discharge from the nipple.

Some idea of the difficulty of diagnosing such cases from cancer, may be inferred from the fact that in five of my twenty-two cases, the breast had been amputated for cancer, and it was only afterwards that its real nature was discovered.

Of this the following is a typical example:<sup>37</sup>—

A pale, but well-nourished and otherwise healthy-looking spinster, aged 32, three years ago first noticed a painful swelling in her breast. It formed without any injury or other known cause. There was family history of tubercle. On examination, in the middle of the left breast there was found a hard mass, about two inches in diameter, not distinctly separable from the surrounding parts. The overlying skin was reddened and adherent, and the nipple was retracted. There was no fluctuation; but the tumour was painful and tender. The axillary glands were normal. Under these circumstances cancer was diagnosed, and the breast amputated. On examination of the part after removal, in the midst of the sclerosed breast there was found a small abscess cavity, about half an inch in diameter, lined with a thin layer of pinkish granulations, and outside this there was a thick layer of sclerosed tissue.

For the *treatment* of these cases it usually suffices to lay open the abscess cavity, scrape it with a Volkmann's scoop, and having washed it out with antiseptic solution, close it with deep and superficial sutures. When there is much sclerosis, the diseased part should be dissected out.

#### § IV.—Inflammatory Diseases of the Nipple, Areola, &c.

As the result of congenital developmental defects, the nipples are frequently short, stunted, depressed, invaginated or otherwise imperfectly formed.\* Defects of this kind predispose

<sup>37</sup> No. 1953 in the *Path. Series, Univ. Coll. Museum*: for a similar case *vide* p. 342.

\* For an estimate of its frequency, *vide* p. 338. Dluski reports that of 433 recently confined women in Baudelocque's clinic, 181 had sore nipples, 99 of the cases being slight. One hundred and eighteen of them had malformed nipples. Those who suckled were less affected than those who did not, in the proportion of 32 to 40 per cent. (*Thèse de Paris*, 1894, "Contrib. à l'étude de l'allaitment maternel").



them to inflammatory and other affections during lactation. On the other hand, inflammatory lesions and irritative states of the part, often cause retraction of the nipple, by inducing spasm of its longitudinal muscle bands. When the extreme delicacy of the skin of the nipple, its intimate adhesion with the subjacent parts, its numerous folds and glands, are borne in mind, we need not be surprised, that at the commencement of lactation, even in women with well-formed nipples, inflammation is so common. Unhealthy conditions of the child's mouth, especially such as are associated with *aphthæ* and other forms of stomatitis, are very apt to cause it. Probably abnormal states of the mother's milk also act injuriously. Certain it is that undue moistening of the part with irritant fluids such as these, leading to maceration and exfoliation of the epidermis, is usually the chief determining factor. Under these circumstances, the nipple becomes red, swollen, and tender. Unless properly treated, erosions, ulcers, and fissures soon form, and the part becomes exquisitely tender. Lesions of this sort are commonest at the base of the nipple, where it joins the areola, and at the mammillary apex.\* When disturbed they are apt to bleed. Several usually exist. They generally form before the fifth day. Such conditions hardly ever arise, except in connection with pregnancy and lactation. They often excite an amount of pain, constitutional disturbance and mental distress, out of all proportion to their size. As a consequence of these lesions, small abscesses—which are often multiple—occasionally form in the areola, or even in the nipple itself. The relation of the foregoing conditions to acute inflammatory diseases of the gland itself, will be discussed in the sequel.

Pregnant women having defectively developed or retracted nipples, should endeavour to remedy these defects by appropriate treatment for some months before their *accouchement*. In slight cases the daily drawing out of the nipple, aided by friction and compression of its base, together with the applica-

---

\* According to Dluski, the seats of the sores in his 181 cases were :—the summit of the nipple in 123, its base in 54, and the areola alone in 4 (*op. cit.*).



tion of lotions for hardening the epidermis, such as aqueous solutions of brandy, *eau de Cologne*, boric acid with borax, or boro-glyceride, will suffice. There can be no doubt but that repeated mechanical irritation of the nipple, by bringing into action its muscle fibres, tends to cause its enlargement. Nothing is more effective in this respect than suction by the mouth of a vigorous child or of another woman. In default of buccal suction the ordinary breast reliever<sup>38</sup> (fig. 73) may be used; or resort may be had to the old-fashioned method of applying over the nipple an inverted soda water bottle, just emptied of hot water. In connection with these means the application

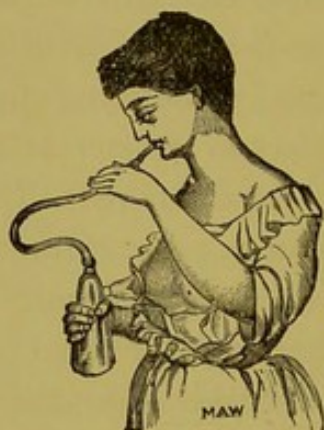

FIG. 73.—Breast reliever.

of thick defensive plaster, having an aperture in the centre corresponding to the nipple, for some months before labour, has proved of great service. The plaster used should be about three inches in diameter and half an inch thick.

When these methods fail, the invaginated nipple may be improved by the operation of *mammilla-plasty*. A circular strip of skin, together with the subjacent fibro-fatty tissue, is excised from the prominent cutaneous fold surrounding the depressed nipple; or instead of a circular strip two crescentic pieces may be removed (Kehrer). Care should be taken to avoid injuring the subjacent ducts; this will be rendered almost impossible by keeping the incisions external to the areola. On suturing together the opposite cut edges of the mammillary

<sup>38</sup> As supplied by Maw, Son and Thompson, of London.



and mammary skin, the nipple will be pulled up into its proper position. In a case reported by Herman<sup>39</sup> the operation resulted in a permanent cure. Of course not much good can be expected from this proceeding when the nipple is congenitally stunted and malformed.

When the time for suckling comes attention should be directed to the mother's nipples, and to the child's mouth. The nipples should be kept as dry as possible, and free from putrescent fluid. To effect this, suckling should be regulated to set hours; and the nipples should afterwards be bathed with 1 in 20 carbolic acid solution, wiped dry, and anointed with boric acid ointment, or dusted with a powder consisting of equal parts of calamine and camphorated chalk. When there is a constant flow of milk, protective glass receivers should be used, in which the overflow collects. To keep the child's mouth sweet it should be given *mel boracis* to suck, with which a little boric acid in vaseline has been mixed.

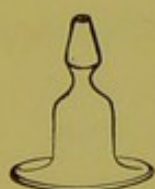

FIG. 74.  
An artificial  
nipple.

If the nipples have become sore and inflamed, an artificial nipple should be provided. A good form consists of a glass shield with an india-rubber teat for the child to suck, fixed to its summit<sup>40</sup> (fig 74). It should be washed before and after use with carbolic lotion. Deep fissures, &c., should be lightly cauterised with a fine, pointed pencil of nitrate of silver. When there is so much pain and constitutional weakness that suckling cannot be continued, means must be taken to relieve the breast of milk and to arrest its further secretion; while at the same time the enlarged organ should be properly supported.

With regard to *eczematous affections* of the nipple and areola, but little need be added to the account given of them when treating of cancer of the mammary integument (ch. xv.). Morbid conditions of this kind sometimes affect both breasts, and not

<sup>39</sup> *Lancet*, vol. ii., 1889, p. 12.

<sup>40</sup> As supplied by Maw, Son and Thompson, of London.



only the nipple and areola, but also the adjacent integument may be invaded. These lesions frequently arise quite independently of lactation and pregnancy. Eczematous disease of the areola and nipple is rarely associated with similar disease in other parts of the body. Sometimes after a time it is followed by chronic mastitis, or abscess of the breast. In this connection Stumpf's<sup>41</sup> observations are of interest. He has demonstrated the presence in this disease of a staphylococcus, morphologically identical with *staphylococcus pyogenes aureus*. The same microbe he found also in the milk of those affected. He considers that this accounts for the rebelliousness of the disease, re-infection constantly taking place from the infected milk. It is generally a very chronic affection, and difficult to cure. As local applications, boric acid or salicylic acid ointment may be used, or the ung. glycerini plumbi subacetatis. Velpeau succeeded in curing many cases with white precipitate ointment.

A pruriginous eruption of the breasts, associated with similar disease elsewhere, is generally due to *scabies*, of which the breast is a favourite seat. It requires to be treated in the usual way with ung. sulphuris, &c.

*Herpes zoster* of the mammary region is occasionally seen.

#### § V.—Acute Inflammation and Suppuration.

Acute inflammatory diseases of the breast rarely supervene except at periods of physiological excitement, when there is naturally considerable local congestion. Hence it is chiefly in the newly born, at puberty, and during the puerperal state, that these affections arise.

(1) In the *newly born* of both sexes, as previously mentioned, considerable formative activity takes place in the breasts, with which there is generally associated true lacteal secretion. These changes attain their maximum between the eighth and fifteenth days. At this period acute inflammation, followed by suppura-

<sup>41</sup> *Münchener med. Wochenschr.*, No. 25, 1888.



tion, is apt to supervene, just as in puerperal women. Some instances of this kind may be traced to improper manipulation of the part by the nurse, with the object of "breaking the nipple strings," or of "rubbing away the milk," in accordance with a pernicious old custom. The local application of belladonna and hot fomentations suffices for the cure of most cases. Care should be taken to recognise the supervention of suppuration at an early date, for once pus has formed the sooner it is evacuated the better. Left to itself suppuration may result in complete destruction of the rudimentary gland, even the nipple and areola sloughing away; or the gland may be thereby otherwise permanently injured.

(2) The physiological congestion, associated with the development of the breasts at *puberty*, occasionally passes on to inflammation, and quite exceptionally the latter ends in suppuration. Even in male subjects similar conditions are occasionally met with. The treatment is the same as for the very similar affections in the newly born.

(3) The great majority of acute inflammatory diseases of the breast arise during the *puerperal state*, nearly all of them being associated with lactation. Winckel<sup>42</sup> estimated that after 1,000 consecutive *accouchements* up to 1878, mastitis developed in 6 per cent. Deiss<sup>43</sup> has since found that after 1,600 consecutive *accouchements* up to 1889, only 3.6 per cent. subsequently developed mastitis. This improved result is probably chiefly due to the greater attention paid to hygienic matters, and to the routine employment of antiseptics.

These diseases are of most frequent occurrence in primiparæ, and there is a consensus of opinion, that those who suckle, are more liable than those who do not; but the most liable are those who, having suckled for a time, then suddenly give it up. Both breasts are not unfrequently affected. Inflammation usually begins at some time during the first four weeks after *accouchement*,

---

<sup>42</sup> *Vide* p. 297.

<sup>43</sup> "Inaug. Diss.," Heidelberg, 1889.



most cases arising at from about the eighth to the tenth days. It rarely originates after the third month, except at quite the end of lactation, when a considerable number of cases arise, especially in those who have unduly prolonged the process.

The pathogeny of puerperal mastitis has long been a debatable subject; and it is still under discussion. As previously mentioned, it is conceivable that pathogenic microbes may enter the breast either by the blood vessels, the lymphatics, or the ducts. With regard to infection by the blood vessels, beyond the fact that it does occur, little else is known of it. As to the respective parts played by the lymphatics and ducts it is not easy to decide. It seems certain, however, that each has its *rôle*. In superficial inflammations of the breast, especially those of erysipelatous origin, most pathologists are agreed that the lymphatics are chiefly concerned in the spread of the disease. In other cases it seems probable that infection takes place chiefly by the ducts. It was formerly very generally believed that overdistension of the ducts with milk, and coincident stasis, were the chief factors concerned in determining puerperal mastitis. It is incontestable that such lacteal engorgement actually does occur, and it is generally admitted to be a potent predisposing cause; but in the absence of pathogenic microbes, it has been proved, as previously mentioned, that these conditions are of themselves insufficient to produce the disease. It is doubtlessly owing to the production of mechanical impediments of this kind, that mammillary imperfections are so frequently associated with puerperal mastitis. Of 97 patients thus affected, Birkett<sup>44</sup> found that no less than 48 were associated with imperfectly developed nipples. In favour of the canalicular origin of most puerperal abscesses, it may be mentioned, that on pressing them pus and milk may often be made to exude from the nipple; and after incision the same combination may be seen in the discharge. Of Birkett's 97 cases of puerperal mastitis, in 19 the disease was associated with fissures or erosions of the nipple,

---

<sup>44</sup> Holmes' "Syst. of Surgery," vol. iii., 1883, p. 435.



&c. Pathologists who maintain the lymphatic origin of most puerperal abscesses have dwelt much on this. Probably these lesions act injuriously in most cases, rather by preventing suckling and so favouring lacteal engorgement and stasis, than as sources of lymphatic injection.

After *accouchement* the breasts naturally become considerably enlarged, tender and reddish, in connection with the establishment of lactation and its concomitant congestion. This physiological fulness, which is attended with some constitutional excitement and uneasiness, generally attains its maximum about the fourth day. The term "*milk fever*" was formerly applied to these phenomena. Recent investigations have, however, demonstrated the complete absence of fever. Hence, when under these circumstances febrile symptoms arise, their presence must be taken to indicate the supervention of some complication, either in connection with the *mammæ* or the genital tract. In patients with large, lax *mammæ* the tendency to congestion is often aggravated by their dependent position. Here relief may be afforded by raising and supporting the enlarged organs. In this congested state comparatively trivial injuries often suffice to determine *inflammation*.

A sense of chilliness, with lobular induration, elevation of temperature, and increase of the congestive symptoms are usually the earliest indications of its supervention. As the induration increases tenderness and pain develop. At first the skin over the affected area is not markedly altered; but as the disease progresses it becomes red, adherent, and even œdematous. By appropriate treatment, begun early, inflammation may be arrested, and the disease may terminate in resolution. More commonly, however, the inflammation spreads and suppuration supervenes. This is accompanied by much pain and constitutional disturbance, only to be relieved by evacuation of the pus. Left to itself this generally takes about a fortnight, but when the suppurative focus is deeply seated it may take longer. Abscesses of this kind are frequently multiple. Sometimes, as soon as one has been evacuated another forms, and so on continuously for



months. Velpeau<sup>45</sup> mentions a case in which forty-six abscesses formed successively in one breast in the course of two or three months. Thus the breast may become riddled with sinuses. This form of suppuration is attended with great debility.

It is usual to classify mammary abscesses according to the situations in which they develop, either as supra-mammary, intra-mammary, or infra-mammary. In the *superficial* varieties the pus points quickly, the disease runs a rapid course, and the concomitant constitutional symptoms are seldom severe. In *intra-glandular* suppuration the pus collects within the *corpus mammæ*. Owing to the unyielding nature of the surrounding structures the progress of the disease is slow, and it is attended by great pain and severe constitutional disturbance, with occasional mental aberration. *Sub-mammary abscesses* are characterised by the extensive formation of pus behind the breast; so that the organ appears to be raised, and pushed forwards by an elastic cushion behind it. The local and constitutional symptoms are usually less severe than in either of the foregoing varieties, and the progress of the disease is by no means rapid. Pus generally points somewhere at the periphery of the organ, usually in the infra-axillary region. This is where fluctuation should be expected, and it is the seat of election for evacuating the pent-up pus. Abscesses of this kind have been known to perforate the *corpus mammæ*, and diffuse themselves over the surface of the gland. This is the form of the disease denominated by Velpeau "*abcès de bouton en chemise*."

In addition to pus and milk, foetid gas has occasionally been noticed to escape on incising these abscesses. Instead of their healing up after evacuation, it not unfrequently happens that a discharging fistula results. When the original abscess has been in free communication with a lacteal duct, the resulting fistula yields chiefly milk; in other cases only puriform fluid is discharged. These fistulæ often become chronic, and prove

---

<sup>45</sup> *Op. cit.*, p. 82



very rebellious to treatment. After the healing of mammary abscesses, localised chronic induration sometimes remains, which may cause the patient much anxiety, especially when associated with tenderness and pain, although there is no real cause for alarm.

A remarkable feature about puerperal abscesses is, that in only a minority of cases are the axillary lymph glands notably affected, and even under these circumstances they rarely suppurate.

Of the complications incidental to puerperal inflammatory affections of the breast, the most grave are those of septic origin, comprising *erysipelas*, *septicæmia* and *pyæmia*. Fortunately, these dread diseases are of rare occurrence in this connection, and there is every reason to believe that improved methods of hygiene and antiseptic treatment will, in the future, render them still more exceptional. In the severer form of erysipelas the whole organ may be very rapidly involved, so as to threaten gangrene unless timely incisions are made.

It follows, from the foregoing account of the pathogeny of the disease, that prophylactic *treatment* is of the greatest importance. This comprises attention to the various methods recommended in the preceding section, for obviating the ill-effects of mamillary defects and inflammation. On the super-vention of lactation great care should be taken to prevent engorgement of the breasts with milk by regular suckling; or in the absence of this, by artificial means—the milk being drawn off either by gentle pressure with the hands, or by a breast evacuator. Attention should also be directed to the child's mouth. When once definite symptoms of acute inflammation have set in it is generally best to stop suckling, and to arrest the secretion of milk. Until the latter object has been effected, suckling must be replaced by mechanical evacuation. The nipple, areola and adjacent parts should be purified by washing with carbolic acid lotion, before and after each evacuation. To arrest the lacteal secretion the breast should be painted with extract of belladonna in glycerine. To allay in-



flammatory irritation, hot boric acid fomentations should be applied over this. In addition the part should be adequately supported; this can usually be done most effectively with long, broad strips of plaster, properly applied. Another necessary precaution is to confine the upper extremity with a sling, so as to prevent its movements. The arrest of lacteal secretion will be materially aided by the internal administration of saline aperients, together with iodide of potassium.

When once pus has formed, the sooner it is evacuated the better. The requisite incisions should be made in lines radiating from the nipple, so as to avoid cutting across the lacteal ducts. The abscess cavity having been emptied, and if necessary scraped, it should be purified by washing out with carbolic acid lotion. Its walls should then be coapted, so as to bring about rapid union; and to render this efficient, deep embedded carbolised catgut sutures should be used if necessary, as well as superficial cutaneous ones. In small abscesses the embedded sutures are usually unnecessary, if well adjusted pressure be applied; and in such cases scraping may often be dispensed with. Of course, to secure the end in view, antiseptic precautions must throughout be employed.

Boeckel recommends that the entire abscess, together with its immediate surroundings, should be extirpated by cuneiform excision; and the resulting wound closed with deep and superficial sutures, so as to secure immediate union. This method seems to me better adapted for the treatment of certain chronic fistulæ, than for acute abscesses.

As soon as the secretion of milk has been arrested, tonic treatment and regimen should be adopted. *Ferri et quinquæ citras* is one of the most suitable tonics for this purpose.

The treatment of fistulæ resulting from mammary suppuration need not be seriously entertained, until the lacteal secretion has been arrested; when after a time they often heal spontaneously. The method hitherto usually adopted for their cure, has been to scrape them out with a sharp scoop, at the same time disinfecting thoroughly by injection of solution of chloride



of zinc (gr. 20 to 40 ad. 1 oz.); and subsequently by compression and the use of gradually shortened drainage tubes, inducing them to heal up from the bottom. This method is now being very generally superseded by excision of the fistulous tract, or cuneiform amputation, with immediate closure of the wound by deep and superficial sutures, so as to secure rapid healing. For intractable fistulæ these proceedings certainly are preferable to Hey's method of slitting up the rebellious sinuses from end to end; and dressing the resulting wounds, so that they may heal up from the bottom.

(4) It is only very exceptionally that inflammatory affections of the breasts are met with, other than at some of the foregoing periods. Nevertheless, cases of mastitis, sometimes followed by suppuration, do occasionally arise in both sexes at other periods, either as the result of injury or without any obvious cause. Probably some of these cases are of rheumatic or gouty origin. Inflammatory affections of the breasts also sometimes arise during malarial and other fevers, such as typhoid; and in the course of "mumps."<sup>46</sup> From abscesses thus arising chronic fistulæ have very rarely resulted in both sexes.

Walther<sup>47</sup> has lately reported the case of a man, aged 40, with a fistula of his right breast, of three years' duration, that supervened after the opening of an abscess.

---

<sup>46</sup> For a case by Comby, with remarks, *vide Le Prog. Méd.*, 18 fev., 1893.

<sup>47</sup> *Bull. de la Soc. Anat.*, 1890, p. 300.



## CHAPTER XXIV.

## TUBERCLE, SYPHILIS, ETC.

## § I.—Tubercle.

THE history of mammary tuberculosis is that of a disease once well recognised, which after a time, having fallen into oblivion, has in comparatively recent times been re-discovered. Astley Cooper,<sup>1</sup> Nélaton,<sup>2</sup> and Velpeau<sup>3</sup> long ago published excellent descriptions of it.

With the exception of histological details, Velpeau's account has never been surpassed. He recognised that the breast may be primarily affected, which is rare; or—the initial outbreak being elsewhere—that it may be secondarily involved, as more commonly happens. Its various manifestations he classed as "*tubercles disséminés*," "*tumeurs lymphatiques*," and cold abscess.

(1) In the disseminated form, numerous nut-sized nodules—apparently formed of altered lobules—are met with. These are often tender, and even slightly painful. Both the parenchyma and stroma are involved. They consist of caseous matter, in which small puriform foci are often noticeable. He described the clinical features of this form as resembling, in its early stage, those of lobular hypertrophy, to which subsequently the signs of chronic mastitis are added. In illustration he

<sup>1</sup> "Illust. of Diseases of the Breast," 1829, ch. viii.

<sup>2</sup> "Thèse d'Aggregation," Paris, 1839.

<sup>3</sup> "Traité des Maladies du Sein," &c., Paris, 1854, pp. 162 and 284.



mentions a case in which the disease lasted four years, and was accompanied by the formation of an enlarged gland in the axilla. The patient was of delicate, lymphatic constitution ; but not obviously affected with tubercular disease elsewhere.

(2) In the second form of the disease, a number of rather large caseous tumours form in the breast, which on section much resemble enlarged strumous lymph glands. He cites two cases of this kind in which the axillary, cervical and other lymph glands were involved as well as the mammæ. In a rare variety of this form, "*tumeurs lymphatiques purulentes*," he describes the disease as presenting as a single, irregular, bossed tumour, with concomitant enlargement of the axillary glands. After a time, which may be long or short, inflammatory symptoms supervene, which result in suppuration. From the loculated abscess cavity, grumous caseous matter and quasi-purulent fluid is discharged. In a case under his observation, three months after excision of the tumour, fatal pulmonary tuberculosis set in, and after death it was found that two fresh abscesses had formed in the same breast. He considers that the phthisical are the most liable to this form of the disease ; although it may occur as a primary affection. Sometimes abscesses of this kind in the mammary region originate from disease of the thoracic skeleton ; or even from intra-thoracic lesions.

(3) Cold abscesses of the breast of tubercular origin he describes as being for the most part secondary to tubercular disease elsewhere, especially in the lungs ; but he also recognises the existence of a primary form of the disease. As an example of the latter form he relates the following case.

A woman, over 40, eighteen months previously first noticed a tumour in her breast, which she thought resulted from a slight blow. It rather quickly increased, but without any pain or inflammatory symptoms. On examination Velpeau found, at the upper and inner part of her right breast, a bossy tumour—the size of a man's fist—which in some places was softish and fluctuating, and in others as hard as scirrhus. On incision grumous material and puriform fluid escaped ; and from the abscess cavity a sinuous tract passed for some distance in the direction of the anterior mediastinum, with which, however, it did not communicate. The adjacent skeletal structures were normal ; and there was no sign of pulmonary disease.



Subjoined is an instance of tubercular abscess *secondary* to phthisis.

A pale and emaciated woman, aged 24, had suffered from phthisical symptoms for about six months, when she noticed a painful swelling in her right breast, in connection with which several nodules were subsequently noticeable. When she was first seen by Velpeau a few months later, the breast was occupied by a mobile, elastic tumour, the size of an apple. It was tender, and caused some pain. The overlying skin was free, and the axillary glands were normal; but the nipple was depressed. In addition to the tumour, there was general lobular hypertrophy of the gland. Soon afterwards fluctuation became obvious, the swelling was incised, and the pus evacuated. A fistulous tract persisted. At about the same time there were marked signs of actively progressive tubercle in the upper lobe of the right lung. Abscesses of this kind sometimes contain fœtid gas.

With this lucid account available, it is not easy to understand how subsequent authors could possibly have overlooked the disease. Yet so it came to pass, English pathologists being particularly deficient in this respect.

Although in his well-known work on "Diseases of the Breast,"<sup>4</sup> published in 1880, Billroth gave an excellent summary of what was then known of the disease; yet it was not until the appearance, shortly afterwards, of Dubar's monograph,<sup>5</sup> that mammary tubercle was generally recognised. What more than anything else contributed to this end was the discovery by Koch,<sup>6</sup> in 1882, of the tubercle bacillus. Since the announcement of this epoch-making discovery, the subject of mammary tuberculosis has been investigated by Ohnacher,<sup>7</sup> Orthmann,<sup>8</sup> Shattock,<sup>9</sup> Mandry,<sup>10</sup> Roux,<sup>11</sup> and many others.

It is now generally agreed that tubercle of the breast is of much commoner occurrence than has hitherto been generally believed. In primary cases it seems probable that infection usually takes place through the milk ducts, although the

<sup>4</sup> *Deutsche Chir.*, Lief. xli., S. 30.

<sup>5</sup> "Des Tubercles de la Mamelle," *Thèse de Paris*, 1881.

<sup>6</sup> "Die Aetiologie der Tuberkulose," *Berl. klin. Woch.*, No. 15, 1882.

<sup>7</sup> *Arch. f. klin. Chir.*, 1883, Bd. xxviii., S. 366.

<sup>8</sup> *Arch. f. path. Anat.*, Bd. c., Heft 3, 1885.

<sup>9</sup> *Trans. Path. Soc. Lond.*, vol. xl., 1889, p. 391.

<sup>10</sup> *Beiträge z. klin. Chir.*, Bd. viii., 1891, Heft 1.

<sup>11</sup> "De la Tuberculose Mammaire," *Paris*, 1891.



microbes may enter from infected fissures, &c., through the lymphatics. Most cases undoubtedly arise secondarily, by auto-infection from a primary focus in some other part of the body, usually the lungs.<sup>12</sup> As a rule the disease soon disseminates in the adjacent axillary lymph glands, &c.

In the breast, as elsewhere, the specific effect of the bacillus of tubercle is to produce chronic inflammatory lesions. These consist largely of granulation tissue, which must be regarded as a protective provision for preventing the spread of the microbes to the surrounding healthy tissues. The degenerative changes that subsequently ensue may be ascribed to local anæmia, and the chemical action of the products by the bacilli. Thus caseation and liquefaction of the cheesy matter into a fluid resembling pus, are caused. The tubercle bacillus of itself, however, produces no suppuration; when, therefore, suppuration supervenes, it must be due to secondary infection from pus microbes. Spontaneous cure may ensue if the bacillus meets with sufficient resistance from the surrounding phagocytes. In such cases, the nutriment in the granulations being at length exhausted, the bacilli die or remain latent; and cicatricial tissue replaces the granulomatous formation. In most cases, however, abscesses and chronic fistulæ eventually result.

The disease debuts in connection with the acini and small ducts. After a time their lining cells disappear, and they are replaced by giant cells surrounded by small round cells. Perfect miliary tubercles, as defined by Virchow, are not usually met with. In this respect the disease resembles synovial tuberculosis and lupus. Moreover, like these lesions, mammary tubercle is of a comparatively mild form, owing to its poverty in bacilli.

As previously mentioned, the disease usually presents as numerous, rather small, pseud-inflammatory nodules, and only exceptionally as single, large, tumour-like swellings.

---

<sup>12</sup> Of 26 cases analysed by Delbet (Duplay and Reclus, *Traité de Chir.*, t. vi., p. 208), 10 were phthisical, and 4 presented tubercular disease elsewhere.



Traumata and conditions connected with the puerperal state favour its development. Most cases arise in patients from 25 to 35 years old, after 40 it is rare, and after 50 most exceptional. It has never been observed under puberty.

The onset of the disease is usually insidious, and its progress slow. It has generally existed for two or three years before abscess formation begins. The bacteriological researches of Schlegtendal,<sup>13</sup> Garré,<sup>14</sup> and others show that a large proportion of cold abscesses are of tubercular origin, and it is highly probable that this conclusion holds also for the breast. It is in the wall of these abscesses that the typical tubercular structures are to be found, including the bacilli. After incision or spontaneous evacuation, should infection by pus microbes take place, these are apt to cause destruction of the protective granulations; which exposes the patient to the risk of rapid dissemination of the tubercular disease, as well as to the risk of septic infection. Hence the necessity for rigid antiseptic precautions in dealing with such cases. Schlegtendal claims to have proved that the bacilli in tubercular abscesses do not grow and multiply.

It is generally believed that the milk from tubercular women does not possess infective properties, unless the mammæ that supply it are themselves tubercular.<sup>15</sup> The like also is true of cow's milk,<sup>16</sup> but these animals are more prone to mammary tubercle than human females.

Nièpce<sup>17</sup> has instanced a case in which a nurse, whose milk contained tubercle bacilli, suckled a child born of healthy parents, with the result that the child soon afterwards died of tubercular meningitis.

It is evident, from the foregoing, that women with tubercular disease of the breast should never, under any circumstances, be allowed to suckle either their own or other people's children.

---

<sup>13</sup> *Fortschritte der Med.*, Bd. i., S. 537.

<sup>14</sup> *Deutsche med. Woch.*, No. 34, 1886.

<sup>15</sup> *Fede, Rif. Med.*, Oct. 25, 1892.

<sup>16</sup> Crookshank, "Tubercular Mammitis in Cows with Experiments relating to the Infectivity of the Milk," *Appendix to Rep. Agricult. Dep.*, 1888.

<sup>17</sup> "De la contagion et de la transmissibilité de la Tuberculose," *Thèse de Paris*, 1886.



Cases seen in an early stage of the disease, when the diagnosis is doubtful, may be treated by local application of belladonna and glycerine with iodide of lead ointment, together with the internal administration of syrup of iodide of iron, and cod-liver oil, or of maltine and hypophosphites. In this way the disease may sometimes be cured. When the disease is more advanced and suppuration has taken place, the breast must usually be extirpated, together with the affected axillary glands. For localised lesions partial amputation may suffice. An alternative method is to lay open and scrape the abscess cavity, sinuses, &c., with a sharp scoop, at the same time syringing with strong solution of chloride of zinc, and afterwards dressing from the bottom with glycerine iodoform emulsion. Of course antiseptic dressings and precautions must be employed.

Instances of tubercle of the *male* breast have been reported by Mandry,<sup>18</sup> Horteloup,<sup>19</sup> and Poirier,<sup>20</sup> but in men the disease is exceedingly rare.

The following cases illustrate the chief features of mammary tuberculosis.

(1)<sup>21</sup> A rather delicate-looking, pale, moderately nourished woman, aged 21, six years ago noticed a small lump in her left breast, which was followed one year ago by enlargement of the axillary glands. There had occasionally been slight pain in connection with the breast tumour. No family history of tubercle. On examination a mobile tumour, rather larger than a hazelnut, was found in the upper and outer segment of the left breast. The overlying skin, when pinched up, dimpled slightly. From the tumour a hard cord extended to an enlarged gland in the axilla. No fluctuation. On exploratory excision, a thick-walled abscess containing a small quantity of thick pus. The tumour was excised, together with the adjacent part of the breast; and several caseous axillary glands, the largest of which was just beginning to soften. A thick layer of granulation tissue lined the abscess cavity. On histological examination numerous giant cells were found in this tissue, but no perfect tubercle systems. Nothing is said about bacilli. The enlarged lymph glands presented the histological characters of caseous tubercle.

(2)<sup>22</sup> A woman, aged 39, the mother of eight children, of whom five had

---

<sup>18</sup> *Op. cit.*

<sup>19</sup> "Des Tumeurs du Sein chez l'Homme," Paris, 1872.

<sup>20</sup> *Ibid.*, 1883.

<sup>21</sup> Shattock, *Trans. Path. Soc. Lond.*, vol. xl., 1889, p. 391.

<sup>22</sup> Hebb, *Trans. Path. Soc. Lond.*, vol. xxxvi., 1888, p. 446.



died of tubercle. She had suffered from phthisical symptoms for many years. About seven weeks ago she experienced pain in her left breast, and some weeks later a tumour was noticed. On examination a hard nodular tumour, about three-quarters of an inch in diameter, was found in the breast, just above and external to the nipple, which was much retracted. It was freely movable, rather painful, and tender on manipulation. There were a few indurated cords stretching towards the axilla; but the axillary lymph glands were not obviously affected. The tumour was excised; and when last seen, four months later, the patient was free from return of the disease. On examination after removal, the tumour consisted of caseous tubercular nodules, some of which were softening in the centre. In some places the tuberculosis seemed primarily to have involved the ducts; but for the most part, the nodules were embedded in the stroma, just external to the glandular structures. They contained well-marked giant cells; but no bacilli could be found even after several searches.

(3)<sup>23</sup>A healthy-looking spinster, aged 38, eighteen months ago noticed a small swelling in the upper part of her left breast. It gradually increased in size, without causing any pain. Six months ago, she noticed another swelling at the inner part of the same breast. This was rather painful, and increased more rapidly than the first one. No history of injury or other known cause. A maternal aunt died of cancer of the breast. There was no family history of tubercle. On examination two swellings were found in the left breast; the one in its upper segment was large, firm and non-fluctuating, the other, in its inner segment, was soft and fluctuating. Both were mobile and devoid of inflammatory symptoms. There was slight enlargement of the adjacent axillary glands. On free incision, the swelling in the inner part of the breast proved to be a puriform collection with a thick granulo-matous wall. On squeezing the other tumour, caseous matter and puriform fluid escaped into the abscess cavity, and it was evident that the two communicated. On opening the upper cavity into the lower one, the latter was found to consist of seven or eight cavities, each about the size of a hazel-nut, containing caseous and puriform matter. Antiseptic irrigation and dressing, with free drainage. No bacilli could be found in the tissue removed. About two months later she again came under treatment with a discharging sinus, and the axillary glands had become considerably enlarged. The breast was now amputated and the axilla cleared. Several of the diseased glands were in close relationship with the large vessels. On section after removal numerous small caseous nodules were found scattered throughout its upper part. The removed axillary glands were similarly affected. About six weeks later the wounds had quite healed.

The integument of the breast is occasionally the seat of *lupus*, which may affect either the areolar region or the skin elsewhere. Its treatment is the same as that for lupus of other parts of the body—scraping with a sharp scoop, igni-puncture, linear scarification, &c.

<sup>23</sup> Lane, *Brit. Med. Journal*, Sept. 13, 1890.



## § II.—Syphilis.

Syphilis of the breast may be met with either in its primary, secondary, tertiary, or hereditary forms.

(1) The *primary* form usually results from inoculation of some small lesion of the nipple or areola, through suckling a syphilitic child. According to some syphilographers, a mother may thus acquire the disease from her own child. Those usually affected are wet nurses. Both breasts are often affected, and the chancres may be multiple. In dealing with cases of this kind, as Heath tritely remarks, the surgeon should keep his eyes open and his mouth shut. After the usual incubation period, a hard chancre forms at the seat of inoculation: subsequently the axillary glands become indurated, and secondary symptoms develop. The disease is best treated by the local application of calomel ointment, and by mercury internally in the form of *pil. hyd. c. opio*, or some other suitable preparation.

(2) *Secondary* syphilis of the breast is most frequently met with in the form of erosions, fissures, papules, tubercles, or mucous patches of the nipple or areola. In women with large pendent mammæ, lesions of this kind may be met with beneath the overhanging breasts, where the two cutaneous surfaces come into contact. These secondary manifestations are often more or less bilateral, and they are usually infectious. They are often accompanied by evidence of specific disease of other parts of the body, or at any rate, on inquiry, history of some of the various manifestations of syphilis can generally be obtained. In selecting a wet nurse it is important to go thoroughly into these matters, for the syphilisation of a healthy child by its nurse is a serious affair. It is believed that the milk of a syphilitic woman cannot communicate the disease, in the absence of some mammary lesion. In support of this Lee<sup>24</sup> cites the following instructive case:—

A healthy married woman, shortly after her last confinement, took a child to nurse in addition to her own. The strange child proved to be syphilitic.

<sup>24</sup> Holmes' "System of Surgery," vol. iii., 1883, p. 344.



Chancre of the breast, with well-marked secondaries, followed in due course. This woman had taken the precaution of keeping each child to one breast. Although she continued to suckle her own child for six weeks after the secondary eruption had appeared, yet it was never infected. This seems conclusive evidence that in the absence of specific disease of the breast itself, syphilis cannot be communicated through the milk.

In the treatment of these affections the same routine is generally requisite as for the primary disease.

(3) The *tertiary* syphilitic manifestations generally present either as a gumma, or as a diffuse infiltration. The gummatous form gives rise to a more or less circumscribed tumour, which may be situated in any part of the breast. It is usually hard, bossed, and painless in its early stages; later softening sets in, and finally it breaks down into an excavated ulcer. In its early stages the overlying skin is generally free, there is no retraction of the nipple, and the axillary glands are seldom affected. In the softening stage the skin becomes adherent and discoloured, preparatory to breaking down. Evolving mammary gummata have often been mistaken for cancer. The diagnosis will be simplified by the discovery of signs of syphilis in other parts of the body. The infiltrated form, in its general features, much resembles chronic mastitis, before contraction sets in. There is ill-defined, painless induration, which may involve the whole gland, or only certain lobules. The overlying skin and the nipple are unaffected, and the axillary glands may or may not be enlarged. Like the gummatous form, it tends to softening and ulceration. These affections are best treated with iodide of potassium internally, and mercurial ointment with belladonna externally.

(4) In the course of *hereditary* syphilis similar lesions may arise in the breast. As I have previously mentioned, instances of mammary atrophy consequent on hereditary syphilis have also been recorded.<sup>25</sup> For further information on the subject of mammary syphilis, the reader is referred to the works of

---

<sup>25</sup> P. 41.



Fournier,<sup>26</sup> Jullien,<sup>27</sup> Bumstead and Taylor,<sup>28</sup> Claude,<sup>29</sup> Landreau<sup>30</sup> and Lancereaux.<sup>31</sup>

### § III.—Diphtheria, Thrush, &c.

The following instance of infection of the mother's breast with *diphtheria* by her suckling child has been recorded by Caddy.<sup>32</sup>

An infant, 6 weeks old, that had hitherto been fed exclusively by the breast, was found to be very ill, temperature 103° F., with acute inflammation of the tonsils, the left being covered with a large patch of white membrane, which extended to the adjacent parts of the uvula and soft palate. The submaxillary glands were somewhat enlarged. The mother was advised at once to cease suckling; but this she declined to do, fearing that the child would die if she did. Five days later, the mother complained of feeling weak and ill, and of having cold shivers, as well as of tenderness in her left breast and axilla. On examination, the breast was swollen, hard, tense and very tender; the nipple was covered with a tough, greyish-white membrane, which, on the axillary side, extended to the outer border of the areola. There were several other small patches of membrane in this vicinity. After removal of the membrane a raw bleeding surface was exposed. For the distance of about an inch around the areola, the breast was red and inflamed. Temperature 103.2° F. The urine contained a good trace of albumen. Under appropriate treatment both mother and child recovered.

In like manner *thrush* may be transferred from the child's mouth to the mother's nipple, although this is a comparatively rare occurrence.

Mention has previously been made of the occasional infection of the mammary integument with *molluscum contagiosum* derived from the child's face.

<sup>26</sup> "De la Syphilis chez la Femme;" "La Syphilis Héréditaire Tardive" (1886); "L'Hérédité Syphilitique" (1891).

<sup>27</sup> "Maladies Vénériennes" (1886).

<sup>28</sup> "Treatise on Venereal Diseases."

<sup>29</sup> *Thèse de Paris*, 1886.

<sup>30</sup> *Ibid.*, 1874.

<sup>31</sup> "Traité de la Syphilis," 1866.

<sup>32</sup> *Brit. Med. Jour.*, vol. i., 1893.



## CHAPTER XXV.

## TRAUMATA, NEUROSES, MINOR SURGERY.

## § I.—Traumata.

THE commonest form of mammary trauma is *contusion*. The ecchymosis consequent on blows of no great violence, as a rule, soon passes away, and is followed by no bad results. Severer forms of injury give rise to extensive ecchymosis or even to hæmatoma. In this connection it is well to recollect that similar lesions may arise in young women, as a form of vicarious menstruation, or from other causes, in the absence of any traumatism. In like manner spontaneous hæmorrhage from the nipple may occur. Hæmorrhagic extravasations, after a time, are generally absorbed, but sometimes chronic induration remains, or a cyst may form. It not unfrequently happens after contusions, that pain is felt for a long time, even when there is no appreciable lesion. Sometimes blows excite inflammation, especially in the puerperal state, when it may easily pass on to suppuration. Belladonna with mercury ointment is a good application for most contusions; and when it can be borne, the breast should be strapped with *emplast. am. c. hyd.*

With regard to *wounds* of the breast, they differ but little from those met with in other parts of the body. Stabbed and bullet wounds are the most serious, and they are relatively of frequent occurrence. Hæmorrhage can nearly always be arrested by judicious compression. In their treatment anti-septic measures should occupy the first place; foreign bodies must be removed; and the wound surfaces be brought together by carefully applied dressings, &c.

Various *foreign bodies*, such as needles, pins and bits of glass, have often been found embedded in the breast. *Burns*



and *scalds*, which are rare, differ in no way from similar lesions elsewhere.

## § II.—Neuroses.

Young adult women not uncommonly experience tenderness in the mammæ at the catamenial periods and at the commencement of pregnancy. Somewhat similar sensations are apt to arise at the climacteric, and in association with various morbid conditions of the pelvic organs. Exaggeration of this sensitiveness leads to *mastodynia*. In this affection the degree of pain experienced is very variable. Sometimes it is so severe that the slightest touch cannot be endured. It may be constant or only occasional. In some cases it is localised to a particular spot; in others it is widely diffused, radiating to the shoulder, arm and side. In most cases there is no obvious mammary lesion; but it occasionally happens that mastodynia is associated with the presence of a small tumour or chronic inflammatory induration.

Those affected are generally of hysterical or neurotic disposition. In this state patients sometimes consult us, firmly convinced that they have cancer, or some other grave disease of the breast requiring operation. These require to be reassured. Local sedatives should be applied, such as belladonna plaster. For general treatment *pil quinæ valerianatis*, or *mist. ferri et quinæ citratis* will suffice. In erotic individuals bromide of potassium, with saline aperients, are indicated. Purely hysterical cases are best managed on the Weir Mitchell principle, including complete change of surroundings. Should catamenial irregularities or diseases of the pelvic organs co-exist, these must be appropriately treated. When mastodynia is associated with chronic induration or tumour, compression is often curative, and in many other cases it may be beneficially employed.

## § III.—Minor Surgery.

One of the most convenient ways of keeping in place fomentations and other applications to the breast is by means of the



*triangular bandage*, which is made from a square yard of calico, cut or folded diagonally. It may be applied in either of the following ways:—(1) In the first method the base of the triangle is passed from over the opposite shoulder, beneath the affected breast, to the back, where the two ends are fastened with safety pins. The rectangular end is then carried over the shoulder of the affected side to the back, where it is also secured. (2) In the second method the base of the triangle is passed round the waist beneath the *mammæ*, the ends being fastened behind; the rectangular end is then passed over the shoulder of the affected side to be fastened to the basal part behind. In fixing the ends of the bandage behind, whichever method is used, care should be taken to avoid having the junctions over the middle line, as otherwise they will cause the patient much annoyance when reclining.

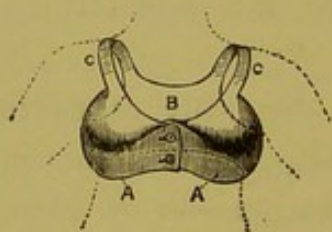


FIG. 75.—Wicker's breast supporter.

A form of made bandage known as "Wicker's breast supporter" is simple and efficient (fig. 75).<sup>1</sup>

Chadbourne's<sup>2</sup> arrangement is also a good one: the breast is embraced between the Y-shaped extremities of a transverse bandage approaching it from opposite sides.

When a certain amount of compression is required together with support, the roller bandage is often employed, although it is a comparatively inefficient application. To bandage *one* breast—let us say the *right*—a roller 3 inches wide and 8 yards long is taken. It is first carried round the waist, immediately below the *mammæ*, beginning in front and passing towards the

<sup>1</sup> Supplied by Arnold & Sons, West Smithfield, London.

<sup>2</sup> Made by Madels, Codman and Shurtleff, Boston, U.S.A.; as described in *Am. Obstet. Jour.*, Nov., 1890, p. 1200.



left side. The bandage being thus fixed, is carried obliquely upwards over the lower part of the right breast to the opposite shoulder, then back by the axilla to the waist, around which it passes so as to fix the oblique turn. By repetition of the above turns, each being a little higher than its predecessor, the breast is covered in. In order to bandage *both* *mammæ* the initial part of the process is the same as for only one. The roller having been carried over the lower part of the right breast to the opposite shoulder and back to the waist by the axilla, is then carried half round the waist and across the back to the right shoulder over which it passes, and then across the sternum under the left breast, and round the back to the right side. By repetition of these turns both breasts are covered in. The objections to bandages are, that they are tedious to apply, that they soon slip, and that they are apt to prove irksome by impeding the respiratory movements.

Another mode of bandaging, sometimes useful in the treatment of mammary diseases, is the *anterior figure of eight*, transversely applied. Starting behind one shoulder, over which the roller is passed, it is carried downwards and forwards across the front of the sternum to the opposite axilla; beneath which it is carried up and over the same shoulder, thence downwards and forwards over the front of the chest to the first axilla, crossing the other turn in the middle line. By repeating this, so that the succeeding turns overlap to the requisite extent, the bandage is completed.

For supporting and compressing the breast *strapping* is much more effective and less incommodious than bandaging, and it should therefore generally be preferred when *support* is the chief object. Strips of plaster from two to three inches wide and about thirty inches long are taken. The breast being held up by an assistant, the end of the strip is fixed to the back over the scapula, it is then brought forwards across the axilla, whence it is passed upwards and outwards beneath the lower part of the diseased breast, over the opposite shoulder, where it is fixed to the back, over the upper part of the scapula. A few other strips,



similarly applied, so that each may overlap its predecessor, completes the application.

When *compression* is the end in view transverse and oblique strips are laid on alternately as in bandaging. The strips should not be more than two inches wide, and the transverse ones only embrace the affected side.

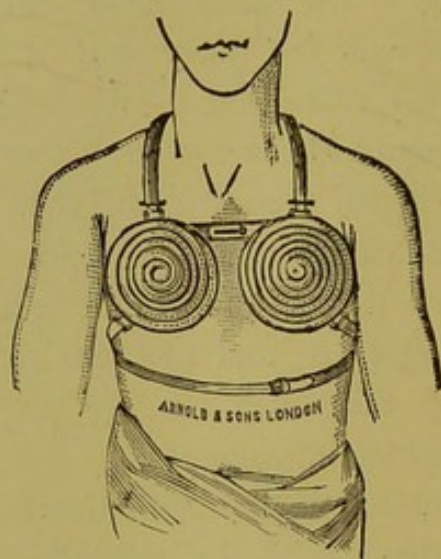


FIG. 76.—Duke's breast supporter and compressor.

For the exercise of long continued *compression*, in cases of chronic tumour of doubtful nature, &c., the most efficient instrument known to me is Arnott's.<sup>3</sup> It is essentially a modified Salmon and Ody's truss, adapted to the breast. The compressing pad is fitted with a slack air cushion. It has the great advantage of not interfering with the respiratory movements.

Where *support* with moderate compression is required Duke's instrument<sup>4</sup> is advisable. By means of a spiral, cone-shaped spring, so arranged as not to interfere with respiration, both support and compression are effected.

<sup>3</sup> Made by Coxeter and Son, Grafton Street, Gower Street, London, W.C.

<sup>4</sup> Made by Arnold and Sons, West Smithfield, London, E.C.



## INDEX.

ABDOMINAL mammae, 46, 59, 60, 71.

Abscess and defective nipples, 38, 297, 338, 542; microbes, 525, 555; cold, 539, 555; acute, 546; tubercular, 555.

Acini, 20.

Acromial mammae, 49.

Adenoma, *vide* fibro-adenoma.

Agalactia, 13.

Amazia, 29.

Anatomy, 16.

Angioma, 489, 512.

Anomalies of secretion, 15.

Areola—Morphology, 16, 23; development, 5; defective, 29, *et seq.*; eczema, 393, 545; cancer, 393, 413; sore, 542; tumours, 461, 493, 506, 514.

Atavistic polymastia, 44, 53.

Athelia, 37.

Atrophy, 39.

Axilla—Anatomy, 25; anatomico-pathological memorabilia, 345; cancer of axillary glands, 179; galactoceles, 67; lymphatics and lymph glands, 185; lumps of Champneys, 3, 25, 517; mammary processes, 63; mammary sequestrations, 67; mammary neoplasms, 74; nipples, &c., 72; neoplasms and tumours, 516; recurrence of cancer in, 217; supernumerary mammary structures, 63; sweat glands, 25.

BANDAGING, 566.

Birth, mammae at, 6.

CALCIFICATION, 22, 169, 228, 434.

Cancer, 132-416.—Acinous, 123, 151; acute, 318; age, 233, 284; alcohol, 290; alimentation, 250, 289; alveoli, 169; amyloid degeneration, 214; anatomico-pathological memorabilia, 345; animals, 299; antecedent inflammation, 297; anxiety and mental distress, 292; apoplexy, 273; arrest and retrogression, 229; arthroses, 274; associated

Cancer—(*continued*).

with sarcoma, 304; with other neoplasms, 309, 384; with hyperplasia, 172; asthenia as mode of death, 216; atrophic, 325; auto-inoculation, 148, 223, 350; axillary, 77; axillary glands, 183; axillary recurrence, 217. Biological distribution, 298; blastema theory, 135; blood changes, 212; blood supply and rate of growth, 193, 224; blood vessels, 170; both breasts, 153, 176, 194, 204, 301, 318; Broussaisian theory, 134, 141, 295. Cachexia, 210; calcifying, 167, 169, 228; capsular lipomatosis, 228; cartilage in the stroma, 170; caseating, 228; caustic treatment, 268; cell theory, 134; cell nuclei, 159; cell vacuolation, 166; cell secretion, 167; centenarians little liable, 241; chemical analysis, 171; chloroma, 333; chronic inflammation, &c., 141, 295; chronic types, 323; clinical features, 152; coagulable lymph theory, 133; coccidial theory, 163; Cohnheim's theory, 73, 137; colloid, 328; complexion, 247; congestion, 171, 224; contagion, 145, 147; continuous development theory, 136; controversy as to origin, 137; constitution, 272, 285; cuirassed, 321; cure—operative, 363; spontaneous, 229, 233; cutaneous, 393; cylindroma, 331; cysts, 228. Deaths consequent on operation, 360; death independently of operation, 216; definition, 151; depraved lymph theory, 133; dermatoses, 292; diathesis, 475; diet, 250, 289; differential diagnosis, 339; diffuse, 318; dimpling of skin, 338; discharge from nipple, 339; dissemination, local, 174; glands, 179; general, 191; seats of, 195; bones, 197; fractures due to, 203, 327; traumatic, 223; rationale, 207; domestication, 299; duct cancer, 384; duration of life, 153, 365. Encephaloid,



**Cancer—(continued).**

an obsolete term, 152; endocytes, 162, 397; enlarged lymph glands, 179; epidemiology, 147; épithéliôme tubulé, 392; erysipelas after operation, 362. Family history, 264; fatty degeneration, &c., 166, 214, 225, 227; fecundity, 275, 288; fractures due to dissemination, 203, 327; due to cachexia, 215; frequency, as compared with other neoplasms, 131. Gall stones, 294; gangrene, 225; general morphology, 151; general pathology, 233; geographical distribution, 249; germs, 139; grief, 292. Hæmorrhage, 227; hæmorrhagic cancer, 228; healing, 229; health, 285, 292; heredity, 260; hereditary proclivities, 270; historical review, 132; homologous and heterologous, 135; hyperplasia concomitant with cancer, 172; humoral theory, 132. Immunity of savages and wild animals, 248, 291, 299; inclusions in cells, 162; increase, 279; infection, 147; inflammation of, 224; inoculation, 145; insanity, 273; integumentary, 393; irritation, &c., 140, 295. Karyokinesis, 160. Lactation, 288; leucocytes, 165, 169; liability to other diseases, 293; lipomatous, 227; local dissemination, 174; localisation, 234; locality, influence of, 151; longevity in cancer families, 274; lymphatics of the breast, 185; lymphatics and cancer, 167, 171; lymph glands of breast, 184; lymph gland enlargement, 179; lymph gland dissemination, 180; lymphocytes, 169. Male breast, 333, 403; malignancy, 174; marriage, 287; mastitis, 297; melanotic, 331, 413; membrana propria, 114, 167; menstruation, 244, 287; metastases, 191; microbes, specific, 137, 143, 163, 171, 397; non-specific, 164, 350; mitoses of cancer cells, 160; morphology, 151; mortality after operation, 360; multiple primary cancers, 300; myxomatodes, 331. Nerves, 171; nipple cancer, 393, 413; nipple discharges, 339; nipple retraction, 297, 337, 542; nitric acid method of examination, 173; non-malignant neoplasms and cancer, 310; nuclei of cancer cells, 161; nutrition in relation to pathogeny, 245; nutrition of cancerous growths, 223; nutrition of cancer patients, 285. Occupation, 292; cedema of upper limb, 185; operative treatment, 344, 352; origin of cancer, 157, 246, 310, 481; ossifying, 170; osteitis deformans, 291. Paget's disease, 393, 413; pain, 336; palliative treatment, 370;

**Cancer—(continued).**

parasitism, 138, 140, 163, 397; pathogenesis, 122, 132, 246; pathology, 233; peripheral neuritis, 213; phagocytosis, 165; prevalence, 279; prevalence greater in rural districts and among the well-to-do, 290; previous health, 293; primary neoplasm, 156; prisons, 290; proclivity, 157; prolongation of life by operation, 365; prostitution, 291. Race, 248; recurrence, 217; retraction of nipple, 337; retrogression, 229; roots, 156; rural districts, 290. Savages, 248, 291, 299; scirrhus, 156; septic diseases after operation, 362; sex, 233; spontaneous cure, 229; spontaneous fracture, 203, 215, 327; sterility, 287; stroma, 168; suppuration, 224; symptoms, 336; syphilis, 291. Tetanus, 362; topography, 253; traumata, 295; traumatic dissemination, 149; trees, 300; treatment—operative, 344; caustic, 368; palliative, 370; tubercle, 270, 285, 286, 294; tubular cancer, 123, 151, 384, 413. Ulceration, 225. Vacuolation of cancer cells, 166; varieties—acinous, 157, 403; acute, 318; chronic, 223; colloid, 328; atrophic, 325; myxomatodes, 331; tubular, 384, 413; villous, 372; cutaneous, 393, 412. Cartilage in stroma, &c., 22, 169, 434, 444, 451, 486, 512. Castration, effect on mammæ, 41. Chloroma, 333. Chondroma, 486, 512. Climacteric mammary changes, 13. Cohnheim's theory, 73, 137. Compressors, 568. Cooper's ligaments, 16, 174, 347. Corpus mammæ, 18. Cylindroma, 331. Cysts—axillary, 68, 517; dermoids, 507, 514, 522; galactoceles, 68, 494, 574; general cystic disease, 497, 514; hydatids, 504; involution cysts, 13, 501; lymphatic, 503; lymphangioma, 522; mucoid, 493, 514; sebaceous, 506, 514, 517. DESCENT of mammals, 2. Development — asymmetrical, 11; defective, 29; excessive, 43, 82; of mamma, 5, 81; of nipple, 9; of neoplasms, 119, 130. Diathesis, neoplastic, 475. Diphtheria, 563. Dorsal mammæ, 47. Ducts, 20, 113. ECZEMA, 393, 545. Erratic mammæ, 47.



- FACIAL** mammæ, 48.  
**Fibroma**, 458, 509.  
**Fibro-adenoma**, 460, 510; axillary, 74; cancer after removal of, 482; chronic mammary tumour, 460; concomitant lobular hypertrophy and hyperplasia, 465; cystic theory of origin, 465; diagnosis, 477; diffuse, 478; in early life, 471; family history and heredity, 475; general pathology, 471; history of discovery, 461; microbe theory of origin, 479; milk secreting adenoma, 462; morphology, 464; neoplastic diathesis, 475; origin of malignant disease from, 310; pathogenesis, 123, 462, 464; plexiform fibroma, 478, 535; recurrence, 480; treatment, 479; true adenoma, 462; Thomas' operation, 480.  
 Foreign bodies in, 506.  
 Frequency of various neoplasms, 127.
- GALACTOCELE**, 494; axillary, 67; in male, 514.  
 Galactophorous ducts, 20, 113.  
 Galactorrhœa, 14.  
 Glandulæ lactiferæ aberrantes (Montgomery's glands), 10, 25.  
 Groin, mamma in, 50.  
 Gynæcomastia, 104.
- HERMAPHRODITISM**, 3, 30, 35, 37, 110.  
 Herpes zoster, 546.  
 Heterochronous lactation, 15.  
 Histology, 23, 113.  
 Homologue of mamma, 4.  
**Hypertrophy**, 82; adults, 91; compensatory, 98; diffuse, 85; etiology, 97; fatty, 88, 94; fibrous, 85; glandular, 92; gynæcomastia, 104; infantile, 83; male animals, 106; morphology, 85; partial, 101; pregnancy, 92; progress, 95; puberty, 85; treatment, 100, 103, 112.
- INFANTILE** lactation, 6, 83.  
 Inflammation and suppuration, 525.  
 Inguinal mamma, 50.  
 Injury in newly born, 33.  
 Innervation, 119.  
 Involution, 13, 39, 501.
- KENOGENESIS** in nipple development, 4.
- LABIUM** majus, mamma in, 51.  
**Lactation**, 12; adenoma, 462; anomalies, 13; cancer, 288; girls, 15; histology, 115; infantile, 6, 82; man and male animals, 16, 105; non-pregnant women and virgins, 15.  
 Ligamenta suspensoria of Cooper, 16, 174, 347.
- Lineæ** atrophicæ, 13.  
**Lipoma**, 126, 483, 511.  
 Localisation of neoplasms, 127, 185.  
 Lymphatics, 114.  
 Lymphatic glands, 183.
- Male breast.** Angioma, 512, 315; cancer, 333, 403; chronic mastitis, 534, 539; cold abscess, 541; chondroma, 512; cysts, 513; fibroma, 509; fibro-adenoma, 510; fistula, 553; galactocoele, 514; gynæcomastia, 105; lactation, 3, 103; lipoma, 511; melanoma, 333, 413; myxoma, 457; osteoma, 512; sarcoma, 456; subacute mastitis concomitant with pulmonary tubercle, 535; tubercle, 559; villous papilloma, 510.  
 Mammæ erraticæ, 47; mammæ in various animals, 43; multiple, 45.  
 Mammary ridges of Schultze, 81.  
 Man, antiquity and descent, 2.  
**Mastitis**, 525; acute, 546; associated with phthisis, 533; chronic, 529; cold abscess, 539; with inflammation, &c., of the nipple, 542; with malformed nipple, 548; in male, 534, 539, 541, 535, 559; microbes, 525.  
 Median nipples, &c., 52.  
 Membrana propria, 114.  
 Micromazia, 33.  
 Moles, 491.  
 Molluscum contagiosum, 563; fibrosum, 460.  
 Montgomery's gland, 10, 25; tubercles, 12, 24.  
 Morphology, 11.  
 Myoma, 491.  
 Myxoma, 125, 450, 457.
- NEOPLASMS**, 73, 119, 127.  
 Neoplastic diathesis, 475.  
 Neuroma, 491.  
 Neuroses, 563.  
 Nerve supply, 119.
- Nipple**, absence, 37; anatomy, 23; cancer, 393, 413; defective, 38, 297, 338, 542, 548; discharges, 339; eczema, 545, 393; histology, 23; kenogenesis, 4; imperforate, 38; inflammation, 542; muscles of, 21; ontogeny, 8; papilloma, 374, 491; phylogeny, 8; relation to subjacent ribs, 17; retraction, 297, 337, 542.
- ONTOGENY**, 3, 8.  
 Origin of mammæ, 1, 8.  
 Osteoma, 486, 512.  
 Ovarian dermoids, containing mammary structures, 54.




- PAPILLOMA, cutaneous, 491; villous, 373, 510.  
 Paramammary neoplasms, 73.  
 Phylogeny of breast, 1; and nipple, 8.  
 Polymastia, 43; animals, 60; associated with other anomalies, 62; axillary, 63, 72; diagnosis, 63; diverse races, 60; erratic, 47; general pathology of, 55; heredity, 56, 62; origin of neoplasms from, 73; phylogenetical, 43; polythelia, 56; reversion, 53; sex, 55; sports, 53; twining, 61.  
 Post-embryonic variations, 11.  
 Pregnancy, mammary signs of, 11.  
 Processes, axillary, 64; cutaneous, 19.  
 Puberty, the mammæ at, 7.
- RETARDED development, 11.
- Sarcoma, 417; adeno-sarcoma, 426; age, 442; alveolar, 448; analysis of thirty cases, 419; axillary glands, 438; clinical features, 443; cysts and intra-cystic growths, 430, 434; dissemination, 439; duration of life, 441; fungus hæmatodes, 437; genesis, 124, 418, 428; heredity, 421, 425, 442; male, 456; malignancy, 438; microbes, 433; myxoma, 450, 457; non-cystic, 429; pure sarcoma, 444; recurrence, 439; relative frequency, 417; rhabdo-myo-sarcoma, 433; sex, 417; statistical summary of cases, 419, 424; stroma, 433; treatment, 443.  
 Scabies, 546.  
 Secretion, mammary, 115.  
 Secretory anomalies, 13.  
 Secondary sexual characters, 2.  
 Segmental organs, the mammæ as, 45.  
 Shape, tricuspid, 19.  
 Shoulder, mamma on, 49.  
 Sinus lacteus, 21.  
 Size of mammæ, 17.  
 Sports, 53.  
 Strapping, 567.  
 Stroma, 22, 114.  
 Sweat glands of axilla, 25.  
 Syphilis, 41, 561.  
 Supernumerary mammary structures, 43.
- THELOTHISM, 22.  
 Thigh, redundant mamma on, 49, 50.  
 Thrush, 563.  
 Traumata, 564.  
 Tubercle, 554.
- VARIATIONS, post-embryonic, 11.  
 Varieties of mammary neoplasms and their relative frequency, 127.  
 Virgins, lactation in, 15.  
 Vulvar mamma, 51.
- WEANING, as cause of atrophy, 40.  
 Weight of mammæ, 17, 40.















Riley, Chase & Wilson Ltd.  
Printers & Stationers  
100, Abchurch Lane, London, E.C. 4



