

**The essentials of histology : descriptive and practical for the use of students / by E.A. Schäfer.**

**Contributors**

Sharpey-Schäfer, E. A. Sir, 1850-1935.

**Publication/Creation**

London : Longmans, Green, 1894.

**Persistent URL**

<https://wellcomecollection.org/works/p9var278>

**License and attribution**

This work has been identified as being free of known restrictions under copyright law, including all related and neighbouring rights and is being made available under the Creative Commons, Public Domain Mark.

You can copy, modify, distribute and perform the work, even for commercial purposes, without asking permission.



Wellcome Collection  
183 Euston Road  
London NW1 2BE UK  
T +44 (0)20 7611 8722  
E [library@wellcomecollection.org](mailto:library@wellcomecollection.org)  
<https://wellcomecollection.org>

ESSENTIALS  
OF  
HISTOLOGY.




SCHÄFER.

M15276






22101017083







# HISTOLOGY





Digitized by the Internet Archive  
in 2014

THE ESSENTIALS  
OF  
HISTOLOGY

DESCRIPTIVE AND PRACTICAL

*FOR THE USE OF STUDENTS*

BY

E. A. SCHÄFER, F.R.S.

JODRELL PROFESSOR OF PHYSIOLOGY IN UNIVERSITY COLLEGE, LONDON  
EDITOR OF THE HISTOLOGICAL PORTION OF QUAIN'S 'ANATOMY'

*ILLUSTRATED BY MORE THAN 300 FIGURES*

FOURTH EDITION

LONDON  
LONGMANS, GREEN, AND CO.  
1894



*BIBLIOGRAPHICAL NOTE.*

*First Edition, May 1885; Second Edition, January 1887; Third Edition, enlarged, May 1892; Fourth Edition, April 1894.*

MIS276

WELLCOME INSTITUTE LIBRARY	
Acc.	340371
Call No.	Q5504 1894 553e

## PREFACE.

THIS BOOK is written with the object of supplying the student with directions for the microscopical examination of the tissues. At the same time it is intended to serve as an Elementary Textbook of Histology, comprising all the essential facts of the science, but omitting unimportant details, the discussion of which is only calculated to confuse the learner. For a similar reason references to authorities have also generally been omitted. Most of the illustrations are taken from Quain's *Anatomy*. Of the remainder, those which have been selected from other authors are duly indicated; the rest have either been drawn expressly for this work, or have been transferred to it from the author's *Course of Practical Histology*.

I am indebted to Dr. Ferrier for permission to use the illustrations of the structure of the spinal cord and cerebral cortex which have been contributed to the second edition of his book, *The Functions of the Brain*, by Mr. Bevan-Lewis.

For conveniently accompanying the work of a class of medical students, the book is divided into forty-five lessons. Each of these may be supposed to occupy a class from one to three hours, according to the extent to which the preparations are made beforehand by the



teacher or are prepared during the lesson by the students. A few of the preparations—*e.g.* some of those of the sense-organs—cannot well be made in a class, but it has been thought advisable not to injure the completeness of the work by omitting mention of them.

Only those methods are recommended upon which experience has proved that full dependence can be placed, but the directions given are for the most part capable of easy verbal modification in accordance with the ideas or experience of different teachers.

# CONTENTS.

## INTRODUCTORY.

	PAGE
ENUMERATION OF THE TISSUES—GENERAL STRUCTURE OF ANIMAL CELLS,	1

## LESSON I.

USE OF THE MICROSCOPE—EXAMINATION OF COMMON OBJECTS, . . .	6
--	---

## LESSON II.

STUDY OF THE HUMAN BLOOD-CORPUSCLES, . . . . .	10
--	----

## LESSON III.

ACTION OF REAGENTS UPON THE HUMAN BLOOD-CORPUSCLES, . . .	15
---	----

## LESSON IV.

STUDY OF THE BLOOD-CORPUSCLES OF AMPHIBIA, . . . . .	18
--	----

## LESSON V.

THE AMOEBOID PHENOMENA OF THE COLOURLESS BLOOD-CORPUSCLES, .	20
--	----

## LESSON VI.

EPITHELIUM—CELL-DIVISION, . . . . .	24
-------------------------------------	----



## LESSON VII.

COLUMNAR AND CILIATED EPITHELIUM AND TRANSITIONAL EPITHELIUM,	PAGE 30
---	------------

## LESSON VIII.

STUDY OF CILIA IN ACTION,	34
---------------------------	----

## LESSON IX.

THE CONNECTIVE TISSUES : AREOLAR AND ADIPOSE TISSUE,	37
--	----

## LESSON X.

THE CONNECTIVE TISSUES ( <i>continued</i> ) : ELASTIC TISSUE, FIBROUS TISSUE, DEVELOPMENT OF CONNECTIVE TISSUE,	45
--	----

## LESSON XI.

THE CONNECTIVE TISSUES ( <i>continued</i> ) : ARTICULAR CARTILAGE,	50
--	----

## LESSON XII.

THE CONNECTIVE TISSUES ( <i>continued</i> ) : COSTAL CARTILAGE, FIBRO- CARTILAGE,	54
--	----

## LESSON XIII.

THE CONNECTIVE TISSUES ( <i>continued</i> ) : BONE AND MARROW,	57
--	----

## LESSON XIV.

THE CONNECTIVE TISSUES ( <i>continued</i> ) : DEVELOPMENT OF BONE,	64
--	----

## LESSON XV.

STRUCTURE OF STRIATED MUSCLE,	72
-------------------------------	----

## LESSON XVI.

STRUCTURE OF STRIATED MUSCLE ( <i>continued</i> ),	75
--	----

## LESSON XVII.

	PAGE
CONNECTION OF MUSCLE WITH TENDON—BLOOD-VESSELS OF MUSCLE— CARDIAC MUSCLE—DEVELOPMENT OF MUSCLE—PLAIN MUSCLE, .	79

## LESSON XVIII.

STRUCTURE OF NERVE-FIBRES, . . . . .	83
--------------------------------------	----

## LESSONS XIX. AND XX.

STRUCTURE OF GANGLIA—STRUCTURE OF NERVE-CELLS—STRUCTURE OF NEUROGLIA - CELLS — DEVELOPMENT OF NERVE - FIBRES — WALLERIAN DEGENERATION, . . . . .	90
--	----

## LESSON XXI.

MODES OF TERMINATION OF NERVE-FIBRES, . . . . .	98
---	----

## LESSON XXII.

STRUCTURE OF THE LARGER BLOOD-VESSELS, . . . . .	107
--	-----

## LESSON XXIII.

SMALLER BLOOD-VESSELS, LYMPHATIC VESSELS, SEROUS MEMBRANES, SYNOVIAL MEMBRANES, . . . . .	112
--	-----

## LESSON XXIV.

LYMPHATIC GLANDS, TONSIL, THYMUS, . . . . .	121
---	-----

## LESSON XXV.

THE SKIN, . . . . .	127
---------------------	-----

## LESSON XXVI.

STRUCTURE OF THE HEART, . . . . .	139
-----------------------------------	-----

## LESSON XXVII.

THE TRACHEA AND LUNGS, . . . . .	143
----------------------------------	-----

## LESSON XXVIII.

	PAGE
STRUCTURE OF THE TEETH, THE TONGUE, AND MUCOUS MEMBRANE OF THE MOUTH, . . . . .	149

## LESSON XXIX.

THE SALIVARY GLANDS, . . . . .	161
--------------------------------	-----

## LESSON XXX.

THE STRUCTURE OF THE STOMACH, . . . . .	167
---	-----

## LESSONS XXXI. AND XXXII.

STRUCTURE OF SMALL AND LARGE INTESTINE, . . . . .	173
---	-----

## LESSON XXXIII.

STRUCTURE OF THE LIVER AND PANCREAS, . . . . .	181
--	-----

## LESSON XXXIV.

STRUCTURE OF THE SPLEEN, SUPRARENAL CAPSULE, AND THYROID BODY, . . . . .	187
---	-----

## LESSON XXXV.

STRUCTURE OF THE KIDNEY, . . . . .	192
------------------------------------	-----

## LESSON XXXVI.

STRUCTURE OF THE URETER, BLADDER, AND MALE GENERATIVE ORGANS, . . . . .	200
--	-----

## LESSON XXXVII.

GENERATIVE ORGANS OF THE FEMALE, AND MAMMARY GLANDS, . . . . .	209
--	-----

## LESSON XXXVIII.

STRUCTURE OF THE SPINAL CORD, . . . . .	216
---	-----

## LESSONS XXXIX. AND XL.

THE MEDULLA OBLONGATA, PONS VAROLII, AND MESENCEPHALON, . . . . .	227
---	-----



## LESSON XLI.

STRUCTURE OF THE CEREBELLUM AND CEREBRUM, . . . . .	PAGE 241
---	-------------

## LESSONS XLII. AND XLIII.

STRUCTURE OF THE EYELIDS AND OF THE PARTS OF THE EYEBALL, .	257
---	-----

## LESSON XLIV.

STRUCTURE OF THE OLFACTORY MUCOUS MEMBRANE AND OF THE EXTERNAL AND MIDDLE EAR, . . . . .	276
---	-----

## LESSON XLV.

STRUCTURE OF THE LABYRINTH, . . . . .	280
---------------------------------------	-----

## APPENDIX.

METHODS USED IN PREPARING SECTIONS, . . . . .	290
---	-----


INDEX, . . . . .	299
------------------	-----



*Hæmatëin.*—Hæmatoxylin-alum solutions acquire their colouring properties only as the hæmatoxylin on keeping becomes converted into hæmatëin. The latter substance may, therefore, as recommended by Meyer, be used advantageously in place of hæmatoxylin. The following mode of preparing the solution may be adopted:—Dissolve 50 grammes of ammonia alum in 1 litre of water, and 1 gramme of hæmatëin in 100 c.c. of rectified spirit. Add the hæmatëin solution gradually to the alum. The mixture is ready for staining at once, either as it is or diluted with water. A small piece of thymol should be added to prevent the growth of moulds.











# THE ESSENTIALS OF HISTOLOGY.

## INTRODUCTORY.

### ENUMERATION OF THE TISSUES AND THE GENERAL STRUCTURE OF ANIMAL CELLS.

**Animal Histology**<sup>1</sup> is the science which treats of the minute structure of the tissues and organs of the animal body ; it is studied with the aid of the microscope, and is therefore also termed *Microscopical Anatomy*.

Every part or organ of the body, when separated into minute fragments, or when examined in thin slices (sections), is found to consist of certain textures or tissues, which differ in their arrangement in different organs, but each of which exhibits characteristic structural features.

The following is a list of the principal tissues which compose the body :—

1. **Epithelial.**
2. **Connective** : Areolar, Fibrous, Elastic, Adipose, Lymphoid, Cartilage, Bone.
3. **Muscular** : Voluntary, Involuntary or plain, Cardiac.
4. **Nervous.**

Some organs are formed of several of the above tissues, others contain only one or two.

It is convenient to include such fluids as the *blood* and *lymph* amongst the tissues, because they are studied in the same manner and contain cellular elements similar to those met with in some of the other tissues.

The elements which compose the tissues are of the nature either of *fibres* or *cells*. Some tissues are composed almost entirely of fibres with relatively few cells interspersed amongst the fibres ; this is the case with most of the connective tissues. Others, such as the epithelial tissues, are composed entirely of cells, whilst nervous and muscular tissues are formed of cells which are partly or wholly extended to form fibres.

**Cells.**—A *cell* is a minute portion of living substance or *protoplasm*, which is sometimes inclosed by a *cell-membrane* and always contains a vesicle which is known as the *nucleus*.

The **protoplasm** of a cell (fig. 1, *p*) is composed of albuminous

<sup>1</sup> From *ιστός*, a web or texture.



substance, which is characterised in typical cells by possessing the property of spontaneous movement. When the cell is unincluded by a membrane a change in the shape, or even in the position of the cell, may be thereby produced (amoeboid movement, see Lesson V.). The protoplasm often exhibits a granular appearance, which, under high magnifying powers, is seen to be due to the fact that it is composed of two distinct substances (fig. 1), one a reticulum or spongework, which appears under the microscope in the form of a network, and the other a clear soft substance which occupies the interstices of the reticulum, and may also cover the surface or

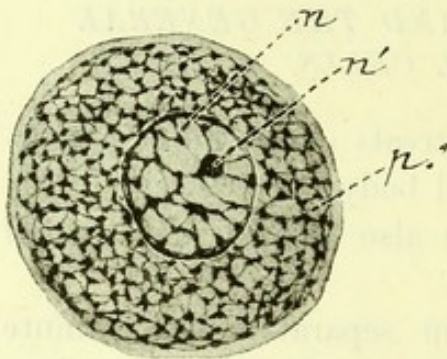


FIG. 1.—DIAGRAM OF A CELL.

*p*, protoplasm composed of spongioplasm and hyaloplasm; *n*, nucleus with intranuclear network; *n'*, nucleolus.

project beyond the rest of the cell. The granular appearance above mentioned is caused by the knots in the network appearing when imperfectly observed as separate granules. The material which forms the reticulum is termed *spongioplasm*; the clear material which occupies its meshes is *hyaloplasm*. The protoplasm often includes actual granules of albuminous or fatty nature, or globules of watery fluid (vacuoles) containing glycogen or other substances in solu-

tion. Materials which are thus included in the protoplasm of a cell are either stored up for the nutrition of the cell itself, or are converted into substances which are eventually extruded from the cell in order to serve some purpose useful to the whole organism, such as the secretion which is furnished by the cells of a gland. The term *paraplasm* has been given by Kupffer to any such material within a cell other than the actual protoplasm. Paraplasm is often present in sufficient amount to reduce the protoplasm to a relatively small amount, the bulk of the cell being occupied by other material, as when starch becomes collected within vegetable cells or fat within the cells of adipose tissue. In some cells there are fine but distinct striæ or fibrils running in definite directions. These are very commonly met with in fixed cells, such as various kinds of epithelium-cells, nerve- and muscle-cells. But besides this special differentiation, which appears to be related to the special function of the cell, and is not universal, there is another definite structure in the cell-protoplasm, which is known as the *attraction-sphere* (fig. 2). This consists of a wheel like arrangement of fine fibrils or rows of granules, which radiate from a clear area, in the middle of which lies a central particle—the *attraction-particle*. The attraction-spheres were dis-



covered by v. Beneden in the ovum or egg-cell, and were at first supposed to be peculiar to the ovum, but they have now been recognised (by Flemming and others) in many cells, and are probably of universal occurrence. They are very often double, the twin

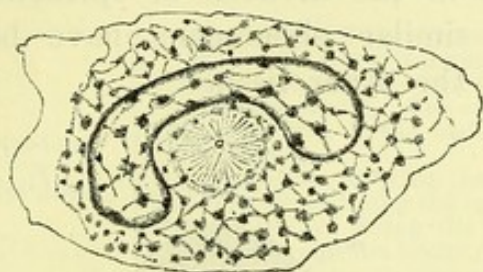


FIG. 2.—A CELL (WHITE BLOOD CORPUSCLE) SHOWING ITS ATTRACTION-SPHERE.

In this, as in most cases, the attraction-sphere lies near the nucleus.

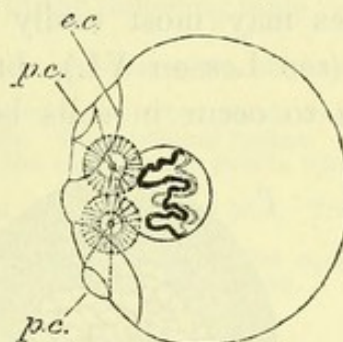


FIG. 3.—OVUM OF ASCARIS, SHOWING A TWIN ATTRACTION-SPHERE. (v. Beneden.)

The nucleus with its contorted filament of chromoplasm is represented, but the protoplasm of the cell is not filled in.

spheres being connected by a spindle-shaped system of delicate fibrils (*achromatic spindle*): this duplication invariably precedes the division of a cell into two (fig. 3).

A *cell-membrane* is rarely distinct in animal cells, nor has its chemical nature been sufficiently investigated. It is formed by the external layer of the protoplasm.

The **nucleus** of the cell (fig. 1, *n*) is a minute vesicle, spherical, ovoidal or elongated in shape, embedded in the protoplasm. It is bounded by a membrane which incloses a clear substance (*nuclear matrix*), and the whole of this substance is generally pervaded by an irregular network of fibres, some coarser, others finer (*intranuclear network*). This intranuclear network often exhibits one or more enlargements, which are known as the *nucleoli*. The nuclear membrane, intranuclear fibres and nucleoli all stain deeply with hæmatoxylin and with most other dyes; this property distinguishes them from the nuclear matrix, and they are accordingly spoken of as *chromatic*, composed of *chromoplasm*, the matrix as *achromatic*. Sometimes instead of uniting into a network the intranuclear fibres take the form of convoluted filaments, having a skein-like appearance. This is always the case when a nucleus is about to divide, but it may also occur in the resting condition. These filaments may sometimes be seen with very high magnifying powers to be made up of fine juxtaposed particles arranged either in single or multiple rows; thus imparting a cross-striated appearance to the filament (see fig. 4, B, C). The fibres within the nucleus have been observed to undergo spontaneous changes of form and arrangement, but these become much



more evident during its division. The division of the protoplasm is always preceded by that of the nucleus, and the intranuclear fibres undergo during its division a series of remarkable changes which are known collectively by the term *karyokinesis* (Schleicher). These changes may most easily be studied in the division of epithelium-cells (see Lesson VI.), but exactly similar phenomena have been shown to occur in cells belonging to the other tissues.

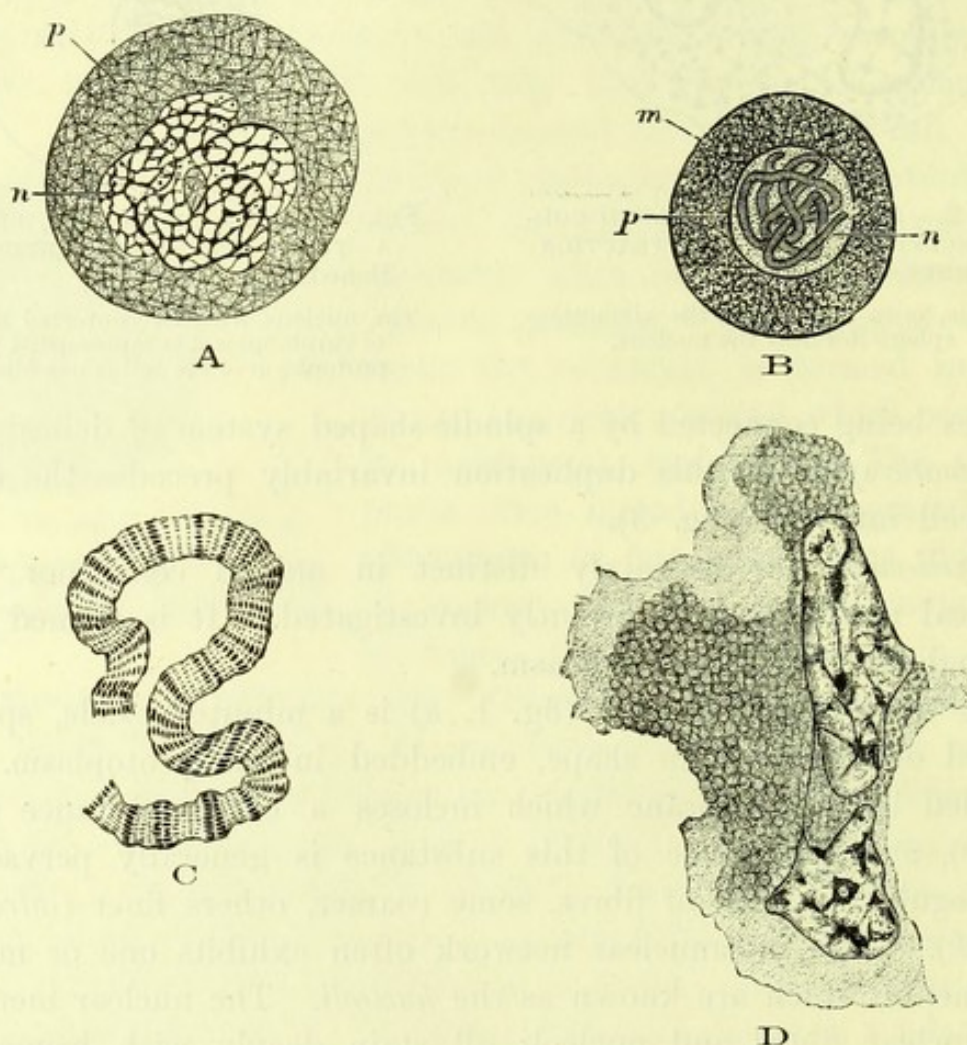


FIG. 4.—TO ILLUSTRATE THE STRUCTURE OF CELLS AND NUCLEI.

A, cell from the marrow; *p*, protoplasm with fine reticulum; *n*, nucleus, long and folded, with intranuclear network. B, gland-cell from a larva of *Nemocera*; *m*, cell-membrane; *p*, protoplasm; *n*, nucleus with convoluted filament. C, part of the nuclear filament in B, greatly magnified. D, an amoeboid-cell (white blood-corpuscle) of the newt, very highly magnified, showing a double nucleus with reticulum of chromoplasm, and the protoplasm composed of two substances (spongioplasm and hyaloplasm). D is from a drawing by Mr. D. Gunn; A, B, and C are from Carnoy.

In the early embryo the whole body is an agglomeration of cells. These have all been formed from the *ovum* or *egg-cell*, which divides first into two cells, these again into two, and so on until a large number of cells (embryonic cells) are produced. Eventually the resultant cells arrange themselves in the form of a membrane (*blastoderm*) which is composed of three layers. These layers are known respectively as the *ectoderm* or *epiblast*, the *mesoderm* or *mesoblast*, and the *entoderm* or *hypoblast*. The ectoderm gives rise to most of the epithelial tissues and the tissues of the nervous system; the entoderm to the epithelium of the alimentary canal (except the mouth), and the glands in connection with it; and the mesoderm to the connective and muscular tissues.



The tissues are formed either by changes which occur in the intercellular substance, or by changes in the cells themselves; frequently by both these processes combined. The cells which are least altered from their embryonic condition are the white corpuscles of the blood, and these may be regarded therefore as typical cells.

The histogenetical relation between the three layers of the blastoderm and the several tissues and organs of the body is exhibited in the following table:—

Ectoderm or Epiblast.	{	The epithelium of the skin or epidermis, and its appendages, viz., the hairs, nails, sebaceous and sweat glands.
		The epithelium of the mouth, and of the salivary and other glands which open into the mouth. The enamel of the teeth. The gustatory organs.
		The epithelium of the nasal passages, and the cavities and glands which open into them.
		The epithelium covering the front of the eye. The crystalline lens. The retina.
		The epithelium lining the membranous labyrinth of the ear.
		The epithelium lining the central canal of the spinal cord, the aqueduct of Sylvius, and the fourth, third, and lateral ventricles of the brain.
		The tissues of the nervous system.
Mesoderm or Mesoblast.	{	The pituitary body. The pineal gland.
		The connective tissues.
		The blood- and lymph-corpuscles.
		The epithelial lining of the heart, blood-vessels, lymphatics, and serous membranes (endothelium).
		The epithelium of the uriniferous tubules.
Entoderm or Hypoblast.	{	The epithelium of the generative organs, and the generative products in both sexes.
		The muscular tissues, voluntary, involuntary, and cardiac.
		The spleen and other lymphatic and vascular glands.
		The epithelium of the alimentary canal (from the pharynx to the lower end of the rectum) and all the glands which open into it (including the liver and pancreas).
		The epithelium of the Eustachian tube and cavity of the tympanum.
		The epithelium of the larynx, trachea, and bronchi, and of all their ramifications.
	{	The epithelium of the pulmonary alveoli.
		The epithelium of the thyroid body. The concentric corpuscles of the thymus gland.
		The epithelium of the urinary bladder.



## LESSON I.

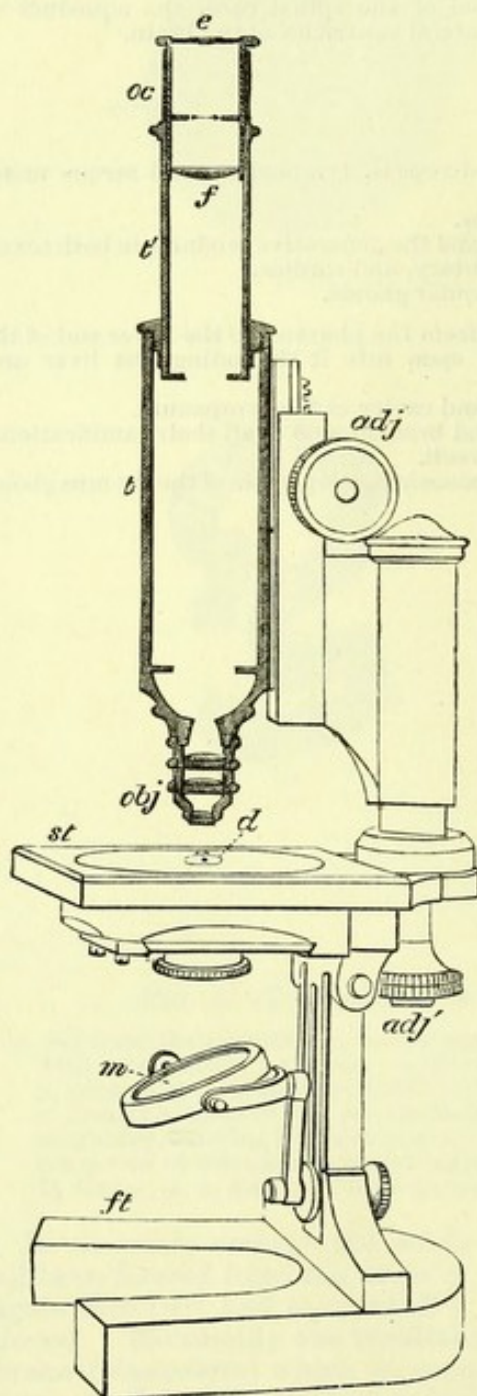
USE OF THE MICROSCOPE. EXAMINATION OF  
COMMON OBJECTS.

FIG. 5.—DIAGRAM OF MICROSCOPE.

THE requisites for practical Histology are a good compound microscope; slips of glass technically known as 'slides,' upon which the preparations are made; small pieces of thin glass used as covers for the preparations; a few simple instruments, such as a razor, a scalpel, scissors, fine-pointed forceps, and needles mounted in wooden handles; and a set of fluid reagents for mounting and staining microscopic preparations.<sup>1</sup> A sketch-book and pencil are also necessary, and must be constantly employed.

Examine the microscope (fig. 5). It consists of a tube (*t t'*) having two systems of lenses, one at the upper end termed the 'eye-piece' or 'ocular' (*oc*), the other at the lower end, termed the 'objective' (*obj*). There should be at least two objectives—a low power working at about  $\frac{1}{2}$  inch from the object, and a high power, having a focal distance of about  $\frac{1}{8}$  inch; and it is also useful to have two or more oculars of different power. The focus is obtained by cautiously bringing the tube and lenses down towards the object by the coarse adjustment, which is either a telescopic or a rack-and-pinion movement (*adj*), and focussing exactly by the fine adjustment, which is always a finely cut screw (*adj'*).

The stage (*st*) upon which the preparations are placed for examination, the mirror (*m*) which serves to reflect the light up through the central aperture in the stage and along the tube of the instrument, and the diaphragm (*d*) below the stage which is used to regulate the amount of light thus thrown up, are all parts the employment of which is readily understood. A substage condenser (not shown

<sup>1</sup>The directions for making the principal fluids used in histological work will be found in the Appendix.



in the diagram), which serves to concentrate the light thrown up by the mirror to the centre of the object, is valuable when high powers and stained preparations are employed.

The combinations of objectives ( $\frac{1}{2}$  inch and  $\frac{1}{6}$  inch focal distance) and oculars above referred to will generally give a magnifying power of from 50 to 400 diameters, and this is sufficient for most purposes of histology. But to bring out minute points of detail in the structure of cells and of certain tissues examination with much higher magnifying powers may be necessary. Objectives of high power are usually made as immersion-lenses; *i.e.*, they are constructed to form a proper image of the object when the lowermost lens of the system is immersed in a layer of liquid which lies on the cover-glass of the object and has a refractive index not far removed from that of the glass itself. For this purpose either water, or an essential oil (*e.g.* oil of cedar) is used. Many advantages are obtained by the employment of these lenses, especially those for oil-immersion.

The best lenses for histological work are those which are made of the so-called 'apochromatic' glass of Zeiss; with these, specially constructed 'compensating' eye-pieces are used. The only obstacle to their general use is their price.

Prepare a scale to serve for measuring objects under the microscope. To do this put a stage-micrometer (which is a glass slide ruled in the centre, with the lines  $\frac{1}{10}$  and  $\frac{1}{100}$  millimeter apart) under the microscope in such a manner that the lines run from left to right (the microscope must not be inclined). Focus them exactly. Put a piece of white card on the table at the right of the microscope. Look through the instrument with the left eye, keeping the right eye open. The lines of the micrometer will appear projected upon the paper. Mark their apparent distance with pencil upon the card, and afterwards make a scale of lines in ink the same interval apart. A magnified representation is thus obtained of the micrometer scale. Mark upon it the number of the eye-piece and of the objective, and the length of the microscope-tube. This scale-card will serve for the measurement of any object without the further use of the micrometer. To measure an object, place the scale-card upon the table to the right of the microscope and view the object with the left eye, keeping the right eye open. The object appears projected upon the scale, and its size in  $\frac{1}{10}$  or  $\frac{1}{100}$  of a millimeter can be read off. It is important that the same objective and eye-piece should be employed as were used in making the scale, and that the microscope tube should be of the same length. The lines on the English stage-micrometers are usually ruled  $\frac{1}{100}$  and  $\frac{1}{1000}$  inch apart.<sup>1</sup>

Before beginning the study of histology the student should endeavour to familiarise himself with the use of the microscope, and at the same time learn to recognise some of the chief objects which are liable to occur accidentally in microscopic specimens. On this account it has been considered desirable to introduce directions for the examination of starch-granules, moulds and torulae, air-bubbles, linen, cotton, and woollen fibres, and the usual constituents of the dust of a room, into the first practical lesson.

1. Examination of starch-granules. Gently scrape the cut surface of a potato with the point of a knife; shake the starch-granules so obtained into a drop of water upon a clean slide and apply a cover-glass.

With the low power the starch-granules look like dark specks differing considerably in size; under the high power they are clear, flat, ovoid particles (fig. 6, *St*), with a sharp outline when exactly focussed. Notice the change in appearance of the outline as the microscope is focussed up or down. On close examination fine concentric lines are to be seen in the granules arranged

<sup>1</sup> For the method of measuring with an ocular micrometer, and for determining the magnifying power of a microscope, the student is referred to the author's *Course of Practical Histology*.



around a minute spot which is generally placed eccentrically near the smaller end of the granule. Sketch two or three starch-granules.

Notice the appearance of air-bubbles in the water. If comparatively

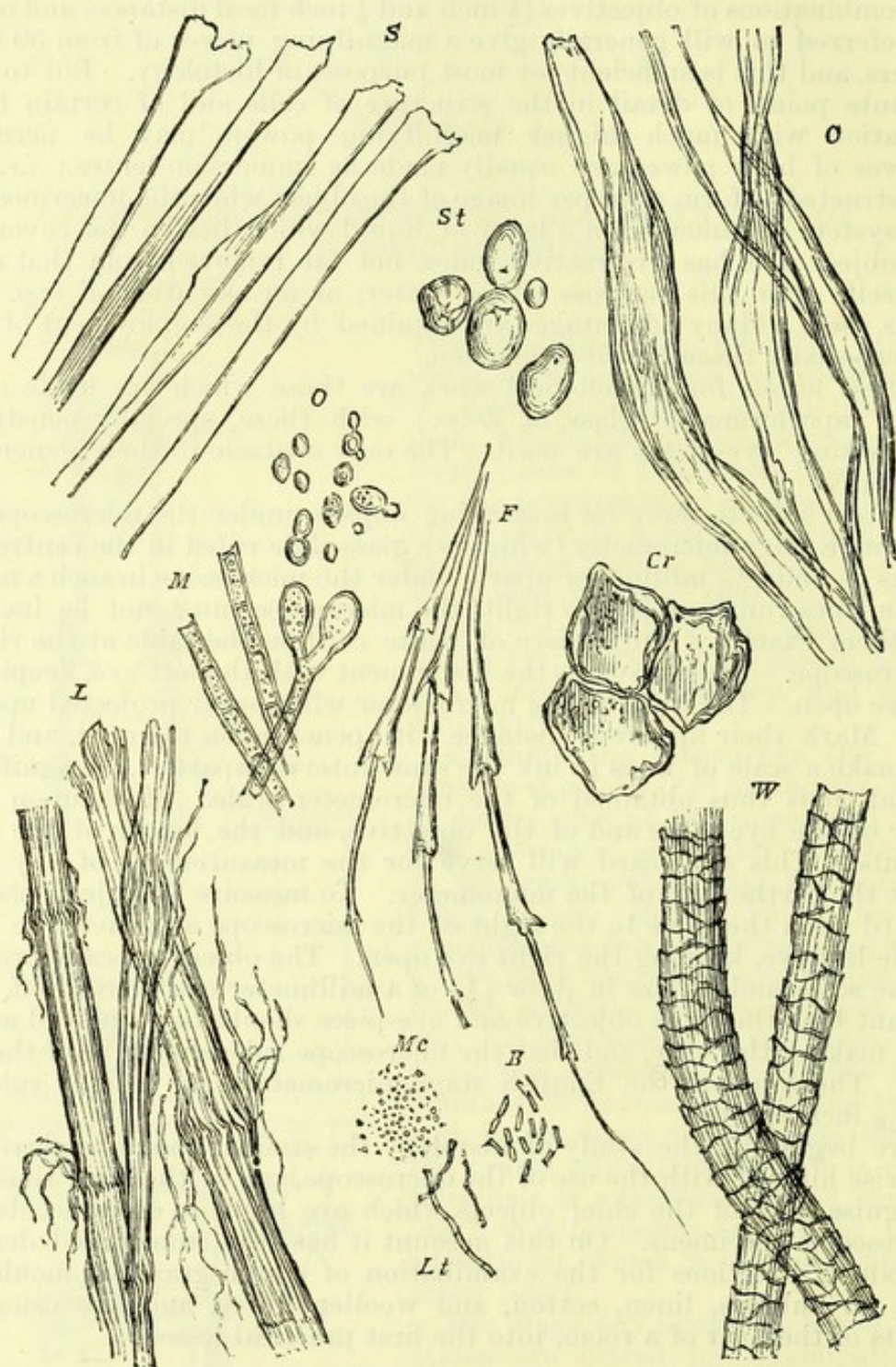


FIG. 6.—ORGANIC MATTERS FREQUENTLY PRESENT IN DUST. (Heitzmann.)

*S*, fibres of silk; *C*, of cotton; *L*, of linen; *W*, of wool; *F*, feather; *St*, starch-granules; *Cr*, cork; *O*, torulae; *M*, mycelium or threads of mildew; *Mc*, micrococci; *B*, bacteria; *Lt*, leptothrix filaments (500 diameters).

large they are clear in the middle, with a broad dark border due to refraction of the light; if small they may look entirely dark.

2. Examine some brewers' yeast which has been grown in solution of sugar. Observe the yeast-particles or torulae, some of them budding. Each torula contains a clear vacuole, and has a well-defined outline, due to a membrane. Sketch two or three torulae.



3. Examine some mould (*Penicillium* or *Mucor*) in water. Notice the long branching filaments (hyphæ), and also the torula-like particles (spores) from which hyphæ may in some instances be seen sprouting. Sketch part of a hypha.

4. Examine fibres of linen and of cotton in water, using a high power. Compare the well-defined, relatively coarse, striated, and slightly twisted linen, with the longer, thinner, and more twisted cotton-fibres. Sketch one of each kind.

5. Mount two or three hairs from the head in water and look at them, first with the low, then with the high power. Examine also some fibres from any woollen material and compare them with the hairs. They have the same structure, although the wool is finer and is curled; its structure may be partly obscured by the dye. Draw one or two woollen fibres.

6. Examine some dust of the room in water with a high power. In addition to numerous groups of black particles of carbon (soot) there will probably be seen fibres of linen, cotton, or wool, and shed epithelium-cells derived from the epidermis.



## LESSON II.

*STUDY OF THE HUMAN BLOOD-CORPUSCLES.*

1. HAVING cleaned a slide and cover-glass, prick the finger and mount a small drop of blood quickly, so that it has time neither to dry nor to coagulate. Examine it at once with the high power.

Note (a) the coloured corpuscles, mostly in rouleaux and clumps, but some lying apart seen flat or in profile; (b) the colourless corpuscles, easily made out if the cover-glass is touched by a needle, on account of their tendency to stick to the glass, whilst the coloured corpuscles are driven past by the currents set up; (c) in the clear spaces, fibrin-filaments and elementary particles or blood-tablets.

Sketch a roll of coloured corpuscles and one or two colourless corpuscles. Count the number of colourless corpuscles in a field of the microscope.

2. To be made like 1, but the drop of blood is to be mixed upon the slide with an equal amount of normal saline solution,<sup>1</sup> so that the red corpuscles tend to be less massed together, and their peculiar shape is better displayed.

Sketch a red corpuscle seen on the flat and another in profile (or optical section). Also a crenated corpuscle.

Measure ten red corpuscles, and from the results ascertain the average diameter of a corpuscle. Measure also the largest and the smallest you can find.

3. Make a preparation of blood as in § 1 and put it aside to coagulate. After fifteen minutes allow a drop of a strong solution of neutral carminate of ammonia to run under the cover-glass. This decolorises the red corpuscles, but stains the nuclei of the white corpuscles and brings the network of fibrin-filaments and the elementary particles clearly into view (fig. 10, A). When the fibrin is fully stained, a drop of glycerine is allowed to diffuse into the fluid. The cover-glass may then be cemented with gold-size and the preparation labelled and kept.

4. Enumeration of the blood-corpuscles. This is done by some form of blood-counter such as the hæmacytometer of Gowers. This instrument consists of a glass slide (fig. 7. c), the centre of which is ruled into  $\frac{1}{10}$  millimeter squares and surrounded by a glass ring  $\frac{1}{2}$  mm. thick. It is provided with measuring pipettes (A and B), a vessel (D) for mixing the blood with a saline solution (sulphate of soda of sp. gr. 1015), glass stirrer (E) and guarded needle (F).

995 cubic millimeters of the saline solution are placed in the mixing jar; 5 cubic millimeters of blood are then drawn from a puncture in the finger and blown into the solution. The two fluids are well mixed by the stirrer and a small drop of this dilution (1 to 200) is placed in the centre of the cell, the cover-glass gently laid on (so as to touch the drop, which thus forms a layer  $\frac{1}{2}$  mm. thick between the slide and cover-glass) and pressed down by two brass springs. In a few minutes the corpuscles have sunk to the bottom of the layer of fluid and rest on the squares. The number in ten squares is then counted, and this, multiplied by 50 gives the number in a cubic milli-

<sup>1</sup> Made by dissolving 6 grammes of common salt in 1 litre of ordinary water.



meter of the mixture, or if multiplied by  $50 \times 200 (= 10,000)$  the number in a cubic millimeter of blood is obtained.

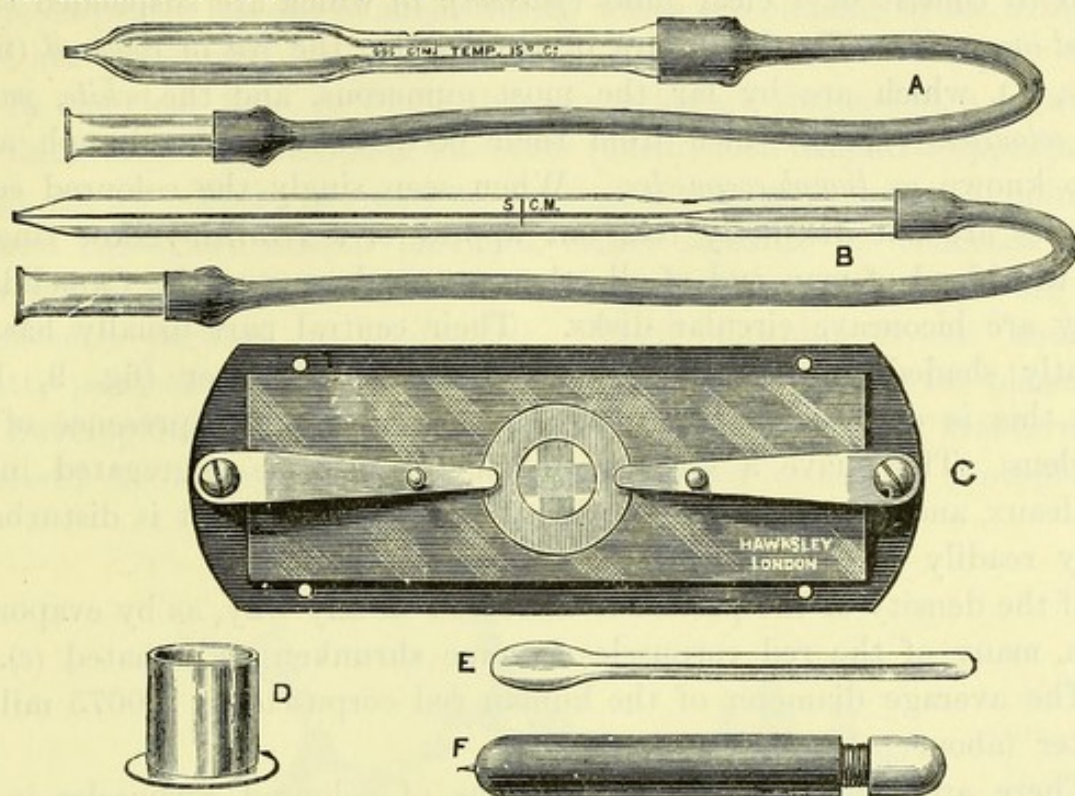


FIG. 7.—HEMACYTOMETER OF GOWERS.

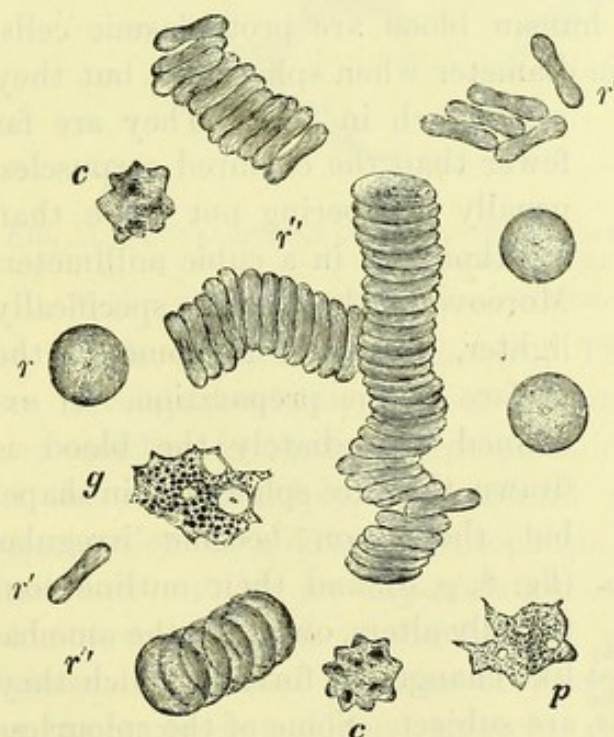


FIG. 8.—HUMAN BLOOD AS SEEN ON THE WARM STAGE. (Magnified about 1200 diameters.)

*r*, *r'*, single red corpuscles seen lying flat; *r'*, *r''*, red corpuscles on their edge and viewed in profile; *r'''*, red corpuscles arranged in rouleaux; *c*, *c*, crenate red corpuscles; *p*, a finely granular pale corpuscle; *g*, a coarsely granular pale corpuscle. Both have two or three distinct vacuoles, and were undergoing changes of shape at the moment of observation; in *g*, a nucleus also is visible.

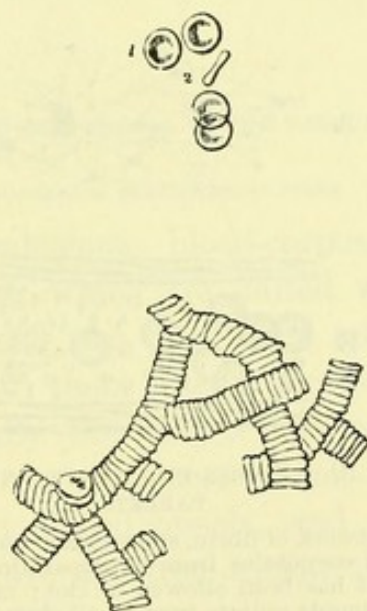


FIG. 9.—HUMAN RED CORPUSCLES LYING SINGLY AND COLLECTED INTO ROLLS. (As seen under an ordinary high power of the microscope.)

1, On the flat; 2, in profile.



**The coloured blood-corpuscles.**—Under the microscope the blood is seen to consist of a clear fluid (*plasma*), in which are suspended the *blood-corpuscles*. The latter are of two kinds: the *red* or *coloured* (fig. 8, *r*, *r'*), which are by far the most numerous, and the *white*, *pale*, or *colourless* (*p*, *g*), which from their occurrence in the lymph are also known as *lymph-corpuscles*. When seen singly the coloured corpuscles are not distinctly red, but appear of a reddish-yellow tinge. In the blood of man and of all other mammals, except the *Camelidæ*, they are biconcave circular disks. Their central part usually has a lightly shaded aspect, under the ordinary high power (fig. 9, 1), but this is due to their biconcave shape, not to the presence of a nucleus. They have a strong tendency to become aggregated into rouleaux and clumps when the blood is at rest, but if it is disturbed they readily become separated.

If the density of the plasma is increased in any way, as by evaporation, many of the red corpuscles become shrunken or crenated (*c*).

The average diameter of the human red corpuscles is 0.0075 millimeter (about  $\frac{1}{3200}$  inch).<sup>1</sup>

There are from four to five millions of coloured corpuscles in a cubic millimeter of blood.

The **colourless corpuscles** of human blood are protoplasmic cells, averaging 0.01 mm. ( $\frac{1}{2500}$  inch) in diameter when spheroidal, but they

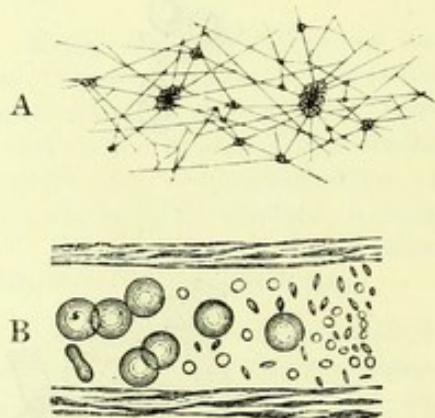


FIG. 10.—FIBRIN-FILAMENTS AND BLOOD-TABLETS.

A, network of fibrin, shown after washing away the corpuscles from a preparation of blood that has been allowed to clot; many of the filaments radiate from small clumps of blood-tablets. B (from Osler), blood-corpuscles and elementary particles of blood-tablets, within a small vein.

vary much in size. They are far fewer than the coloured corpuscles, usually numbering not more than ten thousand in a cubic millimeter. Moreover, they are specifically lighter, and tend to come to the surface of the preparation. If examined immediately the blood is drawn, they are spheroidal in shape, but they soon become irregular (fig. 8, *p*, *g*), and their outline continually alters, owing to the amœba-like changes of form to which they are subject. Some of the colourless corpuscles are very pale and finely granular, others contain coarser and

more distinct granules in their protoplasm. The protoplasm may also

<sup>1</sup> The following list gives the diameter in parts of a millimeter of the red blood-corpuscles of some of the common domestic animals:—Dog, 0.0073; rabbit, 0.0069; cat, 0.0065; sheep, 0.0050; goat, 0.0041.



contain clear spaces or vacuoles, and it has a reticular structure. Each pale corpuscle has one or more nuclei, which are difficult to see without the aid of reagents.

In the clear fluid in which the corpuscles are suspended, a network of fine straight intercrossing filaments (fibrin) soon makes its appearance (fig. 10, A). There are also to be seen a certain number of minute round colourless discoid particles, either separate or collected into groups or masses, which may be of considerable size. These are the *elementary particles* or *blood-tablets*. Their meaning is not known. Fatty particles, derived from the chyle, may also occur in the plasma.

**Development of blood-corpuscles.**—In the embryo, the first-formed *coloured blood-corpuscles* are amœboid nucleated cells, the protoplasm

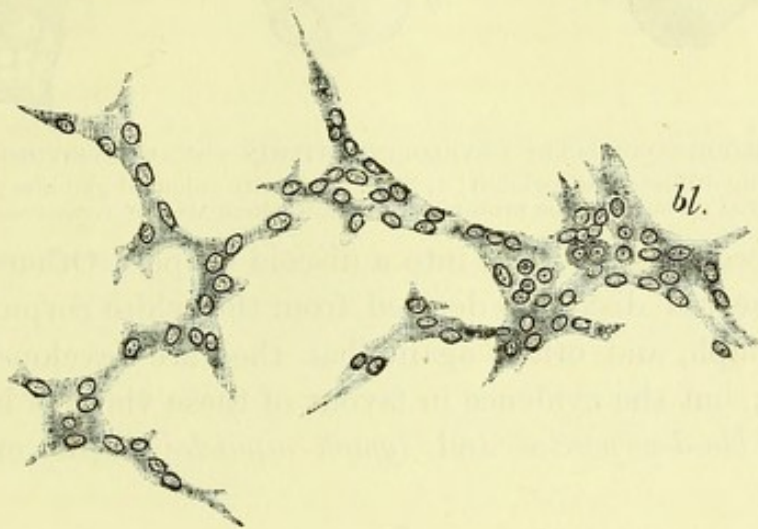


FIG. 11.—DEVELOPMENT OF BLOOD-VESSELS AND BLOOD-CORPUSCLES IN THE VASCULAR AREA OF THE GUINEA-PIG.

*bl.*, blood-corpuscles becoming free in the interior of a nucleated protoplasmic mass.

of which contains hæmoglobin. These embryonic blood-corpuscles are developed within cells of the mesoblast, which are united with one another to form a protoplasmic network (fig. 11). The nuclei of the cells multiply, and around some of them there occurs an aggregation of coloured protoplasm. Finally the network becomes hollowed out by an accumulation of fluid in the protoplasm, and thus are produced a number of capillary blood-vessels, and the coloured nucleated portions of protoplasm are set free within them as the embryonic blood-corpuscles (fig. 11, *bl.*).

In later embryonic life, nucleated coloured corpuscles disappear from mammalian blood, and are replaced by the usual discoid corpuscles. These are formed within certain cells of the connective tissue, a portion of the substance of the cell becoming coloured by hæmoglobin, and separated into globular particles (fig. 12, *a, b, c*), which are gradually moulded into disk-shaped red corpuscles. In the meantime the cells



become hollowed out, and join with similar neighbouring cells to form blood-vessels (fig. 13, *a*, *b*, *c*). The process is therefore the same as before, except that the cell-nuclei do not participate in it.

Although no nucleated coloured corpuscles are to be seen in the blood in post-embryonic life, they continue to be formed in the marrow of the bones (see Lesson XIII.), and in some animals they have also been found in the spleen. It is thought probable that the red disks may be formed from these by the nucleus disappearing and the coloured

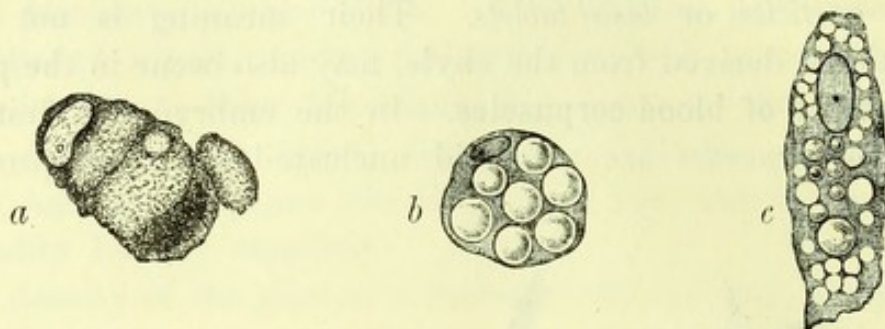


FIG. 12.—BLOOD-CORPUSCLES DEVELOPING WITHIN CONNECTIVE-TISSUE CELLS.

*a*, a cell containing diffused hæmoglobin; *b*, a cell filled with coloured globules; *c*, a cell containing coloured globules in the protoplasm, within which also are numerous vacuoles.

protoplasm becoming moulded into a discoid shape. Others have supposed that the red disks are derived from the white corpuscles of the blood and lymph, and others again that they are developed from the blood-tablets; but the evidence in favour of these views is insufficient.

The *white blood-corpuscles* and *lymph-corpuscles* occur originally as

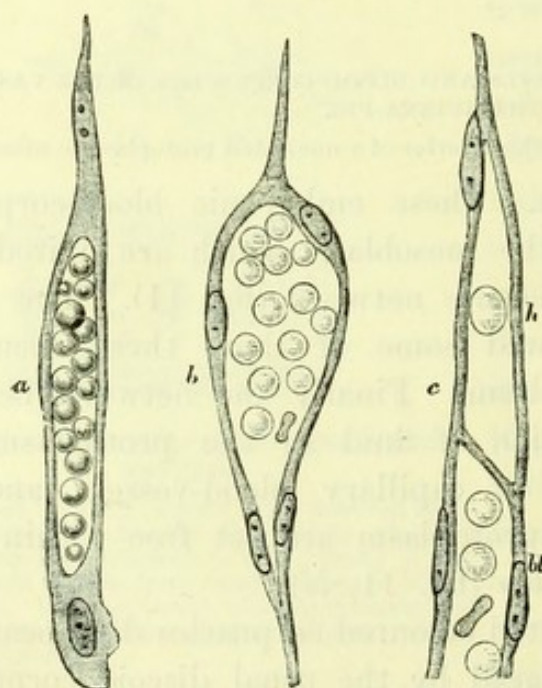


FIG. 13.—FURTHER DEVELOPMENT OF BLOOD-CORPUSCLES IN CONNECTIVE-TISSUE CELLS, AND TRANSFORMATION OF THE LATTER INTO CAPILLARY BLOOD-VESSELS.

*a*, an elongated cell with a cavity in its protoplasm occupied by fluid and by blood-corpuscles mostly globular; *b*, a hollow cell the nucleus of which has multiplied. The new nuclei are arranged around the wall of the cavity, the corpuscles in which have now become discoid; *c* shows the mode of union of a 'hæmapoietic' cell, which in this instance contains only one corpuscle, with the prolongation (*bl*) of a previously existing vessel. *a*, and *c*, from the new-born rat; *b*, from a foetal sheep.

free unaltered embryonic cells, which have found their way into the vessels from the circumjacent mesoblast. Later they become formed in lymphatic glands and other organs composed of lymphoid tissue, and pass from these directly into the lymphatics and so into the blood.



## LESSON III.

## ACTION OF REAGENTS UPON THE HUMAN BLOOD-CORPUSCLES.

1. MAKE a preparation of blood as in Lesson II. 1, and apply a drop of water, at one edge of the cover-glass. Examine at a place where the two fluids are becoming mixed. Notice particularly the first effect of water upon both red and white corpuscles, as well as the ultimate action.

Sketch both kinds of corpuscles under the action of water.

2. Repeat on another preparation, using very dilute alkali (0.2 per cent. potash in salt solution) instead of water. Notice the complete solution first of the white and then of the coloured corpuscles as the alkali reaches them.

3. Repeat on another preparation, using dilute acetic acid (1 per cent.). Observe that the effect of the acid upon the coloured corpuscles is similar to that of water, but that it has a different action upon the colourless corpuscles.

Sketch two or three of the latter after the action is completed.

4. Make a preparation of blood mixed with salt solution as in Lesson II. 2, and investigate the action of tannic acid (1 part tannic acid to 100 of distilled water) in the same way.

Sketch two or three coloured corpuscles after the reaction is complete.

The action of reagents upon the human red blood-corpuscles shows that, although to all appearance homogeneous, they in reality consist of an external envelope of colourless material which forms a thin film enclosing the dissolved colouring matter or *hæmoglobin*. Thus, when water reaches the corpuscle, it passes through the film by osmosis and swells the corpuscle, causing it to become globular; eventually the film is burst through, and the colouring matter escapes into the serum. Salt, on the other hand, by increasing the density of the fluid in which the corpuscles float, causes a diffusion of water out of the corpuscle, and a consequent shrinking and corrugation of the surface, the crenated form (fig. 8, *c*; fig. 14, *f*) being thereby produced. The separation of the hæmoglobin from the corpuscle can be effected not only by water (fig. 14, *a-e*), but also by dilute acids, by the action of heat (60° C.), the freezing and thawing

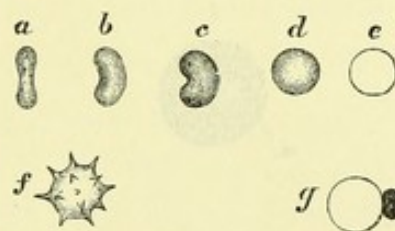

FIG. 14.

*a-e*, successive effects of water upon a red corpuscle; *f*, effect of solution of salt; *g*, effect of tannic acid.



of blood, the vapour of chloroform, and the passage of electric shocks through blood.<sup>1</sup> The mixing of human blood with the blood or serum of various animals also has a similar action, probably owing to differences of density or alkalinity. Tannic acid produces a peculiar effect (fig. 14, *g*); the hæmoglobin is discharged from the corpuscle, but is immediately altered and precipitated, remaining adherent to the envelope in the form of a round or irregular globule of a brownish tinge (hematin?).

Some of these reactions occur by process of osmosis as in the case of water, but in others a physical or chemical solution of the envelope of the corpuscle is produced, and the hæmoglobin is thus allowed to escape. The film or envelope is probably in large measure composed of lecithin and cholesterin (along with a little cell-globulin—Halliburton), and these are substances which possess many of the physical properties of fats, although of a different chemical composition. If we assume this to be its composition the running of the red disks into rouleaux can readily be explained, since it has been shown by Norris that disks of any material, *e.g.* cork, floating in a fluid, tend in the same way to adhere in rouleaux, provided their surfaces are covered with a layer which is not wetted by the fluid.

The envelope of the red corpuscle is often termed the *stroma* (Rollett), but this name rests upon an entirely false conception of the structure of the corpuscle, and although of late years almost universally used, it ought to be entirely abandoned. In adopting the name, it was supposed that the corpuscle is formed of a homogeneous porous material (*stroma*), in the pores of which the hæmoglobin is contained, but there is no reasonable foundation for this belief, whereas the supposition that there exists a delicate external film or envelope enclosing a coloured fluid is in accordance with all the known facts regarding the action of reagents upon these bodies.

The structure of the **colourless corpuscles** is also brought out by the action of some of these reagents. As the water reaches them their amœboid movements cease; they become swollen out into a globular

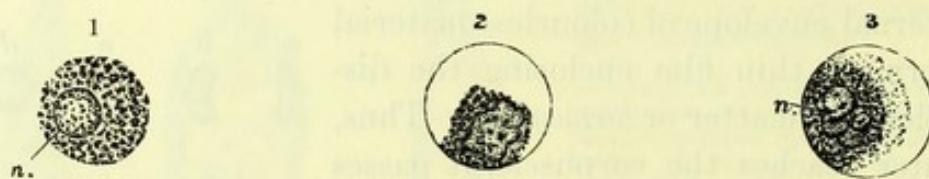


FIG. 15.

1, first effect of the action of water upon a white blood corpuscle; 2, 3, white corpuscles treated with dilute acetic acid; *n*, nucleus.

form by imbibition of fluid (fig. 15, 1), and the granules within the protoplasm can be seen to be in active Brownian motion. Their nuclei

<sup>1</sup>In the blood of some animals crystals of hæmoglobin readily form after its separation by any of these means from the red corpuscles. These crystals are rhombic prisms in most animals, but tetrahedra in the guinea-pig, and hexagonal plates in the squirrel. They are most appropriately studied along with the chemical and physical properties of blood, and are therefore omitted here. The same remark applies to the minute dark-brown rhombic crystals (*hæmin*), which are found when dried blood is heated with glacial acetic acid, and to the reddish-yellow crystals of *hæmatoidin*, which are found in old blood extravasations.



also become clear and globular, and are more conspicuous than before. With the further action of the water, the corpuscle bursts and the granules are set free.

Acids have an entirely different action upon the white corpuscles. Their nuclei become somewhat shrunken and very distinct (fig. 15, 2 and 3), and a granular precipitate is formed in the protoplasm around the nucleus. At the same time, a part of the protoplasm generally swells out so as to form a clear bleb-like expansion (an appearance which often accompanies the death of the corpuscle from other causes).

## LESSON IV.

*STUDY OF THE BLOOD-CORPUSCLES OF AMPHIBIA.*

1. MOUNT a drop of newt's blood obtained from the cut end of the tail. It may be allowed to mix with a very small quantity of salt solution. Examine with the high power. Notice the shape of the coloured corpuscles both when seen flat and edgewise, and the nucleus within each.

Measure ten corpuscles (long and short diameters), and from the results obtain the average dimensions of the newt's blood-corpuscle.

Notice also the colourless corpuscles, smaller than the red, but considerably larger than the pale corpuscles of human blood, although otherwise resembling these.

Sketch two or three red corpuscles and as many white.

Be careful not to mistake the liberated nuclei of crushed red corpuscles for pale corpuscles.

Enormous cells and nuclei belonging to the cutaneous glands as well as the granular secretion of those glands may be present in this preparation.

2. Apply a drop of water to the edge of the cover-glass of the same preparation and notice its action upon the corpuscles.

Sketch two or three corpuscles altered by the action of the water.

3. Mount another drop of blood, and apply dilute acetic acid (1 per cent.) instead of water at the edge of the cover-glass. Make sketches showing the effect of the acid upon both red and white corpuscles.

4. Examine the corpuscles of newt's blood which has been allowed to flow into boracic acid solution (2 per cent.). Notice the effect produced upon the coloured corpuscles. Sketch one or two.

The coloured blood-corpuscles of amphibia (fig. 16), as well as of most vertebrates below mammals, are biconvex elliptical disks, considerably larger than the biconcave circular disks of mammals.<sup>1</sup> In addition to the coloured body of the corpuscle, which consists, as in mammals, of hæmoglobin inclosed within an envelope, there is a colourless *nucleus*, also of an elliptical shape, but easily becoming

<sup>1</sup> The following are the dimensions in parts of a millimeter of some of the corpuscles of oviparous vertebrates:—

	Long diameter	Short diameter
Pigeon, . . . . .	0·0147	0·0065
Frog, . . . . .	0·0223	0·0157
Newt, . . . . .	0·0293	0·0195
Proteus, . . . . .	0·0580	0·0350
Amphiuma, . . . . .	0·0770	0·0460



globular, especially if liberated by any means from the corpuscle. The nucleus resembles that of other cells in structure, being bounded by a membrane, and having a network of filaments traversing its interior (fig. 17). It is not very distinct in the unaltered corpuscle, but is brought clearly into view by the action of reagents, especially acetic acid. The action of reagents upon the red corpuscle of amphibia is otherwise similar to that produced upon the mammalian

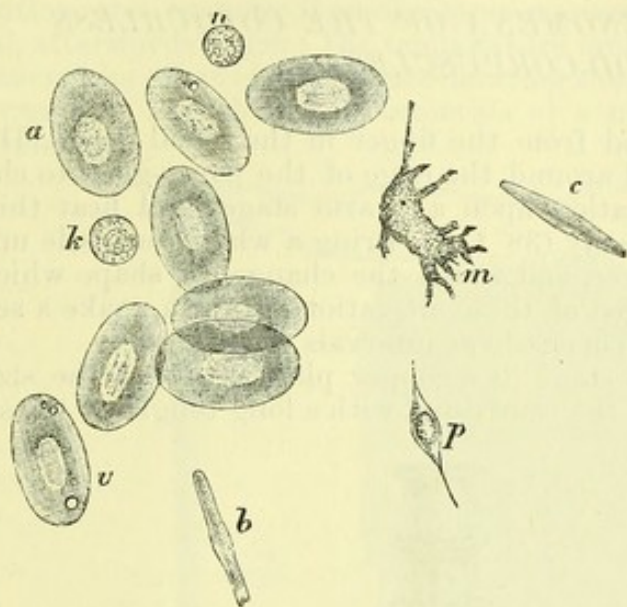


FIG. 16.—FROG'S BLOOD. (Ranvier.)

*a*, red corpuscle seen on the flat; *v*, vacuoles in a corpuscle; *b*, *c*, red corpuscles in profile; *k*, *n*, pale corpuscles at rest; *m*, pale corpuscle exhibiting amoeboid movements; *p*, colourless fusiform corpuscle.

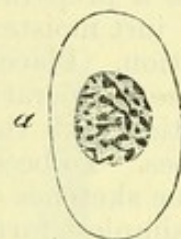


FIG. 17.—COLOURED CORPUSCLE OF SALAMANDER, SHOWING INTRANUCLEAR NETWORK. (Flemming.)

corpuscle, water and acetic acid causing it to swell into a globular form and then to become decolorised; solution of salt causing wrinkling of the envelope, and so on. Boracic acid acts like tannic acid in causing the hæmoglobin to be withdrawn from the envelope; but it becomes partially or wholly collected around the nucleus, which may then be extruded from the corpuscle.

The colourless corpuscles (fig. 16, *k*, *m*, *n*), although larger, are very similar to those of mammals. Like them, they are either wholly pale or inclose a number of dark granules. They vary much in size and in the activity of their amoeboid movements. They may have one or several nuclei. Reagents have the same effect upon them as on those of mammals. The presence of glycogen may be demonstrated in them by its reaction with iodine (port-wine colour).



## LESSON V.

*THE AMŒBOID PHENOMENA OF THE COLOURLESS  
BLOOD-CORPUSCLES.*

1. MAKE a preparation of blood from the finger in the usual way. Draw a brush just moistened with oil around the edge of the cover-glass to check evaporation. Place the preparation upon a 'warm stage,' and heat this to about the temperature of the body ( $38^{\circ}$  C.). Bring a white corpuscle under observation with the high power, and watch the changes of shape which it undergoes. To become convinced of these alterations in form, make a series of outline sketches of the same corpuscle at intervals of a minute.

The simplest form of 'warm stage' is a copper plate of about the size of an ordinary slide, perforated in the centre and with a long tongue of the same

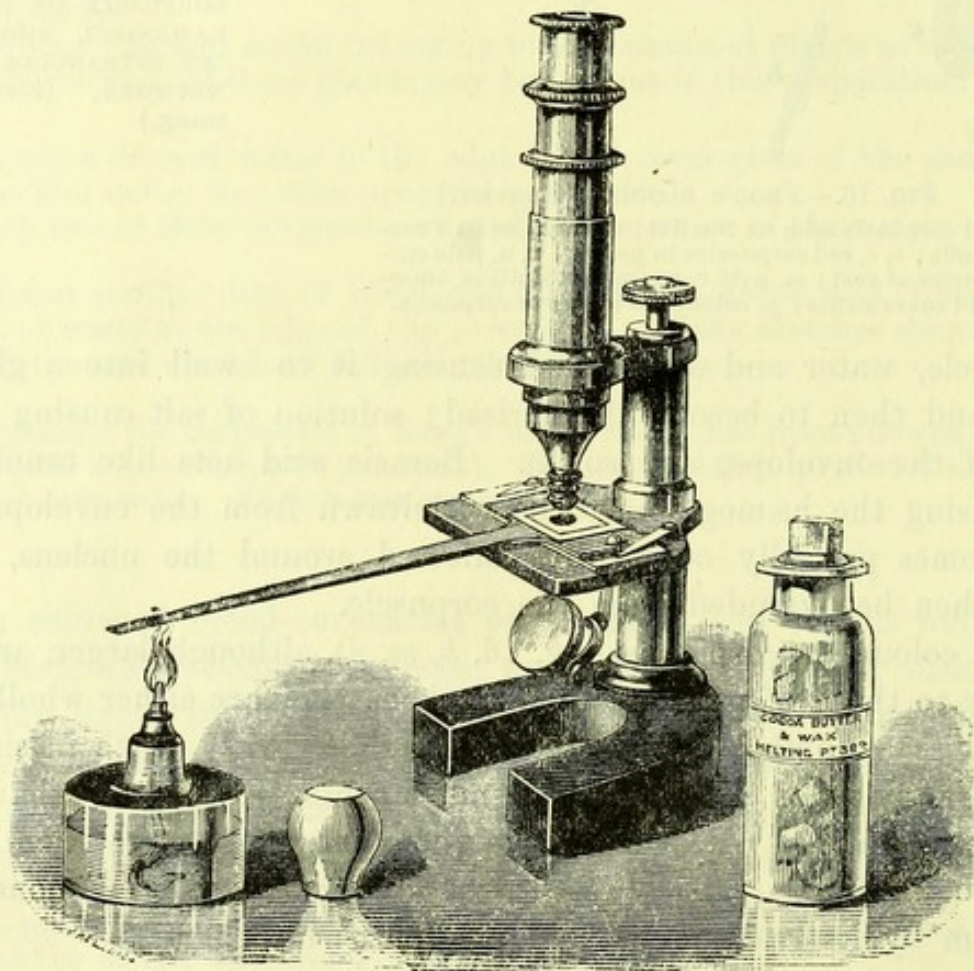


FIG. 18.—SIMPLE WARMING APPARATUS, COMPLETE, SHOWN IN OPERATION.

metal projecting from the middle of one edge (fig. 18). The copper plate rests upon the stage of the microscope with a piece of cloth or other non-conducting material between. The preparation is made upon an ordinary slide, which is placed upon the warm stage and pressed into contact with



it by the brass clips. Heat is applied to the copper tongue by a small spirit-lamp flame, and a greater or less amount is conducted to the warm stage and the superjacent preparation according to the point to which the flame is applied. To ascertain that the right temperature is got and maintained, put two pieces of paraffin, one melting at  $35^{\circ}\text{C}$ . ( $95^{\circ}\text{F}$ .) and another at  $38^{\circ}\text{C}$ . ( $100^{\circ}\text{F}$ .), on the slide, one on either side of the preparation. The temperature must be such that the first piece is melted and remains so whilst the second remains solid.<sup>1</sup>

2. Mount a drop of newt's blood diluted with an equal amount of salt solution, and examine it in the same manner upon the copper stage, at first cold, afterwards warm; the temperature must, however, be kept below  $30^{\circ}\text{C}$ . Observe the effect of heat in accelerating the amoeboid movements of the pale corpuscles. Sketch one at intervals of a minute (*a*) in the cold, (*b*) whilst warmed.

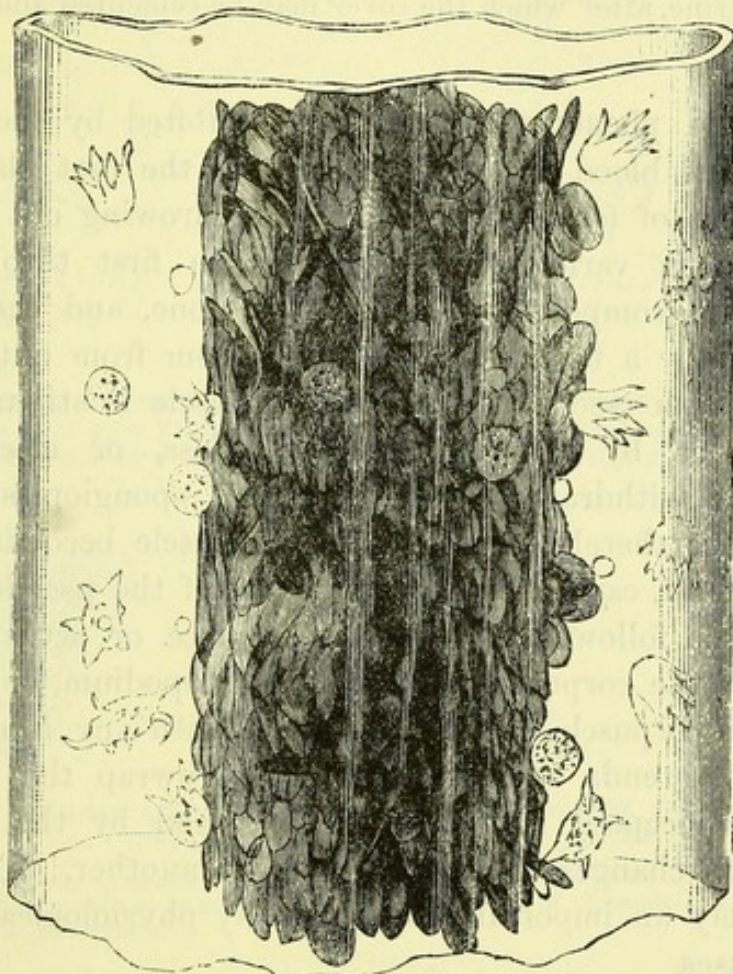


FIG. 19.—WHITE CORPUSCLES OF FROG'S BLOOD MIGRATED FROM SHRUNKEN CLOT WITHIN A CAPILLARY TUBE. (From Sanderson's Handbook for the Physiological Laboratory.)

3. Take some yeast which has been mixed with salt solution, and mix a little of the yeast and salt solution with a fresh drop of newt's blood, slightly oiling the edge of the cover-glass as before. Endeavour to observe the inception of torulae by the white corpuscles. Sketch one or two corpuscles containing torulae.

Milk-globules or particles of carbon or of vermilion may also be used for this experiment, but the process of inception is most readily observed with the yeast particles.

<sup>1</sup> For exact work, an apparatus somewhat more complex than the above is required. For description of such see *A Course of Practical Histology*.



4. At the beginning of the lesson collect a drop of newt's blood into a fine capillary tube, seal the ends of the tube, and mount it in a drop of oil of cedar or Canada Balsam. Towards the end of the lesson examine it again to see white corpuscles emigrating from the shrunken clot (see fig. 19).

5. To obtain a specimen showing white corpuscles in amœboid condition, make a preparation of newt's blood, mixed with salt solution, and set it aside for ten minutes. By this time the corpuscles will be freely amœboid, and will probably show well-marked pseudopodia. To fix them in this condition let a jet of steam from the spout of a kettle play for two or three seconds upon the cover-glass. The heat instantaneously kills the corpuscles, and they are fixed in the form they presented at the moment the steam was applied. They may now be stained by passing dilute hæmatoxylin, eosin, methyl violet or fuchsin under the cover-glass, and the stain may be replaced by dilute glycerine, after which the cover may be cemented and the preparation kept.

The **amœboid phenomena** which are exhibited by the protoplasm of the colourless blood-corpuscles consist, in the first place, of spontaneous changes of form, produced by the throwing out of processes or *pseudopodia* in various directions. When first thrown out the pseudopodia are composed of hyaloplasm alone, and they are probably produced by a flowing of the hyaloplasm from out the meshes of the protoplasm (see p. 2). If the corpuscle is stimulated, either mechanically, as by tapping the cover-glass, or electrically, the hyaloplasm is withdrawn again into the spongioplasm, and the pseudopodia are thereby retracted, the corpuscle becoming spherical. A change of form, caused by the protrusion of the pseudopodia, may, when active, be followed by changes in place or actual locomotion (migration) of the corpuscle. When a pseudopodium, or the external surface of the corpuscle, comes in contact with any foreign particle, the hyaloplasm tends to flow round and enwrap the particle, and particles thus incepted may then be conveyed by the corpuscle in its locomotory changes from one place to another. This property appears to play an important part in many physiological and pathological processes.

It is probable that particles of organic matter which are taken up by the pale corpuscles may undergo some slow process of intracellular digestion within their protoplasm.

The processes of the granular corpuscles are generally quite clear at first, and the granules afterwards flow into them.

The migration of the colourless corpuscles from the blood-vessels into the surrounding tissue, or from a blood-clot into the surrounding serum (fig. 19), is owing to these amœboid properties.

The conditions which are most favourable to this amœboid activity of the white corpuscles are (1) the natural slightly alkaline medium,



such as plasma, serum, or lymph, or faintly alkaline normal saline solution. Any increase of density of the medium produces a diminution of amœboid activity, whilst, on the other hand, a slight decrease in its density has the opposite effect; (2) a certain temperature. In warm-blooded animals the phenomena cease below about  $10^{\circ}\text{C}$ . When gradually warmed they become more and more active up to a certain point, the maximum being a few degrees above the natural temperature of the blood. Above this point they become spheroidal and at

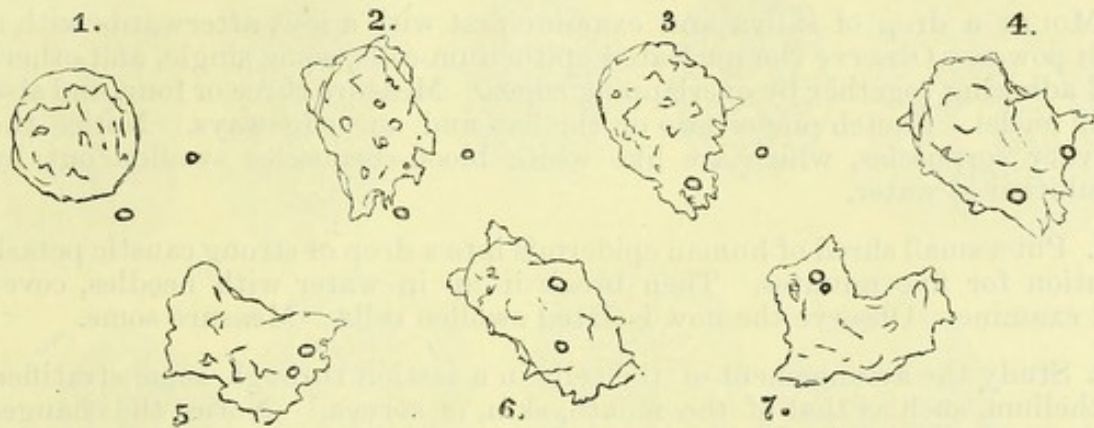


FIG. 20.—CHANGES OF FORM OF A WHITE CORPUSCLE OF NEWT'S BLOOD, SKETCHED AT INTERVALS OF A FEW MINUTES, SHOWING THE INCEPTION OF TWO SMALL GRANULES AND THE CHANGES OF POSITION THESE UNDERWENT WITHIN THE CORPUSCLE.

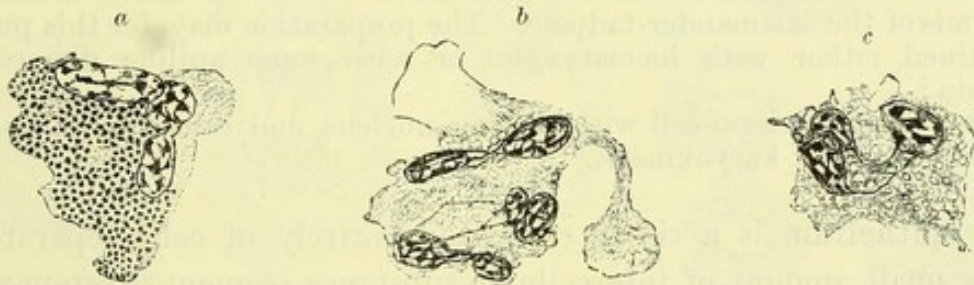


FIG. 21.—THREE AMŒBOID WHITE CORPUSCLES OF THE NEWT, KILLED BY INSTANTANEOUS APPLICATION OF STEAM.

*a*, a coarsely granular cell; *b*, *c*, ordinary cells. The nuclei appear multiple, but are seen to be connected by fine filaments of chromoplasm traversing the protoplasm.

a somewhat higher temperature their protoplasm is coagulated and killed. Acids at once kill the corpuscles and stop the movements. Narcotic gases and vapours, such as carbonic acid gas or chloroform vapour, also arrest the movement, but it recommences after a time if their action is discontinued.



## LESSON VI.

## E P I T H E L I U M.

1. MOUNT a drop of saliva and examine first with a low, afterwards with a high power. Observe the nucleated epithelium-cells, some single, and others still adhering together by overlapping edges. Measure three or four, and also their nuclei. Sketch one or two on the flat and one edgewise. Notice the salivary corpuscles, which are like white blood-corpuscles swollen out by imbibition of water.

2. Put a small shred of human epidermis into a drop of strong caustic potash solution for five minutes. Then break it up in water with needles, cover and examine. Observe the now isolated swollen cells. Measure some.

3. Study the arrangement of the cells in a section through some stratified epithelium, such as that of the mouth, skin, or cornea.<sup>1</sup> Notice the changes in shape of the cells as they are traced towards the free surface. Measure the thickness of the epithelium. Count the number of layers of cells.

4. Study the minute structure of epithelium-cells and their nuclei, both at rest and dividing, in sections of the skin of the newt's tail or in shreds of epidermis of the salamander-tadpole. The preparation may, for this purpose, be stained either with hæmatoxylin or with some aniline dye such as saffranin.<sup>2</sup>

Sketch an epithelium-cell with resting nucleus, and others with nuclei in different phases of karyokinesis.

An **epithelium** is a tissue composed entirely of cells separated by a very small amount of intercellular substance (cement-substance), and generally arranged so as to form a membrane covering either an external or an internal free surface.

The structure of epithelium-cells, and the changes which they undergo in cell-division, are best seen in the epidermis of the newt or of the salamander-tadpole; in the latter especially the cells and nuclei are much larger than in mammals.

**Structure of the cells.**—Each epithelium-cell consists of *protoplasm* containing a *nucleus*. The protoplasm may either look granular, or it may have a reticulated appearance. In some kinds of epithelium it is striated. The nucleus is a round or oval vesicle lying in the protoplasm. Usually there is only one, but there may be two or more.

<sup>1</sup> The methods of preparing sections are given in the Appendix.

<sup>2</sup> The methods which serve the purpose of exhibiting the division of nuclei are given in the Appendix.



The cell-substance is often modified in its chemical nature ; its external layer may become hardened to form a sort of membrane, or the whole cell may become horny (keratinised) ; or the cell may develop fibrils within it, and passing from it into adjacent cells, or lastly, there may be an accumulation of materials within the cell which are ultimately either used by the organism, as in the ordinary secreting glands, or eliminated as waste products as in the kidney.

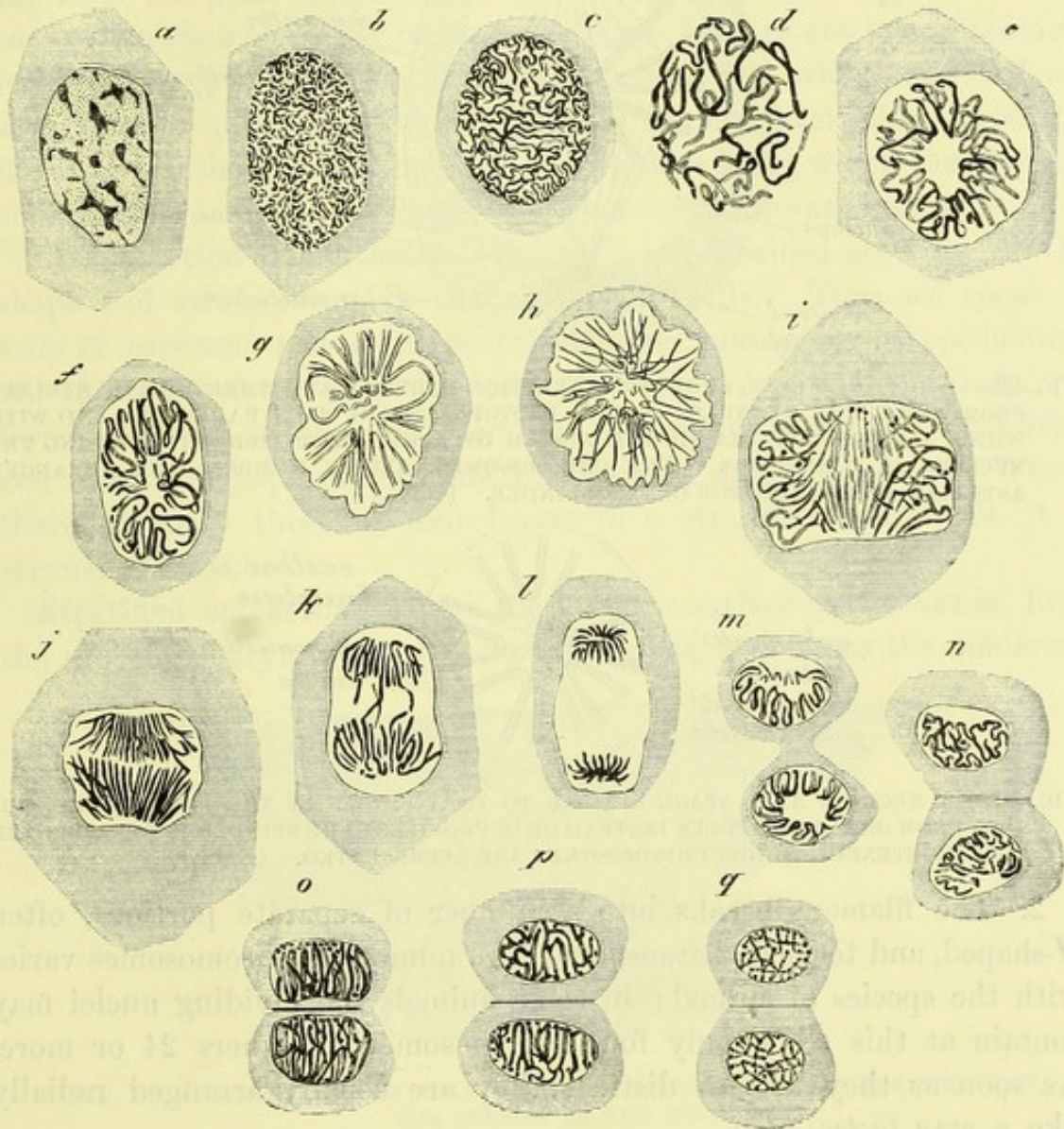


FIG. 22.—EPITHELIUM-CELLS OF SALAMANDER LARVA IN DIFFERENT PHASES OF DIVISION BY KARYOKINESIS. (Flemming.)

**Division of the cells.**—The division of a cell is preceded by the division of its attraction-sphere, and this again appears to determine the division of the nucleus. The latter, in dividing, passes through a series of remarkable changes (fig. 22), which may thus be briefly summarised :—

1. The network of chromoplasm-filaments of the resting nucleus



becomes transformed into a sort of *skein*, formed apparently of one long convoluted filament; the nuclear membrane and the nucleoli disappear or are merged into the skein (fig. 22, *b, c, d*). Sometimes the skein becomes looped in and out of a central space; this form is termed the *rosette* (*e*).

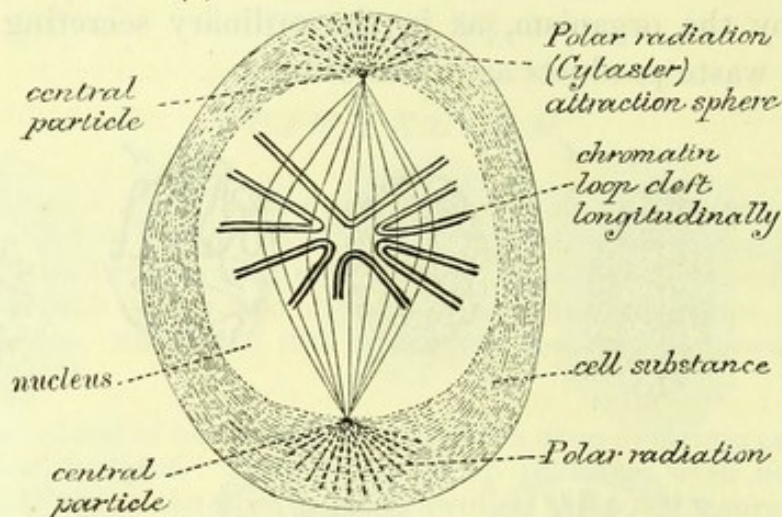


FIG. 23.—A DIVIDING CELL, SHOWING ATTRACTION-PARTICLE AT EITHER POLE OF NUCLEUS FROM WHICH THE GRANULES OF THE PROTOPLASM ARE SEEN RADIATING, AND WITH WHICH ALSO THE SPINDLE-SHAPED SYSTEM OF ACHROMATIC FIBRES TRAVERSING THE NUCLEUS IS CONNECTED. THE CHROMOSOMES, SIX IN NUMBER, ARE ARRANGED ASTRALLY AT THE EQUATOR OF THE SPINDLE. (Rabl.)

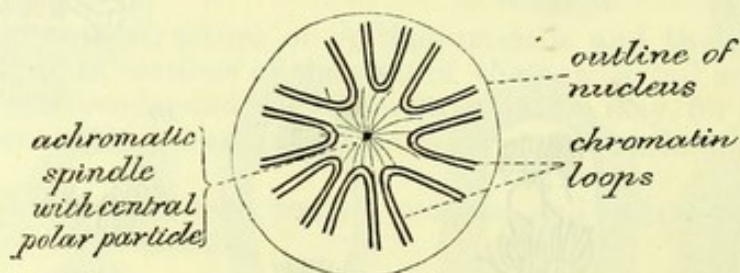


FIG. 24.—A NUCLEUS AT A STAGE SIMILAR TO THAT SHOWN IN THE LAST FIGURE, BUT SEEN FROM ONE OF THE POLES INSTEAD OF IN PROFILE. THE SPINDLE IS REPRESENTED FORESHORTENED. EIGHT CHROMOSOMES ARE REPRESENTED. (Rabl.)

2. The filament breaks into a number of separate portions, often V-shaped, and termed *chromosomes*. The number of chromosomes varies with the species of animal; in some animals the dividing nuclei may contain at this stage only four chromosomes, in others 24 or more. As soon as they become distinct they are usually arranged radially like a star (*aster, f, g*).

3. Each of the chromosomes splits longitudinally into two, so that they are now twice as numerous as before (*stage of cleavage, g, h*).

4. The fibres separate into two groups, the ends being for a time interlocked (*stage of metakinesis, i, j, k*).

5. The two groups pass to the opposite poles of the now elongated nucleus and form a star-shaped figure (*l*) at each pole (*dyaster*). Each of the stars represents a daughter-nucleus.

6, 7, 8. Each star of the dyaster goes through the same changes as



the original nucleus, but in the reverse order—viz., skein at first more open and rosette-like (*m*), then closer (*n*), then a network (*o*, *p*, *q*); passing finally into the typical reticular condition of a resting nucleus.

The protoplasm of the cell divides soon after the formation of the dyaster (*m*). During division fine lines are seen in the protoplasm, radiating from the ends of the nucleus. Other lines produced by a spindle-shaped system of *achromatic* fibres lie within the nucleus, diverging from the poles towards the equator (figs. 23, 24); they are far less easily seen than the other or *chromatic* fibres, but are not less important, for they are derived from the attraction-spheres, which, as we have seen, always initiate the division of a cell. Moreover, the achromatic fibres within the nucleus appear to form guides along which the chromosomes or chromoplasmic filaments are conducted towards its poles.

**Classification of epithelia.**—Epithelia are classified according to the shape and arrangement of the component cells. Thus we speak of *scaly* or *pavement*, *cubical*, *columnar*, *polyhedral*, and *spheroidal* epithelium. All these are *simple* epithelia, with the cells only one layer deep. If forming several superposed layers, the epithelium is said to be *stratified*, and then the shape of the cells differs in the different layers. Where there are only three or four layers in a stratified epithelium, it is termed *transitional*.

**Stratified epithelium** covers the anterior surface of the cornea, lines the mouth, pharynx (lower part), and gullet, and forms the epidermis

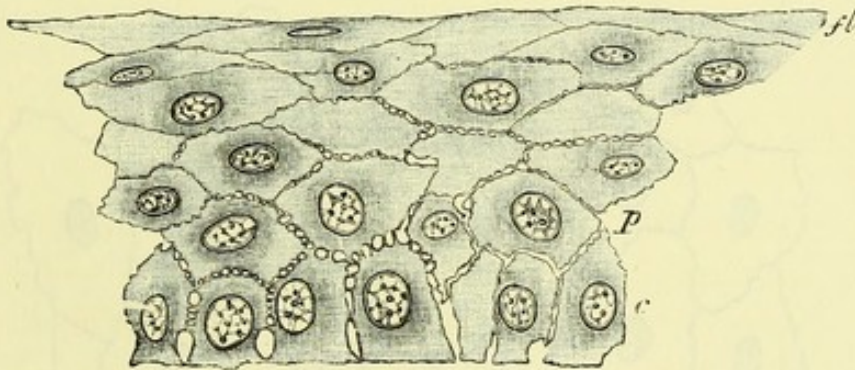


FIG. 25.—SECTION OF THE STRATIFIED EPITHELIUM COVERING THE FRONT OF THE CORNEA OF THE EYE.

*c*, lowermost columnar cells; *p*, polygonal cells above these; *fl*, flattened cells near the surface. Between the cells are seen intercellular channels bridged over by processes which pass from cell to cell.

which covers the skin. In the female it lines the vagina and part of the uterus. The cells nearest the surface are always flattened and scale-like (fig. 25, *fl*; fig. 26), whereas the deeper cells are more rounded or polyhedral, and those of the deepest layer generally somewhat columnar in shape (fig. 25, *c*). Moreover, the deeper cells are soft and protoplasmic, and are separated from one another by a



system of intercellular channels, which are bridged across by numerous fibres passing from cell to cell, and giving the cells, when separated, the appearance of being beset with short spines (*prickle-cells* of Max Schultze).

The deeper cells multiply by division, the nuclei first dividing in the manner just described. The newly formed cells tend as they enlarge to push those external to them nearer to the surface, from which they are eventually thrown off. As they approach the surface they become hard and horny, and in the case of the epidermis lose entirely their cellular appearance, which can, however, be in a measure restored by the action of potash (§ 2). The cast-off superficial cells of the stratified epithelium of the mouth, which are seen in abundance in the saliva (§ 1), are less altered, and the remains of a nucleus is still visible in them (fig. 26).

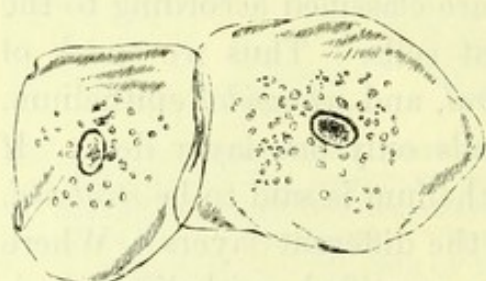


FIG. 26.—EPITHELIUM-SCALES FROM THE INSIDE OF THE MOUTH. (Magnified 260 diameters.)

**Simple scaly or pavement epithelium** is found in the saccules of the lungs, in those of the mammary gland when inactive, in the kidney (in the tubes of Henle), and also lining the cavities of serous membranes (fig. 27), and the heart, blood-vessels, and lymphatics. When occurring on internal surfaces, such as those of the serous membranes, blood-vessels, and lymphatics, it is often spoken of as **endothelium**.

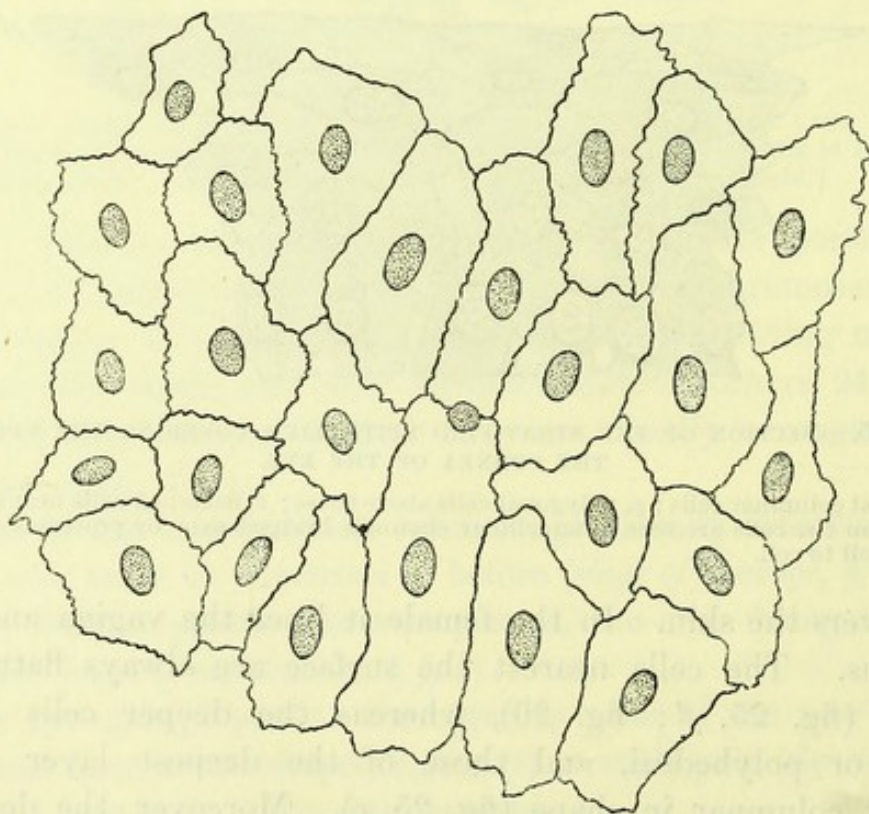


FIG. 27.—PAVEMENT EPITHELIUM OR ENDOTHELIUM OF A SEROUS MEMBRANE. NITRATE OF SILVER PREPARATION.



**Polyhedral or spheroidal epithelium** is characteristic of many secreting glands. **Columnar and ciliated epithelium** are for the most part found covering the inner surface of mucous membranes; which are membranes moistened by *mucus* and lining passages in communication with the exterior, such as the alimentary canal and the respiratory and generative passages.

The detailed study of most of these may be reserved until the organs in which they occur are respectively dealt with.

The *hairs* and *nails* and the *enamel* of the teeth are modified epithelial tissues.

## LESSON VII.

*COLUMNAR AND CILIATED EPITHELIUM, AND  
TRANSITIONAL EPITHELIUM.*

1. TAKE a piece of rabbit's intestine which has been two days in chromic acid solution (1 part chromic acid to 2,000 normal saline solution). Scrape the inner surface with a scalpel, break up the scrapings in a drop of water on a slide. Add a small piece of hair to avoid crushing, and cover the preparation. The tissue may then be still further broken up by tapping the cover-glass. Sketch one or two columnar cells and also a row of cells. Measure two or three cells and their nuclei.

To keep this preparation, place a drop of very dilute hæmatoxylin solution at one edge of the cover-glass. When the hæmatoxylin has passed in and has stained the cell-nuclei, place a drop of glycerine at the same edge and allow it slowly to diffuse under the cover-glass. Cement this another day. Osmic acid (1 per cent.) may be used in place of hæmatoxylin.

2. Break up in glycerine a shred of epithelium from a piece of frog's intestine that has been treated with osmic acid, and has subsequently macerated in water for a few days. The cells easily separate on tapping the cover-glass. They are larger than those of the rabbit and exhibit certain points of structure better. Measure and sketch one or two cells.

The cover-glass may be at once fixed by gold size.

3. Prepare the ciliated epithelium from a trachea that has been in chromic acid solution (1 to 2,000 normal saline) for two days, in the same way as in § 1. Measure in one or two of the cells (*a*) the length of the cells, (*b*) the length of the cilia, (*c*) the size of the nucleus. Sketch two or three cells.

This preparation is to be stained and preserved as in § 1.

4. Make a similar teased preparation of the epithelium of the urinary bladder, which is to be distended with bichromate of potash solution (1 part to 800 of water), and after an hour or two cut open and placed in more of the same solution. Observe the large flat superficial cells, and the pear-shaped cells of the second layer. Measure and sketch one or two of each kind. The cells will vary greatly in appearance according to the amount of distension of the organ.

Stain and preserve as in §§ 1 and 3.

All the above varieties of epithelium will afterwards be studied *in situ* when the organs where they occur come under consideration.

---

**Columnar epithelium.**—The cells of a columnar epithelium (fig. 28) are prismatic columns, which are set closely side by side, so that when seen from the surface a mosaic appearance is produced. They often taper somewhat towards their attached end, which is generally truncated, and set upon a basement membrane. Their free surface is



covered by a thick striated border (fig. 29, *str*), which may sometimes become detached in teased preparations. The protoplasm of the cell is highly vacuolated and reticular, and fine longitudinal striæ may be seen in it, which appear continuous with the striæ of the free border. The nucleus (*n*) is oval and reticular. The lateral borders of the cells are often somewhat irregular or jagged, the result of the pressure of amœboid lymph-cells, which are generally found between the columnar cells, at least in the intestine. After a meal containing fat the cells may contain fat globules, which become stained black in the osmic preparation.

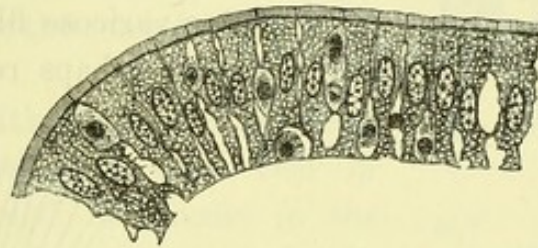


FIG. 28.—A ROW OF COLUMNAR CELLS FROM THE INTESTINE OF THE RABBIT.  
Smaller cells are seen between the epithelium-cells; these are lymph-corpuscles.

Columnar epithelium-cells are found lining the whole of the interior of the stomach and intestines: they are also present in the ducts of most glands, and sometimes also in their secreting tubes and saccules. The epithelium which covers the ovary also has a modified columnar shape, but cells having *all* the structural peculiarities indicated above are found only in the alimentary canal and in its diverticula.

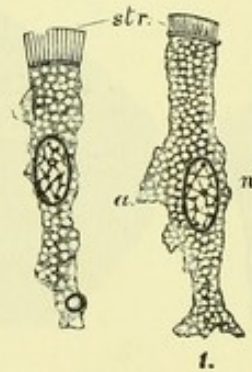


FIG. 29.—COLUMNAR EPITHELIUM-CELLS OF THE RABBIT'S INTESTINE.  
The cells have been isolated after maceration in very weak chromic acid. The cells are much vacuolated, and one of them has a fat-globule near its attached end; the striated border (*str*) is well seen, and the bright disk separating it from the cell-protoplasm; *n*, nucleus with intranuclear network; *a*, a thinned-out wing-like projection of the cell which probably fitted between two adjacent cells.

**Goblet-cells.**—Some columnar cells, and also cells of glandular, ciliated and transitional epithelia, contain mucigen, which is laid down within the cell in the form of granules (fig. 33, *m*<sup>1</sup>, *m*<sup>2</sup>) and may greatly distend the part of the cell nearest the free border. When the mucigen is extruded as mucus, this border is thrown off, and the cell takes the form of an open cup or chalice (fig. 30 and fig. 33, *m*<sup>3</sup>).



**Ciliated epithelium.**—The cells of a ciliated epithelium are also usually columnar in shape (fig. 31), but in place of the striated border the cell is surmounted by a bunch of fine tapering filaments which, during life, move spontaneously to and fro, and serve to produce a current of fluid over the surface which they cover.

The *cilia* are to be regarded as active prolongations of the cell-protoplasm. The border upon which they are set is bright, and appears formed of little juxtaposed *knobs*, to each of which a cilium is attached. In the large ciliated cells which line the alimentary canal of some molluscs (fig. 32), the knob may be observed to be prolonged into the protoplasm of the cell as a fine varicose filament, termed the *rootlet* of the cilium. These filaments perhaps represent the longi-

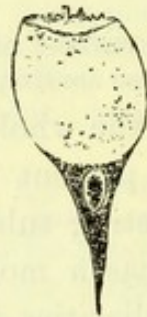

FIG. 30.—GOBLET-CELL  
FROM THE TRACHEA.  
(Klein.)

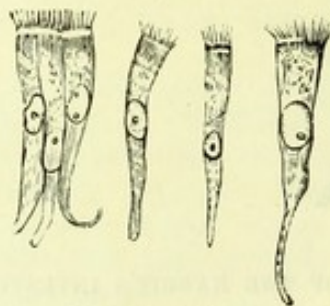


FIG. 31.—COLUMNAR CILI-  
ATED EPITHELIUM-CELLS  
FROM THE LOWER PART  
OF THE NASAL PASSAGES.  
EXAMINED FRESH IN  
SERUM. (Sharpey.)

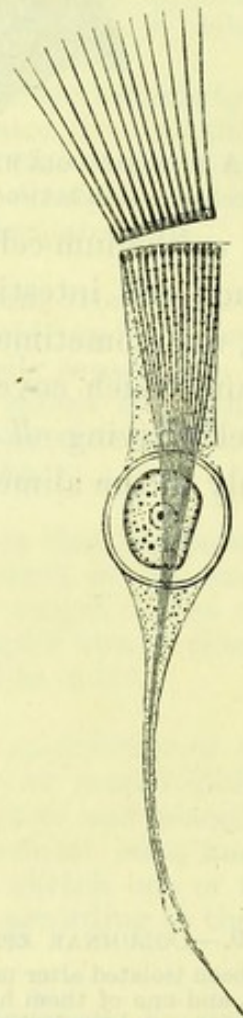


FIG. 32.—CILIATED CELL,  
FROM THE INTESTINE  
OF A MOLLUSC. (Engel-  
mann.)

tudinal striæ often seen in the protoplasm of the columnar cell, the bunch of cilia being homologous with the striated border. The protoplasm and nucleus have a similar vacuolated and reticular structure in both kinds of cell.



Ciliated epithelium is found throughout the whole extent of the air-passages and their prolongations (but not in the part of the nostrils supplied by the olfactory nerves, nor in the lower part of the pharynx); in the Fallopian tubes and the greater part of the uterus; in some of the efferent ducts of the testicle (where the cilia are longer than elsewhere in the body); in the ventricles of the brain, and the central canal of the spinal cord; and, according to some authorities, in the convoluted tubules of the kidney.

**Transitional epithelium** is a stratified epithelium consisting of only two or three layers of cells. It occurs in the urinary bladder, the ureter, and the pelvis of the kidney. The superficial cells (fig. 34, *a*) are large and flattened; they often have two nuclei. On their under surface they exhibit depressions, into which fit the larger ends of pyriform cells, which form the next layer (fig. 34, *b*). Between the tapered ends of the pyriform cells one or two layers of smaller polyhedral

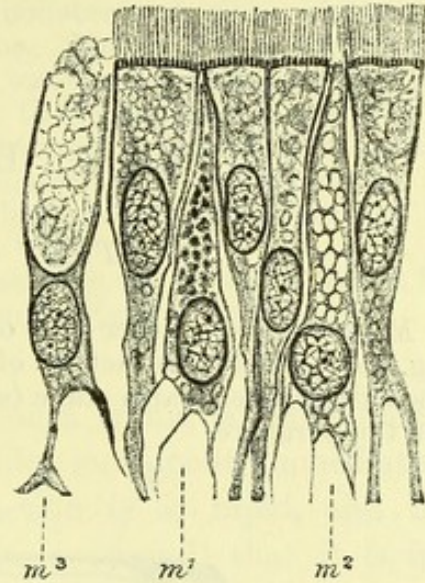


FIG. 33.—CILIATED COLUMNAR EPITHELIUM, FROM THE TRACHEA OF A RABBIT.

*m*<sup>1</sup>, *m*<sup>2</sup>, *m*<sup>3</sup>, mucus-secreting cells in various stages of mucigen formation. The preparation was treated with dilute chromic acid in the manner recommended in the instructions for practical work.

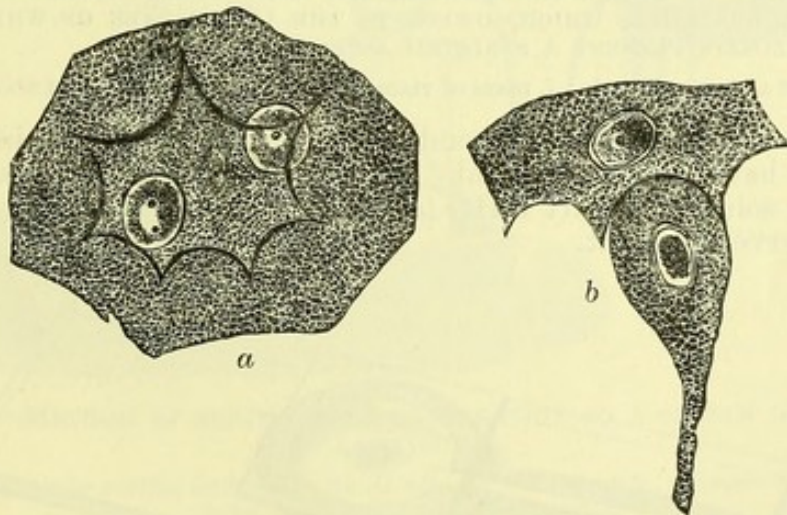


FIG. 34.—EPITHELIAL-CELLS FROM THE BLADDER OF THE RABBIT. (Klein.) (Magnified 500 diameters.)

*a*, large flattened cell from the superficial layer, with two nuclei and with strongly marked ridges and intervening depressions on its under surface; *b*, pear-shaped cell of the second layer adapted to a depression on one of the superficial cells.

cells are found. The epithelium is renewed by division of these deeper cells.



## LESSON VIII.

## STUDY OF CILIA IN ACTION.

1. MOUNT in sea-water one or two bars of the gill of the marine mussel (fig. 35). Study the action of the large cilia. Now place the preparation upon the copper warm stage (see Lesson V.) and observe the effect of raising the temperature.

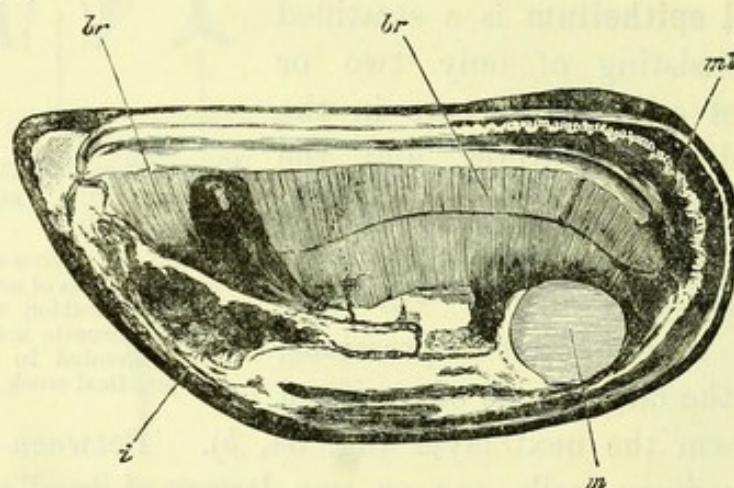


FIG. 35.—VALVE OF MUSSEL (*MYTILUS EDULIS*) SHOWING *br*, *br*, THE EXPANDED GILLS OR BRANCHIÆ, WHICH, OWING TO THE LITTLE BARS OF WHICH THEY ARE COMPOSED, PRESENT A STRIATED ASPECT.

*ml*, mantle; *m*, cut adductor muscle; *i*, mass of viscera; the dark projection just above is the foot.

Keep this preparation until the end of the lesson, by which time many of the cilia will have become languid. When this is the case pass a drop of dilute potash solution (1 part KHO to 1,000 of sea-water) under the cover-glass and observe the effect.

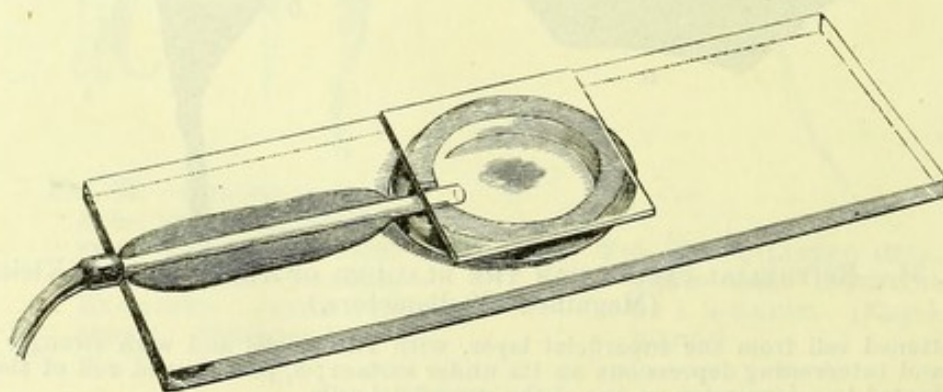


FIG. 36.—MOIST CHAMBER ADAPTED FOR PASSING A GAS OR VAPOUR TO A PREPARATION UNDER THE MICROSCOPE.

2. Cement with sealing-wax a piece of small glass tubing to a slide so that one end of the tube comes nearly to the centre of the slide. To do this



effectually the slide must be heated and some sealing-wax melted on to it and allowed to cool. The glass tube is then made hot and applied to the slide, embedding itself as it does so in the sealing-wax. On this put a ring of putty or modelling wax (half an inch in diameter and rising above the glass tube) so as to include the end of the tube. Make a deep notch in the ring opposite the tube. Place a small drop of water within the ring (fig. 36).

Put a bar from the gill upon a cover-glass in the least possible quantity of sea-water; invert the cover-glass over the putty ring, and press it gently down. The preparation hangs in a *moist chamber* within which it can be studied through the cover-glass, and into which gases or vapours can be passed and their effects observed.

Pass  $\text{CO}_2$  through the chamber, and after observing the effect replace it by air (see fig. 37). Repeat with chloroform vapour instead of  $\text{CO}_2$ .

**The movement of cilia.**—When in motion a cilium is bent quickly over in one direction with a lashing whip-like movement, immediately recovering itself. When vigorous the action is so rapid, and the rhythm so frequent (ten or more times in a second) that it is impossible to follow the motion with the eye. All the cilia upon a ciliated surface are not in action at the same instant, but the move-

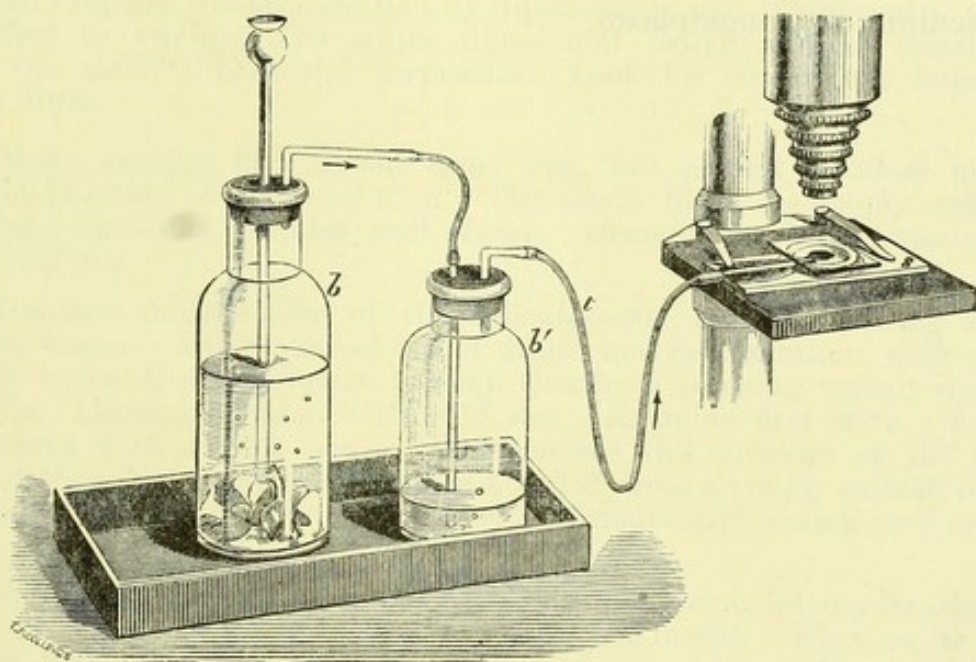


FIG. 37.—METHOD OF SUBJECTING A PREPARATION TO A STREAM OF CARBONIC ANHYDRIDE.

*b*, bottle containing marble and hydrochloric acid: *b'*, wash-bottle, connected by indiarubber tube, *t*, with the moist chamber, *s*.

ment travels in waves over the surface. If a cell is detached from the general surface, its cilia continue to act for a while, but at once cease if they are detached from the cell.

The rhythm is slowed by cold, quickened by warmth, but heat beyond a certain point kills the cells. The movement will continue for some time in water deprived of oxygen. Both  $\text{CO}_2$  gas and chloroform vapour arrest the action, but it recommences on re-



storing air. Dilute alkaline solutions quicken the activity of cilia, or may even restore it shortly after it has ceased.

Various attempts have been made to explain the manner in which cilia act, some supposing that they are themselves contractile, others that their movement is a passive one, and that the real movement is at their rootlets in the protoplasm of the cell. The bending-over action can also be supposed to be due to the alternate flowing and ebbing of hyaloplasm from the body of the cell into hollow permanent cell-processes, *i.e.* the cilia; if we assume that one side of each cilium is less extensible than the other, it must necessarily be bent over in the manner usually observed. Some cilia, however, have a spiral action rather than the simple to and fro movement; in this case we may assume that the line of less extensibility passes not straight along one side of the cilium, but spirally round it.

This hypothesis has the advantage that it permits ciliary motion to be brought into the same category as amœboid movements, in so far that both are explicable by the flowing of hyaloplasm out of and into the reticulum of spongioplasm.



## LESSON IX.

*THE CONNECTIVE TISSUES.*

## AREOLAR AND ADIPOSE TISSUE, RETIFORM TISSUE.

1. TAKE a little of the subcutaneous tissue or of the intermuscular connective tissue of a rabbit or guinea-pig and spread it out with needles on a dry slide into a large thin film. Keep the centre moist by occasionally breathing on it, but allow the edges to dry to the slide. Before commencing put a drop of salt solution on a cover-glass, and now invert this over the film. Examine with a high power. Sketch one or two bundles of white fibres and also one or two elastic fibres, distinguishable from the former by their sharp outline, isolated course, and by their branching. Sketch also one or more connective-tissue corpuscles, if any such are visible in the clear interspaces. Look also for migratory cells (lymph-corpuscles). Next carefully remove the cover-glass and replace the salt solution by dilute acetic acid (1 per cent.). Watch its effect in swelling the white fibres and bringing more clearly into view the elastic fibres and corpuscles. Look for constricted bundles of white fibres.

2. Make another film in the same way, but mount in dilute magenta solution<sup>1</sup> instead of saline solution. The elastic fibres are deeply stained by the dye; the cells are also well shown. Cement the cover-glass at once with gold size.

3. Prepare another film of the subcutaneous tissue, including a little adipose tissue. Mount, as before, in dilute magenta solution, with a piece of hair under the cover-glass to keep this from pressing unduly upon the fat-cells. Cement at once with gold size. Examine first with a low and afterwards with a high power. The nucleus and envelope of the fat-cell are well brought out by the magenta, and if from a young animal, fat-cells will be found in process of formation. Measure and sketch two or three of the cells.

4. Spread out another large film of connective tissue, letting its edges dry to the slide, but keeping the centre moist by the breath. Place on its centre a large drop of nitrate of silver solution (1 per cent.). After ten minutes wash this away with distilled water, and expose to direct sunlight until stained brown. Then dehydrate with alcohol, replace the alcohol by clove-oil, and this by Canada balsam dissolved in xylol. Cover<sup>2</sup> and examine. Sketch the outlines of two or three of the cell-spaces.

5. Mount in dilute glycerine and water, coloured by magenta, a section of lymphatic gland which has been immersed for a few minutes in 0.5 per cent. solution of caustic potash. The alkali destroys the cells, and thus allows the network of fibres which compose the retiform tissue to be seen. They are in all respects like the fibrils of areolar tissue.

<sup>1</sup> See Appendix.

<sup>2</sup> Preparations which are mounted in Canada balsam solution will soon become fixed by the hardening of the Canada balsam at the edges of the cover-glass. They must on no account be cemented with gold size.



The **connective tissues** include *areolar* tissue, *adipose* tissue, *elastic* tissue, *fibrous* tissue, *retiform* and *lymphoid* tissue, *cartilage* and *bone*. All these tissues agree in certain microscopical and chemical characters. They, for the most part, have a large amount of intercellular substance in which fibres are developed, and these fibres are of two kinds—*white* and *yellow or elastic*. Moreover, there are many points of similarity between the cells which occur in these several tissues; they are all developed from the same embryonic formation, and they tend to pass imperceptibly the one into the other. Besides this, their use is everywhere similar; they serve to connect and support the other tissues, performing thus a passive mechanical function. They may therefore be grouped together, although differing considerably in external characters. Of these connective tissues, however, there are three which are so intimately allied as to be naturally considered together, being composed of exactly the same elements, although differing in the relative development of those elements; these are the areolar, elastic, and fibrous tissues. Adipose tissue and retiform tissue may both be looked upon as special modifications of areolar tissue. Areolar tissue being the commonest and, in a sense, the most typical, its structure may be considered first.

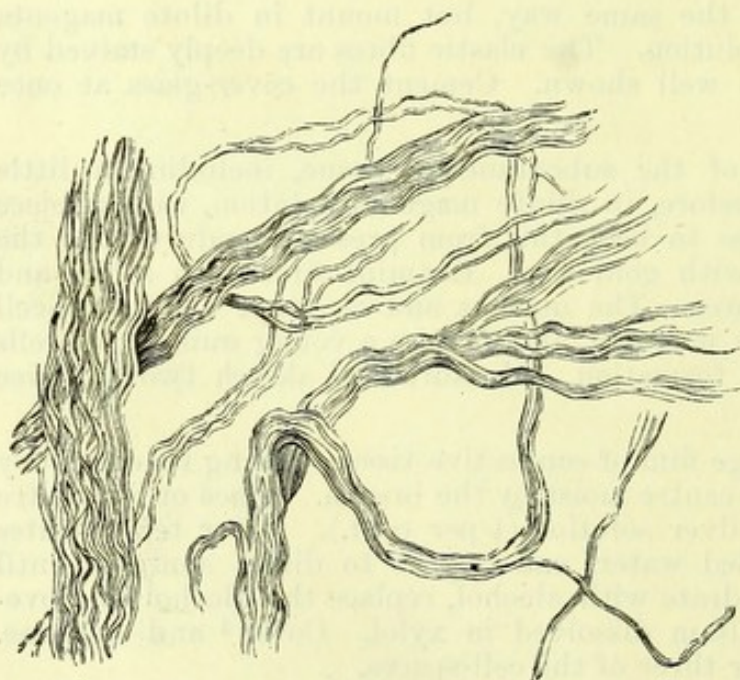


FIG. 38.—BUNDLES OF THE WHITE FIBRES OF AREOLAR TISSUE PARTLY UNRAVELLED. (Sharpey.)

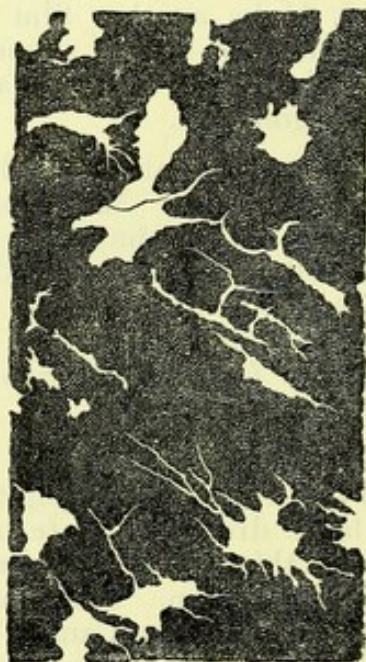

FIG. 39.—GROUND SUBSTANCE OF CONNECTIVE TISSUE STAINED BY SILVER. (The cell-spaces are left white.)

**Areolar tissue.**—The areolar tissue presents to the naked eye an appearance of fine transparent threads and laminæ which intercross in every direction with one another, leaving intercommunicating meshes, or areolæ, between them. When examined with the microscope, these



threads and fibres are seen to be principally made up of wavy bundles of exquisitely fine transparent fibres (*white fibres*, fig. 38). The bundles run in different directions, and may branch and intercommunicate with one another; but the individual fibres, although they pass from one bundle to another, never branch or join other fibres. The fibres are cemented together into the bundles by a clear substance containing mucin, and the same clear material forms also the basis or *ground-substance* of the tissue, in which the bundles themselves course, and in which also the corpuscles of the tissue lie embedded. This ground-substance between the bundles can with difficulty be seen in the fresh tissue on account of its extreme transparency; but it can be brought to view by staining with nitrate of silver, as in § 4. The whole of the tissue is thereby stained of a brown colour, with the exception of the spaces which are occupied by the corpuscles (*cell-spaces*, fig. 39).

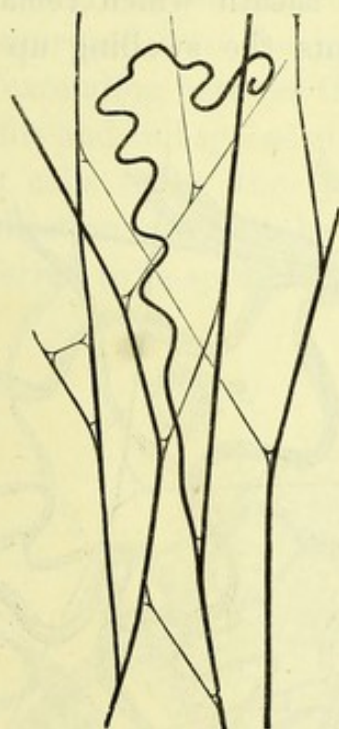


FIG. 40.—ELASTIC FIBRES OF AREOLAR TISSUE. FROM THE SUBCUTANEOUS TISSUE OF THE RABBIT.

Besides the white fibres of connective tissue here described, fibres of a different kind (fig. 40) may be made out in the preparations; these are the *elastic fibres*. They are especially well seen after treatment with acetic acid, and after staining with magenta; but they can be detected also in the fresh preparation. They are characterised by

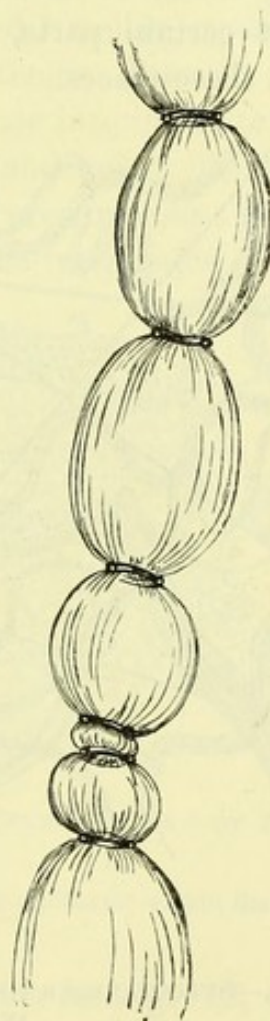


FIG. 41.—A WHITE BUNDLE SWOLLEN BY ACETIC ACID. FROM THE SUBARACHNOID TISSUE AT THE BASE OF THE BRAIN. (From Toldt.)

They are characterised by



their distinct outline, their straight course, the fact that they never run in bundles, but singly, and that they branch and join neighbouring fibres. If broken by the needles in making the preparation, the elastic recoil causes them to curl up, especially near the broken ends. Besides the microscopical differences, the two kinds of fibres differ also in their chemical characters. Thus the white fibres are dissolved by boiling in water, and yield gelatin; whereas the substance of which the elastic fibres are composed (*elastin*) resists for a long time the action of boiling water. Moreover, the white fibres swell and become indistinct under the action of acetic acid; the elastic fibres are unaltered by this reagent.

The bundles of white fibres which have been swollen out by acid sometimes exhibit curious constructions (fig. 41). These are due either to elastic fibres coiling round the white bundles, or to cell-processes encircling them, or to an investment or sheath which remains unbroken at certain parts, and thus prevents the swelling up of the bundle at these places.

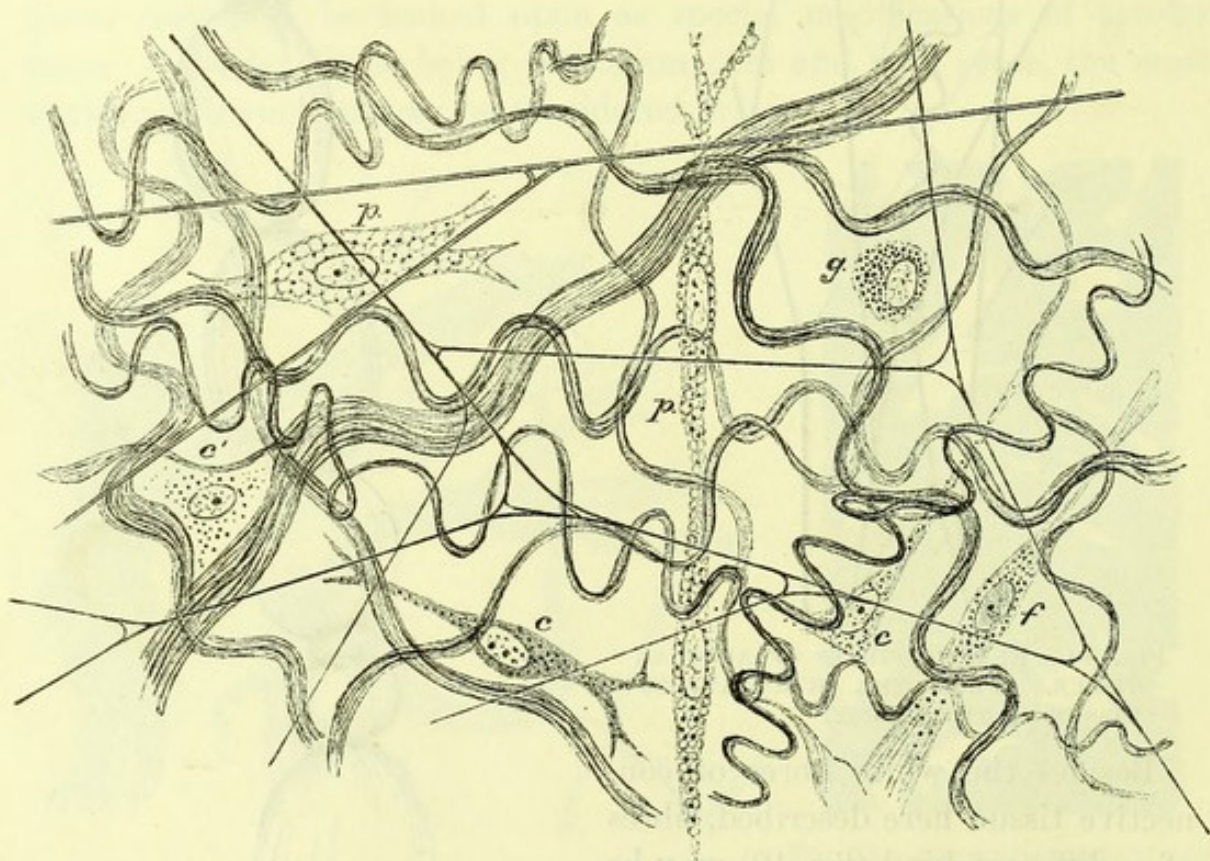


FIG. 42.—SUBCUTANEOUS TISSUE FROM A YOUNG RABBIT, PREPARED AS DIRECTED IN § 1. (Highly magnified.)

The white fibres are in wavy bundles; the elastic fibres form an open network. *p*, *p*, plasma-cells; *g*, granule-cell; *c*, *c'*, lamellar-cells; *f*, fibrillated-cell.

**The cells of areolar tissue.**—Several varieties of connective-tissue cells are distinguished, viz. : (1) Flattened *lamellar-cells*, which are often branched (fig. 42, *c*, *c'*) and may be united one to the other by their



branches, as in the cornea, or are unbranched and joined edge to edge like the cells of an epithelium; the cell-spaces have in all cases a similar arrangement. (2) *Plasma-cells* of Waldeyer (fig. 42, *p*), which are composed of a soft much-vacuolated protoplasm, rarely flattened, but otherwise varying greatly in shape and size. (3) *Granule-cells* (*g*), usually spheroidal or ovoidal in shape, and formed, like the plasma cells, of soft protoplasm, but thickly occupied with albuminous granules, which are deeply stained by eosin and by most aniline dyes. Migratory lymph-corpuscles may also be seen here and there in the areolar tissues (*wander-cells*). In the middle coat of the eye the connective-tissue cells are filled with granules of pigment (*pigment-cells*).

The cells lie in spaces in the ground-substance between the bundles of white fibres. In some parts of the connective tissue the white bundles are developed to such an extent as to pervade almost the whole of the ground-substance, and then the connective-tissue corpuscles become squeezed into the interstices, flattened lamellar expansions of the cells extending between the bundles, as in tendon (see next Lesson).

The cells and cell-spaces of areolar tissue come into intimate relation with the cells lining the lymphatic vessels and small blood-vessels. This connection can best be seen in silvered preparations; it will be again referred to in speaking of the origin of the lymphatics.

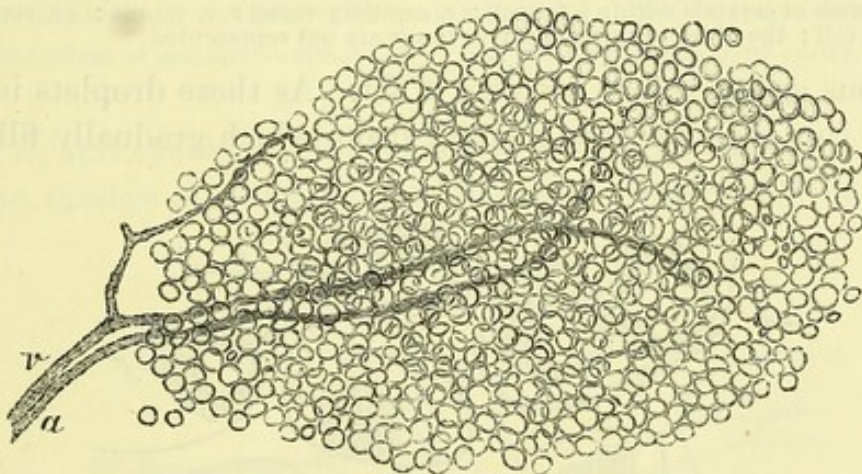


FIG. 43.—A SMALL FAT-LOBULE FROM THE SUBCUTANEOUS TISSUE OF THE GUINEA-PIG. ( $\frac{2}{1}$ .)

*a*, small artery distributed to the lobule; *b*, small vein; the capillaries within the lobule are not visible.

**Adipose tissue** consists of vesicles filled with fat (figs. 43, 44), and collected into lobules, or into tracts which accompany the small blood-vessels. The vesicles are round or oval in shape, except where closely packed, when they become polyhedral from mutual compression. The fat-drop is contained within a delicate protoplasmic envelope (fig. 44, *m*) which is thickened at one part, and here includes an oval flattened



nucleus. The vesicles are supported partly by filaments of areolar tissue, but chiefly by a fine network of capillary blood-vessels.

The fat when first formed is deposited within granular cells of areolar tissue (fig. 45). It appears to be produced by a transformation of

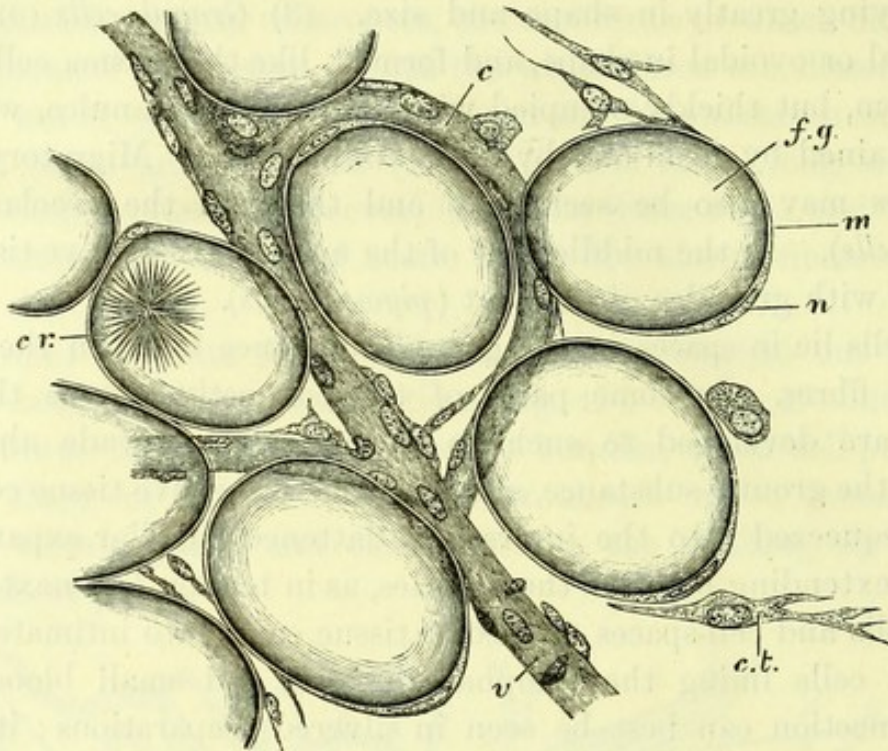


FIG. 44.—A FEW CELLS FROM THE MARGIN OF A FAT-LOBULE.

*f.g.*, fat-globule distending a fat-cell; *n*, nucleus; *m*, membranous envelope of the fat-cell; *c.r.*, bunch of crystals within a fat-cell; *c*, capillary vessel; *v*, venule; *c.t.*, connective-tissue cell; the fibres of the connective tissue are not represented.

albuminous granules into droplets of fat. As these droplets increase in size they run together into a larger drop, which gradually fills the cell

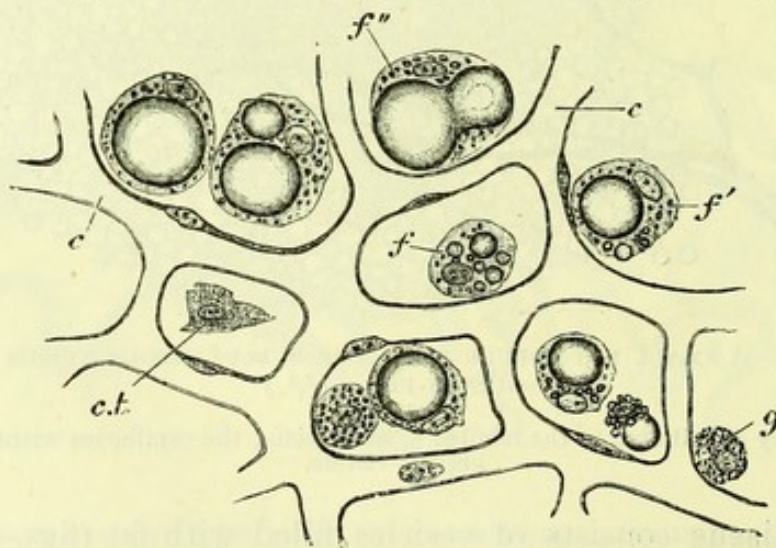


FIG. 45.—DEPOSITION OF FAT IN CONNECTIVE-TISSUE CELLS.

*f*, a cell with a few isolated fat-droplets in its protoplasm; *f'*, a cell with a single large and several minute drops; *f''*, fusion of two large drops; *g*, granular cell, not yet exhibiting any fat-deposition; *c.t.*, flat connective-tissue corpuscle; *c*, *c*, network of capillaries.

more and more, swelling it out so that the cell-protoplasm eventually appears merely as the envelope of the fat-vesicle.



Fat is found most abundantly in subcutaneous areolar tissue, and under the serous membranes; especially in some parts, as at the back of the peritoneum around the kidneys, under the epicardium, and in the mesentery and omentum. The yellow marrow of the bones is also principally composed of fat. There is no adipose tissue within the cavity of the cranium.

**Retiform or reticular tissue** (figs. 46, 47) is a variety of connective tissue in which the intercellular or ground substance has mostly disappeared or is replaced by fluid. There are very few or no elastic

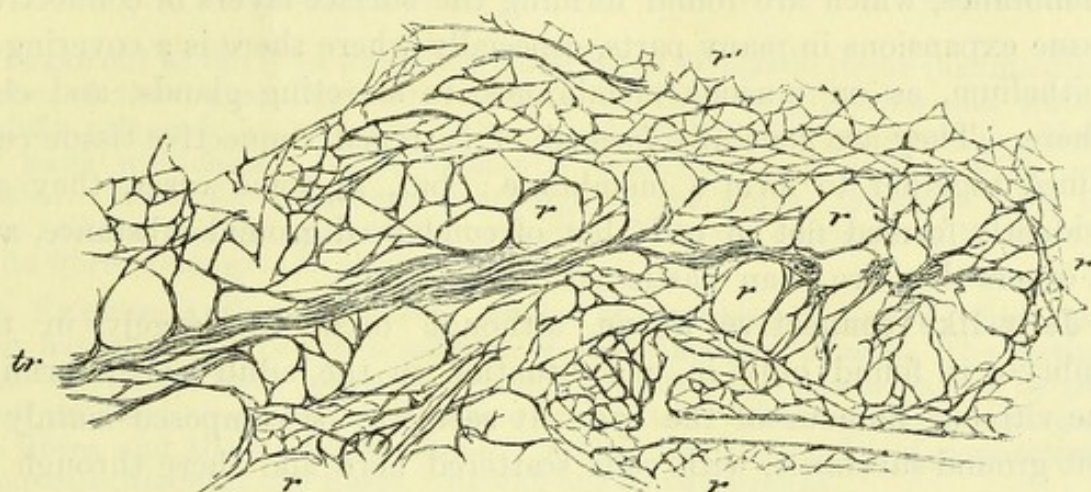


FIG. 46.—RETIFORM TISSUE FROM A LYMPHATIC GLAND, FROM A SECTION WHICH HAS BEEN TREATED IN THE MANNER DESCRIBED IN § 5. (Moderately magnified.)

*tr*, a trabeculum of connective tissue; *r*, *r'*, retiform tissue, with more open meshes at *r* and denser at *r'*.

fibres in it, and the white fibres and bundles of fibres form a dense network, the meshes of which vary in size, being very small and close in

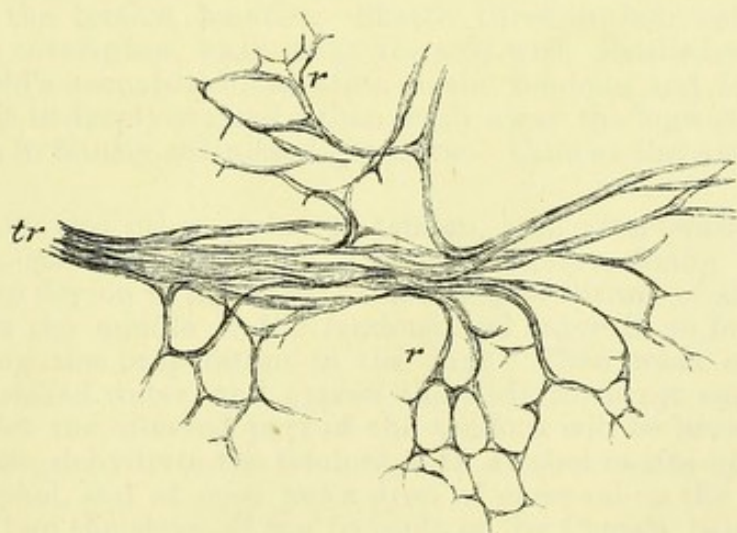


FIG. 47.—PORTION OF THE ABOVE, MORE HIGHLY MAGNIFIED.

some parts; more open and like areolar tissue in other parts. In some places where the tissue occurs the fibres are almost everywhere en-



wrapped by flattened branched connective-tissue cells, and until these are removed it is not easy to see the fibres.

**Lymphoid or adenoid tissue** is retiform tissue in which the meshes of the network are largely occupied by lymph-corpuses. This is by far the most common condition of a retiform tissue, and is met with in the lymphatic glands and allied structures (see Lesson XXII.), and also in the tissue of the alimentary mucous membrane, and in some other situations.

**Basement membranes** (*membranæ propriæ*) are homogeneous-looking membranes, which are found forming the surface-layers of connective-tissue expansions in many parts, especially where there is a covering of epithelium, as on mucous membranes, in secreting glands, and elsewhere. They are generally formed of flattened connective-tissue cells joined together to form a membrane; but, in some cases, they are evidently formed not of cells, but of condensed ground-substance, and in others they are of an elastic nature.

**Jelly-like connective tissue**, although occurring largely in the embryo, is found only in one situation in the adult—viz., forming the vitreous humour of the eye. It seems to be composed mainly of soft ground-substance, with cells scattered here and there through it, and with very few fibres, or none at all. These several varieties of connective tissue will be more fully described in connection with the organs where they occur.



## LESSON X.

*THE CONNECTIVE TISSUES (continued).*

## ELASTIC TISSUE, FIBROUS TISSUE, DEVELOPMENT OF CONNECTIVE TISSUE.

1. TEASE out as finely as possible a small shred of elastic tissue (ligamentum nuchæ of the ox or ligamenta subflava of man) in glycerine and water, slightly coloured by magenta. Cover and cement the preparation. Note the large well-defined fibres constantly branching and uniting with one another. Look for transverse markings on the fibres. Measure three or four. Sketch a small part of the network. Note the existence of bundles of white fibres amongst the elastic fibres.

2. Examine a thin transverse section of ligamentum nuchæ which has been hardened in 2 per cent. solution of bichromate of potash. The section is to be stained with hæmatoxylin and mounted in Canada balsam by the usual process,<sup>1</sup> or simply in glycerine and water. Observe the grouping of the fibres and their angular shape. Notice also the nuclei of connective-tissue cells amongst the fibres. Sketch one or two groups.

3. Pinch off the end of the tail of a dead mouse or rat, draw out the long silk-like tendons and put them into saline solution. Take two of the longest threads and stretch them along a slide, letting the ends dry firmly to the slide but keeping the middle part moist. Put a piece of hair between them and cover in saline solution. Observe with a high power the fine wavy fibrillation of the tendon. Draw. Now run dilute acetic acid (0.75 per cent.) under the cover-glass, watch the tendons where they are becoming swollen by the acetic acid. Notice the oblong nucleated cells coming into view between the tendon bundles. Sketch three or four cells in a row. Lastly, lift the cover-glass, wash away the acid with distilled water, place a drop of Delafield's hæmatoxylin solution on the tendons, and leave the preparation until it is deeply stained; then wash away the logwood and mount the preparation in faintly acidulated glycerine. Cement the cover-glass with gold size.

4. Take one or two other pieces of tendon, and, after washing them in distilled water, stretch them upon a slide as before, fixing the ends by allowing them to dry on to the slide. Put a drop of nitrate of silver solution (1 per cent.) on the middle of the tendons, and leave it on for five to ten minutes, keeping the preparation in the dark. Then wash off the silver nitrate with distilled water, and expose the slide to direct sunlight. In a very few minutes the silvered part of the tendons will be brown. As soon as this is the case, dehydrate the tendons with alcohol *in situ* upon the slide, run off the alcohol, and at once put a drop of clove-oil on the preparation. In a minute or two the clove-oil can be replaced by Canada balsam in xylol, and covered.

5. Stain with magenta solution<sup>1</sup> a thin section of a tendon which has been hardened in 70 per cent. alcohol. Mount in dilute glycerine and cement the cover-glass at once. Sketch a portion of the section under a low power.

<sup>1</sup>See Appendix.



**Elastic tissue** is a variety of connective tissue in which the elastic fibres preponderate. It is found most characteristically in the ligamentum nuchæ of quadrupeds and the ligamenta subflava of the vertebræ, but the connective tissue of other parts may also have a considerable development of elastic fibres. It occurs also in an almost pure form in the walls of the air-tubes, and uniting the cartilages of the larynx. It also enters largely into the formation of the walls of the blood-vessels, especially the arteries.

In the ligamentum nuchæ the fibres are very large and angular (fig. 48); they often exhibit cross-markings or even transverse clefts. When dragged asunder, they break sharply across; they constantly branch and unite, so as to form a close network. In transverse section they are seen to be separated into small groups (fig. 49) by intervening white bundles of connective tissue.

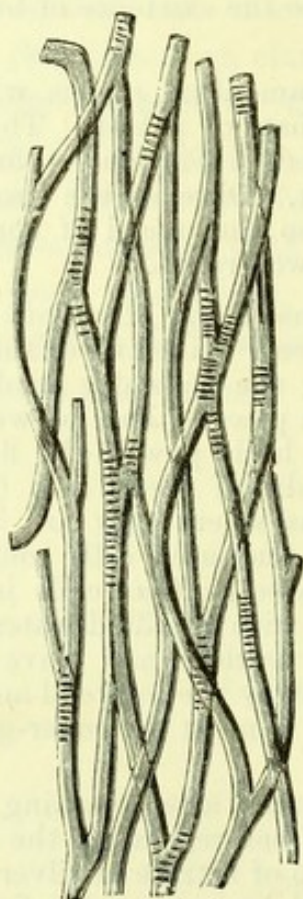


FIG. 48.—ELASTIC FIBRES FROM THE LIGAMENTUM NUCHÆ OF THE OX, SHOWING TRANSVERSE MARKINGS ON THE FIBRES.

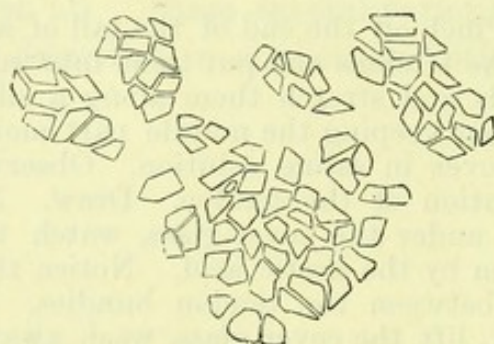


FIG. 49.—CROSS-SECTION OF ELASTIC FIBRES FROM THE LIGAMENTUM NUCHÆ OF THE OX.

Elastic tissue does not always take the form of fibres, but may occur as membranes (as in the blood-vessels). Sometimes the fibres are very small, but their microscopical and chemical characters are always very well marked (see p. 40).

**Fibrous tissue** is almost wholly made up of bundles of white fibres running in a determinate direction. These again are collected into



larger bundles, which give the fibrous appearance to the tissue. The bundles are constantly uniting with one another in their course, although their component fibres remain perfectly distinct.

The interspaces between the larger bundles are occupied by areolar tissue (fig. 50) in which the blood-vessels and lymphatics of the fibrous

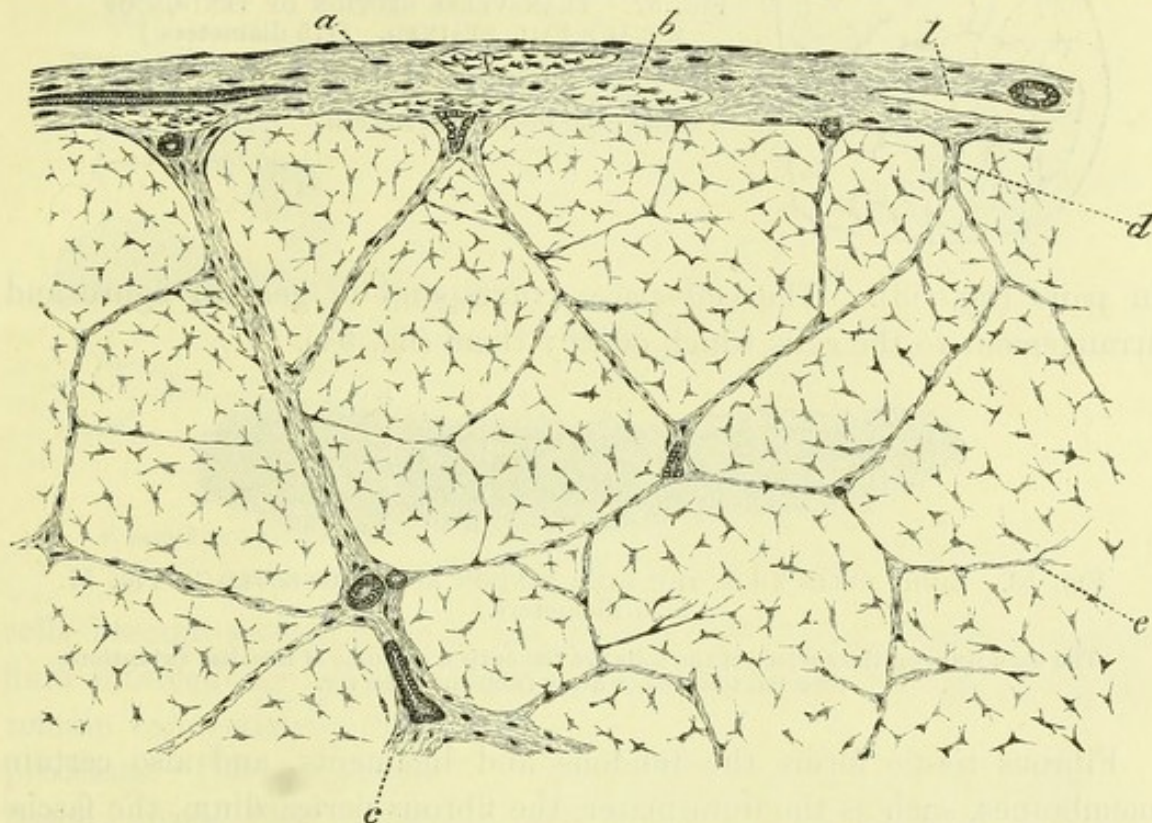


FIG. 50.—PART OF A LARGE TENDON IN TRANSVERSE SECTION. (Moderately magnified.)

*a*, areolar sheath of the tendon, with the fibres for the most part running transversely, but with two or three longitudinal bundles, *b*; *l*, lymphatic cleft in the sheath; immediately over it a blood-vessel is seen cut across, and on the other side of the figure a small artery is shown cut longitudinally; *c*, large septum of areolar tissue; *d*, smaller septum; *e*, still smaller septum. The irregularly stellate bodies are the tendon-cells in section.

tissue are conveyed. The interstices between the smallest bundles are occupied by rows of lamellar connective-tissue corpuscles (*tendon-cells*),

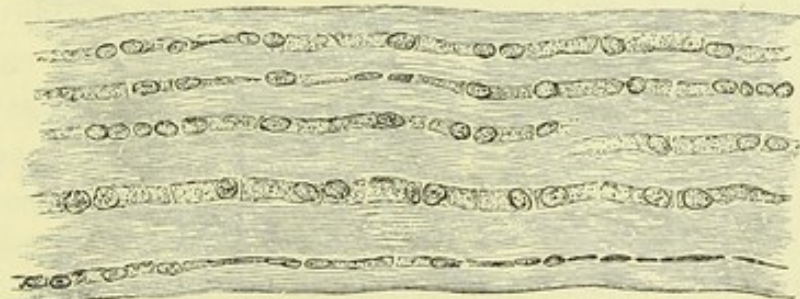


FIG. 51.—TENDON OF MOUSE'S TAIL; SHOWING CHAINS OF CELLS BETWEEN THE TENDON-BUNDLES. (175 diameters.)

which from being squeezed up between three or more bundles become flattened out in two or three directions. In transverse section the cells appear somewhat stellate (figs. 50, 52), but when seen on the flat they appear lamellar (fig. 51), and from this aspect their general shape is



square or oblong. They lie, as before said, in rows between the tendon-bundles, and the nuclei of adjacent cells are placed opposite one another

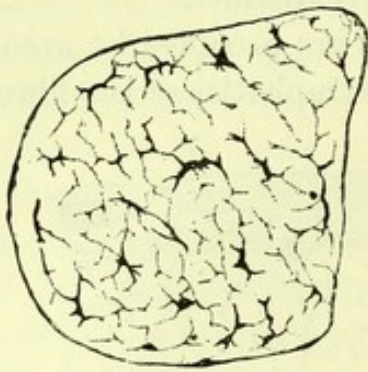


FIG. 52.—TRANSVERSE SECTION OF TENDON OF MOUSE'S TAIL, STAINED. (175 diameters.)

The flattened processes of the tendon-cells appear in section as lines, frequently coming off at right angles from the body of the cell.

in pairs (fig. 53). The cell-spaces correspond in general figure and arrangement to the cells which occupy them (fig. 54).



FIG. 53.—EIGHT CELLS FROM THE SAME TENDON AS REPRESENTED IN FIG. 51. (425 diameters.)

The dark lines on the surface of the cells are the optical sections of lamellar extensions directed towards or away from the observer.

Fibrous tissue forms the tendons and ligaments, and also certain membranes, such as the dura mater, the fibrous pericardium, the fasciæ of the limbs, the fibrous covering of certain organs, etc. It is found wherever great strength combined with flexibility is concerned. It

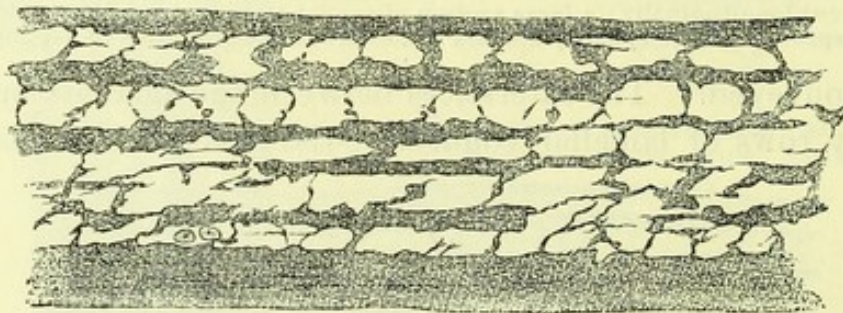


FIG. 54.—CELL-SPACES OF TENDON OF MOUSE'S TAIL, BROUGHT INTO VIEW BY TREATMENT WITH NITRATE OF SILVER. (175 diameters.)

receives a few blood-vessels, disposed longitudinally for the most part, and contains many lymphatics. Tendons and ligaments also receive nerve-fibres, which, in some cases, end in small localised ramifications like the end-plates of muscle, while others terminate in end-bulbs or in simple Pacinian corpuscles. These will be described along with the modes of ending of nerve-fibres.

**Development of connective tissue.**—Connective tissue is always



developed in the mesoblast or mesoderm of the embryo. In those parts of this layer which are to form connective tissue, the embryonic

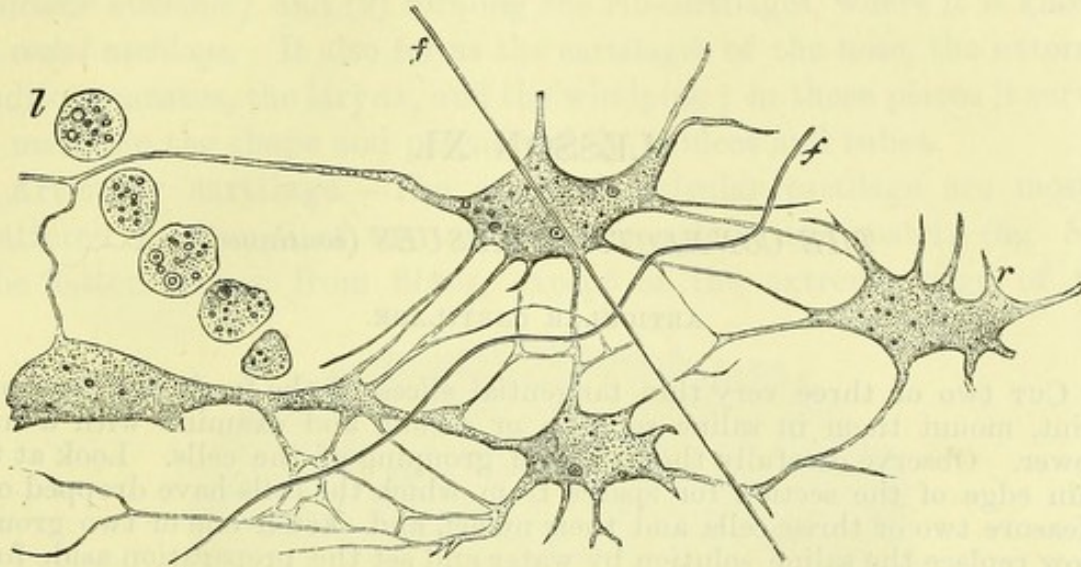


FIG. 55.—JELLY OF WHARTON. (Ranvier.)

*r*, ramified cells intercommunicating by their branches; *l*, a row of lymph cells; *f*, fibres developing in the ground-substance.

cells become separated from one another by a muco-albuminous semi-fluid intercellular substance (ground-substance), but the cells generally remain connected by their processes. The connective-tissue fibres, both white and elastic, are deposited in this ground-substance, the elastic substance usually in the form of granules (fig. 56, *g*), which subsequently become connected together into elastic fibres or laminae, as the case may be, the white fibres appearing at first in the form of very fine bundles, which afterwards become gradually larger; so that in fibrous tissue the whole ground substance is eventually pervaded by them, and the cells of the tissue become squeezed up into the intervals between them. Before any considerable development of fibres has taken place, the embryonic connective tissue has a jelly-like appearance; in this form it occurs in the umbilical cord, where it is known as the *jelly of Wharton* (fig. 55).

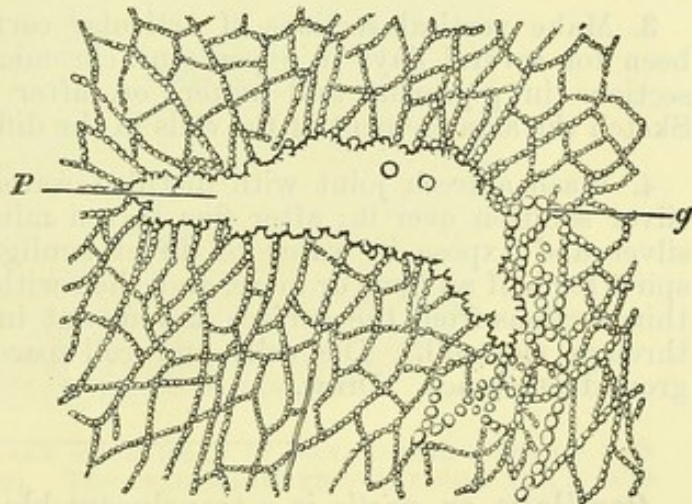


FIG. 56.—DEVELOPMENT OF ELASTIC TISSUE BY DEPOSITION OF FINE GRANULES. (Ranvier.)

*g*, fibres being formed of rows of 'elastin' granules; *p*, flat plate-like expansion of elastic substance formed by the fusion of 'elastin' granules.



## LESSON XI.

*THE CONNECTIVE TISSUES (continued).*

## ARTICULAR CARTILAGE.

1. Cut two or three very thin tangential slices of the fresh cartilage of a joint, mount them in saline solution or serum, and examine with a high power. Observe carefully the form and grouping of the cells. Look at the thin edge of the section for spaces from which the cells have dropped out. Measure two or three cells and their nuclei, and sketch one or two groups. Now replace the saline solution by water and set the preparation aside for a little while. On again examining it, many of the cartilage-cells will be found to have shrunk away from their containing capsules.

2. Make other sections of the cartilage (1) from near the middle, (2) from near the edge. Place the sections for two or three minutes in acetic acid (1 per cent.), wash them with water, and stain with dilute hæmatoxylin solution. When stained mount in dilute glycerine and cement the cover-glass. In (2) look for branched cartilage-cells. Draw one or two.

3. Make vertical sections of articular cartilage from a bone which has been for several days in  $\frac{1}{2}$  per cent. chromic acid solution, and mount the sections in glycerine and water, or, after staining, in Canada balsam.<sup>1</sup> Sketch the arrangement of the cells in the different layers.

4. Wash a fresh joint with distilled water; drop 1 per cent. nitrate of silver solution over it; after five to ten minutes wash away the nitrate of silver and expose in water to direct sunlight. When browned, place in spirit for half an hour or more, and then with a razor wetted with spirit cut thin sections from the surface and mount in Canada balsam after passing through clove-oil. The cells and cell-spaces show white in the brown ground-substance. Draw.

---

**Cartilage** or *gristle* is a translucent bluish-white tissue, firm, and at the same time elastic, and for the most part found in connection with bones of the skeleton, most of which are in the embryo at first represented entirely by cartilage. Two chief varieties of cartilage are distinguished. In the one, which is termed *hyaline*, the matrix or ground-substance is clear, and free from obvious fibres; in the other, which is termed *fibro-cartilage*, the matrix is everywhere pervaded by connective-tissue fibres. When these are of the white variety, the tissue is *white fibro-cartilage*; when they are elastic fibres, it is *yellow or elastic fibro-cartilage*.

<sup>1</sup> See Appendix.



**Hyaline cartilage** occurs principally in two situations—namely (1) covering the ends of the bones in the joints, where it is known as *articular cartilage*; and (2) forming the rib-cartilages, where it is known as *costal cartilage*. It also forms the cartilages of the nose, the external auditory meatus, the larynx, and the windpipe; in these places it serves to maintain the shape and patency of the orifices and tubes.

**Articular cartilage.**—The cells of articular cartilage are mostly scattered in groups of two or four throughout the matrix (fig. 57). The latter is free from fibres, except at the extreme edge of the

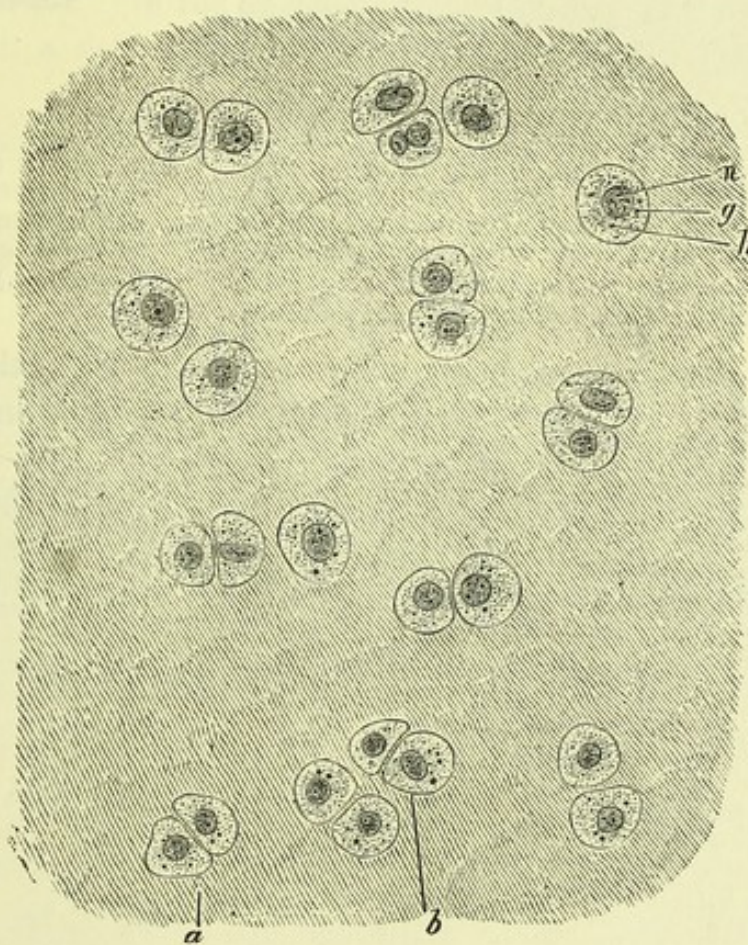


FIG. 57.—ARTICULAR CARTILAGE FROM HEAD OF METATARSAL BONE OF MAN (OSMIC ACID PREPARATION). THE CELL-BODIES ENTIRELY FILL THE SPACES IN THE MATRIX. (340 diameters.)

*a*, group of two cells; *b*, group of four cells; *h*, protoplasm of cell, with *g*, fatty granules; *n*, nucleus.

cartilage, where the connective-tissue fibres from the synovial membrane extend into it; and here also the cartilage cells are often branched, and offer transitions to the branched connective-tissue corpuscles of that membrane (*transitional cartilage*, fig. 58). By long maceration, however, evidence of a fibrous structure may be obtained, even in the matrix of true hyaline cartilage. Some histologists also describe fine communications in the matrix uniting the cartilage-cells with one another, but these are of doubtful occurrence.



The matrix immediately around the cartilage-cells is often marked off from the rest by a concentric line or lines, this part of the matrix,

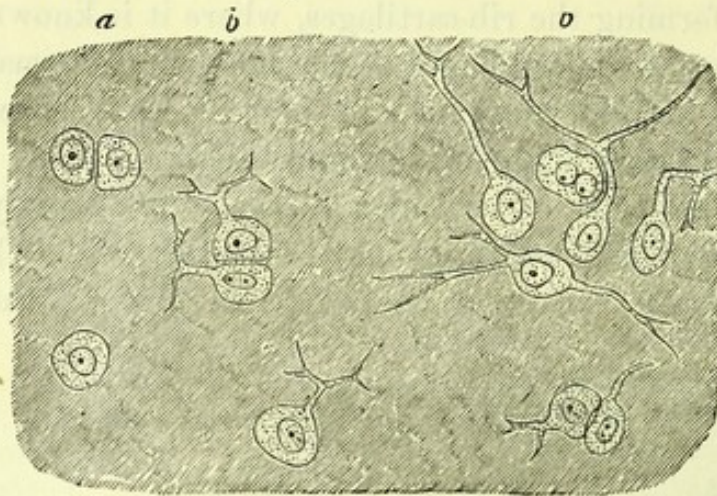


FIG. 58.—BORDER OF ARTICULAR CARTILAGE SHOWING TRANSITION OF CARTILAGE CELLS INTO CONNECTIVE-TISSUE CORPUSCLES OF SYNOVIAL MEMBRANE. FROM HEAD OF METATARSAL BONE, HUMAN. (About 340 diameters.)

*a*, ordinary cartilage-cells; *b*, *b*, with branching processes.

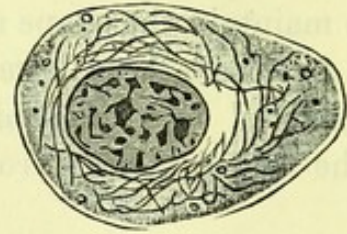

FIG. 59.—A CARTILAGE-CELL IN THE LIVING STATE, FROM THE SALAMANDER. (Flemming.) [(Very highly magnified.)]

which is the latest formed, being known as the *capsule* of the cell. The cells are bluntly angular in form, the sides opposite to one another in

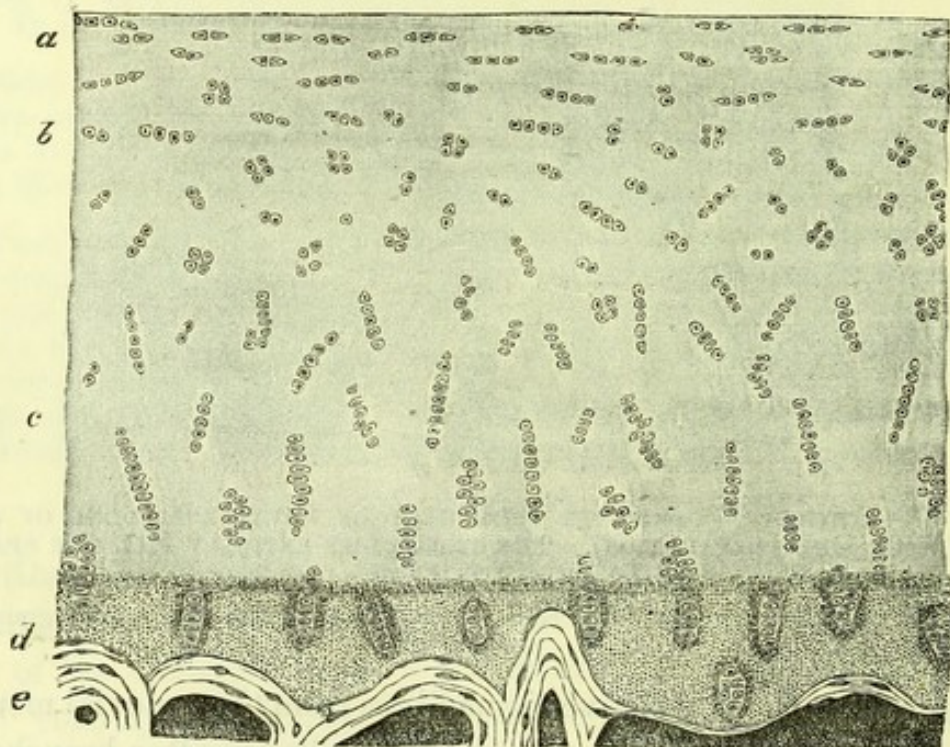


FIG. 60.—VERTICAL SECTION OF ARTICULAR CARTILAGE COVERING THE LOWER END OF THE TIBIA, HUMAN. (Magnified about 30 diameters.)

*a*, cells and cell-groups flattened conformably with the surface; *b*, cell-groups irregularly arranged; *c*, cell-groups disposed perpendicularly to the surface; *d*, layer of calcified cartilage; *e*, bone.

the groups being generally flattened. The protoplasm is very clear, but it may contain droplets of fat; and with a high power fine inter-



lacing filaments and granules have been observed in it (fig. 59). During life the protoplasm entirely fills the cavity or cell-space which it occupies in the matrix; but after death, and in consequence of the action of water and other agents, it tends to shrink away from the capsule. The nucleus is round, and shows the usual intranuclear network.

In vertical section (fig. 60) the deeper cell-groups (*c*) are seen to be arranged vertically to the surface, the more superficial ones (*a*) parallel to the surface; whilst in an intermediate zone the groups are irregularly disposed (*b*). In the deepest part of the cartilage, next the bone, there is often a deposition of calcareous salts in the matrix (*calcified cartilage, d*).

The disposition of the cells of cartilage in groups of two, four, and so on, is apparently due to the fact that these groups have originated from the division of a single cell first into two, and these again into two, and so on (fig. 61). It would seem that the matrix is formed of

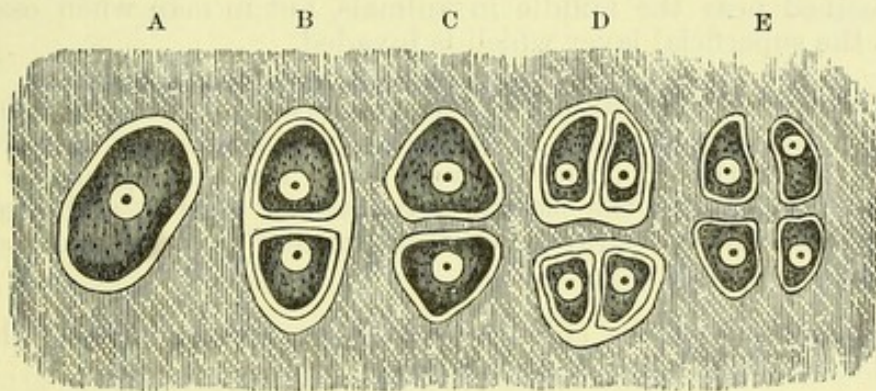


FIG. 61.—PLAN OF THE MULTIPLICATION OF CELLS OF CARTILAGE. (Sharpey.)

A, cell in its capsule; B, divided into two, each with a capsule; C, primary capsule disappeared, secondary capsules coherent with matrix; D, tertiary division; E, secondary capsules disappeared, tertiary coherent with matrix.

successive portions, which are deposited around each cartilage-cell as the so-called 'capsules,' each newly formed portion soon blending in its turn with the previously formed matrix, whilst a new capsule is formed within it. The division of the cartilage-cell, like that of other cells, is accompanied by a process of karyokinesis.

Embryonic cartilage is characterised by the cells being usually more sharply angular and irregular, being even in some cases, markedly branched, like those which occur at the junction of cartilage and synovial membrane in the adult. The cells are also more closely packed, the matrix being in relatively less amount.



## LESSON XII.

*THE CONNECTIVE TISSUES (continued).*

## COSTAL CARTILAGE. FIBRO-CARTILAGE.

1. MAKE transverse and tangential sections of a rib-cartilage, which may either be fresh, or may have been preserved in spirit. Stain them with hæmatoxylin (if fresh, after treatment with acetic acid as in Lesson XI., § 2), and mount in glycerine. Sketch a part of a transverse section under a low power and a cell-group from one of the tangential sections under a high power. Notice especially the arrangement of the cells, somewhat concentric near the surface but radial near the centre. The costal cartilages are often ossified near the middle in animals, but in man when ossification occurs it is the superficial layer which is invaded.

2. Make sections of the cartilage of the external ear, either fresh or after hardening in alcohol. Mount in dilute glycerine faintly coloured with magenta. If from the ox, notice the very large reticulating elastic fibres in the matrix. Notice also the isolated granules of elastin, and around the cartilage-cells the area of clear ground-substance. Draw a small portion of the section.

3. Mount a section of the epiglottis in the same way. Notice the closer network of much finer fibres in its cartilage.

4. Cut sections of white fibro-cartilage (intervertebral disk), which has been hardened in saturated solution of picric acid, followed by spirit, or in spirit only. Stain the sections with dilute hæmatoxylin. Mount in dilute glycerine. Observe the wavy fibres in the matrix and the cartilage-cells lying in clear areas often concentrically striated. Look for branched cartilage-cells. Sketch three or four cells and the adjoining fibrous matrix.

---

**Costal cartilage.**—In the costal cartilages the matrix is not always so clear as in the cartilage of the joints, for it often happens that fibres become developed in it. The cells are generally larger and more angular than those of articular cartilage, and collected into larger groups (fig. 62). Near the circumference, and under the perichondrium or fibrous covering of the cartilage, they are flattened and parallel to the surface, but in the deeper parts they have a more irregular or a radiated arrangement. They frequently contain fat. The cartilages of the larynx and windpipe and of the nose resemble on the whole the costal cartilages, but the study of them may be deferred until the organs where they occur are dealt with.



**Elastic or yellow fibro-cartilage** occurs in only a few situations. These are, the cartilage of the external ear and that of the Eustachian tube, and the epiglottis and cartilages of Santorini of the larynx. The

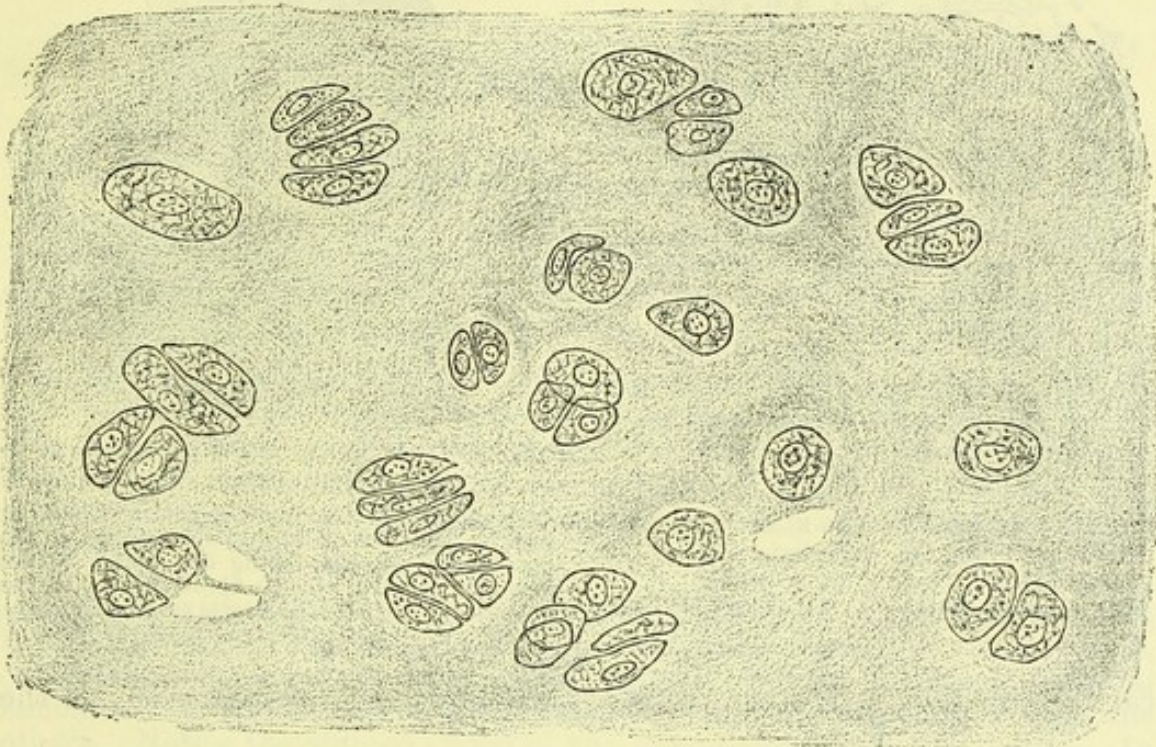

FIG. 62.—SECTION OF RIB-CARTILAGE, SHOWING CELLS AND CELL-GROUPS IN A SOMEWHAT FIBROUS-LOOKING MATRIX.

Two or three empty cell-spaces are seen from which the cells have dropped out in preparing the section.

matrix is everywhere pervaded with well-defined branching fibres, which unite with one another to form a close network (fig. 63). These fibres resist the action of acetic acid, and are stained deeply by magenta; they are evidently elastic fibres. In the ox they are very large, but smaller in man, especially in the cartilage of the epiglottis (fig. 64). They appear to be developed, as with elastic tissue elsewhere (see p. 49), by the deposition of granules of elastin in the matrix, which at first lie singly, but afterwards become joined to form the fibres.

**White fibro-cartilage** is found wherever great strength combined with a certain amount of rigidity is required: thus we frequently find fibro-cartilage joining bones together, as in the case of the intervertebral disks and other symphyses. Fibro-cartilage is frequently employed to line grooves in which tendons run, and it may also be found in the tendons themselves. It is also employed to deepen cup-shaped articular surfaces; and in the case of the interarticular cartilages, such as those of the knee and lower jaw, to allow greater freedom of movement whilst diminishing the liability to dislocation. Under the microscope white fibro-cartilage looks very like fibrous tissue, but its cells are



cartilage-, not tendon-, cells (fig. 65). They are rounded or bluntly angular and surrounded by a concentrically striated area of clear

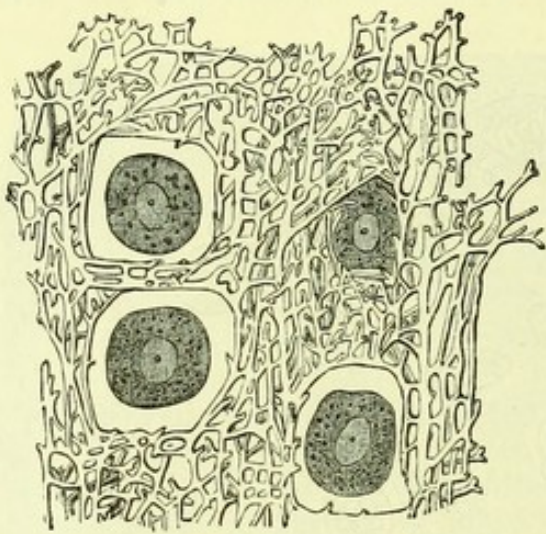


FIG. 63.—SECTION OF THE ELASTIC CARTILAGE OF THE EAR. (Hertwig.) (Highly magnified.)

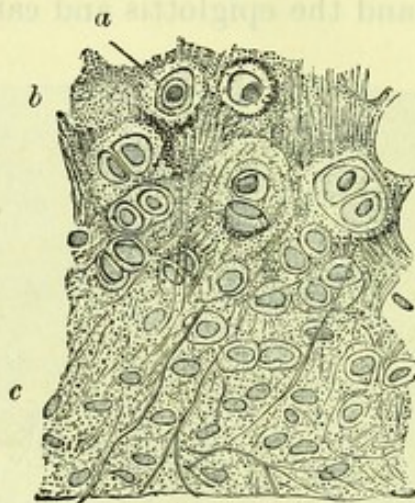


FIG. 64.—SECTION OF PART OF THE CARTILAGE OF THE EPIGLOTTIS. (Ranvier.)

*a*, cartilage cell in clear area; *b*, granular-looking matrix near the middle of the cartilage, the granular appearance being due partly to the fine reticulum of elastic fibres, partly to the presence of granules of elastic substance in the matrix; *c*, clearer matrix with longer fibres.

cartilage-matrix. In some parts of the intervertebral disk many of the

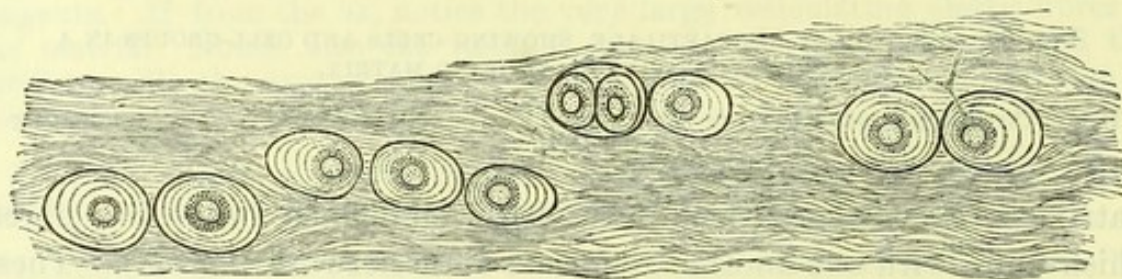


FIG. 65.—WHITE FIBRO-CARTILAGE FROM AN INTERVERTEBRAL DISK, HUMAN. (Highly magnified.)

The concentric lines around the cells indicate the limits of deposit of successive capsules. One of the cells has a forked process which extends beyond the hyaline area surrounding the cell, amongst the fibres of the general matrix.

cells are branched, and may be looked upon as transitional forms to connective-tissue corpuscles.



## LESSON XIII.

*BONE AND MARROW.*

1. In thin sections of hard bone made by grinding, observe the Haversian canals, lamellæ, lacunæ, canaliculi, etc. Make a sketch first under a low and afterwards under a high power.

2. With fine forceps strip off a thin shred from the superficial layers of a bone which has been decalcified in dilute nitric acid and afterwards kept for some time in dilute alcohol. Mount the shred in water. Observe the fibrous structure of the lamellæ. Look for perforating fibres or the holes from which they have been dragged out. Sketch a small piece of the thin edge of a lamella.

3. Stain with dilute magenta very thin sections of compact bone which has been decalcified in chromic or picric acid, and mount in dilute glycerine, cementing at once. Look for fibres of Sharpey piercing the circumferential lamellæ. The elastic perforating fibres are more darkly stained than the others. Notice the stained nuclei of the bone-corpuscles in the lacunæ. In the thinnest parts of the sections try to make out the blood-vessels and other structures in the Haversian canals.

4. Mount in Canada balsam sections of marrow (from a long bone of a rabbit) stained with hæmatoxylin.<sup>1</sup> Observe the fat-cells, the reticular tissue supporting them, the proper marrow-cells in this tissue, etc.

5. Tease in salt solution or serum some of the red marrow from the rib of a recently killed animal. Observe and sketch the proper marrow-cells and look for myeloplaxes and nucleated coloured blood-corpuscles. If examined carefully, amœboid movements may be detected in the latter and in the marrow-cells.

**Bone** is a connective tissue in which the ground-substance is impregnated with salts of lime, chiefly phosphate, these salts constituting about two-thirds of the weight of the bone. When bones are macerated this earthy matter prevents the putrefaction of the animal matter. When bones are calcined they lose one-third of their weight, owing to the destruction of the animal matter; when steeped in acid the earthy salts are dissolved and only the animal matter is left. This, like areolar and fibrous tissue, is converted into gelatine by boiling.

Bony tissue is either *compact* or *cancellated*. Compact bone is dense like ivory; cancellated is spongy with obvious interstices. The outer layers of all bones are compact, and the inner part is generally can-

<sup>1</sup> See Appendix.



cellated, but the shaft of a long bone is almost entirely made up of compact substance except along the centre, which is hollow and filled with marrow. The interstices of cancellated bone are also occupied by marrow. Externally bones are covered except at the joints by a vascular fibrous membrane, the *periosteum*.

True bone is always made up of *lamellæ*, and these again are composed of fine *fibres* lying in a *calcified ground-substance*. Between the lamellæ are branched cells, the *bone-corpuscles*, which lie in cell-spaces or *lacunæ*. The ramified passages which contain the cell-processes are termed *canaliculi*.

In cancellated bone the blood-vessels run in the interstices supported by the marrow. In compact bone they are contained in little canals—the *Haversian canals*—which everywhere pervade the bone. These canals are about 0·05 mm. ( $\frac{1}{300}$  inch) in diameter, but some are

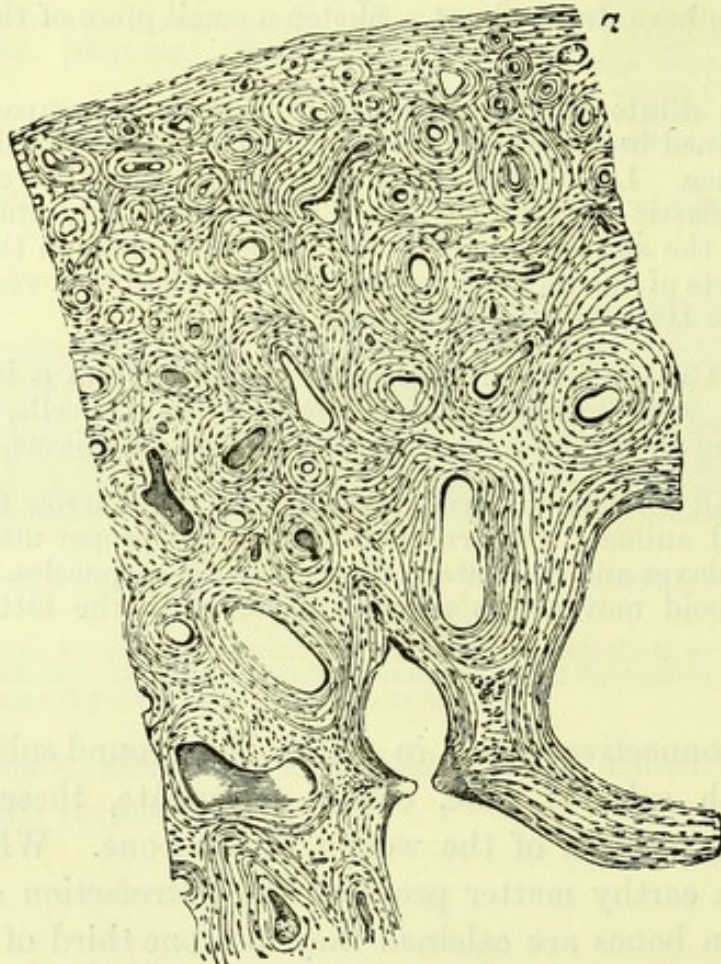


FIG. 66.—TRANSVERSE SECTION OF A BONE (ULNA). (Sharpey.)  
(Magnified 20 diameters.)

The openings of the Haversian canals are seen encircled by concentric lamellæ. Other lamellæ run parallel with the surface (*a*).

smaller, others larger than this. Their general direction is longitudinal, *i.e.* parallel to the long axis of the bone, but they are constantly united by transversely and obliquely running passages. In a section across



the shaft of a long bone they are seen as small rounded or irregular holes (fig. 66). When the section has been made by grinding, the holes get filled up with air and débris, and they then look black by transmitted light, as do also the lacunæ and canaliculi (fig. 67). Most of the lamellæ in compact bone are disposed concentrically around the Haversian canals; they are known as the Haversian lamellæ, and with

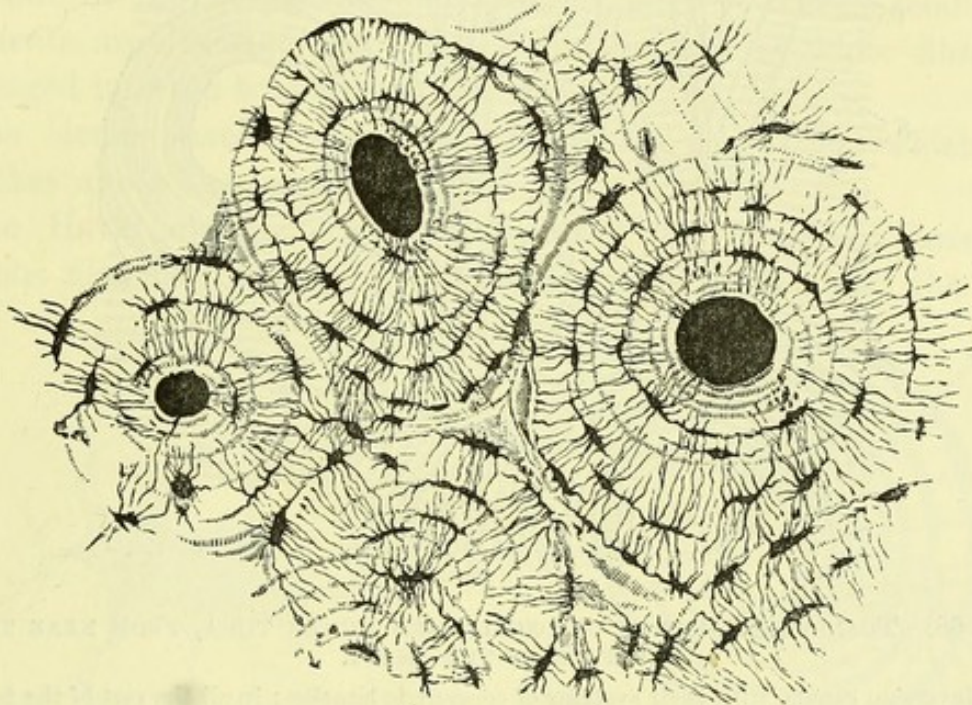


FIG. 67.—TRANSVERSE SECTION OF COMPACT TISSUE (OF HUMERUS.) (Sharpey.)  
(Magnified about 150 diameters.)

Three of the Haversian canals are seen, with their concentric rings; also the lacunæ, with the canaliculi extending from them across the direction of the lamellæ. The Haversian apertures had become filled with air and debris in grinding down the section, and therefore appear black in the figure, which represents the object as viewed by transmitted light.

the included canal form what is known as a *Haversian system*. The lacunæ of a Haversian system communicate with one another and with the Haversian canal, but not as a rule with the lacunæ of other Haversian systems. The angular interstices between the Haversian systems are generally occupied by bony substance, which is fibrous but not lamellar. Besides the lamellæ of the Haversian systems there is a certain thickness of bone at the surface, immediately underneath the periosteum, which is composed of lamellæ arranged parallel with the surface; these are the *circumferential* or *periosteal lamellæ* (fig. 66, *a*). They are pierced here and there by canals for blood-vessels, which are proceeding from the periosteum to join the system of Haversian canals, and also by calcified bundles of white fibres and by elastic fibres which may also be prolonged from the periosteum. These are the *perforating fibres of Sharpey* (fig. 68).

The lamellæ of bone are fibrous in structure. This may be seen in



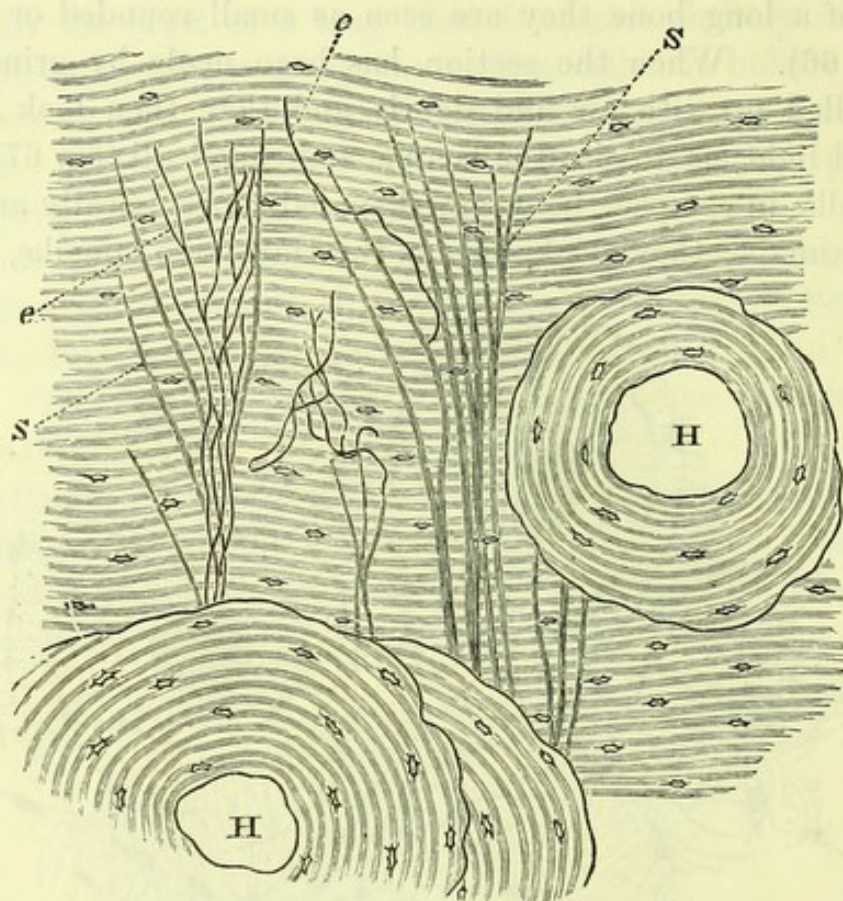


FIG. 68.—TRANSVERSE SECTION OF DECALCIFIED HUMAN TIBIA, FROM NEAR THE SURFACE OF THE SHAFT.

H, H, Haversian canals, with their systems of concentric lamellæ; in all the rest of the figure the lamellæ are circumferential; s, s, ordinary perforating fibres of Sharpey; e, e, elastic perforating fibres. Drawn under a power of about 150 diameters.

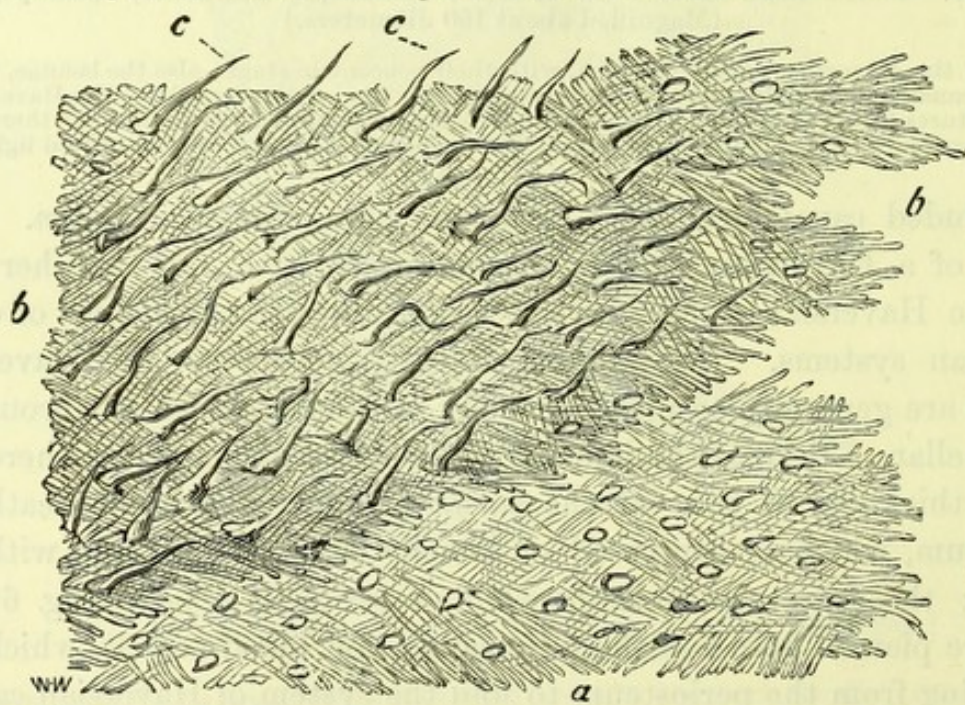


FIG. 69.—LAMELLÆ TORN OFF FROM A DECALCIFIED HUMAN PARIETAL BONE AT SOME DEPTH FROM THE SURFACE. (Sharpey.)

a, lamellæ, showing decussating fibres; b, b, thicker part, where several lamellæ are superposed; c, c, perforating fibres; the fibrils which compose them are not shown in the figure. Apertures through which perforating fibres had passed are seen, especially in the lower part, a, a, of the figure. Magnitude as seen under a power of 200, but not drawn to a scale. (From a sketch by Allen Thomson.)



shreds torn off from the superficial layers of a decalcified bone (fig. 69). The fibres often cross one another in adjacent lamellæ, and in the Haversian systems they run in some lamellæ concentrically, in others parallel with the Haversian canal. In shreds of lamellæ which have been peeled off from the surface the perforating fibres may sometimes be seen projecting from the surface of the shred, having been torn out of the deeper lamellæ (fig. 69, *c, c*). Where tendons or ligaments are inserted into bone, their bundles of white fibres are prolonged into the bone as perforating fibres.

The lacunæ are occupied by nucleated corpuscles, which send branches along the canaliculi (fig. 70).

The Haversian canals contain one or two blood-capillaries and nervous filaments, besides a little connective tissue; and the larger

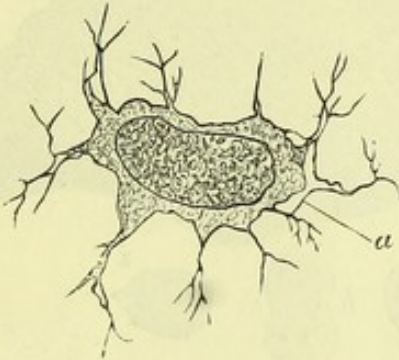


FIG. 70.—A BONE-CELL ISOLATED AND HIGHLY MAGNIFIED. (Joseph.)

*a*, proper wall of the lacuna, where the corpuscle has shrunk away from it.

ones may also contain a few marrow-cells. There are also cleft-like lymphatic spaces running with the vessels and connected through canaliculi with branches from corpuscles within the neighbouring lacunæ of the osseous substance (fig. 71).

The periosteum (which is studied in torn-off shreds, in preparations stained *in situ* with silver nitrate, and in logwood-stained sections from a bone which has been decalcified in chromic or picric acid) is a fibrous membrane composed of two layers, the inner of which contains many elastic fibres. In the outer layer numerous blood-vessels ramify and send from it branches to the Haversian canals of the bone. The periosteum ministers to the nutrition of the bone, partly on account of the blood-vessels and lymphatics it contains, partly, especially in young

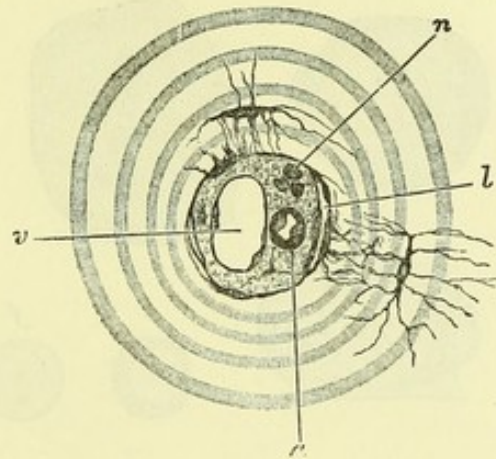


FIG. 71.—SECTION OF A HAVERSIAN CANAL, SHOWING ITS CONTENTS. (Highly magnified.)

*a*, small arterial capillary vessel; *v*, large venous capillary; *n*, pale nerve-fibres cut across; *l*, cleft-like lymphatic vessel; one of the cells forming its wall communicates by fine branches with the branches of a bone-corpuscle. The substance in which the vessels run is connective tissue with ramified cells; its finely granular appearance is probably due to the cross-section of fibrils. The canal is surrounded by several concentric lamellæ.



animals, on account of the existence between it and the bone of a layer of *osteoblasts* or *bone-forming cells*, a remainder of those which originally produced the bone.

The **marrow of bone** is of a yellow colour in the shafts of the long bones, and is there largely composed of adipose tissue, but in the cancellated tissue it is usually red, the colour being partly due to the large amount of blood in its vessels. This red marrow is chiefly composed of round nucleated cells—the *marrow cells* (fig. 72, *e-i*)—which resemble large lymph-corpuscles, and, like these, are amœboid. There are also to be seen mingled with them a number of corpuscles somewhat smaller in size, but nucleated and amœboid, and of a reddish tint (fig. 72, *j-t*). These cells, which are termed *erythroblasts*, resemble the nucleated

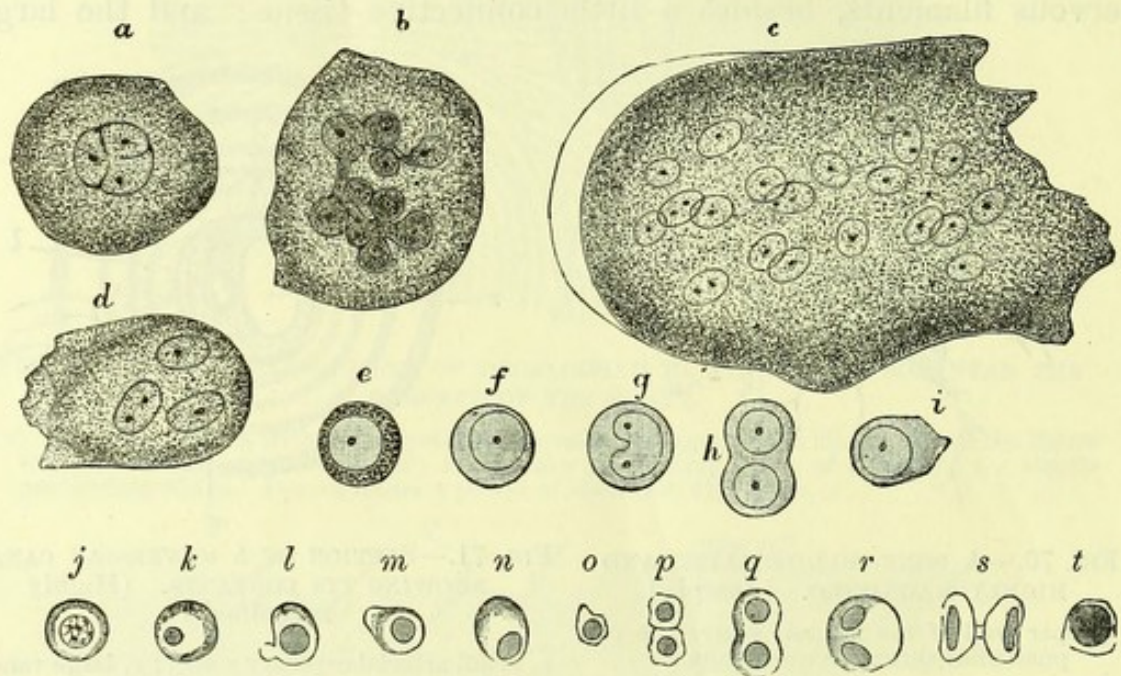


FIG. 72.—CELLS OF THE RED MARROW OF THE GUINEA-PIG. (Highly magnified.)

*a*, a large cell, the nucleus of which appears to be partly divided into three by constrictions; *b*, a cell the enlarged nucleus of which shows an appearance of being constricted into a number of smaller nuclei; *c*, a so-called giant-cell or myeloplax with many nuclei; *d*, a smaller myeloplax with three nuclei; *e-i*, proper cells of the marrow; *j-t*, various forms of coloured nucleated cells, some in process of division.

coloured blood-corpuscles of the embryo, and they are believed to be cells from which the coloured blood-disks become developed (Neumann). Many of them are in process of division by karyokinesis, and others are seen with the nucleus in a more or less atrophied condition; from which it may be inferred that the transformation into a discoid blood-corpuscle is accompanied by the disappearance of the nucleus (Bizzozero). Lastly, the marrow contains a certain number of very large cells with multiple nuclei, the *myeloplaxes* of Robin (fig. 72, *a, b, c, d*). These are especially numerous wherever bone is becoming absorbed, but are not confined to such situations, being indeed normal constituents of marrow. Sometimes, instead of possessing several



nuclei, these cells contain but one large nucleus, which then usually shows an appearance as of budding (*b*). Lastly, the existence of cells within the marrow containing blood-corpuscles in various stages of transformation into pigment, similar to those which occur in the spleen pulp, has also been affirmed (by Osler). The marrow is very vascular, the capillaries and veins being large and thin-walled; indeed, according to some authorities, the walls of the capillaries are imperfect, so that there is an open communication between them and the interstices of the tissue, and in this way it is supposed that the coloured blood-disks, which are believed to be produced from the coloured nucleated cells of the marrow, may get into the circulation.



## LESSON XIV.

## DEVELOPMENT OF BONE.

1. MOUNT in Canada balsam a section of a foetal lower jaw which has been stained in bulk with magenta or hæmatoxylin and embedded in paraffin.<sup>1</sup> Find the part where the lower jaw-bone is becoming ossified, and carefully study the appearance which it presents. The bone is prolonged in the form of osteogenic fibres which are covered with osteoblasts.

2. Intramembranous ossification may also be studied in the parietal bone of a foetus which has been preserved in Müller's fluid. A piece of the growing edge is scraped or brushed free from its investing membranes, and from most of the cells which cover and conceal it, and is mounted in glycerine with or without previous staining with carmine.

3. Mount in Canada balsam sections of a foetal limb which has been stained with magenta. The bones will be found in different stages of ossification, those of the digits being least developed. Make sketches illustrating the three chief stages of endochondral ossification. Notice the peculiar terminal ossification of the third phalanx.

4. Make with a sharp scalpel a longitudinal section at the line of ossification in a more advanced bone which has not been decalcified. Other sections may be carried across a bone near its plane of ossification, and others through an epiphysis. These sections will show the mode of progress of the calcification. The sections can be mounted in glycerine.

---

True bone is essentially formed in all cases by an ossification of connective tissue. Sometimes the bone is preceded by cartilage, which first becomes calcified, and this is then invaded, and for the most part removed, by an embryonic tissue which re-deposits bony matter in the interior of the cartilage, whilst at the same time layers of bone are being formed outside underneath the periosteum. This is *intracartilaginous* or *endochondral ossification*. Sometimes the bone is not preceded by cartilage, and then the only process which occurs is one corresponding to the subperiosteal ossification of the former variety; the ossification is then known as *intramembranous*.

**Ossification of cartilage.**—This may be described as occurring in three stages. In the *first stage* the cells in the middle of the cartilage become enlarged and arranged in rows radiating from the centre

<sup>1</sup>For the methods of staining and embedding 1 and 3, see Appendix, 'Embedding in Paraffin.'



(fig. 73), and fine granules of calcareous matter are deposited in the matrix. Simultaneously with this the osteoblasts underneath the periosteum deposit a layer or layers of fibrous lamellæ upon the surface of the cartilage, and these lamellæ also become calcified (fig. 73, *im*). As they are formed, some of the osteoblasts (*o*) are included between them and become bone-corpuscles.

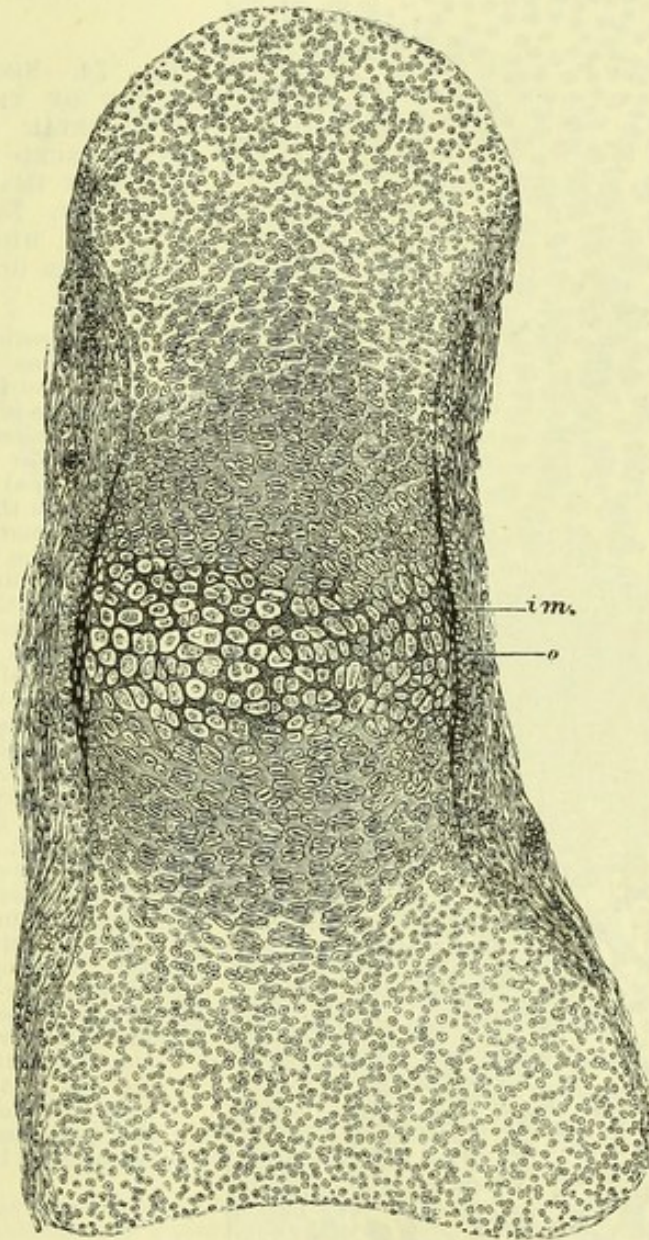


FIG. 73.—SECTION OF PHALANGEAL BONE OF HUMAN FETUS, AT THE TIME OF COMMENCING OSSIFICATION. (From a preparation by F. A. Dixey.) (Magnified about 75 diameters.)

The cartilage-cells in the centre are enlarged and separated from one another by dark-looking calcified matrix; *im*, layer of bone deposited underneath the periosteum; *o*, layer of osteoblasts by which this layer has been formed. Some of the osteoblasts are already embedded in the new bone as lacunæ. The cartilage-cells are becoming enlarged and flattened and arranged in rows above and below the calcified centre. At the ends of the cartilage the cells are small, and the groups are irregularly arranged; the fibrous periosteum is not sharply marked off from the cartilage.

In the *second stage* some of the subperiosteal tissue eats its way through the newly formed layer of bone and into the centre of the



calcified cartilage (fig. 74, *ir*). This is freely absorbed before it (fig. 75), so that large spaces are produced which are filled with osteoblasts and contain numerous blood-vessels which have grown in at the same time. The spaces are termed *medullary spaces*, and this second stage may be termed the *stage of irruption*.

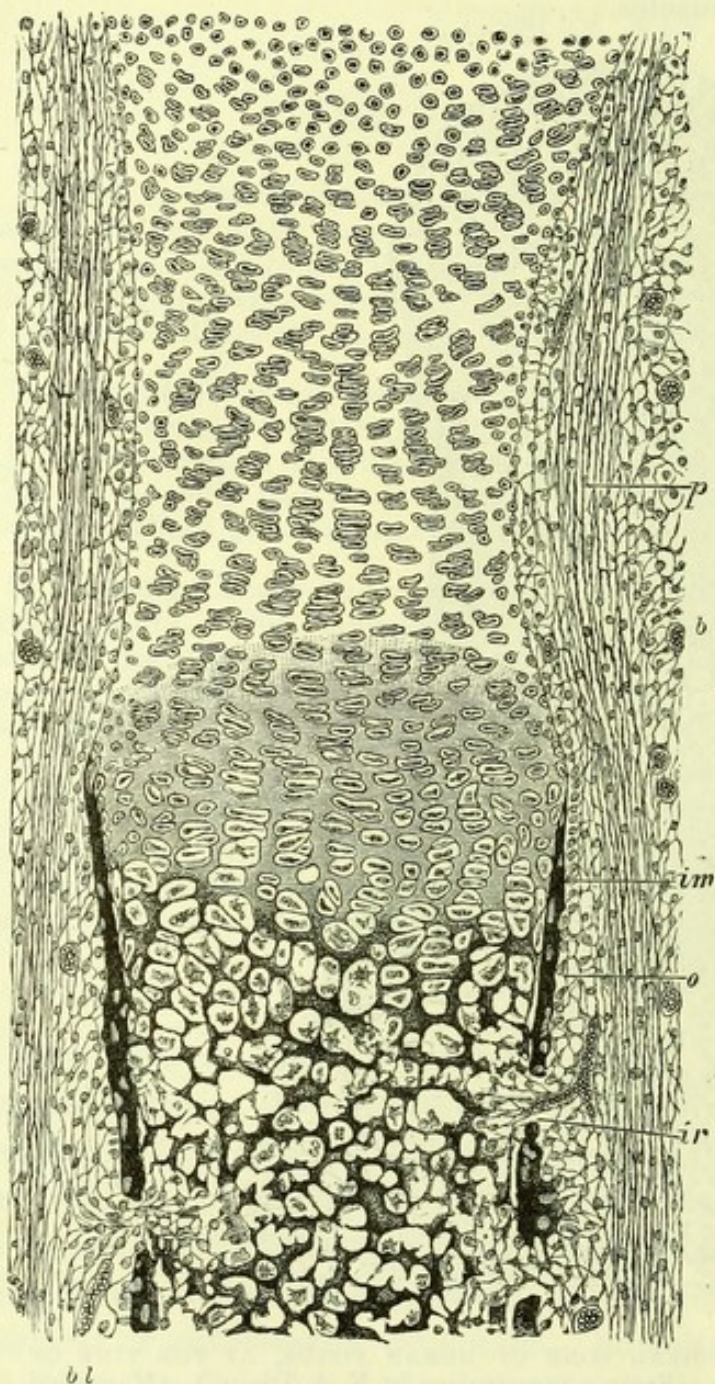


FIG. 74.—SECTION OF PART OF ONE OF THE LIMB-BONES OF A FETAL CAT, AT A MORE ADVANCED STAGE OF OSSIFICATION THAN IS REPRESENTED IN FIG. 73, AND SOMEWHAT MORE HIGHLY MAGNIFIED. (From a drawing by J. Lawrence.)

The calcification of the cartilage-matrix has advanced from the centre, and is extending between the groups of cartilage-cells which are arranged in characteristic rows. The subperiosteal bony deposit (*im*) has extended *pari passu* with the calcification of the cartilage-matrix. The cartilage-cells in the primary areolæ are mostly shrunken and stellate; in some cases they have dropped out of the space. At *ir* and in two other places an irruption of the subperiosteal tissue, composed of ramified cells with osteoblasts and growing blood-vessels, has penetrated the subperiosteal bony crust, and has begun to excavate the secondary areolæ or medullary spaces; *p*, fibrous layer of the periosteum; *o*, layer of osteoblasts, some of them are embedded in the osseous layer as bone-corpuscles in lacunæ; *bl*, blood-vessels occupied by blood-corpuscles. Beyond the line of ossific advance the periosteum may be noticed to be distinctly incurved. This incurvation is gradually moved on, the cartilage expanding behind it until the head of the bone is reached, when it forms the periosteal notch or groove represented in fig. 77, p. 69.

In the *third stage* of endochondral ossification there is a gradual advance of the ossification towards the extremities of the cartilage, and at the same time a gradual deposition of fresh bony lamellæ and spicules on the walls of the medullary spaces, and on the surface of the new bone under the periosteum. The advance into the cartilage always takes place by a repetition of the same changes, the cartilage-cells first enlarging and becoming arranged in rows, the matrix between the



rows becoming calcified, and then the calcified cartilage becoming excavated from behind by the osteoblastic tissue so as to form new medullary spaces (fig. 77). The walls of these are at first formed only by remains of the calcified cartilage-matrix (fig. 77, *c*), but they soon become thickened by lamellæ of fibrous bone (*b*) which are deposited by the osteoblasts, and between which bone-corpuscles become included,

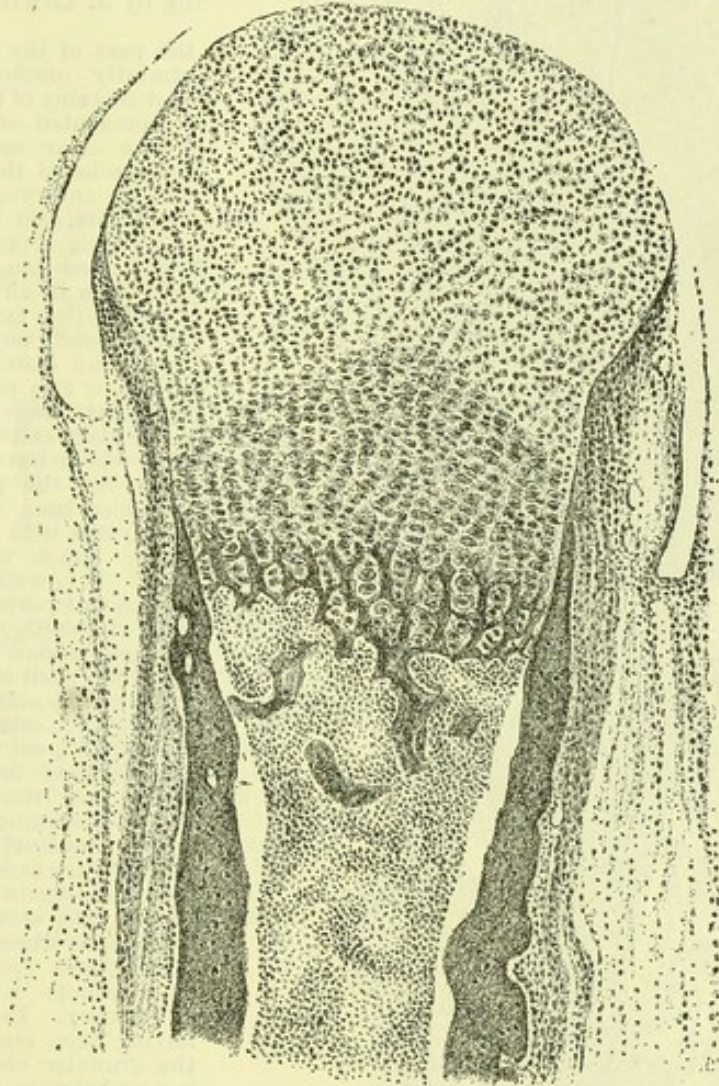


FIG. 75.—LONGITUDINAL SECTION THROUGH PART OF A PHALANX OF A SIX MONTHS HUMAN EMBRYO. (Kölliker.)

The calcified cartilage is completely absorbed almost to the limit of advancing calcification. The darker substance on either side is periosteal bone. The embryonic marrow has shrunk somewhat away from it.

as in the case of the subperiosteal bone. The latter advances *pari passu* with the endochondral calcification, but beyond this the uncalcified cartilage grows both in length and breadth, so that the ossification is always advancing into larger portions of cartilage; hence the endochondral bone as it forms assumes the shape of an hour-glass, the cylindrical shape of the whole bone being maintained by additions of periosteal bone to the outside (see fig. 76). The absorption of the calcified cartilage-matrix appears to be effected, as in the case with



absorption of bony matter wherever it occurs, by large multi-nucleated cells (fig. 77, *f, f*) which are termed *osteoclasts*. They are cells of the

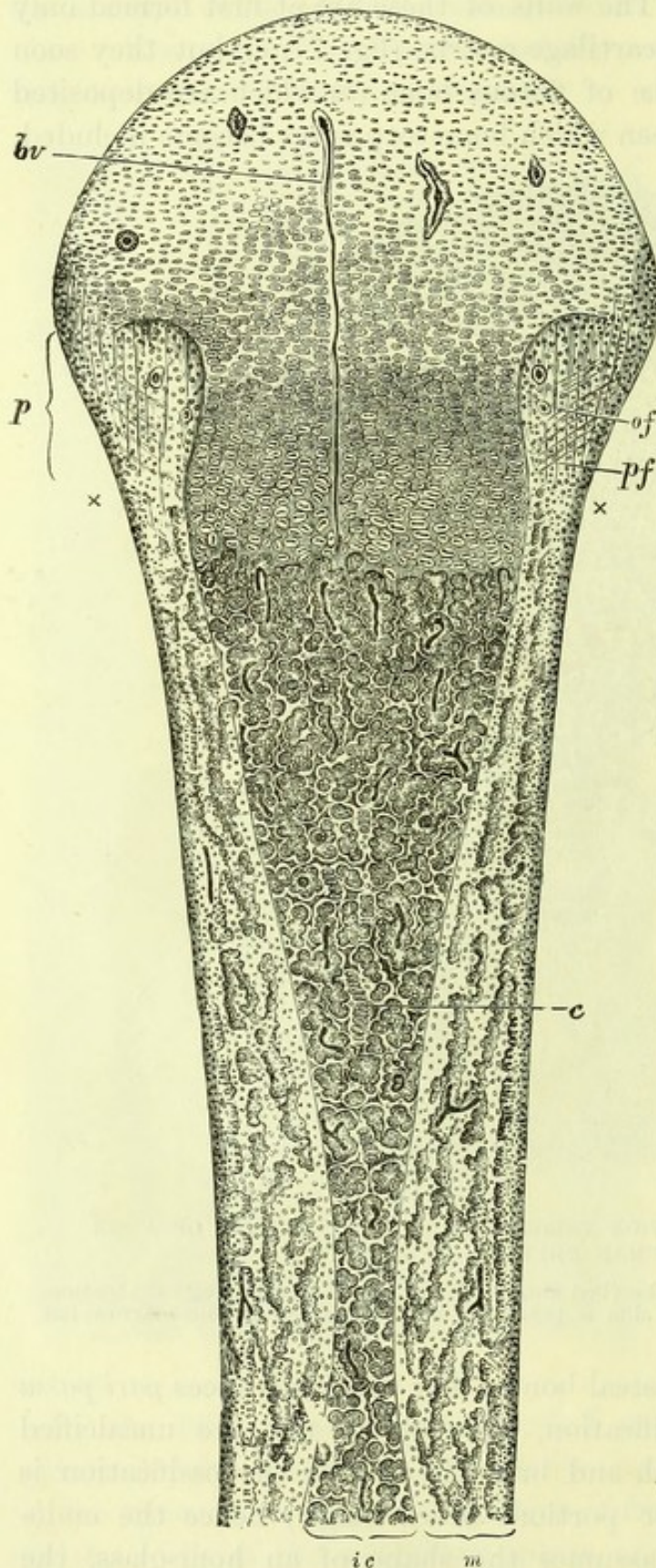


FIG. 76.—LONGITUDINAL SECTION THROUGH THE UPPER HALF OF THE DECALCIFIED HUMERUS OF A FETAL SHEEP, AS SEEN UNDER A MAGNIFYING POWER OF ABOUT 30 DIAMETERS. (From a drawing by J. Lawrence.)

*ic*, the part of the shaft which was primarily ossified in cartilage; what remains of the primary bone is represented as dark, enveloped by the clear secondary deposit. The areolæ of the bone are occupied by embryonic marrow with osteoblasts, and blood-vessels variously cut, represented as dark lines. One long straight vessel (*bv*) passes in advance of the line of ossification far into the cartilaginous head, most of the others loop round close to the cartilage. At one or two places in the older parts of the bone elongated groups of cartilage-cells (*c*) may still be seen, which have escaped absorption. *im*, the part of the bone that has been ossified in membrane, that is to say, in the osteoblastic tissue under the periosteum. It is well marked off from the central portion, and is bounded, peripherally, by a jagged edge, the projections of which are indistinctly seen to be prolonged by bunches of osteogenic fibres. A row of osteoblasts covers the superficial layer of the bone. The subperiosteal layer is prolonged above into the thickening (*p*), which encroaches upon the cartilage of the head of the bone, and in which are seen, amongst numerous osteoblasts and a few blood-vessels, the straight longitudinal osteogenic fibres (*of*), and some other fibres (*pf*) crossing them, and perhaps representing fibres of Sharpey. The calcareous salts having been removed by an acid, the granular ossific deposit passing up between the rows of cartilage-cells is not seen in this specimen; it would have extended as far as a line joining the marks *xx*. Observe the general tendency of the osseous trabeculae and the vascular channels between them to radiate from the original centre of ossification. This is found to prevail more or less in all bones when they are first formed, although the direction of the trabeculae may afterwards become modified in relation with varying physiological conditions, and especially as the result of pressure in different directions.

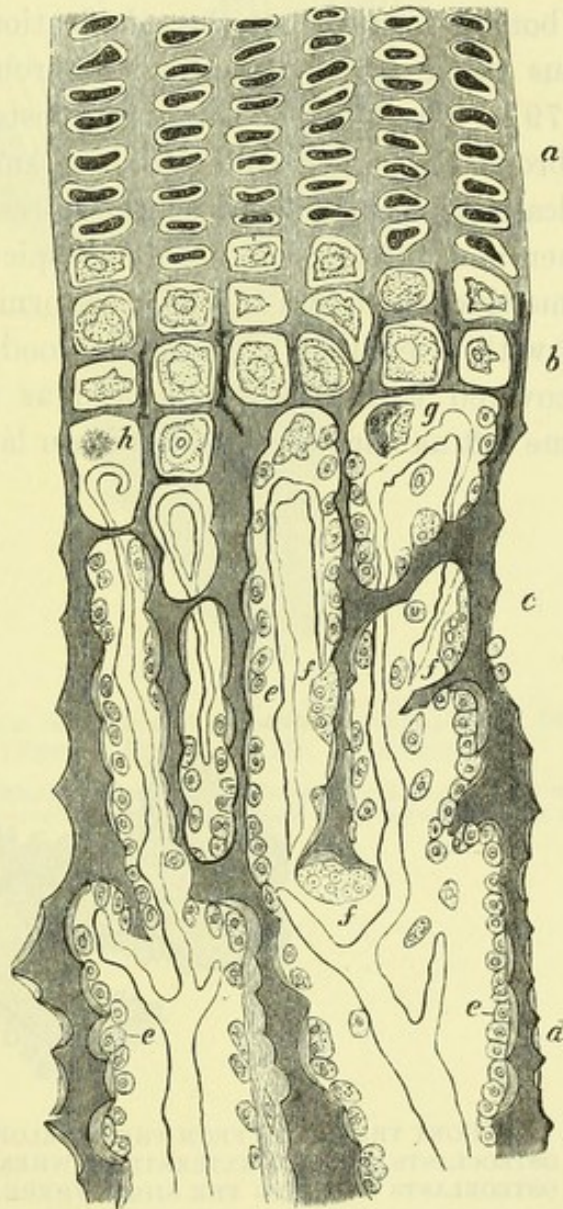
same nature as the myeloplaxes of the marrow, and are as characteristic of absorption surfaces as are the osteoblasts of surfaces where bony deposit is proceeding (fig. 78).



The bone which is first formed is more reticular and less regularly lamellar than that of the adult, and contains no Haversian systems. The regular lamellæ are not deposited until some little time after birth, and their deposition is generally preceded by a considerable amount of absorption. It is about this time also that the medullary

FIG. 77.—PART OF A LONGITUDINAL SECTION OF THE DEVELOPING FEMUR OF THE RABBIT. (Klein.) (Drawn under a magnifying power of 350 diameters.)

*a*, rows of flattened cartilage-cells;  
*b*, greatly enlarged cartilage-cells close to the advancing bone, the matrix between is partly calcified;  
*c*, *d*, already formed bone, the osseous trabeculae being covered with osteoblasts (*e*), except here and there, where an osteoclast (*f*) is seen, eroding parts of the trabeculae;  
*g*, *h*, cartilage-cells which have become shrunken and irregular in shape. From the middle of the figure downwards the dark trabeculae, which are formed of calcified cartilage-matrix, are becoming covered with secondary osseous substance deposited by the osteoblasts. The vascular loops at the extreme limit of the bone are well shown, as well as the abrupt disappearance of the cartilage-cells.



canal of the long bones is formed by the absorption of the bony tissue which originally occupies the centre of the shaft.

After a time the cartilage in one or both ends of the long bones begins to ossify independently, and the *epiphyses* are formed. These are not joined to the shaft until the growth of the bone is completed. Growth takes place *in length* by an expansion of the cartilage (*intermediate cartilage*) which intervenes between the shaft and the epiphyses, and by the gradual extension of the ossification into it; *in width* entirely by the deposition of fresh bony layers under the periosteum. In the terminal



phalanges of the digits the ossification starts, not from the middle of the cartilage, but from its distal extremity.

For the regeneration of portions of bone which have been removed by disease or operation it is important that the periosteum be left.

**Intramembranous ossification.**—In this variety of ossification, the bone is not preceded by cartilage at all, and therefore no endochondral bone is formed, but the calcification occurs in a sort of embryonic fibrous tissue which contains numerous osteoblasts and blood-vessels (fig. 79). The fibres of this tissue (osteogenic fibres), which, like those of fibrous tissue, are collected into small bundles, become inclosed in a calcareous matrix; and as the fibres grow, the calcification extends further and further, so that bony spicules are formed, which, as they become thickened, run together to form reticular layers, leaving spaces filled with osteoblasts around the blood-vessels. The osteogenic fibres are covered with osteoblasts, and as the bone forms, some of these become left as bone corpuscles within lacunæ. Thus in every particular

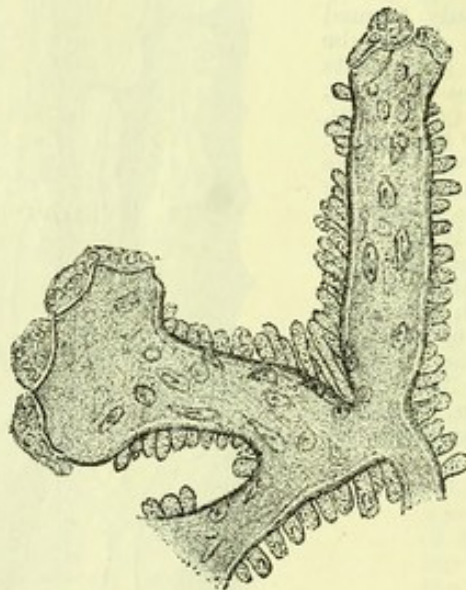


FIG. 78.—BONY TRABECULÆ FROM THE DEVELOPING LOWER JAW OF A CALF, SHOWING OSTEOCLASTS AT THE EXTREMITIES WHERE ABSORPTION IS PROCEEDING, AND OSTEOBLASTS COVERING THE SIDES WHERE DEPOSITION OF BONE IS GOING ON.

the development of these bones resembles that of the subperiosteal layer of endochondral bone; which is also to be considered as an instance of intramembranous ossification, although taking place on the surface of cartilage. Moreover, it is the same subperiosteal tissue which deposits the true or secondary bone upon those parts of the calcified cartilage-matrix which have escaped absorption; and this must also, therefore, be reckoned as developed according to the same type. In fact, even in intracartilaginous ossification, very little of the calcified cartilage-matrix eventually remains; this being almost wholly



absorbed and either replaced by true or fibrous bone which has been formed by osteoblasts, or swept away to form the medullary cavities.

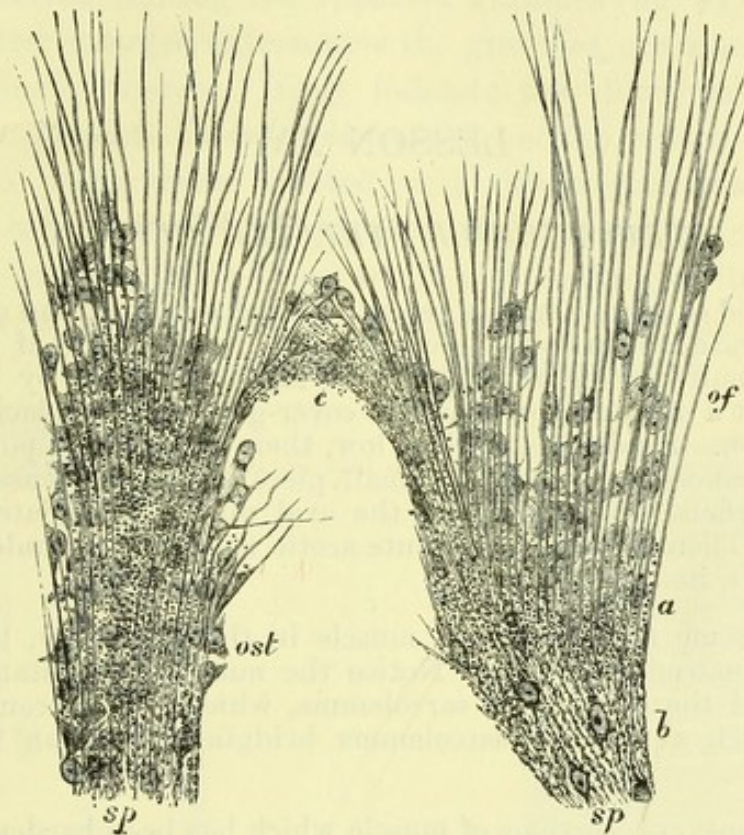


FIG. 79.—PART OF THE GROWING EDGE OF THE DEVELOPING PARIETAL BONE OF A FETAL CAT,  $1\frac{1}{2}$  INCH LONG. (From a drawing by Mr. J. Lawrence.)

*sp*, bony spicules, with some of the osteoblasts embedded in them, producing the lacunæ;  
*of*, osteogenic fibres prolonging the spicules, with osteoblasts (*ost*) between them and applied to them.



## LESSON XV.

*STRUCTURE OF STRIATED MUSCLE.*

1. TAKE a shred of muscle from a recently killed mammal, and on a dry slide carefully separate long pieces of muscular fibre (single fibres if possible) and stretch them out, keeping them moist during the process by breathing on the slide. Put a drop of serum on the cover-glass before placing this over the preparation. Study first with a low, then with a high power. Sketch all the appearances to be seen in a small piece of a fibre, focussing carefully the most superficial layers. Notice the oval nuclei immediately under the sarcolemma. Then allow a little dilute acetic acid to run under the cover-glass and watch its effect.

2. Prepare some fibres of frog's muscle in the same way, but mount in salt-solution instead of serum. Notice the muscular substance shrinking away here and there from the sarcolemma, which then becomes distinctly visible. Sketch a piece of sarcolemma bridging across an interval thus produced.

3. Study transverse sections of muscle which has been hardened in alcohol and stained with hæmatoxylin. Mount in Canada balsam. Examine first with a low and then with a high power. Sketch the appearances which are seen.

In each of the above preparations measure the diameter of some of the fibres.

4. Place in 1 per cent. osmic acid a small shred of mammalian muscular tissue which has been stretched upon a cork. After 24 hours, when it will be deeply stained, wash it in water and with needles break the fibres up in glycerine as finely as possible. Cover and examine with a high power.

---

**Voluntary muscle** is composed of long cylindrical fibres, measuring on an average about  $\frac{1}{500}$  inch in diameter in mammalian muscles, but having a length of an inch or more. Each fibre has an elastic sheath, the *sarcolemma*, which incloses the contractile substance. The sarcolemma is seldom distinct, unless the contained substance becomes broken (fig. 80).

The contractile substance of the fibre is characterised by the alternate dark and light stripes which run across the length of the fibre; hence the name, *cross-striated* or *striped muscle*. On focussing, it can be seen that the stripes pass through the whole thickness of the fibre; they may therefore be looked upon as representing alternate disks of dark and light substance. If the surface be very carefully focussed,



rows of apparent granules are seen lying in or at the boundaries of the light streaks, and very fine longitudinal lines may, with a good microscope, be detected uniting the apparent granules (fig. 81). These fine lines, with their enlarged extremities the granules, are more conspicuous in the muscles of insects. They indicate the divisions between the longitudinal elements (*muscle-columns*, *sarcostyles*) which compose the fibre, and in preparations treated with dilute acid they appear to form part of a fine network, which pervades that substance, and serves to unite the granules both transversely and longitudinally. This network, which is sometimes very distinct in preparations of muscle treated with chloride of gold, is, however, a network in appearance

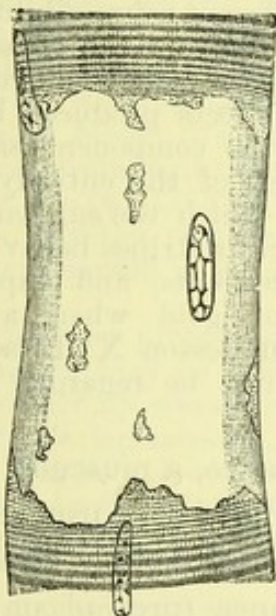


FIG. 80.—SARCOLEMA OF MAMMALIAN MUSCLE HIGHLY MAGNIFIED.

The fibre is represented at a place where the muscular substance has become ruptured and has shrunk away, leaving the sarcolemma (with a nucleus adhering to it) clear. The fibre had been treated with serum acidulated with acetic acid.




FIG. 81.—MUSCULAR FIBRE OF A MAMMAL EXAMINED FRESH IN SERUM, HIGHLY MAGNIFIED, THE SURFACE OF THE FIBRE BEING ACCURATELY FOCUSED.

The nuclei are seen on the flat at the surface of the fibre, and in profile at the edges.

only: in reality it is the optical expression of the interstitial substance which lies between the muscle-columns. This substance is termed *sarcoplasm*.

A fine clear line is sometimes seen running transversely across the fibre in the middle of each dark band. This is termed *Hensen's line*.

On examining the transverse section of a fibre with a high power, it is seen to be subdivided everywhere into small angular fields, the *areas of Cohnheim*. These represent sections of the sarcostyles of which the fibres are composed, and into which they may be split after death, or after being hardened in certain reagents, *e.g.*, chromic acid or osmic acid.



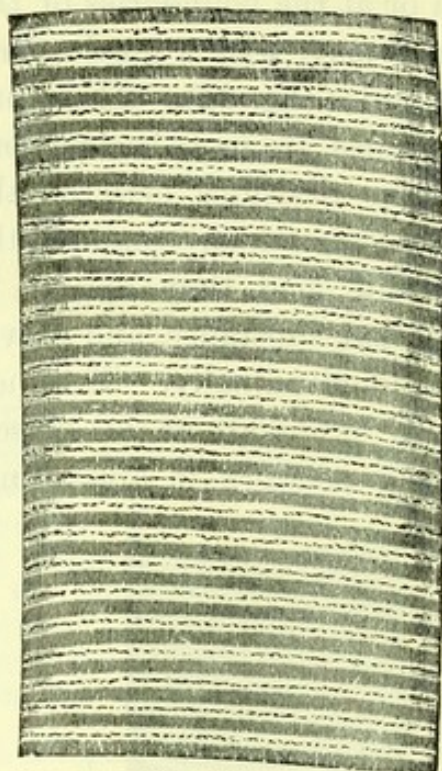


FIG. 82.—PORTION OF A MEDIUM-SIZED HUMAN MUSCULAR FIBRE, SHOWING THE INTERMEDIATE LINE MENTIONED IN THE TEXT. (Sharpey.)

If instead of focussing the surface of the fibre it be observed in its depth, an appearance different from that shown in fig. 81 is frequently visible, namely, a fine dotted line bisecting each clear stripe (fig. 82); this appearance is often considered to represent a membrane (*Krause's membrane*), which subdivides the sarco-styles at regular intervals (see p. 77). But Krause's membrane is rarely, if ever, visible in fresh muscle, and it is much more probable that the line in question is an interference line, caused by the light being transmitted between disks of different refrangibility. Haycraft believes that the cross-striation of voluntary muscle is entirely due to refractive effects produced by a varicosity of the component sarco-styles, but in view of the entirely different manner in which the substance of the dark and clear stripes behave to many staining reagents, and especially to chloride of gold when applied as directed in Lesson XVI., sec. 3, this position must be regarded as untenable.

Besides the sarcolemma and striated substance, a muscular fibre also exhibits a number of oval nuclei which have the usual structure of cell-nuclei: the chromoplasm often has a spiral arrangement. Sometimes there is a little granular substance (protoplasm) at each pole of the nucleus, and the nuclei with the adjacent protoplasm are then spoken of as *muscle-corpuscles*. In mammalian muscle the nuclei usually lie immediately under the sarcolemma (figs. 80, 81, 83),

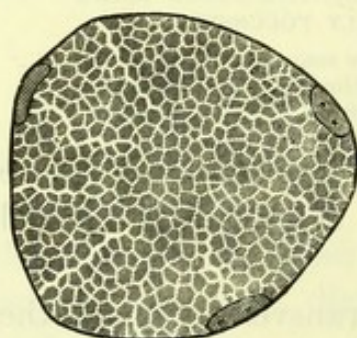


FIG. 83.—SECTION OF A MUSCULAR FIBRE, SHOWING AREAS OF COHNHEIM.

except in certain fibres, which entirely compose the *red* muscles of some animals, such as the rabbit, and which occur scattered amongst the ordinary fibres in mammalia generally. In these the nuclei are distributed through the thickness of the fibre, and this is also the case in all the muscular fibres of the frog. In some muscle-fibres, such as those of the diaphragm, which are in constant activity, the protoplasm of the muscle-corpuscles is often greatly developed.

The transverse section of a muscle shows the fibres to be nearly cylindrical in figure. Between the fibres there is a certain amount of areolar tissue, which serves to support the blood-vessels and also unites them into fasciculi; the fasciculi are again united together by a larger amount of this intramuscular connective tissue (*endomysium*).



## LESSON XVI.

*STRUCTURE OF STRIATED MUSCLE (continued).*

1. Cut off the head of a beetle or other large insect (*e.g.* bee, wasp), and bisect the trunk with scissors so as to expose the interior. Notice two kinds of muscular tissue, the one belonging to the legs greyish in colour, the other attached to the wings yellowish. Preparations of both kinds of muscle are to be made in the same way as living mammalian muscle (see previous Lesson), but it is better to mount them either in a drop of white of egg or of the insect's blood. In both preparations the dark-looking air-tubes or tracheæ form prominent objects ramifying amongst the fibres. Observe the structure of the two kinds of muscle so far as it can be made out in the fresh preparation. If the preparation is made quickly, waves of contraction will probably be observed passing along the fibres.

2. Make another preparation, mounting the muscle in vinegar. (Alcohol-hardened muscle may be used for this purpose.) Notice that the muscular substance swells up somewhat and becomes clearer, whilst the sarcoplasm-network of the leg muscles, with its lines and dots, comes more distinctly into view. In a well-teased preparation of alcohol-hardened muscle, the leg-fibres will be frequently found breaking across into disks. Make careful drawings from this preparation.

3. Place an insect (wasp, beetle) into 90 per cent. alcohol for 24 or 48 hours. Then take a small piece of each kind of muscle, and place in strong glycerine for some hours to remove the alcohol. Transfer to 1 per cent. chloride of gold solution: leave the pieces of muscle in this from 15 to 30 minutes according to their size. From the gold solution they are transferred to formic acid (1 part of the strong acid to 3 of water), and kept in the dark for 24 hours, but they may be kept longer without disadvantage. The muscle is then teased in glycerine. Some of the fibres will be found after this method to have their sarcoplasm darkly stained, and to show, therefore, the appearance of a network both in longitudinal and transverse view: others, on the other hand, have the sarcous elements stained, and the sarcostyles are thereby rendered very evident, but the sarcoplasm is unstained. Some fibres may show an intermediate condition.

---

**Ordinary or leg-muscles of insects.**—In the muscles of insects the stripes are relatively broad, and their structure can be more readily seen than in mammals. In the living fibres from the muscles of the legs, the sarcoplasm presents a striking appearance of fine longitudinal lines traversing the muscle, and enlarging within the light stripes into rows of dots. This is still better seen in fibres and portions of fibres which have been treated with dilute acid. In separated disks produced



by the breaking across of muscle-fibres, the surfaces of the disks show a network with polyhedral meshes in some insects, one formed of lines

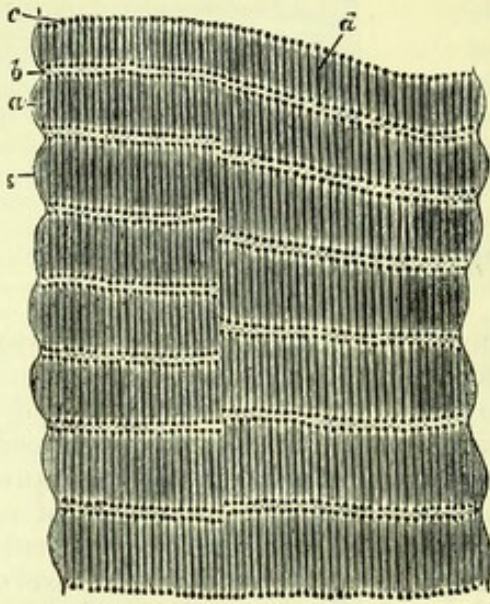


FIG. 84.—LIVING MUSCLE OF WATER-BEETLE (*DYTISCUS MARGINALIS*). (Highly magnified.)

*s*, sarcolemma; *a*, dim stripe; *b*, bright stripe; *c*, row of dots in bright stripe, which seem to be the enlarged ends of rod-shaped particles, *d*, but are really expansions of the interstitial sarcoplasm.

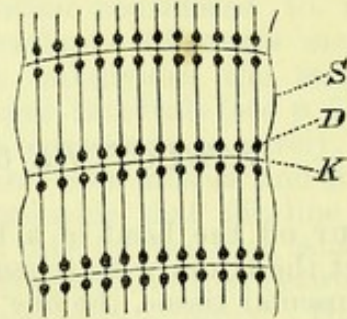


FIG. 85.—PORTION OF LEG-MUSCLE OF INSECT TREATED WITH DILUTE ACID.

*S*, sarcolemma; *D*, dot-like enlargement of sarcoplasm; *K*, Krause's membrane. The sarcous elements are swollen and dissolved by the action of the acid.

radiating from the centre of the fibre in others. The nuclei, with some inclosing protoplasm, usually lie in the middle of the fibre.

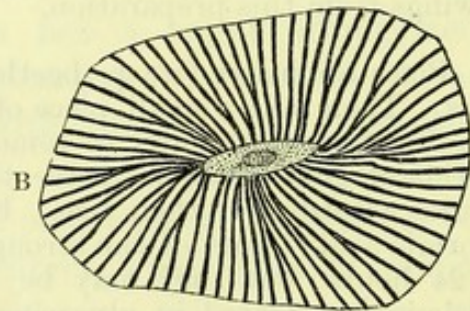
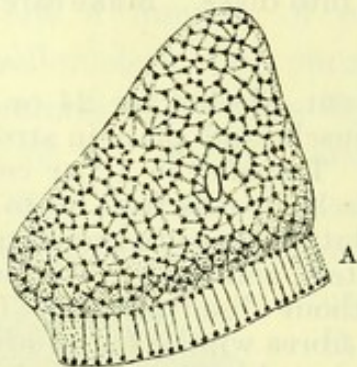


FIG. 86.—TRANSVERSE SECTIONS OF INSECT LEG-MUSCLE, VIEWED IN ISOLATED DISKS, TREATED WITH DILUTE ACID.

*A*, from a beetle. The disk is viewed partly on the flat, partly in profile; the sarcoplasm appears longitudinally as lines, transversely as a network.  
*B*, from a wasp, showing a radial disposition of the sarcoplasm.

**Wing-muscles of insects.**—The wing-muscles of insects are easily broken up into sarcostyles, which also show alternate dark and light striæ.

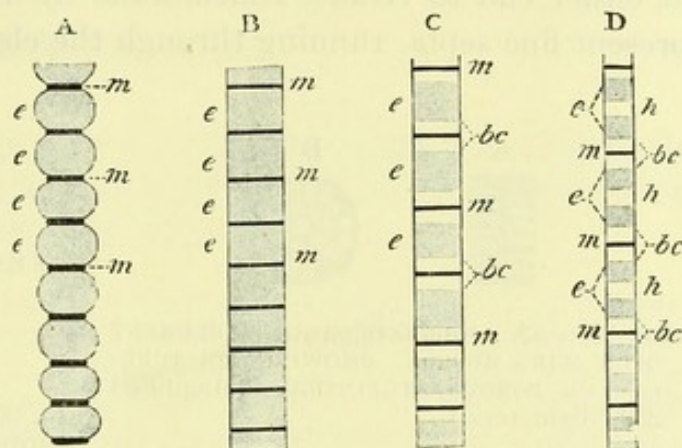
The sarcostyles are subdivided at regular intervals by transverse membranes (*membranes of Krause*) into successive portions, which may be termed *sarcomeres*. Each sarcomere is occupied by a portion of the dark stria of the whole fibre (*sarcous element*): the sarcous element is really double, and in the stretched fibre separates into two at the



line of Hensen (figs. 87, D; 88, B). At either end of the sarcous element is a clear interval separating it from the membrane of Krause: this clear interval is more evident the more the sarcostyle is extended, but diminishes to complete disappearance in the contracted muscle

FIG. 87.—FIBRES OF THE WING-MUSCLES OF AN INSECT. (Ranvier.)

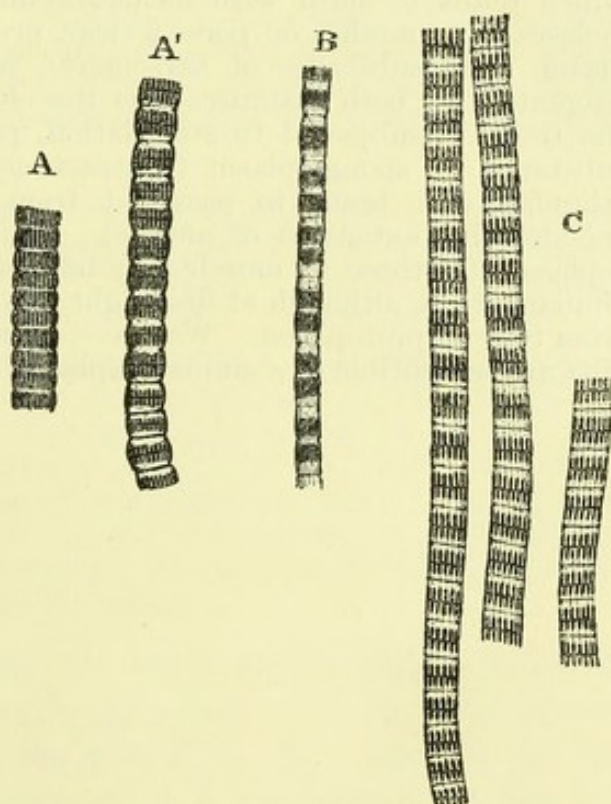
The fibres are in different conditions of extension, from A least extended, to D most extended. *e, e*, sarcous elements; *m, m*, membranes of Krause; *bc*, clear intervals on either side of Krause's membranes, which in the stretched sarcostyles are occupied by fluid which has passed out from the pores of the sarcous elements; *h*, separation of the sarcous element into two parts, a clear interval being left between them.



(figs. 87, 88, A). The cause of this is to be found in the structure of the sarcous element. Each sarcous element is pervaded with longitudinal canals or pores, which are open in the direction of Krause's membranes, but closed at the middle of the sarcous element. In the

FIG. 88.—SARCOSTYLES OF THE WING-MUSCLES OF A WASP, PREPARED IN THE MANNER DESCRIBED IN LESSON XVI., SEC. 3. (Highly magnified.)

A, A', sarcostyles showing degrees of contraction. B, an extended sarcostyle, with its sarcous elements separated at the line of Hensen. C, three sarcostyles moderately extended. The structure of the sarcous elements is shown diagrammatically.



contracted or retracted muscle, the clear part of the muscle-substance has passed into these pores, and therefore disappeared from view, but swells up the sarcous element and shortens the sarcomere: in the extended muscle, on the other hand, the clear part has passed out from



the pores of the sarcous element, and now lies between this and the membrane of Krause, the sarcomere being thereby lengthened and narrowed. The sarcous element does not lie free in the middle of the sarcomere, but is attached laterally to a fine inclosing envelope, and at either end to Krause's membrane by very fine lines, which may represent fine septa, running through the clear substance (fig. 90).

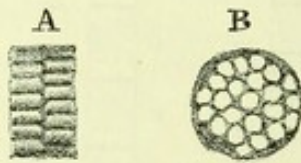


FIG. 89.—AN ISOLATED SARCOUS ELEMENT OF A WING-MUSCLE, SHOWING ITS TUBULAR OR POROUS STRUCTURE. (Magnified 2300 diameters.)

A, profile view ; B, surface view, seen on the flat.

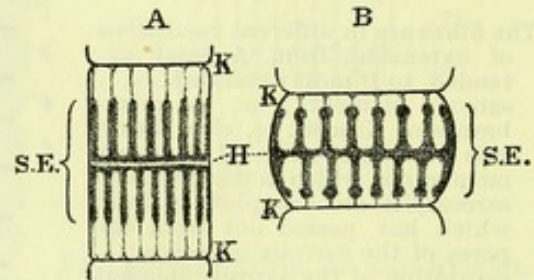


FIG. 90.—DIAGRAM OF A SARCOMERE IN A MODERATELY EXTENDED CONDITION A, AND IN A CONTRACTED CONDITION B.

K, K, membranes of Krause ; H, line or plane of Hensen ; S.E., poriferous sarcous element.

If we compare the structure of the sarcomere with that of the protoplasm of an amœboid cell we find several points in common. In both there is a framework of labile material (spongioplasm, substance of sarcous element), which tends to stain with hæmatoxylin and similar reagents, and which incloses in its meshes or pores a clear, probably semi-fluid substance (hyaloplasm, clear substance of sarcomere), which remains unstained by these reagents. In both instances also the clear substance or hyaloplasm, when the tissue is subjected to stimulation, passes into the pores of the porous substance or spongioplasm (contraction), whilst in the absence of such stimulation it tends to pass out from the spongioplasm (formation of pseudopodia, extension of muscle). Thus both the movements of cell-protoplasm and those of muscle may be described as being brought about by similar means, although at first sight the structure of muscle is so dissimilar from that of protoplasm. We have already noticed that the movements of cilia are susceptible of a similar explanation (p. 36).



## LESSON XVII.

*CONNECTION OF MUSCLE WITH TENDON; BLOOD-VESSELS OF MUSCLE; CARDIAC MUSCULAR TISSUE; DEVELOPMENT OF MUSCLE; PLAIN MUSCULAR TISSUE.*

1. To study the connection of muscle with tendon, a frog is killed by destruction of the brain and spinal cord, and placed in about a litre of water raised to a temperature of  $55^{\circ}\text{C}$ . It is left in this for 15 minutes, the water gradually cooling. It is then easy to dissociate the muscular fibres in large numbers. To observe their attachment to the tendon-bundles a fine longitudinal shred must be snipped off with scissors at the tendinous attachment, and dissociated upon a slide in a drop of water. It will usually be found that the muscular substance is retracted from the end of the sarcolemma tube, which is firmly cemented to the tendon bundle. The structure may be brought more distinctly into view by adding to the dissociated fibres a drop of a weak solution of iodine in salt-solution or in serum (iodised serum).<sup>1</sup> To preserve the specimen, mount it in dilute glycerine coloured by magenta.

2. The blood-vessels of muscle. These are to be studied in longitudinal and transverse sections of injected muscle. It will be noticed that the capillaries are very numerous, and form a network with oblong meshes. In the red muscles of the rabbit, small dilatations are seen on the transverse cords of the network.

3. The muscular tissue of the heart is studied in sections of that organ and also in teased preparations. To prepare the latter, place a small piece of heart-muscle in 30 per cent. alcohol for a few days: stain in picro-carmin solution (see Appendix) for some hours; and tease in dilute glycerine.

4. Tear off a small shred of the muscular coat of a piece of intestine which has been from 24 to 48 hours in  $\frac{1}{2}$  per cent. bichromate of potash solution. Hold the shred with forceps in a drop of water and fray it out with a needle. In this process many cells will be set free and can be seen with a low power. The preparation may then be covered and examined with a high power. Sketch one of the cells. Then allow hæmatoxylin solution to pass under the cover-glass and lastly a drop of glycerine. Sketch another cell after staining. Measure two or three cells and their nuclei.

**Ending of muscle in tendon.**—A small tendon-bundle passes to each muscular fibre and becomes firmly united with the sarcolemma, which extends over the end of the fibre (Fig. 91). Besides this immediate attachment, a further connection is established by the fact that the areolar tissue between the tendon-bundles is continuous with that which lies between the muscular fibres.

<sup>1</sup> This method is the one given by Ranvier (*Traité Technique*, 2me edition, p. 395). The muscle-endings may also sometimes be well seen at the extremities of the tendons, which are removed from the mouse's tail in the manner described in Lesson X., p. 45.



**Blood-vessels of muscle.**—The capillaries of the muscular tissue are very numerous. They run, for the most part, longitudinally, with transverse branches, so as to form long oblong meshes (fig. 92). In the red muscles of the rabbit, the transverse capillaries have small dilatations upon them. No blood-vessels ever penetrate the sarcolemma.

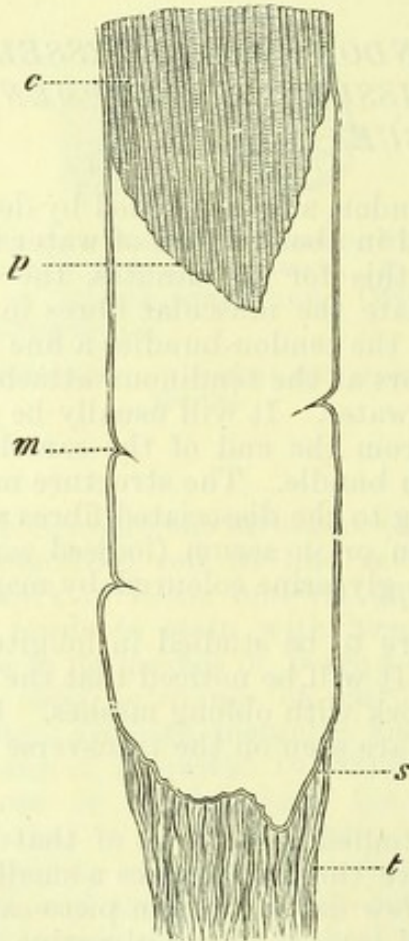


FIG. 91.—TERMINATION OF A MUSCULAR FIBRE IN TENDON. (Ranvier.)

*m*, sarcolemma; *s*, the same membrane passing over the end of the fibre; *p*, extremity of muscular substance; *c*, retracted from the lower end of the sarcolemma-tube; *t*, tendon-bundle passing to be fixed to the sarcolemma.

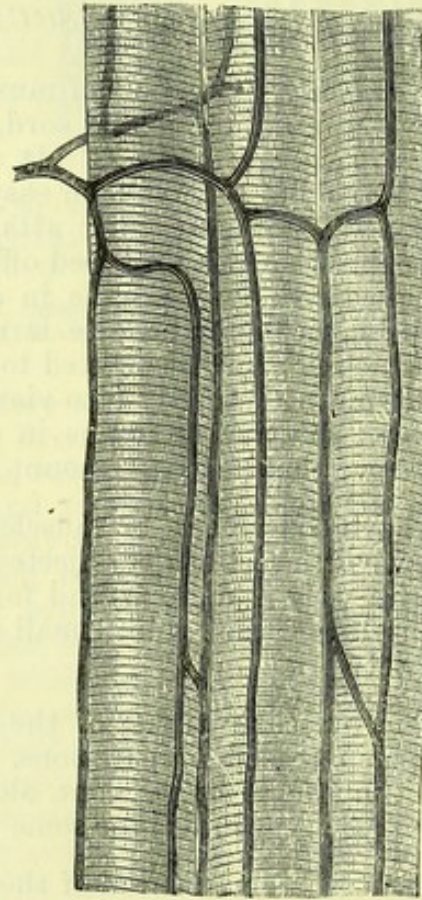


FIG. 92.—CAPILLARY VESSELS OF MUSCLE.

**Lymphatic vessels**, although present in the connective-tissue sheath (perimysium) of a muscle, do not penetrate between its component fibres.

The **nerves** of voluntary muscles pierce the sarcolemma and terminate in a ramified expansion known as an *end-plate* (See Lesson XX.).

**Development.**—Voluntary muscular fibres are developed from embryonic cells of the mesoderm, which become elongated, and the nuclei of which become multiplied, so as to produce long multi-nucleated fusiform or cylindrical fibres. These become cross-striated at first along one side, the change gradually extending around the fibre and



also towards the centre; but the middle of the fibre, to which the nuclei are at first confined, remains for some time unaltered (fig. 93). Eventually the change in structure extends to this also, and the nuclei pass gradually to occupy their ordinary position under the sarcolemma, which by this time has become formed.

The muscular substance of the heart (*cardiac muscle*) is composed of transversely striated muscular fibres, which differ from those of voluntary muscle in the following particulars: their striations are less distinct; they have no sarcolemma; they branch and unite with neighbouring fibres, and their nuclei lie in the centre of the fibres. Moreover, the fibres are composed of a series of short cylindrical cells (figs. 94, 95) joined together end to end, each corresponding to one of the nuclei. The lines of junction of these cells may sometimes be seen in longitudinal sections stained with hæmatoxylin or carmine; but they come much more distinctly into view in sections of the fresh tissue stained with nitrate of silver.

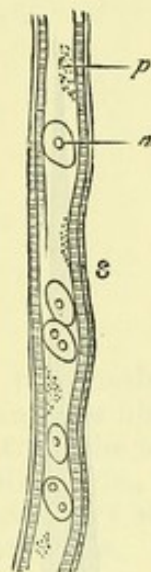


FIG. 93. — DEVELOPING MUSCULAR FIBRE FROM FETUS OF 2 MONTHS. (Ranvier.)

*p*, central protoplasm with several nuclei, *n*, scattered in it; *s*, commencing sarcolemma, with striated muscular substance developing immediately beneath it.

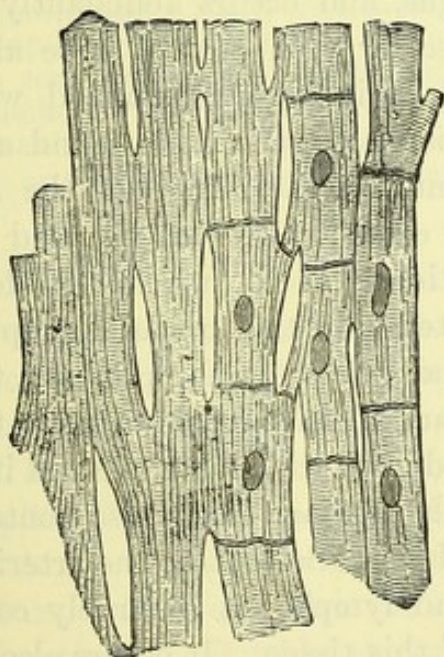


FIG. 94.—MUSCULAR FIBRES FROM THE HEART, MAGNIFIED, SHOWING THEIR CROSS-STRIE, DIVISIONS, AND JUNCTIONS. (Schweigger-Seidel.)

The nuclei and cell-junctions are only represented on the right-hand side of the figure.

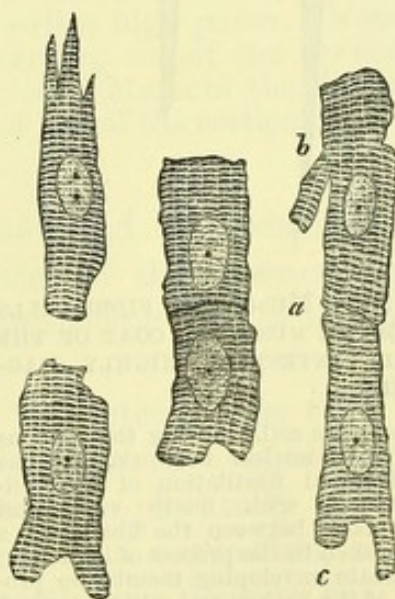


FIG. 95.—SIX MUSCULAR FIBRE-CELLS FROM THE HEART. (Magnified 425 diameters.)

*a*, line of junction between two cells; *b*, *c* branching of cells. (From a drawing by J. E. Neale.)



Involuntary or plain muscular tissue is composed of long, somewhat flattened, fusiform cells (fig. 96), which vary much in length, but are usually not more than  $\frac{1}{800}$  inch (0.05 mm.) long. Each cell has an oval or rod-shaped nucleus, which shows the usual intra-nuclear network and commonly one or two nucleoli. The cell-substance is longitudinally striated, but does not exhibit cross-striæ like those of voluntary muscle. There appears to be a delicate sheath to each cell. There is a little intercellular cementing substance uniting the cells together, which can be stained by nitrate of silver, and this intercellular substance is bridged across by fine filaments passing from cell to cell. The fibres are collected into fasciculi.

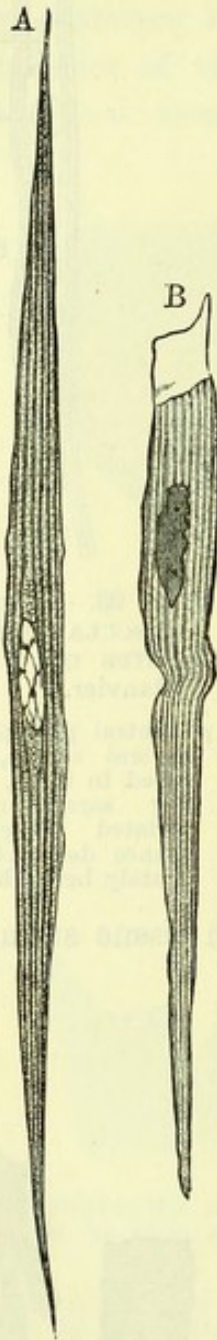


FIG. 96. — MUSCULAR FIBRE-CELLS FROM THE MUSCULAR COAT OF THE SMALL INTESTINE, HIGHLY MAGNIFIED.

A, a complete cell, showing the nucleus with intra-nuclear network, and the longitudinal fibrillation of the cell-substance, with finely vacuolated protoplasm between the fibrils; B, a cell broken in the process of isolation; a delicate enveloping membrane projects at the broken end a little beyond the substance of the cell.

Plain muscular tissue is found chiefly in the walls of hollow viscera; thus it forms the muscular coat of the whole of the alimentary canal below the oesophagus, and occurs abundantly in the muscular coat of that tube also, although it is here intermixed with cross-striated muscle; it is found also in the mucous membrane of the alimentary canal; in the trachea and its ramifications; in the urinary bladder and ureters; in the uterus, Fallopian tubes, and ovary; in the prostate, the spleen, and muscle of Müller in the orbit, and in the ciliary muscle and iris. The walls of gland-ducts also contain it, and the middle coat of the arteries, veins, and lymphatics is largely composed of this tissue. It occurs also in the skin, both in the secreting part of the sweat-glands, and in small bundles attached to the hair-follicles; in the scrotum it is found abundantly in the subcutaneous tissue (dartos), and it also occurs in the areola of the nipple.



## LESSON XVIII.

*STRUCTURE OF NERVE-FIBRES.*

1. TEASE a piece of fresh nerve in saline solution (or by the method of demidesiccation, afterwards mounting in salt solution), injuring the fibres as little and obtaining them as long and straight as possible. Study the medullated fibres, carefully noticing all the structures that are visible—viz., nodes of Ranvier, nuclei of primitive sheath, double contour of medullary sheath, medullary segments, etc. Measure the diameter of half a dozen fibres. Draw a short length of a fibre very exactly.

2. Prepare a piece of a sympathetic nerve in the same way. Measure and sketch as before.

3. Separate (in dilute glycerine) into its fibres a small piece of nerve or nerve-root that has been twenty-four hours in  $\frac{1}{2}$  per cent. osmic acid. The nerve should have been moderately stretched on a piece of cork by means of glass pins before being placed in the acid. Keep the fibres as straight as possible and only touch them near their ends with the needles. Sketch two portions of a fibre under a high power, one showing a node of Ranvier and the other a nucleus of the primitive sheath. Look for fibres of Remak. Measure the length of the nerve-segments between the nodes of Ranvier.

4. Mount in Canada balsam sections of a nerve which has been hardened in picric acid. Stain with picro-carmin or hæmatoxylin. The nerve should be straightened out before being placed in the hardening solution. Examine the sections first with a low and afterwards with a high power. Notice the lamellar structure of the perineurium, the varying size of the nerve-fibres, the axis cylinder in the centre of each fibre, etc. Measure the diameter of five or six fibres, and sketch a small portion of one of the sections.

---

Nerve-fibres are of two kinds, *medullated* and *non-medullated*. The cerebro-spinal nerves and the white matter of the nerve-centres are composed of medullated fibres; the sympathetic nerves are chiefly made up of non-medullated fibres.

The **medullated** or **white fibres** are characterised, as their name implies, by the presence of the so-called *medullary sheath* or *white substance*. This is a layer of soft substance, physically of a fatty nature, which encircles the essential part of a nerve-fibre, viz., the *axis-cylinder*. Outside the medullary sheath is a delicate but tough homogeneous membrane, the *primitive sheath* or *nucleated sheath* of Schwann, but this is not present in all medullated fibres, being absent in those which are within the nerve-centres. The primitive sheath is also known as the *neurolemma*.



The *medullary sheath* is composed of a highly refracting fatty material, which gives a characteristic dark contour and tubular

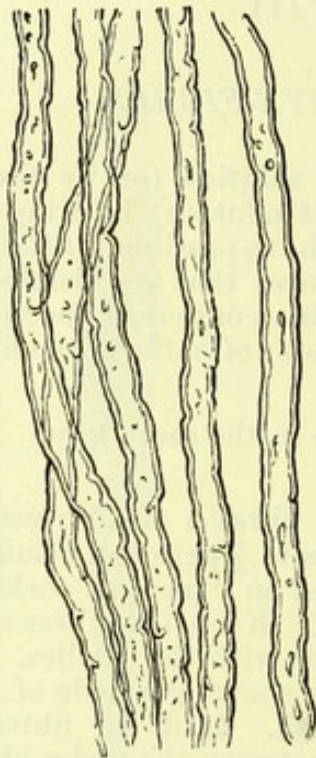


FIG. 97.—WHITE OR MEDULLATED NERVE-FIBRES, SHOWING THE SINOUS OUTLINE AND DOUBLE CONTOURS.

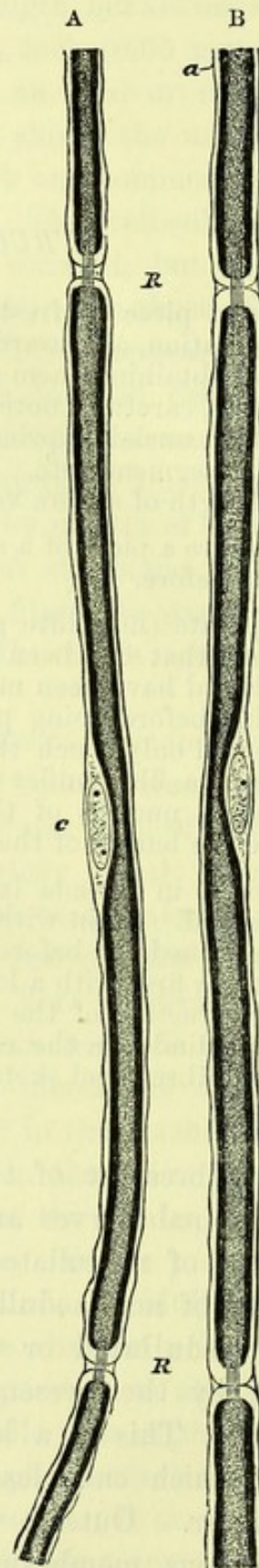


FIG. 98.—PORTIONS OF TWO NERVE-FIBRES STAINED WITH OSMIC ACID (FROM A YOUNG RABBIT). (425 diameters.)

*R, R*, nodes of Ranvier, with axis-cylinder passing through. *a*, primitive sheath of the nerve; *c*, opposite the middle of the segment, indicates the nucleus and protoplasm lying between the primitive sheath and the medullary sheath. In A the nodes are wider, and the intersegmental substance more apparent than in B. (Drawn by J. E. Neale.)

appearance to the nerve-fibres. It affords a continuous investment to the axis-cylinder, except that it is interrupted at regular intervals in the course of the peripheral nerve-fibres, the axis-cylinder at these places



being encompassed only by the primitive sheath. Hence the primitive sheath appears at these spots to produce a constriction in the nerve-fibre, and the interruptions of the medullary sheath are accordingly known as the *constrictions* or *nodes of Ranvier* (fig. 98, R, R; fig. 100, L), the term nodes being applied from the resemblance which they bear to the nodes of a bamboo. The length of nerve between two successive nodes may be termed an internode; in the middle of each internode is one of the nuclei of Schwann's sheath. Besides these interruptions the medullary sheath shows a variable number of oblique clefts (figs. 99, 100), which subdivide it into irregular portions, which have been termed *medullary segments*, but there is reason to believe that the clefts are artificially produced. Osmic acid stains the medullary sheath black.



FIG. 99.—A SMALL PART OF A MEDULLATED FIBRE, HIGHLY MAGNIFIED.

The fibre looks in optical section like a tube—hence the term *tubular*, formerly applied to these fibres. Two partial breaches of continuity are seen in the medullary sheath, which at these places exhibits a tendency to split into laminae. The primitive sheath is here and there apparent outside the medullary sheath, and the delicate striæ which are visible in the middle of the fibre probably indicate the fibrillated axis-cylinder.

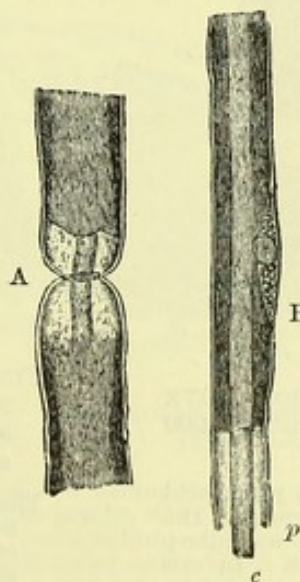


FIG. 101.—TWO PORTIONS OF MEDULLATED NERVE-FIBRES, AFTER TREATMENT WITH OSMIC ACID, SHOWING THE AXIS-CYLINDER, AND THE MEDULLARY AND PRIMITIVE SHEATHS. (Key and Retzius.)

A, node of Ranvier. B, middle of an internode with nucleus. c, axis-cylinder, projecting; p, primitive sheath, within which the medullary sheath, which is stained dark by the osmic acid, is somewhat retracted.



FIG. 100.—NERVE-FIBRE STAINED WITH OSMIC ACID. (Key & Retzius.)



The *axis-cylinder*, which runs along the middle of the nerve-fibre, is a soft transparent thread which is continuous from end to end of the nerve.<sup>1</sup>



FIG. 102. — AXIS-CYLINDER, HIGHLY MAGNIFIED, SHOWING THE FIBRILS COMPOSING IT. (M. Schultze.)

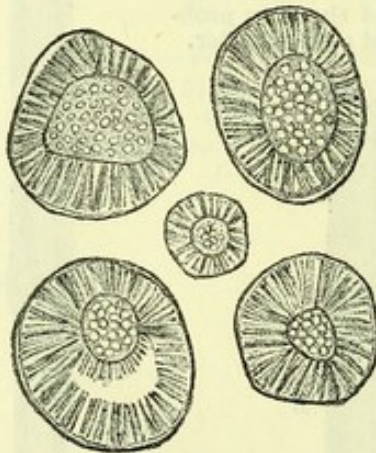


FIG. 103. — SECTION ACROSS FIVE NERVE-FIBRES. (Magnified 1000 diameters.)

The nerve was hardened in picric acid and stained with picro-carmin. The radial striation of the medullary sheath is very apparent. In one fibre the rays are broken by shrinkage of the axis-cylinder. The fibrils of the axis-cylinder appear tubular.

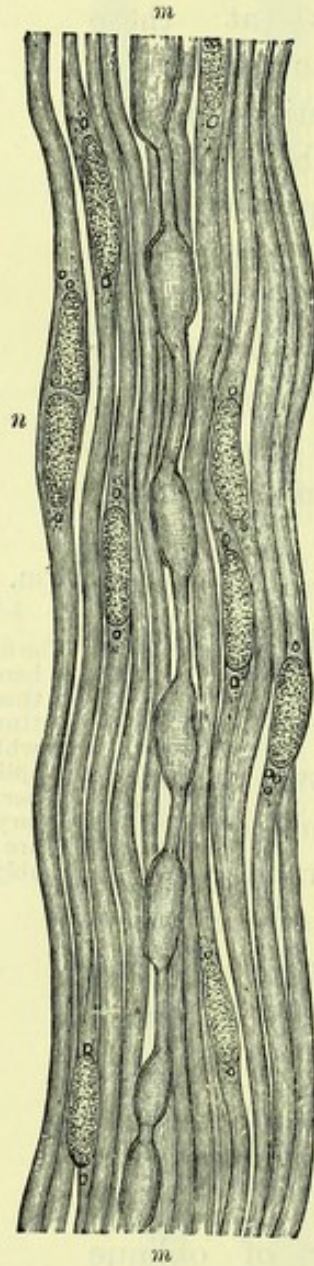

FIG. 104. — A SMALL BUNDLE OF NERVE-FIBRES FROM THE SYMPATHETIC NERVE. (Key and Retzius.)

The bundle is composed of pale nerve-fibres, with the exception of the fibre *m*, *m*, which is inclosed here and there by a thin medullary sheath; *n*, *n*, nuclei of pale fibres.

On account of the peculiar refractive power of the medullary sheath it is difficult to see the axis-cylinder in the fresh nerve except at the

<sup>1</sup> According to Engelmann the axis-cylinder is not structurally continuous across the nodes of Ranvier.



nodes, where it may be observed stretching across the interruption in the medullary sheath, and it may also sometimes be seen projecting from a broken end of a nerve-fibre. It is longitudinally striated, being really made up of exceedingly fine fibrils (*ultimate fibrils*, fig. 102), which are darkly stained by chloride of gold. Staining with nitrate of silver produces a curious transversely striated appearance in the axis-cylinder, but it is not known if this indicates a pre-existent structure. Kühne has described a special reticular sheath of the axis-cylinder lying within the medullary sheath, and composed of a peculiar chemical substance termed *neurokeratin*. The reticulum is, however, produced within the substance of the medullary sheath, probably by the action of reagents.

**Non-medullated fibres.**—Intermingled with the medullated fibres there may always, even in the cerebro-spinal nerves, be found a certain number of pale fibres devoid of the dark double contour which is

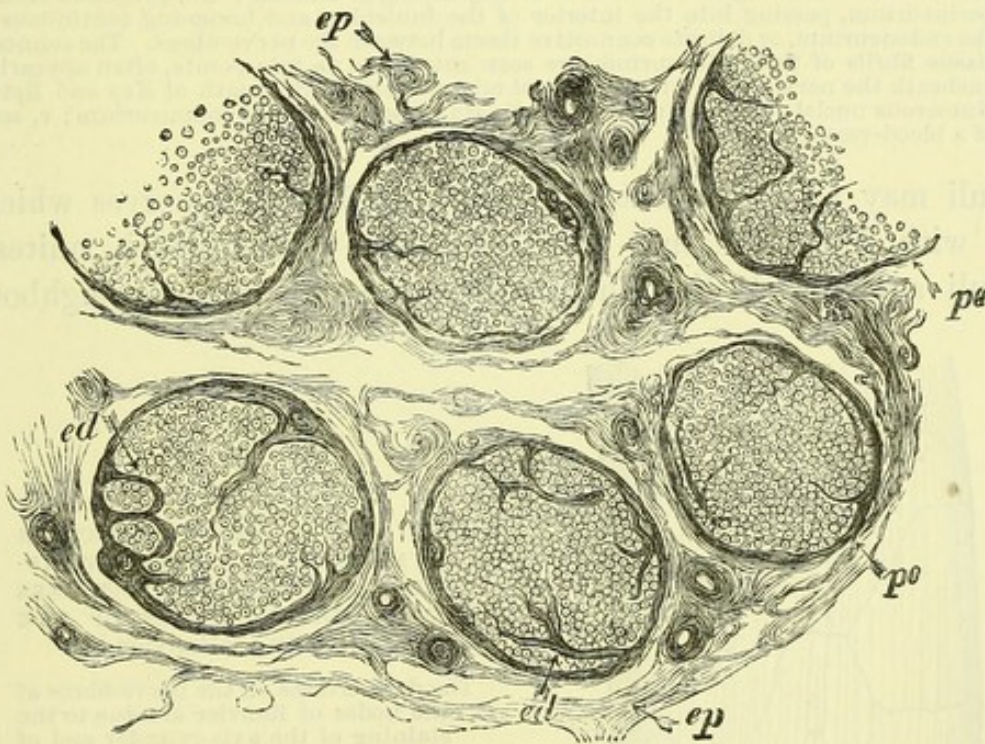


FIG. 105.—SECTION OF A PART OF THE MEDIAN NERVE (HUMAN). (DRAWN AS SEEN UNDER A LOW MAGNIFYING POWER.) (From Landois after Eichhorst.)

*ep*, epineurium, or general sheath of the nerve, consisting of connective-tissue bundles of variable size separated by cleft-like areolæ, with here and there blood-vessels; *pe*, lamellated connective-tissue sheaths (perineurium) of the funiculi; *ed*, interior of funiculus, showing the cut ends of the medullated nerve-fibres, which are embedded in the connective-tissue within the funiculus (endoneurium).

characteristic of the presence of a medullary sheath. There are the *non-medullated fibres*, also called, after their discoverer, *fibres of Remak* (fig. 104). They frequently branch, which the medullated fibres never do except near their termination, and they are beset with numerous nuclei which perhaps belong to a delicate sheath. The sympathetic



nerves are largely made up of fibres of this nature, but, on the other hand, many of the fibres of the sympathetic trunk possess a thin medullary sheath (fig. 104).

**Structure of the nerve-trunks.**—In their course through the body the nerve-fibres are gathered up into bundles or *funiculi*, and the

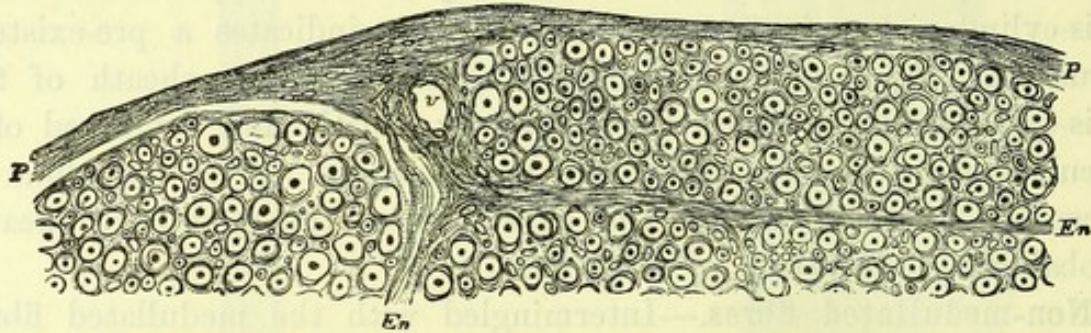


FIG. 106.—PART OF A SECTION OF ONE OF THE FUNICULI OF THE SCIATIC NERVE OF MAN. (Key and Retzius.) (Magnified.)

*P*, perineurium consisting of a number of closely arranged lamellæ; *En*, processes from the perineurium, passing into the interior of the funiculus, and becoming continuous with the endoneurium, or delicate connective tissue between the nerve-fibres. The connective-tissue fibrils of the endoneurium are seen cut across as fine points, often appearing to ensheath the nerve-fibres with a circle of minute dots (fibril-sheath of Key and Retzius). Numerous nuclei of connective-tissue cells are embedded in the endoneurium; *v*, section of a blood-vessel.

funiculi may again be united together to form the nerves which we meet with in dissection. The connective tissue which unites the funiculi and invests the whole nerve, connecting it to neighbouring

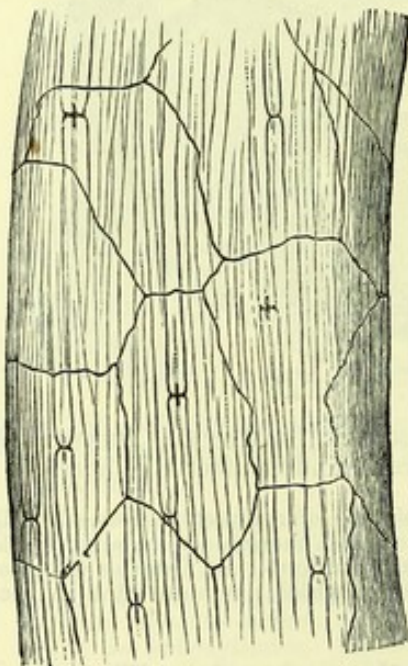


FIG. 107. — NERVE - FUNICULUS STAINED WITH NITRATE OF SILVER, SHOWING THE OUTLINES OF EPITHELIOID-CELLS OF THE PERINEURIUM. (Ranvier.)

The dark crosses on the nerve-fibres at the nodes of Ranvier are due to the staining of the axis-cylinder and of a band of intercellular substance which encircles the axis-cylinder at the node (constriction band of Ranvier.)

parts and conveying to it blood-vessels, lymphatics, and even nerve-fibres destined for its coats, is termed the *epineurium* (fig. 105, *ep*). That which ensheaths the funiculi is known as the *perineurium* (fig. 105, *pe*). It has a distinctly lamellar structure (fig. 106, *p*), the



lamellæ being composed of connective tissue and covered on both surfaces by flattened epithelioid cells (fig. 107). Between the lamellæ are clefts for the conveyance of lymph to the lymphatics of the epineurium. The delicate connective tissue which lies between the nerve-fibres of the funiculus is the *endoneurium* (fig. 105, *ed*; fig. 106, *En*). It assists in supporting the longitudinally arranged mesh-work of blood-capillaries, and its interstices communicate with the lymphatic clefts of the perineurium.

All the branches of a nerve, and even single nerve-fibres which are passing to their distribution, are invested with a prolongation of the perineural sheath, which is there known as the *sheath of Henle*.

The nerve-trunks themselves receive nerve-fibres (*nervi nervorum*) which ramify chiefly in the epineurium and terminate within this in end-bulbs (Horsley).



## LESSONS XIX. AND XX.

*STRUCTURE OF GANGLIA; STRUCTURE OF NERVE-CELLS  
OF BRAIN AND SPINAL CORD; NEUROGLIA-CELLS;  
DEVELOPMENT OF NERVE-FIBRES; WALLERIAN DE-  
GENERATION.*

1. Put a small piece of spinal ganglion into 1 per cent. osmic acid for two or three hours. Place it in water containing a fragment of thymol for two days or more. Tease it in dilute glycerine. Notice the spheroidal ganglion-cells; their large nuclei and distinct nucleoli. Many of the cells may still be seen within their nucleated membranous sheath. Look for cells which still retain the axis-cylinder process and for T-shaped junctions of nerve-fibres with this.

2. Prepare a piece of sympathetic ganglion in the same way. Cells may be found with three or more axis-cylinder processes. If from a rabbit observe that many of the cells are bi-nucleated.

Measure two or three cells in each of the above preparations.

3. Mount stained sections of ganglia in Canada balsam. These will serve to show the arrangement of the cells and fibres in the ganglion and the nucleated sheaths around the nerve-cells.

4. Tease out a portion of the grey matter from a piece of spinal cord that has been a day or two in dilute chromic acid ( $\frac{1}{20}$  per cent.), or in 30 per cent. alcohol. Or a little of the grey matter may, after macerating for a day or two in either of the above fluids, be shaken up with water in a test tube, and after standing a little while some of the sediment at the bottom of the tube may be drawn off and mounted. Before covering, look for the nerve-cells with a low power, and if possible get out one or two clear of the surrounding substance. Mount in water with a thick hair under the cover-glass. Notice the large branching cells, some with a mass of pigment near the nucleus. Observe the fibrillation of the cell-processes. Notice also the reticular character of the tissue in which the cells are embedded. Many axis-cylinders will be seen in this preparation deprived wholly or partially of their medullary sheath, and their fibrillar structure can then also be well seen. Carefully sketch these appearances. To keep this preparation run solution of osmic acid under the cover-glass, and when the cells are stained allow a drop of glycerine to pass in by diffusion. Similar preparations are to be made from the grey matter of the cerebral cortex and cerebellar cortex.

5. Examine the nerve-cells and neuroglia-cells in sections from the spinal cord, cerebrum, and cerebellum of a small animal, *e.g.*, young rat or kitten, prepared by Golgi's method.<sup>1</sup> The sections must be mounted in thick

<sup>1</sup> See Appendix.



Canada balsam without a cover-glass, and the balsam dried rapidly on a warm plate.

6. Make teased preparations from a nerve which, some days previously, has been cut nearer the spinal cord. The nerve should have been prepared with osmic acid, as in Lesson xviii., sec. 3. Notice the breaking up of the myelin of the medullary sheath, varying in degree according to the length of time the section has been made previously. In preparations from the central cut end of the nerve new fibres may be seen budding from near the extremities of the undegenerated fibres of the stump.

**Nerve-cells** only occur in the grey matter of the nerve-centres, and in little groups on the course of certain of the peripheral nerves, these groups often causing nodular enlargements of the nerves, which are known as *ganglia*. The most important ganglia are those which are found upon the posterior roots of the spinal nerves, upon the roots of some of the cranial nerves, and upon the trunk and principal branches of the sympathetic nerve. Minute ganglia are also found very numerously in connection with the nerves which are supplied to involuntary muscular tissue, as in the heart, alimentary canal, bladder, uterus, etc.

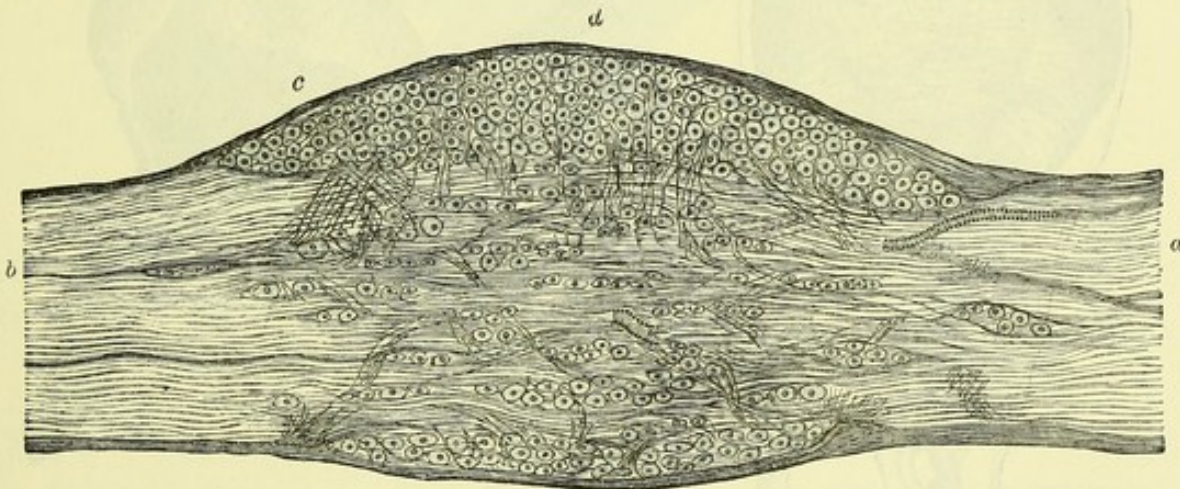


FIG. 108A.—LONGITUDINAL SECTION THROUGH THE MIDDLE OF A GANGLION ON THE POSTERIOR ROOT OF ONE OF THE SACRAL NERVES OF THE DOG, AS SEEN UNDER A LOW MAGNIFYING POWER.

*a*, nerve-root entering the ganglion: *b*, fibres leaving the ganglion to join the mixed spinal nerve; *c*, connective-tissue coat of the ganglion; *d*, principal group of nerve-cells, with fibres passing down from amongst the cells, probably to unite with the longitudinally coursing nerve-fibres by T-shaped junctions.

Nerve-cells vary much in size and shape; many are large, some being amongst the largest cells met with in the body, but others are quite small. The nucleus is generally large, clear, and spherical, with a single large and distinct nucleolus; there is also a network of chromoplasm. The shape depends a good deal on the number of processes, and the manner in which they come off from the cell. If there is but one process the cell is generally nearly spherical. This is the case with



the cells of the spinal ganglia (fig. 108); in these the single process, after a short course, joins one of the nerve-fibres which is traversing

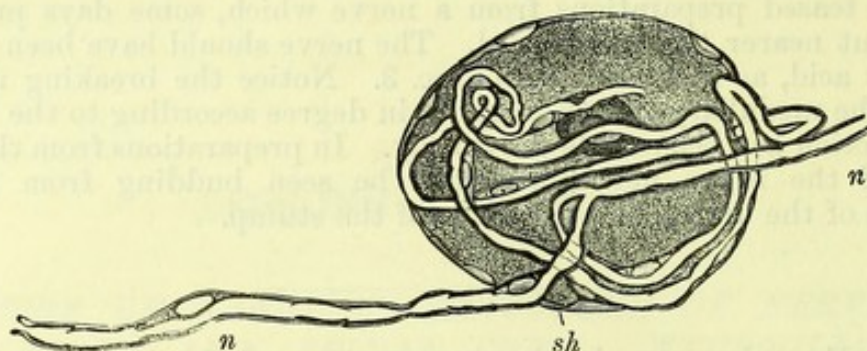


FIG. 108B.—CELL FROM A SPINAL GANGLION. (Retzius.)

*sh*, nucleated sheath of the cell; *n*, *n'*, the nerve-fibre which the single process of the cell, after a number of coils, joins.

the ganglion. When there are two processes, they often go off in opposite directions from the cell, which is thus rendered somewhat

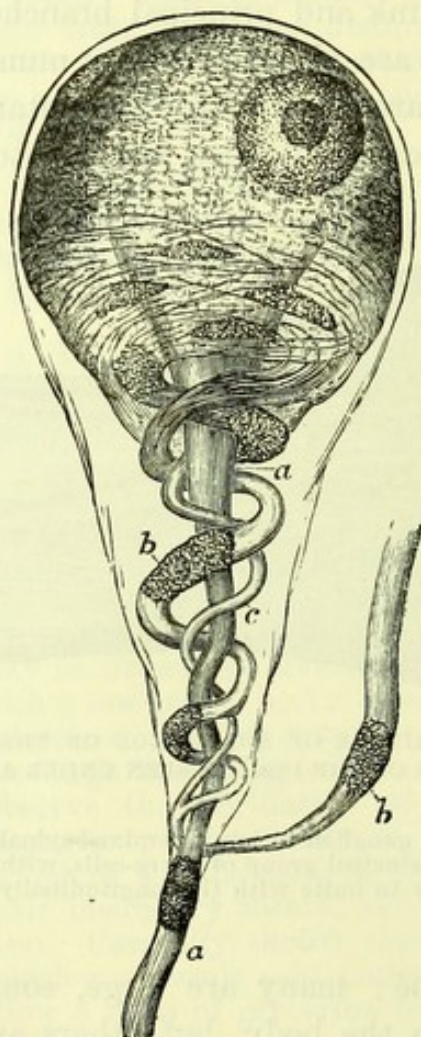


FIG. 109A.—SYMPATHETIC GANGLION-CELL OF A FROG, HIGHLY MAGNIFIED. (Beale.)

*a*, *a*, straight fibre; *b*, *b*, coiled fibre, dividing as it passes to the cell.

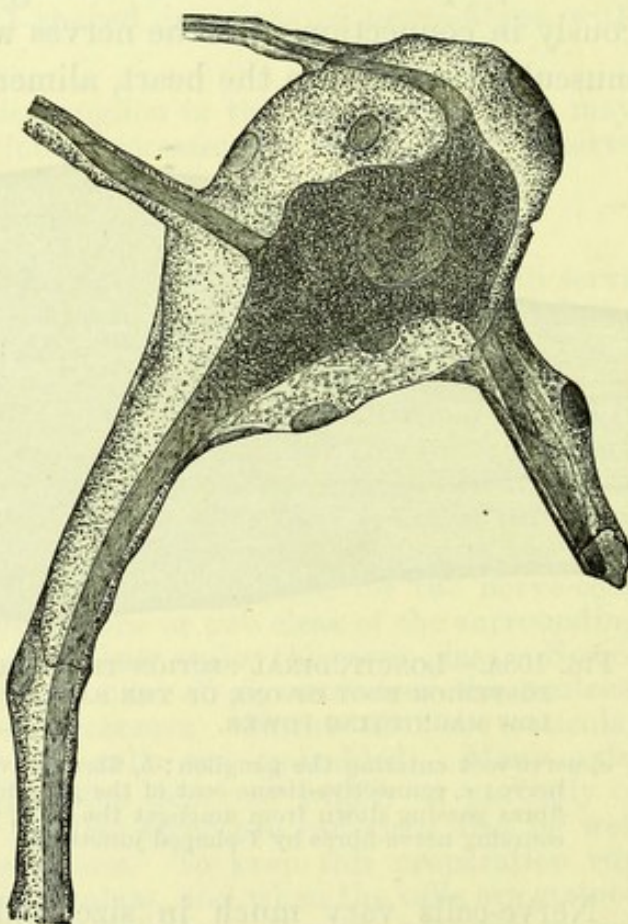


FIG. 109B.—A GANGLION-CELL WITHIN ITS SHEATH; FROM THE HUMAN SYMPATHETIC. (Key and Retzius.) (Highly magnified.)

spindle-shaped, but occasionally they emerge at the same part. In some cases where there appear to be two fibres connected with a cell,



one of them is really derived from another nerve-cell elsewhere, and is passing to end in a ramification which envelops the ganglion-cell; it may be coiled spirally around the issuing nerve-process as in fig. 109A. When there are three or more processes, the cell becomes irregularly angular or stellate. It has been thought that in some instances, as in the sympathetic ganglia (fig. 109B), all the processes become nerve-fibres, but this is by no means certain, and in most other instances, as in the large cells of the grey matter of the spinal cord and of the brain, only one process becomes the axis-cylinder of a nerve-fibre (*process of Deiters, neuron*), the others dividing and subdividing in a ramified manner (*dendrons*), until they end in an arborescence of fine twigs.

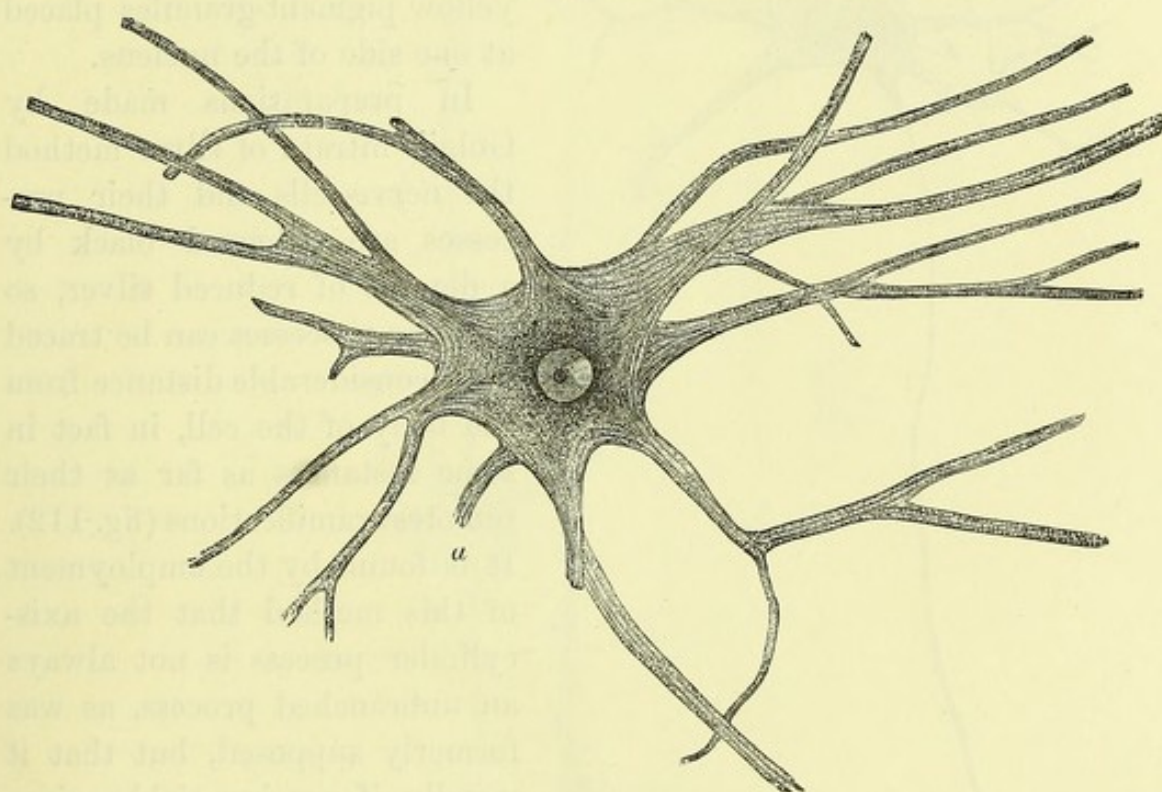


FIG. 110.—NERVE-CELL FROM SPINAL CORD OF OX, ISOLATED AFTER MACERATION IN VERY DILUTE CHROMIC ACID. (Magnified 175 diameters.)

The cell has a well-defined, clear, round nucleus, and a large nucleolus. The cell-processes are seen to be finely fibrillated, the fibrils passing from one process into another through the body of the cell. *a*, axis-cylinder process broken a short distance from the cell.

According to the number of their processes, nerve-cells are termed uni-, bi-, or multi-polar.

In the **ganglia** the nerve-cells have a nucleated sheath (figs. 108B, 109) which is continuous with the sheath of the nerve-fibres with which they are connected. In the spinal ganglia, and in many of the ganglia at the roots of the cranial nerves, the cells are unipolar, and the cell-process joins a traversing nerve-fibre by a T-shaped junction (fig. 108B). In the sympathetic ganglia they are usually multipolar (fig. 109B). The cells are disposed in aggregations of different size,



separated by the bundles of nerve-fibres which are traversing the ganglion (fig. 108A). The ganglion if large is inclosed by an investing capsule of connective tissue which is continuous with the epi- and perineurium of the entering and issuing nerve-trunks.

Many nerve-cells, and notably those of the spinal cord, have a finely fibrillar structure. The fibrils can be traced into the branches of the cells and into the axis-cylinders of nerve-fibres which are connected

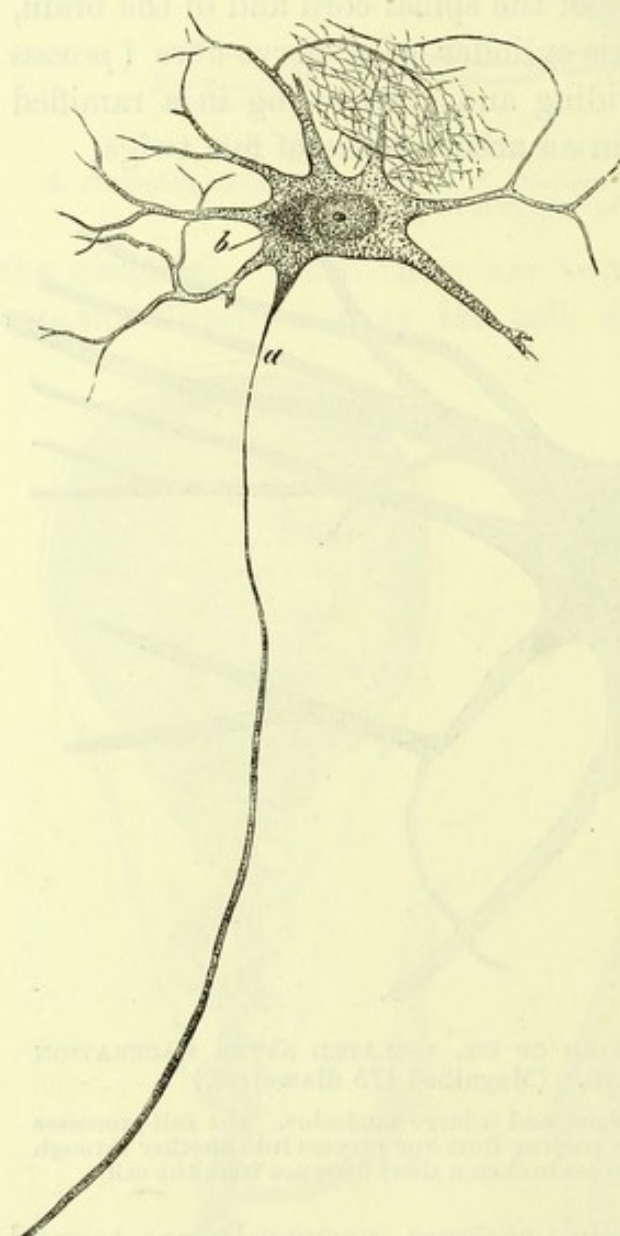


FIG. 111.—MULTIPOLAR NERVE-CELL FROM ANTERIOR HORN OF SPINAL CORD, HUMAN. (Gerlach.)

*a*, axis-cylinder or nerve-fibre process; *b*, pigment.

with the cells (fig. 110). Otherwise the cells have a finely granular appearance; often with a clump of black, brown, or yellow pigment-granules placed at one side of the nucleus.

In preparations made by Golgi's nitrate of silver method the nerve-cells and their processes are coloured black by a deposit of reduced silver, so that the processes can be traced for a considerable distance from the body of the cell, in fact in some instances as far as their remotest ramifications (fig. 112). It is found by the employment of this method that the axis-cylinder process is not always an unbranched process, as was formerly supposed, but that it usually, if not invariably, gives off fine lateral branches (*collaterals*), which themselves tend to ramify in the adjacent nerve-substance. And, although the main part of the axis-cylinder process usually passes on and becomes part of a long medullated nerve-fibre (first type of

Golgi), this is not always the case, for in another type of nerve-cell within the nerve-centres (second type of Golgi), the axis-cylinder process breaks up after a short course into a terminal arborescence, which usually envelops other nerve-cells.

Moreover, even the long process of type 1 (which becomes the axis-



cylinder of a long nerve-fibre) ultimately ends in a similar manner, that is to say, in a terminal ramification or arborescence, as will be

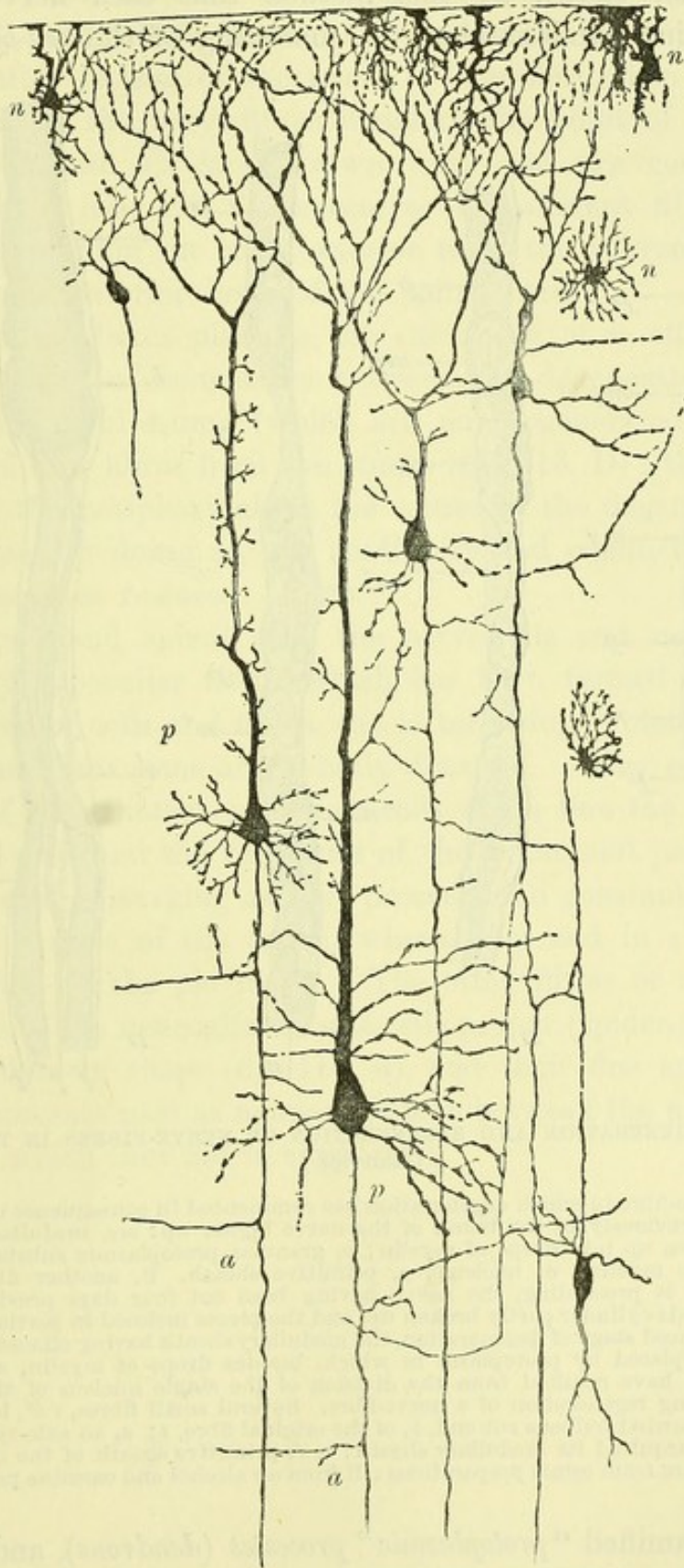


FIG. 112.—FROM A SECTION OF CEREBRAL CORTEX OF A YOUNG RABBIT, PREPARED BY GOLGI'S METHOD. (G. Retzius.)

*g*, nerve-cells ; *n*, neuroglia-cells ; *a*, axis-cylinder processes of nerve-cells.



seen in studying the endings of nerve-fibres, and the structure of the central nervous system.

It is further shown by this method that each nerve-cell is an anatomically independent element, consisting of the *cell-body* with its

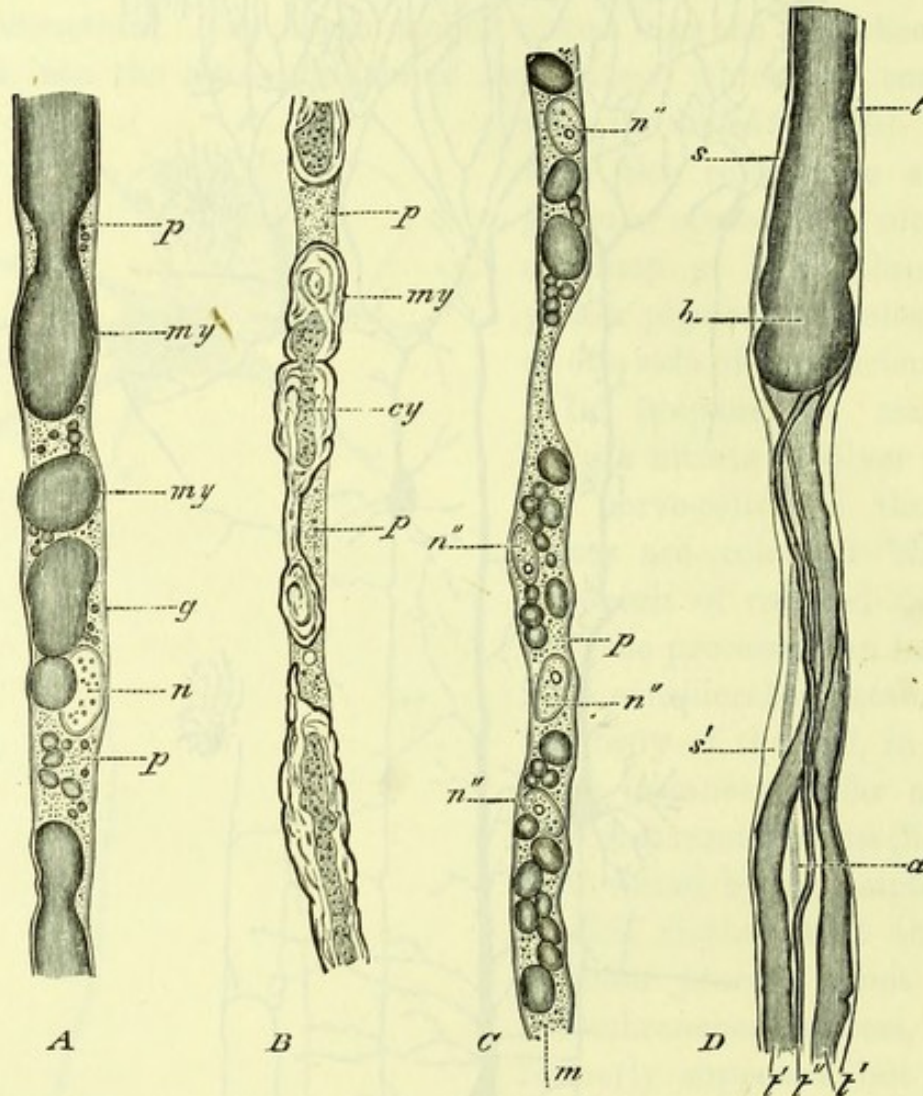


FIG. 113.—DEGENERATION AND REGENERATION OF NERVE-FIBRES IN THE RABBIT.  
(Ranvier.)

A, part of a nerve-fibre in which degeneration has commenced in consequence of the section, fifty hours previously, of the trunk of the nerve higher up: *my*, medullary sheath becoming broken up into drops of myelin; *p*, granular protoplasmic substance which is replacing the myelin; *n*, nucleus; *g*, primitive sheath. B, another fibre in which degeneration is proceeding, the nerve having been cut four days previously; *p*, as before; *cy*, axis-cylinder partly broken up, and the pieces inclosed in portions of myelin. C, more advanced stage of degeneration, the medullary sheath having almost disappeared, and being replaced by protoplasm in which, besides drops of myelin, are numerous nuclei which have resulted from the division of the single nucleus of the internode. D, commencing regeneration of a nerve-fibre. Several small fibres, *t' t''*, have sprouted from the somewhat bulbous cut end, *b*, of the original fibre, *t*; *a*, an axis-cylinder which has not yet acquired its medullary sheath; *s, s'*, primitive sheath of the original fibre. A, C, and D are from osmic preparations; B from an alcohol and carmine preparation.

nucleus, the ramified "*protoplasmic*" processes (*dendrons*), and the *nerve-process* (*neuron*) which becomes the axis-cylinder of a nerve-fibre. It will therefore be easily understood that when a nerve is cut, part of the axis-cylinder will be cut off from the cell to which it belongs, and from



which it has grown. This separated part of the axis-cylinder dies, and its medullary sheath undergoes a gradual process of disintegration into droplets of myelin, which is known as the *Wallerian degeneration* (fig. 113, A to C), and which in man and mammals begin about two or three days after section of the nerve. Therefore when a peripheral nerve is cut, all the nerve-fibres distal to the point of section must degenerate, because all have grown from and are connected with nerve-cells in or near the nerve centre—the afferent fibres with the cells of the ganglion on the posterior root, the efferent fibres with the cells of the anterior horn of the spinal cord.

If regeneration takes place in the cut nerve, it is effected not by a re-establishment of connection between the degenerated fibres and those of the central stump (which are not degenerated), but by an outgrowth of new fibres from the stump (fig. 113, D); these may find their way to the periphery along the course of the degenerated fibres. If they succeed in doing so, the continuity and conducting power of the nerve becomes restored.

In the brain and spinal cord the nerve-cells and nerve-fibres are supported by a peculiar tissue which has been termed the *neuroglia*. It is composed of cells and fibres, the latter being prolonged from the cells. Of the fibres some are radially disposed. They start from the fixed ends of the ciliated epithelium-cells which line the central canal of the spinal cord and the ventricles of the brain, and pass in a radial direction, slightly diverging as they proceed, and constantly branching, towards the surface of the organ, where they end in slight enlargements attached to the pia mater. The other fibres of the tissue are cell-processes of the neuroglia- or glia-cells proper (spider-cells). These cells are stellate in shape (fig. 111, *n*), and their fine and frequently ramifying processes pass as neuroglia-fibres between the nerve-cells and nerve-fibres, which they aid in supporting.



## LESSON XXI.

*MODES OF TERMINATION OF NERVE-FIBRES.*

1. SHELL out a Pacinian corpuscle from a piece of cat's mesentery which has been kept for two or three days in  $\frac{1}{50}$  per cent. chromic acid or 30 per cent. alcohol, and clear it as much as possible of adhering fat, but be careful not to prick or otherwise injure the corpuscle itself. Mount in water with a thick hair to prevent crushing with the cover-glass. Sketch the corpuscle under a low power, and afterwards draw under a high power the part of the core where the nerve enters and the part where it terminates. Notice the fibrous structure of the lamellar tunics of the corpuscle and the oval nuclei belonging to flattened endothelial-cells which cover the tunics. The distinct lines which when seen in the fresh corpuscle are generally taken for the tunics, are really the optical sections of these flattened cells.

2. Mount in dilute glycerine one or more sections of a rabbit's cornea which has been stained with chloride of gold. Notice the arrangement in plexuses of the darkly-stained nerve-fibres and fibrils, (1) in the connective-tissue substance, (2) under the epithelium, and (3) between the epithelial-cells. Make one or two sketches showing the arrangement of the fibrils.

3. Spread out a small piece of muscle which has been stained with chloride of gold by Löwit's method, and examine it with a low power to find the nerve-fibres crossing the muscular fibres and distributed to them.

Try and separate those parts of the muscular fibres to which nerves appear to go, and mount them in glycerine. The pieces of muscle may advantageously be thinned out for observation by pressure upon the cover-glass. Search thoroughly for the close terminal ramifications (end-plates) of the axis-cylinders immediately within the sarcolemma.

It is rather difficult to dissociate the fibres, and much patience is sometimes required in searching for the nerve-terminations, but when they are found the trouble is amply repaid.<sup>1</sup>

**Modes of ending of sensory nerve-fibres.**—Nerve-fibres which are distributed to sensory parts end either in *special organs* or in *free terminal ramifications*. Within the special organs the ending is also usually ramified. There are three chief kinds of special organs, termed respectively *Pacinian corpuscles*, *tactile corpuscles*, and *end-bulbs*. In the *tactile corpuscles* and *end-bulbs* the connective-tissue sheath of a medullated fibre expands to form a solid bulbous enlargement, which is cylindrical or spheroidal in the end-bulbs and ellipsoidal in the tactile corpuscles. In both kinds of end-organ there is a capsule of

<sup>1</sup> For methods of staining with chloride of gold see Appendix. The methyl-blue method of Ehrlich, which is often employed to study these and other modes of nerve-termination, will also be found in the Appendix.



connective tissue within which is generally a sort of core containing

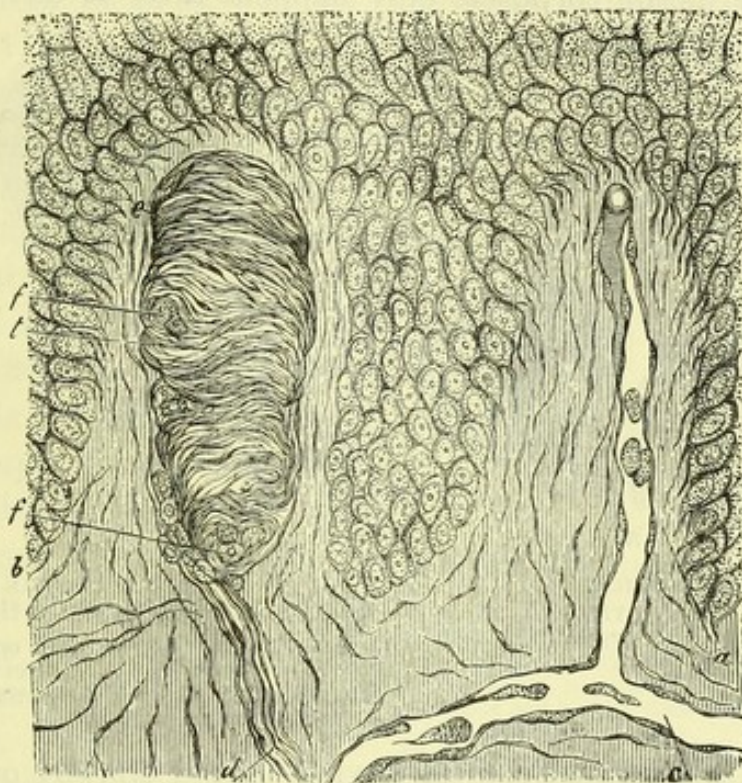


FIG. 114.—SECTION OF SKIN SHOWING TWO PAPILLÆ AND DEEPER LAYERS OF EPIDERMIS. (Biesiadecki.)

*a*, vascular papilla with capillary loop passing from subjacent vessel, *c*; *b*, nerve-papilla with tactile corpuscle, *t*. The latter exhibits transverse fibrous markings; *d*, nerve passing up to it; *f, f*, sections of spirally winding nerve-fibres.

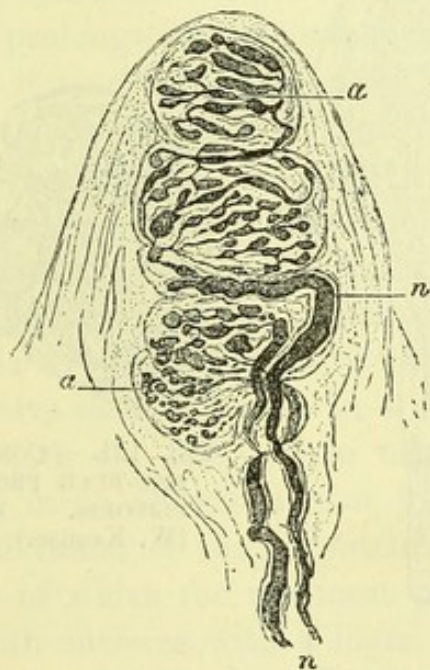


FIG. 115.—TACTILE CORPUSCLE WITHIN A PAPILLA OF THE SKIN OF THE HAND, STAINED WITH CHLORIDE OF GOLD. (Ranvier.)

*n*, two nerve-fibres passing to the corpuscle; *a, a*, varicose ramifications of the axis-cylinders within the corpuscle.

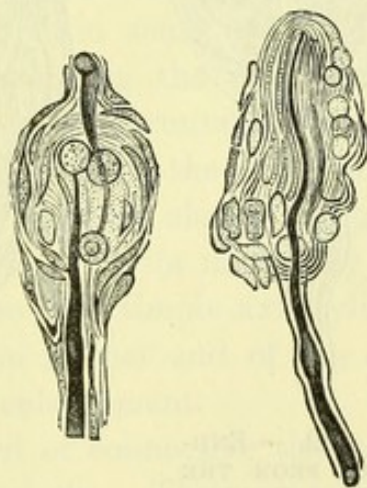


FIG. 116.—SIMPLE TACTILE END-ORGANS FROM THE CLITORIS OF THE RABBIT. (Izquierdo.)



numerous nucleated cells. As the nerve-fibre enters the corpuscle (which in the tactile corpuscle only happens after it has reached the

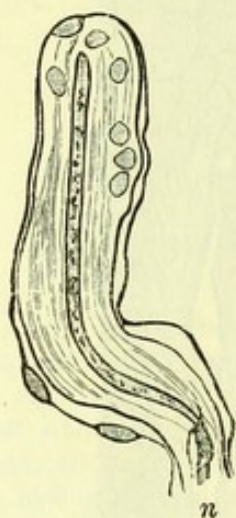

FIG. 117.—CYLINDRICAL END-BULB FROM THE CONJUNCTIVA OF THE CALF. (Merkel.)

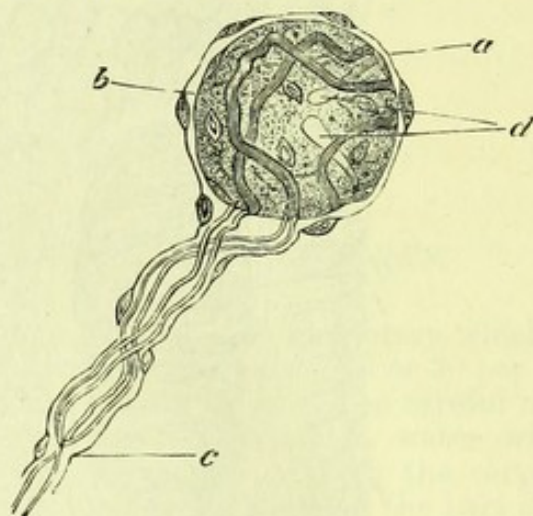


FIG. 118.—END-BULB FROM THE HUMAN CONJUNCTIVA. (Longworth.)

*a*, nucleated capsule; *b*, core, the outlines of its cells are not seen; *c*, entering fibre branching, and its two divisions passing to terminate in the core at *d*.

distal part of the corpuscle, after having wound spirally once or twice round it) it loses its sheaths and is prolonged as an axis-cylinder only,

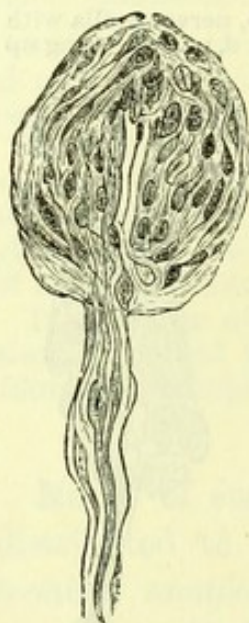

FIG. 119.—END-BULB FROM THE HUMAN CONJUNCTIVA, TREATED WITH ACETIC ACID AND OSMIC ACID.  $\frac{500}{1}$ . (W. Krause.)

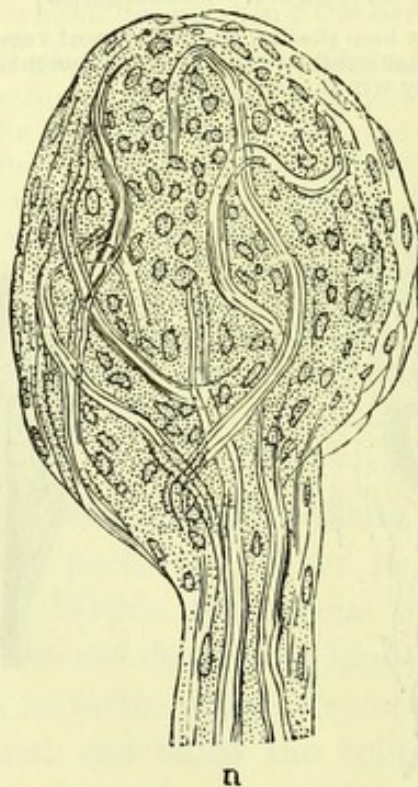


FIG. 120.—ARTICULAR CORPUSCLE, HUMAN.  $\frac{300}{1}$ . (W. Krause.)

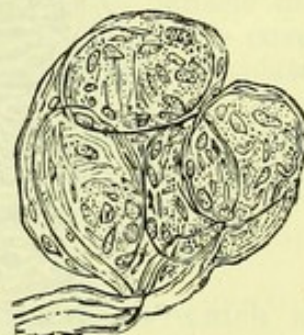

FIG. 121.—COMPOUND END-BULB FROM THE CLITORIS. HUMAN. (W. Krause.)

which terminates after either a straight or a convoluted course within the organ (see figs. 115 to 118). Tactile corpuscles occur in some of the papillæ of the skin of the hand and foot, in sections of which they will



be afterwards studied. End-bulbs are found in the conjunctiva of the eye, where in most animals they have a cylindrical or oblong shape (fig. 117), but in man they are spheroidal (fig. 118). They have also been found in papillæ of the lips and tongue, and in the epineurium of the nerve-trunks, and somewhat similar sensory end-organs also occur in the integument of the external genital organs of both sexes (figs. 116, 121). Similar bodies of larger size are also met with in the neighbourhood of the joints (fig. 120). In the skin covering the bills of certain birds (*e.g.* duck), a simple form of end-organ occurs, consisting of two or more cells arranged in rows within a capsule, with the axis-cylinder terminating in flattened expansions between the cells (*corpuscles of Grandry*, fig. 122).

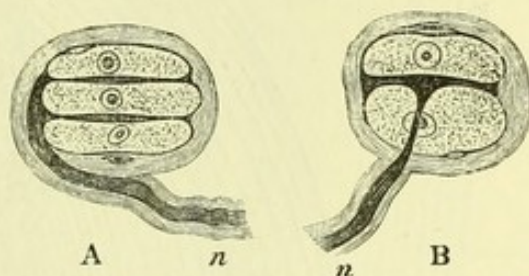


FIG. 122.—TACTILE CORPUSCLES FROM THE DUCK'S TONGUE. (Izquierdo.)

A, composed of three cells, with two interposed disks, into which the axis-cylinder of the nerve, *n*, is observed to pass; in B there is but one tactile disk inclosed between two tactile cells.

The **Pacinian corpuscles** are larger, and have a more complex structure, than the tactile corpuscles and end-bulbs (fig. 123). They are composed of a number of concentric coats arranged like the layers of an onion, and inclosing the prolonged end of a nerve-fibre. A single medullated nerve-fibre goes to each Pacinian corpuscle encircled by a prolongation of perineurium, and within this by endoneurium; when it reaches the corpuscle, of which it appears to form the stalk, the lamellæ of the perineurium expand to form some of the tunics of the corpuscle. The nerve passes on, piercing the other tunics, and still provided with medullary sheath, and surrounded by endoneurium, to reach the centre of the corpuscle. Here the endoneurium is prolonged to form a sort of core of cylindrical shape, along the middle of which the nerve-fibre, now deprived of its medullary and primitive sheaths, passes in a straight course as a simple axis-cylinder (figs. 123, *n'*; 124, *c.f.*) to terminate at the farther end of the core, either in an arborisation or in a bulbous enlargement.

The tunics of the corpuscle are composed of connective tissue, the fibres of which for the most part run circularly. They are covered on both surfaces with a layer of flattened endothelial-cells, and here and there cleft-like lymph-spaces can be seen between them like those between the layers of the perineurium (see p. 88).

When sensory nerve-fibres terminate in **plexuses**, they generally branch once or twice on nearing their termination. The sheaths of the fibres then successively become lost, first the connective tissue or



perineural sheath, then the medullary sheath, and lastly the primitive sheath, the axis-cylinder being alone continued as a bundle of primitive

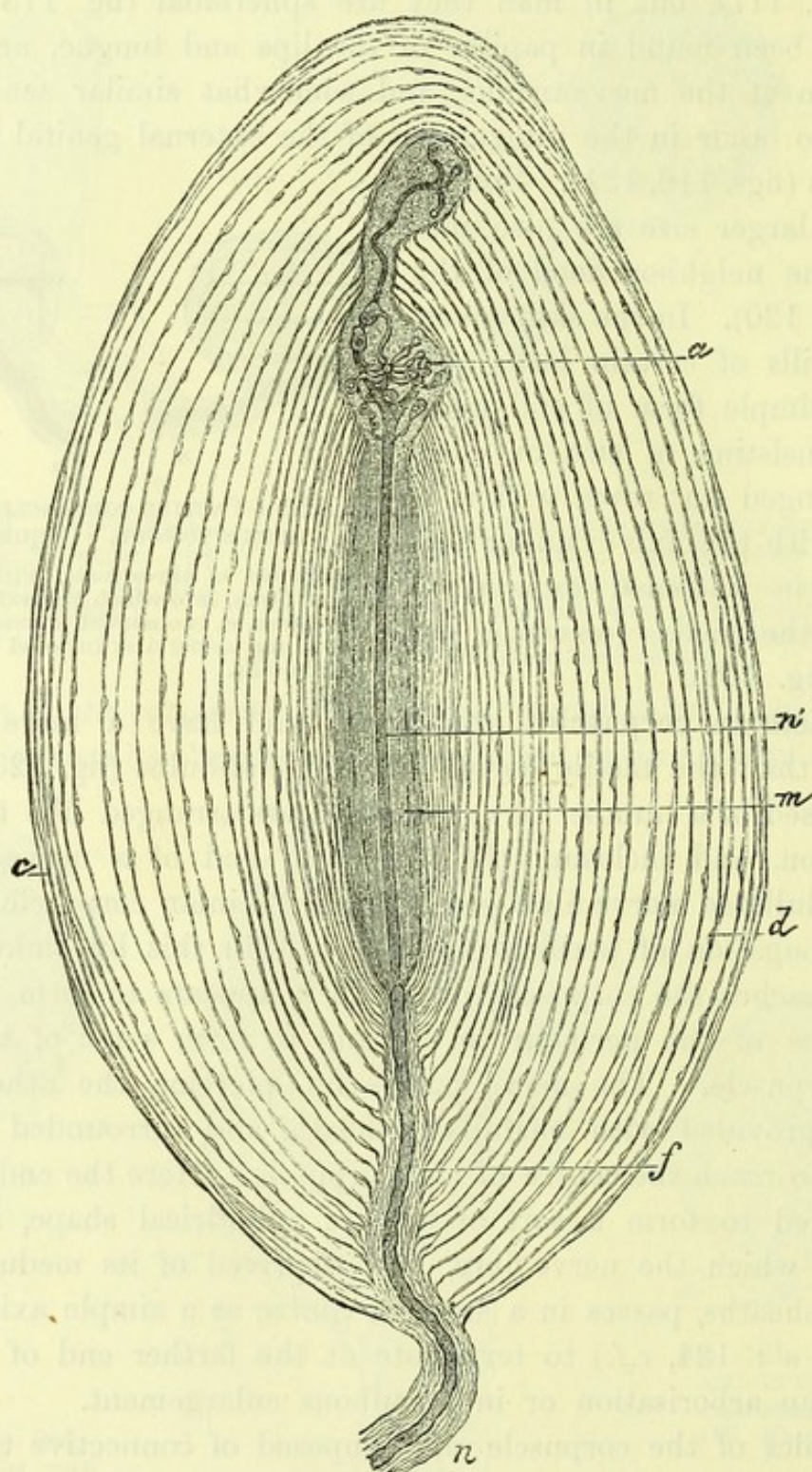


FIG. 123.—MAGNIFIED VIEW OF A PACINIAN BODY FROM THE CAT'S MESENTERY.  
(Ranvier.)

*n*, stalk of corpuscle with nerve-fibre inclosed in sheath of Henle passing to the corpuscle ; *n'*, its continuation through the core, *m*, as axis-cylinder only ; *a*, its terminal arborisation ; *c*, *d*, sections of endothelial-cells of tunics, often mistaken for the tunics themselves ; *f*, channel through the tunics which expands into the core of the corpuscle.

fibrils (fig. 125, *n*). This branches and with the ramifications of the axis-cylinders of neighbouring nerve-fibres forms a primary plexus.



From the primary plexus smaller branches (*a*) come off, and these form a secondary plexus (*e*) nearer the surface, generally immediately under the epithelium if the ending is in a membrane covered by that tissue. Finally, from the secondary plexus nerve-fibrils proceed and form a terminal ramification amongst the epithelium-cells (fig. 126, *p*), the actual ending being generally in free varicose fibrils (*b*). Such a mode of ending in terminal plexuses is most characteristically seen in the cornea of the eye. The nerve-fibrils may be brought distinctly into view by staining with chloride of gold, and then the fibrillar structure of the ramifications of the axis-cylinders also becomes very apparent.

#### Nerve-endings in tendons.

—A special modification of the terminal plexus is met with in many of the tendons, near the points of attachment of the muscular fibres. The tendon-bundles are somewhat enlarged, and the nerve-fibres—one, two, or even more in number—pass to the enlarged part, and penetrating between the fasciculi of the tendon end in a terminal arborisation, beset with irregular varicosities. The whole structure, including the enlargement of the tendon-bundle in which the arborisation occurs, is known as an *organ of Golgi* (fig. 127).

**Ending of motor nerves.**—Lastly the nerves to muscles also terminate in plexiform ramifications, which in striated (voluntary) muscles are collected into special organs termed *motor end-organs*, or, incorrectly, *end-plates*.

In **involuntary muscle**, the nerve-fibres, which near their termination are entirely non-medullated, end in plexuses. The primary plexuses are generally furnished with ganglion-cells in abundance.

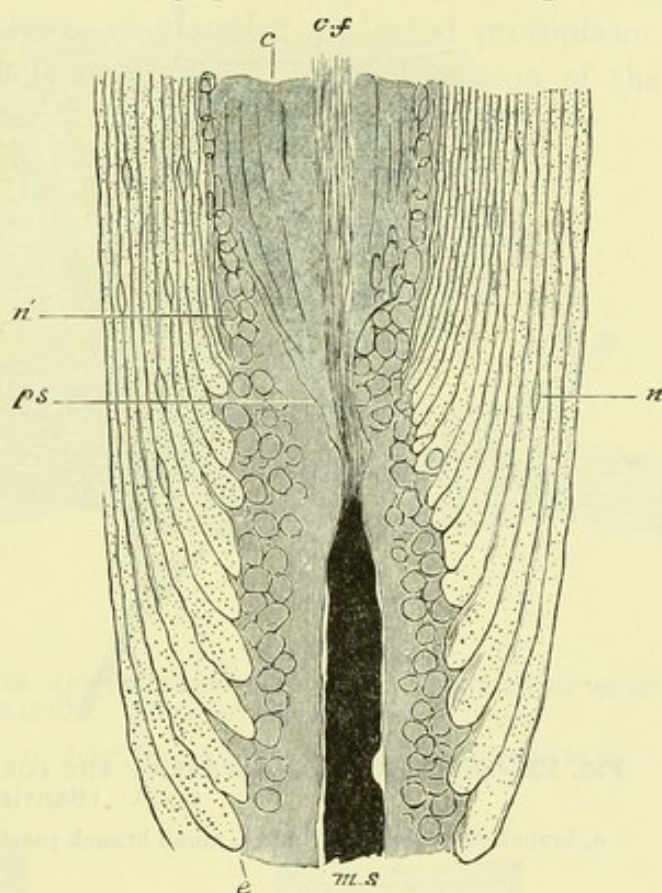


FIG. 124.—PART OF PACINIAN BODY, SHOWING THE NERVE-FIBRE ENTERING THE CORE. FROM AN OSMIC ACID PREPARATION.

*ms*, entering nerve-fibre, the medullary sheath of which is stained darkly, and ends abruptly at the core; *ps*, prolongation of primitive sheath, passing towards the outer part of the core; *c, f*, axis-cylinder passing through the core as the central fibre; *e*, some of the inner tunics of the corpuscle, enlarged where they abut against the canal through which the nerve-fibre passes—the dots within them are sections of the fibres of which they are composed; *n*, nuclei of the tunics; *n'*, nuclei of the endoneurium, continued by others in the outer part of the core.



From these other nerve-fibres pass which form secondary plexuses and terminal ramifications amongst the contractile fibre-cells. These nerves will be more fully studied in connection with the intestine.

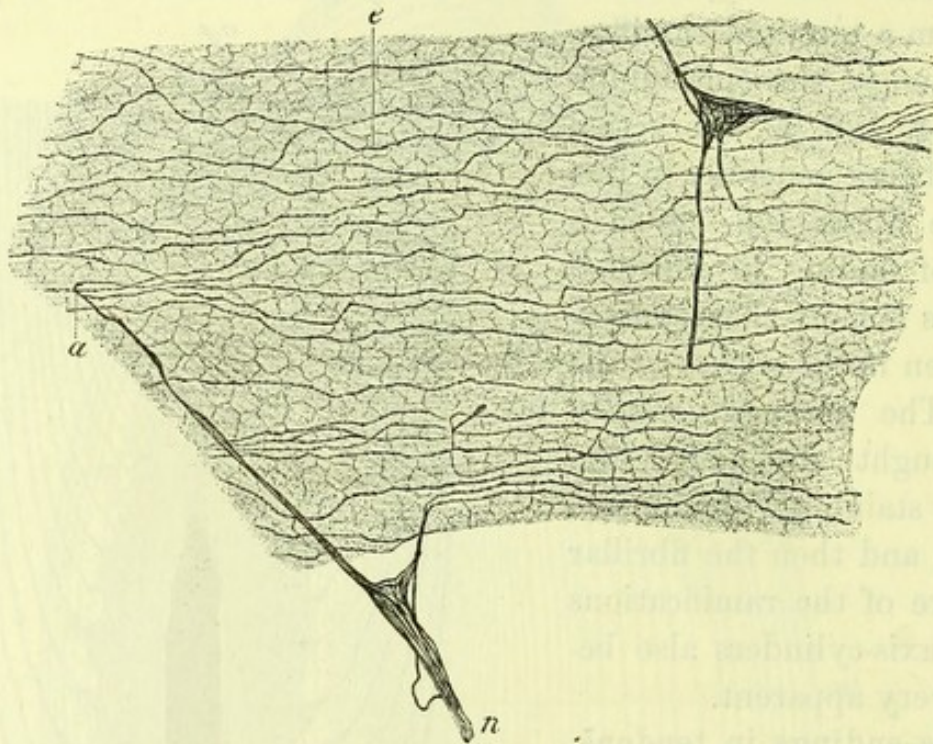


FIG. 125.—SUBEPITHELIAL PLEXUS OF THE CORNEA TREATED WITH CHLORIDE OF GOLD. (Ranvier.)

*n*, branch of primary plexus; *a*, small branch passing to join the subepithelial plexus, *c*.

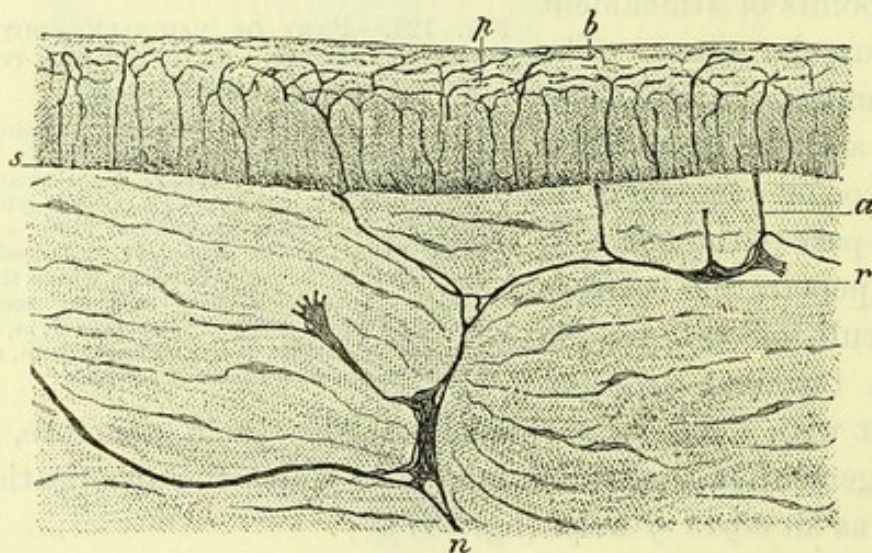


FIG. 126.—VERTICAL SECTION OF CORNEA STAINED WITH CHLORIDE OF GOLD. (Ranvier.)

*n*, *r*, primary plexus in connective tissue of cornea; *a*, branch passing to subepithelial plexus, *s*; *p*, intra-epithelial plexus; *b*, terminations of fibrils.

In voluntary muscle the nerves, which are always medullated, terminate in special motor end-organs. A medullated fibre will branch two or three times before ending, and then each branch passes straight



to a muscular fibre. Having reached this, the neurolemma of the nerve-fibre is continued into the sarcolemma of the muscle, the medullary sheath stops short, and the axis-cylinder ends in a close terminal ramification with varicosities upon its branches (figs. 128, 129). This ramification is embedded in a layer of granular nucleated protoplasm. In some cases the ramification is restricted to a small portion of the

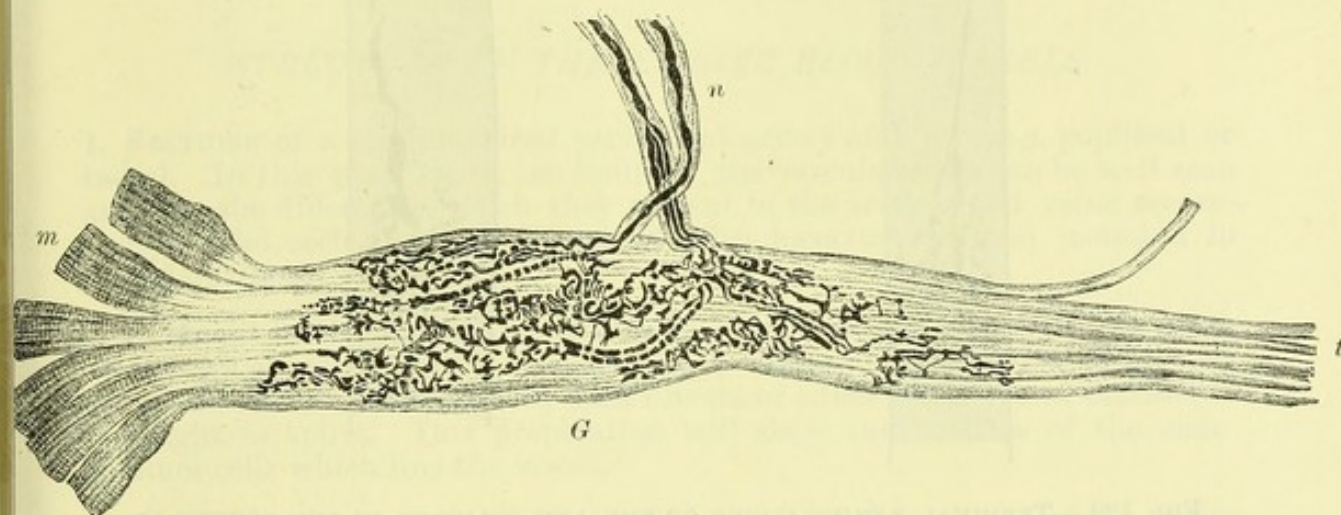


FIG. 127.—ORGAN OF GOLGI FROM THE HUMAN TENDO ACHILLIS. CHLORIDE OF GOLD PREPARATION. (Ciaccio.)

*m*, muscular fibres; *t*, tendon-bundles; *G*, Golgi's organ; *n*, two nerve-fibres passing to it.

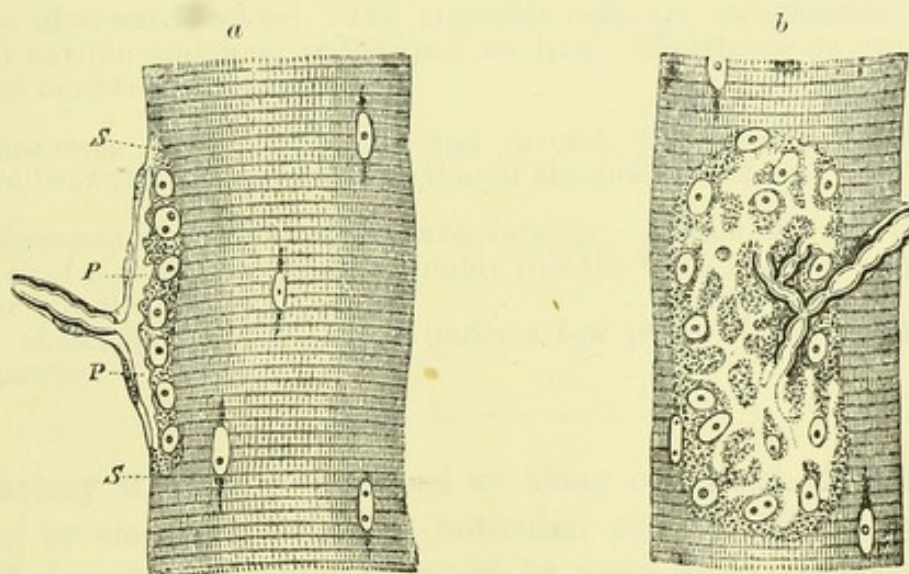


FIG. 128.—NERVE-ENDING IN MUSCULAR FIBRE OF A LIZARD (*Lacerta viridis*). (Kühne.)

*a*, end-plate seen edgewise; *b*, from the surface; *s*, *s*, sarcolemma; *p*, *p*, expansion of axis-cylinder. In *b* the expansion of the axis-cylinder appears as a clear network branching from the divisions of the medullated fibres.

muscular fibre, and forms with the granular bed a slight prominence (eminence of Doyère). This is the case in insects and mammals. In the lizard the ramification is rather more extended than in mammals, whilst in the frog it is spread over a considerable length of the fibre.



In mammals there appears to be only one end-plate to each fibre, while in reptiles there may be several. The end-plate is covered, external to the sarcolemma, by an expansion of the sheath of Henle of the nerve-fibre.

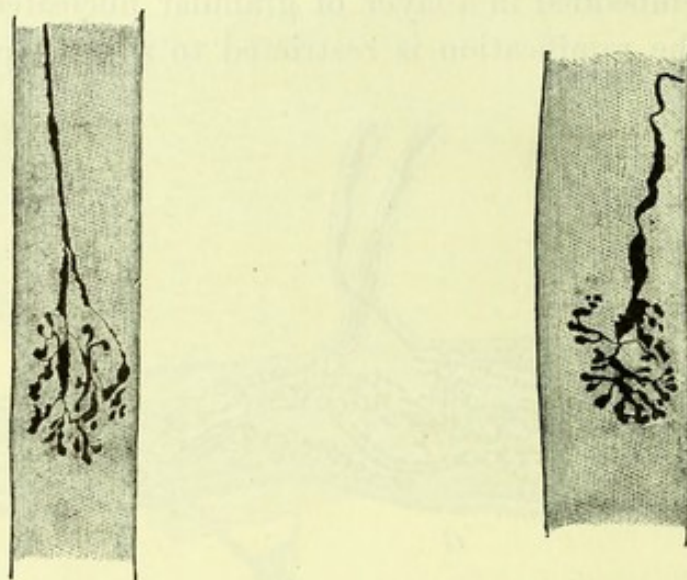


FIG. 129.—TERMINAL RAMIFICATIONS OF THE AXIS-CYLINDER IN END-ORGANS OF MUSCLE, STAINED WITH CHLORIDE OF GOLD. (Ranvier.) The varicosities here seen are probably produced by the reagent.



## LESSON XXII.

*STRUCTURE OF THE LARGER BLOOD-VESSELS.*

1. SECTIONS of a medium-sized peripheral artery and vein, *e.g.* popliteal or radial. In this preparation the limits of the vascular coats can be well seen and also the differences which they present in the arteries and veins respectively. The sections may be stained with hæmatoxylin and mounted in Canada balsam.

2. Mount in Canada balsam a thin slice cut from the inner surface of an artery which, after having been cut open longitudinally and washed with distilled water, has been rinsed with nitrate of silver solution and exposed to the light in spirit. This preparation will show the outlines of the endothelium-cells which line the vessel.

3. A piece of an artery which has been macerated for some days in 30 per cent. alcohol (1 part rectified spirit to 2 parts water) is to be teased so as to isolate some of the muscular cells of the middle coat and portions of the elastic layers (networks and fenestrated membranes) of the inner and middle coats. The tissue may be stained cautiously with diluted hæmatoxylin, and glycerine afterwards added. The muscular cells are recognisable by their irregular outline and long rod-shaped nucleus. Sketch one or two and also a piece of fenestrated membrane.

4. Transverse sections of aorta and carotid. Notice the differences in structure between these and the section of the smaller artery.

5. Transverse section of vena cava inferior. Notice the comparatively thin layer of circular muscle, and outside this the thick layer of longitudinal muscular bundles.

Make sketches from 1, 4, and 5 under a low power, from 2 and 3 under a high power.

---

An **artery** is usually described as being composed of three coats, an *inner* or elastic, a *middle* or muscular, and an *external* or areolar (fig. 130, *b, c, d*). It would, however, be more correct to describe the wall of an artery as being composed of muscular and elastic tissue lined internally by a pavement-epithelium (endothelium) and strengthened externally by a layer of connective tissue. For the present, however, we may adhere to the generally received mode of description. The *inner coat* of an artery is composed of two principal layers. The inner one is a thin layer of *pavement-epithelium* or *endothelium*, the cells of which are somewhat elongated in the direction of the axis of the vessel (fig. 131), and form a smooth lining to the tube. After death



they become easily detached. Next to this comes an elastic layer in the form either of *elastic networks* (fig. 133) or of a *fenestrated membrane* (fig. 132). In some arteries there is a layer of fine connective tissue intervening between the epithelium and the fenestrated membrane (*subepithelial layer*).

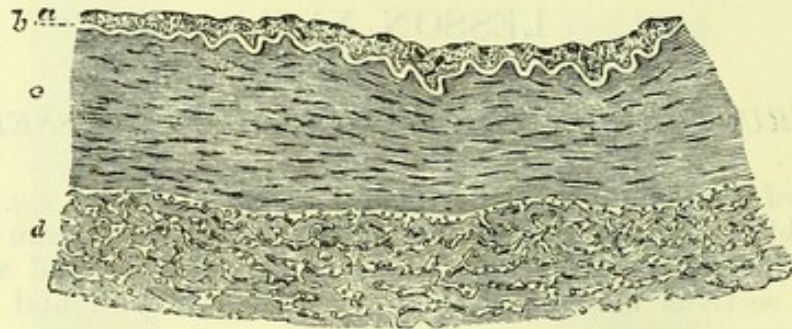


FIG. 130.—TRANSVERSE SECTION OF PART OF THE WALL OF THE POSTERIOR TIBIAL ARTERY. (75 diameters.)

a, epithelial and subepithelial layers of inner coat; b, elastic layer (fenestrated membrane) of inner coat, appearing as a bright line in section; c, muscular layer (middle coat); d, outer coat, consisting of connective-tissue bundles. In the interstices of the bundles are some connective tissue nuclei, and, especially near the muscular coat, a number of elastic fibres cut across.

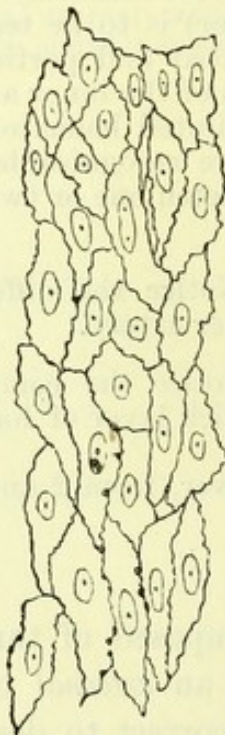

FIG. 131.—EPITHELIAL LAYER LINING THE POSTERIOR TIBIAL ARTERY. (250 diameters.)

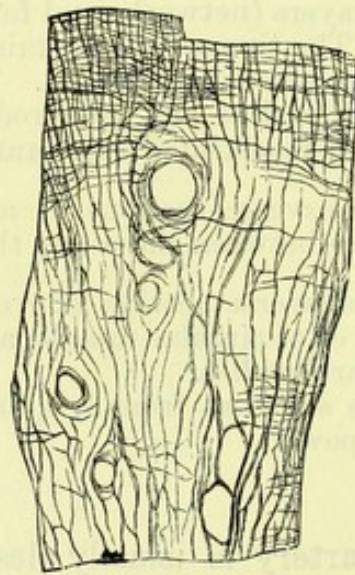


FIG. 132.—PORTION OF FENESTRATED MEMBRANE OF HENLE FROM AN ARTERY. (Toldt.)

The *middle coat* consists mainly of circularly disposed plain muscular fibres, but it is also pervaded in most arteries by a network of elastic fibres which are connected with the fenestrated membrane of the inner coat and are sometimes almost as much developed as the muscular tissue itself. This is especially the case with the larger arteries such



as the carotid and its immediate branches, but in the smaller arteries of the limbs the middle coat is almost purely composed of muscular tissue. The muscular fibres are comparatively short, with long rod-shaped nuclei, and are often irregular in shape (as in fig. 134).

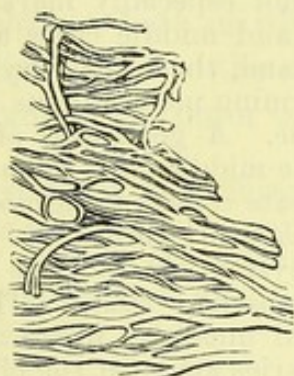

FIG. 133.—ELASTIC NETWORK OF ARTERY.  
(Toldt.)

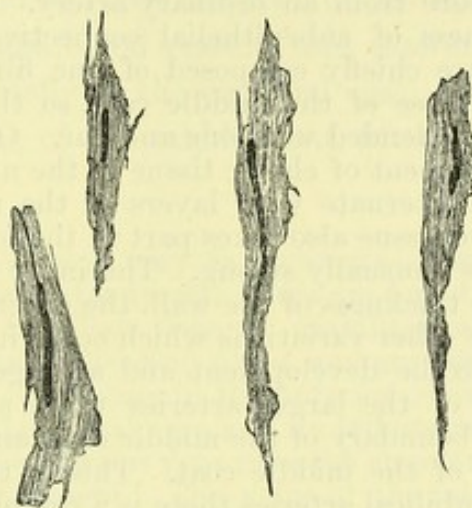


FIG. 134.—MUSCULAR FIBRE-CELLS FROM SUPERIOR THYROID ARTERY. (340 diameters.)

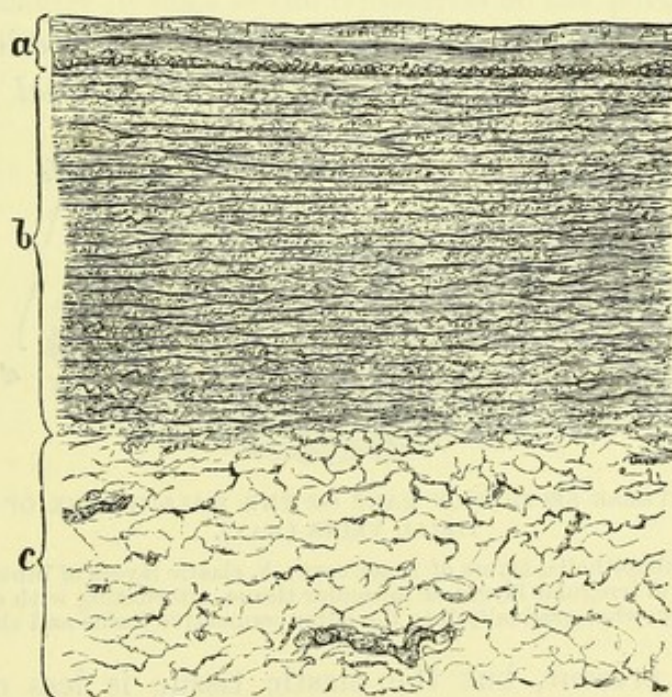


FIG. 135.—SECTION OF THORACIC AORTA AS SEEN UNDER A LOW POWER. (Toldt.)

*a*, the inner coat consisting of three layers, viz.: 1. Epithelium seen as a fine line. 2. Sub-epithelial. 3. Elastic layers. In the part of the inner coat, at its junction with the middle, a layer of longitudinal muscular fibres is represented as cut across. *b*, middle coat with its elastic membrane; *c*, outer coat with two vasa vasorum.

The *outer coat* is formed of connective tissue with a good many elastic fibres, especially next to the middle coat. The strength of an artery depends largely upon this coat; it is far less easily cut or torn than the other coats, and it serves to resist undue expansion of the



vessel. Its outer limit is not sharply marked, for it tends to blend with the surrounding connective tissue (hence it has been termed *tunica adventitia*).

**Variations in structure.**—The *aorta* (fig. 135) differs in some respects in structure from an ordinary artery. Its inner coat contains a considerable thickness of subepithelial connective-tissue, but the elastic layers of this coat are chiefly composed of fine fibres, and are not especially marked off from those of the middle coat, so that the inner and middle coats appear almost blended with one another. On the other hand, there is a very great development of elastic tissue in the middle coat, forming membranous layers which alternate with layers of the muscular tissue. A good deal of connective tissue also takes part in the formation of the middle coat, so that the wall is unusually strong. The inner and middle coats constitute almost the entire thickness of the wall, the outer coat being relatively thin.

The other variations which occur in the arterial system chiefly have reference to the development and arrangement of the muscular tissue. Thus in many of the larger arteries there are longitudinal muscular fibres at the inner boundary of the middle coat, and in some arteries amongst the circular fibres of the middle coat. This is the case in the *aorta*. In some parts of the umbilical arteries there is a complete layer of longitudinal fibres internal to the circular fibres and another external to them, whilst the amount of elastic tissue is very small. Longitudinal fibres are also present in some other arteries (iliac, superior mesenteric, splenic, renal, etc.), external to the circular fibres, and therefore in the outer coat of the artery.

The **veins** (fig. 136) on the whole resemble the arteries in structure, but they present certain differences. In the *internal coat* the same

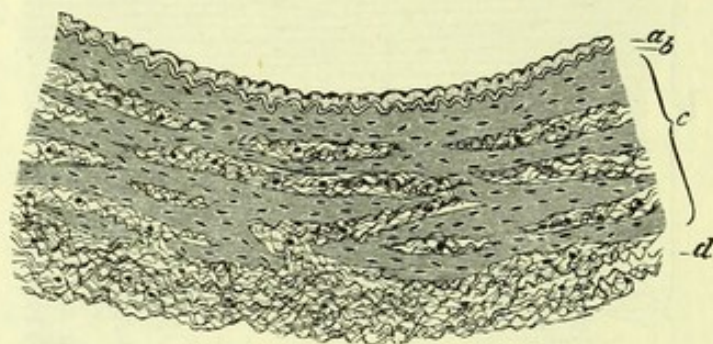


FIG. 136.—TRANSVERSE SECTION OF PART OF THE WALL OF ONE OF THE POSTERIOR TIBIAL VEINS (MAN).

*a*, epithelial and subepithelial layers of inner coat; *b*, elastic layers of inner coat; *c*, middle coat consisting of irregular layers of muscular tissue, alternating with connective tissue, and passing somewhat gradually into the outer connective tissue and elastic coat, *d*.

layers may be present, but the elastic tissue is less developed and seldom takes the form of a complete membrane. The endothelium-cells are less elongated than those of the arteries. The *middle coat* (*c*) contains less elastic tissue and also less muscular tissue, being partly occupied by bundles of white connective-tissue fibres. These are derived from the external coat, which is relatively better developed in the veins than in the arteries, so that, although thinner, their walls are often stronger.

Many of the veins are provided with *valves*, which are semilunar folds



of the internal coat strengthened by a little fibrous tissue: a few muscular fibres may be found in the valve near its attachment. The layer of the inner coat is rather thicker, and the endothelium-cells are more elongated on the side which is subject to friction from the current of blood than on that which is turned towards the wall of the vessel.

The larger arteries and veins possess blood-vessels, *vasa vasorum*, and lymphatics, both of which ramify chiefly in the external coat. Nerves are distributed to the muscular tissue of the middle coat, after forming a plexus in the outer coat.

**Variations in different veins.**—The veins vary in structure more than do the arteries. In many veins longitudinal muscular fibres are found in the inner part of the middle coat, as in the iliac, femoral, umbilical, etc.; in others they occur external to the circularly disposed fibres, and are described as belonging to the outer coat. This is the case in the inferior vena cava, and also in the hepatic veins and in the portal vein and its tributaries. In the superior and in the upper part of the inferior vena cava the circular fibres of the middle coat are almost entirely absent. The veins of the following parts have no muscular tissue, viz., pia mater, brain and spinal cord, retina, bones, and the venous sinuses of the dura mater and placenta.

It is only the larger veins, and especially those of the limbs that possess valves. They are wanting in most of the veins of the viscera (although occurring abundantly in some of the tributaries of the portal vein), in those within the cranium and vertebral canal, in the veins of the bones, and in the umbilical vein.



## LESSON XXIII.

*SMALLER BLOOD-VESSELS. LYMPHATIC SYSTEM.*

1. TAKE a piece of pia mater which has been stained with hæmatoxylin, and separate from it some of the small blood-vessels of which it is chiefly composed. Mount the shreds in Farrant or dilute glycerine. The structure of the small arteries can be studied in this preparation, the nuclei of the epithelium and of the muscular coat being brought distinctly into view by the stain. The veins of the pia mater possess no muscular tissue. Capillary vessels which have been dragged out from the brain in removing the pia mater may also be seen in this preparation. Sketch two small arteries of different sizes, giving also their measurements.

2. Mount in Canada balsam a piece of the omentum of the rabbit, stained with silver nitrate. The membrane should be stretched over a cork or a ring of glass or vulcanite, rinsed with distilled water, treated for five minutes with 1 per cent. nitrate of silver solution, again washed and exposed to sunlight in spirit. When stained brown, the preparation is removed from the light. Pieces may now be cut off from the membrane and mounted, as directed, in Canada balsam; they should include one or more blood-vessels.

This preparation is intended to show the epithelium of the smaller blood-vessels and accompanying lymphatics, and also the epithelium of the serous membrane. Sketch a small piece showing the epithelium of the vessels.

3. Mount in Canada balsam a piece of the central tendon of the rabbit's diaphragm which has been similarly prepared (except that the pleural surface has first been brushed to remove the superficial epithelium so as to enable the nitrate of silver more readily to penetrate to the network of lymphatic vessels underlying that surface). Observe the lymphatic plexus under a low power; sketch a portion of the network. If the peritoneal surface is focussed, the epithelium which covers that surface will be seen, and opposite the clefts between the radially disposed tendon-bundles stomata may be looked for in this epithelium.

4. Carefully study the circulation of the blood either in the web of the frog's foot or in the mesentery or tongue of the frog or toad, or in the tail of the tadpole.

---

The coats of the **small arteries and veins** are much simpler in structure than those of the larger vessels, but they contain at first all the same elements. Thus there is a lining epithelium (endothelium) and an elastic layer forming an *inner coat*, a *middle coat* of circularly disposed plain muscular tissue, and a thin *outer coat*. The same differences also are found between the arteries and veins, the walls of the veins being thinner and containing far less muscular tissue (fig. 137),



and the lining epithelium-cells, much elongated in both vessels, are far longer and narrower in the small arteries than in the corresponding veins (fig. 138).

In the smallest vessels it will be found that the elastic layer has disappeared in the veins, and the muscular tissue is considerably reduced in thickness in both kinds of vessels. Indeed, it is soon represented by but a single layer of contractile cells, and even these no longer form a complete layer. By this time also, the outer coat and the elastic layer of the inner coat have entirely disappeared both from arteries and veins. The vessels are reduced, therefore, to the condition of a tube formed of pavement-epithelium cells, with a partial covering of circularly disposed muscular cells.

Even in the smallest vessels, which are not capillaries, the differences

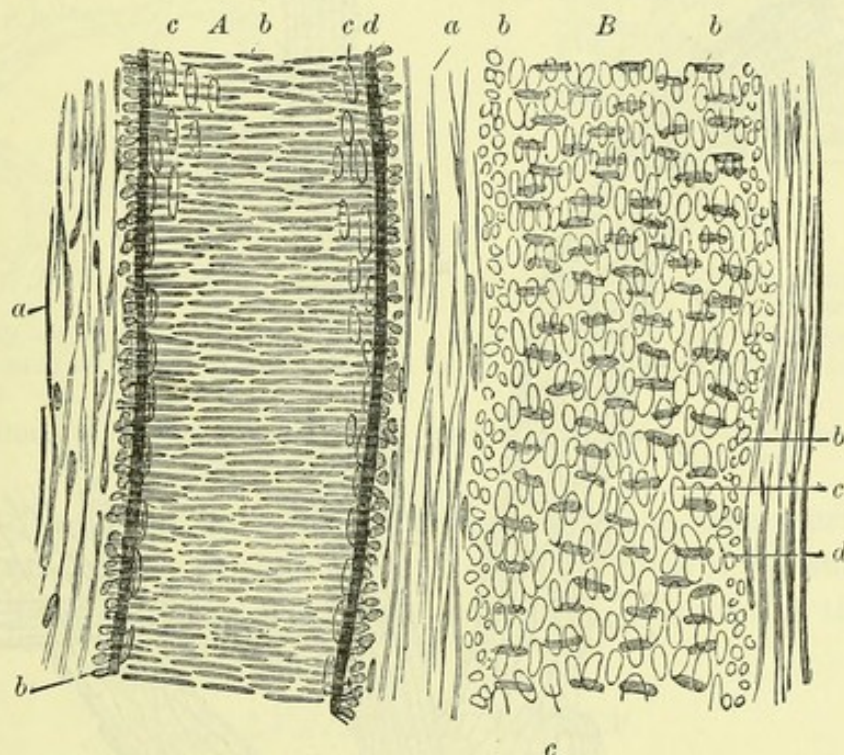


FIG. 137.—A SMALL ARTERY, *A*, WITH A CORRESPONDING VEIN, *B*, TREATED WITH ACETIC ACID. (Kölliker.) (Magnified 350 diameters.)

*a*, external coat with elongated nuclei; *b*, nuclei of the transverse muscular tissue of the middle coat (when seen endwise, as at the sides of the vessel, their outline is circular); *c*, nuclei of the epithelium-cells; *d*, elastic layers of the inner coat.

between arteries and veins are still manifested. These differences may be enumerated as follows:—The veins are larger than the corresponding arteries; they branch at less acute angles; their muscular cells are fewer, and their epithelium-cells less elongated; the elastic layer of the inner coat is always less marked, and sooner disappears.

**Capillary vessels.**—When traced to their smallest branches, the arteries and veins eventually are seen to be continued into a network of the smallest blood-vessels or capillaries. The walls of these are



composed only of flattened epithelium-cells (fig. 139) continuous with those that line the arteries and veins; these cells can be exhibited by staining a tissue with nitrate of silver. The capillaries vary somewhat in size and in the closeness of their meshes; their arrangement in different parts, which is mainly determined by the disposition of the tissue-elements, may best be studied in injected preparations, and will be described when the structure of the several organs is considered.

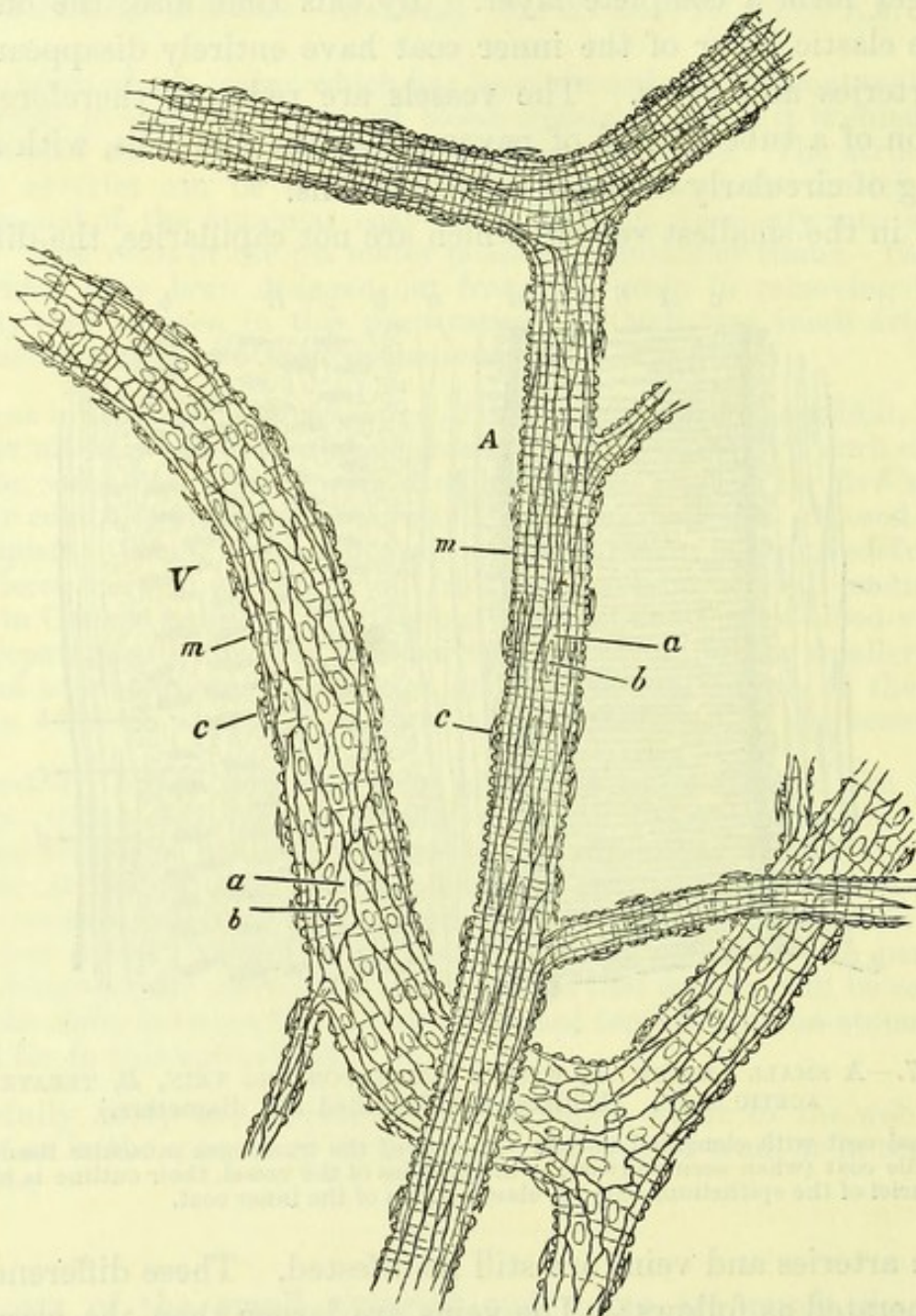


FIG. 138.—A SMALL ARTERY, *A*, AND VEIN, *V*, FROM THE SUBCUTANEOUS CONNECTIVE-TISSUE OF THE RAT, TREATED WITH NITRATE OF SILVER. (175 diameters.)

*a, a*, endothelial cells with *b, b*, their nuclei; *m, m*, transverse markings due to staining of substance between the muscular fibre-cells; *c, c*, nuclei of connective-tissue corpuscles attached to exterior of vessel.

In the transparent parts of animals, the blood may be seen flowing through the capillary network from the arteries into the veins. The



current is very rapid in the small arteries, somewhat less so in the veins, and comparatively slow in the capillaries. The current is fastest in the centre of the vessel, slowest near the wall (inert layer), and with care it may be observed—especially where there is any commencing inflammation of the part, as in the mesentery in consequence of exposure—that the white blood-corpuscles, which always tend to pass into

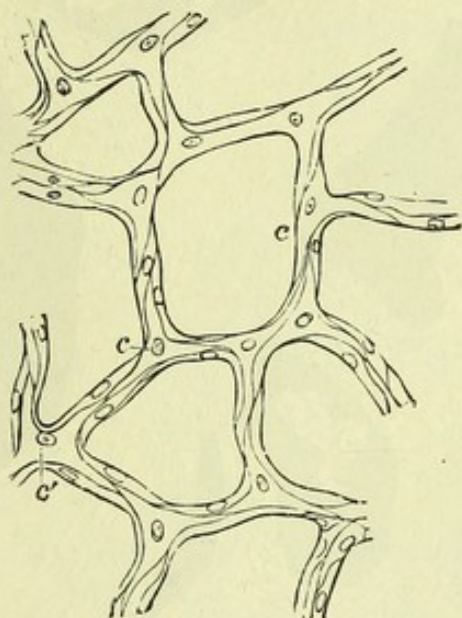


FIG. 139. — CAPILLARY VESSELS FROM THE BLADDER OF THE CAT, MAGNIFIED.

The outlines of the cells are stained by nitrate of silver.

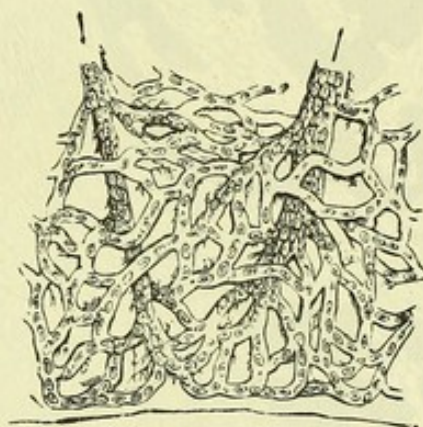

FIG. 140. — CAPILLARY BLOOD-VESSELS IN THE WEB OF A FROG'S FOOT, AS SEEN WITH THE MICROSCOPE. (A. Thomson.)

The arrows indicate the course of the blood.

the inert layer, and to adhere occasionally to the inner surface of the blood-vessels, here and there pass through the coats of the small vessels, and appear as *migratory cells* in the surrounding connective tissue.

### LYMPHATIC SYSTEM.

To the lymphatic system belong not only the *lymphatic vessels* and *lymphatic glands*, but also the *cavities of the serous membranes*, which are moistened with lymph and are in open communication with the lymphatic vessels in their parietes.

The larger **lymphatic vessels** somewhat resemble the veins in structure, except that their coats are much thinner and their valves much more numerous. In lymphatics of somewhat smaller size, the wall of the vessel is formed, first, by a lining of pavement-epithelium cells (lymphatic endothelium), which are elongated in the direction of the axis of the vessel; and, secondly, by a layer of circularly and obliquely disposed muscular fibres. In the smallest vessels (*lymphatic capillaries*, which, however, are generally considerably larger than the blood-



capillaries), there is nothing but the epithelium remaining, and the cells of this are frequently not more elongated in one direction than in another, but have a characteristic wavy outline (fig. 142).

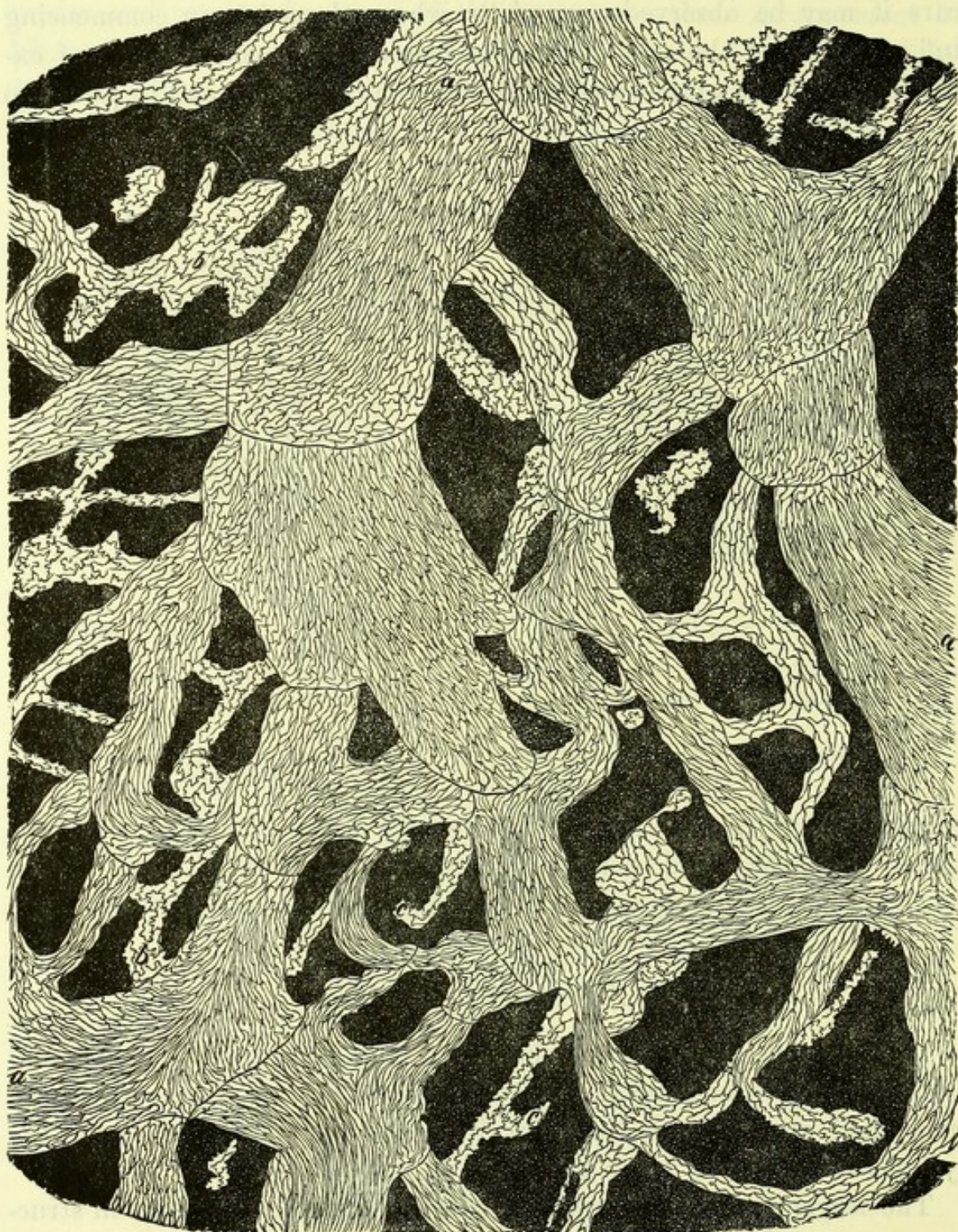


FIG. 141.—LYMPHATIC PLEXUS OF CENTRAL TENDON OF DIAPHRAGM OF RABBIT, PLEURAL SIDE. (Klein.)

*a*, larger vessels with lanceolate cells and numerous valves; *b*, *c*, lymphatic capillaries with wavy-bordered cells.

Lymphatics begin in two ways—either in the form of *plexuses*, as in membranes (fig. 141), or as *lacunar interstices*, as is the case in some of the viscera.



In order to show the lymphatic vessels, it is generally necessary to stain a tissue with nitrate of silver; but they may easily be injected by sticking the nozzle of an injecting canula into any tissue which contains them, and forcing coloured fluid under gentle pressure into the interstices of the tissue.<sup>1</sup>

In silvered preparations it may be observed that the lymphatics always appear in the form of clear channels in the stained ground-

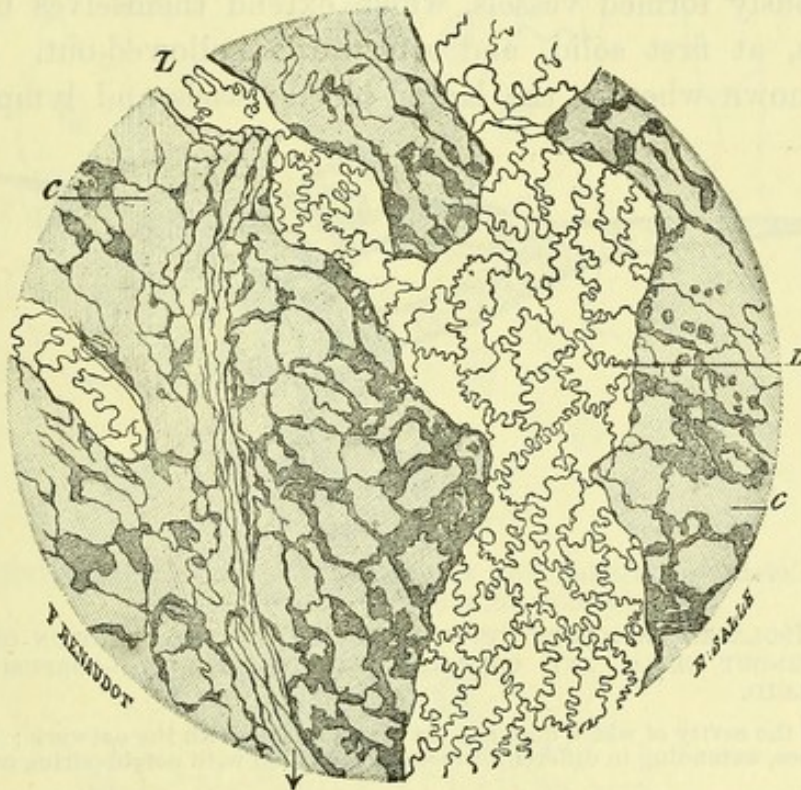


FIG. 142.—A SMALL PART OF THE LYMPHATIC PLEXUS ON THE PLEURAL SURFACE OF THE DIAPHRAGM. (Magnified 110 diameters.) (Ranvier.)

*L*, lymphatic vessel with characteristic epithelium; *c*, cell-spaces of the connective tissue here and there abutting against the lymphatic.

substance of the connective tissue, and that their walls are in close connection with the cells and cell-spaces of that tissue. But, except in the case of the serous membranes, there is no open communication between the lymphatic vessels and the interstices of the connective tissue.

**Development of the blood-vessels and lymphatics.**—The blood-vessels and lymphatics are developed in the connective tissue or in the mesoblastic tissue which precedes it, the first vessels being formed in the vascular area which surrounds the early embryo. Both kinds of vessels are developed from cells (vaso-formative cells or angioblasts) which become hollowed out by an accumulation of fluid in their protoplasm, and in the case of developing blood-vessels coloured blood-

<sup>1</sup> For details of procedure in injecting blood-vessels and lymphatics the student is referred to the author's *Course of Practical Histology*.



corpuscles may also be formed within these cells (see Development of Blood-corpuscles, Lesson II.). The cells branch and unite with one another to form a network, and their cavities extend into the branches. In the meantime their nuclei multiply and become distributed along the branches, cell-areas being subsequently marked out around them. In this way intercommunicating vessels—capillaries containing blood or lymph—are produced (fig. 144). These presently become connected with previously formed vessels, which extend themselves by sending out sprouts, at first solid, and afterwards hollowed-out. It is not precisely known whether the larger blood-vessels and lymphatics are

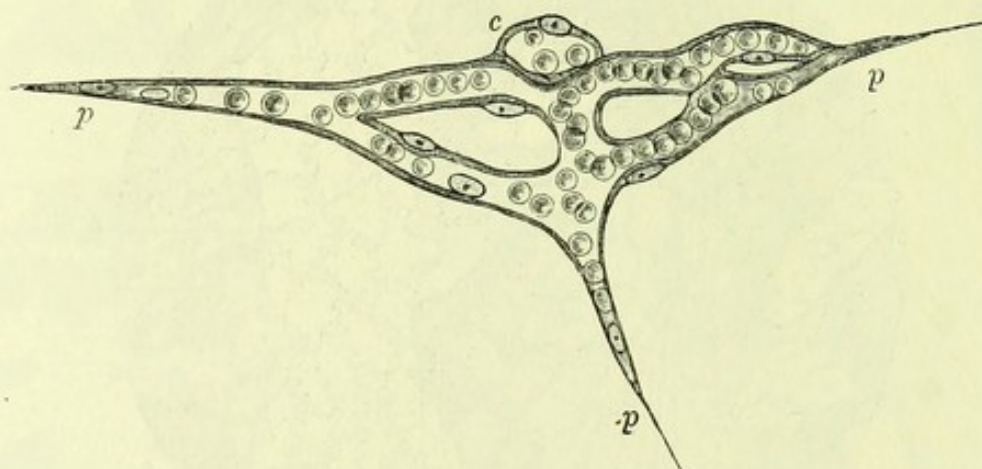


FIG. 143. —ISOLATED CAPILLARY NETWORK FORMED BY THE JUNCTION OF SEVERAL HOLLOWED-OUT CELLS, AND CONTAINING COLOURED BLOOD-CORPUSCLES IN A CLEAR FLUID.

c, a hollow cell the cavity of which does not yet communicate with the network; p, p, pointed cell-processes, extending in different directions for union with neighbouring capillaries.

developed at first as capillaries, the muscular and other tissues being subsequently added, or whether they are formed as clefts in the mesoblastic tissue which become bounded by flattened cells.

#### SEROUS MEMBRANES.

The **serous membranes**, which may be conveniently studied in connection with the lymphatic system, are delicate membranes of connective tissue which surround and line the internal cavities of the body, and are reflected over many of the thoracic and abdominal viscera; in passing to which they form folds, within which blood-vessels, lymphatics, and nerves pass to the viscera.

The inner surface is lined by a continuous layer of *pavement-epithelium* (*serous endothelium*) (fig. 144), which is very distinct in nitrate of silver preparations. In some places there are apertures in the epithelium which lead directly into subjacent lymphatic vessels. These apertures are called *stomata*, and are surrounded by small protoplasmic cells (fig. 145 s, s). They are most numerous upon the



peritoneal surface of the diaphragm, but are present in all serous membranes, and they serve to prevent any undue accumulation of

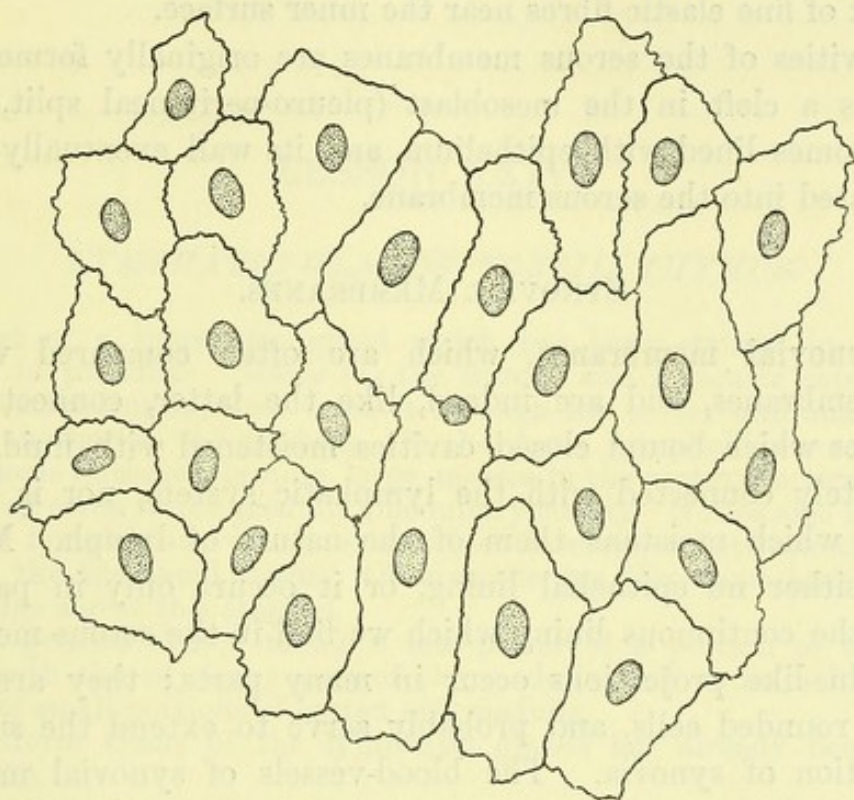


FIG. 144.—ENDOTHELIUM OF THE OMENTUM OF THE RABBIT. NITRATE OF SILVER PREPARATION. (Highly magnified.)

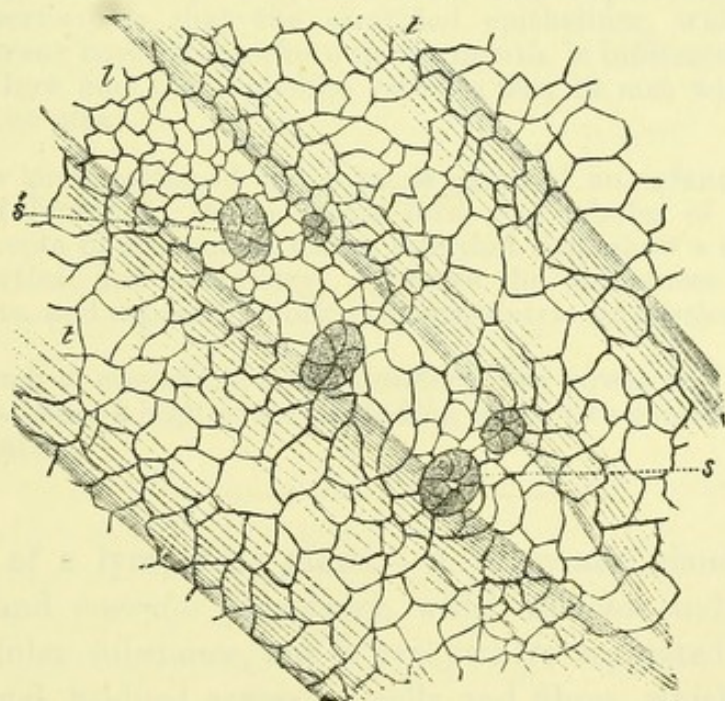


FIG. 145.—SMALL PORTION OF PERITONEAL SURFACE OF DIAPHRAGM OF RABBIT, STAINED WITH NITRATE OF SILVER TO SHOW THE SEROUS EPITHELIUM. (Klein.)

*t*, lymph-channel below the surface, lying between tendon bundles, *t*, *t*, and over which the surface-cells are seen to be relatively smaller, and to exhibit five stomata, *s*, *s*, leading into the lymphatic. The endothelium of the lymphatic channel is not represented.

lymph within the serous cavity during health. The pavement-epithelium rests upon a homogeneous basement-membrane, which is



especially well marked in the serous membranes of man. The rest of the thickness of the membrane is composed of connective tissue, with a network of fine elastic fibres near the inner surface.

The cavities of the serous membranes are originally formed in the embryo as a cleft in the mesoblast (pleuro-peritoneal split, coelom) which becomes lined with epithelium, and its wall eventually becomes differentiated into the serous membrane.

#### SYNOVIAL MEMBRANES.

The **synovial membranes**, which are often compared with the serous membranes, and are indeed, like the latter, connective-tissue membranes which bound closed cavities moistened with fluid, are not so intimately connected with the lymphatic system, nor is the fluid (synovia) which moistens them of the nature of lymph. Moreover, there is either no epithelial lining, or it occurs only in patches, in place of the continuous lining which we find in the serous membranes. Long villus-like projections occur in many parts; they are covered by small rounded cells, and probably serve to extend the surface for the secretion of synovia. The blood-vessels of synovial membranes are numerous, and approach close to the inner surface of the membrane.



## LESSON XXIV.

*LYMPHATIC GLANDS, TONSIL, THYMUS.*

1. SECTIONS of a lymphatic gland which has been stained in bulk and embedded in paraffin.<sup>1</sup> Notice (1) the fibrous and muscular capsule, with trabeculae extending inwards from it through the cortex and anastomosing with one another in the medulla, (2) the dense lymphoid tissue (adenoid tissue of some authors) forming large masses in the cortex (cortical nodules) and rounded cords in the medulla (medullary cords). Notice also the clearer channel or lymph-sinus which everywhere intervenes between the fibrous tissue and the lymphoid tissue. Observe the fine fibres and branched cells which bridge across this channel.

Make a general sketch under a low power of a portion of the cortex together with the adjoining part of the medulla, and under a high power drawings of small portions of cortex and medulla.

The retiform tissue of the lymphatic glands has already been studied (Lesson IX.).

2. In sections of tonsil prepared similarly to those of the lymphatic gland, notice the large amount of lymphoid tissue only imperfectly collected into nodules. Observe also that the stratified epithelium, which covers the mucous membrane here as elsewhere in the mouth, is infiltrated with lymph-corpuscles. Here and there pit-like recesses may be met with, and glands opening into the pits.

3. A similar preparation of the thymus gland of an infant. Notice that the masses of lymphoid tissue which form the lobules of the gland are separated by septa of connective tissue, and that they show a distinction into two parts, cortical and medullary. Observe the differences of structure of these two parts, and especially notice the concentric corpuscles in the medullary part.

Make a sketch of one of the lobules under a low power and of a small part of the medulla under a high power, including one or two concentric corpuscles. Measure the latter.

---

**Structure of a lymphatic gland.**—A lymphatic gland is composed of a *fibrous and muscular framework*, which incloses and supports the proper glandular substance, but is everywhere separated from it by a narrow channel, bridged across by cells and fibres, which is known as the *lymph-channel*. The *framework* consists of an envelope or *capsule* (fig. 146, *c*), and of *trabeculae* (*tr*), which pass at intervals inwards from the capsule, and after traversing the cortex of the gland divide and reunite with one another so as to form a network of fibrous bands. At

<sup>1</sup> See Appendix.



one part of the gland there is usually a depression (*hilum*), and at the bottom of this the medulla comes to the surface and its fibrous bands are directly continuous with the capsule.

The proper *glandular substance* (*l.h*) is composed of lymphoid tissue, *i.e.* a fine reticulum with the meshes thickly occupied by lymph-corpuscles. It occupies all the interstices of the gland, forming comparatively large rounded masses in the cortex (lymphoid nodules, *C*) between the trabeculae, and smaller reticulating cord-like masses (lymphoid cords, *M*) in the medulla.

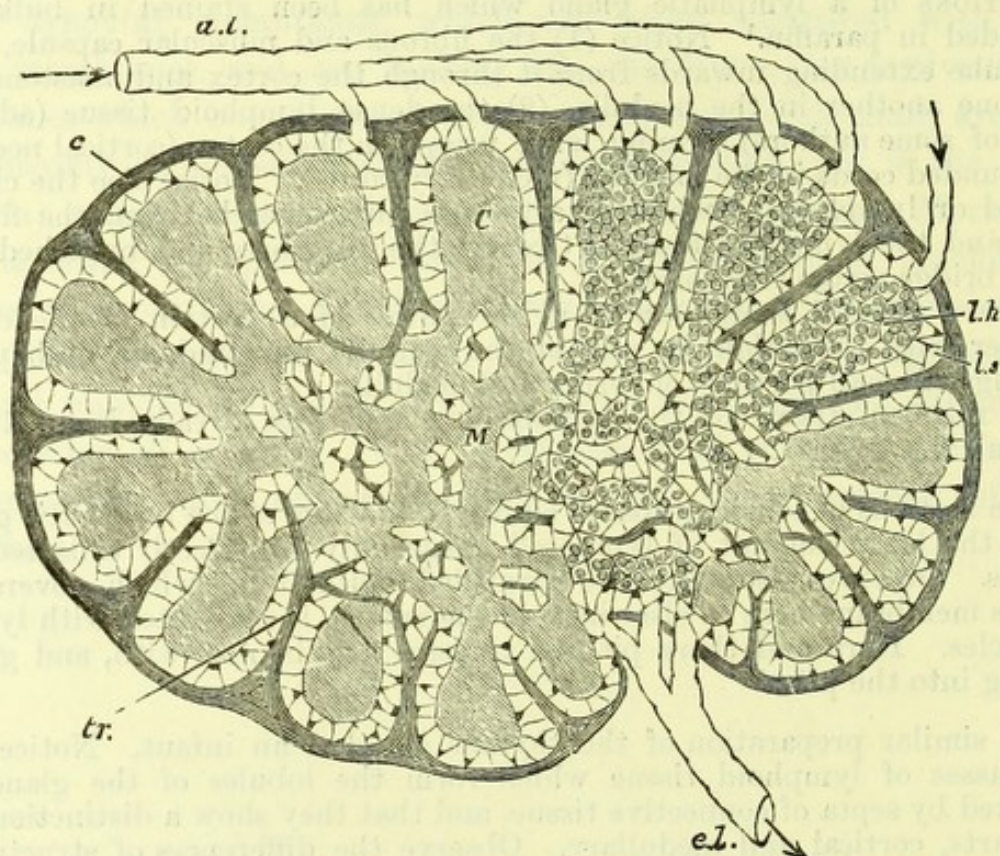


FIG. 146.—DIAGRAMMATIC SECTION OF LYMPHATIC GLAND. (Sharpey.)

*a.l.*, afferent, *e.l.*, efferent lymphatics; *C*, cortical substance; *M*, reticulating cords of medullary substance; *l.h.*, lymphoid tissue; *l.s.*, lymph-sinus; *c*, fibrous coat sending trabeculae, *tr.*, into the substance of the gland.

The cells which bridge across the lymph-channel in the medulla (fig. 147, *c*) are branching nucleated cells which often contain pigment, so that this part of the gland has a dark colour. The lymph-channel is bridged across not only by these, but also by fibres derived from the capsule and trabeculae, which pass to the lymphoid tissue and become lost in its reticulum. But these fibres are often covered and concealed by the branched cells.

Lymphatic vessels (fig. 146, *a.l.*) enter the lymph-channels after passing through the capsule, and the lymph is conveyed slowly along the channels of the cortical and medullary part towards the hilum, taking up many lymph-corpuscles in its passage. At the hilum it is



gathered up by an efferent vessel or vessels (*e.l.*) which take origin in the lymph-sinuses of the medulla.

The efferent lymphatics always contain many more lymph-corpuscles than those which enter the gland, for lymph-corpuscles are constantly being formed by indirect division of the pre-existing cells in the glandular substance, and especially in the cortical nodules (Flemming), and gradually find their way into the lymph-channel.

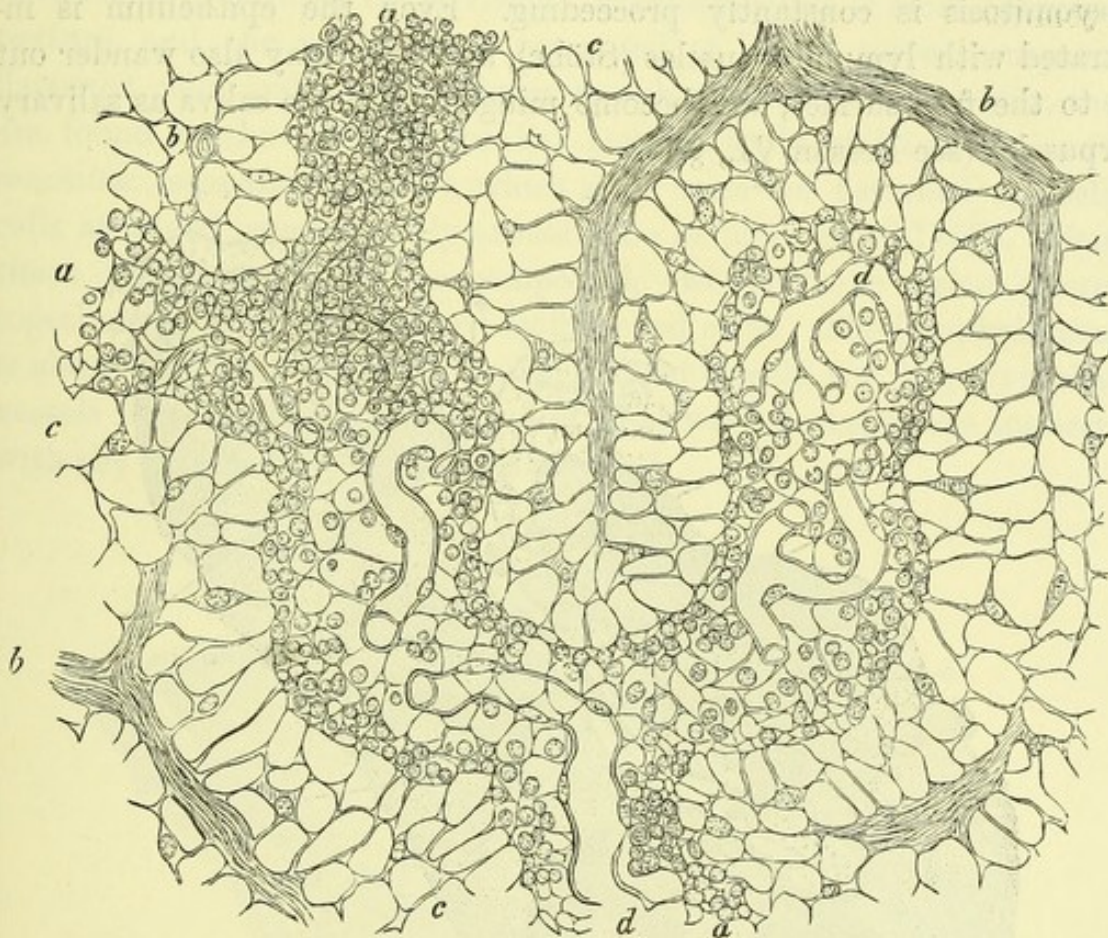


FIG. 147.—SECTION OF THE MEDULLARY SUBSTANCE OF A LYMPHATIC GLAND. (300 diameters.) (Recklinghausen.)

*a, a, a*, lymphoid cords; *c*, lymph-sinus; *b, b*, trabeculae; *d, d*, capillary blood-vessels.

An artery passes into each gland at the hilum; its branches are conveyed at first along the fibrous cords, but soon pass into the lymphoid tissue, where they break up into capillaries (fig. 147, *d*). The blood is returned by small veins, which are conducted along the fibrous trabeculae to the hilum again.

In some lymphatic glands the fibrous trabeculae are very slightly developed.

The **tonsils** are two masses of lymphoid tissue placed one on each side of the pharynx, into which they project. They are covered on the free surface with the stratified epithelium of the mucous membrane, and this surface is pitted with apertures which lead into recesses



or crypts in the substance of the organ (fig. 148). These recesses are all lined by a prolongation of the stratified epithelium, and into them the ducts of numerous small mucous glands open. The tonsils are composed almost entirely of lymphoid tissue, which, besides being diffused over the whole organ, is at intervals aggregated into small nodules, in which the lymph-cells are more closely arranged than elsewhere. In these nodules active multiplication of the lymph-cells by karyomitosis is constantly proceeding. Even the epithelium is infiltrated with lymph-corpuscles (Stöhr), and they may also wander out on to the free surface, and become mingled with the saliva as salivary corpuscles (see Lesson VI., § 1).

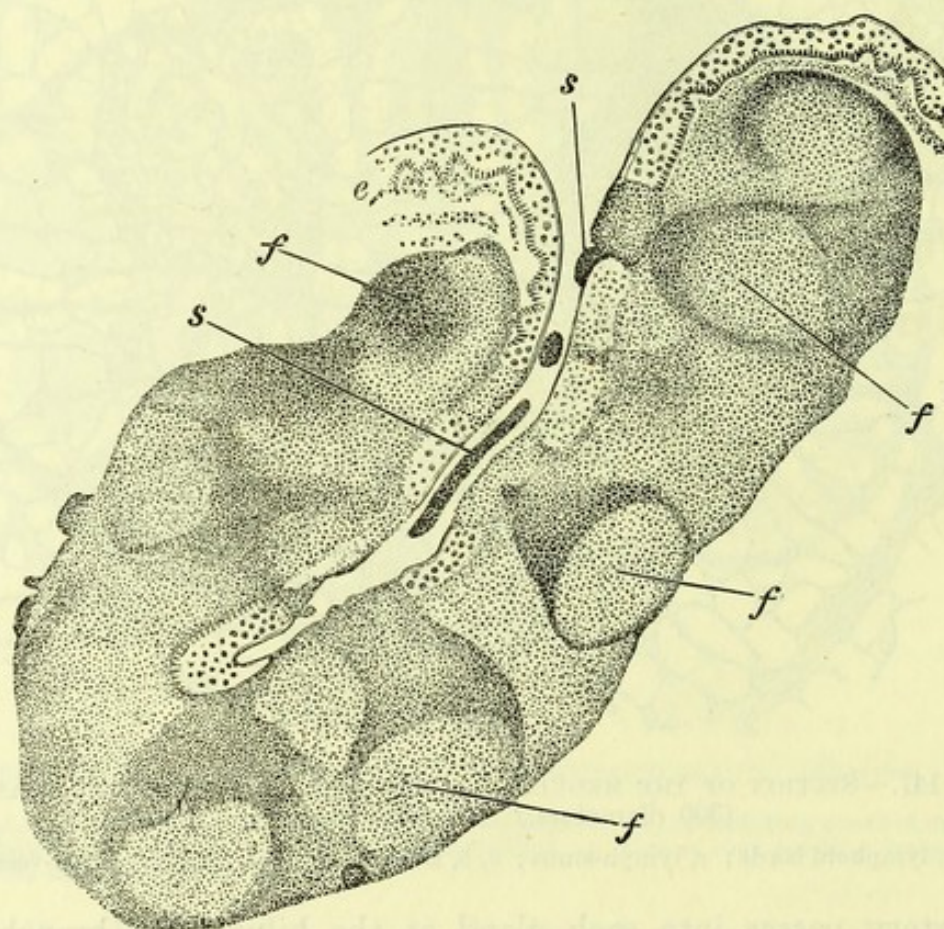


FIG. 148.—SECTION THROUGH ONE OF THE CRYPTS OF THE TONSIL. (Stöhr.)

*e, e*, stratified epithelium of surface of mucous membrane, continued into crypt; *f, f*, follicles or nodules of the lymphoid tissue, which is elsewhere diffuse; opposite each nodule numbers of lymph-cells are passing through the epithelium; *s*, masses of cells which have thus escaped from the organs to mix with the saliva as salivary corpuscles.

The mucous membrane of the neighbouring part of the pharynx and of the back of the tongue is similar in structure to the tonsils.

The **thymus gland** is a lymphoid organ which is found only in the embryo and during infancy. It is composed of a number of larger and smaller lobules (fig. 149), which are separated from one another by



septa of connective tissue, along which the blood-vessels and lymphatics pass to and from the lobules. Each lobule shows plainly, when examined with the low power, a distinction into an outer cortical and an inner medullary portion. The cortical part of the lobule is imperfectly divided into nodules by trabeculæ of connective tissue, and is very similar in structure to the lymphoid tissue of the lymphatic glands and tonsils, with which it also agrees in exhibiting numerous indications of indirect cell-division; but the medulla is more open in its texture, and the reticulum is composed of larger, more transparent, flattened cells, and contains fewer lymph-corpuscles. Moreover, there are found in the medulla peculiar concentrically striated bodies (the *concentric corpuscles*, fig. 150), which are "nests" of flattened epithelial-cells arranged concentrically around one or more central cells. Sometimes these corpuscles are compound, two or three being grouped together and similarly inclosed by flattened cells. The lymphoid tissue is abundantly supplied with capillary blood-vessels, and large lymphatic vessels issue from the organ, but in what way the latter are connected with the lobules has not been ascertained.

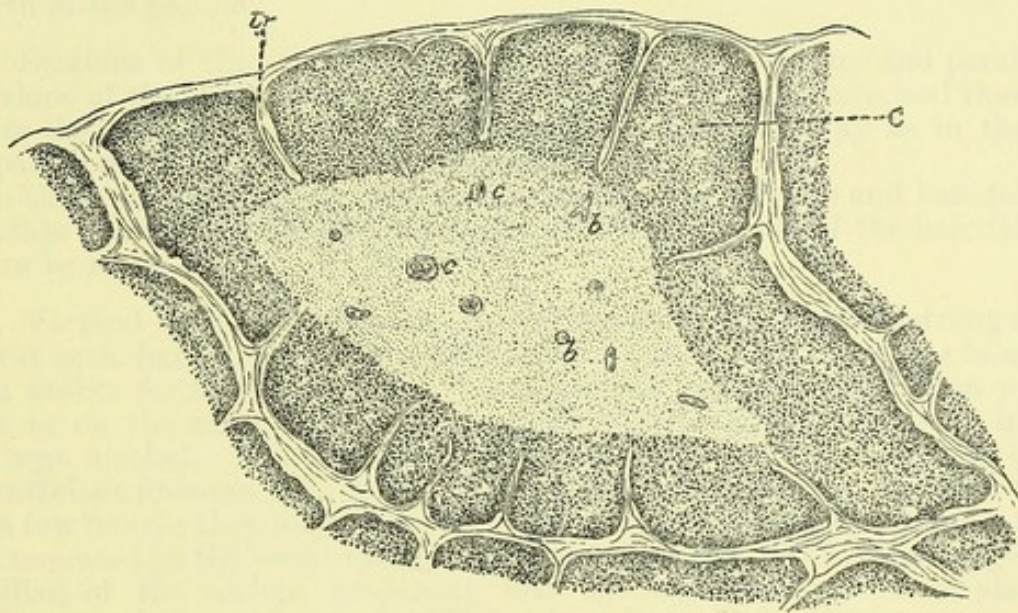


FIG. 149.—A LOBULE OF THE THYMUS OF A CHILD, AS SEEN UNDER A LOW POWER.

c, cortex; c, concentric corpuscles within medulla; b, blood-vessels; tr, trabeculæ.

Lymphoid tissue occurs in many other parts of the body in addition to the lymphatic glands, tonsils, and thymus gland, although it may not, as in these structures, constitute the bulk of the organ. Thus it is found in many mucous membranes, such as those of the intestine and of the respiratory tract, both in a diffuse form and also collected into



nodular masses which are like the cortical nodules of a lymphatic gland, and may, like those, be partially surrounded by a lymph-sinus.

In the spleen also a large amount of lymphoid tissue is found sheathing the smaller arteries, and also expanded into nodular masses (*Malpighian corpuscles of the spleen*). In these organs it will be studied subsequently.

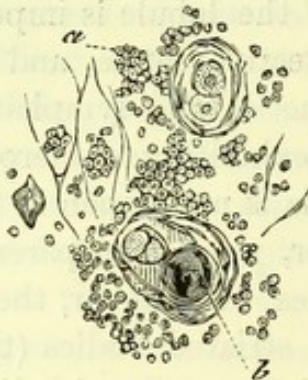

FIG. 150.—ELEMENTS OF THE THYMUS. (300 diameters.) (Cadiat.)

a, lymph-corpuscles; b, concentric corpuscle.

Lymphoid tissue also occurs in considerable amount in the serous membranes, especially in young animals; in the adult it is often transformed into adipose tissue. The tissue is generally developed in connection with lymphatic vessels, an accumulation of retiform tissue and lymph-cells taking place either external to and around the lymphatic (*perilymphatic nodule*); or the lymphatic is dilated into a sinus and the formation of lymphoid tissue occurs within it (*endolymphatic nodule*).



## LESSON XXV.

## THE SKIN.

1. SECTIONS of skin from the palmar surface of the fingers. The sections are to be made vertical to the surface, and should extend down as far as the subcutaneous tissue. They may be stained with hæmatoxylin or picro-carmin and mounted in Canada balsam. In these sections notice the layers of the epidermis and their different behaviour to the staining fluid. Notice also the papillæ projecting from the corium into the epidermis and look for tactile corpuscles within them. In very thin parts of the sections the fine intercellular channels in the deeper parts of the epithelium (see Lesson VI., p. 27) may be seen with a high power. The convoluted tubes of the sweat-glands will be seen here and there in the deeper parts of the corium, and in thick sections the corkscrew-like channels by which the sweat is conducted through the epidermis may also be observed. Make a sketch showing the general structure under a low power, and other sketches to exhibit the most important details under a high power. Measure the thickness of the epidermis and the length of the papillæ.

2. Sections of the skin of the scalp, vertical to the surface and parallel to the slope of the hair-follicles, and others parallel to the surface, and therefore across the hair follicles. Stain and mount in the same way as in the last preparation. Examine also the structure of the hairs.

In these preparations the details of structure of the hairs and hair-follicles together with the sebaceous glands and the little muscles of the hair-follicles are to be made out.

3. Vertical sections across the nail and nail-bed, cut with a strong razor. To cut such hard structures as the nail it is best to soak the tissue in strong gum arabic for a few days, then place it in an appropriate position upon a cork or on the object-carrier of a microtome, and plunge the whole into 70 per cent. alcohol. This renders the gum hard, and enables sections to be cut of sufficient fineness. To remove the gum the sections are placed in water for a few hours; they may then be stained with hæmatoxylin or picro-carmin and mounted in the usual manner in Canada balsam. Notice the ridges (not papillæ) of the corium projecting into the epidermis. Observe also the distinction of the epidermis into Malpighian layer and nail proper.

4. Mount in Canada balsam a section from a portion of skin of which the blood-vessels have been injected, and notice the distribution of the capillaries to the sweat-glands, to the hair-follicles, and to the papillary surface of the corium.

The skin is composed of two parts, *epidermis* and *cutis vera*.

The *epidermis*, or scarf skin, is a stratified epithelium (fig. 151). It is composed of a number of layers of cells, the deeper of which are soft and protoplasmic, and form the *rete mucosum* of Malpighi, whilst the



superficial layers are hard and horny, this horny portion sometimes constituting the greater part of the thickness of the epidermis. The deepest cells of the *rete mucosum*, which are set on the surface of the cutis vera, are columnar (fig. 151, *c*) in shape. In the coloured races of mankind these cells contain pigment-granules. In the layers immediately above them the cells are polyhedral (fig. 151, *p*). Between all these cells of the *rete mucosum* there are fine intercellular clefts which separate the cells from one another, but are bridged across by fine fibres, which pass from cell to cell, and also through the substance of the cells (Ranvier, Delépine). The intercellular channels serve for the passage of lymph, and within them occasionally lymph-corpuscles may be found, often having a stellate figure from compression.

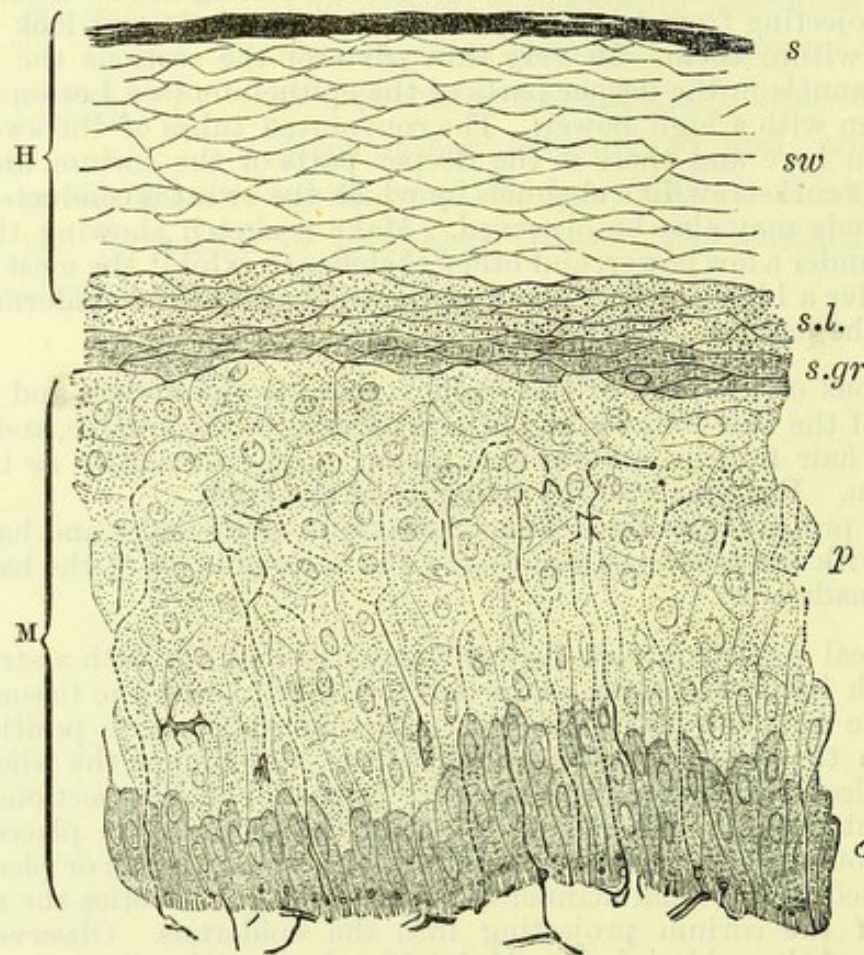


FIG. 151.—SECTION OF EPIDERMIS. (Ranvier.)

H, horny layer, consisting of *s*, superficial horny scales; *sw*, swollen-out horny cells; *s.l.*, stratum lucidum; M, rete mucosum or Malpighian layer, consisting of *p*, prickle-cells, several rows deep; *c*, elongated cells forming a single stratum near the corium; and *s.gr*, stratum granulosum of Langerhans, just below the stratum lucidum; *n*, part of a plexus of nerve-fibres in the superficial layer of the cutis vera. From this plexus fine varicose nerve-fibrils may be traced passing up between the epithelium-cells of the Malpighian layer.

The most superficial layer of the rete mucosum is formed of somewhat flattened granular-looking cells (*stratum granulosum*, fig. 151, *s.gr*; fig. 152, *c*). Immediately above this layer, the *horny part* of the



epidermis commences, as a layer of clear compressed cells several deep (*stratum lucidum*, *s.l.*). Above this comes the main part of the horny layer. It is composed of a number of layers of somewhat swollen cells (*epitrichial stratum*, *sw*), the nuclei of which are no longer visible. These cells are replaced near the surface by thin horny scales (*stratum squamosum*), which eventually become detached (*s*). The epitrichial stratum is only found in certain parts which have a thick epidermis and are not covered with hair (*e.g.* the palms and soles). In the embryo it covers the whole body, but is thrown off when the hairs are developed.

The growth of the epidermis takes place by a multiplication of the cells of the deepest layer. The newly formed cells, as they grow, push towards the surface those which were previously formed, and in their progress the latter undergo a chemical transformation, which converts their protoplasm into horny material: this change seems to occur just above the stratum granulosum (see fig. 152). The granules which occupy the cells of the last-mentioned layer are composed of a substance termed *eleidin*, which according to Ranvier is transformed into keratin.

No blood-vessels pass into the epidermis, but it receives nerves which ramify between the cells of the rete mucosum in the form of fine varicose fibrils (fig. 151).

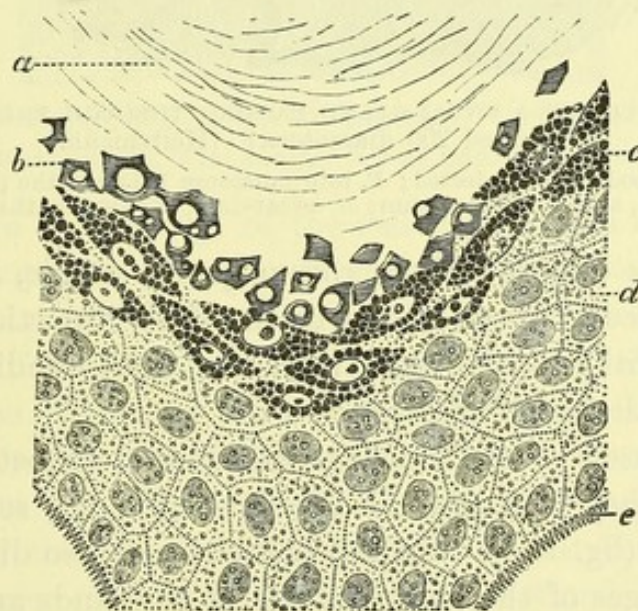


FIG. 152.—PORTION OF EPIDERMIS FROM A SECTION OF THE SKIN OF THE FINGER, COLOURED WITH PICROCARMINATE OF AMMONIA. (Ranvier.)

*a*, stratum corneum; *b*, stratum lucidum with diffused flakes of eleidin; *c*, stratum granulosum, the cells filled with drops of eleidin; *d*, prickle-cells; *e*, dentate projections by which the deepest cells of the epidermis are fixed to the cutis vera.

The *cutis vera* or corium is composed of dense connective-tissue, which becomes more open and reticular in its texture in its deeper part, where it merges into the subcutaneous tissue. It is thickest over



the posterior aspect of the trunk, whereas the epidermis is thickest on the palms of the hands and soles of the feet. The superficial or vascular layer of the corium bears minute *papillæ*, which project up into the epidermis, which is moulded over them. These papillæ for the most part contain looped capillary vessels (fig. 153), but some, especially those of the palmar surface of the hand and fingers, and the corresponding part of the foot, contain tactile corpuscles, to which medullated nerve-fibres pass (fig. 114, *b*, p. 99).

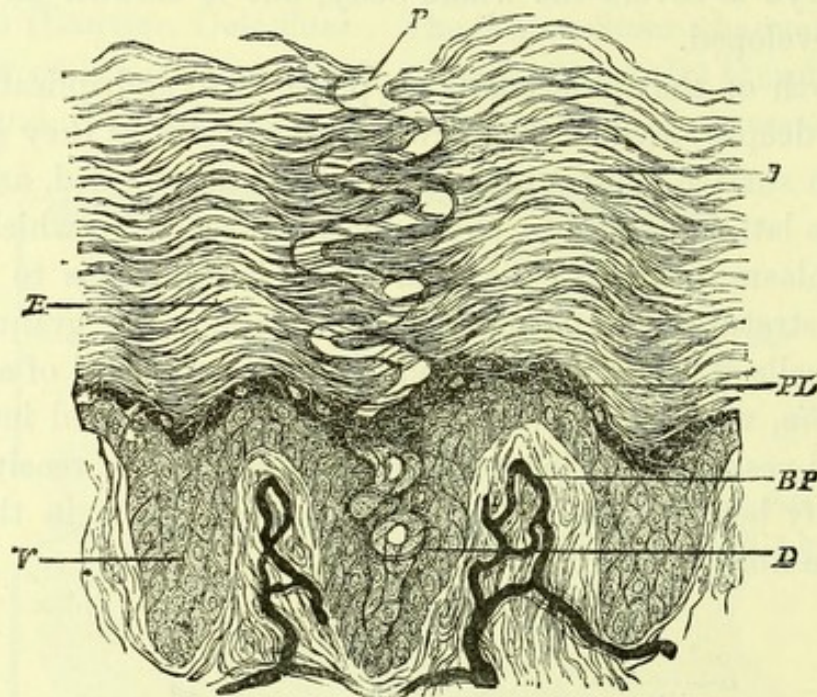


FIG. 153.—DUCT OF A SWEAT-GLAND PASSING THROUGH THE EPIDERMIS.  
(Magnified 200 diameters.) (Heitzmann.)

*BP*, papillæ with blood-vessels injected; *V*, rete mucosum between the papillæ; *E*, stratum corneum; *PL*, stratum granulosum; *D*, sweat-duct, opening on the surface at *p*.

In some parts of the body (scrotum, penis, nipple, and its areola), involuntary muscular tissue occurs in the deeper portions of the cutis vera, and in addition, wherever hairs occur, small bundles of this tissue are attached to the hair-follicles.

The blood-vessels of the skin are distributed almost entirely to the surface, where they form a close capillary network, sending up loops into the papillæ (fig. 153). Special branches are also distributed to the various appendages of the skin, viz. the sweat-glands and hair-follicles, with their sebaceous glands and little muscles, as well as to the little masses of adipose tissue which may be found in the deeper parts of the cutis.

The lymphatics originate near the surface in a network of vessels, which is placed a little deeper than the blood-capillary network. They receive branches from the papillæ, and pass into larger vessels, which are valved, and which run in the deeper or reticular part of the corium.



From these the lymph is carried away by still larger vessels, which course in the subcutaneous tissue.

The **appendages of the skin** are the *nails*, the *hairs*, with their *sebaceous glands* and the *sweat-glands*. They are all developed as thickenings and downgrowths of the Malpighian layer of the epidermis.

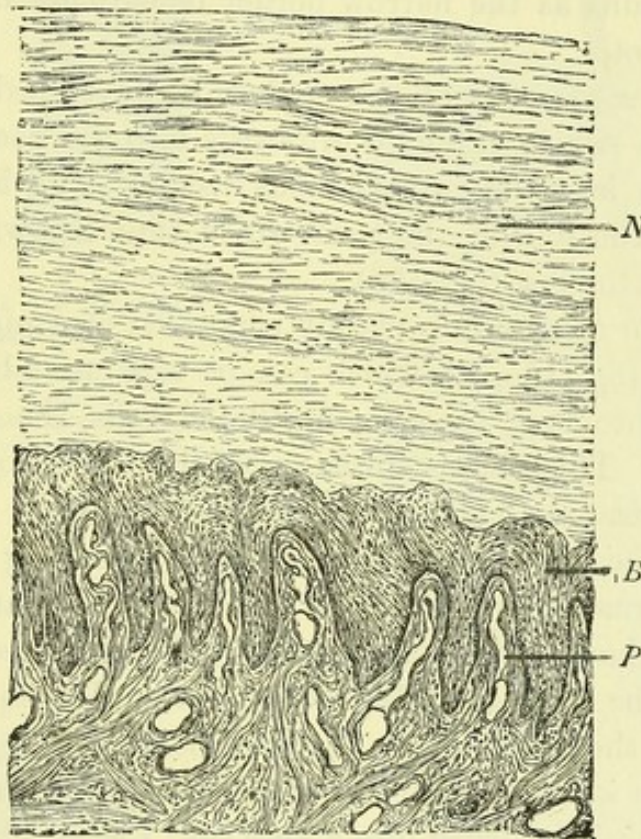


FIG. 154.—SECTION ACROSS THE NAIL AND NAIL-BED. (100 diameters.) (Heitzmann.)

*P*, ridges with blood-vessels; *B*, rete mucosum; *N*, nail.

The **nails** are thickenings of the stratum lucidum of the epidermis, which are developed over a specially modified portion of the corium, which is known as the *bed* or *matrix of the nail*, the depression at the posterior part of the nail-bed from which the root of the nail grows being known as the *nail-groove*. The distal part of the nail forms the *free border*, and is the thickest part of the body of the nail. The substance of the nail (fig. 154, *N*) is composed of clear horny cells, each containing the remains of a nucleus; it rests immediately upon a Malpighian layer (*B*) similar to that which is found in the epidermis generally. The corium of the nail-bed is beset with longitudinal ridges instead of the papillæ which are present over the rest of the skin; these, like the rest of the superficial part of the corium, are extremely vascular. The nails are developed in the fœtus at about the third month, the groove being formed at this time in the corium, and the nail-rudiment appearing in it as a thickening of the stratum lucidum, which lies over the bed. It becomes free in the sixth month,



its free end being at first thin, but as it grows forward over the bed it appears to receive additions on its under surface—at least in the posterior part of the bed—so that after a time the distal end becomes thicker. The epitrichial layer of the cuticle which originally covered the developing nail becomes detached about the fifth month, and, after birth, only remains as the narrow border of cuticle which overlies the *lunula* at the root.

The hairs are growths of the epidermis, developed in little pits—the *hair-follicles*—which extend downwards into the deeper part of the corium, or even into the subcutaneous tissue. The hair grows from the bottom of the follicle, the part which thus lies within the follicle being known as the *root* (fig. 156).

The substance of a hair is mainly composed of a pigmented, horny, *fibrous material* (fig. 155, *f*), which can be separated by the action of sulphuric acid into long tapering fibrillated cells, the nuclei of which are still visible. This fibrous substance of the hair is covered by a layer of delicate imbricated scales termed the *hair-cuticle* (*c*). In many hairs, but not in all, the centre is occupied by a dark-looking axial substance (*medulla*, *m*), formed of angular cells which contain granules of eleidin, and frequently have a dark appearance from the presence of minute air-bubbles. The latter may also occur in interstices in the fibrous substance. When they are present, the hair looks white by reflected light. The *root* has the same structure as the body of the hair, except at its extremity, which is enlarged into a *knob* (fig. 156, *b*); this is composed mainly of soft, growing cells, and fits over a vascular *papilla* (*p*), which projects up into the bottom of the follicle. The follicle, like the skin itself, of which it is a recess, is composed of two parts: one epithelial, and the other connective tissue. The epithelial or epidermic part of the follicle closely invests the hair-root, and is often in great part dragged out with it; hence it is known as the *root-sheath*. It consists of an outer layer of soft columnar and polyhedral cells, like the Malpighian layer of the epidermis—the *outer root-sheath* (figs. 156, *f*; 157, *e*); and of an inner, thinner, horny stratum next the hair—the *inner root-sheath* (figs. 156, *g*; 157, *f*). The inner root-sheath itself consists of three layers, the outermost being composed of oblong cells without nuclei (*Henle's layer*), the next of flattened polyhedral nucleated cells (*Huxley's layer*), and the third—the *cuticle of the root-sheath*—being a thin layer of downwardly imbricated scales, which fit over the upwardly imbricated scales of the hair itself.

The connective tissue or dermic part of the hair-follicle (fig. 157, *a*, *c*, *d*) is composed internally of a vascular layer, separated from the root-sheath by a basement-membrane termed the *hyaline layer* of the



follicle. This inner vascular layer corresponds to the superficial layer

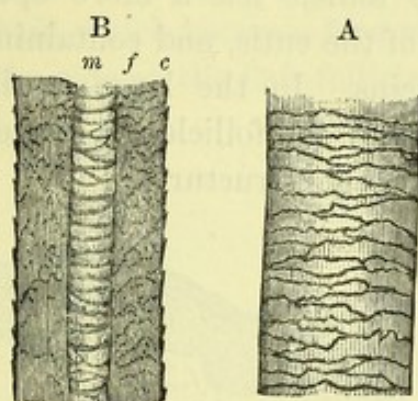


FIG. 155.—PIECE OF HUMAN HAIR. (Magnified.)

A, seen from the surface; B, in optical section. *c*, cuticle; *f*, fibrous substance; *m*, medulla, the air having been expelled by Canada balsam.

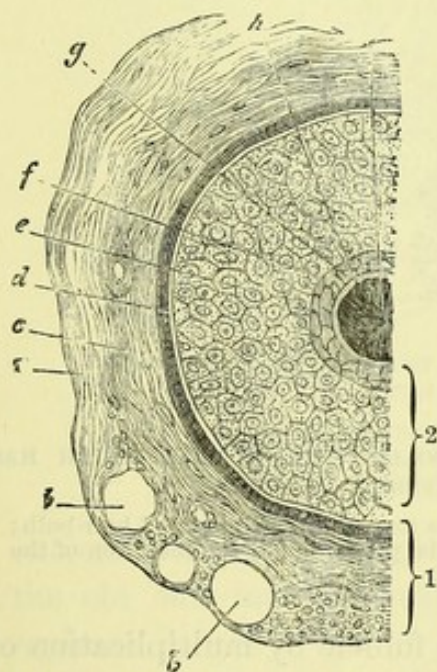


FIG. 157.—SECTION OF HAIR-FOLLICLE. (Biesiadecki.)

1, dermic coat of follicle; 2, epidermic coat or root-sheath. *a*, outer layer of dermic coat, with blood-vessels, *b*, cut across; *c*, middle layer; *d*, inner or hyaline layer; *e*, outer root-sheath; *f*, *g*, inner root-sheath; *h*, cuticle of root-sheath; *l*, hair.

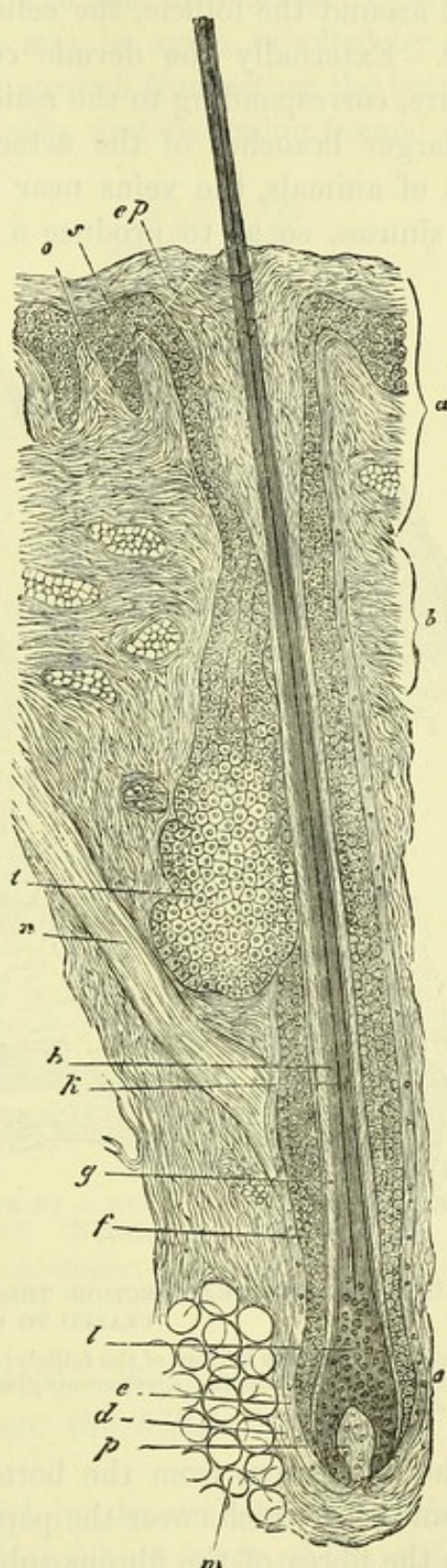


FIG. 156.—HAIR-FOLLICLE IN LONGITUDINAL SECTION. (Biesiadecki.)

*a*, mouth of follicle; *b*, neck; *c*, bulb; *d*, *e*, dermic coat; *f*, outer root-sheath; *g*, inner root-sheath; *h*, hair; *k*, its medulla; *l*, hair-knob; *m*, adipose tissue; *n*, hair-muscle; *o*, papilla of skin; *p*, papilla of hair; *s*, rete mucosum, continuous with outer root-sheath; *ep*, horny layer; *t*, sebaceous gland.



of the cutis vera. Its fibres and cells have a regular circular arrangement around the follicle, the cells being flattened against the hyaline layer. Externally the dermic coat of the follicle has a more open texture, corresponding to the reticular part of the cutis, and containing the larger branches of the arteries and veins. In the large tactile hairs of animals, the veins near the bottom of the follicle are dilated into sinuses, so as to produce a kind of erectile structure.

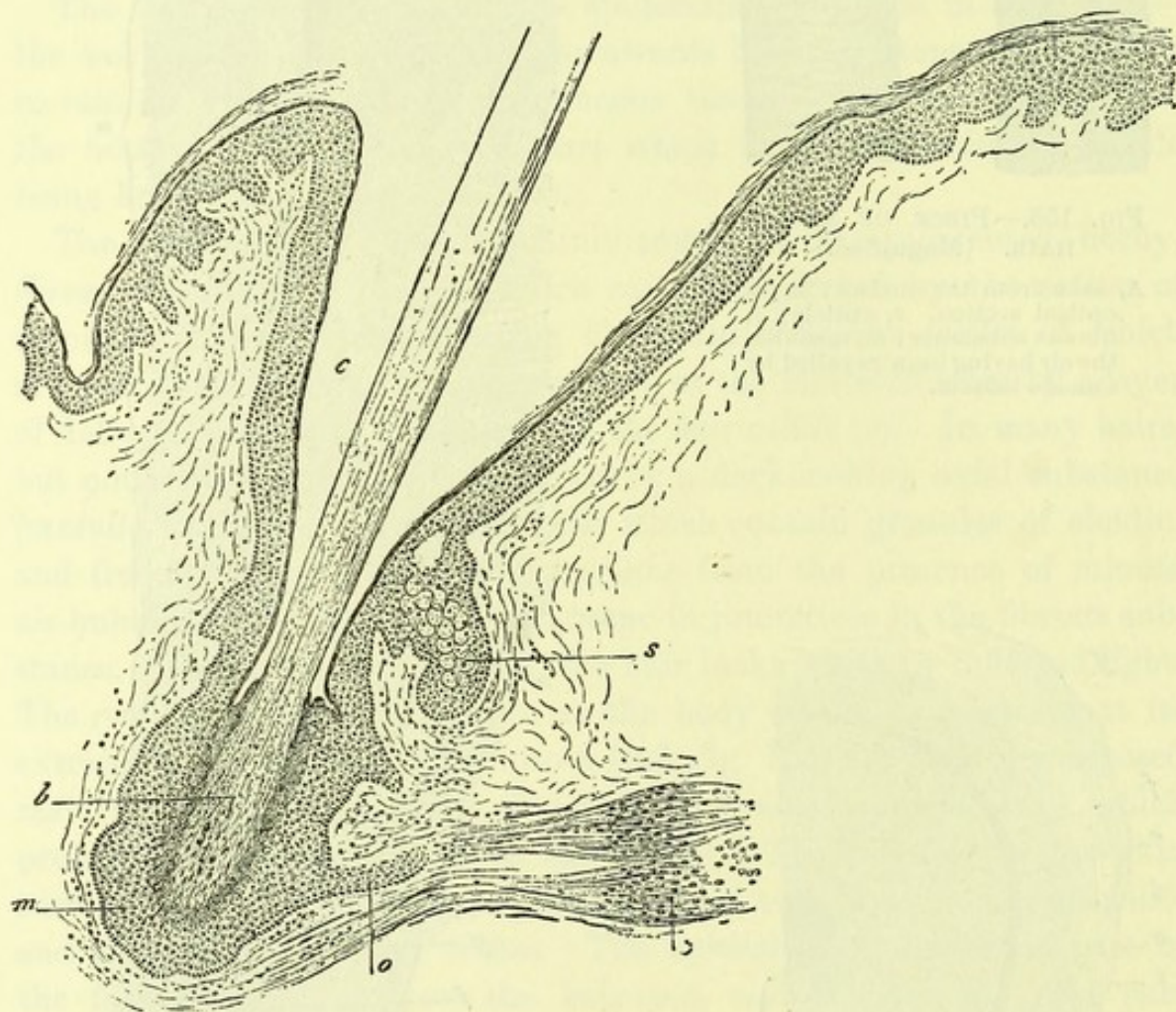


FIG. 158.—LONGITUDINAL SECTION THROUGH THE FOLLICLE OF A HAIR WHICH HAS CEASED TO GROW. (Ranvier.)

*m*, epithelium at the bottom of the follicle (which contains no papilla); *b*, modified hair-bulb; *c*, neck of the follicle; *s*, sebaceous gland; *o*, epithelial projection at the insertion of the arrector pili.

The hair grows from the bottom of the follicle by multiplication of the soft cells which cover the papilla, these cells becoming elongated to form the fibres of the fibrous substance, and otherwise modified to produce the medulla and cuticle.

When a hair is eradicated, a new hair is produced from these cells. It is not uncommon to find hair-follicles in which the whole of the lower part has degenerated in such a way that the vascular papilla, and the soft, growing cells which cover it, may have entirely disappeared, the



hair-bulb being now attached at its sides as well as below to the epithelium of the follicle (fig. 158). The hair then ceases to grow, and eventually becomes lost, but its place may be again supplied by a new hair, which becomes formed in a downgrowth from either the bottom or the side of the hair-follicle, a new papilla first becoming formed at the

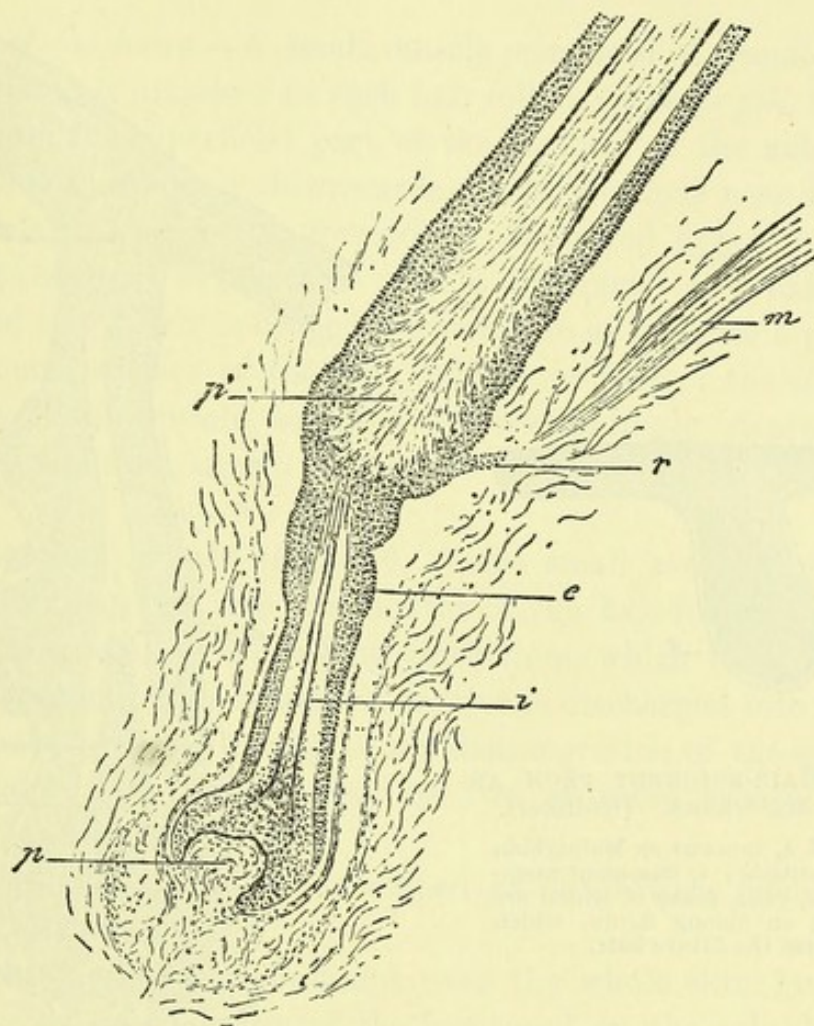


FIG. 159.—REPLACEMENT OF OLD HAIR BY A NEWLY-DEVELOPING ONE IN THE HUMAN SCALP. (Ranvier.)

*p*, papilla of the new hair; *i*, its inner root-sheath; *e*, its outer root-sheath; *p'*, attached lower extremity of the old hair; *r*, epithelial projection at insertion of arrector pili, *m*.

extremity of the downgrowth (fig. 159). If not previously detached, the old hair may be pushed from out the follicle by the one which replaces it.

The hairs are originally developed in the embryo in the form of small solid downgrowths from the Malpighian layer of the epidermis (fig. 160). The hair-rudiment, as it is called, is at first composed entirely of soft, growing cells; but presently those in the centre become differentiated, so as to produce a minute hair invested by inner root-sheath, and its base resting upon a papilla which has grown up into the extremity of the hair-rudiment from the corium (fig. 161, *p*). As



the minute hair grows, it pushes its way through the layers of the epidermis, which it finally perforates, the epitrichial layer being thrown off (p. 129). The hair-rudiments commence at the third or fourth month of foetal life; their growth is completed about the fifth or sixth month, and they form a complete hairy covering termed the *lanugo*.

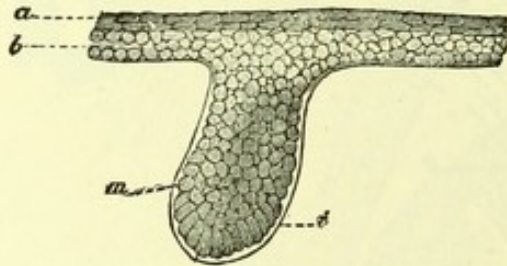


FIG. 160. — HAIR-RUDIMENT FROM AN EMBRYO OF SIX WEEKS. (Kölliker).

*a*, horny, and *b*, mucous or Malpighian layer of cuticle; *i*, basement-membrane; *m*, cells, some of which are assuming an oblong figure, which chiefly form the future hair.

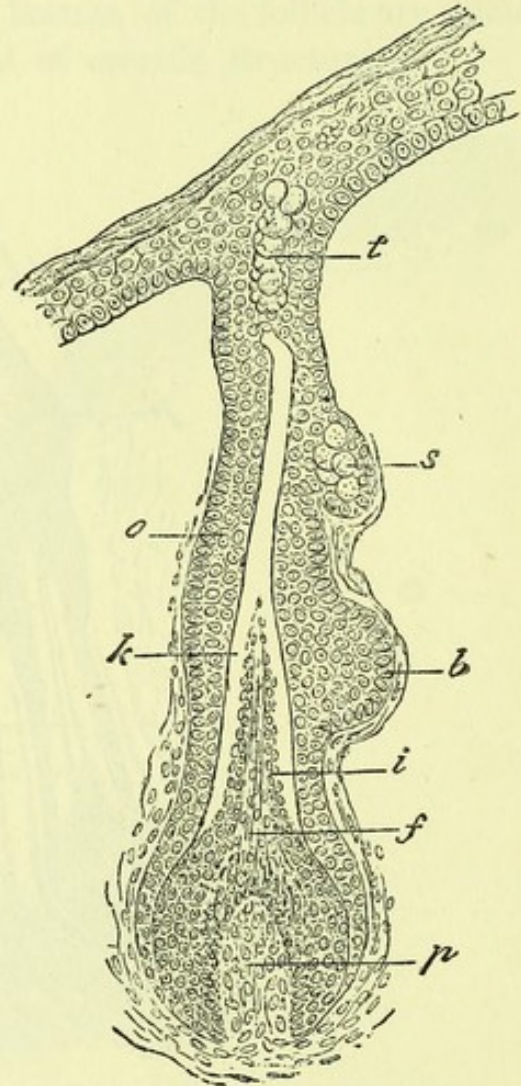


FIG. 161. — DEVELOPING HAIR FROM HUMAN EMBRYO OF 4½ MONTHS. (Ranvier.)

*p*, papilla; *f*, hair-rudiment; *i*, cells forming inner root-sheath; *k*, keratinised part of inner root-sheath, uncoloured by carmine; *e*, outer root-sheath; *b*, epithelial projection for insertion of arrector pili; *s*, sebaceous gland; *t*, sebaceous matter forming independently in the part which will become the neck of the follicle.

This is entirely shed within a few months of birth, the new hairs being formed in downgrowths from the old hair-follicles in the manner already mentioned.

Hairs grow at the rate of half an inch per month. They are found all over the body except on the palms of the hands and the soles of the feet, and on the distal phalanges of the fingers and toes. They usually



slant, and in the negro the hair-follicles are even considerably curved. On the scalp they are set in groups, as is well seen in a horizontal section.

The hairs of animals are often curiously marked by the arrangement of their medulla, the markings being characteristic of particular species.

*Muscles of the hairs.*—A small muscle composed of bundles of plain muscular tissue is attached to each hair-follicle (*arrector pili*, fig. 156, *n*); it passes from the superficial part of the corium, on the side to which the hair slopes, obliquely downwards, to be attached near the bottom of the follicle to a projection formed by a localised hypertrophy of the outer root-sheath. When the muscle contracts, the hair becomes erected, and the follicle is dragged upwards so as to cause a prominence on the general surface of the skin, whilst the part of the corium from which the little muscle arises is correspondingly depressed; the roughened condition known as 'goose skin' being in this way produced.

The **sebaceous glands** (fig. 156, *t*) are small saccular glands, the ducts from which open into the mouths of the hair-follicles. Both the duct and the saccules are lined by epithelium, which becomes charged with fatty matter. This sebaceous matter is discharged into the cavity of the saccule, probably owing to the disintegration of the cells within which it is formed. There may be two or more sebaceous glands attached to each follicle.

The sebaceous glands are developed as outgrowths from the outer root-sheath (fig. 161, *s*).

The **sweat-glands** are abundant over the whole skin, but they are most numerous on the palm of the hand and on the sole of the foot. They are composed of coiled tubes, which lie in the deeper part of the integument and send their ducts up through the cutis to open on the surface by corkscrew-like channels which pierce the epidermis (fig. 153, p. 130).

The *glandular* or *secreting tube* is a convoluted tube composed of a basement-membrane lined by a single layer of cubical or columnar epithelium-cells, and with a layer of longitudinally or obliquely disposed fibres between the epithelium and basement membrane. These fibres are usually regarded as muscular, but the evidence on this point is not conclusive. The secreting tube is considerably larger than the *efferent tube* or *duct*, which begins within the gland and usually makes several convolutions before leaving the gland to traverse the cutis vera. The efferent tube has an epithelium consisting of two or three layers of cells, within which is a well-marked cuticular lining, but there is no



muscular layer. The passage through the epidermis has no proper wall, but is merely a channel excavated between the epithelium-cells.

The ceruminous glands of the ear are modified sweat-glands.

The sweat-glands are developed, like the hairs, from downgrowths of the Malpighian layer of the epidermis into the corium, the rudiments

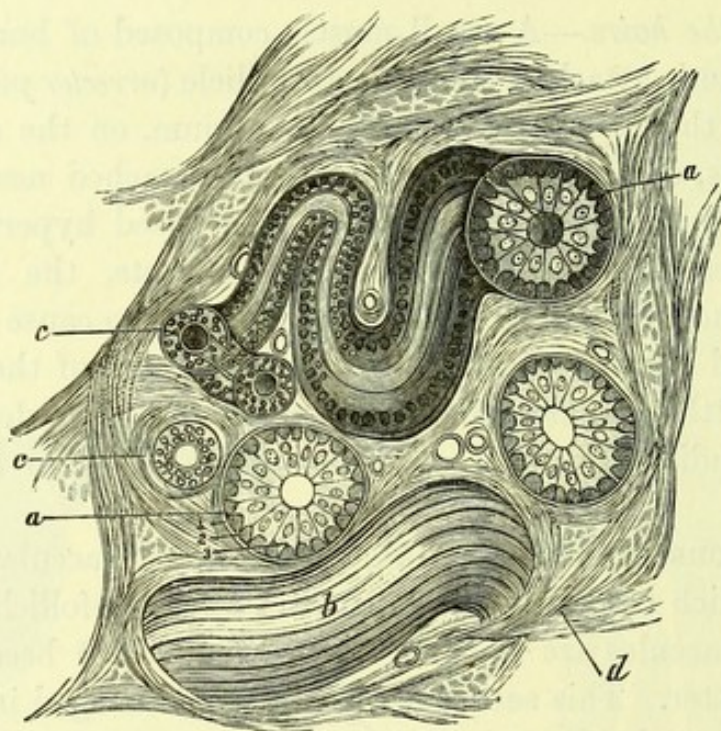


FIG. 162.—SECTION OF A SWEAT-GLAND IN THE SKIN OF MAN.

*a, a*, secreting tube in section; *b*, a coil seen from above; *c, c*, efferent tube; *d*, intertubular connective tissue with blood-vessels. 1, basement membrane; 2, muscular fibres cut across; 3, secreting epithelium of tubule.

which are thus formed becoming eventually coiled up at their extremities and converted into hollow tubes. The (muscular) fibres of the tubes as well as the secreting epithelium-cells are thus epiblastic structures.

The sweat-glands receive nerve-fibres, and each gland has a special cluster of capillary blood-vessels.



## LESSON XXVI.

*STRUCTURE OF THE HEART.*

1. In a section through the wall of the auricle, stained with magenta and mounted in dilute glycerine, or stained with hæmatoxylin and mounted in Canada balsam, notice the relative thickness of the epicardium, myocardium, and endocardium. Observe the blood-vessels and nerve-fibres under the epicardium, often embedded in fat; here and there a ganglion may be seen under this membrane. Notice also the elastic networks under both the pericardium and endocardium. Make a general sketch from this section.

2. Section through the wall of the ventricle, stained with hæmatoxylin and mounted in Canada balsam. The muscular fibres are variously cut. In those cut longitudinally, notice the branching of the fibres and their union into a network. Notice also that although the fibres are cross-striated this is less distinct than in voluntary muscle, and the nuclei lie in the centre of each fibre. Transverse markings may also be seen passing across the fibres between the nuclei and indicating a division into cells. The endocardium is very thin, especially over the columnæ carneæ.

3. If a portion of endocardium of the sheep's heart is spread out on a slide and examined in salt solution, a network of large beaded fibres may be seen with a low power or even with a lens. These are the *fibres of Purkinje*, and they will be seen to be formed of large, square-looking cells, usually containing two nuclei, and having striated muscular substance at their periphery.

4. The lymphatics of the heart are easily injected with Berlin blue by sticking the nozzle of the injecting syringe into the muscular substance, in the interstices of which the lymphatics arise. These commencing lymphatics lead to efferent vessels which pass to the base of the heart under the epicardium.

5. Section through one of the valves of the heart, stained and mounted as in preparation 2.<sup>1</sup>

6. The epithelium which covers the epicardium, and that which lines the endocardium, may be studied in preparations of the fresh organ which have been well washed with distilled water; then treated with nitrate of silver and subsequently exposed to the light and hardened in alcohol.

---

The muscular tissue of the heart (*myocardium*) forms the main thickness of the ventricles and also of parts of the auricles. It is composed of a network of fibres which are formed of uninucleated

<sup>1</sup> The appearances which are to be studied in sections 1, 2, and 5 can all be obtained in one preparation, viz. a vertical section including a portion of auricle and ventricle and a flap of the intervening auriculo-ventricular valve.



transversely striated cells, the structure of which has already been studied (Lesson XVII., p. 81).

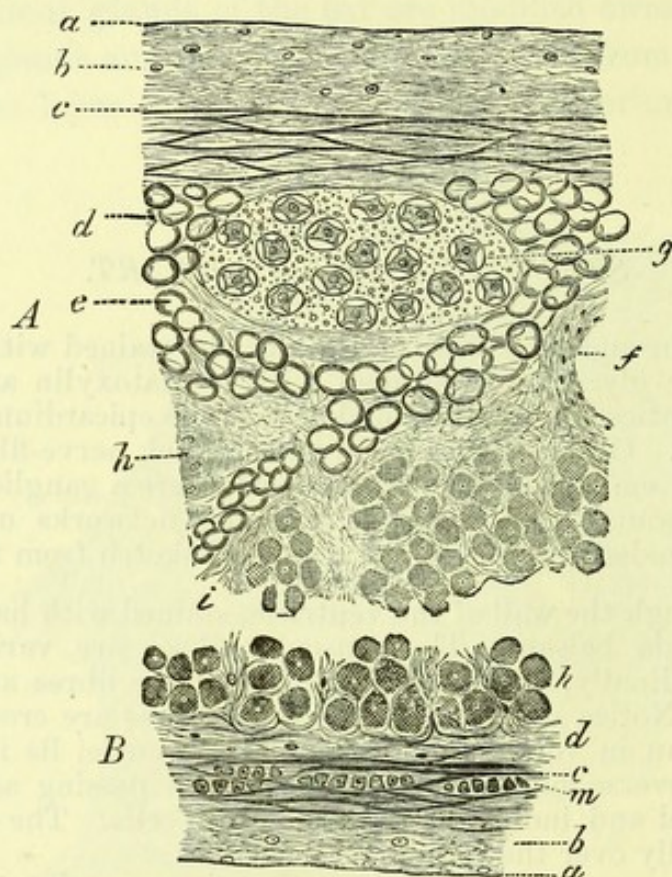


FIG. 163, A.—SECTION OF THE EPICARDIUM OF THE RIGHT AURICLE.

*a*, serous epithelium in section; *b*, connective-tissue layer; *c*, elastic network; *d*, subserous areolar tissue; *e*, fat; *f*, section of a blood-vessel; *g*, a small ganglion; *h*, muscular fibres of the myocardium; *i*, intermuscular areolar tissue.

B.—SECTION OF THE ENDOCARDIUM OF THE RIGHT AURICLE.

*a*, lining epithelium; *b*, connective-tissue with fine elastic fibres; *c*, layer with coarser elastic fibres; *d*, sub-endocardial connective tissue continuous with the intermuscular tissue of the myocardium; *h*, muscular fibres of the myocardium; *m*, plain muscular tissue in the endocardium.

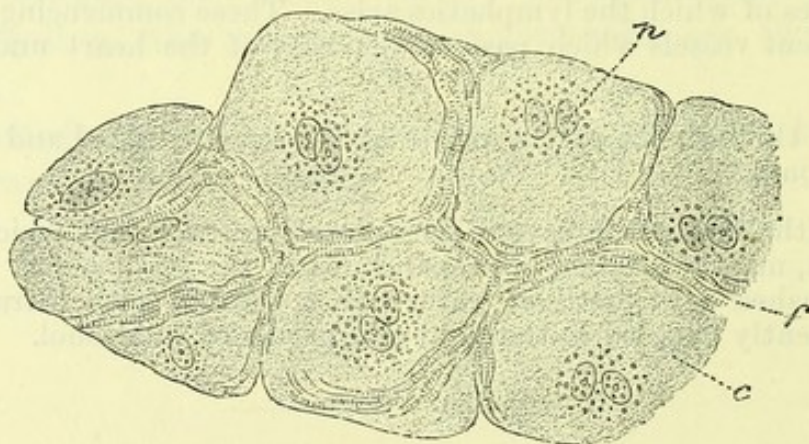


FIG. 164.—FRAGMENT OF THE NETWORK OF PURKINJE FROM THE VENTRICULAR ENDOCARDIUM OF THE SHEEP. (Ranvier.)  $\frac{300}{1}$ .

*c*, cell; *n*, nuclei; *f*, peripheral striated substance.

In the interstices of the muscular tissue there is a little areolar tissue in which run the very numerous blood-capillaries and the lacunar lymphatics.



The myocardium is covered externally by a layer of serous membrane—the *epicardium* (cardiac pericardium, fig. 163, *A*)—composed, like other serous membranes, of connective tissue and elastic fibres, the latter being most numerous in its deeper parts. Underneath the epicardium run the blood-vessels, nerves, and lymphatic vessels of the heart, embedded in areolar and adipose tissue, this tissue being continuous with that which lies between the muscular bundles; and the free surface of the membrane is covered by serous endothelium.

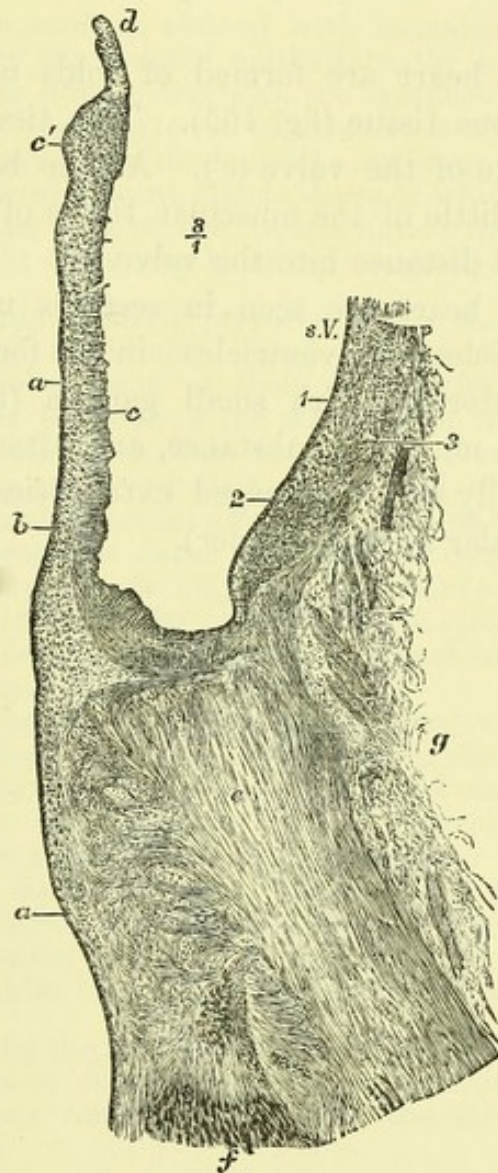


FIG. 165.—SECTION THROUGH ONE OF THE FLAPS OF THE AORTIC VALVE, AND PART OF THE CORRESPONDING SINUS OF VALSALVA, WITH THE ADJOINING PART OF THE VENTRICULAR WALL. (From a drawing by V. Horsley.)

*a*, endocardium, prolonged over the valve; *b*, sub-endocardial tissue; *c*, fibrous tissue of the valve, thickened at *c'* near the free edge; *d*, section of the lunula; *e*, section of the fibrous ring; *f*, muscular fibres of the ventricle attached to it; *g*, loose areolar tissue at the base of the ventricle; *s.V.*, sinus Valsalvæ; 1, 2, 3, inner, middle, and outer coats of the aorta.

The *endocardium* (fig. 163, *B*) has a structure not very unlike the pericardium. It is lined by a pavement-epithelium or endothelium,



like that of a serous membrane, and consists of connective tissue with elastic fibres in its deeper part, between which there may, in some parts, be found a few plain muscular fibres. Fat is sometimes met with under the endocardium.

In some animals, *e.g.* the sheep, and sometimes also in man, large beaded fibres are found under the endocardium. These are formed of large clear cells joined end to end, and generally containing in their centre two nuclei, whilst the peripheral part of the cell is formed of cross-striated muscular tissue; they are known as the *fibres of Purkinje*.

The *valves* of the heart are formed of folds of the endocardium strengthened by fibrous tissue (fig. 165). This tissue forms a thickening near the free edge of the valve (*c'*). At the base of the auriculo-ventricular valves a little of the muscular tissue of the auricle may be found passing a short distance into the valve.

The *nerves* of the heart are seen in sections underneath the epicardium of both auricles and ventricles; in the former situation they are connected at intervals with small ganglia (fig. 163, *g*). Their branches pass to the muscular substance, and after dividing into fine fibrils, these eventually end in enlarged extremities, which are applied directly to the muscular fibres (Ranvier).



## LESSON XXVII.

*THE TRACHEA AND LUNGS.*

1. In sections of the trachea, stained with hæmatoxylin, and mounted in Canada balsam, notice the ciliated epithelium, the basement membrane (of some thickness in the human trachea), the lymphoid tissue of the mucous membrane, the elastic tissue external to this, and lastly the fibrous membrane containing the cartilages. In the mucous membrane and submucous areolar tissue look for sections of mucous glands, ducts of which may be seen opening on the surface. At the back of the trachea notice the plain muscular fibres transversely arranged; there may be larger mucous glands external to these.

2. In sections of lung similarly prepared, notice the sections of the alveoli collected into groups (infundibula). Find sections of bronchial tubes, some cut longitudinally and passing at their extremities into the infundibula, others cut across; the latter show the structure of the tubes best. In each tube notice the ciliated epithelium internally. Next to this the mucous membrane containing numerous elastic fibres and often thrown into folds; then the layer of circular muscular fibres, and, outside this, loose fibrous tissue in which in larger bronchial tubes the pieces of cartilage may be seen embedded. Small mucous glands may also be observed in the fibrous tissue sending their ducts through the other layers to open on the inner surface. Notice always accompanying a section of a bronchial tube the section of a branch of the pulmonary artery.

In the sections of the alveoli observe the capillary vessels passing from one side to the other of the intervening septa; and in places where the thin wall of an alveolus is to be seen in the section, try and make out the network of blood-capillaries upon it. Notice within the alveoli nucleated corpuscles which very frequently contain dark particles in their protoplasm. They are amœboid cells which have migrated from the blood-vessels and lymphatics, and have taken in inhaled particles of carbon. They seem to pass back into the lung tissue, for similar cells may be seen in this. Make a sketch of part of the wall of a bronchial tube and of one or two of the alveoli.

3. In sections of lung the air-cells of which have been filled with a mixture of gelatine and nitrate of silver solution the epithelium of the alveoli may be studied. The sections can be made with the freezing microtome, and mounted in glycerine.

4. Mount in Canada balsam a section of lung in which the pulmonary vessels have been injected. Study the general arrangement of the vessels with a low power, and the network of capillaries of the alveoli with a high power. Observe that the veins run apart from the arteries. Sketch the capillary network of one or two adjoining alveoli.

---

The **trachea** or windpipe is a fibrous and muscular tube, the wall of which is rendered somewhat rigid by C-shaped hoops of cartilage



which are embedded in the fibrous tissue. The muscular tissue, which is of the plain variety, forms a flat band, the fibres of which run transversely at the back of the tube. The trachea is lined by a *mucous membrane* (fig. 166, *a-d*), which has a ciliated epithelium upon its inner surface. The epithelium-cells have been already described (Lesson VII.); they rest upon a thick basement membrane. The mucous membrane proper consists of areolar and lymphoid tissue, and contains numerous blood-vessels and lymphatics. In its deepest part is a well-marked layer of longitudinal elastic fibres (*d*). Many small glands for the secretion of mucus are found in the wall of the trachea. They may lie either within the mucous membrane or in the submucous

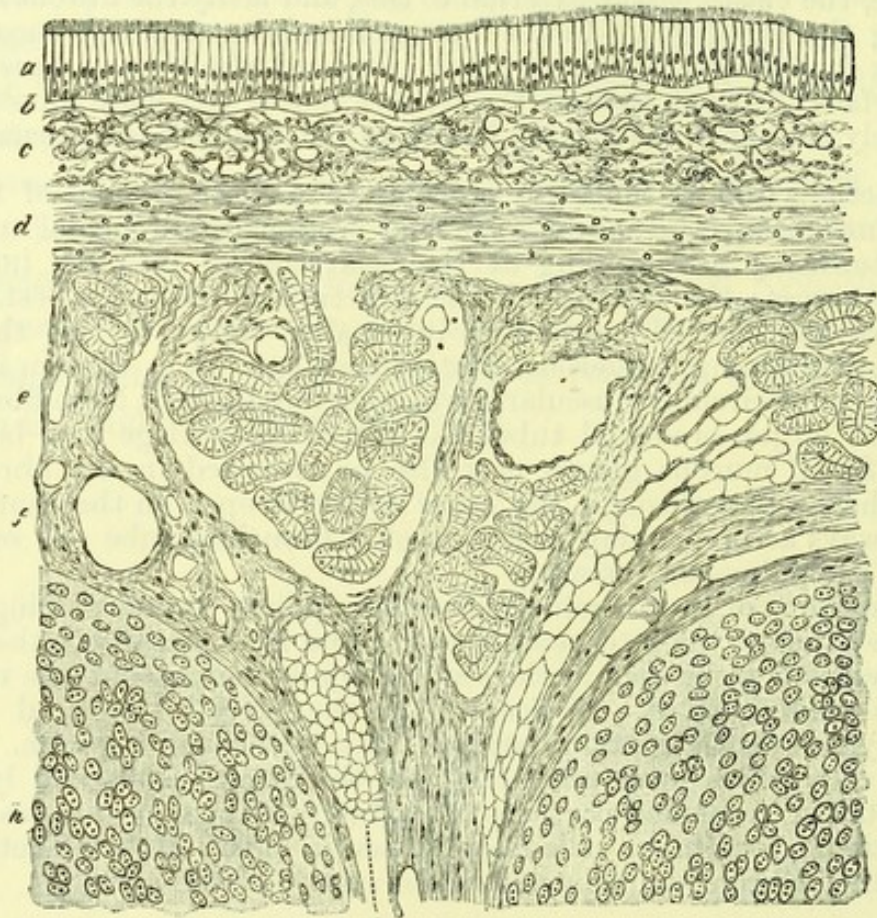


FIG. 166.—LONGITUDINAL SECTION OF THE HUMAN TRACHEA, INCLUDING PORTIONS OF TWO CARTILAGINOUS RINGS. (Klein.) (Moderately magnified.)

*a*, ciliated epithelium; *b*, basement-membrane; *c*, superficial part of the mucous membrane, containing the sections of numerous capillary blood-vessels and much lymphoid tissue; *d*, deeper part of the mucous membrane, consisting mainly of elastic fibres; *e*, submucous areolar tissue, containing the larger blood-vessels, small mucous glands (their ducts and alveoli are seen in section), fat, etc.; *f*, fibrous tissue investing and uniting the cartilages; *g*, a small mass of adipose tissue in the fibrous layer; *h*, cartilage.

areolar tissue (*e*) or, lastly, at the back of the trachea, outside the transverse muscular fibres.

The two divisions of the trachea, the *bronchi*, are precisely similar in structure.

The larynx is also very like the trachea so far as the structure of



the mucous membrane is concerned, but over the true vocal cords and upon the epiglottis, as well as here and there in the part above the glottis, stratified epithelium is found ; and taste-buds (see next Lesson) may occur in this epithelium, except over the vocal cords.

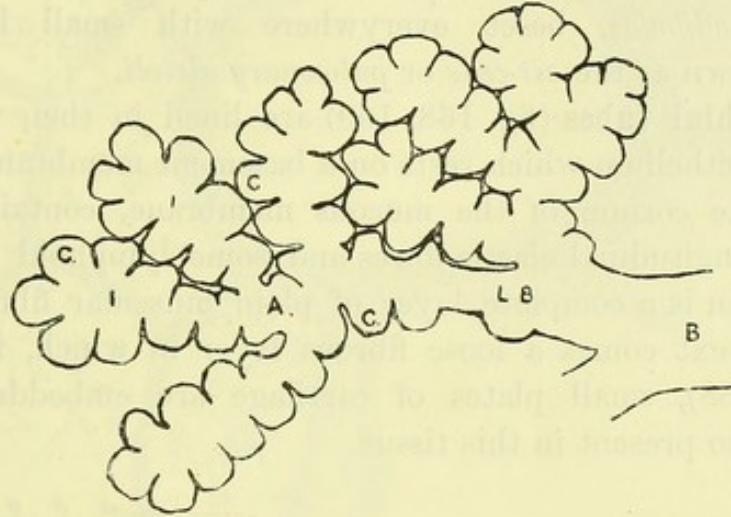


FIG. 167.—DIAGRAMMATIC REPRESENTATION OF THE ENDING OF A BRONCHIAL TUBE IN SACCULATED INFUNDIBULA.

B, terminal bronchus ; L.B., lobular bronchiole ; A, atrium ; I, infundibulum ; C, air-cells or alveoli.

The lymphoid tissue is especially abundant in the mucous membrane of the ventricle of Morgagni, and a large number of mucous glands open into this cavity and into that of the sacculus.

The true vocal cords are composed of fine elastic fibres.

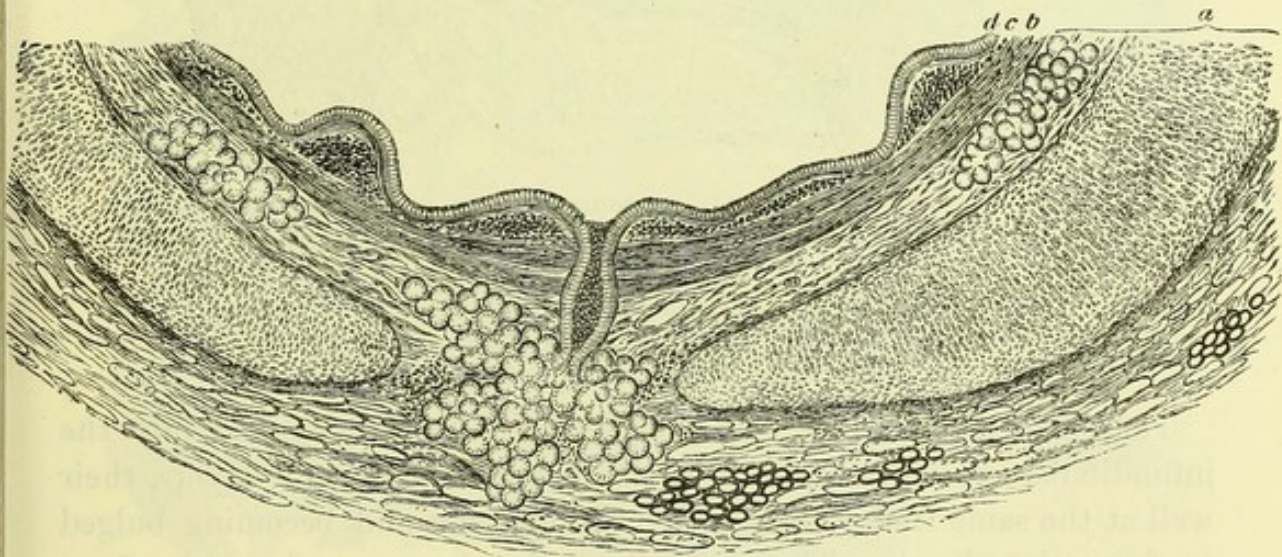


FIG. 168.—PORTION OF A TRANSVERSE SECTION OF A BRONCHIAL TUBE, HUMAN, 6 MM IN DIAMETER. (F. E. Schultze.) (Magnified 30 diameters.)

*a*, cartilage and fibrous layer with mucous glands, and, in the outer part, a little fat ; in the middle, the duct of a gland opens on the inner surface of the tube ; *b*, annular layer of involuntary muscular fibres ; *c*, elastic layer, the elastic fibres in bundles which are seen cut across ; *d*, columnar ciliated epithelium.



The cartilages of the trachea and larynx are hyaline, except the epiglottis and the cartilages of Santorini and of Wrisberg, which are composed of elastic fibro-cartilage.

The **lungs** are formed by the ramifications of the *bronchial tubes* and their terminal expansions, which form groups of sacculated dilatations (*infundibula*), beset everywhere with small hemispherical bulgings, known as the *air-cells* or *pulmonary alveoli*.

The **bronchial tubes** (fig. 168, 169) are lined in their whole extent by ciliated epithelium which rests on a basement membrane. External to this is the corium of the mucous membrane, containing a large number of longitudinal elastic fibres and some lymphoid tissue. Outside this again is a complete layer of plain muscular fibres encircling the tube. Next comes a loose fibrous layer in which, in the larger tubes (fig. 168), small plates of cartilage are embedded. Mucous glands are also present in this tissue.

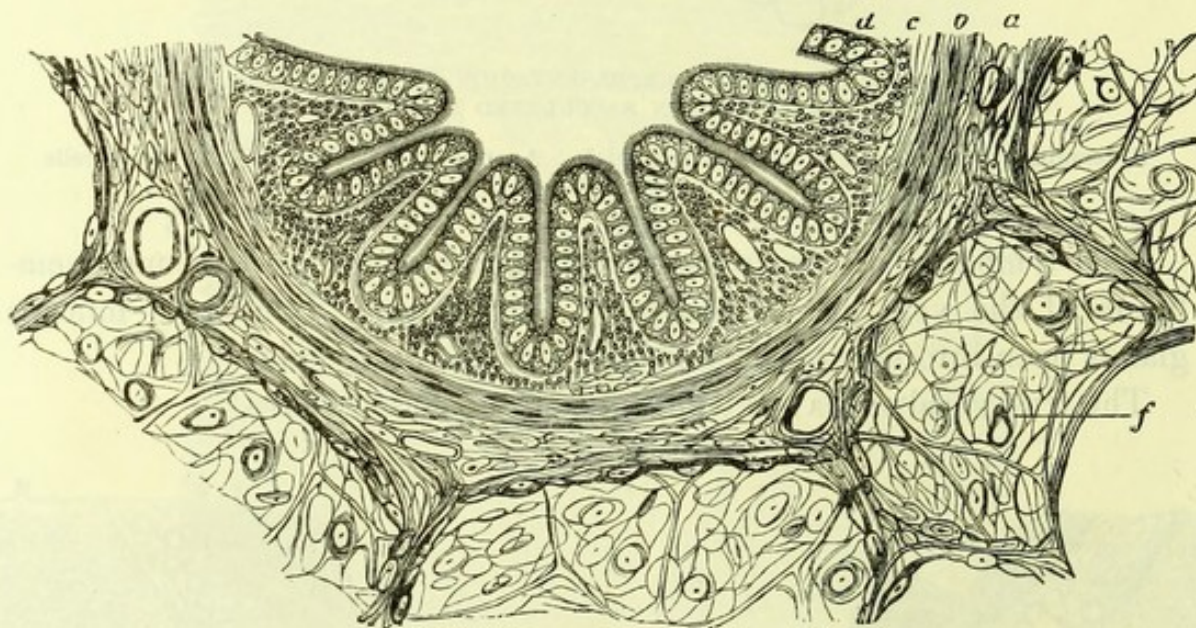


FIG. 169.—SECTION OF A SMALL BRONCHIAL TUBE FROM THE PIG'S LUNG. (F. E. Schultze.) (This section is much more magnified than that represented in the previous figure.)

*a*, fibrous layer; *b*, muscular layer; *c*, mucous membrane in longitudinal folds, with numerous longitudinally running elastic fibres cut across; *d*, ciliated epithelium; *f*, surrounding alveoli.

The smallest bronchial tubes, which are about to expand into the infundibula, gradually lose the distinctness of the several layers, their wall at the same time being greatly thinned out and becoming bulged out to form the alveoli. The epithelium also becomes changed; from columnar and ciliated it becomes cubical and non-ciliated.

In the **alveoli** themselves, besides small groups of cubical cells there are large irregular flattened cells (fig. 170), which form an extremely delicate layer, separating the blood-capillaries from the air



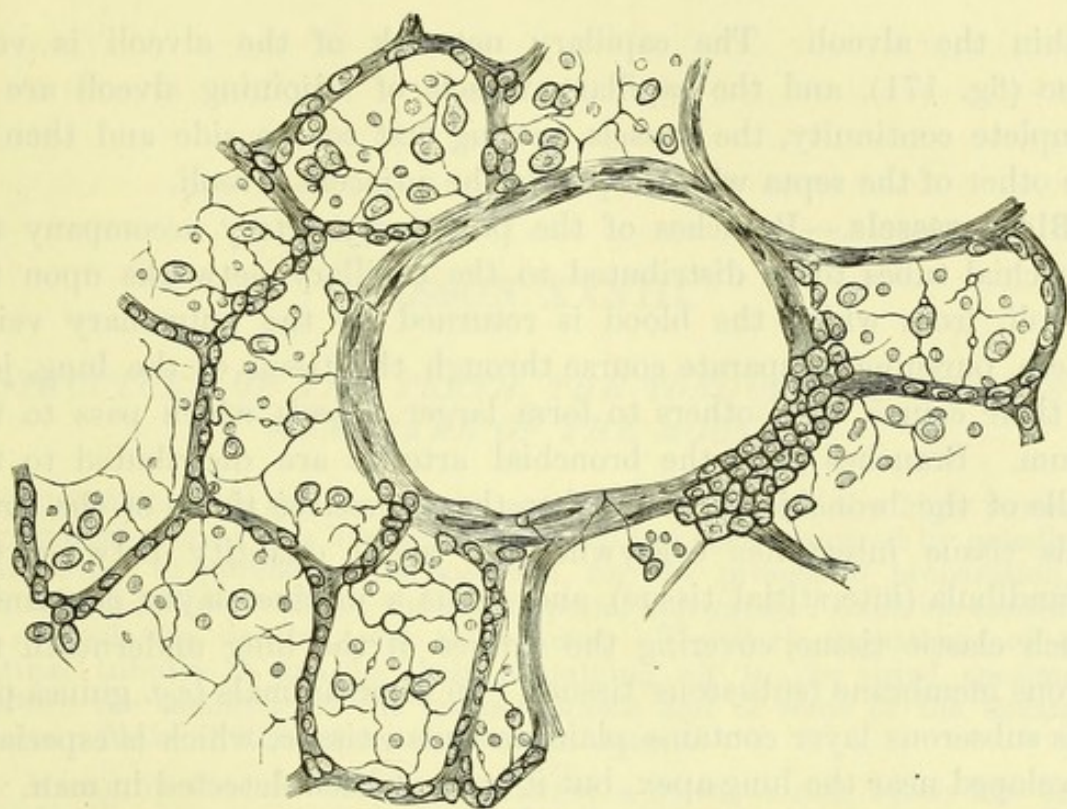


FIG. 170.—SECTION OF PART OF CAT'S LUNG, STAINED WITH NITRATE OF SILVER.  
(Klein.) (Highly magnified.)

The small granular and the large flattened cells of the alveoli are shown. In the middle is a section of a lobular bronchial tube, with a patch of the granular pavement-epithelium cells on one side.

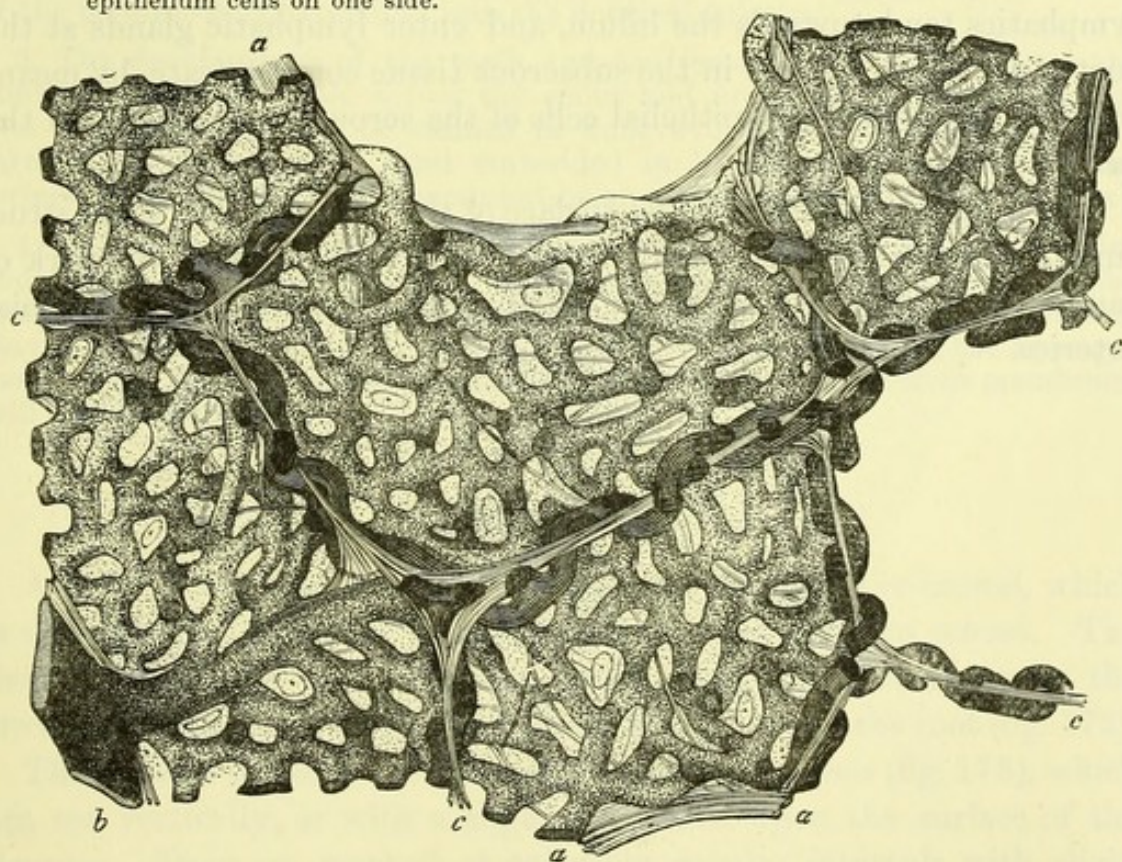


FIG. 171.—SECTION OF INJECTED LUNG, INCLUDING SEVERAL CONTIGUOUS ALVEOLI.  
(F. E. Schultze.) (Highly magnified.)

*a, a*, free edges of alveoli; *c, c*, partitions between neighbouring alveoli, seen in section; *b*, small arterial branch giving off capillaries to the alveoli. The looping of the vessels to either side of the partitions is well exhibited. Between the capillaries is seen the homogeneous alveolar wall with nuclei of connective-tissue corpuscles and elastic fibres.



within the alveoli. The capillary network of the alveoli is very close (fig. 171), and the capillary vessels of adjoining alveoli are in complete continuity, the vessels passing first to one side and then to the other of the septa which separate the adjacent alveoli.

**Blood-vessels.**—Branches of the pulmonary artery accompany the bronchial tubes to be distributed to the capillary networks upon the alveoli, from which the blood is returned by the pulmonary veins. These, pursuing a separate course through the tissue of the lung, join in their course with others to form larger vessels which pass to the hilum. Branches from the bronchial arteries are distributed to the walls of the bronchial tubes, and to the connective tissue of the lung. This tissue intervenes everywhere in small quantity between the infundibula (interstitial tissue), and forms a distinct layer, containing much elastic tissue, covering the surface of the lung underneath the serous membrane (subserous tissue). In some animals (*e.g.* guinea-pig) this subserous layer contains plain muscular tissue, which is especially developed near the lung-apex, but it has not been detected in man.

The **lymphatics** of the lung form two sets of vessels, one set accompanying the bronchial tubes, and another set forming a network in the interstitial connective tissue, and in the subserous tissue. Both sets of lymphatics tend towards the hilum, and enter lymphatic glands at the root of the lung. Those in the subserous tissue communicate, by means of stomata between the epithelial cells of the serous membrane, with the cavity of the pleura.

The **pleura**, which covers the surface of the lung, has the usual structure of a serous membrane. It is provided with a special network of capillary blood-vessels, which are supplied by branches of the bronchial arteries.



## LESSON XXVIII.

*STRUCTURE OF THE TEETH, THE TONGUE, AND MUCOUS MEMBRANE OF THE MOUTH.*

1. STUDY first with the low power and afterwards with the high power a longitudinal section of a human tooth which has been prepared by grinding. It is better to purchase this specimen, for the process of preparation is difficult and tedious without the aid of special apparatus. Examine carefully the enamel, the dentine, and the cement. The dark appearance of the dentinal tubules is due to their containing air in the dried specimen. Measure the diameter of the enamel prisms and of some of the dentinal tubules. Make sketches from each of the tissues.

2. Mount in Canada balsam a section of a tooth, *in situ*, which has been decalcified in chromic or nitric acid and stained with hæmatoxylin or carmine. In this section the mode of implantation of a tooth, as well as the structure of the pulp, can be made out. Make a general sketch under a low power, and under a high power draw a small piece of the pulp showing the processes of the odontoblasts extending into the dentinal tubules.

3. The development of the teeth and the formation of their tissues are studied in sections made across the snout and lower jaw of foetal animals. The preparation should be stained in bulk with alcoholic magenta, borax-carmine, or hæmatoxylin, and embedded in paraffin or celloidin; if the former, the sections must be mounted by an adhesive process (see Appendix).

4. Sections of the tongue vertical to the surface; stain with hæmatoxylin, and mount in Canada balsam. In these sections the arrangement of the muscular fibres and the structure of the papillæ of the mucous membrane may be studied; and if the organ have been previously injected, the arrangement of the blood-vessels in the muscular tissue and in the mucous membrane will also be well seen.

---

*THE TEETH.*

A **tooth** consists in man of three calcified tissues: the *enamel*, which is of epithelial origin, the *dentine*, and the *cement*, or *crusta petrosa*. The dentine forms the main substance of a tooth, the enamel covers the crown, and the cement is a layer of bone which invests the root (fig. 172).

The **enamel** is formed of elongated hexagonal *prisms* (fig. 173), which are set vertically, or with a slight curvature, upon the surface of the dentine. They are marked at tolerably regular intervals with slight transverse shadings producing an indistinct cross-striated appearance. Sometimes coloured lines run through the enamel across the direction of its fibres.



The **dentine** is composed of a hard dense substance like bone, but containing no Haversian canals or lacunæ. It is pierced everywhere, however, by fine canaliculi (*dentinal tubules*, figs. 175, 176), radiating outwards from a central cavity which, during life, contains the pulp. The tubules branch at acute angles as they pass outwards; their branches become gradually finer towards the periphery of the dentine.

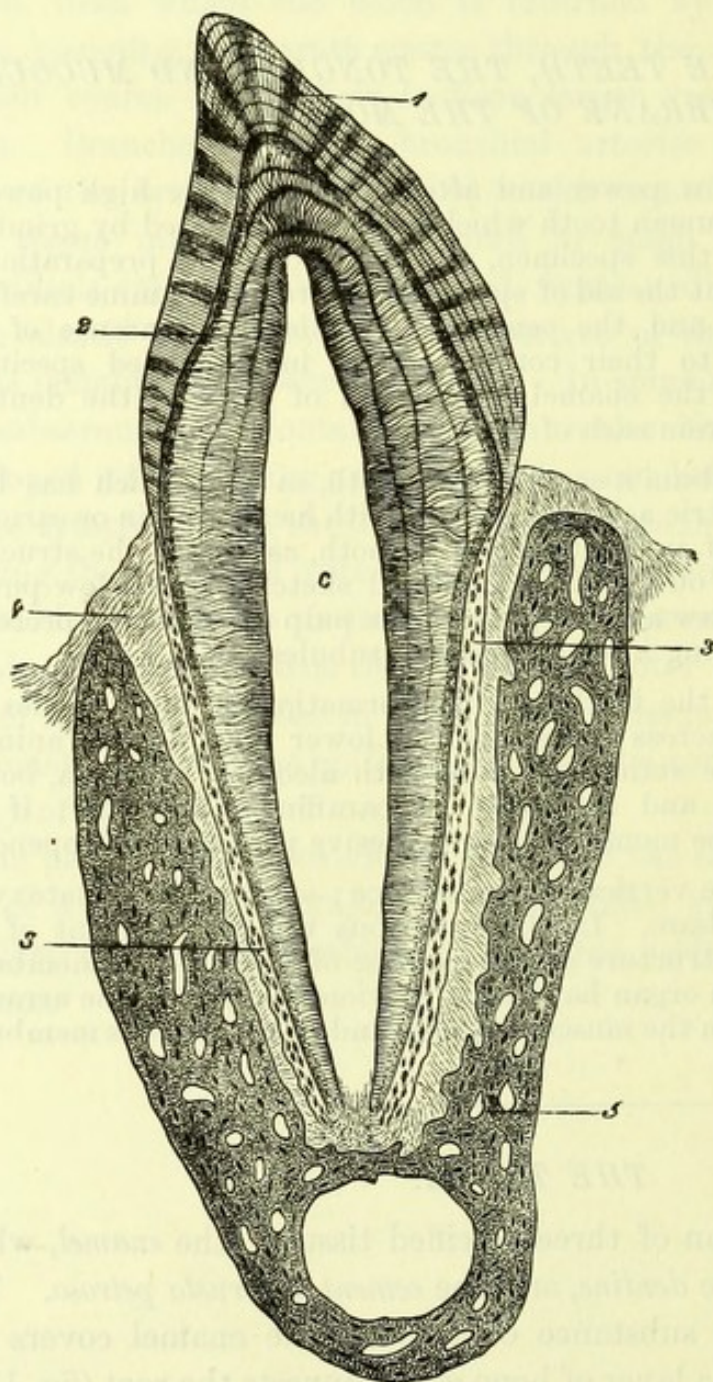


FIG. 172. — VERTICAL SECTION OF A TOOTH *in situ*. (15 diameters.) (Waldeyer.)

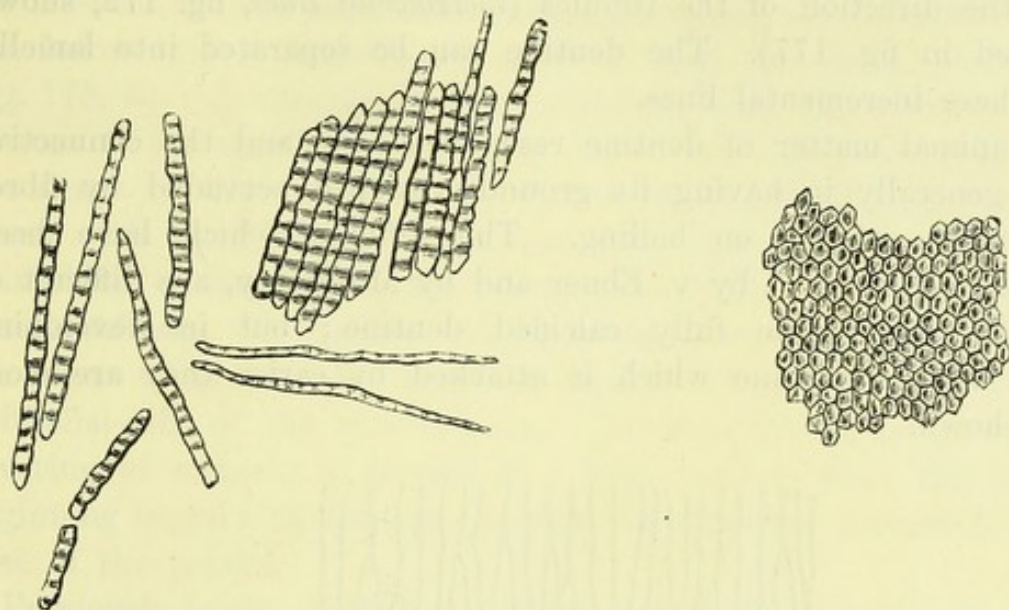
c, is placed in the pulp-cavity, opposite the cervix or neck of the tooth; the part above is the crown, that below is the root (fang). 1, enamel with radial and concentric markings; 2, dentine with tubules and incremental lines; 3, cement or crusta petrosa, with bone-corpuscles; 4, dental periosteum; 5, bone of lower jaw.

The tubules have a proper wall of their own, which can be isolated by steeping a section of tooth in strong hydrochloric acid. In the living tooth they are occupied by protoplasmic fibres, which are prolonged from the superficial cells of the pulp.

The intertubular substance appears for the most part homogeneous, but here and there indications can be seen in it of a globular forma-



tion. This is especially the case near the surface of the dentine, where the globular deposit and the interglobular spaces may produce



FIGS. 173 AND 174.—ENAMEL PRISMS. (350 diameters.) (Kölliker.)

Fig. 173.—Fragments and single fibres of the enamel, isolated by the action of hydrochloric acid.

Fig. 174.—Surface of a small fragment of enamel, showing the hexagonal ends of the fibres.

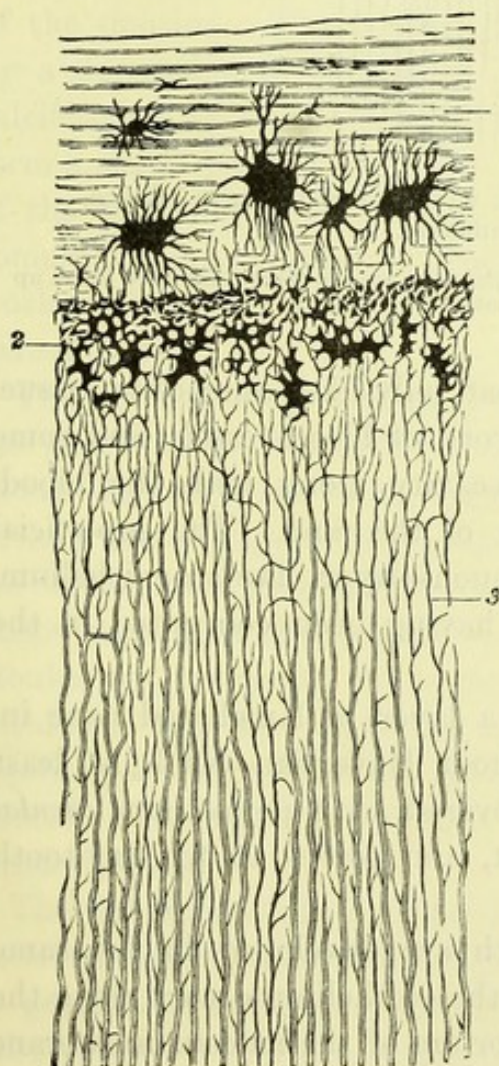


FIG. 175.—SECTION OF FANG, PARALLEL TO THE DENTINAL TUBULES. (Magnified 300 diameters.) (Waldeyer.)

1, cement, with large bone lacunæ and indications of lamellæ; 2, granular layer of Purkinje (interglobular spaces); 3, dentinal tubules.

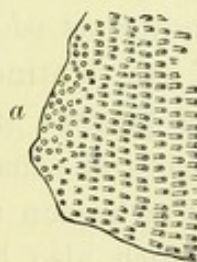


FIG. 176.—SECTIONS OF DENTINAL TUBULES. (Frænckel.)

*a*, cut across; *b*, cut obliquely. (About 300 diameters.)



a granular appearance (*granular layer*, fig. 175, 2), and also in the course of certain lines or clefts which are seen traversing the dentine across the direction of the tubules (*incremental lines*, fig. 172, shown magnified in fig. 177). The dentine can be separated into lamellæ along these incremental lines.

The animal matter of dentine resembles bone and the connective tissues generally in having its ground-substance pervaded by fibres which yield gelatine on boiling. These fibres, which have been especially investigated by v. Ebner and by Mummery, are difficult of demonstration in the fully calcified dentine; but in developing dentine and in dentine which is attacked by caries they are more easily shown.

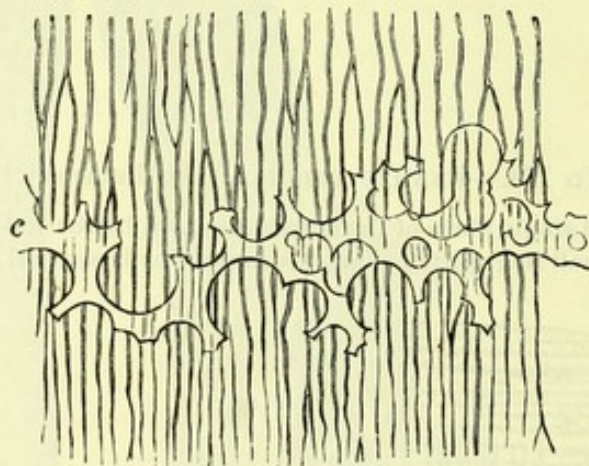


FIG. 177.—A SMALL PORTION OF DENTINE WITH INTERGLOBULAR SPACES.  
(Kölliker.) (350 diameters.)

c, portion of incremental line formed by the interglobular spaces, which are here filled up by a transparent material.

The **pulp** consists of a soft, somewhat jelly-like, connective tissue, containing many branched cells, a network of blood-vessels, and some nerve-fibres which pass into the pulp-cavity along with the blood-vessels by a minute canal at the apex of the fang. The superficial cells of the pulp form an almost continuous layer, like an epithelium. They are known as *odontoblasts*, from having been concerned in the formation of the dentine.

The **crusta petrosa** (fig. 175, 1) is a layer of lamellated bone including lacunæ and canaliculi, but without Haversian canals, at least normally in the human teeth. It is covered with periosteum (*dental periosteum*), which also lines the socket, and serves to fix the tooth securely.

**Formation of the teeth.**—The teeth are developed in the same manner as the hairs. A thickening of the epithelium occurs along the line of the gums, and grows into the corium of the mucous membrane



(*common enamel-germ*, fig. 178, A). At regular intervals there is yet a further thickening and growth from the common enamel-germ into the tissue of the mucous membrane, each of these special rudiments swelling out below into a flask-shaped mass of cells, the *special enamel-germ* (fig. 178, B). A vascular *papilla* grows up from the corium into the bottom of the special enamel-germ (fig. 178, C, D); this papilla has the shape of the crown of the future tooth. Each special enamel-germ, with its included papilla, presently becomes cut off from the epithelium of the mouth, and surrounded by a vascular membrane—the *dental sac*. The papilla becomes transformed into the dentine of the future tooth, and the enamel is deposited upon its surface by the epithelial-cells of the enamel-germ. The root of the tooth, with its covering of cement, is formed at a later period, when the tooth is beginning to grow up through the gum, by a gradual elongation of the base of the papilla.

Previously to the deposition of the enamel, the enamel-germ undergoes a peculiar transformation of its previously-rounded epithelium-cells into three layers of modified cells. One of these is a layer of columnar cells (fig. 179, *d*), which immediately covers the surface of the dentine. These columnar cells form the enamel-prisms either by a deposition of calcareous salts external to them, or by a direct calcification of their protoplasm. The cells next to the dental sac form a single layer of cubical epithelium (*e*), nearly all the other cells of the enamel-germ become transformed into branching corpuscles (*c*) communicating by their processes, and thus forming a continuous network. The enamel-germ, after it is thus modified, is known as the *enamel organ*.

The *dentine* of the tooth is formed by calcification of the surface of the papilla. At this surface there is a well-marked layer of odontoblasts (fig. 180), and these produce a layer of dentinal matrix which forms a sort of cap to the papilla, and which soon becomes calcified by the deposition of globules of calcareous matter. Processes of the odontoblasts remain in the dentine as it is forming, and thus the dentinal tubules are produced. Subsequently other layers of dentine are formed within the first by a repetition of the same process, and in this way the papilla gradually becomes calcified. A part, however, remains unaltered in the centre of the tooth, and with its covering of odontoblasts forms the pulp.

The ten milk-teeth are formed in each jaw in this manner. These, however, become lost within a few years after birth, and are replaced by permanent teeth in much the same way that a new succession of hairs occurs. A small outgrowth takes place at an early period from



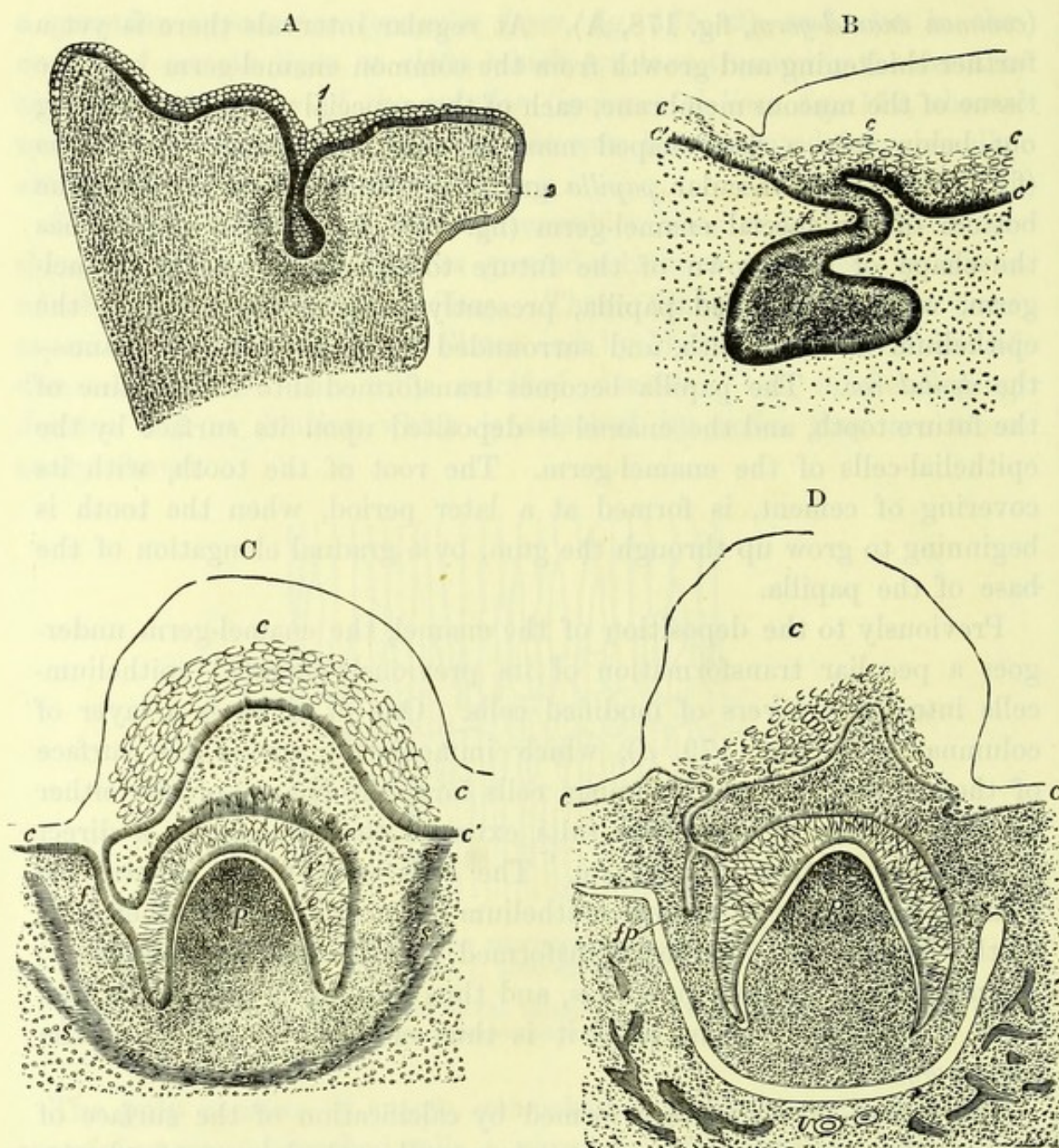


FIG. 178.

A. SECTION ACROSS THE UPPER JAW OF A FETAL SHEEP. (3 centimeters long.) (Waldeyer.)

1, common enamel-germ dipping down into the mucous membrane where it is half surrounded by a horseshoe-shaped more dense-looking tissue, the germ of the dentine and dental sac; 2, palatine process of the maxilla.

B. SECTION SIMILAR TO THAT SHOWN IN THE PREVIOUS FIGURE, BUT PASSING THROUGH ONE OF THE SPECIAL ENAMEL-GERMS HERE BECOMING FLASK-SHAPED. (Kölliker.)

*c, c'*, epithelium of mouth; *f*, neck; *f'*, body of special enamel-germ.

C AND D. SECTIONS AT LATER STAGES THAN A AND B, THE PAPILLA HAVING BECOME FORMED AND HAVING INDENTED THE ENAMEL-GERM, WHICH HAS AT THE SAME TIME GROWN PARTLY ROUND IT. (Kölliker.)

*c*, epithelium of gum, sketched in outline; *f*, neck of enamel-germ; *f'*, enamel-organ; *e*, its deeper columnar cells; *e'*, projections into the corium; *p*, papilla; *s*, dental sac forming. In D, the enamel-germ (*fp*) of the corresponding permanent tooth has become formed.



the enamel-germ of each of the milk-teeth (fig. 178, D, *f p*), and this eventually becomes the germ of the corresponding permanent tooth. It gradually enlarges, acquires a papilla, forms an enamel-organ, in

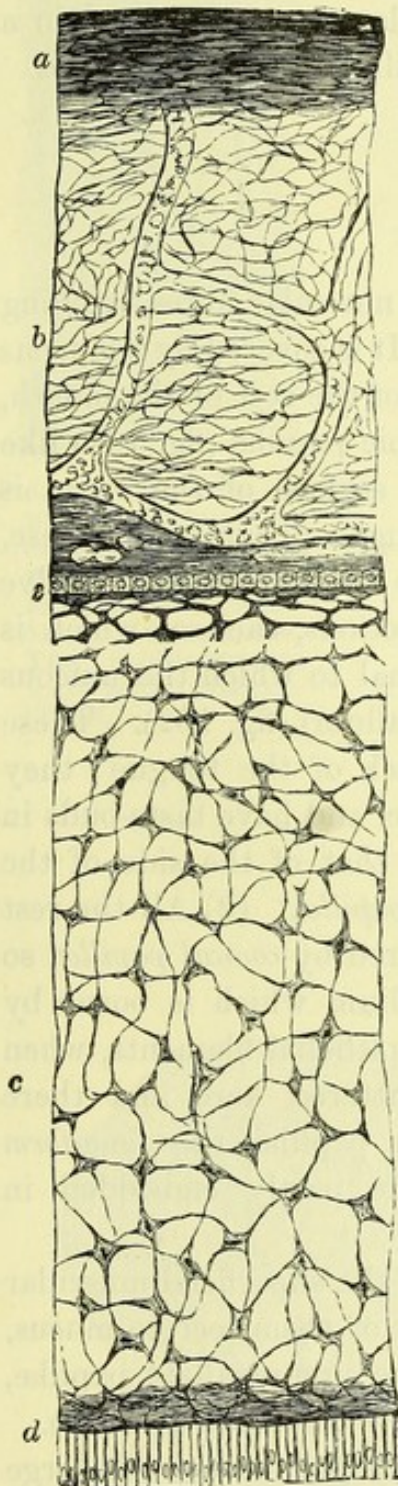


FIG. 179. — A SECTION THROUGH THE ENAMEL-ORGAN AND DENTAL SAC FROM THE TOOTH OF A CHILD AT BIRTH. (250 diameters.) (Köl liker.)

*a*, outer dense layer of the dental sac; *b*, inner looser texture of the same with capillary blood-vessels and a somewhat denser layer towards the enamel-organ; *c*, spongy substance; *d*, inner cells; and *e*, outer cellular layer of the enamel-organ.

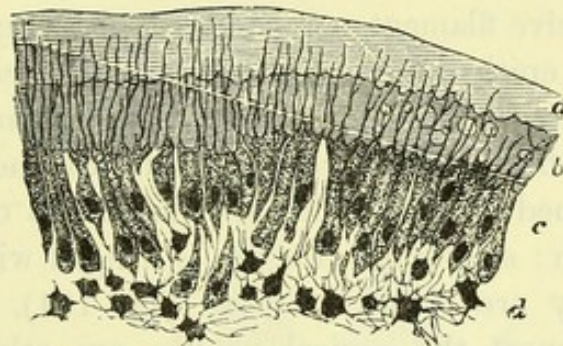


FIG. 180. — PART OF SECTION OF DEVELOPING TOOTH OF YOUNG RAT, SHOWING THE MODE OF DEPOSITION OF THE DENTINE. (Highly magnified.)

*a*, outer layer of fully calcified dentine; *b*, uncalcified matrix, with a few nodules of calcareous matter; *c*, odontoblasts with processes extending into the dentine; *d*, pulp. The section is stained with carmine, which colours the uncalcified matrix, but not the calcified part.

short, passes through the same phases of development as its parent germ, and when the milk-tooth drops out of the jaw in consequence of the absorption of its roots (by osteoclasts) the permanent tooth grows up into its place.

But there are six permanent teeth in each jaw which do not succeed



milk-teeth ; these are the permanent molars. They are developed from an extension backwards of the original epithelial thickening or common enamel-germ and the downgrowth from this into the corium of three successive special enamel-germs at comparatively long intervals of time. Within these the tissues of the permanent molars become formed in a manner exactly similar to that in which the milk-teeth are developed.

### THE TONGUE.

The **tongue** is mainly composed of striated muscular fibres, running some longitudinally, and others transversely. It is covered by a mucous membrane, the epithelium of which, like that of the rest of the mouth, is thick and stratified, and conceals microscopic papillæ (fig. 181) like those of the skin. Besides these, the upper surface of the organ is covered with larger papillæ, which give it a rough appearance. These, which are termed the *lingual papillæ*, are of three kinds: (1) About twelve or thirteen comparatively large circular projections, each of which is surrounded by a narrow groove (fossa), external to which the mucous membrane is raised above the general level (vallum) (fig. 182). These papillæ form a V-shaped line towards the back of the tongue ; they receive filaments of the glosso-pharyngeal nerve, and have taste-buds in the epithelium which covers their sides, and in that of the side of the vallum. They are known as the *circumvallate papillæ*. (2) All the rest of the papillary surface of the tongue is covered by *conical papillæ*, so named from the conical pointed cap of epithelium which is borne by each ; sometimes this cap is fringed with fine epithelial filaments, when they are termed *filiform* (fig. 184). (3) Scattered here and there amongst the conical papillæ are other larger papillæ, the *fungiform* (fig. 183). These are very vascular, and lie partly embedded in little depressions of the mucous membrane.

Small tubular glands may be seen between the superficial muscular fibres sending their ducts to the surface. Most of them secrete mucus, but those which open into the trenches of the circumvallate papillæ, and a few others elsewhere, yield a serous secretion (*glands of Ebner*).

The mucous membrane at the back of the tongue contains a large amount of lymphoid tissue.

**The taste-buds.**—The minute gustatory organs which are known as *taste-buds* may be seen in sections which pass through the papillæ vallatæ or the papillæ fungiformes ; they are also present here and there in the epithelium of the general mucous membrane of the tongue, especially at the back and sides, and occur also upon the under surface



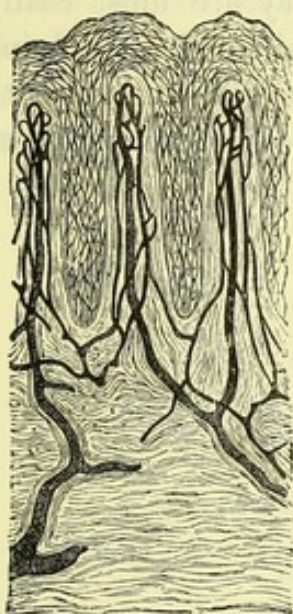

FIG. 181.—SECTION OF MUCOUS MEMBRANE OF MOUTH, SHOWING THREE MICROSCOPIC PAPILLÆ AND STRATIFIED EPITHELIUM. THE BLOOD-VESSELS HAVE BEEN INJECTED. (Toldt.)

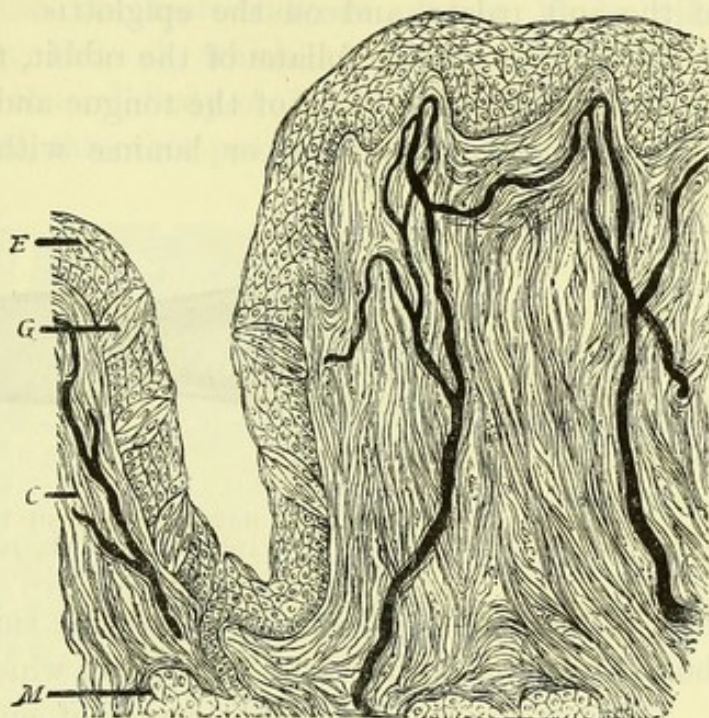


FIG. 182.—SECTION OF CIRCUMVALLATE PAPILLA, HUMAN. THE FIGURE INCLUDES ONE SIDE OF THE PAPILLA AND THE ADJOINING PART OF THE VALLUM. (Magnified 150 diameters.) (Heitzmann.)

*E*, epithelium; *G*, taste-bud; *C*, corium with injected blood-vessels; *M*, gland with duct.

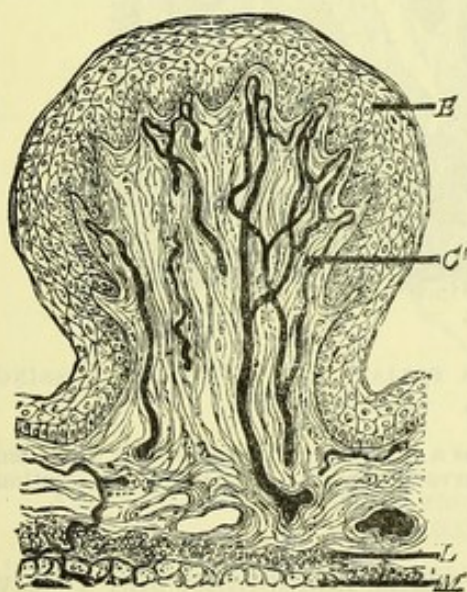


FIG. 183.—SECTION OF FUNGIFORM PAPILLA, HUMAN. (Heitzmann.)

*E*, epithelium; *C*, corium; *L*, lymphoid tissue; *M*, muscular fibres of tongue.

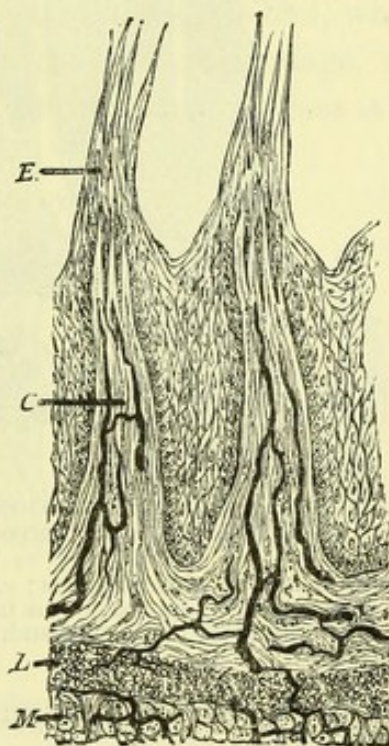


FIG. 184.—SECTION OF TWO FILIFORM PAPILLÆ, HUMAN. (Heitzmann.) (Letters as in previous figure.)



of the soft palate, and on the epiglottis. But they are most easily studied in the papillæ foliatæ of the rabbit, two small oval areas lying on either side of the back of the tongue and marked transversely with a number of small ridges or laminae with intervening furrows (see

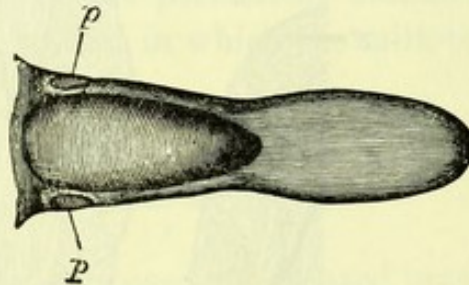


FIG. 185.—TONGUE OF RABBIT, SHOWING THE SITUATION OF THE PAPILLÆ FOLIATÆ, *p*.

figs. 185 and 186). Sections across the ridges show numerous taste-buds embedded in the thick epithelium which clothes their sides.

The taste-buds are ovoid clusters of epithelium-cells which lie in cavities in the stratified epithelium (fig. 187). The base of the taste-

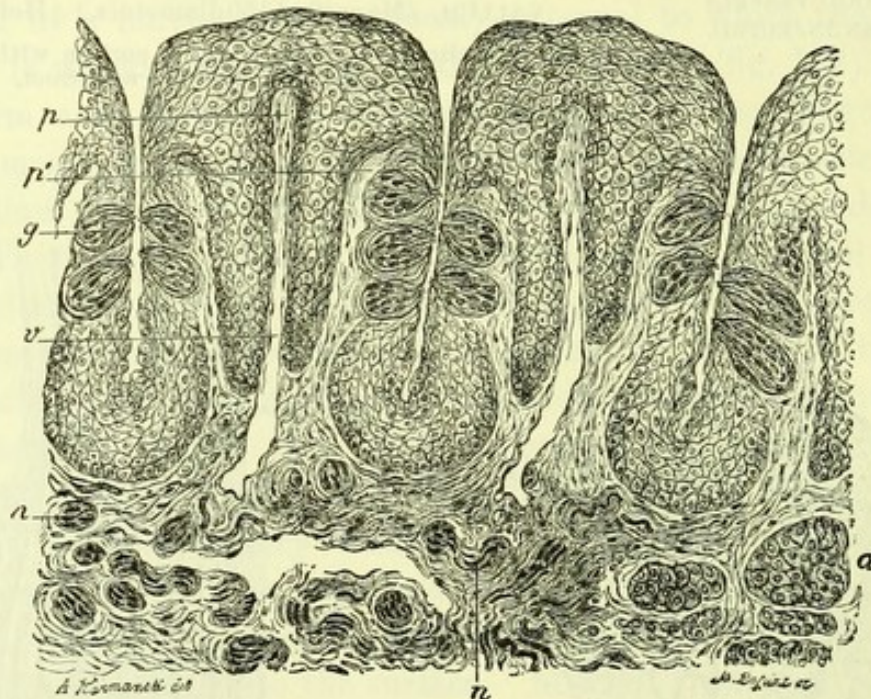


FIG. 186.—VERTICAL SECTION OF PAPILLA FOLIATA OF THE RABBIT, PASSING ACROSS THE FOLIAE. (Ranvier.)

*p*, central lamina of the corium; *v*, section across a vein, which traverses the whole length of the folia; *p'*, lateral lamina in which the nerve-fibres run; *g*, taste-bud; *n*, sections of nerve-bundles; *a*, serous gland.

bud rests upon the corium of the mucous membrane, and receives a branch of the glosso-pharyngeal nerve; the apex is narrow and communicates with the cavity of the mouth by a small pore in the superficial epithelium (*gustatory pore*, fig. 187, *p*).



The cells which compose the taste-bud are of two kinds, viz.: 1. The *gustatory cells* (fig. 188, *a*), which are delicate fusiform or bipolar cells composed of the cell-body or nucleated enlargement, and of two processes, one distal, the other proximal. The distal process is

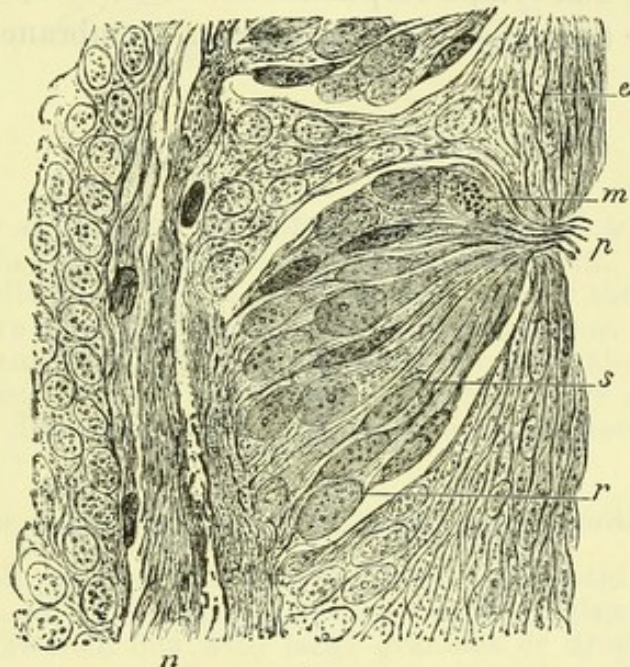


FIG. 187.—SECTION THROUGH THE MIDDLE OF A TASTE-BUD. (Ranvier.)

*p*, gustatory pore; *s*, gustatory cell; *r*, sustentacular cell; *m*, lymph cell, containing fatty granules; *e*, superficial cells of the stratified epithelium; *n*, nerve-fibres.

nearly straight, and passes towards the apex of the taste-bud, where it terminates in a small, highly refracting cilium-like appendage, which projects into the pore above mentioned. The proximal process is more

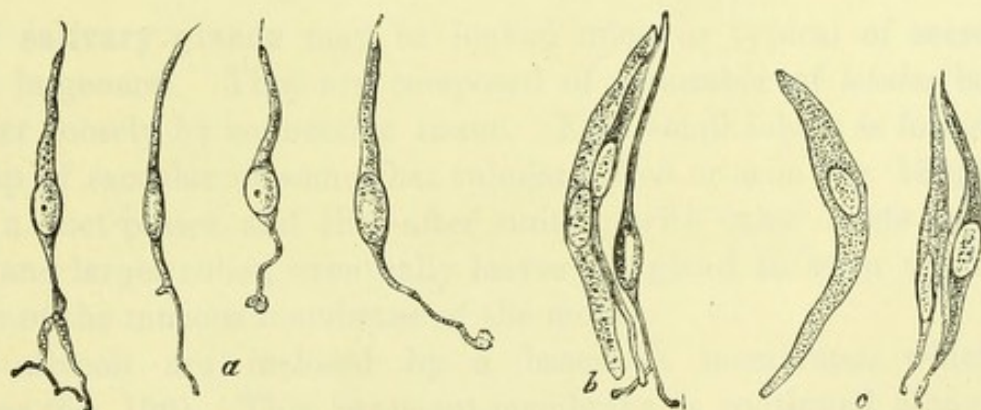


FIG. 188.—VARIOUS CELLS FROM TASTE-BUD OF RABBIT. (Engelmann.)  
(600 diameters.)

*a*, four gustatory cells from central part; *b*, two sustentacular cells, and one gustatory cell, in connection; *c*, three sustentacular cells.

delicate than the other, and is often branched and varicose. The nerve-fibres take origin in ramifications amongst the gustatory cells



(Retzius). 2. The *sustentacular cells* (fig. 188, c). These are elongated cells, mostly flattened, and pointed at their ends; they lie between the gustatory cells, which they thus appear to support, and in addition they form a sort of envelope or covering to the taste-bud. Between the cells of the taste bud lymph-corpuscles are often seen, having probably wandered hither from the subjacent mucous membrane.



## LESSON XXIX.

## THE SALIVARY GLANDS.

1. STUDY carefully sections of the submaxillary gland of a dog. The gland may be hardened in alcohol and stained with hæmatoxylin. Notice the acini filled with clear cells, the nuclei of which usually lie near the basement-membrane. Notice here and there, outside the clear cells, demilunes or crescents of small darkly stained granular-looking cells. Observe also the sections of the ducts with their striated columnar epithelium. Try and find a place where one of the ducts is passing into the alveoli. Sketch under a high power.

2. Study sections of the parotid gland prepared in a similar way.

3. Examine small pieces of both submaxillary and parotid gland of the dog fresh in 2 per cent. salt solution. In the submaxillary gland notice that the alveolar cells are swollen out with large granules or droplets of mucigen, which swell up in water to form large clear vacuoles. Dilute acids and alkalies produce a similar change. The cells of the parotid gland are also filled with granules (zymogen), but they are smaller, and simply dissolve in watery fluids.<sup>1</sup> Make a sketch from each preparation under a high power.

4. Prepare a transverse section of the œsophagus. Notice the thick muscular coat partly containing cross-striated fibres and the mucous membrane with its papillæ and stratified epithelium. Look for mucous glands in the areolar coat. Sketch under a low power.

The **salivary glands** may be looked upon as typical of secreting glands in general. They are composed of a number of *lobules* bound together loosely by connective tissue. Each small lobule is formed of a group of saccular or somewhat tubular *alveoli* or *acini* (fig. 189) from which a duct passes, and this, after uniting with other ducts to form larger and larger tubes, eventually leaves the gland to open upon the surface of the mucous membrane of the mouth.

The *alveoli* are inclosed by a basement membrane, which is reticular (fig. 190). This basement-membrane is continued along the ducts. Within it is the epithelium, which in the *alveoli* is composed of polyhedral cells (fig. 191, *a*), but in the ducts is regularly columnar,

<sup>1</sup>To study the changes which the alveolar cells undergo during secretion, pilocarpine is injected subcutaneously into an animal in sufficient amount to produce copious salivation; after which the animal is killed and its salivary glands are examined as in preparation 3. The granules are not seen in preparations that have been in alcohol, but osmic acid preserves them; they are best seen in the fresh tissue.



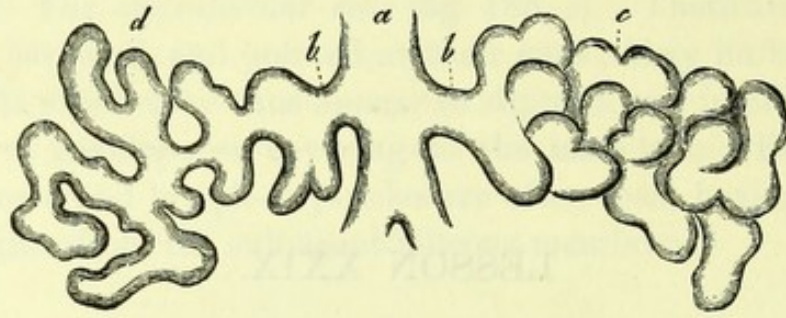


FIG. 189.—DIAGRAM OF THE CONSTRUCTION OF A LOBULE OF A TUBULO-RACEMOSE (ACINO-TUBULAR) MUCOUS GLAND. (Kölliker.)

*a*, duct; *b*, a branch of the duct; *c*, alveoli as they lie together in the gland; *d*, the same separated, showing their connection as an irregular tube.

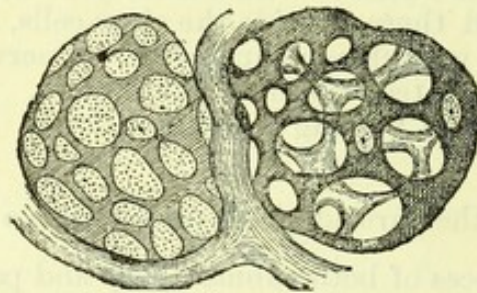


FIG. 190.—MEMBRANA PROPRIA OF TWO ALVEOLI ISOLATED. (Heidenhain.)

The preparation is taken from the orbital gland of the dog, which is similar in structure to a mucous salivary gland.

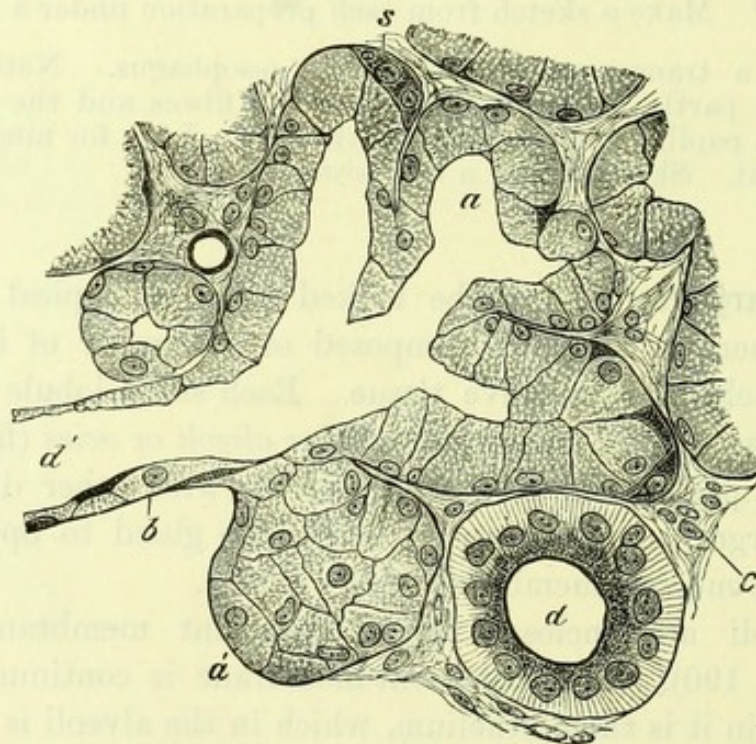


FIG. 191.—SECTION OF THE SUBMAXILLARY GLAND OF THE DOG, SHOWING THE COMMENCEMENT OF A DUCT IN THE ALVEOLI. (Magnified 425 diameters.)

*a*, one of the alveoli, several of which are in the section shown grouped around the commencement of the duct *d'*; *a'*, an alveolus, not opened by the section; *b*, basement-membrane in section; *c*, interstitial connective tissue of the gland; *d*, section of a duct which has passed away from the alveoli, and is now lined with characteristically striated columnar cells; *s*, semilunar group of darkly stained cells at the periphery of an alveolus.



except in that part of the duct which immediately opens into the alveoli (*junctional part*); in this it is flattened (*d'*). The columnar epithelium of the ducts is peculiar, in that the cells show a distinction into two unequal zones, an outer, larger, striated zone, and an inner, smaller, granular one (fig. 191, *d*).

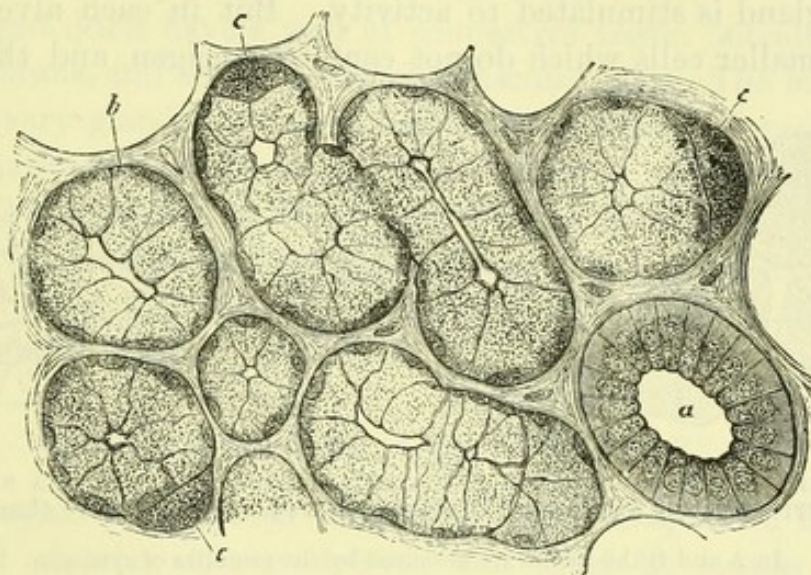


FIG. 192.—SECTION OF DOG'S SUBMAXILLARY, STAINED. (Kölliker.)

*a*, duct; *b*, alveolus; *c*, crescent.

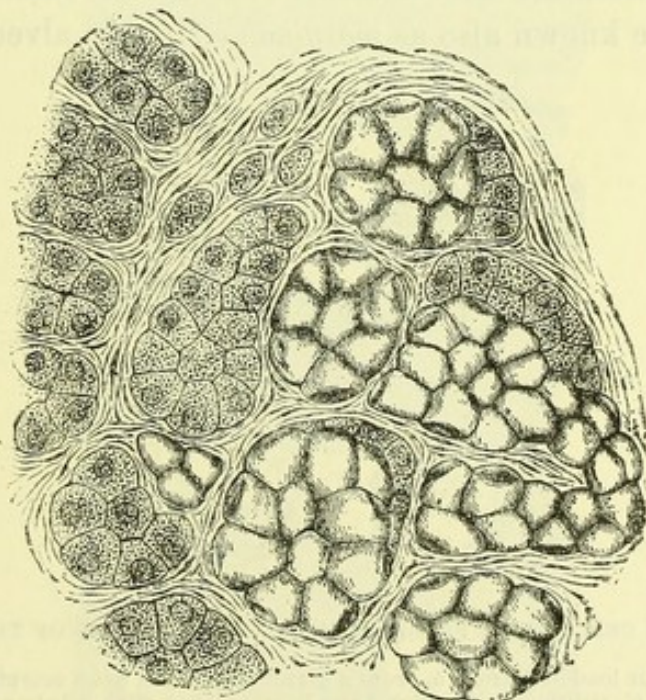


FIG. 193.—SECTION OF PART OF THE HUMAN SUBMAXILLARY GLAND. (Heidenhain.)

To the right of the figure is a group of mucous alveoli; to the left a group of serous alveoli.

The cells of the alveoli differ according to the substance they secrete. In alveoli which secrete mucus, such as all the alveoli of the dog's submaxillary, and some of the alveoli of the same gland in man (fig. 193), the cells, if examined in watery solution or after hardening



with alcohol, are clear and swollen. But if examined rapidly in serum, or in solutions of salt of from 2 to 5 per cent., they are seen to be occupied by large and distinct granules, formed of a substance which is known as mucigen (fig. 195, *a*). This mucigen is dissolved out of the cell and discharged into the lumen of the alveolus, and into the ducts when the gland is stimulated to activity. But in each alveolus there are some smaller cells which do not contain mucigen, and these gener-

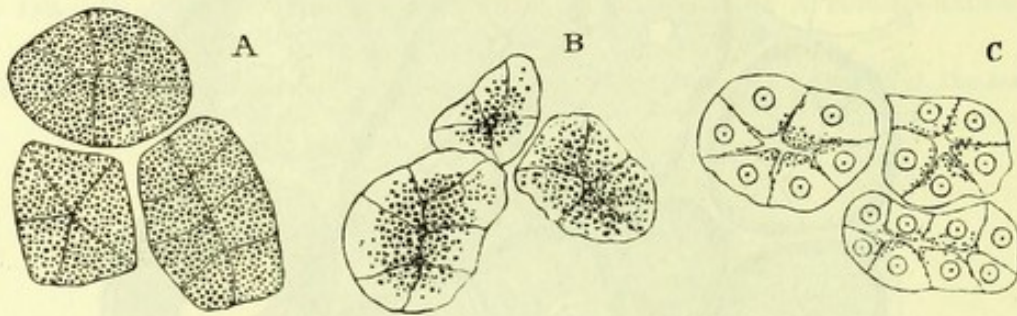


FIG. 194.—ALVEOLI OF A SEROUS GLAND. A, AT REST. B, AFTER A SHORT PERIOD OF ACTIVITY. C, AFTER A PROLONGED PERIOD OF ACTIVITY. (Langley.)

In A and B the nuclei are obscured by the granules of zymogen.

ally form crescentic groups which lie next to the basement-membrane (fig. 192, *c*). These are the so-called *crescents* of Gianuzzi; their constituent cells are known also as *marginal cells*. In alveoli, on the other

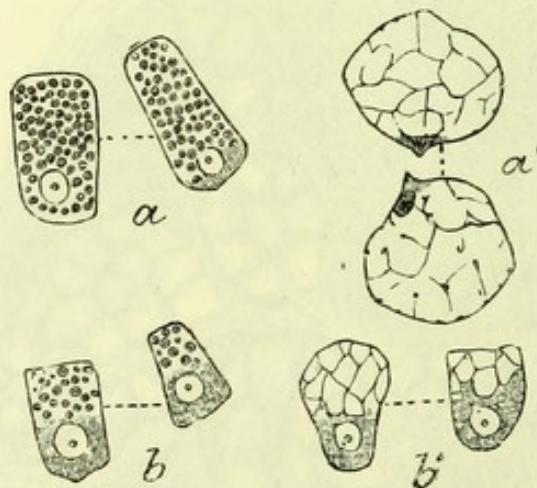


FIG. 195.—MUCOUS CELLS FROM FRESH SUBMAXILLARY GLANDS OF THE DOG. (Langley.)

*a*, from a resting or loaded gland; *b*, from a gland which has been secreting for some time;  
*a'*, *b'*, similar cells which have been treated with dilute acid.

hand, which do not secrete mucus, but watery or serous saliva, such as the parotid in all animals, and some of the alveoli of the human submaxillary, the cells are filled with small granules when the gland is at rest, which do not swell with water nor form mucin; they appear to be albuminous in nature, and probably yield to the secretion of the



gland its ferment (ptyalin) and perhaps its albumin. The granular substance within the cell is not the ferment, but the ferment is formed from it when the secretion is poured out. Hence it has been termed *zymogen* (mother of ferment). The outer part of each cell becomes clear and free from granules after secretion (fig. 194).

The largest ducts have a wall of connective tissue outside the basement-membrane, and also a few plain muscular cells. The blood-vessels of the salivary gland form a capillary network around each alveolus. The lymphatics commence in the form of lacunar vessels encircling the alveoli. The nerve-fibres, which are derived both from the cerebro-spinal nerves and from the sympathetic, have only recently been satisfactorily traced to their termination; they ramify amongst the alveolar cells.

### THE PHARYNX AND ŒSOPHAGUS.

The **pharynx** is composed of a *fibrous membrane*, which is encircled by striated muscles, the *constrictors*, and lined by *mucous membrane*. The mucous membrane is lined in the upper part of the pharynx and

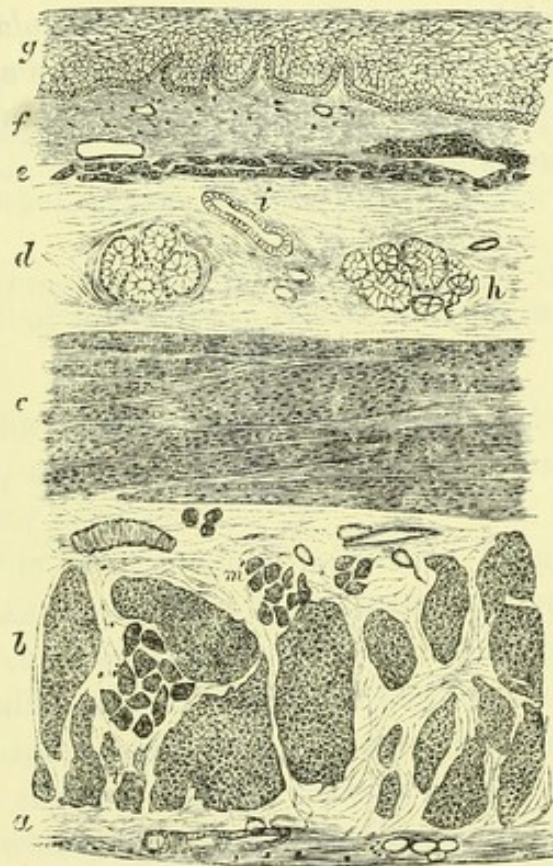


FIG. 196.—SECTION OF THE HUMAN ŒSOPHAGUS. (From a sketch by V. Horsley.)

The section is transverse, and from near the middle of the gullet. *a*, fibrous covering; *b*, divided fibres of the longitudinal muscular coat; *c*, transverse muscular fibres; *d*, sub-mucous or areolar layer; *e*, muscularis mucosae; *f*, papillae of mucous membrane; *g*, laminated epithelial lining; *h*, mucous gland; *i*, gland duct; *m*, striated muscular fibres in section.



on the upper surface of the soft palate with ciliated epithelium, which is continuous with that of the nostrils, and through the Eustachian tube with that of the tympanum. Below the level of the soft palate the epithelium is stratified like that of the mouth and gullet, into which it passes. In certain parts the mucous membrane contains a large amount of lymphoid tissue, especially at the back, where it forms a projection which is sometimes termed the pharyngeal tonsil, and there are numerous mucous glands opening on its surface.

The *œsophagus* or gullet, which passes from the pharynx to the stomach, consists, like the pharynx, of a *fibrous covering*, a *muscular coat*, a lining *mucous membrane*, and intervening connective tissue (*areolar coat*) (fig. 196). The muscular coat is much more regularly arranged than that of the pharynx, and is composed of striated muscle in about its upper third only, the rest being of the plain variety. There are two layers of the muscular coat—an outer layer, in which the fibres run longitudinally, and an inner, in which they course circularly. The mucous membrane is lined by a stratified epithelium, into which microscopic papillæ from the corium project. The corium is formed of areolar tissue, and its limits are marked externally by a narrow layer of longitudinally disposed plain muscular fibres, the *muscularis mucosæ*. This is separated from the proper muscular coat by the areolar coat, which contains the larger branches of the blood-vessels and lymphatics, and also most of the mucous glands of the membrane.



## LESSON XXX.

*THE STRUCTURE OF THE STOMACH.*

1. SECTIONS of the cardiac region of the dog's stomach, cut perpendicularly to the surface of the mucous membrane. The tissue is stained with hæmatoxylin or carmine, and the sections are mounted in Canada balsam.

In these sections the general arrangement of the coats of the stomach is to be studied, and sketches are to be made under a low power illustrating this arrangement, and others under a high power showing the structure of the glands of the mucous membrane.

Measure the whole thickness of the mucous membrane, the thickness of the muscular coat, the size of the columnar epithelium-cells of the surface, and that of the cells in the deeper parts of the glands.

2. Sections of the mucous membrane of the same region, cut parallel to the surface.

These sections will show better than the others the arrangement of the cells in the glands.

3. Vertical sections of the mucous membrane from the pyloric region of the dog's stomach. If the section is taken longitudinally through the pylorus the transition of the gastric glands into the glands of Brunner of the duodenum will be made manifest. Make a sketch under a low power of one of the glands in its whole length, filling up some of the details with the high power.

4. Study the arrangement of the blood-vessels of the stomach in vertical sections of the wall of an organ the vessels of which have been injected.

---

The wall of the **stomach** consists of four coats, which, enumerated from without in, are as follows, viz.: *serous*, *muscular*, *areolar* or *submucous*, and *mucous membrane*.

The *serous coat* is a layer which is derived from the peritoneum. It is deficient only along the lines of the lesser and greater curvatures.

The *muscular coat* consists of three layers of plain muscular fibres. Of these the bundles of the outer layer run longitudinally, those of the middle layer circularly, and those of the inner layer obliquely. The longitudinal and circular bundles become thicker and stronger towards the pylorus, at which they pass into the corresponding layers of the small intestine; at the pylorus itself the circular layer is greatly thickened to form the *sphincter muscle*. The oblique fibres are only present in the left or cardiac part of the stomach.

The *areolar* or *submucous coat* is a layer of areolar tissue, which serves



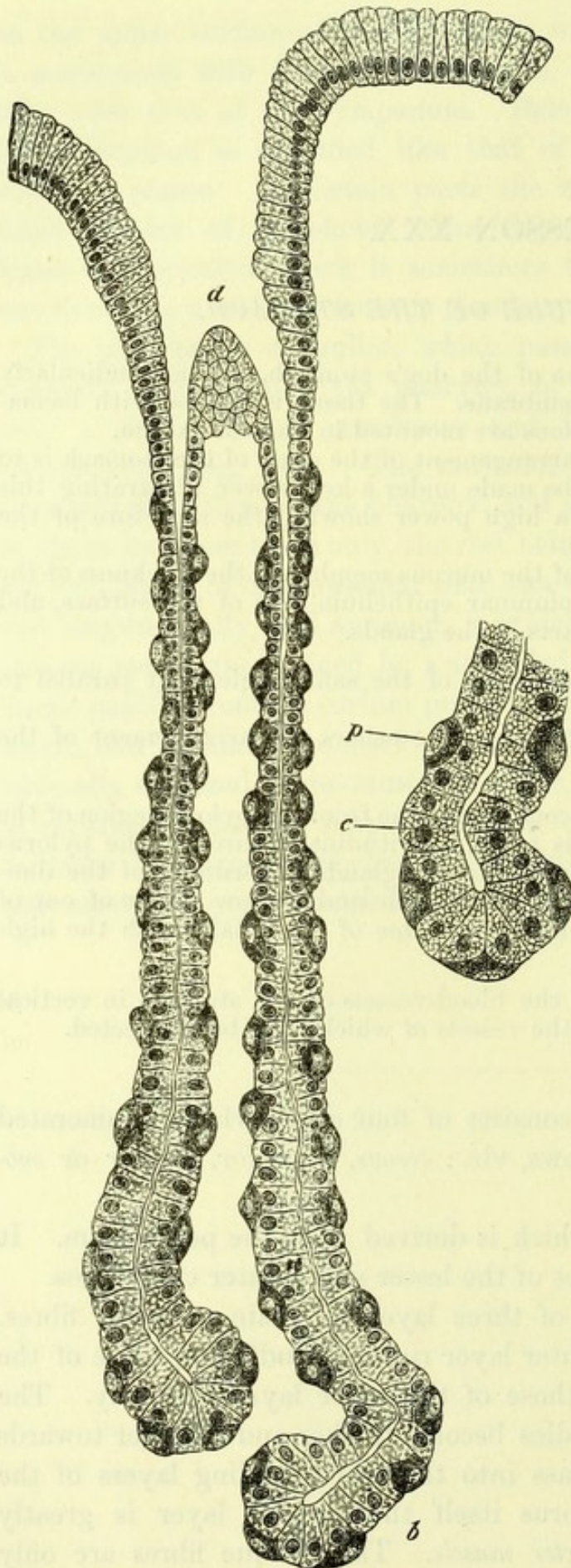


FIG. 197.—A CARDIAC GLAND FROM THE DOG'S STOMACH. (Highly magnified.) (Klein.)  
*d*, duct or mouth of the gland; *b*, base or fundus of one of its tubules. On the right the base of a tubule more highly magnified; *c*, central cell; *p*, parietal cell.

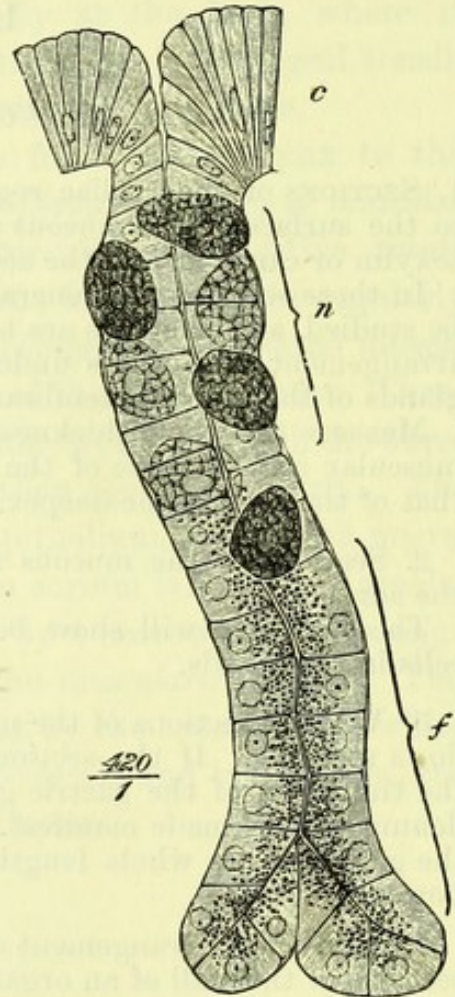


FIG. 198.—A CARDIAC GLAND OF SIMPLE FORM, FROM THE BAT'S STOMACH. (Osmic acid preparation.) (Langley.)

*c*, columnar epithelium of the surface; *n*, neck of the gland with central and parietal cells; *f*, base or fundus, occupied only by principal or central cells, which exhibit the granules accumulated towards the lumen of the gland.



to unite the mucous membrane loosely to the muscular coat; in it ramify the larger branches of the blood-vessels and lymphatics.

The *mucous membrane* is a soft, thick layer, generally somewhat corrugated in the empty condition of the organ. Its thickness is mainly due to the fact that it is largely made up of long tubular glands, which open upon the inner surface. Between the glands the mucous membrane is formed of areolar with much lymphoid tissue. Externally it is bounded by the *muscularis mucosæ*, which consists of an external longitudinal and an inner circular layer of plain muscular fibres. The *glands* are formed of a basement-membrane lined with epithelium. Each gland consists of three or four *secreting tubules*, which open towards the surface into a larger common tube, the *duct* of the gland. The duct is in all cases lined by columnar epithelium of the same character as that which covers the inner surface of the mucous membrane, but the epithelium of the secreting tubules is different from this, and also differs somewhat in the glands of the cardiac and pyloric regions of the organ.

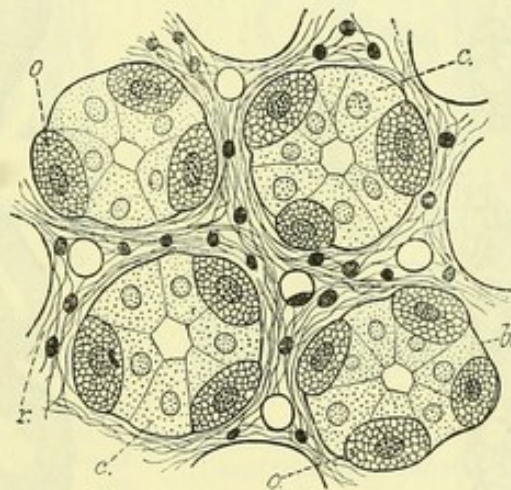


FIG. 199.—SECTION OF THE GASTRIC MUCOUS MEMBRANE TAKEN ACROSS THE DIRECTION OF THE GLANDS (CARDIAC PART).

*b*, basement membrane; *c*, central cells; *o*, parietal cells; *r*, retiform tissue (with sections of blood-capillaries) between the glands.

In the *cardiac glands* (fig. 197) the secreting tubules are long, and the duct short. The epithelium of the tubules is composed of two kinds of cells. Those of the one kind, which form a continuous lining to the tubule, are somewhat polyhedral in shape, and in stained sections look clearer and smaller than the others, but in the fresh glands, and in osmic preparations, they appear filled with granules (fig. 198).<sup>1</sup> These

<sup>1</sup> The granules are most numerous at the inner part of the cell, a small outer zone being left clear. After prolonged activity this outer zone increases in size while the granules diminish in number as in the analogous cases of the pancreas and parotid glands.



cells are believed to secrete the pepsin of the gastric juice, and are termed the *chief cells* of the cardiac glands, or, from their relative position in the tubule immediately surrounding the lumen, the *central cells*. Scattered along the tubule, and lying between the chief cells and the basement-membrane, are a number of other spheroidal or ovoidal cells, which become stained by logwood and other reagents more darkly than the central cells. These are the *superadded* or *parietal cells* (*oxyntic cells*<sup>1</sup> of Langley). Each parietal cell is surrounded

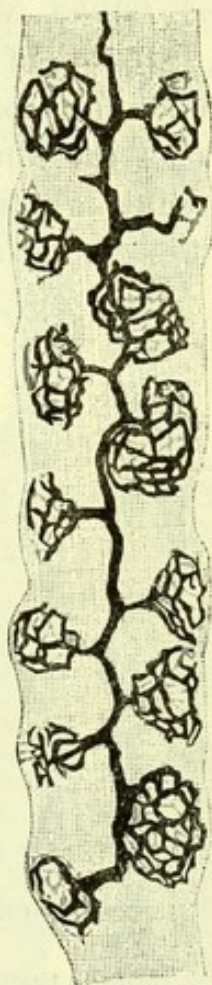


FIG. 200.—A CARDIAC GLAND PREPARED BY GOLGI'S METHOD, SHOWING THE MODE OF COMMUNICATION OF THE PARIETAL CELLS WITH THE GLAND-LUMEN. (E. Müller.)

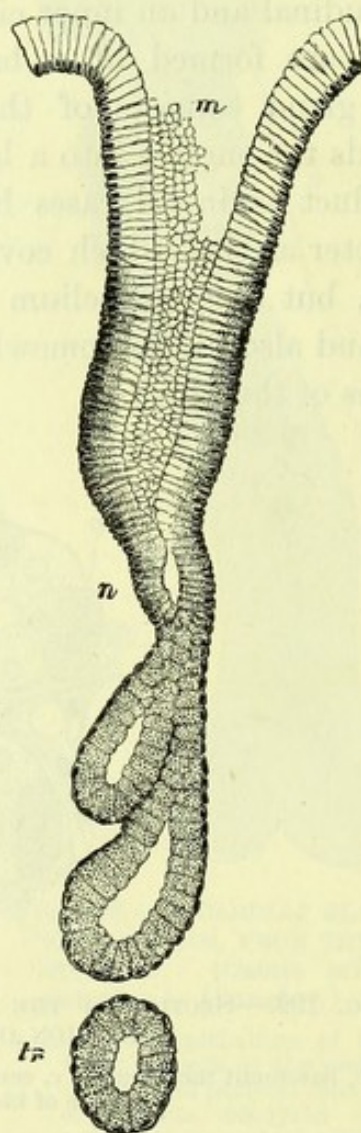


FIG. 201.—A PYLORIC GLAND, FROM A SECTION OF THE DOG'S STOMACH. (Ebstein.)

*m*, mouth; *n*, neck; *tr*, a deep portion of a tubule cut transversely.

by a network of fine passages, communicating with the lumen of the gland by a fine canal, which passes between the central cells (fig. 200).

In the *pyloric glands* (fig. 201) the ducts are much longer than in the cardiac glands, and the secreting tubules possess cells of only one

<sup>1</sup> So called because they are believed to produce the acid of the gastric secretion.



kind.<sup>1</sup> These correspond to the chief cells of the cardiac glands. They are of a columnar or cubical shape, and in the fresh condition of a granular appearance, and quite unlike the columnar epithelium-cells of the surface, which are long tapering cells, the outer part of which is filled with mucus.

At the pylorus itself the glands become considerably lengthened, and are continued into the submucous tissue, the muscularis mucosæ being here absent; they thus present transitions to the glands of Brunner, which lie in the submucous tissue of the duodenum, and send their ducts through the mucous membrane to the inner surface.

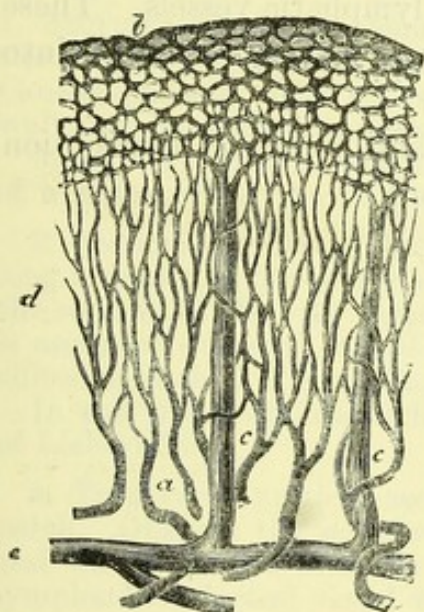


FIG. 202, A.—PLAN OF THE BLOOD-VESSELS OF THE STOMACH. (Modified from Brinton.)

*a*, small arteries passing to break up into the fine capillary network, *d*, between the glands; *b*, coarser capillary network around the mouths of the glands; *c*, veins passing vertically downwards from the superficial network; *e*, larger vessels in the submucosa.

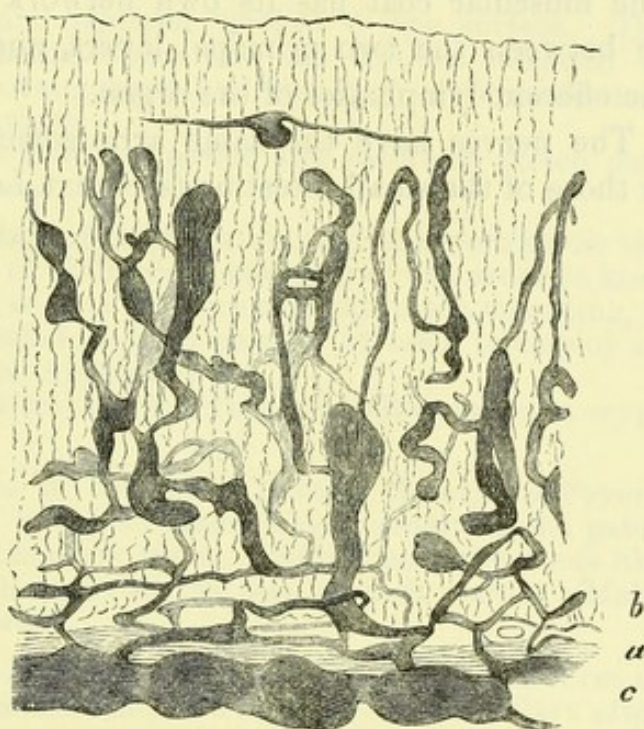


FIG. 202, B.—LYMPHATICS OF THE HUMAN GASTRIC MUCOUS MEMBRANE, INJECTED. (C. Lovén.)

The tubules are only faintly indicated; *a*, muscularis mucosæ; *b*, plexus of fine vessels at base of glands; *c*, plexus of larger valved lymphatics in submucosa.

The *blood-vessels* of the stomach are very numerous, and pass to the organ along its curvatures. The arteries pass through the muscular coat, giving off branches to the capillary network of the muscular tissue, and ramify in the areolar coat. From this, small arteries pierce the muscularis mucosæ, and break up into capillaries near the bases of the glands (fig. 202, A). The capillary network extends between the glands to the surface, close to which it terminates in a plexus of relatively large venous capillaries which encircle the mouths of the glands. From this plexus straight venous radicles pass through the

<sup>1</sup> In man it is only quite near the pylorus that the parietal cells are altogether absent.



mucous membrane, pierce the muscularis mucosæ, and join a plexus of veins in the submucous tissue. From these veins blood is carried away from the stomach by efferent veins, which accompany the entering arteries.

The *lymphatics* (fig. 202, B) arise in the mucous membrane by a plexus of large vessels dilated at intervals, and looking in sections like clefts in the interglandular tissue. From this plexus the lymph is carried into larger valved vessels in the submucous coat, and from these, efferent vessels pass through the muscular coat to reach the serous membrane, underneath which they pass away from the organ. The muscular coat has its own network of lymphatic vessels. These lie between the two principal layers, and their lymph is poured into the efferent lymphatics of the organ.

The nerves have the same arrangement and mode of distribution as those of the small intestine (see next Lesson).



## LESSONS XXXI. AND XXXII.

*STRUCTURE OF THE INTESTINE.*

## LESSON XXXI.

1. SECTIONS of the duodenum and jejunum vertical to the surface. The tissue is to be stained with hæmatoxylin and the sections mounted in Canada balsam. The general arrangement and structure of the intestinal wall is to be studied in these sections.

Make a general sketch under the low power and carefully sketch part of a villus under the high power.

2. Sections parallel to the surface of the intestine, and therefore across the long axis of the villi and glands of the mucous membrane. In order to keep the sections of the villi together so that they are not lost in the mounting, it is necessary either to embed in celloidin or, if paraffin be used, to employ an adhesive method of mounting (see Appendix).

In this preparation sketch the transverse section of a villus and of a crypt of Lieberkühn.

3. Transverse vertical sections of the ileum passing through a Peyer's patch. Observe the nodules of lymphoid tissue which constitute the patch and which extend into the submucous tissue. Notice also the sinus-like lymphatic or lacteal vessel which encircles the base of each nodule. Make a general sketch under a low power.

4. To study the process of fat-absorption, kill a mammal, *e.g.* rat, three or four hours after feeding it with a little fat, or a frog two or three days after feeding with lard. Put a very small shred of the mucous membrane of the intestine into osmic acid (0.5 per cent.) and another piece into a mixture of 2 parts Müller's fluid and 1 part osmic acid solution (1 per cent.). After forty-eight hours teased preparations may be made from the osmic acid preparation, in the same manner as directed in Lesson VII., sec. 2; the rest may be then placed in 70 per cent. alcohol. The piece in Müller and osmic acid may be left for ten days or more in the fluid. When hardened, the pieces of tissue are soaked in gum, and sections made with a freezing microtome and mounted in glycerine. The sections must not be passed through any fluid which dissolves fat.

## LESSON XXXII.

1. SECTIONS of small intestine the blood-vessels of which have been injected. Notice the arrangement of the vessels in the several layers. Sketch carefully the vascular network of a villus.

2. From a piece of intestine which has been stained with chloride of gold tear off broad strips of the longitudinal muscular coat, and mount them in glycerine. It will generally be found that portions of the nervous plexus of Auerbach remain adherent to the strips, and the plexus can in this way easily be studied.



From the remainder of the piece of intestine tear off with forceps the fibres of the circular muscular layer on the one side, and the mucous membrane on the other side, so as to leave only the submucous tissue and the muscularis mucosæ. This tissue is also to be mounted flat in glycerine: it contains the plexus of Meissner.

Sketch a small portion of each plexus under a high power.

3. Sections of the large intestine, perpendicular to the surface. These will show the general structure and arrangement of the coats. Sketch under a low power.

4. Sections of the mucous membrane of the large intestine parallel to the surface, and therefore across the glands. Sketch some of the glands and the interglandular tissue under a high power.

5. The arrangement of the blood-vessels of the large intestine may be studied in sections of the injected organ.

### THE SMALL INTESTINE.

The wall of the **small intestine** consists, like the stomach, of four coats. The *serous coat* is complete except over part of the duodenum.

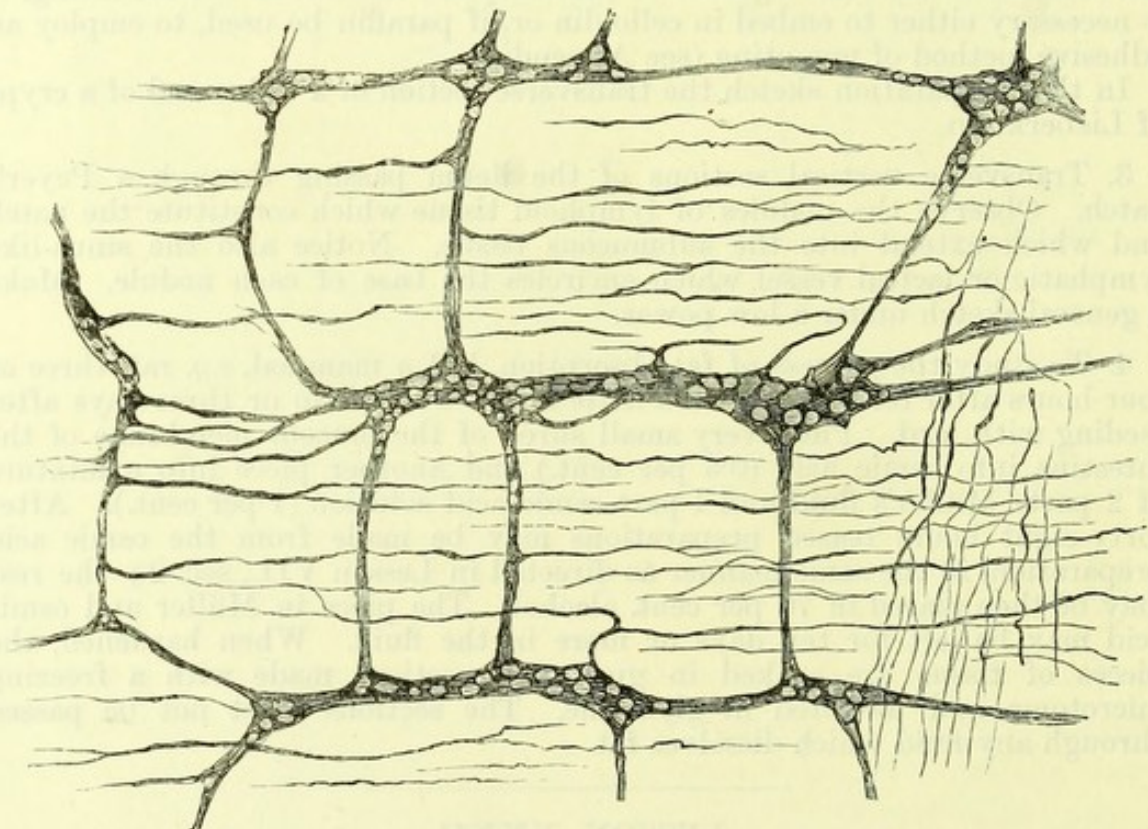


FIG. 203.—PLEXUS OF AUERBACH, BETWEEN THE TWO LAYERS OF THE MUSCULAR COAT OF THE INTESTINE. (Cadiat.)

The *muscular coat* is composed of two layers of muscular tissue, an outer longitudinal and an inner circular. Between them lies a network of lymphatic vessels and also the close gangliated plexus of non-medullated nerve-fibres known as the *plexus myentericus* of Auerbach. The ganglia of this plexus may usually be seen in vertical sections of



the intestinal wall, but the plexus, like the one in the submucous coat immediately to be described, can only be properly displayed in preparations made with chloride of gold (fig. 203) or methyl-blue.

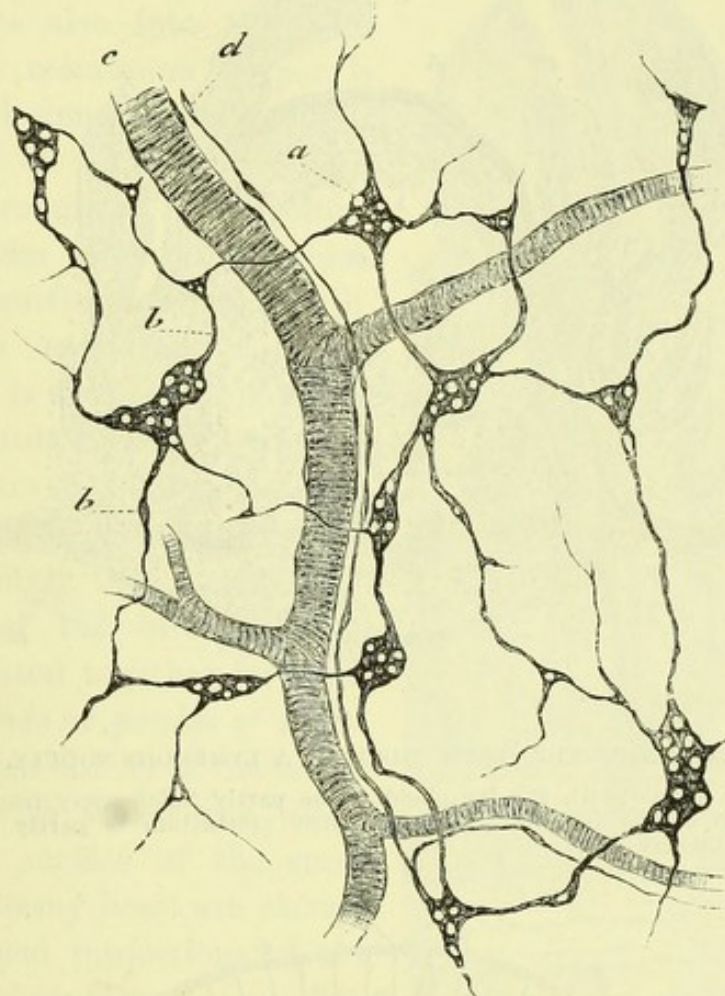


FIG. 204.—PLEXUS OF MEISSNER FROM THE SUBMUCOUS COAT OF THE INTESTINE.  
(Cadiat.)

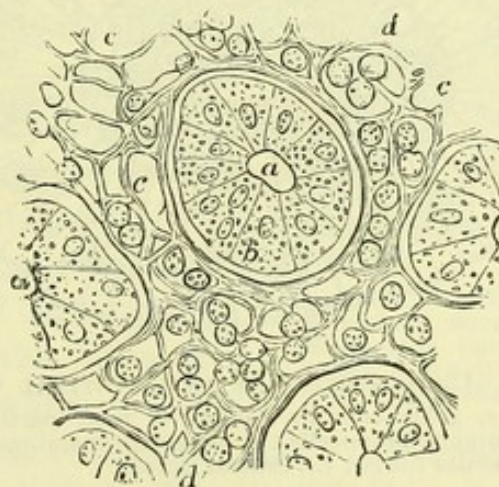


FIG. 205.—CROSS-SECTION OF A SMALL FRAGMENT OF THE MUCOUS MEMBRANE OF THE INTESTINE, INCLUDING ONE ENTIRE CRYPT OF LIEBERKÜHN AND PARTS OF THREE OTHERS. (Magnified 400 diameters.) (Frey.)

*a*, cavity of the tubular glands or crypts; *b*, one of the lining epithelial-cells;  
*c*, the interglandular tissue; *d*, lymph-cells.



The *submucous coat* is like that of the stomach ; in it the blood-vessels and lymphatics ramify before entering or after leaving the mucous membrane, and it contains a gangliated plexus of nerve-fibres—the

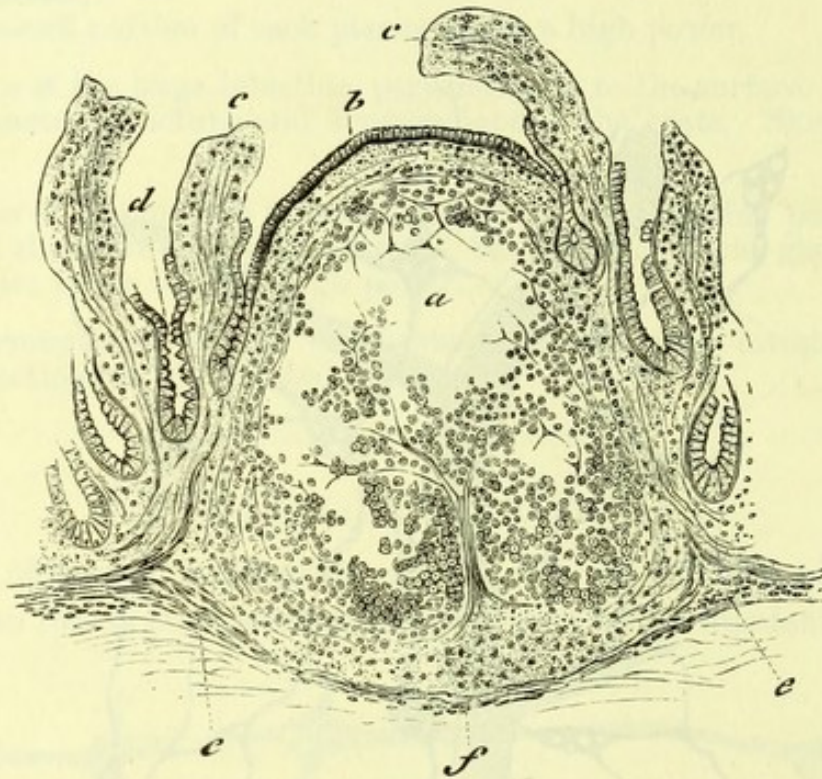


FIG. 206.—SECTION OF THE ILEUM THROUGH A LYMPHOID NODULE. (Cadiat.)

*a*, middle of the nodule with the lymphoid tissue partly fallen away from the section ; *b*, epithelium of the intestine ; *c*, villi : their epithelium is partly broken away ; *d*, crypts of Lieberkühn.

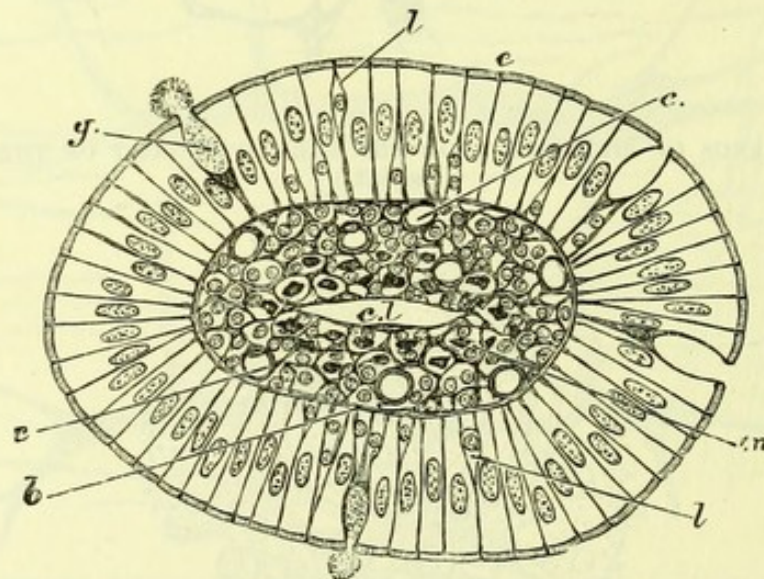


FIG. 207.—CROSS-SECTION OF AN INTESTINAL VILLUS.

*e*, columnar epithelium ; *g*, goblet-cell, its mucus is seen partly extruded ; *l*, lymph-corpuscles between the epithelium-cells ; *b*, basement-membrane ; *c*, blood-capillaries ; *m*, section of plain muscular fibres ; *c.l.*, central lacteal.

*plexus of Meissner*—which is finer than that of Auerbach and has fewer ganglion-cells (fig. 204). Its branches are chiefly supplied to the muscular fibres of the mucous membrane.



The *mucous membrane* is bounded next to the submucous coat by a double layer of plain muscular fibres (*muscularis mucosæ*). Bundles from this pass inwards through the membrane towards the inner surface and penetrate also into the villi. The mucous membrane proper is pervaded with simple tubular glands—the *crypts of Lieberkühn*—which are lined throughout by a columnar epithelium like that which covers the surface and the villi. The mucous membrane between these glands is mainly composed of lymphoid tissue, which is aggregated at intervals into more solid nodules (fig. 206), constituting when they occur singly the so-called *solitary glands* of the intestine, and when aggregated together form the *agminated glands* or *patches of Peyer*. The latter occur chiefly in the ileum.

The *villi* with which the whole of the inner surface of the small intestine is closely beset are clavate or finger-shaped projections of the mucous membrane, and are composed, like that, of lymphoid tissue and covered with columnar epithelium (fig. 207). The characters of this have been already described (Lesson VII.). Between and at the base of the epithelium-cells many lymph-corpuscles occur. The epithelium rests upon a basement-membrane formed of flattened cells. In the middle of the villus is a lacteal vessel (*c.l.*) which is somewhat enlarged near its commencement. It is replaced in some animals by a network of lymphatics. Surrounding this vessel are small bundles of plain muscular tissue prolonged from the *muscularis mucosæ*. The network of blood-capillaries (fig. 208) lies for the most part near the surface within the basement-membrane; it is supplied with blood by

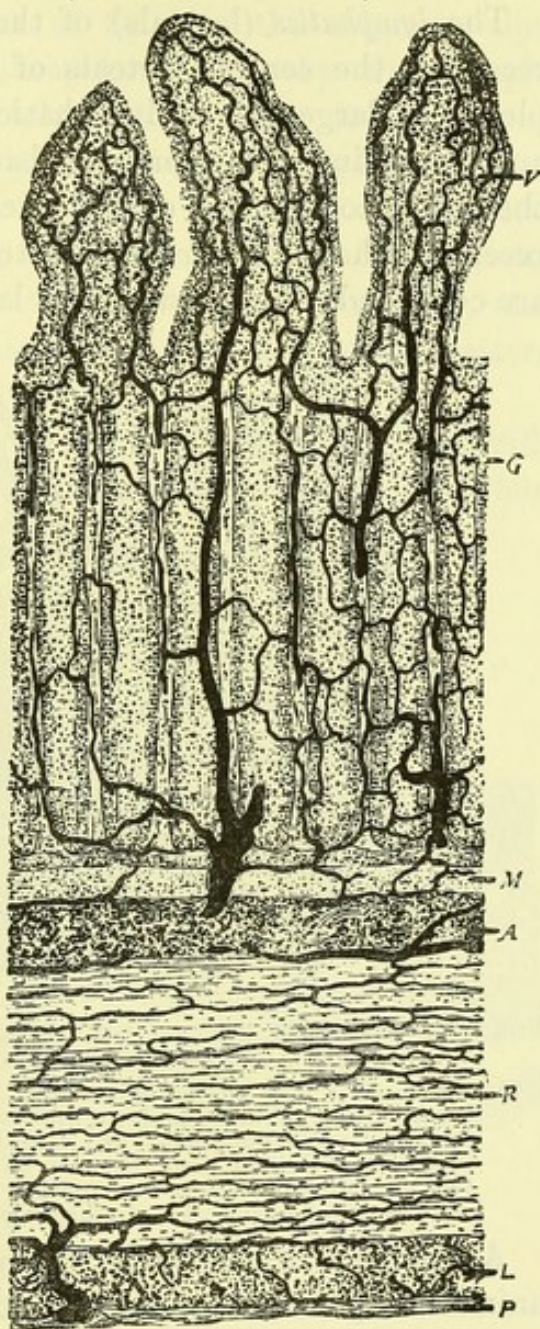


FIG. 208.—SMALL INTESTINE, VERTICAL TRANSVERSE SECTION WITH THE BLOOD-VESSELS INJECTED. (Heitzmann.)

V, a villus; G, glands of Lieberkühn; M, muscularis mucosæ; A, areolar coat; R, ring-muscle (circular layer of muscular coat); L, longitudinal layer of muscular coat; p, peritoneal coat.

It is replaced in some animals by a network of lymphatics. Surrounding this vessel are small bundles of plain muscular tissue prolonged from the *muscularis mucosæ*. The network of blood-capillaries (fig. 208) lies for the most part near the surface within the basement-membrane; it is supplied with blood by



a small artery which joins the capillary network at the base of the villus; the corresponding vein generally rises near the extremity.

The *lymphatics* (lacteals) of the mucous membrane (fig. 209), after receiving the central lacteals of the villi, pour their contents into a plexus of large valved lymphatics which lie in the submucous tissue and form sinuses around the bases of the lymphoid nodules. From the submucous tissue efferent vessels pass through the muscular coat, receiving the lymph from an intramuscular plexus of lymphatics, and are conveyed away between the layers of the mesentery.

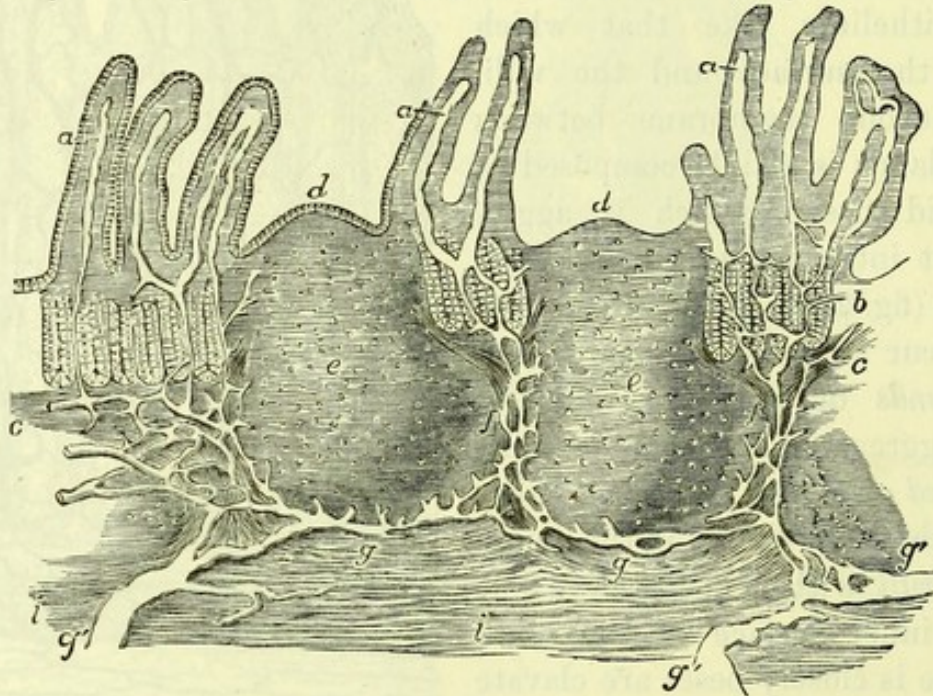


FIG. 209.—VERTICAL SECTION OF A PORTION OF A PATCH OF PEYER'S GLANDS WITH THE LACTEAL VESSELS INJECTED. (32 diameters.) (Frey.)

The specimen is from the lower part of the ileum: *a*, villi, with their lacteals left white; *b*, some of the tubular glands; *c*, the muscular layer of the mucous membrane; *d*, cupola or projecting part of the nodule; *e*, central part; *f*, the reticulated lacteal vessels occupying the lymphoid tissue between the nodules, joined above by the lacteals from the villi and mucous surface, and passing below into *g*, the sinus-like lacteals under the nodules, which again pass into the large efferent lacteals, *g'*; *i*, part of the muscular coat.

**Absorption of fat.**—The lymph-corpuscles of the villi are in some animals—*e.g.* rat, frog—important agents in effecting the passage of fat-particles into the lacteals. In other animals much of the fat is absorbed in the form of soap, and takes a fluid form in its passage into the lacteals of the villi. In order to study the process of transference, it is convenient to stain the fat with osmic acid, which colours it black. It can then be observed that in animals of the former category which have been fed with fat these particles are present (1) in the columnar epithelium-cells; (2) in the lymph-cells; and (3) in the central lacteal of the villus. The lymph-cells are present not only in the reticular tissue of the villus, but also in considerable number between the epithelium-cells; and they can also be seen in thin sections from osmic preparations within the commencing lacteal; but in the last situation they are undergoing disintegration.



Since the lymph-cells are amœboid, it is probable from these facts that the mechanism of fat-absorption in these cases consists of the following processes—viz. (1) absorption of fat into the columnar epithelium-cells of the surface; (2) inception of fat by the lymph-corpuscles in the epithelium, these taking it up after it has passed through the epithelium-cells; (3) migration of the lymph-corpuscle carrying the incepted fat-particles by their amœboid movements through the tissue of the villus and into the central lacteal; (4) disintegration and solution of the immigrated lymph-corpuscles, and setting free both of their fatty contents and also of the proteid matters of which they are themselves composed.

This migration of the lymph-corpuscles into the lacteals of the villi is not a special feature of fat-absorption alone, but occurs even when

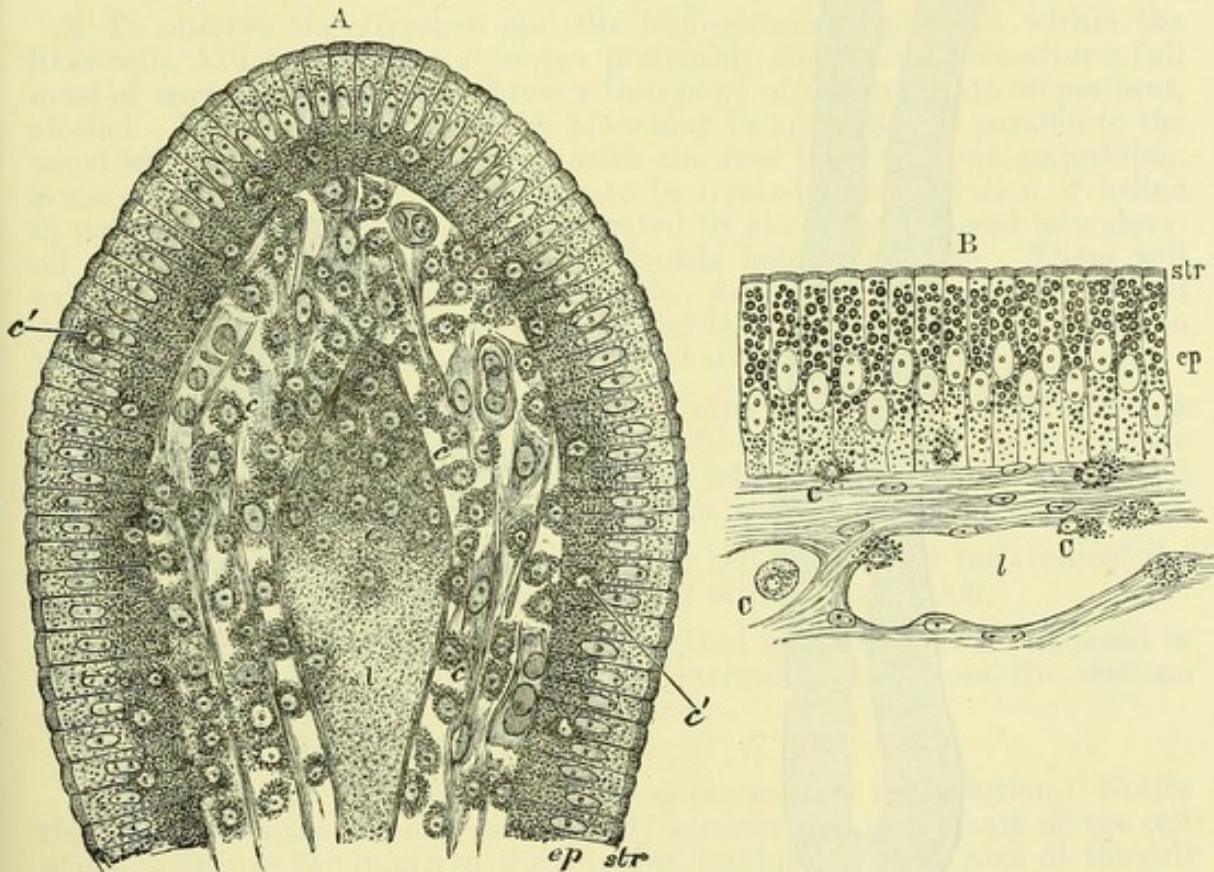


FIG. 210.—SECTION OF THE VILLUS OF A RAT KILLED DURING FAT-ABSORPTION.  
*ep*, epithelium; *str*, striated border; *c*, lymph-cells; *c'*, lymph-cells in the epithelium;  
*l*, central lacteal containing disintegrating lymph-corpuscles.

FIG. 211.—MUCOUS MEMBRANE OF FROG'S INTESTINE DURING FAT-ABSORPTION.  
*ep*, epithelium; *str*, striated border; *c*, lymph-corpuscles; *l*, lacteal.

absorption of other matters is proceeding; so that the transference of fat-particles is merely a part of a more general phenomenon accompanying absorption.

#### THE LARGE INTESTINE.

The large intestine has the usual four coats, except near its termination, where the serous coat is absent. The muscular coat is peculiar in



the fact that along the cæcum and colon the longitudinal muscular fibres are gathered up into three thickened bands which produce puckerings in the wall of the gut.

The *mucous membrane* of the large intestine is beset with simple tubular glands somewhat resembling the crypts of Lieberkühn of the small intestine, and lined by columnar epithelium similar to that of the inner surface of the gut, but containing many more mucus-secreting or goblet-cells (fig. 212). The extremity of each gland is usually slightly dilated. The interglandular tissue is like that of the stomach, as is

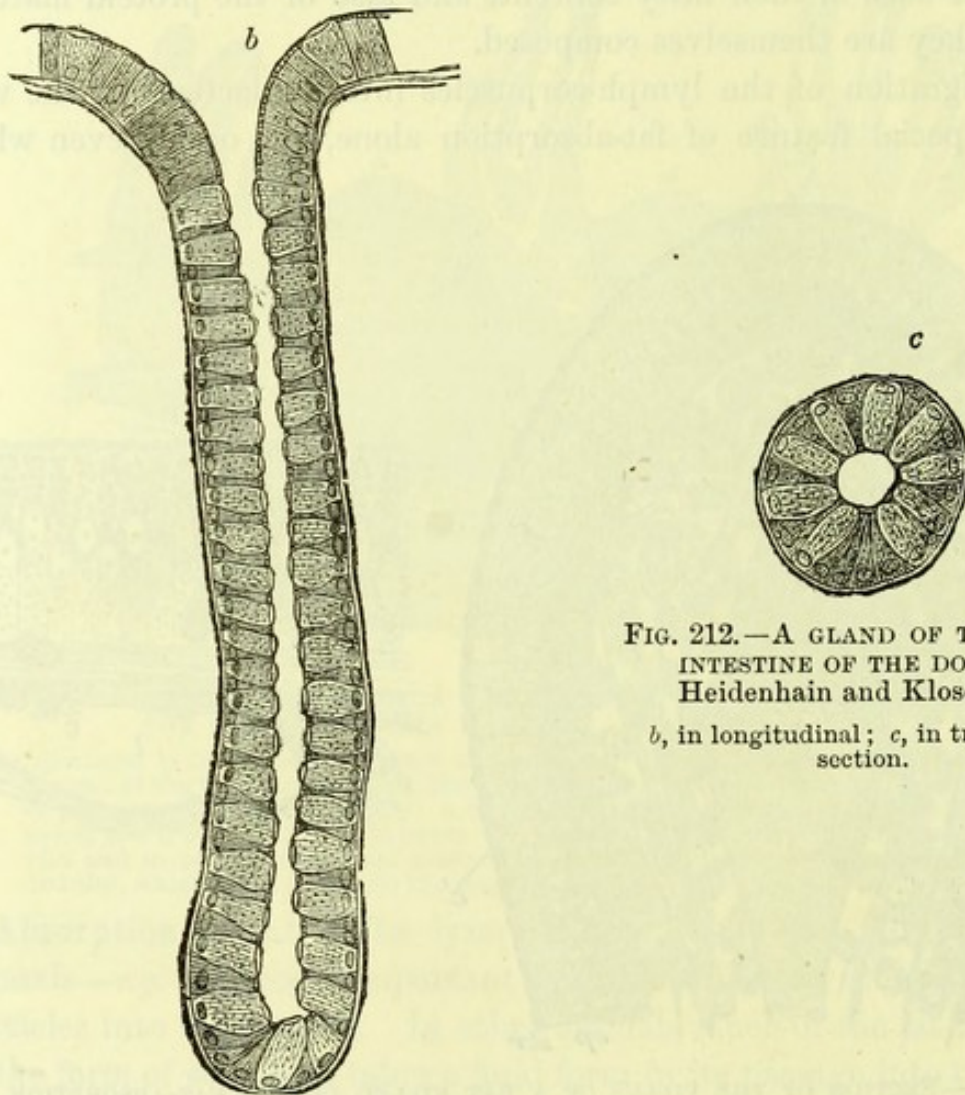


FIG. 212.—A GLAND OF THE LARGE INTESTINE OF THE DOG. (From Heidenhain and Klose.)

*b*, in longitudinal; *c*, in transverse section.

also the arrangement of the blood-vessels and lymphatics in it. The nerves of the large intestine also resemble those of the small intestine and stomach in their arrangement.

At the lower end of the rectum the circular muscular fibres of the gut become thickened a little above the anus so as to form the *internal sphincter* muscle. In this region also there are a number of compound racemose mucous glands opening on to the surface of the mucous membrane (*anal glands*).



## LESSON XXXIII.

*STRUCTURE OF THE LIVER AND PANCREAS.*

1. MAKE sections of liver, pig's and human, from pieces hardened in Müller's fluid, and study them carefully with a low and high power. Sketch the general arrangement of the cells in a lobule under the low power and under the high power. Make very careful drawings of some of the hepatic cells and also of a portal canal.

2. To observe the glycogen and the iron-containing pigment within the liver-cells, kill a rabbit (for glycogen preferably about six hours after a full meal of carrots), and at once throw a thin piece of the liver into 90 per cent. alcohol. When well hardened the piece may be embedded in paraffin in the usual way, or sections may be cut with the free hand without embedding. Some of the sections so obtained are to be treated with a solution of iodine in potassic iodide : then rapidly dehydrated by alcohol and passed into clove-oil. They may now be mounted in Canada balsam solution. These will exhibit the glycogen within the liver-cells. Other sections are to be treated first with potassic ferrocyanide solution and then with hydrochloric acid : in these many of the pigment-granules will be stained blue (presence of iron).

3. Study, first with the low power and afterwards with a high power, a section of the liver in which both the blood-vessels and the bile-ducts have been injected.<sup>1</sup> Make a general sketch of a lobule under the low power and draw a small part of the network of bile-canaliculi under the high power.

4. Tease a piece of fresh liver in serum or salt solution for the study of the appearance of the hepatic cells in the recent or living condition.

5. Stained sections of pancreas from a gland which has been hardened in alcohol. Small pieces of the gland are stained in bulk and the sections mounted in the usual way in Canada balsam.

Make a sketch under the low power.

6. Tease a small piece of fresh pancreas in serum or salt solution. Notice the granules in the alveolar cells, chiefly accumulated in the half of the cell which is nearest the lumen of the alveolus, leaving the outer zone of the cell clear.

Sketch a small portion of an alveolus under a high power.

---

*THE LIVER.*

The liver is a solid glandular mass, made up of the *hepatic lobules*. These are polyhedral masses about 1 mm. ( $\frac{1}{25}$  inch) in diameter, composed of cells, and separated from one another by connective tissue.

<sup>1</sup> For the method of injecting these, see *Course of Practical Histology*. They can also be demonstrated in sections of liver which have been prepared by Golgi's method (see Appendix).



In some animals, as in the pig, this separation is complete, and each lobule is isolated, but in man it is incomplete. There is also a layer of connective tissue underneath the serous covering of the liver, forming the so-called *capsule* of the organ.

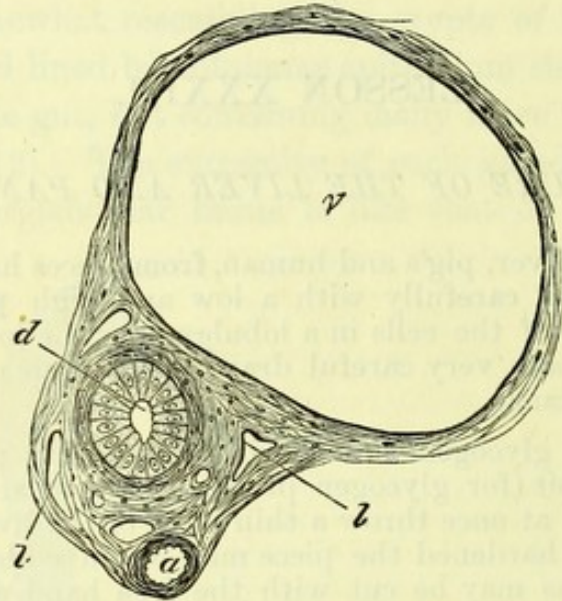


FIG. 213.—SECTION OF A PORTAL CANAL.

*a*, branch of hepatic artery ; *v*, branch of portal vein ; *d*, bile-duct ; *l*, *l*, lymphatics in the areolar tissue of Glisson's capsule which incloses the vessels.

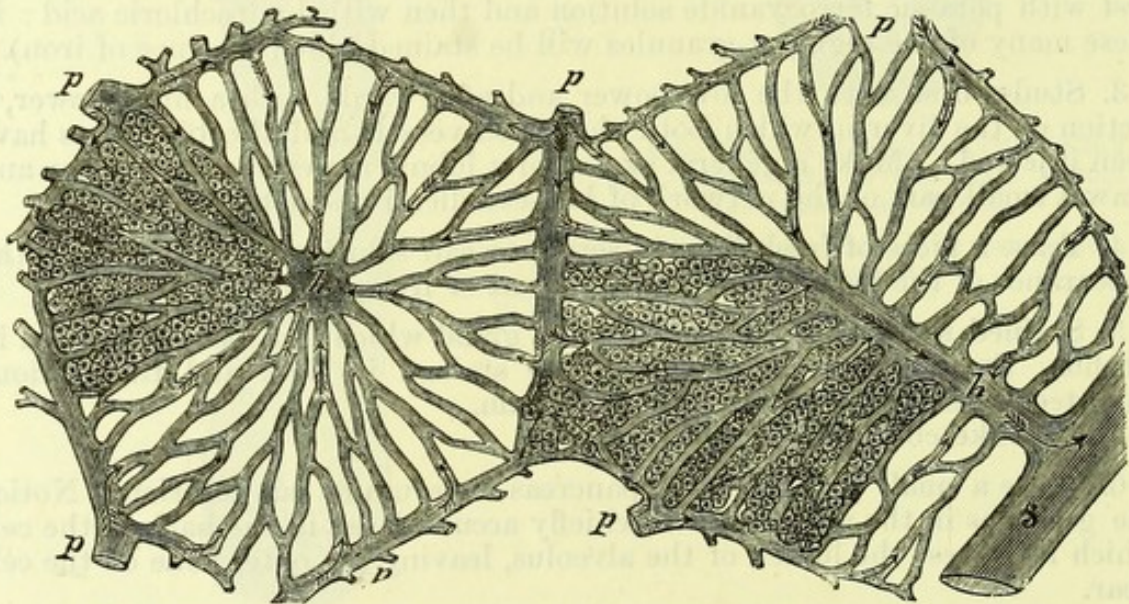


FIG. 214.—DIAGRAMMATIC REPRESENTATION OF TWO HEPATIC LOBULES.

The left-hand lobule is represented with the intralobular vein cut across ; in the right-hand one the section takes the course of the intralobular vein. *p*, intralobular branches of the portal vein ; *h*, intralobular branches of the hepatic veins ; *s*, sublobular vein ; *c*, capillaries of the lobules. The arrows indicate the direction of the course of the blood. The liver-cells are only represented in one part of each lobule.

The *blood-vessels of the liver* (portal vein and hepatic artery) enter it on its under surface, where also the bile-duct passes away from the gland. The branches of these three vessels accompany one another in their course through the organ, and are inclosed by loose connective tissue (capsule of Glisson), in which are lymphatic vessels, the



whole being termed a *portal canal* (fig. 213). The smallest branches of the vessels penetrate to the intervals between the hepatic lobules, and are known as the interlobular branches. The blood leaves the liver at the back of the organ by the hepatic veins; the branches of these run through the gland unaccompanied by other vessels (except

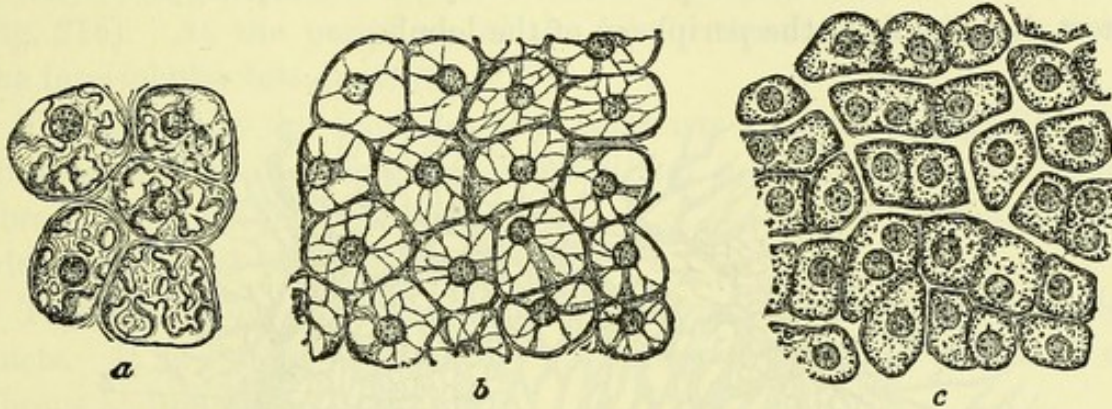


FIG. 215.—HEPATIC-CELLS STILL CONTAINING GLYCOGEN, *a*, AND WITH THEIR GLYCOGEN DISSOLVED OUT, *b*, *c*. (Heidenhain.)

In *c* there was less glycogen present than in *b*, and the section is differently prepared.

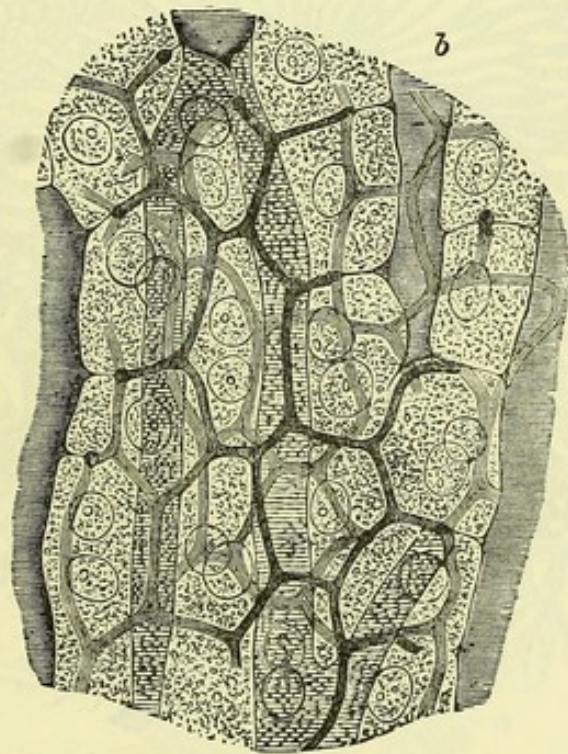


FIG. 216.—SECTION OF RABBIT'S LIVER WITH THE INTERCELLULAR NETWORK OF BILE-CANALICULI INJECTED. (Highly magnified.) (Hering.)

Two or three layers of cells are represented; *b*, blood-capillaries.

lymphatics) and can also be traced to the lobules, from each of which they receive a minute branch (intralobular vein) which passes from the centre of the lobule, and opens directly into the (sublobular) branch of the hepatic vein.



Each lobule is a mass of hepatic cells pierced everywhere with a network of blood-capillaries (fig. 214), which arise at the periphery of the lobule, there receiving blood from the interlobular branches of the portal vein (*p*), and converge to the centre of the lobule, where they unite to form the intralobular branch of the hepatic vein. The interlobular branches of the hepatic arteries join this capillary network a short distance from the periphery of the lobule.

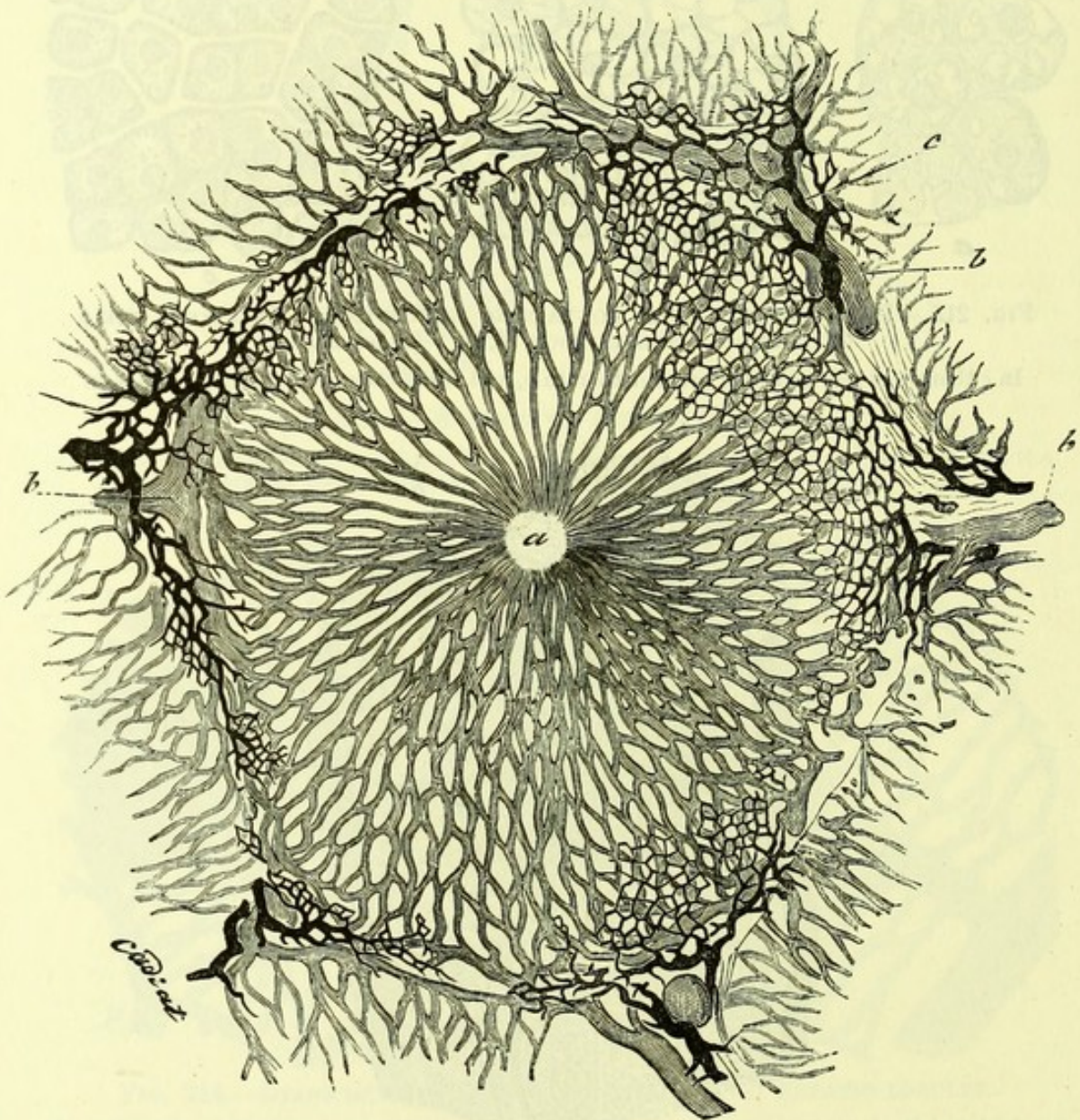


FIG. 217.—LOBULE OF RABBIT'S LIVER, VESSELS AND BILE-DUCTS INJECTED. (Cadiat.)  
*a*, central vein ; *b*, *b*, peripheral or interlobular veins ; *c*, interlobular bile-duct.

The *hepatic cells* (figs. 215, 216), which everywhere lie between and surround the capillaries, are polyhedral, somewhat granular-looking cells, each containing a spherical nucleus. After a meal the cells in the outer part of the lobule may contain fat in some animals, and masses of glycogen can also be seen within the cells if the liver be hardened in



alcohol and treated in the manner described in section 2. The cells also contain pigment-granules, many of which are stained by potassic ferrocyanide and hydric chloride (presence of iron).

The *bile-ducts* commence between the hepatic cells in the form of fine canaliculi, which lie between the adjacent sides of two cells, and appear to form a network, the meshes of which correspond in size to the cells (fig. 216). At the periphery of the lobule these canaliculi pass into the interlobular bile-ducts (fig. 217).

The bile-ducts are lined by clear columnar epithelium (fig. 214, *d*). Outside this is a basement-membrane, and in the larger ducts some fibrous and plain muscular tissue. Many of the larger ducts are beset with small cæcal diverticula.

The *gall-bladder* is in its general structure similar to the larger bile-ducts. It is lined by columnar epithelium, and its wall is formed of fibrous and muscular tissue.

The *lymphatics* of the liver are said to commence as perivascular lymphatic spaces inclosing the capillaries of the lobules. Efferent lymphatics pass away from the organ in the connective tissue which invests the portal and hepatic veins.

### THE PANCREAS.

The **pancreas** is a tubulo-racemose gland, resembling the salivary glands, so far as its general structure is concerned, but differing from them in the fact that the alveoli, in place of being saccular, are longer

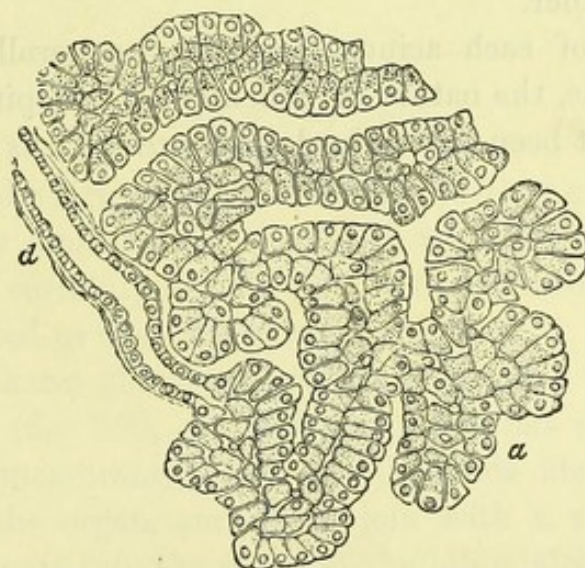


FIG. 218.—SECTION OF THE PANCREAS OF THE DOG. (Klein.)

*a*, termination of a duct in the tubular alveoli, *alv.*

and more tubular in character (fig. 218). Moreover, the connective tissue of the gland is somewhat looser, and there occur in it at intervals small groups of epithelium-like cells, which are supplied with a close



network of convoluted capillary vessels ; their function is unknown, but their presence is very characteristic of the pancreas.

The cells which line the alveoli are columnar or polyhedral in shape. When examined in the fresh condition, or in osmic preparations, their protoplasm is filled in the inner two-thirds with small granules, but the outer third is left clear (fig. 219, *A*). After a period

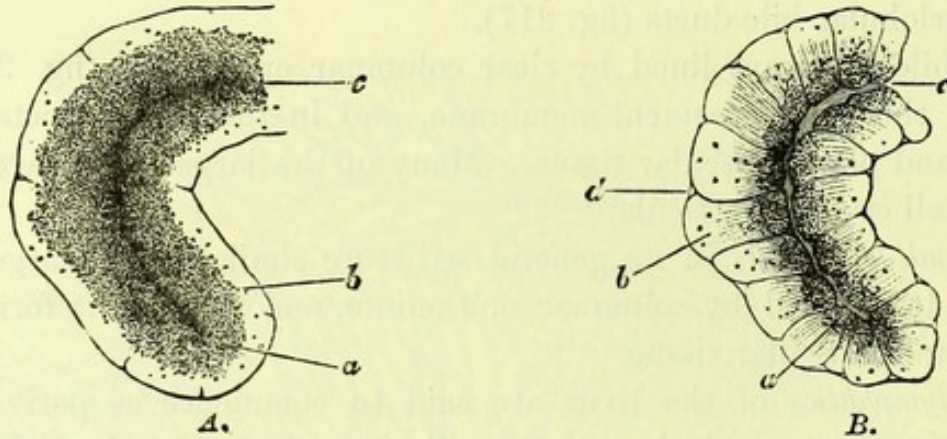


FIG. 219.—PART OF AN ALVEOLUS OF THE RABBIT'S PANCREAS. *A*, AT REST ; *B*, AFTER ACTIVE SECRETION. (From Foster, after Kühne and Lea.)

*a*, the inner granular zone, which in *A* is larger and more closely studded with fine granules than in *B*, in which the granules are fewer and coarser ; *b*, the outer transparent zone, small in *A*, larger in *B*, and in the latter marked with faint striæ ; *c*, the lumen, very obvious in *B*, but indistinct in *A* ; *d*, an indentation at the junction of two cells, only seen in *B*.

of activity the clear part of the cell becomes larger, and the granular part smaller (*B*). In stained sections the outer part is coloured more deeply than the inner.

In the centre of each acinus there may generally be seen some spindle-shaped cells, the nature of which (whether epithelial or connective tissue) has not been determined (*centro-acinar cells* of Langerhans).



## LESSON XXXIV.

*STRUCTURE OF THE SPLEEN, SUPRARENAL CAPSULE, AND  
THYROID BODY.*

1. SECTIONS of the spleen stained with hæmatoxylin. Notice the trabeculæ extending into the substance of the organ from the capsule. Notice also that the glandular substance is of two kinds, (1) lymphoid tissue accumulated round the small arteries and here and there massed to form *lymphoid nodules*—the Malpighian corpuscles of the spleen—and (2) a tissue consisting of a reticulum of branched and flattened cells containing blood in its interstices and pervaded by capillaries and venous radicles.

Sketch part of a section under a low power and a small portion of the reticulum under a high power.

2. Sections across a suprarenal capsule. Examine first with a low power, noticing the general arrangement and extent of the cortical and medullary parts of the organ, making a general sketch which shall include both. Afterwards sketch carefully under the high power a group of cells from each part of the organ.

3. Sections of the thyroid body stained with hæmatoxylin. Notice the vesicles lined with cubical epithelium and filled with a "colloid" substance which becomes stained by the hæmatoxylin. Sketch one or two vesicles. Measure several vesicles.

---

*THE SPLEEN.*

The **spleen** is the largest of the so-called ductless glands. It appears to be functionally connected in some way with the blood, white blood-corpuscles being certainly formed and coloured blood-corpuscles being probably submitted to destruction within it.

Like the lymphatic glands, the spleen is invested with a fibrous and muscular *capsule* (fig. 220, A), and this again has a covering derived from the serous membrane. The capsule sends fibrous bands or trabeculæ (b) into the organ, and these join with a network of similar trabeculæ which pass into the gland at the hilum along with the blood-vessels. In the interstices of the fibrous framework thus constituted lies a soft pulpy substance containing a large amount of blood, and therefore of a deep red colour, dotted within which are here and there to be seen small whitish specks, the *Malpighian corpuscles of the spleen* (c, c). These are composed of lymphoid tissue which is gathered up



into masses which envelop the smaller arteries, whilst the red pulp which everywhere surrounds them and which forms the bulk of the organ is composed of a close network or spongework of flattened and

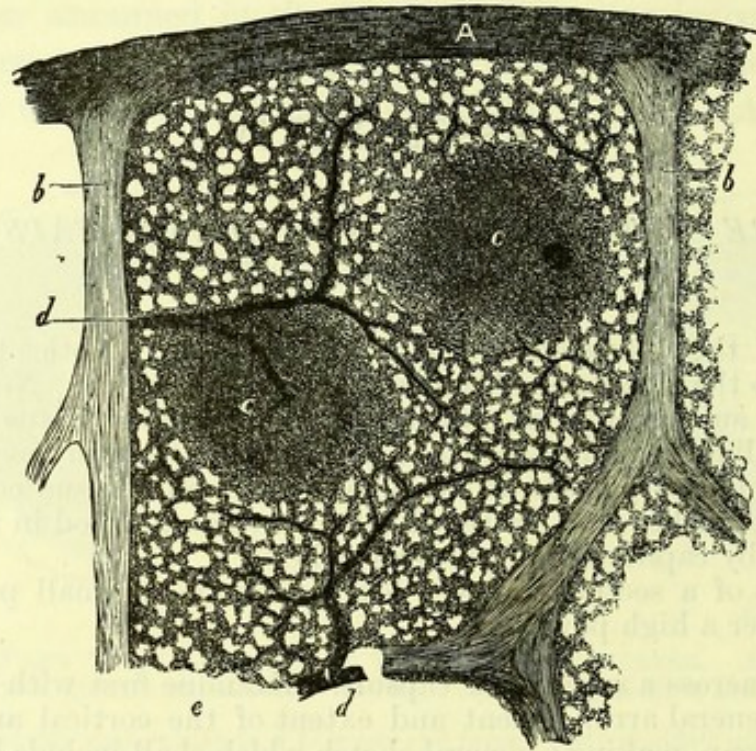


FIG. 220.—VERTICAL SECTION OF A SMALL SUPERFICIAL PORTION OF THE HUMAN SPLEEN, AS SEEN WITH A LOW POWER. (Kölliker.)

A, peritoneal and fibrous covering; b, trabeculae, c, c, Malpighian corpuscles, in one of which an artery is seen cut transversely, in the other longitudinally; d, injected arterial twigs; e, spleen-pulp.

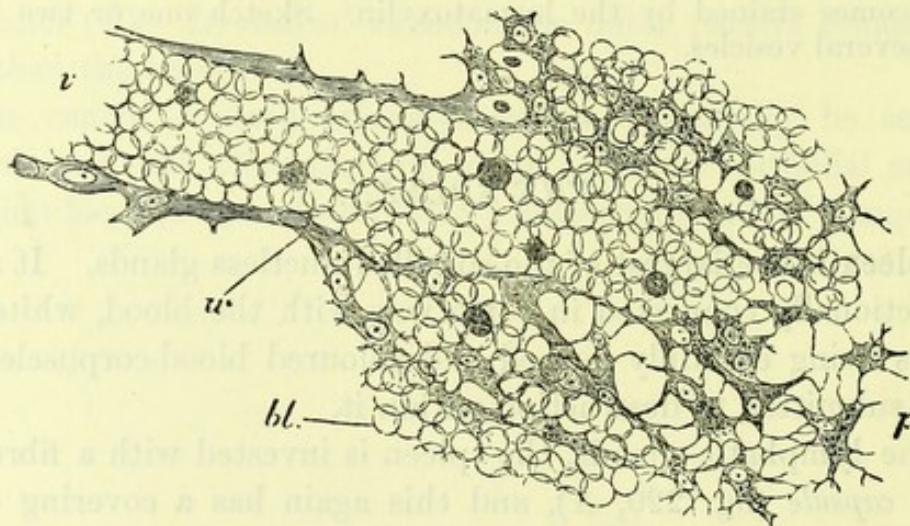


FIG. 221.—THIN SECTION OF SPLEEN-PULP, HIGHLY MAGNIFIED, SHOWING THE MODE OF ORIGIN OF A SMALL VEIN IN THE INTERSTICES OF THE PULP.

v, the vein, filled with blood-corpuscles, which are in continuity with others, bl, filling up the interstices of the retiform tissue of the pulp; w, wall of the vein. The shaded bodies amongst the red blood-corpuscles are pale corpuscles.

branched cells like connective-tissue corpuscles. Coursing through the pulp and communicating with its interstices are capillary blood-vessels which are connected with the terminations of the arteries; whilst in other parts venous channels arise from the pulp, and bring the blood



which has passed into its interstices from the arterial capillaries towards the larger veins of the organ, which run in the trabeculæ, and are by them conducted to the hilum. The arteries, which are also at first conducted from the hilum along the trabeculæ into the interior of the organ, presently leave the trabeculæ, and their external coat becomes converted into a thick sheath of lymphoid tissue which invests them in the remainder of their course, and in places becomes swollen into the Malpighian corpuscles already mentioned. These small arteries distribute a few capillaries to the Malpighian corpuscles, and then break up into pencils of small vessels which open into the pulp in the manner before described.

The cellular elements of the spleen-pulp are of three kinds, viz. peculiar, large, amœboid cells, called *splenic cells*, lymph-corpuscles, and the branched, flattened cells which form the sponge-work. The first-named are frequently found to contain coloured blood-corpuscles in their interior in various stages of transformation into pigment.

The *lymphatics* of the spleen run partly in the trabeculæ and capsule, and partly in the lymphoid tissue ensheathing the arteries. They join to form larger vessels which emerge together at the hilum.

### THE SUPRARENAL CAPSULES.

The **suprarenal capsules** belong to the class of bodies known as ductless glands, but they are entirely different in structure from the spleen and lymphatic glands. A section through the fresh organ (fig. 222)

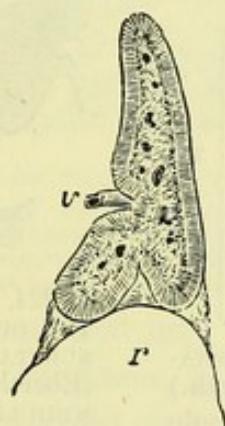


FIG. 222.—A VERTICAL SECTION OF THE SUPRARENAL BODY OF A FETUS, TWICE THE NATURAL SIZE, SHOWING THE DISTINCTION BETWEEN THE MEDULLARY AND CORTICAL SUBSTANCE. (A. Thomson.)

v, issuing vein; r, summit of kidney.

shows a *cortical zone* which is striated vertically to the surface, and of a yellowish colour, and a *medulla* which is soft and highly vascular, and of a brownish-red colour. The whole organ is invested by a fibrous *capsule* which sends fibrous septa inwards to the cortical substance (fig. 223), subdividing this for the most part into columnar groups of cells



(zona fasciculata, *c*). Immediately underneath the capsule, however, the groups are more rounded (zona glomerulosa, *b*), whilst next to the medulla they have a closely reticular arrangement (zona reticularis, *d*), and a similar disposition both of the cells and the connective tissue is noticeable throughout the medulla.

The cells which form the rounded groups and columns of the cortical substance are polyhedral in form (fig. 224, A); each contains a clear round nucleus, and there are often yellowish oil-globules in their protoplasm.

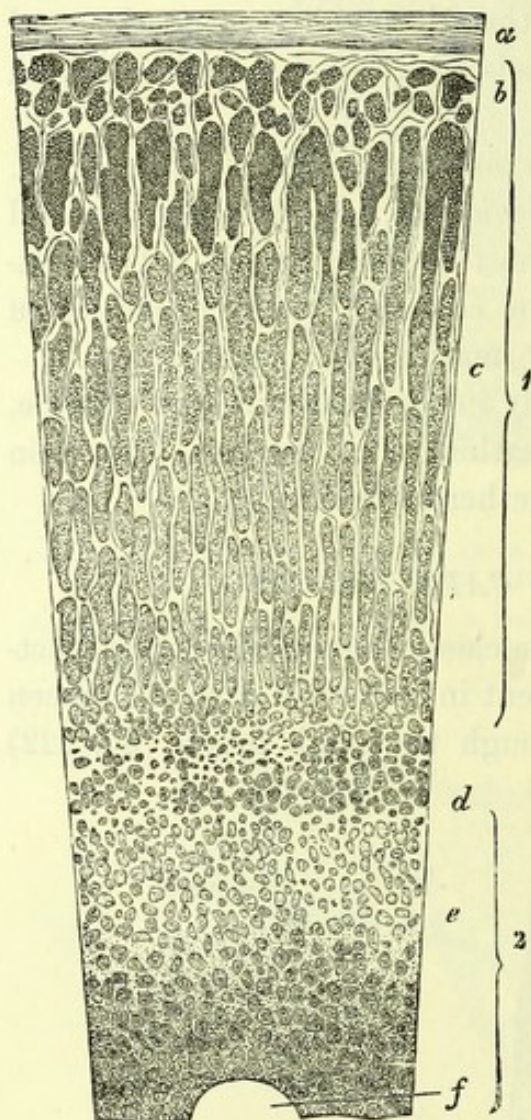


FIG. 223.—VERTICAL SECTION OF SUPRARENAL BODY. (Magnified.) (Eberth.)

1, cortical substance; 2, medullary substance; *a*, capsule; *b*, zona glomerulosa; *c*, zona fasciculata; *d*, zona reticularis; *e*, groups of medullary cells; *f*, section of a large vein.

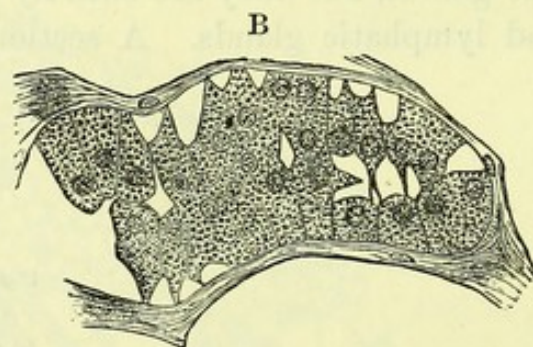
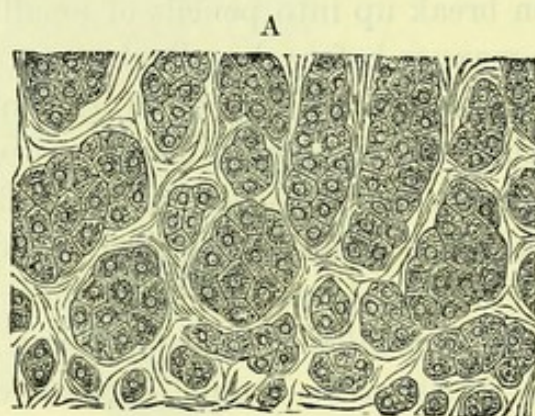


FIG. 224, A.—CELLS AND CELL-GROUPS FROM THE OUTERMOST LAYER OF THE CORTICAL SUBSTANCE OF THE SUPRARENAL BODY. (Eberth.) B.—A SMALL PORTION OF THE MEDULLARY PART OF THE SUPRARENAL CAPSULE OF THE OX. (Eberth.)

No blood-vessels penetrate between these cells, both the blood-vessels and lymphatics of the cortex running in the fibrous septa between the columns; the lymphatics are said to communicate with fine spaces which run between the cells of the columns.

The cells of the medulla (fig. 224, B) are more irregular in shape, and are often branched. Their protoplasm is either clear, or it may in some



animals contain a brownish pigment, but in man the dark red colour of the medulla is largely due to the blood contained in the large venous spaces by which it is pervaded, and which receive the blood after it has traversed the capillaries of the cortex. Investing the larger veins are longitudinal bundles of plain muscular fibres; and numerous nerves, after traversing the cortical substance, are distributed throughout the medulla, where they form a close plexus provided with ganglion-cells. The cells of the medulla are characterised by staining brown by chromic acid and its salts, provided the organ is quite fresh.

### THE THYROID BODY.

The thyroid body consists of a framework of connective tissue inclosing numerous spherical or oval vesicles (fig. 225) which are lined with cubical epithelium. The cavities of the vesicles are filled with a peculiar viscid liquid which is coagulated by alcohol and which then becomes stained with hæmatoxylin. A similar material has been found

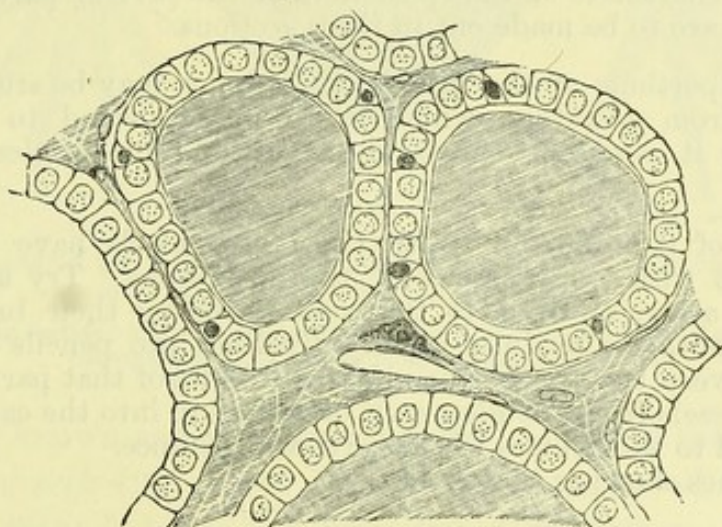


FIG. 225.—SECTION OF THE THYROID GLAND OF A CHILD.

Two complete vesicles and portions of others are represented. The vesicles are filled with colloid, which also occupies the interstitial spaces. In the middle of one of the spaces a blood-vessel is seen cut obliquely, and close to it is a plasma-cell. Between the cubical epithelium-cells smaller cells like lymph-corpuscles are here and there seen.

in the lymphatics of the gland, and may sometimes be detected also in the interstices of the connective tissue, as shown in the figure.

The blood-vessels of the thyroid are exceedingly numerous, and the capillaries form close plexuses round the vesicles. Some of the blood-vessels are distributed to a peculiar highly vascular embryonic tissue which occurs in patches here and there in the organ (Horsley).

Disease of the thyroid or its extirpation is accompanied by remarkable changes in the chemical composition of the blood and many of the tissues, resulting chiefly in the accumulation within them of a large amount of *mucin*; a condition of general myxœdema, and eventually of cretinism, being produced.



## LESSON XXXV.

*STRUCTURE OF THE KIDNEY.*

1. SECTIONS passing through the whole kidney of a small mammal, such as a mouse or rat. These sections will show the general arrangement of the organ and the disposition of the tubules and of the Malpighian corpuscles.

A general sketch should be made of one of these sections under a low power.

2. Thin sections of the kidney of a larger mammal, such as the dog, may next be studied. In some the direction of the section should be parallel with the tubules of the medulla, and in others across the direction of those tubules. The characters of the epithelium of the several parts of the uriniferous tubules are to be made out in these sections.

3. Separate portions of the uriniferous tubules may be studied in teased preparations from a kidney which has been subjected to some process which renders it possible to unravel the uriniferous tubules for a certain distance.<sup>1</sup>

4. Sections of a kidney in which the blood-vessels have been injected. Examine these with a low power of the microscope. Try and follow the course of the arteries—those to the cortex sending their branches to the glomeruli, those to the medulla rapidly dividing into pencils of fine vessels which run between the straight uriniferous tubules of that part. Notice also the efferent vessels from the glomeruli breaking up into the capillaries which are distributed to the tubules of the cortical substance.

Make sketches showing these points.

---

The kidney is a compound tubular gland. To the naked eye it appears formed of two portions—a *cortical* and a *medullary*. The latter is subdivided into a number of pyramidal portions (*pyramids of Malpighi*), the base of each being surrounded by cortical substance, while the apex projects in the form of a *papilla* into the dilated commencement of the ureter (*pelvis of the kidney*).<sup>2</sup> Both cortex and medulla are composed entirely of tubules—the *uriniferous tubules*—which have a straight direction in the medulla and a contorted arrangement in the cortex; but groups of straight tubules also pass from the medulla through the thickness of the cortex (*medullary rays*, see fig. 226).

<sup>1</sup>For a method which may be employed for this purpose, see *Course of Practical Histology*.

<sup>2</sup>In many animals the whole kidney is formed of only a single pyramid, but in man there are about twelve.



The uriniferous tubules begin in the cortical part of the organ in dilatations, each inclosing a tuft or glomerulus of convoluted capillary blood-vessels (*corpuscles of Malpighi*), the dilated commencement of the

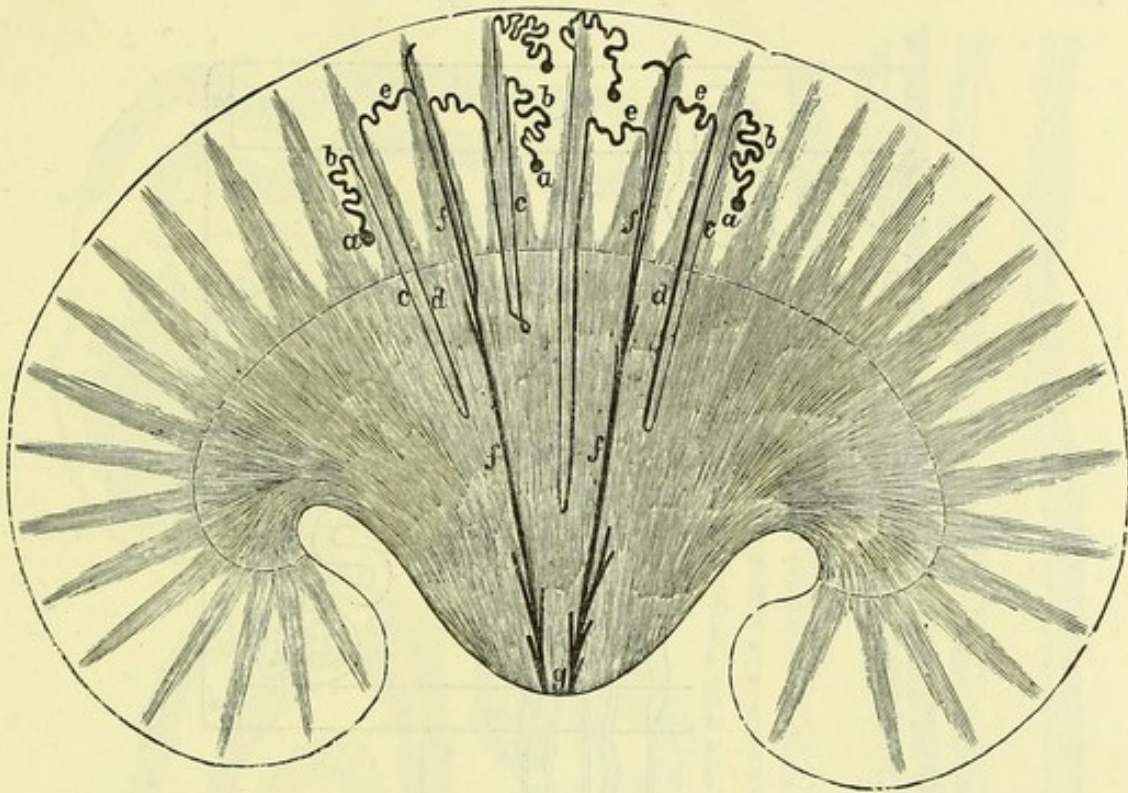


FIG. 226.—DIAGRAM OF THE CURVE OF THE TUBULES IN A UNIPYRAMIDAL KIDNEY, SUCH AS THAT OF THE RABBIT. (Toldt.)

*a*, Malpighian bodies; *b*, first convoluted tubule; *c*, *d*, looped tube of Henle; *e*, second convoluted; *f*, collecting tube; *g*, ducts of Bellini.

tubule being known as the *capsule* (fig. 227, 1). The tubule leaves the capsule by a *neck* (2), which is sometimes narrowed, and in some animals (*e.g.* frog) is long, and has ciliated epithelium; the tubule is at first convoluted (*first convoluted tubule*, 3), but soon becomes nearly straight or slightly spiral only (*spiral tubule*, 4), and then, rapidly narrowing, passes down into the medulla towards the dilated commencement of the ureter as the *descending tubule of Henle* (5). It does not at once, however, open into the pelvis of the kidney, but before reaching the end of the papilla it turns round in the form of a loop (*loop of Henle*, 6) and passes upwards again towards the cortex, parallel to its former course and at first somewhat larger than before, but afterwards diminishing in size (*ascending tubule of Henle*, 7, 8, 9). Arrived at the cortex, it approaches close to the capsule from which the tubule took origin, but at a point opposite to the origin, viz., near the afferent and efferent vessels of the glomerulus (Golgi). It then becomes larger and irregularly zigzag (*zigzag tubule*, 10), and may again be somewhat convoluted (*second convoluted tubule*, 11), eventually, how-



ever, narrowing into a vessel (*junctional tubule*, 12) which joins a straight or *collecting tubule* (13). This now passes straight through the medullary substance of the kidney (14) to open at the apex of the papilla as one of the *ducts of Bellini* (15).

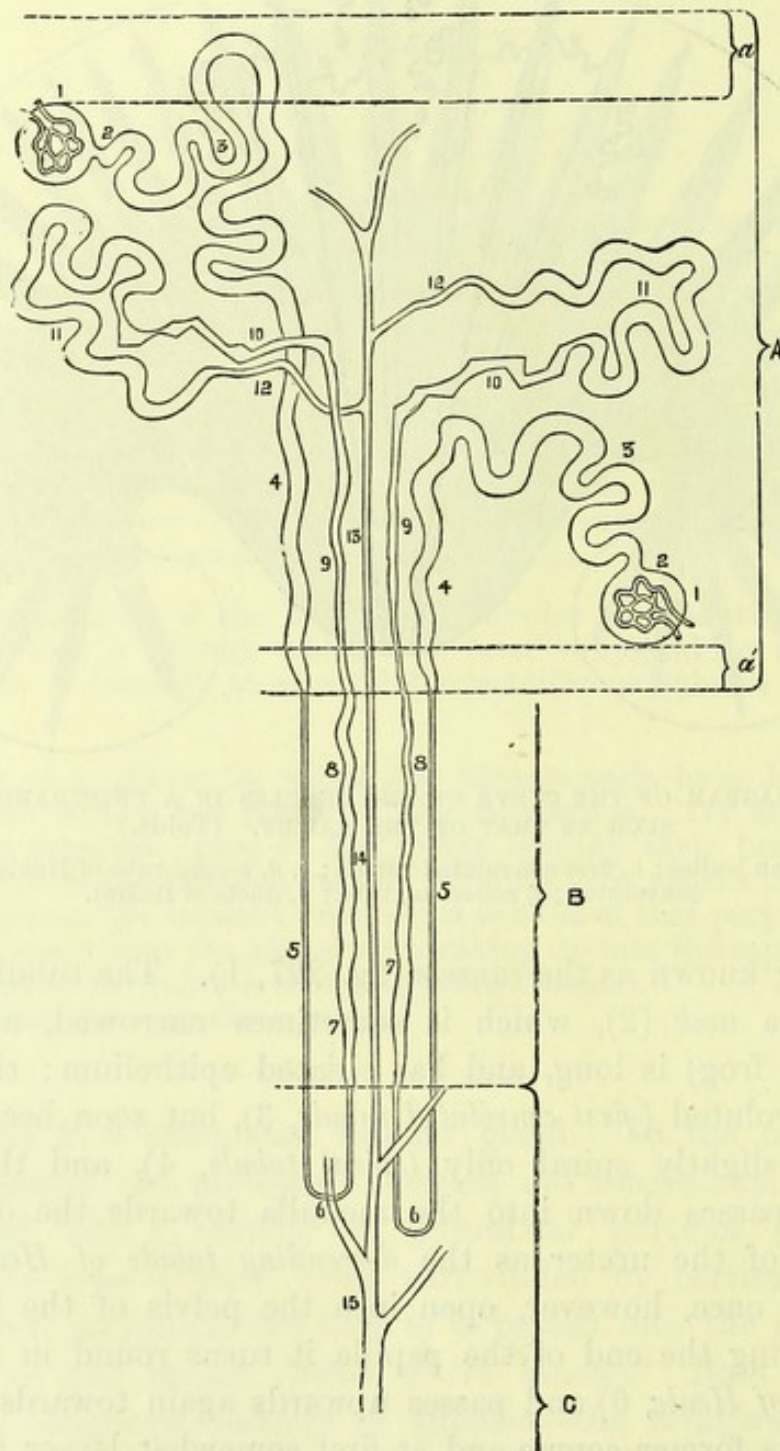


FIG. 227.—DIAGRAM OF THE COURSE OF TWO URINIFEROUS TUBULES. (Klein.)

A, cortex; B, boundary zone; C, papillary zone of the medulla; a, a', superficial and deep layers of cortex, free from glomeruli. For the explanation of the numerals, see the text.

The tubules are throughout bounded by a basement-membrane, which is lined by epithelium, but the characters of the epithelium-



cells vary in the different parts of a tubule. In the *capsule* the epithelium is flattened and is reflected over the glomerulus (fig. 228, *a*). In the first *convoluted* and *spiral tubules* it is thick, and the

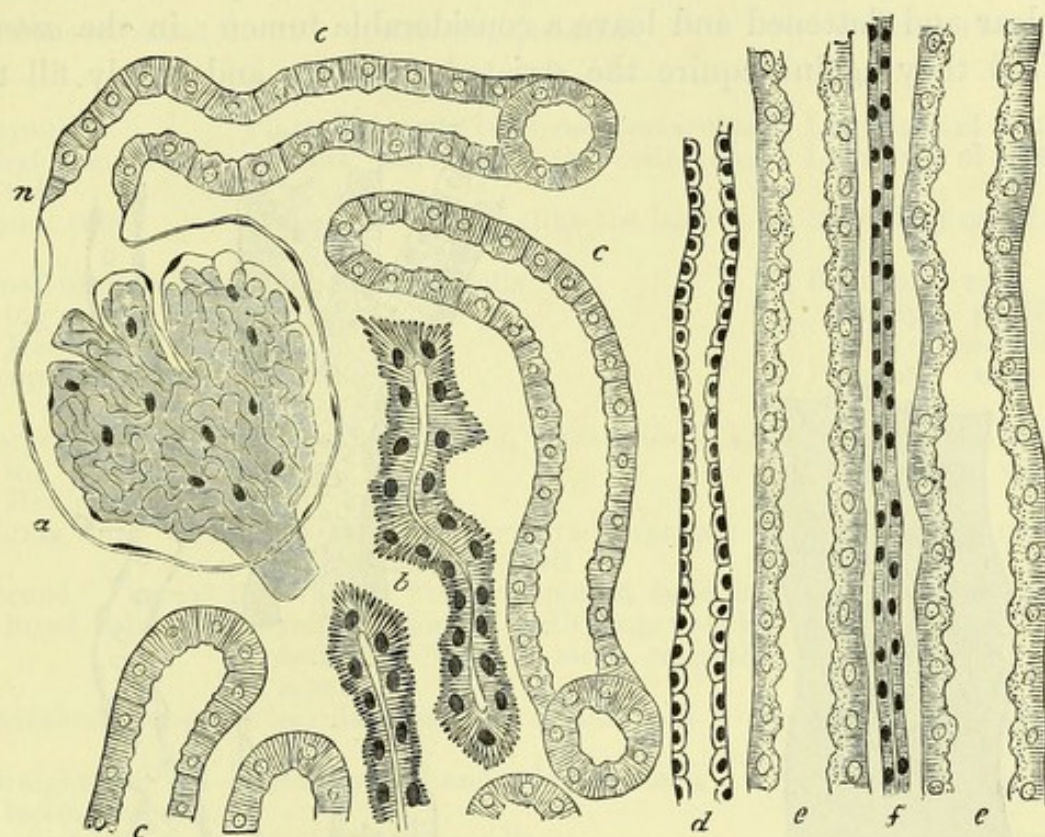


FIG. 228.—TUBULES FROM A SECTION OF THE DOG'S KIDNEY. (Klein.)

*a*, capsule, inclosing the glomerulus; *n*, neck of the capsule; *c*, *c'*, convoluted tubules; *b*, irregular tubules; *d*, collecting tube; *e*, *e'*, spiral tubes; *f*, part of the ascending limb of Henle's loop, here (in the medullary ray) narrow.

cells show a marked fibrillar structure (figs. 229, 230). Moreover, they interlock laterally and are difficult of isolation; in some animals

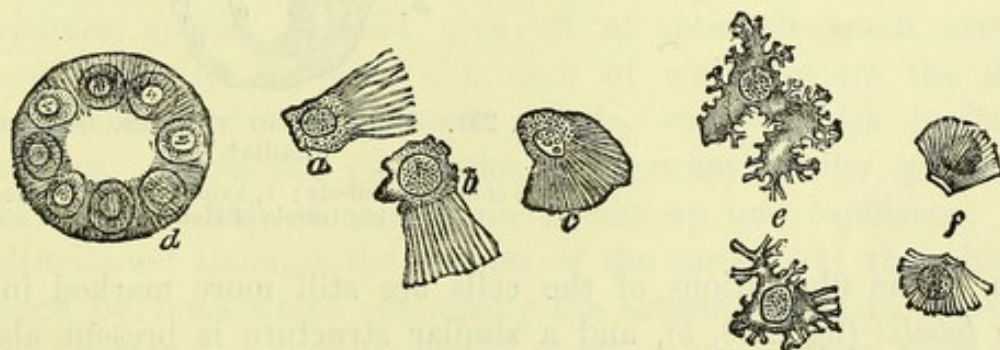


FIG. 229.—STRUCTURE OF THE EPITHELIUM OF THE CONVOLUTED TUBULES. (Heidenhain.)

*d*, section of a convoluted tubule from the rat, showing the unaltered protoplasm occupying a circular area around the nucleus of each cell; *a*, *b*, *c*, isolated cells from the convoluted tubules of the rat; *e*, isolated cells from the dog's kidney, viewed from the inner surface, and showing the irregular contour of the protoplasm; *f*, isolated cells from the newt, showing the rods and a homogeneous cuticular layer.



they have been described as being ciliated. They certainly often exhibit a brush of cilium-like processes projecting into the lumen, but it is doubtful if these are vibratile. In the narrow *descending limb of the looped tubule* (fig. 231, *c*), and in the loop itself, the cells are clear and flattened and leave a considerable lumen; in the *ascending limb* they again acquire the striated structure and nearly fill the

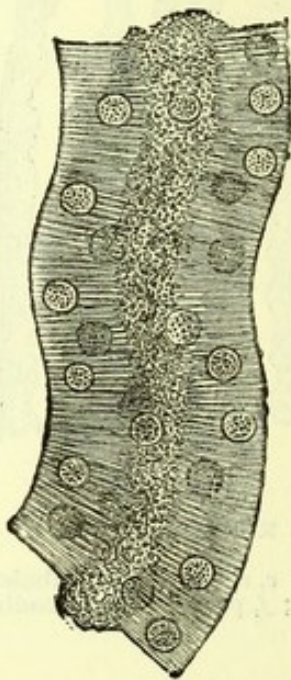


FIG. 230.—PART OF A CONVOLUTED TUBULE FROM THE DOG'S KIDNEY. (Heidenhain.)

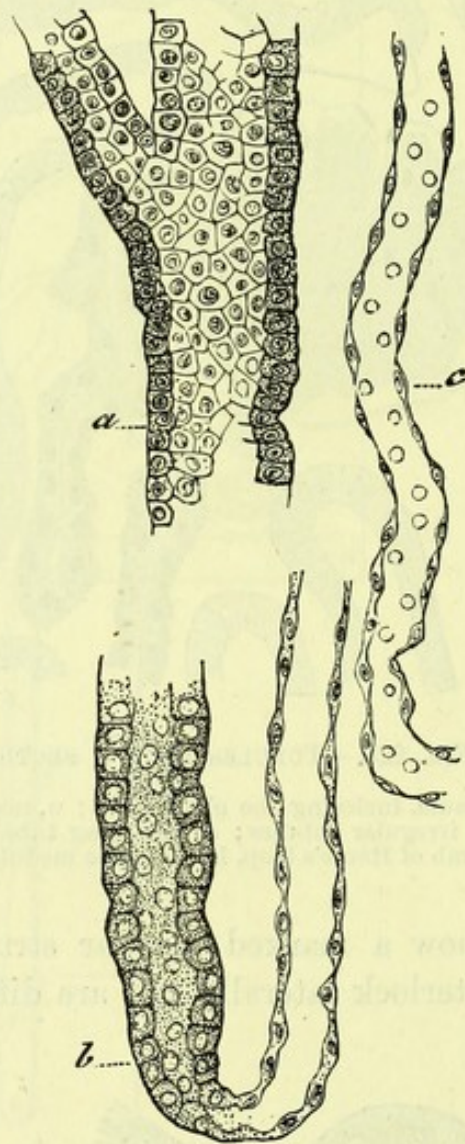


FIG. 231.—PORTIONS OF TUBULES, ISOLATED. (Cadiat.)

*a*, large collecting tubule; *b*, loop of Henle; *c*, descending tubule of Henle.

lumen. The fibrillations of the cells are still more marked in the *zigzag tubules* (fig. 228, *b*), and a similar structure is present also in the *second convoluted tubules*, into which these pass. On the other hand, the *junctional tubule* has a large lumen and is lined by clear flattened cells, and the *collecting tubes* have also a very distinct lumen and are lined by a clear cubical or columnar epithelium (figs. 228, *d*; 231, *a*).



The following gives a tabular view of the parts which compose a uriniferous tubule, and the nature of the epithelium in each part :—

Portion of tubule.	Nature of epithelium.	Position of tubule.
Capsule . . .	Flattened, reflected over glomerulus .	Labyrinth of cortex. <sup>1</sup>
First convoluted tube . . .	Cubical, fibrillated, the cells interlocking	Labyrinth of cortex.
Spiral tube . . .	Cubical, fibrillated (like the last) .	Medullary ray of cortex.
Small or descending tube of Henle . . .	Clear flattened cells . . . . .	Boundary zone and partly papillary zone of medulla.
Loop of Henle . .	Like the last . . . . .	Papillary zone of medulla.
Larger or ascending tube of Henle . . .	Cubical, fibrillated, sometimes imbricated	Medulla, and medullary ray of cortex.
Zigzag tube . . .	Cells strongly fibrillated; varying in height; lumen small	Labyrinth of cortex.
Second convoluted tube . .	Similar to first convoluted tube, but cells are longer, with larger nuclei, and they have a more refractive aspect	Labyrinth of cortex.
Junctional tube . .	Clear flattened and cubical cells . .	Labyrinth passing to medullary ray.
Straight or collecting tube . .	Clear cubical and columnar cells . .	Medullary ray and medulla.
Duct of Bellini . .	Clear columnar cells . . . . .	Opens at apex of papilla.

**Blood-vessels.**—The renal artery divides into branches on entering the organ, and these branches pass towards the cortex, forming incomplete arches between the cortex and the medulla (fig. 233, *a*). The branches of the renal vein form similar but more complete arches (*g*). From the arterial arches vessels pass through the cortex (*interlobular arteries*, *b*), and give off at intervals small arterioles (*efferent vessels of the glomeruli*), each of which enters the dilated commencement of a uriniferous tubule, within which it forms a glomerulus. From the glomerulus a somewhat smaller *efferent vessel* passes out, and this at once again breaks up into capillaries, which are distributed amongst the tubules of the cortex (*e*); their blood is collected by veins which accompany the arteries and join the venous arches between the cortex and the medulla, receiving in their course certain other veins which arise by radicles having a somewhat stellate arrangement near the capsule (*venæ stellulæ*, *j*).

The medulla derives its blood-supply from special offsets of the

<sup>1</sup> The part of the cortex between and surrounding the medullary rays is so named.



arterial arches, which almost immediately break up into pencils of fine straight arterioles running in groups between the straight tubules of the medulla. These arterioles gradually break up into a capillary net-

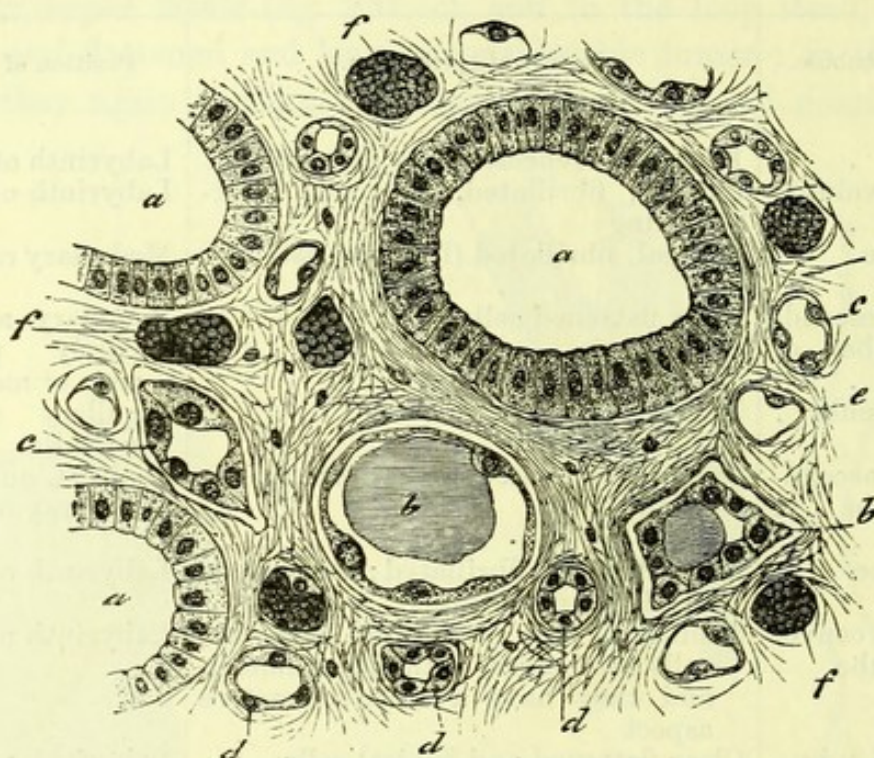


FIG. 232.—SECTION ACROSS A PAPILLA OF THE KIDNEY. (Cadiat.)

*a*, large collecting tubes (ducts of Bellini); *b*, *c*, *d*, tubules of Henle; *e*, *f*, blood-capillaries.

work with elongated meshes which pervades the medulla (fig. 233, *f*), and which terminates in a plexus of somewhat larger venous capillaries in the papillæ. From these and from the other capillaries the veins collect the blood, and pass, accompanying the straight arterioles, into the venous arches between the cortex and medulla. The groups of small arteries and veins (*vasa recta*) in the part of the medulla nearest the cortex alternate with groups of the uriniferous tubules, and this arrangement confers a striated aspect upon this portion of the medulla (*boundary zone*, see fig. 234, *g*).

The efferent vessels of those glomeruli which are situated nearest to the medulla may also break up into pencils of fine vessels (*false arteriæ rectæ*) and join the capillary network of the medulla (fig. 233, *d*).

Between the uriniferous tubules, and supporting the blood-vessels, is a certain amount of connective tissue (fig. 232), within which are cleft-like spaces from which the lymphatics of the organ originate.



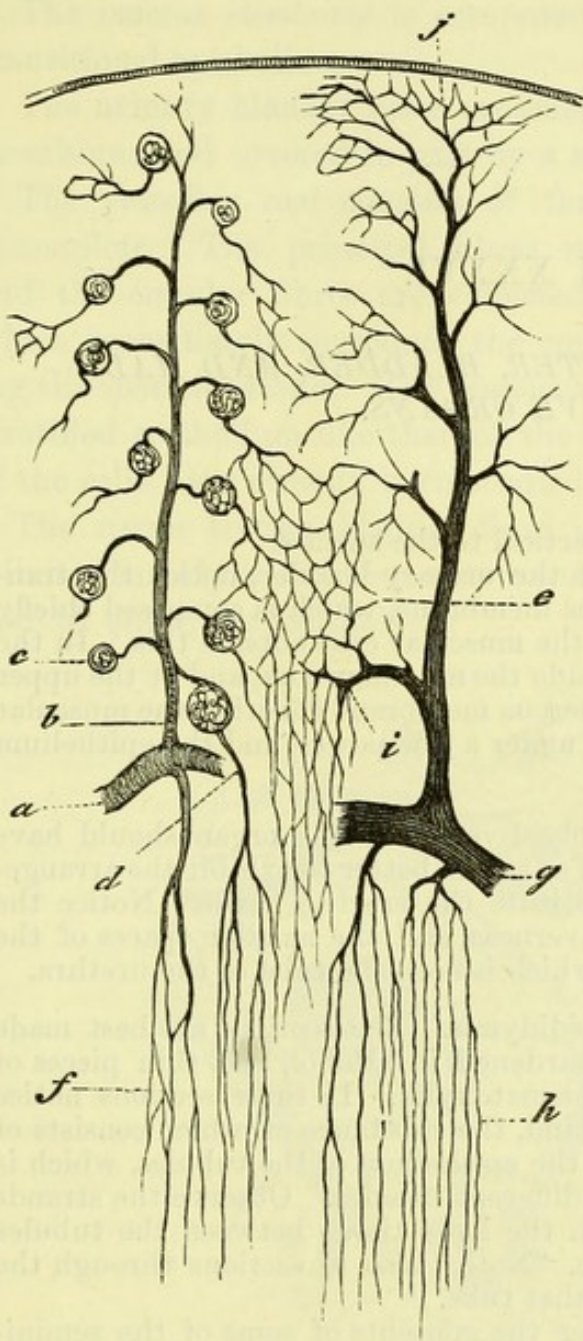


FIG. 233.—VASCULAR SUPPLY OF KIDNEY.  
(Cadiat.) Diagrammatic.

*a*, part of arterial arch; *b*, interlobular artery; *c*, glomerulus; *d*, efferent vessel passing to medulla as false arteria recta; *e*, capillaries of cortex; *f*, capillaries of medulla; *g*, venous arch; *h*, straight veins of medulla; *j*, vena stellula; *i*, interlobular vein.

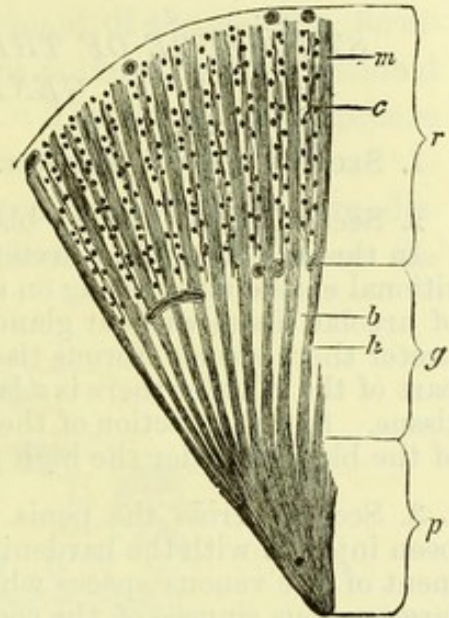


FIG. 234.—SECTION THROUGH PART OF THE DOG'S KIDNEY. (Ludwig.)

*p*, papillary, and *g*, boundary zones of the medulla; *c*, cortical layer; *h*, bundles of tubules in the boundary layer, separated by spaces, *b*, containing bunches of vessels (not here represented), and prolonged into the cortex as the medullary rays, *m*; *c*, intervals of cortex, composed chiefly of convoluted tubules, with irregular rows of glomeruli, between the medullary rays.



## LESSON XXXVI.

*STRUCTURE OF THE URETER, BLADDER, AND MALE  
GENERATIVE ORGANS.*

## 1. SECTION across the ureter.

## 2. Section of the urinary bladder vertical to the surface.

In the sections of the ureter and of the urinary bladder, notice the transitional epithelium resting on a mucous membrane, which is composed chiefly of areolar tissue without glands, and the muscular coat outside this. In the ureter there is some fibrous tissue outside the muscular coat, and at the upper part of the bladder there is a layer of serous membrane covering the muscular tissue. Sketch a section of the ureter under a low power, and the epithelium of the bladder under the high power.

3. Section across the penis. The blood-vessels of the organ should have been injected with the hardening fluid so as the better to exhibit the arrangement of the venous spaces which constitute the erectile tissue. Notice the large venous sinuses of the corpora cavernosa and the smaller spaces of the corpus spongiosum, in the middle of which is seen the tube of the urethra.

4. Section across the testis and epididymis. The sections are best made from a rat's testis which has been hardened in alcohol, and thin pieces of which have been stained in bulk in hæmatoxylin. In these sections notice the strong capsule surrounding the gland, the substance of which consists of tubules which are variously cut, and the epithelium of the tubules, which is in different phases of development in different tubules. Observe the strands of polyhedral interstitial cells lying in the loose tissue between the tubules and the lymphatic clefts in that tissue. Notice also in sections through the epididymis the ciliated epithelium of that tube.

Sketch carefully under a high power the contents of some of the seminiferous tubules so as to illustrate the mode of formation of the spermatozoa.

5. Examination of spermatozoa. The spermatozoa may be obtained fresh from the testis or seminal vesicles of a recently killed animal and examined in saline solution. Their movements may be studied on the warm stage; to display their structure a very high power of the microscope is necessary. Measure and sketch three or four spermatozoa.

---

The *ureter* is a muscular tube lined by mucous membrane. The *muscular coat* consists of two layers of plain muscular tissue, an outer circular, and an inner longitudinal. In the lower part there are some longitudinal bundles external to the circular. Outside the muscular coat is a *layer of fibrous tissue* in which the blood-vessels and nerves ramify before entering the muscular layer.



The *mucous membrane* is composed of areolar tissue and is lined by transitional epithelium.

The *urinary bladder* has a muscular wall lined by a strong mucous membrane and covered in part by a serous coat.

The *muscular coat* consists of three layers, but the innermost is incomplete. The principal fibres run longitudinally and circularly, and the circular fibres are collected into a layer of some thickness which immediately surrounds the commencement of the urethra, forming the *sphincter vesicæ*. The *mucous membrane* is lined by a transitional stratified epithelium like that of the ureter. The shape and structure of the cells have already been studied (Lesson VII.).

The *nerves* to the bladder form gangliated plexuses, and are distributed mainly to the muscular tissue and blood-vessels, but some are said to enter the epithelium.

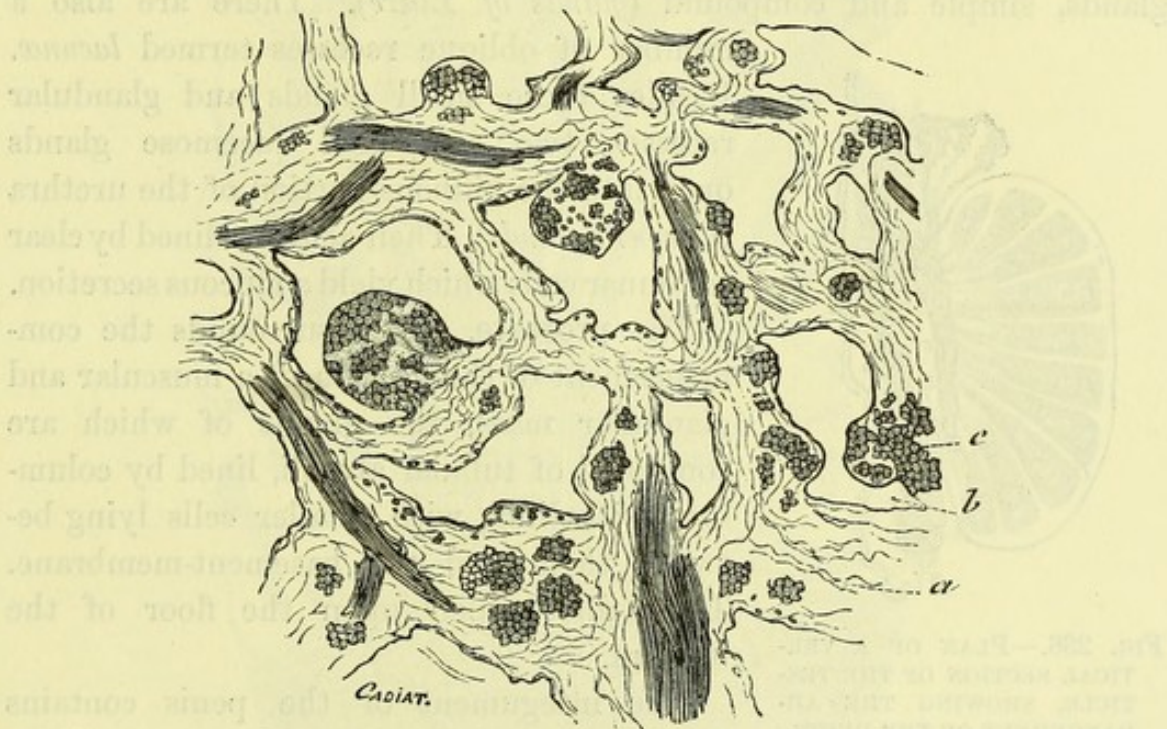


FIG. 235.—SECTION OF ERECTILE TISSUE. (Cadiat.)

*a*, trabeculae of connective tissue, with elastic fibres, and bundles of plain muscular tissue, some cut across (*c*); *b*, venous spaces.

The *penis* is mainly composed of cavernous tissue which is collected into two principal tracts—the *corpora cavernosa*, one on each side, and the *corpus spongiosum* in the middle line inferiorly. All these are bounded by a strong capsule of fibrous and plain muscular tissue, containing also many elastic fibres and sending in strong septa or trabeculae of the same tissues, which form the boundaries of the cavernous spaces of the erectile tissue (fig. 235). The arteries of the tissue run in these trabeculae, and their capillaries open into the cavernous spaces. On the other hand, the spaces are connected with efferent



veins. The arteries of the cavernous tissue may sometimes in injected specimens be observed to form looped or twisted projections into the cavernous spaces (*helicine arteries of Müller*).

**Urethra.**—The cross-section of the urethra appears in the middle of the corpus spongiosum in the form of a transverse slit. It is lined in the prostatic part by transitional, but elsewhere by columnar epithelium, except near its orifice, where the epithelium is stratified scaly. In the female urethra it is scaly throughout. The epithelium rests upon a vascular mucous membrane, and this again is supported by a coating of submucous tissue, containing two layers of plain muscular fibres—an inner longitudinal and an outer circular. Outside this again is a close plexus of small veins which are connected with, and may be said to form part of, the corpus spongiosum.

The *mucous membrane* of the urethra is beset with small mucous glands, simple and compound (*glands of Littré*). There are also a number of oblique recesses termed *lacunæ*. Besides these small glands and glandular recesses, two compound racemose glands open into the bulbous portion of the urethra (*Cowper's glands*). Their acini are lined by clear columnar cells which yield a mucous secretion.

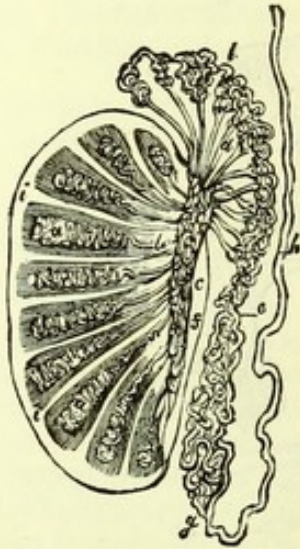


FIG. 236.—PLAN OF A VERTICAL SECTION OF THE TESTICLE, SHOWING THE ARRANGEMENT OF THE DUCTS.

The true length and diameter of the ducts have been disregarded. *a, a*, tubuli seminiferi coiled up in the separate lobes; *b*, vasa recta; *c*, rete vasculosum; *d*, vasa efferentia ending in the coni vasculosi; *e, g*, convoluted canal of the epididymis; *h*, vas deferens; *f*, section of the back part of the tunica albuginea; *i, i*, fibrous processes running between the lobes; *f* to *s*, mediastinum.

The **prostate**, which surrounds the commencement of the urethra, is a muscular and glandular mass, the glands of which are composed of tubular alveoli, lined by columnar epithelium, with smaller cells lying between them and the basement-membrane. Their ducts open upon the floor of the urethra.

The integument of the penis contains numerous special nerve end-organs of the nature of end-bulbs, and Pacinian bodies are also found upon the nerves. Lymphatic vessels are numerous in the integument of the organ and also in the submucous tissue of the urethra.

The **testicle** is inclosed by a strong fibrous capsule, the *tunica albuginea* (fig. 236, *i*).

This is covered externally with a layer of serous epithelium reflected from the *tunica vaginalis*. From its inner surface there proceed fibrous processes or *trabeculae*, which imperfectly subdivide the organ into lobules, and posteriorly the capsule is prolonged into the interior of the



gland in the form of a mass of fibrous tissue, which is known as the *mediastinum* (fig. 236, *f*). Attached to the posterior margin of the body of the gland is a mass (*epididymis*, *e*) which when investigated is found to consist of a single convoluted tube, receiving at its upper end the *efferent ducts* of the testis and prolonged at its lower end into a thick-walled muscular tube, the *vas deferens*, which conducts the secretion to the urethra.

The glandular substance of the testicle is wholly made up of *convoluted tubules*, which when unravelled are of very considerable length.

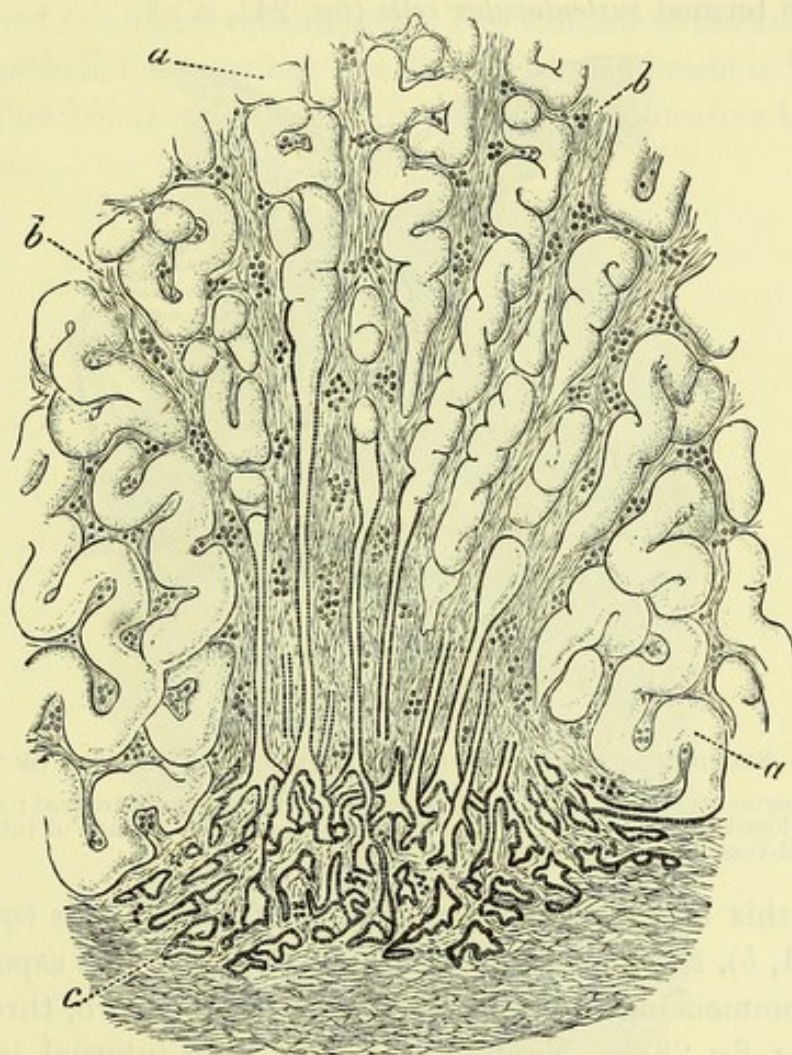


FIG. 237.—PASSAGE OF CONVOLUTED SEMINIFEROUS TUBULES INTO STRAIGHT TUBULES AND OF THESE INTO THE RETE TESTIS. (Mihalkowics.)

*a*, seminiferous tubules; *b*, fibrous stroma continued from the mediastinum testis; *c*, rete testis.

Each commences near the tunica albuginea, and after many windings terminates, usually after joining one or two others, in a *straight tubule* (fig. 236, *b*), which passes into the mediastinum, and there forms, by uniting with the other straight tubules, a network of intercommunicating vessels, which is known as the *rete testis*. From the rete a certain number of efferent tubules arise, and after a few convolutions pass into the tube of the epididymis.



**Structure of the tubules.**—The *seminiferous tubules* are formed of a thick basement-membrane, and contain several layers of epithelium-cells. Of these layers, the one next the basement-membrane is a stratum of clear cubical cells (*lining epithelium*, fig. 241, *a*), the nuclei of which, for the most part, exhibit the irregular network which is characteristic of the resting condition, but in certain tubules they exhibit indications of division. Here and there these epithelium-cells appear enlarged, and project between the more internal layers, being connected with groups of developing spermatozoa. These enlarged cells may be termed *sustentacular cells* (fig. 241, *a'*).<sup>1</sup>

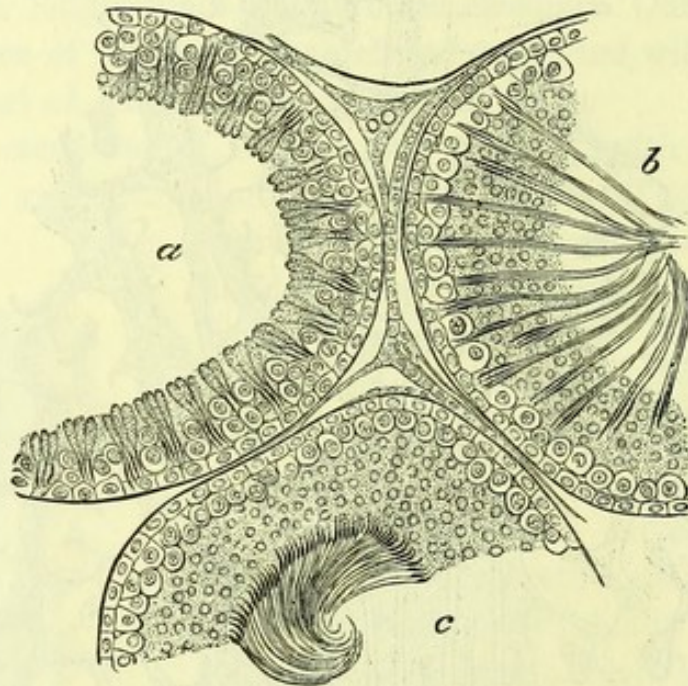


FIG. 238.—SECTION OF PARTS OF THREE SEMINIFEROUS TUBULES OF THE RAT.

*a*, with the spermatozoa least advanced in development; *b*, more advanced; *c*, containing fully developed spermatozoa. Between the tubules are seen strands of interstitial-cells with blood-vessels and lymph-spaces.

Next to this epithelium is seen a zone of larger cells (*spermatogenic cells*, fig. 241, *b*), the nuclei of which have the skein-like aspect which is typical of commencing division; these cells may be two, three, or more deep (as in *a*, fig. 238). Next to them, and most internal, is to be seen in some tubules (*b* and *c*) a large number of small protoplasmic cells with simple circular nuclei (*spermatoblasts*, fig. 241, *c*). In other tubules these cells are elongated, and the nucleus is at one end, and in others again these elongated cells are converted into evident spermatozoa, which lie in groups with their heads projecting between the deeper cells and connected with one of the enlarged cells of the lining epi-

<sup>1</sup> These are the 'spermatoblasts' of some authors—a name given to them on the erroneous supposition that they directly produce the spermatozoa. The term 'spermatoblast' is more applicable to the small cells of the third layer or zone, and will be so applied here.



thelium, and their tails emerging into the lumen of the tubule (fig. 238, *b*). As they become matured they gradually pass altogether towards the lumen, where they eventually become free (*c*). During the time that this crop of spermatozoa has been forming, another set of spermatoblasts has been produced by the division of the spermatogenic cells, and on the discharge of the spermatozoa the process is repeated as before.

The *straight tubules* which lead from the convoluted seminiferous tubes into the rete testis (fig. 237) are lined only by a single layer of clear flattened or cubical epithelium. The tubules of the rete also have a simple epithelial lining, but the basement-membrane is here absent, the epithelium being supported directly by the connective tissue of the mediastinum.

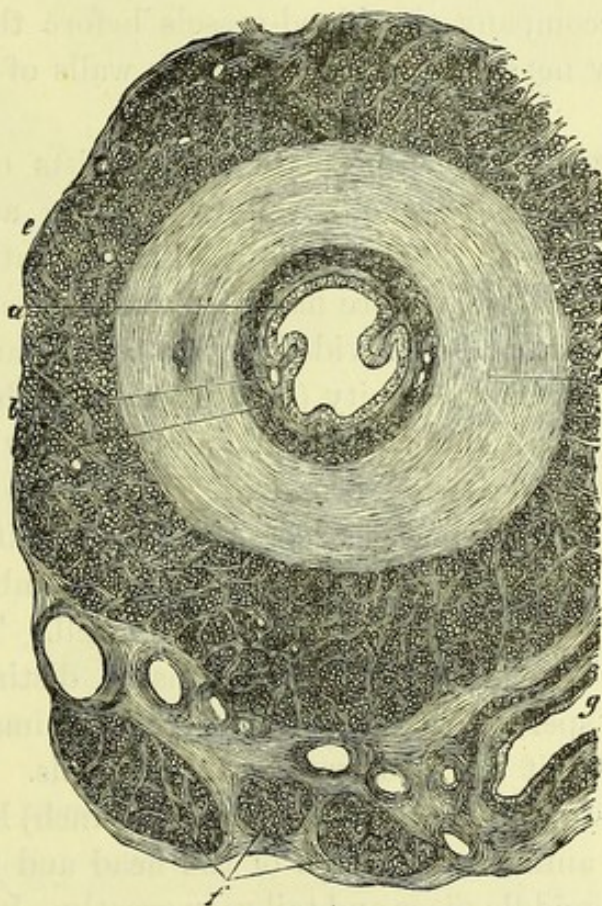


FIG. 239.—SECTION ACROSS THE COMMENCEMENT OF THE VAS DEFERENS.  
(Klein.)

*a*, epithelium; *b*, mucous membrane; *c*, *d*, *e*, inner, middle, and outer layers of the muscular coat; *f*, bundles of the internal cremaster muscles; *g*, section of a blood-vessel.

The *efferent tubules* which pass from the rete to the epididymis, and the *tube of the epididymis* itself, are lined by columnar ciliated epithelium, the cilia being very long; these tubes have a considerable amount of plain muscular tissue in their wall.

The *vas deferens* (fig. 239) is a thick tube, the wall of which is formed of an outer thick layer of longitudinal bundles of plain muscular



tissue; within this an equally thick layer of circular bundles of the same tissue, and within this again a thin layer of longitudinal muscle. The tube is lined by a mucous membrane, the inner surface of which is covered by columnar non-ciliated epithelium.

The *ampullæ* of the vasa deferentia, and the *vesiculæ seminales*, are in structure similar to the vas deferens, but their corrugated walls are much thinner and less muscular.

The connective tissue between the tubules of the testis is of very loose texture, and contains numerous lymphatic clefts, which form an intercommunicating system of commencing lymphatic vessels. Lying in this intertubular tissue are strands of polyhedral epithelium-like cells (*interstitial cells*, see fig. 238) of a yellowish colour; they are much more abundant in some species of animals (cat, boar) than in others. They accompany the blood-vessels before these break up to form the capillary networks which cover the walls of the seminiferous tubules.

**The spermatozoa.**—Each spermatozoon consists of three parts, a *head*, a *middle part* or *body*, and a long tapering and vibratile *tail*.

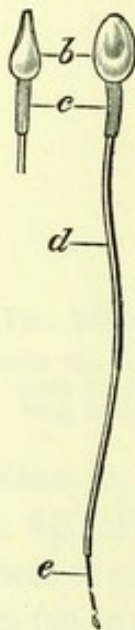

FIG. 240.—HUMAN SPERMATOZOA. (Retzius.)  $\frac{1}{1000}$ .

1, in profile; 2, viewed on the flat; b, head; c, middle-piece; d, tail; e, end-piece of the tail, which is described as a distinct part by Retzius.

In man (fig. 240) the head is of a flattened oval shape, somewhat more flattened and pointed anteriorly; it is said to be provided with a small barb-like projection at its extremity (Dowdeswell). The middle-piece is short and cylindrical, and appears to have a spiral fibre passing round it. The tail is the longest part of the spermatozoon, and during life is in continual vibratile motion, the action resembling that of the cilia of a ciliated epithelium-cell. The extremity of the tail (*end-piece*) forms a distinct part of the spermatozoon, and in some animals may become split up into two or three fibrils. Human spermatozoa are about 0.06 mm. ( $\frac{1}{400}$ -inch) long. In different animals the shape of the head and the extent of the middle-piece and tail vary greatly. In the rat (fig. 242, 7) the head is long, and is recurved anteriorly; it is set obliquely on the middle piece, which is also of considerable extent, and has a closely wound spiral filament encircling it in its whole length (H. H. Brown). In the newt the head is long and tapering, and the tail appears to have a membranous expansion,

attached in a spiral manner along its whole length. This has also been described in the human spermatozoon, but its existence here is doubtful.



*Spermatogenesis.*—The spermatozoa are developed from the small cells (spermatoblasts) which form the innermost stratum of the seminal epithelium, and these are themselves produced by the division of the large spermatogenic or mother-cells of the second layer. It is probable that these mother-cells again are formed by division of some of the lining epithelium-cells. The cycle of changes therefore which appears to take place is as follows:—1. Division of a lining epithelium-cell into two, one of which becomes a spermatogen, and passes into the second layer, while the other remains in the first layer, undergoes enlargement, and becomes a sustentacular-cell. 2. Division of the spermatogen. 3. Further division and multiplication of the spermatogens and the conversion of the resulting daughter-cells into a group of spermatoblasts. 4. Elongation of the spermatoblasts and their gradual conversion into mature spermatozoa. As they

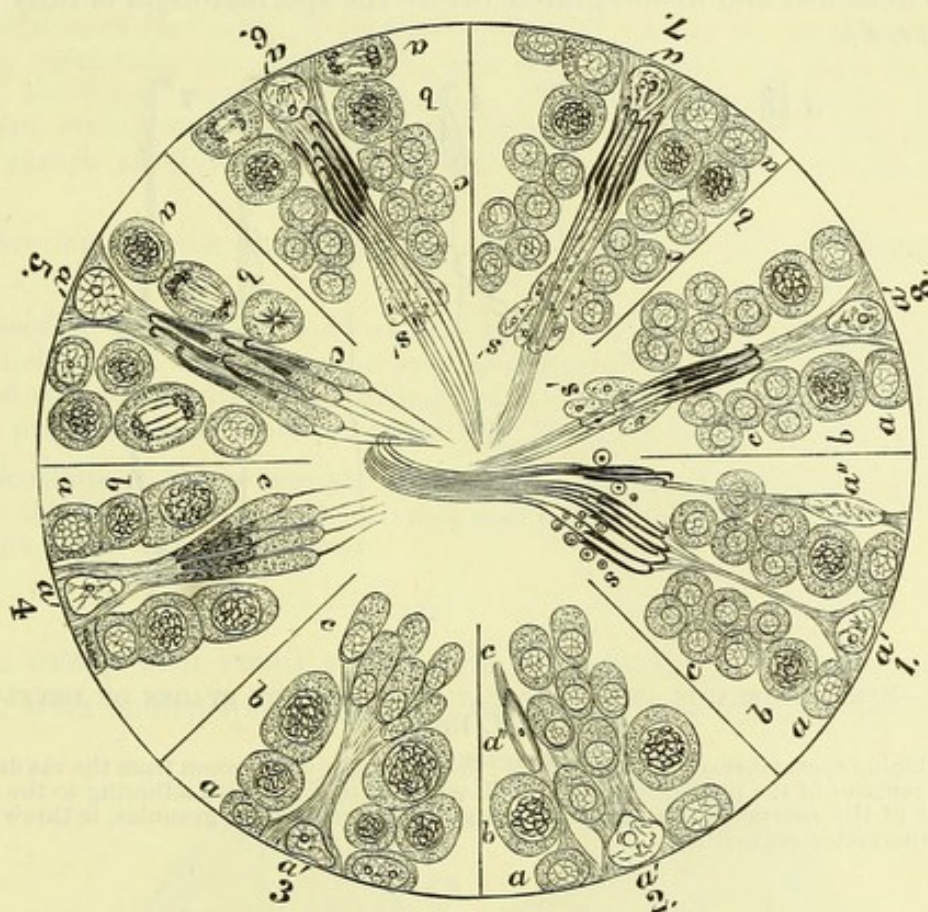


FIG. 241.—DIAGRAM EXHIBITING THE CYCLE OF PHASES OF SPERMATOGENESIS (RAT).

*a*, lining epithelium-cells, seen dividing in 6; *a'*, sustentacular-cells; *b*, spermatogenic or mother-cells, with skein-like nuclear filaments. These cells are seen actively dividing in 5. *c*, spermatoblasts, forming an irregular column or clump in 6, 7, 8, and 1, and connected to an enlarged supporting cell, *a'*, of the lining epithelium in 2, 3, 4, and 5. In 6, 7, and 8 advanced spermatozoa of one crop are seen between columns of spermatoblasts of the next crop. *s'*, parts of the spermatoblasts which are disintegrated when the spermatozoa are fully formed; *s*, seminal granules resulting from their disintegration; *a''* in 1 and 2 are nuclei of supporting cells which are probably becoming extruded.

undergo this conversion their grouping becomes more evident, and each group is found to be connected with a sustentacular-cell, which probably ministers to their nutrition. This cell undergoes a gradual process of elongation so that the spermatozoa by the time they are fully developed are brought to the lumen of the tube, in which they then become free. In the meantime other alternate groups of daughter-cells from which the next crop of spermatozoa will be derived are being formed in the same manner, passing through the same cycle of changes. So that in a section of the same tubule, at least



two different phases of development may be observed, and in different tubules of the same testicle every phase may be traced. The accompanying diagram (fig. 241), which is constructed from drawings by H. H. Brown, illustrates the cycle of changes above described: it is divided into eight parts, each of which shows the condition of the epithelium of a seminiferous tubule at a particular stage.

Each spermatoblast becomes converted into a spermatozoon in the following manner (fig. 242). The nucleus forms the head, while the tail develops as a fine filament within, but subsequently growing out from, the protoplasm, and apparently connected with the nucleus almost from the first. The protoplasm appears to assist in forming the middle piece of the spermatozoon; but a considerable portion of the protoplasm of each daughter-cell containing a number of small darkly staining particles (seminal granules) always becomes detached and disintegrated before the spermatozoon is fully mature (fig. 241, *s*, *s'*).

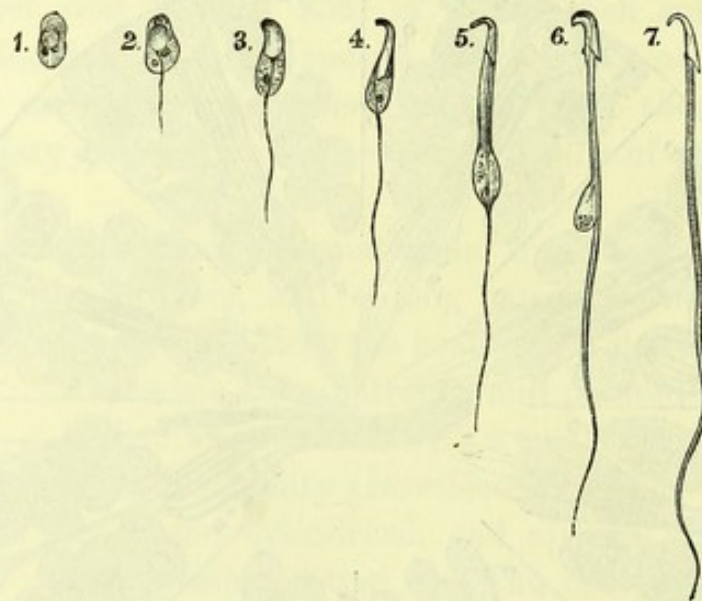


FIG. 242.—SPERMATOBLASTS FROM THE RAT IN DIFFERENT STAGES OF DEVELOPMENT.  
(H. H. Brown.)

1-6, developing spermatozoa from the testicle; 7, a mature spermatozoon from the vas deferens. The remains of the protoplasm of the cell, which is seen in 6 still adhering to the middle piece of the spermatozoon and containing a number of dark granules, is thrown off as the spermatozoon matures.



# LESSON XXXVII.

## GENERATIVE ORGANS OF THE FEMALE AND MAMMARY GLANDS.

1. SECTIONS of the ovary of the rabbit or cat. Study the sections with a low power, observing the small and large Graafian vesicles, each inclosing an ovum, scattered through the stroma. Measure some Graafian vesicles of different sizes; make a general sketch of a section under the low power. Then sketch carefully two or more of the Graafian vesicles with their contents.

2. Sections across the Fallopian tube. Sketch a section under the low power.

3. Section across the body of the uterus. Observe with the naked eye the thickness of the muscular and mucous coats respectively. Notice the ciliated columnar epithelium lining the organ and extending into the glands of the mucous membrane. Draw a part of the section under the low power.

4. Sections of the mammary gland from an animal killed during lactation. Notice the fat-globules in the alveoli and also in the alveolar cells. Draw an alveolus under the high power.

The **ovary** is a small solid organ, composed of a *stroma* of fibrous tissue, with many spindle-shaped cells, and also containing, especially

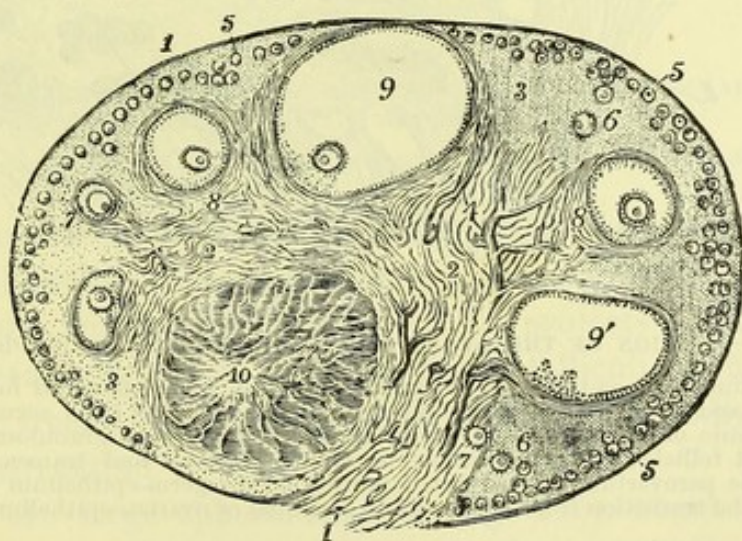


FIG. 243.—SECTION OF THE OVARY OF THE CAT. (Schrön.)  $\frac{6}{1}$ .

- 1, outer covering and free border of the ovary; 1', attached border; 2, the central ovarian stroma, showing a fibrous and vascular structure; 3, peripheral stroma; 4, blood-vessels; 5, Graafian follicles in their earliest stages lying near the surface; 6, 7, 8, more advanced follicles which are embedded more deeply in the stroma; 9, an almost mature follicle containing the ovum in its deepest part; 9', a follicle from which the ovum has fallen out in preparing the section; 10, corpus luteum.



near its attachment to the broad ligament, a large number of plain muscular fibres. It is covered by a layer of small columnar epithelium-cells (*germinal epithelium*, fig. 244, *a*), between which may here and there be seen a few larger spheroidal cells, with large round nuclei

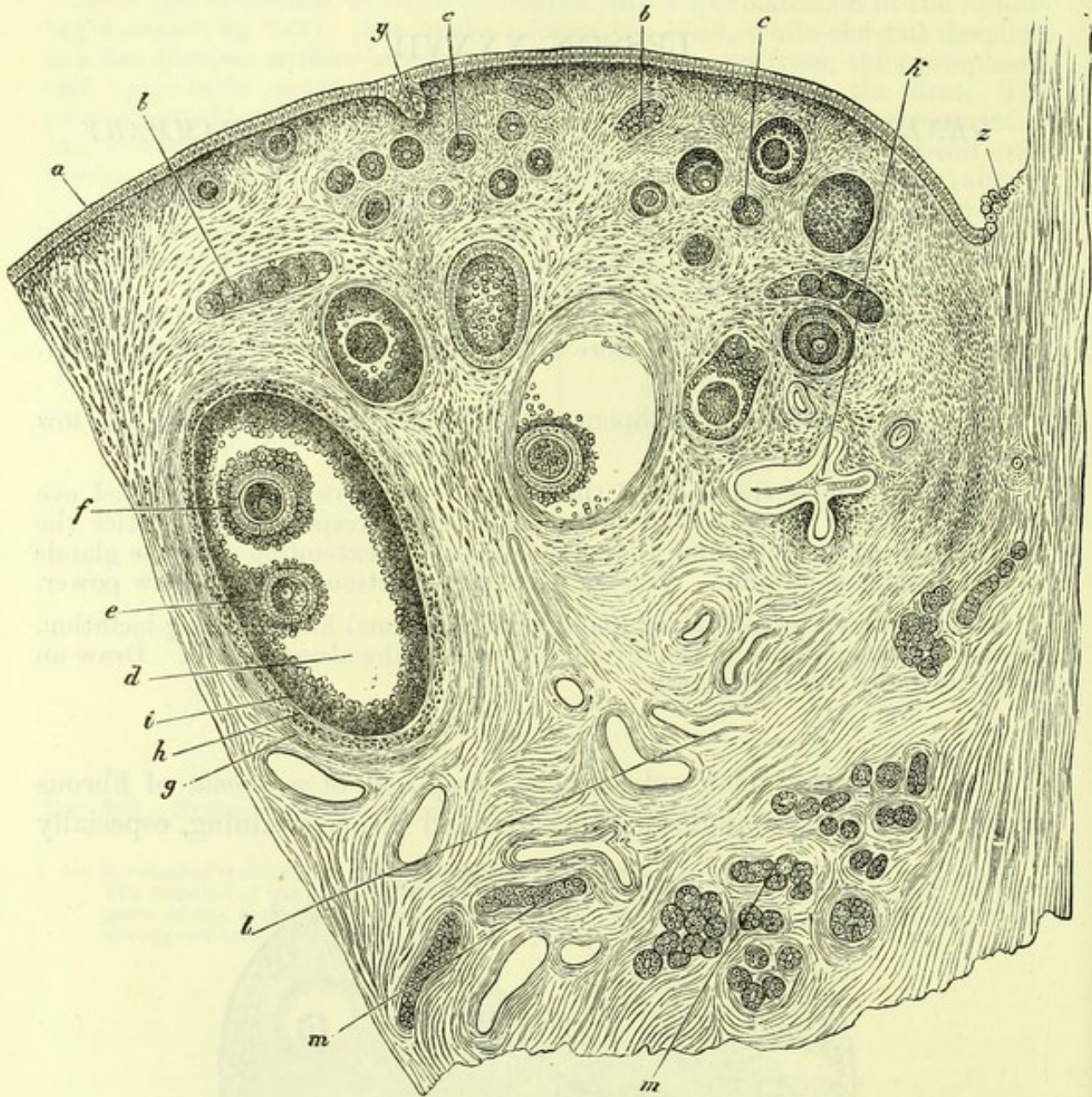


FIG. 244.—SECTION OF THE OVARY OF AN ADULT BITCH. (Waldeyer.)  $\frac{1}{15}$ .

*a*, germ-epithelium; *b*, egg-tubes; *c, c*, small follicles; *d*, more advanced follicle; *e*, discus proligerus and ovum; *f*, second ovum in the same follicle (this occurs but rarely); *g*, outer tunic of the follicle; *h*, inner tunic; *i*, membrana granulosa; *k*, collapsed retrograded follicle; *l*, blood-vessels; *m, m*, longitudinal and transverse sections of tubes of the parovarium; *y*, involuting portion of the germ-epithelium of the surface; *z*, place of the transition from peritoneal to germinal or ovarian epithelium.

(*primitive ova*, fig. 246, *c*). In the young subject the epithelium may occasionally dip down into the subjacent stroma.

The stroma is beset with vesicles of different sizes, the smallest being near the surface of the organ, the larger ones placed more deeply



in the stroma, although, as they increase in size, they may extend towards the surface.

These vesicles are the *Graafian follicles*. Each Graafian follicle has a proper wall (*theca folliculi*) formed of a layer derived from the stroma, and contains an *ovum* and *epithelium*. In the smallest follicles the ovum is small, and the epithelium of the follicle is formed of a single layer of cells, which are flattened against the ovum. In somewhat larger follicles the epithelium-cells are in two layers, and these are columnar in shape. In still larger ones, each of these two layers is formed of several strata of cells, and fluid has begun to collect between the layers at one part. Of the two layers, the one which lines the cavity of the follicle is termed the *membrana granulosa*, while the mass of cells which more immediately surrounds the ovum is known as the *discus proligerus*.

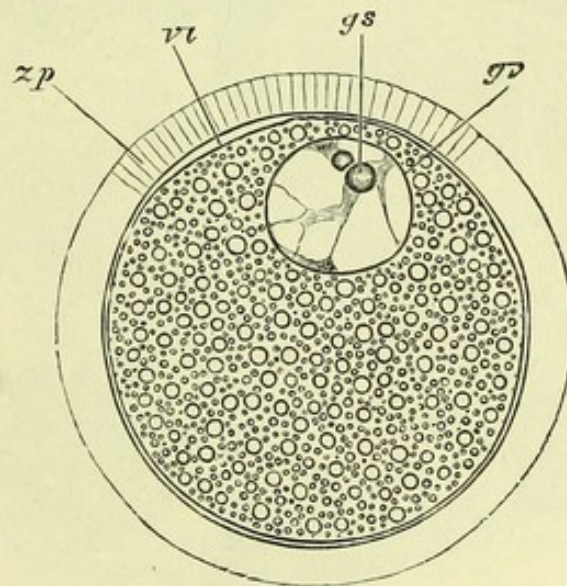


FIG. 245.—SEMI-DIAGRAMMATIC REPRESENTATION OF A MAMMALIAN OVUM.  
(Highly magnified.)

zp, zona pellucida; vi, vitellus; gv, germinal vesicle; gs, germinal spot.

In the largest follicles the fluid has much increased in amount, so that the follicle has become gradually larger and more tense. Finally it reaches the surface of the ovary, and projects from that surface, where it eventually bursts, and the liquor folliculi, with its contained ovum, is set free. This event is believed to occur usually at about the time of menstruation.<sup>1</sup>

The ova are large spheroidal cells (fig. 245), about 0.2 mm. ( $\frac{1}{125}$  inch) in diameter. When mature, as in the largest Graafian follicles, each ovum is surrounded by a thick transparent striated membrane

<sup>1</sup> Some of the Graafian follicles do not burst, but, after attaining a certain stage of maturity, undergo a process of retrograde metamorphosis and eventually disappear.



(*zona pellucida*). Within this is the protoplasm of the cell (*vitellus*), filled with fatty and albuminous granules. Lying in the vitellus, generally eccentrically, is the large clear round nucleus (*germinal vesicle*), which contains an intranuclear network, and usually one well-marked nucleolus (*germinal spot*). Both the ova and the epithelium of the Graafian follicles are developed originally from the germinal epithelium. In the embryo, this forms a thick layer, covering the fibrous and vascular stroma. After a time solid cords of epithelium-cells, which in some animals are partly tubular (*ovarian tubes* of Pflüger), grow down into the stroma, whilst this at the same time grows into the epithelium. The cords presently become broken up by the ingrowths of stroma into small isolated nests of epithelium-cells, each of which

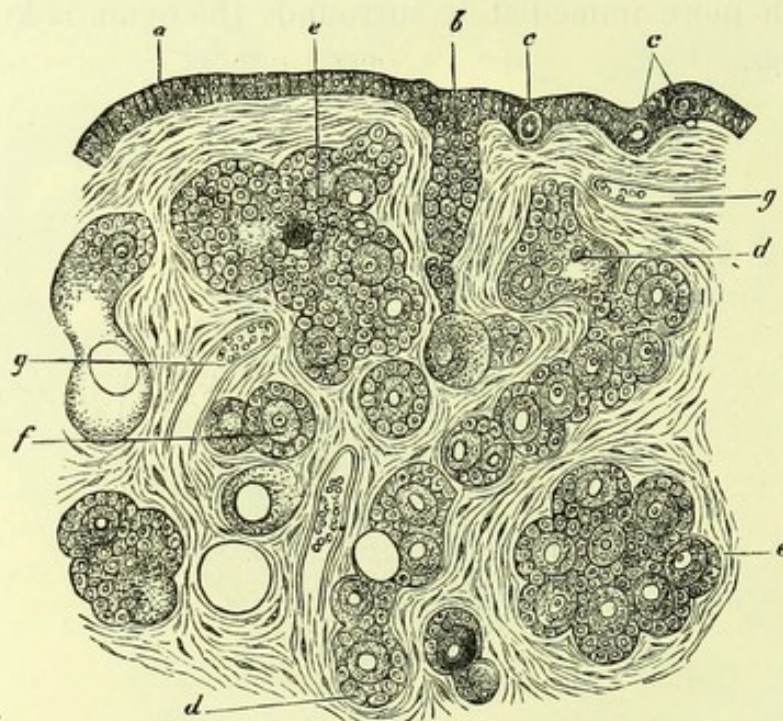


FIG. 246.—SECTION OF THE OVARY OF A NEWLY BORN CHILD. (Waldeyer.)  
(Highly magnified.)

*a*, ovarian or germinal epithelium; *b*, formation of an ovarian tube; *c, c*, primordial ova lying in the germ-epithelium; *d, d*, longer tube becoming constricted so as to form nests of cells; *e, e*, larger nests; *f*, distinctly formed follicle with ovum and epithelium; *g, g*, blood-vessels.

may represent a Graafian follicle. To form the ova, some of the germinal epithelium-cells become enlarged, and usually there is one such enlarged cell in each of the isolated nests. The remaining cells form the epithelium of the follicle (see fig. 246).

The stroma of the ovary contains, besides the spindle-shaped connective-tissue cells and plain muscular fibres already mentioned, a number of epithelium-like *interstitial cells*, like those found in the intertubular tissue of the testis. They are most abundant near the hilum. *Corpora lutea* may also be seen in the stroma. These are large yellow nodules, which are developed out of the Graafian follicles



after the ovum has been extruded. They consist of columns of large yellowish cells, with intervening vascular fibrous tissue, which converge to a central strand of connective tissue occupying the axis of the nodule. The columns of cells are not unlike those of the cortex of the suprarenal capsule. The corpus luteum is derived from the wall of the follicle, which becomes thickened and folded by multiplication and hypertrophy of its cells; between the folds connective tissue and blood-vessels grow in towards the centre, and in this way the columnar arrangement above mentioned is produced. After persisting for a time the corpus luteum gradually disappears, its tissue becoming merged in the surrounding stroma. Corpora lutea grow much larger and remain much longer persistent in the event of pregnancy supervening.

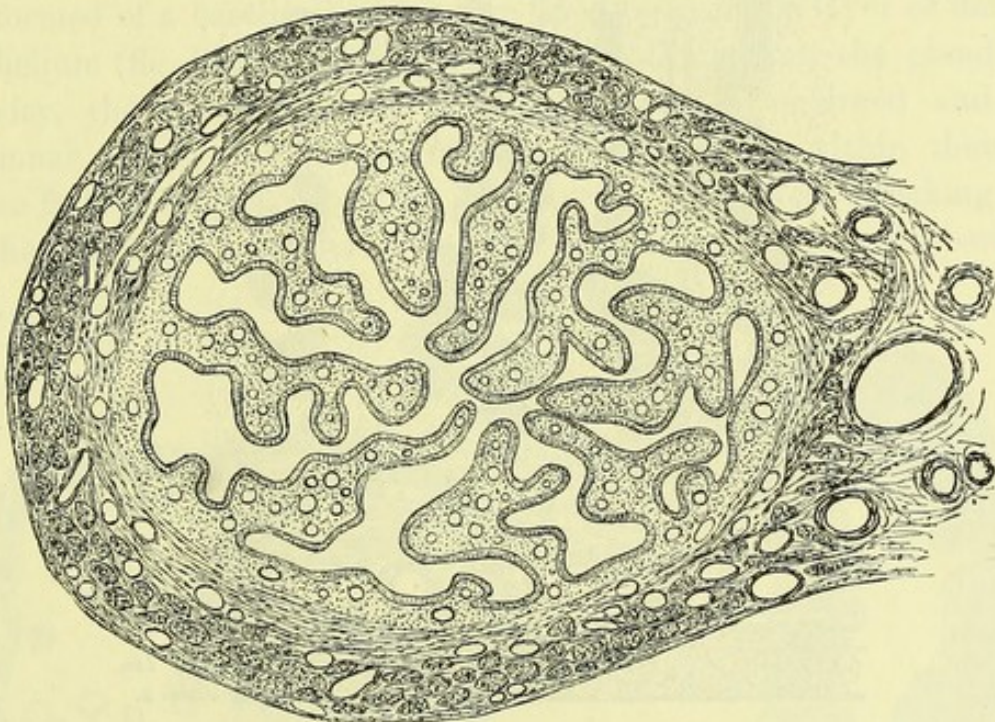


FIG. 247.—SECTION ACROSS THE FALLOPIAN TUBE.

The **Fallopian tubes** are lined by a very vascular mucous membrane which is covered with ciliated epithelium, and has numerous longitudinal folds. Externally they are covered by a serous coat, within which is a thin longitudinal layer of plain muscular fibres overlying circular fibres of the same tissue.

The **uterus** is usually described as composed of two parts, the body and cervix. The wall of the uterus is formed of the following layers:

1. A *serous layer*, derived from the peritoneum, which covers the greater part of the fundus.
2. A *muscular layer*, which is of considerable thickness and is formed of plain muscular fibres disposed in two imperfectly separated strata. Of these the outer is the true muscular coat, and its fibres are arranged partly longitudinally, partly circularly. The inner muscular



layer, on the other hand, is thick ; its fibres run in different directions, but chiefly circularly, and it is prolonged internally into the deeper part of the mucous membrane, the extremities of the uterine glands extending between and amongst its fibres. It is imperfectly separated from the thinner external layer by the ramifications of the larger blood-vessels, and represents a much-hypertrophied muscularis mucosæ.

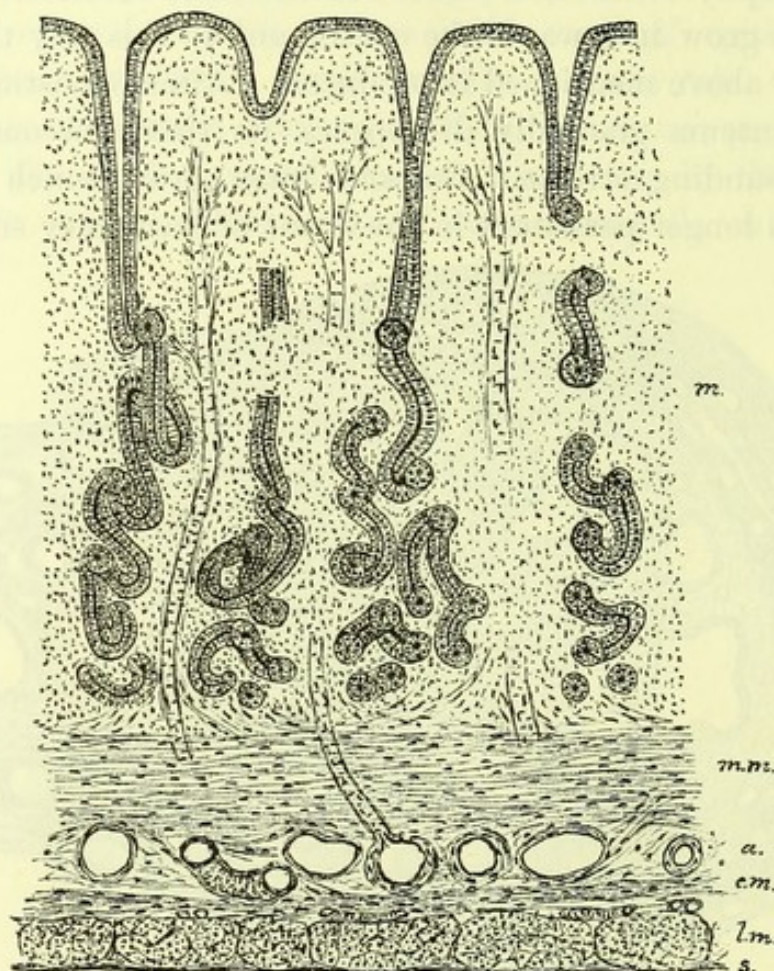


FIG. 248.—SECTION OF THE MUCOUS MEMBRANE OF THE RABBIT'S UTERUS.

*s*, serous layer ; *l.m.*, longitudinal muscular fibres ; *c.m.*, circular muscular fibres of the muscular coat ; *a*, areolar tissue, with large blood-vessels ; *m*, *m*, muscularis mucosæ ; *m*, mucous membrane.

3. A *mucous membrane*, which is very thick and is composed of soft connective tissue containing a large number of spindle-shaped cells. It contains long, simple, tubular glands, which take a curved or convoluted course in passing through the membrane. They are lined by ciliated epithelium continuous with that which covers the inner surface of the mucous membrane. In the cervix the mucous membrane is marked by longitudinal and oblique ridges, and the glands are shorter than those of the body of the uterus. Near the os uteri the epithelium becomes stratified and overlies vascular papillæ of the corium. The mucous membrane is exceedingly vascular, and it also contains a large number of lymphatic vessels.



At each menstrual period the greater part of the mucous membrane of the body undergoes a process of disintegration accompanied by an escape of blood from the capillaries of the membrane. This is succeeded by a rapid renewal of the membrane. Should gestation supervene, the process of renewal results in the formation of a greatly thickened mucous membrane, with long convoluted glands, which is then known as the decidua.

The **mammary glands** are compound racemose glands which open by numerous ducts upon the apex of the nipple. The ducts are dilated into small reservoirs just before reaching the nipple. If traced backwards, they are found as in other compound racemose glands to commence in groups of saccular alveoli. The walls of the ducts and alveoli are formed of a basement-membrane lined by a simple layer of flattened epithelium (fig. 249, *A*). But during lactation, when the gland is in activity, the cells of the alveoli become much enlarged and of a columnar shape, and fatty globules become formed within them (*B*). These fatty globules appear to become set free by the breaking down of the inner part of the cell, the protoplasm of the cells becoming

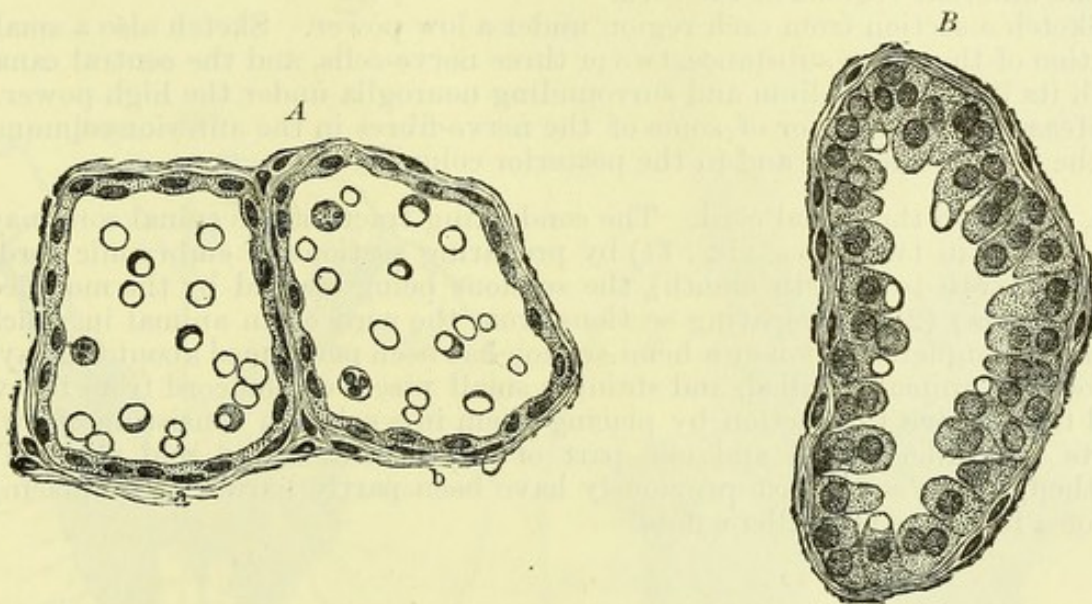


FIG. 249.—ALVEOLI OF THE MAMMARY GLAND OF THE BITCH UNDER DIFFERENT CONDITIONS OF ACTIVITY. (Heidenhain.)

*A*, section through the middle of two alveoli at the commencement of lactation, the epithelium-cells being seen in profile; *B*, an alveolus in full secretory activity.

partially dissolved and forming the proteid substances of the milk. According to Rauber, lymph-corpuscles may also carry fat into the alveoli and there become disintegrated. At the commencement of lactation the disintegration of the cells is imperfect, so that numerous cells containing fat-particles appear in the secretion (*colostrum corpuscles*).



## LESSON XXXVIII.

*STRUCTURE OF THE SPINAL CORD.*

1. SECTIONS of the spinal cord from the cervical, dorsal, and lumbar regions. As it is difficult to obtain the human spinal cord sufficiently fresh, that of a dog, cat, or monkey may be used. It is to be hardened by suspending it immediately after removal from the body in a tall jar of Müller's fluid (see Appendix). After a few hours the fluid is changed, and the cord is then left for about a month, when it will be ready for sections. These are to be made either with the freezing microtome or by the celloidin method. They may be stained by the modified Pal method given in the Appendix, or by aniline blue-black. The latter stains the nerve-cells and axis-cylinders, the former the medullary sheath of the nerve-fibres. Carminate of ammonia may also be employed to stain the nerve-cells and axis-cylinders.

Notice the relative extent of the grey as compared with the white matter in the different regions of the cord.

Sketch a section from each region under a low power. Sketch also a small portion of the white substance, two or three nerve-cells, and the central canal with its lining epithelium and surrounding neuroglia under the high power.

Measure the diameter of some of the nerve-fibres in the anterior columns, in the lateral columns, and in the posterior columns.

2. Tracts in the spinal cord. The conducting tracts of the spinal cord may be studied in two ways, viz.: (1) by preparing sections of embryonic cords (from the 5th to the 9th month), the sections being stained by the modified Pal process; (2) by preparing sections from the cord of an animal in which either a complete section or a hemi-section has been performed about ten days before the animal is killed, and staining small pieces of the cord from below and from above the section by placing them in a solution consisting of two parts of Müller's fluid and one part of 1 per cent. osmic acid (Marchi's method). The cord must previously have been partly hardened by placing it for a few days in Müller's fluid.

---

The spinal cord is composed of grey matter in the centre and of white matter externally. It is closely invested by a layer of connective-tissue containing numerous blood-vessels (*pia mater*), and less closely by two other membranes. One of these is an areolar membrane, resembling a serous membrane in general structure, but non-vascular and more delicate in texture (*arachnoid*). The other, which lines the vertebral canal, is a strong fibrous membrane known as the *dura mater*. At the middle of the anterior and posterior surfaces the pia mater dips into the substance of the cord in the *anterior* and *posterior median fissures*, so as to divide it almost completely into two lateral halves.



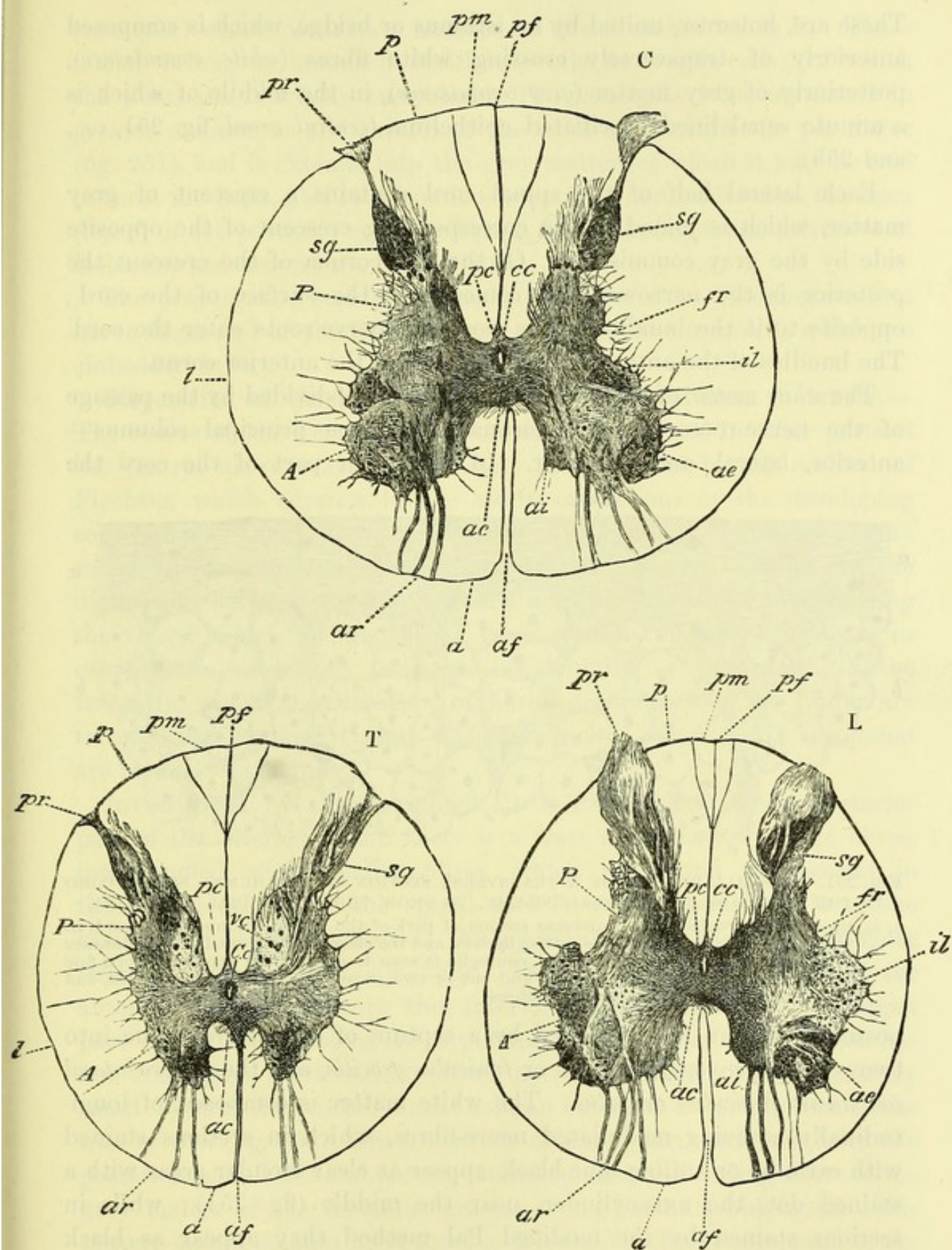


FIG. 250.—TRANSVERSE SECTION OF MONKEY'S SPINAL CORD. (Bevan Lewis.)<sup>1</sup>

C, from the cervical region; T, from the thoracic region; L, from the lumbar region.  
*A*, anterior cornu; *P*, posterior cornu; *a*, anterior column; *l*, lateral column; *p*, posterior column; *ac*, anterior commissure; *ae*, *ai*, external and internal cell-groups of anterior cornu; *af*, anterior median fissure; *ar*, anterior roots; *cc*, central canal; *fr*, formatio reticularis; *il*, lateral group of cells; *vc*, vesicular column of Clarke; *pc*, posterior commissure; *pf*, posterior median fissure; *pm*, postero-mesial column; *pr*, posterior roots; *sg*, substantia gelatinosa.

<sup>1</sup> Taken by permission of the author from Ferrier's *Functions of the Brain*. Second Edition.



These are, however, united by an isthmus or bridge, which is composed anteriorly of transversely crossing white fibres (*white commissure*), posteriorly of grey matter (*grey commissure*), in the middle of which is a minute canal lined by ciliated epithelium (*central canal*, fig. 251, *c.c.*, and 255).

Each lateral half of the spinal cord contains a crescent of grey matter, which is joined to the corresponding crescent of the opposite side by the grey commissure. Of the two cornua of the crescent the posterior is the narrower and comes near the surface of the cord; opposite to it the bundles of the posterior nerve-roots enter the cord. The bundles of the anterior nerve-roots enter the anterior cornu.

The *white matter* of each half of the cord is subdivided by the passage of the nerve-roots into the cornua into three principal columns—*anterior*, *lateral*, and *posterior*. In the upper part of the cord the

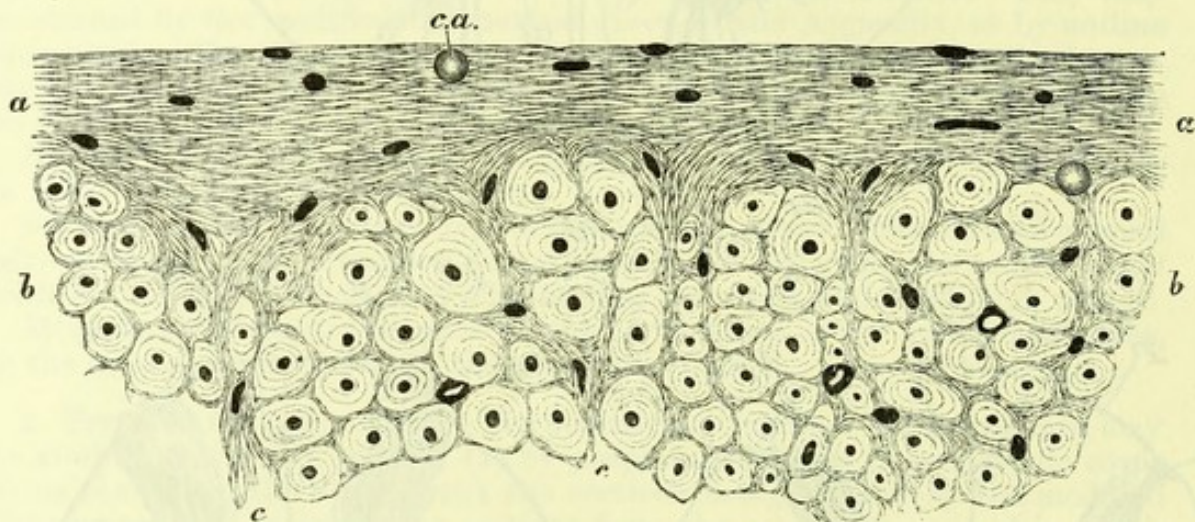


FIG. 251.—A SMALL PORTION OF A TRANSVERSE SECTION OF THE HUMAN SPINAL CORD IN THE REGION OF THE LATERAL COLUMN, TO SHOW THE SUPERFICIAL NEUROGLIA.

*a, a*, superficial neuroglia; *b, b*, transverse section of part of the lateral column of the cord, in which the dark points are the axis-cylinders, and the clear areas the medullary substance of the nerve-fibres. The superficial neuroglia is seen to exhibit the appearance of a fine feltwork in which numerous nuclei and one or two *corpora amylacea* are embedded, and to extend inwards among the nerve-fibres.

posterior column is subdivided by a septum of connective tissue into two—the *postero-mesial column* or *funiculus gracilis*, and the *postero-lateral column* or *funiculus cuneatus*. The white matter is composed of longitudinally coursing medullated nerve-fibres, which in sections stained with carmine or aniline blue-black appear as clear circular areas with a stained dot, the axis-cylinder, near the middle (fig. 251); while in sections stained by the modified Pal method they appear as black circles with a clear centre. The nerve-fibres vary in size in different parts; on the whole those which are nearest the surface of the cord are larger than those nearest to the grey matter, but there is a bundle of very small fibres (*M*, fig. 252) opposite the tip of the posterior horn.

The medullated fibres are supported by a peculiar reticular tissue



(*neuroglia*) which contains a number of nuclei embedded in it. These nuclei belong to branched fibrillated cells (*neuroglia-cells*), of which the *neuroglia* is wholly composed. The *neuroglia* is accumulated in greater amount at the surface of the cord underneath the pia mater (fig. 251), and it extends into the grey matter, of which it may be said to form the basis, and in which it is especially accumulated at the apex (*caput*) of the posterior cornu (where it forms the *substantia gelatinosa* of Rolando) and around the central canal.

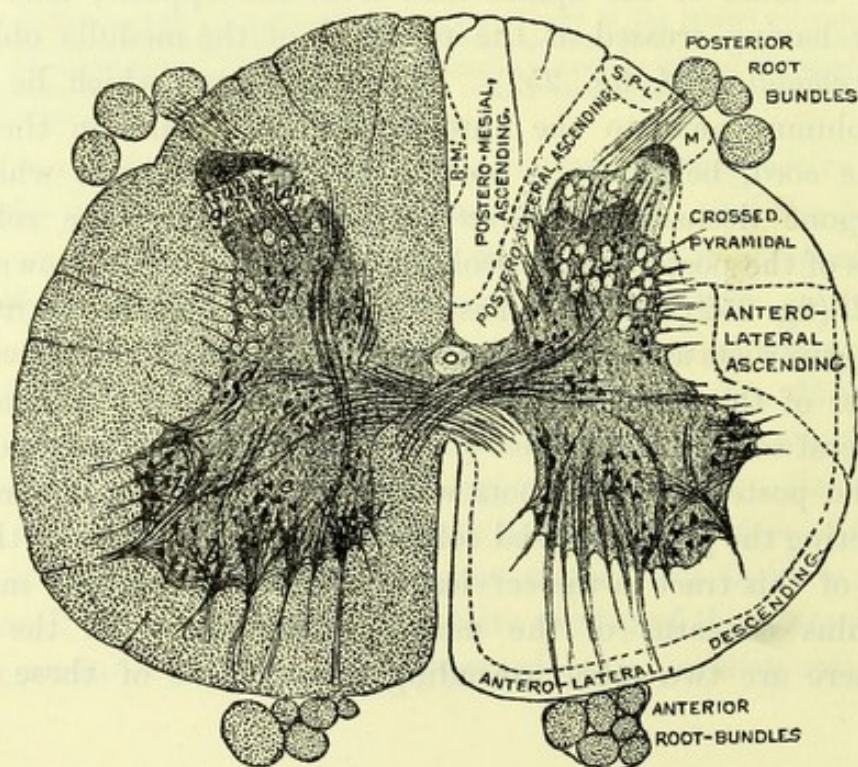
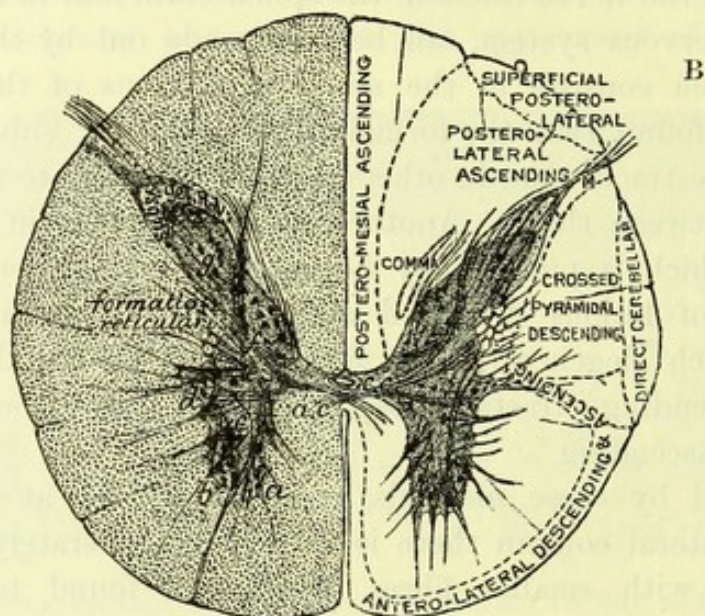
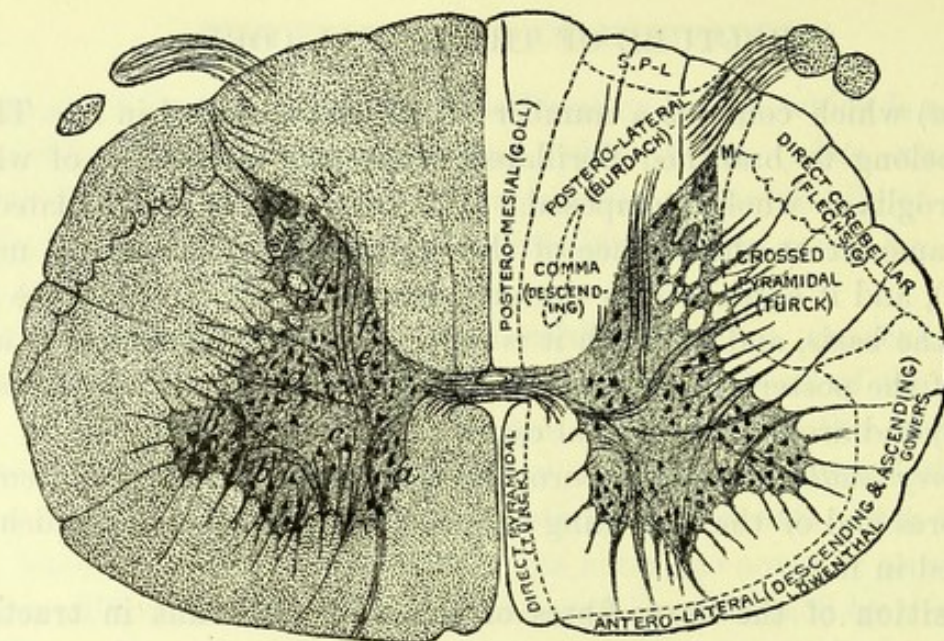
The *grey matter*, besides *neuroglia*, consists of an interlacement of nerve-fibres and of the branching processes of the nerve-cells which are embedded in it.

**Disposition of the nerve-fibres of the white columns in tracts.—**

The course of the nerve-tracts in the spinal cord, and in other parts of the central nervous system, can best be made out by the method of Flechsig, which consists in the study of sections of the developing cord, for it is found that the formation of medullary substance occurs sooner in some tracts than in others, so that it is easy to make out the distinction between them. Another method consists in investigating the course which is pursued by degenerations of the nerve-fibres in consequence of lesions produced accidentally or purposely. Those tracts in which degeneration of fibres occurs below the lesion are termed “descending” tracts; those in which it occurs above the lesion are termed “ascending.”

Investigated by these methods, it is found that at the posterior part of the lateral column there is a tract of moderately large fibres, intermingled with smaller fibres, which are found to descend in the lateral column of the spinal cord from the opposite side of the brain, after having crossed at the pyramids of the medulla oblongata (*crossed pyramidal tract*, fig. 252). The large fibres which lie in the anterior columns next to the anterior median fissure, in the upper part of the cord, belong to a portion of the same tract which has not undergone decussation (*direct pyramidal tract*). The relatively small fibres of the postero-mesial column belong to a tract, known as the *tract of Goll* (fig. 252), which consists of fibres derived below from the posterior nerve-roots and postero-lateral column, and ending above in the grey matter of the funiculus gracilis of the medulla oblongata. The postero-lateral column itself (*tract of Burdach*) is chiefly composed of the fibres of the posterior nerve-roots which run for a short distance in it before entering the postero-mesial column or the grey matter of the cord. The fibres of this tract in the cervical region end in the grey matter of the funiculus cuneatus of the medulla oblongata. In the lateral column there are two other ascending tracts. One of these is only







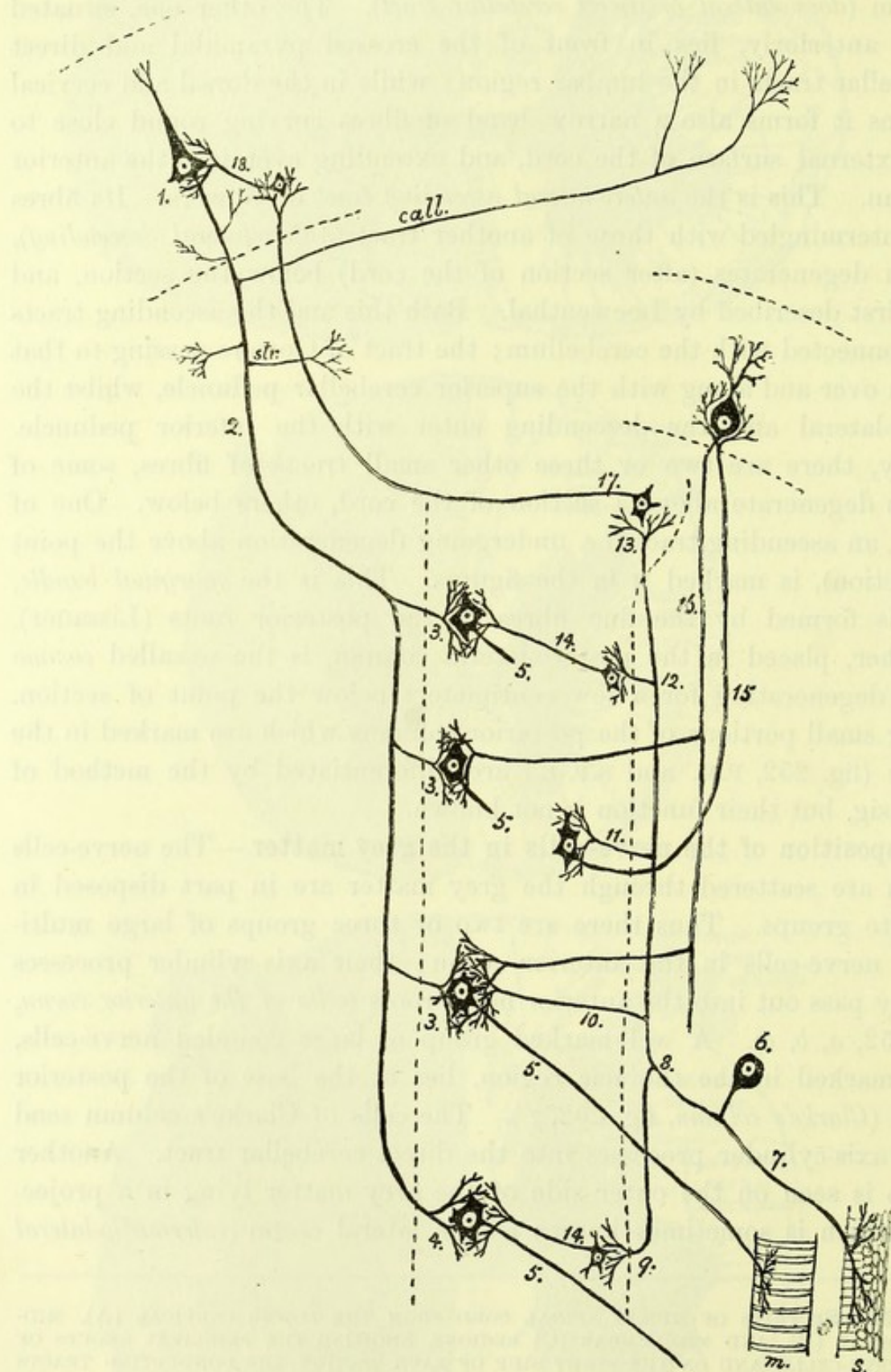
distinct in the cervical and dorsal regions. Here it lies external to the crossed pyramidal tract, and consists of large fibres which are derived from the cells of Clarke's column (fig. 252, *f*) and pass up into the cerebellum (*dorso-lateral or direct cerebellar tract*). The other one, situated more anteriorly, lies in front of the crossed pyramidal and direct cerebellar tracts in the lumbar region; while in the dorsal and cervical regions it forms also a narrow band of fibres curving round close to the external surface of the cord, and extending even into the anterior column. This is the *antero-lateral ascending tract* of Gowers. Its fibres are intermingled with those of another tract (*antero-lateral descending*), which degenerates (after section of the cord) below the section, and was first described by Loewenthal. Both this and the ascending tracts are connected with the cerebellum; the tract of Gowers passing to that organ over and along with the superior cerebellar peduncle, whilst the dorso-lateral and the descending enter with the inferior peduncle. Lastly, there are two or three other small tracts of fibres, some of which degenerate above a section of the cord, others below. One of these, an ascending tract (*i.e.* undergoing degeneration above the point of section), is marked M in the figures. This is the *marginal bundle*, and is formed by the fine fibres of the posterior roots (Lissauer). Another, placed in the postero-lateral column, is the so-called *comma tract*, degenerating for a few centimeters below the point of section. Other small portions of the posterior columns which are marked in the figure (fig. 252, P.M.' and S.P.-L.) are differentiated by the method of Flechsig, but their function is not known.

**Disposition of the nerve-cells in the grey matter.**—The nerve-cells which are scattered through the grey matter are in part disposed in definite groups. Thus there are two or three groups of large multipolar nerve-cells in the anterior cornu; their axis-cylinder processes mostly pass out into the anterior nerve-roots (*cells of the anterior cornu*, fig. 252, *a, b, c*). A well-marked group of large rounded nerve-cells, best marked in the thoracic region, lies at the base of the posterior cornu (*Clarke's column*, fig. 252, *f*). The cells of Clarke's column send their axis-cylinder processes into the direct cerebellar tract. Another group is seen on the outer side of the grey matter lying in a projection which is sometimes known as the lateral cornu (*intermedio-lateral*

FIG. 252.—SECTIONS OF HUMAN SPINAL CORD FROM THE LOWER CERVICAL (A), MID-DORSAL (B), AND MID-LUMBAR (C) REGIONS, SHOWING THE PRINCIPAL GROUPS OF NERVE-CELLS, AND ON THE RIGHT SIDE OF EACH SECTION THE CONDUCTING TRACTS AS THEY OCCUR IN THE SEVERAL REGIONS. (Magnified about 7 diameters.)

*a, b, c*, groups of cells of the anterior horn; *d*, cells of the lateral horn; *e*, middle group of cells; *f*, cells of Clarke's column; *g*, cells of posterior horn; *c, c*, central canal; *a.c.*, anterior commissure.







*tract*, fig. 252, *d*). This is most distinct in the upper dorsal and lower cervical regions. Another group (*middle cell-group*) lies in the middle of the crescent (fig. 252, *e*). The cells of the posterior cornu (*g*) are not collected into a special group.

**Course of the nerve-roots in the spinal cord.**—The *anterior roots* leave the anterior cornu in a number of bundles (fig. 250). Most of their fibres are directly continued from the nerve-cells there. On the other hand, these cells are surrounded by an interlacement of ramified nerve-endings, which are derived from various sources, especially from the collaterals of the posterior root-fibres (see below), and from those of the descending fibres of the pyramidal tracts.

The fibres of the *posterior roots* originate in the cells of the posterior root ganglia (see diagram, fig. 253), and pass into the postero-lateral column, but the smallest fibres enter the marginal bundle, and some pass into the posterior horn of grey matter. On entering the spinal cord the fibres bifurcate (diagram, fig. 253 and fig. 254), one branch passing upwards, the other downwards. Both from the main fibre and from its branches collateral fibres pass at frequent intervals into the grey matter, and end in arborisations of fibrils, which envelop the nerve-cells, both of the posterior and of the anterior horn (see diagram). The main fibres also for the most part ultimately end in a similar manner in the grey matter, some after a short course only, but others after a longer course. A certain number of the last named fibres pass upwards in the postero-lateral and postero-mesial columns (in the latter especially those of the lower spinal nerves), until they arrive at the medulla oblongata, where they have a terminal arborisation around the cells in the nucleus gracilis and nucleus cuneatus.

FIG. 253.—DIAGRAM SHOWING THE PROBABLE RELATIONS OF SOME OF THE PRINCIPAL CELLS OF THE CEREBRO-SPINAL SYSTEM TO ONE ANOTHER.

- 1, a cell of the cortex cerebri; 2, its axis-cylinder or nerve-process passing down in the pyramidal tract, and giving off collaterals, some of which, 3, 3, end in arborisations around cells of the anterior horn of the spinal cord, the main fibre having a similar ending at 4; *coll*, a collateral passing to the corpus callosum; *str*, another passing to the corpus striatum; 5, axis-cylinder process of anterior cornu-cell passing to form a terminal arborisation in the end-plate of a muscle-fibre, *m*.
- 6, a cell of one of the spinal ganglia. Its axis-cylinder process bifurcates, and one branch, 7, passes to the periphery to end in an arborisation in the sensory surface, *s*. The other (central) branch bifurcates after entering the cord (at 8), and its divisions pass upwards and downwards (the latter for a short distance only); 9, ending of the descending branch in a terminal arborisation around a cell of the posterior horn, the axis-cylinder process of which, again, ends in a similar arborisation around a cell of the anterior horn; 10, a collateral passing from the ascending division directly to envelop a cell of the anterior horn; 11, one passing to envelop a cell of Clarke's column; 12, a collateral having connections like these of 9; 13, ending of the ascending division of the posterior root-fibre around one of the cells of the posterior columns of the bulb; 14, 14, axis-cylinder processes of cells of the posterior horn passing to form an arborisation around the motor cells; 15, a fibre of the ascending cerebellar tract passing up to form an arborisation around a cell of the cerebellum; 16, axis-cylinder process of this cell passing down the bulb and cord, and giving off collaterals to envelop the cells of the anterior horn; 17, axis-cylinder process of one of the cells of the posterior column of the bulb passing as a fibre of the fillet to the cerebrum, and forming a terminal arborisation around one of the smaller cerebral cells; 18, axis-cylinder process of this cell, forming an arborisation around the pyramidal-cell, 1.



The **central canal** of the spinal cord is lined by columnar ciliated epithelium-cells, which are surrounded by a quantity of neuroglia. The cells are best seen in the spinal cord of animals and in the child (fig. 255); in the human adult they have frequently become proliferated, and their cilia are no longer visible.

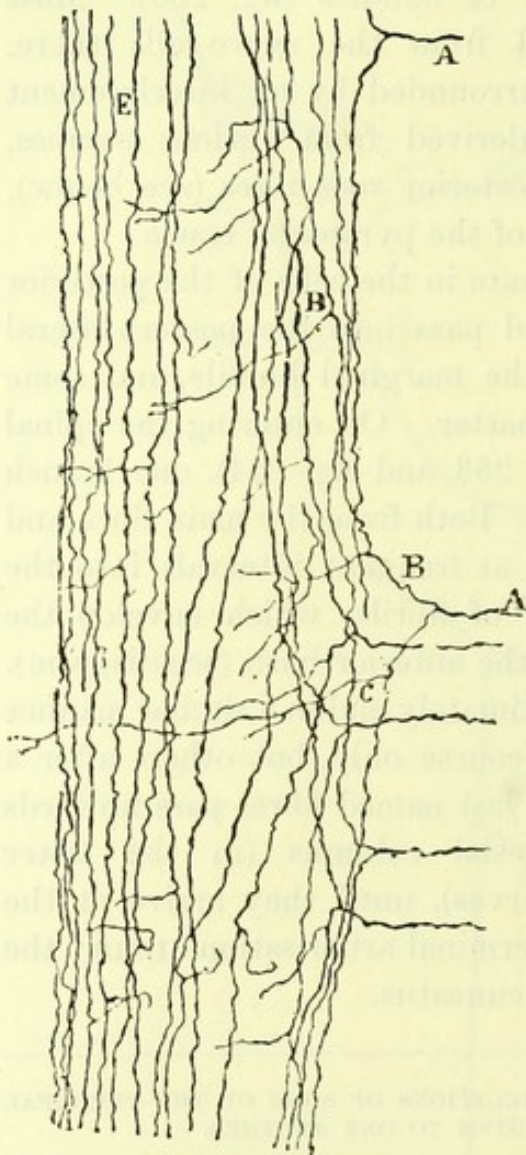


FIG. 254.—FROM A LONGITUDINAL SECTION OF SPINAL CORD, SHOWING THE ENTRANCE OF POSTERIOR ROOT-FIBRES. (Ramón y Cajal.)

A, A, fibres entering the postero-lateral column, and bifurcating into an ascending and descending division; B, C, collaterals passing from them into the grey matter; E, other fibres of the posterior white columns also giving off collaterals.

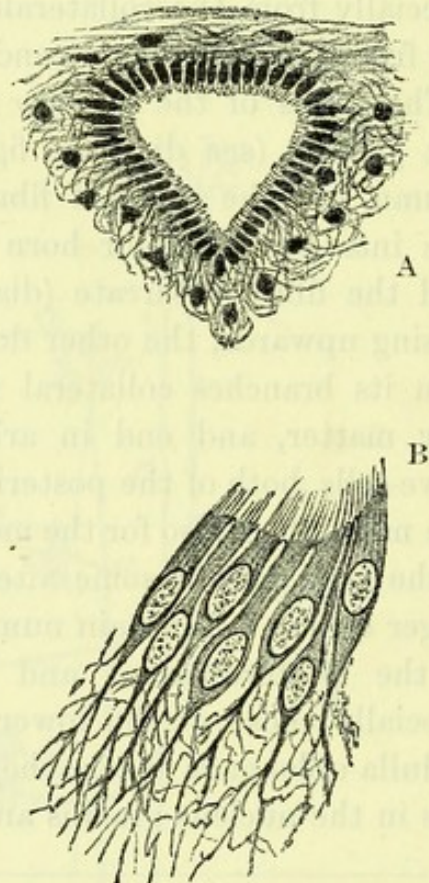

FIG. 255.—A, SECTION OF THE CENTRAL CANAL OF THE SPINAL CORD OF A CHILD, SHOWING ITS CILIATED EPITHELIUM AND THE SURROUNDING CENTRAL NEUROGLIA. (Moderately magnified.) B, SOME OF THE CILIATED CELLS. (Highly magnified.)

**Characters of the spinal cord in the several regions** (figs. 252, 256).—In the *cervical region* the white matter, especially that of the lateral columns, occurs in largest proportion. The grey matter, especially in the cervical enlargement, is in considerable amount (C 5), and it encroaches in the form of a network upon the adjacent part of the lateral



white column. The anterior cornua are thick and the posterior slender. The postero-mesial column is distinctly marked off.

In the *dorsal region* the grey matter is small in amount, and both cornua are slender (D 5). The whole cord is smaller in diameter than

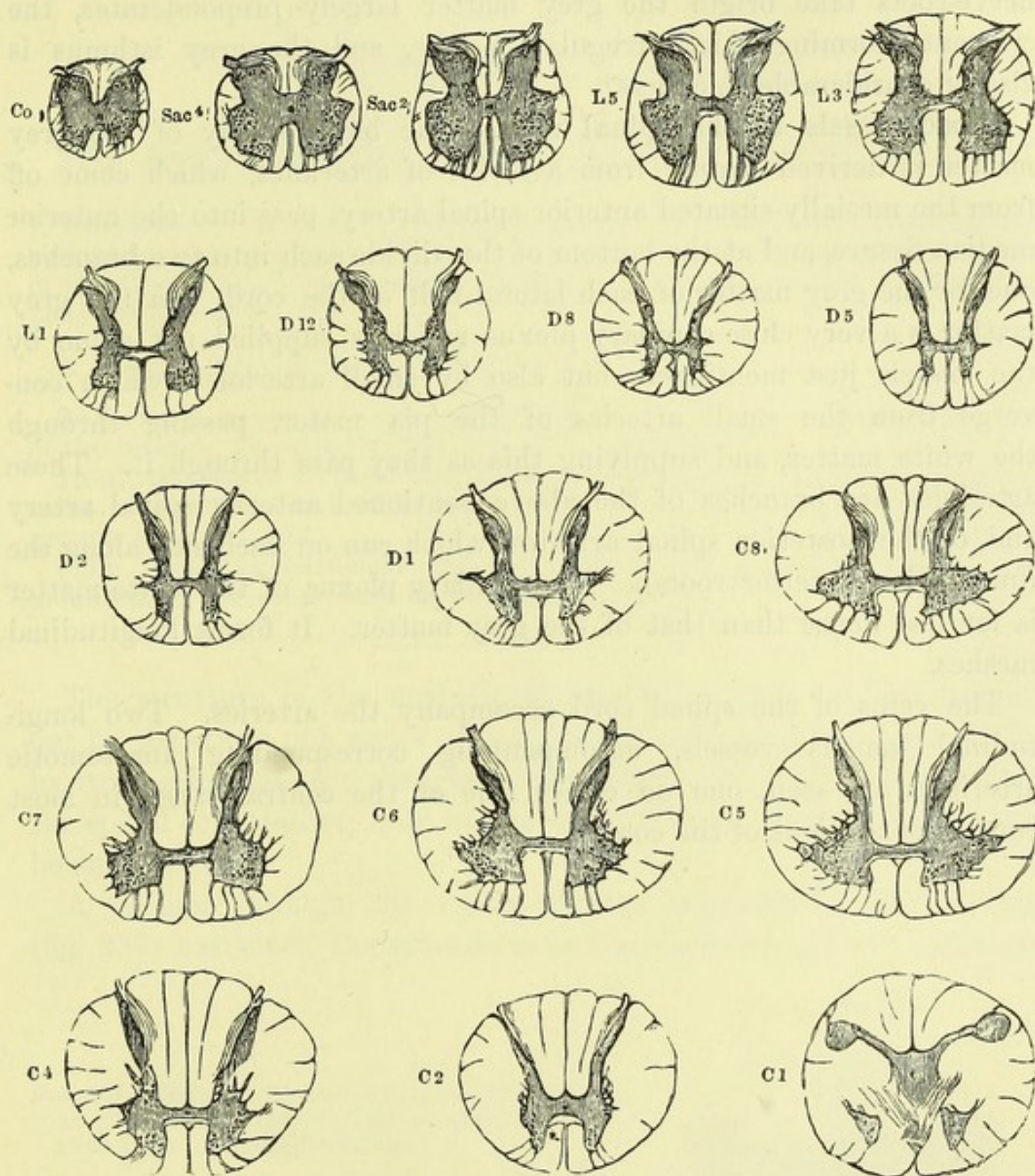


FIG. 256.—TRANSVERSE SECTIONS OF THE SPINAL CORD AT DIFFERENT LEVELS (Gowers.) (Twice the natural size.)

The letters and numbers indicate the position of each section; Ca, at level of coccygeal nerve; Sac 4 of 4th sacral; L 3 of 3rd lumbar, and so on. The grey substance is shaded dark, and the nerve-cells within it are indicated by dots.

either in the cervical or lumbar region. The column of nerve-cells known as Clarke's column, and the intermedio-lateral tract, are well marked.

In the *lumbar region* the crescents of grey matter are very thick, and the white substance, especially the lateral columns, relatively small



in amount (L 5). The isthmus lies nearly in the centre of the cord, whereas in the cervical and dorsal regions it is nearer the anterior surface.

In the part of the spinal cord from which the *sacral* and *coccygeal* nerve-roots take origin the grey matter largely preponderates, the crescents forming thick irregular masses, and the grey isthmus is also of considerable thickness.

**Blood-vessels of the spinal cord.**—The blood-supply of the grey matter is derived mainly from a series of arterioles, which come off from the mesially-situated anterior spinal artery, pass into the anterior median fissure, and at the bottom of this divide each into two branches, one for the grey matter of each lateral half of the cord. In the grey matter is a very close capillary plexus which is supplied not alone by the vessels just mentioned, but also by small arterioles, which converge from the small arteries of the pia mater, passing through the white matter, and supplying this as they pass through it. These arterioles are branches of the above-mentioned anterior spinal artery and of the posterior spinal arteries (which run on each side along the line of the posterior roots). The capillary plexus of the white matter is far less dense than that of the grey matter. It forms longitudinal meshes.

The veins of the spinal cord accompany the arteries. Two longitudinal venous vessels, accompanying corresponding anastomotic arterioles are seen, one on either side of the central canal, in most transverse sections of the cord.



## LESSONS XXXIX. AND XL.

*THE MEDULLA OBLONGATA, PONS, AND MESENCEPHALON.*

1. SECTIONS of the medulla oblongata made, (*a*) at the level of the decussation of the pyramids, (*b*) just above the decussation, (*c*) opposite the middle of the olivary body, and (*d*) either through the uppermost part of the olivary body, or just above it.

2. Section through the middle of the pons Varolii.

3. Sections across the region of the corpora quadrigemina, one at the level of the inferior, the other at the level of the superior, pair.

In all the above sections sketch under a low power the general arrangement of the grey and white matter, inserting the positions of the chief groups of nerve-cells.

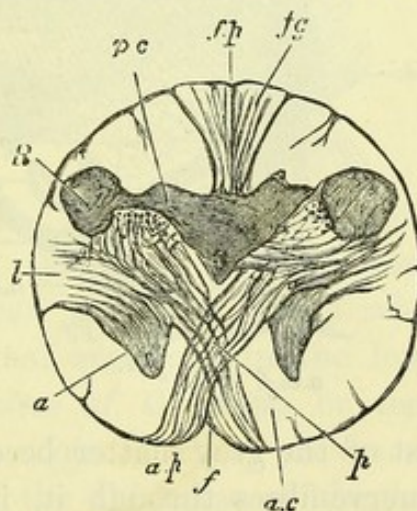
[The tissue is hardened and the sections are prepared, stained, and mounted in the same way as the spinal cord.]

The structure of the **medulla oblongata** or **bulb** can best be made out by the study of a series of sections taken from below upwards, and by tracing in these the changes which occur in the constituent parts of the spinal cord, taking note at the same time of any parts which may be superadded.

A section through the *region of the decussation of the pyramids* (fig. 257) has much the same form as a section through the upper part

FIG. 257.—SECTION OF THE MEDULLA OBLONGATA AT THE MIDDLE OF THE DECUSSATION OF THE PYRAMIDS. (Lockhart-Clarke.)  $\frac{3}{4}$ .

*f*, anterior, *f.p.*, posterior fissure; *a.p.*, pyramid; *a*, remains of part of anterior cornu, separated by the crossing bundles from the rest of the grey matter; *l*, continuation of lateral column of cord; *R*, continuation of substantia gelatinosa of Rolando; *p.c.*, continuation of posterior cornu of grey matter; *f.g.*, funiculus gracilis.



of the spinal cord, and most of the structures of the cord can be easily recognised. A considerable alteration of the grey matter is, however, produced by the passage of the large bundles of the crossed pyramidal



tract (*p*) from the lateral column of the spinal cord on each side through the root of the anterior cornu and across the anterior median fissure to the opposite anterior column of the medulla oblongata, where, together with the fibres of the direct pyramidal tract, they constitute the prominent mass of white fibres which is seen on the front of the bulb, on each side of the middle line, and is known as the *pyramid*. By this passage of fibres through the grey matter the tip of the anterior cornu (*a*) is cut off from the rest and becomes pushed as it were to the side; in sections a little higher up it appears as an isolated mass of grey matter which is known as the lateral nucleus (fig. 258, *n.l.*).

A change also occurs in the posterior cornu in consequence of the increased development of the posterior column of white matter. This causes the posterior cornua (fig. 257, *p c*) to be pushed towards the side, the V which they form with one another being thus opened out; at the same time the tip of the cornu swells out and causes a prominence upon the surface of the medulla, which is known as the tubercle of Rolando (*R*). Grey matter also soon becomes found within the upward prolongations of the postero-mesial column and of the cuneate funiculus (postero-lateral column, fig. 258, *n.g.*, *n.c.*). But

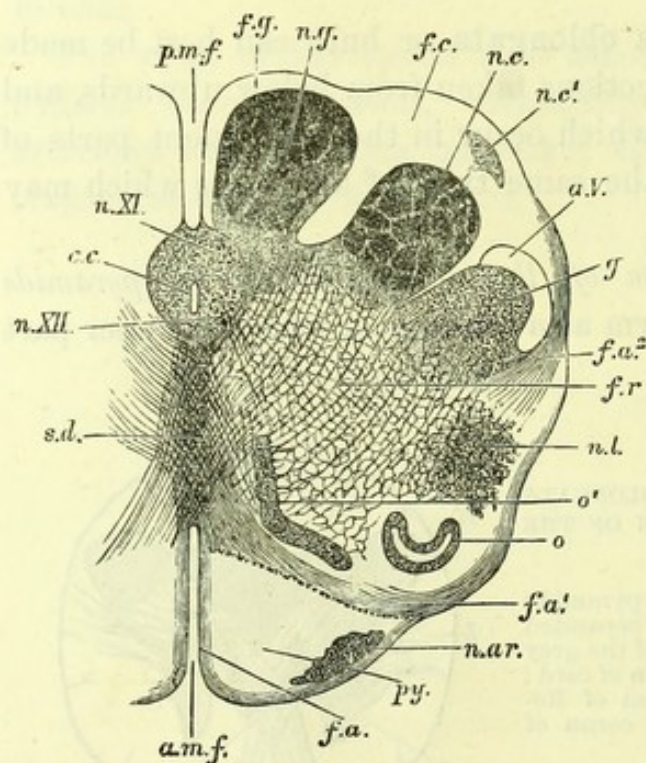


FIG. 258.—SECTION OF THE MEDULLA OBLONGATA IN THE REGION OF THE SUPERIOR PYRAMIDAL DECUSATION. (Schwalbe.) ‡.

*a.m.f.*, anterior median fissure; *f.a.*, superficial arciform fibres emerging from the fissure; *py.*, pyramid; *n.a.r.*, nucleus of the arciform fibres; *f.a'*, deep arciform fibres becoming superficial; *o*, lower end of olivary nucleus; *o'*, accessory olivary nucleus; *n.l.*, nucleus lateralis; *f.r.*, formatio reticularis; *f.a.2*, arciform fibres proceeding from formatio reticularis; *g.*, substantia gelatinosa of Rolando; *a.V.*, ascending root of fifth nerve; *n.c.*, nucleus cuneatus; *n.c'*, external cuneate nucleus; *f.c.*, funiculus cuneatus; *n.g.*, nucleus gracilis; *f.g.*, funiculus gracilis; *p.m.f.*, posterior median fissure; *c.c.*, central canal surrounded by grey matter, in which are, *n.XI.*, nucleus of the spinal accessory; and *n.XII.*, nucleus of the hypoglossal; *s.d.*, superior pyramidal decussation (decussation of fillet).

most of the grey matter becomes broken up, by the passage of bundles of nerve-fibres through it, into a reticular formation (*f.r.*) the production of which is already foreshadowed in the upper part of the spinal cord. The central canal of the spinal cord is still seen in the lower part of the medulla oblongata (*c.c.*), but it comes nearer to the

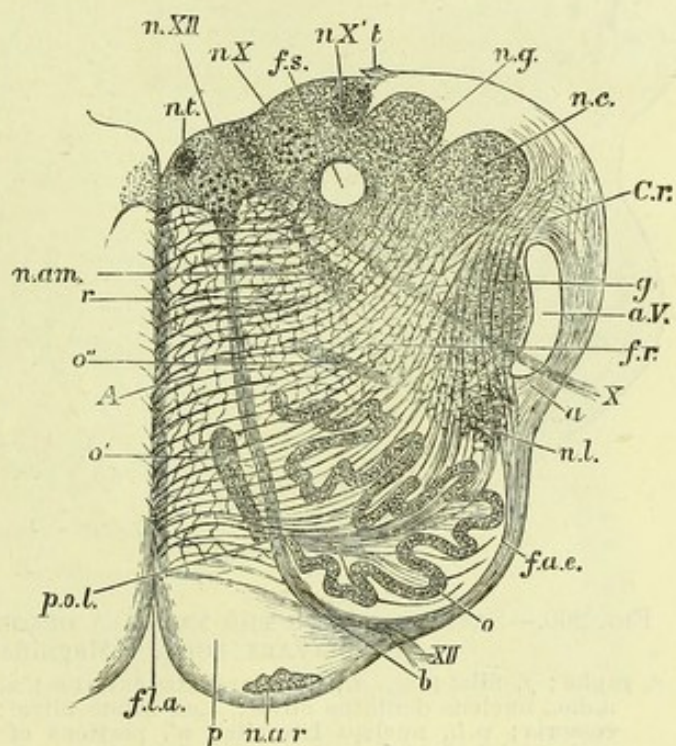


posterior surface. The grey matter which surrounds it contains two well-marked groups of nerve-cells; the anterior of these is the lower part of the *nucleus of the hypoglossal* or twelfth nerve (*n. XII.*), the posterior that of the *spinal accessory* or eleventh (*n. XI.*). Instead of the comparatively narrow isthmus which joins the two halves of the spinal cord, a broad *raphe* now makes its appearance; this is formed of obliquely and antero-posteriorly coursing fibres, together with some grey matter containing nerve-cells.

In the section at *about the middle of the olive* (figs. 259, 260), it will be seen that a marked change has been produced in the form of the medulla oblongata and the arrangement of its grey matter, by the opening out of the central canal into the fourth ventricle. This causes the grey matter which lower down surrounded the central canal to be now spread out at the floor of that ventricle, and the

FIG. 259.—SECTION OF THE MEDULLA OBLONGATA AT ABOUT THE MIDDLE OF THE OLIVARY BODY. (Schwalbe.)  $\frac{1}{4}$ .

*f.l.a.*, anterior median fissure; *n.ar.*, nucleus arciformis; *p*, pyramid; *XII.*, bundle of hypoglossal nerve emerging from the surface; at *b* it is seen coursing between the pyramid and the olivary nucleus, *o*; *f.a.e.*, external arciform fibres; *n.l.*, nucleus lateralis; *a*, arciform fibres passing towards restiform body partly through the substantia gelatinosa, *g*, partly superficial to the ascending root of the fifth nerve, *a.V.*; *X.*, bundle of vagus root, emerging; *f.r.*, formatio reticularis; *c.r.*, corpus restiforme, beginning to be formed, chiefly by arciform fibres, superficial and deep; *n.c.*, nucleus cuneatus; *n.g.*, nucleus gracilis; *t*, attachment of the tænia; *f.s.*, funiculus solitarius; *n.X.*, *n.X'*, two parts of the vagus nucleus; *n.XII.*, hypoglossal nucleus; *n.t.*, nucleus of the funiculus teres; *n.am.*, nucleus ambiguus; *r*, raphe; *A*, formatio reticularis alba; *o'*, *o''*, accessory olivary nuclei; *o*, olivary nucleus; *p.o.l.*, pedunculus olivæ.



collections of nerve-cells from which the hypoglossal and spinal accessory nerves respectively arose now, therefore, lie in a corresponding situation. At this level, however, the outer group which corresponds with the nucleus of the spinal accessory in the lower part of the bulb has become the *nucleus of the vagus* or tenth nerve (*n.X.*). The nerve-bundles of the roots of these nerves can be seen in the sections coursing through the thickness of the bulb and emerging, those of the hypoglossal (*XII.*) just outside the pyramids, those of the spinal accessory and vagus (*X.*) at the side of the medulla oblongata. The two sets of emerging fibres thus appear to subdivide



each lateral half of the bulb into three areas—a posterior, a middle, and an anterior. Of these the posterior is chiefly occupied by the grey matter of the floor of the fourth ventricle, and, with fibres which are passing obliquely upwards and outwards towards the cerebellum, forming its inferior crus (*restiform body, c.r.*); and in addition there is the continuation upwards of the portions of grey matter forming the nuclei of the funiculus gracilis (*n.g.*), of the funiculus cuneatus

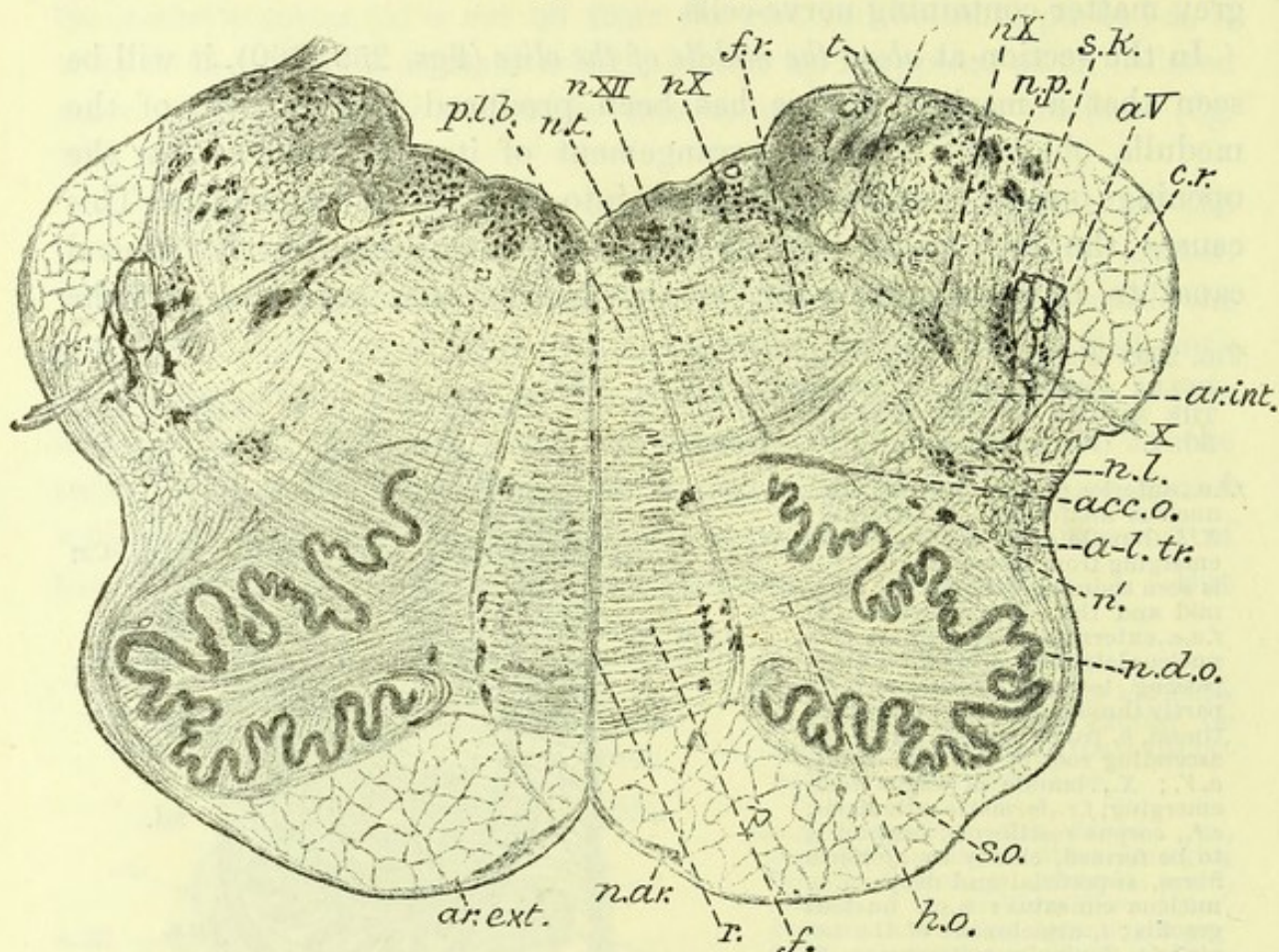


FIG. 260.—SECTION ACROSS THE MEDULLA OBLONGATA AT ABOUT THE MIDDLE OF THE OLIVARY BODY. (Magnified 5 diameters.)

*r*, raphe; *f*, fillet; *ar.ext.*, fibræ arcuatæ externæ; *n.ar.*, nucleus arcuatus; *py*, pyramid; *n.d.o.*, nucleus dentatus olivæ; *h.o.*, hilum olivæ; *s.o.*, siliqua olivæ; *acc.o.*, oliva accessoria; *n.l.*, nucleus lateralis; *n'*, portions of grey matter containing large cells, perhaps detached from the nucleus lateralis; *a-l.tr.*, antero-lateral ascending tract; *X*, tenth nerve issuing from side of bulb; *ar.int.*, fibræ arcuatæ internæ; *α.V.*, ascending root of fifth nerve; *s.R.*, substantiæ gelatinosa Rolandi; *c.r.*, corpus restiforme; *n'.X.*, ventral nucleus of tenth nerve (nucleus ambiguus); *n.p.*, nucleus posterior; *s*, fasciculus solitarius (ascending root of *X* and *IX* nerves); *t*, tænia (attachment of ependymal root of fourth ventricle); *f.r.*, formatio reticularis; *n.X.*, dorsal nucleus of tenth nerve; *n.XII.*, upper part of nucleus of twelfth nerve; *n.t.*, nucleus of funiculus teres; *p.l.b.*, posterior or dorsal longitudinal bundle.

(*n.c.*), and of the tubercle of Rolando (*g*). The anterior or mesial area is occupied in front by the pyramid (*p*), and behind this by a reticular formation (*reticularis alba, A*) composed of longitudinally coursing bundles of fibres interlaced with fibres that are passing obliquely from the opposite side, through the raphe, towards the nuclei of the posterior columns and restiform body (figs. 260, 261). The middle area, which lies between the issuing bundles of the two sets of nerve-roots, consists



in its deeper part of a similar reticular formation (figs. 259, 260, *f.r.*), but with more grey matter and nerve-cells (*reticularis grisea*, fig. 261, *r.g.*). Superficially there is developed within it a peculiar wavy lamina of grey matter containing a large number of small nerve-cells; this is the dentate nucleus of the olivary body (figs. 259, *o*, 260, *n.d.o.*). The lamina is incomplete at its mesial aspect (*hilum olivæ*, fig. 260, *h.o.*), and here a large number of fibres issue, and passing through the raphe course as inner arcuate fibres to the opposite restiform body, and thus to the

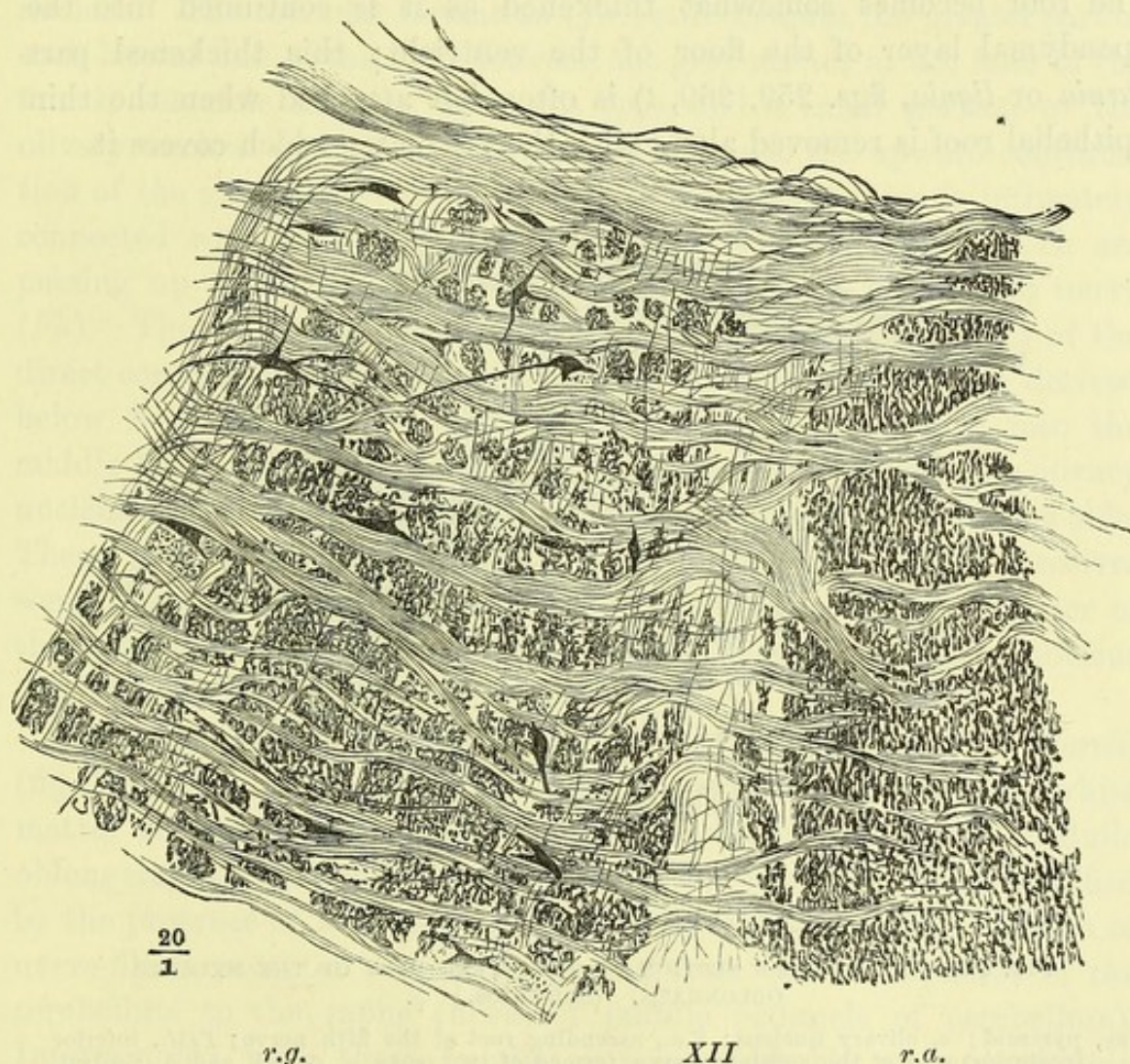


FIG. 261.—PART OF THE RETICULAR FORMATION OF THE MEDULLA OBLONGATA. (Henle.)

*r.a.*, reticularis alba, without nerve-cells; *r.g.*, reticularis grisea, with large nerve-cells; between them a root-bundle of the hypoglossus (*XII*). The longitudinal fibres of the reticular formation are cut across; the transversely coursing fibres are internal arcuate fibres, passing on the right of the figure towards the raphe.

cerebellum. Some, however, turn sharply round and course below the dentate nucleus, forming an investment and capsule to it (*siliqua olivæ*, fig. 260, *s.o.*), and passing towards the restiform body of the same side. Just dorsal, or dorso-lateral to the olive is the continuation upwards of the antero-lateral ascending tract of the spinal cord; the continuation of the direct cerebellar tract is now passing into the restiform body.



The *floor of the fourth ventricle* is covered by a layer of ciliated epithelium-cells, continuous below with those lining the central canal, and above, through the Sylvian aqueduct, with the epithelium of the third and lateral ventricles. The epithelium rests upon a layer of neuroglia known as the *ependyma* of the ventricle. The fourth ventricle is roofed over by a thin layer of pia mater, with projecting choroid plexuses, the under surface of which is covered by a thin epithelial layer continuous at the side with the ciliated epithelium of the floor. The roof becomes somewhat thickened as it is continued into the ependymal layer of the floor of the ventricle; this thickened part (*tænia* or *ligula*, figs. 259, 260, *t*) is often left attached when the thin epithelial roof is removed along with the pia mater which covers it.

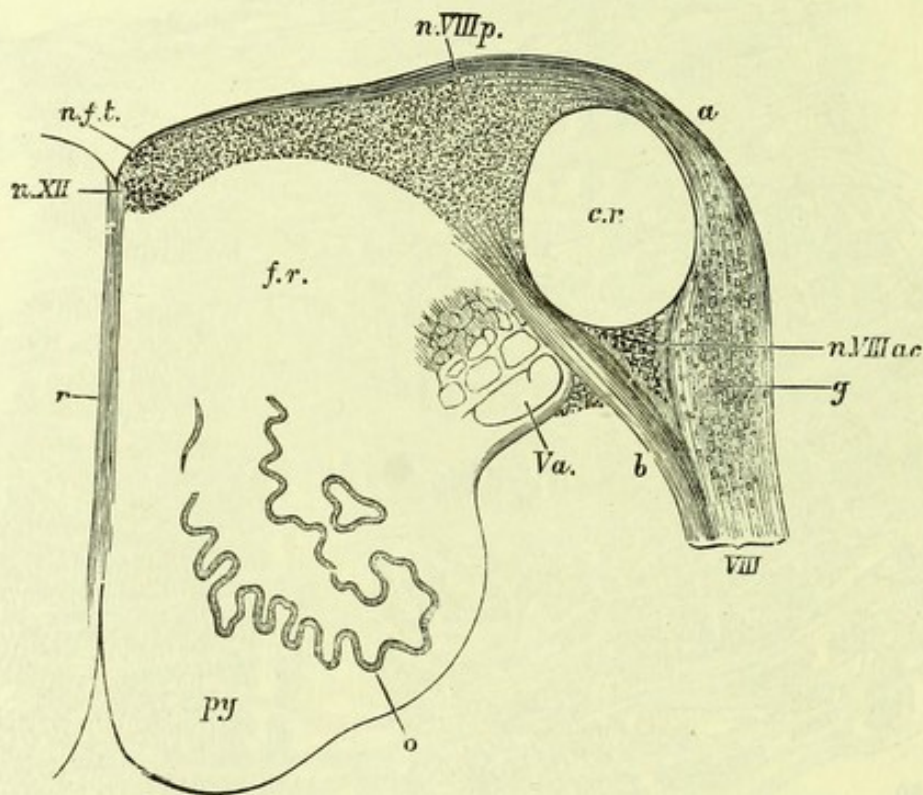


FIG. 262.—TRANSVERSE SECTION OF THE UPPER PART OF THE MEDULLA OBLONGATA. (Schwalbe.)  $\frac{1}{4}$ .

*py*, pyramid; *o*, olivary nucleus; *Va.*, ascending root of the fifth nerve; *VIII.*, inferior (posterior) root of the auditory nerve, formed of two parts, *a*, dorsal, and *b*, ventral, which inclose the restiform body, *c.r.*; *n.VIII.p.*, one of the nuclei of the eighth nerve; *n.VIII.ac.*, accessory nucleus; *g*, ganglion-cells in the dorsal root; *n.f.t.*, nucleus of the funiculus teres; *n.XII.*, nucleus of the hypoglossal; *r*, raphe; *f.r.*, reticular formation.

A section taken *through the uppermost part of the olivary prominence* will still show very much the same form and structural arrangements as that just described. The nucleus of the hypoglossal (fig. 262, *n. XII.*) is still visible in the grey matter of the floor of the ventricle, but the nerve which is now seen arising from the outer part of that grey matter is the eighth or *auditory* (*VIII.*), the bundles of which, as they leave the bulb, embrace the inferior crus of the cerebellum (*corpus restiforme*, *c.r.*), which is now passing into that organ. The origin of



the eighth nerve is thus subdivided into two principal parts, known respectively as the dorsal or lateral and the ventral or mesial roots. The fibres of the dorsal root inclose amongst them numerous ganglion cells; this root becomes the cochlear or true auditory division of the eighth nerve. The ventral root, which becomes the vestibular division of the eighth nerve, is connected with a mass of grey matter mesial to the restiform body (*n.VIII.p.*), and also with a nucleus (*n.VIII.ac.*) lying ventral to the restiform body, and known as the accessory nucleus. The reticular formation (*f.r.*) still occupies the greater part of each lateral half of the bulb between the grey matter at the floor of the fourth ventricle and the pyramids (*py*), and a small portion of the olivary nucleus (*o*) may still be seen, as may also the upward continuation of the grey matter of the tubercle of Rolando; this is intimately connected with some well-marked bundles of nerve-fibres, which are passing up to the pons to join eventually the root of the fifth nerve (*Va*). The restiform body (*c.r.*) is formed partly of the fibres of the direct cerebellar tract of Flechsig of the same side, which are derived below from the cells of Clarke's column, and pass above into the middle lobe of the cerebellum, partly of fibres from the opposite olivary nucleus, and partly of fibres from the olivary nucleus of the same side. These pass to the cerebellar hemisphere mainly. It also receives some fibres from a nucleus which lies just outside the grey matter of the funiculus cuneatus, and is known as the outer cuneate nucleus (fig. 258, *n.c.*).

**Pons Varolii.**—A section through the *middle of the pons Varolii* (fig. 263) shows very much the same arrangement of grey and white matter as that which is met with at the upper part of the medulla oblongata, but the general appearance of the section is much modified by the presence of a large number of transversely coursing bundles of nerve-fibres, most of which are passing from the hemispheres of the cerebellum to the raphe (fibres of middle peduncle of cerebellum). Intermingled with these bundles is a considerable amount of grey matter (*nuclei pontis*). The continuation upwards of the pyramids of the medulla (*py*) is embedded between these transverse bundles and separated by them from the reticular formation. The deeper transverse fibres, those which are nearest to the reticular formation, belong to a different system from those of the middle peduncle. They form what is known as the *trapezium* (fig. 263, *t*); a collection of fibres which perhaps connects the superior olivary nucleus (see below) of one side with the accessory auditory nucleus (fig. 262, *n.VIII.ac.*) of the other side. The olivary nucleus is no longer seen, but there are one or two small collections of grey matter much more conspicuous in some animals



than in man, which lie in the ventral part of the reticular formation, and are known as the *superior olivary nucleus* (*o.s.*). The nerves which take origin from the grey matter of this region are part of the eighth, the seventh, the sixth, and somewhat higher up the fifth cranial nerves (see figs. 263, 264). Of these the eighth and fifth are connected with groups of nerve-cells which occupy the grey matter opposite the external border of the floor of the ventricle; the sixth with a group which is placed also in the grey matter of the floor of the ventricle but nearer

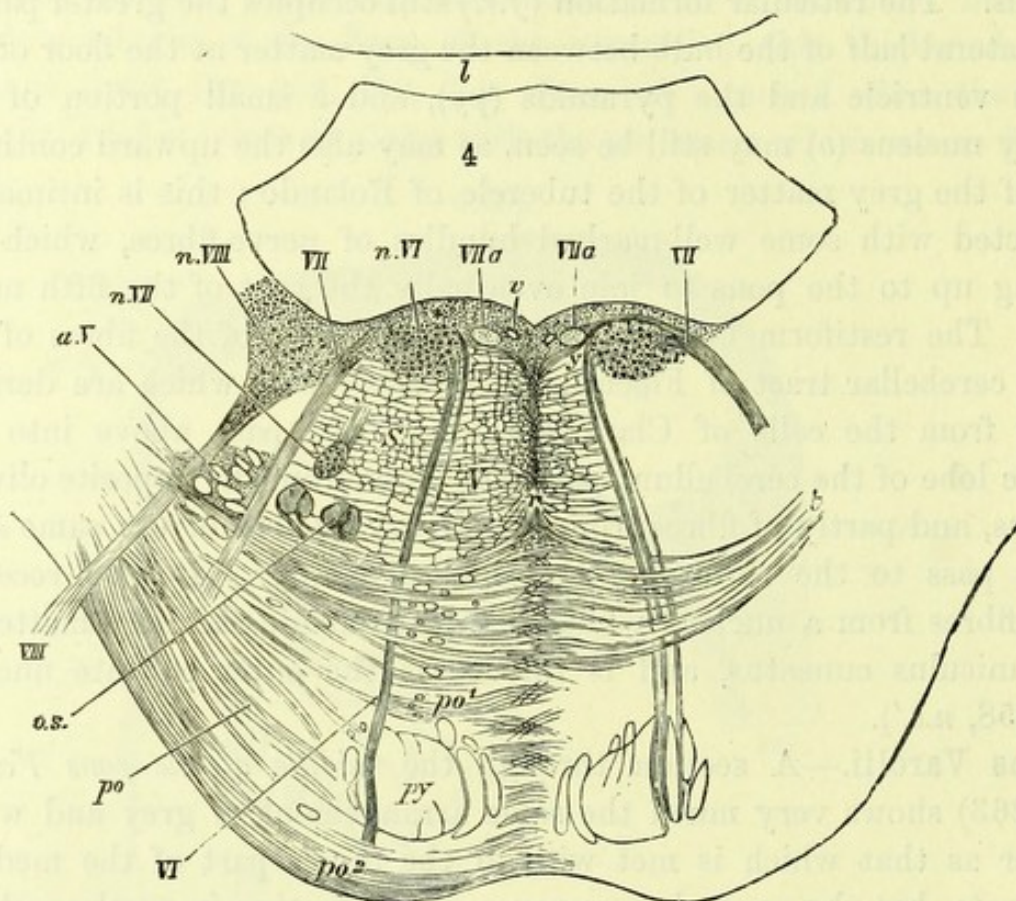


FIG. 263.—SECTION ACROSS THE PONS AT ABOUT THE MIDDLE OF THE FOURTH VENTRICLE. (Schwalbe.)  $\frac{3}{4}$ .

*py*, pyramid-bundles continued up from the medulla; *po*, transverse fibres of the pons passing from the middle crus of the cerebellum, before (*po*) and behind (*po'*) the chief pyramid bundles; *t*, deeper fibres of the same set, constituting the trapezium; the grey matter between the transverse fibres is not represented either in this or in the two following figures; *r*, raphe; *o.s.*, superior olivary nucleus; *a.V.*, bundles of the ascending root of the fifth nerve, inclosed by a prolongation of the grey substance of Rolando; *VI.*, root-bundle of the sixth nerve; *n.VI.*, its nucleus; *VII.*, root-bundle of the facial nerve; *VII.a.*, longitudinal portion of the same; *n.VII.*, its nucleus; *VIII.*, (superior) root of the auditory nerve; *n.VIII.*, its nucleus; *v*, section of a vein.

the middle line, and the seventh partly with a special nucleus which lies in the formatio reticularis, and partly with the nucleus of the sixth. The fibres of the nerve first pass backwards to the floor of the ventricle, then longitudinally upwards for a short distance, and finally bend forwards and downwards to emerge between the transverse fibres at the side of the pons.

At the *upper part of the pons* (fig. 265) the fourth ventricle narrows



FIG. 264.—OBLIQUE SECTION OF THE PONS ALONG THE LINE OF EXIT TRAVERSED BY THE FIFTH NERVE.  $\frac{3}{1}$ .

The section passes through the lower part of the motor nucleus ( $n.v.$ ) from which a bundle of fibres of the motor root is seen passing,  $V'$ ; a part of the upper sensory nucleus ( $nv$ ) is also shown in the section in the form of a number of small isolated portions of grey matter. Amongst these are a few bundles of the ascending root cut across, but most of these have already become diverted outwards to join and assist in forming the issuing part of the main or sensory root,  $V$ ;  $l$ , small longitudinal bundle of fibres near the median sulcus ( $m.s.$ ), passing outwards to join the root of the fifth nerve;  $f.r.$ , formatio reticularis;  $r$ , raphe;  $s.f.$ , substantia ferruginea.

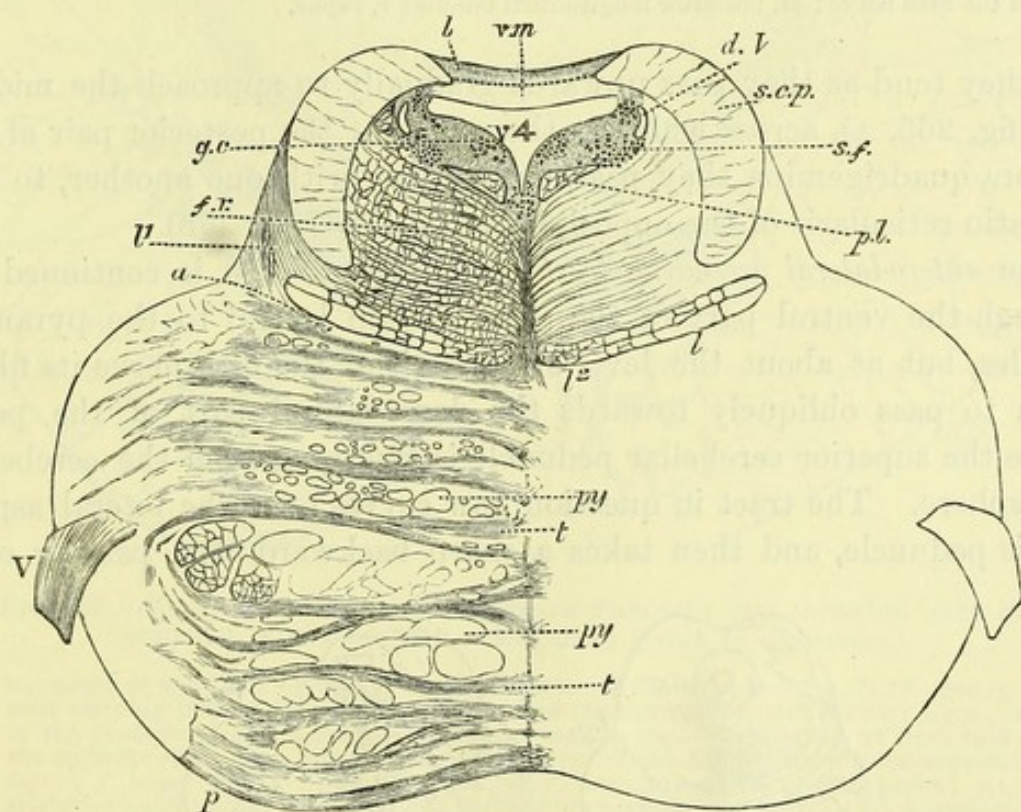
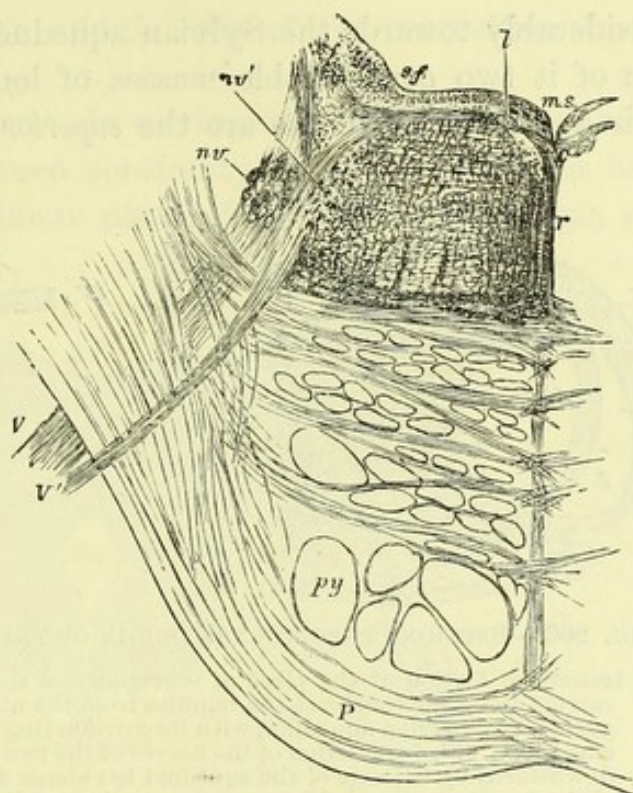


FIG. 265.—TRANSVERSE SECTION THROUGH THE UPPER PART OF THE PONS. (Schwalbe.) (Rather more than twice the natural size.)<sup>1</sup>

$p$ , transverse fibres of the pons;  $py, py$ , bundles of the pyramids;  $a$ , boundary line between the tegmental part of the pons and its ventral part;  $l'$ , oblique fibres of the fillet, passing towards  $l$ ;  $l^2$ , longitudinal fibres of the fillet;  $f.r.$ , formatio reticularis;  $p.l.$ , posterior longitudinal bundle;  $s.c.p.$ , superior cerebellar peduncle;  $v.m.$ , superior medullary velum;  $b$ , grey matter of the lingula;  $v.4$ , fourth ventricle; in the grey matter which bounds it laterally are seen,  $d.V.$ , the descending root of the fifth nerve, with its nucleus;  $s.f.$ , substantia ferruginea;  $g.c.$ , group of cells continuous with the nucleus of the aqueduct.

<sup>1</sup> The details of this and of several of the preceding figures are filled in under a somewhat higher magnifying power than that used for tracing the outlines.



considerably towards the Sylvian aqueduct, and behind and on either side of it two considerable masses of longitudinal white fibres make their appearance. These are the *superior crura of the cerebellum (s.c.p.)*

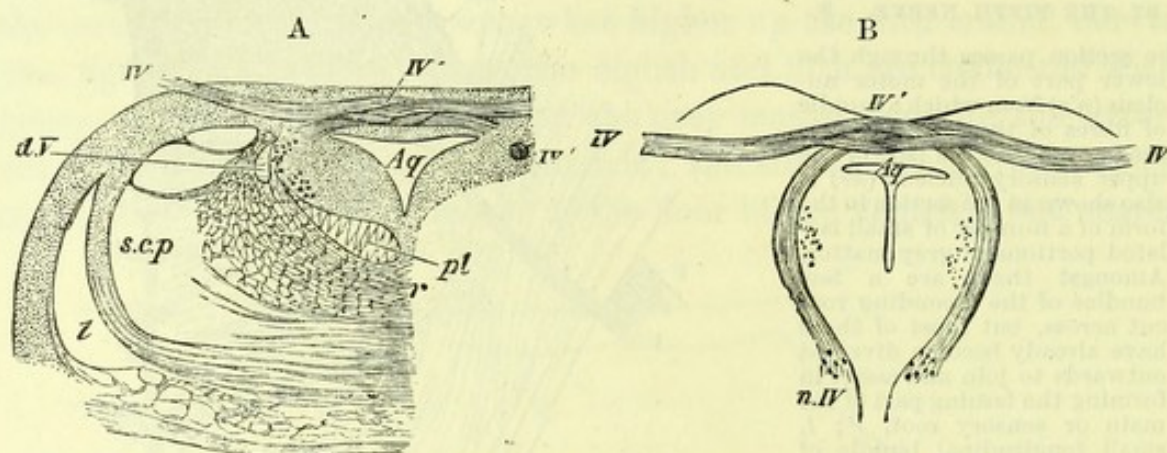
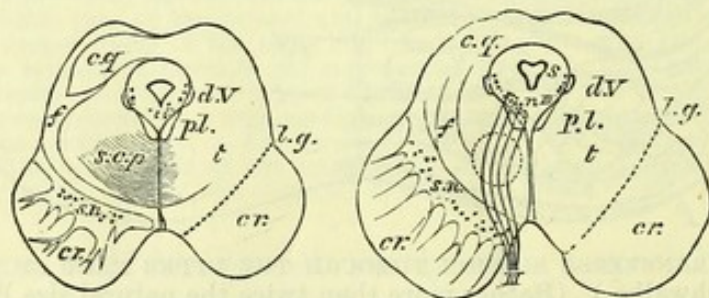


FIG. 266.—SECTIONS THROUGH THE ORIGIN OF THE FOURTH NERVE. (Schwalbe.)  $\frac{3}{1}$ .

A, transverse section at the place of emergence of the nerve fibres. B, oblique section carried along the course of the bundles from the nucleus of origin to the place of emergence. Aq, Sylvian aqueduct, with its surrounding grey matter; IV, the nerve-bundles emerging; IV', decussation of the nerves of the two sides; IV'', a round bundle passing downwards by the side of the aqueduct to emerge a little lower down; n.IV., nucleus of the fourth nerve. l, fillet; s.c.p., superior cerebellar peduncle; d.V, descending root of the fifth nerve; pl, posterior longitudinal bundle; r, raphe.

and they tend as they pass upwards gradually to approach the middle line (fig. 266, A), across which in the region of the posterior pair of the corpora quadrigemina they pass, decussating with one another, to the formatio reticularis of the opposite side (figs. 267, A, 268).

The *antero-lateral ascending tract* of the spinal cord is continued up through the ventral part of the pons Varolii lateral to the pyramid-bundles, but at about the level of the exit of the fifth nerve its fibres begin to pass obliquely towards the dorso-lateral part of the pons, where the superior cerebellar peduncle is emerging from the cerebellar hemisphere. The tract in question now curves over the lateral aspect of this peduncle, and then takes a sharp backward turn, passing over



FIGS. 267, 268.—OUTLINE OF TWO SECTIONS ACROSS THE MESENCEPHALON. (Natural size.)

267, through the middle of the inferior corpora quadrigemina. 268, through the middle of the superior corpora quadrigemina. cr, crusta; s.n., substantia nigra; t, tegmentum; s, Sylvian aqueduct, with its surrounding grey matter; c.q., grey matter of the corpora quadrigemina; l.g., lateral groove; pl., posterior longitudinal bundle; d.V., descending root of the fifth nerve; s.c.p., superior cerebellar peduncle; f, fillet; n.III., its nucleus; III., third nerve. The dotted circle in B indicates the situation of the tegmental nucleus



its dorsal aspect to enter the middle lobe of the cerebellum in the superior medullary velum.

**Mid-brain or Mesencephalon.**—In sections across the mesencephalon (figs. 267, 268, 269), the upward continuity of the parts which have thus been described in the lower parts of the nerve-centres, can still in great measure be traced.

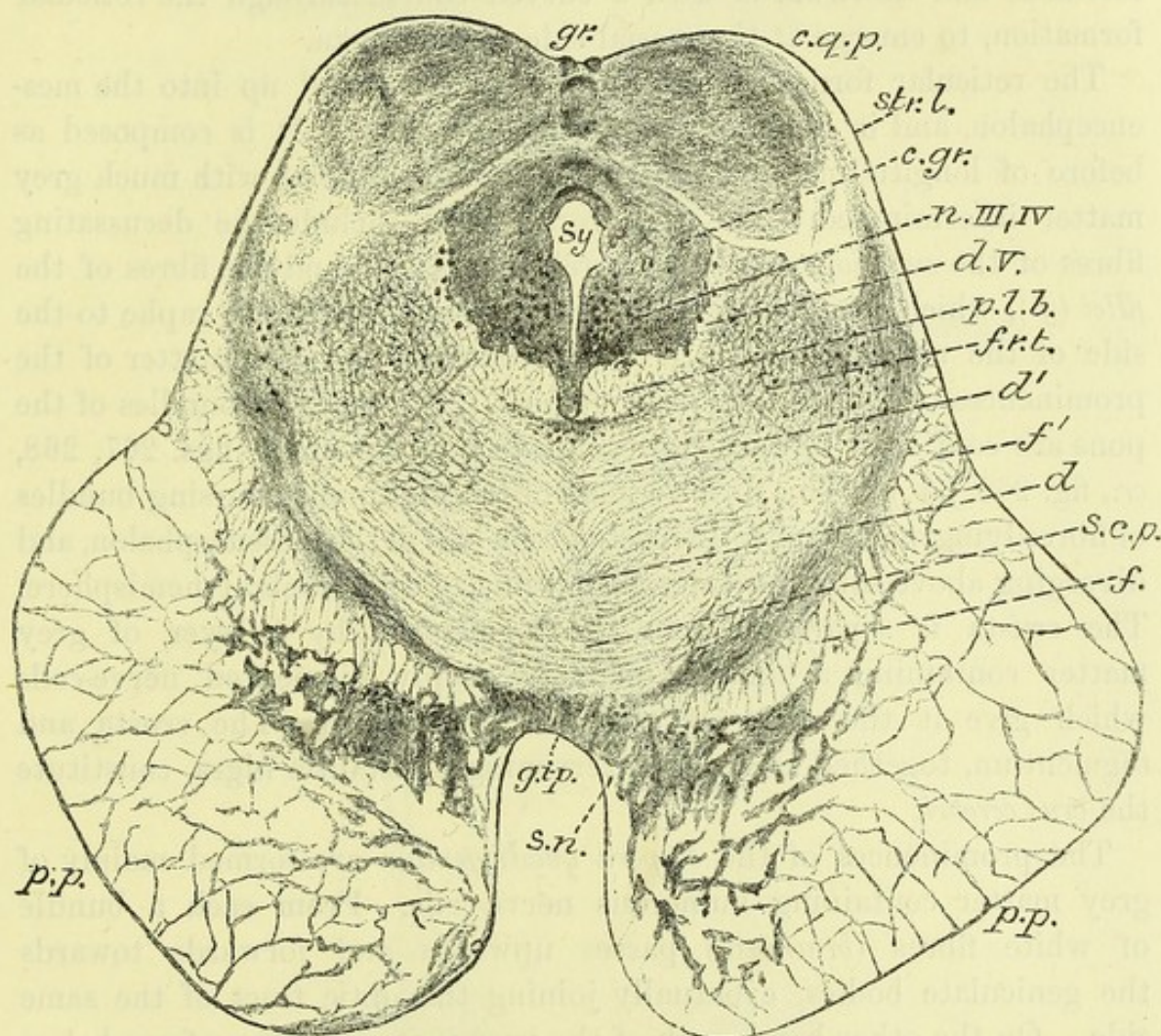


FIG. 269.—SECTION ACROSS THE MID-BRAIN THROUGH THE INFERIOR PAIR OF CORPORA QUADRIGEMINA. (Magnified about  $3\frac{1}{2}$  diameters.)

*Sy*, aqueduct of Sylvius; *c.gr.*, central grey matter of the aqueduct; *n.III.IV.*, group of cells forming part of the conjoined nucleus of the third and fourth nerves; *c.q.p.*, one of the posterior corpora quadrigemina; *gr.*, median groove separating it from that of the opposite side; *str.l.*, stratum lemnisci (layer of the fillet), forming its superficial layer; *f.*, upper fillet; *f'*, lateral fillet; *d.v.*, descending root of fifth nerve; *p.l.b.*, posterior longitudinal bundle; *f.r.t.*, formatio reticularis tegmenti; *d, d'*, decussating fibres of tegmenta; *s.c.p.*, superior cerebellar peduncle; *p.p.*, pes pedunculi (crusta); *s.n.*, substantia nigra; *g.i.p.*, interpeduncular grey matter.

The *Sylvian aqueduct* (fig. 269, *Sy*), with its lining of ciliated epithelium, represents the central canal of the cord and the fourth ventricle of the medulla oblongata. In the grey matter which surrounds it (*central grey matter*) there is seen in all sections of the region a group of large nerve-cells lying anteriorly on each side of the middle line, close to the



reticular formation. From this group the root-bundles of the fourth nerve arise at the lower part of the mesencephalon and pass obliquely backwards and downwards around the central grey matter, decussating with those of the opposite side to emerge just above the pons Varolii (fig. 266). Higher up, the bundles of the third nerve spring from the continuation of the same nucleus (fig. 268, *n. III.*), and these pass forwards and downwards with a curved course through the reticular formation, to emerge at the mesial side of the crura.

The reticular formation of the pons is continued up into the mesencephalon, and is here known as the *tegmentum*. It is composed as before of longitudinal and transverse bundles of fibres with much grey matter intermingled. The transverse fibres include the decussating fibres of the *superior crura of the cerebellum* (*s.c.p.*), and the fibres of the *fillet* (*f*), which are passing in an oblique manner from the raphe to the side of the mesencephalon, to reach eventually the grey matter of the prominences of the corpora quadrigemina. The pyramid bundles of the pons are continued upwards on each side into the *crura* (figs. 267, 268, *cr.*, fig. 269, *p.p.*). This forms a mass of longitudinally coursing bundles of fibres lying on the ventral aspect of each half of the mesencephalon, and diverging above into the internal capsule of the cerebral hemisphere. The crura is separated from the tegmentum by a layer of grey matter containing a number of very deeply pigmented nerve-cells which give it the name of *substantia nigra* (*s.n.*). The crura and tegmentum, together with the intervening substantia nigra, constitute the *crus cerebri*.

The prominences of the *corpora quadrigemina* are formed mainly of grey matter containing numerous nerve-cells. From each a bundle of white fibres (*brachium*) passes upwards and forwards towards the geniculate bodies, eventually joining the optic tract of the same side. On the other hand, each of the prominences receives from below fibres of the *fillet*, which are traceable below into the ventral part of the anterior area of the medulla oblongata, and then through the raphe to the nuclei of the gracile and cuneate funiculi of the opposite side. Since these nuclei contain the terminal arborisations of many of the ascending fibres of the posterior spinal roots (see diagram, p. 222), and the fibres of the fillet emanate from cells in the nuclei, the fillet forms a second link in the chain of afferent fibres leading towards the brain. Some of the fibres of the fillet are continued up beyond the mid-brain into the subthalamie region of the cerebrum. The superior corpora quadrigemina receive many of the fibres of the optic tract which form a superficial white stratum covering the grey matter. These fibres are derived from nerve-cells in the retina (diagram, fig. 270), and having



arrived at the superior quadrigeminal body and formed the stratum in question, they turn into the grey matter and end in arborisations. The cells of the grey matter of this body are very various in form

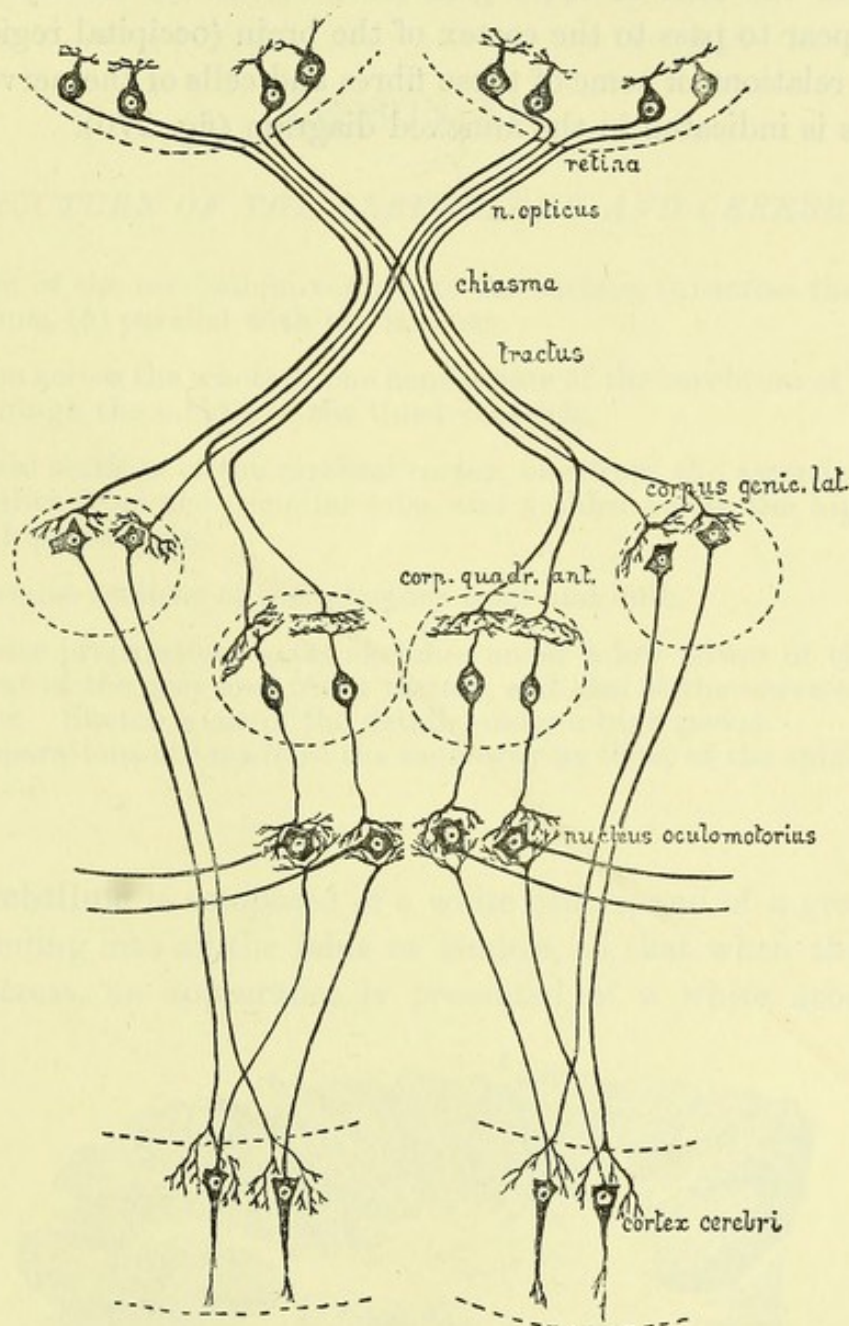
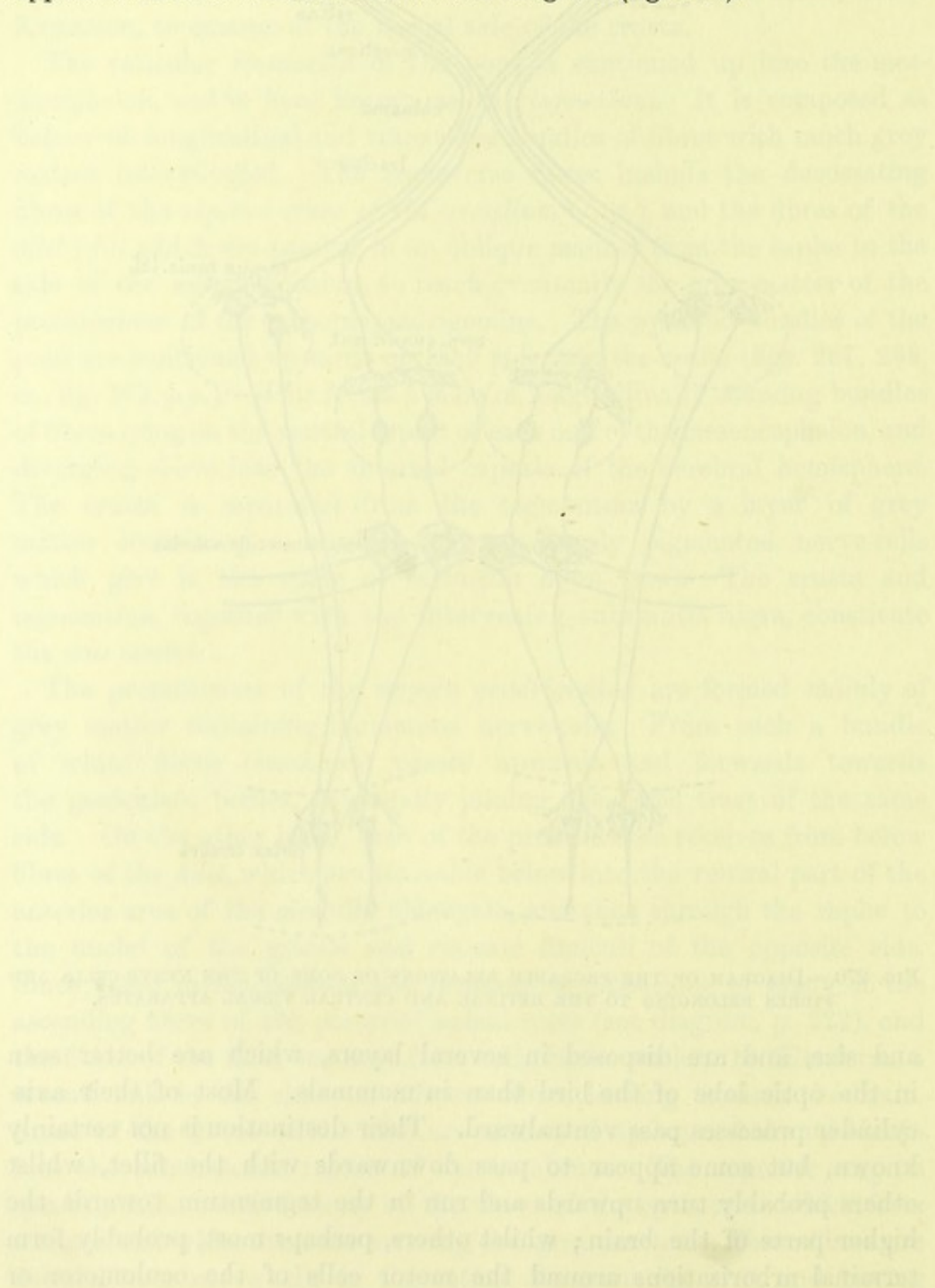


FIG. 270.—DIAGRAM OF THE PROBABLE RELATIONS OF SOME OF THE NERVE-CELLS AND FIBRES BELONGING TO THE RETINAL AND CENTRAL VISUAL APPARATUS.

and size, and are disposed in several layers, which are better seen in the optic lobe of the bird than in mammals. Most of their axis-cylinder processes pass ventralward. Their destination is not certainly known, but some appear to pass downwards with the fillet, whilst others probably turn upwards and run in the tegmentum towards the higher parts of the brain; whilst others, perhaps most, probably form terminal arborisations around the motor cells of the oculomotor or



other motor nuclei. All the nerve-fibres of the optic nerve and optic tract do not enter the corpora quadrigemina. Some pass into the lateral geniculate bodies and form arborisations there. On the other hand, from the cells of these geniculate bodies the axis-cylinder processes appear to pass to the cortex of the brain (occipital region). The probable relations of some of these fibres and cells of the nervous visual apparatus is indicated in the annexed diagram (fig. 270).





## LESSON XLI.

*STRUCTURE OF THE CEREBELLUM AND CEREBRUM.*

1. SECTIONS of the cerebellum vertical to the surface, (*a*) across the direction of the laminae, (*b*) parallel with the laminae.
2. Section across the whole of one hemisphere of the cerebrum of a monkey passing through the middle of the third ventricle.
3. Vertical sections of the cerebral cortex, one from the ascending frontal gyrus, another from the occipital lobe, and a third across the hippocampal gyrus and hippocampus.
4. Transverse sections of the olfactory tract and bulb.

In all these preparations make sketches under a low power of the general arrangement of the grey and white matter, and also of the nerve-cells in the grey matter. Sketch some of the details under a high power.

[The preparations are made in the same way as those of the spinal cord.]

The **cerebellum** is composed of a white centre, and of a grey cortex, both extending into all the folds or laminae, so that when the laminae are cut across, an appearance is presented of a white arborescence

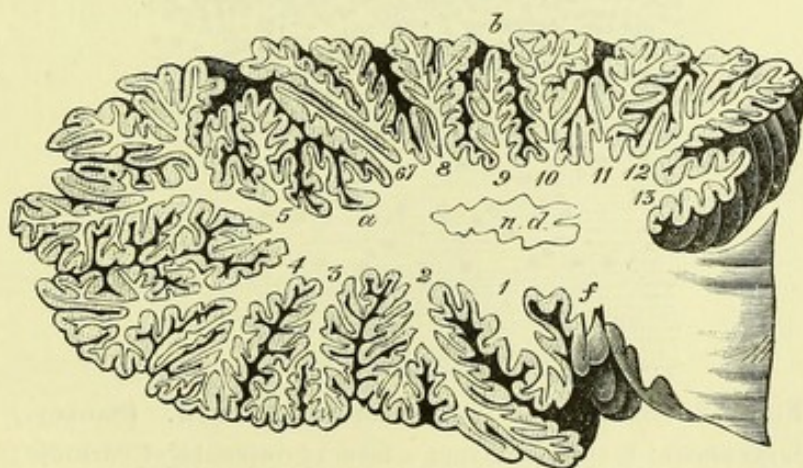

FIG. 271.—SECTION THROUGH ONE OF THE HEMISPHERES OF THE CEREBELLUM ACROSS THE LAMELLÆ, TO SHOW THE MEDULLARY CENTRE AND ITS PROLONGATIONS INTO THE LAMELLÆ.

covered superficially by grey matter. The white matter is in largest amount in the middle of each cerebellar hemisphere (fig. 271). There is here present a peculiar wavy lamina of grey matter, similar to that



in the olivary body, and known as the *nucleus dentatus* (*n.d.*). Other isolated grey nuclei lie in the white matter of the middle lobe.

The grey matter of the cerebellum consists of two layers (fig. 272). The *inner* one (that next the white centre) is composed of a large number of very small nerve-cells intermingled with a few larger ones

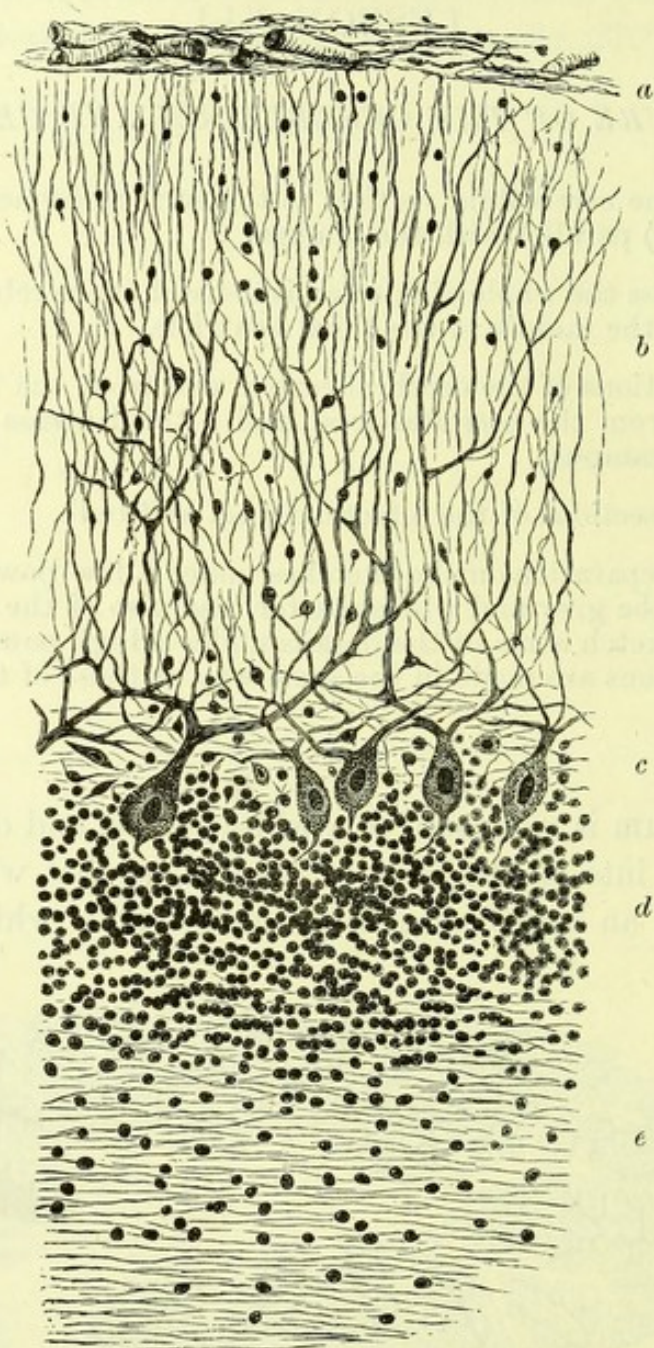


FIG. 272.—SECTION OF CORTEX OF CEREBELLUM. (Sankey.)

*a*, pia mater; *b*, external layer; *c*, layer of corpuscles of Purkinje;  
*d*, inner or granule layer; *e*, medullary centre.

and some neuroglia-cells (*granule layer*, *d*). The *outer layer* (*b*) is thicker, and is formed chiefly of fine nerve-fibres (fig. 273, A) with small nerve-cells scattered through it. Into its outer part processes of the pia mater conveying blood-vessels pass vertically, and there are also in this part a number of long tapering neuroglia-cells, somewhat



like the Müllerian fibres of the retina. Lying between the two layers of the grey matter is an incomplete stratum of large flask-shaped cells (*cells of Purkinje, c*). Each of these gives off from its base a fine process (*neuron*), which becomes the axis-cylinder of one of the medullated fibres of the white centre, while from the opposite pole of the cell large ramified processes spread out into the superficial layer of the grey matter (*dendrons*).

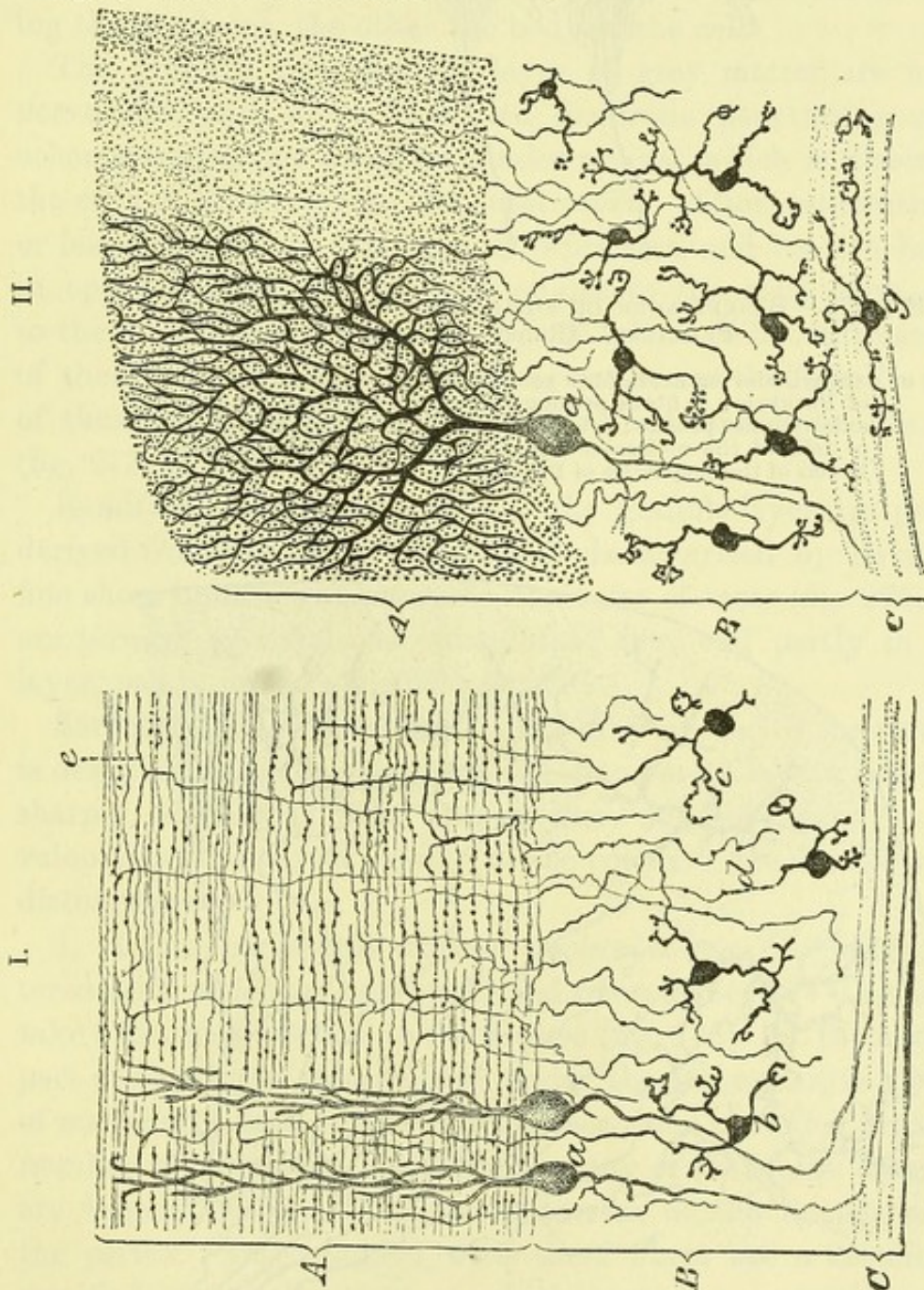


FIG. 273.—SECTION OF CORTEX CEREBELLI STAINED BY GOLGI'S METHOD. (Ramon y Cajal.)

I.—Section made in the direction of the lamina. II.—Section taken across the lamina.

A, outer or molecular layer; B, inner or granule layer; C, medullary centre.  
*a*, corpuscle of Purkinje; *b*, small granules of inner layer; *c*, a protoplasmic process of a granule; *d*, nerve-fibre process of a granule passing into the molecular layer, where it bifurcates and becomes a longitudinal fibre (in II. these longitudinal fibres are cut across and appear as dots); *e*, bifurcation of another fibre; *g*, a granule lying in the white centre.

The dendrons of the cells of Purkinje spread out in planes transverse to the direction of the lamellæ of the organ, so that they present a different appearance according to whether the section is taken across the lamellæ or along them (compare fig. 273, I. and II.). These dendrons are invested at their attachment to the cell, and for some



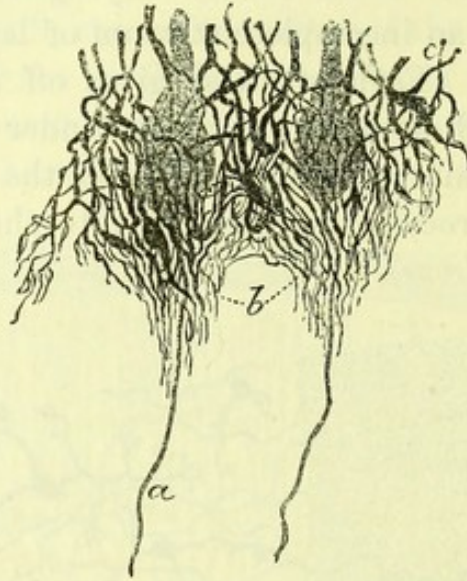


FIG. 274.—BASKET-WORK OF FIBRES AROUND TWO CELLS OF PURKINJE. (Ramon y Cajal.)

*a*, axis-cylinder or nerve-fibre process of one of the corpuscles of Purkinje; *b*, fibres prolonged over the beginning of the axis-cylinder process; *c*, branches of the nerve-fibre processes of cells of the molecular layer, felted together around the bodies of the corpuscles of Purkinje.

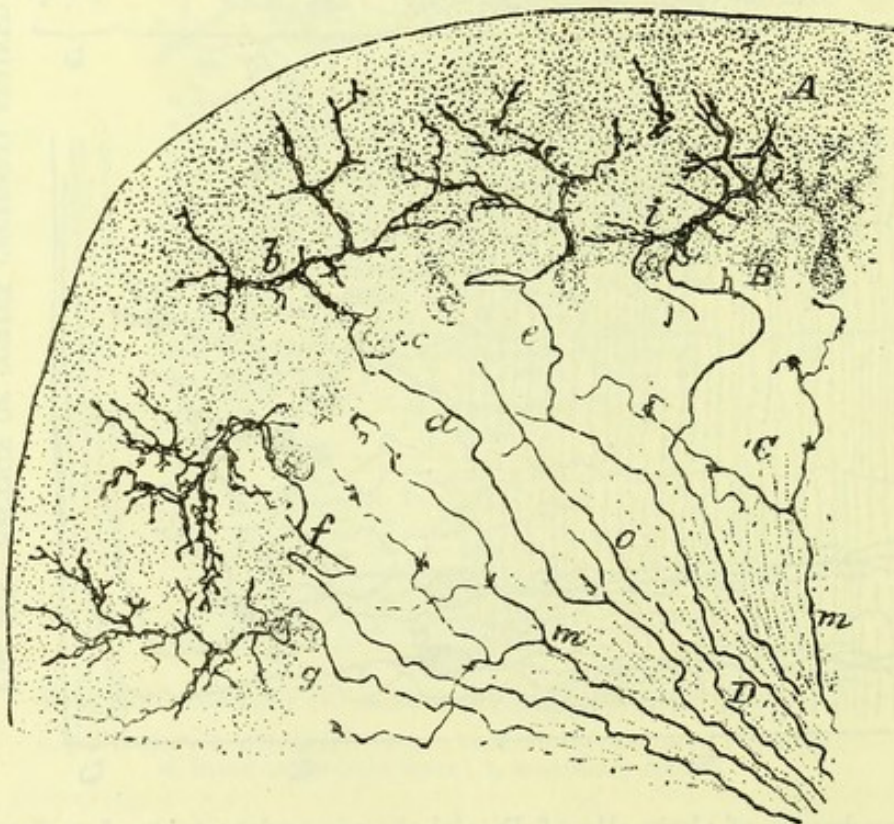


FIG. 275.—TRANSVERSE SECTION OF A CEREBELLAR LAMELLA OF THE ADULT RAT SHOWING THE FIBRES WHICH PASS FROM THE WHITE CENTRE TO THE GREY MATTER. (Ramon y Cajal.)

A, molecular layer; B, level of cells of Purkinje; C, granule layer; D, white substance. *a*, *e*, *f*, *g*, fibres which end in basket-work arborisations, *b*, enveloping the dendrons of Purkinje's cells; *c*, body of cell of Purkinje; *o*, probably an axis-cylinder process from one of the cells of Purkinje; *m*, "moss" fibres ramifying in the granule layer.



extent along their branchings, by a basket-work formed of the terminal arborisation of some of the fibres of the medullary centre other than those which are continuous with the axis-cylinder processes of the same cells (fig. 275). The body of the cell of Purkinje is further invested by a felt-work of fibrils formed by the arborisation of axis-cylinder processes of nerve-cells in the outer layer of the grey matter (fig. 274). Each cell has therefore a double investment of this nature, one covering the dendrons, the other the body of the cell.

The granules of the inner layer of grey matter are mostly small nerve-cells, with a few extended dendrons penetrating amongst the other granules, and an axis-cylinder process which is directed between the cells of Purkinje into the outer layer. After penetrating a greater or less distance into this layer it bifurcates, and its two branches pass in opposite directions at right angles to the main stem, and parallel to the direction of the lamella (fig. 273, I.). What ultimately becomes of them is not known. In sections cut across the lamellæ the cut ends of these fibres give a finely punctated appearance to the outer layer (fig. 273, II.).

Ramifying amongst the cells of the granule-layer are peculiar fibres derived from the white centre, and characterised by having pencils of fine short branches at intervals like tufts of moss (fig. 275, *m*). These are termed by Cajal the moss-fibres; they end partly in the granule layer, partly in the molecular layer.

**Structure of the cerebrum.**—The grey matter of the **cerebral cortex** is described as being composed of a number of layers, but they are not sharply marked off from one another, and they vary in relative development in different regions of the cortex. The following are usually distinguished.

1. A thin peripheral stratum (*molecular layer*) containing a few scattered cells, which are nerve-cells and neuroglia-cells. The latter tend to take a direction vertical to the surface (fig. 276). In the most superficial part of this layer, immediately under the pia mater, is a thin stratum of medullated nerve-fibres, and besides these the layer contains a large number of non-medullated fibres, many of which are ramified. They are largely derived from the processes of the deeper nerve-cells of the cortex. Intermingled with these fibres are a certain number of ramified nerve-cells, most of which have two (sometimes three) axis-cylinder processes, all of which terminate by arborisation within the superficial layer.

2. A layer of closely set small pyramidal nerve-cells several deep (*layer of small pyramids*).

3. A layer of medium-sized pyramidal cells less closely set, with



small granular-like cells amongst them (*layer of larger pyramids*). The pyramidal cells are larger in the deeper parts of the layer.

4. A layer of small irregular *polymorphous cells*. In the psychomotor region of the cortex (portions of the frontal and parietal lobes) pyramidal cells of very large size extend amongst these polymorphous cells, and are disposed in small clusters or "nests" (Bevan Lewis, Betz) (figs. 279, 280).

5. A layer of small scattered cells, many of a fusiform shape. This layer lies next to the white centre. It is not always distinct from the polymorphous layer. In the island of Reil this stratum is considerably developed, and is separated from the rest of the grey matter by a layer of white substance. It is here known as the *claustrum* (see figs. 286, 287, *cl.*).

From the white centre bundles of medullated nerve-fibres pass in vertical streaks through the deeper layers of the grey matter, to lose themselves amongst the pyramidal cells of the more superficial layers. Some of these fibres are continuous with the axis-cylinder processes of the pyramidal and polymorphous cells, and therefore take origin in the cortex; others are passing into the cortex to end amongst the cells of the several layers in free arborisations. The axis-cylinder processes of the pyramidal cells pass into the white centre. Here some of them are continued either directly or by collaterals into the corpus callosum, and go through this to the cortex of the opposite hemisphere (*commissural fibres*); others join *association fibres* which run longitudinally or transversely, eventually to pass again into the grey matter of other parts of the same hemisphere; whilst others again, especially those of the largest pyramidal cells, extend downwards through the corona radiata and internal capsule, and become fibres of the pyramidal tract (*projection fibres*). As they pass down through the grey and white matter of the hemisphere they give off collateral fibres to the adjacent grey matter, to the corpus callosum and to the corpus striatum and optic thalamus (see diagram, fig. 253, p. 222).

There is, as already stated, a great amount of variation met with in the relative extent of development of the above layers. Some of these variations are exemplified in the accompanying drawings of preparations from the monkey's cerebral cortex by Bevan Lewis (figs. 277 to 282). From these it will be seen that smaller-sized cells prevail in the sensory regions of the cortex (occipital, temporal); larger and fewer cells occur in the psychomotor parts. The structure of the hippocampal region presents so many peculiarities as to necessitate a special description.

In the **hippocampus major** and **hippocampal gyrus** (fig. 283) the superficial layer of neuroglia and the white stratum, which overlies it as a thin band in other parts of the cortex, are both very strongly



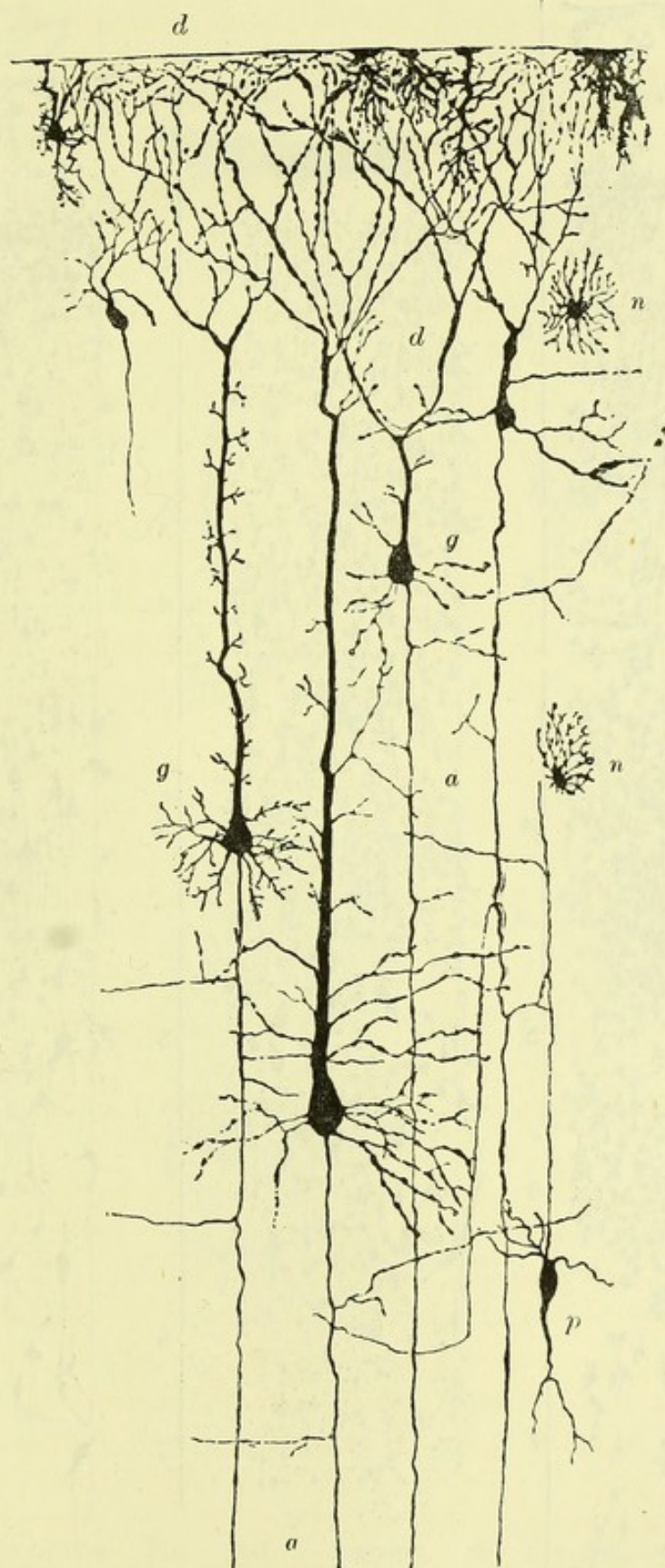


FIG. 276.—SECTION OF CEREBRAL CORTEX OF YOUNG RABBIT, PREPARED BY GOLGI'S METHOD. (G. Retzius.)

*g*, pyramidal cells of second and third layer sending their axis-cylinder processes, *a*, *a*, towards the white centre; *d*, *d*, dendrons of pyramids; *p*, polymorphous cell of fourth layer, with its axis-cylinder extending towards the surface; *n*, *n*, neuroglia-cells.





FIG. 277.—SECTION OF CORTEX OF OCCIPITAL LOBE.

1, peripheral layer; 2, small angular cells; 3, pyramidal cells; 4, angular and granule cells; 5, pyramidal cells; 6, granules and ganglionic cells; 7, spindle-cells.

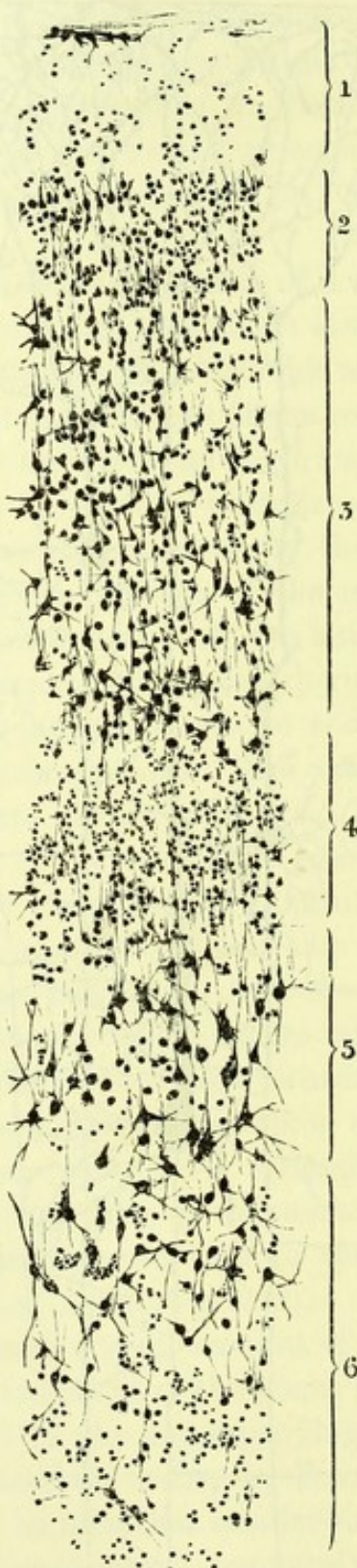

FIG. 278.—SECTION OF CORTEX OF TEMPORAL LOBE.

1, peripheral layer; 2, small angular cells; 3, pyramidal cells; 4, granular layer; 5, ganglionic cells; 6, spindle-cells.



FIG. 279.—SECTION OF CORTEX OF FRONTAL LOBE.

1, peripheral layer; 2, small angular cells; 3, large pyramidal cells; 4, ganglionic cells; 5, spindle-cells.



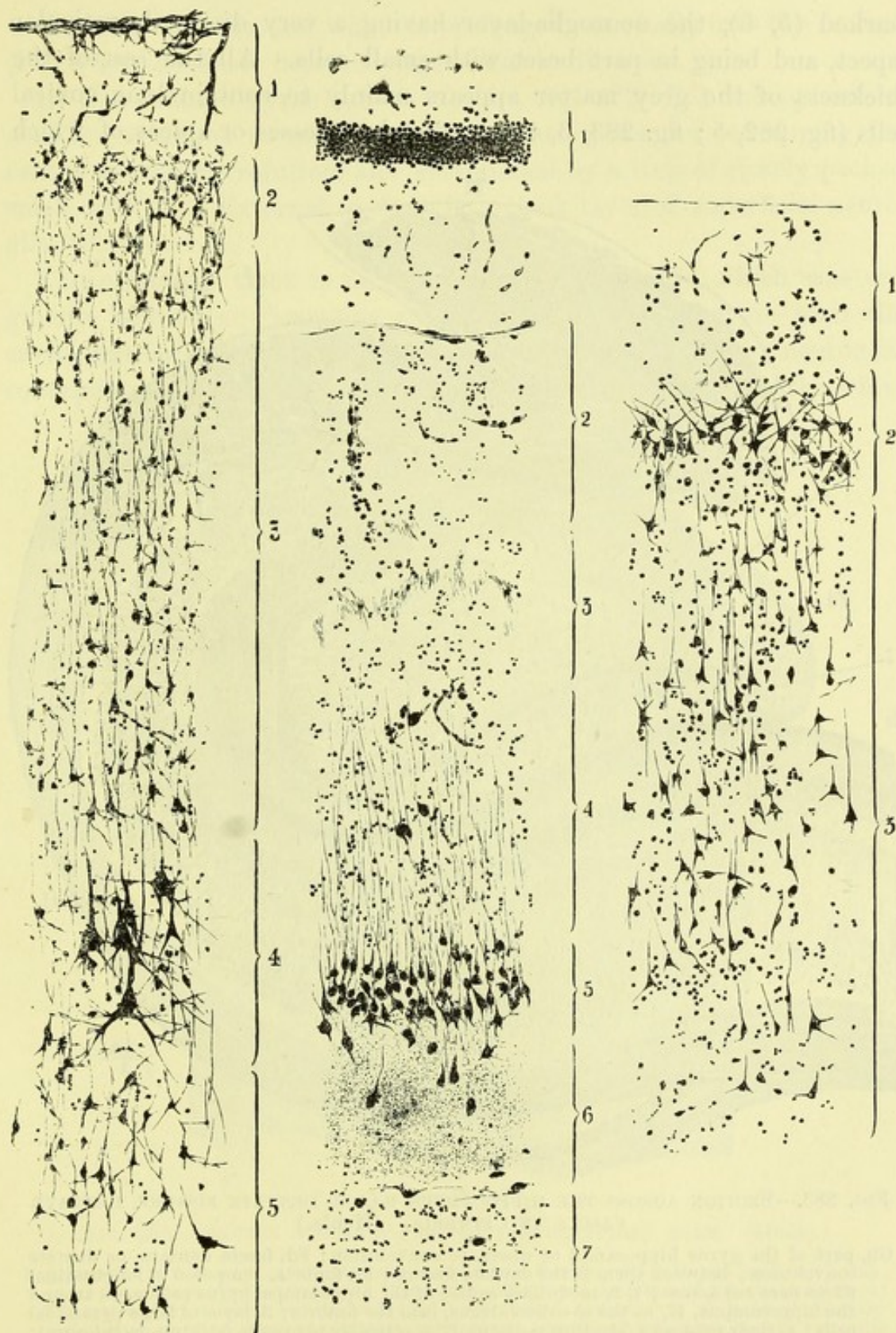


FIG. 280.—SECTION OF CORTEX OF MOTOR AREA.

1, peripheral layer; 2, small angular cells; 3, large pyramidal cells; 4, ganglionic cells and 'cell-clusters'; 5, spindle-cells.

FIG. 231.—SECTION OF HIPPOCAMPUS MAJOR.

1, granular stratum of fascia dentata; 2, nuclear lamina; 3, stratum lacinosum; 4, stratum radiatum; 5, ganglionic layer; 6, molecular stratum; 7, alveus.

FIG. 282.—SECTION OF CORTEX OF GYRUS HIPPOCAMPI.

1, peripheral layer; 2, aggregated pyramidal cells; 3, large pyramidal cells.

Figs. 277 to 282 are taken by the author's permission from Ferrier's *Functions of the Brain*, 2nd edition. They are from preparations and drawings (from the monkey's brain) made by Mr. Bevan-Lewis, and are magnified about 145 diameters.



marked (5, 6), the neuroglia-layer having a very distinctly reticular aspect, and being in part beset with small cells. All the rest of the thickness of the grey matter appears mainly to contain long conical cells (fig. 282, 5; fig. 283, 3, 4), the distal processes or apices of which

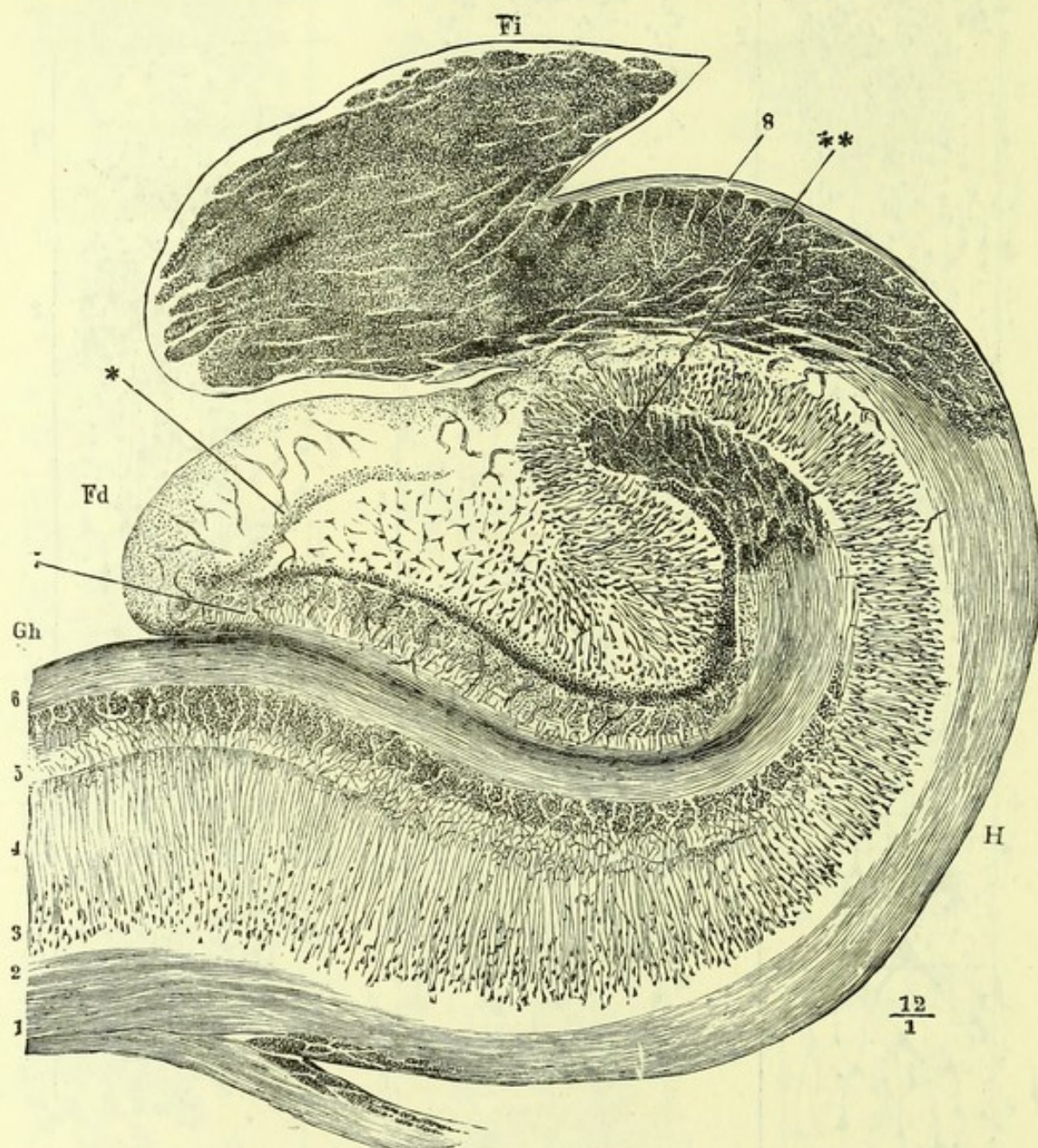


FIG. 283.—SECTION ACROSS THE HIPPOCAMPUS MAJOR, DENTATE FISSURE, DENTATE FASCIA AND FIMBRIA. (Henle.)

Gh, part of the gyrus hippocampi or uncinatæ convolution; Fd, fascia dentata, or dentate convolution; between them is the dentate fissure; Fi, fimbria, composed of longitudinal fibres here cut across; 1, 2, medullary centre of the hippocampal gyrus prolonged around the hippocampus, H, as the so-called alveus, into the fimbria; 3, layer of large pyramidal cells; 4, their processes (stratum radiatum); 5, reticular neuroglia (stratum lacinosum); 6, superficial medullary lamina, involuted around the dentate fissure; \*\*, termination of this lamina, the fibres here running longitudinally; 7, superficial neuroglia of the fascia dentata; \*, ring of small cells within this (stratum granulosum).

are prolonged into fibres which lose themselves in the superficial layer of neuroglia. The pyramidal cells rest upon the white centre, here known as the *alveus* (1), which is the part of the hippocampus seen



within the ventricle, and which is prolonged externally into the fimbria (Fi), where its fibres become longitudinal in direction.

In the **dentate gyrus** (*fascia dentata*, fig. 283, Fd) the pyramidal cells are arranged in an irregularly radiating manner, occupying the centre of the convolution, and surrounded by a ring of closely packed small cells (\*). External to these is a thick layer of superficial neuroglia (7).

The **olfactory tract** is an outgrowth of the brain which was originally hollow, and remains so in many animals; but in man the cavity has become obliterated, and the centre is occupied by neuroglia, containing no nerve-cells. Outside the central neuroglia lies the white

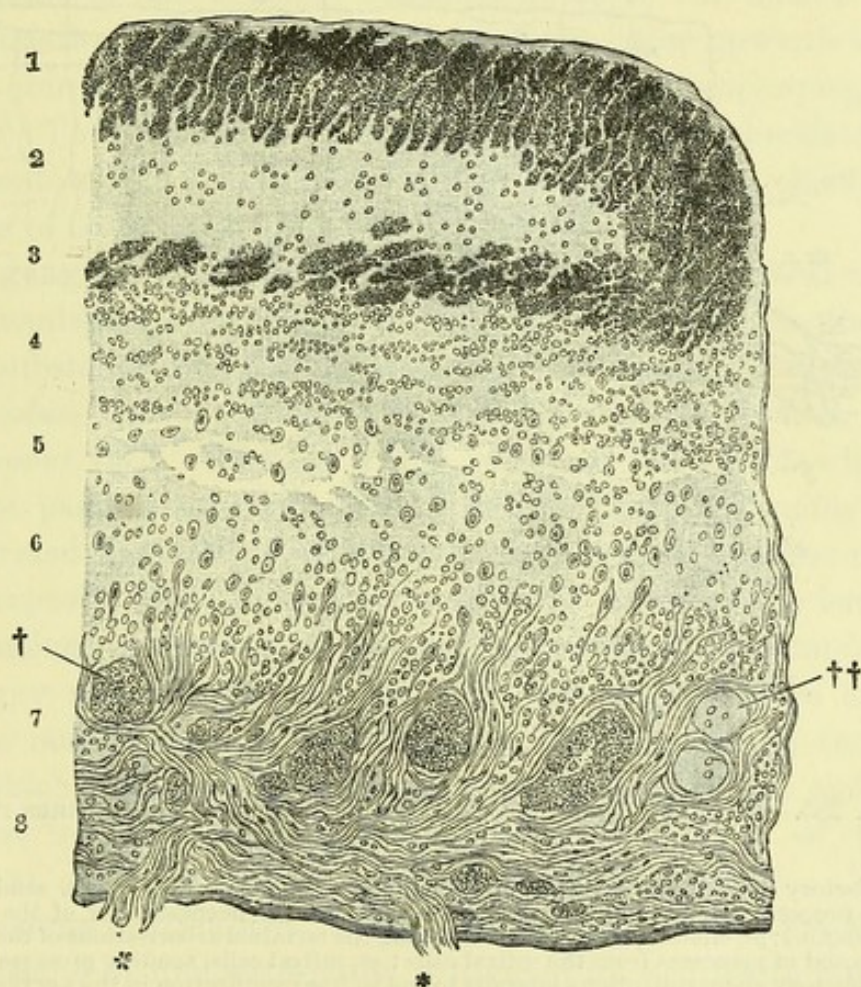


FIG. 284.—SECTION ACROSS A PART OF THE OLFACTORY BULB. (Henle.)

1, 3, bundles of very fine transversely cut nerve-fibres, forming the flattened medullary ring, inclosing the central neuroglia 2: this is the anterior continuation of the olfactory tract; 5, white layer with numerous small cells (granules); 6, mitral layer; 7, layer of olfactory glomeruli, †, ††; 8, layer of olfactory nerve-fibres, bundles of which are seen at \* passing through the cribriform plate of the ethmoid bone.

or medullary substance, consisting of bundles of longitudinal white fibres. Most externally is a thin superficial layer of neuroglia.

The **olfactory bulb** (fig. 284) has a more complicated structure. Dorsally there is a flattened ring of longitudinal white bundles inclos-



ing neuroglia (1, 2, 3), as in the olfactory tract, but below this ring several layers are recognised as follows :—

1. A *white or medullary layer* (fig. 284, 4, 5), characterised by the presence of a large number of small cells ("granules") with reticulating bundles of medullated nerve-fibres running longitudinally between them.

2. A *layer of large nerve-cells* (6), with smaller ones intermingled, the whole embedded in an interlacement of fibrils which are mostly derived from the cell-dendrons. From the shape of most of the large cells of this layer (fig. 285, *m.c.*) it has been termed the "mitral" layer. These

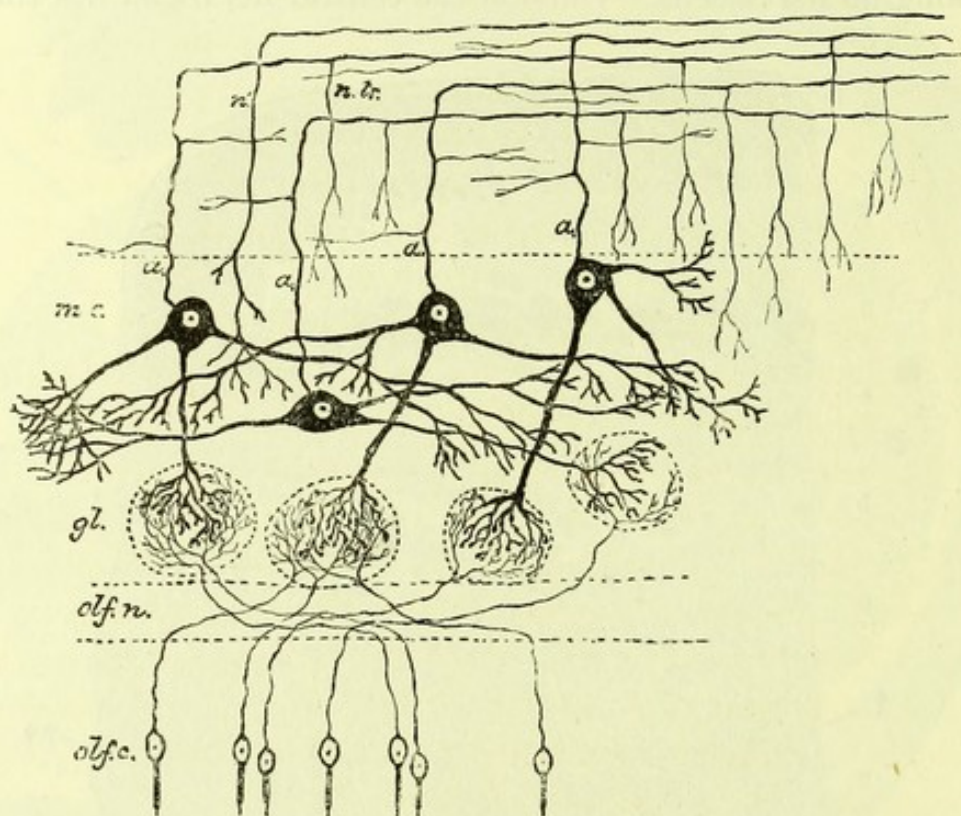


FIG. 285.—DIAGRAM TO SHOW THE RELATIONS OF CELLS AND FIBRES IN THE OLFACTORY BULB.

*olf.c.*, olfactory cells of M. Schultze in the olfactory mucous membrane, sending their basal processes as non-medullated nerve-fibres into the deepest layer of the olfactory bulb (*olf.n.*); *gl.*, olfactory glomeruli containing the terminal arborisations of the olfactory fibres and of processes from the mitral cells; *m.*, mitral cells, sending processes down to the olfactory glomeruli, others laterally to end in free ramification in the nerve-cell layer, and their axis-cylinder processes, *a, a*, upwards, to turn sharply backwards and become fibres of the olfactory tract (*tr.olf.*). Numerous collaterals are seen curving off from these fibres; *n'*, a nerve-fibre of the olfactory tract apparently ending in a free ramification in the olfactory bulb.

cells send their axis-cylinder processes upwards into the next layer, and they eventually become fibres of the olfactory tract and pass along this to the base of the brain, giving off numerous collaterals into the bulb as they pass backwards (v. Gehuchten).

3. The *layer of olfactory glomeruli* (fig. 284, 7; fig. 285, *gl.*) consists of rounded nest-like interlacements of fibrils which are derived on the



one hand from the terminal arborisations of the non-medullated fibres which form the subjacent layer, and on the other hand from arborisations of descending processes of the large "mitral" cells of the layer above.

4. The *layer of olfactory nerve-fibres* (fig. 284, 8). These are all non-medullated, and are continued from the olfactory fibres of the Schneiderian or olfactory mucous membrane of the nasal fossæ. In this mucous membrane they take origin from the bipolar olfactory cells which are characteristic of the membrane (see Lesson XLIV., fig. 309), and they end in arborisations within the olfactory glomeruli, where they come in contact with the arborisations of the mitral cells. The relations of the olfactory cells and fibres to the mitral cells and the continuation of the axis-cylinders of the latter upwards and backwards to join the ~~optic~~ tract are shown in the accompanying diagram (fig. 285). These relations have only recently been elucidated by the employment of the method of Golgi (see Appendix), chiefly by the researches of Golgi himself and of R. y Cajal. *olfactory*

**Basal ganglia.**—Besides the grey matter of the cerebral cortex the cerebral hemispheres conceal in their deeper parts certain other masses of grey substance (figs. 286, 287). The principal of these are the *corpus striatum* (*nucleus caudatus*, *n.c.*, and *nucleus lenticularis*, *n.l.*) and *optic thalamus* (*th.*). Between them run the bundles of white fibres which are passing upwards from the crus cerebri, forming a white lamina termed the *internal capsule*. Above the level of these nuclei the internal capsule expands into the medullary centre of the hemisphere.

The **nucleus caudatus** of the corpus striatum is composed of a reddish-grey neuroglia containing both moderately large and small multipolar nerve-cells. It receives fibres from the part of the internal capsule which separates it from the nucleus lenticularis, and next to the lateral ventricle it is covered by a thin layer of neuroglia (ependyma), and over this by the epithelium of the cavity.

The **nucleus lenticularis**, which corresponds in position internally with the island of Reil externally, is divided by two white laminae into three zones. It is separated from the nucleus caudatus and optic thalamus by the *internal capsule* (figs. 286, 287, *i.c.*), which consists of the bundles of medullary fibres which are passing between the white centre of the hemisphere and the crus cerebri; it receives on its inner side many white fibres from the capsule, and these impart to it a radially striated aspect. Many of the nerve-cells of the nucleus lenticularis contain yellow pigment.

The **optic thalamus**, which lies at the side of the third ventricle and forms part of the floor of the lateral ventricle, is covered externally



by a layer of white fibres, most marked next to the internal capsule, fibres from which pass into the thalamus and serve to connect it with the hemisphere.

The grey matter of the thalamus (fig. 286) is partially subdivided by an oblique white lamina into a smaller, inner (*i*), and a larger, outer, nucleus (*e*); these contain a number of small scattered nerve-cells. Anteriorly another portion of grey matter (*a*) is divided off in a similar way; this contains comparatively large nerve-cells.

Attached to the optic thalamus below and externally are the two *geniculate bodies* which are connected with the optic tract. Of the two geniculate bodies the outer has a lamellated structure consisting of alternating layers of grey and white matter. This external geniculate body also has a much closer connection with the optic tract than the inner; indeed, it is doubtful whether the latter receives any fibres from the tract.

The tegmentum of the crus cerebri is prolonged below the thalamus opticus into a mass of grey substance, with longitudinally and obliquely crossing white bundles, which is known under the name of *subthalamie substance*. In it at least three parts differing from one another in structure may be distinguished (see description of fig. 286).

The **pineal gland**, which is developed in the roof of the third ventricle, is composed of a number of tubes and saccules lined and sometimes almost filled with epithelium, and containing deposits of earthy salts (*brain-sand*). These deposits may, however, occur in other parts of the brain. The follicles are separated from one another by vascular connective-tissue derived from the pia mater.<sup>1</sup>

The **pituitary body** is a small reddish mass which lies in the sella turcica, and is connected with the third ventricle by the infundibulum. It consists of two lobes, a larger anterior, and a smaller posterior. The *anterior lobe* is originally developed as a hollow protrusion of the buccal epithelium. It consists of a number of tubules, which are lined by epithelium and united by connective tissue. In some of the tubes the epithelium is ciliated, and sometimes a colloid substance like that occurring in the vesicles of the thyroid has been found in them.

The *posterior lobe* of the pituitary body, although developed from the floor of the third ventricle, contains scarcely any perceptible nervous elements in the adult. It consists chiefly of vascular connective tissue.

The **membranes of the brain** are similar in general structure to those of the spinal cord, p. 216. The dura mater is, however, more closely

<sup>1</sup> In the chameleon and some other reptiles, the pineal is better developed, and is connected by nerve-fibres with a rudimentary median eye of invertebrate type, placed upon the upper surface of the head.



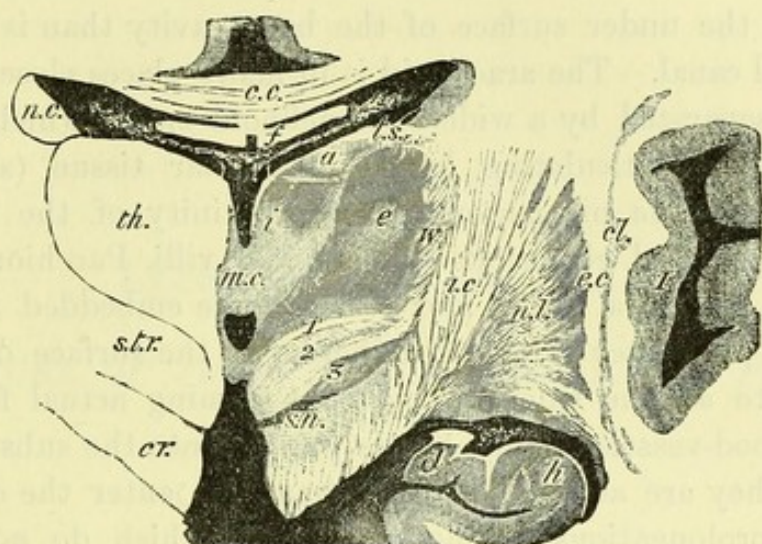
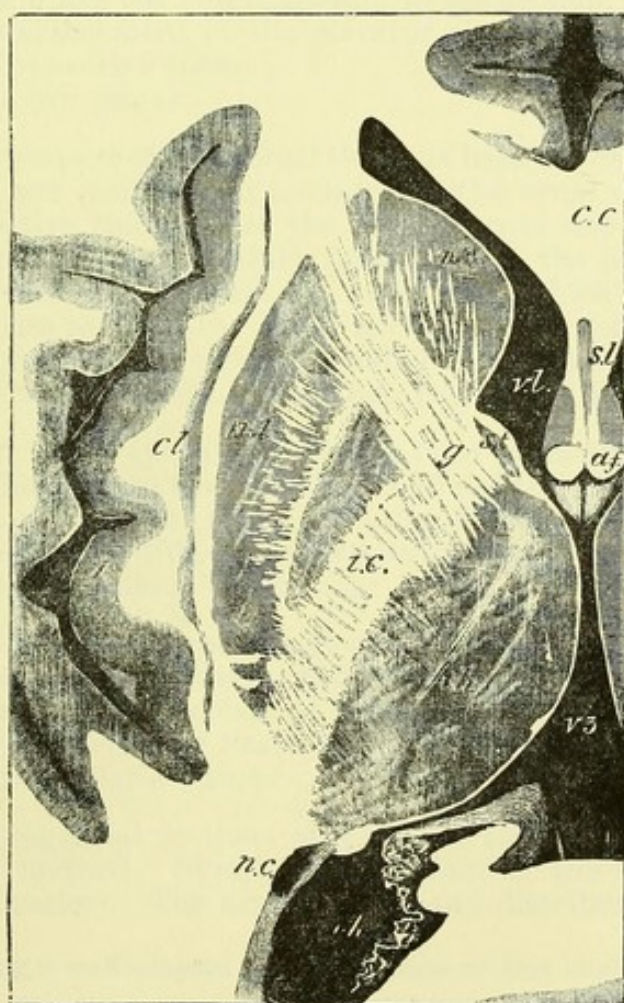


FIG. 286.—SECTION ACROSS THE OPTIC THALAMUS AND CORPUS STRIATUM IN THE REGION OF THE MIDDLE COMMISSURE. (Natural size.)

*th.*, thalamus; *a, e, i*, its anterior, external, and internal nuclei respectively; *v.*, its external white layer; *m.c.*, middle commissure; *v. 3*, third ventricle; a small part is also seen below the middle commissure; *c.c.*, corpus callosum; *f*, fornix, separated from the third ventricle and thalamus by the velum interpositum. In the middle of this are seen the two veins of Galen and the choroid plexuses of the third ventricle: and at its edges the choroid plexuses of the lateral ventricles, *v.l.*; *t.s.*, stria pinealis; *cr.*, forward prolongation of the crura passing laterally into the internal capsule, *i.c.*; *s.t.r.*, subthalamic prolongation of the tegmentum, consisting of (1) the dorsal layer, (2) the zona incerta, and (3) the corpus subthalamicum; *s.n.*, substantia nigra; *n.c.*, nucleus caudatus of the corpus striatum; *n.l.*, nucleus lenticularis; *e.c.*, external capsule; *cl.*, claustrum; *I*, island of Reil; *h*, hippocampus; *d*, fascia dentata.

FIG. 287.—HORIZONTAL SECTION THROUGH THE OPTIC THALAMUS AND CORPUS STRIATUM. (Natural size.)

*v.l.*, lateral ventricle, anterior cornu; *c.c.*, corpus callosum; *s.l.*, septum lucidum; *a.f.*, anterior pillars of the fornix; *v. 3*, third ventricle; *th.*, thalamus opticus; *s.t.*, stria pinealis; *n.c.*, nucleus caudatus, and *n.l.*, nucleus lenticularis of the corpus striatum; *i.c.*, internal capsule; *g.*, its angle or genu; *n.c.*, tail of the nucleus caudatus appearing in the descending cornu of the lateral ventricle; *cl.*, claustrum; *I*, island of Reil.





adherent to the under surface of the bony cavity than is the case in the vertebral canal. The arachnoid is in many places close to the dura mater, and separated by a wide subarachnoid space, which is bridged across by finely reticulating bands of areolar tissue (subarachnoid trabeculæ) from the pia mater. In the vicinity of the longitudinal sinus, small rounded elevations (arachnoidal villi, Pacchionian glands) project into the dura mater, and even become embedded in the skull itself. The pia mater is closely adherent to the surface of the brain, and dips into all the sulci, but without forming actual folds (Tuke). In it the blood-vessels ramify before passing into the substance of the brain, and they are accompanied, as they thus enter the cerebral substance, by prolongations of the pia mater, which do not, however, closely invest them, but leave a clear space around each vessel, presumably for the passage of lymph (perivascular space). The capillary network is much closer in the grey than in the white matter.



## LESSONS XLII. AND XLIII.

*STRUCTURE OF THE EYELIDS AND OF THE PARTS OF THE EYEBALL.*

## LESSON XLII.

1. SECTIONS of the eyelid vertical to its surfaces and transverse to its long axis. The lid should be hardened in alcohol, and the sections may be stained with hæmatoxylin and mounted in the usual manner in Canada balsam.

Notice the long sacculated Meibomian glands lying in dense connective tissue close to the conjunctival surface, and their ducts opening at the margin of the lid. External to these the small fibres of the orbicularis palpebrarum cut across; a few of the fibres of the muscle lie on the conjunctival side of the duct. A short distance from the Meibomian gland may be observed another tolerably large sebaceous gland; outside this again are the eyelashes. In the skin covering the outer surface of the eyelid a few small hairs may be seen. At the attached part of the eyelid are some bundles of involuntary muscular fibres cut longitudinally in the section, and in the upper eyelid the fibrous attachment of the elevator muscle may be observed attached to the dense connective tissue.

Make a general sketch under a low power.

2. Sections through the posterior part of an eyeball that has been hardened in Müller's fluid. The sections are stained and mounted in the usual way. These sections will show the relative thickness of the several coats and the layers of which each coat is formed. Sections which pass through the point of entrance of the optic nerve will also exhibit the manner in which the nerve-fibres pierce the several coats to reach the inner surface of the retina. The modifications which are found in the neighbourhood of the yellow spot may also be made out if the sections have been taken from the human eye.

3. Sections of the anterior half of an eyeball which has been hardened in Müller's fluid. These sections should pass through the middle of the cornea. The lens may be left *in situ*, but this renders the preparation of the sections and the mounting of them much more difficult on account of the extreme hardness which is imparted to the lens-tissue by alcohol.<sup>1</sup>

In these sections make a general sketch under a low power, showing the relations of the several parts one with another; and study carefully, and sketch in detail, the layers of the cornea, the place of junction of the cornea and sclerotic, the ciliary muscle, the muscular tissue of the iris, the mode of suspension of the lens, and the pars ciliaris retinae.

4. Mount in glycerine thin tangential sections of a cornea stained with chloride of gold by Cohnheim's method. Sketch three or four of the connective-tissue cells (corneal corpuscles). The arrangement and distribution

<sup>1</sup> The celloidin method of embedding is well-adapted for preparations of this kind (see Appendix).



of the nerve-fibres and their termination amongst the epithelium-cells as shown in chloride of gold preparations have been already studied (Lesson XXI.).

5. Mount in Canada balsam sections of a cornea which has been stained with nitrate of silver. Notice the branched cell-spaces corresponding with the connective-tissue cells of the last preparation.

[This preparation is best made by rubbing the surface of the cornea with lunar caustic after scraping off the epithelium. After ten or fifteen minutes (by which time the nitrate of silver will have penetrated the thickness of the cornea) the eye is washed with distilled water, and exposed to the light. When brown, tangential sections may be made, for which purpose the cornea may be hardened in spirit.]

### LESSON XLIII.

1. REMOVE the sclerotic from the anterior part of an eye which has been preserved in Müller's fluid, and tear off thin shreds from the surface of the choroid, including amongst them portions of the ciliary muscle. Stain the shreds with hæmatoxylin and mount them in Farrant. Sketch the branched pigment-cells, the elastic network, the mode of attachment of the fibres of the ciliary muscle, etc.

2. Injected preparation of choroid and iris. Mount in Canada balsam portions of the choroid coat and iris from an eye, the blood-vessels of which have been filled with coloured injection. Make sketches showing the arrangement of the capillaries and veins.

3. Teased preparation of retina. Break up with needles in a drop of glycerine a minute fragment of retina which has been placed in 1 per cent. osmic acid solution for a few hours, and has subsequently been kept in dilute glycerine. Complete the separation of the retinal elements by tapping the cover-glass. Draw carefully under a high power some of the isolated elements—*e.g.* the rods and cones with their attached fibres and nuclei, the inner granules, the ganglion-cells, the fibres of Müller, hexagonal pigment-cells, etc. In some of the fragments the arrangement of the elements in the retinal layers may be made out even better than in actual sections.<sup>1</sup>

Measure the length and diameter of some of the cones, the length of the cone-fibres, and the diameter of some of the outer and inner nuclei.

4. Teased preparation of lens. Separate in water the fibres of a crystalline lens which has been macerated for some days in bichromate of potash solution. Sketch some of the fibres, together and separate.

The eyelids (fig. 288) are covered externally by the skin, and internally or posteriorly by a mucous membrane, the *conjunctiva*, which is reflected from them over the globe of the eye. They are composed in the main of connective tissue, which is dense and fibrous under the conjunctiva, where it forms what is known as the *tarsus*.

Embedded in the tarsus is a row of long sebaceous glands (the

<sup>1</sup>The distribution of the nerve-fibres and cell-processes within the retina can only be made out satisfactorily by the employment of Golgi's method (see Appendix).



*Meibomian glands, f*), the ducts of which open at the edge of the eyelid. The rest of the thickness of the eyelid is composed of a somewhat loose connective tissue, and contains the bundles of the *orbicularis* muscle (*b*). In the upper eyelid the *levator palpebræ* is inserted into the tarsus by a fibrous expansion, and some bundles of involuntary muscle are also

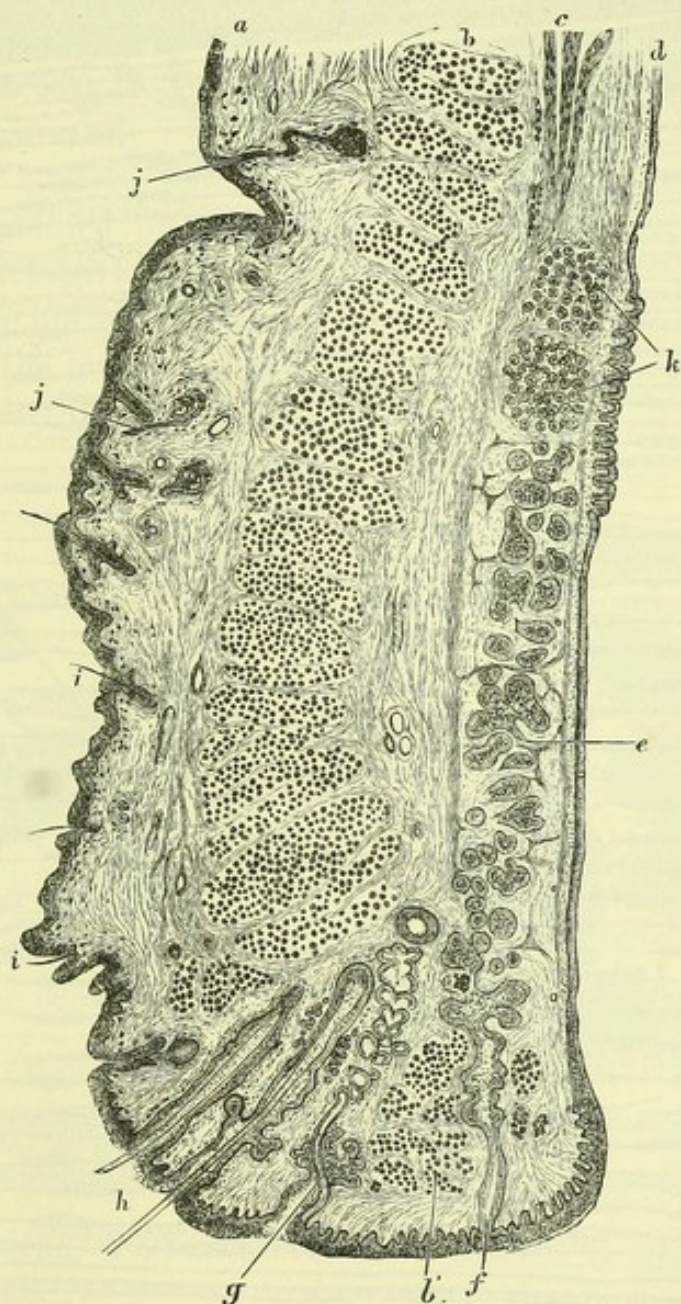


FIG. 288.—VERTICAL SECTION THROUGH THE UPPER EYELID. (Waldeyer.)  
(Magnified.)

*a*, skin; *b*, orbicularis; *b'*, ciliary bundle; *c*, involuntary muscle of eyelid; *d*, conjunctiva; *e*, tarsus with Meibomian gland; *f*, duct of the gland; *g*, sebaceous gland near eyelashes; *h*, eyelashes; *i*, small hairs in outer skin; *j*, sweat-glands; *k*, posterior tarsal glands.

present near the attachment of the eyelid. The skin has the usual structure; it contains small sweat-glands, and the follicles of small hairs, and, in addition, at the edge of the eyelid, the large hair-follicles from which the eyelashes grow. The epithelium of the conjunctiva



palpebræ is columnar, passing at the edge of the lid into the stratified epithelium of the skin; it also becomes stratified in the part which is reflected over the globe of the eye. The nerves of the conjunctiva

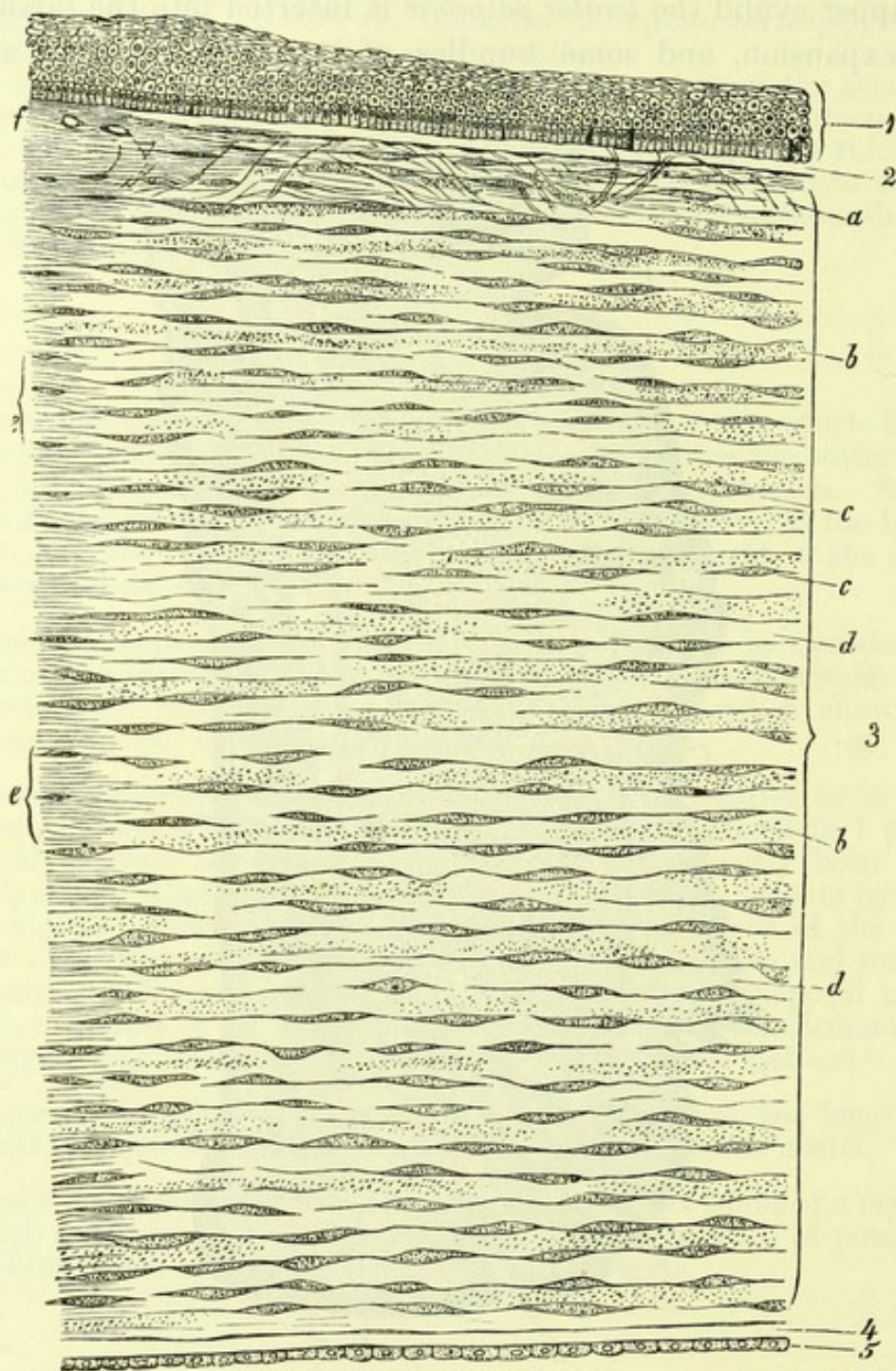


FIG. 289.—VERTICAL SECTION OF HUMAN CORNEA FROM NEAR THE MARGIN.  
(Waldeyer.) (Magnified.)

1, epithelium; 2, anterior homogeneous lamina; 3, substantia propria corneæ; 4, posterior homogeneous (elastic) lamina; 5, epithelium of the anterior chamber; *a*, oblique fibres in the anterior layer of the substantia propria; *b*, lamellæ, the fibres of which are cut across, producing a dotted appearance; *c*, corneal corpuscles appearing fusiform in section; *d*, lamellæ with the fibres cut longitudinally; *e*, transition to the sclerotic, with more distinct fibrillation, and surmounted by a thicker epithelium; *f*, small blood-vessels cut across near the margin of the cornea.

terminate for the most part in end-bulbs, which in man are spheroidal, and formed chiefly of a small mass of polyhedral cells, but in the calf



and most animals they are elliptical, and consist of a core and lamellated sheath (see Lesson XXI.).

The **lachrymal gland** may be briefly mentioned in connection with the eyelid. It is a compound racemose gland, yielding a watery secretion, and resembling in structure the serous salivary glands, such as the parotid. Its ducts, of which there are several, open at the upper fold of the conjunctiva, near its outer extremity.

The **sclerotic coat** is composed of dense fibrous tissue, the bundles of which are intimately interlaced. It is thickest at the back of the eyeball. It is covered externally with a lymphatic epithelium, while internally it is lined by a layer of connective tissue containing pigment-cells, which give it a brown appearance (*lamina fusca*). At the entrance of the optic nerve the sclerotic is prolonged into the sheath of that nerve, the bundles of which, piercing the coat, give a sieve-like aspect to the part (*lamina cribrosa*, fig. 298, L).

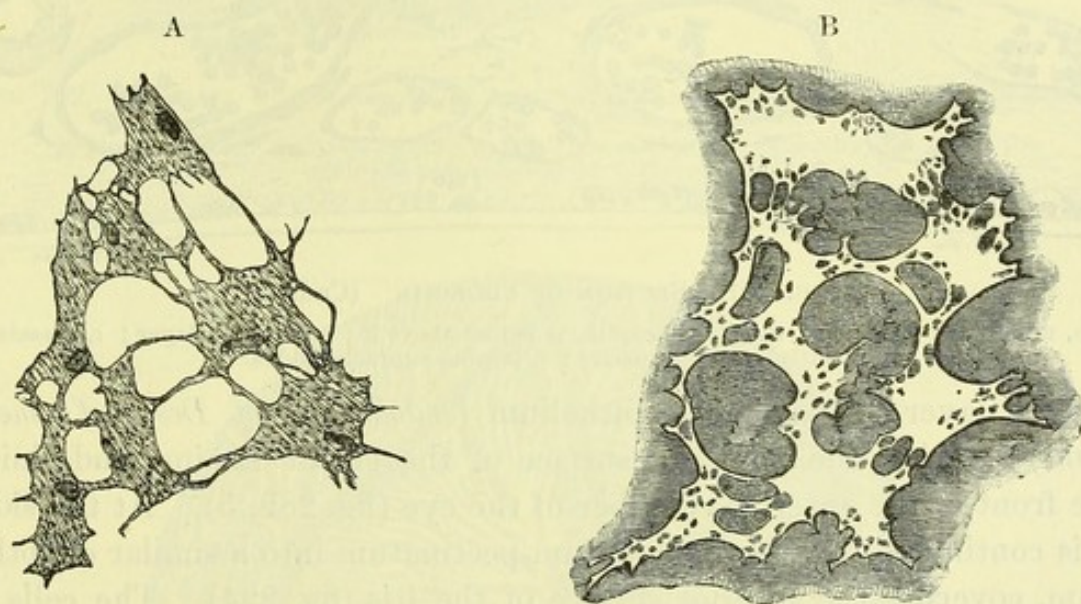


FIG. 290.—A, CORPUSCLES OF THE RAT'S CORNEA. (From a preparation treated with chloride of gold.) B, CELL-SPACES OF THE RAT'S CORNEA. (From a preparation stained with nitrate of silver.)

The **cornea** (fig. 289) consists of the following layers enumerated from before back:—

1. A *stratified epithelium* continuous with the epithelium of the conjunctiva (1).
2. A thin lamina of homogeneous connective tissue (*membrane of Bowman*), upon which the deepest cells of the epithelium rest (2).
3. A thick layer of fibrous connective tissue which forms the *proper substance* of the cornea (3). This is continuous laterally with the tissue of the sclerotic. It is composed of bundles of white fibres arranged in regular laminae, the direction of the fibres crossing one another at right



angles in the alternate laminae. Between the laminae lie flattened connective-tissue corpuscles, which are branched and united by their processes into a continuous network; there is of course a corresponding network of cell-spaces (fig. 290, A, B). In vertical sections the cells appear narrow and spindle-shaped (fig. 289, c). In the superficial laminae there are a few bundles of fibres which run obliquely towards the surface (a).

4. A homogeneous elastic layer (*membrane of Descemet*, fig. 289, 4). This completely covers the back of the cornea, but near the angle which the cornea forms with the iris it breaks up into separate fibres (*ligamentum pectinatum*) which are partly continued into the iris as the pillars of the iris.

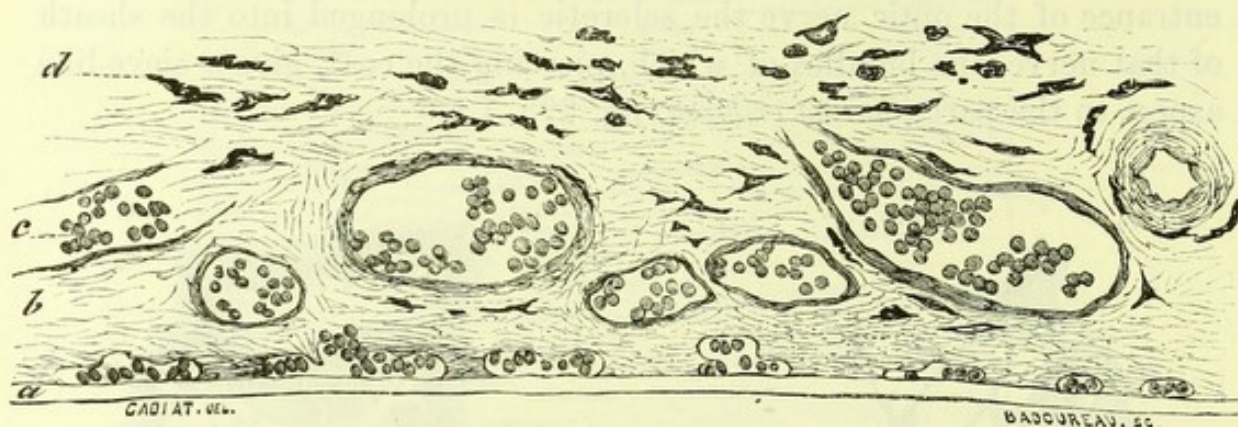


FIG. 291.—SECTION OF CHOROID. (Cadiat.)

a, membrane of Bruch: the chorio-capillaris is just above it; b, vascular layer; c, vessels with blood-corpuscles; d, lamina suprachoroidea.

5. A layer of pavement-epithelium (*endothelium of Descemet's membrane*) covering the posterior surface of the elastic lamina, and lining the front of the anterior chamber of the eye (fig. 289, 5). At the sides it is continued over the ligamentum pectinatum into a similar endothelium, covering the anterior surface of the iris (fig. 294). The cells of the epithelium of Descemet's membrane are separated from one another by intercellular spaces, bridged across by bundles of fibrils which pass through the cells.

The nerves of the cornea pass in from the periphery, losing their medullary sheath as they enter the corneal substance. They form a primary plexus in the substantia propria, a secondary or sub-epithelial plexus immediately under the epithelium which covers the anterior surface, and a terminal plexus of fine fibrils which pass from the sub-epithelial plexus in pencil-like tufts and become lost between the epithelium-cells (see figs. 125, 126, Lesson XXI.). There are no blood-vessels or lymphatics in the cornea, although they come close up to its margin.

The choroid or vascular coat of the eye is of a black colour in many



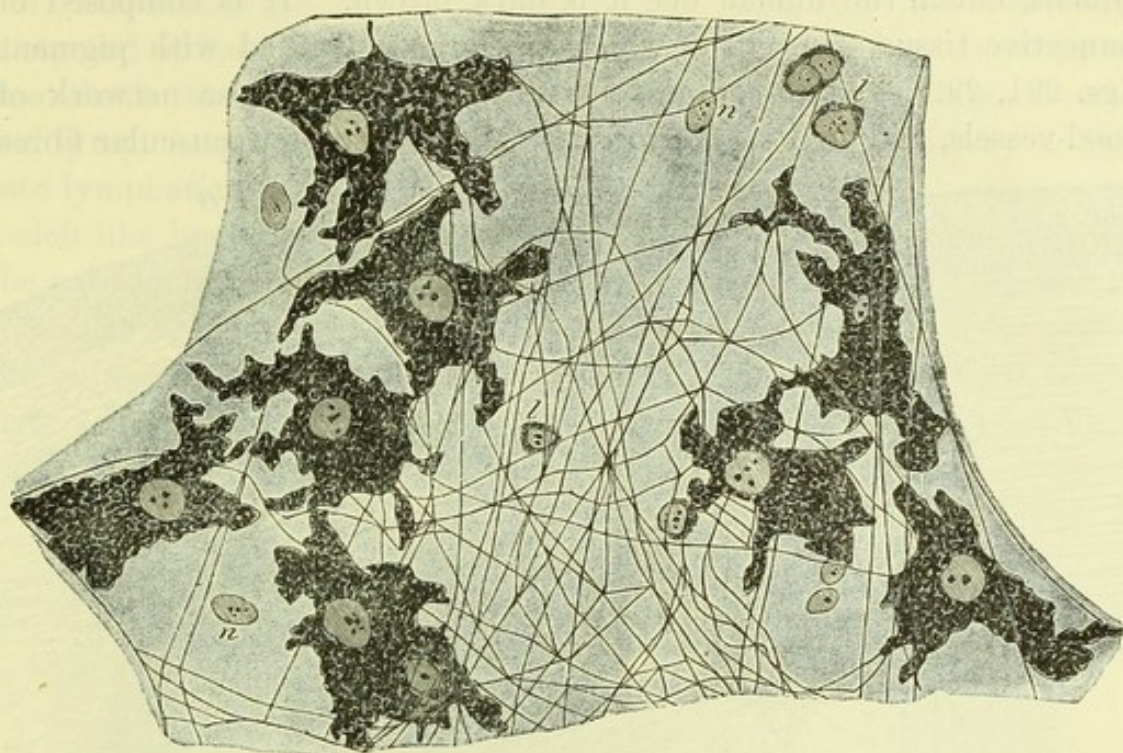


FIG. 292.—A SMALL PORTION OF THE LAMINA SUPRACHOROIDEA. (Highly magnified.)

*p*, pigment-cells; *f*, elastic fibres; *n*, nuclei of endothelial cells (the outlines of the cells are not indicated); *l*, lymph-cells.

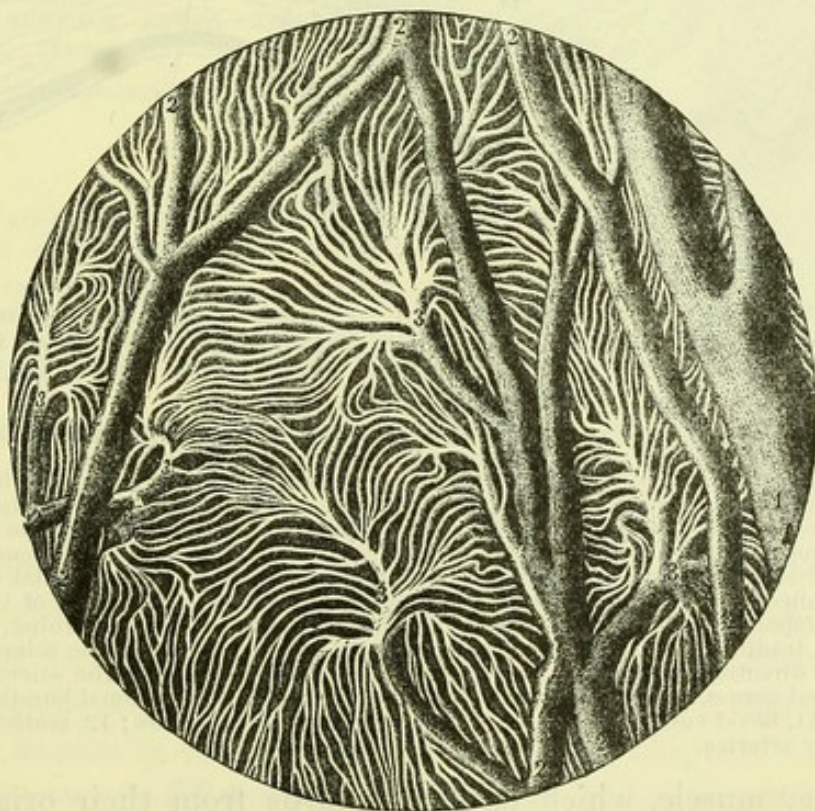


FIG. 293.—INJECTED BLOOD-VESSELS OF THE CHOROID COAT. (Sappey.)

1, one of the larger veins; 2, small anastomosing vessels; 3, branches dividing into the smallest vessels.



animals, but in the human eye it is dark brown. It is composed of connective tissue, the cells of which are large and filled with pigment (figs. 291, 292), and it contains in its inner part a close network of blood-vessels, and in its anterior part the involuntary muscular fibres

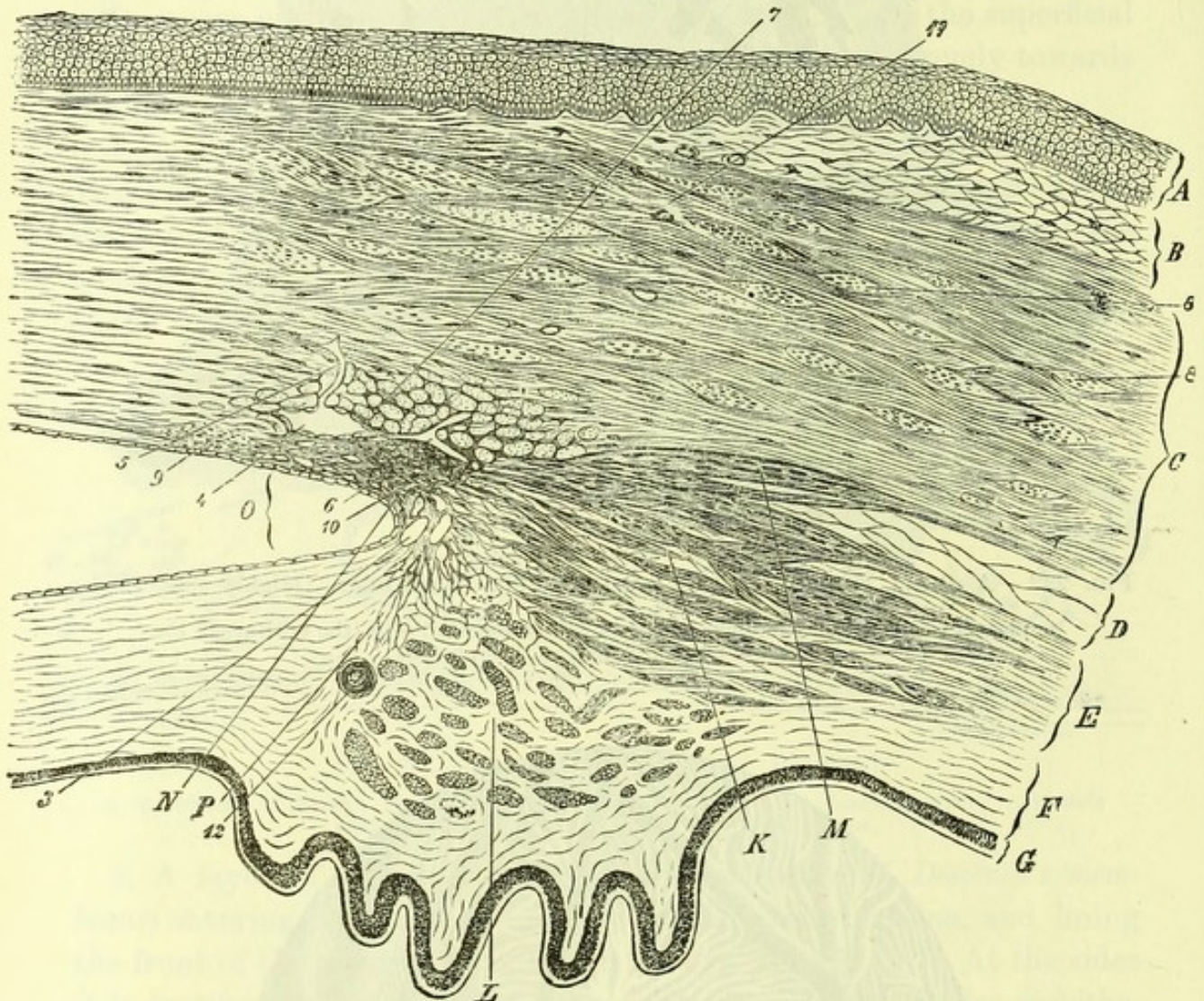


FIG. 294.—SECTION (FROM THE EYE OF A MAN, AGED 30), SHOWING THE RELATIONS OF THE CORNEA, SCLEROTIC, AND IRIS, TOGETHER WITH THE CILIARY MUSCLE, AND THE CAVERNOUS SPACES NEAR THE ANGLE OF THE ANTERIOR CHAMBER. (Waldeyer.) (Magnified.)

A, epithelium; B, conjunctival mucous membrane; C, sclerotic; D, membrana suprachoroidea; E, opposite the ciliary muscle; F, choroid, with ciliary processes; G, tapetum nigrum and pars ciliaris retinae; H, cornea (substantia propria); J, spaces of Fontana; K, radiating and meridional, and L, circular or annular bundles of the ciliary muscle; M, bundles passing to the sclerotic; N, ligamentum pectinatum iridis at the angle, O, of the anterior chamber; P, fibres passing from it to the iris. 1, anterior homogeneous lamina of the cornea; 2, posterior homogeneous lamina, covered with endothelial cells which are continued over the front of the iris; 3, cavernous spaces at the angle of the anterior chamber (spaces of Fontana); 4, canal of Schlemm, with endothelial lining, and with a vessel, 5, leading from it; 6, other vessels; 7, bundles of fibres of the sclerotic having a circular direction, cut across; 8, larger ones in the substance of the sclerotic; 9, fine bundles cut across, at limit of cornea; 10, point of origin of meridional bundles of ciliary muscle; 11, blood-vessels in sclerotic and conjunctiva, cut across; 12, section of one of the ciliary arteries.

of the ciliary muscle, which pass backwards from their origin at the junction of the cornea and sclerotic, to be inserted into the choroid. The choroid is separable into the following layers, enumerated from without in :—



1. The *lamina suprachoroidea* (fig. 291, *d*). This is a thin membrane composed of homogeneous connective tissue pervaded by a network of fine elastic fibres, and containing many large branched pigment-cells and lymph-corpuscles (fig. 292). It is covered superficially by a delicate lymphatic endothelium, and is separated from the lamina fusca by a cleft-like lymphatic space which is bridged across here and there by the passage of vessels and nerves, and by bands of connective tissue.

2. The *vascular layer* of the choroid (fig. 291, *b*), which resembles the suprachoroidea in structure, but contains the blood-vessels of the coat. In its outer part are the larger vessels (arteries and veins), the veins having a peculiar vorticose arrangement; in its inner part

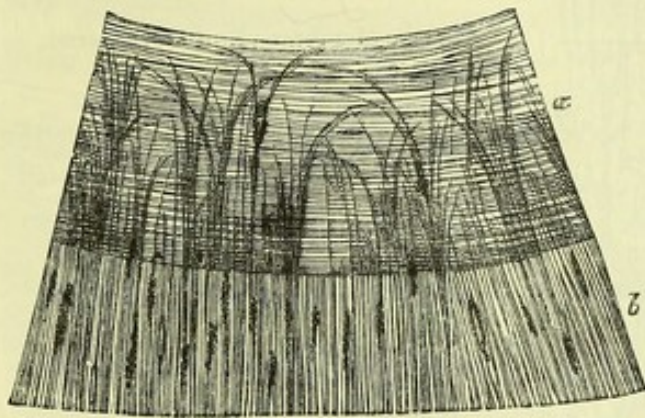


FIG. 295.—SEGMENT OF THE IRIS, SEEN FROM THE POSTERIOR SURFACE AFTER REMOVAL OF THE UVEAL PIGMENT. (Iwanoff.)

*a*, sphincter muscle; *b*, dilator muscle of the pupil.

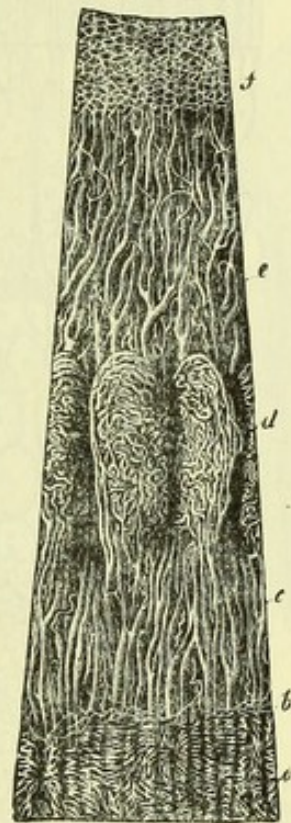

FIG. 296.—VESSELS OF THE CHOROID, CILIARY PROCESSES AND IRIS OF A CHILD. (Arnold.) (10 diameters.)

*a*, capillary network of the posterior part of the choroid, ending at *b*, the ora serrata; *c*, arteries of the corona ciliaris, supplying the ciliary processes, *d*, and passing into the iris, *e*; *f*, the capillary network close to the pupillary margin of the iris.

(chorio-capillaris) are the capillaries, which form an extremely close network with elongated meshes, the capillaries radiating from the extremities of the small arteries and veins in a highly characteristic manner (fig. 293). In the ciliary processes the vessels have for the most part a longitudinal direction, but there are numerous convoluted transversely disposed capillaries uniting the longitudinal vessels (fig. 296).

3. Lining the inner surface of the choroid is a very thin transparent membrane known as the *membrane of Bruch* (fig. 291, *a*).

The *ciliary muscle* of Bowman consists of involuntary muscular bundles which arise at the corneo-sclerotic junction, and pass meridionally backwards to be inserted into the choroid (fig. 294, *K*). Many of the deeper-seated bundles take an oblique direction, and these pass gradu-



ally into others which run circularly around the circumference of the iris, and on a level with the ciliary processes. This set of circularly arranged bundles constitutes the *circular ciliary muscle* of H. Müller (*L*); it is most marked in hypermetropic eyes.

The *iris* is that part of the vascular coat of the eye which extends in front of the lens. It is continuous with the choroid and has a similar

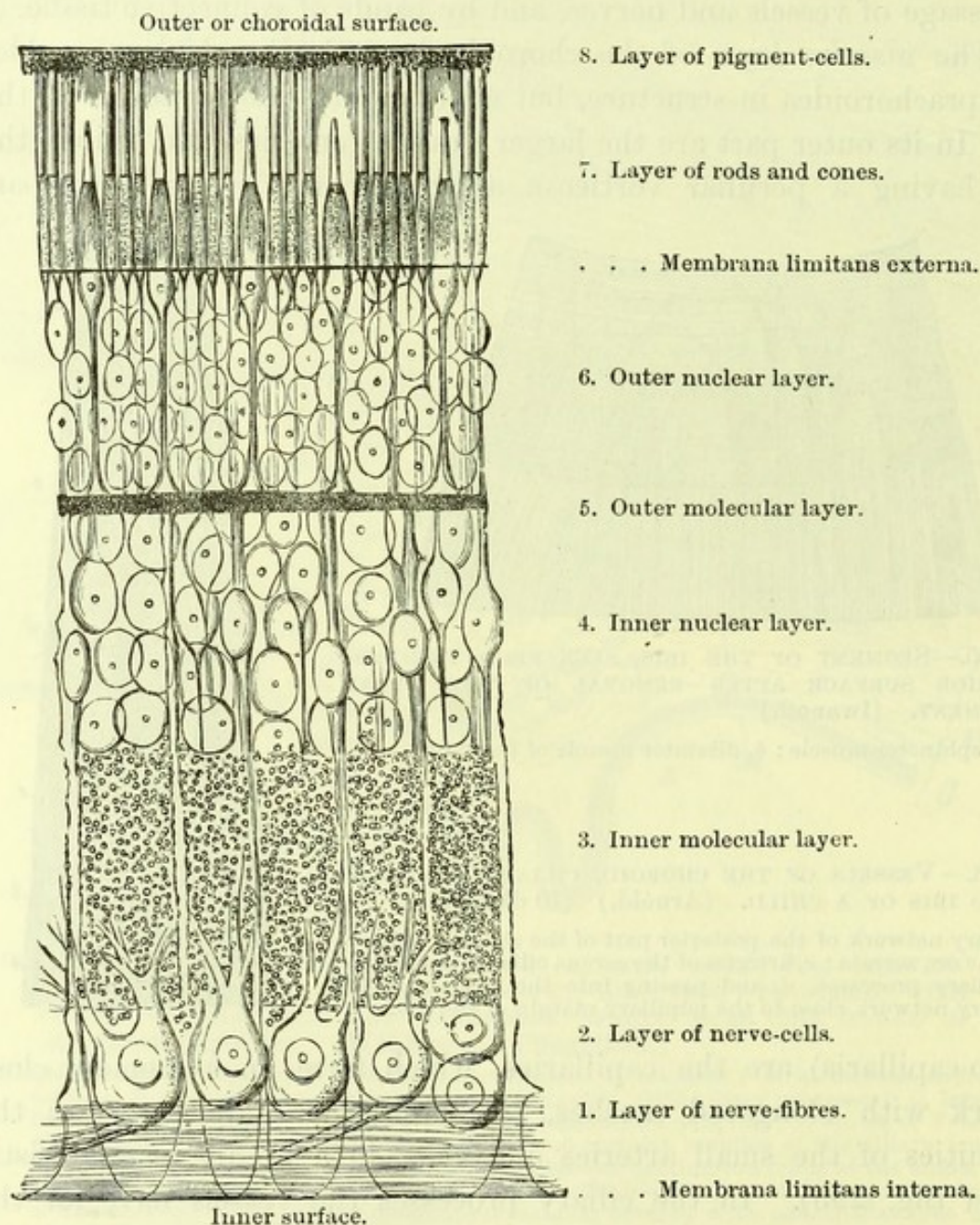


FIG. 297.—DIAGRAMMATIC SECTION OF THE HUMAN RETINA. (M. Schultze.)

structure, but its pigment-cells often contain variously coloured pigment. Besides the homogeneous connective tissue with numerous elastic fibres and blood-vessels of which it is chiefly composed, it contains two sets of plain muscular fibres. The one set forms the *sphincter* muscle (fig. 295, *a*), which encircles the pupil, the other set consists of a flattened layer of radiating fibres which extend from the attachment



of the iris nearly to the pupil, lying close to the posterior surface and constituting the *dilatator* muscle (*b*).<sup>1</sup>

The back of the iris is covered by a thick layer of pigmented epithelium (uvea) continuous with the epithelium of the pars ciliaris retinae.

The blood-vessels of the iris converge towards the pupil (fig. 296, *e*). Near the pupil the small arteries form a small anastomotic circle, from which capillaries arise and pass still nearer the pupil, around which they form a close capillary network.

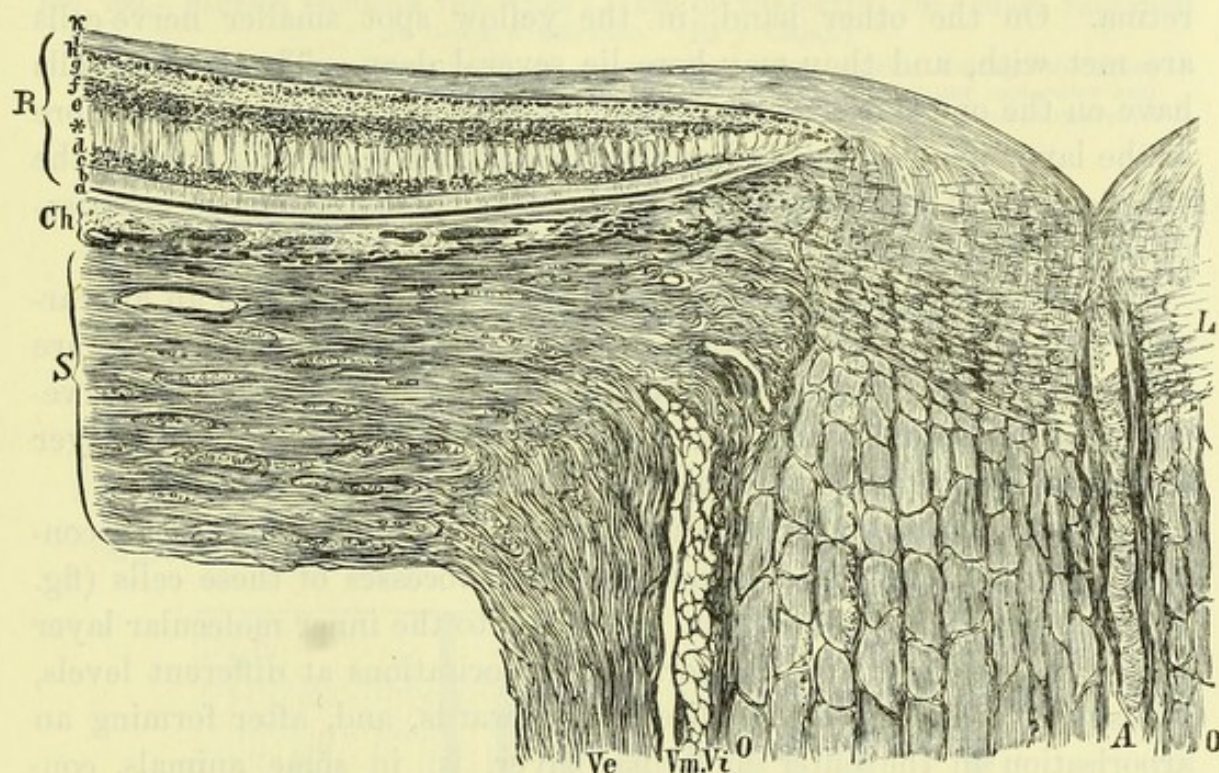


FIG. 298.—SECTION THROUGH THE COATS OF THE EYEBALL AT THE POINT OF ENTRANCE OF THE OPTIC NERVE. (Toldt.)

*Ve*, dural sheath; *Vm*, arachnoidal sheath, and *Vi*, pia-matral sheath of the optic nerve, with lymphatic spaces between them; *O*, *O*, funiculi of the nerve; *L*, lamina cribrosa; *A*, central artery; *S*, sclerotic; *Ch*, choroid; *R*, retina. The small letters refer to the various parts of the retina, *b* being the layer of rods and cones, and *i* that of nerve-fibres.

A large number of nerve-fibres are distributed to the choroid and iris, probably going chiefly to the muscular tissue (ciliary muscle and sphincter and dilatator iridis).

The **retina** consists of the eight layers shown in the accompanying figure (fig. 297), numbered as they occur from within out.

The inner surface of the retina, which is smooth, rests upon the hyaloid membrane of the vitreous humour. It is formed of the united bases of the fibres of Müller, which will be afterwards described.

The *layer of nerve-fibres* is formed by the expansion of the optic nerve after it has passed through the coats of the eye (fig. 298). At its en-

<sup>1</sup>The existence of a dilatator is denied by some histologists.



trance it forms a slight eminence (*colliculus nervi optici*). The nerve-fibres lose their medullary sheath on reaching the retina. Some of the fibres pass through the ganglionic and molecular layers to form a terminal arborisation in the inner nuclear layer (fig. 299). The layer of nerve-fibres becomes gradually thinner in the anterior part of the retina.

The *layer of nerve-cells*, or ganglionic layer, is composed of nerve-cells somewhat like the cells of Purkinje of the cerebellum but varying in size, although those of large size are prevalent in most parts of the retina. On the other hand, in the yellow spot smaller nerve-cells are met with, and they may here lie several deep. These nerve-cells have on the one side a fine axis-cylinder process prolonged into a fibre of the layer just noticed, and on the other a thick branching process, the ramifications of which terminate in the next layer in flattened arborisations at different levels (fig. 300, A, B, C).

The *inner molecular layer* is comparatively thick, and has an appearance very like the grey matter of the nerve-centres. A few nuclei are scattered through it, and it is traversed by the processes of the nerve-cells and of the inner granules, and by fibres from the optic nerve layer as well as by the fibres of Müller.

The *inner nuclear layer* is mainly composed of bipolar nerve-cells containing large nuclei (*inner granules*). The processes of these cells (fig. 301, D) extend on the one hand inwards into the inner molecular layer where they spread out into terminal arborisations at different levels, whilst the other process is directed outwards, and, after forming an arborisation in the outer molecular layer, is, in some animals, continued on as far as the external limiting membrane, where it ends in a free extremity (E). Besides these bipolar nerve-cells, there are other inner granules which are different in character, having ramified processes which only extend into one or other of the molecular layers (fig. 301, A, B, C, H, I), in which the bodies of these cells are often partly embedded. The cells in question have been regarded as of the nature of neuroglia-cells but they are probably all nerve-cells, and some have been noticed to give off, besides branching processes or dendrons, which ramify in the molecular layer, an axis-cylinder process which may extend into the nerve-fibre layer. The fibres of Müller have nucleated enlargements (J) in the inner nuclear layer.

The *outer molecular layer* is thin, and is composed mainly of the arborisations of the inner granules and of the rod and cone-fibres (fig. 301, 5).

As far as the outer molecular layer the retina may be said to consist of nervous elements, but beyond this layer it is formed of modified epithelium-cells.



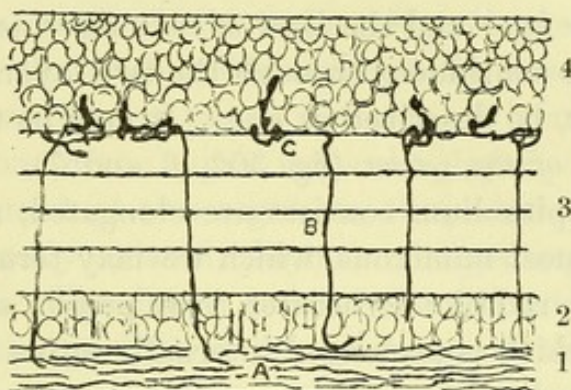


FIG. 299.—SECTION THROUGH THE INNER LAYERS OF THE RETINA OF A BIRD, PREPARED BY GOLGI'S METHOD. (R. y Cajal.)

A, nerve-fibres of optic nerve layer; B, some of these fibres passing through the inner molecular layer to end in an arborisation at the junction of the inner molecular and inner nuclear layers. The layers in this and in the two succeeding cuts are numbered in correspondence with the layers in fig. 297.

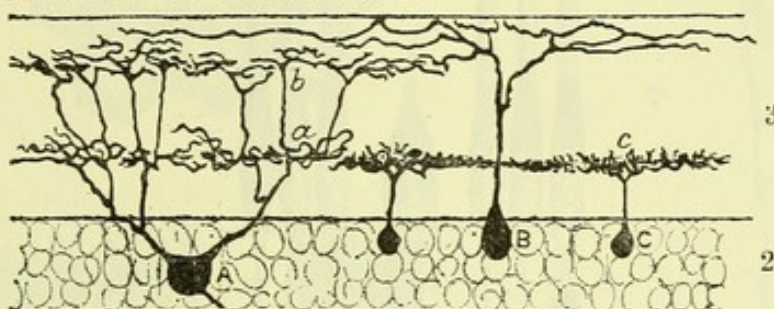


FIG. 300.—SECTION ACROSS THE MOLECULAR AND GANGLIONIC LAYERS OF BIRD'S RETINA, PREPARED BY GOLGI'S METHOD. (R. y Cajal.)

Three or four ganglionic cells, A, B, C, and the terminal arborisations of their dendrons, *a*, *b*, *c*, in the molecular layer, are shown.

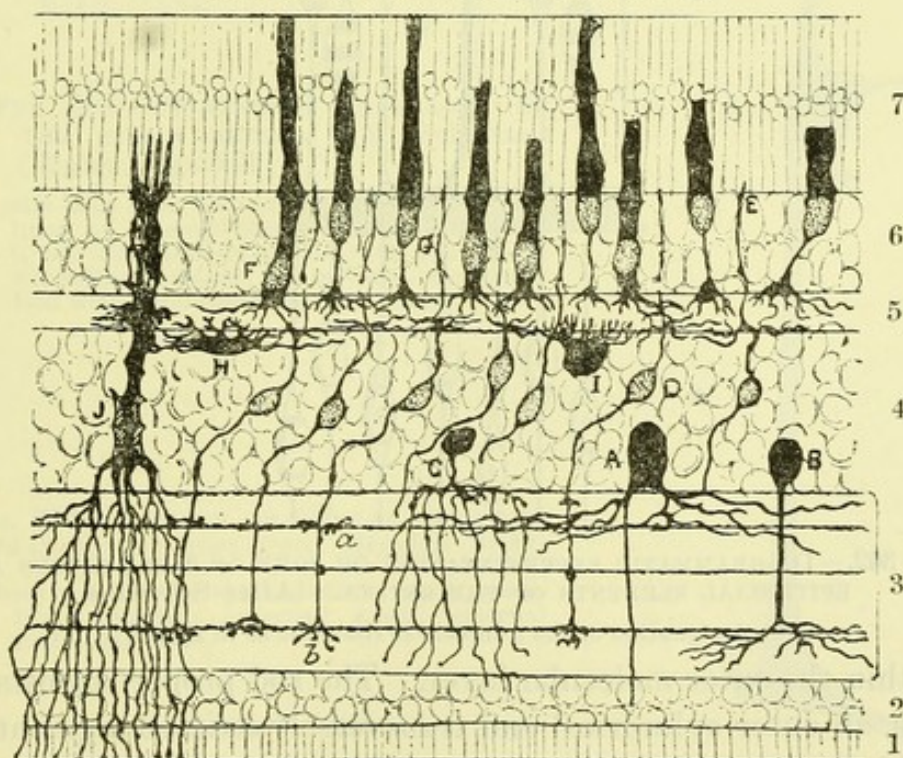


FIG. 301.—SECTION OF BIRD'S RETINA, PREPARED BY GOLGI'S METHOD. (R. y Cajal.)

A, B, large nerve-cells of inner nuclear layer; C, neuroglia-cell; D, small bipolar nerve-cells with one process, *a*, *b*, ramifying in the inner molecular layer and the other one ramifying in the outer molecular layer, and extending (E) as far as the rods and cones; F, G, rod and cone nuclei respectively; H, I, cells with dendrons ramifying in outer molecular layer; J, fibre of Müller.



The *outer nuclear layer* and the *layer of rods and cones* are composed of elements which are continuous through the two layers, and they should properly, therefore, be described as one. It may be termed the *sensory* or *nerve-epithelium of the retina* (fig. 302, 6 and 7). The elements of which this nerve-epithelium consists are elongated, nucleated cells of two kinds. The most numerous, which we may term the *rod-elements*, consist of peculiar rod-like structures (*rods proper*) set closely side by side, and each of which is prolonged internally into a fine varicose fibre (*rod-fibre*) which swells out at one part of its course into a nucleated enlargement, and ultimately ends (in mammals) in a knob-like enlarge-

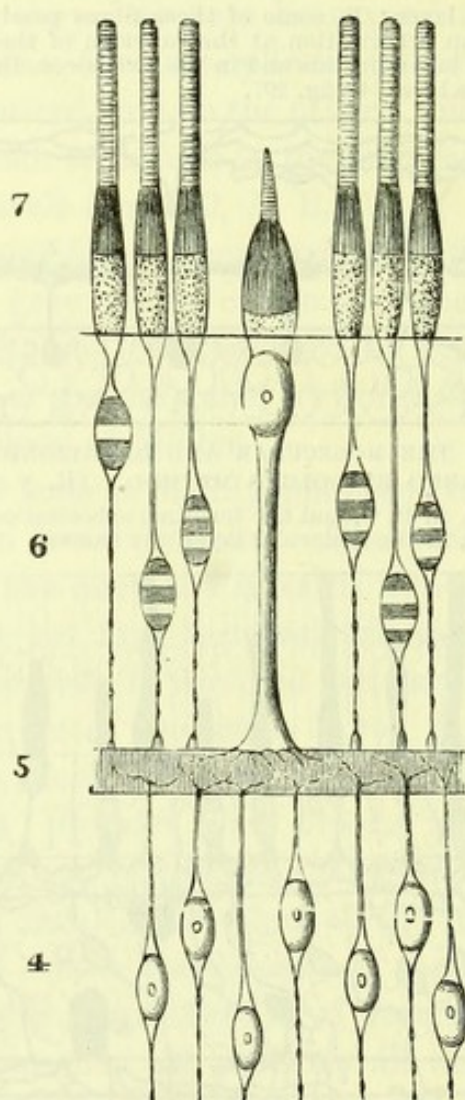


FIG. 302.—DIAGRAMMATIC REPRESENTATION OF SOME OF THE NERVOUS AND EPITHELIAL ELEMENTS OF THE RETINA. (After Schwalbe.)

The designation of the numbers is the same as in fig. 297.

ment within the outer molecular layer. The rod proper consists of two segments, an outer cylindrical and transversely striated segment, which during life has a purplish-red colour, and an inner slightly bulged segment which in part of its length is longitudinally striated. The nucleus of the rod-element often has, in the fresh condition, a transversely shaded aspect (fig. 302). The *cone-elements* are formed of a conical tapering ex-



ternal part, the *cone proper*, which is directly prolonged into a nucleated enlargement, from the farther side of which the *cone-fibre*, considerably thicker than the rod-fibres, passes inwards, to terminate by an expanded arborisation in the outer molecular layer. The cone proper, like the rod, is formed of two segments, the outer of which, much the smaller, is transversely striated, the inner, bulged segment being longitudinally striated. The inner ends of the rod and cone-fibres come in contact with the peripheral arborisations of the inner granules,

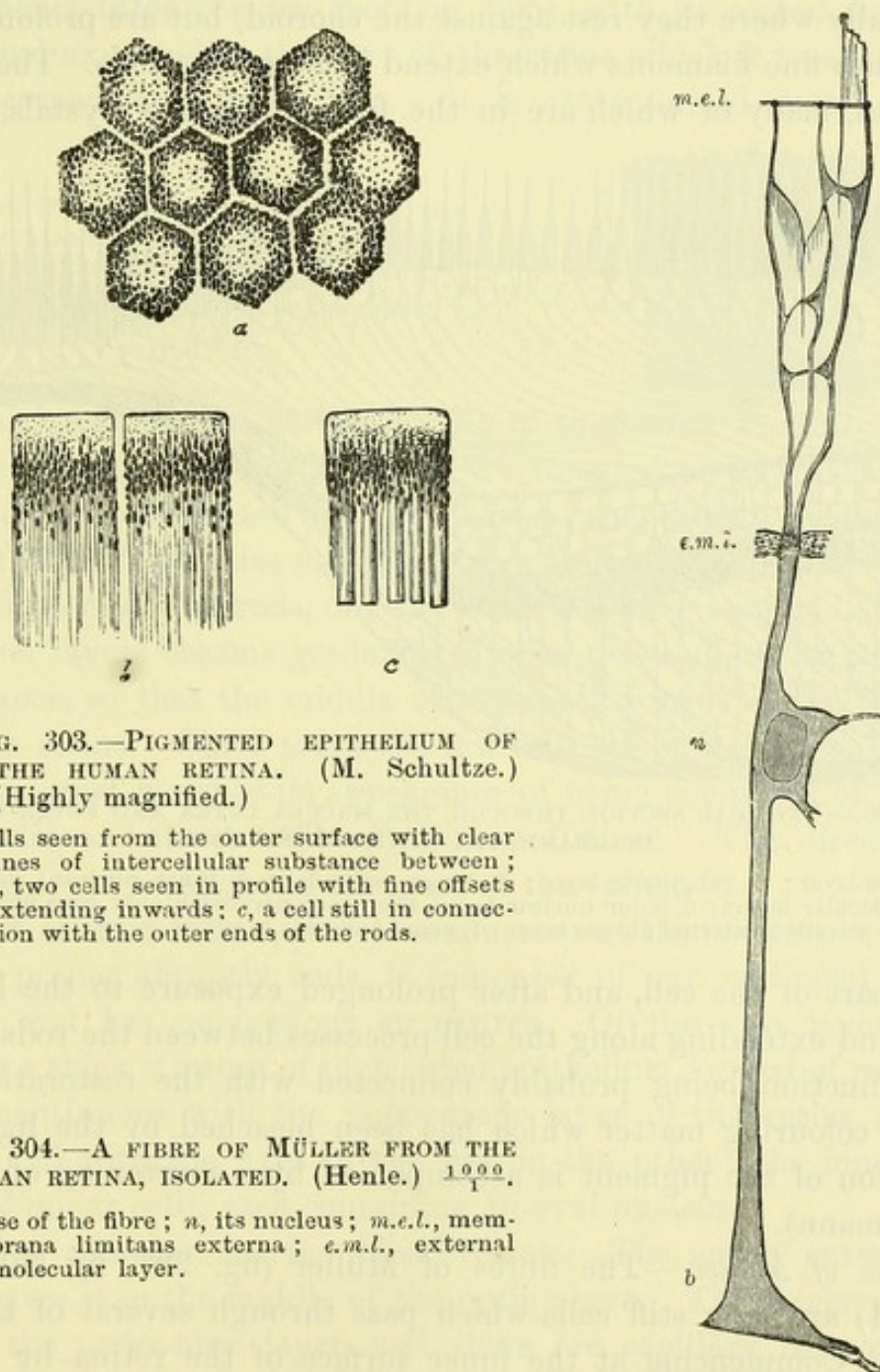


FIG. 303.—PIGMENTED EPITHELIUM OF THE HUMAN RETINA. (M. Schultze.) (Highly magnified.)

*a*, cells seen from the outer surface with clear lines of intercellular substance between; *b*, two cells seen in profile with fine offsets extending inwards; *c*, a cell still in connection with the outer ends of the rods.

FIG. 304.—A FIBRE OF MÜLLER FROM THE HUMAN RETINA, ISOLATED. (Henle.)  $\frac{1000}{1}$ .

*b*, base of the fibre; *n*, its nucleus; *m.e.l.*, membrana limitans externa; *e.m.l.*, external molecular layer.

and through these elements and their arborisations in the inner molecular layer a connection is probably brought about with the ganglionic cells and nerve-fibres of the innermost layers. There appears, however, to be no anatomical continuity between the several



elements, but merely an interlacement of ramified fibrils (fig. 301). In birds, reptiles, and amphibia, a small oil-globule, often brightly coloured red, yellow, or green, is found in the inner segment of each cone, and other variations of structure are met with in animals. The cones are most numerous at the back of the retina; they are fewer in number, and the rods are proportionally more numerous, towards the anterior part.

The *pigmentary layer* forms the most external part of the retina. It consists of hexagonal epithelium-cells (fig. 303), which are smooth externally where they rest against the choroid, but are prolonged internally into fine filaments which extend between the rods. The pigment-granules, many of which are in the form of minute crystals, lie in the

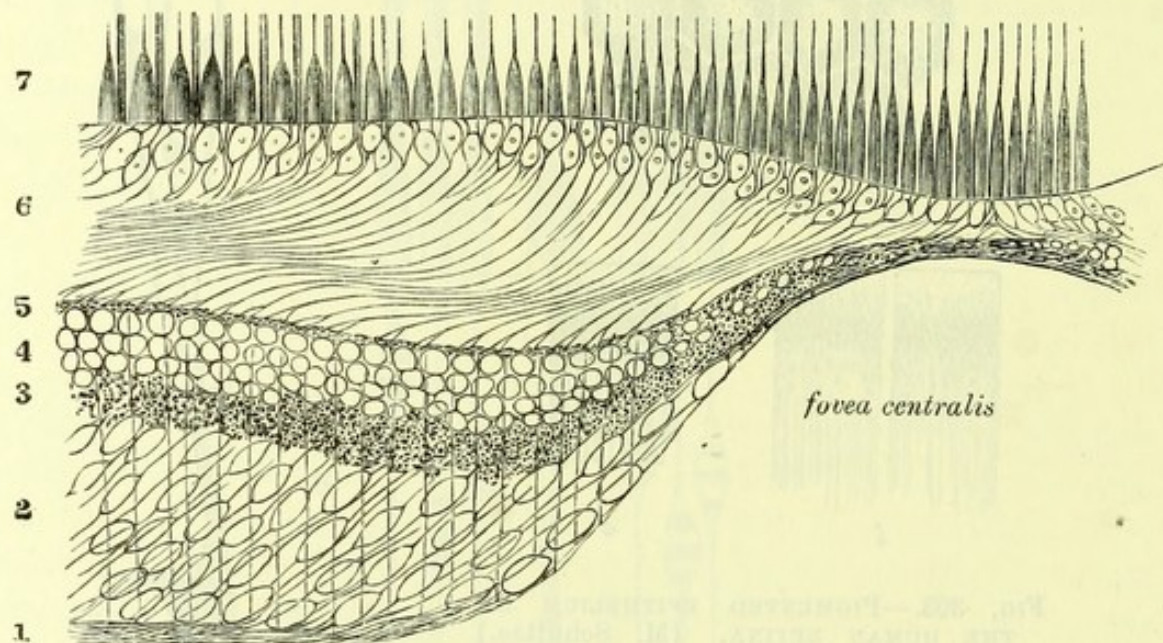


FIG. 305.—VERTICAL SECTION THROUGH THE MACULA LUTEA AND FOVEA CENTRALIS; DIAGRAMMATIC. (After M. Schultze.)

1, nerve-layer; 2, ganglionic layer; 3, inner molecular; 4, inner nuclear; and 5, outer molecular layers; 6, outer nuclear layer, the inner part with only cone-fibres forming the so-called external fibrous layer; 7, cones and rods.

inner part of the cell, and after prolonged exposure to the light they are found extending along the cell-processes between the rods (Kühne), their function being probably connected with the restoration of the purple colouring matter which has been bleached by the light. This extension of the pigment is accompanied by a shortening of the cones (Engelmann).

*Fibres of Müller.*—The fibres of Müller (fig. 297, fig. 301, *J*, and fig. 304) are long stiff cells which pass through several of the retinal layers. Commencing at the inner surface of the retina by expanded bases which unite with one another to form the so-called internal limiting membrane (fig. 297), they pass through all the layers in succession, until they reach the outer nuclear layer. Here they branch and expand into a sort of honeycomb tissue which serves to support the



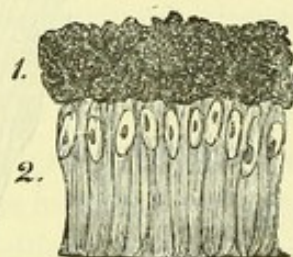
fibres and nuclei of the rod and cone-elements. At the bases of the rods and cones, this sustentacular tissue ceases, being here bounded by a distinct margin which has been called the external limiting membrane (fig. 304, *m.e.l.*), but delicate sheaths pass from it around the bases of the rods and cones. Each Müllerian fibre, as it passes through the inner nuclear layer, has a nucleated enlargement (*n*), indicating the cell-nature of the fibre.

There are two parts of the retina which call for special description.

The **macula lutea** (yellow spot, fig. 305), with its *central fovea*, lies in the visual axis, and is the part of the retina which is most immediately concerned in direct vision. It is characterised firstly by its

FIG. 306.—A SMALL PORTION OF THE CILIARY PART OF THE RETINA. (Kölliker.) (350 diameters.)

1, pigment-cells; 2, columnar-cells.



greater thickness (except at the middle of the fovea), secondly by the large number of ganglion-cells, which are rounded or conical, not oval and oblique as represented in the diagram, and thirdly by the large number of cones it contains as compared with the rods. In the central fovea itself there are no rods, and the cones are very long and slender; all the other layers become gradually thinned down almost to complete disappearance, so that the middle of the central fovea is the thinnest part of the retina. Since there are few rods, the outer nuclear layer (6) loses in great measure its appearance of being composed of closely packed nuclei, and the cone-fibres are very distinct. The direction of these fibres is very oblique in this part of the retina.

The **pars ciliaris retinæ**, which commences at the *ora serrata*, where the retina proper abruptly ends, is composed of two epithelial layers (fig. 306), and has no nervous structures. Of the two layers, the external is a thick stratum of pigmented epithelium formed of rounded cells and continuous with the pigmentary layer of the retina on the one hand, and with the uvea of the iris on the other; the inner is a layer of columnar cells, each containing an oval nucleus.

The retina contains but few blood-vessels. The artery enters and the vein leaves it in the middle of the optic nerve. The larger vessels ramify in the nerve-fibre layer, and there are capillary networks in this layer and in the inner nuclear layer. There are perivascular lymphatic spaces around the veins and capillaries. The sensory epithelium receives no blood-vessels, but is nourished from the vessels of the choroid.



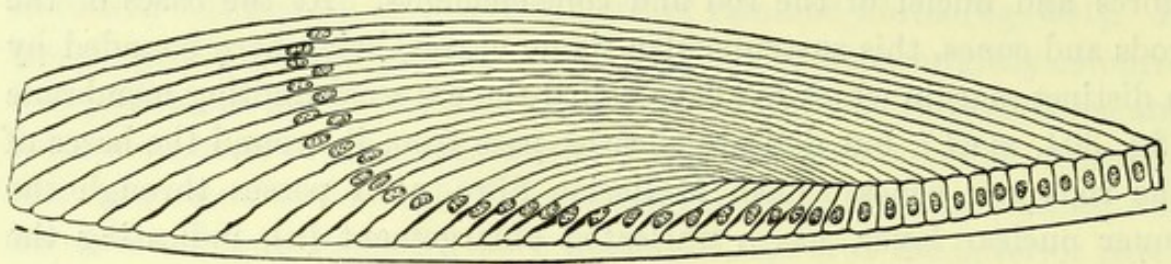


FIG. 307.—SECTION THROUGH THE MARGIN OF THE RABBIT'S LENS, SHOWING THE TRANSITION OF THE EPITHELIUM INTO THE LENS-FIBRES. (Babuchin.)

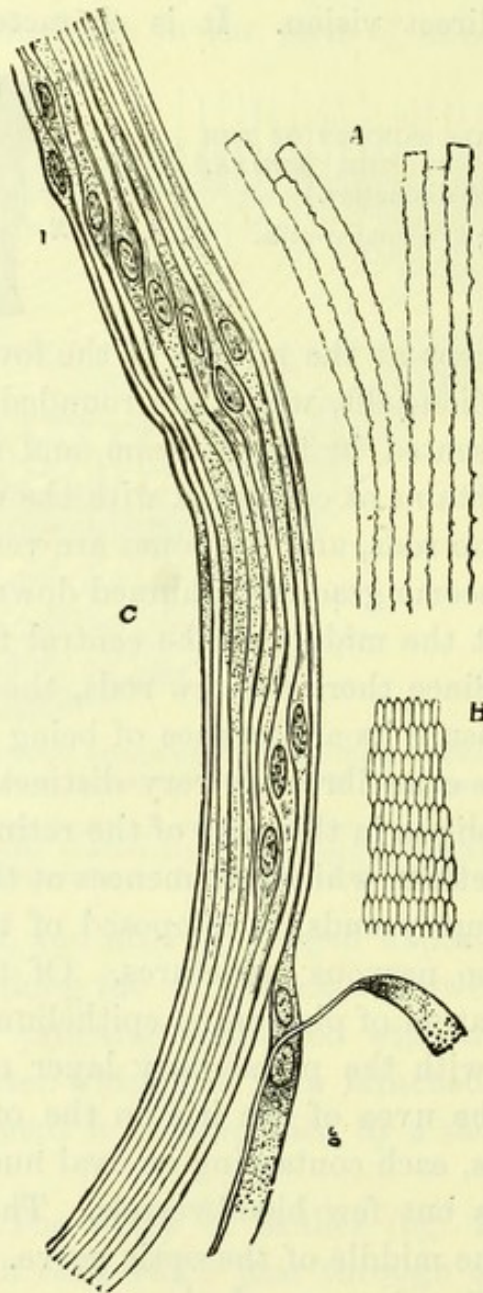


FIG. 308.—FIBRES OF THE CRYSTALLINE LENS. (350 diameters.)

- A, longitudinal view of the fibres of the lens from the ox, showing the serrated edges. B, transverse section of the fibres of the lens from the human eye. C, longitudinal view of a few of the fibres from the equatorial region of the human lens. Most of the fibres in C are seen edgewise, and, towards 1, present the swellings and nuclei of the 'nuclear zone'; at 2, the flattened sides of two fibres are seen. (A and B from Kölliker; C from Henle.)



**Structure of the lens.**—The lens is a laminated fibrous body inclosed by a transparent elastic capsule to which, around the circumference, the fibres of the suspensory ligament are attached. Immediately within the capsule, in front and at the sides, there is a layer of cubical epithelium termed the epithelium of the capsule, but at the margin of the lens the cells become longer and pass by a gradual transition into the lens-fibres (fig. 307). The *fibres* which compose the lens are long and riband-shaped, with finely serrated edges (fig. 308, A); in transverse section they appear prismatic (B). Many of the superficial fibres are nucleated (c), the lens-fibres having originally been developed by the elongation of epithelium-cells.

The **vitreous humour** is composed of soft gelatinous tissue, apparently structureless when examined in the fresh condition, but containing fibres and a few scattered amoeboid cells, the processes of which are often long and varicose, and the cell-bodies distended by large vacuoles. The *hyaloid membrane*, which invests the vitreous humour, is homogeneous and structureless except in the region of the ciliary processes, where it is fibrous in structure, forming the zonule of Zinn and spreading out into the suspensory ligament of the lens. This part of the hyaloid membrane is connected with a circular fibrous portion of the vitreous humour which serves to give additional firmness to the attachment of the fibres of the suspensory ligament of the lens (A. Stuart).



## LESSON XLIV.

*STRUCTURE OF THE OLFACTORY MUCOUS MEMBRANE  
AND OF THE EXTERNAL AND MIDDLE EAR.*

1. VERTICAL sections of the olfactory mucous membrane. The sections may be carried either across the upper turbinate bone, after decalcification in 0·2 per cent. chromic acid, or across the upper part of the nasal septum. Make a sketch under the low power. Notice the difference in the character of the epithelium in the olfactory and respiratory parts of the membrane.

2. Teased preparation of the epithelium of the olfactory mucous membrane. A piece of the membrane is placed quite fresh in osmic acid (1 per cent.) for a few hours, and is then macerated for two days or more in water. The epithelium is broken up in dilute glycerine; the cells easily separate from one another on tapping the cover-glass. Notice the two kinds of cells. Sketch some of the cells under a high power.<sup>1</sup>

3. Sections of the external ear (these have been already studied for the cartilage, Lesson XII.).

4. Sections across the cartilaginous part of the Eustachian tube. Sketch under the low power.

5. Preparation of the membrana tympani. A piece of the membrane, stained with hæmatoxylin, and mounted flat in Canada balsam.

Determine the composition of the membrane—*i.e.* the several layers composing it—by focussing carefully with the high power.

*STRUCTURE OF THE OLFACTORY MUCOUS MEMBRANE.*

The **olfactory region** of the nasal fossæ includes the upper and middle turbinate processes and the upper third of the septum. It is covered by a soft vascular mucous membrane of a yellow colour in man.

The *epithelium* of the olfactory mucous membrane (figs. 309, 310) is very thick and is composed of long tapering cells, set closely side by side and bounded superficially by a cuticular lamina, through which the free ends of the cells project. The cells are of two kinds: 1. Long narrow spindle-shaped or bipolar cells consisting of a larger part or body (*b*), containing the nucleus, and of two processes or poles, one (*c*) straight and cylindrical and extending to the free surface, the other (*d*)

<sup>1</sup> For investigating the connection of the olfactory cells with the olfactory nerve-fibres, the method of Golgi must be employed.



very delicate and varicose, looking not unlike a nerve-fibril and extending down towards the corium. The position of the nuclear enlargement varies, and with it the relative length of the two processes. The distal or free process terminates in a small clear projection, which passes beyond the cuticular membrane; in amphibia, reptiles, and birds, and

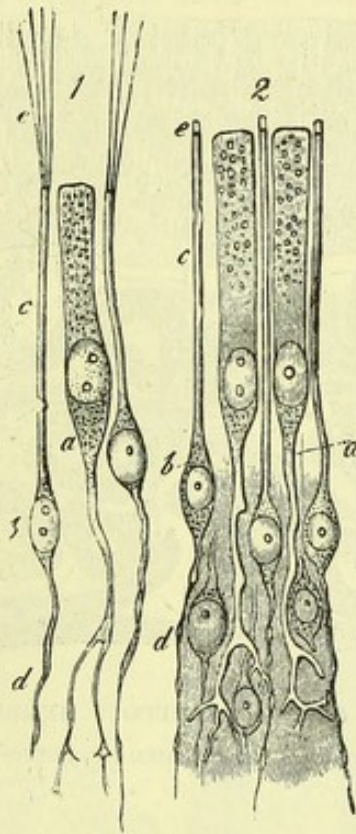


FIG. 309.—CELLS AND TERMINAL NERVE-FIBRES OF THE OLFATORY REGION.  
(M. Schultze.) (Highly magnified.)

1, from the frog; 2, from man; *a*, epithelial cell, extending deeply into a ramified process; *b*, olfactory cells; *c*, their peripheral rods; *e*, their extremities, seen in 1 to be prolonged into fine hairs; *d*, their central filaments.

perhaps in some mammals, it bears fine stiff hairlike filaments (*e*). The proximal or varicose process becomes lost amongst the plexus of olfactory nerve-fibrils at the base of the epithelium; it is connected with one of the fibrils and ultimately passes through the cribriform plate of the ethmoid to end in an arborisation within one of the olfactory glomeruli (see diagram, fig. 285, p. 252). These cells have been termed *olfactory cells*. 2. Long columnar epithelium-cells (*a*), with comparatively broad cylindrical nucleated cell-bodies placed next the free surface, and long, forked, and branching tail-like processes extending down to the corium. These are usually regarded not as sensory epithelium-cells, but merely as serving to support the proper olfactory cells. They are the *columnar* or *sustentacular cells*. 3. Tapering cells are present, at least in some animals, in the deeper part of the epithelium. They rest by their bases upon the corium, and project between the other cells, which they assist to support.



The *corium* of the olfactory mucous membrane is also very thick (fig. 310). It contains numerous blood-vessels, bundles of the olfactory nerve-fibres (which are non-medullated), and a large number of serous glands known as *Bowman's glands* (*b*), which open upon the surface by fine ducts passing between the epithelium-cells.

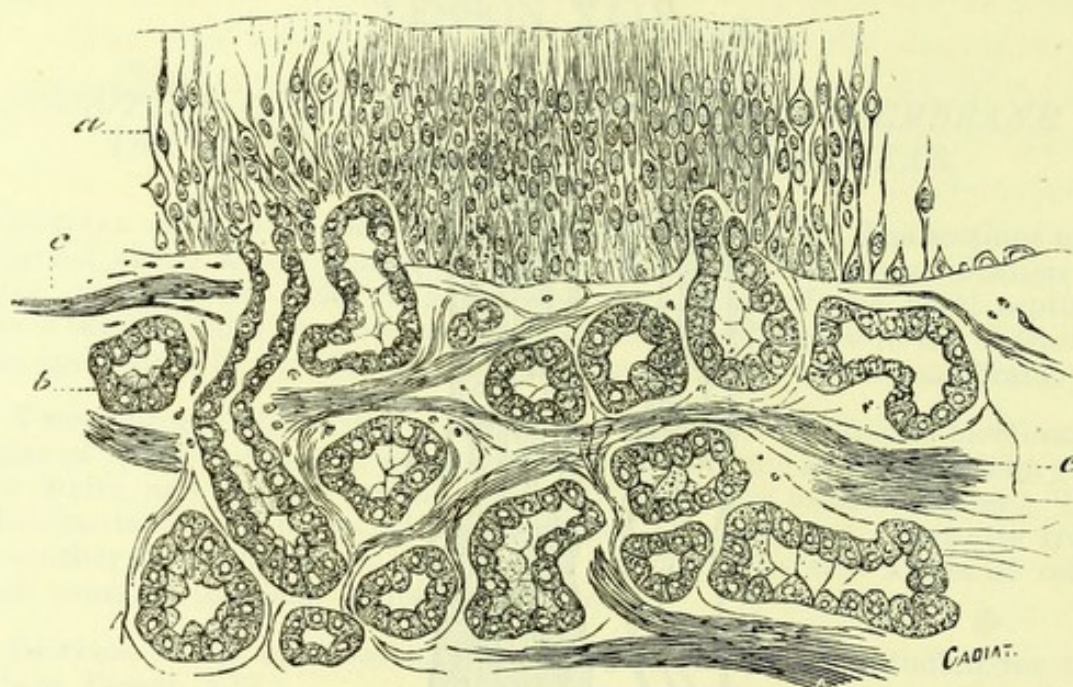


FIG. 310.—SECTION OF OLFACTORY MUCOUS MEMBRANE. (Cadiat.)

*a*, epithelium ; *b*, glands of Bowman ; *c*, nerve-bundles.

### STRUCTURE OF THE AUDITORY ORGAN.

The **external ear** proper (*pinna*) is composed of elastic fibro-cartilage, invested by a thin, closely adherent skin. The skin is covered by small hairs, and connected with these are the usual sebaceous follicles. In some parts—*e.g.* the lobule—there is a considerable amount of adipose tissue ; and voluntary muscular fibres are in places attached to the cartilage, and may therefore be seen in sections of the ear.

The **external auditory meatus** is a canal formed partly of cartilage continuous with that of the pinna, partly of bone. It is lined by a prolongation of the skin and is closed by the *membrana tympani*, over which the skin is prolonged as a very thin layer. Near the orifice the skin has hairs and sebaceous glands, and the meatus is also provided throughout the cartilaginous part with small convoluted tubular glands of a brownish-yellow colour, which yield a waxy secretion (*ceruminous glands*). They appear to represent modified sweat-glands.

The **tympanum** is lined by a mucous membrane which is continuous through the Eustachian tube with the mucous membrane of the pharynx ; it is also prolonged into the mastoid cells. The epithelium



is columnar and ciliated in some parts, but in others—*e.g.* roof, promontory, ossicles, and membrana tympani—it is a pavement-epithelium.

The **membrana tympani** is a thin membrane formed of fibrous bundles which radiate from the umbo. Within the radial fibres are a few annular bundles. Covering the fibrous membrane externally is a thin layer continuous with the skin of the meatus; covering it internally is another thin layer, derived from the mucous membrane of the tympanic cavity. Blood-vessels and lymphatics are distributed to the membrane chiefly in the cutaneous and mucous layers.

The **Eustachian tube** is the canal leading from the tympanum to the pharynx. It is formed of bone near the tympanum, but below, near

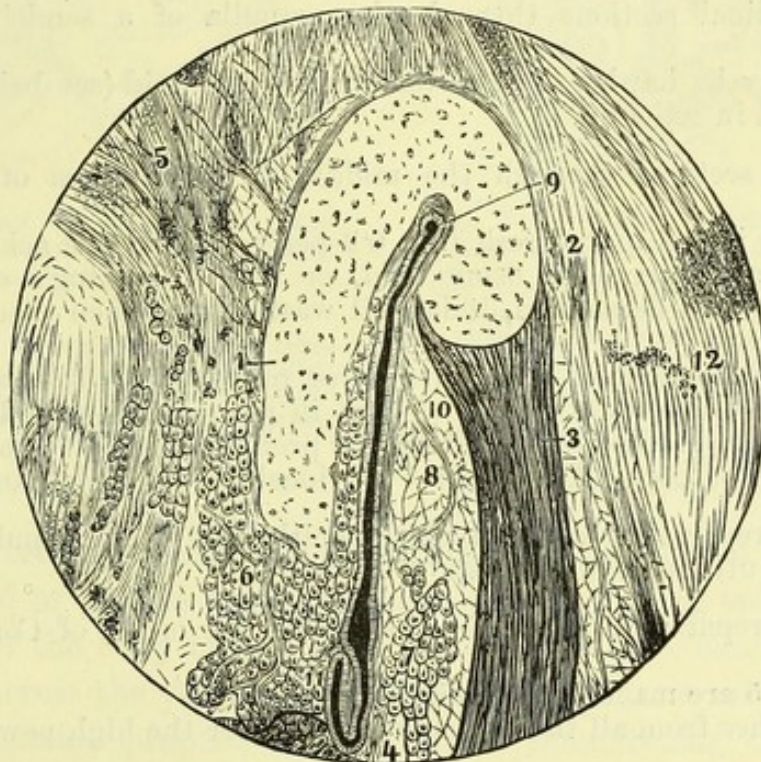


FIG. 311.—SECTION ACROSS THE CARTILAGINOUS PART OF THE EUSTACHIAN TUBE.  
(Rüdinger.)

- 1, 2, bent cartilaginous plate; 3, muse. dilatator tubæ; to the left of 4, part of the attachment of the levator palati muscle; 5, tissue uniting the tube to the base of the skull; 6 and 7, mucous glands; 8, 10, fat; 9 to 11, lumen of the tube; 12, connective tissue on the lateral aspect of the tube.

the pharynx, it is bounded partly by a bent piece of cartilage (fig. 311, 1, 2), partly by fibrous tissue. The latter contains numerous mucous glands (6, 7), which open into the tube, and on the outer side a band of muscular tissue (3) which joins the tensor palati. The epithelium is ciliated.



## LESSON XLV.

## STRUCTURE OF THE LABYRINTH.

1. SECTIONS across one of the membranous semicircular canals of a fish (skate).

2. Longitudinal sections through the ampulla of a semicircular canal (skate).

1 and 2 may be hardened in chromic and osmic acid (see below under 3) and embedded in celloidin.

3. Vertical sections through the middle of the cochlea of a mammal (guinea-pig).

The cochlea is put quite fresh into 0.2 per cent. chromic acid containing a few drops of 1 per cent. osmic acid, or into Flemming's solution (see Appendix). When decalcified, it is well washed, and then placed in spirit for a day or more.

In preparing sections of the above three preparations it is advisable, in order that the epithelium should be kept in position, to embed in celloidin or, if the paraffin method of embedding be preferred, to fix them to the slide by an adhesive process. They should previously be stained in bulk.

4. Teased preparations of the auditory epithelium of an ampulla or of the macula of the utricle, from the fish.

5. Teased preparations of the epithelium of the organ of Corti from the guinea-pig.

Both 4 and 5 are made from osmic preparations.

Make sketches from all these preparations under the high power.<sup>1</sup>

The **labyrinth**, which is the essential part of the auditory organ, consists of a complex membranous tube lined by epithelium and filled with endolymph, contained within a bony tube—the osseous labyrinth—of corresponding complexity of shape (figs. 312, 313). The membranous labyrinth does not wholly fill the bony cavity; the rest of the space is occupied by perilymph. The membranous labyrinth (fig. 312) is composed of the *utricle* (*u*), and the three *semicircular canals*, each with an enlargement or ampulla which opens into it, the *sacculæ* (*s*) and the *canal of the cochlea* (*c.c.*).

The branches of the auditory nerve pass to certain parts only of the membranous labyrinth, viz.—the maculæ of the utricle and sacculæ;

<sup>1</sup>For the methods of obtaining the various parts of the labyrinth for microscopical examination, the reader is referred to the author's *Course of Practical Histology*.



the cristæ of the ampullæ, and along the whole length of the canal of the cochlea (the shaded parts in fig. 312).

At these places the lining epithelium is specially modified to form a sensory or nerve-epithelium; elsewhere it is a simple pavement-epithelium.

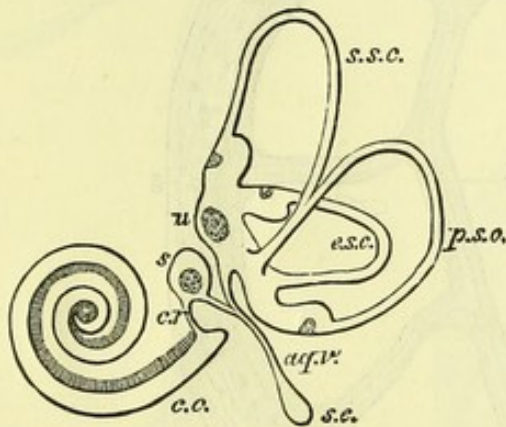


FIG. 312.—PLAN OF THE RIGHT MEMBRANOUS LABYRINTH VIEWED FROM THE MESIAL ASPECT.  $\frac{2\frac{1}{2}}{1}$ .

*u*, utricle, with its macula and the three semicircular canals with their ampullæ; *s*, saccule; *aq.v.*, aquæductus vestibuli; *s.e.*, saccus endolymphaticus; *c.r.*, canalis reuniens; *c.c.*, canal of the cochlea.

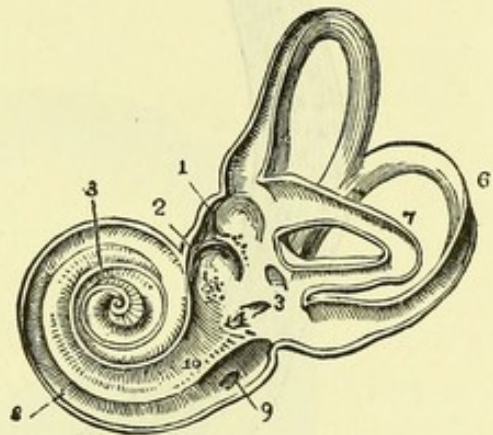


FIG. 313.—VIEW OF THE INTERIOR OF THE LEFT OSSEOUS LABYRINTH.

The bony wall of the labyrinth is removed superiorly and externally. 1, fovea hemielliptica; 2, fovea hemispherica; 3, common opening of the superior and posterior semicircular canals; 4, opening of the aqueduct of the vestibule; 5, the superior, 6, the posterior, and, 7, the external semicircular canals; 8, spiral tube of the cochlea; 9, scala tympani; 10, scala vestibuli.

The membranous semicircular canals and the utricle and saccule are composed of fibrous tissue, which is adherent along one side to the endosteum of the bony canal; from the opposite side bands of fibrous tissue pass across the perilymph. Within the fibrous membrane is a thick clear tunica propria, which, in the semicircular canals, forms papillary elevations in the interior of the tube (figs. 314, 315).

The places of entrance of the nerve-fibres into the ampullæ are marked by a transverse, inwardly projecting ridge (*crista*), in the saccule and utricle by a thickening of the tunica propria (*macula*). The epithelium at these places is formed of columnar cells (fig. 316), which are surmounted by long, stiff, tapering hairs (*auditory hairs*, fig. 316, *h*), and around these *hair-cells* the axis-cylinders of the nerve-fibres ramify (fig. 317); they are therefore—like the rod and cone-elements of the retina, the bipolar cells of the olfactory membrane, and the gustatory cells of the taste-buds—sensory or nerve-epithelium cells. Between them are a number of thin and somewhat rigid nucleated cells (*fibre-cells* of Retzius, fig. 317, *f*), which rest upon the basement-membrane, and are connected at their free extremity with a cuticular membrane, through which the auditory hairs project.



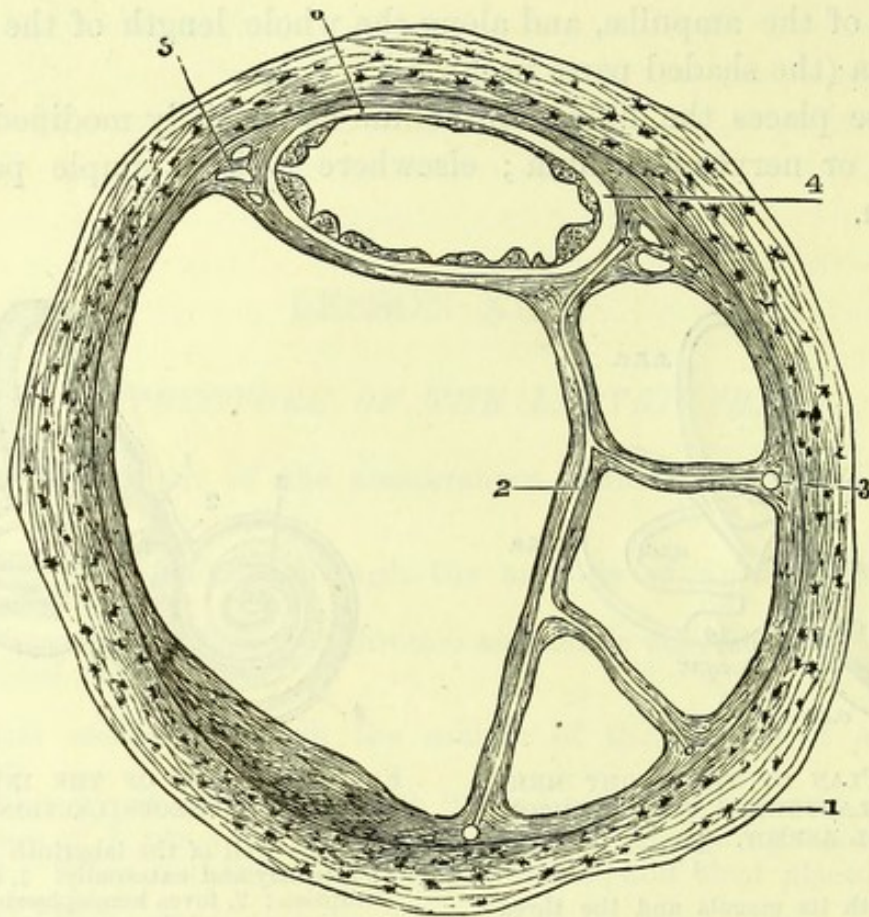


FIG. 314.—SECTION OF ONE OF THE HUMAN SEMICIRCULAR CANALS. (Rüdinger.)  
(Magnified.)

1, osseous wall; 2, fibrous bands with included blood-vessels, united at 3 with the periosteum; 4, membranous canal with its three layers; 5, short fibrous bands (with intervening spaces) uniting the membranous canal firmly to the periosteum; 6, union of its outermost layer with the periosteum.

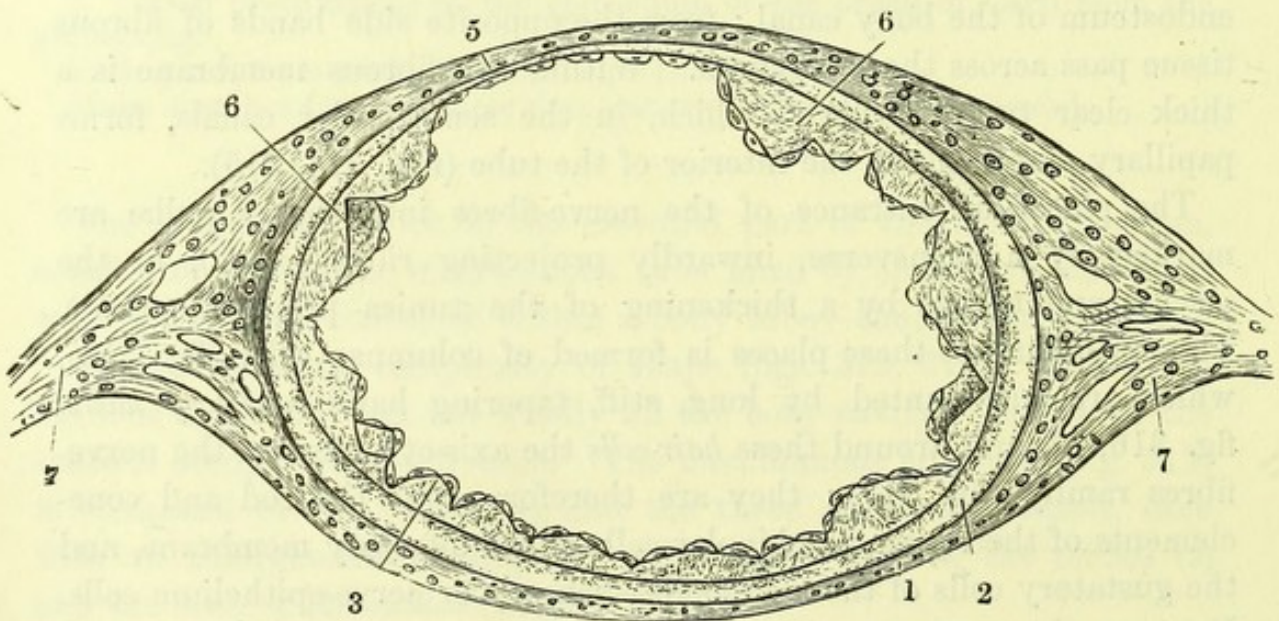


FIG. 315.—SECTION OF MEMBRANOUS SEMICIRCULAR CANAL. (Rüdinger.)  
(Much magnified.)

1, outer fibrous layer; 2, tunica propria; 3, 6, papilliform projections with epithelial covering; 5, fixed side of the canal, with very thin tunica propria without papillae; 7, fibrous bands passing to periosteum.



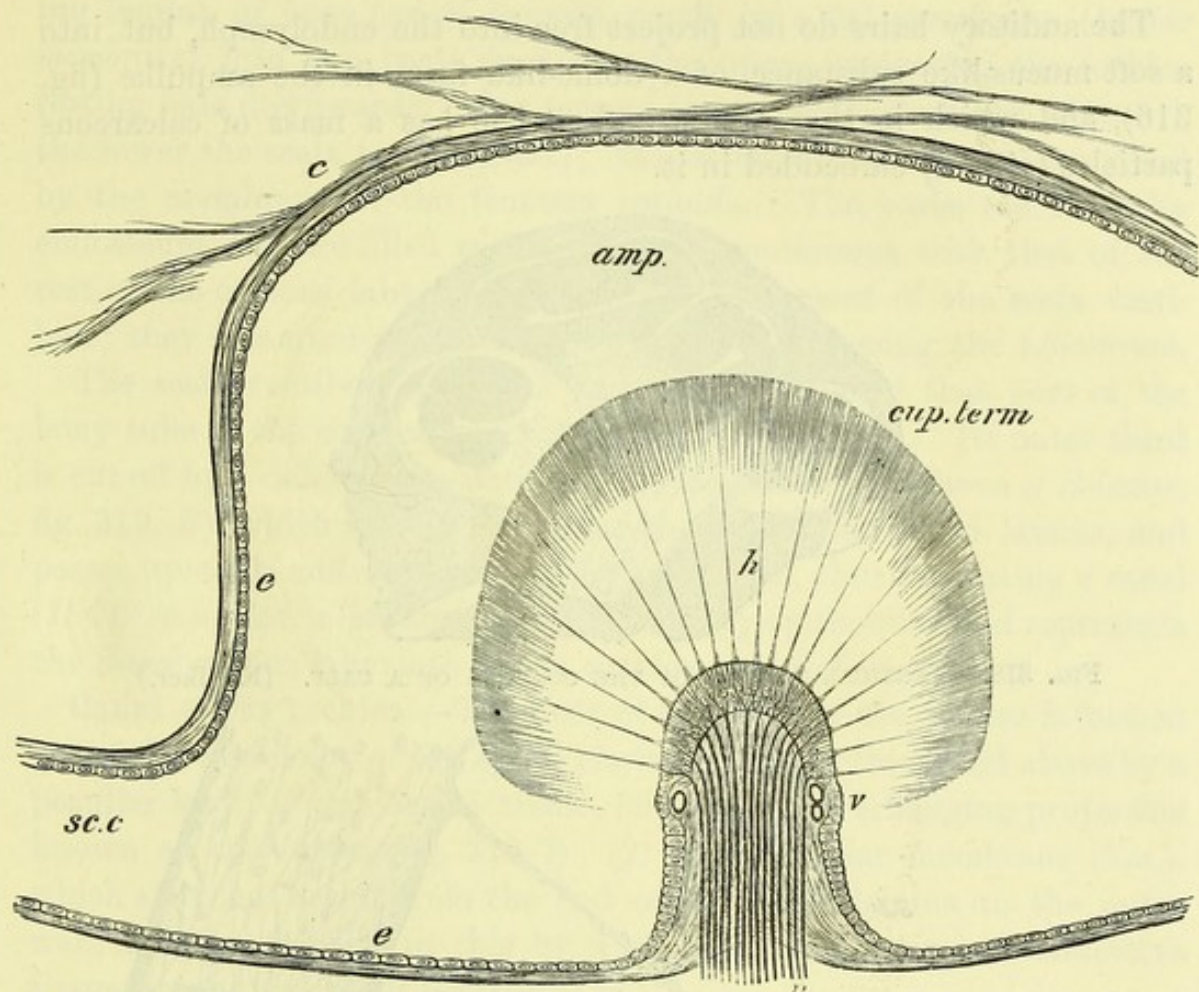


FIG. 316.—LONGITUDINAL SECTION OF AN AMPULLA THROUGH THE CRISTA ACUSTICA.

*amp.*, cavity of the ampulla; *sc.c.*, semicircular canal opening out of it; *c*, connective tissue attached to the wall of the membranous ampulla and traversing the perilymph; *e, e*, flattened epithelium of ampulla; *h*, auditory hairs projecting from the columnar cells of the auditory epithelium into the cupula, *cup. term.*; *v*, blood-vessels; *n*, nerve-fibres entering the base of the crista and passing into the columnar cells.

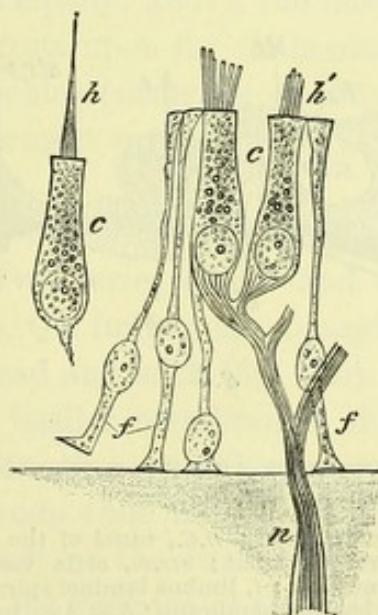


FIG. 317.—AUDITORY EPITHELIUM FROM THE MACULA ACUSTICA OF THE SACCULE OF AN ALLIGATOR. (Retzius.) (Highly magnified.)

*c, c*, columnar hair-cells; *f, f*, fibre-cells; *n*, nerve-fibre, losing its medullary sheath and apparently terminating in the columnar auditory cells: actually, however, the nerve-fibrils arborise around these cells; *h*, auditory hair; *h'*, base of auditory hairs, split up into fibrils.



The auditory hairs do not project free into the endolymph, but into a soft mucus-like substance, of a dome-like form in the ampullæ (fig. 316), and which in the saccule and utricle has a mass of calcareous particles (*otoliths*) embedded in it.

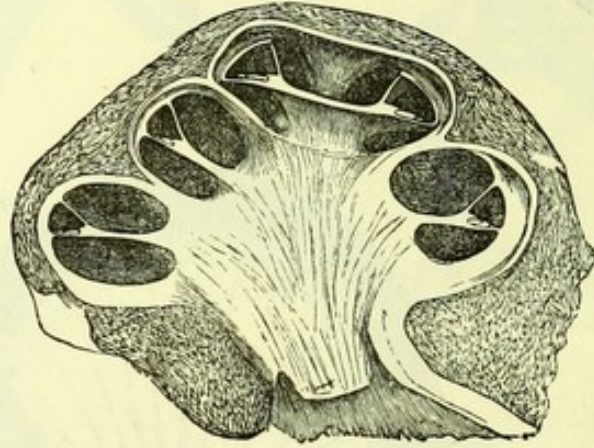


FIG. 318.—VERTICAL SECTION OF THE COCHLEA OF A CALF. (Kölliker.)

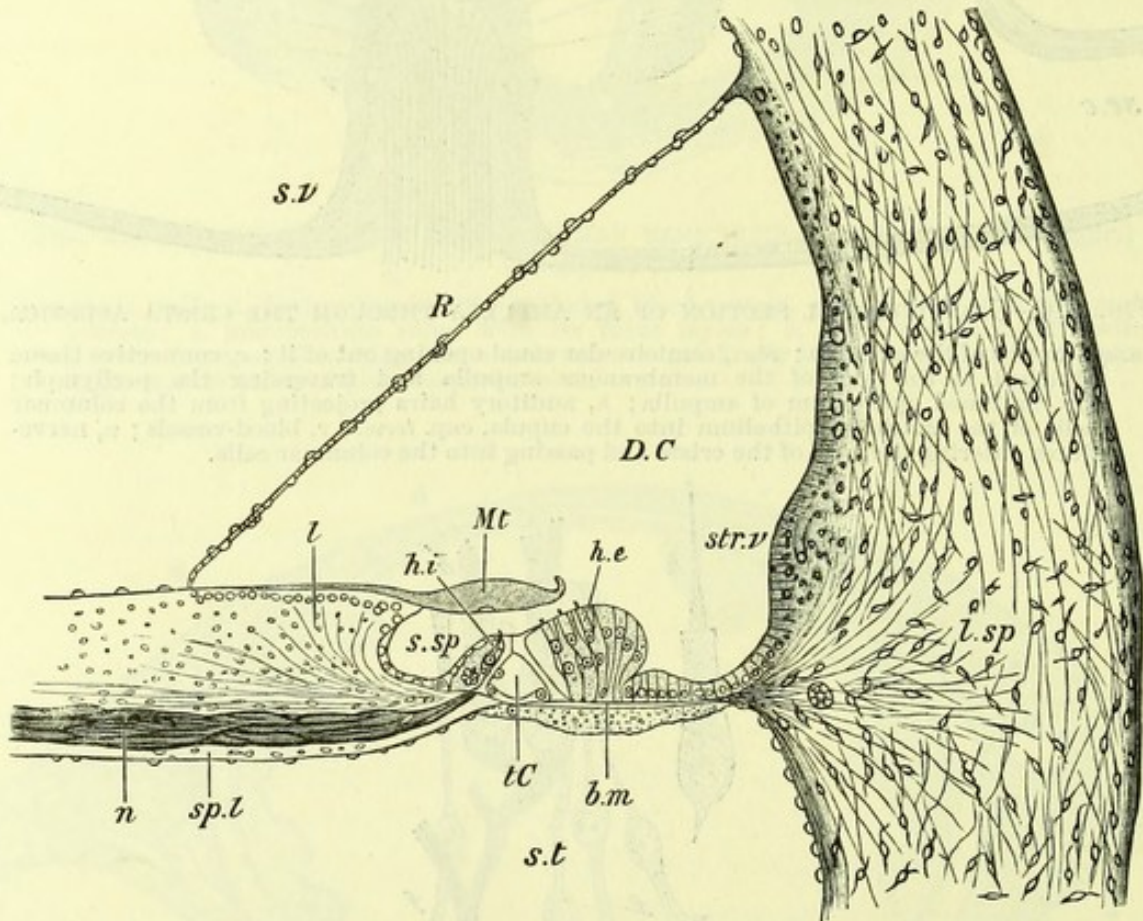


FIG. 319.—VERTICAL SECTION OF THE FIRST TURN OF THE HUMAN COCHLEA. (G. Retzius.)

*s.v.*, scala vestibuli; *s.t.*, scala tympani; *D.C.*, canal of the cochlea; *sp.l.*, spiral lamina; *n*, nerve-fibres; *l.sp.*, spiral ligament; *str.v.*, stria vascularis; *s.sp.*, spiral groove; *R*, section of Reissner's membrane; *l*, limbus laminae spiralis; *M.t.*, membrana tectoria; *t.C.*, tunnel of Corti; *b.m.*, basilar membrane; *h.i.*, *h.e.*, internal and external hair-cells.

The cochlea consists of a bony tube coiled spirally around an axis, which is known as the *columella* (fig. 318). The tube is divided longitudinally by a partition which is formed partly by a project-



ing lamina of bone (*spiral lamina*), partly by a flat membrane (*basilar membrane*), into two parts or *scalæ*; the upper (supposing the cochlea resting base downwards) being termed the *scala vestibuli* (fig. 319, *s.v.*), the lower the *scala tympani* (*s.t.*); the latter is closed at its larger end by the membrane of the fenestra rotunda. The *scalæ* are lined by endosteum, and are filled with perilymph, continuous with that of the rest of the osseous labyrinth at the commencement of the *scala vestibuli*; they communicate at the apex by a small opening, the *helicotrema*.

The *scala vestibuli* does not occupy the whole of that part of the bony tube of the cochlea which is above the partition. Its outer third is cut off by a delicate connective-tissue membrane (*membrane of Reissner*, fig. 319, *R*), which springs from near the end of the spiral lamina, and passes upwards and outwards to the outer wall, thus separating a canal (*D C*) triangular in section, which is lined by epithelium, and represents the membranous labyrinth of the cochlea (*canal of the cochlea*).

**Canal of the cochlea.**—The floor of the canal of the cochlea is formed (1) of the extremity of the spiral lamina, which is thickened above by a peculiar kind of connective tissue, forming an overhanging projection known as the *limbus* (fig. 319, *l*); (2) of the basilar membrane (*b.m.*), which stretches across from the end of the bony lamina to the outer wall, and is attached to this by a projection of reticular connective tissue termed the *spiral ligament* (*l.sp.*).

The *basilar membrane* is composed of stiff, straight fibres, which extend from within out, and are embedded in a homogeneous stratum. It is covered below by a layer of connective tissue continuous with the endosteum of the *scala tympani*; above, the modified epithelium, which forms the *organ of Corti*, rests upon it. It becomes gradually broader in the upper turns of the cochlea (rather more than twice as broad in the uppermost as in the lowermost turn), and its constituent fibres become therefore gradually longer.

The **organ of Corti** consists of the following structures:

1. The *rods of Corti*, two series (inner and outer) of stiff, striated fibres of a peculiar shape, the inner rods somewhat like a human ulna, the outer like a swan's head and neck (fig. 320). They rest by one extremity (the foot) on the basilar membrane a short distance apart, and are inclined towards one another, their larger ends (heads) being jointed together; the series of rods thus inclose a sort of tunnel, the floor of which is formed by a part of the basilar membrane. Close to their feet may usually be seen the remains of the cells from which they have been formed. The inner rods are narrower and rather more numerous than the outer. Each outer rod has a process which extends outwards and is known as the phalangeal process. This forms part of—



2. A *reticular lamina* (fig. 322, *l.r.*), which is a cuticular structure extending like a wire-net over the outer epithelium-cells of the organ of Corti, and is composed of two or three series of stiff fiddle-shaped rings (phalanges) cemented together in such a manner as to leave square or oblong apertures through which the hair-cells (see below) project.

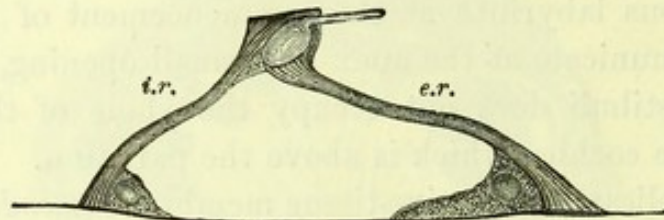


FIG. 320.—A PAIR OF RODS OF CORTI, FROM THE RABBIT'S COCHLEA, IN SIDE VIEW. (Highly magnified.)

*b, b*, basilar membrane; *i.r.*, inner rod; *e.r.*, outer rod. The nucleated protoplasmic masses at the feet are also shown.

3. The *outer hair-cells* placed external to the rods of Corti. These are epithelium-cells of columnar shape, arranged in three or four series (fig. 321, *p, q, r*). The free extremity of the cell is surmounted by a

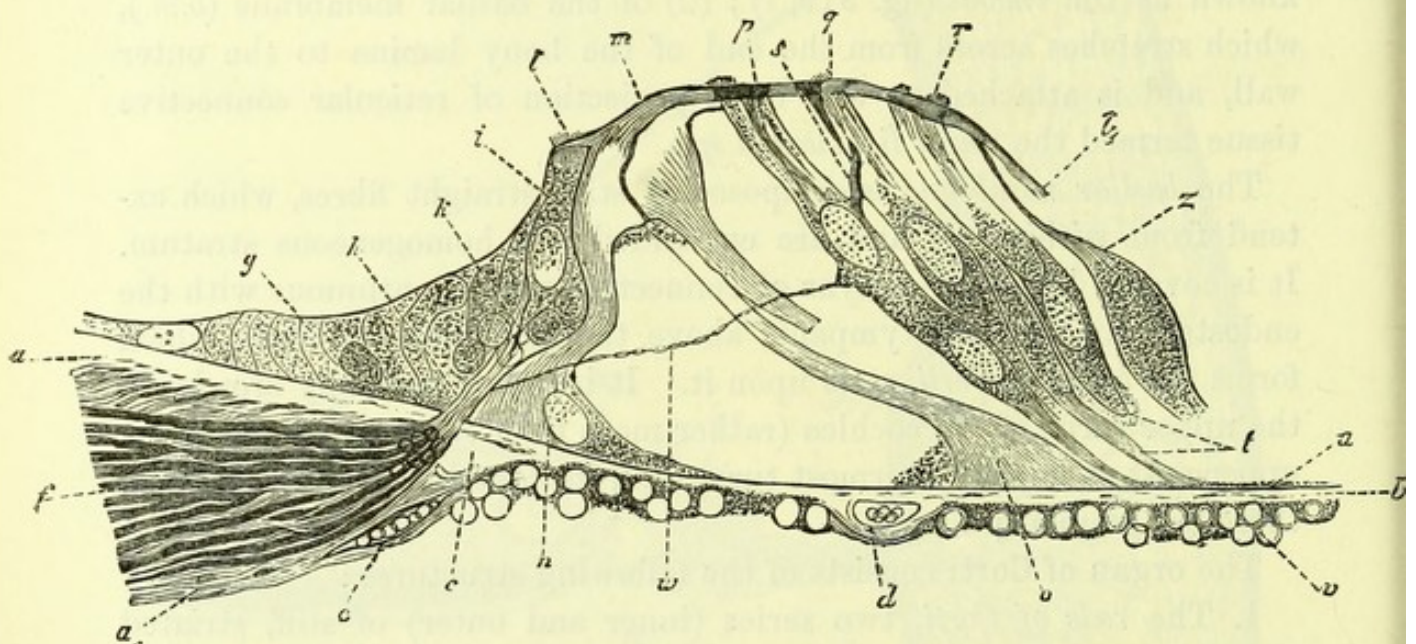


FIG. 321.—SECTION OF THE ORGAN OF CORTI OF THE DOG. (Waldeyer.)  $\frac{800}{1}$ .

*a, a'*, end of spiral lamina; *b, c*, middle (homogeneous) layer of the basilar membrane; *u*, vestibular (striated) layer; *v*, tympanal (connective-tissue) layer; *d*, blood-vessel; *f*, nerves in spiral lamina; *g*, epithelium of spiral groove; *h*, nerve-fibres passing towards inner hair-cells; *i, k*; *l, l'*, auditory hairlets on inner hair-cells; *l, l'*, lamina reticularis; *m*, heads of the rods of Corti, jointed together; *n*, base of inner rods; *o*, base of outer rod; *p, q, r*, outer hair-cells; *t*, lower ends of hair-cells; *w*, nerve-fibrils passing across the tunnel of Corti; *z*, cells of Deiters.

bundle of short *auditory hairs*, and projects through one of the apertures in the reticular lamina; the fixed extremity is prolonged into a stiff cuticular process (fig. 323, *pf*), which is attached to the basilar membrane. Between them are other supporting cells which are tapered in the same



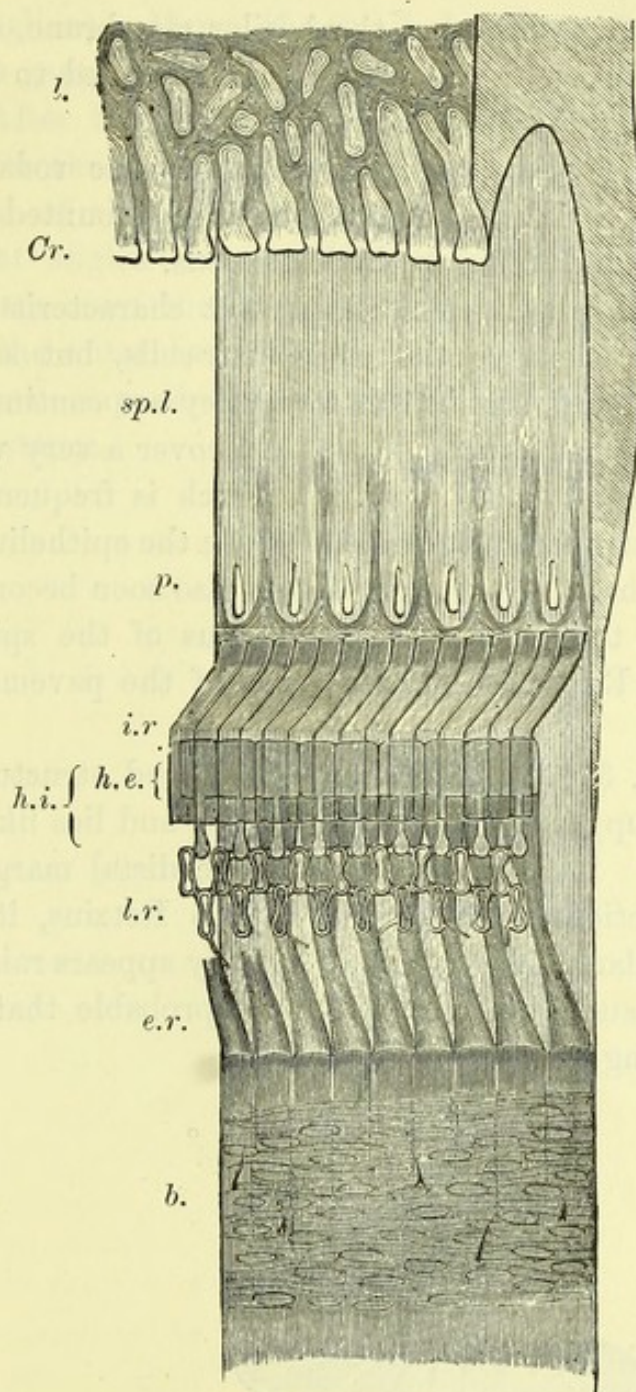
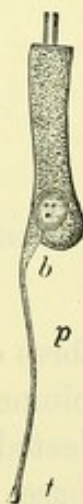

FIG. 322. — SEMI-DIAGRAMMATIC VIEW OF PART OF THE BASILAR MEMBRANE AND TUNNEL OF CORTI OF THE RABBIT, FROM ABOVE AND THE SIDE. (Much magnified.)

*l.*, limbus; *Cr.*, extremity or crest of limbus with tooth-like projections; *b.b.*, basilar membrane; *sp.l.*, spiral lamina with, *p.*, perforations for transmission of nerve-fibres; *i.r.*, fifteen of the inner rods of Corti; *h.i.*, their flattened heads seen from above; *e.r.*, nine outer rods of Corti; *h.e.*, their heads, with the phalangeal processes extending outward from them and forming, with the two rows of phalanges, the lamina reticularis, *l.r.*. At the lower part of the figure the connective-tissue fibres and nuclei of the undermost layer of the basilar membrane are seen through the upper layers. Portions of the basilar processes of the outer hair-cells remain attached here and there to the membrane at this part.

FIG. 323. — AN OUTER HAIR-CELL IN CONNECTION WITH ITS BASILAR PROCESS. From the guinea-pig. (Highly magnified.)

Two auditory hairs have remained attached to the cell; *b.*, bulged lower end of cell; *p.*, basilar process, protoplasmic above, but becoming cuticular below, and slightly expanded at the extremity, *f.*, which is broken away from the basilar membrane. According to some authorities this process is not actually continuous with the hair-cell, but belongs to a cell of Deiters.





manner, but rest by their larger end upon the basilar membrane, and are prolonged above into a cuticular process which is attached to the reticular lamina (*cells of Deiters*, fig. 321, *z*).

4. The *inner hair-cells* (fig. 321, *i*), placed internal to the rods of Corti. They form a single series of columnar cells surmounted by auditory hairs, lying in close apposition to the inner rods.

The rest of the epithelium-cells have no important characteristics. They are long and columnar next to the outer hair-cells, but soon diminish in size, becoming cubical, and in this form they are continued over the outer wall of the cochlear canal. Here they cover a very vascular membrane (*stria vascularis*, fig. 319, *str. v.*), which is frequently pigmented; its capillary blood-vessels penetrate between the epithelium-cells. Internal to the inner hair-cells the epithelium also soon becomes cubical; it is prolonged in this form over the limbus of the spiral lamina. The epithelium of Reissner's membrane is of the pavement variety.

The *membrana tectoria* (fig. 319, *M.t.*) is a soft, fibrillated structure, which is attached along the upper surface of the limbus, and lies like a pad over the organ of Corti. It thins out towards the distal margin, here becoming somewhat reticular, and, according to Retzius, it is attached to the lamina reticularis. In sections it usually appears raised a short distance above the auditory hairs, but it is probable that it always rests upon them during life.

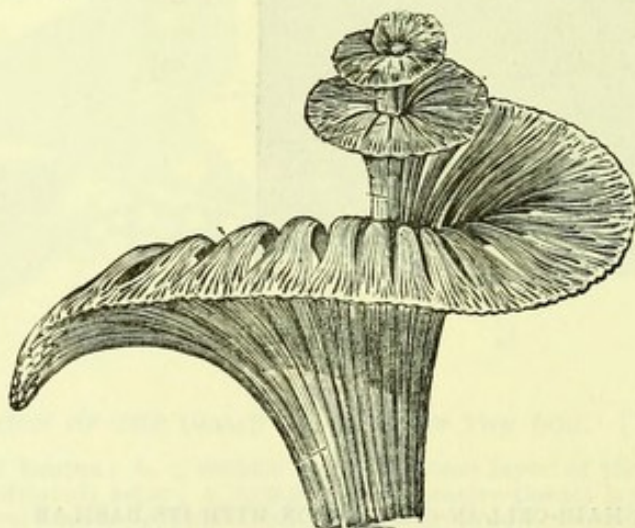


FIG. 324.—GENERAL VIEW OF THE MODE OF DISTRIBUTION OF THE COCHLEAR NERVE, ALL THE OTHER PARTS HAVING BEEN REMOVED.

The fibres of the cochlear branch of the auditory nerve enter the base of the columella, and run in canals through its substance, being gradually deflected outwards as they pass upwards into the spiral lamina, at the base of which they swell out into a ganglionic cord (spiral



ganglion). Many, if not all the fibres, are connected with the cells of this ganglion.

After traversing the spiral lamina they emerge in bundles, and the fibres then, having lost their medullary sheath, pass into the epithelium of the inner hair-cell region. Here some of them course at right angles and are directly applied to the inner hair-cells, whilst others cross the tunnel of Corti, to become applied in like manner to the outer hair-cells and the cells of Deiters; but there does not appear any direct continuity between the nerve-fibrils and the cell-substance.



## APPENDIX.

**General Methods of Preserving and Hardening Tissues and Organs.—**

The fluids which are most commonly used are alcohol, chromic acid solution (1 in 200 to 1 in 500, to which glacial acetic acid may advantageously be added in the proportion of 2 parts acetic acid to 1000 chromic solution), picric acid solution (saturated, either alone or containing 2 parts of sulphuric acid to 1000), osmic acid solution (1 per cent.), bichromate of potash solution (2 per cent.), Müller's fluid (bichromate of potash  $2\frac{1}{2}$  parts, sulphate of soda 1 part, water 100 parts), Erlicki's fluid (which is the same as Müller's, but with sulphate of copper in place of sulphate of soda), and bichromate of ammonia (2 per cent.). For preserving the structure of cells and nuclei the best general fixing and hardening fluid is that recommended by Flemming. This consists of 15 vols. of 1 per cent. chromic acid, 4 vols. of 2 per cent. osmic acid, and 1 vol. glacial acetic acid. It may advantageously be diluted with from two to five times its bulk of water before use. The following methods of hardening the several tissues and organs are found to give good general results :—

Tissue or Organ.	Hardening Fluid.
Bladder, . . . . .	Chromic acid or alcohol.
Blood-vessels, . . . . .	Alcohol or bichromate of potash.
Brain, . . . . .	Bichromate of ammonia or Müller's fluid.
Elastic ligament, . . . . .	Bichromate of potash.
Embryos, . . . . .	Chromic acid or picric acid.
Eye, . . . . .	Müller's fluid.
Eyelids, . . . . .	Alcohol.
Ganglia, . . . . .	Picric acid or Müller's fluid.
Heart, . . . . .	Alcohol or bichromate of potash.
Injected organs, . . . . .	Alcohol.
Intestine, . . . . .	Distend with chromic acid or with a mixture of equal parts alcohol and $\frac{1}{2}$ per cent. chromic acid solution, or with picric acid.
Kidney, . . . . .	Müller's fluid.
Lachrymal gland, . . . . .	Alcohol.
Larynx, . . . . .	Chromic acid and alcohol.
Liver . . . . .	Müller's fluid.



Tissue or Organ.	Hardening Fluid.
Lung, . . . . .	Distend with chromic acid or with alcohol and chromic acid.
Mammary gland, . . . . .	Alcohol.
Marrow of bone, . . . . .	Alcohol.
Muscular tissue, striated, . . . . .	Alcohol.
„ non-striated, . . . . .	Chromic acid.
Nerve, . . . . .	Picric acid or osmic acid.
Esophagus, . . . . .	Distend with chromic acid.
Ovary, . . . . .	Chromic acid.
Pancreas, . . . . .	Alcohol.
Retina, . . . . .	Müller's fluid.
Salivary glands, . . . . .	Alcohol.
Sclerotic and cornea, . . . . .	Alcohol or Müller's fluid.
Skin, . . . . .	Alcohol.
Spinal cord, . . . . .	Müller's fluid.
Spleen, . . . . .	Müller's fluid, picric acid, or alcohol.
Stomach, . . . . .	Distend with chromic acid, or with alcohol and chromic acid, or with picric acid.
Suprarenal capsule, . . . . .	Alcohol.
Tendon and ligament, . . . . .	Alcohol.
Testis, . . . . .	Alcohol.
Thymus gland, . . . . .	Alcohol.
Thyroid gland, . . . . .	Alcohol.
Tongue, . . . . .	Müller's fluid or alcohol.
Tonsils, . . . . .	Alcohol.
Trachea, . . . . .	Chromic acid and alcohol.
Ureter, . . . . .	Chromic acid and alcohol.
Uterus, . . . . .	Chromic acid and alcohol.

Tissues to be hardened in alcohol should usually be placed at once in strong methylated spirit, or, better, in absolute alcohol. They are ready for cutting as soon as they are dehydrated; as a rule they may be left indefinitely in alcohol without deterioration. Organs which contain much fibrous tissue, such as the skin and tendons, should not go into strong alcohol, but should be hardened in about 70 per cent. strength; otherwise they become too hard to cut.

For tissues that are to be hardened in chromic acid an immersion of from 7 to 14 days is generally necessary; they may then be placed in alcohol for preservation and to complete the process of hardening. The spirit should be changed once or twice.

Organs placed in bichromate of potash or Müller's fluid are ready for section in a fortnight or three weeks; they may, however, be left for a much longer time in those fluids without deterioration. With picric acid the hardening process is generally complete in 2 or 3 days; the organs may then be transferred to spirit, which ought to be frequently changed.



The hardening of the brain and spinal cord in Müller's fluid takes from 3 weeks to as many months. It can be hastened by warmth or by placing small pieces in Marchi's fluid (see below), after they have been a week or 10 days in Müller.

In no case should the pieces of tissue to be hardened be too thick for the fluid readily to penetrate to every part. They should be taken as soon after death as possible. Each piece should have from 50 to 100 times its bulk of hardening fluid, and this should always be changed after a few hours.

**Embedding of Hardened Tissues, and Preparation of Sections.**—Sections are most advantageously made with some form of microtome. It is generally needful to support the hardened tissue whilst it is being cut, and with this object it is embedded in some fatty or other substance which is applied to it in the fluid condition and becomes solid on standing.<sup>1</sup> The embedding substance can either simply inclose the tissue, or the tissue may be soaked in it: the latter method is the one most commonly employed.

The embedding substance chiefly used is paraffin of 50° C. melting point.

*Embedding in paraffin.*—Before being soaked in melted paraffin, the piece of tissue is stained, dehydrated by absolute alcohol, and is then soaked in turpentine, xylol, or chloroform. From this it is transferred to molten paraffin, which should not be too hot, and it is soaked in this for one or several hours, according to thickness. It is then placed in the desired position on the microtome and surrounded by melted paraffin. When cold, thin sections can be cut, the paraffin dissolved out by turpentine or xylol, and the sections mounted.

If it be desired to cut a riband of successive sections, the block of paraffin in which the organ is embedded must be cut with square angles, and some paraffin of low melting point smeared over the opposite sides of the block.

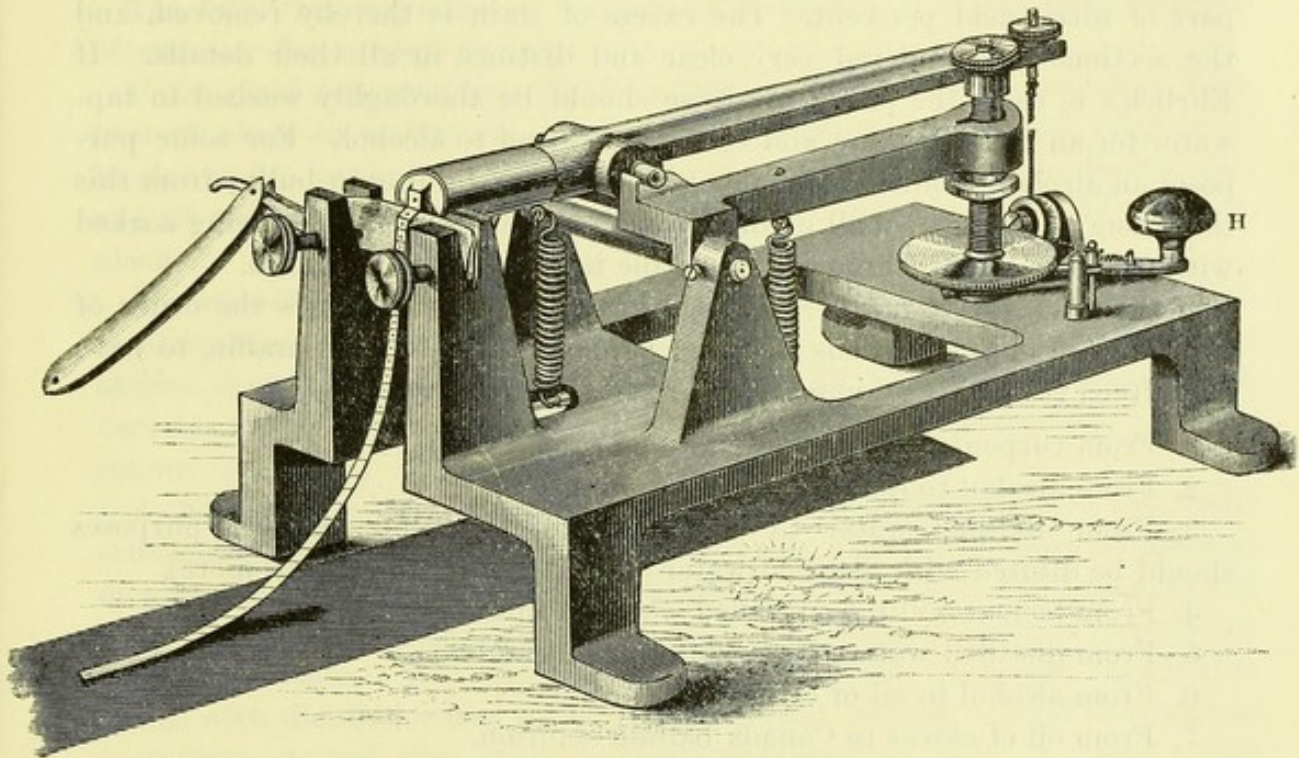
*Preparation of frozen sections.*—The bichromate solutions are the best fluids to use for preserving tissues which are to be frozen in place of being embedded. The tissue requires to be soaked in gum-water before being placed upon the freezing microtome.

*Embedding in celloidin.*—The piece to be embedded is dehydrated by alcohol, and is then placed in a solution of celloidin in alcohol and ether. After 24 hours or more it is removed from the celloidin and placed upon a flat wooden or metal holder (which can be fixed in the microtome when the celloidin has been hardened). When the celloidin is set, the holder is plunged in alcohol (80 per cent.), and after a few hours, sections may be cut with a knife wetted with spirit of the same strength. The advantage of this method is that the celloidin, which is quite transparent, need not be got rid of in mounting the sections, and serves to keep the parts of a section together: it is thus very useful for friable tissues or for large sections. The tissue may either be stained in bulk before embedding, or the sections may be stained. The method is especially valuable for the central nervous system.

<sup>1</sup> For rapid work a split piece of alcohol-hardened liver is often used to support the tissue from which sections are to be taken.



**Microtomes.**—A section-cutting apparatus or microtome is essential for histological work. Several kinds are made, but those which I have found most generally useful are the freezing microtome, the rocking microtome of the Cambridge Scientific Instrument Company for objects which have been embedded in paraffin, and the sliding microtome for celloidin-embedded tissues. The action of the rocker is automatic; that is to say, every to-and-fro movement of the handle, H, not only cuts a section of the tissue of definite thickness, but also moves the paraffin block forwards in readiness for the next section. And by employing a rectangular block of paraffin of the proper consistency, a long series of sections of the same object, of equal thickness, can be obtained and made to adhere together in



ROCKING MICROTOME.

a riband (as shown in the figure). The sections can, if desired, be kept in series by the employment of the creasote-shellac, or some other adhesive method of mounting the riband.

In the freezing microtome the tissue, after being soaked in gum-water, is placed on a metal plate and frozen by playing an ether spray on the under surface of the plate. The plate is moved upwards by a finely cut screw, and the knife or plane used to cut the sections is guided over the plate by passing over glass slides. In using the freezing microtome, especially for the nervous system, it is important not to freeze the tissue too hard, or the section will roll up like an ice-wafer.

For celloidin-embedded preparations it is necessary to cut the sections with a knife kept wetted with spirit. For this purpose a sliding microtome, in which the knife or razor is moved horizontally over the tissue, with the edge obliquely inclined to the direction of movement, is most useful. That designed by Thoma, and made by Jung of Heidelberg, is



admirably constructed, and works with great accuracy. In all cases it is most important that the knife should be in perfect order.

**Staining and Mounting of Sections.**—The fluids most commonly employed for the staining of sections are:—1. A solution of hæmatoxylin and alum; 2. a solution of carmine; 3. a solution of picro-carminate of ammonia. The time of immersion in the staining fluid varies according to the strength of the fluid and the mode by which the tissue has been hardened. The necessity of staining sections may be avoided if the piece of tissue is stained in bulk before embedding. For this purpose either Delafield's or Ehrlich's hæmatoxylin may be used. If Delafield's be employed the piece of tissue is left to stain for 24 hours or more, and is then placed for 15 to 30 minutes, according to thickness, in alcohol containing 1 part of nitric acid per cent. The excess of stain is thereby removed, and the sections are rendered very clear and distinct in all their details. If Ehrlich's is used, the pieces of tissue should be thoroughly washed in tap-water for an hour or more and then transferred to alcohol. For some purposes an alcoholic solution of magenta is used for staining in bulk; from this the tissue goes into a small quantity of oil of cloves, and after being soaked with this it is passed through turpentine into the melted paraffin.

If the tissues have not been stained in bulk, the following is the order of transference of the sections (they are supposed, if cut from paraffin, to have been freed from this by immersion in turpentine or xylol):—

1. From turpentine to absolute alcohol (5 minutes).
2. From alcohol to distilled water ( $\frac{1}{2}$  minute).
3. From distilled water to hæmatoxylin, which for staining purposes should be diluted with distilled water and filtered (5 minutes or more).
4. From hæmatoxylin to distilled water ( $\frac{1}{2}$  minute).
5. From distilled water to alcohol (2 or 3 minutes).
6. From alcohol to oil of cloves<sup>1</sup> (1 minute).
7. From oil of cloves to Canada balsam solution.

If the tissues have already been stained in bulk, the sections are simply mounted in Canada balsam after the paraffin used for embedding has been dissolved away from them in turpentine or xylol.

*Adhesive methods of mounting.*—Friable sections, such as sections of small embryos, and ribands of sections such as are cut with many microtomes, may be mounted in the following way:—The slide is smeared with a solution of shellac in clove-oil, the sections are placed in this and warmed so as to melt their paraffin. They are thus fixed by the shellac, and the slide can be immersed in turpentine to remove the paraffin, and the sections then covered in Canada balsam. For this method the tissue should have been previously stained in bulk.

A simpler method, but one which answers the purpose very well, is to place the riband or pieces of paraffin containing the sections on the surface of warm water (not hot enough to melt the paraffin), to float the sections

<sup>1</sup> Other essential oils, such as oil of cedar, oil of bergamot and xylol, may be used instead of oil of cloves, but the alcohol employed must then be absolute.



on to a slide, then to drain off the water, and put the slide and sections in a warm chamber, hot enough to melt the paraffin, until all the water has been driven off. The sections are then found to have adhered firmly to the slide, but they may be more firmly fixed by now drawing a brush moistened with solution of celloidin in oil of cloves over them. The paraffin can then be removed by washing the slide with xylol or immersing it in xylol. If not previously stained they can then be passed through alcohol into stain and afterwards again through alcohol and xylol, previous to mounting in Canada balsam.

For single sections it is often sufficient to place them in a drop of water, or water and spirit, on the slide, drain off the water and then keep the paraffin melted until the water has been entirely driven off.

The following are some of the principal staining solutions and methods of staining for special purposes:—

1. *Delafield hæmatoxylin*.—To 150 cubic centimeters of a saturated solution of alum in water add 4 cubic centimeters of a saturated solution of hæmatoxylin in alcohol. Let the mixture stand 8 days, then decant, and add 25 cubic centimeters of glycerine, and 25 cubic centimeters of methylic alcohol.

For staining sections add a few drops of this solution to a watchglassful of distilled water. If overstained the excess of colour can be removed by alcohol containing 1 per cent. nitric acid. With long keeping this solution becomes red instead of blue; a trace of ammonia will restore the requisite colour.

2. *Ehrlich hæmatoxylin*.—Dissolve 2 grammes hæmatoxylin in 100 cubic centimeters alcohol; add 100 cubic centimeters water, 100 cubic centimeters of glycerine, and 10 cubic centimeters glacial acetic acid. This solution will keep almost indefinitely: it is valuable for staining in bulk, as it does not overstain tissues. For staining sections it is best to dilute the solution either with distilled water or with 30 per cent. alcohol. After the sections have been stained they must be thoroughly washed with tap-water. This develops the blue colour of the hæmatoxylin.

3. *Kultschitzky hæmatoxylin*.—Dissolve 1 gramme hæmatoxylin in a little alcohol, and add to it 100 cubic centimeters of a 2 per cent. solution of acetic acid. This solution is valuable for staining sections of the nervous system (modified Weigert-Pal process).

4. *Kleinenberg hæmatoxylin*.—This serves well for staining in bulk. Saturate 70 per cent. alcohol first with calcium chloride and then with alum, and after filtration add six to eight volumes of 70 per cent. alcohol.

Take a freshly prepared saturated solution of hæmatoxylin in absolute alcohol, and add it drop by drop to the above mixture until it is of a distinct purplish colour.

This solution improves on keeping. It may if necessary be diluted with more of the mixture.

5. *Heidenhain's method*.—After hardening in alcohol, or in saturated solution of picric acid and then alcohol, place the tissue for 12 to 24 hours in a  $\frac{1}{3}$  per cent. watery solution of hæmatoxylin, and then from 12 to 24



hours more in a  $\frac{1}{2}$  per cent. solution of yellow chromate of potash. Now place in alcohol, pass through xylol, and embed in paraffin.

6. *Carminate of ammonia*.—Prepared by dissolving carmine in ammonia and allowing the excess of ammonia to escape by slow evaporation. The salt should be allowed to dry and be dissolved in water as required.

7. *Picro-carminate of ammonia* (*picro-carmine*, Ranvier).—To a saturated solution of picric acid add a strong ammoniacal solution of carmine, until a precipitate begins to form. Evaporate on the water bath (or, better, allow it to evaporate spontaneously) to  $\frac{1}{3}$ th; filter from the sediment and evaporate the filtrate to dryness. Make a 5 per cent. solution of the residue, diluting further as required.

8. *Lithium-carmine*.—Dissolve  $2\frac{1}{2}$  grammes of carmine in 100 cubic centimeters of a saturated solution of lithium carbonate. This solution is valuable for staining pieces of tissue in bulk. They may be left in it for 24 hours or more, and should then be placed in acidulated alcohol (see below). Sections may be stained by it in a few minutes. The addition of 2 to 3 times its volume of saturated solution of picric acid to the above solution of carmine in lithium carbonate has been recommended as a ready and convenient way of preparing picro-carmine.

9. *Borax-carmine*.—Dissolve 4 grammes borax and 3 grammes carmine in 100 cubic centimeters of warm water. Add 100 cubic centimeters of 70 per cent. alcohol, filter and let stand. This solution improves on keeping. It is useful for staining in bulk.

After staining with lithium-carmine or borax-carmine, the tissue should in all cases be placed in 70 per cent. alcohol containing 5 drops of hydrochloric acid to 100 cubic centimeters.

10. *Magenta*.—Take 5 cubic centimeters of a 1 per cent. alcoholic solution of magenta, and to it add gradually 20 cubic centimeters glycerine. Dilute with water to 100 cubic centimeters. This solution is for fresh tissues and for sections to be mounted in glycerine. For sections to be mounted in Canada balsam a solution in alcohol is used.

11. *Saffranin*.—A saturated alcoholic solution is used for staining cell-nuclei. The tissue-elements having been fixed by dilute chromic and acetic acid, or by Flemming's solution, small shreds or thin sections are placed for 12 to 24 hours in a little of the solution, mixed with half its bulk of water. The shreds are rinsed in absolute alcohol (which may contain a little free hydrochloric acid) until the colour is washed out from everything except the nuclei; they are then at once transferred to clove-oil, and from this are mounted in Canada balsam. Methyl violet and several other aniline colours may be employed in place of saffranin in a similar manner.

12. *Aniline blue-black*.—Dissolve 1 gramme of aniline blue-black in a mixture of 30 parts of water with 20 of alcohol. This is sometimes used for staining sections of the central nervous system.

13. *Marchi's solution*.—This is a mixture of Müller's fluid (2 parts) with 1 per cent. osmic acid (1 part). It is of great value for staining nerve-fibres in the earlier stages of degeneration, before sclerosis sets in (especially a few days after the establishment of a lesion). All the degenerated medullated



fibres are stained black, whilst the rest of the section remains almost unstained. It is best to put thin pieces of the brain or cord to be investigated into a large quantity of the solution (after previously hardening for 10 days in Müller's fluid), and to leave them in it for a week or more; but if necessary sections can be stained; in this case they are left in the solution for a few hours. In either case they are mounted by the usual process in Canada balsam.

14. *Weigert-Pal method*.—This method is of great value for the central nervous system. By it all medullated nerve-fibres are stained dark, while the grey matter and any degenerated tracts of white matter are left uncoloured. The following modification of the original method can be very strongly recommended:—Pieces which have been hardened in Müller's fluid and afterwards kept a short time in alcohol (without washing in water) are embedded in celloidin, and sections are cut as thin as possible. Or sections may be made of the tissue direct from Müller's fluid, if it is first soaked in gum-water for a few hours. In either case they are placed in water, and from this are transferred to Marchi's fluid (see above, sec. 13), in which they are left for a few hours. They are then again washed in water and transferred to acetic acid hæmatoxylin (see above, sec. 3). In this they are left overnight, by which time they will be completely black. After again washing in water they are ready to be bleached. This is accomplished by Pal's method as follows:—Place the overstained sections, first in  $\frac{1}{4}$  per cent. solution of potassic permanganate for 5 minutes; rinse with water and transfer to Pal's solution (sulphite of soda 1 gramme, oxalic acid 1 gramme, distilled water, 200 cubic centimeters), in which the actual bleaching takes place. They are usually sufficiently differentiated in a few minutes: if not, they can be left longer in the solution without detriment. If after half an hour they are not differentiated enough, they must be put again (after washing) into the permanganate for some minutes, and then again into Pal's solution. After differentiation they are passed through water, alcohol, and oil of bergamot (or xylol), to be mounted in Canada balsam. The advantages which this modification has over the original methods are (1) the very finest medullated fibres are brought to view with great surety; (2) the staining of the fibres is jet black, and offers a strong contrast to the colourless grey matter; (3) the sections are easily seen and lifted out of the acid hæmatoxylin, which has very little colour; (4) it is difficult to overbleach the sections; (5) the stain is remarkably permanent.

15. *Staining with chloride of gold*.—*a. Cohnheim's method*.—Place the fresh tissue for from 30 to 60 minutes in a  $\frac{1}{2}$  per cent. solution of chloride of gold; then wash and transfer to a large quantity of water just acidulated with acetic acid. Keep for 2 or 3 days in the light in a warm place. This answers very well for the cornea. If it be principally desired to stain the nerve-fibrils within the epithelium, the cornea may be transferred after 24 hours to a mixture of glycerine (1 part) and water (2 parts), and left in this for 24 hours more.

*β. Löwit's method*.—Place small pieces of the fresh tissue in a mixture of 1 part of formic acid to 2 to 4 parts of water for  $\frac{1}{2}$  to 1 minute; then in 1 per cent. chloride of gold solution for 10 to 15 minutes; then back again into



the formic acid mixture for 24 hours, and into pure formic acid for 24 hours more. After removal from the gold, and whilst in the acid, the tissue must be kept in the dark.

*γ. Ranvier's method.*—Immerse in lemon-juice for 5 to 10 minutes, then wash with water and place in 1 per cent. gold chloride solution for 20 minutes. Then treat either as in Cohnheim's or as in Löwit's method.

16. *Staining with nitrate of silver.*—Wash the fresh tissue with distilled water; immerse in  $\frac{1}{2}$  to 1 per cent. nitrate of silver solution for 5 to 10 minutes; rinse with distilled water and expose to bright sunlight either in water, alcohol, or glycerine. This method is used to exhibit endothelium and generally to stain intercellular substance.

17. *Golgi's nitrate of silver methods.*—These are chiefly employed for investigating the relations of cells and fibres in the central nervous system. Two methods are mostly used, as follows:—

*a.* Very small pieces of the tissue which has been hardened for some weeks in bichromate solution or Müller's fluid are placed for half an hour in the dark in 0.75 per cent. nitrate of silver solution, and are then transferred for 24 hours or more to a fresh quantity of the same solution (to which a drop or two of formic acid may be added). They may then be hardened with 50 per cent. alcohol, and sections, which need not be thin, are cut either from celloidin with a microtome or with the free hand. The sections are mounted in Canada balsam, which is allowed to dry on the slide: they must not be covered with a cover-glass, but the balsam must remain exposed to the air.

*β.* Instead of being slowly hardened in bichromate, the tissue is placed at once in very small pieces in a mixture of bichromate and osmic (3 parts of Müller's fluid to 1 of osmic acid). In this it remains from 1 to 2 days, after which the pieces are treated with silver nitrate as in the other case. This method is not only more rapid than the other, but is more sure in its results.

18. *Ehrlich's methyl-blue method.*—This method is one of great value for exhibiting nerve-terminations, and in some cases the relations of nerve-cells and fibres in the central nervous system. For its application the tissue must be living: it is therefore best applied by injecting a solution of methyl-blue (1 part to 100 of saline solution) into the blood-vascular or into the lymphatic system, but good results can also sometimes be obtained by immersing small pieces of freshly-excised living tissue in a less concentrated solution (0.2 per cent.) In either case the tissue must be spread out in a thin layer freely exposed to the air; the blue colour then appears in the nerve-cells and axis-cylinders, even to their finest ramifications. To fix the stain the tissue is treated for some hours with saturated solution of picrate of ammonia, after which the preparation can be mounted in glycerine.

**Mounting Solutions:**—1. *Saline solution.*—A 0.6 per cent. solution of common salt is used in place of serum for mounting fresh tissues for immediate examination.

2. *Glycerine*, either pure or diluted with water. The cover-glass may be fixed by gold size.

3. *Canada balsam*, from which the volatile oils have been driven off by heat, dissolved in xylol.



## INDEX.

## ADE

- ADENOID tissue, 44.  
 Adipose tissue, 41.  
 Angioblasts, 117.  
 Aorta, structure of, 110.  
 Appendix, 290.  
 Areolar, tissue, 38.  
 Arrector pili, 137.  
 Arteries, nerves of, 111.  
 — variation in structure of, 110.  
 — and veins, smaller, structure of, 112.  
 Artery, coats of, 107.  
 Attraction particle, 2.  
 Auerbach, plexus of, 174.
- BASEMENT membranes, 44.  
 Bile-ducts, 185.  
 Bladder, 201.  
 Blastoderm, 4.  
 Blood-corpuscles, action of reagents upon, 15.  
 — coloured, 12.  
 — colourless, 12, 16.  
 — — amœboid phenomena of, 22.  
 — — migration from blood-vessels, 115.  
 — development of, 13.  
 — enumeration of, 10.  
 — of amphibia, 18.  
 Blood-crystals, 16.  
 Blood-tablets, 13.  
 Blood-vessels, development of, 117.  
 Bone, 57.  
 — development of, 64.  
 — lacunæ and canaliculi of, 58.  
 — lamellæ of, 58.  
 — marrow of, 62.  
 Bowman, ciliary muscle of, 265.  
 — membrane of, 261.  
 — glands of, 278.  
 Bronchi, 144.  
 Bronchial tubes, 146.  
 Brain. *See* Cerebrum, Cerebellum, Medulla oblongata, Mesencephalon, Pons Varolii.  
 — membranes of, 256.

## DES

- CAPILLARIES, 113.  
 — circulation in, 114.  
 Cartilage, articular, 51.  
 — costal, 54.  
 — embryonic, 53.  
 — hyaline, 51.  
 — transitional, 51.  
 — varieties of, 50.  
 Cartilage-cells, 51.  
 — capsules of, 52.  
 Celloidin for embedding, 292.  
 Cells, division of, 4, 25.  
 — embryonic, 4.  
 — structure of, 1.  
 Central tendon of diaphragm, 112.  
 Cerebellum, 241.  
 Cerebrum, 244.  
 — basal ganglia of, 253.  
 Choroid coat of eye, 262.  
 Chromic acid, 241.  
 Chromoplasm, 3.  
 Chromosomes, 26.  
 Ciliary movement, 35.  
 — muscle, 265.  
 Clarke, column of, 221.  
 Cochlea, 284.  
 Cohnheim, areas of, 73.  
 Colostrum-corpuscles, 215.  
 Conjunctiva, 258.  
 Connective tissue, cells of, 40.  
 — — development of, 48.  
 — — jelly-like, 44.  
 — tissues, 38.  
 Cornea, 261.  
 Corpora quadrigemina, 238.  
 Corpus luteum, 212.  
 — striatum, 253.  
 Corti, organ of, 285.  
 Cotton fibres, 9.  
 Crusta petrosa, 152.  
 Cutis vera, 129.
- DEITERS, process of, 93.  
 Dentine, 150.  
 — formation of, 153.  
 Descemet, membrane of, 262.



## DOB

- Dobie, line of, 74.  
 Doyère, eminence of, 105.  
 Dust, 9.
- EAR, 278.  
 Ebner, glands of, 156.  
 Ehrlich's methyl-blue method, 298.  
 Elastic tissue, 46.  
 Eleidin, 129.  
 Embedding, methods of, 292.  
 Enamel, 149.  
 — formation of, 153.  
 End-bulbs, 98.  
 Endocardium, 141.  
 Endomysium, 74.  
 Endoneurium, 88.  
 Endothelium, 28.  
 End-plates, 103.  
 Epicardium, 141.  
 Epidermis, 127.  
 Epididymis, 203.  
 Epineurium, 88.  
 Epithelium, 24.  
 — ciliated, 32.  
 — classification of, 27.  
 — columnar, 30.  
 — stratified, 27.  
 — structure and division of cells, 24, 25.  
 — transitional, 33.  
 Erectile tissue, 201.  
 Erlicki's fluid, 290.  
 Eustachian tube, 279.  
 Eye, 257.  
 Eyelids, 258.  
 Eye-piece, 7.
- FALLOPIAN tubes, 213.  
 Fat, absorption of, 178.  
 Fat-cells, 41.  
 Fenestrated membrane, 108.  
 Fibres, elastic, 39.  
 — white, of connective tissue, 39.  
 Fibrin, 13.  
 Fibro-cartilage, elastic, 55.  
 — white, 55.  
 Fibrous tissue, 46.  
 Flemming's solution, 290.  
 Freezing method for preparation of sections, 293.
- GALL-BLADDER, 185.  
 Ganglia, 91.  
 Ganglion-cells, 93.  
 Gas-chamber, 35.  
 Gland, thymus, 124.  
 — pineal, 254.  
 Glands, anal, 180.  
 — ceruminous, 137, 278.  
 — gastric, 169.  
 — lachrymal, 261.

## LIE

- Glands, lymphatic, 121.  
 — mammary, 215.  
 — Meibomian, 259.  
 — of Bowman, 278.  
 — of Cowper, 202.  
 — of Littré, 202.  
 — salivary, 161.  
 — sebaceous, 137.  
 — sudoriparous, 137.  
 Glomeruli of kidney, 193.  
 Glycogen in colourless blood-corpuscles, 19.  
 Goblet-cells, 31.  
 Gold-methods, 297.  
 Golgi, organ of, 103.  
 — method of preparing the nervous system, 298.  
 Graafian follicles, 211.  
 Grandry, corpuscles of, 101.  
 Ground-substance of connective tissue, 39.  
 Gullet. *See* Oesophagus.
- HÆMATOIDIN, 16.  
 Hæmin, 16.  
 Hæmoglobin, 16.  
 Hair-cells of auditory organ, 281, 286, 288.  
 Hair-follicle, structure of, 132.  
 Hairs, 9, 132.  
 — development of, 111.  
 — muscles of, 137.  
 Haversian canals, 58.  
 — systems, 59.  
 Heart, 139.  
 Henle, fenestrated membrane of, 108.  
 — looped tubules of, 193.  
 — sheath of, 89.  
 Hensen, line of, 73.  
 Hepatic lobules, 181.  
 Hippocampus, 250.  
 Histology, meaning of term, 1.  
 Hyaloplasm, 2.
- INTESTINE, large, 179.  
 — small, 174.  
 Iris, 266.
- JELLY of Wharton, 419.
- KARYOKINESIS, 4, 25.  
 Kidney, 192.  
 — blood-vessels of, 197.  
 Krause, membrane of, 74.
- LABYRINTH of ear, 280.  
 Lacteals, 178.  
 Lanugo, 136.  
 Larynx, 144.  
 Lens, 275.  
 Lieberkühn, crypts of, 177.



## LIN

- Linen fibres, 9.  
 Liver, 181.  
 Lung, 146.  
   — alveoli of, 146.  
   — blood-vessels of, 148.  
 Lymphatic glands, 121.  
 Lymphatics, 115.  
   — connection with cells of connective tissue, 41, 117.  
   — development of, 117.  
 Lymph-corpuscles, 12.  
 Lymphoid tissue, 44, 125.  
  
 MACULA lutea of retina, 273.  
 Malpighian corpuscles of kidney, 193.  
 Malpighian corpuscles of spleen, 187.  
 Marchi's fluid, 296.  
 Marrow, 62.  
 Medulla oblongata, 227.  
 Meissner, plexus of, 176.  
 Mesencephalon, 237.  
 Methods of embedding, 292.  
   — of mounting sections, 293.  
   — of preparing sections, 292.  
   — of preserving and hardening, 290.  
   — of staining, 293.  
 Micrometer, 7.  
 Microscope, choice of, 6.  
   — structure of, 6.  
 Microscopic work, requisites for, 6.  
 Microtomes, 292.  
 Migration of colourless blood-corpuscles, 22, 115.  
 Moist chamber, 34.  
 Mould, 9.  
 Mounting solutions, 298.  
 Mucous membranes, 29.  
 Müller, fibres of, 272.  
 Müller's fluid, 290.  
 Muscle, blood-vessels of, 80.  
   — development of, 80.  
   — ending of, in tendon, 79.  
   — involuntary or plain, 82.  
   — nerves of, 85.  
   — of insects, 75, 76.  
   — of heart, 81.  
   — structure of, compared with protoplasm, 78.  
   — voluntary, 72.  
 Muscle-corpuscles, 74.  
 Myeloplaxes, 62.  
 Myocardium, 139.  
  
 NAILS, 131.  
 Nerve-cells, 91.  
 Nerve-fibres, axis-cylinder of, 86.  
   — — degeneration of, 97.  
   — — medullated, 83.  
   — — medullary segments of, 85.  
   — — — sheath of, 84.  
   — — motor, terminations of, 103.

## SAR

- Nerve-fibres, non-medullated, 87.  
   — — sensory, modes of termination of, 98, 101.  
   — trunk, structure of, 88.  
 Nervi nervorum, 89.  
 Neuroglia, 97.  
 Neurokeratin, 87.  
 Nucleoli, 3.  
 Nucleus, 3.  
  
 OBJECTIVE, 7.  
 Ocular, 7.  
 Oesophagus, 166.  
 Olfactory bulb, 252.  
   — cells, 277.  
   — mucous membrane, 276.  
   — tract, 251.  
 Omentum, 112.  
 Optic thalamus, 254.  
 Ossification in cartilage, 64.  
   — in membrane, 70.  
 Osteoblasts, 62, 65.  
 Osteoclasts, 68.  
 Osteogenic fibres, 70.  
 Ovary, 209.  
 Ovum, 4, 211.  
  
 PACINIAN corpuscles, 101.  
 Pancreas, 185.  
 Papillæ of tongue, 156.  
   — of skin, 130.  
 Paraplast, 2.  
 Penis, 201.  
 Pericardium, 141.  
 Perineurium, 88.  
 Periosteum, 61.  
 Peyer, patches of, 177.  
 Pharynx, 165.  
 Pia mater, 216.  
 Pituitary body, 254.  
 Pleura, 148.  
 Pons Varolii, 233.  
 Portal canal, 182.  
 Prickle-cells, 28.  
 Prostate, 202.  
 Protoplasm, 2.  
 Purkinje, cells of, 241.  
   — fibres of, 142.  
  
 RANVIER, nodes of, 85.  
 Remak, fibres of, 87.  
 Retiform tissue, 43.  
 Retina, 267.  
   — macula lutea of, 273.  
   — pars ciliaris of, 273.  
  
 SACCULE, 281.  
 Saline solution, 298.  
 Salivary glands, 161.  
   — corpuscles, 24, 124.  
 Sarcolemma, 72.



## SAR

Sarcomeres, 76.  
 Sarcoplasm, 73.  
 Sarcostyles, 73.  
 Sarcous elements, 76.  
 Schwann, sheath of, 83.  
 Sclerotic coat of eye, 261.  
 Sections, preparation of, 292.  
 Semicircular canals, 281.  
 Seminiferous tubules, 203.  
 Serous membranes, 118.  
 Sharpey, fibres of, 59.  
 Silver-methods, 297.  
 Skin, 127.  
 Spermatogenesis, 207.  
 Spermatozoa, 206.  
 Spinal cord, 216.  
 — — blood-vessels of, 226.  
 — — central canal of, 224.  
 — — characters in different parts, 224.  
 — — membranes of, 216.  
 — — nerve cells of, 221.  
 — — tracts in, 219.  
 Spleen, 187.  
 Spongioplasm, 2.  
 Staining of sections, 293.  
 Starch granules, 7.  
 Stomach, 167.  
 — glands of, 169.  
 — blood-vessels of, 171.  
 — lymphatics of, 172.  
 Stomata, 118.  
 Suprarenal capsule, 189.  
 Synovial membranes, 120.  
  
 TACTILE corpuscles, 98.  
 Taste-buds, 156.  
 Tendon, 48.

## YEA

Tendon cells, 47.  
 Tendon, nerve endings in, 103.  
 Testicle, 202.  
 Thymus gland, 124.  
 Thyroid body, 191.  
 Tissues, enumeration of, 1.  
 — formation from blastodermic layers, 4.  
 Tongue, 156.  
 Tonsils, 123.  
 Tooth, 149.  
 — formation of, 152.  
 — pulp of, 152.  
 Trachea, 143.  
 Tympanum, 278.  
  
 URETER, 200.  
 Urethra, 202.  
 Urinary bladder, 201.  
 Uriniferous tubules, course of, 193.  
 Uterus, 213.  
 Utricle, 281.  
  
 VAS deferens, 205.  
 Vasa vasorum, 111.  
 Vaso-formative cells, 117.  
 Veins, structure of, 110.  
 — variations in, 111.  
 Vesiculæ seminales, 206.  
 Villi, 177.  
 Vitreous humour, 275.  
  
 WARMING apparatus, 20.  
 Weigert-Pal method for staining sections of the nervous system, 296.  
 Woollen fibres, 9.  
  
 YEAST, 8.













A LIST OF WORKS ON  
MEDICINE, SURGERY  
AND  
GENERAL SCIENCE,  
PUBLISHED BY  
**LONGMANS, GREEN & CO.,**

39, PATERNOSTER ROW, LONDON.  
15, EAST 16<sup>th</sup> ST., NEW YORK.

---

*Medical and Surgical Works.*

---

**ASHBY.** NOTES ON PHYSIOLOGY FOR THE USE OF STUDENTS PREPARING FOR EXAMINATION. By HENRY ASHBY, M.D. Lond., F.R.C.P., Physician to the General Hospital for Sick Children, Manchester; formerly Demonstrator of Physiology, Liverpool School of Medicine. Sixth Edition, thoroughly revised. With 141 Illustrations. Fcap. 8vo, price 5s.

**ASHBY AND WRIGHT.** THE DISEASES OF CHILDREN, MEDICAL AND SURGICAL. By HENRY ASHBY, M.D. Lond., F.R.C.P., Physician to the General Hospital for Sick Children, Manchester; Lecturer and Examiner in Diseases of Children in the Victoria University; and G. A. WRIGHT, B.A., M.B. Oxon., F.R.C.S. Eng., Assistant Surgeon to the Manchester Royal Infirmary and Surgeon to the Children's Hospital; Examiner in Surgery in the University of Oxford. Enlarged and Improved Edition. With 178 Illustrations. 8vo, price 24s.

**BARKER.** A SHORT MANUAL OF SURGICAL OPERATIONS, HAVING SPECIAL REFERENCE TO MANY OF THE NEWER PROCEDURES. By ARTHUR E. J. BARKER, F.R.C.S., Surgeon to University College Hospital, Teacher of Practical Surgery at University College, Professor of Surgery and Pathology at the Royal College of Surgeons of England. With 61 Woodcuts in the Text. Crown 8vo, price 12s. 6d.

**BENNETT.**—*WORKS* by WILLIAM H. BENNETT, F.R.C.S., Surgeon to St. George's Hospital; Member of the Board of Examiners, Royal College of Surgeons of England.

CLINICAL LECTURES ON VARICOSE VEINS OF THE LOWER EXTREMITIES. With 3 Plates. 8vo. 6s.

ON VARICOCELE: A PRACTICAL TREATISE. With 4 Tables and a Diagram. 8vo. 5s.

CLINICAL LECTURES ON ABDOMINAL HERNIA: chiefly in relation to Treatment, including the Radical Cure. With 12 Diagrams in the Text. 8vo. 8s. 6d.



**BENTLEY. A TEXT-BOOK OF ORGANIC MATERIA MEDICA.**

Comprising a Description of the Vegetable and Animal Drugs of the British Pharmacopœia, with some others in common use. Arranged Systematically and Especially Designed for Students. By ROBERT BENTLEY, M.R.C.S. Eng., F.L.S. With 62 Illustrations on Wood. Crown 8vo, price 7s. 6d.

**CLEWOW. THE CHOLERA EPIDEMIC OF 1892 IN THE**

RUSSIAN EMPIRE. With Notes upon Treatment and Methods of Disinfection in Cholera, and a short account of the Conference on Cholera held in St. Petersburg in December, 1892. By FRANK CLEWOW, M.D. Edin., Member of the Epidemiological Society of London, &c. Royal 8vo, 5s.

**COATS. A MANUAL OF PATHOLOGY.** By JOSEPH COATS,

M.D., Pathologist to the Western Infirmary and the Sick Children's Hospital, Glasgow; Lecturer on Pathology in the Western Infirmary; Examiner in Pathology in the University of Glasgow. Second Edition. Revised and mostly Re-written. With 364 Illustrations. 8vo, price 31s. 6d.

**COOKE.—WORKS by THOMAS COOKE, F.R.C.S. Eng., B.A., B.Sc.,**  
*M.D. Paris, Senior Assistant Surgeon to the Westminster Hospital.*

**TABLETS OF ANATOMY.** Being a Synopsis of Demonstrations given in the Westminster Hospital Medical School in the years 1871-75. Eighth Thousand, being a selection of the Tablets believed to be most useful to Students generally. Post 4to, price 7s. 6d.

**APHORISMS IN APPLIED ANATOMY AND OPERATIVE SURGERY.** Including 100 Typical *viva voce* Questions on Surface Marking, &c. Crown 8vo, 3s. 6d.

**DISSECTION GUIDES.** Aiming at Extending and Facilitating such Practical Work in Anatomy as will be specially useful in connection with an ordinary Hospital Curriculum. 8vo, 10s. 6d.

**DICKINSON.—WORKS by W. HOWSHIP DICKINSON, M.D.**  
*Cantab., F.R.C.P., Physician to, and Lecturer on Medicine at, St. George's Hospital; Consulting Physician to the Hospital for Sick Children.*

**ON RENAL AND URINARY AFFECTIONS.** Complete in Three Parts, 8vo, with 12 Plates and 122 Woodcuts. Price £3 4s. 6d. cloth.

\* \* The Parts can also be had separately, each complete in itself, as follows:—

PART I.—*Diabetes*, price 10s. 6d. sewed, 12s. cloth.

„ II.—*Albuminuria*, price £1 sewed, £1 1s. cloth.

„ III.—*Miscellaneous Affections of the Kidneys and Urine*, price £1 10s. sewed, £1 11s. 6d. cloth.

**THE TONGUE AS AN INDICATION OF DISEASE;** being the Lumleian Lectures delivered at the Royal College of Physicians in March, 1888. 8vo, price 7s. 6d.

**THE HARVEIAN ORATION ON HARVEY IN ANCIENT AND MODERN MEDICINE.** Crown 8vo, 2s. 6d.



**DUANE.** THE STUDENT'S DICTIONARY OF MEDICINE AND THE ALLIED SCIENCES. Comprising the Pronunciation, Derivation, and Full Explanation of Medical Terms, together with much Collateral Descriptive Matter, numerous Tables, &c. By ALEXANDER DUANE, M.D., Assistant-Surgeon to the New York Ophthalmic and Aural Institute, Reviser of Medical Terms for "Webster's International Dictionary." 8vo, 21s.

**ERICHSEN.**—*WORKS* by JOHN ERIC ERICHSEN, F.R.S., LL.D. (Edin.), Hon. M. Ch. and F.R.C.S. (Ireland), Surgeon Extraordinary to H.M. the Queen; President of University College, London; Fellow and Ex-President of the Royal College of Surgeons of England; Emeritus Professor of Surgery in University College; Consulting-Surgeon to University College Hospital, and to many other Medical Charities.

THE SCIENCE AND ART OF SURGERY; A TREATISE ON SURGICAL INJURIES, DISEASES, AND OPERATIONS. Tenth Edition, Edited by Professor BECK, M.S. & M.B. (Lond.), F.R.C.S., Surgeon to University College Hospital, &c. With Illustrations. 2 Vols. 8vo.

ON CONCUSSION OF THE SPINE, NERVOUS SHOCKS, and other Obscure Injuries of the Nervous System in their Clinical and Medico-Legal Aspects. Crown 8vo, 10s. 6d.

**FRANKLAND.** MICRO-ORGANISMS IN WATER, THEIR SIGNIFICANCE, IDENTIFICATION, AND REMOVAL. Together with an Account of the Bacteriological Methods Involved in their Investigation. Specially Designed for the Use of those connected with the Sanitary Aspects of Water Supply. By Professor PERCY FRANKLAND, Ph.D., B.Sc. (Lond.), F.R.S., Fellow of the Chemical Society; and Mrs. PERCY FRANKLAND, Joint Author of "Studies on Some New Micro-Organisms Obtained from Air." With 2 Plates and numerous Diagrams. 8vo. 16s. net.

**GAIRDNER AND COATS.** ON THE DISEASES CLASSIFIED by the REGISTRAR-GENERAL as TABES MESENTERICA. LECTURES TO PRACTITIONERS. By W. T. GAIRDNER, M.D., LL.D. On the PATHOLOGY of PHTHISIS PULMONALIS. By JOSEPH COATS, M.D. With 28 Illustrations. 8vo, price 12s. 6d.

**GARROD.**—*WORKS* by Sir ALFRED BARING GARROD, M.D., F.R.S., &c.; Physician Extraordinary to H.M. the Queen; Consulting Physician to King's College Hospital; late Vice-President of the Royal College of Physicians.

A TREATISE ON GOUT AND RHEUMATIC GOUT (RHEUMATOID ARTHRITIS). Third Edition, thoroughly revised and enlarged; with 6 Plates, comprising 21 Figures (14 Coloured), and 27 Illustrations engraved on Wood. 8vo, price 21s.

THE ESSENTIALS OF MATERIA MEDICA AND THERAPEUTICS. The Thirteenth Edition, revised and edited, under the supervision of the Author, by NESTOR TIRARD, M.D. Lond., F.R.C.P., Professor of Materia Medica and Therapeutics in King's College, London, &c. Crown 8vo, price 12s. 6d.



**GRAY.** ANATOMY, DESCRIPTIVE AND SURGICAL. By HENRY GRAY, F.R.S., late Lecturer on Anatomy at St. George's Hospital. The Thirteenth Edition, re-edited by T. PICKERING PICK, Surgeon to St. George's Hospital; Member of the Court of Examiners, Royal College of Surgeons of England. With 636 large Woodcut Illustrations, a large proportion of which are Coloured, the Arteries being coloured red, the Veins blue, and the Nerves yellow. The attachments of the muscles to the bones, in the section on Osteology, are also shown in coloured outline. Royal 8vo, price 36s.

---

**HALLIBURTON.**—*WORKS by W. D. HALLIBURTON, M.D., B.Sc., M.R.C.P., Professor of Physiology at King's College, London; Lecturer on Physiology at the London School of Medicine for Women; late Assistant Professor of Physiology at University College, London.*

A TEXT-BOOK OF CHEMICAL PHYSIOLOGY AND PATHOLOGY. With 104 Illustrations. 8vo, 28s.

ESSENTIALS OF CHEMICAL PHYSIOLOGY. 8vo, 5s.

\* \* This is a book suitable for medical students. It treats of the subject in the same way as Prof. SCHÄFER's "Essentials" treats of Histology. It contains a number of elementary and advanced practical lessons, followed in each case by a brief descriptive account of the facts related to the exercises which are intended to be performed by each member of the class.

---

**HASSALL.**—*WORKS by ARTHUR HILL HASSALL, M.D., London.*

THE INHALATION TREATMENT OF DISEASES OF THE ORGANS OF RESPIRATION, INCLUDING CONSUMPTION.

With numerous Illustrations. Crown 8vo, price 12s. 6d.

THE NARRATIVE OF A BUSY LIFE: an Autobiography. 8vo. 5s.

---

**HOLMES.** A SYSTEM OF SURGERY, Theoretical and Practical. Edited by TIMOTHY HOLMES, M.A.; and J. W. HULKE, F.R.S., Surgeon to the Middlesex Hospital. Third Edition, in Three Volumes, with Coloured Plates and numerous Illustrations. 3 Vols., royal 8vo, price £4 4s.

---

**LANGTON.** ABDOMINAL HERNIA. By JOHN LANGTON, F.R.C.S., Surgeon to St. Bartholomew's Hospital, Senior Surgeon to the City of London Truss Society, Member of the Council and Court of Examiners of the Royal College of Surgeons of England. With numerous Illustrations. *In the press.*



**LIVEING.**—*WORKS* by **ROBERT LIVEING, M.A. & M.D. Cantab.,**  
*F.R.C.P. Lond., &c., Physician to the Department for Diseases of the Skin at the*  
*Middlesex Hospital, &c.*

**HANDBOOK ON DISEASES OF THE SKIN.** With especial  
reference to Diagnosis and Treatment. Fifth Edition, revised and enlarged.  
Fcap. 8vo, price 5s.

**ELEPHANTIASIS GRÆCORUM, OR TRUE LEPROSY;**  
Being the Goulstonian Lectures for 1873. Cr. 8vo, 4s. 6d.

---

**LONGMORE.**—*WORKS* by **Surgeon-General Sir T. LONGMORE,**  
*C.B., F.R.C.S., Honorary Surgeon to H.M. Queen Victoria; Professor of Military*  
*Surgery in the Army Medical School.*

**THE ILLUSTRATED OPTICAL MANUAL; OR, HAND-  
BOOK OF INSTRUCTIONS FOR THE GUIDANCE OF  
SURGEONS IN TESTING QUALITY AND RANGE OF  
VISION, AND IN DISTINGUISHING AND DEALING WITH OPTICAL  
DEFECTS IN GENERAL.** Illustrated by 74 Drawings and Diagrams by  
Inspector-General Dr. MACDONALD, R.N., F.R.S., C.B. Fourth Edition.  
8vo, price 14s.

**GUNSHOT INJURIES.** Their History, Characteristic Features, Com-  
plications, and General Treatment; with Statistics concerning them as they  
are met with in Warfare. With 58 Illustrations. 8vo, price 31s. 6d.

---

**MURCHISON.**—*WORKS* by **CHARLES MURCHISON, M.D.,**  
*LL.D., F.R.S., &c., Fellow of the Royal College of Physicians; late Physician and*  
*Lecturer on the Principles and Practice of Medicine, St. Thomas's Hospital.*

**A TREATISE ON THE CONTINUED FEVERS OF GREAT  
BRITAIN.** Edited by W. CAYLEY, M.D., F.R.C.P. With 6 Coloured  
Plates and Lithographs, 19 Diagrams and 20 Woodcut Illustrations. 8vo,  
price 25s.

**CLINICAL LECTURES ON DISEASES OF THE LIVER,  
JAUNDICE, AND ABDOMINAL DROPSY;** Including the Croon-  
ian Lectures on Functional Derangements of the Liver, delivered at the Royal  
College of Physicians in 1874. Revised by T. LAUDER BRUNTON, M.D.  
8vo, price 24s.



**NEWMAN.** ON THE DISEASES OF THE KIDNEY AMENABLE TO SURGICAL TREATMENT. Lectures to Practitioners. By DAVID NEWMAN, M.D., Surgeon to the Western Infirmary Out-Door Department; Pathologist and Lecturer on Pathology at the Glasgow Royal Infirmary; Examiner in Pathology in the University of Glasgow; Vice-President Glasgow Pathological and Clinical Society. 8vo, price 16s.

**OWEN.** A MANUAL OF ANATOMY FOR SENIOR STUDENTS. By EDMUND OWEN, M.B., F.R.S.C., Senior Surgeon to the Hospital for Sick Children, Great Ormond Street, Surgeon to St. Mary's Hospital, London, and co-Lecturer on Surgery, late Lecturer on Anatomy in its Medical School. With 210 Illustrations. Crown 8vo, price 12s. 6d.

**PAGET.**—*WORKS* by Sir JAMES PAGET, Bart., F.R.S., D.C.L. Oxon., LL.D. Cantab., &c., Sergeant-Surgeon to the Queen, Surgeon to the Prince of Wales, Consulting Surgeon to St. Bartholomew's Hospital.

LECTURES ON SURGICAL PATHOLOGY, Delivered at the Royal College of Surgeons of England. Fourth Edition, re-edited by the AUTHOR and W. TURNER, M.B. 8vo, with 131 Woodcuts, price 21s.

CLINICAL LECTURES AND ESSAYS. Edited by F. HOWARD MARSH, Assistant-Surgeon to St. Bartholomew's Hospital. Second Edition, revised. 8vo, price 15s.

STUDIES OF OLD CASE-BOOKS. 8vo, 8s. 6d.

**POOLE.** COOKERY FOR THE DIABETIC. By W. H. and Mrs. POOLE. With Preface by Dr. PAVY. Fcap. 8vo. 2s. 6d.

**POORE.** ESSAYS ON RURAL HYGIENE. By GEORGE VIVIAN POORE, M.D., F.R.C.P. Crown 8vo.

**QUAIN.** A DICTIONARY OF MEDICINE; Including General Pathology, General Therapeutics, Hygiene, and the Diseases of Women and Children. By Various Writers. Edited by RICHARD QUAIN, Bart., M.D.Lond., LL.D.Edin. (Hon.) F.R.S., Physician Extraordinary to H.M. the Queen, President of the General Medical Council, Member of the Senate of the University of London, &c. Assisted by FREDERICK THOMAS ROBERTS, M.D.Lond. B.Sc., Fellow of the Royal College of Physicians, Fellow of University College, Professor of Materia Medica and Therapeutics, University College, &c.; and J. MITCHELL BRUCE, M.A.Abdn., M.D.Lond., Fellow of the Royal College of Physicians of London, Physician and Lecturer on the Principles and Practice of Medicine, Charing Cross Hospital, &c. New Edition, Revised throughout and Enlarged. In 2 Vols. medium 8vo. cloth, red edges, price 40s. net.



**QUAIN. QUAIN'S (JONES) ELEMENTS OF ANATOMY.**

The Tenth Edition. Edited by EDWARD ALBERT SCHÄFER, F.R.S., Professor of Physiology and Histology in University College, London; and GEORGE DANCER THANE, Professor of Anatomy in University College, London. (In three volumes.)

VOL. I., PART I. EMBRYOLOGY. By Professor SCHÄFER. Illustrated by 200 Engravings, many of which are coloured. Royal 8vo, 9s. [Ready.]

VOL. I., PART II. GENERAL ANATOMY OR HISTOLOGY. By Professor SCHÄFER. Illustrated by nearly 500 Engravings, many of which are coloured. Royal 8vo, 12s. 6d. [Ready.]

VOL. II., PART I. OSTEOLOGY. By Professor THANE. Illustrated by 168 Engravings. Royal 8vo, 9s. [Ready.]

VOL. II., PART II. ARTHROLOGY, MYOLOGY, ANGIOLOGY. By Professor THANE. Illustrated by 255 Engravings, many of which are Coloured. Royal 8vo, 18s. [Ready.]

VOL. III., PART I. SPINAL CORD AND BRAIN. By Professor SCHÄFER. Illustrated by 139 Engravings. Royal 8vo, 12s. 6d. [Ready.]

VOL. III., PART II. PERIPHERAL NERVES. [In preparation.]

VOL. III., PART III. ORGANS OF THE SENSES. By Professor SCHÄFER. Illustrated by 178 Engravings. Royal 8vo, price 9s. [Ready.]

VOL. III., PART IV. VISCERAL ANATOMY. [In preparation.]

**RICHARDSON. THE ASCLEPIAD.** A Book of Original Research in the Science, Art, and Literature of Medicine. By BENJAMIN WARD RICHARDSON, M.D., F.R.S. Published Quarterly, price 2s. 6d. Volumes for 1884, 1885, 1886, 1887, 1888, 1889, 1890, 1891, 1892 & 1893. 8vo, price 12s. 6d. each.

**SCHÄFER. THE ESSENTIALS OF HISTOLOGY:** Descriptive and Practical. For the Use of Students. By E. A. SCHÄFER, F.R.S., Jodrell Professor of Physiology in University College, London; Editor of the Histological Portion of Quain's "Anatomy." Illustrated by more than 300 Figures, many of which are new. Third Edition, Revised and Enlarged. 8vo, 7s. 6d. (Interleaved, 10s.)

**SCHENK. MANUAL OF BACTERIOLOGY.** For Practitioners and Students. With especial reference to Practical Methods. By Dr. S. L. SCHENK, Professor (Extraordinary) in the University of Vienna. Translated from the German, with an Appendix, by W. R. DAWSON, B.A., M.D., Univ. Dub.; late University Travelling Prizeman in Medicine. With 100 Illustrations, some of which are coloured. 8vo, 10s. net.



**SEMPLE.** ELEMENTS OF MATERIA MEDICA AND THERAPEUTICS. Including the whole of the Remedies of the British Pharmacopœia of 1885 and its Appendix of 1890. With 440 Illustrations. By C. E. ARMAND SEMPLE, B.A., M.B. Camb., L.S.A., M.R.C.P. Lond.; Member of the Court of Examiners, and late Senior Examiner in Arts at Apothecaries' Hall, &c. Crown 8vo, price 10s. 6d.

**SMALE AND COLYER.** DISEASES AND INJURIES OF THE TEETH, including Pathology and Treatment: a Manual of Practical Dentistry for Students and Practitioners. By MORTON SMALE, M.R.C.S., L.S.A., L.D.S., Dental Surgeon to St. Mary's Hospital, Dean of the School, Dental Hospital of London, &c.; and J. F. COLYER, L.R.C.P., M.R.C.S., L.D.S., Assistant Dental Surgeon to Charing Cross Hospital, and Assistant Dental Surgeon to the Dental Hospital of London. With 334 Illustrations. Large Crown 8vo, 15s.

**SMITH (H. F.).** THE HANDBOOK FOR MIDWIVES. By HENRY FLY SMITH, B.A., M.B. Oxon., M.R.C.S. Second Edition. With 41 Woodcuts. Crown 8vo, price 5s.

**STEEL.**—*WORKS* by JOHN HENRY STEEL, F.R.C.V.S., F.Z.S., A.V.D., late Professor of Veterinary Science and Principal of Bombay Veterinary College.

A TREATISE ON THE DISEASES OF THE DOG; being a Manual of Canine Pathology. Especially adapted for the use of Veterinary Practitioners and Students. 88 Illustrations. 8vo, 10s. 6d.

A TREATISE ON THE DISEASES OF THE OX; being a Manual of Bovine Pathology specially adapted for the use of Veterinary Practitioners and Students. 2 Plates and 117 Woodcuts. 8vo, 15s.

A TREATISE ON THE DISEASES OF THE SHEEP; being a Manual of Ovine Pathology for the use of Veterinary Practitioners and Students. With Coloured Plate, and 99 Woodcuts. 8vo, 12s.

OUTLINES OF EQUINE ANATOMY; a Manual for the use of Veterinary Students in the Dissecting Room. Crown 8vo, 7s. 6d.

**"STONEHENGE."** THE DOG IN HEALTH AND DISEASE. By "STONEHENGE." With 84 Wood Engravings. Square crown 8vo, 7s. 6d.

**THORNTON.** HUMAN PHYSIOLOGY. By JOHN THORNTON, M.A., Author of "Elementary Physiography," "Advanced Physiography," &c. With 267 Illustrations, some of which are Coloured. Crown 8vo, 6s.



---

**WALLER.** AN INTRODUCTION TO HUMAN PHYSIOLOGY.

By AUGUSTUS D. WALLER, M.D., Lecturer on Physiology at St. Mary's Hospital Medical School, London; late External Examiner at the Victorian University. Second Edition, Revised. With 305 Illustrations. 8vo, 18s.

---

**WILKS AND MOXON.** LECTURES ON PATHOLOGICAL

ANATOMY. By SAMUEL WILKS, M.D., F.R.S., Consulting Physician to, and formerly Lecturer on Medicine and Pathology at, Guy's Hospital, and the late WALTER MOXON, M.D., F.R.C.P., Physician to, and some time Lecturer on Pathology at, Guy's Hospital. Third Edition, thoroughly Revised. By SAMUEL WILKS, M.D., LL.D., F.R.S. 8vo, 18s.

---

**WILLIAMS.** PULMONARY CONSUMPTION: ITS ETIO-

LOGY, PATHOLOGY, AND TREATMENT. With an Analysis of 1,000 Cases to Exemplify its Duration and Modes of Arrest. By C. J. B. WILLIAMS, M.D., LL.D., F.R.S., F.R.C.P., Senior Consulting Physician to the Hospital for Consumption, Brompton; and CHARLES THEODORE WILLIAMS, M.A., M.D. Oxon., F.R.C.P., Senior Physician to the Hospital for Consumption, Brompton. Second Edition, Enlarged and Re-written by Dr. C. THEODORE WILLIAMS. With 4 Coloured Plates and 10 Woodcuts. 8vo, 16s.

---

**YOUATT.**—*WORKS by WILLIAM YOUATT.*

THE HORSE. Revised and Enlarged by W. WATSON, M.R.C.V.S. Woodcuts. 8vo, 7s. 6d.

THE DOG. Revised and Enlarged. Woodcuts. 8vo, 6s.

---

General Scientific Works.

---

**ARNOTT.** THE ELEMENTS OF PHYSICS OR NATURAL

PHILOSOPHY. By NEIL ARNOTT, M.D. Edited by A. BAIN, LL.D. and A. S. TAYLOR, M.D., F.R.S. Woodcuts. Crown 8vo, 12s. 6d.

---

**BENNETT AND MURRAY.** A HANDBOOK OF CRYPTOGAMIC

BOTANY. By A. W. BENNETT, M.A., B.Sc., F.L.S., and GEORGE R. MILNE MURRAY, F.L.S. With 378 Illustrations. 8vo, 16s.



---

**CARNEGIE.** LAW AND THEORY IN CHEMISTRY: A COMPANION Book for Students. By DOUGLAS CARNEGIE, sometime Scholar and Demonstrator in Chemistry of Gonville and Caius, Cambridge. Crown 8vo, 6s.

---

**CLERKE.** THE SYSTEM OF THE STARS. By AGNES M. CLERKE, Author of "A History of Astronomy during the Nineteenth Century." With 6 Plates and Numerous Illustrations. 8vo, 21s.

---

**CLODD.** THE STORY OF CREATION. A Plain Account of Evolution. By EDWARD CLODD, Author of "The Childhood of the World," &c. With 77 Illustrations. Crown 8vo, 3s. 6d.

---

**CROOKES.** SELECT METHODS IN CHEMICAL ANALYSIS (chiefly Inorganic). By W. CROOKES, F.R.S., V.P.C.S., Editor of "The Chemical News." Third Edition, re-written and enlarged. Illustrated with 67 Woodcuts. 8vo, 21s. net.

---

**CULLEY.** A HANDBOOK OF PRACTICAL TELEGRAPHY. By R. S. CULLEY, M.I.C.E., late Engineer-in-Chief of Telegraphs to the Post Office. With 135 Woodcuts and 17 Plates, 8vo, 16s.

---

**GANOT.** ELEMENTARY TREATISE ON PHYSICS; Experimental and Applied, for the use of Colleges and Schools. Translated and edited from GANOT's *Eléments de Physique* (with the Author's sanction) by E. ATKINSON, Ph.D., F.C.S., Professor of Experimental Science, Staff College, Sandhurst. Fourteenth Edition, revised and enlarged, with 9 Coloured Plates and 1,028 Woodcuts. Large crown 8vo, 15s.

NATURAL PHILOSOPHY FOR GENERAL READERS AND YOUNG PERSONS; Being a Course of Physics divested of Mathematical Formulæ, and expressed in the language of daily life. Translated from GANOT's *Cours de Physique* (with the Author's sanction) by E. ATKINSON, Ph.D., F.C.S. Seventh Edition, carefully revised; with 37 pages of New Matter, 7 Plates, 569 Woodcuts, and an Appendix of Questions. Crown 8vo, 7s. 6d.

---

**GOODEVE.**—WORKS by T. M. GOODEVE, M.A., Barrister-at-Law; Professor of Mechanics at the Normal School of Science and the Royal School of Mines.

PRINCIPLES OF MECHANICS. New Edition, re-written and enlarged. With 253 Woodcuts and numerous Examples. Crown 8vo, 6s.



**GOODEVE.**—*continued.*

**THE ELEMENTS OF MECHANISM.** New Edition, re-written and enlarged. With 342 Woodcuts. Crown 8vo, 6s.

**A MANUAL OF MECHANICS :** an Elementary Text-Book for Students of Applied Mechanics. With 138 Illustrations and Diagrams, and 141 Examples taken from the Science Department Examination Papers, with Answers. Fcp. 8vo, 2s. 6d.

**HELMHOLTZ.**—*WORKS by HERMANN L. F. HELMHOLTZ, M.D., Professor of Physics in the University of Berlin.*

**ON THE SENSATIONS OF TONE AS A PHYSIOLOGICAL BASIS FOR THE THEORY OF MUSIC.** Second English Edition ; with numerous additional Notes, and a new Additional Appendix, bringing down information to 1885, and specially adapted to the use of Musical Students. By ALEXANDER J. ELLIS, B.A., F.R.S., F.S.A., &c., formerly Scholar of Trinity College, Cambridge. With 68 Figures engraved on Wood, and 42 Passages in Musical Notes. Royal 8vo, 28s.

**POPULAR LECTURES ON SCIENTIFIC SUBJECTS.** With 68 Woodcuts. 2 Vols. crown 8vo, 3s. 6d. each.

**HERSCHEL.** **OUTLINES OF ASTRONOMY.** By Sir JOHN F. W. HERSCHEL, Bart., K.H., &c., Member of the Institute of France. Twelfth Edition, with 9 Plates, and numerous Diagrams. 8vo, 12s.

**HUDSON AND GOSSE.** **THE ROTIFERA OR 'WHEEL ANIMALCULES.'** By C. T. HUDSON, LL.D., and P. H. GOSSE, F.R.S. With 30 Coloured and 4 Uncoloured Plates. In 6 Parts. 4to, price 10s. 6d. each ; Supplement, 12s. 6d. Complete in Two Volumes, with Supplement, 4to, £4 4s.

\* \* The Plates in the Supplement contain figures of almost all the Foreign Species, as well as of the British Species, that have been discovered since the original publication of Vols. I. and II.

**KOLBE.** **A SHORT TEXT-BOOK OF INORGANIC CHEMISTRY.** By Dr. HERMANN KOLBE, late Professor of Chemistry in the University of Leipzig. Translated and Edited by T. S. HUMPIDGE, Ph.D., B.Sc. (Lond.), late Professor of Chemistry and Physics in the University College of Wales, Aberystwyth. New Edition. Revised by H. LLOYD-SNAPE, Ph.D., D.Sc. (Lond.), Professor of Chemistry in the University College of Wales, Aberystwyth. With a Coloured Table of Spectra and 66 Woodcuts. Crown 8vo, 8s. 6d.



**LADD.**—*WORKS* by **GEORGE T. LADD**, *Professor of Philosophy in Yale University.*

**ELEMENTS OF PHYSIOLOGICAL PSYCHOLOGY:** A TREATISE OF THE ACTIVITIES AND NATURE OF THE MIND FROM THE PHYSICAL AND EXPERIMENTAL POINT OF VIEW. With 113 Illustrations. 8vo, price 21s.

**PSYCHOLOGY, DESCRIPTIVE AND EXPLANATORY:** A Treatise of the Phenomena, Laws, and Development of Human Mental Life. 8vo. 21s.

**OUTLINES OF PHYSIOLOGICAL PSYCHOLOGY.** With numerous Illustrations. 8vo. 12s.

**LARDEN.** **ELECTRICITY FOR PUBLIC SCHOOLS AND COLLEGES.** With numerous Questions and Examples with Answers, and 214 Illustrations and Diagrams. By **W. LARDEN**, M.A. Crown 8vo, 6s.

**LINDLEY AND MOORE.** **THE TREASURY OF BOTANY, OR POPULAR DICTIONARY OF THE VEGETABLE KINGDOM:** with which is incorporated a Glossary of Botanical Terms. Edited by **J. LINDLEY**, M.D., F.R.S., and **T. MOORE**, F.L.S. With 20 Steel Plates, and numerous Woodcuts. 2 Parts, fcp. 8vo, price 12s.

**LOUDON.** **AN ENCYCLOPÆDIA OF PLANTS.** By **J. C. LOUDON.** Comprising the Specific Character, Description, Culture, History, Application in the Arts, and every other desirable particular respecting all the plants indigenous to, cultivated in, or introduced into, Britain. Corrected by **Mrs. LOUDON.** 8vo, with above 12,000 Woodcuts, price 42s.

**MARTIN.** **NAVIGATION AND NAUTICAL ASTRONOMY.** Compiled by Staff-Commander **W. R. MARTIN**, R.N., Instructor in Surveying, Navigation, and Compass Adjustment; Lecturer on Meteorology at the Royal Naval College, Greenwich. Sanctioned for use in the Royal Navy by the Lords Commissioners of the Admiralty. Royal 8vo, 18s.

**MENDELÉEFF.** **THE PRINCIPLES OF CHEMISTRY.** By **D. MENDELÉEFF**, Professor of Chemistry in the University of St. Petersburg. Translated by **GEORGE KAMENSKY**, A.R.S.M. of the Imperial Mint, St. Petersburg, and Edited by **A. J. GREENAWAY**, F.I.C., Sub-Editor of the Journal of the Chemical Society. With 97 Illustrations. 2 Vols. 8vo, 36s.

**MEYER.** **OUTLINES OF THEORETICAL CHEMISTRY.** By **LOTHAR MEYER**, Professor of Chemistry in the University of Tübingen. Translated by Professors **P. PHILLIPS BEDSON**, D.Sc., and **W. CARLETON WILLIAMS**, B.Sc. 8vo, 9s.



**MILLER.**—*WORKS* by WILLIAM ALLEN MILLER, M.D., D.C.L.  
LL.D., late Professor of Chemistry in King's College, London.

THE ELEMENTS OF CHEMISTRY, Theoretical and Practical.

PART II. INORGANIC CHEMISTRY. Sixth Edition, revised throughout, with Additions by C. E. GROVES, Fellow of the Chemical Societies of London, Paris, and Berlin. With 376 Woodcuts. 8vo, price 24s.

PART III. ORGANIC CHEMISTRY, or the Chemistry of Carbon Compounds. *Hydrocarbons, Alcohols, Ethers, Aldehydes and Paraffinoid Acids.* Fifth Edition, revised and in great part re-written, by H. E. ARMSTRONG, F.R.S., and C. E. GROVES, F.C.S. 8vo, price 31s. 6d.

**MITCHELL.** MANUAL OF PRACTICAL ASSAYING. By JOHN MITCHELL, F.C.S. Sixth Edition. Edited by W. CROOKES, F.R.S. With 201 Woodcuts. 8vo, 31s. 6d.

**MORGAN.** ANIMAL BIOLOGY. An Elementary Text Book. By C. LLOYD MORGAN, Professor of Animal Biology and Geology in University College, Bristol. With numerous Illustrations. Crown 8vo, 8s. 6d.

**MUIR.** THE ALCHEMICAL ESSENCE AND THE CHEMICAL ELEMENT: an Episode in the Quest of the Unchanging. By M. M. PATTISON MUIR, Fellow of Gonville and Caius College, Cambridge. 8vo. 4s. 6d.

**ODLING.** A COURSE OF PRACTICAL CHEMISTRY, Arranged for the use of Medical Students, with express reference to the Three Months Summer Practice. By WILLIAM ODLING, M.A., F.R.S. With 71 Woodcuts. Crown 8vo, 6s.

**OSTWALD.** SOLUTIONS. By W. OSTWALD, Professor of Chemistry in the University of Leipzig. Being the Fourth Book, with some additions, of the Second Edition of Ostwald's "*Lehrbuch der Allgemeinen Chemie.*" Translated by M. M. PATTISON MUIR, Professor of Gonville and Caius College, Cambridge. 8vo, 10s. 6d.

**PAYEN.** INDUSTRIAL CHEMISTRY; A Manual for use in Technical Colleges or Schools, also for Manufacturers and others, based on a Translation of Stohmann and Engler's German Edition of PAYEN's *Précis de Chimie Industrielle.* Edited and supplemented with Chapters on the Chemistry of the Metals, &c., by B. H. PAUL, Ph.D. With 698 Woodcuts. 8vo, 42s.

**REYNOLDS.** EXPERIMENTAL CHEMISTRY for Junior Students. By J. EMERSON REYNOLDS, M.D., F.R.S., Professor of Chemistry, Univ. of Dublin. Fcp. 8vo, with numerous Woodcuts.

PART I.—*Introductory*, 1s. 6d. PART III.—*Metals and Allied Bodies*, 3s. 6d.

PART II.—*Non-Metals*, 2s. 6d. PART IV.—*Chemistry of Carbon Compounds*, 4s.



## PROCTOR.—WORKS by RICHARD A. PROCTOR.

OLD AND NEW ASTRONOMY. In 12 Parts. Price 2s. 6d. each ; supplementary section, 1s. ; complete, 36s. cloth.

LIGHT SCIENCE FOR LEISURE HOURS ; Familiar Essays on Scientific Subjects, Natural Phenomena, &c. 3 Vols. crown 8vo, 5s. each.

THE ORBS AROUND US ; a Series of Essays on the Moon and Planets, Meteors, and Comets. With Chart and Diagrams, crown 8vo, 5s. Cheap Edition, crown 8vo, 3s. 6d.

OTHER WORLDS THAN OURS ; The Plurality of Worlds Studied under the Light of Recent Scientific Researches. With 14 Illustrations, crown 8vo, 5s. Cheap Edition, crown 8vo, 3s. 6d.

THE MOON ; her Motions, Aspects, Scenery, and Physical Condition. With Plates, Charts, Woodcuts, and Lunar Photographs, crown 8vo, 5s.

UNIVERSE OF STARS ; Presenting Researches into and New Views respecting the Constitution of the Heavens. With 22 Charts and 22 Diagrams, 8vo. 10s. 6d.

LARGER STAR ATLAS for the Library, in 12 Circular Maps, with Introduction and 2 Index Pages. Folio, 15s., or Maps only, 12s. 6d.

NEW STAR ATLAS for the Library, the School, and the Observatory, in 12 Circular Maps (with 2 Index Plates). Crown 8vo, 5s.

THE STUDENT'S ATLAS. In 12 Circular Maps on a Uniform Projection and 1 Scale, with 2 Index Maps. Intended as a *vade-mecum* for the Student of History, Travel, Geography, Geology, and Political Economy. With a letter-press Introduction illustrated by several cuts. 5s.

ELEMENTARY PHYSICAL GEOGRAPHY. With 33 Maps and Woodcuts. Fcp. 8vo, 1s. 6d.

LESSONS IN ELEMENTARY ASTRONOMY ; with Hints for Young Telescopists. With 47 Woodcuts. Fcp. 8vo, 1s. 6d.

FIRST STEPS IN GEOMETRY : a Series of Hints for the Solution of Geometrical Problems ; with Notes on Euclid, useful Working Propositions, and many Examples. Fcp. 8vo, 3s. 6d.

EASY LESSONS IN THE DIFFERENTIAL CALCULUS : indicating from the Outset the Utility of the Processes called Differentiation and Integration. Fcp. 8vo, 2s. 6d.

THE STARS IN THEIR SEASONS. An Easy Guide to a Knowledge of the Star Groups, in 12 Large Maps. Imperial 8vo, 5s.

STAR PRIMER. Showing the Starry Sky Week by Week, in 24 Hourly Maps. Crown 4to, 2s. 6d.

ROUGH WAYS MADE SMOOTH. Familiar Essays on Scientific Subjects. Crown, 3s. 6d.

HOW TO PLAY WHIST : WITH THE LAWS AND ETIQUETTE OF WHIST. Crown 8vo, 3s. 6d.

HOME WHIST : an Easy Guide to Correct Play. 16mo, 1s.

OUR PLACE AMONG INFINITIES. A Series of Essays contrasting our Little Abode in Space and Time with the Infinities around us. Crown 8vo, 5s.

STRENGTH AND HAPPINESS. Crown 8vo, 5s.

[Continued.]



**PROCTOR.**—*WORKS by RICHARD A. PROCTOR—continued.*

**STRENGTH :** How to get Strong and keep Strong, with Chapters on Rowing and Swimming, Fat, Age, and the Waist. With 9 Illustrations. Crown 8vo, 2s.

**THE EXPANSE OF HEAVEN.** Essays on the Wonders of the Firmament. Crown 8vo, 5s. Cheap Edition, crown 8vo, 3s. 6d.

**THE GREAT PYRAMID, OBSERVATORY, TOMB, AND TEMPLE.** With Illustrations. Crown 8vo, 5s.

**PLEASANT WAYS IN SCIENCE.** Crown 8vo, 5s. Cheap Edition, crown 8vo, 3s. 6d.

**MYTHS AND MARVELS OF ASTRONOMY.** Crown 8vo, 5s. Cheap Edition, crown 8vo, 3s. 6d.

**CHANCE AND LUCK ;** a Discussion of the Laws of Luck, Coincidences, Wagers, Lotteries, and the Fallacies of Gambling, &c. Crown 8vo, 2s. boards, 2s. 6d. cloth.

**NATURE STUDIES.** By GRANT ALLEN, A. WILSON, T. FOSTER, E. CLODD, and R. A. PROCTOR. Crown 8vo, 5s. Cheap Edition, crown 8vo, 3s. 6d.

**LEISURE READINGS.** By E. CLODD, A. WILSON, T. FOSTER, A. C. RUNYARD, and R. A. PROCTOR. Crown 8vo, 5s.

**SLINGO AND BROOKER.** ELECTRICAL ENGINEERING FOR ELECTRIC LIGHT ARTISANS AND STUDENTS.

(Embracing those branches prescribed in the Syllabus issued by the City and Guilds Technical Institute.) By W. SLINGO, Principal of the Telegraphists' School of Science, &c., &c., and A. BROOKER, Instructor on Electrical Engineering at the Telegraphists' School of Science. With 307 Illustrations. Crown 8vo, 10s. 6d.

**SMITH.** GRAPHICS ; OR, THE ART OF CALCULATION BY DRAWING LINES,

applied to Mathematics, Theoretical Mechanics and Engineering, including the Kinetics and Dynamics of Machinery, and the Statics of Machines, Bridges, Roofs, and other Engineering Structures. By ROBERT H. SMITH, Professor of Civil and Mechanical Engineering, Mason Science College, Birmingham.

PART I. Text, with separate Atlas of Plates—Arithmetic, Algebra, Trigonometry, Vector, and Locor Addition, Machine Kinematics, and Statics of Flat and Solid Structures. 8vo, 15s.

**THORPE.** A DICTIONARY OF APPLIED CHEMISTRY.

By T. E. THORPE, B.Sc. (Vict.), Ph.D., F.R.S., Treas. C.S., Professor of Chemistry in the Royal College of Science, London. Assisted by Eminent Contributors. To be published in 3 vols. 8vo. Vols. I. and II. £2 2s. each, Vol. III. £3 3s.



**TYNDALL.**—*WORKS by JOHN TYNDALL, F.R.S., &c.*

FRAGMENTS OF SCIENCE. 2 Vols. Crown 8vo, 16s.

NEW FRAGMENTS. Crown 8vo, 10s. 6d.

HEAT A MODE OF MOTION. Crown 8vo, 12s.

SOUND. With 204 Woodcuts. Crown 8vo, 10s. 6d.

RESEARCHES ON DIAMAGNETISM AND MAGNE-CRYSTALLIC ACTION, including the question of Diamagnetic Polarity. Crown 8vo, 12s.

ESSAYS ON THE FLOATING-MATTER OF THE AIR in relation to Putrefaction and Infection. With 24 Woodcuts. Crown 8vo, 7s. 6d.

LECTURES ON LIGHT, delivered in America in 1872 and 1873. With 57 Diagrams. Crown 8vo, 5s.

LESSONS IN ELECTRICITY AT THE ROYAL INSTITUTION, 1875-76. With 58 Woodcuts. Crown 8vo, 2s. 6d.

NOTES OF A COURSE OF SEVEN LECTURES ON ELECTRICAL PHENOMENA AND THEORIES, delivered at the Royal Institution. Crown 8vo, 1s. 6d.

NOTES OF A COURSE OF NINE LECTURES ON LIGHT, delivered at the Royal Institution. Crown 8vo, 1s. 6d.

FARADAY AS A DISCOVERER. Crown 8vo, 3s. 6d.

**WATTS' DICTIONARY OF CHEMISTRY.** Revised and entirely Re-written by H. FORSTER MORLEY, M.A., D.Sc., Fellow of, and lately Assistant-Professor of Chemistry in, University College, London; and M. M. PATTISON MUIR, M.A., F.R.S.E., Fellow, and Prælector in Chemistry, of Gonville and Caius College, Cambridge. Assisted by Eminent Contributors. To be Published in 4 Vols. 8vo. Vols. I. II. 42s. each. Vol. III. 50s. Vol. IV. 63s.

**WEBB.** CELESTIAL OBJECTS FOR COMMON TELESCOPES.


By the Rev. T. W. WEBB, M.A., F.R.A.S., Vicar of Hardwick, Herefordshire. Fifth Edition, Revised and greatly Enlarged by the Rev. T. E. ESPIN, M.A., F.R.A.S. (Two Volumes.)

VOL. I. With Portrait and a Reminiscence of the Author, 2 Plates, and numerous Illustrations. Crown 8vo, 6s.

VOL. II. With Illustrations and Map of Star Spectra. Crown 8vo, 6s. 6d.

**WRIGHT.** OPTICAL PROJECTION: A Treatise on the Use of the Lantern in Exhibition and Scientific Demonstration. By LEWIS WRIGHT, Author of "Light: a Course of Experimental Optics." With 232 Illustrations. Crown 8vo, 6s.







1



