

The use of the laryngoscope in diseases of the throat : with an appendix on rhinoscopy / by Morell Mackenzie.

Contributors

Mackenzie, Morell, 1837-1892.

Publication/Creation

London : Longmans, Green, 1871.

Persistent URL

<https://wellcomecollection.org/works/bn578v93>

License and attribution

This work has been identified as being free of known restrictions under copyright law, including all related and neighbouring rights and is being made available under the Creative Commons, Public Domain Mark.

You can copy, modify, distribute and perform the work, even for commercial purposes, without asking permission.



Wellcome Collection
183 Euston Road
London NW1 2BE UK
T +44 (0)20 7611 8722
E library@wellcomecollection.org
<https://wellcomecollection.org>





22101030200



R.S. Q. C. (2)

THE
USE OF THE LARYNGOSCOPE
IN
DISEASES OF THE THROAT.

By the same Author.

ESSAYS ON DISEASES OF THE THROAT.

BASED ON THE

JACKSONIAN PRIZE ESSAY FOR 1863.

No. I.

HOARSENESS, LOSS OF VOICE, AND STRIDULOUS BREATHING,
IN RELATION TO NERVO-MUSCULAR AFFECTIONS OF THE LARYNX.

No. II.

Just published, profusely illustrated with Wood-engravings and
Chromo-lithographs,

GROWTHS IN THE LARYNX:

WITH REPORTS, AND AN ANALYSIS OF ONE HUNDRED CASES TREATED
BY THE AUTHOR, AND A TABULAR STATEMENT OF EVERY
TREATED CASE PUBLISHED SINCE THE INVENTION
OF THE LARYNGOSCOPE.

J. & A. CHURCHILL, 11, NEW BURLINGTON STREET.

73336

THE
USE OF THE LARYNGOSCOPE

IN
DISEASES OF THE THROAT:

WITH AN
APPENDIX ON RHINOSCOPY.

BY
MORELL MACKENZIE, M.D.LOND., M.R.C.P.,
PHYSICIAN TO THE HOSPITAL FOR DISEASES OF THE THROAT, AND TO THE ROYAL SOCIETY
OF MUSICIANS; AND ASSISTANT-PHYSICIAN AND LECTURER ON DISEASES
OF THE THROAT AT THE LONDON HOSPITAL.

THIRD EDITION, REVISED AND ENLARGED.

LONDON:
LONGMANS, GREEN, & CO.

—
1871.

[The right of Translation is reserved.]

LARYNGOSCOPY, Texts : 17 cent

PROCEEDINGS OF THE SOCIETY OF THE THROAT

PROCEEDINGS OF THE SOCIETY OF THE THROAT

195, 1956 (2)



M20290

WELLCOME INSTITUTE LIBRARY	
Acc.	73336
Call No.	WV500
	1871
	M15u

To the Memory of

FREDERICK RYLAND,

AUTHOR OF THE JACKSONIAN PRIZE ESSAY FOR THE YEAR 1835,


"ON INJURIES AND DISEASES OF THE LARYNX & TRACHEA,"

These Pages are Dedicated,

IN GRATEFUL APPRECIATION OF HIS VALUABLE RESEARCHES

MADE AT A PERIOD ANTECEDENT TO THE INVENTION

OF THE LARYNGOSCOPE.



PREFACE TO THE THIRD EDITION.

THIS little work has remained for some time out of print, my numerous professional engagements having unfortunately delayed its revision, and thus prevented its re-issue.

Considerable additional matter and numerous wood-cuts have been added, and no effort has been spared to render the treatise a thorough guide to the theory and art of Laryngoscopy, as now practised.

The best evidence of the appreciation of a book is no doubt to be found in its sale; but were I to seek for further testimony, I should refer to the fact, that the only other systematic text-book on the Laryngoscope, published in this country, is based entirely on my treatise, and to the circumstance, that its author has paid me the very flattering, though somewhat unusual, compliment, of allowing several of my drawings to appear as his own.

13, Weymouth Street, Portland Place,
May, 1871.

PREFACE TO THE SECOND EDITION.

THE rapid exhaustion of the first edition of this treatise, and its reprint and favourable reception in America, may, perhaps, without egotism, be regarded as indications that the little work supplied a definite want in Medical Literature.

This circumstance, together with the fact that it is at present in the hands of a French translator, has stimulated me, by careful revision and amplification of the text, and by the addition of new woodcuts, to render it more worthy of the flattering reception it has already experienced.

October, 1866.

PREFACE TO THE FIRST EDITION.

VISITING Professor Czermak, at Pesth, in the year 1859, I became acquainted with Laryngoscopy, whilst the art was still in its cradle. Since then, I have devoted much time and attention to this new department of practical medicine; and I trust that this treatise—though merely an outline of the subject—will show **that my labour has not been altogether in vain.**

Whilst paying due regard to the theoretical aspect of Laryngoscopy, I have especially endeavoured to elucidate its practical bearings. In entering into minute details concerning the mode of employing the laryngeal mirror, in accurately describing the various laryngeal instruments and in carefully explaining their manipulation, it is my hope that the art of Laryngoscopy may be more readily understood and more widely practised.

To enter into the pathology and treatment of laryngeal disease in general, would have been quite foreign to the object of this manual; but, I trust, before long, to bring the subject under the notice of the medical public in a manner worthy of its importance.

I take this opportunity of thanking the numerous members of the profession who have kindly placed cases at my service; and I must acknowledge my obligations to Dr. Frodsham in particular—himself a practised laryngoscopist—for his personal assistance at many delicate operations, performed with the aid of the laryngeal mirror.

January, 1865.

TABLE OF CONTENTS.

CHAPTER I.

HISTORY—LEVRET—BOZZINI—DE LATOUR—SENN—BABINGTON— BENNATI—BAUMÊS—LISTON—WARDEN—AVERY—GARCIA— TÜRCK—CZERMAK	<i>Page 1</i>
---	-----	-----	-----	---------------

CHAPTER II.

DESCRIPTION OF THE LARYNGOSCOPE—THE LARYNGEAL MIRROR— REFLECTOR—LAMPS—LIGHT-CONCENTRATORS—OXY-HYDROGEN LIGHT—DIRECT AND REFLECTED LIGHT COMPARED—SUN- LIGHT—ILLUMINATION BY TRANSPARENCY	...	<i>Page 32</i>
---	-----	----------------

CHAPTER III.

THE ART OF LARYNGOSCOPY—PRINCIPLES—PRACTICE—FAULTS TO BE AVOIDED—SPECIAL DIFFICULTIES...	...	<i>Page 53</i>
---	-----	----------------

CHAPTER IV.

THE HEALTHY LARYNX AS SEEN WITH THE LARYNGOSCOPE.	<i>Page 69</i>
---	----------------

CHAPTER V.

ACCESSORIES OF LARYNGOSCOPY—AUTO-LARYNGOSCOPY—RECIPRO-
LARYNGOSCOPY—INFRA-GLOTTIC LARYNGOSCOPY—MAGNIFYING
INSTRUMENTS—MICROMETERS—THE EPIGLOTTIC PINCETTE—
THE SELF-HOLDER, SOUNDS, LARYNGOSCOPIC CHAIRS, HEAD-
RESTS, ETC. *Page 77*

CHAPTER VI.

THE APPLICATION OF REMEDIES TO THE LARYNX WITH THE AID
OF THE LARYNGOSCOPE—SOLUTIONS—INHALATIONS—POW-
DERS—SOLID NITRATE OF SILVER—ESCHAROTICS—FARADISA-
TION *Page 96*

CHAPTER VII.

OPERATIONS ON THE LARYNX—SCARIFICATION—THE EXTIRPATION
OF GROWTHS, AND REMOVAL OF FOREIGN BODIES. *Page 118*

CHAPTER VIII.

THE MANIPULATION OF LARYNGEAL INSTRUMENTS—CONCLUDING
REMARKS ON LARYNGOSCOPY—BIBLIOGRAPHY... *Page 154*

APPENDIX.

RHINOSCOPY—HISTORY—THEORY—PRACTICE—THE RHINAL IMAGE
—SPECIAL DIFFICULTIES—ANTERIOR RHINOSCOPY—USE OF
RHINOSCOPY—BIBLIOGRAPHY. *Page 159*

INDEX.

TABLE OF ILLUSTRATIONS.

	PAGE
<i>Fig. 1.</i> —Bozzini's Laryngeal Speculum (<i>after Hufeland</i>) ...	9
<i>Fig. 2.</i> —Dr. Babington's Laryngeal Mirror	14
<i>Fig. 3.</i> —Avery's Laryngoscope	24
<i>Fig. 4.</i> —Laryngeal Mirror	33
<i>Fig. 5.</i> —Reflector attached to Spectacle-frame	37
<i>Fig. 6.</i> —Rack-movement Lamp	33
<i>Fig. 7.</i> —Clinical Lamp	40
<i>Fig. 8.</i> —Light Concentrator	41
<i>Fig. 9.</i> —Oxy-hydrogen Light and Examining Chair ...	46
<i>Fig. 10.</i> —Diagram showing the relative positions of the planes of the larynx and laryngeal mirror ...	54
<i>Fig. 11.</i> —Drawing showing the relation of parts in the larynx and the laryngeal mirror	56
<i>Fig. 12.</i> —The position of the hand and mirror, when the latter has been properly introduced for obtain- ing a view of the larynx.	60
<i>Fig. 13.</i> —Diagram shewing the angles of incidence and reflexion in ordinary and infra-glottic laryngo- scopy	63

	PAGE
<i>Fig.</i> 14.—Laryngoscopic drawing, showing the vocal cords drawn widely apart, and the position of the various parts above and below the glottis, during quiet inspiration	70
<i>Fig.</i> 15.—Laryngoscopic drawing, showing the approximation of the vocal cords, and the position of the various parts in the act of vocalisation ...	70
<i>Fig.</i> 16.—Dr. Smyly's Recipro-Laryngoscope	81
<i>Fig.</i> 17.—The Epiglottic Pincette... ..	86
<i>Fig.</i> 18.—The Self-holder, or <i>Fixateur</i>	88
<i>Fig.</i> 19.—Laryngeal Sounds	91
<i>Fig.</i> 20.—The Head-rest	92
<i>Fig.</i> 21.—Laryngoscopic Chair	94
<i>Fig.</i> 22.—Mayer's Atomiser	100
<i>Fig.</i> 23.—Siegle's Apparatus	101
<i>Fig.</i> 24.—Eclectic Inhaler	103
<i>Fig.</i> 25.—The Laryngeal Electrode No. 1, and Necklet ...	108
<i>Fig.</i> 26.—The Laryngeal Electrodes, Nos. 2 and 3 ...	110
<i>Fig.</i> 27.—The Laryngeal Lancet and Knives	119
<i>Fig.</i> 28.—Chronic œdema of the larynx	122
<i>Figs.</i> 29 and 30.—Œdema of the epiglottis and ary-epiglottic fold	123
<i>Fig.</i> 31.—The Tube-Forceps and Scissors	127
<i>Fig.</i> 32.—Ordinary Laryngeal Forceps	131
<i>Fig.</i> 33.—Diagram showing direction of author's Rectangular Forceps... ..	132
<i>Fig.</i> 34.—Stoerck's Laryngeal Instruments for the Removal of Growths	134

	PAGE
<i>Fig.</i> 35.—Guarded-wheel Ecraseur	135
<i>Fig.</i> 36.—Laryngeal Rigid Wire Loops	137
<i>Fig.</i> 37.—Excrescences in the larynx	138
<i>Fig.</i> 38.—Excrescences on, and beneath, the vocal cords...	140
<i>Fig.</i> 39.—A small wart on the left vocal cord	141
<i>Fig.</i> 40.—Warts on the vocal cords	143
<i>Fig.</i> 41.—A small polypus, attached near the anterior insertion of the vocal cords	144
<i>Fig.</i> 42.—Warts on the vocal cords	146
<i>Fig.</i> 43.—Warty growth attached to right vocal cord ...	149
<i>Fig.</i> 44.—Contraction of the left glosso-epiglottic fold ...	152
<i>Fig.</i> 45.—The posterior nares, as seen in Rhinoscopy ...	163
<i>Fig.</i> 46.—Swelling of the mucous membrane of the posterior nares	169
<i>Fig.</i> 47.—Ulcers in the posterior nares, causing ozoena ...	170

THE LARYNGOSCOPE.

CHAPTER I.

HISTORY OF THE INVENTION OF THE LARYNGOSCOPE.

“Honour belongs to the first suggestion of a discovery, if that suggestion was the means of setting some one to work to verify it; but the world must ever look upon this last operation as the crowning exploit.”—BAIN.

IT may seem strange to some that it was not till the middle of the last century that an instrument was invented for examining the lower part of the throat during life, nor till more than a hundred years later that that instrument was sufficiently improved and simplified to be capable of general application. The dentist's mirror seems to have been used from time immemorial,* and polished tubes for passing into the external canals of the

CHAP. I.
—

* In the Augustan age, dental surgery had attained a degree of perfection which implies the employment of mirrors for examining the inner surface of the teeth.—Celsus, lib. vii, cap. xii.

CHAP. I. body, and thus obtaining an inspection, are of very
— ancient origin.*

A mere transfer of the dentist's mirror from the mouth to the back of the throat was not however sufficient to give birth to the laryngoscope; and the speculum (which is simply a rigid tube meant to press back the flaccid walls of a straight canal, and thus allow luminous rays to pass through it) was not applicable to the examination of a part situated at an angle to the line of vision. It was only by a combination of these two elements (reflexion and illumination) that the interior of the larynx could be seen in the living subject. This fact, together with the circumstance that it was not till comparatively recently, that physicians attempted to discriminate between diseases of the fauces and those of the windpipe, will perhaps account for the non-invention of the laryngoscope at an earlier date. Whatever the cause may be, however, there is no trace of a laryngoscope before the middle of the eighteenth century.

Levret. In the year 1743, and probably some years previously, M. Levret, a distinguished French accoucheur, whose highly inventive genius had led him to contrive surgical instruments of almost every

* Some of my readers, who have been in Italy, may have seen the speculum found in excavating the buried city of Pompeii.

description, occupied himself in discovering means, whereby polypoid growths in the nostrils, throat, ears, and other parts, could be tied by ligatures.* It is unnecessary to describe here, the various ingenious instruments which he invented for the purpose, and it is only requisite to observe that in using them he employed a speculum which differed from the various *specula oris* then in use. It consisted mainly of a plate of polished metal (*plaque polie*), which “reflected the luminous rays in the direction of the tumour,” and at the same time received the image of the tumour on its reflecting

* “*Mercure de France*”, 1743, p. 2434. The extract from the “*Mercure de France*”, which relates to the employment of the speculum, forms the first article of the appendix to M. Levret’s well-known work “*L’Art des Accouchements*” (second edition, Paris, 1761). In this article, the term “Gozier” is used in one place, and “Gosier” in another. In the latter, the expression used is—“mais pour en appliquer l’usage [of the instrument for carrying the ligature] aux Polypes du Gosier, situés derrière la voile du palais, il a fallu pratiquer.....” From this, it may seem probable to some, that Levret, in using the term “Gosier”, meant the posterior nares. Such an employment of the word would, however, be quite exceptional; and it is much more likely that he referred to the “throat” generally. In the third edition of Levret’s work (the only one I have had the opportunity of consulting), the particular extract from the “*Mercure de France*”, which is quoted above from the second edition, has been omitted. I have to thank Dr. Christie, of Aberdeen, who was the first to call attention to Levret’s claims, for very kindly copying the entire extract, and placing it at my service.

CHAP. I. surface. It is evident that this little mirror* was
— regarded as a mere appendix of that which Levret considered much more important,—viz. his method of applying ligatures; and that he did not recognise its value as a means of diagnosis in diseases of the larynx. The whole subject was soon lost sight of, and it was not till more than fifty years later that it again excited attention.

Bozzini. Then it was that a certain Dr. Bozzini, of Frankfort-on-the-Maine, made a great sensation throughout Germany, with his invention for illuminating the various canals of the body. About the year 1804, he first made known his ideas, which in the beginning were treated with derision. Gradually, however, the fame of the physician spread, the value of his invention was enormously exaggerated, and not only the professional press, but even political and literary journals, teemed with accounts of the wondrous apparatus. In the year 1807, Dr. Bozzini published a work on the subject of his invention, entitled "The Light-Conductor, or Description of a Simple Apparatus for

* Since I first published a detailed history of the invention of the laryngoscope, a more extensive description of Levret's instrument has been given by Sir Duncan Gibb. ("The Laryngoscope", 1868, p. 4.) From this it appears that Levret's instrument partook more of the nature of a pharyngoscope than a laryngoscope.

the Illumination of the Internal Cavities and Spaces in the Living Animal Body.”* About this time, the public seem to have become still more impressed with the value of Dr. Bozzini’s invention, and an absurd idea appears to have got abroad that the apparatus would enable practitioners to inspect, not merely the outlets of the body, but even the internal viscera. There was nothing in the work, except perhaps its rather ambitious title, to encourage this idea; but this did not save it from incurring the wrath of the profession. It is curious, that the feeling against the invention should have been strongest in the very city from which so many of the earliest and most valuable laryngoscopic observations afterwards issued. The faculty of Physicians of Vienna, in concert with the Members of the Joseph’s Academy, passed a very damaging opinion on Dr. Bozzini’s invention. They prefaced their admonition by remarking that “premature conclusions were likely to be arrived at concerning the instrument;” and “that perhaps even there might be an outlay of money (!!), which might

* “Der Lichtleiter, oder Beschreibung einer einfachen Vorrichtung, und ihrer Anwendung zur Erleuchtung innerer Höhlen, und Zwischenräume des lebenden animalischen Körpers.” Von Philipp Bozzini, der Medizin und Chirurgie Doctor, mehrerer gelehrten Gesellschaften Mitgliede, u. s. w. 23 Seiten in Fol. geheftet. Weimar, 1807.

CHAP. I. afterwards be regretted." They then went on to say that "only very small and unimportant parts of the body could be examined;" that "the illuminated spot was so small—its diameter being never more than an inch—that if a person did not know beforehand exactly what he was to look at, he would not generally be able to tell what part of the body was presented to view."*

This was the spirit in which Bozzini's invention was received; a description† of it will show that it deserved a better fate. It consisted of two essential parts: 1st, a kind of lantern; and 2ndly, a number of hollow metal tubes (*specula*) for introducing into the various canals of the body. The lantern was a vase-shaped apparatus made of tin, in the centre of which was a small wax candle. The top of the apparatus was covered; but a large aperture at the upper part, and some holes in its base, allowed sufficient supply of air for the candle; the latter was fixed in a metal tube, and forced upwards by a spring, after the manner of a Palmer's lamp. In the side of the apparatus there

* "Salzburg Med.-Chi. Gaz.", Feb. 23rd, 1807.

† I have not been able to find Bozzini's original pamphlet; but an abridgment of it appeared in the "Salzburg Medico-Chirurgical Gazette", February 26th, 1807, and another in the seventeenth volume of Hufeland's "Arzeneikunde". The latter is illustrated with plates.

were two round holes, a larger and smaller one, opposite each other. To the smaller one an eye-piece was fixed, to the larger the speculum was fitted. The flame of the candle came just below the level of these two apertures. The mouth of the speculum—a tube of polished tin or silver—was always the same size; but the diameter of the tube beyond varied according to the canal into which it had to be introduced. The apparatus was about thirteen inches high, two inches from before backwards, and rather more than three from side to side. These measurements were considered necessary, in order that there should be sufficient space for the candle to burn steadily, and that the lantern should not become too hot. The eye-piece was arranged to fit the eye, so that everything was hidden from view, except the spot seen through the speculum. It may be remarked, that the vase-shaped chamber lined with tin constituted, in fact, two concave mirrors, one behind and the other in front of the candle; the posterior reflector (if the expression may be used) being perforated by a hole for the eye-piece, and the anterior by another for the speculum.

It is not necessary to enter into details concerning the different canals for which this “simple apparatus” was recommended; but the following

CHAP. I. quotation* shows that the requisites for making a
— laryngoscopic examination were fully appreciated by Dr. Bozzini :—“ *If a person wishes to see round a corner into a part of the throat,† or behind the palate into the posterior nares, the rays must be broken, and a mirror is required for illumination and reflexion.*” In employing reflected light, Bozzini had the speculum divided by a vertical partition, so that there were, in fact, two canals and two mirrors. One of these mirrors was intended to convey the light, the other to receive the image. We now know that this arrangement is quite unnecessary, as one mirror is able to serve both purposes. The annexed woodcut shows Bozzini’s speculum ; it is seen to bear a strong resemblance to the instrument invented at a later period by Avery. (See Fig. 3.)

This ingenious apparatus soon ceased to attract attention, and even the historical fact of its former existence was entirely overlooked for several years after the invention of the modern laryngoscope. Whether its neglect was due to the exaggerated

* Hufeland’s “Arzeneikunde”, bd. xvii, s. 116.

† The word used is “Schlund”. This term is now employed, anatomically speaking, for the pharynx ; but it is often used to express the throat generally, and by Hilpert is considered synonymous with “Kehle”, the larynx.

FIG. 1.

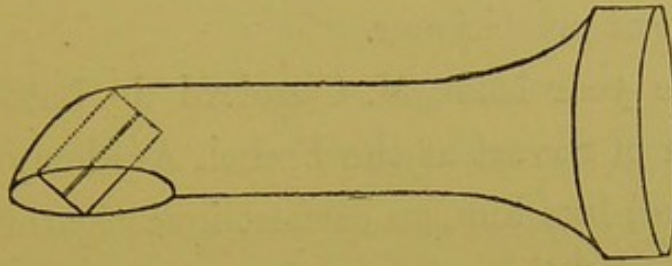


Fig. 1.—BOZZINI'S LARYNGEAL SPECULUM (*after Hufeland*).

The speculum was divided by a vertical partition, and two mirrors were placed at its extremity. In the drawing from which this is taken, the mirrors are directed upwards, as they would be when employed in rhinoscopy.

expectations, and subsequent disappointment of the public, to the organised opposition of the profession, or to certain constructive defects in the apparatus, it is now impossible to say; but probably they all combined towards the same end. The elements of laryngoscopy were undoubtedly contained in the "Light Conductor"; but it has been justly remarked* by one of the greatest living writers that "no art is complete, unless another art, that of constructing the tools *and fitting them for the purpose of the art*, is embodied in it." In this instance, the tools were not fitted for the purpose of the art; the latter, therefore, was never developed, and even the existence of the apparatus

* "System of Logic", Introduction, § 7. By John Stuart Mill.

CHAP. I. soon passed away from the burdened memory of
 — the medical practitioner.

*Cagniard de
 Latour.*

In the year 1825, M. Cagniard de Latour, the successor of Savart at the French Academy of Sciences, and, like him, an earnest investigator of the physiology of the voice, made an unsuccessful endeavour to examine the larynx during life.* His attempt is thus described in the *Institut*, No. 225. "M. Cagniard de Latour then introduced a little mirror to the back of the throat, hoping, with the aid of the solar rays and a second mirror, to be able to see the epiglottis, and even the glottis ; but by employing these means he was only able to see the epiglottis, and that imperfectly."

Senn.

In the year 1827, twenty years after the publication of Bozzini's pamphlet, Dr. Senn, of Geneva, tried to examine the larynx of a little girl, suffering from difficulty of breathing, and extreme dysphagia. The case was not a favourable one for the trial, and the attempt failed ; but as Dr. Senn did not employ any means for throwing a light into the larynx, it is not likely that his efforts would, under any circumstances, have proved more successful. He did not, like Bozzini before and Babington after him, perceive that in laryngoscopy, two factors

* "Physiologie de la Voix". Par Edouard Fournié. Paris : 1865, p. 352.

(illumination and reflexion) must always be employed. The following are Dr. Senn's remarks upon the subject:—"I had a little mirror constructed for introduction to the back of the pharynx; with it I tried to see the upper part of the larynx—the glottis; but I gave up its use on account of the small size of the instrument. However, I believe that this method could be employed with advantage in the case of adults, and that in certain cases of laryngeal phthisis it might assist in diagnosis.* Though this attempt was made in the year 1827, it was not recorded before the end of the year 1829; even then the account of the employment of the mirror was not embodied in the text of the report, but was merely appended as a note to the communication. The case was one of considerable interest, both on account of its general features, and especially from its having been one of the first in which a canulâ had been worn in the trachea for any length of time. It was particularly with reference to this circumstance, that the case had been brought before the Académie des Sciences on the 10th December, 1827.† In the published account of the séance there is no mention of any attempt at laryngoscopy.

* "Journal des Progrès", 1829, p. 231, note.

† "Journal Général de Médecine", tom. cii, Janvier, 1828.

CHAP. I.
—
Babington. In the year 1829,* Dr. Benjamin Guy Babington exhibited at the Hunterian Society of London, an instrument closely resembling the laryngoscope now in use. Two mirrors were employed by this physician, one, the smaller, for receiving the laryngeal image, the other, larger, for concentrating the solar rays on the first. The patient sat with his back to the sun, and, whilst the illuminating mirror (a common hand looking-glass) was held with the left hand, the laryngeal mirror—a glass one coated with quicksilver—was introduced with the right. By a very simple mechanism, a tongue-depressor was united with the laryngeal mirror, and thereby one of the most serious obstacles to laryngoscopy was attempted to be overcome. A spring was fixed between the shanks of the laryngeal mirror and spatula, in such a way, that, by pressing the two handles together, the tongue was depressed. At a later period (between the years 1829 and 1835), Dr. Babington abandoned the attractive combination of mirror and spatula, and had mirrors made, which closely resemble those now in general use. The mirrors were made of polished steel, and were, like those now in use, inclined to the shanks at an angle of about 120 deg. Though Dr. Babington used his laryngoscope on many patients, there are no cases recorded in which the instrument was employed.

* "Lond. Med. Gaz.," vol. iii, p. 555. London: 1829.

Priority of publication has long been the established touchstone, by which the disputed claims of inventors have been tested. Tried by this criterion, Babington must be regarded as the inventor of the laryngoscope; for, whilst an account of his invention was published in London, in March 1829, Senn's attempt to examine the larynx was not recorded in Paris till after August in the same year.* The claims of Babington, however, rest on something better than a technical basis; for whilst Senn merely attempted to employ a *laryngeal mirror*, Babington invented a *laryngoscope*. With the mirror alone it was impossible to see the interior of the larynx; but when a method of illumination was at the same time employed, the inspection became, if not easy, at any rate practicable. The only difference between Dr. Babington's laryngoscope and the one now in general use is, that whilst in the latter the light is thrown into the larynx (or rather on to the laryngeal mirror) by a circular mirror attached to the head of the operator, in the former the illumination was effected by a mirror held in the operator's hand. Dr. Babington, moreover, does not appear to have employed

* Dr. Senn's letter to the editor of the "Journal des Progrès", which accompanied the report of the case, is dated August. Probably it was not published till a month or two later.

FIG. 2.

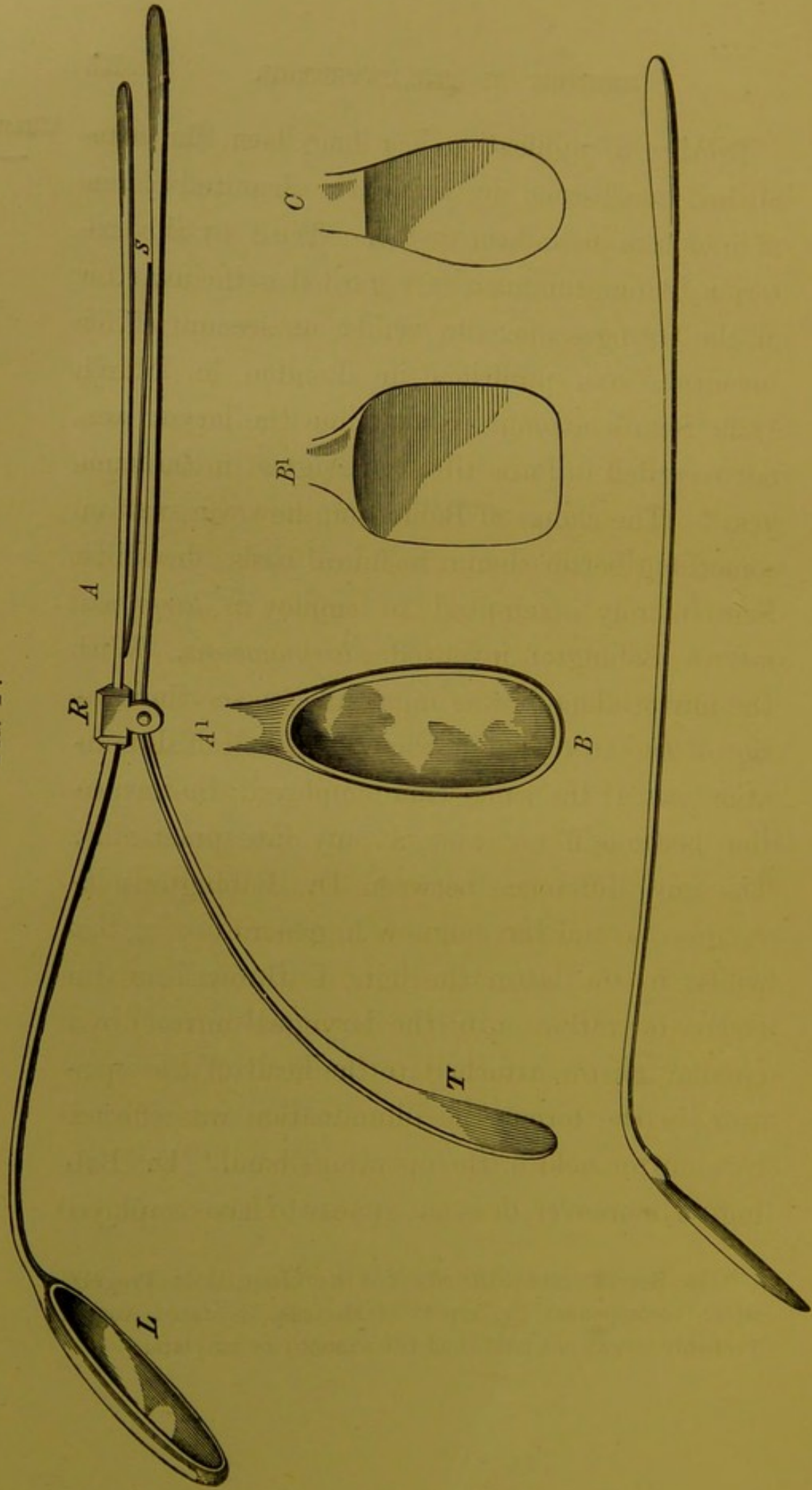


Fig. 2.—DR. BABINGTON'S LARYNGEAL MIRRORS.

DR. BABINGTON'S LARYNGEAL MIRRORS.

- A. The instrument, from which this drawing was taken, was exhibited by Dr. Babington at the Hunterian Society in 1829, and it was again shown, together with Dr. Babington's other mirrors, by me at the Medico-Chirurgical Society, April 26th, 1864.—(*Medical Times and Gazette*, vol. i, 1864, No. 723.)
- L. The laryngeal mirror. The steel stem of the mirror widens at one extremity into a frame which contains the glass.
- T. The tongue-depressor.
- R. A ring which connects the two instruments.
- S. A spring which presses the tongue-depressor down, when the two handles are held together.
- A¹. Front view of the mirror made in 1829.
- B. Side view of steel mirror made between the years 1829 and 1835.
- B¹. Front view of the same mirror.
- C. Oval mirror made between 1829 and 1835.

(These drawings are the exact shape and size of the instruments themselves.)

CHAP. I. artificial light; and his mirrors were of more clumsy construction than those now used. Those who have learnt to use the laryngoscope, will readily appreciate the difficulties of illuminating the larynx with a hand mirror; whilst in this country, where the sun very often does not shine brightly for weeks together, the art of laryngoscopy could never have flourished till artificial light had been substituted for the uncertain solar rays. 15'

Bennati. In the year 1832,* whilst Babington was still working with his "glottiscope", to use the term employed by him at the time, Dr. Bennati, of Paris, asserted his ability to see the vocal cords. A mechanic, named Selligie, who was suffering from laryngeal phthisis, had invented a double-tubed speculum, of which one tube served to carry the light to the glottis, and the other to bring back to the eye the image of the glottis reflected in the mirror, placed at the guttural extremity of the instrument. A complete recovery rewarded the ingenious patient for his clever invention, and with this instrument Bennati professed to be able to see the glottis. Trousseau, however, disbelieved his statements, and devoted several pages of his well-

* "Recherches sur le Mécanisme de la Voix Humaine", p. 37, note. Bennati uses the expression "au moyen d'un speculum que j'ai imaginé." As Trousseau, however, speaks

known work* to prove, that the epiglottis formed an insuperable impediment to a view of the interior of the larynx. This renowned physician had an instrument constructed after the model of Selligue's, but he does not appear to have attempted its use. It is worthy of note, that Selligue's laryngeal speculum closely resembled that of Bozzini, for whilst the latter was made in one tube divided by a vertical partition, the former consisted of two tubes.

In the year 1838,† M. Baumès exhibited at the Medical Society of Lyons a mirror about the size of a two-franc piece, which he described as being very useful for examining the posterior nares and larynx.

In the year 1840,‡ Liston, in treating of œdematous tumours which obstruct the larynx, observed

emphatically of *Bennati's experiments with Selligue's mirror*, and as there is no doubt that Selligue did invent a laryngeal mirror, I have adopted the view that his instrument was employed by Bennati. I have not thought it necessary to mention Gerdy in this historical notice of the *laryngoscope*, inasmuch as his allusion to the use of a mirror in 1830 ("Physiol. Med." p. 503) has reference only to the contraction of the *pharynx*.

* "Mémoire sur la Phthisie Laryngée". Par MM. Trousseau et Belloc. Mémoire de l'Académie de Médecine", tom. vi, 1837.

† "Compte Rendu des Travaux de la Société de Médecine de Lyons", 1836-38, p. 62.

‡ "Practical Surgery", third edition, p. 417. 1840.

Baumès.

Liston.

CHAP. I.

as follows: "The existence of this swelling may often be ascertained by a careful examination with the fingers, and a view of the parts may sometimes be obtained by means of a speculum—such a glass as is used by dentists on a long stalk, previously dipped in hot water, introduced with its reflecting surface downwards, and carried well into the fauces." When the real art of laryngoscopy was founded almost twenty years later, the name of our talented countryman was prominently associated with its invention. But it is obvious, from the above passage, that Liston never contemplated an inspection of the vocal cords. It is plain that in his estimation the sense of touch was more to be relied on than that of sight; and the fact that the fingers were to be used, indicates pretty clearly that Liston was referring rather to the epiglottis than the parts below.

Warden.

In the year 1844,* Dr. Warden, of Edinburgh, conceived the idea of employing a prism of flint glass for obtaining a view of the larynx. The success which had attended his efforts to inspect the membrane of the tympanum, induced him to apply

* Royal Scottish Society of Arts. Description, with illustrations, of a Totally Reflecting Prism for Illuminating the Open Cavities of the Body, etc., etc. May 1844. See also "Lond. Med. Gaz.", vol. xxiv, p. 256.

the principle of the prism to other canals. He reported two cases* in which he considered that he had had "satisfactory ocular inspection of diseases affecting the glottis." The possibility of inspecting the larynx in this way admits of no doubt,† but Dr. Warden's method of employing the prism was not calculated to bring about very favourable results. The particulars of one of the cases referred to are given; but in the other "the appearances were so far similar as to render their detail unimportant." The patient whose case is narrated was a lady, "who had been the subject of medical treatment for chronic inflammation of the pharynx of nearly a year's duration;" the inflammation had latterly spread in the direction of the glottis, and painful deglutition and paroxysms of suffocation now supervened. "After the preliminary examination, and quieting the irritability of the parts by touch with the finger, there was no longer any impediment or inconvenience experienced from the tendency to retching.....*The dilator faucium was employed to depress the tongue and expand the isthmus of the fauces.*" The result of the examination was that the epiglottis was seen to be very much thickened and inflamed, "but it was

* "Month. Journ. Med. Science", July 1845, p. 552.

† See page 34.

CHAP. I. only when efforts to swallow were made or repeated that the ary-tænoid cartilages, in a similar condition of thickening, were raised out of concealment, and brought brilliantly to show their picture in the reflecting face of the mirror." For the purpose of illumination, Dr. Warden employed "a powerful argand-lamp, with a large prism attached, so as to throw the full light of the lamp into the fauces and pharynx." That is to say, instead of the two plane mirrors we use (one for illumination, and the other for reflexion), he employed two prisms. In concluding the report of these cases, Dr. Warden remarks that "experience afforded by both gives ground for the same conclusion, that the instrument made use of can have no farther range than the bottom of the pharynx and mouth of the glottis,* and of the latter only so often as it is raised from its natural depth, by the contraction of the muscles employed in the act of deglutition.

* In using the expression "mouth of the glottis", Dr. Warden probably meant the upper opening of the larynx; that is to say, the opening bounded by the ary-epiglottic folds. He could not possibly have imagined that in deglutition the true vocal cords would be left uncovered by the epiglottis. It should be borne in mind (especially in reading cases reported a few years ago), that the term "glottis", now very properly confined to the aperture bounded by the true vocal cords, had till quite lately a very vague signification.—See Dunglison, "Dict. Med. Science".

By this means, therefore, we can obtain no assistance in the investigation or treatment of disease below the pharynx." It is not surprising that Dr. Warden should have expressed himself thus unfavourably concerning his attempts to examine the larynx. What "with quieting the irritability of the throat by touch with the finger, depressing the tongue, dilating the fauces, and encouraging the patient to swallow", it was utterly impossible for him to have succeeded. No disciple of Czermak could hope to see the vocal cords were he to prepare his patient in the way described by Warden; and when we remember how limited was his experience, and how imperfect his instruments, the appearances described by him can scarcely be regarded otherwise than the baseless fabric of a very imperfect vision.

In the year 1844, whilst Dr. Warden was still trying to employ the prism for examining the various canals of the body, Mr. Avery, of London, was seeking to accomplish the same end with the aid of the speculum and reflector. In principle Mr. Avery's laryngoscope was very similar to that now in use; and even in its details it did not differ widely from the modern instrument. Like Bozzini, forty years previously, Mr. Avery perceived the value of artificial light; and, like

Avery.

CHAP. I. Czermak after him, he employed a large circular reflector, perforated in the centre for concentrating the luminous rays on the laryngeal mirror. The reflector was attached to a frontal-pad; and this was retained in its place by two springs which passed over the operator's head to the occipital protuberance, where there was a counter-pad. There were two defects, however, in Avery's apparatus; the one was, that the laryngeal mirror (instead of being fixed to a slender shank) was placed at the end of a speculum; the other, that instead of employing the reflector for receiving the rays from a lamp placed on the table or elsewhere, Avery used his large circular mirror for the purpose of increasing the luminous power of a candle held near the patient's mouth. This candle was (like Bozzini's) a miniature Palmer's lamp, and was also attached to the frontal-pad.

A piece of bent wire, terminating in a circular loop, projected from the candle-lamp, and was meant to steady the speculum, and keep its axis in a line with the hole in the reflector. The reflector was five inches in diameter, and the apparatus which had to be worn by the operator weighed altogether nearly a pound. For those who preferred it, however, the candle-lamp and reflector could be fixed into the top of the box,

which contained the apparatus when not in use. The candle and reflector, fixed in this way and placed on a table, bore a strong resemblance to the "Light Conductor" of Bozzini, except that in the latter the light was entirely enclosed within the cavity of the vase-shaped lantern. By an ingenious double-rack movement, the reflector could be made to move either laterally or horizontally. This arrangement allowed for considerable range of distance between the nose and eyes, a high or low forehead, etc., and thus permitted different people to employ the same reflector, and still have the circular hole always opposite the pupil. It was difficult, indeed almost impossible, to introduce Avery's speculum, without irritating the base of the tongue and other contiguous parts, and thus causing a disposition to vomit. This feature alone would have been sufficient to ensure the failure of Mr. Avery's attempts at laryngoscopy, had not the cumbersome reflecting apparatus combined to produce the same result. The resemblance which Avery's laryngoscope bears to Bozzini's on the one hand, and to Czermak's on the other, is very striking. In all of them, artificial light, circular reflectors, and small laryngeal mirrors, were used. In the laryngoscope of Bozzini and Avery, the lamp and the reflector are combined, whilst in the

FIG. 3.

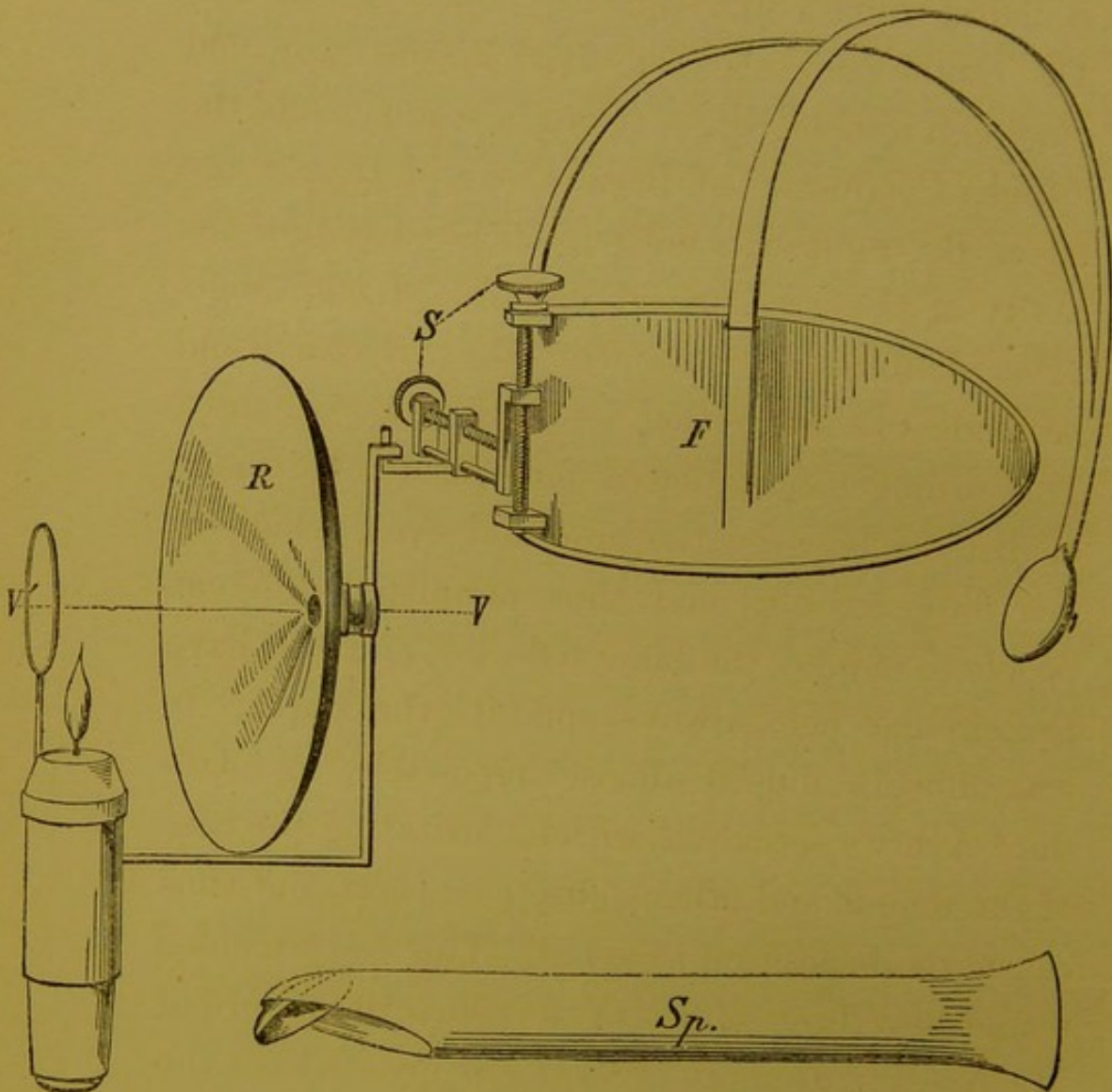


Fig. 3.—AVERY'S LARYNGOSCOPE.

- F.* One side of the frontal pad which supports the mirror. From it a double spring passes backwards to a counter-pad, which, when the instrument is worn, rests under the occipital protuberance. In the drawing, the occipital-pad is drawn forwards by the unopposed strength of the spring.
- S.* Screws by which the reflector can be made to move laterally and perpendicularly.
- R.* Reflector.
- V V.* Line of vision.
- Sp.* The speculum.

modern instrument they are separate. The laryngeal mirror of Bozzini and Avery was placed at the end of a speculum ; Czermak's was a modification of the dentist's mirror. Mr. Avery's invention was not placed on record* till some time after the modern laryngoscope had come into use. The laryngoscope from which the drawing on page 24 was taken, was supplied by Messrs. Weiss to the London Hospital, in the year 1846.

In the year 1854,† “the idea of employing mirrors for studying the interior of the larynx during singing” occurred to M. Manuel Garcia. He had often thought of it before, but, believing it impracticable, had never attempted to realise the idea. M. Garcia, though long a distinguished singing-master in London, was a Frenchman by birth, and a Spaniard by descent ; and, though his observations with the laryngoscope were first published in England, they were first made in France.

Garcia.

In the month of September 1854, whilst Garcia was spending his holidays in Paris, he determined to clear up his doubts concerning the possibility of

* “Med. Circ.”, vol. xx, June 1862 ; and “Introduction to the Art of Laryngoscopy”, by Dr. Yearsley. London : 1862.

† “Notice sur l'Invention du Laryngoscope”. Par Paulin Richard. Paris : 1861. See M. Garcia's letter to Dr. Larrey, dated May 4, 1860 (page 12 in Richard's pamphlet).

CHAP. I.
—

inspecting the larynx. His efforts were crowned with success, and the following year he presented a paper to the Royal Society of London, entitled "Physiological Observations on the Human Voice".* This paper contained an admirable account of the action of the vocal cords during inspiration and vocalisation; some very important remarks on the production of sound in the larynx; and some valuable reflections on the formation of the chest and falsetto notes. M. Garcia's laryngoscopic investigations were all made on himself; indeed, he was the first person who conceived the idea of an autoscopic examination.

His method, which he believed had never been employed by any one before, consisted in introducing a little mirror, fixed to a long stem, suitably bent, to the top of the pharynx. He directed that the person experimented upon should turn towards the sun, so that the luminous rays falling on the little mirror should be reflected into the larynx;† but he added in a foot-note, that "if the

* "Proc. Royal Society of London", vol. vii, No. 13, 1855; "Philosoph. Magazine and Journal of Science", vol. x, p. 218; and "Gaz. Hebdom. de Méd. et Chir.", Nov. 16, 1855, No. 46.

† It is worthy of note, that Garcia really never followed this plan, but, in point of fact, always used a second mirror for throwing the solar rays on to the laryngeal mirror. In the mirror which he used as a reflector, he also saw the autoscopic image.

observer experiments on himself, he ought, by means of a second mirror, to receive the rays of the sun, and direct them on the mirror which is placed against the uvula." In practising auto-laryngoscopy after the manner of Czermak, three mirrors are employed ; one for illumination, another for introducing to the fauces, and a third to enable the observer to see the image in the mirror held in his own throat. Garcia employed only two mirrors : a small one at the end of a long stem for introducing to the pharynx, and a large one, which served the double purpose of illuminating the little mirror, and enabling the operator to see the image formed on it. It will be seen that Garcia's method was precisely similar to that employed by Babington ; the one, however, limited his observations to his own larynx, the other never made an attempt at auto-laryngoscopy. Garcia's communication to the Royal Society, though causing little stir at the time, was destined to experience a fate in many respects similar to that which befell the paper of our countryman, Mr. Cumming.* Treated with apathy, if not with incredulity in England, both papers passed into the hands of foreign professors, and whilst Helmholtz matured the ophthalmoscope, Czermak developed the laryngoscope.

* "Transactions of Med. Chir. Soc.," 1846.

CHAP. I.

In the year 1857, during the summer months, the late Dr. Türck, of Vienna (who had read Garcia's paper), endeavoured to employ the laryngeal mirror in the wards of the General Hospital. He was not successful, however, at first, and at the end of the autumn he seems to have abandoned his fruitless attempts. Trusting entirely to the solar rays, having no apparatus (no second mirror) for concentrating the light on the laryngeal mirror, and the latter being a clumsy hinged instrument, it was scarcely possible for him to succeed. When at a later period, however, Czermak proved the practical value of the laryngoscope, Türck put forth his claims to priority. Nevertheless, in the very communication* in which he asserted his pretensions, he observed that "he was very far from having any exaggerated hopes about the employment of the laryngeal mirror in practical medicine." This unfortunate remark shows that he did not even then recognize the value of the laryngoscope.

Czermak. In the year 1857, in the month of November, Professor Czermak, of Pesth, borrowed from Dr. Türck the little mirrors which that gentleman, in spite of the exhortation of his friends, had thrown

* "Zeitschrift des Ges. der Aerzte zu Wien", April 26th, 1858.

aside as useless.* In a short time, his superior genius, untiring perseverance, and natural dexterity, enabled him to overcome all difficulties. When the dentist's mirror passed into the hands of Dr. Czermak, the examination of the larynx was dependent—so to speak—on the clock and the barometer—and he soon relieved it from both these troublesome monitors. Artificial light was substituted for the uncertain rays of the sun; the large ophthalmoscopic mirror of Ruete was used for concentrating the luminous rays; the awkward hinge which united the laryngeal mirror to its stem was dispensed with; and mirrors were made of different sizes. Thus it was that Czermak created the art of laryngoscopy. Others before him had contrived instruments, with which they had sometimes succeeded in inspecting the interior of the larynx, but “the tools fitted for the art” of laryngoscopy were not constructed before his time. His first publication appeared in March 1858,† and a month later a very important paper of his was brought before the Academy of Sciences of Vienna.‡ In claiming for Czermak the honour of

* Professor Brücke's Letter to Czermak. “Selected Monographs: New Syd. Soc.”, vol. xi.

† “Wien. Medizin. Wochenschrift”.

‡ “Physiolog. Unters. mit Garcia's Kehlkopfspiegel”, mit iii. Tafeln. Sitzber. d. k. k. Akademie d. Wiss. in Wien, vom 29

CHAP. I.
— having so modified the laryngoscope, that its application became comparatively easy, it would not be right to withhold from Dr. Türck the merit of having patiently and productively worked at the subject at a later period. A careful investigation of facts and dates, however, must convince every disinterested person, that Türck's subsequent successful labours were prompted by the proofs which Czermak had given of the value of the laryngoscope.

Czermak's investigations were at first confined to his own larynx, and his success must in part be attributed to his great physical advantages. Possessed of a most capacious pharynx, small tonsils and uvula, and a large laryngeal aperture, it would be difficult to find a subject better suited for laryngoscopy. Notwithstanding the beautiful simplicity effected by Czermak in the details of the laryngoscope, the profession might not, however, have become impressed with the value of the instrument, had not his brilliant demonstrations delighted and astonished the medical public throughout Europe. The general employment of the laryngoscope in practical medicine must, therefore, be attributed not less to his enthusiastic and uni-

April, Bd. xxix, p. 557. (Afterwards reprinted in a separate form.)

versal teaching—to his brilliant demonstrations and personal influence—than to his entire remodelling of the instrument itself. The fact, that no improvement has been made in the mechanism of the laryngoscope for the last ten years, though a great number of practical men in all parts of the world have been constantly working at the subject, is the strongest testimony to the value of Czermak's labours.

CHAP. I.
—

CHAPTER II.

DESCRIPTION OF THE LARYNGOSCOPE.

DEFINITION.—An instrument for obtaining a view of the interior of the larynx during life. It consists of two parts: 1st, a small mirror fixed to a long slender shank, which is introduced to the back of the throat; and 2ndly, an apparatus for throwing a strong light (solar or artificial) on to the small mirror. For thus projecting the luminous rays, a second (larger) mirror, which reflects the light from a lamp or the solar rays, may be employed; or artificial luminous rays may be concentrated by a lens directly on to the small mirror. When artificial light is employed, the illuminating mirror is slightly concave; when sunlight is used, its surface is plane.

SECTION I.—*The Laryngeal Mirror.*

CHAP. II. **T**HE laryngeal mirror may be made of polished steel, or of glass backed with amalgam. Though, on theoretical grounds, the steel mirrors give the more perfect image, they so readily become tarnished and rusty from the least moisture, are so immediately spoilt by the accidental contact of the medicated solutions used in treating laryngeal disease, and so soon become scratched in cleaning, that they are not found convenient in practice. The glass mirror is generally mounted

in German silver; for though the metal is too favourable to the rapid cooling of the mirror, and the consequent deposit of moisture upon it, it is more easy to fix the shank of the instrument to a frame of metal than to any other substance of inferior conducting power. The mirrors should not be more than one-twentieth of an inch in thickness.

The reflecting surface of the laryngeal mirror may vary from half an inch to an inch and a quarter in diameter. It is well to be provided with at least three mirrors, varying in size between the dimensions specified. The largest sized mirror is called No. 1, the middle sized one No. 2, and the smallest No. 3.

FIG. 4.

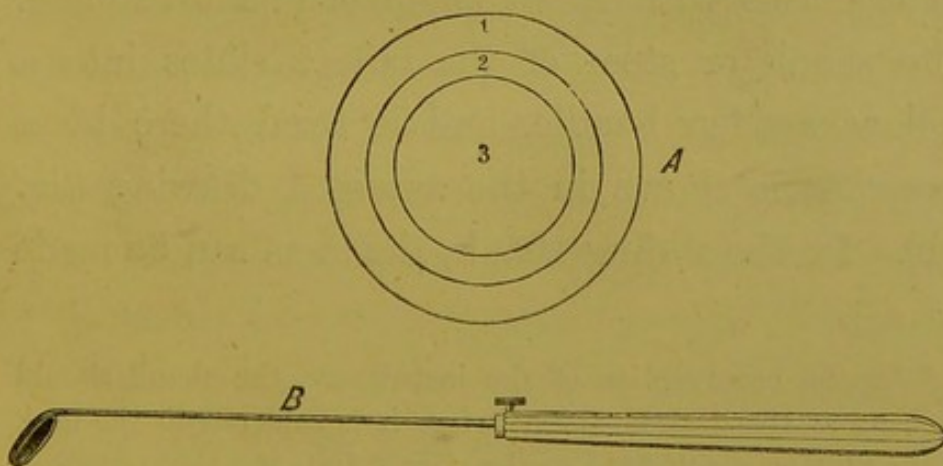


Fig. 4.—THE LARYNGEAL MIRROR.

- A.* Diagram showing the exact sizes of the reflecting surface of the mirrors Nos. 1, 2, and 3.
B. The mirror and holder (half size) seen in profile.

CHAP. II.

For ordinary purposes, a No. 2 mirror will be found most convenient. It may be of square, circular, or oval shape. The circular mirrors cause least irritation, except when enlarged tonsils are present. In those cases the oval mirrors are most suitable. The use of concave mirrors for magnifying the laryngeal image has been suggested (Wertheim); but whilst they only enlarge the image very slightly, their employment is objectionable optically, on account of the varying distance from the mirror of the parts reflected (Türck). The shank of the mirror should be of German silver; it ought to be about four inches in length, and one-tenth of an inch in thickness. It should be soldered* to the back of the mirror, so that the latter forms with it an angle of about 120 deg. The shank or stem of the mirror slides into a hollow wooden handle, and is fixed there by a screw, as is shown in the annexed drawing (fig. 4 B). In the sliding shank, the stem can be made

* In the construction of the instrument, the shank should be bent at the desired angle before it is soldered to the back of the mirror; for, if fixed to the mirror first, the angle (instead of being formed at the junction of the mirror and the shank) is obliged to be about one-tenth of an inch or more from the mirror. The space (viz., that between the mirror and the angle of the shank) which is thus lost would afford room for the employment of a larger mirror.

shorter or longer, according to the depth of the mouth from before backwards in different cases, but this is scarcely necessary. The handle should be about three inches in length, and rather more than a quarter of an inch in thickness. The little screw referred to is, however, apt to get loose, and if the stem is made moveable, the end had better be screwed into the handle—the end of the stem itself forming the screw.* It is better, perhaps, to have the stem and handle a fixture, as firmness is thereby ensured.

By my directions, some totally refracting prisms have been constructed,† with which I have frequently examined patients and demonstrated my own larynx. As the base of the prism is, however, necessarily almost a third larger than its refracting surfaces, the use of this kind of mirror implies a considerable loss of space. The prismatic mirrors are also much more difficult to introduce than the common flat ones, and the inferior surface of the prism is extremely likely to come in contact with the tongue; this, of course, for the time interferes with the passage of light through the prism. In the application of remedies to, or at

*Prismatic
Laryngeal
Mirrors.*

* I believe that this plan was first introduced by Dr. Elsberg of New York.

† By Mr. Ladd, of Beak Street.

CHAP. II. all events in delicate operations on, the larynx, the projecting triangle of the prism is likely to be in the way. Finally, the prismatic mirrors are much more expensive and more easily damaged than the flat ones. These conclusions from my experiments with prismatic mirrors are briefly related here for the purpose of deterring others from fruitless trials of a similar character.

SECTION II.—*Illumination.*

Reflector.

For throwing a light on to the laryngeal mirror, and thus into the larynx, it will be found most convenient to employ a circular mirror about three inches and a half in diameter, with a small hole in its centre.* When artificial light is employed, the mirror should be slightly concave and have a focal power of about fourteen inches; but when solar light is made use of, the surface of the mirror should be plane. The mirror may be attached in some way to the operator's head, or fixed to a horizontal arm which is connected with the body of the lamp (Tobold). The former plan is by far the

* The reflector should not merely be left unsilvered in the centre, but should be actually perforated. In the former case, the glass makes a slight focal inequality between the two eyes. Laryngoscopes, made in every respect according to my directions, are sold by Messrs. Mayer and Meltzer, 59, Great Portland Street.

FIG. 5.

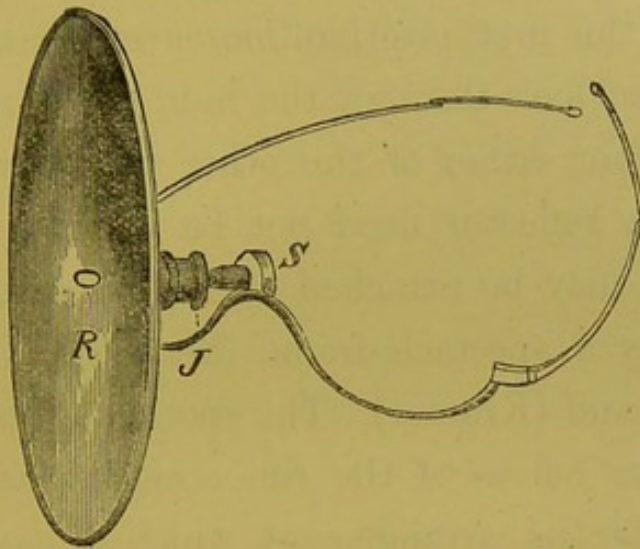


Fig. 5.—REFLECTOR ATTACHED TO SPECTACLE-FRAME, FROM WHICH THE UPPER HALVES OF THE RIMS HAVE BEEN REMOVED.

At the back of the reflector (*R*) is a small cup, into which a ball connected with the spectacle-frame fits. A ring is screwed over the ball, and the joint is thus formed at *J*.

most convenient, and the mirror may be worn either opposite one of the eyes (Czermak), in front of the nose and mouth (Bruns), or on the forehead (Fournié, Johnson, Mason, etc.). Of these positions, the first is, on theoretical grounds, the most perfect; the last the easiest in practice. The plan of looking through the hole of the reflector offers the great advantage of entirely protecting the observer's eyes from the glare of the light; for whilst the luminous rays necessarily fall obliquely on the mirror, and therefore do not reach the pupil of the eye immediately behind the mirror, the other eye

CHAP. II. is also within the shadow of the reflector. It is only in the first position, moreover, that the observer can look through the hole in the reflector; if, therefore, either of the other methods is practised, the reflector need not be perforated. The reflector may be attached to the operator's head either by a spectacle-frame (Semeleder), or by a frontal band (Kramer). The spectacle-frame, with the upper halves of the rim removed (as seen in Fig. 5), is the arrangement which I have found most convenient. In either case the mirror should be connected with its support by a ball-and-socket joint. The hole in the centre of the reflector should be oblong, and when placed in front of the eye, its long diameter should correspond with the long diameter of the eye. A hole of this shape allows for the varying distance between the nose and eyes in different people, and for the varying position of the centre of the reflector, in its different degrees of inclination.

It should be remarked that, though the employment of the reflector greatly facilitates the inspection of the larynx, a laryngoscopic examination can be effected without it. In this case a strong light must be thrown directly on to the laryngeal mirror.

Light.

Any lamp that gives a bright steady light

answers the purpose perfectly well. Many of the most valuable observations have been made with a common "moderator". An argand gas-burner will be found very convenient, especially if constructed on the reading-lamp principle, so that it can be fixed at different heights. My rack-movement laryngoscopic lamp, which readily admits of perpendicular and horizontal movement will be found to greatly facilitate the management of the light.

CHAP. II.

Lamps.

FIG. 6.

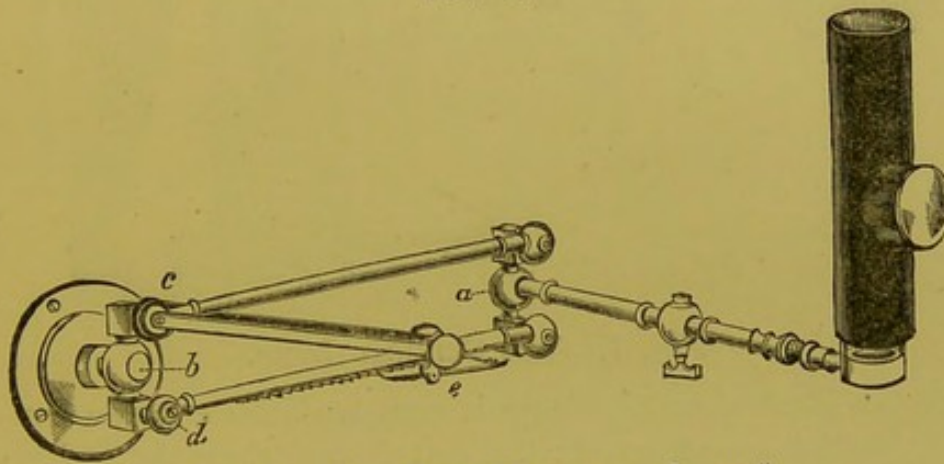


Fig. 6.—THE RACK-MOVEMENT LAMP.*

At *a* and *b* the horizontal movements can be effected; at *c* and *d* the vertical movement takes place. The gas passes only along the upper horizontal tube from *c*; in the lower tube is a rack which regulates the height of the lamp through the little handle *e*. The chimney of the lamp is made of metal, a round hole being left where the lens fits in.

Its action is shown in fig. 6. The power of the light may be advantageously increased by one or more lenses placed in front of the flame.

* Made by Mayer and Meltzer, of Great Portland Street.

CHAP. II.

For use at the bedside, where gas is not at hand, my new clinical lamp will be found very serviceable. It has the same action as the rack-movement lamp, but paraffin is used for illumination

FIG. 7.

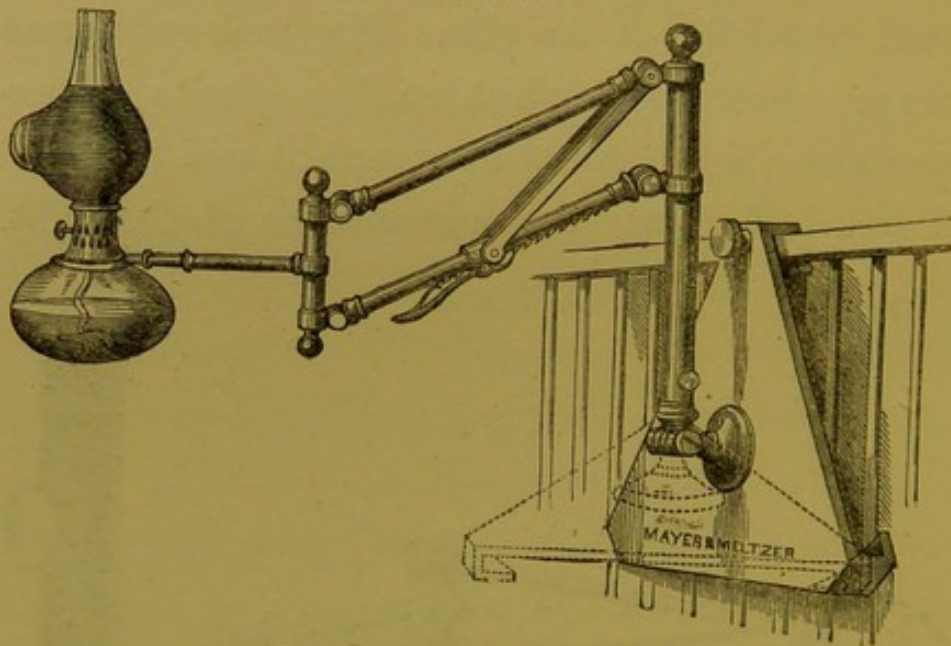


Fig. 7.—THE CLINICAL LAMP.

In the illustration, the lamp is seen hooked on to the horizontal bar of a bed; the dotted lines shew the position of the base when the lamp is standing on a table.

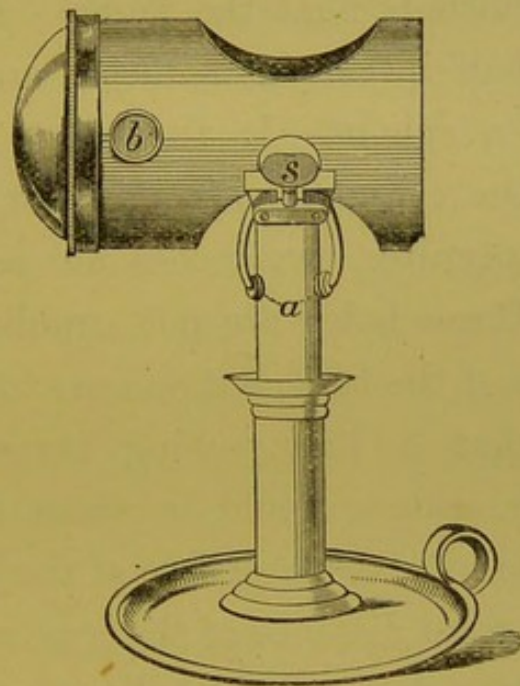
instead of gas. It makes a very useful lamp for the consulting-room. By reference to the woodcut (fig. 7), it will be seen that the base of the apparatus can be hooked on to the bar of a bed, and that the perpendicular stem rotates, so as to adapt itself to this position. On the other hand, when in use on the table, the stem can be easily adapted to the upright position by means of the screw at its foot.

In the various lamps or lanterns recommended by different foreign laryngoscopists (Tobold, Vol-
tolini, Moura-Bourouillou, etc., etc.), the arrange-
ment of lenses in each of them is only applicable
to the particular lamp for which it was contrived.
This serious objection to the various kinds of illu-

CHAP. II.

*Light Con-
centrator.*

FIG. 8.

*Fig. 8.*—THE LIGHT CONCENTRATOR.

In the drawing, the concentrator is fixed on to a candle by means of two arms (*a*). In using a lamp, the arms embrace the chimney: *s*, screw for tightening the arms; *b*, one of the cork knobs for taking hold of the concentrator when hot.

minating apparatus hitherto in vogue, led me to contrive a light-concentrator of more extensive application. It not only gives a very brilliant light,

CHAP. II. but is at the same time much smaller, and therefore much more portable than any of those hitherto in use, and it can be employed with any kind of lamp, or even a candle. It consists of a small metal cylinder, three and a half inches long, and two and a half in diameter. This is closed at one end, and at the other there is a plano-convex lens, the plane surface of which is next the flame. The lens is two and a half inches in diameter, and is about one-third of a sphere. In the upper and under surfaces of the cylinder (opposite each other) are two round apertures, two inches and a quarter in diameter. These holes are not equidistant from the two ends of the tube, but so near to the closed extremity, that a line passing perpendicularly through their centres would be about two inches and a half from the plane surface of the lens. This is the proper focal distance of the lens, and rays of light pass through in parallel direction. At the lower part of the tube are two semicircular arms, which, by means of a screw at the side, can be made to grasp tightly the largest lamp-chimney, an ordinary candle, or even the narrow stem of a single gas jet. The practitioner, therefore, who, in visiting patients, carries my light-concentrator, can always feel certain of being able to illuminate the fauces. The apparatus is passed over the chimney,

till the centre of the lens is opposite the most brilliant part of the flame, and then, by a few turns of the screw, the concentrator is fixed in position. When a candle is employed, the flame is in the centre of the tube.

In the side of the tube near the lens are two ivory knobs covered with cork, which enable the practitioner to hold the concentrator and remove it from the lamp, even when it is extremely hot. For the consulting-room the light-concentrator may be most advantageously employed either with an argand gas-burner, a parafine, moderator, or reading lamp. The latter kind of lamp, with an argand gas-burner, will be found convenient, though my rack-movement laryngoscopic lamp is the best that can be employed.

The light of a candle, strengthened by this concentrator, will be found to equal that given by an ordinary lamp. When the practitioner has only a centre gaselier at his command, the light concentrator should be applied to the only jet which is lighted; and as it is not generally possible to pull a gaselier sufficiently low down to make the examination in the ordinary way, under these circumstances both patient and practitioner must stand upright.

Besides the concentrator just described, I have

CHAP. II. had a smaller illuminating apparatus constructed, which is called my "miniature light-concentrator". The principle is the same in both; but in the latter the metal cylinder is only two inches in length, and an inch and a half in diameter: it is only suited for the small parafine lamp, which is sold with it. This lamp, which measures only four inches from its foot to the top of the chimney, is like a little vial, and has a metal screw stopper, so that it can be carried about with safety. This miniature lamp and light concentrator has been greatly improved by Dr. Offley Shore, of Stamford. He recommends the use of the petroleum oil with ten grains of camphor to the ounce, as employed by Dr. Cruise, of Dublin, for endoscopy. This lamp can be conveniently used for direct illumination, but is not suitable where a reflector is employed. It should be held in the left hand, close to the patient's mouth. Of the two, I recommend my larger concentrator, because in using the smaller apparatus, the body of light, though very brilliant, has, of course, a very small diameter. In the construction of an apparatus for increasing the light, it may be well to observe—1st. That if a lens is used, it should always be placed at its exact focal distance from the flame: this causes the luminous rays to pass through the lens in pa-

rallel direction, and thus throws a body of light a considerable distance. 2ndly. That since, when rays fall on a convex surface, a certain number are refracted, and do not pass through it, the plane face of a plano-convex lens should be placed next the flame. 3rdly. That, except when a lens is used, no mirror or reflector should be placed behind the flame for the purpose of strengthening the light; for any scratches or spots on it are apt to be reflected on to the illuminating mirror, and thence again on to the laryngeal mirror. This, of course, interferes with the distinctness of the laryngeal image.

It has been already observed that the employment of a reflector is not absolutely necessary for throwing a light on to the laryngeal mirror. When the observer does not make use of a reflector, the lamp must be placed very near to the patient's mouth, or else the luminous rays must be projected from a lamp in less close proximity by a lens placed in front of the flame.

*Direct
Light.*

For direct illumination the oxy-hydrogen lime light is by far the best that has yet been invented, and is the best adapted for demonstrations of cases to a number of persons. Not only is the light superb, but the mode of illuminating is much less fatiguing to the operator when a large number of

CHAP. II. cases have to be seen, and the heat, if not actually less, is less felt on account of its being further removed from him.

The oxy-hydrogen light consists of a lantern which contains the burner, and a long telescope-tube, in which the lens is placed for conveying the luminous rays to the patient's mouth. The practitioner sits directly opposite the patient, and the end of the conducting tube of the lantern is placed at the side of the practitioner, so that the light is thrown directly into the patient's mouth (not indirectly, as is the case when a large circular reflector is used).

The lantern stands on the table, which is three feet high, three and a half feet long, and only one foot broad; one end of the table is immediately behind the operator, and on each side of it stools (the front lower than the back) are placed, so that several spectators, in addition to the operator, can look on to the laryngeal mirror at the same time. The conducting tube serves to direct the eyes to the right point of view, so that those looking on have no difficulty in seeing the laryngoscopic image.

The lantern permits horizontal and vertical movement, but of course the light itself is a fixed point. A most brilliant and perfectly clear light is easily




Fig. 9.—THE OXY-HYDROGEN LIGHT AND EXAMINING-CHAIR.
H, Hydrogen jet; O, Oxygen jet; L is the Concentrating Lens.

CHAP. II. — thrown on to the laryngeal mirror by focussing the lens situated in the conducting tube, with the aid of its telescope arrangements. In the apparatus which I am in the habit of employing, the tube is thirty-seven inches long, and a concavo-convex lens is used, but the length of the tube must necessarily vary according to the focal power of the lens.

Though the apparatus itself is rather large, it need not take up much space, for the oxygen can be kept under pressure in a room below, and brought up through an ordinary gas-pipe, as will be seen in the annexed cut (fig. 9), and in place of hydrogen, common gas may be used. The two gases (H, hydrogen, or common gas, and O, oxygen) are entirely distinct, and only become united in the flame. This precaution, which slightly diminishes the intensity of the illumination, removes all possibility of an explosion.*

In using an ordinary lamp for direct illumination, either a common plano-convex lens may be used, or a large glass globe about six inches in diameter, filled with water. The latter kind of concentrator (the so-called Schuster-kugel) was first

* This apparatus is used by me every Thursday, at 2.30 p.m., at the Hospital for Diseases of the Throat, on which day Laryngoscopic Demonstrations are regularly given to medical practitioners who care to attend.

recommended by Türck, and afterwards adopted by Stoerck ; but, whilst the former has abandoned its use in favour of the reflector, the latter still employs it. This apparatus is also recommended by Dr. Walker,* of Peterborough, who has greatly improved it by substituting an elegant metal frame for the cumbersome wooden affair of Stoerck. It gives a brilliant light, which is most intense, about twenty inches from the globe. As it is quite impossible to carry this enormous glass globe about, its use is necessarily confined to the practitioner's consulting-room.

A much more convenient plan is that adopted by several of the French physicians, and which may be thus described : A lamp provided with a lens is placed on a table so narrow, that the laryngeal mirror can be used by the practitioner, on a patient, sitting on the opposite side of the table. A shade screens the light from the observer's eyes, whose face, in this mode of examination, is close to the lamp. In applying remedies, the lamp is between the arms of the practitioner, who, as it were, embraces it. Dr. Fauvel, of Paris, uses a table about three feet long and one foot broad, in three leaves ;

* "The Laryngoscope and its Clinical Application." By Thomas J. Walker, M.D.Lond., etc. London: T. Richards. 1864. P. 13.

CHAP. II. the centre leaf, on which a moderator lamp rests, can be screwed up and down to different heights for different patients. Dr. Krishaber,* of the same city, employs a simple round table of small dimensions.

*Direct and
Reflected
Light com-
pared.*

A comparison of the respective merits of direct and reflected light, shows (1) that, for merely making an examination, either method may be used; (2) that, for demonstrating a patient's larynx to a class of students, the direct method is most convenient, as the operator does not obstruct the view of others, to the same extent as when a reflector is used; (3) that, for applying remedies to, or operating on the larynx, reflected light is most suitable, on account of the operator being nearer the patient, and being able to sit in a less constrained posture, and also because he can thus more easily follow the slight movements of his patient.

When, however, the luminous ray, instead of corresponding, or nearly corresponding, with the visual ray, forms a considerable angle with it—as it must do when Stoerck's method is employed—there is a great probability of the two rays not falling within the area of the larynx. Again, by Stoerck's plan, as the rays must pass to the mirror

* Art. "Laryngoscope", in the "Dict. Encyclop. des Sciences Médicales". Paris: 1868.

from the side (instead of from behind forwards, as in using reflected light), they have also a lateral deflection, and are thus likely to illuminate only one side of the larynx. In employing direct light, the side of the cheek often throws a shadow on the laryngeal mirror; and in the application of remedies, the practitioner is apt to obstruct the luminous rays. These objections, it is true, do not apply to the French method, in which the light passes directly from behind forwards; but the distance which the patient is from the practitioner, and the position of the lamp, rather impede manipulative procedures.

The solar rays, or diffused light, on a bright day, may be concentrated on the laryngeal mirror. In the former case, the surface of the reflector must be plane; in the latter, the usual concave mirror may be used. The patient should sit with his back turned obliquely to the window, and the practitioner opposite him. The sunlight in this way passes over the patient's shoulder to the reflector, and is thence projected on to the laryngeal mirror. In other respects the examination is conducted in the same way as when artificial light is used.

Sunlight.

Before finally dismissing the subject of illumination, a few remarks may be made on what has been called illumination by transparency.

CHAP. II.

—
*Illumina-
tion by
Transpa-
rency.*

If sunlight is concentrated on the side of the neck, and the laryngeal mirror is then introduced, a more or less distinct image is obtained. Even under most favourable circumstances, however, where the neck is thin and long, the image is not sufficiently clear to be of any real value; whilst if the neck is short and muscular, or the glands are at all enlarged, nothing at all can be seen. This kind of illumination was first suggested by Czermak, though he does not attach any importance to it.

CHAPTER III.

THE ART OF LARYNGOSCOPY.

The proper employment of the already described instruments constitutes the art of laryngoscopy. It may be practised by the physiologist for investigating the healthy appearance and normal action of the larynx, or by the physician for inspecting, and, if possible, improving, the condition of the parts when diseased. It is only with reference to the last purpose that it will be here considered.

SECTION I.—*Principles of the Art.*

THE only principle concerned in the art of CHAP. III.
 laryngoscopy is the optical law, that when Principle of
 rays of light fall on a plane surface, the angle of Simple
 reflexion is equal to the angle of incidence. Reflexion. A
 small mirror is placed at the back of the throat, at
 such an inclination that luminous rays falling on it
 are projected into the cavity of the larynx; at the
 same time the image of the interior of the larynx
 (lighted up by the luminous rays) is formed on the
 mirror, and seen by the observer. The mirror is
 held obliquely, so that it forms an angle of rather
 more than 45 deg. with the horizon. The plane of
 the laryngeal aperture (bounded by the epiglottis,

CHAP. III. the ary-epiglottic folds, and the arytenoid cartilages), is also oblique, the epiglottis being higher than the apex of the arytenoid cartilage.

*Vertical
Reflexion.*

The annexed diagram shows the position of the different parts, and explains their reflexion. Let

FIG. 10.

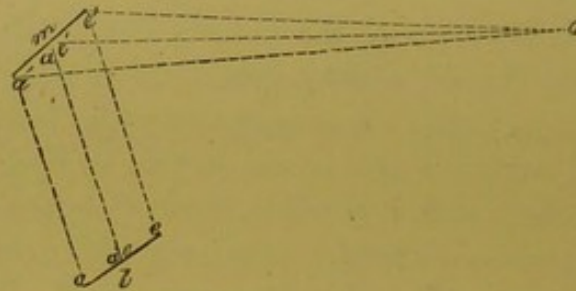


Fig. 10.—Diagram showing the relative positions of the planes of the larynx and laryngeal aperture.

m represent the plane of the laryngeal mirror, l the plane of the upper opening of the larynx, and o the observer. In the plane of the larynx, a represents the arytenoid cartilages, ae the ary-epiglottic folds, and e the epiglottis; the rays from these parts impinge on the mirror, as a' , ae' , and e' , and are thence reflected to the observer at o . Thus the epiglottis, which is really the highest in the throat, appears at the upper part of the mirror, the ary-epiglottic appear rather lower and at each side of the mirror, whilst at the lowest part of the mirror are the arytenoid cartilages. These remarks apply to the vertical reflexion.

The only inversion which takes place in the formation of the image is in the antero-posterior direction; the part which in reality is nearest to the observer, the anterior commissure of the vocal cords (*ac* in B, fig. 11), becomes furthest in the image (*ac* in A, fig. 11), and the posterior, or interarytenoid commissure (*pc* in B, fig. 11), which, in reality, is farthest from the observer, becomes nearest in the image (*pc* in A, fig. 11).^{*} The symmetrical character of the image, which makes it impossible to judge of right and left, and this antero-posterior inversion which actually takes place, often leads people to form erroneous opinions concerning the two sides of the larynx.

The lateral relation of parts in the image must now be considered. The mirror being placed above and behind the laryngeal aperture, the rays of light proceeding from the larynx pass directly upwards and backwards, and the patient's right vocal cord is seen on the left side of the mirror, and the left vocal cord on the right side of the mirror (just as the patient's right hand is opposite the ob-

^{*} This is in accordance with the fundamental optical law: *That if a diverging pencil of light fall upon a plane reflecting surface, the focus of the reflected pencil will be at the same distance from the surface as that of the incident pencil, but on the opposite side of it.*

CHAP. III. server's left, and his left hand opposite the observer's right).

FIG. 11.

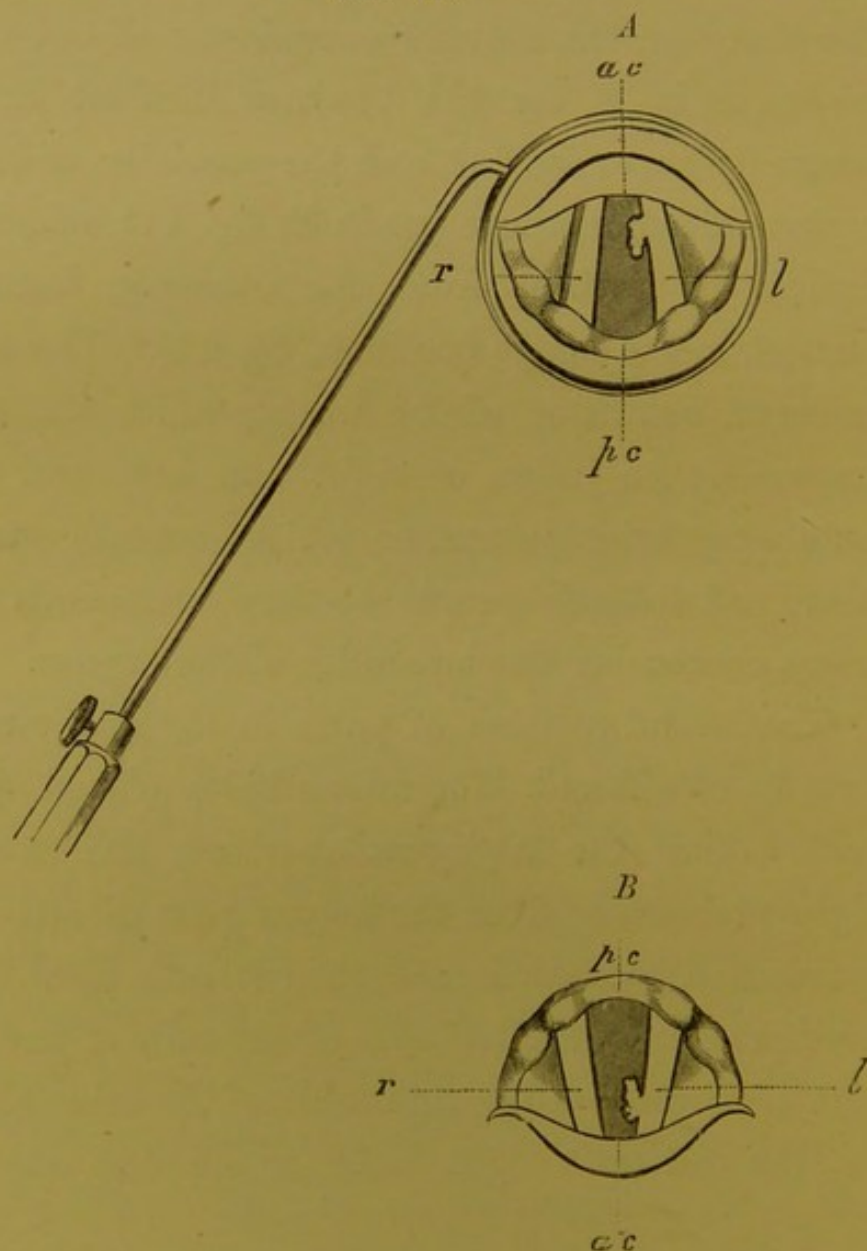


Fig. 11.—Drawing showing the relation of parts in the larynx (*B*), and the laryngeal mirror (*A*). *ac*, anterior commissure of the vocal cords; *pc*, posterior commissure of the vocal cords; *r*, right vocal cord; *l*, left vocal cord, with a wart on it.

In the annexed cut (fig. 11), a wart is seen on the left vocal cord of the larynx (B); this is opposite the observer's right hand, and it appears on the same side in the image (A). In consequence, however, of the antero-posterior inversion which takes place, as explained in the last paragraph, if the fact that the representation of the larynx (A) is an image is not borne in mind, it would lead to the deceptive idea that the wart was on the right vocal cord. In examining a laryngoscopic drawing, a person must not make his own larynx the mental standard of comparison as regards right and left, but must recollect that the picture represents an image formed on a mirror held obliquely above and rather behind the larynx of another person.

SECTION II.—*Practice of the Art.*

The patient should sit upright, facing the observer, with his head inclined very slightly backwards. The observer's eyes should be about one foot distant from the patient's mouth, and a lamp burning with a strong clear light should be placed on a table at the side of the patient, the flame of the lamp being on a level with the patient's eyes.

Method of Examination.
Stage 1.

CHAP. III. The observer should now put on the spectacle-frame with the reflector attached, and directing the patient to open his mouth widely, should endeavour to throw a disk of light on to the fauces, so that the centre of the disk corresponds with the base of the uvula. If the observer has much trouble in projecting the light on to the fauces, he will find it convenient to incline the reflector at a suitable angle before putting on the spectacle-frame. This may be done as follows: Taking the spectacle-frame in the hand, with the mirror attached, so that the central aperture in it would come opposite to the pupil of the operator's right eye, and fixing the joint so that the back of the mirror is parallel with the spectacle-frame, the outer edge of the reflector should be pushed rather more than a quarter of an inch forwards or backwards, according as the lamp is on the right or left side of the patient. If the observer has chosen his position and placed the lamp as directed, on putting on the spectacle-frame, a beautiful luminous disk will appear at the back of the throat. When direct light is used, the first stage is much simplified, as the patient has simply to sit opposite the lens of the lamp, as described at page 50.

Stage 2.

The patient should be directed to put out his tongue, and the observer should hold the protruded

organ gently but firmly between the finger and thumb of his left hand, the thumb being above and the finger below. To prevent the tongue slipping, the observer's hand should be previously enveloped in a small soft cloth or towel, and he should be careful to keep his finger rather above the level of the teeth, in order to prevent the frænum being torn. In cases that are likely to require local treatment, the patient should be taught to hold out his own tongue, in order that the operator may be able to introduce the mirror with his left hand, whilst with the right he applies the remedy to the affected part. CHAP. III.

When the observer has practised the first two stages, he should take a small laryngeal mirror, about half an inch in diameter, and after warming its reflecting surface for a few seconds over the chimney of the lamp* (to prevent the moisture of the expired air being condensed on it), should in- *Stage 3.*

* A very ingenious plan of keeping the mirror at a suitable and uniform temperature, by the aid of the electric current, has been suggested, and indeed carried out, by the late Dr. H. C. Wright. At the back of the mirror is a small shallow cell, which contains a carefully insulated loop of platinum wire; this loop is in communication with a battery of two or three cells, by means of two fine copper wires, which pass through the hollow shank and handle of the mirror. This contrivance is calculated to prove useful in the consulting-room of those much engaged in laryngoscopy; but the fact that the mirror

CHAP. III. — introduce it to the back of the throat. In holding a mirror over a lamp, the little glass is first covered with a film of moisture, which quickly clears away. Directly the glass is clear, it is the right temperature—neither too hot nor too cold—to be introduced. Before introducing the mirror, however, lest it should be accidentally too hot, the practi-

FIG. 12.

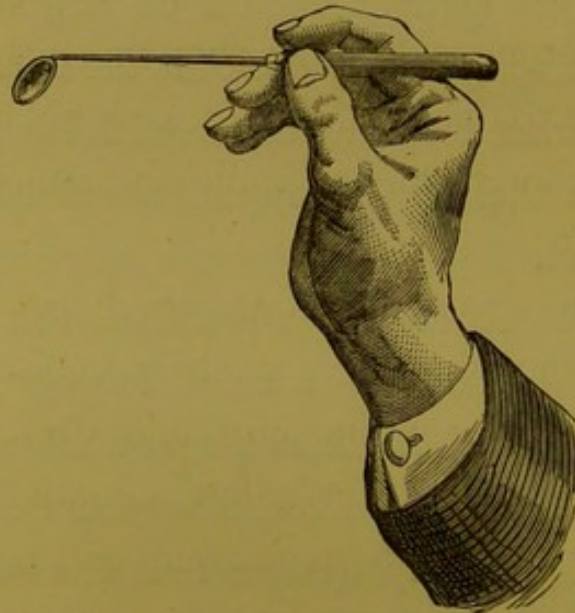


Fig. 12.—The position of the hand and mirror, when the latter has been properly introduced for obtaining a view of the larynx.

tioner should test its temperature, by placing it on the back of his hand. To pass the mirror to the back of the throat with as little annoyance as pos-

does not become dimmed, must not be regarded as a reason for keeping it a longer time than usual in the patient's mouth. Such a procedure could only end in failure.

sible to the patient, the following method should be adopted: The handle of the mirror should be held like a pen in the right hand, and quickly introduced to the back of the throat, its face being directed downwards, and kept as far as possible from the tongue (fig. 12). The posterior surface of the mirror should rest on the uvula, which should be pushed rather upwards and backwards, towards the posterior nares (fig. 13). When the mirror has thus been introduced without irritating the fauces, the observer should raise his hand slightly and direct it outwards towards the corner of the mouth. This rotatory movement, which alters the inclination of the mirror, and turns its face more towards the perpendicular (whilst the hand is thereby kept entirely out of the line of vision), should be effected rather slowly, so that it can be arrested directly the larynx comes into view. After introducing the mirror, the observer can, if he chooses, steady it, by resting the third and fourth fingers against the patient's cheek. The exact angle which the mirror should bear to the laryngeal aperture must depend on a number of circumstances, such as the degree of flexion backwards of the patient's head; the particular angle which the plane of the laryngeal aperture bears to the horizon in the case undergoing inspection; and on the direction which

CHAP. III. the ray must take to reach the observer's eye—that is to say, on the position of the observer (fig. 13). The practitioner should learn to introduce the mirror with either hand, for by so doing any false ideas concerning a supposed asymmetrical condition will be at once corrected; but whilst, for the purpose of diagnosis, it is very desirable to be able to use either hand, in the application of remedies to the larynx, ambidexterity is absolutely essential.

Faults to be avoided.

Beginners, in their anxiety to get a good view, often give rise to faucial irritation, by keeping the mirror too long in the patient's mouth; the same condition is also often produced by moving the mirror too much about at the back of the throat after its introduction. The practitioner should recollect that when an act of retching has once taken place, it is afterwards often impossible to get a good view of the larynx at the same sitting. Moreover, the act of retching always causes considerable temporary congestion of the laryngeal mucous membrane, and thus is apt to lead the inexperienced to very erroneous conclusions. It is, therefore, better to introduce the mirror any number of times, keeping it in the throat only for a few seconds each time, than to let it remain longer, and thus limit the examination to one inspection. The novice must be careful to avoid touching the

FIG. 13.

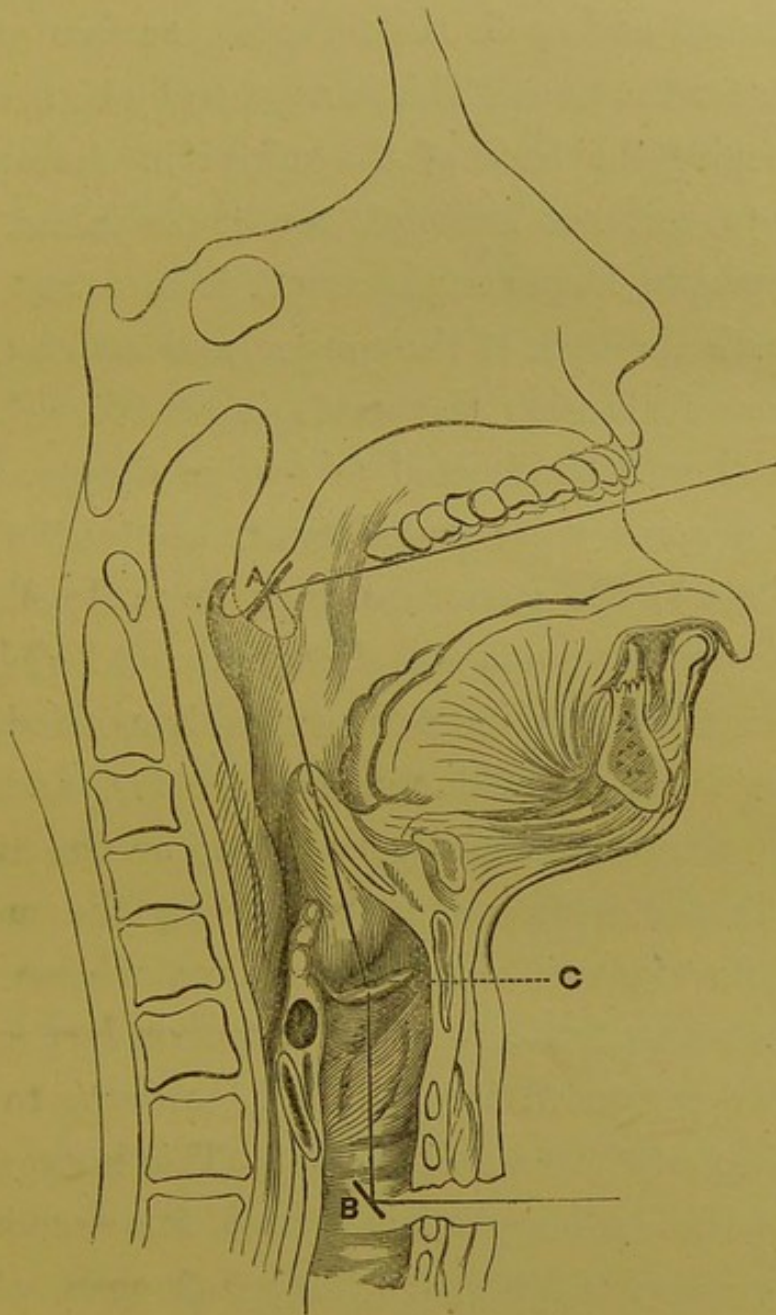


Fig. 13.—DIAGRAM SHEWING THE ANGLES OF INCIDENCE AND REFLEXION IN ORDINARY AND INFRA-GLOTTIC LARYNGOSCOPY.

- A.* Side view of mirror, when properly introduced. It is seen to push back the uvula towards the posterior nares.
- B.* Side view of infra-glottic mirror.
- C.* Vocal cord.

CHAP. III.

tongue with the mirror, for this procedure irritates the throat and spoils the reflecting surface of the mirror for the time. This can generally be avoided by keeping the back of the mirror in close proximity to, but not letting it touch, the palate. In some people, however, the uvula is in actual contact with the back of the tongue, and as in inspiration or vocalisation the uvula is raised, such patients should be directed to inspire deeply, or to produce some vocal sound (such as "ah," "eh," "oh," etc.); the mirror can then be easily slipped in between the uvula and the tongue. All violence or even roughness must be carefully avoided, the tongue must be held out most gently, and the laryngeal mirror placed very lightly on the uvula. Complicated instruments for holding the mouth open almost invariably lead to failure. Hence I do not recommend the gigantic "*spéculum laryngien*" recently presented by Dr. de Labordette to the Academy of Sciences of Paris.* This instrument is like the ordinary specula used for examining other canals; and it keeps the mouth open, whilst by a powerful spring it presses the tongue forwards and downwards. It is, in fact, an instrument of a retrograde character, combining the de-

* Note, Sur le spéculum laryngien. Par Dr. de Labordette. Delahaye : Paris, 1866.

fective features both of Babington's and Avery's CHAP. III.
mirrors.

The difficulties solely dependent on the practi- *Special*
tioner's want of dexterity have been already con- *Difficulties.*
sidered, but a few words must be devoted to those
in part due to the patient. The obstacle may be
either undue irritability of the fauces, a peculiar
action of the tongue, an abnormal size of the ton-
sils, or a pendent condition of the epiglottis. As
regards faucial irritability, it is to be observed
that though this condition sometimes exists of
itself, it is far more often caused by the clumsi-
ness or inexperience of the practitioner. Most
patients can be examined with facility at the first
sitting, and only a small proportion require any
training. With timid patients—especially women
—on first using the laryngoscope, it is well to
place the mirror for a second on the back part of
the palate, without being too particular about see-
ing anything. By introducing the mirror once or
twice in this way, the patient's confidence is se-
cured, and a more fruitful examination may after-
wards be made.

For reducing an unusually irritable condition of
the fauces, the internal administration of the bro-
mides of potassium and ammonium has been recom-
mended; but my experience has proved the total

CHAP. III. inutility of their employment. Some advise that the patient should be directed to inhale a few whiffs of chloroform; but in those rare cases, which present much difficulty, I have found the best effects result from sucking ice for about ten minutes before the mirror is to be introduced. The most irritable fauces cannot resist this plan. The conformation of parts sometimes causes some difficulty. Thus, when the tongue is drawn out, it sometimes forms an arched prominence behind, which causes trouble in introducing the mirror, and difficulty in seeing it when *in situ*. It is due to reflex action, and will be best avoided by pulling the tongue less out than usual, keeping it level with the mouth (that is to say, not holding it down towards the chin), and by cautioning the patient not to strain. Enlarged tonsils sometimes embarrass the operator. In this condition a small oval mirror should be used.

An unusually large or pendent epiglottis causes a more serious impediment to laryngoscopy. When the valve is very large, it sometimes shuts out the view of the larynx; but the same result is more often caused by unusual length or relaxation of the glosso-epiglottidean ligaments. In the production of high (falsetto) notes, the epiglottis is generally raised, and this also happens when a person

laughs; the observer will, therefore, do well to take advantage of these physiological facts. In a certain number of cases, however, the epiglottis remains obstinately pendent. For elevating the valve in these cases, various instruments have been invented (by Voltolini, Bruns, Fournié, Lewin, and others),* and I have myself had one contrived which has proved useful in some cases (fig. 17). Some of the German laryngoscopists recommend that a thread should be passed with a curved needle through the epiglottis. An assistant, standing behind the patient, draws the thread over the patient's face and head. In some cases, the opposite end of the thread is tied round one of the patient's ears.† Most of the instruments hitherto invented, however, cause so much irritation, that

* Dr. P. C. Smyly describes (*Dub. Quart. Journ.*, Feb. 1866) an ingenious arrangement, by which, in one of these cases, complicated by a very large and tongue-tied tongue, he succeeded in making a satisfactory inspection. Forceps which dilated the larynx, and pushed the epiglottis down on the tongue, were held by the thumb and little finger, whilst the stem of an ordinary laryngeal mirror was attached to the index-finger by an India-rubber nipple worn as a finger-stall.

† This plan of passing a thread through the epiglottis and slinging it over the ears, reminds me of the suggestion of an eminent physician, who, when once complaining to me of the difficulties which the front teeth cause in laryngoscopy, proposed, that, in all cases where the laryngoscope had to be used, a dentist should first remove the two upper central incisors.

CHAP. III. they cannot often be employed with advantage.

— When the epiglottis covers the larynx in the manner described, the laryngeal mirror should be introduced lower in the fauces, and more perpendicularly than is usually suitable. In almost all cases, the arytenoid cartilages, surmounted by the capitula Santorini, can be seen, and from them we can judge with tolerable certainty as to the mobility of the vocal cords ; the state of the mucous membrane of the larynx in other parts cannot, however, be safely inferred from the condition of that which covers the arytenoid cartilages.

CHAPTER IV.

THE HEALTHY LARYNX (AS SEEN WITH THE LARYNGOSCOPE).

IT is not intended to enter into the anatomy of CHAP. IV.
the different parts of the larynx as seen on
dissection of the dead subject, for this is treated
of in various works on general anatomy. In other
words, the description will be confined to the in-
ternal surface of the larynx, and no mention will
be made of parts, the contour of which cannot be
seen in the mirror. The rationale of the formation
of the image has already been explained (page 53),
the special description of its individual parts will
therefore be now undertaken. In some cases, on
introducing the laryngeal mirror, only the epi-
glottis may be visible, with perhaps just the tips
of the capitula Santorini at the posterior part ;
whilst in others, the entire length of the vocal
cords, the ventricular bands (false vocal cords), the
small cartilages of Wrisberg and Santorini, a por-
tion of the cricoid cartilage, the rings of the
trachea, and perhaps even the bifurcation of the

CHAP. IV. bronchi below it, can be seen with perfect distinctness. The view varies in different cases between these two extremes.

FIG. 14.

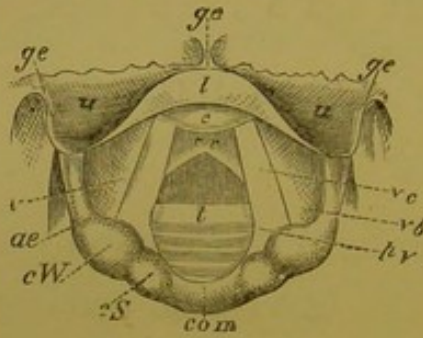


FIG. 15.

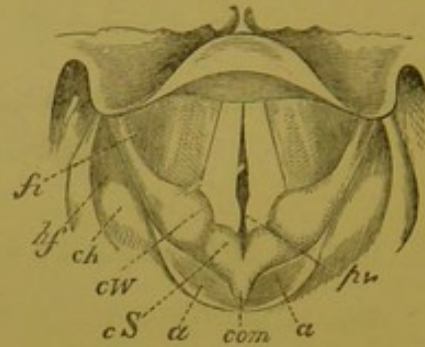


Fig. 14.—Laryngoscopic drawing, showing the vocal cords drawn widely apart, and the position of the various parts above and below the glottis, during quiet inspiration.

- ge.* Glosso-epiglottidean folds.
u. Upper surface of epiglottis.
l. Lip of epiglottis.
c. Cushion of epiglottis.
v. Ventricle of larynx.
ae. Ary-epiglottic fold.
cW. Cartilage of Wrisberg.
cS. Capitulum Santorini.
com. Arytenoid commissure.
vc. Vocal cord.
vb. Ventricular band.
pv. Processus vocalis.
cr. Cricoid cartilage.
t. Rings of trachea.

Fig. 15.—Laryngoscopic drawing, showing the approximation of the vocal cords, and the position of the various parts in the act of vocalisation.

- fi.* Fossa innominata.
hf. Hyoid fossa.
ch. Cornu of hyoid bone.
cW. Cartilage of Wrisberg.
cS. Capitulum Santorini.
a. Arytenoid cartilages.
com. Arytenoid commissure.
pv. Processus vocalis.

Epiglottis. The epiglottis varies very much in appearance in different individuals: for it may be large or small,

broad or narrow, long or short. In most cases there is seen—1st, A portion of its upper surface on either side (*u*); 2ndly, its free edge and a small portion of its under surface turned up in the centre, and forming a kind of lip (*l*); and 3rdly, another portion of its under surface, below and behind the lip, projecting as a rounded prominence,—the cushion (*c*). The upper surface is of a dirty pinkish hue; the lip is of a decided yellow colour, though it has a slight shade of pink; and the cushion is invariably bright red. In some cases the whole of the under surface of the epiglottis is seen, and then it is of a bright red colour. This normal colouration of the under surface of the epiglottis is apt to be mistaken (by those unaccustomed to the use of the laryngoscope) for congestion of the mucous membrane.

In some cases, the epiglottis is broad (see fig. 37), whilst in others it is extremely narrow (fig. 38); and whilst in some people only the upper surface can be seen (fig. 40), in others, where the epiglottis is drawn tightly to the tongue, only the under surface is visible (fig. 37). In the centre of the free edge is a slight notch (fig. 37), which gives to the epiglottis, when seen in its entirety, its foliate appearance. But the free edge of the valve is more often turned

CHAP. IV. upon itself, so that in the reflection the notch is lost sight of, and the border appears round (figs. 39, 41, and others).

In some cases, on account of the inclination of the epiglottis, only the profile of its free edge is visible in the mirror (fig. 38). In these cases the valve is represented by a thin line. Above the epiglottis, the glosso-epiglottic folds (*g e*) may be seen, passing upwards and backwards to the tongue; the profile of the latter—that is to say, of its posterior superior border—is seen as a horizontal line, which, on account of the projecting papillæ, is somewhat uneven.

Ary-epiglottic folds.

The ary-epiglottic* folds (*a e*) which form the lateral boundaries of the upper laryngeal aperture, can be seen in the mirror extending obliquely downwards and backwards from the epiglottis to the arytenoid cartilages. Near the latter are the slight pinkish prominences of the cartilages of Wrisberg (*c W*), and a little beyond the cartilages of Wrisberg, in the same fold of mucous membrane, are two other small prominences, the capi-

* On account of the extreme length of the term arytæno-epiglottidean folds, following the German, I have dropped the third and fourth syllables, and also shortened the last syllable, of this unnecessarily and inconveniently long word.

tula Santorini (*cS*), surmounting the arytenoid cartilages. CHAP. IV.

The cartilages of Wrisberg generally appear round, but sometimes, especially in thin people, they have a triangular shape,—the apex of the triangle being directed outwards. The capitula Santorini have a roundish shape in the healthy larynx. Both these cartilages are most distinct when the vocal cords are approximated, but the clearness with which these small laryngeal cartilages can be seen, depends upon their degree of development, and also upon the amount of submucous areolar tissue surrounding them ; sometimes the cartilage of Wrisberg is not to be seen at all, whilst occasionally there are small cartilages between it and the capitula Santorini. The breadth of the ary-epiglottic folds varies in different people, and in different states of the larynx, appearing broad when they are relaxed, that is in inspiration, and narrow when they are tense, as in the approximation of the cords,—especially in the production of high notes. The ary-epiglottic folds have been well described by Stoerck, as having almost the same colour as the gums. The cartilages of Wrisberg and Santorini are of a rather brighter and deeper colour than the rest of the mucous membrane.

Cartilages of Wrisberg.

Capitula Santorini.

CHAP. IV.

*Arytenoid
Cartilages.*

The arytenoid cartilages (*a*) are easily recognized by the small cartilages of Santorini which surmount them. They can be best seen when the vocal cords are approximated. The mucous membrane covering them is generally of a rather redder tinge than that forming the ary-epiglottic folds. Between the arytenoid cartilages is a fold of mucous membrane, the inter-arytenoid fold or commissure, which is most apparent when the glottis is widely open (fig. 14, *com*); when the arytenoid cartilages are approximated, the commissure folds together, and is directed backwards, (fig. 15, *com*). It is of a yellowish-pink colour.

*Ventricular
Bands.*

The ventricular bands (*vb*), commonly called the false vocal cords,* are the folds of mucous mem-

* *Note on Nomenclature.*—The retention of the term “false vocal cords” not only perpetuates the memory of a physiological error, but makes it necessary to qualify the real vocal cords by the term “true”. Whilst a subject attracts but little attention, its nomenclature is not a matter of much importance; but when, on the other hand, it excites general interest, incorrect or inconvenient terms should be carefully avoided. The upper ligaments of the larynx have, in their normal state, no direct influence on vocalisation, but merely bind the ventricular orifice. In calling these ligaments “ventricular bands”, I may observe that the corresponding term, “taschenbänder”, is beginning to be used in Germany. In support of my nomenclature I may further observe, that if the ventricular bands were called the superior ligaments of the larynx, the vocal cords would become, by contradistinction, the inferior laryngeal ligaments. The mistake of giving such a name to parts having so important a function would be manifest to every one.

brane which are seen below the ary-epiglottic folds, passing obliquely in the antero-posterior diameter of the larynx, from the arytenoid cartilages to the epiglottis. They are thick, rather prominent, and of a deeper red colour than the ary-epiglottic folds. Being rather thinner, and more prominent at their lower edge (which borders on the ventricle) than elsewhere, this part has a lighter tint when illuminated than the rest of the ligament. When the vocal cords are approximated, a small depression may be seen near the epiglottis between the ventricular bands below and the ary-epiglottic folds above, which I propose to call the fossa innominata (*f v*)

*Fossa-inno-
minata.*

The openings of the ventricles (*v*) can sometimes be seen, as dark lines, between the ventricular bands and vocal cords. They are best seen in the healthy larynx of a thin subject—especially when there is a slight disposition to spasm.

*Ventricles of
the Larynx.*

The vocal cords (*vc*) when visible, cannot be mistaken. They are seen as two pearly-white cords, passing from the base of the arytenoid cartilages to the angle of the thyroid cartilage. On inspiration, they appear almost to touch each other at their anterior insertion, but to be separated from a quarter to half an inch posteriorly. On phonation, they become parallel, and appear to approximate.

Vocal Cords.

CHAP. IV. Each vocal cord is seen to terminate in the angle at the base of the arytenoid cartilages, called the vocal process (*vp*). On inspiration, this angle is directed outwards, and the glottis has a lozenge shape; but when the vocal cords approach one another, the angle is turned inwards. This process divides the inter-cartilaginous and inter-ligamentous portions of the glottis.

*Sub-glottic
View.*

Below the vocal cords, appears the broad yellow cricoid cartilage (*cr*), and below it, again, the rings of the trachea (*t*) are seen elevating the mucous membrane, which between them is of a pale pink colour. Occasionally, two indistinct dark circles (the openings of the bronchi), on either side of a bright projecting line (the angle of division between the bronchi), indicate the bifurcation of the trachea. In some rare cases a ray of light may be thrown down the right bronchus.

*Hyoid
Fossa.*

Though external to the larynx, it is necessary to mention the hyoid fossa (*hf*) in which foreign bodies are extremely likely to become lodged. It is bounded on the inner side by the ary-epiglottic folds, and on the outer side by the inner surface of the thyroid cartilage. Projecting from the outer wall and sometimes forming the floor of the fossa, the greater cornu of the hyoid bone (*ch*) is sometimes seen glistening beneath the mucous membrane.

CHAPTER V.

ACCESSORIES OF LARYNGOSCOPY.

SECTION I.—*Auto-laryngoscopy.*

THOSE who desire to acquire dexterity in introducing the mirror at their own expense, rather than that of their patients, or those who wish to demonstrate their larynx to others, should learn to employ the laryngoscope on themselves. CHAP. V.

When auto-laryngoscopy is practised, it is requisite that, besides the circular reflector and laryngeal mirror, another mirror should be used: this must be placed in such a position that the image reflected in it from the throat-mirror can be seen by the autoscopist.

For practising auto-laryngoscopy, Professor Czermak contrived a special apparatus. It has a large reflector and quadrilateral mirror, each supported on perpendicular bars. These mirrors are fixed about a foot apart, and both can be turned in almost any direction, and fixed at any height. In using this apparatus, the observer should sit at a table with the quadrilateral mirror

CHAP. V. a few inches in front of his mouth, and the reflector again a foot further back. The flame of the lamp should be near the quadrilateral mirror, the upper edge of which should be level with the lower edge of the reflector behind it. The observer now throws the light into his fauces with the reflector, introduces the warmed laryngeal mirror, and sees the image in the quadrilateral one. People facing the demonstrator can see the image in the laryngeal mirror, and those behind him in the one which he looks at. For those who wish to make accurate physiological observations, this is the best method of practising auto-laryngoscopy.

Those who object to purchase a special apparatus can use the ordinary reflector for auto-laryngoscopy. In this case, all that is requisite is a perpendicular telescope-bar, capable of being made about a foot and a half in length, and having a broad firm base: at the top of the bar is a small projecting ball, which fits into the socket at the back of the ordinary reflector. The reflector is placed on a table, at about eighteen inches from the observer, between whom and the reflector there must be a small toilet mirror or hand-glass, the frame of which ought not to be very thick. In other respects, the examination will be conducted as already described.

A very ingenious, useful, and simple method of practising auto-laryngoscopy has been recommended by Dr. George Johnson. The observer puts on his ordinary reflector, as though he were going to examine a patient, and sits facing a toilet mirror. A lamp is placed on one side of the observer, in a line with the mirror, or slightly behind it. The observer, by manipulating the reflector, now throws the light on to the image of his fauces, as seen in the toilet-glass. He then introduces the laryngeal mirror into his throat, and the image of the larynx formed on it, is seen in the toilet-glass, both by the demonstrator and by the persons standing behind him. In practising auto-laryngoscopy in this manner, the practitioner has to manage the light in the same way as in examining patients, and he thus learns to overcome one of the difficulties of laryngoscopy. The only disadvantage of this method, as compared with that of Czermak, is that by it the rays of light undergo an additional reflexion before they reach the larynx, and thus the image is not quite so distinct.

CHAP. V. SECTION II.—*Recipro-laryngoscopy** (or the Demonstration of a Patient's Larynx to others).

In seeing patients in consultation, the laryngoscopist may often desire to have the benefit of the opinion of a colleague, who may not himself be able to use the laryngoscope; or a teacher may desire to demonstrate a patient's larynx to students. The inconveniences of showing the larynx to a third person in the ordinary way have been pointed out

* Laryngoscopy is the term used when one person examines another's larynx. Auto-laryngoscopy means the examination of one's own larynx. Recipro-laryngoscopy expresses that particular mode of practising the art, in which a person's larynx is reciprocal to two or more people. If any one can suggest a less pedantic, but equally correct term, I shall be ready to adopt it. The author of an able review of "Recent Works on the Laryngoscope", in the *Brit. For. Med.-Chir. Rev.*, October, 1865, objects to the name *recipro-laryngoscopy* in the following language: "We may well question whether this so-called art requires a special appellation; its end and aim are readily definable by ordinary English words, and the proceeding appears to require contorted derivatives from the Greek language to express it, no more than does the very common act of beholding one's natural face in a glass, and having its image simultaneously gazed on by others."

With all respect for my critic, I venture to suggest, that it is the systematic arrangement of this treatise which makes the term "*recipro-laryngoscopy*," or some equivalent, necessary; and that, if a systematic work were to be written on the examination of the images of people's "own natural faces" in glasses, by themselves and others, corresponding explanatory terms would have to be employed.

by Dr. Smyly, of Dublin, and he has contrived the means of overcoming them. To use his own words: "In the ordinary method, when the examiner has a full view of the vocal cords of the examinee, he calls upon his colleague to view the parts; who, when he places his head beside that of the examiner, only gets a partial view—a portion of the epiglottis, one arytenoid, and perhaps

FIG. 16.

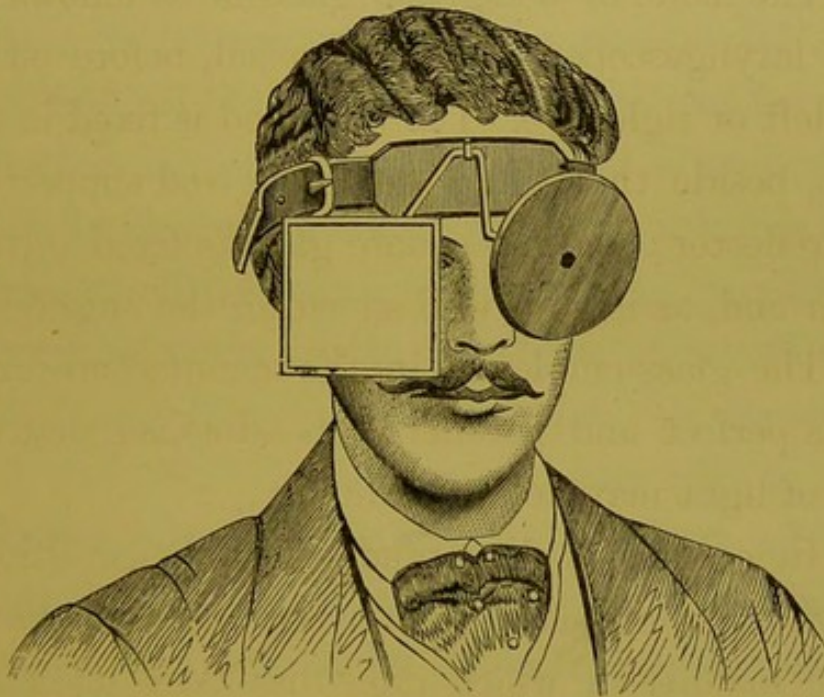


Fig. 16.—DR. SMYLY'S RECIPRO-LARYNGOSCOPE.

a vocal cord. In endeavouring to see more, he pushes the examiner's head, so as to displace the light, or shakes his hand, so as to bring on nausea. Many other inconveniences will occur to the mind

CHAP. V. of the practical laryngoscopist which I shall not
— here allude to.

“My addition consists of a simple square piece of very good plate glass mirror, set in brass, like the ordinary concave mirror. A second split tube is soldered on close to the tube which exists on all Weiss’s frontal bands, and a brass rod, the ends of which are bent in opposite directions, at an angle of 45 deg.

“The mode of using this glass is as follows:—The laryngoscope is fixed, as usual, before either the left or right eye. The brass rod is fixed in the tube, beside that which holds the rod supporting the reflector; and my square glass is fixed on the other end, as is very well shown in the engraving.

“The glass employed in the manufacture must be as perfect and parallel as possible, so that the loss of light may be a minimum.

“In conclusion, I may add that the additional weight of the square glass, when made in the artistic manner in which mine has been made, by Messrs. Spencer and Son, of Aungier Street, Dublin, is scarcely perceptible.”—*Dublin Quarterly Journal*, vol. xxxvi, Aug. 1863.

SECTION III.—*Infra-glottic Laryngoscopy, or Tracheoscopy.**

Where tracheotomy has been performed, and a fenestrated canula is worn, a very minute mirror may be introduced through the tube with its face directed upwards; or the canula may be removed, and the mirror passed into the wound (fig. 13, p. 63. In this way the observer obtains a view of the larynx from below.

This method was first suggested by Dr. Neudörfer, in 1858, and was first carried out by Professor Czermak in the following year. Since then, various observers have examined patients in this way, and I have myself had an opportunity of examining several cases. Some very interesting observations made by a medical man on himself in this way, have been recorded by Dr. Semeleder. This mode of examining the larynx, though of very limited application, is extremely valuable, because it generally happens, in cases where a canula is worn, and air is inspired mainly through the trachea, that the epiglottis does not rise up, but remains pendent, in inspiration; in post-tracheotomy

* As it is not the trachea which is examined, the term tracheoscopy is obviously incorrect, and the expression infra-glottic laryngoscopy would more correctly describe this method of investigation.

CHAP. V. cases, also, it often happens, that the epiglottis is bound down over the larynx by old cicatrices, and consequently ordinary laryngoscopy is useless. It is well to remark that the vocal cords, when observed from below, have a reddish colour, and do not present the peculiar white appearance which is seen, when the laryngeal mirror is placed on the uvula.

SECTION IV.—*Magnifying Instruments.*

Various instruments have been invented for increasing the size of the laryngeal image, but they are of no use in the treatment of disease. As early as 1859, Dr. Wertheim, of Vienna, recommended concave laryngeal mirrors for this purpose; and later, Dr. Türck, calling attention to the fact that the laryngeal image is made up of a number of parts at different distances, suggested the use of a small telescope (!) which he had fitted to his illuminating apparatus. Finally, Voltolini, by removing the ocular, adapted an opera-glass (!!), which, however, he was only able to use with sunlight.

SECTION V.—*Micrometers.*

For measuring the exact size of different parts of the larynx, and for estimating distances, Merkel, of Leipsig, and Mandl, of Paris, have sug-

gested the plan of having a scale scratched on the laryngeal mirror. Dr. Semeleder objects to this mode of measuring, as it takes so much away from the reflecting surface of the mirror, and he recommends that the scale should be drawn on the frame of the mirror. Though these scales might, perhaps, be advantageously employed for physiological investigations, they are of no use to the medical practitioner.

SECTION VI.—*The Epiglottic Pincette.*

In a certain proportion of cases, it is impossible to obtain a satisfactory view of the larynx, on account of the pendent condition of the epiglottis. This peculiarity, which depends on the length of the glosso-epiglottic ligaments, is probably more often congenital, but sometimes it may—to a certain extent—be due to a relaxed condition of the system generally. In cases, where it does not occlude the whole of the larynx, it often hides the anterior third of the vocal cords. After inventing various instruments which did not answer the purpose, I hit upon the pincette, of which the annexed woodcut is a representation. In constructing an instrument to hold and draw forward the epiglottis, it must not only effect its end, but must do so without irritating the patient's throat. I have used the pincette in a few cases with

FIG. 17.

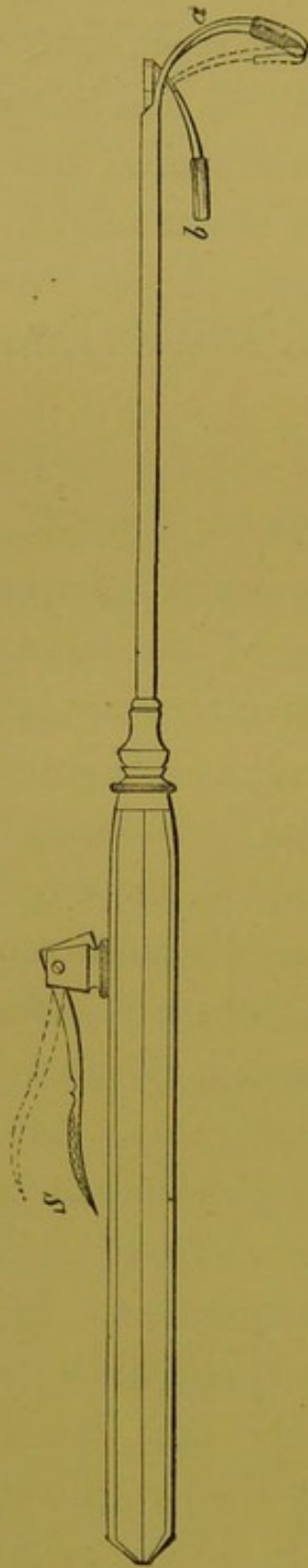


Fig. 17.—THE EPIGLOTTIC PINCETTE.

Whilst the spring, *S*, is kept down, the two blades, *a* and *b*, remain widely open, and the blade, *b*, should come right up to the tube, which is about a quarter of an inch above it in the woodcut. The operator passes the blade, *a*, behind and below the epiglottis, and draws the valve slightly forwards and upwards; on then raising his finger from the spring, *S*, the blade, *b*, advances to *a*, and the epiglottis is held gently between them. The blades, *a* and *b*, are a quarter of an inch broad, slightly convex from side to side (the convexity being directed forwards), and covered with India-rubber.

advantage, but I would specially call the attention of inventive laryngoscopists to this subject, as I believe that a thoroughly effective instrument for drawing forward the epiglottis would be, without exception, the most useful addition to the art of laryngoscopy. In my pincette the anterior blade curves round, so that it can be passed behind and under the epiglottis, whilst the posterior blade, which alone moves, opens to the extent of almost half an inch, and lies flat on the tube which contains the wire by which it is moved. The instrument is kept open by the pressure of the index finger on a spring in the handle, and when the anterior blade has been passed under the epiglottis, and has drawn it slightly upwards and forwards, the operator removes his finger from the spring, and the blades close and hold the valve in the desired position. The blades are broad, flat, and covered with India-rubber.

SECTION VII.—*The Self-holder or Fixateur.*

In applying remedies to, or operating on, the larynx, in those cases where the pincette is used for drawing forward the epiglottis, one hand is employed in introducing the instrument (brush,

CHAP. V. lancet, or forceps, as the case may be), and the
 — other holds the pincette, so that it becomes necessary to employ some apparatus for holding the

FIG. 18.

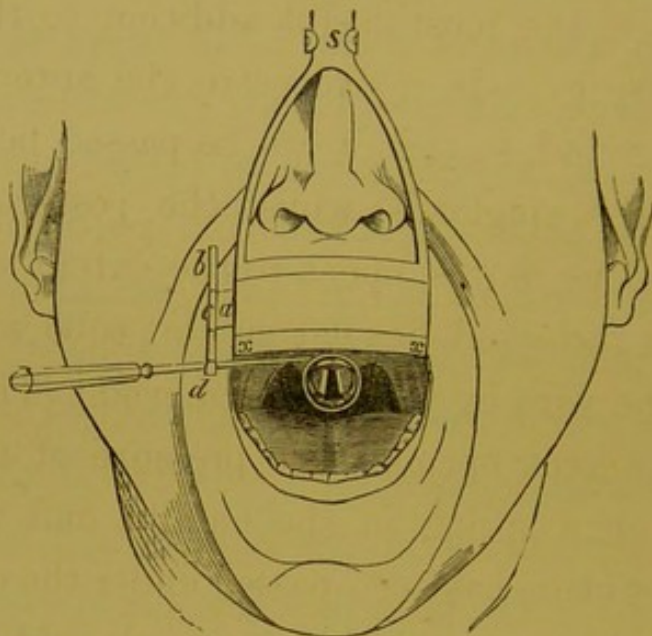


Fig. 18.—THE SELF-HOLDER, or *fixateur* for holding the laryngeal mirror after introduction. A broad plate of metal rests against the upper lip, and from its lower border, *x*, a small metal plate passes backwards under the upper teeth.

s. Steel spring, which passes upwards and backwards over the head, to below the occipital protuberance, where there is a pad.

a. Small metal plate, which can be inserted into either the right or left side of the large hollow plate, which contains it. The small plate can be drawn out to any extent desired, so that its free extremity can always be brought to the corner of the mouth. It terminates in

c, a ring which holds—*b*, a perpendicular bar that can be fixed at any height in the ring.

d. Termination of the bar in a kind of spring forceps; the blades of the forceps are very broad, and each is curved outwards, so that they form a kind of groove into which the stem of the mirror easily passes, and can be as easily withdrawn. As the perpendicular bar can be made to turn round in the ring, *c*, the blades can be made to open in any direction.

laryngeal mirror. Various instruments have been invented for this purpose, and one of my own design was described in the year 1863.* I have since greatly improved this instrument, so that it can be used in any case. It consists of a mouth-piece, and a steel band which passes from its upper part, round the head, to beneath the occipital protuberance, where there is a broad pad to keep it in position. The mouth-piece is composed of perpendicular and horizontal portions; of these the perpendicular portion is two inches long and one inch broad, and it rests against the upper lip; the horizontal portion is kept in the mouth, so that the inner angle of union of the two parts corresponds to the points of the front teeth; the upper surface of the horizontal portion is covered with a thin layer of wood, to save the teeth from coming in contact with the metal. In the perpendicular portion, there is a groove passing through its entire length, and in it a thin steel plate runs, which has a broad ring at its extremity. Through this ring there passes a perpendicular bar, having at its extremity two broad steel blades. These blades, which open at a considerable angle, close by their own elasticity, and hold the mirror firmly. The perpendicular bar moves

* "Medical Times and Gazette", Aug. 8th.

CHAP. V. in the ring, so that it can be fixed at any height, and so that the blades can be turned in any direction. As the steel plate also can be drawn out of its groove, the laryngeal mirror can, in all cases, be brought as near to the corner of the mouth as desired. The steel plate can also be passed into the groove from either side, so that the laryngeal mirror can be fixed at either the right or left side of the mouth. The woodcut on page 88 explains the action of the instrument, and shows the mirror *in situ*.

SECTION VIII.—*Sounds*.

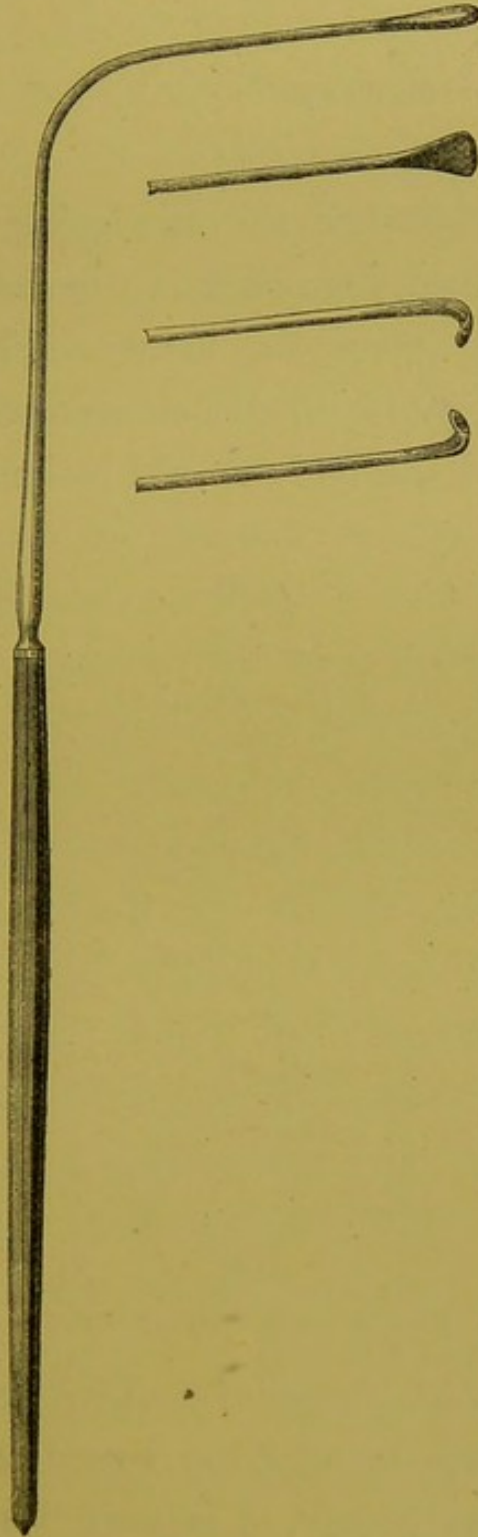
It occasionally happens that it is desirable to introduce sounds within the larynx. By means of such instruments the exact origin of a growth may sometimes be ascertained, when, with the unaided laryngeal mirror, this is impossible.

Again, sounds are sometimes of use in ascertaining the density of a neoplasm, and are also recommended by some laryngoscopists for accustoming the larynx to the introduction of foreign bodies, before any attempt at operation is made; for the latter purpose, however, I have never found them requisite. In cases of ulceration over the arytenoid cartilages, they often enable the practitioner

to ascertain the extent of the burrowing and the condition of the cartilages themselves. In cases of

CHAP. V.

FIG. 19.

*Fig. 19.*—LARYNGEAL SOUNDS.

CHAP. V. altered sensibility of the lining membrane, relative differences may be appreciated.

SECTION IX.—*Laryngoscopic Chairs, Head-rests, etc.*

Most people, when they are going to have the throat examined, lean back in the chair, throw up the head, and open the mouth. This attitude, however, is very ill suited for laryngoscopy, where both the head and body should be kept erect. In

FIG. 20.

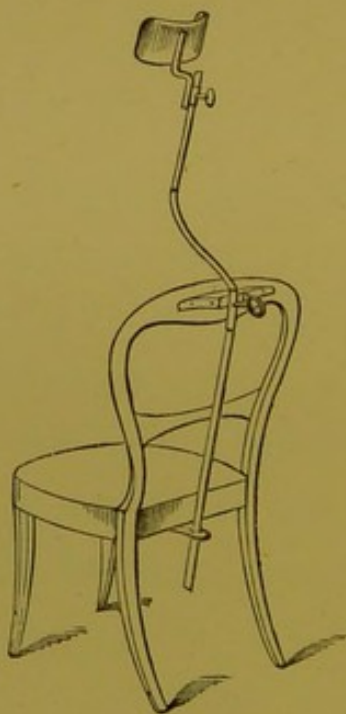


Fig. 20.—THE HEAD-REST.

many cases also,—especially where the patient is at all nervous,—in applying remedies to, or operating on, the larynx, it is very desirable to be

able to steady the head. I now use in private practice a narrow-seated high-backed chair. The seat measures only a foot in depth, and the back is thirty-four inches high. This kind of chair obliges the patient to sit upright, and greatly assists in steadying the head. I formerly employed a head-rest (fig. 20), very much like that employed by photographers, except that instead of having a stand of its own, it is fixed to a chair. A strong metal plate, terminating in a ring which projects behind the seat, is screwed to the back of an ordinary chair, to the under surface of the frame which supports the seat; and another similar projecting ring is screwed to the top bar of the chair. A strong iron bar passes perpendicularly through these rings; just above the upper ring it bends obliquely forwards for about half a foot, and then again passes perpendicularly upwards for another foot. This bend in the bar prevents the patient leaning back. Sliding on the perpendicular bar, is a broad, curved, semicircular pad, which supports the head, and can be fixed at any height. It allows the patient to raise his head, but prevents any movement backwards or laterally. The apparatus is not unsightly, if the metal part is made of brass; and when the support is not required, the perpendicular bar and head-rest can be altogether put

CHAP. V. away. The use of the head-rest not only saves
 — the practitioner's time, but the patient's efforts to
 restrain himself are greatly spared, and he conse-

FIG. 21.

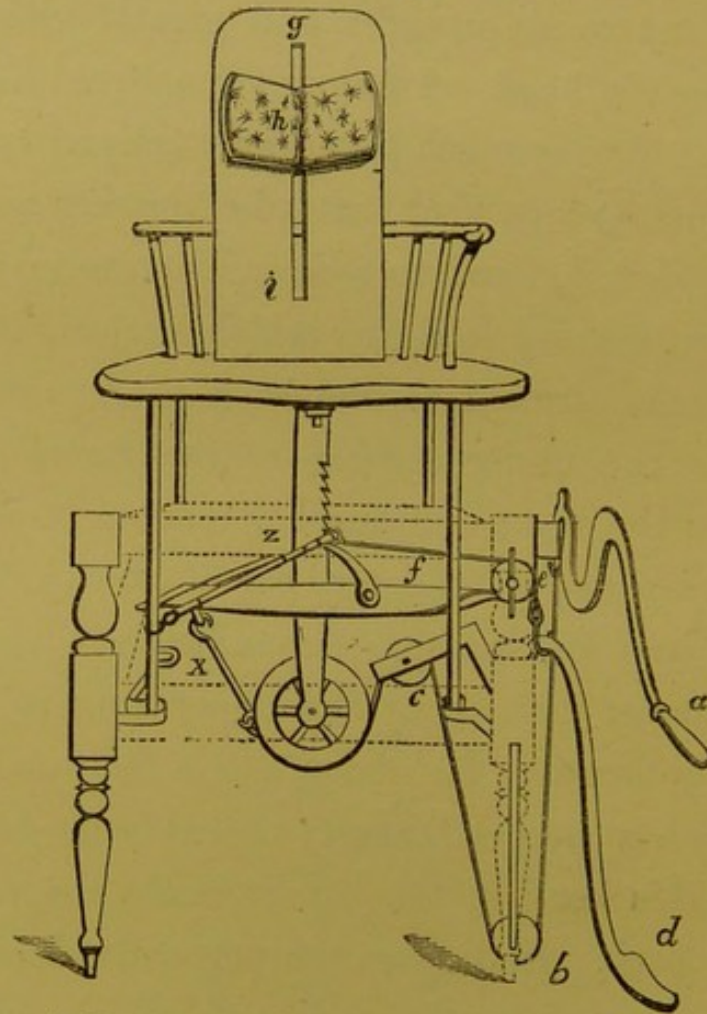


Fig. 21.—A LARYNGOSCOPIC CHAIR, ESPECIALLY ADAPTED FOR HOSPITAL PURPOSES.

quently suffers much less from exhaustion. For hospital practice, and especially when the oxyhydrogen light is used, the laryngoscopic chair represented in the accompanying woodcut will be found the most convenient. A side view of this

chair is shown in fig. 9, and a more diagrammatic and direct view in fig. 21. By reference to the latter cut, it will be seen that by pressure on the handle (*a*) a lever of the second kind is brought into play through *b* and *c*, the fulcrum being at *x*. No great exercise of power is required, for the leverage is very great, and the handle is so convenient that by merely leaning on it (as the operator is doing in fig. 9) a man fourteen or fifteen stone in weight can be easily raised, and when raised is kept in the desired position through the rack arrangement in the axis of the chair. On the other hand, by touching the pedal (*d*) with the foot, the catch of the rack is raised, and the seat of the chair is lowered. By means of this chair, the operator can easily and rapidly put the patient at any convenient height, without himself rising from his chair.

A high broad back, from its breadth, being sometimes inconvenient where assistance is required at operations, I have had fixed to this chair a narrow backboard (*g*) with a moveable head-rest (*h*), which slides up and down the groove, *i*, and can be fixed at any height by a screw at the back.

CHAPTER VI.

THE APPLICATION OF REMEDIES TO THE LARYNX
WITH THE AID OF THE LARYNGOSCOPE.SECTION I.—*Solutions.*

CHAP. VI. **F**OR applying solutions to the larynx, squirrel's
 or camel's hair pencils,* cut square at the end,
 and firmly attached to aluminium wire bent at an
 angle of about 90 deg., will be found most suit-
 able. Brushes of different lengths and of different
 sizes are required in different cases. For ordinary
 use, three brushes will be sufficient, and these are
 made of definite dimensions. The shortest size
 (No. 1) measures two inches in length, from the

—
*The Laryn-
 geal Brush.*

* A facetious author observes, that "these brushes should be prepared by the practitioner himself, and never purchased", and that "a person who can prepare his own brushes is a fit manipulator for local treatment of diseases of the larynx." In a future edition, I have no doubt that he will recommend the laryngoscopist to catch his own camel, or, at least, ensnare his own squirrel, and he will then remark that "a person who can penetrate the African desert in search of the camel, or climb the gnarled oak in pursuit of the nimble squirrel, is a fit manipulator for local treatment of diseases of the larynx."

angle to the end of the brush. The length in the medium size (No. 2), from the angle is two inches and a half. In the longest (No. 3) the length is three inches. In all cases the metal shank of the instrument should measure an inch, and the wooden handle about seven inches. The handle should be octagonal, and should taper down towards the metal; and in hospital practice, or where a large number of cases are seen, it saves a good deal of trouble, in sorting and selecting, to have the handles of brushes Nos. 1, 2, and 3, coloured white, red, and black, respectively.*

The laryngeal brush is well adapted for applying astringent, or other solutions to the larynx.

So many cases of acute and chronic inflammation of the larynx, successfully treated by topical remedies, have been related in the medical journals, that it is scarcely necessary to bring forward here any proofs of the value of local treatment.

The various forms of laryngeal inflammation are for the most part analogous to similar morbid conditions occurring in other parts of the body, and the practitioner, in the selection of particular remedies, will be guided by his general experience. I shall merely remark, therefore, that amongst

* Brushes made in every respect according to these directions are sold by Mayer and Meltzer, 59, Great Portland Street.

CHAP. VI. the remedies I have found most efficacious are solutions of perchloride of iron (gr. 60—120 ad fl. oz. j), chloride of zinc (gr. 20—30 ad fl. oz. j), sulphate of copper (gr. 15 ad fl. oz. j), sulphate of zinc (gr. 5 ad fl. oz. j), alum (gr. 30 ad fl. oz. j), chloride of aluminium (gr. 30—60 ad fl. oz. j); aluminate of iron (gr. 30—60 ad fl. oz. j), carbolic acid (the crystals) (gr. 30 ad fl. oz. j), and tincture of iodine. The perchloride of iron and chloride of zinc are the solutions I use most largely. Glycerine will also be found a most useful solvent for these agents, as its consistence is better calculated than that of water, to keep up prolonged and close contact between the remedy and the affected membrane. I seldom employ solutions of nitrate of silver as applications to the larynx, for whilst I have not found them more beneficial than other mineral astringents, they are much more likely to produce spasm and nausea. The alternation of topical remedies is often as efficacious in the cure of chronic laryngitis, as it is in the treatment of chronic inflammation of other mucous passages.

*Laryngeal
Injector.*

Various kinds of syringes have been invented for injecting fluids into the laryngeal cavity. I do not recommend this method of treatment, but those who wish to practise it will find my modifi-

cation of Rauchfuss's injector a very manageable instrument. It is a hollow tube made of vulcanite, and suitably curved for introduction into the larynx. Near where the tube is fixed to the handle, at the upper part of the instrument, is a small hollow caoutchouc ball, which communicates with the interior of the tube. The injector is filled by pressing the air out of the ball, and inserting the point of the instrument into the solution to be used. This injector is made in two parts, so that the same handle can be employed with different tubes; the points of the tubes are also made in different ways, some having a number of small holes, so that the stream is diffused; some with only a hole at one side, so that the fluid only passes in one direction, etc., etc. The injector is held between the thumb and second finger, and the index finger remains free to press on the ball, when the point of the instrument has been passed into the larynx. An instrument of this sort was used by the late Dr. Theophilus Thompson, and an apparatus of a similar kind was described by Dr. Scott Alison* as far back as the year 1853. A somewhat similar injector is now known as Gibb's laryngeal syringe.

* "The Medication of the Larynx and Trachea", Churchill, page 40.

CHAP. VI. The principal objection to the use of injectors is, that they have a tendency to cause more spasm than brushes, and with them it is more difficult to limit the amount of the application, or to restrain it to certain spots.

FIG. 22.

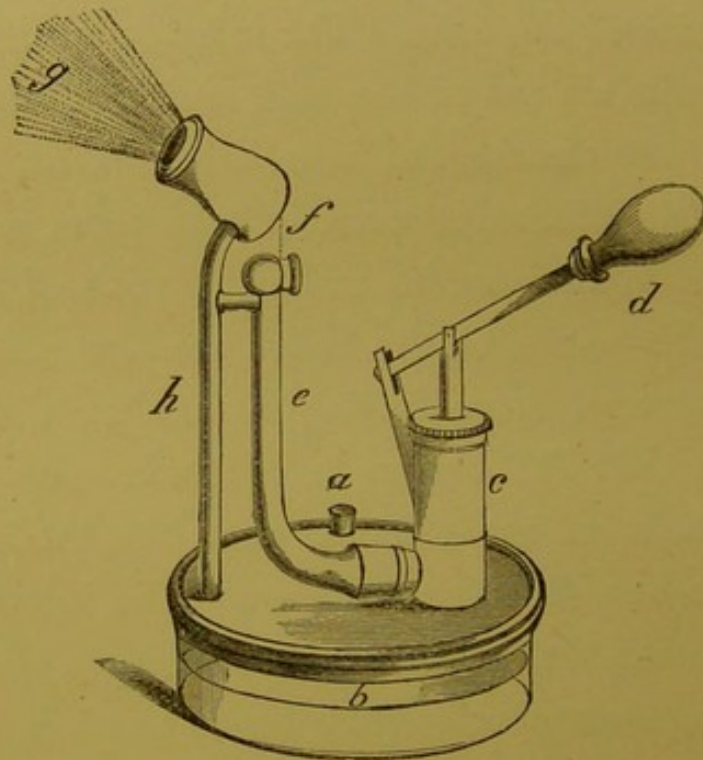


Fig. 22.—MAYER'S ATOMISER.

The medicated liquid is poured by a little funnel, *a*, into a glass vessel, *b*; it is then drawn up by the pump, *c*, acting by the handle of a lever, *d*, along the vulcanite tube, *e*, through the minute opening, *f*, whence it passes into a bell-shaped vulcanite chamber, and becomes atomised at *g*. The waste liquid passes down *h*, and thus is returned to *b*. It is to be observed, that the medicated liquid only comes in contact with glass and vulcanite. The patient inhales the atomised liquid at *g*—that is to say, a few inches from the mouth of the instrument.

SECTION II.—*Inhalations.*

For the application of liquids to the larynx in *Atomizers.* the form of a very fine spray, many kinds of

FIG. 23.

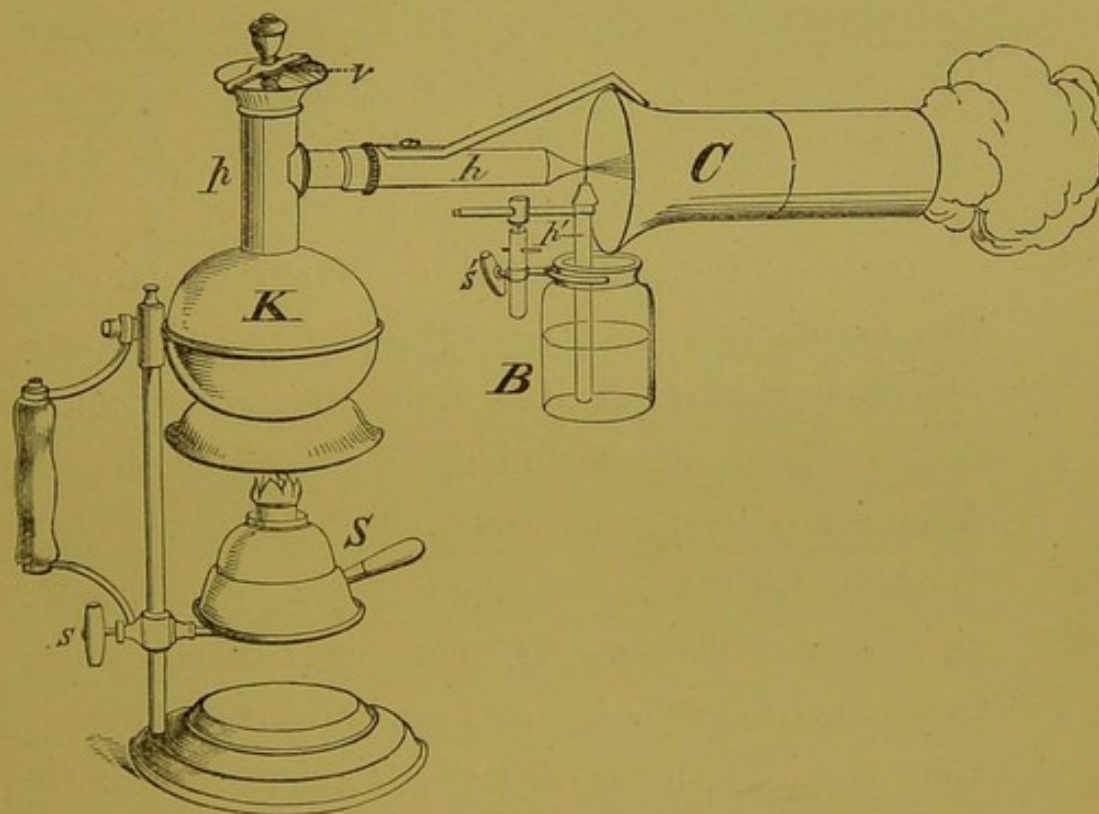


Fig. 23.—SIEGLE'S APPARATUS.

K, kettle, with perpendicular pipe, *p*, above which is the safety valve, *v*, and leading from which is the horizontal pipe, *h*, terminating in a very fine perforated conical extremity; immediately below this extremity is a fine perpendicular tube, *p'*, which dips into the bottle, *B*, containing the medicated fluid; by means of the screw, *s'*, the height of the bottle can be regulated. *S* is a spirit lamp, the height of which is regulated by the screw, *s*. *C* is the conducting tube which conveys the spray to the patient.

CHAP. VI. "atomisers" have been invented. Of these, Mayer's modification of Matthieu's apparatus is one of the best (fig. 22); but Bergson's tubes have, in point of fact, superseded all others. Of these, Dr. Andrew Clark's well-known handball spray producer, in which an india-rubber ball supplies air as the motive power, or Siegle's* apparatus (fig. 23), in which the "atomisation" of the fluid is effected by steam, are the best. These instruments certainly produce a finer spray than those in which the fluid is pulverised by being projected in a fine jet against a disc or button; but they are open to the serious objection, that in all cases a very strong current of air or steam accompanies the atomised liquid. Where any dyspnoea exists, this is a very objectionable feature. The employment of atomisers in throat affections is more particularly indicated in cases where, from circumstances, the patient cannot visit his medical attendant sufficiently often, and is thus obliged to carry out the treatment himself. Weak solutions of carbolic acid (gr. v ad oz. j), tannin (gr. v ad oz. j), and perchloride of iron (gr. iii ad oz. j), have been advantageously employed by me in this way. I do not re-

* This instrument is supplied by Krohne and Sesemann, of 241, Whitechapel Road, and 8, Duke Street, Manchester Square.

FIG. 24.

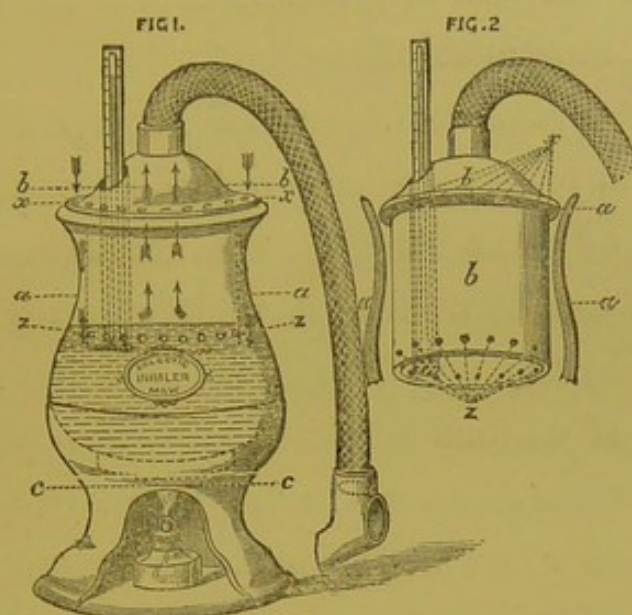


Fig. 24.—ECLECTIC INHALER.

The inhaler consists of three parts—*a*, *b*, and *c*.

A is an open vase, and is essentially the containing vessel, into which the hot water and medicated solution are put. It is shown in fig. 24, 1, with a pint of water in it, and above the water-line is a large space for steam.

B is a kind of lid, resembling an inverted tumbler. It is shown (in fig. 24, 1) forming the lid of the containing vase, and (in fig. 24, 2) with the sides of the vase drawn diagrammatically. The bottom of the tumbler forms the covering of the vase, and the sides of the tumbler dip down into it, leaving an air-chamber between the two parts. When the vase has its proper quantity of water, the sides of the inverted tumbler or lid dip down only about half an inch below the water-line. The circumference of the lid is perforated with small holes, as seen in *x*, and the circumference of what would be the rim of the tumbler is perforated in the same way at *z*. The apertures, both above and below, communicate with the air chamber. When the patient inhales, air rushes through the various holes above at *x*, then through the air chamber, again through the series of holes at *z*, and finally up to the mouth-piece, as shown by the course of the arrows. In the centre of the upper surface of the lid is a projecting nozzle, to which is attached a flexible tube, provided at its extremity with a double-valve earthenware mouth-piece. There is an opening in the lid through which a thermometer, registering high pressure, passes into the water.

C is a stand on which the vase rests, and is made hollow, so as to hold a spirit-lamp.

CHAP. VI.

commend the use of these atomisers for the inhalation of caustic solutions.

In the topical treatment of laryngeal diseases, vapours impregnated with volatile principles will be found of great benefit. The inhalation of such remedies can be well carried out with my Eclectic Inhaler (fig. 24), which, whilst combining the good qualities of various kinds of apparatus previously in use, possesses several entirely new features. It requires no effort in inspiration, insures the thorough medication of the vapour, and accurately maintains the temperature desired. The vegetable kingdom furnishes an abundant variety of stimulant, sedative, and narcotic principles which can be utilised for inhalation.*

* For various formulæ, the reader is referred to the Pharmacopœia of the Hospital for Diseases of the Throat (Churchill, 1871); but I may mention that the oil of the silver fir (commonly called fir-wool oil), the oil of the scented flag, of myrtle, lemon, and the compound tincture of benzoin, are amongst some of the most serviceable medicaments. In prescribing inhalations containing the essential oils, light carbonate of magnesia, in the proportion of half a grain to each drop of oil, will be found a suitable medium. The following is the mode of prescribing which I adopt. *R.* Ol. pini sylvestris, fl. dr. ij; magnes. carb. lev., gr. 60; aquæ ad fl. oz. iij. *M.* "A teaspoonful to be added to a pint of water at 150 deg. Fahr., and inhaled for five minutes each time of using the mixture." The addition of 20 grains of camphor to the three-ounce mixture is often a useful means of increasing the stimulating effect of any of the essential oil inhalations.

SECTION III.—*Powders.*

Powdered substances may be introduced into the larynx either by insufflation or by various kinds of injectors. This plan of treatment was introduced by Aretæus,* and is still employed by Fournié and a few others, but it cannot be recommended.

SECTION IV.—*Solid Nitrate of Silver.*

For applying the solid nitrate of silver to the larynx, the only instrument which is thoroughly safe, and at the same time easy to use, is the “laryngeal cauterizer”. It consists of a piece of aluminium wire, bent at the same angle, and of the same length above and below the angle, as the laryngeal brush. The wire is roughened at its extremity, and then dipped into some nitrate of silver fused over the spirit-lamp. In this way a certain quantity of the nitrate adheres firmly to the wire. An ingenious *porte-caustique* has been invented by Fauvel, in which, whilst the stick of nitrate of silver is safely enclosed, the point, by a spiral spring behind it, is always kept protruding.

* “De Causis et Signis acut. et diutur. Morb.”, lib. iv, cap. 9.

CHAP. VI. Dr. Stoerk, of Vienna, also, when laryngoscopy was quite in its infancy, contrived a porte-caustique, in which the caustic remains concealed till brought to the part desired to be touched, when, by pressure on a spring in the handle, it is made to protrude.

My laryngeal lancet is provided with a small piece of aluminium wire, which can be fitted on in place of the cutting-blade : in this way it becomes a guarded porte-caustique. The nitrate of silver is attached to the wire by fusion in the way already described.

Besides these instruments, various others have been invented ; but the simple aluminium wire, which I am in the habit of employing, answers the purpose perfectly well. The solid nitrate will be found useful for touching ulcers, condylomata, and the base of growths after evulsion has been practised.

SECTION V.—*Escharotics.*

If to the stock and tube of my laryngeal lancet, a piece of aluminium wire, roughened at its extremity, is fitted on, in place of the cutting-blade, escharotics can be applied without danger, and often with great benefit. Instead of the duck-

billed tube which fits on at the joint below the angle, a large silver tube should be adjusted, so that there is some space between the aluminium wire and the inner surface of the tube. For applying escharotics, I have also used a simple glass brush, firmly fixed to the end of a piece of curved aluminium wire. The brushes, however, do not answer well, as the fine glass hairs, though they do not break, are apt to come out. Where the greater part of the mucous membrane of the larynx is covered with vegetations, as not unfrequently happens, it is often difficult to eradicate them by the mouth. In these cases, the greatest benefit may result from the use of escharotics; and I have, on different occasions, applied nitric and chromic acids, and London paste—a mixture of caustic soda and unslaked lime. The most satisfactory results have followed the use of the last preparation. *This class of remedies should only be employed by those who have had considerable practice in introducing instruments into the larynx.*

SECTION V.—*Faradization.*

By a very simple instrument of my contrivance, *Laryngeal Electrodes.* the vocal cords can be easily faradized. It consists

CHAP. VI. of two parts, viz., the necklet which the patient wears, and to which one chain of the battery is

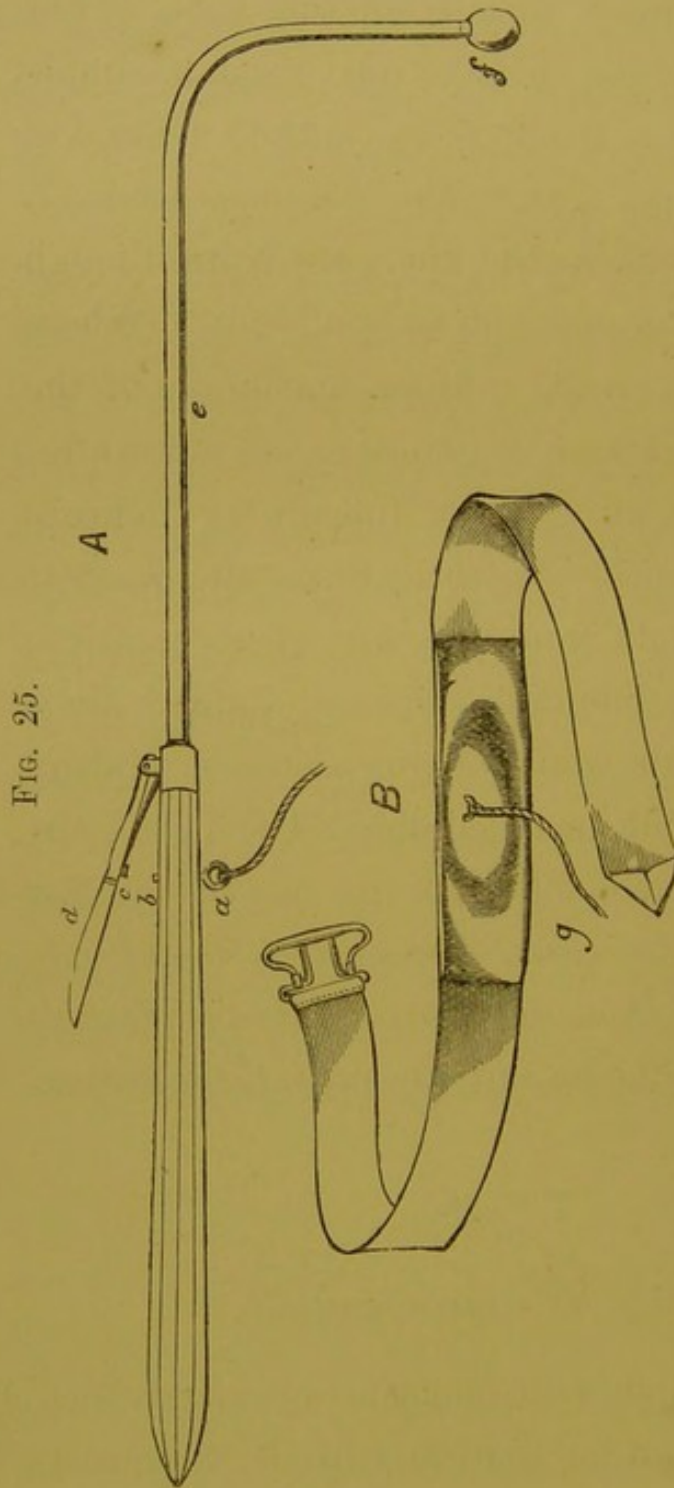


FIG. 25.

Fig. 25.—ELECTRODE AND NECKLET.

A. The laryngeal electrode. *a*, a metal ring by which the electrode is connected by a chain either with a battery or a magneto-electric machine; *b*, the extremity of a wire communicating with *a*; *c*, metal point, which, when the ivory handle, *d*, is pressed upon, touches *b*. The current then passes along the wire, *e* (which is insulated in caoutchouc), to the sponge, *f*. The handle of the instrument is of wood or glass.

B. The necklet, which the patient wears. *g*, the chain by which the necklet is connected with the apparatus producing the electricity.

attached, and the laryngeal electrode itself, which is connected with the other conductor. The important feature in my laryngeal electrode is, that the current does not pass beyond the handle, till the sponge is in contact with the vocal cords. The instrument is held in the hand, between the thumb and second finger, and when the sponge is in contact with the vocal cords, the operator with his index finger presses on the spring in the handle, and the electric current passes through the larynx to the skin externally. By placing the sponge of the electrode on the arytenoid cartilages, both branches of the pneumogastric nerve are stimulated. My instrument is now extensively employed in France, Germany, and this country; and Drs. Smyly, George Johnson, Fauvel, Tobold, and others, have borne testimony to its value. Its employment is indicated in functional aphonia, and in most cases of vocal weakness, where there is no structural disease. In some cases, one application of internal electricity is sufficient to effect a permanent cure; whilst in others the shocks are required to be repeated daily, on alternate days or less frequently for several weeks. I generally introduce the electrode into the larynx three or four times at each sitting, keeping it in, each time, for a few seconds.

I have also frequently employed my laryngeal

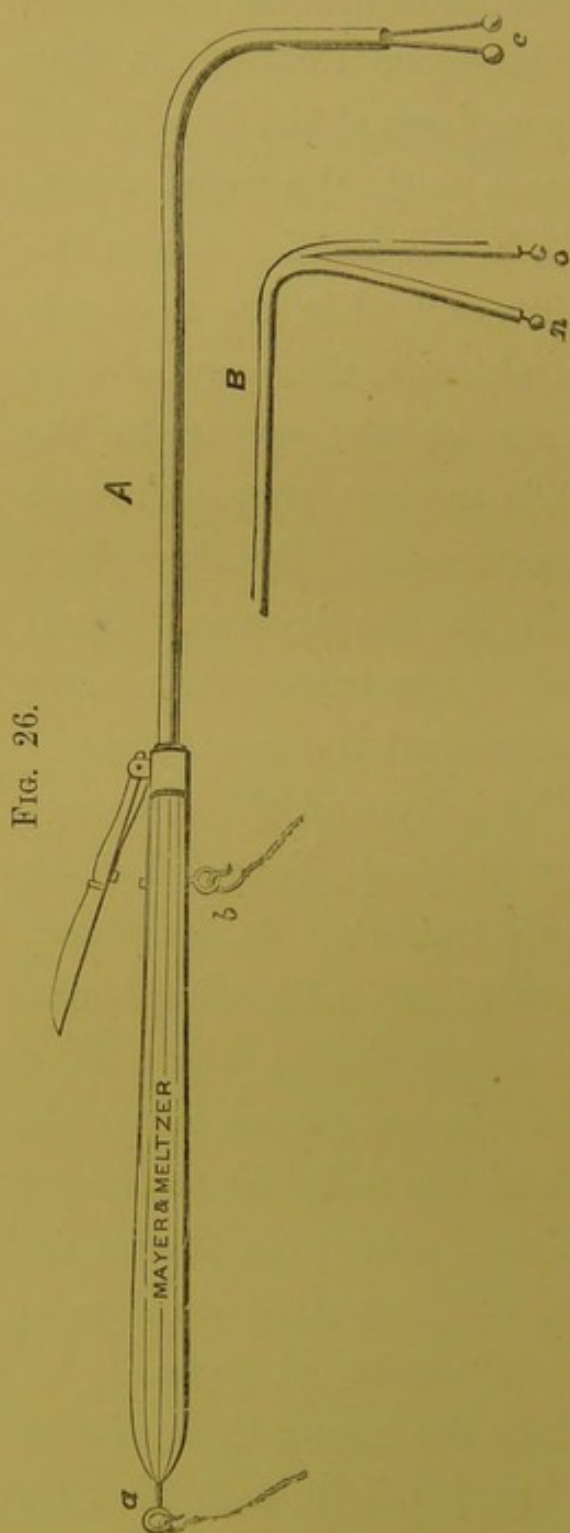


Fig. 26.

Fig. 26.—LARYNGEAL ELECTRODES, Nos. 2 and 3.

The two poles are united in the same instrument—one wire going to the ring, *a*, the other to the ring, *b*. The two rods are carefully isolated, so that when the little handle on the upper part of the instrument is touched, the current passes between the two brass knobs.

A represents No. 2 electrode. This is useful for faradizing the surface of the vocal cord, (and indirectly the thyro-arytenoid muscles) the arytenoideus proprius, and the posterior crico-arytenoid muscles. The current passes between the two knobs at *c*.

B represents No. 3 electrode. This modification is especially useful for faradizing the lateral abductors (the lateral crico-arytenoid muscles). It is introduced into the larynx in such a way that the pole, *o*, is in contact with the vocal cord, and *n* passes into the hyoid fossa. In this way, the lateral crico-arytenoid is embraced between the two poles. The extremity of the hyoid electrode should be about five-eighths of an inch distant from, and slightly posterior to, the pole which is applied to the vocal cord.

electrode in a modified form. I call the original instrument (fig. 25) No. 1. Then I have an instrument No. 2 (fig. 26 A), which contains two electrodes together, carefully insulated and separated at their extremity by about one-eighth of an inch.* This is very useful for faradization of the thyro-arytenoid, arytenoideus proprius, or posterior crico-arytenoid muscle. In laryngeal electrode, No. 3 (fig. 26 B), the extremities of the two poles are separated about five-eighths of an inch, or rather more. This instrument is introduced in such a way that the extremity of one pole is in the larynx, the other in the hyoid fossa. In this way, the current passes right through the lateral adductor of the vocal cord to which it is applied. This instrument is particularly useful in cases of unilateral paralysis of the adductors of the vocal cords.

The following six cases, which appeared in the second edition of this work, are sufficient to illustrate the value of faradization of the larynx; but several hundred similar cases have been treated by me during the last ten years.

Complete Loss of Voice of two years' standing cured by one application of Galvanism.

Case 1.—Miss T., æt. 26, was sent to me March 7, 1864, by Dr. C. J. B. Williams. For the last two years her voice had

* This modification of my instrument was first proposed and employed by Dr. Fauvel, of Paris.

CHAP. VI. been entirely suppressed, and she had only been able to speak in a feeble whisper. The aphonia originally came on with cough and cold, and when I saw her, she was rather delicate, had a bad appetite, and was easily fatigued. Her medical attendant in the country had tried local and constitutional treatment, and various tonics had also been prescribed for her by Dr. Williams, but all without effect. On examining this patient with the laryngoscope, and finding the vocal cords perfectly healthy, though relaxed, I passed the electric current through them. The voice was immediately restored. I saw the patient once or twice afterwards, but there was no relapse.

P.S.—In June 1866, I accidentally heard that the cure of this case had been permanent.

Loss of Voice, of three years' standing, cured by eight applications of Faradization internally; a hoarse voice returning after the fourth application.

Case 2.—Miss Kate H., æt. 26, consulted me in March, 1863, for loss of voice. The young lady looked rather delicate, but did not complain of weakness. She was of a cheerful disposition, and did not appear in the least degree hysterical. She informed me that, in April, 1860, she took cold, had an ulcerated sore throat, and lost her voice. She afterwards wrote me a more detailed account of her aphonia, which I shall give as far as possible in her own words. “After recovery from the sore throat, the voice did not return; and in October, 1860, my regular medical attendant applied caustic twice to the throat, but without any effect.” She then consulted some of the leading London physicians, and, amongst others, Dr. Walshe, who clearly recognised the nervous character of the disease, and “recommended galvanism to be applied, first by one of Pulvermacher’s chains, and afterwards, if that did not succeed, by means of a battery. Neither produced any effect.” This distinguished physician then “strongly urged her to leave it to nature, which she did till April, 1862, when she had the throat

painted with iodine, with no other result than making it very sore on the outside." In May, another eminent practitioner prescribed "zinc pills, which were taken three times a day for a month, without any result. In June, 1862, Dr. Blandford met Dr. Czermak, to examine the throat with the laryngoscope. Galvanic shocks were strongly advised"; and, in the following November, Miss H. placed herself under a physician who has paid especial attention to medical electricity. "He applied galvanism every day with a metallic brush, and afterwards in a stronger form for a fortnight. All this time there was not the least return of the voice."

Miss H. applied to me in March, 1863, and, on making a laryngoscopic examination, it was seen that, though the vocal cords approximated well, they were distinctly relaxed, and bulged upwards towards their centres.

I at once faradized the cords, by means of my "laryngeal electrode." The operation was repeated every two or three days; and, after the fourth application of the electro-magnetic current, the voice returned. It was very gruff at first, and "came and went"; so that, though the young lady recovered her voice one evening, when she came to tell me of her good fortune the next day she was unable to produce a sound. Gradually the voice became more constant, though its monotony was very striking; every syllable and every sentence was pronounced in the same tone, with an entire absence of expression. After the larynx had been faradized altogether eight times, the voice was completely restored, and perfect as regards modulation. The laryngoscopic evidence of relaxation of the cords disappeared after the third faradization.

Many people would consider this case an example of hysterical aphonia; but I must again repeat, that the patient never showed a single hysterical symptom. Being anxious to investigate the case thoroughly, I wrote to Dr. Alfred J. Tapson (of Gloucester Gardens), the regular professional adviser of the young lady, and he kindly replied as follows:—"Miss Kate H.

CHAP. VI. has been a patient of mine for a good many years, and I well
— recollect her illness in 1860. She suffered from intense headache, a remarkably quick pulse, and total loss of appetite, attended with great prostration, emaciation, and loss of voice. *She had no hysterical symptoms.* Dr. Todd saw her several times, and was quite puzzled what to make of her symptoms. We both had some suspicions that she might be going to have tubercle in the brain or elsewhere. She gradually recovered her health and strength, but never her voice (though I and many others tried all we could think of). She gave everything a fair trial, being most anxious to regain her voice."

I have entered somewhat minutely into the history of this case, because I am anxious to show that it was entirely free from hysteria, and that the aphonia was dependent on profound disturbance of the nervous system. There were, as Dr. Tapson says, "intense headache, a remarkably quick pulse, and total loss of appetite, with great prostration and emaciation." It is scarcely necessary to observe that such symptoms imply impaired innervation of the most extreme form.

Faradization was clearly indicated in this case. Dr. Walshe, from general investigation, and Dr. Czermak, from special examination of the larynx, both recommended it. External faradization was vigorously employed by an experienced galvanist, "without the least return of the voice". Faradization applied directly to the vocal cords succeeded rapidly in restoring the voice, which had been completely lost for three years. No comment on the superiority of the internal method of employing faradization is required.—*British Medical Journal*, 1863.

Aphonia of four and a half years' standing cured by the repeated application of Faradization internally.

Case 3.—Miss D., from Rainham, Kent, consulted me on Dec. 8th, 1864, on account of loss of voice of four and a half years' standing. The patient, æt. 30, was tall, thin, and delicate. She

stated she had always been weak, and at one time had suffered from slight spinal curvature. She had consulted several practitioners, and everything had been tried to restore the voice, but in vain. Dr. Penfold, of Rainham (who informed me that he had never noticed any symptoms of hysteria in the patient) had applied very powerful electric shocks to the neck externally, but without restoring the voice. The laryngoscope showed complete paralysis of the adductors of the vocal cords. I faradized the vocal cords, and after a few repetitions the voice was restored. At the end of a month the patient was able to speak in a clear and natural voice. I saw the lady a few weeks ago (in December, 1865), and heard from her own lips that the cure had been permanent.

Loss of Voice of three years' standing. The voice brought back by one application of Faradization internally. Permanent cure after several applications.

Case 4.—Martha B., æt. 24, a young woman of hysterical temperament, was sent to me at the Hospital for Diseases of the Throat, by Mr. Jenkins, of Philpot Lane, on March 20th, 1865. She had lately been out-patient at Guy's Hospital, at which institution external electricity had been persevered with under the directions of an able physician. The first time that the vocal cords were faradized, the voice was immediately restored, but after a few days it was again lost. The current had to be repeated at gradually lengthening intervals, for some months before the voice was permanently restored.

Loss of Voice of eight years' standing, cured by a single application of Faradization to the Vocal Cords.

Case 5.—Miss C., æt. 44, of Bartle, consulted me on April 24th, 1865, on account of aphonia of eight years' standing. Local, constitutional, and counter-irritant treatment, had been unsuccessfully employed. She was thin, pale, and weak; but stated she had never been hysterical, and she showed no sign of

CHAP. VI. hysteria. The laryngoscope demonstrated paralysis of the vocal cords. On attempted vocalisation, they remained perfectly quiescent. The application of faradization to the vocal cords was followed by the immediate restoration of the voice, and the patient left me speaking in a clear natural tone. A week later, I repeated the operation, though the voice had remained perfect. On the 30th August, I received a note saying that the patient's voice continued strong. The history of this interesting case is known to Dr. Watts, of Battle.

Case 6.—Miss R., æt. 25, was sent to me by Dr. Lanchester, of Croydon, on account of aphonia of six years' standing. The patient was in a fair condition of health and strength. The loss of function came on originally with cold, cough, and hoarseness, but remained after these symptoms had passed off. At that period, the patient occasionally suffered from "hysterics". The most suitable treatment (consisting of electric shocks through the hands, counter-irritation, the application of caustics internally, shower baths, the inhalation of chloroform, tonics, and repeated change of air) has been ineffectually tried.

With the laryngoscope, the paralysis of the vocal cords was seen to be complete. I repeatedly attempted to faradize the vocal cords, but the patient always shut her mouth before I could introduce the laryngeal pole. I then put the patient partially under the effect of chloroform, and applied extremely powerful shocks. The stronger shocks once or twice produced inarticulate sounds, but the voice could not be restored. In the beginning of November, the patient having given up the chloroform, I was able for the first time to introduce the electrode into the larynx, and on the 16th of that month the voice was fully restored, though a fortnight previously it began to return. It is now strong and natural. Though faradization was applied a great number of times without any result, I believe that the first time the current actually reached the vocal cords the desired effect was produced. The fact

that, whilst the patient was perfectly under the influence of chloroform, she whispered (not spoke), is a proof that the loss of function was not due to hysteria. CHAP. VI.

The four last cases are copied, with slight technical alterations, from the *Dublin Medical Press* (Jan. 11, 1866). It is to be observed that in four out of the six cases here reported as illustrations of the value of internal faradization, the external current had proved ineffectual. For further illustrations of the value of faradization, I must refer to my pamphlet on "Hoarseness, Loss of Voice, and Stridulous Breathing, in Relation to Nervo-Muscular Affections of the Larynx" (2nd Edition). Churchill, 1868.

CHAPTER VII.

OPERATIONS ON THE LARYNX.

SECTION II.—*Scarification and the Opening of Abscesses and of Cystic Tumours.*

CHAP. VII.
—
*Laryngeal
Lancet.*

FOR scarifying the mucous membrane of the larynx, in acute or chronic œdema, for opening abscesses, and, in some rare cases, for dividing laryngeal growths, I have contrived an instrument which, in many instances, has proved very serviceable. It consists of a small double-edged knife or lancet, which is contained in a hollow tube, suitably curved for introduction into the larynx. The point of the lancet is concealed in the duck-billed extremity of the tube, till forced out by pressure on a spring in the handle. The stock of the instrument is provided with tubes bent at different angles, and below the angle is a joint which enables the operator to lengthen or shorten the tube. This arrangement allows for the varying inclination which the plane of the laryngeal aperture bears to the horizon, and renders the lancet fit for operating either at the upper or lower part of

FIG. 27.

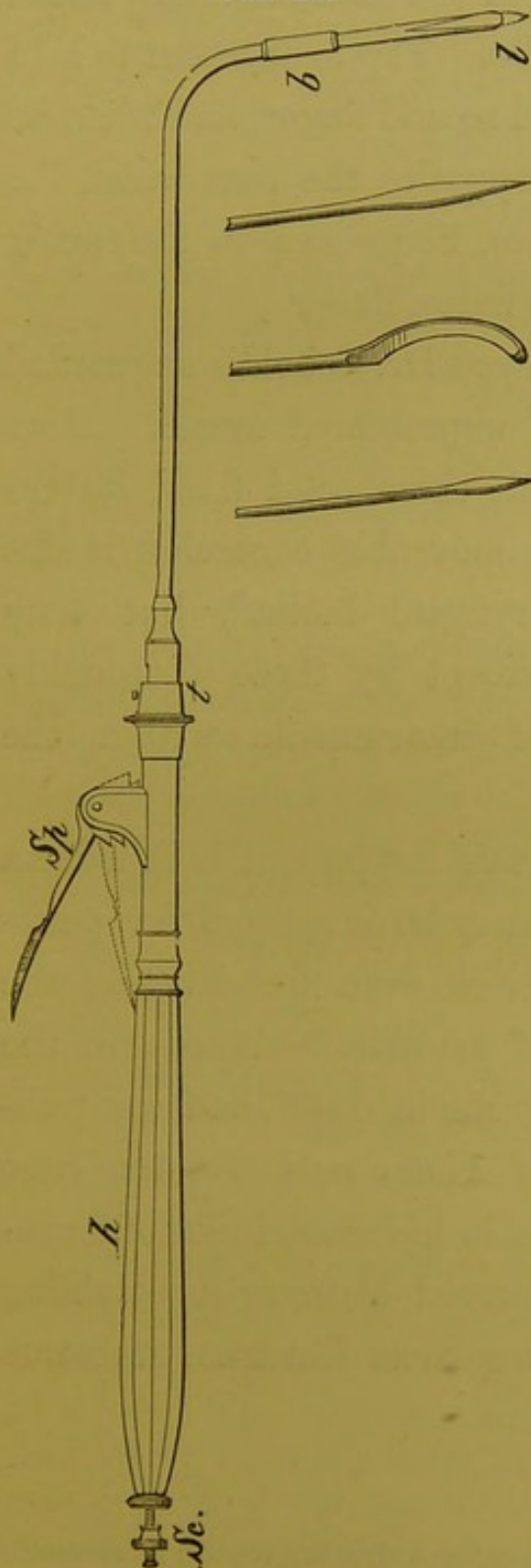


Fig. 27.—THE GUARDED LARYNGEAL LANCET, AND VARIOUS KNIVES.

Sp. The spring which forces out the lancet : when it is pressed down to the dotted line, the lancet, *l*, protrudes.

h. The handle—the same as that used for the forceps.

Sc. The screw, by turning which, the length of the point of the lancet can be regulated.

t. Junction of the barrel and stock of the instrument. At this point, barrels curved at different angles, can be applied. This part of the instrument is thicker than it need be, when each instrument (forceps and lancet) has a separate stock. To the left side of *t*, a small disk has to be inserted, which fixes the tube, and allows the chain inside to move. In the forceps, on the other hand, the chain is fixed, and the tube moves.

b. The bayonet joint. A shorter or longer tube can be put on here, according to circumstances, and the blade can be taken out and cleaned.

The engraving also shows the various blades recommended by Tobold. These can be protected by

a sheath, as in the laryngeal lancet, or the naked blades can be employed after the manner of Tobold.

CHAP. VII. the larynx. The length of the blade is regulated by a screw in the handle. The instrument is held between the thumb and second finger, and when its extremity is brought opposite the part which the operator wishes to lance, he presses on the spring in the handle with his index finger.

I have latterly employed Dr. Tobold's unguarded knives, as well as an unprotected lancet. More power is obtained with these solid fixed instruments than with the moveable concealed blades of my protected "laryngeal lancet", but they should not be used except by those thoroughly skilled in the use of instruments within the larynx.

The principal use of this instrument is in œdema of the glottis, but it may be employed for puncturing cystic tumours, or even for dividing the base of other kinds of growths.* A case of the latter kind occurred to me in 1866, and was published in the *Medical Times and Gazette*, June 13th, 1868; and Bruns, in his second case of laryngeal growth, used a curved bistoury for dividing its base. The following cases illustrate its value in œdema :—

* Dr. Tobold, of Berlin, considers that knives are more useful than any other kind of instrument for operating on growths.

Chronic Œdema of the Right Ventricular Band (causing great difficulty of breathing, hoarseness, and pain), cured by scarification. CHAP. VII.

Case 7.—Charles C., æt. 22, applied at the Hospital for Diseases of the Throat, May 4, 1863, on account of great difficulty of breathing, hoarseness, and pain in the throat. He had suffered since March, 1861; and for more than a year he had never been able to lie down at night. When he did get to sleep (in an arm-chair), he often woke with the most distressing dyspnoea, and said he felt as if he should be strangled. He had attended at the Middlesex, Brompton, and other hospitals. On making a laryngoscopic examination, the right ventricular band and ary-epiglottic fold formed together a large tumour which projected across the glottis, and concealed from view the anterior two-thirds of the left vocal cord. The swelling was of a deep purple-red colour. The mucous membrane over the arytenoid cartilage was also inflamed and swollen. The case was diagnosed to be one of chronic œdema of the larynx, and was freely touched with a strong solution of nitrate of silver. This treatment was continued every other day for a month, with little benefit to the patient; indeed, though the œdema did not increase, the patient became weaker, and the voice was completely extinguished.

June 8th.—I scarified the œdematous swelling, and, after the operation, the patient expectorated a considerable quantity of blood and frothy fluid.

June 10th.—On examining the larynx, the swelling did not appear much diminished. I again lanced the part freely. The next day the patient was greatly relieved; he had slept well for some hours, and woke refreshed and comfortable—a pleasure that he had not known for more than two years. The laryngoscope showed that the swelling had gone down very much, and the right vocal cord was now seen to be rather congested. I again scarified the part.

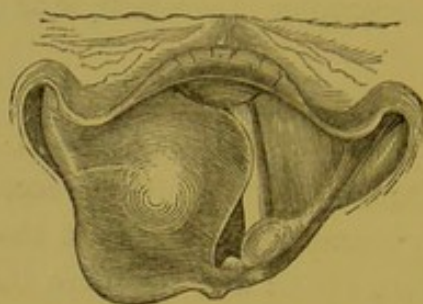


Fig. 28.—CHRONIC ŒDEMA OF THE LARYNX.

A large semi-transparent tumour formed by the right ary-epiglottic fold and ventricular band. It projects across the glottis, and eclipses part of the left vocal cord.

June 15th.—The patient said that he felt quite well, and asked if he could return to his work. Scarcely a trace of the œdema remained ; but there was still a slight abnormal projection situated posteriorly over the right arytenoid cartilage, and the mucous membrane of the larynx generally was also rather redder than the normal condition. The voice was at first a little hoarse, but soon became natural ; and the respiration was free from any embarrassment. This patient occasionally calls at the Hospital just to show himself ; but he is perfectly well, and has been so ever since his larynx was lanced.

*Œdematous Inflammation of the Epiglottis ; Scarification ;
Recovery.*

(*Med. Times and Gazette*, March 31, 1866.)

Case 10.—“John R., æt. 30, applied at the Hospital on October 14, 1865, on account of difficulty of swallowing and pain in the throat, which had been gradually coming on for a fortnight. For a week he had not been able to swallow solids, and for the last thirty-six hours liquids could not be taken. Attempted deglutition now invariably resulted either in a violent paroxysm of coughing, or in the forced ejection of the liquids through the

nares. A laryngoscopic examination showed the epiglottis to be of a bright red colour and enormously swollen. The normal contour of the epiglottis was completely lost, and the valve presented the appearance of three red, slightly projecting, semi-transparent tumours, the largest one being on the right side. The œdematous epiglottis covered the right half and the greater part of the left side of the larynx. The parts which could be observed were seen to be much congested. The appearance is

FIG. 29.

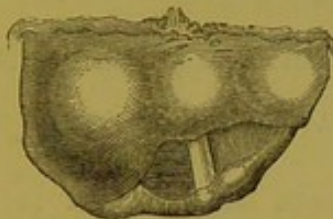


Fig. 29.—ŒDEMA OF THE
EPIGLOTTIS.

FIG. 30.

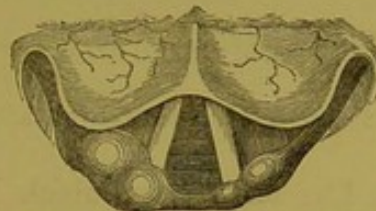

Fig. 30.—The same case a day
after scarification. Œdema of
the right ary-epiglottic fold
can now be seen.

shown in fig. 29. The patient was ordered to inhale hot steam continuously, and blistering fluid was applied externally beneath the angle of the jaw.

“October 15.—Patient much worse. Completely unable to swallow, and so weak that enemata of beef-tea and brandy were thought necessary. Dr. Mackenzie scarified the epiglottis freely with his laryngeal lancet, and afterwards the patient bled a good deal. Half an hour after the scarification the patient was able to swallow, though it caused him some pain. In the evening a laryngoscopic examination was made, and the swelling of the epiglottis was seen to have greatly diminished.

“Oct. 16.—The patient was able to swallow without difficulty. The epiglottis was seen to be no longer swollen, though the marks of the punctures were visible as minute hæmorrhagic spots. The return of the epiglottis, however, to a healthy condition, permitted a more general inspection of the larynx, and the right ary-epiglottic fold was seen to be œdematous.

CHAP. VII. The laryngoscopic appearance is shown in fig. 30. The œdematous fold of mucous membrane was freely scarified.

— “Oct. 17.—The œdema had completely disappeared, though some congestion remained.

“Oct. 20.—The patient was discharged cured.”

SECTION II.—*The Extirpation of Growths and the Removal of Foreign Bodies from the Larynx.*

The extirpation of growths from the larynx, which was at one time* scarcely heard of, is now by no

* The only cases which I have been able to find in pre-laryngoscopic times are the following:—

1st. It appears that a certain Koderik once successfully operated on a case of laryngeal growth, with a curved flexible instrument (*rosenkranzartig*). Nothing further is known of this case. (George Herbinaux, “*Parallèle des differens Instruments*”, etc. A la Haye, 1771.

2ndly. Regnoli in the year 1836 published a case in which, after performing tracheotomy, he removed a polypus about the size of a hen’s egg, situated between the arytenoid cartilages. The growth recurred, and was again removed. The patient, who was a woman, aged 70, died shortly after the second operation. (“*Osservazion Chirurg.*”, etc. Pisa, 1836.)

3rdly. Sir Astley Cooper removed a large cancerous tumour, about the size of a hen’s egg, with his finger, from the under surface of the epiglottis. It grew again, and was again removed, and the patient finally died from hæmorrhage. The specimen is preserved in the Museum of Guy’s Hospital (No. 1685).

4thly. Ehrmann removed a growth from the left vocal cord in the following way: Tracheotomy was first performed by dividing the cricoid cartilage and several of the upper rings of the trachea. After the patient had had a respite of forty-eight hours, the larynx was divided in the median line, up to the base

means an uncommon operation. Evulsion or ex-
cision may be effected in various ways. I am in the
habit of using tube-forceps, ordinary forceps, cut-

CHAP. VII.

of the hyoid bone. When the two halves of the thyroid cartilage were drawn apart, the growth was seen on the left vocal cord, and removed with the knife. The patient recovered from the operation at the end of three weeks, *but the aphonia remained*. He unfortunately died five months later from typhus. ("Histoire des Polypes du Larynx". Strasbourg, 1850.)

5thly. Dr. Horace Green removed a pedunculated tumour (about the size of a cherry), which was (thought to be) attached to the left vocal cord. When the mouth was widely opened, and the patient coughed, a round white fibrous looking tumour could be seen projecting upwards between the ary-epiglottic folds. Green succeeded in seizing the growth with the ordinary tonsil forceps, and then in dividing it with a long slender knife. ("Polypi of the Larynx", p. 56. New York, 1852.)

6thly. Professor Middeldorpf, of Breslau, succeeded in removing a tumour from the upper opening of the larynx, by means of the galvano-caustic wire. "The sarcomatous growth showed a high degree of cell-development", and as a portion remained behind, a very doubtful prognosis was given: solutions of nitrate of silver were afterwards used. Rühle, who saw the case six years after the operation, states "that there was no symptom at that time of any return of the growth." ("Die Galvanokaustik", p. 212, and Rühle, "Die Kelkopfkrankheiten", p. 229.)

7thly. Prat performed sub-hyoid laryngotomy, at Papiete, in the island of Otaheite in the year 1859, for the removal of a tumour, which grew on the left half of the under surface of the epiglottis, and which, though it projected into the fauces, could not be got at from above. A firm, fibrous, greyish-white growth was extirpated. The symptoms were relieved, but the patient died shortly afterwards from phthisis. ("Gazette des Hôpitaux", 1859, No. 103, p. 809.)

From an analysis of the five latter operations (and the first one is so vague that it must necessarily be excluded), it ap-

CHAP. VII. ting-forceps, *écraseurs*, and wire loops. The teeth of the tube-forceps are made to approximate by the passage of the tube over the shoulder of the blades. In seizing growths, the extremity of the instrument, therefore, scarcely moves at all. The tube which contains the forceps is made of steel, and has a diameter of one-tenth of an inch; it is bent at an angle of 90 deg., but to the same stock, barrels of different angles can be applied. Just below the angle is a joint, which enables the practitioner to clean the forceps, and apply shorter or longer blades, as the case may require. The spring which forces the tube over the forceps, is at the anterior and upper part of the handle; and the operator, holding the instrument between his thumb and second finger, presses on the spring with his index

pears that, in those cases where the growths were removed by instruments introduced through the mouth, they could all be seen, and in two instances (the cases of Sir Astley Cooper and Professor Middeldorpf) could be felt with the finger. In Dr. Green's case, the tumour could be seen; and, though it was thought to be attached to the vocal cord, it more probably grew from the ventricular band or ary-epiglottic fold. If the polypus had been attached to the vocal cord, it could not have been seen projecting through the opening of the larynx, unless it had been unusually large, or its pedicle had been much longer than is usually the case. It does not appear that either of these conditions existed. In the cases of Ehrmann and Prat, the operations were indirect, and preceded by tracheotomy. Since "the eye learnt to direct the hand" to the interior of the larynx, an immense number of cases of laryngeal growth have been successfully removed.

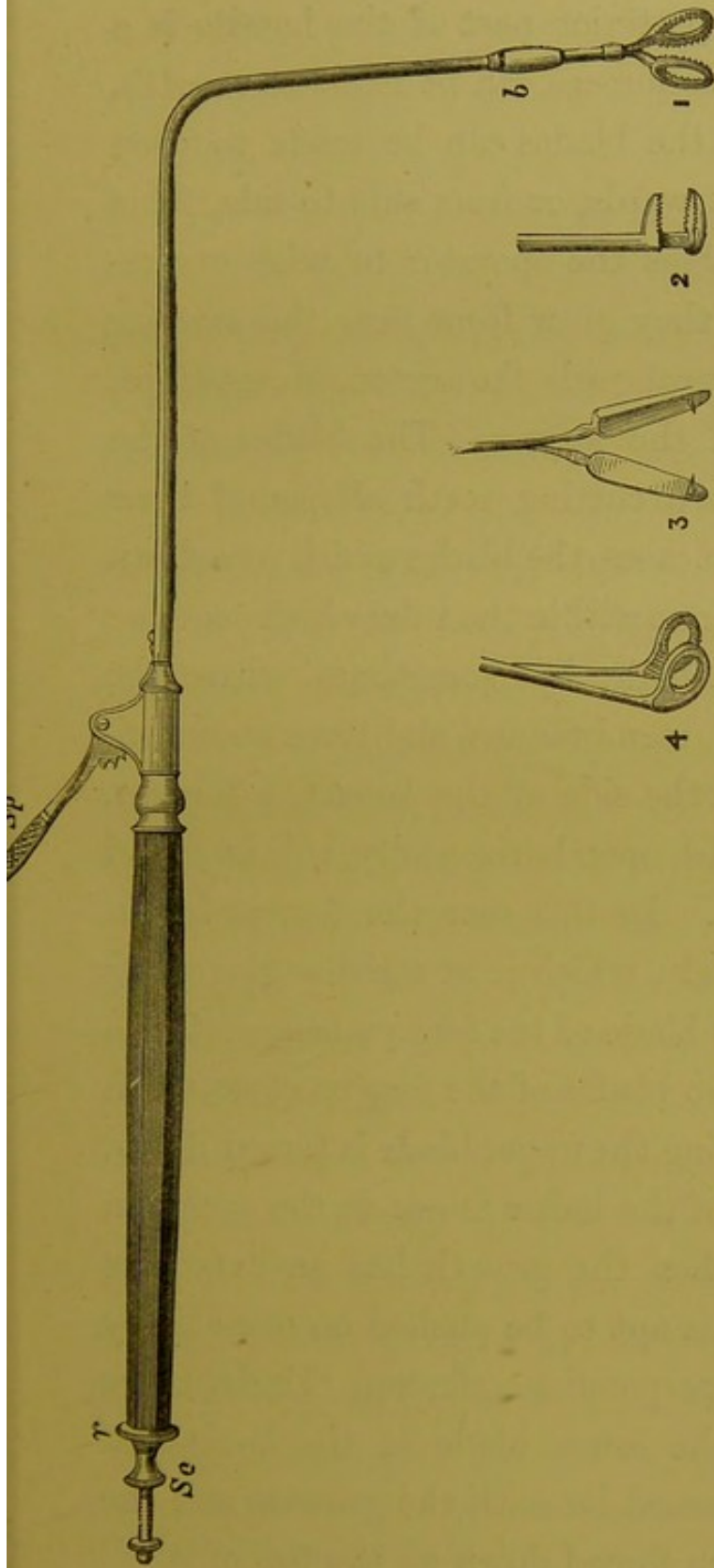


Fig. 31.—THE LARYNGEAL TUBE-FORCEPS, AND SCISSORS.

Sp. The spring, by pressing on which, the tube is forced over the base of the forceps.

b. The joint at which longer or shorter tubes may be applied, and the blades taken out and cleaned. (This joint has been made unnecessarily large by the draughtsman.)

r. The ring, by turning which the forceps revolve, so that the blades open in any direction.

Sc. Screw for taking the instrument to pieces, cleaning it, etc.

1. The perpendicular blades.

2. The horizontal blades.

3. The scissors, with hooks attached to them.

CHAP. VII. finger. At the posterior part of the handle is a ring, by which the forceps can be made to revolve, and in this way the blades can be made to open backwards and forwards, or from side to side. This arrangement enables the operator to seize excrescences, whether they grow from near the anterior insertion of the vocal cords, the arytenoid cartilages, or either side of the larynx. The blades of the forceps have sharp cutting teeth all round their edges. For most cases, the blades which pass down perpendicularly from within the tube which contains them, are convenient; but sometimes, where the growths are thin, membranous, and have an extensive origin from the side of the larynx, a forceps, the blades of which open horizontally, will be found more convenient. In this case the forceps has in fact only one blade, which is at right angles to its shank, the other blade of the forceps being let into the tube: the two blades of the forceps close, when the tube containing the upper blade is forced down, by the pressure of the index finger on the spring in the handle. When the growth has an extensive lateral origin, it is apt to be pushed on one side by the blades of the perpendicular forceps. Under these circumstances, the lower blade of the horizontal forceps can be passed beneath the growth, and the upper one is then forced down on the top of it.

*Perpendicular
Blades.*

*Horizontal
Blades.*

To recapitulate: the advantages of this instru-
 ment are, first, that it can be made of any length ;
 secondly, that it can be inclined at any angle ; and,
 thirdly, that the blades can be opened in any direc-
 tion. The use of this instrument is illustrated a
 little further on by several cases.

At the joint below the angle of the instrument
 just described, instead of the forceps, scissors can be
 fitted. In order that the blades should cut well and
 easily, the shanks of the scissors should cross one
 another above the blades ; the scissors have hooks on
 each blade, which seize the divided particles, and
 prevent their falling into the trachea. I have also
 sometimes employed scissors for cutting through
 cicatrices : in this case the hooks are not required.

It is to be noticed that in my forceps the tube
 passes over the blades, whilst in the lancet the tube
 does not move, but the blade advances. By an
 ingenious arrangement* the same stock has been
 made to answer for both forceps and lancet.

Common forceps, curved so that they can be in-
 troduced into the larynx, are often useful. They
 should be made of different lengths and curved at
 different angles, and some should open like ordi-

* This was effected at my request by Mr. Mayer, who also
 combined the *écraseur* in the same instrument. To avoid com-
 plicated mechanism, however, it is better to have each instru-
 ment separate.

CHAP. VII. nary forceps, laterally (fig. 32, *A*), whilst others open backwards and forwards (fig. 32, *B*). I have removed several growths with these forceps.

Most practitioners have their laryngeal instruments curved like a catheter, but I have long employed them of a more angular form. In a catheter, the two extremities are at right angles to each other, but the angle is reduced to a minimum by a large curve or sweep. This curve, though well adapted for the urethra, is much less suitable for the larynx; but if, on the other hand, the right angle (slightly smoothed down) is left, the instrument, in passing into the larynx, is kept free of the epiglottis. My meaning will be at once clear on reference to fig. 33. It will be seen that both the catheter-curved instrument (indicated by dotted lines) and my rectangular instrument reach the same spot; but whilst the former touches, and even presses against the epiglottis, and base of the tongue, the latter avoids these parts.

Forceps.

Latterly I have had these forceps made with cutting edges, and have found them so useful that I now employ them more often for the removal of growths than any other kind of instrument. Larger experience has also convinced me that forceps should not be slender, but, on the other hand, rather stout. There is too much vibration and too little firmness in the slender instruments, and,

FIG. 32.

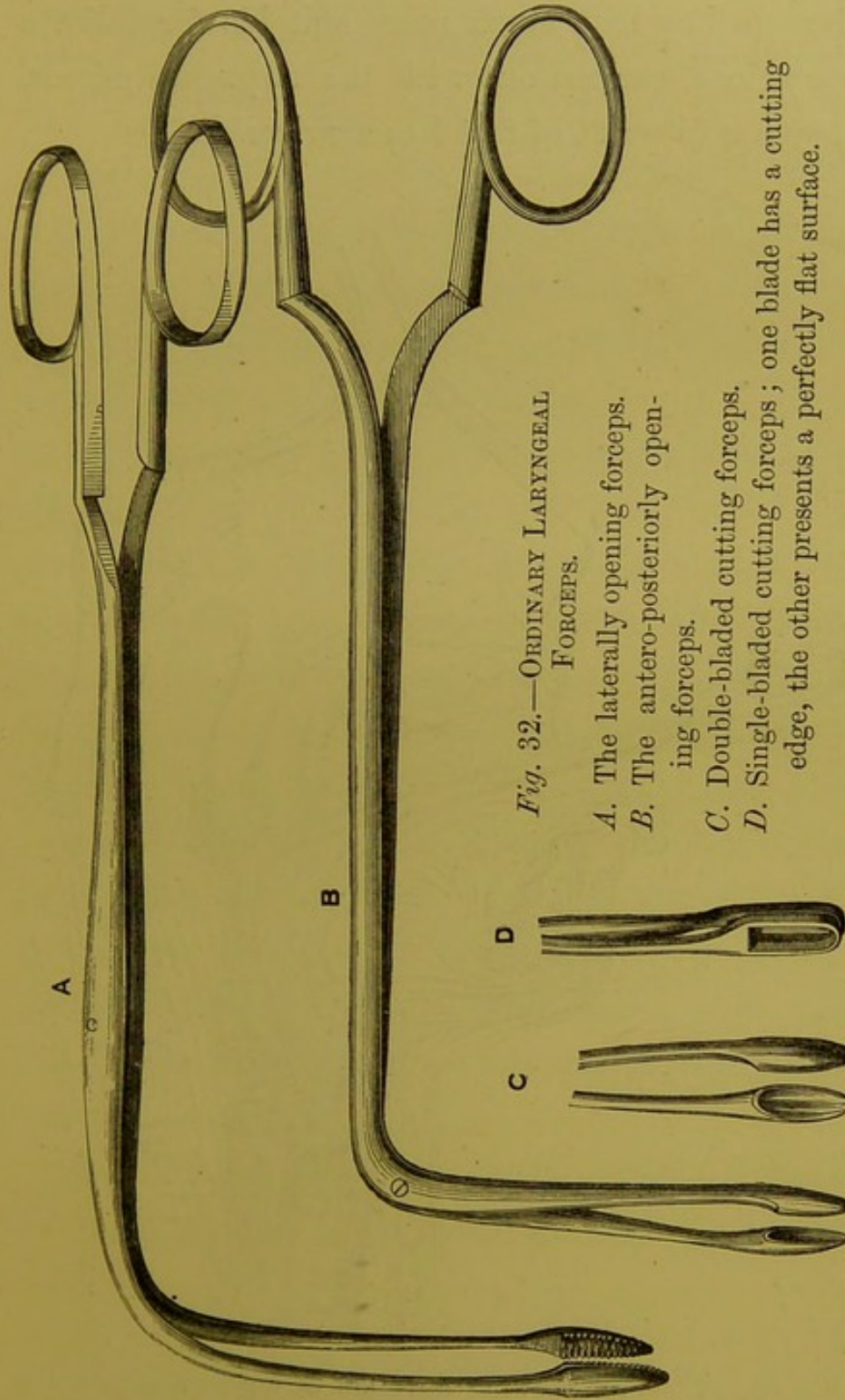


Fig. 32.—ORDINARY LARYNGEAL FORCEPS.

- A. The laterally opening forceps.
- B. The antero-posteriorly opening forceps.
- C. Double-bladed cutting forceps.
- D. Single-bladed cutting forceps; one blade has a cutting edge, the other presents a perfectly flat surface.

CHAP. VII. though they look much more suitable for delicate operations, carried out with the laryngeal mirror, they are in point of fact less serviceable.

FIG. 33.

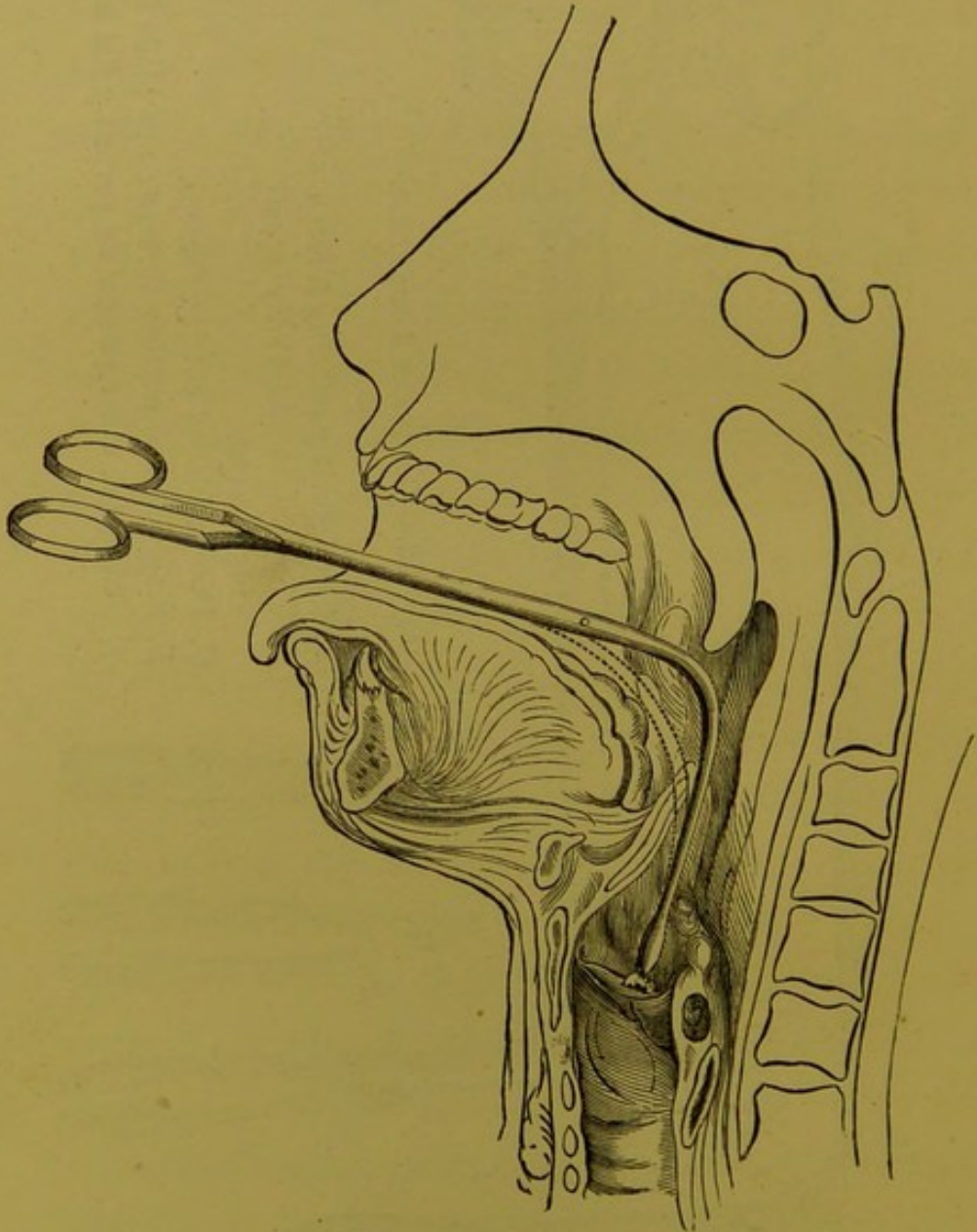


Fig. 33.—Diagram showing direction of author's rectangular forceps. The dotted line shows the position of ordinary catheter-curved forceps.

Ecraseurs of different construction have been used for the removal of laryngeal growths, with more or less success since the invention of the laryngoscope. In this country Drs. Walker,* Gibb, and George Johnson have employed them; whilst in France, an *écraseur*, combined with a kind of dart, which is said to transfix the growth, has been recommended by Moura-Bourillou. CHAP. VII.
—
Laryngeal
Ecraseur.

To these instruments I always entertained the objection that the wire was very likely to be displaced, and that the growth could only be accidentally ensnared after repeated trials. This inconvenience has, however, been overcome by Dr. Stoerk, of Vienna, who has had an *écraseur* (fig. 34) constructed in such a way, that the wire is concealed in a solid loop of metal. This prevents the wire being pushed aside, and enables the operator to put it over the growth. The instrument is thus rendered much more serviceable, but it really acts more on the principle of a *guillotine* than an *écraseur*. *Stoerk's*
Ecraseur.

For operating on very large growths I have, however, used a modification of Stoerk's instrument. *Guarded-*
wheel Ecraseur.

* Dr. Walker, of Peterborough, was the first practitioner in this country who succeeded in removing a laryngeal growth. He used a modification of Gooch's double canula, which he called an *écraseur*. (*Lancet*, Nov. 1861.)

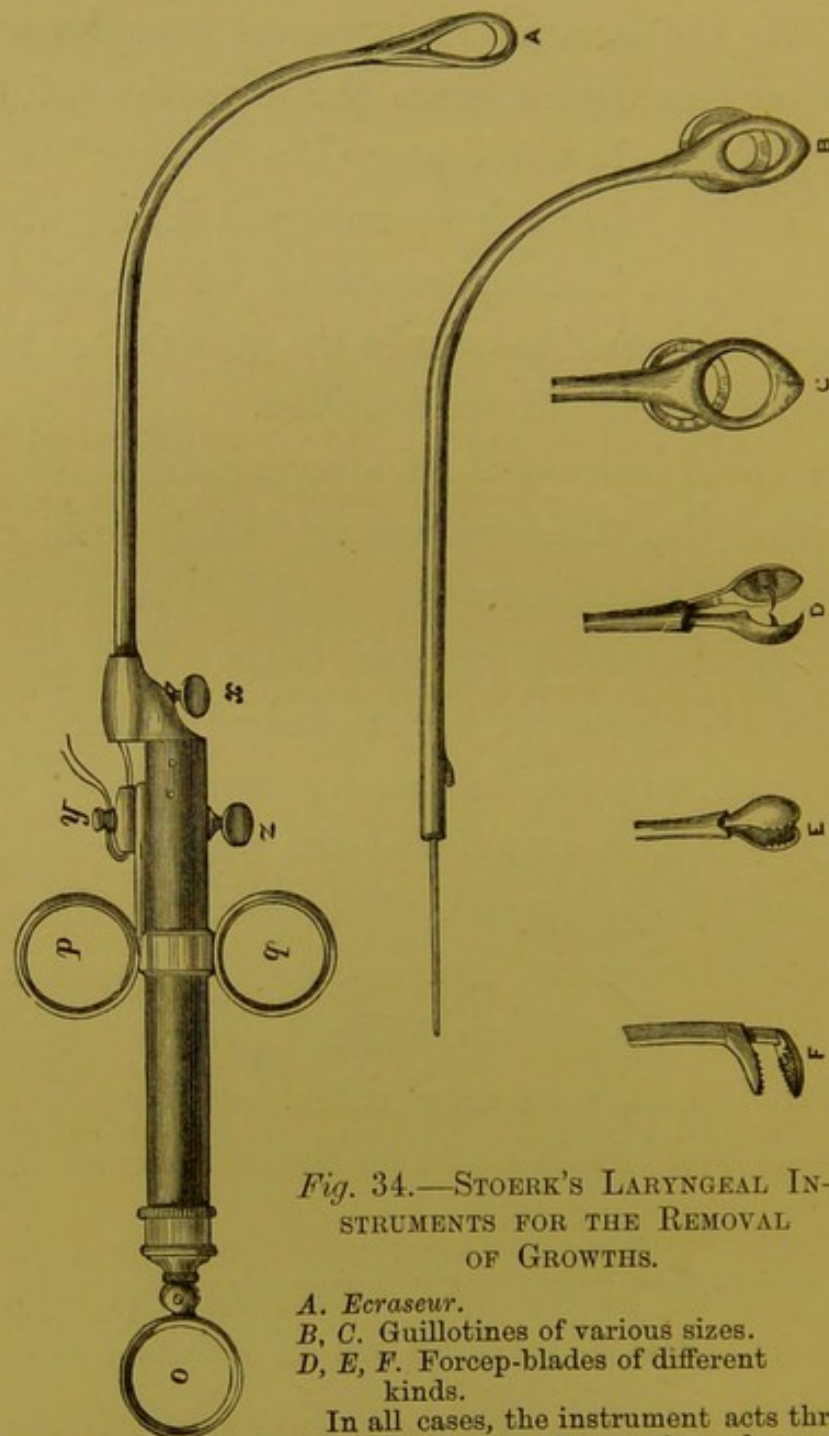


Fig. 34.—STOERK'S LARYNGEAL INSTRUMENTS FOR THE REMOVAL OF GROWTHS.

- A. *Ecraseur*.
 B, C. Guillotines of various sizes.
 D, E, F. Forcep-blades of different kinds.

In all cases, the instrument acts through an internal rod, or double wire being drawn through a tube-shank, which is attached to the handle at *x*. The moveable part of the instrument is attached by the screw, *z*; and, in the case of the *écraseur*, the ends of the wire are twisted round the peg, *y*. In using the instrument, the operator puts his thumb into the ring, *o*, and his index and second fingers through the rings, *p* and *q*, and when traction is made on these rings the *écraseur* or forceps is drawn upwards.

ments, in which, by means of a cog-wheel, which can be turned by the index finger (fig. 35), the wire slowly *crushes* through the growth, on the true principle of the *écraseur*. I have called this

CHAP. VII.

FIG. 35.

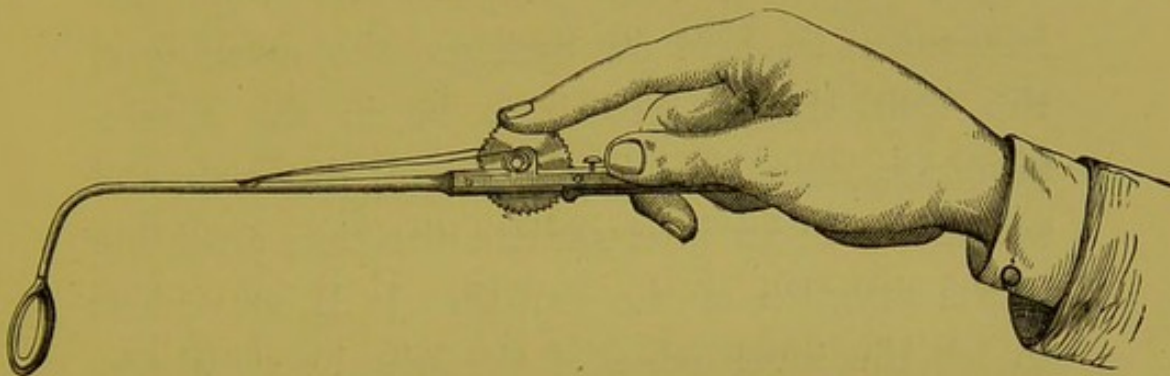


Fig. 35.—THE GUARDED-WHEEL ÉCRASEUR.

instrument the guarded-wheel *écraseur*. Two cases in which it had been employed were recently brought by me before the Pathological Society.* Both these growths were so large that it would have been difficult for them to fall down the trachea, or even to be swallowed; and I may here remark that the risk which I formerly apprehended of particles dropping down the trachea, and giving rise to subsequent disease, does not appear to have been well founded.

Ecraseurs are much less useful than forceps, and

* "Transactions of Pathological Society", vol. xxi, p. 51 et seq.

CHAP. VII. are only suitable for pedunculated growths, which are much rarer than the sessile neoplasms.

Loops or rings of rigid wire can sometimes be employed where other instruments cannot be introduced. They should be curved at different angles and of different lengths, and when the instrument is held in position, the opening of the loop should sometimes be in the antero-posterior, sometimes in the lateral direction, and sometimes in an intermediate direction, according to the situation of the growth. It is convenient to let the inner edge of the wire be sharp like a knife (fig. 36, *z*) and a kind of angular collar (fig. 36, *b*) is not without advantages.

I here append a few cases of growths successfully treated; but for further particulars on this important class of diseases, I must refer the reader to my "Essay on Laryngeal Growths",* in which I have given reports in detail of one hundred cases which have occurred in my own practice, as well as a tabular statement of every other published case, treated since the invention of the laryngoscope.

* London: Churchill. 1871.

FIG. 36.

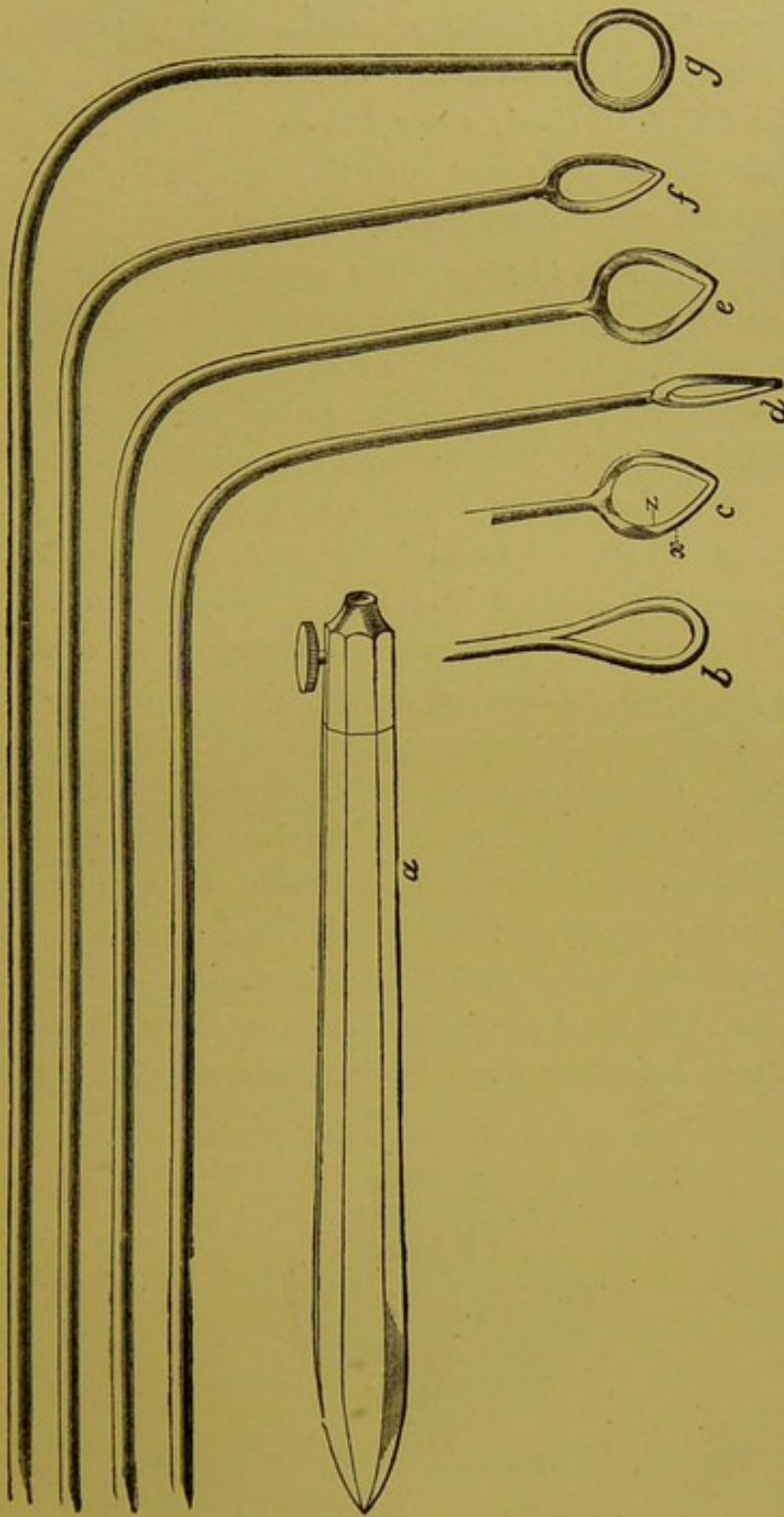


Fig. 36.—LARYNGEAL RIGID WIRE-LOOPS.

a. Handle with screw for holding wire. *b, c, d, e, f, g.* Different wires showing different kinds of loops. *x.* Outer smooth edge of a loop. *z.* Inner cutting edge of a loop.

CHAP. VII.

Five large Papillomatous Excrescences in the Larynx; one on the under surface of the Epiglottis; another on the Right Ventricular Band; a third on the Left Ventricular Band; a fourth on the Left Vocal Cord; and a fifth on the Right Vocal Cord and the Mucous Membrane below the Cord. The four upper excrescences were removed with tube-forceps.

Case 9.—W. W., æt. 44, a carpenter, applied to me April 10th, 1863, on account of loss of voice. He stated that his general health was very good, but that three years ago he had caught a cold and bad sore throat, and since then he had not been able to speak a word out loud. At Christmas his breathing was much affected, and he thought he should have been suffocated; but the attack passed off, and he said that, with the exception of not being able to speak out loud, he was now quite well. He had never had syphilis. On making a laryngoscopic examination, the laryngeal mucous membrane, above and below the vocal cords, was seen to be covered with dark reddish spongy excrescences. One was situated on the right side of the under surface of the epiglottis; another involved the whole right ventricular band; a third covered the whole of the right vocal cord; a fourth occupied half of the left ventricular band; and a fifth the anterior half of the left vocal cord.

Below the right vocal cord a number of smaller excrescences were also seen extending down into the trachea. The appear-

FIG. 37.

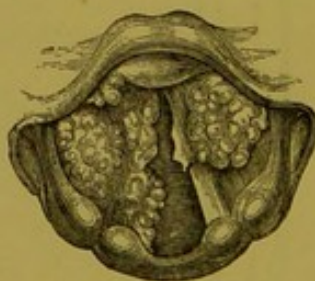

Fig. 34.—EXCRESCENCES IN THE LARYNX.

ance is shown in Fig. 37. This case was seen by Drs. Czermak, Frodsham, George Johnson, Wahltsch, and others. With my tube-forceps, I succeeded, in a number of sittings, in

removing, in small fragments, the whole of the four upper excrescences. This included the one seated on the left vocal cord. These fragments were kindly examined for me by Dr. Andrew Clark. He "found them to consist of numerous yellowish, hard, nodular, or warty-looking particles. Under the microscope, some of these masses consisted entirely of enlarged racemose glands, the terminal vesicles of which were filled with minute nucleated cells and granular matter. Others were true papillary growths, consisting of more or less perfect connective tissue, clothed with many layers of epithelium, the outermost layer of which was in a state of partial desquamation. A few of the papillæ were either quite hollow, or had contained fluid." He regarded the case as one of "Granular Wart." The small particles which were torn away with the forceps produced so little effect on the bulk of the large growth on the right vocal cord, that I was induced to try the effect of escharotics. Nitric acid and chromic acid were both applied several times with decided advantage; but the greatest benefit resulted from the application of "London Paste."* The growth was reduced to a quarter its former size, and the patient recovered a loud and tolerably clear voice.

Warty Excrescences on and beneath both the Vocal Cords (causing loss of Voice of four years' standing) removed with tube-forceps.

Case 10.—Mrs. A., æt. 35, applied at the Hospital in April, 1863, though, in consequence of my absence from town, she did not come under my care till the following month. I had previously (in December, 1862) seen the patient, at Mr. Maunder's request, in conjunction with Dr. Gibb, and the latter author has published the case,† and given a rough sketch of the laryngoscopic appearance. The patient stated that she

* This escharotic consists of equal parts of caustic soda and unslaked lime, and when required for use is made into a paste with water. It is much more manageable than the "Vienna Paste."

† "Diseases of the Throat". London, 1864. P. 156.

CHAP. VII. caught cold in 1859, was very hoarse for two years, and — that in 1861 her voice had become quite suppressed. For the last two years, she had always spoken in a whisper. There was no history nor symptom of syphilis or phthisis. With the laryngoscope, both vocal cords were seen to be of a dirty greyish colour, and in an irregular papillomatous condition: the appearance is shown in fig. 38. Subsequently I discovered two growths—one below each vocal cord. As the diseased condition of the cords was so general, and the growths on the cords were so imperfectly developed, I thought that the case would be most easily treated by caustics. Strong solutions of nitrate of silver were accordingly applied, but they produced so much dyspnœa, that the treatment was obliged to be discontinued. Under these circumstances, I tried to use the forceps; but the patient being unable to open her mouth widely, the laryngeal aperture being exceedingly small, and the growths on the vocal cords most minute, great difficulty was experienced, and it was only after repeated failures that I ultimately succeeded in clearing the vocal cords of the warty growths which covered them. The growths below the cords, which afterwards became distinctly visible, being of larger size, were removed

FIG. 38.

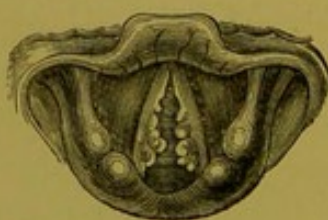

Fig. 38.—PAPILLOMATOUS EXCRESCENCES ON, AND BENEATH, THE VOCAL CORDS.

with much less difficulty. A month after the removal of the last growth, the patient's voice was completely restored. I have not seen her now for some time, but I received a note (dated October 31st, 1864) from Mr. Brown, of Finsbury

Circus, who sent the patient to me, in which he says, "I called on Mrs. A. this evening, and am pleased to find her voice is entirely restored by your treatment." CHAP. VII.

Loss of Voice of nine years' standing, caused by a small Excrescence on the Left Vocal Cord; the Warty Growth was removed with Tube-Forceps, and the Voice completely restored at the end of a month.

Case 11.—Henry R., æt. 45, a gas-fitter, applied at the Hospital, May 1, 1863, on account of loss of voice of nine years' standing. He stated that he had attended at various metropolitan hospitals, and had lately been at the Brompton Hospital. On examining his throat with the laryngoscope, a small round excrescence, about the size of a pea, was seen on the left vocal cord. The warty growth was situated on the free edge, and exactly in the middle of the cord, and on attempted phonation it was seen that, owing to the projection of the growth, the cords could not become approximated. On the right cord, exactly opposite to the wart on the left cord, there was a distinct round indentation. The laryngoscopic appearance is seen

FIG. 39.

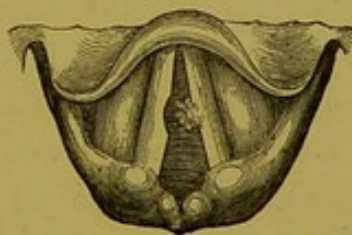

Fig. 39.—A SMALL WART ON THE LEFT VOCAL CORD.

in fig. 39. I had the opportunity of exhibiting this patient to Drs. Czermak, Wahltuch, and others. There was some difficulty in removing this growth, owing to its small size, and the more than usual awkwardness of the patient, and it was not till the fourth sitting that it was successfully seized and removed. Dr. Andrew Clark examined microscopically the portions removed

CHAP. VII. with the forceps, and the following was his report:—"The growth was found to consist of two sets of particles, one membranous, the other warty or obscurely papilliform. The membranous portions consisted of from twenty to thirty layers of scaly epithelium, surrounded and penetrated by a confervoid growth. The epithelial cells composing the layers were polygonal, flattened, nucleated, and easily affected by weak alkalis and acids. The nucleus of each cell was oval, abruptly defined, rather large in proportion to the containing cell, in most cases surrounded by a clear halo, and in some showing signs of division. The papillary portions consisted of simple outgrowths of nucleated connective tissue and rudely-formed blood-vessels, clothed with numerous layers of scaly epithelium, similar to those already described. Some of the papillæ exhibited large vacuoles, or spaces filled with colloid matter, which, in one or two instances had burst through the covering epithelium." Dr. Clark considered the tumour to be a true wart. Immediately after the operation, the patient spat up a few teaspoonfuls of blood, and the same day he was able to sound his voice. The next day he complained of a feeling of great soreness, and there was so much involuntary objection to a laryngoscopic examination, that I was unable to see exactly how the wound looked. Nine days later, however, the mucous membrane over the left vocal cord, where the growth had been, looked rather puckered, and the depression on the right cord was still visible. At the end of a month, the voice was perfect, and all morbid appearance in the larynx, including the little pit on the edge of the right cord, had completely disappeared.

Warty Growths on the Vocal Cords (causing Dysphonia of five years' standing) removed with Tube-Forceps.

Case 12.—William J., æt. 40, applied to me in May, 1863, on account of hoarseness of five years' standing. His general health was good, but fifteen years ago he had a primary venereal sore. He had never suffered from any secondary

symptoms. The voice was harsh, but not suppressed ; and with the laryngoscope a large, thin, flat, membranous growth was seen to project horizontally from each vocal cord, and to meet in the centre. On account of the pendulous condition of the epiglottis, it was difficult to get an extensive view of the larynx, and consequently the growths could not be seen in their entirety. The appearance is shown in fig. 40. The smallness of the laryngeal aperture was still more inconvenient in operating ;

FIG. 40.

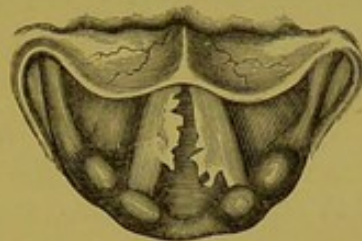

Fig. 40.—WARTS ON THE VOCAL CORDS.

(This view of the Larynx was obtained by raising the Epiglottis with the Pincette.)

and it was only after several unsuccessful attempts that I managed to remove a small portion of the growth on the right vocal cord. Under these circumstances, I endeavoured to divide the left growth through its base, with my laryngeal lancet. After the operation, the patient left me, but soon returned, spitting up considerable quantities of blood. On examination with the laryngoscope, the mucous membrane was seen to be covered with blood ; but the exact source of the hæmorrhage could not be ascertained. I applied a strong solution of perchloride of iron to the interior of the larynx, and directed the patient to suck ice. The hæmorrhage, however, which continued for some time—to an extent that was really alarming—was ultimately arrested by the patient gargling with, and swallowing, a saturated solution of tannin. The first mouthful of the tannin that was swallowed stopped the bleeding entirely. A day or two after the operation, a careful examination of the

CHAP. VII. larynx was made both by Dr. George Johnson and myself, but we were neither of us able to ascertain the source of the hæmorrhage. I have since removed several fragments by using the horizontal blades of my forceps, and the patient's voice is now clear ; he still complains, however, of a slight tickling in the throat.

Hoarseness of seven years' standing caused by a Polypus attached just above the anterior insertion of the Vocal Cords. The Polypus was removed with the Forceps, and the Voice restored.

Case 13.—Morris B., æt. 41, shoemaker, and formerly singer, applied at the Hospital for Diseases of the Throat, August 20, 1863. He stated that he had been extremely hoarse for seven

FIG. 41.

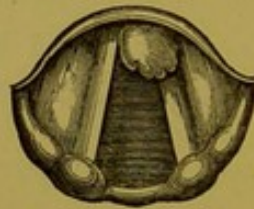

Fig. 41.—A SMALL POLYPUS ATTACHED JUST ABOVE THE ANTERIOR INSERTION OF THE VOCAL CORDS.

years, but had never suffered from complete loss of voice. He had had primary syphilis when he was sixteen. A physician had recommended him to have his uvula removed, but the operation had not improved his voice. A laryngoscopic examination showed that there was a yellowish-pink growth, about the size of a small bean, just above the anterior insertion of the vocal cords. It was moveable (and therefore probably pedunculated), but the base was hidden by the tumour, and therefore its exact origin could not be ascertained. When the glottis was closed, the growth rested on the extremities of both the cords ; sometimes, however, lying more on the right, and sometimes on the left cord. The appearance is shown in fig. 41.

August 21.—I had the advantage of a consultation with Dr. George Johnson and Mr. Mason, who entirely concurred in my diagnosis.

Aug. 24.—In the presence of these two gentlemen, I removed the excrescence with my laryngeal forceps. The growth was successfully seized at the first trial, and all of it, except a small portion of its base, was brought away. After the operation, we examined the patient with the mirror, and the base of the growth covered with blood was indistinctly seen. I was disposed to remove this small remaining fragment, but after a consultation, it was thought better to leave it alone, under the idea that it would probably wither away.

Immediately after the operation, Dr. Johnson thought he noticed an improvement in the voice.

Aug. 26.—There being still a small portion of the base of the growth remaining, I removed it with the forceps; and at the end of a fortnight the man spoke perfectly well.

“The morbid growths,” according to Dr. Andrew Clark, “consisted of three or four minute, shapeless pieces of yellowish colour, streaked with red, and of a horny consistence. On account of their hardness, their structure could not be very easily determined. On the free surface, however, were several layers of thin, scaly epithelium, few of the elements of which exhibited any nuclei. In fact, but for the absence of cholesterine, the cell elements might have been most readily mistaken for those of cholesteatoma. Beneath the epithelial coverings were minute extravasations of blood, and amorphous masses of a coagulated proteine compound.” Though in this case the proteine compound had not developed fibres, the case was regarded by Dr. Clark as one of commencing “Fibro-Epithelial Growth.”

Growths on both Vocal Cords (causing aphonia of nine months' standing), removed with the forceps.

Case 14.—Miss Mary B., æt. 30, was sent to me by Mr.

CHAP. VII. Parsons, of Bridgewater, April 7, 1864. This patient lived in London, and, after she had been suffering from loss of voice for some months, a distinguished physician recommended "change of air to her native place." On arriving there (Bridgewater) she was recommended to return back to London to see me, and the laryngoscope at once revealed the cause of the hoarseness.

A small growth was seen on the right vocal cord, and afterwards, when the patient had been examined once or twice, another growth was perceived on the left cord, near to its anterior insertion. The appearance is shown in fig. 39. The

FIG. 39.

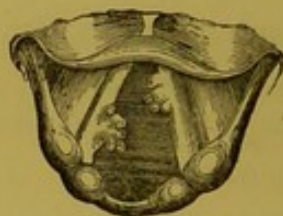

Fig. 39.—WARTS ON THE VOCAL CORDS.

history of the case seemed to show that these growths originated in chronic laryngitis. After twenty attempts, only four of which were successful, the growths were entirely removed with the forceps. After the removal of the warts from the vocal cords, a small growth was seen lower down; but as the voice was restored, no further treatment was adopted.

Growth attached to the right Vocal Cord of a child, aged four years (causing aphonia and dyspnœa), removed with tube-forceps.

Case 15.—Caroline M., æt. 4, was brought to me Nov. 7, 1864, on account of aphonia, dyspnœa, cough, and expectoration. The symptoms had come on two years previously, but had lately become much aggravated; cold was the attributed cause of the affection. The patient had never had croup; but on making a laryngoscopic examination, a growth about the size

of a cherry was seen in the larynx, attached apparently to the right vocal cord, but occupying the anterior three-fourths of the glottis. The growth was of pale colour and covered with papillary prominences. By a succession of operations, I succeeded with my tube-forceps in removing, in fragments, the whole of the growth. Mr. Mason kindly made a laryngoscopic examination both before and after the removal of the growth, and both the patient and specimen were exhibited at the Pathological Society in December 1864. (See *Transactions*, vol. xvi, p. 38.) It was not till some months after the removal of the growth that the voice was fully restored.

Warty Growths on both the Vocal Cords of a child, aged six years, removed with the Tube-forceps.

Case 16.—Ellen B., æt. 6, was brought to the Hospital for Diseases of the Throat, on Nov. 20, 1864, on account of loss of voice of two years' standing. The laryngoscope showed warty growths on both the vocal cords. By a series of operations I ultimately succeeded, with the tube-forceps, in removing the whole of the growths; there remained only a slightly roughened condition of the vocal cords. The voice was "loud and distinctly phonetic, though still a little hoarse." when I brought the patient before the Pathological Society (See *Transactions*, vol. xvi, p. 39). Here, again, I enjoyed the advantage of Mr. Mason's co-operation.

Papilloma of the Larynx; a large portion removed with the wire-loop.

Case 17.—Eliza W., æt. 45, applied at the Hospital for Diseases of the Throat, Jan. 18, 1866, on account of complete loss of voice and shortness of breath. She stated that for the last twenty-five years she had been hoarse, and that for the last eight her voice had gone altogether; latterly she had occasionally suffered from distressing attacks of suffocation. She stated that two months previously she had been an out-patient at one of the general hospitals, where electric shocks

CHAP. VII. were applied to the neck, but without advantage; and that since — then she had been under private medical treatment, and twenty-seven blisters had been applied consecutively to the neck, with no other effect than causing great swelling of the sub-maxillary glands. On examination with the laryngoscope, a large excrescence was seen occupying the space between the vocal cords. Its exact origin could not be ascertained, but it appeared to grow from the anterior third of the left vocal cord, and on inspiration closed the anterior three-fourths of the laryngeal canal.

The upper opening of the larynx was small, and in other respects the case was a difficult one for operative manipulation. Under these circumstances I was unable to use forceps, but with my wire-loop I succeeded in jerking off into the mouth a large piece of the growth. A portion still remains, but the patient now speaks in a hoarse voice, instead of, as formerly, in a whisper, and the respiration is now perfectly easy. The piece of growth removed was pronounced by my colleague, Dr. Andrew Clark, after a careful microscopical examination, to be "highly developed typical epithelial cancer—pathologically speaking, the most malignant variety that he had ever seen of any small growth in that locality." The specimen was exhibited at the Pathological Society, Feb. 20, 1866. The clinical history of this case did not accord with the microscopical examination, for no subsequent development of the growth took place, and a year later the patient had a loud, though rather hoarse, voice.

*Growth removed with the Tube-forceps from the Right Vocal Cord
of a child aged twelve years.*

Case 18.—Conway C., æt. 12, from Gosport, was brought to me in January 1865, on account of loss of voice and dyspnoea. When five years old the boy had suffered from croup after measles, and since then had not been able to speak out loud. For the last eighteen months he had experienced shortness of breath, being quite unable to play at any games, and several times

during the last year he had "seemed as if he would be strangled." On making a laryngoscopic examination, a growth was seen attached to the right vocal cord and beneath the anterior commissure. The appearance is shown in the annexed wood-cut

FIG. 43.

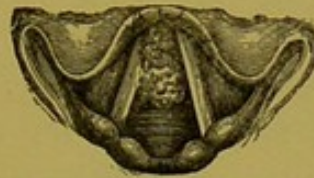

Fig. 43.—WARTY GROWTH ATTACHED TO THE ANTERIOR HALF OF THE RIGHT VOCAL CORD.

(fig. 43). On Feb. 3, Mr. Mason kindly made a very careful laryngoscopic examination and drawing of the case. After a great many attempts, I ultimately succeeded with my tube-forceps in removing the whole of the growth; and in the following June, to use Mr. Mason's expression, there was nothing to see but "a slightly uneven condition of the cords"; this afterwards passed away. Dr. Andrew Clark described the specimens which were brought before the Pathological Society, December 19, 1865, as being "examples of simple papillary, warty, or cauliflower growths." The voice was completely restored.

Large Growth attached to the Left Vocal Cord; Aphonia of six and a half years' standing; Evulsion of Growth; Recovery of Voice.

(*From Medical Times and Gazette, October 27, 1866.*)

Case 19.—"Eliza P., æt. 31, a stout healthy looking woman, from Gravesend, was sent to Dr. Morell Mackenzie, in June 1865, by Mr. John A. Kingdon. She stated that in the winter of 1858-59 she had a bad cough and cold, and that the hoarseness which came on at that time, passed in a few months into complete loss of voice; since then she had not been able to speak a word out loud. In 1860 she was an in-patient in a

CHAP. VII. provincial hospital, and there shower-baths were used, but in vain, to restore the voice. In the following year she was admitted into one of the metropolitan hospitals, and here the treatment consisted in blistering the neck ; afterwards iodine, mustard poultices, and turpentine stupes, were used, and general remedies (quinine, iron, etc.), but all without effect. She further stated that she always suffered now from shortness of breath, and that lately she had had two attacks of great difficulty of breathing, which had lasted for several days. On making a laryngoscopic examination, an irregular lobulated growth, about the size of a sparrow's egg, was seen to be attached to the entire length of the left vocal cord ; it projected up into the laryngeal cavity and across the glottis. At the patient's second visit, Dr. Mackenzie first attempted to seize the growth with his tube-forceps, and on the first trial a large piece was seized and brought away. On several other occasions fragments were removed, but at several visits the attempts to seize the tumour were quite unsuccessful. On account of the distance at which the patient lived, she was not able to attend at all regularly, and long intervals often intervened between her visits. Accordingly it was not till March 7th, 1866, that Dr. Mackenzie succeeded with a pair of ordinary forceps (opening in the antero-posterior direction) in completely clearing the larynx. Dr. Pratt was present on this occasion, and made a laryngoscopic examination both before and after the removal of the last piece. The patient attended twice at the hospital afterwards, and the larynx was seen to be perfectly healthy. The voice was clear and natural. A portion of the growth examined by Dr. Andrew Clark was pronounced to be 'an ordinary cauliflower or warty growth.' "

A small Fish-bone Removed with the Forceps from the Larynx of a child.

Case 20.—C. C., æt. 12, was brought to the Hospital for Diseases of the Throat, Feb. 8, 1864, by an elder sister. She was crying, and

her sister stated that, on the previous evening, she had swallowed a herring-bone. She said that she felt the bone whenever she swallowed. She had put her fingers down her throat to try and get it up, and had been sick several times. I examined her with the laryngoscope, but could only see that the mucous membrane of the larynx was much congested. Not being able to perceive the bone, I thought she had probably swallowed it, and recommended an inhalation of hot steam to relieve the irritation. I should mention that I passed a bougie into the stomach without difficulty. The next day the child was again brought to me. Her breathing was slightly stridulous; and a medical man, who had seen her in the meantime, had told her mother that "croup was coming on". On examining the patient with the laryngoscope, the ary-epiglottic fold and ventricular band on the right side were seen to be much swollen, and of a bright red colour, and a portion of the bone was distinctly seen lying across the right ary-epiglottic fold, near the epiglottis. Apparent as it was, and easy as it seemed to seize, the greatest difficulty was experienced in getting it between the blades of the forceps. In the first attempt, the mucous membrane was slightly wounded, and the bone became obscured by the blood. After an interval of half an hour, the bone again became visible, and it was fortunately grasped between the blades of the forceps. The bone was three-quarters of an inch long, and very thin. The patient complained of a little pricking in the throat for a day or two, but on the following Friday (the accident happened on Sunday) was quite well.

Contraction of the Left Glosso-epiglottic Fold from the healing of an ulcer; Extreme Dysphagia; Relief from Division of the Stricture.

Case 21.—Charlotte D., a married woman, æt. 24, was sent to me by Mr. Shillitoe, June 18th, 1864. She stated that since November, 1863, she had not been able to swallow a particle of

CHAP. VII. solid food ; that she had lived entirely on liquids ; and that bread soaked in milk was the nearest approach to a solid which she was able to get down. Even in swallowing liquids, a portion "went the wrong way", and she never attempted to drink, or rather sip, anything, without a violent and prolonged fit of coughing. Her symptoms all dated from an attack of ulcerated sore throat which she had suffered from in October. Five years previously she had suffered from primary syphilis, and since then had had secondary symptoms.

On looking into the throat, numerous white cicatrices were seen on the posterior wall of the pharynx, and on using the laryngoscope, the left side of the epiglottis was seen to be drawn upwards, forwards (towards the tongue), and slightly inwards towards the median line (fig. 44). I at first thought that the left ary-epiglottic fold was adherent to the fauces, but on subsequent examination, I found that such was not the case. The

FIG. 44.

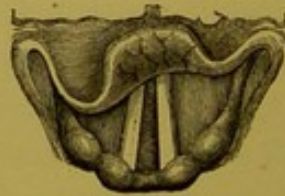

Fig. 44.—CONTRACTION OF THE LEFT GLOSSO-EPIGLOTTIC FOLD, causing obliquity of the epiglottis, non-closure of the valve over the larynx, and (consequently) extreme dysphagia.

left glosso-epiglottic fold was seen to be greatly thickened, white, prominent, and shortened, and it was obvious that this was the principal cause of the dysphagia. The dense band—raised not less than a quarter of an inch—could be felt with the finger. A bougie was passed down into the stomach without any difficulty, so that there was no doubt that the difficulty of swallowing depended mainly on the non-closure of the epiglottis over the larynx. I had the advantage of the opinion of Dr.

Smyly, of Dublin, in this rare and difficult case. I at once determined on dividing the cicatrix, but its position in the antero-posterior diameter of the larynx made it difficult to use the lancet. With the laryngeal scissors, however, in two operations I succeeded in dividing it. There was very little hæmorrhage, and the patient, after a few weeks, was apparently able to swallow as well as most people ; she still, however, complained of slight difficulty. I have not seen this patient now for some months, but should not be surprised at her return any day, with her old symptoms. I should mention, that the epiglottis did not recover an entirely normal position ; but, instead of hanging very obliquely across the laryngeal aperture, the free edge of the valve became nearly horizontal.

Since this case occurred, I have had the lancet modified, so that the cutting edge of the blade can be made to move in the antero-posterior or lateral diameter, according to the wish of the operator.

CHAPTER VIII.

THE MANIPULATION OF LARYNGEAL INSTRUMENTS,
AND SOME CONCLUDING REMARKS ON LARYN-
GOSCOPY.SECTION I.—*Method of employing Laryngeal
Instruments.*

CHAP. VIII. — **I**N applying remedies to, or operating on the larynx, the practitioner should introduce the laryngeal mirror with his left hand, so that he may have his right hand free for using the necessary instrument. In employing the laryngeal brush, the operator should hold it like a pen, and introduce it quickly but steadily to the desired spot. In using any other instrument, the operator should hold it between the thumb and second finger, so that the index finger remains free, to press on the spring in the anterior and upper part of the handle.

Most of the laryngeal instruments invented by foreign physicians have the spring on which their action depends situated at the posterior extremity of the handle. The instruments are directed to be held between the first and second fingers, whilst the

thumb pushes on the spring at the end of the handle. CHAP. VIII.
In this method, the back of the operator's handle is directed towards the patient's face, and half the mouth is covered by the operator's third, fourth, and fifth fingers. In another plan, the instrument may be held between the first two fingers, and the spring at the posterior part of the handle may be made to act by the pressure of the palm of the hand. A cross-bar near the anterior extremity of the handle, on which the two fingers can rest, facilitates the employment of instruments of this construction, but the great objection to them is, that the pressure forwards on the spring at the end of the handle greatly alters the position of the point of the instrument. In using instruments made after my model—that is to say, with the spring on the upper and anterior part of the handle—the position of the extremity introduced into the larynx is not altered by the slight pressure of the index finger on the spring. This is a matter of the greatest importance in using the lancet or forceps.

Before dismissing this subject, I would call attention to the unity of action of all my laryngeal instruments. He who learns to use one, can use all; and the constant repetition of a particular act gives to it a delicate precision, which is not otherwise attainable.

CHAP. VIII.

SECT. II.—*Concluding Remarks on Laryngoscopy.*

In this little work, many instruments and various kinds of apparatus have been described and recommended; but before concluding I would remark, that, with very few and very simple appliances, the most satisfactory results may be accomplished,—not only in the diagnosis, but in the treatment of laryngeal disease. I have already observed that many of the most valuable laryngoscopic investigations have been made with a common moderator lamp, and would call attention to the fact, that laryngeal growths have been removed with forceps of the most simple description. My common forceps, which have no complicated mechanism, can be employed in the great majority of cases with success. Those who do not intend to take up the subject from a special point of view, but merely wish to use the laryngoscope in general practice, will do well to provide themselves with a reflector, a couple of laryngeal mirrors, a light-concentrator (which can be used with different kinds of lamps) a few laryngeal brushes, and my laryngeal electrode. A very large proportion of laryngeal diseases can be treated with the brush alone, and obstinate cases of functional aphonia cannot resist the internal ap-

plication of electricity. An additional recommend-
ation to these instruments is, that even when em-
ployed injudiciously or ineffectively, they are not
likely to do any harm. It is only after the eye and
the hand have had much practice in applying reme-
dies to the larynx, that the lancet can be used with
safety, or the forceps with effect. In conclusion,
"I feel it a duty to remark," with Dr. Johnson,
"upon the possibility that the larynx may get too
much of local treatment. The laryngoscope has
brought this organ so completely within our reach,
that we are all exposed to the temptation of being
too meddlesome. If we can avoid the error to
which I have here alluded, the introduction of the
laryngoscope will be an unmixed good both to our-
selves and to our patients, and it will soon be ac-
knowledged to be one of the most valuable additions
that have ever been made to our means of diagnosis
and treatment."

CHAP. VIII. The following works bearing on the use of the
— Laryngoscope may be consulted :—

Czermak, "Der Kehlkopfspiegel und seine Verwerthung für Physiologie und Medizin." Zweite Auflage. The first edition has been translated from a French version, and published by the New Sydenham Society, Vol. x.—Türck, "Praktische Anleitung zur Laryngoskopie." Wien, 1860; and "Recherches Cliniques sur diverses Maladies du Larynx." Paris, 1862.—Semeleder, "Die Laryngoskopie und ihre Verwerthung für die Aertzliche Praxis." Wien, 1863.—Tobold, "Lehrbuch der Laryngoskopie." Berlin, 1863.—Bruns, "Die erste Ausrottung eines Polypen in der Kehlkopfhöhle." Tübingen, 1863.—Sieveking, "Practical Remarks on Laryngeal Disease." Lond., 1862.—Russell on "Laryngeal Disease, etc." Lond., 1864.—Gibb, "Diseases of the Throat, etc." Lond., 1864.—"Walker on the Laryngoscope." Lond., T. Richards, 1864.—Smyly, "Lectures on the Laryngoscope." Dublin, 1864.—Johnson's "Lectures on the Laryngoscope," delivered at the College of Physicians. Lond., Robert Hardwicke, 1864.—Türck, "Klinik der Krankheiten des Kehlkopfes." Wien, 1866.—Prosser James, "Sore Throat: its Nature, Varieties, and Treatment." Lond., Churchill, 1868.—Bruns, "Polypen des Kehlkopfes." Tübingen, 1868.—Krishaber, "Dict. Encyclopéd. des Sciences Médicales." Art. "Laryngoscope." Paris, 1868.—Gibb, "The Laryngoscope, etc." Third Edition. London, 1868.—Marcet, "Clinical Notes on Diseases of the Larynx." London, 1869.—Scott Alison, "Morbid Conditions of the Throat in their Relation to Pulmonary Consumption." London, H. K. Lewis, 1869.—Durham, "Holmes's System of Surgery," Vol. iv. Art., "Diseases of the Larynx." London, 1870.—Norton, "Affections of the Throat and Larynx." London, 1871.—Reports of cases, and suggestions on the employment of the instrument, by Tonge, Mason, Buzzard, and many others in the *Med. Times and Gaz.*, *British Med. Journ.*, and *Med. Circ.* Also, some interesting reviews on the subject in the *Brit. and For. Med.-Chi. Rev.*, Oct. 1862, July 1864, and Oct. 1865, and an original article in the same journal, Jan. 1863, by Mr. Windsor. To the latter I am indebted for several references bearing on the history of the invention of the Laryngoscope.

A P P E N D I X .

RHINOSCOPY.

THE idea of examining the posterior nares and Eustachian tubes, by placing a mirror at the back of the mouth, with its reflecting surface directed obliquely upwards, appears to have occurred to Bozzini, Baumês, Wilde, and probably to others; but the practical application of this method of examination is undoubtedly due to Professor Czermak. The art of Rhinoscopy dates from a paper published by him in August, 1859.* Since then, Semeleder, Stoerk, Voltolini, Wagner, and others, have published various articles on the subject, but the first-named physician has especially developed, simplified, and proved the value and practicability of the art.

The principle of simple reflexion alone is concerned in Rhinoscopy; but, as in the kindred art of Laryngoscopy, it is necessary to illuminate the parts desired to be inspected. A small mirror is placed

APPENDIX.

History.

Theory.

* "Wien Medicin. Wochenschrift", Aug. 6, 1859.

CHAP. VIII. at the back of the throat, at such an angle, that luminous rays falling on it, are reflected into the nares, whilst, at the same time, the image formed on the mirror is seen by the observer.

Practice. For examining the posterior nares there are required, 1st, a small mirror; 2ndly, a reflector, for concentrating the luminous rays; 3rdly, a tongue-spatula; and perhaps 4thly, a palate-hook for raising the uvula, and pulling it forward. The rhinal mirror should be made like the laryngeal mirror, but its reflecting surface should not be more than five-eighths of an inch in diameter, and it should be fixed to its shank at a right angle. The reflector is the same as that used in Laryngoscopy. The tongue-spatula should have the part which is introduced into the mouth an inch longer, and should form a more acute angle with the handle than the ordinary instrument. The palate-hook is generally made of German silver; it is about four inches long, narrow where it is fixed into the handle, and gradually getting broader at the opposite end, where it turns round at a right angle, and extends upwards for a quarter of an inch. This instrument, though recommended by Czermak, is seldom of much use. He advises that it should be made of different sizes, bent at different angles, and in some cases fenestrated.

The examination should be conducted as follows:

The lamp should have the same position as in Laryngoscopy, but the practitioner, in using the reflector, must throw the rays rather lower in the fauces. The patient should sit upright, with his head erect, or bent slightly forwards (as suggested by Moura-Bourouillou), so that the uvula may hang forwards; the patient is then directed to open his mouth widely, and the tongue is pressed forwards and downwards with a spatula, or with the index finger of the left hand; the mirror should then be introduced to the back of the throat (its upper border being a little below the uvula), so that the plane of the reflecting surface forms with the horizon an angle of about 130 deg. If the uvula happens to be drawn upwards and backwards, as is often the case, the patient must be directed to expire gently or to produce some nasal sound. Straining and forced inspiration must be especially avoided.

The practitioner will find it a good plan to introduce the small mirror between the anterior pillar and the uvula on one side first, and then to withdraw it and introduce it again in the same manner, on the opposite side. In this way he will be able to inspect the whole of the posterior nares, and by first slanting the mirror a little towards one side, and then towards the other, the

APPENDIX. orifices of the Eustachian tubes will become visible.

— After introducing the mirror in the way described, the observer can steady it, by resting his third and fourth fingers on the patient's lower jaw. As already stated, Professor Cżermak recommended the use of the palate-hook for raising and drawing forwards the uvula. Where there is unusual insensibility of the fauces, and the uvula is long, this procedure may sometimes be accomplished, but I can recall few instances where it has facilitated my examination of the posterior nares. In using the palate-hook, it must be first warmed, then passed behind the uvula, and moved gently forwards. I have had an instrument made, in which the tongue-spatula and mirror are combined, and I have since ascertained that a similar rhinoscope is employed and strongly recommended by Dr. Voltolini, of Breslau. The spatula has a narrow groove in which the shank of the rhinal mirror runs, so that it can be passed a shorter or a longer distance into the pharynx, according to the dimensions of the mouth. In cases where there is a considerable space between the uvula and the posterior wall of the pharynx, and where the palate-hook has to be used, this combination of tongue-depressor and mirror will be found useful, as one hand is thus set free to elevate the uvula.

The appearance seen with the rhinal mirror is very different to that which might be anticipated from an anatomical acquaintance with the structures; and the parts, from their position, being seldom seen in the dissecting-room, and still more rarely in the dead-house, the novice in Rhinoscopy

APPENDIX.

The Rhinal Image.

FIG. 45.

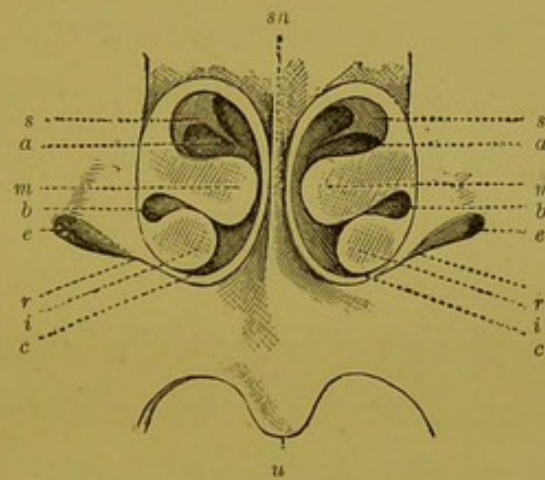


Fig. 45.—THE POSTERIOR NARES AS SEEN IN RHINOSCOPY.

- sn.* Septum nasi.
s. Superior turbinated bone.
m. Middle " "
i. Inferior " "
a. Superior meatus.
b. Middle "
c. Inferior "
e. Eustachian orifice.
r. Ridge between the Eustachian opening and
 lower border of the nasal fossa.
u. Uvula.

has but little preliminary knowledge, as regards the view of the nares from behind forwards. It is seldom that the whole of the posterior nares can

APPENDIX. be seen with the mirror, as the soft palate generally eclipses the lower third.

The drawing (fig. 45) is as accurate as possible, as regards form and size, but it is made up out of a number of images, obtained by holding the mirror in different positions. In the middle is seen the septum (*sn*). The mucous membrane in this situation is extremely thin, and appears almost white from the projection of the bone beneath it. The septum generally slants a little to one side, more often to the left, and it is rarely so symmetrical as in the annexed drawing.

Projecting from the outer walls of the nares on each side, and extending inwards towards the septum, the middle turbinated bones (*m*), covered with pale mucous membrane (beneath which there are often a few muscular fibres), are seen, as two oblong tumours somewhat resembling polypi.* The superior turbinated bones are indistinctly seen, as narrow projections of somewhat triangular shape, the apex appearing to extend

* So much, indeed, do the turbinated bones resemble polypi, that on one occasion a surgeon—not much practised in Rhinoscopy—brought me a case in which he imagined he had discovered a polypus in each nostril. It was only after demonstrating several other cases to him, that he became convinced that the supposed polypi were really the healthy turbinated bones.

downwards, inwards, and backwards. At the base of the nasal fossæ, the inferior turbinated bones are seen, as two pale, roundish, solid-looking tumours. They do not project quite so far towards the septum as the middle bones. The superior meati (*a*) are the largest of the three passages between the turbinated bones, the middle meati (*b*), are most distinctly seen towards the outer wall of the fossæ, and the inferior ones appear only as thin dark lines. On each side of the inferior turbinated bones, though further back and in a different plane, are the orifices of the Eustachian tubes; they appear as two irregular openings looking downwards and outwards. "The upper and posterior edge of the trumpet-shaped opening of the Eustachian canal being bevelled off, we see the inner surface of the anterior lip, buried in the pharyngeal wall, apparently of a lighter colour than the surrounding mucous membrane, and having a yellow tinge communicated by the cartilage." (Walker.)

There is a prominent ridge (*r*) extending downwards and inwards from the lower edge of each Eustachian orifice (caused by the levator palati muscle on each side), and from the upper edge of the Eustachian opening is a depression in the mucous membrane, extending upwards and inwards. Beneath the nasal fossæ is the soft palate, uvula, etc.

APPENDIX. The principal difficulties in Rhinoscopy consist in
Special an unusual length and breadth of the uvula, or a
Difficulties. too short distance between the anterior pillars of
the fauces and the posterior walls of the pharynx.
The former obstacle may be overcome by following
the directions already given, but the latter is insu-
perable. In a certain number of cases, it is quite
impossible to practise Rhinoscopy, and it is gene-
rally easy by examining the fauces, and observing
whether this space exists, to tell beforehand whether
an inspection of the nasal fossæ is possible.

Anterior
Rhinoscopy.

By examining the nares through their external
orifice, useful information can sometimes be ob-
tained. The want of suitable specula had hitherto
prevented this method of inspection being satis-
factory; but Dr. Thudichum* has lately invented
an exceedingly useful form of speculum. It con-
sists of "two valves, which are held together by a
spring, and, when compressed, form a canal of
oval bore, about three-quarters of an inch in
length. The valve which expands the ala is from
one-quarter to three-quarters of an inch longer
than the valve which is placed along the septum.
This latter inner valve should never be long
enough to reach the sensitive part of the mucous

* "On Polypus in the Nose and Ozæna". By John W.
Thudichum, M.D. London, Churchill. 1869.

membrane of the septum. It follows from this, that each nostril requires its own speculum. There must, therefore, be for each case a right and a left speculum. As nostrils are of different sizes, different sizes of pairs of specula must be at hand in practice. The speculum is inserted into the nostril while closely compressed; the moment the spring is liberated the nostril is fully expanded, and if the operator now draws the spring, which serves also for a handle, upwards, the cavity of the nose can be fully inspected. The speculum, therefore, is designed exclusively to expand the atrium, or membrano-cartilaginous part of the nostril; if it were allowed to enter beyond this, and to reach the isthmus formed by the unyielding cartilaginous septum and the nasal margin of the ascending branch of the upper maxillary bone, it would cause pain, and narrow by its own thickness this small passage."

Though of comparatively limited, and rather difficult application, the art of Rhinoscopy proves useful in cases of obstruction of the nasal passages by polypi or thickened mucous membrane, in that most troublesome affection, ozæna, and in the various forms of ulceration of the hard and soft parts of the nose. In cases of deafness dependent on obstruction of the Eustachian orifice, it not only

*Use of
Rhinoscopy.*

APPENDIX. enables the practitioner to diagnose the affection, but also to carry out suitable treatment.

For the application of solutions to the interior of the nose, my No. 1 laryngeal brush will be found useful. Atomised inhalations can be administered with Clark's or Siegle's apparatus, while, for the inspiration of medicated vapours, a nose-piece has been adapted to my Eclectic inhaler. In numerous chronic diseases of the nose, the continuous nasal douche, first recommended by Dr. Thudichum, is of great value. Polypi may be removed either with the forceps, wire-loop, galvanic cautery, or electrolysis.*

The following two cases, selected from among many others in which the result was not less satisfactory, illustrate the value of Rhinoscopy :

Obstruction of the Left Nasal Passage from thickening of the Mucous Membrane over the Left Middle Turbinate Bone. Constant sensation of obstruction in the nose, and inability to blow the left nostril. Relief by local treatment.

Case 24.—Mrs. E., æt. 41, applied to me in June, 1863, on account of a constant feeling of stuffiness and troublesome pricking sensation in the nose. She said that for the last three

* An interesting case, treated by electrolysis, is reported by Dr. Althaus in the *Med. Times and Gazette*, April 8th, 1871. The operator was Professor Von Bruns, of Tübingen; and, though the treatment occupied ten months, the polypus, which was large, had been previously unsuccessfully treated by other means.

years she had always felt as though she had a cold in her head, but there was no discharge. She had also constant inclination to sniff through the left nostril. She had taken a great deal of medicine, and had tried sniffing alum through the left nostril, but without any benefit. The physical conformation of parts was favourable to Rhinoscopy, and with the mirror the mucous membrane over the middle turbinated bone on the left side was seen to be so much swollen that it completely blocked up the left nasal passage (fig. 46). The mucous membrane was of a deep red colour. With a curved brush I applied various caustic solutions to the affected part. Solutions of nitrate of silver, sulphate of copper, and iodine, were each used for some weeks, but the greatest benefit resulted from the last-named agent. At the end of four months, the subjective features of the disease had entirely given way, and the patient considered herself cured. All the inflammation had subsided; but the mucous membrane, though no longer at all congested, was still a little swollen. Four months after the last application to the nares, the patient still felt perfectly well. The appearance of parts when first seen, is shown in fig. 46, *A*, and the improvement after treatment in fig. 46, *B*.

FIG. 46.



Fig. 46.—SWELLING OF THE MUCOUS MEMBRANE OF THE POSTERIOR NARES.

- A.* The mucous membrane over the middle turbinated bone, in the left nasal fossa (the right in the drawing), is seen to be so much swollen, that it nearly occludes the nasal passages.
- B.* The swelling of the mucous membrane is seen to have almost subsided.

APPENDIX. *Ozoena of two years' standing, caused by Ulcers on the Vomer and Right Middle Turbinated Bone. Cured by local treatment.*

Case 25.—Henry W., æt. 41, a shoemaker, applied at the Hospital for Diseases of the Throat, in January, 1864, on account of a constant discharge from the nose and throat, from which he had been suffering for eleven months. The larynx appeared to be healthy; but an ulcer was clearly seen at the upper part of the septum, and another on the right middle turbinated bone (fig. 47). On probing the ulcer on the septum with a piece of

FIG. 47.

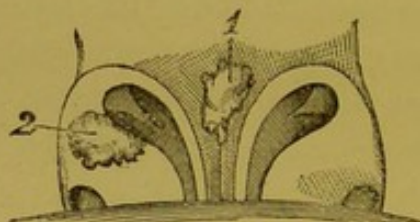


Fig. 47.—ULCERS IN THE POSTERIOR NARES CAUSING OZÆNA.

1. Ulcer on the septum.
2. Ulcer on the right middle turbinated bone.


curved aluminium wire, the rough bony structure could be distinctly felt. On inquiry, it was ascertained that two years previously the patient had suffered from constitutional syphilis.

The internal use of iodide of potassium, and the local application of a solution of nitrate of silver, effected a complete cure in six weeks.

On the subject of Rhinoscopy, the reader may be referred to—

APPENDIX.
—

Semeleder's interesting work, "Die Rhinoskopie und ihr Werth für die Aertzliche Praxis", Leipsig, 1862; Voltolini, "Eine monographische Arbeit zur fünfzigjährigen Jubelfeier der Universität Breslau", Aug., 1861; and various papers by that author in "Virchow's Archiv", "Jahrbücher der Gesellschaft der Aerzte zu Wien", "Deutsche Klinik", etc. (1860 and 1861); Thudichum, "On Polypus in the Nose and Ozæna: their Successful Treatment by New Methods". Churchill, 1869. Article, "Diseases of the Nose," by Arthur Durham, F.R.C.S., in Holmes's "System of Surgery." Second Edition. Vol. iv. Longmans, 1870.



INDEX.

- ABSCESSSES of larynx, 118
 Antero-posterior reflexion of the larynx, 55
 Aphonia cured by faradisation, 111 to 117; from excrescences,—*see* Excrescences.
 Application of solutions to the larynx, 96
 Ary-epiglottic fold, healthy, 72; contraction of, 152
 Arytenoid cartilages, 75
 Atomised liquids, 99
 Atomiser, Mayer's, 100
 Auto-laryngoscopy, 77
 Avery, Mr., his laryngoscope, 21

 BABINGTON, Dr., his laryngoscope, 12
 Baumès, Dr., " " 17
 Bennati, Dr., " " 16
 Bibliography of laryngoscopy, 158
 " " rhinoscopy, 171
 Bozzini, Dr., his laryngoscope, 4
 Brush, the laryngeal, 96

 CAPITULA Santorini, 73
 Cauteriser, laryngeal, 105
 Chair, laryngoscopic, 92
 Cricoid cartilage, 76
 Cystic growths, 120
 Czermak, Prof., his laryngoscope, 28

 DIRECT light, 45; ditto compared with reflected, 50

 ECLECTIC inhaler, 103
 Écraseur, guarded-wheel, 133; laryngeal, 133; Stoerck's, 133
 Epiglottis, healthy, 70
 Epiglottic pincette, 96
 Escharotics, 106
 Excrescences removed with forceps, 138 to 149
 Extirpation of growths, 124

 FALSE vocal cords,—*see* Ventricular Bands.
 Faradisation, internal application of, 107
 Faults in practising laryngoscopy, 62
 Fish-bone removed from larynx with forceps, 150
 Fixateur, 88
 Forceps, tube, 125
 " " common, 129
 " " cutting, 130
 Fossa innominata, 75

 GARCIA, M., his laryngoscope, 25
 Growths, extirpation of, 124

 HEAD-REST, 92
 Healthy larynx, 69
 History of the invention, 1
 Hyoid fossa, 76

 INFRA-GLOTTIC laryngoscopy, 83
 Inhalations, 101
 Inhaler, Eclectic, 103
 " " Siegle's, 101
 Injector, laryngeal, 98
 Illumination, 38

 JOHNSON, Dr., his method of practising auto-laryngoscopy, 79

 KNIVES, laryngeal, 120

 LAMP, different kinds of, 39
 " " clinical, 40
 " " rack-movement, 39
 Lancet, laryngeal, 118
 Laryngoscopic drawings, 56
 Laryngeal brushes, 96
 " " knives, 120
 " " lancet, 118
 " " mirror, 33
 " " sounds, 90

- Lateral reflexion of the larynx, 55
 Latour, M. de, his laryngoscope, 10
 Levret, M., " " 2
 Light-concentrators, 41
 ——— direct, 45
 ——— oxy-hydrogen, 45
 Loops, wire, 137
- MAGNIFYING instruments, 84
 Manipulation of laryngeal instruments, 154
 Micrometers, 184
- NITRATE of silver (solid), 105
 Nomenclature, note on, 72
- CEDEMA cured by scarification, 121 and 123
- POWDERS, the application of, to the larynx, 105
 Practice of laryngoscopy, 57
 Principles of laryngoscopy, 53
 Prismatic laryngeal mirror, 35
- RECIPRO-LARYNGOSCOPY, 80
 Reflected light, compared with direct, 50
 Reflector, 36
 Rhinal image, 163
 Rhinoscopy, anterior, 166; difficulties of, 167; history of, 159; practice of, 160; cases illustrative of, 168
- SCARIFICATION of the larynx, 118
 Scissors, Laryngeal, 129
 Self-holder, or *fixateur*, 88
 Senn, Dr., his laryngeal mirror, 10
 Siegle's inhaler, 103
 Sounds, laryngeal, 91
 Smyly, Dr., his mode of demonstrating a patient's larynx, 80
 Special difficulties in laryngoscopy, 65
 Sunlight, 57
- TRACHEOSCOPY,—*see* Infra-glottic Laryngoscopy.
 Transparency, illumination by, 52
 Türk, his first employment of the laryngeal mirror, 28
- VENTRICLES of the larynx, 75
 Ventricular bands, 74
 Vertical reflexion of the larynx, 54
 Vocal cords, 75
- WALKER, his light concentrator, 49
 Warden, his prismatic laryngoscope, 18
 Wertheim, his magnifying mirrors, 84
 Wrisberg, cartilage of, 73



THE USE OF THE LARYNGOSCOPE.

BY

MORELL MACKENZIE, M.D.LOND., M.R.C.P.

OPINIONS OF THE PRESS.

(*Second Edition.*)

"This new edition of a work already well known to the profession, does not require a lengthened notice from us; it is sufficient to say, that Dr. Mackenzie has considerably increased its value by the careful revision which he has given to it, and the new matter which he has introduced. Of all the works in this country which have described the application of laryngoscopy and rhinoscopy, that of Dr. Mackenzie is the clearest and most reliable guide, and the one which gives the greatest amount of useful information."—*Lancet*, Feb. 29, 1868.

"It is always satisfactory to the profession to find that new, and so-called 'special', means of diagnosis and treatment are taken up by men who have a thorough insight into the whole circle of professional knowledge, and who, consequently, are not prone to that constant harping on one string, and abuse of one set of local remedies, which are the alleged vices of specialists..... This second edition is evidently a complete work, bearing the stamp of original treatment, and we are glad to see that it is undergoing translation into French."—*Medical Times and Gazette*, March 16, 1867.

"The first edition of Dr. Morell Mackenzie's work on the Laryngoscope appeared at the beginning of last year, and has already been exhausted. This was but a natural result of its merits. He has now issued a second and revised edition; which, we have no doubt, will more than sustain the reputation of its predecessor as a most complete treatise on this subject."—*British Medical Journal*, Dec. 1, 1866.

"The new edition, whilst possessing the advantages of its predecessor—completeness, conciseness, and perspicuity—has been further improved by careful revision and amplification of the text, and by the addition of several new woodcuts..... It is undoubtedly the best work of the kind hitherto published."—*The British and Foreign Medico-Chirurgical Review*, January, 1867.

(*First Edition.*)

"It is a thoroughly practical book; and to all who desire to become acquainted with these methods of exploring and treating throat affections, it must prove of great value. Its author is already well known to the profession as an earnest and successful investigator of these forms of disease..... We have much satisfaction in recommending this book to the profession. It is just what such a treatise ought to be—brief, clear, and systematic; whilst every page exhibits the results of the author's matured experience and reflection."—*Edinburgh Medical Journal*, March, 1865.

"While laryngoscopy was in its infancy, and before it had begun to engage to any extent the attention of the profession, it was studied with the greatest care and enthusiasm by the author of this treatise. A personal friend of Czermak's, who has done more than any other continental physician to introduce the laryngoscope into practice, he has profited by the opportunities which he thus possessed of becoming acquainted with the anatomy and morbid anatomy of the larynx. But he has done much more than this. As will be seen by a perusal of

OPINIONS OF THE PRESS.

this treatise, he has modified the instruments at present in use for the examination of the larynx, and has invented others for therapeutical purposes..... Those who are anxious to study the diseases of the larynx, and the mode of using the laryngoscope, cannot do better than purchase the treatise before us, as it is by far the best which has been published in this country, and is thoroughly to be relied upon."—*Glasgow Medical Journal*, April, 1865.

"The book before us is not only a well got up work, but is in every respect a useful manual to whoever—student or practitioner—may wish to know how to use the laryngoscope..... In addition to a most lucid and accurate description of the instrument, the mode of using it, and various ingenious appliances for introducing remedies, and performing operations in the larynx, he gives a short and well written history of its discovery..... The woodcuts throughout the book are excellent."—*Dublin Medical Press*, August 9th, 1865.

"This book is well calculated to popularise the method of investigation which passes under the name of laryngoscopy. It is throughout amply illustrated by well executed and very clear woodcuts, and we have no doubt ourselves that it will meet with a rapid and extensive sale."—*Medical Times and Gazette*, March 28th, 1865.

"Dr. Mackenzie has given us all that is known up to the present time both of the instrument and of its capabilities. The work is well written, and the subject systematically treated."—*British Medical Journal*, January 28th, 1865.

"Brief, but with sufficient detail, clear, excellently illustrated, and (no unimportant consideration) well printed, this book forms a capital guide to the art of laryngoscopy."—*Ranking's Abstract*, July, 1865.

"Much valuable information is to be derived from this excellent work; and, so far as we are aware, no work on the subject contains so much in so small compass. It deserves a place in the library of every intelligent reading physician..... The appendix is devoted to an exceedingly interesting and instructive article on Rhinoscopy."—*Philadelphia Medical and Surgical Reporter*, October 14th, 1865.

"This is a well written monograph, excellently arranged, and answering the purpose for which it is intended..... It will be seen that the author is not so special in his views as to exclude every other branch of the profession, but desires simply to make his art an adjuvant. We advise all of our readers who feel an interest in this subject to peruse this work."—*St. Louis Med. and Surg. Jour.*, Jan., 1866.

See also *The Athenæum*, March 18th, 1865; *Medical Circular*, February 15th, 1865; *Medical Mirror*, February, 1865; and other Medical Journals for 1865.

D U L A R Y N G O S C O P E, & c. PAR MORELL MACKENZIE.

Traduit de l'Anglais sur la 2de Edition, par le Dr. ÉMILE NICHOLAS.

"Morell Mackenzie paraît posséder à un haut degré les qualités qui appartiennent à sa race: il est précis, il est méthodique, il va droit au but pratique. Des figures bien faites et assez nombreuses facilitent d'ailleurs l'intelligence du texte."—*Union Méd.*, Juillet, 1867.

"Ce petit manuel est remarquable par la précision, par la clarté avec laquelle l'auteur a exposé le sujet. Il mène son lecteur par la main, et lui fait traverser le plus habilement du monde les sentiers les plus difficiles. Pour cela, il se souvient toujours qu'il parle à des médecins à qui il veut enseigner ce qu'il sait si bien."—*Journal de Médecine*, Septembre, 1867.

